

TRANSACTIONS

OF THE

SIXTEENTH ANNUAL MEETING

OF THE

AMERICAN LARYNGOLOGICAL ASSOCIATION

HELD IN THE CITY OF WASHINGTON, D. C.

MAY 30, 31, AND JUNE 1

1894

NEW YORK
D. APPLETON AND COMPANY
1895

PRESIDENTS OF THE ASSOCIATION

ELECTED.

- 1879. LOUIS ELSBERG, M. D.
- 1880. J. SOLIS-COHEN, M. D.
- 1881. FREDERICK I. KNIGHT, M. D.
- 1882. GEORGE M. LEFFERTS, M. D.
- 1883. F. H. BOSWORTH, M. D.
- 1884. E. L. SHURLY, M. D.
- 1885. HARRISON ALLEN, M. D.
- 1886. E. FLETCHER INGALS, M. D.
- 1887. R. P. LINCOLN, M. D.
- 1888. E. CARROLL MORGAN, M. D.
- 1889. JOHN N. MACKENZIE, M. D.
- 1890. W. C. GLASGOW, M. D.
- 1891. S. W. LANGMAID, M. D.
- 1892. MORRIS J. ASCH, M. D.
- 1893. D. BRYSON DELAVAN, M. D.

OFFICERS

(ELECTED JUNE 1, 1893)

PRESIDENT

D. BRYSON DELAVAN, M. D., NEW YORK

1st VICE-PRESIDENT

J. C. MULHALL, M. D., ST. LOUIS

2d VICE-PRESIDENT

W. E. CASSELBERRY, M. D., CHICAGO

SECRETARY AND TREASURER

CHARLES H. KNIGHT, M. D., 147 WEST FIFTY-SEVENTH STREET, NEW YORK

LIBRARIAN

J. H. BRYAN, M. D., WASHINGTON, D. C.

COUNCIL

HARRISON ALLEN, M. D., PHILADELPHIA

W. C. GLASGOW, M. D., ST. LOUIS

S. W. LANGMAID, M. D., BOSTON

MORRIS J. ASCH, M. D., NEW YORK

TABLE OF CONTENTS.

	PAGE
Address of the President, Dr. DELAVAN	1
<i>Papers :</i>	
I. Papillary Hypertrophy of the Nasal Mucous Membrane compared with a True Papilloma Dr. WRIGHT	13
II. A Plea for Early Operation in Diseases of the Antrum of Highmore. Dr. DALY	20
III. Report of a Case of a Foreign Body (Cocklebur) in the Larynx. Dr. SHIELDS	31
IV. Report of a Case of Epithelioma and of one of Sarcoma of the Larynx. Dr. BLISS	32
V. A Cyst of the Larynx cured by Injection of Carbolic Acid; and a Report on Mycosis of the Pharynx and Tonsils. Dr. INGALS	37
VI. Mycosis Tonsillaris. Dr. BEAN	43
VII. Aspergillus Mycosis of the Antrum Maxillare. Dr. MACKENZIE	46
VIII. Nasal Polypus: its Association with Ethmoiditis and its Treatment by Resection of the Middle Turbinated Body. Dr. CASSELBERRY	49
IX. Observations on Some of the Results of Cutting Operations on the Nasal Septum. Dr. FRENCH	67
X. The Use of Metallic Electrodes in the Treatment of Nasal and Post-Nasal Disease. Dr. RICE	81
XI. A Case of Compound Follicular Odontoma Invading the Right Antrum of Highmore and Obstructing the Corresponding Nasal Fossa, with an Apparatus for Administering Anaesthetics, Especially Adapted to Operations in the Mouth, Nose, and Throat. Dr. DE ROALDES	91
XII. A Case of Foreign Body (Gold Coin) Engaged in the Ventricles of the Larynx. Dr. DE ROALDES	102
XIII. Three Cases of Laryngeal Neoplasm. Dr. C. H. KNIGHT	104
XIV. A Case of Laryngectomy by a Novel Method. Dr. SWAIN	110
XV. Singers' Nodes. Dr. F. I. KNIGHT	118
XVI. A Case of Exudative Pharyngitis. Dr. GLASGOW	124
XVII. A Case of Sarcoma of the Tonsil. Dr. WATSON	125

	PAGE
XVIII. The Importance of an Early Diagnosis of Malignant Tumors of the Throat. Dr. GLEITSMANN	127
XIX. Neurotic Phenomena in Throat Diseases, with Illustrative Cases. Dr. PORCHER	135
XX. Contribution to the Study of the Ætiology of Rheumatic Affections of the Body Due to Tonsillar Diseases. Dr. H. L. WAGNER	141
XXI. Demonstration of Skulls showing the Effects of Cretinism on the Shape of the Nasal Chambers. Dr. ALLEN	142
XXII. Discussion on the Accessory Sinuses. Drs. BOSWORTH, BRYAN, MACKENZIE, and ROE	145

Presentation of Instruments.

Tonsillotome and Volsella. Dr. CASSELBERRY	168
Electrolytic Needle-Holder. Dr. DE ROALDES	169
Report of the Delegate to the International Medical Congress at Rome, Dr. LOWMAN	172
Business Meetings	176
List of Fellows, 1894	179

TRANSACTIONS
OF THE
SIXTEENTH ANNUAL MEETING
OF THE
AMERICAN LARYNGOLOGICAL ASSOCIATION,
HELD IN THE CITY OF WASHINGTON, D. C., MAY 30 AND 31, AND
JUNE 1, 1894.

ADDRESS OF THE PRESIDENT.

By D. BRYSON DELAVAN, M. D.

FELLOWS OF THE AMERICAN LARYNGOLOGICAL ASSOCIATION: In opening our sixteenth annual congress, let me heartily welcome you to what gives every promise of being a most useful and enjoyable meeting. The support which you have given it, both by your presence and by the scientific contributions provided, has been spirited and generous, and I am assured that you will still further co-operate with me in carrying it through to a harmonious and successful close.

As president, the option is accorded me of inaugurating our exercises with the time-honored ceremony of a presidential address. While some have held the value of this in question, I believe that such an address should be considered, in like manner with our annual dinner, as a very desirable, if not an indispensable, part of each yearly gathering, affording as it does an opportunity to call attention to ideas and suggestions of timely interest which could hardly otherwise be presented, and to record and study events of historic value in the career of the association.

Surely the experience gained in sixteen years should give light enough to illuminate for us the present and enable us to look forward somewhat into the future. In trying to forecast the future, too, it is eminently right that we should indulge in retrospect, particularly for the benefit of any who may but recently have come

among us and to whom our early history may be unknown. I shall aim, therefore, to go backward with you over the life of the association, review the means by which it has attained its ends, estimate fairly its present standing, and, finally, study the methods by which its mission of usefulness for the future may be most surely and successfully accomplished. In doing this I trust that our older members may be stimulated by the story of their success, and our younger ones made to realize the full meaning and value of their admission into what has rightly become to its fellows an honored and cherished institution.

The history of our association is almost the history of laryngology, not only in this country, but in the world, for Manuel Garcia, the discoverer of the laryngoscope, is still living and one of our honorary members, while the list of our corresponding fellows has contained the names of the most distinguished specialists of the time. It must always be a cause of regret that Horace Green, our thrice-distinguished countryman, should have ended his invaluable labors before this association came into existence. As the pioneer specialist in diseases of the throat, his works now prove that he led the world, along a path indeed made rough and thorny by those who should have been his aids. Between the dark age in which he struggled and the brilliant era ushered in by Czermak, how great a change! Then, blind groping after truth; now, learning guided by the electric light of modern scientific methods. Then, ignorance, opposition, misrepresentation; now, an acknowledged department of science, recognized and honored wherever known. Then, practically in the grasp of one man; now, universal. Truly, our earliest motto was well chosen—“*E tenebris lux.*”

According to Elsberg, the laryngoscope was first introduced into this country in 1860. By 1878 its use was being taught in twenty-five different institutions, and the specialty had gained a position of acknowledged respectability. Elsberg, eminently qualified for such a task, has given a complete history of the study of disease of the throat in this country, which those who own the first volume of our *Transactions* will find a most interesting record. In the same essay also he pointed out the rare possibilities of usefulness which lay in the path of our then youthful association, the birth of which had taken place but a year before. Concerning this happy event, let me refresh your memories by recalling the fact that the inaugural meeting of the American Laryngological Association was held in Buffalo on the 3d of June, 1878, in response to an invitation by

Dr. Frank H. Davis, of Chicago, issued on May 10, 1878, to the following-named gentlemen: Dr. J. Solis-Cohen, Dr. Carl Seiler, Philadelphia; Dr. Clinton Wagner, Dr. George M. Lefferts, Dr. Louis Elsberg, Dr. Beverley Robinson, New York; Dr. Frank Donaldson, Dr. J. H. Hartman, Dr. Samuel Johnston, Baltimore; Dr. Frederick I. Knight, Dr. E. Cutter, Boston; Dr. E. L. Shurly, Detroit; Dr. William C. Glasgow, Dr. William Porter, Dr. Thomas F. Rumbold, St. Louis; Dr. Hosmer A. Johnson, Dr. E. Fletcher Ingals, Dr. M. Monnheim, Chicago. These gentlemen, together with Dr. Rufus P. Lincoln and Dr. F. H. Bosworth, of New York, met together, as above stated, for the purpose of forming a national association for the advancement of laryngology. Very justly, therefore, they should be considered the founders of this organization. From the minutes of this first meeting we learn that it was called to order by Dr. Lefferts, who acted as secretary, and that Dr. F. H. Davis occupied the chair. Dr. Louis Elsberg, in his inaugural remarks as first president, re-echoed the experience of Horace Green when, in speaking of his own twenty years of special labor, he said: "The road has been a rugged one, and few of you can realize to-day the uphill work, the obstacles, and obloquy encountered." And then, in the spirit of the true enthusiast that he was, he quickly adds: "In the pursuit of our specialty I have found much happiness, reward for all endeavor, satisfaction from consciousness of good work done, gratitude from patients, recognition from the profession, and altogether greater success, perhaps, than I have deserved." It was right that Elsberg should have been the association's first president. Holding that office for two successive terms, he gave in his inaugural addresses the principles upon which the society has since been conducted, with a degree of success which would argue ill for any serious departure that might in future be made from them.

The motives which actuated the leaders in the founding of our society were eminently philanthropic, noble, and ambitious. No one can question that these were exemplified so clearly and forcibly by the four distinguished men who first presided over us that we need never think of failure as long as the ideas which they advanced continue to be kept in view. Their organization of the society was a preconceived movement in the direction of a higher and broader education; an intelligent, vigorous effort to advance and disseminate the knowledge of our special work. By means of its annual meetings, by the publication of its transactions, by the encouragement of

the special literature of our department, both scientific and critical, by the bringing forward of youthful aspirants for laryngological fame, and, finally, by the study and practice of the best methods of instruction in our medical schools, it was hoped that the association might attain usefulness in no ordinary degree. How well these hopes have been realized will shortly appear.

Never since its formation has the association failed to hold its regular annual congress at the time and place formally agreed upon. Its meetings invariably have been well attended, both by its older and younger members. Every year new contributions, often of great scientific value, have been presented. The discussions have been remarkably full, original, and helpful. Indeed, if there is one thing to which we can point with just pride, it is the tangible essence of these meetings represented by our published *Transactions*. Fifteen volumes, models of excellence in all that goes to make a perfect book, each one in itself sufficient to form a most worthy monument to the genius, the devotion, and the progressive spirit of the society, have gradually accumulated upon our shelves. According to the published records and to the programme now before us, original articles have been contributed since the beginning of the society to the number of more than three hundred and thirty, a large proportion of which have been of unusual value. Comparing these papers with the best that the world has produced, they will be found to be scholarly, accurate, and exhaustive, while, scientifically speaking, many of them are historic, marking, as they do, the original discovery of important scientific facts, and in some instances inaugurating new eras in the departments of which they treat. The foreign relations of the association have always been intimate and agreeable, and there has never been a congress of any note in which it has not been ably represented.

Our association is intimately related also to another important educational factor. In the department of journalism its history has been honorably associated with the progress of the special literature of our department. As showing the advances made since our beginning, all of this, with the exception of the laryngological department of the *Monatsschrift für Ohrenheilkunde*, first edited by Professor Schrötter, of Vienna, and *Les annales des maladies*, etc., founded in Paris by Isambert, Krishaber, and Lacharrière, just twenty years ago, has been started since 1878.

A glance at them reveals an array of magazines which represent many languages, and which, in literary style and scientific excellence,

are a credit to laryngology. These journals may be divided into two classes: those which devote themselves especially or in part to the publication of original matter, and those which merely pretend to give a critical synopsis of the current literature of the specialty. Of the journals of the first class, none has played a more important part or attained a higher plane of excellence than did the *Archives of Laryngology*, founded in 1878 by our fellow-members, Dr. Knight, Dr. Cohen, Dr. Elsberg, and Dr. Lefferts, and by them so conducted as to have made the magazine a model guide for the future management of such enterprises. One valuable feature of it may have escaped your attention—namely, its bibliographical records, which form an important link in the following chain:

As a part of his inaugural address, the late Dr. Elsberg presented to this society a complete bibliography of laryngology up to the year 1878. The work of recording the current literature of the day had already been undertaken by Lefferts, who, beginning in 1875, published quarterly in the *New York Medical Journal* a carefully prepared digest and complete bibliography of the subject, and transferred his reports to the *Archives of Laryngology* when that journal was started in 1880. Here they were continued, to be taken up and carried onward by other magazines, now easily accessible to all, up to the present time. To Dr. Lefferts, therefore, belongs pre-eminently the credit of this most helpful contribution, which, long antedating the *Index Medicus*, will be appreciated by every one of us who attempts to study or to write in this department, and which, combined with the bibliography given in the work of Sir Morell Mackenzie, presents the completest available record of the special literature of our subject.

Of the journals now in existence, that which is the oldest still continues to be one of the foremost and best, and the editors of *Les annales* may look with well-earned satisfaction upon the twenty splendid volumes with which their labors have been rewarded. No journal since the death of the *Archives* has filled more acceptably a place of higher usefulness than the present *Journal of Laryngology*, founded by Sir Morell Mackenzie, and a worthy monument to him. By the English-speaking contingent, who are able to appreciate its value and compare it with others of its kind, it will easily be accorded the highest rank.

Turning from the department of journalism to that of book making, what changes have taken place with us since the days of Beunati and Horace Green! While a literature of extraordinary

proportions has been steadily accumulating in this country, it may at present be said that the standard literature of laryngology began with Solis-Cohen in 1879 and ended with Bosworth in 1892.

Last and best of all, the influence of the association upon its active fellows has been stimulating and salutary. All will readily admit this, while there are some among us to whom it has been a veritable inspiration.

Thus the American Laryngological Association, completely successful from its inception, has steadily advanced upon the even tenor of its way, each year adding to its usefulness, its influence, and its reputation.

Meanwhile, as compared with ours, what has been the progress of the outside world in this direction? The story of foreign national associations is briefly told. While there are various local societies and sections of laryngology, national associations have, until very lately, been unknown; now, however, their value is beginning to be recognized. First in the order of priority is the British Laryngological and Rhinological Association, founded in 1888 by that greatest of laryngologists, Sir Morell Mackenzie, ten years after the first meeting of our association. In 1890 successful associations were begun in France and in Belgium, in 1892 one in Italy, and, most recent of all, the Laryngological Association of Holland was started in 1893 with an active membership of twenty-five. Scandinavia, Russia, Germany, Austria, and Spain are as yet unrepresented. The American Laryngological Association, therefore, is nearly as old as all other similar associations combined. The fact that others are following its example proves that the ideas it has implanted, although slow in being accepted, are at last beginning to bear fruit.

But while upon the subject of such organized work in laryngology, it would not be fair to pass without notice the numerous local societies and special sections of large general medical bodies which have been formed for the advancement of our specialty. Indeed, here again America may claim priority, for five years before our national association was started there was organized, at the suggestion of Dr. Clinton Wagner, the Laryngological Society of New York. The story of its founding is worthy of your hearing, as it bears directly upon the subject of our discourse. It is herewith given in the words of Dr. Wagner himself:

"In the autumn of 1873, appreciating the advantage to be de-

rived from a society for the consideration of laryngological work, I wrote to a number of men, many of whom had studied diseases of the throat in Vienna and elsewhere and who held positions at throat clinics in this city, requesting them to meet at my residence for the purpose of organizing such a society. Early in October, 1873—I can not remember the exact date—the following responded to the invitation: Dr. G. M. Lefferts, Dr. Woolsey Johnson, Dr. Charles McBurney, Dr. F. H. Bosworth, Dr. M. J. Asch, Dr. M. D. Mann, Dr. F. P. Kinnicutt, and Dr. H. Bridge. The New York Laryngological Society was then organized, having for its object the ‘promotion of the study of diseases of the larynx, pharynx, and adjacent parts.’

“Dr. McBurney and I were appointed to draw up the by-laws. A large number of new members were shortly afterward admitted. The society flourished until the American Laryngological Association appeared, and later on, when the Laryngological Section of the New York Academy of Medicine was established, it was merged into it.

“It was the *first* society devoted exclusively to laryngology and rhinology established either in this country or in Europe. At Buffalo, in June, 1878, four members of the New York Laryngological Society—viz., Lefferts, Bosworth, Elsberg, and myself—took part in founding the American Laryngological Association; we were the only New Yorkers present.

“In the obituary notice of my friend, Dr. Elsberg, which appeared in the New York *Medical Record*, it was stated that he had founded the New York Laryngological Society. I am quite sure that Elsberg never said anything to create such an impression.

“As a matter of fact, Dr. Elsberg did not join the society until 1875 or 1876—I think the latter date.

“I have not written this to detract in any way from the well-earned laurels of my friend Elsberg, and at the time of the publication of the notice I, of course, said nothing. I furnish the information now at your request to aid you in putting facts on ‘permanent record.’

Very truly yours,

“CLINTON WAGNER.”

The Section in Laryngology and Rhinology of the New York Academy of Medicine now numbers more than sixty active members, its monthly meetings are fully attended, and its scientific work is of a high order.

Within the last few years a great change has come about. All

over Europe signs of increased interest have become manifest in the rapid increase of these special societies. Thus highly successful local societies have been started in London, Berlin, and other centers. The latest report is that one has been formed in Budapest. Existing national societies and the special laryngological sections of general bodies, such as the Laryngological Section of the British Medical Association, the Laryngo-rhinological Section of the German *Naturforscherversammlung*, and the Laryngological Section of the American Medical Association, are all progressively more active; new societies, sections, and associations are rapidly being formed, and everywhere a spirit of progress is showing itself most gratifying to such as have the advancement of science truly at heart.

The effect of centralized effort of that healthful competition which is the inevitable and invaluable result of the free intercourse and friendly rivalry made possible by these societies has nowhere shown its influence more potently or with more gratifying results than in England, where lately the study of laryngology has been advanced with the energy and enthusiasm of a genuine renaissance. Wherever successful associations have been established, their influence has been invariably elevating and inspiring, as shown in the improved quality and amount of the scientific work done and in the general tendency toward the attainment of higher planes of professional education and culture.

It is indeed a satisfaction that this strong onward movement should have been headed, and at so great a distance in advance, by this country, and it is surely not unpardonable that we should express ourselves as the occasion warrants. In the midst of these self-congratulations, however, let us not for a moment be deceived or carried away.

Far from arousing other feelings than those of humility, let us remember that the success attained, the honorable place fairly and honorably won, the flattery of delayed but now widespread imitation—all impose added responsibility and weightier obligation. To be an example to the world, we must strive for superiority. Nay, even if we are to hold the place which has been won, it must be through increased diligence in our own work, and an ever-broadening receptivity to the ideas of others.

Having thus suggested a few points in the history of the association, let us study out, if possible, what has been its most important function in the past and wherein lie its greatest possibilities of usefulness for the future. Unquestionably, the keynote of

the whole matter was struck by our first secretary when he selected as the motto for our programme the words "*Docendo discimus*"—By teaching we learn. If the association is to attain and to maintain the highest place, it must itself be the exemplar and the guide; and, first qualifying itself by absolute purity of purpose, oneness of aim, and actual scientific superiority, then proceed to study and to carry out such plans for the advancement of the specialty as shall place the greatest amount of sound learning in the hands of the largest number of well-qualified men. The question of education, in other words, is vastly the most important, the most interesting, and the most opportune by which our attention could possibly be engaged. In it lies the hope of the future, both as to our own reputations and, what is of far more importance, as to the beneficent ends to which we fondly hope that our specialty may attain. This, in the origin of our association, was its grand, primal idea, inculcated first and last by the ablest and wisest of its founders, and interwoven by them into its very existence and being. Does one doubt this, let him read the enthusiastic addresses of our first president, Dr. Elsberg, the admirable thesis upon this very topic by our second president, Dr. Knight, and the more recent remarks of Dr. Glasgow; let him consider the unflagging enthusiasm, both in precept and example, of such men as Cohen, Lefferts, Shurly, French, Ingals, Mackenzie, and others of our older members, and he will see the truth more clearly than words of mine can tell it. Teaching has been and always will be the society's most important office. It is, in very truth, a teacher of teachers, and as such should not alone confine itself to the advancement of laryngological science through the influence which it has had upon the establishment of other societies, the fostering of good journalism, and the encouragement of original scientific work. The science of pedagogy, in so far as it relates to our own department, is a topic which should engage our most serious attention. The very fact that the leading teachers of the country are our fellow-members imposes upon the association an obligation to the profession at large which can not be underrated, still less set aside.

Starting, then, with the excellent beginnings made by the writers already mentioned, it is not strange that undergraduate teaching should have reached with us a high degree of perfection. Indeed, the plan of instruction, the equipment, and the general discipline of at least one of our leading medical colleges is of conceded superiority and stands unrivaled whether at home or abroad. Other schools in

many different parts of the United States are doing good work. The question of the instruction of the undergraduate in this department, therefore, may be said to have been fairly considered and successfully met.

With the progress of time, however, new and strange necessities have arisen among us, and within ten years there has been inaugurated in this country one of the most significant and wonderful advances that the history of medicine has ever seen. The failure of the undergraduate medical school to answer all of the needs of the higher medical education has been acknowledged and a new era has been ushered in by the establishment of institutions for the special instruction of graduates.

This movement, together with the vast increase in the literature of the department, has given to laryngology an almost startling popularity. All over the country the extension of laryngology, or, more correctly speaking, the multiplication of the number of practitioners who assume to treat diseases of the throat, has been enormous and has called loudly for increased and improved facilities for instruction. This want, so urgent and at the same time so creditable, has been met by the system of the graduate school. Beginning in New York, the value of the work has been speedily appreciated by the whole country, and not only are the original schools crowded with students from all over the continent, but in many other cities similar institutions have been established, until to-day Boston, Philadelphia, Baltimore, Cincinnati, Chicago, St. Louis, and San Francisco are provided for and new ones are springing up all over the country. Those of us who have been for years personally engaged in this most interesting field of labor have realized the intense zeal and devotion shown by our pupils, who, representing every section of our country, every possible grade of intelligence and education, and every conceivable variety of personal need, have come to us for such instruction as we, on the one hand, have been able to give them, and as they themselves, on the other hand, have been able to receive.

Dealing with such men, the problem of their education becomes to us the most important one of the day. The undergraduate question is much more easily solved, as between him and the graduate the case in our department is very different, undergraduates being, as a class, of about the same age, general training, and advancement in their medical education, and each individual requiring about the same courses of instruction to introduce him fairly to our science.

With the graduate student, as has already been suggested, the case is very different, in that a vastly greater variety of personal needs must be met.

To satisfy the diversified necessities of these students imposes upon the graduate director a weighty task. The theory of graduate instruction in this country is an established and triumphant success. The popularity of the demand for it is beyond question. How, then, can we best attain the practical ends required by it? How can we best infuse the ferment of sound learning into this unleavened but well promising mass?

If called upon to name the most important factors in the improvement of graduate instruction, the unhesitating answer would be—

I. A higher and more thorough general medical education on the part of the student.

II. The most careful selection in the choice of instructors.

III. A modification of the best undergraduate methods, to suit the needs of the older men.

IV. The more general recognition of the value of graduate schools to the physician, and hence to the public at large, and of the importance of so endowing them that they may be able to perform the most extensive and efficient service to their pupils with the least amount of difficulty to their instructors.

The second consideration mentioned above is one of great importance, and we should endeavor to fill each teaching position under us with men who are both able and willing to acquire the necessary preparation and then to teach for teaching's sake—for the advancement of sound learning rather than for that of self.

As to the student himself, he must be impressed with the real gravity of the task which he has undertaken. It is unfair to allow him to believe that he can learn the whole subject in a short course of study, or to underrate to him the difficulties of special operations. In short, he must have placed before him, truthfully and fairly, as well the difficulties of our work as its successes. He must know that before he can be a surgeon he must be an anatomist, and before a special surgeon, at least a fairly qualified general one. He must be taught not alone from the book, but from the living experience of skilled, well-grounded, wise instructors, who, under the general guidance of the chief professor, shall start him upon the right path and lead him as far as his time and his capabilities will permit him to go. And, last of all, when he has read his books, learned the use

of his instruments, and attended for as long as possible the daily clinic of some good man, he must realize that to the attainment of the highest skill he must devote the unremitting labor of years. Thus may be fulfilled to the utmost what has been defined as the vocation of the specialist—namely, to make discoveries and then to give them to the world. In no department has this already been done more loyally or at greater personal sacrifice than in laryngology.

Ever mindful of its obligation to the world at large, may it never happen that our association shall fail to hold in remembrance its duty to itself. While its future is full of promise, it is also not devoid of possible dangers. Lack of interest on the part of the older members, the multiplication of other societies, and, finally, those two elements which are the greatest bane of association work, namely, the introduction of society politics and the inordinate desire for self aggrandizement—pecuniary and social—all of these may hover over the future of any organization, ready to confront it with deadly peril.

As to our founders, their lively interest in all that pertains to our success eloquently proves that their loyalty is as strong to-day as was their faith in '78.

With regard to the multiplication of special sections and societies, the more good ones we can have, the better. Than through them there is no surer way to stimulate interest and advance learning. To them we must look for the development of our own future members. The national association has thus far easily maintained the leading place; this will continue as long as we insist upon selecting as our fellow-members none but men of high principle and liberal education, who will fully appreciate the aims of the association and contribute to it their best work. Indeed, the recognition of merit and the encouragement of the best young element have from the very first been insisted upon by the society quite as emphatically as the suppression of charlatanism or the unmasking of pretense. As to the last-named evils, the surest guarantee for the future will be adherence to the high principles which have actuated the past.

And now a word as to ourselves, and I close. Since this society was formed, laryngology has undergone a revolution. Then it was in the hands of a few men, who, under the stimulating influence of the earliest enthusiasts, formed a veritable aristocracy of learning. All this has been changed; where lately our association represented

not only the best but the most of laryngology in this country, its devotees may now be numbered by thousands. A spirit of liberality has been among us, a veritable socialism of science, which, having acquired a rich and rare possession, seeks not to hoard it for itself but to spread it broadcast and with lavish hand to the remotest corners of the world. True, such leveling can not take place without danger of loss. If in this vast extension of knowledge our standards of excellence are to be lowered, and work, not of the worthiest, accepted at equal value with the best, the results will be disastrous to humanity and to the true advance of science. Such a calamity, however, I am unable to foresee. The outside competition which is crowding in upon us will only stimulate to higher attainment and greater skill, while from this vast body of new aspirants must arise men who will carry still farther upward and forward the light of truth for the illumination of those hidden mysteries which it has not as yet been our good fortune to see revealed. With the progress of the present day this society is responsible in no ordinary degree. Nurtured by ardent toil, enthusiastic interest, and no little self-sacrifice, the fate of the American Laryngological Association is in your hands. See to it that the future shall secure, so far as in you lies, the rich fulfillment of the hopes of those who gave it to you.

It is wrong that your patience should be longer trespassed upon. What has been said, although so imperfectly, may, I hope, be of interest and help to some. It implies congratulations to you for the association's successful past, with ardent hope and abiding faith for its ever brighter and increasingly prosperous career in time to come.

Paper.

PAPILLARY HYPERTROPHY OF THE NASAL MUCOUS MEMBRANE
COMPARED WITH A TRUE PAPILLOMA.

BY JONATHAN WRIGHT, M. D.

THREE years ago, in a paper on Nasal Papillomata read before this association, I tried to show the error in nomenclature and the consequent confusion in nasal pathology introduced by some of our German *confrères*.

This has gone to such an extent in Germany that when they speak of nasal papillomata they have to stop to explain that they don't mean true papillomata, but Hopmann's papillomata.

Three years ago I presented the drawing of a section of a papillary hypertrophy, removed by Dr. Knight from the region of the middle turbinated bone, as an illustration of Hopmann's papilloma. Since then I have been in hopes of meeting with a true nasal papilloma, either in my own practice or in that of some of my friends. This hope has not been realized.

It has happened this spring that I removed from the middle of the inferior turbinated a mulberry growth which exactly corresponds to Hopmann's description as quoted in my paper referred to above. About the same time Dr. Newcomb gave me for examination a typical papilloma from near the edge of the soft palate, where they are so common.

Having examined these growths simultaneously, it occurred to me that it might be of interest to present drawings to this society which would illustrate the total radical differences in the character of the two growths, disclaiming, however, any pretense of making any statements which are not generally accepted by histologists.

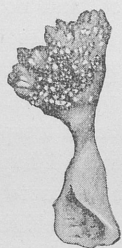

FIG. 1, A ($\times 4$).—Fibroma papillare from the soft palate.

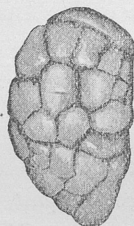


FIG. 1, B ($\times 4$).—Nasal papillary hypertrophy.

That these differences have not been generally appreciated by rhinologists is my excuse for taking your time.

Fig. 1, A, represents the external appearance of a pedunculated growth which we would all recognize clinically as a papilloma. Virchow says it really should be called a fibroma papillare, and it is so labeled in some works on pathology. You will observe that it consists, roughly speaking, of a thick stem, at the end of which we have a number of irregular sprouts: some, simply conical in shape, spring directly from the central stem, but the larger number are again divided into stem and sprouts. At a glance it looks like a budding, tuberous vegetable.

Fig. 1, B—a drawing of the nasal growth—shows a symmetrically rounded mass divided by cross-lines into more or less regular

portions. This we are familiar with under the name of a mulberry hypertrophy, which so frequently occurs at the posterior ends of the inferior turbinated bones, but which in this case was found more

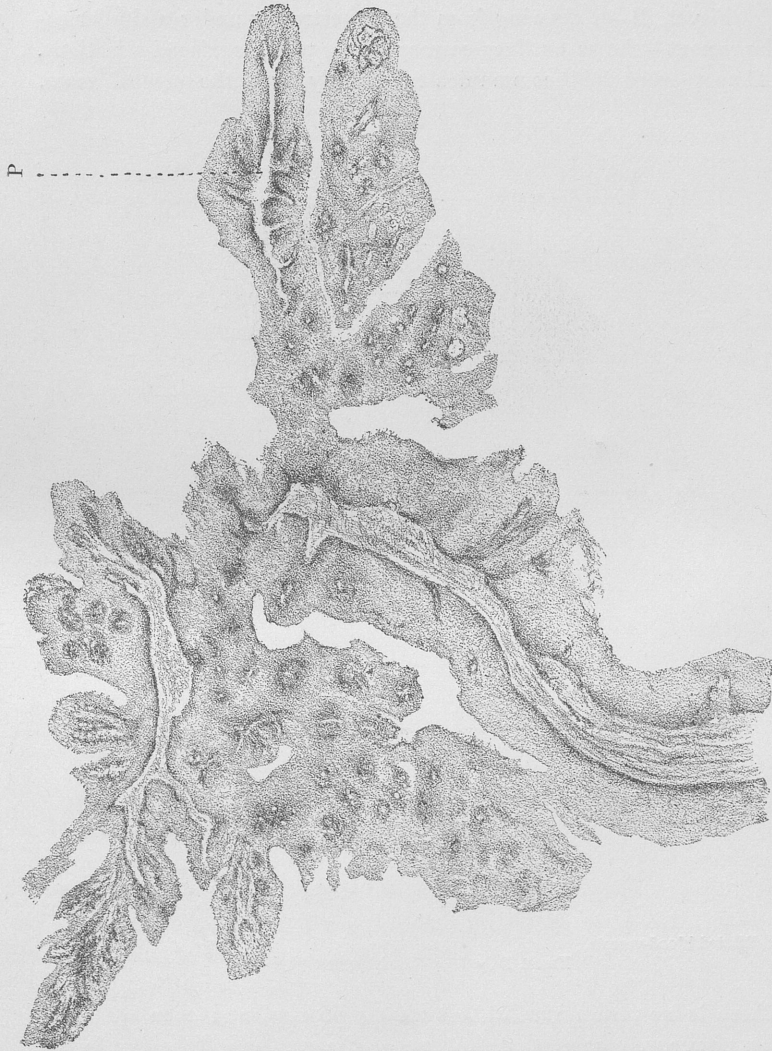


FIG. 2, A ($\times 10$).—Fibroma papillare.

anteriorly as a sessile but perfectly circumscribed movable growth. Its removal by the cold snare, although occupying three quarters of an hour, was followed three hours later by severe hæmorrhage.

Fig. 2, A, is a drawing of a section of the papilloma under a low-power objective (Zeiss). You notice at once that the budding appearance of the papilloma in Fig. 1, A, is so emphasized here as to resemble the small branches and leaves of a plant.

Fig. 2, B—a drawing from the hypertrophy under a similar enlargement—shows outlines corresponding to the surface indications. Almost every fold communicates directly with the central mass.

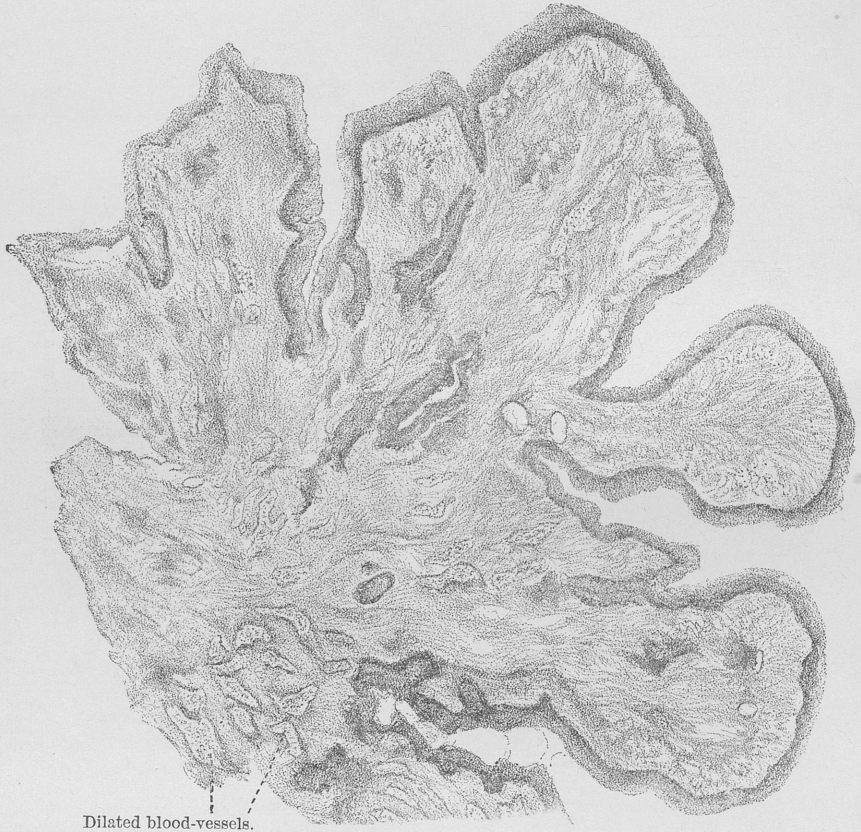

FIG. 2, B ($\times 10$).—Nasal hypertrophy.

There is no appearance of a budding process, and even with the low power we can see that the line of the surface epithelium is not especially thickened or irregular.

Fig. 3, A, shows the minute structure of the papilloma. It is very simple. There is a slight branching framework of fibrous tis-

sue containing no glands, and only small capillaries. Everywhere, however, this framework is covered by a large number of regularly striated layers of flat epithelial cells. With a still higher power they would be seen to be "stickle cells," similar to those of the epidermis and of the mucous surface of the palate from which the tumor sprang.

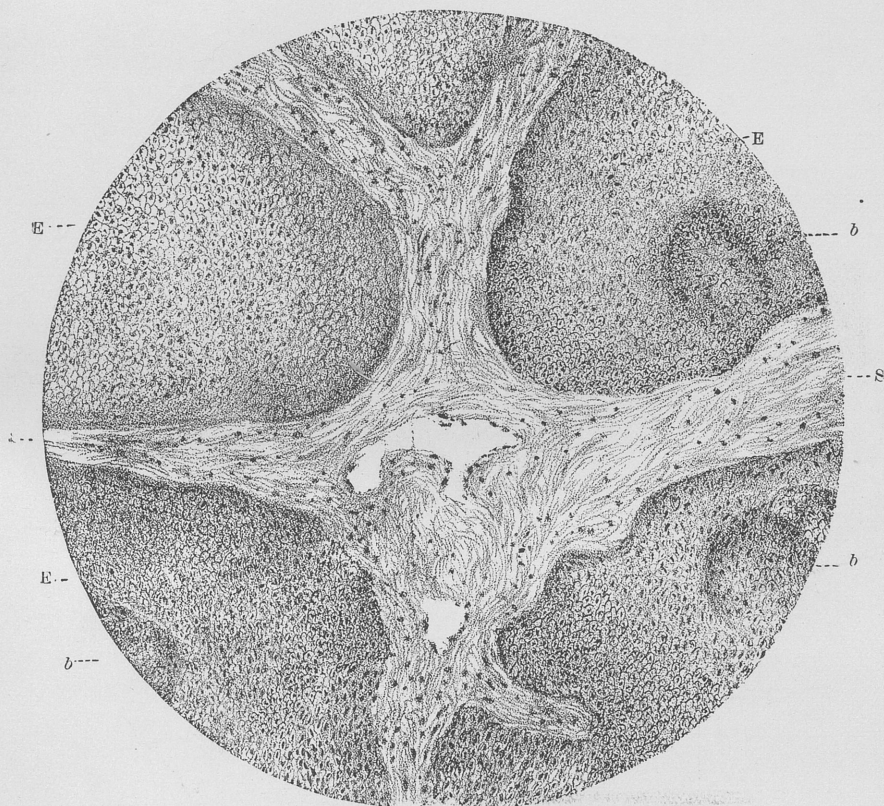


FIG. 3, A ($\times 300$).—Taken from "P" in Fig. 2, A. Fibroma papillare. E, squamous epithelium
S, stroma; b, buds.

This epithelial proliferation is very marked and very characteristic. In other forms of papilloma—the mucous wart, or pachydermia laryngis—digitations of the proliferated epithelium dip down into the stroma. The surface itself may be smooth and only the digitations exist in the stroma, as in some of the smooth warts on the septum near the columna.

All these are closely related epithelial growths. None of them bears any relation or even close resemblance to the "mulberry hypertrophy."

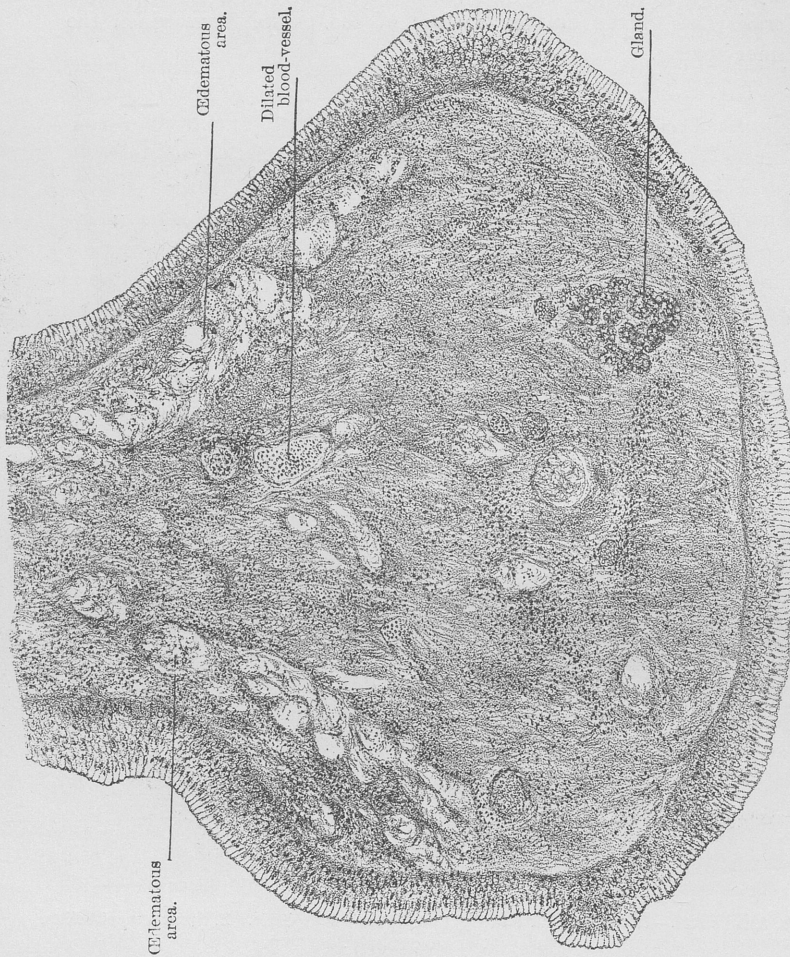


FIG. 3, B ($\times 300$).—Nasal hypertrophy.

Fig. 3, B, together with Fig. 2, B, explains the more complex structure of the nasal growth. It consists of all the constituent parts of the mucous membrane of the inferior turbinated body. You notice a few glands. The ectasia of the venous sinuses filled with blood is especially noticeable. There is a considerable increase in the amount of fibrous connective tissue. This, at the periph-

ery, is divided into regular processes covered by epithelium and separated from one another by depressions, giving to the surface its folded, creased appearance, which, in this particular instance, is very marked, the depressions being very deep.* In such growths all gradations in the depth of these grooves exist, up to their merely making a nodular surface.

The cause of this folding and crumpling, I conjecture, is the continued and exaggerated contraction and dilatation of the venous sinuses in a stroma deprived by chronic inflammation of much of its elastic and muscular fibers, and having in their place a considerably larger amount of non-contractile fibrous tissue. This exaggerated vaso-motor action is indicated in the clinical history these patients give of alternating and varying degrees of nasal stenosis.

You will see that in this specimen the glands are scanty and the growth could not possibly be called an "adenoma papillare" as suggested by Hopmann as an alternative designation with papilloma. Papillary hypertrophy might be allowed.

Before closing I desire to call your attention to an appearance not directly connected with the purpose of this paper, but of some interest as an illustration of the connection which exists between the different results of chronic inflammation of the nasal mucosa. Last year I tried to show that the ordinary polypus was not a myxoma, but was one of the ultimate manifestations of a chronic inflammation characterized by an œdema of the tissues. I then stated that small areas of this œdema were frequently seen in hypertrophies of the inferior turbinated bodies. In Fig. 3, B, you will notice close beneath the epithelium one of these areas.† They are common in all cases of marked hypertrophy of the nasal mucous membrane, but

* Since this paper was written and the drawings made, Dr. George A. Richards of New York, has sent me another such tumor, half of which I show you here. You will see that in this case the papilliform processes are still further developed, and that this, externally, really does closely resemble a papilloma. A glance, however, at this section made from the other half, under a low power, shows an exactly similar structure to that figured and described under Fig. 3, B. They are both papillary hypertrophies of the erectile bodies of the inferior turbinated bones.

† Similar areas are also to be seen in Dr. Richards's case. In the May number of the *Journal of Laryngology*, Professor O. Chiari, of Vienna, takes the same view of the so-called fibromata of the vocal cords—viz., that they are œdematous hypertrophies, the result of chronic inflammation, and not true fibromata.

usually only reach the dimensions of the œdematous polypus in the region of the middle turbinated bone or above it.

Discussion.

Dr. H. L. SWAIN, of New Haven, said that one would certainly be rather bold to attempt to add anything to the statements made by Dr. Wright. Years ago he had had two cases of papilloma which had presented similar gross appearances. They had differed, however, microscopically. One had been from the larynx and the other from the ear. The latter had corresponded with some of Dr. Wright's drawings from the nose. He thought Dr. Wright's classification of tumors in the nose was very appropriate.

Paper.

A PLEA FOR EARLY OPERATION IN DISEASES OF THE ANTRUM OF HIGHMORE.

By W. H. DALY, M.D.

SINCE the antrum is a closed cavity, excepting through a single opening by which it is closely related with the nasal, buccal, and other cavities, it of necessity follows that any disease of it may soon produce morbid conditions in one or more of the other accessory cavities.

This may follow the drainage of pus into the nasal cavity with subsequent inflammation of the mucous membrane. It may follow the obstruction of the separating bony wall by pressure, absorption, caries, or necrosis. There is also serious liability to damage to the eye, so that I make the plea that for all conditions in which severe inflammation, pus, tumors, or necrosis are present we should, as soon as the diagnosis is established, deal with the condition surgically, in order that the integrity, not only of the antrum itself, but the surrounding parts, be maintained to the greatest extent possible; and even if there is some doubt existing as to the disease of the antrum, or in cases that are otherwise somewhat masked, I would strongly advise an exploratory opening for diagnostic purposes, which may be made very small and yet efficient, and one which will close and heal up in a very short time if sufficient disease is not revealed to call for keeping it open.

I have had many cases of chronic as well as malignant disease of the antrum to deal with in the past twenty years, and the sum of

my experience is, that for want of early diagnosis and operative treatment some of the patients have perished that with early operation could certainly have been permanently cured.

I am not quite sure that the specialist in rhinology is not sometimes to blame, as well as the general practitioner, for not taking early and active surgical measures in these cases instead of resorting to ordinary topical or medical treatment.

In August of 1888 I had a conversation with Mr. Lennox Browne, in London, on the subject of early operation on the antrum of Highmore.

He was then engaged in treating a number of cases, and making some observations upon their pathology and etiology.

Mr. Browne began by asking me the question, Do you see many cases of purulent catarrh of the antrum of Highmore in your practice? I told him I had seen a rather large number of them, and had reported two cases to the American Laryngological Association as early as 1882, six years before;* since that time some twenty-seven cases have fallen under my care, and I now have four cases under surgical treatment.

I was then, as I am now, in favor of early operation, whenever it is possible to see the cases early. In this view Mr. Browne agreed fully, and I see he has publicly verified his opinions by publishing in the March 31, 1894, number of the *British Medical Journal* a case, of which the following is a summary :

The patient, a young woman, aged twenty years, had been attacked with influenza about six weeks previously to presenting herself at the hospital. On the subsidence of the acute stage, she suffered severely from toothache, which involved the first and second bicuspid teeth in the right upper jaw ; subsequently she experienced severe pain with swelling of the right cheek, which somewhat subsided on the occurrence of a yellow and rather thin discharge from the right nostril.

After removal of the first bicuspid, the antrum was opened through the socket, the cavity was curetted and syringed out with a weak antiseptic solution, and the hole kept open by a hickory-wood plug.

The cure was complete in a few days, thus distinguishing it from cases of a chronic nature, the characteristic of which is their strong resistance to treatment.

This was not the first example of acute inflammation of the antrum which Mr. Lennox Browne had had to deal with, and now

* Naso-antral Catarrh and its Treatment. *Archives of Laryngology*, vol. iii, No. 4, October, 1882.

that attention had been drawn to the subject, the malady would in all probability be found to be less rare than had been hitherto considered.

Through the esteemed courtesy of Dr. G. Lenox Curtis, of New York, I was permitted a few weeks ago—in the early part of May, 1894—to examine a number of his cases of antral disease which he has operated upon at various recent periods.

Nearly all of the cases, excepting one or two, submitted to my examination by Dr. Curtis were of a non-specific type, and one of the exceptional cases was a most unusual one—viz., symmetrical in character, though not simultaneously so, the right side having been operated upon some months ago, and the left side was, at the time of examination, giving such evidence of disease as to call for operative interference. A curious phase of this case was the patient's ability to take a mouthful of cleansing or antiseptic fluid, and by a self-trained voluntary, atmospheric and bucco-lingual pressure cause the fluid to flow from the buccal cavity through the antrum and out of the nostril.

I am under the impression that with a little teaching other patients could learn as well to do this, as, for example, when traveling, it is not always possible for a patient to use a syringe, and cleanliness must be observed to get desired results.

I should qualify the remark about the above case of double antral disease by saying that while non-specific double cases are rare in my experience, we all know that a strong characteristic of syphilitic disease, even throat or palatal ulcerations or patches, is their usual symmetry. So this case of double antral disease, while it might be unusual as simple catarrhal disease, is another evidence of the symmetrical characteristic of specific disease.

As to the point of election for entering the antrum, I am of the opinion that the natural opening is not desirable, as it seems too much like trifling with treatment to endeavor to cleanse this cavity with a small syringe, with a curved point, entered at the natural antro-nasal opening; better far to make an opening either through the alveoli, the socket of a tooth, or through the bony wall of the antrum just below the malar bone, about the region just external to and above the second bicuspid tooth.

While I was formerly in favor of making a large opening, I find, after experience, that the opening should never be larger than a small goose quill, as a large one may cause whistling by air currents and permits the entrance of food.

In my opinion, the best means of cleansing the cavity is with the ordinary soft rubber compression-bulb syringe of the Davidson pattern, and a proper-sized tip. This affords nearly a continuous flow, with which a pint of antiseptic fluid can be pumped through the cavity and allowed to flow out through the naris, carrying with it the diseased secretions.

Care should be taken to break down the lamellæ of bone that sometimes exist in the diseased antrum, confining the pus or other inflammatory products. This can be done by entering a strong, curved, steel exploratory probe or curette.

I have more than once trephined the antrum, and experienced a feeling of disappointment and surprise until I had, by exploratory breaking down of the lamellar walls or partitions, released purulent matter of a most sickening odor. Always remove all necrosed bone or teeth that may be found in the cavity of the antrum.

The operation is of the simplest character, and is best done by using a conical burr-headed drill, which, with slight pressure, enters the cavity.

The results of the operation, however, are by no means always free from danger, since some of us can call to mind that one of the most talented of men, Dr. Beard, of New York, died some years ago, in less than a hundred hours, from septic pneumonia following an operation for antral disease by Dr. Goodwillie, of New York, a most clever operator, and a gentleman of large experience in this class of cases.

I have also frequently observed serious constitutional disturbance following the operation, but no fatality in my own practice.

It is true that, in cases of chronic catarrh of the antrum with suppuration, treatment may be carried on through the natural opening into the nasal cavity; but this is difficult and unsatisfactory, and certainly the most rational course is trephining at the most dependent part, and thus securing good drainage and an opportunity to effect thorough cleanliness and the application of local remedies.

By the introduction of a plugged cannula or simple wooden plug the swallowing of the discharges, with consequent gastric disturbance, may to a great extent be avoided.

Further, in cases of abnormal growths, being confined as they are in a closed space, early surgical methods ought to be adopted for their removal.

It goes without saying that growths and sequestra in any location

should be thoroughly removed; but when the antrum is involved this removal should be at the earliest possible moment.

In cases of foreign growths, especially those that have passed from the region of the benign into that of the malignant—a condition that is a very probable one in a large percentage of cases—then we have a condition to deal with that calls for most serious surgical consideration, since nothing short of removing bodily all of the diseased structures, whether bony or soft, will at all insure safety from a return of the disease.

A number of these undesirable cases have in the past ten years fallen under my professional care for the purposes of surgical operation, and I candidly say I always shrink from the professional responsibility of them, as the percentage of malignity is large among them, and the operation so often involves the removal of all of the malar and generally a part of the superior maxillary and nasal bones, together often with the floor of the orbit and sometimes the eye.

That the death-rate is large and the operation itself of the most appalling character, and that the disease is liable to return, can not be doubted, and hence an added plea for early operation.

In a large proportion of my own cases, as well as that of other specialists, I learned that, especially in the severe cases, the pain is always referred to the region above the eye. Now, why that is the case it is difficult to explain and I shall not attempt it, but the clinical fact remains and is worth noting. It is illustrated by the following:

CASE I.—Mrs. J. M. K., aged fifty-four years, married, mother of five children, never very robust, suffered from malaria for several years. No history of other sickness previous to present one. In December, 1891 complained of an oppressive feeling in head, part of the time being confined to bed.

January 1, 1892.—Dr. W. N. Bailey, of East Liverpool, Ohio, family physician, was called and prescribed for malaria.

2d to 8th.—Away on a visit; suffered greatly; had some dyspnoea.

On February 29th Dr. W. N. Bailey was again called. Patient complained of pain above the left eye, beginning about 9 A.M., gradually subsiding toward evening. Weak with loss of flesh. All remedies prescribed gave no relief.

March 3d.—Nasal cavities examined and growths, diagnosticated to be nasal polypi, discovered.

4th.—With cocaine, with a Jarvis snare, a part of the growth which had impacted the nasal cavity was removed. Operation interfered with

by hæmorrhage. Much relief afforded. Operation repeated with like result on March 14th, 22d, and 29th.

April 13th.—I was called in consultation by Dr. W. N. Bailey. I trephined and curetted the antrum, and, with the doctor's assistance, removed a quantity of polypoid myxomatous masses, equal in amount to the capacity of the antrum.

The hæmorrhage was very copious, and the eyeball, which was protruding on the same side, gave evidence of much more mischief to be feared, and on June 16th the doctor sent for me again to come prepared to remove the entire mass, which had grown very rapidly since clearing out the antrum on April 13th.

I found the eye much more protruded; the face swollen and distorted; the discharge through the naso-antral opening sanious and offensive. There was some enlargement of opening by ulcerative absorption at the seat of the last operation through the alveolus.

With the assistance of the late Dr. James McCann, of Pittsburgh, Dr. W. N. Bailey, Dr. W. R. Clark, and Dr. J. M. Kelly, of East Liverpool, O., the latter a son of the patient, I did Langenbeck's operation, carrying an incision from the edge of the lip upward, following a line along the nose to near the naso-orbital angle, thence laterally along the lower rim of the orbit and eyelid to a point below the outer canthus of the eye, dissecting this flap back and fastening it out of the way.

I then cut through the ala nasi and septum and laid the nose over to the other side; then with a saw and strong cutting and lion-jawed bone forceps I proceeded to remove half of the upper jaw, malar bone, part of the ossa nasi, including all of the bony walls of the antrum. The floor of the orbit was found absorbed by pressure of the growth.

The hæmorrhage was tremendous, and as no blood-vessels could be found with sufficient strength of walls to permit torsion or ligation, we were much delayed by having to resort to packing the rather appalling cavity made by the removal of the diseased tissue. The eye was left in a faint hope that it might be preserved. The superficial parts were brought together with silver-wire sutures, the nose being replaced and all nicely completed, first packing the cavity with iodoform gauze.

Some idea of the cavity left by the removal of the diseased mass of bone and soft tissue can be formed by the fact that about three yards and a half of iodoform-gauze bandage three inches wide was required to pack the chasm.

As the ossa nasi of the diseased side was also removed, there was no trouble about sufficient outlet in removing the packing and restoring fresh. The hæmorrhage was controlled, and the patient, who was a very courageous woman, rallied, and under the care of Dr. W. N. Bailey promised fairly for the three days following the operation; but on June 19th there were slight rigors followed by some elevation of temperature.

June 22d.—Paralysis of right side.

23d.—Clonic convulsions, which continued until death on January 25th.

I had in the meantime submitted a specimen of the tumor to Professor Matson, of Pittsburgh, an accomplished pathologist and microscopist, who pronounced it a giant-celled sarcoma.

CASE II.—J. H., male, aged forty-four years, married. Father died of pulmonary disease in May, 1892. Noticed pain over right eye; most felt in the evening and at night; rest broken.

August, 1892.—Dr. Treacy, the family physician, with Dr. McLaren operated upon the case by drilling into the antrum through the hard palate, and, following treatment of the cavity, there was relief.

In January, 1893, patient caught cold, and had intense pain again above the eye of the affected side, and he sought again his family physician, Dr. Treacy.

There was not much swelling or pain about the antrum, but a blister formed on the hard palate about the seat of the former trephining.

Some teeth were now removed by Dr. McLaren with relief of the pain.

November 29, 1893.—Dr. Treacy sent the patient to me for treatment. His face was much distorted by swelling on the right side and the eye protruding. A large swelling in the submaxillary triangle of the same side of the size of a goose egg. Pain intense over right eye. General condition of the patient was very bad. The discharge from the naris on the affected side copious and foul to an extreme degree.

I trephined the antrum the following day and removed a quantity of blackish-brown masses coequal with the antral capacity. These masses resembled old coffee grounds; they had a heavy, sickening, burned-chestnut odor.

After getting the patient cleaned up by antiseptic washes and free use of iodoform, I poulticed the swelling on the neck, and, with the exhibition of arsenic, cod-liver oil, and malt, in three months the tumor disappeared by absorption and the case was in a most promising condition. A cauliflower-like excrescence around the large opening I made in the antrum disappeared also, and I flattered myself for a time that the case had broken the record by turning from the threatening malignant to the benign; but untoward changes again occurred, largely from the erratic habits of the patient, and now at this writing, May 12, 1894, the case involves the eyeball, all of the malar bone and upper jaw of the affected side, the ossa nasi, and the disease is undoubtedly malignant.

An operation is under consideration by the patient, in fact, has been under consideration ever since the time when the conditions were favorable and safe, which I regret to say they now no longer are.

This patient disappeared some six weeks ago, when I advised that he allow me to cut down and remove a part of the ossa nasi and the upper and inner part of the antral walls. He declined being operated upon then. However, he returned about four weeks later, mentally ready for the operation; but in the meantime the case had, in my opinion, progressed beyond the reach of safe operative measures, at least beyond the

point where hope for the non-return of the disease is assuring, and he passed from my professional care.

Note.—Six weeks later I learned that this patient had been operated on by a surgeon of Pittsburgh who removed all the diseased mass except the protruding eyeball. Death followed in a few weeks. I could adduce many other cases from my note-books which would serve to strengthen my plea for early operations on the antrum.

Discussion.

Dr. A. W. DE ROALDES, of New Orleans, said he agreed fully with Dr. Daly in regard to the necessity of early interference in all diseases of the antrum. Leaving aside those of dental origin, the purulent inflammations of the antrum, he thought, generally followed an acute coryza or an attack of influenza. In such cases he certainly would not resort to the extraction of a sound tooth in order to make an exploration. The wife of a medical gentleman, a timid person with a fine set of teeth, had last year been his patient. She was very nervous, and would have objected to the loss of a tooth. He had confirmed the diagnosis by catheterizing the antrum and washing the same through its opening in the nostril. The treatment was continued by repeating these injections, and after a short lapse of time the case was discharged cured. For several years he has made it an invariable rule to confirm or deny a diagnosis of purulent sinusitis of the antrum by washing the cavity with a proper cannula introduced through the hiatus semilunaris. In all his experience, extending over one hundred and fifty to two hundred cases, he could recall but two in which the attempt was a failure. In several observations of acute or subacute inflammations this treatment was all that was required to effect a permanent cure. In chronic cases, especially those of dental origin, he could not agree with the author of the paper in regard to the formation of a small opening. In such cases the condition of the mucous membrane was an unknown quantity, but a very important one in the successful handling of the disease. While large polypi, like the beautiful specimens exhibited by Heymann at the congress of Berlin, were comparatively rare, he had often met with a hypertrophied, fungating lining membrane and a polypoid degeneration of the same, which called for a thorough scraping of numerous small, pealike, gelatinoid bodies. He doubted very much if a small opening in the alveolus would allow a satisfactory manipulation of the curette in all directions. He believed in using a large crown of trephine through the alveolar border, and never considered the question of the passage of food or of germs from the mouth.

His own experience had not been free from some of those chronic and rebellious abscesses of the antrum which were so very difficult to radically cure. In those cases the sooner the antrum was widely opened in the canine fossa and under the influence of a general anæsthetic, the better for the patient and attendant. The finger and the eye must assist in helping to remove all abnormities which would at times more than

explain the intractability of the case. The thorough packing of the cavity with iodoform gauze and the subsequent treatment of the case on broad surgical lines would generally be satisfactory.

As to the method of Luc, alluded to by the speaker, of allowing the patient to wash out his own antrum by passing water from his mouth into the sinus and nose through forcible compression of the cheeks, it was more ingenious than useful. It would do very well for a week, but after this each attempt would congest the head, and a small stream or a few drops only would flow out of the nostril. He favored the use of a Davidson's syringe and a good cannula.

Dr. M. R. BROWN, of Chicago, said he was heartily in favor of the views expressed in the paper. He had himself presented to the association some years ago a thesis on a similar subject. The method of opening had interested him particularly, as he had himself lost a tooth in this way. The best point at which to open the antrum was lower down between the roots of the teeth, near the lower border of the gum. At this point the drill would enter the floor of the antrum and admit of securing good drainage. In the first instance he would make an opening large enough to pass a cannula to which was attached a Davidson syringe. If pus were found, he would enlarge the opening with a burr, No. 18, on the dental scale, until the cannula could be passed into the antrum. He had treated some cases by allowing a tube to remain in the opening, but suppuration had invariably taken place, and he had found it necessary to remove the tube in order to stop the suppurative process. He had cured a few cases by injecting an antiseptic solution into the antrum. The presence of pain above the eye and extending upward, the formation of pus in the nose, and the result of transillumination, were all that could be desired to make a diagnosis. He had used peroxide of hydrogen, but it was not necessary, as a diagnosis could be made without it.

Dr. BRYAN said he thought this was a very timely subject, and he would take this opportunity of making a plea for more conservative surgery in treating this affection. While the opening into the cavity should always be sufficiently large to admit of the thorough local treatment, he did not think such radical procedures as suggested by Dr. de Roaldes should always be resorted to. He found that in the alveolar operation an opening varying from three to five millimetres was ample in recent cases. Of course, in abscesses of long standing where it became necessary to resort to more radical procedures the opening must be made larger.

Dr. C. M. SHIELDS, of Richmond, said he had seen several cases like those described by one speaker, in which suppuration continued so long as the tube remained in the opening. One gentleman had been troubled this way for six months, and he had tried various antiseptic washes, but finally becoming disgusted, he had withdrawn the tube, and at once the man began to get well.

He had been in the habit of getting a dentist friend to make a thin gold tube about the size of a small lead pencil, with a thin collar. The

tube could be closed by a valve of vulcanite, which projected a little beyond the cannula. This tube had not given rise to granulations. He saw no objection to making a large opening. This should close in a week or ten days unless there was a specific history.

Dr. W. E. CASSELBERRY said that, in addition to the paper which he had read yesterday on a similar subject, he wished to call attention to the fact that suppuration of the antrum of Highmore rarely occurred alone. It was frequently associated with empyema of the ethmoid cells, the sphenoid cells, or frontal sinuses, and coexisted with nasal polypus. All polypi should be removed, and also the anterior end of the middle turbinated body. The curette should be used thoroughly. He had found the pain above the eyes an almost constant symptom in his cases, but he attributed it to the conjoined involvement of the ethmoid cells, or, as in one case which was related in his paper on this subject, to empyema of the frontal sinus, the pain, previously intense, having disappeared as soon as this cavity was drained. Although this symptom was an important one, it could hardly be considered as absolutely diagnostic of empyema of the antrum.

Dr. J. C. MULHALL, of St. Louis, said he thought much could be accomplished in these cases by following the lines of general surgery. In cases of purulent infiltration of the antrum, simple surgical procedures would yield very good results. In bad cases of empyema of the lung the resection of a rib sometimes became imperative. Where there was some possible disease of the ethmoid cells, in addition to the disease of the antrum, he did not think so trivial an opening as that made through an alveolus would cure the case. In one case he had made an entrance into the antrum through an alveolus, and had kept hard-rubber plugs in the opening. In the course of a short time several of these disappeared, and it was supposed that they had been swallowed, although the patient was not conscious of having done so. He finally concluded that they had gone into the antrum, and this proved to be the case. An opening was made with a chisel over a molar tooth and just under the malar prominence, and the four rubber plugs were found and removed. Free drainage was established with iodoform gauze, and in a month a case that had lasted two or three years was cured.

The speaker said that he thoroughly believed in the radical operation as the only means of relief and cure. Yesterday some of the speakers had advised against entering the cavity of the ethmoid cells, fearing perforation of the brain cavity, yet they admitted that they had had no experience in such cases. When there was an abscess or a tumor in the skull it was generally conceded that an operation was demanded. When there was an abscess chronic and foul in the antrum of Highmore, he advocated free opening just below the malar bone and above the molar teeth in preference to the alveolar opening. When a chronic nasal purulent discharge was caused by a diseased ethmoid, as was often the case,

ordinary surgical principles of curetting and drainage must prevail in order to obtain a cure.

Dr. DALY said that one of the first cases he had operated upon was one of this kind. The patient was a young attorney who came to him with many of the symptoms that had been mentioned in this discussion. After studying the case for some time he had arrived at the diagnosis of abscess in the antrum. The patient was a powerfully built man with a beautiful set of teeth. He was the son of a country dentist. After much persuasion he finally had his tooth extracted, and an opening was made into the antrum through the alveolus. Nothing was found immediately to confirm the diagnosis. The man then upbraided him in very strong language, saying: "You have sacrificed a tooth for which I would not have taken a large sum of money, and in addition you have made a mistake, and have failed to find any disease of the antrum." The speaker said that without replying to the man he inserted a strong curette through the opening, and broke down some lamellæ in the antrum, when at once there was an immediate and profuse flow of purulent matter, so foul in character that he was obliged to open the window.

He did not now think we were justified in extracting a tooth unless it were diseased. In his opinion, the best place to enter the antrum was above and outside the second bicuspid tooth. There was one objection to the method, and it was a grave one—viz., that while the valvelike action of the cheek prevented air from getting into the antrum, it allowed of the entrance of food while masticating; the latter, of course, could be prevented by inserting a wooden plug.

Dr. MULHALL asked why it could not be packed with iodoform gauze.

Dr. DALY replied that the treatment was so often prolonged, and for the patients to pack the antrum themselves was a very inconvenient procedure, and all patients could not or would not do it for themselves. There was this to be said in favor of the small opening: that it lessened the entrance of air and food. Moreover, if the opening were made large, there would be difficulty in closing it by a subsequent operation. Those who would follow this advice and use a small opening would profit by his long experience.

Dr. HINKEL asked if he were referring to the treatment of acute cases only.

Dr. DALY replied that he was referring to all cases.

Paper.

REPORT OF A CASE OF A FOREIGN BODY (COCKLEBUR) IN THE LARYNX.

By CHARLES M. SHIELDS, M. D.

ON the morning of December 4th last Mr. W. M. P., of Halifax County, Virginia, came into my office breathing with difficulty, and with a most anxious expression of countenance. In a voice reduced to a hoarse whisper he made the following statement: He said that while riding through his farm the afternoon of the preceding day he had seen some dogs chasing one of his hogs. He rode after them to rescue the animal until the bushes and undergrowth prevented his proceeding farther on horseback, when he dismounted and continued the pursuit on foot. The exercise caused him to breathe rapidly with his mouth open. When just within reach of the animal he was suddenly stopped by feeling that he had drawn something into his throat which made him gasp for breath and prevented his calling for help. In looking about him for the cause, he found that he was in the midst of bushes filled with cockleburs that had been rendered very dry and loose by the recent frosts, and the burs were easily dislodged by his movements. He at once rode to the nearest doctor, who shared the opinion that he had probably drawn one of the loose burs into his windpipe in his rapid efforts at breathing, but was unable to determine it positively. At his advice the patient took the first train to Richmond.

The patient was an exceedingly nervous man and had a most sensitive throat. His efforts at breathing, in addition, made it impossible to get even a glance at the larynx until a ten-per-cent. solution of cocaine had been repeatedly sprayed over the parts. Then the offending body was seen to be a cocklebur situated at the anterior commissure of the glottic space, its long axis lying antero-posteriorly. It was just below the surface of the cords, and had evidently been grasped by them just in the act of passing through. When the vocal bands, which with the surrounding tissues were considerably swollen, closed, they would cover from view all of the bur except some of its spurs which projected above.

As the subsequent efforts at removal showed, the grasping of the bur by the bands in such a small angle was so great as to firmly fasten it in position by forcing its spurs into the tissues. So closely was it adherent on both sides that no space was available for an instrument to catch hold. Mackenzie's and several other varieties of forceps opening laterally were tried; but for the above-mentioned reason and because of the excessive irritability of the throat causing closure of the glottis as soon as an instrument was brought near, a great many unsuccessful attempts were made. Then a loop of stiff wire run through a properly curved cannula

was used with the hope that it could be pulled up on the bur and tightened; but the contraction of the quickly closing bands invariably flattened the loop. Trying to engage its prickles by cotton wrapped on a curved probe was equally unsuccessful. It is a matter of interest in connection with this expedient, as showing how practical measures are suggested to the uneducated as well as the educated mind, that the patient advised me to try the cotton in very much the same way as was reported by Crawley in 1886 in a somewhat similar case. Then a blunt, curved curette, large enough to go over the body, was passed below it, but did not bring it up on being withdrawn. In fact, I was afraid of making much effort with this last instrument, or any other that would not hold it firmly, lest it might be only dislodged and drop into the bronchi. The numerous efforts at removal had now exhausted the patient, whose apprehensive fear of suffocation constantly increased, and I resolved to do an external operation. As one last effort prior to that, however, Schrötter's tube forceps, which had previously been tried, was again used. This time, after passing it through closed, and as the vocal bands tightened on it, I opened the blades forcibly and drew them forward, forcing them between the bands and the bur, and then, closing them, withdrew the forceps quickly and had the satisfaction of bringing the bur out entire, and it is here presented.

In looking over the literature of the subject, I have found four other cases of cockleburrs in the larynx reported. One, by J. N. Outen, in the *American Practitioner*, 1884. Another, by Max Thorner, in the *Cincinnati Lancet-Clinic*, July 24, 1886, which was removed by Voltolini's sponge method. A third, by Crawley, in the *Philadelphia Medical News*, extracted by means of cotton wrapped around the index finger of the operator, entangling the prickles in its meshes. The fourth, reported in the *St. Louis Courier of Medicine*, 1884, by E. Van Note, in which laryngotomy was necessary for its removal.

Paper.

REPORT OF A CASE OF EPITHELIOMA AND OF ONE OF SARCOMA OF THE LARYNX.

By ARTHUR AMES BLISS, M.D.

CASE I. *Squamous Epithelioma of the Larynx*.—William B., aged forty-six years, married; printer. The family history of this patient was good, nor was there evidence of syphilitic infection. Tobacco, in the form of pipe-smoking, had been used in great excess.

The first symptoms which called the patient's attention to disease

within the larynx originated about two years ago. It was then noted that the voice was slightly hoarse. This hoarseness increased steadily and was associated with slight soreness, which the patient could not locate exactly, but which he referred to the hyoid and subhyoid region. Gradually, interference with respiration developed and the lymphatic glands of the neck—most markedly on the left side—became hard and swollen. The three conditions of hoarseness, enlargement of the lymphatics, and dyspnoea notably increased, until, when the patient was first seen by me at the German Hospital, the act of inspiration was most difficult and the voice scarcely above a hoarse whisper. The conditions seen in the laryngeal mirror will be described later.

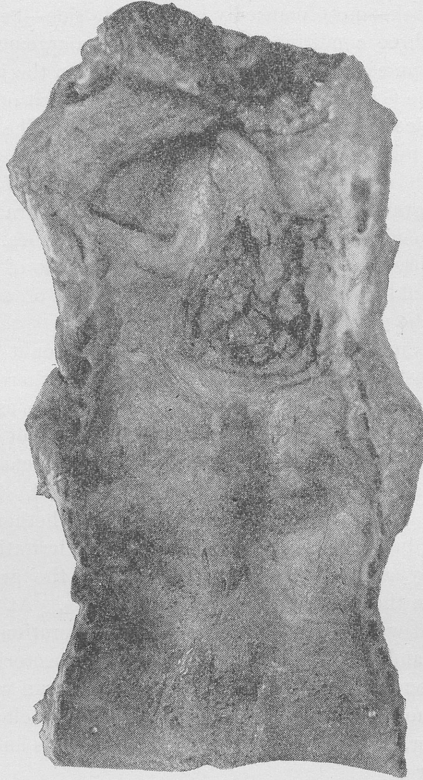The patient delayed operative treatment until it was forced upon him by the extreme gravity of his condition. I performed tracheotomy in the high position, opening the first two rings of the trachea. This location was selected in preference to a lower opening, because of my expectation that consent would be gained for the performance of an operation for the removal of the growth at some subsequent time.

The patient's urine contained a considerable amount of albumin but was free from casts. As the heart sounds indicated atheroma, being weak and irregular, though free from valvular murmurs, we used ether as the anæsthetic. At about the completion of the first stage of etherization the patient's glottis closed tightly. No air entered the chest, the face became cyanosed, and the man was apparently moribund. This rendered a very rapid operation necessary. I am uncertain whether the closure of the glottis was due to spasm induced by the local irritation of the ether or was caused by accumulation of secretion from the growth. The patient remained in the hospital for about four weeks. At no time during this period could we have attempted a radical operation, as he was exceedingly weak and was liable to attacks of angina pectoris. Respiration was good, the general condition improved, and the man was on the point of leaving the hospital. The morning before the day chosen for his departure, however, he had an attack of angina pectoris and died suddenly from heart failure.

The view obtained by the laryngeal mirror revealed a large, swollen, partly oedematous mass of tissue occupying the seat of the left arytenoid, and involving the ventricular band of the same side. The left vocal cord was not visible, as it appeared to lie beneath the swelling. The right cord was seen clearly, appeared to be free from disease, and its movements, though much restricted by the presence of the swelling on the left side, were normal. The swelling itself extended so far beyond the median line, however, that the right cord was forced into a position of semi-abduction. Below the level of the cords I could not obtain a view, and had no exact idea of the conditions existing there. Externally, there was no abnormal widening or stretching of the thyroid cartilage. At no time did the patient complain of pain during deglutition.

As a result of the autopsy I am able to present the larynx and also

a very good photograph of the specimen. A large area of granulation tissue is to be noted, extending from the location of the apex of the left arytenoid cartilage, over the entire left side of the larynx, extending as low as the inferior border of the cricoid cartilage. The left vocal cord



Squamous epithelioma of the larynx. Case I, William B.

has disappeared entirely. A probe passed through sinuses in the posterior part of this area which led into a sac between the larynx, in its left postero-lateral part, and the œsophagus. In this locality, within the cellular tissue between larynx and œsophagus, was a large abscess filled with greenish pus. The œsophageal walls appeared to be free from disease.

It would seem that the localization of this lesion to the left half of the larynx, and the fact that the wall of the œsophagus was not involved, would have rendered this case a favorable one for partial laryngectomy. The patient's family did not regard this operation

with favor, nor was his general condition such as to encourage me in attempting this procedure. The autopsy showed the lungs to be normal. The pericardium was thickened, the heart muscle fatty, but the valves normal. The kidneys showed chronic parenchymatous nephritis.

CASE II. *Small Round-cell Sarcoma.*—John H., aged fifty-five years, married; laborer.

Family and personal histories are good. There is no evidence of syphilis. Tobacco, in the form of pipe-smoking, he has used in excess, smoking fifteen to twenty "pipefuls" daily, using, most commonly, a clay pipe. He has been a steady whisky-drinker, but showed no evidence of alcoholism.

About eighteen months before admission to the German Hospital the patient began to be annoyed by sensations of swelling within the throat, associated with hoarseness. Shortly after the onset of these symptoms the lymphatics below the angles of the jaw became enlarged. Six months before admission interference with respiration began to be noted; inspiration was attended with stridor; dyspnoea became very marked upon exertion; the patient suffered greatly at night from occasional attacks of suffocation, which increased rapidly in frequency and severity.

At my first examination I found the pharynx normal. The epiglottis was covered with a large fungoid mass which had altered its shape completely, and which caused such enlargement of the part as to render a view of the vocal cords impossible. Portions of the arytenoid cartilages could be seen. The right arytenoid was swollen and oedematous. Externally there was no swelling over the thyroid cartilage, but the suprahyoid tissues were much swollen, while the lymphatic glands at the angles of the jaw were greatly enlarged and of almost stony hardness. This condition was most pronounced upon the right side. Much pain was complained of, extending along the course of the right Eustachian tube. The patient's voice was reduced to a harsh-sounding whisper, occasionally breaking into a hoarse, resonant note. No relief to the symptoms followed the use of potassium iodide and mercury. Dyspnoea became so severe as to endanger the patient's life. A radical operation was refused, but the patient consented to tracheotomy. I performed the high operation, hoping that consent would be obtained for a more radical procedure later. Naturally, great relief followed the insertion of the cannula, but the patient was not to be persuaded to allow an operation for the removal of the growth. He lived for a year after the tracheotomy, continuing to wear the cannula, and died from exhaustion. His family would not allow a post-mortem examination to be made. A large piece of the granulation tissue, removed by a Mackenzie forceps from the epiglottis, was examined by Dr. Stengel, pathologist of the hospital, and the growth was pronounced to be a small round-cell sarcoma.

The patient never showed symptoms suggesting that the œsophagus was involved.

Both of these cases of laryngeal neoplasms, so far as the local conditions were concerned, appeared to be favorable for partial laryngectomy; yet how much this operation would have prolonged life in excess of that gained by tracheotomy is very doubtful. Dyspnœa of an alarming degree never occurred in either case after the insertion of the cannula. The case of sarcoma appeared to terminate in the normal way for such conditions. From all appearances the case of epithelioma would have continued living for an indefinite number of months had there been no cardiac or nephritic disease. My thanks are due to Dr. Stengel for his examinations and reports and to Dr. Page and Dr. Hand, residents of the hospital; to the former, for notes of the case of epithelioma and for preparation of the specimen; to the latter, for his excellent photograph of the larynx.

Discussion.

Dr. DE ROALDES said he would in such cases advise the use of bromide of ethyl preliminary to using chloroform. It was less irritating to the air-passages and almost suppressed the period of excitement and thereby reduced to a minimum the danger of spasm of the glottis. In less than a minute the patient was relaxed, and the anæsthesia was then kept up with chloroform.

The PRESIDENT was glad that Dr. Roaldes had called attention to the use of bromide of ethyl. The anæsthetic had been introduced into New York city in 1879 and given a fair trial at one of the largest hospitals. It had been pronounced unsatisfactory and had been abandoned. It was to be hoped that of late years it had become possible to manufacture a better article. This indeed seemed to be the case, as those who had lately employed it had been favorably impressed.

Paper.

A CYST OF THE LARYNX CURED BY INJECTION OF CARBOLIC ACID; AND A REPORT ON MYCOSIS OF THE PHARYNX AND TONSILS.

BY E. FLETCHER INGALS, A.M., M.D.

CYST OF THE LARYNX.

THE following case of cyst of the larynx, because of its deep location and the fortunate results of treatment, appears to me of special interest:

Mr. D. M., aged forty-three years, came to me April 5, 1893, complaining of soreness of the throat, which he said had annoyed him, especially when talking, for about two years. He had been frequently troubled by cough, and for seven months the soreness and cough had been nearly constant. He was very hoarse, and for about a week he had suffered from almost continuous burning pain in the throat. One brother had died of consumption, but there was nothing in the patient's personal or hereditary history which seemed to account for his symptoms. His general health was good, weight normal, temperature and pulse normal. He had a deep, loose cough, and expectorated about half an ounce of muco-pus daily; the respirations were eighteen; there was no dyspnoea; and the digestive and secretory organs were in good condition. He complained of occasional obstruction of the nasal cavities, and upon inspection I found the right naris two thirds and the left one half closed by swelling; however, the subsequent history showed that this was a temporary condition. Physical signs over the chest were normal. Upon examination of the larynx I found a large swelling of the left ventricular band and aryteno-epiglottic fold, as shown in Fig. 1. This was so large that it was impossible to see the cord upon the left side, and the cord upon the right side was covered by what appeared to be temporary swelling of the right ventricular band. The larynx was congested about twenty-five per cent. (the normal condition being taken as a unit and the deepest congestion as one hundred per cent.). The subsequent history showed that the congestion of the right side and of the trachea was temporary, and it was probably from the acute inflammation that he experienced the burning pain which had lasted for a week. The swelling of the left side had a smooth, uniform surface, and

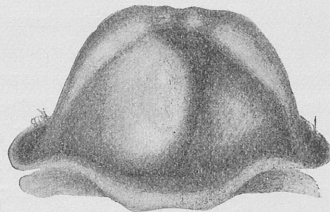


FIG. 1.

the appearance, excepting in the smoothness, of a solid growth; the mucous membrane being uniformly congested and at no part having the lighter color which we would expect to find over collections of fluid.

At first being somewhat puzzled as to the character of the tumor, and doubtful as to the best thing to do for the patient, I adopted palliative local treatment for the acute inflammation, consisting of astringent sprays which were applied once in four or five days, the patient in the meantime being given chloride of calcium in doses of from fifteen to twenty-five grains three times daily, with the hope of promoting the absorption of inflammatory products and possibly decreasing the size of the tumor. The internal and local remedies were followed up for about a month, by which time the congestion had disappeared from the right side, but the swelling of the left side remained as large as ever, though the mucous membrane had become somewhat paler and was not congested more than ten per cent. The mass was so firm to the touch that I feared it was a solid tumor, and thought it probable that nothing less than laryngectomy would prove of any avail. I determined, however, to try first the influence of deep injections of lactic acid. Upon the 3d of May, nearly a month after I had first seen the patient, I injected ten minims of a thirty-per-cent. solution of lactic acid; three days later, fifteen minims of the same solution; and two days later, twenty minims of the same solution. I found in making the injection that the needle felt as though it passed through four or five millimetres of firm, soft tissue into a cavity filled with fluid. This needle (Fig. 2) consisted of a hypo-

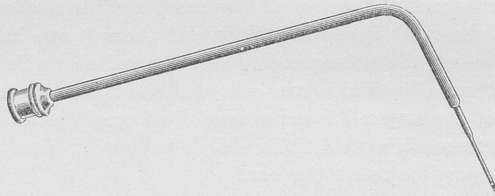


FIG. 2.—Hypodermic needle for deep injections into larynx.

dermic point attached to a stout brass tube which was fitted to a hypodermic syringe. Three days after the third injection I inserted a laryngeal lancet into the swelling and obtained a little thick, semi-transparent, grayish fluid. When the patient returned four days later I found that the swelling was only half its former size; at this visit an astringent application to the congested mucous membrane was the only treatment. I find from my notes that the patient subsequently returned to see me about once in four or five days, and that astringent sprays were applied, but at the end of four or five weeks (June 8th) the notes state that the patient's throat was feeling badly, he was still very hoarse, and the swelling had increased to nearly its original size. At this visit I injected into the cyst

six minims of an eight-per-cent. solution of carbolic acid in glycerin and water; three days later there was too much soreness to admit of a repetition of the injection, but three days subsequently fifteen minims of the eight-per-cent. solution were injected into the cyst; a week later twenty minims of a ten-per-cent. solution were thrown in; similar injections were repeated about once a week for five times, when the cyst had nearly disappeared and the injections were discontinued to ascertain whether or not it would again enlarge. He was subsequently seen at intervals of three or four weeks for three months after the last injection. On the date of his last visit my notes state that the cyst had been obliterated and there was no evidence of its recurrence. The patient felt that his throat was perfectly well. I have not seen the patient since November 20, 1893, but as at that time the larynx appeared normal, and as he had been very faithful in his treatment formerly, I feel confident that the disease was cured. I can not attribute any portion of this effect to the astringent applications nor yet to the lactic-acid injections, because it was not until I began to use the carbolic acid in strong solution that I discovered decided improvement, and then the diminution of the cyst was rapid and continuous until it entirely disappeared. From the deep-seated position of this cyst it would have been impossible to remove it by any crushing, tearing, or cutting operation short of removal of the greater portion of the left side of the larynx; therefore I felt that the patient had reason to be congratulated on the outcome of the treatment.

MYCOSIS OF THE PHARYNX AND TONSILS.

Although nothing new has been recently developed in our knowledge of mycosis of the pharynx, the comparative rarity of the disease appears to be sufficient excuse for placing on record the histories of those which have come under my observation. During the last three years I have seen among private patients twelve cases of this affection in which the symptoms and signs were typical. One of these was not treated, one was treated but once, and two but twice; therefore, in these four no results can be recorded. In the other eight thorough cauterization of the affected part with the galvano-cautery, repeated until all of the morbid masses were destroyed, effected a cure, and I believe in none of them has the disease recurred. This form of treatment appears to me thoroughly satisfactory, and, although in some cases I have adopted other measures coincidentally, I am under the impression that the good results were dependent mainly, if not entirely, upon the cauterization. In one of the first four cases, treated by the application of full-strength lactic acid, no benefit was derived. Although I have at times used the bichloride-of-mercury solution and other powerful antiseptics with

various astringents, I have been unable to discover that any of them had any influence upon the disease.

The histories are as follows:

CASE I.—Mrs. K. F., aged twenty-eight, had complained of slight soreness of the throat for a month which was referred to the region of the tonsils; the general health was good; an examination showed several well-marked mycotic patches; cauterization was recommended, but no treatment was instituted.

CASE II.—Miss C. H., aged twenty-two years, had suffered from slight catarrhal symptoms all her life, but for two months had noted whitish patches in the throat with slight soreness; the general health was good; several mycotic patches were observed upon both tonsils. Several of these were destroyed by the galvano-cautery at two different sittings, but the result is unknown.

CASE III.—J. C. H., aged twenty-seven years, complained of catarrhal symptoms and was subject to frequent colds; several mycotic patches were found upon both tonsils, three of those upon the right side being cauterized at the first visit. The patient did not return, and the result is unknown.

CASE IV.—W. A. B., aged thirty years, male. This patient had been troubled for the last three or four years with dryness and accumulation of mucus in the throat and an irritable cough; he stated that he took cold very easily; the general health was fair; appetite not very good and digestion poor when he first came to me in July, 1890. I saw him two months later and again in the following spring, and the notes show that the throat condition remained much the same, but at that time there was *no* mycosis. He called upon me February 6, 1893, complaining of some trouble in the throat, which I found to be well-developed mycosis of the tonsils. He objected to cauterization. Lactic acid was applied to these patches on two different occasions, and he was recommended to continue its use, as he desired to carry out the treatment himself. My notes indicate that no decided benefit was obtained from the lactic acid.

CASE V.—Mr. E. H. F., aged twenty-three years, came to me in April, 1891, complaining of hawking and spitting, with frequent hoarseness; the general health was fair, but he suffered some from dyspepsia. I found well-marked mycosis affecting both tonsils; two or three spots were cauterized upon one tonsil, and the treatment repeated five times at intervals of a week, when the disease had been cured. I saw the patient six months later, and no recurrence had taken place.

CASE VI.—Mr. F. M. D., aged thirty-two years, had been under my care at intervals for six years for disease of the throat and nose. He came to me in the latter part of September, 1892, complaining of hacking cough and a good deal of trouble in clearing the throat, especially mornings; this, however, appeared to be due to the collection of mucus in

the naso-pharynx. On examination was shown well-marked mycosis of the tonsils. His general health was fair, but I found an herpetic ulcer at the end of the tongue. An astringent application was made to the throat and soothing troches given, to be used as he might desire. For some reason, which does not appear in my notes I did not see him again for two weeks, and subsequently only about once a month for three months; on two of these occasions three or four of the mycotic patches were thoroughly cauterized, and the disease was cured. Three months later there had been no return of the trouble.

CASE VII.—Miss F. T., aged sixteen years, had been troubled with sore throat frequently for the last six years. For the past year the throat had given her much annoyance, and she told me that the white spots upon the tonsils had frequently been present during the last five years; general health good, digestion perfect; several well-marked mycotic patches were found upon both tonsils; two or three of these were cauterized at each of eight sittings at intervals of from five to twenty days, when the disease had been eradicated.

CASE VIII.—Miss M. G., aged fourteen years, had been troubled with the throat ever since early childhood, and was subject to frequent colds, but complained of no special symptoms in the throat; the appetite was only fair; digestion poor; general health not materially affected. Several well-marked mycotic patches appeared on both tonsils and on the base of the tongue; from two to four of these were cauterized at each of eight sittings, at intervals of about a week, when all of them had been destroyed. I have reason to believe that there was no recurrence, though the proof is not positive in this case.

CASE IX.—Mr. J. H. P., aged sixty-three years. This patient had been under my care at intervals for six years, and had consulted me for neuralgia and general debility about two months previous to the discovery of the mycosis. At that time there was no evidence of the throat disease, though the parts were carefully examined. In July, 1893, I found well-marked pharyngo-mycosis. The throat was cauterized six times, at intervals of from five to seven days, two or three spots being treated at each sitting; the disease was cured. I saw the patient six months later, and there had been no recurrence.

CASE X.—Miss S. F., aged seventeen years. This patient had been under my care at intervals for about two years, but had complained of slight soreness of the throat for only a month preceding the discovery of the mycosis, which was well developed on both tonsils. The disease was cured in four treatments, three or four points being cauterized each time, at intervals of from one to two weeks. She has not since reported, and, inasmuch as she had formerly come to me whenever the throat gave her annoyance, I believe there has been no recurrence.

CASE XI.—Mr. F. A. P., aged thirty-four years, stated that he was subject to frequent sore throat, and that he had seen yellow spots in the

tonsils at intervals for several years. I found him suffering from laryngo-tracheitis, the general health not materially affected and the digestive organs normal. It is noted that at first the tonsils were somewhat swollen, with several diseased follicles, and it was not until two weeks later that mycosis was discovered. From two to four places were cauterized at each of six sittings with intervals of from five to ten days between treatments. At the end of this treatment the disease had been cured. In this case I feel confident that the disease was not present when he first visited me, but I am equally confident that it was well developed about three weeks later. There has been no recurrence.

CASE XII.—Mr. E. F. W., aged forty-one years. This patient had been under my care at intervals for several years for nasal and throat trouble, and I had seen him about six weeks before the discovery of the mycosis; at that time he did not complain of the throat, and my notes do not show whether or not it was examined; but, from the fact that he had frequent trouble with the pharynx and that it was customary always to examine his throat, I am under the impression that there was no trouble at this time. When the patient last consulted me for his throat I found him somewhat debilitated and annoyed by well-marked mycosis. Ten cauterizations were needed to effect a cure. They were made at intervals of from five to fourteen days. There was no recurrence.

An examination of these cases shows that in seven, or in fifty-eight per cent., the patient had for many years frequently suffered from sore throat; that in eight, or sixty-six per cent., soreness of the throat had been present from four to eight weeks, and that in only one, or eight per cent., was there distinct evidence of previous follicular tonsillitis. In one there had been specific sore throat; one was suffering from general debility, though not very pronounced, and in three, or twenty-five per cent., symptoms of dyspepsia were present, but in fifty per cent. it is stated that the patients were in general good health. It is shown that in all of my cases where the throat was treated by thorough cauterization, which appears to me to be the most effective method, the mycosis was cured and I believe it has not returned in any. I am certain there has been no return of the affection in any of the patients that I have seen since the treatment.

In these cauterizations it has been my custom to destroy the diseased mass and to burn about an eighth of an inch into the tissue beneath it; to cauterize two or three patches at one time, and to repeat the operation, if convenient for the patient, two or three days after all soreness from the former operation had disappeared. In two or three cases I have given sprays of bichloride of mercury

or other antiseptics, but generally have ordered nothing of the kind. Where there has been general debility tonics have been given; and where digestive disorders were present, nux vomica, the hydrochloride of hydrastine, quinquina, and papain have been commonly prescribed. In some cases I believe that the disease exists for many years before it is discovered, but in most of the cases that I have observed it has apparently been of only a few weeks' duration. In two of the cases, which were not treated more than once or twice, I am under the impression that the remainder of the disease has gradually disappeared from natural causes, because it occurred in patients who would have been almost certain to return for treatment if any white spots could be seen by them in the throat.

Paper.

MYCOSIS TONSILLARIS.

By C. E. BEAN, M. D.

THE occurrence of mycosis tonsillaris is sufficiently rare to merit special mention when the disease is encountered. The older authorities on laryngology make no mention of it, and it has only lately become recognized, notwithstanding the first case was reported by B. Fraenkel* in 1873. Since then it has been reported by quite a number of writers, mostly foreign, it being rather infrequently met with in this country.

Lennox Browne† says the disease is rare in England and that he has seen very few cases of fungoid growth in the pharynx, but that in every instance the pathological report was that leptothrix was the prevailing parasite present.

Decker and Sieffert made a report to the Medico-physical Society of Würzburg in January, 1888, of thirty-four published cases.

Oltuszewski‡ reports a case occurring in a patient at the age of sixteen where there was intense fever, and where, after six months' treatment, fresh colonies of leptothrix constantly reappeared. This case was treated by removing the deposit with forceps and gargles of corrosive sublimate (1 to 2,000).

* *Berl. klin. Woch.*, 1873.

† *Diseases of the Throat*, third edition, London.

‡ *Gazette Lekarka*, No. 4, 1888.

The disease is due to the presence of the specific spore upon some portion of the mucous membrane. Its primary source is not so easy of definition, although the anterior part of the mouth is probably the immediate source of the spore which gives rise to the fungous development in the mucous membrane of the throat, it having been found in large quantities in the masses of decomposition within and between the teeth. Impaired general health is no doubt a prominent predisposing factor in the ætiology of the disease, for the *Leptothrix buccalis* is probably more or less present in all buccal secretions.

In a case of pharyngo-mycosis Schmiegelow, of Copenhagen, found a bacterium not yet described and called it the *Bacillus anthracoides buccalis*.

Hemenway,* in his cases, did not find a constant form of leptothrix, and doubts the evidence that the growth is a result of the leptothrix. Certainly *Leptothrix buccalis* is found in nearly if not all of these cases of mycosis; but then, on the other hand, this parasite is found in other parts of the buccal cavity where the fungus never grows.

The special variety found is the *Leptothrix maxima*, "an organization consisting of long, thick, or slightly curved filaments resembling the *Buccalis maxima*, of which it is probably a variety."

The location of the fungus is on "the tonsil, base of the tongue, posterior wall of the pharynx, and glosso-epiglottic pillars and folds." †

Bosworth ‡ says the most frequent starting point is the faucial tonsil and that it is very rarely seen on the pharyngeal tonsil.

Semon reports a case where the growth was on the soft palate and uvula.

It is essentially a chronic disease, though it may be developed during an attack of acute amygdalitis.

Metzner # reports a case following acute amygdalitis where death occurred in two days. The post-mortem examination revealed purulent mediastinitis, pericarditis, and purulent pleuritis; also an abscess in the right tonsil.

While usually a disease of adult life, it has been observed by

* *Medical News*, Philadelphia, January, 1892, p. 38.

† Rualt. *Sem. méd.*, 1893, No. 17.

‡ *Diseases of the Nose and Throat*, vol. ii, p. 189, 1892.

Journal of Laryngology and Rhinology, November, 1889, p. 463.

Baginsky * in a child twelve years old and by Heryng † in a patient aged sixty-two. Damoschino ‡ regards an acid reaction of the oral secretions as favorable to the development of the spores.

With these cases there is an unusual amount of mental depression which seems to be characteristic of the disease, thus increasing the deterioration of the general health.

The following case illustrates some of the peculiarities of the disease:

Mrs. —, aged twenty-six years, was referred to me by a brother practitioner in May, 1893. She had been subject to attacks of follicular amygdalitis for seven years and had had the throat burned with nitrate of silver on several occasions. The last attack had begun two months before she consulted me. There had been a great deal of pain in the throat and very high fever, and the usual remedies for acute amygdalitis had been used with little benefit. The pain and the fever had gradually but slowly subsided, the white spots remaining on the tonsils and causing a considerable degree of irritation in the throat with a constant desire to cough. The disease had at this time extended to both tonsils and base of the tongue and was especially pronounced high up in the angle between the anterior and posterior palatine folds. In this latter place the disease was the most difficult to eradicate. It presented itself in small conical shaped elevations to the number of fifty or sixty, entirely separate and distinct, which were extremely hard and difficult to remove. The fungus was, under the use of cocaine, removed thoroughly as far as could be by means of a curette, and the galvano-cautery point applied to the parts. By September of 1893, or four months after treatment began, there was complete disappearance of the fungus and there has been no return up to this date.

At the same time she was given iron, strychnine, and quinine internally and alkaline gargles on the theory that the leptothrix germs only occur when there is an acid reaction to the oral secretions.

Some of the points of deposit of the fungus were treated as many as a dozen times before it was entirely removed.

Various modes of treatment have been suggested for this disease. Ruault advised one of his patients to smoke ten cigarettes daily, and with no other treatment the patient in two weeks showed manifest improvement.

Dembecki proved upon himself the value of tobacco smoke in curing in three months a case which had resisted every other form of treatment.

* *Protocol. der Berl. klin. Gesell.*, May, 1876.

† *Zeitschrift für klin. Med.*, 1884, vol. ii, p. 363.

‡ *Gazette des hôpitaux*, Paris, 1888, vol. iii.

Baber * reports a case affecting both tonsils and base of the tongue that had improved by the persistent painting with alcohol and the removal of the deposits containing leptothrix.

Nitrate of silver, tincture of iodine, and bichloride of mercury locally have all been recommended; but the use of the curette, followed by applications of the galvano-cautery, with attention to the general health, will do more to accomplish a successful cure than any other combination of remedies.

Paper.

ASPERGILLUS MYCOSIS OF THE ANTRUM MAXILLARE.

By JOHN N. MACKENZIE, M. D.

WHAT I have to say will rather be in the line of some preliminary remarks than in an attempt at a full presentation of the subject. The matter is still under observation, and at this stage no definite conclusions can be drawn. The patient whose history forms the basis of my remarks was a young woman, about thirty-five years of age, who was brought to me in the early part of last fall. I shall not give a complete history of the case, but simply call attention to a few salient points.

In 1883 she consulted Dr. Theobald on account of a pain in the right ear, which he said was as well marked a case of pure otalgia as one often sees. This, according to the note which he kindly wrote me, was the usual symptom which brought her to see him from time to time. Often there was nothing wrong to be seen in the ear, but at other times there would be some swelling of the outer third of the meatus, and tenderness on pressure. On March 4, 1889, a threatening furuncle appeared in the auditory canal; in October, 1887, an abscess of the lobe of the ear was opened by Dr. Theobald. There never was at any time aspergillus in the ear, nor even a condition which would suggest the probability of its presence. Dr. Theobald first noticed a swelling on the right side of the face in January, 1889, and a week later recognized the presence of disease of the antrum, the patient having had a discharge of pus from the nose, with relief of pain and diminution of swelling of the cheek in the meantime. In February, 1891, he noted some swelling over the root of the nose, with pain over the right eye, and he feared that there was trouble beginning in the frontal sinuses. These symptoms disappeared later. Dr. Theobald was disposed to think that the disease in the antrum had some-

* *Journal of Laryngology and Rhinology*, February, 1888, p. 91.

thing to do with the ear symptom, and perhaps was the chief cause of the otalgia which she had from time to time.

About two years ago her dentist brought her to Baltimore in consultation with Dr. James H. Harris, and, from the history which Dr. Harris got of her antral trouble, he seemed to think that it was due in the first instance to caries of a molar tooth, possibly originating in periodontal inflammation, with subsequent antral trouble. The antrum was opened at that time (the second molar tooth was extracted and the floor perforated by a large drill) and an immense amount of pus washed out with a syringe. She was seen subsequently by several general surgeons, who insisted upon scraping out the antrum. She was a little afraid of the operation and declined it. So things have been going on for the past two years, the antrum being syringed out daily with various alterative, astringent, and antiseptic solutions. The only drug which seemed to give her any relief at all was nitrate of silver in strong solution. This would stop the discharge for a week or two, and then it would become as bad as ever. About two months ago a new feature appeared in the case, which gives it its present peculiar interest. At that time she began to pass through the opening made in the antrum from the mouth shreds of false membrane which varied very much in length, some being as long as the index finger. These passed off at intervals of a few days to a week or ten days. This process went on in spite of nitrate of silver and strong applications to the interior of the antrum, and finally the case was seen by me in consultation with Dr. Harris and at once commanded my very great interest.

The chief point of interest was the passage of a false membrane from the antrum. We are taught that the antral mucous membrane is incapable of producing a false membrane. Zuckerkandl, who, of recent German authors, has most carefully studied the normal and pathological anatomy of the antrum, lays it down as a dictum that, owing to the anatomical structure of the antral mucous membrane, the presence of a diphtheritic or other membrane is utterly impossible. I obtained some of the membrane and sent it to Dr. Flexner, associate in pathology in the Johns Hopkins University, who prepared some sections. It consists of three layers. The first layer consists of a mass of round cells, with some loose epithelium of the mucous membrane of the sinus. The second layer is apparently one of pure necrosis, which does not stain. Upon this layer rests a mass of aspergilli. The variety of the aspergillus has not been determined. Dr. Flexner rather inclines to the belief that it is the *Aspergillus fumigatus*. The aspergillus sends its spores in two directions, off from the free surface and down into the deeper layers.

The subject of aspergillus infection is receiving some attention at the present day. There are three varieties that create most devastation—the niger, the flavus, and the fumigatus. From what I have read on the subject, more trouble follows in the wake of the fumigatus than in that of either of its brethren, the flavus or niger. The *Aspergillus niger* is familiar to us all as the parasite that infests the auditory canal, and also the eye, where it is found on the cornea. I have not gone sufficiently deep into the literature of the subject to warrant the assertion that this is the first case of aspergillus infection ever discovered in the antrum, but I never read of such a case, and I can state, from a tolerably fair familiarity with the literature, that very little is known about it, if such a case has ever even been reported. It is quite familiar as a disease of some birds, such as the dove and various other smaller birds. In them the *Aspergillus fumigatus* is found in the air-passages, and, according to some writers, it produces a pneumonia, with necrosis of the lung tissue. The aspergillus that does this harm is generally the fumigatus. I think experiment has shown that the *Aspergillus niger* is far less infectious than either the flavus or fumigatus.

An interesting point in this case is the mode of infection. I can find no evidence whatsoever that this patient has ever, at any period of her life, had a parasitic disease of the mouth or nasal passages. The probabilities are that the aspergillus reached the antrum through the mouth, but why it did not tarry in the mouth, but proceeded at once to the antrum, is very difficult to understand.

Another interesting point is this: The united testimony of all observers affirms that the aspergillus does not develop during the process of active suppuration, and yet here is a case in which the antrum has been for years the seat of a virulent suppurative process, not yielding to treatment, and these parasites have developed in large numbers. Another point in connection with these aspergilli is that they are readily formed in oily substances, and in all fatty substances which undergo rapid decomposition. As far as I can learn, no such substances were ever employed by the patient as a wash, and we can hardly assume that the aspergillus found its way into the antrum through the hands of the surgeon.

In this country we rarely see parasites in the nasal passages or in the accessory cavities. In India they are quite common. People who live in dirt and filth are apt to have them, and among our own negroes in the South the blue-bottle fly is a frequent visitor to the sad nostrils of the young African as he basks in the sun; they

deposit their ova there, and these, finding a fertile soil, grow up into full-fledged maggots. The following is a copy of Dr. Flexner's report :

Dr. Mackenzie brought us in alcohol a piece of tissue having the appearance of a coiled-up false membrane. The thickness of the separate layers did not exceed three to four millimetres, and the membrane was found to be very friable. Sections made of the membrane which had been imbedded in celloidin showed on microscopical examination several layers. The undermost layer, corresponding with its attachment to the mucous membrane of the antrum, was composed of a layer of polynuclear leucocytes. This varied in thickness in different parts and formed about one third of the entire thickness of the false membrane. A few cells of a different type, larger, with more protoplasm and vesicular nuclei, being sometimes flat and scalelike and again narrow, elongated, and columnar, were present in the layer of leucocytic aggregation. They were oftenest in the lower part of the membrane nearest the points of attachment to the mucous membrane of the antrum. These epithelial cells presented evidences of degeneration in the staining properties of the protoplasm as well as in the shriveled appearance and diffuse staining of the nuclei. Above the layer of leucocytes an indefinite substance was found, composed of granules and fiberlike processes which stained poorly in hematoxylin and eosine. But in the specimens stained in Weigert's fibrin stain this layer was seen to be felted and composed in large part of mycelia of a fungus. The uppermost layer of the membrane is composed of branches from the mycelia below, bearing on their summits the fruit-bearing heads. The fungus was recognized as belonging to the aspergilli, and Dr. Lotsy, who kindly examined the specimen, informs me that it is the *Aspergillus fumigatus*. The fruit-bearing heads were found only on the summit of the membrane in its most superficial parts, but in sections stained, as before mentioned, with Weigert's fibrin stain the mycelia were especially well shown, and these could be traced at intervals below into the deepest part of the membrane. No fibrin was made out in the membrane.

Paper.

NASAL POLYPUS: ITS ASSOCIATION WITH ETHMOIDITIS AND ITS TREATMENT BY RESECTION OF THE MIDDLE TURBINATED BODY.

By W. E. CASSELBERRY, M. D.

THE analysis of forty cases of nasal polypus, drawn from private practice, which will be outlined in this essay, confirms the view which I have advocated in previous papers that nasal polypus is not a primary or independent affection, but that it is a symptom, or at

least a concomitant, of other nasal maladies which stand to it in the relation of cause and effect. This fact, however, should not lessen our efforts to elucidate the pathologic relationships of polypus, since thereby we will not only acquire more intimate knowledge of the underlying conditions, especially the various forms of ethmoiditis, but will also be led to devise more effective methods of treatment.

In 1888, in a paper on Nasal Myxomata read before the Chicago Medical Society, I advised a vigorous surgical treatment, having for its object, first, access to and then eradication of the actual seat of attachment. Zuckerkandl's* researches on cadavers were summarized, by which he demonstrated that two thirds of all nasal myxomata originated from the middle meatus beneath the middle turbinated body, and that approximately two thirds of this number took origin from the edges of the hiatus semilunaris, which is a crescentic opening into the infundibular space whose upward and downward continuations enter, respectively, the frontal and maxillary sinuses, and which is located high up beneath the middle turbinated body.

In Fig. 1, which is accurately drawn from a divided skull, the middle turbinated body has been broken and turned upward, in order to disclose the hiatus semilunaris and bulla ethmoidalis.

In that paper it was recommended that hypertrophied inferior turbinated bodies be reduced to a normal size by cauterization, in order to facilitate the transmission of light and the passage of instruments to the seat of polyp growth, and also by the restoration thus of proper nasal drainage to prevent damming up of mucopurulent secretion in the middle meatus.

For the same reasons, septal excrescences, so frequently present, were to be removed. Meanwhile, as opportunity offered, the myxomata were to be carefully snared off close to the base by means of a cold wire snare, when, in some instances in which sufficient space existed, it would be found possible to insinuate a slightly curved cautery point electrode beneath the middle turbinated body with which to destroy the actual seat of attachment. Further experience taught, however, that there were many cases in which this latter procedure was inadvisable on account of the tendency to the formation of adhesions, and to the production of a septic eschar in a circumscribed location. Recently I have substituted satisfactorily curetting of this area for cauterization. A small but firm and sharp curette is insinuated upward beneath the middle turbinated body, in the direction from which the polyps proceeded, and their at-

* *Anatomie der Nasenhöhle*, pp. 64 et seq.

tachments, especially the borders of the hiatus and the bulla ethmoidalis, are well scraped.

In 1891, in a supplementary paper before the American Laryngological Association, I advised, as part of the radical treatment of nasal polypus, in certain cases in which the polyps emanated from

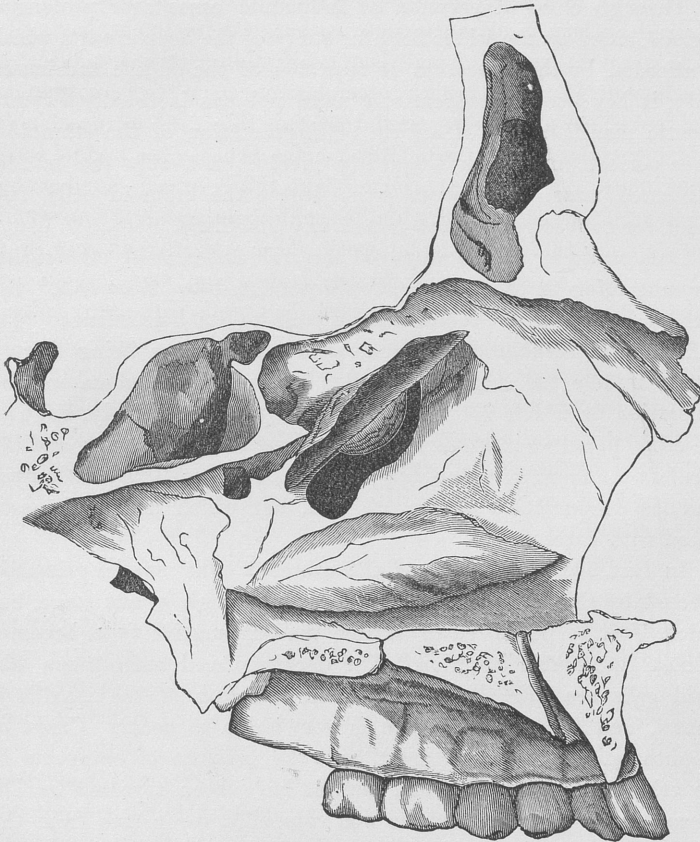


FIG 1.—Representing the outer wall of the left naris with the middle turbinated body turned upward to show beneath the hiatus semilunaris, to the edges of which polyps are frequently attached.

the region of the hiatus semilunaris, the removal of the antero-inferior part of the middle turbinated bone in order to facilitate access to the actual points of development. Additional experience with this operation has but confirmed its utility and demonstrated

its harmlessness, so that it will presently be referred to again more in detail. It was pointed out that the middle turbinated body, a process of the ethmoid bone, was rarely itself in a healthful condition in these cases; that it was often enlarged, or degenerated, or in a cystic state—a phase of the subject which it is desired to amplify in the present paper.

Through close observation of individual cases over prolonged periods, aided by the wider field for study of the deeper parts which is afforded by the operation of resection of the middle turbinated body, it has become evident that nasal polypus is usually a symptomatic manifestation of a form of degeneration of the ethmoidal muco periosteum, which frequently involves not only the middle turbinated bone, but also to some degree the ethmoid cells, and which for convenience is designated as ethmoiditis.

As a reminder of the scope of the various forms of ethmoiditis I would refer to the classification formulated by Bosworth,* but without intention of committing myself to its limitations: “(1) Extracellular myxomatous degeneration, the disease being limited to the middle turbinated body; (2) intracellular myxomatous degeneration, in which not only the middle turbinated body, but also the ethmoid cells had undergone myxomatous degeneration; and (3) purulent ethmoiditis, which may or may not be associated with myxomatous degeneration of the ethmoid, but which usually is associated with nasal polypi.”

In fact, any or all parts of the ethmoid bone may be primarily affected by this process, which is serious enough in any stage, but which, if it be permitted to assume the suppurative type, becomes a most formidable affection. The deeply placed anfractuous ethmoid cells are difficult to drain, and infection of the maxillary, frontal, and sphenoidal sinuses is very liable to occur. Cases of exophthalmia with loss of sight from the pressure of empyema of the ethmoidal and sphenoidal sinuses have been reported by Dr. Hermann Knapp,† in which he was compelled to operate from the orbit. Fatal termination by infection of the cerebral meninges must also be regarded as among the possibilities in such cases. Mention is made of these points because it will appear from the cases reported as typifying the various forms of associated ethmoid disease that polypus is commonly one of the earliest prominent manifesta-

* *Transactions of the American Laryngological Association*, 1891.

† *Journal of the American Medical Association*, December 2, 1892.

tions of ethmoiditis, and that when present the case should not be dismissed with a simple snaring as adequate to the occasion, but that it should be viewed as at least suggestive of a developing disorder which is liable to culminate seriously unless controlled. Furthermore, the treatment advised, especially resection of the middle turbinated bone, in addition to its efficacy for the polyps themselves, should be regarded as a prophylactic measure against the development of the more serious suppurative type of ethmoiditis by facilitating drainage from the ethmoid cells.

There is little to suggest concerning the ultimate cause of simple cedematous or myxomatous ethmoiditis beyond a possible impairment of the vaso-motor nerve force supplied to this area, which, however, is more manifest in the next variety of the disease, which I will designate as vaso-motor ethmoiditis. The following types, suppurative ethmoiditis and necrosing ethmoiditis, can reasonably well be traced as outgrowths of the former varieties.

Regarding the microscopic structure of nasal polypi and of myxomatous tissue, there is nothing to add to the studies of Jonathan Wright,* recently reported to this association, in which he described distinctions between the so-called nasal myxoma and true myxoma, the inference being that the nasal growths are of inflammatory origin and to be ascribed to hypertrophic rhinitis. This limited causation is exemplified in my series, but only by a few cases, and the reason for the comparatively rare transformation of the common hypertrophic process into one of mucoid or cedematous character still remains a mystery.

I will attempt a clinical classification of the various conditions which are found associated with and underlying the formation of nasal polypus:

TYPE I. NASAL POLYPUS WITH HYPERTROPHIC RHINITIS.

CASE I.—Miss T., aged ten years, has enormous hypertrophy of the left inferior turbinated body and numerous polyps which proceed from the middle meatus and are closely impacted between the neighboring turbinated bodies and the septum (Figs. 2 and 3). They are continuously imbedded in a mass of thick, viscid muco-purulent secretion. In the other nostril hypertrophy is present, but it is insufficient to obstruct the drainage, and no polyps are visible. Operations first by the cold wire snare resulted in the removal of numerous growths, but they redeveloped as rapidly as removed, springing up like mushrooms in the sod-

* *New York Medical Journal*, November 4, 1893.

den soil maintained by the imprisoned secretions. Then, after several weeks of such trials, the inferior turbinated body was cauterized along

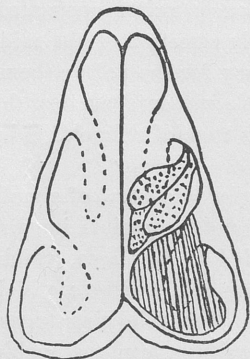


FIG. 2.

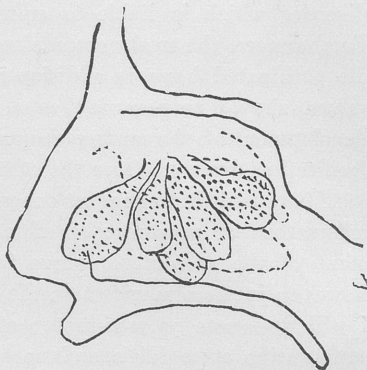


FIG. 3.

its entire extent, being reduced in front, where it especially interfered with drainage, almost to a rudiment. One was then enabled to trace the tumors to their exact seat of attachment in the immediate vicinity of the hiatus semilunaris, and to thoroughly eradicate them by reaching that position with a cautery point. No recurrence. Cure complete, as verified by several re-examinations during the past six years.

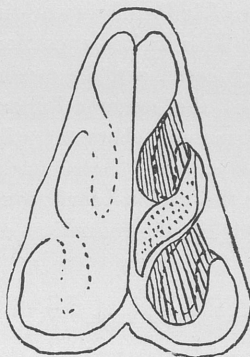


FIG. 4.

This patient presented no symptoms of ethmoiditis other than the suggestiveness of the polyps, and since permanent recovery followed promptly on reduction of the hypertrophic rhinitis, it is a fair inference that the latter affection alone, leading to defective drainage, was the antecedent condition to the development of

nasal polypus. This case may be considered as fairly typical of a group of six selected from the entire series of forty cases. One of them possessed but a single polypus which grew from the middle meatus and has not recurred in the past five years (Fig. 4). Another was affected with a large single polypus which projected into the nasopharynx and has not recurred for one year. The others have passed from observation.

TYPE II. NASAL POLYPUS WITH SIMPLE MYXOMATOUS ETHMOIDITIS.

CASE II.—Mr. B., aged forty years, complains of pressure in the ethmoid region. He had several polyps removed five years ago. Examination discloses great enlargement of the middle turbinated bodies, which press firmly against the septum on each side. They have a glistening aspect and a pultaceous touch, indicative of œdematous or myxomatous degeneration rather than of ordinary hypertrophy (Fig. 5). A compact bunch of small polyps juts out from beneath each middle turbinated body, having in the course of time forced the latter quite a distance from the external wall of the nose, the space thus made being so much wider than usual that the polyps can readily be inclosed by a snare close to the hiatus semilunaris, through which they seem to project as if emanating from points in the ethmoid bone still higher up.

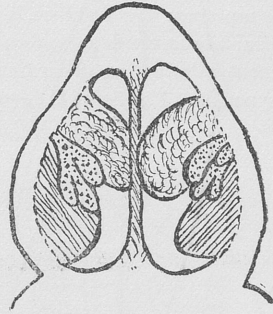


FIG. 5.

The patient has a peculiar facial aspect; the base of the nose, externally, is broadened, this deformity being produced by actual thickening of the superior maxillary bone near the line of articulation with the nasal bone, and there is infraorbital swelling of a quasi-œdematous nature, which simulates the physiognomy of Bright's disease. Such facial swellings, bilateral or unilateral, I have observed in other cases, both of nasal polypus and of ethmoiditis without polypus, and have ascribed them to intranasal pressure from distention in the ethmoid region.

After removal of the polyps by the cold wire snare the borders of the hiatus semilunaris were scraped to the bone by insinuating a small sharp curette upward and outward beneath the middle turbinated body. The middle turbinates were then cauterized as if for hypertrophic rhinitis, which materially reduced their size. Resection of the middle turbinated bodies, not seeming absolutely necessary, was not done in this case, although it is possible that such would have been the better line of treatment, and that it will be required at a future time. The facial swellings have been greatly improved and the intranasal discomfort suspended by the treatment.

In this case, the myxomatous degeneration of the middle turbinated bodies (processes of the ethmoid bone) and the polyps themselves, which project at least from the immediate vicinity of the median ethmoid cells, together with the facial deformities, indicate considerable involvement of the ethmoid structure; but the designation œdematous or myxomatous ethmoiditis is more certainly justi-

fied by the next case, which presents the same pathologic conditions in kind, only more advanced in degree :

CASE III.—Mr. N. M., aged fifty years, first came under treatment in 1884, at which time I removed a few polyps and reduced by the cautery and snare the *inferior* turbinated bodies, which were then greatly hypertrophied. He has continued to suffer a variety of noteworthy reflex symptoms: for instance, a sense of pressure far back between the eyes becomes at times so severe as to induce a high degree of nervous excitement culminating in cardiac palpitation, which occasionally leads to actual syncope. The heart is devoid of organic lesions. Re-examination in 1894

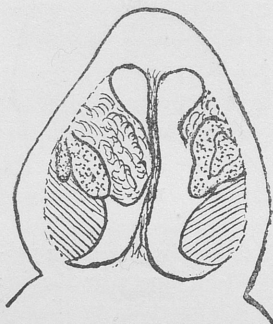


FIG. 6.—Representing on one side polyps growing from the ethmoid region, visible only after resection of the middle turbinate body.

discloses enormous osseous overgrowth with polypoid degeneration now of the *middle* turbinated bodies, which together with a few small polyps literally pack the upper channels of the nose. The cautery here was obviously inadequate to the requirements, so I performed resection of the middle turbinated bodies, piecemeal, by means of the snare, serrated scissors, and bone forceps. This laid bare the ethmoid cells, from which polyps could be seen to protrude, and whose walls were in a similar state of polypoid degeneration. These parts were scraped by a sharp curette. On the left side, curiously, no true polyps had been visible until after removal of the middle turbinated body, when two, of good size but of flat shape, were exposed which projected from the region of the ethmoid cells (Fig. 6). The antrum of Highmore had been opened in 1893 by the patient's dentist, two small polyps being found therein but no pus.

This case would conform to the variety of ethmoid disease designated by Bosworth* "intracellular polyp without pus discharge," of which his series comprised but a single case. It only differs from my preceding case, however, in the degree of development of the "intracellular" polyps, and these two cases will serve to typify a group which comprises fourteen of the entire series of forty cases.

In most of the fourteen cases the middle turbinated bodies presented evidence of myxomatous degeneration, and two of them had each a large typical polypus developed from this process of the ethmoid, which was removed in each instance together with a part of the bone itself. Five in all of the fourteen cases of this group

* *Transactions of the American Laryngological Association*, 1891.

were subjected to resection of the antero-inferior part of the middle turbinated bone, which operation exposed the hiatus semilunaris and the nasal surface of some of the ethmoid cells, especially the bulla ethmoidalis, and in those so treated these parts of the ethmoid mucosa were found to be the seat of polypoid excrescences. In all of the cases of this group not thus exposed by operation, polyps were observed to project from beneath the middle turbinated bodies, which were traceable toward the hiatus semilunaris and ethmoid cells. It would seem but natural that many of the polyps should form attachments to the edges of the hiatus, as was demonstrated by Zuckerkandl, while they are gravitating through this groove or being forced through it by œdematous pressure in the cells above. The point is that, though distinct polyps are found to be attached to the borders of the hiatus, it is probable that in a large proportion of cases the initial lesion is a diffuse mucoid or œdematous ethmoiditis.

TYPE III. NASAL POLYPUS WITH VASO-MOTOR ETHMOIDITIS.

CASE IV.—Miss McC was referred to me by Dr. E. J. Gardiner in 1889. She had suffered from complete nasal obstruction for several years, together with asthma and hay fever. There were multiple polypi, which, after removal, would redevelop with astonishing rapidity, growing in profusion not only from the middle meatus, but also from the superior meatus posteriorly, and from both the middle and superior turbinated bodies. The entire nasal mucosa was in a state of œdematous tumefaction, as if devoid of vaso-motor control.

The nostrils at best would have been considered narrow, the middle turbinated bodies were crowded, and drainage was defective. Efforts at cauterization resulted in troublesome adhesions and accomplished but little good. I ultimately removed the antero-inferior part of each middle turbinated body with the greatest possible benefit to the patient. Drainage was thereby restored throughout the middle and superior nasal channels as well as from the ethmoid cells, and the parts began to assume a healthier aspect.

The hiatus semilunaris and the ethmoid cells just above, which were thus exposed, were found filled and covered with polyp buds and myxomatous tissue. These were scraped by sharp curettes and picked off by cutting forceps—a process which was found much more effective in this region than cauterization. The patient is still seen at monthly intervals, when I sometimes pick off a polypoid excrescence or a piece of suspicious tissue to insure against redevelopment. She suffers only an occasional “filling up” of the nose, respiration being at most times free. She has escaped hay fever during the past three seasons, and is practically but not absolutely free from asthma.

This case is remarkable as an extreme example of the type—vaso-motor ethmoiditis; for the length of time, five years, during which she has persistently submitted to treatment; for the quantity and novel character of the surgical treatment, and for the satisfactory result attained.

The case is typical of a group which comprises nine of the entire series of forty cases, the salient features of which were the same in kind in all of the nine cases, although differing somewhat in degree. Three other patients of the group were subjected to the operation of resection of the middle turbinated bodies on one or both sides, and the same myxomatous degeneration and tumefaction of the mucosa of the underlying ethmoid cells was disclosed.

Asthma was a universal symptom, which to some extent has influenced the grouping together of these particular cases, since I am convinced that asthma of this variety is caused by a similar vaso-motor tumefaction of the bronchioles. Four of the nine cases suffered from hay fever or, as it is termed also by Bosworth, vaso-motor rhinitis, which further indicated the possession of a fundamental neurotic habit. Distention of the erectile tissues of the nose was common to the group, but in addition they all presented a super-sensitiveness in excess of that which attaches to ordinary hypertrophic rhinitis, various irritants, such as dust, coal-smoke fog, aroma from horses, etc., sufficing at any season to excite a form of tumefaction suggestive of vaso dilatation. The ethmoid region in most of the cases seemed especially sensitive.

All points considered, the descriptive term, vaso-motor ethmoiditis, would seem justified as applied to this group of cases.

TYPE IV. NASAL POLYPUS WITH SUPPURATIVE ETHMOIDITIS.

CASE V.—Mr. McC., aged fifty years, has suffered from nasal polypi for ten years. One year ago intense pain commenced over the left *frontal* sinus, then supraorbital bulging and tumefaction, and finally, after months of intense suffering, spontaneous discharge of pus occurred from the frontal sinus, having forced its way through the bony wall of this cavity and opened between the eyeball and the supraorbital arch of the frontal bone.

He then applied to Dr. Christian Fenger, who referred him to me with a view to avoidance of an external operation by reopening, if possible, the natural channel by intranasal treatment.

The left middle turbinated bone was enormously enlarged and in an advanced state of myxomatous degeneration, the whole mass, together with some small polyps, being packed in place so firmly as to obliterate

the middle meatus and to press the septum toward the opposite side. I removed this diseased mass, bone and all, in fragments at different sittings by means of cutting forceps, which operation also served to expose polypoid excrescences with suppuration of the ethmoid cells, which were then scraped and drained. The other nostril required similar treatment, but to a less extent. The result is satisfactory concerning the nose, but the frontal fistulous discharge, although greatly diminished, is still perceptible, which indicates continued obstruction of the natural drainage channel, doubtless by polypoid tissue beyond intranasal reach. Attempts at catheterization of the frontal sinus *via* the nose and infundibulum were not entirely successful even after the removal of the degenerated tissue which had represented the middle turbinated body.

Polypus, in association with suppurative ethmoiditis, is represented in this series of forty by a group of six cases, of which the one detailed is essentially typical. It alone, however, was complicated by empyema of the frontal sinus. It and three others of the group, making four out of six, were complicated by empyema of the maxillary sinus.

In the case related the suppurative ethmoiditis and polyp formation were bilateral, although worse on the left side, on which the complications occurred. In the other three cases polyps existed in both nares, although suppuration of the ethmoid cells was unilateral in each and occurred on the same side as the empyema of the antrum.

In three of these cases the maxillary sinus was opened and drained, then resection of the middle turbinated bone was made, and in one case the posterior ethmoid cell was well opened by revolving burrs, which was done by following the lead of a probe which could be passed into this suppurating cavity. One case declined operation other than removal of the polyps; and the diagnosis of suppurative ethmoiditis was made by observing the escape of pus through the superior meatus into the nasopharynx, which indicated involvement of the posterior ethmoid cells.

The two remaining cases of this class were subjected to resection of the middle turbinated bodies, by which better drainage was secured, this making five of the group of six cases which were thus treated, in addition to other measures, all being thereby immensely benefited.

Curiously enough, none of these cases suffered from asthma. In two, denuded bone could be felt by a probe before operating, and in one case the odor was indicative of necrosis.

I believe that purulent ethmoiditis with polypus is to be regarded as a sequel to the simple myxomatous type; that suppura

tion of the ethmoid cells occurs only after myxomatous tissue has accumulated sufficiently to obliterate their natural drainage channels. This view is substantiated by Case V, in which suppuration of the frontal sinus occurred in conjunction with obliteration of its outlet. As mentioned by Bosworth,* "the natural result of a damming back of a mucous secretion is the development of a purulent inflammation." The sequence of events would then be, first, simple myxomatous ethmoiditis, which may assume as a variation the type of vaso-motor ethmoiditis with asthma, then nasal polypus, and finally suppuration of the ethmoid cells and of the collateral sinuses by obstruction to their outlets either by distinct polyps or myxo-degenerated tissue.

Herein lies the prophylactic value of the operation of resection of the middle turbinated body in cases belonging to type ii, polypus with simple myxomatous ethmoiditis, and to type iii, polypus with vaso-motor ethmoiditis, for in addition to exerting a curative influence over these earlier forms of the disease, it will tend to prevent the culmination of the suppurative type of ethmoiditis, by maintaining drainage from the ethmoid cells and by facilitating access to the hiatus semilunaris for the radical removal of polypoid tissue. In like manner it should tend to prevent the troublesome complications of empyema of the maxillary and frontal sinuses, and the not impossible fatal contingency of infection of the cerebral meninges.

I would not imply that the operation should be made in every case; but it should be done in most cases in which the middle turbinated body has undergone myxomatous degeneration with downward and lateral enlargements, so that it packs the space in which it lies, and in certain other cases in which by reason of abnormal conformation it exerts undue pressure on the septum, or when it is necessary to gain space for drainage or instrumental manipulation.

Conversely, if the middle turbinated body be of normal contour, and present no impediment to drainage, to the transmission of light or instruments, there will then be no occasion to interfere with it, and, it may be further said, under such conditions it would be most difficult to perform its resection.

TYPE V. NASAL POLYPUS WITH NECROSING ETHMOIDITIS.

Grouped together under the name of necrosing ethmoiditis, Dr. Edmond Woakes † gave the first succinct account of some of the

* Various Forms of Disease of the Ethmoid Cells. *Trans. of the Am. Laryn. Assoc.*, 1891.

† Nasal Polypus, etc., in Relation to Ethmoiditis, 1887.

conditions which have been described and classified in this paper. His contention that nasal polypus indicated a chronic inflammation of the tissues of the ethmoid is in large measure substantiated by the foregoing analysis of cases; but that necrosis or even caries of bone is a "usual" accompaniment is not confirmed, so that it would seem wise to limit the term necrosing ethmoiditis to the class of cases in which necrosis, or at least caries, actually exists and can be unmistakably demonstrated.

Exactly what determines necrosis is not yet clear, but it is evident that certain cases of "polypus with simple myxomatous ethmoiditis" and of "polypus with vaso-motor ethmoiditis" may exist for years without necrosis, other cases finally succumbing to this complication, while still others present the element of necrosis almost from the incipency and as the main feature of the disease.

Of the entire series of forty cases only five were accompanied by unmistakable necrosis of bone, of which one has already been classed under type ii and two under type iii, the necrosis being an incidental rather than a predominating feature of these cases. The remaining two cases were characteristic of the disease as portrayed by Woakes. The details of one will suffice:

CASE VI.—Miss P., aged twenty years; catarrhal symptoms for years. Examination discloses atrophic naso-pharyngitis, with horribly fetid incrustation. The right middle turbinated body is much enlarged and has undergone cleavage, presenting the appearance of two bodies side by side. From the cleft protrude several small polyps or polyp buds, and others exist in the immediate vicinity. A fine probe inserted into the fissure detects denuded bone (Fig. 7).

Resection of the middle turbinated body should have been made in this case, but its treatment antedated my experience with the operation. Thorough cauterization and other appropriate measures sufficed to ameliorate the symptoms, and the patient passed from observation.

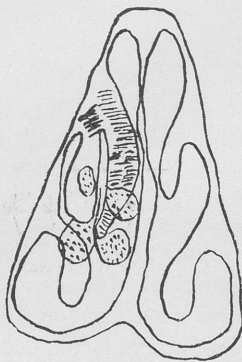


FIG. 7.

Annotations on Treatment.—The general surgical treatment of nasal polypus and its complications has been outlined in the body of the paper, and it only remains to describe briefly the technique of resection of the middle turbinated body, and to describe the instruments which I have devised and adapted for this use.

Only rarely can the operation be wholly accomplished by the snare alone; but a snare is useful either to remove a piece of the bone which happens to project sufficiently to be enveloped by the wire, or to finish a resection that has been partly made by serrated scissors. The snare must be capable of manipulation by one hand, and should combine lightness and balance with strength of construction. These requirements are fulfilled by the mechanism of Slover Allen.

The curved, serrated scissors (Fig. 8) which I have devised for the purpose can be insinuated, one blade on each side of the anterior end of the bone, and a cut made for a variable distance backward, when the operation, if not complete, can be finished by the snare or forceps.

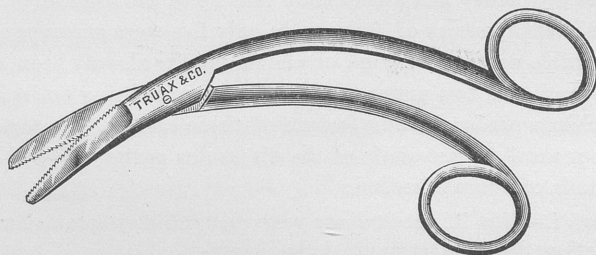


FIG. 8.

I have also devised a bone cutting forceps for this purpose, but, in addition, I have found two other forceps of service, especially for the removal of the bone in fragments; one of these was devised by Prince to aid in removal of the inferior turbinated bone, and the other, the sharpest of all, was evidently devised for septum work. Unless it be an easy case, it will be unnecessarily painful to the patient to remove the desired quantity of the bone at a single operation. I more often accomplish it fragment by fragment, always desisting for the time as soon as hæmorrhage obscures the view, and this method is absolutely necessary in case the middle turbinated body is greatly enlarged and closely impacted within its space. The exact amount removed has varied in different cases, from a small fragment of the antero inferior part to a maximum of about one half of the entire bone.

As enumerated, group by group, I have made the resection in thirteen of the forty cases, and in retrospect it seems to me that there were still others in whom the operation was both indicated

and feasible, probably enough to raise the proportion to about one half of the entire series.

Discussion.

Dr. W. H. DALY, of Pittsburgh, said that one of the most valuable points in the paper was the statement regarding the removal of the bone beneath the polypus in several severe cases. He believed the removal of diseased growths without including a section of the bone beneath was a futile task.

Dr. F. H. BOSWORTH, of New York, said the paper had given him the impression that ethmoiditis was the most frequent complication of nasal polypus. This idea he was hardly prepared to accept. On the contrary, he thought that nasal polypus was the result in many cases of ethmoid disease and rarely if ever the cause. This development, however, of polypi was purely inflammatory, he thought, in its origin, and not through what Woakes called "necrosing ethmoiditis." This question of necrosis had been a little exaggerated. It was a question whether we should call it necrosis or not. No one could enter fully into this subject who had not made examinations of such cases. His probe told him that what he felt was not necrosis, but rather gave the sensation of a bone covered by a very soft and thin membrane—not a dead bone, but still a live bone. The author had spoken of the odor of necrosed bone, but in his experience he did not get that odor, but rather the odor of sulphureted hydrogen and possibly that of pus. The more he saw of these cases the more he was disposed to say there was but one cause—that which we call myxomatous, and which rapidly advanced from the outside.

The speaker then asked to be allowed one word in friendly criticism. It seemed to him that the further we went into this matter the less we talked about reflexes. In his opinion an inflammation extending to the ethmoid cells gave rise to vaso-motor changes in the mucous membrane due to some effect on or interference with the vaso-motor center itself. These vaso-motor changes, however, were not inflammatory.

Dr. BRYAN stated that he did not believe in the theory of Woakes that necrosing ethmoiditis was the cause of nasal polypi, although they were frequently associated. Regarding the examination of the nose he found the probe deceptive, for frequently small spicula of bone, the product of an inflammation of the muco-periosteum covering the turbinates, are thrown out across the vestibule of the nose, and the probe coming in contact with them gives one the impression of the presence of necrosis when that condition is not present. A much more satisfactory idea of the interior of the nasal cavities can be obtained by examination with the little finger, a method suggested to me by Dr. Harrison Allen.

The theory of Dr. Bosworth that this is a myxomatous inflammation is the true one, and the only logical treatment is that described by Dr. Casselberry in his very excellent paper.

Dr. MACKENZIE remarked that while he believed that ethmoiditis is responsible for many cases of rebellious catarrh which can be relieved only by surgical means, he wished to advocate more conservatism in the treatment of the condition. In many cases of nasal polypi, for example, the associated purulent discharge will cease after removal of the growth or the use of simple local medication. Much of the error in the practical handling of these cases has arisen from the mistaken theory that ethmoiditis is the cause of polypi. Such an aetiological relationship might exist in certain cases—for example, syphilitic or traumatic cases—but aside from these conditions it is extremely rare.

Dr. F. W. HINKEL, of Buffalo, said he wished to second what Dr. Mackenzie had said of the possible dangers of interference with the ethmoid bone.

He recalled a case in point from his own experience. Three years ago he had removed the anterior extremity of the left middle turbinate, using Knapp's angular scissors and Bosworth's forceps. The patient was a woman about forty years of age. She had always been in excellent health, with the exception of a troublesome asthma. He performed the operation to relieve pressure on the septum and for hidden polypi, using cocaine. As he snapped the forceps and removed a piece of bone, she placed her hand to her head and complained of severe pain. She recovered after a while and, leaving his office, went to her boarding house. Three days afterward a medical friend asked him to go to see her with him. He then learned that after she had reached her room she became demented and said nothing but "yes" to everybody who spoke to her. She recognized him when he entered the room. In about four weeks she died. The prominent symptoms at the last were those of brain abscess. Dr. Roswell Park trephined the frontal bone above the left orbit. About half an ounce of pus was evacuated with a trochar. Patient died next day. The post-mortem examination showed the brain filled with multiple abscesses. There was a thrombus of the left middle meningeal artery. Unfortunately no examination of the heart was made. The thrombus might have originated from embolism from a detached valvular vegetation. He had been unable to trace the steps of the abscess. There were no evidences of intranasal inflammation.

It might have been a latent abscess, but all her symptoms followed the operation. He had since performed the operation not infrequently, but always with a recollection of that case.

Dr. J. C. MULHALL, of St. Louis, said he hoped there would be a full and free discussion on this subject. He was glad to hear the experience of Dr. Hinkel with regard to hidden polypi. The general profession was absolutely ignorant of the relations of soft nasal polypi to bone disease in the nose. He had seen a number of cases in which specialists had removed polypi, and had told their patients they would have no more trouble. Some of them had been having these polypi removed for twenty and thirty years. He had seen such cases, and they had all had bone disease

of the adjacent cavity, usually the ethmoid. Grünwald, of Munich, had written an excellent book on purulent discharges from the nasal cavity, and had shown the value of carefully studying the conditions of the ethmoidal sinuses.

Of course, all radical procedures were attended with more or less danger, but when patients had had polypi for perhaps twenty or thirty years they were willing to undergo a severe operation in order that they might be rid of these polypi permanently. He had been greatly interested in Grünwald's account of those who had recovered from melancholia, and those whose sense of smell had been restored, after a purulent discharge of many years' standing had been cured. So much impressed had he been with this writer's description of the diseased conditions present in recurrent soft polypi that he obtained from Grünwald a set of his instruments. He had been able in one case, where as a complication eczema of the upper lip had existed for six years, caused by polypi and purulent rhinitis, by curetting the ethmoid cells, to cure the eczema. The nasal curette and bone forceps were used, and the anterior ends of the middle turbinated bones were removed in order better to enter the ethmoidal sinuses.

Dr. JONATHAN WRIGHT, of Brooklyn, said he had been deeply interested in the valuable paper. Dr. Mackenzie's advice to the younger men in regard to a better knowledge of anatomy was very good and quite acceptable. There was one point which was very important. When the bone was diseased the formation of a communication with the cerebral cavity was very easy. He was surprised that the accident did not happen more frequently. He had had occasion quite recently to open quite a number of skulls, and this had taught him that it was very easy indeed to make an opening into the cerebral cavity. All skulls were not alike, some requiring considerable force to make an opening into the cerebral cavity, while others, being mere shells, were very easily punctured. He was in accord with Dr. Mackenzie concerning trephining. He differed somewhat from the reader of the paper regarding the removal of the anterior end of the middle turbinated bone. He had used serrated scissors and many other instruments, including some which he had had made according to Grünwald's published directions. He had found that there must have been some mistake in these directions, as the instruments were about four times too large. At any rate, their dimensions were greater than those of American noses, and consequently they could not be used for nasal operations in this country. They should have been made about the size of those presented by Dr. Mulhall.

Dr. WILLIAM H. DALY, of Pittsburgh, said that no case should be considered cured until one, two, three, four, or even five years had elapsed without a return of the polypi. The question was how to get a cure. And the way to get it is to change the soil and subsoil from which the polyps grow, by after-treatment.

Dr. CLARENCE C. RICE, of New York, said that he stood on the side

of Dr. Mackenzie regarding the radical treatment of ethmoiditis. The removal of polypi and special resection of the middle turbinated bone were well enough, but he deprecated the wholesale removal of the middle turbinated bone.

Dr. F. H. BOSWORTH, of New York, said that if the disease extended into the middle turbinated bone it should be attacked there, but only by a radical operation. He knew of no case on record which had succumbed except to radical methods. He would attack it unhesitatingly with the snare and with the drill. From his experience with the drill he thought he could safely say that there was no other instrument with which one could so delicately gauge what was being done. His plan was to drill a little into the ethmoid and then feel with the burr; then drill a little further and once more feel with the burr; and thus push ahead guardedly and safely in the effort to break down the trabeculæ. It should be remembered that one had to deal with a great mass of honeycomb cells filled with diseased tissue, and that there was a considerable intracellular pressure. That pressure must be relieved. It could not be done by the cautery; it could only be done by surgical measures. From his experience he regarded such measures as unattended by dangers. In one suppurative case of seventeen years' standing he had effected a cure by this method, and the same result could be obtained in other cases, suppurative or non-suppurative. Of course, in the non-suppurative cases the percentage of successful results is much larger.

Dr. CASSELBERRY, in closing the discussion, said that he thought some criticisms of the paper resulted from an incomplete understanding of the classification proposed. For instance, the term "vaso-motor ethmoiditis" was introduced more as a variety of "myxomatous ethmoiditis," as a clinical recognition particularly of those cases associated with asthma. Dr. Hinkel's unfortunate case, not exemplifying any form of myxomatous degeneration of the middle turbinated body, could not be regarded as entirely pertinent to the subject of resection of the middle turbinated body when that bone, as was pointed out in the paper, had undergone rarefaction or cystic change, which was usual with myxomatous degeneration. Its resection was then not only easier to accomplish, but it was followed by less inflammatory reaction and hemorrhage than when the bone of normal or increased thickness and density was resected, as in Dr. Hinkel's case.

The instruments of Grünwald, which he saw now for the first time, seemed well adapted to the purpose.

Paper.

OBSERVATIONS ON SOME OF THE RESULTS OF CUTTING OPERATIONS ON THE NASAL SEPTUM.

BY THOMAS R. FRENCH, M.D.

THE few remarks which I have to make, which are presented with the hope of eliciting fruitful discussion more than for the purpose of contributing any special innovations, deal with facts which, for the most part at least, are recognized by the members of this association, but which, so far as I am aware, have not been presented for discussion. These remarks will be directed to a brief consideration of two conditions which may present as the result of cutting operations for the removal of spurs and thickened deflected septa—viz., perforations and membranous adhesions.

Perforations.—To rectify deviations of the cartilaginous septum without thickening, the advice usually given is to destroy the resiliency of the cartilage by cutting through it in various ways, fracturing the fragments, forcing them up to the median line, and holding them in position until healing has occurred. Although by the admirable operative methods suggested by Asch, Roberts, and Steele the best results are often obtained, it is nevertheless a fact that in some cases it is impossible to obtain sufficient relief by such means. By those methods the septum can not always be brought to a perfectly perpendicular plane, and unless it is, the greater air pressure on the concave side, together with the natural resiliency of the cartilage, not infrequently forces the septum further toward the narrow naris. This is particularly apt to be the case during the period of the greatest constructive activity, a period in which operations on the septum are most commonly demanded.

If, as is maintained by some writers, ulceration or erosion of the edges never occurs when a perforation is made through the septum with a cutting instrument if the wound is protected from irritation, or, when ulceration exists, it can always be made to heal, and there is no danger of ultimate loss of the septum or even external deformity resulting from a perforation, there can be no objection to deliberately cutting away all of the obstructing cartilage, and so opening up both nasal passages and obtaining an abundant supply of air through the nose. But is it a fact that ulceration never occurs when a perforation is made with a cutting instrument if the wound

is protected from irritation, or that ulceration, when present, can readily be made to heal, or that external deformity never results from perforation of the cartilaginous septum? The danger of perforating is spoken of in almost all writings on operations on the septum, and it is the natural inference that it is the belief of the authors that ulceration or erosion is apt to follow perforation. Zuckerkandl* says that in the cases of healed perforation of the septum dissected by him the mucous membrane on the border of the hole was found to be very thin, and I presume that is generally if not always so; but this thin covering will, I believe, always be developed if the wound made in perforating the septum with a cutting instrument is carefully dressed and protected from irritation; but the patient not infrequently dislodges with his finger a few of the crusts formed in the process of repair, and ulceration is eventually produced, which in the course of time slowly progresses, filling the nasal passages with obstructing secretions and causing extensive destruction of the septum. Because of this danger I have thus far never perforated the septum unless reasonably certain that the edges could be adjusted so that an opening would not be left. I may have overestimated the danger of leaving a hole in the septum, but in the light of the evidence presented by a considerable number of cases falling under my observation of the destruction resulting from perforation, I have been constrained to avoid making one if a successful result can be obtained in any other way. I have seen a number of cases in which perforation has been deliberately made with the most satisfactory results, and many others in which the results were far from satisfactory; but in none of the latter had careful after-treatment been carried out. If it can be demonstrated that with proper surgical precautions and after treatment the edges of a perforation can always be made to heal, I feel sure that we would all resort to this method of operating in certain cases as being altogether the surest way of obtaining permanent relief.

Perforation of the cartilaginous septum, as a result of a non-specific ulceration or erosion, is described in most modern textbooks on diseases of the nose, and has been made the subject of a number of special articles; but this condition has been so little considered in its relation to septal operations that I desire to present for discussion a question which has frequently arisen in my mind—viz., If a successful result can not be obtained in any other way, are

* *Anatomie der Nasenhöhle*, vol. i, second edition, Vienna and Leipsic, 1893.

there not conditions under which perforation of the cartilaginous septum can be made a perfectly justifiable procedure?

Delavan,* in referring to Blandin's operation by means of the punch, says that "this procedure is eminently clumsy and unsurgical, and in reality is unjustifiable as being liable to do more harm than good."

Roe† condemns the use of the punch for the removal of the angular portions of a deflected septum. He asserts that "by its use we simply cut away a deformity which we should correct, and leave a hole through the septum in which crusts and secretions constantly accumulate, thus becoming a lasting source of irritation."

Lennox Browne,‡ in commenting upon Bosworth's statement that he had only once perforated a septum, remarks: "Looking moreover to the comparative frequency of septal perforations, unassociated with any dyscrasiæ, caries, or necrosis, and their non-liability in such circumstances to cause deformity—a point correctly insisted upon by Bosworth himself—one hardly sees why a perforation should be so much dreaded." Elsewhere in the same work he writes: "The entire closing of a perforation by healing process is unknown in my experience, and it is doubtful if such a happy result ever occurs; but spontaneous or induced arrest of the ulceration is the rule."

Bosworth,# in writing on perforations due to erosion, expresses his belief that their clinical significance is trivial, that they do not weaken the support of the nose to the extent of causing external deformity.

Greville Macdonald,|| in writing on deflections of the septum, says: "Almost always, however, there is a certain amount of thickening in the cartilaginous septum, the paring down of which will generally prove sufficient for the removal of symptoms. Should there not be sufficient material for this, no objection can be raised to cutting off enough of the projecting angle with the saw, although we thereby make an opening into the other side. From such a procedure there is no risk of subsequent deformity to the nose."

McBride^ is of the opinion that falling in of the nose does not

* *Reference Handbook of the Medical Sciences*, vol. v, p. 272.

† *New York Medical Journal*, April 7, 1894.

‡ *Diseases of the Throat and Nose*, London, 1893.

Diseases of the Nose and Throat, New York, 1889.

|| *Diseases of the Nose*, London, 1892.

^ *Diseases of the Throat, Nose, and Ear*. Edinburgh and London, 1892.

occur. He mentions the case of a medical student in whom the cartilage was deficient from just within the nostrils almost if not quite to the dorsum of the nose. The tip of the nose was a little lowered, but no deformity could be said to exist.

Morell Mackenzie,* in writing on traumatic rhinitis, says that "the lower and anterior part of the cartilage always remains intact; the bridge of the nose never falls in, . . . although, when perforation has once taken place, it is difficult to prevent the formation of a tolerably large hole in the septum; the morbid action is strictly confined to a small area, beyond which its ravages never extend. The use of simple sprays will soon restore the surrounding mucous membrane to a fairly healthy condition."

Lefferts,† after giving suggestions as to the course to be pursued in the treatment of erosion or perforation of the septum due to mechanical irritation, says: "Care, patience, and persistence are the only elements now necessary for the attainment of success."

Robinson,‡ in writing on hæmorrhage due to erosion or ulceration of the septum, asserts that a plan of very simple treatment, when persisted in, will bring about a complete cure in one or two months.

E. J. Moure,# in discussing the value of electrolysis for the destruction of deviations and spurs of the nasal septum at the Eleventh International Medical Congress held in Rome last month, said that, in cases of marked deviation without thickening, he preferred a quickly made perforation, permitting the access of air into both nasal fossæ; and Ruault, at the same meeting, in referring to the possibility of perforation occurring as the result of the use of electrolysis, expressed the opinion that it was "absolutely immaterial; indeed, it is often necessary to seek it in place of endeavoring to avoid it, as this is the only rational intervention in cases of total lateral deviation."

It will be seen from the foregoing quotations from the writings of careful observers that there is no diversity of opinion regarding the danger of external deformity occurring as the result of perforation of the septum, that they are generally agreed that perforations due to erosion do not extend beyond the cartilage, and that, even

* *Diseases of the Throat and Nose.* London, 1884.

† *Medical News*, vol. xl, 1882.

‡ *American Laryngological Transactions*, 1887.

Journal of Laryngology, Rhinology, and Otology, vol. viii, New Series, No. 5, 1894.

after the destructive process has continued for a long period of time, it can be arrested, and the edges made to heal under appropriate treatment. The question is simply as to whether a perforation ever constitutes a morbid lesion unless subjected to mechanical irritation. I do not recall having seen a case of non specific perforation with unhealed edges in which the parts were not being subjected to irritation of some kind.

I am not aware that the presence of a perforation with healed edges is in any way harmful, even though it has considerable dimensions. A certain amount of catarrhal disease of the mucosa is usually present in these cases, but there is no evidence to prove that the perforations bear any causative relation to it unless the edges have for a long time been the seat of ulceration. If, therefore, a perforation does not in any way interfere with the proper physiological function of the nose, its presence can be a matter of but little consequence so long as its edges are healed.

After the study of perforations in a large number of cases, I am inclined to the belief that, with proper care in the after-treatment, perforations can be deliberately made without injury and with great relief in a certain class of cases; that, if the breath-way through the obstructed side can not be obtained without leaving a hole in the cartilaginous septum, such a procedure is justifiable if the patient can be impressed with the necessity of leaving the parts alone, and it is reasonably certain that the case can be carefully followed until the healing of the edges has occurred. Otherwise, I believe it to be an unjustifiable method of operating. I except from this statement the perforations made near the entrance of the nostrils, particularly in a septum bent obliquely across one or both openings by the Blandin punch. This method of securing an increased supply of air is, it seems to me, a highly objectionable one for several reasons: (1) because of the irritation to the edges which is certain to be produced by the stream of air drawn through the opening; (2) because of the easy access of the finger to dislodge accumulated crusts; (3) even when the edges are healed, it is apt to give rise to a whistling sound, which is annoying to the patient as well as to others; and (4), while perhaps supplying a sufficient amount of air for respiration, it does not restore the normal function of the obstructed naris. I believe it is safe to say that, if a perforation is made in the septum of a subject free from dyscrasia, and the edges are not irritated, but rather subjected to careful antiseptic treatment, they will heal. Under such circumstances I believe that the pro-

cedure is safe, is justifiable, but under any other conditions it is to be condemned. The removal of the ban which has been placed on this method of operating to the extent which has just been indicated would, I feel sure, result in relief to a considerable number of cases which no other means now employed will effectually reach.

Large perforations increase the liability of fracture of the nose; but, if the edges are healed, that certainly is a preferable condition to the possession of a stout septum, if such can only be maintained at the expense of an obstructed naris. My contention, therefore, is this: that, in any case without dyscrasia in which it is known that the after-treatment can be thoroughly carried out, and the intelligence of the patient is sufficient to guarantee that the wound will not be subjected to mechanical irritation, there can be no objection to the removal of a portion of the cartilaginous septum for the relief of stenosis due to angular deflection without thickening, or to the septum being much too large for the bony framework of the nose.

I am well aware of the dangers associated with this teaching; that, if perforation of the septum is sanctioned, it will be greatly abused; but this does not alter the fact that if the osseous portion of the septum is not encroached upon and the after treatment is all that it should be, greater relief can often be obtained from this procedure than can be afforded by any other method of operating.

Membranous Adhesions.—I do not doubt that you will agree with me when I say that one of the most disappointing and annoying things in association with nasal surgery is the occurrence of adhesions within the nasal passages. That they are in the majority of cases the result of operations performed by unskillful hands is undoubtedly true, but that they occur not infrequently after operations performed by surgeons of large experience and possessing skill and judgment is equally true.

In addition to the ordinary surgical knowledge one needs to possess something of the art of the sculptor as well as the skill of the mechanic in order to cope successfully with the class of cases to which I refer. What may appear to be a perfectly satisfactory result immediately after an obstructing mass of cartilage has been removed may in a few weeks prove to be extremely disappointing and unsatisfactory because of the formation of extensive adhesions binding the walls of the passage together. Such cases reflect discredit upon the operator, and certainly in most cases the reflection is just and proper, for a want of care in operating is no doubt the commonest cause of adhesions; but there are cases in which the

exercise of the utmost skill and care would seem to be insufficient to prevent their occurrence.

It is, I think, generally agreed that adhesions do not occur after operating on the turbinated bodies unless that part of the septum lying directly opposite has been injured; and that they do not occur after cutting operations on the septum unless the turbinated tissue opposite the wound has been broken during the operation, or has recently been subjected to some operative procedure, the wound from which has not completely healed; in other words, that adhesions can not occur after operating on either wall of the naris if the mucous membrane on the opposite side is intact. The sides of a nasal passage may be brought into contact after removal of redundant cartilage by the collapse of the outer wall, or by turgescence of the turbinated structure opposite as the result of irritation from the wound on the septum, thus causing contact for a varying length of time. It is during this period in such cases that adhesions occur if there is a solution of continuity on both walls at points lying directly opposite each other; but if the mucous membrane on one wall is unbroken and smooth, adhesions will not take place no matter how much swelling there may be or how long the parts remain in contact during the process of repair.

Occasionally the results of operations on the septum performed by careful surgeons look like bungling attempts to secure relief, for, after the parts are healed, a portion of the opposite wall is found to have become adherent to the wound, and the condition of the patient is worse than that for which the operation was originally performed, and yet the operator may feel certain that the opposite wall had not been injured by his instruments or been the seat of recent treatment of any kind. I believe that many such cases can be explained by a fact which seems to have been overlooked, and has apparently been proved by my experience in a number of cases—viz., that cut surfaces on the septum will become adherent to scar tissue on the turbinates made by the galvano-cautery at some previous time. My meaning may perhaps be made clearer by referring to the cases of three patients quite recently under my care for relief of nasal stenosis and in whom adhesions followed operation on the septum.

I was asked to operate in the late spring for the removal of an overgrowth of cartilage in a very narrow nasal passage of a young lady whose inferior turbinates had been considerably reduced in size by the aid of the galvano-cautery point several months before. I removed the redundant cartilage with the saw and immediately after-

ward the patient left town for the summer. When she reported again in the autumn I found a long and narrow bridge across the naris corresponding in length and width to the wound which I had made in removing the cartilage. As during the sawing operation the greatest care was taken to prevent injury to the opposite wall, I could find no other explanation for the adhesions than that they had occurred between the cut surface of the septum and the surface of the inferior turbinated body made rough and uneven by the previous application of the galvano-cautery.

In another case in which an operation of a similar character was performed in the late spring, and in which equal care was taken to avoid injury to the opposite wall, adhesions occurred during the summer, and I am convinced that they were not due to injury of the turbinated tissue during the operation. I had advised the removal of a large spur on the septum of this patient a year before, but as she objected to a cutting operation at that time I contented myself by destroying with the galvano-cautery a considerable amount of hypertrophied turbinated tissue lying opposite the portion of the cartilage which was removed a year later. I am unable to find any other explanation for the adhesions in this case than that the scar tissue resulting from the galvano-cautery incisions formed a good surface for the granulations of the septal wound to become attached to.

In still another case, operated upon for the removal of an ecchondrosis, just before the summer vacation, quite extensive adhesions were found to be present in the autumn. In this case applications of the galvano-cautery had been made to the turbinated tissue in the same naris by another physician some months before she came under my care.

What the characteristics of cicatrices produced by the galvano-cautery on turbinated tissue are, that render them liable to become engaged in the process of repair of a wound in contact with them, I am unable to say. The microscope will, no doubt, assist in making this plain, and I regret that I have not had an opportunity to make such an investigation. It is more than likely that their liability to become attached to cut surfaces depends largely upon the character and extent of the burned surface of the turbinates—that is, whether the scar is the result of a wound made by incisions with the edge or point of a loop, or by a flat burner.

If my deductions, in regard to the liability of adhesions occurring between cut surfaces on the septum and cicatrices on the tur-

binated tissue resulting from the use of the galvano-cautery knife, are correct, then in patients who present themselves for treatment, whose nares have never been subjected to operative procedures, and in whom there is need of the destruction of turbinated tissue and removal of obstructing cartilage or bone, the septum should be operated upon first, when, after a month or more has elapsed and it is certain that the mucous membrane is completely reformed, the turbinates can be safely destroyed by any method. If, however, as is not infrequently the case, patients object to a cutting operation on the septum, but are willing to submit to the destruction or removal of the turbinated hypertrophy, preference should be given to the use of the snare or acids, in order to avoid the possibility of leaving a surface which might become adherent to a wound opposite in the event of a cutting operation on the septum being performed later. In all cases requiring cutting operations on the septum, inquiry should be made to determine whether the galvano-cautery has been used on the turbinated body opposite. If it has been, it is advisable to keep the wound under observation for at least two or three weeks in order to prevent adhesions, should a tendency to their formation be shown.

Without doubt adhesions are frequently occasioned by saws with unprotected ends, and the unskillful use of trephines and cutting forceps in narrow passages. A distinct advance will be made when all instruments used for septal operations are constructed with a view to preventing the possibility of wounding the outer wall of the naris. I believe that severe hæmorrhages following cutting operations on the septum are not uncommonly due to injury of turbinated tissue, and a pointed saw seems to be peculiarly adapted to insure injury in a narrow passage.

An error which experience has taught me is that of cutting outward with the saw at the floor of a narrow naris in finishing a section from above downward. Injury of the inferior turbinated body is apt to be produced in this way and result in adhesion of the sides at, or just above, the floor, which not only cuts off a part of the breath-way but interferes with proper nasal drainage.

In my opinion the upward cut ought always to be made first in dealing with large spurs or deflections, for, if the section is begun above, the lower portion of the part to be removed is almost instantly obscured from view by the blood clots which form on the floor of the naris. This remark is especially applicable to sawing operations performed while the patient is under the influence of

ether. If a septal projection is removed by cutting entirely in one direction, a ridge is not uncommonly left at the edge of the wound which necessitates further operative interference to eradicate. It is a good rule, in operating with the saw, to begin the section by cutting upward, and finish it by cutting downward; but whether it is begun from above or below, the section should be finished by a cut from the opposite direction, for in this way the maximum amount of tissue can be removed from the septum with the least danger of injury being done to the outer wall.

Discussion.

Dr. F. H. Bosworth said he wished to speak on but one point—that of perforation of the nasal septum. He had operated in quite a number of cases, and thought perforation had no weakening effect on the cartilages of the nose. If the edges of the perforation projected into the ingoing current of air, there was liable to be erosion. If we could secure such a position, so that the perforation was in an antero-posterior line, there would be no projecting edges, and the patient would be perfectly safe from any discomfort or erosion. The hæmorrhages could usually be controlled by the use of the cautery.

Dr. JOHN O. ROE, of Rochester, said: I do not regard the perforation of the septum in adults as a serious accident, because the supporting structures of the nose are developed and will maintain their position. But in children, where the nasal structures are imperfectly developed and still in the process of growth, perforation of the septum is quite liable to cause a falling in or depression of the top of the nose, and particularly in the cartilaginous portion. In performing operations upon the septum the accident of perforating it will sometimes occur, particularly if great care is not exercised; but the intentional perforation of the septum, because it is deviated or deformed, should never be resorted to, and is, in my opinion, entirely unjustifiable. I regard it as bad surgery, for we thus resort to cutting away a deformity which we should correct. At the last meeting of this association I described the plan which I pursued in the correction of deviations of the septum, and also described the instruments which I had some time before devised for this purpose. The instruments which I then described I have since improved and perfected, a set of which I have brought with me for your inspection. They are, as you see, made in different sizes to fit different cases, and so arranged that all the blades fit into one handle. The screw in the handle permits the adjustment of the blades, so that the exact amount of force required can be employed, and in the employment of the cutting blades for straightening the cartilaginous portion they can be so adjusted as not to cut through the mucous membrane on one side, which, being preserved, serves the purpose of a splint to hold the fragments together

until healing ensues. In the employment of these instruments the danger of perforating the septum during the operation of straightening it is removed, and the ease with which the operation can be performed will, I am sure, commend these instruments to you.

Dr. WILLIAM H. DALY said he was of the opinion that in the discussion of this subject perforation of the nasal septum should never be mentioned except to condemn it; we should endeavor to avoid this unfortunate condition. He had been of this opinion when the first paper on this subject was read twelve years ago before the American Laryngological Association. He had at that time condemned the operation as being unsurgical, and since then had found no valid reason for changing his views. The old saying, "As the twig is bent the tree is inclined," found a stubborn proof in cases of deflection of the nasal septum.

In his own practice he had examined many cases which had been treated by others and dismissed as cured, and he had found that after one, two, three, four, or five years, or less, there had been a measurable or full return of the deformity. He had come to the conclusion that this was due to certain habits or practices of the patient, such as lying on one side continuously while in bed, or in using the handkerchief in some peculiar manner, or by pressure on one side of the nose more than the other, etc. He believed that this class of surgery was yet in its infancy. Dr. Roe had done much to advance this line of surgery, and his instruments represented some important steps in the practical treatment of these cases. In his own practice he had obtained good results by careful attention after the operation in preventing the return of the deformity. Dr. Daly said he had always protested against the use of the punch, for he had never seen any really good results from its use. This field of surgery was limitless, as there was scarcely a strictly symmetrical nose in existence. The speaker predicted that in the next ten years such an advance would be made in the treatment of these cases as would bring great credit and honor on the profession. Dr. Roberts, of Philadelphia, a very skillful surgeon, had advised and published an account of an operation which personally he had found to give very unsatisfactory results. True, the immediate results were good, but the deformity would return in about three months or more if the cases were not watched. In another of his cases, which had been operated upon five years previously by a very competent and skillful (now deceased) surgeon, after Dr. Roberts's method, the deformity was at present just as great as before the operation.

Dr. C. M. SHIELDS, of Richmond, said that this branch of nasal surgery seemed to him a more difficult problem than anything connected with the treatment of nasal diseases. In one case of deviated septum upon which he had operated by incision, where simple straightening might have answered, he was greatly disappointed at the condition he found on examining the patient two or three years after the operation. Now he made it a rule to tell his patients at the outset that the result

was likely to be unsatisfactory, and that subsequent treatment would probably be demanded. He never used the punch except where it was absolutely necessary, as he preferred the knife. His plan was to make an incision through the septum, and use the knife in the incision with great care. His objection to the punch was that it divided the septum into small pieces. One of the methods which he had practiced was to make two parallel incisions from behind forward, and let the upper lip of the two flaps thus formed project, something after the way in which one half of a window overlaps the other half. These were united in the center, and then pressed backward. The parts usually united rapidly without suppuration. He had used this method with satisfaction for two years past.

Dr. W. E. CASSELBERRY objected to perforation of the septum on æsthetic grounds. No one should deliberately practice perforation, but when it happened accidentally he did not worry about it. He had had two cases where this had occurred. He operated for deviation of the nasal septum with excrescences. The septum in one case was duplicated and extended far on one side, the two parts lying so close together that in making the examination the probe would stop short of the actual depth of the concavity. In cutting off what he thus thought a safe amount, he passed through both thicknesses above and below. As a result, there was an antero-posterior perforation, an eighth to a quarter of an inch wide, and extending back almost an inch. The patient was greatly pleased with the result. A few erosions gave some annoyance, but they yielded to applications of the yellow oxide of mercury ointment.

He would like to dissent from the opinion that adhesions never formed except when the opposite side of the nose was wounded. He had seen adhesions in the nostrils when no operation had ever been performed. The following case, although not nasal, had convinced him of this possibility. It was a case of naso-pharyngeal fibroma, in which adhesions had formed around the tumor from the pressure on the opposing surfaces.

He had a variety of correcting instruments, but preferred to use the scalpel for correction of deviation limited to the cartilaginous septum and without excrescence.

Dr. M. J. ASCH said that he had operated in a good many cases of the kind by the method described by him at a previous meeting of this association, and had received reports from others who had operated by this method. He had found that a good result was invariable except where the operator had been careless as to some detail either of the operation or the after-treatment. It did not suffice to merely operate and leave the septum to itself. Such an operation required two or three months of attention by the surgeon. If this was given the result would be good, and there would be no complaint of the inadequacy of the operation. It sometimes happened that an edge of the incision

overlapped, though usually it was smooth; in such cases the overlapping edge was easily smoothed down by scissors or the electric trephine. In but one of his cases was there a resulting perforation, this was of a pinhole size and gave rise to occasional hæmorrhage. It persisted for some years and then healed up and gave no further trouble. In all of his cases he introduced the blunt blade of the scissors described by him in the nostril in which the convexity of the deviation existed. When it was necessary to know the exact thickness of the septum, which not infrequently happened, it could be ascertained by means of the septometer, an instrument devised for this purpose. He desired to impress the fact that in all cases of deviation of the cartilaginous nasal septum he had every reason to be satisfied with his results.

NOTE.—In response to an inquiry by Dr. French, Dr. Asch emphatically reiterated his entire satisfaction with the results obtained by his method of operating. It has been the good fortune of the secretary to observe several of Dr. Asch's cases. The results have certainly been better than those after other methods.

Dr. GLEITSMANN said that the failure to relieve the symptoms in many of these cases arose from the fact that back of the septal deformity, there is frequently an enlargement of the inferior turbinates. The latter may swell up in the air, rarefied by the septal obstruction.

He regretted that so little reference had been made to the prevention and management of adhesions. In spite of the utmost care they would frequently occur and prove very troublesome.

Dr. S. W. LANGMAID, of Boston, said he agreed with Dr. Gleitsmann with regard to adhesions. If the operation under discussion is performed, the patient should not be lost sight of until the wound is healed, or nearly so. If the patient can not be under observation for three weeks the operation should not be undertaken. Granulations follow the curetting of adhesions. If they are not destroyed they will cause fresh adhesions.

Dr. M. R. BROWN, of Chicago, spoke of the bleeding following operations on the septum. He cited a case, occurring in the practice of another physician, in which an operation had been attempted and abandoned on account of the bleeding, which, according to the description, was very active and profuse. When the speaker was called to the case the anterior and posterior nares had been plugged and the bleeding thus brought under control. The examination made at a later date confirmed the opinion as to the source of the hæmorrhage, it being found that the exostosis extended outward, and so far occluded the nares that it was almost impossible to have wounded the turbinated body.

Dr. Brown had never seen a case where the nose had fallen in following operations on the septum. In those instances where the nose had become depressed from loss of the septum, it had been brought about by a specific condition and not by the simple removal of this parti-

tion. The contraction of the tissues following the ulceration seemed to have more effect in causing the depression than the removal of the support alone. The speaker said that he had recently had an opportunity of examining several cases in which the septum had been entirely removed, the shape of the nose remaining the same after the operation as it had been before.

Experience had taught him that there was a period in childhood when growths on the septum are progressive. This was about the age of puberty. Such cases when operated upon would almost invariably require a second operation at a later date.

Dr. Brown thought it was seldom necessary to perforate the septum in operations on that partition. In one case, however, the deflection was such that he felt it was imperative, and made the perforation with the trephine. The relief in this case was greater than he had reason to expect.

The PRESIDENT considered it very important that all injury, both to the septum and to the parts adjacent to it, be avoided in this class of operations. It was possible that a small, round perforation, such as that made by a Blandin's punch, might not be harmful. Perforation occurring in the course of the removal of a longitudinal bending of the septum, erroneously supposed to be a spur, was not likely to result in a small, circular opening, however, but in a long, narrow slit, running parallel with the floor of the nose and unlimited in extent. In a young lady whom he had lately seen, an opening an inch and a half in its antero-posterior diameter had been made. While the effect of such a loss of tissue upon the blood vessels of the septum might not be irremediable, the speaker regarded the division of a large number of filaments of the naso-palatine nerve as a very serious matter. In his own practice he had perforated the septum on but two occasions. The patients were both gentlemen. In the younger the accident was followed immediately by mydriasis of the right eye. In both there was pronounced and long-continued nervous irritation, while the nasal obstruction was but imperfectly relieved. The same conditions had existed in the case of the young lady mentioned. He had seen other cases similar to the above, and had never failed to find that more harm had resulted than good. He therefore strongly deprecated any such procedure, and believed that instruments like the Blandin punch, if employed at all, should be used with the exercise of great judgment. He cordially indorsed the views expressed by Dr. Langmaid as to the importance of careful after-treatment. Much of the lack of success in operations upon the septum, such, for instance, as delayed recovery, failure to relieve obstruction, and the formation of adhesions, was due to lack of care in this particular. He considered it necessary to keep the patient under observation at intervals for some time after operation.

Dr. FRENCH: I agree with Dr. Casselberry that severe hæmorrhage sometimes occurs from the septum after operations upon that cartilage.

I desired especially to direct attention in my paper to an avoidable cause of hæmorrhage in such operations—viz., injury to the turbinated bodies. Hæmorrhage from the septum can not, of course, be prevented, but such safeguards should be employed as will make injury to the turbinates next to impossible. Dr. Casselberry contends that it is not necessary that there should be a solution of continuity of both surfaces of opposing mucous membranes to permit them to become adherent, and cites a case in which he had seen a naso-pharyngeal polypus adherent to the mucous membrane.

Is it not reasonable to suppose that the friction resulting from the movement of the polypus caused abrasion of both surfaces, which afterward adhered to each other? I wish very heartily to indorse all that the president and Dr. Langmaid have said regarding the necessity for care and observation after any of the minor operations done within the nasal passages. Were the need of such care more generally appreciated, I feel certain that the results obtained from such operative procedures would be far more satisfactory to both patient and operator.

It seems to me that this discussion has shown that while an unnecessary perforation is always to be most carefully avoided, with proper care the occurrence of a perforation need not be greatly dreaded.

Paper.

THE USE OF METALLIC ELECTRODES IN THE TREATMENT OF NASAL AND POST-NASAL DISEASE.

By CLARENCE C. RICE, M. D.

TO employ the galvanic electric current to decompose a metal, to form a new salt, and to transfuse this salt into animal tissues, all by a simultaneous action, for therapeutic reasons, it must be admitted is a remarkable scientific procedure, whether the benefit obtained thereby be great or small. The use of the constant current with an *oxidizable* metallic electrode does all of this. It is pre-eminently the Gautier method, he having devised it and given to it the name of "interstitial electrolysis" or "medicamental electrolysis."

Dr. William J. Morton, of New York, who first called my attention, more than a year ago, to the usefulness of the application of such electrodes as those made of copper, zinc, and iron to the mucous surfaces, has given to this electrical procedure the names of "electric medicinal diffusion" and "metallic electrolysis," which seem to me better titles.

In the short paper which I shall present to this association, as I am in no sense an electrician, I shall be obliged to quote largely for my scientific data from the writings of Gautier,* from information very kindly given me by Dr. W. J. Morton, and also from the most admirable paper on Metallic Electrolysis read by Margaret A. Cleaves, M. D.,† of New York, at the third annual meeting of the American Electro-therapeutic Association.

This Gautier method consists simply in using a solid metal electrode for the positive pole, which is to be applied to the part to be treated, while the negative pole is the ordinary rubber-covered sponge electrode, three or four inches square, applied to any portion of the body, preferably to the back of the neck or to a location somewhat near the part to be treated by the copper end. The application of this method is comparatively recent, Dr. Gautier having brought it into therapeutic use within the past three years.

Dr. Cleaves gives this definition of "metallic electrolysis," that it is "a method which makes use of the chemic action of the positive pole, both upon foreign substances—that is, metals, such as copper, zinc, and iron—and the tissues at the same time."

Gautier experimented with the copper electrode for the purpose of ascertaining what the effect of the electrical current was upon the copper electrode—that is, what change was effected in it by the passage of the current and also what the effect was upon the tissues to which the copper was applied. He first discovered that in using two copper needles, with a current of five milliamperes, inserted into the muscles of a rabbit's leg, after an application of ten minutes these needles were perceptibly diminished in weight and the copper thus lost was found to be infused in the muscles of the rabbit. His next experiments were performed to see what the nature of this newly formed copper salt was, and whether it was poisonous to the living tissues. He ascertained that the salt was an oxychloride of copper, and that it produced no harmful results when a two-per-cent. solution was injected into rabbits.

Dr. Cleaves in her paper explains the electrical action which takes place in this way: "So far as conductivity is concerned, the human body may be regarded as a two-per-cent. solution of sodium chloride. By electrolysis of the tissues in contact with the positive pole there are always set free oxygen, acids, and chlorine; these, in

* *Technique d'électrothérapie.* Gautier et Larat, p. 169.

† Cleaves. Metallic Electrolysis. *Jour. of the Amer. Med. Assoc.*, January 20, 1894.

turn, attack the soluble metallic electrode, whether sound or needle, and we have formed as a result an oxychloride of copper, zinc, or iron, as the case may be."

It may be doubted whether the benefit of the application of oxidizable metallic electrodes to the nasal and pharyngeal mucous membrane depends in any sense upon any germicidal effect of the copper or of the current, but Gautier carefully tested the effect of the positive pole upon the *Bacillus pyogenes*, and he found that the oxychloride of copper at the positive pole destroyed the pus bacillus after fifteen minutes' application of a forty-milliampère current. The influence exerted by non-oxidizable electrodes by the Apostoli method was much less.

In addition to the electrolytic action of the current, whereby an oxychloride of copper is formed, we are told that another action, scientifically designated as the cataphoric property, is of equal importance in this method of electrical application. This cataphoric property causes the surrounding tissues to become impregnated with the copper salt for a distance around the needle depending upon the intensity of the current and the duration of its application.

The following experiments at Dr. Morton's office have been effected: A copper needle attached to the positive pole was inserted into a piece of meat or hard-boiled egg, the negative pole being a platinum needle. It was found that by using a current of forty milliampères for five minutes the copper salt was transfused through the meat or egg for the distance of a third of an inch around the copper needle.

The physiological action of the copper electrode is more easily studied upon the uterine cavity than in the nose or throat or upon the eye. It has been found that the diffusion of the copper salt in the uterine mucous membrane, submucous and muscular tissues first causes a temporary congestion of marked degree, and I understand that it is not uncommon to apply a current of such strength that there is more or less exfoliation of the mucous membrane; but I have never seen this occur in applications to the nose and throat.

This Gautier application differs quite markedly from the "galvano-caustic" method bearing the name of Apostoli. This latter method is, as you all know, electrolytic in its action. It has always been the custom in this procedure to use non-oxidizable electrodes, such as platinum, etc., or, if oxidizable electrodes have been employed, such as copper wire or nickel-plated copper points, they have been used at the negative pole, which is inactive—that is, not

affecting the electrode. Dr. Morton tells me, however, that it has recently been discovered that there is action at the negative pole on aluminum. In the Apostoli method the tissues only are acted upon and separated into their original elements—at the positive pole acids, chlorine, and oxygen, and at the negative, alkalies and hydrogen.

As you will all remember, Dr. Shurly,* of this association, read a paper in 1880 upon the treatment of pharyngitis sicca by the use of the galvanic current. He applied the positive pole to the mucous surfaces, but I do not find any mention as to what kind of an electrode he employed. If it was the ordinary nickel-plated copper, then there would have been decomposition of this electrode, first the nickel and then the copper, and they would have been transfused into the tissues, which is practically the Gautier method.

Dr. Delavan,† in 1887, read a paper on The Treatment of Atrophic Rhinitis by the Application of the Galvanic Current. He employed the copper-wire electrode covered with wet absorbent cotton; but this was at the negative pole, so that the action was exerted on the tissues alone, and the character of the electrode was not significant. If the positive pole had been used the cotton would have prevented the diffusion of the copper into the tissues.

The application of the galvanic current by the Apostoli method to mucous membranes must always be considered as either astringent or caustic in its effect, according to the intensity of the current. In the Apostoli method the energy of the current is used in its decomposing action upon the tissues; in the Gautier it is exhausted in the decomposition of the metallic electrode and in its transfusion into the tissues.

Dr. Morton, who has made careful experiments in order to ascertain the difference in effect between the use of the galvano-caustic method with the platinum electrode and that of the copper electrode, as applied to the uterine mucous membrane, reports that with a current strength of fifty milliampères with a platinum electrode the mucous membrane was very much congested and the positive pole was surrounded by dilated blood-vessels which did not contract in a satisfactory manner. With a copper electrode and with the same strength of current and length of application there were no traces of destruction of tissues or surrounding inflammation.

* Shurly. On Atrophic Pharyngitis. *Transactions of the American Laryngological Association*, 1880.

† Delavan. The Treatment of Atrophic Rhinitis by Applications of the Galvanic Current. *Transactions of the American Laryngological Association*, 1887.

Dr. Cleaves writes that the Apostoli or galvano-caustic method is characterized by unoxidizable electrodes, high intensity, and short duration of application, and the Gautier method by oxidizable electrodes, low intensities, and long sittings.

It is maintained that the advantages of the Gautier method of applying such astringents as copper and zinc over the topical application of such metals in solution are that in electrolysis the copper can be carried accurately to the most obscure and inaccessible part; second, that salts in this newly born state are much more active than in chemical combination; third, that as pathological conditions usually lie deeply under the mucous membrane, they can be reached by the impregnation of the tissues with the copper salt far better than when it is simply applied to the mucous surface; and fourth, benefit is claimed for the action of the electric current itself.

I believe that Dr. A. H. Goelet, of New York, devised the first copper electrodes used in this country for uterine work. Dr. Morton has had shorter ones made, which are preferable to the longer ones for nasal and post-nasal application. These copper electrodes can be tipped at the end with hard rubber to make the point inactive, and they can be insulated for nearly their entire length with a sheath, or they can be entirely insulated on one side with hard rubber, as Dr. Cleaves has done with the small, ingenious copper electrodes which have been used by her and others in the treatment of trachoma. The needles employed in what Dr. Morton styles cupric puncture were devised by him.

In gynaecological work we are told that a current strength of from twenty-five to fifty milliamperes may be used, and the length of a sitting should be about fifteen minutes. Of course the current is accurately measured by its passage through a milliamperemeter. In the uterine cavity, where this intensity is used, and where it is difficult to keep the electrode in motion, it is apt to become fastened to the mucous membrane, and it becomes necessary to loosen this by a reversal of the poles, using a current of five or ten milliamperes. I have never found this necessary in the nose or pharynx, not, as a rule, using more than five milliamperes, and being able to keep the copper electrode moving. In uterine work they are accustomed to make these applications not oftener than three or four times a month. In most nasal cases I have used the Gautier method twice a week.

Something more than a year ago Dr. Morton called my attention to the usefulness of this application to nasal and throat disorders. He had at that time, I believe, used it in a few cases in his private

practice, and upon a larger number at his clinic. His results have not yet been published, but he tells me they are satisfactory.

I began the use of metallic electrolysis in that line of cases of nasal disorder in which no marked hypertrophy was present, either of the septum or turbinates, or in which hypertrophy had been removed by operation, and where that annoying symptom, supersecretion, remained. You all know that there are many cases of nasal disease in which supersecretion is pretty satisfactorily checked by the removal of nasal obstruction. Unfortunately, there are many others in which, though the breathing is improved by operation, the uncomfortable symptom of hawking and clearing the throat to remove collections of mucus is not greatly abated. I commenced using the copper electrode with the hope of diminishing the abnormal amount of secretion in these cases.

The Gautier method did not seem to me to be a rational substitute for operative work in the removal of either soft, cartilaginous, or bony enlargements, although Dr. Morton and Dr. Cleaves have, I believe, used it with more or less satisfaction in cases of nasal stenosis.

In the eleven clinical cases reported in Dr. Cleaves's paper, four were applications made for uterine disease, three in cases of trachoma, and four for nasal and throat trouble.

In her first nose and throat case the prominent symptoms seem to have been an irritating cough and a disposition to swallow almost constantly. She simply says that six applications were made and that all the symptoms disappeared. Exactly what the pathological condition was we do not know.

The next case was in a child of nine years of age having a mucopurulent discharge, with nasal and pharyngeal obstruction. Fourteen applications were made, and the abnormal symptoms disappeared. We are not told what the condition was here, but it would look as though it were adenoid enlargement at the vault of the pharynx.

We should not recommend the metallic electric treatment in the removal of adenoid, since it can be taken away so expeditiously by the usual methods.

I do not propose to give a detailed history of any of the many cases in which I have applied the copper electrode during the past year. Some of them have presented quite marked improvement. I have been able to check an irritable cough due to pharyngeal or laryngeal catarrh by two or three applications; but it has seemed

to me that this was accomplished rather by the galvanism than by the effect of the copper. I have used the cupric puncture with Dr. Morton's needles in cases of enlarged follicles on the posterior wall of the pharynx, and have satisfactorily reduced them in size. It is a slower process than the use of the actual cautery, and perhaps is no better.

As I have said before, my nasal cases which have been selected for this treatment have usually been those in which the two symptoms were catching cold easily and frequently, and the presence of an annoying amount of mucus in the nose and pharynx. These cases I have treated about twice a week, and have not often used a stronger current than five milliampères, as, in going beyond this strength, the patient complains of pain and dizziness in the head unless cocaine is employed, and it seems to me wiser not to use cocaine, in order to obtain the benefit of the patients' sensations.

I have treated my cases twice each week, and in the following manner: First, the mucous membrane is thoroughly cleansed by an alkaline wash, then the large negative sponge electrode is placed on the back of the neck and the small nasal copper point is rubbed thoroughly both along the septum and on the turbinated side, and so through the nasal channels into the vault.

Patients complain of burning and stinging in the anterior nares with a current of five milliampères, which is increased to a pain in the upper teeth if it is made stronger. A salt taste in the mouth, thickened tongue, and a general sensation of an electrical current in the head are the other symptoms. When the electrode is applied to the posterior end of the nasal chambers there is a slight feeling of dizziness with five milliampères, which is very uncomfortable with eight or ten milliampères. This is in addition to the local burning and pain. Flashes of light before the eyes are sometimes noticed by patients. Directly following the nasal applications we find the mucous membrane congested, the turbinates swollen, and the transudation of serum abundant—the symptoms of an acute coryza, which last for two or three hours and have disappeared by the next day.

I have succeeded in decidedly diminishing the amount of nasal and post-nasal secretion in perhaps six cases out of twenty, and have lessened it somewhat in seventy-five per cent. of all the cases. It is difficult to give this method of treatment a thoroughly fair trial, because one is apt to use watery or oily sprays without intending to do so, and some credit should be given to them.

I have the history of three nasal cases, in all of which the prominent symptom was epistaxis and the usual ulcerations at the anterior end of the cartilaginous septum were present. The application of the copper sound to these healed them within two weeks, and there was no return of the bleeding. I should say that the diffusion of copper in this line of cases was preferable to its application in solution.

I have succeeded in diminishing the size of anterior turbinated swellings with the cupric puncture. The appearance of such hypertrophies is quickly changed by the injection of the copper salt. I think the copper needle will prove of value here, and it is a better agent than the caustic acids, which have been too liberally daubed over the turbinates during the past ten years. Localized congestions at the vault of the pharynx, when there is little enlargement, are diminished by the application of the broad copper electrode introduced through the mouth.

I have not tried to reduce nasal obstructions on the septum, or post-nasal enlargements, by the copper method. The cupric puncture may be found to be useful in enlarged tonsils, but will hardly supplant the tonsillotome or galvano-cautery point. Its use would seem to be more reasonably indicated in the reduction of enlarged lingual adenoid.

Finally, I believe that if it is found that the use of the copper electrode by the Gautier method is a valuable therapeutic agent in the treatment of catarrhs of the upper air-passages, it will be in that line of cases where, after all obstructions and hypertrophies have been removed, there still remains an annoying amount of secretion to be checked.

Discussion.

Dr. JONATHAN WRIGHT said that stimulated by the papers of Dr. Delavan and Dr. Shurly on the treatment of atrophic rhinitis, he had used the instrument in ten or twelve such cases, and had observed the same symptoms as had been described in the paper—coryza and an excess of watery secretion from the nose. Electricity was not to be relied upon at all, either for cauterization or motor work. In consequence of this he had abandoned its use. He could see no reason why in atrophic rhinitis there should be an increase in the secretion of watery fluid, or why in hypertrophic rhinitis there should be a diminution in quantity.

Dr. DE ROALDES, of New Orleans, said he had listened with great interest to Dr. Rice's paper, and regarded it as a commendable step in the direction of the application of electricity to our specialty. He was glad to see the method of interstitial electrolysis, with the production of medi-

cinal agents in the nascent state, as devised several years ago by Dr. Gautier, of Paris, undergo new tests on this side of the Atlantic with new and improved electrodes. The good results obtained were, however, in his opinion, due as much to the beneficial effects of the galvanic current as to the action of the nascent oxychloride of copper.

The penetration of the tissues by this agent was undeniable. The unipolar method was used; he thought, however, it would be preferable to resort to the bipolar method.

In regard to the amperage used in these applications, now that electricity was being more generally used in the nose and post-nasal space, he would like to remind the fellows of the importance, in comparing notes, of experimenting with reliable galvanometers of a uniformly standardized type.

Dr. Moure, of Bordeaux, two years ago, at a meeting of the Société française de laryngologie, had been astonished at the intensities of eighty and ninety milliamperes used in the nose by Dr. Garrigou-Desarènes, of Paris, while twenty to thirty milliamperes was the maximum he had been able to reach consistently with the safety and comfort of the patient. He was disposed to explain these differences of intensities by the varieties of milliamperemeters used in the registration of the current. Dr. Garrigou-Desarènes added in explanation that such high intensities (ninety milliamperes) had been reached in patients of Northern origin like Russians and Poles, thus seeming to lay great stress on racial resistance. Dr. de Roaldes said further that his experience on this point had left quite an impression on him.

The Eye, Ear, Nose, and Throat Hospital, of New Orleans, was provided with a special and very complete electrical room, which had been thoroughly fitted under the able supervision of one of his assistants, Dr. William Sheppegrell; the galvanic current was so distributed as to allow of the treatment of three patients at the same time. The three different seats were supplied with rheostats and milliamperemeters of different makers. Six months ago he had determined to make use of electrolysis, with tolerably high intensities, in a case of recurrent fibrosarcoma of the post-nasal space. The intensities, as endured by the patient, were so variable from day to day that, overlooking the question of resistance of the parts, the reliability of the instrument was at once suspected. One day the three different milliamperemeters registered so wide apart that they were tested with a standardized Weston instrument and found to register from thirty to fifty per cent. too high.

Since that he had adopted in his private office the last-named milliamperemeter, which, while costly, was certainly the most trustworthy instrument in the market. He thought that much greater accuracy of observation would be obtained in our electrical applications if the intensity of the current used was registered by thoroughly reliable and properly standardized milliamperemeters, and also if the resistance of the

parts, by means of a simple and practical device, could be readily calculated by the operator.

Dr. JOHN O. ROE, of Rochester, said: I have had considerable experience in the use of the galvanic current, especially in the treatment of atrophic rhinitis. The electrodes that I have employed have been either nickeled electrodes or a flattened copper wire wound with cotton saturated with a saline solution before being introduced; and the beneficial results I have attributed solely to stimulation of nutrition. The employment of copper electrodes, such as those described by Dr. Rice, I have had no experience with, but shall certainly give them a trial, and hope to have as excellent results from their use as those obtained by him.

One word in regard to the employment of the milliamperemeter for indicating the strength of current that should be prescribed in different cases. In the first place, my experience accords with that of Dr. de Roaldes that, as a rule, milliamperemeters are more or less unreliable in indicating accurately the strength of the current; and secondly, that the strength of the current employed in the treatment of one patient is no indication of the amount that should be employed in the treatment of another patient. This is owing to the variation of the internal resistance of the body, not only of different persons, but of the same persons at different times. The same strength of current that one patient will take with perfect comfort may be exceedingly painful or unendurable by another patient. I regard, therefore, the sensation of the patient as a much more reliable guide for indicating the strength of the current to be applied in each particular case than the employment of the milliamperemeter, which can only be of service for measuring the strength of the current to be employed when the internal resistance of the body has been carefully ascertained.

Dr. WILLIAM H. DALY said he considered the milliamperemeter as comparatively unreliable as our gas and water meters. While electricians had done much, they had not yet reached that point where they could construct a reliable milliamperemeter. The resistance to the electrical current differed, as Dr. Roe had said, in different individuals, and in the same individual on different days, and at different times on the same day.

Dr. CASSELBERRY was skeptical as to any permanent effect being obtained in chronic cases, and attributed the changes to the copper salt rather than to the electrical action.

Dr. RICE said that it remained to be proved how much benefit was to be credited to the diffusion of the copper. In Dr. Delavan's cases the negative pole had been placed on the mucous membrane. How much benefit was to be derived from the application of a copper sound or electrode to the mucous membrane had yet to be determined. He was in accord with Dr. Roe regarding the variable strength of the milliamperè. He trusted entirely to the sense of his patient. He found that he could not use more than eight or ten milliamperès in the nose, and some patients complained of three milliamperès.

Paper.

A CASE OF COMPOUND FOLLICULAR ODONTOMA INVADING THE RIGHT ANTRUM OF HIGHMORE AND OBSTRUCTING THE CORRESPONDING NASAL FOSSA, WITH AN APPARATUS FOR ADMINISTERING ANÆSTHETICS, ESPECIALLY ADAPTED TO OPERATIONS IN THE MOUTH, NOSE, AND THROAT.

BY A. W. DE ROALDES, M.D.

ODONTOMATA are still more or less rare, especially those of the variety to which belongs the specimen which I am to submit to you to-day; every case, therefore, deserves to be made public. Our own American literature is, so far as my reading extends, very barren on the subject. French and English authors, particularly during the last twenty-five years, have illustrated the subject with interesting series of cases (Forget, Robin, Broca, Magitot, Panas, etc.; Tomes, Heath, Lloyd, Sutton, etc.). These considerations have induced me to lay before you the following case, which, after starting in the border line of general and oral surgery, certainly passed into our domain when the growth invaded the antrum and obstructed the nostril. You will therefore excuse me if, owing to its great interest, I introduce before you this subject, germane to our special studies:

Daniel A., aged nine years, of Natchez, Miss., was brought to my office in the first days of February, 1894. His previous history, as ascertained subsequently through the kindness of Dr. George W. Rembert, of Natchez, is, in the doctor's own words, as follows:

Previous History.—"It was in July, 1892, in the office of Dr. N. L. Guice, and by his invitation, that I first saw the little fellow. An examination revealed *two points* of disease, separate and apart and differing in pathological conditions: 1. On the socket of the previously lost deciduous right central incisor (superior) was found a *fibrous* tissue completely filling the interspace and extending considerably below the line of the adjacent teeth. It also extended above the alveolar border. For some reason (possibly the result of pressure) there was found a deficiency of osseous structure at this point, while the surrounding bone did not appear carious.

2. "Beginning opposite the right canine and extending posteriorly alongside the internal plate of the alveoli to near the tuberosity of the maxilla, and covering a considerable portion of the right palatal bone, was found located an osseous tumor (osteoma) evidently of several months' development. An appointment was given for the day following, and both

tumors were removed, with the result that there has been no return of the fibrous, but a partial reproduction of the other growth.

"I again," continues the doctor, "had this little boy for a patient in the spring of 1893. At this time I found an osseous tumor located on the external plate of the alveoli, right side, superior, and covering a portion of the external surface of the right maxillary in the region of the canine fossa. With the kindly and skillful assistance of Dr. Lamkin and Dr. Beekman, this growth was removed on June 20, 1893, and we had hoped a speedy cure might result from it; but in a very short while we discovered that there was necrosis of the maxilla at the point operated upon; and in September following, with the patient chloroformed, we succeeded in removing different fragments of dead bone, resulting in an exposure of the antrum of Highmore. At this time we saw no osseous deposit within the sinus, but noticed the growth that is now most noticeable, being external to the antrum and encroaching upon the orbital and nasal regions. Not knowing for certain whether this enlargement was a reproduction of the original disease or but a hypertrophied condition due to the inflammatory action incident upon the necrosis, we deferred to operate, thinking it wisest to await further development. We are now convinced it is the same in character as the tumors previously removed, and agree with you in advising active surgical interference."

Upon actual examination I find young Daniel A. to be a well-built child of sound parentage, who has always enjoyed good health. No indication of any rickety tendency in early age, nor any history of a fall or blow on the face. Occupying the front of the right cheek is a uniformly hard, painless tumor, covered by sound skin, evidently springing from the superior maxilla, and limited externally and superiorly by the malar bone and by the upper wall of the antrum of Highmore, without, however, any apparent encroachment of the orbit, although upon inquiry the child is found affected with diplopia. The growth is limited toward the middle line by the nose, which on that side of the face is somewhat flattened and more continuous with the cheek than on the other side, as if the ascending process of the maxillary bone has been lifted up slightly. An examination of the right nasal fossa reveals a marked stenosis due to the bulging in the lumen of that channel of the external wall of the fossa. There exists a slight chronic rhinitis, but no exposed bone is found by the most careful probing. The voice is somewhat nasal; there is no perversion of the sense of smell; no lacrymation; no neuralgia, and there are no ganglionic enlargements. By digital examination, the post-nasal space and especially the right choana are found to be free of all swelling. Upon examination of the buccal cavity, a hard tumefaction of the palatal portion of the right superior maxilla is observed, which measures an inch and a quarter antero-posteriorly and nearly an inch transversely. The external and anterior boundaries are fused with the alveolar border. This process is very much increased in width, especially in its posterior half, and on its border are to be found the following teeth, to wit: the right

central incisor of second dentition (scarcely erupting), the lateral incisor, the cuspid, the second molar of the deciduous set, and the first or sixth-year molar of the permanent set. In the place of the canine is to be seen an oblong, hard, exposed structure, looking like a piece of necrosed bone, but perfectly fixed in its position; between it and the second molar is a small, irregular depression, leading in the direction of the antrum, in which the patient generally packs a plug of absorbent cotton. There is no discharge of consequence, and the probe when introduced is soon arrested by a hard, denuded, bony resistance.

By forcing water through with a small antral cannula, a few drops are observed to dribble out from the right nostril. Heryng's lamp reveals an absolute opacity of the right cheek and a total destruction of perception of light in the corresponding eye. The diagnosis of a benign neoplasm of the maxilla, probably an osteoma, was made with a reserve, however, to be cleared by obtaining subsequently, from his physician, the previous history of the case in regard to the eruption of the missing teeth, in the socket of which the disease was represented as having first appeared. A radical operation is advised. The patient was brought back a few weeks later, ready to submit to surgical interference, which had to be delayed some days owing to a recent attack of malarial fever.

He entered the New Orleans Sanitarium and Training School for Nurses, and on March 4th, with the valuable assistance of Dr. Souchon, Dr. McShane, Dr. Landfried, and Dr. Delaup, in the presence of members of the polyclinic class, a modified Vallet's* operation was performed under the influence of chloroform.

An incision commencing just below the inner canthus of the eye was carried down the nasal furrow to the ala of the nose, and around it to the inner border of the nostril and median line, then completely dividing the upper lip outside of the frenum. Upon a complete dissection of the cheek flap, and a partial one of the nose flap, the bony opening of the right nostril, together with the anterior wall of the superior maxillary bone, was fully exposed.

After lifting the periosteum a section of bone was made with a chisel, commencing at the lower border of the bony opening of the nostril and extending outward and parallel with the alveolar border as far back as the tuberosity. A similar section was made higher up, just outside the nasal process, without entering the nostril, however, parallel and extending outward, just below the infraorbital foramen.

The inner ends of these sections were united by a third one, taking care, as much as possible, to spare the ascending nasal process. The outer ends were similarly joined by a vertical section, and with strong forceps the whole anterior surface of the superior maxilla was removed from the nostril to the tuberosity and from the infraorbital plate to the

* Résection partielle de l'os maxillaire supérieur pour l'extraction de polypes volumineux des fosses nasales, du pharynx et du sinus maxillaire, par M. Vallet d'Orleans. See *Gazette des hôpitaux*, March 31, 1859.

alveolar border. Vallet's removal of the outer wall of the nostril was judged unnecessary, as digital examination of the posterior nose had revealed no radiating pressure of the tumor in that direction, and the preservation of the nasal process was considered as very important for subsequent cosmetic effect.

The main mass of the tumor was found on the floor of the antrum corresponding to the canine fossa. Considerable difficulty was found in chiseling it out on account of its eburnated consistence, and also in avoiding fracturing the alveolar border, and hard palate, which, when used as a fulcrum to dislodge the growth, showed manifest weakness. On the surface of the tumor were tufts of hard, adherent tissue, resembling the lining of an alveolus; a large number of smaller masses, to the number of fifty or more—as a few were lost during the operation—some of them tooth-shaped, were found sequestered in various parts of the surrounding bone under the orbit, and as far back as the tuberosity. They were, however, gouged out thoroughly and easily. The growth had invaded and dilated the whole antrum, leaving no vestige of its lining membrane. After a complete curettage of this large cavity it was carefully packed with iodoform gauze, and the soft parts neatly brought together by six points of suture, with a harelip pin passed through the upper lip, over which an antiseptic dressing was applied.

Outside of a slight attack of otitis which developed on the third day in the left ear, due to a nasal injection when the right nasal fossa was completely occluded, the case progressed rapidly toward recovery, and the patient was sent back home on the 23d of March, since which time he has been attended by Dr. George W. Rembert, who, on May 14th, kindly writes: "It has now been ten weeks since the operation, and the cavity is probably two thirds filled." He thinks it will be necessary, later on, to adopt an obturator in connection with the dental plate. "The right corner of the mouth is slightly drawn backward and upward," adds the doctor, "and quite *likely* will increase some *in the future*, but I do not anticipate any great disfigurement; on the contrary, considering all things, I accept it as fortunate indeed for the young man that it is not much greater. Should he, in after years, wear a moustache or beard, it will be next to impossible to detect the shortening of the right side of the face and the changes in the mouth that will *probably* follow."

As to the cosmetic effect, this post-operation photograph of the patient, just received, and which I beg to pass around, will show, better than any conjecture, how little disfigurement, if any, has resulted from the operation. My only regret is that, owing to a malarial attack, a pre-operative photograph was not taken; I will, however, supplement this desideratum by the accompanying drawing, the dotted lines showing schematically the location and apparent size of the odontoma.

As the microscopical examination of this tumor offered a great interest from the standpoint of the determination of its dental origin,

I sent the specimen to Dr. W. C. Borden, U. S. Army, whose kindness and competency I have often put to task. In return I received from him the photographs which I to-day submit to you for inspection, with the accompanying note:

"The specimen received, and I beg to report that it is a compound follicular odontoma. It consists of hypertrophic tooth capsule which ossified in places (sporadically), producing a number of denticles which had originally probably all been bound together by periosteum, the denti-

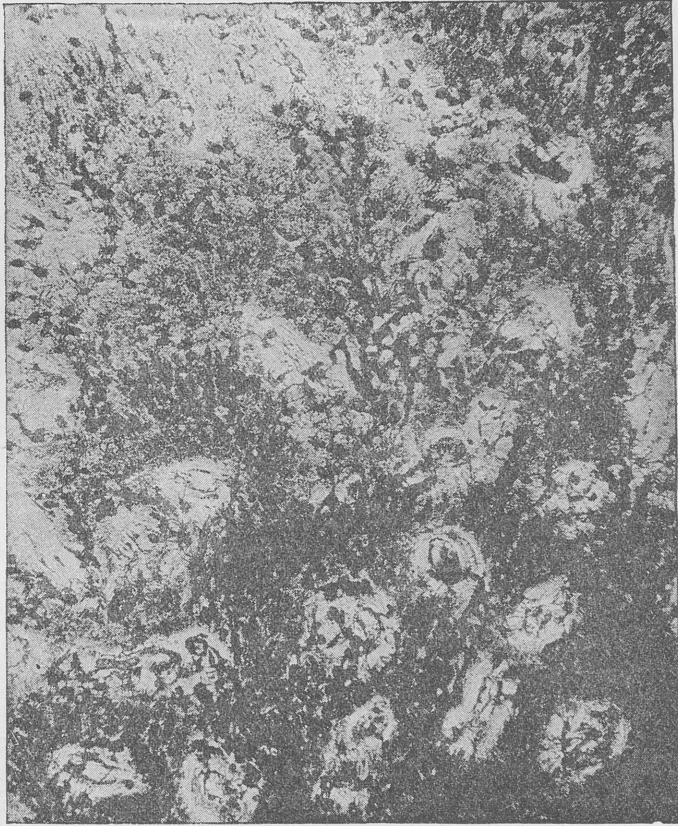

FIG. 1.—Photomicrograph, $\times 125$ diameters, showing the cementum substance from this compound follicular odontoma. The histological structure is that of cementum of tooth.

cles being imbedded in the fibro-vascular structure, much as plums are in a plum pudding. The denticles consist entirely of cementum. A photomicrograph of a ground-down slice of one shows a structure identi-

cal with that of cementum of teeth. This osseous structure is very hard and identical with that of the roots of a tooth. The denticles appeared so hard that before I made a section I thought they consisted of cementum, dentin, and enamel, but they have neither of the latter histological structures. I notice that Sutton states that these denticles may consist of either cementum or dentin, or may even be ill-formed teeth, having all the structures of those organs. In this case the neoplastic centers developed in the fibro-vascular structure, grew as cementum only, and did not progress as far as dentin or enamel formation, or rather, as enamel is of epiblastic origin, odontomata of this type are probably hypertrophic growths from cementum centers. The tumor is a very interesting one."

If we accept J. Bland Sutton's classification of odontoma, which, in my opinion, is more advanced and much more satisfactory than Broca's, this growth as removed and presented to you belongs to the division called by him a "compound follicular odontoma." In regard to these he writes in his last work on *Tumors, Innocent and Malignant* (1893), page 36: "If the thickened capsule ossifies *sporadically* instead of *en masse*, a curious condition is brought about, for the tumor will then contain a number of small teeth or denticles, consisting of *cementum or dentin* or even ill-shaped teeth composed of three dental elements—cementum, dentin, and enamel.

The number of teeth and denticles in such tumors varies greatly and may reach a total of three or four hundred. This last number, however, has never been found, to my knowledge, in the human subject. His citation concerning such numbers refers to a case in the horse, mentioned by Logan (*Jour. of Comparat. Med. and Sur.*, New York, 1887), which contained four hundred denticles. He himself has reported the case of a compound follicular odontoma from a thar, which had a growth in each upper jaw, the denticles numbering in all three hundred. After careful researches on the subject I do not know of any case that can be compared, as to the number of denticles, to the one I to-day bring before you.

The case of Sims contained forty, the one of Tellander twenty-eight, and the one of Mathia's fifteen (all figured in Sutton's work).

Henry L. Albert and Hildebrand are quoted by Sutton as having reported a similar case, but referring to the original observations, I find no mention made of the number of denticles. Strange to say the growth in almost every one of these five cases was located in the upper right maxilla. I know that Sutton, who was rather arbitrary several years ago in his assertions of the extreme rarity of the odontoma of the superior maxilla, as compared with those which develop in the lower jaw, has now modified his views, as more cases are pub-

lished and a more thorough microscopical examination is made. The fact is that evidently before Broca, in his remarkable memoir, called the attention of surgeons to this subject, a great many cases described as fibrous tumors and exostoses of the antrum were nothing but odontomata. Such cases are now very well defined by careful microscopical investigation, and shown to be neoplasms composed of dental tissues (enamel, dentin, and cementum) in varying proportions and different degrees of development, arising from tooth germs or teeth still in the process of growth—in fact, real odontomata. While unable to substantiate the statement on histological grounds, it is to be presumed that in this case what was described by Dr.

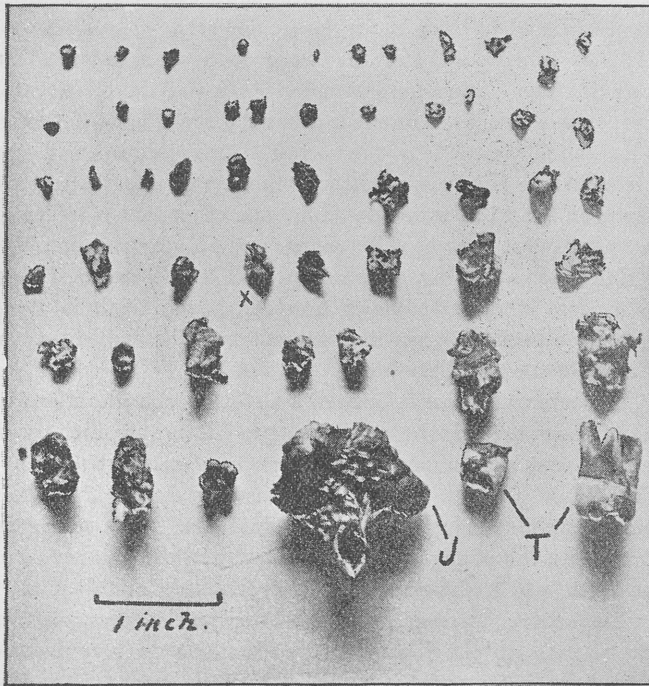


FIG. 2.—Photograph representing T, teeth; J, part of jaw with teeth attached. The other fifty pieces are denticles consisting of cementum. A selection of the denticle marked X is shown magnified in Fig. 1.

Rembert as a fibrous growth and removed by him, without any reproduction since, was a fibrous odontoma in connection with the right central incisor, which was supposed to have been lost by premature dissolution of its fang, but which I am more inclined to

believe had not erupted. If this view is taken, the location of this odontoma in the incisor region would be a real curiosity, as Professor von Metnitz, of Vienna, in describing a case of that kind, *believes it to be unique* (see abstract of case in the *British Journal of Dental Science*, 1891, vol. xxxiv, page 211).

It is more difficult to explain why, as has been observed, these tumors should more generally affect the right upper and lower jaws. As to the growth which came under my observation for operation, it was undoubtedly connected with the canine tooth which had not erupted. Even that connection is very unusual, as Broca can only cite one case of odontoma developed in the canine region. As a rule, the points of selection for these growths are the pre-molar and molar teeth, and in these last more particularly.

It is to be supposed that the two growths were independent and represented two distinct odontomata. Cases of double odontomata in the same subject are on record, but the growths do not generally develop on the same side of the maxilla. In regard to the diagnosis, "it is a curious fact," says Sutton, "that up to this date there is no instance on record in which an odontoma, other than a follicular one (dentigerous cyst), has been diagnosticated before operation." This assertion is too sweeping, as can be proved by the case of Panas and two or three others. It shows, however, how difficult is a positive diagnosis, especially when the growth remains imbedded in the thickness of the maxillary bones.

The factor which must outweigh all other considerations in the mind of the surgeon is the one relating to the age at which the tumor makes its first appearance; it is pretty safe to assert that any neoplasm which presents itself in the maxillary bones after the completion of dental evolution is not an odontoma. This consideration, coupled with the young age of the patient and the absence of one or more teeth, will assist materially in overcoming our doubts. It is most important, however, to arrive at a precise diagnosis, as the study relating to the literature of odontoma is very instructive. Inasmuch as it shows that patients have in many instances been subjected to operations needlessly severe and dangerous.

Before proceeding to excise a portion of the mandible or maxilla, the surgeon must satisfy himself that the tumor is not an odontoma, for this kind of growth generally requires only enucleation and vigorous gouging.

Although the result has been as satisfactory as possible in my case, I now think that a more conservative procedure, through the

mouth and canine fossa, might have been adopted with equally good results.

In conclusion, I wish to say that at the request of my friend, Professor Edmond Souchon, of New Orleans, the new apparatus which he has contrived for administering anæsthetics was made

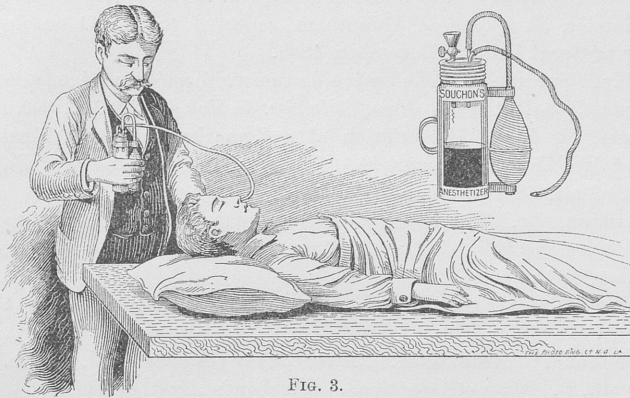


FIG. 3.

use of in connection with this case. Chloroform was administered by the ordinary method; but from the moment the operation began, the anæsthesia was kept up with the above-mentioned apparatus for over an hour, to the thorough satisfaction of myself and of all present. The anæsthesia was perfect during the whole operation, and I did not have to stop a minute until it was completed. At one time, owing to accumulation of blood in the throat, due to the fact that the artery had been severed close to its exit from the infra-orbital canal and could not be seized with the forceps, the head of the patient was lowered and kept in Rose's position quite a while without any interference whatever of the anæsthetist with the operator. Barely three quarters of an ounce of chloroform was used. Professor Souchon, who was kind enough himself to administer the anæsthetic, informs me that he has tried his apparatus with equal satisfaction in several operations at the Charity Hospital.

Bibliographical References.

Oudet. Case of Odontoma, communicated to the Faculty of Medicine of Paris in 1809.

Dupuytren. Kyste à parois osseuse et contenant une tumeur fibreuse, etc. *Gaz. des hôp.*, tome ii, 1829-'30, p. 134.

Owen, R. *Atlas of Odontography*, 1840-'45, plate 27.

Forget, A. Notes sur les tumeurs dentaires, leurs variétés, leurs diagnostic et leur traitement. Nouvelle observation d'odontome cémentaire. *Union méd.*, Paris, 1868, pp. 629, 635.

Forget, A. Étude histologique d'une tumeur, etc. *Bull. de la Soc. de chir.*, Paris, 1861.

Mathias, C. Case of Odontoma, recorded by Sir John Tomes. *Trans. of the Odontological Soc. of Great Britain*, vol. iii, 1861-'63, p. 365.

Tellander, C. Case of Odontome, reported to the Odontological Society of Great Britain, December, 1862.

Robin. Sur une nouvelle espèce de tumeur formée au dépens des tissus des bulbes dentaires. *Mem. de la Soc. de biologie*, 1862, p. 199.

Tomes, Sir John. Description of a Remarkable Case of Exostosis (case of Mr. Hare, of Limerick). *Trans. of the Odontological Soc. of Great Britain*, 1861-'63, p. 335.

Harrisson, Dr. W. A. Case of Odontoma, Communication to the Odontological Society of Great Britain. *Brit. Jour. of Dental Science*, December, 1862.

Walker, J. On Exostosis. *Trans. of the Odontological Soc. of Great Britain*, 1861-'63, p. 313.

Hildebrand, C. Odontome. *Zeitschrift für Chirurgie*, Bd. xxxi, p. 282.

Bilroth, C. Case of Odontoma. *Virchow's Arch.*, Bd. viii, p. 426.

Forget, A. *Des anomalies dentaires*, Paris, 1859; also in Heath's work on *Injuries and Diseases of the Jaws*.

Forget, A. Des tumeurs dentaires—odontomes fibreux. *Union méd.* Paris, 1868, pp. 165-170.

Broca, C. Recherches sur un nouveau groupe de tumeurs désignées sous le nom d'odontomes. *Bull. de l'Acad. des sci.*, Paris, 1867.

Letenneur, C. Odontome radiculaire cémentaire. *Gaz. des hôp.*, Paris, 1868, p. 158.

Weinlechner, C. Case of Odontoma. *Wochenblatt der Gesellschaft der Wiener Aerzte*, 1869, No. 29.

Broca, C. Odontomes. *Traité des tumeurs*. Paris, 1869, tome ii, p. 265.

Heider and Wedl. *Atlas zur Pathologie der Zähne*. Leipsic, 1869, plate iii, Figs. 34-39.

Magitot. Odontome développé sur la défense d'un éléphant, pièce présentée à la Société de chirurgie. *Gaz. méd. de Paris*, 1869, p. 176.

Guyon et Monod. Art. Odontomes. *Dict. encyclopédique des sciences méd.*, 2me série, vol. v, p. 444.

Tomes, Charles. Case of Mr. Hare Re-examined and Redescribed, and Considered To-day as a Genuine Odontoma. *Trans. of the Odontological Soc. of Great Britain*, 1872.

Annandale. Case of Odontoma. *Edinb. Med. Jour.*, January, 1873.

Scheff, J. Ueber Odontombildung. *Wiener med. Presse*, vol. xvii, 1876, pp. 890-919.

Panas. Odontome odontoplastique fibreux, avec grains dentinaires

eparpillés, etc. *Bull. et mémoires de la Soc. de chir. de Paris*, pp. 347-356.

Salter, S. J. A. Two Odontomas, associated with Cysts. *Guy's Hosp. Reports*, London, vol. xxi, 1876, pp. 220-226.

Magitot. *Traité des anomalies du système dentaire*. Paris, 1877, p. 232.

Moon. Case of Odontoma. *Trans. of the Odontological Soc. of Great Britain*, vol. x, 1877-'78, p. 30.

Fothergill, Edward. Case of Odontoma, exhibited to the Odontological Society, by Mr. Coleman. *Trans. of the Odontological Soc. of Great Britain*, 1879-'80, p. 2.

Uskoff. *Ueber ein grosses Odontome der Unterkiefer*. Virchow's *Arch.*, Bd. lxxxv, 1881, p. 537.

Heath, Christopher. A Case of Odontoplastic Odontoma. *Trans. of the Clinical Soc. of London*, vol. xv; *Dental Record* vol. i, 1881, p. 199; also in *Lancet*.

Praeger, Alfred J. A Case of Odontoplastic Odontoma. *Dental Record*, vol. i, 1881, p. 198.

Underwood, A. S. A Remarkable Odontoma. *Jour. of the Brit. Dental Assoc.*, vol. iii, 1882, p. 103.

Fergusson, Sir William. Case of Odontoma. See Tomes's *Dental Surgery* or Heath's *Injuries and Diseases of the Jaws*, 1884, p. 217.

Heath, Christopher. Odontoma. *Brit. Med. Jour.*, 1887, vol. i, p. 155.

Lagrange. Notes sur un cas d'odontome embryoplastique, etc. *Gaz. hebdomadaire*, 1885, p. 241.

Sutton, J. B. Comparative Dental Pathology. *Trans. of the Odontological Soc.*, 1884-'85, p. 42.

Sutton, J. B. On a Remarkable Case of Odontoma in a Thar. *Jour. of the Brit. Dental Assoc.*, vol. xxxi, 1888, pp. 301-303.

Sutton, J. B. On the Relation of Rickets to some Form of Odontoma. *Trans. of the Odont. Soc.*, 1888-'89, p. 138.

Sutton, J. B. Paper on the Classification of Odontomas. *Jour. of the Brit. Dental Assoc.*, vol. iii, 1882, p. 103.

Arkovy, J. Notes on an Odontoma, with Histological Drawing. *Jour. of the Brit. Dental Assoc.*, vol. viii, 1887, pp. 3-43.

Simms. Case of Odontoma, reported by Prof. Windle and Mr. Humphreys. *Jour. of Anat. and Physiol.*, vol. xxi, 1887.

Lloyd, Jordan. Composite Odontoma of the Upper Jaw. Removal. *Lancet*, 1888, vol. i, p. 64.

Goodwillie. Case of Odontoma, mentioned in Agnew's *Surgery*, vol. ii.

Logan, A. H. Case of Cystic Tumor, Extirpated from the Facial Sinus of a Horse. *Jour. of Comparative Med. and Surg.*, New York, 1887.

Albert, Henry L. Successive Eruption of Supernumerary Teeth from a Bony Tumor of the Upper Jaw. *Illustrated Med. Jour.*, August 10, 1889, p. 125.

Von Metznitz. Case of Odontoma. Abstract in *Brit. Jour. of Dental Sci.*, 1891, p. 21.

Heidenrich, A. Odontomes. Duplay, *Traité de chirurgie*, Paris, 1891, vol. v, p. 137.

Dunkerly, J. W. Odontomas. *Brit. Jour. of Dental Sci.*, vol. xxxv, pp. 1-11.

Sutton, J. B. *Tumors, Innocent and Malignant*. Philadelphia, 1894.

Paper.

A CASE OF FOREIGN BODY (GOLD COIN) ENGAGED IN THE VENTRICLES OF THE LARYNX.

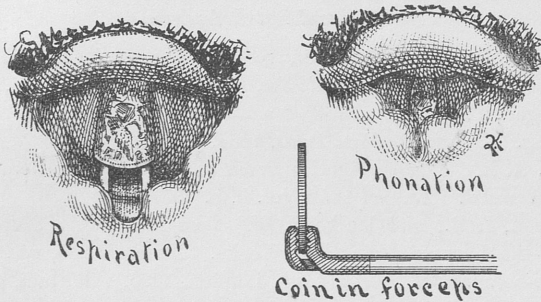
BY A. W. DE ROALDES, M.D.

SOME months ago, Lester C., aged twenty-five years, a powerfully built man, in good health, but somewhat addicted to alcoholic abuses, was talking with some friends in a farmer's house near Crowley, La. One of the men present produced a \$2.50 gold piece and displayed it somewhat as a curiosity. The patient snatched the coin from the hand of his friend by way of a joke, and, putting it in his mouth, announced that it would be the last seen of the coin, as he was going to swallow it. Something was said in the conversation which excited laughter, and the coin dropped down in the man's larynx. He was immediately seized with intense dyspnoea, and very severe cough and gagging. After a while the breathing became easier and the cough abated. Was seen, by Dr. Morris, of Crowley, and another physician, who advised his removal to New Orleans; he was brought by his friends to my office thirty hours after the accident.

The voice was simply husky, but otherwise he breathed now quite freely. There is a slight difficulty on swallowing. Upon pressure of the larynx, the patient referred the position of the coin to a spot over the region of the ventricles and vocal cords. The coin was readily detected by the laryngoscopic mirror. Everything was prepared for its extraction and for a possible tracheotomy in case it slipped lower down in the attempt at removal. A five-per-cent. solution of cocaine was liberally sprayed into the larynx, and with the aid of a heliostat the rays of a bright sunlight were reflected in the larynx, and the parts were accurately drawn by Dr. G. Q. Kohnke, of this city, who was sent for and kindly consented to come to my office.

As you will see in his excellent drawing, the coin was seen impacted in the larynx between the vocal cords and the ventricular bands, with its surfaces up and down, reverse uppermost, almost completely filling up the chink of the glottis, only a small, transversely oblong breathing space being left in ordinary respiration between the south pole of the coin in front and the hyperæmic mucous membrane of the inter-arytænoid space behind (inverted image). The segments of the coin cor-

responding to the extremities of its equatorial line were protruding into the ventricles and well imbedded under the false vocal bands. These



covered a portion of its circumference at each side, leaving exposed a triangular metallic surface, the base of which was formed by the free edge of the coin, while the apex was overhung by the epiglottis.

The coin was solidly fixed, as could be demonstrated by tapping its upper surface with a stout laryngeal probe. When attempting to phonate the vowel A, the arytaenoids and processus vocales were seen to approximate. When asked to try and emit forcibly a sound in the upper register, as "I," for instance, the coin was completely surrounded and encircled by the soft parts of the rima glottidis and the patient at once suffocated. This condition is well shown in the drawing. After demonstrating at leisure the case to those present, and having obtained an abolition of the laryngeal reflexes, thanks to the careful cocainization of the parts by my assistant, Dr. Scheppegegrell, I at once introduced, with the help of a laryngeal mirror, a Schrötter's forceps with jaws, possessed of an up-and-down power of prehension, the instrument being introduced laterally at first, so that the lower jaw would clear the posterior edge of the coin. The handle was then brought in the middle line, and the jaws of the forceps were then closed by the lever in the handle, and the coin removed.

The resistance offered by the vocal bands was such that, feeling that my hold was slipping, and fearing a repetition of the accident which happened in Dr. Ives's case (swallowing of the coin), or falling of the coin into the trachea, I hastily put aside the mirror, as Grazzi did in his observation, and strengthened my hold by additional pressure with my left hand on the handle of the instrument, and jerked out the coin, as it were, from its bed. The patient was discharged the next day in very good condition.

With this experience I can not recommend too highly the use of a strong Schrötter's forceps, and advise the operator to lay aside his laryngeal mirror after having grasped the coin, in order to strengthen his hold at the handle with the fingers of the left hand,

which might also be used to lift up the instrument on the course of its stem.

Bibliographical References.

Duncan, J. Removal of a Coin from the Larynx by Inversion of the Body. *Northern Journal of Medicine*, Edinburgh, 1845, vol. ii, p. 220.

Geoghegan, T. G. Expulsion of a Coin from the Larynx by an Act of Coughing. *Dublin Medical Press*, 1854, p. 225.

Adams, A. L. A Sovereign Impacted in the Larynx; Removal Two Months afterward. *Lancet*, 1859, vol. ii, p. 395.

Sanderson, J. B., and Hulke, J. W. Case in which a Sixpence was Lodged in the Larynx during Ten Weeks. *Lancet*, 1865, vol. ii, p. 39; also *Medico-chirurgical Transactions*, London, 1865, vol. xlviii, p. 201.

Cameron, J. Case of Removal of a Penny which had been Impacted for Six Years in the Larynx. *Liverpool Medical and Surgical Reports*, 1870, vol. iv, p. 180; reported also by James Petrie in *British Medical Journal*, August 20, 1870, pp. 186-187.

Smith, Henry. Case where Half a Sovereign was Impacted in the Larynx. *British Medical Journal*, 1871, vol. i, p. 7.

Grazzi, Vittorio. Storia della penetrazione nella larynge di una moneta di due centesimi estratta dopo 43 giorni per le vie naturali. *Bolletino delle malattie dell' orecchio, della gola e del naso*, 1882, vol. ii, p. 77.

Ives, Frank L. Two Cases of Foreign Body (Coins) in the Larynx: Removal. *Archives of Laryngology*, New York, 1883, vol. iv, p. 204.

Weir. Removal from the Larynx of a Two-cent Piece and a Penny. *New York Medical Journal*, 1890, vol. ii, p. 243.

Paper.

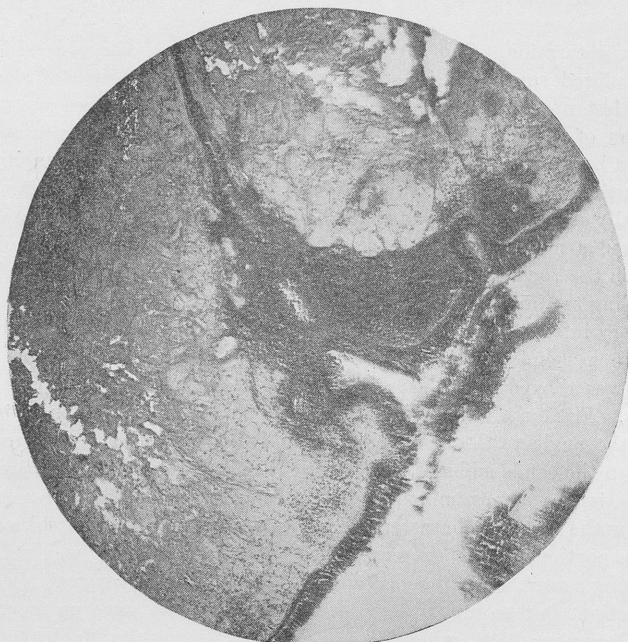THREE CASES OF LARYNGEAL NEOPLASM.

BY CHARLES H. KNIGHT, M. D.

LARYNGEAL growths are so rare in this country that it seems desirable that all cases observed should be placed on record. In this way we may hope to reach trustworthy conclusions as to the relative frequency, the diagnosis, and the best method of treating the several varieties of neoplasm. Two of the three cases which I have to report present little or nothing unusual. The first case, which might be properly denominated a process of degeneration rather than a neoplasm, is at least very exceptional. In a partial review of the literature of the subject no similar case has been discovered.

CASE I. *Diffuse Subglottic Myxoma; Partial Removal by the Mouth with Mackenzie's Forceps; Tracheotomy and Radical Extirpation of the Growth through the Wound.*—A. M'G., aged forty-eight years, first came under my observation at the Vanderbilt Clinic in the summer of 1890. For a year or more she had noticed increasing hoarseness and wheezy respiration, especially on exercise. She had some cough, with rather free expectoration. She supposed she had asthma. The general health had suffered somewhat in consequence of the disturbance of sleep at night, but no pulmonary lesion could be detected, and there was no indication of constitutional disease. The patient had the appearance of being a heavy drinker. She had a high grade of chronic pharyngitis and laryngitis, with considerable thickening of the mucous membrane, as is generally seen in the throats of alcoholics. In addition the laryngoscope disclosed a mass of finely lobulated tissue extending from immediately beneath the vocal bands for an indefinite distance downward, completely encircling the air-tube and markedly diminishing its caliber. The patient was very intractable and for many weeks it was found unsafe and impossible to use endolaryngeal instruments. In the meantime the local irritation was allayed in a measure by sedative steam inhalations and menthol sprays. Finally, a Mackenzie forceps with extra long blades (three inches from the angle to the tips) and cutting antero-posteriorly was crowded between the bands and masses of the neoplasm were nipped off. Sections of this tissue were examined under the microscope and were pronounced to show the features characteristic of papilloma. At several subsequent sittings portions of the growth were removed in a similar way until the breathing ceased to be impeded and the voice became comparatively clear. The patient felt so much more comfortable that she gave up treatment until December, 1891, when she came to my clinic at the Manhattan Eye and Ear Hospital. She then had a good deal of dyspnoea and her breathing was very stridulous. It did not appear that the growth had recurred at the region reached by the forceps, but lower down the neoplasm was encroaching upon the lumen of the windpipe. It seemed to be impossible to get at the growth through the larynx, and an external operation was advised. For six months no very marked change in the condition took place. Then the obstructive symptoms became aggravated and the patient concluded to submit to operation. On June 23, 1892, six minims of a ten-per-cent. solution of cocaine having been injected under the skin just below the cricoid cartilage, an incision two inches and a half long was made over the upper rings of the trachea. The wound was bathed with cocaine solution as the layers of tissue were divided until the trachea was exposed. The bleeding having been controlled by pressure and torsion, the trachea was opened by section of its first three rings. The walls of the trachea being retracted, the morbid tissue was removed with cutting forceps and curette. The growth was found to involve the entire circumference of the windpipe from the under surface of the vocal bands to a point a half to three quarters of an inch below

the lower limit of the wound. Hæmorrhage from the tracheal wall was very moderate. The patient made no complaint of pain or special discomfort during the operation, and no difficulty whatever was experienced. A trachea tube was inserted and the wound sutured above and below



A. McG., August, 1890. Subglottic myxoma.

it. The tube was removed on the third day. With the exception of a mild attack of bronchitis on the ninth day there was no unfavorable symptom. At the end of the third week the tracheal fistula had healed and the patient was discharged. Photomicrographs of sections of the tissue removed at this operation have been made for me by Dr. Leaming and are here exhibited. The growth appears to be made up chiefly of myxomatous tissue, and has a striking resemblance under the microscope to the morbid condition frequently met with at the posterior end of the inferior turbinated body. No structure typical of papilloma can be discovered.

The special points of interest to me in the foregoing case were: (1) The facility with which the trachea was opened and cleared with the aid of cocaine, and (2) the microscopic structure of the lesion itself. It is rather remarkable that the first report should have made it papilloma without reservation, while the latest examination is un-

able to discover any papillomatous tissue whatever. Either the tissue must have undergone a transformation, or the first examination must have been faulty. The latter conclusion is the only tenable one in view of the absence of all traces of papillomatous structure at present, and of the improbability of a change from papilloma to myxoma. In order of frequency benign neoplasms of the larynx are usually enumerated as follows: papilloma, fibroma, cystoma, myxoma, adenoma, lipoma, angioma. Myxomata are generally pedunculated and form distinctly circumscribed, smooth, or lobulated tumors, but, as in my own case, the neoplasm may assume the form of a sessile myxomatous degeneration. In most of the cases reported their point of attachment has been one of the vocal bands, and of benign growths in general it may be said that they rarely invade the infraglottic region. As regards situation and form the foregoing case would seem to be extraordinary.

CASE II. *Papilloma of the Larynx; Removal with Mackenzie's and the Schrötter-Türk Forceps; Electric Cauterization of the Base of the Growth.*—J. C. H. aged twenty-eight years, was sent to me by Dr. S. D. Powell on March 31, 1894. The history of the case is very brief and simple. The family record is quite free from taint. The patient himself has not been ill since childhood. During the spring of 1893 he noticed that his voice was getting weak. As he expresses it, he found himself unable to "holler." He has no recollection of ever having had a severe cold, but has long been in the habit of talking a great deal and in rather a loud tone of voice. He gradually became worse until in October, 1893, eight months ago, his voice completely left him, and since then he has been able to speak only in a whisper. His general health has been good. He has had no cough and no constitutional disturbance. With the mirror, an irregular lobulated tumor, pale in color and immovable, was seen to occupy the anterior third of the larynx above and between the vocal bands. A small tab of hyperplastic or neoplastic tissue, independent of the main tumor, projected from the right vocal band posteriorly. There was more or less diffuse hyperæmia, but the contour of the larynx in general was unchanged. There was no lesion of other parts of the upper air-passages aside from a moderate degree of chronic rhinopharyngitis. The patient was quite tolerant, and with the aid of cocaine no difficulty was found, on his second visit, in removing a piece of tumor with the Schrötter-Türk forceps. At subsequent visits on alternate days the Mackenzie cutting forceps was used to much better advantage, until in two weeks all the growth had been removed from above the vocal bands, and the patient was able to speak in a loud voice. There still remained below the right vocal band a strip of tissue to which a curved cauterizing electrode was applied without damaging the band. In

the meantime the larynx was sprayed each day with a solution of alumnol, twenty grains to an ounce. The patient was then obliged to return home. He was accordingly sent away, warned of the possibility of recurrence, and with instructions to use the alumnol spray daily and to talk as little as possible. The latest report in this case, within a week, states that there has been steady improvement in the quality of the voice, which is now almost natural and nearly as strong as ever. No microscopic examination has yet been made of this growth, but its character seems to be unmistakable.

There are two points of interest in this case: (1) The rapid and complete restoration of voice after its prolonged abolition, and (2) the efficacy and safety of the electric cautery point in attacking a neoplasm below the vocal bands. The question also arises whether alumnol may prove to be an agent of value in limiting a tendency to recurrence on the part of growths of this kind.

CASE III. *Multiple Papilloma of the Larynx; Removal with Mackenzie's Forceps; Recurrence and Removal in Twelve Months; Second Recurrence and Removal Five Years Later.*—This patient was a native of Bermuda, a man about thirty years of age, in perfect general health. The only symptom complained of was loss of voice, which had been coming on for a year or more. The patient says that he gradually became conscious of something flapping up and down in his throat during forced respiration and on attempting to speak. He was a very intelligent and tolerant subject, and no difficulty was found in relieving him by means of Mackenzie's forceps of a neoplasm as large as a cherry stone which was attached to the right vocal band near the anterior commissure, and of a smaller one which sprang from the left ventricle. The voice was very much improved, but did not become entirely clear. A year later he returned, and the condition was found to be rather worse than at first. Several weeks were spent in clearing out the larynx, the growths having recurred at the original sites and a new growth having arisen from the right vocal band at about its middle. From this time there was no trouble, except occasional hoarseness, for nearly four years. In October, 1893, more than five years after the second operation, the patient came to me a third time, unable to speak with loud voice. The anterior commissure and the left ventricle were again the affected points. There had been no new developments, and the larynx in general looked better than on his second visit. A third time the larynx was freed with Mackenzie's forceps, especial attention being given to the ventricular neoplasm. Laryngeal sprays of alumnol were used in this as in the preceding case after the final operation, and the patient states that he is now better than he has been at any time within the last six years. Dr. H. B. Douglass, one of the pathologists at the Manhattan Eye and Ear Hospital, has been

kind enough to examine these several specimens and reports that the growth last removed, like the others, is a pure papilloma.

It is somewhat difficult to say what may be the causes of recurrence in certain cases of papilloma of the larynx. A continuance of the conditions—local, climatic, and hygienic—which originally favored the growth doubtless predisposes to relapse. It is probably true that some mucous membranes have an inherent tendency to proliferation or neoplastic development. Finally, the inaccessible situation of certain neoplasms—for example, the ventricle, the anterior commissure, or the under surface of a vocal band—may render complete removal difficult, if not impossible. In this connection the question arises, When should we suspend endolaryngeal manipulations and resort to an external operation? Spontaneous disappearance of laryngeal papillomata has been observed in children, and is especially favored by that condition of physiological rest which follows a tracheotomy. Such an event is certainly less probable in adults. On the other hand, the immediate dangers of a thyrotomy, the absence of positive assurance against return, even when this method has been employed, and the risk to the integrity of the vocal bands, or of their imperfect reposition with consequent impairment of function, should deter us from precipitate interference by an external operation. In order to secure more accurate readjustment of the parts it has been suggested that section of the thyroid cartilage should not be complete, its upper border being left intact. While in adults this method may be feasible, in young subjects the field of operation would be contracted by such a procedure to an embarrassing degree. The existence of dangerous dyspnoea or dysphagia as a complication of laryngeal neoplasm has been pronounced by some authorities the only indication for a thyrotomy. The idea of possible transformation from a benign to a malignant character as a result of traumatism from repeated use of instruments seems to have been satisfactorily disproved. Finally, the introduction of cocaine may be said to have revolutionized intralaryngeal surgery. Operations that formerly would have been impossible may now be done with the greatest ease and deliberation. In view of these facts the conclusion seems to be justified that we may safely prolong attempts at removal of benign neoplasms by the natural passages to an indefinite extent.

Paper.

A CASE OF LARYNGECTOMY BY A NOVEL METHOD.

BY H. L. SWAIN, M.D.

THE only excuse which I have to offer in appearing before this association with the report of a single case of laryngectomy is the desire to submit to your judgment the method adopted, that, by the light of your scrutiny, it may be decided whether a repetition of the procedure would be warranted in future cases. At the same time, as removal of the larynx is not a frequent operation, a discussion of the method will not, I trust, be wearisome to you.

An operation for the removal of a carcinoma from any organ or portion of the body is looked upon with favor, accordingly as it more or less perfectly accomplishes the complete removal of said growth. And, in the second place, any given mode of operating takes precedence of the others as it is able to accomplish the first results with the least danger to the life of the patient, the least impairment of function and usefulness of the part, the least discomfort to the patient, and the least outward deformity, in the order named.

I take it that the experience of the gentlemen present agrees with my own in the particular that in only very rare and exceptionally favorable cases can we by any other than complete laryngectomy successfully remove the malignant growths of the larynx. What Dr. Delavan said last year in his paper concerning the withholding of statistics as regards the removal of malignant growths from the larynx I believe to be very true. If every case were reported, a different-looking table of mortality would appear, and hitherto the record has been bad enough and far from encouraging. But I think the attempts at removal by the less radical measures have been less generally reported when unsuccessful. The major operations are reported, the minor (such as thyrotomy and half removal of the larynx) are forgotten and unreported, because so very frequently followed by recurrence. Hence statistics show wrongly for both. Certainly, my own experience in such minor operations, though limited, has not been encouraging. The last thyrotomy, which was done only last year, when every chance of success seemed to be on the side of the operation, was followed by recurrence and death of the patient within fourteen months. But, granted that

my own experience may have been limited and sad, still, theoretically, the complete removal of the larynx offers the surest way to secure a removal of an intrinsic carcinoma beyond the possibility of a recurrence. This being acknowledged, one must consider the objections to the operation. Certainly it is a dangerous operation, for, as has been shown again and again, many of the cases die from the immediate effects of the operation itself. The mortality has been shown to be due to the following events: The shock of the operation as such; the effect of the removal of the larynx upon the heart and general circulation; the loss of blood; the penetration of this latter into the lungs at the time of the operation; secondary hæmorrhage; inspiration of the discharge from the wound, making a septic pneumonia; the infection of the general wound by the penetration of the secretions of the mouth pure and simple, and, when containing portions of food, increasing the danger of septic pneumonia; the difficulty in feeding the patient after the operation even by a tube, and the large wound, which must heal up by granulation, free to infection. The operation being recovered from, there remains a hole from the patient's pharynx into the neck, which keeps the danger of inspiration pneumonia still hanging over the patient like the sword of Damocles, and the usual tracheal opening, while between lies the large median wound to slowly heal. The patient can not talk, can not eat, can not even enjoy the luxury of a swallow of cold water, unless he effects a closure of the wound in the pharynx. He is still fed, but through an œsophageal tube, for a long time, and finally, when that is dispensed with, can only swallow as he stops up the opening from the throat. When later the condition of the wound permits, if his surgeon is gifted with the proper ingenuity, an artificial larynx is inserted, and, with a caricature of a voice, he is released from the hospital—alive, to be sure, but is he very happy? Notwithstanding all these dangers and discomforts, the operation, even by the older methods, is deemed and is justifiable.

Now, any method of operating which would lessen any one or all of these dangers would especially recommend itself as of value according to the premises at the beginning of this article. The chiefest danger to life outside of unskillful technique and accidents occurring in performing the operation is unquestionably that of septic infection or septic pneumonia.

Bardeleben found that sewing the trachea to the skin and shutting off the communication with the mouth changed his mortality after the operation from four deaths in five to four straight suc-

cesses. He later opened the wound in the neck to make room for the artificial larynx.

Poppert, of Giessen, following the same idea, operated in a case, sewing up the pharynx wound permanently and stitching the trachea forward into the median incision in the neck. The patient was immediately able to swallow fluids, and could speak in whisper tones. The voice later increased in power.

Hans Schmid,* as long ago as 1888, reports a case where inadvertently the same result was obtained and the patient was able to speak in a hoarse monotone voice, but withal sufficient to get along with under ordinary circumstances.

In addition to these examples of operating without the pharynx opening, you will all surely remember a certain Quaker City patient who was exhibited by Professor J. Solis-Cohen at the last meeting of our association. Here was a man who, without his larynx, spoke easily and audibly by what was termed a buccal voice. No communication existed from the pharynx with either the trachea or exterior of the neck, save a very small fistula opening externally. The patient was able to swallow liquids and solids easily and comfortably, and, moreover, was able to get along without any tube in the tracheal opening. His larynx had been entirely removed by a series of operations, the lips of the wound sewed together, and the wound into the pharyngeal cavity altogether closed. This made an anterior wall to the œsophagus, and, being elastic and distensible, the patient had succeeded in learning to dilate it sufficiently to afford a reserve of air—a sac—which enabled him to say a word or two without refilling. It was this air which the patient propelled against some tense, vibratory surface, tension being produced by the constrictors of the pharynx, and produced sounds which, modified by the mouth, tongue, and lips, became speech †—a wonderful exhibition of how Nature may be depended upon to help fill the gaps in space and function when intelligently assisted. Save for the fact that the patient was unable to make any connection between his lungs and his mouth, and did not get his air properly moistened, sifted, and warmed, he was every whit as comfortable as the generality of people, and his functional capacity in the world but little damaged.

* These references are excerpts from an article by J. Solis-Cohen in the *Archiv für Laryngologie und Rhinologie*, Band i, Heft 3.

† In the *Medical News* of March 17, 1894, Harrison Allen gives a number of very interesting facts concerning the production of voice in this case. It is somewhat disappointing that Professor Allen could not have kept up these observations longer, as he had desired to do.

The salient points were, then, that he could talk as well and better than most patients with an artificial larynx, he could swallow immensely better, he had no mechanical contrivance which might at any time get out of gear, which needs attention and constant cleansing, and he had no other wound or disfigurement of the neck than the tracheal wound, which latter he could cover up very nicely. A further advantage was that there was no irritation of the wound from the tubes—tracheal and artificial larynx—and he was in no way worse off than those who have to breathe through a tracheotomy tube.

It will be thus seen that these cases—the results some of chance, others of a definite purpose—were better than the older methods in these following particulars:

1. The danger to life from inspiration pneumonia was very much less, owing to the shutting off of the mouth.

2. The patients could swallow with the greatest of ease as freely as usual.

3. The most wonderful of all, in at least three of the cases a voice useful if not beautiful, and fully as satisfactory as with any artificial larynx, was obtained, and that without the bother or trouble which the latter always is, while, furthermore, the possibility of starting a recurrence by the irritation of a constantly present foreign body—the artificial larynx and tube—could be entirely avoided.

4. The patients were very comfortable and not nearly as disfigured as with the artificial appliances.

Therefore all the conditions demanded at the beginning of the article were fulfilled.

A case of epithelioma of the larynx having presented itself, after much serious discussion of the matter with Dr. W. H. Carmalt, the attending surgeon at the State Hospital, it was determined to remove the larynx according to the methods to be related. On the day previous to that set for the operation Dr. Carmalt and the writer rehearsed the operation on the cadaver and found it possible to outline every step as it later was accurately carried out on the patient.

The previous history of the patient is as follows:

Mr. S., a German, joiner by trade, consulted me at the dispensary on the 18th of October, 1892, for a hoarseness which had existed without pain or coughing since last summer. Patient was not aphonic, but simply very hoarse. Never previously hoarse for long at a time. Family history good.

Status Præsens.—A healthy-appearing man of middle height, forty-two years old, well nourished, with no outward deformity of neck or chest. Lungs, chest, and abdominal organs were healthy. Mouth in order. Pharynx bluish-red, as so often seen in smokers and beer-drinkers. Larynx slightly congested in appearance, but presenting on the right vocal cord a tumor. The latter was as large as a good-sized pea, projected from the free edge of the cord in about the middle, and possessed of a broad base and firm consistence. Color was light red, evidently due to its abundant vascularity. No swelling or infiltration of the rest of the true or false vocal cord. No immobility of the cord other than pure inertia.

Diagnosis was made of a fibroma of the vocal cord and attempts were immediately begun toward its removal. Owing to the broad attachment and firm consistence of the tumor, forceps proved useless and so did the snare. The attempt was about to be made to slit it off with the knife when patient disappeared and returned in December last after more than a year's absence with a vastly different condition of things present. Instead of a tumor, there was an ulcer and a defect of the vocal cord where it had been. The false vocal cord had begun to swell. There was no excrescence of any kind visible. Later a very distressing cough developed, and as the swelling and ulceration began to increase, a question as to tuberculosis arose. This was finally settled negatively and the cough got better about February 1st. Just previous to this time some subchordal swelling developed, and later the whole lateral surface of the larynx seemed to be elevated and narrowed the lumen. The false vocal cord was smooth and swollen sufficiently to completely cover in the true, and, although the diagnosis was made of epithelioma, nothing presented itself until the 1st of March which could be removed to examine microscopically. The glands in the neighborhood were enlarged. There were no subjective pains; some soreness on swallowing.

At this time the stenosis of the larynx had become so alarming that the patient was admitted to the hospital for tracheotomy. This was done March 5th under cocaine. Patient recovered from the operation quickly, and the swelling in the glands disappeared in a few days. About this time a small excrescence appeared, jutting out from the ventricle. Attempts were frequently made to get a piece out large enough to make an accurate preparation for the microscope in order to settle the little remaining doubt of the existence of a true carcinoma. This was finally done just previous to the operation.

The condition of the larynx was then as follows: Right half of larynx completely filled out by swelling, which, at least in the case of the false vocal cord, completely blocked the larynx, leaving just space enough to see the left cord on its posterior third. This part, the epiglottis, and both arytenoids were entirely free from disease. No glimpse of the interior of the larynx was to be had, but, as its exterior was perfect, the conclusion was fair that the whole of the tumor could be removed.

The operation was performed on March 18th by Dr. Carmalt, assisted by Dr. W. W. Hawkes and the writer and in the presence of Dr. J. Solis-Cohen, of Philadelphia, whose advice on the occasion was very helpful. The integuments having been cleansed, the anæsthesia was begun at 10.30 A. M. The first step was to carry the incision from the lower border of the tracheotomy wound down to the sternum. The trachea was bared and the incision carried down through the third and fourth tracheal rings. The old cannula was withdrawn and a sponge Trendelenburg cannula introduced. This had been so arranged that the sponge was very dry and absolutely flattened around the tube. A little water was conducted to it through the usual tube for inflating the regulation rubber bag. The sponge immediately swelled enormously and perfectly closed the trachea so that only once during the operation did it leak air, and on its final removal had only let through a very little blood. This was due to the sponge not being absolutely round. It also caused no irritation. Threads were secured to the cut ends of the first tracheal rings, but only one held, the cartilage being too brittle. The incision in the skin was then extended upward to the hyoid bone in the median line and a cross cut made to the sterno-cleido-mastoid of either side. The larynx was then carefully laid bare. Each bleeding point was checked as we went along. When finally all was cleared away, a director was carefully passed back of the trachea between it and the œsophagus and acted as a guide to the bistoury which severed the larynx from its neighbor, the trachea. A strong hook now was stuck into the larynx, and very carefully the latter was dissected away from the anterior wall of the œsophagus from below upward. When the ary-tænoid cartilages were reached the direction of the incision was changed and directed toward the base of the epiglottis, including in its path the mucous membrane covering the ary-tænoids and portions of the ary-epiglottic folds. The long cornu of the thyroid cartilage was cut across. The epiglottis was finally cut across just through the tuberculum and the larynx soon freed from all attachments. Careful examination showed only one slightly suspicious spot on the mucous membranes in this locality, which had been retained, and that was carefully removed. The epiglottis was then stitched to the posterior border of the opening which had previously been the rima glottidis and closed the ring completely, thus bringing the epiglottis in contact with the ary-tænoid mucous membrane, converting the ring into a linear wound running from side to side. A perfect anterior wall was thus made for the œsophagus.

Examination of the upper border of the trachea showed that on the right side there was a decided evidence of epithelioma, and so a portion of two rings on that side had to be pared away. The other side was trimmed to match.

Everything being ready and all hæmorrhage having been stilled, the wound was sewed up with continuous catgut suture, beginning with the cross incision in the skin at the top of the wound. When the trachea was reached a few strong sutures were introduced in front to prevent the

trachea slipping downward, and then the cannula was removed. This was followed by the complete stitching in of the trachea into the wound, making a round opening which turned upward and forward. Wound was dressed with simple dry dressing. No tracheal tube was inserted. Operation was finished at 1.30 P. M.

During the entire time the patient had been perfectly anæsthetized and only once gave any signs of weakness. This was when the larynx was being taken out. Whether the vagus was a little pressed upon in some way by the instruments or cannula or whether the tracheal tube was stopped did not appear. He did not breathe for a few seconds, but later concluded to go on and there was no further trouble.

He recovered well from his ether, and, save for a little nausea, was very comfortable. He was made to lie flat on his back and the foot of his bed was kept raised, so that the head was lower than the feet for twenty-four hours. When thirsty he was allowed to sip a little sterilized water, which he swallowed easily and without much pain. He was fed through a tube in the œsophagus.

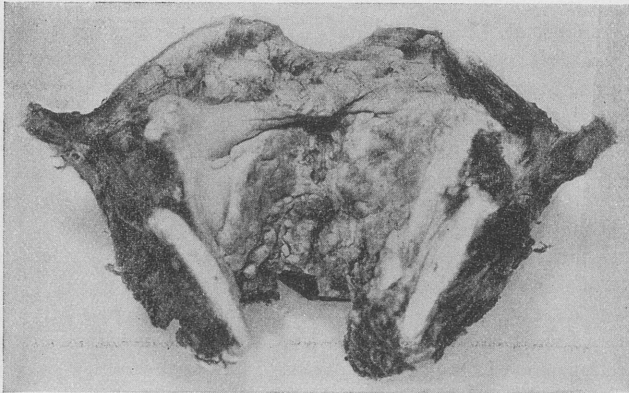


FIG. 1.—Photograph with illumination from above. The whole interior of the larynx is covered with the epithelioma, which can be seen to extend from the free edge on the right to within a short distance of the same on the left.

During the first few days the mucus stuck most tenaciously to the opening of the trachea, and when later the wound swelled up, especially at the sternal border, the tracheal opening was considerably below the level of the neck, and thus the removal of mucus was very difficult. The swelling caused a stitch or two to tear out on the third day, and ice was kept constantly upon it. Gauze wet with Thiersch's solution covered the opening, the same being used to cleanse the wound. The temperature did not get above 100° at any time, and on the third day began to go down. On the 22d a pus cavity was found above the opening of the trachea, where one of the stitches had pulled out from the upper posterior

border of the trachea. The cavity held a half-teaspoonful of pus and lay behind the integument flap in front of the œsophagus. This healed up in a few days. There was no other trouble with the rest of the wound. The

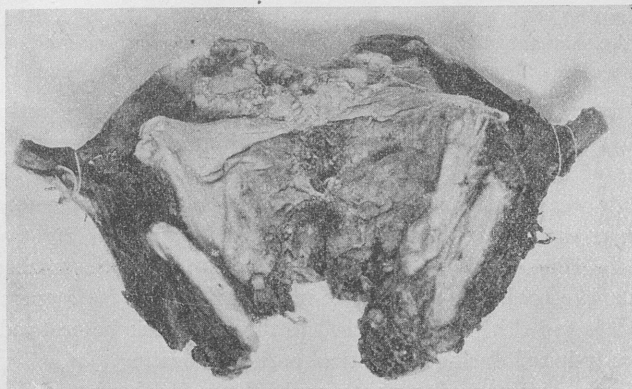


FIG. 2.—The same, illumination from below.

wound in the mouth, or rather pharynx, healed apparently by first intention. No trouble was found in swallowing small quantities slowly, and so on the 26th the patient was allowed to swallow all his nourishment, it, of course, being all fluid. Up to this time the œsophageal tube had been passed easily.

By April 1st the patient's wounds were all in such good condition that he was put upon regular hospital diet. About this time it was noticed that the tracheal opening, instead of remaining round, was becoming slit-like, and it was decided to put a tube in to make it regain the right shape. Since that time the patient has had no especial trouble and has been of no inconvenience to his medical attendants, except in getting the right kind of a permanent tube. Some of these latter, for he has had several, gave him a peculiar pain when out of position or when he coughed. The pain would streak down to the neighborhood of the heart and then run down his arm, exactly like the pains of angina pectoris. I could produce them by pressing the tube downward against the sternum. Of course, patient was very quiet at first and did not disturb his nurses by talking too much, but later in his constant efforts at talking the merest trace of a whisper could be heard. This was in pronouncing *s*, *z*, and *ch* in German. Later the whisper became more evident on these same letters, and by watching lips the whispered consonants made his speech quite intelligible. Even now words are not clearly spoken, but at the present writing I am able to understand short sentences or single words very satisfactorily with my back turned and he several feet away. His German is better understood than his English, although he speaks the latter perfectly well.

He can whistle, as he says, "ganz gut," and he craves to smoke, a thing which he can accomplish. By developing the power to whistle he will add to his ability to speak. Certainly he is making constant progress in this direction. In every other respect he is perfectly well and nothing seems wrong with the wound inside or out. Inside, the epiglottis joins on to the remnant of the arytenoids, which show as two small hillocks at the base of the former. There is no marked depression between.

I can see nothing in this case to discourage me in operating in the next in the same way, and the only thing which suggests itself by way of criticism of the procedure is that the next time I should advocate wearing the tracheal tube from the start. Expectoration would be easier, and then the wound would assume the right shape from the start. I think it is an advantage to have the trachea accustomed to breathing air directly into it before the main operation, as both it and the patient are used to the conditions beforehand and are less irritated during the critical period of healing.

For the accompanying photographs I am indebted to Professor M. C. White, who has skillfully reproduced for you the appearance of the larynx after splitting open subsequent to the removal.

Paper.

SINGERS' NODES.

BY FREDERICK I. KNIGHT, M. D.

THE affection of which I wish to say a few words consists, as I have seen it, of a small ovoid nodule situated on the edge of one or both vocal cords at about the junction of the anterior and middle thirds, and can usually be attributed to extraordinary or improper use of the voice. It has been described as one of the conditions found in chronic laryngitis, but also as "trachoma of the vocal cord" and "chorditis tuberosa." It occurs, however, as has been pointed out by Rice,* as a primary affection, with or without subsequent general laryngitis. I described a case as "trachoma" in the *Archives of Laryngology* for 1883. The cases of Türk, who suggested this name, presented multiple granulations not only on the edge but on the upper surface of the cords, and the name seems most appropriate for these cases. The single nodule on one or both cords, although it may be pathologically the same, consti-

* *Transactions of the Am. Laryngological Assoc.*, 1890.

tutes clinically a distinct affection, and is, I think, entitled to a separate designation. Whether the term "chorditis tuberosa," which Dr. Rice adopts, is entirely satisfactory is doubtful, as there may be little or no chorditis, and this term has been also unfortunately applied to the diffuse form. Singers' node is not exactly appropriate, because the subject, though usually, is not always a singer. To be exact, we can only at present say that we find a node on the vocal cord in the above-mentioned site. This is usually whitish or yellowish-white in appearance, of the size of a millet seed or larger. There may be a depression in the edge of the opposite cord in the corresponding spot, or a little nodule here also. The mucous membrane of the adjacent parts of the cord may show signs of inflammatory action, but in the beginning this is often absent. The cause of this condition will almost always be found to be strain or wrong use of the voice in singing or speaking. It is said that friction of the edges of the cords is greatest at this point, hence the pathological change. The nature of this development has been but little studied histologically. Kanthack * examined three specimens from Krause's clinic, and found in one a simple local hyperplasia; in the second, cornification; and in the third, such a growth as comes from chronic irritation. No glands or vestiges of such were found.

The examinations were made on account of a statement by B. Fraenkel that these nodes were of glandular origin. Kanthack also examined twenty larynges, and found no glands in the vocal cords.

Rice had sections examined from two nodules which he removed from the vocal cord by a small snap guillotine, and the result in both cases was connective tissue and epithelial elements in largely increased numbers. M. Sabrazes and M. Freche † report on the microscopic examination of three specimens, that they are to be considered as circumscribed hypertrophies of the epithelium and chorion of the mucous membrane. Sometimes the thickening of the epithelium predominates, sometimes it is rather the papillary prolongations of the chorion; mostly both participate in the hypertrophy. Wedl ‡ made an examination of post-mortem sections of a "trachomatous" vocal cord in a patient of Türck, and found only hypertrophied connective tissue and proliferation of nuclei. This patient had the diffuse granular condition of both cords. She died

* *Internationales Centralblatt für Laryngologie*, etc., 1890.

† *Ibid.*, 1893.

‡ Türck. *Klinik der Kehlkopfkrankheiten*, 1866.

of tuberculosis. It will be noted that histologically the nodules were of the same character as the single ones which we are discussing.

The symptoms produced by these little nodes vary from slight hoarseness to complete loss of voice. In the latter case there is usually a considerable amount of laryngitis, or paresis of the tensors.

The prognosis depends largely on the duration of the condition, and the ability and willingness of the patient to carry out instructions. When seen early, and the patient is able to rest the voice, the prognosis is, in my experience, good; but if the patient is obliged to use the voice, especially if his method is wrong, it is serious, and under these circumstances the growth will probably continue and gradually increase, leading to the various secondary conditions, and, as in the case of all such developments, the older it is the harder is it to cause absorption or get a good result from operation.

The treatment of these nodules must vary with their size and form. Those which I have seen have been so small and sessile, so thoroughly incorporated with the cord, that any operative procedure seemed inadvisable, not only on account of the difficulty of extirpating the growth, but for fear of injuring the vocal cord. Sabrazes and Freche state that the nodule may be pedunculated, in which case the operation would be comparatively trivial. I have never seen such, and should doubt their identity with the kind I have described. I should have hesitated to cut into the vocal cord in any of the cases I have seen, unless the voice seemed ruined forever, as it was, and this gave the only hope, for the integrity of the singing voice depends on the integrity of the edge of the vocal cord. In the few comments published on the treatment of this condition there has been a great confusion of this and the diffused trachoma of Türk, from which it must be distinguished, notably in the discussion at Baltimore on Dr. Rice's paper. Dr. Rice himself, in the illustration of his article and in his remarks on treatment, evidently had in mind the single nodule on the edge of one or both cords, but at the beginning of the article he says that Türk's description of this condition is comprehensive, whereas Türk describes only the diffused condition occurring on the surface as well as edge of the vocal cord. Dr. Westbrook describes a nodule on the vocal cord of one of his patients growing from the vocal process forward. Dr. Daly said that the condition was not uncommon in tuberculous families, evidently referring to a diffuse granular condition of the cords. Dr. Delavan spoke of the recommendation of forcing a probang covered with cotton through the glottis in the hope that the granulations

might thus be scraped away, and that he had not found this method a success. This method was suggested by Voltolini for papillomata, which are often friable, but I can not conceive how any one could recommend it for the hard, closely incorporated nodule such as I have described. Neither should I expect to accomplish anything in this form but irritation—by scraping with the finger nail—as done in one case by Dr. Daly, even if I could reach the vocal cord. The epiglottis and tips of the cartilages of Santorini are as far as I can reach with my forefinger in most cases, and the vocal cords are considerably further off.

Dr. John N. Mackenzie said we should distinguish between a mere granular condition and the genuine chondritis tuberosa, evidently meaning by this latter term the diffuse form, as he says the whole cord is converted into a band like a granular lid, and is usually incurable.

In my cases so far I have found that by rest and astringents, if there was also inflammation of the surrounding mucous membrane, the voice has been so far restored that I did not feel justified in risking cutting operations; but if after this treatment there was still no useful voice, I should not hesitate to employ Dr. Rice's guillotine and remove the protruding portion of the growth, if it could be engaged, hoping that the remainder would be more readily absorbed. I have not been able, from Dr. Rice's published paper or his remarks in the discussion, to find out just how much of a voice the patients whose nodules he excised ever acquired after the operation. Neither have I been able to learn how the nodules were removed nor the resulting condition of the voice in the cases of MM. Sabrazes and Freche (Lichtwitz's clinic) nor in the cases of Kanthack (Krause's clinic).

The object of this brief paper is, first, to call attention to the imperfect nomenclature of this affection, and to recommend the abandonment of the term "trachoma of the vocal cord" for the form of the affection which I have described, and the restriction to that form of the term "chondritis tuberosa," if it should seem best to retain it; and in the second place to elicit reports of operations on single nodules (unilateral or bilateral) situated as I have described, and especially the effect of their excision on the singing voice.

Discussion.

Dr. GLEITSMANN had used the galvano-cautery in these conditions, and had been well satisfied with the result. He also advocated chromic and trichloroacetic acid.

Dr. S. W. LANGMAID said he believed destruction of the nodule was the proper procedure. It was to be regarded as a tumor. There was great danger of recurring chondritis in these cases, for which rest and topical medication were the remedies. In his opinion unskillful use of the voice and prolonged vocal efforts predisposed to this condition. He had seen these nodules on the vocal cords of singers whose voices were still beautiful, but in such cases the nodule did not extend to the free border of the cord. If it did, the singing voice was necessarily injured or destroyed. He had never seen the nodule removed except by forceps.

Dr. T. M. MURRAY said he had seen four cases of singers' nodes. The first was in Vienna, and was treated by Professor Stoerk. The result was good. The next time he saw such a case he tried Stoerk's method himself, and was much pleased with the result. The operation consisted in simply touching the spot once with nitrate of silver fused upon a silver laryngeal probe. The patient should not speak once for twenty-four hours after the application. One of his cases was a child of seven years. One, an actress whom he had treated in this manner, regained her voice completely.

Dr. J. WRIGHT said he could indorse the statement made by Dr. Langmaid concerning chondritis. In some cases the cords looked as if they were powdered at their middle. In these cases the nodule disappeared by an application of nitrate of silver or other metallic astringent. In one of his cases the condition disappeared spontaneously. He had never used the guillotine and forceps, and he thought in the majority of cases a mild solution of nitrate of silver would suffice. In exceptional instances there seemed to be a diathesis, particularly among phthisical patients. He would like to hear from others as to whether there usually was any association of these conditions.

Dr. FRENCH said that he had had an opportunity to treat quite a number of cases of the disease which Dr. Knight so well described, and had been impressed with the value of local applications of astringent and alterative remedies in those cases in which he had been permitted to continue them for a considerable length of time. The first opportunity he had had to test their value under such conditions was in the case of a young woman on the edge of whose left vocal band several nodules developed as the result of serious abuse of the voice. Her voice was so powerful, its quality so good, and she was so intelligent and enthusiastic regarding vocal music that the leader of the volunteer choir to which she belonged took advantage of her good nature and used her voice out of all reason to show those less gifted how the music ought to be sung. In the course of a year her voice began to grow hoarse, and in a short time afterward it broke down completely and she placed herself under my care for treatment. The left vocal band was found to be much thickened and congested, and upon its edge were two flattened nodular masses of considerable size, which may be appreciated by in-

specting this photograph taken of her larynx at the time treatment was begun.

The changes were rung on weak solutions of the various astringent and alterative remedies, which were applied on an average of three times a week for two years and a half, when the vocal band regained its normal appearance and her singing voice was completely restored. She was now singing in a quartet choir, and her friends thought that her voice was as brilliant in quality as it ever had been.

Surgical measures were but seldom indicated in these cases. Certainly in those in which the vocal band was thickened such measures could be of no avail. The existence of a condition which would be benefited by the use of the little guillotine described by Dr. Rice must be very rare.

In his opinion there was no relation between tuberculosis and the disease under consideration.

Dr. W. K. SIMPSON, of New York, said the development of singers' nodes depended not so much on the wrong method of using the voice as on its immoderate use by whatever method. He did not think they were necessarily tubercular, but a tubercular subject would be more disposed to their formation. They sometimes began by slight hæmorrhages which became organized. The main point of treatment was rest.

The PRESIDENT said he had never found any connection between the condition under discussion and the tubercular diathesis. Surgical treatment was appropriate only for those cases in which the nodes were of considerable size. He had treated many of these cases by local applications, and had obtained as good results as from surgical measures. One such patient had been under his observation for ten years. In her there were nodes in the middle of both vocal bands. She received local treatment for a year and a half, and was then put under the care of a good musical instructor. The nodes never entirely disappeared, but she had steadily improved in her singing, and had been promoted to one of the best professional positions in the city, singing acceptably in church, concert, and oratorio.

Dr. F. I. KNIGHT said he would like to ask Dr. Murray if the solid stick of nitrate of silver were used for its destructive effect or to stimulate absorption.

Dr. MURRAY replied that it was his impression that it had been used to stimulate absorption.

Dr. KNIGHT said that if he desired to destroy tissue he would use caustic potash. He had never seen any evidence of the tubercular diathesis in any of his cases. He was sorry that he had failed to elicit any information in regard to the permanent effect of surgical operation on these nodes upon the voice.

Paper.

A CASE OF EXUDATIVE PHARYNGITIS.

BY WILLIAM C. GLASGOW, M. D.

I AM indebted to Dr. E. W. Saunders, the physician in charge, for the history of this case:

Child, aged ten months, very large and robust; previous health perfectly good. After unusual exposure to cold was seized with an otalgia; no fever. After two days the earache ceased, coryza set in, and fever developed. The temperature gradually rose to 104° in the evening, with marked morning remissions. Torrents of mucus were unceasingly poured out from the nares, blistering not only the muco-cutaneous surfaces but even the skin of the neck and hands wherever it touched. The secretion from the fauces was almost as abundant.

There then developed an exudate upon the tonsils, the uvula, the soft palate, and the pharynx; none was visible in the anterior nares. The patches were persistently white, very much elevated, easily detached, and left no ulcerated surface, except on the palate, where it was probably due to mechanical irritation. The larynx could not be seen; but there was aphonia, lasting far into convalescence.

Dyspnœa became so urgent that preparations for intubation were made. Deglutition was so difficult that the child took nothing willingly, and at every effort some fluid was returned, very much as in a case of diphtheritic paralysis.

The lesions upon the skin were very similar to those upon the mucous membranes, only the edges were raised, and upon an excoriated base the exudate appeared. There was no lymphadenitis. The bronchial mucous membrane was never involved, neither was that of the stomach and intestines. The nutrition was remarkably preserved, owing to forced feeding with skillful nursing. The resemblance to scarlet fever or diphtheria was not close enough to make the differential diagnosis very difficult at any stage of the case.

The treatment was benzoate of sodium, salol, brandy freely administered, and locally the peroxide of hydrogen with boro-glyceride (8 to 1) diluted with warm water and sprayed into the nose and throat. When a little bicarbonate of sodium was added to this solution the irritating effect became immediately apparent (just as in cases of scarlet fever), and the reason for this is obvious when it is taken into consideration that the discharge is highly alkaline.

Aristol was found to be very healing to the skin lesions. Convalescence was remarkably rapid and complete, being only slightly interrupted by a suppurative otitis.

The whole duration of the case was about three weeks. A bacteriological examination of the secretion showed a large number of streptococci.

I have considered this case to be one of the protean forms of influenza. The points of interest are the mild resemblance it bears to diphtheria and the enormous amount of alkaline discharge, together with the peculiar character of the exudate.

Discussion.

Dr. JONATHAN WRIGHT, of Brooklyn, said he was very much interested in this question of "streptococcus throat," as Dr. Glasgow had called it. He doubted very much if there were any significance in the finding of streptococci in this lesion, because they had been found in perfectly normal throats, and they were found in diphtheria. It seemed to him that the surgeon should consider other factors than this as the cause of the lesion. It was a remarkable fact that while such cases had been reported in Philadelphia, St. Louis, and Baltimore, there had not been one as yet in New York, notwithstanding its wealth of clinical material.

Dr. GLASGOW asked to be allowed to cite an instance bearing on the remarks just made by Dr. Wright. A few years ago a singer had come to him in St. Louis. He had lost all power over his voice about ten days previous to his visit. It was learned that he had come from Brooklyn. His true cords were found to be extremely swollen and oedematous. After being under treatment for ten days he was able to sing as well as ever. He had lost his voice in Brooklyn. The speaker said he had seen these cases from all parts of the country—New York and Boston, as well as the western slope.

Paper.

A CASE OF SARCOMA OF THE TONSIL.

By ARTHUR W. WATSON, M. D.

THAT sarcoma of the tonsil, although a rare affection, is not so infrequent as was formerly taught would appear from the long list of cases now on record and the fact that the list is growing rapidly. In his article on Malignant Disease of the Tonsil (*Am. Journal of the Med. Sciences*, 1892) Newman mentions having collected fifty-two reported cases. Since that time I have found ten more recorded, two of which were reported during the past winter.

Compared with carcinoma of the tonsil, sarcoma may be con-

sidered uncommon. The variety of sarcoma most frequently found in the tonsil is the round-celled; it is also the most malignant.

The following case is one of round-celled sarcoma:

Mrs. F., aged fifty-three years, a German, came to the throat clinic of the Philadelphia Polyclinic, January 15, 1894. She stated that she had been well, with the exception of an attack of influenza, up to Christmas day, when she was taken with a severe sore throat, which the physician who then attended her pronounced an abscess of the tonsil. She thought there had been a slight discharge of pus, but there had been no relief of the pain, which continued to increase. At the time of her first visit to the clinic she complained of continuous severe pain in the left side of the throat, aggravated by attempts at swallowing, especially solids. The pain extended to the ear, where it was very acute, effectually preventing sleep.

When the throat was examined there was found moderate swelling of the left tonsil, to which the anterior pillar of the fauces, thickened and spread out, was adherent. Both the tonsil and anterior pillar were greatly congested; a network of engorged capillary vessels could be seen covering the surface. There was general congestion of other parts of the fauces. One enlarged lymphatic gland, the size of a bean, could be felt beneath the angle of the jaw. There was no ulceration or infiltration of surrounding tissues, except the anterior pillar. The patient's general condition was good, although she was reduced from pain and loss of sleep.

At first, as the diagnosis was uncertain, she was given general remedies and local applications. As there was, from the history of the attack, a possibility of retained pus, and as the patient herself was possessed with the idea that she had an abscess, a deep incision was made into the tonsil. No pus, however, was found, but the bleeding was very free. Later, a piece of tissue was removed and was submitted to microscopic examination, which showed it to be a sarcoma of the round-celled variety.

As the patient readily consented to an operation, no more time was lost, and on the 14th of February, about six weeks from the onset of the disease, the tonsil and anterior pillar were removed. The operation was done under cocaine anæsthesia, the patient seated in a high-backed chair, and the head steadied by an assistant. The parts having been thoroughly cocaineized, the tonsil was caught with a tenaculum and drawn inward, and with a flat galvano-cautery knife was dissected out entire, together with the anterior faucial pillar. The dissection was made by short strokes of the cautery, and there was no difficulty in keeping the knife hot. There was no bleeding, and very little pain until toward the last. For a few days after the removal of the tonsil there was considerable pain, but it was relieved by sedatives and gargles. After the operation the wound became covered with a thick, white slough, which in a week had cleared off, and a few days later the throat was entirely healed. Three weeks after the operation the following notes were taken: The patient can swallow without difficulty; the pain in the ear is almost gone; she sleeps

well; the gland beneath the angle of the jaw has disappeared. The patient has been seen recently and is still doing well. It is now over three months since the tonsil was removed.

Some of the symptoms in this case are worthy of notice as being out of the common: The apparently sudden onset of the disease, simulating an acute amygdalitis; the marked pain and dysphagia, in the absence of ulceration or extensive infiltration. The first, I find, is noted in some of the reported cases. These symptoms certainly increased the difficulty of early diagnosis.

Removal of the tonsil by the cautery knife has been done in several of the reported cases. Thus, in the well-known case of Gorecki, in which no recurrence had taken place in two years, the thermo-cautery knife was used. In a case of epithelioma of the tonsil reported by Newman (*Am. Jour. of the Med. Sci.*), in which there was no recurrence, the galvano-cautery knife was employed. Several operations are reported where the cautery loop was used; the results in some of them were very good; but I do not think the loop is as efficient as the knife, as it does not remove all of the gland, and can not be made to include other structures that may be involved. It seems to me that this method of cutting out the parts with the cautery is preferable to the use of the knife or curette, in that there is no hæmorrhage (an important point in operating in the mouth), the operation can be made thorough, and the wound is effectively cauterized—a precaution which is often taken after removal by the knife.

Paper.

THE IMPORTANCE OF AN EARLY DIAGNOSIS OF MALIGNANT
TUMORS OF THE THROAT.

BY J. W. GLEITSMANN, M. D.

ALTHOUGH I shall not be able to present any new facts in connection with this subject, I venture to make these remarks on account of recent observations which have left a lasting impression on my mind. It has fallen to my lot to see during the last few years an unusually large number of malignant tumors of the throat and its adjacent regions, and the unsatisfactory results obtained have very naturally created the desire to better, if possible, the chances of the patient.

When a patient calls on us in whom, after a careful examination

and possibly prolonged observation, we have made the diagnosis of a malignant growth, there are, so far as the writer's knowledge goes, not many means open for us to deal with the affection. I shall not ventilate the question of the possibility of an operation in cases which are so far advanced that the decision has to be left to the patient, whether he will slowly die after the performance of tracheotomy to relieve stenosis, or take the risk of a probable death by an attempt at removal. I shall confine myself to speaking of three methods which are practiced at the present time, and which have been followed by cure in a certain number of cases.

The first method, which naturally has most interest for the laryngologist, is the endolaryngeal operation. It has been proved by a number of instances, to which I shall presently briefly refer, that not only temporary removal but also a lasting cure can be attained by this procedure. It is to be regretted that such opportunities are so rare, as in my opinion endolaryngeal treatment could be much more frequently resorted to if the patients came early enough for examination. The majority of those I have seen did not come directly to me on account of their throat trouble, but were sent by physicians, and in no case was endolaryngeal treatment feasible or rational.

The first endolaryngeal operation for epithelioma of the vocal cords was done by Schnitzler in the year 1867, with no recurrence twenty years later. He published a record of his operation as late as 1888, and was, therefore, antedated by B. Fraenkel, who demonstrated his well-known first case of a cure of laryngeal cancer *per vias naturales* before the congress of German surgeons, 1886. Fraenkel also relates in his treatise on cancer of the larynx five more cases operated upon in the same manner, the result of one of which is unknown; one patient was permanently cured, one had had no relapse in two years, another none in six months. In one patient the operation was a failure. Schnitzler also cites in his paper Türck, Mackenzie, Fauvel, Navratil, and Gottstein as endolaryngeal operators in this field. Finally, Schech removed a large laryngeal sarcoma with the galvano-cautery snare. These few citations, which are by no means intended to be exhaustive, illustrate sufficiently that in isolated suitable cases the endolaryngeal method is justifiable and entitled to a trial.

As I said before, the laryngologist has only very seldom the opportunity of trying his skill in curing or even completely removing a malignant neoplasm by methods pertaining to his specialty.

We, therefore, have to look for other means, when the growth has transgressed the domain of our working power, or when the lymph glands have already become affected.

Fortunately, a short time ago a method was devised which seems to be efficacious in at least one class of malignant tumors—viz., sarcoma. I refer here to the method of Dr. Coley of inoculations of erysipelas and later on of its toxic products, obtained by the cold process. As Dr. Coley will read a paper on this subject before the Surgical Association, I feel somewhat restrained as to anticipating his statements, but he very kindly, at a personal visit, gave his consent to my giving his views to this association. His publications on this subject are to be found in the May number of the *American Journal of the Medical Sciences*, 1893, in the *Post-Graduate* in August of the same year and the Supplement of Wood's *Reference Handbook*, 1894. As this method seems to me a very important one, I beg your indulgence while I reiterate briefly what has already appeared in print and is well known to you. Dr. Coley states in the *Post-Graduate* that he inoculated twelve patients with inoperable malignant tumors with the living cultures of the streptococcus of erysipelas, in four of whom he succeeded in producing a true attack of erysipelas. All four patients had sarcoma, one of them of the tonsil, which diminished considerably in size, and had not increased after two years. In Case No. 1, related in the same paper, the patient had a sarcoma of the abdomen and pelvis measuring five inches by seven inches. After three months' treatment the tumor was reduced to two inches in diameter, and by verbal communication on April 18th it was learned that the boy was perfectly well, only a very small mass remaining in the inguinal region. This patient, as well as five others, were treated with the toxic products. Dr. Coley further permits me to state that in Case No. 3 in Wood's Supplement, with sarcoma of the soft parts of the back seven inches by five inches, and metastatic growths in the groin, the patient had recurrence after surgical operation. The first and second series of injections were made with erysipelas, the third with toxic products, and the patient remains cured now, over a year. The doctor's cases were all inoperable; he has also noticed improvement, but no cure yet, in cancer, and he finally obtains the best effect when the injections are made into the tumor itself. The zeal and devotion with which Dr. Coley develops his mode of treatment promised to inaugurate a new era for such poor sufferers, and I have no doubt will also yield encouraging results in our special departments.

In this connection must also be mentioned the application of methyl blue to cancerous tumors, with which our New York colleague, Dr. Willy Meyer, has made extensive experiments. He has informed me that his results from local applications have not been very satisfactory, but better from internal administration.

As it is evident from the foregoing that only a very limited number of cases can be satisfactorily treated by the above-mentioned methods, we naturally look for surgery as the best means for relief.

As to the surgical aspects, the throat is not different from other parts of the body, and, if we choose two examples, the larynx and pharynx are analogous to the breast and uterus. By referring to the development of surgery in these last-mentioned two regions we shall find that, not many years ago, at a time when antisepsis was not practiced, the operation for removal of the breast for cancer was complicated with immediate danger, the mortality at the time being about thirty-three per cent., while now it is reduced to three per cent. After elimination of the danger of sepsis surgery grew bolder and the operations more numerous, and, when complete eradication could be accomplished, the number of cures became larger. The operation on the breast having once been established and recognized, the same principle was adopted for the uterus, and here also the results are good if the growth is endometrial and thoroughly removed.

If this argument is correct as to the breast and uterus, it must also hold good for the pharynx, larynx, etc., and we can go a step further and say for all accessible parts of the human body.

But, with all the strides surgery has made in technique and anti-septic methods, there is also a line drawn for the surgeon which stays his hands and compels him to lay his instruments aside. I am convinced from my own observations and from conversation with some of our representative surgeons that by far too large a number of cases are seen by competent men only when the patient has reached a stage where an operation is either impossible or extremely hazardous. All the gentlemen spoken to commit themselves unqualifiedly by saying that the majority of cases come to the surgeon at too late a stage for favorable results. Excepting traumatism and sepsis, delay in operating is the most potent factor for bad results in surgery. I willingly concede the difficulty of a diagnosis, especially of an early one, in many such cases, and also fully appreciate the delicacy with which some of them have to be treated before the final overture. But the diagnosis once having been made by the

practitioner or consultant, delay from any cause whatsoever is unjustifiable and unpardonable. If a patient is horrified at the idea of an operation, he can easily be induced to submit to it when told that he has a tumor in his throat which, if not removed, would grow and endanger his life. Many of my patients have been operated on without the word "cancer" ever having been mentioned to them either before or after the operation.

Although laryngology embraces only a small part of the human body, the same considerations hold good in this region as in others, and the laryngologist can speak the more forcibly as to the necessity and the frequent neglect of an early diagnosis, as he can not be accused of any selfish motives, in view of the fact of his not being the operator in the majority of cases. It is not within the range of this paper to discuss the merits of the different operations, and it must be left to the surgeon in each individual case to decide if he will perform tracheotomy only, or extirpate the larynx *in toto*, or do modified laryngectomy, as recommended by our esteemed member, Dr. J. Solis-Cohen, in suitable cases, or practice laryngofission. As to the latter, the record of the Russian surgeon, Pieniazek, deserves mention (*Zeitschrift für Chirurgie*, vol. xxxvi), he having published a series of thirty-seven cases of laryngofission done with the head hanging down, and followed by two deaths only, one from diphtheria, the other from tuberculosis.

I shall not tax your time or patience with a history of my patients, but only give a short *résumé*. Of a total of thirteen cases, the pharynx was diseased six, the larynx seven times. Carcinoma of the pharynx was seen four times—at the lateral wall, at the posterior wall, at the palate, and at the base of the tongue, implicating the epiglottis at the time of first examination. The patient with affection of the palate was operated upon three months ago, and feels well at present; the others died. Of two cases of sarcoma of the tonsil, one proved inoperable, in the other the patient lived over two years without recurrence after removal of the tonsil, tongue, and infiltrated submaxillary glands, but committed suicide, being unable to earn a livelihood. As to the larynx, six patients had cancer, and all six are dead; one with alveolar sarcoma is living without recurrence, according to latest report obtainable. Laryngofission, with removal of diseased tissue, was performed twice; unilateral as well as total extirpation, twice each; tracheotomy alone, in a far advanced case, once. The growth had its origin, so far as could be ascertained, twice at the ventricular bands, with implication of Morgagni's

ventricle; twice at the vocal cords; once at the glosso-epiglottic and arytaeno-epiglottic folds; and twice its origin could not be determined, as the larger part of the larynx was filled with the neoplasm. Death ensued twice from shock soon after the operation, twice from pneumonia on the second and third day; one patient had a recurrence after six months, and died subsequently from exhaustion. The last one, with total extirpation of the larynx, did very well for several months, the wound had healed kindly, and the patient had regained his strength. He awaited with impatience the insertion of an artificial larynx, which had been imported from Europe, when he suddenly died from appendicitis.

It is, of course, impossible and fruitless at the present time to reason as to how many patients would have survived the operation and lived without recurrence of the growth if they had not died from shock or intercurrent affections. But it is clear, at least to my mind, that the number of survivors would be larger if they had come earlier to examination, and an operation involving less risk and less loss of tissue had been possible.

If I have in my remarks entered more fully into the treatment of the subject than the title of the paper indicated, it has been done for the purpose of showing the futility of our attempts at relief when the neoplasm has reached a certain dignity as to its extension, and to appeal earnestly to the profession at large to make an early diagnosis of malignant tumors of the throat.

Discussion.

The PRESIDENT said that Dr. Coley, of the New York Cancer Hospital, had lately written upon this important subject, and had reported twenty per cent. of successful cases. It was of great interest to us to know just what the value of this method really was. Thus far the injections had proved sufficiently successful to warrant some hope of future advance in this direction.

Dr. JONATHAN WRIGHT said that the paper was very valuable indeed, for no doubt every member of this society had had more or less frequent occasion to answer for himself the question of operation for malignant growth. The most important element was in the diagnosis. In nearly every case of tuberculosis or cancer the great cry was, "We did not see the case early enough!" In the early stage of epithelioma it was often extremely difficult to make a diagnosis. It was in many cases necessary to wait until the microscope decided whether it was a benign or a malignant growth. The same was true of sarcoma. But in many cases there was no way of making a diagnosis until the clinical history had made it

evident. There certainly were some cases of sarcoma and carcinoma reported as cured where there was a mistake in diagnosis. It must have occurred to those who had been fortunate enough to discover their error in diagnosis before operating that there must be a great many cases operated upon and reported as cured in which there was really no malignant disease.

Regarding the injections of streptococci or of their toxins the speaker said that there were many cases reported in which the patients had received injections and no reactionary results at all had been obtained. In some cases it was justifiable to use almost anything. It was the height of cruelty to tell a patient you could do nothing for him. Something should be done, even if the patient were to die on the operating table.

Dr. H. L. SWAIN, of New Haven, said that the last speaker had mentioned a good many things which he had intended to say regarding the difficulty of making an early diagnosis. It was all very well to say that all cases should be seen early. He recalled a case which he had just reported where the patient had originally suffered from benign tumor of the larynx. Examination revealed one year later an ulcerative condition of the larynx and a swelling of the parts where the benign tumor of the vocal cord had been. The patient had also developed a cough. The patient was kept under observation for three months. The malignant growth developed rapidly, and only by obtaining a piece of it with great difficulty at the end of this time and examining it in sections an absolute diagnosis was reached. Three months had thus elapsed. In the removal of the growth the larynx was removed, and the operation conducted as described in his paper of yesterday. He had had some experience with operations upon the larynx, and if he ever had occasion to do the radical operation for cancer again he would do it in this same way. He had lately seen three such operations. One died of septic pneumonia. In the other two cases thyrotomy was performed, and every portion of the growth, which was circumscribed, was removed thoroughly. The growth returned in less than six months. To remove the whole growth in the case related it became necessary to do laryngectomy. This patient was now very well and would soon be able to talk distinctly. By this method of operating the danger from septic pneumonia was reduced to an absolute minimum. Four operations by an older method were on record by Bardeleben in which all four of the patients were lost; of the next five, by a method similar to the one mentioned, four lived.

The question of removal of tumors from the fauces reminded him of a recent hospital patient in which there was an extensive carcinoma. The patient strongly urged operation. The surgeon did operate, somewhat against his judgment, and was able to get around every part of the growth and get it out completely. It embraced the surface below the tonsil on one side and both pillars of the fauces. It was scraped and cauterized by the Paquelin cautery. Ligation of the external carotid assisted greatly in preventing hæmorrhage. It was now six weeks since the operation, and

there was no serious recurrence. He would add that the anæsthetic was administered through the trachea by a cannula, but the operation could have been done without this arrangement. The same patient had been subsequently etherized for the removal of a nodule which escaped the first operation, and this time, although the ether was administered through the nose, there was no trouble with the larynx. He would like to ask Dr. Watson if he thought his patient suffered much during his operation.

Dr. WATSON replied that the patient was a rather courageous woman, and had not complained of any pain until the operation had been nearly completed. In doing the operation he had started above and behind the tonsil and had passed down between that and the posterior pillar, and had come down through the anterior pillar. The removal had been accomplished by successive strokes of the knife. Cocaine was applied to the surface, not hypodermically.

Dr. W. K. SIMPSON, of New York city, asked how much cocaine was necessary in the operation, what was the strength of the solution, and whether the patient presented any symptoms of cocaine poisoning.

Dr. WATSON said in reply to Dr. Simpson's questions that he had used a ten-per-cent. solution of cocaine, and that there had been no symptoms of cocaine poisoning.

Dr. CASSELBERRY, of Chicago, said that he had had an unfortunate experience in a case similar to Dr. Watson's, only that it was more advanced. The patient was a young man, seventeen years of age. He had done the operation in the same way, using injections of cocaine. The operation revealed a sarcoma which was not confined to the tonsil, but involved other parts of the pharynx, including the pillars of the fauces, and the infiltration extended to the tissues of the neck. The growth could be but partially removed, and recurrence was rapid. An external operation was rejected by the patient's friends, and the case terminated fatally.

Concerning intralaryngeal operations for sarcoma of the larynx, he had seen recurrence in two cases, and he believed the method was not sufficiently radical and was prone to delay too long the more radical external operations by holding out what would prove to be a false hope to the patient.

Dr. SWAIN said, regarding the possibility of operating through the neck, that the operation mentioned was an external one. When the second nodule was removed they did not go through the neck again and had got along very well. He did not favor the external operation in such cases if it could be avoided.

Dr. GLEITSMANN said that he would confine himself to answer the remarks made in regard to endolaryngeal treatment and diagnosis.

He was still of the opinion that endolaryngeal treatment of a malignant growth was rational, but that it could be carried out only in isolated, selected cases, as had been said in the paper. He had a patient under

observation who complained of hoarseness, and presented on inspection a small nodule at the edge of one vocal cord. The surrounding hyperæmia, a slight sluggishness in the movement of the cord, made him suspicious of its character, and he advised endolaryngeal removal. The patient was unwilling to undergo any operation, and suffered now from a well-developed carcinoma. In this case endolaryngeal treatment had been feasible and probably successful, although he was well aware that, as a rule, growths in the larynx were much larger in reality than they appeared in the image.

As to the difficulty alluded to in the discussion, he would say that his paper had less reference to incipient cases in which the diagnosis might be in doubt than to cases presenting well-established symptoms in which a competent examination ought not to be delayed if relief was expected. He cited two cases—one related to him by a surgeon of his city, the other from his own practice.

In the first case—one of cancer of the breast—the patient had been allowed to go on without treatment until ulceration had reached an advanced stage, and then the surgeon had been asked to operate because, as the attending physician thought, “he had brought the patient just at the right time to operate.” The other case was that of a man, sixty years of age, who complained of being unable to swallow. On examining his fauces there appeared at first nothing but a chronic hyperæmia and thickening of the mucous membrane, but on attempting to examine a bulging of the posterior pillar there was a gush of foul air. The posterior wall opened like a valve and exposed a deep cavity a quarter of an inch in diameter, containing a cancerous growth in an advanced stage of ulceration.

Such cases, which he was confident had been seen by all the members in their practice, showed plainly the propriety of drawing once more the attention of the profession to the necessity not to delay diagnosis and proper action in malignant growths.

Paper.

NEUROTIC PHENOMENA IN THROAT DISEASES, WITH ILLUSTRATIVE CASES.

BY W. PEYRE PORCHER, M. D.

IT is not the purpose of the writer to bring forward anything especially new in this very brief and hastily prepared paper, but simply to record a few cases selected at random and to ask your attention to some phenomena which are familiar to specialists, but which a great many physicians either attribute to incipient or advanced

tubercular lesion, or simply ignore by relegating them to the list of "*les maladies imaginaires*." I allude to the neurotic phenomena in throat diseases.

A very large proportion of the cases which come to us for treatment consist of what may be called neurasthenic throats, or cases in which either no actual inflammation exists or in which a previous inflammation has already subsided, and left a throat given over to neurotic reflexes, such as irritative coughs, paralysis of one or both vocal bands, spastic hysterical or functional aphonia, imaginary foreign bodies in the throat, etc.

When these cases come to the specialist they are at once classified and treated according to the neurotic symptoms which they present. Not so with very many of the general profession. Neurotic reflexes, irritative coughs, etc., in the larynx and pharynx are often at once attributed to some disease of the lungs or bronchi, and even when there is no physical sign of lung involvement a diagnosis of latent tubercular disease is made with or without hereditary taint.

As the nerve supply of the larynx and pharynx is so intimately connected with every organ of the body, it would be of the greatest value if we could separate those neuroses which are due solely to irritation in the upper respiratory tract from all those reflexes which are produced by inflammation or irritation of the lower respiratory tract, or from other organs at a distance.

Fortunately, reflex irritation from other organs can almost always be detected by the peculiar sound of the coughs or other symptoms which they present; for instance, the short, dry, jerky cough with accompanying stitch of pleurisy, or the deep, basilar cough of pneumonia, or the hollow, resonant cough of advanced phthisis. There can be no question that the number of coughs or the different reflex irritations which are produced by inflammation of those organs at a distance from the upper respiratory tract form but a very small proportion of those which have their origin in and are solely produced by local irritation in the larynx, pharynx, and nose.

These irritations occur generally either as itching, stitching, or gagging, or simply hoarseness in the throat, and the desire to cough is irresistible and uncontrollable. They are invariably present in one form or another, in almost every case of phthisis, and it is impossible to say just what part the bacillus plays in their production, but a cough resulting from one or the other of these sensations, unless

checked in the incipency, generally forms the early history of most phthisical cases.

I hope you will not infer from this that I am attempting to underrate the germ theory of this disease, but it is manifestly evident that if some of the following cases, which had many of the symptoms of incipient phthisis, and surely offered as good a nidus for germs as any other cases, had been treated by the administration of germicides, the results obtained, which were exceedingly rapid and satisfactory, would certainly have been very different. Without further preliminary remarks I will report briefly the outlines of a few cases which, to the writer at least, in each instance proved to be separate and instructive lessons.

CASE I. *A Barking Girl*.—Miss G., aged about twenty years, presented the following history: Patient was suddenly taken with a spasmodic cough, which increased in violence as time progressed. No sputa were brought up, but the paroxysms were so violent that a physician was called in and various cough mixtures, etc., were administered for several weeks, with no perceptible influence on the cough. Finally, in desperation, the paroxysms being so severe, violent, and exhaustive, she was brought to me.

The paroxysms would then recur every ten or fifteen seconds, shaking her whole system while they lasted. They did not end in any whoop, nor was there any suspicion of whooping-cough present. I examined her lungs critically, but found not the least evidence of disease in the chest, throat, or nose. I recognized her as a "barking girl," and pronounced it to be a case of chorea laryngis. I told her she would be compelled to stop coughing, and that immediately. For the sake of the moral effect, however, I cauterized some enlarged follicles on the back of the tongue, and applied a solution of nitrate of silver to the posterior pharynx. I also administered quite a sharp cathartic, because I believe that a free evacuation of the whole alimentary tract exerts an extremely beneficial influence upon the neuroses, as well as upon inflammation of the upper respiratory organs. I need not add that the result entirely satisfied my expectations. The girl reported two days afterward that she had not coughed a single time after leaving my office.

I would not have you suppose that there was the least sign of hypnotism about the treatment of this case. The correct diagnosis was first made—namely, that the cough was entirely due to a neurotic reflex irritation in the larynx and pharynx.

The cautery was applied partly for the moral effect, as I said above, but also to make the cough a very disagreeable effort. She was then ordered to resist the impulse, which she did, and achieved the most satisfactory results.

CASE II. *Irritative Cough*.—A young lady, about sixteen years of age,

had not slept through a single night in three weeks on account of persistent and annoying cough, which she had had for several months. Many things had been given by her family physician with the hope of stopping it, but all of no avail. Among them was a spray of cocaine to the posterior pharynx, but this also had no curative influence. On examination, I failed to detect any throat inflammation sufficient to account for the cough, nor any symptoms of disease in the chest whatsoever. I therefore unhesitatingly pronounced it to be a hysterical neurosis, and ordered her a mercurial cathartic, also codeine sulphate, three quarters of a grain three times a day, and applied a solution of nitrate of silver to the posterior pharynx every other day. Some hypertrophies of the lingual tonsil were also reduced with the galvano-cautery. The result was most gratifying. She promptly responded to treatment, her cough rapidly ameliorated until it finally disappeared entirely, and she has had no return in five or six months.

CASE III. *Irritative Cough*.—S. B., white, aged about thirty-five years; occupation, bookkeeper; came to me in June, 1893. He stated that he had had a severe cough and night sweats for six months. His face was pale and haggard, and he had every appearance of a man who had given himself up to the ravages of consumption. Marked dullness was found all over the left lung, with compensatory respiration on the left side.

He was told that his chances of recovery rested entirely upon the possibility of controlling the cough, and that the inflammation then present in the lungs could not and would not be allayed as long as the cough lasted.

He was ordered a mixture of codeine sulph., acid hydrocyanic dil., spts. chloroform, and glycerin.

Local applications of nitrate of silver were made every other day to his posterior pharynx, and he was told to sleep in a bed by himself, as the weather was quite warm.

At the end of one month his cough had entirely stopped, as well as the night sweats. Examination, however, showed not the least change in the dullness over the lung, and the patient was sent to the mountains of North Carolina for rest and change. After a month's absence he returned to me. On physical examination the dullness was found to have completely disappeared, and there was no return of the cough or night sweats. The patient had also fattened greatly, and had postponed his consumption to a future date. He is now in excellent health in every respect.

CASE IV. *Bilateral Adductor Paralysis*.—This case was one of spastic or hysterical aphonia, but, unlike most cases, it began first with an acute follicular tonsillitis. She was a school-teacher, aged about twenty-five years, and came to me about the 20th of March. Her sore thro it began February 12th, and she became almost aphonic, and remained so until I began to treat her. At that time and for some time after she could not possibly pronounce the vowel *e*.

On attempting to phonate, the vocal cords were plainly seen in the mirror to approximate to about an eighth of an inch of each other, but she could not bring them actually in contact. Her pronunciation was exactly similar to what is heard in the hobbledehoy age, the voice breaking at every attempt to talk. I thought it possible that there might be some remnant of the tonsillar inflammation left, so I gave her a hot pine-oil inhalation and a gargle of chloride of iron and com. tinct. of cinchona. I also destroyed some enlarged follicles on the posterior pharynx with the galvano-cautery. All this, however, proved of no avail, so I at once began the intralaryngeal application of electricity, and she can now speak distinctly and controls her voice entirely.

CASE V. *Bilateral Adductor Paralysis*.—M. P., colored washerwoman, aged about forty, attempted to call me from a little distance to request me to examine her throat. Her voice was so hoarse, however, as to be almost inaudible. I immediately supposed that I had a case of œdema glottidis or ulcerated laryngitis to treat, and proceeded to introduce the laryngoscopic mirror. On requesting her to phonate, with the laryngeal mirror in her mouth, she did so without hesitation, her fright enabling her to overcome the adductor paralysis and approximate the vocal bands.

I found no sign of œdema, ulceration, or acute laryngitis, and hence it was immediately shown to be nothing more than a case of hysterical aphonia.

I ordered a simple gargle, to satisfy her that something was being done, and told her that she would immediately recover her voice.

She continued to speak clearly while in my office. About a half hour after leaving it, however, she returned, saying that she had again completely lost control of it. I simply assured her that it would again return as it had done before. This proved to be the case, and she has never required any further attention.

CASE VI. *Abductor Paralysis of the Right Vocal Cord from Disease of the Recurrent Laryngeal Nerves due to Central Lesion*.—The patient was a negro man, aged about fifty. As is usual with colored patients, the history is very obscure. He states, however, that about two years ago he fell from a scaffolding and was unconscious for some time.

He recovered perfectly, however, and has not been sick since, except some fever and giddiness during last summer. His present state began with a violent toothache five years ago in the lower jaw. The tooth was extracted, but it left a severe pain in the right ear, and his voice became hoarse. He has had frequent attacks of gasping for breath, and food and liquids occasionally regurgitate through his nose.

There is no direct history of syphilis, but he acknowledges that he has had what he calls a hair cut on his penis, but no bubo or eczema.

The mirror shows the right vocal cord bound down, and the chink of the glottis running in an oblique direction from left to right. On phonation, the left cord moves over to meet the right. There is a marked drooping and loss of motion in the soft palate. The most careful exam-

ination of the chest shows no sound of aneurysmal bruit. Nor is there any visible tumor or pressure on the recurrent laryngeal nerve. There is no pain nor marked anæsthesia, the only sign of anæsthesia being the frequent tendency of particles of food to enter the larynx, producing violent fits of coughing and drooping of the soft palate, of which the patient complains greatly, and begs that it be lifted up.

This case is interesting, first, because it involves the right cord instead of the left; and, second, because in simple abductor paralysis the chink of the glottis is in perfect alignment from before backward, whereas in paralysis of the recurrent laryngeal nerve the direction is oblique, and there is no aneurysm of the subclavian or innominate, and as the soft palate is also paralyzed, together with the general history of the case, it would appear that the existence of a central lesion would be beyond question. The patient has therefore been ordered large doses of iodide of potassium and intralaryngeal applications of electricity.

We hope for marked amelioration of the condition as soon as the patient becomes thoroughly iodized.

As already stated, these cases are not intended to show anything rare or uncommon, but rather as typical illustrations, where cough, gagging, and other reflexes, whether produced by inflammation or neurotic reflex irritations, were limited entirely to the throat, they should be treated alone by local applications to the throat, except where central lesions or disease of other organs at a distance exists.

1. In these neurasthenic cases the lung involvement is always a secondary result, and occurs only after a cough has existed for a long time, as proved by the local absence of all physical signs of lung disease.

2. As the bacillus has often been found in the throat and nose before it has invaded the lungs, being a proof of primary tuberculosis of the throat, and as it has never been found in the lung until the disease is well advanced, therefore a critical examination should be made of the throat in all cases of cough or diseases of the respiratory organs before a grave prognosis be given.

Paper.

CONTRIBUTION TO THE STUDY OF THE ÆTIOLOGY OF RHEUMATIC AFFECTIONS OF THE BODY DUE TO TONSILLAR DISEASES.

By H. L. WAGNER, M. D.

THE tonsil has been justly termed by Gerhard a physiological wound—an inlet into the system guarded by leucocytes, which we have learned of late protect the body against the invasions of various micro-organisms. If through inherited or acquired predisposition the energy of these leucocytes is diminished, or if the tonsil in a diseased state does not allow these corpuscles to migrate, then a soil may be given for infectious diseases, such as diphtheria, scarlatina, amygdalitis, etc.

The sequences which sometimes follow these diseases are important to observe—paralysis of various parts of the body after diphtheria, and also articular rheumatic affections following follicular amygdalitis. The results gained by clinical studies and bacteriological investigations in follicular amygdalitis, followed by rheumatic affections, are what I particularly desire to refer to.

The question which presents itself is, whether these rheumatic affections are produced by the germs (*Staphylococcus albus et aureus*, Fraenkel's pneumococcus, etc.) migrating from the tonsillar tissues into other portions of the body, causing rheumatism, or whether they remain in or about the tonsils, sending forth and distributing their ptomaines or poisonous products into the system.

The results of my investigations, which I will give you in brief, show in follicular amygdalitis a migration of these germs, proving that rheumatism here is not caused directly by ptomaines.

Clinical observations show that the joints which are mostly in use are the ones generally affected; for instance, the arytaenoid cartilages of the larynx of singers (five cases), the knee joints of shoe dealers, owing to the constant kneeling posture (two cases), and the wrist joint of a violinist (one case) and bookkeepers (two cases). Referring to the two cases above mentioned, where rheumatism of the knee joint developed, the bacteriological investigation showed that the synovial fluid obtained by tapping of the joint contained the same micro-organisms as were found in the diseased tonsil. I was also able to identify the same germs in the urine of nearly all the

cases. The family and clinical history of all these patients showed no signs of rheumatism before the attack of this tonsillar disease.

Paper.

DEMONSTRATION OF SKULLS SHOWING THE EFFECTS OF CRETINISM
ON THE SHAPE OF THE NASAL CHAMBERS.

BY HARRISON ALLEN, M. D.

MEDICAL observers in America have had little opportunity of studying cretinism. But I believe that we are apt to make a mistake in not bearing in mind the possibility of this morbid condition being met with in our clinical services. In metropolitan hospitals examples of cretinous dwarfs are not rarities. As for the conditions described by European writers as those of semi-cretins and cretinoids, I believe that they are numerous, but are not so often sought for as they should be.

According to F. R. Sensberg (*Der Cretinismus mit besonderer Rücksicht auf dessen Erscheinung im Unter Main und Rezat-Kreise des Königreiche Bayern*, Würzburg, 1825) the skull in cretinism is not of a single type. In the true cretin, that is to say, one associated with goitre, with deep nose root and a bulldog-like head, the skull is thick, the occiput is flat, the sides of the head are broad and usually asymmetrical. The sutures are disposed to disappear early or at least irregularly. Virchow (*Untersuchungen über die Entwicklung des Schädelgrundes in gesunden und krankhaften Zustände und über den Einfluss derselben auf Schädelform, Gesichtsbildung und Gehirnbau*, Berlin, 1857) describes an entirely different type of cretin skull from the foregoing. It exhibits a tendency to synostosis, while a disposition exists to excess as well as in unusual positions of the Wormian bones.

Another cretinoid skull is known in which the bones are thin and in various places are without diploic structure. The mastoid processes are weak. The Valsalvian foramen at the angle of the occiput is large, and the opening between the basilar process and the petrous portion of the temporal bone nearly obliterated, affording but a small space for the passage of the nerves. The basilar process itself is nearly horizontal, thus resembling the condition known as the soft occiput of Elsasser.

Rosch (*Amt. Bericht über die Versamm. deutsch. Natur. u. Aerzte*,

1842, xx, 238-245) describes a cretin's skull in which the occiput, instead of being flat, exhibits a capsule-like projection of the under part; the forehead is low and slightly rotund; the two halves of the head are apparently shoved one on the other ("die beiden Hälften des Kopfs verschoben und die eine steht hinter der andern zurück"). This language of Rosch is somewhat figurative, but doubtless refers to the fact that the two frontal eminences are asymmetrical, as also are the two sides of the occiput, that side of the occiput which projects farthest corresponding to the side of the skull at which the frontal eminence recedes. This peculiarity of the cranium is by no means confined to the cretin, but is mentioned by other writers, and is ordinarily attributed to Broca; the observation is thus found to be anticipated by Rosch by many years. Rosch describes another form of the skull—namely, the one in which the bones are thin. The dimensions are too small. The form of the skull is rotund; it may be so high on the sides as to constitute the sugar-loaf head (in some cases the occiput markedly projects, constituting what is called "cat head"), while all prominences and muscular impressions are inconspicuous.

I herewith exhibit two specimens of skulls belonging to the Wistar and Horner Museum of the University of Pennsylvania, showing what I venture to call cretinoid deformation; they are without history, but they conform in a manner sufficiently exact to the descriptions of foreign writers to permit me to so identify them.

In one of these specimens the bones are thick and appear to be imperfectly calcified, while the nose is prominent, the facial portions are stunted, the hard palate being small. I call attention particularly to the projection of the occiput; the occipital bone appears to have effected union with the parietals in such wise as to present a conspicuous depression between them. This appearance is called by some of the older writers "cat head" (Rosch, *supra*); it is by no means an uncommon contour, and can readily be detected in living subjects.

In the second example I show you of cretinoid deformation the nasal bones, instead of being prominent, are inconspicuous; indeed one may say that there is no bridge to the nose, for the nasal bones instead of being inclined forward and downward, are vertically disposed, and do not project in the least beyond the plane of the ascending processes of the maxillæ. It might at first sight be inferred that this was nothing more than the "falling in of the nose" as a result of loss of the normal structures by the ravages of

syphilis; but the most casual observer will be convinced that this skull was not taken from a syphilitic subject. As in the first specimen, all the facial portions are dwarfed, the bones are thickened, and the hard palate is small.

In both specimens the inferior turbinated bones are lodged high up in the nasal chambers and give the impression of being of great size. It is probably owing to the extreme shortening of the face that a compensatory growth occurs in these bones in the vertical direction, the posterior nares in both specimens being disproportionately large. The floor of the nose is greatly depressed below the level of the anterior aperture. The frontal regions in both specimens are broad and thick, giving the appearance of the so-called "apple head" in dwarfs. The suture between the halves of the frontal bones is apparent.

Bearing in mind the immense variety of appearances that one can secure in phases of malnutrition as affecting the head, and remembering that one must not expect to institute exact standards of comparison in studies of this kind, enough remains for me to be willing to state that the nutritive and developmental processes are evidently at fault in the cretinoid skull. In patients in whom I detect a bulb-like forehead with unnaturally projecting occiput, with depression between it and the parietal bone, where the external nose is dwarfed (or even, as opposed to this, the nasal bones are preternaturally high), the hard palate is small, and the posterior nares are of inordinate size, I should not hesitate to characterize such individuals as being cretinoid. If these conditions exist in persons of small stature (here not speaking of typical dwarfs) I should feel more than ever satisfied in using such a term in describing them.

These remarks are made with the hope that further observations may be elicited on the subject at the hands of those having large opportunities in public services. In these days of extensive immigration which brings large numbers of the impoverished class of Europe to our shores, it is not irrational to assume that many examples of "semicretins" or "cretinoid" individuals may be recorded. It is evident that important phases of prognosis and treatment of diseases of the nose and throat enter into conditions of this kind, and that all states of the development of the head should be known in studying the diseases of the nasal chambers.

DISCUSSION ON THE ACCESSORY SINUSES.

Ethmoidal Disease.—Dr. F. H. BOSWORTH, of New York, said: Ethmoidal disease, both from the anatomical character of the regions involved and with reference to the symptoms to which it gives rise, differs essentially from diseased conditions found in any of the other accessory cavities of the nose; for whereas the maxillary, frontal, and sphenoidal sinuses present to us a single cavity confined by bony walls, the ethmoidal cells consist of a large quadrangular mass of small cells, or trabeculæ, varying in size, and each cell more or less completely separated from its neighbor by a thin, bony partition. This is fairly well shown in Fig. 1,

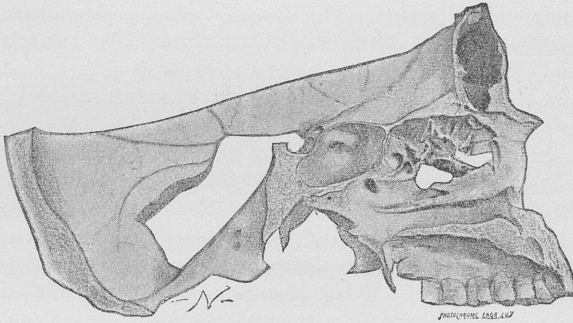


FIG. 1.—The trabecular character of the ethmoid cells shown after the removal of the middle turbinated bone, from a specimen in the writer's collection.

the turbinated bone having been removed. Hence, while the problem which presents itself to us in dealing with the morbid condition in the other cavities consists simply in making an opening for proper drainage and irrigation, in dealing with diseased processes in the ethmoidal cells the radical arrest or cure of the disease, especially where suppuration has taken place, demands the opening of each of the large number of small cells which compose this mass. This is impossible. Hence we are compelled to resort to the breaking down of these small partitions within the ethmoid body in such a way as to convert it into one single cavity. And here, perhaps, it may be proper to say that in a diseased condition of any of the accessory cavities I think we will all recognize the fact that the tendency in every case of a simple inflammatory process which does not undergo resolution and which develops into a chronic inflammation is to result in suppurative action, and thus the establishment of a more or less permanent pus discharge through the normal opening—namely, into the nasal cavity. The other respect in which disease of the ethmoidal cells differs from that of the larger sinuses is that whereas in the latter we have simply a purulent discharge, in the former diseased action sets

up a train of symptoms more or less neurotic in character, such as watery discharge from the nose, violent sneezing attacks, asthma, headache, neuralgias, which, according to Berger and Tyrman* (compare also Schech) are usually intermittent in character, certain disturbances in the muscular control of the eyeball, asthenopia, and especially what has been called aprosexia. This latter really constitutes one of the most distressing symptoms of the disease, and has been described to me by patients as a sort of blanket over their brain, which interfered with mental activity and the free use of their faculties. It is what the Germans call *Retentions Erschöpfung*, and is defined in Billings's dictionary as "inability to fix the mind upon a subject or to retain a lesson, accompanied by headache, and due to overstudy or prolonged irritation in the throat or nasal passages."

The topic which I am asked to discuss to-day, as I understand it, is the surgical treatment of ethmoidal disease. Practically, I suppose when we speak of ethmoidal disease we refer to suppuration in these cavities. The subject of ethmoidal disease is to me exceedingly interesting, and is, I think, perhaps the most interesting which is engaging the attention of laryngologists. I hope therefore that I may be allowed to refer somewhat briefly to the whole question of diseased processes here, prefacing this by the statement that I regard ethmoidal disease as not only by far the most frequent of all diseases of the accessory cavities, but as of very much more frequent occurrence than we ordinarily have been taught to believe, as will be inferred by the statement that in the past five years ninety-eight such cases have come under observation in my private practice.

In the chapter on acute rhinitis, in all of our text-books on throat diseases, Bosworth among others, there is described a disease characterized often by nasal stenosis, frontal headache, intra-orbital pressure, asthenopia, watery discharge, and violent sneezing, which, I very frankly confess, I have rarely seen where I was enabled to detect a rational explanation of the symptoms in the morbid condition of the nasal mucous membrane alone, as seen by ocular inspection. I contented myself with the old teaching that these symptoms were to an extent reflex in character. I do not hesitate to say that I believe a very large proportion of the cases of so-called acute rhinitis are really instances of acute ethmoiditis, and that such inflammation as may exist in the nasal mucous membrane is really secondary to the graver and more distressing conditions of the lining membrane of the ethmoidal cells. I thus indorse the statement made by that excellent observer, Moritz Schmidt, of Frankfort,† who assigns these symptoms of a head-cold to an involvement of some of the accessory sinuses, not confining it, however, to the ethmoid cells.

Among the cases which I shall briefly analyze later are a number of

* *Diseases of Ethmoidal and Sphenoidal Sinuses*, Wiesbaden, 1886.

† *Krankheiten der oberen Luftwege*, Berlin, 1894.

instances, both of acute ethmoiditis and suppurative disease, which have had their onset in unmistakable attacks of *la grippe*, which leads me to hazard the suggestion that the influenzal type of *la grippe* is really an invasion of the ethmoid cells by the specific bacillus which is supposed to be the exciting cause of that disease.

In a paper on ethmoidal disease,* published two years and a half ago, I described five varieties of diseased conditions of these cells, which practically reduced themselves to three—viz., (1) extracellular myxomatous degeneration; (2) intracellular myxomatous degeneration; and (3) purulent ethmoiditis. I really think that practically we have but one primary morbid condition in the ethmoid cells, which progressively and with more or less rapidity develops into these three. In other words, that these three conditions are successive stages of one and the same disease. An acute inflammatory process of the mucous membrane lining these cells very soon either results in resolution or a chronic morbid process. Owing to the peculiar anatomical character of this membrane, a chronic inflammation tends to develop a soft, jellylike thickening of the tissue which takes on what we may describe as a myxomatous character. Now, this may persist for a somewhat prolonged period of time, giving rise to distention of the cells, with its train of symptoms already alluded to, which are watery or muco-purulent discharges, violent attacks of sneezing, headache, intra-orbital pressure, aprosexia, etc., and if the constitutional habit be neurotic, hay fever and asthma, these symptoms being simply exaggerated on the occurrence of more or less frequently repeated attacks of acute inflammation, to which the patient is liable.

The further course of this disease I take to be, in a certain small percentage of cases, the crowding out from the ethmoid cells, through the normal opening, of this myxomatous tissue which presents in the nasal cavity in the form of small polypi. Not that I believe the large proportion of cases of nasal polyp have their origin in the ethmoidal cells, for Zuckerkandl† has demonstrated conclusively that this is not the case. As the result of this inflammatory process within the cells the thin walls become distended, and we have a somewhat curious development by which the outer wall of the cells yields before the pressure, and we have the middle turbinated bone crowded outward, and gradually an extension of these cells into this body. (See Figs. 2 and 3.) And here for the first time there presents a condition by which we may recognize a morbid process in the ethmoid cells by ocular inspection through the nose; in other words, as far as rhinoscopic examination goes in the inflammatory stage of the disease, this distention of the cells and extension into the middle turbinated body gives rise to a protuberance into the middle meatus which is easily recognized, the middle turbinated body presenting as a rounded, ovoid mass usually in contact with the septum and en-

* *New York Medical Journal*, November 7, 1891.

† *Norm. und path. anat. der Nasenhöhle*, Band 1, Auflage 2, S. 360.

croaching notably upon the middle meatus of the nose. At the same time this curious myxomatous degeneration of the mucous membrane and

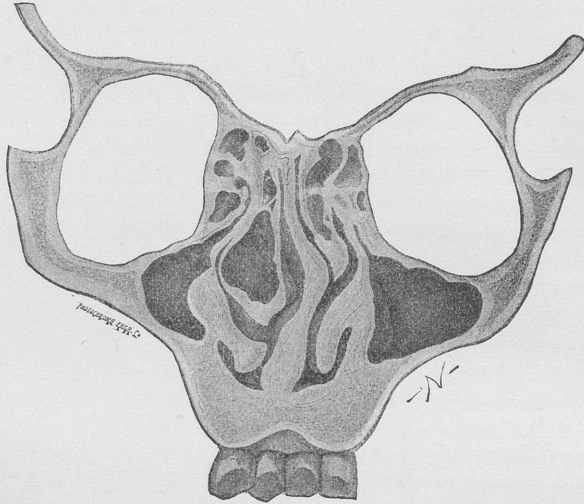


FIG. 2.—Distention of the ethmoid cells, with extension into the middle turbinated body (Zuckerlandl.)

lining cells conveys itself to the mucous membrane covering the outer wall, which is now the middle turbinated body in the nose, and lends additional aid in the recognition of the condition.

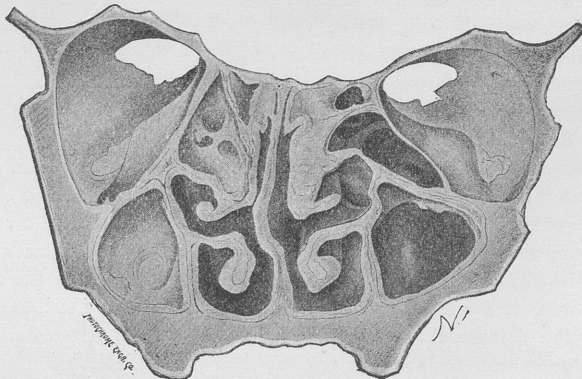


FIG. 3.—Distention and extension of the ethmoid cells, with displacement of the middle turbinated body. (Zuckerlandl.)

These two conditions constitute what Zuckerlandl has termed "ethmoiditis superficialis" and "ethmoiditis profunda," the former term ap-

plying to the disease when it is confined within the cells, and the latter designating the disease when the myxomatous degeneration has extended to the nasal cavity, making its appearance on the surface of the middle turbinated body.

The next stage in the development of the disease consists in suppuration. The time of its development may be very early or very late in the history of the disease, this being governed somewhat by adventitious circumstances. The method of its development seems very clear. The inflammatory process involving the membrane within the cells necessarily gives rise to hypersecretion, which materially contributes to the intracellular distention, and also results in a closure of the normal orifice. The necessary consequence is practically the formation of an acute abscess, which, failing resolution, soon develops into a chronic abscess, or chronic suppuration of the cells, for I believe it to be an almost universal rule that where we have a chronic inflammation of the mucous membrane with hypersecretion in a closed cavity, the tendency of the process is very rapidly to develop into purulent action. We thus have established a chronic suppurative disease. The pus finds its exit through either the anterior or posterior ethmoidal cells, and I may state here, from a practical point of view, that the anatomical division of these cells into the anterior and posterior group is of no special interest to us in dealing with the diseased conditions, in that, I believe, they are really converted into a single group of cells by either a normal or a rapidly established abnormal opening between the two. The pus makes its way into the nasal chambers through one of the normal openings either in front into the hiatus semilunaris, or through the posterior opening into the superior meatus. Thus on ocular inspection we may find the pus making its appearance either from beneath the middle turbinated body or from between the middle turbinated body and the septum above. As a rule, the pus from the anterior and lower opening makes its way into the lower meatus and is expelled through the anterior nares, while the discharge from the posterior opening makes its way into the pharynx, giving rise to the symptoms so often complained of—viz., that of dropping in the throat, in which way the disease may be confused with an ordinary nasopharyngeal catarrh, although I should say here that the secretion of this latter disease is usually thick and adherent, and expelled by somewhat violent nasal screatus, whereas a dropping in the throat should always suggest the great probability of an empyema of either the ethmoidal cells or the sphenoidal sinus.

While the most natural exit for the pus is into the nasal cavity, this is by no means its invariable course, as is shown by the large number of cases in which the pus escapes through the os planum into the orbital cavity, giving rise to exophthalmos and orbital disease. Furthermore, we occasionally meet with exophthalmos from distention of the cells in the cavity without escape of pus, as is still further and notably illustrated by

the case reported by Bull* of ethmoidal suppuration, in which an artificial puncture through the orbit was followed later by a spontaneous rupture into the nasal cavities, the ultimate cure resulting probably from the latter.

As the result of the persistent suppuration, the lining membrane of these cells necessarily becomes soft and very much thinned. The much-discussed question of necrosis of bone never has interested me greatly, because I regard its importance as much overestimated. Zuckerkandl† states that he has never seen caries of the ethmoid cells, thus contravening Woakes,‡ who describes what he calls a necrosing ethmoiditis as practically the sole cause of nasal polypi. The membrane covering the bone is so far thinned and softened that to the impact of the probe it gives the sensation of being exposed. That it is genuinely necrosed I do not believe. The odor, moreover, which is almost constantly present in these cases in the later stage is the odor of sulphureted hydrogen developed from retained pus, and not the odor of bone necrosis. Hence, in making our diagnosis, I should not be disposed to attach so much importance to the use of the probe as many writers do, depending mainly for the diagnosis on the appearance about the middle turbinated body of distention, and on the myxomatous degeneration of the mucous membrane covering it. This deceptive sense of necrosed bone can be obtained by passing the probe either beneath the middle turbinated body toward the hiatus semilunaris or above it toward the opening of the posterior ethmoidal cells in the superior meatus. I have not infrequently detected it in a normal and healthy nose.

Our most important consideration, of course, has to do with the question of treatment, and that this should be instituted early in the history of the disease, and before the suppurative process has ensued, need not be urged, in view of the very serious discomfort and even danger which attends the stage of empyema, and the great difficulty with which it is brought under control after pus formation has become chronic. In acute ethmoiditis the ordinary measures which our text-books recommend in the treatment of acute rhinitis are indicated of course, and need not be dwelt upon further than to say that, of all measures, I regard the use of the douche as most potent, directing that from one to two gallons of water rendered thoroughly saline be passed through the nasal cavities by means of the Thudichum douche at least twice daily. The water should be as hot as can be borne. This instrument I regard as devoid of the danger to the ears of which Roosa has warned us, provided that the patency of each nostril be tested before its use, and that the stream be made to pass into the narrower naris, thus emerging without obstruction from the more patent side.

When the disease has reached the chronic stage without suppuration,

* *New York Med. Jour.*, 1893, vol. lvii, p. 75.

† *Loc. cit.*, p. 361.

‡ *Nasal Polypus*, Am. ed., Philadelphia, 1887, p. 8 *et seq.*

I believe that, other measures failing, surgical interference should be resorted to in all cases, as we here have to deal with an affection which does not tend to undergo resolution, but one in which there is imminent danger of suppuration setting in at any time. The test that this chronic stage has been reached is to be found in the swollen and distended condition of the ethmoid cells, as shown by the projecting and swollen turbinated body, whether the mucous membrane covering it be in a state of myxomatous degeneration or simply turgescient. The object to be accomplished is to relieve intracellular pressure, and this is accomplished by uncapping, as it were, the ethmoid cells. The steel-wire loop of the Jarvis, or Bosworth, snare is easily slipped over the projecting turbinated body and the whole mass removed, presenting usually in the form of an elongated ovoid shell. This also reveals to us the condition of the mucous membrane within the ethmoid cells, which may be either in a simple state of turgescence, or, as has not infrequently happened in my own experience, a soft, gelatinous mass of myxomatous tissue is found filling the cavity thus opened. If this does not drop out of place, it is very easily removed by the mouse-tooth forceps or the snare.

After pus formation has occurred, the problem before us, as before stated, consists in converting the large number of small cells which compose these bodies into a single cavity, and establishing thorough drainage. In these cases the primary procedure is, as before, to uncap the cells by the use of the snare, and after that I believe our best instrument consists in the use of the dental burr. Schaeffer, Moure, Cozzolino, Gleitsmann, and others prefer the use of the curette. I have never been able to freely manipulate this instrument in the ethmoidal cells or to break down the trabecular walls by its use. Its manipulation is hampered, and its action, to my mind, seems inefficient and not radical enough in extent. Grünwald's sharp spoon is a more efficient instrument, but still hampered in its action. The same criticism applies to the forceps and sharp spoon as advocated by Zarniko.

That this disease can be radically cured, or even modified or controlled to any great extent, by the use of disinfecting lotions, as recommended by Lichtwitz,* Hartmann,† Michel,‡ Schalle,§ Myles,|| and Moure,^ I do not believe. The small round or oval burr attached to the dental engine, or, better still, to the De Vilbiss engine, in my hands has answered a better purpose than any other device. Manipulated with the De Vilbiss engine it is made to enter the ethmoidal cells either before or after uncapping, as the trabecular walls are easily broken down

* Diseases of the Accessory Cavities of the Nose. *Bul. méd.*, Paris, 1893, lxxxv, 963.

† Quoted by Berger and Tyrman. *Dis. of Ethmoidal and Sphenoidal Sinuses*, Wiesbaden, 1886, p. 12.

‡ *Idem.*

§ *Idem.*

|| *Medical Record*, 1892, vol. xlii, p. 607.

^ *Manuel pratique des fosses nasales*, Paris, 1893, 2d ed., p. 535.

or burned away. Its motion can be instantly arrested at will, when it can be made to act as a probe, exploring the cavity for exposed bone or such parts as it is desired to remove. In this manner our operation becomes not only intelligent, but, I think, absolutely safe, a consideration which, of course, is to be very carefully borne in mind when we remember not only that we are separated in our operation from the orbit of the eye by an exceedingly thin plane of bone, but, if we progress very far, we are getting in close proximity to the base of the brain. I do not mean to intimate that at a single session all the trabeculae which constitute the ethmoidal cells can be opened out and thoroughly drained. In many of my cases the operations have been repeated a number of times at intervals varying from one week to a month, or even longer. During the intervals, of course, the patient is directed to use disinfecting lotions with as much intelligence and thoroughness as can be accomplished by the ordinary devices which we place in the hands of our patients for use. I have no special suggestion to make as to the character of these lotions, as thoroughness of application is of more value than the special character of the antiseptic used. Moreover, it should be stated that the operation is not attended with anything like the pain that we should suppose when we consider the exceedingly sensitive character of the parts operated upon. Of course the procedure is not an agreeable one, but it is not an especially painful one, provided that we can sufficiently reach the parts to thoroughly saturate them with a cocaine solution.

I may seem to the general practitioner to be discussing and describing not only radical but perhaps rough and even dangerous methods, but when we consider not only the great discomfort and distress to which a patient suffering from ethmoidal disease is subjected, but the still greater danger which threatens him, as has occurred, of involvement of other sinuses or neighboring cavities—such as the orbit—or even the development of the disease in the brain tissue itself, I think there can be no question that these radical procedures are not only fully warrantable but absolutely indicated.

The charge has not been infrequently made in the past few years that intranasal surgery has been very greatly overdone. Some of our English friends have delicately suggested that we attack the nasal tissues “with the energy of the backwoodsman,” “with more energy than discretion,” with recklessness and without justification.

These charges are not deserved, and are unjust. We do not confine our work to the saw and burr and drill. The very large majority of our cases are dealt with without resort to surgical measures, but we recognize a large number of cases in which other measures are inadequate, and then we attack, not with the energy of the backwoodsman, but with the trained and delicate hand of the surgeon, who recognizes unmistakable indications and carries them out, the gratifying result fully justifying the means.

As before stated, during the past five years I have recorded in my pri-

vate practice ninety-seven of these cases, a brief summary of which I append. Of these ninety-seven cases, three were carcinoma and one sarcoma of the ethmoidal cells, which may be left out of consideration. As regards age, three occurred in the second decade of life, fourteen in the third, twenty-three in the fourth, twenty-eight in the fifth, eighteen in the sixth, and seven in the seventh decade. Sixty-one were males and thirty-two were females. Fifteen cases were inflammatory in character without suppuration or polypoid degeneration. Of these, nine were cured, three were improved, and three disappeared. Twenty-nine cases showed myxomatous degeneration without suppuration. Of these, twelve were cured, ten improved, and seven were seen but once or twice and their progress not known. Twenty-two cases showed myxomatous degeneration or fully developed polypi together with pus discharge. Of these, nine were cured, ten improved, and three disappeared. Of the purely suppurative cases there were twenty-seven, of which eight were cured, twelve improved, both as regards subjective symptoms and the amount of discharge, while seven were seen but once or twice and not further noted. In nearly all these cases radical operative measures were instituted, as carrying out the suggestions already made. In many of them the simple irrigating measures failed to give relief, either to subjective or objective symptoms. And the cells were opened either by the saw or drill, or, as in many cases, both were used.

Surgery of the Maxillary Sinus.—Dr. J. H. BRYAN, of Washington, D. C., said: In considering the subject of the surgery of the maxillary sinus, it will be necessary to mention the various pathological conditions that affect this cavity. Among them may be mentioned inflammation of the lining membrane, varying in intensity from a simple catarrh, with its resulting accumulation of mucus, a condition known as mucocoele, to a suppurative inflammation which may be either acute or chronic; foreign bodies, including insects; and morbid growths, which may be either benign or malignant. As the indications for treatment of mucocoele and empyema of the maxillary sinus are the same, it will be considered as referring to the latter affection.

Of the surgical affections of the antrum, empyema, as far as frequency of occurrence is concerned, plays the most important part. While the study of suppuration of this cavity has made great strides within the last ten years, commensurate only with the advances that have been made in the whole field of rhinology, there still remains a great deal to be explained both in regard to the ætiology and the resistance which many of these abscesses show to the most careful and persistent treatment. This disease, as we understand it to-day, is an entirely different one from that described by the older authors, who considered it an affection of rare occurrence, and described it as producing a marked bulging and thinning of the walls of the sinus. We, on the contrary, know that it is of frequent occurrence, and marked distention of the walls of the sinus is

rarely met with. The only conclusion to be drawn from their works is that they described, under the head of empyema of the antrum, cysts and other tumors of this cavity.

Without encroaching too much upon the subject for discussion, it will be necessary to make a slight reference to the ætiology in order to appreciate the indications for treatment, for upon the cause of the abscess frequently depends our choice of operation.

Situated as this cavity is with the lateral wall of the nose for one of its boundaries, and with the root of the first and second molar teeth in such close relation with its floor, it is especially prone to be affected by the extension of any pathological process that may exist in either one or the other of these localities. A wide difference of opinion exists as to which is the more common.

The treatment of abscess of the antrum has of late given rise to a great divergence of opinion as to the best method of opening the cavity, almost as much so as to the ætiology, the development of rhinology causing a tendency on the part of modern surgeons to return to the practice of treating the sinus through the nose. The method first proposed by Hunter and put into practice by Jourdain of washing the cavity out through the natural opening in the middle meatus has found strong advocates in Störk, Hartmann, and others. In recent abscesses I have relieved several cases in this manner, but in chronic inflammations the procedure is too tedious and the results are too uncertain to waste much time with it. In the majority of cases it will be necessary to make an artificial opening.

Among the earliest of the recorded operations, and one which it is only necessary to mention for the sake of historical interest, is that of Molinetti, who, in 1675, opened the maxillary sinus by making a crucial incision in the cheek and then perforating through the canine fossa. Naturally this operation found few advocates.

Up to 1886 there were three methods of opening the maxillary sinus in use, and all of these derived from the surgeons of the latter part of the eighteenth century. It was about this time that Cooper opened the antrum by extracting a tooth and breaking down the thin lamella of bone between the alveolus and the cavity above. This is, without doubt, the most readily performed of all the operations proposed. If there is a carious tooth present, which in the majority of cases, according to my experience, is the most common cause of the abscess, it should be extracted. Frequently the cavity will be opened by this procedure; if not, then it will be necessary to establish a communication with it by means of a strong trocar, or, which is much safer and more satisfactory, by means of a small trephine propelled either by a surgical engine or an electrical motor. This instrument should be directed slightly forward and inward in order to penetrate the cavity at its most dependent part, and upon the withdrawal of the instrument it will be followed by a dis-

charge of pus into the mouth. The opening should be sufficiently large to permit of the passage of a small metallic drainage-tube, varying from three to five millimetres in diameter, after which the local treatment can be carried out. The advantages of this operation are: 1. In many cases it removes the origin of the disease. 2. That the opening is at the most dependent part of the cavity, and therefore the drainage is most perfect. 3. The patient can readily carry out, to a certain extent, the necessary local treatment, which is a very great advantage when it becomes necessary to wash out the cavity several times a day.

There are, however, many opponents to this operation who argue (1) that it is frequently necessary to extract a healthy tooth; (2) that the constant flow of pus into the mouth is very annoying to the patient; and (3) that by creating an opening between the mouth and the antrum particles of food and pathogenic organisms may pass into the cavity and keep up the suppuration. The second and third objections can readily be obviated by wearing in the metallic drainage-tube a small conical rubber plug.

If for any reason it is not desirable to extract a tooth, or if the anterior wall of the antrum should show signs of weakening and bulge forward in the canine fossa, the sinus can be opened at this point, as first recommended by Desault, and latterly by Küster, who has modified the original operation by making a muco-periosteal flap and then perforating through the fossa, making an opening sufficiently large to admit of the thorough exploration of the interior of the cavity.

The operation of Bertrandi, of perforating the hard palate, is one that is rarely resorted to now, and it should be reserved for those old and neglected cases where the hard palate shows signs of weakening and the abscess is about to discharge into the mouth.

If, for any reason, it is desirable to enter the cavity through the nose, then the method proposed by Mikulicz, in 1886, or some modification of it, should be adopted. Mikulicz advised opening the sinus through the inferior meatus with a spear-shaped knife bent at an obtuse angle, and having a projecting flange to regulate the depth of the incision. This instrument is introduced into the nasal chamber with its point toward the floor, and when at a point just under the natural opening of the sinus into the nose, the instrument is turned outward, and, with a sharp thrust, the knife is made to penetrate the inferior meatus into the cavity. A large triangular opening is thus established sufficiently near the floor to permit of easy drainage and the ready application of antiseptic lotions. Owing to the troublesome hæmorrhage that frequently follows the use of this instrument, it is better to make the opening into the sinus with the curved trocar and cannula of Krause, or with the antrum drill of Solis-Cohen. This operation is not practicable (1) when the nasal chambers are unusually narrow; (2) when there is a deflected septum; and (3) when there is a marked hypertrophy of the inferior turbinated body. It

has also the disadvantage of requiring all applications to be made by the surgeon.

It will thus be seen that we have numerous procedures for opening the maxillary sinus, and while it is impossible to lay down any rule which would be applicable to all cases, yet in a general way it may be said that in recent abscesses of nasal origin the intranasal operation will be found to offer many advantages over the others. In those cases due to dental caries, the alveolar method is the one indicated. The opening through the canine fossa should be reserved for those cases, be they of intranasal or dental origin, which have resisted treatment by either the method of Mikulicz or Cooper, where it becomes necessary to resort to more radical measures, as will be seen when we come to consider the local treatment it is frequently necessary to do.

I know of no affection that will try the patience of both doctor and patient more, and the final issue of which is so uncertain, as a chronic abscess of the maxillary sinus. The local treatment is, therefore, very important, and upon the careful and methodical manner in which this is conducted depends the successful issue of the case. After opening the cavity, it should be washed out with a mild antiseptic lotion. If the case be one of mucocele, or acute abscess, the inflammation will frequently quickly subside, requiring, in many instances, only a few irrigations. In chronic abscess, however, we can hope for no such speedy subsidence of the inflammation.

The local treatment may be said to consist in the frequent irrigations with antiseptic solutions; the dry method, first advocated by Friedlander, of insufflating iodoform, iodol, or aristol; the application of caustics; tamponing the cavity with iodoform or bichloride gauze; and, finally, when the suppuration continues in spite of everything that has been done, of curetting the lining membrane of the sinus.

Irrigation may be done by means of a strong syringe with a curved tip, or through a Eustachian catheter, filling the cavity to its fullest capacity, for it must be borne in mind that it is irregular in shape and it is frequently subdivided by bony partitions thrown out from the floor into smaller incomplete cavities. Unless the sinus is filled with the antiseptic solution, the source of the suppuration, especially if it be a localized one, may escape the applications.

I will not take up your time by enumerating the various antiseptics that have been used and are recommended in this affection, but will only state that, so far as my experience goes, I have found the simpler and less irritating the application, the more rapidly the secretion of pus subsides. After the cavity is opened it should be washed out with a warm saturated solution of boric acid, and continued until all reaction has subsided; then a solution of the peroxide of hydrogen is injected, varying from one half to full strength, according to the indications. This form of treatment is continued until all signs of suppuration have ceased, after which it will

frequently be found advisable to use a mild astringent application before the flow of mucus ceases, and for this purpose I have found a solution of the sulphocarbolate of zinc, varying in strength from two to five grains to the ounce, advantageous. A great many cases will be met with that will not respond to this simple line of treatment. Then we must have recourse to one of the other methods already referred to.

As to the method of Friedlander of washing the cavity out once and then insufflating iodoform or some other antiseptic powder, I have not met with much success; principally owing to the irregular shape of the cavity, it is impossible to deposit the powder on the whole of the inflamed surface.

In order to discover the underlying cause for the continued suppuration, it will be necessary to enlarge the alveolar or canine fossa opening sufficiently to admit the thorough exploration of the sinus with the probe and little finger. Elsewhere I have advocated the application of the principle of endoscopy to this sinus as an aid to its thorough exploration, and for this purpose I have employed the endoscope of Dr. Otis with its tubes shortened, and to which has been added a small metallic mirror which can be introduced through the tube into the cavity, and the whole of its interior brought into view. This instrument, together with the probe and little finger, has revealed numerous causes for these prolonged suppurations, such as frequent accumulation of granulation tissue, ulcerations, extensive caries and necrosis of the walls of the cavity, foreign bodies, such as supernumerary teeth, cystic degeneration of the lining membrane, polypi, and other tumors which have not reached an advanced stage of development.

Ulcerations and isolated granulations located by means of the endoscope can be treated with suitable caustic applications on an ordinary applicator passed through the tube, thus doing away with the necessity of making a large opening for that purpose. If, however, as occasionally happens, the membrane is the seat of much granulation tissue, cystic degeneration, or polypoid formation, then the opening should be enlarged sufficiently to admit of a thorough removal of the diseased tissues by means of a sharp curette, the cavity being then washed out with an antiseptic solution and packed with iodoform gauze. The operator, in curetting the very vascular tissue from this cavity, must be prepared to meet with a sharp hæmorrhage, and one sometimes difficult to control.

Any foreign body, such as supernumerary teeth, or teeth pushed into the cavity through clumsy dental manipulation, necrosed or carious bone, or any bony plates that may have formed, must be removed through an opening sufficiently large for the purpose, and the sinus treated on general surgical principles.

The majority of cases of abscess of the maxillary sinus will respond to one or the other of the modes of treatment described above; occasionally, however, some cases, especially when associated with atrophic rhi-

nititis, and where the lining membrane of the cavity has undergone atrophic degeneration, will resist all known methods of treatment.

Tumors of the Maxillary Sinus.—Up to the year 1882 tumors of the maxillary sinus were supposed to be of not very frequent occurrence, but since the systematic study of the pathological anatomy of this cavity by Zuckerkandl, and more recently since the appearance of an instructive monograph on the benign growths of the antrum of Highmore by Heymann,* we know that they occur much more frequently than was formerly supposed. Heymann examined two hundred and fifty heads, and in five hundred antra he found thirty-one benign growths—that is, about one in every eight subjects had a tumor of the antrum. In none were there any external evidences of their presence.

Tumors in this region may be either benign or malignant, and they originate more frequently from the muco-periosteum than from the alveolar ridge. According to some authorities, about two thirds of the morbid growths of this cavity are malignant.

According to the classification of Zuckerkandl, the benign growths of the antrum are divided into cysts, polypi, osteomata, and fibromata.

Cysts of the antrum are of three varieties: those which are due to a dilatation of the follicles of the lining membrane—and they may be single or multiple—cystic degeneration of polypi, and dentigerous cysts, of which there are the external and internal variety.

The simple cyst, when small, may not give rise to any external evidence of its presence, and it is only discovered when exploring the cavity for some other object; but when it becomes sufficiently large to fill the cavity and causes a distention and thinning of its walls, it will be recognized by the distortion of the face and the characteristic symptom of crepitation when pressure is made with the fingers.

The internal dentigerous cysts are occasionally found attached to the roots of the molar teeth, and sometimes extend into the antrum. They give rise to no symptoms generally, and they are only recognized upon the extraction of the tooth. The external variety are without the antral cavity, and by their gradual growth they cause a marked distention of the face. They sometimes reach such a size that the maxillary sinus is encroached upon and nearly obliterated, as in one case reported by Zuckerkandl, in which the antral cavity was almost completely obliterated, being separated only by a thin lamella of bone. Occasionally this bony partition is absorbed and the cyst breaks through into the antrum, discharging its contents into the nose.

The treatment of these cases is generally simple. The bony wall being, to a great extent, absorbed, it is only necessary to make a free incision in the distended wall above the alveolar ridge, and the cavity is then washed out with an antiseptic lotion.

Of the more solid neoplasms, polypi occur most frequently. The most

* Virchow's *Archiv*, vol. cxxix, 1892.

common form met with is the myxomatous polyp. There are three varieties met with in the antrum: the typical pedunculated myxomatous polypi; a bridgelike formation extending across the cavity between its two walls; and the flat variety, which seems to be nothing more than a hypertrophy of the mucous membrane which forms its base. These growths sometimes extend into the nose and into the post-nasal space, as occurred in a case that recently came under my observation. In this case the polypus filled the antrum, the corresponding nasal chamber, and, the posterior wall of the sinus having undergone absorption, it extended backward into the post-nasal space.

These growths are very vascular, bleeding freely when interfered with, and they are sometimes the forerunners of malignant growths.

Osteomata and fibromata are occasionally met with, springing from the walls of the sinus. These tumors sometimes reach an enormous size, producing great deformity of the face and destruction of the parts upon which they make pressure. In removing these solid growths from the antrum it will generally be necessary to lay open the cheek by the usual incision for the more formidable operation of excision of the upper jaw, when the interior of the cavity can be exposed by cutting away its anterior wall sufficiently to permit of the thorough extirpation of the growth, whether it be a polypus, osteoma, or fibroma.

Among the malignant growths met with in the cavity may be mentioned epithelioma, carcinoma, and sarcoma.

The treatment of these tumors consists in thorough extirpation, either by partial or total resection of the upper jaw.

Remarks on the Surgery of the Accessory Sinuses.—Dr. JOHN N. MACKENZIE, of Baltimore, spoke as follows: I have listened with great interest to the excellent papers of Dr. Bosworth and Dr. Bryan. Knowing that they were to precede me, and fearful of the danger of too much unnecessary repetition, I have chosen simply to enter the discussion rather than prepare an elaborate article on the subject selected for debate. Until within comparatively recent times the average general surgeon never examined the nasal chambers, except when in quest of a polypus, or when his attention was irresistibly attracted to these cavities by the horrible stench of an *ozæna*. With many other common affections, such as, for example, deflection of the septum, they had little or no concern. Even until our own time, observers have busied their brains with the burning question whether the deflected septum was turned more frequently to the right than to the left, never concerning their faculties with the remedial aspects of the subject; and in the presence of that overshadowing conundrum, the treatment of the condition has been lost. Even so radical a surgeon as Marcus Aurelius Severinus declared that, inasmuch as the deflected septum was doubtless placed in that position by the will of God, it would be eminently sacrilegious to interfere with such conspicuous manifestation of the Divine dispensation, and therefore it should be left severely alone.

Not so with the antrum. Cooper and the two Meibomii, father and son, lent the weight of their names to the necessity of investigation of antral diseases and to the surgical measures for their relief. In their day more attention was paid to this subject than to many more common surgical diseases.

At a recent meeting of the British Medical Association a distinguished surgical authority apparently went out of his way to affirm that scarcely anything had been accomplished in the domain of rhinology in recent years. While all who are neither ignorant nor prejudiced know this not to be true of the nasal passages, it must be confessed that the stricture touches pretty closely on accuracy in the case of the accessory sinuses. While we have made great advances in technique, while the dawn of a new era in the treatment of this class of affection is breaking, it must nevertheless be confessed that we follow very closely to-day the teachings of those masters of long ago.

The chief interest in the surgery of the accessory sinuses centers in the manner of reaching their interior. The consideration of this question naturally involves an inquiry into the most convenient and satisfactory avenues by which to approach them from without.

In regard to the antrum maxillare—the most generally interesting of the accessory cavities—the question arises, Why not enter here through the aperture which Nature has already provided—the naso-antral opening? This was the inquiry which apparently occupied the minds of the older surgeons until Cooper and the two Meibomii pointed out a better and easier method of procedure.

When we remember that we sometimes have to search for this foramen in the fresh cadaver, we can readily appreciate the difficulties that we may encounter in the living subject in reaching and evacuating the antrum by this method. Moreover, by incautious attempts at penetration, injury may be done to the floor of the orbit, with disastrous results. In cases in which the naso-antral aperture is not readily accessible, it has been suggested to remove the entire middle turbinated bone or its anterior portion. This, it seems to me, would be only justifiable as a last resort. When, then, the inaccessibility of the naso-antral opening, the discomfort to the patient not only in the penetration of the sinus but in the subsequent syringing, are taken into consideration, I think we may lay it down as a good rule of practice that this operation should only be undertaken when other methods are contraindicated, or in cases in which, from extensive atrophy or congenital absence of portions of the intranasal framework, the aperture is readily accessible.

The operation of opening the antrum through the inferior meatus owes its present popularity in Germany to the advocacy of Mikulicz, who opens the antrum wall just below the naso-antral foramen and close to the floor of the inferior meatus. The same objection of inaccessibility of the point of puncture obtains here as in the case of operation through the

naso-antral opening. The antral wall is often very dense at this point, causing difficulty of penetration and great pain, and puncture is not infrequently attended by severe hæmorrhage. Should this operation be undertaken, the opening should be made with a drill or similar contrivance, and not with the spear-shaped instrument used by German surgeons.

In my judgment by far the best method of entering the antrum is from the mouth, by extracting a molar tooth and drilling through the antral floor. Authorities differ as to which tooth should be taken. If there be a diseased tooth, sacrifice that by all means; but, when the choice is given, extract the second molar.

The advantages of this method are sufficiently obvious. First and foremost, by it we secure the best possible drainage of the antral cavity—not only drainage through the alveolar opening, but also through the nose—the greatest surgical advantage—drainage by counter openings. In the second place, the operation is more easily performed than the nasal operation, the loss of blood is almost nil, and the patient himself can attend to the subsequent cleansing of the cavity—a process which may extend over months and even years—a consideration of no small value.

The objections which have been urged against this operation are: (1) That it frequently involves the sacrifice of a good tooth; (2) that there is danger from entrance of food into the antrum; and (3) that septic infection may occur from the mouth.

In regard to the first objection, there are few who would hesitate between the loss of a molar tooth, even though sound, and the loss of the middle turbinated bone or the establishment of a large opening in the outer nasal wall; whereas, if the tooth be diseased, by its extraction two birds are killed with one stone. The second objection is purely fanciful. The cannula or other device used to keep the alveolar wound open may be suitably plugged if necessary and foreign substances thereby excluded. But, as a matter of fact, food does *not* commonly enter the open antrum. To get there it would have to travel a long distance, for the antral cavity is quite far removed from the buccal. I have known patients wear an open antral cannula for years without the occurrence of such an accident.

As far as the third objection is concerned, infection is liable to occur through any open wound, whether in mouth or nostril; but, while the former is the lurking place of many a congregation of well-known and nondescript disease producers, the latter can hold its own successfully against it as the abiding place of myriads of infective agencies. Which wound, too, can be kept cleaner and therefore safer from infection, that easy of access in the mouth or that in the depths of the nasal chambers?

There is one contraindication to the alveolar operation which I may mention, and that is extensive induration and thickening of the alveolar process and floor of the antrum. Should such a condition, which occurs in the edentulous, exist, the operation should be abandoned for one of the nasal methods, or the antrum may be entered somewhere above the sock-

ets of the teeth. The latter method often gives good results, but the opening is necessarily small.

I have had very little personal experience with the drilling operations on the ethmoid bone, but I have had thrilling adventures with the almost, and in one case actually fatal results of that procedure in unskillful hands. I do not wish here to be misunderstood. I believe that a large proportion of inveterate and rebellious nasal catarrhs are due to ethmoid disease, and can only be cured by surgical measures addressed to the ethmoid bone. A great deal has been already accomplished in the surgery of this region and more good will follow shortly. It is no portion of my creed that the ethmoid is only in exceptionally rare cases the seat of diseased action, but I must protest against the wholesale destruction of this bone, of which we have in recent years seen too many conspicuous examples. The ethmoid region is one to be explored only by the expert, and hence when I see around me inexperienced men, following the lead of too enthusiastic operators, drilling the ethmoid bone with a ruthless recklessness which almost causes coagulation of the blood, there looms up before my mind the well-known narrative of the lithotomist of Indian story, who, according to the legend, after he had operated many thousand times for stone without a knowledge of the anatomy of the parts, threw down his knife in fear and refused to operate again when the mysteries of myriad vein and artery in the track of his incision were revealed to his untutored mind.

Before considering the question of operating on the ethmoid, as, for example, in cases of nasal polypi with purulent discharge, it should be forever kept in mind that in the large majority of such cases the removal of the growth alone is sufficient to dissipate the concomitant discharge, and a reasonable time, therefore, should be allowed to elapse before going further with surgical treatment. Even if the discharge does not subside in a few days, much, if not all, may often be accomplished by simple topical medication.

Much error has arisen, too, from the confusion of cause and effect in this class of cases, and much needless surgery has been done by those who accept the harmful doctrine preached in recent years that ethmoiditis, simple or necrosing, is responsible for the genesis of nasal polypi. That it may sometimes be the responsible agent admits of no doubt—as, for example, in the case of polypi found in syphilites—but, as far as my observation of the subject goes, a primary simple ethmoiditis (aside, of course, from that produced accidentally by traumatic causes) is very rarely met with, and is more often due to the surgeon than to original disease. The myriad cellular chambers of the ethmoid (and middle turbinated bone, which in reality is a part of the ethmoid) offer safe asylum for germs, and become readily depots for septic infection. We should also remember that the brain is not far off and therefore in this class of cases, as well as in all operations of the kind in the nose, the operator should proceed with great care and under strictly antiseptic precautions.

The Surgery of the Accessory Sinuses of the Nose.—Dr. JOHN O. ROE, of Rochester, N. Y., said: The subject of the surgery of the accessory sinuses of the nose has been so thoroughly discussed, and the ground so fully gone over by my friends who have preceded me, that it would be a useless repetition for me to take up this subject from the same standpoint and discuss it in all its particulars. I will therefore base the few remarks which I have to make mainly upon my own observations and experience, and briefly report some cases that will serve the purpose of illustrating and emphasizing certain important points.

It may be stated in a general way that the treatment of nearly all the diseases affecting the accessory sinuses of the nose is surgical. This is owing to the fact that these cavities are so hidden in the deeper structure of the head and face that when diseased they are not readily accessible for thorough medication through their natural openings, and not infrequently these passages are so hidden by their anatomical irregularities or so obstructed by disease that they can not be explored.

In studying the diseased conditions affecting these cavities they should be divided into two main classes: acute and chronic. The acute form comprises simple inflammation, phlegmonous inflammation, erysipelatous and diphtheritic inflammation. The chronic form comprises empyema, mucocoele, tuberculosis, and growths of nearly every variety, such as cystoma, fibroma, osteoma, sarcoma, and carcinoma. The acute affections rarely require surgical interference, whereas the chronic almost invariably do.

The symptoms attending acute inflammation of the maxillary sinuses were so well described by John Hunter that they have served as a guide to all writers on this subject nearly to the present time; and those described by him have been regarded as so necessarily present in every case that it has not been believed until quite recently that diseases of the antrum could supervene when none of these symptoms were present.

Christopher Heath was the first to call attention to the fact that purulent discharges from the antrum originated without acute symptoms. The recognition of this fact, that affections of the maxillary sinuses and also of the other accessory sinuses may supervene without subjective or objective symptoms, has given the impetus to the present enthusiastic study of this subject. We believe, however, that much more rapid progress would be made in the diagnosis and treatment of the diseases of these cavities if empyema or purulent discharges from these cavities were looked upon as a symptom rather than a disease.

During acute inflammation these cavities frequently become distended by the inflammatory exudate which usually finds an exit through the natural openings, often bursting through like the contents of an abscess and followed by a subsidence of the trouble.

In the chronic form the discharge of pus into the nares is the principal and often the only symptom, and the source sometimes remains for a

long period unrecognized. If not offensive, no matter how profuse it is, it is often regarded as a catarrhal condition of the nasal passage. If offensive, it may be thought to be an ozæna, or secretions which have undergone decomposition within the nasal passage. I am firmly of the opinion that nearly all cases diagnosticated as ozæna are foetid discharges from some one or more of the accessory sinuses of the nose, which accounts for the inability of pathologists to find in the tissues of the nasal passage, upon which these secretions become incrustrated, an adequate pathological explanation of this condition.

As I have already stated, a purulent discharge, as a rule, gives no indication as to the nature of the exciting cause. It may be due to a simple catarrhal inflammation, a cystic or other degenerative condition of the lining membrane, to foreign bodies, to caries, to necrosis, or to a foreign growth, and still there may be an entire absence of symptoms indicative of any one of these causes. This is very clearly illustrated by the following case of polyps of the right maxillary sinus which I will briefly cite:

Miss S., aged twenty-two years, consulted me December 15, 1893, on account of an offensive discharge from the right side of her nose. She had had a mild nasal catarrh for several years, but it was only about two months before I saw her that the discharge had begun to have a disagreeable odor and taste. This odor was perceived by herself more than by others. Her general health had always been good, and she had not been troubled with sore throat.

On examining her nose the right passage contained more or less purulent discharge. The left nostril was in a comparatively healthy condition. After wiping this purulent discharge away, pus could be seen slowly exuding from the maxillary opening just beneath the middle turbinated body, which was considerably hypertrophied and pressed against the septum.

Owing to irritation in the nostril caused by an enlarged turbinated body, I advised the removal of a sufficient portion of it to render the passage free, which was accordingly done. After the parts had healed I began the catheterization of the right antrum through the ostium maxillare by means of Myles's tubes, which are far superior to all others. For about two weeks the cavity was washed out daily with an antiseptic solution, with but little apparent lessening of the discharge or fœtor.

Being convinced of the obstinate character of the disease in the antrum, although the patient had not suffered from any pain or tenderness of the face or jaw, I made an external incision through the canine eminence, sufficiently large to permit of a free exploration of the whole cavity, and much to my surprise I found the cavity filled with mucous polyps, the existence of which had not in the slightest degree been suspected. These were thoroughly removed by curettement and the cavity packed with iodoform gauze.

There is now little or no discharge from the cavity, and the fœtor entirely disappeared when the polyps were removed.

The opening is still maintained, to insure the complete removal of all the diseased process and the non-reappearance of growths before it is allowed to close.

I have also at the present time two other cases of polyps of the maxillary sinuses, one the right sinus and one the left, in which there was no evidence, aside from the fœtid discharge, to indicate the existence of the growths. The treatment in these cases has been the same as that instituted in the one already stated, with a like excellent result.

Such cases as these illustrate more clearly than words can express the importance of a free external opening and thorough exploration of the cavity in all cases where the discharge will not readily subside, and the uselessness of depending upon drainage-tubes, the employment of ordinary forms of antiseptic or astringent washes, or other forms of local medication.

What holds good for the maxillary sinuses also applies to the other sinuses of the head, for in them will be found chronic diseased conditions that can only be removed by appropriate and radical surgical treatment.

In cases where growths of any considerable size spring from the sinuses, and especially if they become sufficiently large to distend the cavity, their nature is readily manifest, and the appropriate operation for the removal is at once indicated.

I present you in this connection the picture of a woman with a very large myxomatous growth springing from the right maxillary sinus that had been preceded for a considerable period by a muco-purulent fœtid discharge. The distention of the face and nose shows very clearly the size to which the growth had attained.

This woman was sixty-one years old, and had for several years a profuse muco-purulent fœtid discharge from the right nostril which supervened without assignable cause. After a time the nostril became completely blocked, and soon after she began to experience a sensation of pressure in the cheek. Shortly afterward the cheek and side of the nose began to bulge outward and the growth appeared in the lower portion of the right nostril. She then began to have a choking sensation and fullness in the throat and much difficulty in swallowing. On being called to see her I found a large growth occupying the right nostril and the maxillary sinus, extending backward into the throat, so that the lower border of the growth was visible below the soft palate. I succeeded in removing the greater portion of this growth by means of a cold wire *écraseur*, but the part which occupied the antrum I was unable to reach by this method. Owing to the size of the growth it was impracticable to attempt its removal through an incision made under the cheek from the inside of the mouth; accordingly, a horizontal incision was made just below the zygoma, and also a vertical incision along the side of the nose joining the

former incision, after the plan of Demarquay's operation. The flap was turned upward and the anterior wall of the antrum removed. The growth was found to be from the whole interior of the antrum and from the outer wall of the nasal passage opposite the antrum. The growth was thoroughly removed and the external wound closed.

This case is exceedingly interesting on account of the large size of the growth and the length of time that its appearance was preceded by the muco-purulent and foetid discharge.

The successful application of surgical principles to the treatment of diseases of these cavities depends on two factors: 1. To definitely ascertain the presence and location of the disease. 2. To definitely ascertain the pathological condition. The former simply locating the diseased process, the latter indicating the appropriate treatment.

In many instances the diagnosis is extremely simple, while in others it is attended with great difficulty. This can be readily appreciated on considering the hidden location and the very limited space in which these four sinuses communicate with the nasal cavity.

It is needless to detain you by giving the details of the symptoms and differential diagnosis of the diseases of these cavities. The methods of detecting the source of the pus by position, as proposed by Fränkel; by the intermittent or constant flow of the discharge, as emphasized by Luc; by the location of the pain, when present; by the diaphaneity of the tissues of the face with transmitted light, as pointed out by Voltolini, Heryng, and Vohsen, but observed, however, more clearly in the eye, as shown by Davidson; by the demonstration of the presence of pus by injection of a solution of peroxide of hydrogen, as proposed by Brown; by puncturing the maxillary antrum through the inferior meatus with a strong, curved aspirating needle, as proposed by Moritz Schmidt, are methods and expedients familiar to you all and clearly described in recent works and articles upon this subject.

After having located the disease, the same principle holds good for the treatment of the disease located in either cavity.

A great many different operative procedures and methods are recommended by the numerous writers upon this subject. I will briefly enumerate the surgical methods that have given me the best results. In the case of the maxillary sinus, when the disease is recent, being the direct or indirect result of an acute inflammatory affection, I begin the treatment by washing out the cavity, when it can be done, through the natural passage. In some cases this plan may serve in a short time to bring about a cure. During the past winter I successfully treated in this manner two patients in whom the acute inflammation of the antrum followed attacks of influenza. When catheterization is impossible, a small preliminary artificial opening should be made. The plan of attempting to enlarge this natural passage, as proposed by some authors, is, I believe, ill-advised, and rarely fails to result in a complete closure of the orifice.

If a bicuspid has previously been extracted, the opening can be made through the socket. When the teeth are sound, an opening should be made obliquely through the lower portion of the canine eminence, just above the alveolar process; or it may be advisable to make it through the outer wall of the nasal passage, close to the floor of the inferior meatus, and through this opening the cavity can be washed, medicated, and drained. Ofttimes through a small opening the condition of the interior of the cavity can be detected by the careful use of the probe. If we detect foreign growths in the cavity, or if the disease does not readily subside by careful and thorough medication, the disease must be dealt with surgically, and a free opening, so large that the interior of the cavity can be inspected or explored with the finger or suitable instrument, should then be made, and the growths or the degenerated tissue found within the cavity thoroughly removed. After the removal of the diseased condition, the opening in the cavity should be maintained for a considerable period, until we are assured that the disease in the cavity is entirely cured, when the opening can safely be permitted to close. The most favorable site for this external opening, and the point at which the floor of the antrum is most readily reached, is through the zygomatic ridge just above the alveolar ridge.

In the diseased conditions of the frontal sinus we can succeed in some cases in medicating these cavities through the infundibulum; but in cases where the disease of the antrum requires surgical interference, an incision through the anterior wall must be resorted to and the cavity freely opened, similar to the manner of incising the maxillary sinus through the canine eminence. The incision through the skin should be made along the inner portion of the supraorbital curve so that the eyebrows will obscure any scar that may result.

When the ethmoid cells are diseased we usually find polyps, hypertrophies, or a diseased condition of the middle turbinated body, a condition that Woakes attributes to a necrosing ethmoiditis.

When the ethmoid is extensively invaded by disease it is frequently necessary to remove the cap or the greater portion of the middle turbinated body, in order to gain access to these cells for curettement and thorough treatment. For this purpose I have found the small bow saw that I devised the most serviceable instrument.

The sphenoid antrum can be more readily medicated through its natural passage than can either of the other cavities. It is best done by passing the long, slender nozzle of a syringe horizontally between the middle and superior turbinated body, using the upper border of the middle turbinated body as a guide, when, by slightly depressing the handle of the syringe, the nozzle will readily pass into the opening.

In cases in which it is necessary to freely open this cavity, it can be done with a drill or gouge, or with a hooked cutting instrument, having the cutting edge turned forward by which the edges of the wall can be

caught and thereby chipped off. Operations upon the ethmoidal and sphenoidal sinuses are, however, hazardous, and should only be attempted with the nasal passages very brightly illuminated, and with a very clear understanding of the anatomy of the parts by the operator.

The points which I wish briefly to emphasize are these:

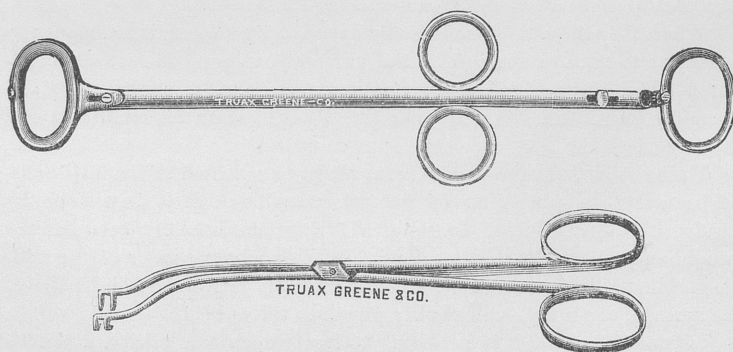
1. That purulent discharges from the accessory sinuses of the nose should be regarded as a mere symptom only.
2. That the very common belief that drainage and cleansing is the treatment required, regardless of the exciting cause of the discharge, should be abandoned.
3. That the exciting cause of the purulent discharge will be found, in a much larger proportion of cases than heretofore believed, to be poly-poid or other foreign growths.
4. That in all cases, recent or obscure, where the purulent discharge does not cease after exploratory punctures, washing and drainage for a reasonable time, the cavity should be so freely laid open that the exact pathological condition can be ascertained and the disease radically removed.
5. That a free opening should be maintained for examination, and the cavity thoroughly and carefully treated until the disease is cured.

Presentation of Instruments.

TONSILOTOME AND VOLSELLA.

BY DR. CASSELBERRY.

DR. CASSELBERRY, of Chicago, presented a tonsillotome which was somewhat similar to Mathieu's tonsillotome, except that the fork was taken off and the sliding mechanism removed, which left a



simple ring guillotine for cutting purposes. For withdrawing and fixing purposes he had devised a tonsil volsella to be used with the tonsillo-

tome as a substitute for the ordinary fork attachment, but to be held in the other hand.

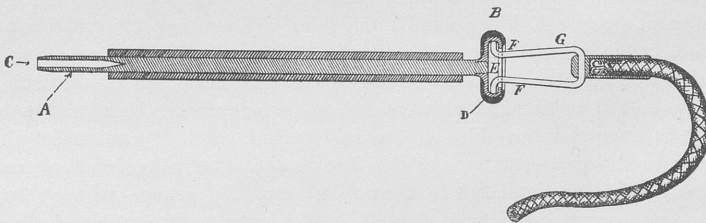
The new instrument, assisted by the volsella, will abscise many tonsils that could not be satisfactorily grasped by the old mechanism, and it will abscise all tonsils with a reasonable degree of accuracy at the desired line.

ELECTROLYTIC NEEDLE-HOLDER.

BY DR. DE ROALDES.

TO such of you, gentlemen, as are inclined to utilize electrolysis in the treatment of hypertrophies or of neoplasms of the nose and post-nasal space, I wish to pass around for your inspection the herein-figured needle-holders. The limited space for work, the restriction of cavities by growths, the general preference given to-day to the bipolar over the monopolar method, the advantage of dispensing with screws, of insuring reliable electrical contact, of avoiding shock, and other reasons, have caused me to devise these new handles, which I can strongly recommend as an improvement over those actually in use. Their description is as follows:

A represents the main body of the needle-holder, having at its end B a circular disc, and at its end C a hole bored longitudinally to admit any size of needle, from the largest to the smallest. On one side of this



hole, and at the very bottom, is a hole which serves for the purpose of a vent to allow the escape of any confined air or other gas that may be generated or confined by the sealing wax used for fixing the needle. The body A is composed of a No. 14 American gauge platinum wire about five inches long. Platinum is used in preference owing to its great resistance to corrosion, which will always insure a good contact with the needle free from all oxide. The circular head or disc at the end B, of the body A, is made of brass and nickel plated, and on the outside circumference of it there is fitted a hard rubber ring, D, serving for the sole purpose of preventing the accidental contact of the disc B with the other disc, or with the body or connections of the other handle, as the case may be, which would, of course, cause a short circuit resulting in a severe

shock to the patient under treatment. The disc B is hollowed out on its outer face, and a groove is undercut at E for the purpose of receiving the tips F of the spring catches G. This groove allows the spring catches G to be attached at any angle with reference to the face of the disc B and also in any position circumferentially therewith. In other words, it forms a very effective universal joint and one that is applied with ease and certainty, and at the same time by its elasticity insures a perfect electrical contact, and has sufficient grip to resist any ordinary strain tending to pull the same apart. The conducting cord is fastened to the catches G in the center of their loop, and soldered thereto so as to insure a good contact. This conducting cord is of a quality to be as light as possible consistent with strength and proper conducting capacity. The spring catches G, as well as the end of the conducting cords, are covered with a hard rubber varnish, which serves the double purpose of insulating the said catches G so as to guard against the accidental contact of one with the other, but also to render a part of the cord waterproof, and thus protect it from the liquids that may follow the course of the needles and handles and finally make their way over the cords, and not alone soil but also rot them, and render it difficult to keep them properly aseptic.

The tips of the spring catches G are so curved that they allow of the body, with cord attached, to assume a vertical position, which holds the cords in a particularly desirable position, and thus relieves undue strain on the needles when imbedded in the soft tissues, and any motion of the cord is followed by a hinging action between the said tips and the undercut groove E, but at the same time without any interruption of the electric circuit. The spring catches enable the operator to connect and disconnect the cords at pleasure with the minimum of disturbing action on the needles and greatest ease and promptness, it being necessary only to compress the sides of the said spring catch G and insert the tips into the undercut part of the disc B, and upon releasing the pressure the said tips will fasten themselves into the groove without any other care or precautions; it also affords the same facilities for removing. Over the body A there is slipped a piece of soft rubber tubing of suitable bore to fit and of suitable length to cover the needle as far as may be necessary to protect the same.

In this manner we can allow only a small fraction or the whole of the operating needle to project from the handle, as may be desired, the balance being electrically protected from adjacent tissues and from the possibilities of accidental contact with the opposite pole handle or needle, as the case may be. The main objects of making the handle as a whole in the manner indicated in this drawing is to have as little weight to the parts as possible, and to reduce bulk and insure ease of manipulation not to be attained by any other instruments now in use.

Not the least important of the whole combination is the method of

fastening the needles in the bar or handle A. It will be again noted that this handle is made of platinum to insure noncorrosion, as we have no certainty at any time that blood or matter and antiseptics will not make their way into the hole C and in time corrode the same to such an extent as to destroy the electrical conductivity and thus impair the efficiency of the instrument. Then, again, we use sealing wax to fasten and firmly hold the needles in place, the object of which is threefold, first of which, by having the hole C large enough to easily accommodate the largest size needle and filling in with the wax all the extra space that forms when smaller sizes of needles are used. This then forms a chuck, and not only a chuck that holds very firmly, but that is hermetically sealed against all liquids that might accidentally enter and destroy the efficiency of the device by corrosive action or otherwise upon the steel needle used. Then we have a chuck that accommodates all sizes of needles indiscriminately within certain predetermined limits. The bottom of the hole C is drilled V-shaped or conical, so that when the needle is made to enter and touch the bottom it will be centered, and at the same time be jammed by the conical sides and thus insure a good contact at all times. The sealing wax is, of course, a nonconductor of electricity, but we overcome this difficulty by so inserting the needle while the wax is still hot and soft as to bring about an absolute contact between the metal on the needle and that of the handle or bar A, always, however, at the bottom of the hole C, where it is coned, as before specified. Good contact, irrespective of the insulating properties of the wax, is always obtained by taking care to exert a fair amount of pressure downward toward the bottom of the hole C, and at the same time giving the inserted needle a rotary motion to a limited extent. This rotary motion grinds the wax from the point of the needle and bottom of the hole. Instead of sealing wax, ordinary gum shellac and other substances may be used, but, as sealing wax is to be found almost everywhere, it is perhaps the best to use.

It requires but a very small amount of heat to melt the sealing wax, and this affords a ready means of quickly inserting a new needle or removing an old one, or one of different size. Then having a low specific heat, this wax cools very rapidly, and consequently hardens promptly enough to entail no loss of time on the part of the operator while making these changes, which is a great advantage.

REPORT OF THE DELEGATE TO THE INTERNATIONAL MEDICAL
CONGRESS AT ROME.

BY J. H. LOWMAN, M. D.

MR. PRESIDENT AND FELLOWS: Permit me to thank the Association, the Council, and the President for the opportunity of serving as your delegate to the recent congress at Rome. It was a rare privilege to represent so honorable and distinguished a body. It gave me the means of seeing the Eternal City under the most favorable and delightful circumstances, and of participating in the exercises of the congress in the most agreeable and valuable way.

The Eleventh International Medical Congress was received at Rome with a royal welcome. All classes seemed glad that it was to be at Rome. But the number of guests so far surpassed the expectation of the hosts that their plans could only *be carried out with difficulty*. Rome never had had so many guests. Besides the representatives of medicine, there were many there for the Easter festivities. Between five thousand and six thousand medical men were present, and with them two thousand ladies or friends, who were also to be invited to the social parts of the programme. Long before the congress opened it was impossible to get a room in a hotel. Some who arrived late in the evening spent the night in a cab. The arrangements of the Entertainment Committee were severely strained, and by the sufferers severely criticised.

The seat of the organization of the congress was at Genoa, the home of Professor Maragliano. His arrangements of committee and plan of organization were excellent, but he was too far from the scene of action. He went to Rome with his corps of aids a month before the congress convened, and daily found new and unexpected detail crowding upon him. A great anxiety seized those in authority. At the last moment the publishing of abstracts of papers was abandoned, and also certain almost necessary arrangements concerning the places of meeting failed of realization.

The arrangement for receiving and registering delegates and members was very good. There were enough interpreters, and everything was made easy for the foreigner who knew no language but his own. There apparently was no accessible list of members who had paid their fees. Many stated they had paid by postal order, but had received no answer. They were immediately given cards without reference to any list. There was no committee room provided for American delegates. Several incidents of this nature exposed the embarrassment of the local committees. They were overpowered by numbers. They were very active and courteous, and were often fatigued by their efforts.

The physicians of Rome felt that many of the mistakes might have been avoided had the organization of the congress been in Rome. Un-

doubtedly a lesson can be learned from this. The place of the meeting was at the Polyclinic Umberto. This is outside the city, and not very accessible except by carriage. It consists of a series of seven buildings, admirably arranged for a polyclinic, both for medical and teaching purposes. It is operated in conjunction with the University of Rome. It was built entirely by King Humbert, who deserves high praise for this unusual interest in medical science.

The administration building is in the center, and is a very beautiful building, with tiled floors and marble staircases. The three pavilions on one side are dedicated to medicine and its specialties, and the three on the other to surgery and its branches. It can be safely said that no other city will have so admirable an arrangement of buildings for clinical purposes when the Roman polyclinic is completed. All the section work was done in the polyclinic. The general meetings were held in a temporary building in the city, which was wholly inadequate for the purpose. It was too small. Its seating capacity was not more than five or seven hundred, and it was noisy and uncomfortable.

As a result, the general meetings were sparsely attended. This, however, was partly due to the fact that many of the members devoted themselves to sight-seeing in the afternoon.

The scientific work was done in the morning. The sections convened about 9 or 9.30 A. M. and continued their work until one o'clock. All were more or less active, but I believe that in no section was the work more energetically pushed than in the laryngological. Professor Massei was an admirable president. He was at home in speaking Italian and French, and could get on in English and German. He was energetic and active, and had his section well in hand all the time. The room was oftentimes crowded, and there was always a good attendance. Often I glanced into the rooms devoted to the other sections and found them empty. I several times heard the remark that the laryngological section seemed very active. I was thus impressed with the earnestness of the men who follow this specialty. The papers were so numerous that all of them could not be read.

Discussion usually followed a paper and oftentimes was general.

There is no doubt that the laryngological work compared more than favorably with that of the other sections, and the men themselves were a pleasure to meet. My only regret was that there were so few of my compatriots there.

Among those present were Chiari, Moritz Schmidt, Schmiegelow, Fränkel, Semon, Gouguenheim, Moure, Massei, Masini, Grazi, Egidi, Toti, Sendziak, Heryng, Sokolowski, Navratil, Burger, Schmidthuyzen, and Botey.

The number registered in this Section was over a hundred and twenty. The language used was almost invariably French. The business in every section was conducted in French. The discussions were usually in the

same language. Spaniards, Italians, Russians, and sometimes Germans read their papers in French.

A large part of one of the mornings was devoted to papers and discussions of vibratory massage. Braun, of Trieste, declared that he had cured many cases of ozæna by stroking the lining membrane of the nose. This, done by the unaided hand, he knew to be fatiguing, and admitted the usefulness of various devices, electrical and otherwise, to carry out the method. Several speakers seemed to favor this means as a good therapeutic measure. Chiari, however, dissented, and declared that he saw no more benefit from massage than from painting the mucosa. On this and on several occasions, as also in his paper on Pachydermia of the Larynx, Chiari seemed to me to show a wholesome skepticism. He has a strong, healthy mind, talks fluently and modestly, and has a thoroughly comprehensive and practical grasp of his subject.

Among those whom we all recognize as most prominent among laryngologists he was equally foremost, and were it not that he has so long been preceded in his own university by such distinguished lights as Schroetter and Stoerk, he would be an even more striking figure.

Moure's paper on Electrolysis in removing Spurs from the Nose and correcting Septum Deviations attracted considerable attention, although there was not much more in it than in his contribution to the Berlin Congress. He claimed again to remove bony spurs at one sitting by the bipolar method. He uses steel needles insulated with gutta percha, and places the negative pole on the summit of the spur and the positive but slightly removed. There is but little pain and blood in the process. Those of us who have seen dangerous hæmorrhages from the use of the saw would like to believe in electrolysis as a reliable substitute. Many were skeptical as to the time required. Chiari again doubted that the needle could work so rapidly in any but small spurs or those that were not very dense. Some excellent bottled specimens of pachydermia of the larynx were shown, but the papers and discussions, though taking much time, were in the nature of *résumés* of the subject.

Onodi, of Budapest, showed an excellent series of casts of the nasopharyngeal region. His method of obtaining them is somewhat as follows: He molds on to a strong curved sound, that will easily go behind the soft palate, a piece of the compound that is used by dentists in taking impressions of the mouth. This he warms and makes pliable, and then forces behind the palate. He leaves it there for three or four minutes, gently molding it into place. Then he withdraws it, and has an impression of the fossæ and their reduplications. From this he makes a plaster cast which he colors. Thus he has an admirable reproduction of the nasopharynx. The casts show the vault, the Eustachian orifices, the posterior nares, the posterior turbinates to the distance of a quarter of an inch or more. He had with him as many as fifty specimens. Some represented the normal in a variety of subjects and some the nasopharynx in a patho-

logical state. They are useful, especially to those beginning the study of the throat and nose.

The innervation was the subject of desultory discussion, which was enlivened, however, by Professor Masini, of Genoa. The next morning, at the Physiological Institute, he attempted to demonstrate the motor centers of the larynx in the frontal convolutions of a dog. He trephined and used a mild galvanic current which he did not measure. The experiment proved nothing. It demonstrated nothing.

Masini claimed that he had often proved that the cords would close on applying the positive electro to the anterior part of the brain. His dog on this occasion was not anæsthetized and continued to whine, which undoubtedly kept the cords in apposition and interfered with the experiment.

The section work was earnest until the last, and the verdict of those familiar with similar meetings was that this one had been very harmonious and successful.

There was much delightful social life in Rome during the week of the congress. The Romans revived their old motto, "*Roma Communis Patria*," and tried to make every one think himself at home. There were balls, receptions, parades, illuminations, breakfasts, dinners, and excursions to such an extent that it was impossible to attend them all. The city was most lavish in its hospitality. Among the many and brilliant attentions and courtesies offered the guests of the congress I recall with especial pleasure the breakfast given by the Italian Laryngological Association to certain members of the Section in Laryngology. It was a most charming and graceful affair, and left an ineffaceable impression of pleasure upon those who were fortunate enough to be present.

As a whole, the congress was a decided success, and must have fully rewarded those who labored so diligently to promote it, as well as those who traveled far to participate in it.

BUSINESS MEETINGS.

THE Sixteenth Annual Congress of the American Laryngological Association was convened by the President, Dr. Delavan, at the Arlington Hotel, Washington, D. C., on Wednesday, May 30, 1894, at 10 A. M. There were present during the session the following Fellows:

D. BRYSON DELAVAN, New York, President.
 J. C. MULHALL, St. Louis, First Vice-President.
 W. E. CASSELBERRY, Chicago, Second Vice-President.
 CHARLES H. KNIGHT, New York, Secretary and Treasurer.
 HARRISON ALLEN, Philadelphia, Member of Council.
 M. J. ASCH, New York, Member of Council.
 W. C. GLASGOW, St. Louis, Member of Council.
 S. W. LANGMAID, Boston, Member of Council.
 J. H. BRYAN, Washington, Librarian.
 A. A. BLISS, Philadelphia.
 F. H. BOSWORTH, New York.
 M. R. BROWN, Chicago.
 A. COOLIDGE, JR., Boston.
 W. H. DALY, Pittsburgh.
 J. W. FARLOW, Boston.
 T. R. FRENCH, Brooklyn.
 J. W. GLEITSMANN, New York.
 J. H. HARTMAN, Baltimore.
 F. W. HINKEL, Buffalo.
 S. JOHNSTON, Baltimore.
 F. I. KNIGHT, Boston.
 J. H. LOWMAN, Cleveland.
 ALEXANDER W. MACCOY, Philadelphia.
 J. N. MACKENZIE, Baltimore.
 T. MORRIS MURRAY, Washington.
 J. E. NEWCOMB, New York.
 W. PEYRE PORCHER, Charleston.
 C. C. RICE, New York.
 A. W. DE ROALDES, New Orleans.
 BEVERLEY ROBINSON, New York.
 J. O. ROE, Rochester.
 C. M. SHIELDS, Richmond.
 W. K. SIMPSON, New York.
 H. L. SWAIN, New Haven.
 A. W. WATSON, Philadelphia.
 J. WRIGHT, Brooklyn.

The President, after having delivered his address, invited Dr. J. H. Lowman, delegate to the International Medical Congress at Rome, to present his report. At the conclusion of the scientific proceedings of the day the Association went into executive session. The President appointed Dr. Coolidge and Dr. Brown a committee to audit the Treasurer's ac-

counts. In accordance with an amendment to the Constitution adopted at the last annual meeting, the following committee was elected to nominate officers for 1894-'95: Dr. French, Dr. Daly, Dr. Farlow, Dr. Wright, and Dr. Swain. The following candidates, having been proposed in due form by the Council, were then elected to fellowship in the Association. Active Fellows: G. A. Leland, M. D., of Boston, who presented a thesis on Reposition of the Septum Nasi; and W. H. Park, M. D., of New York, who presented a thesis entitled Some Studies on the Relation of Bacteria to Acute Inflammation of the Upper Air-passages. Corresponding Fellows: R. Norris Wolfenden, M. D., of London; John Macintyre, M. B., of Glasgow; Edgar Holden, M. D., Ph. D., of Newark, formerly an active Fellow; and C. E. Sajous, M. D., of Paris, France, who is transferred from the active list at his own request.

A business meeting was held in the morning of the second day, at which a communication was read from Wyatt Wingrave, Secretary of the British Laryngological Association, regarding a combined meeting of the British and American Laryngological Associations. It was voted to direct the Secretary to make due acknowledgment, and to express the hope that such a meeting might be arranged.

After some discussion of the question of forming a permanent collection of instruments and apparatus devised by Fellows of the Association, it was voted that a committee of two be appointed to consider the subject and report at the next meeting. Dr. Porcher and Dr. Bryan were named such a committee.

The Committee on Nominations reported the following ticket for officers for 1894-'95:

President.—JOHN O. ROE, Rochester.

First Vice-President.—C. C. RICE, New York.

Second Vice-President.—S. H. CHAPMAN, New Haven.

Secretary and Treasurer.—CHARLES H. KNIGHT, New York.

Librarian.—J. H. BRYAN, Washington.

Member of Council.—D. B. DELAVAN, New York.

Secretary's Report, 1894.

I have the honor of presenting an unbound copy of the fifteenth volume of *Transactions*. The bound volumes will be distributed during the coming week. Two of the papers on the programme of the New York meeting were received too late for publication, and one of these will appear in the sixteenth volume. No remedy has yet been devised for the delay in publishing our transactions, and, as will appear from the minutes, the Council voted to invite suggestions looking to a correction of the evil. All the Fellows, active and corresponding, elected at the last meeting, have accepted and qualified. One active Fellow has been dropped in accordance with the provisions of our constitution, leaving our active membership at fifty-nine. One meeting of the Council has been held, the record of which will be read.

*Treasurer's Report, 1893 '94.**Receipts.*

Brought from 1893 account	\$85 43
Dues, 1892 (1)	5 00
Dues, 1893 (3)	15 00
Dues, 1894 (53)	265 00
Assessments, 1893 (56)	280 00
	<hr/> \$650 43

Disbursements.

Printing	24 45
Stationery	38 75
Postage on programmes, etc	8 60
<i>Transactions</i> , 1892	232 04
Programmes, 1893	23 75
Programmes, 1894	23 75
Stenographer, 1893	76 20
	<hr/> \$427 54
Balance	\$222 89

A. COOLIDGE, JR., }
M. R. BROWN, } *Auditing Committee.*

Librarian's Report, 1894.

The Librarian has to report the reception of seventy-one pamphlets since the last meeting of the Association.

The library now consists of 1,022 volumes.

Respectfully submitted, J. H. BRYAN, *Librarian.*

In executive session on the third day it was moved and carried that the usual expenditures be authorized and that the *Transactions* of the Association be published as heretofore.

By unanimous vote the Secretary was directed to cast a ballot for the officers proposed by the Nominating Committee.

It was moved and carried that the place of the next meeting be Rochester, N. Y., and that the selection of the time of the meeting be referred to the Council with power.

After a vote of thanks to the Fellows residing in Washington, whose efforts contributed much to the success and pleasure of the meeting, and to the outgoing officers, the newly elected officers were installed and the congress adjourned.

ACTIVE FELLOWS.

- ALLEN, HARRISON, 1933 Chestnut Street, Philadelphia, Pa.
 ASCH, MORRIS J., 5 West Thirtieth Street, New York.
 BEAN, C. E., Germania Life Building, St. Paul, Minn.
 BIRKETT, HERBERT S., 123 Stanley Street, Montreal.
 BLISS, ARTHUR AMES, 1832 Race Street, Philadelphia, Pa.
 BOSWORTH, FRANCKE H., 26 West Forty-sixth Street, New York.
 BROWN, M. R., 34 Washington Street, Chicago, Ill.
 BRYAN, J. H., 818 Seventeenth Street, Washington, D. C.
 CASSELBERRY, WILLIAM E., 34 Washington Street, Chicago, Ill.
 CHAPMAN, S. H., 193 Church Street, New Haven, Conn.
 COHEN, J. SOLIS-, 1431 Walnut Street, Philadelphia, Pa.
 COHEN, S. SOLIS-, 219 South Seventeenth Street, Philadelphia, Pa.
 COOLIDGE, A. JR., 1 Exeter Street, Boston, Mass.
 DALY, WILLIAM H., 135 Fifth Avenue, Pittsburg, Pa.
 DEBLOIS, T. AMORY, 372 Marlborough Street, Boston, Mass.
 DELAVAN, D. BRYSON, 1 East Thirty-third Street, New York.
 FARLOW, J. W., 234 Clarendon Street, Boston, Mass.
 FRENCH, THOMAS R., 150 Joralemon Street, Brooklyn, N. Y.
 GLASGOW, WILLIAM C., 2847 Washington Avenue, St. Louis, Mo.
 GLEITSMANN, J. W., 46 East Twenty-fifth Street, New York.
 HARTMAN, J. H., 5 West Franklin Street, Baltimore, Md.
 HINKEL, F. WHITEHILL, 274 Delaware Avenue, Buffalo, N. Y.
 HITCHCOCK, URBAN G., 51 West Twenty-ninth Street, New York.
 HOPE, GEORGE B., 34 West Fifty-first Street, New York.
 INGALS, E. FLETCHER, 36 Washington Street, Chicago, Ill.
 IVES, FRANK L., 117 East Thirtieth Street, New York.
 JARVIS, WILLIAM C., 142 Madison Avenue, New York.
 JOHNSTON, SAMUEL, 204 West Monument Street, Baltimore, Md.
 KNIGHT, CHARLES H., 147 West Fifty-seventh Street, New York.
 KNIGHT, FREDERICK I., 195 Beacon Street, Boston, Mass.
 LANGMAID, SAMUEL W., 373 Boylston Street, Boston, Mass.
 LEFFERTS, GEORGE MOREWOOD, 6 West Thirty-third Street, New York.

LELAND, GEORGE A., 669 Boylston Street, Boston, Mass.
 LINCOLN, RUFUS P., 22 West Thirty-first Street, New York.
 LOWMAN, JOHN H., 441 Prospect Street, Cleveland, O.
 MACCOY, ALEXANDER W., 1417 Walnut Street, Philadelphia, Pa.
 MACKENZIE, JOHN N., 605 North Charles Street, Baltimore, Md.
 MAJOR, GEORGE W., 82 Union Avenue, Montreal.
 MULHALL, J. C., 3609 Lindell Avenue, St. Louis, Mo.
 MURRAY, T. MORRIS, Seventeenth and H Streets, Washington, D. C.
 NEWCOMB, JAMES E., 118 West Sixty-ninth Street, New York.
 PARK, W. H., 128 West Eleventh Street, New York.
 PORCHER, W. PEYRE, 4 George Street, Charleston, S. C.
 PORTER, WILLIAM, 3886 Washington Avenue, St. Louis, Mo.
 RANKIN, D. N., 85 Lincoln Avenue, Allegheny, Pa.
 RICE, CLARENCE C., 123 East Nineteenth Street, New York.
 ROALDES, A. W. DE, 136 Gravier Street, New Orleans, La.
 ROBINSON, BEVERLEY, 37 West Thirty-fifth Street, New York.
 ROE, JOHN O., 28 North Clinton Street, Rochester, N. Y.
 SEILER, CARL, 1204 Walnut Street, Philadelphia, Pa.
 SHIELDS, CHARLES M., Fifth and Franklin Streets, Richmond, Va.
 SHURLY, E. L., 32 Adams Avenue, W., Detroit, Mich.
 SIMPSON, W. K., 952 Lexington Avenue, New York.
 SWAIN, H. L., 238 York Street, New Haven, Conn.
 THRASHER, A. B., 296 Walnut Street, Cincinnati, O.
 VAN DER POEL, S. OAKLEY, 47 East Twenty-fifth Street, New York.
 WAGNER, CLINTON, 19 East Thirty-eighth Street, New York.
 WAGNER, HENRY L., 506 Sutter Street, San Francisco, Cal.
 WATSON, A. W., 162 North Twentieth Street, Philadelphia, Pa.
 WRIGHT, JONATHAN, 73 Remsen Street, Brooklyn, N. Y.

HONORARY FELLOWS.

GARCIA, MANUEL, 1 Bentinck Street, Manchester Square, London, England.
 * MACKENZIE, SIR MORELL, 19 Harley Street, W., London, England.

CORRESPONDING FELLOWS.

BROWNE, LENNOX, 36 Weymouth Street, London, England.
 DE LA SOTA Y LASTRA, R., 7 Calle de Torqueros, Seville, Spain.
 DESVERNINE, C. M., Cuba 52, Havana, Cuba.

* Deceased.

- GUGUENHEIM, A., 73 Boul. Hausmann, Paris, France.
HOLDEN, E., 13 Central Avenue, Newark, N. J.
KRAUSE, H., Neustädt. Kirch-Strasse 13, Berlin, Germany.
LABUS, CARLO, Via St. Andrea 8, Milan, Italy.
MACINTYRE, JOHN, 179 Bath Street, Glasgow, Scotland.
MASSEI, F., 4 Piazza Municipio, Naples, Italy.
MEYER, WILHELM, Nørrefarimagsgade 19, Copenhagen, Denmark.
MOURE, E. J., 25 Cour du Jardin-Public, Bordeaux, France.
SAJOUS, C. E., 28 rue de Madrid, Paris, France.
SCHROETTER, LEOPOLD V., Schwartzberg-Strasse 8, Vienna, Austria.
SEMON, FELIX, 39 Wimpole Street, Cavendish Square, London, England.
STOERK, CARL, Wallfischgasse 13, Vienna, Austria.
WHISTLER, W. McNEIL, 28 Wimpole Street, Cavendish Square, London, England.
WOLFENDEN, R. NORRIS, 35 Harley Street, W., London, England.

