Transactions of the ... Annual Meeting of the American Laryngological Association, Volume 25

American Laryngological Association

This book was originally published prior to 1923, and represents a reproduction of an important historical work, maintaining the same format as the original work. While some publishers have opted to apply OCR (optical character recognition) technology to the process, we believe this leads to sub-optimal results (frequent typographical errors, strange characters and confusing formatting) and does not adequately preserve the historical character of the original artifact. We believe this work is culturally important in its original archival form. While we strive to adequately clean and digitally enhance the original work, there are occasionally instances where imperfections such as blurred or missing pages, poor pictures or errant marks may have been introduced due to either the quality of the original work or the scanning process itself. Despite these occasional imperfections, we have brought it back into print as part of our ongoing global book preservation commitment, providing customers with access to the best possible historical reprints. We appreciate your understanding of these occasional imperfections, and sincerely hope you enjoy seeing the book in a format as close as possible to that intended by the original publisher.

Transactions of the ... Annual Meeting of the American Laryngological Association, Volume 25

American Laryngological Association

TRANSACTIONS

OF THE

Twenty-fifth Annual Meeting

OF THE

AMERICAN LARYNGOLOGICAL ASSOCIATION

HELD AT

WASHINGTON, D. C.

May 12th, 13th and 14th, 1903

NEW YORK
PUBLISHED BY THE ASSOCIATION
1903

BOSTON MEDICAL
SEP 28 1903
LIBRARY.

3325

ROONEY & OTTEN
PRINTING CO.
NEW YORK

CATALOGUED
SEP 28 1903
E. H. B.

PRESIDENTS OF THE ASSOCIATION.

1879. LOUIS ELSBERG, M.D.
1880. J. SOLIS-COHEN, M.D.
1881. FREDERICK I. KNIGHT, M.D.
1882. GEORGE M. LEFFERTS, M.D.
1883. F. H. BOSWORTH, M.D.
1884. E. L. SHURLY, M.D.
1885. HARRISON ALLEN, M.D.
1886. E. FLETCHER INGALS, M.D.
1887. R. P. LINCOLN, M.D.
1888. E. CARROLL MORGAN, M.D.
1889. JOHN N. MACKENZIE, M.D.
1890. W. C. GLASGOW, M.D.
1891. S. W. LANGMAID, M.D.
1892. MORRIS J. ASCH, M.D.
1893. D. BRYSON DELAVAN, M.D.
1894. JOHN O. ROE, M.D.
1895. WILLIAM H. DALY, M.D.
1896. CHARLES H. KNIGHT, M.D.
1897. THOMAS R. FRENCH, M.D.
1898. W. E. CASSELBERRY, M.D.
1899. SAMUEL JOHNSTON, M.D.
1900. HENRY L. SWAIN, M.D.
1901. JOHN W. FARLOW, M.D.
1902. JOSEPH H. BRYAN, M.D.

OFFICERS.

(Elected May 28th, 1902.)

PRESIDENT.

JOSEPH H. BRYAN, M.D., Washington, D. C.

1st VICE-PRESIDENT.

GEORGE A. LELAND, M.D., Boston, Mass.

2nd VICE-PRESIDENT.

T. MELVILLE HARDIE, M.D., Chicago, Ill.

SECRETARY AND TREASURER.

JAMES E. NEWCOMB, M.D., New York City.

LIBRARIAN.

JOSEPH H. BRYAN, M.D., Washington, D.C.

COUNCIL.

WILLIAM E. CASSELBERRY, M.D., Chicago, Ill.
SAMUEL JOHNSTON, M.D., Baltimore, Md.
HENRY L. SWAIN, M.D., New Haven, Conn.
JOHN W. FARLOW, M.D., Boston, Mass.

TABLE OF CONTENTS.

Address of the President, JOSEPH H. BRYAN, M.D. . . . 1

Papers and Theses:

I. Medical Treatment of Adenoids and Enlarged Tonsils. WILLIAM C. GLASGOW, M.D. 13

II. Tertiary Syphilis of the Nose and Pharynx. (Candidate's Thesis.) W. SCOTT RENNER, M.D. . . . 15

III. Congenital Laryngeal Stridor. JAMES E. NEWCOMB, M.D. 45

IV. Operations for the Relief of Malignant Growths of the Larynx with Report of Seven Cases. (Candidate's Thesis.) WILLIAM LINCOLN, M.D. 54

V. Nasal Polypi; A Study of One Hundred and Forty-seven Cases. J. PAYSON CLARK, M.D. 64

VI. Some Cases of Facial Erysipelas from Erosions of the Nasal Septum. JOHN W. FARLOW, M.D. . . . 72

VII. Some Remarks on the Etiology of Hyperplasia of the Pharyngeal Tonsil in the Light of Recent Investigations. (Candidate's Thesis.) THOMAS J. HARRIS, M.D. . 75

VIII. Some Further Investigations of the Chemic Pathology of the Saliva. D. BRADEN KYLE, M.D. 85

IX. Cicatricial Deformities in the Respiratory Tract Due to Causes Other Than Syphilis and Traumatism. G. HUDSON-MAKUEN, M.D. 93

X. Complete Removal of the Left Vocal Cord for Malignant Disease; Presentation of the Patient. WALTER F. CHAPPELL, M.D. 98

XI. Hypertrophic Tuberculosis of the Larynx. (Candidate's Thesis.) CLEMENT F. THEISEN, M.D. 104

XII. A Case of Gangrene of the Tonsil. CHARLES W. RICHARDSON, M.D. 119

XIII. Perichondritis of the Larynx Following Typhoid Fever with Report of Case. EMIL MAYER, M.D. . . . 121

XIV. Removal of a Naso-Pharyngeal Tumor; Report of Case and Description of a New Instrument for the Operation. E. FLETCHER INGALS, M.D. 132

PAGE.

XV. Additional Notes Upon the Treatment of Naso-Pharyngeal Fibroma. D. Bryson Delavan, M.D. . . . 135

XVI. A Method of Rapid Extirpation of Naso-Pharyngeal Fibromata with Report of Cases. Gordon King, M.D. . 139

XVII. A Case of Early Appearance of Paralysis of the Vocal Cords in Mediastinal Tumor. William K. Simpson, M.D. 150

XVIII. The Etiology of Nasal Polypi with Especial Reference to Their Association with Other Pathological Conditions. (Candidate's Thesis.) Francis R. Packard, M.D. . 157

XIX. Notes on a Case of Foreign Body in the Left Bronchus; Attempted Removal with Forceps and Electro-Magnet; with Skiagraph. Thomas Hubbard, M.D. . . . 166

XX. Some Cases of Cancer Treated by the X-Ray. Arthur Ames Bliss, M.D. 168

XXI. The Arch of the Palate. Henry L. Swain, M.D. . . 175

XXII. Adenoid Growths with Special Reference to Adult Conditions. James E. Logan, M.D. 191

XXIII. How shall the Diagnosis of Post-Natal Adenoids be made in Young Children when Rhinoscopic Examination is impossible? Clarence C. Rice, M.D. . . 198

XXIV. A Case of Sarcoma of the Naso-Pharynx. William K. Simpson, M.D. 206

XXV. Notes on Cases of Nasal Sarcoma with Exhibition of Pathological Specimens and Micrographs. J. Price-Brown, M.D. 209

XXVI. Facial Neuralgia due to Disease in the Nose and Antrum. Six Cases. W. Peyre Porcher, M.D. 220

XXVII. My Latest Improvement, in the Radical Treatment of Chronic Suppurations of the Accessory Cavities of the Nose. H. Luc, M.D. 227

XXVIII. Diseases and Treatment of the Sphenoid Cells with Report of Cases and Presentation of Instruments. Robert C. Myles, M.D. 238

XXIX. Observations on the Diagnosis of Nasal Sinusitis. Walter J. Freeman, M.D. 242

XXX. A Bony Cyst of the Antrum of Highmore. Cornelius G. Coakley, M.D. 249

XXXI. The Removal of Obstructions and Cicatricial Contractions of the Nose by the Plastic Method. John O.

PAGE.

XXXII. Immediate Tracheotomy for Foreign Body; Recovery. W. Peyre Porcher, M.D. 265

New Instruments and Specimens 273

Business Meeting 275

Obituaries: S. Hartwell Chapman, M.D. 281

Edward Thayer Dickerman, M.D. 282

List of Active Fellows, 1904 285

Honorary Fellow 287

Corresponding Fellows 287

Past Members 289

Past Officers 291

BOSTON MEDICAL
SEP 28 1903
LIBRARY.

TRANSACTIONS OF THE TWENTY-FIFTH ANNUAL MEETING OF THE AMERICAN LARYNGOLOGICAL ASSOCIATION.

HELD IN THE CITY OF WASHINGTON, D. C.

MAY 12, 13, AND 14, 1903.

THE PRESIDENT'S ADDRESS.

BY JOSEPH H. BRYAN, M.D.

Fellows of the American Laryngological Association: My first duty is to convey to you my sincere thanks for the high honor which you have conferred upon me in electing me your presiding officer. To be at any time chosen to fill such a position is a distinction of no little importance, not only on account of the prominent position this Association holds in the world, but also on account of the eminence of my predecessors in this office. In the list of our ex-presidents from Elsberg the first, to Farlow, our late president, will be found names illustrious not only in this country, but known the world over in the department of medicine which this Association represents. With such worthies preceding me, I feel as though one more deserving of this honor should have been chosen to fill this position. It is an especial pleasure for me to occupy the chair on this occasion, for to-day we celebrate the twenty-fifth anniversary of our existence. While twenty-five years is not a very old age, still it represents the passage through the trying period of infancy to that of manhood, a period we reach to-day, strong and vigorous, ready to start on another twenty-five years of life. I hope that when the presiding officer of this Asso-

ciation, at its semi-centennial anniversary, looks backward over the next twenty-five years of its life, he will find the society as strong and vigorous a body as I do to-day.

It is not my purpose to occupy much of your valuable time with an elaborate address, for we have, owing to the energetic efforts of our able secretary, a programme that is full of interest to you all from a scientific standpoint. I feel, however, that I should not let this occasion go by without some retrospection, and, in doing so, I wish to congratulate the founders of this Association upon the wonderful good to the profession and to the public that resulted from the establishment of such a scientific body as the American Laryngological Association, and I wish also to call the attention of the younger Fellows to the high honor that has been conferred upon them by admitting them as associates of men whose ideals are the highest, whose sole aim is the scientific advancement of the department of medicine represented by laryngology, and who thus add a boon to suffering humanity.

The history of this Association should be studied by every thoughtful student of laryngology. It will be found to be responsible, either directly or indirectly, for the principal advances made in the study of diseases of the throat in this country and for developing this specialty and placing it upon a truly scientific basis. The history of this Association is not only the history of laryngology in America, but also of the world. We have the discoverer of the laryngoscope, Manual Garcia, as an Honorary Fellow, while most of the distinguished specialists of Europe will be found in our list of Corresponding Fellows.

The study of diseases of the throat in America may be divided into three periods: the first or prelaryngoscopic period, when guess work played such an important part in our knowledge of the diseases of the upper respiratory tract. There was one figure that stood out so boldly at this time, one whose knowledge of these affections seems to us to-day to be short of marvelous when we consider the lack of the many aids for diagnosis and treatment which we, to-day, consider essential to a correct interpretation of the pathologic conditions affecting the larynx and its contiguous parts. This man was Horace Green, the first in this country, and probably the first in the world, to devote himself specially to a study of the diseases of the respiratory tract. In 1832 he became very much discouraged with the treatment then in vogue for

laryngitis, and he set about to discover some more effective methods for the relief of this affection; but it was not until 1838 that he entertained the idea of treating diseases of the larynx by local agents. In 1840 we find him making applications of solutions of nitrate of silver from ten to thirty grains to one ounce of water, introduced into the glottis by a sponge probang. He continued to treat successfully diseases of the upper respiratory tract locally to within a short time of his death, working long enough to live down the opposition pioneers usually meet with in introducing measures radically different from those in vogue, and he had the satisfaction of seeing some of his remarkable predictions come true after the discovery of the laryngoscope.

In 1854, Manual Garcia, a singing teacher in London, practicing autolaryngoscopy, in endeavoring to solve the mysteries of the mechanism of the singing voice, saw, for the first time, the vocal cords of the living subject. He communicated his discovery to the Royal Society, and when he suggested to Doctor Mandl and Doctor Segond that they should test its usefulness in the practice of healing, he says he was far from anticipating the brilliant future reserved for it in the science of medicine. The idea was taken up by two eminent Viennese physicians, Türck and Czermak, the latter travelling through the various capitals of Europe demonstrating its usefulness as an aid to the diagnosis and treatment of diseases of the larynx. It was undoubtedly the indefatigable zeal and exertion of the latter that resulted in the creation and rapid development of the art of laryngoscopy.

Six years afterward, that is, in 1860, the laryngoscope was introduced according to Elsberg into America. We find him one year later, lecturing on laryngology in the medical department of the University of the City of New York. In 1863 he established a clinic in connection with the University for the benefit of the poor suffering from throat disease with which he combined clinical instruction. This was the first public throat clinic in this country, if not in the world.

Thirteen years after the introduction of the laryngoscope into America, we note the establishment of the New York Laryngological Society, October 13, 1873, for the purpose of promoting the study of affections of the larynx, pharynx and adjacent parts. It was through the efforts of Dr. Clinton Wagner that this society was organized, and it was the first society devoted exclusively to

laryngology and rhinology, established either in this country or abroad.

The success which the New York Laryngological Society met with was the direct cause of the organization of a National Society, known as the American Laryngological Association, which occurred in the city of Buffalo in June, 1878, twenty-four years after the discovery of the laryngoscope, and eighteen years after its introduction into America.

I will not be able to go as fully into the history of the organization of this Association as I would like to do, but I would refer those interested to the masterly addresses of Dr. Louis Elsberg and Dr. D. Bryson Delavan. The latter has gone very carefully into the history of this body, and I find, upon referring to his address, that this Association held its first meeting in Buffalo in response to an invitation by Dr. Frank H. Davis of Chicago issued to the following named gentlemen: Dr. J. Solis-Cohen, Dr. Carl Seiler, Philadelphia; Dr. Clinton Wagner, Dr. George M. Lefferts, Dr. Louis Elsberg, Dr. Beverly Robinson, Dr. Rufus P. Lincoln, Dr. Francke H. Bosworth, New York; Dr. Frank Donaldson, Dr. Samuel Johnston, Dr. J. H. Hartman, Baltimore; Dr. Frederick I. Knight, Dr. E. Cutler, Boston; Dr. E. L. Shurly, Detroit; Dr. Wm. C. Glasgow, Dr. Wm. Porter, Dr. Thomas Rumbold, St. Louis; Dr. Hosmer Johnson, Dr. E. Fletcher Ingals, Dr. Monheimer, Chicago. Of these twenty-one, the founders of the Association, nine are still alive and Active Fellows.

The first president was Dr. Louis Elsberg, described by J. Solis-Cohen in the dedication of his text-book, as the most accomplished laryngoscopist in America. He was selected to fill this office for two successive terms, and it is the only instance in which a Fellow has been elected president for a second term. It was probably fortunate that it was so, for in starting a new society, representing a specialty so young, especially at a time when specialties were not as popular as now, it needed a strong and enthusiastic character like that of Elsberg to give life to the new organization and to launch it on a successful course. In his inaugural address, he states that what had been accomplished up to the time of the foundation of the Association was the "result of individual effort, which must not be relaxed, but continually increase, and can be healthily stimulated and supplemented by associated endeavor." He pointed out the direction in which its energies should be exert-

ed, and the interests which should be its chief object to promote. These interests referred to, first, the laryngological personnel; second, its literature, and third, the relation of laryngology to the profession and to the public.

Has the Association lived up to the principles laid down by our first president? I think I can safely say that it has not only done so, but has been far more successful than the most sanguine of its founders ever expected. It has brought seventy-five of the most prominent laryngologists of this country together, bringing about an intimate personal acquaintanceship between them, furnishing a meeting ground for discussion and enabling them to freely discuss differences of opinion in the presence of one another. The majority of the papers that have been read before this Association are classical, and mark the development and progress of laryngology. The discussion which has followed the reading of the papers has always been earnest and spirited, the Fellows endeavoring not only to understand each other, but to clear up, as far as possible, the many difficult problems that confront us in our daily life as laryngologists.

The relation of laryngology to the profession and to the public in this country to-day, is due entirely to the influence of this Association which has, through its high ideals, placed the specialty on the highest plane. It has created a demand for laryngological teaching in the medical departments of all our principal universities, whereas, in 1878, there were only twenty-five recognized teachers of laryngology in the United States, and they were as follows: Full professorships, 2; clinical professorships, 4; instructorships, 2; lectureships, 11; clinical lectureships, 4. In nearly all of our best medical schools, the chair of laryngology is held by a full professor of this branch of medicine, and the course which formerly was optional with the student is now obligatory; such is the transformation that has taken place in the teaching of our specialty in the United States during the past twenty-five years.

As a stimulus to original research and independent observation, Elsberg recommended the giving of a prize for a meritorious contribution to laryngology. As far as I am aware, this has never been done. I take this opportunity of repeating this recommendation, and believe, if done, it will accomplish much good and redound to the credit of this Association. The prize need not be a large one from a monetary standpoint, and it should not be con-

fined to the fellows of this Association, but should be thrown open to all laryngologists of this country. The prize winner, other things being equal, may find it a stepping stone for membership in this Association, or, instead of a money prize, a gold medal might be awarded, to be known as the Medal of the American Laryngological Association.

Let me now pass in review the progress made in our specialty during the past twenty-five years. In reviewing the work done by this Association since its organization, I find there have been five hundred and forty-eight papers read and published in our transactions. Many of these papers are classical and show not only extreme care in their production, but also demonstrate the practice of the art of laryngology to-day. These productions mark the progress made in our specialty from the time when the laryngoscope was a novelty to the present time, when its use is familiar to every thoroughly equipped physician.

It is interesting to note that in the beginning the larynx commanded the principal attention of investigators, and it was not until after 1881 that the nose, a terra incognita, or, a much neglected organ up to this time, commenced to attract the attention it deserved. With the introduction of cocaine in 1884, the examination of the nose was greatly facilitated, and its importance recognized, and diseases hitherto not understood became easily amenable to treatment—for example, catarrhal inflammation of the ear and larynx, found in many instances to be dependent upon pathologic conditions causing occlusion of the nares, which had resisted all known methods of treatment, yielded readily as soon as the obstruction was removed and free nasal respiration established.

Certain diseases formerly considered rare are now known to be very common, as for example hypertrophy of the post-nasal lymphoid tissue or adenoids, recognized as far back as the time of Hunter, but was not considered of much importance until our distinguished Corresponding Fellow, the late Dr. Wilhelm Meyer, pointed out, in 1855, the baneful influence of this growth upon the hearing and the general economy of the growing child. It remained for our late lamented Fellow, Dr. Franklin Hooper, of Boston, to demonstrate the frequency of the occurrence of these growths, and it was not until he did his pioneer work in this direction that the importance of the removal of these growths was thoroughly appreciated in this country. We are indebted to Asch

for one of the most ingenious operations for correcting deflections of the nasal septum, an operation which will be a lasting monument to the memory of one whose loss we have but recently been called to mourn.

With the opening up of the nose as a new field for research, much enthusiasm resulted, and many men, unqualified from every standpoint, entered the specialty. The nose was attacked unmercifully. Pains in the most distant parts of the body were referred to a so-called nasal reflex, a nasal neurosis, or, if perchance, there was a pathologic condition present, it was assigned as the cause of some obscure condition not located in the nose, and in many instances unnecessary surgical means were resorted to. Fortunately, a much healthier view now prevails, and I believe that it has been largely brought about by the conservative men who make up this Association. These men, whenever an opportunity has offered in their papers and discussions before this body, and in their teachingings to their students, have shown their decided disapproval of all such radical and unnecessary surgical work. One of the most important advances made in this department within the last few years is in the study of the diseases of the accessory cavities. While much has been done in unraveling the mysteries of the diseases affecting these sinuses, we are only on the threshold of our knowledge of this department of rhinology. It is a field which offers much to the investigator, but it is one that should only be undertaken by one thoroughly skilled as a surgeon, for it concerns a dangerous region, one in which much harm can be done if one is rough and unaccustomed to surgical methods. As showing the importance of this subject, our programme for this meeting contains no less than four papers relating to sinus affections by men who have become known in this department of rhinology. We are fortunate in having with us to-day, Dr. Luc, who has done more probably than any living man to develop this department of surgery, and who will give us his latest improvements in the treatment of these obstinate affections. We have too, a valuable paper by Dr. Myles on sphenoid disease. We will look forward with keen interest to the information brought out in this paper and in the discussion which will follow. This is a most important subject, one that is comparatively new, and I trust the members will give their experiences freely in regard to these obscure affections.

With the introduction of serum therapy, an antitoxin for the

dreaded disease, diphtheria, has been given us, a remedy which has saved thousands of lives. The results of the treatment of this disease by the modern methods are something short of marvelous, and if some of our prelaryngoscopic friends could look in upon us to-day, they would stand amazed at the results obtained. Antitoxin, together with intubation, has removed many of the terrors of a disease whose mortality, before their discovery, rendered it one of the most fatal of maladies. While the discovery of intubation was due to a Frenchman, still its development and perfection were the result of the experiments and labors of our late lamented fellow-countryman, Joseph O'Dwyer, to whom belongs the entire credit for its introduction in medicine. While to the scientific world no monument is needed to perpetuate the name and fame of this modest physician, one who labored unostentatiously, leaving his family in anything but comfortable circumstances, still something more is needed to show our appreciation of this man who did so much for suffering humanity, and through the results of whose labors so many thousands of lives have been saved. The laryngologists of the civilized world, aided by the varied contributions from many of the little ones suffering from adenoid growths, erected at Copenhagen some years ago a monument to Wilhelm Meyer; why should not this society, in conjunction with the American Pediatric Society, start a movement for the erection of a monument in this country to perpetuate the memory of a man who has done so much to save human life?

Four years after the foundation of this Association, Koch gave to the world his wonderful discovery of the bacillus of tuberculosis. This discovery has enabled us to better understand this disease, and may eventually lead to some remedy by means of which it can be relieved. The terrible suffering accompanying the local manifestation of this disease in the larynx naturally led to radical measures for its relief. When the milder measures failed, Krause and Heryng proposed and practised the curetting and excision of the tuberculous infiltration in the larynx, and it was hoped that this procedure might be followed by some beneficial results, but unfortunately it was indiscriminately practised and naturally the results proved most disappointing. The operation is, however, justifiable in those cases where the disease is superficial and limited to the larynx. The study of nasal reflexes, especially the vasomotor disturbances, originated in this body, and much valuable in-

formation regarding these troublesome affections has been contributed from time to time by its members. While much valuable information regarding malignant disease of the larynx has been contributed from time to time by members of this Association, we are still in the dark regarding its etiology, and there is a wide diversity of opinion as to the best methods of relief. We have to choose between the radical extirpation, with loss of function, as advocated by J. N. Mackenzie and the less radical methods of B. Fränkel, and Sir Felix Semon, whose success with laryngofissure has been most remarkable. Many still believe the only justifiable operation is the palliative tracheotomy, simply staying the activity of the disease, and prolonging life as far as possible.

With the introduction of the X-ray and the reported success met with in the treatment of superficial cancers, we are led to hope that this wonderful discovery may be of some benefit to the sufferers from this dire disease. Delavan, in the report of his investigations of this subject before this Association last year, states that he was unable to find a single authentic case of cure of carcinoma of the larynx by the X-ray. It is very difficult to tell whether some of the so-called cures were really cases of malignant disease, and if so, not sufficient time has elapsed to justify one in calling them cures.

The plastic surgery of the nose has been highly developed by at least one member of this Association. John O. Roe, with his wonderful skill in this direction, has transferred many an ill-formed nose into a symmetrical and beautiful organ, enabling these unfortunate subjects to live happy lives, and not be a source of repulsion to their fellow-beings.

Recently Gersuny of Vienna, has been using with success subcutaneous injections of paraffine, and it is being widely experimented with, both in this country and abroad. It is an operation which requires the greatest care, and is especially applicable to the depression of the nasal bridge, known as the saddle-back nose. Unfortunately this operation is not always successful—the violent reaction setting up a suppuration, which leaves the parts much more seriously deformed.

I cannot refrain from mentioning the excellent work done in the study of the pathology of the diseases of the nose and larynx by Jonathan Wright and J. L. Goodale, hoping the scientific work

done by these two men will stimulate others to follow in their footsteps and reap the reward that will surely follow.

Such, gentlemen, is a brief and very incomplete review of the progress of laryngology since the foundation of this Association.

It becomes my sad duty to announce to you that death has removed from our midst our lamented ex-president, Morris J. Asch, —S. H. Chapman, E. T. Dickerman, Active Fellows, and Lennox Browne, Corresponding Fellow. This is a very heavy blow to our Association. Although of late years, through ill-health, Dr. Asch had been prevented from attending our meetings, still we can look back with pleasure at meeting him at our annual gatherings. He had a most interesting career. Serving his country as an army surgeon during those trying days of the war of the Rebellion, he was with Sheridan in New Orleans, where he passed through two epidemics, one of cholera in 1866, and of yellow fever in the following year. We next find him accompanying this great commander through one of the most arduous Indian campaigns known to history. He resigned his commission some years after, when past middle life, and became a civil practitioner. He was, however, to the last, a service man in thought and feeling. He will be best known for the work done on the nasal septum, and his fame will increase with the growing popularity of the operation bearing his name.

Our younger colleague, Dr. E. T. Dickerman, one of our more recent members, died suddenly of pneumonia during the early part of this year. He was a man of most attractive personality and exceptional mental endowments. Had he lived and enjoyed good health, he would have become one of the strong and prominent characters of this Association. Stricken practically at the outset of his professional career, Dickerman left a reputation of which many an older man might justly be proud.

Dr. S. H. Chapman was one of the older members, and took a much more active part earlier in our proceedings than he has been able to do of late years. The announcement of his death will be heard with sincere regret.

Lennox Browne, one of our most distinguished Corresponding Fellows, has passed away and with him the connecting link between the old and the new laryngology. Following Sir Morrell Mackenzie, for many years he was one of the most prominent figures in laryngology in London. He was a remarkably versatile man, be-

ing almost as clever with his brush as with his pen. Lennox Browne accomplished a great deal that was good, but the two works, "Voice, Song and Speech," in connection with Emil Behnke, and "The Throat and Nose and Their Diseases," are two works which will live for many years to come and ever increase the fame of this interesting character.

And now before closing let us consider ourselves as we are at present and look somewhat into the future. Do not fold your hands and say that you have reached such a height of perfection that it is impossible to advance further, but continue to work, admitting that there is room for advancement. In order to accomplish this, a very radical change must take place in our Association. I have been a careful observer of the progress we have been making during the past few years, and I believe I see not a waning interest in the Association, but a disposition to be less active. The Secretary has greater difficulty each year in securing a programme. Now we are all growing older and, with increasing years, we are losing some of that enthusiasm which is so characteristic of youth. Our membership is limited by our Constitution to seventy-five; a membership far too small for a National Association. Of this number, twenty-four are members of twenty years standing and over, and are exempt, according to Article IX of the By-Laws, from the compulsory furnishing of a paper once in three years. It will thus be seen that the Association must depend upon the remaining fifty-one members for its literary programmes. Now, when we consider that many of these members live in distant parts of this great country, and have ever increasing responsibilities at home, the time is rapidly approaching when the attendance at our meetings will be greatly reduced and the work of maintaining the Association at its present high standard will fall upon a very few men. Fortunately, this is not quite a true picture of the situation, for many of our older fellows are still some of the most active and enthusiastic members attending our meetings. This is a most fortunate sign, as it shows the strength and healthfulness of the Association. It is to be hoped they will always be able to take an active part in our proceedings. We need them to encourage us, and at the same time to have a soothing influence on the impetuosity of the younger members. We need them for their good fellowship, which has always been manifest at our annual gatherings. These men should feel, how-

ever, that they can come to the meetings without being importuned to bring a paper.

The Council has for some time viewed with concern the dangers that await us in the future. It has felt the urgent need of bringing new life into the Association; bright young and active minds will bring new ideas with them and stimulate some of us who are disposed to rest on our laurels to an increased activity. With this end in view, the Council recommends an amendment to Article III, Section 2, of the Constitution, so that it shall read: "The Fellows shall not exceed 100 in number." You will not be called upon to vote on this amendment until next year, but I bring the subject up in order that you may give it your earnest consideration between now and the time you are called upon to express your desires regarding it.

A word or two regarding our financial condition seems to me to be eminently proper. You are well aware that from time to time, about once in three years, it has been necessary to call for an extra assessment to meet the deficiency in our treasury. The expense of publishing our Transactions is much greater than it was by our former method, and it has been necessary for the treasurer, on several occasions, to make use of his own funds to meet the pressing demands upon the treasury. This is undignified for such an Association as ours. The annual dues should be sufficiently large, not only to pay the running expenses of the Association, but also to leave a surplus in the treasury which frequently has demands upon it for other than the current expenses. The Council has, therefore, recommended an amendment to Article VII, Section 1, of the By-Laws, so that it shall read: "Every Fellow shall pay in advance the sum of ten dollars annually." This amendment will be voted on at this meeting, and I trust it will meet with your approbation.

I have already taken up too much of your time from the scientific programme, and will therefore, on behalf of the profession of Washington, bid you a hearty welcome to our city, and trust that your time will be both pleasantly and profitably spent while with us.

I cannot more fittingly bring these remarks to an end than by quoting the closing remarks of our first president, which are especially for the benefit of the fellows who have in recent years become members of this Association: "Let us cherish it warmly, serve

it willingly in every way and at all times, and make its future as sure as its present promise is bright."

And now, gentlemen, I declare the twenty-fifth annual meeting of this Association open for business.

Paper.

THE MEDICAL TREATMENT OF ADENOIDS AND ENLARGED TONSILS.

BY WILLIAM CARR GLASGOW, M.D.

SOME three years ago, observing the good results obtained in reducing enlarged cervical glands through the use of the iodides, I thought that possibly a similar reduction of enlarged tonsils could be obtained by the same medication. I then commenced using the iodides for certain cases and was pleased with the results. In a late journal I have seen an extract from a French journal in which the tincture of iodine was recommended to produce absorption of the glandular tissue. The following case will show the results of this treatment:

R. W., 7 years old, has been a mouth-breather for several years. He was anemic and delicate and showed the pinched nose and facial deformity which we usually associate with adenoids. The tonsils were enlarged with a projecting upper lobe which interfered with the soft palate. The breathing at night was noisy and obstructed. In short, it was a typical case for operative measures. The mother, however, was averse to surgical interference and willingly gave a trial to medical treatment. He was given six drop doses of a saturated iodide of strontium solution for six weeks. After an interval of several weeks, this was again repeated during a period of six months. There was a gradual improvement after the first month and this continued. I saw him last in March. He had grown stouter and his nutrition was greatly improved. His face had lost its pinched look and his mother stated that his breathing was perfectly satisfactory. She considered him well. The tonsils were greatly reduced—fully two-thirds, and seemed to

offer no obstruction to breathing; the stumps presented a shriveled appearance.

Another case, a girl of 9 years, who had suffered the previous winter with recurrent attacks of middle ear suppuration, was given the iodide treatment during a period of three months, When, however, she complained of pain in the ear and the mother dreaded a recurrence of her former trouble, it was decided to operate. I removed the adenoids and was surprised at the small amount of bleeding during the operation. It was in strong contrast to the free hemorrhage which we usually expect as a result of this operation.

In order to see the effect of the iodine treatment on these glandular enlargements, I submitted the excised part of the adenoid to Dr. Henry Rohlfing, a most competent pathologist and microscopist, who rendered me the following report:

"The specimen of tonsils and adenoid tissue submitted for microscopical examination shows hyaline degeneration about the stroma with atrophy of cellular elements; obliteration of the vascular vessels with narrowing and hyaline degeneration of the tunica intima of the blood vessels and a general contraction of the gland proper.—Henry Rohlfing."

The result of the microscopical examination shows the manner in which the favorable results are obtained from the iodine treatment. The growth is diminished in size through absorption of the glandular tissue; the connective tissue is softened and disintegrated and the blood vessels are destroyed.

The administration of iodine can then be advised:

In cases where an operation is not deemed advisable or absolutely necessary.

In cases of old adenoids, the post-puberty period, where the mass of the growth consists largely of connective tissue.

In cases in which a free bleeding is undesirable.

Candidate's Thesis.

TERTIARY SYPHILIS OF THE NOSE AND PHARYNX.

BY W. SCOTT RENNER, M.D.,

THE division of syphilis into primary, secondary and tertiary stages was first adopted by Phillipe Ricord and, although this division is convenient for descriptive and therapeutic purposes, it has no claim to scientific accuracy, and it is not clinically correct for, as in other infective diseases, the signs and symptoms of the various stages are often co-existent and thus blend insensibly one with another. Therefore we must remember that the expression tertiary syphilis is only used for the sake of convenience to express the latest manifestations of syphilis which are more refractory to treatment than the earlier signs.

The signs of the tertiary stage usually appear during the third and fourth year after infection and after all secondary symptoms of the disease have disappeared. They may, however, occur much earlier during the secondary stage of the disease, as early as a few months after infection, or they may be delayed until some debilitating cause weakens the general health of the patient, sometimes as long as ten, twenty, thirty and even fifty years after infection. The late manifestations however generally occur between the eighth and fourteenth year after infection.

In favorable cases and under proper treatment no tertiary manifestations may present themselves, the patient having been cured during the secondary stage of the disease. Halsund[1] has pointed out that the tertiary manifestations make their appearance either on account of want of treatment, insufficient treatment or treatment commenced too late in the progress of the disease. He found that of 514 cases of tertiary syphilis, 160 cases had had no treatment, 284 had had insufficient treatment, and that only 70 had had energetic treatment.

Tertiary syphilis is a part of either the acquired or the hereditary form of the disease. The acquired form of course is most

frequently found in adult life, while the hereditary form is most frequently found in children.

Tertiary lesions of hereditary syphilis occur at two periods of child life.

First. In children who soon after birth had secondary syphilis and who have not been properly or successfully treated. In them the tertiary stage is apt to show itself during the second year. It, however, may occur earlier or later in these children, as late for instance as in the second class of children about to be mentioned.

Second. As the form of the disease known as syphilis hereditaria tarda or congenita tarda. This form occurs in children whose parents had the disease a long time before their marriage, on account of which the poison had become unusually weakened. This form occurs at about puberty, or more correctly from the eighth to the fifteenth year, although it may be delayed until much later.

This form of latent hereditary syphilis must be distinguished from what Erb[2] has described as the occult form, which is a late form in which there has been no primary or secondary evidence of the disease. This occurs sometimes in women at the climacteric period whose husbands had syphilis before marriage, so that the child or children became infected through the semen of the father and the infection was carried from the child through the placenta to the mother, in whom no recognized manifestations of the disease were found until the tertiary lesions made their appearance at the menopause, probably twenty years after the birth of the child who infected her.

Tertiary lesions of the nose and throat may occur at any time at which other tertiary lesions are found in other parts of the body, but when tertiary manifestations of syphilis make their appearance twenty, thirty or fifty years after infection, they invariably appear in the nose or throat, and when a patient has a gumma or gummata in the nose or throat later than ten years after infection, one can safely promise that tertiary lesions will not show themselves in other parts of the body later. It is remarkable how frequently it occurs to any laryngologist to see tertiary lesions of the nose and throat in patients who have never had any other tertiary lesions. Many of these patients give no history of a primary or secondary stage. Some of these, of course, are of the occult form, occurring in women at the menopause. Two such women have quite recently come under my observation.

Gumma followed by disintegration and cicatrization is as characteristic of the tertiary stage as condoloma is of the secondary stage, or as the hard chancre is of the primary stage of syphilis.

Lesions of tertiary syphilis occur in the nasal, naso-pharyngeal or oro-pharyngeal cavities either as manifestations of the acquired or of the hereditary disease, and both forms may leave evidences of their having occurred in the shape of deformities of the exterior of the nose or of the interior of the nasal and pharyngeal cavities; the degree of deformity depending not only upon the amount of destruction caused by the disease, but more especially upon the extent of contraction the scar tissue thrown out by the healing process may have undergone. The tertiary lesions here, as elsewhere, of both hereditary and acquired disease, are identical in most respects. There are, however, some distinctive signs not found in the respiratory tract which distinguish them. Other slight differences are dependent more on the time of life than upon the form of the disease.

The ulceration in congenital syphilis is, however, usually much more rapidly destructive than in the acquired form of the disease.

Tertiary syphilis of the upper air passage occurs principally in the mucous membrane or in the bony and cartilaginous framework of these parts. In the mucous membrane the sub-mucosa is primarily affected by the development of a gummatous change. This change occurs in two forms, *i.e.*, either as a diffuse infiltration or as a circumscribed node known as a gumma. Both of these forms of infiltration are at first made up of granulation tissue resembling the granulation tissue of the primary sore. This tissue is mostly made up of small spheroidal cells, but polyhedral and giant cells are occasionally found. Very few blood vessels are found in this new tissue.

The gummata found in the nose, mouth and pharynx may vary greatly in size from the size of a grain of wheat to that of a hickory nut. In the tongue and some parts of the body where there is abundance of tissue gummata are found the size of a walnut or of an apple, but in the mucous membrane of the upper air passages they naturally cannot attain such a size, especially in the nose and pharynx where the mucous membrane is often at the same time the mucous lining of the nasal and pharyngeal cavities and the periosteum or perichondrium of the underlying bony or cartilaginous framework. Here the gummatous process commencing

in the mucous membrane may extend to the bone and cartilage, or commencing in the bone may extend to the mucous membrane.

The diffuse gummatous infiltration, like the circumscribed gumma, commences in the mucous membrane. It is simply a superficial infiltration of the membrane which breaks down to form a superficial ulcer. This form of gummatous deposit was first described in 1877 by Schuster and Sanger.[3] They described it as a transition stage between a condyloma and a true gumma.

I shall describe in detail the various manifestations of the circumscribed gumma, also known as node or syphiloma, and the diffuse gummatous deposit, with their results and variations in the various parts under consideration commencing in the nose with the circumscribed node or gumma. (I have included in my description the nose, mouth and pharynx, on account of the intimate relation of the mouth to both pharynx and nose.)

Nose.—Gummata are much more frequently found here than are the diffuse forms of infiltration, and occur as a rule much later in the course of the disease, frequently ten to twenty years after infection, the patient having in the interim not suffered from any manifestation of the disease whatever. In other cases they occur a few months after infection and before the secondary symptoms have disappeared. Gummata are most frequently found upon the anterior portion of the septum and on the lower turbinated bones, but may attack the mucous membrane of any part of the interior of the nose. A gumma here, as on all parts of the mucous membrane, is a flat oval tumor raised considerably above the surrounding mucous membrane, deep red in color. It is covered with an intact mucous membrane, is soft in the center, from which point it eventually begins to break down to form a characteristic ulcer. Before it breaks down it cannot be distinguished from a tuberculoma by its appearance. It, however, seldom is seen by the physician at this stage because it is not accompanied by any pain. It is easily distinguished from a traumatic hematoma of the anterior portion of the nasal septum and the abscess which usually follows such an extravasation of blood. Such abscesses are always caused by some injury, such as a blow or fall on the nose, and their formation is always accompanied by pain and some fever. They are almost always bilateral, while the development of a gumma is insidious, without pain and is usually unilateral. A gumma is sometimes difficult to distinguish from an hypertrophy of the nasal mucous

membrane, especially when occurring in the mucous membrane of the turbinated bones.[4] Gummata may also be confounded with sarcomata and carcinomata, especially if the surface be smooth. Antisyphilitic treatment will soon clear up the diagnosis in doubtful cases. Usually when the case comes under observation the gumma has already broken down, when the resulting ulceration is characteristic. This ulcer is round or oval in form with sharp cut smooth borders. The ulcer is deep and its base is covered with a thick adherent yellow or yellowish-white deposit of necrotic tissue. The surrounding tissue is very red and very much thickened. The discharge from the ulcerated surface is serous and bloody, and sometimes more or less purulent, and frequently has an offensive odor. The odor is not as characteristic as it becomes when the bone is involved, which will be described later.

When the mucous membrane of the nose is attacked the gummatous process, especially in its circumscribed form, unless promptly arrested by antisyphilitic treatment, extends to the underlying portion of the bony framework as a periostitis or a perichondritis. In this way but a small portion of the septum or of a turbinated bone may be affected. But if the whole interior of the nose is destroyed, we cannot consider that the destruction has been unusually extensive or severe. When the periostitis is established there is considerable pain which persists until the pus breaks through, when the pain disappears. The fistula through which pus discharges from such a periostitis, especially of the nasal septum, looks like an ulceration. At the bottom of such an ulceration or fistula denuded bone can be made out with a probe. Such a periostitis may, like the circumscribed gumma of the mucous membrane over the anterior portion of the nasal septum, be mistaken for a traumatic abscess, except that there is not a history of trauma, etc.

Syphilitic periostitis in the nose is always accompanied by a characteristic odor, which is very offensive. If the case does not come under observation until some time after the formation of a fistula, one will find necrotic pieces of the bony framework robbed of their membranous covering. Some of these pieces of bone may be found lying loose in the nasal cavity, others are probably still adherent. Sometimes individual bones, such as the lower turbinated bones or the vomer, are necrosed entire, which causes difficulty in removing them through the anterior nares. Sometimes the necrosed bones

separate themselves and fall into the pharynx and even into the larynx. Death has resulted from such an accident. Or we may not have an opportunity of seeing the case until the septum and the turbinated bones have all necrosed and fallen out, when we find the interior of the nose filled with hard dried crusts of mucus and pus more or less offensive in odor, but not having the extremely foul odor which is encountered while there are still portions of necrosed bone in the nose. This destruction of the framework often unites the nasal fossa with the maxillary sinuses and may extend to the outer wall of the antrum and into the frontal sinuses and their outer walls.

Destruction of the nasal septum is almost always of syphilitic origin, especially when the bony as well as the cartilaginous portion is attacked. The cartilaginous portion may be perforated by a simple catarrhal erosion of the part, or lupus or tuberculosis may destroy it. Tuberculosis but rarely attacks the bony septum, the hard palate or the cervical vertebræ.

Circumscribed and diffuse gummatous formations may attack the external nose. Circumscribed gummata may attack the nasal bones or the nasal processes of the superior maxillary bones.

The ossa nasi are sometimes attacked so that the periostal syphilitic process surrounds them completely and they become completely necrosed. This results in the most severe grade of saddle nose. As a rule, however, the saddle nose is caused by the contraction of the scar tissue on the inside of the nose, and where there has been no implication of the nasal bones the force exerted by the contraction of the syphilitic scar tissue is then sufficiently strong to overcome the resistance of the outer bony framework of the nose and cause many unsightly deformities, of which the "nez en lorgnon" described by Fournier is the most characteristic. In this particular deformity the upper bony part of the nose is intact, while the lower movable part seems to be shoved into it, as the small tube of an opera glass is shoved into the larger one. There results from this at the union of these two parts of the nose a fold of the skin on each side which gives its characteristic appearance to the nose. By pulling down the tip of the nose in these cases the deformity and the folds disappear and the nose becomes straight.

The alæ nasi are not infrequently attacked by the gummatous process. Here it is known as lupus syphiliticus. It is found as a tumor-like enlargement of one or both alæ of the nose. This may

be nodular or the whole surface may be uniformly indurated. The surface of such a tumor is bluish-red or copper-red in color. The breaking down of this lupoid form is followed by perforation of the ala of the nose or by an irregular defect of it, or its complete destruction.

The case which I am about to narrate illustrates this condition. It is one of a very few cases of lupus syphiliticus which have come under my observation. It is as follows:

CASE I.—Mr. E. S. came to consult me on the 10th of June, 1902. He stated that he came to consult me for an ulceration of the right ala of the nose, which had been treated for some time for lupus of the nose by four different physicians, one of whom was an oculist; the other three were men thoroughly familiar with the lesions of syphilis.

On examination I found a flat glistening scar of the upper lip on the right side which extended in the nose to a perforation of the cartilaginous portion of the nasal septum whose borders were still ulcerated. The whole of the tip of the nose was much indurated and a small portion of the right ala of the nose was destroyed. The parts about the destroyed part were much indurated. He could remember nothing of having been infected with syphilis, could give no history of primary or secondary lesions. I told him his trouble was of syphilitic origin, although it resembled lupus very much, but that it could be arrested if he followed out instructions. Inunctions of blue ointment and the ingestion of iodide of potash soon benefited him and convinced his physicians, who were personal friends of his, of the nature of his lupoid trouble. His nose was cured in a short time with but little external deformity, and that may be easily corrected by a small plastic operation which we hope to do as soon as he has been under treatment for a little while longer.

Besides the saddle nose mentioned above, other unsightly deformities of the external nose may follow in the more destructive cases. The nostril may be narrowed or completely occluded by membranous and fibrous adhesions, or the cutaneous portion of the nose, or the tip of the nose, may be pressed down even with the face by becoming adherent to the upper lip; or the nose may become very small on account of the destruction of the tip and alæ by the gummatous process.

The diffuse gummatous infiltration in the nose is much rarer than the circumscribed gumma. It was first described as it occurs in the nose by Chiari of Vienna[5] and by J. N. Mackenzie of Baltimore[6] in 1887. Chiari described it as usually occurring on one side of the nose. It occurs here as a considerable thickening of the

mucous membrane of the turbinated bones and of the septum. It is usually accompanied by a moderate amount of bad smelling discharge. The diagnosis of this diffuse infiltration in the nose is usually very difficult for the primary infection of the patient has probably taken place years before the patient came under observation, and no association is found in the mind of the patient or physician between the old trouble and the present nasal obstruction. Indeed, in many of these cases the patient has no knowledge of ever having had any syphilitic trouble. Therefore the present condition of the nasal mucous membrane is quite likely to be mistaken for an ordinary chronic hypertrophic rhinitis or for the thickening surrounding a foreign body impacted in one of the fossa, or for the thickening of the nasal mucous membrane which so often accompanies a purulent discharge from one of the accessory sinuses of the nose. This form of gummatous deposit here, as elsewhere in the respiratory mucous membrane, breaks down to form what Bosworth has described as superficial syphilitic ulcer in the second edition of his book on "Diseases of the Nose and Throat."[8]. He describes this form of ulcer in the following words: "This form of ulcer is usually met with on the septum, although it is to be found on the floor of the nose or on the surface of the turbinated bodies. Its borders are moderately well defined and the mucous membrane surrounding it is perfectly natural in appearance, there being no areola of redness. Its surface is, however, somewhat depressed in the center, although it is usually flush with the surrounding membrane. Its surface is covered with a coating of thick, stringy and grayish-yellow muco-pus, usually discolored by the deposit of impurities from the inspired current of air. If the deposit be removed, the exposed surface is found to be of a grayish-pink color."

The difficulties which may arise in recognizing the superficial infiltration in the nose are illustrated in the cases which I am about to report.

CASE II.—Mr. K. came to me on the 4th of January, 1896, complaining of nasal obstruction, for which he had been treated for a long time by a physician who suspected him of having no constitutional trouble but lithemia. His nose had had several operations performed upon the turbinated tissue and the septum just previous to his coming under my observation. I found upon examination that these cuts had not healed, that there were superficial raw surfaces upon both lower turbinated bones and upon

both sides of the septum. These surfaces appeared to be ulcerated, at least they had not the healthy granulating appearance that such surfaces should have after operations of the sort they had been subjected to. This made me suspect syphilis ar tuberculosis. I questioned him closely concerning syphilis. He persistently, and I believe honestly, denied any knowledge of having had such a trouble. He had nothing about him except loss of flesh which might indicate tuberculosis, and a thorough search for physical evidence of such a disease in his lungs and elsewhere proved negative, although he was in ill health, was losing flesh and was unable to do his work. No gummata or scars were to be found anywhere. I refrained from any radical treatment of the nasal obstruction of which he still complained, put him upon tonic treatment, but did not give him any antisyphilitic treatment, with the idea of waiting a few days until I had a chance to cure the sores by local treatment if possible, for he was so positive that he had not had syphilis and I was not certain that the ulcerations might not be simply the operation wounds, although I very much doubted it, but felt that if they healed under antisyphilitic treatment that I would not know whether they were cured by the local or constitutional treatment. After waiting but a week he presented himself one morning with a small gumma of the hard palate about an inch from the alveolus in front, and at one side also near the alveolus there was a broken down gumma, the last of which had commenced to form about the time he came to me and which neither of us had noticed, for it was not as large as a pea when it commenced to break down. The one in the median line was not larger than an ordinary bean and of about that shape. Both of these gummata had practically developed and the one broken down since I had last seen him, for I had not seen him from the 6th to the 10th of the month. I discovered them on the 10th.

The diagnosis was now easily made and under proper antisyphilitic and local treatment the gumma disappeared. The ulcerations in the nose and mouth healed. The nasal obstruction became absorbed and his general health improved with marked increase in weight in a very short time. After undergoing a proper course of treatment he has remained free from all syphilitic manifestations up to the present time. Neither he nor I have been able to find out when he had the initial lesion.

Case III.—Mr. C. came to me for treatment of nasal obstruction on the 12th of October, 1896. He had a deflected septum and both nasal passages were very much obstructed by what appeared to be ordinary hypertrophic tissue. On the convex side of the deflection there was some superficial ulceration. I questioned him very closely concerning whether he had had syphilis. This he denied, and as both his wife and children were healthy and he was too young to have had syphilis a great many years before marriage, I dismissed the suspicion and thought that the erosion was

probably due to the formation of crusts over the convex portion of the septum. I operated several times on his nose. The relief to the obstruction was not satisfactory; the wounds did not heal readily. I questioned him repeatedly in regard to a history of syphilis with the same answer. I finally saw him but occasionally and, although he could breathe through the nose, the result was not satisfactory to me, until one day he presented himself for examination and incidentally informed me that his family physician had opened a boil on his mouth just back of the front teeth. This I recognized on examination to be a small gumma. I again questioned him in regard to syphilis. He finally admitted that he had had a sore that his old family physician who had recently died had thought might be specific. An experienced dermatologist had said, however, that it was not. This had taken place some time before marriage. He had had no recognized secondary lesions and had had no antisyphilitic treatment. He improved very rapidly under inunctions of blue ointment, the ingestion of iodide of potash and cleansing washes, and all nasal trouble disappeared. There was also improvement of his general health, which had been more or less impaired. No destruction of any part of the bony framework occurred in either of these cases, although they were both operated upon during the active disease of the parts. He had from time to time small gummata upon the posterior wall of the pharynx and in the nose, but these have not made their appearance since 1899.

CASE IV.—Mr. T. came to me for sore throat and nasal obstruction on the 7th of July, 1897. The throat trouble soon disappeared. He had a spur on the nasal septum and what appeared to be hypertrophic rhinitis. I operated for the relief of both these conditions with some relief which was, however, only temporary. The wounds healed in this case so slowly that I feared that there might be some constitutional trouble. There were no evidences of tuberculosis. I questioned him in regard to syphilis, which he emphatically denied having had. The nasal obstruction was complete and, although I again attempted to operate, each sitting was followed by some loss of flesh and want of appetite, but no fever. Finally he was referred to his family physician for general treatment. This physician, an able and distinguished general practitioner, found evidences of intestinal indigestion, for which he treated him for two or three weeks until one day he discovered an ulcer on the posterior pharynx wall, just back of the palate. He sent him back to me, when I immediately recognized the ulcer on the posterior pharynx wall to be syphilitic in character. He also had a characteristic syphilitic ulcer on both the left side of the septum and the lower left turbinated bone. The ulceration of the septum evidently was due to a syphilitic periostitis, but it was fortunately well back on the septum and at a point on which I had not operated. I curetted the ulcer on the septum and turbinated bone

at once, and touched both the septum and the turbinated bone with a strong solution of nitrate of silver. I also touched the ulcer in the naso-pharynx with the same solution and gave him cleansing washes to use with an insufflation of aristol.

Although he had been treated for months and was almost discouraged, I could now reassure him. In three or four weeks the ulcers had healed, with only a small perforation well back on the bony part of the septum, where it can do no harm. He gained in health, strength and weight, and was for a time quite well, but ultimately became insane and is now in the Buffalo State Hospital, where he has been for a couple of years.

CASE V.—Mr. P. came to me in January, 1898. He had been extensively operated upon for an hypertrophied condition of the nasal mucous membrane, which was replaced by superficial ulcerations over the places that had been operated upon. I had no hesitation in telling him that he had syphilis. He said that he knew nothing of having been infected and for the time being I lost my patient. He returned to me, however, later and said that after leaving me he had consulted both his family physician and the specialist who had operated upon him. The first advised him not to take any of my medicine. The specialist admitted that I probably was correct. He did not return to me for several months. When he returned I put him on inunctions of blue ointment and iodide of potash internally. He improved quickly under this treatment, so much so that I turned him over to his family physician in a very short time, who continued the antisyphilitic treatment for some time after to my knowledge.

CASE VI.—Mrs. S., a young woman 26 years of age, came on the recommendation of her physician to see me on the 10th of September, 1902. She said that she had suffered from an ulcerated condition of the interior of her nose for a long time. Examination of her nose revealed the fact that both sides of the interior of her nose were extensively ulcerated, over the anterior surface of the cartilaginous part of the septum, and the anterior ends of both turbinated bones. These ulcerations seemed to me from their appearance to be breaking down diffuse gummatous infiltrations. I sent her back to her physician for a history of her case. From his letter I gleaned these facts: "That nine months before he sent her to me she went to him to consult him regarding a vaginal discharge which he diagnosed as gonorrhea, which diagnosis was confirmed by the microscope. Three weeks later she developed a pelvic peritonitis of gonorrheal origin. This disease was contracted from her husband and she tried to get a divorce on that ground but was denied it." The physician further stated in his note that he considered her virtuous, and that he did not believe that she ever had syphilis. He also stated that the ulcers in the nose were much like those she had in her pharynx. In an earlier part of his letter describing her personal history he described a pharyngeal

ulceration which he had treated in the following words: "About two years ago she had a bad chronic ulcerative pharyngitis which responded well to local and tonic treatment. I was suspicious at the time of tuberculosis."

On further questioning my patient as to her past history I learned the following facts: That she had been treated seven or eight years before for a disease of her eyes by Dr. Elmer Stair, an ophthalmologist, whom I called upon, and from whom I learned that he had treated her for an iritis which he had suspected was specific, although he had not been able to discover any history of infection. I further learned from her that a short time before she was treated by Dr. Stair she had an attack of what was called typhoid fever. While she had the typhoid (?) she had a swelling of her cervical glands on the right side, which persisted for a long time, and she had in her throat a large ulcer which also lasted for a long time, and which was covered with a white coating. When the coating came away it left a hole which she thinks was in her tonsil. Could a better description of a primary sore of the tonsil be given than she gave me, several years after its occurrence? Her typhoid may have been only the general manifestation of her infection. The moral part of this case is not really important in this paper, but it is interesting from the fact that she was then "keeping company" with the man who subsequently married her and who eventually gave her gonorrhea. I easily made a diagnosis of tertiary syphilis of the nasal cavity in this case. The nasal ulceration healed readily under cleansing local treatment. She was at once put on inunctions of mercury and iodide of potash internally. She has greatly improved and is now earning her living working in a dry goods store and is keeping up the constitutional treatment.

Ordinary and characteristic lesions of the nasal fossæ and the exterior of the nose are easily recognized, and they require no histories of cases to illustrate their recognition, but the cases which as you see have given the most trouble are those in which there was either an infiltration of the nasal mucous membrane, resembling hypertrophic rhinitis, or where the infiltration was partly broken down into superficial ulceration, a condition which, although only suspicious, would be easily recognized as syphilis if the patients had given a history of having had the primary or secondary disease. Therefore it became necessary to wait until some characteristic sign showed itself before a positive diagnosis could be made. It is true I might have given iodide of potash or mercury in those cases, but then, although the cases should have improved, I should never have felt as certain of the diagnosis as I was after I saw the small gummata; and I believe we should

have a positive diagnosis before the treatment of the case. It may seem peculiar that so many people should have had the disease and not know it. Some, of course, know it and deny it, but a great many patients have the first and second stages in so light a form that they do not know that they have had anything the matter with them. Then, again, many physicians do not recognize the signs of syphilis on the skin and mucous membrane, although they are well marked. Many ladies have acquired it and it is not thought best by the physician in attendance that they should know the nature of their trouble; or they may have it in the occult form as we said before at the menopause.

FIBROID DEGENERATION OF THE NASAL MUCOUS MEMBRANE.

John N. Mackenzie, of Baltimore, was the first to call attention to this condition of the nasal mucous membrane as a tertiary lesion of syphilis in an article published in the Journal of Laryngology and Rhinology in the April number of 1889.[9] He found the condition in both the congenital and acquired disease. This fibroid change generally attacks the turbinated bodies, although it occasionally affects the septum and other parts of the interior of the nose. The turbinated bodies are, according to Mackenzie, very much enlarged and appear as dense, hard, whitish-yellow or red sessile masses, or are converted into distinctly pedunculated growths, which not only resemble but actually are fibroids of this region. These fibroid masses, he says, obstruct the passage of air and often alter in a marked degree the anatomical relations of the parts. They are sometimes attacked by ulceration, or they may be bound as the result of ulceration to neighboring parts by firm bands of cicatricial tissue. Under the microscope the turbinated tissue is found to have changed into dense fibrous tissue. This occurs less frequently in the pharynx than in the nose. These tumors do not respond to anti-syphilitic treatment. They were recognized as a syphilitic lesion in the larynx before Mackenzie pointed them out as occurring in the nose and pharynx.

SYPHILOMA.

I shall next speak of a rare form of tumor occurring in the nose and naso-pharynx to which the name syphiloma has been given by

the late Professor Kuhn[10] of Strassburg and his assistants, Mannasse and Frank. Syphiloma is a name which was first applied to a gumma by Wagner[11] in an article which appeared in the Archiv für Heilkunde in 1863. Virchow in two publications[12 13] which appeared at about that time objected to the use of this name and substituted for it syphilitic granuloma. Both of these names are now used to describe this rare syphilitic tumor. These names, however, are also used to describe a gumma, especially in Germany, which will of course cause much confusion.

These tumors are found most frequently upon the cartilaginous portion of the nasal septum, but they may occur upon the lower turbinated, upon the floor of the nasal fossæ, or in the nasopharynx. These tumors may, according to Kuhn, occur in either the acquired or hereditary form of the disease. Of his three cases, two were in the acquired disease, the third was a case of hereditary syphilis. According to Mannasse[14] their surfaces are smooth, but Kuttner[15] of Berlin in an article written in 1898 states that they are also uneven. The color of their surface varies from a grayish-white to a grayish-red, according to Frank.[16] Mannasse describes them as varying from gray to red in color. Krieke's case[17] was grayish-yellow and Kuttner describes them as varying in color from a reddish-gray to a bright red. These authors describe these tumors as being of soft consistency, except one case of Krieke's which was accidentally very hard and disappeared very slowly under antisyphilitic treatment. In two of Kuttner's cases the surface of the tumor was covered with an adherent purulent and fibrinous exudation. These tumors have but little tendency to bleed, but they are accompanied by an abundant secretion which is without odor. The septum narium is perforated in many cases. The tumors are usually single but may be multiple. They are pedunculated or sessile. While gummata are imbedded in infiltrated mucous membrane, syphilomata are not surrounded by any swelling whatever, but stand out sharply from the surrounding tissue, according to Mannasse. According to Kuhn, Mannasse and Kuttner, while the gumma is an inflammatory deposit in the mucous membrane and does not reach far above its surface and soon breaks down in the center to be followed by ulceration, the syphiloma simply has its origin from a small circumscribed part of the mucous membrane and develops into a tumor of considerable size, which shows no tendency whatever to break down.

Kuttner says that a syphiloma undergoes degeneration but that disintegration commencing in the center of the tumor never occurs. Kuhn, Mannasse, Frank, Krieke and Kuttner, who have been already mentioned, along with Ripault[18] of Dijon, France, and C. F. Theisen[19] of Albany, have described cases of this sort. Theisen has recently published three such cases. Prof. M. Schmidt[20] of Frankfort-am-Main has been mentioned as publishing such a case. He, however, calls his case a gumma and describes it in these words in the second edition of his valuable work: "Gummata may also occur quite isolated in the nose, and sometimes attain there, a very large size. Kuhn has described three cases which, on account of their size, were mistaken for sarcomata. Krieke saw in two patients similar tumors in the naso-pharynx. I had under observation an ulcerating gumma in a lady of rather high social position who consulted me for hoarseness. She had some redness of the left vocal cord. I consider this suspicious when the lungs are healthy. An inquiry into the previous history was in her case impossible. I found, however, on the median line of the lower turbinated a sharply defined tumor the size of a bean, which was ulcerated on the tip. She had been unsuccessfully treated for her hoarseness for a long time. When on iodide of potash for three weeks she was relieved of all her troubles. She told me later of her own accord that her first husband was syphilitic."

Anton Lieven[21], bath physician in Aachen, a man who is in a position to see many unusually serious cases of this disease (for Aachen is celebrated for its baths for syphilis), and who has written extensively upon syphilis of the nose, mouth and throat, says: "Extremely large gummatous neoplasms have received the name syphilitic tumors (Schmidt, Frank, Kuhn). The last author will establishes direct histological differences between these and gummata of the mucous membrane which extend themselves out upon the surface and reach but a little above the surrounding tissues. I think it better to call the latter gummatous infiltration, the tumors, gummata, here, as they are called on all other parts of the body." Dr. Ph. Schech[22] of Munich in Heymann's Handbuch, says: "There is already a rather abundant literature dealing with syphilitic tumors or granulation growths, yet there is no unity concerning the meaning of the expression. Some assign the name

to extremely large gummata, while others use it to describe neoplasms on a syphilitic base."

I quote these passages simply as the opinions of others regarding these cases. I have no intention of offering any opinion regarding them, for I have never recognized cases of this sort. One naturally doubts their being very frequent, for none have been reported that I know of from the larger climes of either Europe or this country.

The form of tumor, according to these authors, with which these are most likely to be confounded are tuberculomata of the nasal cavity. Both occur most frequently upon the cartilaginous part of the septum. Tuberculomata were found by Chiari[23] to occur 18 out of 21 times in this location in an analysis made by him. They likewise occur in the other positions in the nose in which syphilomata were found.

The syphilitic tumor has been found to have a tendency to return after extirpation, which is also found to be the case with the tuberculous tumor, but not as universally so.

Tuberculous and syphilitic tumors are found, according to the authors who describe these cases of syphilomata, to be almost identical in their histological structure and in these very cases examination of the lungs will not be of any assistance, for in the cases of tuberculoma analyzed by Chiari he only found general or pulmonary tuberculosis in four cases, and in three of these it had already developed before the tumors were discovered.

The tuberculomata have a greater tendency to break down and usually have superficial ulcerations upon their surfaces. Histologically the diagnosis is generally easily reached. Goerke[24] claims that the finding of tubercle bacilli in these tumors is a positive diagnostic sign. The syphiloma is made up microscopically of round cells with spindle cells in small quantities between them. There is also a formation of connective tissue. The walls of the blood vessels are thickened. There are never real tubercles with cheesy centers, and very rarely tubercle bacilli are found as in the tuberculoma. When these tumors are suspected of being syphilitic, the diagnosis is confirmed by antisyphilitic treatment, under which they disappear. They are also distinguished from malignant tumors by their structure and by a course of antisyphilitic treatment.

ATROPHIC RHINITIS.

Another result besides the formation of gummata, granulomata and fibromata of the nasal mucous membrane is said to be a syphilitic atrophy of it. According to Philip Schech of Munich[25] there remains in all severe cases of tertiary syphilis after it heals up a more or less marked atrophy of the mucous membrane. This is often, according to Michelson, a very rapidly accomplished process. The picture in cases where there has been no gummatous destruction of the septum and turbinated bodies is the same as that seen in ordinary atrophic rhinitis or ozena. Such atrophy generally attacks first the lower turbinated bone and next in order the middle turbinated. Some German authors, such as Schech, Gerber and Lang, regard this form the direct product of syphilis; while Jarasz and Moldenhauer consider that it is simply a complication not a part of the syphilitic process. Just here a very important question arises, and that is whether the genuine atrophy or ozena which so often begins before or at puberty has not some etiological relation to hereditary syphilis. E. Frankel, Schaffer, Schroeder, Ruault and Golding-Bird are mentioned by Gerber[26] as believing that it is probably so, and he states further that Stoerk was the first to state that it is a late manifestation of syphilis. Gerber also believes that it is among others, and he claims to have found that in 43.3 per cent. of the cases of genuine atrophy the outer nose has a characteristic syphilitic deformity; the most of these cases have a characteristic snub nose. Between this form and the saddle nose all grades of variation are to be found in the atrophic rhinitis of puberty, and these deformities occur without any destruction of the interior of the nose. Another deformity of the nose met with in ozena is that in which it looks as if pressed in from the sides, the "Kniefer Nase." Gerber claims that this form of nose is also met with in acquired syphilis.

We will now turn to a consideration of the third stage of the disease as it occurs in the pharynx and mouth. Were it not a well-known fact that tertiary lesions occur much less frequently in the mouth and pharynx than the secondary lesions in this region, we, as laryngologists, would be tempted to say that the contrary is true, for the lesions of syphilis concerning which we are consulted are most always tertiary.

PHARYNX.

Tertiary lesions of the pharynx are identical in character with those found in the nose, *i.e.*, they occur as superficial gummatous infiltrations, and gummata. Syphilitic granulomata in the naso-pharynx have been described. A favorite situation of gummata is in the plica salpingo pharyngea at the mouth of the Eustachian tube. They are seen on the posterior rhinoscopic mirror as smooth, round, yellowish-red tumors varying in size from a pea to a cherry. It is rare, however, to see them at this stage. They are usually first seen as characteristic crater-like ulcers with deep undermined walls which are rather difficult to make out, on account of the fore-shortening of the image on the mirror. When these ulcers heal over they are likely to obliterate the cartilaginous part of the Eustachian tube, or membranous closure of the posterior nares may take place. Gumma followed by ulceration may also attack the roof of the naso-pharynx either in the pharyngeal tonsil or the roof just behind the posterior nares. Tertiary lesions may be confined to the naso-pharynx, which is rare, or other parts of the nose and pharynx may be affected at the same time, or the disease may be found at the same time in other parts of the body.

When a syphilitic infiltration, diffuse or circumscribed, attacks the posterior pharynx wall, it is less characteristic than in any other part of the respiratory tract. Sometimes such a gumma or ulcer is found in the median line. Sometimes a long ridge of gummatous infiltration is found in the angle between the posterior pharyngeal wall and the posterior palatine fold. This ridge resembles the thickening of the posterior pharyngeal wall known as pharyngitis lateralis or small spots scattered about the posterior wall may present themselves upon viewing the pharynx not unlike the larger patches found in granular pharyngitis. The true character of these ridges and patches is not known until they ulcerate, which of course never occurs in pharyngitis lateralis of catarrhal origin.

Rarely a gumma of the posterior wall may become so completely softened internally as to resemble a fluctuating tumor or retro-pharyngeal abscess. In severe neglected cases ulceration here has been known to extend from the mucous membrane to the bone beneath, resulting in caries and necrosis of the cervical vertebræ,

even to laying bare the spinal cord. L. Fischer and Mackenzie saw cases in which pieces of the axis and atlas came away.

Gummata of the soft palate and uvula cannot be easily mistaken for any other conditions. The first stage of their development is generally overlooked, for the infiltration usually commences in the mucous membrane of the posterior or pharyngeal surface of the velum. The gumma then enlarges and involves usually the whole thickness of the velum, reaching in this manner its anterior surface, or it commences on the anterior surface of the velum at the junction of the hard and soft palate. It may attack likewise the palatine folds. The neighborhood of a gumma of the soft palate is very hyperemic. The whole velum and uvula are usually edematous. If the infiltration is very diffuse, the velum, uvula and palatine folds are thickened and dark red in color. The infiltration soon breaks down in these gummata. It commences as a small yellow point or streak which rapidly spreads until all the infiltration is changed into an ulcer, which perforates the two surfaces of the palate or uvula. Such a perforation may be much larger than was anticipated, on account of a want of knowledge regarding the extent of the gumma projecting into the nasopharynx from the posterior surface of the soft palate. Sometimes there are several gummata in the soft palate, which break down one after another and perforate the palate with great loss of substance. The velum may be completely destroyed, generally only a part of it disappears. When the gumma is at the base of the uvula it may be separated by the ulcerative process or it may remain attached by one or more strands of tissue. Adhesions may take place between the palate and the posterior wall, and so occlusion or partial occlusion of the posterior nares may be caused.

The healing of deep ulceration is followed by the formation of a white glistening star-formed cicatrix, which is characteristic and which from its contraction draws on the neighboring tissue and results in various deformities. Owing to the formation of scar tissue and interstitial myositis in what remains of the soft palate, its movements and contractibility are lessened and sometimes completely destroyed. Where no adhesion has taken place between the velum and posterior wall it is impossible to shut off the nasopharynx from the oro-pharyngeal cavity. During the healing process small perforations become smaller and may become completely closed by the cicatricial tissue. Larger perforations be-

come smaller, but still remain large enough to affect the speech. When gummata occur in the tonsils they may become so enlarged as to extend across the isthmus of the fauces to the opposite side. If the infiltration is upon the surface of the tonsil that organ appears to be uneven or nodular. Each nodule is represented later on by a crater-formed ulceration. These ulcerations ultimately unite to form one, which gives the tonsil a torn, worm-eaten appearance.

Besides the superficial nodular form of gummatous tonsillitis just described, there occurs at times a deep-seated circumscribed gumma of the tonsil which from its nature and rapid breaking down might be described as acute gummatous tonsillitis. The patient with this condition has usually fever with a bad odor from the mouth, and when an examination is made a very prominent dark red tonsil is found, the follicles of which are filled with plugs and the surface may be covered with a membranous exudation. All of the surrounding parts, such as the soft palate, may be edematous; this edema may extend to the glottis. The breaking down of such a gumma results in a deep cavity in the tonsil. Natier[27] collected the histories of fifteen such cases, two of which were operated upon for cancer. One of these was operated upon through an external incision in the cervical region. The operation was followed by complete recovery and healing of the wound. After six months, however, the tumor reappeared with the same characteristics and in the same place, but spread rapidly over the whole pharynx. It was considered an incurable case, but in despair was given iodide of potash, which cured the condition in three months.

Chancre of the tonsil resembles a gumma of this region very much in many cases, except that there is marked enlargement of the cervical glands on the corresponding side accompanying the chancre. The chancre of course is liable to be mistaken for several days for an ordinary peritonsillar abscess. I remember vividly to-day the first case of chancre of the tonsil I ever saw. At first I thought that it was a quinsy. When it broke down I felt that I had surely a gumma, until a beautiful secondary rash made its appearance and that impressed upon my mind the importance of suspecting all tonsils which are inflamed and accompanied by cervical enlargement, where the trouble has persisted for more than a couple of weeks. The breaking down of the primary infiltration

is as characteristic of the primary sore in the tonsil as it is of the gumma. Of course all tonsillar chancres do not resemble a gumma as much as this one, but their description is foreign to this paper.

A rare form of specific lesion in the pharynx, or rather in the naso-pharynx, is the syphiloma or syphilitic granuloma which has already been described at length as occurring in the nose. Krieke[17] described two cases in the naso-pharynx. These tumors, according to Krieke, may attain the size of a pigeon's egg. They are grayish-white in color in the naso-pharynx; have a smooth surface; and are unusually hard. I should suppose that they might be mistaken in this region for fibromata and other hard tumors of the naso-pharynx. They are recognized by their disappearing under anti-syphilitic treatment.

The chief symptom of syphilitic infiltration and ulcerations in the pharynx are various degrees of disturbance in swallowing. At first there is little or no difficulty, but as the tumor develops there is a sensation of a foreign body in the throat. This may be accompanied by dryness of the throat or increased secretion. As soon as ulceration makes its appearance in the lower pharynx, swallowing becomes very painful, and the act of deglutition is greatly interfered with. The timbre of the voice becomes nasal or anginose. If the velum is indurated or perforated, food, especially fluid, passes into and through the nose.

Syphilis of the naso-pharynx may not interfere with deglutition. The principal symptoms of trouble here, however, are the enormously increased secretion with headache, loss of flesh and cachexia.

THE MOUTH.

Circumscribed and diffuse gummatous infiltration are found in all parts of the mouth. They are seldom found in the mucous membrane of the cheeks and when they do occur it is near the corners of the mouth; they may also be found on the lips. In these locations the infiltration is usually in the form of diffuse hard indurated patches covered with a deposit of gray epithelium. Rarely are the gums and floor of the mouth attacked.

The tongue is the part of the mouth which suffers most frequently from tertiary syphilis, and then usually in men in whom

the irritation of alcohol and tobacco contribute considerably to the production or increase of the trouble.

Fournier,[28] who wrote an article on tertiary glossitis as long ago as 1877, has divided tertiary syphilis of the tongue into a gummatous and a sclerotic form, and both of these he divides again into superficial mucous and deep parenchymatous forms.

The sclerotic forms of glossitis do not break down and ulcerate like a gummata here and elsewhere, but the inflammatory processes are at once transformed by shrinking into sclerotic cicatrices. Gummata of the tongue form either in the mucous membrane of the tongue or in the muscles or interstitial tissue of that organ, and vary in size when circumscribed from a pea to an apple. They occur most frequently in the anterior portion of the tongue, but may be found on the edges, in the middle or on the tonsil of the tongue. Dr. G. H. Makuen[31] of Philadelphia read a paper in 1901 before the American Medical Association describing an ulcerated gumma confined to the lingual tonsil. This was the only evidence in the case that the patient was suffering from tertiary syphilis. Escat[32] has described in his own practice two cases of gumma of the lingual tonsils with no other manifestations of the disease. Several authors[33] have described gummata of the lingual tonsils, which, however, were accompanied by gummata elsewhere, either in the faucial tonsils or on the edges of the tongue. Escat says that gummata in the lingual tonsil develop slowly and appear after a few months as smooth, claret-colored tumors. As they break down, they are said by Seifert[34] to be difficult to diagnose from carcinomata. Sometimes several small and large gummata are found near each other upon the surface of the tongue, or the whole of one side or the whole of the anterior portion of the tongue is a hard gummatous mass. Gummata of the tongue develop as hard elastic circumscribed nodes, which involve either the mucous membrane or are situated just beneath it or are deep seated. They consist of large or small flat or uneven tumors. When the superficial gummata break down they form characteristic ulcers with undermined borders. But when the ulceration commences deep in the substance of the tongue there may be seen only a tear in the mucous membrane of the tongue. When the borders of this fissure are separated, a deep ulcerated cavity is brought to light. Many gummata have no tendency to break down and remain for years as hard tumors of the tongue.

Recently a case of tertiary syphilis of the tongue came under my observation where a fissure of the tongue led to a deep ulcer on the side of the tongue near the base, where the only symptom besides difficulty in swallowing was severe otalgia. Otalgia has been pointed out as a constant symptom of syphilitic ulceration in this location. This patient was referred to me for treatment of her ear, as she was suffering likewise from chronic deafness.

In the sclerotic form of syphilitic glossitis extremely hard infiltration of the tissue takes place, either on the surface in the mucous membrane or in the deep parenchyma. This takes place usually on the dorsum of the tongue. The patches of induration upon the surface are raised somewhat above the surrounding tissue of the tongue, are oval in form, and are sharply defined, and their surface is smooth as if shaven, due to the destruction of the papillæ upon their surface. These spots are closely packed together or are spread out in flat indurated areas.

The first stage of the deep parenchymatous form of sclerotic glossitis is less striking. Here the infiltrations are still covered by a smooth unaltered portion of the tongue. They show the same smooth and deep red mucous membrane as the other form but are not at all, or but slightly, raised. This form is also multiple, as is the other form.

A frequent complication of both forms of sclerotic glossitis are the fissures and erosions which occur, especially on the borders of the tongue, which are usually occasioned by some mechanical influence, such as the rough stump of a tooth or the tartar on the teeth, which comes in contact with the diseased tongue which has lost its natural softness and elasticity. These crevices and fissures may attain great depth and often get into a very painful condition, any movement of the tongue during chewing or speaking being very painful. The tubercular ulcer of the tongue is not usually on the dorsum but on the under surface of that organ. The use of alcohol and tobacco greatly increases the severity of the painful condition. Although these conditions are greatly aggravated by alcohol and tobacco, yet these fissures may attain great size in cases where neither are used. In both forms the deposit of inflammatory tissue is changed into a form of scar tissue. The character of this of course varies with the position of the infiltration. The superficial infiltrations change to more or less broad dense patches on the surface of the tongue over which the mucous

membrane extends. The surface, as said before, is deprived of its papillæ and looks pale and atrophic. The deep inflammation on account of the contraction of the sclerotic tissue is followed by deep-cut furrows. These usually leave a furrow in the median line which, together with those on each side, form a meshwork resembling the veins in the leaves of a tree. The ultimate result of this is a picture resembling somewhat the congenital furrowed tongue, the so-called lingua-plicata.

The surface of the folds in the congenital lingua-plicata has papillæ, while the furrows are devoid of papillæ. In the sclerotic glossitis of syphilis the papillæ are destroyed and the surface is as smooth as if shaven. The most characteristic condition of the congenital lingua-plicata is the regularity and equality of the folds and intervening furrows. This condition extends all over the superior surface of the tongue, even to its tip, which is not the case with the sclerotic syphilitic form.

The hard palate is a favorite location for the formation of gummata. They occur usually in the median line, sometimes more anteriorly, sometimes more posteriorly, but especially on the border line between the hard and soft palate. They are found as one or sometimes more circumscribed livid red spots which press out the mucous membrane in the form of knob-like elevations. In more or less time yellowish-white streaks or points show themselves upon the most prominent parts of these swellings, a sure sign that they are beginning to break down. It is not unusual in a case of syphilitic caries of the floor of the nose to find the raphé of the hard palate discolored and thickened with a ridge-like elevation along the raphé or suture. Through the breaking down of such a gumma, or on account of syphilitic ostitis or periostitis, round or long perforations through the whole mucous membrane and bone take place and cause a communication between the mouth and nose, leading to nasal speech and regurgitation of food. The destructive process may end with the perforation of the soft and hard palate, or may extend to the exterior of the nose.

Gummata in the mouth produce but few symptoms before they break down. If they are situated on the tongue, the patient will complain of stiffness of the tongue or difficulty in moving it during speaking and eating. If the tumors are large or numerous, the speech is not understood. If the gumma is in the angle of the

mouth, there will be a feeling of stretching and tearing when the mouth is opened. Ulceration is accompanied by pain. This may be but slight, but it becomes severe if the ulcers are on the borders of the tongue, where they are subjected to mechanical irritation from the teeth.

DIAGNOSIS OF SYPHILIS OF THE NOSE AND THROAT.

Although there are in many cases great difficulties to be encountered in making a diagnosis of a tertiary lesion of syphilis, which has been illustrated by the histories of some of the cases which I have reported, yet the majority of the cases should be diagnosed by the appearance of the lesion and that without fear of making a mistake, and independently of obtaining any history of infection. And yet there are many physicians devoting their lives entirely to the treatment of diseases of the upper air passages who talk learnedly of correcting deformities of nasal septa, who discuss the best methods of treating the diseases of the nasal accessory sinuses and of the mastoid process and who have received special training in diseases of the nose, throat and ear, when they cannot and do not recognize the usual and characteristic lesions of syphilis, or even suspect them; because they have not gotten a history of primary infection, or because they think it could not occur in the patient, possibly a respectable married woman with grown up children, or because a child with a characteristic faucial lesion has no Hutchinson's teeth. Where there is any doubt, there are however apt to be found some of the accompanying conditions about to be mentioned, which will confirm the diagnosis. There may be osteoscopic pains in the head at night; there may be nodes on the shin or frontal bones; there may be skin eruptions, such as psoriasis of the flexor surfaces of the extremities; horny formations upon the palms of the hands or soles of the feet; rupia and horse-shoe formed skin ulcerations may be found. Besides these, there may be oculo-motor paralysis, cerebral symptoms, apoplexy in people under fifty years, or a tendency to abortion in women and the birth of dead children. Other less certain conditions might be mentioned. The above, however, are syphilitic lesions and can be depended upon. This is necessary only when the throat lesion itself is not characteristic, and when the lesion first discovered is not characteristic, it is not unusual to find some lesion

in other parts of the respiratory tract which is characteristic. The loss of the nasal septum or of the epiglottis will naturally greatly aid us in deciding the character of a suspected swelling in other regions.

Gummata of the hard palate are easily diagnosed. They could only be mistaken for phosphorus poisoning, scleroma, which is seldom seen in this country, malignant tumors and lupus.

The greatest difficulty in the mouth arises in the case of an isolated suspected gumma of the tongue, where it may be difficult to say whether it be a primary syphilitic sore, a gumma, or a carcinoma. Here we are aided by remembering that cancer is usually accompanied by pain from the outset, and that a gumma is not accompanied by much swelling of the lymphatic glands, while both a chancre and cancer are; but in the case of a chancre by the time that the glands are much infiltrated, the skin eruption can be found if looked for. The infiltration of a gumma is usually more circumscribed than that of a cancer. If we feel that the case is probably one of cancer a microscopic examination of an extirpated piece of the tumor will confirm our diagnosis. When the lesion is syphilitic it will disappear quickly under the proper treatment. Cancer and tuberculosis do not respond to such treatment. The diagnosis of lesions of the nose and pharynx has been already indicated. The destruction of any part of the bony septum is almost pathognomonic of tertiary syphilis.

There are many traditions which linger in medicine, and they are often very intimately associated with medical progress. Scrofula used to include much that is now known to be tuberculous, but there are certain cases which were called scrofulous, and which are now called tuberculous by many practitioners, which are in no way connected with tuberculosis. Such are certain cases of Syphilis Hereditaria Tarda. I have seen children with a characteristic perforation of the soft palate or some other marked lesion of the upper respiratory tract treated for tuberculosis by men who are expert diagnosticians of tuberculous conditions of the lungs, when the only sign which could point to such a condition was the emaciation of the patient. Such cases are fed cod liver oil. The consequence is that many children have died of scrofula or tuberculosis who, had they been treated for hereditary syphilis, would have recovered good health in a very short time.

These mistakes seem to arise from the fact that it is considered necessary to have interstitial keratitis, Hutchinson's teeth and evidences of ulceration at the corners of the mouth order to establish a diagnosis of hereditary syphilis; yet the diagnosis should be just as easily made if a perforating ulcer of the soft palate or any other evidence as easily recognized as gummata of the upper air passages is found. Such traditions linger, not because the truth has not been pointed out by the best teachers and writers, but because the majority of the profession have not been instructed and have failed to inform themselves in regard to the characteristic appearance of an ordinary tertiary lesion of syphilis wherever found, for such mistakes were pointed out long ago by Fournier, when he said that the history of Syphilis Hereditaria Tarda was chiefly the history of the mistakes regarding scrofula.

It must not be forgotten when we are considering syphilis in children that young children frequently acquire the disease accidentally. Frequently whole families of children are accidentally infected or it is carried from one to another by dishes, playthings, etc.

THE PROGNOSIS.

The prognosis for the healing of perforations and ulcerations is always good in these cases, except in a certain number of cachectic individuals in whom the anti-syphilitic treatment has no influence in arresting the destructive progress of the disease. Usually tertiary lesions of the nose and throat heal promptly under specific treatment, especially when it is accompanied by proper local treatment.

The prognosis for the life of the patient is always favorable, except when the ulceration is in the neighborhood of vital parts which, if the disease is very virulent, may be attacked. If the disease attacks the cribriform plate of the ethmoid bone or the body of the sphenoid, *i.e.*, the roof of the nose, the meninges of the brain may be involved and death result therefrom. Similarly, when the pharyngeal disease causes necrosis of the cervical vertebræ, the spinal cord may become affected, or ulceration of the lateral pharyngeal wall, especially of a deep gumma of the tonsil, may perforate the carotid artery, resulting in a fatal hemorrhage.

The first question usually asked by patients with nasal syphilis

is: "Must I expect disfigurement of my nose?" The answer to this question must be very carefully given, for it is often impossible to say what changes may be going on in the bony framework near an ulceration, which of itself does not seem dangerous to the external form of the nose, and which may greatly disfigure the nose by the contraction of the cicatricial tissue which forms during the healing of the ulcerations. Fortunately much can be done to overcome such deformities by plastic operations, subcutaneous injection of paraffin, etc. The technique of such operations cannot be described here without making this paper, already too long, very tedious. Such operations should not be undertaken until the specific treatment has been carried out a sufficiently long time to be sure that no return of the disease will take place.

The loss of the sense of smell may be due to ulceration in the upper part of the nose, as on the middle turbinated bones, when the prognosis for the recovery of the olfactory sense is bad; but when the condition is due to obstruction of respiration by disease of the tissues in the lower part of the nose, olfaction will be restored when the healing of the parts takes place and respiration through the nose is restored. Nasal speech is certain to follow perforation of the hard palate when such a perforation is much larger than the head of a pin. This can be overcome only by wearing an obturator or by doing a plastic operation, which is usually not successful. Adhesions between the palate and the posterior pharyngeal wall, which are most prone to occur in hereditary syphilis, are very difficult to remedy, failure often occurring after repeated operations.

Lieven of Aachen found from his personal experience that tertiary syphilis of the nose occurring during the third and fourth year post infection was but a link in the chain of several severe tertiary manifestations. The other links of the chain occur simultaneously or later such as rupia of the skin, nodes on the cranial and shin bones; but he admits that his experience may be due to the severe character of the cases which come to Aachen for treatment. He also states, as has been already pointed out, that it has been his experience that the occurrence of syphilis in the nose later than ten years post infection is the last syphilitic manifestation that the patient will experience.

BIBLIOGRAPHY.

1. Halsund. Cited by T. Bloebaum, "Syphilis in Nase, Rachen. Ohr. u. Auge."

2. Erb. Cited by Bloebaum.

3. Schuster and Sanger. Beitr. z. Path. d. Nasen Syphilis Viertej. f. Derm. u. Syph. IV. 1877 u. V. 1878.

4. Chiari, O. Krankheiten der Nase Wien, 1902.

5. Chiari, O. Cited by himself, "Krankheiten der Nase," 1902.

6. Mackenzie, J. N. Reference Handbook of the Medical Sciences, First Edition.

7. Mackenzie, Morell. Diseases of the Nose and Throat.

8. Bosworth. Diseases of the Nose and Throat. Second edition. New York, 1896.

9. Mackenzie, J. N. Journal of Laryngology and Rhinology. Vol. III., page 139. And article in System of Genito-Urinary Diseases, Syphilis and Dermatology, Vol. II., page 325.

10. Kuhn. Syphilitische Tumoren in der Nase. Deutsche Med. Wochenschrift, 1896, No. 5, S. 35. Article Syphiloma in Bibliothek Med. Wissenschaften.

11. Wagner, E. Archiv. für Heilkunde, 1861, S. 1.

12. Virchow. Die Krankhaften Geschwulste, Berlin, Aug. Hirschwald, 1864-1865.

13. Virchow. Ueber die Natur der Constitutionell Affectionen. Virch. Archiv. XV., Bd.

14. Manasse, P. Ueber Syphilitische Granulations Geschwulste der Nasenschleimhaut, etc. Virchow's Archiv., Br. 147, S. 23, 1897.

15. Kuttner. Die Syphil. Granulome d. Nase. Arch. f. Lar. u. Rhin., VII., 2, 3, 1898.

16. Frank. Ueber Syphilitische Tumoren der Nase. Dissert. Strassburg, 1894.

17. Krieke, E. Form. von Syph. Granulations Geschwulste im Rachem. Munich. Med. Woch., No. 47, 1894.

18. Rupault. Syph. nas. Veget. a la periode secunde de la Syphilis.

19. Theisen, C. F. An unusual case of nasal Syphilis in a child and a consideration of Syphilitic nasal tumors (Syphilomata). The Journal A. M. A., Feb. 28, 1903.

20. Schmidt, M. Der Krank. d. o. Luftwege 2 Auft. Berlin, 1897.

21. Lieven, Anton. D. Syphilis d. ob. Luftwege unter besond Berucksicht d. different. Diagn. u. d. loc Therapie. Haug's Samlu, 1898.

22. Schech, Ph. Syphilis der Nase. Hand. b. der Laryng. u. Rhin., III.

23. Chiari, O. Ueber Tuberculose der Nasenschleimhaut Arch. f. Laryng., Bd. 1, 1894.

24. Goerke, Max. Zur Pathologie u. Diagnostik der Nasen Tuberculome. Fränkel, Arch. f. Laryngol., Bd. 9, S. 50, 1899.
25. Schech. Cited by Gerber in 26.
26. Gerber. Spatformen Hereditary Syphilis in der oberen Luftwege. 1894.
27. Natier. Gommes Syphilis des Amygd. Paris, 1891.
28. Fournier. Cited by Micklicz and Kummel.
29. Micklicz and Michelson, Atlas, 1892.
30. Michlicz and Kummel. Die Krankheiten des Mundes, Jena, 1898.
31. Makuen, G. H. Report of a Case of Unusual Tertiary Manifestations. Journal of A. M. A., Aug. 17, 1901.
32. Escat. Rapp. d. la Soc., franc d. otol., Mai, 1898.
33. Hopmann. Handbuch der Laryn. u. Rhin., Vol. II., page 790.
34. Newcomb. Med. News, July 2, 1892.
35. Seifert. Die Syph. d. Zungentonsille, Wien, 1898, u. Munich Med. Woch., No. 6, 1898.
36. Schech, Ph. Die Krankheiten d. Mundhöhle, des Rachens und der Nase. 6th Auf., 1902.
37. Gerber. Atlas der Krankheiten der Nase, 1902.
38. Mackenzie, J. N. A contribution to the study of Congenital Syphilis. Trans. Am. Laryn. Assoc., 1884. pages 13-23.
39. Knight, Chas. H. The Sequelæ of Syphilis and their Treatment. Nasal Syphilis. Trans. Am. Laryn. Assoc., 1896.
40. Nichols. The Sepuelæ of Syphilis in the Pharynx and their Treatment. Trans. Am. Laryn. Assoc., 1896.

Paper.

CONGENITAL LARYNGEAL STRIDOR.

BY JAMES E. NEWCOMB, M.D.

DURING the last few years the writer has seen three cases diagnosticated as the so-called Congenital Laryngeal Stridor, and though the circumstances in each case have been such that it could not be followed and its later history obtained, he has been deeply interested in the study of the subject and has deemed it one not unworthy of the attention of this Association. The literature is not voluminous and pretty much all that has been written has come under examination.

By the clinical terms describing the condition is meant a stridor coming on within a few days of birth, continuing for a certain period, measured usually in months but possibly in years, apparently not doing the child much if any injury and finally subsiding of its own accord without sequelæ. It seems to have been first described by Rilliet and Barthez in 1853. It has been variously termed "Inspiratory Stridor of Nurslings" (Avellis), "Stridulous Respiration of the Newly-born" (Comby), "Clonic Glottis Spasm of Nurslings" (Löri), "Respiratory Croaking of Babies" (Gee), "Posticus Paralysis of Infants" (Robertson), and "Congenital Laryngeal Stridor" (Rocaz, Suckling, Stamm). No therapeutic measures have seemed to shorten or essentially modify its course. Consequently the literature has mainly concerned itself with theories of etiology and criteria of differential diagnosis.

As frequently happens in case of rare diseases, some of the writers have endeavored to establish from a very limited experience a too rigid symptomatology and in the light of our present knowledge have too sharply drawn the lines of their clinical picture. This fact is illustrated in the statements collated on the topic in the recent book of P. Watson Williams. Thus, he remarks that "the usual physical signs of obstruction are present during the exacerbations such as cyanosis, retraction of the epigastrium, and lower ribs and depression of the supra-clavicular

fossa and episternal notch." On the other hand, the majority of those who have described the condition deny the presence of these clinical features. No such evidence was presented in the cases seen by the writer.

The malady seems to predominate in male babies, though no reason is assigned therefor. In so far as laryngeal examination has been applicable, it has revealed a malformation of the laryngeal vestibule, epiglottis and ary-epiglottic folds. The epiglottis has lacked its normal curvature, being folded on itself so that its shape has been that of an arched or curved roof; or, the ary-epiglottic folds have been devoid of their usual firmness and their free ends being thin and flabby, have nearly touched. In some instances the upper part of the larynx has seemed contracted by protuberances capable of vibrating and of playing the rôle of supplementary cords. In a second and less marked variety, the changes have been rigidly confined to the epiglottis and ary-epiglottic folds, the former being rolled on itself like the end of a flute, the folds themselves approximating only anteriorly and the ensemble vibrating under the effect of the air.

The causes of this condition are not always easy to find. In view of its suggestion to the familiar laryngismus stridulus and the fact that many cases of the latter occur in rhachitic subjects, some have supposed that rachitis is at the bottom also of congenital stridor. In a general way the most common causes of laryngeal spasm in children are rachitis and digestive disturbances; to these may be added reflex disturbances from lesions of the nasopharynx, brain and respiratory organs. In the experience of certain observers the stridor cases have been badly nourished, but this is contrary to common observation. Some have regarded the stridor as merely a modification of the nervous mechanism of the larynx which is within the limits of health and is analogous to the cardiac arrhythmia observed during the first years of life (Politzer). As a rule there has been no tendency to cyanosis or convulsions such as would indicate air-hunger. The overwhelming testimony has been to the effect that the health has generally been good. In fact, the disorder has been looked on as "more an annoyance to others than to the child itself."

The time of onset may be any period from the first day of life. In the 18 cases reported by Sutherland and Lack, the onset occurred on the first day in 11. These authors believe it rare to

have the onset delayed after the second week. The character of the sound made varies considerably within type-limits. It may be a stridor, a croak, a cluck, etc. The inspiratory sound may be the louder. With superficial breathing it may completely intermit, to be reproduced and become continuous when the breathing becomes deep or irregular. It is increased by changes of temperature, excitement, sudden waking, coughing, sitting up in bed, too rapid feeding and flatulency. It sometimes stops when the position of the child is changed from the back to one side or when the head is placed at a lower level than the body (Gähnen). It continues during sleep though never aggravated thereby and persists during chloroform anesthesia.

Mendez has reported one case, that of a child of seventeen months in whom the stridor accompanied and was synchronous with inspiration; then ensued a period of quiet expiration for about one-third of the expiratory period when the stridor reappeared and accompanied expiration to its close. At other times, the breathing appeared to assume the Cheyne-Stokes type. Mendez was inclined to refer the inspiratory stridor to the pharynx and not to the larynx.

Goodhart states that respiration is accompanied under certain circumstances by a curious clucking or croaking sound instead of by a true stridor and that the latter is practically constant in expiration as well as in inspiration.

In view of the scattered reports of the cases and the fact that no one writer has seen very many of them, it is not surprising to find a wide diversity of theories as to the underlying cause of the condition. Let us consider seriatim the various hypotheses submitted:

1. *Thymus Enlargement Causing Pressure.*—In referring to a case of Herzfeld's, Avellis states his belief in this theory and believes that the lesion may prove fatal. A woman of thirty years came under his observation, having a narrowed trachea referred to thymus pressure. She had suffered from stridor in infancy and it recurred on violent exertion after she had grown up. He reports another case in which removal of a part of the thymus relieved the stridor or at least the stenotic symptoms. Stamm denies that true laryngeal stridor is ever due to this cause. It is an undeniable fact that thymus enlargement has not been present

except in a small proportion of cases; when present, there has been expiratory as well as inspiratory stridor.

2. *Cicatricial Band Across the Larynx.*—This theory can hardly be regarded as tenable. If it were, we should expect to have children born with stridor, but of such instances we have no such record. Laryngeal bands in infancy are uncommon and are generally referable to some pathological process as syphilis or diphtheria. A few cases of congenital laryngeal bands or webs are on record, but these cases have not presented the stridor of which we speak. The diagnosis of the condition in the earliest period of life is most difficult, often only conjectural. Such cases are apt to suffer in the later period of life from dyspnea on the slightest exertion.

3. *Acquired Brain Lesion Causing Anatomical Deformity.*—Stamm reports a case of stridor, the child dying in convulsions soon after birth. The respiration was very rapid, running from 150 to 200 per minute. There was a deep inspiration and then a relatively long pause. The child had fallen on the head during the completion of the parturient act and there was probably some central disturbance but the respiratory abnormality did not come on till the fourth day of life. The seat of the trouble was considered to be in the region of the calamus scriptorius in which locality according to the researches of Semon and Horsley, lies the coördinating center for involuntary laryngeal movements.

4. *Lack of Development of the Cortical Centers of Respiration, especially of the Laryngeal Centers.*—Evidence on this theory is manifestly only conjectural. Autopsy alone could verify the truth of any such hypothesis and such testimony is lacking.

5. *Posticus Paralysis.*—This theory has received the advocacy of W. Robertson, who reminds us that bilateral paralysis of the abductors with secondary contracture of the adductors is a common phenomenon in nervous pathology. He finds the starting-point of the process in irritation arising from the region of the pharynx and post-nasal space. It is probably transmitted to the region of the medulla, there exciting and exhausting the accessory vagus and this leads to the depraved innervation of the muscles in question. The latter structures are also acted on unfavorably by the collateral catarrh of their enveloping mucosa.

The position of Robertson has been vigorously attacked by Semon, who regards the cases ascribed to paralysis as being due

to spasm. In such cases he notes (Heymann's Handbook) that the cords come together in such a way that the rima glottidis remains closed for an instant while with the beginning of expiration the cords separate. He would regard the condition of Robertson's cases as analogous to that described in adults as "perverse action of the vocal cords." He admits that in children it is often difficult to distinguish between clonic inspiratory spasm and bilateral paralysis of the abductors. In both there is a constant stridulous breathing with a free voice. Laryngeal examination in young children offers the most severe difficulties and in both conditions the laryngeal image is very similar at the height of inspiration. Points of difference are (1) that in spasm the stridor usually disappears during sleep though this is not always the case and (2) bilateral paralysis of the abductors in nurslings has never been positively determined. At any rate it is a very rare affection and in cases such as those reported by Robertson, Semon maintains that the a priori conclusion is that we have to do with clonic spasm rather than with paralysis.

6. *Muscular Spasm, either glottic or sub-glottic and possibly phrenic.*—McBride would regard the laryngeal stridor cases as due to spasm and not to paralysis. He would consider them as similar in etiology to laryngismus stridulus, adding that this view is probably correct in so far that both are due to cortical irritation, yet admitting that there are marked clinical differences.

7. *Adenoids.*—Eustace Smith advanced the theory that the condition is due to adenoids in the naso-pharynx, placing himself on record as never having failed to find the latter or a thickened granular state of the mucosa. One of his cases was cured by curetting of the vault. In this case the larynx was of normal size and development. Jackson has reported the case of a boy of seven months with stridor and adenoids, but removal of the latter did not cure the former, which persisted eight months longer and then gradually disappeared. In reply to Eustace Smith, Lack contends, 1st, that the stridor in Smith's cases was increased during sleep; second, that it ceased under chloroform anesthesia; third, that it was increased by closure of the mouth in feeding; and fourth, that the patient was subject to suffocative attacks such as are very common in adenoids but very rare in the affection called congenital laryngeal stridor. In reply to Smith's contention that stridor is caused by the spasm of the ary-epiglottic

folds and that this spasm is due to the irritation set up by the adenoids, Lack replies that the spasm is probably due to the examiner's finger and the presence of the mirror in the infant's throat—a not uncommon reflex.

Finally we come to the theory advanced by Lack himself and the one that has met with the most general acceptance.

8. *Congenital Deformity of the Superior Laryngeal Aperture aided by the Flaccidity of the parts in Infancy but not entirely dependent thereon.*—The upper laryngeal aperture acts as a valve. Its lateral walls fall in during inspiration. As the patients grow and the parts become firmer this lateral prolapse gradually ceases. In this theory Thomson and Logan Turner agree and they have reproduced the stridor in the cadaveric larynx of children by imitating forcible inspiration through the glottis. Thompson believes that in life the laryngeal deformity arises from disturbance of respiratory coördination resulting in a constant sucking in of the upper margins of the infantile larynx, "a process strictly analogous to the formation of pigeon-breasts."

BOSTON MED. LIBRARY SEP 28 1901

Naturally but few cases have afforded an opportunity for the examination of the larynx. Numerous variations occur in the few statements on record. Rocaz reports one case in which the epiglottis was bent from without inwards. In another case by the same author it is said that the ary-epiglottic folds were hypertrophied so that the true cords could not be seen. The mother of the last-named patient was tuberculous. Rocaz suggests that nervous heredity may be a factor in the problem. In his first case the father was bitten by a mad dog about the time conception occurred in the mother and he considers that this fact suggests a possible toxic infection.

In one of Gee's cases the larynx was easily seen and appeared normal. Lees found the epiglottis excessively curved in its vertical axis as if it had been bent in half down the middle, and then the ary-epiglottic folds brought almost into apposition, leaving only a narrow chink between them. Sutherland and Lack examined the larynx by passing the index finger of the left hand over the tongue and hooking its terminal phalanx around the hyoid bone, which was then pressed well forward. The epiglottis was found folded on itself, the ary-epiglottic folds were approximated and the laryngeal entrance was reduced to a narrow slit, their

flapping folds seeming to bound the aperture. Examination of the naso-pharynx was negative.

In a few instances post-mortem examination has been made. Lees reports one case dying of diphtheria at the twelfth month. Examination of the larynx one month previously had revealed its upper aperture as a narrow median slit extending from above downward, the epiglottis being folded on itself so that the posterior surfaces of its lateral halves were almost in contact. It the case of Refslund, the parts had the shape of a jewsharp. In another instance autopsy showed in a boy of two and a half years the epiglottis furrowed in the middle. The furrowed part separating the cartilaginous leaves was fastened throughout by a connective tissue band to the base of the tongue. Into this furrow the epiglottis was bent so that the inner surfaces of the lateral halves touched.

This latter condition Refslund considers one always to be thought of in explaining mysterious cases of laryngeal dyspnea in children. This latter statement, however, casts doubt on the correctness of the diagnosis in this special case for in true congenital stridor, dyspnea is wanting; in fact its absence is one of the most striking features of the disease.

Variot reports two cases. His first case was that of a boy brought to the hospital with laryngeal hoarseness. No diphtheria could be made out. The voice was clear in cry and speech. He was intubated, but dislodged by coughing the tube from the glottis and it started down the esophagus but was recovered by the thread. The mother stated that normally the stridor was present during sleep and nursing. A second tube was inserted, but was in a few minutes rejected. As far as could be ascertained the epiglottis seemed folded over the tube. The patient died of scarlatina and broncho-pneumonia. Autopsy showed the epiglottis elongated so as to form a trough from approximation of its lateral borders. The ary-epiglottic folds instead of diverging in the usual V-shape formed a slit 1 cm. high and were in contact. Variot had another case with adenoids but curetting did not relieve the stridor.

Prognosis.—In weakly children the condition may lead to thoracic distortion and may prove fatal. As a rule, it passes off by the end of the second year. It may return during periods of excitement or of ill health. It generally increases in severity for

some weeks after its appearance, then becomes stationary until about the eighth or ninth month and then gradually diminishes until a period from the eighteenth to the twenty-fourth month, when it disappears.

Differential Diagnosis.—This is called for from (1) papilloma, (2) catarrhal laryngitis, (3) essential spasm of infants, (4) phreno-glottic spasm, (5) congenital retraction of larynx, (6) paralysis of dilators, (7) hereditary syphilis, (8) retro-pharyngeal abscess, (9) adenoids, and (10) laryngismus stridulus. The latter alone need concern us here and now. Laryngismus stridulus is favored by the onset of the first dentition. The patients are rachitic and may have tetany, convulsions or other nerve disturbance. The spasms are of long duration and the patients become cyanotic. Crying may set the spasm up or aggravate it and attacks are more frequent during night hours.

Stridor comes on soon after birth. It is slight and there is no cyanosis. Crying stops it. Deglutition has no effect upon it. Sleep never aggravates it and may stop it. In other words we have to do with a condition in which there is a temporary anatomical deformity and an alteration of the relations between the muscles of the throat and those of the larynx. There may be the added factor of a central nerve disturbance. Some cause may act on the adductors more strongly than on the abductors. Semon and Horsley have shown that there are cortical fibers for adduction but none for abduction. It is furthered by backward development and irritable weakness of the central mechanism controlling respiration, just as the tendency to laryngismus in a rachitic child has been referred to a deficiency in the higher controlling centers. In other words there enters into the question the factor of a development neurosis. It is analogous to occupation spasm, urethral spasm and stammering.

Treatment.—Robertson orders ammonium bromide, alkaline sprays and resorcin in mineral oil. He also advises the clearing out of the pharynx and naso-pharynx before secondary contracture sets in. Such a therapy is based of course on his theory of etiology. Variot has suggested partial resection of the ary-epiglottic folds if dyspnea should ensue and threaten life. Merklen and Devaux summarize treatment as bromides, strychnine, warm baths, eucalyptus inhalations and antisepsis of the upper air tract.

On the basis of the theory which we have accepted in this paper, a general tonic régime is all that is called for.

Dr. Delavan has kindly sent me the notes of two cases that have come under his personal observation.

CASE I. is that of a boy now thirteen years old who has suffered from birth from laryngeal stridor. At first it was so severe as to threaten life. Exertion now of any kind brings on an attack. Removal some time ago of a pharyngeal adenoid was followed by a distinct improvement in the severity of the condition. At present there is a slight laryngitis but the boy is in fair health, is moderately well developed and ignores his laryngeal handicap though almost any kind of exercise, as running, riding the wheel, etc., brings on an attack. All these he does in spite of the temporary discomfort.

CASE II. is that of a boy now nine years old. The difficulty began a day or two after birth. As far as is known, parturition was normal, delivery being rapid. Stridor came on every time he was put to the breast, but it did not seem to interfere with nursing. It lasted for a short time after nursing until he went to sleep, and the total duration of the trouble was between three and four weeks, when it stopped of itself. No treatment seemed called for and none was attempted.

The bibliography of the subject is given in full by Mendez, and need not be reproduced here. (Pimentel-Mendez, "El Estridor Congénito de los Niños de Teta" Tesis para el Doctorado en Medicina, Santiago, 1902.) I am able to add the following more recent references:

Wright. "Three Cases of Congenital Stridor in Infants." Homeopathic Eye, Ear, Nose and Throat Journal, August, 1902.

Martin. "Du Stridor larynge congenital des Nourrissons." These de Bordeaux, 1902.

Devaux. Gaz. des Hopitaux, June 7, 1902.

Bruder. Trans. Madrid Med. Congress, 1903.

Variot. Medicine Moderne, January 7, 1903.

Greene. Bost. Med. and Surg. Jour., June 11, 1903.

Herrman. Trans. Sec. Pediat., N. Y. Acad. Med.; N. Y. Med. Rec., October 18, 1902.

Northrop. Idem.

Candidate's Thesis.

OPERATIONS FOR THE RELIEF OF MALIGNANT GROWTHS OF THE LARYNX, WITH REPORT OF SEVEN CASES.

BY WILLIAM LINCOLN, M.D.

In an examination of the literature relative to operations for the relief of laryngeal cancer for the last ten years, one is strongly impressed that from a condition of almost hopeless discouragement in the early years of the decade, writers upon this subject have come gradually to assume a view much less gloomy and to advocate, in many instances, measures, which only a few years back their published opinion condemned as useless if not altogether unjustifiable. The subject is certainly a most important one, and has engaged the close attention and study of many of the minds foremost in both general and special surgery.

In America, Cohen, Delavan, Mackenzie, Knight, Keen, Hartley, Crile, Halstead.

In England, Butlin, Semon, Thompson, Harvey.

On the Continent, Sendziak, Gottstein, Förderl, von Bergman.

This is but a partial list of general surgeons and laryngologists who have aided materially in the last ten years by careful study and reports and by improvement of method to bring about a more satisfactory sentiment in regard to laryngeal cancer and its relief.

In the present paper no use whatever has been made of the tables of cases reported in former studies of this interesting subject for the reason that, in 1900, it was clearly shown by Delavan, that the statistics usually studied in this connection were, in a great measure, unreliable as to the things which they attempt to demonstrate as well as extremely misleading to any proper study of the matter which has as its end in view the determination for laryngologists of the questions: (1) What operation is advisable in laryngeal cancer? (2) If operations involving a small area are inadequate, whether extensive removals, viz.: laryngectomies. should be early or indeed should ever be resorted to, and the

same author strongly urged that the appropriate method by which the subject should be studied was to collect a new set of statistics, but that these should be gathered and recorded more carefully, from surgery more carefully planned and executed. This suggestion has seemed to the writer most important and timely and he feels sure that it is only by following it out that we can expect to make progress in this difficult matter. Instead of trying then to come to a conclusion as to these grave vital questions by a comparison of percentages derived from these more or less incomplete compilations of cases, which have been shown by Delavan's paper to be in many instances, not only mere reduplications, but which, it is firmly believed, contain, at best, only a proportion of the cases operated upon, I have thought it would be more certainly helpful to adopt this valuable suggestion and take a much more limited number of cases occurring in the practice of one operator, who, by particular study, by processes both of accretion and elimination, has done much to perfect in time and technique one of the most difficult of surgical procedures. The general tone of discouragement which is encountered in the discussion among laryngologists concerning operations for the relief of laryngeal cancer, arises, I feel certain, in a large measure, from the too steady contemplation of the published cases alluded to, and it is the purpose here to show results of more carefully planned and executed surgery, in which the results are, I think, such as to afford a basis for a more encouraging outlook.

If such results can be obtained, we, as laryngologists, may be, at least in many cases, somewhat relieved from the harrowing experience unfortunately so familiar, of watching cases of laryngeal carcinoma from the first occasion, when the fatal diagnosis has been made through the months and years of suffering till the end has been brought about by a mercifully fatal pneumonia or metastasis and with no resource but to attempt to palliate pain or to weakly acquiesce in the delusion of the patient and his friends with the many vaunted but alas perfectly worthless measures, such as endolaryngeal operations, sub-mucous injections, X-ray applications, electric cataphoresis and the like.

If the circumstances of the case admit, by which I mean early clear diagnosis, circumscribed and favorably located growth, confinement to voice box, and non-involvement of lymphatics, in other words if the growth is truly intrinsic, then the operation by laryn-

go-fissure or thyrotomy should receive attention. While I have no personal experience of this operation and its results, I feel sure, from the work of others, notably that of Butlin and Semon, that it is a procedure which has been proven to be most useful.

It appears to me that many of the unfavorable reports concerning it have occurred from its having been undertaken in unsuitable cases in which the growth was wholly or in part extrinsic, or when the patient had so little vitality left at the time of operation that the outlook for any surgical interference was very gloomy. If thyrotomy is performed in suitable cases and conducted in the manner elaborated by Butlin it will prove to be, I think, the means of saving many cases of laryngeal cancer.

Butlin, in 1901, reported that in the many cases he had operated by thyrotomy since 1896, there had been no deaths, and he states it as his belief, based on the improvements in the technique of the operation, and upon the fact that the operations are now, as a rule, performed at a more favorable stage of the disease, that "one hundred thyrotomies ought to be performed at the present time for intrinsic laryngeal carcinoma with a mortality of three or four, perhaps even less than this."

When however we come to consider the graver question of interference in cases where growths, by reason of their size or location, or because of cervical glandular involvement, are not to be removed by thyrotomy, and have therefore to choose between partial or complete laryngectomy and entire inactivity, or worse still to content ourselves with meddlesome local measures, there has been, as I said above, brought to our notice an ill assorted lot of statistics which are used as a means to quiet our own better impulse to help, as well as to satisfy the patient's mind as to the necessary fatality and inevitable mutilation, with resulting helplessness, of any radical attempt to relieve him; and thus a fair chance is in many cases allowed to pass by. I say a fair chance, because I firmly believe that the operation of complete or partial extirpation of the larynx if done at the proper time, and by the proper surgeon, will yield much better results than have been reported, or than we have heretofore experienced, and that the mutilation and helplessness resulting from it have been greatly exaggerated. I also believe the statements so emphatically made by the patients I have observed, that they were much more comfortable, mentally and physically, after, than before laryngectomy

was performed. • In saying this I do not wish to be understood to in any way minimize the danger of the operation itself, nor to blink the fact, that, in the great majority of such cases we have a return of malignancy, either locally or metastatically, but I do wish to say that in my opinion, even with these truths before us, the operation and its results are greatly to be preferred to what, in my own experience of unoperated cases, has inevitably been a more or less prolonged period of the most frightful mental and bodily anguish.

Of the seven cases I report here, four died from a return of the trouble and one from septic pneumonia, but all of them firmly stated that after laryngectomy they were much more comfortable than before, even those who realized the certainty of the return of the disease. All of them were advanced cases, in fact only one of them (Case VII) came for operation at a time favorable to the chances for cure, so that I feel this fatality can hardly be considered a reproach to the operation itself, but rather to a so-called conservatism which delayed surgical interference until it was a last resort and in fact was undertaken more to insure comfort, than in the hope of a cure.

When laryngeal carcinoma is compared in its clinical history and in its pathological significance with malignant neoplasms elsewhere in the body, one is forced to conclude that here we have a field for surgery which should be of great promise, where the strong cartilaginous barriers to the spread of the disease are aided by the meagre distribution of lymph channels and nodes in not only encapsulating, as it were, the growth for months and years, absolutely within the walls of the larynx, but also in preventing the debility and cachexia so early noted in cancers in other parts. The problem and the danger then which confront the operator is not so much that he has a really malignant growth to contend with as it is to overcome the risks incident to the total removal of an extremely sensitive organ from its setting in an intricate network of tissues which have the most powerful and complex associations with the vital parts of heart and brain.

This problem must be solved by the development of a greater skill and rapidity in operating, in more exacting and perfected technique on the part of the general surgeon while the laryngologist must see to it that the cases are put in the hands of the surgeon at the earliest possible moment. With this in mind and

considering what comparatively good results are here shown I would join in the suggestion which has already been made, that in each community these unfortunate cases be transferred by laryngologists to a general surgeon who has specially qualified himself to operate upon them, and that this should be done early enough to admit of more fortunate results than have been achieved heretofore. The value of this is evidenced by the results obtained by Hartley in a series of five cases reported a few months ago.

I do not doubt that in every considerable city, if we encourage it, some one or two surgeons will be found to so study the subject, to so perfect the technique of the operation, and to so train their assistants that before long many of us will be able to report brighter results in our cases of laryngeal cancers and will no longer delay these results by either intralaryngeal meddling or extralaryngeal methods of futility. The question of whether with the larynx all the anterior cervical lymphatics should be removed could best be determined by such qualified surgeons, working in the manner above indicated. Certainly we know that lymphatic transference of the growth does not take place through the body of the laryngeal cartilages for they contain no lymph channels and it is probable therefore that, in fortunate and early cases, in which the clearly demonstrated malignancy is confined to parts with cartilaginous base, removal of lymphatic glands may with safety be omitted. We can all appreciate the importance of shortening and simplifying cases of laryngectomy when we realize that nearly all the deaths shortly after operation occur from shock received through the unavoidable trauma sustained by the larynx and by the pneumogastrics in searching for proliferations of the growth in the cervical lymph nodes.

As to certainty of early diagnosis in these cases, equally brilliant laryngologists consider it both possible and impossible to diagnose malignant from benign growths at an extremely early stage by laryngoscopic inspection, and this lack of concurrence, I take it, leaves the situation in a mixed state.

I can only say that those who are confident of this knowledge of early and certain diagnosis without histological examination are most fortunately situated for the relief of their patients inasmuch as they can strongly urge them at a very early date to avail themselves of the less dangerous and more hopeful operation of thy-

rotomy. To those who cannot feel so sure by examination with the laryngoscope alone, the assistance afforded by the careful removal of a section of growth including some of the sound tissue and its thorough examination by a competent pathologist must always be of the most vital importance, and, in cases where for this purpose intralaryngeal operations are impossible, exploratory thyrotomy is in my opinion, not only justifiable, but is demanded.

Upon the question of the advisability of performing tracheotomy preliminary to excision of the larynx, opinions of operators differ. Keen, who has carefully elaborated a method of operating, rather discourages it, but others, including the operator in the following cases, consider that in cases in which dyspnea is at all marked a preliminary tracheotomy, after the method of Cohen, results in a decided lessening in the danger of shock during the laryngectomy, by shortening the time of operation, and what is equally important much decreases the chances of subsequent pneumonia and has also an additional advantage in fixing the trachea, and thereby preventing later retraction. In general the method of operation as described in the cases here reported calls for no special remark, and yet I feel that it is important to call attention to a few of the points which are of particular value in securing good results.

The most important point, *i.e.*, of earliness and thoroughness of operation I have already mentioned and now emphasize.

In what other surgical procedure of whatsoever hopelessness is such delay allowed as is observed in these cases, even if the outcome promises only a small chance for success or indeed merely a short period of increased comfort?

Next in importance is, I think, the prevention of shock during operation. Butlin considers as a frequent cause of death after laryngectomy collapse and paralysis of the heart, and that we have no means of guarding against it. In the cases I detail however this complication was met very successfully by two methods, namely, anesthesia of the nerves carrying inhibitory cardiac impulses by preliminary applications of cocaine and hypodermic injection of atropia and also by the maintenance of an equable and full blood pressure by mechanical appliance. Rapidity and convenience of operation, a third and not less important requisite, has been secured by perfection of operative technique.

The question has often been debated whether laryngectomy should be performed by laryngologists or by general surgeons. For reasons which this paper, I hope, makes clear, my opinion is decidedly that it should be undertaken by general surgeons, but only by such general surgeons as have made special preparation. I feel however that the laryngologist's influence and encouragement is much needed to form such talent.

To summarize the results of these cases but not to deduct percentages from them I will add, all were relieved from pain which had been in nearly all of an extreme degree. Cough disappeared in all of them.

Dysphagia was relieved in all except Case IV, in which it returned in the last month of life, and in Case VI, in which it was not relieved at all.

Dyspnea disappeared in all cases.

In most cases there was a gain in weight, and in all, by their own statement, and to all appearances, greatly increased comfort and interest in living.

Two of the seven cases are still living, one six years and one four and a half months after operation.

In conclusion, I wish to state that I am much indebted to Dr. Geo. W. Crile, who operated these cases, for permission to use his notes.

CASE I.—Male, æt. 60. Has had occasional hoarseness for a long period. Difficult breathing experienced for sometime finally necessitated tracheotomy. A few weeks afterwards laryngectomy performed. It was discovered that the disease had progressed beyond the larynx. Operation—

After adjusting a breathing anesthetizing apparatus to the tracheal opening, a horseshoe-shaped flap was made, the skin deflected, and caught upon this tube with the forceps. A straight incision was then carried up to a point above the level of the hyoid bone in the median line. The soft parts were separated from the box of the larynx, and by adjusting the larynx from side to side, it was freed from its muscular attachments. After the cricoid was separated from its attachments, a special-shaped curved periosteotome was employed in separating the cricoid. After this was completed the trachea was cut across, and the free end carried forward to prevent blood entering. The larynx was then raised up and in the further dissection, respirations suddenly ceased, the patient becoming very cynotic. The pulse was slow and intermittent and it seemed quite certain that death would quickly ensue.

Respirations were finally resumed and the operation was completed. In the light of later experimental work, this was clearly a case of reflex inhibition through the superior laryngeal nerves.

After History: The patient lived for 2½ years in a condition of greatly increased comfort and died of pneumonia, glandular metastasis having appeared.

CASE II.—Male, 32. Large tumor nearly filling the larynx. Diagnosed carcinoma by inspection and by microscopic examination. Tracheotomy performed.

Two weeks later laryngectomy after method described in Case I.

Rapid recovery. Sat up on fourth day. Left hospital at end of two weeks. The patient was relieved entirely from the extreme pain radiating to his ears from which he had suffered for over a year before operation; wound healed rapidly. Patient lost cough and fever, and in two months gained 38 pounds and resumed work as blacksmith which was continued for several months.

He was able to care for the tracheal tube himself and could make himself easily understood by buccal speech.

After six months a large gland was removed from neck. Six months later patient returned with an inoperable growth involving anterior and lateral part of neck. Died sixteen months after operation.

CASE III.—Negative family history. Hoarseness began two years ago. At that time had what appeared to be a papilloma of left vocal cord; later growth appeared suspicious and piece was excised and examined. Pathologist reported it to be carcinoma. Laryngectomy performed. Beside the growth, which was found to involve the base of the tongue and to extend below the cords, there was saculation of pus about the upper rings of the trachea. Recovery rapid. Sat up in bed afternoon of day of operation. Out of bed in one week, very comfortable. Returned to his work as a barber. Gained rapidly in weight and strength and has had no recurrence in six years. He has, by training and use of his buccal and pharyngeal muscles a very serviceable voice. No tracheal tube is worn.

CASE IV.—Male, 63. Growth in larynx; section excised for microscopic examination. Report, carcinoma.

Preliminary tracheotomy. Laryngectomy by same method as other cases. Complete arrest of respiration occurred in spite of precautions taken, due of course to mechanical irritation of the superior laryngeal nerves. The anesthetist maintained artificial breathing by blowing in the rubber tracheal tube a few minutes while the removal of the larynx was completed. Application of ice and heat alternately on the chest and abdomen also proved an efficient respiratory stimulant. Recovered from operation very well. Discharged from hospital in three weeks. Relieved entirely

of pain and from the recurrent attacks of broncho-pneumonia. Returned to work.

In ten months inoperable glandular cancer had developed. In this case from return of the growth in situ, and consequent irritation swallowing became so painful that the latter month of the patient's life was almost as wretched as before laryngectomy.

CASE V.—Male, 56. Has had for some time past attacks of dyspnea difficulty in swallowing, cough and hoarseness. Laryngoscopic examination shows intralaryngeal growth of malignant appearance occupying entire right side of larynx.

Potass iodid pushed to tolerance made no effect upon the growth. Meanwhile microscopic examination pronounced growth carcinoma. Dyspnea was now very marked and growth was spreading rapidly. Tracheotomy performed.

Patient declined laryngectomy and returned home.

In two months, his suffering having become insupportable, he returned for radical operation.

He had now a high constant fever harassing and almost incessant cough. Bronchial rales on both sides and there was perforation into esophagus. Operation delayed one week, when total laryngectomy was performed.

The result of this operation was only to relieve cough and attacks of broncho-pneumonia. His dysphagia was not relieved.

Had a deeper dissection and more thorough operation been made it is thought the patient would have been more benefitted.

Died 2½ months after operation from recurrence in situ.

CASE VI.—Male, 63. Family and personal history negative as to present trouble, which began three years ago in attacks of hoarseness. These gradually increased in frequency and severity and were accompanied by dyspnea and finally required tracheotomy.

Laryngeal condition diagnosed carcinoma by laryngoscope and microscopic examination. He wore at first a silver tracheal tube, and later a flexible rubber tube until six months later when laryngectomy was performed. An an inerval of three years had elapsed since the last case the operation in the present case and the next merit a short description.

Horseshoe incision above opening of tracheal wound. Skin dissected back, the muscles separated. On the right side a group of enlarged glands were found beneath the sterno-mastoid muscle. These were dissected out, together with the internal jugular vein which was ligated and severed. The superior nerve was exposed cocainized and severed. The greater portion of the thyroid gland was also dissected out and removed in the block dissection. The whole mass was next cut below the hyoid bone and deflected downwards thereby exposing the pharynx and esophagus. These were found infiltrated with the carcinomatous growth and consequently were also dissected from the vertebral column and removed in the

block dissection which extended to the fifth tracheal ring at which point the trachea was severed. The esophagus to which a portion of the pharyngeal wall was attached was sutured to the integument to the left of the median line. The integument was next loosened around the old tracheotomy wound and the stump of the trachea having pulled through this opening was sutured to the integument.

Recovered well from the operation and was discharged from the hospital.

About one month ago the patient returned for a recurrence of the carcinomatous growth in the operative wound, but was otherwise in good condition. Removal of the recurrent growth. Discharged from the hospital. He expressed himself as being very greatly relieved. Can make his wants known and converse by buccal speech. It is now 4½ months after operation.

Patient has gained much in weight and is able to feed himself through the open end of esophagus. Is quite vigorous and happy. No tracheal tube worn.

Before operation this patient was in a most pitiable condition of emaciation and suffering great pain.

CASE VII.—Male, æt. 51. No family history of malignancy. Eighteen months ago noticed slight hoarseness. Examined by two laryngologists who recognized a small swelling or growth on vocal cords but did not suspect malignancy. Local applications and internal medication, including potass iodid, tried fruitlessly for one year. Six weeks ago diagnosis of carcinoma was made by inspection and by microscopic examination. Patient in very good physical condition consents very willingly to laryngectomy.

No preliminary tracheotomy performed.

Operation: A median incision was made over the larynx and the skin dissected back a short distance. A small gland which felt hard was found lying on the larynx. After a more thorough examination a laryngectomy was deemed necessary. A lateral incision was made at the top of the median incision which extended beneath the jaws for about 2½ inches on each side. Inferiorly a semi-circular incision extending from the middle of each clavicle and with its convexity upwards also joined the median incision. The skin flaps were dissected well back exposing the whole anterior surface of the neck. The structures in the carotid sheath were separated. All gland-bearing tissue was left attached to the larynx. The superior laryngeal nerve was exposed, cocainized and cut, the trachea was isolated below and cut off at the second ring. It was immediately deflected forwards, the mucosa cocainized for a short distance and a rubber tube with a funnel attached inserted for the purpose of anesthetizing. The dissection was continued upwards and the entire larynx with the attached tissues removed. A part of each lobe of the thyroid gland was removed in the block dissection. The pharynx was

closed with interrupted silk sutures. An incision was then made in the inferior semi-circular flap and the end of the trachea inserted therein and sutured to the integument with interrupted sutures.

Made good recovery from the immediate effects of the operation and was sitting up. At the end of two weeks when his recovery seemed assured, he died in about 24 hours after first symptom of inflammation of the vagi characterized by marked inhibition alternating with acceleration of the heart.

Paper.

NASAL POLYPI: A STUDY OF ONE HUNDRED AND FORTY-SEVEN CASES.

BY J. PAYSON CLARK, M.D.

ALTHOUGH the existence of nasal polypi was recognized early in the history of medicine, and although more has probably been written about them than about any other affection of the nasal chambers, our knowledge of them is still, in many respects, far from satisfactory. What are the immediate causes of the growth of nasal polypi?* What are the predisposing causes? Can all cases be permanently cured, or only certain varieties? Such are some of the questions which continue to puzzle many of us, and to no one of which would any single answer be universally acceptable or satisfactory. It was with the hope of eventually being able to throw a little light on one or more of these unsettled questions that I began, about seven years ago, to get as complete a history and keep as perfect a record as possible of all the cases of nasal polypi which came under my observation. This I kept up with occasional interruptions but with more or less regularity for several years, during which time I collected the records which form the basis for this paper. In order to have the histories as uniform as possible and not to omit any point that might be of importance, I had cards printed, giving brief headings, indicating the various questions to be asked and the symptoms and appearances to be observed, leaving space for a description of the treatment and subsequent history. Although I had taken, as I thought, a good deal of pains in the preparation of these cards I found, as time went on, that they might have been improved

upon in a number of ways in their general arrangement and that I had omitted some questions which might have been of value, such as the question of previous injury to the nose and the condition of the lower turbinates. As to the two items mentioned, records were obtained in many of the cases but not as a routine. In presenting the result of this clinical experience, I shall not advance any new theories but simply add the support of such evidence as I have been able to collect to statements already made by others or show where this evidence does not support them.

The greatest hindrance which I experienced in making a study of these cases and noting the result of treatment was the difficulty of sufficiently impressing upon patients the importance of following up treatment and reporting as often as desired for observation. In spite of strict injunctions to the contrary, the majority of patients in my experience, cease coming as soon as their nasal respiration is free, and only appear when their noses are again occluded. Strange to say this statement seems to apply in a great many cases to those who also have a purulent discharge from some sinus as well as to those who have only vaso-motor symptoms. The nasal discharge is disregarded if the nose is clear.

Pathology.—This portion of the subject has been so thoroughly presented by such able observers as Jonathan Wright, Hopmann, Chiari, Hajek, Swain, John Mackenzie and others that I shall pass it over with only a brief statement, which I believe nobody will now dispute, namely, that true myxomatous tissue never occurs in nasal polypi, which must, as a rule, be considered histologically as stretched and edematous mucous membrane. To quote from Wright: "while the amount of fibrous tissue varies between *nil* and a condition which might well be given the name of fibroma, the vast majority of polyps consist simply of the normal amount of loose areolar tissue infiltrated and stretched with serous exudate." As to the site of these growths, Zuckerkandl's researches have shown that the usual situation is in the region of the middle turbinated bone, from some portion of the outer wall of the nose concealed by the middle turbinate, but more commonly from the turbinate itself, either from the lower border or from the outer or (more rarely) the inner surface. In all of my cases, the site of the polyps is recorded as being "on the middle turbinate," "under the middle turbinate," "in the region of the middle turbinate," and in a few cases, "above the middle turbinate." In several

cases I have a note of polyps visible only in the posterior nares, and having their origin distinctly above the middle turbinate. Of 146 cases 107 had polypi in both nostrils, nineteen in the left and twenty in the right only. Seventeen cases in which the polypi were in one nostril only, were seen last by me over five years after they had been conscious of unilateral obstruction, and in not one of them was there the slightest evidence of polypoid degeneration of the mucous membrane in the other nostril. This experience leads me to believe that it is not as rare an exception as Bosworth states for these growths to remain unilateral.

Etiology.—As far as my records go, I can find no evidence of any constitutional diatheses or impairment of the general health standing in any causative relation to this affection; indeed the large majority of my cases were in excellent health. Heredity appears to play no part in causation. In 102 cases only ten knew of any relative who had polypi, one a mother (doubtful), three a sister, three a brother, one a father and two a grandfather. These cases are so few that one seems to be justified in considering them simply coincidences. Of 146 cases seventy-six were males and seventy females. These figures lend only a very slight support to the statement, generally found in text-books, that these growths are more common in males. More than half of the cases (78) were between thirty and fifty years of age. There were twenty-nine between twenty and thirty and the same number between fifty and sixty. The extremes were one at thirteen and one at seventy-eight. In thirty-seven cases there existed a deformity of the septum, causing obstruction, more or less marked, of one nostril. Twenty-one of these are recorded as deviation, eleven as a ridge and five as ridge and deviation. Small spurs and ridges and slight deviations were not considered. Bearing in mind the frequency of the occurrence of septal deformity without nasal polypi and *vice versa,* it seems very doubtful if the former ever stands in any causative relation to the latter. I should rather be inclined to the opinion (which, it seems to me, has some foundation in fact) that any injury to the nose which might result in a deformed septum might also bring about a condition favorable to the growth of polyps. This leads me to speak of the theory, expressed by MacDonald, that polypi begin with a localized inflammation of a mucous surface followed by the formation of edematous granulations, which later become covered with epithelium and form

what we recognize as polypi. He states further that they may also begin by the accumulation of small round cells in the muco-periosteum which gradually project from the surface until covered only by epithelium . It certainly seems most plausible to suppose that some cases of nasal polypi have their origin in granulation tissue. Such a theory would explain the fact just mentioned, which it seems to me has not been given the importance it deserves, that some of these cases trace their origin very directly to an injury to the nose. A neglected injury to the nose with its attendant nasal obstruction, impairment of the circulation by pressure, and irritating muco-purulent or purulent discharge from the injured portion, might quite conceivably result in the formation of edematous granulations which would eventually develop into full-fledged polyps. Bosworth says that a case has been reported by Gerdy in which they occurred as a result of a fracture of the vomer. Downie reports a case of large polyp in the left nostril of a woman aged seventy-four which she considered the result of a blow on the head received in early life. Unfortunately, as I have said, the question of injury as a routine one was omitted from my records, nevertheless I find that five of my cases traced the beginning of nasal obstruction to a blow on the nose. It seems to me that injury to the nose may be a factor in causation oftener than we have been accustomed to think and that it might be profitable to question patients regularly on this point. This idea of the causative influence of previous injury is especially interesting in the light of the statements of Jonathan Wright regarding the blood supply of the mucosa. Any injury to the canals in which the arteries and veins lie would affect the veins more than the arteries and cause that edematous condition of the mucosa which may develop into polypi.

Another predisposing cause of the growth of nasal polypi is suppuration of one of the accessory sinuses. Again in this condition we undoubtedly have a similar disturbance of the "bony canals" of the blood supply. MacDonald says: "Generally speaking when we have suppuration we find more or less development of granulation tissue, which tissue may be ultimately indistinguishable, histologically, from ordinary large polypi." While it is generally accepted that nasal polyps by obstructing the nose may lead to suppuration of one or more of the accessory sinuses, it is also true that a discharge of pus from a sinus may cause a

growth of polypi or "edematous granulations histologically indistinguishable," which are not cured until suppuration ceases. Of forty-nine of my cases in which the purulent discharge was due to a sinus affection, in one the pus came apparently from the antrum only, in eleven from the ethmoid only, in eleven from the ethmoid and antrum and in twenty-six probably from the ethmoid. In this last group the patients were not seen sufficiently often to make an absolutely positive diagnosis. In those cases in which the discharge was the principal symptom and in which obstruction to breathing was little if at all noticeable, it is probable that the sinus trouble caused the polyps. I have records of several cases which support this view. In these cases polypoid tissue rapidly disappeared after getting rid of a purulent discharge, leaving a healthy mucous membrane. But in those cases in which the nasal obstruction was the principal symptom it was generally impossible to determine with any surety which was the underlying condition. In some it was no doubt the ethmoiditis, in others it was equally fair to assume that the ethmoid cells had become infected as a result of the presence of the polypi. In seven of my cases the polyps were bilateral while there was only a unilateral purulent discharge. In these cases the most logical conclusion is that the sinus disease resulted from infection of a nostril already occluded by polypi.

As to the theory of some writers that all nasal polypi owe their origin to ethmoid diseases, I will only say one word. As long as many skilled and careful observers see cases in which, after the most painstaking scrutiny, they can find no evidence of ethmoid disease and as long as there are other conditions which can just as reasonably be considered causes, it seems to me that the burden of proof lies with those who hold this view to show that ethmoiditis exists in these cases and to show us a satisfactory method of determining its existence.

All but about a fifth of the cases gave a history of frequent head colds. Some of these so-called colds were no doubt, only symptoms of existing polypi. That frequent colds are a factor in other cases is quite probable. They indicate, among other things, an abnormal sensitiveness of the Schneiderian membrane. This membrane thus kept in a more or less congested condition with increased serous transudation, one can readily see how the "water-

soaked" condition, spoken of by Bosworth, might be acquired. It is undoubtedly a fact that a profound local vaso-motor disturbance is present in a great many cases and it is hard to conceive that such a disturbance does not stand in a causative relation to the polypi. Its existence is shown by the presence of sneezing and a watery dscharge. Frequent sneezing and a watery discharge were noted in about one-third of my cases, and asthma, which also shows the constitutional tendency to vaso-motor instability was present in one-sixth of the cases. In the few cases, fifteen in number, in which the polyp is put down as single, the pedicle was small and only a small area of the mucous membrane was affected.

Symptoms.—In a very large proportion of cases obstruction to respiration is the first symptom which calls the patient's attention to his nose. Sneezing, as I have already said, was marked in about a third of my cases. While often an early symptom it was by no means always such, not appearing in some cases until considerable obstruction existed. Of ninety-three cases questioned as to the sense of smell, in thirty-nine it was lost, in four much impaired and in twenty-seven impaired, leaving twenty-seven in whom the sense of smell was presumably about normal. Undoubtedly if all these patients had been subjected to a practical test it would have been found that the olfactory sense was lost or impaired in a still larger proportion of cases. Two or three of the patients in whom the polyps were unilateral stated that the sense of smell was wanting on the affected side. In many cases the smell does not return after the removal of the growths, due, as Bosworth puts it, to "a certain disorganization which occurs in the mucous membrane lining the olfactory region." The character of the discharge varies from watery to mucous, muco-purulent and purulent. Of 134 cases in which the character of the discharge was noted, in thirty-nine it was watery, in eighteen mucous, in thirty-seven muco-purulent and in thirty-two purulent. In eight cases the discharge, first noted as watery, became purulent later owing to the starting up of an ethmoiditis.

Sequelæ.—Bronchitis was noted as present in twenty-one cases, in all probability as a direct result of the obstruction to nasal respiration. Asthma was associated with ten, asthma and bronchitis with fourteen and hay-fever with four cases, while there were two cases of hay-fever with asthma and two doubtful cases of hay-fever. I am inclined to think that it is extremely rare for

a nasal polyp to take on a malignant character. No such case has ever come under my observation.

Treatment.—The aim of any treatment must be the complete removal of the polypi and the restoration of the mucous membrane to a healthy condition so that there will be no further growth. In the first place it goes without saying that the growths should be removed with as little violence to the surrounding structures as possible. No one will dispute, I think, that the cold wire snare is today the instrument *par excellence* for their removal. This instrument must be supplemented in most cases by the use of cutting forceps of suitable shapes and sizes for reaching the parts affected. Where the polyp is single and growing from a small pedicle a simple removal is often all that is necessary and there may never be a recurrence. But in those cases in which the growths are numerous and diffuse the middle turbinate will usually be found to be so deeply affected by the process that only its thorough removal will suffice to eradicate the disease. I have never used the galvano-cautery or chromic acid to destroy the base of these growths because their irritating qualities, especially the galvano-cautery, may tend to excite that condition in the mucous membrane which we are trying to get rid of. It is unnecessary to speak of the possible dangers of using the cautery in the ethmoid region. I have thought that the application of 95 per cent. alcohol on pledgets of cotton to the site of the growths has been of assistance in preventing the recurrence of polypi in some cases. I often prescribe also the use of the distilled extract of hamamelis in a spray. Alcohol has been long ago recommended by McBride, Griffin, Cohen and others, and I simply wish to add my endorsement to its apparent value.

Prognosis.—The prognosis is largely affected by the perseverance with which a patient returns for treatment as desired. I have already spoken of the difficulty one experiences in making patients follow up treatment. Eighty-three of my cases were under observation for a year or less and the majority of them were seen only two or three times. And many cases which were under observation for a longer period did not return until again troubled by nasal obstruction. Twenty-five cases were seen at various intervals for more than one and less than five years and twenty-six cases were seen in this way for five years or over. In these last two groups of cases no polyps were present one year after treat-

ment in five cases. In eight cases no polyps were seen more than one or less than five years after the last treatment and in thirteen there were none five or more years after. In seven cases there was a recurrence on one side, but not in the other, one or more years after the last treatment. I have included in the above list three or four cases in which there were present at the last visit one or two minute polypoid excrescences in the region of the middle turbinate, but as these had remained unchanged without treatment for one to three or four years I felt I was justified in including them among the cured cases.

The points which I wish to especially emphasize in closing are: (1) The question of a previous injury to the nose is to be considered in the etiology of the polypi. (2) Probably only a small proportion of cases are caused by sinus disease (usually ethmoiditis). (3) A local vaso-motor disturbance, which may be of constitutional origin, stands in a causative relation to polypi in a certain proportion of cases. (4) The removal of the whole middle turbinate will be found necessary in many cases where the growths are diffuse. (5) Many cases of nasal polyps can be cured if patients will return for treatment as instructed.

References.

Bosworth, "Diseases of the Nose etc.," 1889.
Downie, Glasgow Medical Journal, 1890, XXXIV, 112.
Dabney, Med. & Surg. Reporter, Phila., 1892, LXVII, p. 645.
Griffin, N. Y. Med. Record, 1890, XXXVII, p. 727.
Wright, N. Y. Med. Jour., 1893, LVIII, p. 251.
Wright, The Laryngoscope, April, 1899.
Wright, N. Y. Med. Record, January 28th, 1901.
Macdonald, Intern. Clinics, Phila., 1895, 4s. LV, 327.

Paper.

SOME CASES OF FACIAL ERYSIPELAS FROM EROSIONS OF THE NASAL SEPTUM.

BY JOHN W. FARLOW, M.D., BOSTON.

In all cases of erysipelas it is of great importance to find out, if possible, the point at which the infection enters the system. In scalp wounds, especially before the days of antiseptic surgery, erysipelas was the complication most feared. In obstetric practice tears of the genitals were recognized as furnishing easy means for the much dreaded infection. In fact, all lesions of the skin or neighboring tissues may be the starting point where the germ of erysipelas finds lodgment and begins its rapid extension.

There is one form of erysipelas, facial, which seems particularly prone to occur where there has been no injury, a sort of "medical" erysipelas in contradistinction to the "surgical" form, and, as there is no external lesion, a point of entrance is not looked for. The usual description of the disease speaks of it as beginning generally on one side of the cheek and then going over to the other side of the nose and face. As the outside of the nose is often the first part involved and as germs in the air are naturally drawn into the nose, it is certainly reasonable to look inside the nose and see where such germs may find lodgment on a broken surface. Cracks and fissures of the vestibule, as well as pustules forming around hair follicles may in certain instances become infected, but, in such cases, the first manifestation would probably not be at the bridge of the nose nor would the redness tend to spread so soon over the nose to the other side of the face.

The septum is the usual seat of nosebleed, erosion, ulcerations and perforations, and I think we may say without fear of being disputed that these lesions of the septum, especially erosions, are much more common than all other lesions of the inside of the nose. If the septum is bent or irregular, or the mucous membrane atrophic, crusts form and are dislodged by the finger or by blowing, a raw surface is left and whatever enters the nose must pass

this unprotected spot. The symptoms, other than profuse nose-bleed, may be so insignificant that the patient is unaware that there is a very important lesion of the nose. No examination is made, and the negative history causes the nose to be overlooked as a possible starting point of infection. If an examination is made when the erysipelas is well established the nostrils may be found inflamed and filled with secretion and crusts which are looked upon as merely part of the disease and no special attention is paid to anything but the outside of the nose.

If surgical erysipelas spreads from an external wound proper cleansing and treatment of the wound itself are recognized as essential. The fact that erysipelas does not often result from surgical operations on the inside of the nose may perhaps be accounted for by the attention paid to the wound at the time of operation and its after-treatment; whereas in cases of septal erosions the crusts may serve to hold the germ in contact with the wound and there is no free secretion to dilute it and and wash it away.

The ethmoid region suggests itself as a possible starting point for erysipelas infection as being in close proximity to the part of the nose where the external redness commonly begins, but ethmoid disease is not nearly so common as are erosions of the septum and from its more protected situation is probably not so likely to furnish a favorable situation for the lodgment of germs other than those of influenza.

I was quite forcibly struck with the probable septal origin of a case of facial erysipelas in a lady seventy-five years of age, whom I saw several years ago. I was called to see her in consultation on account of occasional spasm of the throat. There was nothing of importance found in the throat, but I made note of an erosion and crust of the septum in the right nostril. Two months later I was called again and found her with a temperature of 101°, headache, septum very red and swollen, and a decided erosion on the right side of the septum on which was some pus. The bridge of the nose on the right side was very red, tense and painful and the redness was spreading toward the cheek and eye. I removed the secretion from the nose and used antiseptic washes and powders as dressing for the wound. She had a bad night and the temperature the next morning was 103°. She was mildly delirious and looked and was very ill. The erysipelas had spread to the other side of the face. The septum was again thoroughly

cleansed, as well as every part of the nose, and her physician and nurse were most assiduous in seeing that the nose was kept free from secretion. The outlook seemed bad, but the next morning she was decidedly better and on the following day the conditions, local and general, had much improved and she was soon convalescent. Her physician agreed with me that the recognition and treatment of the intra-nasal condition were the important factors in preventing what looked like a fatal termination.

Miss L., forty years of age, had had a number of severe attacks of facial erysipelas at frequent intervals. She had a marked erosion of the septum which I treated. On one occasion the septum became reddened and there was beginning pain and redness of the bridge of the nose just as her former attacks had begun, according to her story. Thorough cleansing of the nose caused the symptoms to disappear in a short time and she went nine years without another attack, dying of renal disease.

Mr. A., fifty-two years, had a very severe attack of facial erysipelas. I examined his nose later and found a marked septal erosion with bloody crusts. On one occasion the nose became reddened on the outside, but treatment of the septum seemed to stop what the patient was very much afraid would be an attack similar to his former one.

These three patients had never complained of the nose sufficiently to lead them to have their noses examined, yet each had a large open wound at the time that I saw them.

I am told that at the Massachusetts General Hospital all cases of facial erysipelas coming to the Department for Diseases of the Skin are referred to the Department for Diseases of the Nose and Throat for examination of the nose.

Very possibly if this custom were more prevalent, cases of recurrent facial erysipelas might be much diminished in number.

Discussion.

Dr. A. A. BLISS expressed his surprise that in view of the large amount of work done on septal erosions we so seldom saw cases of erysipelas. In his own experience he knew of but one such case. The reports of Dr. Farlow showed the real dangers occurring from neglect of a proper examination and care of cases often regarded by the general practitioner as unimportant.

Dr. SAMUEL JOHNSTON had seen one case of facial erysipelas having its origin, apparently, in a perforation of the nasal septum.

Dr. Farlow's paper was timely, and showed conclusively the great importance of careful examination of the nasal passages in cases of erysipelas of the face.

Dr. E. L. SHURLY said that it was a matter of classic medical knowledge that facial erysipelas was supposed to start from inside the nose. It was a question, however, whether such nasal or facial erysipelas was not merely an incident or sequence, whether the patient must not be in some peculiar physical condition at the time in order to suffer from an outbreak of the disease. In his own city of Detroit there were many Poles who were inveterate snuff users, at least the men were, and the intra-nasal condition of many of these patients (who were always numerous in institution services), was unsanitary in the extreme, yet he could not remember of ever having seen more than two instances of facial erysipelas among them, and never a case following an operation.

Dr. FARLOW in closing the discussion observed that cases of erysipelas usually fell into the hands of the general practitioner and not into those of the rhinologist. The former should be urged to make careful examination of the nasal interior in every case. With reference to the Poles mentioned by Dr. Shurly it might be that the snuff was sufficiently antiseptic to prevent infection.

Candidate's Thesis.

SOME REMARKS ON THE ETIOLOGY OF HYPERPLASIA OF THE PHARYNGEAL TONSIL IN THE LIGHT OF RECENT INVESTIGATIONS.

BY THOMAS J. HARRIS, M.D.

A LEADING rhinologist has recently said, "The contributions to the subject of adenoids in the last two decades have been well nigh inexhaustible, and yet little of value has been advanced not contained in William Meyer's original paper." After such a sweeping judgment from one who is intimately acquainted with the entire literature of the subject it seems indeed like presumption to add to this accumulated store, especially as it is frankly admitted that nothing strictly new will be advanced or claimed by the writer. Whatever may be held however regarding the completeness of our knowledge of the diagnosis and therapy of adenoids, it will be generally conceded that the question of

their origin is still almost as much of a closed book as it was in Meyer's time. The causal factors in respect not merely to adenoids but post-nasal catarrh as well, are to-day receiving and deserving of more and more consideration. The pendulum is on the backward swing. For many years the rhinologist has seen causes of catarrh in every spur and turbinal. To-day we are recognizing that these are too often only accidents or possible results and the true cause is remote and out of sight. The medicine of the future will not be chiefly therapeutic but prophylactic. No longer will we content ourselves with relieving results, but in preventing them. The subject of the etiology of adenoids is, on account of its importance deserving then of further brief consideration.

We propose to consider in the following pages, the more important views as to their origin, and try in this way to arrive at some reasonable conclusions.

At the outset we are confronted with the difficulties of obtaining a suitable definition of pharyngeal hyperplasia. The presence normally of a certain amount of lymphatic tissue at the vault of the pharynx as well as in the fauces, at the base of the tongue, on the floor of the nose and in the mouth of the Eustachian tubes, has long been demonstrated. Histologically the adenoid growth in most instances differs in no wise from this normal lymphatic tissue, but where the one ends and the other begins, it is impossible to say aside from the symptoms produced by the growth. The writer first quoted justly remarks that many healthy pharyngeal tonsils have been scraped away through the overzeal of some too ambitious operator. This normal lymphatic tissue has no constant size. It varies decidedly in different individuals, resembling in this particular its analogue, "Peyer's patches," in the intestines. That the adenoid growth is then a hyperplasia and not a neoplasm, must be constantly borne in mind.

For many years certain *constitutional factors* have been regarded with favor as predisposing causes.

Heredity seems to play a limited rôle at least. Various observers have reported the presence of adenoids in children at birth. This is however rare. Meyer found them most common after five years of age. Certain cases occur where one or both parents suffered in *childhood* from adenoids. It is true however as Brieger observed, that while many parents with pharyngopathies have descendants, suffering from adenoids, an equal number of children

with adenoids have parents with all these symptoms lacking. Further the almost universal presence of catarrh in our climate militates against too sweeping conclusions in this particular.

Tuberculosis.—A certain percentage of adenoid cases show the presence in the growth, of the tubercle bacilli. The frequency of their occurrence and the significance, vary much according to the individual observer In the last few years, several men have busied themselves with this subject. Dieulafoy, in 1895, published his results which were as high as 20 per cent.; Pluder and Fisher of Hamburg examined thirty-two cases of adenoid hypertrophy, with 15 per cent, showing tubercle bacilli; McBride and Turner, (Edinburgh Medical Journal, 1897) found only three per cent. Clinically the latter figure would seem much nearer correct. Certainly it is open to question that all these are cases of primary tuberculosis. Many cases of pulmonary tuberculosis show no tubercle bacilli in the growth.

Syphilis as a common predisposing cause is of little importance except in an indirect way, just as faulty hygiene, diet, etc. Chappell found 3 per cent. of adenoids in 2,000 school children, Harrison Allen found 33 per cent. It is probable that a mean between these two extremes is nearest the truth. For such a number of cases syphilis cannot possibly account.

Scrofula.—But for many years the favorite and certainly most plausible theory has been a direct or indirect association with scrofula or struma. Certain symptoms were recognized as peculiar to both and the immediate deduction was drawn of a cause and effect. In recent years, however, it has been pointed out that many of these symptoms disappear on the removal of the adenoids. A more exact definition too for struma has been demanded. It is true that we are wont to find hyperplasia of the pharyngeal tonsils in blond children with glandular enlargements. We meet it however continually where such enlargements are lacking. Meyer has shown that the Hebrew race is especially predisposed to this hyperplasia. Negroes, on the contrary, frequently the subject of rickets, are singularly free. This latter fact has been explained on the ground of their flat open nares and the character of the palatine arch. Further it is a fact that while we meet adenoid cases with marked glandular enlargements, this is rare and it is not found in the vast majority of cases. Masini (Annali di Laringologia, Vol. 3) has made a number of elaborate

experiments to account for some of the most striking of these symptoms just referred to. He believes in a process of intoxication as a result of the adenoids, due to insufficiency or failure of a particular secretion of the glands. His line of study was directed; (1) to the consideration of the effect of this pharyngeal secretion upon the cardio-vascular system; (2) as to insufficient respiration in adenoid cases; (3) as to hypo-oxygenation of the blood as a result of corpuscular resistance and alteration in these corpuscles. He found (1) Arterial pressure as a result of the injection was raised. There was a slowing of the pulse; the ventricular contraction was lessened. (2) Under *respiratory insufficiency*, the question of mouth breathing was considered. By careful experiment he shows that a man can take up only just so much oxygen for change into oxyhemoglobin. When the nose becomes obstructed the system gradually adapts itself to obtaining the necessary amount of air through the mouth. For an adult, 100 c.c. of oxygen is the limit for each respiration, or 516, 500 c.c. in 24 hours. Now it is demonstrable that a person with nasal stenosis, breathing through the mouth, does not take in this amount although a condition of hypo-oxygenation of the blood is continually in progress, due to permanent incapacity to introduce air under normal physiological conditions. The vital capacity (23,220 c.c.) of adults is not found proportionately in children with adenoids, due as he shows to insufficient fullness of the thorax and poor development in the muscles of the respiration. By ingeniously devised instruments, he registered the expansion of the thorax and the vital capacity in (1) children with adenoids; (2) children with nasal stenosis due to other causes; (3) healthy children. In the first class he found inspiration and expiration were less full than in the healthy children although as a result of frequency of respiration, the same quantity of air enters the lungs in the same unit of time. The accompanying tracings showed it is not absolutely impossible to obtain the necessary amount of air by the mouth. Deficient respiration by the mouth is not due to the mouth but to poor respiratory muscle action. The half open mouth is intended to prevent too large a quantity of air going in. The lips act as the alæ of the nose and produce the same effect. The great difference in children with adenoids is in the vital capacity. In the second class of cases the vital capacity is fuller, the color is better and the expansion of the thorax is larger. Respiratory in-

sufficiency, however, is not the principal cause of cachexia according to him, but rather blood changes due to the presence of faulty gland secretion just mentioned. The hemoglobin is less firmly fixed in the red corpuscles and attains its proper color more slowly. He found fewer white corpuscles by a fifth. The presence of macrocytes is noticeable. The resisting power of the red corpuscles is reduced. Poikilocytes representing necrobiotic processes abound. The leucocytes are increased, with many lymphocytes. Such in a few words are Masini's conclusions which are here given as worthy of consideration.

While we are forced to revise our former views as to the relation of scrofula and pharyngeal hyperplasia, it is true however that some diathetic condition seems to be at the bottom of a large number of cases. Bosworth (Diseases of the Nose and Throat, Vol. I, page 541), with his usual clearness of observation and judgment, fully stated this many years ago and his position is still deserving of recognition. There is what he calls a lymphatic habit or, quoting Potain, "a lymphatismus." This means a particular susceptibility in children for lymphatic tissue to take on inflammation and so increase in size. This peculiar property of lymphatic tissue is further borne out by the marked tendency now well recognized, of the adenoid vegetations to recur after operation. Up to the time of Hopkins' paper written some ten years ago, it was generally held that such recurrence did not take place. We know now that it is by no means uncommon. Recently Görke (Fraenkel's Archives, Vol. XII., page 279 sq) has discussed the subject in an exhaustive manner, especially from the histological standpoint. After stating the two commonly held explanations for the recurrence, viz.; malignancy and imperfect operation and giving convincing proof that neither of these reasons can be the cause in the majority of cases, he shows that the structure of the growth resembles in the main that of the ordinary pharyngeal hyperplasia but differs in this particular, "that a sharp division of the different layers is not possible." This lymphatismus is not a pathological but a normal process; it is not scrofula or struma but carried a step further it may become so. We shall consider in a few moments, the occasion for this physiological process. We know this tendency to lymphatic enlargement disappears as adult life is reached. Recognizing this property of infant lymphoid tissue to take on enlargement, it follows that any distinct and persisting cause is liable

to produce this effect. Mulford (N. Y. Medical Journal, 1897), as a result of the observation of many cases and of two cases reported, believes some blood diathesis is always at work, often allied in effect to that of uric acid in the blood, which if not cured will render invalid any operative measures on the throat. Haig in his book, "Uric Acid in the Causation of Disease," refers to a communication from Dr. Mackie of Nottingham which may be of interest in that there is noted an almost constant connection between catarrhal conditions of the nose and throat, adenoids, etc., and the uric acid diathesis. Mackie has read two papers on the subject before the medical society of Nottingham and he says in a letter to Haig that "he has hardly ever seen a case of adenoids, say in a child, but where there is arthritic or migrainous parentage and it is obvious that such conditions may quite easily occur from recurrent uratic irritations." As a further illustration of a remote cause acting on normal lymphatic tissue, Kyle ("Diseases of the Nose and Throat") states, "he has frequently met enlargement of the pharyngeal tonsil which is not a hyperplasia at all but a turgescence and cyanotic congestion with watery infiltration of the nasal and post-nasal space." This is a result of intestinal irritations, such as constipation, and will disappear at once under appropriate treatment of the bowels. The writer is convinced he has more than once met such cases where no inquiry was made as to the condition of the gastro-intestinal canal and where at operation, little save normal tissue was discoverable.

Climate has been often advanced as an important factor in a causative way, also the *dusts of cities,* but without sufficient reason save as all unhealthy conditions serve to irritate tissue easily irritated. The distribution of the diseases is uniformly widespread, although observers have noted its relative infrequency in savage life.

Inflammation.—Whatever may be correct regarding the importance of a diathetic cause, that of inflammation is generally conceded. Catching cold, whatever that is, is characterized by acute inflammatory swelling of the pharyngeal tonsil. This leads without question to chronic enlargements. Some writers, notably Greville MacDonald ("Diseases of the Nose and Throat") have sought to discover a similar result from pronounced nasal stenosis or obstruction. MacDonald states that, "In a large proportion of cases we find at the same time obstruction of the nasal fossæ

in one form or another." The commonest of these is engorgement of the erectile tissue which in some cases has advanced to actual hyperplasia of the inferior spongy body. Next in point of frequency we find a septum variously deflected and hypertrophied, sufficiently to cause considerable stenosis of one or both sides. So frequently does some other source of obstruction co-exist together with the post-nasal adenoids, that it is exceptional to find respiration completely restored by removing the adenoids, some further treatment of the anterior region being demanded before the patient will instinctively keep the mouth closed." The total number of MacDonald's cases however was 154. The writer's experience covering a large clinical service for the last ten years is decidedly at variance with MacDonald's. Hypertrophies of the turbinals are rare, while septal deformities of any considerable degree have scarcely ever been met with. Nor has it been our experience to find the majority of cases requiring any post-operative treatment. The most common nasal condition present was a boggy swollen condition of the inferior turbinals, which rapidly subsided after the removal of the adenoid growth. Repeatedly cases have been referred to us where all previous treatment directed to the nose alone had failed to relieve nasal stenosis, but where the obstruction at once disappeared after adenotomy. In many cases however no pronounced nasal obstruction is discoverable. To our mind the commonly held views that the nasal condition is a result of post-nasal obstruction is the much more natural one and in the majority of cases represents the proper relation of cause and effect. The *infectious diseases* however, scarlet fever, diphtheria, typhoid, etc., have been generally regarded as common inflammatory causes. That the hyperplasia develops after the attack seems beyond cavil. We have failed however to find any series of cases reported where a previous examination before the sickness had been made and the presence of hyperplasia definitely excluded. It seems in many cases the hyperplasia was already present and the inflammation acted as the diathesis already referred to, to excite its further growth.

The most encouraging and promising grounds for explaining these clinical phenomena has been along the line of investigation and study of the tonsil function. Many observers have busied themselves in this direction and certain well-accepted facts secured. It is now held by most writers that the tonsil, and here we

include the faucial tonsil as well, has a definite function though there is a difference of opinion as to how important this is. Harrison Allen many years ago, called attention to the probability of its sharing as a blood making organ. How largely this is developed is questionable. That such is the case seems reasonable when we consider the richness of the blood in lymphocytes in childhood, and their gradual disappearance in adult life. Stöhr has shown a constant emigration of leucocytes out of the tonsil to the surface. Metchnikoff definitely proved the function of phagocytosis in the tonsil epithelium. Numerous careful observers have showed the intimate relation of tonsillitis and articular rheumatism in many instances. Recognizing this diapedesis of the lymphocytes, we have to inquire; (1) What effect, if any, does the hyperplasia have on their activity? (2) What does the microscope show to point to an inflammatory origin? (3) What is the end and aim of such diapedesis? Brieger has exhaustively treated this question in a recent number of Fraenkel's Archives (Vol. VII., page 254 sq). Brieger and Wex found certain inflammatory changes in the tonsil as follows: (*a*) In spots the columnar epithelium is replaced by squamous. This occurs independent of the size of the tonsils and of inflammatory changes in the propria. It does not necessarily depend on inflammation, as Wex saw it in a child five days old. Diapedesis contrary to the assertion of Hill, goes on as in the normal tonsil though less actively in the squamous areas. Collections of leucocytes were seen beneath the surface resembling a picture of small cell infiltration. *Lymphocytes* predominate in the epithelium as in the propria. Polynuclear leucocytes are also found in the propria occasionally. Some areas contain leucocytes alone. This does not occur often enough to suggest acute inflammation. The difference in the number of leucocytes in the hyperplastic tissue and in the inflammatory process, is very noticeable. (*b*) The lymphatic structure is unchanged. The follicles in older children may fail or appear as sharply defined round cell collections with clear nuclei. (*c*) Blood vessel changes are seen which point to inflammatory processes, such as swelling in the endothelium or even complete obliteration, also at times hyaline degeneration. (*d*) The reticulum shows no change. Now all these inflammatory changes are distinguished by not attacking all layers uniformly. They are found in the hyperplasia of leucemia and are lacking altogether in

large adenoid vegetations. This in Brieger's opinion can mean only accidental occurrence taking place on one or several definite occasions. If such hyperplasia takes place without necessary inflammatory changes, attended by undisturbed diapedesis, what deduction has to be drawn as to its origin? It would clearly point to some function the tonsil discharges, which can better be discharged by an increase in size. The phagocytic power of the tonsil mucous membrane is well established. Equally recognized is the peculiar susceptibility in childhood to infectious diseases. This susceptibility, however, is entirely out of proportion to the constant exposure and the number of bacteria of a virulent nature in the air. Now the lining membrane of the nose possesses a certain protecting power against bacteria. The pharyngeal tonsil is decidedly freer from bacteria than the anterior part of the nose. The ciliated epithelium of the nose assists in effecting this result. This power is however limited and depends on circumstances. In a child with hyperplastic tonsil where mechanical cleansing of the nose through sneezing is impossible, the tonsil is covered with numerous bacteria. Further, as shown by St. Clair Thomson and Hewlett, while usually removed from the nose in a short time, they can occasionally be found there after several hours. They are under normal conditions avirulent, but disturb this normal protecting medium and at once they become virulent. The nose is then not sufficient in its protecting power. What of the tonsils themselves? Their surface presents only apparent defects in its continuity; in reality it is unbroken. The exits in the lacunæ are at once filled with the cement substance of the epithelium. The bacteria do not penetrate to the interior. Experiments to test this resisting power have been carried on by Hendersohn (Idem. Vol. VIII., Page 476) and Goodale, independently, which would seem to discredit the above assertion of Brieger. They employed various coloring powders dusted on the tonsils. Hendersohn found (1) fifteen minutes after the application of the powder, fine coal particles in the tonsil inside the epithelium. (2) The longer they remain the deeper they penetrate. (3) They are partially in the cells and partially in the lacunæ. If these experiments were fully established, the tonsil resisting function would certainly be proved useless. Brieger however has carried out some similar investigations which do not at all correspond with these. In certain

spots a small amount of coloring matter was found in the propria, but no collections. It is further true that even granted bacteria do penetrate, it is rare in proportion to the innumerable exposures. It is further open to serious doubt whether any such experiments correspond to the actual condition in life. This protection admitted, and it seems reasonable to recognize that it does exist, where in the tonsil does it reside? Most clearly it is in some way associated with the constant, unceasing outward flow of the lymphocytes. The statement that it ceases in certain diseases, as in leucemia, is not correct. It is lacking in spots but elsewhere it is found undisturbed. It even goes on in pathological conditions of the tonsil itself as in tuberculosis. Brieger has further shown that the lymphocytes in themselves are not bactericidal. This must mean that the property resides in the medium in which they reach the surface. This is not capable of demonstration because the fluid cannot be recovered. We can however reason by analogy from the antiseptic quality of the fluid sneezed from the nose. It is possible, too, that in the rapid disappearance of the leucocytes on reaching the surface, this quality is evolved. It is at once apparent that wherever the quality resides, the call for greater activity which is being continually sent out in childhood, means increased size of the organ producing it; namely, the tonsil itself and we arrive thus at a reasonable explanation of the hyperplasia. Nor must the seeming relation to the recent view of the nature of inflammation be omitted, viz., that the piling up of numerous small round cells is really a natural method of erecting a wall against the invasion of the bacteria. If there is truth in this, we can easily see that the two theories as to the origin of hyperplasia are not so far apart.

As regards this and as to many other points in connection with this interesting subject, much work still remains to be done. It is not claimed that the views just set forth will explain every possible query. For instance; why in a family of several children one should have adenoid vegetations and the other be entirely free. It may be that in this case as in that of different families, the resisting power to excessive lymphatic development (lymphatismus) is less strong through certain embryonic influences in the child affected, than in the others. Just as in such a family, one will be weakly while the others are all strong.

Two facts however are beyond dispute. First, the peculiar susceptibility in childhood to infectious diseases. Second, the mode of invasion is by the upper respiratory tract.

Conclusions.—As corollary to these we venture to add as a result of this study, the following conclusions First, the pharyngeal tonsil possesses a distinct function or functions. Second, this function is of the nature of a defense against the entrance of bacteria and consists in a certain irrigation of the tonsil surface by a lymph stream loaded with lymphocytes. Third, this protection function carries with it the inherent qualities of the tonsil to enlarge on the slightest irritation for the affording of further power of defense. Fourth, this inherent tendency of the tonsil to enlarge, is further seen in the frequent recurrence of the tonsil after removal. Fifth, strictly speaking then, in the great majority of cases such enlargements are not a pathological but a physiological process.

Paper.

SOME FURTHER INVESTIGATIONS OF THE CHEMIC PATHOLOGY OF THE SALIVA.

BY D. BRADEN KYLE, M.D.

LAST year in my papers on the subject of nasal and salivary secretions I treated the chemic aspects rather from a practical application in the diagnosis and treatment of disease, purposely omitting the more intricate features of organic chemistry. It seems to me not unwise at this time to deal more fully with some of the chemic phenomena through which we may account for the production of certain pathologic compounds.

Altered systemic conditions which affect the excretory or secretory glands, causing altered products, can be demonstrated in the saliva, or, in other words, altered chemistry of the secretion can be traced to faulty digestion, faulty elimination from the kidneys or liver, or intestinal tract, when there are thrown into the system, materials which at once alter the chemistry of the saliva. As the saliva is taken back into the system, we have produced

certain reactions. This is unquestionably true as the salivary glands derive their constituents from the blood.

By analysis of what may be considered normal saliva we find that the sulfocyanids and the ammonium salts are in about equal proportion. In hyperacid conditions the sulfocyanids are in greater proportion than the ammonium salts, and the secretion is less irritating; while in the hypoacid state the ammonium salts are in excess of the sulfocyanids and the secretion is decidedly irritating. In many cases in which I have been able to examine the secretion, especially of hay fever patients this hypoacid condition has existed. This is not true in all cases, and I believe different irritants may be the cause in different individuals and it is for the physician to study and determine the irritant present or produced by the chemic alteration of the secretion.

It is a clinical and chemic fact that when there is an excess of nitrogenous material the ammonium salts are always in excess.

Ammonium is a hypothetical alkaline base, having the composition of NH_4; it does occur in a free state, however, in the form of ammonia gas, NH_3, the inhalation of which is very irritating to the mucous membrane and causes suffocation and edema of the glottis. As the ammonium salts usually exist in combination with other materials, is it not likely in certain conditions in which the secretions are hypoacid, that, when the secretion comes to the surface of the mucous membrane, owing to its chemic combination with oxygen there is liberated NH_3, the irritating ammonia gas? surely the symptoms in many cases justify this conclusion. Illustrating this condition, I wish to report the following case: Dr. B., who had been suffering from an irritating, rasping cough since September, 1902, was referred to me in January for an examination of his throat. The symptoms presented were principally the cough, with hyperemic and irritated mucous membranes, though the congestion and swelling were not in proportion to the severity of the cough. The cough was persistently spasmodic, resembling almost paroxysms of whooping cough, except more often repeated. There was decided hoarseness and congestion of the vocal cords. The chest examination was negative, with the exception of slight bronchial rales. Here and there on the mucous membrane were small hemorrhagic spots which I believe had been produced by the violent irritation caused by the spasmodic cough.

In so many cases in which the objective symptoms were in

excess of that which the local lesion would justify I have found that the irritation was brought about by some altered chemistry of the secretion and that the local lesion was merely a manifestation and result of this alteration. Thus, on examinination of his saliva it was found to be hypoacid, the ammonium salts being in excess, and when the secretion came to the surface there was liberated free ammonia gas which was in sufficient quantity to produce the irritation. On this basis the treatment was administered, all the organs of elimination were stimulated, and the chemistry of the secretion changed to acid or neutral reaction, following which change, the irritation rapidly subsided and in ten days all inflammation had disappeared with the exception of some slight localized areas, which probably had been brought about by the persistent coughing, and these areas rapidly yielded to local treatment.

Another class of cases which further illustrates this point is hay fever, to which I have previously alluded. The numerous theories as to the etiologic factor in this disease prove conclusively that as yet there has not been established a definite cause. It may be that different conditions act as etiologic factors; in fact, it is my belief that not all cases which we call hay fever, or hyperesthetic rhinitis, are due to any one cause; if to any one factor, that factor must be in the altered chemistry of the secretions of the individual. In fact, I am persuaded, after making a series of examinations of the saliva in certain individuals afflicted with hay fever and those not afflicted with the disease, that in some cases the causes, direct or indirect, of local irritation in the nasal mucous membrane are brought about by some chemic change in the constituents of the secretions of the mucus-secreting glands. Sensitive areas within the nasal cavities, or irregularities in formation of the cavities themselves, are factors in some cases, yet such areas or irregularities instead of being etiologic, are merely auxiliary factors which render the individual more susceptible to the irritant from within

It is a well-known fact that in many cases of hay fever the irritation is not limited to the nasal mucous membrane; the conjunctival, buccal, pharyngeal and laryngeal mucosa and even the mucous membrane of the stomach and bladder may be markedly irritated, which could scarcely be explained on the basis of a reflex neurosis. In such cases the mucous membrane suddenly becomes

engorged, and is exceedingly sensitive, with profuse watery, irritating discharge. This comes on suddenly, often without any apparent external irritant, and at times looks very much as though there was an effort on the part of the mucous membrane to rid the system of material which had just reached a certain point of accumulation. Or, the human body is nothing more than a chemic laboratory, performing its daily function and manufacturing and liberating certain normal chemic ingredients and constituents, and under certain conditions the chemistry of these secretions is altered, and the manufactured product, instead of performing a physiologic function, serves as an etiological factor in producing a pathologic process. This may be in the form of a secretion or in the form of an infiltration or deposit. We have such a condition exemplified in uric acid diathesis, but I believe in many cases in which we attribute the symptoms present to uric acid, that we have instead of uric acid some other organic compound formed due to perverted chemistry, which product is deposited on or within the tissue.

As to the effect of pollen in certain cases, it is not impossible that, owing to some peculiar constituent of the secretion of the mucous gland, there are deposited in or on the nasal mucous membrane certain materials which, when brought in contact with certain extraneous materials, as pollen, through some chemic action produce a material which brings about the irritation and causes an attack of what is known as hay fever; or else that the extraneous materials merely act as a stimulant to the mucous glands, and cause a flow of mucus, which, owing to its altered chemistry acts as an irritant. This is exemplified in the cases in which the ammonium salts bring on an attack identical with that produced by the rag-weed pollen. That the chemistry of the secretions has to do with the causal factor in some cases I have illustrated by rapidly changing the reaction of the secretion either from acid to alkaline of from alkaline to acid, or rendering it neutral, and in many instances I have been able either partially or wholly to cure the attack.

It has been clinically observed that very few children suffer from hay fever. Is it because the sensitive areas within the nasal cavities are not fully developed, or is it because in children we have rapid elimination, open lymphatic system and rapid metabolic change, which enable the system to get rid of irritating material and with less chemic change in the secretions? Another in-

teresting clinical observation is that hay fever never manifests itself in an individual who is suffering from atrophic rhinitis, and in this condition the atrophic process not only involves the sensitive areas, but also the mucus-secreting glands.

Certain individuals will have at any time in the year an attack which is quite similar to hay fever. The individual may be sitting comfortably at home, subject to no draughts or exposure whatever, when he is suddenly seized with congestion of the nostril, followed rapidly by the thin watery discharge of a decidedly irritating nature, free lacrimation, with burning and itching in the nasal cavities, eyes and naso-pharynx. Frequently associated with this is a slightly asthmatic tendency. It cannot be cold; it is something in the nasal secretion, and when the secretion comes to the surface and in contact with the air, there is liberated some material (chemic) which acts as an irritant to the vaso-motor system (peripheral terminal nerve filaments), and causes sudden congestion. Such attacks are quite like inhaling ammonia fumes and in such cases there is present an excess of ammonium salts in the saliva. Owing to some chemic change in the secretions of the individual there is accumulated within the system a material which in the point of accumulation reaches that period in which it overflows, and the secreting glands liberate on the surface this material, which when exposed to the air undergoes a chemic change. In many instances on examination of the saliva and nasal secretions there has been found an excess of the sulfocyanids and the ammonium salts. When this secretion is exposed to the air there is liberated free ammonia, which I believe to be in many cases the cause of the attack. The symptoms are identical with those of the inhalation of ammonia fumes.

As to the sulfocyanids which are present in the saliva, it is a chemic and therapeutic fact that most of the cyanids are actively poisonous. A cyanid is formed or is a compound of cyanogen with a metal or radical. A sulfocyanid is a salt in which the sulfur takes the place of the oxygen in the acid radical. Cyanogen is a radical molecule having the structure CN, an acid compound of carbon and nitrogen. A radical is a group of atoms having an unsatisfied valency, an unsatisfied molecule which goes into or out of combination without change to itself and which determines the character of compounds. A sulfocyanid is a combination then denoting the chemic combination of sulfur with a radical. When a sulfocyanid is eliminated the secretion in which the

ammonium salts are in excess is alkaline, but when it comes in contact with the air, owing to the chemic change which takes place, it becomes acid in reaction. Hence in many instances in which from our test we believe the secretion to be acid, it is really hypoacid (alkaline). This is most important and in many instances in which from the test reaction we are led to conclude the reaction to be acid, it is in reality in the system alkaline and only becomes acid when, owing to chemic action due to exposure to the air, certain materials are eliminated and the reaction changed. In some of the sulfocyanid combinations in which we get the bad odor, as illustrated in the case I reported in my previous paper, the chemic change causing such odor is as follows: Sulfur itself is an acid element which unites with oxygen to form an acid radical, but in a sulfosalt the sulfur takes the place of the oxygen in the acid radical. The sulfocyanid itself would be a sulfosalt in which in combination the sulfur would take the place of the oxygen and give off sulfuretted hydrogen. In a sulfosalt the sulfur takes the place of the oxygen in combination to form an acid. A sulfocyanid is a sulfosalt and when the sulfocyanid is in excess and is liberated, coming in contact with the secretion which contains H_2O, the sulfur would unite with the hydrogen giving off free oxygen and forming hydrogen sulfid. A radical is a group of atoms having an unsatisfied valency and is really unsatisfied molecules which go into or out of combination. It is possible then to have almost any chemic combination take place.

While I do not mean to say that in every case the gland secretion has to do with the irritation of the mucous membrane, yet I do believe that the chemic change of the secretion in many cases is an etiologic factor from the local irritation and that it must be considered from three standpoints: (1) individuals in whom the secretion from some altered chemistry is precipitated on the surface of the mucous membrane as an irritant; (2) individuals in whom the secretion comes to the surface as a nonirritant; when it comes in contact with the air, owing to chemic changes which take place, there are produced or liberated irritant materials, and (3) individuals in whom the secretion comes to the surface as a nonirritating material, but when it comes in contact with extraneous material on the surface there is produced an irritating material. I think in many cases in which the reaction of the secretion is apparently acid and in which there really is present an alkaline

condition, we have explained many of the cases in which from an acid basis our treatment has failed. That such a condition may exist has been shown by Douin and Gautrelet, who found in their studies of the blood, that the reaction of the plasma is really acid, and if waste products are not eliminated this acidity is increased. The secretions and excretions then also become of an acid reaction.

The irritating gases which form in the stomach and intestines and produce laryngeal and pharyngeal irritation are the result of chemic change in the intestinal secretion and such chemic change in the secretion can be demonstrated by a study of the saliva. That autoinfections and chemic changes in intestinal secretions have marked general effect on the individual is well known. Such material absorbed into the system will unquestionably alter the chemistry of all the secreting glands, and the compounds formed by such alteration which affect the individual can only be determined by the study of organic chemistry. The asthmatic conditions which are not associated with any organic lesion can all be explained I believe, on this basis, and when treated accordingly can in many instances be relieved.

In examining the secretion and excretion of the body we can obtain a better index of the systemic condition of the individual by a study of the saliva than by a study of the urine, since in the urine we have only an index of the waste material, while in the saliva we have products of elimination which go back into the body to perform a physiologic process. Another important factor to be worked out are the different chemic changes which take place in individuals suffering with the so-called functional diseases and those suffering from organic or structural changes. In the functional we have a perverted chemistry which may be brought about by many causes, such as faulty elimination from the kidneys or liver, any perversion of secretion from the intestinal tract, autoinfection from the intestinal tract; also chemic changes of the secretion illustrated in mental tension, from fright, worry and anger; while in the organic lesions we have to deal with a structural change in tissues with retrograde metabolic changes in which there are also associated inflammatory processes with their accompanying phenomena and physiologic and pathologic effect on the individual.

Discussion.

Dr. EMIL MAYER said that it might be possible that these investigations of the chemic pathology of the saliva would help us to answer the question of susceptibility or idiosyncrasy of the individuals who are subject to hay fever. In this connection he would say that this is one of the undecided questions—namely, why one individual of a family should be the only one subject to hay fever.

He called attention to the recent work of Prof. Dunbar. The latter had definitely shown that the pollen of certain grasses would produce attacks of hay fever in certain individuals, while in non-susceptible persons no attack whatever followed its application. Having determined this and procured a toxin, he then injected these toxins into animals, thus securing an antitoxin. The experiments thus far made would seem to indicate that toxins applied to mucous membranes in susceptible individuals produce a distinct attack of inflammatory disturbance; that if the toxins are mixed with antitoxins no reaction follows, and that finally when the effect of the toxins becomes insupportable, the patient is promptly relieved by the use of the antitoxin. The speaker was about to make some investigations into this subject and expected at some future time to present his results.

Dr. H. L. SWAIN wished to compliment Dr. Kyle on his excellent paper. If there had been any one thing which contributed very largely to bring the comprehension of diseases of the stomach out of the mist of the Middle Ages, it had been the fact that specialists started to wash out stomachs and to chemically examine their contents. He welcomed the sort of work Dr. Kyle had presented as possibly the dawn of a new era. He hoped the investigations might be continued until a flood of light should be shed on the subject.

Dr. W. K. SIMPSON would like Dr. Kyle to give some reason why hay fever is so much better with change of climate and weather. Could this improvement be explained by chemic changes in the saliva?

Dr. KYLE replied that it was a well-known fact that chemic changes and climatic conditions affect the secretions. This was especially evident in localities where the climatic changes are many and sudden.

Paper.

CICATRICIAL DEFORMITIES IN THE RESPIRATORY TRACT DUE TO CAUSES OTHER THAN SYPHILIS AND TRAUMATISM.

BY G. HUDSON-MAKUEN, M.D.

CICATRICIAL deformities in the respiratory tract are by no means uncommon if we include those arising from syphilis and traumatism. Indeed so often do we find these deformities following syphilitic ulceration that we have come to regard nearly all of them as sequelæ of this disease. Traumatism is also a common factor in their causation, especially in the nostrils, larynx and trachea. One case has been reported to me also of considerable deformity of the fauces and pharynx due to the use of the electro-cautery snare.

By traumatism of course we mean any injury done to the mucous membrane and underlying structures by external violence. This would include operations by means of cutting or sawing instruments, the electric or chemic cautery, the cold or electro-cautery wire, intubation and tracheotomy tubes. Congenital deformities also occur but they can scarcely be regarded as cicatricial in their nature.

The comparative rarity of cicatricial deformities due to causes other than syphilis and traumatism and suggested by a case in point, which I shall presently describe, has led me to make some investigations as to their frequency, the result of which will be herewith embodied.

The case above referred to is that of Miss M. M., aged twenty-eight years, who first consulted me in October, 1901. She complained of sore throat, cough and choking sensations. At five years of age she had diphtheria followed by a severe attack of scarlet fever. The only apparent sequela of these diseases was a unilateral otitis media purulata which, however, speedily healed, and gave no further trouble, until five years ago when she had an attack of la grippe. This was attended by an acute abscess in the

same ear, and there has been an intermittent discharge ever since. There is a large perforation of the posterior quadrant of the membrana tympani. The patient has been but little annoyed by the ear disease, and she has been able to keep it in check by the use of an antiseptic lotion applied with a match stick armed with cotton.

The pharyngeal condition, however, following scarlet fever and diphtheria, although overlooked at the beginning, has gradually come to be a source of much discomfort. There is always a sensation of dryness with occasional spells of coughing and choking, and every few days there is an acute sore throat.

The pharynx becomes very dry especially at night, and she has a cough with slight expectoration in the morning.

Upon examination of the pharynx we find the marks of extensive ulceration. A careful inquiry has failed to elicit any history of syphilitic infection, either inherited or acquired, and inasmuch as the attack of diphtheria and scarlet fever was a severe one attended by unusually pronounced pharyngeal symptoms, we must conclude that the condition is the result of this infection.

The posterior oro-pharyngeal wall shows a considerable loss of tissue, with web-shaped cicatricial contractions, and adhesions between it and the posterior pillars of the palate. The cicatrix extends downward nearly to the entrance to the esophagus. Although the movements of the soft palate are not so limited as we often find them, and the opening leading into the naso-pharynx not so small, yet they are sufficiently so to cause considerable annoyance. I am now undertaking to divide the adhesions between the posterior pillars of the palate and the pharyngeal wall by a method that is not altogether new in its application to this region and it has also been employed in operations for the relief of cicatricial contractions in the nostrils. It consists in passing a thread through the pillar at its outermost point of contact with the pharyngeal wall and leaving it there until the borders of the wound have healed. It is similar to the operation for piercing the lobes of the ears for rings. When the borders have healed the thread will be removed, and the adhesion divided with a bistoury throughout its entire length. By this method it is hoped that further contractions and the adhesions which usually follow operations for this condition may be avoided.

I suppose I have seen my share of cicatricial deformities in

various parts of the respiratory tract, but my only other marked case of pharyngeal deformity, and all the cases I have seen in other regions, were due to either syphilis or traumatism, and in my desire to have the experience of others in this matter I issued about three hundred letters to as many laryngologists in the United States and Canada asking for case records. The letters read as follows: "Dear Doctor: Will you kindly tell me how many cases you have seen of acquired cicatricial deformities in the respiratory tract, due to causes other than syphilis and traumatism, and exclusive also of tonsillar adhesions. Please give number in, 1st, the nostrils; 2d, the pharynx; 3d, the larynx, and 4th, the trachea."

The reports were interesting and instructive, some of them giving details of special cases, and operative measures for their relief, but owing to the nature of the case the answers to my questions were only approximately correct, because some of the men gave the number under each heading from memory only. This is as I anticipated, because the rarity of the condition makes it unlikely that all cases would be classified under that heading, and the difficulties of going over, in some instances, thousands of records would be almost insurmountable. On the other hand the very rarity of the condition has doubtless served to impress upon the memory of observers the cases that have been seen, and, therefore, the reports may be regarded as being at least approximately accurate.

NOSTRILS.

In the nostrils diphtheria claims 27 cases, scarlatina 14, membranous rhinitis 10, catarrhal erosion 9, tuberculosis 3, smallpox 3, scleroma, septal abscess, measles, and typhoid fever 2 each, lupus, erysipelas and pemphigus 1 each, and no cause could be determined in 271 cases.

PHARYNX.

In the pharynx diphtheria claims 41 cases, scarlatina 21, diphtheria and scarlatina combined 6, lupus 10, tuberculosis 3, and no cause was discovered in 6 cases.

LARYNX.

In the larynx typhoid fever claims 4 cases, diphtheria 3, lupus 2, scarlatina, measles and tuberculosis each 1, and no cause was discovered in 2 cases.

TRACHEA.

In the trachea influenza was the cause of 1 case.

In the nostrils there were 347 cases, pharynx 87, larynx 14, and trachea 1. Total 449.

Thus we find that 300 observers have seen 449 cases of cicatricial deformities in the respiratory tract that appear not to be due to syphilis or traumatism, and that 16 per cent. of these were caused by diphtheria, 8 per cent. by scarlatina, 3 per cent. by lupus, 1.6 per cent. by tuberculosis, 1.5 per cent. by scarlet fever and diphtheria combined, 1.1 per cent. by typhoid fever and 0.5 per cent. by measles. Other causes given in the nostrils are membranous rhinitis, catarrhal erosion, smallpox, scleroma, septal abscess, erysipelas and pemphigus.

This report would seem to emphasize the importance of giving more careful attention to the nose and throat in the treatment of the above-mentioned diseases.

Discussion.

Dr. J. W. FARLOW had received one of Dr. Makuen's circulars, but was at a loss to know how to reply to it. In thinking over the cases he had seen, he had always, in the absence of definite information, regarded the deformity as of specific origin. He had seen several cases of pharyngeal deformity referred to diphtheria in which there was an adhesion between the posterior pillar of the fauces and the wall of the pharynx. In these cases there had often been a history of a very mild diphtheria, but in his own personal experience adhesions had never resulted from diphtheria, so that the question would arise, were such cases really the result of this disease.

In replying to Dr. Makuen's circular he would be obliged to say that, in his experience, all deformities were referable either to a cause not known, or to specific disease.

He had seen one case of medico-legal importance in which adhesions were said to have been the result of trauma, the patient denying syphilitic infection. There was no definite history of

trauma, and he himself gave the opinion that the deformity was of specific origin. Others had expressed different opinions in the case, hence the replies to Dr. Makuen's circular raised a doubt as to the reliability of his statistics, though the writers, of course, were honest in the expression of their opinion.

Dr. EMIL MAYER called attention to the fact that Dr. Makuen had limited his statistics to replies of American laryngologists. It was a remarkable fact that very few cases of post-typhoid laryngeal stenosis had been reported by American observers, and a still more remarkable fact that in a very extensive literature on the subject of stenosis after typhoid, in Landgraf's article in Heymann's Handbook, no attention whatever to some very excellent work done by our American associates seems to have been given.

Dr. FARLOW believed that the statements of patients were often unreliable on this point, as while they may have been honestly made, the patients may be suffering from syphilis transmitted through the second or third generation.

Dr. W. K. SIMPSON said that as concerning the pharynx and the larynx, the only cases of permanent cicatricial deformity he had ever seen were due either to syphilis or trauma. As to the diagnosis of diphtheria causing this condition, one must see the case at the time of the diphtheria in order to determine its causative effect. He had never himself seen post-diphtheritic cicatrization; all the cases he had examined, some of which were called diphtheritic, had, in his judgment, been specific, and unless the diphtheria was very malignant he did not see how it could cause any marked cicatrization.

Dr. C. F. THEISEN had seen one case of post-typhoid laryngeal stenosis calling for low tracheotomy. Patient was a man of 40 years and dyspnea was present during and after the febrile course. Later there was a partial loss of the arytenoid cartilage and an entire loss of the cricoid. The larynx was filled with a mass of cicatricial tissue. He was unable to pass an intubation tube or a probe through the laryngeal chink, even though the probe was inserted through the tracheal wound.

In a second case of laryngeal stenosis following influenza, an immediate tracheotomy had been necessary. Later six to eight ounces of putrid pus were evacuated from the trachea and there was at that time a cicatricial deformity in the trachea. Patient died subsequently of a pneumonia.

Dr. J. PRICE-BROWN had seen one case of laryngeal stricture due to tuberculosis. Tracheotomy had been done in this case six months ago. The epiglottis was infiltrated unilaterally, so that the left side was considerably the larger. The infiltrated mass had been gradually absorbed after the tracheotomy, so that the epiglottis had been shortened and drawn downward and backward. As a result of this, the larynx could not be seen. The patient was still wearing his tracheal tube but was much improved in health.

Dr. MAKUEN in closing the discussion stated that he was well aware of the difficulties of collecting statistics in this line and realized how difficult it was to be absolutely certain of the diagnosis, nevertheless the fact that three hundred different men had reported four hundred and forty-nine cases of cicatricial deformities in which no history of syphilis or traumatism could be obtained, gave to his statistics, he believed, considerable value. Prof. Jacob Bartolf of Basle had reported sixty-nine cases of cicatricial deformity in the lower portion of the pharynx and in only three of them could syphilis be excluded.

Paper.

COMPLETE REMOVAL OF THE LEFT VOCAL CORD FOR MALIGNANT DISEASE: PRESENTATION OF THE PATIENT.

BY WALTER F. CHAPPELL, M.D.

A FAVORABLE experience in the treatment of malignant disease of the larynx should undoubtedly be reported, as too often the results of treatment in these cases are discouraging, and lead many to believe that an early diagnosis, and the best of efforts are of no avail.

I will not repeat the statistics of results in the operative treatment of malignant disease of the larynx, but any one interested in this subject will find them brought up to date, and fully and explicitly discussed by Dr. Frank Hartley, in the *New York Medical Journal* for December 13 and 20, 1902.

Some two years ago one of my patients presented himself at my office, complaining of hoarseness which on examination I found was caused by a general laryngitis, and a minute laryngeal tumor. From the first I feared the growth was malignant, but it was very small and resembled a large granulation seen in chronic laryngitis. I did not have the courage of my convictions so far as to recommend an immediate operation, but decided to take a middle course and carefully watch the larynx and the growth, and to select such treatment as the symptoms and appearance indicated. Full history of the case is as follows:

William T., age 56. Family history negative regarding tumors

or growths. One brother died of pulmonary trouble, presumably tubercular. Two brothers and one sister alive and in good health.

Past History.—Has had no serious illness, but for many years suffered more or less from colds and catarrh of the upper air tract, which he thought was due to excessive smoking, having at one time averaged fifteen large cigars a day. For years during the cold weather he was hoarse and his voice became weak and husky at times.

During the winter of 1900, he was quite hoarse for a couple of weeks, and while speaking would suddenly lose control of his voice and emit a high squeaking sound. To prevent this he was obliged to lower his voice and speak in a whisper. He always recovered from his hoarseness and voice attacks as soon as warm weather returned.

Early in January, 1901, Mr. T. contracted an unusually severe cold, which took the form of a rhinitis and laryngitis. The nasal symptoms and other evidences of cold continued for about three weeks, but the hoarseness remained. He did not consult a physician for this attack, or for the remaining hoarseness, as he considered it one of his usual winter colds. He came under my observation on the first of April, 1901, as his family were anxious about his voice, which was becoming more hoarse although the weather was warm.

On examination the following conditions were found:

Laryngoscopic Examination.—The mucous membrane of the pharynx and larynx was generally red and thickened; this was especially marked over the ventricular bands and vocal cords, in fact it was hard to define a dividing line between them. The arytenoid bodies were slightly enlarged and did not move with readiness. The epiglottis was the largest I have seen, also thick and stiff, and had to be thoroughly cocainized and held forward by a specially designed retractor before the interior of larynx could be seen. A small red growth was then visible anteriorly on the left cord, extending to its attachment and on to its under surface into the anterior commissure. For some time it was uncertain whether the growth was attached to the tracheal wall or not, but eventually it was decided that it did not include the trachea. The body of the growth did not exceed in size a small French pea, but its base was considerably thickened and gradually joined the surrounding tissues. Daily applications of adrenalin solution, followed by weak

astringents, were made to the interior of the larynx for a month. The mucous membrane improved in appearance and as there was no apparent change in the growth the tentative treatment was continued through May. In last few days of May it was noticed that the growth was increasing in size, but still remained a deep red color with no ulceration. The patient was told that the condition of his throat was a serious one, and that the growth was probably malignant in character.

During the month of June the case was seen by Drs. Knight, Rice and Delavan of New York, who all expressed their belief that the laryngeal growth was an epithelioma. Up to this time no effort had been made to remove any pieces of the growth, as it was feared that by so doing the infection would be extended. During the month of July there was no appreciable increase in size of the tumor, and Mr. T. was very comfortable, but during August there was again some evidence of growth, and by September it had attained the size of a marrowfat pea. In appearance it was still very vascular, but had several whitish-looking spots on its surface, but no ulceration. Early in September the breathing was somewhat obstructed, especially at night and on exertion. Considerable coughing and mucus secretion appeared about this time. Two small pieces of the growth were removed by a snare on September 18th. This was done under great difficulties on account of the position and shape of the epiglottis, which eventually had to be held forward by a piece of silk, which was passed through it by a specially constructed needle. The following reports were received from the gentlemen who examined the pieces removed from the larynx:

Mr. L. B. Goldhorn of the Carnegie Laboratory reported the growth as an epithelial carcinoma showing an active growth.

H. T. Brooks reported squamous-celled carcinoma, so called epithelioma. The stained preparations were further submitted to other competent observers who concurred in these opinions.

In view of these reports and the renewed activity of the growth it was felt that a crisis in the case had been reached, and that on our decision the entire future of the patient would depend.

Early in October Dr. William T. Bull of New York City saw Mr. T., and concurred in the opinions already obtained as to the nature of the growth and the necessity for an immediate restricted radical operation.

A preliminary tracheotomy was done on October 10th under cocaine anesthesia. Nothing special occurred after this operation, the temperature not ranging above 100, and in a few days Mr. T.

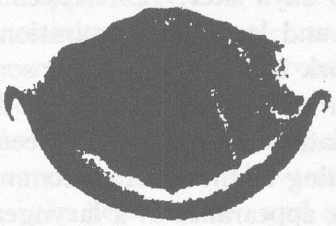

was up and about the house as usual. On October 22nd, 1901, the operation of thyrotomy was done by Dr. William T. Bull. The water color I pass is a good representation of the laryngeal growth as it appeared three days before the operation.

NOTES OF OPERATION.

Heart, lungs and kidneys normal. Head and shoulders in the Rose position. Ether followed by chloroform anesthesia. After the cutaneous incision and the necessary dissection was made to expose the cricoid and thyroid cartilages, the crico-thyroid membrane was divided in the median line.

The scissors were then used from below upward to split the thyroid cartilage and expose the interior of the larynx, showing the growth in position as seen through the laryngeal mirror.

The growth with the anterior half of the left vocal cord was removed. A section frozen and examined showed squamous epithelioma extending into the cord and the thyro-arytenoid muscle. The rest of the cord and the thyro-arytenoid muscle and all the immediate surrounding tissues were removed down to the internal surface of the left wing of the thyroid cartilage, the surface of which was scraped and brushed with a solution of iodoform and tincture benzoin co. Very little bleeding occurred and the interior of the larynx was packed with iodoform gauze, and the margins of the thyroid cartilage brought together. A small opening was left in the lower part of the wound, through which the iodoform gauze protruded. A mild bronchitis accompanied by a great deal of coughing followed the operation, but otherwise the patient made an excellent recovery. The usual care was taken in giving nourishment and sixteen ounces of broth were taken the

first twenty-four hours and the quantity daily increased. On November the 8th, the last of the packing was removed from the larynx but small pieces had previously been pulled out at intervals. The external wound closed two days later. On November 14th, the tracheal tube was removed and laryngeal respiration effected without difficulty. A rubber cork had been worn for some hours each day for the previous week. On examination with the laryngeal mirror considerable granulation tissue could be seen beneath the left ventricular band and filling in the anterior commissure of the larynx. This tissue had the appearance of a laryngeal tumor, but it gradually subsided, leaving a mass of thickened tissue, which is still apparent.

The following report of the growth was received on October 30th, 1901, from Dr. S. C. Wood and confirmed by Dr. Prudden:

"I enclose a slide from the tumor removed from the larynx of Mr. T. As you will see the growth is an early epithelioma. The tumor growth is still superficial and has not extended deeply into the submucous connective tissue. The second fragment on the slide is sectioned from the portion of the thyro-arytenoid muscle removed by Dr. Bull during the second step of the operation and shows the thickening of the epithelial layers, and in one part near the edge of the incision the submucous connective tissue in this fragment is slightly infiltrated with small round cells, but not with cells from the epithelioma. It is evident that the line of incision for removal of the tumor has been wide of the growth."

Immediately after the tracheal tube was removed Mr. T.'s appetite improved, and his weight was 139½ lbs., (stripped). He soon began an increase in weight which eventually reached 173 lbs. in comparison with 154 lbs.,—his maximum former weight. This great increase was possibly due in part to his having ceased smoking. In a few weeks Mr. T. resumed his usual duties and business, and has been perfectly well ever since,—in fact he has never been better. The voice was weak, coarse and whispering for some months, but it has gradually improved, and its present condition answers all the usual purposes of his life. He says that many of his friends think it an effort for him to speak, but it really is not, and he never has any discomfort.

A careful examination of the upper air tract has been made once a month since the operation, and beyond the changes which took

place during the two or three months, subsequent to the operation, the tissues of the larynx have remained in their present condition.

The nasal and pharyngeal mucous membrane is now paler and healthier in appearance than when he was smoking. The laryngeal mucous membrane is also paler and less thickened than formerly. The left ventricular band is broader in every way and seems to overlap the right one during phonation, and it doubtless takes the place of the left cord in producing vocal sounds.

About seventeen months have now elapsed with no recurrence.

Mr. T. is in better health and stronger than he has ever been, and I think we can reasonably hope that his improved physical state, and the absence of any hereditary taint, and the cessation of smoking will minimize the chances of a return of the growth. It is not often that a malignant disease is discovered early, but when it is all the evidence is now in favor of an immediate operation. If there is any doubt in the diagnosis of a growing laryngeal tumor, an exploratory thyrotomy should certainly be done. A general improvement in the statistics of all serious operations on the pharynx, larynx and trachea may be expected from an improved technique in local anesthesia.

Discussion.

Dr. R. C. MYLES recalled a case that he saw two years since of a gentleman beyond middle life who presented a fungating mass on the larynx occupying the position of the processus vocalis. After removal with forceps it was diagnosticated as epithelioma by a very able microscopist. Nothing had been done since and the man has been perfectly well. We cannot always be certain of the correctness of microscopical diagnosis.

Dr. H. L. SWAIN had had an experience confirming the last observation of Dr. Myles. He had seen one case looking like a papilloma on an inflamed base and the microscopical examination gave specimens which were gravely suspicious. It recurred and was removed two months later. Microscopic examination was more favorable. It recurred and was removed a third time and now for the last two years the patient had been free from any return. The last specimen seemed quite benign. If the reverse changes had occurred, namely from favorable to unfavorable microscopical reports, the case would have been regarded as an instance of the change of a benign to a malignant growth.

Dr. D. BRYSON DELAVAN had examined Dr. Chappell's patient, operated upon by Dr. William T. Bull, before operation and said

that the clinical appearances of the laryngeal growth were typical of epithelioma, which diagnosis had been amply supported by the history of the case. The report of the microscopist has placed the matter beyond question The speaker referred to a similar case of his own, now alive and well seven years after operation and a favorable candidate for life insurance. The vital point in these cases was early diagnosis and prompt removal.

Candidate's Thesis.

HYPERTROPHIC TUBERCULOSIS OF THE LARYNX.

BY CLEMENT F. THEISEN, M.D., ALBANY, N. Y.

The classical picture of laryngeal tuberculosis makes the recognition of this condition, as a rule, quite easy. The history of the case, the fact that there is in almost every case a pulmonary involvement, the finding of tubercle bacilli in the sputum or in scrapings from the larynx, the well-marked constitutional symptoms, and the steady advance of the pulmonary symptoms, are factors which always clear up the diagnosis. Add to this the typical changes in the larynx, the infiltration, aphonia, and characteristic ulceration, and we have a symptom complex which is practically peculiar to laryngeal tuberculosis only. The character of the *ulceration,* particularly, is the symptom of the clinical presentation, which is peculiar to the type of tuberculosis of the larynx usually observed. Hypertrophic, or, as it may perhaps properly be called, hyperplastic tuberculosis of the larynx, which will be the only form of the disease considered in this paper, presents an altogether different clinical picture. The following case, observed by the writer, is a good illustration of this very unusual type of laryngeal tuberculosis. This case is of particular interest because of the great diversity of opinion in regard to the patient's condition. He was seen by a number of laryngologists in different parts of the country, and different diagnoses were made.

Mr. M. I., aged 40 years, native of Germany, merchant, married and having two children, consulted the writer February 19, 1901, for hoarseness that had existed for a year. His family history was negative, there having been no cases of tuberculosis so far as he

knew. He had always been subject to colds. Syphilis was denied. His physical condition at this time was excellent, weight about 175 pounds, and he had only lost about five pounds during the past six months. He was very hoarse, the voice being decidedly weak, in fact the aphonia was nearly complete. His appetite was excellent, and he had no night sweats. He coughed very little at this time, and several careful examinations of the lungs gave absolutely negative results. We did not discover tubercle bacilli in the sputum, but Dr. Roarke, of Troy, who had also examined his throat and made a diagnosis of tuberculosis, told me that a few had been found in a former examination. His nose, naso-pharynx and pharynx, with the exception of a chronic follicular pharyngitis, did not show any particular changes. His larynx, however, presented the following interesting condition: the mucosa was generally somewhat reddened and thickened, with a well-marked thickening in the inter-arytenoid space, which was firm to the touch. Both arytenoids were thickened and infiltrated, this being more marked in the left than in the right. Both cords were thickened, and there was a circumscribed thickening of considerable size on the left cord, near the processus vocalis. There were circumscribed hypertrophied areas on both ventricular bands, with broad bases, not presenting the appearance of new growths, but rather of hyperplasia of the tissues. They were covered with a perfectly intact, smooth mucous membrane, and were of a grayish-red color. This was one of the interesting features of the case. The epiglottis was not involved, nor did the process appear to extend below the cords. There was absolutely *no* ulceration anywhere in the larynx. A diagnosis of laryngeal tuberculosis was made by the writer, in spite of the atypical laryngeal conditon, and the negative examination of the lungs. The patient was told that he had a good chance for recovery in Denver. This favorable prognosis was given, because his lungs at this time did not show *any* evidence of tuberculosis on physical examination. He started for Denver, but on the way consulted a well-known laryngologist, who gave it as his opinion that the case was *not* tuberculous. I believe he was given potassium iodide for some time, with local treatment, but did not improve. I would like to state at this time, that this paper is *not* written in a spirit of criticism. The physician who examined him in the West, did *not* know that tubercle bacilli had been found in the sputum. Nobody, being ignorant of this, could have made a positive diagnosis. Because, however, this case has already been published elsewhere, as one of pachydermia laryngis, and on account of the different diagnoses that have been made, but particularly because the outcome of the case justified the diagnosis of tuberculosis, a thorough and impartial presentation of its clinical history, was considered important. The patient then returned to New York, where he was under the care of a laryngologist, and was seen by a number of others, one or two of whom agreed with

the writer's diagnosis. The physician who treated him in New York reported the case as one of pachydermia laryngis (*N. Y. Med. Monatschrift,* Nov., 1901, p. 528). In this article he states that a laryngeal ulcer was discovered in Albany. This is an erroneous statement, because at no time while the patient was under the observation of either Dr. Roarke or the writer, was there any evidence at all of ulceration. Repeated examinations of the sputum in New York, failed to show the presence of tubercle bacilli. This fact was stated, in a letter to the author, by the patient's physician there, and the statement was also made, "that as there were no signs over the chest, the case, if not pachydermia, could only have been primary tuberculosis of the larynx." The patient grew steadily worse, and was finally sent to Saranac Lake, in June, 1901, where he was under the care of Drs. Trudeau and Baldwin. He died there August 4th, with well-marked laryngeal and pulmonary tuberculosis. In answer to inquiries in regard to the patient's condition at Saranac, letters were received from Drs. Trudeau and Baldwin, from which I will give abstracts. (Dr. Trudeau's letter was in answer to an inquiry whether in his experience, tuberculosis of the larynx often developed after pachydermia.) "I often find," he wrote, "that pachydermia laryngis *co-exists* with tuberculous laryngitis, but I don't think I have ever had much reason to believe, that the warty growths were anything more than a *complication* of the original tuberculous process." Dr. Baldwin sent me the following record of the patient's condition when seen by him June 10, 1901. "Advanced pulmonary and laryngeal tuberculosis, dullness at the right apex, with prolonged expiration, moist rales to the fourth rib." I also quote the following from his letter: "The patient came to me with fully developed pulmonary and laryngeal tuberculosis on June 10, and died August 4th. Your letter indicates that he had more signs on the left side of the larynx; by June however the right arytenoid and cord were more infiltrated, and there was some ulceration of the cords. He died without ulceration of the arytenoids or epiglottis." The writer has been careful *not* to call this even a *probable* case of primary tuberculosis of the larynx, although in other parts of the body this hypertrophic form of the disease, sometimes precedes the lung involvement. In the larynx, however, primary tuberculosis is excessively rare, and I have always been of the opinion that it practically did not occur, because post-mortem findings have demonstrated the fact over and over again, that tuberculous processes in the lungs *had* existed in cases of laryngeal tuberculosis, even though they were not discovered during life in the most careful physical examination. One of the only positive cases of primary laryngeal tuberculosis that I have been able to find in literature, is the case reported by Fraenkel (See Duesberg's article 30). In this case the patient had been treated for five years for laryngeal tuberculosis. At the autopsy neither in the lungs, nor in any other

organ except the larynx, was there any evidence of tuberculosis. This is one of the few cases on record in which the diagnosis was proved post mortem. Cohen has reported three cases that were also probably primary.

A resumé of the clinical history of this case, brings out some interesting points, *i.e.*, a tuberculous condition of the larynx that existed for a year and a half before any ulceration developed; the normal physical examination of the lungs up to the time the patient went to Saranac; the well-marked circumscribed hypertrophies of the ventricular bands; the decided thickened areas on the vocal cords, and the swelling of the arytenoids. This swelling of the arytenoids was of the nature of a thickening of the tissues, and not the edema usually found. Taking all these facts into consideration. I believe a diagnosis of hypertrophic tuberculosis was justified.

Diagnosis.

In considering the diagnosis of this unusual form of laryngeal phthisis, we must first dispose of the differential diagnosis of the writer's case from pachydermia, particularly as it was published as a case of pachydermia. The fact that a thickening of the vocal cords existed near the processus vocalis, a common seat for pachydermic masses, was *not* an argument for pachydermia in this case, because there was not only not the usual depression on the surface of the nodule, which is caused by the pressure of a nodule directly opposite on the other cord, during phonation, (*pachydermische Dellen*), and which is characteristic of pachydermia, but in fact a node on the other cord, opposite the one on the left cord, did *not* exist. We have abundant authority in the literature of the subject, for this characteristic appearance of the pachydermic node. Fraenkel (24), Virchow, Symonds (26), and others, have described it as characteristic. Pathologically, pachydermia can *not* be considered a condition *sui generis*, but merely a result of the chronic laryngitis of alcoholics, inveterate smokers, or a part of the clinical picture of tuberculosis or syphilis. I believe alcohol and tobacco are the most important factors in producing pachydermia. (The writer's patient was a man of excellent habits.) Great stress is laid upon this by Sturmann (25). Really only the diffuse form of pachydermia need be considered in the writer's case. In this form the products of the

hypertrophy of the epithelium very often break down rather easily, forming cracks or superficial ulcers on the surface of the pachydermic nodes. Habermann (27) mentions the frequency with which this ulceration occurs in pachydermia. He found it 21 times in 15 larynges. Moll (23) considers pachydermia simply a form of chronic catarrhal laryngitis. Zwillinger (28) thinks it is akin to leukokeratosis, and claims that the two conditions have the same etiology, and are identical clinically and anatomically. To conclude the differential diagnosis of pachydermia and hypertrophic tuberculosis then, we may *exclude* pachydermia, when the characteristic circumscribed hyperplasia of the ventricular bands, or other parts of the larynx, is present, when we do not get a history of excessive drinking and smoking, when syphilis can be excluded, when the depression on the pachydermic node is absent (this was always present in cases observed by the writer) and when all other factors that would cause a chronic laryngitis can be excluded. In the writer's case, the condition certainly simulated a diffuse pachydermia, but as later developments proved, it was *not* pachydermia but tuberculosis all the time. It is much more difficult to make a diagnosis in a case in which carcinoma develops from, or co-exists with, an apparent condition of pachydermia. Fraenkel (29), in his able article, thoroughly discusses this point, and in conclusion states that carcinoma develops not infrequently from pachydermia. He reports cases to prove this statement.

General, or circumscribed hyperplasia of certain parts of the larynx is characteristic of the form of tuberculosis under discussion, and this hyperplasia of the tissues occurs in other parts of the body as well, as a manifestation of hyperplastic tuberculosis. Lartigau (34) in his article "Hyperplastic Tuberculosis of the Intestine etc." mentions this as the fundamental lesion. One of the most interesting and characteristic features of the intestinal form, are the polypoid and papillomatous formations mentioned by Pilliet -Lartigau (34). These tumor-like formations are not very common in the larynx, and a number of the recorded cases unquestionably belong to this type of laryngeal phthisis. In order to get a thorough idea of the diagnosis of this interesting form of laryngeal tuberculosis, it will be necessary to briefly review the cases in the literature. There are only a few on record with the title "hyperplastic tuberculosis," although I have been able to find a number of others that belong in this classification. If, for example, we

give the term hypertrophic or hyperplastic tuberculosis, its widest meaning, we must include certain forms of tuberculous tumor formations, in which the tumors are covered with intact mucous surfaces (although some ulceration may be present in some other part of the larynx), and in which the tumor developed *before* the ulceration. I do not think that tuberculous granulomata, for example, which develop at the site of an ulcer, and which break down easily, belong in this class. I quite agree with Schech's (31) statement that "tumors should only be called tuberculous, in which earlier ulceration at the site of the tumor can be excluded." The following classification of hypertrophic tuberculosis of the larynx, is suggested by the writer as a convenient one. No arbitrary classification can be made. It is of course understood that no case will be included in which a positive diagnosis was not made. The following cases, although not entirely complete, are practically all that I could find in a thorough search of the literature, in which the diagnosis of tuberculosis was proved.

CLASS I.—Cases in which the characteristic changes in the larynx consist of either a marked hypertrophy or hyperplasia of the tissues, or in which tumor-like formations *without* ulceration, occur.

CLASS II.—Distinct tumors, usually covered with intact mucous surfaces and called by the French the "type d'Avellis" and which seem frequently to originate in the ventriculus Morgagni. These tumors may or may not be pedunculated.

CLASS I.—The following rare cases, of which I will give brief abstracts, belong in this class.

John N. Mackenzie's Case (1).—He reports two cases observed by him in the Rudolph Hospital, Vienna. The specimens, which were removed at autopsies by Dr. Hans Chiari, were examined by M. microscopically. (1) Tuberculous tumor of the trachea. Pharynx, larynx, and trachea were free from ulceration. A circumscribed tumor was found in the trachea, about 1½ cm. above the bifurcation, and was about the size of a bean. A similar one was found in the pericardium. Microscopically, the tumors consisted of tuberculous nodules set in a network of hypertrophied connective tissue. (2) Tuberculous growth of the vestibulum laryngis. Patient died of pulmonary tuberculosis. The epiglottis, aryepiglottic fold, and ventricular bands presented a remarkable granular appearance, due to the presence of small, smooth, dense, nodular growths. No trace of ulceration in the pharynx, larynx or trachea.

Microscopical examination disclosed the same appearances as in case I. He also describes tuberculosis of the laryngeal muscles, and reports a case, in which large, well-marked tubercles were found embedded in the muscular tissue, and absolutely unconnected with the tuberculous infiltration of that part of the larynx. This case is extremely rare, and bears out Heinze's (32) similar investigations.

Foa's Case (2).—Foa reports a rare case of this form of tuberculosis. I will give only the post-mortem findings. There was well-marked evidence of pulmonary tuberculosis, as well as of the ileum and mesenteric lymph glands. In the larynx, at the base of the epiglottis, on its inferior surface, in the region of the arytenoids, and on the cords, there were numerous eminences, from 2 to 4 mm. long, and 2 to 3 mm. wide. Absolutely *no* ulceration of the laryngeal mucosa. On microscopical examination, the vegetations were made up mainly of connective tissue, and contained some giant cells and epithelioid cells. An inflammatory condition of the mucosa, with a well-marked hyperplasia could be made out. Tubercle bacilli were found in portions of the tissue removed.

Lermoyez's Case (3).—A man, aged 40 years, entered the hospital Bichat in Gouguenheim's service. Had had severe hemoptysis. There was difficulty in breathing, marked aphonia, and inspiratory dyspnea. A large mass was seen in the larynx, in the region of the cords. It was difficult to determine the exact point of origin. During inspiration the growth descended below the glottis. A tracheotomy was performed, and a large sub-glottic growth similar to a polypus was found. Patient died five days after the operation. At the autopsy, a large mass attached in the angle of insertion of the right cord was found. This is rare in the history of tuberculous vegetations. There was tumefaction of the left cord, and beginning vegetations.

Ariza (4) has contributed several articles on this subject. In the first, he simply and very incompletely reviews the literature, and describes the vegetative or hypertrophic form of laryngeal tuberculosis. There are sometimes enormous localized hypertrophies of the tissues. He also refers to the fact that there may be no ulceration in these cases. In the second article, he mentions the great difficulty in making a diagnosis, and that the hypertrophy is seen chiefly on the ventricular bands and cords, and may be so extensive as to make tracheotomy imperative.

Doleri's Case (5).—The patient, aged 63 years, had severe hemoptysis, and dyspnea at night. Complete aphonia had existed for six months. Death occurred suddenly with symptoms of asphyxia. At the autopsy, the following interesting changes were found in the larynx: There was marked hypertrophy of the entire mucous membrane, the thickening being so great that the lumen of the larynx was reduced to one-quarter the normal size. The cords were effaced. The epiglottis and ary-epiglottic folds were

thickened, and there was some sub-glottic hypertrophy. The mucous membrane was very pale. There was slight ulceration in the region of the right ventricular band. Pulmonary tuberculosis was also found. There was marked sclerosis of areas of lung tissue, and a formation of fibrous tissue. A cavity existed in the right lung as large as a small orange.

Schnitzler's Case (6).—The patient, a young man, came to Schnitzler's clinic for the relief of urgent dyspnea. Laryngeal examination showed the presence of several grayish-white tumors, varying in size from a bean to a hazel nut, not ulcerated, situated mainly in the ventricles of Morgagni, and almost completely filling the upper part of the larynx. S. makes the statement in this article, that laryngoscopically, these tuberculous tumors had almost never before been observed, and later, in another article (*Wiener Med. Presse,* Nov. 16, 1884) he questions Dr. John N. Mackenzie's right of priority in describing such tuberculous tumors. Mackenzie's cases *were* certainly published before Schnitzler described the above case. It was seen by Schnitzler (see Crepon's article, 11), in 1882, but it was not reported until 1884. Tracheotomy was performed by Billroth in Schnitzler's case, and then by an endolaryngeal operation, the tumors were removed. The microscopical examination proved the diagnosis.

Dehio's Case (7).—Tumor of the larynx. No ulceration. The tumor was attached to the left ventricular band by a broad base, covering the whole band. There was great thickening of the right ventricular band. On microscopical examination, no evidence was found of caseation of the tubercles. There were bacilli in the tissue removed for examination.

Henning's Case (8).—Man, aged 52 years, good family history. In the region of the left cord, there was a round smooth tumor with a broad base, and covered with normal mucous membrane. The tumor covered the posterior two-thirds of the left cord, left ventricular band, and ventriculus Morgagni. It probably originated in the ventricle. Laryngo-tracheotomy was performed. Diagnosis was proved by the microscopical examination.

Koch's Case(9).—Tuberculous tumor of the larynx removed by laryngo-tracheotomy. Diagnosis verified by microscopical examination.

Hopmann's Cases (10).—(Reported by Karl Becker.) (1) Tuberculous tumor of the anterior commissure. Laryngotomy. (2) Tumors of the ventricular bands and cords. Laryngotomy. Death in two months from pulmonary tuberculosis. (3) Tumor of the anterior part of the right cord Two operations were performed and eleven years after, the patient, who was a minister, had suffered no recurrence, and could use his voice both for speaking and singing. (Remarkable case.) (4) Tumor nodules of the anterior part of the cords and the epiglottis. (5) Large tumor of the an-

terior commissure. Pulmonary tuberculosis. Operation, followed by cure.

Küster's Case (11).—Woman, aged 46 years. Prominent tumor in the anterior commissure. There was very slight ulceration in the larynx. A laryngo-tracheotomy was performed.

Josephsohn's Case (12).—Reported as a case of primary tuberculosis, but as there was no autopsy, it can not be so called. Girl, aged 12 years, with marked tumefaction of the epiglottis, and hard infiltration with tumefaction of the arytenoids. Symptoms on the part of the lungs did not appear until shortly before death. There was slight ulceration on the posterior wall of the larynx.

Kidd's case is not included in this classification, because there was some doubt about the diagnosis.

Castex (13) has called attention to certain nodules occurring on the cords, to which he has given the name nodular tuberculosis. They frequently become tuberculous, and are grayish-red in color.

CLASS II.—While this class of pedunculated tumors can perhaps not be called typical examples of hypertrophic tuberculosis, they must be considered a form of the disease. Lartigau includes papillomatous excrescences, and polypoid formations, as a type of hyperplastic tuberculosis of the intestine.

Billroth's Case (14).—Two pedunculated, papillary excrescences of the left cord, with a sub-glottic tumor. A diagnosis of epithelioma was made, but after the growths were removed, they were found to be tuberculous. No ulceration in the larynx.

Panzer's Cases (15).—Reports three cases. Two, apparently ordinary polypi of the cords, were found on histological examination to be tuberculous. In the third case, there were papillary excrescences on the left vocal cord. In two of the cases the tumors occurred in otherwise perfectly healthy larynges.

Clark's (16).—Woman, aged 21 years; no evidence of pulmonary tuberculosis. Had been hoarse for three years. Pedunculated tumor in the larynx, attached to the left ventricular band. The diagnosis was proved after the removal of the growth. No recurrence after a year and a half.

Kirkpatrick's (17).—Papillomatous mass in the inter-arytenoid fold. Diagnosis proved microscopically.

Bronner's (18).—Pedunculated new growth attached to the left cord in a tuberculous subject. Found to be tuberculous on microscopical examination.

Sachs's Cases (19).—Two cases of laryngeal tumors with normal lungs. (He considered them primary but I could find no record of autopsy.) One of the most important works on the subject of tuberculous tumors has been written by Avellis (20). He has reported thirteen cases observed by himself. There are cases belonging to both classes. The tumors in his cases were circumscribed, and there was no laryngeal ulceration. He states

that this form is probably sometimes primary. In this connection, a series of cases studied by Möser (21) is of interest. He describes cases in which practically the only evidence of laryngeal tuberculosis, was the thickened and nodular epiglottis. As a rule there was either no ulceration, or very little, in the larynx. Sometimes this same thickening was noticed in the larynx. Some of these cases are undoubtedly examples of hyperplastic tuberculosis. A case of lupus of the epiglottis has recently been reported by Chambers (*Laryngoscope,* Feb., 1903) which simulates somewhat Möser's cases. It is of interest in this connection, because a section was sent to Dr. A. O. J. Kelly, of Philadelphia, who reported that the case was one of hyperplastic tuberculosis. Jonathan Wright was more inclined to the opinion that it was lupus. Gouguenheim and Tessier (22), in their admirable work, were the first to describe cases occurring in children as "pseudo-polypoid sclero-papillary" forms. "La texture est toujours la même; ce sont des hypertrophies papillares, développeés sur la muqueuse tuberculeuse á l'occasion action irritative ou inflammatoire." These cases they claim may sometimes be primary. As before stated, however, I believe that primary cases of this, or any other form of laryngeal tuberculosis, occur with extreme rarity. Fraenkel's case is the only one I could find in which the diagnosis was verified by autopsy. It is possible that Hopmann's third case, in which there was no recurrence for over eleven years after the removal of a tuberculous growth, was primary. It is more than likely, if the lungs had been involved in this case, that the patient could not have lived so long without a recurrence. Dehio's case (7) may also have been primary. There were, however, no autopsies in these two cases.

A study of the cases described in this paper, would appear to the writer sufficient to clear up the diagnosis of the different forms of hyperplastic tuberculosis. A histological examination will usually settle all doubt, although there are cases in which the histological structure simulates sarcoma. Attention has been called by Koschier to the occurrence of rhino-scleroma associated with tuberculous infiltration of the pharynx, and of both arytenoids. In connection with the diagnosis of the writer's case this condition need hardly be considered. In the first place rhino-scleroma is excessively rare in this country, and secondly primary scleroma of the larynx is very rare. In almost every case the characteristic lesions in the nose will be found. Schrötter (35) has also called attention to the occurrence together of scleroma and tuberculosis. Hypertrophic tuberculosis must also be differentiated from lupus, syphilis, sarcoma and carcinoma. Lupus as stated by Emil Mayer *is*

tuberculosis, but occurs in another form. It differs from the form of tuberculosis under discussion, in that in the larynx, it usually involves the epiglottis. Primary laryngeal lupus is, too, extremely rare, although it has been mentioned by Mayer, (*N. Y. Medical Journal,* 1898). Macroscopically, lupus tissue has rather a different appearance. There are usually pale, elevated nodules, which sometimes ulcerate at their apices. These ulcers heal very slowly, and as one cicatrix forms another nodule may break down, giving a characteristic appearance which differs essentially from that of hyperplastic tuberculosis. A histological examination of lupus is not always of much help, and the diagnosis must often be made by exclusion. The fact that the lingual surface of the epiglottis is usually affected first, and the very slow course of the disease will assist in clearing up the diagnosis. Then of course in the vast majority of the cases, lupus is a secondary process. True syphilitic tumors (syphilomata) when they occur in the larynx, present many more diagnostic difficulties. There is a form of syphilitic tumor which I have observed several times, and which like the tuberculous tumor, may or may not be pedunculated, is covered with an intact mucous membrane, and may not break down for a long time. Such cases are extremely difficult to differentiate clinically, from hyperplastic tuberculosis. A history of syphilis can however usually be obtained, and even if not the administration of potassium iodide will settle all doubt. Syphilitic hyperplasia, which is made up of simple granulation tissue, quickly breaks down forming the typical ulceration. This is true also of the syphilitic granuloma, which is simply an inflammatory condition that develops around an ulcerated surface, and of the gumma. From beginning carcinoma and sarcoma the hyperplastic form of tuberculosis can be differentiated by the histological examination. The further course of the disease, and the typical laryngeal appearance in advanced carcinoma, will clear up the diagnosis.

Exception may be taken to the writer's classification of hyperplastic tuberculosis. If we were to include cases in which the laryngeal changes consisted simply of circumscribed hyperplasia or hypertrophy of parts of the mucosa, we would have practically only Mackenzie's second case, Doleri's case, Foa's case, possibly Lermoyes' case, and Ariza's description of the condition. In all the other cases there was distinct tumor formation of some kind. I believe these cases should be included, particularly where there is

absence of ulceration. Ulceration, however, *may* occur in some part of the larynx, late in the course of the disease. When this occurs, it does not affect the diagnosis of this form of tuberculosis in any way, because the characteristic lesions, the tumor formations are not involved in the ulcerative process. In the writer's case it is true, slight ulceration of the cords developed just before death, but the characteristic circumscribed hypertrophies of the ventricular bands, and the thickened arytenoids, remained unaltered. Tumor formation occurring in this form of the disease, is perhaps nothing more than a circumscribed hyperplasia of the tissues, with the typical histological changes.

A review of the recorded cases of the forms of hyperplastic tuberculosis of the larynx described in this paper, brings out some interesting facts. We find, where the age of patients was mentioned, that adults between the ages of 31 and 63 years were mainly affected. About an equal number of men and women had the disease. One of the youngest patients in which this form of tuberculosis occurred, of which I could find any record, was in a girl of twelve years (Josephsohn's case 12). Gouguenheim and Tessier are among the only other authors who have described this form of tuberculosis in children, and Mackenzie and Heinze are among the few authors who have described tuberculosis of the laryngeal muscles. The favorite sites for the laryngeal lesions, are, in the order of frequency, the vocal cords, ventriculus Morgagni, ventricular bands, epiglottis, arytenoids, and the anterior commissure. There was only one case in which the tumor formation was limited to the inter-arytenoid fold, and only two in which subglottic tumors occurred. The ventriculus Morgagni alone was involved in two cases, the cords alone in six, the ventricular bands alone in two, the epiglottis alone in some of Möser's cases, and the anterior commissure alone in three. The epiglottis was involved with other parts of the larynx in three cases, the epiglottis and arytenoids together in one case, the arytenoids and cords together in one, and the ventricular bands and cords together in one. Mention is made of pulmonary tuberculosis in the majority of the cases. In the few cases, before enumerated, in which no evidence of pulmonary tuberculosis was found, there is no mention of autopsies, so that this fact can not be considered of much importance.

Treatment.—Only one phase of the treatment will be considered,

and that is a proper climate. I firmly believe with Chappell (43), that *any* chance should be taken in a *good* climate, rather than the *best* treatment in a poor climate. The climate in the Hudson Valley, around Albany, is certainly poor enough. For this particular form of the disease, proper treatment in a good climate would be ideal, because ulceration is either *entirely* absent or does not develop until very late in the course of the disease. I am convinced, in considering my own case, that if the patient had gone to Denver, and remained there, he would be alive to-day. Another important point to consider in such cases is that, in these early forms, physical examination of the lungs is sometimes negative. They are certainly more favorable cases for a change of climate, than the cases of laryngeal tuberculosis usually seen.

Conclusions.

(*a*) Hypertrophic or hyperplastic tuberculosis of the larynx, must be considered a distinct and unusual form of the disease.

(*b*) As a rule there is no ulceration, but there may be some late in the course of the disease.

(*c*) Ulceration may be present at the same time as the hyperplasia of the tissues, in some part of the larynx, but the characteristic circumscribed hypertrophies and tumor formations do not break down.

(*d*) It is practically always secondary to the pulmonary involvement, but there appears to be some evidence in support of the statement that particularly *this* form of tuberculosis may at times be primary.

Bibliography.

Class I.

1. Mackenzie, J. N. Tubercular Tumor of the Windpipe. Tuberculosis of the Laryngeal Muscles etc. Archives of Medicine, Vol. VIII., No. 2, p. 107, 1882.

2. Foa, Pio. Di una forma rara di Tuberculosi della Laringe. Archives per le scienze Mediche. VII., No. 13, p. 203, 1883-'4.

3. Lermoyez, M. Vègétation Tuberculeuse ènormé, formant polype mobile, implanteé au bord de la corde vocale droit et a son insertion anterieure, etc. Annales des Maladies de l'Oreille et du Larynx. Vol. 10, p. 183, 1884.

4. Ariza R. Tuberculosis laryngea hypertrofica. El Siglo Medico, Madrid, V. XXX., p. 259, 1883.

Ibid. La Traqueotomia en la Tuberculosis laringea. Vol. XXX., 1883.

5. Doleris. Laryngite hypertrophique. Tuberculose et sclerose partielle du poumon. Bull. de la Societe anat. de Paris., p. 128, 1876.

6. Schnitzler, J. Tuberculöse Tumoren im Larynx etc. Wiener Med. Presse, XXIV., S. 446, 1883. Ibid. Wiener med. Presse, No. 44-46, 1884.

7. Dehio. St. Petersburger med. Wochenschr., No. 10, 1888.

8. Heming, A. Berliner klin. Wochenschr., No. 28, 1888.

9. Koch. Ref. in Monatschr. f. Ohrenheil. Larynxtuberculose mittelst Chir. Behand. S. 124, 1891.

10. Hopmann. Zur Statistik der Laryngo-fissur. Münch. med. Wochenschr., Nos. 16, 17, 18, 1877.

11. Küster. Die Behandlung der Larynxtuberkulose durch Laryngofissur. (Reported by Crepon.) Crepon, Ernst. Inaugural dissertation. Marburg, 1894.

12. Josephsohn, J. Ueber die Frühformen der tuberkulösen Erkrankung des Larynx etc. Inaug. dissert., Königsberg, 1895.

13. Castex. Rev. hebd. du Larynx, etc., No. 26, June 26, 1897.

CLASS II.

14. Billroth. (Crepon's article). Inaug. dissert., Marburg, 1894.

15. Panzer. Ueber tuberculöser Stimmbandpolypen. Versammlung. Deutscher Naturforscher und Aerzte, Sept. 27, 1893.

Ibid. Wiener med. Wochenschr., Nos. 3, 4, 5, 1895.

16. Clark, J. P. Tubercular Tumors of the Larynx. American Journal Med. Sciences, May, 1895.

17. Kirkpatrick, E. A. Tubercular Tumor of the Larynx. The Maritime Medical News, Jan., 1896.

18. Bronner, A. Trans. London Laryngol. Soc., Dec. 9, 1896.

19. Sachs. Primäre tuberculöse Geschwülste in Nase und Kehlkopf. Münch. med. Wochenschr., No. 38, 1897.

Ibid. Münch. med. Wochenschr., No. 42, 1897.

20. Avellis, G. Tuberkulöse Larynxtumoren, 1891.

21. Möser, H. Die Infiltration d. Epiglottis als primär Erscheinung der Phthisis laryngis. Wiener med. Presse, XXVI, p. 206, 1885.

22. Gouguenheim et Tessier. De la phthise larynge pseudopolypeuse, 1888.

MISCELLANEOUS. ARTICLES USED FOR DIAGNOSIS, ETC.

23. Moll. Behandlung d. diffusen Pach. d. Stimnbändern. Trans. French Laryngol. Soc., May, 1893.

24. Fränkel. Pach. Laryngis, ihre Geschichte, path. Anat., u. Path. Archiv f. Laryngol und Rhinol. Bd. 11, Hf. 1.

25. Sturmann. Klinische Geschichte d. Pach Laryngis. Berlin, 1894.

26. Symonds, C. London Laryngol. Soc., March 14, 1894.

27. Habermann. Beiträge z. Kenntniss d. chron. Laryngitis, etc. Zeitschr. für Heilkunde, Prag. XVI., Hft 2,3, 1895.

28. Zwillinger. Ueber d. Verhältniss d. Pach., Laryngis Z. d. Leukokeratosen. Wiener klin. Wochen., No. 8, 1896.

29. Fränkel, B. Pach. und Carcinom, nebst Bemerkungen ü. d. Entwickelung u. d. Diagnose d. Carcinoma. Archiv f. Laryn. u. Rhinol. Bd. XIII., Heft 1, 1902.

30. Duesberg, W. Ueber Laryngofissur bei tuber. Ulcer. Inaug. Dissert. Düsseldorf., 1898.

31. Schech. Die tuber. Erkankung des Kehlkopfes u. d. Luftröhre. Handbuch d. Laryn. u. Rhinol. Bd. 1, lief. 12, S. 1,110-1,194, 1898.

32. Heinze. Die Kehlkopfschwindsucht. Leipzig, 1897, S. 69.

33. Henning, A. Berl. klin. Wochenschr., No. 28, 1898.

34. Lartigau, A. J. A Study of Chronic Hyperplastic Tuberculosis of the Intestines, with Report of a Case. Journal of Experimental Medicine. Vol. VI., No. 1, Nov. 29, 1901.

35. Schrötter. Bemerkungen uber die Bedeutung eines systematischen Studiums des Skleroms, 1901.

36. Mandl. Tr. prat. d. Mal. d. Larynx., Paris, 1892.

37. Gussenbauer. Prag. med. Wochen., 1883.

38. Schäffer u. Nasse. Deutsche med. Woch., No. 12, 1887.

39. Gerster, Arpad. N. Y. Med. Rec., 1889.

40. Hajek. Tuberk, Larynxtumoren. Int. klin. Rundschau, No. 38, 1893.

41. Beitter-Seiffert. Beitr. z. cas. d. tuberk. Larynxtumoren, Würzburg, 1891.

42. Grünwald. Beitr. z. Chir. d. oberen Luftwege, etc. Münch. med. Wochen., No. 41, 1891.

43. Chappell, W. F., The Early Appearances, Diagnosis, and Treatment of Tuberculosis of the Upper Air Tract. Jour. of the Amer. Med. Ass., Feb. 21, 1903.

Paper.

GANGRENE OF THE TONSIL.

BY CHARLES W. RICHARDSON, M.D.

Gangrenous destruction of the tissues of the fauces is of such an infrequent occurrence that I thought such a case worthy of presentation before this association.

In looking over the literature on gangrenous destruction of faucial tissue, excepting of diphtheritic origin, I find an unusually small number recorded. In my experience, this, the case which I now report to you, has been the first which I have ever seen.

On March 1st I was called in consultation to see a patient residing about nine miles from Washington. It was late in the afternoon when I reached the patient's house, and it was nearly an hour later before the consultants were with me.

On the presentation of the case to me by one of the consultants, and carefully going over the history and the temperature sheets, I could see at once that the case, whatever might be its cause, was one of extreme sepsis. The history as presented to me was as follows:

The patient was a man of robust physique, of forty-five years of age, addicted to excesses. About ten days before, he had returned from a trip to the North, at which time he had been using alcoholics to excess. When he first came under the observation of the physicians in charge, he had considerable difficulty in swallowing, marked infiltration of the right side of the neck, with other characteristic symptoms of quinsy. In a couple of days it was stated that the patient had a discharge of pus from the nose and mouth, with which there was a subsidence of the swelling in the right side of the neck, a restoration of the normal voice, no further difficulty in deglutition, and the return of the ability to open the mouth freely and widely. About two days thereafter, the physician in charge saw what he supposed to be some white spots on the right tonsil. He then thought that the case was probably one of diphtheria, although there was a doubt in his own mind as to the diagnosis. The next day, however, he administered 3,000 units

of antitoxine. On the second day thereafter, there were 3,000 more units given. From first administration until I saw him, he received, in all, 16,000 units of antitoxine. Even under this repeated use of antitoxine, there was no improvement in the patient's condition. He gradually, but progressively, grew worse. On the ninth day of his illness the patient became delirious, and on the tenth, and last day of his life, I was called in consultation.

At this time, the patient's temperature was 102°, his pulse 120, soft and compressible; and he was in a muttering delirium. On inspection, which was comparatively easy for one in a delirium, and in such a serious condition, I was first struck by the absence of the characteristic diphtheritic odor of the breath, and was impressed by the peculiar odor which is due to sloughing tissue. On depressing the tongue, I was quite unprepared for the sight which I observed. On the right side, the tonsil, the anterior and the posterior pillar, and as far down in the pharynx as I could see, was one continuous mass of greyish, brownish slough. The left side and the curtain were perfectly normal. I particularly noticed the fact that there had already formed a complete line of separation between the necrotic and the normal tissue. The examination was prolonged until a careful and thorough inspection was made of the diseased area, and both the consultants had examined it with the same care. On consideration of the case, they both told me that the first they had noticed of the sloughing was the day before when there was a narrow white line of diseased tissue, but, from the complete line of separation, I was rather inclined to believe that their examination was not as perfect a one as had been made by me. The patient was in extremis and died two hours after I first saw him.

In consideration of this case, as to its nature and the cause of the gangrene, there are several interesting points to decide. The long distance from the city, the tedious trip out and back, made it impossible, on account of want of facilities, to do anything in a bacteriological way. I was, unfortunately, not supplied with culture tubes or glasses to make smears. This, of course, makes the case rather incomplete as to its bacteriological study. Our consultants had made no bacteriological examination for the bacilli of diphtheria; but from the fact that antitoxine had been so inefficacious, and from the clinical history of the case, I

think we can exclude the possibility of diphtheria playing any role in regard to its etiology.

Of course, not having made any smears, it is impossible to exclude the spirillum as an etiological factor, but the amount of destruction, the extent of destruction, and the depth of the necrotic tissue would seem almost to exclude this possible origin. If it were a case of spirillum infection, it was certainly a most marked manifestation of this condition.

It seems to me that the most possible and plausible origin of this destructive process is as follows:

In the first place, the patient evidently had a quinsy, which was attended with considerable infiltration of the peritonsillar tissues, the infection being due, in all probability, to the streptococcus. This invasion being of such an intense nature, it resulted in the gangrenous destruction of the surrounding tissues. It is also possible that the invasion and raising of the tissues, due to the accumulation of pus, had caused an occlusion of the tonsillar and ascending pharyngeal arteries, thus adding to the impairment of the nutrition of the tissues and allowing the infected agents to more thoroughly do their work.

Paper.

PERICHONDRITIS OF THE LARYNX, WITH REPORT OF A CASE.

BY EMIL MAYER, M.D.

DISEASED conditions of the larynx as a complication or sequel of typhoid fever are by no means rare, and their presence may be of diagnostic value. Schmidt, speaking of the aids to early diagnosis of typhoid, says that inflammation and infiltration of the epiglottis form a characteristic condition and enable us to make the diagnosis of typhoid positive. Kobler, on the diagnostic value of affections of the epiglottis in typhoid, reports two cases: "There was much infiltration and deep ulceration of the epiglottis in both cases and white cicatrices resulted. Aside from the differential diagnosis, this condition is of value in prognosis—as long as the infiltrate exists the typhoid is still at its height. In all cases of

cicatrices of the epiglottis, inquiry should be made for previous typhoid to avoid a diagnosis of lues."

The more serious conditions, stenosis resulting from typhoid fever, occur from time to time and there are a considerable number recorded in medical literature, yet in the individual experience of most physicians they are certainly rare.

Morrell Mackenzie says: "My statistics are not at all reliable as regards the relative frequency of perichondritis in different affections, for whilst I see many cases of tuberculosis, cancer and syphilis, I scarcely ever meet with typhoid fever; indeed, all the cases of that disease in which I found disease of the cartilage came under my notice formerly, at the time I was physician to the London Hospital." Landgraf has bibliographic reference to two hundred and sixty-six articles on this subject in Heymann's Handbook. According to Keen, the large majority of these cases occurred in Germany and on the continent, fewer in the British Isles and still fewer in this country. A search in the twenty volumes of the American Laryngological Association fails to note the report of a single case from its members. Some of our text-books fail to mention its occurrence; others barely note that it may occur, while Keen, Bosworth, Kyle and Newcomb give it more extended notice. The logical sequence of these facts is that the statement that stenosis of the larynx consequent to typhoid fever is much less frequent in America than elsewhere, is proven.

Pathologically it may be considered to occur in the following manner: Commencing with hyperemia and congestion there rapidly follows an inflammatory edema with exudation into the surrounding or adjacent soft structure, which on account of the location and the limit set by the cartilaginous wall of the larynx, must extend inward and rapidly lessens the lumen of the larynx. This edematous stage and the stage of ulceration which has gone on to necrotic involvement of the cartilages, differ only in degree but not in kind. The cartilages of the larynx are at best poorly supplied with blood, rendering them at all times susceptible to necrotic change. When during the course of typhoid fever the nutrition is lowered throughout the body, circulation in this locality suffers to a greater extent, as it is dependent on surrounding tissue for its blood supply and rapidly undergoes necrosis, which may slough out in small pieces or be discharged en masse. This breaking down of tissues, as in abscess formation,

may penetrate toward the point of least resistance, rupture and virtually form an ulcer. In the majority of instances of perichondritis or chondritis due to typhoid fever, the infection and inflammatory process are similar to those seen in abscess formation, which making for the point of least resistance, open in ulceration on the mucous surface. The ulceration is only situated posteriorly and the cartilaginous inflammation on the side and toward the back part of the larynx. Thrombosis may take place in this area, due also to the added weight of the decubital position. If only a part of the cartilage has been destroyed and the perichondrium remains, there may be a reproduction of the cartilage; in any event, it is likely that the abscess will be followed by a fistula and suppuration without necrosis of the cartilage may occur.

Other and varied views as to the pathology of this condition have been expressed. In a paper read before the Laryngological Society of London, Kanthack and Drysdale said that these defects are situated generally over the tip and edges of the epiglottis and in the neighborhood of the processus vocalis. It is not true that the laryngeal lesions invariably appear during the acute period of the fever before healing commences. They support Rheiner's view that the ulcers are produced by small repeated injuries acting on debilitated tissue. They declare as incorrect the view that the ulceration affects the adenoid tissue of the larynx, for along the tip and edges of the epiglottis and over the processus vocalis no such tissue ever develops.

The question as to whether these are specifically typhogenetic is negatived. Undoubtedly the lesions are caused by micro-organisms; there is the strongest evidence that these are the pyococci, and not, except rarely, the typhoid bacilli. While the latter may be the cause, the soundest possible observations are necessary to make them convincing. The ulcers occurring during the course of typhoid fever are caused by fresh infections with pyogenic organisms which always abound in the larynx and which gain a firm foothold on the debilitated tissues, although they cannot deny that in an individual case the typhoid bacillus may have escaped and caused the lesion. In the discussion Watson Williams, Jobson Horne and Sir Felix Semon participated.

More recently (1902) Samuel West in his article on "Perichondritis, Necrosis and Caries of Cartilage" says: "In typhoid fever this lesion is usually described as commencing as a perichondrial

infiltration which is held to be of the same nature, to run the same course and to break down in the same way as the infiltration in the intestines. It is possible that the perichondritis is not primary in the strict sense of the term, but is the result of previous ulceration near to the affected part."

Among recent reports of bacteriological examinations Schulz (1898) was enabled to demonstrate the presence of typhoid bacilli in the laryngeal mucous membrane. Strazza, in the Italian Laryngological, Otological and Rhinological Congress at Rome in 1899, showed a specimen with extensive ulceration on the surface and in the deeper parts. In this preparation micro-organisms in the form of cocci could be seen.

Rethi (1901) says it is now generally accepted that various even specific affections of the larynx, are due to the bacillus of Gaffky. Finally, E. Bendix and A. Bickel (1902) make the very interesting statement that in a case of typhoid fever complicated by severe laryngeal symptoms, they found on each palatoglossal arch and on the epiglottis, an elevated plaque-like area, while the surrounding tissues were unaffected. They introduced a platinum needle into one of these plaques after carefully sterilizing the surface, and obtained cultures of a bacillus that was identical with the typhoid bacillus and that gave the serum reaction with the blood of another patient with typhoid fever. The plaques ulcerated slightly but soon healed. This seems to be the first satisfactory intra vitam demonstration of typhoid bacilli in throat lesions.

Perichondritis may be present in any part of the larynx, mainly, however, in the supraglottic region. There may be infiltration alone, a deep ulceration with subsequent necrosis, or extensive submucous infiltration. The case here presented is one of the latter variety.

In the forenoon of January 19th, 1903, I received an urgent message to see Mrs. H. H., aged twenty-eight, native of Norway (eighteen years in the United States), in consultation. I saw the patient within half an hour and found her half lying on the bed, gasping for breath from some form of laryngeal stenosis. The livid expression of her face, the rapid, wearisome respiration, the stridor, inspiratory depression of the neck and chest wall, the cyanotic lips and anxious expression of the countenance showed the unrest of despair, the struggle with death.

The history given was that on October 18th, 1902, she had an attack of typhoid fever; four days later she was taken to one of

our large hospitals and an unusually severe attack of the fever occurred. The temperatures were persistently high, remaining at 106° to 107° and requiring an ice bath of 45 minutes' duration; pleurisy with effusion, an abscess in the arm and phlebitis followed. At the end of two months she was discharged as cured on December 13th.

Quite early in her illness hoarseness developed, but no laryngoscopic examination was made. This hoarseness remained and still exists. Four days previous to my seeing her, dyspnea began on slight exertion. In spite of local applications her condition became worse.

Examination.—Patient much emaciated. Supported in an upright position a good view of the larynx was obtained. On the right half of her larynx was a large mass beginning on a line with the ventricular band and extending down into the trachea, narrowing the lumen to a mere chink. Temperature 101½° F., pulse 126, respiration 36. The diagnosis of post-typhoid laryngeal perichondritis was made and immediate tracheotomy was advised. This was agreed to and at one P.M., two hours later, under chloroform administered by Dr. M. L. Maduro, with the assistance of Drs. J. L. Adams and R. L. Longacre, I performed tracheotomy.

On January 20th a large edematous swelling appeared over the right arytenoid, the larynx meantime being completely occluded. The edematous swelling caused pain in swallowing, was punctured and a quantity of serous fluid exuded. The tissues of the neck now became involved and there was considerable bulging, mainly on the right. On the 23rd the whole neck was swollen and Dr. F. W. Murray saw the patient with us. He considered the swelling to be of an evanescent nature and advised temporizing. This was done and the swelling gradually subsided. At this time I found a large swelling occupying the posterior wall of the pharynx which I incised and a quantity of serous fluid exuded. Her temperature now fell each day so that on the 25th it was 100° F., respiration 22, pulse 100.

March 1st, 1903.—The history of the patient from the last note up to the present time has been that of steady progress for two weeks, interrupted then by threatened phlebitis, which was avoided by the skillful care of her attending physician, and in the last few days of February she became able to walk about and on March 11th came to see me in my office.

Examination of her larynx shows a degree of swelling extending from the false vocal cord downward. From the uppermost portion of the swelling there projects a globular mass, white in color and the size of a pea. The vocal cords which can now be seen, are clearly white and apparently adherent posteriorly in one-third of their length. There is fixation of the left half of the larynx. There are abundant granulations about the tube externally and granulation tissue growing into the orifice of the tube

in the trachea. The voice is reasonably clear. Respiration may be carried on for half a minute with the tube occluded; at the end of that time marked dyspnea occurs.

On March 13th, under cocain anesthesia, I removed the white globular swelling, which on examination showed to be granulation tissue. On the 15th, 17th and 19th I introduced graded sizes of Schrötter's tubes. I also made various attempts at intubation with the O'Dwyer tube attached to a hollow handle devised by myself and shown to this Association at a previous meeting. These latter were not successful, owing probably to the large size of the tube. On March 19th I introduced a pair of long laryngeal forceps and stretched the larynx fully, hoping thereby to separate the adherent vocal cords. A great deal of reaction followed this procedure; there was much edema, dysphagia lasting several days so that divulsion had to be interrupted and sedatives applied.

March 24th.—Intubation by Schrötter's tubes continued with increasing sizes every other day without further dysphagia.

April 11th.—Examination showed the cords to be less adherent and quite some induration in the trachea immediately below the right vocal cord. Adult intubation tubes of the O'Dwyer pattern, marked five, six and seven, were now introduced, but rested only on the vocal cords and were promptly ejected. Subsquently a number five Schrötter's tube was introduced, entering the trachea readily, and through this the patient breathed.

April 19th.—Schrötter tubes introduced every other day. Various atempts to introduce O'Dwyer tubes failed, the requisite force being too painful for the patient.

On April 20th, under chloroform narcosis, a number seven O'Dwyer tube was readily introduced and retained by the patient. A hypodermic injection of morphia, one-fourth grain was given. Intubation was done at 2 P.M. Patient vomited once or twice within the next three hours but rested quietly, breathing well. At 4 P.M. she swallowed cold water in the Casselberry position and subsequently swallowed milk in the same way.

April 21st.—Slight vomiting at midnight, due in all probability to the morphia given at 10 P.M.

April 22nd.—No more vomiting; coughs, swallows well in the usual position but liquids only. Evening temperature 100° F. morning 99° F.

April 23rd.—Morning temperature 100° F., evening temperature 102° F. Coughs less; complains of pain in her throat.

April 24th.—Normal temperature; swallows better; went home after four days in hospital; has been eating all kinds of food without discomfort.

May 11th.—The tube has now been worn for three weeks. Patient goes about feeling entirely well, swallows all kinds of food and has no complaint whatever.

During the last two years eight cases of stenosis of the larynx

have been recorded in this country and a *rèsumé* of these is here appended.

J. P. Crozer-Griffith (March, 1900) reports a case of stenosis of the larynx after typhoid fever in a boy aged nine years. The case was seen by Dr. W. J. Freeman who found edema of both arytenoids and swelling of the left ventricular band and right vocal cord. Recovery.

Alexander Lambert reported a case of membranous laryngitis complicating typhoid fever before the New York Pathological Society on February 14th, 1900. A male alcoholic subject entered the hospital with marked dyspnea, severe cough and laryngitis. Leucocytes were only five thousand, hence diagnosis of typhoid was made. At the end of the third week the temperature had fallen and every evidence of improvement was noted. About this time the laryngeal symptoms were more severe and in three days aphonia was complete. Tracheotomy performed; patient died the same day of heart failure.

Necropsy.—A thick membrane was found extending from the epiglottis down into the larynx and into the trachea and in the sulcus on the left side was an abscess cavity. In the membrane from the pharyngeal surface of the aryteno-epiglottic fold there had been a diphtheritic inflammation and a line of demarcation had formed, causing a loosening of the necrotic tissue. A little beneath this line of demarcation there was an acute exudative inflammation with interstitial hemorrhage. Apparently there had been two infections—an earlier one causing necrosis of the surface and a later one causing an interstitial hemorrhage at the base of the granulation tissue. On the inner aspect of the aryteno-epiglottic fold there was a fibrinous exudate on the surface with granulations beneath and a rather excessive diapedesis of red corpuscles. This was probably due to the second infection. Nearly all the organisms found were diplococci and streptococci.

M. H. Fussell (May, 1900) reports two cases of perichondritis of the larynx in typhoid. In the first case five days after temperature was normal, symptoms of stenosis and swelling of the external parts of the larynx occurred. Tracheotomy was advised and declined. Patient died.

Second Case: Thirteen days after cessation of fever, chill. This seemed to be due to an abscess on the arm as temperature ceased when this was incised. At this time stridor occurred on excitement and heavy respiration in sleep. Stenosis became apparent and tracheotomy was performed. Two days later the abscess broke and it was clear that death would have occurred had the cannula not been in situ. Subsequently the necrotic arytenoid was thrown off; there was anchylosis of the crico-arytenoid joint and fixation of the cords. The cannula was worn for five months; was removed but later re-inserted.

L. B. Lockard (January 30th, 1900) on the laryngeal manifesta-

tions of typhoid fever reports the case of a male aged 35 years. In the sixth week pain and dyspnea due to an abscess on the left arytenoid occurred. Tracheotomy and endolaryngeal incision of the tumor evacuated considerable pus. The left vocal cord was fixed in adduction due to ankylosis of the cricoarytenoid articulation. The right cord was abducted and perfectly rigid, due, no doubt, to the perichondritis that had extended across the median line. Dilatation daily; cords readily separated but would immediately fall back into their old position. Schrötter's and O'Dwyer's tubes were tried but without benefit. The tracheal cannula was constantly worn except when the patient was at rest. The cords were removed piecemeal by the curette of Heryng, with recovery as to breathing but voice was almost entirely lost.

William B. Robertson and C. C. Biedert (December, 1901) report a case of Ludwig's angina complicating typhoid fever. Male, aged 22; during the third week of typhoid difficulty in breathing occurred; swelling on the left side of the neck, tender on pressure. board-like in hardness. Edema of the pharynx, larynx and epiglottis; larynx almost entirely closed. Six hours later dyspnea requiring tracheotomy; ten hours later patient died of some myocardial change.

Necropsy.—Tissue about the neck edematous and swollen but showed no evidence of breaking down. Mucous membrane of the larynx, especially about the left vocal cord and that of the epiglottis, was edematous, greatly swollen and almost purple in color. Cultures from the spleen showed Eberth's bacillus. Microscopic section from the larynx showed a pure streptococcus infection.

L. D. Brose (February, 1902) reports the case of a girl who had typhoid in the fall of 1899. When seen by the writer (six months later) she had paralysis of both adductors which he regarded as myopathic and due to a catarrhal laryngitis following typhoid. Recovery resulted.

F. Alan G. Murray (March 7th, 1903) reports a case of typhoid fever complicated by Ludwig's angina. Death from edema of the larynx. Male, aged 32; on the twenty-fifth day a swelling appeared on each side of the neck under the sternomastoid muscle. This swelling did not extend up to the angle of the jaw and was hard and painful on pressure. Voice harsh and metallic; dysphagia; breathing obstructed and labored. Tonsils not swollen; there is no record of a laryngoscopic examination.

At the necropsy the mucous membrane of the larynx was found congested, cords swollen and edematous and the passage almost closed.

Among the eight cases recently reported as occurring in America two recovered completely, two partially, that is to say, the tube is still worn, while four died. This indicates the serious nature of this affection.

I am inclined to question the diagnosis of Ludwig's angina in the two cases and believe they have been perichondritis of the larynx of the submucous infiltrate variety.

The study of these cases with my own leads me to believe that early tracheotomy, subsequent dilatation and intubation is the best method of treatment.

My own case has features of interest: The early development of laryngeal symptoms during the disease, though unfortunately not recognized, the enormous submucous infiltration, both before and after tracheotomy, the success that followed dilatation, making intubation under anesthesia very easy of accomplishment, and the subsequent ease of deglutition with the tube in situ. The extraction of the tube will show whether there is any paralysis or crico-arytenoid affection.

The subsequent history of this case is as follows:

May 28, 1903.—After wearing the tube for five and a half weeks, it was readily removed and the patient carefully watched. No dyspnea resulted. Laryngoscopic examination showed slight adhesions of the vocal cords with some sub-cordal thickening. For four days there was no dyspnea; during the next three days dyspnea gradually increased and on June 4th the trachea was again opened by myself in the hope of removing any intratracheal induration if present. There was none and the dyspnea appeared to be due to retraction at the cicatrix of the tracheotomy wound. Three days later I removed the cannula and intubated under cocaine anesthesia.

July 14th.—Now wearing the intubation tube, which creates absolutely no discomfort. This tube will be left in until Sept. 1st. If, as I confidently anticipate, the large tube will have sufficiently distended her larynx for continued breathing purposes and there is no paralysis resultant from the typhoid, I shall be able to add the word "recovery," and further to claim this as the first case thus successfully treated, to record one more success for the O'Dwyer tubes and a triumph for modern surgery.

Bibliography.

Franz Schmidt, Arch. f. Ohrenheilkunde, No. 4, 1901.

G. Kobler, Wiener klin. Rundschau, No. 17, 1899.

Morrell Mackenzie, A Manual of Diseases of the Nose and Throat, 1890.

Landgraf, Heyman's Handbuch d. Laryngol. und Rhinol., 1898.

Price-Brown, Diseases of the Nose and Throat, 1900.

Bishop, Diseases of the Nose and Throat, 1899.

Shurly, Diseases of the Nose and Throat, 1900.

Kyle, Diseases of the Nose and Throat, 1899.

Burnett, Ingals and Newcomb, Diseases of the Nose and Throat, 1901.

Posey and Wright, Diseases of the Nose and Throat, 1903.
Bosworth, Diseases of the Nose and Throat, 1897.
Grayson, Diseases of the Nose, Throat and Ear, 1902.
Keen, Surgical Complications of Sequels of Typhoid Fever, 1898.
Kanthack and Drysdale, Journal Laryngol., Rhinol. and Otol., April, 1896.
Jobson Horne, idem.
Watson Williams, idem.
Felix Semon, idem.
Samuel West, Diseases of Organs of Respiration, 1902.
M. R. Ward, Trans. Amer. Laryngol. Ass'n, 1902.
Schulz, Berliner klin. Wochenschr., No. 34, 1898.
Strazza, Internat. Centralbl. f. Laryng., Nov., 1900.
Rethi, Krankh. des Kehlkopfes, 1901.
E. Bendix and A. Bickel, Deutsche med. Wochenschr., June 5, 1902.
J. P. Crozer-Griffith, Annals Gynecol. and Pediat., March, 1900.
Alex. Lambert, N. Y. Medical Record, April 14, 1900.
M. H. Fussell, N. Y. Medical News, May 12, 1900.
L. B. Lockard, N. Y. Med. Jour., June 30, 1900.
W. E. Robertson and C. C. Biedert, American Medicine, Dec. 28, 1901.
L. D. Brose, N. Y. Med. Jour., Feb. 15, 1902.
F. Alan G. Murray, Amer. Medicine, March 7, 1903.

Discussion.

Dr. D. Bryson Delavan stated that he had within the last year published two cases of the nature described in Dr. Mayer's paper. He had formerly seen an occasional case among the broken down patients in the City Hospital. As far as statistics go, 94 per cent. of typhoids with this complication result fatally. Many interesting questions suggested themselves in connection with this subject. Attempts at dilatation in these cases were not as a rule successful. The only rational treatment seemed to be that with the O'Dwyer tube. Among the many points worthy of consideration was that of the proper cleansing of the upper air passages as a routine measure in fever cases. We could keep the nose and pharynx reasonably clean. This might not greatly help the larynx but it was the only measure in this respect at our disposal. In one of the cases seen by him, the infectious nature of the lesion was very evident and the typhoid bacillus was found locally. The appearance of the laryngeal ulceration was quite different from that of ulceration due to any of the usual causes.

Dr. W. K. Simpson believed that intubation under ether in Dr. Mayer's case might possibly have rendered dilatation with the

Schrötter tubes unnecessary. An anesthetic often afforded us an opportunity for using considerable force in the introduction of the largest sized tubes without previous dilatation.

Dr. H. L. SWAIN recalled one case seen in 1889 of post-typhoid perichondritis of the laryngeal cartilages resulting fatally. The first symptom had been a double abductor paralysis calling for immediate tracheotomy. The entire cricoid cartilage was found at autopsy to be necrosed and lying in a circular abscess surrounding the entire larynx. If he could have intubated at that time he might have prolonged the patient's life and even saved it. It was very evident that the fatal result was due not to the typhoid proper but to a secondary infection from the local process in the larynx.

Dr. MAYER said in closing the discussion that he regretted the omission of the two cases recorded by Dr. Delavan. Adding these two cases to the eight already mentioned the phrase would read "three recovered completely, three partially, while four died." The case he had presented illustrated the need of the examination of the larynx in typhoid fever, and was perhaps a striking commentary on the absence of careful laryngoscopic work in general hospitals. As long as any thickening was present, or ulceration existed, we should be on our guard and ready to intervene as soon as symptoms of stenosis presented themselves. The proper care of the parts might readily prevent the occurrence of a serious stenosis.

Some very serious and good work had been done in this country and cases of post-typhoid stenosis had been reported, and the writer had already called attention at this session to the fact that American statistics on this subject were practically ignored by Continental writers.

While under certain circumstances intubation might be done without previous dilatation, still in this particular case the slow dilatation made intubation very easy of accomplishment, and very likely had much to do with the ease with which the patient swallowed food and bore the intubation tube.

Paper.

CLAMP-FORCEPS FOR REMOVAL OF NASO-PHARYNGEAL TUMORS.

BY E. FLETCHER INGALS, M.D.

THE report of the following case is made to illustrate the advantage of having a suitable clamp to aid in the removal of naso-pharyngeal tumors by the galvano cautery and to call attention to an instrument which I believe will be found advantageous in very many cases. It will also aid in the removal of some growths by the cold wire snare.

The patient E. J., a young man 22 years of age had been troubled with partial occlusion of the nares and the necessity for frequently clearing the throat for about five years. Latterly, there had been complete occlusion of the left naris, but the right was permeable a part of the time. There had also been frequent bleeding of the nose. The patient's personal and hereditary history gave no clew to the cause of the trouble. The thoracic signs were normal. Upon examination of the nares I found the right side ¾ closed by swelling of the inferior turbinated body; the left side was free at its upper and front part, but was completely closed posteriorly by a growth in the naso-pharynx. Upon rhinoscopic examination, I discovered a fibrous tumor with a broad base attached to the vault and posterior part of the naso-pharynx, measuring about 1½ inches in length and about ¾ of an inch in its other diameters. This growth three-quarters filled the naso-pharynx. Its surface was smooth and marked by several enlarged blood vessels. It was hard to the touch and firmly attached, with but a slight groove at the lower part between the tumor and the pharyngeal wall, so that a wire could not be made to hold. The left naris and the naso-pharynx were anesthetized as thoroughly as possible with cocaine and through the left naris I passed into the naso-pharynx and brought out at the mouth a No. 5 soft male catheter, both ends of which were then held to the left. A similar catheter of different color was next passed through the same naris in like manner and both of its ends were held to the right. The two ends of a long No. 20 platinum wire were then introduced into the ends of the catheters that came out of the mouth and

passed back until they came to the turn in the naso-pharynx. The catheters were then drawn out through the nostril until the ends that protruded from the mouth were out about four inches nearer the lips. This caused the wire to make the turn in the naso-pharynx after which both ends were easily pushed in until they came out of the catheter through the nostril. I then passed the clamp-forceps through the mouth, into the naso-pharynx and crowding upward and backward grasped the tumor firmly and locked the clamp on its base. Next the loop of wire protruding from the ends of the catheters out of the mouth, was carried under the handles of the forceps and drawn back into the mouth so that it must of necessity slide up behind the blades. The catheters were then removed, the wires being carefully held so they could not become crossed in the naris. Next, these wires were slipped through the tubes of a galvano-cautery ecraseur and the electrode and wires



Author's clamp forceps for removal of naso-pharyngeal tumors (⅓).

were made fast to the handle. The loop was now made tight on the tumor by turning the rachet on the handle. I then told the patient that as we burned off the tumor, it would necessarily cause pain, but I wished him to stand it as long as he could, and that I would cut off the current the instant he requested it. With this understanding, the current was turned on, the loop heated and allowed to burn into the tumor for about three seconds when at the patient's signal the current was cut off. He was allowed to rest for a minute or two and then the current was again turned on in the same way, the rachet being tightened in the meantime. Thus I proceeded burning into the base of the tumor about a sixteenth of an inch at a time until it was completely cut off, without very great discomfort to the patient and without hemorrhage. In this

case the clamp was of signal service because it would have been impossible to engage the tumor in the galvano-cautery loop without it. I believe that the instrument will greatly facilitate the removal of many of these tumors and will make the operation more thorough even when they might be removed without it, for with it the tumor can be secured at once and the loop of the snare when carried under the handles and drawn back into the mouth must necessarily engage the base of the tumor.

The naso-pharyngeal clamp-forceps has the general form of Loewenberg's naso-pharyngeal forceps. The blades, however, are longer and much more curved. The curved portion, which is two inches in length, is so shaped as to accurately fit the vault of the pharynx in the ordinary adult; each blade is protected at the back and outer side by a piece of ivory so that a short circuit will not be made when the galvano cautery snare is applied and the roughened faces of the blades are each provided with four short sharp spikes to prevent slipping. When the instrument was first made the curve was not so great as at present and the blades were not provided with the spikes. I found that it did not accurately fit the vault of the pharynx and furthermore that it would slip when the tumor was grasped. The present form appears to meet the conditions perfectly. The handles are provided with an arrangement for locking, similar to that used with many other forceps.

Paper.

ADDITIONAL NOTES UPON THE TREATMENT OF NASO-PHARYNGEAL FIBROMATA.

BY D. BRYSON DELAVAN, M.D.

At a certain scientific meeting held in London a few years ago, Mr. Thomas Annandale presented the history of a case of fibroma of the naso-pharynx which he had removed by the aid of a particularly severe preliminary operation.

In the discussion of the subject it was suggested that such heroic procedures were undesirable in view of the fact that much better results were obtainable through the newer electrical methods. To this Mr. Annandale replied that the best proof of the superiority of his method was the circumstance that the patient whose case was under discussion had been referred to him by the leading laryngologist of Edinburgh.

If any apology were needed for the continued presentation of this topic it would be well expressed in the above narrative. Notwithstanding the fact that methods which do not involve the formidable preliminary operations of older surgeons have been under successful trial for many years, and with incomparably brilliant results, even the members of our own special department have not in all cases learned to appreciate them, often advising a principle of treatment which should long ago have been abandoned.

In our Transactions of two years ago I published a series of statistics based upon the histories of a number of cases which had appeared during the past ten years. Believing that my search had not been complete and that it would be well to carry the investigation backwards to the date reached by Dr. R. P. Lincoln in his paper published in our Transactions for 1883, I have gone over the ground wth considerable care, investigating a very extensive amount of literary material, including current literature, text-books, theses and hospital reports. As complained of in my former paper the recording of the histories of these cases has been incomplete in so many instances that a large number of them are without the slightest value. Essential details are constantly

omitted from them, and time and again there is given a carefully written account of the operation and the histological findings without any reference whatever to the final outcome of the case. The hospital reports are especially noteworthy in this particular, only one great hospital in the world giving the simplest statements as to treatment, diagnosis and results. The institution which enjoys this highly creditable distinction is the Royal Infirmary of Edinburgh.

While the additions to my former list of cases have not been as extensive as the work expended upon the material would seem to warrant they are of considerable value, for it has been possible to select from the whole number of histories studied only such as appeared to be of undoubted reliability and to finally present a mass of them sufficient to furnish incontestable proof.

The result of these researches has been most satisfactory, for it has established the much disputed fact that the treatment of nasopharyngeal fibromata, formerly considered to be in the exclusive province of the surgeon is no longer justifiable by means of the formidable preliminary operations heretofore practiced. Contrasting the rate of mortality of the cases so operated upon amounting as it does to nearly 25.9 per cent.; of recurrences, 15.4 per cent.; making 40.75 per cent. of failures, with the record of 66 cases without a single death and comparing the other features of the statistics of the two classes of operation such as hemorrhage, recurrence and injury to the parts, it will be seen that the new methods have achieved a triumph so signal as to place them beyond the reach of further criticism or opposition and that the teachings of Voltolini and Lincoln have been completely vindicated.

In compiling the final results of treatment in the cases studied it has been necessary to use some discretion. Thus in all three divisions, namely cases treated by preliminary operation, by surgical methods through the natural passages and by electricity, certain cases have been reported as "improved." This word as applied to a case surgically treated would certainly mean that the patient had derived only temporary benefit from the operation. It could not be understood as implying a perfect and permanent cure. On the contrary, the final report would probably be to the effect that recurrence had taken place. In the cases treated by electrical methods the statement "improved, still under treatment" would have a far different significance and would imply an excellent

prognosis. It has seemed entirely justifiable therefore to omit the former class of cases altogether and to include the latter under the head of "cured." Should objection be made to this the removal of the cases from the statistics reported as "improved" would not practically alter their results.

It appears from the histories herewith presented that with one exception no one now living has had any considerable number of cases. The exception is the achievement of a member of this Association. I refer to the work of Prof. E. Fletcher Ingals, of Chicago, who seems to have operated upon a greater number of patients than anyone in this country or abroad. Moreover, his original contributions to the treatment of the disease, notably the suggestion as to the injection of lactic acid into the substance of the growth, have been of great practical value.

Many of the points which would suggest themselves from the cases which have been studied in the preparation of this paper were noted in my article of two years ago. In again calling your attention to the subject I have been actuated by a strong desire to establish the truth and to place it clearly and forcibly upon record. By reason of the peculiar difficulties in the way the material has been less abundant than we could have forseen and the information derived from it by so much the less complete. Therefore, "let us cherish a sober mind and take for granted that in our best performances there are latent many errors which in their own time will come to light."

However it may be in the present instance, we may at least console ourselves with this, that the treatment of fibroma of the naso-pharynx has passed from the hands of the general surgeon and that hereafter the application of simpler methods at the hands of the skilled rhinologist will be the approved and the successful means by which these distressing cases will be cured.

	TOTAL	CURED	DIED	RECUR	HEM.
BY PRELIMINARY OPERATION					
Resection of Palate.....	2	1		1	1
" Sup. Maxilla....	15	8	5	2	2
Temporary Resect. Sup. Max.	4	4			
Resection of Nose.....	3	1	2		1
Resect. Palate: Galv. Caut.	3	2		1	
Total.....	27	16	7	4	4
		59.25%	25.9%	11=40.75 15.4%	15.4%
BY NATURAL PASSAGES Surgical.					
Evulsion.....	20	19	1		
Cold Snare.....	21	20	1		
Total.....	41	39	2		
		95%	5%		
BY NATURAL PASSAGES Electrical.					
Electrolysis.....	37	37			
Galvano-Caustic Loop.....	12	12			
Galv. Caust. Loop and Electrol	8	8			
Galvano-Cautery.....	5	5			
Evulsion and Galv. Caut.....	4	4			
Total.....	66	66			
		100%			

Paper.

A METHOD OF RAPID EXTIRPATION OF NASO-PHARYNGEAL FIBROMATA, WITH REPORT OF CASES.

BY GORDON KING, M.D.

In the improvement and perfection of surgical procedures, I consider that simplicity, both in technique and in instrumentation, should always be an important desideratum.

In this age of active progression, many older methods of practice are becoming obsolete, and there is a feverish strife constantly going on among surgeons for the introduction of novel methods and appliances, the practical applicability of which is often seriously compromised by their complexity. It is painfully apparent at times that the author of a new method or device is impelled more by selfish craving for notoriety and gain than by the worthy desire to benefit humanity and elevate the standard of his profession.

This brief preface is to inform you that the operative procedure I desire to bring to your notice on this occasion bears no great claim of originality for the author of this paper and requires no studious attention to details or special instruments for its application. It is simply a plan of operating on post-nasal fibromata which has afforded me encouraging success when other means have failed of their purpose in my own hands.

To the subject of post-nasal fibromata and their successful treatment, every rhinologist must at some time give his most serious attention if he desires to entirely fulfil the exactions of his rôle and be prepared to do valiant battle with any nature of disease that comes within the scope of this work; for we must all confess that the management of these formidable tumors presents one of the most trying situations we are called upon to face, and our utmost resources may be brought to bear to avoid a fatal issue.

To be as brief as possible in the presentation of a very broad subject, I shall begin by excluding those forms of growths rather vaguely referred to as pseudo-polypi of the naso-pharynx, which have their point of attachment usually by a small pedicle in the

posterior part of the nasal cavity and become pendulous in the pharynx. Such growths generally offer but little danger or difficulty in their removal, as they seldom give rise to serious hemorrhage and can be extirpated by the ordinary well-known method of snaring. What we shall consider in particular is the true fibromata of this region, becoming evident usually during the period of adolescence, springing from the margin of the posterior choanæ or the pharyngeal vault, highly vascular in structure, though tough and fibrous, and with an almost malignant tendency to rapid development and invasion of contiguous parts.

Their clinical appearance and pathological features are too well-known to warrant further description than will be brought out in the histories of the three typical cases I shall cite; therefore, I shall devote no time to details of examination and diagnosis.

When a case of this kind comes under our care, the only serious question involved is, "How can we best accomplish its complete removal and incur the least risk to the patient?"

Shall we be conservative and resort to such plans of treatment by which we may hope to bring about its slow destruction or retard its growth until the active stage of its development is past, or shall we face the situation boldly and attempt a radical extirpation?

Before deciding this momentous question, let us consider briefly what these different plans of treatment offer in the way of advantages and disadvantages.

The wisdom in conservatism here must hinge upon two questions: Does the condition of the patient permit of any temporizing method? Do any of the conservative measures offer reasonable hope of destroying the growth or preventing its development?

Unfortunately, these cases are often brought to us only when the tumor has already attained considerable dimensions and a state of cachexia similar to that accompanying cancer has become apparent. We know that at a certain stage these growths may seriously interfere with rest by causing pain from pressure and obstructing the nasal respiration, and that they may affect the general nutrition by their tendency to slough and bleed.

In such conditions, delay is more dangerous than an attempt at immediate removal of the growth and we should so advise our patient, and only upon the refusal of radical operation are we justified in attempting a conservative course of treatment.

If this be the case or the general condition of the patient is satisfactory enough to permit of a slow treatment, let us consider what means we have at our disposal to gradually destroy the tumor, cause its absorption, or prevent its development until the patient arrives at the age of twenty-five years, when we know the growth may reach its maturity and remain in statu quo, or undergo a process of atrophy.

Records of cases successfully managed on this plan are exceedingly rare, and on the other hand we have but to consult our own experience and that of others to realize how ineffectual, as a rule, are all the methods that have been applied to accomplish such results. Ignipuncture, while it may cause some destruction of the mass by producing a slough, seems to excite too much inflammatory reaction which tends to increase the rapidity of growth rather than retard it.

Electrolysis causes sloughing which may lead to serious hemorrhage and bring about a state of cachexia.

The situation of the growth renders its proper application also very difficult at times. The same may be said of application or injection of acids and escharotic agents. It may be said, in general, that all methods, the purpose of which is to produce sloughing of the tumor, are unreliable and unsatisfactory in their results.

Restriction of the blood supply by ligation or compression of the arterial trunks might in other situations afford a favorable means of arresting the progress and perhaps of causing ultimate atrophy of the tumor; but these tumors are so situated as to receive their blood supply from the carotids of both sides, and hence it is extremely difficult to obtain sufficient diminution in the supply by compression or ligation to have great influence on the growth.

This plan of treatment, however, offers a fruitful field for experiment and I believe may lead to interesting results. Some facts noted in the history of my third case are of interest in this connection.

We may mention still another conservative method of treatment which has been tried for the cure of neoplasms of this nature, and that is the Roentgen rays.

Since its advent into the field of therapeutics, volumes have been already learned of its inefficiency in curing tumors other than epithelioma of the skin and, so far as I can ascertain, no case of this kind has ever been cured or even markedly influenced by it.

If we reject as hopeless or uncertain these various conservative methods, and the decision as to radical operation is left to our judgment, why hesitate to attempt extirpation of the growth? In my opinion hesitation should be based alone on choice of operation, for, knowing the malignant tendency of the growth, it is only by operation that we can conscientiously assure our patient of a chance for his life. While we are to be influenced in great measure by the special features of the individual case, there are three obstacles that beset the path of the operator, whatever plan he may decide upon. They are (1) difficulty of access to the growth for its complete removal; (2) danger of excessive hemorrhage; (3) danger of suffocation and pneumonia from aspiration of blood into the lower air passages.

Recurrence of the growth is the rule, unless the extirpation is complete and includes the base of attachment. It is highly important, therefore, to ascertain, if possible, before operation, the situation and extent of its attachment. This may offer serious difficulty on account of the volume of tumor mass, which, in its rapid development, may entirely occupy the post nasal space and send prolongations into the nasal cavity, so that no definite idea can be formed of its base by visual examination alone. Digital examination is then necessary, but should be made with gentleness and caution for fear of hemorrhage being provoked by the manipulation.

If the tumor be freely movable and attached by a pedicle much smaller than its body, its removal may be effected more easily and with less hemorrhage than when the growth is sessile and invades the surrounding regions.

The excessive volume of the growth may also greatly hamper the manipulation of instruments through the nose or mouth, and this fact has led to the performance of preliminary external operations, such as temporary resection of the maxilla, division of the palate, etc. to allow freer access to the region. Such operations, I believe, are seldom justifiable, except where extensive invasion into the spheno-maxillary fossa or antrum has occurred, for the patient is thereby subjected to unnecessary disfiguration, shock and hemorrhage. The technical skill of the trained specialist should enable him to overcome the obstacle presented by the apparent inaccessibility of the growth and effect its removal by the mouth or nose. How that may be accomplished we shall presently see.

Excessive hemorrhage is always the greatest source of danger, howsoever we may attempt the removal of these tumors. Even careful manipulation sometimes leads to sudden and violent hemorrhage from the substance of the growth, and this fact renders the piecemeal method of removal extremely dangerous and tedious. To cut into the body of the tumor or to remove a piece, leads to such a gush of blood that we are compelled to give our entire attention to checking it and hence can proceed but slowly. It is a known fact, however, that once the pedicle is cut through or the body of the mass removed, the hemorrhage tends to subside spontaneously or can be quickly controlled by packing.

This shows the necessity of operating quickly, of attacking the pedicle at once and extirpating the body of the growth. When this can be accomplished there is little need for temporary or permanent ligation of the carotids in the neck as a preliminary measure, unless the patient is in an extremely weak condition, or anemic from former hemorrhages.

The third danger to be encountered is the embarrassment of the respiration caused by the manipulation through the mouth or by the flow of blood into the larynx. This latter accident may produce immediate suffocative symptoms or later lead to pneumonia. The Rose position is not always sufficient to prevent this and the hemorrhage is undoubtedly increased by the pendant position of the head. To avoid any trouble from this source and to allow of free manipulation through the mouth, I think it usually advisable to perform a preliminary tracheotomy, the tracheal wound to be closed when the tumor is out and all bleeding checked. A Trendelenburg cannula is not required if the Rose position is maintained during the period of active hemorrhage while the pedicle is being cut through.

If we accept the correctness of these observations concerning the necessity for rapid excision of the growth without preliminary external operation other than tracheotomy, how then shall we proceed to accomplish this trying task? It is needless to say, we should have at hand everything needed to arrest bleeding by packing the nasal cavities and naso-pharynx and for ligating the carotids as a last resort, if necessary, and for saline infusion.

For most pedunculated growths of the nasal or postnasal cavities the cold wire snare or the galvanic loop can be used to great

advantage, but for these fibrous tumors they often fail of their purpose.

The structure of the pedicle is so dense and tough that a cold wire will almost invariably give way when tightly drawn and break without cutting through. Theoretically, the galvanic loop offers the best chance of extirpation with little loss of blood, but its practical application is generally disappointing, as the heating of the loop is difficult to regulate and it stands little strain when tightened around the pedicle.

Doyen, of Paris, and Escat, of Toulouse, have had excellent success with special instruments they have devised for rapid removal of such tumors through the mouth. I tried them on one of my cases with most unsatisfactory result and am of the opinion that they are only applicable in a certain number of cases where the volume of the mass is yet small. My failure, however, I confess, may have been due to lack of skill in the use of them, which these operators exhibit to a remarkable degree.

My own plan of action is simple in detail, inflicts less traumatism and has enabled me to excise the bulk of the growth more quickly and effectively than other means I have essayed. It is as follows:

Under chloroform anesthesia a high tracheotomy is performed and a tube inserted. With the patient in the Rose position, the head supported by an assistant, and a mouth gag in place, the index and little finger of the left hand are introduced in the nasopharynx to carefully ascertain the outlines of the tumor and the position and extent of its base of implantation. This step in the operation is of great importance, for as soon as the size and point of origin of the pedicle is made out, the fingers are to serve as a guide for the operation of a pair of scissors introduced through the nose on the side where the pedicle is more accessible. The scissors to be used for this purpose are a strong pair with long handles and short blunt blades, slightly curved on the flat. The long handles offer a strong leverage, so that the toughest tissue can be cut through with them. The closed blades are introduced carefully along the septum until the point can be felt in the nasopharynx. It is then guided by the fingers to the pedicle and with the convexity of the blade uppermost the pedicle is vigorously attacked and divided. As soon as the tumor is felt to be detached in the pharynx, it can be drawn out by the fingers through the mouth, and immediate attention be given to checking the flow of

blood which gushes copiously from the moment the first cut is made.

The introduction of a gauze pack aided by the natural tendency to spontaneous arrest when the tumor is removed will check the bleeding in a very short time.

The head can then be brought to a level with the table and if we are satisfied that none of the body of the growth remains behind, we can proceed to remove the tracheal tube and close the wound. In this manner the bulk of the growth, at least, can be removed and if the hemorrhage has been copious, the patient should be allowed a few days to recuperate before being subjected to further operation for the complete removal of what may remain behind.

Too much time should not be lost, however, in attacking the root of the tumor, which, as early as possible, should be examined closely by anterior and posterior rhinoscopy. Remaining fragments can be removed under light with snare, cutting forceps or scissors or destroyed by the use of cautery, without further danger of serious hemorrhage. Knowing the tendency such tumors sometimes exhibit to recur rapidly after removal, great care should be taken to make the extirpation as complete as possible and the case should be kept under observation for several weeks to suppress any new development.

The following cases demonstrate the practicability of the method of extirpation by the bucco-nasal route alone, whether aided or not by the precautionary measures of tracheotomy and carotid ligation.

Case I.—H. L., a mulatto, farm laborer, 20 years of age, native of Louisiana. Mother has tuberculosis and father has large tumor of chest wall, which from patient's description seems to be a lipoma. Patient has been subject to frequent colds and had pneumonia and measles in his earlier youth.

Six months before coming under my care had a polypoid growth removed from nose, the recurrent symptoms of which, associated with epistaxis and headache, brought him to consult at the clinic of the Eye, Ear, Nose and Throat Hospital of New Orleans in the month of November, 1899.

Examination at that time revealed a fibrous growth filling right nasal fossa, with a similar mass hanging in post-nasal space. Two attempts were made to remove it with strong piano wire and Bosworth snare, and each time the wire broke, under great strain, without cutting into the tissue. A third loop was thrown over it

and the slow method tried, the snare being kept on for 24 hours and gradually tightened. It broke, as did the others, and considerable loss of blood resulted. I then attacked it with long scissors, introduced through the nose under partial cocaine anesthesia, and succeeded in removing the growth *en masse*. Hemorrhage rather violent, but quickly controlled by pressure with tampons. Point of origin of tumor found to be vault of pharynx and upper margin of right posterior choana, which was afterwards subjected to galvano-cauterization. Three months later no evidence of recurrence could be observed.

Case II.—J. U. B., white boy, 14 years of age, from Northern Louisiana, with fibrous growth about size of small hen's egg in naso-pharynx, with small prolongation in right nasal fossa. History of nasal obstruction beginning about two years previously and lately associated with occasional hemorrhages, one attack of which had been very alarming. General condition fairly good. Digital examination cautiously made to avoid bleeding showed growth to be only slightly movable and attached by rather broad base to vault or pharyngeal walls.

The little patient was kept in bed for six days before operation, given strychnine as a tonic and allowed full nourishing diet. A cleansing alkaline spray was ordered for nose on account of free muco-purulent discharge from the right nostril.

Preliminary to attacking the growth, preparation was made for saline infusion and for post-nasal plugging. Tracheotomy was then performed, a mouth gag inserted, a piece of heavy ligature silk passed through tongue to make traction and a small rubber catheter passed through the left nostril and the ends tied over lip to retract the palate. When this was done, the tumor could be plainly seen hanging below the palatal border. With the patient in the Rose position, the index and middle fingers of left hand were introduced behind it and with the scissors plied through the right nostril the pedicle was vigorously attacked and cut through. Blood flowed freely for a moment, but as soon as the mass was removed from the mouth, a gauze pack quickly inserted and the head raised to a level, the hemorrhage was controlled.

The tracheal tube was removed and the wound closed with sutures.

On third day the temperature began to rise and a bad odor emanated from the gauze packs, so they were removed. No bleeding of consequence occurred. Inspection of the nasopharynx revealed some slough fragments and a small part of the tumor left behind. These were removed under cocaine anesthesia by means of forceps applied through the nose. Ten days later he was allowed to return home, instruction being given parents to have the boy kept under close observation and to bring him back at once when any tendency to a recurrence manifested itself. Six months

passed and no return of the growth was reported. It is now almost a year since its removal and the boy is still well.

Microscopical examination was made of the growth at the New Orleans Clinical Laboratory and it was reported as a fibro-sarcoma, but the clinical history of the tumor was sufficient, I think, to confirm the diagnosis of pure fibroma.

[Since reporting the above observation Case No. II returned with a recurrence of the tumor slightly smaller in size than the original mass. Its removal was effected by the same method without tracheotomy, and special precautions were taken to make the extirpation complete and prevent its return a second time.]

Case III.—H. B., a youth 15 years of age from Connecticut, came under the care of Dr. de Roaldes and myself in the month of December, 1901, through the courtesy of our esteemed friend and fellow member, Doctor H. L. Swain, of New Haven, who had directed him brought to our genial clime to avoid the severity of the New England winter. The case had been under his observation for about three years and on account of the parents' refusal to consent to a radical operation Dr. Swain had been forced to resort to conservative treatment. At that time the tumor, which was an exceedingly vascular fibroma attached in the pharyngeal vault and with a nasal prolongation occupying and dilating the right fossa, had already reached the sloughing stage, and several abundant hemorrhages had weakened and exsanguinated the patient very much. When he first came under our observation surgical interference was not considered advisable on this account, but under the influence of our mild climate, a nourishing diet and tonic medication his state of health improved so much in two months that we felt justified in attempting radical removal of the growth, and so advised the parents. The tumor had been gradually increasing in size until the nasal portion reached anteriorly to within half an inch of the vestibule of the nose. In the right cheek could be seen and felt a rounded movable fibrous tumor about the size of a walnut, apparently independent in its development of the postnasal growth. Parental consent being finally obtained for operation, I decided to attempt its removal with the Doyen instruments under cocaine anesthesia. Accordingly, on February 25th cocaine and adrenaline were freely applied and with the brave little patient in the sitting posture I endeavored to forcibly detach the pharyngeal portion by the Doyen method and remove the nasal prolongation with cutting forceps. The pain inflicted by the effort and the great loss of blood forced me to desist before I had succeeded in removing more than a third of the tough resistant mass. Microscopical examination of the part removed gave report of a telangiectasic fibroma, which corresponded with the diagnosis made by Dr. Swain. The shock and loss of

blood so debilitated the boy that we had to give attention to building him up before any further intervention could be practised.

A seven weeks' sojourn in the country did much towards restoring his former strength and vigor, so that upon his return preparation was again made for operation. After consultation with Dr. F. W. Parham of our city, we decided to operate under chloroform anesthesia and to adopt the precautionary measures of preliminary tracheotomy and carotid ligation. Twelve days previous to operation he was kept in bed, given stimulants, tonics, strengthening diet and daily inhalations of oxygen. Operation May 6th. The carotids were exposed by Dr. Parham. The right external was tied, and ligatures were passed under the common carotids of both sides to make compression if necessary when the tumor was being cut through. I then performed tracheotomy, transfixed the tongue with a strong silk ligature, tied the palate forward with a rubber catheter passed through the left nasal cavity, inserted a mouth gag, and placed the patient in the Rose position. While compression was being made on the free arterial trunks I attacked the growth with the scissors, as in the preceding cases, and by vigorous efforts cut through the thick fibrous mass close to its attachment and brought it out through the mouth. In spite of our control of the arteries the hemorrhage was almost overwhelming for the patient, and when controlled by gauze packs saline infusion had to be practised immediately. This was skillfully done by Dr. E. D. Martin, whose valuable assistance we had obtained also. The patient responded well to the infusion, and as bleeding into the pharynx had ceased, the tracheal tube was removed and the wound closed. The carotid compression was removed except for the right external which was left ligatured with a view towards prohibiting the tendency to recurrence. Again the boy showed remarkable recuperative powers and on the fourth day allowed me to remove the gauze packs and inspect the nasal and post-nasal cavities. The vomer was found to be displaced completely over to the left side, and the right nasal cavity enormously dilated. A small part of the base remained attached to the body of the sphenoid in the posterior part of the nasal fossa. In addition to this the tumor had sprung from a broad base including nearly the half of the pharyngeal vault. Rapid convalescence took place and in ten days after operation the patient was taken to his home in New Haven with instructions to put himself under the care of Dr. Swain immediately upon his arrival. No attempt had been made to remove the tumor in the cheek, but at the time of his departure there had been a considerable diminution in its size, which we attributed to the effect of the carotid ligation.

I am much indebted to Dr. Swain for the previous history of the case and for information as to the subsequent course of it, which has been a very unfavorable one. A recurrence had taken place involving the antrum and perhaps invading the pterygo-maxillary

region, and as the parents radically object to another surgical intervention, the X-ray was being used with the hope of staying its progress or causing its absorption.

I regret exceedingly that the time limit does not permit me to record in full the details of this case, as it presents a fund of interesting facts I am forced to omit.

Discussion on the Papers of Drs. Delavan and King.

Dr. W. P. PORCHER exhibited a naso-pharyngeal fibroma removed through the mouth with the cold snare. The mass was six inches long and weighed three hundred and ten grains. The patient was a negro boy aged 16 years. Removal in July, 1900, was easily effected without hemorrhage. There had been no recurrence to date, as far as he knew.

Dr. R. C. MYLES was greatly interested in the history of the last case mentioned by Dr. King, as he had had one like it. Treatment had been by electrolysis and the case was undoubtedly included in Dr. Delavan's list. Later there had been a recurrence of the growth involving the molar bone and superior maxillary. Dr. Wyeth had done an external operation, in the course of which the internal maxillary artery had been cut into with the saw. Bleeding was profuse but was checked by packing and the operation continued.

The antrum was found full of the growth, which was a vascular fibroma and had extended from the sphenoid through the internal nasal wall. Forceps evulsion removed a very large tumor *en masse* and apparently complete. The patient at the time was over 21 years of age.

Recurrence took place in a few months, involving especially the sphenoid and posterior pharyngeal wall. The growth had been exceedingly rapid. With the galvano-cautery snare, several pieces had been removed so as to allow sufficient space for breathing. A second recurrence was followed by the same treatment. At the age of 27 the tumor had entirely disappeared and the patient was well when heard from a few years later. If we could keep these recurring growths, by our intervention, down to a reasonable size, age would finally cure them.

Dr. H. L. SWAIN referred to the case which had been sent by him to Dr. King and mentioned in the latter's paper. Up to the present time the boy had suffered from a sloughing of the tumor every six months. At such times masses came away from the tumor proper nearly equal in the aggregate what is shown in the bottle. Masses also came from the part in the cheek and apparently came through the wall of the antrum out into nose. The tumor was now growing again and the boy was under the electrolytic treatment. Radical measures and temporizing in this case had both failed. Each time the sloughing took place the boy was

brought down to the valley of the shadow of death and from the excessive bleeding it had been necessary on one occasion for a physician to remain constantly at the patient's house for a period of seven days.

Dr. DELAVAN in closing the discussion called attention to the many peculiar features of Dr. Swain's case and said that while microscopical examination of the tumor had always resulted in the diagnosis of fibroma the clinical history of the growth was far from typical.

Paper.

HISTORY OF A CASE OF EARLY APPEARANCE OF BILATERAL ADDUCTOR PARALYSIS OF THE VOCAL CORDS, DUE TO A MEDIASTINAL GROWTH (CARCINOMA), WITH RADIOGRAPH.

BY WILLIAM KELLY SIMPSON, M.D.

History.—W. B., male, age 44, admitted April 4th, 1902. Died July 29th, 1902. Father died of cancer of the throat, mother died of apoplexy, three brothers still living, all nervous, father non-alcoholic, but was very nervous. Venereal, but no specific history, has been moderately alcoholic, but of late years abstemious, heavy smoker, excepting last three months, moderate coffee drinker, excessive tea drinker. Measles in childhood. Before eighteen had several attacks of bilious (?) fever. Fever twelve years ago (intermittent fever) and severe nervousness at the same time. At that time his physicians said he had some heart trouble—he could not sleep at night without sitting propped up in a chair. There was slight discomfort over heart.

Has been in this country ten years, and for last seven years has had attacks of dragging down sensations, sleeplessness, sweatings, and has been very nervous all the time. Last June he began to have attacks of retching and discomfort in the epigastrium; these persisted for some days and then the voice began to get weak; for two days it was completely lost. The aphonia was not complete as in this present attack. It persisted for almost a week when the voice gradually returned.

Present Illness.—About eight weeks ago he began to notice the

voice getting weaker again. It gradually became more so for fourteen days when his present state of aphonia was reached. Preceding this aphonia he had a bad cough for four months of severe paroxysmal character, but with very slight expectoration. Once or twice the sputum was blood tinged. He thinks that for a few days and before the onset of the aphonia he had a slight pain in the right shoulder.

He went to one hospital for three weeks where a diagnosis of tubercular laryngitis was made. Then he came under my observation at the Vanderbilt Clinic for the first time, suffering from complete aphonia which was practically the only symptom presented; the vocal cords showing a complete bilateral adductor paralysis, the cause of which for the moment could not be definitely made out, though it was ascribed to a probable mediastinal pressure, as there were indefinite physical signs pointing to such a conclusion. He subsequently entered another prominent hospital where, after careful watching for ten days he was discharged with a diagnosis of hysterical aphonia. There has been some sweating at night and loss of eight pounds in four weeks. He then entered the Presbyterian Hospital at my request, on April 4, 1902, at which time the above history was elicited, and from which date the remainder of the history is continued, being taken from the official records of the hospital.

Physical Examination.—Patient well nourished. Does not appear anemic. Tongue moist, highly coated. Pharynx and tonsils congested, otherwise normal. No pharyngeal anæsthesia. Voice almost completely lost, can only speak in a whisper. Pupils are equal and react to light, somewhat contracted, no corneal anæsthesia. Slight enlargement of the superficial glands in right axillary and both inguinal regions.

Heart.—Apex impulse not visible, barely palpable in fifth space four inches to right of midsternum just inside of mid-clavicular line. Sounds are best heard at this point. Left limit of dulness one-quarter inch inside this line. Action is regular and slow. Sounds are distant but clear and of good force. Basal sounds are of normal intensity. No murmurs could be made out. Pulse is regular, of good force, no increase in tension, the two radial pulses are of equal volume and force, also synchronous.

Thorax.—Thorax is symmetrical, no pulsations or bulging made out.

Lungs.—Anteriorly, slight comparative dullness in first left space, for a distance of two and a half inches to left of sternal border. In first left space the breathing is high pitched and somewhat tubular in quality. Over the whole of left chest expiration is prolonged and higher pitched than on right side. Posteriorly these signs obtain as low as spine of left scapula, but no dullness is present.

Liver.—Percusses from fifth space to free margin of ribs, the edge cannot be felt. Spleen does not percuss, large, edge cannot be felt.

Abdomen.—Soft, not distended, no tenderness.

Extremities.—Upper are normal excepting for tendency to clubbing of finger tips and slight cyanosis. Lower extremities normal.

Special Senses.—There is no contraction of visual field, no loss of sensation to pain, touch or temperature. There is some bilateral loss of taste. Patient cannot taste salt placed on circumvallate papillæ, no anosmia.

Larynx.—Examination made by myself. Complete bilateral adductor paralysis of vocal cords, inability to make any expulsive cough; any attempt at coughing being with great effort and with very weak sound (voiceless cough) with no motion of cords during the attempt and great difficulty in dislodging any accumulation of mucus in the larynx.

The irritation from the accumulation of mucus in the trachea and larynx, and the desire to expel it, coupled with the inability, produced almost constant severe efforts at expulsion which became more and more marked as the case progressed. The mucous membrane of the larynx was extremely pale in color, there being but little contrast between the vocal cords and the rest of the intra-laryngeal surface. There was no other intra-laryngeal lesion.

April 10th.—Dyspnea is more marked; coughing spells more severe and frequent. Condition seems worse each day since admission.

April 13th.—Electric sparks were drawn from anterior aspect of neck last night, which seemed to temporarily strengthen the voice.

April 23rd.—Patient is coughing up large amounts of watery expectoration. Expiration at the apices posteriorly is markedly prolonged and higher pitched, an occasional subcrepitant râle

heard. There has been a slight rise of temperature for three days. Cause not discovered.

April 25th.—Temperature rose from 99 to 104 during last night. This morning it is down to 100. Slight chilly sensations. Still no cause for rise of temperature ascertained.

April 29th.—Temperature continues irregular. Tubular breathing is more marked this morning, on left side it extends down as far as spine of scapula, no change in percussion note or breathing sounds.

May 4th.—Laryngeal examination my myself reveals no change from former condition.

May 6th.—Patient is gradually losing ground.

May 15th.—This morning complains of pain shooting down right arm. Temperature 101.5. No change in physical signs observed.

Since May 15th several injections of toxines of streptococcus, have been employed with moderate reaction. Patient continues to lose weight, signs in the chest same.

June 14th.—Patient feels weaker; there is some loss of power in both hands especially in the left, complains of considerable pain in back of neck. No appreciable change in thoracic symptoms. Very little reaction from injections of Coley's fluid.

July 3rd.—Patient is losing strength and flesh, voice much weaker, some tubular breathing at apices posteriorly, slight bloody expectoration.

July 29th.—Patient has continued to lose ground, had a bad attack of dyspnea which lasted all night. Great difficulty in breathing this morning. Became rapidly worse and died at 9.10 P.M.

Autopsy.—Made by Dr. Tuttle. Frame, medium; adipose scant; muscle atrophied.

Diaphragm.—Fourth rib left. Fourth rib right.

Heart.—Pericardium contains 240 c.c. of turbid serum. Valves normal. Muscle appears a little atrophied, brownish.

Pleural Cavities.—Some slight adhesions around the bronchi. In lower part of upper lobe is an area of pneumonia, yellowish grey in color. There is a mass of cancerous lymph nodes around the bronchi, and the new growth ramifies along the bronchi throughout the lower lobe and causes an uneven thickening of the walls of the larger bronchi.

Right Lung.—A little adherent on inner surfaces to mediastinal

growth. The bronchial lymph nodes and the walls of the large bronchi are cancerous. Remainder of right lung normal.

Peritoneum.—There is a mass of retroperitoneal lymph nodes moderately enlarged and cancerous and a few scattered ones just down along the lumbar vertebræ.

In the superior mediastinum is a hard irregular mass extending from the sternum in front to the vertebral column and from near the thyroid cartilage above, down behind the precordium nearly to the diaphragm. It surrounds the bifurcation of the trachea and the large vessels passing to both lungs completely surrounding the arch of the aorta and the large ascending branches. In front is a flattened layer about three-quarters of an inch thick occupying the position of the thymus gland and the remainder being made up of cancerous lymph nodes.

On laying open the esophagus a portion lying behind this mass shows a number of whitish nodules projecting on the inner surface and without any ulceration, the mucous membrane apparently being intact. The two large bronchi also show cancerous masses narrowing the lumen but without any apparent ulceration.

Abnormal Conditions.—Carcinoma of mediastinal glands. Carcinoma of left lung. Carcinoma of retro-peritoneal glands. Acute lobar pneumonia.

Microscopical Report: Liver.—Quite diffuse capillary dilation. Small angioma, more or less injury to hepatic tissue in neighborhood.

Lungs.—Extensively invaded by cancerous growth. The cell groups are of variable size and shape. The cells themselves mostly medium, large and round. Much connective tissue formation with small groups of leucocytes and slight hemorrhages have extensively obliterated structure of lung. Some small pneumonia areas. Some normal alveoli.

Mediastinal tissue also cancerous but the connective tissue is more dense and the cell pockets are larger.

During the patient's early stay in the hospital the radiograph was made which I here present. It shows to a certain extent the outline of the mediastinal tumor, on the left, which corresponds to the physical examination as reported.

In the recital of this history I have omitted the details of treatment, bedside notes, and the various blood examinations

which have been strictly performed but bear no especial relation to the progress of the case.

The object of presenting the history of this case from a laryngeal standpoint is three fold.

First, to record an instance of complete permanent bilateral paralysis of the vocal organs which is the rarest form of laryngeal paresis.

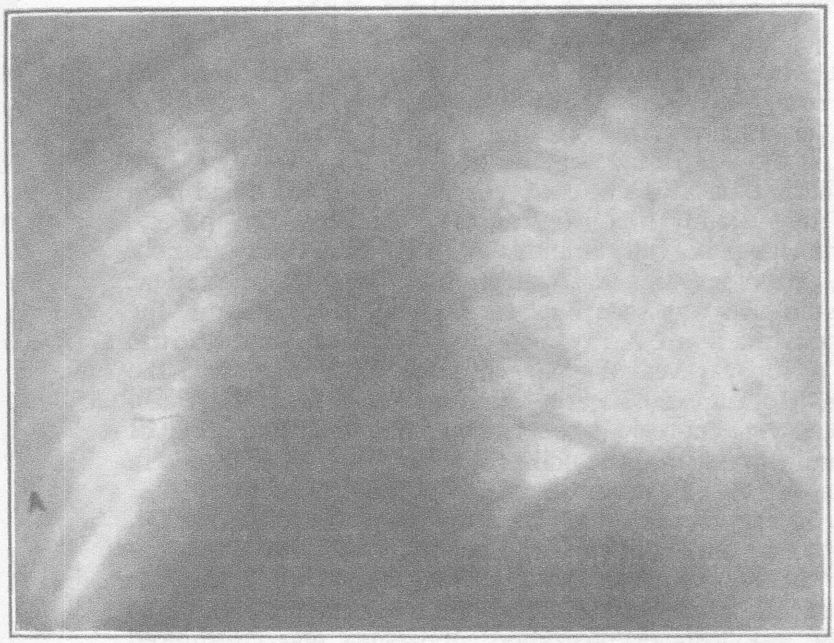

Second, to emphasize the early appearance of laryngeal paralysis as an indication of intra-thoracic pressure, which is so commonly observed in unilateral paralysis and often, as in this instance, antedating any positive physical signs within the chest, and,

Third, to note the difficulty of exactly defining the lesion even when autopsy has proven it to be extensive, and, as an additional reason, the diagnostic assistance rendered by an X-ray examination.

In using the term complete bilateral adductor paralysis in this case, I do so with due caution and appreciation of the term "cadaveric" position, which is, I think, but comparative and according to Fein[1] a misnomer—he having found ten different positions

[1]Mayer, in Posey and Wright's Text Book, 1903, p. 1153.

in the cadaver. I made repeated examinations of the larynx and was much impressed with the completeness of the abduction, it having much more than the usual appearance of the so-called cadaveric position.

I wish to acknowledge the assistance of members of the medical House Staff at the Presbyterian Hospital and Dr. S. F. Jones, pathological interne, in presenting this report.

Discussion.

Dr. EMIL MAYER wished to ask if any spinal conditions had been found, or any erosions indicating pressure on the cord, at the postmortem examination.

Dr. C. F. THEISEN stated that he had seen, a few years ago, a case of unilateral paralysis of the recurrent nerve which had been reported in the "Albany Medical Annals," October, 1899, p. 547. The left cord was practically immovable in the cadaveric position. Dyspnea had been severe and tracheotomy advised. The patient went to Boston and was seen by Drs. Farlow and Williams, the latter of whom made an X-ray examination and reported aortic aneurysm. Autopsy revealed enlarged retro-tracheal glands, the size of a small orange, implicating the recurrent nerve and also the pneumogastric; there had been an anomalous distribution of the latter trunk, pressure on which probably caused sudden death. The tumor seen behind the aortic arch simulated aneurysm.

Dr. J. W. FARLOW stated that when the case referred to by Dr. Theisen first came under his observation there was extreme dyspnea and the question came up as to whether tracheotomy was advisable. There was a paralysis of the recurrent nerve, but no laryngeal swelling, ankylosis or ulceration. Dyspnea was considered as due, not to laryngeal obstruction, but to some infraglottic cause. There were no pulse changes and there was no tracheal tugging.

The condition as seen by the fluoroscope strongly suggested aneurysm and the diagnosis was made of probable aneurysm of the aorta not sufficiently large enough to cause tracheal tugging or pulse changes. This was several years ago when the limitations of X-ray methods were not as well defined as they are now.

Dr. SIMPSON in closing the discussion stated that no spinal lesions had been found. Great interest attached to the peculiar distribution of the cancerous mass in the bronchi as it nearly obliterated them all the way down.

Candidate's Thesis.

THE ETIOLOGY OF NASAL POLYPI, WITH ESPECIAL REFERENCE TO THEIR ASSOCIATION WITH OTHER PATHOLOGICAL CONDITIONS.

BY FRANCIS R. PACKARD, M.D.

On but few subjects in rhinological literature has there been more written than upon nasal polypi, and upon no subject does there seem to exist quite as much confusion in the matter of nomenclature. As these growths occur with such frequency, and lend themselves so readily to microscopical study, it is greatly to be regretted that more laboratory work has not been done in the effort to clear up their true nature. The real stumbling block has been due to the fact that so many rhinologists have described them solely from their clinical aspects, and without any effort to study their histology.

A brief study of the nomenclature employed in reference to nasal polypi is sufficient to convince us of the confusion or ignorance which exists in the minds of many rhinologists as regards these frequently found tumors, and should stimulate us to a more scientific study of their pathological anatomy, and of the morbid conditions producing or accompanying them. Jonathan Wright ("Trans. Am. Lar., Rhin. and Otol. Soc.," 1901) has recently contributed a most interesting resumé of the historical side of the subject, beginning with the views of the ancients, and coming down to the most recent time, comprehending not only the work of rhinologists, but also that of the pathologists. It is unnecessary to quote from Dr. Wright's article at length, as it is readily accessible and should be consulted by those interested in its entirety. It is, however, of importance that we should direct attention to his authoritative statement as to the non-myxomatous character of nasal polypi. He regards them as "Pendent tissue in the nose which has assumed that shape because of the effusion of serum into it from the blood vessels"—and after distinctly stating that they are in no way to be regarded as myxomatous tumors, he gives

the following able summary of their true pathological histology: "while in the fluid of a polyp, there is some mucin derived from glandular structure the polyp may contain, while here and there by careful focussing, an occasional embryonal new connective-tissue cell may be seen, there is little or no new formation of tissue, but on the contrary a separation of the fibers of the pre-existing sub-epithelial stroma by serous effusion. In not a few cases, these stroma fibers are so scanty, or the effusion of serum is so directly under the epithelium that the coagulated fibrin threads form the sole framework of the tumor, holding a few leucocytes in their meshes." Goodale has recently ("A Treatise on Diseases of the Eye, Nose, Throat and Ear," edited by Posey and Wright, 1902) expressed the same view stating that "true myxoma has not been reported from the nose." He regards nasal polypi as "circumscribed hypertrophies," and writes "The stroma of these growths consists of more or less connective tissue, the meshes of which contain round cells and albuminous fluid. They are covered by a cylindrical epithelium which in places exposed to external irritation, tends to become altered into pavement epithelium. The glands of the growth may be increased in number, having in the majority of cases the character of mucous glands. At times there occur in them so-called serous glands. The acini of the glands often show cystic dilatation, which may at times be so marked as to form a cyst occupying the greater portion of the growth." E. Fletcher Ingals ("Diseases of the Nose, Throat and Ear," by Burnett, Ingals and Newcomb, 1901) likewise writes as follows: "Nasal mucous polypi are not myxomata, but outgrowths from the connective tissue of the nasal mucous surface, and hence are to be considered fibromata," representing "a hyperplasia in a state of edema."

At the meeting of the American Laryngological Association in 1899 there was a symposium on the relation of pathological conditions of the ethmoid region of the nose to asthma. Dr. Henry L. Swain discussed the matter from a pathological standpoint. He stated that in his view nasal polypi were simply edematous hypertrophies, and traced their etiology to hypertrophies of the turbinal tissue, which as a result of repeated attacks of congestion had become stretched and flabby, and as a result of their dependent position infiltrated with clear serum. Drs. Clarence C. Rice and E. Fletcher Ingals wrote on the clinical phases of the relation of the

ethmoid disease to asthma, pointing out the frequency with which they were found together. Dr. F. H. Bosworth, in the closing paper of the symposium, in writing on the subject, stated that he believed "Polypoid degeneration of the mucous membrane of the nose, edematous hypertrophy of the mucous membrane of the nose, and nasal polypi all indicate and are clear symptoms of ethmoiditis," and he strongly urged rhinologists to bear in mind the fact that polypi were symptoms of an underlying ethmoiditis. The discussion of the four papers elicited the usual variety of views as regards the etiology and pathology of intranasal polypi.

The fact that they are not true myxomatous tumors is asserted by Kyle ("Text-book of Diseases of the Nose and Throat," 1901) who, while dealing with polypi under the heading "Nasal Myxoma" states that they are the result of myxomatous degeneration of the mucous membrane and are in no sense new growths. Bosworth, on the other hand ("Treatise on Diseases of the Nose and Throat," 1893, Vol.I, page 387) entitles chapter XVIII of his book, "Nasal Polypus or Myxoma," and writes "The prevailing type of these tumors is that of pure myxoma, with certain more or less well marked variations, attendant probably, either on their immediate origin, or perhaps on certain adventitous features of their subsequent development, surroundings, or life." Bosworth's classification is that which was used by J. Solis-Cohen and Morell Mackenzie in their treatises, and is probably that which is most commonly adopted by the authors of articles on polypi in the current periodical literature.

In foreign rhinological literature the same confusion of terms exists. Zuckerhandl ("Normale und Pathologische Anatomie der Nasenhöhle") was inclined to regard polypi as adenomata, although as Bosworth points out his classification included within its limits some formations which can hardly be properly considered as true polypi, such as hypertrophy of the mucous membrane covering the posterior extremities of the lower turbinates, and papillomatous growths.

Probably no one man has done more to clear up the true nature of nasal polypi than Hopmann.* He states that they are edema-

*(Hopmann's articles on the subject begin with a paper which he published in Virchow's Archives in 1883, No. 93, and were followed by a number of contributions appearing subsequently as follows: Monatsschr. f. Ohrenheilk, June, 1885, Archiv f. Ohrenheilk, Vol. XXI, No. 5,

tous fibromata basing this largely on their microscopic structure, and on the fact that they react to heat in the same manner as egg albumin, whereas mucin does not. Of late there has appeared a tendency among many rhinologists to revert somewhat in the direction indicated by Woakes ("Lancet," 1885, No. 11, page 108, "Nasal Polypus with Neuralgia, Hay Fever, and Asthma in Relation to Ethmoiditis," London, 1887) and attribute the existence of polypi to disease of the periosteum and osseous structure of the ethmoid cells. Thus, Lambert Lack ("Jour. Lar., Rhin. and Otol.," February, 1901) holds that a polypus is "a simple localized patch of edematous mucous membrane and that this edema is a result of disease of the underlying bone." He has examined pieces of bone removed with polypi from over thirty cases, and in every instance has found a rarefying osteitis which commences with a proliferation of cells in the deeper layer of the periosteum. Accordingly he substantially agrees with Woakes in his theory of the origin of polypi as a result of bone disease, as did many other participants in the discussion in which he made this statement.

Grünwald ("A Treatise on Nasal Suppuration," New York, 1900) believes that "Polypi in a majority of cases are almost as good as pathognomonic of empyemata of the accessory cavities or focal suppuration in the nasal passages." He sums up the results of his examination of eighty-two persons in whom polypi were observed—seventy-one of whom were certainly the subjects of focal suppuration. Grünwald states that "when Woakes maintains that he has never seen a case of nasal polypus in which he could not find necrosis, he is contradicted by my experience as detailed above, but only in part. It is decidedly a one-sided view to refer all polypi to ethmoidal disease, seeing that other empyemata and focal suppuration are just as potent in causing them; in the same way Woakes' statement that he has never seen a normal

---

1887, page 124, wherein he announced his intention of publishing a series of articles, substantiating his contention that polypi were edematous fibromata and not myxomatous growths. These articles were entitled "Was ist man verechtigt Nasenpolyp zu nennen?" Beginning in Volume XXI, No. 6, page 152, they continue through three subsequent numbers. He was incited to write these articles by the statement made by Kiesselbach in Monatsschrift f. Ohrenheilk, Vol. XXI, No. 4, page 89, 1887. Kiesselbach wrote a reply which was published in the Monatsschrift f. Ohrenheilk, Vol. XXII, No. 12, 1888. This whole series of articles will well repay perusal.)

middle turbinal can be characterized only as an incomprehensible exaggeration."

John N. Mackenzie ("Jour. Lar., Rhin. and Otol.," February, 1897) has made a thorough study of the pathological anatomy of ethmoid disease, based on careful microscopical investigation of the tissues removed from a case under his observation. Among his conclusions, we find: that nasal polypi are not myxoma, nor are they the result of a myxomatous degeneration; that purulent ethmoiditis may continue for years without any involvment of the bone; that in the ethmoid and middle turbinated regions the ordinary nasal polypus is developed as follows: "The first stage consists in the formation of young granulation tissue, the result of inflammatory action. In the second stage this tissue becomes gradually converted into definite adult connective tissue, which in the third stage gradually separates and causes more or less complete obliteration of the normal structures, and in the fourth stage converts them into a fibrous mass." He says he cannot go as far as Grünwald in attributing polypi to suppuration. They are in the vast majority of cases due to inflammation. The presence of suppuration he regards as an incidental phenomenon, and as of secondary importance.

When we take into consideration the ample opportunity afforded for the study of intranasal polypi, one may well wonder at the diversity of the views expressed concerning their nature, and yet a thorough understanding of these growths is of the utmost importance to their proper treatment. Bosworth in repeating Zuckerkandl's often quoted statement that he had found polypi or polypoid degeneration in one out of every eight or nine autopsies, adds that in his own experience of 1,418 cases of ordinary catarrhal disease seen in private practice, 134 showed the presence of fully developed polypi, or about one case of polypus for every eleven cases of ordinary catarrhal trouble. Other statements might be adduced to strengthen the proof of their frequent occurrence, but it is a matter of almost daily experience with rhinologists and can therefore be passed by with the statement that their frequency should have led to a more complete knowledge of their pathological histology.

Another matter of common experience is the frequency with which they recur after apparently complete extirpation. This feature should certainly teach us the necessity of ascertaining the

real cause of their presence in every case, and if possible removing it. This point I consider of particular importance as I believe recurrence is especially frequent when polypi are the result of caries or necrosis of the ethmoid bone, and that they can only be finally extirpated by the removal of the diseased bony tissue. A most apt confirmation of this view has occurred to me in six cases of intranasal polypi, which have recently come under my care in my private practice. Of these four presented a history of previous removal of polypi. In each of them both nostrils were more or less completely blocked by poylpi, and after the removal of one or more of the growths rough bone could be detected with a probe in the region of the middle turbinate. The polypi were all removed, and with them a large part of the whole of the middle turbinate and in every instance, although many months have elapsed, there has been no recurrence. In the two remaining cases there was no history of the previous removal of polypi, but in both of them there was a suppurating ethmoiditis, and after removing one or two polypi, I was able to remove dead bone from the middle turbinate region. There has been no evidence of trouble since. I am convinced that in all six cases the polypi were present as a result of the disease of the bone, that the recurrence in four was due to failure to recognize their etiology and remove the cause, and that they would have recurred again in all six cases had I not found the necrosed bone and removed it.

I have of late been making it a routine practice to have sections cut of every polypus which I remove from the nose. The accompanying two cases I submit as very characteristic in their clinical history and microscopical characteristics of the conditions under which nasal polypi generally present themselves.

CASE I.—A man, white, aged forty years, who has always considered himself particularly strong and healthy, and could not recall ever having had any serious illness. Eight years ago fourteen polypi were removed from his nasal chambers. He says that at that time both nostrils were completely blocked, and that the reremoval of the growths seemed to give him absolute relief. For the last two or three years he has noticed increased obstruction to nasal respiration. On examination polypi could be seen almost protruding from each nostril anteriorly. Under cocaine, with the cold wire snare, I succeeded in removing in all eleven polypi from the left, and four from the right nostril. Dead bone was felt with a probe in both nostrils in the middle turbinate region. The patient

objected, however, strongly to further operative procedures for its removal. He is still under my care, and has lately told me that he would submit to the removal of dead bone owing to my repeated statements to him that I was sure the polypi would recur again unless thorough erasion of the bone was made.

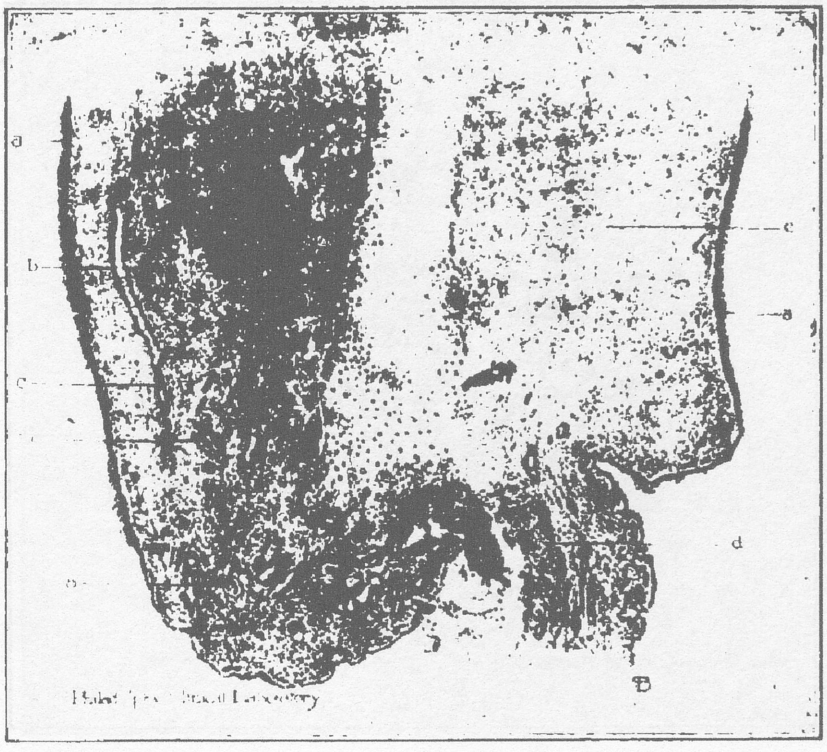

PLATE I.

Nasal polyp drawn from author's specimen: *a.* epithelium; *b.* blood-vessel; *c.* gland; *d.* fibrous connective-tissue; *e.* mucoid matrix.

Plate I shows a section (under low power) of one of the polypi removed from his nose. The fresh tissues were fixed in Orth's fluid, and embedded in celloidin. The section was from three to five microns in thickness, and was stained in Ehrlich's acid hemotoxylin, with an eosin counterstain. Its gross appearance was typical of the ordinary nasal mucous polypus; as the section shows it was covered with normal epithelium, and consisted of a mucoid matrix, with some fibrous connective tissue, and quite a few glands. Plate II shows a field drawn from the same section under high power. The most interesting feature shown by it is the gland (f) which was beginning to undergo a mucoid degeneration.

CASE II.—A girl eighteen years old, was referred to me complaining of tinnitus and considerable deafness in the right ear; the condition had lasted for six months. She had had chronic suppurative otitis media in the same ear when a child. Examination revealed a very much retracted, fibrous, and scarred right mem-

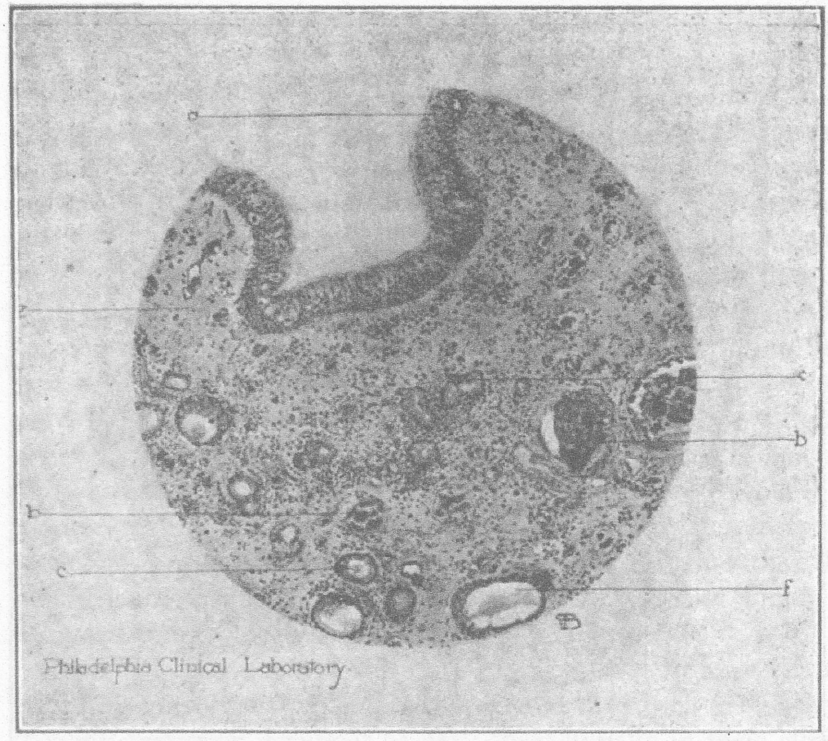

PLATE II.

Nasal polyp drawn from author's specimen: *a.* epithelium; *b.* blood-vessel; *c.* gland; *e.* mucoid matrix; *f.* beginning mucoid degeneration of gland.

brana tympani. The right nostril was almost completely filled both anteriorly and posteriorly with a mass of polypi. These were gradually removed at repeated sittings by the cold wire snare: I also removed a large mass of necrosed bony tissue from the region of the middle turbinate This patient has now normal hearing, and has no tinnitus in her right ear. Plate III is a section of a polypus removed from her nose. It was fixed in alcohol then decalcified in nitric acid, embedded in celloidin, and stained in Ehrlich's acid hemotoxylin, with an eosin counterstain.

Clinically it was most deceptive. When my wire came in con-

tact with the calcareous material with which it was infiltrated, I supposed that it was bony in character, as I had already removed dead bone from the same nostril.

In the numerous sections which I have cut, there has been absolutely no evidence of anything in the nature of a true myxoma-

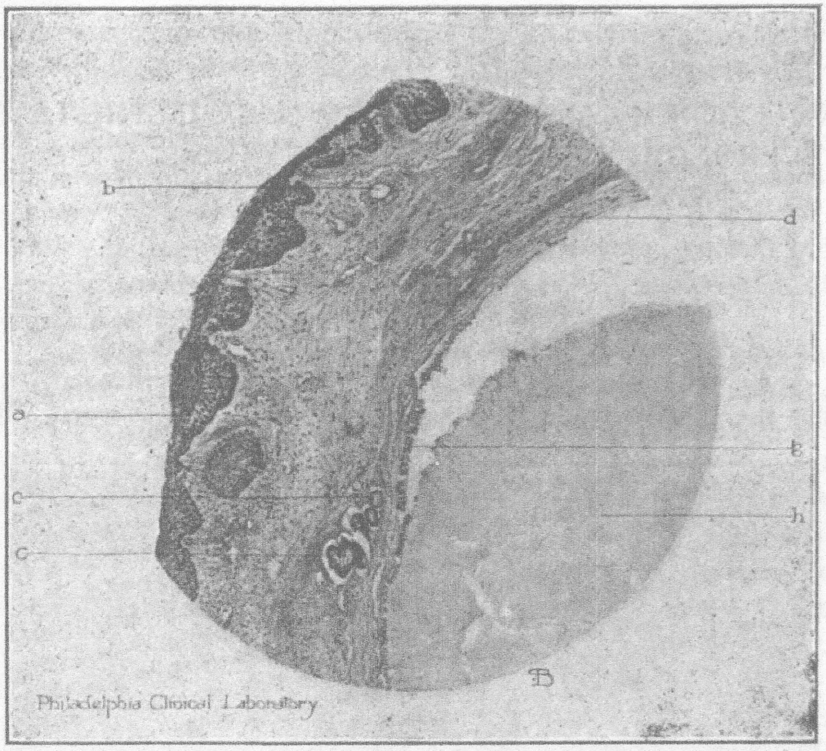

PLATE III.

Nasal polyp from author's specimen: *a.* flat-celled epithelium; *b.* blood vessel; *c.* gland; *d.* connective tissue; *g.* degenerated gland epithelium; *h.* mucoid degeneration with calcareous infiltration.

tous tumor; on the other hand mucoid degeneration was commonly found. In both these very typical cases which I have detailed the growth was associated with the presence of dead bone.

My object in presenting this present incomplete study of the subject is to add my mite to the work of those interested in establishing our clinical work on a scientific basis. I believe that if only sufficient attention is persistently directed to this important subject, the heretofore prevailing laxity in nomenclature will disappear; and when rhinologists have learned that nasal polypi are symptoms of underlying conditions, and not "tumors," the mere

removal of which will result in a complete cure, it will redound greatly not only to the credit of the profession, but to the benefit of the patient, by greatly lessening if not altogether abolishing the frequent recurrence of polypi after their removal by operation.

Paper.

NOTES ON A CASE OF FOREIGN BODY IN THE LEFT BRONCHUS: ATTEMPTED REMOVAL WITH FORCEPS AND ELECTRO-MAGNET; WITH SKIAGRAPH.

BY THOMAS HUBBARD, M.D.

A BOY of nine years drew an upholsterer's brass-headed tack into the trachea while lying on his back. There was very little

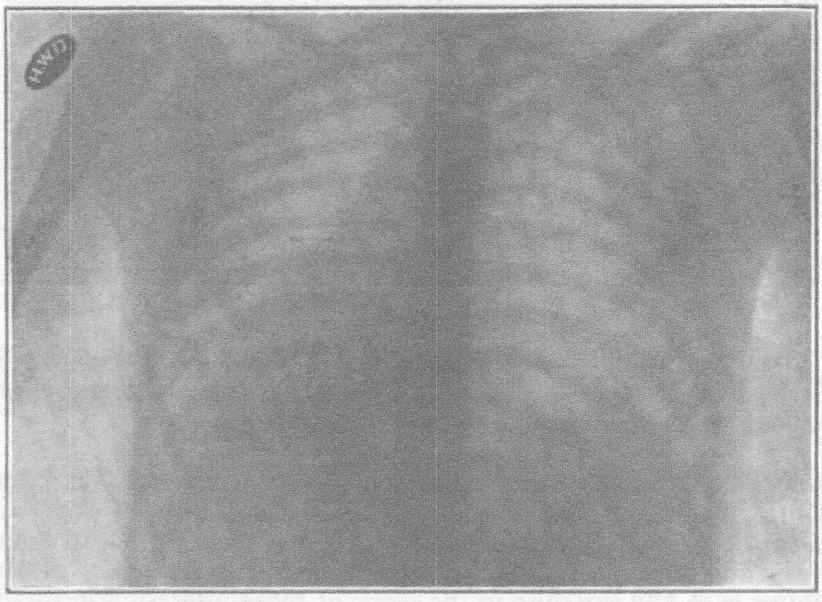

laryngeal spasm although the brass head measured 8 mm. diam. and the pointed shaft about 2 cm.

I saw him within two hours and on physical examination could

locate the tack by the sibilant rhonci. After removal to the hospital the skiagraph was taken verifying the diagnosis as to location. With the fluoroscope it could be clearly seen and as in the picture it was found that the tack entered head first and that the shaft lay in a nearly horizontal bronchus, sixth intercostal space, left side.

The shadow of the heart obscured the tack during its diastole. The respiratory excursion is shown by the blurred image of shaft. Aside from diminished vesicular murmur below that portion of the lung around the foreign body, and sibilant râles, there were no symptoms of importance. Coughing was effectually suppressed, and there was very slight rise of temperature.

On the third day consent was obtained to attempt removal, and it was undertaken with little hope of success, the low position of the tack making accurate manipulation impossible.

A low trachcotomy was performed, and it was found that by pulling the lower part of the trachea forward forceps of various curves and sizes could readily be introduced even to the supposed depth of the tack, 3 to 3½ inches from lower edge of tracheal opening. The up and down movement of the bronchi made it apparent that to grasp such a body, near the point as was necessary, would be a matter of mere chance. [It was not practicable to use the fluoroscope at the time of operation. This would have aided materially in determining the relation of forceps to the tack, but even then it would be quite another matter to grasp it.]

A Johnson induction magnet, 110-volt constant current, was tried. It would draw a similar tack about four inches on a level plane, and it was found that the brass head had more steel in it than the shaft. Repeated trials with the largest steel forceps introduced into the bronchus serving to extend the magnetic field were unsuccessful. Chloroform anesthesia had been very skilfully maintained without marked depression.

These manipulations lasted about an hour and a half. The trachea was then stitched to the skin and the wound packed. It remained open three days. Recovery was very satisfactory, and there was no febrile reaction during the following week.

About three days after his return home, he had a few days of acute broncho-pneumonia symptoms, but for now more than five weeks he has been in fair general condition.

Examination on May 10th was as follows: Slight loss of flesh;

intermittent evening temperature of less than 100°; no coughing except after sleeping; tidal respiration suppressed on the left side and exaggerated supplemental on the right. The suppression of cough and respiration seems voluntary, there being no degree of infiltration sufficient to account for absence of vesicular murmur in other than in the region of the obstruction. Sibilant rhonci not heard except after coughing and free expectoration. The boy can still taste brass when he raises sputum.

As to the question of early tracheotomy in foreign bodies in the trachea and bronchi a case of this kind emphasizes the fact that there are foreign bodies and foreign bodies. Each case must be decided according to its own peculiarities, and in many instances *tracheotomy and exploration can be successful only after there are evidences of dislodgment.* This implies an uncertain risk of laryngeal occlusion of course, but it is unavoidable. As a general rule the longer the foreign body is retained the more likely is it, once dislodged, to be coughed out. Accumulated secretions and even blood clots aid in expulsion. The habit of expelling masses of the debris of tissue destruction brings about a degree of tolerance in the larynx, and even in a case of this kind there is still a fair chance of recovery with a considerably damaged lung.

NOTE.—Dr. A. V. L. Brokaw, St. Louis, reports in Annals of Surgery, Feb., 1903, a case like the above, differing only in the condition that the tack entered the right bronchus and seemed to be dislodged spontaneously at times. At a second operation the tack was located and extracted by forceps passed through a cystoscope.

This ingenious method seems to be feasible in my case and I hope to make a favorable report soon.

Paper.

NOTES ON CASES OF CANCER TREATED BY THE X-RAY.

BY ARTHUR AMES BLISS, M.D.

It is the fate of new methods of treatment in medicine and surgery that, received with doubt and suspicion when first advocated, they may soon achieve a false reputation for efficiency and become a fad of the day. Then, as a result of application and failure, often in cases in which benefit from their use could not with reason be expected, they are condemned unjustly and the new method is declared a failure. Every mode of treatment has, naturally, its limit of application, which can be learned only by clinical experience; by a process of exclusion after trials and failures, until the range of its action is learned definitely. The brief notes presented in my paper are merely a contribution to the study of the new light treatment by means of the Roentgen ray, and, far from being a final judgment, may yet be of aid, when joined to the great body of evidence from many different sources, towards fixing the limit of usefulness of the new treatment.

Case I.—Wilhelm N., a German, 63 years old, a man of splendid physique and with an excellent personal and family history. The patient is a veteran of the Franco-Prussian war of 1870. All evidence of syphilitic infection is lacking. The history of the patient indicates an unusually clean, orderly life, with healthful outdoor employment and possession of ample means for comfortable living. A blow on the right side of the face, just beneath the orbit and over the nasal and lachrymal bones of this side, is the only trace of a possible traumatic cause for the origin of the very extensive lesions which involve all the ethmoid sinuses of both sides, the frontal and sphenoidal sinuses, as well as both orbits. The cranial cavity is exposed over the area covered by the roof of the nose and by the inner and upper walls of the orbits. The man's intellect is not yet impaired, and there are no indications, as yet, that the growth, filling the anterior spaces of the face, has extended into the posterior base of the cerebrum or the cerebellum.

The existing conditions are described as having commenced

their development about three years ago. At the time of my first examination of the case, the right side, including the orbit and eth-



Case I. Wilhelm N. Carcinoma of orbits and nasal sinuses. Use of X-ray during six months.

moid sinuses, was all involved in the extension of the neoplasm. An operation was performed which cleared the ethmoid sinuses, and the right eye was enucleated and the orbital contents thoroughly cleared. The clearing of the spaces occupied by the ethmoid and frontal sinuses, as well as the removal of all the portions of the growth extending into and occluding the nasal passages, has, since the original operation, been done very frequently. The growth has now advanced into the sinuses and orbit of the left side of the face. Microscopic study of the mass resulted in the report that it is a carcinoma.

The use of the X-ray was commenced late in this case, after the left side of the head had become involved, and when the growth was increasing with great rapidity. It has now been used since October, 1902. The applications of the light are made three times weekly, for periods of from three to four minutes. I will refer to the apparent action of the light, after a brief description of the other case in which it has been tried.

CASE II.—The second patient is a man with a very different life history from that of Wilhelm N. An American, 45 years of age, J. S., the patient, is a small, feeble individual, whose naturally slight body is greatly emaciated. Twenty years ago, J. S. contracted syphilis and neglected any specific treatment. For many years, his tongue has been covered, on the left side, with a dendritic mass of closely-growing, horny papillæ. At the time of his first visit to me, the tongue was so infiltrated beneath this rough, horny overgrowth, which had now commenced to spread over the left side also, that it felt like a hard, stony structure, the same condition being noted in the tissues between the chin and the hyoid bone, indicating that the process of infiltration extended through the entire thickness of the tongue, as well as into the lymphatic glands on the right side of the neck. It was believed that no operation short of a complete excision of the tongue and the surrounding lymphatics would be indicated in this case; and the man, already sufficiently miserable, would have been rendered still more wretched by the conditions produced by such an operation, unless, by good fortune, the procedure could have terminated his existence. Under large doses of potassium iodide and active mercurial treatment, continued over a period of several months, there was no arrest of the process of infiltration. I cleared the surface of the tongue of the dendritic growth, resembling warts, but these soon recurred again after each removal. No microscopic examination of the mass has been made in this case, as no tissue has been excised from the deeper portions of the tongue. I believe that it is an epithelioma.

The specific treatment, actively pressed for many months, did not have the slightest influence in arresting the growth in its rapid development beneath the chin. Hard nodules began to appear at the seat of the lymphatic glands to the right of the median

line. I now stopped all anti-syphilitic treatment, placing the patient on stimulating and tonic drugs, with full diet in that class



Case. II. J. S. Neoplasm believed to be epithelioma involving entire thickness of tongue and tissues between chin and hyoid bone. X-ray used on area shown in illustration during ten months.

of foods possible for him to swallow. The use of the X-ray was commenced at the same time, in June, 1902, and has been continued up to the present time. The applications are made twice weekly, the duration of each sitting being from three to four minutes. The rapid progress of the growth in the neck has lessened slightly since the use of the light. The X-ray apparatus used for these cases is one furnished with an induction coil. The length of the spark is about two inches and the tube is placed about four inches from the surface treated. The healthy skin is protected by several layers of tin foil. The duration of each treatment has been from three to four minutes. In each case, the light has, occasionally, produced burns, which made an interruption of the treatment necessary. Such burns have been very superficial and have healed readily. The whole detail of the treatment has been conducted by Mr. M. I. Wilbert, who has charge of the X-ray laboratory of the German Hospital of Philadelphia.

In forming an estimate of the real value of a new plan of treatment, we cannot but acknowledge the tendency to overvalue its results. We anticipate consequences, and, the wish being father to the thought, we are apt to see that for which we hope. The two cases reported are not the best that could have been selected upon which to study the action of this peculiar form of treatment. Both are far advanced in the conditions presented; both, in fact, are beyond the help of all the usual methods of treatment, operative or therapeutic. Taking into account, however, the tendency to over-estimate the value of a treatment as yet little known, and considering, also, the unfavorable character of the cases reported, we can acknowledge some evidence of a slight degree of benefit. Objectively, this benefit declared itself in a lessened rapidity in growth of the outer or superficial parts of the new formations. This tendency was more decided in the case of J. S., Case II. Here, the light has been used on the tissues of the throat, only, over an area of nodules, which, before the employment of the treatment, had increased rapidly in size and were causing much pain. Until but very recently, the mass did not increase at this point since the treatment with the X-ray was commenced. At my last examination, I found that renewed activity had developed in this area. In the case of Wilhelm N., Case I., the light was used chiefly at the inner angle of the supraorbital ridge, on the left side. Here, the process of infiltration was comparatively recent.

The subjective sign of benefit was a certain degree of relief of pain. The patient with carcinoma, Case I., stated that his nights were more comfortable following the days on which the X-ray had been applied, while both patients would not have persisted in the long continuance of this method of treatment, entailing some inconvenience to both of them, if each had not been conscious of some relief to his ever present suffering.

The light has been given a fair trial in both these cases, and the

experience, thus gained, can be of some value, perhaps, in the question of its range of usefulness for cases of this severe and extensively involved type. In the two respects mentioned, alone, have we noted any advantage from its use. On the masses, in general, it has had absolutely no influence. In each instance, the great body of the neoplasm has, apparently, followed the same course of infiltration and necrosis that belongs to its nature, unaffected in the least by the Roentgen ray. This is disappointing; especially, as most gratifying results are undoubtedly obtained from the light in cases of superficial epithelioma, lupus vulgaris, and rodent ulcer; in short, in cases of superficially growing neoplasms. For malignant growths within the nasal chambers, my experience, from the two cases so long under its use, would indicate that the X-ray, as now employed, can have little influence for good. In cases of an inoperative character, the method appears to give some relief to pain originating in the superficial parts of the growth, and gives the patient a certain amount of encouragement in his hopelessness, in that something is being attempted to relieve his condition.

When a radical operation can be performed with a reasonable hope of success, the surgeon should not dissuade himself or his patient from such operative treatment, on the ground that the X-ray, as developed in its application, at present, will offer an effective substitute for the knife and curette.

Discussion.

Dr. D. BRYSON DELAVAN stated that the negative results of his own paper presented last year at Boston had been borne out by the history of the last twelve months. During the year, a case of cancer treated by the X-ray had been wrongfully reported as cured. The truth was however that within three months the disease had begun to advance very rapidly, destroying the patient's life in a few months. It was unfortunate that in the interest of scientific accuracy the complete history had not been published as extensively as had been the premature report of the case.

The experience of those most interested in the application of the X-ray had been invariably negative with regard to the permanent benefit of tumors of the neck. In many cases, several of which had occurred in the practice of the writer, marked relief had been experienced from distressing symptoms and the life of the patient apparently prolonged. The value of the ultra-violet rays had not yet been fully investigated and deserved more careful study.

Dr. H. L. SWAIN had seen one case in which the X-ray had had a temporary effect. The patient was benefited for something like three months but about that time the growth recurred and the patient died. His own experience in this line of work had been nil.

Dr. H. S. BIRKETT had nothing encouraging to report on the subject. Last year he had seen two cases of cancer treated by the rays for a period of six weeks. In one case temporary relief was afforded but any permanent relief had seemed out of the question.

Dr. W. K. SIMPSON stated that the rays might possibly be of some value in superficial types of malignant growths.

Dr. BLISS remarked in closing the discussion that he saw no reason why men who are interested in this line of work should not continue their experiments. The future might have better results than we had yet attained.

Paper.

THE ARCH OF THE PALATE.

BY HENRY L. SWAIN, M.D.

THE study of nasal pathology received a marked stimulus as well as a relief from some previous obscurity of conception when it was explained that the narrowing of one nostril by abnormalities of the septum led in general to unequal use of the two sides, to bad drainage and aeration, as well as to vagaries of pressure, causing by all these chronic congestion and inflammation of the mucous membrane. It was further explained that some of the changes in the septum, how many it was never quite clear, were entirely due to traumatism, some entirely to developmental processes, and others to both in varying degrees. It was reasoned, à priori, that if lack of use on one side and too much on the other produced first chronic catarrhs and variations in the bony nasal frame-work, so prolonged disuse of the nose, following the great law that the proper function or activity of any organ or part is essential to its proper and perfected growth, would lead to inevitable deformities or variations from the normal both in structure and in function.

An immediate application of this idea was evident when it was thought how through the early years of the growth of some children, owing to the enlargement of the third or pharynx tonsil, the nose for long periods would be entirely inoperative; hence not li-

able to perfect development. Furthermore, by the same reasoning, the mouth being open, it would become larger, *i.e.*, the palate would usually become more arched. This last was the outcome of various observations and might be expressed in the rule that the less the nose was used, the more the palate arched. This latter, and perhaps other causes, it was declared made the septum bend because the vertical distance between the summit of the arch of the palate and the base of the skull was not large enough to allow of placing the full grown septum therein without bending. This suggestion was offered because it was reasoned or supposed that every septum was destined to grow a given amount before ceasing no matter how changed the conditions were which surrounded it, a rule which is supposed to work quite the reverse in most of the arguments we are later to adduce. Altogether, however, this made a very pretty explanation, which I have no doubt we, all of us, who teach, annually call into requisition as we unfold to our classes some of the secrets of nasal pathology.

Following out these suggestions it presently seemed rational to put the horizontal bends, especially of the bony septum, into the developmental class, while all others, especially of the cartilaginous portion, were called traumatic, it being of course admitted that formative processes might accentuate a traumatic deviation into a grotesque bend, or vice versa.

Having in this sweeping manner explained all the curves of the septum we had in a measure reduced all the problems of nasal disease to simple fractions with a common denominator and were prepared to explain each new phase of clinical experience thereby, for are not vagaries of pressure, aeration, drainage and functional use, the chronic incitors of catarrh, always present in the stenosed nose as a result of that one factor, an erring septum lacking in proper rectitude? In this one paramount idea one sees the excuse of any excess in the way of "cabinet-maker's" surgery provided only that the septum is made more nearly plumb. We are strictly Jesuitical in that the end sought justifies any means, no matter how severe.

Now, it is not the purpose of this brief sketch to take any broad issue with any of the above statements except, perhaps, to show up an occasional weak spot in the chain of evidence or at least demonstrate some actual exceptions to the purely à priori method of reasoning which we have employed in the above.

The first rude shock which the writer's faith in the orthodox belief suffered was when he observed the palates of young children arching higher than normal when to the positive knowledge of the writer there had never been for more than a few days at a time any difficulty in breathing through the nose, certainly no adenoids. There was, furthermore, the observation that some adenoid children persisted in having normal palates in spite of well-nigh useless noses. This was some years ago, and yet is the reason that you, gentlemen, are at this time suffering under this outburst of eloquence.

Soon to substantiate this phantom of heterodoxy, to prove that other causes than nasal disuse and traumatism must contribute to the excessive arching of the palate and lack of room for the full-grown septum, it was suggested that the shape of the skull determined the kind of arch possessed by any individual. An article by Grosheintz[1], in 1898, summed up the previous literature on the subject very carefully, and accepting the statement as one of fact that a given number, 45.9, expressed the average index of the height as related to the breadth of European palates, in a certain museum he found 16 skulls of various nationalities which could be considered as having a higher index than the normal, and endeavored by measuring and studying them to draw some deductions regarding the height and width of the face, the shape of the skull and the anomalies of the palate. I will give you a translation of his summary from these observations. "A high and narrow palate is usually combined with a small development of the upper part of the face. Small nasal and orbital cavities are associated in the rule with highly arched palates. The highly arched palate usually depends upon a congenital racial peculiarity of the skull and not upon the later extra-uterine influences of nasal stenosis." The last seemed a strong statement and certainly sufficed to arouse and emphasize my interest in the subject. Subsequently in talking with my erudite friend, Dr. Wright, of Brooklyn, he suggested that much that had been done in the way of measurements needed to be rehearsed, and the most important point was to get measurements of races which are notably not sufferers from adenoids. Another suggestion was, whether anything in the early life of the child, the use of a spoon, artificial nip-

[1]Grosheintz, Fraenkel's Archiv, Bd. VIII, S. 395.

ple, etc., might not give an added impetus to natural forces resulting in the higher arching of the palate.

There exists in New Haven the Marsh collection of the skulls of various races, in some cases the numbers being very large, and along the lines of Dr. Wright's suggestion, with the kind permission and help of Prof. Beecher and Dr. MacCurdy, we took a series of 120 skulls of the presumably original Hawaiians. Twenty-four were selected as being normal and possessed of all their teeth, *i.e.*, belonging to young vigorous adults, and were measured by the same methods as those of Grosheintz in his work. The index as calculated out by Brackett[2] was 45.7. This, you see, is very close to what had been accepted as normal by Grosheintz and the observers who antedated him. The index is found by dividing the height by the breadth and multiplying by 100. These measurements were very carefully taken, and the shape of the skull was also taken into consideration in the same way that Grosheintz had done, and developed some of the same conclusions. Brackett differed slightly however when he observed that there could be no direct connection established between the height of the palate and the shape of the skull. Evidently a non-adenoid race developed a palate of the European standard shape.

While these investigations had been going on, by a strange misfortune, the loss of a certain periodical in the mails, I had been unaware of Alkan's[3] work, which seems to me, up to date, to be the most thorough and satisfactory of any that I have found. He made very careful observations upon the living subjects both children and adults, and found that an average of adults with normal palates would give an index of 45.7. These were presumably of the Saxon race, as the Doctor's investigations were conducted in the city of Leipsic. He, however, conducted his measurements in a slightly different way so that when he came to measure skulls a slightly higher index was obtained. For instance, he took 30 European skulls representing some twelve nationalities and found, as an index, 52.6, which you see is very close indeed to the measurements of Grosheintz, who also took from a collection of various nationalities, those where the index was over 46, and got his index 53.9, leaving the inference that the skulls as found in European museum collections had a slightly

[2]Brackett, E. S., Graduating Thesis, 1902, Med. Dept., Yale Univ.
[3]Alkan, Fraenkel's Archiv, Bd. X, S. 441.

higher index than the average. Alkan then measured 12 negro skulls, and contrary to the natural expectation found the palate to average considerably higher, the index being 59. Eighteen Malays were found to have an index of 54.3, very close to the Europeans. He then went into the question of how much children who suffered from adenoids would differ in palate measurements from those who possessed normal nasal conditions. He found an average normal index for children from three to fourteen years of age to be represented by the figures 43.5, while those with nasal stoppage had an index of 50, showing that there were undoubted alterations as a result of the pernicious influences. Strangely enough, there is no apparent difference in the length-breadth index. In all these measurements he very carefully compared the shape of the palate arch with the shape of the skull, and from the number of his observations and the care with which they were taken would seem to be entitled to as much credence as speaking with authority as any observer that I have consulted. His final conclusions will bear a moment's consideration.

"First, the hard palate of the new born child is characterized by its shortness. With increasing age, the height and breadth increase but slowly while the length becomes proportionately rapidly greater. Second, in people afflicted with adenoid vegetations we find on the average a high, long and narrow palate, *i.e.*, a form which does not represent the normal. Third, the shape of the hard palate has no connection with the shape of the skull. Fourth, anomalies in the position of the teeth are of frequent occurrence in those afflicted with deformities of the palate or the upper jaw and may be looked upon as due to the latter."

It would seem as though enough had been done to assume from the study of the various races as well as conditions of man that the shape of the skull and the different environment during early life had but little or nothing to do with the arching of the palate, but in general all observers agree with Brackett, who concluded from his observations of the Sandwich Island skulls that "while the height of the palate bears no absolute relation to the shape of the face, still a long narrow face with high narrow anterior nares and orbit more often exists with a high palate than a low one."

My attention having been called while working with the Sandwich Island skulls to a collection from the Flat-head Indians, who, it will be remembered, have for generations deformed the heads

of their children by a binding process during the first year of their lives, it seemed to me that if any disturbance of the skull could influence the shape of the palate this must. H. S. Arnold[4] undertook a series of measurements on a large number of these skulls, being particularly careful to follow the methods of Alkan. His results show that we have a much broader, flatter, and shorter palate than in any of the other races which have been so far measured. The height-breadth index is 33.0, while the length-breadth index is 73.2. It will be remembered that the average for European races was 52.6 and 63.5, making evident a very marked difference. Arnold has photographed an average Flat-head with an average Hawaiian skull, and Figure I shows a comparison of

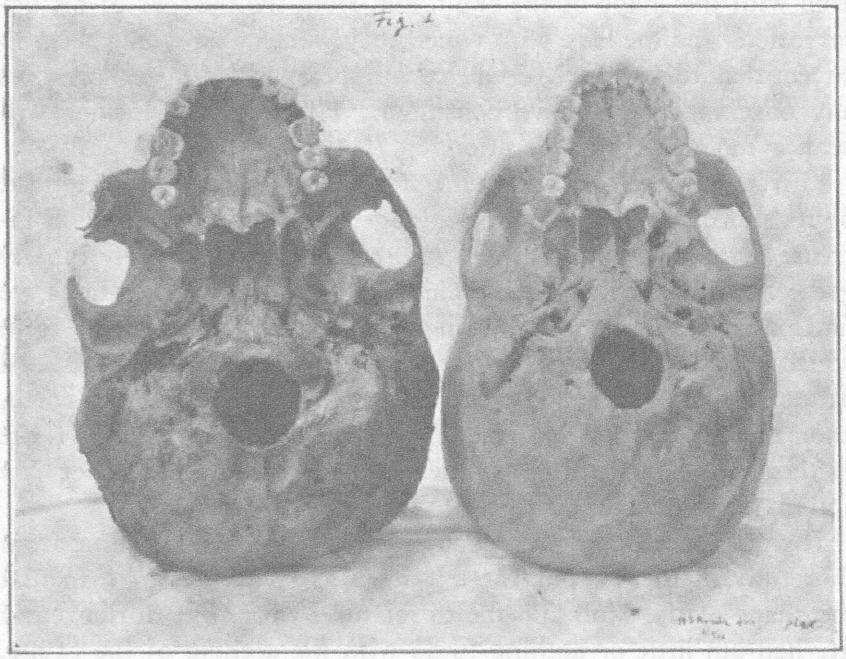

Fig. 1.

the breadth of the two plates, and Fig. II of the height, and in both cases the difference is very apparent. Here therefore we have the apparent absolute contradiction of what has gone before; it is therefore an extremely interesting and valuable observation and may be accepted as a proof positive that some agencies outside

[4]Arnold, H. S., Graduating Thesis, 1903, Med. Dept., Yale Univ.

of the merely respiratory or nasal can change the shape of the hard palate. A comparison of the skulls as shown in the photograph



Fig. 2.

shows that the vertical diameter of the nose is very notably shortened in the case of the Flat-head as well as broadened. Attention should also be called to the fact that while the vertical diameter of the nose in this case is so much shorter, the septum is as straight as in the splendid specimen of the Hawaiian skull. Is not this an apparent contradiction of the rule which we noticed earlier in the article and which was used to explain why the septum bent when the palate arched too high? If, as supposed, the septum always grows to the full size intended as normal for that individual independent of what is transpiring and influencing the neighboring bones, why does it not in this instance of the Flat-head also have "to stoop to conquer" when such a notable shortening of the entire nasal cavity takes place? Evidently there are circumstances when even the stiff-necked septum becomes convinced of the error of its way and conforms to the rules governing its environment. It will be noticed that while the Hawaiian skull is an extremely fine and

well-developed specimen of its kind, normal apparently in every measurement, it is much narrower than is the skull of the Flat-head, indicating how great the pressure was which produced this amount of deformity.

Another interesting fact is that the adult Flat-head skulls (understanding under the term "adult" those over 14 years of age) show apparently more deformity than the child skulls, showing that the nutritive processes have been so altered as to influence those changes which take place and are so apparent in the skull bones near the time of puberty. As, of course, this may be considered in every sense of the word a measurement of a deformity, it does not materially alter or vitiate any of the statistics that have been given before, merely weakening the statement that there is absolutely no connection between the shape of the palate and the shape of the head.

Alkan's measurements of children, however, seem to contradict the final conclusions as given by Grosheintz that the shape of the palate was not materially influenced by extra-uterine conditions, for by actual measurement there is not the slightest doubt that when adenoids exist in the naso-pharynx of children they can and do alter the shape of the hard palate. They may not always do it, just as there may be also high arched palates which have absolutely no connection with this naso-pharyngeal stoppage. These latter two exceptions to the rule are however not numerous.

Let us now consider for a moment what are supposed to be the influences or forces which are operative in these cases of nasal stoppage and disuse, in the growing child, and which may be said to bring about the abnormal arching of the palate. The forces are numerous and are of a decidedly complex nature. Many of the most ingenious explanations have been offered by various observers, but it will be safe to assume that only certain forces are really potential and that no one single suggested explanation quite covers all the points that may be brought up. As we together look the matter over to-day it seems to me that one point of view should ever be in mind and that is that we are dealing with an organ, the nose, which is either imperfectly functioning or is non-operative, and consequently the observations fall under the rule deduced earlier in the paper that the proper physiological activity of any organ or part is necessary to its proper and perfected growth. A nose, therefore, through which during the growing years but

little or no air passes and a mouth through which no respiratory air is supposed to habitually pass cannot develop along the normal lines. A closed nose and an open mouth are the reverse of the natural order. Why should not all the developmental processes in the nose be retarded and all the natural forces leading to growth and expansion of the mouth be increased? If, for example, the nose has but little air passing through it, the call of blood to it cannot be anywhere nearly as great as when it has to warm and moisten a normal quantity of air. If this is the case the entire process of growth and mucous membrane formation are bound to be influenced by the decreased blood supply. The converse is true in the case of the mouth.

Now what arches the palate? In the new born babe the hard palate at the height of the arch is considerably above the level of the Eustachian tube; in the child at puberty it is considerably below the Eustachian tube. Consequently the palate has grown away from the base of the skull. What has accomplished this? It has been the downward growth of the superior maxillary bone, the septum and the pterygoid processes of the sphenoid, so that in a certain sense of the word the palate of the young child is supposed to grow down instead of up. It is safe to assume, therefore, that this downward growth is an extremely important process in our present consideration, and it may be looked upon as a part of the normal growth of the superior maxillary bone. Suppose, then, that anything should happen to retard the downward growth of the superior maxillary bone or lessen its increase in all directions. It would be easy to conceive this to be operative under the general law that the nose is not functioning and hence the component parts are not subject to that subtle but powerful influence of proper growth stimulated by proper functon. The septum, however, is also supposed to grow along the same lines and *pari passu* with the superior maxillary bone. If, then, the superior maxillary bone did not grow and the septum did, with similar conditions influencing both, it must be assumed that something specifically operated to retard the development of the superior maxillary, and this I would suggest might be conceived to be the fact, that inasmuch as air is not streaming back and forth through the nose, in fact it being sometimes impossible for the little patients to blow any air out through the nose, the stoppage from the adenoids being so great, the air within the maxillary sinuses could not be properly

changed. Might not it be supposed that the openings could become entirely closed by pressure from deformed septum, or swelling, or otherwise, and that without the proper change of air from the cavity of the maxillary sinus there must be an atrophy of it?

Some observer, I think Ziem, has produced some of these changes by the blocking up of the nose in young animals for a long period with cotton, the alteration produced being most obvious when only one nostril was blocked. There was a large arrest of development not only of the upper jaw, but of the palate bone, and even of the whole side of the face. If, therefore, the septum grew faster than the superior maxillary and palate bones that would account for the bends in the septum without it being necessary to bring in the arching of the palate as a necessary feature. Another point is that septa are rarely bent behind. This is readily to be accounted for by the fact that the pterygoid processes against which the posterior part of the superior maxillary and palate are securely articulated grow to their full stature irrespective of nasal conditions, consequently the palate behind is carried down and the septum has plenty of room to develop downward in a straight light. If this explanation be true it would result that the highest point of the palate would be often in front which observation, you will all concur, you have often made.

Now we are bound to consider the fact that the child who goes around with his mouth open, tends to have the muscular force, the weight of the jaw, the lack of the restraining influence of the upper lip, and the streaming of the air through the mouth which adds to the buccal tension and removes the tongue away from exercising any influence upon the upper jaw, all tending in the one direction of drawing down the outer side of the superior maxillary bone, thus pressing together or approximating the alveolar processes of the two sides, and as this takes place in an elastic bone buttressed behind against the pterygoid processes of the sphenoid but one result could follow, namely, that the arch of the palate would become narrower. As the palate bone and palatal process of the superior maxillary are bound to follow the same law as we consider holds true in the septum they must grow to a certain width, and must necessarily bend upward in order to come between the narrowed arch. Now the lower jaw when closed requires but very little or no muscle force to keep it in place. When, however, the mouth is open the strain and weight falls largely upon the

muscles of the cheek when the process of mastication is not operative, and consequently there is a steady, never ending tension upon the buccal muscles and a dragging downward by this weight. It seems to me that these features are sufficiently powerful to produce the results that we observe. It is surely to be assumed that from the time the child begins to open its mouth in this way and have the pressure and weight brought upon the superior maxillary bone, even if it did not make it actually grow narrower it must exercise a restraining influence toward the actual and normal broadening out.

Then we have to consider that when the mouth is open the upper lip is drawn upward and above the alveolar processes so that if we took the resultant of these forces and calculated what would be the result upon a soft bony structure which was subject to just the forces that we are here considering we would reason that not only could the palate not grow to its full breadth, but it would also have to grow in some other direction in order to satisfy the tendency to growth inherent within itself. As by this assumption it has only two possible ways of growing, it must either grow long or grow high. It is restrained from growing broad. The lengthening process takes place in front rather than behind first because the upper lip is not operative to restrain the projection forward, and the pterygoid processes which are behind prevent growth backward. We have therefore here the explanation of the projecting incisor teeth and of the arching of the palate under the same heading. The extreme effects of this deformity would be those cases of projecting teeth and V-shaped arch of palate which we have all seen.

In stating some of these facts before the New Haven Dental Association there came out during the discussion the expression of a very general belief among them that the shape of the adult palate as well as the alignment of the second teeth was dependent upon the preservation of the deciduous or milk teeth and in general upon the care of the teeth of the young child. This was to me a somewhat novel view, and is not often stated in purely medical works.

We had been accustomed to view the disturbed eruption of the second teeth as due to the fact that the palate was narrower and there was not space enough for the teeth to come out in line and consequently there were crooked, twisted and deformed teeth. The present idea carries this point further and says that the circumfer-

ence of the horizontal arch and the perfect anterior curve are influenced by the retention of the first teeth as long as possible. When, for example, the first teeth are early lost, the six year molars which are permanent teeth being unrestrained by a row of teeth between and in front of them tend to crowd forward and thus lessen the space in which a greater number of larger teeth are to arrange themselves as the second dentition takes place. Furthermore the removal of the teeth retards the alveolar process in its growth, and it might even suffer some resorption as we are familiar is the case in old people. And thus at the very time when the bones need to be most carefully nourished in order to develop out the full round, anterior curve of the alveolar process, at this very time, it suffers retarding influences. It is easy to conceive that removal of the deciduous teeth might not only make the alveolar process thinner, but the whole bone might have its nutrition so interfered with as to be softer and less resilient.

Now suppose this condition exists where there is nasal stoppage; it is easy to see that the forces which usually act to narrow and arch the palate will have aid and abettance in this weakened condition of the horizontal buttresses. It is not difficult to conceive that not only will the horizontal curve suffer by the moving forward of the six year molars and the pressure in from the sides, but that as the incisor teeth project forward by the growth of the intermaxillary bone there will be also a motion toward each other of the sides of this horizontal arch whose keystone, the unrestrained intermaxillary bone, has been thrown out of its proper line of support. We have before mentioned how the palate behind cannot give way, as the pterygoid processes are so solid and firm, so that the effect of this must be instead of having the palate develop round and U-shaped in the horizontal direction, it must be more or less V-shaped, with the apex ending in the incisor teeth, sometimes twisting the latter so that their posterior surfaces look toward one-another. If this change takes place in the horizontal curve from the U- to the V-shape some alteration is bound to take place in the vertical direction in the arch of the palate proper. To further substantiate this, we are assured by our friends, the dentists, that an analogous process takes place in the lower jaw where there is nothing in the surroundings to influence the altered growth of the bone as is the case in the upper jaw. Furthermore, when the individual in question grows older if the upper jaw grows narrower

and smaller than the lower the latter may bite outside rather than inside of the upper, and constant pressure of this prognathism in chewing tends to still further limit the spread and growth of the palate arch.

Of all the arguments presented by the dentists, the strongest evidence is that which appears when we consider the trifling force they are constantly using in the shape of a spring of piano wire and rubber bands to spread the abnormally contracted jaw in order to give space for replacing the teeth that are out of line. If with these comparatively insignificant forces in the period of from six months to a year they are able to produce space which did not exist and to straighten out deformities that were so much in evidence, then there is thereby given to the explanation previously offered a greater show of probability, because if a slight force in one direction corrects, it is reasonable to suppose that in the reverse direction deformities are produced by forces so slight and subtle as would otherwise be scarcely thought potential or harm-producing. And it is only by continuous and combined action of these various factors that gross changes are produced. From the present study we may conclude that it has been demonstrated:

First, that it is possible by deforming processes which artificially alter the shape of the skull to produce a change in form and shape of the hard palate.

Second, that under these above mentioned conditions the septum seems to conform itself to the altered development of the rest of the face, rather contrary to our previous ideas regarding the habits of this structure.

Third, that if from arrested or retarded development of the superior maxillæ the palate fails to descend to its proper level, a bent septum is as liable to be produced as when the palate is arched too greatly by an unnatural narrowing process. Hence a palate of perfectly normal height as compared to breadth may produce a bend in the septum.

Fourth, that in considering the various causes which produce the abnormalities of the palate, we must lay more stress upon the lack of proper aeration of the maxillary sinuses retarding their development and hence that of the whole superior maxilla.

Fifth, that the conservation and general care of the deciduous teeth help to produce a normal horizontal curve in the hard palate and lessen the tendency to narrowing.

A TABLE OF MEASUREMENTS OF THE PALATES FROM 33 SKULLS OF THE FLATHEAD INDIANS BY H. S. ARNOLD.

	Length	Molar I—II Width	Premolar I—II Width	Average	L. W. Index	Measured Indirectly Height	W. H. Index	
2	57.	39	36	37.5	65.7	1.4	37.3	
3	53.	42	37	39.5	74.5	1.5	30.8	
4	52.	41	40	40.5	80.6	1.0	20.4	
5	51.50	37	34	35.5	68.9	1.3	36.6	
6	56.	41	38	39.5	70.5	1.1	27.9	
7	56.	41	38	39.	69.9	1.6	41.0	Very high alveolar processes.
8	61.50	44	40	42.	68.2	1.0	23.7	Very low alveolar processes.
9	55.	43	47	40.	72.7	1.4	35.0	
10	56.	43	39	41.	73.2	1.3	31.7	
11	48.	37	32	34.5	72.8	1.1	31.4	
12	54.	37	35	36.	66.7	1.4	38.8	
13	47.	46	39	42.5	89.3	1.4	33.3	Very wide.
14	59.	44	38	41.	69.5	1.5	36.5	
15	57.	38	32	35.	61.4	1.7		Borders covered with exostoses. Very high—impossible to measure.
16	53.	42	34	38.	71 7	1.5	39.5	
17	50.	39	33	36.	72.0	1.3	31.7	
18	55.	39	36	37.5	67.3	1.1	29.7	
19	55.	43	38	40.5	74.5	1.3	31.7	
20	50.	39	37	38.	76.0	.9	25.0	
21	47.	44	38	41.	87.2	1.2	29.2	Wide.
22	56.	41	36	40.	71.5	1.3	33.7	
23	53.	40	34	37.	69.9	1.2	32.5	
24	49.	37	35	36.	73.5	1.4	38.8	
25	54.	44	39	42.	77.7	1.2	30.0	
26	56.	42	35	38.5	68.7	1.4	36.3	
27	54.	42	37	39.5	72 2	1.5	39.9	
28	50.	44	36	40.	80.	1.3	32.5	
29	48.	42	33	37.5	78.1	1.2	32.0	
30	51.	46	41	43.5	85.3	1.2	27.5	
31	52.	38	35	36.5	6.94	1.4	38.7	
32	46.	35	30	32.5	70.5	1.00	30.8	
33	49.	39	35	37.	75.5	1.3	35.0	
		Average W. L.	Index 73.2			Average W. H.	Index 33.0	

Discussion.

Dr. D. Bryson Delavan referred to the work of the late Dr. Harrison Allen who had undobtedly devoted more time and attention to this subject than anyone else. He regarded Dr. Swain's paper as an admirable contribution to it. He had seemed to establish satisfactorily very many points which had been previously advanced but not proved; he had also brought up several points of very great importance, among them the proper alignment of the teeth and care of the first teeth. This fact had not been previously sufficiently emphasized. It was of interest to note how as case after case was reported, we were finally brought back to a

very old idea, namely, the effect on the palate of obstructed nasal respiration. In the ideas advanced by Dr. Swain we seemed to have a fair explanation of the facts as we find them. Now the aim should be to pay more attention to the young child and to the early recognition of the various factors affecting palatal formation.

Dr. J. W. GLEITSMANN found in the views expressed by Dr. Swain a corroboration of the views advanced by himself in a paper read before the Academy of Medicine, New York City, in 1895, entitled "Influence of Adenoid Vegetations on the Growth of the Upper Maxilla in Young Children." In that paper he drew attention to the effect of nasal obstruction, adenoids and the obstruction of the choanæ. His views had met with opposition but he felt convinced he was right and Dr. Swain had corroborated the opinions before expressed by him. Others had denied the influence of anterior and posterior nasal obstruction on palate formation.

Dr. J. PRICE-BROWN stated that three or four years ago he examined the Indian skulls in the Archeological Museum of Toronto. There were about two hundred in all; but only half that number were sufficiently well preserved to found any pathological data upon. In about fifty per cent. of these the septum and hard palate formation was normal. Among them were a few skulls of Flat-head Indians and Mound-Builders; and in these also the proportion was about the same.

Dr. EMIL MAYER thought that the weight of the lower end of the superior maxillary bone was one factor in palate deformity. Regarding the influence of the deciduous teeth as a factor in addition to those previously named, while he believed it might be possible, yet at the same time it was a question for further consideration and determination.

Dr. G. H. MAKUEN called attention to the fact that probably seventy per cent. of all people were more or less addicted to mouth breathing. In many instances not calling for operative procedure he had tried the practice, with success, of placing a strip of silk isinglass court plaster over the mouth. The strip should be about an inch wide. It was well borne and acted as a reminder to the patient. Mouth-breathing occurred in many instances in which it was really unnecessary and was only the sequel of a habit formed in childhood and adolescence. If attention was called to this habit, as happens with the court plaster, it could be corrected.

Dr. W. K. SIMPSON desired to ask Dr. Swain as to the relative effects of nursing, both breast and bottle, in the formation of the arch of the palate, as it undoubtedly had some influence. Nearly all people were mouth-breathers under circumstances requiring extra exertion, thus, the runner is always more or less of a mouth-breather. He regarded mouth breathing at night as often a matter of the position of the child. Children would breathe through the

mouth when lying on the back, but if they were turned on the side the mouth breathing would often cease.

Dr. G. A. LELAND called attention to the pushing up as it were of the palatal arch in which process the negative air pressure in the nose and the positive in the mouth perhaps might be important factors which of course would but add to the influence of the improper development of the hard palate. This latter having an inherent power of growth had to bend upward because of the failure to spread of the alveolar processes, they being held inward by constant pressure of the cheeks in mouth breathers. The arch therefore assuming more or less the gothic form, shortened the space between the intermaxillary ridge and the top of the nose, *i.e.*, the vertical space taken from the nose was added to the mouth. Now the dentist in his processes of orthodontia by means of a wire spring fastened to the teeth either inside to push, or outside to pull on these alveolar processes, sought to quickly overcome the results of this retarded development by broadening the arch, which in the nature of things ought to increase the space in the nose by diminishing the sharpness of the arch. This resulted in giving more space for the septum, and it might be found that certain forms of deflection of the septum, especially those not evidently traumatic, could by thus reversing their etiological process, be corrected without resort to radical intranasal operation. He was free to say that these ideas came to him in conversation with a general practitioner and that he was watching the process in the daughter of a brother physician.

It went without saying that if success could attend such a procedure, the younger the subject the better, though the marvelous changes produced in the upper jaws by some dentists, even in patients of middle life, would seem to promise that under 35 years or perhaps 40, much might be accomplished.

Dr. GORDON KING called attention to the racial characteristics of the negro as of interest in the present discussion. The negro had a broad palate; it was rare to see in that race any marked palatal deformity from adenoids. Septal deviation in the child was rare as compared with the white child. The negro palate was larger and wider, as was also the nose, in comparison with the white race, so that even voluminous adenoid masses did not cause the same obstruction.

Dr. R. C. MYLES would like to ask Dr. Swain if he had any statistics of the septal deviations at birth, in other words, was septal deformity a condition beginning in utero?

Dr. SWAIN in closing the discussion remarked that no accurate series of comparisons had ever been made as to the effect of either the natural or artificial nipple in nursing. Statements on this point were merely the result of casual observation. The skulls of the Sandwich Islanders, a race that used neither spoons or artificial nipples, did not vary from normal Anglo-Saxon measure-

ments. He should think that constant suction downward of empty nipples as some mothers allowed would have a certain effect on the side walls of the face, but it must be remembered that the empty nipples did not allow the passage of any air and that while they were in use, the little people usually breathed through the nose.

In reply to Dr. Leland he would state that the question of straightening out the septum by palatal changes was still under discussion. Dentists were keeping casts of their patients made at different times. There was no doubt but that under proper mechanical treatment the palate could be greatly widened out, but the condition of the septum in these cases of palatal development had not been noticed.

Concerning Dr. King's observations, it was well known that the deciduous teeth in the negro lasted better than in white people and this might have some effect on the palatal development.

As to Dr. Myles' question concerning intrauterine changes, it must be stated that in some patients there seems an inherent tendency to palate malformation. This did not explain matters but merely stated a fact.

Paper.

ADENOID GROWTHS WITH SPECIAL REFERENCE TO ADULT CONDITIONS.

BY JAMES E. LOGAN, M.D.

It is not the purpose of this paper to enter into any detailed account of the causes, pathology, symptoms, or treatment of adenoid vegetations, but to bring to the minds of its hearers a few points of interest not hitherto dwelt upon at any length by those who have contributed to its literature. Brevity will of necessity be a virtue by reason of the lack of information available. A careful search through text-books and journals covering a period of twenty years gives us but little data touching the points we desire to bring to your attention. Not that what we may say carries with it anything new, but we hope to interest you in some phases of the subject that have not been deemed as important as we believe they deserve to be. The early recognition of this growth by the general practitioner claims especial emphasis. Not many

years ago the family physician knew but little of this trouble. Children in countless numbers were brought to him exhibiting distressing symptoms, such as turbulent sleep, mouth breathing, contracted chest walls, middle ear abscesses, impoverished blood, and many other attendant ills without his being able to recognize the condition. To-day this state of affairs does not exist to such an extent. However, we believe that even now the younger members of our profession are not taught sufficiently well the importance of thorough examination in every case in which the slightest possibility of this malady exists. When we look back over our early experience in epidemics of scarlet fever, measles, and diphtheria, and contemplate the many sequelæ we tried so hard to avoid, we cannot fail to appreciate our lack of knowledge and our causes of failure. Few of us if any ever thought of disinfecting a naso-pharynx. Seldom if ever did we realize that in this locality were bred and cultivated the very germs of these wide-spread infections.

It might be well to consider here the part played by the gland of the vault and oro-pharynx in the propagation of germ diseases occurring in childhood. Among the very first evidences of infection in any of the exanthemata are inflammations of the nasal and pharyngeal mucous membranes. Why then, is it not reasonable to believe that here exists the culture beds of these bacteria? If this be true, then might it not be possible to lend valuable aid in the prevention of these diseases by ridding the individual of the soil in which this infection is developed? In the light of our own experience we believe this can be accomplished. To state the point more clearly we believe that the early recognition of these enlarged and pathological lymphoid glands, and their removal, will lend great assistance in the prevention of such diseases as measles, scarlet fever, chicken-pox, and we may add diphtheria and possibly pneumonia.

If in our enthusiasm we have reckoned too far in what we have just said, we believe that every laryngologist will concur in the statement that most of the distressing middle ear sequelæ attending these diseases may be averted by proper attention directed to this locality. The general practitioner should carefully examine every child for adenoids whenever he has reason to believe they have been exposed to any of the diseases before named, and should insist upon their removal if present. This can be done without

subjecting the patient to any danger as serious as would occur if left unattended. If this opportunity is not afforded during the period of incubation, then he should resort to proper cleansing and disinfection of the parts in the hope of preventing infection of the middle ear.

Another important point we desire to call to your attention, is the co-existence of enlarged faucial tonsils and adenoids in children. A careful examination of many hundreds of cases reveals the fact that with very few exceptions, where we found enlarged faucial tonsils there existed the same condition in the vault. Our records show but few exceptions, so few indeed that we are forced to accept it as the rule; on the contrary, we have seen many cases exhibiting large pharyngeal hypertrophies with faucial glands very small if not entirely absent. An explanation of this may be founded on an embryological fact that the pharyngeal tissue developes first and arrest closely follows in the glands below. This might be of value to the practitioner if he would realize that the condition of the faucial glands is an index to what exists above. It would also guard against the oft-repeated neglect of removing what appears below as offending, leaving the real disturbance unattended.

We now come to a phase of this subject which we believe to be of great importance, viz., adenoids in *adults,* or more properly speaking, pathological conditions of the lymphoid tissue in the adult vault. It is our belief that the lack of proper diagnosis in those cases accounts for our lack of success in the management of many intractable diseases of the upper air passages and middle ear—indeed many persistent affections of the pharynx, larynx and bronchial tubes may find a remote cause in this condition. The oval-shaped fibrous mass at the junction of the occiput and sphenoidal body is too often overlooked or passed by as unoffending. Too often we fail to use our probe, by the employment of which we may find beneath this resisting cover, a mass of diseased lymphoid tissue, with pockets lined with pyogenic membrane, pouring out their material ladened with all kinds of infectious bacteria.

Much has been written upon this condition in child life, but seldom do we find more than occasional mention of its existence in matured age. Delavan in an article appearing in the *New York Medical Journal* Oct. 12, 1889, referred to cases he had seen

that had persisted through childhood to middle life, and in some the hypertrophy had apparently developed after puberty, especially in women of stout figure who had suffered from catarrh of the upper air passages and dyspepsia. He observed that singers were especially liable to this condition. W. Meyer in his analysis of 102 cases, found but eight affected after the twenty-fifth year. Bosworth found but four after the thirtieth year in seventy-five cases reported.

Hallat reported a few cases in adults between the ages of eighteen and twenty-five years, and suggests that in a great many cases over twenty years there are adenoids that require operation.

At a meeting of the French Laryngological Congress in 1890, Raulin of Marseilles called attention to the existence and relative frequency of adenoid growths in adult age, and we ask the indulgence of our hearers while we quote at length the report made of his remarks by the *Journal of Laryngology and Rhinology* in the July number of that year.

"Observed in persons of forty, fifty, sixty and even of seventy years, they date generally from childhood, as is proved by recollection, osseous deformity of the head, and by the chronicity of the trouble of hearing. Formed most frequently by the hypertrophy of a single group of closed follicles—it may be of the pharyngeal tonsil or of that of the fossæ of Rosenmüller—these tumors are surrounded by traces of their congeners, which have not escaped as they have, atrophy and retrogression. The symptoms are of little importance; respiratory troubles are absent, or, if present are due to the passive congestion of the cavernous tissue of the turbinated bones. The patients complain, in the majority of cases, either of naso-pharyngeal catarrh or of deafness. This last symptom is in no way influenced by the destruction of the growths, on account of the long continuance of the lesions of the middle-ear. The most advantageous treatment is by removal with different kinds of adenotomes; ablation is more completely effected than with the forceps with which it is not possible to seize the more or less atrophied remains of growth which surround the tumor."

Haight of Chicago, in a paper read before the Sixth International Otological Congress in London, Aug., 1899, entitled, "Naso-Pharyngeal Adenoids as a Causation Factor in Ear Diseases," stated that he had operated upon patients over sixty years

of age, and had often removed them in patients between the ages of thirty and forty years.

Careful search through the literature of this subject fails to find more than a passing notice, suggesting always that such conditions are very rare and bearing little clinical importance. In the experience of the writer the reverse condition predominates. The child may pass through its early life carrying with it the many ills attendant upon an overcrowded vault, without results so serious as to endanger its life, or subsequent usefulness. With all of these, and more, are the ills of those who have suffered through infancy, youth, adult life, and even to old age. Were we to enter into a detailed account of the cases we herein report, it would unfold history of great suffering, great privation and much mental anguish. We have in mind a fair example in a man who consulted us. He gave a history of repeated attacks of middle ear inflammation in childhood—difficulty in breathing, inability to obtain an education in keeping with his ambition, gradually increasing deafness with every cold. At the age of twenty years sought medical attention, and so continued with varying success until he had about given up all hope of relief. At the time of his visit to us, his condition was as he remarked "unbearable," unable to attend to his business, stayed away from his friends, cared not to attend a theatre or church, in fact never thought of going to such places. Examination revealed no watch hearing except when placed on mastoid. Every test save bone conduction was negative. Distressing tinnitus at times—not constant—marked retraction of drumheads, ossicular chain crowded high into the attic, thickening and evidences of old inflammation in Schrapnell's membrane—beginning evidences of labyrinthine tension, all were present. Examination of the nose and naso-pharynx proved *this* to be the evil cause. With hypertrophy of all the turbinal bodies, and a vault filled with a large mass of lymphoid and fibrous tissue, you will all agree with me that this was not, to say the least, a promising case for prognosis. After performing the various necessary operations, and conducting a treatment consisting of Eustachian catheterizations, and bougies also aural massage, etc., through a period of nearly three years, we are glad to report that this patient is able to conduct his business with comparative comfort, and can hear ordinary conversation

at a fairly long range. Other histories might be recited that were just as unfavorable, and just as interesting; some in which results were most gratifying, while in others our efforts were without appreciable avail.

An interesting question just here suggests itself—Do pharyngeal tonsils when once pathologic, tend to atrophy? The history of all these cases herein reported, brought out the fact of difficulty more or less severe, beginning in early life. Most every case dated back to measles, scarlet fever, small-pox, or diphtheria as the occasion of greatest severity. In the light of our experience, we believe that when once this tissue becomes diseased, it rarely atrophies. It may and does diminish in size in many cases, but whenever established as a diseased process it seldom disappears except by removal. To define our position more clearly, if the child in whom hypertrophies on the vault exist is the victim of any pathological process sufficiently severe to establish trophic changes in the structure of the gland, then there is little likelihood of its disappearance at puberty. To draw conclusions more closely, we believe that in nearly every case of hypertrophied vault tissues where measles, scarlet fever or diphtheria have intervened, we will find evidences of this hypertrophied gland in adult life. From clinical experience we are constrained to differ with those who believe that these conditions begin in patients of mature age. In none of the cases under our observation have we ever failed to obtain a fairly definite history of early involvement.

Of the sixty-five cases we have to report, thirty-five were males and thirty were females. Thirty-two occurred between the ages of twenty-five and thirty-five years. Twenty-nine between thirty-five and forty-five, and four between forty-five and fifty-two years. Fifty-four had co-existing nasal hypertrophies of varying severity. Three had atrophy of nasal membrane. In two the atrophic process was found in both nostrils; in one it existed only upon one side—the left. It is interesting to note that in this case last mentioned, the vault tissue appeared as a cicatricial mass with a band of adhesion extending from the fossa of Rosenmüller to the posterior Eustachian lip. The patient exhibited marked deafness in the left ear, greatly in excess of that existing in the right. Removal of this scar tissue brought about a noticeable improvement in hearing power.

Forty-seven of the sixty-five suffered from some form of mid-

dle ear disease. Nine exhibited chronic suppurative otitis media in one or both ears. Twenty-three had had recurrent attacks of acute catarrhal or suppurative otitis media. Twenty-two showed progressive deafness dependent upon sclerotic changes undergone in the conducting media.

The results obtained in a large per cent. of these cases were not in keeping with the statement of Raulin, who said that the deafness attending these growths was in no way influenced by their removal. Three of the nine cases of chronic suppurative otitis media were relieved without additional operative interference directed to the ears, other than proper attention to cleanliness by antiseptic irrigations and such measures as would establish thorough drainage and ventilation of tympanum. Four were benefited to the extent that recurrent attacks of suppuration have been very infrequent, appearing only during acute inflammation of nasal and naso-pharyngeal mucous membranes. In two the aural conditions were of such severity that removal of the pharyngeal growth was performed only to further aid the results to be obtained from a complete cleaning out of the contents of the middle ear. Of the twenty-three cases with recurrent acute attacks of catarrhal and muco-purulent inflammations of one or both ears, twelve, or about fifty per cent., have had as yet no subsequent return, and the existing deafness improved in degree proportionate to the amount of permanent injury to the affected organs. In the twenty-two exhibiting sclerotic changes in the conducting media, our results were less gratifying. These cases are usually of such long standing, and degenerative process are so extensive, that but little improvement results from any line of treatment.

Notwithstanding the fact that an unfavorable prognosis in these cases must be made, it is our duty nevertheless to rid the sufferers of these disturbances in the hope of arresting the progress of their unfortunate disease.

We ask your further indulgence while we summarize the points desired to be brought out by this paper.

First.—The early recognition of adenoid growths in children by the general practitioner.

Second.—Prompt removal when so extensive as to interfere with the development of the child, and especially when the patient has been exposed to any of the exanthemata.

Third.—When present in patients suffering from the above

eruptive diseases, attention must be directed to proper disinfection of the pharyngeal vault.

Fourth.—*In patients exhibiting enlarged faucial glands there generally exist hypertrophies in the vault*—the reverse condition does not always obtain.

Fifth.—Hypertrophy of the pharyngeal glands in adults is *not* a rare condition, and as a rule it is dependent upon pathological changes during childhood, and is not developed after puberty.

Sixth—Operative interference is warranted in every instance not only to relieve existing dependent conditions, but to prevent impending complications.

Paper.

HOW SHALL THE DIAGNOSIS OF POST-NASAL ADENOIDS BE MADE IN YOUNG CHILDREN WHEN RHINOSCOPIC EXAMINATION IS IMPOSSIBLE?

BY CLARENCE C. RICE, M.D.

WE very much doubt if any expert rhinologist finds it difficult to determine the presence or absence of enlarged post-nasal lymphoid tissue even when a rhinoscopic examination is impossible. There are only one or two special points relating to this very large subject to which we should like, very briefly, to call the attention of this Association.

In two or three papers relating to the ease or difficulty of rhinoscopic examination of children the opinion has been quite freely expressed that it is usually an easy matter to use the post-nasal mirror successfully with young patients. Let us consider this matter for a moment. Practically speaking, we might divide young children into two classes: those treated at dispensaries and those seen in private practice. This division is useful for the purpose of discussion, since the conditions surrounding the two classes—the one in the private office and the other at the clinic—are so very different. It is one thing to make a successful rhinoscopic examination alone with the mother and child in the quiet of the office when the physician is not specially pressed for time, and quite another

thing for the hurried operator to make a successful demonstration for students on a child who is badly frightened and surrounded by other crying children. We believe that the successful use of the rhinoscopic mirror cannot often be accomplished with children under seven years of age except with the aid of cocaine and the expenditure of much time and patience. In dispensary practice, therefore, and especially at a clinic, the operator must determine positively, and quickly, too, whether in a seeming case of nasal catarrh the real source of the trouble is enlarged lymphoid tissue in the post-nasal pharynx. In very young children, three or four years old, the post-nasal space is so shallow that the vault may be examined without a mirror by lifting up the uvula with a palate hook; but this is not a practical procedure with the majority of children.

The rhinologist of experience quickly and surely, almost without an examination, determines the presence or absence of post-nasal obstruction by the process of exclusion. If the patient presents the ordinary symptoms of nasal hyper-secretion and some degree of impaired nasal respiration, the examiner after he notes that obstruction in the nasal passages proper is not present, and that enlarged faucial tonsils are not a factor in the case, may readily conclude that the real difficulty in nasal respiration is occasioned by an abnormal amount of tissue in the vault of the pharynx.

Clinically, we know that cases of post-nasal tissue enlargement may be roughly grouped into two classes, and first that larger class in which although but a moderate amount of enlargment is present yet the patient furnishes the usual symptoms of mouth breathing, frequent coryzas and constant nasal discharge. These patients are able to breathe through the nose more or less during the day, but sleep with the mouth open; they can blow the nose in a fairly satisfactory manner. Here the diagnosis is moderate enlargement of the lymphoid tissue, probably localized in the median line of the vault. In the other class of cases, more rarely seen, the mouth is always open day and night. No air can be forced through the nasal passages, and the stupid expression completes the diagnosis of a post-nasal vault completely filled with adenoid tissue. In this class of cases the rhinoscopic mirror is entirely unnecessary for diagnostic purposes because all other possible obstructive factors may be seen at a glance to be absent. We are satisfied that the post-nasal space is completely filled with adenoids

and that nothing except their thorough removal under complete anesthesia can secure proper nasal respiration.

Now I wish to lay emphasis on two points; first, that there is a moderate amount of lymphoid enlargement in ninety per cent., I would almost venture to say ninety-five per cent., of all the cases of so-called nasal catarrh in children; and the enlargement, however moderate in degree, is the real cause of the entire group of catarrhal symptoms. To state it in another way,—There may be but slight lymphoid enlargement, but there is some in nearly all cases of nasal catarrh in children, and a little is sufficient to do the harm. The second point is to recommend most strongly the post-nasal curette as the best means of determining the condition of the vault when the post-nasal mirror cannot be easily used. We hear all the time that the old, unsatisfactory, unnecessary, and almost brutal practice of employing the finger as a means of diagnosis is still employed. The principal object of this short paper is to deprecate the use of the finger, and as strongly to advocate the employment of the curette as the best medium of diagnosis. The objection may properly be made that the curette may be a dangerous instrument and that harm may be done by its use where no abnormal condition of the vault exists. We quickly agree that no one should curette the post-nasal pharynx who has not had proper training; but if he is one who cannot use the curette properly he probably will not be able to see understandingly with a mirror or examine intelligently with his finger. The trained rhinologist will do no harm with the post-nasal curette whether the vault is free from or filled with enlarged lymphoid tissue. In a doubtful case the curette in the hands of a skillful operator can be introduced with much less discomfort to a small patient than can a large index finger. We have always believed, too, that the finger, unless it is exceedingly well-trained, gives to the examiner very little positive knowledge of the condition of the vault. After the introduction of the finger, which determines nothing, the curette is still to be used—two procedures and two occasions of discomfort, where only one is required. With the curette the spongy pad at the vault may be easily felt and quickly removed. The large number of cases of moderate enlargement of lymphoid tissue at the vault of the pharynx are especially adapted to the use of the curette without an anesthetic because the tissue does not extend away across the vault from one Eustachian orifice to the other where

only post-nasal forceps can reach it, but lies in the median line where it can be readily removed by the curette.

I must not touch upon the general subject of adenoids, for this short paper is read only to present these points:

First, the rhinoscopic mirror cannot be successfully used in a large percentage of young children, and especially in clinical work, without using cocaine and expending much time and patience.

Second, the presence of enlarged lymphoid tissue in the post-nasal pharynx is readily appreciated without a mirror, and by the process of exclusion.

Third, the presumption that enlarged tissue is present, is well founded, because probably in nine-tenths of all the cases of so-called nasal catarrh in children which present the ordinary symptoms, the real commencement and cause of impaired nasal respiration and nasal discharge is adenoid enlargement in the vault. And again, in a large number of adenoid cases the enlargement is so moderate in degree and so strictly confined to the median line that it can be quickly removed by one introduction of the curette alone, without forceps and without much pain to the child. This is eminently a practicable procedure in dispensary and clinical work. And finally the curette, skillfully used, is the best means of exploring the vault, because with it the diagnosis can be made and the tissue removed at a single introduction, without the useless and uncomfortable method of exploring the vault with the finger.

Discussion on the Papers of Drs. Logan and Rice.

Dr. D. Bryson Delavan said one might have supposed that the subject of adenoids had been pretty well exhausted but Dr. Logan had shown the contrary. He had seen some cases in adults in whom a condition of atrophy had been preceded by adenoid hypertrophy and later in life this had atrophied to such an extent as to produce an annoying condition difficult of relief. In regard to the second paper there were many things with which he could not agree. The first one was that the curette was the best instrument for the relief of the lymphoid growths. This instrument in the hands of any one but a skillful person was dangerous and much harm might be done with it. The use of the mirror was possible in the case of many children over four years of age and he frequently made satisfactory examination with it in those still younger, much preferring this method when possible, to palpation. He considered

the Gottstein knife as commonly fashioned an unsatisfactory instrument. In very young children the pharynx could often be satisfactorily investigated by the aid of a small probe made of one of the smallest English woven catheters. The presence of tonsillar hypertrophy was commonly accompanied with hypertrophy of the vault. One strong reason for operating in these cases under anesthesia was that the removal of all the hypertrophied masses, both tonsils and adenoids could be effected at once and under favorable conditions.

Dr. J. W. FARLOW quite agreed with many of the points mentioned by Dr. Delavan concerning the curette, which he considered a painful instrument. He had often been able to determine the presence of adenoids by passing a small rhinoscopic mirror up behind the palate into the post-nasal space, the mirror striking against soft tissue giving a very different impression to the examiner from that obtained when the mirror touched only hard bony walls. This can be carried out quickly if it proves impossible to get a look at the vault with the mirror. It is often possible to see adenoid disease through the nose, especially in children, where the septum is generally straight. A little adrenalin or cocaine opens the nostrils sufficiently to permit a view of the tissue behind the nose.

With reference to Dr. Logan's paper, he thought that adenoid disease in adults was not given the attention it deserved. He had been surprised at times in operating in such cases to find how large an amount of adenoid hypertrophy existed where to the mirror the vault had not looked as if there were much hypertrophy. It was not always possible to tell in advance how high the vault is and how thick the adenoid tissue is.

Dr. J. N. MACKENZIE said that the subject of adenoids had been more frequently talked to death and more frequently resurrected than any other topic in laryngology. He thought most men of large experience would agree with him in approval of Dr. Logan's paper. There was one statement therein however open to criticism in the earlier portion. In describing the lesions found, he believed Dr. Logan had mistaken cause for effect. Dr. Mackenzie would also take exception to Dr. Rice in regard to the employment of cocaine in young children. He never used it and believed we could get along just as well without it. In regard to statistics as to the frequency of adenoids, he fully agreed with Dr. Rice. It almost seemed as if the twentieth century child was not complete without adenoids. It was hard to find even a French doll without its mouth wide open.

Dr. J. W. GLEITSMANN said that although objection seemed to be raised by some of the speakers to the examination of the rhinopharynx with the finger in case of suspected adenoids, he saw no reason for the objection. The finger was certainly the most delicate and at the same time the surest means of establishing the di-

agnosis. If inserted with only moderate skill, it caused little or no pain. In small children under one year of age, he had often used the little finger for this purpose. He had also often made a second examination immediately before the operation, when too long a period had elapsed between the second and first examination, to refresh his memory as to the size, extent and density of the growth, all of which factors necessarily bore some relation to the operation itself.

Dr. EMIL MAYER stated that the diagnosis of post-nasal adenoids in young children could almost invariably be made by the presence of lymphoid masses on the posterior wall of the pharynx. These masses would in adults be called follicular pharyngitis, but in young children seemed to be the overgrowth of adenoid tissue along the posterior pharyngeal wall. He was surprised that the reader of the paper had omitted this entirely from consideration. The speaker had for a long time refrained from the use of the finger in making a diagnosis—it was all-sufficient for him to diagnose the presence of adenoids and it was quite enough to introduce the finger at the time of operation when, the patient being anesthetized, the location and size could readily be determined. Nor did he think it safe for those who are teaching physicians to use an instrument which really would amount to an operation, for the purpose of making diagnosis.

Dr. J. PAYSON CLARK had found that where examination with the mirror was impossible or difficult a finger examination was really not objectionable. Although the child might be momentarily frightened, its attention could be quickly diverted and in a few minutes it had entirely forgotten about it. Experience with adults showed that while the introduction of the finger into the nasopharynx caused only some discomfort, the removal of an adenoid with the curette was often exceedingly painful. Diagnosis was one thing and treatment quite another and the two could not properly be combined. If adenoids in children require removal the operation should be thorough and this thoroughness could only be obtained under general anesthesia. He would not be satisfied with the use of the curette in the manner described by the writer.

Dr. H. L. SWAIN had been brought up in the belief that if a person only lived long enough he would outgrow his adenoids but we now know this idea to be erroneous. A very pretty case illustrating this point had been brought to the attention of this Association some years ago by Dr. Farlow, who showed one of the largest masses of adenoid tissue he had ever seen, which he had removed from a woman of about 60 years of age. Evidently she had waited quite long enough for absorption to take place.

Dr. Logan's paper was very timely and threw none too much emphasis on the necessity of radical treatment of adult "adenoids." Recently he had occasion to remove a large mass from the nasopharynx of a patient whose hearing was much improved as a re-

sult. This patient had been treated by electrolysis of the Eustachian tube without effect, illustrating the point mentioned by Dr. Bliss in his paper, viz., how often disrepute is thrown upon new methods by ill-considered application of them by physicians too eager to try something of recent date.

As regards Dr. Rice's suggestion and the facts brought out in the discussion, Dr. Swain stated that he believed thoroughly in the idea expressed by Dr. Mayer that large follicles on the posterior pharyngeal wall were presumptive evidence of "adenoids," but that in cases too young to use posterior rhinoscopy, or when one was too hurried to care to spend the necessary time in getting the patient to permit a good examination in that way, one could readily use weak cocaine solution with extract of suprarenal glands to spray the nose. Dr. Farlow had mentioned the method and he (Dr. Swain) was much pleased to have these observations confirm statements made by himself at the Boston meeting. Even in quite young children it was perfectly feasible by thus spraying the nose and contracting the turbinate bodies, to see quite readily into the naso-pharynx and make yourself perfectly sure that the pharynx tonsil is enlarged. One could very accurately estimate how low the masses hang and thus have a correct idea whether operation is necessary. We thus did away with the necessity for either finger or curette until operation was decided upon and the little patient had no dread whatever when subsequent attendance on the part of the physician is necessary.

Dr. R. C. Myles said that nearly every person had some adenoids as a legacy from childhood. He had not been as successful as he would have liked in removing with the finger those that formed the synechia between the Eustachian tube and the tissues over the basilar process of the occipital bone. In some cases it was better to use a general anæsthetic and the forceps.

Dr. W. K. Simpson had had his own experience with adenoids and it was a new idea to him to use the curette for simply making a diagnosis. Was he to understand that in all cases of adenoids in children, Dr. Rice advised the curette for diagnostic purposes? Was he going to remove the growths then and there or was he going to remove the curette and then do the operation subsequently? In a great many cases we did not really need to make much examination. He thought that the mirror and the intelligent use of the finger were the best means for diagnosis.

Dr. J. E. Newcomb alluded to the fact of the anterior projection of the bodies of the upper vertebræ as an obstacle to examination of the pharyngeal vault and in one or two cases had found it difficult to introduce any instrument or even the finger but by using a small instrument had managed to surmount the difficulty. In most instances he kept his finger in the vault during the operation with both forceps and curette. In this way he knew exactly what the cutting edge was doing. After operation he always

carefully explored the vault with the finger in order to assure himself of complete removal of the growths.

Dr. LOGAN stated, in closing, that he greatly appreciated the kind treatment his paper received. The point he desired especially to bring out, omitted in the discussion, was the great amount of adenomatous tissue found in the adult vault, when examination revealed but little evidences of it. In regard to the suggestion of Dr. Rice with reference to the use of the curette as a means of diagnosis, it would seem to him that every case should be handled according to the conditions. In some the use of the curette might be the easiest method, in others the digital examination might be necessary, and in other cases we were able to diagnose these growths by introducing a probe through the nasal cavity, a method he often employed.

Dr. RICE, in closing, said that he did not advise the use of cocaine to assist in making a rhinoscopic examination and did not, himself, use it. He had only said in his paper that in many cases it would be absolutely necessary to spend a great deal of time and to use cocaine in order to make a rhinoscopic examination in children. He felt that it was the practice of nearly all rhinologists to diagnose the presence of adenoids by a process of exclusion for certainly rhinoscopic examinations were not made in very many cases. He had also said in his paper that some degree of adenoid enlargement was present in nine tenths of all children who presented the ordinary symptoms of nasal catarrh.

The first question to be decided was whether an anæsthetic was necessary. In a very large number of dispensary cases the amount of lymphoid tissue was so moderate that it could be quickly removed without an anæsthetic and that too, without giving the child much discomfort, far less in fact than would be given by the administration of an anæsthetic and confining the child to the hospital for several days. He still affirmed that the curette properly used could be much more intelligently employed than could the finger in making a diagnosis and with less discomfort to the child.

Dr. Mackenzie's disapproval of the curette seemed to be based on his preference for the forceps. He (Dr. Rice) quite understood that each operator became accustomed to and consequently preferred his own instruments and method to all others. Dr. Delavan had said that great harm could be done with the curette. Great harm could be done with any instrument but it was always understood that no instrument was to be employed in the nose or throat for the destruction of tissue except by properly trained rhinologists. He himself had employed the curette in hundreds of cases and never with any bad results. Children were curetted at the dispensary for small amounts of adenoid tissue and went to their homes all over the city after a detention of only half an hour. No one could possibly deprecate brutal methods with children more than himself.

Paper.

A CASE OF SARCOMA OF THE NASO-PHARYNX.

BY WILLIAM KELLY SIMPSON, M.D.

MALE patient, aged 27, first seen by me April 27th, 1902. He consulted me for a slight coryza accompanied by an attack of acute catarrhal otitis media, principally of the right ear. He had some slight impairment of hearing for a number of years, which gave him but little trouble, other than when he suffered from attacks similar to the present one. There was considerable feeling of fulness in the ears and also a feeling of nasal and post-nasal occlusion. The impairment of hearing and other aural symptoms, including a slight watery discharge, were confined almost entirely to the right ear.

In examining the naso-pharynx for possible cause of the present attack, I found that space to be almost completely filled with a mass giving the appearance of an ordinary adenoid growth as seen in the adult, but was quite surprised to find it so extensive in a person of his age.

When questioned as to his knowledge of its existence he said that he had never been informed of it before despite the fact that he had been under treatment for previous similar attacks. This can be somewhat accounted for, I think, from the fact that it was very difficult to make a posterior rhinoscopic examination curette. The operation was successfully performed and I was able make a satisfactory one.

One characteristic of the growth which I noticed at this examination was its tendency to bleed easily under manipulation. I suggested the advisability of removal of the growth, but as the attack of otitis cleared up in two or three days with ordinary means of treatment, and as the adenoids gave him apparently no further trouble, it was not done and I did not see the patient again until November 25th of the same year, a period of seven months.

At this time he consulted me relative to attacks of nasal hemorrhage which had persisted for some little time and had become

almost constant; sometimes very excessive. Although there were some hemorrhages which seemed to flow mostly from the naso-pharynx, the majority of them came through the anterior nares.

Remembering the fact that at the previous examination I had detected adenoid growths which showed a tendency to bleed, I was quite sure that the hemorrhages had their origin in the adenoid mass. This was confirmed by further examination and by local application which I made to the growths, which produced a very severe hemorrhage.

The growth at this time presented a somewhat different aspect from that noted at the previous examination; it was considerably larger and somewhat paler excepting the inferior border which was almost entirely in a condition of superficial erosion with slight sloughing appearance, presenting more or less a bleeding granular surface.

These hemorrhages continued at irregular intervals, but being quite thoroughly controlled by the application of adrenaline through the anterior nares, until January 15th of the present year when the patient concluded to have the adenoid mass removed.

From the appearance of the growth, and from the great tendency to copious bleeding, and from the general appearance of the patient, which was rather cachectic, I had come to the conclusion and had so informed the patient, that the growth was more than an ordinary adenoid growth, and was probably sarcomatous in nature.

On January 15th, 1903, under cocaine and adrenaline, I undertook the removal of the growth by the means of a large Gottstein curette. The operation was successfully performed and I was able to remove the mass almost in its entirety, and much to my satisfaction, with practically no hemorrhage, which latter fact I attribute to the marvelous hemostatic effects of the adrenaline solution.

From the hemorrhagic nature of the growth and from the previous hemorrhages produced by manipulating it, I expected and prepared myself to meet with an alarming hemorrhage at the time of operation and was very much relieved that no such accident supervened. I am quite sure without the use of adrenaline that such good fortune would not have been obtained, and in my experience it is the most marked instance of the hemostatic effect produced by that drug.

Aside from the previous hemorrhages which had originated from the growth, I had noted in some of the previous examina-

tions that all of the naso-pharynx and of the post-pharyngeal wall. down into the oro-pharynx, presented a very livid and sometimes a very bluish appearance of the mucous membrane.

The gross appearance of the mass removed did not differ very much from the appearance of an ordinary adenoid growth. The major portion of it was rather firm in consistency, but the inferior dependent portion was rather soft, presenting a hemorrhagic surface above alluded to, but there was nothing in its gross appearance which would positively stamp it as being sarcomatous.

I submitted the growth for microscopic examination to Drs. Thatcher and Tuttle, pathologists at the Presbyterian Hospital, and herewith append their report.

Pathologists' Report.—Microscopic Examination.—"Much lymphoid tissue, few groups of gland alveoli, some fibrous connective tissue and many patches and strands consisting of rather large cells with rounded and oval nuclei 20 to 40 m.m. in diameter, containing less chromatin than leucocytes, presenting many mitoses. The outlines of these groups are, as a rule, not perfectly sharp, but in some fields give a distinct alveolar impression. They are found not only in the lymphoid tissue but also in the fibrous connective tissue. In the latter situation they appear to contain more chromatin. Some areas are extremely vascular. Looks very much like sarcoma."

In further conversation with Dr. Tuttle, he told me that he had shown the growth to another pathologist, whom he considered of best authority on new growths, and that he had reported that the growth would certainly have become malignant had it not been removed. He considered it on the border line of a variety of sarcoma. Although the consensus of opinion of those who examined the growth, was that it was probably a form of sarcoma, at the same time there were some points about the growth which made a definite result somewhat obscure and puzzling.

The question of recurrence naturally came up for consideration, but it was the opinion of those who examined the growth that the chances were against such a recurrence taking place.

The subsequent history of the case has been most favorable from all points; the aural symptoms have much improved; there have been no recurring hemorrhages excepting a slight ichorous discharge which persisted for a short while after the operation, but which at the present time has entirely disappeared. The patient's

general health, condition and appearance have very much improved, and careful, repeated examinations up to the present time, May 1st, have not shown any indications of a recurrence of the growth.

The general appearance of the naso-pharynx is fairly normal, excepting a somewhat deeper color of the mucous membrane than ordinary, and at one point in the right upper portion, there is a small area which seems to be a little more granular in appearance than the rest of the cavity.

Although four months have elapsed since the operation and no recurrence has taken place, I cannot say that such will not be the case, but in any event the present appearance of the site of the original growth does not show any tendency towards recurrence.

The points of interest to be drawn from the recitation of the above history are:

1. The necessity of making a thorough examination of the naso-pharynx in patients presenting a train of symptoms similar to the above.
2. The importance of regarding hemorrhages as a sign pointing to the malignant nature of the growth.
3. The hæmostatic effect of the adrenalin chloride solution.
4. A possible prevention of malignancy by early operation.

Paper.

NOTES ON CASES OF SARCOMA OF THE NOSE WITH PRESENTATION OF PATHOLOGICAL SPECIMENS AND MICROGRAPHS.

BY J. PRICE-BROWN, M.D.

CASE I.—Eight years ago, at the meeting of the Laryngological Section of the American Medical Association, at Baltimore, I read the report of a case that I styled "Recurrent Fibroma of the Nose;" using the term "fibroma," because the pathologist who examined a section for me distinguished it by that name. I also stated that a previous pathologist, in Hamilton, and another in Boston, after microscopical examination, had declared the growth, of which this was a recurrence, to be sarcoma. As I reported at the time, I had removed the growth by a succession of intranasal operations.

From then until now, a period of eight and a half years, the man has enjoyed uninterrupted good health. At my request he came for examination again three or four weeks ago, and I found no return whatever of the disease.

My own impression, from later experience is, that it was really a case of sarcoma; and that my own pathologist, happened to examine a section that was chiefly fibrous in character.

CASE II.—About a year ago, a stoker in a large manufactory, aged 50, was referred to me by Dr. Cleland. He had been suffering from nasal stenosis for a year or two and latterly had several very severe nasal hæmorrhages from left side. On examination I found a red fungoid bleeding tumor, not very large, growing from the upper part of left side of perpendicular plate of the ethmoid. I removed a section and had it examined microscopically by Drs. Davis and Carveth. They pronounced it to be round-celled sarcoma. This I removed by electro-cautery operations. The patient made a good recovery. He has been working uninterruptedly for nine months and up to the present time there has been no return.

The success attending the treatment of these two cases inspired me with confidence to undertake another which I will report in detail.

CASE III.—On October 31, 1902, Mr. L. R. P., aged 21 years, presented himself at my office for examination. I found a large growth which completely filled the left nasal cavity. It distended the nostril, flattening that side and producing partial frog-face. Posteriorly it filled the post-nasal cavity, pressing the soft palate downward, rendering it rigid and immobile. The septum was pushed over to the right by the growth, so that nasal respiration was impossible. The tumor was of a pinkish color, particularly the posterior end, and was smooth, glistening and firm. The lower part of left cheek was protuberant and pendulous, though not diseased. The sense of smell was entirely absent. Physically the man was well nourished, and plethoric in color. There was neither glandular enlargement nor pain; but there was very great distress accompanied by a full bursting sensation.

Two and a half years previously, the growth was already large and attended by many hæmorrhages. Dr. Wishart took away a section at the time, and on microscopical examination found it to be sarcoma. Excision by external surgical operation, based upon the diagnosis, was then advised, but it was declined. Subsequently, various methods of treatment were tried by different medical men including electrolysis and the use of the X-ray, but all without avail. The tumor steadily enlarged and every time it was interfered with would bleed.

Taking all these facts into consideration, it was not without a good deal of trepidation that I ventured to take charge of the

case; and before doing so a full explanation of the dangers from hæmorrhage, the possibility of not being able to remove the entire growth, and even the likelihood of its return, was given to both the patient and his friends.

The first attempt at treatment was on November 13. Dr. Wilson kindly assisting. The application of a solution of cocaine, followed by a 1 in 2,000 of adrenalin, rendered the anterior end of the tumor pallid. The idea was to remove several segments if possible by snare. It was found, however, that although the loop would slide in between the nasal wall and the side of the tumor, the latter was so round and dense that but slight hold could be obtained and little else but mucous membrane came away. Still the hæmorrhage was so severe that the nose had to be plugged tightly at once.

Several days elapsed before all the tampons were removed. Consequently operating did not really commence until November 18.

From that date until February 2, when an operation under chloroform was done, of which I will speak later, I removed 12 pieces of the growth by means either of the snare or scissors; and operated upon it also 49 times with the electro-cautery. Before each cautery operation I sprayed the nasal cavity out with an alkaline solution, and then removed the sloughs, occasioned by the previous operation, with forceps. A large number of these I kept preserved in alcohol and here they are.

By the date mentioned or ten weeks after commencement, the great body of the tumor had been removed. But there was still a large piece attached to the vault of the left side of the naso-pharynx and posterior end of the septum. I tried several times to get a loop upon it, but the patient could not bear my fingers behind the palate to adjust the snare.

The result was that on February 2nd I operated under general anesthesia. Dr. Gullen kindly administered chloroform. A mouth gag was inserted. I passed a screw snare through the nose to the naso-pharynx with the right hand, and with the fingers of the left in the naso-pharynx adjusted it in position around the base of the tumor. Dr. Gullen then turned the screw until the hold was secure. After which it was tightened by degrees until the growth was cut off and drawn into the nose, where it acted as a plug, the snare separating from it. The hæmorrhage was exces-

sive, and the gag being still in the patient's mouth, I pressed in behind the palate a number of large wads of absorbent cotton, completely filling the cavity and retaining pressure for some time with my hand.

Quarter of an hour later, after hæmorrhage had ceased, the piece was pulled out of the nasal cavity with forceps. Here it is When fresh it weighed nearly three drams, and as you will notice the base was nearly as large in every direction as the diameter of the tumor itslf.

Between the time of this operation under chloroform and the last one on April 7th, I had 25 other electro-cautery operations upon parts of the tumor not entirely removed. These were chiefly in the turbinal region. The whole of it now seems to be eradicated. This bottle contains some of the fragments taken out during this latter period.

There are a number of points of interest in this case that it may be well to touch upon.

1. The attachment of the tumor. It was immensely sessile, as sarcoma of the nose usually is. It had grown from the whole length of the left inferior and middle turbinal regions and the posterior part of the vault above. The attachment extended over the upper part of the left palate bone, the body of the sphenoid, the inner surface of the internal plate of the pterygoid, and the posterior end of the vomer. Except the front end the bone of the inferior turbinal had been entirely absorbed, as well as the greater part of the middle turbinal; also a portion of the face of the body of the sphenoid; for instead of the ordinary opening into the sphenoidal sinus, there is now a large perpendicular oval opening, which in all likelihood was made by pressure absorption.

2. Method of operating. As I expected to do nearly the whole work by the use of the electro-cautery, I considered it best to work into the body of the tumor first. By this means no injury could accrue to sound mucous membrane. In each operation, under cocaine anesthesia, I cut as deeply and widely with the electro-cautery knife as safety would permit. On the following day, or at most with an interval of two days, the parts would be cleansed, the sloughs removed, and the operation repeated. After getting out a portion in this way, and making a good hole into the tumor, I would remove successively pieces of the shell that was left. This would be done either by snare, scissors or electro-cautery,

as seemed best. After that a deeper portion of the tumor would be attacked in a similar manner; and so on until the great bulk had been removed.

3. In operating I took care not to injure sound mucous membrane. Very rarely did I use the cautery from the outside wall of the tumor; and when I did the blade was passed between the true mucous membrane and the growth, and the latter pressed away from the former before the heat was turned on.

4. A word about hæmorrhage and the use of adrenalin. In the

Picture of patient one month after last operation.

deeper or central parts of the neoplasm, hæmorrhage was always severe if not properly guarded against. The blood vessels all through the body of the growth were large, and upon these, although I used it regularly, adrenalin seemed to have no controlling influence whatever. But I soon found that a wad of absorbent cotton pressed by curved forceps or cotton holder directly upon the site of hæmorrhage, would arrest it very quickly; and when once arrested it would not recur.

Upon the thin shell, however, adrenalin had an excellent effect;

and I frequently removed large segments of this part of the tumor practically unattended by bleeding.

One other remark I might make here. While adrenalin in ordinary nasal operations will almost completely prevent bleeding at the time, the danger of subsequent hæmorrhage has always to be guarded against. In the case of this sarcoma, however, it was different. In not a single instance, although it was used in almost every treatment, did hæmorrhage occur after leaving my office. The bleeding was always during or immediately after operation. But having once ceased, it never commenced again.

On only three occasions were tampons required, after the first tentative treatment, after the removal of the post-nasal growth under chloroform, and once only after cautery operation deeply into the middle turbinal region.

One point with regard to the temperature of the cautery. The tumor was so dense that an ordinary red heat had little effect upon it. Hence the whole of the operations were done with the cautery knife at a white heat. On the whole they occasioned very little pain—a sense of heat being the chief thing complained of—the patient always turning up cheerfully smiling for the next seance.

The patient has regained the sense of smell, nasal respiration is restored, his weight has increased twenty pounds since the operation under chloroform on Feb. 2, and for five weeks he has been carrying on his regular occupation as mail clerk in a publishing house.

Histological examination has been made of several sections of the tumor for me; and I hereby append Dr. Davis' report with micro-photographs.

In closing I plead for early intra-nasal operative treatment in sarcoma of the nose; and the treatment above all others, I believe to be well-guarded operations with the electro-cautery. This is an instrument whose actions can be perfectly controlled; and with proper light, a wide nasal speculum, and the judicious application of cocaine, aided in some instances by adrenalin, the growth can be regularly and systematically dissected out. It takes prolonged time, a great deal of patience, and numerous operations, but the end justifies the means.

The advantages of intra-nasal cautery and snare operations over the external cutting operations are very great. In the former you remove the tumor only, leaving the whole framework in its

PATHOLOGICAL REPORT OF DR. DAVIS UPON FIG. A AND FIG. B.

Microscopical examination of sections removed from the portions of the tumor removed from the naso-pharynx.

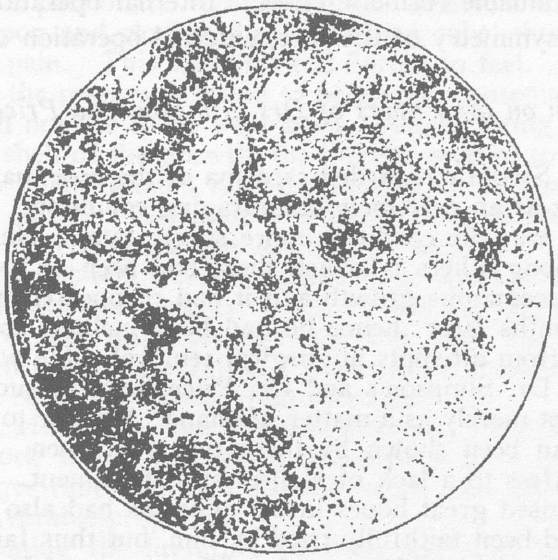

(*a*) Small round sarcoma cells with a small amount of fibrous tissue and some myxomatous tissue, numerous blood vessels and blood spaces. *Low power.*

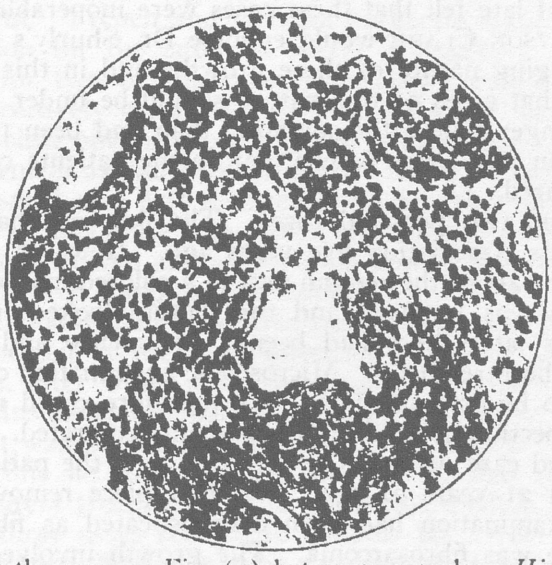

(*b*) Much the same as Fig. (*a*) but more vascular. *High power.*

normal position, as well as a wide cavity open for constant inspection. This, with the improved methods of examination and operative treatment now in use, enables the surgeon to again attack the growth in its earliest stage, should recurrence take place. There is also the valuable cosmetic effect. Internal operation does not destroy the symmetry of the face, external operation does.

Discussion on the Papers of Drs. Simpson and Price-Brown.

Dr. E. L. SHURLY regarded sarcoma of the nose, naso-pharynx and pharynx as an extremely discouraging condition. In no part of the body was the condition more surely fatal. He mentioned one case among others in which there had been an extensive removal of sarcomatous growth and it had reappeared in the brain eighteen months later; hence he had been inclined to refrain in these cases from attempts at surgical removal. He would therefore regard Dr. Simpson's and Dr. Price-Brown's success as remarkable, not merely as a matter of chance, but due to the special skill that had been shown by these two gentlemen. Personally he must confess to a lack of skill in such treatment. The Coley fluid had roused great hopes in his mind, as had also the X-ray, and they had been faithfully tried by him, but thus far only with the result of arresting the growth. The papers of Drs. Simpson and Brown had given him new hope and new courage and he was glad to have heard them. Sarcoma in these situations was a horrible disease at best and he was glad to have his hopes raised, for he had of late felt that these cases were inoperable.

Dr. J. PAYSON CLARK would endorse Dr. Shurly's views as to the discouraging nature of these growths and in this connection would add that cases of this nature should be under observation for a far longer time after operation than had been the cases of Drs. Simpson and Price-Brown, before the patients could be regarded as cured.

He recalled two personal cases. The first one had been reported to this Association five years ago. It was a sarcoma of the posterior part of the septum nasi in a colored man of 35 years. The growth was removed and the septum looked healthy, but four months later there had been a recurrence and the whole septum had been removed. Microscopic examination of this mass showed it to be osteosarcoma. We therefore could not be sure by mere inspection how deeply the growth penetrated.

The second case was seen seven years ago, the patient being a woman then 21 years of age. The first piece removed for microscopic examination had been diagnosticated as fibroma; the second piece was fibrosarcoma. The growth involved the right nares and naso-pharynx. It was removed under general anæsthe-

sia by the palate-splitting operation. He had recently seen the case after the elapse of seven years during which time she had been free from any trouble. Recently she had begun to complain of pain in the vertex with insomnia, also pain in the right ear. Examination showed a rounded smooth growth completely filling the posterior part of the right nostril and adherent to the septum. pressing upon and closing the Eustachian tube, thus accounting for the ear pain. This was firm and fibrous in feel. Under ether anæsthesia the mass was found to be sessile, consequently cutting forceps and not the snare were used. After cutting through the outer firm shell of the growth, the interior seemed to be soft, and access was finally gained to the sphenoid, as determined by the finger and curette. Bleeding was free; checked under packing. Packing was removed a few hours later and was followed by a slight gush of blood but the hæmorrhage quickly ceased. The vertex pain was temporarily relieved; not so, however, the ear pain, which was unaffected. Since this time the patient had passed from under observation. Microscopic examination of the pieces last removed showed fibrosarcoma.

Dr. T. J. HARRIS wished to compliment Dr. Price-Brown on his faithful work which deserved permanent success, but we must wait a longer time than had elapsed in the case before we could render a favorable prognosis.

In examining the literature of these growths, he had found reports of about one hundred cases. From these cases prognosis seemed to rest on the attachment of the sarcoma. Pedunculated septal growths would ultimately recover under operation, but in diffuse growths involving the ethmoid or other cells, the result was different. French and German surgeons favored the external operation for the latter as surest of success. It would be necessary for two or three years to elapse before Dr. Brown could be positively certain in his prognosis. It was almost impossible to clear out the growth completely in cases of such extensive involvement as had been mentioned in Dr. Brown's case.

In a personal case first seen ten years ago there had been four relapses. In this case the ethmoid, sphenoid and maxillary sinuses were involved and at one time also the frontal. External operation allowed complete eradication.

Dr. J. E. LOGAN had seen three cases. One case had been previously reported at the Pan-American Congress and had lived eight years, after which time the disease recurred in the bowel, involving also the spleen, pancreas and greater end of the stomach. The patient was 40 years old at the time of death.

At the time he had reported the case he had suggested the galvano-cautery treatment as the preferable method and the later results in these cases seemed to endorse his view. The microscope had shown the tumor to be a round-celled sarcoma.

Since that time he had seen two additional cases, one resulting

fatally and the other was still under observation. His experience with bleeding had not been as fortunate as that of Drs. Simpson and Brown. In one case in which there had been noticed a post-nasal pulsation of the tumor, the common carotid had been tied, and yet at the time of the removal of the tumor a large amount of blood was lost. For removal, scissors had been used, guided by the finger in the naso-pharynx. The patient was saved at the time of operation only by transfusion. Four and a half months later the growth recurred but Dr. Logan no longer regarded the case as operable. The patient went to Chicago and was examined there, report on the growth being made that it was only fibrous. This was because a portion only of the cortex of the growth had been examined and not a mass illustrating its entire composition. The patient was placed on the table for operation but suddenly died.

In the second case, seen eighteen months ago, removal of the major part of the growth had been effected by electrolysis while the pedicle was removed with the snare. The middle turbinate bone had been absorbed and the mass projected into the antrum. He would again emphasize the cautery and electrolysis as the preferable plan of treatment.

Dr. R. C. MYLES was a firm believer in the radical operation in cases of sarcoma of the sinuses, nose and naso-pharynx. He had had favorable cases under observation for seven years.

About these tumors there were one or two interesting points. He had noted in the anatomy room when examining tissues from the region between the basilar process of the occipital and sphenoid bones in young people, a small cartilaginous mass measuring about 10 mm. in diameter, and he would ask was not this cartilage a source of these tumors? Cartilage forms in youth, and becomes more or less bony in after life. Many of the cases had gotten well as age advanced. A tumor from this region occurring in a patient under 27 and considered sarcoma, he would view with suspicion.

Dr. WILLIAM LINCOLN reported the case of a boy of nineteen years seen six years ago. The tumor involved the left nasal fossa of the boy and bled freely when irritated. Attempts at removal with both hot and cold snare were unsuccessful. Bleeding was immediate and copious and there seemed to be an impaction of the mass in the upper nares; hence external operation seemed the only feasible plan. This was finally done, the nose being loosened from the face along one side. The cause of the impaction was found to be dense adhesions through which the wire would not cut and they were finally separated by a spatula; then the cold snare quickly removed the tumor which grew from the under surface of the middle turbinate. Bleeding was considerable but was controlled by the actual cautery and the boy was now in good health.

There was no deformity as he had been careful to make the incisions follow the lines of the face down to the angle of the nose.

Histological examination of these growths is not entirely satisfactory. Frequently they are at first regarded as fibroma, then as fibrosarcoma and finally as pure sarcoma.

Dr. J. N. MACKENZIE said that his views as to malignant growths of the upper air passages and the proper method for their removal were well known to this Association and had been vigorously combated by many outside. He again felt compelled to utter a protest against the precipitate haste with which reports of such cases as had been recited to-day were rushed into print. What possible guarantee of the ultimate success of an operation done as recently as February of this year could we have in the following May? The Fellows would recall the case of Dr. Gleitsmann of sarcoma of the trachea reported to the Association last year at the meeting in Boston. He was informed by the Doctor that recurrence had already taken place. Cases reported at an early date after operation are utterly valueless considered either clinically or as contributions to literature.

Dr. GLEITSMANN admitted that recurrence had taken place in his patient, but only as late as two weeks ago (over sixteen months after the operation). All this time the patient had enjoyed perfect health, had had a good voice and had attended to his daily work, which would have been impossible had a complete laryngectomy been done, an operation which in this particular case would have required to be supplemented by the removal of one or two of the tracheal rings. The speaker referred to his own cases of complete laryngectomies by competent surgeons. In these cases the growths had been circumscribed but the operations had been followed by speedy recurrences. On the other hand he drew attention to the good results of others, especially of Semon and Horsley, with laryngotomy in suitable cases.

He had recently had under observation a case of angio-sarcoma of the post-nasal space about the size of a walnut, entirely preventing nasal respiration. He had first removed a large piece with a curved snare and his irido-platinum wire through the rhino-pharynx, and had then used electrolysis through the anterior nares in order to enable him to pass a snare around the growth which completely blocked both choanæ. He succeeded in removing the larger part of the growth. This manouvre performed on both sides established free nasal respiration and left only a small slough in the rhino-pharynx which was still being treated. One nasal operation had been followed by severe hæmorrhage, necessitating anterior and posterior tamponment.

Dr. SIMPSON in closing said that he had reported his own case to emphasize the necessity of early recognition. Many of them, if not all, did recur, but if this case had been allowed to go on so that the growth infiltrated all the surrounding

structures, the aspect of the case would have been entirely changed. He did not wish to be understood that he presented this case thus early as a permanent cure, and added that he would report its further progress.

Dr. PRICE-BROWN said that it was because there had been no recurrence in his first two cases reported—the one after a period of eight years, and the other after nine months—that he had ventured to operate upon the third and most difficult one in a similar way. What the result would ultimately be it was impossible to tell. In the meantime the tumor had been removed, the patient made comfortable, and he was enabled to resume his ordinary occupation.

Paper.

FACIAL NEURALGIA DUE TO DISEASES IN THE NOSE AND ANTRUM.—SIX CASES.

BY W. PEYRE PORCHER, M.D.

IN looking up the history of facial neuralgia, trigeminal neuralgia, tic douloureux, I have found but seven (7) cases reported in the Index Medicus of the Surgeon General's Office which were attributed alone to disease in the nose and antrum. When we consider the endless number of cases in which stretching, resection or total removal of the various nerves and ganglia has been done for the relief of this condition we are impressed with the fact that the true etiology of this disease must have been entirely overlooked in the great majority of cases.

It is beyond question that as a rule rather than the exception the disease is a reflex neurosis or pressure symptom from inflammation in the nose and antrum, and that in any event it is far more rational to seek for and remove the cause of the neuritis rather than to remove the nerves or ganglia themselves. Owing to the fact that orbital neuralgia is so often due to errors of refraction and inflammatory conditions in the eye it has come to be considered that tic douloureux or facial neuralgia is mainly if not entirely due to the same cause. So general is this belief that practically speaking we may say every case heretofore has been treated by a surgical operation on one or other of the nerves in the face.

I shall endeavor to show in this paper that the most frequent cause of severe facial neuralgia is a localized inflammation in the nose, antrum or teeth, since in the last six (6) cases which have been treated by me the chief and only cause of the trouble was found in these organs. As may be supposed many of the severest cases of trigeminal neuralgia come under the observation of the dentist and two of the cases which I shall report were referred to me by a very observant dentist who suspected the antrum on account of the intractable nature of the pain and because he did not detect sufficient disease in the teeth to account for it. Of course if resection or removal of the Gasserian ganglion, the sphenopalatine or the infraorbital nerve is performed the pain must temporarily be abated, but that does not at all prove that the original cause of the neuritis or the inflammation in the nose, antrum or the teeth has been removed.

Of the seven cases reported in the Index Medicus the first one was published in the archives of Laryngology by Elsberg in 1883 entitled "Reflex and Other Phenomena Due to Nasal Disease." A second case was published in the same year by E. M. Gillian in the *New York Medical Journal,* entitled "Tic Douloureux resulting from an Exostosis of the Septum Narium." E. S. Peck also in 1890 published an article on Reflex Occular and Facial Symptoms of Nasal Disease, *International Journal of Dentistry,* New York and Philadelphia; also Transactions of the New York Odontological Society for the same year. Two cases of "Inveterate Tic Douloureux of Nasal Origin" were published in 1892 and 1893 in the *Virginia Semi-Monthly* by John Dunn of Richmond, Va., in which the paroxysms of pain were entirely relieved. In the *London Lancet* only two cases are reported, entitled "Two Cases of Severe Trigeminal Neuralgia Due to Nasal Disease," by M. P. Colyer, M.D., in 1895. In all the cases which I have attended most of which had undergone considerable treatment at the hands of other men before coming to me, no examination whatsoever had been made of the nose nor had attention been called in any manner to the fact that the seat of the trouble might be found in those organs. All specialists are aware that patients may have numerous abnormalities in the nose without being in the least degree aware of their presence. This was notably so in the cases reported below. I will refrain from quoting any of the innumerable number of cases in which

almost all the nerves of the face have been either removed or resected for the relief of facial neuralgia. It is not rational to assume that the results obtained from the removal of pressure symptoms in the nose or antrum were only psychical in character because there were no other causes to which the inflammation could be attributed, and besides when the septum had been mashed almost flat upon itself no notice had been taken of it even after the patients had been subject to many surgical operations on other portions of the face without obtaining more than temporary relief.

Without further comment here I will as briefly as possible report the following cases:

CASE I.—*Facial Neuralgia from Pressure of Hypertrophied Turbinates.*—A lady, aged about 65, nervous, hysterical, almost weak-minded, said that she had suffered intolerable pain in the face for many years with periods of temporary relief and exacerbation. She had been attended by many physicians and every kind of local application had been made. She had been saturated with iodide of potash and other drugs. I was inclined at first to think that she was a hypochondriac and therefore I would pinch her nose and face when her attention was distracted to see if her ailment was imaginary or real. I very soon discovered that it was by no means all assumed but I was at a loss to discover the cause of the reflex pain. Her turbinates were hypertrophied but there was no other derangement that I could find. I therefore determined to reduce them as much as possible with the electric cautery and I also ordered an anodyne liniment of aconite, arnica and laudanum, to be applied on the face. This treatment proved to be very effective and with the exception of occasional repetitions of the treatment the cure was complete.

CASE II.—*Facial Neuralgia from Inflammation of Antrum.*—Case II. was of brief duration. The trouble was limited to inflammation in the antrum, as the sequel will show.

W. S., white, æt. about 35, was referred to me by Dr. C. S. Patrick, D.D.S., of Charleston. He had intolerable paroxysms of pain which Dr. P. thought were due to the antrum because there were no teeth sufficiently diseased to account for it. I made a small opening through the canine fossa and through the floor of the nose, but not wishing to injure the roots of the other teeth I sent him back and told him to have the tooth drawn below the antrum so that the opening in the alveolus could be enlarged. To my surprise I learned subsequently that he had derived complete relief from the first operation and did not return to the dentist again. He has since remained well.

CASE III.—*Facial Neuralgia Due to a Deflected Septum.*—This case was in the nature of a *cause célèbre* because of the

intense and prolonged suffering that the patient endured and because of the fact that he had undergone treatment at the hands of several physicians for so-called tic douloureux. He had had strychnia and other drugs injected over the supra- and infra-orbital nerves with electricity locally applied, and almost every internal remedy with but very temporary relief. Finally he was sent North to consult a noted neurologist, who gave him aconitia and other powerful sedatives internally. He returned home unimproved and it was thought that his usefulness was at an end. He could only take food with difficulty and everything which he did excited paroxysms of pain. In a condition bordering on desperation he consulted the same dentist who referred Case II to me and asked him to extract all the teeth from the upper jaw in hopes that he might get relief in that manner. The dentist suspected trouble in the antrum and brought him to me. On examination I not only found there were signs of inflammation of the antrum but the septum of the nose was mashed down and pressed upon the turbinates on the right side with almost complete occlusion of that nostril. He told me that no one had examined his nose or antrum nor called his attention to the fact that the pain might alone be produced by diseases of those organs. The antrum was opened and the septum straightened under chloroform anæsthesia. In addition I gave him the anodyne liniment above mentioned with strychnine grs. $^1/_{40}$ three times a day internally.

With the exception of very slight twinges of pain at long intervals when he would catch cold and renew the pressure in the nose he has had no return and has been steadily at his work.

Case IV.—*Facial Neuralgia Due to Pressure Upon the Turbinates and Abscess of Antrum.*—This was a veritable *cause célèbre* because the gentleman had already been subjected to four (4) operations under chloroform, the last being no less than the complete removal of the Gasserian ganglion during which the patient nearly lost his life from hemorrhage. The first operation consisted in the entire removal of his teeth from upper and lower jaws. From this he got no relief. In June, 1896, the spheno-palatine ganglion was removed and there was no return of the paroxysms for two years. In September, 1898, the pains having returned with all their former intensity a resection of the supra-orbital nerve was performed. This produced prolonged ptosis of the lid, but again he got relief for two years with the exception of occasional spasms. Fearing that some of the roots of the nerves had not been entirely removed because of the return of the pain he had all the tissue separated from the molar bone on the right side. This gave him no relief. In a fit of desperation from great agony he next insisted upon the removal of the Gasserian ganglion, although he had been informed that the chances of recovery were but one in one hundred. During the operation a vein was opened and the hæmorrhage becoming uncontrollable the external carotid was

ligated. About a gallon of normal salt solution was transfused into the veins of the leg to resuscitate him. He recovered from this operation and had partial relief from pain for nearly two years. The right antrum must have been opened because the patient tells me that a seton was passed through the upper jaw down into the mouth.

And now comes the most surprising part of this case. During all these operations and all the treatment none of the doctors looked into the patient's nose nor called his attention to the fact that the original cause of the pain might be found in that organ. Hearing of my success with Case III. and his pains again returning with all their former intensity he came to inquire if the pain in his case may not also be produced by the same cause. I found the septum mashed down upon itself as though he had been in a prize fight. The right nostril was so occluded that I could not introduce a probe. I opened the antrum, liberated a quantity of pus, corrected the septal deformity and he has had no pain since then.

CASE V.—*Aggravated Facial Neuralgia from Disease in the Nose and Antrum.*—Case V was a physician and his symptoms were all similar to the foregoing. His left nostril was almost completely obstructed. He asserted that he would have committed suicide had the means to do so been at hand. I did the same operation as in the other cases and the doctor is now back at his work. He has no return of his headache or facial neuralgia.

CASE VI.—*Aggravated Facial Neuralgia from Disease in the Nose and Antrum.*—While writing the above a gentleman was brought to me with a history of having suffered severely from facial neuralgia since 1894. He also had the Gasserian ganglion removed with only temporary relief. I found his right nostril occluded and with the electric light in the mouth his right antrum showed an umbra. Much to my surprise I found no pus on opening the antrum. I corrected the deflected septum and ordered the liniment of aconite, etc., which was used above. I also gave him strychnine internally. He still complained greatly of the spasms of pain and I then discovered that he was in the habit of using almost every known form of narcotic internally and the hopelessness of the case became apparent. As soon as I attempted to limit his supply of narcotics he promptly took ship and sailed for New York, where he is no doubt at present harassing some unfortunate doctor with his ceaseless complaints.

When the third case of intolerable pain in the face was brought to me I naturally concluded that the cause would be found in some of the underlying structures or in some of the nearest organs. I did not for a moment associate the cause of it with any of the orbital contents because the man did not complain of his eye in

any respect. I was told that a diagnosis of tic douloureux with inflammation of the spheno-palatine ganglion had been made, but I did not attach any importance to this, as I thought it was more rational to look for the cause of the trouble in the nose and antrum. I did not at that time know of any of the seven cases reported in the Index Medicus nor had I consulted any authorities on the subject. It may be maintained by some that these cases were coincidental; that numberless cases of nasal occlusion from deflected septa had existed without any symptoms of facial neuralgia or tic douloureux.

On the other hand it must be maintained that when intense facial neuralgia is found and when complete relief is obtained from opening of the antrum without any other treatment whatsoever as in Case II above mentioned, the etiology is proved and, I might be permitted to go further and say that the presence of a deflected septum with a facial neuralgia is presumptive evidence of cause and effect, or perhaps it might have been called *prima facie* evidence, although the evidence was found within the face rather than on the outside of it.

It is perhaps unnecessary to say anything more in regard to these cases. There was no history in any of them of injury sufficient to account for the amount of deflection and consequent obstruction in the nostril. I have always believed that severe inflammation in the nose was sufficient to produce considerable deflection of the septum without traumatism, because the septal partition is limited above and below by bone, and therefore must bend in order to allow inflammatory turgescence. The pressure upon the turbinates in each case was very great, and had evidently existed for a considerable time. As is usual where there is so much nasal obstruction the antrum was found to be involved in most of the cases either with or without pus. It was not to my mind such a matter of surprise that the operations gave relief as it would have been had I failed to find the cause of the neuralgia in the nose to which I had naturally attributed the trouble.

Discussion.

Dr. JOHN O. ROE had seen many cases of facial and supraorbital neuralgia, due to intranasal pressure. He had also seen many cases in which the pain was reflected from the nose to the different surrounding parts, and sometimes to distant parts. In one case

the pain was reflected to the chest, so that the patient supposed he had some trouble in his lung, especially as there was a family history of pulmonary trouble. Chest examination was negative, and the only abnormal condition that could be found in the upper air passages aside from a slight naso-pharyngeal catarrh was a spur on the septum, prodding the inferior turbinated body. This was removed, and one hour later the pain in the chest entirely and permanently disappeared.

Dr. Roe also recalled a case of facial neuralgia due to antral trouble. The patient, a lady about thirty years of age, had been thrown from a carriage, striking on her face. The face was very much swollen at the time, but she was not aware of having sustained a fracture of any bones. About six months later she began to suffer quite severely from facial neuralgia, being mainly centered in the region of the left antrum. On careful examination no condition of the teeth or nasal passages could be found to which the pain could be referred. As the antrum was the undoubted seat of the trouble, it was freely opened through the canine fossa and a bony spiculum was found running across it. After the removal of this spiculum the neuralgia entirely disappeared, and about one year later, when last heard from, the patient had remained entirely well.

Dr. G. A. LELAND referred to the previous papers on this subject of Dr. Harrison Allen[1] and Dr. Roe[2] (see references below), published seventeen and fifteen years ago, respectively, and opined that the field thus outlined had not been markedly cultivated. Much had been written about the effects of errors of refraction on painful affections of the trigeminal nerves congestive headaches, etc. Patients came usually already fitted to glasses before they came under the care of the rhinologist. The lesson was that much remained to be revealed by more careful examination of the nose.

Dr. PORCHER in closing the discussion said that the strangest feature of these cases is that none of the physicians who attended them before they came under his care ever examined the nose or any of the surrounding organs. Even in Case IV in which four operations had been performed under general anæsthesia he was assured that no examinations had been made of the nose by any of the physicians who had operated upon him. It was hardly conceivable that so grave an operation as the removal of the Gasserian ganglion with ligation of the carotid, etc., would have been entered upon without a thorough examination of all the surrounding organs. In fact the assertion was so incredible that one was almost inclined to doubt the veracity of the patients, but they all made the same statement and he had every reason to believe that they told the truth.

Dr. Roe's case of reflex pain in the chest from a nasal cause was interesting to him because he knew of other reflex neuroses which were quite as remarkable. One was a case reported by himself sev-

eral years ago in which a young man who was supposed to have softening of the brain was entirely cured by the removal of a papilloma of the septum narium.

References.

1. On the Headaches which are associated clinically with Chronic Nasal Catarrh. Med. News, 1886, Vol. XLVIII., p. 290.
2. The Frequent Dependence of Persistent and so-called Congestion Headaches upon Abnormal Conditions of the Nasal Passages. The Medical Record, Aug. 25, 1888.

Paper.

MY LATEST IMPROVEMENTS IN THE RADICAL TREATMENT OF CHRONIC SUPPURATIONS OF THE ACCESSORY CAVITIES OF THE NOSE.

BY H. LUC, M.D.

WHILE accepting your amiable invitation to join this meeting of my American colleagues, I could not forget the kind appreciation which my personal contribution to the radical treatment of the chronic suppurations of the accessory cavities of the nose found in your country, and I came to the conclusion that I could not better interest you than by submitting to you the result of my recent attempts and investigations in this special department of nasal pathology.

In this analysis of the modifications and improvements which I have been gradually induced to bring into my first methods I will successively consider the chronic suppuration of:

A. The maxillary sinus.
B. The frontal sinus.
C. The ethmoidal cells.
D. The sphenoidal cavity.

A.

At the outset of this first chapter allow me to say that I completely share the views expressed on the same subject by my colleague and friend, Lermoyez, in several of his publications:

1. That the surgical treatment is to be strictly limited to the chronic forms of the disease.

2. That, as regards these chronic forms, a distinction is to be admitted between the properly called suppurative sinusitis caused and kept up by a primitive infection of the mucous membrane of the antrum, soon ending in a fungus degeneration of its tissue, and the maxillary empyema in which the pus did not originate in this cavity, but simply accumulated in it, its source being either a frontal or a dental abscess. In the latter case the sinusal mucous membrane may remain in contact with the pus, without becoming infected and undergoing the above mentioned degeneration, and a simple washing of the cavity, after previous suppression of the source of the pus, may suffice to obtain a definitive cure.

Lermoyez's conclusion to which I was brought by my own experience is that it is not advisable to adopt the radical operation in any case of chronic abscess of the antrum without having previously attempted to cure it by one, or rather several, washings of the diseased cavity, after a puncture has been made in the inferior meatus.

Entering now the subject of the radical cure of chronic maxillary suppuration, for which I proposed seven years ago a new operative method which has since then been successfully performed in nearly all countries, allow me to tell you that, if it bears the name of your countryman, Caldwell, associated with mine, I have always been ready to acknowledge his priority as regards the paternity of the concerned operation; but I was able to prove on many occasions that I had invented my own proceeding in complete ignorance of the article in which Caldwell had described his method. Allow me to add that this article had passed nearly unnoticed in your country and that it was only brought to my knowledge a whole year after the publication of my own description.

It is not my intention to renew this description here. I will only call your attention to a few technical details which were suggested to me by the experience acquired after operating on about a hundred cases.

My double aim, while performing the operation in question, is to make two large bony resections: the one at the expense of the anterior wall of the sinus, in order to obtain a wide but transitory communication between the sinus and the mouth, and to remove

thoroughly the pus and the diseased mucous membrane, the other at the expense of the internal or nasal wall of the sinus, in order to create a wide and permanent communication between the antrum and the nasal fossa. This latter resection which requires the simultaneous ablation of the greatest part of the middle and inferior turbinals, is greatly facilitated by the introduction of the little finger into the nostril, which enables the surgeon to avoid any lesion of the septum and to ascertain that the free communication desirable has been obtained and that no fragment of the turbinal mucosa, likely to be in the way of the further drainage, has escaped the cutting forceps.

I cannot too much emphasize the fact that the antro-nasal communication must be a large and permanent one, whereas the antro-buccal one is only to last just as long as is necessary for the cleaning and curetting of the sinusal cavity. This operation has become such a current one in my practice that, for more than three years, I have left off keeping a regular statistical account of my operated cases, and I feel bound to say that, since I adopted the principle of substituting for the small artificial hiatus made on my first operated patients a large resection of the greatest part of the internal wall of the sinus, I have met no instance of any case, however chronic it may have been, that did not radically heal within a lapse of four or six weeks.

It was a great satisfaction for me to find my own results in accordance with the brilliant statistics presented last year by my friend Lermoyez at the congress of Manchester.

I call your attention to the fact that the principle of this operation, which gave us such rapid, radical, and let me say, unheard of results, is based on a scrupulous regard for the laws of Nature, according to which the sinusal cavities are to communicate with the nose, but not with the mouth. My aim was then simply to substitute for the natural hiatus so unfavorably situated and so insufficient, as regards its size, a considerable opening not amounting to less than the third part of the wall at whose expense it is made, thus making of the maxillary sinus a sort of lateral prolongation of the corresponding nasal fossa, likely to get cleaned as well as the latter, when the patient is blowing his nose. Not only were the results of this operation most brilliant and satisfactory, but I dare say they were somewhat unexpected and caused some surprise especially in Germany, where the radical cure of suppurating cavi-

ties was based on two principles (the suppression of the cavity, or the epidermisation of its walls by means of epidermic laps) which were totally disregarded here.

The opportunity I had in two cases of reopening maxillary sinuses of patients previously operated upon by my method, and on whom a relapse had been wrongly suspected, enabled me to ascertain the mechanism of the cure thus obtained. In fact I found the sinusal cavity completely filled up with a sort of fibrous hypertrophy, which at the same time perfectly accounted for the permanent impermeability of the corresponding eye to light, when an electric lamp was put into the mouth, according to Heryng's method.

A new proof that principles, as well in surgery as in other things, are not eternal!

B.

It seems to me quite as superfluous to describe here the Ogston-Luc method for the radical cure of frontal abscesses, as I thought it was to describe the Caldwell-Luc operation in the preceding chapter, for the reading of your Transactions showed me that both have been often performed in this country, and it is my conviction that they could find no better support than that given by the well known skill of American surgeons.

But, however strange it may appear to you, it is my chief aim, while alluding to the operation proposed by me years ago for the radical cure of the chronic frontal empyema, to point out its drawbacks and dangers, and allow me to say that I feel some pride at recording that I have been the first to lay stress upon its weak points.

Of course the principle on which it is based (immediate closing of the frontal wound after thorough cleaning of the sinus, and further and exclusive drainage through the nose) was most temptnig, and it is a matter of fact that it was often crowned with a rapid and brilliant success, the patient quickly recovering with a hardly visible scar. But such were only the favorable cases, and it is our chief duty to consider more attentively the unfavorable ones, consisting in an abnormal extension of the sinus quite out of proportion with the caliber of the fronto-nasal outlet entrusted with its drainage. The course of things too often observed under

such conditions was the following: About the twentieth day after the operation a swelling appeared in the operated region, ending with a spontaneous reopening of the wound, with the formation of a fistula, and with the necessity of a new operation.

The natural consequence of such accidents was to throw a considerable disrepute on the method; in fact while some surgeons remained faithful to it, others returned to the old practice of keeping the wound open for a while, and others adopted the method of Kuhnt, consisting in the total resection of the anterior wall of the sinus and in the consequent suppression of its cavity, without regard for the considerable disfigurement inflicted thereby on the patient.

Things were in this unsatisfactory condition when Killian, of Fribourg in Brisgau, proposed a new method which is a sort of combination of the Ogston-Luc with Kuhnt's and Jansen's operations, or rather a combination of the advantages of all three.

In imitation of the Ogston-Luc method it implies the immediate closing of the wound and the consecutive drainage by the nose. Like Jansen's method it opens the floor of the sinus. Like Kuhnt's it removes the greatest part of the anterior wall; but its chief originality consists: (1) in preserving between the two mentioned breaches a sort of bony bridge corresponding to the orbital arcade, which greatly preserves the normal aspect of the face; (2) in extending the inferior bony opening to the ascending branch of the maxillary bone, which gives to the surgeon hitherto unknown facilities for widening the fronto-nasal outlet and curetting the ethmoidal cells.

Allow me to record here that I am the first to have done this operation in France and to recommend it to my countrymen. After obtaining a complete success with it in the eight patients on whom I performed it, I feel bound to proclaim here that I regard it as being at present the surest and safest method for the radical cure of chronic frontal suppurations in cases whose surgical treatment is made particularly difficult by abnormal dimensions of the sinusal cavity and especially by its extension to the temporal region, whereas the Ogston-Luc method, to which the double advantage must be granted of an easier performance for the surgeon and of less disfigurement for the patient, finds its ideal application in patients favored with a sinus of small dimension.

C.

With exception of a dubious case in which the region of the middle nasal meatus presented itself rhinoscopically filled with creamy pus, while the frontal, as well as the maxillary sinus, showed themselves perfectly permeable to translumination, I have no personal record of a single example of an isolated ethmoidal suppuration, and I had consequently only to deal with this affection in connection with frontal or maxillary suppurations.

The ethmoidal labyrinth can be attacked either through the natural way of the nose, or in a word, rhinoscopically, or, thanks to its proximity to the frontal and maxillary sinuses, surgically, through an artificial breach, as a sequel of the radical operation for empyemas of the latter cavities.

This is a subject to which I have always devoted special attention and regarding which the result of my personal experience may be of some interest to you. I will then successively consider the surgical opening of the ethmoidal cells (1) through the normal way of the nose; (2) during the maxillary operation; (3) during the frontal operation. A preliminary point on which I beg to dwell here is that there is no possible hope of destroying completely the ethmoidal labyrinth through the nasal cavities. For, whilst the middle and even the posterior cells, (including the sphenoidal cavity, which may be considered as the most remote of them) are within reach of our eyes and our instruments, I cannot say the same of the most anterior cells that line the naso-frontal outlet, and which, in consequence of the extreme narrowness of this region of the nasal fossa, will always be sure to escape our reach unless we make a previous bony breach.

Therefore, while describing here the method of destruction of the ethmoidal cells based on a new technic and instrumentation, which I have been using successfully for about two years for the radical cure of the nasal myxoms, I do not mean to present it to you as a means of radical cure for ethmoidal suppurations, but simply as a preliminary step to the fronto-maxillary operation, whose aim is to clear away the polypoid growths and hypertrophied parts of the mucous membrane, and thus facilitate the nasal part of the operation.

Another result of my experience has been to induce me to

abandon entirely the use of the so-called nasal curettes for the removal of the hypertrophied, more or less myxomatous parts of the mucosa, as well as the bony cells themselves, after finding out how powerless those instruments are in both cases. I do not doubt that your own records based on your personal experience will make you share my conclusion, that the largest curettes which we can introduce into the nasal cavities while endeavoring to clear off myxomatous growths, simply penetrate their soft tissue without removing more than a few shreds of it, and that they have hardly better grasp upon the bony ethmoid walls, the greatest number of which, after breaking easily under the pressure of the instrument, remain hanging in the nasal fossa, and I need not remind you how quickly such attempts are checked by the abundant bleeding which prevents any further view of the field of operation.

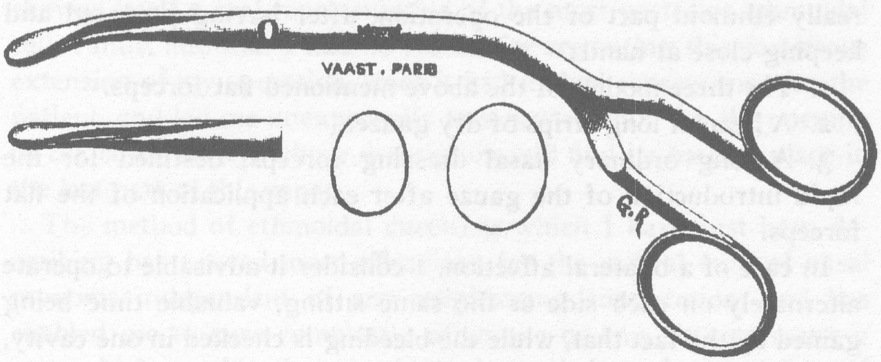

I was then soon led to the practical conclusion, that the only instrument likely to deal successfully with the soft and easily bleeding myxomatous tissue, as well as with the honeycombed bony tissue of the ethmoidal labyrinth, was best represented by a special forceps whose blades are large enough to seize much at a time and flat enough to be easily thrust into the deepest and narrowest recesses of the middle meatus.

I have the honor to present you here three specimens of different sizes of that instrument, which have been made according to my instructions by Mr. Vaast, of Paris. One or other of these is to be used according to the spaciousness of the nasal cavity and to the dimension of the piece of tissue to be extracted.

The technic of the operation is as follows:

If the nasal fossa is filled with abundant and pediculated

myxoms, the first task is to remove the greatest number of them by means of the cold snare, until the middle turbinal becomes apparent. In case of persistent bleeding it is advisable, after plugging the bleeding region with dry gauze, to postpone the second part of the operation until the following day, when, the hemorrhage being checked, it will be possible to anesthetize duly the ethmoidal region. This is best carried out by means of a long and thick strip of gauze, which, after being soaked with a solution of muriate of cocaine (one to five) with addition of a few drops of a solution of adrenaline (1 to 1,000) is pushed deeply into the middle meatus. Another similar strip wet with the same solution is then inserted between the middle turbinal and the septum, and under the free edge of the former, and both are to be left in situ during at least 10 minutes, when the region may be considered as thoroughly anesthetized and the surgeon may proceed to the really ethmoid part of the operation, after having prepared and keeping close at hand:

1. The three models of the above mentioned flat forceps.
2. A heap of long strips of dry gauze.
3. A long ordinary nasal dressing forceps, destined for the rapid introduction of the gauze after each application of the flat forceps.

In case of a bilateral affection, I consider it advisable to operate alternately on each side at the same sitting, valuable time being gained by the fact that, while the bleeding is checked in one cavity, the curetting may be continued in the other.

The middle turbinal is to be first attacked with the largest possible type of flat forceps, whose blades are kept, during its introduction, sufficiently open to enable them to pass along each side of the turbinal and to be pushed as far as the insertion of the latter, when they are strongly pressed against one another, squeezing bone, mucosa and myxoms, then tearing them off thanks to a rapid twisting movement. Before the bleeding has time to reproduce itself a new application of the forceps is made on the remaining part of the turbinal which, thanks to the large grasp of the blades, can be completely removed after three or four similar applications. One or two of the strips of gauze are then rapidly seized with the dressing forceps and thrust into the meatus, where they must be firmly pressed on the bleeding surface, and exactly fill up the place of the removed turbinal. After the lapse of a few

minutes the gauze may be extracted, and the bleeding is then generally found to be sufficiently checked or diminished for the further curetting of the ethmoidal cells. Under the removed turbinal are generally discovered myxomatous masses which would have remained unnoticed but for that previous operation and which it is now an easy task to extract. I dare say that at this phase of the operation, after the middle turbinal has been mostly removed, the surgeon need not mind the hindrance caused by the bleeding, since he has henceforth to rely less on his sight than on his tactile sensations: any myxomatous mass, any brittle bony trabecule met by the forceps are to be seized till the instrument finds no other resistance than that of the bony walls limiting the nasal cavity, which are not likely to be interfered with by its blades. The only wall which I several times happened to open involuntarily is the anterior wall of the sphenoidal sinus, which in that circumstance showed itself a real representative of the most posterior ethmoidal cell, I must add that I had no reason for regretting this fortuitous extension of my operation, since it had no bad consequence for the patient, and led me unexpectedly to a new method for the opening of the latter cavity, whose description will find its natural place in the last part of this paper.

The method of ethmoidal curetting which I have just been describing has proved most efficacious for the radical cure of nasal myxoms independent of any neighboring suppuration, and has enabled me to cure completely after one or two sittings many a case which would otherwise have demanded much more time, if operated upon with the snare, according to the old proceeding; I may add that it left the patient far less exposed to relapses, thanks to the destruction of the greater part of the ethmoidal cells which further enabled the surgeon to detect any beginning myxomatous growth and to extract it easily on its very first appearance.

As I clearly stated on entering this chapter, the method just described, when applied to ethmoidal suppurations complicating a frontal or maxillary empyema, can but be considered as a preliminary step to the radical operation of the latter diseases, since the Caldwell-Luc as well as the Killian method afford the surgeon every facility for the opening and the curetting of the neighboring cells.

I have already had many opportunities of dwelling on this subject in various articles devoted to the question of the radical treat-

ment of chronic maxillary abscess, but I feel bound to say that, as regards the curetting of the ethmoidal cells in connection with the radical operation of frontal empyema, no method seemed to me abler than Killian's proceeding to give the most radical and satisfactory results, thanks to the resection of the upper part of the ascending branch of the maxillary bone and to the large opening thus created exactly in front of the ethmoidal labyrinth, which it then becomes an easy task to open and destroy freely without any risk of the instrument penetrating the cranial cavity.

D.

Like the ethmoidal cells the sphenoidal cavity, in case of chronic empyema not likely to be cured by such simple means as catheterism and washing, can be either opened by the rhinoscopic way or with the help of a previous artificial breach.

While discussing the choice of either of those methods, we shall have to consider (1) the greater or less convenience afforded to the surgeon by the spaciousness or the narrowness of the corresponding nasal fossa for an intranasal proceeding; (2) the coincidence or non-coincidence of an empyema of the maxillary antrum, the latter cavity having been pointed out by Jansen, by myself and Furet as offering the safest and easiest way to the sinus in question.

In case of the integrity of the maxillary sinus, the nasal way is only to be given up as being too narrow, if this narrowness cannot be corrected by an intranasal operation, for I need not say that such an obstacle as a projection or deviation of the septum ought to be previously removed.

When no more hindrances are left for getting at the sphenoidal front wall than the middle turbinal and the posterior ethmoid cells, I think there can be no simpler method for reaching and opening the concerned sinus than the one I described above for the intranasal curetting of the ethmoidal cells. It is a matter of fact that, while performing this curetting progressively and systematically from before behind with my flat forceps, the surgeon is naturally and, as it were, inevitably led to opening the last of them which is nothing else but the sphenoidal sinus itself. Only in case of an abnormal resistance of the anterior wall of this cavity, it would be advisable to have recourse to a perforator, and the open-

ing thus made should then be enlarged by means of a cutting forceps. This having been done, my flat forceps will prove again more efficacious than any other instrument and especially than the common nasal curettes for curetting the inside of the cavity, thanks to the breadth of their blades which clearly accounts for their firm grasp on the myxomatous tissue, often enabling the surgeon to remove the totality of the degenerated mucosa in a single piece. I cannot too much emphasize the necessity of removing the greatest possible part of the front wall of the sinus for the same reasons which make me advise the largest possible resection of the internal wall of the maxillary antrum during the radical cure operation for empyema of this cavity, experience having shown what extraordinary tendency such artificial openings have to shrink and close up rapidly after the lapse of a few weeks.

The coincidence of an antral empyema with the sphenoidal suppuration should remove any hesitation as to the choice of the best way to be followed in order to get at the sphenoidal cavity; the antral one being, as above emphasized, under such circumstances, the safest and easiest.

As is often the case for little as for great discoveries, it was by a mere accident that I was led to find (after Jansen, but thoroughly unaware of his contribution to this subject) this surgical way to the sphenoidal cavity. While curetting the posterior ethmoidal cells through a maxillary antrum whose front and internal walls had been extensively laid open, I felt that my forceps was entering a very large bony cavity, which after due investigation proved to be the sphenoid antrum.

This proceeding has since then been the subject of very careful study on the part of my colleague and friend, Furet, who came to the same conclusion as I: that the maxillary way, after a large resection of the anterior and internal walls of this sinus, is the most direct and the simplest to reach the sphenoidal cavity, and that owing to the complete harmlessness of this method, there should be no hesitation as to its adoption even in case of a complete integrity of the maxillary antrum, when the anatomical conditions of the nasal fossa leave no hope of getting at the sphenoid sinus by the nasal route.

Paper.

DISEASES AND TREATMENT OF THE SPHENOID CELLS, WITH REPORT OF CASES AND PRESENTATION OF INSTRUMENTS.

BY ROBERT C. MYLES, M.D.

THE subject of sinusitis of the sphenoidal cells was treated in an able and instructive manner by Dr. Hinkel before this Associatoin in 1902. I will be brief, therefore, in my remarks and in the reports of some of my cases. Everyone who has had much experience in dissecting and making sections of heads, agrees concerning the great irregularity in size and position of the sphenoidal sinuses. The surgical anatomy concerns us most, and this is embraced chiefly in the area of the anterior upper wall. It is through this region that the normal secretions issue, and it is also through this space that we operate to secure proper curettage, drainage and admission of air. I present a wet specimen which demonstrates the normal opening with the sphenopalatine artery as it passes across the operative field. The internal carotid is shown lying against the thin external wall, where it can easily be wounded by the slightest deviation from the narrow, surgical path. These cells are frequently affected by acute inflammatory processes, caused by invasion of bacteria which become more or less completely pent up.

The extent of the pathological condition depends upon the virulent activity of the microbes present and the amount of obstruction in the normal opening. The gummatous changes of syphilis occasionally destroy part of the sphenoidal cells. The destructive softening processes of the gumma make it rather easy to perform whatever surgery may be indicated. The sphenoidal cells are more frequently diseased than we are taught to believe. If the method of diagnosis is adopted, which requires that the condition of every part of the nasal fossæ, as well as that of every accessory sinus, should be accounted for as far as our skill and art will permit, we will have more cases of diseased sphenoidal cells to re-

port. When muco-pus is seen in the superior meatus or between the middle turbinal and the septum, the probe and cleansing swab should be used until the secretion is traced to its origin. Sometimes it will be necessary to remove the posterior half of the middle turbinal before the proper investigation of the region can be carried out.

I think that we are often too conservative, when serious disease is suspected, in not removing this body earlier, and more fre-



No. 1.



No. 2.



No. 3.

No. 4.



No. 5.

No. 1. Guarded Hand Drill. No. 2. Protected Chisel. No. 3. Guarded Hand Chisel or Drill. No. 4. Guarded Trephine. No. 5. Guarded Electric Drill.

quently. The soft silver probe should be used after proper cocainization and when the natural opening has been found in the latent cases, the probe should be passed in and out, with the hope of drawing some of the pus with it. When the diagnosis has been made and the character of the case approximately determined, we should endeavor to make an opening of 10 to 15 millimeters in the anterior superior wall. The section should commence at the lower border of the natural opening and extend downward in a vertical

line, rather close to the septum. I present a series of instruments for your inspection and consideration, and sincerely hope, that, with continued efforts, we will be able to secure safer and more effective instruments for this operation. I regret that an error occurred in the preparation of the title of my paper for the programme. I intended it to read with report of cases and presentation of instruments. I have selected two cases, which present interesting types.

CASE I.—This was a young man, 30 years old, who gave a history beginning several years back. He had suffered from pain in the temporal, occipital and frontal regions, and also back of the eyes and throughout the space of the accessory sinuses. There was a peculiar, degenerative process going on in all of the nasal sinuses, except the left antrum of Highmore, the left posterior ethmoidal cells and the left sphenoidal sinus. The pathological changes seemed to resemble granulation more than polypoid tissue. In certain areas the granulations were so large that sarcoma was suspected, but the microscopical examinations demonstrated only true granulation tissue. The right sphenoidal cell was constantly full of pus, which was in a state of fetid decay. After the middle turbinate had been removed, an opening was made in anterior wall of sinus, a few millimeters beneath the natural opening. The wall was penetrated with a small gouge. Then the aperture was enlarged with curettes and cutting forceps until the vertical diameter was about 15 millimeters in length. The sinus was carefully curetted over the lower and inferior walls, which were covered with large polypoid granulations and putrid debris.

There was an immediate improvement in the profound depression from which the patient had been suffering, and the pain which had been vaguely located in the deeper central parts of the head gradually disappeared. Repeated curettage was necessary. A membranous band formed over the opening which was easily removed and without pain. The hole is now permanent and is about 12 millimeters in diameter. The sinus can be inspected and is perfectly well. All of the other diseased cells were treated by the radical operative method, and are in good condition, with the exception of the occasional occurrence of a little muco-pus in two of them.

CASE II.—The patient was a man aged 22 years who suffered from atrophic rhinitis associated with empyema of the ethmoidal and sphenoidal cells, those on the left being the most seriously diseased. The pain was most severe directly posterior to the left orbit, and in the deep temporal and occipital regions. His mind was gradually becoming affected. He was losing weight steadily and he insisted that I should perform a radical operation. There

was a copious flow of pus which was decidedly fetid. I removed the posterior half of the partially atrophic middle turbinate and the floors of the left posterior ethmoidal cells. The discharge diminished. Most of the pain disappeared. A free inspection of the natural opening of the sphenoidal cell was secured and a small accessory opening was found, situated about ⅓ of an inch below the normal opening near the outer wall. While using the soft, silver probe some ugly pus issued through it. I enlarged this opening with a long trephine and then the small forceps and curettes for further enlarging the aperture. The cavity was cleansed and dressed with aristol and boric acid. The patient did well and improved for nine days, when he had a violent hemorrhage. The patient stated that from two to three pints of blood were lost, within 10 minutes. My assistant visited him and reported that there was evidence of his having lost considerable blood. As the bleeding had stopped no tampon was used. I visited the patient on the afternoon of the twelfth day after the operation and found him quietly sleeping. When awakened he jumped up suddenly and blood gushed from his nostrils and mouth so rapidly and in such quantity that I immediately suspected the carotid artery. Between one and two pints were lost in less than five minutes. Tampons saturated in tannogallic acid solution, which were fortunately already prepared, were rapidly and firmly placed in position, in and over the sphenoidal wound. The patient was removed in a carriage to the Polyclinic Hospital. The writer accompanied him because he had no confidence in the hæmostasis. The patient suffered from prostration and discomfort caused by the packing. On the fifteenth day after the operation the packing was removed, but this was followed by a slight flow of blood. During the night another hæmorrhage similar to the previous one occurred. The house surgeon tamponed both nostrils and the posterior nares. Very thin blood, with but slight power of coagulation, continued to ooze through the tampons. The patient was gradually losing strength. The pulse was rapid and very weak. It was not considered safe to administer an anesthetic, so I asked Dr. J. A. Bodine to tie the left external carotid by his hypodermic cocaine method, using $^{1}/_{10}$ of a one-per-cent. solution. There was no manifestation of pain during the procedure, except when the cocaine was being introduced, and when an enlarged cervical gland was touched. A catgut ligature was left in place around the common carotid artery for 24 hours, after the ligation of the external carotid, for the purpose of controlling any bleeding that might occur, from the internal carotid. The packing was gradually removed during the next three or four days, and though considerable oozing occurred after each disturbance of the tampons, there was no alarming hemorrhage. The patient after several weeks of slow convalescence, commenced to improve rapidly and now weighs about 15 pounds more than he did at the time of the operation.

I saw him a few weeks since and could find no pus in the sphenoidal cells. Several cases somewhat similar to this one, have been reported and it is a question in the minds of operators as to which artery was to be considered responsible for the hemorrhage. Another important question is whether we should permit patients who have been operated on for sphenoidal disease to pass from under our control for at least three weeks after operation.

Paper.

OBSERVATIONS ON THE DIAGNOSIS OF NASAL SINUSITIS.

BY WALTER J. FREEMAN, M.D., PHILADELPHIA.

Most of the points to which I shall call your attention to-day are doubtless well known to all of you, but nasal sinusitis is so common, and the diagnosis of its exact location often so difficult, that I wish to emphasize the particular significance of certain signs as indications of its presence in one sinus or another. The frequent failure of the transillumination test renders it more than ever necessary that we should perfect and extend all other methods of examination. While the ease and rapidity with which this test can be used make it advisable that it should be employed as a routine measure, as by its means much valuable information and corroborative evidence may be secured, the reliance that has been placed upon it in the past has no doubt caused many a failure to recognize cases of inflammation of the antrum and frontal sinuses in which the physical signs were poorly accentuated. A point to be noted in this connection is, that the antrum, acting simply as a reservoir for pus from the frontal sinus, does not usually answer to the shadow test in transillumination, as pus alone does not hinder the transmission of light rays.

One of the greatest hindrances encountered in reaching a correct diagnosis is the fact that the sinusitis very frequently occurs in the narrower side of the nose. This is in part due to interference with proper ventilation and drainage, such as we see under like conditions in the middle ear. The presence of polypi, which are almost always found in chronic cases, also frequently interferes with the detection of the cavity affected. Edema or even con-

gestion of the mucous membrane in the immediate neighborhood of a sinus ostium is most significant and should draw our attention to this cavity. As the disease progresses the membrane becomes more edematous, forming polypi, which Grünwald states are almost pathognomonic of sinusitis.

Taking up the anterior group of cells, comprising frontal sinus, antrum and anterior ethmoid cells, we come first to the frontal. The clinical history of the late morning headache; fulness over the eyes on leaning over; exquisite tenderness at the inner angle of the orbital roof, causing that characteristic shrinking even before pressure is applied, backed by the discovery of muco-purulent secretion at the peak of the vestibule, present a clinical picture sufficiently clear for an exact diagnosis. When, however, the disease is of less pronounced character, or when there is co-existing inflammation in some of the other sinuses, many difficulties in making even a probable diagnosis arise. In the absence of pain, usual where there is free drainage, our attention may not be directed to the frontal as the cause of a purulent rhinitis or of reflex disturbances at a distant seat, but the persistent appearance of pus on the agger nasi or in the upper angle of the vestibule is so characteristic that a positive diagnosis of frontal sinusitis may be made from this sign alone. That pus from the frontal sinus tends to flow down over the agger nasi and into the vestibule, rather than through the hiatus groove, is due partly to capillary attraction, the septum here being so close to the outer wall, and partly to the coincident swelling of the mucous membrane under the middle turbinal which prevents its escape in this direction.

In the diagnosis of antrum inflammation, whether acute or chronic, especially where there is only a small amount of discharge, no sign has stood me in such good stead as the discovery of pus flowing over the upper surface of the posterior end of the inferior turbinal. By this appearance alone my attention has been repeatedly called to cases of indolent or latent suppuration in which there were none of the usual symptoms, and yet in which most distressing and obstinate inflammation of both upper and lower respiratory tracts was evidently caused by the pus from this cavity. Not infrequently also I have been able to make a tentative diagnosis of sinusitis by certain well-defined odors, those of sour pus and of sulphuretted hydrogen. These odors are very different from that found in antrum suppuration due to dental caries, the

latter being more foul and clinging, and seldom noticed by the examiner. These cases are often mistaken for cases of parosmia, and may be reduced to the verge of melancholia, unwilling to come near any one for fear of the odor being detected. The symptom of intermittent cacosmia is very significant of sinus suppuration, and the antrum will usually be found to be the cavity affected. In my experience, the continued presence of foul odor of the antrum secretion almost unerringly points to the teeth as the cause of the inflammation, and this would account for the frequency of its occurrence in antrum suppuration. An exception to this will be found in cases of diseases of any of the sinuses in which the foul odor is due to syphilitic necrosis.

The presence of discolored molars or bicuspids, even when they are not known to be dead, should always be viewed with suspicion, and the tests of heat and cold and of transillumination should be applied. The roots may not enter the antrum, and there may be no recognized alveolar abscess, but the presence of a carious tooth near the cavity may be the cause of repeated attacks of acute antrum sinusitis. A capped sixth year molar is always most suspicious, and before instituting any treatment of the maxillary cavity, the cap should be removed and the pulp chambers explored, although it should also be remembered that any tooth from the wisdom to the central incisor may be the cause of inflammation of the antrum. It may be that the examination of the root will reveal only a fetid odor, but the removal of the tooth should be insisted upon if the sinusitis does not quickly yield to treatment.

In endeavoring to wash the antrum through the normal opening, I have found it of value to explore first with a delicate cotton-wound probe, *the point curved downward*, as it thus enters the hiatus groove more readily, and after the opening has been detected and the correct curve attained, to fashion the curve of the cannula exactly after it. A difference of a couple of degrees in the angle will often make the difference between success and failure in entering the cavity. In this connection I wish to present an irrigation cannula, made by Ferguson, of Philadelphia, which has proved of great service to me. It is of hard rubber and a second's heating enables one to fashion it to any desirable curve, and being elastic, it will often bend and conform to the irregularities of the surface and slip into the opening without injury to the delicate soft parts. Among other advantages over the metal tube are, that it does not

cause so much discomfort, and that its lightness often permits one to allow it to hang in the sinus ostium while preparing solutions, powders, etc., to be introduced. In this way one introduction suffices to wash and medicate, when repeated introductions would cause additional pain and sacrifice time and patience. It has always been my custom to enter in the notes of each patient a drawing of the proper curve of the instrument, for there is such variation in cases that much time is lost in seeking the proper angle anew at every visit.

In considering diseases of the ethmoid cells, I feel that in expressing my opinions I am treading on dangerous ground. While acute inflammation of these sinuses is one of the commonest conditions observed during the prevalence of grippe epidemics, I have yet to see a single exception to the rule that complete resolution takes place within a few weeks under appropriate local and constitutional treatment. That chronic suppuration of the ethmoid cells exists to the extent that certain statistics would lead us to expect I cannot believe. Most of the cases I have seen have been inherited from other operators, and have been cured by treatment of a hitherto unsuspected antrum, frontal or sphenoid suppuration. I believe that most errors in diagnosis of ethmoidal trouble have been due to the false impression arising from probing in this region. As Zuckerkandl first pointed out, one readily obtains the feeling of bare bone where the mucous membranes are thin, as they are around the sinus openings. Woakes went so far as to claim that a special disease of the middle turbinal existed, to which the name of Necrosing Ethmoiditis was for a while applied, evidently being misled by the false impression of bare bone on probing and the appearance of the bulging wall of the antrum. Time and again cases answering to his description have been brought in consultation, and the so-called necrosing ethmoiditis has been cleared up by removal of the polypi and lavage of the antrum. By this irrigation many an unsuspected collection of pus will be found, which bulging the nasal wall inward and forcing the middle turbinal against the septum, would seem to give warrant for the removal of the turbinal. The cases of turbinectomy in which death has followed are lessons to be carefully heeded, for a fatal termination after operation seems more frequent than should be expected from the disease itself, as Semon states that brain complications are rare contingencies in

ethmoiditis. Therefore, before sacrificing the middle turbinal, as is now done yearly in thousands of cases, it is due the patient at least to suspect the antrum and to try irrigation, even if on account of the impossibility of reaching the normal opening it becomes necessary to puncture the sinus. When pus is not immediately found on puncture and thorough irrigation, one should conclude that a failure has been made in diagnosis. The frequently repeated punctures, which are reported after a time to have demonstrated pus, must be viewed with the suspicion of having been the cause of the suppuration.

As regards the frequency with which disease of the antrum is overlooked and ethmoid suppuration diagnosed, Lichtwitz found the former cavity affected 155 times in 243 of his cases, the ethmoids in only 11 cases. Comparing this statement with that of another well-known writer who found 150 cases of ethmoid disease, and who considers it "by far the most frequent of all diseases of the accessory cavities," and with the report of a more recent writer who found the ethmoids involved 44 times in 50 cases, it would seem that attention is still being directed too much to the ethmoids, and the antrum too much disregarded.

Except in atrophic rhinitis, or in rare cases of deformity of the septum with accompanying lack of development of the turbinals, the direct flow of pus from the sphenoid opening can seldom be seen. If viewed posteriorly, there is no certainty that the pus does not come from the posterior ethmoid cells, unless one accepts the assertion that secretion appearing at the upper part of the choanal arches is pathognomonic of sphenoid disease. Holmes in 50 cases found the ostium of the sphenoid from 1 to 15 mm. from the opening of the posterior ethmoid cell, with an average distance of 5½ mm. With such a short distance between the exits of the two cavities no one can make a differential diagnosis merely from the appearance of pus here. Edema or swelling of the mucous membrane at the upper portion of the septum posteriorly should direct our attention to the sphenoid sinus, just as similar conditions in the region of other openings call for examination of the other sinuses. That the formation of crusts in the vault, as asserted by Schäffer and others, warrants a probable diagnosis of sphenoid disease, I believe to be misleading. So far as I have seen, except in cases of atrophy, pus from any of the other sinuses does not form into crusts, but rather excites an active

flow of mucus and serum wherever it touches the mucous membranes. Why, then, should that from the sphenoid act differently? It is true that crusts are found in the nose and vault in cases of sphenoid sinusitis, but so are they usually present when the other sinuses are involved. This is due, not to the drying of the pus from the sphenoidal sinus, but to the collection of secretion as the result of inflammation of the mucous membrane caused by the irritating sinus pus. The same dry catarrhal inflammation will be found spreading to the pharynx and larynx in these cases, and will clear up as soon as the irritating character of the sinus discharge is modified by cleansing the affected cavity, even though the discharge from the sinus still continues. As to probing the sphenoid sinus, Holmes found in the examination of the above fifty specimens that it would have been impossible during life in 61 per cent. This assertion, however, may yet prove to rank with that of Cryer, who states that the antrum cannot be irrigated through the normal opening, an observation known from daily experience to be false. An appearance which is apt to deceive one is the yellow color of the body of the sphenoid just within the choana. This so closely resembles pus that I have at times been unable to convince myself of my mistake until I had thoroughly cleansed the surface.

Vertigó, and pain at the occiput, deep in the eyes and in the ears, may be caused by the disease of any one of the sinuses, and the distressing pain across the bridge of the nose, considered so characteristic of ethmoid disease, I have repeatedly caused by manipulations within the cavity of the sphenoid. Indeed, in sphenoid inflammations the close proximity of the fifth nerve to the lateral wall of the sinus and the nearness of the spheno-palatine ganglion make reflex pain to any part of the head possible by reason of the rich anastomoses of the branches. I have had cases in which the frontal or the antrum were positively the only cavities involved, in which pus in these cavities would give rise to intense earache, sometimes of the corresponding side, sometimes of both together, the pain disappearing each time the cavities were irrigated. Again, I have seen pain and edema of the orbital tissue arise when only the antrum was involved, though one might rather expect ethmoiditis. In one case, frequent attacks of pain in the mammary region, in another pain under the shoulder blade, were relieved only by washing the antrum. As to placing great

reliance, therefore, on pain as pointing to the sinus involved, it seems well established that it cannot be done, although, on the other hand, absence of pain should not cause one to exclude sinusitis.

In regard to the ocular manifestations in diseases of the accessory sinuses, Posey says that general symptoms of asthenopia which are obstinate and not relieved by glasses should direct attention to the nasal sinuses. He further states that a slight veiling of the edges of the optic nerve with a dilation of the retinal veins and a choking of the lymphatics around the central vessels of the retina occur in latent cases of sphenoid sinusitis, while in severe cases the ordinary signs of optic neuritis are present.

When the drainage is abundant and the turbinal swollen, a positive diagnosis of the special cavity affected is at first often impossible; but by thorough contraction by cocaine and repeated cleansing by anterior and posterior syringing, one can usually arrive at a fairly accurate diagnosis by watching the pus make its reappearance at the characteristic locations. This washing should be done so that the water may be caught in a black basin, for by this means one may obtain really valuable hints as to the quantity and consistency of the nose and throat secretions. The use of suprarenal extract is not advisable in examination for sinus suppuration, as the blanching of the surface prevents the recognition of small amounts of secretion. A point I have found of value in carrying out the Fränkel and other position-tests, is to have the patient close the opposite nostril and sniff and blow alternately. By this means the pus is rapidly drawn from the sinus, and much time saved. Where there is difficulty in detecting the affected cavity by reason of the small quantity of pus, the patient should be examined early in the morning before the sinus has emptied, or late in the evening when the sinus, drained, it may be, during the night, has had a chance to refill. The morning is favorable for detecting pus from the frontal and ethmoids, the evening for secretion from the antrum and sphenoid.

Paper.

A BONY CYST OF THE ANTRUM OF HIGHMORE.

BY C. G. COAKLEY, M.D.

Large bony-walled cysts that completely fill the cavity of the maxillary antrum are of such infrequent occurrence that the writer thinks the case reported may prove of interest.

H. G. A., female æt. 29, born in Scotland, remembers that when 9 or 10 years of age she had a swelling appear on the face just beneath the left side of the nose. At or about the same time a lump appeared on the roof of the mouth to the left of the median line. To the best of her recollection neither swelling was painful. The swelling on the face gradually subsided after the left median incisor tooth was extracted. At the present time there is but one incisor tooth in the upper jaw on the left of the median line, and there has been but one since the extraction above mentioned. The lump on the hard palate has persisted as a painless one all these years, merely giving some annoyance during mastication and phonation.

About two years ago the second bicuspid tooth of the upper jaw on the left side pained her considerably, and accompanying it there was a marked swelling over the anterior surface of the left antrum. This tooth was extracted, the pain subsided, but the swelling persisted.

In January, 1903, Miss A. contracted the grippe. In addition to the usual symptoms of the disease the patient noticed a great increase in the swelling on the face and on the hard palate. The patient could swallow only with difficulty on account of the mechanical impediment that the latter mass offered. The increase in size was not accompanied by any pain. There was no nasal obstruction, nor any evidence of a difference in the character or amount of secretion in either naris.

Dr. Lindenbaum of Jersey City, in order to relieve the dysphagia, incised the mass on the hard palate. After the knife had penetrated about an eighth of an inch of soft tissue it entered a

cavity from which there escaped a thick, light yellow, turbid, inodorous fluid. The amount was about "two table-spoonfuls." The immediate relief was great, but at the end of 48 hours the mass and the attendant discomfort were as great as ever. Repeated incisions at intervals of two or three days were practised for about a month when it was noticed that the discharge had become much thinner and of a decidedly foul odor. The swelling on the face over the antrum kept increasing and became painful. The gingivo-buccal fold bulged outward and incisions were also made into its most prominent part. The discharge had the same appearance and foul odor as that obtained from the palatal incisions.

At the end of a month of this treatment, the patient not having improved, Dr. Lindenbaum referred the patient to me on March 5th.

Examination.—The patient's left side of the face is greatly swollen and tender, but not discolored. An ovoid, tense, slightly red mass occupied the entire left half of the hard palate, the lower surface of which was convex instead of concave. It extended beyond the median line to the right spreading over about half of the hard palate on that side. The gingivo-buccal fold was bulged outward by a hard mass. In it, opposite the first bicuspid tooth there was a small fistula from which oozed on pressure a few drops of offensively smelling pus. The nares, both anterior and posterior, were normal with the exception of a slight bulging on the floor of the left just within the vestibule.

Transillumination of the face showed complete darkness on the left side even down to the level of the teeth.

A probe inserted into the fistula readily entered a large cavity. A cannula was next inserted into the cavity through the fistula and the cavity irrigated with normal saline solution. Considerable pressure was needed to get a return flow, the irrigation fluid mixed with pus returning around the side of the cannula. None of the fluid passed into the naris.

The patient was advised to enter Bellevue Hospital for operation. This she did on March 6th, and on the same day under ether administered by Dr. Creevy, by the Crile method, I made an incision two inches long in the gingivo-buccal fold parallel to and one-fourth of an inch above the lower border of the gums. It was practically impossible to strip up the periosteum from the

anterior surface of the superior maxilla, as the two were so intimately adherent and the bone so thin and porous that the elevator kept penetrating the cavity. I pushed my index finger through the wall which was more like a pyogenic membrane infiltrated with bone salts than anything else I can liken it to. The finger reached the level of the orbit, and passed beneath the anterior third of the nose as far as the middle of the hard palate. My opening was enlarged until it was about an inch in diameter, and I proceeded to curette the cavity. The material that came away had much the appearance of that found in chronic empye-

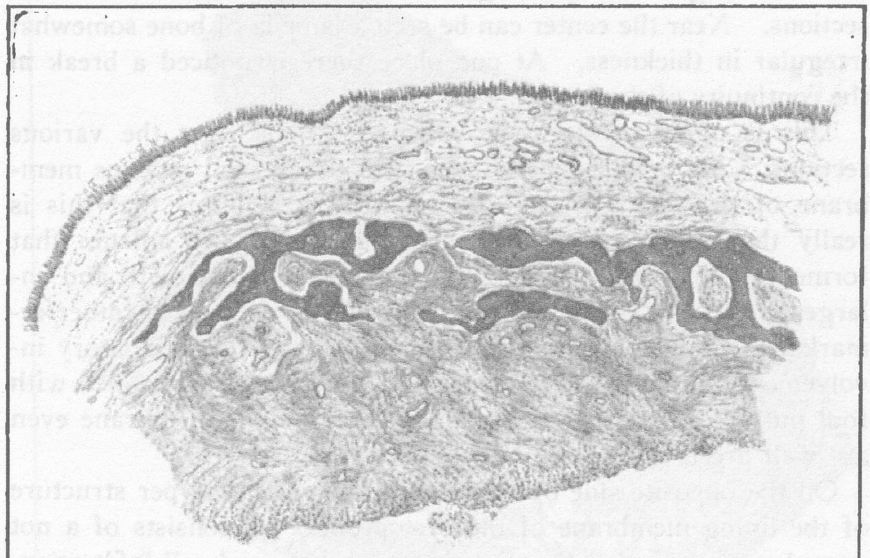

FIG. 1.

mata of the antrum, viz., grayish, gelatinous, polypoid masses. The hæmorrhage was considerable. On seizing some of this tissue with a forceps a piece of the lining more than an inch square came away from the vault. It retained its dome-like shape, and was found to have a thin bony wall. Several other pieces, not so large, were similarly removed. The greatest difficulty was experienced in cleaning the anterior wall of the antrum on account of the intimate adherence to the muscular tissue. No bone was encountered in curetting the prolongation under the nose and in the hard palate. When scraping in the latter region the curette at one place entered the floor of the nasal cavity. The

wound was packed with a long strip of iodoform gauze. This was removed at the end of 48 hours, the cavity irrigated with normal saline and repacked. This procedure was repeated at intervals of two or three days for about two weeks. The patient left the hospital on the tenth day after the operation.

The subsequent treatment has consisted in repacking the cavity, without irrigation, every three or four days.

Microscopical Examination.—The large domelike piece of tissue removed was placed in 4-per-cent formalin solution for two days, then decalcified in sulphurous acid, washed, re-hardened, and cut. Fig. 1 is a drawing made from a portion of one of the sections. Near the center can be seen a lamella of bone somewhat irregular in thickness. At one place there is noticed a break in the continuity of the bone.

This is of frequent occurrence as we look over the various sections. Above the bone will be seen the normal mucous membrane of the interior of the antrum. My belief is that this is really that part of the mucous membrane of the antrum that formed the floor of the antrum and that with the growth and enlargement of the cyst it was carried up before it. It is rather remarkable that this membrane shows no signs of inflammatory involvement although in such close proximity to a cavity filled with foul pus for a month at least. The cilia on this membrane even are well preserved.

On the opposite side of the bone is shown the deeper structure of the lining membrane of the cyst proper. It consists of a not very dense connective tissue with moderate round cell infiltration. Blood vessels of various sizes are quite numerous, but no glandular structures are to be seen. Only a portion of the cyst wall remains attached to the bone, the superficial portion having been removed in the earlier curetting.

Fig. 2 is a section, slightly oblique, from the curettings of the cyst. Its lower portion has a structure like that attached to the bone in Fig. 1. Its superficial portion is much more densely filled with round cells. Again no glands are found. In this respect the lining of cysts of dental origin differ from the polypoid hypertrophies of the mucous membrane of the antrum found in chronic empyemata of the antrum. The epithelial lining is seen to be with flat cells, arranged in two or three layers.

A most exhaustive study of dentigerous cysts was made by

Magitot. His researches appear in the *Archives Generales de Medicin*, Vol. II, 1872, pp. 399-414 and pp. 681-699; also in Vol. I, 1873, pp. 155-174. It seems probable that in our case we had a cyst forming from the root sac of the left upper median incisor and that it first invaded the hard palate, pushed its way under the nasal cavity, and finally invaded the antrum. The root of the second bicuspid was probably pressed upon, its circulation inter-

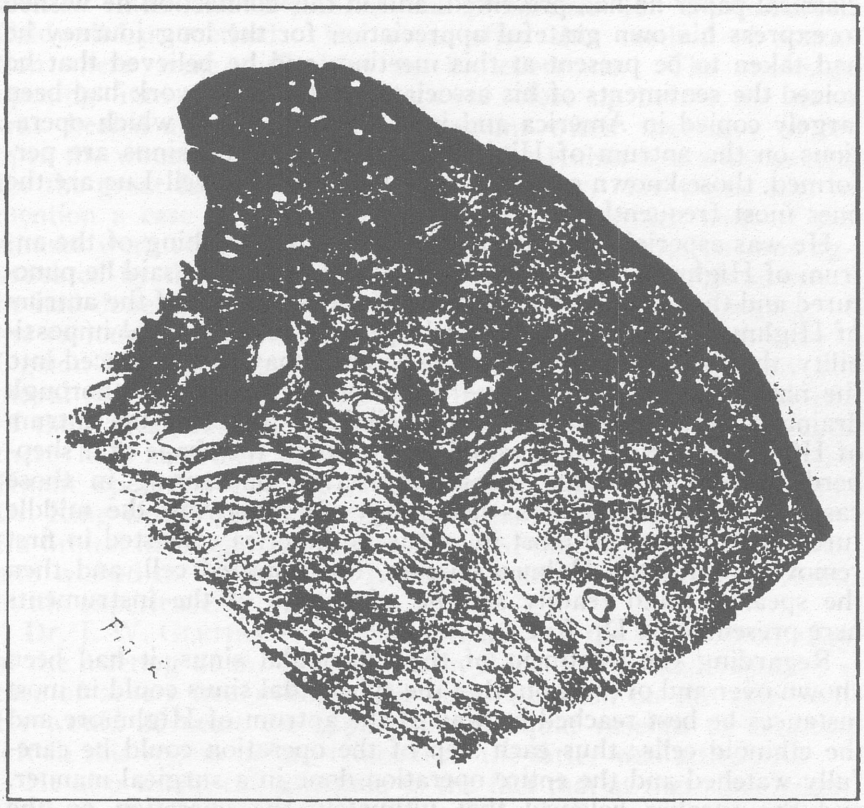

fered with and thus diseased. The irritation from this diseased tooth produced an increase in the secretion of the sac and a considerable increase in its size. On the extraction of this tooth the cyst remained quiescent until the attack of grippe caused such an increase in the fluid as to get the patient to seek relief from the mechanical effect. With the entrance of pus-producing germs through the incisions about a month later, the pain, mild sepsis, and fetid discharge kept up until the time of operation.

DISCUSSION ON THE PAPERS ON SINUS DISEASE.

DR. J. H. BRYAN called attention to a specimen he wished to present which showed a peculiarity of the sphenoid sinus, which was unusually large and extended down into the pterygoid process. If entrance to the sphenoidal cells had been attempted in this case through the antrum the lower extension of the sphenoid would not have been reached.

Dr. EMIL MAYER stated that he would like to express to Dr. Luc his very extreme pleasure at having been able to hear the classical paper he had presented, and in this connection he wished to express his own grateful appreciation for the long journey he had taken to be present at this meeting, and he believed that he voiced the sentiments of his associates. Dr. Luc's work had been largely copied in America and in most instances in which operations on the antrum of Highmore and the frontal sinus are performed, those known as the Ogston-Luc and Caldwell-Luc are the ones most frequently performed.

He was especially pleased to note that when washing of the antrum of Highmore was spoken of by Dr. Luc that he said he punctured and then washed out. Ordinarily washing out of the antrum of Highmore through the natural openings is a practical impossibility, that is to say, that while the cannula may be introduced into the natural opening and some fluid forced into it, yet thorough drainage becomes a practical impossibility. To enter the antrum of Highmore the cannula would have to have the shape of a shepherd's crook, hence the speaker preferred puncturing in those cases where treatment was necessary. In removing the middle turbinate, the method most in vogue in America consisted in first removing, with the Holmes scissors, the enlarged cell, and then the speaker could readily see the advantage of the instruments here presented by Dr. Luc.

Regarding the treatment of the sphenoidal sinus, it had been shown over and over again, that the sphenoidal sinus could in most instances be best reached by way of the antrum of Highmore and the ethmoid cells; thus each step of the operation could be carefully watched and the entire operation done in a surgical manner, and the speaker believed that ultimately the operation on the sphenoidal sinus would be done in this way. He had seen Jansen enter the sphenoidal sinus frequently in this way and the manner of procedure had struck the speaker as being rational, as complete control of the field of operation was thus obtained. In this connection the speaker presented an instrument for retraction of the cheek (instrument shown). The advantages were that it would not slip and afforded a most admirable exposure of the field for operation and dressing.

Dr. T. J. HARRIS referred to his experience with Dr. Luc's

method in frontal sinus disease. His results at first had been excellent; later less so. He had carefully studied Killian's operation, and thought the removal of the lower inferior wall of the frontal sinus would be found difficult. It was the difficult step of the whole procedure. Concerning the functions of the antrum and its relation to intranasal secretion, he would say that whenever he found pus in the nose he suspected antrum disease. He daily used the Myles antral trocar and found it a most useful instrument.

Dr. GORDON KING enumerated the various operations on the frontal sinus and expressed his preference for the modified Caldwell-Luc method. But even after this method of operation there were difficulties to be overcome. The drainage opening into the nose was apt to close up before the sinus was healed and it was on this account often necessary to reopen the wound. He was in favor of the Kuhnt operation except for the great facial deformity caused thereby. He would like to mention a case of double frontal sinusitis in which both of the sinuses were very large and in which the sinus condition was aggravated by the presence of an orbital abscess. In this instance he had done an operation which was essentially a combination of the various methods mentioned in the present discussion, a Kuhnt-Ogston-Luc operation with drainage into the nose and the removal of the anterior wall of the frontal sinus and implantation of the flap against the posterior wall of the sinus. In this case there had naturally followed the customary deformity of the Kuhnt operation but the ultimate result had been satisfactory. Dr. King would also call attention to the fact that a temporary infra-orbital neuralgia sometimes followed the Ogston-Luc method, and wished to know if Dr. Luc had ever observed such a result in his experience.

Dr. J. W. GLEITSMANN called attention to the fact that in 1895 at the meeting of the Association in Rochester he had reported a case of severe hemorrhage following operation on the sphenoid. He would advocate the application of liquid vaseline to tampons left in this region before removal of the latter was attempted.

He also would call attention to the fact that at that same meeting he had stated that the distance through the anterior nares between the middle turbinate and the septum, to the anterior sphenoidal wall, was three and one-half (3½″) to four (4″) inches, and to the posterior ethmoidal cells six and one quarter (6¼″) inches. He was now speaking of chronic cases, for in acute disease the anterior wall was, as a rule, not corroded. He had, however, recently seen a case of a slender man, six feet tall, in whom the antero-posterior distance from the tip of the nose to the sphenoid was five and three quarter (5¾″) inches. There consequently could be no invariable rule as to this distance.

Dr. BRYAN wished to ask if there had been much tendency in the antro-sphenoidal route to closure of the openings made?

Dr. LUC replied, in closing, that he had not noticed any tendency to closure of the openings made in the antro-sphenoidal method. He expressed his harmony with the views of those who favored large openings—in order to cure well we must see well, and large openings allowed a better treatment of the bleeding. It was difficult to resect the floor of the frontal sinus, but after incision and removal along the anterior edge of the wound we have a complete view of the floor.

Killian's operation was of great importance. We have to choose between the open method of wound treatment of a suppurating cavity and the closed method with the disfigurement of the patient. An unexpected result followed in one patient operated on with Killian's method. It was a rise of the fatty tissue in the orbit helping to support and maintain the general contour of the face. In this way we could suppress the cavity and retain facial symmetry.

The introduction of the finger is of the greatest importance and we should carefully follow along the anterior part of the bony bridge so as to know just what we want to do, hence we establish complete drainage between the nose and the frontal sinus. Replying to the inquiry of Dr. King, he would say that he had not found neuralgia following any of his operations. For a while the tissues about the frontal and maxillary sinuses were devoid of their usual sensibility, but there was no neuralgia.

Dr. MYLES was always glad to follow the methods of Dr. Luc. He believed antral irrigation through the natural opening quite feasible and in this matter would have to take issue with Dr. Mayer. In a healthy sinus irrigation might not be possible, but wherever there is an extensively diseased condition, the hiatus semilunaris is usually pressed inward and thickened and a cannula with the proper curve will generally reach the antrum.

Dr. FREEMAN, in closing, said he entirely agreed with Dr. Myles that the ostium maxillare was more readily probed when the sinus was diseased than in the normal state. This is due to the bulging of the wall inward and to the unfolding of the hiatus groove. As a rough estimate, he thought that in four-fifths of such cases the cavity could be irrigated, and that some could be cured by this method alone. Of course, where there were granulations or polypoid degeneration of the lining membrane, irrigation alone would prove of little service.

Paper.

THE REMOVAL OF OBSTRUCTIONS AND CICATRICIAL CONTRACTIONS OF THE NOSE BY THE PLASTIC METHOD.

BY JOHN O. ROE, M.D.

Obstructions, congenital narrowing, cicatricial contractions and occlusion of the nasal passages are so frequently met with in our daily work that it may seem superfluous to attempt a discussion of such commonplace occurrences. But as these seemingly simple maladies often tax to the utmost our patience, our skill and even our ingenuity in dealing with them, perhaps some suggestions regarding their treatment may not be without interest.

The anterior nasal openings are most frequently narrowed or obstructed by cicatricial contractions that have resulted from injuries or burns, or from ulcerative processes of the skin, such as syphilis, lupus and smallpox. In some cases the atresia may be congenital.

In the anterior portion of the nose cicatricial obstructions in the form of synechiæ, the result of inflammatory or ulcerative processes, are most frequently met with. These synechiæ may occur in any portion of the nasal passages, from the vault to the floor, from the vestibule to the posterior portion of the septum and turbinated bodies, uniting any of the different structures normally separate.

They may consist in the adherence of the upper surfaces, occluding the vault entirely, or the lower portion, contracting the floor, or even the entire passage, or they may be limited to bands of cicatricial tissue, extending across at some intermediate place, the most frequent site being between the middle turbinated body and the septum.

In the treatment of these conditions, when the atresia is located at the anterior nasal orifice, dilatation by means of conical plugs, expanding bougies, or instruments, is commonly advised and employed. In the case of synechiæ in the interior of the nose, the methods employed are division or removal of the adhesion or

contraction by the knife, scissors or punch-forceps, and the interposition of a metallic, hard rubber or celluloid plate, or similar substances, or gauze or cotton, or the simple passing of a probe or sound frequently between the parts to keep them separated until the opposing surfaces are healed.

In the majority of cases the result is unsatisfactory, on account of the length of time the appliance is required to be worn to prevent a recurrence, and on account of the readiness with which the bands re-form or re-adhesion takes place, or contractions go back to their old conditions after these attentions are discontinued.

In all operations within the nasal passages the important precaution must be taken to avoid wounding opposing surfaces since in some cases synechiæ have followed or have been caused by operative procedures in the nose. This accidental complication can be avoided by operating on one side of the passage only at one time, so as to maintain the mucous membrane of the opposite wall intact until the site of the operation is thoroughly healed before operating upon the opposite wall, should the latter be necessary. This is very essential in all cases in which the surfaces are not so widely separated but that the formation of a band is possible after the operation.

In order to secure this condition after operations for the removal of synechiæ or other contractions of the passages in which opposing raw surfaces are unavoidable, it occurred to me that the denuded surface on one side might be covered with skin or mucous membrane or healed tissue taken from the surface of the contraction or band or wall of the passage, so that reunion of the surfaces would be impossible.

This plastic method of dealing with these conditions in the interior of the nose was suggested by my subcutaneous plastic work, that has so much interested me in connection with the correction of nasal deformities. This method I have now employed for a considerable time, and the excellent results obtained have induced me to present it for your consideration.

Before I employed this method the plan that gave me the best results in the treatment of synechiæ was to touch one side with the galvano-cautery after the band had been cut away, for the reason that cut and cauterized surfaces do not readily grow together. In the case of slender bands this method is simple and effective, but where the cut surfaces are extensive and the passage narrow

the method of covering one side with mucous membrane is far superior. In each case, however, the method must be modified to meet the requirements of the conditions present.

In the treatment of contracted conditions of any portion of the nasal passages, whether located in the vestibule or elsewhere, if we

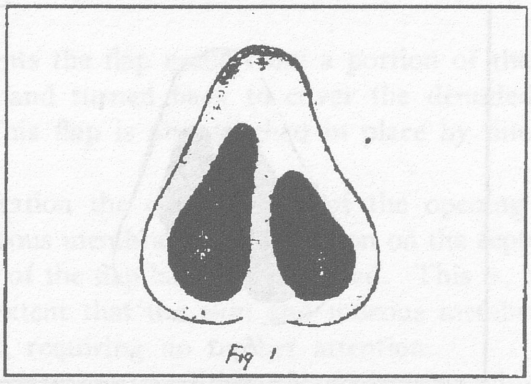

Fig 1

attempt to enlarge the passage by simply cutting out the inside of the contraction, we not only fail to obtain the desired result, but the effect is to increase the difficulty by reason of diminishing the amount of skin or mucous membrane on the interior of the ring, so that when healing takes place the opening becomes smaller than

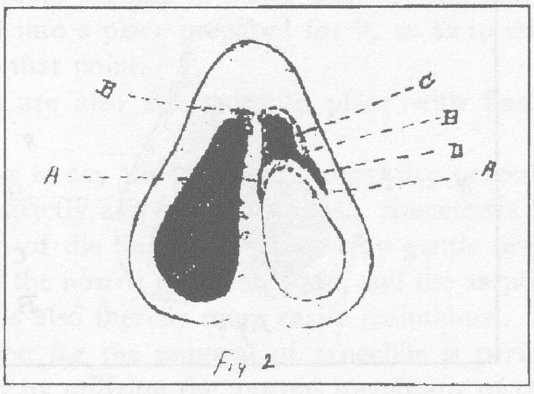

Fig 2

before the operation. In dealing with such contractions, therefore, we must not only increase the extent of skin surface or mucous membrane, but we must interpose on one side of the passage at least an unbroken surface of skin or mucous membrane, to prevent the union of the surfaces. This is particularly true if the contraction is located in one of the angles of the passages; for if

there is no such area of sound skin, or mucous membrane at the junction of the two sides to arrest the reunion of the surfaces (as is necessary in the case of webbed fingers to prevent their reunion when separated), nothing can prevent the surfaces from gradually growing together again, no matter how widely sep-

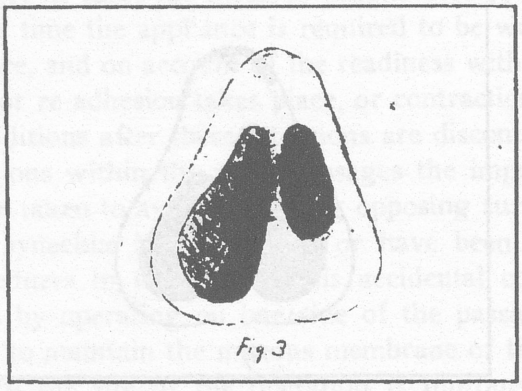

Fig 3

arated by plugs or dressing for an indefinite period of time they may be.

In order to explain more clearly the plastic method employed for the correction of these different conditions, I have attempted

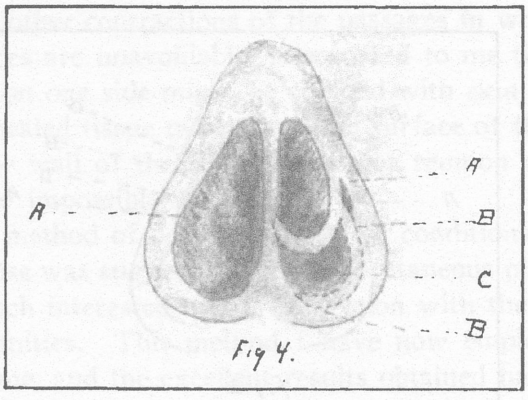

Fig 4.

to show by these diagrammatic illustrations the different steps in the operations.

In atresia of the anterior nasal passage Figure 1 represents a contracted condition of the upper portion of the opening and the vestibule.

Figure 2 shows the line of the incisions for correcting this condition.

The incision "AA" represents the method for making the flap of skin to be turned up into the apex of the opening after the redundant tissue has been removed.

The line "BB" shows the incision for the removal of this tissue, and also represents the flap after it has been turned up into the apex of the opening and stitched there by very fine horse-hair sutures.

"C" represents the flap made from a portion of the redundant skin removed and turned back to cover the denuded border at that point. This flap is also stitched in place by fine horse-hair sutures.

In this operation the only portion of the opening uncovered by skin or mucous membrane is the portion on the septum at "A," where the end of the flap has been removed. This is, however, of such limited extent that the skin and mucous membrane readily spread over it, requiring no further attention.

Figure 3 represents a condition of atresia, occupying the lower portion of the vestibule, which is dealt with in a manner similar to that occupying the upper portion of the vestibule, just described.

The line "AA" shows the incision for raising the flap, to fill in the lower border when the redundant tissue has been removed.

"BB" represents the flap in place, and "C" the portion of skin turned inward into a place prepared for it, so as to cover the denuded wall at that point.

These flaps are also stitched into place with fine horse-hair sutures.

It is needless to say that the whole operative procedure should be done with strictly aseptic precautions. Sometimes the coaptation and union of the flaps is facilitated by gentle pressure from the packing of the nostril for a few days, and the aseptic condition of the nostril is also thereby more easily maintained.

The operation for the removal of synechiæ is performed in a similar manner by utilizing the mucous membrane of the band for covering the denuded surface on one side of the nostril where the band has been cut away.

When the synechia is limited in extent or thickness a flap from one side, preferably the upper side, is sufficient to cover the surface where one of the ends of the band has been cut away. The flap is best raised by a small knife similar to a tenotomy knife

with its point curved on the flat and double edged, thus enabling the operator to go part way around the band with the knife and thereby secure a broader flap. When this is done the remaining portion of the band had best be removed before either end of the flap is cut loose.

Figure 5 represents synechiæ between the middle turbinated bodies and the septum and the method of making the flaps for covering the denuded surfaces on one side of the passages after the bands have been cut away.

On the right hand side of the drawing is shown a condition in

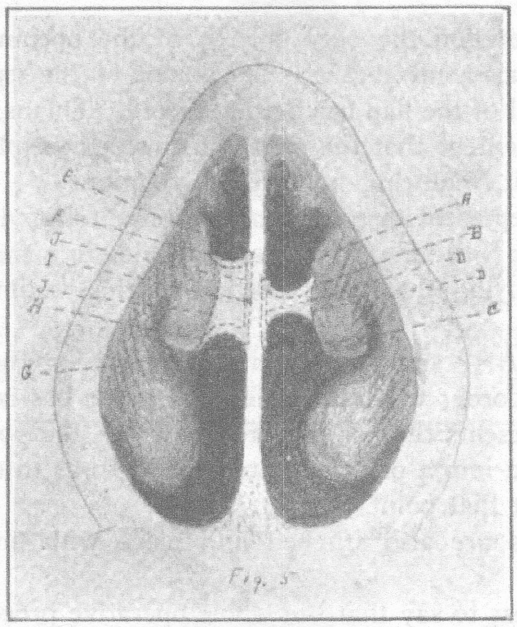

which but one flap only (preferably from the upper side of the band) is required for covering the denuded space on the septum.

"AB" shows the line of incision for making the flap. "AC" shows the flap applied against the septum where the band has been cut away at "DD."

On the left hand side is represented a more extensive synechia, in which the flap from both the upper side "EF" and the lower side "GH" is required to cover the denuded surface on the septum. "EF" shows the two flaps placed against the septum and stitched together at "I" with fine horse-hair sutures after the synechia has been cut away at "JJ."

The side to which the flap should be left attached depends upon

the condition and position of the parts. If the septum is not bent in this direction and sufficient underlying tissue can be removed to make a place for the flap, it is far preferable to place it on the septum; if not so placed, it should be placed against the turbinated body or the outer wall of the nose, as the case may be.

By the turning of the flap downward instead of upward it is much more readily held in place, and its union can be very much facilitated by the insertion of a Simpson's Bernays intra-nasal plug. In using such a plug, one of a size, to exert only gentle pressure when expanded should be carefully selected.

In those cases in which the band is very wide and covers a large extent of surface, a flap taken from one side of the band is insufficient unless the incision is carried high up on the opposite wall. In this case flaps should be taken from both the upper and lower sides of the synechia, which, after the synechia has been removed, can be cut loose at one end, turned in and stitched in place with horse hair. Simpson's Bernays intra-nasal plug is then introduced as in the other case. These stitches can readily be inserted with small curved needles held by a handle into which different size needles can be inserted. These needles which I show you here I have found very serviceable for intra-nasal work. They are made for me in a very admirable manner by George Tiemann & Co.



In the treatment of synechiæ occupying the vault of the passage the plan of operation for the covering of one side with mucous membrane is similar to that for restoring the skin to one side of the vault of the vestibule in the first case described. This operation, however, is made more difficult owing to the normal narrowing of this portion of the passage. The flaps in this region are usually best held in place with packing carefully applied or with a

small, properly fitted Simpson's Bernays plug or tampon. In the lower portion of the passage, owing to the wider and more ample space, stitching the flaps is readily done, although careful packing of the passage ordinarily is quite sufficient.

This plastic method can be employed for preserving the mucous membrane, in operations for the removal of hypertrophied turbinated bodies, bony spurs from the septum, excresences, etc. By first raising a flap of the mucous membrane sufficiently thick to be certain of retaining its vitality, the turbinated body or bone or the spur, or excrescence, can be cut away and the flap allowed to fall into place covering the wound. By this method no open wound is left and the parts heal very speedily if maintained aseptic.

In this connection I will mention a simple but effective operation for collapsed alæ, so frequently the cause of obstruction of the anterior nasal openings.

Collapsed alæ may be caused by a variety of conditions. The most frequent are paralysis of the dilating muscles of the alæ and a deformed and collapsed condition of the lateral shield cartilage. Sometimes a bent or dislocated triangular cartilage will so obstruct the entrance of the nostril that the current of air on inspiration will suck the ala in against the septum.

A normally expanded condition of the ala can be made by simply incising the shield cartilage from the inside through to the skin at the point of the greatest depression, and removing a small wedge-shaped portion of the cartilage with the base of the wedge toward the interior of the nose. Then by stitching these edges together with one or two horse-hair sutures, as the case may require, the ala is given the outward bulge characteristic of a normal nose.

Discussion.

Dr. Emil Mayer desired to make one suggestion in connection with the prevention of adhesions in the nose, in that he followed the method of employing the so-called "Cargile membrane" which had been advocated by Dr. Goldstein of St. Louis and Dr. Mosher of Boston. It could not be used immediately after operation, as it must be employed on a dry surface. After breaking down the synechia and using half of a Simpson's Bernays splint, in a day or two the field could be covered with nosophen and the nose tamponed with half a package of the Cargile membrane, firmly inserted. In one or two days later it had become dissolved and the nasal mucosa healed under it.

Paper.

IMMEDIATE TRACHEOTOMY FOR FOREIGN BODY; RECOVERY.

BY W. PEYRE PORCHER, M.D.

THE following case is reported because of its successful termination and the narrow escape of the infant. A child eight (8) months was brought to my office with the statement that it had inhaled a small green pine bur about eighteen hours previously. On introducing the finger in the pharynx the bur could be plainly felt impacted in the glottis. The point of the bur was directed downward, and so situated that it did not greatly impede respiration. The leaves of the bur had become very much softened from the surrounding moisture, and being on that account somewhat loosely attached, every bite of the forceps would bring away one or more of them, and this of course only served to reduce the size of the bur to a certain extent. All at once the bur became small enough to be lifted out of its bed, and it was sucked into the larynx and respiration was shut off. I immediately plunged a bistoury into the trachea, pulled open the lips of the wound and respiration was again set up. A tube was then introduced, and the child was sent to the hospital. The bur was left in position, as it was thought best to postpone further effort to extract it until general anesthesia could be given. The following day, assisted by the late Dr. R. B. Rhetta, a catheter was passed into the wound and the bur pushed up into the mouth. It was found necessary to wait 21 days before the tube could be permanently removed. At intervals of a week or so efforts were made to remove it, but each time the child became cyanotic and the tube had to be replaced. The child recovered perfectly, and its articulation is fairly good.

EXHIBITION OF SKULL SECTIONS.

IN connection with the papers on sinus disease, Dr. George B. Wood, of Philadelphia, presented, by invitation of the Council, a series of sections through the facial structures of a child six months old. Dr. Wood's accompanying remarks were as follows:

Mr. President and Members of the Association: I thank you for the honor of being invited to exhibit before this meeting a series of sections through the facial structures of a child six months old.

These sections have been prepared at the Wistar Institute of Anatomy of the University of Pennsylvania, and I am indebted to Dr. Greenman of that institute for much help and many suggestions.

The technique of their preparation was briefly as follows: The head while frozen was sectioned with a band saw just above the

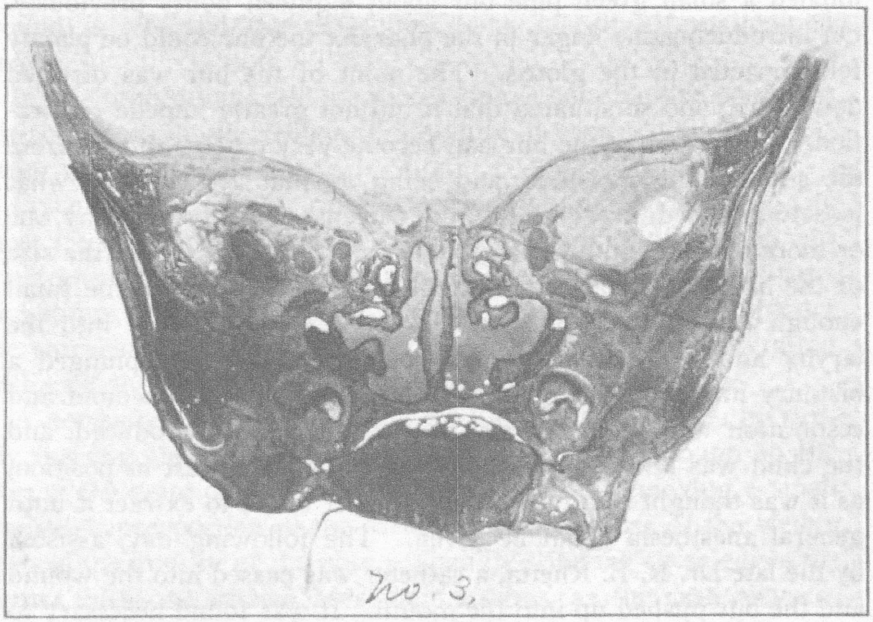

No. 3.—Extreme breadth of nasal fossæ. Posterior thickening of the mucosa of the septum. Irregularity in the descending ossification of the perpendicular plate of the ethmoid.

ears and eye-brows, this being done so that fluids might readily permeate the interior of the cranial cavity. The head was hardened in formalin and then placed in a decalcifying fluid of nitric acid and alum for about three weeks. It was then easily cut into coronal sections, each section being about two inches thick. The first line of division passed through the naso-pharynx, just missing the septum, and only the facial structures in front of this line were used in making the sections presented. The face was imbedded in celloidin in a manner similar to that employed in making

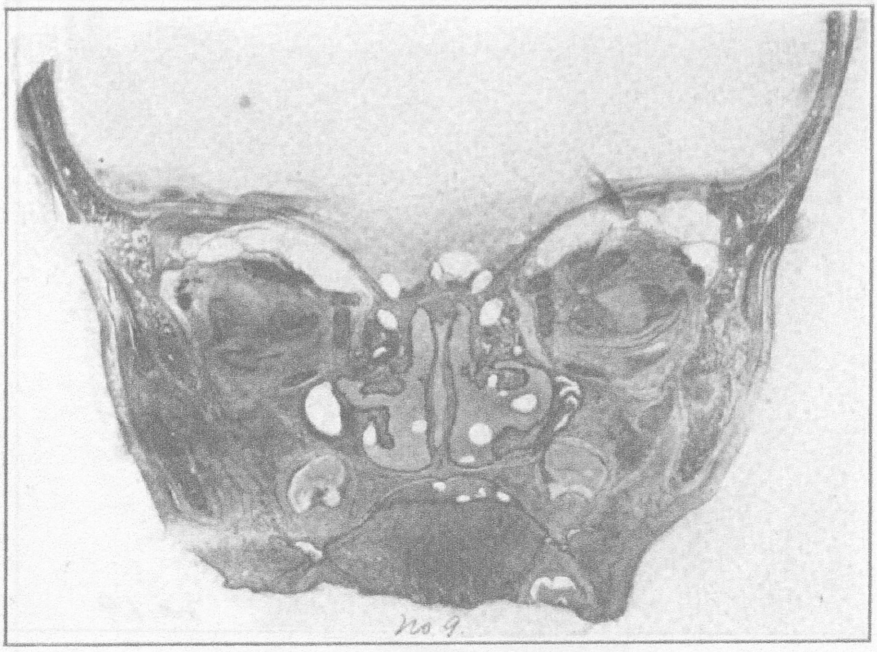

No. 9.—Second molars; descent of the perpendicular plate of the ethmoid in two laminæ. Accessory groove in the left middle turbinate. Asymmetry of the fossæ and antra especially well shown. Molar teeth in close proximity to antra.

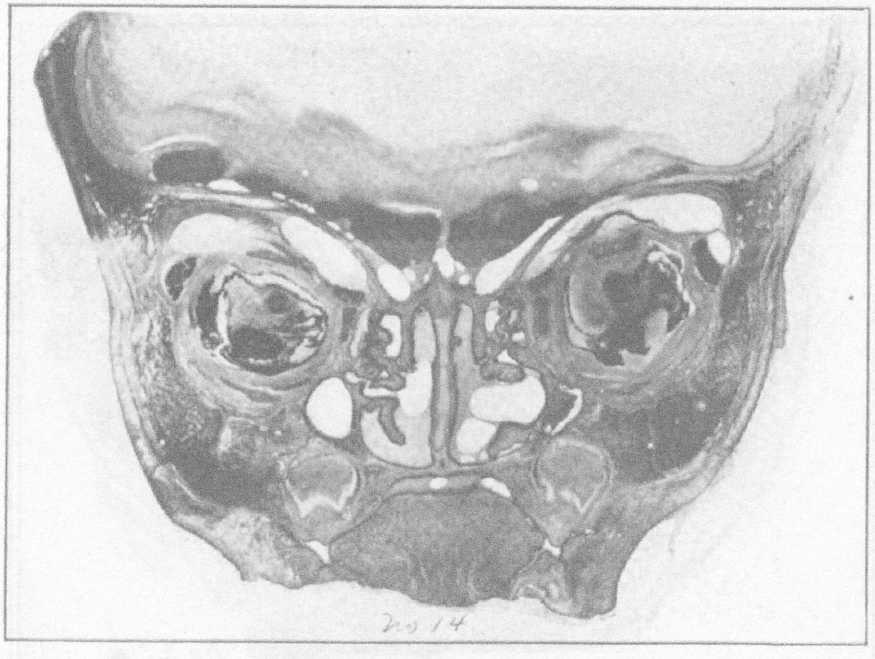

No. 14.—Second molars; descending ossification of the perpendicular plate of the ethmoid in two laminæ. Anterior end of the superior turbinate. Opening of the ethmoidal cells into the middle meatus.

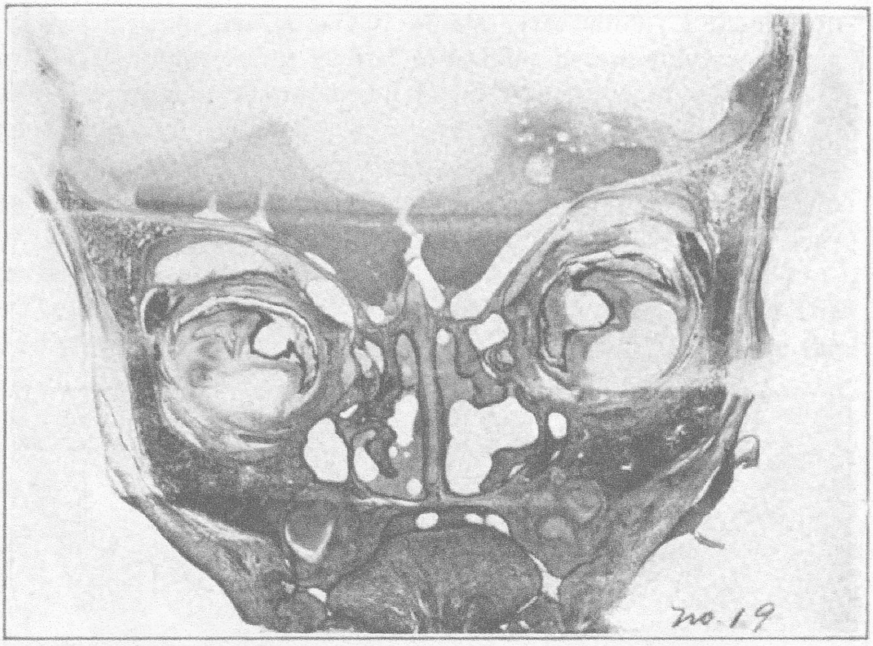

No. 19.—Second molars; unciform process; bulla ethmoidalis on left side: ethmoidal cells opening into middle meatus. Lacrimal glands. Beginning ossification of the perpendicular plate of the ethmoid from both sides of the cribriform plate.

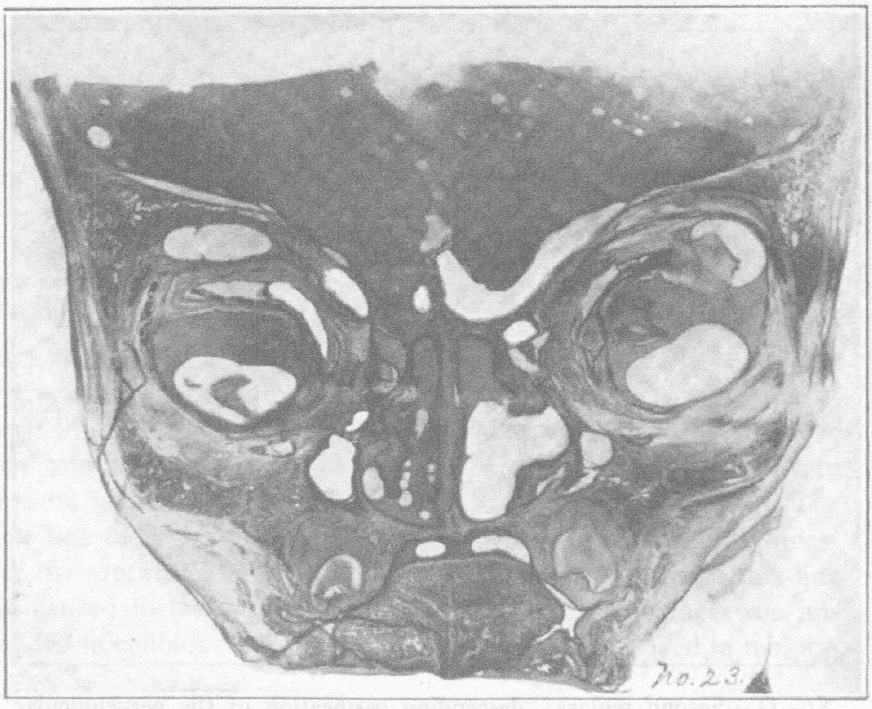

No. 23.—First molars. Hiatus semilunaris. Ostium maxillare on left side. Opening of the anterior ethmoid cells into the middle meatus. Anterior end of lacrimal glands.

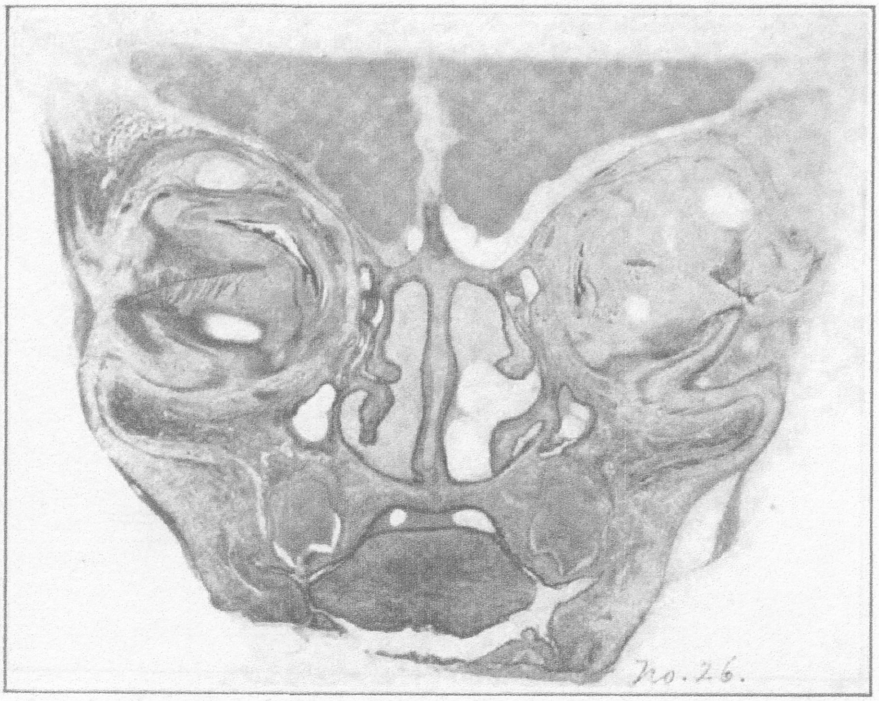

No. 26.—Eruption of first molar on the right side. Posterior end of nasal duct. Arrangement of the Meibomian glands very well shown on the right side.

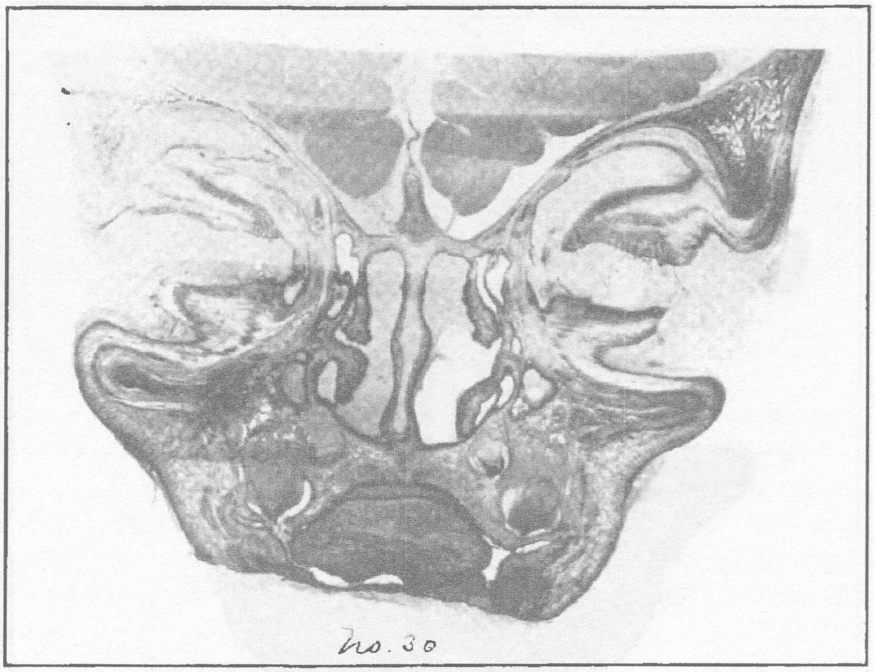

No. 30.—Canines. First molars. Antrum and nasal duct on the left side. Upper part of lacrimal sac and antrum on right. High position of an anterior ethmoidal cell on the right side, possible indication of future frontal sinus.

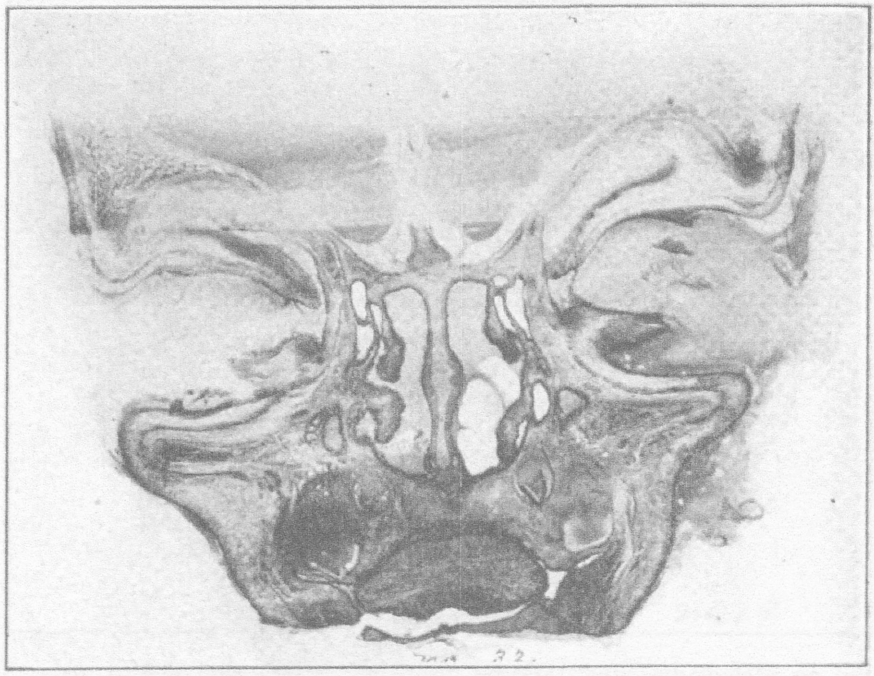

No. 32.—Canines. First molars. Anterior palatine canal. Anterior end of antra. Opening of the nasal duct into the inferior meatus. Upper portion of the lacrimal sac. Opening of the anterior ethmoidal cells into the middle meatus. Cribriform plate, lacrimal puncta.

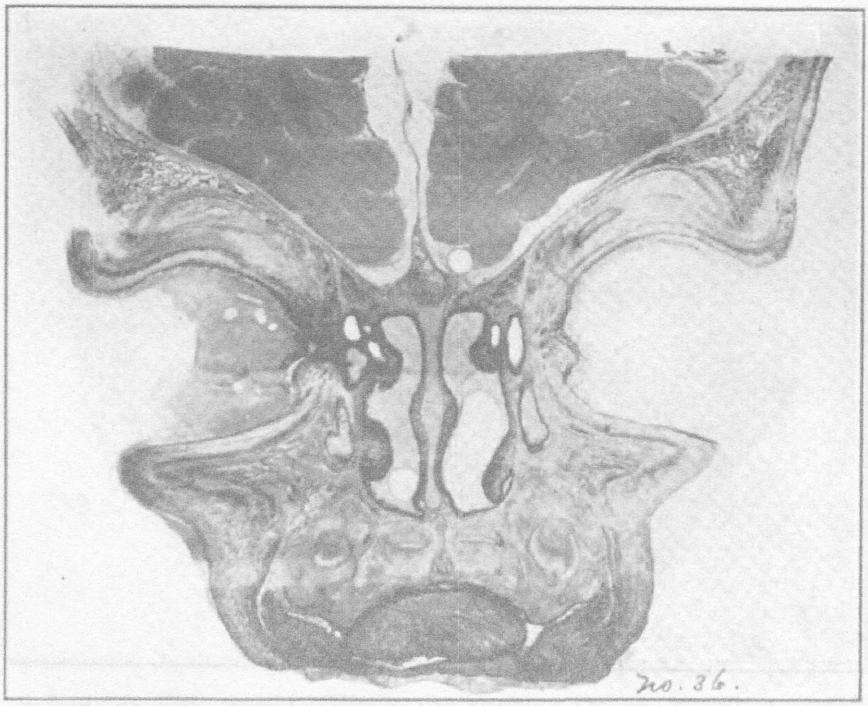

No. 36.—Central incisors. Lateral incisors. Canines. Anterior palatine canal. Nasal duct. Tubercle of the septum with fusiform thickening of the septal cartilage. Anterior ethmoidal cells. Canaliculi. Crista galli.

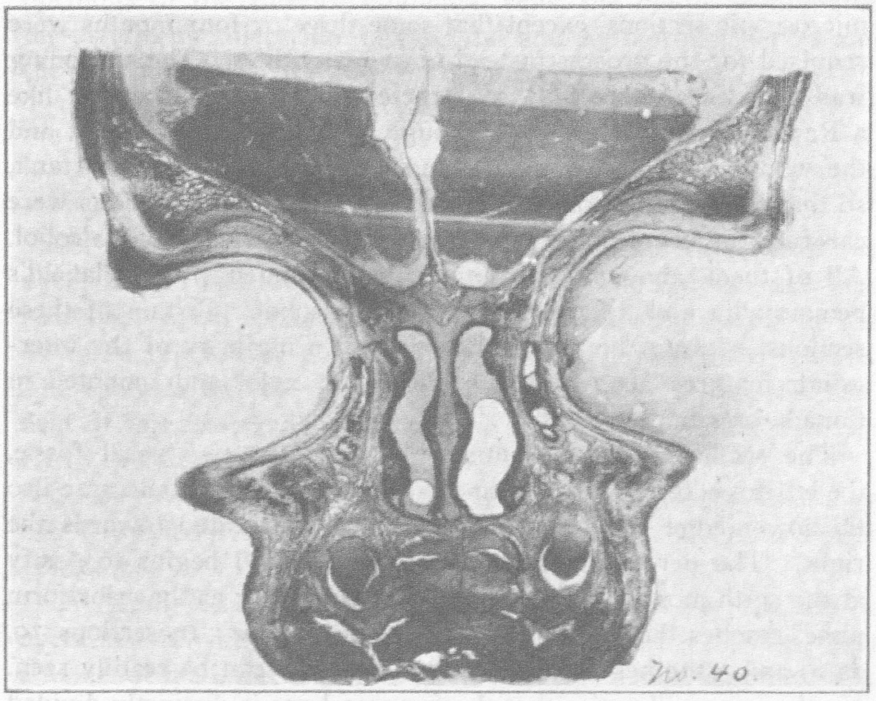

No. 40.—Central incisors. Lateral incisors. Canines. Septum not yet united to maxilla. Anterior end of Jacobson's organ. Tubercle of the septum. Anterior end of the middle turbinal. Anterior end of the lacrimal sac.

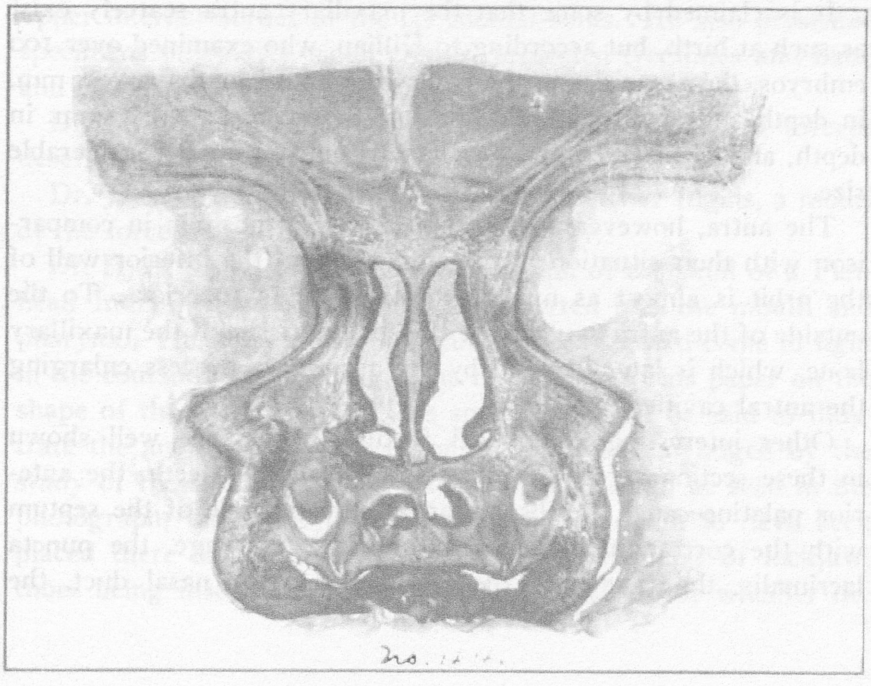

No. 44.—Central incisors. Lateral incisors. Canines. Septum not yet united to maxilla. Anterior end of inferior turbinal. Tubercle of the septum.

microscopic sections, except that some three or four months were required for the process instead of so many days. The sectioning was done on an especially constructed microtome, somewhat like a Ranvier's hand microtome, though of course much larger, and the whole apparatus was surrounded by a galvanized iron tank, so that the sections could be cut under water. The sections were carefully numbered and placed in series in 80 per cent. alcohol. All of them, about 50 in number, were stained with Delafield's hematoxylin and differentiated in acid alcohol. Certain of these sections, because they seemed to present a majority of the interesting features, were selected, cleared in xylol and mounted in Canada balsam.

The sections show asymmetry between the two nasal fossæ, the left fossa being enlarged at the expense of the left antrum; also the lower edge of the septum is slightly dislocated towards the right. The perpendicular plate of the ethmoid begins to ossify at the sixth month, and this ossification, starting at the cribriform plate, reaches the vomer at about the third year. In sections 19, 14, 9 and 3 the beginning of this ossification can be readily seen. Further you will notice that the forming bone is distinctly divided into two lateral laminæ, which are just starting in their downward growth toward the vomer. The cartilaginous part of the septum does not show this separation into two laminæ.

It is claimed by some that the maxillary antra scarcely exist as such at birth, but according to Killian, who examined over 100 embryos, these cavities in the embryo of four months are ½ mm. in depth and at nine months, or just before birth, are 5 mm. in depth, and in my sections they have reached quite a considerable size.

The antra, however, still occupy a median position in comparison with their situation in the adult, so that the inferior wall of the orbit is almost as much external as it is superior. To the outside of the antra you can see the spongy tissue of the maxillary bone, which is later invaded by the absorptive process enlarging the antral cavities.

Other interesting anatomical features which are well shown in these sections are: The developing deciduous teeth, the anterior palatine canal, Jacobson's organ, the tubercle of the septum with the corresponding thickening of the cartilage, the puncta lacrimalis, the canaliculi, the lacrimal sac, the nasal duct, the

openings of the anterior ethmoidal cells, the hiatus semilunaris, the ostium maxillare, the infraorbital and supraorbital nerves and the arrangement of the Meibomian glands.

PRESENTATION OF INSTRUMENTS AND SPECIMENS

Dr. D. Bryson Delavan exhibited in connection with his paper a wax model of a very large retro-nasal fibroma, the first naso-pharyngeal tumor ever removed in the United States by the Voltolini method of electrolysis and the galvano-cautery snare. The operator was the late Dr. Rufus P. Lincoln, a former President of this Association. The above specimen is deposited in the Army Medical Museum.

Specimens of naso-pharyngeal tumors were also presented by Dr. J. Price-Brown (sarcoma) and Dr. W. Peyre Porcher (fibroma).

Dr. Emil Mayer presented a large cheek retractor for use in operations on the antrum and during subsequent irrigation; also a model of the latest O'Dwyer adult intubation tube, together with the introducer.

Dr. Robert C. Myles presented an injected wet specimen showing the course of the naso-palatine artery as related to operations on the sinuses; also showing the internal carotid artery at the upper internal border of the sphenoidal sinus. He also presented specimens of gouges, small chisels, protected trephines and hand and power drills.

Dr. H. Luc presented various sizes of the intra-nasal forceps described in his paper.

Dr. J. E. Rhodes presented for Dr. F. Fletcher Ingals, a model of the forceps described in the latter's paper.

Dr. H. L. Swain presented a photograph of the skull of a Flat-head Indian, showing copper tubes inserted into the mouth and pharynx. He stated that this peculiar specimen had come to light in the course of the investigations referred to in his paper on the shape of the palatal arch. This specimen might be said to illustrate the ancient way of performing intubation. Judged by the study of the skull, the tubes were inserted, as can be seen in the photograph, way back into the pharynx and seem to have been placed there before death. Whether it was a case of lockjaw, tubes being inserted in order to feed the patient, or whether the

nose was occluded and the tubes were used to allow of air while the spasm was shutting the mouth, does not of course appear. In any case, it is safe to assume that this was an attempt on some one's part to ease the agony of some poor sufferer, and it is to be hoped that he was at least rewarded for his cleverness by some relief to the patient. It demonstrated anew that much in medicine, as in other lines of activity and research, was in reality a re-discovery, for this was a crude attempt to intubate and presupposed some thought and some anatomical knowledge, as well as ability to put to new uses homely and common things. Thus the old Indian



medicine man left for a moment his silly, useless incantations and endeavored to give his patient what he needed most, air or food, or both. Two tubes, one on either side, probably indicated some reasonable attempt to carry out some other idea, for one would certainly supply a fair amount of air.

The skull is probably several hundred years old, and the copper tube is made by twisting a narrow, flat piece of the metal spirally into tubular form. Numerous such tubes (but smaller) were found by Dr. Swain in his investigations and were worn in common use, suspended by a string, which was sewed into the flesh of the ears, as an ornament.

AMERICAN LARYNGOLOGICAL ASSOCIATION.

BUSINESS MEETING.

THE Twenty-fifth Annual Congress of the American Laryngological Association (held in connection with the Sixth Triennial Congress of American Physicians and Surgeons) met at the Cosmos Club, Washington, D. C., Tuesday, May 12th, 1903. The Association was called to order by the President, Dr. J. H. Bryan, at 10 A.M., who introduced to the meeting Dr. H. Luc, of Paris, Corresponding Fellow. During the sessions of the Congress, the following Active Fellows were registered:

H. S. BIRKETT, Montreal, Canada.
A. A. BLISS, Philadelphia, Pa.
J. PRICE-BROWN, Toronto, Canada.
J. H. BRYAN, Washington, D. C.
W. F. CHAPPELL, New York City.
J. PAYSON CLARK, Boston, Mass.
D. BRYSON DELAVAN, New York City.
J. W. FARLOW, Boston, Mass.
W. J. FREEMAN, Philadelphia, Pa.
W. C. GLASGOW, St. Louis, Mo.
J. W. GLEITSMANN, New York City.
T. MELVILLE HARDIE, Chicago, Ill.
T. J. HARRIS, New York City.
J. H. HARTMAN, Baltimore, Md.
THOMAS HUBBARD, Toledo, Ohio.
FRANCK HYATT, Washington, D. C.
SAMUEL JOHNSTON, Baltimore, Md.
GORDON KING, New Orleans, La.
F. I. KNIGHT, Boston, Mass.
D. BRADEN KYLE, Philadelphia, Pa.
G. A. LELAND, Boston, Mass.
WILLIAM LINCOLN, Cleveland, Ohio.
J. E. LOGAN, Kansas City, Mo.
J. H. LOWMAN, Cleveland, Ohio.

A. W. MacCoy, Philadelphia, Pa.
J. N. Mackenzie, Baltimore, Md.
G. H. Makuen, Philadelphia, Pa.
Emil Mayer, New York City.
J. F. McKernon, New York City.
T. Morris Murray, Washington, D. C.
R. C. Myles, New York City.
J. E. Newcomb, New York City.
F. R. Packard, Philadelphia, Pa.
W. P. Porcher, Charleston, S. C.
W. S. Renner, Buffalo, N. Y.
J. E. Rhodes, Chicago, Ill.
C. C. Rice, New York City.
C. W. Richardson, Washington, D. C.
J. O. Roe, Rochester, N. Y.
E. L. Shurly, Detroit, Mich.
W. K. Simpson, New York City.
H. L. Swain, New Haven, Conn.
C. F. Theisen, Albany, N. Y.
A. W. Watson, Philadelphia, Pa.
Jonathan Wright, Brooklyn, N. Y.

The first session was occupied in the reading of the President's Address and of the papers assigned for the day. The Association then went into executive session. The first order of business was the election of new members. The following were the nominees:

For Corresponding Fellowship:

Dr. P. McBride, Edinburgh, proposed by Drs. Kyle and Swain.

Dr. A. Onodi, Buda-Pesth, proposed by Drs. Wagner and Farlow.

Dr. Herbert Tilley, London, proposed by Drs. Bryan and Leland.

For Active Fellowship:

Dr. Thomas J. Harris, New York City, proposed by Drs. Simpson and Swain. Title of thesis, "Some Remarks on the Etiology of Hyperplasia of the Pharyngeal Tonsil in the Light of Recent Investigations."

Dr. William Lincoln, Cleveland, O., proposed by Drs. Low-

man and Hubbard. Title of thesis, "Operations for the Relief of Malignant Growths in the Larynx."

Dr. FRANCIS R. PACKARD, Philadelphia, Pa., proposed by Drs. Kyle and Bryan. Title of thesis, "The Etiology of Nasal Polypi with special reference to their Association with other Pathological Conditions."

Dr. W. SCOTT RENNER, Buffalo, N. Y., proposed by Drs. Gleitsmann and Hinkel. Title of thesis, "Tertiary Syphilis of the Nose and Pharynx."

Dr. CLEMENT F. THEISEN, Albany, N. Y., proposed by Drs. Mayer and Mackenzie. Title of thesis, "Hypertrophic Tuberculosis of the Larynx."

Drs. Watson and King were appointed as tellers. The election resulted in the unanimous choice of all the nominees.

Drs. Rhodes and Freeman were appointed a committee to audit the Treasurer's books and annual report.

The election of a Committee of Five to nominate officers for the following year resulted as follows: Dr. Birkett, Chairman; Drs. Clark, Gleitsmann, Mackenzie and Shurly.

Following adjournment the Association was entertained at lunch at the residence of the President, Dr. Bryan.

At the executive session preceding the reading of papers on the second day, Wednesday, May 13th, the following reports were read and accepted:

Report of the Secretary.

Following precedent the Secretary herewith presents a copy of the Transactions of the Congress of 1902. The volumes were distributed to the Fellows in December of that year. Owing to the absence of tabulated matter the expense of publication was considerably less than that of last year.

During the past year three deaths have occurred, that of Dr. Lennox Browne, Corresponding Fellow, and those of Drs. S. Hartwell Chapman and Edward T. Dickerman, Active Fellows. In case of both the latter, messages of condolence were sent by the Secretary on behalf of the Association.

It was the intention of the Council at its meeting in December, 1903, to nominate candidates for all existing vacancies in the

list of Active Fellows. Owing to the two deaths referred to, there are still two vacancies under the present limit. Including the gentlemen elected at the present Congress, there are now seventy-three Active Fellows and twenty-nine Corresponding Fellows, there being one vacancy in the latter list.

During the year, two meetings of the Council have been held and the minutes will now be read.

Respectfully submitted,

JAMES E. NEWCOMB, *Secretary.*

Annual Report of the Treasurer, 1902-1903.

Receipts.

Balance from old account	$233.29
Arrears of dues	40.00
Dues for current year	300.00
Assessment of 1902	325.00
Sale of Transactions	37.50
Subscriptions annual dinner, 1902	175.00
Loan from Treasurer	160.00
Total	$1,270.79

Expenditures.

Repayment of Loan	$400.00
Annual dinner, 1902	175.00
Paid Sec. American Committee XIV International Congress	25.00
Stenographer's bill, 1902	97.50
Transactions for 1902, Rooney & Otten Co.	413.06
Programmes, 1903	22.75
Postage on programmes	3.50
Expenses of Secretary and Treasurer for year	60.53
Total	$1,197.34
Balance to new account	73.45
Total	$1,270.79

Statement of Assets and Liabilities.

Assets—Cash in bank	$68.45	
Cash in office	5.00	
Total cash assets	$73.45	
Postage in office, value	5.82	
Arrears dues and assessments	90.00	$169.27
Liabilities—Loan due Treasurer		160.00
Making net assets of the Association May 13th, 1903		$9.27

Respectfully submitted,
JAMES E. NEWCOMB, *Treasurer.*

Audited and found correct.
Signed
J. E. RHODES,
W. J. FREEMAN,
Auditing Committee.

Report of the Librarian.

The Librarian has to report that since the last meeting 23 unbound volumes and 1 bound volume have been added to the library.

Respectfully submitted,
J. H. BRYAN,
Librarian.

The Committee on Nominations presented the following report:

For *President*—Dr. J. H. Hartman, Baltimore.

For *First Vice-President*—Dr. J. H. Lowman, Cleveland.

For *Second Vice-President*—Dr. W. P. Porcher, Charleston.

For *Secretary and Treasurer*—Dr. J. E. Newcomb, New York City.

For *Librarian*—Dr. J. H. Bryan, Washington, D. C.

For *Member of the Council*—Dr. Jonathan Wright, Brooklyn.

The next Congress shall be held at Atlantic City, N. J., the date to be determined by the Council.

The following Amendment to the Constitution was formally offered by Dr. Swain (to be voted on at the next Congress):

Section 2, Article III, of the Constitution shall read: "The Fellows (Active) shall not exceed one hundred (100) in number."

The following Amendment to the By-Laws was passed:

Section 1, Article VII, of the By-Laws shall read: "Every Fellow shall pay in advance the sum of ten dollars annually."

Voted to levy an extra assessment of five dollars for the year 1903 in order to repay monies borrowed and to provide a working capital for the Association.

At the close of the executive session the reading of papers and discussions was resumed. Adjournment was taken at one o'clock. The Association was then entertained at lunch at the residence of Dr. C. W. Richardson, whose guests included the members of the American Climatological and Otological Associations.

In the evening at seven o'clock, the annual dinner of the Association was served at the New Willard Hotel. Thirty-seven members were in attendance.

At the executive session following the conclusion of the reading of papers and of discussions on the third day, Thursday, May 14th, it was announced on behalf of the Council that the Association would publish its own Transactions for the year, 1903.

A vote of thanks was passed to the Governors and Members of the Cosmos Club for courtesies extended during the sessions of the present Congress; also a similar vote to the Washington Fellows of the Association for their hospitality.

The Report of the Nominating Committee was then re-read and the Secretary instructed to cast an affirmative ballot for the nominees named. This was done and they were declared elected.

The President-elect, Dr. Hartman, was then introduced by the retiring President, Dr. Bryan, and expressed thanks for the honor conferred upon him. There being no further business, the Congress adjourned.

JAMES E. NEWCOMB,
Secretary.

Following adjournment the Fellows were entertained at lunch at the Metropolitan Club by Drs. Murray and Hyatt.

OBITUARY.

SHERMAN HARTWELL CHAPMAN, M.D.

In the death of Sherman Hartwell Chapman, which occurred at his residence in New Haven, April 15th, 1903, the Association has lost a member who, though not actively participating in its work of recent years was closely identified with its earlier history.

Dr. Chapman was the son of Timothy Pitkin and Rachel Thompson (Hartwell) Chapman and was born in New Haven Feb. 22nd, 1846. At an early age he removed to New York, where he prepared for college at the Columbia Grammar School. He then entered the Academic Department of Yale University, from which he graduated with the degree of A.B. in 1866. Succeeding years were spent in post-graduate study at the Sheffield Scientific School of the University, and in 1869 he received from Yale the degree of A.M. In this same year, he also received the degree of M.D. from the New York College of Physicians and Surgeons (now Columbia). Following his medical graduation, he spent a few months in the New York Hospital as interne and then went abroad, where he studied at Vienna, Berlin and the Soho Square Hospital, London. He then returned to New Haven and entered on the practice of his profession.

Dr. Chapman's society memberships included the New Haven City and County and Connecticut State Societies, the American Medical and American Climatological Associations and the American Laryngological, Otological and Rhinological Society. He was an honorary member of the Laryngological Societies of Paris and Berlin. He was elected to our own Association in 1882, the title of his candidate's thesis being, "The Use of Cold in Diseases of the Upper Air Passages."

In 1879 he was appointed Clinical Lecturer on Diseases of the Nose and Throat in the Medical Department of Yale and held this position for six years, resigning in 1885. At one time he was connected with the Connecticut State Hospital at New Haven and with the New Haven Dispensary.

Dr. Chapman was twice married. His first wife was Maria Louise Eustis, daughter of the Rev. Dr. Wm. T. Eustis, of New

Haven. She died in April, 1901. In June, 1902, he married Miss Helen Baldwin, of Danbury, Conn., who survives him. He left no children, his only child, Miss Rachel, dying in 1888 at the age of seventeen years.

His final illness lasted about ten days and began with an attack of the grippe. Heart complications quickly developed and finally cerebral hemorrhage, which was the immediate cause of death. He was buried at Stockbridge, Mass., beside his first wife and daughter. His medical library, containing volumes of considerable literary and historical value, was bequeathed to Yale University.

From the commencement of his practice Dr. Chapman devoted special attention to diseases of the throat and chest and acquired a reputation by no means limited to his city or State. During his connection with our own Association he presented papers on the following topics: "Herpes Laryngis" (1884), "Myalgia of the Pharynx and Larynx" (1887), "Some Pathological Conditions of the Upper Air Passages coincident with Attacks of La Grippe" (1892), and "Notes on the Treatment of Diphtheria" (1896). Of recent years he had taken no active part in the work of the Association. He was a man of marked ability, and of versatile temperament. Music and the fine arts found in him an appreciative admirer, and it is a matter of great sadness to his colleagues that he was called to lay down his life work when the future years promised him so much of enjoyment and well-earned repose. J. E. N.

EDWARD THAYER DICKERMAN, M.D.

Dr. Edward Thayer Dickerman, one of the most popular members of the younger medical profession of Chicago, died on Jan. 23, 1903, of an acute pneumonia following a severe attack of influenza after an illness of five days, aged 35 years. He was born in Springfield, Ill., Aug. 10, 1867. After graduating from the Springfield High School he entered upon his medical studies at the Northwestern University Medical School, Chicago Medical College, from which he was graduated in 1890. He then served a year as interne in the Mercy Hospital, Chicago, and to continue his studies in the specialty upon which he had decided, went to Vienna and there studied for two years at the University, acting

as assistant to one of the most distinguished ear and throat specialists at that institution.

On his return to the United States in 1893 he located in Chicago where for ten years he practiced with great and continually growing success. He was always a close student and kept himself fully abreast of the best thought and latest discoveries in the world of medicine and particularly in his own specialties. At the time of his death he was Professor of Laryngology in the Chicago Polyclinic, a position which he had held since 1898, and Associate Professor of Otology at the Rush Medical College. During his professional life he was a member of the staff of the Chicago Polyclinic and Hospital, of the Central Free Dispensary and was attending ear surgeon at the Illinois Charitable Eye and Ear Infirmary. He was a member of the American Medical Association, Chicago Laryngological Society, American Pathological Association, Illinois State Medical Society, Chicago Medical Society and the Physicians' Club and a Fellow of the Chicago Academy of Medicine.

His chief contributions to literature were as follows:

"Nasal Papilloma or Papillary Fibroma," *American Ophthalmological and Otological Journal,* St. Louis, 1896.

"Hysterical Aphonia," *Journal of the American Medical Association,* 1899.

"Papillomata of the Larynx in Children," *Journal of the American Medical Association,* Oct. 27, 1900.

"Hypertrophy of the Pharyngeal Tonsil," *Illinois Medical Journal,* 1901.

"Laryngologic Aspects of Pregnancy," *Journal of the American Medical Association,* Jan. 26, 1901.

"Anatomy of the Naso-Frontal Passage from a Clinical Standpoint," Candidate's Thesis, American Laryngological Association, 1901.

On January 17, 1903, Dr. Dickerman went to Springfield, Ill., to perform an operation. On the next day he had a chill and symptoms of pneumonia. The disease ran a rapid course and despite the greatest and most affectionate care, he died five days later. The funeral at Springfield, January 25, was attended by a number of Chicago physicians, and floral tributes were sent by the Faculties of Rush Medical College and the Chicago Polyclinic. At the meeting of the Physicians' Club, January 26, Dr. Dicker-

man's death was formally announced and resolutions of regret and sympathy were adopted.

At a meeting of the Gamma Chapter, Phi Rho Sigma Fraternity, the following resolutions were adopted:

"Whereas, Almighty God in His Providence has seen fit to remove our beloved brother, Doctor Edward Thayer Dickerman; and,

"Whereas, Brother Dickerman was for many years a faithful and devoted brother, always looking to the interests of his Fraternity and ever willing to help his Chapter; therefore, be it

"Resolved, That the Illinois Gamma Chapter of the Phi Rho Sigma Fraternity feels the deep loss to the Chapter and mourns with the family in their sad bereavement; and, be it further

"Resolved, That a copy of these resolutions be sent to the bereaved family, that they be published in the *Journal,* and that they be spread upon the minutes of this Chapter."

Our deceased colleague was a man of sterling qualities. Though personally known to his Eastern associates for only a short time, he had impressed upon them the force of his manly character, the loftiness of his ideals and the high quality of his professional abilities. Rarely if ever has the Association lost through death a member of such promise. To all those who were intimately connected with him and above all to the sorrowing members of his own family, this Association tenders an assurance of its deepest sympathy. M. R. B.

LIST OF MEMBERS.

ACTIVE FELLOWS.

1904.

1880. BEAN, C. E., Germania Life Bldg., St. Paul, Minn.
1893. BIRKETT, HERBERT S., 123 Stanley St., Montreal.
1893. BLISS, ARTHUR AMES, 117 South 20th St., Philadelphia, Pa.
1878. BOSWORTH, FRANCKE H., 41 Park Ave., New York.
1901. BROWN, J. PRICE, 37 Carlton St., Toronto, Can.
1892. BROWN, M. R., 34 Washington St., Chicago, Ill.
1891. BRYAN, J. H., 818 17th St., Washington, D. C.
1889. CASSELBERRY, WILLIAM E., 34 Washington St., Chicago, Ill.
1896. CHAPPELL, W. F., 7 East 55th St., New York.
1897. CLARK, J. PAYSON, 409 Marlborough St., Boston, Mass.
1902. COAKLEY, C. G., 49 West 58th St., New York.
1899. COBB, FREDERIC C., 11 Marlborough St., Boston, Mass.
1878. COHEN, J. SOLIS-, 1824 Chestnut St., Philadelphia, Pa.
1893. COOLIDGE, A., JR., 613 Beacon St., Boston, Mass.
1882. DEBLOIS, THOMAS AMORY, 48 Gloucester St., Boston, Mass.
1881. DELAVAN, D. BRYSON, 1 East 33d St., New York.
1892. FARLOW, J. W., 234 Clarendon St., Boston, Mass.
1901. FREEMAN, W. J., 1832 Spruce St., Philadelphia, Pa.
1879. FRENCH, THOMAS R., 150 Joralemon St., Brooklyn, N. Y.
1897. FROTHINGHAM, RICHARD, 7 West 39th St., New York.
1878. GLASGOW, WM. C., 2847 Washington Ave., St. Louis, Mo.
1880. GLEITSMANN, J. W., 46 East 25th St., New York.
1898. GOODALE, J. L., 307 Beacon St., Boston, Mass.
1896. HARDIE, T. MELVILLE, 34 Washington St., Chicago, Ill.
1903. HARRIS, T. J., 117 East 40th St., New York.
1878. HARTMAN, J. H., 5 West Franklin St., Baltimore, Md.
1888. HINKEL, F. WHITEHILL, 412 Franklin St., Buffalo, N. Y.
1881. HITCHCOCK, URBAN G., 51 West 29th St., New York.
1893. HOPE, GEORGE B., 133 West 72d St., New York.

1895. HOPKINS, F. E., Springfield, Mass.
1895. HUBBARD, THOS., 205 Ontario St., Toledo, O.
1901. HYATT, FRANCK, 1022 14th St., N. W., Washington, D. C.
1878. INGALS, E. FLETCHER, 36 Washington St., Chicago, Ill.
1882. IVES, FRANK L., 117 East 30th St., New York.
1878. JOHNSTON, SAMUEL, 204 West Monument St., Baltimore, Md.
1901. KING, GORDON, 624 Gravier St., New Orleans, La.
1885. KNIGHT, CHARLES H., 147 West 57th St., New York.
1878. KNIGHT, FREDERICK I., 195 Beacon St., Boston, Mass.
1898. KYLE, D. BRADEN, 1517 Walnut St., Philadelphia, Pa.
1880. LANGMAID, SAMUEL W., 71 Newbury St., Boston, Mass.
1878. LEFFERTS, GEORGE MOREWOOD, 212 Madison Ave., N. Y.
1894. LELAND, GEORGE A., 669 Boylston St., Boston, Mass.
1903. LINCOLN, WILLIAM, Lennox Bldg., Euclid Ave. and Erie St., Cleveland, O.
1897. LOGAN, JAMES E., 1208 Wyandotte St., Kansas City, Mo.
1888. LOWMAN, JOHN H., 441 Prospect St., Cleveland, O.
1886. MACCOY, ALEXANDER W., 1338 Walnut St., Philadelphia, Pa.
1883. MACKENZIE, JOHN N., 605 Washington Place, Baltimore, Md.
1898. MAKUEN, G. HUDSON, 252 South 16th St., Philadelphia, Pa.
1896. MAYER, EMIL, 25 East 77th St., New York.
1899. MCKERNON, J. F., 62 West 52d St., New York.
1892. MURRAY, T. MORRIS, 17th and H Sts., Washington, D. C.
1901. MYLES, R. C., 46 West 38th St., New York.
1893. NEWCOMB, JAMES E., 118 West 69th St., New York.
1903. PACKARD, FRANCIS R., 1831 Chestnut St., Philadelphia, Pa.
1892. PORCHER, W. PEYRE, 85 Broad St., Charleston, S. C.
1878. PORTER, WILLIAM, 3886 Washington Ave., St. Louis, Mo.
1903. RENNER, W. SCOTT, 361 Pearl St., Buffalo, N. Y.
1897. RHODES, J. EDWIN, 100 State St., Chicago, Ill.
1884. RICE, CLARENCE C., 123 East 19th St., New York.
1902. RICHARDSON, C. W., 1317 Connecticut Ave., Washington, D. C.
1893. ROALDES, A. W. DE, 624 Gravier St., New Orleans, La.
1879. ROE, JOHN O., 28 Clinton Ave. North, Rochester, N. Y.

1879. Seiler, Carl, 203 Jefferson Ave., Scranton, Pa.
1878. Shurly, E. L., 32 Adams Ave. W., Detroit, Mich.
1892. Simpson, W. K., 952 Lexington Ave., New York.
1889. Swain, H. L., 232 York St., New Haven, Conn.
1903. Theisen, Clement F., 172 Washington Ave., Albany, N. Y.
1892. Thrasher, A. B., The Groton, 7th and Race Sts., Cincinnati, O.
1888. Van der Poel, S. Oakley, 47 E. 25th St., New York.
1892. Wagner, Henry L., 522 Sutter St., San Francisco, Cal.
1892. Watson, A. W., 126 South 18th St., Philadelphia, Pa.
1896. Ward, M. R., 611 Penn Ave., Pittsburgh, Pa.
1890. Wright, Jonathan, 73 Remsen St., Brooklyn ,N. Y.

HONORARY FELLOW.

1880. Garcia, Manuel, 1 Bentinck St., Manchester Square, London, England.

CORRESPONDING FELLOWS.

1880. Bruns, Paul, Tübingen, Würtemberg, Germany.
1896. Chiari, Ottokar, Bellariastrasse 12, Vienna, Austria.
1901. Collier, Mayo, 133 Harley St. W., Cavendish Square, London, England.
1890. De La Sota y Lastra, R., 7 Calle de Torqueros, Seville, Spain.
1893. Desvernine, C. M., Cuba 52, Havana, Cuba.
1901. Grant, Dundas, 18 Cavendish Square W., London, England.
1902. Heymann, Paul, 60 Lützowstrasse W., Berlin, Germany.
1894. Holden, E., 13 Central Ave., Newark, N. J.
1892. Krause, H., Neustädt, Kirch-Strasse 13, Berlin, Germany.
1881. Labus, Carlo, Piazza Castello 28, Milan, Italy.
1902. Lermoyez, Marcel, 20 Rue de la Boetie, Paris, France.
1897. Luc, H., 54 Rue de Varenne, Paris, France.
1903. McBride, P., 16 Chester St., Edinburgh, Scotland.
1896. Macdonald, Greville, 85 Harley St., London W., England.

1894. MACINTYRE, JOHN, 179 Bath St., Glasgow, Scotland.
1892. MASSEI, F., 4 Piazza Municipio, Naples, Italy.
1887. MOURE, E. J., 25 Cour du Jardin-Public, Bordeaux, France.
1896. MYGIND, HOLGER, 31 Havnegade, Copenhagen, Denmark.
1901. NATIER, MARCEL, 12 Rue de Caumartin, Paris, France.
1903. ONODI, A., o' Uctza 12, Buda-Pesth, Hungaria.
1894. SAJOUS, C. E., 2043 Walnut St., Philadelphia, Pa.
1901. SCHMIDT, MORITZ, Sachsenhausen, Schaumainkai, 15, Frankfort, Germany.
1896. SCHMIEGELOW, ERNEST, 18 Nörregade, Copenhagen, Denmark.
1881. SCHROETTER, LEOPOLD V., Schwartzenburg-Strasse 8, Vienna, Austria.
1881. SEMON, FELIX, 39 Wimpole St., Cavendish Square, London, England.
1902. THOMSON, ST. CLAIR, 28 Queen Anne St., Cavendish Square, London, England.
1903. TILLEY, HERBERT, 89 Harley St. W., Cavendish Square, London, England.
1901. WINGRAVE, WYATT, 11 Devonshire St., Portland Place, London, England.
1894. WOLFENDEN, R. NORRIS, Rougemont, Seaford, Sussex, England.

PAST MEMBERS.

Honorary Fellow.

*1881. Sir Morell Mackenzie, London, England.

Corresponding Fellows.

*1892. Lennox Browne, London, England.
*1887. A. Gougenheim, Paris, France.
*1880. Wilhelm Meyer, Copenhagen, Denmark.
*1881. Pugin Thorton, London, England.
*1881. R. Voltolini, Breslau, Germany.
*1880. W. McNeil Whistler, London, England.

Active Fellows.

*1880. Harrison Allen, Philadelphia, Pa.
*1878. Morris J. Asch, New York.
1895. J. E. Boylan, Cincinnati, O.
*1883. C. W. Chamberlain, Hartford, Conn.
*1882. S. Hartwell Chapman, New Haven, Conn.
1884. S. Solis-Cohen, Philadelphia, Pa.
1880. E. W. Cushing, Boston, Mass.
1878. Ephraim Cutter, Boston, Mass.
*1880. W. H. Daly, Pittsburgh, Pa.
*1878. F. H. Davis, Chicago, Ill.
*1901. E. T. Dickerman, Chicago, Ill.
*1878. Frank Donaldson, Baltimore, Md.
1886. Frank Donaldson, Jr., Baltimore, Md.
*1879. J. H. Douglas, New York.
*1879. W. F. Duncan, New York.
*1878. Louis Elsberg, New York.
†1879. Edgar Holden, Newark, N. J.
*1882. Franklin H. Hooper, Boston, Mass.
*1878. Hosmer A. Johnson, Chicago, Ill.
*1879. Woolsey Johnston, New York.

* Deceased. † Corresponding Fellow.

*1880. William C. Jarvis, New York, N. Y.
1879. R. H. Kealhofer, St. Louis, Mo.
*1878. Rufus P. Lincoln, New York, N. Y.
1881. G. W. Major, Montreal, Canada.
1879. Charles McBurney, New York, N. Y.
1885. H. Clinton McSherry, Baltimore, Md.
*1881. E. C. Morgan, Washington, D. C.
*1886. J. C. Mulhall, St. Louis, Mo.
*1881. H. Mynter, Buffalo, N. Y.
*1895. J. E. H. Nichols, New York.
1879. H. K. C. Oliver, Boston, Mass.
1894. William H. Park, New York, N. Y.
*1880. D. N. Rankin, Allegheny, Pa.
1881. J. M. Robertson, Detroit, Mich.
1878. Beverly Robinson, New York.
*1878. T. F. Rumbold, St. Louis, Mo.
†1880. Charles E. Sajous, Paris, France.
*1893. Charles M. Shields, Richmond, Va.
1879. Andrew H. Smith, New York.
1879. Bernhardt Tauber, Cincinnati, O.
*1899. Max Thorner, Cincinnati, O.
1878. Clinton Wagner, New York, N. Y.
1879. G. Whitefield Ward, New York, N. Y.
*1886. Benjamin F. Westbrook, Brooklyn, N. Y.
1896. Greene V. Woollen, Indianapolis, Ind.

* Deceased. † Corresponding Fellow.

PAST OFFICERS.

Presidents.

1879. Louis Elsberg.
1880. J. Solis-Cohen.
1881. F. I. Knight.
1882. G. M. Lefferts.
1883. F. H. Bosworth.
1884. E. L. Shurly.
1885. Harrison Allen.
1886. E. Fletcher Ingals.
1887. R. P. Lincoln.
1888. E. C. Morgan.
1889. J. N. Mackenzie.
1890. W. C. Glasgow.
1891. S. W. Langmaid.
1892. M. J. Asch.
1893. D. B. Delavan.
1894. J. O. Roe.
1895. W. H. Daly.
1896. C. H. Knight.
1897. T. R. French.
1898. W. E. Casselberry.
1899. Samuel Johnston
1901. H. L. Swain.
1901. J. W. Farlow.
1902. J. H. Bryan.

Vice-Presidents.

1879. F. H. Davis.
1880. W. C. Glasgow, J. O. Roe.
1881. E. L. Shurly, W. Porter.
1882. C. Seiler, E. F. Ingals.
1883. S. W. Langmaid, S. Johnston.
1884. J. H. Hartman, W. H. Daly.
1885. H. A. Johnson, G. W. Major.
1886. E. C. Morgan, J. N. Mackenzie.
1887. J. N. Mackenzie, S. W. Langmaid.
1888. W. C. Glasgow, C. E. Sajous.
1889. E. Holden, C. E. Bean.
1890. J. O. Roe, J. H. Hartman.
1891. M. J. Asch, S. Johnston.
1892. S. Johnston, J. C. Mulhall.
1893. J. C. Mulhall, W. E. Casselberry.
1894. C. C. Rice, S. H. Chapman.
1895. J. Wright, A. W. de Roaldes.
1896. T. M. Murray, D. N. Rankin.
1897. A. W. MacCoy, H. S. Birkett

1898. J. W. Farlow, F. W. Hinkel.
1899. T. A. De Blois, M. R. Brown.
1900. H. L. Wagner, A. A. Bliss.
1901. J. W. Gleitsmann, D. Braden Kyle.
1902. G. A. Leland, T. Melville Hardie.

Secretaries and Treasurers.

1879. G. M. Lefferts.
1882. D. B. Delavan.
1889. C. H. Knight.
1895. H. L. Swain.
1900. J. E. Newcomb.

Librarians.

1879. F. H. Bosworth.
1883. T. R. French.
1893. J. H. Bryan.

APR 8 - 1904
APR 15 1904

17 1904

MAY 28 1904

Made in the USA
Coppell, TX
10 February 2023

ULAN Press

This book was originally published prior to 1923, and represents a reproduction of an important historical work, maintaining the same format as the original work. While some publishers have opted to apply OCR (Optical Character Recognition) technology to the process, we believe this leads to sub-optimal results (such as typographical errors, strange characters and confusing formatting) and does not adequately preserve the historical character of the original artifact. We believe this work is culturally important in its original archival form.

While we strive to adequately clean and digitally enhance the original work, there are occasionally instances where imperfections such as blurred or missing pages, poor pictures or errant marks may have been introduced due to either the quality of the original work or the scanning process itself. Despite these occasional imperfections, we have brought it back into print as part of our ongoing global book preservation commitment, providing customers with access to the best possible historical reprints.

We appreciate your understanding of these occasional imperfections, and sincerely hope you enjoy seeing the book in a format as close as possible to that intended by the original publisher.