

*Med
A*

TRANSACTIONS

OF THE

Twenty-seventh Annual Meeting

OF THE

AMERICAN LARYNGOLOGICAL ASSOCIATION

HELD AT

ATLANTIC CITY, N. J.

*370686
28.8.39*

June 1st, 2nd and 3rd, 1905

NEW YORK
PUBLISHED BY THE ASSOCIATION
1905

RF

1

A5

v.27

ROONEY & OTTEN PRINTING COMPANY
First Avenue and 31st Street
New York

PRESIDENTS OF THE ASSOCIATION.

(DATE OF ELECTION.)

- 1879. LOUIS ELSBERG, M.D.
- 1880. J. SOLIS-COHEN, M.D.
- 1881. FREDERICK I. KNIGHT, M.D.
- 1882. GEORGE M. LEFFERTS, M.D.
- 1883. FRANCKE H. BOSWORTH, M.D.
- 1884. ERNEST L. SHURLY, M.D.
- 1885. HARRISON ALLEN, M.D.
- 1886. E. FLETCHER INGALS, M.D.
- 1887. RUFUS P. LINCOLN, M.D.
- 1888. E. CARROLL MORGAN, M.D.
- 1889. JOHN N. MACKENZIE, M.D.
- 1890. WILLIAM C. GLASGOW, M.D.
- 1891. SAMUEL W. LANGMAID, M.D.
- 1892. MORRIS J. ASCH, M.D.
- 1893. D. BRYSON DELAVAN, M.D.
- 1894. JOHN O. ROE, M.D.
- 1895. WILLIAM H. DALY, M.D.
- 1896. CHARLES H. KNIGHT, M.D.
- 1897. THOMAS R. FRENCH, M.D.
- 1898. WILLIAM E. CASSELBERRY, M.D.
- 1899. SAMUEL JOHNSTON, M.D.
- 1900. HENRY L. SWAIN, M.D.
- 1901. JOHN W. FARLOW, M.D.
- 1902. JOSEPH H. BRYAN, M. D.
- 1903. JACOB H. HARTMAN, M.D.
- 1904. CLARENCE C. RICE, M.D.

OFFICERS.

(ELECTED JUNE 4TH, 1904.)

PRESIDENT.

CLARENCE C. RICE, M.D., NEW YORK CITY.

1st VICE-PRESIDENT.

THOMAS HUBBARD, M.D., TOLEDO, OHIO.

2d VICE-PRESIDENT.

WALTER J. FREEMAN, M.D., PHILADELPHIA, PA.

SECRETARY AND TREASURER.

JAMES E. NEWCOMB, M.D., NEW YORK CITY.

LIBRARIAN.

JOSEPH H. BRYAN, M.D., WASHINGTON, D. C.

COUNCIL.

HENRY L. SWAIN, M.D., NEW HAVEN, CONN.

JOHN W. FARLOW, M.D., BOSTON, MASS.

D. BRYSON DELAVAN, M.D., NEW YORK CITY.

JACOB H. HARTMAN, M.D., BALTIMORE, MD.

TABLE OF CONTENTS.

	PAGE.
Address of the President, CLARENCE C. RICE, M.D.	I

Papers and Theses:

I. Angio-Neurotic Oedema Involving the Upper Respiratory Tract. (Candidate's Thesis.) THOMAS H. HALSTED, M.D.	7
II. Some Follies of the Vocalist. (Candidate's Thesis.) CHARLES P. GRAYSON, M.D.	25
III. Deflections of the Nasal Septum; a Critical Review of the Methods of Their Correction by the Window Resection, with a Report of 116 Operations. (Candidate's Thesis.) OTTO T. FREER, M.D.	29
IV. The Treatment of Chronic Laryngeal and Tracheal Stenosis. JOHN ROGERS, M.D., and D. BRYSON DELAVAN, M.D.	79
V. Complete Adhesion of the Vocal Bands with Laryngeal Stenosis following Diphtheria. D. BRADEN KYLE, M.D.	101
VI. Gangrene of the Tonsil. CHARLES W. RICHARDSON, M.D.	106
VII. Sequel of a Case of Epithelioma of the Larynx Shown to the Association Two Years Ago. WALTER F. CHAPPELL, M.D.	113
VIII. The Choice of Operation for the Relief of Chronic Empyema of the Frontal Sinus and the Anterior Ethmoid Cells. (Candidate's Thesis.) LEWIS A. COFFIN, M.D.	116
IX. My Personal Experience with Empyemata of the Frontal Sinus, with Deductions Therefrom. (Candidate's Thesis.) GEORGE L. RICHARDS, M.D.	125
X. Rest in the Treatment of Laryngeal and Pulmonary Tuberculosis. W. PEYRE PORCHER, M.D.	149
XI. The Relation Between Laryngeal and Pulmonary Tuberculosis. WALTER F. CHAPPELL, M.D.	153
XII. Further Report of a Case of Primary Lupus Vulgaris of the Oro- and Naso-Pharynx Treated by X-Rays. HERBERT S. BIRKETT, M.D.	170

	PAGE.
XIII. Intra-Nasal Drainage of the Frontal Sinus. E. FLETCHER INGALS, M.D.	173
XIV. Papilloma of the Larynx in Children. J. PAYSON CLARK, M.D.	185
XV. Two Cases of Foreign Body Impacted in the Oesophagus. GORDON KING, M.D.	200
XVI. A Case of Laryngeal Diphtheria in an Adult (necessitating intubation) Complicating Cerebro-Spinal Meningitis. WILLIAM K. SIMPSON, M.D.	205
XVII. Papilloma of the Naso-Pharynx Simulating Epithelioma. THOMAS J. HARRIS, M.D.	209
XVIII. Fibroma of the Larynx in a Child of Three Years, Necessi- tating Tracheotomy; Subsequent Laryngo-Fissure for Its Removal Followed by Prolonged Intubation. THOMAS J. HARRIS, M.D.	212
<i>Symposium on Sinus Disease.</i>	
XIX. A. What Symptoms in Diseases of the Nasal Sinuses Dem- and Radical Surgical Intervention?	
B. What Have Been the Comparative Results of Con- servative and Radical Methods of Treatment?	
The Maxillary Sinus { ROBERT C. MYLES, M.D.	214
{ GEORGE A. LELAND, M.D.	216
The Frontal Sinus { CORNELIUS G. COAKLEY, M.D.	222
{ WILLIAM E. CASSELBERRY, M.D.	227
The Ethmoidal Sinus { JOHN O. ROE, M.D.	231
{ JOHN W. FARLOW, M.D.	238
The Sphenoidal Sinus { JOSEPH W. GLEITSMANN, M.D.	241
{ T. PASSMORE BERENS, M.D.	244
General Discussion on Sinus Disease	249
XX. A Further Study of Hay Fever. Clinically, with the Em- ployment of Pollantin. ALEXANDER W. MACCOY, M.D.	262
XXI. The Lymphatic Drainage of the Faucial Tonsils. (Candi- date's Thesis.) GEORGE B. WOOD, M.D.	269
XXII. Partial Turbinectomy Followed by Acute Otitis, Mastoi- ditis, Sigmoid Sinus Thrombosis, with extension to In- ternal Jugular Vein. CHARLES H. KNIGHT, M.D., and JAMES F. MCKERNON, M.D.	282
XXIII. The Treatment of Acute Inflammation of the Nasal Ac- cessory Sinuses. THOMAS HUBBARD, M.D.	290

	PAGE.
XXIV. Deflection of the Nasal Septum in Children. ARTHUR AMES BLISS, M.D.	305
XXV. A Second Note on a Case of Sarcoma of the Nose. J. PRICE-BROWN, M.D.	322
XXVI. Tonsillotomy, the Basis for the Treatment of Tonsillar Af- fections. GEORGE B. HOPE, M.D.	332
XXVII. An Unusual Case of Oedema of the Glottis. EMIL MAYER, M.D.	340
Presentation of Instruments and Specimens	344
Business Meeting	346
List of Active Fellows, 1906	353
Honorary Fellow	355
Corresponding Fellows	355
Past Members	357
Past Officers	359

TRANSACTIONS OF THE TWENTY-SEVENTH
ANNUAL MEETING OF THE AMERICAN
LARYNGOLOGICAL ASSOCIATION.

HELD AT ATLANTIC CITY, N. J.

JUNE 1, 2, AND 3, 1905.

THE PRESIDENT'S ADDRESS.

BY CLARENCE C. RICE, M.D.

Fellows of the American Laryngological Association: Your Council deemed it wise to meet for a second time at this delightful resort by the sea. The second trial of an innovation is, after all, its crucial test. The novelty has somewhat disappeared, and we can calmly compare the advantages of the home city of the presiding officer with those of such neutral ground as Atlantic City, Niagara Falls, New London, etc., as a meeting-place for this Association. I pleaded at the Council meeting that since nearly all the former presidents had been given the rare pleasure of entertaining you in their own homes, I was loth to waive my right. I felt that in years to come it would be no small matter to be able to say, "My own house has harbored this group of celebrated physicians." But your Council decided—and most wisely, I believe—that an association of toilers such as this needed to be taken away from the turmoil of a great city to a restful environment quite as much as it needed the stimulation which comes from an interchange of scientific thought and discussion, and *here* both needs can be obtained; food for thought, but administered amid restful surroundings. And since we cannot welcome you to our own home, let us rather say that we are delighted, after a long year's work, to be together once more at this our Twenty-seventh Annual Meeting. I appreciate more keenly than I can easily

express to you the great honor you have bestowed upon me in allowing me to act as your President at this session.

In the few words of welcome which I am permitted to say to you at the opening of this, the Twenty-seventh Congress of the *oldest* Laryngological Association of the world, I wish I might be so fortunate as to strike the one true note to which this meeting could be most advantageously attuned. A composite photograph of a group of notable men, each individual of a remarkable type, would lose power and character by the blending, but if it were possible to take the inaugural addresses of the twenty-five great presidents who have preceded me, combine them and offer the result to you to-day, such an address would stir you beyond all your experience.

We are properly encouraged when we realize that we have in our membership not only the selected talent of all the great cities of the United States, but that we are receiving each year new blood and energy and fibre, the best material to be found in the country. The future well-being of our Association must depend largely upon the loyalty of its younger and newer members to it and their efforts for it. They must put their shoulders to the wheel, not in a few years, but at once, and they must contribute high scientific thought, in their papers and discussions, that the quality of our Transactions may be continued at the high standard of the years gone by. The Association expects and demands much from them.

Last year, after careful and long deliberation, we voted to increase our membership from seventy-five to one hundred. This Association has always been noted for its conservative thought and action, and this was a most important step. It is a new régime, however, which I believe we may all feel will be well safeguarded by your Council. Perhaps it is not out of place for me to say here that I have never sat in a deliberative body of any kind where the entire committee acted, in its recommendations, so absolutely for the interests of the Association which it represented as did your Council. Probably every individual present had some friend he would have been pleased to welcome here, but no such influence was exerted, and nothing but a unanimous recommendation availed to select the men whose names are presented to you for election at this session. I have never witnessed a more dignified proceeding.

I cannot refrain from speaking of the very valuable service which is being constantly rendered to our Association by our Secretary. The work of the presiding officer is nothing compared with *his* arduous labors: in fact, he really performs the work of the presiding officer without letting him know it. It is a pleasure to work with him, because he so thoroughly understands all our needs.

I am pleased to refer you for information regarding what was accomplished in the Garcia Memorial matter to the addresses of two of our members, that of Dr. John N. Mackenzie and of our Secretary, Dr. Newcomb, delivered at the Garcia Jubilee Meeting at the New York Academy of Medicine on March 17th. The Secretary informs me that a total of eight hundred pounds sterling was raised by the London Committee, which amount paid for the portrait and furnished a handsome testimonial for the celebrated old gentleman. I am sure America contributed her share of this amount.

Many of this Association attended the dinners given to Sir Felix Semon and to Dr. Osler, so that this winter has given us unusual opportunities of meeting one another.

We can most happily state that none of our members have been taken away by death during the past year, nor do we learn of any serious illness in our list of membership. We must all appreciate the great sacrifice which many of our Fellows, coming from a distance, must make in order to be with us. San Francisco, St. Paul and St. Louis come East; when shall we be ready to go to the Pacific?

We are told by our Secretary that this is to be the largest attendance we have ever had at any Annual Meeting—a very encouraging omen. The reason for this may be fairly attributed to the remarkable interest which our Fellows take in the Association, in the attractive scientific program and ensuing discussion, in the larger desire to meet each year in a social way, and, perhaps, in the fact that a meeting held at Atlantic City gives a larger measure of rest than one held in an inland town—whichever of these may be the larger influence, it matters little, so long as our attendance increases each year. It seems to us that the program this year is particularly attractive. The Symposium on Sinus Diseases was arranged by your Council because they felt that a full discussion of this subject was in much need at this time.

We are more than a quarter of a century old, and yet many of the founders are with us to-day, and are still most heartily interested in the welfare of the Association. A great effort was made to secure the presence of all the older presidents at this session. Not their appearance, nor the quality of their daily work proclaim them old. The term of their membership in the Association alone shows how long they have made our specialty a notable profession. They are young because they have filled their days and hours with self-sacrificing work. Dr. Conan Doyle, the physician and writer, in an address recently delivered in England, speaks most enthusiastically of the magnificent training which the medical man must receive if he would become a successful member of our profession. This training, which he considers more strenuous than that exacted by any other calling, necessarily separates the earnest worker from the laggard. It is, he says, a school for building up character, for strengthening the power of observation, for fitting the individual generally for the battle of life. He feels that the study of medicine demands more sterling qualities than the preparation for any other profession, and he remarks that if officers in the British army could be as well trained in their profession as doctors are in theirs, the army would be the terror of Europe.

Let us not believe that our own specialty is becoming, as the time goes on, more limited in its scope. Each year we reach certain goals that have been prominently before us. But this is not the end of our work, but is rather the preparation for greater achievement. Our specialty is holding a more surely dignified position each year, and our American Association commands the highest respect, not only in this country, but abroad.

This is the *American Laryngological Association*, and its name never can be changed, no matter how much its interest and attention must necessarily be absorbed by the study of nasal and aural disease. It cannot accomplish greater things by calling it by any different or longer name. It must, and will, contribute its share of all that can be discovered regarding the pathological conditions of not only the respiratory tract proper, but of all parts which have relationship to it. The work before us is limitless, for it requires the experience of a life's work not to call a disease by a name, and not to endeavor to control it by the methods of to-day, but to understand the peculiar tendencies of each individual case,

and to appreciate the subtle beginnings and the trend of pathological processes. In years to come the Fellows of our Association may perhaps learn by a sort of wireless telegraphy what now is kept hidden from our cruder methods of examination. It is the work of this Association to study and to understand the *qualities* of the mucous membrane, which are probably much more varied than we to-day suspect. Do we understand the inherent quality which in one case produces atrophy and in another enlargement of tissue? In our zeal to find quickly the best methods of controlling the many diseases of the respiratory tract, which are comparatively easy of diagnosis, we have not appreciated as fully as we should how large a work belongs to our own specialty. It is our special province to determine what conditions of the nasal passages and of the throat are most favorable for the entrance of the many varieties of bacteria, not only for those germs which we have long known find their entrance through these channels, but of disorders whose methods of attack are less thoroughly, or perhaps not at all, understood. Do not the bacilli of many diseases gain an entrance which might be hindered or stopped altogether if we understood better the method of entrance and all the pathological peculiarities of mucous membranes? Is there, for example, a condition of the nasal passages by reason of which the germ of cerebrospinal meningitis finds easy access into the organism? No Association has greater responsibility in fighting the ravages of tubercular infection than has ours. Who can better determine the subtle differences between a benign and a malignant growth, or discover the methods of prevention?

Some of our members have done pioneer work in tracing the relationship between tonsillar derangement and such disturbances as leucaemia, pernicious anemia, endocarditis, pleuritis, chorea, and many of the phases of tubercular infection. What constitute *all* the factors of immunity? When can we *surely* discover the cause and cure of hay fever and asthma? We have not fully appreciated how dignified a position our specialty commands among the various branches of medical research. The *well-being* of the entire respiratory surface, which it is our duty to safeguard, means in a large measure comfortable protection against the attacks of innumerable varieties of infection.

Our yearly program must consider all the important topics of the times; it must discuss all disputed subjects; it must inves-

tigate all unknown points of etiology and pathology. Perhaps it will be a wise provision to have your Council or a special committee empowered to arrange a schedule of work for the Annual Sessions, which will cover all the burning questions of the day, and to appoint commissions to investigate such vital subjects as the phases of tubercular infection, malignant growths, etiology of hay fever, etc. Why should not such committees report at later meetings that our Association may place itself on record and so keep fully abreast of progress in all scientific research? I ask you to consider this matter.

But I have spoken for too long a time. Did you know that six of the twenty-five great men who have bidden you welcome during the last quarter of a century have finished their work and left us? We should speak of these men without sadness or regret, but with thankfulness for their lives—thankfulness for what they have done for this Association and for us: the great Elsberg, our first President, who left for us such an example of scientific achievement that in spite of the great progress this Association has made since his departure, he always seems easily abreast of our strongest efforts; and Harrison Allen, the gentlemanly student, who accomplished so much, in so unobtrusive a manner that we had small idea of the greatness of his work until he had gone away and we had opportunity to examine; Morgan, of Washington, the hero, who, although fighting against the tremendous odds of a disease he knew must be quickly fatal, was still able to greet us with all cheerfulness. He said, "Few among you can appreciate my joy to-day at being spared to greet this Association in my native city;" and Asche, and Lincoln, and Daly, who, though overwhelmed by large professional responsibilities, were still able to contribute their best efforts to the work of this Association. Is not this an inheritance of which to be proud? But the high course which these pioneer presidents marked out for us is not easily followed. Some day we must erect a monument in memory of these great men.

We will, if you please, commence the regular program.

(Candidate's Thesis.)

ANGIO-NEUROTIC OEDEMA INVOLVING THE UPPER RESPIRATORY TRACT.

BY THOMAS H. HALSTED, M.D.

ANGIO-NEUROTIC OEDEMA, as defined by Collins,¹ is a "vasomotor neurosis or an angio-neurosis, characterized by the appearance of circumscribed swellings on various portions of the surface of the body and the mucous membranes, by preference the face, throat and extremities, without apparent cause or premonition, and non-inflammatory in character."

As it affects the skin the disease was first described by Quincke as "An Acute Circumscribed Oedema," and from his first description the disease was early called "Quincke's Disease." Shortly after Strübing² described it as it affected the throat, calling it an "Angio-Neurotic Oedema of the Throat," regarding it as a vasomotor neurosis, developing rapidly, without fever, after exposure to cold or some traumatism.

The disease is frequently described in books on Diseases of the Skin, under the heading of Urticaria. Crocker regards it simply as one of its varieties, giant urticaria. Stelwagon treats of it under a heading of its own, recognizing its similarity in many cases to urticaria, but in other cases says it is entirely, or sufficiently independent of it to warrant its description under its own title. Montgomery and Hyde say it should not be confused with erythema multiforme, erythema-nodosum or giant urticaria. Kaposi and Shoemaker refer to it as a distinct disease, but closely allied to giant urticaria, with which, however, it is not to be confounded.

Osler³ has been greatly interested in the disease, and in 1888 reported a case of angio-neurotic oedema, investigating particularly the question of heredity. Since then he has made three notable communications,⁴ reporting in the three papers twenty-nine cases, and in the last one reviewing them all under the title of "The

Visceral Complications of the Erythema Group of Skin Diseases."⁵ In this paper, and based upon his cases, he shows very conclusively that simple erythema, erythema exudativum, erythema nodosum, certain of the purpuras, urticaria, and angio-neurotic oedema, are all very intimately related; that the lesions of any or all of these various affections may, and often do, occur in one individual during the course of his disease, or even during one attack of the disease, so that at one time one observer might make a diagnosis of urticaria; in a subsequent attack another may call it angio-neurotic oedema, or during another attack peliosis rheumatica. In a word, a patient observed for a number of years is likely to present at one time or another a variety of lesions, all of them, however, vaso-motor neuroses, and so he prefers to classify them under the general head of "The Erythema Group of Skin Diseases." He divides the complications into two great groups, the angio-neurotic and the inflammatory. To the angio-neurotic belong the swellings of the fauces, oedema of the glottis, changes in the bronchial mucosa, causing asthma, and the colic due to oedema of the gastro-intestinal tract. The inflammatory group are more serious and include endocarditis, pericarditis, pleurisy, pneumonia and nephritis.

It is unfortunate that so many writers in reporting their cases have used the term "urticaria" in describing "angio-neurotic oedema," this being apparent from their description of the lesions, and it has led to much confusion.

While all text-books on the skin describe this disease under one heading or another, and nearly all refer to the fact that the lesions affect the tongue, fauces and larynx, yet text-books on the nose and throat, with few exceptions, have neglected any reference to or description of the disease in any way. This is particularly so in the case of American text-books. Of sixteen of these latter but three (Kyle, Posey and Wright, Bosworth) make any mention whatever of the disease, and in but one (Bosworth) is there any description at all.

CASE I.—J. B., male, æt. 24, single, blonde, of a marked neurotic temperament, consulted me at 7 o'clock in the morning of April 4th, 1893, twelve years ago, because of difficulty in swallowing and speaking, and of a swelling in the throat which had come on suddenly three hours before, wakening him from sleep. He had gone to bed feeling perfectly well.

The open mouth, fixed jaw, thick speech, and evident pain or discomfort in speaking at once suggested quinsy.

On examination I found a pale yellow, almost translucent, oedematous swelling of the right side of the fauces, almost completely filling this half of the faucial opening. The parts involved were the anterior and posterior pillars, the right half of the velum palati, the uvula, and the lateral wall of the pharynx of the same side. The tonsil itself was not swollen, though pushed out as in quinsy. Excepting for the swelling there were none of the signs of inflammation, the color being a pale yellow, the contour alone resembling a peritonsillitis. The larynx was normal, excepting for the slight congestion of the vocal cords; tongue not swollen but thickly coated; some earache. He complained of a slight dyspnoea and marked dysphagia. Temperature normal, pulse 90, constipated. Has now, and has had, some gastric disturbance. Urine 1022, acid, no albumen. He gives this history:

About a month ago, for the first time in his life, there appeared, without apparent cause, a localized oedematous swelling, without pain or redness, just above the olecranon of the right elbow, followed the next day by a similar swelling over the biceps of the same arm. These were soon followed by like swellings in both feet after a long walk, then in both hands; in a day or two another swelling made its appearance in the left shoulder following a bruise. The next swelling was in the fauces somewhat similar to the present one, excepting that it was on the opposite side and was very much smaller. This, as had those in the skin, disappeared within twenty-four hours of the onset, and he had a respite for three or four days. The next was serious enough to threaten life. At this time there came on rapidly great difficulty in breathing, rapidly increasing, so that he immediately consulted the laryngologist who had been treating him, and who had the previous day applied a zinc chloride solution to the larynx. After examination he was told there was an oedema of the larynx, pale in color, and in appearance resembling a polypus, but which his physician regarded as urticarial. The dyspnoea was so great that it was feared tracheotomy might be required at any moment. However, without any local treatment beyond the use of a cocain spray and the internal use of salines, the dyspnoea gradually diminished and the swelling disappeared entirely within thirty-six hours.

His tongue and right cheek were next affected. A day or two later, following a bicycle ride, there came on quickly a swelling of the genitals, the scrotum and penis being enormously swollen, as well as the inner aspects of both thighs, extending from the anus behind to Poupart's ligament and over the hypogastrium in front. This swelling was not painful beyond the feeling of distension; did not burn or itch, and was not reddened. It kept him in bed, and disappeared in forty-eight hours. From this time until I saw

him he had several minor oedematous swellings on the hands and feet.

I scarified with a small bistoury the mucous membrane in a number of places, causing immediate relief to the discomfort and distension, and a marked subsidence of the oedema. Ordered discontinuance of cocain and antipyrin spray, which he was using, and prescribed saline purgatives. Nine hours later the swelling in the throat was almost entirely gone, pulse and temperature normal. Felt well, but there had suddenly appeared since morning an oedema of the upper and lower lids of the right eye, closing it. Two days later there was no swelling whatever in the throat, and none in the eyelids, but one was just beginning over the left mastoid.

The patient, who had come on a visit to his parents, from Brooklyn, the night before I saw him, now returned, and I did not see him again for several years, but from a letter a few weeks later learned that he had a few slight swellings in hands and feet, but nothing serious. In writing he called my attention to the fact that all three acute attacks in the throat followed the free use of the cocain and antipyrin spray, which had been prescribed for nasal obstruction, of which he had been having a great deal of late.

These different swellings of the throat and of the skin were all characterized by coming on suddenly; were circumscribed, oedematous, did not pit on pressure, and there was an absence of redness, heat, pain and throbbing, not at all resembling an urticarial wheal excepting in the suddenness of occurrence and subsidence.

Family history.—On mother's side, grandmother and her sisters had, as children, urticaria severely. One uncle has an attack of it after eating canned fruit. This uncle's son, as a child, had the disease so badly that "he would go into spasms." Patient's mother, five years ago, had urticaria off and on for six months, being under medical care continually for it. It disappeared after a successful perineal operation. The mother's family have for years regarded urticaria as a family disease. They are also distinguished among themselves by a peculiar gastric affection, which they designate as the "S—stomach." No other family history of gout or rheumatism.

The attack in which I first saw this patient occurred twelve years ago. He was at that time a director of a gymnasium. He is now a physician, and in reply to a letter written him recently, he writes me, under date of April 3, 1905, that up to about two and a half years ago he had considerable local trouble in the head and throat of a catarrhal nature, but without the recurrence of the previous oedema experienced when he was under my care twelve years ago. On two separate occasions five years ago he had serious attacks of intestinal hemorrhage. These were preceded for a day or more by a feeling of weakness, depression, weight in the

epigastrium, followed by a condition of collapse resembling a moderate degree of shock. This was followed in a day or two by a profuse tar-colored stool, staining the water red, and with it much prostration for a few days, followed by a gradual recovery. For seven years, from 1896 to 1903, he had considerable intestinal trouble, the principal manifestation being the enormous accumulation of gases, which would rise into the stomach and be belched up; very little passing through the bowels. For the past two years he has been gradually improving, very little of the catarrhal trouble in nose and throat, and the gastro-intestinal difficulty gradually but steadily lessening.

This patient has had the disease twelve years. He had the typical angio-neurotic oedema of the skin, fauces, larynx and nose twelve years ago, almost requiring tracheotomy on one occasion, and in the nose so badly that for a time the only relief obtained from the nasal obstruction was through the use of cocain. In addition to the lesions affecting the skin and upper respiratory tract, he had, five years ago and again two years ago, evidences of the same disease affecting locally the gastro-intestinal tract as well as hemorrhages, probably due to purpura, from the intestinal mucous membranes.

His family history shows the influence of heredity in a marked manner. Being a physician, he was greatly interested in the cause of the various attacks, but was never able to determine the immediate cause excepting that on two occasions he thought the attacks followed traumatism. He never discovered that any particular article of food produced an outbreak.

CASE II.—A. M., *et.* 55, a manufacturer; of a decided nervous temperament. Has been under my observation, off and on, for nasal and throat difficulty for about six years. He came under my care first because of nasal obstruction, which would come on suddenly and as quickly disappear. There was no periodicity noticed about it, and it occurred at all seasons of the year; would last a few hours or days; no sneezing, and none of the usual signs of a cold in the head, nor did it act like hay fever. The peculiarity was that this obstruction came on usually during the night and by morning was gone. He also had suddenly arising swellings in the throat, the uvula and soft palate would become oedematous, and the dyspnoea would waken him from sleep, so that he was often compelled to sit up to breathe. The voice would become thick and husky at times. There was no oppression or râles in the chest. He insisted the dyspnoea was not that of asthma, but due to the swelling in the throat. The condition would usually

begin to improve in a few hours, and in twenty-four to thirty-six would usually have disappeared. An examination of the nose showed at times a rather pale oedematous infiltration of the turbinates, sometimes of one, sometimes of all, but on another visit there would be no sign whatever of any thickening, hypertrophy or oedema. The only constant abnormality appeared to be a thickening of the septum opposite the middle turbinate on the right side. This thickening of the septum and the anterior end of the middle turbinate I removed, and while it improved his nasal breathing it did not do away with or lessen the frequency of these suddenly occurring obstructions. These nasal and pharyngeal swellings would be preceded or followed by or there would occur at the same time pale, yellow swellings of the skin of various parts of the body, notably the eyelids, the scrotum and penis, the feet and hands. These attacks would last from a few days to two weeks, and he might be as long as two months, and occasionally has gone six months without an attack. They have been recurring during the past eighteen years. He is at the present time having an attack, and a description of it will answer for all.

It is two months since the previous outbreak. A few evenings ago, while attending a banquet, the left side of the tongue began to swell; on reaching home he took a large dose of alkalithia, hoping to ward off the attack. The following morning he came to my office with the right upper eyelid oedematous and swollen, and the eye closed; it was pale yellowish, did not burn or itch. No throat or nasal lesions, and the swelling of the tongue gone. That night he awoke finding the nose obstructed and the throat swollen, and in the morning I saw him. There was a patch of oedema larger than a bean on the left side of the hard palate, and a pale oedematous swelling involving the uvula and the left posterior pillar of soft palate, extending down the lateral side of the pharynx to the pyriform sinus. The mucous membrane of the left arytenoid was as large as a cherry. The obstruction in the nose had disappeared, and there were no oedematous spots here. There was no pain in the throat, but merely a sense of fulness with slightly obstructed breathing. On the skin there was a swelling under an inguinal truss and the scrotum was swollen. There is, and has been, no disturbance with digestion; bowels regular. Dr. Dutcher examined the urine and reported as follows: "Color pale amber, slightly cloudy, faintly alkaline, sp. gr. 1023, no albumen; no sugar; urea 2 per cent; slight indican, no excess of uric acid. Microscopic examination showed mucus and an occasional epithelial cell." The oedema in the throat and skin entirely disappeared during the day and there was no reappearance for three days, when the right upper and lower eyelids became swollen and closed the eye. This is a typical attack, such as he has been having at intervals for the past eighteen years. The swelling in the feet prevent his wearing his shoes and confine

him to the house at times. The dyspnoea is often alarming, but he has never had to call a physician during the night. He says the attacks are becoming less frequent than formerly, and attributes this to the fact that he thinks he knows when they are coming on by his urine becoming more acid, and at once he resorts to alkalies. He has watched his diet during all these years, and has finally given up thinking any specific kind of food provokes the attacks, as he has from time to time excluded almost everything without that making much difference.

Family history.—He has two children, both of whom have been under my care. The son had asthma until ten year of age, and I removed the adenoids because of this ten years ago, and with an apparent relief of the asthma. I have not seen him since, and his father says he has had no attacks in several years. He has never had urticaria or the angio-neurotic oedema as had his father.

The daughter had repeated attacks of what I thought was rheumatic pharyngitis, which recurred with great frequency. I was never satisfied with my diagnosis, and as she was under my care before her father it did not occur to me that the difficulty might be one allied or related to angio-neurotic oedema. Her father says she never had hives or his disease.

The patient had one brother, who, during the latter years of his life, suffered repeatedly and severely from attacks of what were diagnosed as "gall stone colic," and had outbreaks of a skin disease, said to have been eczema. Two years ago he fell, injuring one of his knees. One month later, while in apparently good health, after being at stool, he suddenly fell and died immediately. A searching autopsy was made, but failed to find any cause of death. An embolus in the brain was suspected, but was not found, and as the case came into court through an action to recover from an Accident Company, the cause of death was thoroughly canvassed. The autopsy revealed no cause whatever for the gall stone colics from which he had suffered. In the light of the angio-neurotic disease in my patient, his brother, the history of gall stone colic for years, without a discoverable cause at autopsy, and the fact that, as Osler has reported, suddenly arising oedemas occur in the brain, it is fair to question whether this might not have been such a case.

The next case appears to be a genuine one of urticaria, affecting the pharynx, larynx, and probably the nose, and shows both the similarity and the difference in the lesions and subjective symptoms of angio-neurotic oedema and urticaria.

CASE III.—E. R., æt. 35, merchant; of a highly nervous temperament, consulted me June 24, 1904, because of what he called "a sudden swelling of the tonsils and a feeling of impending suffocation at such times." He snored a great deal at times, and at others not at all. The day before consulting me he had entertained a number of men at his country house, which had made him very nervous, and had drunk quite a little beer, and that night thought he would die before relief could be had because of the sudden swelling of his throat and obstructed breathing. This came on in a moment, and gradually subsided, passing off in half an hour. These attacks of dyspnoea and the desire to constantly swallow have been occurring for about five years. The first attack followed an outbreak of what he called hives all over the body, including the face and lips, which became greatly swollen. Since that first attack there have been no skin lesions. The swellings in the throat had, of late, been coming on every day or two, though at times he would go a couple of weeks or even a month. He has been treated by a number of physicians without relief. On examination I found a deflected septum, partially obstructing the left naris, tonsils somewhat enlarged, and the uvula slightly elongated. I could discover no oedematous swelling in the throat nor any other local trouble. He was not having any symptoms at the time of the examination. He had never had asthma or colic. The urine examined the next day was amber, clear, highly acid, sp. gr. 1030, urea 4 per cent; no albumen; no sugar; no indican; a very large excess of acid; no casts, no pus.

I made a diagnosis of angio-neurotic oedema, prescribed alkalies and large quantities of water, and explained the nature of the trouble, and asked him to come in again on recurrence of the first attack. He did not return, however, and I did not see him again for nine months; in the meantime he had been under the care of several specialists, one of whom partially excised one tonsil, without, however, affecting the sudden swelling of the throat; another proposed uvulotomy, and the third assured him his symptoms were entirely nervous and largely imaginary. When I saw him recently he was having what he called an attack. He came to my office greatly excited; said his throat felt as though it would close up, and he could not breathe. He was greatly alarmed, and I expected to find a great deal of swelling. On examination, however, the tonsils, soft palate and uvula and larynx were entirely normal, and I was about to conclude that my diagnosis of nearly a year ago was wrong, when I discovered, with the mirror, on the posterior wall of the laryngo-pharynx three elevations about the size of a split pea. They were raised above the surface, red, not at all oedematous in appearance, but resembled the wheal of urticaria as seen on the skin. Irritating the membrane half a dozen other elevations soon appeared, in size from a pin head to larger than a pea. The patient said there was no pain, no burn-

ing, but a sense of enormous fullness, and he could hardly believe my statement of the size of the swellings. They were evidently urticarial wheals. In him they would be produced by any slight psychical irritation or annoyance, such as for instance, being kept waiting at the telephone, or a person with whom he had an appointment being late, or the unexpected meeting of a friend. These attacks would come on immediately, so that he could not speak for a few moments, but would clutch his throat, begin to swallow rapidly, often to the great consternation of the person with whom he was attempting to converse. An attack would begin often with the sense of burning at the end of the penis with the desire to urinate, and then this feeling of swelling in the throat would come on.

Family history.—His father died a few years ago, and as far back as the patient can remember he suffered from colic, walking the floor nights repeatedly, suffering great pain and the belching of gas because of it. He was said to have had "nervous dyspepsia." He never had asthma. He died after five days' illness of acute uraemic poisoning without a previous history of nephritis.

A sister of the patient has had urticaria twice during the past two years. She has had a great deal of indigestion with pyrosis.

This appears to be a genuine case of urticaria affecting the pharynx and larynx and the nose. That it may be easily overlooked is seen by the fact that within a year three different specialists who saw him failed to appreciate the condition, probably because no lesions were present when he was examined. Goodale⁶ states that urticaria, although observed upon the mucous membrane of the tongue, does not appear to have been found upon the mucous membrane of the nose or throat. Certainly these throat lesions of his resemble the wheal of urticaria observed on the skin. The amount of local irritation and the subjective symptoms produced were out of all proportion to their size, in this respect greatly differing from the lesions of angio-neurotic oedema, as seen, for instance, in the throats of Cases I and II, in which there were ten times the amount of swelling and mechanical obstruction without anything like the amount of subjective symptoms.

The acute circumscribed swelling of angio-neurotic oedema as it appears in the mucous membranes of the respiratory and the gastro-intestinal tract appears to resemble that on the skin. It comes on suddenly, in a few moments or sometimes minutes, without warning, while the patient is asleep or awake, and the symp-

toms it produces seem to be largely due to mechanical obstruction. In the nose the symptoms are those of obstructed breathing, not much sneezing, and no excessive secretion, differing in this respect from hay fever, but resembling it in the suddenness of occurrence and subsidence. Doubtless many cases of this disease affecting the nose are diagnosed erroneously as hay fever, which disease it closely resembles both in its etiology and pathology. Both are vaso-motor neuroses, both are markedly hereditary, and occur in persons of neurotic temperament, while the oedema of angio-neurotic oedema is usually transient, lasting from a few hours to a day or two; that is not always the case. Bloodgood⁷ has reported what appears to be a genuine case of this disease and which he calls "Angio-Neurotic Erythema Persistens," in which the parts involved in the oedema were the mucous membrane of both maxillary sinuses and the skin of both cheeks. The oedema persisted for months. He opened both antra through the canine fossae, finding the mucous membrane greatly oedematous. The relief following this operation was but temporary, the erythema and oedema recurring until neurectomy of both infraorbital nerves was done. This gave permanent relief, although the same condition appeared later on the skin of the abdomen.

Osler has also reported cases in which the oedema persisted for a long time. Some of the cases of what are sometimes called perennial hay fever may be those of this disease in which the swollen and oedematous mucous membrane of the nose is not transient but persists. Haviland Hall says "Urticaria is frequently associated with hay fever," and there is certainly a family likeness between hay fever on the one hand and urticaria and angio-neurotic oedema of the nasal mucous membranes on the other.

The relation of angio-neurotic oedema and more particularly urticaria to asthma has been frequently noted. F. A. Packard⁸ reported three cases of his own in which attacks of asthma alternated with outbreaks of urticaria on the skin, the cough and dyspnoea being relieved upon the occurrence of the hives, and up on a subsidence of the latter a return of the asthma. The asthma was caused apparently by the presence of wheals on the bronchial mucous membrane. Packard made a thorough search of the literature and in addition to his own cases found and ab-

stracted the reports of thirty-four other cases in which there was a close connection between urticaria and asthma. Throughout his paper he uses, unfortunately it seems to me, the term "urticaria" to include "angio-neurotic oedema."

In a case of asthma under the writer's care twelve years ago, the patient, a man of 65, had had the disease for about thirty years and had been under the care of many excellent men, but never received more than temporary relief. He was referred to me because of a possible nasal cause, and I found the mucous membrane of all the turbinateds hypertrophied, gray in color, at times greatly oedematous, obstructing the nose completely, and at such times the asthmatic dyspnoea was always greatest. There were no polypi and the septum was straight. He was scarcely ever entirely free from dyspnoea during the year I saw him, and at times, both day and night, in his office or on the street, the dyspnoea was so great that he was a most pitiful object. I cauterized his turbinateds as well as removed the inferior borders of both lower turbinateds, giving him temporary relief only. The asthma soon recurred as badly as ever, and we agreed that the nose was certainly not an important etiological factor. On one occasion he came to the office with one eye closed from an acute circumscribed oedema, and a number of similar oedematous patches on the face and scalp. They were not red, did not pit on pressure, nor did they burn or itch. On inquiry, he said he frequently had these outbreaks, usually on the head, and to which he paid no attention. I failed to appreciate at that time the probable relation of the asthma and the skin lesions. It is probable that his asthma was due to an angio-neurotic oedema of the bronchial mucous membrane, which had become more or less persistent.

As it affects the larynx angio-neurotic oedema becomes immediately a serious affection. It appears to come on during the night while the patient is asleep. Such was the case with two of my patients. It is entirely probable that many obscure and sudden deaths, occurring during the night, are of this nature, and an autopsy, unless this cause were looked for, would fail to find the cause. During the past few years cases are reported by Woodbury,⁹ Hallock,¹⁰ Lederman,¹¹ Taylor,¹² Chittenden,¹³ Ballenger,¹⁴ and others, in which a threatening dyspnoea from this cause occurred. Fatal cases are reported by Osler and Griffith.

Griffith's¹⁵ case, in which both father and daughter died of

oedema of the larynx from this disease, is reported in the *British Medical Journal* of June 14, 1902, and should be read in its entirety. He reports the case as "Hereditary localized oedema."

The patient, a woman, was first seen by him in 1886, when she was 18 years of age, because of dyspnoea, hoarseness and dysphagia and oedema of the arm and hand. The oedema involved the epiglottis and aryepiglottic folds, obscuring the view of the vocal cords. Tracheotomy was considered, but did not become necessary, and in a few hours the oedema disappeared. She gave a history of having had these transient oedemas, affecting all parts of the body from birth. There was no periodicity in their recurrence. There was no history or evidence of any other disease, excepting that she was subject to bilious attacks.

Her father, from his earliest infancy, had the same kind of swellings, and on three occasions they affected his throat; the first attack at the age of 21 years, the second a few years later, and the third at 29 years, when he died as a result of it. In this last attack he came home from work, said his throat was swollen, and his physician was sent for. He came, but returned to his office for something to relieve him, but before his return the patient became suddenly cyanotic and died, asphyxiated.

For sixteen years, from 1886 to 1902, Griffith saw his patient during many attacks affecting different parts of the skin and throat. The swellings were diffuse or circumscribed, usually pale, sometimes pink, did not pit on pressure and were never bullous or vesicular. Twice the laryngeal dyspnoea was alarming. The tongue and buccal mucous membranes were at times the site of the oedema. The swelling came on suddenly, without warning, and almost as quickly disappeared. Finally, she had an attack which proved fatal. At 10:30 A. M. she told her mother her throat was swollen, but that it was subsiding. At noon her husband came home, found her sitting on the floor amusing her child by spinning a top, and apparently free from dyspnoea. Suddenly she dropped the top, tried to, but could not speak, clutched at her throat, got blue in the face, and died at once. Her mother, who was present at her death, said she died exactly as had her father before her. Griffith saw her a half hour after death. The features were livid, tongue protruded, some fulness about the neck. The autopsy showed the larynx to be very oedematous, tense and pale, and the sides of the laryngeal cavity in contact with each other. Transverse sections of the larynx showed that the oedema affected not only the mucous membrane but the underlying deeper connective tissue and muscles. The oedematous fluid was serous, untinged with the coloring matter of the blood, and the tissue covering the true cords was decidedly affected.

The etiology of this peculiar disease is not at all clear. There are certainly three, and perhaps four, main etiological factors. Heredity is clearly shown in the classic case of Osler, reported in 1888, in which the disease appeared in five generations, and of the thirty-nine members of this family nineteen had angio-neurotic oedema, two dying of oedema of the glottis. Griffith's case, just reported, is a striking one. All of my cases show the element of heredity. The peculiarity transmitted, Osler says, must be either a morbid susceptibility of tissue or an inherited peculiarity of metabolism, or both combined. The individual attacks are probably provoked by some toxin produced within the body as in the gastro-intestinal tract, or in some other organ or tissue of the body, or it may be introduced from without. Gout and rheumatism are often mentioned as causes, but it is very doubtful if there is any connection. It is more probable that this disease is often mistaken for manifestations of gout and rheumatism. A certain poison, or a certain kind of food, may cause an attack in one person and not in another, or it may not produce a second attack in the same individual. My patients arrived at this conclusion in their own cases. Strawberries, fish, coffee, ice-cream, contact with a jelly fish, are all given in the reports of cases as causes, but these cases are almost always simply the reports of single attacks. Exposure to cold and traumatism, worry, anxiety, mental excitement and fright are doubtless all immediate causes for outbreaks. Antitoxin, as will be referred to later, is probably one of the various causes. These patients are invariably of a marked neurotic temperament. An interesting and an important question is as to the local condition determining, in a predisposed individual, the localization of the lesions, and Osler seems to think this is an important one in any individual case.

Collins found that in eighty-three cases studied by him the lesion first appeared in the larynx six times. He says the occurrence on any particular part of the skin or mucous membrane predisposes that part to other attacks.

There has been much question as to whether the colic, which occurs so frequently in the course of the disease, is the cause or the result of the outbreak as it appears on the skin or in the throat. There is no doubt but that in mostly all cases the colic is the effect of the acute oedema localized in the stomach or intestinal tract. Morris¹⁶ reports a case in which a portion of the gastric

mucosa became detached in using the stomach tube. It was examined histologically and showed an extreme oedema of the interstitial tissue, the lymph spaces and vessels being enormously dilated. The abdomen has been opened for supposed appendicitis when the condition was one of angio-neurotic oedema of the intestinal mucous membrane.

The histological examination in Griffith's case of fatal oedema of the larynx showed that the oedema involved not only the mucous membrane but the deeper connective tissue and underlying muscles. Crocker says that everything points to the disease being primarily a vaso-motor disturbance, direct or reflex, central or peripheral; that a spasmodic contraction of the vessel is followed by a paralytic dilatation and stasis or retardation of the circulation in the papillary layer of the skin. Serous exudation then ensues, producing acute oedema. The same thing occurs in the mucous membranes and readily explains the sudden oedema and enormous swelling that comes on in a few seconds or minutes.

This same kind of oedema occurs in the brain and in the kidneys, and probably in every organ or tissue of the body. Grüss¹⁷ reports a case in which acute circumscribed oedema caused an acute retrobulbar oedema producing proptosis, and associated with cerebral symptoms. Osler's Case XV had repeated attacks of aphasia and hemiplegia, the lesions on the skin being those of purpura, urticaria and angio-neurotic oedema during the fourteen years of the disease. Ten days after the injection of antitoxin, given for prophylactic or therapeutic purposes, eruptions on the skin occur in a considerable percentage of the cases injected. These eruptions belong to the erythema group, and are in the order of their frequency, urticaria, erythema, purpura, angio-neurotic oedema. The joints frequently become swollen, and there are evidences of acute swellings in the mucous membranes of the respiratory and gastro-intestinal tracts.

Antitoxin from the same bottle may be injected into several children and yet but one may have a skin eruption develop later, showing that the serum is not alone at fault, but that there exists in the affected patient a "peculiar susceptibility of tissue" or an inherited tendency toward one of the erythematous diseases, the antitoxin, or something in it, being simply the poison that provokes the attack in that particular person. Morse¹⁸ reports a case in which five days after a prophylactic dose of 500 units the child

complained of chilliness, prostration, vomiting and oedema of the uvula and pharynx, the acute symptoms subsiding in thirty-six hours. Two years before this same child, after a prophylactic dose of 700 units, developed an urticaria of the skin.

It can readily be seen that when diphtheria exists in the throat an acute oedema developing during the course of the disease would be attributed to the diphtheritic infection rather than to the antitoxin injected a few days before, and yet it might be due entirely to the latter. From our knowledge that angio-neurotic oedema and urticaria occur in the throat, there is no reason to suppose that antitoxin causes these lesions in the skin and not in the fauces, pharynx or larynx. There is every reason to suppose it does, and it is quite presumable that some of the suddenly fatal dyspnoeas occurring in diphtheria are the result of the remedy operating on a peculiarly susceptible individual, rather than to the disease, diphtheria. The real cause of death in such cases would be overlooked, being masked by the disease. It is possible that the local lesions of diphtheria, as well as the toxæmia, might prevent the development in the throat of lesions which the antitoxin might, however, produce on the skin.

The cases which have attracted most attention have been those suddenly occurring deaths immediately following the injection of antitoxin, and usually in persons who did not have diphtheria but were given prophylactic doses because of their exposure. The cause and effect here are not open to much question, but there has been much discussion as to how and why the antitoxin caused death.

It appears to the writer that in these cases the children have probably an inherited tendency to angio-neurotic oedema, that the antitoxin has been the exciting cause of an attack, and that the swellings have occurred in the larynx, or the lungs, producing a sudden oedema that causes asphyxiation, or the oedema may have occurred in the medulla or the brain, causing a paralysis of the respiratory or cardiac centers with resulting death.

For instance, Halderman¹⁹ gave a prophylactic dose of antitoxin to a 5 year old child who did not have diphtheria. It was asleep when the injection was given, and almost immediately the lips began to puff up, and in five minutes breathing ceased. Ninfong²⁰ gave a 15-year-old boy a prophylactic dose of 1,500 units. Ten minutes later the boy became pale, extremities numb, cyano-

sis developed, the cheeks became swollen, and free vomiting occurred. Nitro-glycerine was given and artificial respiration was resorted to, but the boy died thirty-five minutes from the time of injection. Professor Langerhans'²¹ son was given a prophylactic dose of antitoxin, and almost at once he began to vomit and soon died of suffocation. The autopsy revealed the trachea and bronchi filled with stomach contents and the uvula swollen. Adamkiewicz thought death was due to shock or pain resulting from the forcible injection under the skin of a large amount of fluid. Langerhans insisted that death was due to the poisonous action of the serum upon a healthy subject when unneutralized by a pre-existent toxin.

These cases would seem to have had an acute circumscribed oedema: in the first case of the lips and probably of the larynx; in the second of the cheeks, the stomach and the larynx; in the third of the uvula, and probably of the stomach, in each case the oedema coming on within a few minutes and causing death in from five to thirty-five minutes. None had diphtheria, all having received prophylactic doses.

Kortright²² gave a 16 year old girl 10 c.c. Behring's antitoxin making the injection in the left side of the abdomen. She immediately said she "felt a lump in the stomach," and Kortright assumed she meant that she felt the swelling of the injected serum under the skin, but it is equally probable that what she felt was an acute swelling in the gastro-intestinal tract. Five minutes later she complained of tingling and became restless, and immediately had a general convulsion. This was followed by general tonic and clonic convulsions, opisthotonos, cyanosis and cessation of breathing. Artificial respiration was kept up till heart ceased in three minutes, death occurring in eight minutes from time of injection. An autopsy made eighteen hours later showed the brain and meninges, kidneys and liver all markedly congested; no foreign body in larynx or trachea.

In Applegate's case a boy of four years having diphtheria was given 15 c.c. antitoxin. One hour later he became very restless, vision was completely lost, and three hours after injection he died in convulsions.

Kortright was of the opinion that his case died because of something undiscoverable connected with the antitoxin or the injection. It is probable that had another child received the same

injection nothing untoward would have followed, there being in his case the unfortunate combination of a predisposed patient and an exciting cause. In these two cases the localized oedemas were probably in the brain.

If these statements regarding antitoxin be true, it is not a reason or an argument against the use of this specific in the treatment of diphtheria, because it has saved thousands upon thousands of lives which otherwise would have been lost and has probably caused the death of but a very few. It is, however, an argument against the indiscriminate use of antitoxin for prophylactic purposes, because a single death from its administration in a person who has been simply exposed and has not contracted, and might not contract the disease, is frightfully deplorable. When it is used prophylactically, the previous personal and family history of the patient as regards the erythematous skin diseases should be inquired into, and if this develop the presence of or tendency to any of these diseases, then the antitoxin should be withheld until diphtheria actually occurred, or at least until a bacteriological examination of the throat in such an exposed person shows the Klebs-Loeffler bacillus.

Some makes of serum seem to have a larger percentage of skin eruptions follow than others, and we see much less of these eruptions now than three or four years ago, showing apparently that the present method of preparing and "ripening" antitoxin is eliminating some of its deleterious properties, and it may be that in the future antitoxin may become inert as a cause, in predisposed individuals, of the production of the erythematous lesions on the skin and mucous membranes.

The treatment of angio-neurotic oedema as it affects the upper respiratory tract may be divided into the management of the various acute attacks as they arise, the correction of any local disease which may possibly determine the localization of the lesions or oedemas in the air passages, and the treatment of the constitutional disease back of the attacks. Of the last I have nothing to say beyond the fact that each individual case must be studied by itself, and if possible the underlying cause found, and if it can be, corrected. Osler has called particular attention to the fact that of his twenty-nine cases of the Erythema Group, 24 per cent finally died, five of the seven deaths being due to uraemia. He has never seen, however, a case of pure angio-neurotic oedema develop

nephritis, and the fact is that cases in which angio-neurotic oedema is the only lesion throughout the course of the disease are very few. For eighteen years my Case II has apparently been such a case.

The treatment of the localized oedemas in the fauces, pharynx and larynx would depend upon the severity. I have used both adrenalin and cocain locally with apparent benefit, and in more severe cases scarification of the pharyngeal and laryngeal oedemas. Should the dyspnoea increase and threaten life, tracheotomy should be done without hesitation or delay. Ice locally is probably contraindicated and might add to the oedema. Delbril advises brisk friction of the skin to induce an attack of urticaria on the skin when there is oedema of the larynx. Packard's cases of asthma would bear out the wisdom of this. Quiet in bed, reassurance, and, as far as possible, the removal of anxiety are important. These patients are highly neurotic and fright alone might precipitate a sudden and fatal termination. Internally saline laxatives and alkalines to reduce the usual hyperacidity of the urine and increase the quantity are indicated. My patient, Case II, felt that he knew when an attack was coming on by the increased hyperacidity of his urine and at once began to take alkali, which he thought lessened the frequency and mitigated the severity of his attacks, though it did not prevent them.

It would seem to be a sensible thing to treat and remove if possible between attacks any local disease that may exist in the throat or upper air passages with a view to removing the localization of the acute circumscribed oedemas in these areas. It is doubtful if this would accomplish such a highly desirable result, but it certainly should be attempted.

REFERENCES.

1. Collins. Reference Handbook of Med. Sciences (second edition).
2. Strübing. Moritz Schmidt. Die Krankheiten der oberen Luftwege.
3. Osler. Amer. Journal Med. Sciences. April, 1888.
4. Osler. Amer. Journal Med. Sciences. December, 1895.
5. Osler. Jacobi Jubilee Volume.
5. Osler. Amer. Journal Med. Sciences. January, 1904.

6. Goodale. Posey and Wright Dis. Eye, Ear, Nose and Throat, page 690.
7. Bloodgood. Johns Hopkins Bulletin. May, 1903.
8. Packard. Archives of Pediatrics. October, 1899.
9. Woodbury. Journal of Laryngology. October, 1898.
10. Hallock. Annals Laryngology, Rhin. and Otology. November, 1898.
11. Lederman. The Laryngoscope. September, 1898.
12. Taylor. Phila. Med. Journal. April 2, 1898.
13. Chittenden. Amer. Journal Med. Sciences. October, 1898.
14. Ballenger. Journal of Laryngology, Rhinology and Otology. May, 1896.
15. Griffith. Br. Med. Journal. June 14, 1902.
16. Morris. Amer. Journal Med. Sciences. November, 1904.
17. Grüss. Crocker, Diseases of Skin. 1905, page 156.
18. Morse. Boston Med. and Surg. Journal. February 17, 1898.
19. Halderman. Journal Amer. Med. Ass'n.
20. Ninfong. Annals Otology, Rhinology and Laryn. August, 1898.
21. Bishop. Diseases of Nose, Throat and Ear.
22. Kortright. Brooklyn Med. Journal.

(Candidate's Thesis.)

SOME FOLLIES OF THE VOCALIST.

BY CHARLES P. GRAYSON, M.D.

THE laryngologist needs but a moderate experience in the care of vocalists to discover that there are extraordinarily few of them, be they professional or amateur, who do not habitually indulge in some one or more indiscretions that affect injuriously the beauty of their voices. No doubt, in most of them, it is ignorance that is responsible for these errors, and it is astonishing that so many of those who sing should know so little, not only of the instrument that they use, but of the many things that influence the tone it produces. I fancy that the majority of singers regard the larynx with its contained vocal cords as being in itself the complete musical instrument. With so limited a conception of what it really

comprises we can scarcely expect them to recognize or to assign due weight to the many disturbing influences that may directly or indirectly affect the singing voice. It is probable that all of them discover, sooner or later, that when they are fatigued or suffering from any indisposition they will not be in good voice, but it has seemed to me that very few of them are thoughtful enough to learn from this the lesson that the health and vigor of the whole body are intimately associated with the purity and vigor of their voices. That which is true concerning the dependence of mental upon bodily soundness is even more emphatically true of vocal soundness, and so we may alter the old maxim for these people and make it read "*Vox sana in corpore sano.*" Unfortunately, in this country at least, the average amateur is content to sing just well enough to please the average listener, and he doesn't have to sing very well to do that. This class of vocalist is not to be taken seriously, and it is usually a waste of time to try to do anything more than keep his larynx in approximately good condition. To the young man or woman, however, who is in earnest, who wishes to develop and cultivate the voice to a creditable extent, and who has some higher aspiration than to sing the mandolin melodies that are termed "popular," it is well worth while to explain and to insist upon the necessity for raising the bodily health to and maintaining it at the highest possible standard. The earlier the student learns and accepts the law that the life of the singer is one of constant and rigid self-denial, the more rapid and gratifying will be his progress. His physical training should be almost as strict as that of the athlete and every detail of his personal hygiene should receive scrupulous attention. The laws governing diet, exercise and rest, clothing and bathing, should be closely observed, but it is these that are most frequently violated. The singer can commit no greater folly than to imagine the health of the larynx to be quite independent of that of the rest of the body. It is this blunder that is accountable for the dietetic indiscretions that tax the digestive and nutritive functions, for the omission of a proper amount of wholesome exercise, for the indulgence in pleasures and with dissipations that curtail the time that should be given to sleep, and for obedience to the laws of fashion rather than those of good sense in adapting one's apparel to the calendar instead of to actual weather conditions. All these are departures from the narrow path of health that exert a distinctly depressing effect upon

the general vitality and that will to a precisely proportionate extent lessen the brightness and vigor of the voice.

It is this lowering of the general systemic tone that very often leads the singer into another folly—that of seeking the help of tonics and alcoholic stimulants to carry him through some period of hard vocal work. Occasional at first, the resort to these things soon becomes habitual. Surely no argument is needed to demonstrate the injury to the voice that this habit will inevitably produce. If one or all of the muscles concerned in voice production are not equal to the accomplishment of a certain piece of work, no form of medical whip and spur can safely make them so. Nature prescribes a definite limit to the amount of work that the muscles can perform without injurious strain. The sensation of fatigue is the signal that this limit has been reached, and if this warning sensation be delayed or blunted through the exhilarating effects of strychnine, or coffee and cognac, or vin Mariani, or any of the other commonly used alcoholic stimulants, a degree of exhaustion may be almost unconsciously reached that will be very slowly if ever completely recovered from. Even with intelligent and careful use the life of the singing voice is a comparatively brief one, and when it is repeatedly driven beyond its proper distance its career will be very materially shortened.

Somewhat closely related to this abuse of stimulants is the probably even more prevalent abuse of the so-called "voice tablet." For certain simple catarrhal conditions of the larynx, and within strictly therapeutic limits, medicaments in this form may perhaps be used with some little temporary relief or actual benefit. The large majority, however, of these combination of remedies employed in lozenges are flung together by the manufacturing chemist rather than the physician, and when the vocalist chooses from among them for himself, as he too often does, he is as apt to select one that will be harmful as one that will have a favorable action. So many of them contain cocaine, now and then some form of opiate, and almost always one or more of the stimulating expectorants, that their indiscriminate and often unlimited use may prove directly and seriously prejudicial to the voice. Indirectly, also, the excipient that forms the basis of many of these throat tablets may have a detrimental effect upon the larynx. The fruit pastes, the sweetened gums and gelatins that are often used for this purpose are by no means innocuous as regards their effect

upon the digestive tract, and I have frequently thought myself justified in holding them responsible for much damage to the voice through their interference with normal appetite and digestion.

Considerable difficulty will often be experienced in inducing the vocalist to abandon one other favorite folly—the over-protection of the neck during the colder seasons by means of furs or silk and woolen mufflers. We may not be disposed to criticise the covering of the mouth and the muffling of the neck when emerging into the cold outer air after some hours of singing in an overheated room or auditorium, but it is the habit of doing this sort of thing whenever one may be out-of-doors that is to be strongly deprecated. The physiological reasons for opposing this habit are perfectly manifest to the physician, but usually they must be explained and reiterated again and again to the singer before he will relinquish his conviction that the protective tissues with which Nature has covered the larynx are insufficient and are in need of reinforcement.

It is, no doubt, the vocal instructor who should caution his pupil as to the dangers of singing too much and of practicing always with the full volume of his voice, very common faults with the beginner, who is apt to strive rather for quantity than quality of voice, but our warning must often be coupled with that of the singing-master in order to give it an emphasis that will prove effective in correcting these faults.

To conclude this brief selection from among the many blunders that tend to weaken and discolor the singing voice, I would call attention to the too frequent and too forcible clearing of the throat that is commonly employed for the removal of some flake or small shred of mucus. In spite of the fact that they may fully realize the delicacy of the vocal apparatus, many vocalists treat it with a roughness that cannot but prove harmful. Instead, for instance, of coaxing any excess of secretion from the larynx by the gentlest of efforts, they usually resort to violence and in this way provoke an initiative hyperemia that only aggravates the vascular and secretory disturbances from which they may be suffering.

(Candidate's Thesis.)

DEFLECTIONS OF THE NASAL SEPTUM; A CRITICAL
REVIEW OF THE METHODS OF THEIR CORREC-
TION BY THE WINDOW RESECTION, WITH
A REPORT OF 116 OPERATIONS.

BY OTTO T. FREER, M.D.

IN this article I again describe my methods of operation as further experience has improved them and contrast my work with that of others; for since the appearance of my last paper, the "Window Resection" (Journal of the American Medical Association, December 5, 1903), several articles on the submucous resection of deflections of the septum have been published. The most complete of these is that of Killian (Die submucoese Fensterresektion der Nasenscheidewand, Fraenkel's Archiv fuer Laryngologie, Vol. 16, page 362, 1904), but Hajek (Bemerkung zu der Krieg'schen Fensterresektion, Fraenkel's Archiv fuer Laryngologie, Vol. 15, page 45, 1904); Menzel (Zur Fensterresektion der verkrueemnten Nasenscheidewand, Fraenkel's Archiv, Vol. 15, page 48, 1904); Leon E. White (Resection of the Nasal Septum, Boston Medical and Surgical Journal, Vol. CL, page 419, April, 1904); Weil (Ueber die submucoesen Resektionen an der Nasenscheidewand, Fraenkel's Archiv, Vol. 15, page 578, 1904); Zarniko, (Ueber die Fensterresektion der Deviatio Septi, Fraenkel's Archiv, Vol. 15, page 248); Erhard Mueller, (Zur Technik der Fensterresektion, Fraenkel's Archiv, Vol. 15, page 312), and Spratt (The Removal of Septal Spurs and the Correction of Deviations of the Septum, American Medicine, May 7, 1904), have also written important papers on the subject.

The Nature of the Deflections Encountered.—The number of submucous resections of deflections of the septum performed by me to the present time is 116. Ninety-six of my patients were males, 20 females; a disproportion in accord with general experience. Sixty-seven were young adults, 20 were middle aged;

23 cases were between 12 and 17 years of age, and 6 were children, 2 of them eight, 2 nine, 1 ten, and 1 eleven years old. Fifty-six of the deviations were in the left naris, and 52 in the right—an inconsiderable difference. Eight deflections were sigmoid horizontally and obstructed both nares at the same time. In 12 patients the deflection was so extreme that the septum applied itself along nearly its whole length to the lower and middle turbinated bodies, causing obliteration of the nostril. In these cases the operation had to practically create a new nasal fossa. Only 41 of the deviations were purely cartilaginous, 66 were composed of bone and cartilage, while 9 were entirely bony. The majority

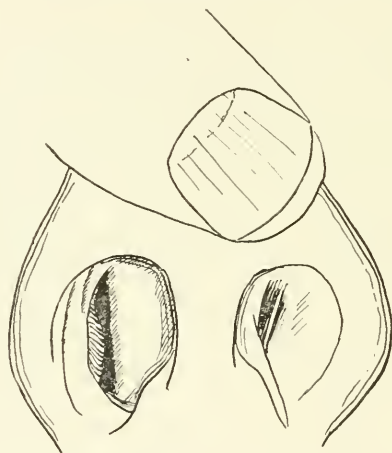


Fig. 1. Deflection showing vertical angle. From life.

of the deflections, 66, were double-angled, of the type which presents a distinct vertical angle (Figs. 1 and 2) in the cartilage, extending in rare cases up into the perpendicular plate, and a horizontal angle beginning commonly in the cartilage and extending backwards and upwards, usually along the superior border of the vomer, in the form of a wedge, the crista nasalis inferior (crista incisiva) and the vomer curving outwards above the nasal floor to form its lower plane. On the concave side in the double-angled deflection is seen a trough with V-shaped bottom ascending upwards and backwards, corresponding to the horizontal angle on the convex side, while the vertical angle, which usually juts out strongly on the side of the convexity of the deviation,

is generally merely indicated by a gentle depression. Another type of angular deviation, which I call the crest-like deflection, appeared 22 times among my cases. In this class the vertical angle is absent, there being merely a horizontal angle, not differing from the one just described. It is this variety of deviation that is commonly sawed as a "ledge, crest, ecchondrosis or exostosis," under the impression that the septum is plane, or nearly so, on the other side, for the concavity may not be seen because hidden deeply in the naris, but more often it is simply not looked for. The insight into the septal skeleton given me by my resections, has convinced me that solid crests or ledges resting upon a plane septum or even upon the summit of a deviation are much rarer

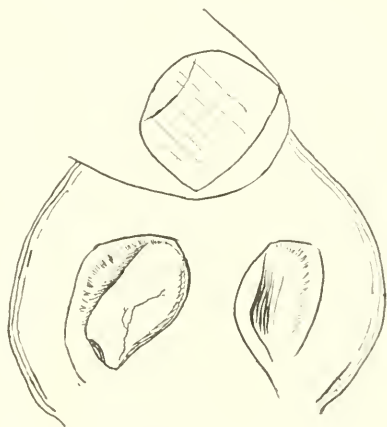


Fig. 2. Deflection showing vertical angle. From life.

than evenly hollowed out deflections, the acute angle of whose apex simulates a solid prominence. Among all of my deflections, but 6 possessed noteworthy crests as a complication. Personal association with operators has shown me that the impression prevails that solid ledges arising from a straight or slightly deviated septum are frequent, and under this impression the summit of deflections is sawed off, leaving the mass of the deviation to continue to obstruct the naris, or else, if the saw penetrate deeply, a perforation is made.

The posterior part of the horizontal angle of deflection is often visible by posterior rhinoscopy, and seen to extend near or even up to the posterior border of the vomer. (Fig. 3.) The latter,

however, almost always stands vertically in the center. Figures 4 and 5 show deflections in which this was not the case. One

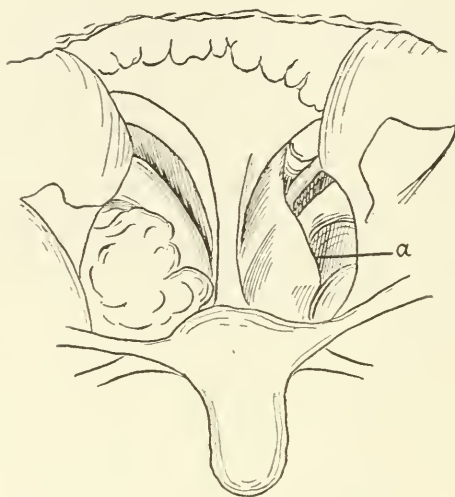


Fig. 3. Posterior view of a bony deflection. *a*, deflection. From life.

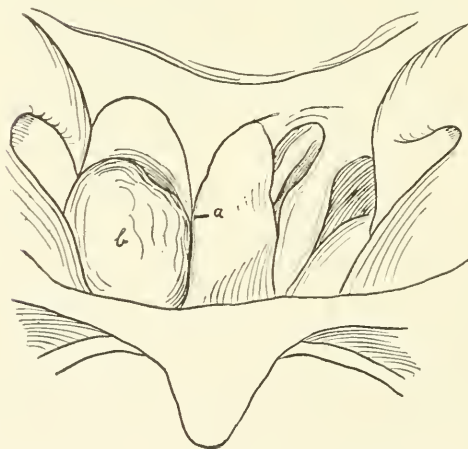


Fig. 4. View of a deflection of the posterior end of the vomer. *a*, deflection; *b*, intumescent inferior turbinate. From life.

of these patients had not only marked deflections of the entire septum, but also a congenital bony atresia of the choana, shown in the drawing.

Eight of the deflections were bowed or C-shaped, horizontally and vertically. Bowled deflections are frequently extreme, begin far in front, and often look like a red tumor projecting into the nostril. The vertical angle is replaced by a rounded bulging of the front of the septum into the obstructed naris, usually beginning at the anterior inferior free border of the quadrangular cartilage, which projects across into the opposite nostril. The bowed deflections are apt to extend far back into the bony

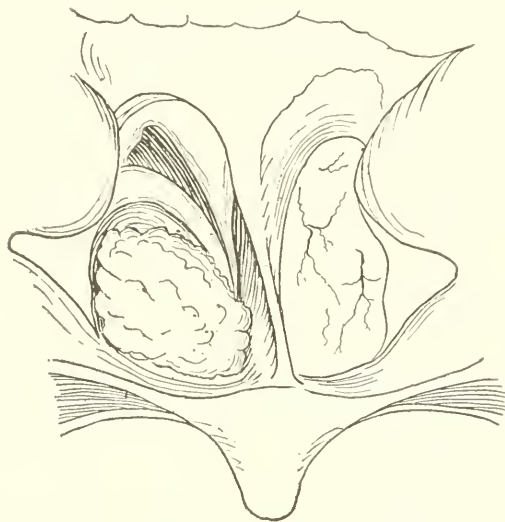


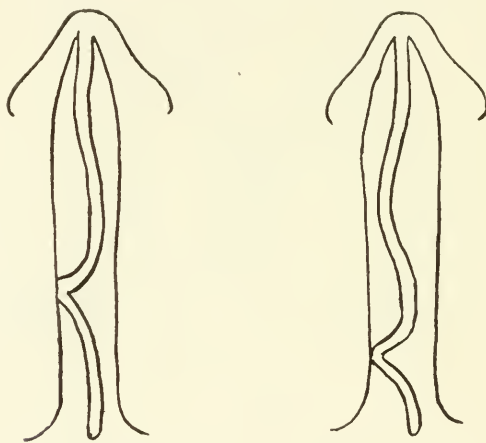
Fig. 5. View of a deflection of the posterior end of the vomer. Congenital atresia of the left choana. From life.

septum, the bony part of the deviation usually presenting the typical horizontal angle described.

Ten of the deviations were of such an irregular form that they could not be classified. In two of these the vomer was bent horizontally upon itself in its posterior half, producing an acute angled vertical deviation that projected transversely across the naris, crowding into the lower turbinated body (Figs. 6 and 7), and making the resection very difficult. In 20 cases the dislocation of the anterior inferior free border of the quadrilateral cartilage (so-called columnar cartilage) from its proper seat above the septum cutaneum (septum anticum of Kretschmann) (Fraenkel's *Archiv fuer Larygologie*, Vol. 14, page 562, 1903),

referred to under bowed deflections, occurred. In these deviations the anterior plane of the vertical angle lies across both nares obliquely from behind forward, the anterior angle of the quadrilateral cartilage being displaced from its normal position between the median plates of the alar cartilages and the inferior angle from its attachment to the crista incisiva, so that the dislocated anterior interior free border of the cartilage of the septum is seen as a projecting ridge under the skin in the nostril of the concavity beside the septum cutaneum. (Fig. 8.)

Seven deviations were sigmoid horizontally, blocking both nares. Fourteen perforations into the opposite naris occurred.



Figs. 6 and 7. Horizontal section of septum showing sharp vertical deflection of vomer.

Nine of them were minute; the largest of the size of a pea. Three were larger, of the size of a thumb-nail. Six perforations were made in my first 15 cases; 3 were unavoidable, as they were made in cicatrices due to previous operations. In the last 101 cases there were 5 perforations. None of them lead to scabbing or caused their possessors discomfort.

Killian's Grouping of Deflections.—Killian divides deflections into two groups—one due to faulty growth of the septum, and one due to traumatism. In describing the former group he says that the strongest convexity, as a rule, corresponds to the upper border of the vomer, but that the quadrilateral cartilage may be bent below or high up (in what form is not stated), in the latter case

the deviation usually involving the perpendicular plate. He states that crest formation is seldom absent in natural deviations, and that these crests always follow the superior border of the vomer, ascending obliquely from below upwards. He finds marked deviations usually associated with the formation of a marked ledge or crest.

Traumatic deflections, Killian describes as always occupying the anterior part of the septum, in the region of the cartilage, but he says that they may extend more or less extensively into the

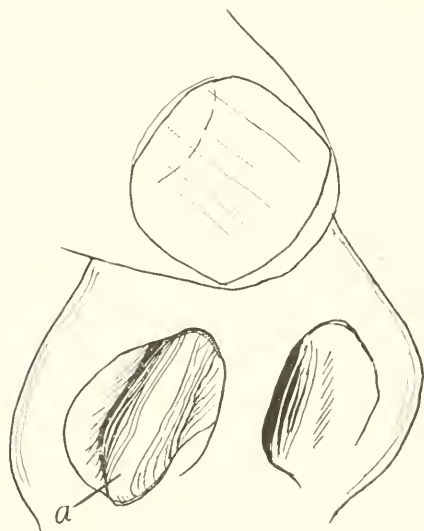


Fig. 8. Greatly thickened anterior inferior free border of the quadrangular cartilage lying beside septum cutaneum. *a*, cartilage. From life.

bone, and that the type of deflections due to injury is acute-angled, the fractured lamellæ of the quadrangular cartilage forming a sharp angle, whose planes approach each other from above and below, the groove of the concavity extending from before backward. The anterior portion of the septum undergoes torsion about its vertical axis and closes the hollow of the concavity from in front, its free border projecting into the open nostril, its anterior surface presenting broadly in the obstructed one. Where the fractured lamellæ are joined the cartilage is thickened and the fragments may overlap.

Portions of this description by Killian bring to my mind deflections as I have found them, but I fail to recognize what has seemed to me typical in a great part of it. I certainly have found nothing that suggested to me a division into a traumatic group and one due to faulty growth. I do not think that a deflection should be called traumatic simply because its shape indicates traumatic origin, even though this suggestive form be accompanied by the patient's history of an injury to the nose in the past, for blows upon the nose are so common that he is quite sure to recollect one to which his trouble might be attributed, even though his deflection be obviously not traumatic, as for instance, a bony deviation far back. The majority of my deviations had an acute vertical angle, usually far forward in the naris, that would have accorded with Killian's description of a traumatic deflection, yet in only a few of these did the patients date their trouble distinctly from a violent blow upon the nose, and in these there was usually a clear history of fractures of the nasal bones. Even in fresh cases of injury where a blow was violent enough to fracture or displace the nasal bones from their attachment I have commonly merely found the cartilage of the septum carried over to the right or left, or gently curved, and I have not seen acute-angled fractures of the cartilage shaped like an angular deflection, even in these severer injuries. I have no doubt that they occur where the cartilage is unusually brittle, but as a rule, it is so resilient that it springs back into its original shape. This is proven by the difficulty experienced in preventing the elasticity of the cartilage from reproducing deflections corrected by the fracturing operations. Acute-angled deviations of the cartilage are extremely common, yet, according to my experience, their acute production from fracture is very rarely seen, though an injury sufficient to create such a fracture would certainly be severe enough to bring the patient to the surgeon for inspection. Killian speaks of traumatic deviations that are continued into the bone. It does not seem mechanically reasonable that force enough should be conveyed by the elastic cartilage of the septum to its bony skeleton to break either the perpendicular plate or the vomer. The fact, therefore, that a cartilaginous deflection is continued into the bone is to my mind an argument against its traumatic origin. I think, therefore, that while traumatic deviations occur their frequency is overestimated, and that it is better to leave the

supposed etiology of deflections out of the question in grouping and describing them.

The Influence of Age upon the Operation. Children.—The ages of my patients as shown varied between the extremes of 50 and 8 years. The healing in my middle-aged and oldest patients was as rapid as in the younger ones. Killian advises against intranasal surgery in old persons except for urgent indications. Aged people have never demanded the operation of me, but I should perform it upon robust patients up to the age of 60.

Killian's statement that as a general thing children younger than twelve are not fit subjects for the window resection is not in accord with my experience, and I should operate on children at any age, though so far my youngest patient was eight years old. Dr. Herman Stolte, of Milwaukee, successfully resected the septum of a child of five. Erhard Mueller reports 3 successful operations upon children under 10, one of them 6 years old. Killian contends that the smallness of the field in children, the need of general narcosis and our inexperience as to the effects of further growth of the septum are contraindications. I have not found my 6 operations on children difficult, as my slender instruments are perfectly adapted to a small operative field and the combination of cocaine anaesthesia with chloroform makes the slightest narcosis suffice.

To investigate the effects of growth upon the resected septum I recalled for examination my 3 first child patients of the ages of 9, 8 and 9 at the time of operation, and operated upon respectively 18, 10 and 7 months before the time of reinspection. All of these children had had unusually extensive osseo-cartilaginous deflections, and in all of them the septum had become entirely firm at the site of the window and the cartilage and bone seemed to be replaced. The deflection in the first child was partly reproduced. The result in the other two remained perfect.

The first child had a double-angled deflection of extreme type, causing obliteration of the right naris. The external bony and cartilaginous nose was curved in the form of a C towards the obstructed nostril, and the whole septum was arched over into the occluded fossa. A large window was made extending from the nasal vestibule far back into the bony septum. The anterior inferior free border of the quadrangular cartilage projected somewhat into the left naris, but not enough to make its removal seem

necessary. When the patient was re-examined after 18 months the cartilaginous part of the deflection was found to be one-half reproduced, the naris being one-half clear in front, instead of entirely free, as it was a few weeks after the operation. There was no reappearance of the bony obstruction.

The second child had required an extensive resection of a crest-shaped deflection from the front of the nostril to nearly the posterior border of the vomer. The re-examination in this case in 10 months showed a straight septum and ideal result.

The third child had an extreme angular deflection with double-angle obliterating the right naris. The bony deflection extended back to near the posterior border of the vomer. In this case the naris was also found perfectly free 8 months after operation. The first case shows that growth in children tends to reproduce a deflection in part unless every vestige of it be removed, for I do not think that there would have been a return even in this extreme case if I had resected the dislocated anterior inferior portion of the quadrangular cartilage from the naris of the concavity, for it was this residue of the deviation that caused the front of the septum to continue to grow in a faulty direction.

My conclusion, therefore, is that the operation is proper for children at all ages but that it does not suffice to resect enough cartilage and bone to establish free respiration, but that even slight remains of the deflection must be extirpated to enable the septum to grow in a vertical plane.

Permanency of Result.—To test the permanency of the result of the operation in adults, I have sent letters to a number of my earlier patients, and so far 10 have responded. The time elapsing between operation and examination was 2 years and 11 months in 2 cases, 2½ years in 5 cases and about 2 years and 2 months in 3 cases. In 5 of these patients the site of the window was firm, showing that probably the cartilage and bone were reproduced. In 4 cases all of the window except an area in the centre of the size of a bean to a dime was firm, showing that probably some cartilage had reformed from the edges of the window. I think that my more recent cases will show a larger percentage of entirely firm windows, as practice enables me to save the periosteum better than I did.

In one case a perforation made by the operation existed. It had smooth borders, did not scab and caused the patient no in-

convenience. The result was ideal in all of the cases re-examined, nasal respiration was free, it was usually impossible to see that there had been an operation, and in no case was there any sinking in of the bridge of the nose or formation of scabs.

Possibility of Damage to the Nasal Profile.—Some operators hesitate to adopt the window resection, urging that though it does not itself cause the bridge of the nose to sink in, its support is nevertheless weakened, so that a blow on the nose would readily flatten it. The effect of severe blows upon the nose has been tested in four of my cases. Two of them were boys, one aged 15 and the other 16. In the first case the deflection was confined to the cartilage, a large window being made, reaching from the nasal floor high up to the perpendicular plate. Seven days after the operation the patient was struck violently on the nose by a man's elbow, nosebleed for fifteen minutes resulting. When seen two days later the bridge of the nose was not depressed in the least and the septum remained straight.

In the second case the deflection was also cartilaginous with a sharp vertical angle, and extended from the front of the septum to its bony part. Twelve days after the operation the patient bumped his nose forcibly into another boy while running. Prolonged nosebleed followed, but when he was examined 19 days after the operation, there was not only no deformity of the external nose, but the window was already filled with tissue as firm as cartilage.

The third patient came to me 2½ years after the operation. He had received a blow on the nose a week before he came for re-examination. The nasal bones had been dislocated to the left, their connection with the frontal processes of the superior maxillary bone being broken. They had been replaced, and the bridge of the nose was still swollen, but was not depressed in spite of this violent injury and the septum remained straight. In this case an angular, purely cartilaginous deflection, extending high up into the perpendicular plate, had been resected. The fourth patient received a blow from a man's hand on his nose, 3 weeks after an extensive resection of an osseo-cartilaginous deflection, reaching to the front of the septum and upward into the perpendicular plate. No damage beyond nosebleed.

Mueller says that a slight saddle nose may result if a wide enough strip of the anterior highest part of the quadrangular

cartilage be not retained, as this part supports the dorsum of the nose. Mueller especially warns against pulling or breaking away cartilage in this region, as several times when he did this, distinct, but not marked sinking in of the nasal bridge followed. Pulling or breaking out of fragments of cartilage has always been excluded from my method, and there is no need of it, as my cartilage knives pare off the cartilage cleanly and exactly where it is desired.

Mueller has also, he thinks, seen slight retraction of the profile from cicatricial retraction of the septum as a postoperative sequel. This may be due to the fact that he sacrifices the mucosa of the convexity after Krieg, and so creates a large cicatrizing surface.

Menzel says that "one is certain to obtain a saddle nose, a sinking in of the cartilaginous bridge, if one resects the cartilaginous septum too closely to it." He saw such deformities among his first cases due, he thinks, to retraction of scar tissue forming between the two layers of the mucosa. Menzel advises the re-entention of the portion of the cartilage of the septum corresponding to the dorsum of the nose to the extent of a strip 1 to $1\frac{1}{2}$ centimeters in width.

I agree with Mueller that in some deviations high up and far forward, the under surface of the lateral cartilages of the external nose must be approached more closely than this, in resecting, to sufficiently free the naris. Although I have never seen the least sinking in of the nasal bridge after the operation, and Killian does not even mention it, I think that, nevertheless, Mueller's and Menzel's warning should be heeded, and that, in deflections far forward, a buttress of cartilage at least one-half a centimeter deep (Fig. 9, *b b*) should be left behind the nasal bridge above the alar cartilages. In the great majority of cases it is needless to resect so closely to the nasal bridge that its support comes into question.

In distinction to the part of the quadrangular cartilage immediately underneath the lateral cartilages just mentioned, all of the lower portion of the quadrangular cartilage, extending back horizontally behind its free border and anterior angle, up to the level of the top of the alae nasi, may be resected back to the bone without fear. (Fig. 9, *a a*). The needlessness of this part of the cartilaginous septum is shown by the many cases where it naturally extends across both nostrils, curled up, dislocated from its attachments, and obviously supporting nothing, the nasal profile

of the individual, nevertheless, being faultless, in spite of the many accidents to which noses are exposed. Though I agree with Weil, that only deflected cartilage should be sacrificed, and that for this reason, it is objectionable to begin the resection at the free border of the cartilage for all deviations, even for those beginning a distance behind it, as is done by Hajek and Menzel, I do not think with him, for the reasons stated, that the support of the external nose depends at all upon the lower portion of the cartilage outlined above. In a number of cases I have resected this portion of the cartilage when deflected, from the anterior an-

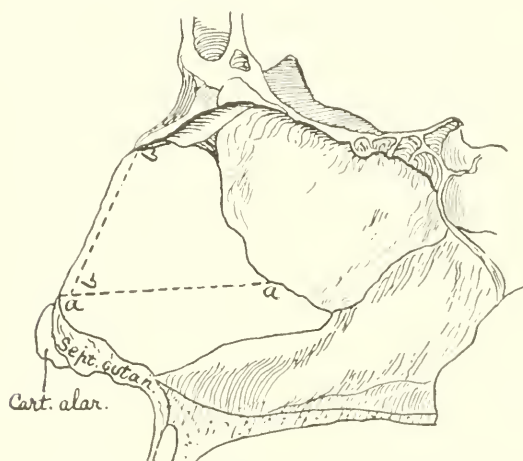


Fig. 9. The nasal septum. *a a*, line below which the cartilage may be completely removed. *b b*, posterior limit of strip of cartilage under nasal bridge to be preserved.

gle and free border far back into the bony septum, and the bridge of the nose has always stayed straight.

Incomplete Operations.—Some operators speak of the window resection as a simple little operation that may be done with a few ordinary instruments. In a series of resections some will always prove easy, and a number of these among the first cases readily leads to thinking all of them so. In addition, there is a tendency among some operators to resect only enough of the deflection to partly free the naris. Thus, only the cartilaginous part of the osseocartilaginous deviation, or only the prominent parts of the

bone and cartilage may be removed. A half operation of this kind is of course usually easy, but it is sometimes a fatiguing and difficult matter, requiring special instruments to radically extirpate a deflection to its limits. This should always be done, however, for the cocain and adrenalin employed make the naris for the time abnormally clear, and when the shrinkage of the mucosa they have created passes off, the nostril does not remain sufficiently open unless all of the deviation be gone. The result is satisfactory when the posterior wall of the nasopharynx and the motions of the levator palati muscle can be plainly seen through the naris which has contained the deflection.

Description of the Operation. Preparations.—The operation is to be done according to the rules of aseptic surgery, a knowledge of which may be presupposed. Though it is desirable, as Killian does, to operate in a special aseptic operating room, most rhinologists have to do the work in their offices, or in clinical rooms used for all cases. Though this has been my case, I have had no trouble from sepsis, except in 3 early cases where there was transient suppuration of the wound, which hardly delayed healing. There has been nothing of the sort in my last 74 operations. An important preparatory step is the clipping away of all vibrissae, so that the nasal vestibule may be well cleaned and the view of the operation be unobstructed.

Though the nasal fossae back of the vestibule, as Killian states, contain no virulent germs when healthy, and need no cleansing before an operation, the surgeon may be called upon to perform it in nares affected with acute or chronic rhinitis, secreting mucus and obviously superficially infected. Killian says that in these cases "if the submucous operation be, nevertheless, indicated, one may try to cleanse the nose and weaken the virulence of bacteria by irrigation with weak antiseptic solutions." This treatment would merely remove virulent secretion from the surface and leave the tissues still infected, and in such cases I defer the operation until I have subdued the suppuration with daily irrigations, followed by swabbing of the general mucous surface and meatuses with a 25 per cent. solution of argyrol. This penetrating silver salt usually stops the infectious discharge and makes the operative field safer than if one resected at once. In sinus disease it may be necessary to operate in spite of chronic suppuration.

Position of the Patient.—The sitting position for the patient seems to be the only one employed, excepting by Leon E. White and myself. In my earlier operations I also used no other, but since my 29th resection I usually, during the greater part of the resection, have the patient lie upon an operating table that can raise or lower his head to the required level. The patient lies upon his back while the operator stands at ease beside him, instead of bending over towards him in a strained position, as he does when both are sitting. When the patient reclines, the assistants holding the retractors, and swabbing, can see better what they are doing. The patient is at rest, has none of the attacks of faintness at the beginning of the operation that he is liable to when he sits up, and he does not suffer the discomfort of having to hold his head fixed in a rigid position. The flow of blood is usually so slight that it is all, or nearly all, swabbed away, the few drops that run back into the pharynx being swallowed by the patient or hawked up at intervals so far apart that the course of the operation is hardly disturbed. Operating in the cartilaginous septum and in the bone above the lowest parts along the nasal floor is made less difficult by the patient's recumbent position, but it is easier to resect a deflected crista incisivæ or foremost part of the vomer when he is sitting. When the patient sits I employ a head-rest for him, or have an attendant steady his head. Some full-blooded people, in lying down, have continuous oozing of blood from the wound, and such persons should also sit in the chair.

Lights Employed.—I still regard the Kirstein electric headlamp (Fig. 10) as the most suitable light. It makes the operator independent of a source of light for reflection, a great advantage, for such a light is in the way of assistants, and as it usually cannot be used when the patient is recumbent, the operation is interrupted if he needs to lie down because of faintness. The Kirstein light is preferable to the other electric headlamps, as it is the only one which permits the operator to see deeply, as its rays are parallel to the axis of the surgeon's eye, which looks through the hole in the mirror. This is important in resecting bone far back in the naris where it is hardest to see and where a good illumination is needed. The objections to the Kirstein light are the frequent burning out of the expensive lamps, the frail connections, the need of a rheostat and the difficulty some have in adjusting the mirror to the eye. Those who prefer it may use a pigtail filament, 50 candle-power,

stereopticon, Edison incandescent light, attached to a cord, plug and socket (Fig. 11) for reflection with the headmirror. This

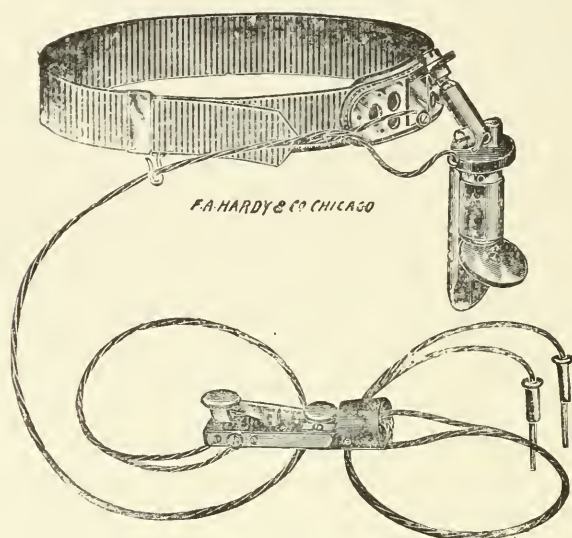


Fig. 10. Kirstein headlamp.

light gives an intense homogeneous field of illumination and may be adjusted so that it may be reflected from while the patient is recumbent.



Fig. 11. Edison stereopticon electric light.

Some operators have complained to me that they could not make the Kirstein lamp shine brightly enough. In these in-

stances I found that a rheostat was being used that did not permit enough current to pass. The Kirstein lamps require from 8 to 12 volts and from $\frac{3}{4}$ to 1 ampere to make them glow with a brilliant white light, a much stronger current than is needed for the little diagnostic lamps in common use. I employ a so-called O. C. rheostat with a 50 candle-power lamp in series and obtain a very bright light with it.

Anaesthesia.—Killian employs submucous injections of a one-half per cent. solution of cocain with 4 drops of suprarenum hydrochloricum (a German adrenalin preparation, 1 to 1,000 in physiologic salt solution) to 2 c.c. of cocain solution. Preceding this injection, he applies a 20 per cent. cocain solution to its intended site on the anterior lower part of the septum. He tries to force the fluid through a long needle between the perichondrium and cartilage if possible. One c.c. is injected on each side of the septum, and the anaesthetic gradually spreads until large portions of the septum lose their sensibility. Killian waits 15 minutes for local insensibility, and immediately before operation also applies a 20 per cent. cocain solution to the mucous surface.

White packs the convex naris for one-half an hour with a pledget of cotton soaked in a 4 per cent. cocain solution.

Menzel paints the mucosa of both sides of the septum with a 20 per cent. solution of cocain and 1 to 1,000 adrenalin, then he uses Schleich's infiltration at the site of the incision and backwards between mucosa and cartilage on both sides.

In the exceptional cases where I resect from the free border of the cartilage, as I do where it is dislocated into the naris of the concavity, I inject submucously a 2 per cent. cocain solution on each side of it, for the thick epithelium over the foremost, lowest part of the septum hinders absorption from the surface. In all other cases, as formerly, I first swab adrenalin 1 to 1,000 upon both sides of the septum, following it in about three minutes with pure powdered cocain, rubbed with a minute moist swab on to the same region. The concentration of the drug produces profound local insensibility, which is confined to the operative field and is so rapid that the first cut may be made in about five minutes after the application. Some who have watched me have contrasted the painlessness of my resections with the greater suffering caused by other operators, and they attributed the perfect insensibility to the rubbing in of powdered cocain. I have never seen note-

worthy cocain intoxication, though as the operation proceeds, I repeatedly apply the pure drug to the wound surfaces to maintain the anaesthesia and as a haemostatic. The entire amount of cocain absorbed is small, and much of it is swabbed off again. I employ this method for all intra-nasal operations, and except in the locality mentioned, I can see no reason for the troublesome submucous injections, which combined with additional swabbing with a 20 per cent. solution of cocain, certainly lead to the absorption of as much of the drug as my method does.

Weil suggests possible injury to the vitality of the flaps from Schleich's infiltration.

For children, I combine chloroform narcosis with the application of cocain. Just enough chloroform is used to keep the child unconscious of its surroundings. As a rule hardly a half narcosis is maintained.

Assistance.—An attendant is needed to hold the nostril open with retractors, and it is well to have one to swab the field of operation or hand swabs to the surgeon. At least 60 cotton swabs upon pointed applicators should be ready, to avoid the need of rolling new ones during the resection.

Specula.—Killian justly refers to the unfitness of the usual specula for the operation, and has an attendant hold a single tracheotomy retractor to keep the naris open. I use my original flat retractors (Fig. 12, R, S.), one narrow and one broad, and find that a much better view is obtained with both of them than with a single retractor.

The Incisions in the Mucous Membrane.—Opinions all agree that it is best to resect from the convex side if possible.

For the usual deflection with a vertical angle, however slight, and a horizontal angle, I now make an incision of the shape of a capital L looking backward, the vertical cut, as of old, following the angle of the vertical deflection and beginning high up on the septum above the deviation, the horizontal cut extending forward from the bottom of the vertical one along the crest of the horizontal deflection, if it be acute and projects greatly. If it be little pronounced, the incision is made along the nasal floor. The cut should extend to the very front of the septum in most cases. (Fig. 13). This outlines an anterior flap with its base forward. The posterior extension of the horizontal cut, which gave the older incisions the form of an inverted T, I only use in bony deflections

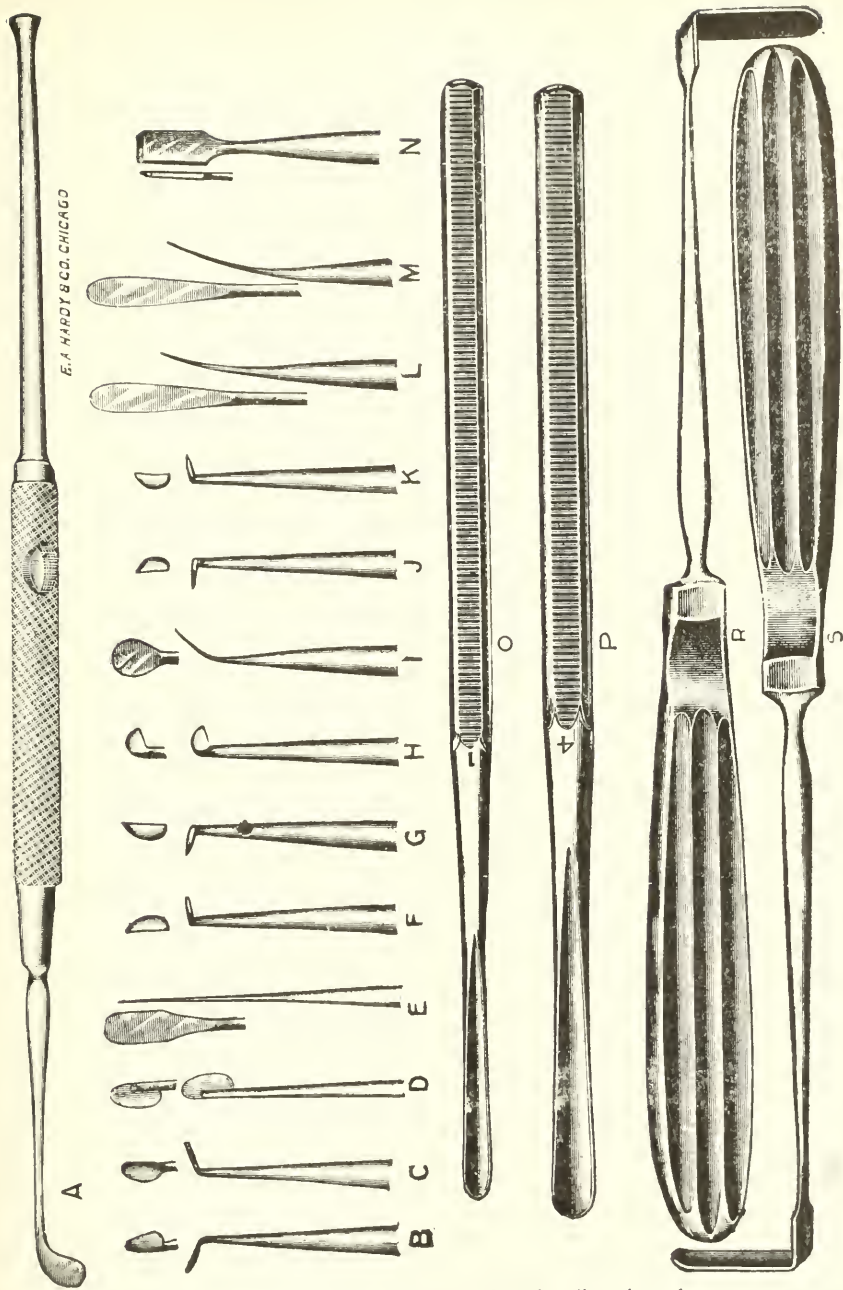


Fig. 12. *A*, round-bladed knife, bent on edge, for dissection of mucous membrane from concave side of bony base of deflection; *B* and *C*, half round-bladed angular knives for vertical incision in mucous membrane when deflection is far back; *D*, half round-bladed straight knife for vertical incision in mucous membrane when the deflection is nearer the front and for first cut in the cartilage; *E*, flat, round-bladed dissecting knife; *I*, angular round-bladed knife; *F*, *G*, *J* and *K*, sharp pointed, angular cartilage knives for cutting through back and upper part of cartilaginous deflection; *H*, Ingals' submucous cartilage knife; *M*, dull-edged elevator for uplifting of mucosa; *L*, sharp-edged elevator for dissecting up mucosa in adherent places; *N*, chisel; *O*, *P*, gouges; *R*, *S*, retractors for holding nostril open.

hard to reach. The reason for usually making the horizontal cut along the crest of acute-angled horizontal deflections and not along their base is the frequently great adherence of the mucosa at the apex of the horizontal deflection and below it, so that its separation from below is difficult, and it is better to dissect it off downward from an incision made along the crest.

For crestlike deflections reaching well forward an incision is made from behind, forward along the whole length of the crest

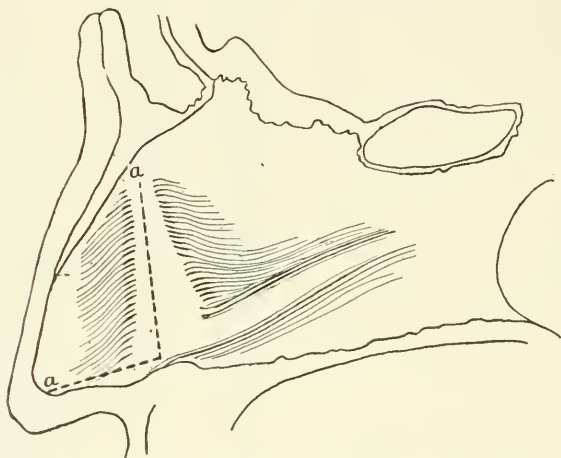


Fig. 13. Lateral view of convexity of double-angled deflection. *a a*, outline of mucous membrane incision.

of the deflection, curving the cut upwards at the front. This outlines a superior instead of an anterior flap. (Fig. 14.)

In the common form of crestlike deflection beginning far back in the naris in or near the bony septum a single vertical incision, reaching from the nasal floor high up on the septum, is made just in front of the beginning of the deflection, and the resection is conducted from this, for in this type of deviation there is but an insignificant or no cartilaginous deflection to be removed in the anterior part of the naris and the principle of entering the deflection from a mucous membrane cut in front of it is the one best followed in this instance.

The mucous membrane cuts are made with the knives with half round edged or rounded-edged blades (Fig. 12, *D, C, B, E, I*) *C* and *B* being used for vertical angles occurring far back, and *I*

along the base of the septum in front. The incision should go through the perichondrium, so that it can be elevated from the subjacent cartilage. If the cut does not go down to the cartilage the dissection takes place between mucosa and perichondrium, a difficult process only possible with keen blades. Where the deflection extends across both nostrils and the anterior inferior free border of the septum is displaced into the naris of the concavity enough to obstruct breathing, I begin the resection by an incision from the free border of the septum on the concave side, and from this dissect out as much of the deflection as can be reached in this way. If it extend far back into the bone, I then make my usual vertical cut along the vertical angle on the side of the convexity and dissect from this (Fig. 15). The general principle of my in-

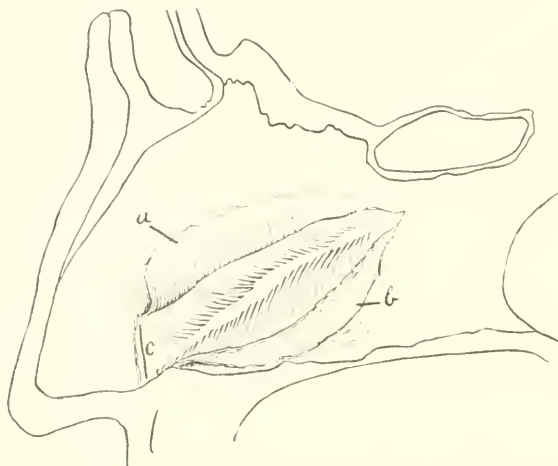


Fig. 14. Lateral view of convexity of crest-shaped deflection. *a*, superior flap; *b*, mucous membrane pouch formed below; *c*, first cut through cartilage in front of deflection.

cisions, in short, is to follow the summit of the angle or angles of deviation wherever they may be, excepting in the case of the deep-seated crestlike deviations mentioned. In distinction to my method all other authors describe their mucous membrane incision as made at the front of the septum and in front of the deviation instead of over it. Thus Killian makes a single cut about one-half a centimeter behind the border of the septum mobile (*cutaneum*), but not parallel to it, for it ascends from behind and below upward

and forward. White's cut is made vertically, just anterior to the deflection from above its top to the nasal floor. Hajek and Menzel make a single cut beside the septum mobile directly upon the free border of the quadrangular cartilage, their incision being curved backward at each end. Krieg, Mueller and Boenninghaus make three incisions, one upon the free border of the cartilage, a second extending parallel to the back of the nose backward and a third along the floor of the nose. The Krieg type of incision gives good access to the deflection, but leaves a loose flap badly shaped for preservation, and which it is the intention of Krieg and his followers to cut off at the end of the operation.

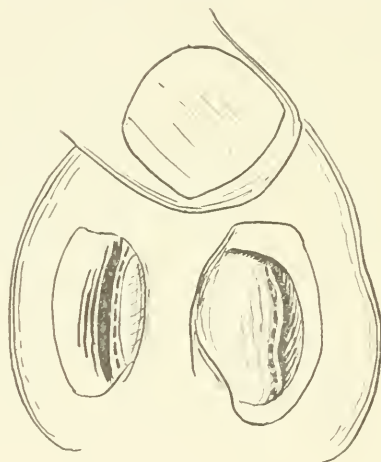


Fig. 15. Deflection showing vertical angle in left naris and dislocation of free border of cartilage into naris of concavity. Dotted line shows site of mucous membrane incisions.

As the Killian, Menzel, Hajek and White incision is made in the foremost part of the septum, the remotest and most difficult part of the deflection behind must be reached from a point on the septum at the greatest distance in front of it. Their cuts give ready access to the anterior part of the deviation, but sacrifice present gain for future difficulty, for it makes the portions of the deflection far back less accessible and so encourages imperfect removal of the bony part of deflections.

With the incision at the front of the septum the operator resects under a long sac of mucous membrane on the convex side

of ever increasing depth, so that it becomes more and more awkward to keep the detached mucosa out of the way, and for this reason Killian has added as a complication to the operation the use of his long speculum for rhinoscopia media (Fig. 16) to spread open the mucous coverings on both sides of the septum. Even a short speculum I have always found much in the way of sight and the free use of instruments, especially cutting forceps, where the deeper parts are to be operated upon, and I do not wonder that Killian does not think the operation suited to little children if he blocks their little nostrils with his speculum.

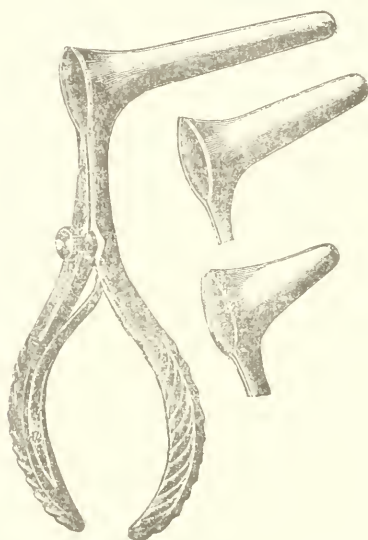


Fig. 16. Killian's long specula for rhinoscopia media.

Another objection to the mucous membrane incision far in front is the fact that it coincides with the first cut through the cartilage, so that if a perforation be made here it penetrates both coverings of the septum at once, and hence remains permanent, while my anterior flap in this region overlies an accidental perforation through the mucosa of the concavity and closes it. The foremost part of the septum is the worst place for a perforation, as it crusts for a long time.

Mueller, in speaking of Hajek's and Menzel's incision, and this applies as well to Killian's and White's, says: "How often does

one meet with massive deepseated obstructions, angular bends, bony prominences and spines in complicated noses, after free space has been made in the anterior half of the naris. To obtain a perfect result it is absolutely necessary to remove such obstacles. To reach them from a buttonhole incision, seated in front in the region of the septum mobile, is very difficult, tedious and often absolutely impossible. In such cases one is forced, if one expects to succeed with Hajek's method, to be satisfied with a less perfect freeing of the nasal passage than those obtain who operate by Krieg's method."

Zarniko says: "I have discarded the simple straight cut of Menzel with short curved continuations at the ends, as the view into the depths of the mucous membrane pocket did not suffice."

My incisions give as much access to the deeper parts and as much freedom for operation as Krieg's and, nevertheless, the mucosa of the convexity is preserved. My mucous membrane pocket begins not far in front, but at the vertical angle or summit of deflection so that the separation of this posterior part of the mucosa of the convexity is easy and the short sac created by its elevation stays open, no long speculum being needed, the separated mucosa clinging with its epithelial surface to the turbinals or at the most needing to be held off with a slender spatula. The greatest advantage of my incisions, therefore, is the creation of flaps that make the deepest bony parts of the deflection readily accessible. This is true of the reversed L, inverted T and single cut along the horizontal angle. *The readiest access to a deflection is obtained by a cut along its summit.*

The Instruments for the Separation of the Mucous Membrane.
—The principles of this part of the operation do not seem to be clearly conceived by all, to judge from the number of unnecessarily large and massive instruments devised. The heavy bone implements of the general surgeon seem to have served as models for some of them. The problem is not so much to scrape off the perichondrium and periosteum from the septum as one would denude the tibia, as to carefully *undermine* the coverings of the deflection, for the instruments, on account of the position of the septum between two narrow cavities, must of necessity work nearly parallel to the surface attacked, especially on the concave side, so that scraping is only possible to a limited extent in front. In addition the soft, yielding, springy cartilage is not suitable as

bone for scraping with chisel-like instruments. The undermining must be done in narrowest places, around corners and often at a great depth in the naris, by actual measurement in many of my cases two to three inches behind the front of the external nostril. The type of elevator demanded is therefore thin-edged, and flat, so that it may undermine readily, narrow, so that it may fit small nares, long and gently curved so that it may work around corners and keep its edge always close to the surface to be denuded lest it perforate the mucosa. A sharp and dull separator are needed, the dull one being merely without keen edge, but never blunt, as blunt instruments perforate readily by punching through in front of adherent places. The sharp elevator, and in addition my round-edged knives of various forms (Fig. 12, *L, E, D, I,*) are used for keen dissection in places where the covering of the septum is adherent. In the large majority of cases all of the separation may

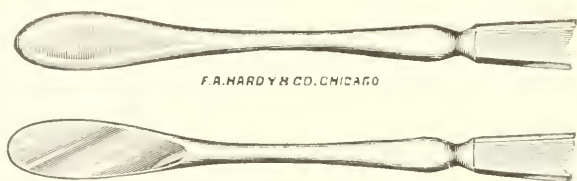


Fig. 17. Hajek's elevators, blunt and sharp. Natural size.

be done with the dulled separator, but the crests of deflection, the bottom of the concavity, cicatrices after previous operative attempts, quite often both sides of the crista incisiva and vomer below the horizontal angle of deflection, and occasionally the foremost part of the cartilage, are places where the covering may need to be dissected away in places instead of separating readily throughout.

The type of elevators used by Hajek and Spratt do not conform to the requirements mentioned. Spratt's are veritable chisels. Hajek has a blunt and a sharp elevator (Fig. 17). Both are clubbed at the end, straight, five-sixteenths of an inch wide and one-eighth of an inch thick. Such large instruments hide the view in narrow nares, and would be quite unfit for the minute nostrils of children. In the eleven cases of obliteration of the nostril encountered they could hardly have been wedged between the deflection and the inferior turbinated body, not to speak of

conducting the elevation of the mucosa in such a narrow fissure. The sharp elevator has a thick edge, rounded on one side, and flat on the other, and is more like a chisel than a dissector. A blunt, round-edged separator like Hajek's is apt to plunge through the often frail perichondrium, periosteum and mucosa of the con-

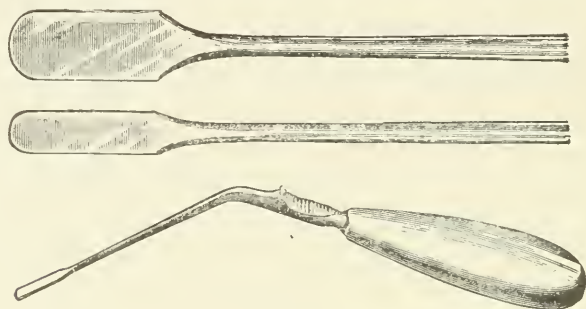


Fig. 18. White's separators.

cavity if even moderate force be used in front of slightly adherent places, where a thin-edged, dull separator will undermine the covering, a fact that made me abandon blunt separators long ago. Hajek's elevators are made for an operation of strength rather than of delicacy. White's separators (Fig. 18) have a better

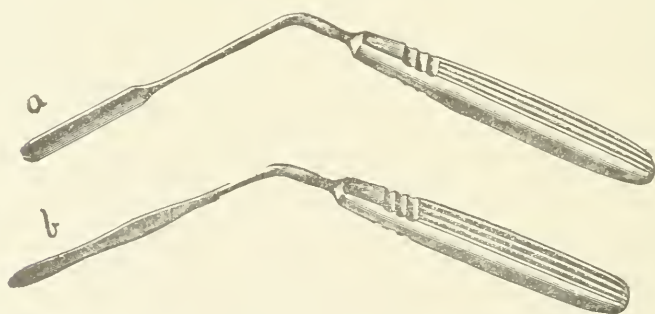


Fig. 19. Killian's blunt elevators; *a*, straight; *b*, curved.

form, but are straight and designed only for roomy noses. He speaks of "freeing the cartilage from its mucosa in a short time with these powerful instruments." He mentions no instrument for sharp dissection.

The most important instrumentarium recently brought to notice

is that of Killian. His separators are thinner and better fitted for the work than those mentioned. For blunt separation he has a straight one (Fig. 19, *a*) and one curved (Fig. 19, *b*) at the end on the flat, both about one-fourth of an inch wide, and, though I regard these instruments as too large for operating in children's noses, I think they would fit the average case.

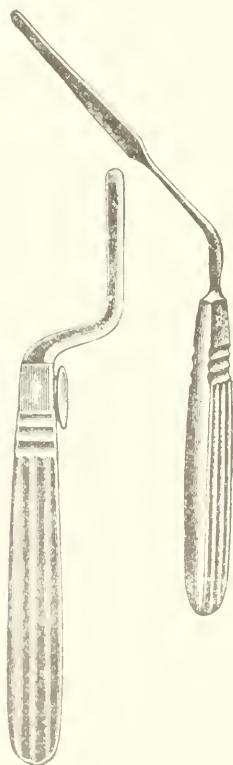


Fig. 20. One of Killian's right and left bayonet-shaped sharp elevators; old model sharp elevator.

The bayonet-shaped sharp elevators (Fig. 20) are designed to start the separation of the mucosa from Killian's incision in the front of the nostril. The other sharp elevator, "old model" (Fig. 20) is also described as used merely to begin the resection in front.

It is long and straight and could be used deep in the nares, but its edge, as well as that of the bayonet-shaped separators, is thick,

flat on one side and so rounded on the other so that it could only be used for scraping and not for cutting, a type of edge I abandoned with the use of Ingals' spud. Killian has no keen-bladed instrument for sharp dissection with its front end (tip), as his little knife (Fig. 21) cuts only from its side, while even my half-round-bladed knife (Fig. 12, *D*) has its edge carried over its back, and the round-bladed knife (Fig. 12, *E*) and sharp elevator (Fig. 12, *L*) may be also used for this purpose. Cutting with the front end of the knife is needed in dissecting out the anterior inferior portion of the cartilage from its free border and in liberating adherent places in the hollow of the concavity.

An objection to Killian's and White's instruments is the use of an angular attachment of the handle to the shank, the so-called nasal angle, designed to keep the hand below the level of the nose under the supposition that it gets in the way of sight when holding a straight instrument. Mine are all made straight, yet I can

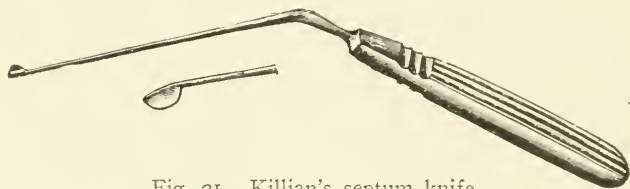

Fig. 21. Killian's septum knife.

always see the field of operation perfectly. Even slight pressure against the distal end of an angular instrument tends to rotate the handle, which, therefore, has to be held firmly, either in the fingers, or as is easiest, grasped in the whole hand. This effort implies a stiff wrist and fingers and makes it necessary to make the motions of the instrument with the coarse muscles of the arm and shoulder instead of the finer ones of the hand and fingers, which are capable of more accurate and controlled work. Straight instruments can be held lightly and easily while at work, as their motion is direct and the muscles that move them are those of the hand and fingers. The presence of an angle also complicates the movements needed and disturbs the sense of direction.

The Separation of the Mucosa on the Convex Side.—In order to reach the deepest parts of the nares my spatulae or elevators (Fig. 12, *L*, *M*) have been lengthened since their last description.

The mucous membrane and perichondrium of the septum, as I

have found them, form two distinct layers. The perichondrium is thin and transparent and is readily overlooked because the whiteness of the cartilage shines through it, and the inexperienced operator therefore, not seeing it, imagines that he has a surface of bare cartilage before him, and so, instead of lifting the perichondrium from the cartilage, a task of easy performance, is apt to attempt to liberate the mucosa from the perichondrium, a feat impossible for dull instruments and difficult for sharp ones. Killian emphasizes this point well. It is, therefore, necessary to search for the beginning of the thin film of perichondrium at the edges of the incisions, gently scraping it up with the dulled separator until the instrument will pass underneath it, when the mucosa may usually be readily lifted off with it. Nevertheless, there are places where the perichondrium or periosteum clings to cartilage or bone, and here the dulled instrument is laid aside for a moment and a sharp dissector used until the elevation with the dulled spatula may be resumed.

In the double-angled deflections the anterior flap should be reflected in this way, a little beyond the limits of the deflection, so that it will fold back and stay out of the way.

The pocket of mucous membrane behind the vertical angle is made next by undermining perichondrium and periosteum over the entire area of the deflection, backward, and, if possible, downward to the base of the septum. The separation upwards and backwards is usually very easy, but along the crest of and below the horizontal angle of deflection, keen dissection with the sharp spatula is often required and the elevation of the mucosa may be so difficult that it may even have to be deferred until removal of the cartilage makes the bony deviation more accessible.

In the anterior crestlike deflections an upper flap is made following the incisions described. It should be large enough to fold upward as much out of the way as possible. The separation is then continued below the horizontal crest, a mucous membrane pocket being created which reaches the base of the septum, the crista incisiva and vomer being thus bared below the horizontal angle (Fig. 14). As stated, sharp dissection is often needed in this region.

In deep-seated deflections beginning near the bone the separation is conducted from the vertical cut in front of the deviation described.

In the anterior deflections that require dissection from the free border of the quadrangular cartilage in the naris of the concavity, keen dissection with the round-bladed knife (Fig. 12, *E*) is sometimes needed for a distance back of about one-half to three-quarters of an inch before dull separation becomes possible.

Even when a deflection has a very acute, prominent vertical angle pressing into the inferior turbinal, there is no trouble in lifting off the mucosa back of it with my thin curved spatula, which follows around the angle from the vertical incision. Killian says that "the sharp-angled, traumatic deviations of the cartilago quadrangularis create especial difficulty, and that whoever attempts to separate the mucosa around these corners will perforate as a rule." This is true of his operation from an incision in front of the deflection, but the difficulty is obviated by my vertical cut along the vertical angle.

The First Cut Through the Cartilage.—Killian makes his first cut through the cartilage with his sharp-edged elevator, "scratching the cartilage in the direction of the mucous membrane cut, and trying slowly to work through it." The instrument is applied in nearly a sagittal direction, while the little finger guards the mucosa in the other nostril. Mueller also scratches through the cartilage. Zarniko uses a gouge. As Menzel dissects from the free border he does not need to cut through the cartilage.

A clean cut through the cartilage with my thin-bladed, razor-edged knife (Fig. 12, *D*) is less apt to perforate the mucous membrane of the concavity than tedious scratching through with a thick-edged, sharp instrument, for the keen knife cuts with slight strokes and is held lightly like a pen in relaxed fingers, while it is necessary to hold the thick-bladed instrument more firmly and to make pressure on the septum with it in order to make it cut, hence it is liable to suddenly plunge through the mucosa of the concavity when the cartilage is pierced. The light stroke used in cutting with a thin blade permits a delicate sense of touch which tells the operator when he has penetrated the cartilage. For this reason I have abandoned the use of the little finger in the other nostril to feel for the edge of the knife under the mucosa, for this divides the attention. When the knife seems to have severed the cartilage along a line of about one-half an inch, the cut edge is felt for with a dull spatula, lifted up, and seized with delicate rat-toothed forceps (Fig. 22) which pull upon it while the pene-

trating cut is finished with the severed edge of cartilage in plain view as a guide. I always operate with the right hand, no matter in which nostril the deflection is, and I do not agree with Killian that "he who wishes to, always operate upon the convex side, that is at one time in the left and again in the right nostril, must be able to use the knife and elevatorium with the left as well as with the right hand."

Before making the first cartilaginous incision in the common double-angled deflections the anterior flap is held out of the way

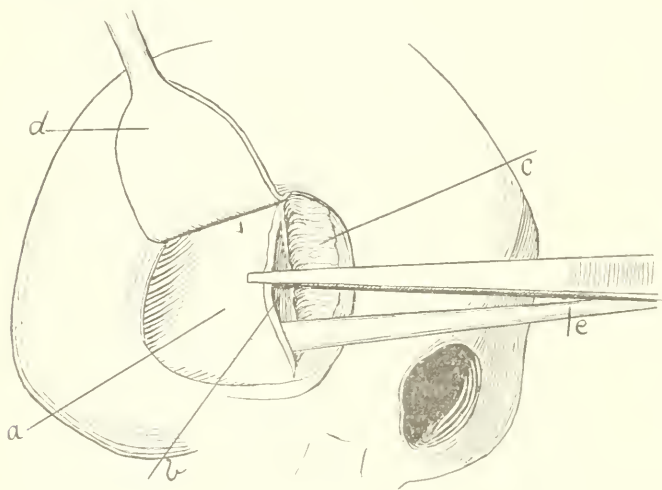


Fig. 22. Denuded deflection in the right naris seen somewhat from the side. The posterior edge of the slit in the cartilage is held with the rat-toothed forceps after it has been lifted up with the elevator. *a*, cartilaginous deflection; *b*, inner surface of the alae nasi of the concavity; *c*, anterior flap; *d*, retractor lifting the wing of the nose; *e*, elevator underneath the cartilage.

with the retractor which holds the nostril open or with a fine double tenaculum. The first cut through the cartilage is then made as formerly, along the entire base of the reflected anterior flap (Fig. 23). In the region below the level of the anterior angle of the quadrangular cartilage, that is, below the upper boundary of the alae nasi, the incision may be made at the very front of the cartilage, if the deflection extend so far in front, above this boundary, where the quadrangular cartilage underlies the lateral cartilages of the external nose, the incision should leave a distance of

at least one-half a centimeter, about a quarter of an inch, between it and the under surface of the nasal bridge in order to furnish the support for the external nose demanded by Mueller and Menzel. In making the first cut the blade is not held at a right angle to the surface, but is slightly inclined away from the operator. This makes an oblique cut into which the spatula is readily inserted for lifting up the cartilage. I no longer conduct the whole of the elevation of the mucosa of the concave side through a single anterior incision in the cartilage, but merely free a small strip of the cartilage back of the incision, working the spatula downward on the concave side until I reach the base of

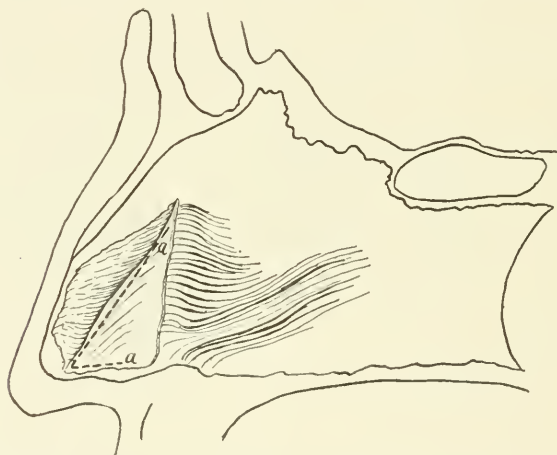


Fig. 23. Lateral view of the septum; *a a*, first incisions in cartilage outlining a tonguelike flap.

the septum. The Ingals' cartilage knife is then introduced into the small space created under the cartilage, its point is turned away from the mucosa of the concavity and a small horizontal incision is made in the cartilage along its base toward the front. This produces a small angular cartilaginous flap which gives more room for freeing the mucosa of the concavity than the single cut does (Fig. 23, *a, a*).

The rarer crestlike deflections usually begin deeper in the naris than those with double angle. The first incision in the cartilage in these is made vertically in the plane septum just in front of the beginning of the deflection (Fig. 14, *c*). This plan is adhered to

even where the deflection is wholly osseous, the cartilage being undermined until the bone is reached. If desired a small anterior flap can be made to cover the site of the first cut.

The Separation of the Mucosa on the Concave Side.—The separation of the mucosa of the concavity may be watched from the nostril of the convexity or of the concavity of the deflection. In the latter case the motions of the instruments may be plainly seen under the covering of the septum. The little angular cartilage flap just described gives such a free approach to the parts underneath the cartilage that I now almost always look into the naris of the convexity while conducting the separation of the opposite mucosa, only occasionally glancing into the other to see that no perforation has occurred and that the hollow of the concavity is becoming effaced.

As Killian states, the elevation of the mucosa of the concavity, if strictly subperichondrial, is usually easy, and it may generally be conducted with the dulled separator, but he also speaks of the adhesions in deep grooves and depressions. In my experience not infrequently a rapidly progressing, manifestly subperichondrial elevation is unexpectedly checked by an area of firm cohesion between the perichondrium and periosteum and the cartilage or bone so that a dull separator would punch through, progress becoming impossible except by dissection with the sharp spatula. The separation is also apt to be tedious where the concavity forms a very deep hollow whose curved walls are hard to follow with the separators.

Where Killian encounters adherent areas he advises waiting to release them until a good-sized piece of cartilage is resected to give access to them. This is a good method where the area of adhesion is large or inaccessible. Usually I finish the separation in one act, dissecting off the adherent places. While the elevation of the mucosa of the concavity progresses the rat-toothed forceps pull aside the freed portion of cartilage. In separating the perichondrium the curve of the spatula should look toward the cartilage in order to keep the end of the instrument upon its surface. The most difficult separation is usually found below the deepest pit or trough of the concavity on the side of the vomer or crista and the separation of the periosteum from here may have to be deferred until the resection of the cartilage gives better access.

The separation on the concave side is not finished until the mucous membrane hangs away from the hollow of the deflection and the septum looks straight in the nostril of the concavity.

The Resection of the Cartilage.—Before cutting away the cartilage the operator must be sure that it is entirely bared of its coverings on both sides lest a piece of mucosa be torn out with it when it is removed.

Since my earliest operations, as described in my first paper, in March, 1902 (the correction of deflections of the nasal septum with a minimum of traumatism, *Journal of the A. M. A.*, March 8, 1902), I have usually succeeded in removing all, or the greater part of the cartilaginous deflection in one piece. I have never had to change the method of doing this.

The bared cartilage is pulled outward with the rat-toothed forceps, while Ingals' cartilage knife (Fig. 12, *H*) is introduced underneath it to the back of the pocket of mucosa on the concave side of the deflection. Its point is directed toward the *convex* side and its *back* toward the mucosa of the *concavity*, it is then made to prick through the cartilage at the bottom and hindmost part of the cartilaginous deflection, and its blade is then drawn forward cutting through the bottom of the cartilage along its whole length, from the concave toward the convex side, and severing the cartilaginous deflection below. To cut through it at the back, an angular cartilage knife is chosen whose edge looks downward when its point is directed away from the concavity. This knife is also passed to the bottom of the mucous membrane pocket of the concavity underneath the cartilage (Fig. 24), its point turned away from the concavity, made to prick through the cartilage at the highest point in the rear of the cartilaginous deflection and the blade is then made to sweep downward, severing the cartilage at the back. The other of the pair of angular cartilage knives is now inserted into the slit made by the first one, the handle depressed and the blade made to sweep forward cutting through the cartilage above. The piece being now severed at all of its boundaries is readily drawn out of the nostril.

I regard the exsection of the cartilaginous deflection as one of the simplest acts of the whole performance. If the cartilage be thick, repeated strokes of the knives instead of one will finally cut through it, but for very thick cartilage I have an extra pair of longer angular blades (Fig. 12, *F, G*). They are very seldom

needed, and a convenience rather than a necessity. The whole maneuver is done with the aid of vision and under the intelligent guidance of the hand, so that one can exactly outline the piece to be removed. Remaining vestiges of the cartilaginous deflection

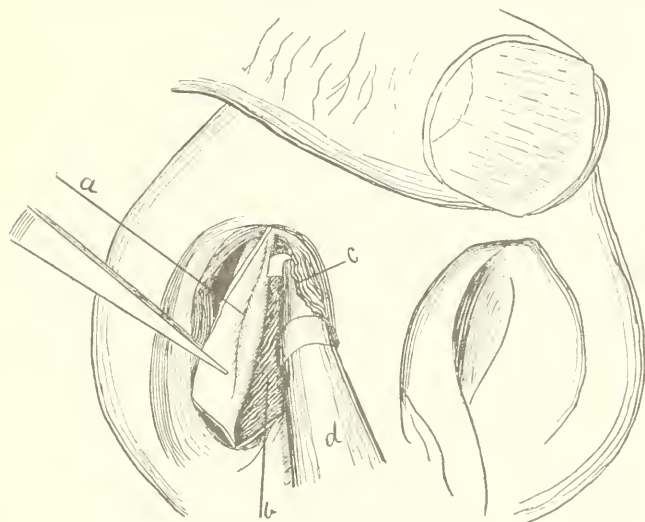


Fig. 24. The cartilaginous deflection, including the vertical angle *a*, has been cut through at its base and in front and is being severed behind and above by the angular cartilage knives; *b*, inner surface of the mucosa of the concavity of the deflection; *c*, anterior flap folded out of the way; *d*, angular cartilage knife.

may be pared off strip by strip with the angular knives, the sharp separator or Ingals' knife, and I rarely now use cutting forceps on the cartilage.




Fig. 25. Killian's forked cartilage knife.

In distinction to this method Killian uses a forked cartilage knife (Fig. 25) with a little blade between the tines of the fork designed to cut horizontally from in front. This knife is pushed backward, the cartilage entering the space between the tines of

the fork as the knife advances into it. In this manner a cut is made at the bottom and top of the deflection. The piece between these incisions is then removed with dressing forceps ("Kornzange"). It is to be inferred from this that its posterior attachment is torn away. This is not exact surgery, for the tough cartilage is apt to tear through in an unwished for place, so that one may remove too little or too much, and so tear out unseparated mucosa behind. I quote Killian literally: "Das Instrument wird in der Weise verwandt, dass man das zu resezierende Knorpelstueck zuerst oben, dann unten in der Richtung von vorn nach hinten durchschneidet und dann *das zwischenliegende Stueck mit der Kornzange entfernt.*" Killian says that the distance between the tines of his fork "corresponds to the thickness of the cartilage of the septum." This distance, as I have measured it, is three-thirty-seconds of an inch. In sixteen of my cases the cartilage was either uniformly or in places one-eighth to five-sixteenths of an




Fig. 26. Ballenger's swivel cartilage knife.

inch thick, and in these it could not have been made to enter a fork whose tines were three-thirty-seconds of an inch apart, so that the advance of the knife in these cases would have been impossible.

W. L. Ballenger has greatly improved Killian's knife by making the blade movable on a swivel joint, so that no matter what the position of the fork the edge of the knife is always in advance (Fig. 26). In this way he can cut above and behind and thus remove a piece in one process.

Ballenger's knife, though it has the tines of the fork three-sixteenths of an inch apart, has a blade no wider than Killian's, about three-thirty-seconds of an inch, and it would therefore also be useless where the septum is thicker than this. If the blade be made wider the tines of the fork must also be further apart and Ballenger did not find this practical. His fork necessarily projects beyond the seat of the knife so that an excess of separation of the mucosa is needed behind to make room for this in

cutting upward, and a strip of bared cartilage therefore remains attached posteriorly. In an instance that has come to the author's knowledge, the cartilage was so thick that it pried the advancing fork open causing the blade to drop out, showing that cartilage may be encountered that is too thick for even Ballenger's broad fork. Barring these objections Ballenger's knife is undoubtedly serviceable, but I can see no need of a substitute for my simple knives whose fixed blades are more accurately guided than a swinging swivel blade between the tines of a fork. Besides, my knives can cut any thickness of cartilage encountered.

White and Menzel remove the cartilage piecemeal with cutting forceps. Mueller cuts above and below with scissors and breaks out the pieces with dressing forceps. The first method is needlessly tedious and the second rough surgery.

The Resection of Bony Deflections. The Instrumentarium.—The punch forceps, according to my experience, removes bony deflections with more accuracy and less pain than any other instrument. A forceps designed for the resection of the bone should be slender, so as not to obstruct the view and to move freely in the cavity of the naris; the part in front of the lock should be straight and at least $3\frac{1}{2}$ inches (9 centimeters) long, for bone may have to be cut at a distance of $2\frac{1}{2}$ to 3 inches from the front of the nostril and a little length to spare is needed. The jaws should hinge on a rivet at the end of the forceps, so that they will separate widely in a small space and so that the opening of the instrument will not obstruct the view, as it does when the jaws are moved on the rivet of the lock of the forceps. The forceps should be of the "punch" variety, one jaw fitting within the other instead of merely having its cutting edge applied to that of its fellow, as this latter type of instrument will not cut bone unless it be made so heavy that it blocks the nostril. In spite of the qualities of length and slenderness the instrument should be so strong that it will easily cut through the thickest and hardest bone found in the septum.

The Gruenwald forceps, which I have used for years, possesses these qualities to perfection except the last. For bone was occasionally met with which this forceps, strong as it is, could not cut through, or only after the jaws were repeatedly closed upon it. I have therefore strengthened Gruenwald's forceps by giving it a forceps handle instead of a scissors handle and by other

changes, so that I now have an instrument that will cut through the heaviest bone in the septum, even the crista and anterior end of the vomer, with a moderate pressure of the hand. The slenderness and length of the forceps has been preserved and the jaws open laterally instead of vertically, as in the original, adapting the instrument still better for the septum. The blades are made only partly fenestrated, a ledge remaining designed to preserve the strength of the blade and to retain the excised pieces and keep them from falling out in the nose. My modified forceps (*Fraenkel's Archiv fuer Laryngologie*, Vol. 17, page 172), like

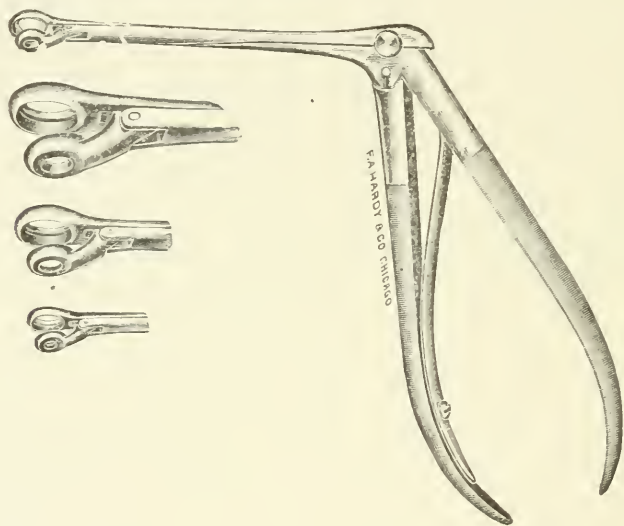


Fig. 27. Freer's modified Gruenwald forceps.

Gruenwald's, is made in 3 sizes. (Fig. 27.) The operator needs the middle and smallest sizes. The large one is an occasional convenience.

Killian employs Hartmann's (Fig. 28) punch forceps. This does not nearly equal Gruenwald's in strength, for its rivet is too weak and the distance from it to the end of the blades is too long. It is too light to be reliable for cutting bone and would break easily.

The Jansen-Middleton forceps (Fig. 29) has been lately recommended for the operation. It is powerful, yet, on account of its spoon-shaped blades, whose edges merely meet instead of fit-

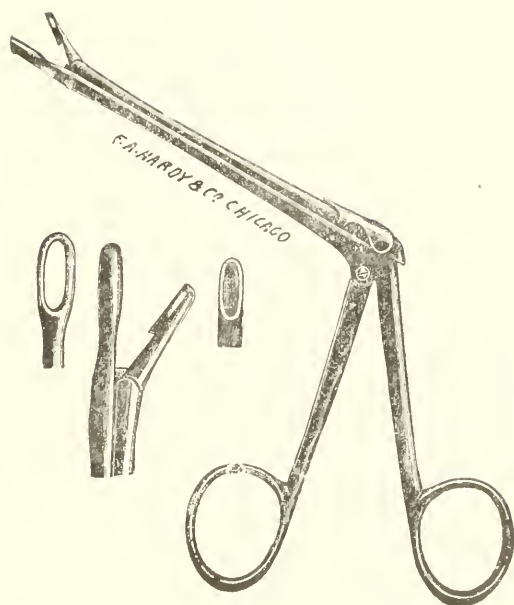


Fig. 28. Hartmann's punch forceps.

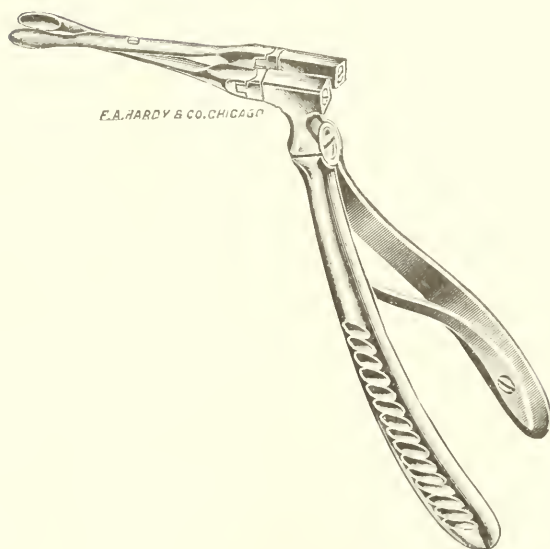

Fig. 29. Jansen-Middleton forceps.

ting into each other, it cannot make a clean cut in bone. Hajek (Fig. 30) has adapted the punch and die system to this same forceps and his modification does cut bone. Both patterns of forceps, however, are only fairly slender for $1\frac{1}{2}$ inches back of

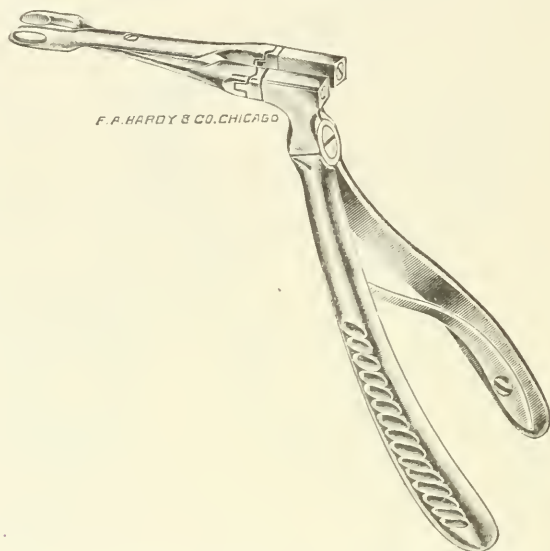


Fig. 30. Hajek's modification of the Jansen-Middleton forceps.

the cutting end, behind this the broad square sockets of the joints make them too large to enter the nostril, hence they cannot be employed deep in the naris.

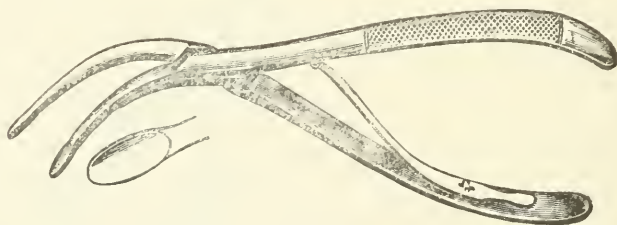


Fig. 31. White's forceps.

White states that the distance from the lock to the ends of the cutting blades of his forceps (Fig. 31), which is of the Hartmann rongeur pattern and is not a punch but a spoon-bladed one, is 7 centimeters, but not more than 5 centimeters of this length

is available, because of the strong curve of the blades whose massiveness unfits them for work in a narrow cavity.

In addition to punch forceps, a chisel or gouge (Fig. 12, *N, O, P,*) is required for the removal of the deflected crista and the anterior end of the vomer. Killian employs a strong bayonet-shaped gouge, the distance from the cutting end to the bayonet angle being $1\frac{1}{4}$ inches, so that the instrument could only be used an inch back of the anterior nasal spine. (Fig. 32.)

The saw is not suited to the operation, and most authors do not mention it.

Scissors only cut to advantage horizontally in the nose and the bone of the septum is too strong for them in most places.

I have employed the dental motor and trephine but 3 times in my last 50 operations. I restrict it to cases where there is need of removal of the anterior plane of a thick vertical deflection far back in the vomer. (Figs. 6 and 7.) Such obstructions lie across the naris like a wall and are hard to grasp with forceps. The



Fig. 32. Killian's gouge.

trephine I use is unguarded, $1\frac{3}{4}$ inches long, and its diameter is three-sixteenths of an inch.

The Removal of the Bone.—The bony part of the operation receives such slight mention from most authors and the means described for its performance are so inadequate that the inference is natural that it is frequently not thoroughly done. Yet it is often the most difficult act of the resection, and unless all vestiges of the bony deviation be removed a half result is likely to occur, for which the surgeon will always feel apologetic.

In most bony deflections, in looking directly *backward* in the naris of the convexity, after completion of the resection of the cartilage, one sees the steep superior border of the vomer joined above, at an angle caused by the deflection, by the anterior inferior border of the perpendicular plate or more often by a remnant of cartilage which is the posterior angle of the quadrangular cartilage. The angle of deflection mentioned is the horizontal angle in vertical section and appears like a V lying upon its side (Fig. 33), and it is this V and the parts back of it that are to be resected posteriorly. Looking *downward* at the floor of the

nose the continuation of the superior border of the vomer forward and the crista are seen, freed of cartilage, the vomer and crista curling over towards the naris of the convexity, sometimes so strongly that they lie nearly flat on the nasal floor, making the surface belonging to the concave side look upward and simulate the bottom of the naris.

The bony resection begins with the extirpation of the posterior V mentioned. The operator should assure himself beforehand that the bone is completely freed from its covering on both sides. It is easy to avoid injuring the liberated mucosa and no long speculum is needed in my operation to hold the mucous

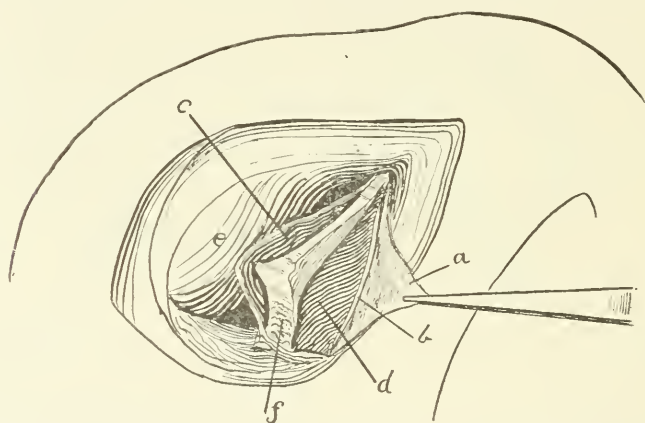


Fig. 33. V-shaped profile of bony deflection seen after removal of cartilaginous deviation; *a*, anterior flap; *b*, anterior cut edge of cartilage; *c*, separated mucosa of convexity of deflection; *d*, inner surface of mucosa of concavity of deflection; *e*, inferior turbinate; *f*, vomer.

sacks open: at the most the spatula is required to lift away the mucosa of the convexity: that of the concavity hangs away. The forceps is now introduced, its jaws slipped as far onto the bone as possible, piece after piece bitten out, and the V followed upward and backward until completely removed, even if it extend to the posterior end of the vomer. Where in an extreme deflection the V crowds firmly against the inferior turbinate, it is sometimes difficult to wedge even the blade of the forceps, not to speak of it and a speculum blade into the fissure so created, and I do not see how Killian can cut out bony deflections of this nature between the blades of his long speculum. In these very difficult

deflections one cannot always save all of the hindmost part of the mucosa of the convexity and the operator should not let the wish to preserve it or the fear of a possible perforation keep him from a thorough resection of the bone, for the loss of some of the mucosa or the occurrence of a perforation far back in the naris are of little consequence, while an imperfect result is a great disappointment.

After the resection of the V posteriorly the curved over maxillary crest and front of the vomer, on the nasal floor, next need removal. They should be reinspected to see whether they are denuded of their covering, for the separation of the mucosa over these bony parts has very often to be put off until the last because of the difficulty of its removal. It is frequently firmly adherent because, as Killian states, the front end of the vomer and the crista are enveloped in their own periosteum, which therefore covers their upper border after the cartilage has been resected from it. This periosteum is continuous with and has the same color as the perichondrium lining the inner surface of the mucosa of the concavity, so that no boundary is visible where this is reflected onto the bone, and the edge of the bone can therefore not be seen but must be felt for and cut down on with the round-edged knife. The bone often needs to be dissected out from its coverings by keen dissection with the sharp spatula and the knife *A* (Fig. 12), which is designed to release it on the concave side, for the periosteum in this region is frequently too adherent to be scraped away.

When the anterior end of the vomer and the crista stand bare they may be cut away with my forceps if they project enough to be seized with it. If not, the chisel is applied in front and driven back as far as the bone is deviated with light taps of a small mallet. Killian advises to then lift the chisel and to break off the severed strip behind. This is an excellent method. It is also proper in this locality, and this only, to twist off with dressing forceps the posterior attachment of the fragment partly detached with the chisel, for no harm can come from doing this so near the nasal floor.

The chisel is only suited to the strong, well-supported base of the vomer and crista, and should not be used higher up on the septum, as it is liable to shiver the frail and brittle bone in these regions and create far-reaching fissures.

Breaking out of pieces of bone by twisting with forceps is also to be avoided except in the one place mentioned for the same reasons. It causes great pain, and the result of the violence may be fracture in distant places.

When the resection seems complete an attempt should be made to smooth down the flaps on the septum. If remnants of the deviation exist above or below, the mucous membrane will not lie down and the projecting bone or cartilage must be trimmed off until it does.

The concave side should also be inspected to see whether the hollow be effaced.

Killian directs the operator to cut away the thin part of the vomer and lamina perpendicularis with the Hartmann forceps above the crest, and then, with the same instrument, to resect the vomer below it, behind the part cut away with the gouge. The

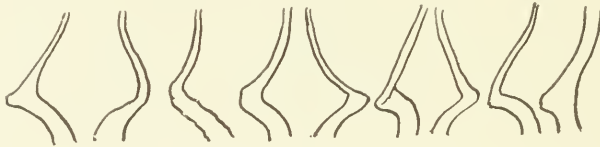

Fig. 34. Vertical profile of some of the bony deflections encountered showing thick vomer.

crest of the deflection he then breaks out with the forceps after it is thus freed from above and below. I agree with Killian that the bone above the crest is usually thin, but am not in accord with his statement that "the vomer below a deviation and crest is always very thin." On the contrary, I have found the vomer below the horizontal crest of deflection so often strong and massive that I regard thickness, and not thinness, of this part as typical. (Fig. 34.) I do not think the weak Hartmann forceps could have cut the bone I encountered in many cases. To break out the strong angle of the bony deviation from its often frail and brittle setting behind, after it has been freed above and below, as Killian does, is inexact surgery, would be very painful and might lead to fractures in the lamina perpendicularis, reaching far beyond the intended break.

Mueller outlines a tongue of cartilage and bone above and below with scissors and with dressing forceps twists out the devia-

tion in one piece or several fragments: a primitive and painful method that includes the danger mentioned.

Suturing.—Killian says that, as a rule, he no longer sews, and he only recommends sutures if a perforation through both layers of the mucosa in the same place has occurred.

White has a special pair of alligator needle holders, and sews his flap with them in about ten minutes.

Krieg and Mueller, of course, do not sew, as they remove the mucosa of the convexity.

Zarniko has ceased to sew, and Weil depends on the tampon, as I do, to retain the flap in place.

I regard sutures as unnecessary. White and Menzel are, therefore, the only ones who make suturing a regular step of the operation, and I think that in time it will disappear from it, except for

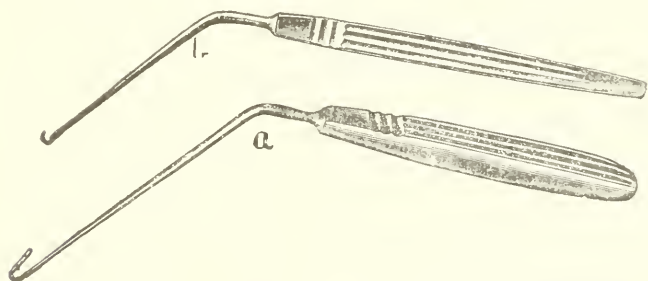


Fig. 35. Killian's needle, *a*; *b*, fine hook to catch thread.

the purpose indicated by Killian. For sewing in the deeper parts of the naris Killian employs a needle (Fig. 35, *a*) bent at an acute angle on the end of a long stem attached to a handle. The threaded needle is passed through both edges of the wound in the mucosa from before backward, the edges being steadied with forceps. The thread is then caught with a minute hook (Fig. 35, *b*) and the needle pulled out, leaving the thread in place. It is then tied with the aid of dressing forceps.

The Tamponade.—Mueller and Zarniko permit the patient to go home without packing the nostril; all of the other authors use a tampon.

I have always packed the naris in all of my cases, and nevertheless twice, merely because I tamponed too loosely, I have had severe delayed hemorrhage occur about two hours after the operation. I regard it as dangerous to dismiss a patient unless the

naris be evenly plugged on the operated side and on both, if there has been a perforation.

Killian always plugs both sides. I regard this as needless discomfort to the patient.

I still use sterilized lint, impregnated with subnitrate of bismuth, for my tampon, and in no case, even when the plug has been in the nose a week, has it become offensive. Bismuth is far superior to iodoform as an antiseptic in these cases.

I no longer pack with one long strip, but introduce the lint in successive layers. It is cut in ribbons one-quarter of an

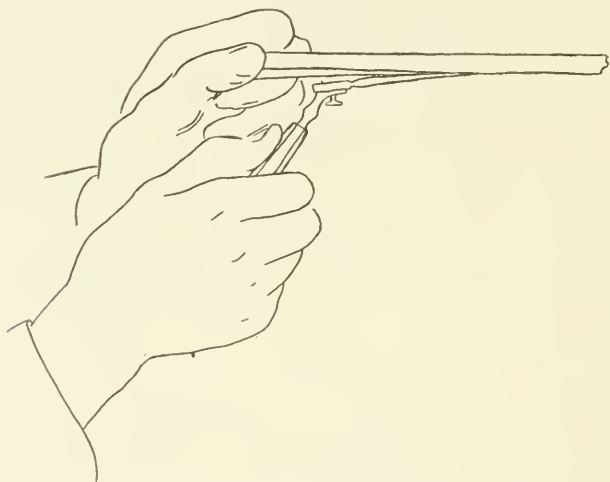


Fig. 36. Strip of bismuth lint pulled taut against end of probe for introduction.

inch wide and eight to ten inches long. Before packing the nose the flaps are smoothed down into the place with a small swab and readily adhere. I have long discarded the use of a metal guard to protect the wound while packing, as it prevents the even filling of the naris and leaves the tampon loose when the guard is withdrawn.

To begin the packing, a strip is folded in its middle, the ends being held between the thumb and index finger of the left hand, while the right pushes the end of a stiff nasal probe, such as Gruenwald's, against the bottom of the fold to hold the strip taut. (Fig. 36.) Its ends may also be held with the thumb and

finger of the same hand that holds the probe. The strip, stretched in this manner, is passed in along the nasal floor to a little beyond the posterior end of the window. It is then pressed down on the nasal floor with the probe. If the resection of a crestlike deflection has left an inferior flap or pocket of mucosa, it is to be supported by the strip. In the same manner successive strips are then introduced (Fig. 37), one above the other, until the nose is nearly full, the ends of those in the naris being held against the upper lip with the ring finger of the left hand while the next one is passed in. As the tampon builds up it sustains the flaps so that they can-

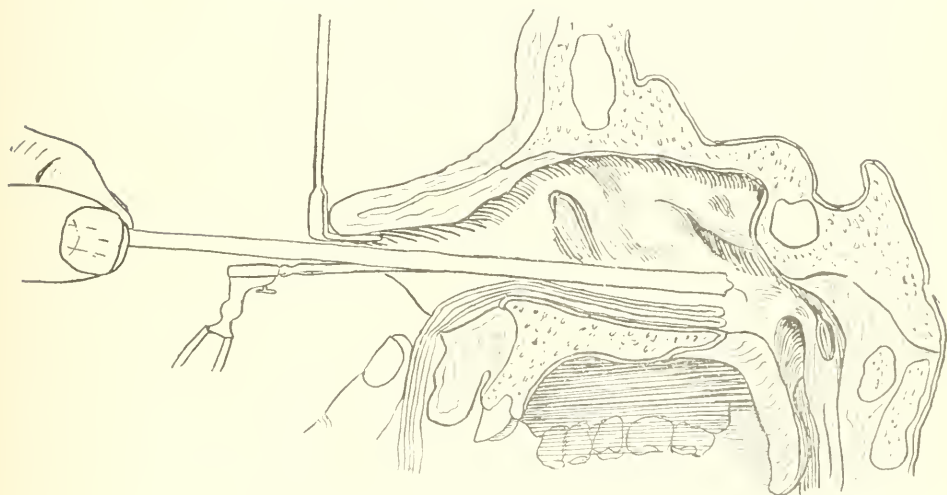


Fig. 37. Lateral view of nasal fossa. Two folded strips of the tampon lie in the naris, the loose ends being held with the finger against the upper lip. A third strip is being introduced stretched against the end of a probe.

not become displaced. They are not always redundant enough to meet exactly at their edges, but a small raw surface left by their retraction is of no moment. The last strip is longer than the others and is tucked in on top in successive little folds, as was done in my older method of packing, completing the filling of the naris.

This packing may be relied upon to prevent hemorrhage, but an hour or two after the operation, no matter how completely the naris be stuffed, a watery, free, mucous discharge, tinged with blood, usually sets in and is caused by the relaxation of the vessels constricted by the adrenalin and cocain. If the patient

be not warned of this discharge he is apt to think that his nose is bleeding, and in his alarm to needlessly disturb the surgeon.

The removal of the packing is begun on the second day after the operation by withdrawing the top strip and as much of the others as will pull out easily and without bleeding. When all hold fast, or when a few drops of blood appear, the removal of the rest is deferred until the next day. In the average case the tampon is out by the third day. The parallel situation of the strips prevents excessive bulging of the mucosa over the window into the naris of the concavity.

The patient only needs to stay in bed on the day of the operation. After that he may be up and about, but should not go to work for a week.

The after-treatment is simple. For the first ten days the naris is kept closed with a pledget of cotton in the nasal vestibule to exclude dust and keep the secretions moist. After this the patient may use the naris for respiration, is told to spray it out with normal salt solution and to insert a little plug of wet cotton in the nostril for a few hours whenever needed to soften dried secretion. In addition an ointment of salicylic acid, 10 grains to 6 drachms of lanolin and 2 drachms of vaselin is swabbed into the nasal vestibule by the patient to prevent hardened mucus from adhering. After four to six weeks the nose needs no further treatment.

During the first two to three weeks after the operation the soft parts of the septum are somewhat swollen, so that the patient has not the free breathing he obtains later, nasal respiration continuously improving until after six weeks the naris becomes ideally clear.

A review of the literature of the subject of the window resection has shown me that each author has created his own methods with little heed for what others have done, so that to the novice the already large list of ways of doing the operation must be bewildering. Comparison of methods and custom will in time evolve an operation of classic uniformity, and it is to be presumed that the best will survive.

Suckstorff, in his brief history of the window resection, says that "through Killian's modification the submucous resection has been elevated to a height that should satisfy all reasonable demands." Neither Killian's views, instrumentarium or methods, seem to me so faultless that they deserve this praise. His state-

ment that he does the operation in the average time of twenty minutes sounds rather like quick, than careful, surgery. I quote literally from Killian's article: "Zur Vornahme der ganzen Operation brauche ich im *Durchschnitt* 20 Minuten." The *minimum* time that I need for a purely cartilaginous deflection is twenty minutes, but the average time for my operations is at least three-quarters of an hour to an hour, for in 60 per cent. of my cases more or less difficult bony deflections needed removal. An average time of twenty minutes for me would mean that my purely cartilaginous deviations were resected in about five minutes, or else that I did not extirpate the bony deviations completely. It may be urged that Killian is a rapid operator, and that his method saves time. As to the method, if I had to resect the numerous massive, deep-seated, prolonged bony deviations that I have met, by means of a button-hole incision in front, a long speculum to obstruct the entrance of the naris, the weak Hartmann forceps, Killian's short gouge and a dressing forceps, I should take much longer than I do now. Granting that Killian is the speediest of operators, he cannot so far outstrip all others that he can do in an average of twenty minutes what other operators of great experience admit has the one fault of a tedious operation. The depth and narrowness of the field in the bony operation, the strained vision needed to see to slip the blades of the forceps over the edge of the bone, the difficulty of wedging a blade between marked deviations and the inferior turbinate, the need of frequent wiping, as a drop of blood obscures the remote, contracted field, these are all factors that make the bony operation necessarily prolonged, if it is to be well done by any operator.

Conclusions.—1. The appearance of deflections does not divide them naturally into two great groups with distinct aspect, one obviously traumatic and the other due to faulty growth, as is taught by Killian. To consider etiology in this way in the description of deflections is merely confusing, and it is better as heretofore to group them according to their shape.

2. The window resection is adapted to children, but the chance of a possible recurrence from the effects of growth demands a very complete removal of the vestiges of the deflection.

3. The firmness, and therefore probably the cartilage and bone

of the septum, is completely or nearly completely reproduced in the window after the resection.

4. Cases seen two and a half years after the operation show permanency of the result.

5. Though the author has never seen a case of sinking in of the nasal bridge after the window resection, Mueller's and Menzel's warning should be heeded, to retain a strip of the cartilage of the septum under the lateral cartilages of the external nose.

6. The lower portion of the quadrangular cartilage, as high as the level of the alae nasi, may be resected without fear from its anterior inferior free border horizontally back to the bone.

7. The recumbent position of the patient is the best for the operation, except in operating along the nasal floor.

8. The Kirstein light is the most suitable one.

9. The use of powdered cocaine, applied with a swab, gives a perfect and safe local anesthesia, and the submucous injection of cocaine is needless except at the very front of the septum.

10. The best access to a deflection for its resection is obtained by mucous membrane incisions along its vertical and horizontal crests, and not by means of a button-hole cut in front of it, such as is made by Killian and others.

11. The separators used for the elevation of the mucosa should be thin, curved and either dulled or knife-edged for dissection.

12. The presence of a nasal angle in an instrument complicates its movements, and makes it necessary to hold it with a stiff wrist and fingers, thus sacrificing the lightness and accuracy of motion of straight instruments.

13. It is better to make the first cut through the cartilage with a keen, thin, round-bladed knife than with a thicker, sharp edge that scratches through.

14. Even if strictly subperichondrial, the elevation of the mucosa is apt to encounter adherent places that need separation by keen dissection.

15. The cutting out of the denuded cartilage in one piece is the easiest part of my method of operation.

16. With the exception of fragments cut with the chisel from the crista incisiva or anterior end of the vomer, neither cartilage nor bone should ever be broken, twisted or torn from its attachment, but should always be cleanly cut away.

17. The author's modification of Gruenwald's punch forceps

has proven the best instrument he has used for resecting the bone, as it is slender and long, and yet easily cuts through the thickest bone encountered.

18. There is a tendency to hasty and incomplete removal of the bony part of the deflection.

19. Sewing is needless.

20. Strips of lint impregnated with subnitrate of bismuth make the best tampon. The author introduces the strips in layers as described, so that the flaps are perfectly held in place.

21. Considering the many difficult bony resections met with the author does not think that the operation can be well done in the average time of twenty minutes, the estimated time of Killian.

THE TREATMENT OF CHRONIC LARYNGEAL AND TRACHEAL STENOSIS.

BY JOHN ROGERS, M.D., AND D. BRYSON DELAVAN, M.D.

THE invention of O'Dwyer, now exploited throughout the world, seems capable of wider and wider application as time advances and experience demonstrates its increasing possibilities of usefulness. Well as its merits have been appreciated, however, the knowledge of some of its most valuable applications seems hardly yet understood, and while more or less regarding them was suggested by O'Dwyer himself, it has remained for others to bring to full development the splendid contribution which he made.

This has been particularly true in the employment of the O'Dwyer tube for the cure of chronic stricture of the larynx and trachea. Recently, however, in the presence of two of the most distinguished of living laryngologists the history of a case of chronic stenosis of the larynx then under treatment by the method about to be described was related. Both at once insisted upon the uselessness of the attempt, giving as a reason that Schroetter's method for the cure of such cases had been a failure, and, consequently, that this new device would not be likely to succeed. Without commenting upon this illogical conclusion I have quoted it to illustrate the general lack of understanding which prevails, even among the most advanced specialists, with regard to the value of

Dr. O'Dwyer's suggestions in the application of his method to a certain difficult class of cases, and to the admirable development of it at the hands of a well-known American surgeon.

I refer to the work of Dr. John Rogers, of New York City, through whose keen appreciation of the possibilities in the case, rare technical skill and untiring ingenuity and patience a new era in the history of chronic laryngeal stenosis has been established. It may be said, indeed, that Dr. Rogers has illuminated every department of this subject. Thus, he has analyzed and explained the various accidents by which chronic stenosis may be produced, and has differentiated between the different kinds of stricture thus resulting. He has made valuable additions to the O'Dwyer tube itself, having devised an attachment to it which renders its use possible in cases where the ordinary tube cannot be retained. He has mastered the technique of the adjustment of the tube to the given case and of the operative processes necessary for the final placement of the tube in the larynx. He has made valuable suggestions as to the practical details of the after-care of patients in process of treatment. Finally, he has accumulated a series of original cases relieved which emphatically establishes the success of the method and which reflects unusual credit upon himself.

As his work has been done quietly and in the spirit of the genuine investigator, unwilling to publish until able to confirm, no apology is necessary for presenting an epitome of it to the Association and in doing this directly from his own hand. The entire article, including a collection of more than twenty original cases, will be published elsewhere.

The causes of chronic obstruction in the larynx and upper trachea are generally classified as follows:

1. Cicatrices of traumatic, operative or inflammatory origin.

When following tracheotomy the deformities may be due to: (a) Contraction of the posterior soft part of the trachea following separation anteriorly by the canula, of the tracheal rings; (b) Dislocation of the cricoid forward and downward, especially when the fistula is through or close to it; (c) Overriding of the cut anterior ends of the tracheal cartilages in too long a fistula; (d) Inversion of the cut anterior ends of the tracheal rings, especially if the fistula is to one side of the median line; (e) Contraction of the trachea around the canula, due to sloughing of the cartilages or rings; (f) Spur formation posteriorly (as after enterostomy),

especially in combination with contraction of the posterior soft portion of the trachea, or dislocation of the lower segment forward and the upper backward, or both.

II. Granulations around a canula or intubation tube, which are much less common than is generally believed.

III. Hypertrophic subglottic laryngitis, most commonly encountered in retained tube cases.

IV. Prolonged and repeated diphtheritic inflammation, which must be exceedingly rare in these days of antitoxin, although it is worth noting that there is at least one case on record in which the exudate was demonstrable on the 151st day.

V. Post-diphtheritic paralysis of the laryngeal abductors, which is sometimes described and must be very rare, but clinically is indistinguishable from

VI. Atrophy of the laryngeal abductors from disuse in retained tube and tracheotomy cases.

VII. Obturation or compression of the respiratory tract by neoplasms.

To make clear the explanation of the treatment proposed I must anticipate by stating that by a "normal" tube is meant one of the ordinary O'Dwyer instruments as originally made by George Ermold & Co. in seven sizes, usually distinguished as suitable, respectively, for a child 1 year old or younger, 2, 3, 4-5, 6-7, 8-9, and 10-12 years of age. For adults the sizes run from 1 to 10, inclusive. By a "special" tube is meant one of the same length as the normal, but in which the neck or constricted portion just below the head or lower end is greater in the transverse diameter, generally by $\frac{1}{32}$ of an inch, or some multiple of this amount. The "retaining swell" or bulging central portion of the tube must at the same time have a transverse diameter at least $\frac{3}{32}$ of an inch greater than the neck, or the tube will certainly be coughed out. In cases of hypertrophic laryngitis which are totally unable to breathe without a tube this difference is too slight, and a difference of $\frac{4}{32}$, or even $\frac{5}{32}$ of an inch, may be required. Life will often depend on this $\frac{1}{32}$ of an inch.

By a "plugged" tube is meant one fitted with a plug made to screw accurately into a perforation in the anterior wall of a normal or special tube, through a tracheal fistula. The plug is perforated at its inner end by a hole which exactly corresponds in size with the lumen of the tube. The plug is provided with a re-


taining pin which, when the plug is in place, prevents it from rotating and so obstructing in the slightest way the lumen of the tube. By previous measurement the tube has a hole bored in its anterior wall, which, when the tube is inserted, lies opposite the tracheal fistula. Into this hole the plug is then screwed and



"Plugged" tube with its opening opposite the fistula through which after the tube is inserted, the "plug" perforated at its inner end to exactly correspond to the lumen of the tube, is screwed into place. The lumen of the tube and that of the plug are kept in exact continuity by the "pin" which is pushed along the groove in the plug into a notch in the tube. The cap screws over the pin and plug and prevents the escape of the pin and so the rotation of the plug.

"pinned" at right angles to the tube. By a "clamped" tube is meant one fitted with a detachable pair of metal clamps made on the principle of an obstetric forceps. In the sides of the tube are cut grooves, which, when the instrument is in place, lie at the

level of the tracheal fistula. Through this the clamps are made to grasp the tube and are then held in place by a collar screwed down around them until the collar touches the tube. The plugged or clamped tube is a guarantee against autoextubation, and at the same time keeps the tracheal fistula from closing.



"Clamped" tube grooved opposite the fistula to receive the clamps which are detachable and applied like an obstetric forceps. The cap screws over them when in place and so retains the clamp in position. This tube also illustrates the principle of a "special" tube, having an abnormally large neck to dilate the strictured area in this instance above the fistula.

The statistics of the 22 histories, which can be submitted in full, include 1 death from nephritis and pneumonia, 2 deaths from asphyxia, 3 failures to cure, 2 relapses many months after apparent cure and still under treatment, 4 apparently cured but under observation or still wearing intubation tubes, 10 cured, that is, without sign of relapse for at least a year.

From these I submit the histories of Cases 9, 21 and 22 as fair examples.

Operations for stenosis of the larynx or trachea are notoriously unsatisfactory except for the removal of new growths, which include granulations. Nevertheless, conditions must occasionally be encountered which can only be remedied by more or less extensive plastic or other surgical interference, and even in these subsequent cicatricial contraction will generally have to be anticipated. Intermittent dilatation with Schroetter's tubes will sometimes succeed, but in the vast majority of these cases the only hope for a permanent cure lies in prolonged dilatation with the O'Dwyer tube, modified if need be, as will be indicated, to suit the individual condition. The inventor of the instrument long ago pointed out its usefulness in this field, but he died before the details of the management could be worked out.

Grouping the cases as they are most frequently met with under the headings of (a) cicatrices, (b) hypertrophic laryngitis, (c) spasm of the adductors, (d) and granulations, it is necessary first to go briefly into the differential diagnosis. Beyond the history and laryngoscopic examination very little need be said about cicatrices except to call attention to the deformities enumerated as following a tracheotomy. But in addition to the resistance they offer to dilatation in the way to be described, after the insertion of an intubation instrument for any considerable period, they re-contrast, if they do so at all, slowly, within days or weeks. A hypertrophic laryngitis, however, is almost always in these days preceded by intubation, and offers no resistance to instrumentation, but after withdrawal of the tube or dilator, the recurrence of the obstruction is immediate, and often complete. Unfortunately, this condition is not generally recognized, being mistaken for edematous cicatrix, or ulcer, or "granulations." One or more of these latter may coexist with the hypertrophic laryngitis, but the latter is the essential lesion, as I have verified by two autopsies and several laryngotomies.

The condition was described many years ago by Köhl (*Archiv f. Klin. Chir.*, 1887, Vol. 35), as a common obstacle to decanulization after tracheotomy for laryngeal diphtheria, and since then seems to have been forgotten. When a combination of hypertrophic laryngitis with cicatrices or ulceration occur together, as seems to be not infrequent in intubated cases, the history coupled

with the resistance to instrumentation and the sudden recurrence of dyspnea after it, should present no great difficulties in diagnosis, although any traumatism of the larynx may give rise to an oedema of quite sudden onset.

The spasm of the adductors, though not strictly speaking a cause of chronic obstruction, so closely simulates it, especially hypertrophic laryngitis, that a little explanation is required. When the larynx is placed at rest for a long time, especially with the large "special" tube about to be recommended, the abductors undergo an atrophy of disuse. After removal of the tube the hypertrophied adductors may close the larynx immediately, or within the next few days, after any slight attack of coughing. A sudden spasm, and that, too, of very dangerous dyspnoea, generally occurring at night, and inspiratory rather than expiratory, is quite characteristic. When the condition is suspected, especially in a patient who has been intubated, the diagnosis can generally be confirmed by extubating under a general anesthetic. This does away with "reflexes" and fright, and normal respiration may be discovered, where it might not otherwise be anticipated.

Granulations may be found by sight or touch, bleed easily, and are characterized in a case which has been wearing a tube or canula by a spasmodic cough with a gradually increasing obstruction, either to inspiration or expiration, seldom to both at once. In my experience they have been very much less commonly encountered than hypertrophic laryngitis or adductor spasm.

In a former article on this subject I recommended the long continued use of as large a normal intubation tube as the larynx would admit, but experience has caused me to modify this treatment very materially for the different conditions. Simple chronic hypertrophic subglottic laryngitis is probably the most common cause of obstruction after intubation. This ought to read "after diphtheria," because it seems unfair to imply that it is due to intubation, inasmuch as it was recognized as one of the most frequent obstacles to the removal of a tracheal canula long before intubation was invented.¹ It may also occur entirely independently of any acute disease, and Case 1 seems to be an example of this. There will, however, be considerable difficulty in convincing most intubators that unskilled or rough instrumentation does not have something to do with its inception or continuance. For

¹Köhl.

a certain number of these cases will get well in the course of days or weeks with careful and frequent change of a tube, smaller if need be than the development of the patient would ordinarily indicate, the object being to minimize traumatism. Local astringents, as advised by Dr. O'Dwyer, applied to the interior of the larynx in a coating of gelatin or other substance adhering to the outer surface of the tube, may also succeed. But there are a number of cases—about one in every 100—intubated, as estimated from the statistics given in my previous paper, which will resist all these efforts for their relief. If the stenosis of this character has persisted for about a month in spite of all the usual plans of treatment, and spasm of the adductors can be excluded, another method must be adopted. Some of the patients will recover if as large a normal tube as can pass the cricoid cartilage is used for 5 to 6 months and changed at intervals only for cleansing. At the end of every four or five weeks the tube becomes foul and causes a bad odor in the breath and considerable cough. But usually in a persistent case it is better to start with a "special" tube or one having the neck one or more thirty-seconds of an inch larger in the transverse diameter than the normal instrument with the object of applying pressure upon the thickened area within the larynx. As this area generally extends from above the vocal cords to or through the cricoid cartilage, and as the retaining swell of the tube must be enlarged with the "neck" to prevent auto-extubation, the retaining swell of the special tube must be enlarged along with the neck; and the same must be done with the head or there is danger of the instrument slipping below the epiglottis, which will then more or less completely occlude the upper aperture. Practically in these cases I am accustomed to make trials with normal tubes of increasing calibre, under complete anaesthesia if necessary, until I have found the largest tube which will enter and pass through the larynx with some slight force. The "special" tube is then made of the length of the normal tube proper for the age and development of the patient, but with a retaining swell having the diameter of the trial tube. The neck must then be at least three-thirty-seconds of an inch smaller than the retaining swell and the head six-thirty-seconds of an inch larger. If a metal tube is to be used its weight is better and more safely sustained by a head which is at least seven-thirty-seconds of an inch larger than

the retaining swell and a large tube should have eight-thirty-seconds of an inch difference. If the child is under four or five years of age and so needs the smaller sized tubes, the thirty-seconds of an inch difference should be altered to sixty-fourths of an inch. Moreover, a difference of three-thirty-seconds of an inch between the neck and retaining swell is the minimum difference which I have found by experience sufficient to keep the tube in place. Some patients will require four-thirty-seconds or even five-thirty-seconds of an inch difference. In the first part of the treatment of a hypertrophic laryngitis, especially if the stenosis is complete as is frequently the case, it is wise to start with a special tube having the diameter of the neck five-thirty-seconds of an inch less than that of the retaining swell. Care in these seemingly minute details may mean all the difference between life and death, as unexpected autoextubation or aspiration of the tube into the trachea can easily be fatal accidents. After a special tube thus carefully made has been worn a month or six weeks, it usually must be changed and cleaned or the accumulation on it may cause it to clog suddenly or produce ulceration or a septic bronchitis or pneumonia. Another tube should be at hand of one-sixty-fourth or one-thirty-second of an inch larger diameter through the neck and retaining swell than the last. Some slight improvement in the stenosis can generally thus be detected in the resistance offered to intubation if it is not clinically apparent. The judgment of the operator must determine the amount of pressure which can be borne without sloughing. Fortunately the larynx seems capable of bearing much more traumatism in these chronic conditions than one would think possible, and if some little ulceration occurs, as it often must, the epithelium will, in course of time, cover the raw area unless the pressure is extreme. Furthermore this ulcerative process, if not too extensive, may actually be the way in which cure takes place in these cases of simple hypertrophic laryngitis. Scattered areas of fibrous cicatricial tissue may, in contracting against the cartilages, do away with the preceeding chronic exudative and productive inflammation. A most important question in these, and to a less extent in other cases having another etiology, lies in the use of metal or vulcanized rubber tubes. The metal instrument is usually made of bronze or some less expensive compound, heavily gold plated. At any rate, it is composed of two different metals, the exposed

part being gold. In two or three of the cases of hypertrophic laryngitis described above, absolutely no progress could be made after weeks or months of treatment with hard rubber tubes so constructed as to make all the pressure the larynx seemed able to bear. Then after the substitution for the special rubber tube of a similar or slightly smaller compound metal tube, either a cure or very marked improvement was found at the next change or within four or five weeks. I am unable to explain this fact, except on the theory of some electrolytic action. The metal instrument is far heavier than the rubber and pressure may have something to do with its advantages, but I doubt it, as I know I have made more pressure with a large rubber than with any metal tube, and there must be some other reason for the difference. The claims for electrolysis are generally regarded with suspicion, but these metal tubes, after being worn a month or two, become heavily coated wherever they press most upon the larynx, that is chiefly around the head and neck, with a stony, calcareous deposit, and under and around this the gold plating entirely disappears. There is, of course, no acid or alkali in the body which can dissolve gold, and it does not chip off, but apparently dissolves. The external calcareous deposit of course roughens the surface, and if the tube is worn for a long time, may reach such proportions as to prove a very serious obstacle in extraction. I once met with such a case in the practice of a colleague in which the tube, having been in place for several months, required for removal general anaesthesia and a strong pair of forceps to permit a firm grasp of the head of the tube. The metal tube will, however, if so constructed as to exert moderate pressure upon all the thickened tissue of a hypertrophic laryngitis, sooner or later produce a cure. But the patient who wears one must be constantly watched, as it has a tendency to clog and it thus asphyxiated one of my cases (Case 5) and very nearly did the same with another (Case 15), and, naturally, after those experiences, I have always been afraid of these tubes and only resort to them when the special hard rubber instrument after thorough trial in increasing sizes, proves a failure.

Autoextubation is a frequent and very dangerous complication in any intubated case, but especially dangerous in hypertrophic laryngitis and consideration of it introduces the "special" or normal "clamped" or "plugged" tubes. Some patients will cough

out any tube which has not such a mechanical attachment to keep it in place, and as autoextubation is most common with hypertrophic laryngitis, I have come to believe that some degree of this condition is, if not the primary, at least the secondary cause of the difficulty. The chronically inflamed tissues, are irritable and their contact with the tube excites coughing, accompanied by retching or involuntary expulsive contraction of the pharynx. The combination of an attempt to cough and vomit at the same time seems the surest way for the patient to get rid of the tube, and life generally depends on its immediate reinsertion or a hasty tracheotomy. The latter operation, probably by giving rest to the larynx, seems occasionally to produce a cure, but ordinarily it only adds a cicatrix and a possible tracheal deformity to an already bad enough condition. If there were no other way to escape the dangers of autoextubation it might be justifiable, but hypertrophic laryngitis used to be one of the most frequent obstacles to decanulization, and it seems hardly proper to inflict a tracheal fistula for its cure. Hence the tube must be kept in the larynx, and for this purpose I offer the "clamped" or "plugged" instrument. If autoextubation is at all frequent the trachea is carefully opened in the median line through the second and third rings and the intubation tube while in position marked to correspond with the incision, or if a tracheal fistula has already been made the tube is inserted and marked at a point coinciding with the fistula. During the few succeeding days required to make the instrument, the canula will have to be worn, but this inflicts the least possible damage. Some explanation is required as to the comparative advantages of a "clamped" or "plugged" tube, and as to the use of such an instrument in general. It is assumed that the trachea is opened carefully in the median line, well below the cricoid and only enough to comfortably admit the canula and subsequently the retaining attachment for the tube. Deviations from these rules, as indicated previously, promote cicatrices and tracheal deformities. If the fistula is already existant when the patient comes for treatment, as is frequently the case, there is of course nothing to be gained and much may be lost by enlarging or altering the position of the fistula, and it is then only a question of a normal or "clamped" intubation tube. The self-retaining instrument is far preferable to a tracheal canula, to which it is the only alternative in hypertrophic laryngitis complicated by

frequent and dangerous autoextubation, if only because it places the patient in a practically normal condition with the single exception of a whispering voice. For less serious cases of stenosis, especially those which experience has demonstrated, can breathe for an hour or two without mechanical assistance, the self-retaining tube may be thought to possess doubtful advantages. But in these there are many factors to be considered. To be sure, at least one of the patients in this series could not swallow while wearing the instrument, but that experience is very exceptional, and in adults, especially "nervous" subjects, equally common with the normal tube. That the clamp or plug may act like the canula in promoting or maintaining a tracheal deformity or favor a necrosis of cartilage has always been my fear, and hence I never use it except in cases of necessity; but experience seems to show that no ill effects are to be anticipated, and hence I have no hesitation in recommending it whenever there is the least anxiety as to autoextubation or subsequent adductor spasm. In my earlier cases, owing to unwarranted suspicion of the self-retaining tube, I believe I have taken great and improper risks in using the "special" tubes, although they are less unsightly and more ideal in effect. The perpetuation of the fistula by the "plug" also offers the distinct advantage of a sense of security in adults who are relieved of the dread of autoextubation, and in case of clogging of the tube, can remove the plug and cleanse the interior of the instrument by simply poking a feather through the opening. Indeed, I was first forced to employ this kind of tube in Case 15; the normal (metal) tube previously used became obstructed one day quite unexpectedly, and so nearly produced asphyxia that a substitute arrangement seemed imperative. This woman thereafter cleansed her tube in the way suggested every morning, and never again had difficulty. After removal of any tube, particularly a large or special one which has been worn a long time, there is great danger of sudden adductor spasm and strangulation, and an opening in the trachea already present is a great safeguard. The spasm, however, usually occurs some days or hours after the removal of the tube (and plug), and the "fistula," when not kept patent artificially, is apt to nearly or quite close before this dangerous incident. The usual curved canula which could be employed in the interim, is manifestly improper, as it drags the lower segment of trachea forward and pushes the upper back, and

therefore I recommend a perfectly straight cannula so fitted to its shield that it can be pushed in or pulled out and thus stay with its inner extremity protruding into the lumen of the trachea. The diameter of the straight cannula should not be over an eighth or fourth of an inch to avoid undue separation of the tracheal rings and approximation of their unsupported posterior extremities, and at the same time it must be large enough to permit, if need be, the insertion of a tracheal dilator through the fistula it maintains. This straight cannula only need be worn for the first two weeks after removal of the intubation tube. Subsequently to this period I have never met with an adductor spasm and any other obstructions occurs slowly and can be met by reintubation.

The plugged tube cannot be made in small sizes, as either the plug or the tube or both must be constructed of vulcanized rubber, and there is a limit to the strength of this material. The plug and tube cannot both be made of metal as the calcareous deposit which always takes place on the surface of a metal tube is very hard and firmly attached and might easily prevent the removal of the plug if the latter were likewise made of metal. The workmanship must also be of the best and very exact because the least irregularity in correspondence between the lumen of the plug when screwed in place and that of the tube will cause rapid clogging. Possibly a metal tube with a hard rubber plug is the best combination for cheapness, strength and durability, and as the retaining rod and cap are also of metal, it offers possibilities for attempts at electrolysis for those who believe in such treatment. The "clamped" tube is the only one I have found capable of construction in the small sizes for children under 10 years, and it is very useful. The tube has to be grooved on its outer surface to smoothly and exactly receive the clamp, as any irregularities or roughness will produce ulceration. The tube must be of rubber and the clamp preferably of silver, as a metal tube and a metal clamp would speedily become inseparable on account of the calcareous deposit previously mentioned. Also a clamp fashioned like an obstetric forceps is much better than one having the blades pinned together as in a pair of ice tongs. The disarticulated blades, though somewhat difficult to insert in a squirming frightened child, will enter a very small hole, and also there is no pin to break and drop into the trachea. The "cap" of metal then screws down snugly on the tube over the shanks of the

clamp and should leave no rough or irregular interval to produce irritation.

The treatment of the adductor spasm which is particularly to be dreaded after using large or "special" tubes for the cure of a hypertrophic laryngitis, has been partly outlined in the advice given as to maintaining the patency of a tracheal fistula. It is dangerous and must always be watched for after any prolonged intubation; as it is apparently due to an atrophy of disuse in the adductors, a small tube which permits them to functionate and at the same time maintain respiration, is a logical procedure. After determining, if necessary, with the aid of anaesthesia, that the hypertrophic condition has subsided, a normal tube of the size proper for the age and development of the child is inserted and left for about one or two weeks. During this period and for a week longer assistance must be constantly near at hand in case of autoextubation. If, however, a clamped tube has been used and the small straight canula retained in the fistula the danger is very slight. The nurse or any attendant, should difficulty occur, can readily push the straight canula or a curved one for that matter into the trachea. The straight canula is apt to slip outside the cartilaginous rings, especially when worn with an intubation tube. A curved canula, by the way, inserted alongside the tube or into a fenestrum in its anterior wall, I have found to be an utter failure.

A cicatricial stenosis, particularly if a hasty tracheotomy has at some earlier stage been performed, is often complicated by a contracted trachea with a spur opposite the fistula; and if there has been a tracheotomy for the autoextubation following laryngeal diphtheria, there is in addition probably more or less hypertrophic laryngitis. But even when there is a history or probability of considerable loss of cartilage (see Case 9) and contraction of the larynx until the lumen seems practically obliterated (Case 15), experience has shown me that the prognosis is still good. In the milder cases without a tracheal fistula insertion of a normal hard rubber intubation tube for from one to six months will invariably effect a cure. Cocain is a sufficient anaesthetic, and if the resistance to a tube of the proper size seems too great a smaller one can be employed for a few days and then a larger substituted. In the tighter and more deforming strictures general anaesthesia is required to permit the necessary preliminary dilata-

tion. The bad strictures always have had a tracheotomy at some earlier period or need it urgently when first seen, and the fistula serves admirably for the introduction of urethral sounds which are excellently adapted for the purpose. Beginning then with the smallest size which will pass through the contracted area others are passed in rapid succession until the intubation tube can be inserted. Some judgment must of course be used to avoid the possibly fatal accident of making a laceration which may extend into the pharynx or cesophagus, but though I have done the operation many times and used very considerable force, I have never encountered this or any ill results. Nevertheless, the possibility of its happening must not be overlooked. Occasionally, as in Case 15, the stricture may be so tight or tortuous that its lumen may have to be opened by a careful dissection like a strictured urethra, but as long as any traces of mucous membrane are left and a tube can be passed from the pharynx into the trachea, over or through the remains of the epithelium, there can be good hopes of a cure. Even very extensive loss of cartilage, as in Case 9, may be repaired, although Dr. O'Dwyer¹ cites one instance in which, as the result of diphtheria, the whole cricoid had sloughed out, and this he considered irremediable except by tracheotomy. I should not, however, be inclined to condemn such a case without a trial.

In addition to the stricture, which is generally worse above the fistula, there will always be one at and just below this point, especially if the cannula has been worn long, and this also must be dilated like the one above. Then when inserting the tube the spur opposite such an old fistula in the posterior tracheal wall will be a serious obstacle to pass unless a small right-angled blunt retractor or hook, grooved on its convexity to receive and guide the entering tube downwards and backwards, is placed in the lower angle of the fistula, dragging the inferior tracheal segment forward. In adults I have several times had to exert all the force possible in two fingers, pushing down from above on the head of the tube, while counter pressure was made externally on the larynx with the other hand, to pass this point with its spur.

The comparative advantages of using a normal, a special or a "clamped" or "plugged" tube in these cases has already been discussed. As a rule, a combination of a plugged, with the principle

¹Am. Surg., May, 1900.

of a special, tube is the best. The plug is a safeguard against clogging and autoextubation and maintains the fistula as a subsequent escape from the difficulty of adductor spasm; the feature which, for brevity, I have called "special" in the instrument, means an enlargement of some portion of the diameter over the corresponding diameter of the normal tube to exert a dilating pressure upon some particular part of the larynx or trachea. The normal tube is long, as it was designed by Dr. O'Dwyer to pass as deeply as possible into the trachea beyond any diphtheritic process. Its lower end is constricted from side to side to pass harmlessly through the glottis, the retaining swell is as large as will pass easily through the ring of the average cricoid, and from this point upwards the tube is again flattened from side to side to fit the larynx. The "special" tube must always have the retaining swell, and this can be larger than the normal, as a diphtheritic swelling within the cricoid and consequent sloughing from traumatism at this point need not be considered; but at its neck, or its lower end, its diameter must be increased to stretch the stricture to be combated up to the largest possible normal lumen of the air passages. No exact measurements for this can be given, and they can only be approximately estimated and by a trial of different tubes. If, for example, the stricture is in the trachea at the lower end of a canula (rare, though I have seen one case at the Willard Parker Hospital), the tube from the retaining swell down must be of the same diameter throughout and long enough to pass the contracted area. Again, if there is a hypertrophic laryngitis complicating a cicatrix the tube must have the diameter of its neck increased, although (unless it is a clamped or plugged tube) the transverse diameter of the retaining swell must always exceed that of the neck by $\frac{3}{32}$, or preferably, $\frac{4}{32}$ of an inch.

A rough estimation of normal measurements, which I have found useful, is obtained by comparison with the patient's index finger, which is somewhere near the calibre of his trachea, below the cricoid. The length of this finger is also about the distance from the supra-sternal notch to the tracheal bifurcation.

The prognosis of a cicatricial stricture is difficult to give. Some cases seem to recover permanently after a few weeks or months of continued dilatation; others, especially those in which the rules for a proper tracheotomy, have not been or could not be carried out, will relapse from time to time and prove very discouraging.

In a few instances I have attempted to dissect out all cicatricial tissue, and by accurate suture of the trachea and overlying soft parts over a well-fitting tube, to obtain a primary union, and so do away with these annoying and dangerous relapses. But the results have not been encouraging, possibly because asepsis is practically impossible. In Case 2, although the wound united throughout by first intention, the stricture was again evident within a few days after the removal of the tube. In the others infection took place and the wound broke down in whole or in part. On the other hand, persistence in the dilatation for months or years (Case 7) has seemed finally to yield a permanent cure, and hence in general, cicatricial strictures of the larynx or trachea should be continuously dilated for at least six months. An attempt may then be made to do without the tube (with proper regard to adductor spasm) and at the end of a week the larynx and trachea tested for recontraction by insertion of the tube last worn. If none is apparent the test should be repeated once every one or two weeks for a month or more. At the first sign of recontraction the tube should be inserted and worn for another six months, and then again tested. But if the stricture is once allowed to contract seriously, beware of attempting to intubate without preparations for tracheotomy. Such a recurrent stricture, especially if near a previous tracheal fistula, is apt to be very tight before it causes distress, and very resistant to tubage. It is wisest to first attempt a passage with the Schroetter dilators, and if these fail, do another careful tracheotomy in the old cicatrix when present and then dilate again with urethral sounds, followed by intubation as at first. Perhaps the safest rule after a cure seems obtained in these cases is intubation for a week every couple of months, or oftener if required, for several years, or until no tendency to contraction can be detected during a considerable period. A pure hypertrophic laryngitis is, if anything, more difficult to handle than the cicatricial form of obstruction, as there is no time to think in the interval of changing the tube—generally for weeks or months the obstruction remains complete and the clean tube has to be immediately reinserted, and it takes longer to cure the condition. But after it is once well I have never met with any recurrences of the stenosis. The average duration of treatment has been from about six months to a year, although one case recovered permanently within four weeks, and another, complicated by

numerous cicatrices, to be sure, required nearly three years before natural breathing was finally obtained. This very long period was, however, largely due to my inexperience at that time.

Granulations as a cause of chronic obstruction are, I am convinced, rare, and when present are fortunately easily handled. Their removal, like any other new growth, by cauterization, excision or curettage, is, of course, the first step, and this can generally be accomplished through the mouth or tracheal fistula, although the latter may have to be enlarged to provide access. To prevent recurrence, sources of irritation must be eradicated by making a new fistula, or by changing the shape or length of the tube. Granulations are most common at the base of the epiglottis around the head of the intubation tube, and Dr. O'Dwyer describes two cases in which they were finally overcome in this situation by so building up and remodelling the head of the instrument as to distribute the pressure it exerted over a large area. In Case 9 the difficulty was satisfactorily met by using a smaller than normal tube. The principle, of course, is to remove the traumatism, or at least minimize it, and thus the details for individual instances can be readily adjusted.

A word as to feeding may be necessary. For the first few days after intubation liquids only are permissible, and they should be taken in the Casselberry position, with the mouth lower than the pharynx and it lower than the œsophagus. But it is surprising how quickly these patients learn to swallow a varied diet, and how few abnormalities they display. Even if an intubation tube should have to be worn permanently it is far preferable to the alternative of a tracheal canula.

CASE IX.—Stenosis due to hypertrophic laryngitis following intubation for laryngeal diphtheria; thyrotomy followed by sloughing of the cartilages; permanent cure after three months of proper treatment; total duration of tubage, two years.

I. B., aged four, admitted with diphtheria to Willard Parker Hospital, and intubated.

Dec., 1896. The stenosis persisted and necessitated retention of the tube.

Feb., 1897. Frequent and dangerous auto-exubation began, and to prevent asphyxia tracheotomy had to be performed on February 20.

March, 1897. A month later intubation with a normal 4-5 tube was practiced with the tracheal canula in place. No auto-exubation occurred, so the canula was removed and the fistula allowed

to heal. Complete stenosis persisted and she was transferred to Gouverneur Hospital.

Oct. 15, 1897. A week later the tube was coughed out and a hasty tracheotomy performed by the house surgeon.

Nov., 1897. Later the canula removed and intubation again attempted.

Jan. 10, 1898. As respiration was impossible without the tube I explored the larynx by median vertical incision through the thyroid and cricoid cartilages. The tissues were thickened and soft throughout the whole interior of the larynx in which there were no ulcerations and no cicatrices. By bringing the parts together it was found that the hypertrophied mucous membrane completely occluded the lumen of the larynx. With the idea of producing a vertical cicatrice on each side of the larynx and so retracting the swollen soft parts, I passed a silk suture through the cartilage and thickened mucous membrane on each side, and tied it on the outer surface of the corresponding thyroid ala. This retracted the tissues sufficiently to allow easy breathing and the larynx was closed, but infection followed, and in the course of the next few weeks apparently the greater part of the thyroid and cricoid cartilages sloughed out.

April 20, 1898. The patient was discharged, seemingly in a hopeless condition, and condemned to the permanent use of a tracheal canula.

Aug., 1898. The patient returned with a dense cicatrice occupying the position of the larynx, but under chloroform, with some difficulty a probe was passed from the tracheal fistula up into the mouth. This was followed by the passage of sounds of increasing calibre until the larynx and the entrance to the trachea had been dilated, up to No. 24 F. A normal 4-5 tube was then inserted, and the canula removed and the fistula allowed to close.

Oct. 1, 1898. The tube was removed and a 6-7 normal tube substituted. The stenosis was still nearly complete. At the next change natural breathing was found possible, and the tube was left out.

Nov., 1898. For the first two weeks there were several attacks of inspiratory dyspnoea, especially at night, but under the administration of a little morphine these gradually disappeared. Since then the cure has remained permanent and the voice is fairly good.

CASE XXI.—Stenosis due to an intra-laryngeal tumor. Thyrotomy. Infection of the wound and bad cicatricial contraction and deformity of the larynx and trachea; rapid dilatation, followed by the prolonged use of a very large clamped "special" tube which overdistends the whole cicatricial area; persistent fistula which was exercised together with much cicatricial tissue; primary union and cure. (?)

B. W., aged three, a patient of Dr. Harris, came to him with a history of laryngeal dyspnoea gradually increasing for

several months. For this Dr. Harris performed a thyrotomy and removed an angio-fibroma from within the anterior portion of the larynx.

Aug. 10, 1904. The wound suppurated and the larynx was packed, leaving the cricoid cartilage partially exposed and undivided and the canula in the tracheal fistula just below it.

Sept. 28, 1904. The wound having healed and the larynx being so contracted that no air could pass through it, under chloroform, with Dr. Harris' assistance, I rapidly dilated the larynx with urethral sounds, beginning with a No. 5 F and continuing up to No. 28 F. These were entered through the fistula. The stricture seemed to occupy, as might be expected, nearly the whole laryngeal space, from the fistula up, and though evidently fibrous, was not very resistant. A large special tube of the 4-5 length was inserted. Considerable reaction followed; the temperature rose to 104 the next day; and some purulent discharge showed through the fistula, but this gradually subsided.

Oct. 14, 1904. The tube was coughed out, nearly causing asphyxia. The house surgeon failed to intubate, and so reinserted the tracheal canula by dilating the nearly closed fistula. As the child was in poor general condition, this was left until

Nov. 14, 1904, and then with cocain application locally, the larynx was found to have become not only stenosed but deformed. There was also some "spur" formation posteriorly opposite the fistula. After many attempts, Dr. Harris finally managed to pass the smallest sound he had (a No. 5 F) from the fistula into the pharynx. The stricture was then rapidly dilated up to No. 25 F, and a large special clamped tube of the 4-5 length inserted. The manipulations with intervals for breathing occupied over an hour, and some reaction in temperature followed, but no pneumonia could be detected.

Nov. 24, 1904. The clamped tube became foul and was removed. There was no difficulty in breathing with the tracheal fistula occluded, but another very large clamped tube was inserted to overdilend the extensive cicatrix.

Jan. 1, 1905. This large clamped tube was removed and a normal tube substituted to test the amount of contraction which would take place.

Jan. 10, 1905. The large tube was found to enter the larynx without undue force; in other words, there seemed to be no tendency to recontraction, but to make sure the large clamped tube was left in place until

Feb. 1, 1905. On this date, as respiration was free and the fistula in the neck present in case of adductor spasm, the tube was removed.

Feb. 5, 1905. Some "spasm" occurred during the night, and the house surgeon inserted a normal tube without difficulty. The cervical fistula had contracted to a very small opening. A few

days later a sharp attack of pneumonia developed, and I removed the tube with the idea of leaving the child in as natural a condition as possible to combat the disease. Although I have several times observed a pneumonia, in these tube cases, run a perfectly normal course unaffected by the tube, I have always felt that an unobstructed larynx was preferable to one containing a foreign body. Hence, as there proved to be no obstruction in this larynx the tube was not replaced. At the end of a week the pneumonia subsided and a slow convalescence ensued.

Feb. 25, 1905. The house surgeon on this date noted some noisy respiration while the child was sleeping, and, fearing a sudden "spasm," inserted a normal tube. Three days later a small pustule appeared near the upper end of the cicatrix over the thyroid cartilage, and, after evacuating a drop or two of thin pus, I removed the tube again. There was no difficulty in respiration. There had apparently been some infection through the pharynx or larynx, and the consequent oedema had seemed to require the tube. As no recontraction nor dyspnoea followed, and the fistula into the trachea in the lower part of the cicatrix had become lined with epithelium, on

March 8, 1905, under chloroform, I excised the fistulous tract and the surrounding cicatricial tissue up to the cricoid cartilage, and exposed and brought into accurate coaptation over a special tube, the cut anterior ends of the tracheal rings. No ulcerations were visible within the larynx or trachea. Four days afterwards the superficial parts of the wound broke down, but as the wound in the trachea and overlying muscles held together, there was some hope that the stenosis, apparently cured before the operation, might not recur.

March 20-25. Tube allowed to remain out. No difficulty in respiration, but on March 25th, on replacing it, there seemed a trifle more resistance than there should be, and therefore, the tube was left in place.

April 19, 1905. Tube changed and cleaned, as, during the past few days some slight fever had appeared. Cleansing the tube caused this immediately to subside.

May 16, 1905. Tube removed. Everything seems satisfactory. Some inspiratory effort is noticeable during sleep, but none while the child is awake. The larynx was examined by Dr. Harris with a laryngoscope under general anesthesia and appeared widely open. The vocal cords were not distinguishable. The rest of the larynx appeared congested, but there was no sign of ulceration nor cicatrix.

CASE XXII.—Of doubtful origin. Still under treatment.

M. C., thirty-eight years of age, began in June, 1901, to suffer from "hoarseness," which was evidently regarded by her physician as due to tubercular laryngitis. The larynx was several

times "cauterized," but in spite of climatic and other treatment, pain, dysphagia and dyspnoea finally developed, and on

Nov. 1, 1902, she was intubated with the 10-12 child's tube for a short time. After its removal the dyspnoea recurred, and on

Jan. 11, 1903, she was tracheotomized at New York Hospital, and afterwards could not breathe without the canula. She came under Dr. Delavan's care, and with his assistance and advice the present treatment was inaugurated. With the greatest effort it was found that enough air could be forced through the larynx to make articulation barely intelligible, though examination revealed no aperture, the larynx apparently being occluded at and below the vocal cords. The cervical fistula was large, and through the second and third tracheal rings, a little to the left of the median line, and covered with epithelium throughout.

March 22, 1905. Under chloroform the smallest urethral sound could not be made to pass the stricture, either from below or above, but by working from below through the fistula a fine probe was finally passed up into the pharynx. This was followed, first by a fine dilating forceps, and then by urethral sounds of increasing calibre in rapid succession, entered through the fistula, until No. 40 F was admitted with considerable resistance. The stricture seemed to be of the nature of a thick diaphragm at and below the vocal cords. Strangely enough, there was no contraction or deformity around the fistula, and no troublesome "spur" opposite it posteriorly.

A No. 6 adult intubation tube was then inserted without difficulty, and worn with very little complaint until

March 29, 1905, for one week. After its removal the larynx, including the cords, seemed normal except for some ulceration, especially under and involving the right cord. She was inspected daily, and as the ulceration was very close to the anterior commissure, and as a band seemed to be developing at that point, on

April 3, 1905, the No. 6 tube was reinserted without difficulty, to be worn until this ulceration could have healed.

May 8, 1905, the tube was removed and everything found normal; the mobility of the cords was excellent, but they were deeply congested. A small whitish protuberance existed just below the anterior commissure. This seemed to be the remnant of the original cicatricial diaphragm, but there was no obstruction to respiration.

May 15, 1905. These protuberances had slightly enlarged within the last few days, and although there was no obstruction to respiration, it seemed wise to reinsert the tube in hope that they might ultimately disappear.

COMPLETE ADHESION OF THE VOCAL BANDS, WITH
LARYNGEAL STENOSIS FOLLOWING
DIPHTHERIA.

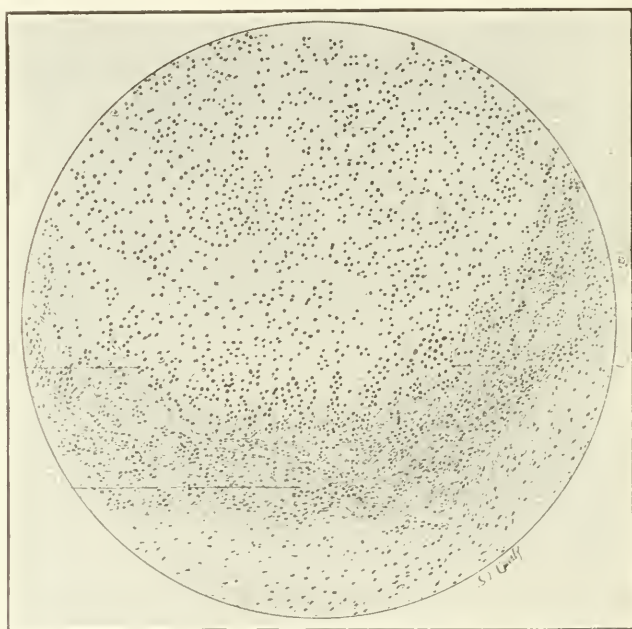
BY D. BRADEN KYLE, M.D.

THIS surgical condition of the larynx is by no means rare and the journalistic literature contains many reports of the successful treatment by surgical interference. Such men as Wagner, Newman, Rogers, Long, McCosh, Largnon, Mayer, Duel, Price-Brown, as well as many others, have contributed to the literature of this interesting condition.

The case I wish to report is as follows: B. K., aged 6 years, was referred to my clinic at the Jefferson Medical College Hospital by Dr. B. Franklin Royer, Chief Resident Physician at the Municipal Hospital of Philadelphia. Nine months previous the child had suffered from a virulent attack of diphtheria, in which it was impossible to retain the intubation tube, which necessitated tracheotomy. There was at this time, according to the history, considerable ulceration of the vocal bands and of the structures within the vestibule of the larynx and evidently extending much further down into the laryngeal structure, although it was impossible to prove this by laryngeal examination, the deduction being made from the symptoms present rather than by inspection.

When I saw the child on December 7th, it presented the following condition: The child had been wearing a tracheotomy tube for nine months. The edges of the tracheotomy wound were entirely healed and scar tissue had formed. Laryngeal examination showed fairly free movement of the epiglottis, but the lumen of the larynx was entirely occluded. The surface presented was irregular and nodular. There was complete absence of phonation. A fenestrated tracheotomy tube was inserted to determine, if possible, whether or not there was any passage of air through the larynx. The tracheotomy tube was then closed, but the child was unable to get the slightest amount of air through the larynx. I then decided to attempt a procedure

which had been used very successfully at the Municipal Hospital by Dr. Royer, that of first establishing by means of small forceps an opening through the occluded larynx and then resorting to gradual and repeated dilatation. The child was anesthetized, the tracheotomy wound enlarged and a pair of small, slightly-curved hemostatic forceps were gradually worked up through the structures until the end of the instrument could be felt distinctly by the finger underneath what should have been the vocal bands. The structure was then separated by means of a short, curved



bistoury and the laryngeal dilator introduced. I then decided to use the long intubation tube, which is about one-half inch longer than the longest O'Dwyer tube. After considerable difficulty this tube was inserted and passed into the larynx extending below the tracheotomy wound. The tracheotomy wound was then temporarily closed by means of adhesive strips and the child breathed perfectly through the intubation tube. The respiration was perfectly normal other than that the child was suffering slightly from shock. After three or four minutes the child's

respirations began to diminish and grew more shallow and less frequent until its condition became alarming. The temporary dressing over the tracheotomy wound was instantly removed and the intubation tube withdrawn above the point of the tracheal incision. Even with artificial respiration the condition was unimproved and the intubation tube was at once removed. Under artificial respiration the child quickly recovered and the respirations again became normal. A second time the tube was introduced with exactly the same results as before. I then concluded that from pressure of the intubation tube either on the recurrent laryngeal nerve or else the internal branch of the superior laryngeal nerve this inhibitory action of respiration had been caused. Feeling sure that this was the case, I decided to abandon an attempt at establishing laryngeal breathing by this method and at a later date split the larynx and dissect out the new inflammatory obstructing tissue. The child rapidly recovered from this operation, and for several days was able to produce some little sound and in fact quite distinctly pronounce several words, but the speech was largely limited to lip enunciation. The parents of the child were very anxious to have it home during Christmas week, and he was allowed to leave the hospital on December 22nd. The child's physical condition improved and arrangements were made to admit him to the hospital on January 15th. There was some delay, however, on the part of the parents, and the matter was deferred until January 30th. Unfortunately, on the 29th the child contracted a severe cold and developed pleuro-pneumonia and died in twenty-four hours.

Dr. Royer was fortunate enough to procure the larynx at the post-mortem examination. The specimen hereby presented shows the most interesting condition. Usually following ulceration of the mucous membrane or where there is hyperplasia following inflammatory processes the new tissue is purely of the connective tissue type and passes through the physiologic and histologic changes peculiar to that structure. The hyperplasia in this case, however, was largely made up of cartilaginous cells. This presents an interesting feature should the operation of splitting the larynx and dissecting out the tissue have been resorted to, as we would have had an entire denuded surface of cartilaginous cellular structure, which in turn would have reproduced cartilaginous cells and brought about a secondary stenosis. It

would also have been impossible from a histologic standpoint to have successfully skin grafted the larynx. This fact may explain why the transplantation method has failed in some cases. The accompanying illustration shows the well-marked distribution of the cartilage cells in the structure.

The two points of interest in this case which would seem to me to be of sufficient importance to warrant reporting were (1) the inhibition to respiration caused by the introduction of the intubation tube, and (2) the interesting histo-pathologic condition of cartilaginous cell formation within the inflammatory structure.

Discussion on the Papers of Drs. Rogers, Delavan and Kyle.

DR. JOHN ROGERS (by invitation).—Thank you very much for your courtesy in allowing me to say a few words. The treatment can be summarized very briefly in that it consists simply in long continued pressure on the obstructed part of the larynx or trachea. The only difficulty is the length of time the pressure has to be kept up. In one or two of these cases I have had them run on for 2 or 3 years, and one particularly ran for something like 46 months, and that child has remained cured for three or four years with no sign of recurrence and with excellent voice. One point about which I wish to speak is the pathology of these retained tube cases. I became interested in the subject as a surgeon to a general hospital, where several children with retained tubes or retained tracheal cannulae had been sent from the Willard Parker Reception Hospital after the subsidence of their diphtheria. The cause of the persistent stenosis was not recognized even by Dr. O'Dwyer. Under the mistaken impression that the obstruction was due to cicatrices or granulations, I attempted laryngotomies and in each instance found only a diffuse thickening of all the intra-laryngeal soft parts: in other words, a chronic hypertrophic laryngitis. The operations proved useless, or they were harmful when infection, sloughing and cicatrices followed. By questioning colleagues I discovered others had had similar experiences, and one or two autopsies confirmed the clinical and gross findings. Then partly by accident and partly by experiment I found that long continued dilatation, especially with metal tubes, cured the hypertrophic laryngitis cases as Dr. O'Dwyer had promised it would cure the cicatrices. I was much interested in Dr. Kyle's case, which shows the possibility of the production of cartilage. In one of my cases, a simple hypertrophic laryngitis, I tried to make a vertical cicatrix in the hypertrophied tissue by suturing it to the thyroid alae. It ended in a slough of apparently the whole thyroid, but subsequently, under

long continued tubage, the last cartilage seemed to be entirely restored, presumably from the perichondrium.

As regards the treatment of Dr. Kyle's case, it is not probable that the method I have used would succeed. The production of new cartilage seems to have been the result of chronic inflammation, and while it is not probable, it is not impossible that any continued pressure might cause it to atrophy. Fortunately, a condition such as Dr. Kyle presents must be extremely rare.

DR. CLARENCE C. RICE.—The Association desires to thank Dr. Rogers for his valuable addition to the program.

DR. WILLIAM K. SIMPSON.—While undoubtedly a chronic hypertrophied laryngitis is one of the main causes of retained intubation tubes, there is another important point which has not been solved, and that is what causes the first necessity for reintroducing the tube, given an ordinary case of intubation in diphtheria and the tube is taken out at the expiration of the ordinary time. Now what is the first cause for that tube to be put back in one out of 50, 75 or 100 cases? That has never been solved. Dr. O'Dwyer was extremely doubtful as to its cause. I should like to hear Dr. Rogers' idea on that point.

DR. JOHN ROGERS.—Köhl wrote an article in the *Archiv. für Klin. Chir.*, for 1887, on retained tracheal cannulae. He describes one of the commonest causes of this difficulty after diphtheria as chronic hypertrophic sub-glottic laryngitis. Apparently the intubation or tracheotomy has nothing to do with it. The immediate or postponed recurrence of the stenosis after the removal of the tube would be dependent upon the amount of fibrous tissue in the hypertrophied soft parts. If there was little fibrous tissue and a great many new vessels and exudation the stenosis would be immediate and complete as soon as the tube was removed. If the fibrous tissue was abundant and the vessels scanty when the tube was removed the edema would recur more or less slowly, but in either case the stenosis is very serious. I believe it is purely a matter of the diphtherial inflammation in the first place.

DR. WILLIAM E. CASSELBERRY.—Dr. Kyle's specimen of adhesion of the vocal bands following high tracheotomy exemplifies the main objection to this latter operation, viz., the fact that when the tube is worn for any length of time adherent inflammation takes place between the vocal cords and obstruction of the larynx is more apt to be produced. I notice in the specimen passed that it was a high tracheotomy with the tube entering just below the thyroid cartilage through the cricoid, and I recall from Dr. Kyle's remarks that the tube was worn for a considerable length of time. Now while this may or may not have had anything to do with the stenosis in his case, I think it is important that we should keep in mind this point, and although a high tracheotomy is often easily made, still if there is any prospect that the child will be obliged to

wear the tube for a long period the situation of a low tracheotomy seems to afford it better immunity from unpleasant after consequences.

Concerning the second paper on the subject of Dr. Rogers' tubes, I wish to voice the admiration of every Fellow here for the wonderful ingenuity, patience and perseverance which have been displayed in this modification. Any of us who has had a somewhat extended experience with intubation in chronic stenosis of the larynx will recall the many difficulties encountered in our efforts to cause retention of the tube. I am sure all laryngologists, intubationists and the profession at large are under deep obligation to Dr. Rogers for his modified tubes.

GANGRENE OF THE TONSIL.

BY CHARLES W. RICHARDSON, M.D.

At the twenty-fifth annual meeting of the American Laryngological Association, held in Washington, I had the pleasure of presenting a case of this unusual condition, which was read by title. Since the report of this case I have had the fortune to observe another case of a similar character, and, as the condition seems to be of such unusual character, I have incorporated my first case in this paper, as well as given abstracts of the only three cases which I find under the title of gangrene of the tonsil in medical literature. It seems passing strange that this condition should be so infrequently observed; more strange, if, of such infrequent occurrence, that I should have had two cases under my observation within fourteen months. The diagnosis presents no difficulty; the physical signs and the constitutional manifestations are too positive. The exclusive bacteriological investigation and the rapid fatal termination can leave no doubt in the minds of the most sceptical diagnostician. The characteristic stench of the disorganized tissue is, like the odor of atrophic rhinitis, once recognized, never forgotten.

CASE I.—On March 1st I was called in consultation to see a patient residing about nine miles from Washington. It was late in the afternoon when I reached the patient's house, and it was nearly an hour later before the consultants were with me.

On the presentation of the case to me by one of the consultants,

and carefully going over the history and the temperature sheets, I could see at once that the case, whatever might be its cause, was one of extreme sepsis. The history as presented to me was as follows:

The patient was a man of robust physique, of forty-five years of age, addicted to excesses. About ten days before, he had returned from a trip to the North, at which time he had been using alcoholics to excess. When he first came under the observation of the physicians in charge he had considerable difficulty in swallowing, marked infiltration of the right side of the neck, with other characteristic symptoms of quinsy. In a couple of days it was stated that the patient had a discharge of pus from the nose and mouth, with which there was a subsidence of the swelling in the right side of the neck, a restoration of the normal voice, no further difficulty in deglutition, and the return of the ability to open the mouth freely and widely. About two days thereafter the physician in charge saw what he supposed to be some white spots on the right tonsil. He then thought that the case was probably one of diphtheria, although there was a doubt in his own mind as to the diagnosis. The next day, however, he administered 3,000 units of antitoxins. On the second day thereafter there were 3,000 more units given. From the first administration until I saw him, he received, in all, 16,000 units of antitoxine. Even under this repeated use of antitoxine there was no improvement in the patient's condition. He gradually, but progressively, grew worse. On the ninth day of his illness the patient became delirious, and on the tenth and last day of his life I was called in consultation.

At this time the patient's temperature was 102°, his pulse 120, soft and compressible; and he was in a muttering delirium. On inspection, which was comparatively easy for one in a delirium, and in such a serious condition, I was at first struck by the absence of the characteristic diphtheritic odor of the breath, and was impressed by the peculiar odor which is due to sloughing tissue. On depressing the tongue I was quite unprepared for the sight which I observed. On the right side, the tonsil, the anterior and the posterior pillar, and as far down in the pharynx as I could see, was one continuous mass of greyish, brownish, putty-like slough. The left tonsil and the curtain were perfectly normal. I particularly noticed the fact that there had already formed a complete line of demarkation between the necrotic and the normal tissue. The examination was prolonged until a careful and thorough inspection was made of the diseased area, and both the consultants had examined it with the same care. On consideration of the case they both told me that the first they had noticed of the sloughing was the day before, when there was a narrow white line of diseased tissue, but judging from the complete line of separation, I was rather inclined to believe that their examination

was not as perfect a one as had been made by me. The patient was in extremis, and died two hours after I first saw him.

CASE 2.—On May 17, 1904, I was called in consultation by Dr. Edward F. Pickford, to see an unusual case of ulceration of the tonsil. The subject was a man of thirty-six years of age. His occupation was that of an insurance agent. He was married, and, as far as could be ascertained, led a moral life in every respect. Denied the existence or possibility of venereal infection—no past evidence of such infection. Personal habits good. So far as could be elicited, he had led a uniform, regular life, from which there had been no deviation in past six months. Family history good. Had had the usually infectious diseases of childhood. Dr. Pickford told me that he had been called to see the patient on May 4th. The patient stated to him that he had had a sore mouth and sore throat for several days. Mastication and deglutition were very painful and difficult. The patient was very fretful and extremely despondent. The temperature was 99.8° . On inspection, the breath was noted to be extremely foul; the tongue heavily coated; the gums congested, swollen, bleeding readily, and separated from the teeth. There were some isolated grayish patches along the lower borders of the gums. The tonsils, particularly the right one, was very much enlarged, and tender to the touch, at this time showing no evidence of ulceration. Two days later ulcerative patches were manifest on the right tonsil. By May 12th, patient's condition had markedly improved. The patient's temperature was normal; he could eat and drink with comfort, and his depression of spirits had given way to his usual happy demeanor. The swollen gums had receded, the patches on gums and tonsils had disappeared, and the tonsils were much reduced in size. Dr. Pickford discharged himself, but was recalled to the patient May 15th. On this latter visit Dr. Pickford found quite a change in the condition of his patient. The principal lesion was now in the tonsillar region. The left tonsil was covered with a dirty, grayish looking patch. The mouth was nearly normal. The throat was extremely sore and the patient was extremely irritable, and greatly depressed. Temperature, $99\frac{3}{5}^{\circ}$. As the deposit on the tongue looked diphtheritic, Dr. Pickford made a culture, with negative result. Dr. Pickford told me, on our consultation, that he thought the case at first to be one of ulcerative stomatitis of scorbutic origin. Examination made by Dr. Pickford of other systems and organs of the body showed them to be in apparent normal condition. When I first saw this patient I noticed that he wore on his countenance an exceedingly anxious expression; was very restive, but not unduly nervous. Complained greatly of difficult breathing, and was excessively despondent and anxious as to his welfare. Told me that his throat pained him greatly; that it was almost impossible to swallow food, and that he feared to assume a recumbent posture for fear that his throat would close

up. Temperature, $100\frac{1}{5}^{\circ}$. On examination, under excellent illumination, I found no change in the buccal cavity. There was a redness along the edges of the gums and they seemed slightly raised from the teeth. On examination of the fauces the change in the right tonsil impressed me at once. The whole surface of the right tonsil was covered with a blackish scab like exudate, which had an exceedingly offensive odor. There was no change in the left tonsil, or in the other portions of the oral pharynx. The blackish exudate was subjected to a most vigorous curetting, nevertheless, without being able to reach healthy tissue. The tissue removed had all the appearances and smell of necrotic tissue. A bacteriological examination had already excluded the presence of the Klebs-Loeffler bacillus. The case was diagnosed as dry gangrene of the tonsil. On May 18th I again saw the patient. His general condition was slightly improved, his temperature the same, although the local condition looked more unfavorable. There was a recurrence of the slough all over the area from which it had been removed the day before, as well as extending to the pillars of the fauces. Again, very active curettement was carried out. Smears were then made and placed in the hands of Dr. D. W. Prentiss, who made the following report:

"Smear from tonsil—Dr. Charles W. Richardson's case, May 21, 1904. A diplococcus resembling the *D. lancolatus* more abundant than any other organism. Staphylococci fairly abundant. No bacilli having the characteristics of the fusiform bacillus of Vincent present. No spirillæ nor tubercular bacilli present.

"D. W. PRENTISS."

I saw the patient again on May 20th. The necrosis was not only more extensive in depth but also in area. Some attempt was made to curette away the necrotic tissue at this visit, but the hopelessness of the case, the weakness of the patient, and his pleas caused us to desist. The patient died from exhaustion June 1, 1904.

In order to make my paper complete clinically as possible I shall here give in abstract the three other reported cases.

ABSTRACT 1.—The case was that of a negro man forty-five years of age, who was admitted to Roosevelt Hospital August 13th. Indications are given in the history, which is quite full, of a sore throat, first noted on the 18th. The patient was rebellious against the use of the depressor, and little was seen in the pharynx. Note of August 20th recites the death of the patient from hemorrhage from the mouth and nose. At the autopsy, "A large ulcerated area was found in the pharynx, occupying the site of the right tonsil and extending for some distance on the post-pharyngeal wall; to this a large slough was attached by one extremity. The odor was very offensive." *Gangrenous Tonsillitis, Fatal Hemorrhage*. E. B. Cragin, N. Y. Med. Jour., Vol. XLVIII, September 1, 1888, p. 233.

ABSTRACT 2.—The patient was a young man of twenty-six. Had been attended a week for a sore throat when seen by Dr. Howe. "He had the peculiar pallor and partial stupor or lethargy of considerable toxaemia. The stench in the room was simply fearful, and at once suggested some necrotic process." At the beginning he had the ordinary symptoms of a peritonsillar abscess. There was a foetish, brownish fluid issuing from his mouth. Deglutition was almost impossible from the great pain; temperature, 104.4° ; pulse, from 110 to 120. "On looking in his mouth I found his gums, the inner surface of the labia and the under surface of his tongue greatly swollen and covered with deep excoriation or ulcers. Both tonsillar organs were swollen and of a deep red or purplish color, indicating considerable stasis. On the left side was a large tumor that involved the entire tonsillar region, extending beyond the median line nearly to the opposite tonsil and well up into the naso-pharynx. On the anterior surface of this tumor was a circular necrosed spot about half an inch in diameter, of a peculiar greenish color of gangrenous tissue, and in its center was a perforation through which came a dark-brownish, grumous discharge." The mass, when removed, was black and firm, and could be sliced much as putty or moulding clay can. It had all the appearance of having undergone a dry, gangrenous process. The odor was intense. "The removal of the tonsil exposed a large cavity lined with half an inch or more of greenish black, necrosed tissue." The treatment was cutting away gangrenous tissue, spraying with hydrogen dioxide and the application of nitric acid. By this procedure the gangrenous tissue was entirely removed and patient recovered in about three weeks. About three months later the patient succumbed to another attack. Report of a case of Gangrene of the Tonsil, by Alexander C. Howe, *Phil. Med. Journal*, Vol. V, No. 11, March 17, 1900, p. 643.

ABSTRACT 3.—The case described by Dr. McVeigh occurred in a young miss of ten years of age. The gangrene affected both tonsils. The odor emitted was the characteristic gangrenous stench, which, from his description, must have been very penetrating. The diseased condition had existed for several weeks before coming under his observation. The child succumbed one week after being under his care. He discusses the case, and, from his remarks we can readily judge that he was alive to the nature of the case and its differentiation from the tonsillar ulceration of scarlatina, diphtheria, measles, and abscess.

Dublin Quarterly Journal of Medical Science, Vol. 44, 1867, p. 78. Gangrenous Eschar of the Tonsils, Death, by John Francis McVeigh.

REMARKS.—When preparing the report of my first case of gangrene of the tonsil I had occasion to look up the literature on the subject, and was quite surprised at the small number of re-

ported cases. While preparing this paper, I again carefully searched the cards of the Surgeon-General's Library on the subject of the tonsil, with the result of finding only the three cases which I have above abstracted.

In my first case, on account of the circumstances attendant upon the location of the patient and his rapid death, no satisfactory study could be made as regarded the exact method of infection. Every effort was made to trace out the source of infection in the second case—the result was as fruitless as that in the first case. The patient was in perfect health at time of infection, giving daily attention to his business. All organs of the body were functioning normal. Neither in his domicile nor in the food taken could the source of infection be traced. The bacteriological examination does not furnish us with much positive information as to the infecting organism. A diplococcus is not the usual type of organism producing gangrene, yet it is the one most abundantly found in this case. The investigations are of more value in a negative way—we know that there were no fusiform bacilli of Vincents, no Klebs-Loeffler or tubercular bacilli. I was greatly disappointed with the laboratory investigation. The most impressive feature of this second case was the intense and penetrating odor of the necrotic tissue. It is also interesting to note in the two cases reported by me that the one represents the moist, and the other the dry type of gangrene.

Unfortunately, no autopsy was attainable in either of the two cases which were under my observation. In the first case, for various personal reasons, it was not suggested; in the second, I was, unfortunately, absent from the city at the time of the patient's death.

Discussion.

DR. EMIL MAYER.—I would like to ask Dr. Richardson whether in the treatment of these cases he used any antistreptococcic serum?

DR. CLEMENT F. THEISEN.—I think we are all indebted to Dr. Richardson for his paper, particularly as gangrene of the tonsil is so rare. Seven or eight years ago I observed a case of gangrene complicating diabetes, and I think that is an etiological factor in these cases. This man, middle aged, came to the hospital, and when I examined his throat I was much surprised to see that the entire uvula was gangrenous, and sloughing, with a sharp line of demarkation close to the arch of the soft palate. The gangrenous process was extending from the uvula, on that side, to the tonsil, although the process was involving the tonsil very slowly. This man had diabetes in a very bad form, and, of course, was dying from that. He went from our observation, but not until we were able to try iodide of potash, without effect. It was a perfectly

characteristic case of gangrene and was probably due to blocking up of blood vessels. It is well known, of course, that diabetes causes gangrene in other parts of the body, and in my case there is no question whatever that the gangrene of the uvula complicated diabetes. I did not put the case on record because I could not follow it up. I do not know what the ultimate result of the case was. The patient is undoubtedly dead by this time. It is important in these cases to make an analysis of the urine, and see whether or not diabetes is an etiological factor in the case.

DR. THOMAS HUBBARD.—I have seen two cases of circumscribed gangrene of the tonsils. The condition in one case simulated diphtheria and there was a progressive destruction and sloughing of nearly all of one tonsil, the fibrous tissue of the tonsil being very slow in sloughing off. In one case, a woman of seventy, I immediately suspected some organic disease, and examined carefully for Bright's or diabetes, but found neither. Klebs-Loeffler bacilli not present. The case ran a course of about ten days and recovered slowly. The other case was that of a man of seventy-five, a bridge mechanic, and it ran a very similar course to the previous one. There was no marked elevation of temperature, but considerable prostration, and as in the first case, one tonsil completely sloughed out. It seems to me that the disease as described in these cases should be called *cancrum tonsillaris*, from its resemblance to *cancrum oris* or *noma*.

DR. CHARLES W. RICHARDSON.—In answer to Dr. Mayer's question regarding the use of antistreptococcic serum, in the second case it was considered, but not used. In regard to the etiology in the first case I believe, although I did not mention it in this paper, I referred to it in the original report of these cases, that it was due to thrombosis of the tonsillar and ascending pharyngeal arteries, thus cutting off the nutrition of the tonsil. I believe the peritonsillar abscess was the direct cause of the gangrene in the first case. In the second case, of course, I cannot give any idea as to the etiology. We carefully examined the urine and all organs of the body in this second case. We had abundance of time to make these examinations, but found no systemic disturbance to account for the local condition.

Referring to Dr. Hubbard's case, I had one case exactly like his, in which there was a simple sloughing out of the tonsil without any involvement of the neighboring tissues. In both the cases reported there was involvement of the pharyngeal walls.

SEQUEL OF A CASE OF EPITHELIOMA OF THE
LARYNX, SHOWN TO THE ASSOCIATION
TWO YEARS AGO. (Transactions, 1903, P. 98.)

BY WALTER F. CHAPPELL, M.D.

Mr. Chairman and Gentlemen:—At our last meeting in Washington I presented before you a Mr. T., who in October, 1901, had thyreotomy performed, for malignant disease of the left vocal cord. This gentleman continued in good health afterward and was seen by me about once a month.

During last October Mr. T. complained of a little difficulty in breathing while he exercised. The laryngeal picture was not a very definite one, but I could not make out any special change since he had recovered from the previous operation. Soon after this Mr. T. was seen by a distinguished laryngologist, who was visiting this country, who stated that he would consider it a cured case.

On the 14th of November, 1904, while walking to the elevated station, Mr. T. had a hemorrhage from the throat. I saw him a few minutes later and found three tag-like masses in the anterior commissure of the larynx, one of which was bleeding. These masses were of grayish appearance with a red streak in the centre. Dr. Chas. H. Knight and Dr. William T. Bull, of New York, saw Mr. T. on the same day and all agreed that it was a malignant growth. The laryngeal mass increased daily in size and we decided to do an immediate operation. Tracheotomy was performed on November 20th, and laryngectomy on November 27th, by Dr. William T. Bull, of New York.

A median line incision was made one-third of an inch above the low tracheotomy wound and carried upward to the hyoid bone. The thyroid cartilages were held together by fibrous tissue; this and the cricoid were divided with angular scissors and the two halves of the larynx widely retracted. The trachea above the tube was stuffed with two sponges on strings and a bit of dry gauze above that. A little blood reached the trachea,

but was promptly coughed up, and during the rest of the operation respiration was quiet. I might mention here that chloroform was the anesthetic used, administered by Dr. Thomas L. Bennett.

The growth was made out to involve the cord and ventricular band on the right side and to extend across the anterior commissure and embrace part of the structure of the left side. We had hoped that the growth would not be so extensive as it was found to be, and that a second complete thyrectomy would suffice. After a consultation this procedure was thought to be unsafe, and a complete laryngectomy was decided upon.

The muscles overlying the thyroid cartilage were diverted back with a scalpel and elevator till the posterior and upper borders were freely exposed. The vessels were tied and cut, one inferior thyroid artery bled a great deal and gave much annoyance before it was safely secured. The trachea was then divided at the junction of the cricoid and held forward with catgut sutures. The larynx was separated from the oesophagus by blunt dissection and the mucous membrane of the pharynx and hyoid membrane divided with scissors. The epiglottis was then hooked down and cut off at the base. Five silver wire sutures were passed through the upper end of the trachea anchoring it securely to the skin at the lower angle of the wound. Silk sutures were used to unite the margin of the pharyngeal mucous membrane, and below the hyoid bone catgut sutures were employed. Two small wicks of gauze were placed in the centre and one at the lower end of incision. The skin edges were closed with three silk worm gut stitches. The tracheotomy wound was pulled together with adhesive strips, and after removing the tampons a silver tube was placed in the end of the trachea and the usual gauze dressing applied.

Nothing was taken by the mouth for ten days. Two of the silver sutures tore through the tracheal wall on the right side, but as the others held, nothing was done to bring the skin and trachea together and the space filled with granulations. This took some time and was not quite as satisfactory an edge as that on the left where the skin and the mucous membrane of the trachea joined.

In fourteen days after the operation Mr. T. was able to sit up and was soon around the house taking lessons how to talk under the new conditions. In this he has succeeded very well

and can carry on a conversation and be heard six feet away. Much to my surprise and pleasure, Mr. T. has been able to smoke, as he says, "just as well as ever," and blows the smoke through both nostrils with great ease and satisfaction.

Considerable trouble was experienced in getting rid of the long tracheal tube which was first used. It lay out half an hour Mr. T. had difficulty in breathing and the tube had to be replaced at once. This surprised me at first, as a good view was possible down the trachea, and nothing unusual was apparent about the tracheal tissues.

An examination of the interior of the trachea every fifteen minutes, with the tube out, showed an increasing redness, until at the end of an hour it belled into the lumen of the trachea and flapped back and forth with each inspiration and expiration. . . . This condition was overcome by gradually shortening the tube, and at the present time we have little more than a silver collar, which fits into the tracheal opening.

It is now over six months since the laryngectomy was done. Mr. T. never enjoyed better health than he now does; he goes about in all kinds of weather and never experiences any trouble. He has recently learned to take out the tube and reintroduce it without any help. He sleeps and eats well and goes to business daily and fulfills all his positions in life without any trouble. I have with me a sample collar and tie as used by Mr. T.; they are so arranged to the shirt that the tube is covered, and from appearances it would be impossible to pick Mr. T. out in a crowd as the one who was wearing a tube.

I append a report by Dr. F. C. Wood, who also made an examination of the growth removed at the first operation in October, 1901.

REPORT BY F. C. WOOD, Dec. 12, 1904.

The results of sectioning the material which was removed from the interior of the larynx of Mr. T. shows nothing new beyond the facts which I gave you at the time of the operation.

The mass which was removed at that time by stripping up the inner surface of the thyroid cartilage shows, as I then stated, that the epithelial growth had involved much of the soft tissues of the inner surface of the larynx down to the perichondrium. Sections

of the specimen made since Dr. Pool turned the whole larynx over to me show the following:

1. A vertical section through the middle of the left vocal band shows that portion of the larynx to be free from new growth, though the whole tissue is much infiltrated with leucocytes and inflamed.

2. A section taken just to the left of the median line from the posterior portion of the larynx over the cricoid cartilage shows a slight invasion of the tumor from the right side.

3. Another fragment taken from the anterior portion of the right side of the thyroid cartilage near the place where the incision was made into the larynx shows a few fragments of epithelium.

4. Another section of the outer surface on the right side of the larynx shows no new growth.

In other words, the tumor involved practically all of the inner surface of the right side of the larynx, but had not extended into the tissues outside of that organ, nor to any great extent, to the tissues of the left side of the larynx.

(Candidate's Thesis.)

THE CHOICE OF OPERATION FOR THE RELIEF OF CHRONIC EMPYEMA OF THE FRONTAL SINUS AND THE ANTERIOR ETHMOIDAL CELLS.

BY LEWIS A. COFFIN, M.D.

IN considering the choice of operation for the relief of chronic disease of the frontal sinus and the anterior ethmoidal cells, it is assumed that these cavities may be independently or dependently diseased. The deductions drawn are from a personal experience of several years' work in dissecting and operating upon fresh and dried skulls, together with a clinical experience of over ten years, during which time much attention has been given to disease of the accessory sinuses of the nose and to the literature on that subject.

Most of the operations described and used to-day have been

developed and described within the last decade. In 1884 Ogston¹ described the operation which bears his name. Ogston used at first a poor incision, but his was an all-sufficient method of treating an independent disease of a large class of frontal sinuses. Since this time, to meet the varying anatomical conditions of the sinus, to obviate deformity and prevent relapse due to anatomical peculiarity or associated ethmoidal disease, many modifications have been described, and each time a new name has been added to the list of operations. The principal operations so described are as follows: Jansen² in 1894; Kunts³ in 1895; Luc⁴ in 1896; Tilley⁵ in 1896; Hajek⁶ in 1898; Grünwald⁷ in 1900; Lermoyez⁸ in 1902; Killian⁹ in the same year; Jacques¹⁰ and Durand in 1903.

Of these, the principal ones, or those which have been most used in this country, are the Ogston-Luc, the Killian and the open method, by which is meant the packing of the operated cavity through external opening until it is obliterated. The open method is not, as a rule, applied to the cavity formed by the cleaning out of the ethmoidal tract, but I have so used it in ten cases with most satisfactory results.

The fact that each of these operations has been done, together with the fact that each at times has led to most satisfactory results, while, on the other hand, each has at times been most disappointing, would cause one to think that each perhaps has its place, or, in other words, is particularly adapted to a certain class of cases.

This I believe to be the case. I have obtained the most satisfactory results from the more simple operations, and again have several times been obliged, during a secondary operation, to change from the simple open method, or the Ogston-Luc, to a Killian in order to effect a cure. The Killian will, as a rule, result in a complete cure, but it is more radical than is frequently demanded by the case in hand.

The results desired in any case are as follows:

1. Relief of symptoms.
2. Eradication of disease.
3. A minimum of deformity.
4. The preservation of nasal functions, as far as possible, and future comfort of the patient.

To the reverse of these may be added as results to be avoided, injury to other organs, as the eye and brain. For the relief of

symptoms and eradication of disease, all operators must agree to the surgical principle that all diseased parts must be reached and treated. When we remember the great variation in the anatomical structure and arrangement of the sinuses in question, as well as the many bad cosmetic results that have occurred as a consequence of effort to apply this principle, we are not surprised at the many modifications that have been made to the simpler operations that were at first done.

At this point I will digress long enough to frown upon and condemn certain procedures which should be denominated "frenzied surgery" applied to the accessory sinuses of the nose. By this I mean the wanton cleaning out of all sinuses on one or both sides of the head with what seems to be absolute disregard as to whether they are diseased or not.

Mackenzie¹¹ reports having been consulted by a man who had previously consulted a leading surgeon laryngologist who had proposed cleaning out his ethmoids, which Mackenzie found not to be diseased, through a healthy antrum. This is an extreme case, but I think the majority of laryngologists believe that many a sinus is attacked that might have been spared to the everlasting comfort of its possessor. One sees frequently in the man who tells of and reports these cases a sort of chesty, vain-glorious feeling that he has been able to do such extensive destruction without having sacrificed the life of his patient.

The sphenoid, I believe, is frequently attacked and demolished for no other reason than the pleasure derived from the attack, on the excuse that it is done for diagnosis.

Within a month I was told by a laryngologist of high standing that he had gone through the antrum into the sphenoid simply for purposes of exploration in the vain hope that he might find some peculiar and hidden disease to account for a *tic-douloureux* from which the man had long suffered. No intra-nasal condition pointed to disease of the sphenoid, nor was disease of that sinus found.

This I suppose was on account of the report by Berens¹² in 1904 of the cure of a *tic* from operating on the sphenoidal sinus.

In 1900 Koyle¹³ reported a cure of the same disease from cutting certain muscles of the eye. To cut the muscles of the eye which had been found on examination to be normal is on the same order of surgery as to operate on a sphenoidal sinus showing no

evidence of disease. Lately I have been creditably informed that one of our leading specialists finds it necessary in his private practice to frequently operate on both frontal sinuses and both antra at the same time. I can hardly conceive that these four sinuses, disassociated as far as the two sides of the head are concerned, are so frequently diseased as this would indicate. I do not believe that any body of laryngologists will assent to such a proposition.

During a clinical experience of seventeen years in an institution devoted to diseases of the throat and nose, we have never had to exceed two or three such cases. I do not wonder that Mackenzie stands appalled before the nasal surgery of the day, and all laryngologists I am sure smile intelligently, if sadly, when he says he is reminded of the injunction of the Irishman at Donnybrook, namely: "If you see a head, hit it."

In the surgery of the head one should be, it seems to me, conservatively rather than radically radical. In order to do this, one should, by most careful and repeated examinations, determine, if possible, previous to beginning work, just what operation will give the best result. By such examination one is able to determine whether there be independent or associated disease of the sinuses, and, further, one may form a fairly good idea as to the extent of the ethmoid involvement. As, for instance, as to whether the middle turbinated and bulla are involved, and the condition of the mucous membrane covering them. Although not altogether reliable, one gains much knowledge as to presence, size, and degree of disease of the frontal sinus by transillumination. A good skyagraphic picture is of the greatest benefit, as it gives knowledge not only of the size, outlines and internal structure of the frontal sinus, but it shows the relations of the anterior ethmoidal cells to that sinus. I am very skeptical as to its demonstrating disease of this sinus. Unfortunately a good skyagraph is difficult to get. I know but one man who is able to produce them. I shall assume that the various operations previously named are known, and shall discuss simply those conditions which seem to indicate which operation shall be chosen for any particular case.

Independent diseases of the frontal sinus cannot always be definitely diagnosed, but when symptoms and signs point to such a condition, all possible knowledge of the sinus should be obtained

by transillumination and radiography. If these be not at hand, or are not satisfactory, an exploratory opening will enable one by use of probe to determine the character of sinus to be dealt with. If it be small, or, in fact, if it be regular, the exploratory opening through the anterior wall and near the median line should be enlarged sufficiently to allow the curettement of every part of the sinus. If the fronto nasal duct be patent, no work should be done between the sinus and nasal fossa.

In my hands the open method, that is, packing through the external wound to effect the obliteration of the sinus, in this class of cases has given the most satisfactory results. The incision in these cases may be along either border of the eyebrow.

The primary opening is made at the lower border of the anterior wall near the median line. It may be enlarged downward across the supra-orbital ridge and latterly at the expense of the lower border of the anterior wall. The wound should be stitched from its external end to the inner end of the eyebrow. Through the opening left near the inner canthus of the eye the sinus should be packed. Any deformity will be a slight retraction at this point. I have seen a great many so treated in whom one might say there was no deformity. At times the wound at the point of packing refuses to close. This I believe to be generally due to an involvement of the most anterior ethmoid cells, and one must resort to an attack on these cells with an opening in the nasal process of the superior maxillary bone (the second part of the Killian operation). Remembering that this can be done at any time will frequently obviate doing it at the time of first operating, and may obviate doing it at all. In extremely large sinuses, or in sinuses having one or more septa as much of the anterior wall of the sinus must be removed as will allow exposure and curettement of every part of the sinus and the cutting away of all septa. If the sinus is to be packed and obliterated, the procedure is as above.

If, on the other hand, the wound is to be closed at time of operation, the floor of the sinus (orbital roof) should be removed for the double purpose of establishing better drainage and allowing the orbital tissues to ascend into the sinus and thus minimize the space to be filled by granulation. Great care should be exercised in the removal of the floor that no harm be done the trochlea. The best method of doing this is as described by Killian in his

account of his operation. Eggers¹⁴ says, speaking of choice of operation, "When the sinus is known to be small, one should commence by the method of Ogston-Luc, and if necessary resort to the Killian."

INDEPENDENT DISEASE OF ETHMOIDS.

In case one has to deal with independent disease of the ethmoids, or such as is not associated with disease of the frontal sinus, much can be done intra-nasally through the vestibule of the nose, by what is often called conservative methods.

However, I have seldom been able to accomplish a thorough clearing out of the ethmoidal tract intra-nasally without general anaesthesia except at great pain and nervous strain to my patient, to say nothing of the loss of time, etc. Patients weary of it, and either ask that a radical operation be done, or seek relief at other hands. I am convinced that cure can be effected by this method when the disease is confined to the middle and posterior third of the ethmoidal tract. When independent disease of the ethmoids exists, I am of the opinion that the most anterior cells are not often affected. I have never been able to reach intra-nasally those cells called by Mouret the ethmoido-lachrymal, nor those cells which extend over the orbit. Approach to these two groups of cells I believe also to be impossible through the maxillary antrum. If after all intra-nasal work which seems justifiable has been done, there still persists a sufficient discharge of pus to warrant further operative procedure, it is best done by an opening through the nasal process of the superior maxillary bone. This opening enables one at once to reach and clear out the diseased cells, and all points of operation are directly under the eye of the surgeon. In making the incision and subsequent opening through the bone, much care should be exercised that no injury be done the lachrymal sac or the tear duct.

To my mind this operation gives better results than one obtains from attacking the ethmoidal cells through the antrum, although that sinus be diseased. By doing the operation as recommended above, and doing a simple Luc-Caldwell operation on the antrum, it seems to me, we better preserve the functional integrity of the nose. Who that is in the habit of treating the nose will doubt that the large and shapeless cavity left after all the

accessory cavities of the nose have been thrown into one irregular hole, has not scab-bedecked walls of the greatest annoyance to its possessor? Further, the operation through the antrum may and often does destroy healthy parts of the nose.

ASSOCIATED DISEASE OF THE SINUSES.

In associated disease of the cavities, it is the writer's opinion that the most anterior ethmoidal cells are diseased. The operation to be done will depend largely upon the structure and size of the frontal sinus and its relation to the ethmoidal cells, as shown by the skyagraphic picture, or in the absence of this, upon the exploratory opening of the frontal sinus, and its investigation by means of the probe and small electric lamp introduced into the sinus. If the sinus be found to be small and regular and the ethmoidal cells do not extend over the orbit, an opening through the anterior wall near the median line of sufficient size to allow curettement of the entire sinus and extending across the supra-orbital ridge toward the nasal opening, allowing the breaking down of the anterior ethmoidal cells in front of and about the fronto-nasal duct, is all that is required. The surest results can be obtained from this operation by treating the wound by the open method, that is, packing for obliteration of the sinus. In large, irregular sinuses, or those having large ethmoidal cells between the floor and the orbit, to my mind, the operation of choice is the Killian. The wound can be closed at once. Primary union is the rule, although, as has been said, stitch abscesses may, and in fact are, liable to occur at a point opposite the inner canthus of the eye. The Killian operation marks a great advance in the operative procedures for the relief of empyema of the frontal sinus and the ethmoid cells. So far as I know, but three accidents can occur.

1. Injury to the pulley of the superior oblique, causing diplopia.

2. Injury to the lachrymal sac or tear duct.

3. Injury to the cribriform.

One should be every mindful during this operation of these dangers. He should inform himself thoroughly as to the anatomy of the parts, exercise the utmost care, and the dangers minimize, and the possible accident should not occur.

Whatever operation is decided upon, or whatever operative procedure is developed, one should be careful not to sacrifice healthy parts if they can possibly be saved. We hear a great deal about saving the nasal mucous membrane as flaps for lining the various denuded sinuses and passages. Now, the mucous membrane over a very diseased structure is, in the writer's opinion, not worth saving as a flap, and on the other hand as a general proposition when the membrane is worth saving as a flap the part which it covers is worth saving. It is on this principle that I am opposed to the destruction of the ethmoids through the antrum, although that sinus be diseased, and it is on account of the same principle that I have in doing an otherwise typical Killian operation, saved the middle turbinated body when it has not shown marked evidence of disease.

The following notes, taken from the hospital history of a recent case, will illustrate some of the points I have endeavored to make:

F. C., age 20, domestic, admitted to Manhattan Eye, Ear and Throat Hospital January 11, 1905. Family history negative. For four years patient had headaches and general malaise, and was bothered with a profuse discharge from nose, especially the right side, at times purulent and bloody. In damp weather had difficulty in nasal respiration. Also complained of hoarseness.

Examination showed turbinated somewhat enlarged and congested. Pus discharge from both nostrils, more profuse from right side showing in middle meatus. Pain and tenderness over floor and anterior wall of right frontal sinus; no external redness nor swelling. Temperature normal.

Treatment.—Placed in ward, given cathartics and steam inhalations. January 12th and 13th, patient somewhat relieved of headaches. January 14th, headaches returned. Very severe tenderness over right frontal sinus. Evening temperature, 103 F. No discharge from nostrils. Examination of eyes showed congestion of retinas, most marked in right eye. Operation advised and performed that night by Dr. Coffin. Killian's operation on frontal sinus was done. Opening and thorough curettement of the ethmoidal cells, care being taken to preserve middle turbinated bone. Drainage was established through nasal cavity. Foul smelling pus and granulation tissue were found in both frontal sinus and ethmoidal cells. Cavity was packed with iodoform gauze and external wound closed; silk sutures. January 16th, some swelling in region of wound. Wound found closed except in region of internal canthus. Some discharge at this point.

January 17, swelling about wound remains; the packing removed and cavity irrigated. Stitches removed and gauze drainage inserted in opening opposite inner canthus. Fundi still choked. Right eye turned in. No headache. Temperature varying between 98 and 100. Lower lid somewhat swollen.

January 20th, swelling of lower lid incised. Pus evacuated and drain inserted.

January 21st, patient complains of diplopia when bandages are removed.

January 27th, drainage through nose found to be insufficient.

Dr. Coffin, under cocain, broke down the bulla, establishing better drainage. Through this tract the former opening into the ethmoidal cavity made through the external opening was packed.

January 28, eyes converge; diplopia.

February 7th, wound healed except for slight fistula near inner canthus. Temperature normal. All symptoms relieved. Good drainage through nose. Eyes still converge and patient was advised to use glasses and return to clinics three times a week for treatment.

February 20th. Patient re-admitted to hospital. Temperature normal. Wound in lower lid had re-opened and was discharging clear fluid, which increased when eyes watered or patient cried. Fundi less congested; eyes still converged. Injury to lachrymal sac was diagnosed and extirpation determined upon.

February 22nd. Operation for removal of lachrymal sac was performed by Dr. Frank Parker.

March 2nd. Wound clean and dry.

March 13th. Patient discharged. Wound entirely healed. Very little if any discharge from the nose. Very little deformity.

April 2nd. Patient examined in clinic. Wound entirely healed. Very little scar present. Fundi showed no effects from congestion. Vision good, eyes parallel, muscular movements normal. Patient, entirely relieved of all symptoms, was discharged.

1. Medical Chronicle, p. 235.

2. Archiv. für Laryngol., Rhin., Bd. I., s. 144.

3. Kuhnts' Book, Ueber die Entzündliche Erkrankungen, etc., 1895.

4. Archiv. Internat. de Laryngol. 1896, Vol. 9, p. 170.

5. Lancet, 1896.

6. Pathol. und Ther. Entzündliche Erkrankungen, etc., 1st Edition, 1898; 2nd Edition, 1903.

7. Lamb's Translation, 1900, p. 293.

8. Annales des Maladies de L'Oreille, Vol. xxviii, 1902, No. 11, p. 389.

9. Annales des Maladies de L'Oreille, Vol. xxviii, 1902, No. 9, p. 205.

10. *Annales des Maladies de L'Oreille*, Vol. xxix, 1903, No. 8, p. 129.
11. *Jour. Laryngol., Rhinol., and Otology*, March, 1905.
12. Author's reprint, 1904.
13. *Laryngoscope*, October, 1900, p. 253.
14. *Annales des Maladies de L'Oreille*, 1903, Vol. xxix, No. 11, p. 508.

(Candidate's Thesis.)

MY PERSONAL EXPERIENCES WITH EMPYEMATA
OF THE FRONTAL SINUS, WITH DEDUCTIONS
THEREFROM.

BY GEORGE L. RICHARDS, M.D.

At the present moment the therapy of frontal sinus affections is one of the much discussed and still unsettled problems in rhinology. During the last ten years various methods have been proposed, enthusiastically commended, and then allowed to drop more or less into disuse. These have varied from the simplest to the extremest methods of operation within the nasal canal, and from simple opening and prompt closure externally to the present much advocated, very radical procedure of Professor Killian. As a contribution to the general subject, the writer begs leave to offer for the consideration of this Association his own personal experiences in empyemata of the frontal sinus, together with some deductions from these experiences, and some observations as to what he regards as the probable future trend of operative procedure in this locality.

While the number of cases presented is not large, and while it is unsafe to reason too much from too limited experience, it is hoped that the deductions may have some value. The cases are reported somewhat in detail, the exact operative procedure being described, rather than named after anybody in particular.

In his address at Atlantic City before the American Medical Association, 1904, Professor Logan Turner stated that what was really needed at the present time was an accurate report of the chronicity of the cases, the number of cases affected, the surgical method employed in operating, the treatment of the wound, and

the results obtained as regards cure, relapse, the amount of disfigurement produced, and the fatal issue. As a contribution to such a qualified investigation I offer the present cases.

At the outset a certain amount of differentiation of cases must be made. I discard entirely that large group of acute inflammations of the frontal sinus which occur perhaps more and more often as accompaniments or sequelæ of grip, which may or may not be accompanied with purulent exudate, and which recover promptly under simple nasal treatment, sometimes with, sometimes without, removal of the anterior end of the middle turbinate.

The chronic cases of empyemata may also be divided into two classes: First, those in which the reasonable persistence of intranasal therapeutic measures has brought about success, and those in which, after the persistence for a reasonable time of such intranasal therapeutic measures as we have at our command, are still uncured or not sufficiently improved, and in which an external operation seems imperatively demanded.

Of the first group of cases the following four are examples:

CASE I.—Retired sea captain, 70 years of age. This case was referred to me on account of a great deal of muco-purulent discharge of long standing from the left nostril, in a man of far from robust health, and subject to attacks of heart difficulty.

There were numerous polypi in the left nostril, which were removed, leaving behind a steady discharge of foul pus in the middle meatus, with bare bone in the region of the frontal sinus outlet. Exploratory incision was made into the antrum, but there was no pus. Was able to pass a canula into the frontal sinus after cutting away some diseased tissue in the region of the outlet with the Grünwald cutting forceps. The middle turbinate, as a whole, was not removed. The quantity of pus diminished, the odor gradually grew less, and the patient's general condition better. The sinus was syringed out every other day with 1-8000 corrosive sublimate. On one occasion this syringing made him very dizzy, requiring hypodermic of strychnia and morphia before he was able to go home.

The discharge steadily diminished, and on April 1, 1902, he having come under observation on November 26, 1901, there was absolutely no pus discharge and he felt perfectly well. He was seen occasionally from this time until December 10, 1903, and at no time was there any sign of discharge from the nose or any trouble in the sinus.

This case shows what can be done under apparently difficult

conditions even with a foul purulent discharge. I was not allowed from start to finish to do anything but the mildest kind of operations, such as could be done with a snare or a few strokes of a cutting forcep, yet, to all intents and purposes, this patient was as perfectly cured by treatment within the nose as he would have been by any external operation. Three years have now elapsed without any return of the trouble. I have recently seen him and he remains in good health. There has been no nasal discharge since the cessation of treatment.

CASE 2.—Sub-acute inflammation of the frontal sinus cured by intra-nasal treatment. Mrs. W. H., age 26. First seen January 28, 1903. Had history of pain in the head following grip three months ago, with a discharge from the right nostril for five weeks. Complained of pain in the right side of the head and soreness in the inner angle of the eye. Pain was very much worse when leaning over, and of a throbbing character. There was pus in the right nostril. The middle turbinate was crowded against the septum and against the bulla so that the space for drainage was very poor. Could not probe the sinus. Provisional diagnosis of sub-acute empyema of the right frontal sinus.

The next day removed anterior portion of the right middle turbinate in order to get better drainage. The pain over the right eye soon diminished, and in a few days she was quite comfortable. The pus discharge continued, gradually diminishing. Was able to carry canula up into the sinus and syringe it out, but only with the greatest difficulty.

Two months later there was still discharge from the nose in spite of daily treatment. It was difficult to wash out the sinus very successfully, and I thought the only cure would be by means of an external operation which I advised, but which was refused. A few days after this I removed the rest of the middle turbinate and was able to get farther up towards the opening to the frontal sinus, but its washing out was only fairly successful, owing to a very narrow passage.

As, however, the patient refused any external operation and the discharge slightly lessened, and as the infundibular opening was gradually enlarged so that various solutions could be carried up into the sinus, the idea of an external operation was given up, and on May 19 there was apparently a cure of the sinus condition, and the case was dismissed. Six months later there was no apparent difference on transillumination between the two sinuses, and no sign of trouble in the nose. At the present time, a year and a half later, there has been no further trouble. Her husband, however, reported to me that following an acute cold this winter, there was a little sinus pain, which soon disappeared.

In this particular instance, although there has been an apparent cure by intra-nasal methods, I think it would have been better surgery to have opened externally, as I think there is a likelihood

of a return of the trouble after an attack of grip or any acute infective disorder.

CASE 3.—Dr. E. E. R., age 45. Has a history of several times in the past having what was called severe neuralgic pains of the right side of the head, right eye and region of the right sinus. At one time gave up his work for nearly an entire year, not having any relief at all until after three or four months in the summer in the dry air of the highlands of New Hampshire, after which he was free from this pain for several years. While traveling in a sleeping car recently, March 12, 1904, was taken with severe pain in the region of the right frontal sinus. Had no relief from treatment. Had to give up his work, that of an active physician.

Examination of the nose showed the right middle turbinate engorged, so much so that adrenalin did not blanch it. No pus was visible. The right middle turbinate was at once removed, giving some relief to the severe pain. Could enter the sinus with a probe. The pain greatly diminished until, four days after first seeing him, was able to wash out the right frontal sinus through a canula, removing a considerable quantity of muco-pus, with immediate relief of all the symptoms. Washing was continued, and at the end of a week he was well, and has continued so to the present time.

This was one of those cases of severe involvement of the frontal sinus in which, if the removal of the middle turbinate can be promptly done, the sinus drained, and relief of the engorgement brought about, a cure will be effected without further operative procedure.

CASE 4.—Sub-acute inflammation right frontal sinus. A. S., age 44, designer, came on April 12, 1904, complaining of great pain over the right eye, which he thought was due to trouble with his glasses. The oculist reported that they were all right. All nasal structures on that side congested. Treatment, nasal irrigation.

April 14, pain had been almost continuous. Unable to sleep. I at once removed the middle turbinate on the right side. After the operation was able to pass a curved canula directly into the right frontal sinus, washing out some thick purulent débris.

April 15, in spite of the pain which followed the operation and the necessity of wearing a cotton tampon, has had a better night than for weeks. Washed out the frontal again. April 16, washed out the frontal sinus. No further pain over the eye.

April 19, tried to go to his work, but gave it up and went to bed. Some reaction evidently following the operation. Washed out the sinus, but no pus. From this time on the nasal discharge entirely ceased. He had an attack of acute rheumatism, for which he went into the hospital, but there was no pain in the region of the frontal sinus, and when seen the last time, on May 12, there was no discharge, and he was perfectly well.

This was a case of sub-acute inflammation of the frontal sinus with an acute exacerbation in which the prompt establishment of free drainage cured the case. It was also one of those cases which, improperly diagnosed, tend to go on to a chronic condition with constant pus discharge.

The following group of cases belongs to class two, viz.: those which remain uncured or insufficiently improved after faithful use of intra-nasal measures, or in which, for urgent or other reasons, intra-nasal measures are manifestly not indicated.

CASE 5.—Mrs. G., 35 years, seen October 17, 1899, on account of severe headaches. Examination showed pus in each nostril, with polypi. The polypi were removed and then each middle turbinate.

December 15, 1899, the right frontal was opened externally under ether, at the inner angle of the eye underneath the supra-orbital ridge. There was fluid pus but no granulations. The opening was extended down into the nose. The external wound was treated as an open wound for two weeks, and then allowed to close, at which time the probe passed easily into the nose from the right sinus. There was improvement of the pain, but the pus discharge continued, and later complaint was made of pain over the left sinus. This was then opened in the same manner, and the right one re-opened. The two did not communicate. The opening into each nose was made larger than at the first operation on right sinus with good-sized curettes, iodoform gauze wicks passed through, followed in a few days by good-sized rubber drainage tubes passed clear into the nose and retained for four weeks. The wound was then allowed to close externally. The patient's general condition was much improved, although some pus discharge continued, varying more or less in amount.

A few months later the sinuses were again operated on and larger drainage tubes kept in for several weeks. There was improvement as before, but the pain returned again some months later and the discharge, which had never stopped, became worse, so another operation was done July 27, 1900. This time the incisions were made above the supraorbital ridge. It was found that the right sinus, except at its most dependent portion, was completely closed with osseous growth, as the result of the former operation, but there was pus in the left sinus.

For something over a year the condition was not very troublesome, but November 8, 1901, on account of throbbing pain and some pus discharge, the sinuses were each opened at the most dependent portion of the inner angle of each eye, found nearly closed with bone, the trouble being mostly at this time in the cells in the dependent portion of the sinus. All of the ethmoidal cells which could be reached were curetted and destroyed. The

rubber tubes were inserted and retained five days, followed by silver tubes worn for three weeks. She was seen occasionally for some months, then I observed that there was an empyema of the left antrum. This was due to infection, as on previous occasion both antra had been found free from pus.

On July 23, 1902, a radical operation for the empyema of the antrum was performed through the canine fossa, followed by rapid healing; the antrum at the time of the operation containing considerable granular débris. After this was done she was not seen for a year, during which time she became pregnant, and had a normal labor. At this time nothing special was found in the nose, although she still claimed to have more or less pus discharge.

July 12, 1904, she was examined. There was a little muco-pus in the nose, but she was practically well and in good health, all the pain having disappeared.

April 11, 1905, re-examined; both frontal sinuses apparently obliterated. There was a little dried scabbing in the floor of the nose, due apparently to atrophic conditions. Probe detected bare bone in the right sphenoid; could not find the opening in the left sphenoid. The patient's general condition is good. This case is a cure so far as the empyemata of the frontal sinuses are concerned. It is doubtful whether all of the ethmoidal cells are in healthy condition.

Criticism.—This was a case of extensive ethmoiditis with involvement of the sinuses, and later, infection of the left antrum from the sinus. My early operations were, without doubt, incomplete. Not having been followed by complete obliteration of the sinuses there was continual reinfection, until, as a result of the many operations, a final cure was effected. The early operations were too timid and the openings into the nose were not large enough, nor the infected ethmoidal cells thoroughly destroyed. The sinuses were not extensive in area, and had complete obliteration by packing been attempted a cure would no doubt have been effected much earlier.

CASE 6.—Mr. F. W. N., 32 years of age, milkman, resident of Martha's Vineyard. Seen in November and December, 1898, for polypi and pus discharge lasting a long time. The polypi were removed, with so much improvement that he did not present himself again for a year, at which time the pus was still present and the polypi had recurred.

The middle turbinate was removed, and, under ether, January 12, 1900, I made an opening into the right frontal sinus at the inner angle of the eye, making an incision in the ridge from the supraorbital foramen to the nasal process of the superior maxilla. The opening into the sinus was made at about the mediate point of this incision, around the inner angle of the eye. The sinus was filled with free bleeding granulation tissue, all of which was curetted out, and the opening enlarged so as to get free drainage

into the nose. A wick of iodoform gauze was carried down into the nose, followed with rubber drainage tubes, and at the end of two weeks, the sinus being apparently in good condition, the external opening was allowed to close, and the patient returned home.

He was seen once or twice afterwards and then not again for something over a year, when he reported that there was some pus in the right antrum, easily blown out when the right cheek was uppermost. He was not seen again for a year, when, January 7, 1902, he reported that there was some discharge from the nose in winter. Examination showed no pus presenting at the fronto-nasal canal, but a little bare bone could be felt with the probe, and there was no doubt but that the sinus was not perfectly healed.

April 10, 1905. This patient has just been re-examined. There is no sign whatever of pus in the nose, and he states that there has been no discharge from the sinus, so far as he knows, for five years. Two or three times in the winter he has had a little sense of pain in the right maxillary sinus, followed by a discharge of mucus and muco-pus, quickly stopping. This would apparently be due to a mild attack of inflammation of the maxillary sinus, to which reference has already been made as having occurred in the past. Transillumination of both frontals was done, the right frontal showing almost entire obliteration, the left frontal extending high up on to the forehead, with two or three septa plainly visible. Transillumination of the two antra showed each one perfectly free, so that at the present time a perfect cure of all the accessory sinus trouble has apparently occurred.

Criticism.—This was another one of the cases in which, viewed in the light of later events, I think that complete obliteration of the sinus should have been attempted at the original operation, and that presumptively the small amount of pus remaining, with the possibility of colds and inflammatory action in the nose, very likely infected the maxillary sinus. As, however, the patient was dependent upon his daily labor for existence, and as he lived where he was practically inaccessible, it seemed as though the less radical operation would probably answer, and this has, in fact, occurred, as, with the lapse of time, a perfect cure has resulted.

CASE 7.—L. J., student, first seen April 5, 1899, when 16 years of age. Brought on account of fear that he had tuberculosis. Had had a cough for ten years. One sister had died of tuberculosis, and he had spent the previous two years in Colorado and New Mexico. Was unable to find any tubercle bacilli in the lungs, but micrococcus tetragenus aureus and streptococci were abundant. Under treatment the chest conditions improved. During this time he had an acute otitis media in both ears; relieved by incision. Was under my care at intervals for a year, during which time I removed a few polypi from the right nostril, and a year later,

June 27, 1900, recorded that the nose was running a good deal. There was some discharge apparently from the left frontal sinus. Transillumination did not show any very well defined shadow. He was relieved by washing out the nose with hot Seiler's solution, which treatment he continued on his own account. About this time he entered Brown University, completing his course there in about three years.

From June 27, 1900, to May 29, 1903, I have no record in regard to him, though I saw him occasionally. The lung conditions had very much improved. At this time he came complaining of discharge from the nose, which he said had continued more or less for several years. Examination showed pus in the nostril, and exploratory puncture demonstrated it in each maxillary antrum. These were washed out at intervals and numerous polypi removed. The right middle turbinate was also removed. Diagnosis of empyema of frontal, as well as maxillary sinuses, and operation advised.

On June 17, 1903, he was operated on in the hospital, the left sinus, the left antrum, the right sinus and the right antrum all opened. Pus and diseased mucous membrane and polypoid degenerative material was found in each cavity, the antra being practically filled. The frontal sinuses were opened at the inner angle of the eye, underneath the supraorbital ridge, the greater part of the front wall of each being cut away, while the fronto-nasal canals were each enlarged sufficiently to take a large drainage tube, and the adjacent ethmoid cells curetted. The entire mucous membrane of each sinus was curetted out. The sinuses did not communicate and were of ordinary size, both as regards extension upward and outward. A large drainage tube was carried down into the nose from each sinus. Each maxillary antrum was opened through the canine fossa; all the diseased mucous membrane curetted away, and a large counter opening made underneath the floor of the nose. All the cavities were packed with gauze.

The after-treatment was uneventful so far as the maxillary sinuses were concerned. The gauze was kept in fifteen days and then not replaced. A gutta percha obturator was kept in each antral opening for about two weeks afterwards. Then they were allowed to close. There has been no further trouble from them. The opening underneath the inferior turbinate has continued to the present time.

The frontal sinuses at this time were granulating in a healthy way and were being allowed to close in, gauze dressings being retained, the tubes having been removed about ten days after the operation. The gauze put in was saturated with Balsam of Peru. At this time I was taken ill with typhoid fever, and did not see the case again for nearly three months, during which time he was under the care of a colleague, who allowed the openings to close

up. When I saw the patient they had broken out again at the surface, and the right one, he said, had never entirely healed. Both were curetted. The left one had a very little superficial pus. The right one showed some soft bone under the supraorbital ridge and some thick pus with some polypoid tissue at the nasal outlet. Gauze drains were replaced.

October 24, three weeks after, both sides were closed; the right nostril was discharging a little pus; the left, none. November 18, 2 month later, there was a little accumulation of pus from the right sinus. December 24, the left middle turbinal, which had not been previously removed, was taken out and a few polypi from the region of the right fronto-nasal canal.

February 2, 1904, the right sinus broke out again with slight pus discharge, but the probe followed only a narrow track. Did not find much of a cavity. Opening into the nose still patulous. Curetted.

May 9, 1904, reported that he had some mucus discharge from the nose, but did not find any source from which it came. May 28, found several small polypi in the right infundibulum and just a suggestion of pus. Curetted a little. Some anterior ethmoidal cells not wholly cured.

July 15, 1904, pocketing of pus had again occurred on the right side. On opening was able to pass a probe through a small opening down into the nose. The left sinus remained completely closed. Remnant of the right sinus very small. Curetted thoroughly. Washed down into the nose with pyoktanin solution, and allowed to close again in the hope that complete obliteration would this time take place.

January, 1905. There is occasionally some muco-pus from the right nostril. He is, however, in good health and is a student in the Harvard Law School, and bids fair to become perfectly well. No appreciable scar remains as the result of the operative measures.

April 20, 1905, re-examined. No sign of any trouble in the nose; now visible.

Criticism.—As the sinuses in this case did not extend upward or outward beyond the ordinary average limits, and as the external wound could have been kept open sufficiently long for the obliteration method, I think this case would have done better if, at the time of the original operation, the opening down into the nose had been made larger, the anterior ethmoidal cells curetted more vigorously, the bone opening continued lower down, cutting away a portion of the nasal process of the superior maxillary, and then the external wound maintained by gauze packing until complete obliteration had taken place. This was in my mind to do, but unfortunately, my own illness prevented, nor had I at that time become so thoroughly convinced as at present of the absolute

necessity of obliterating the sinus in order to prevent a recurrence. Nevertheless, I believe that a cure has finally occurred.

CASE 8.—G. F., age 26. First seen June 21, 1899, having developed a frontal sinus trouble as the result of trauma, he having been injured in a railroad accident. The exact nature of the trouble was not discovered for some time, the case having first been reported to me as a case of atrophic rhinitis with a foul discharge. Was treated by the usual washing methods for a while, with opening through the canine fossa made with motor drill. The pus continuing in spite of pretty free drainage from the antrum, the question of frontal sinus trouble came up. He was seen by Dr. Leland, who thought the frontal sinus involved, and advised an operation on the sinus. He was complaining of a good deal of headache, which seemed to be due to the frontal sinus trouble.

On June 19, 1900, the right frontal sinus was opened at the inner angle of the eye. Pus was present but not in large amount. There was no odor and very little granulation tissue. Sinus area extended up about one-half inch and outward one and one-half to one and three-quarters inches from this point. The opening down into the nose was enlarged and a large sized piece of gauze put in. The right maxillary antrum was then freely opened through the canine fossa above the place previously opened, and filled with gauze. The frontal sinus opening was packed with gauze two or three weeks, the gauze being followed by small gold tube which was worn for two or three months. Its removal was followed by complete closing of the frontal sinus opening, the sinus being completely obliterated.

This was in July, 1900, and there has never been any reopening of the frontal sinus, nearly five years having now elapsed. There has been occasionally a little bit of muco-pus in the antrum, and he has insisted all these years on maintaining a small opening from the mouth into the antrum, which he washes out once or twice a week. I have not been able for some three years to demonstrate any pus in the antrum, but he feels better if he can wash out the antrum occasionally, and now and then imagines that he has a little pus. Practically, however, the case has remained perfectly well for the last four years, and the frontal sinus has never broken out.

In this instance, with a comparatively small sinus and rapid formation of granulation tissue after the operation the gold tube seems to have worked as well in maintaining the opening, and to have been rather more comfortable to wear than the gauze. One reason for good result may have been due to the fact that infection was secondary to antrum trouble and there was not extensive involvement of neighboring ethmoidal cells.

At the present time there is no appreciable scar, close search being required to determine site of operation.

CASE 9.—O. M., 17 years old, spinner. First seen February 11, 1902, at which time she complained of a nasal discharge and pain in the region of the right frontal sinus. Gave a history of the discharge from the right side of the nose for one year with pain in the right side over the right eye. Examination showed pus in the right nostril, coming from high up in the nose. Probe detected bare bone in the infundibular region. Transillumination was negative. Probable diagnosis of empyema of the frontal sinus made.

February 15, removed the entire middle turbinate on the right side. Diagnosis then positive. Could pass the canula into the sinus and syringe out the pus.

On March 5 was operated on at hospital for empyema. Incision made beneath the supraorbital ridge at the inner angle of the eye. Periosteum laid bare. Bone darker than normal; thin over the sinus wall; opened—pus and granulations—no odor. Enlarged the opening; removed the granulations. Enlarged the opening into the nose so that a fair sized rubber drainage tube was easily passed into the nose. There were no symptoms pointing to antral trouble, so the antrum was not opened. There was no connection between the two sinuses. The area of the frontal sinus was not excessive, not going very high above or outwardly.

Treatment in the hospital uneventful. Occasional slight temperature rise for a few days. Dressing changed on the third day for the first time. New tubes put in on the seventh day. Left the hospital on the twelfth day, at which time the drainage tube was still in and the pus discharge very slight. The tube was removed a few days later, followed by gauze in the external opening. Pus discharge almost stopped, but did not entirely. From this time until May 3 the nose and the external wound were washed out every other day, the external wound being practically closed in.

As there was still some discharge from the nose, I punctured the right antrum and found pus, and on May 7, two months after the first operation, again put her in the hospital and did a radical antrum operation. There was some pus, but not much degeneration of the mucous membrane. A large opening was made into the canine fossa with a counter opening underneath the anterior end of the inferior turbinate. This was packed with gauze. The frontal sinus was again curetted. At the external wound there was no pus, but there was more or less rather poor granulation tissue. The opening was packed with gauze. Slight rise of temperature after the operation, but hospital record practically negative.

On May 15 the communication between the sinus and the nose had closed. There was some pus discharge from the frontal sinus wound around the gauze, but it was granulating and filling in. May 20 there was no pus in the nose from the frontal sinus. On

May 24 the frontal sinus wound was still discharging a little pus. She was given chloroform in the office, and some low form of granulation tissue re-curetted, and instead of the gauze I put in a curved silver tube, carrying it down into the nose, preparatory to letting the cavity close.

The antrum wound had had the gauze dressing continued and had done perfectly well. From May 27 to June 5 there was no apparent pus from either cavity, and the case being apparently cured, was discharged.

On August 28, three months later, she returned with the opening in the frontal sinus broken out, a small accumulation of pus causing some edema in this region. Under chloroform, skin incision was made, the opening down into the nose found with the probe, and the cavity packed with gauze. The dressings were then done every other day, and on September 9 there was complete healing apparently, and the case was again dismissed.

Two months later she was again seen. There had been no trouble. Not seen again until ten months later, June 2, 1903, when she returned with a small area of pus presenting from the right sinus. Chloroform was given and the pus evacuated. It seemed to be in the surface only. The sinus was apparently obliterated and the probe did not go any distance. A gauze drain was put in, and on June 9 there was apparently complete healing. Case has been well ever since, and there is no deformity.

Criticism.—In this case the antrum was probably infected from the frontal sinus, and the diagnosis of the antrum trouble should have been made coincidently with the diagnosis of the trouble with the frontal, and both operations should have been done the first time, providing there had been pus in the antrum.

With reference to the treatment of the frontal, in which there was a recurrence of trouble in the granulating area on three different times, this should have been treated by the method of absolute obliteration with gauze drainage from the start, and the opening into the nose should have been made sufficiently large so there would be no likelihood of its closing during the period of granulating above. So far as can be seen, a perfect cure resulted with complete obliteration of the sinus, but the time required seems to me to have been longer than it should have been.

CASE 10.—Mrs. E. S., age 46. Came on account of catarrh on April 10, 1903. Examination of the nose showed numerous small polypi around the anterior end of each middle turbinate. These were removed, and on April 15 the right inferior turbinate was removed. She suffered greatly from inability to sleep. April 25 several polypi had come down from the ethmoid region where the turbinate was snared off.

May 15, some pus from the frontal sinus. Washed out with-out difficulty. Probable diagnosis of old empyema of frontal. The sinus was washed out for a number of days and the infundi-

bular region everted of polypoid tissue. The pus lessened in amount but continued. The antrum was opened exploratorily but no pus found.

On June 17 the right sphenoid sinus was opened and cleaned out with a curette. The walls were rough, but no apparent pus. On June 24 the right frontal sinus was opened under ether. It was small in area with soft anterior walls, filled with pulpy mucous membrane, which was removed entire, the opening into the nose enlarged, large drainage tube inserted, and sinus cavity packed with gauze.

The after-history is uneventful with the exception that on July 7, two weeks after the operation, she complained of seeing double. The affected eye could be rotated in every direction, and I was not conscious at the time of operation of injuring the pulley of the superior oblique. This wound was treated by the method of obliteration, the gauze being retained until the sinus was absolutely obliterated. The double vision gradually lessened, and on November 28, had entirely disappeared, and she was perfectly well. This case has been recently seen, and there has been no recurrence. The opposite side, which had shown some polypi, has ceased to trouble her, and there is no pus discharge or any trouble whatever.

Criticism.—In this case the anterior bony wall of the antrum was so soft as to break away easily under the use of a curette, hence extraordinary care should have been taken when in the region of the pulley of the superior oblique. This is the only case of double vision which I have seen following frontal sinus trouble.

CASE II.—W. G., age 29. First seen March 22, 1903, on account of pus in the right nose and right ear. Said to have followed an attack of grip. There was an otitis media purulenta with perforation.

The right nostril was filled with polypi and there was a constant pus discharge. Exploratory puncture into the antrum showed the presence of pus, and the case was treated by washing methods. The polypi were removed, after which it was possible to probe the frontal sinus and wash out through a canula. The frontal sinus was irrigated daily with a great deal of care, and this method of treatment carried on an entire month without much of any improvement except temporarily. Radical operation was then advised.

The right frontal sinus was opened underneath the supra-orbital ridge on the right side. Pus immediately welled out in considerable quantity. The opening was enlarged. The sinus itself was very, very large, extending clear over to the left side as far as directly above the supraorbital foramen on the left side, and quite a distance up on the forehead. I thought at first there was a communication between the right and left sinuses, and was

on the point of opening the left sinus, but did not do so. Cleansed out considerable polypoid tissue in addition to the pus. Opening into the nose enlarged and drainage tube inserted.

A radical operation was then done on the antrum. It was found partly filled with large polypoid masses, some of them of considerable size. The usual counter opening was then made into the nose. He was kept in the hospital two or three weeks. Had more or less pain and swelling of the eye.

At this time I was away for three weeks, when he was under the care of another physician. Both cavities had been washed out daily. This was on May 16. Examination showed the antrum apparently nearly healed. The frontal sinus had a silver tube in it. Opening down into the nose still present and of fair size.

Decided to open the left sinus for fear that the two sinuses communicated, and if this were not done, some pus pocket might be left which would cause trouble in the final healing. On May 17 the left sinus was opened under ether. Could not find any communication whatever with the right one. This sinus was very small and quite limited in extent, communicating freely with the left nostril. The mucous membrane was pulpy, detached at one place, and on pulling, came away entire. Made a good sized opening into the nose. This sinus promptly healed by the obliteration method, and has caused no trouble since. The other sinus continued to discharge a little. The patient, however, went back to work. Felt perfectly well. Gold tube was kept at the external angle of the wound, and he was seen by me once or twice a week.

October 24, had been at work through the summer, but reported at this time on account of some pain in the left eye. The opening between the two divisions of the sinus had closed, and pus had accumulated in the left side. This portion of the sinus was curetted as thoroughly as possible under ether, and gauze drain put in.

For the next two or three months there was slight discharge. Various things were used for syringing, and the discharge became small in amount. Still there was always a little through the external opening, the edges of which having skinned over, showed no tendency to close. During the following spring solutions of pyoktanin and boric acid were used to wash out the cavity, and under this the discharge became almost nothing. The opening down into the nose remained, and on January 30, at the meeting of the Eastern Section of the American Laryngological, Rhinological and Otological Society, he was seen in consultation with Dr. C. G. Coakley, who thought that permanent cure would not be reached until every particle of mucous membrane was removed, which could be done, in his opinion, best by taking off the entire front plate of the sinus. It might be attained by opening up through the already obliterated left sinus. As, however, the patient was in good condition, able to work, and unable to

afford the time to lie up, it seemed to me doubtful if any further operation was then advisable.

From this time for the following four or five months the discharge was almost nil. Four, five or six days would elapse without any, and then there would be a little at the angle of the eye. Examination with the probe on June 15 showed the sinus to be apparently closed on the left side; on the right it seemed much smaller but some bare bone was still evident in the region of the supraorbital foramen and the probe passed readily down into the nose. Cured toward the outer portion of the cavity to the right, and a drop or two of pus came out. Removed a couple of polypi from the nose. At this time I used pyoktanin in powder form, blowing it into the cavity.

From July, 1904, to December, 1904, he was seen by me only three times. On December 14 he reported there had been no pus discharge for an entire week. The probe did not hit any bare bone. There was almost no trouble in the nose. Up to the present time an occasional polyp had formed at the nasal outlet of the frontal sinus opening.

There has been no discharge of any account since December. Recent examination shows small external opening into the right sinus. The portion of the sinus leading to the left side obliterated, or else, which is more probable, division wall grown up so there is no communication. Right sinus much smaller. Opening into the nose can be found with a probe. Small amount of pus around this opening. No extreme discharge. Patient not at all annoyed.

This is one of the cases where, in the light of subsequent history, either an entire resection of the front wall of the sinus ought to have been done at the time of the first operation, or else at the time the second operation on the left frontal sinus was done this should have been opened clear up so as to throw the cavity of the right and left into one, thereby giving better access to the cavity of the left sinus. The entire treatment consisted of drainage only, and as I was unable to remove the entire mucous membrane at any one operation, the case can hardly be called an absolute cure, even though for the last year or year and a half there are practically no symptoms. Should he have an acute infection or an attack of grip or something of that sort, I think this sinus is liable to be reinfected, and although I have an apparent cure, I can hardly report this case as an absolute cure. At the same time the patient, who was very much run down physically when first seen, is strong and well and hearty, and has had no pain or discomfort from the sinus for more than a year.

CASE 12.—Dr. C. First seen January 27, 1904, with a history of illness for several weeks and a left-sided nasal discharge, for which his physician wished me consulted. Examination showed creamy pus, coming apparently from the left frontal sinus, per-

haps from the antrum as well. Transillumination showed extreme darkness as compared with the opposite side. There was some darkening over the left antrum. Exploratory puncture, however, showed the antrum to be clear. Nose was washed out for several days, giving some relief, and February 8 he had an acute otitis media, for which the drum was incised and gauze drainage used. There was some mastoid tenderness, but recovery from the ear trouble occurred without real trouble with the mastoid.

The sinus was washed out with pyoktanin solution for one or two weeks. Soon after this pus appeared to come from the right frontal sinus as well as the left. Both middle turbinates were then removed. The discharge from the sinuses diminished but did not disappear.

April 15, 1904, decided to do a radical operation. Opened the left frontal sinus by curved incision between the root of the nose and the inner line of the eyebrow. There was no fluid pus but a pulpy condition of the entire mucous membrane. Sinus in area about the average, not running up on the forehead to any great distance, though farther on the right side than the left. The entire mucous membrane was pulpy, thickened, and everywhere diseased. Removed it entire with thorough curetting. Underneath the membrane the bone seemed hard and sound. Just above the root of the nose was a small opening about 3 mm. in diameter communicating with the opposite sinus, and through which it is probable that the left sinus infected the right, although there seemed to be no direct communication between the two membranes. After thorough curetting of the interior, the probe was passed down into the nose and this opening enlarged to carry good-sized rubber drainage tube. It was fastened above and below and the cavity packed with gauze.

The right sinus was then opened in the same way; the front wall, however, was very much thinner on this side, and the periosteome easily penetrated the sinus when engaged in stripping the periosteum. On incision through the mucous membrane of the sinus, fluid pus was found to fill the sinus. This sinus extended quite a way over the eye and also above much farther than on the left side. The entire mucous membrane was curetted out and removed, and the opening down into the nose enlarged as before and drainage tube inserted. The bony opening between the two sides was then enlarged and gauze placed between. Each cavity filled with small strips of iodoform gauze.

The after-history of this case is uneventful. It was kept packed with iodoform gauze, soaked at intervals in Balsam of Peru, and changed every day or every other day, and on August 12, 1904, the case was dismissed, complete healing having taken place. The point which filled up last, and which was in the end the most annoying, was the small bony septum between the two sides, to

which the granulations did not seem to attach very well, probably because of its insufficient blood supply, and I regretted that I had not enlarged the opening between the two sinuses more. This is the only criticism I have to offer on this case. Healing up to the present time has been complete, and the patient, who had suffered from various vague head symptoms for many years, is better than he ever remembers himself to have been before.

CASE 13. M. B., age 25. First seen with nasal symptoms on March 2, 1900, at which time some pus presented from underneath the left middle turbinate, and two small polypi were removed from this space. Probe was carried up into the frontal sinus. Transillumination showed opaque left antral region as against lightness on the opposite side. Pus was very apparent in the middle meatus. Diagnosis made of pus in the antrum, perhaps in the frontal.

March 7, was operated on under ether, a radical antrum operation being done. The antrum contained pus and soft, pulpy mucous membrane. This was entirely removed and the usual counter opening made into the floor of the nose. Frontal sinus not opened. The healing of the antrum was uneventful, but after this occurred, there was some pus still apparent in the nose, which did not disappear after syringing, and on April 23, 1900, the frontal sinus was opened underneath the supraorbital ridge at the inner angle of the eye. The bone was very thick. Pus abundant and foul. Rubber drainage tube carried down into the nose and maintained for some time.

On May 14 the cavity had been allowed to close, trusting to nasal drainage. On June 8, 1900, there was a drop or two of pus exuding through the wound so that a small curette was put in. Cavity curetted and packed with gauze. Healing of the external wound promptly took place, and I did not see him for some time, but on August 7, 1900, he complained of pain. Could not find any sign of pus in the external wound or nose. Seven days later, however, there was some sign of pus externally. The affected area was curetted. Gold tube placed in for drainage, and the probe carried down into the nose, readily finding the remnant of the opening made for the tube. Tube was maintained as long as possible, but the latter part of August the opening had closed, and September 19, the case showing a tendency to continually re-open, he was again etherized. The frontal sinus was re-curetted thoroughly; some soft bone found; the opening into the nose re-opened and enlarged, and the whole packed with gauze. By October 25 the opening had nearly closed, gauze having been kept in continuously, and the opening was allowed to heal up.

On November 8, 1900, the wound broke out again. There was a small amount of pus present. The whole area of softened bone again curetted. Small piece of gauze inserted. November 17

and 22, drop or two of pus found in each instance, and the latter time was able to carry the probe clear down into the nose. Syringed some peroxide through. The opening again allowed to close.

December 3, pus again found in considerable amount in the upper portion of the frontal sinus. Cured again. Piece of gauze put in. December 10, 1900, under cocain, curetted the upper portion of the frontal sinus over against the dividing line from its fellow of the opposite side. Put in gauze drain again. Washed out every day for the next month. December 29, no pus found in the sinus. January 15, 1901, a drop or two of pus showed in the angle of the wound. Frontal was again opened with the knife. On February 11, 1901, there was apparently complete cure.

For the next three years there was no sign of pus or trouble or anything of the kind. The young man went to the College of Physicians and Surgeons to study medicine, where, early in April, 1904, having had no trouble whatever for three years, he was taken with an attack of grip while on ambulance service: had pain and signs of pressure over the right eye in the region of the scar of the former operation. He was put in the St. Luke's Hospital, New York. Incision made. Some pus found. This incision was allowed to close, then re-opened, and fistulous opening had been maintained for three weeks at the time I saw him.

This was on May 20, 1904, at which time examination showed a fistulous tract, very narrow at the soft parts but leading into a wider, but not very large cavity in the bone, apparently not communicating with the nose, of limited area, and very painful to the touch. Managed to curette a little. Enlarged the opening sufficiently to get a tube $2\frac{1}{2}$ mm. into the opening. Curetting of this area was very painful. It was evident that no healing was going to take place from the bottom until the external wound was enlarged and the drainage improved.

He was put into the hospital and again given ether. Re-opened along the incision of the New York operation. Dissected up the periosteum. Found the surface bone soft, the sinus obliterated on the periphery over toward the eye, but at the center soft and containing punky, purulent material. No fluid pus. Cut away the bone almost the entire length of the sinus outwardly, as far as over the supraorbital foramen, but not injuring it. Just about the center of the foramen found one cell containing a little pus. At first I thought this cell led into the right sinus, but it only led to the median partition, which was a little to the right of the exact center. Then dissected downwards, opening one large cell leading to the nose, which contained more or less soft material. Almost the entire front wall of the sinus was taken off, leaving a little bit overhanging so as to retain the ridge. A large opening was made down into the nose and all ethmoidal cells de-

stroyed, and a large size gauze wick was put in. Apparently sound bone left everywhere. Compared with the preceding operation of three or four years ago, the sinus was smaller, showing a portion of it to have filled in with solid bone. The center had evidently remained open and had been re-infected through a small tract, probably from the nose, which opening had not been obliterated.

The after-history of the case was uneventful. There was some pain and photophobia, but no iritis. The cavity was kept firmly packed with iodoform and Balsam of Peru gauze, the external opening being maintained until absolute obliteration took place, which, so far as is known, is the case. On September 10, 1904, there was apparently complete healing. There was no discharge from the nose. The sinus was completely closed in. Nine months have since elapsed without any further trouble. As in all of the other operations there was repeated breaking out of pus from the external wound, and as there has been none this time since discharged, I feel that the case has been completely healed.

Criticism.—This case illustrates very well the necessity of complete obliteration of the sinus, as there had been on previous occasions two apparently complete cures after the two former operations, and after the last no recurrence for three years. As, however, the center of the sinus had not been entirely obliterated and there was still some communication with the nose, there was a chance for re-infection, which took place. The mistake which I made in the earlier instances was in allowing the external wound to close, so much so as to be unable to work through it satisfactorily, without being satisfied that every bit of the center was filled with firm bone before so doing.

CASE 14.—Mrs. B. Patient seen by Dr. S. on January 13, 1905, complaining of pain in the region of the right eye and right frontal. Next day right eye bulged very much forward. Next day bulging still the same. Pain rather diminished. Considerable pus discharge. Seen by Dr. J., an oculist, who thought the condition was probably frontal. Seen by me on January 16. Examined carefully in bed. Slight frontal sinus tenderness; no pus in the nose; right eye protruding very markedly. Deemed it advisable to open the right sinus as an exploratory measure.

Admitted to the hospital. Temperature normal; pulse 68. Opened sinus in the internal angle under the ridge. On opening found some grumous-looking pus, not especially great in quantity, which welled forward, but was apparently not under much pressure. Entire sinus did not extend very far upward, but a probe easily went down in the region of the orbit and behind it. Enlarged the bone incision with cutting forceps so as to take away a portion of the nasal process of the superior maxillary. Made large opening into the nose, which opening was apparently closed as a probe would not go through it at first. Extended

bone incision upwards and removed major portion of the anterior sinus wall, curetted out the entire mucous membrane, which was degenerated. Found that there was a good-sized opening into the opposite sinus at about the root of the nose. Opened the left sinus in a similar manner, making incision through the opening downward about as far, and upwards towards the notch of the supraorbital nerve, but not as far as this. Good sized opening made into the nose, large enough to admit very large curettes. Scooped out all the degenerate mucous membrane. Packed both sinuses with gauze.

January 19. Dressing not done for three days. Temperature has been normal. Practically no pain. On removing the dressings, no sign of pus. Eye has gone backwards to its natural position to quite a degree. Is not yet quite normal.

January 22. Changed the dressings. Not much attempt at healing as yet.

January 27. Some pus discharge on the dressings, which have a little odor at the end of two days. Right eye has resumed nearly its natural position. The only swelling seems to lie in the partition between the two sinuses curetted. There is free drainage into the nose. Patient has normal temperature; is feeling well.

January 28. Is beginning to form granulations on the floor of the sinus all around. Sinuses do not extend upwards a great distance. Cut away small amount of bone with the Kerrison forceps. Patient's general condition all right.

March 31. Considerable degree of filling in has occurred. Sinuses now very much smaller. Do not extend outwardly more than half an inch from the external opening. Right one extends upward a short distance. Left one practically filled except for the center. Eye apparently normal.

June 24. Left sinus entirely filled, right one open about the size of a large pea; still communicates with the nose. Now filling rapidly. Patient has been at work for several weeks. Scar on the left side inconsiderable. Case practically well; will probably be so within two weeks.

While the treatment in this case has lasted a considerable length of time, from the middle of January until the last of June, which length of time might be considered as a fair criticism of the method, it must be remembered on the other hand that each sinus was of large extent and that complete obliteration has been obtained without scarring to any extent.

CASE 15.—W. F. T. age 60. Came November 26, 1904, on account of a sore in the external nose, about midway between the bridge and the angle of the eye on the right side, which was discharging pus. This had lasted for several months. He had been treated by two ophthalmologists for abscess of the tear duct. Examination with the probe showed this space to have

no relation whatever to the tear duct, but to lead upward into the frontal sinus and downward into the nose. Was able to syringe directly from without into each cavity. Examination of the nose showed the whole condition to have been due to a polyp or bullous-like formation of the anterior end of the right middle turbinate, obstructing the natural outlet from the sinus. The sinus washed out several times with a canula. The anterior end of the right middle turbinate was then removed, and as the symptoms were disappearing, he did not wish any radical operation done.

December 3. Re-washing of the sinus brought away dark muco-pus, but the fluid pus seemed to have disappeared for the time being, and the external wound had healed, although the probe easily traversed the region around the sinus. There was more or less bare bone around the opening from the external nose. Radical operation was urged, but he did not feel as though he could afford to lie up for permanent operation.

January 31, 1905. The external wound seems to have permanently healed. The discharge now comes entirely down through the nose, and he is having no conscious trouble with it. The case is by no means cured, but as it is not troubling him any he declines to have anything more done.

Careful examination of the case showed that he had presumptively had a chronic sinus trouble for a good many years, the pus discharge being denominated as merely catarrh, and up to the point where the internal drainage was interfered with and the pus broke through externally, he was not conscious of much of any trouble. This case illustrates the fact that many persons will stand a pus discharge from some one of the accessory sinuses without being conscious of very much trouble for many years, and only seek relief when some concurrent inflammatory condition blocks the outlet and causes absorption of the pus. In this instance the patient thinks that my operation of the removal of the middle turbinate has cured him, whereas, as a matter of fact, I have only made the drainage from the cavity better.

Of the cases cited, those operated upon, namely: Numbers 5-14 inclusive, briefly analyzed, show the following results: In seven the sinus was opened at the inner angle of the eye, nasal drainage established, with subsequent closure of the external wound after a varying period, the so-called Ogston-Luc method or some modification of it. Of these two showed a cure without recurrence, four had one or more recurrences with final cure, one certainly by obliteration, the others probably, one is still under treatment, but is practically cured, but has had more or less recurrence. Three cases were treated by the method of obliteration, and of these there have been no recurrences. The cases which showed recurrence were all of them accompanied by more or less ethmoidal suppuration or occurred in connection with maxil-

lary antrum suppuration. In the paper by Logan Turner, already referred to, he states that, in sixty-two per cent. of 172 cases, histories of which were examined by him, the ethmoidal cells were implicated, and that in 55 cases operated upon by the Ogston-Luc method, there were 33 cures and 22 failures, showing probably that the successful cases were those in which there was little or no involvement of the ethmoidal cells, while the cured cases were those of pure frontal sinus trouble without ethmoidal involvement.

My own statistics are, of course, too few of themselves to generalize from. In the main, however, it would seem to me that the cases in which the simple opening and drainage of the sinus have been immediately successful, were those in which the ethmoids were involved either but little or not at all. The cosmetic results have been good in all the cases, even those where there were several recurrences.

Conclusions.—What then shall be our attitude with reference to the treatment of chronic frontal sinus suppuration? What operation would seem to offer the best chance for the patient? Certain things must enter into the consideration of each individual case, such as the length of time the suppuration has lasted, the degree of discomfort, the probable danger to life, and the age, sex and social condition of the patient. The intra-nasal method of treatment should certainly be tried if it offers any chance of a permanent cure or of sufficient degree of relief to satisfy the needs of the patient. If persisted in for a reasonable length of time without result, the question of external operation should be considered.

Of the external operations, viewed in the light of the past and present experiences of the majority of rhinologists, what is the one to be chosen? In simple suppuration, not long continued, I agree with the conclusion of Luc as referred to by Logan Turner that in cases where the dimensions of the sinus are limited and the fronto-nasal canal is roomy and the ethmoidal labyrinth free from suppuration, and where the inflammation has not lasted any considerable length of time, the simple operation of opening and draining the sinus, with closure of the external wound, will effect a satisfactory cure. In all other cases, especially those associated with ethmoidal troubles, accompanied by the formation of polypi, and the probable implication of the sphenoidal or maxillary sinuses or both, it seems to me, as the result of my own and the experience of others, that some form of the obliteration method is the operation to be chosen. Whether it shall be that which I have myself performed, namely: the taking away of a sufficient portion of the anterior wall of the sinus below the supraorbital ridge to gain access to the sinus, and so much of the floor of the nose and the nasal process of the superior maxilla as may seem necessary, followed by a prolonged packing,

a method which, while reasonably certain to effect a cure, necessitates a disagreeable and long continued amount of after-treatment if the sinus be at all large, especially long and disagreeable if both sinuses are affected, or the method of obliteration described and followed by Dr. Coakley, namely: the taking away of the anterior wall of the sinus above the supraorbital ridge, with immediate obliteration and closure of the fronto-nasal duct, partial suture of the skin opening, with packing of the cavity until obliteration takes place, this being materially aided by the partial sinking in of the soft parts, or the more radical and much discussed operation of Killian, must be determined by the individual case, the social status of the patient, and the individual skill and proclivities of the operator. The decision in many cases can hardly be made prior to the time the patient is on the table and the sinus opened, as, although transillumination gives us considerable information in many cases, it frequently does not absolutely show the extent of the sinus, hence the operator should be sufficiently conversant with all the methods of treatment so that he may, at the time of the operation, be prepared to do that one which, in the light of his knowledge, then and there offers the best results for his patient. The question of the cosmetic result must be carefully considered, as cosmetic results which would be considered good in Germany would not be so considered here.

The published statistics of Killian's operation seem to show it to be satisfactory in its results, at the same time not all of the cases showed immediate cure, and in some of them there was more or less pus discharge for a considerable length of time thereafter. Killian's operation is also not wholly devoid of danger, as Freudenthal has recorded cases where he found the dura instead of the sinus in opening up above the bridge after the method of Killian. This, of course, could be obviated by invariably opening against the inner angle of the eye, where, if any sinus is present at all, it will be found. Of the cases reported as cures, I think some of them may justly be doubted whether they are cures or not, as so long as the discharge from the nose has not entirely stopped, the case can hardly be considered as an absolute cure even though the patient feels no discomfort. This may be illustrated in the last case reported by myself where the patient regards himself as cured, although that is far from being the case. Better drainage does not necessarily mean a cure, although it means relief.

Another operation has just been brought to my attention by Lothrop. This is a modification of the Ooston-Lue operation, which seems to have all the advantages of the latter without the danger of recurrence of symptoms of obstruction. At the same time it possess the advantages of the Killian, but is not followed by the deformity which this operation produces. A short in-

cision is made under the inner end of the eyebrow so as to approach the orbital floor of the frontal sinus. The sinus is opened by this route and the whole of the nasal floor of the frontal sinus is removed chiefly by means of curettes, thereby taking away all the ethmoid cells situated in the vicinity of the ostium frontale limited externally by the inner wall of the orbital fossa and internally by the inner wall of the lateral mass of the ethmoid, a part of which is removed. This opening embraces, therefore, as great a space as the anatomy of the parts will allow. The anterior wall of the sinus remains intact. Lothrop states that none of these operations have been followed by obstruction and that drainage is free.

It is fair also in considering any report of cases to assume that in many patients it may be impossible to get a perfect cure, as the anatomical conditions and pathological changes militate against this and do not allow the operator with safety to his patient to remove a sufficient amount of tissue, cases in which no form of operation will produce an absolute cure. I think the operator should feel fairly well satisfied with his results when he has gotten his patient free from recurrence, free from annoying nasal discharge, free from pain, even though there may still continue to be a moderate amount of ethmoidal muco-pus which, in the majority of instances, will not be noticed by the patient as anything more than ordinary nasal discharge.

The whole subject of nasal suppuration demands more consideration from the general practitioner than it has yet had, and in view of the fact that nearly every winter epidemics of grip bring about attacks of acute sinusitis, many of which can be prevented from becoming chronic under proper methods of treatment, it becomes the duty of members of societies such as this, by their written and spoken word, to educate the average practitioner into the need of proper nasal treatment for these conditions in order that they may be recognized early, and cases of acute sinus inflammation prevented from becoming chronic.

REST IN THE TREATMENT OF LARYNGEAL AND PULMONARY TUBERCULOSIS.

BY W. PEYRE PORCHER, M.D.

IT is a well-known fact that it is impossible to repair a watch while it is running. It is equally true that rest, partial or complete, is necessary to restore any diseased limb, impaired function or organ of the body. If the eye is diseased, we must rest that; if a limb should be wounded, we must rest that; why, therefore, should we not be equally stringent in insisting that a diseased throat should be rested?

By resting the larynx, I mean total cessation of phonation, the cough being limited by judicious local and constitutional treatment to the least possible quantity. Certainly next to violent paroxysms of cough and perhaps exceeding them, reckless and prolonged phonation does more toward destroying the laryngeal mucous membrane than any other factor. We have all borne witness to this truism in case of preachers, lawyers, singers, hucksters and all those whose livelihood depends to a greater or less extent upon vocalization.

Never shall I forget the impression made upon me many years ago by a preacher whose vocal integrity had been restored by a few months' rest in a mountain region. On his return home, after describing his trip to numerous friends, preaching, etc., he became entirely aphonic and he early filled a consumptive's grave.

It is not alone in cases of laryngeal tuberculosis that complete rest of the larynx and pharynx is indicated. In ordinary pulmonary cases efforts to phonate excite hypersecretion and contraction of the laryngeal muscles. Therefore, complete cessation of phonation will lessen the amount of cough and consequent prostration, hyperpyrexia, perspiration, etc.

It has been found that this absence of movement does not result in ankylosis of the joints, even after a period of several months. The explanation of this fact appears to be that in ordinary respiration there is still sufficient motion to prevent it, and it might be

well for us to here recall that we are not concerned alone with the larynx because we know that vocalization can be entirely destroyed by traumatism or other interference with the integrity of the pharynx.

During respiration or swallowing the laryngeal muscles are in a state of comparative rest, but in coughing or phonation every muscle is active. Hence if the integrity of the mucous membrane of the larynx has been destroyed, rest, partial or complete, is imperative before the restorative processes might naturally be expected to set in.

It has been urged by many writers that cough up to a certain amount should be encouraged instead of hindered in order that the tubercle bacilli may be ejected. A limited amount of cough may be said to be unavoidable in some cases to remove accumulated excretion, but certainly it should in no wise be encouraged, first because the patient could derive but small benefit from the ejection of a certain number of bacilli when the tissues were left saturated with them, and second, because we cannot account for the manner in which nature absorbs or throws off the bacilli in some cases in which they seem to have disappeared.

Some sanatoria in the North and West have achieved great success by reliance alone upon the open-air treatment, with almost total exclusion of all local and even constitutional medication. It would appear, therefore, that if such good results were to be obtained alone by the aid of atmospheric invigoration, nature was quite competent to take care of the bacilli, but if this be true, how much greater and quicker results should accrue with the aid of complete rest of the diseased organ combined with the judicious use of anodynes internally and local applications to heal intractable ulcers.

It has been and still is advocated by some laryngologists that in order to obtain total and complete rest the respiratory function should be abolished by the aid of tracheotomy. This would be ideal indeed were it possible to accomplish such results by this measure. Unfortunately, however, apart from the infection of the wound by the bacilli, the secretions become agglutinated by the inflammatory exudates from the wound, the cough is aggravated thereby, liability to pneumonia is set up and the efforts to get rid of the sputa are rendered so difficult that the advantages gained are far more than offset by the disadvantages.

The great benefit derived from the non-use of the voice is so striking that no one can fail to appreciate it if he watches the progress of a case. The simple effort to phonate is aggravated a thousand per cent. when the larynx is whipped up to do a normal amount of work, namely, the overcoming of the noises of traveling, etc., other voices and the continuous effort to do even more than is ordinarily required of it.

A patient who recently came under my care reported that he had been coughing for over a year. He had been rooting at football games, taking part in college sports, and teaching school under the poorest hygienic surroundings. Of the five physicians who had attended him, not one had urged him to discontinue the use of his voice. Severe infiltration of the entire laryngeal mucous membrane was found, but the arytenoid prominences were not enlarged nor was there any ulceration of the vocal cords or epiglottis. There was marked dullness under the left clavicle, loud vesicular murmur and engorgement at the base of the left lung as a result of old pneumonia. Tubercle bacilli were found in his sputa. He had a temperature varying from 99 to 101 degrees. On the slightest exertion his pulse ran up to 100 and over. Complete cessation of phonation was exacted of him; he was given small doses of Dover's powder and quinine at night in order to secure sleep and during the day took three doses of an emulsion of turpentine and ammonia with morphine gr. $\frac{1}{6}$. He also took at intervals palmyracol, thiacol and beechwood creosote. Locally, applications of a ten-per-cent. solution of a formalin solution were made to the larynx. Occasional applications of nitrate of silver were also made to the pharynx. He was ordered to drink milk in place of water and eat as many raw eggs as he could assimilate. As a result of this treatment his symptoms have all abated, he has gained flesh steadily, the laryngeal inflammation has almost entirely disappeared and he is deeply impressed with the benefit derived from the non-use of his voice.

It is interesting to note that the improvement in this case has taken place without any special reference to climate. He has not been sent off to the mountains nor required to sleep out of doors nor to do anything else except to keep fresh air in his room and to stay in when the weather was inclement. Had he failed to respond to this rest and conservative treatment, he would undoubtedly have left for some higher clime, as do so many persons who are deluded

with the idea that their only chance of cure lies in a high and rigorous climate. Many of these unfortunates sacrifice all that care and attention which they would receive at home for the discomforts and even privations which they often find unavoidable among strange surroundings. No patient with tuberculosis should be allowed to leave home unless he can get every luxury usually obtainable only by the wealthy, with the care of a skilled nurse and medical attendant.

The chief advantage patients receive at sanatoria which they do not get from their home physicians is that more absolute control is exercised over them, and their daily outgoings and incomings are more closely watched. For example, if a physician at home were to exact absolute silence of a patient it would be regarded as unnecessarily strenuous treatment, even in the laryngeal cases, whereas it is no less indicated in the one than in the other.

It is astonishing how many so-called cures have been recorded of laryngeal tuberculosis by different authors and under different forms of treatment, where patients were often allowed to follow their daily avocations, use tobacco, smoke cigarettes, etc.; yet no one has denied the efficacy of complete rest to the throat nor that the use of tobacco was injurious.

Failure to observe the precautionary measures of laryngeal and bodily rest in tuberculosis during any degree of pyrexia is simply criminal. This being the case, is it not equally indicated in the apyretic stage? By complete rest we increase the physiologic power of the patient to resist the disease, and as there is no drug or serum thus far discovered which has proven to be a panacea, we are forced to rely on rest, fresh air, good food and those drugs which we now know limit all inflammatory processes.

In conclusion, we must estimate the amount of advantage to be derived from rest and complete absence of phonation in tuberculosis of the respiratory organs. The violence and amount of cough determines the amount of injury done to these organs and the consequent amount of pyrexia. Every symptom productive of cough is at variance with a return to health. Rest, either partial or complete, should be paramount in all cases.

RELATIONSHIP OF LARYNGEAL TO PULMONARY
TUBERCULOSIS.

BY WALTER F. CHAPPELL, M.D.

Introduction.—Naturally the relationship between two coincident localisations of tuberculosis may be considered from several different points of view; for example, first, the purely casual, relating to the part played by one focus in the production of another, or the common relationship of the two to an antecedent or primary focus; or, second, the independent aspect, which considers in what degree a localisation of disease in one organ is entirely independent of a localisation in another organ; or, third, the purely clinical or statistical aspect, which illustrates the frequency with which one localisation of a given type is found to coincide with another localisation, also of a given type. Other possibilities readily suggest themselves.

In the present paper we naturally lack the time to cover all these points with the same degree of thoroughness. While we have sought to ignore no individual phase of our subject, we have chosen to lay the most stress upon the etiological relationship of thoroughness. While we have sought to ignore no individual phase of our subject, we have chosen to lay the most stress upon the etiological relationship of the lesions. While convinced that in the majority of cases the larynx is infected late in the course of pulmonary disease by auto-inoculation, we are equally certain that in a goodly minority of cases the laryngeal localisation is wholly independent of the pulmonary implication, and has its own causation, pathology, diagnosis, prognosis and treatment.

Prevalent Views.—In an address delivered before specialists a statement of prevalent teachings is hardly called for. The writer does not represent views which materially antagonize those of his colleagues. It is enough to state that the subject of this paper deals with debatable material; and most of my colleagues, while not actually convinced of the independence of the two localisations, may lend a perfunctory support to the claim that

laryngeal tuberculosis begins practically in the lungs. That they are actually committed to such a view, and are unaware of the possibilities of independent infection, is nowhere apparent. Hence the relative silence of authors upon this point, and the mere reiteration of the belief that laryngeal tubercle is secondary to pulmonary localisation, must not be construed as furnishing an occasion for my taking a stand in opposition to the views of the majority of practical laryngologists.

Doctrine of an Independent Type of Laryngeal Tubercle.—The textbook attitude undoubtedly holds good for the majority of cases seen by the busy physician who has no time to deal with theories and who does not feel called upon to account for anomalous cases, especially when these occur in the practice of others. But it has been said that all the advances of science have come about from a study of the exceptions to general rules. And even if we accept as a generalisation the statement that laryngeal tuberculosis is an evident auto-infection from the lung, the evidence which opposes this view may indicate a formidable minority.

We think it a conservative statement that laryngeal tuberculosis has not been duly studied in comparison with tuberculosis of other organs in their relation to pulmonary infection. A general study of this entire subject leads inevitably to the conclusion that there is a great local difference as to predisposition to tuberculosis.

The apex of the lung, beyond the age of childhood, undoubtedly possesses an extreme vulnerability to this infection while virtually immune to most other forms of disease. But the various tissues of the body in a given instance may show a marked individuality of predisposition. If we compare the larynx to an external organ, we know that the exposed parts of the body may be the seat of a tuberculous or mixed infection, or may simply harbor bacilli without being themselves infected; and that in any of these instances the adjacent lymph nodes may become tuberculous. The tuberculosis may remain strictly localized, or after a certain period the lungs may develop tubercle, but should they do so, we have no right to assume that this must come about from auto-infection.

While the apex may be infected from the local lesions, we have an equal right to suspect an independent apical infection from without. The patient is doubtless a more or less tuberculizable subject, whose tissues have a common disposition to the disease.

but not to the same degree. Why should not a patient with a local tuberculosis develop independent pulmonary phthisis as readily as one without such local lesions? The majority of phthisiologists favor the external or aspiration theory of apical infection.

Suppose we regard the larynx as an internal organ. It is conceded that tubercle bacilli may reach the blood and be deposited in some locally predisposed organ. It is idle to discuss the manner in which they reach the blood, for we have reason to believe that they may do this without causing lesions in transit. But we know that they by no means necessarily attack the apex by preference: for in a great many cases other organs appear to suffer first. In other words, the local predisposition of the kidney, epididymis, meninges, etc., may in some people be greater than that of the lungs.

There is a distinct type of isolated, local tuberculosis of the kidneys (usually unilateral) which may persist as such for a long period. If such a kidney can be extirpated in time, the patient may never become tuberculous; or he may suffer from phthisis many years later. That the kidneys in such an individual are specially disposed to this infection is shown by the fact that the opposite kidney may be separately attacked after the extirpation of its fellow.

Time does not permit us to cite further examples. We think it can be abundantly shown that tuberculosis may attack two entirely different localities of the body independently, and that in each region attacked the disease may pursue its own course without reference to the other. One lesion may be acute, another chronic, a third may undergo arrest or cure, etc.

Naturally this doctrine of individualism has limits. The bacilli in one local lesion may infect other organs in various ways—by the blood or lymphatics, or by propagation along various mucous canals. Or we may see a circumscribed or general military tuberculosis develop. But it does not antagonize the view that perfectly independent local foci may coexist for a long period, may originate, run their course and terminate without any reference to other tuberculous manifestations in the body.

This quality of independence should not be difficult to understand. Tuberculosis resembles in many respects the conditions induced by the familiar pyogenic organism. There are unlimited possibilities for independent local infections, which may exist side

by side. Under certain circumstances pyogenic cocci may be propagated in the blood or lymphatics, causing secondary local lesions, yet without setting up any constitutional symptoms. It is only when actual septicaemia develops that a really specific and universal affection is in evidence.

The case is very different in syphilis, for example, where a primary local lesion invariably means a complete infection of the entire body.

It has often been emphasized that tuberculosis is not essentially a malignant general disease. We see malignancy develop from incidental factors. Thus in acute general miliary tuberculosis we have a true tubercle sepsis, comparable to ordinary septicemia, etc. In tuberculous meningitis, the malignancy grows out of the localisation; in pulmonary phthisis it is not the tubercles which make the condition malignant, but the secondary streptococcus infection, the patient perishing virtually of a chronic sepsis and progressive suppuration of the lungs.

Tuberculosis itself, although it includes a number of types of specific lesion, is not so complicated a process as it seems. Many of its phenomena are due to the effects of associated infection with other germs. Naturally the structure of the organ, the local vulnerability of the tissues, the presence of antecedent disease, and the number and virulence of the bacilli are all factors of importance in determining the clinical picture of the disease: and in a highly complex organ like the larynx, a great clinical divergence is to be expected.

Let us now consider the relations of laryngeal and pulmonary lesions from what has been said. It may be urged that the proximity of the two localities excludes them from all that has been said as to independent infection. This objection can hold good only in a limited degree. It was formerly the custom to speak of uro-genital tuberculosis in the male as an entity. We now know, however, that urinary tuberculosis has no necessary connection with the genital variety; while the two often coexist, they may often occur independently.

We make no further claim than this; that the subject of independent tuberculosis of the two organs—lung and larynx—has not received due consideration. Much has indeed been written upon primary laryngeal tuberculosis and priority of laryngeal implication. But the subject of primacy or priority is a mere phase

of the much greater subject of independent origin. If the laryngeal lesion can pursue for a long period an entirely independent course, the mere fact of priority is of minor significance.

We may take it for granted that a patient with tuberculous laryngitis is strongly predisposed to pulmonary lesions, and that very early manifestations in the lungs are very difficult to demonstrate. It is also easy to understand that a person with tuberculosis of the larynx may already have suffered from tuberculosis within the thorax; that he may have latent or healed apical foci, or caseous bronchial glands. Practically, however, it makes no difference whether a patient with well-developed tubercle of the larynx has no demonstrable lesions of the lungs, or suspected incipient or latent lesions. If the patient is in good general condition we have a distinctly local malady to deal with.

If the lungs are free they are still prone to become attacked, not from the larynx necessarily, but from natural predisposition. The treatment of the lung is the same, whether the patient is a mere candidate for the disease, a suspect, or one with demonstrable early lesions. The treatment of the larynx, however, being largely topical, must differ with the case. While we do not intend to take up the subject of treatment in this paper, we must insist that the physician who always regards laryngeal phthisis as essentially a secondary and dependent affection must be more or less of a fatalist in his views, and must lean toward palliative measures. His hopes of cure are based upon the chances of recovery from the pulmonary state.

What limits shall be assigned for a local independent tuberculosis of the larynx? Generally speaking, any condition antedating bacillary expectoration from the lungs. Naturally the majority of cases develop after this period, and while the minority, in which we are now interested, antedate this period, yet since we do not see the larynx until pulmonary softening has begun, the question of independence loses much of its force, for secondary laryngitis may pursue a very rapid course and give the impression that it is much older than it is.

At the same time we wish to emphasize that there is no case of tuberculous laryngitis, however late its development, which may not be conceived as having had an independent origin; this possibility rests upon the remarkable immunity of so many larynges.

Wherein do the lesions of an independent laryngitis differ from those of the so-called secondary form? In theory no great difference should obtain. In each case the larynx has its own predisposition, resistance and immunity, and is attacked by the bacilli under similar conditions of exposure.

Therefore an independent laryngitis may be of high degree, while a secondary case may be of slight degree. As a matter of fact, cases of apparent independent infection appear to present the greatest variety in clinical appearances. We can only judge of independent laryngitis by a study of cases in which there is the clearest evidence that the disease is localized and isolated. We then find certain forms of independent laryngitis which could hardly occur in the secondary form. These are necessarily very rare.

In a certain class the lesions do not seem to be tuberculous clinically, and only the microscope or animal inoculation reveals the true nature of the malady. Naturally other diseases of the larynx are simulated. Such cases seem to be the purest examples of mild independent inoculation. The disease is not of sufficient virulence to cause typical lesions of tuberculosis, but only a chronic irritation which explains the simulation of other conditions.

Under this head authors have described pachydermia laryngis (known to be produced under various circumstances), smooth polypi, and a peculiar vegetating papilloma, which readily recurs after curettage and simulates epithelioma. Isolated tuberculous tumors—so-called tuberculous gummata—have been described, and these simulate syphilitic gummata.

Finally, we must add primary lupus of the larynx. There is another condition which could hardly be recognized during life (although some laryngologists claim to have seen something similar), and of which we learn through autopsy. This is a submucous deposit of non-caseated tubercles.

We shall not discuss in this connection certain prodromal symptoms, such as simple obstinate chronic laryngitis, anaemia of the larynx, neuroses, etc., for there is no evidence that these conditions are in themselves tuberculous. They are best considered under predisposition, immunity, etc.

Authors have also described undoubted examples of independent infection of the larynx in which the tissues presented many

of the phenomena of active tuberculosis, differing in no wise from secondary forms. Bernheim has described infiltration and oedema of the arytenoids, epiglottis, etc., and even of the whole larynx. Isolated perichondritis and necrosis of cartilages may occur. Several writers mention nodules upon the true cords—usually unilateral—which may simulate "singers nodes," and the condition known as the gray infiltration is a familiar one. Some writers mention active ulcerative processes. In a word, all of the phenomena of advanced laryngeal tuberculosis have been seen in subjects with minimal evidences of lung disease and good general health.

Is there anything peculiar about the course and termination of independent tuberculous laryngitis? There is much consensus of opinion that it is very rebellious to treatment. Spontaneous arrest, as well as recovery under relatively mild measures, has been noted in not a few cases, but tendency to recurrence is also mentioned. There is almost a unanimity of opinion that no matter how well localized the disease may be, pulmonary lesions are very prone to develop, although the interval may vary greatly.

PREDISPOSITION, INFECTION AND IMMUNITY.

The subject of predisposition may be opened advantageously by a consideration of the various conditions of the larynx seen from first to last in the course of tuberculosis, using the latter term in a general sense.

First of all, it is not uncommon for the larynx to remain in perfect health throughout the entire course of a pulmonary tuberculosis. Not only may it be normal in structure, but its functions may be normally performed, and the voice loud and clear to the last. In other cases the voice may have become weak or whispering as the pulmonary disease advanced; yet under some emotional influence, it may show its original quality. This remarkable immunity of the larynx is illustrated likewise in those cases in which after death bacilli have been found in normal laryngeal tissues; perhaps also in others where non-caseated submucous tubercles have been demonstrated, the larynx being otherwise normal.

Certain states of the larynx have been described which present nothing characteristic of tubercle. One of these is congestion of

the entire organ, and some writers describe a passive congestion in which the mucosa has a peculiar livid hue. Conversely anemia of the mucosa is very commonly mentioned: it appears to depend upon general anemia, which may or may not be regarded as evidence of actual tuberculosis. While these circulatory anomalies are usually mentioned as prodromes, no evidence has been adduced to show that they are necessarily followed by infection.

Much more important is the simple chronic laryngitis which is said to be present in the majority of larynges which do not become tuberculous, and to precede many cases of infection. As but one consumptive in five develops laryngeal tuberculosis, this condition must be present in a very large proportion of cases in which the larynx does not become infected. Hence the claim that this condition is a common link in the chain of infection seems weak. This form of laryngitis is said to differ in no way from the common type seen in all mankind. It occurs by preference in voice-users, alcoholics and sufferers from nasal and pharyngeal troubles, but it is claimed that in the tuberculous, whatever the association, it is rebellious to treatment. In fact, a refractory simple laryngitis is often regarded as suspicious of a beginning tuberculosis, especially when the process is limited chiefly to the cords and interarytenoid space.

Many writers put special emphasis upon a circumscribed laryngitis upon one cord which passes directly into a tuberculous lesion with a tendency to form vegetations and eventually to ulcerate. There seems to be no very good reason why a common chronic laryngitis in a tuberculous subject, or one who is a suspect, should be innately rebellious to treatment.

On the other hand, it is more likely that the circumscribed lesion on the cord already mentioned represents an actual tuberculous lesion akin to the tuberculous tumor which simulates singers node, and which has been discussed under strictly primary manifestations. If this is the case, its refractoriness to treatment would be readily accounted for, and its presence would also cause more or less simple laryngitis.

The frankly tuberculous conditions of the larynx, whatever their connection with pulmonary phenomena, are abundantly discussed in standard works: so that they require little mention here. We may, however, devote a few lines to certain unusual types. In general acute miliary tuberculosis the larynx may, of

course, be involved; there is also a partial miliary tuberculosis which may involve the larynx in connection with the pharynx and fauces: other deposits existing, perhaps, in remote localities.

Hybrid forms of tubercle with syphilis, epithelioma, laryngotyphus, ariola, etc., have been described. Finally, must be mentioned arrested, latent and healed tuberculosis, with or without resulting deformity.

Direct Exposure from Without.—While exposed in a measure to food-infection, and to the contact of infected moisture (droplet-infection), the chances of infection are so slight here as to be negligible. It is otherwise with dust infection. Here contaminated dust reaching the nasal cavities and mouth, and mingling with mucus and saliva, which is being constantly swallowed, would be in more or less intimate contact with the supra-glottic portions of the larynx.

The exposure of the larynx to dust is therefore analogous to that of the pharyngeal and faucial tonsils, which are known to harbor bacilli in a certain percentage of cases, and to become themselves tuberculous, as well as affording a port of entry for lymphatic and hematogenous infection. Nevertheless the larynx is probably considerably inferior to these tonsillar bodies in the matter of exposure and retention of bacilli; especially if we accept the view that most cervical adenitis is derived from the tonsil. According to the numerous advocates of the dust-inhalation theory of pulmonary infection, the lungs would be exposed under similar circumstances to an equal degree.

This, however, would not mitigate against the fact of independent infection of the two organs from a common source. And when we bear in mind the natural protective resources of the lung, in which the larynx plays the chief rôle, we must admit that the supra-glottic portions of the larynx, which are not specially protected, may be even more exposed than the lung itself.

Infected material from without, coughed from the lungs or expelled by ciliary motion, might also be arrested in the larynx. Here again independent infection might be possible; for even if the lungs became infected, the implication of the larynx from the return dust would not constitute an auto-infection. Hence in all exposure to tuberculous dust we find conditions which favor independent infection of the larynx—a fact to be borne in mind in individual cases.

Hematogenous Infection.—The apex of the lung is much more predisposed to this form of infection than the larynx. From analogy of other independent and isolated infections—kidney, epididymis, etc.—it is not to be doubted that in very exceptional cases the larynx may be infected in this manner. Naturally it participates in acute general miliary tuberculosis.

Lymphogenous Infection.—In realization of the difficulties of explaining the infection of the larynx in many cases, writers have sought to invoke the aid of lymphatic propagation of disease of the larynx, chiefly from the lung. This theory appeared at first sight to be supported by the alleged frequent unilateral correspondence of pulmonary and laryngeal lesions.

Krieg's statistics showed that over a third of all cases exhibited such correspondence. Magenau, however, analysed a large material from the same standpoint, and not only did he find little evidence of such conformity, but he concluded that this theory, however plausible, was not adopted to the statistical method. The writer has also failed to find any evidence supporting such a theory.

Auto-Infection from the Lung.—This method has been generally accepted as the natural method of propagation in all cases wherein the larynx is involved after the pulmonary disease has reached the stage of softening, and indeed with most authors even after pulmonary lesions are demonstrated or suspected, and generally in the vast majority of all cases.

Since the kidney can infect the ureter and bladder, and swallowed sputa the intestines, it appears reasonable to believe that the lung can infect the larynx. But this does not account for the implication of the larynx before bacilli enter the sputa, nor for the immunity of the larynx in four cases out of five, even although it is generally in a receptive vulnerable state.

And despite the wide acceptance of this view, the immunity of the larynx in the great majority of all cases with these factors in evidence, causes us to suspect that auto-infection is much less common than has been believed.

Extension from Contiguous Tissues.—This might occur in theory under a variety of circumstances. Perhaps the most familiar example is the extension of lupus from the upper food passages to the larynx. The preponderance of evidence is that infection of the larynx is essentially a surface infection whether the

latter is independent or due to auto-infection. The bacilli find lodgment in excoriations or in the mouths of the glands, and are even able to penetrate the intact epithelium (Wright). It is by no means impossible that the system at large may be infected in this manner before or without the participation of the larynx—either through the blood or lymph. Hence the lungs may be implicated while the bacilli are lying fallow in the tissues of the larynx.

According to Mayer, tubercles may form in the deeper strata of the laryngeal mucosa without any active manifestations, perhaps to be roused later into activity. Hence there are at least two ways in which the lungs and larynx may be involved at nearly the same period. First, when both are independently attacked by infectious dust; and, second, when the larynx alone is infected, but can implicate the lung by the blood route while its own lesions are developing.

In a third class of cases the larynx becomes the seat of tuberculous ulcers, and the bacilli are inspired directly into the bronchi. It is doubtless true that an independent infection of the larynx is nearly certain to be followed by pulmonary disease in time, but the *modus operandi* need not be the same in all cases.

Let us next consider the factors which predispose the larynx to tuberculous infection. These are both general and local and each must be considered incidentally from the standpoints of independent and secondary infection. Immunity may be discussed at the same time.

Of general factors the tuberculous cachexia must be first considered, naturally in connection with auto-infection for the most part. The majority of all cases occur late in the course of pulmonary phthisis, and it has been noted that laryngeal lesions tend to develop with the advance of the cachectic state. Naturally this frequency has also been explained by the ever increasing amount of bacilli-bearing sputum which passes over the larynx, and this necessarily increases the exposure, but the cachectic state of the entire economy weakens the defense.

The very common immunity of the larynx, even in presence of such powerful factors, is most remarkable, but it must be borne in mind that the larynx has means of defense, in that it is able to free itself from much of the sputa which otherwise would cling to it. It is therefore not entirely impossible that the general

cachexia may act by enabling bacilli already concealed in the laryngeal mucosa and sub-mucosa to become active and cause an independent infection.

The one or more out of five or six cases in which the larynx is infected during the cachectic period might be accounted for in this manner. This is, of course, a mere guess at the reason for the immunity of so many individuals.

In regard to the tuberculous diathesis as a predisposing cause, little is positively known. The pallor, flaccidity, and weakness, which is in evidence in so-called candidates for tuberculosis, tuberculosis suspects, and individuals who show incipient deposits on the lungs, appear to be expressed in a certain state of the larynx characterized by anemia, functional weakness, etc. It is usually mentioned as a prodromal stage, but is it not equally common in those who never develop laryngeal lesions, or do not develop them until the cachectic period? Is this condition cause or effect?

Cheval and Rousseau, voicing the opinions of many writers, regard this anemia as of a general and not a tuberculous character. Lung symptoms, while suspected, cannot be demonstrated. Upon this anemic substratum the disease appears as a gray tubercular infiltration. Since cough and expectoration are absent in these cases, the question of auto-infection from the lung is excluded. On the other hand, the best defined types of isolated laryngeal tuberculosis do not begin in this fashion.

We must, nevertheless, conclude that bacilli have at some time penetrated into the tissues, and that the general state of anemia has so weakened the natural resistance of the organ that they have been roused to activity.

While cachexia and anemia really throw but little light on the rationale of weakened resistance of a particular organ, we find something more tangible in the strumous diathesis. This denotes in modern phraseology a peculiar laxity or penetrability of tissues which invites attack from a variety of bacteria, and which need not be of the same degree in all organs of the same individual.

Cornet, Ponfick and others have shown that an entire series of so-called scrofulous affections may be caused by ordinary pyogenic organisms alone. Especially prone to be involved in the so-called lymphoid tissue, whether in lymph nodes, tonsils, sub-mucous tissues, lymphoid follicles, etc.; since this tissue is evi-

dently intended to arrest the progress of bacteria which succeed in penetrating the skin, mucosae, etc.

In the language of bacteriologists, this tissue constitutes the "first line of defence" of the organism. Some authorities have not hesitated to place the larynx among these structures because of its submucous lymphoid tissue; and have made use of this view to explain the frequency with which the larynx is involved in typhoid fever, a disease which tends to attack by preference structures which contain an abundance of lymphoid tissue—notably the intestine. It has even been asserted that a typhoid infection may be limited to the larynx.

Anything which makes an added demand on the defensive powers may act as an ally to the tubercle bacillus. Naturally any profound disturbance of nutrition would operate in this direction; this possibility we have already discussed. There is, however, another element of local character, viz., the coöperation of other forms of bacteria. So-called scrofulous tissues are permeable to various forms of bacteria, especially to the ordinary pyogenic germs. While the very great frequency of congestion and inflammation of the larynx in phthisical subjects is well known, we do not know very much of the part played therein by micro-organisms. We know that simple (and syphilitic) laryngitis have been regarded as predisposing causes of laryngeal tuberculosis, but we also know that in the majority of cases in which such laryngitis is present tubercle does not develop.

In a word, mere congestion or inflammation is not a necessary link in the chain of infection. Doubtless this hyperaemic state of the larynx is due to a variety of causes, many of which are non-bacterial (mechanical, reflex, etc.); if of ordinary bacterial origin, the germs may cause a mere surface irritation. In other cases the bacteria may tend to penetrate into the tissues, causing a reaction in the deeper strata. If tubercle bacilli pre-exist in the latter, we then have conditions favoring a mixed infection, which would explain many of the phenomena of laryngeal tuberculosis as seen clinically.

To sum up, the following are factors which seem to make possible a tuberculosis of the larynx which is essentially of independent origin, despite the presence of pulmonary tubercle:

- 1st. Direct prolonged exposure of the larynx to infected dust.
- 2nd. Penetration of tubercle bacilli beneath the superficial

tissues, whether by natural or artificial openings or through the intact epithelial covering.

3rd. A lax permeable state of the tissues in special cases, which permits tubercle bacilli to enter in large quantities and reach the sub-mucous lymphoid tissue.

4th. Ability of the tubercle bacilli to survive for a long period in these tissues without causing active changes.

5th. Rousing of bacilli to virulence by a lowering of vitality incident to anemic or cachectic states, etc.

6th. Coincidence of mixed infection, which not only promotes the virulence of tubercular bacilli, but determines many of the clinical forms of the local disease.

Statistics and Clinical Types.—The writer has a summary of a series of 50 cases of laryngeal tuberculosis with notes on the pulmonary conditions treated at the Loomis Sanitarium. Unfortunately these throw little light upon the problem of independent infection of the larynx, but they have been useful in showing that the state of the larynx is first known in the majority of cases only when the lungs have become deeply involved.

In another series of fifty cases taken mostly from private practice, five furnish strong evidence of primary or independent infection of the larynx. One case has been under my observation for six years, and has acute and quiescent attacks at the site of the laryngeal infection, similar to those seen in pulmonary tuberculosis. A second case came under my care in September last and the laryngeal invasion took the type of grey infiltration; no pulmonary infection has been discovered, and the patient is making a good recovery.

To obtain material which will throw light on the question of independent tuberculous laryngitis would naturally demand much arduous labor. Something could be accomplished by a systematic microscopic study of the larynx in autopsy material, especially in cases of accidental death of healthy subjects. This method was applied by Birch-Hirschfeld in locating the earliest lesions of pulmonary tuberculosis, and has been used to a very limited extent in the larynx. The pharyngeal and faucial tonsils have been extensively studied from this point of view with positive results. Much might be accomplished by making cultures from the mucus which collects habitually in the lower portion of the larynx, with the view of determining the germ-content of this

locality; although it is well enough known that tubercle bacilli frequently find their way into the mouths and throats of healthy individuals.

In all cases of non-tuberculous laryngitis, or whenever secretion forms in the larynx from any cause (the bronchi being healthy), a bacteriological study should be of use. Any product from the diseased larynx—fragments of polypi, etc., pus, membrane—should be tested for the presence of tubercle. More than once has it happened that a bit of supposed epithelioma, papilloma, polypus, etc., has been shown by animal inoculation to have harbored tubercle bacilli, or to have been actually tuberculous.

The laryngologist has excellent opportunities for noting the state of the larynx in many people who are healthy at the time, but may eventually become tuberculous. He might limit his material to certain classes—the notably strumous, the so-called candidates for tuberculosis—as determined by hereditary predisposition or general appearance—and those who are prone by occupation, mode of life, environment, etc., to become infected.

When the larynx is actually tuberculous no opportunity should be lost for investigating the possibility of associate infection with pyogenic or other germs. In pulmonary softening what relationship exists between the streptococci of the sputa and the development and clinical type of late tuberculous laryngitis?

Finally, something might be learned from animal experiment, although thus far not much has been accomplished along this line.

In all diseases which prevail extensively, the question of a classification by clinical types is always of interest. As any of such types have been described in connection with tubercular laryngitis, it might appear at first sight that a classification of the entire clinical material from this standpoint would not only be instructive in itself, but would be of material use in illuminating the connection between laryngeal and pulmonary lesions. We soon learn, however, that these well-defined types constitute very rare exceptions.

A rough clinical classification may be made as follows:

1st. Cases in which laryngeal lesions appear to antedate pulmonary lesions by a reasonable margin.

2nd. Cases in which the two localities appear to be involved at about the same time—the question of precedence being non-determinable.

3rd. Cases in which the larynx is not involved until pulmonary phthisis is well under way.

This arrangement may be of service for want of something better, but as an overwhelming majority must occur in Class 3, and as the matter of independent infection of the larynx is scarcely involved, such an arrangement of material can hardly be expected to contribute much to the solution of the main problem.

Discussion on the Papers of Drs. Porcher and Chappell.

DR. JOHN O. ROE.—During a vacation trip to Florida last winter I had the pleasure of stopping at Charleston and visiting Dr. Porcher, and the satisfaction of seeing this case he has reported. I could not help but note the beautiful result that he had obtained in the treatment of this case by means of rest. There were marked evidences of laryngeal involvement, the typical appearance of laryngeal tuberculosis in a mild degree. There is no doubt that the greatest benefit in this case came about through rest and that if that larynx had been used as they usually are, if the patient had kept on speaking with it, the disease would have gone on to the ulcerative stage and proved fatal. The importance of rest in all laryngeal affections is well known. I think if we would impose *absolute rest* of the larynx in all cases of acute laryngitis, and in fact in all cases of acute inflammations of the throat, we would get much speedier and better results and followed less often by thickening and chronic inflammatory conditions.

We are certainly indebted to Dr. Porcher for reporting this case, illustrating the importance of complete rest or non-use of the voice in the treatment of tuberculous laryngitis. This method is far preferable to tracheotomy, which has in some instances been practised for this purpose, and we hope Dr. Porcher and also other members of the association will report further observations on the value of complete vocal rest in the treatment of laryngeal affections.

DR. GEORGE B. WOOD.—In connection with Dr. Porcher's paper I recall two cases of laryngeal tuberculosis in which tracheotomy was performed for the relief of dyspnœa. In one case the stenosis of the larynx was due to excessive infiltration; the patient lived for a month after the operation. Of course the larynx was by the operation put in absolute rest, and the effects of this rest was shown at the autopsy. The ulcers were almost all healed and the infiltration was less, though still marked.

The second case was, a rather unique one, of double recurrent paralysis due to a probable involvement of the recurrent laryngeal nerves in the apical disease. The operation was done about six months ago, and though the patient is still alive the lung involve-

ment is so great there is no hope for recovery. The laryngeal involvement in this case was not very great, though distinct enough for a fairly positive diagnosis. The rest afforded by the tracheotomy has apparently had no effect upon the condition of the larynx.

Concerning the advisability of performing tracheotomy in cases of laryngeal tuberculosis there is one very strong objection, and that is the infection of the tracheotomy wound. In both of these cases the wound did very badly; it was very slow in healing, and in the first case there was more or less sloughing.

DR. WALTER F. CHAPPELL.—Regarding rest in tubercular laryngitis, I would say that Dr. Wood's remarks have brought to my mind a case occurring last September. A woman came under my care with severe laryngitis, with edema of the cartilages and ventricular bands, and it was so great that a tracheotomy had to be done. She was sent to Ward's Island and kept there for some time. The diagnosis of tuberculosis was made. She gained thirty pounds in weight and finally we were able to take out the tube and I have seen her twice since and the edema and general infiltration have almost entirely disappeared, so that it seems there will eventually be a complete arrest of the tuberculosis in the larynx.

DR. J. PRICE-BROWN.—With regard to rest treatment, I believe that tracheotomy is advisable in certain cases. A gentleman about 23 years of age had been four years under treatment. He improved very much, but the trouble was chiefly in the larynx. In November, two and a half years ago, his physician at the sanatorium sent him to me, saying that if I could not remove the infiltration the end would speedily be fatal. The only thing I could do was a tracheotomy. I put in a tube without delay. There was no subsequent treatment of the larynx, particularly, but the infiltration gradually disappeared. That man is alive to-day, wears a tube and is working eight hours a day. He cannot breathe without the tube, owing to the dense cicatrices within the larynx, produced during the process of healing.

DR. JOSEPH H. BRYAN.—In regard to the rest treatment for the cure of tuberculosis of the larynx properly followed, I think it is well illustrated in the case of a distinguished foreign colleague of ours. I saw him last summer and he showed me drawings of his larynx at the time he was taken sick and certain evidences of marked tuberculosis were present at that time. When I saw him there was nothing present to suggest any active inflammation of the larynx. He devoted himself entirely to the rest treatment and for one solid year he did not speak or whisper. Everything he wanted was entirely made known by writing, and I think it shows the admirable fortitude of the man to be able to do that. It is certainly a most wonderful result and proves the value of absolute rest.

DR. W. PEYRE PORCHIER.—I only wish to thank you in closing

for the way in which my paper has been received, and also to state that some of my friends thought that the method was impracticable, saying that you could not exact rest on the part of a patient and that you couldn't keep a woman quiet for two months. My first patient was a woman. She did keep absolutely quiet for two months. When on a particular occasion she was forced to speak, she found that her voice was clear. I believe that if in the beginning of ordinary pulmonic cases silence was insisted upon, the cough would be ameliorated and that nothing but good would result.

FURTHER REPORT OF A CASE OF PRIMARY LUPUS VULGARIS OF THE ORO- AND NASOPHARYNX, TREATED BY X-RAYS.

BY HERBERT S. BIRKETT, M.D.

At the last meeting of this Association I had the honor of presenting "A Report of a Case of Primary Lupus Vulgaris of the Oro- and Nasopharynx, Treated by X-Rays," and some of the members kindly requested that I should report further upon the progress of this case under the treatment then adopted and I have much pleasure in complying with their wish on the present occasion.

I last saw this patient in May, 1904. At that time the lesions which had shown themselves in the nose, oro- and nasopharynx had entirely disappeared. It was not until December of the same year that the patient again presented himself at the Nose and Throat Out-patients' Department of the Royal Victoria Hospital. He came, not that there were any symptoms which needed attention, but merely to report. Examination of the sites of the former lesions, namely, the oro- and nasopharynx and the cartilaginous portion of the septum, showed the local conditions to have remained absolutely healed and the only indications of their former presence were fine linear cicatrices.

Upon examining the larynx the epiglottis was noticed to be swollen and infiltrated and its surface studded with minute infiltrations, pin-head in size. At the extreme periphery of the epi-

glottis these infiltrations stood out individually; but proceeding from this point to the body of the epiglottis they gradually became smaller and finally merged into the smooth surface of the mucous membrane. The epiglottis was so swollen and enlarged that when lying in a quiescent state it came in contact with a point directly opposing the posterior wall of the pharynx. In this portion of the pharynx a small ulcer was noticed, in size about 7 mm. wide and 5 mm. broad, and in outline almost circular, the edges of which were infiltrated with small, round, nodular thickenings, in color slightly paler than the surrounding mucous membrane, and corresponding exactly in color with those on the edge of the epiglottis.

The subjective symptoms were entirely negative and the patient was unaware of the newly-existing conditions in his throat. There was no question from the appearance of the local trouble that we had the same pathological process as that which existed in the upper portions of the respiratory tract, making itself known in another region.

The application of X-rays was at once begun. They were applied externally through the tissues in the front of the neck corresponding to the parts invaded within. The same precautions were observed in treating this new area of infection as were carried out when applying the treatment to the previously invaded region. The applications were made four times a week, the duration of the application being increased from ten minutes to twenty minutes. This treatment has resulted in definite cicatrisation of the right half of the epiglottis. This is proceeding satisfactorily towards the remainder of the epiglottis and the ulceration on the posterior wall of the pharynx has been so far diminished in size that it measures 3×2 mm.

In the report of this case presented last year, I made a brief note of a patient who was suffering from lupus of the nose, which, before coming under observation, had destroyed the greater portion of the nose and had involved the epiglottis in a similar process. X-ray treatment was instituted in this case at that time. I have had the opportunity of seeing this patient only quite recently and am glad to be able to report a complete disappearance of the lesion involving the epiglottis, with the result, however, that it has left the epiglottis destroyed to half its extent.

Whilst I do not care to make definite statements regarding the

usefulness of this form of treatment for lupus of the mucous membrane of the respiratory tract, yet I think, with a fair amount of justice, one may look upon the results obtained in these two cases as sufficient to warrant its trial in the place of so many other therapeutic measures, the results of which have been anything but satisfactory.

Discussion.

DR. EMIL MAYER.—I should like to ask Dr. Birkett whether any tubercle bacilli have been found in the sputum of either of the patients or in sections of the diseased tissue?

It is a very noteworthy fact that primary lupus of the upper air passages has very definitely been ascertained to exist, a thing which was doubted by some of our very well-known members some years ago, and a most particularly interesting point is that so much destruction can exist without the patient's being at all aware of so terrible a process as we find in these cases. It is particularly remarkable that they complain neither of any difficulty in swallowing, and in none of the instances I have seen was the voice affected.

DR. HENRY L. SWAIN.—I should like to ask Dr. Birkett how the X-ray was applied to the larynx? Through the side?

Answer—Yes.

Question—How old was the first patient?

Answer—Eighteen.

DR. WILLIAM E. CASSELBERRY.—When this subject was under discussion a year ago, I mentioned two cases of tuberculosis of the larynx, one of which was in chronic form, sometimes entitled lupus, which I had subjected to a thorough X-ray treatment. I reported them both as having received no notable relief from the treatment. I wish to amend that somewhat, since one of the cases, that which I reported under the designation of chronic tuberculosis of the larynx, had run a prolonged course of no great severity, and in a man whose vigor was much impaired, has since that time very markedly improved. His voice has returned approximately to the normal, the swelling of the epiglottis has reduced so much that on casual inspection it is not noticeable. The improvement seemed to come during the course of many months after the cessation of the treatment. The treatment had been most thorough. He had as many as from 60 to 70 exposures to the X-ray at intervals of every alternate day or every third day, with some longer intervals due to burning of tissue, which obliged cessation at times. There were tubercle bacilli in great numbers found in his sputum, yet it is not an advanced case of pulmonary tuberculosis, evidently a small focus somewhere in the lungs, complicated by pronounced infiltration of the larynx, and impairment

of the voice which laryngeal complications have disappeared. The other case, one of typical laryngeal tuberculosis, was not benefited by X-ray treatment of equal thoroughness.

DR. HERBERT S. BIRKETT.—In answer to Dr. Mayer's question, I would say that the pathological findings were: (1) microscopical sections taken from the site of infection and showing definitely the tubercle bacillus; (2) inoculation into the guinea pig producing definite glandular tuberculosis; (3) but, especially, the use of tuberculin, the patient (not having a febrile temperature) reacting under its use; thus, I think, proving by a definite circle of events that the case undoubtedly is one of lupus.

INTRA-NASAL DRAINAGE OF THE FRONTAL SINUS.

BY E. FLETCHER INGALS, M.D.

THE objections to opening the frontal sinus by an external operation have led to many efforts to obtain intra-nasal drainage; but the danger attendant upon enlarging the naso-frontal canal by most of the methods heretofore proposed has been great, and the drainage secured imperfect, and because of a tendency to speedy closure of the opening, the various operations proposed have been found very unsatisfactory. I desire to call your attention to an operation that I believe will be found of great value in many cases, and in so doing I wish to present the histories of a few cases that illustrate the technique of the operation and show its results. I do not offer this operation as a certain cure for chronic suppurative sinusitis, but it is safe, efficient and causes no scar, and I confidently recommend it in suitable cases for establishing free drainage, which is an essential factor in the curative treatment of every case.

In the early part of 1904 I had under my observation a lady suffering from suppuration of the frontal sinus, who had been under my care at intervals for 16 years. A reference to the old record shows that at the first visit there were polypi in the left nasal cavity. In the spring of 1893 suppuration of the ethmoid cells was noted, and in February, 1895, I find the first record of having washed out the frontal sinus through the natural opening with antiseptic solutions. Subsequent to that she had been treated for the discharge and other catarrhal symptoms by detergent and

antiseptic washes and sprays, but at no time had I been able to induce her to accept a radical operation for the suppuration of the frontal sinus. Suppuration of the antrum of Highmore had also developed, and an opening had been made through the alveolar process by which free drainage had been established. When her symptoms were especially bad, I would occasionally see her frequently, but at other times several months or even years would intervene between her visits to my office. All of this time, however, more or less purulent discharge was escaping from the left naris. During the fall of 1902 her symptoms became so annoying that the frontal sinus was washed out frequently with a saturated solution of boric acid which was followed by 4 per cent. solution of protargol or a 10 per cent. solution of argyrol or by acetozone 1 to 1,000. In the meantime the partitions between the ethmoid cells had been broken down, the cells cleared out and the antrum of Highmore had healed. During June of 1902 the case was seen frequently. The frontal sinus was washed out with boric acid solution and peroxide of hydrogen, which was followed by 3 to 5 per cent. solution of protargol. She improved considerably, but again in the latter part of July and the early part of August she was treated about every third day in this manner. It is recorded by one of my assistants on Sept. 2nd of that year that there was no more purulent discharge, and neither pain nor fullness in the frontal region. In October, however, the discharge had returned, and from that time forward until March of 1904 she was treated irregularly, but on an average of nearly once a week. At this time her persistence in declining a radical external operation and the continuance of the discharge led me to devise a new operation for internal drainage. I had frequently given this matter considerable thought in connection with that particular case, but had never struck upon an idea that worked out satisfactorily. I finally conceived the idea of making a hollow drill or burr, which could be run in over a pilot and thus enlarge the normal opening without danger to adjoining parts. In working out the problem, I very naturally met with discouragements, but finally perfected an instrument that yielded most satisfactory results. The instrument consisted of a steel pilot from 1 to 2 m.m. in diameter, a hollow burr attached to a flexible hollow wire cable and this to a hollow steel tube, which had a shank for attachment to the chuck of a dental engine; also a spiral steel tube that fitted easily over the cable of the burr which was designed to prevent irritation of the nasal mucous membrane when the instrument was in operation. In addition to these a packer similar to a uterine packer, but bent at a curve, corresponding to the outlet from the frontal sinus, was made for drying out or cauterizing the frontal sinus after the canal had been enlarged. Later a self-retaining gold tube with an internal calibre of 5 m.m. was made; also a simple instrument for its introduction and a

small syringe for subsequent treatment of the frontal sinus by the patient. I experimented with the instruments upon the cadaver until I had them perfected. On March 25, 1904, I operated upon the patient. First I washed out the sinus thoroughly with equal parts of peroxide of hydrogen and a saturated solution of boric acid and followed this by a saturated solution of boric acid, which left the cavity clean. I then introduced into the frontal sinus a 10 per cent. solution of cocain with 1 to 4,000 of suprarenaline. By this, anesthesia was secured in a few minutes. I then introduced the pilot and passed in over it the hollow burr, and over this the spiral tube; the burr was then connected to the chuck of an electric motor. I then had the patient inhale chloride of ethyl for about two minutes, by which time she was unconscious. The electricity was then turned on, gentle pressure made and the burr ran into the frontal sinus in about 6 seconds. I then introduced a curette which had been made for the purpose and cut away the mucous membrane about the opening from the frontal sinus into the enlarged canal. After this was completed, I introduced the curved packer and passed through it a one-inch strip of absorbent gauze until the sinus was filled. This was left for a few minutes and then drawn out, when bleeding seemed to have entirely ceased. I then introduced through the packer a strip of the same gauze saturated with a 95 per cent. solution of carbolic acid. This cauterized the inner part of the frontal sinus quite thoroughly and was then withdrawn through the packer. I next introduced through the packer a strip of gauze of the same kind which had been saturated with iodoform and left it in that position for three days. At the end of that time the patient reported that she had suffered a good deal of pain, and I found that temperature had run up to 103.6° F. On account of the pain she had removed the packing herself. No bleeding had occurred. At this time I hoped that the large canal, which was 6 m.m. in diameter, would remain patent until the empyema of the sinus had been cured. Subsequently the patient washed out the frontal sinus daily with a solution of boric acid and followed this by a 5 to 10 per cent. solution of argyrol. I applied a stronger solution about once a week when she came to my office. The discharge from the frontal sinus steadily diminished, and it appeared as though she would speedily recover, but in about 6 weeks the pains returned over the frontal sinus and upon investigation I found that the canal had been narrowed to about 2 m.m. in diameter at a part of its course by the formation of new bone tissue. After anesthetizing the parts, I again ran the burr in over the pilot and then introduced a self-retaining gold drainage tube like the one I had made for Case 2. Subsequently I saw the patient about once in from four to eight weeks until she came to me on the 8th of December, when I discovered that the gold tube had gradually worked its way downward nearly half an inch. In the meantime the puru-

lent discharge from the frontal sinus had ceased, but in her attempts to wash out the naris she had discovered that there was something wrong with the tube. The gold tube in this case had retained its position about 6 months. I withdrew the tube without difficulty and opening out the springs farther so as to make its retention more sure, I reintroduced it, and she has worn it without any change in position and without any discomfort up to the present time. When I removed the tube on the 8th of December, 1904, I examined the canal with a probe and it felt as though it was covered with mucous membrane throughout its entire length. There has been no purulent discharge from the frontal sinus for many months, and the patient is considered cured, although as a precaution she is still wearing the tube. I shall advise its removal the next time I see her.

This case illustrates the possibilities of intra-nasal drainage even in very protracted suppuration of the frontal sinus. From it I learned that the tube had a tendency to gradually work downward, but I found that by opening the gold springs outward so as to bring their outer ends about 13 m.m. apart (instead of 9 m.m., as at first) this tendency was overcome.

CASE 2.—M. R. P., male, age 42, came to me from Mississippi in March, 1904. He stated that 16 years previously, after a hard cold, he had been left with an offensive purulent discharge from the right naris. This had continued ever since. Nine years before I saw him, empyema of the antrum of Highmore had been diagnosticated, a bicuspid tooth had been drawn, a free opening made into the antrum, and the patient had washed this cavity regularly ever since. His general health was fairly good, although his digestion was poor and he was suffering at the time from a mucous colitis. There were no symptoms of pulmonary disease; the fauces and larynx were normal. I found tenderness over the right frontal and maxillary sinuses. Both nares were $\frac{4}{5}$ closed as a result of an acute rhinitis. There was some pus in the right naris and a mucous polypus was found in the middle meatus. There was a small opening through the alveolar process into the antrum, through which the patient washed out the cavity. Transillumination showed a distinct shadow over the right antrum of Highmore, and a less marked shadow over the right frontal sinus with normal conditions on the left side. A diagnosis of suppuration of the frontal sinus was made. The same day I removed the polypus and the anterior end of the middle turbinated body from the right side and packed the naris with iodoform gauze. The packing was removed three days later and the naris cleaned with antiseptic solutions. April 4th a detergent and antiseptic solution was given the patient with which he was to keep the naris free and clean. April 5th, I cleaned out the middle meatus thoroughly of all polypoid tissue, opened a couple of ethmoid cells and removed a polypus from one of them and again

packed the naris to prevent bleeding. The next day I removed most of the packing and the following day a large mass of fibrinous deposit was removed from the same side, but the upper part of the naris was so swollen that I could not inspect it. At this time I passed a large bent trochar into the right antrum through the inferior meatus, and after withdrawing the stylet packed the cavity through the tube with a one-inch strip of absorbent gauze that had been treated with iodoform. This was allowed to remain four days. The next day the swelling of the upper part of the naris having partially subsided, I passed a silver canula into the frontal sinus, washed it out with peroxide of hydrogen and a boric acid solution; washed out the antrum with the same solution and later injected 10 per cent. of argyrol into both of these cavities. This treatment was continued 3 or 4 days to allow healing of the wound, and on the 16th of April I enlarged the naso-frontal canal in the manner described in Case 1 by the hollow burr passed over the steel pilot. In this instance the burr passed into the frontal sinus in less than a second—in so short a time indeed that I did not know it had entered. The noise caused by the hollow cable turning on the pilot was so like that of the burr cutting bone that I thought I was still drilling, and this was kept up for several minutes. I knew that the projecting end of the pilot would surely prevent injury to the upper wall of the frontal sinus so that I did not hesitate. Finally, as I was making no progress, I withdrew the burr and then discovered that it had been in the frontal sinus for several minutes. I canterized the frontal sinus with a strip of gauze saturated with 95 per cent. of carbolic acid carried through the packer, as in the former case, and then introduced a virgin silver tube, both ends of which had been split down 12 m.m. in several places, and then I attempted to bend out these ends both above and below with various instruments, but there was a good deal of bleeding, so that it was very difficult to see, and as a result this part of the operation was tedious and unsatisfactory. I washed out the sinuses as before for the next five days, and then becoming satisfied that the silver tube would not answer the purpose, I removed it. In the meantime I had made a tube of spring gold 3.5 c.m. long, 5 m.m. internal diameter, with an ovoid, cup-shaped lower extremity and upper extremity slit down 18 m.m. in 6 places, so as to make 6 gold springs each 2.5 m.m. in width. The upper end of each spring had been bent over so as to make a blunt end that would not irritate the lining of the frontal sinus. This tube was bent to correspond to the curve of the canal. The springs were bent outward so that they would flare at the upper end 9 m.m. In introducing this tube the springs were pressed together and enclosed in a gelatine capsule. An obturator was passed into the tube and it was quickly carried up the canal into the frontal sinus. The capsule dissolved in a few seconds so that the springs were released and the tube was firmly

held in position. Subsequently there was perfect drainage from the frontal sinus and the patient could easily wash out the cavity and apply remedies. He also washed out the antrum regularly. As the patient was very anxious to return to his home in the South, he was given directions about washing out the sinuses and allowed to go. Four months later he reported that there was still a purulent discharge from the nose, that the opening into the antrum had apparently closed, but that he could wash out pus through the fistulous track in the alveolar process. He stated that the frontal sinus tube had apparently worked down a little way and asked if it should be removed. I advised him not to do so. Three months later he reported that the frontal sinus tube had worked down nearly to the nostril. As he could not return to Chicago, I advised that his local physician get the necessary instruments, remove the tube and enlarge the canal again if necessary.

In this instance the tube gradually worked down so that at the end of four months it should have been replaced. Although it allowed perfect drainage from the frontal sinus the latter continued to suppurate and it seemed probable that an external opening and curettage would finally be necessary.

In reply to my letter of inquiry, I recently received a letter from the patient dated May 10th, 1905, thirteen months after the operation, in which he states that the gold tube gradually worked down to the lower part of the naris, when it was removed by his local physician between eight and nine months after the operation. A free permanent drainage canal into the frontal sinus remained, through which he could easily wash out the cavity and all purulent discharge from the sinus has ceased, although there is still some discharge from the antrum.

CASE 3.—Miss L. M., aged 25, came to me April 25, 1904, with the following history: For 4 years she had suffered from an offensive purulent discharge from the right naris with severe pains over right eye. There was also tenderness over right antrum of Highmore, over the right side of nose and throughout an area of 8 c.m. in diameter at the top of the head. She had considerable cough and much trouble with her stomach, which was apparently caused by swallowing of the pus from the naris. Her appetite was poor and for several months she had had frequent pains in the stomach. She had lost a little flesh, was not up to her full strength, and when I first saw her she had tempeprature of one degree. Examination of the chest and abdominal organs yielded negative results. Marked tenderness of supraorbital plate just beneath inner portion of eye-brow. Transillumination showed marked shadow over right frontal sinus and right antrum. I had no difficulty in passing a probe and canula into the right frontal sinus, the anterior end of the middle turbinated body having been removed before the patient saw me. At her first

visit, I removed the anterior end of the inferior turbinated body in preparation for an opening into the antrum from the inferior meatus. March 4th, I washed out the frontal sinus thoroughly with peroxide of hydrogen and a saturated solution of boric acid, then introduced a small quantity of a 20 per cent. solution of cocain in a 1 to 4,000 of supraenaline. In about 3 minutes I followed this by the introduction of the pilot, slipped the burr over it, connected this with the chuck, then gave the patient chloride of ethyl, by which she was completely anesthetized in about two minutes. The motor was turned on and the burr passed into the frontal sinus in about a second. It was withdrawn, the packer introduced and through it a strip of gauze saturated with 95 per cent. carbolic acid, which was allowed to remain about 5 minutes. It and the packer were withdrawn, and with a ring knife the mucous membrane was cut away about the opening from the frontal sinus into the canal, it having been shown in the operations upon the cadaver that the burr did not make an opening through the mucous membrane more than about half the diameter of the opening through the bone. This same plan had been followed in previous operations, but subsequently I dispensed with the cutting away of the mucous membrane because the gold tube perfectly prevented it from interfering with drainage and its presence appeared to me likely to facilitate by just that much lining of the canal with new mucous membrane. I then introduced the gold tube with a capsule over the end into the frontal sinus, introduced a probe to push off or break the capsule, and the operation was complete. The patient was then given chloride of ethyl for a minute and with a Krause trochar I opened through the inferior meatus into the antrum. This opening I enlarged with a sharp spoon, hoping to make it permanent. The same packer that was used in the frontal sinus was then introduced into the antrum and the cavity was filled with iodoform gauze and a portion of the naris was also packed with gauze, which was allowed to remain two days; then the antrum and frontal sinus were again washed out. The patient was instructed how to wash both cavities herself and a 10 per cent. solution of argyrol was ordered to be used after washing them each day. I saw her again in 6 weeks and found that she had been doing very well until a few days previous to the visit, when she began having pain in the head. The tube had apparently been crowded down a little, but it was not removed. A week later, on a careful examination, I found that the tube had been crowded down about 9 m.m. and it was held firmly. Passing a steel probe through it, I felt what appeared to be new bony tissue closing the canal into the frontal sinus, just above the end of the tube. I removed the tube and found that the opening through the upper part of the canal, which had been partially closed by new bony formation, was apparently only about $1\frac{1}{2}$ m.m. in diameter. I introduced

the pilot into the frontal sinus, anaesthetized the patient and easily ran the burr over it into the frontal sinus. I bent out the springs of the tube so that they would be separated from each other about 12 m.m. and then re-introduced it. I found also that the opening into the antrum through the inferior meatus had completely closed. This was opened again and reamed out to a c.m. in diameter. The patient was directed to continue the home treatment in essentially the same way as before. I saw her again the next week and washed out the sinuses. The following week it was noted that the pains in the head and the nose had practically ceased and that the antrum was not suppurating, though pus was still coming from the frontal sinus. About two months later it was noted that there was still suppuration from the frontal sinus and she was having some pain over the right eye and in the top of the head, but there was no pain over the antrum. I recommended opening through the front wall of the sinus for curettage, but she would not submit to the operation at that time. On the 7th of February, 11 months after the operation, I removed the drainage tube and explored the canal and the frontal sinus with a probe. The canal seemed to be lined with mucous membrane, but I did not deem it wise to remove the tube permanently until after the frontal sinus had been curetted. The opening into the antrum had again nearly closed and was enlarged. At this time we endeavored to set a time for the radical operation, but circumstances prevented us from doing so. May 12th, 1905, in response to my letter of inquiry, the patient called at my office. She stated that she was worse than ever, and I found a profuse purulent discharge from the naris. The opening into the antrum of Highmore through the inferior meatus had closed. Three months ago a radical operation had been done on both the frontal sinus and the antrum. The operation seemed to have been well done, but instead of improvement she reported herself worse, and she had been considerably disfigured by the operation. Upon examining the drainage canal that I had made, I found it of full size with smooth walls, evidently lined with mucous membrane. She had worn the gold tube until it had been removed at the time of the radical operation. In this case I established free permanent drainage and accomplished much more for the patient's comfort than did the radical operation.

CASE 4.—M. C., 30 years of age. I was called to see this patient in consultation with Dr. L. N. Grosvenor, who had been treating the nasal cavities for about 8 weeks, having removed considerable tissue that appeared like granulation tissue. The symptoms indicated disease of the frontal sinus. The patient was having much pain and running a temperature of 102° or 103°. We anaesthetized the patient and I introduced a silver drainage tube made in the same form as the gold ones that I had previously used. The next day the temperature was only 99, and the patient

appeared to be considerably relieved. I was called to see him again a few days later and I found that the drainage from the frontal sinus was free, but the nasal cavity was nearly filled by a rapidly growing tumor which we decided to be of a malignant nature. The patient died of the disease about 4 weeks later. This patient had to be operated on in bed, but the position caused no difficulty.

CASE 5.—M. T., age 41, came to me in April of this year complaining of suppuration of the frontal sinus, for which he had already undergone a radical operation, but the drainage canal into the nose had become nearly closed and an opening remained at the inner end of the eyebrow through which pus escaped every day. His pulse was 100, temperature 99° $\frac{1}{4}$. Transillumination showed a distinct shadow over the right antrum, but the frontal sinus was translucent. On account of the contraction of the canal from the frontal sinus, I enlarged it with the pilot burr as in the operations already reported, and put in the gold tube. I found, however, that the upper end of the tube apparently struck against the upper wall of the frontal sinus, so that the flange at the lower end was about 5 m.m. below the nasal opening of the canal. I therefore had another tube made about 7 m.m. shorter and substituted it for the first one. Thereafter he was able to wash out the cavity easily and was given directions for its care similar to those I had used in previous cases. He was under my observation about two weeks and everything appeared to be doing well. He returned two weeks later and said that he had no difficulty in treating the sinus, but the amount of discharge appeared to be about the same as formerly. He was directed to wash it out with a 5 per cent. solution of protargol.

These cases have been reported as they came to me in order to give you an opportunity for an unbiased judgment of the value of this operation. The first case, although of many years' duration, was cured within nine months. The second case probably began 16 years before I saw it. The patient was allowed to go home the day after the gold tube was inserted, since which time he has attended to the treatment himself. The tube was removed in about 9 months; the large drainage canal remains and in less than 13 months he reports that there is no discharge from the frontal sinus. He does not state just when it ceased, but from his letter I should think it was within ten months after the operation. The third case was of four years' duration, and the purulent discharge was very profuse. Free drainage was established and remained, although the tube was removed at the end of about eleven months. A radical operation through the front wall of the sinus has increased the discharge and discomfort, but she had perfect drainage. All these cases were complicated with empyema of the antrum of Highmore.

In three of the cases the tube worked down within from a

month and a half to four months, so that it had to be removed and reintroduced. From the fact that after opening out the springs wider the tubes have all been retained for several months without displacement, I think that the cause of their gradually working down has been overcome. The operation can be recommended only in cases where it is practicable to introduce a probe, but in all such I believe that it is safe and efficient in establishing drainage. I am confident that in many instances free drainage will effect a cure, but where the frontal sinus is much diseased, curettage may be necessary. Even in the worst cases I think this operation might be very advantageously done before the radical operation, thereby establishing free nasal drainage and securing practically normal tissues in the nose before the curettage of the frontal sinus and thus limiting very materially the annoyances and dangers of the radical operation, because the nasal cavity and the drainage canal would not be sore and the wound through the eyebrow could be immediately closed.

The following conclusions seem to me reasonable:

a. This operation for intra-nasal drainage of the frontal sinus can be easily, quickly and safely done in those cases where it is possible to introduce a probe through the naso-frontal canal.

b. It establishes free drainage and furnishes a means whereby the patient may without aid wash out and medicate the sinus as desired.

c. I cannot perceive of a hemorrhage resulting from this operation that could not be checked by the packing, except in a hæmophilic.

d. The pilot effectually prevents perforation of the cerebral wall of the sinus.

e. The patient's consent can be obtained for this operation much more easily than for an opening through the eyebrow, and thus many cases may be cured in their incipency that would otherwise prove very tedious and would ultimately demand a more serious operation.

f. This operation would probably prove curative in nearly all cases of acute suppurative frontal sinusitis.

g. It will prove curative in a large percentage of chronic cases.

h. It will be a valuable preliminary to the radical operation in practically all cases.

i. From the curative results in 2 out of 3 chronic cases, and from the marked benefit in the third, it would appear that the

advantages of this operation are so marked that it should be recommended in preference to the external operation in practically all suitable cases, for even if a cure should not result, the conditions will be improved for a radical operation.

Discussion.

DR. JOSEPH H. BRYAN.—I have been interested in this paper, and I believe Dr. Ingals is on the right track when he says this method of treatment is applicable in *selected* cases. But in going into the frontal sinus with a probe how can we be sure we are in the sinus? We frequently go into the fronto-ethmoidal cavities, but in those cases in which we are sure we are in the cavity it is all right, by men who are skilful, but if not it is a most dangerous procedure. The cases which are suitable for this operation are certainly not those of long standing. I do not see how it is possible to curette in the deeper recesses of the frontal sinus through such an opening.

In regard to the drainage tube I believe that is right, and is going to solve the problem of frontal sinus disease in the future. I believe if a suitable tube can be devised that is going to be the future method of treating these cases, by keeping the opening sufficiently free and open long enough to bring about a cure.

DR. LEWIS A. COFFIN.—I am particularly interested in this device which has been shown us. It seems that it is practical in those cases of independent disease of the sinus. Some one has asked how we can know whether we are in the frontal sinus or not? This can be easily determined by the X-ray.

I cannot agree with Dr. Ingals in this, that it puts the patient in a better condition for a radical operation. It is, however, a most useful procedure and one I shall be anxious to try.

DR. HENRY L. SWAIN.—I would like to ask Dr. Ingals if, in the two cases he says are cured, the frontal duct is wide open? (Answer, "yes.") I should think it would be an objection to have it large, the chance of re-infection later being greater. Perhaps, however, the greater the opening, the better the drainage, and therefore the less intensity in the subsequent congestion.

DR. WILLIAM E. CASSELBERRY.—Dr. Ingals was kind enough to show me this instrument more than a year ago, and at that time I was impressed with its ingeniousness and practical applicability. It fulfilled what we had long desired—a reasonably safe way of entering the frontal sinus from the nose. The case in which I have used it was reported briefly in my contribution to the symposium on sinus disease yesterday. I do not know that Dr. Ingals will be grateful to me for having modified his method in my use of his instrument. In the first place, I gave no general anesthetic, the patient being 65 years of age and having albu-

minuria, but used local cocain anesthesia, 5 per cent. solution, injected through the frontal duct into the sinus. Secondly, I did not use the electric motor, but screwed on a firm handle and simply used hand rotation. Thirdly, I made the penetration in three steps at successive sittings, although nearly all the boring was done at the last sitting, the first two being more in the nature of trials. Absence of resistance after having penetrated the sinus, and then the ease with which the sinus could be syringed and probed afterwards, was evidence that the burr really had penetrated to the sinus. I did not cauterize with carbolic acid and inserted no drainage tube. The patient remains free from urgent symptoms, but not perfectly well one year after. I wish to inquire of the essayist whether he cauterizes with carbolic acid with a view to the destruction of granulation tissue which may be present, and whether the 95 per cent. acid is adequate to accomplish that purpose?. I did not think it would and I did not know of any other purpose of cauterizing with the carbolic acid, and was afraid to set up that much inflammatory action in such close proximity to the brain.

DR. E. FLETCHER INGALS.—I want to first think Dr. Casselberry for his innovation, for I am glad to know he could get the burr in by hand so quickly, I thought this might be done, but I have not tried it myself. It has been suggested that the operation is dangerous. I suppose there is a certain amount of danger in this, as in other operations, but it is very small. If we were to have a case in which the frontal sinus was extremely narrow from before backward not more than 2 m.m., I can understand how the burr might go through the cerebral plate, but if it did so I doubt if it would cut the dura. Even if there is danger in enlarging the normal canal by this burr to 6 m.m. in diameter, it is no greater than that of making an opening of this size in any other way. Even if we should open a way for infection from the nose, it would be no more than would occur by any other operation. Excepting in very, very rare cases, I do not think the operation dangerous, and even in these I do not think it more dangerous than any other operation. What harm is there if we run the burr into the ethmoidal cells? None whatever. The burr can only go just so far, for it is necessarily stopped by the projecting pilot. The suggestion that this operation is not suitable in chronic cases is answered by the fact that after it a considerable proportion of chronic cases get well. I have cured cases of ten to fifteen years' duration by simple drainage and washing. It was suggested that the danger of reinfection of the frontal sinus was greater by a large opening. Possibly so, but if reinfection should occur, the chances are that recovery would speedily follow. There are many cases of acute suppurative sinusitis which get well without treatment, and I think most of them would get well if drainage was instituted.

Cauterization with carbolic acid was not done with the hope of curing or getting rid of polypoid growths or granulation tissue in the sinus, but with a view to cauterizing the raw surfaces made by the instrument, so as to reduce to the minimum the chances of infection. I must say, however, that there is a certain amount of danger in the use of carbolic acid in this way. I have never seen it, but my friend, Dr. Hyde, told me he had seen three cases of serious sloughing after application of strong carbolic acid on the skin. Perhaps a solution of chloride of zinc would be better in the frontal sinus. I think some kind of cauterization after operations in these cases very desirable.

PAPILLOMA OF THE LARYNX IN CHILDREN.

BY J. PAYSON CLARK, M.D.

THE etiology of this variety of benign tumor, especially in children, is still unknown. If papilloma of the larynx is the result of a microbic infection, the specific bacterium is yet to be discovered.¹ "The respiratory tract being derived from the epiblast, its papillomata are classed with skin warts."² But this Association does not help us since dermatologists are equally in the dark regarding the etiology of *verruca vulgaris*. That the laryngeal variety has the same "mild contagiousness,"³ which has been more or less generally accepted, of the skin wart of childhood is strongly supported by the frequent appearance of papilloma in a new part of the larynx after operative interference. Indeed, this fact furnishes a strong argument for the expectant treatment to be spoken of later. Diphtheria, measles and other affections, which sometimes appear in the histories of these cases to be associated with their origin, must be looked upon as merely secondary or exciting causes, acting principally, if not solely, by increasing the circulation in the affected parts, but possibly also by lowering the resistance of the organism to infection, if it is a germ disease.

Papilloma may grow from the laryngeal surface of the epiglottis, the aryepiglottic folds, the arytenoids, the ventricular bands, the ventricles, the vocal cords, the interarytenoid space, and from the tracheal wall below the glottis. The rarity of this affection

in Europe is shown by Schroetter's and Rosenberg's statistics. The former, among 7,324 children up to ten years of age, inclusive, found 10 cases of papilloma; while the latter, among 5,808 children up to thirteen years old in the Polyclinic for Throat Diseases in Berlin, found 16 cases. During the years 1889 to 1904, inclusive, there were seen in the Throat Department of the Massachusetts General Hospital about 12,623 children under fourteen years of age (the number for the year 1904 is estimated). Of this number 12 are recorded as papilloma of the larynx. It would thus appear, as far as these records go, that this affection is even rarer in the United States than in Europe. The symptoms have been so well described in various text-books that I shall not touch upon them, but pass at once to the consideration of treatment and prognosis, which sides of the subject will repay further consideration. In the first place, as a result of my own experience with these cases and from a study of those reported by others, I wish to lay down as a fundamental proposition that these growths will not yield to any form of treatment which has been attempted, however radical, until the *period of active growth* has passed. Cases of rapid recurrence belong exclusively, as far as I can discover, to childhood, when the cell activity of the organism is at its height. Our ignorance of the etiology and ultimate pathology of these growths leaves us utterly unable to define the extent or significance of this *period*, but our clinical experience assures us of its existence. It is one of my objects in writing this paper to show that the above proposition is fully borne out by practical experience. Although the statement of Bosworth that "it is probable that the failure to thoroughly extirpate the growth is in no small degree responsible for the recurrence when it takes place" is doubtless true of most cases in adults, and may be true of some cases in children, still it fails to account for recurrence on a different site or for the fact that of two given cases operated on by the same man with equal thoroughness, one is cured, while the other may show a more active and extensive growth. Nor does this statement explain the frequent recurrences in cases treated by thyrotomy where every portion of the growth can be removed with the utmost thoroughness. Not a few such cases have been reported, but it will, perhaps, be sufficient, for the sake of illustration, to cite without comment the following most striking one of Abbe's.⁴ The pa-

tient was a girl of thirteen years in whom he did a tracheotomy, followed by a laryngofissure and thorough removal of the papilloma. Recurrence took place in two months. He then performed laryngofissure a second time, and applied the actual cautery to the site of the growth. Another recurrence in a few months led him to a third laryngotomy, and the application of monochloroacetic acid to the site of the growth. Another recurrence seemed to call for a fourth laryngotomy and the application of carbolic acid to the site. The tracheotomy tube, which had been left in for only brief periods after the previous operations, was now left undisturbed for six years. It had been removed a year before the case was reported and there had been no recurrence. Lindt,⁵ Chiari,⁶ and Summers⁷ also report striking cases of this sort. It is not my intention nor does it seem necessary to discuss this method of operating, for it is doubtful if one could find to-day a champion of it. Harmer,⁶ who is strongly opposed to it, writing in 1908, quotes the views of the writers on this subject. He found that the great majority of them were opposed to laryngotomy. The greater familiarity of operators with the use of Kierstein's autoscope and Killian's tubes has made more remote still the possible necessity of resort to this method in any case. The writer is entirely in accord with G. Hunter Mackenzie⁸ that thyrotomy for papilloma in children is unjustifiable.

What course of treatment shall one pursue in these cases? In drawing conclusions on this point from the literature one must bear in mind that it is undoubtedly true, as Mackenzie says, that some published results are invalidated by premature publication. Case 4 is an example. While quoting Mackenzie I will say that he favors treatment by tracheotomy and non-interference with the growth. He reports 7 cases treated by this method which were under observation for two years or more. Five completely recovered after wearing the tube for six to fifteen months. One, which had had a previous thyrotomy, disappeared after two and a quarter years, wearing tube, and one very badly nourished child died of independent disease about two years after tracheotomy. Mackenzie is of the opinion that original cases are more rapidly benefited by tracheotomy than those which have undergone thyrotomy or endolaryngeal operations. He cites a number of writers who have reported one or more cases successfully treated by tracheotomy. Many of these had had previous unsuccessful

endolaryngeal operations or thyrotomies. He thinks it a safe rule to open the tracheal whenever complete permanent aphonia is present without waiting for dyspnoea. The statement that tracheotomized children seldom reach puberty is disproved by the statistics of Jacobi and others. The danger of respiratory affections is not great according to Mackenzie's experience.

Summers, influenced by a case which had undergone two unsuccessful thyrotomies and was finally cured by wearing a tracheotomy tube for two years, treated 2 cases by simple tracheotomy with the result that one was cured after wearing a tube sixteen months and the other after five months. In the later case, however, the diagnosis might be questioned, as the boy was only fifteen months old when tracheotomized and there is no mention of a laryngeal examination. Bruns,⁹ whom Summers quotes, records 127 children with papilloma. 48 were not operated on, of which number 32 died, 28 by suffocation. 3 were cured spontaneously. 26 cases were tracheotomized, 7 dying after the operation. Of 21 which underwent laryngotomy, only 8 were cured. 40 treated by intra-laryngeal methods showed 13 cured. Rosenberg's¹⁰ statistics, which include Bruns', give 109 cases which had laryngotomy, 52 not over four years of age. 20 died, mostly from suffocation from recurrence. Recurrences occurred in 43 cases after repeated operations. 40 (36 per cent.) were cured, 10 with more or less impaired voice. 88 cases were treated by intra-laryngeal methods, 13 being not over four years old. 3 died. 40 (45 per cent.) were cured. 16 of these, however, are of too recent date to know final outcome.

The writer has collected the following 14 cases from the records of the Massachusetts General Hospital:

CASE 1.—J. T., male, aged four years, entered the hospital in May, 1873. Had had measles six months before and since then increasing dyspnoea. Examination of the larynx (by Dr. F. I. Knight) in March had shown fungous growths on anterior wall of larynx, nearly occluding glottis. Now has bronchitis, from which he has suffered for several weeks. Tracheotomy was done on account of dyspnoea. The patient died in six days of bronchopneumonia, which was confirmed by autopsy.

CASE 2.—George E. C. D., male, aged five years, came to the hospital in November, 1888, with the history of "croupy spells," lasting two or three days whenever he caught cold, during the previous three years. Has been hoarse for two years and aphonic for one year. Nine months before admission he had bronchitis

for two months. Now has marked dyspnoea. A laryngoscopic examination shows large white masses on both vocal cords. Tracheotomy was done on December 3rd, and on the 12th Dr. F. H. Hooper operated by means of the laryngoscope and direct sunlight, removing considerable growth with the Mackenzie forceps and Hooper laryngeal curette, the patient being under ether. On December 14th the tube was removed after having been corked for twenty-four hours and the patient was discharged on the 16th, breathing well. He could speak in a loud whisper. The subsequent history of this case is not known. A letter sent to the address given at the time was returned unclaimed. This case has been already reported.

CASE 3.—Bertha M., aged seven years, was admitted to the hospital on January 28, 1889. Her general health was good. She began to be hoarse a year ago. Hoarseness has gradually increased. There has been no dyspnoea. Laryngoscopic examination shows a papilloma, especially on the left side, arising from the vocal cord and parts above. On February 2nd, with the patient under ether and without a previous tracheotomy, Dr. Hooper attempted to remove the growth, but failed on account of the persistence of the pharyngeal reflexes. The patient was discharged, to return again in ten days. There is no further record of the case, and a letter sent to the address given at that time was returned.

CASE 4.—Earl K., aged two years, was admitted to the wards on May 14th, 1889. He is a strong and healthy boy. His voice began to be husky three or four months ago. He grew gradually worse until two months ago, when he lost his voice entirely. The respiration has also been labored and difficult for two months. Tracheotomy was done on the 15th. While recovering from tracheotomy he had an attack of measles, and on recovering from this affection he was ill for over two months with broncho-pneumonia. He continued to wear the tracheotomy tube, and nothing was done for a year and a half. In December, 1890, he was readmitted. An examination under ether by Dr. Hooper showed a grayish white mass nearly filling the glottis below the vocal cords, probably attached to the anterior wall of the larynx. On January 15, 1891, under ether, several pieces, from the size of a pin's head to a pea, were removed with the curette. Two days later, as he was found to breathe well with a cork in the tube, the latter was removed. On January 20th, the opening in the neck had healed, he breathed naturally, and his voice could be heard across the ward. He remained in the hospital until February 23rd, and was discharged in excellent condition. This much of the case has already been reported.¹¹ On December 18, 1894, the child was again admitted. He was small and poorly developed, and was breathing with great difficulty. On the 20th, tracheotomy was done, under ether, with considerable difficulty,

owing to the poor condition of the patient and the scar of the previous operation. A regular tracheotomy tube could not be introduced, but a piece of catheter was put in, stitched to a piece of plaster, which was fastened to the neck. The patient was restless through the night. He had three attacks of cough and dyspnoea. The tissues about the neck and down on chest to axillae and over to scapulae and up on to both cheeks was emphysematous and distended. During third coughing attack he coughed the catheter partly out. Before it could be reintroduced he ceased to breathe. Artificial respiration was of no avail and the patient died. A post-mortem examination of the larynx showed just above the ventricular bands a rounded papilloma, size of a pea, which, from its situation and size, must have almost completely closed the glottis. Just beneath the true cords was a similar growth of much smaller size and more sessile.

CASE 5.—Albert D., aged five years, entered the hospital November 9th, 1892. He is a well-developed and nourished boy. Since he was three months old his voice has been little better than a whisper. Examination shows a papilloma on the left side of the larynx anteriorly, apparently sessile. On November 11, with the patient under ether, Dr. Clark removed a small amount of the growth with Schroetter tube forceps. On the next day the patient coughed a small piece, and on the 17th another small piece was removed under ether anaesthesia. On the 19th he was discharged to report later. He was not seen again, but in answer to a letter the following report from his mother was received in January, 1905: "Albert is now a big, strong boy of fifteen, and has never, since the operation, had the least trouble with his throat, not even when he has a cold."

CASE 6.—Russell F., aged three years, entered the hospital June 22nd, 1896. He has been troubled for about a year with hoarseness and gradual loss of voice, with occasional attacks of choking and dyspnoea of a croupy character. He speaks only in a faint whisper. Physical examination shows a very well developed and nourished boy, apparently in excellent health. In the larynx is a papilloma involving the right vocal cord and the base of the epiglottis. On the morning of the operation the child was given 1/200 grain of atropia by the mouth and was then transferred to another ward. Here the dose was repeated, the house officer not knowing that it had already been given, so that he had in all 1/100 grain of atropia. The operation, under ether, was performed by Dr. Clark. The patient was held upright in a nurse's lap, a mouth gag was inserted and the tongue drawn forward. A portion of the growth was removed by laryngeal forceps. The patient took ether apparently well, and, although the throat was dry and free from saliva owing to the atropia, a good view of the larynx could not be obtained owing to the persistence of the throat reflexes. The child was carefully watched through the

operation, and the pulse was taken from time to time. Suddenly the child was noticed not to be breathing so well and soon stopped altogether. Tracheotomy was performed at once, artificial respiration, oxygen and electricity tried and the child worked over for an hour, but in vain. There was considerable frothy mucus discharged through the tracheotomy tube, which suggested edema of the lungs. There was no autopsy and the question still remains as to the exact cause of death; whether there was an edema brought on by the fact that the boy did not get sufficient air into the lungs through the partially obstructed larynx and whether the atropia had anything to do with death. In the latter case the patient must have been unusually susceptible to the drug, for the dose, while large, should not have been a dangerous one even for a child of three, especially as it was given in divided doses at an interval of fully an hour.

CASE 7.—William F., age five years, entered the hospital June 20th, 1897. Family history is negative. Began to be hoarse after whooping cough a year ago. Breathing became noisy soon after and has continued so ever since. This spring the boy has had attacks of dyspnoea at night. They usually come on after he has been asleep for a short time, starting with a fit of coughing. At times cyanosis has been great. Physical examination shows a well developed and nourished boy. Heart and lungs are negative. The whole larynx is filled with a papillomatous mass whose origin cannot be made out. Several attempts at removal without ether were unsuccessful. He was kept under observation for a week and discharged untreated. He was readmitted to the hospital in December, 1901. Breathing has been slowly becoming more difficult. Has had occasional attacks of dyspnoea at night, but does not become cyanotic. Is now poorly nourished. Tracheotomy was done under chloroform, from which there was an uneventful recovery. Some growth was removed by Dr. Coolidge under ether on January 10th, and on the 27th ether was again given, and in the Rose position the growth was partially removed with a snare and curette through the Kierstein's auto-scope. Bleeding was inconsiderable. On February 4th and 8th more growth was removed in the same manner. On the 11th of February the tracheotomy tube was removed, and on the 14th the wound was closed except for superficial granulation tissue. The patient was discharged to the out-patient department. Here the records show that in November, 1903, a small papilloma was seen on the right cord anteriorly, and that in five visits during March, April, May and June a few small pieces were removed with laryngeal forceps, using head and throat mirrors. Also in December a piece was removed in the same manner. In January, 1905, and in March also, a small piece was removed with the Mackenzie forceps.

CASE 8.—James J., aged eleven years, was admitted to the hos-

pital in April, 1898. He began to be hoarse three years ago, and has been growing rapidly worse for the past six months. He coughs and breathes with difficulty, especially at night. He is aphonic. A papillomatous mass grows from the laryngeal surface of the epiglottis and from the ventricular bands, concealing the vocal cords. Several pieces were removed, without ether, by means of the Hooper curette, at a number of sittings, and the patient was discharged on April 23rd, breathing well. From that date until December 14th he was treated as an out-patient, having pieces of the papilloma removed from time to time, showing its rapid growth. On the date last mentioned, while a piece of the growth was being removed, the boy became cyanosed and could breathe only with the greatest difficulty, probably the result of a sudden congestion of the larynx. Tracheotomy was done under cocain anaesthesia, from which recovery was uneventful. Portions of the papilloma were removed from time to time until April 6, 1899, when he was discharged to report to the Out-Patient Department. There is no further record of this case, and a letter sent in May, 1905, to the address given was returned unclaimed.

CASE 9.—Everett E. L., age six years, was admitted February 8, 1901. The boy was always well until a year ago, when he had gripe. Since then he has been growing more and more hoarse and for the past few months has been aphonic. Five days ago he began to have dyspnoea. He is well nourished and developed. Heart and lungs are normal. Inspiration is very labored, expiration unimpeded. There is no cyanosis. Tracheotomy was done, from which the recovery was uneventful. On the 15th, the tonsils, which were very large, were removed under ether anaesthesia, and several days later a large papilloma was removed with the Hooper curette. On March 13th, the boy was discharged wearing the tube, although he could breathe well with the tube closed. He was readmitted in October. The larynx below the arytenoids was filled with the warty growth and a piece the size of a bean was removed by Dr. F. C. Cobb with the curette under ether anaesthesia. He had a slight bronchitis after the operation, from which he quickly recovered, and on November 5th, another piece of the growth was removed in the same manner, and he was discharged on the 11th. While at home he coughed up two or three pieces through the tube. He was readmitted in February, 1902, when an examination showed the larynx apparently clear above the cords, but a growth below the glottis and also in the trachea above the tracheotomy wound. On February 21st, the patient was again discharged, the growth being so extensive and recurring so rapidly that it seemed best to leave it entirely alone for a time. This policy has been pursued ever since, the patient reporting at periods of three to six months for observation. At first he coughed up pieces of papilloma from time to time, but

for the past year he has not coughed up any. During this time his health has greatly improved and he has had no illness. He goes regularly to school, and is up with boys of his own age. When seen last (in October, 1904), he could breathe perfectly with a cork in the tube and spoke clearly. There was a small growth below the glottis apparently growing from the anterior tracheal wall. If this is still present when I see him again this summer and has not apparently increased in size, I shall probably remove it. If it has disappeared, I shall, of course, remove the tracheotomy tube.

CASE 10.—George W., age nine years, was admitted to the hospital in August, 1904, with a history of gradually increasing hoarseness for six months and marked dyspnoea on exertion for two weeks. A large papilloma was seen attached to the anterior part of the right cord and the anterior commissure and causing considerable obstruction. Repeated attempts to remove the growth under cocain failed, and Dr. D. Crosby Greene, who was on service at the time, did tracheotomy, from which the child made a good recovery, and was discharged in a few days from the hospital. He was readmitted the latter part of September, when I operated on him by means of the Kierstein autoscope and Nernst lamp, removing some of the growth with a small pair of straight alligator forceps. It was impossible to obtain a complete view of the larynx owing to the difficulty of sufficiently depressing the tongue. Another similar operation was done in February, 1905, at which time the larynx appeared more filled than ever with the papilloma. At a more recent examination the growth was found as large as ever, showing great activity, and it was decided to let it entirely alone, the patient continuing to wear the tube.

CASE 11.—Ethel S., age two and a half years, was admitted March 2nd, 1903. General health is good. Her voice began to be husky a year and a half ago. This has gradually increased until the voice is entirely gone. During the past month there has been gradually increasing dyspnoea, worse at night and when lying down. The child is well developed and nourished. The heart and lungs are normal. She speaks only in a whisper. The breathing is noisy and harsh, and evidently somewhat difficult. There is no cyanosis. On March 4th, tracheotomy was done. On the 5th the temperature was 105, pulse 150, of poor quality, and respiration 50. The child coughed a purulent material out of the tube; there were rales over both lungs and later signs of consolidation. The child died early in the morning of the 6th of pneumonia.

CASE 12.—Florence K., age three years, was admitted June 13, 1904. She has always been well, but has never been able to use her voice. Whenever she takes cold she has severe choking spells and difficulty in breathing, and often gets black in the face. A laryngeal examination under ether three days before entrance

showed papilloma growing from both sides of the larynx and causing considerable obstruction. Cyanosis is marked at times. Tracheotomy was done, from which the recovery was uneventful, and the child was discharged in a week. The following entries occur on the Out-Patient record: August 24th. Cough, with considerable discharge from tube, otherwise well. Sept. 2nd. Sonorous and musical rales through chest. No dullness. Sept. 12th. Still has cough and considerable discharge. Sept. 17th. Mother reports child is very ill. Readmitted. Sept. 19th. Larger tube inserted. Sept. 22nd. Left ear discharging; large perforation. She was etherized on the 27th and operated on in the same manner as Case 10. An excellent view of the larynx could be obtained and almost all the papillomatous mass was removed from the ventricular bands to which it was attached. Sept. 30th. Discharged, Nov. 16th. Coughing considerable. Inner tube cleansed. Nov. 25th. Discharge of muco-pus from tube is profuse. She had a bad spell since last visit and a doctor was called in to clean tube. Dec. 2nd. Tube was removed to clean and child became blue in a short time, showing marked laryngeal obstruction. Jan. 11th, 1905. Tube removed and numerous small fragments of papilloma removed through the tracheotomy wound. Breathing was much embarrassed while tube was out. About a month after the last visit we learned that the child had died at her home of broncho-pneumonia. She was one of a large family of children of very poor parents, and showed marked evidences of neglect whenever she was brought to the clinic, and her general condition improved rapidly both times she was admitted to the hospital. It seems fair to say that if her home surroundings had been better she probably would not have died as she did.

CASE 13.—Nellie S., age six years, entered the hospital July 5th, 1904. Her family history and previous history were good. Her voice is hoarse and at times entirely lost. She has severe choking attacks whenever she has a cold. The patient is a well developed and nourished child. Examination shows a large cauliflower-like growth, completely hiding the glottis. Tracheotomy was performed, from which recovery was uneventful. She wore the tube without symptoms until Sept. 26th, when she was readmitted and operated on under ether in the same manner as Cases 10 and 12. The growth was very large, covering the whole laryngeal surface of the epiglottis and completely concealing the glottis. A splendid view of the growth was obtained, and almost all of it was removed. In the course of the operation the child suddenly stopped breathing entirely once so that artificial respiration had to be resorted to. An examination under ether on the 30th showed the larynx well cleared of growth except a little on the laryngeal surface of the epiglottis. She was discharged on October 1st, wearing the tube. The following notes occur in the Out-Patient record: Dec. 14th. Papilloma grow-

ing from posterior surface of epiglottis, region of left ventricle and interarytenoid space. Feb. 9th, 1905. Considerable increase of papilloma on interarytenoid space and vocal cords, and some through fenestrum of tube. At more recent examinations, besides the growth in the larynx, which has remained undiminished, there is a papilloma which hangs down over the tracheotomy wound when the tube is removed. The child was etherized at this time with the idea of a second operation, but in view of the great activity of the growth it was decided to leave it entirely alone for the present. The child gets along with perfect comfort with the tube.

CASE 14.—Jennie M., age two years, was admitted August 10th, 1904, on account of gradually increasing hoarseness and dyspnoea for six months. Her voice is now entirely gone and dyspnoea on exertion has been marked for the past month. Two months before entrance she had her tonsils and adenoid removed. Her health in general has been good. A laryngeal examination showed the glottis almost filled with papillomatous growth, both ventricular band and the base of the epiglottis being the sites of the vegetations. On the 11th, Dr. Greene did tracheotomy under ether anaesthesia, and on the 17th he removed a small portion of the growth, also under ether, with Mackenzie forceps. The patient was discharged on the 19th. She was admitted again in October, and operated on under ether by Dr. Coolidge. The child was put in the Rose position, the autoscope introduced, and then a Killian tube into the upper part of the larynx and the growth removed piecemeal with forceps, under direct vision. The larynx was then curetted with gauze on an applicator, and left apparently free from papilloma. The child was discharged, still wearing the tube, on the 11th. A note on the Out-Patient record, February 3rd, 1905, says: "Papilloma present on both sides of the larynx." In this case, also, the growth has recurred so rapidly that non-interference for the present seems to be indicated.

Of these 14 cases, 9 were boys and 5 were girls. Age: One case, according to the parents, dated from birth. In another case the symptoms began at the age of three months. Five other cases were two years old or under when they first showed evidence of laryngeal trouble. Of the remainder, one was three years old, one four, two five, one six, and two eight years old when the first symptoms appeared. The time elapsing between the appearance of the first symptoms and application for treatment varied from four months to four years and nine months. In the majority this period was from one to three years. In one case

the symptoms began to appear after an attack of measles, in one after whooping-cough, and in one after grippe.

Treatment without previous tracheotomy was attempted in 4 cases. One of these died under the operation, one was lost sight of, one was successful, and one, after several successful operations, required tracheotomy for a sudden attack of dyspnoea during an operation. Preliminary tracheotomy was done on the 10 remaining cases. Of these latter, 4 died; 3 of broncho-pneumonia and 1 of suffocation after a difficult second tracheotomy. One of those dying of broncho-pneumonia had bronchitis at the time of the operation, which was necessitated on account of severe dyspnoea, and one died so long after tracheotomy (eight months) that death cannot be directly attributed to that operation. Case 4, which died of suffocation after a very difficult second tracheotomy necessitated by the recurrence of the growth, illustrates the importance of not removing the tube until there is no vestige of papilloma or until the child is old enough to be treated as an adult. Cases 9, 10, 13 and 14 are incomplete, and a further report will be made on them at some future time.

Treatment.—The two methods employed for seeing the papilloma were the indirect (laryngeal mirror) and the direct (Kierstein's autoscope or Killian's tubes). The instruments used in the former case were Mackenzie's forceps, Schroetter forceps and Hooper curette. In the latter case, small alligator forceps and curette were used. It is important before operating to spray the larynx with a 1 per cent. cocain solution to prevent, if possible, reflex inhibition of respiration. This occurred during the operation in Case 13, necessitating artificial respiration. As a result of his own experience and a review of the reported experience of others, the writer will in the future employ for these cases the treatment by tracheotomy and absolute non-interference with the growth. For although Case 5, and possibly Case 2, which was not heard from after leaving the hospital, recovered after one or two removals of the growth, in the rest of the cases where operative interference was resorted to, the growth returned with increased activity. Besides, it is quite possible that Case 5, in which the indications for operation were not urgent, there being no dyspnoea, might have recovered without operation. But in view of the fact that it is impossible to tell in a given case how attempts at removal will affect the papilloma, and in view of the fact

that in the large majority of cases such attempts affect it unfavorably, the best procedure seems to be to follow Mackenzie's rule to open the trachea in every case whenever complete permanent aphonia is present.

Children can, apparently, wear a tracheotomy tube with comfort and without interference with the health for years (see Case 9) if necessary. It is possible that a given case will not yield to simple tracheotomy. Dundas Grant¹ reports such a case: A girl who had had tracheotomy performed for papilloma at the age of four months and at the age of twenty-two years, was still wearing a tube and had a larynx almost filled with multiple growths. These growths were removed at one sitting and never recurred. This result of treatment in an adult agrees entirely with the writer's experience in cases already reported¹³ and in others which he has seen since. If, when the tracheotomized child reaches an age when such growths begin to lose their activity, the papilloma is still present, then endolaryngeal removal may be tried by one of the methods described above, or, without a general anaesthetic, by means of laryngeal mirrors and some form of laryngeal forceps or snare, as in the adult. At what age this treatment should be begun varies with each case, but it seems safe to say that it could not be attempted with any hope of success before the age of ten years.

Summary.—Papilloma of the larynx in children is a very serious condition, the cause of which is unknown. The best method of treatment in all cases is tracheotomy and non-interference with the growth. If, under this treatment it still persists after an age when the child can be treated as an adult, it has probably lost its activity of reproduction and attempts at its removal may be made.

References.

1. Dundas Grant, *Jour. of Laryngol., etc.*, Dec., 1904, p. 637.
2. W. E. Casselberry, *Diseases of the Eye, Nose, Throat and Ear*, Posey and Wright, 1903, p. 899.
3. Stelwagon, *Diseases of the Skin*, 1902, p. 517.
4. Robert Abbe, *Med. Record*, April 28, 1900, p. 739.
5. W. Lindt, *Corresp.-Bl. f. Schweiz. Aerzte*, Feb., 1902.
6. L. Harmer, *Arch. f. Laryngol.*, 1903, xiv, Hft. 1.
7. J. E. Summers, *N. Y. Med. Jour.*, Aug. 22, 1903.
8. G. Hunter Mackenzie, *Jour. of Laryngol.*, Sept., 1901.
9. P. Bruns, *Handbuch der practischen Chir.*, 1902.

10. Rosenberg, Arch. f. Laryngol., 1896, v.
11. F. H. Hooper, Internat. Clinics, Oct., 1891.
12. E. T. Dickerman, Jour. Am. Med. Assoc., Oct. 27, 1900.
13. J. P. Clark, Boston Med. & Surg. Jour., May 25, 1893.

Discussion.

DR. HENRY L. SWAIN.—I am reminded of a case I had years ago of papilloma in a child about four years old; he was a tractable little fellow. I tried to remove the growth by cutting out fractional portions of it from time to time, but something would always happen to result in the leaving of a part of the mass there. I had four such trials in six or eight years. In the intervals he talked a little hoarse and nothing further was done in the treatment. He grew to be a lad of 15, and then I found the growths entirely gone. There was no apparent coughing up or any thing of that description; it had simply disappeared. I had another case where operative interference had the result which Dr. Clark has noted—the more the patient was operated on the more the growth seemed to spread. Finally a thyrotomy was done, and the girl has remained with no recurrence to date, although it is twelve years ago.

DR. E. FLETCHER INGALS.—I recently operated for papilloma of the larynx on a child two years old through the Killian tube, but was obliged to do tracheotomy before I could proceed with the intra-laryngeal operation. I then cleared out the larynx completely. The child had a bronchial pneumonia following, but recovered in four or five days, when the tracheotomy tube was removed and the child left the hospital practically well. But many of these tumors in children can be removed by the Voltolini method, which is much simpler and safer. I recall the case of a child aged five years, when I simply rubbed the growth with a rough sponge tied on a steel applicator perhaps once a week for five or six weeks. As a result the tumor entirely disappeared, and I saw the child a year or two afterwards; there had been no recurrence. It takes very little in some cases to remove the growth, and I am inclined to think friction in this way is one of the best methods for children. The instrument can be introduced in the same manner as an intubation tube and the friction is quickly done. A little cocain may be applied previously to prevent pain, but I think it would be safe in cases in children to give a little chloroform; I know that this is frequently done in treating the eye. I saw a child many years ago, about ten years of age, that had a papilloma just below the cords. At that time we had no cocain, and I had to practice for a long time before I could even see the growth. I fortunately was not very busy at that time, so that I could sometimes spend an hour with her. After several months I finally succeeded in seizing the

growth with forceps. I pinched it firmly, but it was so resistant that I did not dare to pull it off for fear of doing damage. The next time the child returned, in about three weeks, the growth had disappeared, and it never recurred.

DR. WILLIAM E. CASSELBERRY.—My experience with laryngeal papilloma in children is hardly sufficient to warrant me in making criticisms, but I wish to mention an element which bears upon the prognosis in treatment by prolonged wearing of a tube. The presence of a tracheotomy tube in a patient who is depending upon it for respiration extending over a period of time is in itself a menace to the life of the child. This was emphasized in my practice by the case of a boy who had a papilloma of the larynx of sufficient size to cause dyspnoea. He was wearing a tracheotomy tube. He was awaiting operation at the hospital, which had been postponed from time to time for one reason or another, and one night, while occupying a room with his mother, who had for a long time given successful attention to the tube, the tube got out and the boy suffocated before the mother could get it in again. Thus, had the operation of thyrotomy been not postponed, and the tube dispensed with, the life would have been saved. All sorts of things happen to tracheotomy tubes when they are worn for long periods. The patients may pass from observation for months at a time. I would hesitate to adopt it as a routine method of treatment.

DR. J. PAYSON CLARK.—In regard to Dr. Swain's case, a girl of 15, on whom he did thyrotomy, I should have been inclined to have tried intra-laryngeal methods in that case because she had reached an age where these would have been successful.

Dr. Ingals referred to the Voltolini method of using a sponge. I have never used it myself, but it has been used by some of my colleagues at the Massachusetts General Hospital very satisfactorily.

Dr. Casselberry spoke of the risk of tracheotomy. Of course, that has to be taken into consideration, but the prolonged use of a tracheotomy tube seems to me better and less dangerous than repeated thyrotomies with repeated occurrences. The literature of the subject abounds in cases in which a second and even a third thyrotomy was demanded by the rapid recurrence of the papilloma in spite of its very thorough removal at the first operation. In the last four cases, which I did not read in detail, the recurrence of the growth was so tremendously rapid and in new parts of the larynx that it did not seem that any operation for the removal of the growth would be advisable. My experience in one case reported, and also the experience of other writers, notably Hunter Mackenzie, in the use of prolonged tracheotomy tubes, has been quite satisfactory, and it is the method of procedure, as far as I can see now, that I shall adopt in future.

TWO CASES OF FOREIGN-BODY (IMPACTED) IN THE
OESOPHAGUS.

BY GORDON KING, M.D.

THE lodgment of foreign bodies in the oesophageal tract is of such common occurrence that literature is replete with reports of such cases, and the subject might be considered a trite one were it not for the interest attached to the devious and sometimes ingenious methods resorted to for their removal and the serious results occasionally following such accidents.

The two cases I have thought worthy of record present two features of sufficient interest. I think, to solicit your attention—the difficulty of dislodging the body on account of its firm impaction in both cases, and the grave complication supervening in one case after the operation of oesophagotomy.

CASE I.—Pauline B., a negro child two years of age, was brought to the Eye, Ear, Nose and Throat Hospital of New Orleans July 21st, 1904, with the history of having a foreign body lodged in the larynx or some part of the throat for more than a month. Some attempts had been made by physicians in the neighborhood to remove it without success. The child had a hoarse voice, was only able to swallow liquids, and showed a very bad state of nutrition. Temperature was slightly elevated and respiration unimpaired. A glimpse of the larynx with the laryngoscope revealed nothing abnormal except some inflammatory thickening of the arytenoids. By introducing the index finger into the mouth of the oesophagus the foreign body could be felt as a rounded edge of metal, giving the impression of being a wire loop or ring. The parents were unable to say what nature of foreign body had been swallowed by the child, but were under the impression that it was a small wire hook, such as is used instead of buttons on dresses. I could not reach far enough with the finger to touch more than the upper edge of the object, which seemed to be firmly fixed at the level of the cricoid, but succeeded in grasping this edge with laryngeal forceps and endeavored to lift it out. After several unsuccessful attempts to dislodge it in this way I was forced on account of the feeble condition of the little patient to postpone further efforts until the following day, when I again essayed vigorously to extract it by means of forceps, blunt

hooks, wire loops, etc, without avail. Prolonged manipulation could not be practiced on account of the embarrassment to the respiration by the flow of mucus and blood into the larynx and of the general weakness. The child's vitality, in fact, was so low that I decided to give her a few days of rest and stimulation, and then do a temporary tracheotomy, and if necessary, oesophagotomy. Five days elapsed before it was deemed wise to bring the child to the operating room again, and even then weakness was so pronounced that I concluded I would make one more effort to extract the body by mouth before subjecting the child to the danger of anaesthesia and the shock of a cutting operation.

With the aid of strong forceps and by careful manipulation I succeeded at last in bringing out the offending article, not, however, without some laceration of the mouth of the oesophagus and posterior surface of the larynx, which caused considerable bleeding. The flow of blood into the larynx, together with the general weakness, put a stop to the respiration and asphyxia was imminent, and only by energetic efforts did we succeed in restoring the respiratory action and avoid the necessity for tracheotomy, which I was prepared with knife in hand to perform. Five days later the patient was discharged in good condition, though we had feared some obstruction of the larynx on account of the traumatism. The foreign body proved to be a patent brass bachelor's button, the smaller disk of which with its sharp edges was firmly imbedded in the oesophageal wall anteriorly. It was the edge of the larger disk that could be felt posteriorly and grasped with the forceps, and liquids when ingested passed between the two disks.

CASE 2.—Stephen M., a sailor, 34 years of age, came under my observation March 2nd, 1905, with the history of having swallowed a piece of beef bone three days before while eating soup, and the bone had lodged in his throat. Since then had been unable to swallow solid and very little liquid food, and complained naturally of feeling rather weak and hungry. Patient indicated that he thought the bone was lodged just above the sternum, and a bougie introduced to the depth of ten inches from the teeth met an obstruction about the level of the thyroid gland. The Killian oesophagoscope was then used, and at the end of the tube could be discerned what appeared to be a triangular piece of bone firmly impacted in the gullet at the point indicated.

Owing to the rather short neck and prominent front teeth of the man it was difficult to reach the body with the Killian tube and keep it long in view, nor could its dimensions be accurately determined, as was demonstrated later. Repeated efforts were made to extract it under light with the forceps and blunt hooks, and as a last resort with the coin catcher. The latter instrument could be passed beyond the impacted bone, but when it became engaged the fear of tearing the oesophageal wall when force was used

prevented me from relying greatly upon that method of extraction. Once I had great difficulty in disengaging it from the oesophagus after getting it in beyond the foreign body. Further attempts were suspended for the time and on the following day the patient was unable to swallow even liquids and had elevation of temperature to $101\frac{3}{4}$. A feeding tube could not be passed, so rectal feeding was instituted.

On March 5th, under chloroform anæsthesia, I again used the oesophagoscope, saw the bone and made repeated efforts to remove it. It proved to be too well fixed to even dislodge, and as the patient's condition was critical, I hesitated no longer to perform oesophagotomy. Bleeding was quite free from the mouth of the gullet and threatened to interfere seriously with respiration. Slight emphysema could be detected in the neck. The oesophagus was exposed on the left side of the level of the thyroid body, the isthmus of which had to be divided to reach it at that point. The outline of the impacted bone could be easily felt through the oesophageal wall, which was ready to slough from pressure. An opening was made and a large jagged piece of bone was removed with forceps. Its size and shape left no doubt as to the necessity of an external operation, which would have been done without delay had we known the true state of affairs. The friability of the oesophageal wall made it impossible to close the opening with sutures, so the wound was packed with gauze and allowed to drain freely. The after course of the case was unfavorable, the patient developing an empyema of the thorax, which became apparent about March 28th. Aspiration brought out a quantity of clear fluid from the side of very offensive odor, and later a resection of a rib was done under cocain anæsthesia and a large quantity of foul pus evacuated. The oesophageal wound suppurated freely and particles of slough came off, evidently from the gullet wall. Rectal alimentation was given and well received until March 10th, when a stomach tube was passed and nourishment carried on thenceforth by that method. By March 17th the neck wound had contracted to a mere fistula leading into the oesophagus, and when this was closed with the finger the patient could swallow food easily.

He was afterwards transferred to the Charity Hospital, where he is still under treatment for the empyema.

Since the advent of the X-ray and the perfected oesophagoscope the detection and removal of foreign bodies of the gullet and air passages have been greatly facilitated, and any one called upon to relieve such cases is no longer justified in resorting to the older methods of blindly groping for the body by means of the horse-hair probang, the oesophageal sounds, forceps, or the Graefe coin catcher, although in certain favorable cases these instruments have all done valiant service in the past. I cannot let pass the opportunity here to enter protest against the indiscrimi-

inate use of the Graefe instrument, which in my opinion is not only very limited in its usefulness, but under certain conditions and in unskilled hands may be the cause of serious injury to the oesophagus. I find by reviewing the literature relative to this subject that my own unpleasant experience with the coin catcher is by no means the first to be recorded. In a case reported by Sebileau death occurred from tearing the oesophageal wall in efforts to extract a coin.

Felizet was called to a case in which the Graefe basket had been broken off and lodged in the gullet with the coin, for the extraction of which it had been employed. I think its use should be limited to cases of foreign body of the flat circular variety, such as coins and buttons, and if the exact nature of the object is not known it should be determined by means of the X-ray or the oesophagoscope. With the latter instrument, of which I am a strong advocate, one can not only locate and see the foreign body, but also remove it under light with forceps or blunt hook provided it is not too firmly impacted. When such is the case, oesophagotomy or gastrotomy should be performed without delay, the choice of operation depending upon the point of impaction.

Discussion.

DR. J. W. GLEITSMANN.—I am glad to see that the Killian method of oesophagoscopy is much more popular in this country and used more extensively than formerly. I think the first case of the use of the instrument was reported by our member, Dr. Coolidge. I would like to draw the attention further to a case which has been reported at the Laryngological Association of the New York Academy. It was quite a coincidence. I intended to demonstrate the use of Killian's bronchoscope, but a few days before the meeting I broke my arm and Dr. Mayer kindly consented to take my place. His assistant a few days before removed with this instrument the pit of an orange from the right bronchus of a child ten months old. I consider Killian's bronchoscope one of the most valuable additions to our modern therapeutics, which is attested by the increasing number of publications of the successful removal of foreign bodies from the trachea and bronchi, which otherwise in more than one instance would have endangered the patient's life.

DR. WILLIAM E. CASSELBERRY.—I would like to ask Dr. King if in the close of the discussion he will tell us what sort of illumination he finds best adapted to the Killian oesophagoscope. We have two methods, one the Kirstein light, and the other the small electric lamps which are carried down to the bottom of the tube, and I think it would be of interest to get his experience as to what sort of illumination he has found most satisfactory.

DR. JAMES E. LOGAN.—It has been my misfortune to have three

or four of these cases, but as far as the difficulty in finding out the location of these foreign bodies, I have never had any experience. The X-rays have proven satisfactory in each case. Two of them were in children, one in a grown person. I find in children the foreign body usually lodged at the second constriction of the oesophagus. At this point pressure upon the left bronchus causes difficulty in breathing, and we are liable to mistake the case for one of asthma. Difficulty in swallowing, of course, is the guide to diagnosis. One of my cases was in a child of eighteen months, who had swallowed two pennies. These had lodged at the second constriction of the oesophagus. After the X-ray examination had convinced us of the location, we introduced a probang and pushed the coins into the stomach. Another case was in a child two and one-half years old, who had swallowed a tin whistle; I saw the case eight months after the accident and found it lodged behind the left bronchus. A steel-wire snake-toothed forceps was introduced and the foreign body easily removed. One of the most difficult cases in my experience was the removal of a large piece of an oyster shell from the oesophagus of a woman thirty-four years of age; the rough edges of the shell caused much tearing of the structures, and some trouble in swallowing has resulted from the cicatrix.

DR. GORDON KING.—In answer to Dr. Casselberry's question about the light, I would say that I have tried all kinds, but prefer a small electric lamp which throws a light down into the tube, and you simply look over the edge of the instrument. There is nothing to obstruct the view. I think this is a far better light than the small ones, because they are so easily broken. I have also tried the reflected headlight with the head mirror, which is very good, only the movement of the patient throws the light off. I have tried another lamp as a test; it is attached to the head and there are three miniature lamps together. You put this over the head and it throws the light down the tube. I do not, however, find it as clear a light as the other.

As to the use of this oesophagoscope which Dr. Gleitsmann has mentioned, I think it is exceedingly useful and very valuable. The X-ray is necessary sometimes, and had I used it in the second case, in which I did not know how large the bone was, and could not determine with the oesophagoscope, I would have had a much better idea of it, and would not have attempted any prolonged efforts to remove it through the mouth, because the X-ray would have shown that it had become firmly impacted and could not be removed without tearing the oesophageal wall. I do not know how to account for the infection which took place in the thorax. The man, after going to the hospital, had two ribs resected because he had a most foul suppuration. It was reported afterwards that he had gangrene of the lung also. I think the source of the infection was probably inhaling some infected par-

ticles around the oesophageal wound. Whether the trachea sloughed or not I cannot determine. There was apparently no opening in the trachea; we could feed him; he did not cough until later, and yet in three or four weeks he developed this violent inflammation. It evidently originated from the operation or impaction of the foreign body, and I do not know what the ultimate result of the case has been. (I have since learned that the patient died from the empyema.—G. K.)

On the other hand, foreign bodies may remain in the oesophagus for quite a while without causing trouble. In looking over the literature I find a number of cases in which they remained for a long time without causing much trouble.

I was very much amused some time ago in reading the report of a case of a man who used an ingenious method of removing an impacted piece of food in the oesophagus. The patient was on board a ship and a German physician, who was on board at the time, reported the case. He had no instruments to get the thing out with. The patient could not swallow anything at all, and he tried various methods of massage, etc., to see if he could not force the mass down. He finally gave a seidlitz powder in the effervescent state, and the gas forced it to the stomach and the man was relieved.

A CASE OF LARYNGEAL DIPHTHERIA IN AN ADULT (NECESSITATING INTUBATION), COMPLICATING CEREBRO-SPINAL MENINGITIS.

BY WILLIAM K. SIMPSON, M.D.

THE object of reporting the following case is to demonstrate that cerebro-spinal meningitis and true diphtheria may co-exist in the same patient and that the respective bacilli are not necessarily antagonistic one to the other. The importance of recognizing the fact of this co-existence comes with great force at the present time, since during the recent epidemic of cerebro-spinal meningitis in and about New York the assertion gained some credence that the two diseases could not occur together, and, based upon this assumption, the treatment of cerebro-spinal meningitis by injections of anti-diphtheritic serum was extensively indulged in with the hope that a true specific might be at hand. Unfortunately, the results of the treatment were such that, at

present, it has been practically abandoned, with a consensus of opinion that it had no appreciable effect on the course of the disease.

Seemingly this should prove that the two diseases are separate entities, but a stronger proof is afforded, I think, when we can find the two diseases actually existing at the same time, as was stated in the outset of this paper, and which the history will sustain.

The patient was a married woman, aged 27 years, first seen by me in consultation January 10th of this present year. She had been ill for 22 days, beginning with symptoms which finally terminated in a well-marked case of cerebro-spinal meningitis, having all the classical phenomena, namely, eruption (which occurred December 30th), haemorrhagic in certain areas, stiffness of neck, prostration, restlessness, photophobia, delirium, Kernig's sign, exaggerated reflexes, small feeble pulse, irregular and elevated temperature, and facies typical of meningeal involvement.

On January 9th, the day previous to my first seeing her, and while she was still in the midst of her cerebro-spinal symptoms, she complained of hoarseness, some croupy cough, and beginning laryngeal dyspnoea. These symptoms steadily continued to increase, so that at the time of my first examination, January 10th, they were pretty well advanced. On examining the larynx at this time I found the entire lumen of the larynx filled with a distinct thick membrane, markedly impeding respiration, and peculiarly limited above by the arytenoid cartilages, there being no membrane at this time, or subsequently, in the pharynx.

The membrane had all the characteristics of being diphtheritic in nature, and I attempted to take a laryngeal culture, but owing to the increased dyspnoea which the effect produced I was only partially successful, and the culture proved to be negative. The laryngeal dyspnoea continued in severity to that extent that within a few hours after my examination intubation became necessary. This was successfully performed and gave marked relief to the difficult breathing.

The following day and again subsequently large pieces of membrane were expelled through the tube, from which pure cultures of the Klebs-Loeffler bacilli were procured, thus confirming beyond question the diagnosis of laryngeal diphtheria. The tube was removed at the end of the fifth day, and during the time it

was in situ there was complete relief from the dyspnoea. Examination of the larynx after extubation showed some redness and swelling about the superior portions of the larynx. Hoarseness, cough, and some spasmodic breathing remained during some days following extubation, but at no time was it considered at all necessary to reintubate, nor was there any subsequent appearance of membrane.

Immediately after the first laryngeal examination, January 10th, antitoxin was administered by injection, and was continued until January 19th, 30,000 units being given within that period.

Inasmuch as this case occurred at the time when the treatment of cerebro-spinal meningitis by the injection of anti-diphtheritic serum was being advanced, the effect of the administration of the serum on the cerebro-spinal symptoms was most carefully watched and recorded, and without going into detail which is not within the scope of this article, I may say that the opinion of those immediately in attendance was that there was no appreciable effect produced on the course of the cerebro-spinal meningitis. On the contrary, it was during the administration of the serum, and also after it was stopped, that lumbar puncture was performed, in all, three times, January 13th, 22nd and 26th, there being drawn off respectively two ounces, one ounce and ten drachms. In each instance were found the characteristic meningococci intra-cellulares.

It is possible to suppose that if diphtheritic antitoxin was in any way antagonistic to cerebro-spinal meningitis its administration would show its effects in the destruction of these characteristic cocci.

There were times after the onset of the diphtheria and during the administration of the antitoxin when some of the cerebro-spinal symptoms *seemed* to modify, especially in the occasional mental clearness and stiffness of the neck, but these changes, together with marked irregularity of heart action, were no more than occur in uncomplicated cases of cerebro-spinal meningitis. The subsequent progress of the case was marked by the continuance of irregularity of heart action, irregular and high temperature, and the development of pneumonia, death occurring on January 26th, apparently of heart failure, being thirty-eight days from the beginning of her illness and seventeen days after the onset of the diphtheria.

No autopsy was held.

The importance of making a laryngeal examination in this case, and in all acute cerebral diseases, at the onset of laryngeal symptoms cannot be too strongly emphasized, for had not an examination been made in this instance at the very outset, the patient would surely have succumbed to acute laryngeal obstruction, and the cause might have been attributed to pressure symptoms due to extension of the cerebral lesion. That the degree of the diphtheritic involvement was extensive is shown in the production of such marked stenosis, for we know that it is comparatively rare for diphtheria in the adult to produce sufficient laryngeal obstruction to require operative interference.

It is not my intention in the recital of this case to enter at all into its minute detailed history, but only to record the co-existence of the two diseases with such other data as would naturally be considered. A most complete bedside history is on file, which may be consulted.

I wish to acknowledge the kindness of Dr. John S. Thacher, of New York, to whom I am indebted for being called in consultation, and through whose courtesy I am permitted to make this report; also to Dr. A. J. Brown, of the Presbyterian Hospital, for his assistance in preparing the notes.

Discussion.

DR. HENRY L. SWAIN.—I believe in the State of Connecticut much has been said as to the use of antitoxin in cerebro-spinal meningitis, and I am glad Dr. Simpson has reported this interesting case. It is interesting that the two forms of infection took place in the same individual, both running distinct courses.

DR. JOHN ROGERS (by invitation).—I might state that I have lately been visiting in Gouveneur Hospital, where we tried very extensively this diphtheria antitoxin for cerebro-spinal meningitis, and apparently without the least bit of benefit. I think this will be the report made by the New York Board who had it under examination, that it has no effect on the epidemic of cerebro-spinal meningitis.

DR. W. K. SIMPSON.—There is one point regarding the rare coincidence of two distinct diseases occurring together in the same individual which may be accounted for from the fact that, when taken ill, the patient is put to bed and protected from subsequent infection. This patient, however, traveled from Chicago to New York with beginning cerebro-spinal symptoms, and naturally must have come in contact with diphtheritic infection on the way.

PAPILLOMA OF THE NASO-PHARYNX SIMULATING EPITHELIOMA.

BY THOMAS J. HARRIS, M.D.

MRS. R., age 60, presented herself at my clinic in the New York Post-Graduate Hospital, January, 1904, with the history that for four months she had had occasional prickings in her throat and some difficulty in breathing through the nose. The patient was a well nourished woman of good color, showing no adenopathy, and stated she had a fair appetite and had not lost weight. Posterior rhinoscopy, together with digital examination, showed a tumor partially obstructing the pharynx and attached to its posterior and upper wall. It had a cauliflower appearance, was not pedunculated, was not painful to touch and only slightly vascular. The growth was removed under ether by means of the forceps and curette. A clinical diagnosis of a malignant growth, probably a sarcoma, was made. Dr. Jonathan Wright, who kindly examined the growth, made the following report:

"At first sight, with low power under the microscope, this growth has the appearance of a papilloma. The epithelial hyperplasia is squamous celled, and so completely is the type of cell changed from the normal that there are 'stickle-cells' in places. As a rule, the epithelium is fairly well separated from the supporting stroma by a basement membrane. In one or two places, however, and especially at the tips of the digitations the border line is indistinct. In many places there is much fragmentation of the nuclei, free nuclei, and granular degeneration of the cell bodies. There are a large number of whorls with hyaline centers forming fairly typical 'pearls.' Lastly, there seems to be unequal karyokinesis in many of the cells. The stroma in some places is evidently the site of acute inflammatory changes.

"Papilloma and squamous celled epithelioma are both equally rare in the naso-pharynx. One of these forms of growth is here present. The histological appearances are not conclusive of carcinoma, but there are so many features exceptional in a papilloma that with the age, situation of the growth, its rather rapid occurrence and clinical appearance, I am inclined to believe it will turn out to be an epithelioma."

The patient was last seen by me in April of this year, fifteen months after the removal of the growth, and there was not the slightest suggestion of any recurrence. I submitted the specimen and report again to Dr. Wright for his consideration. After a careful study of the specimen, he was inclined to adhere to his original conclusion, urging me, however, to submit the slide to some other pathologist for an independent opinion. Acting upon his suggestion, the specimen was submitted to Dr. Harlow Brooks, of the University and Bellevue Hospital Medical College, who reported as follows:

"The growth seems to be a fairly typical papilloma and I fail to find anything about it which would, in my opinion, warrant a diagnosis of epitheliomatous alterations. The 'cell nests' which appear in this specimen are not those typical of epithelioma, but



are such as one commonly finds in papillomata springing particularly from the mucous surfaces normally covered in by squamous epithelium.

"Of course, these papilloma are very prone to undergo epitheliomatous alterations, but I fail to find anything in this specimen indicating such a tendency at present."

In this diagnosis Dr. Henry T. Brooks, of the New York Post Graduate School and Hospital, agreed.

At about the same time we were shown a specimen of a tumor of the rectum which presented almost identically the same appearance microscopically as the specimen in our own case. Whatever degree of doubt there may be microscopically as to the character of the growth, the clinical appearance is without question that of a benign tumor.

The case is reported both because of the interest attached to the diagnosis and also because of the great rarity of such growths. A rather hasty examination of the literature does not reveal any case of true papilloma springing from the posterior or upper wall of the naso-pharynx. Two cases are on record, but in each instance, as far as could be gained from the rather imperfect report, they had their origin not in the naso-pharynx but in the nose. Sendziak reports in the "*Kronika Lek.*" No. 5, 1894, a case of a man 52 years old, from whom he removed with a cold wire snare a large papilloma 6 cm. long, 4 cm. broad and $2\frac{1}{2}$ cm. thick, which sprang from the inferior turbinated bone and obstructed the nostril on that side, as well as the naso-pharynx.

The second case was reported by Newman before the Laryngological Society of London in March, 1898. The report was very brief and incomplete, simply stating that he removed a papilloma from the side of the naso-pharynx. There was no mention made of the point of attachment nor whether a microscopical examination had been made. The growth reported by Sendziak was examined microscopically and pronounced a papilloma.

Quite recently a case was presented by Dr. H. W. Loeb at the Middle Section meeting of the American Rhinological, Laryngological and Otological Society. Dr. Loeb was kind enough to allow me to see a section of the growth. This clearly was a case of papillary hypertrophy of the nasal mucous membrane, a subject which it will be recalled Dr. Wright has written upon at length and on several occasions spoken upon before this Association.

FIBROMA OF THE LARYNX IN A CHILD OF THREE
YEARS, NECESSITATING TRACHEOTOMY AND
SUBSEQUENT LARYNGO-FISSURE FOR ITS
REMOVAL, FOLLOWED BY PROLONGED
INTUBATION.

BY THOMAS J. HARRIS, M.D.

BERNICE W., age 3, was admitted to the Manhattan Eye, Ear and Throat Hospital June, 1904, suffering from great difficulty in breathing. Tracheotomy was hastily performed by the house surgeon. The child had previously been in the children's ward of the New York Post Graduate Hospital for a number of weeks, admitted there, as far as I could learn, for a slight difficulty in breathing. There she was operated upon for adenoids, and, according to the house surgeon, was discharged nearly well. Shortly afterwards, however, dyspnoea set in, necessitating immediate tracheotomy. The child's throat was very tolerant, and I was able after a little to get a view of the larynx and to recognize a distinct neoplasm. A piece of this was removed for examination by the pathologist, who pronounced it an angiomatous fibroma. This in our judgment excluded the possibility of a cure through prolonged tracheotomy, and although the child had had a great deal of discharge from the tracheotomy wound, at the end of two months I determined to resort to a laryngo-fissure for the removal of the growth. This was performed with considerable difficulty on account of the proximity of the tracheal wound and the narrow field of operation. The fibroma was found attached anteriorly to the thyroid cartilage and removed. As was feared, infection took place in the wound from the amount of secretion into the trachea below, and it had to be allowed to heal over by granulations. The child, however, did very well at the time, and when I returned from my vacation in the fall, with the kindly and valuable assistance of Dr. John Rogers, under ether I dilated the larynx, which had closed, and introduced a large swelled-neck tube, making at the same time measurements for a T tube, such as has been advised to secure safety in retention. In the meantime, however, the little girl coughed up her tube, and the house surgeon had to perform a second tracheotomy with the child in almost a dying condition from asphyxia. In November we again dilated the larynx and introduced the T tube. Since then her

history has been a checkered one. The tube was worn continuously for two months and then removed, the tracheal wound allowed to close, and the former intubation tube introduced. At this time Dr. Rogers was good enough to receive the patient in Gouvencur Hospital, under whose care she has been since. During this time she has had two attacks of bronchial pneumonia and a reopening of the wound in the neck, which required curetting in order to close it. On May 1st there was still a moderate degree of dyspnoea at night due probably to some spots of ulceration in the aryteno-epiglottic folds caused probably by pressure of the tube. The rima glottis, however, was entirely free from all such bands. An extra long tube has been inserted and it is confidently hoped that before long the cicatrices will be so overcome that the tube may be permanently removed.

Conclusions.—Fibroma of the larynx is not a particularly rare form of tumor, occurring, according to Sir Felix Semon, only second in frequency to papilloma. Cases of fibroma in children are, however, rare, and we have failed to discover a similar case in which tracheotomy was called for on account of the degree of dyspnoea.

Again, while laryngo-fissure is regarded as one of the forms of procedure in exceptional cases of multiple papillomata, we do not recall a case where it has been practiced in an infant for fibroma. Since operating upon this child there has been considerable question in our mind as to the wisdom of the step. It has seemed to us that considering the degree of tractability which the little patient showed for examination that it might have been possible to remove the tumor intra-laryngeally by means of the Dundas-Grant safety forceps, either under cocaine or under ether. The possibility of wounding the vocal cords is, of course, to be considered. It is questionable if the ultimate results, as far as restoration of the voice is concerned, would not be as good by this method as by means of the laryngo-fissure. At the time of this report Dr. Rogers informs me that in his judgment the child is entirely well, making the proviso that a year must pass before a relapse can be excluded.

Discussion.

DR. JOHN ROGERS (by invitation).—I am very glad to refer to the case mentioned by Dr. Harris. I endeavored to pass an instrument through the larynx and tracheal fistula from above, but had to give it up, as there was such a tight contraction. Then Dr. Harris took the case in hand, and after half an hour's manipulation succeeded in getting a fine sound through the larynx. The case seemed, however, absolutely hopeless. The larynx was dilated under anaesthesia. The patient wore the tube three or four months, and at the present time seems perfectly cured. Dr. Harris mentions that fact that I have reported that she was well.

About the sixth day of May, however, we removed the tube, and she is now breathing better from week to week. I lately tested the larynx to see if there was any sign of contraction, but I found none.

DR. J. PAYSON CLARK.—In regard to Dr. Harris' case of fibroma in the larynx in a child, I think it would have been an excellent case to admit the use of the Kirstein autoscope. I find that in most cases of children, putting the child in the Rose position and using this instrument with reflected light, it is wonderful what a clear, direct view one gets of the larynx, so that one feels perfectly secure in performing even the most delicate operations.

DR. D. BRADEN KYLE.—Is there any difficulty in doing this without previous tracheotomy? Is there apt to be hemorrhage?

DR. J. PAYSON CLARK.—I always do a previous tracheotomy in operations on laryngeal growths in children. The hemorrhage has never, in my experience, been serious but is often troublesome, necessitating delays in the operation to wipe away the blood.

SYMPOSIUM ON SINUS DISEASE.

a. What symptoms in diseases of the Nasal Sinuses demand radical surgical intervention?

b. What have been the comparative results of conservative and radical methods of treatment?

THE MAXILLARY SINUS.

BY ROBERT C. MYLES, M.D.

THE symptoms that demand radical surgical intervention vary so much in the individual cases of disease of the antrum of Highmore that it would require hours to describe them accurately and properly. To be as brief as possible, one will have to make many epitomized statements.

In the writer's opinion, radical surgery should be employed on nearly all cases of exposed bone necrosis beneath the periosteum and at the roots of the teeth; on all cases of extensive polypoid changes in the mucosa—chiefly indicated by a very large and protruding lip of the hiatus semilunaris associated with

chronic ethmoiditis; on all cases of osteomyelitis, which is usually evidenced by a discharge of a peculiar offensive wine-colored secretion, which upon irrigation, fills the returning fluid with small black particles of putrid debris of blood. Nearly all cases of neoplastic growths require extensive radical surgery. The earlier and more complete the surgical procedures, the more favorable the results will be.

It is in the long-standing cases of purulent and mucopurulent discharge, with all their varying degrees of activity, that we are often baffled as to the conscientious course to pursue. Foul-smelling pus of a mealy character when mixed with water is not a symptom that always demands radical surgery. The writer, after having performed several hundred operations through the canine fossa and malar ridge, and more or less thoroughly curetting the antral walls, has practically abandoned the procedure, and has on several occasions warned the profession against overcurettage of the edematous membranous walls, unless provision is made for a permanent opening from the antrum into the nose through the inferior meatal wall, in order that drainage and free ventilation may take place, while the walls denuded of the internal vestments may at best slowly cicatrize and in a measure reproduce themselves.

In Regard to the Comparative Results of Conservative and Radical Methods of Treatment.—Radical treatment is supposed to remove the pathological conditions as well as the cause or root of the disease, and to leave no cause for a future diseased condition. I have experimented for years with conservative and radical methods, and have tried to be fair to the patients and to the respective methods. The irrigation method through the normal opening was carried out during a series of years on certain classes of cases—some on account of the demands of the patients and others for scientific reasons. A number of patients were cured, but the treatment was too slow and too uncertain to merit more than occasional favor. As above stated, the operation through the canine fossa and malar ridge has been abandoned in the ordinary suppurative cases. Such good results have been secured in this class of cases by a conservative operation, that the writer, in almost every case, uses it as a curative procedure, or as a preliminary operation to the canine fossa one.

This conservative treatment consists of an operation with

curved chisels which cut going in and coming out, the use of the rongeur forceps, and with the occasional aid of the electric trephine. As much of that part of the antro-nasal wall which is situated within the inferior meatus is removed as possible, and in certain cases it is best to remove a part of the inferior turbinal, and the upper part of the median wall in the middle meatus. After irrigation the cavity is carefully curetted with the malleable-handle curettes, and packed with $\frac{1}{2}$ -inch iodoform gauze. The cavity is irrigated through this opening until the discharge practically ceases. So far, the results in a series of cases after this procedure have been better than those of the other methods.

THE MAXILLARY SINUS.

BY GEORGE A. LELAND, M.D.

CHRONIC empyema of the antrum of Highmore presents itself in such various aspects as to symptomatology, etiology and treatment, recent literature on it is so vast and comprehensive, that one might be pardoned a feeling of diffidence when asked to condense into ten minutes his conclusions on this subject. But the very fact that there are so many writers and opinions shows that it is a difficult one, and that it will probably be some time yet before the last word is said.

Now, it is doubtless true that the two extremes of cases, the very severe and the very mild, leave no room for doubt as to their proper handling; and first, that the very severe uncombined cases demand radical treatment at once. In this class are those where intra-antral pressure of polypoid degenerated mucosa, of quasi cholesteatomatous masses, of bony cysts or of neoplasms cause intense suffering from pain, neuralgic or hemicranic, or from reflex neuroses such as asthma; also where there is danger of bony distension so as to produce deformity, or absorption of the outer walls so as to infect the soft parts, and where there is extensive necrosis. These demand the radical Caldwell-Luc operation. But they are few, even when are included those intractable ones set up by the presence of a foreign body, such as a lost drainage

tube or a piece of exfoliated bone—probably less than one-tenth of the cases.

Second. On the other hand, are those very mild cases of slight discharge of muco-pus or even of pus, intermittent, with only occasional odor, with no pain and almost no discomfort, where the principal complaint is of a rather frequent use of the handkerchief, which is perhaps markedly soiled; or where the discharge is especially prolonged after a cold. Such patients often prefer to sustain their slight catarrhal discharge, even over a period of years, rather than to focus their discomfort into intense suffering for a week or more, since we cannot promise them with truth that they will then be wholly free. For it seems to be the opinion of the best authorities, and I am sure my own experience bears it out, that after the radical operation, patients are by no means restored to a normally comfortable condition. I briefly cite one case, that of a lady about thirty years of age, who suffered intensely for nine months before the operation, with pain, headache, vertigo, insomnia, foul discharge, etc., where a dentist had perforated the alveolar process above and anterior to the first molar, a perfectly sound tooth. He syringed it out frequently through a rubber drainage tube. The perforation gradually closed so that the tube could not be reinserted after a time, and he then passed in a roll of rubber dam and did not anchor it. One morning after breakfast this was lost. After this, syringing was continued through the aperture till it became so narrow that it was impossible to introduce the probe-pointed syringe. Suffering at this time began to be more intense, but operation was delayed because of a soon expected confinement, and her family physician did not dare risk it. It was notable that transillumination showed that side as clear and bright as the other, and the pupil illuminated as well, convincing us that the antrum was full of polyps, the layers of pus being too thin to cast a shadow. At the operation the canine fossa was entered, the anterior wall resected up to the infra-orbital foramen, an enormous mass of polypi curetted out, together with the rubber dam. The anterior end of the lower turbinal was removed, and a large opening made into the nose. A strip of iodoform gauze, one-half inch wide and three feet long, was packed rather firmly into the cavity and the end left presenting at the introitus nasi. The periosteum, etc., was brought down over the anterior opening,

and the alveolar wound sutured. The patient, a very nervous neurotic lady, suffered intensely for several days, even after the gradual removal of the gauze, and irrigation and insufflation of powders into the antrum through the nose was carried out till the antrum ceased to discharge, and it's interior is now apparently in a satisfactory state. But the vertigo continues, "sinking spells," as she calls them. Headache was very intense, so severe that the second turbinal had to be mostly removed, because it pressed on the septum and outer wall—but she still suffers, and there is an annoying formation of crusts which require constant care, evidently due to cicatricial tissue over the stumps of the turbinals, especially the lower; and there is no evidence of other sinus disease, though carefully searched for. An untoward result in this case is that a large area of the cheek, just external to the nose, and the lip below it, is still anaesthetic, so that discharges from the nose run down to the mouth unawares, a distressing source of complaint to a sensitive lady. And when the distribution of the terminal twigs and filaments of the infra-orbital branch is considered, both inside and outside of the antrum, I do not see why this result of the operation is not more often mentioned. Were it not that there was a foreign body here present, I should feel very uncomfortable to have left her in such a state.

Another case of far less severity, but where radical treatment was called for, is still annoyed by this crust formation on the stumps of the turbinals, though the antrum is dry, and a probe introduced through the opening in the outer nasal wall shows it to be nearly filled with fibrous tissue covered by a mucous membrane apparently healthy.

But third, nine tenths of the cases constitute the great middle class to which attention is especially called, and here it may be profitable to spend a few moments on the etiology of these affections. Most writers who express any opinion attribute about one-half the cases to dental and the other half to nasal origin, the latter being the result of invasion in the course of the infectious diseases, especially of influenza, and probably the great increase of these affections dates from our first marked epidemic of influenza in 1889.

However, those attributed to dental origin are usually described as coming from carious teeth, abscess at the roots, exfoliation of the roof of the tooth-sockets, etc. But in my experi-

ence another etiological factor has been apparent, viz., a periostitis of the alveolar process, caused by improper striking of the cusps of the teeth, increased by conscious or unconscious grinding, one tooth in either jaw having moved slightly, its neighbor which kept it in proper apposition having perhaps been lost. The same effect may be produced by a pulp-stone in an upper tooth. These cases require no interference from the rhinologist, the condition rapidly subsiding after the dentist has corrected the abnormal condition.

Another etiological factor is perversion of the respiratory function of the nose. Mr. Mayo Collier, of London, in a little brochure a few years ago, showed how the alternate condensation and rarefaction of the air in the nose caused a pumping action which seems to explain how these accessory cavities (including the middle ear) ventilating into the nose are able to keep their orifices free and their interiors clean. The *introitus nasi* is a much smaller orifice than the choana, and of course much smaller than the lumen of the *naris*. The effort of inspiration draws much more air backwards and downwards than can readily pass through the anterior orifices, causing a partial vacuum in the nasal chambers, the air from the sinuses rushing out to correct this negative pressure. Per contra, the current passes back into the sinuses during the act of expiration when more air is forced into the nose than can in the same time rush through the narrow *introitus*. That this is true of the middle ear, was shown some years ago by a German observer who, by applying an iridescent paint to the drum-head, saw corresponding movements in a case in which the Eustachian tube was normal.

Trusting to the aid of this respiratory function, and not forgetting that the natural exit of the antrum is in certain positions of the body at the bottom, and also that the normal cavity is lined by ciliated epithelia, and trusting also to the regenerative power of the intra-antral mucous membrane after that which keeps up its morbid action has been given an outlet by freeing and at times increasing the size of the natural opening, and moreover, avoiding as a vicious proceeding, far reaching in its results, the sacrifice of the inferior turbinals, the writer has conducted many of these cases of chronic empyema of the maxillary sinus in the last few years to a successful termination, without the suffering and mutilation of the radical operation, assisted sometimes by irriga-

tion, but often without. To this end irregular septa nasi may have to be corrected, hypertrophic mucous membrane in or around the second meatus may have to be reduced, an enlarged uncinatè process or obstructing ethmoidal bulla may have to be removed, the second turbinal may have to be displaced inward, or a large artificial opening may have to be made through the second meatus where the bone is thin and easily punctured or cut away, or where a bony dehiscence may make it only necessary to remove the double membrane. For making this opening he has had constructed a sharp, strong hook-like instrument of toughest steel, the blade a little longer and wider than Hajek's, with a sharp cutting edge on the inside (7 mm. long and 2 mm. wide) which fits into the same handle. This can be easily thrust through the outer wall, just above the lower turbinal, where there is space enough to avoid the orbit, and at about the middle of the second turbinal's lower edge. A cut is then made forward about one-half inch. If the bone resists, the point may be turned upward and inward at either or both ends of this cut and made to break its way through the bone into the nose, and then with Luc's small forceps the opening may be sufficiently enlarged. (This permanent opening through the second meatus and the preservation of the lower turbinal, in which lies most of the respiratory function of the nose, has been lately advocated with much force and reason by Gerber, of Königsberg, in the 17th Vol. first part, of *Fränkel's Archiv*, though he does it after clearing out the cavity through the canine fossa, thus modifying the Caldwell-Luc operation.) The opening thus made is then kept open by washing through an irrigation tube (Hartmann's, or better, a large Eustachian catheter properly bent) once or twice a week, keeping clear of granulations by forceps or caustics. And the patient is instructed frequently to cant the head in the proper direction to bring the orifice as near underneath as possible, and then to blow forcibly through the nostril to syphon the contents out of the cavity.

By means of the enlarged hiatus thus made and thus treated a case has lately been discharged *well* which was of fifteen years' standing, accompanied by all the symptoms of almost constant headache, foul discharge, ill health, melancholic mentality, aprosexia, etc., for which several surgeons and specialists had advocated and urged the radical operation as a *sine qua non*,

and that only two or three months after this large opening had been made, though a considerable time had been previously spent in getting the second turbinal into a normal condition. The state of this lady is infinitely better than those above mentioned who suffered the radical operation and are still suffering from it.

The displacement of the second turbinal is above mentioned. This I have found to be a useful procedure when it hugs the outer wall too closely, and especially if it rests on an enlarged uncinatè process. It is not always necessary to remove this bone, especially if it is reasonably healthy, or can be made so, but by the use of an elevator, or far better by the use of Killian's long nasal speculum, this may be pressed inward till the bony attachment cracks; it may be then kept in its new position by a small packing in the second meatus for a few days, when it will remain there permanently, thus giving a second meatus sufficiently wide for drainage in not a few cases.

By these comparatively simple conservative measures, following out nature's laws and methods, the writer is convinced that this large middle class of cases may be still further enlarged to include many of those now considered to demand radical surgical interference. And at any rate, such methods should be given a thorough trial before the severe ones are resorted to. For though "there is a divinity that shapes our ends, rough hew them how we may," we do not believe that that divinity shaped our upper end to be unnecessarily rough hewn by every ambitious rhinologist, young or old, with a surgical bent, who may have observed in our large municipal or perhaps European clinics a bold, fascinating, almost reckless dexterity applied to the worst cases that can be found among the lower classes of society where the finer sensibilities are in abeyance, or where the victims through fear of, or in gratitude to, their surgeon do not magnify their post-operative discomforts, disregarding their lesser ills because relieved of the greater; but this is rarely the case in private practice, and for this reason these conclusions have been drawn from the behavior of those in the higher walks of life.

Permanent or temporary openings into the mouth except because a diseased tooth socket affords a convenient route, should be condemned for the very valid objection that they give access to the antrum through the most infectious cavity that we know of, and for another objection that pus-flavored food is not appe-

tizing. And yet this is the method of the dentist, though as far as I can learn, the best of them never sacrifice nor jeopardize a sound tooth for this purpose.

Finally, it must not be forgotten that many of these patients are in very poor health and should have the advantage of vigorous building-up treatment.

THE FRONTAL SINUS.

BY CORNELIUS G. COAKLEY, M.D.

IN the short time (ten minutes) allowed for the presentation of this subject, one must necessarily be brief in discussing many points which deserve fuller consideration. I shall confine myself strictly to answering the questions propounded, basing my statements upon my personal experience in treating diseases of the frontal sinus.

ACUTE FRONTAL SINUSITIS.

A. The following symptoms demand external opening of the frontal sinus:

First. Edema and redness of the upper eyelid, accompanied by throbbing pain over the sinus, provided they show a tendency to increase in severity for more than 24 hours after the resection of the anterior third of the middle turbinate and the thorough contraction of the mucous membrane in the middle meatus by means of local applications of adrenalin and cocain.

Second. Marked prolapse of the orbital wall of the frontal sinus.

Third. Displacement of the globe of the eye downwards and outwards, accompanied by diplopia.

Fourth. The development of a fistula at the upper angle of the orbit, as evidenced by redness, great swelling, and fluctuation in this region.

Fifth. Intense supra-orbital and frontal pain which cannot be relieved by establishing adequate drainage through the naso-frontal duct, with a tendency to an elevation in temperature and symptoms of beginning meningeal inflammation.

B. Comparative results.

Fortunately the above named symptoms, demanding external operation in acute frontal sinusitis, are not very frequently encountered. In a series of 58 cases of acute frontal sinusitis occurring in my private practice, between January 1st, 1903, and January 1st, 1905, 54 made complete recoveries as a result of intra-nasal treatment, such as the excision by forceps and snare of so much of the middle turbinate as lay anterior to the opening of the naso-frontal duct in the middle meatus of the nose, in conjunction with the use of douches of hot normal saline and the local contracting effects of adrenalin and cocain applications. One patient seen for the first time, forty hours after the onset of the attack, in which the left ethmoid and sphenoid were involved, died twenty-three hours later from an acute meningitis with symptoms of great intra-cranial pressure as evidenced by a pulse of forty. The anterior third of the middle turbinate was excised, and judging from the discharge, drainage was good. I believe the infection of the meninges occurred prior to the time I saw the patient, but whether through the blood-vessels of the nose or through the frontal, ethmoid or sphenoid, I cannot state. No autopsy was obtained.

Of the three cases operated on externally for the relief of symptoms, one was found not to have any frontal sinus on the affected side, merely a markedly congested diploe, which bled profusely during the operation. The patient recovered.

A second case operated upon was found to have an enormously large frontal sinus which extended from the external angular process of the orbit on the left side to the middle of the supra-orbital arch on the right; radical operation performed; the patient recovered.

The third case operated on was in a patient who had syphilis; the antrum had been opened a week before through the canine fossa; the floor of the orbit was found entirely necrosed and removed. As symptoms of meningitis and sepsis developed with marked displacement of the eyeball downwards and outwards and exophthalmos, a radical operation was performed on the frontal sinus and ethmoids. The floor of the frontal was necrosed and the cavity filled with pus. The ethmoids were also badly necrosed; the patient died 48 hours later from meningitis and sepsis.

CHRONIC FRONTAL SINUSITIS.

Chronic suppurative frontal sinusitis as a distinct entity, unassociated with suppuration in some of the neighboring sinuses is a condition I have never met. There has always been an ethmoiditis present, and the antrum in a large percentage of cases was either diseased or the receptacle for pus (reservoir) flowing down from the frontals and ethmoids.

A. The following symptoms demand radical operation:

First. Chronic suppurative frontal sinusitis accompanied by multiple polyp formation in the nose. These cases are always associated with an ethmoiditis. The removal of the polypi, curettage of the ethmoids, dilatation of the naso-frontal duct and irrigation of the frontal sinus ameliorate the symptoms for a few months. In a large percentage of cases the polypi and symptoms recur, and the process of relief is again undertaken. In elderly people, or those with marked organic lesions of the heart, lungs or kidneys, a radical operation may be unadvisable. To all other patients a radical operation is proposed if they desire to be permanently rid of their disease.

Second. A radical operation is indicated in severe acute exacerbations of the chronic condition whenever any of the symptoms enumerated under acute frontal sinusitis develop.

Third. If intra-nasal treatment of a frontal does not suffice to prevent the discharge from passing into the antrum and the odor and taste of the fetid discharge from the latter annoy the patient, then in order to cure the antrum the frontal must be operated upon radically.

Fourth. Very large frontal sinuses with multiple septa, and particularly those with recesses extending backwards over the roof of the orbit, can be but imperfectly irrigated. Until recently we have had no means of ascertaining these facts. Skiagraphy, however, as now practised, will give us the exact height and breadth of the frontal sinus, indicate the number and position of the septa, in many cases inform us of the presence of an orbital recess. The radical operation should be advised for such patients.

Fifth. Patients with narrow nasal cavities offer greater difficulty for carrying out intra-nasal treatment than those with more patent nares. When the drainage is poor and headaches frequent these patients gladly submit to a radical operation.

Sixth. There is a large class of patients living at some distance from the larger cities who journey thence to get relief from their suppuration. Considerable sacrifice is entailed in their absenting themselves from home and business. They desire to be cured, and that as quickly as possible. Intra-nasal treatment is slow and the results uncertain. A radical operation may take as long to effect a cure, but when obtained it is permanent.

Seventh. The neurasthenic patient who is prostrated each time intra-nasal treatment is attempted, and rarely submits to enough being done at any one time to make much progress, is more satisfactorily treated by the radical method. There is seldom any pain after the second dressing by the latter method.

Eighth. If a fistula has formed leading into a frontal sinus, a radical operation is the only treatment likely to effect a cure.

B. Comparative results.

First. *Conservative Treatment*.—I regret that my statistics on the intra-nasal method of treating chronic frontal sinusitis are not more exact. We find a record of 79 such cases. We feel quite confident that 11 or 14 per cent. of them may be considered cured as they have been seen at least two years after having been discharged as cured, and although afflicted with the usual slight head colds once or more times, have had no hypersecretion from the nose after the cold disappeared. Of the remaining 68 cases, 27, or 35 per cent., have been lost sight of, and whether they are cured or not is uncertain. Of the remaining 41, 24, or 30 per cent., have returned with recurrences once or more times a year. Twenty-two of these cases have polypi. The remaining 17 cases, after having been under treatment for a period varying from six weeks to three years, finally consented to a radical operation, and all have been cured. To recapitulate: 14 per cent. were cured by conservative treatment, 51 per cent. were improved but not cured, and in 35 per cent. the result is unknown.

Second. *Radical Treatment*.—Several types of radical operation have been used for chronic suppurative frontal sinusitis.

A. *The Ogston-Luc Operation*.—Briefly, it consisted in opening the anterior wall of the sinus, imperfectly curetting the mucous membrane, dilating the naso-frontal duct, usually inserting a rubber drainage tube through the latter into the nose for a few days, sewing up the frontal wound and trusting that the better nasal drainage would eventually result in establishing a cure. My ex-

perience with this operation was decidedly unsatisfactory. We performed it about 25 times, and fully half the cases had a return of their secretion and headache after contracting a severe rhinitis a few weeks or months later. The cosmetic effects were elegant, merely a linear scar. To my mind little more can be accomplished by this operation than by thorough intra-nasal treatment.

B. The Kuhnt Operation.—Kuhnt removed the entire anterior wall of the frontal sinus, eviscerated the entire mucous membrane in the cavity, naso-frontal duct, and adjacent ethmoidal cells, sewed up the skin wound, and placed drainage from the bottom of the wound into the nose. This operation appealed to me as being a better one than the Ogston-Luc, but I felt that the nasal drainage was inadvisable. One could not tell how much of a cavity was still left to be infected through the nose.

C. The Open Operation.—My experience with mastoid operations led me to believe that it might be possible to treat a frontal sinus similar to a mastoid, *i. e.*, to operate in the manner of Kuhnt, but to pack the frontal sinus and naso-frontal duct so that granulations would spring up and first occlude the narrowest part of the cavity, the bottom of the naso-frontal duct. This having been accomplished, the condition would be the same as in a mastoid wound after the closure by granulations of the aditus and antrum, and it would be merely a matter of time for the upper part of the frontal sinus to fill with granulations and become completely obliterated. There is, of course, some deformity depending upon the size of the cavity. If the operation is properly done, there is no greater danger of recurrence than in a mastoid.

From the spring of 1901 until January 1, 1905, we have operated on 104 patients by this open method. In nine of them both frontals were involved, making 113 frontal sinuses treated. One patient still has, two and a half years after the operation, a small fistula practically not discharging. Two patients had fistulæ, one nine months after the operation, and the other fourteen months. Both were operated on a second time, and it was found that some of the mucous membrane had been left at the first operation: both are cured. Two of the 104 patients are dead—one died from chloroform anesthesia seven weeks after the operation on both frontals, which had healed, after operating on the maxillary sinus. One died of pneumonia, five months and six days after

operation, the frontal sinus having healed. There have been no relapses.

Thus of the 104 cases, two are dead, one has fistula and 101 are living, cured of the frontal sinusitis. Seven are under occasional treatment. Three of the seven have sinuses in their antra, six of the seven have occasional discharge from the sphenoid.

D. Killian's Operation.—This is preferred by the Continental rhinologists. It is an operation requiring more time, but supposedly removes all the ethmoidal cells in addition to obliterating the frontal sinus. I have never operated by this method, as the results obtained by the open method have been very satisfactory.

THE FRONTAL SINUS.

BY WILLIAM E. CASSELBERRY, M.D.

IN conforming to the suggestion to discuss the treatment of chronic suppuration of the frontal sinus from a conservative standpoint, it is not my intention to espouse conservatism to the exclusion of radical methods which are at times imperatively indicated. Nor do I understand as "conservative" a policy of mere expectancy or inert medication, but rather a reference to the intra-nasal minor operative methods including partial middle turbinectomy, enlargement of the naso-frontal duct and adjoining ethmoidal cell curettement, which have for their purpose effective drainage, hence substantial betterment and occasionally recovery. These methods hold an important place in practice, but since the introduction of the new external operations of Killian and of Coakley, which commend themselves as scientific and more satisfactory, affording a reasonable expectation of cure without the extreme of deformity, and moreover with our present realization of the frequent large formations of pyogenic granulation tissue within the sinus, there is reason to consider whether it is wise longer to recommend or to countenance conservatism with a view to the avoidance of a radical operation, and if yes, then when and why, and conversely what are the conditions which demand an uncompromising attitude favorable to radical intervention?

The surgery of the frontal sinus involves cosmetic considerations which do not pertain to the other nasal sinuses. Most patients influenced by repugnance to facial disfigurement have, in my experience, rejected the idea of an external operation except as a last resort, hence one must often sanction less radical means or accomplish nothing. The patient perhaps conceding the possibility even of brain infection will still hesitate, content to weigh his chances pro and con. The actual liability to brain complications from frontal sinusitis must be far less than is familiar from suppurative otitis, and it appears from Onodi¹ that they are relatively fewer than from sphenoidal sinus suppuration. Not many cases of complicating brain infection are recorded. Logan Turner² and Killian³ collate forty-two. Wertheim⁴ cites only three records from ten thousand autopsies. My search through the last decade of the *Journal of Laryngology* disclosed but one, aside from several cases of fatal osteomyelitis, due to the external operation itself.

This post-operative mortality is another disquieting feature of radical methods. As indicated by Logan Turner, who collates twenty-four strikingly similar operative fatalities, infection of the diploë of the frontal bone occurred contemporaneously with the operation probably through the necessary removal of the granulation tissue, and not particularly by the too forcible removal of it.

The demand for radical surgical interference is imperative when there are actually present symptoms of commencing intracranial infection, such as severe persistent headache, chills, fever, centric paralysis, etc., but the mere indefinite chance of complications of this kind does not necessitate an external operation without additional valid reasons, inasmuch as one risk may be said to balance the other. Hence the intra-nasal or conservative methods are especially suitable for latent and mildly chronic uncomplicated single sinus suppurations.

It is alleged, although not proven, that sinus suppuration is contagious, that the uncured patient is a menace to his intimates. Certainly the recurrent attacks of tonsillitis and erysipelas to which sinus patients in my observation are prone are communicable to others. The frequency of multiple sinusitis and the fact that with the frontal sinus one or more ethmoidal cells are often affected are indications of a liability to the spreading of

the infection from one sinus to another in the same patient. But scarcely do these considerations demand radical interference without additional reasons, although they will justify it, as soon as any external method is demonstrated to be successful with reasonable certainty, at the expense of but slight deformity and without special hazard. Whether or not this desired culmination is already at hand, it is hoped may appear from the present discussion. Meanwhile drainage by intra-nasal methods certainly tend to prevent an extension of the infection.

Additional valid reasons for the external operation are persistent failure of the general health or impaired vitality from septic absorption, serious mental depression, distension of the sinus, abscess of or encroachment upon the orbit, external fistula, impermeability of the naso-frontal duct, syphilitic necrosis, inveterate multiple sinusitis, and economic conditions or occupations which preclude the more tedious efforts. But even so, inasmuch as a middle turbinectomy preliminary to a radical operation is usually desirable, this or other methods of the conservative class may be, or perhaps even should be, first invoked, provided the symptoms be not urgent, and further provided the patient's available time be not wholly thus exhausted.

To illustrate the foregoing conclusions, I have traced the subsequent history of a few cases, which serve also the purpose of describing briefly the conservative treatment and the degree of success and the lack of success attained.

Cases 1 to 5 were all similar to J. B. M., who exemplified the mildest type, a latent chronic frontal sinusitis, for which conservative methods seemed suitable. There was no continuous discharge, but severe subacute attacks were repeated every 8 or 9 months, until the middle turbinated bodies were well reduced by deep cauterizations, when the attacks ceased for eleven years, with but one trilling recurrence since.

Case 6, also of mild type, Gen. L., had only an intermittently conspicuous discharge. Irrigation of the left frontal sinus after middle turbinectomy evacuated pus. Three years later he reports that the discharge gradually lessened and finally stopped.

Cases 7 to 9 were similar, all multiple sinusitis, and in all I advised but did not insist upon a radical operation. All suffered moderately from headache and impaired health, which were remedied by drainage, established by means of middle turbinectomies, curettement and irrigation. One of them, Miss B., rejected an external operation in fear of deformity. She had also pulmonary tuberculosis, so after several months of nasal treat-

ment she moved to California. Eight years later her father, a physician, writes that she is in good health, the sinus suppuration having apparently ceased several years ago. Another, Mr. G., rejected an external operation because he could not risk losing a salaried position by "laying up." Three years later he writes: "After your operation in the nose the constant use of the cleansing lotion keeps down the acute symptoms. I do not suffer to the same degree." The third, Mr. J. A. M., aged 65, suffered also from albuminuria, hence he rejected an external operation in fear of the prolonged anesthesia. I cautiously enlarged the naso-frontal duct with Ingal's instrument under cocain anesthesia in three sittings. Some months later his family physician wrote that he was well by comparison with his former state, and one year later the patient writes that this improvement is maintained.

Cases 10 to 12 were much like the last group, except that being poorly circumstanced, treatment was too early interrupted, and while benefit accrued, it was far from a cure. Middle turbinectomies were made to substantiate the diagnosis, and as a preliminary step to radical operation, but the latter never was reached. One of them, Miss W., with bilateral frontal and ethmoidal suppuration, had had forty-four attacks of facial erysipelas, and still has them, notwithstanding distinct betterment in discharge and odor. In another, Mrs. H., the headache disappeared, but the secretion continued, while Mr. K. acknowledges but little change. Entrance to the hospital and the most expeditious radical means are economic necessities with this class, else little is accomplished.

In Cases 13 and 14 the naso-frontal duct was impervious even after middle turbinectomy. Mr. McC. had suffered spontaneous rupture with remaining fistula, and Mr. I. M. had frontal prominence and tenderness. They were not benefited by intra-nasal treatment, but rejected the external operation, which I should now more confidently insist upon under like conditions.

In Cases 15 and 16 syphilis was the underlying cause, yet anti-syphilitic treatment had little influence. From clinical reports it would seem that syphilitic cases are especially prone to brain complications through necrosis of bone; hence in them radical treatment should not be too long deferred.

Summarizing the results of the conservative treatment in these sixteen cases, six were of a mild type, and these are now well. Of the remaining ten typically severe cases only one can be called cured, two are much improved, suffering but little inconvenience, three more are somewhat improved, but are still dissatisfied sufferers, and the remaining four are unbenefited.

1. Onodi, *Jour. of Laryn., Rhinol. & Otol.*, 1904, p. 617.
2. Turner, *Jour. Am. Med. Assoc.*, 1905, p. 347.
3. Killian, *Heymann's Handbuch*, Bd. III., S. 1131.
4. Wertheim, *Archiv. fur Laryngologie*, Bd. XI., S. 169.

THE ETHMOIDAL SINUS.

BY JOHN O. ROE, M.D.

IN a short paper one can be expected to touch upon only the most salient points of the subject, those that are of the most practical importance from a pathological and surgical standpoint.

While the frontal, maxillary and sphenoidal sinuses vary greatly as to size, shape and general contour, they bear a very constant relation to one another, and are remarkably uniform when compared with the almost infinite variations of the air spaces occupying the ethmoid region, very properly called the ethmoid labyrinth.

In the case of these sinuses we rarely or never find but two cavities, although in exceptional instances there may be an absence of one or both, whereas in the case of the ethmoid sinuses the same number of cells is never found in any two cases, nor on the two sides in the same case, nor are they alike in size, shape or general conformation.

Also in diseases of the other sinuses the same pathological conditions give rise to symptoms more or less constant, varying little in different cases, and the same methods of diagnosis are of service in detecting each particular disease, and the same methods of treatment in different cases are quite uniformly successful. On the other hand, in the case of the ethmoidal cells, the extreme variation in their number and location, many of them being deeply hidden from reach, and the inaccessibility of their ostia for exploration, render the disease of these cavities often most obscure and most difficult to treat, and the symptoms being correspondingly varied oftentimes give no indication of the exact location or the nature of the disease process.

The ethmoid cells constitute the middle section of this chain of air spaces, extending around the outer border of the roof of the nasal chambers from one frontal sinus to the other, and form the connecting links, on each side, between these different cavities.

By the way of classification and for convenience for study,

they have been sub-divided by some anatomists into anterior, middle and posterior cells; while others, from a clinical basis, have divided them into the anterior and posterior groups, according as they communicate with the different regions of the nose. Thus those located in front and communicating with the middle meatus of the nose below the base of the middle turbinated bone are termed anterior ethmoidal cells, while those located behind and communicating with the superior meatus above the base of the middle turbinate are termed the posterior ethmoidal cells. The anterior group of cells are closely associated with the ostium frontale and the floor of the frontal sinus, forming a distinct prominence upon its floor, termed the bulla frontalis, while just posterior to this region we find in relation to the nasal aspect a rounded bony prominence, the bulla ethmoidalis, containing an important cavity, often or usually communicating with the surrounding air spaces or cells.

The posterior ethmoid cells are related to the sphenoidal sinus and maxillary antrum, although not in direct communication with them. The ostia of these different ethmoid cells are by no means constant. The larger cells usually communicate with the nasal passages by separate ostia, some of them, however, having two or more openings. These openings are generally on the superior portion of the cavity and so deep-seated in the superior meatus as to be invisible on a rhinoscopic examination and usually inaccessible for exploration.

The bony laminae which intervene between the various ethmoid border cells and the frontal, maxillary and sphenoidal sinuses are usually so extremely thin that in case of chronic suppuration of these cells, caries of the laminae is quite liable to occur, followed by perforation and subsequent infection of the neighboring cavities. This, Turner states, may afford an anatomical explanation of the frequent occurrence of suppuration in two or more of the accessory sinuses, associated with a similar affection of the ethmoid cells. (Turner, "Accessory Sinuses of the Nose," p. 32, 1902.)

In considering the symptoms that indicate the necessity for radical surgical intervention, we may classify them under one of two heads, viz., pus or pain; that is, those associated with the formation of pus and those in which the presence of pain is manifest. Radical measures may be regarded as rather an am-

biguous term at the present time, for what one surgeon records as radical another considers quite conservative. But in a general way, however, we may regard all operative measures as radical, varying, of course, in degree, and all forms of medication, both local and constitutional, as conservative treatment.

Acute inflammatory conditions rarely demand surgical intervention, except where they are engrafted upon a chronic condition, as in the case of a fresh infection superimposed on a chronic catarrhal process or a chronic empyema. In other cases, where an acute condition becomes chronic and purulent, resisting all local measures of a detergent or antiseptic nature, radical measures are demanded.

A woman, aged 40, who had had for several years a chronic catarrhal condition about the upper portion of the nasal fossae, with much discomfort about the nose, contracted an influenza, causing a severe inflammation of the turbinated tissues, attended by a profuse discharge, which soon became purulent. She had also severe pain in the side of the face and distress about the bridge of the nose and frontal headache.

By contracting the tissues with adrenalin and with the aid of the probe the discharge was traced to the ethmoid cells, the bulla ethmoidalis being markedly distended. This cell, on being opened, was found unusually large and filled with a mucopurulent material containing some streptococci. The surrounding ethmoid cells in communication with this cavity were also involved; they were freely opened and drained, when the nasal disturbance subsided. Many so-called ozaenas and purulent conditions of the accessory sinuses result from the early neglect of catarrhal conditions of the ethmoid cells which might be prevented by timely radical measures of a comparatively conservative nature.

A young woman, of 25 years, recently came under treatment for ozaena, which she had had since her twelfth year, and which followed a severe influenza contracted by holding her head under a cold water faucet to cool off on a hot day, in imitation of her older brothers. Soon after she began to have a profuse discharge from her nose, which in a short time became foetid and continued so until I saw her, notwithstanding the constant use of sprays, washes, etc. The ozaena odor at this time was marked and the crusts were large and blown out frequently. The tissues of the whole interior of the nose were characteristically atrophied, but the

mucous membrane was smooth and unbroken. In a short time after cleaning the nose these crusts would reappear in the usual mysterious manner on the unbroken membrane. On wiping the membrane dry with cotton and watching for the reappearance of the discharge, a small amount was seen to stealthily creep out from the ethmoid region in the vicinity of the bulla, and could be seen to reappear after being wiped away. This I traced with a bent, blunt-pointed slender probe to its origin in the ethmoid cells.

After cocainization I opened the whole chain of diseased cells with a Grünwald cutting forceps. A deep furrow was made through the bottom of these cells, and, so far as could be detected with a probe, all the diseased and necrosed cells were excavated. It was interesting to note the immediate disappearance of the foetor, and the rapid drying up of the discharge as the parts healed. This case is but a type of such cases, and the more of them I see the more I am convinced that so-called ozaena is nothing but a foetid discharge from some of the accessory sinuses, usually the ethmoid.

Disease of the frontal, maxillary and sphenoidal sinuses is usually detected and properly treated, but when hidden in the ethmoid cells it frequently goes undetected, causing a slow necrosis of the cells and the consequent odor and also the atrophy of the surrounding soft parts arising from the associated disturbance of nutrition.

The foul discharges and crusts that so mysteriously appear on a smooth unbroken mucous membrane, the cause of which it has been claimed "no fellow could find out," have been attributed to perversion of the secretions of the mucous glands in some unaccountable manner, to special dyscrasias, and to various other causes. These will be found in nearly all cases, I believe, to have their origin in some of the ethmoid cells, although perhaps too deeply hidden to be readily detected, and it is only by radical methods of treatment that the cause of this trouble can be reached and cured. This is illustrated by many cases I could cite, did time and space permit.

Increasing familiarity with the cellular structures of the nose leads us to recognize the early stages of diseased conditions, which, if dealt with in a radical manner (as is practised in disease of the mastoid antrum and cells), will not only prevent the es-

tablishment of a chronic disease of these cavities, but will often forestall conditions, as in the case of chronic aural diseases, which may lead to serious consequences. This is illustrated by "A Fatal Case of Necrosis of the Sphenoidal and Posterior Ethmoid Cells," recently reported by Whitehead, of London. (*Jour. Lar. Rhi. and Otol.*, 1904, p. 179.)

A woman, aged 47, in good health had had for two years a purulent discharge from the left side of the nose, said to have followed an attack of facial erysipelas. For five weeks there had been frequent and very severe headaches and attacks of vertigo; for three days occasional attacks of vomiting, slight rigors, fever, a general sense of malaise and diplopia in the left eye.

On examination of the nose, thick creamy pus was seen descending between the septum and the middle turbinated bone on the left side. Under ether, the posterior ethmoid cells and the anterior wall of the sphenoid, on being found soft and carious, were removed and the cavity curetted. The general septic condition, however, was not arrested and the patient died. Staphylococci were found in the nasal discharge and in a culture from the blood.

Post-mortem examination showed only the posterior ethmoid cells, the cavernous sinus and the sphenoidal cavity involved in the diseased process. No disease was present in the anterior ethmoid cells, in the antra, in the frontal sinus or in the orbit. The brain and meninges were healthy. The condition was clearly one of chronic suppuration in the sphenoid sinus and posterior ethmoid cells, with an acute staphylococcus infection occurring three or four days before she was first seen. The opening and draining of the sinus and the cells were powerless to arrest the spread of the pyemic infection.

The author very truly says that the importance of treating chronic nasal suppuration is still not fully realized by our profession at large. A persistent discharge from the nose is regarded with the same slight interest that a chronic otorrhea attracted a few years ago; nevertheless, the present case illustrates the danger of leaving untreated a suppuration in close proximity to a vital organ.

Orbital abscess and cerebral symptoms sometimes complicate ethmoidal abscess and urgently demand the most radical measures for their relief.

Many cases of persistent headaches, facial neuralgia, migraine and tic-douloureux are caused by pressure within the ethmoid cells. In some cases this intra-cellular pressure may be caused by purulent or other accumulations confined by the occlusion of the

ostia. In others it may result from intra-cellular polypoid or other growth distending the cell, while in still others it may be purely bony, from osseous thickening resulting from injury or from a chronic inflammation of the cells.

As illustrating the latter condition, I cite briefly the following case:

A lawyer, aged 35, was sandbagged by a revengeful criminal whom he had prosecuted. The impact of the blow was over the base and bridge of the nose, and although the nose was not fractured sufficiently to cause marked depression, there was an impaction of the ethmoid cells and a resultant ossific deposit that soon began to produce such intense headaches as to incapacitate him for work or even for social intercourse with friends or family. These headaches were also attended with most pronounced melancholia. This suffering he had endured for over a year when I first saw him, four years ago.

On examination there was found a condition of chronic inflammation and infiltration in the posterior ethmoid region which could only be approached in the most cautious manner, and it was only after most careful work that the infiltrated structures were safely removed. As the pressure was removed the pain slowly subsided until at the end of about two years his local and general condition had so far improved as to enable him to resume his professional work.

Facial neuralgia is so frequently caused by intra-nasal pressure in the region of the middle turbinate that treatment of the pain should never be instituted without carefully interrogating the ethmoid region. This must often be done with the probe, sometimes requiring the use of cocain, for by simple inspection only, the condition of the parts cannot be specifically ascertained. In purulent cases the appearance of pus is an aid in directing up to the diseased region, but as the pain in most neuralgic cases is associated with a condition of catarrhal thickening of the tissues, physical exploration for such condition is necessary.

I wish to mention one point in the etiology of sinus disease, and especially in regard to the method by which infection is frequently forced into the cells. This is by the forcible blowing of the nose during a coryza, or while infected with an influenza, or whenever pus is lodged in the nose. By this means, and especially if the pressure is increased by closing one nostril, infection is frequently forced into normal cells that otherwise would remain healthy.

One or two points in regard to the radical measures resorted to in dealing with diseased ethmoid cells, and I am done. The use of the ring knife or sharp curette is not only ill-advised, but in many cases positively dangerous, when used in proximity to the lamina papyracea, os planum or the cribriform plate. It is in cases of polypoid growths within the cells only that the use of the curette is admissible, for in the case of simple suppuration of the cells perfect drainage is the desideratum, and not the destruction of the mucous membrane. The curette tears more readily than it cuts, and therefore the danger of laceration of the deeper structures is apparent.

In all ordinary cases of ethmoid disease the cells can be freely and safely opened by means of Grünwald's punch forceps, with the assistance of the probe to determine the parts requiring removal, which fact has been clearly pointed out by Thomson. (*Diseases of the Nose, Throat and Ear*; Ed. by Wright, Phila., 1902, p. 971.) In the use of the forceps, by removing only what falls within their grasp and avoiding twisting or pulling away any portion, and working upward and outward, away from the cribriform plate, the operation of excavating the ethmoid cells is rendered comparatively free from danger, and it is in those cases only, which are complicated with disease of the frontal sinus that the external operation is required.

The results of conservative and of radical measures of treatment in diseases of the ethmoid cells attended by the symptoms of pus or pain, therefore, are not to be compared. In the one we have a long continued effort at cure by washes, sprays or other forms of medication, with an uncertain or doubtful recovery, and the constant danger, in the purulent cases, of the infection extending to other sinuses or to the cerebral cavity. On the other hand, by the radical measures, the abscess cavity is properly opened, thoroughly drained and medicated, the danger of infecting other sinuses or parts is avoided, and in painful conditions, if the intra-nasal or intra-cellular pressure is removed, recovery is comparatively certain, speedy and permanent.

THE ETHMOIDAL SINUS.

BY JOHN W. FARLOW, M.D.

THERE has been so much activity in recent years in the study of the anatomy and disease of the accessory cavities that the thought naturally arises whether modes of treatment which have been found to be possible have as yet shown that their advantages are sufficiently great to counterbalance many risks and dangers which attend them. The ethmoidal cells are in proximity to the frontal, antral and sphenoidal sinuses and are near the orbit, the cribriform plate and the meninges of the brain. If ethmoidal disease is the cause of extension of suppuration to these important structures, the question of thorough methods for opening up, draining and removing these cells would seem to admit of only one solution.

As symptoms which call for operative interference, one of the most common is headache, which is sometimes referred to the back of the occiput. This may be due to a complication with frontal disease, from inability of the latter to drain itself on account of enlargement of the ethmoidal bulla filling up the hiatus semilunaris. The headache may be caused by a pushing of the middle turbinate against the septum or the development of one or more large cells in the turbinate, thus causing painful pressure against the septum. The presence of polypi, caused by ethmoidal disease may serve to cause retention of secretion, pressure and headache. In my experience such cases have not been uncommon, a small polyp, even granulation tissue or swollen mucous membrane sufficing as an obstacle.

The eye is often involved where there is ethmoidal suppuration, especially if there is marked retention of secretion. Swelling of the lids or conjunctiva, troubles of vision, displacements of the eye, abscess of the orbit, all these symptoms are to be laid at the door of severe ethmoidal disease and require thorough treatment. Meningeal inflammation, acute or chronic, has been noted in some instances.

Tertiary syphilis not infrequently attacks the ethmoid, showing itself by suppuration, crusts, necrosis and pain. The pus may find exit externally near the root of the nose and external operative procedures may be necessary in order to remove the large mass of necrosed bone.

The sense of smell may be much impaired or entirely destroyed in the nostril where the ethmoidal disease exists, but, unfortunately, the methods of treatment necessary for removing the diseased structures which cause the impairment of the olfactory sense cannot leave the nerve filaments in condition to resume their normal function. An attempt should, however, always be made to respect, as much as possible, the region where this important sense is situated.

Suppuration, causing a long continued flow of pus into the middle meatus, showing itself either anteriorly or posteriorly in the post nasal space, with resulting pharyngitis, laryngitis, asthma, etc., and not amenable to ordinary treatment may require surgical procedures for its abatement.

As a result of the irritating local action of the pus, the development of polypi in the middle meatus and a severe polypoid degeneration of nearly the entire middle turbinal may be so rebellious to all ordinary snare and curetting operations that removal of the ethmoidal cells and the turbinal may be necessary.

If the ethmoidal secretion is in such relation to the opening into the antrum that the latter acts as a reservoir for the pus, an opening into and removal of the ethmoidal cells may be advisable in order to cure the secondary antral symptoms.

We may summarize the symptoms of ethmoidal disease calling for surgical intervention: severe or long continued headache, disturbances of vision, displacement of the eye, orbital abscess, inflammation of the meninges, syphilis and forms of necrosis, obstinate polypi, especially when combined with polypoid degeneration of the middle turbinal, frontal disease caused by ethmoidal obstruction, pus in the antrum of ethmoidal origin, severe or obstinate forms of ethmoidal suppuration with pus flowing into the post-nasal space causing laryngitis, bronchitis, asthma, or other disease of the upper air passages.

An advantage possessed by the ethmoid cells over the antrum, frontal and sphenoidal sinuses as regards treatment is that the former are accessible by intra-nasal procedures, and they can be

opened, curetted, drained and treated without external openings. It is true that when the upper part of the nostril is narrow, from a general narrowing of the nose or from a bent septum, it may be difficult to gain access to the cells, but, usually, after removal of the anterior end of the middle turbinal (which is often diseased at the same time) we are able to penetrate the cells, break down the cell walls, give vent to the pus and curette the secreting tissues. In my own experience I have found almost no cases where other than persistent, perhaps long continued intra-nasal treatment has seemed to me to be advisable. It is not easy to say exactly what the terms conservative and radical mean when applied to the thorough, instrumental treatment of ethmoidal disease. If removal of a considerable portion of the middle turbinal, followed by opening and curetting of the cells, is conservative, then I should say that this treatment is very satisfactory in nearly all ethmoidal affections, even the severe forms, although a certain amount of discharge may persist after the active symptoms have been relieved. I am not in favor of too vigorous treatment, especially in the region of the orbit or the cribriform plate, as an element of danger is unnecessarily added, out of proportion to the symptoms of the patient.

The fact that some of the ethmoidal cells may project so far into the frontal duct as to cause frontal sinus disease may lead to the necessity of a radical frontal operation with incidental treatment of the ethmoid in order to gain adequate drainage into the nose, but this phase of the subject would fall more naturally into the discussion of frontal sinus disease.

For the removal of obstructive polypi or the ethmoidal bulla, causing retention of secretion, pressure on the septum, pain or headache, the snare, curette, punch-forceps or various hooks are sufficient to remove the hypertrophies, drain the diseased cells and permit the use of antiseptic solutions. Where pus has extended in such a manner as to cause troubles with the eye, exophthalmos or other displacement, the same sort of intra-nasal treatment is to be carried out with the object of establishing sufficient nasal drainage as soon as possible. In my experience it has not been necessary or advisable to operate externally except where there was an orbital abscess or where the pus had already formed or was on the point of forming an external opening; for instance, near the root of the nose. I have seen cases of syphilis

and necrosis in which an external opening was necessary in order to remove the diseased bone.

I cannot recall any instances, other than these orbital abscesses and cases of necrosis, in which I have operated other than intranasally for ethmoidal disease uncomplicated by disease of the antrum, the frontal or sphenoidal sinus. Perseverance on the part of the physician and great patience on the part of the sufferer from the disease are of the greatest importance, and even then there may remain a certain amount of nasal discharge, but if the active symptoms of obstruction, pain and headache are relieved, the continuance of a moderate amount of nasal suppuration is easily tolerated.

THE SPHENOIDAL SINUS.

BY J. W. GLEITSMANN, M.D.

ALTHOUGH several publications on diseases of the sphenoidal sinus appeared before 1892, it was the late Max Schaeffer, of Bremen, who, by his exhaustive treatise based on 19 acute and 53 chronic cases, drew the medical attention to the importance and frequent affection of this locality. Subsequent observers and also the writer of this essay could not confirm the relative proportion of his acute and chronic cases, more than one of the former to three of the latter, but the symptoms were described by him so completely and minutely, that very little new has been added since. We still follow in principle his method of entering the ostium and the sinus, and reserve the newer, more radical measures to protracted obstinate cases and to such with extension to the orbit or neighboring parts—a feature upon which Dr. Berens will enlarge.

The sphenoidal sinus can either be diseased by itself alone or in conjunction with other sinuses, of which we have to consider for diagnostic purposes principally the posterior ethmoidal cells, as their discharge appears in the same locality, viz., the olfactory fissure. To differentiate the secretion of these two cavities it is necessary to enter a probe in the well-known manner between the middle turbinal and the septum into the sphenoidal ostium,

which proceeding being easy with a spacious, open olfactory fissure, in other cases requires either pushing away of the middle turbinal or Killian's long nasal specula or most advantageously resection of part of the turbinal. The errors to which we may be subjected in seeking the ostium are graphically stated in the drawing by Hajek, which I hand you for inspection. If, after thorough syringing of the sinus and cleaning of the olfactory fissure, no pus appears in the latter, we can exclude disease of the posterior ethmoidal cells. But if we discover pus after one or more of such proceedings, it is necessary to exclude the possibility of pus running from the ethmoidal cells into an otherwise healthy sinus by ascertaining if only one or both cavities are affected. If we insert a tampon into the well cleaned sphenoidal sinus, and leave it there several hours, pus will flow out through the ostium in case of its being diseased, whilst when both cavities are affected the anterior part of the tampon is also covered by secretion.

I do not consider it to be within my province to give a complete symptomatology, but only shall enumerate such symptoms, which, in my opinion, call for either a conservative or radical treatment. The majority of the acute cases, as also the few observed by the writer, take a favorable issue by releasing the pent-up secretion, although in some instances, especially if complicated with severe acute coryza, the symptoms are well pronounced, fever, insomnia, general debility. Headache, sometimes very severe, is more frequent than in chronic cases; as a rule, the pain is in the region of the occiput, in the rear of the bulbus, also in the frontal or orbital region. At the commencement of acute cases the amount of secretion in the nose and rhinopharynx is often very small, the middle turbinated is turgescient, swollen, pressing against the septum, and when pushed away, the secretion having free exit, is seen in the olfactory fissure. The majority of acute cases, as formidable as they may sometimes appear, take a favorable issue without radical operation, but generally the ostium must be enlarged and kept well open by removal of part of the anterior wall with suitable hooks and nippers, a proceeding which I still consider the conservative method. Disinfectant, later astringent solutions, cauterizations, sometimes curetting of the mucous membrane, will constitute the treatment. In the extremely acute cases brought on by severe infection with danger

of extension to the orbit or sella turcica, radical measures cannot be long delayed.

Chronic affection of the sinus is either a sequela of the acute form or is simultaneous with disease of other sinuses and due to the same infection. The subjective symptoms are of a varying nature and less pronounced than in acute cases. The pain is less severe, either in the occiput or temples or frontal region. Sometimes vertigo is present when bending down, stiffness of neck, neuralgia, *tic-douloureux*, also *aproxexia*, aversion to work, even mental depression. As in the majority of chronic conditions the other sinuses are diseased at the same time. It is difficult to ascribe one or the other symptoms to the sphenoidal sinus alone. We observe instead of the liquid secretion of acute cases more frequently a crust at the middle turbinal as well as in the rhinopharynx, which when removed from the former makes the pus appear between the septum and turbinal. The quantity of the secretion is subject to great changes, sometimes it has a penetrating, disagreeable odor, which was the cause why at one time sphenoidal sinus disease was considered the principal cause of so-called *ozæna*.

At inspection we find the changes in the olfactory fissures more developed. The mucous membranes are thickened, in a state of hyperplasia, which is apt to involve also the septum. Polypoid excrescences, small polypi, all impeding the outflow of pus from the sinus, make their appearance. If the disease has assumed this character, conservative methods will be of little avail in my opinion, and a thorough opening of the sinus with more or less radical removal of its integument will be necessary. Nevertheless, in one of my cases of this nature I succeeded by less heroic means in effecting a cure. The patient presented the peculiar feature of having the greatest discomfort whenever a small crust formed at or near the ostium, but felt well when the sinus was firmly tamponed with aseptic gauze. After thorough access to the sinus, enlargement of the ostium, repeated curetting and cauterizing and proper home treatment, the case took finally a successful issue.

I may be permitted to say a few more words about the more vital affections of the sinus, necessitating radical measures. The relations of the posterior ethmoidal cells and the sphenoidal sinus to the orbital canal have recently been very carefully

studied and beautifully illustrated by Onodi, and that disturbances of vision, even blindness, can be due to diseases of these cavities has been confirmed by cured cases on record as well as by autopsies. Cerebral lesions often ushered in by fever and mainly due to perforation of the upper wall were tabulated by Dreyfuss: a fatal hemorrhage by perforation of the upper external wall into the cavernous sinus is recorded by Scholz. Secondary hemorrhages were reported by Hinckel, Hajek and the writer, which were arrested by anterior and posterior tamponade; another by Myles after trephining and curetting, necessitating ligation of the external carotid artery. Although secondary tumors due to extension from other localities are not so seldom, primary tumors are, according to Citelli, very rare, and he could find only 5 cases in addition to his own. It is superfluous to say that all the last named affections require radical and drastic measures, but when applied in time and carefully executed we can even in a fair number of desperate cases expect to relieve the patient and to save his life.

THE SPHENOIDAL SINUS.

BY T. PASSMORE BERENS, M.D.

IN considering the comparative results of conservative and radical methods of treatment of the sphenoid sinus, it is, perhaps, wise to define what is meant by each method, as operators on the sinuses differ widely in their definitions. Taken in a broad sense conservative treatment may be defined as the treatment of the sinus by various medicaments applied by means of various devices through the ostium—possibly through an artificially enlarged ostium—after access to it has been gained by minor surgical measures, such, for instance, as the removal of a nasal obstruction caused by an enlarged turbinate or by a septal deformity. Radical treatment of the sphenoid sinus may be defined as any procedure whereby as much as possible of the whole of the interior of the sinus is exposed by removal of the anterior wall, its contents removed and the remaining cavity treated in

accordance with modern surgical ideas; in other words, it is an attempt at obliteration of the sinus as a closed cavity.

Conservative treatment is always accomplished by way of the intra-nasal route, while radical treatment is accomplished by way of one of several routes. The anterior wall of the sinus may be removed by way of the intra-nasal route through a part of the ethmoid labyrinth; or by way of the antrum of Highmore and ethmoid cells, when a multiple sinusitis involving these sinuses is present; or by way of the frontal sinus through the ethmoid cells, when this group is involved in the sphenoid disease. The writer considers a radical operation on the sphenoid sinus via the nasal route as quite feasible in many cases.

A comparison of results from the various procedures should take into consideration the topography of the sphenoid region in each individual as well as the character of the disease. Obviously, a marked deflection of the septum or a large middle turbinate will influence the operator in his course of procedure, just as the presence of disease of contiguous pneumatic cells will guide him in selecting the route. Indeed, it is an established fact that the judicious treatment of encroaching diseased ethmoid cells will prevent the necessity of operative interference with the sphenoid in cases of pyosinus of the latter, the term pyosinus being used to indicate that the cavity is acting as a reservoir for pus formed elsewhere (Killian, quoted by Hajek, *Archiv. fuer Laryngologie und Rhinologie*, Bd. XVI.). Again, in the treatment of sphenoid disease associated with or caused by multiple sinusitis, including the ethmoid and antrum or the ethmoid and frontal, it is necessary to treat those cavities also. The particular external operation to be employed depends on the preference of the operator, while the operation is extended thence by way of the ethmoid labyrinth into the sphenoid sinus.

The writer looks on the sphenoid sinus from a purely clinical standpoint as the most posterior of the ethmoid cells, and it is rarely, indeed, that the probability of disease of the ethmoid cells can be excluded when making a diagnosis of sphenoid disease. He has seen only 7 cases in which he could be fairly certain that the sphenoid alone was diseased, while in 37 other cases he has found its disease associated with or caused by disease of the ethmoid, of which number 28 had also either frontal or antral disease or complete pansinusitis of the affected side.

Of the 37 cases of multiple sinusitis in which the sphenoiditis formed part of the disease, one was a case of pansinusitis involving all of the accessory sinuses of the nose except one frontal sinus; 3 were cases of unilateral pansinusitis; 17 were cases of sphenoiditis with tissue changes in the sinus complicated by ethmoiditis; while of the remainder 20 cases were of multiple sinusitis involving the antrum of Highmore, the ethmoid labyrinth and the sphenoid sinus, and 7 were cases involving the frontal sinus, the ethmoid labyrinth and the sphenoid sinus. In many of these cases disease of the sphenoid was not suspected until its presence was noted while operating on the ethmoids, the ethmoids communicating by disease with the sphenoid.

Of those affected with sphenoid disease alone the writer acknowledges the possibility of error in his diagnosis; he is reasonably certain, however, that the diagnosis was correct because of the results obtained from the treatment. Of the 7 cases, 2 were acute and 5 were chronic. One of the acute cases yielded rapidly to conservative measures—adrenalin and douching through the ostium—which was readily accomplished because of the peculiarly normal anatomical topography of the nose. The second case was successfully treated by lavage and medicaments through the ostium, only after the removal of adenoids and the middle turbinate, the removal of the turbinate being necessary on account of the presence of a deflection of the septum. The cure of one of the chronic cases was effected by treatment of the sphenoid sinus carried on through a slightly enlarged ostium, after the removal of a spur from the septum and the removal of an enlarged middle turbinate. Another was cured by the free application of mono-chlor-phenol (ortho) applied through an enlarged ostium after the removal of the middle turbinate. The after-treatment in both of the latter cases was by means of argyrol applied on a cotton-armed applicator. In these cases no lavage was resorted to. The third case was cured by removal of the middle turbinate, breaking away overhanging healthy ethmoid cells and through them entering the sphenoid sinus. The ostium was not found. This treatment was necessary because of the presence of a large deflection of the upper posterior end of the septum. The fourth case was of especial interest because there had been a fairly thorough curettement of the ethmoid region before it came under the writer's observation. The disease was cured by

the removal of a large amount of granulation tissue from the cavity of the sphenoid after the removal of its anterior wall. The fifth case has been under treatment for about ten years, refusing an operation because of a severe hemorrhage experienced many years ago during a curettement of the ethmoids while in other hands. These last two cases were probably originally cases of multiple sinusitis.

Of the number of multiple sinusitis cases in which the sphenoid disease was a prominent factor, 27 were cases of ethmoid and sphenoid disease, while 20 were of sphenoid, ethmoid and antrum of Highmore, and 7 were of sphenoid, ethmoid and frontal. Owing to the time-limit set upon the reading of this discussion, it is impossible to go into the details of these cases. It will suffice to say that they were all cases of well-marked suppurative disease. Of the sphenoid and ethmoid disease, 10 were acute or subacute, while the remaining 17 were chronic. Of the acute cases, 3 yielded to adrenalin, douching and other mild measures; 4 required the removal of the middle turbinate because of its enlargement or of a septal deformity. Three cases after several months of treatment in vain, were operated upon by the removal of the ethmoids and the anterior wall of the sphenoid through the nose under cocain anaesthesia. These acute cases all promptly recovered.

Of the chronic cases of combined ethmoid and sphenoid disease, 17 in number, not one yielded permanently to conservative treatment after a fair trial; they were all eventually operated upon by removal of the posterior ethmoid cells and the anterior wall of the sphenoid sinus,—except two, who would not submit to operation, and have passed from observation. Of the cases operated upon, those in which the operation was most radical, namely, by the total removal of the ethmoids and a large opening made in the sphenoid, all made good recoveries. Five that were incompletely curetted have been troubled with crust formation and a return of many of their symptoms.

The writer's experience leads him to believe that the treatment of chronic sphenoid disease when complicating a chronic multiple sinusitis involving the ethmoids and either the maxillary antrum or the frontal sinus, yields the best results from operative procedures carried out by way of the maxillary antrum or frontal sinus, and thence through the ethmoid labyrinth into the sphenoid

sinus. The results from these operations have been satisfactory. Of the 27 cases of extensive operation but 7 still have to resort occasionally to treatment for the removal of crusts in the nose. The favorite location of these crusts is along the site of the ethmoid cells. In each instance the crust formation is directly attributable to an incomplete removal of ethmoid cells. Crust formations have not been noted in the sphenoid sinus after this operation, and where the operation on the sphenoid has resulted in a permanent large opening, pus has promptly disappeared from this sinus in every case. In 3 cases the large openings resulting from the operations subsequently closed, and in each of those cases pus accumulated, while in one case the symptoms (*tic-douloureux*) returned. These 3 cases were promptly relieved by again taking down the anterior wall.

While the writer is fully aware that the number of cases herein reported is small and the description of the cases inadequate, yet he feels that the careful study he has made of each individual case, though not permitted to be given in this brief discussion in full, justifies him in presenting the following conclusions: Acute uncomplicated empyema of the sphenoid sinus is amenable to conservative treatment provided that the ostium is accessible through the nose. Acute multiple sinusitis involving the sphenoid is amenable to conservative treatment—provided drainage is not blocked by anatomical deformities or diseased conditions. Anatomical deformities may render surgical procedures necessary to gain access to the ostium. Acute or chronic pyosinus of the sphenoid can be cured only by removal of its cause, *i. e.*, by treatment of the disease of the ethmoids. Simple chronic empyema of the sphenoid sinus alone, when unaccompanied by serious tissue changes in the interior of the sinus, is amenable to conservative treatment. Chronic empyema of the sphenoid sinus when, however, it occurs as a complication of diseases of other sinuses, as it frequently does, or when accompanied by tissue changes in its interior, can be cured only by radical procedures involving not only the destruction and removal of all of the tissues diseased, but also the removal of all other tissue that may be a hindrance to drainage and to after-treatment. The tendency of the anterior wall of the sphenoid sinus to reform is a sufficient warrant for as complete a removal of it as possible. The location of important vessels in the region of the sphenoid is a strong argument in favor of the

maxillary route when the antrum is involved, for this route gives double access to the sphenoid sinus and thus the more readily permits of proper instrumentation.

General Discussion on Sinus Disease.

DR. HENRY L. SWAIN.—I most heartily concur in what has just been said, that the Association should feel itself highly complimented that before this body there has been presented such a complete exposé of the subject of sinus disease, not only the eight papers this afternoon, but also the very illuminating discussion of the morning on the acute phases of the subject now at hand. There is an old saying that "Every surgical operation is a confession of failure," and it seems to me to-day that we have a beautiful illustration of that thought. Those of us who have observed a great many acute cases of sinusitis and have transilluminated as routine work all severe cases of acute rhinitis, will bear out the statement that a large number of the cases of acute inflammation of the sinuses cure spontaneously; here Nature has been sufficient. The parts are so normal in their making that she cures them by her own method of free drainage. That we have to resort to other measures of treatment is a confession on the part of Nature, that failure is due to lack of drainage in two senses. The thing which interferes most with the drainage from the cavities, is the formation of granulation, or oedematous tissue. Pus, when retained for any length of time on any mucous membrane, always tends to the formation of polyp-tissue, and therefore the process of cleansing is most important, not merely the cleansing to get rid of the accumulation in and around the cavities, but to stop the resulting pathological changes in the mucosa. We may have to remove or reduce the swollen tissue, and, failing to reduce the inflammation in the sinus by these measures, we are called upon to perform the operations which we have heard discussed more in detail this afternoon. All this, it seems to me, has been presented in a very able way, and has been most valuable to me. I would like, before sitting down, to ask Dr. Coakley whether in all of his 104 successful cases (and I congratulate him for this splendid result), the frontal inlet into the nose closed. (Answer, "Yes".) It seems to me that represents a step in advance in the treatment of these cases, when a gentleman of Dr. Coakley's ability can say that by this method of operating he has produced absolutely radical cures, as in mastoiditis, when we obliterate the cavity. We cannot do that with the ethmoid, sphenoid or with the maxillary antrum. I would then like to ask Dr. Coakley if he would, in closing, state which method he pre-

fers in operating, whether the removal of the front wall or lower wall when he does his so-called "radicals"?

DR. CLEMENT F. THEISEN.—During the past winter I had the pleasure of seeing Dr. Coakley perform his open operation, and later in his office, saw quite a number of his cases in different stages, in which the radical frontal sinus operation had been performed by the open method, and I must confess I have become an enthusiastic advocate of that method. It seems to me that in every frontal sinus operation, the thing to be sought for is to get a thorough obliteration of the sinus. I do not see how you can be sure of *positively* accomplishing that by any other method. I do not see how you can be absolutely certain after the completion of the operation, whether or not you are going to have a complete obliteration of the frontal sinus, if the wound is immediately completely closed. Since seeing Dr. Coakley's work, I had the pleasure of performing two operations by the open method, one in a case of three years' standing, with extensive ethmoid involvement, and I am certain that the frontal sinus in this case is obliterated, and that the naso-frontal opening is closed. The nose is absolutely free from any secretion whatever. I think, too, it is an important thing to remember what Killian says in his valuable atlas of the accessory sinuses of the nose, that we should look for large anterior ethmoid cells in performing the radical frontal sinus operation, which so frequently dip well over the supra-orbital wall, and also look for all pockets of pus and orbital recesses. I think the most important thing is to get out every bit of mucous membrane from the frontal sinus. Otherwise, we cannot be certain of future results being good. My experience in this work has been very limited, but I simply wanted to add my slight testimony to what Dr. Coakley has said, and to advocate the open method.

DR. GEORGE L. RICHARDS.—I have a few specimens here that illustrate particularly well the impossibility of having one operation, even though it be of the most radical nature, which will satisfy all cases. Here, for instance, are two frontal sinuses of enormous extent. Here is another which shows the frontal sinus going a long ways backward and another one with the fronto-nasal duct draining into the antrum on each side. In several of these specimens the frontal sinus communicates with a number of the ethmoidal cells.

It seems to me in the Killian and other radical operations we will come up against the occasional case where it is either impossible or impracticable to treat the sinus in such a way as to effect an absolute cure. Dr. Coakley's method of obliterating the sinus appeals to me more than the method of Killian. I have been in the habit of operating underneath the ridge of the inner angle of the eye, first by the Caldwell-Luc method and latterly by keeping the cavity packed until its absolute obliteration has

taken place. This requires from several weeks to four or five months, but the resulting deformity amounts to nothing. It is hardly noticeable at the inner angle of the eye, and when a cure has finally resulted there are no recurrences. In the Killian operation it must be borne in mind that there is a certain amount of danger in connection with it. You may occasionally find one sinus small and the other large, and you may get close to the brain above the supra-orbital ridge on one side and not on the other. As Dr. Theisen just said, the rule in any frontal sinus work is to get obliteration if possible. Make the widest possible opening into the nose and destroy all contiguous ethmoidal cells.

Another important point in connection with this discussion should be mentioned, namely, the view which the patients themselves take with reference to the question of operation. They are often satisfied, and you have to content yourself to let them stay so, with a slight muco-purulent discharge. If you have obtained fairly good drainage they will prefer this to a more radical operation with the chances of a long course of after-treatment. This slight muco-purulent discharge annoys them very little. They simply regard it as a little catarrh. I have one patient who had a frontal sinus empyema discharging externally. I took off the middle turbinate and enlarged the fronto-nasal opening and told him that a radical external operation ought to be done. He, however, on the establishment of better drainage, declared he was well and said he had always had catarrh, and was entirely satisfied with the result, although there is still a muco-purulent discharge from the sinus, and from the rhinological standpoint he is not cured.

This last specimen illustrates a point which Dr. Berens has made, namely, that the sphenoidal is practically and anatomically a posterior ethmoidal cell.

DR. OTTO T. FRIER.—I permit myself to change the subject from the frontal sinus to the maxillary antrum, as I do not think that the radical operation of the latter cavity through the nasal wall has been considered in this discussion. This procedure includes as a preliminary the removal of a large portion, usually the anterior two-thirds of the inferior turbinated body. Although objection has been made to sacrificing a part of this structure, my personal experience has rather convinced me of the harmlessness of doing so. Though I have frequently resected large portions of the inferior turbinated bodies when they blocked the nares from hypertrophy, I have never seen the permanent crusting and scabbing mentioned by others, and I think that where it is found after turbinotomy its continuance is due to pathological conditions such as abnormal secretion from suppurating sinuses or metaplasia of the ciliated epithelium of the nasal mucosa into pavement epithelium as the result of chronic purulent rhinitis. In my experience, if the mucous membrane of the nasal cavity

be healthy, crusting and scabbing after resection of the inferior turbinated body is but temporary and ceases after cicatrization of the wound, even though the naris be made abnormally roomy.

Réthi was the first to perform the radical intra-nasal operation for empyema of the antrum mentioned, a method which I think is destined largely to supplant the often needlessly extensive Caldwell-Luc procedure. In the intra-nasal operation nearly the entire nasal wall of the antrum, from a little above the inferior border of the middle turbinated body above to the floor of the nose below, and from the anterior end of the middle turbinated body in front as far back as to the posterior third of the lower turbinated bone is removed with trephine, burr and punch forceps through the nostril. The operation accomplishes in most cases all that the Caldwell-Luc does, and in a far more conservative way. It is eminently the method for the rhinologist, whose peculiar instrumentarium and skill enable him to avoid the more direct but more damaging route of the general surgeon through the facial (buccal) wall. Since Réthi's first publication, Claoué of Bordeaux and Holbrook Curtis of New York have advocated the procedure in a somewhat less radical, and I think, therefore, less efficient manner than Réthi. As the operation is a new one, my experience is still limited but very satisfactory. I supplemented it by a number of cadaver operations and found that usually the field of operation is quite accessible, and that the view of the interior of the antrum obtained is surprisingly extensive, considering that one operates through the nose. I employ a pair of large curved punch forceps, Rhodes', that enable one to reach every part of the antrum after it is opened through the nasal wall, and permit the cutting off of granulations and polypoid masses. A flexible curette may also be introduced, and palpation of the posterior one-half to two-thirds of the cavity is possible with the little finger.

As to the intra-nasal resection of the nasal wall of the antrum represents the last step of the Caldwell-Luc operation, the latter is already half done should it become indicated after all. The great majority of the cases that have been reported, however, recovered as the result of the intra-nasal operation, which establishes the freest drainage and, what is just as important, perfect ventilation of the antrum. In addition patients will submit to it when they will object to having the bones of the face attacked.

DR. JOSEPH H. BRYAN.—There has been a very radical wave which has been going over the whole world, the continent of Europe, the British Isles and our own country in regard to the treatment of these suppurative conditions of the accessory sinuses. There is no question about it, there has been entirely too much done, and in too radical a way, but nevertheless, taking first the maxillary sinus, it is necessary to be radical in the majority of cases, that is in the chronic suppurative cases of long duration.

In the subacute or chronic abscess of short duration the intra-nasal methods, such as have been spoken of, may be sufficient, but I do not believe that it is possible to cure these cases of several years' or more standing by such methods, and it thus becomes necessary to remove the anterior wall of the sinus. With regard to the curetting of this sinus, we find the mucous membrane very much thickened, and it is only possible to get the curette down to the bone through a large opening in the canine fossa. These cases are very obstinate and often defy the most radical methods to relieve them.

With regard to the frontal sinus operation: In 1890 I did my first sinus operation, and I tried it by the open method. I treated that case for one solid year, operating on it twice. The parts closed so that it was impossible to make any local applications through the external wound. I was unduly timid at that time and did not remove enough of the ethmoid, although I did make a sufficient passage from the fronto-ethmoid region to bring about what I supposed was sufficient drainage. Unfortunately, the granulations were weak and broke down, but the external wound closed so that it was impossible to keep the parts open. So that is not a method by which you are positively sure you can bring about a cure after operating even a second time. I wish to take exception to the statement that it is impossible to cure these cases except by the open method. I have cured the majority of my cases by the closed method. I have tried every method known to-day except the Killian. Possibly I do not understand this operation. I have done it several times on the cadaver, but when I see cases going round as in Europe, showing a furrow sufficiently deep to put your forefinger in, and at the same time cannot feel sure then that a cure has been accomplished, I cannot bring myself to operate by this method. I saw one case of Killian's which had to be operated on three times, so that is another evidence that the Killian method is not a positive cure. I have resorted to the so-called Luc method in the majority of my cases and all are well to-day. I am free to say all have not been cured by one operation, however. Why send these patients out looking like a lot of flatheads, when by one or two operations you can keep their normal appearance? Now, in regard to the cure by the so-called closed method. The same process of cure goes on that occurs in the open method, granulation tissues form to fill the cavity. I have been unfortunate enough to open two cases unnecessarily; in one the sinus was filled with firm bone tissue and in the second case it was filled with granulations so firm it was difficult to remove them with the curette. I believe, however, that in this closed method you do not disfigure your patients to the same degree as by the Killian method.

DR. LEWIS A. COFFIN.—It is very difficult to determine what is conservative and what radical. Where one method begins the

other ends. Both words are capable of comparison and either may modify the other, so that the line of demarcation is exceedingly indistinct. It strikes me that we shall come to consider not what is the most conservative and what the most radical, but rather what method best lends to a satisfactory cure of the disease, and that will be, I am convinced, the most conservatively radical thing that can be done. I have been particularly interested in this symposium, and I congratulate the writers on the excellent and conservative tone of all papers presented. The writers have been hampered perhaps to a certain extent by the fact that each has been obliged to deal with a single sinus, because in practice most cases are complicated, one sinus being associated in disease with one or more others. Considerable discussion has been presented on the maxillary antrum. I am thoroughly in sympathy with what Dr. Bryan has said with regard to the external opening of that sinus where radical work is necessary, although it is not necessary at first; the intra-nasal operations can be done and the more conservative method tried to be followed by the more radical if necessary. I am particularly interested in the frontal and ethmoidal sinuses. In 1892, in Washington, in a symposium somewhat similar to this, I had the honor to read on the frontal sinus, and then named and described the open method, recommending it as what to me at that time seemed the best for all cases. I reported having cases that were not in any way scarred and in whom there had been no recurrence. I have no case to-day that is not well, but I have one case in which it was necessary to operate the third time. It was a hospital case and the external opening never closed completely. At the third operation on the boy I did practically a Killian, and the boy has since that time made a complete and rapid recovery. The trouble was that I did not get into his anterior ethmoidal cells, which persisted in keeping up the discharge. Now I believe the open method is applicable to certain classes of cases only. Given a small, smooth sinus independently diseased the open method, is, to my mind, the operation of choice. If obliged even to do work between the frontal sinus and nose, enlarging the frontal duct by the destruction of the ethmoidal cells about it, your opening is made particularly large, and particularly large in comparison with the sinus to be filled with granulation, I think you will have no trouble and no recurrence.

But lately I have done the Killian in several cases, and I must say that I am thoroughly converted to this method of operating in the majority of cases; that is, in cases of large, irregular sinuses complicated by ethmoiditis. In these cases that I have done, three only, I have no flat heads, and in fact practically no deformity. There are men here who know the cases. In one case a young man in whom I took off the entire anterior wall of both sinuses, leaving neither septum nor zone of bone over its

site, there is no deformity of the forehead. In a case I treated by the open method I took off the entire anterior wall, leaving a narrow strip of bone over the septum; there is no deformity. She had as large sinuses as I ever saw, except the retraction at the point kept open for packing; very regular, however. The deformity is greater than that following the Killian method.

Most of our failures come, I think, from the involvement of the ethmoidal cells along with the frontal sinus, and unless we tackle these it is very difficult to get our frontal sinus to obliterate or the external opening to close up. This can best be done by the Killian method, and if the sphenoidal sinus be diseased it can be opened most easily by way of the ethmoidal labyrinth.

Now I want to say a word in regard to the ethmoidal sinus. I believe that we do the most conservative work by the external operation. That is to say, a case comes with an involvement of the ethmoids demanding operation. If there is a fairly healthy middle turbinate it seems too radical to take out the middle turbinate, as must be done either by intra-nasal operation or by going through the antrum. By the external operation we need not necessarily sacrifice neither the inferior nor the middle turbinates. If we have disease of the anterior ethmoidal cells then the ethmoidal route should be used for reaching the sphenoid. If not, I almost wonder if it would not be a fair proposition to go through the antrum, though healthy, into the sphenoid. I feel very much opposed to this operation on the ethmoids and sphenoids through the antrum, by which the entire destruction of the internal wall to the antrum is brought about. I cannot see in the future condition of a such a case anything that approaches a functioning nostril, and I have my doubts as to the future well-being of the patient. Dr. Berens brought one to me the other day which he had operated upon most thoroughly, opening all the sinuses into one, and it was absolutely clean, but the case was of recent date, and what the condition of that mucous membrane will be in a few years is a great question to my mind.

DR. THOMAS J. HARRIS.—I hope that we shall not lose sight in our discussion of the titles under which the various writers have written their papers. I think we have turned too much into a discussion as to the best operation for the relief of empyema of the frontal sinus. I am not unmindful of that stirring paper of Dr. Mackenzie last year about radical work, and I am rather hoping he has a little fire left to use before we get through. It seems to me we have to bear in mind this point, that leaving out the conditions which Dr. Coakley, among others, has enumerated in which the radical operation is required, there is a large group of cases of sinus disease that fall into a class by themselves, *i. e.*, of a certain amount of discharge without other prominent symptoms in which it is an open question if any radical procedure is demanded. I hope, too, we won't lose sight of the fact, which

the speaker has emphasized, that we must regard these sinuses together, not separately. If we forget this we forget the most important thing. The writer in the paper on ethmoiditis did not dwell on this sufficiently, that cases of ethmoiditis are not simply involvement of the ethmoid cells but cases often associated with disease of the sphenoidal sinus. Almost invariably inflammation of the frontal sinus has been associated with ethmoid disease, and it is equally true of the maxillary sinus. In fact, using a quotation of Dr. Lermoyez, wherever you have an antrum of Highmore holding one and a half cm. you have it simply acting as a receiver. Are we finding it necessary to-day to operate upon our cases for the simple question of chronic discharge? Are we not able to get sufficient benefit to satisfy our patients without the radical treatment which has been very much dwelt on to-day? The statistics collected by Dr. Turner, of Edinburgh, will bear emphasizing. As I recall them he has collected 42 cases of intra-cranial complications causing death, also 24 cases of death following operation on the frontal sinus, and in my knowledge there have occurred in the last year three or four besides that. Of these 24 cases in which death has resulted following the operation either in the frontal or other sinus (23 of the operations known), 17 followed the Luc operation, showing that operation certainly is not free from danger. It seems to me that where we have indications as clearly stated as by Dr. Coakley there is no question about the necessity for radical procedure, but it is a very grave and large question. I should be very glad to hear from others along this line. Let us not lose sight of the fact that we can very easily be dealing with complications that will produce very serious, if not fatal, results in these operations upon either the sphenoidal or frontal sinuses.

DR. J. PAYSON CLARK.—There is one point in regard to empyema of the antrum which has not been touched upon in the papers or discussion which seems to me should be mentioned, and that is that there are two distinct forms of empyema as regards etiology: one is the empyema arising from some disease of a tooth, and the other is the empyema arising from infection through the nasal cavity. In my experience those cases arising from a bad tooth are very amenable to treatment. I have in mind one case where a purulent discharge from one nostril had existed for seven years. On the removal of a diseased tooth and washing out for three weeks twice a week it was entirely cured. I think one point needs to be remembered, that if a tooth is the source of the infection it acts very much as a foreign body, but when it is removed the case gets well. Another point regarding the radical or Luc operation on the antrum and packing the antrum afterwards. I used to pack it with gauze, but I found that it caused a great deal of pain and discomfort, and I could not see there was anything to be gained by it, so in the

operations I have done in the last two years I have not packed the antrum at all. I have opened the canine fossa, explored the antrum, removed the thickened membrane, made a large opening into the nose, then allowed the wound in the cheek to close. The patient has been much more comfortable after the operation, and I have not been able to see that the result was not just as good as with packing.

With regard to the operation on the frontal sinus my experience in radical operations has been very small; the only operation I have done has been the Ogsdon-Luc operation. I shall still, with my experience, continue to try that operation on cases in which a more radical operation than an intra-nasal one seems to be called for.

DR. J. PRICE-BROWN.—I should like to say a word or two on disease in the antrum and ethmoid cells. I was glad to hear Dr. Bryan speak so favorably of the operation through the canine fossa. In my experience it is an excellent method. It has certain advantages which the radical operation has not. Radical operations in which you remove portions of the internal surface of the antrum, put the patient in a condition in which he cannot, as a rule, treat himself; the operator or nurse has to do it for him. After an operation through the canine fossa the patient can attend to the wound admirably and practice irrigation if needed. Another point: in a good many of our cases the disease does not arise from a diseased tooth but from inflammatory action or polypoid thickening in the neighborhood of the ostium, and by making an opening of sufficient size through the canine fossa you can curette the antrum much more thoroughly than through the inferior meatus. It is not so radical an operation. My method of treatment has been to make a good-sized opening into the antrum, then to put in a soft rubber tube, the outside end being rolled upon itself. This tube is permitted to remain open, but by its pressure it prevents granulation. If left in for a sufficient length of time, you have, on taking it out, a perfect sinus. This can be left open as long as required for irrigation, and then allowed to close. If the anterior ethmoidal cells are diseased the probability is that the frontal sinus is also diseased. In like manner disease of the posterior cells is usually attended by disease of the antrum of Highmore.

The treatment of the ethmoid cells alone has rarely been sufficient to produce a cure in my hands, but the operation spoken of, and treatment through the antrum, together with curettement of the cells, has produced a cure.

DR. EMIL MAYER.—One group of cases has been omitted in the descriptions here presented, and those are the acute cases of frontal sinus disease. In these the patient rapidly passes into a condition of extreme danger of his life. There are early meningeal symptoms without involvement of the middle turbinates, the principal complaints being violent headaches and extreme tender-

ness over the sinus. In these cases removal of the middle turbinate will be of no avail and prompt external operation is indicated.

In the operation for more chronic conditions, I believe that the suggestion made by Dr. Coakley is applicable, that is, that there should be a skiagraphic picture on hand. The ordinary method of making such pictures consists in having the weight of the patient on the glass, but there are instances given where the glass has been broken by this method. This has been overcome by a table devised by Dr. W. M. Brickner, which consists of a top so arranged that the plate is placed under the board, hence not coming in contact with the patient at all.

Regarding the radical operation where all the sinuses are cleaned out, it does certainly seem that every other method should be patiently tried first before resorting thereto, and I recall the appearance of patients who have been thus operated, presenting two unsightly horns on the forehead from which they pulled out approximately a yard of gauze on each side, and then drawing out their cheeks would pull out a similar packing from each antrum of Highmore, and do this for a long time until healing was established. The operation itself as I have seen it is such a bloody one, the patient swallowing enormous quantities of blood, that I would like Dr. Berens, in closing the discussion, to state if he has in any way been able to modify the operation to avoid this great loss of blood.

DR. ROBERT C. MYLES.—The discussion has been extremely interesting, and we are indebted to those who have spoken so freely. It is the only way that we will ever solve this problem. I commenced about fifteen years since to perform a series of these frontal sinus operations, and I have done all the operations except the Killian. My experience has been that I have had in many cases good results with all methods, but my best results, taking them altogether, have been by the conservative methods, and when we think of the death rate of twenty-four collected and reported by Turner, and how many more there are no one knows, it is something to make us hesitate and think more.

If one can cure eighty per cent. of all sinus cases by the internal conservative route he has only twenty per cent. to treat radically.

It is necessary to make large openings into the seriously diseased sinuses, and openings which will remain open, in order to effect cures by the internal conservative treatment.

DR. CORNELIUS G. COAKLEY.—In answer to Dr. Swain's remark—he spoke of acute cases curing themselves spontaneously in many cases—I agree with him that many of these cases do cure themselves spontaneously, but I know that a large percentage of the chronic frontal sinusitis patients who come under our care are those who give a history of intense pain, supra-orbital neuralgia, for one, two or three weeks, the pain then disappearing

and the discharge continuing to the time of observation. Some of the cases have been of such long standing the patients have no recollection of the origin. I believe that if most of their cases had been treated properly in the acute stage they would have been cured and not become chronic.

In regard to the closure of the nasal frontal duct, I have kept a careful record of all cases of chronic sinusitis in which I was able to probe the frontal sinus. In most of the cases I tried the various intra-nasal methods for curing the disease. I found most cases of chronic frontal sinusitis accompanied by ethmoiditis, the antrum also infected and the sphenoid not infrequently. If there were polypi present all were removed intra-nasally and the ethmoids curetted and opened with forceps, and then when that failed, as in a large percentage of cases it did, resort was made to the radical operation. Having been able to pass my probe into the naso-frontal duct before operation I knew how far it went, and then when the case was healed I attempted again to probe the duct. One can then seldom pass a probe up more than quarter of an inch; it is impossible to go above the level of the inner canthus of the eye. Two cases in which I was able to do that during the process of healing came back for a second operation, so that I feel that unless the naso-frontal duct is closed we have probably left something in the way of ethmoidal cells or mucous membrane at the lower portion of the naso-frontal duct which is bound to secrete. That was the condition of these cases operated on a second time. In one there was superiorly also under a little shelf of bone not taken off an area of gelatinous polypi similar to those found at the first operation. That case had a fistula form and discharge for a week, then close up, and in three or four weeks break down and remain so for fourteen months, when the patient underwent a second operation and is to-day well.

I think in doing this operation certain things are necessary. In the first place it is necessary to absolutely remove every vestige of the membrane lining, not only the frontal sinus, but the diseased ethmoidal cells, and the naso-frontal duct. I do not think it is possible to do this with the ordinary daylight illumination, but only with a brilliant electric light. One must be careful to search for those orbital recesses so frequently found. They go back over the orbit and I know of nothing so important as the removal of the membrane from these recesses.

Dr. Swain has asked what I have removed in operating. I removed at first three-quarters of the anterior wall, leaving a part of it overhanging, enough to get at all portions of the cavity. I later found that the removal of all the anterior wall gave less deformity and lessened the time of healing. The size of the sinuses varies considerably. I have found some unusually large ones.

The larger the cavity, the longer the time required (other things being equal) to obliterate it. In two cases in which I have ope-

rated a second time, where I had expected to find connective tissue I found bone. At first the connective tissue and periosteum are firmly bound down; later on they become freely movable.

I would like to speak about Dr. Bryan's remark. I feel where a case has been operated on twice, at least in my own cases, that I have left something the first time which ought to have been removed.

In packing the wound I separate the edges widely. The outer part of my incision is united by two or three sutures, about an inch of the median portion is left unsewed and the margins are separated by the gauze packed into the cavity.

DR. WILLIAM E. CASSELBERRY.—I have only an additional word to say. I did not understand that the discussion was to embrace acute sinusitis, consequently I said nothing in the paper with respect to the acute form of frontal sinusitis. I agree that nearly all acute cases recover spontaneously, leaving only a small percentage to require radical operation. As I understand it, Dr. Coakley was assigned to consider frontal sinusitis from the radical operative standpoint, and I from the conservative standpoint, and I have been pleased to see how close together we come with regard to the treatment. I am in harmony with him as regards the main indications for and the method of external surgical operation, and from what he says of the intra-nasal conservative methods I feel that he gives them also a fair field in his practice.

DR. JOHN O. ROE.—Those who have participated in this discussion seem to have lost sight of the subject and have discussed only the radical measures to be adopted in the treatment of extreme cases. The external operation for frontal sinus disease has been mainly considered, while the less radical methods of treatment have received little or no attention. The ethmoidal cells, also, have been almost entirely overlooked, and they I consider quite as important as any of the other cells we have to deal with, because they are the ones first diseased, and from these the sphenoid and other cells become infected.

It may be a pertinent question to consider, in connection with this discussion, what may be regarded conservative treatment and what radical. Formerly conservative treatment would have been considered the use of sprays or washes for syringing the cavity, and the local application of remedies where feasible or possible; while radical treatment included all surgical measures, such as opening the cells or cavity to give free drainage and the removal of polyps or other growths that may be found. At the present time the latter measures are considered quite conservative, while the radical ones consist not only in freely opening the diseased cavity by an external operation and the entire removal of the mucous or lining membrane, but in the complete obliteration of the cavity. Therefore, the measures regarded by one operator

as conservative might be considered by another as quite radical, and *vice versa*.

There was one point mentioned by Dr. Coffin, that it is regarded necessary to remove the middle turbinate in order to get at the ethmoidal cells. This is a mistake, and I am very glad that Dr. Myles has also alluded to it. The middle turbinate is simply an appendix of the ethmoid bone and the ethmoidal cells can be freely opened without the removal of the middle turbinate at all. The bullæ ethmoidales, the anterior and also the posterior ethmoidal cells can be very readily opened and removed from under or behind the middle turbinate without removing it.

In none of these cases do I regard the external operation necessary except, as I stated in my paper, when the ethmoid disease is complicated with an intractable disease of the frontal sinus. Therefore, in simple or uncomplicated disease of the ethmoid cells the external operation is unwarranted. I quite agree with Dr. Harris that the sphenoidal cavity is almost invariably infected by disease of the ethmoidal cells. In dealing with the diseases of the sphenoidal cavity, therefore, it is of the utmost importance to remove the posterior ethmoid cells.

DR. T. PASSMORE BERENS.—In answer to Dr. Mayer's question, I understood him to ask me to describe the radical operation by way of the maxillary antrum. Owing to the time limit placed on the discussion, I must decline to describe it and refer him to *The Laryngoscope* of 1904. There is one point in the operation to which he particularly referred and I should like to take issue with him upon it. We both saw the operation performed in Berlin, and considerable blood did enter the pharynx. This is prevented by the insertion of a post-nasal tampon, a procedure I always follow. An assistant takes care of the slight amount of blood coming through the mouth wound. In a case of sphenoid sinus disease, accompanied by ethmoid disease and disease of the antrum of Highmore, I believe that the sphenoid disease should be operated upon by way of the antrum of Highmore and the ethmoid cells. If the sphenoid disease is complicated or caused by an ethmoid disease, if the nasal route is accessible I believe we should use it. There are certain conditions that render this route impracticable; for instance, a very marked deflection of the septum, especially at its upper posterior end. I recently saw a case in which the septum entirely occluded not only the ostium of the sphenoid, but went very far over on to the pars-ethmoidalis of the sphenoid. In that case it would have been impossible to operate through the intra-nasal route. In such cases I think the operation should be by the antral route, even if the antrum is healthy, and especially if the sphenoid and ethmoid disease is causing constitutional symptoms.

The fact that deaths are reported as following operations on the accessory sinuses should lead us to be the more careful not only

in our technique, but also in the selection of our cases for operation.

We must remember in operating in the ethmoid labyrinth that we are dealing with a cellular structure not unlike in many respects the cellular structure of the mastoid cells, and we should have as clean and smooth a wound in the one as in the other. An incomplete operation on the ethmoid cells is always followed by prolonged suppuration, while the surface secured by a complete operation heals very rapidly.

A FURTHER STUDY OF HAY FEVER, CLINICALLY, WITH THE EMPLOYMENT OF POLLANTIN.

BY ALEXANDER W. MAC COY, M.D.

AN article which I read before the Section on Otology and Laryngology of the College of Physicians on October 21, 1903, appeared in the *New York Medical Journal* and *Philadelphia Medical Journal* of November 21, 1903, under the title: "A clinical study of the use of antitoxin serum (Dunbar's) in hay fever, during the season of 1903. A new and distinct advance in its management." This article was a short summary of my clinical experience with my private patients during the *autumnal* attacks. As the study in 1903 did not begin until September 1, by reason of my absence from Philadelphia during August, the cases were fully declared, and, as the report shows, exhibited the full train of symptoms and were beyond the stage of *prevention*. The pollantin which I used, kindly given to me by Merck & Co.—then agents for the serum—proved to be most efficacious, and made me a convert to its employment in the periodic cases of hay fever. For the inspiration to use the serum, I am wholly indebted to my friend, Dr. Emil Mayer, of this Association. Happening to meet him in New York in June, we fell into a discussion concerning *vernal conjunctivitis*, for which I was eager to find a cure, as one of my friends had been a sufferer from the annoying complaint for several seasons. Dr. Mayer mentioned his interest in the study of Dunbar's antitoxin for hay fever, and it occurred to me to try it for the vernal conjunctivitis. I asked Dr. Mayer to send me

several vials for trial. After my return home in September, a number of hay fever patients were under my care, and I at once wrote to the agents for a supply of the antitoxin, which was generously sent me. From my satisfactory experience with the serum, I looked forward with interest and enthusiasm to the season of 1904. When the early season arrived, I began the use of the new serum sent out by Prof. Dunbar for 1904. The early cases did well; some were magically relieved and all were so controlled that the subjects were rendered immune. Many of them were enthusiastic about the results. When the late autumnal cases began to appear, I at once began the use of the serum, confidently expecting the satisfactory results of 1903. Much to my chagrin, a number of patients using it reported no relief, and *none* who came before the time for the attack were rendered immune from the attack. During July, August and September I saw a number of cases; some were rendered comfortable if the serum was used continuously every day. A certain percentage passed through all the stages of the disease, and a few declared that they were made worse and refused to pursue the treatment further. I was greatly perturbed by the results in these cases, for the contrast to the results in 1903 was so striking.

A most graphic exhibition was made when many of the 1903 cases presented themselves for treatment, and instead of being relieved of every symptom in a week's time, obtained little or no relief, the asthmatic cough and seizure being hardly ameliorated!

About this time I had the pleasure of a call from Dr. Dunbar. We went over the subject together, and I then learned the cause of my failures. Dr. Dunbar informed me that not one bottle of serum similar to that of 1903 had been sent out! That in conversation with several American physicians who had visited him in Hamburg, he had been informed that "pollantin made from *grasses* was the only kind required for the American trade." Why these distinguished gentlemen were led to make this dictum, I am unable to discover. Certainly they had no data to warrant such an opinion. I told Dr. Dunbar that I was convinced that it was a mistake; and that if I could get serum similar to that of 1903, I could ask no better. It was so late in the season that I could not hope to receive more of the 1903 serum, but, fortunately, I had a few vials left over. Dr. Dunbar assured me that *it* could be relied upon and would undoubtedly be perfectly good, and that

he himself was using it. He used it in my presence, and gave me a few more vials for experimentation.

I immediately began to apply what Dr. Dunbar had given me and what I had left, with the same remarkable results as during the previous season, but the amount was far too small to accommodate the people I had under my care—portioning it ever so carefully.

In attempting to formulate any conclusion from two seasons' trials with two different serums, one can but infer that matters are still sub judice. The prestige of 1903 was greatly hurt by the percentage of failures in 1904. We are warranted in the belief, from the two seasons' experiences, that the toxins reacting in the large class of graminacea are *not* identical with toxins found in certain American weeds, that two sera, or more, or a composite serum, will be required to cure or correct the disease causes acting in American subjects of hay fever. The pollantin sent out in 1904 was the product of *grasses only*, and perfectly adapted to the cure of *early* attacks, while inactive for many of the later attacks. Therefore we see the necessity for the production of a serum adapted to the needs of *American* patients for both the early and the late attacks. Again, not only was the 1904 pollantin composed solely of the antitoxin of grasses, but it was twice the strength of the 1903 pollantin, and of this fact I was ignorant. This led me into the error of pushing the 1904 product in cases showing little or no response, and thereby causing local irritation in the nasal chambers from its too frequent use.

Hay fever being an acute toxemia, can be rendered harmless by the proper antitoxins, and, with sera of fixed units of strength, adapted to the varying conditions of the inhabitants of the American continent, the immunization and cure of all cases of hay fever is, practically, an assured fact. With the *two* sera now at my command, I feel confident of favorable therapeutic results for the season of 1905.

Discussion.

DR. CLEMENT F. THIESEN.—As Dr. MacCoy states, the great difficulty in this country, with our American variety of hay fever, would be to obtain pollantin or a mixture of sera for each particular variety of hay fever. During the late spring of 1903 Professor Dunbar published his results, and I wrote to him and obtained seven vials of his pollantin, which was then called anti-

toxin. It was made from the true grasses, mainly from maize, Indian corn and barley. That was the serum used mostly at that time, and whether for that reason, or whether our variety of hay fever is very frequently produced by the pollen bodies of ragweed and goldenrod, my results then were not very good. I started using the antitoxin very late in the season. During the past summer of 1904 we were able to obtain the pollantin in this country, and my results were better. I used it in twelve cases. One lady was referred to me during the height of her attack, not only suffering from irritation of the nostrils and severe conjunctival symptoms, but also from a severe reflex asthma. In her case the use of pollantin completely relieved the symptoms. That is the only severe case in which the pollantin gave such good results. In one case last summer the patient told me that pollantin relieved him very much. In the other cases the patients had to use it constantly every few hours, and the immunity did not last. I do not think Professor Dunbar claims it lasts more than from six to twelve hours. It must be used several times a day. Prausnitz, writing from the Hygienic Institute in Hamburg, makes the statement that immunity does not last in the majority of the cases longer than from six to twenty-four hours. I think the important thing would be to determine that the pollen-toxin really brings on attacks of hay fever in our own patients, and to find out to which variety of pollen-toxin they are susceptible. In some cases Prausnitz states that 1-4,500 mg. of the pollen-toxin was sufficient in midwinter to bring on a typical attack of hay fever, with reflex asthma, in control subjects.

Fritzsche Bros., in New York, have the pollantin now which is made from ragweed and goldenrod, and so this summer our results in the treatment of hay fever may be very much better than during the past spring and summer.

DR. JOHN N. MACKENZIE.—Shortly after the publication of his treatise on the subject, Professor Dunbar sent a quantity of his toxin and antitoxin to the Johns Hopkins Hospital, to Professor Welch, who turned the supply over to Dr. Campbell Howard and myself for experimentation. We selected subjects for experiment with especial reference to their intelligence and power to interpret aright any phenomena that might be produced. Our cases were taken mainly from medical students and physicians suffering from the disease, and we reported our results at the meeting of the Medical and Chirurgical Faculty of Maryland in 1904. They may be briefly stated without going into detail. Suffice it simply to say that they were practically absolutely negative. We did not rush into print for the reason that we did not think we had at that time experimented on a sufficient number of patients, and, besides, we had lost all interest in the matter from one reported failure to produce results. With regard to the observations of others, also, it seemed to us, speaking

in general terms, that they were far from satisfactory and not at all convincing.

A curious observation made by Dr. Dunbar is to the effect that he has been unable to isolate a toxin from the rose, and yet if there is any flower on earth that is supposed to produce the disease it is the queen of the flowery kingdom.

Even if the most sanguine expectations of Dunbar are realized, the results obtained throw light on only one phase of this many-sided subject. They also come into jarring collision with a host of well-known clinical facts and phenomena which are familiar to every student of this disorder. It is also a question whether the symptoms produced by the introduction of the toxin are the counterpart of the symptoms of hay fever, or whether they are not the result of an irritation which may be produced by other and indifferent forms of matter; by suggestion, as in my rose experiment; or by other causes which readily suggest themselves to the investigator of this disease.

In regard to treatment, the best that can be said for the Dunbar antitoxin is that it can only overcome the local irritation made by pollen or its equivalent, as represented by the pollen-toxin. It can have no effect on the local or systemic condition of the individual or upon the predisposition to the disease. Then again, the same, if not better and more enduring results, may be obtained by other and simpler means.

I wish to pay my respects to the painstaking and scientific researches of Dr. Dunbar, whose observations and opinions are entitled to the highest consideration; but at the same time I think that his conclusions should be accepted with caution; that he has given us a too inadequate and contracted view of the question, and that this spectacular resurrection of the pollen theory by no means represents the complete or final solution of the problem.

DR. E. FLETCHER INGALS.—I rose partly to ask whether the author enforced the various restrictions upon the patient's movements that are recommended in the circular that accompanied the remedies used in the Dunbar treatment? I did not know of these directions when I began to use the pollantin, and none of my patients followed them. My impression is that if patients would follow out these directions carefully the majority would get a good deal of relief without the use of anything else. So far as the pollantin itself is concerned, I have only had the specimens sent out in 1903. I tried them in a number of cases with good results in one, but in no others, so far as I can remember. In this one case I gave the patient the pollantin without any restriction as to his mode of life, and he came back in about a week and told me the effects were excellent. I saw him again after a few weeks, when he said, "It was no good at all." During 1904 I did not have any of the remedy in my office, but I prescribed it a few times without any satisfactory results. I have therefore

reached the conclusion that it is not much good, but I sincerely hope the author of this paper is not entirely in the wrong in his conclusions.

DR. EMIL MAYER.—There are a few things to consider in regard to pollantin, and the important thing is that we should reach every possible conclusion that we can with open minds. Dimbar is by no means a man whose work is to be slighted. He is attempting to bring his theories before the medical profession and has tried to select men who would try the agent seriously. I believe he was rather discontented because my report was not as enthusiastic as his own, but his visit to America has taught him that there is a vast difference between the hay fever in Germany and the hay fever in America. He has learned that, and by the results of his later experiments we will be able perhaps to treat the condition in our country more satisfactorily.

In regard to the statement by Dr. Mackenzie that the results were negative as far as the effects of the toxin were concerned, I may say, that was my own experience so far as our autumnal hay fever was concerned, but the contrary was the result in every single one of rose cold, June or spring hay fever that we have in this country. One of my patients, a lawyer, received the toxin in one eye and a drop of serum in the other eye, and in a few minutes I could determine every single symptom as Dimbar has explained. He was relieved of his annoyance by the use of the antitoxin. This man has not only the fall hay fever, but also the spring hay fever. I think as far as the question of the palliative effect of the remedy is concerned, and the question as to whether it meets but one phase of the matter, that these limitations doubtless exist. Nevertheless, there are thousands and thousands of people who are affected by the ragweed or the goldenrod, and if we can relieve, as I believe is done, 60 or 75 per cent. of the people, we are relieving a large majority.

I am in hopes that with the new pollantin now prepared to meet some of our American requirements we will be able to report very good results, and that we will study and keep on studying the question if the ultimate results have the good effect that we may hope to obtain.

DR. HENRY L. SWAIN.—It seems to me Professor Dimbar presented this matter before the profession in no uncertain way, in a very fine scientific spirit, and has certainly brought, in the strict sense of the word, an antitoxin to our notice. It seems impossible that we should cure all cases by any one remedy. An interesting case of a baker came to my notice, as reported by Dr. Stein. In this case the dust of flour in making bread produced all the ordinary hay fever symptoms. The patient was so much helped by the use of pollantin as to make it possible for her to go back to her employment as a baker. This shows there is a peculiar effect of the antitoxin on the mucous membrane which is

of distinct value and help to us in handling of cases not strictly hay fever. Some problems are, however, not yet explained. For instance, a person who never has hay fever suddenly becomes attacked and is subject from then on. What alteration took place in his tissues, which in one case made him perfectly immune and in the other so suddenly and terrifically subject to the condition? That phase of the question is by no means clear, and presents the thought to us whether we ought to slight it as we have been doing. In many of these cases great good has been done by the local treatment in the nose. Shall we not in these cases continue our intra-nasal treatment, and then, perhaps, if the pollantin is successful in ameliorating or relieving the case for a season or two, may we not ultimately hope to obtain immunity for these sufferers? It seems to me that we should test this matter thoroughly.

DR. ALEXANDER W. MACCOY.—What impresses me chiefly in the Dunbar theory is that it is essentially a straight scientific proposition. I am simply interested in this matter clinically and thought it well to report what results I had obtained. I am satisfied that the *grass* serum is not sufficient for this country. The serum that I used most effectually was that distributed in 1903, made from ragweed and goldenrod.

I am perfectly open-minded; I am only hoping to find something which will help me out better than anything we have had as yet. Dr. Mackenzie was kind enough to state he had something better and more accurate. I have, I think, never seen anything which in its results compares with this agent. My patients are placed under no restrictions whatever. I want to determine whether or not they can carry out their ordinary mode of life.

I believe that the reason why some people cannot ride behind horses, even in the winter season, is because some of this toxin is in the horse's hide, and no matter how well the horse is groomed it is impossible to free it from the toxin.

(Candidate's Thesis.)

THE LYMPHATIC DRAINAGE OF THE FAUCIAL TONSILS.

BY GEORGE BACON WOOD, M.D.

(From the Wistar Institute of Anatomy of the University of Pennsylvania.)

THAT various micro-organisms may gain access to the general system through the tonsillar tissues of the throat has been so firmly established that it is not necessary again to demonstrate that the tonsils have absorbing properties and that various infections may enter through this portal. The fate of the micro-organisms which have entered the parenchyma of the tonsil is dependent upon two factors; first, the pathogenic potency of the germ itself, and second, the vital resistance offered by the tissues to its invasion. If a non-pathogenic germ enters a crypt it is destroyed probably by the phagocytosis of outwandering polymorphonuclear leucocytes. On the other hand if the vitality of the germ is sufficiently great it lives and may penetrate through the epithelium into the interfollicular tissue.

It has been proven by several very thorough and capable investigators that foreign bodies in the crypts can pass through the epithelium into the interfollicular tissue. This absorption is probably dependent upon two factors; first, the action of the muscles of the throat during their various physiologic movements, and second, the presence of a lymph current in the tonsil. The palato-glossal muscle and the palato-pharyngeal muscle during deglutition compress the faucial tonsil and force the centrally lying, movable bodies toward the periphery. If the foreign body is at the bottom of the crypt it is pushed in an outward direction, and finding no appreciable barrier in the differentiated epithelium passes into the tonsil parenchyma. The second factor in the absorption of foreign bodies from the crypts is the constant production of lymphoid cells in the follicles. The interfollicular tissues of the tonsils consist of a fine connective tissue reticulum interspersed

with numerous lymphoid cells. These lymphoid cells may be looked upon as being in constant motion, passing from the follicles in the direction of least resistance. If the cellular metamorphosis of the epithelium has weakened this barrier so that the crypt is in the direction of least resistance, the lymphoid cells break through and pass into the crypt, but more commonly the lymphoid cells pass into the lymph spaces which terminate in the trabeculae of the tonsil, and which in their turn empty into the efferent lymphatics of the tonsil. Therefore, the production of lymphoid cells in the follicles causes what we might term a lymphoid current, and this lymphoid current, except when there is an accidental rupture of the cryptal epithelium, is toward the connective tissue trabeculae of the tonsil, and thence through the lymph radicles to the periphery. A foreign body having gained access to the interfollicular tissue must be influenced by this current.

As regards the absorption of living virulent micro-organisms, it must be remembered that bacteria are not inert foreign bodies, but possess certain vital properties which influence their entrance into living tissue. When uninfluenced by extraneous forces a micro-organism invades living tissue by two methods, first, if it belongs to the motile class the individual bacterium by its own locomotion may carry itself to some more or less distant spot, and second, micro-organisms may invade tissue by the very act of their growth. This last is the most important method by which the pathogenic germs gain entrance into their host.

It is practically impossible to establish with absolute certainty the relative importance of the different lymphatic masses in the throat as gates of infection. Circumstantial evidence, however, both clinical and experimental, tends to show that the larger the lymphatic mass and the deeper its crypts, the more readily do pathogenic germs pass through the tonsillar tissues to the tonsillar efferents.

The research outlined in this paper is a preliminary report of a series of investigations concerning the lymphatic anatomy and drainage of the tonsils and surrounding portions of the throat. My first investigations concern the faucial tonsil because in the etiology of infections it is the most important tonsillar structure, and I have not been able to find any reliable published data concerning the glands that receive its efferent lymphatics.

The lymphatic glands of the neck constitute one of the most important chains of glands in the whole body, and is probably the chain which is most frequently diseased. The infection which inoculates a lymph gland may possibly come through its efferent lymphatics by a retrograde thrombosis, but much more frequently it follows the current of the lymph stream and enters through the afferent vessels. In the large majority of cases the infection of the cervical lymphatics comes from the nose, mouth or throat. As a general rule the efferent lymphatic vessels from a given structure drain into that lymphatic gland which is nearest it, and therefore to understand the importance of the different structures of the nose, throat and mouth as portals of infection it is essential to have clear in our minds the topographical relations of the deep and superficial lymph glands.

The cervical glands of the neck are divided into two main groups, the superficial or collecting glands and the deep or terminal glands. The *superficial* are arranged as a sort of collar around the upper part of the neck with a few irregular extensions. This pericervical glandular circle is composed of the following subgroups:

1. Suboccipital group and aberrant glands of the nape of the neck.
2. The mastoid group.
3. The parotid and subparotid groups.
4. The submaxillary group with the facial glands as an offshoot.
5. The submental glands.
6. The retropharyngeal glands.

The *terminal or deep glands* of the neck form a perpendicular chain beneath the sterno-cleido-mastoid muscle. This main set of glands is flanked by several secondary chains of less importance. The superficial glands constituting the pericervical collar receive their afferents from those portions of the external and internal head, which are in more or less close relation with the individual group. The efferents of all these collecting glands empty into the deep chain. The deep cervical lymphatics or the substerno-cleido-mastoid glands constitute in appearance a continuous chain, but for convenience sake they may be divided into an external and internal group. The external glands are placed posteriorly and rest indiscriminately on the insertions of the splenius, levator an-

guli scapulæ and scalene muscles, and they are usually continuous with the glands occupying the supraclavicular triangle. The internal glands of the substerno-cleido-mastoid group may be termed the internal jugular chain because they rest either directly on the internal jugular vein or are immediately adjacent to its external border. The glands of this subgroup are larger than the glands of the external, and some of them are fairly constant in their position. One or two large glands are constantly found beneath the posterior belly of the digastric just above the spot where the thyro-lingual-facial vein opens into the internal jugular. A few glands are sometimes found between the internal jugular and the prevertebral muscles. These two main groups of deep glands, the external and internal chains, are united by a great many anastomoses. The external glands receive their afferents from the posterior part of the head and neck, while those of the internal group receive their afferents from the anterior portion of the neck and head, from the mouth, nose, pharynx, larynx and thyroid body. While the majority of the afferents of the deep glands of the neck are the efferents from the superficial glands, quite a number of lymph vessels pass directly from the lymph-radicles of the throat and nose to the deeper chain of glands. For instance, the majority of the lymph vessels from the vault of the pharynx drain into the retro-pharyngeal glands, but some of them pass directly to the upper glands of the deep cervical chain without any interruption.

The method of injection employed in the present research was essentially that devised by Gerota. It consisted in rubbing up Berlin blue with pure spirits of turpentine until it assumed the consistency of a rather thin syrupy liquid. A small quantity of ether is added and the mixture filtered through chamois skin. The coarser granules of the Berlin blue are held back in the filter, while a clear, thin blue liquid passes through as the filtrate. Gentle agitation of the fluid while it is filtering insures a better mixing of the turpentine, ether and Berlin blue, consequently a deeper color to the filtrate. The injecting apparatus consisted of a fine glass needle drawn out of a glass tube and attached by a piece of rubber tubing to the nozzle of an easy working syringe holding about 10 c.c.

The glass needle was inserted beneath the mucous membrane covering the tonsil, and held very carefully in its place, while an

assistant made gentle but gradually increasing pressure, according to the ease with which the fluid entered the tonsil. The amount injected was regulated somewhat by the amount of resistance felt in the syringe and also by the distension of the tonsillar tissues. If the injection was properly made the tonsil gradually swelled out, becoming two or three times its normal size and of a deep blue color. The fluid in these injections was not forced in too hurriedly, as a certain amount of time was necessary for it to find its way into the lymph spaces and thence through the lymph radicles to the lymph vessels. In injecting the tonsil it frequently happened that the fluid returned through the crypts. When this regurgitation was so free that internal pressure could not be exerted, the point of the needle was changed until a position was found from which the injected material did not so readily gain access to the crypts. After the injection had been made the excess of material was washed from the surface by a stream of cold water. Gentle massage of the tonsil with the finger helped to force the injected fluid further into the tissue. The fresh material was left in plain water for several hours before fixing it in 10 per cent. formalin. After fixing the specimen the dissections were made and the injected glands sought for, especial care being exercised to avoid wounding any of the injected lymph vessels.

Eight injections were made, some of them resulting in failure, but the majority showing distinctly that the tonsillar lymph follows a fairly constant route. The direction of this drainage, as established by these injections, is as follows:

The lymph vessels pass from the external portion of the tonsil through the peritonsillar connective tissue, the pharyngeal aponeurosis and the superior constrictor of the pharynx, and as one or two or more fine small vessels run obliquely in a downward, posterior and outward course, passing below the facial artery. Bending more posteriorly the lymph vessels next run between the internal jugular vein and the stylo-hyoid muscle, reaching finally an enlarged lymph gland placed just beneath the anterior border of the sterno-cleido mastoid muscle, where it is crossed by the posterior belly of the digastric muscle. The efferent vessels from this gland are generally two or three in number and pass into the neighboring glands of the internal jugular group. Further anastomoses which connect the lower glands of the internal jugular group with those receiving the tonsillar drainage form a complete

lymph channel through which the tonsillar lymph finally empties into the jugular lymph trunk.

In none of the preparations did the injected fluid enter into superficial glands except in one case where there was a small aberrant gland lying on the facial artery near its origin. This gland seemed to be simply an interrupting nodule in the course of the tonsillar efferents. The statement in some text-books on

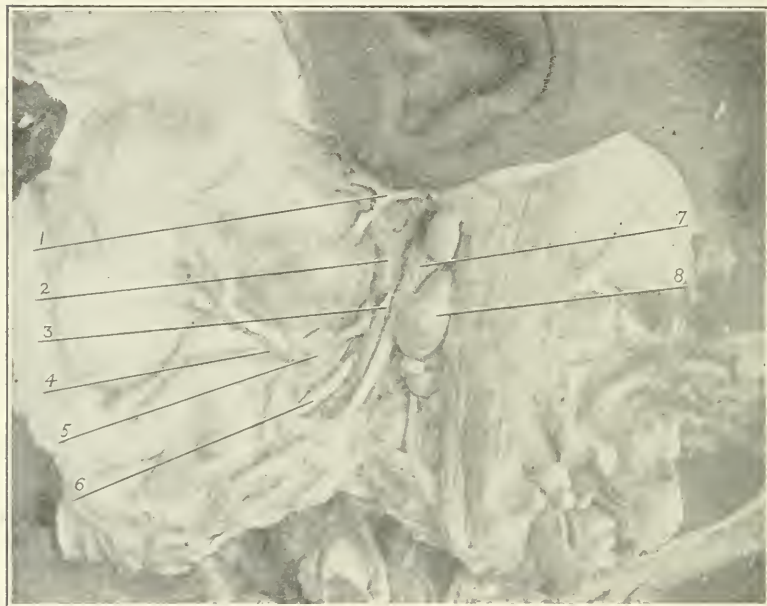


Fig. 1. Dissection of the neck of a child, showing an enlarged tonsillar lymph gland and its relation to the digastric and stylohyoid muscles: 1, facial nerve; 2, external carotid artery; 3, stylohyoid muscle; 4, facial artery; 5, submaxillary lymph gland; 6, hypoglossal nerve; 7, posterior belly of the digastric muscle; 8, tonsillar lymph gland.

anatomy that the tonsil drains into the posterior gland of the submaxillary group would seem to be absolutely erroneous and very misleading.

Clinically, the gland which becomes enlarged during tonsillar infection appears to be superficial, and possibly it is this appearance that has led to the belief that the posterior gland of the submaxillary group is infected through the tonsils. The tonsillar

gland, if I may be pardoned for using the term, is placed external and slightly anterior to the internal jugular vein and is imbedded in loose areolar tissue containing more or less fat. Consequently enlargement of this gland means its dislocation outwards and forwards, and especially so if the other glands of the internal jugular group become consequently enlarged; also the action of the sub-

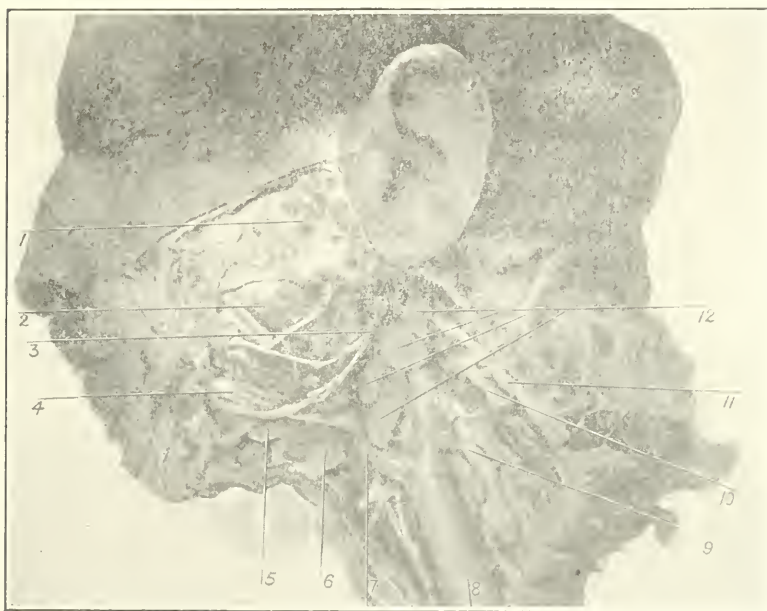


Fig. 2. Dissection of the neck of an adult, showing enlarged internal jugular lymph glands: 1, parotid gland; 2, masseter muscle; 3, facial nerve; 4, facial artery; 5, submaxillary lymph gland; 6, submaxillary salivary gland; 7, thyrofacial lingual vein; 8, internal jugular vein; 9, brachial plexus of nerves; 10, superficial cervical plexus; 11, spinal accessory nerve; 12, internal jugular lymph glands.

sternocleidomastoid muscle would tend to force it anteriorly. If an enlarged gland found at the angle of the jaw belongs to the deep substernocleidomastoid group it may be pushed back under the muscle of the same name. In cases of enlargement of the submaxillary glands, such as result from infection from carious teeth, the glands are found along the edge of the jaw and cannot be displaced backward and only slightly downward. In the description

of the anatomy of the cervical lymphatics previously given it was stated that where the posterior belly of the digastric muscle crossed the sternocleidomastoid, there were constantly found one or two large glands. In a child one week old in which I was able to trace the course of the tonsillar efferent vessels, this gland was very little larger than many more of the external jugular

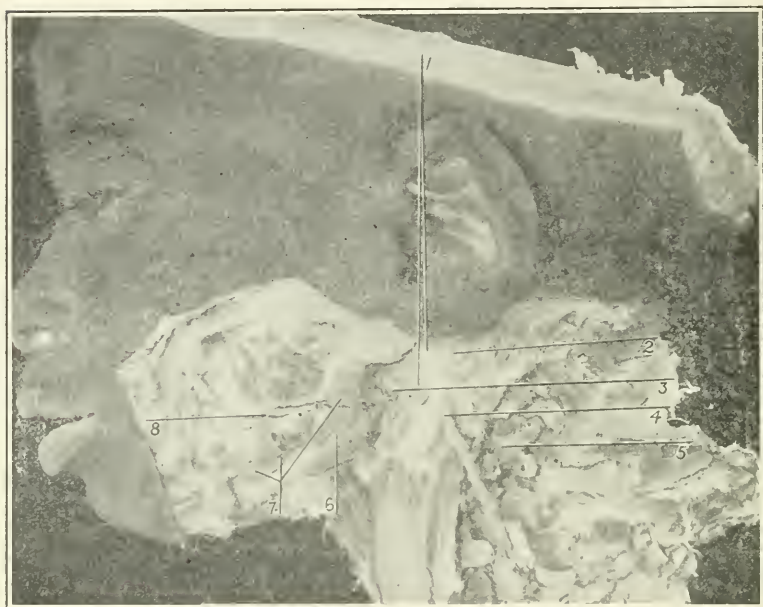


Fig. 3. Superficial dissection of Specimen No. VI., showing enlarged tonsillar lymph gland projecting just beyond the edge of the sternocleidomastoid muscle: 1. external jugular lymph glands; 2. great auricular nerve; 3. tonsillar lymph gland; 4. external jugular vein; 5. external glands of the substernomastoid group; 6. submaxillary salivary gland; 7. submaxillary lymph glands; 8. facial artery.

group. In children who have reached six or more months of age this gland was generally twice or three or four times larger than any other, and in every injection of the tonsil it was this enlarged gland that primarily received the blue injecting fluid. Does it not seem possible that this enlargement consequent to birth may be due to the absorption of toxins through the faucial tonsils?

I have chosen to call the lymphatic gland which receives the

efferents of the tonsil the *tonsillar lymph gland*. This term is not sufficiently comprehensive because other lymph vessels from the throat besides those from the tonsil drain into this gland, but the most important infections of the cervical lymphatics originate through the tonsil, and because of the importance of the tonsil in the origin of infections I feel that the term tonsillar is a most




Fig. 4. Deep dissection of Specimen No. VI., showing the tonsillar lymph gland and its relation to the substernomastoid group: 1. reflected sternocleidomastoid muscle; 2. tonsillar lymph gland; 3. spinal accessory nerve; 4. branch of cervical plexus; 5. internal jugular vein; 6. omohyoid muscle.

appropriate one. Certainly it is convenient to be able to easily designate so important and constant a lymphatic gland.

Following are the descriptions of the individual injections of the tonsils. The technique was practically the same in all of them.

SPECIMEN I.—Child about six months old. The injection in this case failed probably because there was some obstruction in the injecting needle. Dissection of the neck showed hypertrophy of the tonsillar lymph glands.

SPECIMEN II.—Child about six months old. The injection in this case was very successful. The tonsil itself became enlarged and there was a slight overflow of the fluid toward the faucial pillars, the blue color, however, was limited to the fauces. A few

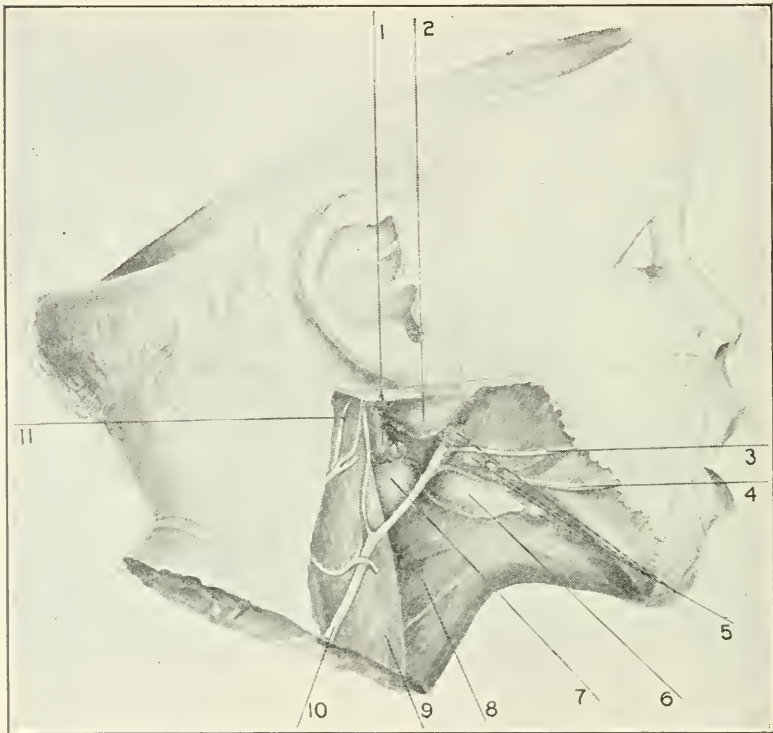


Fig. 5. Superficial dissection of Specimen No. II., showing portion of tonsillar lymph gland and its relation to the sternocleidomastoid muscle and the external jugular vein; 1. lymph glands of the internal jugular group; 2. parotid gland; 3. facial vein; 4. facial artery; 5. submaxillary lymph glands; 6. submaxillary salivary gland; 7. tonsillar lymph gland; 8. omohyoid muscle; 9. sternocleidomastoid muscle; 10. external jugular vein; 11. great auricular nerve.

injected lymph vessels were seen running posteriorly into the sinus pyramidalis and anteriorly toward the base of the tongue. The dissection of the neck showed that the blue fluid had entered a slightly enlarged lymph gland situated just below the point where the anterior border of the sternocleidomastoid muscle is

crossed by the posterior belly of the digastric. The gland was superficial to the digastric muscle just above the facial vein where it joins the external jugular. A deeper dissection demonstrated

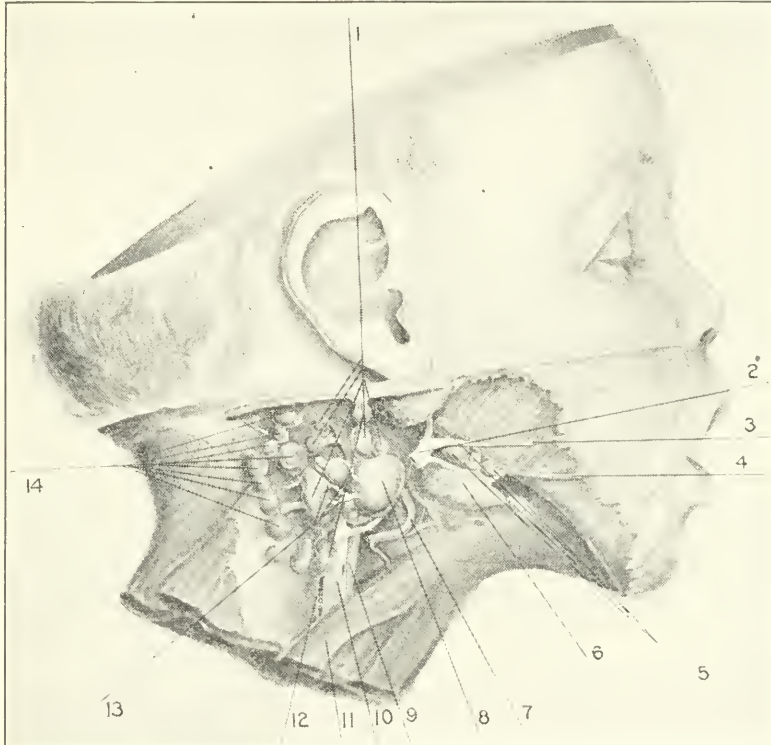


Fig. 6. Deep dissection of Specimen No. II., showing position of tonsillar lymph gland and its connection with other glands of the substernomastoid group: 1, internal substernomastoid lymph glands; 2, external jugular vein; 3, facial vein; 4, facial artery; 5, submaxillary lymph glands; 6, submaxillary salivary gland; 7, superior thyroid artery; 8, tonsillar lymph gland; 9, common carotid artery; 10, internal jugular vein; 11, omohyoid muscle; 12, jugular lymph trunk; 13, efferent vessels of tonsillar lymph gland; 14, external substernomastoid lymph glands.

that the injected gland belonged to the anterior group of the upper deep cervical lymph glands and had three efferent vessels which also contained the blue injecting fluid. The connecting lymph vessels between this gland and the jugular trunk were dissected

out. The most direct route showed that the lymph current from the tonsil in order to enter the jugular trunk had to pass through two more glands after leaving the tonsillar lymph gland. In this

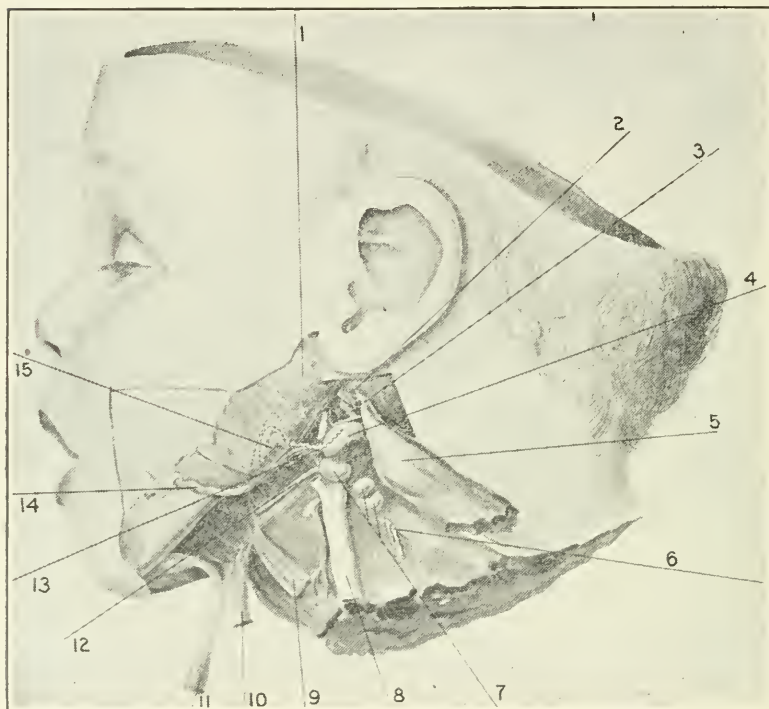


Fig. 7. Deep dissection of Specimen No. IV., showing the efferent lymph vessels of the faucial tonsil entering the tonsillar lymph gland. The posterior belly of the digastric muscle and the whole of the stylohyoid muscle have been reflected downward: 1, parotid gland; 2, stump of the stylohyoid muscle; 3, stump of the posterior belly of the digastric muscle; 4, tonsillar lymph gland; 5, reflected sternocleidomastoid muscle; 6, brachial plexus of nerves; 7, substernomastoid lymph glands; 8, internal jugular vein; 9, omohyoid muscle; 10, stylohyoid muscle; 11, posterior belly of the digastric muscle; 12, hypoglossal nerve; 13, efferent lymph vessel of the faucial muscle; 14, facial artery; 15, position of faucial tonsil.

specimen, however, I was unable to find the lymphatics running from the tonsil to the tonsillar lymph gland. Plates I. and II. were made from this specimen.

SPECIMEN III.—Child one week old. Only a small quantity of

fluid was injected into the tonsil. The dissection showed a slight injection of the glands situated just below the posterior belly of the digastric.

SPECIMEN IV.—Child one week old. A rather full injection of the tonsils was made, and there was some infiltration of the surrounding mucosa. This injection was very instructive, as by careful dissection lymphatic vessels could be traced running from the infiltrated tonsil directly to the gland situated just below the posterior belly of the digastric beneath the anterior border of the sternocleidomastoid muscle. This lymph gland was considerably injected, but the importance of the specimen was in the demonstration of the efferent lymphatics of the tonsil. The course which the lymphatic vessels took was as follows: Leaving the tonsillar mass and running posteriorly and inferiorly they pass slightly outwards beneath the facial artery running along the upper border of the lingual vein, then turning directly posterior they pass between the stylo-hyoid muscle and the internal jugular vein, reaching the upper surface of the tonsillar lymph gland. Plate III. was made from this specimen.

SPECIMEN V.—Child about three months old. Too much fluid was injected in this specimen, and although the tonsillar lymphatic gland and its efferents contained the blue solution, the extravasation through the connective tissue of the neck was so great as to make it impossible to recognize the topography.

SPECIMEN VI.—Child about three months old. This injection was a most successful one. Quite a large amount of fluid was injected in this case without any extravasation. In the throat the fluid was limited to the confines of the tonsil, and in the dissection followed the lymph vessels through six or more of the upper deep cervical glands. The efferents from the tonsil could be traced passing in a direction very similar to that described under Specimen IV. There were two or three lymph vessels which ran closely together in a more or less parallel course. At first they passed obliquely downward, posteriorly and outward until they reached the facial artery. Running beneath this and internal to the stylo-hyoid muscle and the posterior belly of the digastric muscle, they entered the internal side of the tonsillar lymph gland.

In closing I desire to express my thanks to Dr. James M. Stotenburg, and especially to Dr. Harold D. Senior, for their skillful aid in making the injections.

PARTIAL TURBINECTOMY FOLLOWED BY ACUTE
OTITIS, MASTOIDITIS, SEPSIS; PARACENTESIS,
MASTOIDECTOMY, LIGATION AND EX-
CISION OF INTERNAL JUGULAR
VEIN; RECOVERY.

BY CHARLES H. KNIGHT, M.D., AND JAMES F. M'KERNON, M.D.

IN our routine work we are apt to lose sight of the risks attending what we call minor operations, until brought to realize them by a rude shock like that experienced in the following case. It is quite possible that similar cases, more or less serious, are not infrequent, since we seldom care to exploit our misadventures, and only our more brilliant achievements meet the public eye. In this connection may be recalled an interesting paper presented to this Association in 1904, by F. R. Packard, entitled "A Study of the Fatal Results of Operations Upon the Nose and Throat." We may be surprised at the small number of fatal accidents this author has collected, yet we are quite ready to accept one of his conclusions to the effect that "meningitis as a complication of intranasal operations should not be lightly regarded."

The narration of this history may be of advantage if it enforces a lesson of caution and conservatism, although we are not prepared to admit the absence of these qualities in this particular instance. The details of the ear complication are given by Dr. McKernon, who ultimately took charge, and brought the case to a successful termination.

It is difficult to trace the precise source of infection. The usual precautions as regards cleanliness and asepsis were observed. In scope and duration the operation of turbinectomy is not to be compared with others of almost daily experience. It did not seem that the patient suffered an excessive degree of surgical shock, and so far as can be discovered, she was not subjected to any special exposure. We leave the solution of the problem to others, merely suggesting the possibility that certain pathogenic bacteria of unusual virulence find their opportunity in an organism of low resisting power. Under ordinary circumstances we successfully

combat their encroachments; in conditions of depressed vitality they gain ready access, and pursue their destructive invasion with fearful and oftentimes fatal consequences.

The patient was a married lady, about 25 years of age, of rather nervous temperament but in excellent health, and as afterward appeared in the third month of pregnancy. She had never had any marked ear disturbance, except occasional tinnitus and slight impairment of hearing. Considerable nasal stenosis, excessive post-nasal secretion, tendency to take cold, and above all, the existence of several cases of catarrhal deafness in her family, led her to seek treatment for her nasal condition. She was found to have a septal ridge opposite the inferior turbinate, running obliquely upwards and backwards and partially occluding the right inferior meatus. The middle meatus on the same side was blocked by a cystic expansion of the middle turbinate. Owing to the difficulty of engaging the saw in the septal over-growth, it was decided to first attack the turbinate. Accordingly the anterior end of the latter was removed with the cold wire snare and nasal cutting forceps. It was necessary to make liberal use of cocain (20 per cent.) and adrenalin chloride (1-1,000) in order to get satisfactory anesthesia, as the parts were very hyperesthetic and resistant. But little blood was lost, the patient was remarkably brave, and was able to go home in the course of an hour in fairly good condition. No intra-nasal plug was used; the nose was merely sprayed with mentholized albolene and a light pledget of sterilized cotton was placed in the anterior naris. The following day the systemic depression was extreme, and there was some febrile reaction on the second day. On the third day there was slight improvement in these particulars, but on the morning of the fourth day she was awakened by sharp pain in the right ear, which had troubled her somewhat the previous evening. In the meantime there had been more or less pain in the nostril but no bleeding, and there had been no nasal treatment except a few instillations of mentholized oil. In spite of the usual remedies the pain in the ear persisted, and a few hours later the drum ruptured.

Only a few drops of thin fluid escaped. Relief was partial and temporary. The same evening Dr. McKernon was called upon to do a paracentesis, as the discharge had ceased, the pain had returned, and there was some rise of temperature. The next day decided tenderness developed over the mastoid, which increased

so rapidly that further delay was deemed unsafe, and a very thorough mastoidectomy was done within forty-eight hours after the tympanum had been incised.

At the time of Dr. McKernon's first examination, the right auditory canal was found partially filled with blood-stained serous discharge. The drum membrane was bulging over the whole posterior quadrant, and looked red and angry. There was a small perforation in front of the umbo through which the discharge has passed. The mastoid process was tender upon pressure. Gas was administered, a free incision was made in the posterior quadrant, and a smear was taken, which, upon examination, showed that infection was due to the streptococcus. Dry heat in the form of a hot water bag was applied to the ear and mastoid, and warm bichloride irrigations (1-4,000) were used every two hours.

About forty-eight hours later the patient was found suffering acute pain in the ear. The bloody discharge was still present, and the temperature was 101° F. The systemic prostration was most profound, and the mastoid was exquisitely tender.

At this time the operation of opening the mastoid was proposed, and complete mastoidectomy was done. The cortex was very dark, and on exposing the mastoid cavity an extensive empyema was found. Every cell had been invaded, including those in the zygomatic roots, and the medullary spaces posterior to the sigmoid groove. There was no exposure of the dura, but the whole inner table was of much darker color than is usually found, and especially the bone covering the sigmoid groove was almost black.

The patient bore the operation well, and save for a rise of temperature eight hours afterward to 104° F., the eight days following were uneventful, the temperature never going higher than 101° F., and most of the time remaining below 100° F.

The flaps, however, did not heal kindly, and at the first dressing on the third day after operation the stitches were removed and the wound left open. It was dressed again the following day and the soft parts were found to be bathed in pus, but there was not a drop of secretion from the bone cavity. The sigmoid groove was very dark in color, and there was not a vestige of granulation tissue present. The tongue was dry and heavily coated, and the patient suffered from extreme depression.

On the tenth day following the mastoidectomy, there was a sud-

den rise of temperature to 103.8° F. She complained of headache, and referred most of her pain to the vertex. During the night the temperature dropped to 101.8° F., to rise on the following day to 105° F.

A diagnosis of involvement of the sinus was made, but owing to the extreme weakness of the patient, who had to be stimulated constantly, it was decided to wait for a time before operating. Clinical experience has taught us that those who are operated upon while the temperature is high, and the system markedly weakened, do badly, and a certain per cent. of them never rally from the shock of the operation, while those who undergo the operation when the system has been supported and the temperature is lower, bear the shock much better, since the vital forces more readily respond when not encumbered by additional handicaps of high temperature and pronounced weakness.

On the twelfth day following the operation, a consultation was held with an eminent general surgeon, who said he thought the case was one of general pyæmia, and that he did not believe any involvement of the sinus existed.

For the next five days all our efforts were directed toward keeping up the patient's strength. She was fed every two hours and given large quantities of water and stimulants. The temperature during this time ranged all the way from 104° F. to 97° F., as may be seen by the temperature chart, the characteristic curve of which is clearly indicative of pus.

On the sixth day following, making eighteen days from the time of the mastoid operation, the patient being stronger, and the temperature lower, 102° F., it was decided to operate.

Chloroform was administered, and the sinus exposed from just above the bulb, almost back to the torcular. The bone covering it was very dark, nearly black in color. From the knee of the sinus backward, the dura was lustreless, and over a greater portion of its area, white or yellowish. It was opened freely and a clot removed from the knee, which extended backward toward the torcular for about two inches. Free hemorrhage followed, which was easily controlled by packing gauze into the lumen of the vessel. In the lower part of the vein was a disintegrated clot with pus. Owing to the presence of the latter condition, it was decided to expose, ligate and resect the internal jugular vein.

This was done, the lower point of ligation being below the clav-

icle, the upper point at the exit of the vein from the skull. The facial vein was also thrombosed for about an inch where it empties into the internal jugular, as were also both of the thyroid veins, which were ligated well beyond the thrombotic points and resected.

There were a number of large glands along the course of the vein which were removed. After resection of the vein the lower end of the sinus was freed from a quantity of broken-down material.

The wound in the neck was closed by a continuous suture, a drain being inserted at the lower angle. The patient bore the operation very well, the only stimulation being a hot saline enema during the latter part of the operation, and this was repeated half an hour after she was placed in bed.

The subsequent history was uneventful, there being only one rise of temperature on the second day, which was caused by a focus of pus in the neck, on account of which two of the stitches were removed.

Healing was rapid, and the resultant scar smaller than might have been expected from the suppuration that at one time threatened the soft tissues in this region.

The findings of the pathologist in the specimens removed were that the clot in the vein, the walls of the vein, and the glands, all contained large numbers of streptococci.

The fact that the walls of the vein are so impregnated in these cases teaches us how important it is that the vein should be removed in its entirety, from its exit at the skull to the clavicle, or even lower, if necessary. For even though the vein be opened, and the clot removed, the wall of the vein, and the sheath, containing as they do, the micro-organisms of infection, if left intact, only seem to disseminate the poison still further through the system.

It is interesting to note that in this case there were no chills, nausea or vomiting throughout the entire course of the disease. Only twice did the patient complain of slight chilly sensations, but these sensations when present in a case like this, are valuable diagnostic signs.

We were particularly fortunate in that the patient improved in strength during the few days prior to the second operation, as it gave us, so to speak, an elective time for doing the final operation.

If, however, such improvement had been absent, and the patient had not shown daily gain in strength, the operation would have been done early, as it is much wiser to operate upon these cases as soon as the diagnosis is made, provided the general condition permits.

Discussion.

DR. JOSEPH H. BRYAN.—I should like to ask Dr. Knight if the operation was done during the presence of an epidemic of influenza? (Dr. KNIGHT: "I cannot say positively; we have had some of this disease in New York all winter.") I had a case recently in which I attempted to break up a very simple synechia, and the patient apparently was in excellent condition at the time. In forty-eight hours, however, she came down with severe abscess of the middle ear and had a general influenzal attack, and I think that she was in this condition at the time this operation was done. It shows that we should be most cautious in operating during these prevailing epidemics.

DR. WILLIAM K. SIMPSON.—The question of the manner of infection of these cases is very important. There is one point which has afforded me, I think, some benefit, and that is douching the nose out in cases of intra-nasal operations through the non-operated side, so that the current runs down and through the operated side, thus preventing the inflammatory products from lodging in the posterior nares.

DR. ROBERT C. MYLES.—In this case I believe it was a mere matter of coincidence that the streptococcus happened to infect the ear. It would seem that the patient had a weak ear caused by abnormal conditions in the nose, and that this only rendered it more liable to surface infection.

DR. CORNELIUS G. COAKLEY.—I saw a case this winter which happened to be one of Dr. McKernon's patients. The child was wearing glasses, and on account of headache, associated with frontal sinus suppuration, was referred to his oculist to see how much likelihood there was that the headache was due to any abnormal condition in the eyes. In January, in coming to my office from the oculist's (I had not seen the child for two weeks), he said, "I have a pain in my ear." I was about to douche the nose and make an examination when I looked at the right drum membrane and found it red, not bulging, however. I referred the child at once to Dr. McKernon, who did a paracentesis, and later another. The child had a great deal of mastoid pain and discharge, but fortunately the otitis media cleared up. Undoubtedly, had I not looked at the child's ear and had I douched the nose I should have been considered partly to blame for having induced an otitis media. I think we have all seen otitis media quite frequently result from the improper use of nasal douches, by which some ma-

terial has been carried back into the nasal pharynx and infected the ear. I had such a case five or six years ago. After operation the patient remained in the hospital a week and then went home. She lived some distance away, so that it was not possible for me to see her frequently. Another physician therefore took charge of the case. One afternoon the antrum was irrigated. About six o'clock the next morning came she to my office with a very severe otitis media. I did a paracentesis, but a few days later had to operate on the mastoid. Pus from the ear and nostril contained streptococci. The patient developed an erysipelas, but finally recovered. In this case I think there was a direct infection of the middle ear and mastoid through the Eustachian tube as a result of irrigating the antrum.

DR. WILLIAM E. CASSELBERRY.—I find myself not quite in sympathy with the previous speakers with reference to the coincidence theory. In my experience infection of the middle ear has followed nasal operations not with great frequency, but yet too often to have it a mere coincidence, and I think it is one of the hazards to be anticipated and provided against as far as possible. I have seen otitis media follow cauterization of the turbinals, I have seen it follow light packing of the nasal channel for hemorrhage after operations and for spontaneous hemorrhages, I have seen it follow the removal of polypi and adenoids, and in all with a frequency which has convinced me that it is not merely coincidental. Otitis media is a recognized hazard of any sort of nasal operation. Two points follow. The first is to prevent otitis media. How can we provide against it in our nasal operations? The second is to what extent are we justified in performing operations in spite of this well known hazard? I do not think that we have ever come to any definite conclusion as to the amount of sterilizing efforts that should be made in the nose preliminary to operations, and to the kind of dressings that should be applied after a nasal operation with a view to preventing sepsis, either by the air or through parts of the wound. It has been my own habit not to try to make the nostril absolutely sterile. Spraying the nostril which is to be operated upon with an alkaline and slightly antiseptic solution I think better than the use of stronger irritating solutions, but in this respect there are differences of opinion. It has been my habit, after nasal operations, especially nasal turbinectomy, to apply a light tampon of antiseptic gauze; there are also differences of opinion in this. I think we want to study, as far as possible, the methods of preventing otitis media and to come to a conclusion as to the extent of antiseptics desirable both before and after the operation in the nose, with a view to preventing otitis media and other complications. The second point concerns the degree of hazard and the question of justification of turbinectomy and other nasal operations notwithstanding complications in the form of otitis, hemorrhage, sepsis, etc., which

may possibly occur. There is risk pertaining to all operations, minor and major. There is risk pertaining to every procedure in life, and I am apt to bring this slight operating risk, as well as the risk of anesthesia in connection with throat and nasal operations, home to my patients by comparing it to the familiar risk of railroad travel in which occasionally an accident happens. The benefits to be derived from judicious nasal operating on the whole certainly justify the surgeon and patient in assuming some risk.

DR. HENRY L. SWAIN.—We all have had experience along this line, and a case that I have recently seen is perhaps not without interest, where the operation might have been blamed as causing the otitis media, whereas it was the patient's method of cleansing his nose that produced the result. He had been in the habit of using one of these douches, the Birmingham nasal douche, that sends the fluid through one side and out the other. I presume there had been some little infection of the nasal mucus following the operation. On the fourth or fifth day, in cleansing his nose with the douche he felt that the fluid went up to his ear and he got his otitis media as a result. I think there is a lesson in this which should be noted. The fact, first, that this little douche can produce otitis media, and, secondly, that it was the patient's way of following directions which produced the result. He had been directed to spray his nose with a simple atomizer, as in this way nothing could possibly be harmed. He happened to have a Birmingham douche, not an atomizer, and made the mistake of using it. He had an active otitis media, but fortunately it did not traverse the severe course of Dr. Knight's case. I think this last shows up in no uncertain light the dangers that the otitis media may itself produce and the wonderful resources of our present day surgery in taking care of such a serious and well-nigh fatal case.

DR. WILLIAM K. SIMPSON.—I would like to ask Dr. Knight if he does not think the dangers of subsequent infection, like involvement of the middle ear, follow the operations on the turbinal bone more frequently than operations on the septum, and if the avenue of infection is necessarily through the Eustachian tube?

DR. T. PASSMORE BERENS.—It seems to me we can look on this case, as Dr. Myles has suggested, as a matter of coincidence.

DR. ROBERT C. MYLES.—My point was that I was discussing this particular case and not general infection from the nose.

DR. CLARENCE C. RICE.—It is my firm belief that wounds produced by operation in the nasal passages are much more safely and surely protected from subsequent infection by the use of powders than by any form of irrigation, no matter what amount of discretion is used. All forms of washing the nose after nasal operations increase the tendency to infection.

DR. CHARLES H. KNIGHT.—My experience with sepsis of nasal origin, happily very limited, would indicate that the turbinates,

especially the middle, more frequently than the septum are sources of infection. I recall a case in which the ear involvement was so immediate that it is difficult to conceive that infection could have traveled along the Eustachian tube. Is it not more reasonable to suppose that the reduced resisting power attending operative shock persuaded to activity certain pathogenic bacteria already present in the middle ear? I do not believe that absolute asepsis of the nasal chambers is possible, but yet I would by no means discourage antiseptic precautions.

“THE TREATMENT OF ACUTE INFLAMMATION OF THE NASAL ACCESSORY SINUSES.”

BY THOMAS HUBBARD, M.D.

“No doubt many of the cases of acute purulent catarrh of the accessory sinuses undergo spontaneous cure and it is often difficult to decide what the unfavorable conditions are which determine chronicity” (Grünwaldt).

This quotation from the writings of a master in the special surgical art fairly expresses the current opinion of the day on the question of the spontaneous cure of acute suppurative catarrh of the sinuses. But it is the opinion of the surgeon, and exhibits a lack of confidence in natural healing power, which is, it seems, scarcely warranted. In its tone of doubt there is a suggestion of ultimate surgical procedure in acute purulent conditions in general.

In our special literature there is a rather meagre allowance of space devoted to the treatment of the acute stage of infectious inflammation of the sinuses, the surgical chapters having overlapped and crowded out the rather uninteresting details of special therapeutics.

There is no sharp dividing line between acute catarrhal and acute purulent inflammations of mucous-lined cavities, virulency of type of infection and systemic resistance, rather than specific character of the infecting agent, being the determining factors, especially where chronic catarrhal lesions exist. A badly treated acute catarrh in an individual weak in resistance may become a chronic purulent condition, and a virulent attack of purulent

sinusitis may terminate in a catarrhal flux as the end process. An abundant purulent or muco-purulent discharge is a general indication of sinus infection, exceptions being in such diseases as diphtheria of the nares, in gonorrhoea and also in erysipelas. In the first mentioned a superficial coagulation necrosis of a limited area may be the source of pus, and in the latter the condition is rather a cellulitis, and may be circumscribed. There are other infections causing suppuration without involvement of the sinuses, but as a rule pus means sinus inflammation.

Acute purulent inflammation of one or more sinuses may occur without apparent general involvement of the nares, and this is suggestive of the pre-existence of chronic or latent empyema without usual symptoms, or, as in the case of the maxillary antrum, direct infection of dental origin, but these may be regarded as belonging to the chronic class.

The sinuses are often involved in pneumonia, typhoid fever, and especially in the exanthemata, but they rarely demand special treatment during the acute stage as the true condition is masked and other indications are so much more urgent.

A certain type of sinusitis, which is rather a vaso-motor neurosis than an inflammation, may present many of the symptoms which characterize acute infections, such as tension pains and neuralgia, and the special indications for the therapeutic measures must be considered in this paper, although it is not an infectious sinusitis.

Concerning the nature of the infection causing sinusitis I will only say that I have nothing original to add to the extensively published laboratory reports and the question has no particular bearing on treatment, but the factors which are contributory to causing purulency and empyema should be mentioned and remedial treatment outlined. I am strongly of the opinion that what we term virulency of infection is often determined by the systemic condition at the time of infection. For example, we have ample proof that an injudicious exposure during the period of incubation of an exanthema may be followed by a malignant type of the disease. Resistance is dissipated and the disease runs riot in an unconventional manner. The same is true in any acute infection of the upper respiratory tract. Any degree of auto-intoxication of gastro-intestinal origin, so-called lithaemia or gout, and especially in organic diseases of the eliminative organs, the health restoring processes are already over-taxed and ordinary

infection causes extensive purulency through lowered resistance due to co-incident toxæmia.

The ordinary regimen of acute disorders in general, implying rest, restricted diet, and eliminatives, will generally correct gastro-intestinal toxæmia and bring curative forces up to normal, but in all severe acute infections showing tendency to chronicity, organic diseases should be naturally suspected. For instance, I have several times made the primary diagnosis of acute and chronic Bright's disease and diabetes in patients having acute sinusitis, as the result of routine examination of the urine. Appropriate systemic is of more importance than local treatment in such cases. Acute sinusitis, and likewise acute otitis media, may be one of the first manifestations of acute rheumatic fever. Certain skin diseases such as ordinary erythema, urticaria and eczema occasionally are manifested on mucous membranes. These and kindred conditions, detected only by a habit of careful systemic examinations, are factors in prognosis and treatment and should not be overlooked in our zeal in the special art. Syphilis of the nasal tissues may be manifested in a manner to lead one to treat it as an acute sinusitis, but usually other symptoms will suggest the true nature of disorder.

Anatomical peculiarities, with especial reference to sinus drainage, should be mentioned, as the indications for operative interference even during acute attacks may be imperative. Obstructing polypi and oedematous pendulous turbinates may be the causes of local acute sinusitis and may be removed.

The symptoms of acute sinusitis are tension pains and neuralgia of various branches of the fifth, periosteal tenderness over the frontal and maxillary sinuses, when they are involved, and general or localized headaches, frontal, temporal or occipital.

The secretion is first sero-mucous, then muco-purulent, or pus. In acute infections we may have a general hyperaemia of all sinuses, even though there be actual invasion of only one. This is a physiological conservative process of flushing sinuses with sero-mucus to prevent infection. Micro-organisms cannot invade a mucous membrane after the flow is established from its substance. This gives the primary indication for treatment. A sero-mucous flow is the first step in resolution as well as the natural method of guarding against infection.

This physiologic process is decidedly overdone in the neuro-

pathic condition, of which vaso-motor rhinitis is the type, and the tension pains caused thereby simulate actual sinusitis. Treatment of this vaso-motor neurosis of the nares and accessory sinuses has special indications. Vaso-motor tonics such as strychnin, opiates and atropin, with local applications of cocaine in normal saline detergent solutions, and adrenalin, are useful. Tension pains may be relieved by camphorated inunctions and dry heat. The purpose of medication is to gradually check sero-mucous flow. This is mentioned to emphasize a prevalent therapeutic indiscretion into which our proprietary advisers have led us. "Coryza" and "rhinitis" tablets all contain quinine, atropine, morphine and camphor. They are indicated in conditions of vaso-motor instability and not in actual inflammatory conditions of nares and sinuses. During the stage of acute hyperaemia following infection of sinuses one may administer small doses of an opiate with ipecac, such as the Dover combination, to relieve mucous membrane irritation and start secretions. A very careful hygienic regimen should be established and free elimination encouraged. Neuralgia may be relieved by phenacetin in small doses, care being taken not to cause diaphoresis, since this condition simply means a decided disturbance of vaso-motor equilibrium. As in ordinary coryza, and particularly that of the influenza type, I have found that bi-carbonate of potassium in doses of twenty to thirty grains administered in an ounce of camphor water in a half teacup of water every two hours is especially efficacious and fulfills many indications as a routine procedure. By virtue of its alkalinity it neutralizes the products of disordered digestive metabolism incident to the febrile state, causes copious diuresis, and the camphor is a very proper vaso-motor tonic. In severe general sinusitis dry heat, even when applied continuously, gives but little relief, and moist heat should be advised according to the following detail manner. Cover the eyes with pads of dry cotton, and then poultice the face thoroughly, as hot as will be tolerated, four changes an hour for about two hours. Then dry the surface and apply a mask of quilted cotton, holes having been cut for the eyes. This latter precaution is essential whether dry or moist heat is used. The primary effect of this treatment may be to increase tension pains, but there is no doubt but that it relieves venous and lymph stasis even in the deeper tissues, and soon there will follow evidences

of resolution—a more or less copious sero-mucous flow—and bone pains and neuralgia are alleviated. This should be repeated, with intervals of two to four hours rest, until general resolution is established. Even then it may be necessary to apply moist heat once daily for several days, since there is usually a period of daily tension pains due to filling of certain poorly drained sinuses.

The theoretic objections to moist heat in favor of cold applications emanate from the laboratory and in my experience are not sustained in clinical practice. After years of experience in the use of ice-coil, otologists have decided, I believe, that the cold application over an inflamed mastoid is not abortive, does not aid resolution, and, in fact, it merely numbs the cortical tissues to the temporary relief of pain.

In the interval between the hot applications it is advisable to apply a chloroform-camphor liniment, or better the vasogen camphor-chloroform preparation, rubbed into the skin of forehead and nose and superior maxillary region, the cotton mask being reapplied. The inhalation of the vapor is refreshing to the congested nasal tissues and drainage is favored by the vaso-motor tonic effect.

A certain method of treatment of all kinds of purulent diseases of the nasal fossae, disastrously popular with general practitioners and the laity, is the use of the naso-pharyngeal douche. This is a recurrent plague revived in some form or other about once in a generation, and we have it bad at present. That little duck-shaped douche flask with pink contents has caused more trouble than can be estimated, and it is time that protest is entered. The Bermingham douche is more harmful in the aggregate than was the Weber, because its deleterious effects are more insidious, and it is so thoroughly commercialized that it has passed beyond medical restraint. Not one in ten can use a naso-pharyngeal douche of any kind without causing damage to the Eustachian tube in the form of an acute or chronic catarrh or stenosis and subsequent middle ear involvement. In this connection I would also add a caution against the indiscriminate use of chilling sprays, such as cold detergent solutions and menthol oil sprays. They may be temporarily soothing and cleanse the passages mechanically, but the reaction is decided and muco-periosteal pain is increased following the shock of the cold blast. Sprays or douches

of antiseptic character should be employed only in very diluted state, lest in the effort to sterilize we cause superficial destruction of delicate epithelium.

All applications to the nares should be warm and applied without force. An approximately normal saline solution (to sodium chlorid can be added other normal blood salines or sodium baborate to the amount of about a teaspoonful of the combined salts to the pint of sterilized water) to which are added a few grains of cocain or adrenalin and menthol and about six drops of carbolic acid, makes a very satisfactory cleansing solution. If applied by atomizer it should be heated so that when delivered by coarse spray it will be appreciably warm. Oily medicaments are useful in the later stages, and should be non-irritating and warm. If the congestion of turbinates be such as to interfere with nasal respiration and thus disturbs sleep, it is allowable to use an ointment applied to the anterior nares composed of bismuth subnitrat five grains; cocain one grain; menthol two grains to the half ounce of sterilized vaselin. This encourages continuous drainage through the congested ostia of the sinuses.

There is a method of using a douche which prevents the fluid from reaching the naso-pharynx, and in selected cases may be used satisfactorily in general sinusitis. The head should be held face downwards so that the floor of the nares is vertical. The nostrils are immersed in a two-ounce glass even full of a carbolized, coacainized normal saline solution of 105° F., and then by closing one nostril with pressure on ala and exerting gentle suction a solid volume of the warm solution can be drawn up into the anterior third or half of the nasal chamber and then allowed to flow back into the glass. After a few trials this can be accomplished without sucking up any air, and if the head be held in position as directed none of the fluid reaches the naso-pharynx.

This can be repeated with freshly made solutions in the other naris. The effect of the hot solution is very soothing to the inflamed tissues, much the same as moist heat over an area of tender periosteum, but, as above stated, it can be advised only for patients who will follow direction cautiously. It may be repeated every few hours, and always after using the nostril should be closed by cotton for a short time, as the inspiration of air of ordinary temperature will cause a slight reaction.

In cases showing a tendency toward chronicity of purulent dis-

charge, it is advisable to stimulate sero-mucous secretion by using vasogen-iodin inunctions, ten to fifteen drops of the ten-per-cent preparation being rubbed into the skin daily, causing a more watery flow and flushing of purulent deposits. This may cause increase of tension pains, and unless flow is promptly established it should be discontinued.

Direct irrigation of sinuses is rarely indicated in acute sinusitis, but may be necessitated if the symptoms do not abate under the above treatment in a reasonable time, or if the discharge becomes distinctly purulent, or if there be odor indicating empyema. I have never succeeded in irrigating other than frontal, maxillary and anterior ethmoidal sinuses. In more than half of the cases the maxillary ostium is inaccessible, but the sinus can be penetrated and irrigation can be easily accomplished by the Freeman trocar and permanent cannula. The frontal sinus cannulæ are here presented for inspection. They are highly satisfactory, and with a set having a greater variety of curves and angles irrigation can be successfully accomplished in a large percentage of cases.

Preceding irrigation a flexible probe should be passed, thoroughly anointed with cocain-adrenalin ointment, and this may be of itself sufficient to clear the obstruction.

There seems to be a decided tendency to recurrence of localized sinusitis with each attack of severe coryza, and in the interval following an attack obstruction to free drainage should be removed. Pendulous turbinates or enlargements or polypoid growths should be ablated and general prophylactic methods advised.

Discussion.

DR. JOHN O. ROE.—The admirable directions for the general treatment of acute sinusitis given by Dr. Hubbard in his paper cannot fail to meet with our unanimous approval. There are, however, some measures not mentioned by him that I have found of special advantage in the treatment of these conditions.

In the treatment of acute frontal sinus inflammation I have found in the early congestive stages the use of leeches of special service in relieving the sensation of tension or pressure felt just above or below the eyebrow and in cutting short the inflammation. These are to be followed by hot applications to promote bleeding to relieve the congestion of the deeper parts. Another measure of much service is the use of hot antiseptic douches to relieve

congestion and to render the nasal cavity aseptic. As the continuous douche is dangerous to the ears, I always use a piston syringe both anteriorly and posteriorly. When entrusting it to patients and using it anteriorly, I always instruct them to hold the head well forward and to open the mouth as wide as possible during the injection of the fluid, which should always be injected in the more obstructed side. In this manner there is no danger of the water being forced into the middle ear because it is only during the act of swallowing—which opens the mouth of the Eustachian tube—while the douche is being used, that there is danger of fluids finding their way up the tube. In all purulent or septic cases the remedial agent which I have found most effective is a solution of formalin 1-1,000. This is the best antiseptic I know of. The solution is made up, of course, with a normal salt solution, to which may be added boric acid. Most bichloride and other antiseptic solutions that have any special antiseptic power cause more or less irritation, but the little smarting caused by formalin speedily disappears, leaving no irritation behind it.

DR. J. PAYSON CLARK.—I have been very much interested in Dr. Hubbard's paper on the treatment of the acute inflammations of the nasal sinuses, and I simply want to add a method of treatment which I have found very useful in some cases of inflammation of the frontal and ethmoid sinuses. I think Dr. Hubbard did not mention the use of cocain and adrenalin applications in the nose. I have found that in the case of an acute frontal sinusitis with pain and marked swelling of the middle turbinates and the ethmoid region, with or without the appearance of a purulent discharge from that region, that the application of a solution of cocain about four to five per cent, *on cotton* is most beneficial. I lay stress on this point—I think it is much more efficacious than the use of any spray, but should be done by the physician himself. A pledget of cotton soaked with cocain is applied to the inflamed part, followed by a pledget of cotton soaked with adrenalin 1-1,000, leaving it there until the membrane becomes more or less shrunken and blanched. I find this causes great relief in a large number of acute frontal and ethmoid sinuses, and without any other treatment, except that the patient should use a spray of 1-5,000 or 1-10,000 adrenalin solution in the nose every three hours, but the applications should be made by the physician once or twice a day; twice seems as often as necessary. This treatment will give a great deal of relief and will often make the patient comfortable until the inflammation subsides. I also use hot applications externally.

In regard to the acute inflammations of the antrum, I think that in many cases where there is no pain but simply a muco-purulent discharge from the antrum, these cases will get well of themselves; that is, they will get well by keeping nasal drainage free

by the use of adrenalin and possibly by a mild saline solution in a spray or douche.

In acute cases of the antrum where there is rather more purulent discharge and where there is a good deal of pain in the face and also in the upper teeth on that side, where the patient is suffering, I find that the use of a sterile salt solution, washing out either through the ostium maxillary or else by puncturing through the inferior meatus and washing out once or twice, seems to give relief more quickly than allowing the case to resolve itself.

In regard to what Dr. Hubbard said of the importance of removing marked deflections of the septum in cases of sinus inflammation, I think in the case of an ethmoid or frontal infection in a narrow nostril where there is a very large middle turbinate, abnormally large, *thorough* removal of the enlarged portion during the acute stage is often of great benefit.

As regards the use of the Bermingham douche I must beg to differ a little with Dr. Hubbard. I think that if the Bermingham douche is used with proper precautions and if the physician gives directions regarding the danger of its improper use to the patient that risk to the ears is very slight. We use it almost as a routine in the hospital, and rarely see an acute ear as a result. I have the patient hold the breath with the mouth open and allow the solution to run into the nose; then, still holding the breath, throw the head forward and let it run out. It is important not to blow the nose immediately afterwards. Following these directions I do not see how any fluid can get into the middle ear.

DR. CLEMENT F. THEISEN.—I am very glad Dr. Hubbard has sounded a note of warning regarding the use of the nasal douche in acute inflammations of the accessory sinuses, but I do not think it is emphasized even strongly enough. I question very much if douching the nose in cases of acute inflammation of any of the accessory sinuses does much good at all when we consider that in an acute inflammation of the antrum, or frontal sinus for example, we have an inflammatory process in a cavity surrounded on all sides by bone, with a comparatively very small outlet. Dr. Hubbard spoke of the muco-serous secretion being physiological in many of the cases. I do not know whether a muco-serous secretion from the sinuses is even strictly physiological. The danger is that it may become very readily purulent. We very frequently have a streptococcus infection. It seems to me the important thing is to get good drainage in these cases, and as Dr. Clark suggested, I believe that is best accomplished by soaking pledgets of cotton with cocain and adrenalin, and carrying them into the middle meatus, thus contracting the swollen mucous membrane.

I believe the only douche permissible at all in cases of acute inflammation of the accessory cavities, when you have a muco-serous discharge and later perhaps a muco-purulent discharge, is a very, very fine spray, not a douche at all. I think a very fine

spray with 1-20,000 of warm adrenalin and a weak solution of cocain is the best spray to use in these cases, or if not a spray, then a pledget of cotton soaked with this solution. Particularly in those cases where there is a muco-serous or purulent discharge, I believe there is very great danger of carrying the infection toward the Eustachian orifice and then to the middle ear. Douches in such cases should be done away with. I believe the majority of the cases of acute inflammations of the sinuses, if you have good drainage, will get well if you do nothing at all. In fact, the less you do the better it is for your patient in many cases. Sometimes external applications of heat are good. In cases of acute inflammation of the maxillary antrum, particularly when there is much secretion in the antrum, frequent punctures with Dr. Myles', or some other instrument, are very valuable indeed. They relieve the tension pain more than anything else. In some of these cases, after we make repeated punctures, and the condition does not clear up, if we establish a small opening through the nasal wall, one to remain if only a few days, it does acute cases a great amount of good.

DR. ARTHUR W. WATSON.—I agree with Dr. Theisen and Dr. Clark that the chief consideration in the treatment of these cases is free drainage, and to establish this the shrinking of the swollen membrane by cocain adrenalin is the best method. I have the cocain and adrenalin applied by a dropper and not on a tampon. The treatment has to be applied frequently, and therefore must be used by the patient. I do not see any danger in putting the solution into the hands of the patient in these cases. Having the application made at intervals throughout the day is advisable. After the thorough opening of the nose by the cocain and adrenalin, I think that it is well to wash the nose out with a normal salt solution. I do not think that there is any danger in the use of a douche, one which will hold a very small quantity of solution. The one I have used for some time is a small douche made of soft rubber, holding about a half ounce; probably you all know it. It is a very useful little instrument, and holds such a small quantity of fluid that it seems impossible to fill the naso-pharynx and nasal cavities, especially after the nose has been opened by the use of adrenalin and cocain. I think in some cases the puncture and washing out of the antrum is of great service. I have seen many cases get well after a long persistent treatment by this method. As I said in the first place, I think the drainage is the important point in the treatment.

DR. CORNELIUS G. COAKLEY.—I think we should thank Dr. Hubbard for presenting to our association so many and excellent points in the general treatment, the constitutional treatment, if we may speak of it in that way, and of the non-operative local treatment. Undoubtedly many neglect this part of the treatment,

and in milder cases the general treatment may be all sufficient. In more severe cases, however, it seems to me that the sooner we establish and maintain drainage the quicker the patient will get well. The matter of douching is something I think very important. I do not believe in the use of the douche; I have seen a good deal of harm done with it—the Kress-Owen douche. If there is any cleansing to be done or any form of irrigation I do it myself or have a trained nurse do it with a syringe, not a fountain douche, but a syringe, and only if both nasal passages are open. If one is partly occluded as the result of a deflected septum, I inject through the side obstructed so that the fluid will return without hindrance through the unobstructed side.

If I understood correctly, the essayist advocated that the medications in the form of a douche or spray should be warm, and also at the same time he spoke of using an atomizer with the solution warm. Can you tell me of any type of atomizer that will spray a warm solution? The air blown into the atomizer cools the solution so that at the second or third pump you are expelling a cold spray. I understood the doctor, in speaking of obstructions in the middle meatus, to mention polypi. When I see a case of acute sinusitis associated with polypi, I at once put that down as an acute exacerbation of a chronic case.

The matter of turbinectomy, it seems to me, has not been given sufficient place in the reader's paper. By turbinectomy I mean partial turbinectomy. If the local non-operative treatment does not suffice in the course of twenty-four hours to relieve the pain I think we have not done that which we are seeking to do, namely, afford proper drainage from the accessory sinuses involved. If it is the antrum, if one cannot irrigate through a cannula passed into the normal opening, then puncture and irrigate through the inferior meatus with a Myles' trocar. In the case of a frontal sinus I must bow to the doctor if he can catheterize a frontal sinus that is acutely inflamed. The middle turbinate is always swollen in these cases, and even when contracted with cocain and adrenalin I have not found patients sufficiently plucky to allow me to probe around much in the region of the opening of the nasal frontal duct or put a probe or catheter into the frontal sinus. I have tried to push over the middle turbinate with Killian's median rhinoscopic speculum, but that is exceedingly painful in acute cases, and very few patients will submit to it. Unless you take off the anterior third of the middle turbinate, which usually covers the lower orifice of the nasal frontal duct, I have found it impossible to catheterize the acute cases. In ninety per cent. of the chronic cases the frontal sinus can be easily catheterized.

DR. GORDON KING.—I think there is another plan of treatment that has not been brought out here. I had some rather satisfactory experience with it in the past year. It is the use of menthol in the form of steam vapor. I think Lermoyez was the first to

advocate this in the acute cases before suppuration has become formed. His plan is simply to mix an alcoholic solution of menthol to the strength of about one dram of menthol to one ounce alcohol in an ordinary little cup of, say, half a pint of boiling hot water. He puts into that two tablespoonfuls of this alcohol-menthol solution and the patient inhales that. It has an irritating effect and brings about the result which Dr. Hubbard mentioned, the loosening of the secretion. I must say, however, that I am not a very strong advocate of this conservative means of treatment unless it produces a very good effect in the first twenty-four hours, particularly in cases of frontal sinusitis, as in these cases the pain is extremely aggravating and you have to give some relief. You cannot sit down and content yourself with general remedies or the ordinary douching of the nose. I may have used undue temerity in catheterizing these cases, but I almost invariably do it where it can be done. Occasionally it is difficult in the frontal sinus without first removing the anterior end of the turbinal, and it is not always advisable to attempt it before removal of the anterior end of the turbinate because in doing so you may lacerate it and this gives rise to coagulation necrosis or to swelling of the turbinate, a condition which prevents the drainage afterwards, and in the cases of suppuration and rapid accumulation in the cavity you will have as much or more trouble in the second syringing as at first.

In such cases I would remove the anterior end of the turbinate. In a case just a week ago I had to catheterize the frontal sinus two or three times, which gave the patient temporary relief, but he would come back in twenty-four hours complaining of pain. In that case I removed the anterior end of the turbinate and there was no further necessity for catheterizing the cavity.

As to the douche, I do not think I am wrong in using the douche so freely. I have an instance in the case of a very hysterical woman with double frontal sinusitis coming on in the course of an influenza. She would not let me catheterize her. She took to her bed, which made it very inconvenient to do anything with her propped up in bed. However, she allowed me to attempt to catheterize her sinus once, but it gave her so much pain I did not attempt it again. I used cocain and adrenalin solution; that seemed to give temporary relief only so far as the nasal symptoms were concerned. So I began the douching, using a hot douche of saline solution continuously every two hours, day and night, and she gained more relief from that than anything else. I do not mean to overlook the dangers of the douche in these cases, but I have had very little trouble with ear complications. I take the precaution to not use the douche too strong; I use an ordinary fountain syringe for the purpose. I do not believe much in the Birmingham douche, either, and have always made it a rule to advise my patients not to make use of such a douche.

DR. JOSEPH H. BRYAN.—Aside from the constitutional treatment so well brought out in the medication of these cases, I think the secret of success in the treatment of acute sinusitis is due to drainage. That, of course, can be best established as has been spoken of so frequently to-day, by means of cocain and adrenalin in the middle meatus, and if that is not sufficient, in the course of twenty-four or forty-eight hours we have to do something else, and it is then often necessary to take off the anterior end of the middle turbinate. But when I hear anyone say they can catheterize an acutely inflamed frontal sinus I often wonder what kind of skulls my confrere's patients must have. Such do not come to my office. Now I think in many of these acute conditions the pain is agonizing; it is not always due to an accumulation of secretion in the sinus; how often do we meet with great pain after the absolute evacuation of these cavities; in such instances I believe it is due to an absence of air in the cavity. It is only time and persistency that are going to bring about a subsidence of the swelling of these fronto-nasal ducts through which air can pass in and out again and the patient will then be absolutely free from pain.

I cannot agree with Dr. Roe when he says that he can put a syringe in the hands of a patient and not feel the patient will do himself harm. How many syringes are there a patient can use freely without having a poor action of the instrument? If you use a little more force at one time than at another you are apt to send the solution into the Eustachian tube.

DR. ROBERT C. MYLES.—My experience in this class of cases of acute sinusitis is that the majority of the cases do better without manipulation of the intra-nasal tissues. When the evidence shows there is some retention with decided pressure, then we must act, and the methods of procedure must be determined by the individual case and the character of the infection and the respective sinus affected. I have found it best to order the patient to remain perfectly quiet, and in severe cases in a dark room which is well ventilated. I use from time to time a vapor of boiling water impregnated with a teaspoonful of a mixture of carbolic acid, eucalyptol and turpentine. My experience with cocain has not been so favorable as it seems to have been with the others who have spoken. I think the general result of the use of cocain on the nasal membrane is that it brings on a passive oedema and causes a condition difficult to relieve and adds to the stenosis of the normal openings of the sinuses. I use it very guardedly and very cautiously. Adrenalin I use more freely. In those cases in which drainage is a necessity and pressure unbearable, in my judgment, cocain is then called for, but only for a brief space of time. The sinus must be relieved from the pressure at all hazards. The intra-nasal route is preferable, not only from one's own standpoint, but also from that of the patient. I have had moderate success in catheterization of cases of acute sinusitis. Of the

chronic cases I believe ninety per cent. of them can be catheterized.

DR. EMIL MAYER.—I am very glad to hear Dr. Myles make the statement relative to cocain, as I felt from the discussion that I would be the only one to rise and protest against its use in the manner indicated.

To my mind small doses of cocain are much more apt to produce constitutional symptoms than the larger ones. And furthermore, its effects are so evanescent as to render the patient much more uncomfortable than before its use.

My own form of treatment in these cases is to instill a weak solution of adrenalin into the nose, immediately followed by a two-per-cent. solution of menthol dissolved in some form of liquid vaselin.

I consider douching of the nose by the patient as harmful and never advise its use, because the relief afforded by the treatment just mentioned is sufficient to keep the patient comfortable.

I do not mean to say that the cavities should not be cleansed, but it should be done by the physician whenever it is possible to do so.

I have been on record more than once as stating that any of these cavities are very difficult of entrance.

While some are more skillful than others, I must acknowledge my own inability to always enter the ostium maxillare, which is undoubtedly the easiest of access.

In the discussion held a year ago before this body, it was then stated that when inflammation exists the maxillary sinus could be entered much easier, while to-day we are informed that it cannot be reached when inflamed. There is no question, but these cavities can be entered and may be irrigated; the question is, how to do it, and in what manner irrigation should be accomplished in order that there shall be a constant and decreasing stream, rather than one with too much or too little force.

I have presented in another place a wash-bottle which answers the purpose excellently.

The bottle is filled with liquid of a proper temperature, and compressed air is forced into it through the ordinary tank. By the simple turning of a stop-cock the liquid is forced through a rubber tube and properly shaped cannula whose tip is introduced in the opening into the accessory cavity.

Its great advantage lies in the decreasing force after washing has once begun.

DR. WILLIAM K. SIMPSON.—It seems very singular that after twenty-seven years of experience the members of this Association should split on the fundamental principle of washing out the nasal cavity. There have been various means advised and many means deprecated. Now there comes a time when it is absolutely necessary to wash out the nasal cavities. I am in favor of the nasal douche,

based on a long experience. I must say I have used it thousands of times and have never seen but one instance of middle ear complication, and that was in a patient who had a congenital stenosis of the posterior naris which contained pus. Any patient may be taught to use it, but it is better, of course, to use it yourself. I think the condition we want is a continuous flow. I think the trouble with most of the commercial douches is that they give no flow or force whatever. The proper way is to use a nasal douche of the Thudicum variety. As has been mentioned, fluid entering the nose is irritating, but that can be overcome by spraying the nose with one-half of one per cent. of cocain. That prevents any struggling and gagging on the part of the patient. If you charge them to hold the mouth open and hold the breath or breathe easily you will have no trouble whatever.

I think it is well right here to settle some proper means of washing out the nose.

DR. J. PAYSON CLARK.—I want to make clear my remarks with regard to the use of the douche. I was referring to the use of the douche in general catarrhal cases. In the special cases which Dr. Hubbard's paper deals with I use the douche only where there is a tendency to collection of thick secretion in the nose.

DR. THOMAS HUBBARD.—In reply to Dr. Clark's remarks in reference to the use of cocain and adrenalin on cotton, I think it a very useful method. I advocated a solution of warm saline with cocain and adrenalin which produces a similar effect. With regard to the Bermingham douche, I must express my surprise that there is not a more uniform opinion with regard to it. I have seen many cases of chronic catarrh of the Eustachian tube, to say nothing of several cases of acute otitis media and mastoiditis undoubtedly due to its use. I think that this Association should unanimously protest against its employment. The discussion has brought out many important points, and I feel under obligations to those who have added to the therapeutic suggestions in the paper.

DEFLECTION OF THE NASAL SEPTUM IN CHILDREN.

BY ARTHUR AMES BLISS, M.D.

DEFLECTION of the nasal septum, in children, to a degree sufficient to cause occlusion of the nares, is one of the less frequent causes for mouth-breathing. Yet, when it exists, the resulting stenosis of the anterior nares blocks the nasal passages almost as completely as does hypertrophy of the adenoid tissue; while the deformity of the jaws and bad alignment of the teeth are quite as liable of development, as from the presence of the growth in the posterior nares. Indeed, the two conditions are, at times, associated in the same individual, complicated even by the presence of hypertrophied tonsils. The removal of the overgrown lymphoid tissue in such cases will not give the result sought for, unless the stenosis in the anterior nares can be relieved. In most of the cases, within my experience, the fauces and naso-pharynx have been free from obstructing growths, and the lesions there have been those peculiar to mouth-breathing alone, the mucous membrane showing the alterations which group themselves under the general term, sclerosis. The deforming influences of the deflected septum upon the development of the face, mouth, nostrils, and the muscles whose proper development and balance have so much to do with facial expression, is very striking. There is a constant effort on the part of the patient to open the stenosed naris by action of the muscles, the elevator of the ala of the nose and upper lip. This causes a grimace that can not but deform the most attractive countenance, giving a sneering, sinister expression, which can easily become a fixed one, stamping an ugliness there even more pronounced than that caused by strabismic eyes. The effects of pressure are shown, also in reflex irritation outside of the nares, notably in the eyes, particularly in that of the occluded side. Pressure upon the nasal nerve produces sensations of pain in the area supplied by the infratrochlear nerve. The ganglionic and ciliary branches of the nasal nerve, itself a branch of the ophthalmic nerve, uniting with the ophthalmic

ganglion of the sympathetic, and supplying the ciliary body, may induce a series of irregular symptoms in the eye that could simulate or complicate eye-strain, but would require removal of the nasal cause before relief could be expected. The nerve reflexes through Meckel's ganglion are so well recognized that these require mention only in passing.

Efforts have been made to account for deflected septa in children by explanations that have a science-like complexity, but which do not account for the condition any more reasonably than the less complicated but more common-sense view that the lesion results from congenital malformation and from traumatism. Congenital malformation is the less frequent cause. It is most evident in dolichocephalic skulls. It is manifested by an irregularity of development, rather than by actual deformity at birth. In the narrow, elongated skulls, the nasal passages will be found to be so narrow that very little room exists for a deflection of the septum that does not cause contact and pressure between the convexity of the bends and the outer nasal walls. The palate in such skulls is gothic-arched, and the alveolus of the upper jaw, its lateral arms brought near together, projects its anterior segment forward in the form of a wedge. So comes a crowding of the teeth, rendered even worse by the large size of the upper incisors, as found especially in the English and Scotch people. The upper thrust of the gothic-shaped palatal arch and the downward pressure of the developing cranial floor exert themselves to bend the nasal septum into a letter S-like deflection, in order to adapt itself to the contracted space. Indeed, the septum is thus too large for the space it must occupy, and is forced into folds and bends in the lines of least resistance. Such skulls and noses are found among certain races, and, markedly, members of certain families for many generations; so the septal deflection can be looked upon as a congenital malformation. The other and more frequent cause for septal deflections is traumatism. As the development of the nose is not complete until about the twelfth year of life, it is exposed from birth, and during all its formative period, to an endless series of accidents and disasters. Indeed, the circumstances of birth itself may in some cases constitute the traumatism in deliveries requiring the use of forceps or other instruments, or where version is needed. Later in child life come the frequent falls on the face during infancy, and the

injuries from the games, sports and battles of childhood, in which the nose suffers from the disadvantages of its exposed position. With the three elements of its structure still ununited, it is remarkable that serious fractures and displacements of the septum are not more frequent.

The most serious injury is that which crushes downwards from above and backwards from in front, giving a sharp, angular, vertical fracture and a horizontal deflection as well. Such an injury expends its force on the anterior third of the septum, the greatest deflection being on the plane of the outer edge of the nasal process of the superior maxilla, above the maxillary crest, called also the anterior nasal spine. This is the very entrance to the nares, its narrowest part. The angle of the vertical fracture is driven against the edge of the nasal process of the superior maxilla, or anterior, to this edge, and the anterior fragment of the fractured bridge is bent sharply across the entrance of the nostril. The column cartilage, displaced at its base, is thrust out from the median line, and projects across the vestibule of the other nostrils, seldom entirely closing it, but narrowing its calibre. Beyond the occluding angle of fracture, even in the naris having the convexity of the displaced bridge, there will be usually a fair degree of space, but the angle itself blocks the passage completely.

Another form of deflection is horizontal in character, the projecting point of the angle being formed along the junction of the vomer and triangular cartilage and perpendicular plate of the ethmoid. The projection is thus low down, near the floor of the nares, anteriorly, but ascends in the line of the vomerine margin as it extends into the interior of the nasal chamber. When turgescient, the lower turbinated body of the nasal passage occluded by the angle swells around the angle so that the latter appears to be buried in the swollen mass; or, as a result of continuous pressure, there is a depressed groove formed, into which the projecting angle has fitted itself, while the lower turbinate swells out into the greatly narrowed space above and below the angle. In both these forms of septal deflection, the vertico-horizontal and the simple angular, the fibres of tissue forming the septum are continuous on the side of the concavity of the deflection. On the convex side, however, there has been a break in the continuity of the fibres. In short, the deformity is a "green

stick" fracture. At the line of such fracture, the hyperplasia of tissue, bone and cartilage, developed for its repair, produces a thickening, appearing as an ecchondrosis or exostosis, more frequently as both combined. In the vertico-horizontal fracture, this thickening, at the extreme crest of the deflection, is quite anterior and about on the level of the margin of the nasal process of the superior maxilla. In the simple angular deflection, it is seen extending inwards and upwards and backwards along the vomerine margin.

A third form of deflection produces a rounding bulging of the anterior part of the septum, chiefly cartilaginous; or a straight line, vertically, descending to the floor of the vestibule and extreme anterior nares. In the latter case the curve, which always exists, is scarcely apparent, being below the soft tissue of the floor of the nose and to the corresponding side of the anterior nasal spine. In this third form of deflection there is seldom any thickening of tissue along the sides of the septum, such thickening occurring only over the anterior nasal spine. When it exists in this location it is caused, probably, as a result of detachment of the septum, and hyperplasia resulting from this traumatism.

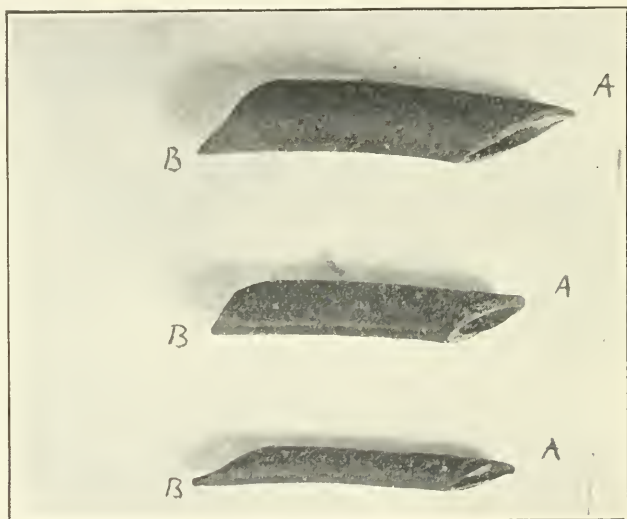
Associated with all these forms of deflection is the well-known tendency of the lower turbinated body of the non-occluded naris to swell into the concavity of the deflected septum, thus greatly narrowing the nasal passage that would naturally be the free and open one. This engorgement of the erectile tissue may result from derangement of vaso-motor balance, caused by the constant pressure and stenosis within the occluded nasal passage. Irritation of Meckel's ganglion, through pressure on the nasopalatine nerve and other branches of the fifth, acting reflexly on the local vaso-motor system, possibly through the Vidian nerve and the carotid plexus, may account for this turgescence of the erectile tissue. Both lower turbinates are turgescient, but the condition is seen most readily in that of the side having the concavity of the septal bend. The swelling may take the form of a true hypertrophy, and be constant. More frequently it is due to a chronic, passive congestion, or venous stasis.

The forms assumed by the septum, as a result of any cause producing deflection, are the same in children as in adults. In childhood, however, the degree of organized hyperplasia and ossification, at the lines of fracture, is less marked than in adult life.

The tissues yield more readily and are more plastic. In removing projecting angles and thickenings, the knife can be used in place of the saw more generally than is the case in similar operations upon adults.

It would seem that the best time to correct septal deflections would be in childhood; yet at this period the lesion is not observed, is ignored, or its correction is deferred until the full development of the nose is completed. It is slightly more difficult to replace the deflected septum in a child than in an adult. With the latter, cocain is an efficient anaesthetic; the parts are well in view and the nose sufficiently large to permit easy manipulation. With a child all this is reversed; small nostrils, difficulty of manipulation and the need for a general anaesthetic. Then, too, there is the belief that the replacement will be more secure and permanent after the parts involved have become fixed and developed. A circumstance, too, that works to the disadvantage of the child is that after an injury to the nose the septal deflection is seldom recognized. Parents are advised to "wait until the swelling goes down," or the general surgeon applies the conventional fracture dressing. This can in no possible way relieve a deflected septum. It is applied across the nasal bones and is plastered down on the face, pressing on the septum, if at all, in a way rather to increase than to relieve any deflection. I would advocate the prompt and careful examination of a child's nose after an injury, even should it be necessary to give a general anaesthetic. Any bend of the septum can be replaced readily at this time without waiting for the dreaded swelling to go down. If the operator's little finger cannot be introduced into the narrowed nostril and the septum pushed into place, a dressing forceps, wrapped with sterile gauze, can be used to accomplish this result. A piece of rubber drainage tube, large enough to fit firmly into the naris, should be cut to a piece of about one inch and one-half to two inches in length. Both ends of the tubing should be cut obliquely, the end for the anterior of the nostril being well trimmed to a rounded point, and having slightly concave edges. The idea is, to insert the tube into the nostril so that the projecting point of the anterior end, coming forward over the triangular cartilage, will fit snugly up into the hollow in the extreme end of the nose. This anchors the tube in place. The oblique cut at the posterior end of the tube is to remove unnecessary sub-

stance, render the introduction easier, and lessen pressure against the middle turbinated body. For this reason the point projects from the lower side of the tube, while the anterior point projects from the upper side. Sometimes, to obtain sufficient pressure, it is necessary to stuff the tube with iodoform gauze, although this is not always needed. I find it well in some cases to place a tube of similar shape and size, usually smaller, in the other nostril, as well as in that into which the deflected septum projects. This aids in supporting the septum, and is of especial



A—Anterior end. B—Posterior end. Rubber tubing used as support for the septum, after resection operations.

use when the injury causes a vertical as well as a horizontal bend. Cold dressings of gauze, wet with sterile water, are placed over the external nose and neighboring part of face, when conditions demand such treatment. Any of the external supports for use after displacement of the nasal bones can be used even with better effect while the tube supports the septum.

Attention is called to this treatment of acute fractures because I have found the same kind of tubing a very efficient splint for the septum after any of the methods used for resection. For this operation I have found either the "button-hole" method, some-

times known as the Watson-Gleason operation, or the Harrison Allen operation, to be the most satisfactory. The special form of operation must depend upon the character of the deformity. No one method can be used for all cases. The rubber tubing makes a secure support, which at the same time is sufficiently soft to adapt itself to the tissues, never causes erosions and can be cleaned easily. It makes an excellent protection for any wound that it covers; allows, unless stuffed with gauze, a wash to be sprayed through it into the naris, and does not interfere with respiration. It is, of course, occluded when the gauze stuffing is used, but this need not be continued for more than four or five days, after which the tube can be left open. The patient is soon taught to remove, wash and replace it himself. I have found it a most satisfactory dressing and prefer it to the hard rubber or metal tubes made especially for the resection operation. A good splint, but of much softer texture than the ordinary rubber drainage tube, is Goodwillie's nasal intubation tube. This must be cut to fit the naris into which it is to be placed, but is so flexible and soft that it is always necessary to pack it with antiseptic gauze. When properly used, it is a comfortable and effective dressing. In cases in which the lower turbinated body of the non-occluded side, that having the concavity of the deflected septum, is persistently engorged, it is well to reduce it by electro-cautery incision before the resection operation is performed. When the wound has healed, this side of the nose will not be occluded by the replacement of the septum. The engorgement or hypertrophy of the turbinated bodies is less commonly found in children than in adults. Only occasionally a case presents itself requiring this treatment preparatory to the resection operation.

The author believes that traumatism is the most frequent cause for septal deflections in children, and that when this is the case the resulting deformity should be corrected as soon as possible after its production. He believes, also, that in cases of deflection of long-standing and unknown origin it is unnecessary to defer the operation of resection and replacement until the development of the nose is completed. The operation upon children is attended with certain difficulties which do not exist, or exist to a less degree, in the case of adults. In this paper the author outlines some impressions and some methods of work which are the outcome of his personal experience. The technique described is

simple and effective. It is not the author's intention to imply that other methods are inferior in efficiency.

Discussion.

DR. W. PEYRE PORCHER.—In regard to the etiology to which the doctor alluded, we have had a good many discussions on this subject in past years, and many men have attributed septal deflections to traumatism. It brings home to us the fact that these deflections are due to natural causes much more than to traumatism, because in young children especially, these deflections are very uncommon. The base of the partition being bony above and below (in the case of an acute inflammation), there is very little room for much swelling and the septum becomes bent upon itself. The result is that, although little children have a great many falls on the nose, we do not find these deflections so frequently as in adults who have many attacks of acute rhinitis. There is one other point I would like to allude to, and that is that the nasal obstructions affect the eyes. There have been a good many articles recently, notably one by Dr. Gould, of Philadelphia, claiming that almost every disease in creation was due to refractive errors in the eye, and there have been very few explanations given of the cause of these refractive errors. We have all had cases in which the patients after an operation on the nose with removal of nasal obstructions have said that their glasses had become too strong; and that as a result of the operation their sight was improved. An oculist friend of mine paid me an unintentional compliment some time ago by saying that a mutual patient's eyes were greatly benefited after she had undergone an operation on her nose with removal of the nasal obstruction. I have had several instances of this fact, and it seems to me strange that this point has not been alluded to more often, and attention called to it. There is only one other point, and that is I was glad to hear again of use of Goodwillie's nasal intubation tubes. I procured a new set only the other day; they have been very useful in my hands. I have found the hard rubber tubes very difficult to fit into the nostril, and they are apt to slip out of position.

DR. THOMAS J. HARRIS.—A single point is suggested by this very timely paper in reference to the treatment. I did not hear the reader allude to methods other than operative for the cure of these deformities. A short time ago, as some of the gentlemen will recall, Dr. Quimby, of New York, reported the case of his young daughter, a child of twelve, who he noticed began to develop a deformity of her cartilaginous septum. Attention, however, was attracted more particularly to the overlapping of her teeth in the upper jaw. He began a correction of the upper jaw by bridge work of his own construction. When he found that the

jaw had been replaced at the end of a year or more he found that the nasal septum had entirely gone into proper position. With regard to what has been suggested by a number of the Fellows of our Association, notably Dr. Kyle and others, of the power of splints to reduce the deformity in the septum, in children especially, it has been my experience that that has been a very satisfactory method. I would like the writer to give us his experience with reference to this. This past winter I have seen three or four cases in which my assistants have attempted to treat in that way. They have used usually the Bernays sponge, suggested by Dr. Simpson, putting it in in the proper size and shape. They have combined that occasionally with the use of the finger. At first I was entirely incredulous about its value. I had to admit at the end of several weeks that it was a good thing, and the patients themselves were thoroughly satisfied with the results. I rather question whether we sometimes are not a little premature in operating upon these cases in children. Let us remember that the parts are very soft and very tractable, and what we may not be able to accomplish in adults it may be possible to do in children.

DR. GEORGE L. RICHARDS.—I have been observing these cases in children for ten years with special reference to etiology. I formerly thought they were all due to falls and blows, but now think that they are in most instances really due to developmental conditions. The benefit derived from splints, etc., only proves this the more. If each part of the septum grows at the same rate it is a straight septum; if one grows faster from its individual centre, you get a pushing from one side to the other, and I think the majority of these cases are due to developmental failures.

I was also interested in what the essayist had to say with reference to the question whether to leave these deflections in children until past the growing age. My earlier operative cases were rather failures. In one case I noticed the same child four or five years later, and he did not seem to have obtained the good I had hoped. The nose had filled up again. I think we can do a great deal with these cases by the simple methods.

DR. J. PRICE-BROWN.—I am exceedingly interested in this paper. I like it because it speaks of the use of rubber tubes. I think we can improve on the use of rubber tubes by the use of rubber splints. These cases as a rule are formed when they come under observation; they are not cases in which the patient has been under the charge of a physician, as in Dr. Harris' case. If they were children of physicians such treatment as suggested could be carried out. I have found that the best treatment I can use is the insertion of a splint, but instead of inserting the splint while the cartilaginous septum is still curved and rigid, it is first made pliable by operation. In young children I usually operate by one of two methods. Either by knife, cutting the septum from back to front in one or two slits parallel to each other, bevelling

the cuts so that the sections will slip over one another. Or by saw, cutting from back to front as before, in some cases even through the septum. Then a splint of rubber sheeting with smooth surfaces cut to suit the size, and made sufficiently thick to hold the septum in position, is inserted, the upper and back part of the splint being shaped so as not to allow it to slip into the post naris. The splint in position will hold the septum in place, and is not removed until it loosens itself. The patient should be kept under observation, and the opposite nostril regularly cleansed by cotton, etc., also the anterior portion of the nostril in which the splint is inserted, but the splint left undisturbed. The operation is done under chloroform, and there is a little suffering for one or two days. It takes, as a rule, from two to three weeks for the splint to work loose. I have had a number of cases under observation for several years and the septum does not change its position. There is no danger of sepsis from the splint remaining in position—you can leave it two, three, or four weeks, if necessary.

Rubber tubes, or tubes of any kind, are objectionable, as they permit of foul secretions accumulating within their cavities, necessitating frequent removals in order to be cleansed. Rubber splints being solid bodies, and impenetrable to microbic invasion, can remain *in situ* for prolonged periods without injury to the patients, until the work for which they were inserted has been accomplished.

DR. EMIL MAYER.—I wish that my patients would be as docile as the little Canadians are. Whenever I do a cutting operation on the septum, and I put in the rubber tube, that tube gets full of all kinds of crusts, secretions form and the rubber becomes soft, and in a very short space of time it is a foul mass. My own individual experience in the subject under consideration is that there are two principal causes of deflection in children, one, as the writer has said, traumatic, the other that the septum itself is the seat of an overgrowth, and you can watch this growing in children. There is one other cause to be added to the condition, and that is the presence of adenoid vegetations. I have seen children whose septa were being bent over, and who certainly in due time would be completely occluded, who had masses of adenoids upon the removal of which the septum straightened up in due time. When it comes to the question of operative procedure I understood the writer to say he would operate in cases where stenosis was sufficient to warrant operation. As long as there is sufficient breathing room he would leave the septum alone as far as cutting operations are concerned. In my hands the operation known as the Watson-Gleason has been the best in children. As to the use of the tube I feel that a properly fitting tube of solid consistence is the tube to use. When I say properly fitting I mean exactly what I say, for the reason that there is no tube made that can be

made to fit the noses of the patients as they come. It requires a certain amount of assistance on our part, and in little children in whose nostrils it is impossible to put your little finger, the small Asch tubes go exceedingly well. I have found rubber to be a very unsatisfactory substance for use in the nose.

DR. E. FLETCHER INGALS.—I cannot understand how the author's patients have been able to tolerate the rubber tube in the naris. A round rubber tube, large enough to make pressure, has always given my patients so much pain that they have not been able to tolerate it, and it is singular that a child can wear it when it is paining it all the time, but I think that children learn to tolerate pain, and say nothing about it. I recall the case of a little fellow who had dislocated his collar bone, and the surgeon in putting on a dressing pinned through the skin, but after a day or two the little fellow made no complaint about it while the dressing remained on. I think probably this is the way the children tolerate rubber tubes in the nose. I have tried repeatedly to use round rubber tubes in the nose, but the pressure has always caused intolerable pain. I think a solid tube of the right form much preferable, but I do not know of any solid tubes of the right form. I have tried the various tubes on the market, but they do not occupy a correct position in the nose. All of them pass upward and backward and hold only a small portion of the septum in place. I much prefer a tube passing horizontally backward. I have made many of them myself out of the base plate gutta percha used by dentists, but it is a mean job. If we could get rubber tubes made of the dental material, which would soften in water, it would be very easy to form them for individual cases.

DR. ARTHUR W. WATSON.—With regard to the etiology of these cases, there are, I think, two points to be considered. One is that they are due at times to trauma, and the other, that they may result from developmental errors of the facial bones. If we find a large projection in the anterior inferior angle of the septal area, the cause is, as Dr. Bliss has said, generally traumatic. The cases resulting from developmental errors frequently present themselves with a rounded curve of the entire septum. I agree with Dr. Mayer's statement that the principal cause in developmental errors is the presence of adenoids. I incline to think, however, that inherited peculiarities in the formation of the teeth and jaw may have something to do with the case. We naturally find it difficult to remedy such conditions in children, owing to the smallness of the nasal passages into which it is often impossible to insert the finger for the purpose of replacing the septum, though this result can be attained with forceps. This difficulty leads many surgeons to defer the operation until later in life, though I think that this is a mistake. I believe that the removal of adenoids, if present, will often tend to arrest the condition.

Some years ago I made, in conjunction with Dr. Cohen, a num-

ber of experiments in the line of replacing the septum and endeavoring to hold it in line by simple pressure. We found even in comparatively young subjects that the result was a total failure. The new position was maintained for a time, but invariably the former mal-position eventually returned. It was this fact which led to the devising of the operation which consists in the overlapping of the septal fragments.

I regard Dr. Bliss' words as to the importance of early treatment of fractures of the nose in children as of special significance. I have seen many cases which have been allowed to persist too long to offer any hope of a satisfactory operative result. Children with fractured nasal bones usually present in addition a hematoma of the septum with subsequent abscess, and this combination hides the original injury so that it is overlooked.

A word in regard to splints. I have used many kinds, and some years ago discarded the use of all forms of hard material for this purpose. Partial satisfaction was derived from the use of gutta percha, the splint being fashioned by me according to the needs of each individual case. I regard rubber in the nose as most undesirable, for it quickly becomes foul. At present I use iodoform (or other antiseptic) gauze, folded into pads or splints of appropriate size and shape for the case.

DR. OTTO T. FREER.—I am in accord with Dr. Porcher and Dr. Richards in respect to the rarity of traumatism as a cause for deflections of the septum. Injury is usually assumed as a reason for their existence simply because they have a shape that suggests their production from an injury. Killian even groups his deflections from their appearance alone into two classes, traumatic and non-traumatic. I do not think that the evidence of previous trauma offered by the mere form of a deflection is so convincing that it justifies the assertion that an injury is its cause unless a reliable observer has rhinoscopically observed the acute production of the deviation from a fracture of the cartilage in a previously straight septum. The history offered by parents and patients can not be accepted as evidence, for there is always a bump on the nose, however slight, that is alleged as the source of the deflection even when it exists far back in the bone beyond the reach of its production from any accident short of a crushing in of the face. The cases that impressed me as distinctly traumatic were always associated with a deformity of the nasal bones suggesting their previous fracture or their dislocation from the frontal processes of the superior maxillary bone, for when the buttress offered by the nasal bones gives way the cartilage is subjected to much more violent kinking than if protected by the external bony nose. I think that the great rarity of actually observed fractures and acutely formed deflections of the cartilaginous septum in proportion to the enormous total of the deviations of the nasal septum seen, proves that traumatic deflections are few in number. Many

sharp-angled deflections in the cartilage that look decidedly traumatic, extend so far back into the vomer beyond the reach of a trauma that their origin from an injury seems very doubtful, when it is considered that the elastic yielding cartilage can not possibly carry a fracturing force back into the bony septum.

Deflections of the septum in children I have corrected exclusively by the window resection method. The minuteness of the field and the need of a general anesthesia to help out the cocaine insensibility make the operation somewhat more difficult than in the adult. In my reports of children I do not include those 12 years old and over, for these have always submitted to the operation with merely local anesthesia, and I refer merely to smaller children from the tenth year downward. My youngest child case was 8 years old.

To allow for the tendency of growth to reproduce the deflection in children, one must remove every vestige of the deviated bone and cartilage and some of my most extensive deviations, nearly obliterating the nostril, occurred in children. The healing is far more rapid than in the adult, and the firmness of the septum is so quickly reproduced that the window may be filled with cartilage in a few weeks. I have never seen any sinking in of the nasal bridge even in the most extensive resections in children, in fact I have never seen it after any window resection.

DR. THOMAS HUBBARD.—One word with reference to the making of splints. We can ourselves make the splints, which can be perfectly adapted to the contour of the cavity by using the ordinary dentist's sheet gutta percha and a cement made by dissolving a small portion in chloroform. By using the chloroform cement you can produce a splint of any desired thickness, one that is flexible at a temperature of 110° to 115° . I think this is the most serviceable of protective splints for external use as in traumatism, or as a splint to be used in any post-operative work. It can be adapted to any size or shape desired.

DR. JOHN N. MACKENZIE.—I deprecate the indiscriminate performance of operations on the septum in childhood, especially those procedures from which deformity might result. Nasal obstruction in children is nearly always post-nasal, and with the removal of the obstruction in the upper pharynx respiration is usually restored to its normal channel. In early life, except in the case of congenital deformity, symmetry of the nasal passages is the rule, and traumatic dislocation of the septum is surprisingly infrequently met with, especially when one takes into consideration the frequency with which the child's nose is subjected to injury.

Most of the splints sold in the market are worthless. For a number of years I have been accustomed to send my patient, after the deformity has been corrected, to the dentist, who takes a cast of the nasal passages from which is made a delicate shell of hard rubber, vulcanite, etc., which accurately fits the obstructed nostril.

permits absolute freedom of respiration through it and can be worn indefinitely without discomfort to the wearer. In many cases splints can be done away with entirely and the fragments held in position simply by the pressure of a packing of antiseptic gauze or other surgical dressing.

DR. WILLIAM E. CASSELBERRY.—I do not find myself quite in accord with the last speaker, for I have seen many cases of septal deflections in children which were in real need of correction. I would not consider them "rare." Some of them certainly are slight, and do not require interference, or only such mild measures as proposed by Dr. Harris, yet others are very pronounced deflections, so much so, in fact, as to cause serious nasal stenosis, annoying facial grimaces and sometimes a progressive lateral slant or curve to the external nose. I recall two recent cases in which there was such a pronounced deflection of the cartilaginous and bony septum that it would have been futile to rely on mere digital pressure without operation, and in which it would have been idle to think that the removal of an adenoid growth would have had any effect upon the septal deformity. I have removed the adenoid growths in certain cases, and have waited to see whether the effects upon the septum would be sufficient, but in almost every instance I have been disappointed, and the septal deformity did not spontaneously disappear after the removal of the adenoids. I am not going to particularize as to the method of operation or kind of splint or dressings to use, but I am under the conviction that we should operate on the pronounced cases for the purpose of relieving the stenosis and facial deformities, and that an operation properly done in these cases is lasting, even though done at the age of five or six years.

I think the etiology, whether traumatic or non-traumatic, is of some importance, because, if the effects of traumatism are recognized it will encourage preventive measures at the time of or soon after the accident. If a fracture is suspected general anesthesia is suitable for diagnosis as well as adjustment. I quite agree with the essayist as regards the main views of his paper, that these cases require attention, that they are particularly frequent, and that it is advisable to operate.

DR. ROBERT C. MYLES.—My observations have led me to believe that the cases have been due to traumatism, but I can understand how Dr. Richards, Dr. Porcher and Dr. Mackenzie find so few of them, for where the pavements are hard you expect a great many more than where there is grass. I have collected evidence from patients which proved that the cause was trauma; fathers or mothers bring the child with a history of a fall out of the window, off the porch or down the steps, and since that time the external part of the nose has also been deformed. I do not think there is any doubt that the majority of cases that need attention are due to trauma. In regard to splints, I think the difficulty with all

splints is that the splint about fits the nose when put in, but the resistance of the septum has not been thoroughly overcome, and we do not allow for the swelling, and this swelling pushes the splint so hard against the septum or outer wall that there is a certain amount of sloughing.

DR. CHARLES W. RICHARDSON.—With regard to the etiology I agree with the essayist that in many of these cases post-nasal obstruction has a decided influence in producing deformities of the septum, and the relief of this obstruction is not always attended with an arrest of this tendency or a restoration of the deflection to the normal. I make this statement from observation of my own cases and observation of cases that have been operated on by skilled men that have come under my care after the posterior obstruction has been removed, who would not have overlooked a pronounced deflection at the time of the original operation. I have operated on deflections of the septum in children who had had their adenoids removed by men for whom I have the highest opinion, and yet I have found several years later these septa in apposition to the outer wall of the nose. These deflections must have developed after the removal of the adenoids or continued to increase. In my own cases I have several times seen moderate deflections at the time of the removal of the adenoids and have then told the parents, in several instances, that the child would probably at a later day, have to be operated on for a deflected septum, and in half a dozen cases they have returned to me several years later with a more marked deflection than at the first examination, so that I feel warranted from my own observation in stating that the removal of the post-nasal obstruction does not always arrest the continuation of the development of the deflection.

In the doing of the operation we all have our various methods. There is one point I have observed with regard to performing the operation, and that is that in children we must be extremely careful not to *over* correct the deflection. We must put it in the exact position we wish it to maintain, because union is very rapid in children, and the septum becomes fixed very quickly, and usually remains permanently in the exact position in which we place it. In adults we frequently over correct, because after we remove our retaining apparatus we expect a slight going back.

The time to operate is another point not much discussed, and yet it is an important point for consideration. Other things being equal I would rather wait until the child reaches the age of twelve or fourteen. By saying other things being equal I mean if the deflection is not marked and does not produce any disturbance. I have had three or four cases in which I have seen moderate deflections in young children between five and eight years of age, not sufficient to cause any disturbance and not interfering to any marked degree with the breathing through the affected side, in whom when presenting themselves for the purpose of having the

deflection corrected some four or five years later. I have then found the septum nearly straight. Only a few months ago I had a case return after three years for correction of the deflection, but when I examined it I found the septum was almost straight; so nearly so in fact, and so free from obstruction that I could find no reason to operate. I could hardly believe it was possible that the child ever had a deflection until I looked up the history and found the exact drawing of the previous condition.

DR. JOHN O. ROE.—I wish to add just a word in regard to the etiology and treatment. There is one point in the etiology relating to the development of the nasal septum which has been entirely overlooked in this discussion. The vomer at an early period is composed of two laminae, each having an independent centre of ossification and each developing separately. Ossification begins about the sixth week of foetal life, but is not completed until after puberty. Coalescence of these two laminae takes place from behind, beginning about the third year, and is completed by the time ossification takes place, although in some instances union does not take place at all, leaving a space between them. It will, therefore, be readily seen that anything disturbing the equal development of the two sides of the septum, causing one side to grow more or less rapidly than the other, will cause the septum to be bent to one or the other side. There is no question that traumatism in a great many cases has a great deal to do with deflections of the septum, not so much due to fracture of the septum as to its interference with the equal development of the two sides, and deformity of the osseous portion will also cause a distortion of the cartilaginous portion of the septum as development takes place.

It is quite rare to find a deflection of the osseous or the cartilaginous portion of the septum alone. Deflections of the septum are in about ninety per cent. found to be a combination of both—an osseo-cartilaginous deflection. In correcting the deflection it is important that this osseo-cartilaginous portion of the deflection be fractured so as to change the angle of the attachment of the cartilage, when, by forcing the cartilage over into the median line, and holding the parts in place by a suitable support until fixation of the fractured portions has taken place, requiring about four days, the deflection is permanently corrected. Exostoses, enchondromas and other thickenings are to be removed to render the septum of normal thickness.

The method I have found most serviceable for correcting deflected septa is by means of the fenestrated forceps that I devised for this purpose. I will not have the assurance of the restaurant man who put on his sign: "He who dines here once will never dine anywhere else," but I will say that he who becomes familiar with this method of correcting deviations of the septum will be highly gratified with his results.

DR. JAMES E. LOGAN.—There is one suggestion I have to make. It would seem to be a most urgent condition of deflection in a child that would require an extirpation of the triangular cartilage or any portion of the septum sufficient in amount to destroy the support that would come in the formative stage of that nostril or nose. I cannot see how we can reasonably act in such an extreme or radical way upon children as the nostrils are developing, and I am very much afraid if Dr. Freer carries his extirpations on as he suggested we will find more flat-nosed children all the time. I offer this simply as a caution. Our pendulum is swinging a little too far in these septum operations, and I believe many of the septa to-day in children should not be operated upon until the stage of formation is more fully developed.

DR. WALTER F. CHAPPELL.—There is one point not hitherto mentioned, the matter of treatment. I, like many others, have given up the use of splints. After correcting the deformity by selected method I cover over the surface of the wound with a solution of iodoform and tincture of benzoin, and then introduce a rubber tissue over the surface and pack it thoroughly. I have found that this keeps the cartilage in perfect position, and after a few days I can slip it out readily and reintroduce the rubber tissue as long as it becomes necessary to keep up the pressure.

DR. ARTHUR A. BLISS.—There may be a resemblance between the Canadian children and those of Philadelphia, as has been emphasized in the long-suffering patience that will stand this sort of thing better than children do in the greater centres like New York; but I can only say that with the children who have come to me with whom I have used the tube, I have never had the slightest trouble in employing this treatment. I have been well satisfied with the result. I would not be satisfied to have the tube get into the condition of being fouled with crusts, however. This will not happen with strict care, proper local cleansing, and control of the little patient. The tube is not a round tube; after being introduced it becomes an oval shape, adapting itself readily to the tissues.

From my own experience, I am convinced that most deflections are traumatic, and not due to any special malformation or over development, although every one must acknowledge that congenital malformation is one potent cause for deflected septa. The class of cases referred to as needing operation are those in which there are distinct symptoms produced by the bend in the bridge.

A SECOND NOTE ON CASES OF SARCOMA OF THE NOSE.

BY J. PRICE-BROWN, M.D.

THIS is merely a short continuation of a report which I had the honor of presenting to this Association two years ago and which appeared in the transactions of that year. (Transactions, 1903, page 209.) It consisted of brief mention of two cases of nasal sarcoma which had previously been treated, and a longer report upon a more recent case.

In the first, that of Mr. A. V. P., it is now ten and a half years since I operated upon him. His weight was then 130 pounds. He is now 31 years of age, weighs 170 pounds, and reports himself as perfectly well. His only complaint is that the right nasal passage from which the growth was removed is always so open that it sometimes becomes dry; while the slightest cold will block up the left passage so effectually that he cannot breathe through it at all.

The second case, it may be remembered, occurred in a Mr. B., a stoker, aged 50 years. The growth was on the left side of the perpendicular plate of the ethmoid. Like the previous case, it was removed by electro-cautery operations and was reported nine months after treatment was completed. Both cases had been pronounced sarcoma after careful microscopical examination, and both before operation had been subject to severe recurrent hemorrhages. On Saturday last Dr. Cleland, the family physician, at my request, sent Mr. B. over to my office for examination, and I find that after a lapse of two years from my last report, or two years and nine months after operation, there has been no return whatever either of hemorrhage or of the growth.

It is of the third case, however, that I desire to speak a little more fully. To briefly recapitulate. The patient, Mr. L. P., was 21 years old when I first saw him. Three years before that time he became subject to hemorrhages from a tumor in the left nostril. This was found upon microscopical examination to be round-

celled sarcoma. External operation was advised, but declined. Finally he consulted me, and in my former paper I described his condition, the treatment and the result, at the same time showing pathological specimens, of the weight of over two ounces, which I had at different times removed through the left nasal passage—the largest piece, after evulsion by cold snare, weighing nearly three drams.

When I reported the case, the man had recovered from the operation, was strong again, the nasal passage and naso-pharynx were both clear, and he had been working at his business in an office for a number of weeks.

During the discussion which followed several gentlemen censured so early a report of the case; so when asked by our Secretary to present a short paper upon cases in practice at this meeting, I did not think I could do better than give a second note upon this one.

In doing so I would lay stress upon the fact that, although the original tumor was attached to almost the whole length of the left middle and lower turbinal regions, also the vault, the perpendicular plate of the ethmoid and the vomer, these parts were entirely freed by successive electro-cautery operations, and that except upon the left ala of the vomer there has not been any return. In the basilar region, however, over the spheno-occipital union, the inner surface of the inner pterygoid plate, and the ala of the vomer, the site from which the large solid portion of the tumor had been removed by snare, there has been repeated recrudescence, and a continued fight between the operator and the disease from then until now. Two months after our meeting in Washington, the growth commenced to develop again at the upper and back part of the left nasal fossa, extending backward somewhat into the region of the naso-pharyngeal vault. This spot agrees very closely with the one mentioned two years ago by Dr. Myles, when discussing the cases of Dr. Simpson and myself. He spoke of a small, cartilaginous mass which formed in some cases at the junction of the sphenoid with the basilar process of the occipital, and which might possibly be the point of origin of these malignant growths. This theory, although reasonable, could scarcely apply to this case, for although the growth became enormous, it never covered the right side of the spheno-occipital suture.

The extent of area which the new growth covered in July, 1903, seemed to be about an inch square, and when discovered was already growing rapidly, the patient feeling quite well and entirely unconscious of the change. Through the wide nasal cavity, however, it could be distinctly seen, and also by means of the post-nasal mirror. It had a bright red appearance, was dense on pressure and yet would bleed when touched by the probe.

As there was ample room for examination and treatment through the nasal passage, I concluded, upon the earnest wish of the patient, to continue the contest upon the old lines—believing then, as I believe now, that the growth was entirely confined to the soft tissues, all osseous involvement being in the nature of pressure absorption.

So, after an adequate application of solutions of cocain and adrenalin, I made a succession of cuts into the growth with the electro-cautery point at a bright red heat. There was some hemorrhage at the time, but it ceased before the patient left the office.

I will not weary you with a detailed account of the next series of operations, but will simply say that from July 5th to Oct. 31st, 1903, I used the electro-cautery 29 times in a similar way. This was upon an average of nearly twice a week. Of this series of operations only the last one was attended by hemorrhage severe enough to require plugging. I attribute this to the immense advantage which adrenalin affords and to the care and exactitude with which the electro-cautery work was done. At the same time the growth of the tumor was so rapid that fewer operations at longer intervals would not have succeeded so well. With this last effort the disease seemed to be entirely removed again and operative treatment ceased.

Four months later, however, in February, 1904, it suddenly reappeared in the same old site, and for several weeks grew with more rapidity than I could control by means of the electro-cautery. It was too flat to be seized by a snare. So on March 31, under chloroform anaesthesia, I curetted through the nose and naso-pharynx a large section of the basic tumor away. Still, from difficulty of access to instruments, I could not get it entirely removed. The hemorrhage was enormous, and to check it I packed the huge cavity through the post-pharynx with large pledgets of absorbent cotton. The posterior naris on that side was so large that the packing filled the nose before the bleed-

ing ceased. This, unfortunately, was followed by extensive ecchymosis over the eye, nose and cheek. The eyeball escaped, but the lids became badly swollen and two days later were covered with blebs. Absorption, however, quickly took place, and in two or three weeks the discoloration had disappeared.

Two weeks after the operation, when able to come to my office, I found that there was still a segment of the tumor left, and it took occasional burnings until June 25th to destroy it. During the next nine months, or up to March of the present year, there was very little return of the growth. On only three occasions during that time did I require to singe the granulations with electricity in the speno-vomeric region.

Three months ago, however, recrudescence began to show itself vigorously upon the internal surface of the inner pterygoid plate, and from that date until May 26, at intervals of a week, I have applied the electro-cautery about 12 times, and on each occasion as thoroughly and extensively as I deemed safe. Now it seems to be well under control again, the nasal passage and the vaults both being clear of abnormal tissue. It is useless to believe that the battle is over, but the contest is still worth pressing; and I think the odds are again in favor of the patient.

There are several objective points of which he handed in a report a week ago that may be of interest.

Five months after presenting his case to this Association, he commenced attending a school of telegraphy. Seven months later, or one month after the operation under chloroform, of March 31, 1904, he took a situation in the G. N. W. Telegraph office on day work. This he occupied for six months. Then he was transferred to night work. During the whole of this time, over a year now, he has worked 8 hours in each 24, and notwithstanding the operative treatment, has only lost three days' time. His physical health is very good and he says that the operation has caused very little inconvenience and scarcely any pain. He never was so heavy in his life, his present weight being 145 pounds.

In closing, I want to plead more earnestly than ever for electro-cautery treatment of sarcoma of the nose. Although in this case the latter indications have all been at the junction of the posterior naris with the naso-pharynx, three-fourths of the original tumor was within the nose and attached therein; and it is

this fact that has enabled me to keep it under control through the wide nasal chamber in its successive developments during the past two years—attacking it vigorously whenever it made its appearance without injury to the surrounding healthy tissues. Another point worthy of mention also is the comparative painlessness of sarcomatous tissue. Week after week this young man has come to my office about 4 p. m., submitted to an operation, returned home for tea, gone to his office at 6 p. m. and worked until 2 a. m. For the ensuing week I would not see him, but the daily routine of work would continue, until he would turn up smiling for the next seance—the only home treatment he would have being a spray at intervals of one of the hydro-carbon oils.

Discussion.

DR. JOHN N. MACKENZIE.—I do not wish to question the correctness of the diagnosis in Dr. Brown's cases, but simply desire to call attention to the fact that it is often an easy thing to confuse the masses of granulation tissue found in accessory sinus disease with sarcoma, not only macroscopically, but often under the microscope. I have in mind a case in point in which a distinguished pathologist (whom every one would recognize as a great authority, were his name to be mentioned), who was with difficulty convinced that a granulation tumor, brought to him for examination, was not a round-celled sarcoma. Any operation on sarcoma of the nose short of the most completely radical one is worse than useless. The prognosis is bad enough even if the disease can be apparently thoroughly removed. Incomplete attempts at removal, no matter what method be used, is simply playing with fire, only to accelerate the end.

DR. CORNELIUS G. COAKLEY.—With relation to the difficulty of diagnosis I would like to report a case which came to my notice last June, that of a little girl, eight years old, who had had polypi removed a number of times in the preceding two years, and at the last removal the physician in whose charge she was had the tissue submitted to a microscopist for report and the diagnosis of sarcoma was made. As the result of this diagnosis the rhinologist made an unfavorable prognosis. The child came to New York for advice. I examined the nose and found the right nasal passage absolutely occluded by what had all the appearance of polypi. Similar tissue was seen on post-nasal examination projecting half an inch down the naso-pharynx. I removed the growth and the report of my pathologist was simply oedematous hypertrophy of the connective tissue. The polypi recurred, and when I returned from my vacation I put the child under a general anaesthetic, and,

believing these polypi were associated with ethmoiditis, and as the nasal cavities were too small to get at the ethmoid cells through the nares, I opened the right antrum and found it completely filled with the same polypi, which were removed. I went from the antrum to the ethmoid cells, removing as many of the cells as seemed infected. The tissue had no appearance of sarcoma and the child has had no recurrence of polypi, the discharge has entirely stopped, and the antrum as well. Subsequently I operated on the antrum on the other side for polypi. In this particular case there was nothing but granulation tissue which was mistaken for sarcoma. I feel that sarcoma is a disease hard to differentiate at times from a granuloma and one seldom cured.

DR. GORDON KING.—I recently have had experience with a case of that nature which is behaving in a peculiar manner. It was a case of a young lady seventeen years of age, who came to my office with the idea that she had simply a turbinal enlargement. I found on examination, however, that while the inferior turbinate was apparently enormously enlarged it was enlarged in a degenerative form; in other words it was almost granular on the surface, neoplastic, and bled very freely on touching with the probe. The upper turbinal region was also filled with this apparently large turbinal tissue, and there was a certain amount of protrusion of the eye on that side, and some interference with the vision. I held a consultation with a local surgeon and we decided that it was sarcoma and probably inoperable, that it had already reached the orbit, and that that alone would make it inoperable. However, we decided upon an exploratory operation. We opened the antrum through the canine fossa and removed quite a mass of granulation tissue, which bled most freely and was very friable. The hemorrhage was so severe that we did not attempt to remove more than two or three drachms of it for microscopical examination. We had to pack the antrum very thoroughly in order to stop the hemorrhage, and nothing further was done. We decided it was inoperable. It was kept under observation for about three weeks. At the end of that time the nasal cavity was almost entirely opened up; what appeared to be the tumor invading the inferior turbinate had disappeared, and the turbinate was in normal condition, except at the posterior extremity, where there was still some enlarged growth. The orbital symptoms had partially disappeared. We could not see into the antrum any more because it had closed up. We still consider it a sarcomatous case and are keeping it under observation. We advised against radical operation; we have not the slightest doubt that it is sarcoma; the microscopical report was mixed-celled sarcoma.

I have another case which was one of the nature referred to by Dr. Mackenzie, perhaps, with the exception that the patient has some orbital symptoms which could not have come from ethmoi-

ditis. I was struck by the amount of hemorrhage which occurred from an ordinary polypoid formation. He complained of intense neuralgia on that side, and at the first examination I pronounced the case ethmoiditis. He came back, however, two weeks later with double vision on that side whenever he looked down, and considerable apparent exophthalmos on that side and the reformation of all the tissue taken from the ethmoidal region. I look upon that case, although I have not had a pathological examination made, as carcinoma or sarcoma.

DR. OTTO T. FREER.—I wish to call attention to a supplementary operation that I have found of great use in removing malignant growths of the palate, pharynx or naso-pharynx. I refer to the ligation of one or both of the external carotid arteries. It is much more difficult than the tying of the common carotid, but unlike this, is a harmless procedure. In order to keep in practice one needs to occasionally tie the external carotids on the cadaver, but is decidedly worth while to do this, for it makes the removal of even large, broadly adherent growths practically bloodless.

In one of my cases a large sarcoma originated in the right fossa of Rosenmueller, filled the naso-pharynx, producing profound deafness and descended in the posterior pharyngeal wall to behind the larynx. This tumor I dissected out deliberately and with practically no hemorrhage after tying the external carotid arteries. The growth was a round-celled sarcoma, and its widespread attachment and deep infiltration of the tissues made me appreciate that my operation was merely palliative, and I did it simply to give the patient relief from the encroaching tumor masses. The effect of the ligation upon the tendency of the tumor to return was nil, for it speedily reappeared.

Another of my cases illustrated the enormous malignancy of some sarcomas. In this patient the tumor originated in the right lower turbinated body. I removed this structure in my first operation with apparently all of the neoplasm and hoped for the possibility of recovery, as some nasal sarcomas are of slight malignancy, but there was a complete recurrence within two weeks, and in a second operation I found that the tumor had absorbed the entire nasal wall of the antrum of Highmore so that when the tumor masses were removed I could freely inspect this cavity. A third return of the growth took place in a few weeks, and the patient's face became hideously deformed by the resistless advance of the tumor to which he speedily succumbed.

DR. JAMES E. LOGAN.—I agree with Dr. Mackenzie and Dr. Coakley as to the necessity of thorough investigation of the pathological condition first, determining surely whether we have a sarcoma or granulation tissue, it being entirely impossible, under ordinary examinations, to determine this point. I have had three cases of sarcoma under observation: two of these cases were in young boys, one of fourteen and the other of sixteen years. The boy of

sixteen was a Swede, who applied to me for operation some four years ago. I found an enormous mass in the vault of the pharynx, with attachments so far as to completely bind the middle turbinated body. I tried various means of relief, the galvano cautery, etc., but the hemorrhages were so profuse that it was impossible to get a galvano cautery near enough to be effective, and I decided to operate. I tied the common carotid first, hoping to get the tumor removed before any collateral circulation would be established. My apprehension was duly justifiable for the reason that I had an enormous hemorrhage. Before I got through with the operation it was necessary to transfuse the patient. This tumor I removed partially by morcellation, and the rest by the cold wire snare. I removed it very completely, taking out the entire external nasal wall; all the sinuses were completely obliterated to the orbital cavity. This case promptly recurred and in the course of time was taken to Chicago because of my refusal to operate. His case was diagnosed there a simple fibroid. He was placed upon the table for operation and promptly died. Post-mortem examination revealed the presence of sarcoma. The second case, the boy of fourteen, was brought to me by his family physician. A careful examination of the growth microscopically revealed a sarcoma. In the light of my previous experience I determined to follow conservative minds. The patient returned home with his physician, who used electrolysis with good success. The growth was very large, filling up the entire right nostril and posterior nares. This method of treatment proved very slow, but very efficient, requiring about six weeks to remove. These cases present such difficulties, and are so disastrous to leave, that I would urge a radical operation only as a last resort. I am inclined to believe that electrolysis offers the best results, its slowness being the only drawback. My third case has been reported previously, and it is hardly necessary to refer to it.

DR. ROBERT C. MYLES.—My experience with sarcoma has not been like that of Dr. Mackenzie. One case which I reported six or eight years ago had been operated upon two or three times previous to my seeing the patient. When he came to New York his antrum was opened and in swabbing it out thick, white, firm tissue was found. After the microscopical examination it was pronounced sarcoma. It had infected all of the antral walls. I asked the general surgeon, Dr. Wyeth, to remove the entire right superior maxilla, which he did, and he also removed the pterygoid bones and muscles and a part of the soft palate, and the specimen showed a protrusion of the sarcomatous mass between the pterygoid bones. There was no doubt about the diagnosis and there has been no recurrence. Another case was that of a woman who had apparently an inoperable sarcoma of the left tonsillar region.

On February 12th, 1897, I removed a part of the soft palate, the palato-glossus and palato-pharyngeus muscles, all of the tonsil

including capsule and part of the superior constrictor muscle and some of the lateral wall of the oropharynx near the base of the tongue. Four pathologists made separate examinations of the tissue, and all reported that it was sarcoma. There has been no recurrence, but the patient has had some neurotic disturbance, due probably to some injury to the pneumogostic nerve.

These are apparently two inoperable cases, both recovered, so I do not think I would let these cases go on to death without an attempt at operation.

DR. ARTHUR W. WATSON.—There seems to be considerable difference in the malignancy of these sarcomas of the nasal cavities. I have met with quite a number, and have formerly looked upon them as hopeless, all having proved fatal, even after extensive external operations. Recently, however, I have seen a case which was under my care ten years ago and for which excision of the jaw was done. The disease recurred in the orbit and the patient disappeared from my observation. I thought he was dead. In reality he had a second operation, and is now—ten years after—perfectly well. About two years ago a girl of sixteen was sent to me, having a growth which filled the nasal cavity and naso-pharynx. Her history was that the growth had been removed a year before but had quickly returned. From that time at short intervals large portions had been removed but had rapidly grown again. I cleared the nose out, but the growth rapidly recurred. The bleeding was profuse. Several other attempts were accompanied by free hemorrhage and were apparently without result. Suspecting that the growth originated in the antrum, I opened the latter through the canine fossa. I found the cavity filled by a growth, which I thoroughly removed, together with that in the nasal cavity. The whole inner wall of the antrum had been destroyed, as well as the turbinates. The result was a complete Caldwell-Luc operation. The pathologist's report was sarcoma. My prognosis was, of course, very unfavorable. Now, however—two years later—the girl is perfectly well.

Recently I have seen reported a somewhat similar case, in which the growth sprang from the antrum but invaded the orbit. In this case curettement of the antrum resulted in cure, and yet the specimens showed sarcoma.

DR. J. PRICE-BROWN.—I am very much pleased that this paper has caused so much discussion, for it deals with a very important subject. I am a little surprised, however, at Dr. Mackenzie's criticism. About two years ago when I first reported the case he did not object to the diagnosis of sarcoma, but now doubts if it is sarcoma at all. The prominent symptoms of the case were constantly recurring hemorrhage and growth. With regard to the microscopic examination, it was examined by three microscopists, all pronouncing it round-celled sarcoma. It has been in the hands of four laryngologists; the first one wanted to perform a

radical operation in order to remove it. He stated that the hemorrhage had been so great that he could not possibly give a prognosis that it would be a cure, or that it would not return. The operation was declined. He was treated for a long time by the X-ray before he came under my hands.

Then, with regard to the treatment. Should I have operated or not after removal the first time? The first time you heard the report of the case there was, so far as could be seen, a complete removal. It has recurred in only one region, the spot upon which the large growth shown two years ago was originally attached. Another point, how should I operate? You would not advise an external operation when the growth could not be seen except by the use of the rhinoscope. If I had tried curetting, the hemorrhage would have been very great. Over and over again the hemorrhages have been severe, but controlled during the treatment by the use of adrenalin and cocaine. It seems to me I was justified in what I did. The first interval of relief was three months; the second was four months; the last interval was nine months; and now I have to wait again. The patient feels perfectly well. The pain is nil, the applications of cocain and adrenalin completely take away all suffering at the time of operation, and he is able to work immediately afterwards. In 1904, the second operation under chloroform, the growth had grown so rapidly that it pressed on the soft palate. This could not have lasted long without producing very serious results; but by removing it, it cleared up entirely. It seems reasonable to continue in the future by the old method, if the growth should again return.

I must say that as some of the gentlemen to-day have reported cases of sarcoma with no return after complete removal, I can believe my own case to be one in which such a result may at least be hoped for.

TONSILLOTOMY, THE BASIS FOR THE TREATMENT
OF TONSILLAR AFFECTION.

BY GEORGE B. HOPE, M.D.

DURING the course of a lecture recently delivered by Sir Felix Semon, at the Long Island Medical College, on Acute Septic Influences of the Throat and Neck, the speaker emphasized the liabilities and dangers of a direct and remote septic influence that lies latent in the morbid conditions of the faucial tonsil. Although the fact is by no means unknown, the variable consequences of neglected tonsillar disease hardly reach a correct appreciation, until owing to extremes of symptoms an ablation is undertaken as a later necessity rather than a preventive in the earlier stages of development. Without directly reaching this conclusion, the lecturer clearly implied that his cases illustrating the abrupt and fatal termination from laryngeal infection would not have occurred except for the presence of this source of origin. Notwithstanding all the advances that the practice of specialism has made in the rational treatment of developing complications, unquestionably very many lives are lost through ineffectual prophylactic measures that allow recurrent and progressive states of disease.

It is notably singular that any definite function for the tonsil has remained among the confessed uncertainties of physiology. Superstitious vagaries have not ceased to envelop this organ with the most varied phenomena: even the virile function, voice alteration, recrudescence, are among the living fallacies that still linger with its association in the minds of the multitude, and are not altogether absent from the consideration of not a few practitioners, and so tend to offer encouragement to the sufferer to bear the ills they have rather than risk the unknown effects and the supposed dangers that stand in the way of a radical relief.

Amygdale, the nomenclature followed by the French, is in some respects preferable to our own, as it implies an approximate measure of shape and size, according to which abnormal contrasts

can be best appreciated. Anatomically considered as within the boundary of the alimentary canal, it is not exaggeration to regard the tonsil as a rudimentary Peyer's patch, possessed of corresponding lymph nodules enveloped in a dense adenoid tissue. However this may be for an organ so diminutive and apparently so unimportant, there are, within the range of a faculty development, disorders among the most striking in the category of organic and reflective disease.

How far can a tonsil be regarded as normal and innocuous? Dr. Bosworth takes the radical view that practically there are no tonsils in the healthy throat. In the progressive purpose of this paper and from clinical observation this dictum is accepted as freely within the limits intended by the author; not that all illustrations of a tonsil present in a degree are in themselves harmful, but that there exists a menace to later secondary conditions advancing after their own kind, and on occasions of extreme exposure they furnish a standing liability to arouse into activity symptoms that otherwise would have remained dormant. Moreover, postponed until a time of necessity, their removal is more apt to be accompanied by greater difficulty and increased risk than is counterbalanced by the earlier appreciation of these consequences.

All anginas are of infectious origin, most generally from without or secondary through constitutional septicaemic production. With reference to this Semon states: "that the infection is usually in the tonsils is easily explainable by the anatomical structure of the parts, because the epithelium covering the glands shows gaps large enough to allow a transit of leucocytes, so that their crypts almost, so to say, invite pathogenic micro-organisms to make the tonsils their first habitat when invading the body." While still without a positive demonstration, it is reasonable to accept the proximate belief that a considerable number of the specific diseases that assail the early years of childhood have some reference to the faucial area as their focus of origin. Diphtheria, without immunity against recurrence, scarlet, measles, parotitis, cervical adenitis with tubercular disposition, laryngeal complications according to varying causations, the habit of mouth-breathing, that is claimed to promote a rapid increase of bacteria to complicate and intensify co-existing conditions, are among the consequences that may be suggested. The relation

between adenoid and tonsil hypertrophy is obscure, but their association in a large proportion of cases suggest some interdependence of development in which the tonsil may play more than a passive role.

With the progression of the tonsil age there are somewhat different conditions that arise as natural consequences to the established hypertrophy. Infantile contagious diseases give place to those in which exposure to more adult environments of climatic changes and the habit of careless living largely constitute the exciting causation. It is doubtful if a lymph body once the seat of an acute inflammatory process ever completely resolves to an original function, and moreover it retains a state of diminished resistance. Among many it is the habit to encourage the belief that time will bring about a stage of atrophy, or an immunity will follow in the course of a maturing constitution, or that the age of puberty will surely eliminate the vicious habits of tissue derangement. The truth lies far from this, and it is in fact that during the later periods the specialist is ever engaged in the treatment of the tonsil sequelae and the effects that are remote but still within its influence. With the most correct intention towards the patient a host of remedies, topical and constitutional, are employed to promote absorption or to seal the mouths of the enlarged crypts, while tonics and alteratives provide against the supposed strumous and rheumatic dispositions. At best the success is but partial and the subject continues his halting way with an imperfect health. In tonsillar mycosis that must run a prolonged and painful treatment, chronic ulcers, recurrent mucous patches, purulent cysts, crypts crowded with malodorous smegma are sufficient indications in favor of more than palliative drugs. The question as to the best rule of action with reference to tonsillotomy in cases of frequent interstitial or peri-tonsillar inflammation that exhibit the supreme type of infectious angina, is answered without hesitancy except for the dread of uncertain hemorrhage, that so naturally influences in the direction of some alternative, even if the results are without the limits of a permanent control. From this point of view it is proper to claim that notwithstanding the reports of free or alarming hemorrhage, these have mostly so far fallen within the resources of the operator as to leave the instances of a fatality to the most minimum figures. Theoretically the vessels supplying the tonsil

are imposing, but practically they appear to be fully able to meet the requirements of physiological haemostasis of contraction-retraction and proper clot formation. A total sum of four fatalities constitute the maximum of cases gathered from all sources at home and abroad by Harmon Smith, and precisely the same number have a place in the list of F. R. Packard.

If statistics possess much of value they are also apt to be misconstrued without a standard of measure by which a collection of isolated cases can be made to agree in the matter of extent and surrounding. This touches closely all reports of hemorrhage that by their apparent frequency have led so many to avoid the tonsillotomy operation altogether or to undertake it only under the most urgent necessity. If it is the part of wisdom to be forewarned against an emergency, however unexpected, it is also injudicious to hesitate over dangers that are sufficiently rare in their happenings and not uncontrollable in their sequence. In the clinics of the Metropolitan Throat Hospital over two thousand cases have received the operation of tonsillotomy, generally double, and commonly with adenoid, and with but two instances of free hemorrhage that were thought of sufficient importance to be placed on record. Extending through a period of more than thirty years, this history can afford to be offered in evidence of the average statistical comparison between the rule and the exception, and establishes so wide a margin of safety as to justify the selection of a procedure that appears to fulfil the most radical and effective conclusion wheresoever a tonsillar degeneracy prevails.

Discussion.

DR. THOMAS J. HARRIS.—I would like to emphasize one point which is also in line with the earlier paper of the morning upon the deflections of the septum in children, namely, that in my judgment there is need of greater care in our tonsillotomies in children. We have been too much in the past in the habit of doing incomplete tonsillotomies in children. We have long since, I think, gotten to the point where our work is thorough when done on an adult, but too often do I see a slice taken off the tonsil in children. The operator working very rapidly for the removal of the adenoid growth and the tonsils finishes the whole operation in a minute and a half and hands the patient over to his assistants. In my judgment, just as the writer of the paper has emphasized, it is very important that we should take out all of the

tonsil that seems to be bulging and in the way, and this cannot, at least in most cases, be accomplished by any one instrument or by any of the rapid methods commonly employed. Too often we are compelled to take five or ten minutes to get all the tissue out thoroughly, and yet I feel when we do this we will not have the complaint which we now so often have from the parents, that the results hoped for have not been realized.

DR. ROBERT C. MYLES.—We have excellent advice in regard to the best methods of procedure in certain classes of tonsillar disease, but for the many classes of basic, basi-lateral and so-called submerged diseased conditions we need more definite rules for the best procedure in the individual conditions.

DR. GEORGE B. WOOD.—I have been especially interested in the tonsillar structures for a number of years. Under the microscope both large and small tonsils are very similar, and outside of the acute conditions and specific inflammations it is most difficult to tell by a microscopical examination whether a tonsil is diseased or in a normal, healthy condition. An hypertrophied tonsil does harm chiefly because of its increased size interfering with the normal functions of the throat; and also because the increased depth of the crypts furnishes a better lodging-place for micro-organisms. The peculiar rarefied condition of the cryptal epithelium is not a sufficient barrier against entrance of micro-organisms and hence the liability to infection. In early childhood the tonsil is undoubtedly physiologically a very important organ; it belongs to the lymphatic system and is very active in the production of leucocytes. The germinating follicles are one source of manufacture of the lymphoid cells. Another source of the lymph cells, peculiar to the tonsillar tissues, is to be found in the metamorphosis of the epithelial cells of the crypts into true lymphoid cells. The epithelium of the crypts is in a state of active growth, both superficially and also towards the tonsil parenchyma; the cheesy material found when there is stenosis of the opening of the crypts is in large part made up of desquamated epithelial cells. The growth of the epithelium into the parenchyma of the tonsil is exaggerated in simple hypertrophy of the tonsil, and its ramifications may frequently be traced through every portion of the tonsil.

The question of surgical interference with the tonsillar tissues of the throat depends upon the seriousness of the symptoms caused by these organs. I do not believe that the tonsil should be removed simply because it exists. On the other hand, if hypertrophy of the organ brings about mechanical obstruction, or recurrent attacks of acute inflammation of the tonsil are interfering with the child's health, or there are evidences of infection of the cervical lymphatics into which the tonsils drain, the importance of the tonsil as a physiological organ becomes insignificant and surgical interference is demanded.

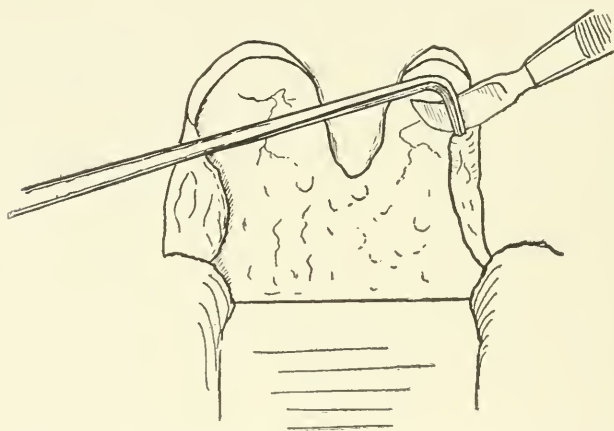
When operating on adults the tonsillar tissues may be removed as thoroughly as possible without interfering with the hematopoietic function of the organism, as most probably Peyer's patches, the adenoid tissue of the appendix, and in fact any adenoid tissue coming into intimate contact with the epithelium carry on the work of the tonsillar tissues of early childhood. In childhood operation on the pharyngeal tonsil should be thorough to an extreme degree; whereas in operating on faucial tonsils in very early childhood I remove only the obstructing portion of the tonsil unless there exists some especial indication for complete removal. In early childhood life it has been my experience that acute inflammation of the faucial tonsils is comparatively rare, whereas inflammation of the pharyngeal tonsil is very common. As the child grows into adult life the reverse of this gradually takes place.

DR. ARTHUR A. BLISS.—I think that Dr. Wood has voiced the opinions of all men who have had experience in this work, that the only treatment for hypertrophy of the tonsils is excision, and now after a long time of uncertainty in the use of instruments we are approaching the use of an instrument of a certain definite type that would seem to give better results than other forms of surgical treatment. I agree thoroughly with the speaker who says there is no known instrument to rely on, but I think of all the instruments devised the tonsil punch in its varying forms is being most universally exploited for this purpose. Long before this was devised I read a paper on the use of a combination of two instruments, the crocodile-jawed forceps and the angular scissors, made in such a way as to prevent separation of the cutting edges of the scissors. Of all the tonsil punches I have tried the one giving me the most satisfaction is that devised by Dr. Farlow. I do not know whether many of you have used it or not. There are two sizes, and the smaller punch is in my hands a most excellent instrument. It has a round cutting jaw and you can remove tissue with great rapidity; it is small enough not to obstruct the view of the field of operation, and is most thorough in its work.

DR. E. FLETCHER INGALLS.—I read a paper last spring at the American Medical Association on the old subject of removal of tonsils by means of a snare, which seems to me an operation that quite meets the indications. By it the tonsil is thoroughly removed, and I believe that thoroughness is necessary. By this operation the tonsil is lifted out of its bed with the forceps and the snare slipped over the end of the forceps is drawn down under the gland so that it practically prevents bleeding and removes the whole mass. I have removed thousands of tonsils in this way, and I do not now recall more than three cases in which there has been a recurrence. However, sometimes even by this method a stump of the tonsil is left, and for this reason I have

adopted a different method when the tonsil cannot all be easily included in the wire loop. In such cases, after separating the tonsil from the pillars of the fauces with the forefinger of my left hand, I separate the tonsil from its capsule before catching it with the tonsil forceps, then I am sure to get the whole mass. In this way the wire slips under the gland, the blood vessels are crushed off, and excepting for the bleeding caused by the separation of the pillar of the fauces there is practically no blood; I think a drachm would cover it all in almost every case. However, large the tonsil it seems to me one can certainly get it off in this way.

DR. OTTO T. FREER.—In a number of cases I have encountered good-sized deep pockets in the shrunken remains of atrophied



Method of opening tonsillar pockets. Pierce's tonsil explorer is inserted in the pocket while the Stacche scalpel, placed external to the explorer, is made to shave off the inner wall of the cavity from above downward.

tonsils in adults giving rise to a chronic, purulent discharge. Norval Pierce has described the situation of these pockets in his article on cholesteatomatous disease of the tonsils in the *Laryngoscope* for May, 1904, and it has been my fortune to several times find suppuration of the sack, which he describes as descending external to the tonsil from the supratonsillar fossa and internal to the tonsillar fascia. He calls this cavity the appendix to the supratonsillar fossa. In addition to suppuration of this appendix I have found dilated suppurating pouches resulting from diseased lacunae also descending to a considerable depth behind or within the tonsil and discharging offensive pus. Mere slitting of these pouches in my experience does only temporary good, as

the wound surfaces created reunite again. For this reason it is my practice now to enter the pouch with Pierce's tonsillar explorer, a rectangular, stiff steel probe, and with this instrument to pull the inner, faucial wall of the pouch strongly inward towards the cavity of the mouth, while a long-handled Stacke scapel, curved on the flat, is passed behind the shank of the probe, between it and the parts above the entrance to the pouch (see illustration), and made to shave off the entire front wall of the cavity broadly from above downward, liberating the probe, and making an open wound of the pocket.

I think that infected pockets of the kind described are often the source of recurrent peritonsillar abscesses.

DR. GEORGE B. HOPE.—I desire to call attention to the importance of having the fauces clean and aseptic, and not to measure so much the size of the tonsil as its other abnormalities. The accepted normal tonsil appears to be merely a fold of tissue, such as one can observe only by close examination, within the cleft formed between the pillars. Ordinarily in this proportion we have a normal tonsil with its covering not rarified and irregular, with the exaggerated crypt formation which encourage any course of local disease; but it is with reference particularly to the phases of the abnormal tonsil in which the infections seemed to find their best point for development in the crypts and recesses, and in which the earlier extirpation of the tonsil seems to be thoroughly satisfactory in relieving not only a present status but also the tendency to intercurrent diseases.

With reference to Dr. Myles' question as to the difficulties in the removal of the tonsil it seems to me the more instruments one possesses the more at a loss one becomes in a reliance upon their efficiency. It should not be necessary to have a special instrument for every case. For many years back the Mackenzie tonsillotome has been in use almost altogether in the 2,000 operations which have taken place at the Throat Hospital and in which no difficulty has been encountered.

AN UNUSUAL CASE OF OEDEMA OF THE GLOTTIS.

BY EMIL MAYER, M.D.

THE patient, a male, aged 51, was admitted to the surgical ward of Mt. Sinai Hospital in the service of Dr. A. G. Gerster, with the diagnosis of dyspnoea.

His history, for which I am indebted to the courtesy of Dr. S. Heiman, house surgeon, was as follows: Family history negative. Had typhoid at the age of ten. Had a chronic cough with muco-purulent expectoration, never bloody; no night sweats or dyspnoea; no swelling of feet; had never had syphilis or gonorrhoea; is a heavy smoker. Married, the father of two children, both of whom are living. His voice has always been clear; has never had an attack like the present one, but has awakened at night with a sensation of choking, which he attributed to his cough.

His present illness began on April 1st, when he awoke with a pain in the neck on the right side, the attack of dyspnoea coming on suddenly. He rapidly became worse in spite of leeches to his neck and cups to his chest. His voice was that of a whisper, and no relief forthcoming, he was transferred to the hospital April 2nd, at 4 p. m.

On admission he had severe respiratory dyspnoea and could not lie down; his lips and finger-tips were cyanosed. All accessory muscles of chest were brought into play on inspiration and expiration and many moist rales. Respiration 14 per minute. Heart action rapid and forcible. Pulse equal, rapid and regular; slight tension. Profuse mucous discharge from mouth and throat; breath foetid and the epiglottis could be felt as a thick, hard ridge.

Two hours later, in response to an urgent summons, I saw the patient. He was seated upright in the room adjacent to the operating theatre, whither he had been conveyed preparatory to a tracheotomy, if such was deemed necessary.

The history given by Dr. A. A. Berg, the adjunct attending

surgeon, was that as outlined above. The dyspnoea had been constant for the last 36 hours, steadily increasing since his admission.

The expression of the patient was most anxious; he was cyanotic, his breathing very labored with notable inspiratory difficulty. There was a gurgling sound to each inspiratory effort and quantities of mucus were expelled.

The laryngoscopic examination showed a large glistening mass at the base of the tongue, at the right side, filling the entire pyriform sinus on that side and extending over the epiglottis to such an extent as to leave but a narrow opening on his left side for breathing.

The appearance of the mass was that of an oedematous infiltration, immobile on respiratory effort, yielding to the touch of a probe. Except on the left side the epiglottis could not be seen and an intralaryngeal examination was impossible.

The diagnosis of an acute septic inflammation was made, the parts were freely cocaineized and a deep incision was made with the Hartman laryngeal knife in the presence of Dr. Berg, Dr. Moschowitz, Dr. Libman and the house staff. A quantity of thick, bloody and ill-smelling fluid exuded, and the patient was returned to the ward.

A spray of adrenalin 1-5,000 was frequently applied, subsequently alternating with steam inhalations. His urgent distress was promptly relieved, his breathing became quieter from hour to hour, and all inspiratory difficulty ceased on the second day.

A laryngoscopic examination then showed a large white slough where the oedematous mass had been. A portion of this was removed and examination showed the presence of staphylococcus albus and streptococcus. His dysphagia also became less and less, the lymph deposit entirely disappeared and in the same place there was now a solid mass of new growth of firm consistency lying in the pyriform sinus covering three-fourth of the epiglottis, but not adherent thereto, and which did not interfere with deglutition or respiration. The glands of the neck were not enlarged.

The patient's recovery was rapid, and on April 15th he was discharged from the hospital as cured of his dyspnoea and became an ambulatory patient in my service in the out-patient department of the hospital.

A small piece of the mass was now removed with the punch for the purpose of ascertaining the true nature of the growth, and as the report of the pathologist was negative a much larger portion was then removed with the snare to insure an examination of the deeper tissues. The report of the pathologist, Dr. F. S. Mandelbaum, was that there was no evidence of anything other than connective tissue in either specimen.

The question of malignancy having been thus excluded it was evident that this mass was of recent formation and composed of purely inflammatory tissue. Within a short time no further evidence of the growth could be seen and there were no symptoms of any annoyance referable to the throat.

A laryngoscopic examination of the patient made six weeks after the attack showed a most unusual state of affairs as regards the epiglottis. More than half of the epiglottis on the patient's right had sloughed away and a band of adhesion formed, running across the lateral pharyngo-laryngeal space on that side. The remaining portion of the epiglottis on the patient's left stood erect, like an index finger, and here two bands of adhesion existed from the epiglottis to the lateral pharyngeal wall. Both of these bands were about one-half inch in length; there was no abnormality within the larynx.

The patient has regained his former health and strength and bears all the outward appearance of being entirely well.

The point of interest in this case lies in the fact that we have before us a case of oedema of the glottis engrafted upon an hereditary syphilis of the epiglottis, which latter never produced any notable symptoms relative to the throat except perhaps the constant cough of 28 years' duration. The patient recalls that fluids would often come through the nose of late years. The absence of any initial lesion, as also of any evidence of the disease elsewhere, would point most strongly to the hereditary nature of the affection. In fact, the only other condition aside from malignancy that could be present is lupus, and this may be excluded by the absence of tubercle bacilli in any of the specimens examined by the pathologist, and also by the absence of any breaking down of the cicatrized surface, a fact which would occur in all probability immediately after the acute process just ended.

The presence of so large a mass of inflammatory tissue beneath an oedematous process is also remarkable.

This case further illustrates the advantage of prompt, free and deep incisions into the oedematous tissue, thus avoiding the graver operation of tracheotomy, and emphasizes the value of adrenalin in the subsequent treatment of these conditions, corroborating the statement made in a recent article by Dr. Thomas R. French, of Brooklyn.

Discussion.

DR. HENRY L. SWAIN.—I think Dr. Mayer's paper is a most interesting demonstration of how we occasionally are thoroughly in the dark as to the sort of lesion with which we have to deal. I had a similar experience where I was called in, in the case of oedema following tonsillitis. There was enormous arytenoid swelling and oedema; the distress in breathing was extremely threatening. The patient walked into my office, but I did not know whether he could get out without a tracheotomy. Apparently he seemed to react and to get a good deal of satisfaction out of the usual form of treatment, spraying with adrenalin and multi-puncture. I felt satisfied he would get home all right and without trouble. As I later became better acquainted with the case I found that part of the enlargement of the arytenoid was chronic. The oedema was not as great as I at first supposed, and the lumen of his larynx was normally extremely small for a man of his stature. I have watched him for about six years now, and find he is developing acromegaly with probable constant enlargement of the laryngeal cartilages.

DR. ROBERT C. MYLES.—This case reminds me of one I had not long since which was very interesting in its pathology. The patient was a man about fifty years old whom I was treating for an ear affection. He came from a distant city. One morning he stated that he had difficulty in breathing. I therefore looked into the larynx and found the left vocal cord to be four or five times larger than the right, perfectly clear and jelly-like in appearance with oedema. There was decided oedema of the left arytenoid. His tonsils did not seem to be very large but there was a little redness. The base of the tongue was swollen on the left near the hyoid bone and he complained of some feeling of fullness there. I made several incisions into the arytenoid and let out a lot of serum, reduced the swelling a little and commenced to investigate the right tonsil; the upper part seemed to be fairly normal, but beneath the lowest part of the tonsil there was a swollen and hardened condition. I dissected the tonsil out and found beneath a cavity full of pus about one inch long and one-half inch wide, with a cystic wall, and which had evidently been

there for a long time, and I removed part of its wall and could introduce an instrument almost down to the arytenoid. It had evidently been discharging through a fistula, and if I had not opened this abscess, which was very obscure, a tracheotomy would have been necessary. There was some oedema of the epiglottis also. The patient recovered rapidly.

DR. CHARLES W. RICHARDSON.—When we have seen such cases as have been narrated by the essayist, and I have seen several, it must interest us to know what treatment others apply to meet existing conditions. I saw one case this spring, which, on account of the attending circumstances, was extremely distressing. It is not necessary to go into details. I would simply note the marked relief given to the oedema by incision into the oedematous tissues. After the oedema subsided there were noted large masses on each side of the pharynx, excluding any view of the laryngeal interior. This case was a constitutional one, being secondary to diabetes. The distress in breathing disappeared and the patient died, apparently from diabetic coma. Another case which I saw corresponded in every detail to the one spoken of by Dr. Myles, excepting there was no destruction of tissue as obtained in his case. Undoubtedly it was of syphilitic origin. This brings me to the point wherefore I arose to speak, and that is in these cases of oedema, gradual or sudden in onset, we should bear in mind the possibility of a constitutional vice which is producing, or rather is the great underlying cause of the oedema. I have noted the conditions secondary to gonorrhea. I observed one very interesting case secondary to a gonorrheal inflammation of the arytenoid articulation. They are the conditions, the constitutional disturbances, which are the underlying factors in these cases of marked oedema. Of course, in Dr. Myles' case it appears as though the condition was local in origin. Nevertheless, we know in those cases where we have destruction of tissues attended with edema that there may be a systemic infection.

DR. EMIL MAYER.—I am glad to hear of corroborative cases. I have heard it said that a distinguished otologist once stated that the laryngologists and rhinologists were not worth much because they did not save life, anyway. I think the few cases presented here gives the contradiction to that without any question. I would like to emphasize again the fact that adrenalin seems to have a very beneficial effect in all cases of acute septic conditions, and, as far as I know, Dr. French, of Brooklyn, was the first to call attention to this and the first to report a successful case.

PRESENTATION OF INSTRUMENTS AND SPECIMENS.

Dr. John M. Ingersoll presented sections of the nasal structures and accessory cavities prepared from the skulls of man, the monkey, bear, wolf, fox, seal and sheep. Studies based on these

preparations were presented as his candidate's thesis for membership in the Association in 1904. (See Transactions, 1904, page 276.) Remarks on the preparations were made by Drs. Simpson and Bryan.

Dr. Francis R. Packard exhibited a painting showing a large vaccination sore just within the left nasal vestibule. The patient was a girl, nine years of age, who had a typical vaccination sore on her left arm. She scratched the sore and subsequently picked her nose, the result being the appearance of the sore above described. The sore in the child's nose healed without any complications within one week after its appearance.

Dr. James E. Newcomb referred to a similar case recently reported in one of the journals (*Lublinski Münch. Med. Wochenschr.*, No. 52, 1904). In this instance the mother of a child with a discharging vaccine vesicle had used her handkerchief to remove the discharge and had thereby infected her own nostril. (The literature of the subject is summarized in the article referred to.)

Dr. J. Payson Clark exhibited a scissors which he had found of service in performing the "window-resection" operation upon the nasal septum.

Dr. Robert C. Myles exhibited a set of instruments devised by him for various intra-nasal operations. The collection included scissors, cutting forceps, curved chisels and hooks.

Dr. Gordon King showed a vegetable preparation called Penghawar-Djambi, which has been used for purposes of hemostasis. It consists of a fuzzy, silky material derived from certain species of East India ferns and resembles in general appearance finely picked oakum. It is applied directly to the site of operation and has a decided astringent effect. It probably contains a large proportion of tannin and possibly some iron salts. Most of the writers who have reported on its use have inclined to regard its action as mechanical, as, owing to its fine structure, it permits of the easy formation of the clot. Dr. King stated that he had used it several times with considerable satisfaction. It comes in a sterile form in tin boxes and is prepared by the Pharmacie Vicario, 17 Boulevard Haussmann, Paris.

Dr. James E. Newcomb stated that he had procured some of the preparation one year ago and had used it at times since, but was not prepared to accept, on the ground of his own personal experience, the truth of the remarkable claims made for its efficiency by the French writers.

AMERICAN LARYNGOLOGICAL ASSOCIATION.
BUSINESS MEETING.

THE Twenty-seventh Annual Congress of the American Laryngological Association assembled at the Hotel Chelsea, Atlantic City, N. J., Thursday, June 1st, 1905, and was called to order by the President, Dr. Clarence C. Rice, of New York City, at 10 A. M. During the sessions of the Congress, the following Active Fellows were registered:

T. P. BERENS, New York City.
H. S. BIRKETT, Montreal, Canada.
A. A. BLISS, Philadelphia, Pa.
J. PRICE-BROWN, Toronto, Canada.
J. H. BRYAN, Washington, D. C.
W. E. CASSELBERRY, Chicago, Ill.
W. F. CHAPPELL, New York City.
J. P. CLARK, Boston, Mass.
C. G. COAKLEY, New York City.
L. A. COFFIN, New York City.
D. B. DELAVAN, New York City.
W. J. FREEMAN, Philadelphia, Pa.
O. T. FREER, Chicago, Ill.
RICHARD FROTHINGHAM, New York City.
J. W. GLEITSMANN, New York City.
T. H. HALSTED, Syracuse, N. Y.
T. M. HARDIE, Chicago, Ill.
T. J. HARRIS, New York City.
J. H. HARTMAN, Baltimore, Md.
G. B. HOPE, New York City.
F. E. HOPKINS, Springfield, Mass.
THOMAS HUBBARD, Toledo, Ohio.
FRANK HYATT, Washington, D. C.
E. F. INGALS, Chicago, Ill.
J. M. INGERSOLL, Cleveland, Ohio.
SAMUEL JOHNSTON, Baltimore, Md.
GORDON KING, New Orleans, La.

C. H. KNIGHT, New York City.
D. B. KYLE, Philadelphia, Pa.
J. E. LOGAN, Kansas City, Mo.
A. W. MACCOY, Philadelphia, Pa.
J. N. MACKENZIE, Baltimore, Md.
G. H. MAKUEN, Philadelphia, Pa.
EMIL MAYER, New York City.
T. M. MURRAY, Washington, D. C.
R. C. MYLES, New York City.
J. E. NEWCOMB, New York City.
F. R. PACKARD, Philadelphia, Pa.
W. P. PORCHER, Charleston, S. C.
C. C. RICE, New York City.
G. L. RICHARDS, Fall River, Mass.
C. W. RICHARDSON, Washington, D. C.
J. O. ROE, Rochester, N. Y.
W. K. SIMPSON, New York City.
H. L. SWAIN, New Haven, Conn.
C. F. THEISEN, Albany, N. Y.
A. B. THRASHER, Cincinnati, Ohio.
A. W. WATSON, Philadelphia, Pa.
G. B. WOOD, Philadelphia, Pa.

Total, 49.

After the reading of the President's Address, and the papers assigned for the morning, the Association went into executive session. The first order of business was the election of new members. The following were the candidates:

For Active Fellowship:

Dr. LEWIS A. COFFIN, New York City, proposed by Drs. Simpson and Harris. Thesis, "The Choice of Operation for the Relief of Chronic Empyema of the Frontal Sinus and the Anterior Ethmoid Cells."

Dr. OTTO T. FREER, Chicago, Ill., proposed by Drs. Ingals and Casselberry. Thesis, "Deflections of the Nasal Septum; a Critical Review of the Methods of their Correction by the Window Resection, with a report of 116 Operations."

Dr. CHARLES P. GRAYSON, Philadelphia, Pa., proposed by Drs. Makuen and Kyle. Thesis, "Some Follies of the Vocalist."

Dr. THOMAS H. HALSTED, Syracuse, N. Y., proposed by Drs.

Renner and McKernon. Thesis, "Angio-Neurotic Oedema involving the Upper Respiratory Tract."

Dr. GEORGE L. RICHARDS, Fall River, Mass., proposed by Drs. Coakley and C. H. Knight. Thesis, "My Personal Experience with Empyemata of the Frontal Sinus with Deductions Therefrom."

Dr. GEORGE B. WOOD, Philadelphia, Pa., proposed by Drs. Bliss and Bryan. Thesis, "The Lymphatic Drainage of the Faucial Tonsils."

The Tellers, Drs. Frothingham and Theisen, reported that all the candidates had been unanimously elected.

Drs. Berens and King were appointed a committee to audit the Treasurer's accounts.

The election of a Committee of Five to nominate officers for the ensuing year resulted as follows: Dr. Bryan, Chairman; Drs. Makuen, Casselberry, Roe and King. Adjournment at one o'clock.

The Congress re-assembled at three o'clock and the afternoon was given up to the symposium on sinus disease and discussion thereon. In the evening the Association dined with the President at the Café of the Hotel Windsor.

At the executive session preceding the scientific business of Friday, June 2nd, the following reports were read and accepted:

Secretary's Report.

In accordance with the requirements of the Constitution, the Secretary herewith presents the Transactions for 1904, which were distributed December 1st. His absence from home for the summer months was the cause of this late distribution. The latter may be expected under our present publishing arrangement about October 1st of each year.

There have been no deaths among the membership during the year. One Active Fellow has resigned. With the gentlemen elected yesterday, the Active Fellowship now numbers 79; the Corresponding Fellowship, 30, the constitutional limit.

At the Congress of 1904 it was voted that the Association should send a congratulatory letter to our sole Honorary Fellow, Senor Manuel Garcia, on the occasion of his centenary celebration on March of the current year. By vote of the Council at the January meeting of this year, the letter was engrossed and sent in creditable form. The text of the letter was as follows:

THE AMERICAN LARYNGOLOGICAL ASSOCIATION.

TO SENOR MANUEL GARCIA.

Greeting.

With feelings of great gratification the American Laryngological Association has heard from its sister society in London of the proposed celebration of your centenary birthday, and begs to assure you of its hearty sympathy with the arrangements for the commemoration of this remarkable event.

As the oldest national society devoted to the study of diseases of the nose and throat, it extends to you its sincere congratulations. For twenty-four years your name has been on the roll of its Honorary Fellowship and it has been deeply conscious of the honor this name has conferred upon it. It congratulates you upon the rounding out of a century of useful life. Your great discovery of fifty years ago unlocked the portals to a portion of the body whose maladies were previously hidden from a clear understanding by the medical practitioner. To few men is it given to see the results of their work so redound to the welfare of mankind. Through the outcome of your genius physicians the world over have been able to do much to relieve human suffering and prolong human life.

That your last days may be your best days is the ardent wish of all the members of this Association who count themselves happy in joining in the tribute of respect which comes to you from all lands wherein scientific medicine has a home.

By direction of the Twenty-sixth Annual Congress of the Association, held at Atlantic City, N. J., June 2nd-4th, 1904.

J. H. HARTMAN, M.D., Baltimore, Md., *President*.

J. E. NEWCOMB, M.D., New York City, *Secretary*.

A reply was received from Senor Garcia, and is herewith presented:

MON ABRI, CRICKLEWOOD, Mars 17me, 1905.

THE AMERICAN LARYNGOLOGICAL ASSOCIATION.

En vous adressant ces mots, Messieurs, j'obéis aux sentiments qui m'inspirent et qui me remplissent le coeur. Je viens vous exprimer ma vive reconnaissance non seulement pour toutes les marques de bonté, de bienveillance, de sympathie que j'ai reçues:

mais encore pour les honneurs dont vous m'avez comblé qui dépassent tout ce que des rêves ambitieux auraient pu suggérer.

Je voudrais que chaque Société, chaque membre qui l'a représentée sache que je sens et apprécie profondément l'importance des démarches de toutes sortes qu'ils ont du faire sans égard aux inconvénients possibles.

Croyez moi, votre sincère,

MANUEL GARCIA.

During the year two meetings of the Council have been held, and the minutes will now be read.

In reply to inquiries on the subject, the Secretary would state that the Association has on hand a number of copies of Transactions of past years. Some of the earlier issues as well and the issue of 1894 are out of print. These volumes are sold to all purchasers at the uniform price of \$2.50 per volume. By a vote of the Council, they are donated at the discretion of the Secretary free of cost to medical libraries desiring them, except that a charge as above indicated is made for all volumes previous to 1888.

Respectfully submitted,

JAMES E. NEWCOMB, M.D., *Secretary*.

Annual Report of the Treasurer, 1904-1905.

Receipts.

Balance from old account.....	\$299.87
Sale of dinner tickets, 1904.....	200.00
Sale of Transactions.....	36.52
Contributions to Garcia Memorial Fund.....	265.00
Arrears of dues and assessments.....	65.00
Dues for current year.....	680.00
Exchange on check.....	.25
Total	\$1,546.64

Expenditures.

Paid annual dinner, 1904.....	\$205.00
Stenographer's bill, 1904.....	90.20
Publishing Transactions, 1904.....	644.70
Payments to London Treasurer Garcia Fund.....	265.00

Engrossing Garcia Address.....	20.00
Programmes, Congress 1905.....	21.50
Printing and stationery.....	46.60
Expenses of office of Secretary and Treasurer.....	24.73
	<hr/>
Total expenditures.....	\$1,317.73
Cash to new account.....	228.91
	<hr/>
Total	\$1,546.64

Statement of Assets and Liabilities, June 1st, 1905.

Assets—Cash in bank as per report.....	\$228.91
Unpaid dues.....	60.00
Postage in office.....	1.81
Due from E. R. Pelton.....	5.00
	<hr/>
Total assets.....	\$295.72
Liabilities, none.	

Respectfully submitted,

JAMES E. NEWCOMB, *Treasurer.*

Atlantic City, June 2nd, 1905.

Audited and found correct.

(Signed)

T. PASSMORE BERENS,
GORDON KING,

Auditing Committee.

Report of the Librarian.

The Librarian has to report that since the last meeting 60 pamphlets and 2 bound volumes have been added to the library.

Respectfully submitted,

J. H. BRYAN,
Librarian.

The Committee on Nominations presented, through its Chairman, Dr. Bryan, the following report:

For *President*—Dr. J. W. Gleitsmann, New York City.

For *First Vice-President*—Dr. J. L. Goodale, Boston, Mass.

For *Second Vice-President*—Dr. C. W. Richardson, Washington, D. C.

For *Secretary and Treasurer*—Dr. J. E. Newcomb, New York City.

For *Librarian*—Dr. J. H. Bryan, Washington, D. C.

For *Member of the Council* (to serve for four years)—Dr. C. C. Rice, New York City.

The date and place of meeting for 1906 shall be left to the discretion of the Council.

The following resolutions were adopted:

Voted, That the Association shall continue to publish its own Transactions:

Voted, That the Treasurer be and hereby is authorized to borrow, if necessary, funds not exceeding five hundred dollars to defray the cost of their publication for 1905.

Voted, That an appropriation of twenty-five dollars be made toward the expenses of the American Committee of the International Medical Congress of 1906.

At the close of the executive session the reading of papers was resumed and was continued at the afternoon session. At seven in the evening the annual dinner was held at the Hotel Chelsea. Forty Fellows were in attendance and two guests, Drs. John Rogers, of New York City, and George Scott, of Atlantic City.

At the closing session of Saturday morning, June 3d, the reading of papers and discussion thereon was concluded. At the executive session following, the report of the Nominating Committee was again read and the Secretary was instructed to cast a ballot in its favor. This was done and the nominees were declared elected.

The retiring President, Dr. Rice, appointed Drs. Johnston and Hardie a committee to escort the President-elect, Dr. Gleitsmann, to the chair. On taking the chair, Dr. Gleitsmann made a few remarks expressing his sense of the honor conferred upon him and, by vote of the Fellows, conveyed the thanks of the Association to Dr. Rice for the latter's faithful service and courtesies to the Fellows. Dr. Rice, in turn, expressed the very great pleasure the Congress had afforded to all present and thanked the Fellows for their cordial support.

There being no further business, the Congress adjourned.

JAMES E. NEWCOMB, M.D.

Secretary.

LIST OF MEMBERS.

Active Fellows.

1906.

- 1880. BEAN, C. E., Germania Life Bldg., St. Paul, Minn.
- 1904. BERENS, T. PASSMORE, 35 Park Ave., New York.
- 1893. BIRKETT, HERBERT S., 252 Mountain St., Montreal.
- 1893. BLISS, ARTHUR AMES, 117 South 20th St., Philadelphia, Pa.
- 1878. BOSWORTH, FRANK H., 41 Park Ave., New York.
- 1901. BROWN, J. PRICE, 37 Carlton St., Toronto, Can.
- 1892. BROWN, M. R., 34 Washington St., Chicago, Ill.
- 1891. BRYAN, J. H., 818 17th St., Washington, D. C.
- 1889. CASSELLBERRY, WILLIAM E., 34 Washington St., Chicago, Ill.
- 1896. CHAPPELL, WALTER F., 7 East 55th St., New York.
- 1897. CLARK, J. PAYSON, 409 Marlborough St., Boston, Mass.
- 1902. COAKLEY, C. G., 49 West 58th St., New York.
- 1899. COBB, FREDERIC C., 11 Marlborough St., Boston, Mass.
- 1905. COFFIN, LEWIS A., 49 West 50th St., New York.
- 1878. COHEN, J. SOLIS, 1824 Chestnut St., Philadelphia, Pa.
- 1893. COOLIDGE, A., JR., 613 Beacon St., Boston, Mass.
- 1882. DEBLOIS, THOMAS AMORY, 48 Gloucester St., Boston, Mass.
- 1881. DELAVAN, D. BRYSON, 1 East 33d St., New York.
- 1892. FARLOW, J. W., 234 Clarendon St., Boston, Mass.
- 1901. FREEMAN, W. J., 1832 Spruce St., Philadelphia, Pa.
- 1905. FREER, OTTO T., 34 Washington St., Chicago, Ill.
- 1879. FRENCH, THOMAS R., 150 Joralemon St., Brooklyn, N. Y.
- 1897. FROTHINGHAM, RICHARD, Sydenham Bldg., Madison Ave. and 58th St., New York.
- 1878. GLASGOW, WM. C., 2847 Washington Ave., St. Louis, Mo.
- 1880. GLEITSMANN, J. W., 46 East 25th St., New York.
- 1898. GOODALE, J. L., 397 Beacon St., Boston, Mass.
- 1905. GRAYSON, CHARLES P., 251 South 16th St., Philadelphia, Pa.

1905. — HALSTED, THOMAS H., 831 University Block, Syracuse, N. Y.
1896. HARDIE, T. MELVILLE, 34 Washington St., Chicago, Ill.
1903. HARRIS, T. J., 117 East 40th St., New York.
1878. HARTMAN, J. H., 5 West Franklin St., Baltimore, Md.
1888. — HINKEL, F. WHITEHILL, 581 Delaware Ave., Buffalo, N. Y.
1881. HITCHCOCK, URBAN G., 51 West 29th St., New York.
1893. HOPE, GEORGE B., 133 West 72d St., New York.
1895. HOPKINS, F. E., Springfield, Mass.
1895. HUBBARD, THOS., 205 Ontario St., Toledo, O.
1901. HYATT, FRANCK, 1022 14th St. N. W., Washington, D. C.
1878. INGALS, E. FLETCHER, 36 Washington St., Chicago, Ill.
1904. INGERSOLL, JOHN M., 50 Euclid Ave., Cleveland, Ohio.
1882. IVES, FRANK L., 117 East 30th St., New York.
1878. JOHNSTON, SAMUEL, 204 West Monument St., Baltimore, Md.
1901. KING, GORDON, 624 Gravier St., New Orleans, La.
1885. KNIGHT, CHARLES H., 147 West 57th St., New York.
1878. KNIGHT, FREDERICK I., 195 Beacon St., Boston, Mass.
1898. KYLE, D. BRADEN, 1517 Walnut St., Philadelphia, Pa.
1880. LANGMAID, SAMUEL W., 71 Newbury St., Boston, Mass.
1878. LEFFERTS, GEORGE MOREWOOD, 212 Madison Ave., N. Y.
1894. LELAND, GEORGE A., 669 Boylston St., Boston, Mass.
1903. LINCOLN, WILLIAM, Lemox Bldg., Euclid Ave. and Erie St., Cleveland, O.
1897. LOGAN, JAMES E., 1208 Wyandotte St., Kansas City, Mo.
1888. LOWMAN, JOHN H., 441 Prospect St., Cleveland, O.
1886. — MACCOY, ALEXANDER W., 216 South 15th St., Philadelphia, Pa.
1883. MACKENZIE, JOHN N., 605 Washington Place, Baltimore, Md.
1898. MAKUEN, G. HUDSON, 1627 Walnut St., Philadelphia, Pa.
1896. MAYER, EMIL, 25 East 77th St., New York.
1899. MCKERNON, J. F., 62 West 52d St., New York.
1904. MOSHER, HARRIS P., 828 Beacon St., Boston, Mass.
1892. MURRAY T. MORRIS, 17th and H Sts., Washington, D. C.
1901. MYLES, ROBERT C., 46 West 38th St., New York.
1893. NEWCOMB, JAMES E., 118 West 69th St., New York.
1903. PACKARD, FRANCIS R., 1831 Chestnut St., Philadelphia, Pa.

1892. PORCHER, W. PEYRE, 85 Broad St., Charleston, S. C.
 1878. PORTER, WILLIAM, 3886 Washington Ave., St. Louis, Mo.
 1903. RENNER W. SCOTT, 361 Pearl St., Buffalo, N. Y.
 1897. RHODES, J. EDWIN, 100 State St., Chicago, Ill.
 1884. RICE, CLARENCE C., 123 East 19th St., New York.
 1905. RICHARDS, GEORGE L., 84 North Main St., Fall River,
 Mass.
 1902. RICHARDSON, C. W., 1317 Connecticut Ave., Washington,
 D. C.
 1893. ROALDES, A. W. DE, 624 Gravier St., New Orleans, La.
 1879. ROE, JOHN O., 44 Clinton Ave. South, Rochester, N. Y.
 1878. SHURLY, E. L., 32 Adams Ave. W., Detroit, Mich.
 1892. SIMPSON, WILLIAM K., 952 Lexington Ave., New York.
 1889. SWAIN, HENRY L., 232 York St., New Haven, Conn.
 1903. THEISEN, CLEMENT F., 172 Washington Ave., Albany,
 N. Y.
 1892. THRASHER, A. B., The Grotton, 7th and Race Sts., Cin-
 cinnati, Ohio.
 1892. WAGNER, HENRY L., 522 Sutter St., San Francisco, Cal.
 1892. WATSON, A. W., 126 South 18th St., Philadelphia, Pa.
 1905. WOOD, GEORGE B., 129 South 18th St., Philadelphia, Pa.
 1890. WRIGHT, JONATHAN, 44 West 49th St., New York.

HONORARY FELLOW.

1880. GARCIA, MANUEL, Mon Abri, Shoot-up-Hill, Cricklewood,
 London, N. W., England.

CORRESPONDING FELLOWS.

1880. BRUNS, PAUL, Tübingen, Württemberg, Germany.
 — 1896. CHIARI, OTTOKAR, Bellariastrasse 12, Vienna, Austria.
 1901. COLLIER, MAYO, 145 Harley St., Cavendish Square, Lon-
 don W., England.
 1890. DE LA SOTA Y LASTRA, R., 7 Calle de Torqueros, Seville,
 Spain.
 1893. DESVERNINE, C. M., Cuba 52, Havana, Cuba.
 — 1904. FRAENKEL, B., Bellevue-Strasse 4, Berlin W. 9, Germany.

- 1901. GRANT, DUNDAS, 18 Cavendish Square, London W., Eng-
land.
- + 1902. HEYMANN, PAUL, 60 Lützowstrasse, Berlin W., Germany.
- 1894. HOLDEN, E., 13 Central Ave., Newark, N. J.
- 1892. KRAUSE, H., Kronprinzenufer, 15, Berlin, N. W., Germany.
- 1881. LABUS, CARLO, Piazza Castello 28, Milan, Italy.
- 1902. LERMOYEZ, MARCEL, 20 Rue de la Boetie, Paris, France.
- 1897. LUC, H., 54 Rue de Varenne, Paris, France.
- 1903. MCBRIDE, P., 16 Chester St., Edinburgh, Scotland.
- 1896. MACDONALD, GREVILLE, 85 Harley St., Cavendish Square,
London W., England.
- 1894. MACINTYRE, JOHN, 179 Bath St., Glasgow, Scotland.
- 1892. MASSEI, F., 4 Piazza Municipio, Naples, Italy.
- 1887. MOURE, E. J., 25 Cours du Jardin-Public, Bordeaux,
France.
- 1896. MYGIND, HOLGER, 31 Havnegade, Copenhagen, Denmark.
- 1901. NATIER, MARCEL, 12 Rue Caumartin, Paris, France.
- 1903. ONODI, A., o' Uctza 12, Buda-Pesth, Hungary.
- 1894. SAJOUS, C. E., 2043 Walnut St., Philadelphia, Pa.
- 1901. SCHMIDT, MORITZ, Sachsenhausen, Schaumainkai, 15,
Frankfort, Germany.
- 1896. SCHMIEGELOW, ERNEST, ix—2 Mariannengasse 3, Copen-
hagen, Denmark.
- 1881. SCHROETTER, LEOPOLD V., Schwartzenburgstrasse 8,
Vienna, Austria.
- 1881. SEMON, SIR FELIX, 39 Wimpole St., Cavendish Square,
London W., England.
- 1902. THOMSON, ST. CLAIR, 28 Queen Anne St., Cavendish
Square, London W., England.
- 1903. TILLEY, HERBERT, 89 Harley St., Cavendish Square, Lon-
don W., England.
- 1901. WINGRAVE, WYATT, 11 Devonshire St., Portland Place,
London W., England.
- 1894. WOLFENDEN, R. NORRIS, Rougemont, Seaford, Sussex,
England.

PAST MEMBERS.

Honorary Fellowe.

- *1883. Sir Morell Mackenzie, London, England.

Corresponding Fellowes.

- *1892. Lemox Browne, London, England.
- *1887. A. Gouguenheim, Paris, France.
- *1880. Wilhelm Meyer, Copenhagen, Denmark.
- *1881. Pugin Thorton, London, England.
- *1881. R. Voltolini, Breslau, Germany.
- *1880. W. McNeil Whistler, London, England.

Active Fellowes.

- *1880. Harrison Allen, Philadelphia, Pa.
- *1878. Morris J. Asch, New York.
- 1895. J. E. Boylan, Cincinnati, Ohio.
- *1883. C. W. Chamberlain, Hartford, Conn.
- *1882. S. Hartwell Chapman, New Haven, Conn.
- 1884. S. Solis-Cohen, Philadelphia, Pa.
- 1880. E. W. Cushing, Boston, Mass.
- 1878. Ephraim Cutter, Boston, Mass.
- *1880. W. H. Daly, Pittsburgh, Pa.
- *1878. F. H. Davis, Chicago, Ill.
- *1901. E. T. Dickerman, Chicago, Ill.
- *1878. Frank Donaldson, Baltimore, Md.
- 1886. Frank Donaldson, Jr., Baltimore, Md.
- *1879. J. H. Douglas, New York City.
- *1879. W. F. Duncan, New York City.
- *1878. Louis Elsberg, New York City.
- †1870. Edgar Holden, Newark, N. J.
- *1882. Franklin H. Hooper, Boston, Mass.
- *1878. Hosmer A. Johnson, Chicago, Ill.
- *1879. Woolsey Johnson, New York City.
- *1880. William C. Jarvis, New York City.

*Deceased.

†Corresponding Fellow.

1879. R. H. Kealhofer, St. Louis, Mo.
*1878. Rufus P. Lincoln, New York City.
1881. G. W. Major, Montreal, Canada.
1879. Charles McBurney, New York City.
1885. H. Clinton McSherry, Baltimore, Md.
*1881. E. C. Morgan, Washington, D. C.
*1886. J. C. Mulhall, St. Louis, Mo.
1881. H. Mynter, Buffalo, N. Y.
*1895. J. E. H. Nichols, New York City.
1879. H. K. C. Oliver, Boston, Mass.
1894. William H. Park, New York City.
*1880. D. N. Rankin, Allegheny, Pa.
1881. J. M. Robertson, Detroit, Mich.
1878. Beverly Robinson, New York City.
*1878. T. F. Rumbold, St. Louis, Mo.
†1880. Charles E. Sajous, Paris, France.
1879. Carl Seiler, Scranton, Pa.
*1893. Charles M. Shields, Richmond, Va.
1879. Andrew H. Smith, New York City.
1879. Bernhard Tauber, Cincinnati, Ohio.
*1899. Max Thorner, Cincinnati, Ohio.
1888. S. O. Van der Poel, New York City.
1878. Clinton Wagner, New York City.
1896. Marshall R. Ward, Pittsburgh, Pa.
1879. Whitfield Ward, New York City.
*1886. Benjamin F. Westbrook, Brooklyn, N. Y.
1896. Greene V. Woollen, Indianapolis, Ind.

*Deceased.

†Corresponding Fellow.

PAST OFFICERS.

Presidents.

(Year of Election.)

1879.	Louis Elsborg.	1892.	M. J. Asch.
1880.	J. Solis-Cohen.	1893.	D. B. Delavan.
1881.	F. I. Knight.	1894.	J. O. Roe.
1882.	G. M. Lefferts.	1895.	W. H. Daly.
1883.	F. H. Bosworth.	1896.	C. H. Knight.
1884.	E. L. Shurly.	1897.	T. R. French.
1885.	Harrison Allen.	1898.	W. E. Casselberry.
1886.	E. Fletcher Ingals.	1899.	Samuel Johnston.
1887.	R. P. Lincoln.	1900.	H. L. Swain.
1888.	E. C. Morgan.	1901.	J. W. Farlow.
1889.	J. N. Mackenzie.	1902.	J. H. Bryan.
1890.	W. C. Glasgow.	1903.	J. H. Hartman.
1891.	S. W. Langmaid.	1904.	C. C. Rice.

Vice-Presidents.

1879.	F. H. Davis.
1880.	W. C. Glasgow, J. O. Roe.
1881.	E. L. Shurly, W. Porter.
1882.	C. Seiler, E. F. Ingals.
1883.	S. W. Langmaid, S. Johnston.
1884.	J. H. Hartman, W. H. Daly.
1885.	H. A. Johnson, G. W. Major.
1886.	E. C. Morgan, J. N. Mackenzie.
1887.	J. N. Mackenzie, S. W. Langmaid.
1888.	W. C. Glasgow, C. E. Sajous.
1889.	E. Holden, C. E. Bean.
1890.	J. O. Roe, J. H. Hartman.
1891.	M. J. Asch, S. Johnston.
1892.	S. Johnston, J. C. Mulhall.
1893.	J. C. Mulhall, W. E. Casselberry.
1894.	C. C. Rice, S. H. Chapman.

1895. J. Wright, A. W. de Roaldes.
1896. T. M. Murray, D. N. Rankin.
1897. A. W. MacCoy, H. S. Birkett.
1898. J. W. Farlow, F. W. Hinkel.
1899. T. A. DeBlois, M. R. Brown.
1900. H. L. Wagner, A. A. Bliss.
1901. J. W. Gleitsmann, D. Braden Kyle.
1902. G. A. Leland, T. Melville Hardie.
1903. J. H. Lowman, W. Peyre Porcher.
1904. Thomas Hubbard, W. J. Freeman.

Secretaries and Treasurers.

1879. G. M. Lefferts. 1889. C. H. Knight.
1882. D. B. Delavan. 1895. H. L. Swain.
 1900. J. E. Newcomb.

Librarians.

1879. F. H. Bosworth. 1883. T. R. French.
1893. J. H. Bryan.

RF American Laryngological
l Association
A5 Transactions of the
v.27 annual meeting
Biological
& Medical
Serials

PLEASE DO NOT REMOVE
CARDS OR SLIPS FROM THIS POCKET

UNIVERSITY OF TORONTO LIBRARY

STORAGE

