





*Med  
A*

# TRANSACTIONS

OF THE

## Thirty-first Annual Meeting

OF THE

## AMERICAN LARYNGOLOGICAL ASSOCIATION

HELD AT

BOSTON, MASS.

*370690  
28.8.39*

*May 31st, June 1st and 2nd, 1909*

NEW YORK  
PUBLISHED BY THE ASSOCIATION  
1909

RF  
1  
A5  
v.31

The McConnell Printing Company  
230-242 William Street  
New York

## PRESIDENTS OF THE ASSOCIATION

(YEAR OF ELECTION.)

- 1879. LOUIS ELSBERG, M. D.
- 1880. J. SOLIS-COHEN, M. D.
- 1881. FREDERICK I. KNIGHT, M. D.
- 1882. GEORGE M. LEFFERTS, M. D.
- 1883. FRANCKE H. BOSWORTH, M. D.
- 1884. ERNEST L. SHURLY, M. D.
- 1885. HARRISON ALLEN, M. D.
- 1886. E. FLETCHER INGALS, M. D.
- 1887. RUFUS P. LINCOLN, M. D.
- 1888. E. CARROLL MORGAN, M. D.
- 1889. JOHN N. MACKENZIE, M. D.
- 1890. WILLIAM C. GLASGOW, M. D.
- 1891. SAMUEL W. LANGMAID, M. D.
- 1892. MORRIS J. ASCH, M. D.
- 1893. D. BRYSON DELAVAN, M. D.
- 1894. JOHN O. ROE, M. D.
- 1895. WILLIAM H. DALY, M. D.
- 1896. CHARLES H. KNIGHT, M. D.
- 1897. THOMAS R. FRENCH, M. D.
- 1898. WILLIAM E. CASSELBERRY, M. D.
- 1899. SAMUEL JOHNSTON, M. D.
- 1900. HENRY L. SWAIN, M. D.
- 1901. JOHN W. FARLOW, M. D.
- 1902. JOSEPH H. BRYAN, M. D.
- 1903. JACOB H. HARTMAN, M. D.
- 1904. CLARENCE C. RICE, M. D.
- 1905. JOSEPH W. GLEITSMANN, M. D.
- 1906. ARTHUR W. DE ROALDES, M. D.
- 1907. HERBERT S. BIRKETT, M. D.
- 1908. ALGERNON COOLIDGE, JR., M. D.

## OFFICERS

(ELECTED MAY 13, 1908.)

### *PRESIDENT,*

ALGERNON COOLIDGE, JR., M.D., BOSTON, MASS.

### *FIRST VICE-PRESIDENT,*

EMIL MAYER, M.D., NEW YORK CITY.

### *SECOND VICE-PRESIDENT,*

FRANCIS R. PACKARD, M.D., PHILADELPHIA, PA.

### *SECRETARY AND TREASURER,*

JAMES E. NEWCOMB, M.D., NEW YORK CITY.

### *LIBRARIAN,*

JOSEPH H. BRYAN, M.D., WASHINGTON, D. C.

### *COUNCIL,*

The above ex-officio and

CLARENCE C. RICE, M.D., NEW YORK CITY.

JOSEPH W. GLEITSMANN, M.D., NEW YORK CITY.

ARTHUR W. DE ROALDES, M.D., NEW ORLEANS, LA.

HERBERT S. BIRKETT, M. D., MONTREAL, CANADA.

## TABLE OF CONTENTS.

---

	PAGE
Address of the President. ALGERNON COOLIDGE, JR, M. D. . . .	I
<i>Papers and Theses:</i>	
I. Further Report on a Case of Cancer of the Tongue. ROBERT C. MYLES, M. D. . . . .	8
II. An Investigation of Post-Operative Conditions Five to Ten Years After Intubation. (Candidate's Thesis.) BURT R. SHURLY, M. D. . . . .	10
III. Sloughing Fibroma of the Naso-Pharynx. HENRY L. SWAIN, M. D. . . . .	29
IV. The Nose and Naso-Pharynx in Infants and Young Children. JOHN M. INGERSOLL, M. D. . . . .	38
V. Nasopharyngeal Fibromata. (Candidate's Thesis.) ALBERT C. GETCHELL, M. D. . . . .	50
VI. The Action of the Respiratory Muscles in the Produc- tion of Voice. G. HUDSON MAKUEN, M. D. . . . .	59
VII. A Case of Primary Carcinoma of the Trachea. T. PASS- MORE BERENS, M. D. . . . .	70
VIII. Bacteriology of the Normal Nose. FREDERICK C. COBB, M. D., and E. V. NAGLE, M. D. . . . .	73
IX. A Case of Laryngeal Carcinoma under Observation for Thirteen Years; Ultimate Laryngectomy. HARMON SMITH, M. D. . . . .	79
X. Nerve Distribution in Relation to Nerve Reflexes simu- lating Local Inflammation. ARTHUR AMES BLISS, M. D. . . . .	94
XI. Nasal Tuberculosis: Two Cases, One involving Right Ethmoid Bone, with Recovery After Operation. OTTO T. FREER, M. D. . . . .	103
XII. Nasal Tuberculosis: A Case and Remarks. W. SCOTT RENNER, M. D. . . . .	120

	PAGE
XIII. A New Method of Packing the Nostril, Designed to prevent Post-Operative Hemorrhage, and a new Quadri-valve Self-Retaining Nasal Speculum. WILLIAM E. CASSELBERRY, M. D. . . . .	129
XIV. An Embryological Study of the Metaplasia of the Epithelium of the Tonsillar Crypts: A Contribution to the Origin of Lymphocytes. GEORGE B. WOOD, M. D. . . . .	135
XV. The Tonsil of the Infant, the Child and the Adult. HARRY A. BARNES, M. D. . . . .	156
XVI. Report of a Fatal Case of Status Lymphaticus occurring in a Patient operated on for Tonsillar Hypertrophy under Cocaine-Adrenalin Anesthesia. THOMAS J. HARRIS, M. D. . . . .	165
XVII. Elongated Styloid Process. CHARLES W. RICHARDSON, M. D. . . . .	171
XVIII. Reports of Cases illustrating our Progress in the Surgical Treatment of Chronic Stenosis of the Larynx and Trachea. JOHN R. WINSLOW, M. D. . . . .	177
XIX. Some Observations upon the Complete Extirpation of the Diseased Faucial Tonsil. JOSEPH S. GIBB, M. D. . . . .	191
XX. Cavernous Sinus Thrombosis; Teratoma of the Soft Palate; Case Reports. LEWIS A. COFFIN, M. D. . . . .	210
XXI. Some Recent Cases of Nasal Sarcoma: Submitted as a Corollary to a Former Paper upon the Same Subject. J. PRICE-BROWN, M. D. . . . .	219
XXII. Contribution to the Etiology and Pathology of Dentigenous Cysts. D. CROSBY GREENE, M. D. . . . .	231
XXIII. Hemophilia, with Remarks on the Hemorrhagic Diathesis; Case Reports. THOMAS HUBBARD, M. D. . . . .	238
XXIV. Clinical Experience with Calcium Lactate in Hemorrhages of the Upper Air Tract. WILLIAM K. SIMPSON, M. D. . . . .	250
XXV. The Choice of an Operation for the Correction of Obstructive Deviations of the Nasal Septum: A Personal Point of View. WILLIAM L. BALLENGER, M. D. . . . .	268

# Joint Session of the American Otological Society and the American Laryngological Association.

*Subject for Discussion: Nasal and Pharyngeal Conditions as Causative Factors in Aural Disease.*

	PAGE
XXVI. First Paper. GEORGE A. LELAND, M. D. . . . .	275
XXVII. Second Paper. NORVAL H. PIERCE, M. D. . . . .	287
XXVIII. Third Paper. D. BRADEN KYLE, M. D. . . . .	293
XXIX. Fourth Paper: Chronic Epipharyngeal Periadentitis in Adults. JAMES E. LOGAN, M. D. . . . .	300
XXX. Fifth Paper: The Importance of the Thorough Study of the Naso-Pharynx in the Treatment of Diseases of the Ear. FRANCIS R. PACKARD, M. D. . . . .	313
XXXI. The Anatomical and Clinical Relations of the Sphenopalatine (Meckel's) Ganglion to the Nose and Its Accessory Sinuses. (Candidate's Thesis.) GREENFIELD SLUDER, M. D. . . . .	329

## *Symposium on the Surgery of the Esophagus.*

XXXII. First Paper: From the Standpoint of the General Surgeon. SAMUEL J. MINTER, M. D. . . . .	342
XXXIII. Second Paper: From the Standpoint of the Laryngologist. CHEVALIER JACKSON, M. D. . . . .	348
XXXIV. Third Paper: Three Esophageal Cases. HARRIS P. MOSHER, M. D. . . . .	359
New Instruments and Specimens . . . . .	372
Business Meeting . . . . .	374
Obituary:—DR. FREDERICK IRVING KNIGHT . . . . .	385
DR. EDGAR HOLDEN . . . . .	393
DR. CARLO LABUS . . . . .	395
List of Active Fellows, 1910 . . . . .	397
Honorary Fellows . . . . .	400
Corresponding Fellows . . . . .	400
Past Officers . . . . .	402
Past Members . . . . .	404





TRANSACTIONS OF THE THIRTY-FIRST ANNUAL  
MEETING OF THE AMERICAN LARYN-  
GOLOGICAL ASSOCIATION,

HELD AT BOSTON, MASS.,

MAY 31, JUNE 1 AND 2, 1909.

---

THE PRESIDENT'S ADDRESS.

BY ALGERNON COOLIDGE, JR., M.D., BOSTON, MASS.

*Fellows of the American Laryngological Association:*

We have met here for our thirty-first annual congress, with a programme which gives promise of an interesting session and valuable results. You know the history of our association, its foundation, its membership, the work that it has done and the charm of its meetings. The meetings have been held in different places, each with its distinctive surrounding atmosphere, as it were different frames to the same picture. This is the fourth time that we have met together in Boston, and we, the Boston members, cordially welcome you again. You have made me their spokesman for this occasion, and I wish that I could express as I feel, the honor which you have conferred on me. Since you were last here, seven years ago, these buildings have been finished and dedicated to the teaching and advancement of medical science, and I think that I may truly say that every one connected with their administration looks upon them as a noble gift, given in trust for the benefit of the profession as a whole. I hope, therefore, that you will each receive and retain the interest in these surroundings of an associate rather than that of a guest. I am very glad that, at this meeting, the association comes into especially close re-

lationship with the Harvard Medical School. Many of our members are teachers, and many of the larger medical schools in the country are represented in this society.

Our association has much in common with our universities, and among these not the least with Harvard. We are, and always shall be, the oldest national laryngological society, as Harvard is, and always will be, the oldest university in the country. With age comes dignity, responsibility for example and opportunity for judgment with authority. The society is thirty-one years old and the university two hundred and seventy, but neither could be much older; they were both founded as soon as the pioneers in their respective fields could well get together. Even our mottoes bind us together. Harvard has upon its shield "Veritas"—find the truth and teach it. "Docendo discimus"—by teaching it we learn.

An association such as ours is particularly fitted to act as a judicial court between experience and enthusiasm, to weigh the evidence in favor of and against new methods, and to guide those whose duty it is to guide and to teach our successors. A university may aid all subdivisions of knowledge by applying to them its methods of study, and on the other hand, is often largely dependent upon the practical worker for the facts which she teaches. The teacher must constantly review the whole structure of our science. This structure is based upon what is often called the academic side of his subject, the facts and the theories which form the foundations upon which the practical worker builds. But these theories are constantly growing and enlarging, often changing, and even what are supposed to be facts may be doubted. The academic worker may or may not be the pioneer, but he is the co-worker and the helpful critic of the practitioner. A theory to be well established must receive the endorsement of both. As different men are said to be theoretical or practical, so also are they said to be radical or conservative. This means only that they are departures from the type of a perfect man, whose judgment is always the best and whose preparation is complete. Not only the individual man, but the spirit and habit of the day may incline towards one or the other extreme.

The special work which is included under the historic name of Laryngology has been expanding and increasing at a rate which demands energy to keep abreast of it. A few years ago it would have seemed incredible that there should be so many instruments for sale in the country especially adapted for attacks upon the septum, the turbinates, the accessory sinuses and the tonsils. Most of this is progress in the right direction, but experience shows that enthusiasm will sometimes carry the medical profession, as well as other groups of men, beyond proper limits. No removable source of possible serious danger should be neglected, but series of operations followed by no advantage to the patient brings the work of all into disrepute. Improved methods and skill in treatment and in operating should be in every way encouraged and taught, but good judgment still more so, as it is harder to acquire.

Good judgment demands that the problems should be seen not only with a knowledge of details, but also with a broad perspective. For the latter we should teach ourselves and our students the difference between what we really know and what we think, between well-established facts and the latest theories, between symptoms which are obviously due to what nection with it. Few of us will doubt, for instance, that a large amount of unnecessary and sometimes pernicious operating is done in a blind chase after reflex nervous disturbances. Experimental operating is sometimes justifiable, but for the good of all a proper prognosis should precede it. The perspective with which the teacher approaches his own cases should be shown to the student with as much care as the scientific and technical details. The student will then start with what he would otherwise have to acquire for himself. The most satisfactory results in teaching will be gained by setting our own standards for the best man, giving him all the opportunities for learning that can be given him and showing him how to take advantage of those opportunities.

The long connection of our association with Harvard is brought especially to our attention now by our loss of Dr. F. I. Knight, one of the founders of the society, as well as of the Laryngological Department in the Medical School, both of

which he served with such unselfish devotion. In 1872 he established, at the Massachusetts General Hospital, one of the first laryngological clinics in the country, and with the opening of the Medical School in that year he began instruction in the new art of laryngoscopy. For twenty years he did this work, developing it as the specialty developed, and then handed it over to other members of this association, whom he had instructed and encouraged. The loss of his immediate successor, Franklin H. Hooper, will always be remembered by those who were members of the association at the time. The work which Dr. Knight accomplished in this and in other fields, his preparation and achievements, will appear in another place on our records, but my welcome to you this year and in this place would be incomplete without an expression of appreciation of the spirit in which he met his colleagues in the association, and in which he taught his students in the school. For this spirit I can find no better term than the inadequate word, unselfishness. To this were added high standards, diligence and good judgment. If we maintain these qualities, the legacies of our founders, there will be no question of the future of our society. Dr. Knight was present at the first meeting which was held to discuss the details of this congress, and a few days before his death expressed his interest and desire to take part in it. I know that the members of the association, especially the older ones, will feel that this meeting is incomplete without him.

A few words about this medical school may be of interest here. For some years the school has required an A. B. or equivalent degree for admission. In so doing it has lost in number of students, and is somewhat out of line in its admission requirements with that adopted by most of the other schools of the country. With the latter the tendency is to increase the number of specified studies which a student must take before applying for admission. Often two years of undergraduate work are demanded, and must include biology, chemistry, physics, modern languages, or other special subjects. In this school the only requirement in addition to the A. B. is chemistry. The relative merits of these plans have led to much

discussion, which would be out of place here. The medical faculty have been encouraged in their choice of the A. B. requirement by the sentiment of the other departments of the university.

During his first three years in the school the student follows a regular curriculum. The fourth year is elective. During his last year the student may take any subjects which he chooses. He may, for instance, devote most of his time, or even the whole of it, to laryngology. This is done by the co-operation of the different departments. As an example, we will suppose that a man wishes to spend a year on laryngology and otology combined. In the forenoons he would take four courses of two months each in one or more clinics. In the afternoons he would have special courses of two months each in the laboratories of comparative anatomy, physiology, pathology and anatomy.

The required work in laryngology comes in the third year and consists of about twenty-four lectures for the class as a whole, and twelve clinical exercises in small sections, for each man. This is as much time as can be found for this subject during the first three years in the school.

The teaching in the Department of Laryngology is done by eight instructors, and we hope during the course of the congress to show all of you who are interested some of the details of the work and to receive your comments and criticisms. I wish especially to call to your attention an exhibit of anatomical and pathological specimens which have been arranged in the museum by Dr. Mosher.

The value of a congress to its members is not, and should not be, limited by the subjects of the papers on its programme and their discussion. There are many problems which vex us, and new ones every year. Many of them can not, or do not, become the subject of formal discussion, yet the opinion of our colleagues and their methods of dealing with these problems may be of the greatest value to us. I am not advocating that we should, as might be said, talk shop out of hours, but that at the proper times we should acquire the custom of asking questions in small groups, and of explaining our favorite



theories to each other. When we find differences in theories or in methods of treatment we may often find good reasons for changing our own for the better. In this way, as well as by our published records the influence of the society upon its members and upon the students of its members will be increased.

The welcome of Harvard to our association will be given by President Lowell, who is not at this moment in Boston, but who will meet us at the opening of the afternoon session at 3 o'clock to-day.

The association knows that Dr. de Roaldes has given us a sum of money for the establishment of a prize to be awarded periodically for the best essay submitted on some subject connected with our special work. Your council believe that this prize should be in the form of a medal. A committee was asked to suggest designs, and their report will be presented at this meeting.

There has during the past two years been a movement towards a codification of medical nomenclature. At the last annual meeting you appointed a committee consisting of three members, who were also a committee of the American Laryngological, Rhinological and Otological Society, and also of the corresponding section of the American Medical Society, working also in connection with the general society and with the Bureau of Vital Statistics of the United States Census. It is obvious that any attempt to revise the nomenclature of our branch of medicine must have the co-operation, not only of as large a proportion of representative societies of that branch, but also of other departments of medicine. Your committee was fortunate in having as a member Dr. Kyle, whose exceptional preparation for this work has made it possible to present to you the report, which is the same as that to be presented to the other societies.

During the last day and a half of our meeting the Otological Society will be in session in the same building. Several of our members are members also of that society. During the last three days of this week two more societies numbering many of us in their membership meet at Atlantic City and at Fort-

ress Monroe, and next week is the meeting of the American Medical Society. It seemed to your council, and also to the Otological Society, that the season of meetings should not be prolonged, and that the advantages of this dual meeting outweigh the danger that some men may wish to hear two papers that are being read at the same time. This danger is less than it is every third year in Washington, and the opportunity for pleasant companionship with our elder sister society is greater.

I should fall far short of my duty if I did not tell you that whatever you may find outside of the regular sessions prepared to interest or please you is mostly due to the kindness and to the work of my Boston colleagues, a group in which you will all agree I am most fortunate. As those of you who have preceded me in this office of president have good reason to know, the success of our sessions is principally due to the work and devotion of our secretary.

The programme is before us and the regular work of our thirty-first congress will now begin.

## FURTHER REPORT ON A CASE OF CANCER OF THE TONGUE.

BY ROBERT C. MYLES, M.D.

The writer promised, in 1907, when he presented his report of a case of cancer of the tongue, to make a further report at some subsequent meeting. The history of the case and a description of the operation were published in the Annual Transactions of this association for that year. Repeated examinations have been made at stated intervals for the purpose of detecting any symptoms of recurrence. About two months ago the patient consulted me, complaining of pain and soreness in the operation scar. There was a crater-like ulcer, about 8 millimetres in diameter, in the centre of the cicatrix, on the side of the tongue. I suspected an inferior molar tooth, which leaned inward, to be the causal factor, and my suspicions were confirmed by prompt healing of the ulcer after the extraction of the tooth.

Some most interesting phenomena have been observed in the behavior of the tongue. At first the left, or operated, side of the base of the tongue dropped back against the post-pharyngeal wall; later, it atrophied and shrank until it was about one-third of an inch further forward and downward than the other side of the base. The tip of the left side of the tongue, which was not removed in the operation, shrivelled, curled up, became distorted and remains in a state of tremor. The patient has complained constantly and bitterly of its interference with the use of his tongue, declaring that he can neither speak nor eat without great discomfort. This annoying condition is apparently caused by the removal of sections of the muscles—longitudinal bands—thus breaking their attachments and connections, and by the cutting off of the nerve and blood-vessel supply at the base of the tongue. Dr. Bodine and the writer believe that it would have been better to have



removed the entire anterior left side of the tongue. The unhampered right side of the tongue could then have performed the functions of the organ normally. This patient has a friend upon whose tongue Dr. Bodine operated for cancer, removing the entire left (?) half, and he has had but little difficulty in using it both in speaking and eating.

My object in making this further report is to emphasize the importance of a prompt diagnosis in cases of suspicious growth about the mouth and throat, and (under reasonable justification) to insist upon thorough removal of the growth and adjacent lymphatic glands. The patient has not yet passed the possible time limit of recurrence, though two years and six months after the operation there are no symptoms indicating probable recurrence of the neoplasm.

*Candidate's Thesis.*

## AN INVESTIGATION OF POST-OPERATIVE CONDITIONS FIVE TO TEN YEARS AFTER INTUBATION.

BY BURT R. SHURLY, M.D.

Any investigation into the results of surgical work, five, ten or fifteen years afterward, proves most fascinating and valuable. Medical literature does not afford, so far as the writer can determine, a record of post operative conditions some years after intubation.

As the results of many operations are reported immediately after the work is done, it may be of interest to enumerate some of the observations after Dame Nature and Father Time have poured their soothing syrup over the surgical field. The object of this investigation is to determine the later after effects of intubation, laryngeal diphtheria and antitoxin (if any) upon the structures of the upper respiratory tract in particular.

A series of interesting problems is at once presented for analysis.

1. Does intubation produce scar tissue or predispose to pathologic change in the larynx?
2. Are there late sequelae of laryngeal diphtheria?
3. What is the condition of the tonsillar or lymphoid ring?
4. What are the effects on the general susceptibility of the parts to other infections?
5. Are there any remote effects from the antitoxin used?
6. Is intubation ever followed by laryngeal paralysis of any variety, or by any impairment of phonation?

To answer authoritatively these questions would require a larger series of observations than these cases afford. It is possible, however, to obtain facts that will hold true in general.

Laryngeal diphtheria is more prevalent in our city among the ignorant, unsanitary foreigners, who live upon unpaved streets in thickly settled communities.

The difficulties of locating patients five to twelve years after operation is much greater than would be anticipated. Of a carefully recorded series of 437 intubations for laryngeal diphtheria, eighty per cent of whom were alive when the tube was removed, I have been able to locate and examine at the present writing thirty of the older cases.

Among superstitious and ignorant people the dread of a doctors' office is both apparent and ridiculous. Apprehension and mental panic can often be depicted in those individuals where the family physician, as such, is unknown; where the children are controlled by fear, and it is therefore difficult for them voluntarily to submit to examination.

The patients were reached (when possible) by earnest personal solicitation, by mail, by telephone or by messenger. In these observations a definite plan was followed. The method of examination included a reference to a detailed record which was made at the time of operation and to a series of ten simple questions as follows:

1. From what illness has your child suffered since operation?
2. Has the child suffered from hoarseness at any time?
3. What throat trouble has been present?
4. Can the child breathe through the nose?
5. If not, what adenoid or other obstructive symptoms are present?
6. Have any diseases of childhood developed since operation?
7. Has any chest or ear trouble developed?
8. Does the child catch cold more easily since the attack of diphtheria?

9. Has the child had enlarged glands of the neck?
10. Has the child had shortness of breath, asthma or hay fever?

The usual examination of the nose, throat and larynx by means of the full office equipment was then made. In addition to this, any other family history of importance was sought for.

The complete case report in detail is as follows:

Case 1. E. E., present age 18 years; intubated March 26, 1897; laryngeal diphtheria; six days since first appearance of exudate; doses of antitoxin 2,500 units; tube removed 97 hours after; sequelae, none; other cases in family, none.

Result of examination twelve years later, March 5, 1909—Mild atrophic rhinitis right side; posterior discharge; hypertrophic tonsil left side; adherent pillars post-pharyngeal wall; laryngitis, with areas of atrophy; buried tonsil—right—with adherent anterior pillar; some thickening of lateral walls; post-nasal discharge; some adenoid remnants; series of sore throat and tonsillitis every winter; no hoarseness nor cough; two sessile adenoid papilla on the right of the median line in the region of the lingual tonsil, touching the anterior subglottic wall, size of the head of a tack; no asthma; no bronchitis; all chest conditions negative; chronic naso-pharyngitis; no trouble during the summer; slight hypertrophy of the left post-cervical chain of lymphatics. Tonsil operation advised.

Case 2. E. W., present age 17 years, 3 months; intubated March 2, 1896; laryngeal diphtheria; antitoxin 1,000 units; tube removed 60 hours after; sequelae, none.

History since operation—Pneumonia two weeks in 1900; hoarseness occasionally in the fall; clears throat often; chokes before talking; no other throat trouble; no adenoid symptoms; does not catch cold more easily; no asthma or shortness of breath; hypertrophy of thyroid, prominent sterno-cleido-mastoid muscle.

Result of examination thirteen years later—Deflection upper

third septum, first degree to the right. Spur cartilaginous anterior at the floor of nose, left side. Granular pharyngitis, atrophic areas. Slight atrophic naso-pharyngitis, in initial stage; throat never treated for any morbid condition; crescentic epiglottis; enlarged papillae; larynx slightly hyperemic; laryngoscopic examination difficult on account of neurotic condition. Shortening of the rim of the epiglottis, with deep clover leaf cleft in the median line. Shortening of the ary-epiglottic folds; no scar tissue visible.

Case 3. R. W. H., present age 14 years, 3 months; intubated August 20, 1897; two days after first appearance of exudate; antitoxin 2,500 units; tube removed 96 hours after; no other cases in family, but one across the street.

History since operation—Measles four years ago; chicken-pox, mild; no hoarseness, or throat trouble; does not catch cold more easily.

Result of examination twelve years after—Slight hypertrophic rhinitis inferior and middle; very slight spur floor right septum; very slight pharyngitis, with areas of highly atrophic tissue between; slight enlargement of the right tonsil; adhesions of the pillars, with negative symptoms; some adenoid—central; hypertrophic rhinitis continued to the posterior ends—mild; large lingual tonsil; epiglottis small—normal; larynx normal; slightest fullness of the mucous membranes just below the inter-arytenoid fold.

Case 4. M. K., present age 15 years, 5 months; intubated July 8, 1897; four days since first appearance of exudate; antitoxin 1,500 units; tube removed 98 hours after; sequelae, none; other cases in family, none; considerable cough after removal of tube.

History since operation—Pneumonia two years ago, sick one week; slight enlargement of the left post-cervical chain; otherwise negative.

Result of examination twelve years later—Slight anemia; deflected bony and cartilaginous septum right side, with almost complete occlusion. Moderately high arched palate; teeth reg-

ular; enlarged tonsils; crypts exuding cheesy material; chronic lacunar tonsillitis; some adenoid. Post-rhinoscopic examination shows roomy posterior openings, slight bony deflection, but not obstructive. Slight dry cough through the winter, but not in the summer. Subglottic region on the anterior wall to the right of the median line is a slight elevation of the mucous membrane the size of the head of a tack; mucus between the cords, which are normal in color. Operation recommended.

Case 5. L. K., present age 10 years; intubated February, 1900, antitoxin 3,000 units; tube removed 92 hours after.

History since operation—Had scarlet fever lasting ten days; no hoarseness; snores some at night; does not "catch cold" more easily; no chest or ear trouble; no asthma or shortness of breath; two very slightly enlarged glands (left).

Result of examination nine years later—Left nasal passage normal; anterior right inferior turbinate slightly intumescent; very slight deflection of the upper third of the cartilaginous septum; non-obstructive. No enlarged adenoid; tonsils normal; lingual tonsil normal; slight thickening of the crest of the epiglottis, especially the median third. Laryngoscopic image normal.

Case 6. E. S., present age 18 years, 1 month; intubated December 22, 1896; antitoxin 1,000 units; tube removed (coughed out) 72 hours after; sequelae, none; other cases in family, none.

History since operation—Measles a few weeks after the operation; no hoarseness; earache occasionally; took cold once this winter, but not especially predisposed; no asthma, hay fever or shortness of breath.

Result of examination thirteen years later—Anterior nares normal; no spurs or deflections; follicular pharyngitis; irritable throat; no hypertrophy of cervical glands; slight acute nasopharyngitis, otherwise normal; epiglottis normal except injected with the coryza; laryngeal appearances are normal.

Case 7. J. A., age 19 years, 2 months; intubated February 8, 1897; six days since first appearance of exudate; antitoxin



1,500 units; tube coughed out nineteen hours after, reinserted two days later. Sequelae, none; other cases in family, one (brother).

History since operation—Has not seen a doctor since. Sore throat last week, but not before this time. None of the diseases of childhood.

Result of examination twelve years later—Acute coryza; intumescent turbinates; acute pharyngitis and naso-pharyngitis; slight hyperemia of tonsils; follicles swollen and mucous membrane injected; small amount of mucus over post-inferior turbinate; membrane bathed in extra secretion; hyperemia of the larynx; slight proliferation of mucous membrane to right of median line one-eighth of an inch below inter-arytenoid space; good view down to bifurcation; membrane normal; cords without scar; epiglottis normal.

Case 8. E. F., present age 13 years, 9 months; intubated August 9, 1900. Three days since first appearance of exudate; antitoxin 1,500 units; tube removed sixty hours after.

History since operation—Measles at 6 years; cold and cough most of the time, with expectoration usually. Slight laryngitis at present, "but not for a long time before." Sore throat and tonsils swollen twice since, croupy a good deal of the time. Never been able to breath through nose since. Snores at night. "Catches cold" more easily. No asthma nor shortness of breath.

Result of examination nine years later—Nasal passages roomy; slight spur, cartilaginous and bony, left; small deflection at the floor, anteriorly; post-nasal discharge every morning; hypertrophic lacunar tonsillitis, with very large inflamed crypts; inferior laryngeal wall atrophic; muco-purulent secretion; large adenoid in median line, with additional portion to the right of the median line the size of one-half the uvula; left posterior inferior turbinate hypertrophic and intumescent; cervical glands normal; croupy cough at present; lingual tonsil enlarged; upper laryngeal area above the vocal cords hyperemic and slightly swollen; film of mucus between cords; small layer of mucus on the anterior laryngeal wall one-quarter of an inch below the

vocal cords; roughness of inter-arytenoid fold. Operation recommended.

Case 9. E. Q., present age 11 years 10 months; intubated October 4, 1899; five days after first appearance of exudate; antitoxin 4,000 units; other cases in family, none.

History since operation—Bronchitis and hoarseness every winter until two years ago; cannot breathe through nose well, and cannot blow nose well; measles, mumps and chicken-pox since; trouble with right ear two years later; "catches cold" more easily since operation; no enlarged glands; for eight years had "asthma" at night (probably adenoids). Operation advised.

Result of examination nine years later—No enlarged cervical glands; thick crust over turbinate, left; roomy nasal passages; slight cartilaginous spur, anterior; moderately high arched palate; no crowded teeth; throat red; tonsils not enlarged, ragged in appearance; slight papillary eminence at the junction of the uvula and anterior pillar, left side. Moderately enlarged adenoid glands, central mass; tonsils adherent to the pillars; appearance of extensive old inflammatory condition; clears throat a great deal; epiglottis rather thick, not abnormal; laryngeal examination difficult. Adenectomy advised.

Case 10. R. E., present age 17 years, 7 months; intubated November 5, 1899; first appearance of exudate (tonsils) two weeks, larynx three days; antitoxin 2,500 units; other cases in family, one; sequelae, none.

History since operation—Had scarlet fever; acute laryngitis four days last winter; one attack of bronchitis; does not "catch cold" more easily; lower jaw prominent.

Result of examination ten years later—Symmetrical deviation of the septum, left; right nostril roomy and normal; hard palate somewhat high arched; uvula smaller than normal and triangular in shape; chronic lacunar tonsillitis; crypts large, without cheesy deposits; posterior pillars thickened extends into the uvula; left tonsil hypertrophied slightly; right tonsil adherent and not protruding beyond the pillars; naso-pharynx, very slight



amount of adenoid tissue. Rhinoscopic picture normal; epiglottis slightly more hyperemic than normal, slightly roughened with fine papillæ. Impossible to get a view further down than the top of the arytenoids, which seemed normal. Very slight enlargement of the anterior cervical glands.

Case 11. A. L., present age 15 years; intubated November 7, 1899. Four days since first appearance of exudate; antitoxin 2,000 units; tube removed 108 hours after; sequelæ none; other cases in family none.

History since operation—Measles about a year after; no hoarseness; clears throat some; does not catch cold more easily; has attacks of "nose bleeding"; no enlarged glands excepting with "a cold."

Result of examination ten years later—Slight bony cartilaginous ridge left; good breathing space anteriorly; right anterior view normal; chronic hypertrophic lacunar tonsillitis; central adenoid with muco-purulent secretion extending over the vomer; otherwise rhinoscopic picture normal, very slight thickening of mucous membrane just to the left of the median line on the lower border of the inter-arytenoid fold. Vocal cords normal. A view down to the bifurcation. Tracheal wall rather dry; no evidences of scar tissue in subglottic region. Adenectomy advisable.

Case 12. E. K., present age 14 years; intubated November 2, 1900; five days after first appearance of exudate; antitoxin 2,500 units; tube removed 96 hours after; sequelæ none; no other case in the family.

History since operation—Sore throat every winter since; no doctor since; slight huskiness of voice; no diseases of childhood since; does not "catch cold" more easily; no enlarged glands, no asthma nor shortness of breath.

Result of examination nine years later—Slight cartilaginous spur-right; otherwise, anterior view of both nostrils normal; chronic hypertrophic lacunar tonsillitis; slightly hypertrophic adenoid covered with muco-purulent secretion; slightly enlarged lingual tonsil; laryngoscopic image normal except for slight

thickening of the vocal cords; no hyperemia; no scars apparent; uvula normal; laryngeal wall bathed with mucus.

Case 13. L. K., present age 12 years, 11 months; intubated April, 1900. Antitoxin 2,500 units; sequelæ none; tube removed 96 hours after.

History since operation—No diseases of childhood; voice husky at times during winter; hard breathing at night (winter), snoring some; prominent teeth, upper jaw crowded with teeth; catches cold more easily since; no enlarged glands; no asthma nor shortness of breath; one year later, another child in the family died of nasal diphtheria.

Result of examination nine years later—Teeth crowded, high arched palate; deflection of septum; cartilaginous; breathing room—fair left side, anterior nasal passages (right) normal anteriorly; large central adenoid bathed in secretion; hypertrophic chronic lacunar tonsillitis; mouth breather. Distance between tonsils about three-eighths of an inch; adherent at pillars; glands of posterior cervical chain-left, slightly enlarged; lingual tonsil large; upper border of epiglottis median line curled over and thickened; hyperemic condition of the larynx, thickening of the inter-arytenoid fold; vocal cords normal; no scar tissue apparent. Operation advised.

Case 14. E. K., present age 11 years, 10 months; intubated November 11, 1898. Thirty-six hours after first appearance of exudate; antitoxin 3,000 units; no other cases in the family.

History since operation—Had whooping cough the summer after operation; German measles at six years of age; hoarseness continued for a year after the operation; breathes through nose; conjunctivitis after antitoxin; "inflammation of the lungs" twice—soon after; "sickly for a year." Discharge from ear three months before operation, none since; does not "catch cold" more easily since; no enlarged glands; no asthma nor shortness of breath.

Result of examination ten years later, March 27, 1909—Anterior nasal view normal, excepting slight thickening of carti-

laginous septum—right side; slight fissure on the floor of nose at the juncture of the skin and mucous membrane, from which there has been a series of expistaxes; pharyngoscopic view normal; post-rhinoscopic view shows slight chronic naso-pharyngitis with the posterior wall bathed with muco-pus; adenoid tissue very slightly enlarged; very slight enlargement of the post-cervical chain of glands more on the right than the left side; arytenoid cartilage smaller than normal; larynx smaller than normal; child developing; clears throat before speaking; voice breaks on the first word frequently; vocal cords smaller than normal; larynx seemed rather dry; no scars visible; mucus between the vocal cords; subglottic region bathed with mucus; inter-arytenoid fold normal (smooth).

Case 15. E. G., present age 12 years, intubated November 22, 1898.

History since operation—Stuttered ever since operation; tonsillitis every winter; no hoarseness; breathes through nose; ear-ache for four days, three weeks ago; had three “colds” this winter; stops stammering when he takes a short breath and then speaks. Makes a hissing sound when stammering.

Result of examination nine years later—Slight enlargement of cervical glands; small cartilaginous spur anterior (left); slight deflection of upper third of cartilaginous bony septum (right). Palate arched more than normal; one large central pharyngeal follicle; “buried tonsils” with pathologic crypts; mucus in the naso-pharynx; adherent tonsils to anterior and posterior pillars; patient has collar tic; central adenoid extending down over the posterior wall; posterior nares normal; very large lingual tonsil, filling the region between the tongue and epiglottis; no cough; anterior tracheal wall bathed with mucus, no scars visible; no proliferations; larynx slightly hyperemic; film of mucus between the vocal cords in the region of the anterior commissure; otherwise normal; atrophic areas on the posterior pharyngeal wall. Operation refused.

Case 16. W. P., present age 14 years; intubated March 19, 1898. Three days after first appearance of exudate; antitoxin 2,000 units; tube removed 124 hours after; sequelæ none; a fatal case in the house (downstairs) a year before.

History since operation—Had hoarseness two months after tube was taken out, none since; breathes through nose; none of the diseases of childhood; discharge from ear twice, all right now, hearing good; does not "catch cold" more easily; no enlarged glands; no asthma, nor shortness of breath.

Result of examination eleven years after—Anterior nasal region normal; slight fulness of the cartilaginous septum; some dryness of the nasal mucous membrane; very large tonsils; large central adenoid that extends down the posterior wall of nasopharynx; not many "colds"; clears throat a good deal; breathes through nose; no deflected septum; no mouth breathing; examination difficult on account of tonsils coming together, much gagging; larynx shows no scar tissue; hyperemia of the larynx; lingual tonsil very much enlarged; posterior wall of the epiglottis bathed with mucus. Operation advised.

Case 17. F. S., present age 15½ years; intubated February 21, 1900.

History since operation—None of the diseases of childhood; no hoarseness; has had shortness of breath; "colds" occasionally—recovering quickly; no chest or ear trouble.

Result of examination nine years later—Dyspnea, not now as much as three years ago; remnant of adenoid; some coryza; hyperemia of inferior turbinates and moderate intumescence; small amount of muco-pus in naso-pharynx; pharyngeal wall shiny and without follicles; atrophic in appearance; larynx normal but hyperemic; no scars; vocal cords normal; trachea is visible for an inch.

Case 18. G. P., present age 12 years 2 months; intubated October 2, 1899. Thirty-six hours after first appearance of exudate; antitoxin 2,500 units; tube removed 108 hours after.

History since operation—"Colds" and sore throat; curvature of the spine; tonsillitis this winter; snores at night, but breathes all right; no enlarged glands; no asthma, hay-fever nor shortness of breath.

Result of examination ten years later—Anterior nares normal; enlarged adenoid; chronic lacunar tonsillitis; larynx hyperemic;

no scars; mother died seven years ago during parturition; father died last June of carcinoma of the stomach. Operation advised.

Case 19. D. G., present age 14 years; intubated December 2, 1896; two days after first appearance of exudate; antitoxin 1,500 units; tube removed 96 hours after; sequelæ none; no other cases in family.

History since operation—Had measles some years ago; no hoarseness; no throat trouble; no ear or chest trouble; no enlarged glands; no asthma, hay-fever nor shortness of breath.

Result of examination twelve years later—Very narrow nasal passage—left with some thickening and deflection of the septum at the base; right nasal passage wider than normal; papillomatous eminence at the junction of the anterior fold of the pillar and uvular fold on either side and symmetrically; tongue stubborn; small adenoid bathed with muco-pus; slightly enlarged lingual tonsil, cauliflower formation made up of a large number of little papillomatous excrescences and touching the epiglottis at a number of points; epiglottis small; larynx slightly hyperemic; laryngeal image normal.

Case 20. G. H., present age 14 years 11 months; intubated October 22, 1899. Two days after first appearance of exudate; antitoxin 1,500 units; tube removed 96 hours after; no other cases in family.

History since operation—Had measles two years after; mumps every winter; hoarseness every winter, sometimes expectorates blood; sore throat, tonsils swelling; tonsillitis every winter; "catches cold" more easily; had four "hard colds" this winter; has enlarged glands, which the patient calls mumps; no shortness of breath, asthma or hay-fever.

Result of examination nine years later—Nose-anterior, normal; slight hypertrophy of follicles of pharynx; hyper. (mod) of tonsils, especially right; slightly enlarged adenoid with rugæ; larynx normal; arytenoids small, larynx developing; child just developed. Operation advised.

Case 21. H. S., present age 11 years, 2 months; intubated Jan., 1901, seven days after first appearance of exudate; antitoxin; tube removed 116 hours after; no other cases in family.



History since operation—Had chicken-pox, no doctor since; hoarse for two weeks, no other throat trouble; breathes through nose; "catches cold" more easily; has cough with any cold; no enlarged glands; no asthma; no shortness of breath nor hay fever.

Result of examination eight years later—Slight cartilaginous knob (anterior) at the floor of nose, otherwise normal, left; right side anteriorly, normal, slight enlargement of lymphatic post-cervical chain, (left and right); teeth widely separated and even; small uvula; tonsils normal; slightly anemic; mild follicular pharyngitis; naso-pharynx normal; laryngeal image normal, excepting hyperemic through crying; "slight cold" for a few days, lately; pharynx hyperemic; tonsils buried and normal.

Case 22. C. V., present age 16 years; intubated October, 1897; antitoxin.

History since operation—Had measles, mumps, chicken-pox and influenza; sore throat and la grippe every winter, treated at first with salt pork, if not better, gets doctor, usually once during winter; cough with "colds" usually, no discharge from ears; no asthma; no hay fever nor shortness of breath.

Result of examination 12 years later—Slight cartilaginous spur (left); right nasal passage normal, excepting muco-purulent discharge from posterior entrance. Chronic lacunar tonsilitis, buried and adherent tonsils, giving the appearance of much old inflammation; central adenoid is shrinking; posterior hypertrophies of the septum; posterior nares normal; slight thickening at the interarytenoid fold, slight scar on the anterior wall of larynx; vocal cords very dry; film of mucus between the vocal cords; adenoid remnants give appearance of hypertrophy in earlier life; chronic lacunar tonsilitis, with muco-purulent discharge from the naso-pharynx; granular pharyngitis; little areas of atrophy. Operation advisable.

Case 23. G. J., present age 9 years; intubated Dec. 14, 1904, seven days after first appearance of exudate; antitoxin; tube removed 48 hours later; replaced and removed the fifth day. No other case in family.

History since operation—None of the other diseases of child-

hood; had no doctor since; continuous hoarseness, sometimes quite marked; "catches cold" more easily; no asthma, nor shortness of breath nor hay fever.

Result of examination 5 years later—Eczema left nostril with muco-purulent discharge; right turbinat intumescent; "cold all winter." Tonsils and larynx examined by Dr. E. L. Shurly and myself; normal to all appearances. Huskiness due to muscular or nervous insufficiency? Naso-pharynx, remnant of adenoid; three patali of adenoid on left anterior surface of naso-pharyngeal anterior wall, a finger-nail breadth above pillars; tonsils buried; no lingual hypertrophy.

Case 24. R. H., present age 12 years, 5 months; intubated Dec. 31, 1902, 5 days after first appearance of exudate; anti-toxin 2,000 units; no other cases in family.

History since operation—Had stiff neck or "rheumatism" for one week; no hoarseness; cannot breathe through nose very well; high arched palate; none of the other diseases of childhood; one very small gland—right side; no asthma, nor hay fever nor shortness of breath.

Result of examination 6 years later—Slight deflection of nasal septum—right; chronic follicular pharyngitis; moderate enlargement of central adenoid—not sufficient for operation; slight amount of hypertrophy of lingual tonsil; epiglottis narrow, long and thin; larynx normal; patient of slender build but "wiry."

Case 25. E. M., present age 11 years, intubated May 31, 1903.

History since operation—Has not had any illness or trouble of consequence since; some hoarseness for a month after; breathes through nose all right; no other diseases of childhood; does not "catch cold" more easily; two or three small enlarged cervical glands; no asthma, hay fever nor shortness of breath.

Result of examination six years later—Slight deflection of nasal septum (left), nasal passage roomy though; slight adenoid enlargement; faucial tonsils quite large and irregular; pharynx and upper larynx rather red; epiglottis quite pointed; arytenoids on uneven plane; vocal cords all right—but wet; trachea normal; no scar, no flattening of larynx.

Case 26. E. W., present age 23 years, intubated Nov. 14, 1907; antitoxin 3,500 units; tube removed 78 hours after; sequelæ, paralysis; no other cases in family.

History since operation—Had mumps two years ago; one attack of hoarseness three years ago; breathes through nose all right; no other diseases of childhood; slightly enlarged cervical glands; tonsilitis every winter until having diphtheria, none since.

Result of examination 12 years after—Cartilaginous spur left; bleeding point on the anterior end, inferior turbinate; right anterior turbinate swollen; high arched palate; chronic lacunar tonsilitis; cheesy deposit in the upper crypts; anemic pharyngeal wall and somewhat atrophic; slightly enlarged adenoid tissue of right faucial tonsil, none of the left; all naso-pharyngeal paralysis complicating past; diphtheretic cast of trachea removed before operation; very slight enlargement of post-cervical glands; did have enlarged glands of anterior right side—lower set—but these have almost faded away. Slight adenoid, shrinking; thickening of the septum posteriorly; absolutely no throat symptoms except clearing the throat occasionally; lingual blood vessels enlarged; epiglottis smaller than average; vocal cords slightly dry; slight thickening of the opposing parts of the vocal cords at the posterior third; trachea bathed in mucus; slight atrophic areas.

Case 27. C. M., present age 16 years, 9 months; intubated July 11, 1897. First appearance of exudate on tonsils, two weeks after, and larynx two days after; antitoxin 1,000 units; tube removed 96 hours after; no other cases in family; sequelæ, bronchopneumonia.

History since operation—Has not had any illness since; no other diseases of childhood; no hoarseness; no asthma nor hay fever.

Result of examination 11 years later—Slight extra dryness of nasal mucous membrane with crust formation; slight atrophic rhinitis with crusts; marked atrophic pharyngitis; tonsils slightly enlarged; clears throat often; pharynx bathed in mucus; some slight enlargement of the post-cervical chain (left); epiglottis very erect and small; roomy spaces in lingual tonsillar region; vocal cords slightly dry; tracheal rings very prominent; larynx otherwise normal; the opening bounded by the arytenoids slightly smaller than average.



Case 28. W. G., present age 15 years, 7 months; intubated Jan. 18, 1897, nine days after first appearance of exudate (tonsils) croupous two days; antitoxin 2,000 units; tube removed 96 hours after; one other case in family, and one next door.

History since operation—Had scarlet fever at eight years of age; mumps shortly after that; rheumatism last year, very lame now, uses a cane to walk; tendons of right foot contracted; mouth breather part of time; tonsillitis just before rheumatism, lasting a month; no ear trouble since diphtheria, when purulent otitis med. developed; does not "catch cold" more easily; three moderately enlarged post cervical glands (left).

Result of examination twelve years later—Anemic; had rheumatism; lately, again; septum straight; middle turbinate enlarged; anemic appearance of mucous membrane; right side deflection of nasal septum, in upper third; slight cartilaginous spur anteriorly, lower turbinate and along floor; tonsils buried; faucial pillars markedly adherent anteriorly and posteriorly; atrophic pharyngitis; adenoid glands bathed with muco-pus; very small choanae; large erect epiglottis; arytenoids small; tracheal wall atrophic; large larynx; vocal cords flabby; upper part of the larynx normal; vocal cords injected and appear as if epithelium were changed, pearly white color is lost; grayish, red and streaked, instead they are large, flat and flabby.

Case 29. M. R., present age 13 years, 8 months; intubated May 21, 1897; thirty-six hours after first appearance of exudate; antitoxin 2,000 units; no other case in family.

History since operation—Had measles eight years ago; whooping cough seven years ago; has chronic conjunctivitis; no hoarseness; "sore throat often"; snores, is restless; dry cough most of the time; catches cold more easily; two moderately enlarged cervical glands (left); no asthma, nor shortness of breath, except with so-called "catarrh"; operation recommended.

Result of examination twelve years later—Anterior nasal passages on the left side roomy; posteriorly there is pus on the middle turbinate: the inferior turbinate shows marked intumescence plugging the right passage, large amount of thin muco-purulent secretion. Hypertrophy of both tonsils with marked adhesion to the

anterior and posterior pillars. Two calcareous flat patches not rising above the surface, on both vocal cords, beginning about one-sixteenth of an inch from the anterior commissure. Arytenoids slightly swollen; no scars visible; the tonsil concretions removed with the laryngoscopic mirror during examination. Operation advised.

Case 30. M. McK., present age 16 years, 2 months; intubated January 27, 1897; three days after first appearance of exudate; antitoxin 1,500 units; tube removed 124 hours after; no sequelae.

History since operation—Had measles at six years of age; one cold each winter; dry cough since last winter; breathes through nose all right; does not catch cold more easily; no asthma, shortness of breath, nor hay fever.

Result of examination twelve years later—Slightly intumescent right inferior turbinate; good nasal breathing; slight cartilaginous spur (right side), non-obstructive; crowded teeth; tonsils not projecting beyond posterior pillar; slight follicular enlargement of posterior pharyngeal wall; adherent tonsils throughout entire posterior border; anterior free; right tonsil somewhat smaller than the left. No history of tonsillitis or other inflammatory conditions since. Posterior choanae small, normal passage; slight mucus discharge, non-pathologic; no adenoid hypertrophy. Slight thickening of lingual tonsil. Hyperaemic arytenoids. No scars on the cords nor interarytenoid folds; trachea normal.

### *Summary of Examination.*

Of the thirty cases examined all had clinical laryngeal diphtheria.

The age varied at operation from seventeen months, the youngest, to eleven years, the oldest.

The smallest dose of antitoxin given was one thousand units; the largest four thousand units.

The time during which the tube was worn collectively was from forty-eight hours to one hundred and twenty-four hours.

No instance of retained tube occurred in any of these cases. Four cases required reintubation.

In one case intubation had been attempted by two other operators during some hours, without success.

Other cases of diphtheria appeared in the same family or in the neighborhood, from which the contagion could be traced in five of these cases.

The subsequent statements show the extent of susceptibility to infectious or contagious diseases in these cases, as follows: Measles, ten cases; chicken-pox, four cases; mumps, four cases; whooping cough, two cases; scarlet fever, three cases.

Partial or complete aphonia remained from one day to seven years after the removal of the tube.

"Throat disease" was claimed in ten cases.

Four cases were partial, periodic or complete mouth breathers.

Other adenoid symptoms were present in six cases.

Lung or heart disease was noted in six cases.

Affections of the ears were acknowledged by four.

A greater susceptibility to coryza was observed in seven cases.

Dyspnea, asthma or hay fever in two cases (from adenoids).

The examination was made five years after intubation in one case, and from eight to twelve years later in the other cases.

Nasal conditions requiring operation—Deflected septum, four; intumescent and hypertrophied turbinates, two.

Naso-pharyngeal conditions requiring operation—Adenoids, six cases.

Pharyngeal conditions requiring operation—Eight cases (tonsils).

Laryngeal conditions requiring operation—None.

Enlarged cervical glands were found in nine cases.

Thickening of the interarytenoid fold was observed in four cases.

#### CONCLUSIONS.

Every case in this series was intubated for laryngeal diphtheria.

1. Intubation in laryngeal diphtheria is required more frequently where marked tonsillar hypertrophy exists.

2. Pathologic adenoid and tonsils are prominent predisposing factors in diphtheretic infections of the larynx.

3. No deleterious effects of antitoxin were noted.

4. Laryngeal paralysis is extremely rare after intubation.
5. Little attention is often given by the physician or patient to nasal obstruction until serious damage results to the general health.
6. Numerous pathologic conditions of the upper respiratory tract may exist without symptoms or annoyance.
7. Scar tissue was observed in two cases. The cicatrix was insignificant and apparently produced no modification in function.
8. No case of marked laryngeal paralysis was found, although one with motor insufficiency was observed.
9. The pathologic effects of diphtheria on the tonsillar ring are numerous and aggravated.
10. Children developing laryngeal diphtheria show a marked tendency to other infections in childhood.
11. So-called chronic catarrhal inflammation of the upper respiratory tract is usual after severe diphtheria.

## SLOUGHING FIBROMA OF THE NASOPHARYNX.

BY HENRY L. SWAIN, M.D.

Some years ago our distinguished Fellow, Dr. E. Fletcher Ingals, made to the association a brief statement which was of the utmost comfort and support during the many trying hours which a certain case of sloughing fibroma gave me. The hope given in the statement that I might carry my patient through years enough until he finally outgrew the tendency to recurrence, was so helpful in the dark hours of almost sure defeat, that I consider it to be my bounden duty to briefly chronicle what happened to my patient, supporting, as it does, what Dr. Ingals has said. I hope hereby to doubly fortify some other much-to-be-pitied colleague who may have resting upon him the freighting of another life to a safe and sound state of health.

Dr. Ingals stated, as most of you will remember, that there came to him, after years of absence, a man who, when last seen, had been given up to die from the ultimate results of a recurring fibroma of the nasopharynx. All that the skill of our versatile colleague and friend could accomplish had been exhausted. Radical and conservative measures alike failed. At some certain period the growth ceased to enlarge, shrank, and finally disappeared, leaving desolate and empty the enlarged nasal chambers which it had so completely filled in the past. Other than the evident deformity of one side of the face and his dreadful experience, the young man had nothing to show of all that he had been through.

On the 28th of October, 1899, there came to me a young boy of thirteen years, whose brother I had treated for adenoids some years previously. The general idea which the mother had of the case was that her son had nothing more the matter with him than had ailed his brother, only that the obstruction which seemed to have come in his nose was worse than in the older boy. She had, however, had a dream that the present patient had been suffering from tumor in the nose, had had a dreadful operation, and had

died as a result of it, and it was this spectre in the background which colored and shaped the future clinical history, as will appear in the subsequent statements. I found that the young man was suffering from a rather typical appearing, firm, round, nasopharyngeal tumor, which I took surely to be of the fibromatous type, and which sprang from the upper right portion of the lateral wall of the nasopharynx, the typical position.

Various attempts were made in the subsequent few weeks to remove the growth with a snare, but all of them failed because the young man had not then learned the amount of self-control which he later developed to a remarkable degree.

On the 1st of January, there seeming no other way to get around the difficulty, and mindful of the splendid work of Dr. Lincoln and Dr. Delavan with electric currents, I conceived the idea that it might be possible to shrink this mass down by ignition, exactly as we are so often able to accomplish with even quite firm tonsils, and was much pleased to find that I was able to produce thereby a considerable slough.

On the 15th of the month the patient was very desirous of trying again to have the growth removed by the snare, but the attempt failed because of the bleeding which was started up, and which was quite severe and lasted an hour. It was then evident to me that, unless it was by cauterizing, further attempts at removal had better be stopped unless most radical and under anæsthetics, and Dr. William H. Carmalt, of New Haven, who had been called in consultation in the case, felt also that perhaps the slower method would be the better one. Radical measures were also refused by the family.

From that time until the first of May, once every week or ten days, the portions of the tumor which presented in the nose, which could be reached from in front, were freely cauterized, the aim being to attack the pedicle of the tumor as much as possible, with the idea that the subsequent cicatrization might, by including the nutrient vessels, cause a loss of nutrition and subsequent decrease in the size of the tumor. The patient had begun to bleed quite freely whenever the slough, which sometimes was considerable, came away from the cauterized area. Also various attempts were made from time to time to cauterize the nasopharyngeal



surface by passing the electrode up behind the palate. These were not wholly successful. Later so much bleeding took place from the nasopharyngeal surface of the tumor that he was given a powder of ferripyrin and tannin, equal parts. The insufflation of this into the nasopharynx would usually stop the bleeding.

On the 26th of May the patient began having a good deal of odor to the breath, and this was accompanied by some swelling of the tumor. On the 31st the patient bled, according to the statement of the mother, a full quart. Allowing it to be a pint, it was surely a very considerable hemorrhage. I being out of town at the time, the patient was brought, on a mattress, in a fainting condition, to Dr. Carmalt's office. The effort and the physical exertion, or something, had so stopped the bleeding that when they arrived at his office, Dr. Carmalt merely swabbed the nasopharynx out with some tannic acid and antipyrin solution, and sent the boy back home again.

We again talked the matter over as to whether a radical operation was not advisable, and also brought in the opinion of Dr. Delavan, and supported by him, all our views concurring, we continued to wait for the electricity to accomplish what it could before resorting to such measures. No serious hemorrhage took place, and considerable slough kept forming.

Not much was done during the summer months, and the growth seemed to have ceased to enlarge. On the 7th of September a large slough came away, and as this slough had formed after an interval of a month or six weeks, during which time nothing had been done in the cauterizing line, it occurred to me that the sloughing was really the result of natural processes rather than entirely the outcome of my own efforts at cauterizing. The slough which now came away was of a considerable size, and following its removal half a teacupful of blood was lost. As a result, the tumor certainly began to shrink somewhat, and we were much encouraged. One could look through the nose below the tumor and see the posterior wall of the nasopharynx below the growth, a thing that had not happened since the start.

On the 23d of November the tumor was again markedly swollen, as though about ready to slough, and for the first time it was evident that the growth was tending to advance into the



nose rather than to grow lower down into the pharynx. Again following the release of a large slough the growth contracted, and this time the upper and medium part seemed to have shrunk.

With varying fortunes, the growth, on the whole, apparently somewhat increased, and a very bad bleeding spell took place upon the 29th of April, 1901, as the result of the coming away of a very foul-smelling scab, and he bled in spurts for two hours. I found him practically exsanguinated, pulse hardly palpable at the wrist, and so weak that it seemed every moment as though he must pass away. A little powder up into the nasopharynx seemed to stop the bleeding, and the pulse tension was immediately raised by the dropping of an adrenalin solution, 1 to 500, under the tongue. Giving him plenty of water and using the adrenalin, we finally restored his pulse to something like a commendable volume, and he pulled through the difficulty with the tumor very much smaller than it had ever been. This was the case all summer, until late in September it again began to grow, especially out into the nasal cavity.

Having satisfied myself that direct ignipuncture surely was insufficient, and having for the purpose installed a suitable electric controller, on November 1st I attacked the tumor again as soon as it started to enlarge, by the bipolar electrolytic method, using a Casselberry electrode. We used as strong currents as the patient could possibly bear, and applied the electrolysis as frequently as it seemed at all possible, and the result was that the patient was very little different, if any, by the middle of December.

It having occurred to the mother that during both summers we had had less trouble than during the winter, we thought it might be wise to avoid the extreme cold weather, and the query was whether a milder climate might not help to keep the patient from having these dreadful sloughing times. As another sloughing period seemed imminent, as judged by the odor, at my advice they went to New Orleans, and came under the care of Drs. De Roaldes and King. His description, as taken from Volume XXV. of our own transactions, page 147, will indicate the condition in which the patient arrived in his care:

"The tumor was an exceedingly vascular fibroma, attached to

the nasal wall, with a nasal prolongation occupying and dilating the right nasal fossa. It had already reached the sloughing stage, and several abundant hemorrhages had weakened and exsanguinated the patient. When he first came under our observation surgical interference was not considered advisable on this account, but under the influence of our mild climate, a nourishing diet and tonic medication, his state of health improved so much in two months that we felt justified in attempting radical removal of the growth, and so advised the parents. The tumor had greatly increased in size, until the nasal portion reached anteriorly to within half an inch of the vestibule of the nose. In the right cheek could be seen and felt a rounded, movable tumor about the size of a walnut, apparently independent in its development of the post-nasal growth. Parental consent being finally obtained for operation, I decided to attempt its removal with Doyen instruments, under cocaine anesthesia."

The attempt resulted in failure owing to the enormous loss of blood, and a microscopic examination showed the growth to be a telangiectatic fibroma.

Removal was again attempted under an anesthetic on the 6th of May, after the patient had recovered from the bleeding, which had thoroughly exhausted and exsanguinated him following the former effort. Again I will quote: "Operation May 6th. The carotids were exposed by Dr. Parham, the right external was tied, and ligatures were passed under the common carotids on both sides to make compression, if necessary, when the tumor was being cut through. I then performed tracheotomy, transfixed the tongue with a strong ligature, tied the palate forward with a rubber catheter passed through the left nasal cavity, inserted a mouth gag, and placed the patient in the Rose position. While compression was being made on the free arterial trunks I attacked the growth with the scissors, as in the preceding operation, and by vigorous efforts cut through the fibrous mass close to the attachments, and brought it out through the mouth. In spite of all our control of the arteries, the hemorrhage was almost overwhelming for the patient, and when controlled by gauze packs saline infusion had to be practiced immediately. This was skilfully done by Dr. E. D. Martin, whose valued assistance we

had also obtained. The patient responded well to the infusion, and as the bleeding into the pharynx had ceased, the tracheal wound was closed." Examination after the patient recovered from the effects of the operation showed that the septum was displaced completely over to the left side, and the right nasal cavity was enormously dilated. A small part of the base remained attached to the body of the sphenoid in the posterior part of the nasal fossa. In addition to this the tumor had spread to a broader base, including nearly half of the pharyngeal wall.

On the 4th of June, the patient having returned to New Haven, we were sorry to have to chronicle the fact that the growth seemed to be returning in what might be called the middle part of the base, *i. e.*, tending to grow into the nose rather than into the nasopharynx.

On the 17th of July the nose was partly filled up by the growth, where in the region of the middle fossa it was certainly growing rapidly. The facial part of the growth was much enlarged.

The patient was then referred to Dr. Sprenger, of this city, for X-ray treatment. These treatments were given to him as often as he could stand them until the 15th of November, the only effect appearing to be to make the facial and more superficial parts of the growth a little smaller, but the back part of the growth, toward the nasopharynx, increased rapidly in size. Then the usual sloughs began to appear, and with them the hemorrhages.

On the 4th of December the patient had an enormous, sudden hemorrhage, which, inside of fifteen minutes, had brought him nearer to the grave than at any of the previous occasions. He was kept completely plugged behind and in front for a week, and when the plugs were finally safely removed, it was found that the facial tumor which, during the packing, had swollen up considerably, went down as though a large abscess cavity had emptied itself, and both it and the internal tumor decreased enormously in size. By the time the shrinkage was over the whole mass was scarcely one-third the size which it was previous to the formation of the sloughs and the fearful hemorrhage. It was evident that the tumor on the face connected with the antrum, and that the nasal wall of the antrum had atrophied by

pressure, and that the whole antrum and nasal cavity were united into one irregular space. The patient also ran a temperature at this time and succeeded in getting up a middle-ear infection upon that side. During the time of quiescence which followed this tremendous change and destruction of tissue, the patient's physical condition gradually returned to somewhat nearly normal. For a month immediately following this episode he could scarcely be moved from his bed.

In the late spring, apparently with the return of the full vitality of the patient, the growth started once more to recur, and feeling that the patient ought to have the benefit of all the resources that we could command, I referred him to Dr. Delavan, of New York, to see if electrolytic treatment at his hand might not be of more benefit than it had been at my own. During the latter part of the spring and throughout the summer Dr. Delavan, and later Dr. Harris, gave the patient electrolytic treatment to the anterior part of the tumor. Still later, both into the nasal and the nasopharyngeal part, injections were made of trichloroacetic acid, the patient going weekly to New York for the treatment.

Early in September, this being the year 1903, a sloughing spell came on, during which he was taken to New York and remained at the Manhattan Eye and Ear Infirmary. The sloughs came away without any terrible hemorrhage, although he had to be plugged for twenty-four hours on one occasion owing to the severity of the bleeding.

In the third week of September he developed a severe attack of erysipelas, which nearly cost him his life. Having recovered from that, the tumor presented a smaller, hollowed-out appearance on the anterior and under surface. It still extended into the nose, so that it was almost as far front as the anterior end of the inferior turbinate, and behind extended well down toward the palate.

During the next year the patient had more or less of the same treatment. He had one or two serious bleeding spells, but none of the extent and terrible force of the former experiences. He spent the two subsequent winters in Pasadena, Cal., or in that neighborhood, during which time he had only one slight slough-

ing spell. He developed a fistula in the external part of the face, which apparently connected with the parotid gland, so that he had continuous flow of at first matter and finally only clear fluid, for over two years. This gradually also closed down as the tumor became smaller and smaller, but still persists.

The last three winters he has spent at home, and at the present writing there is nothing but scar tissue to be seen in the vault of the pharynx where the tumor masses had come and gone. His nasal cavity is filling in somewhat. There is a partial attempt at restoration of the inferior turbinate, but the middle turbinate and the nasal wall of the antrum have disappeared as by pressure, as has the posterior half of the nasal septum. His chief difficulty now lies in keeping the nostril clean, because, as it often happens in atrophic rhinitis, it is difficult to keep the mucus from inspissating and giving odor to the breath and otherwise disturbing the patient when the cavity is so large. He has had no hemorrhages to amount to anything for the last two and one-half years, and apparently, then, has fulfilled the hope that, through all his distressing history I have held up to him, that he might be another case like Dr. Ingals's.\* His present age is twenty-two, so that I feel he has lived beyond the probability of recurrence and well-nigh the possibility of it.

Dr. Harris, in replying to a recent letter which inquired as to his views of this particular case, closed his letter with a statement so admirably worded to express my own views that I reproduce it as the closing sentence of this brief chronicle of this most remarkable instance of nasopharyngeal growth which my experience has included. He said:

"Viewing it in the light of subsequent events, with a strong desire to give all credit to the treatment, I must confess that to-

---

\*Since writing the above, on the 25th of June, the patient, while quietly sitting eating some ice cream, was taken with a violent hemorrhage and lost, even for him, an enormous amount of blood. The druggist in whose store the bleeding took place solemnly swears that it was at least three quarts. While we discredit this amount, it was evidently a very large quantity. There has been no return of the tumor. The patient has had one or two bleeding spells previous to this large one, and at that time, a month or more ago, he had an attack of rheumatism, which still troubles him. Presumably then, as a result of some scabbing process within the nose, and perhaps antrum, some of the large vessels which used to nourish the tumor have been opened.

day I am skeptical as to the real benefit derived. It has seemed to me that the history of this remarkable case, while it was under my care, conformed entirely to the periods before and after, and that we were dealing with a neoplasm which possessed the peculiar power of sloughing away and then recurring.

"It is gratifying to learn that the history here conforms to the history of other similar cases, namely, that if the patient can be kept alive for a period of years the growth will of itself disappear. In all my reading and clinical work I have never known a case of such severity where the ultimate outcome has been so satisfactory."



## THE NOSE AND NASOPHARYNX IN INFANTS AND YOUNG CHILDREN.

BY JOHN M. INGERSOLL, M.D.

The shape and the relative size of the nose and the nasopharynx change very much between the time of their development in the embryo and their permanent form later in life. The changes which take place in these structures in infants and young children have a decided influence upon the pathological conditions which may develop in the nose and nasopharynx, and make any kind of obstruction in these regions a much more serious matter in young children than in adults.

### THE DEVELOPMENT OF THE NOSE AND NASOPHARYNX.

The nose is primarily a special sense organ. In man, however, its respiratory function has become even more important than the olfactory function. The evolution of the organ of smell may be epitomized in the statement that the olfactory epithelium is a patch of infolded ectoderm, with highly specialized cells, which are brought into relation with the central nervous system by means of the outgrowth from the latter, of the olfactory lobe.

Early in intra-uterine life the olfactory plates appear just above the oral fossa, and owing to the rapid outgrowth of the surrounding tissue these plates become relatively depressed and form the nasal pits (about the twenty-eighth day). The nasal pits are separated from each other by a broad mass of tissue, called the nasofrontal process, which thickens along its lateral margins and forms the globular processes (Fig. 1). At the same time the lateral nasal processes bud out from the nasofrontal process, above the nasal pits, and growing downward form the external boundaries of the pits. Inferiorly the pits are directly continuous with the oral fossa.

About the end of the sixth week the nasofrontal process is joined on each side by the united maxillary and the lateral nasal



processes, and the nasal pits are thus shut off from the oral fossa. The orifices of the nasal pits form the anterior nares and the pits have become short canals opening through their deep orifices, the posterior nares, into the primitive mouth cavity behind the maxillary processes.

The nasal fossae are widely separated by the broad nasofrontal process, but during later development this process nar-

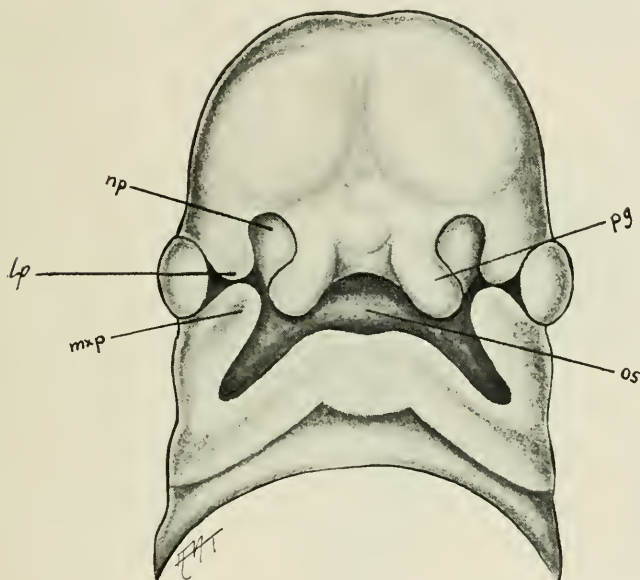


Fig. 1.

Face of embryo of 8 mm. (enlarged from His.); m. x. p., maxillary process; n. p., nasal pit; o. s., oral fossa; p. g., processus globularis; l. p., lateral nasal process.

rows down to form the septum and is gradually elevated above the surface of the face. As the nasofrontal process grows narrower, the globular processes are brought nearer together and, fusing in the median line, form the premaxillae and the middle third of the upper lip. Dr. H. P. Mosher has shown that the irregular development of the premaxillae is one of the important factors in causing deviations of the nasal septum. The palatal shelves grow toward the median line and uniting with each other

and with the nasofrontal process prolong the nasal fossae posteriorly so that at the end of the third month the posterior nares open into the nasopharynx instead of the mouth.

At least three, and sometimes four or five, folds of the ectodermic lining on the external lateral walls of the nasal fossae project horizontally inward and form the maxillary and ethmoidal turbinates. Each fold contains a fold of mesodermic tissue, which develops into cartilage and later into bone.

The maxillary sinus is formed during the third month by an

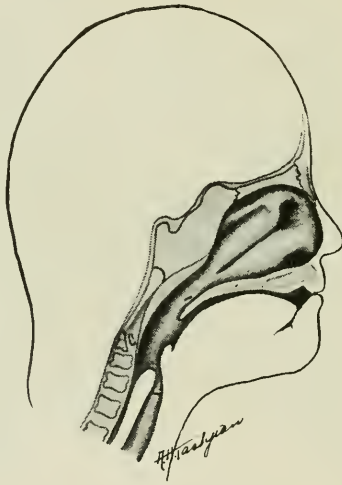


Fig. 2.

Section showing the left nasal fossa, nasopharynx and pharynx of a foetus about the twelfth week. In this specimen there are only two ethmoidal turbinates—the agger nasi shows quite distinctly as a prolongation forward of the ethmoidal turbinate.

evagination on the lateral wall of each nasal fossa, between the maxillary and ethmoidal turbinates. The ethmoidal, frontal and sphenoidal sinuses are formed later, and the last two are not completed until after birth.

Very early in the development of the nose a small invagination appears on each side of the median wall of the nasal pits. During the fourth month this becomes a small pouch in the septum, ending blindly posteriorly. This is the rudiment of Jacobson's organ,

which in macrosomatic animals is much more highly developed, communicates with the mouth and contains olfactory cells, connected with the olfactory lobes of the brain. In the lower animals

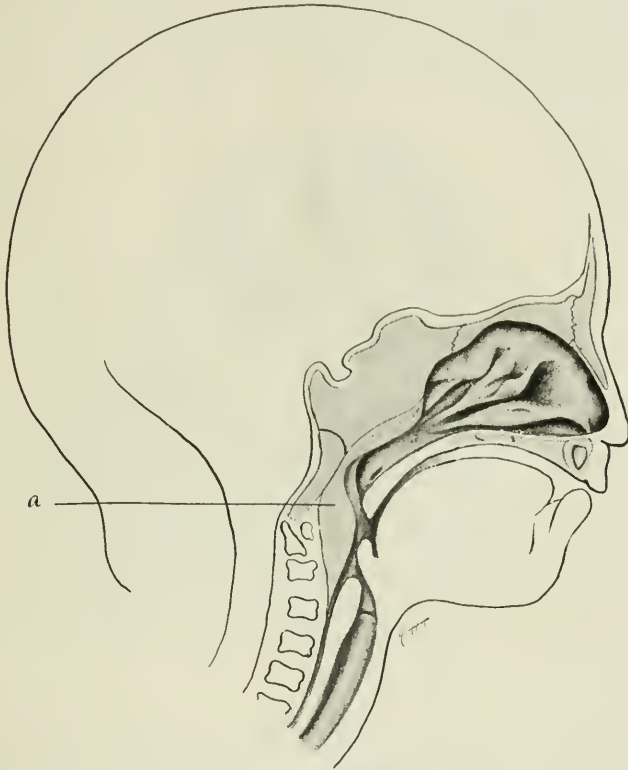


Fig. 3.

Longitudinal section, showing the left nasal fossa nasopharynx and larynx of a six-months-old foetus (a) adenoid tissue. The maxillary turbinate is well developed; four ethmoidal turbinates can be seen; the nasopharynx contains quite a large mass of adenoid tissue; the inferior border of which extends down below the opening of the larynx.

its function probably consists in bringing the food in the mouth under direct control of the olfactory nerve.

*Foetus, about the twelfth week, Fig. 2.*—The length of the nasal fossa in a foetus three months old is about 1.4 cm., its height about 0.7 cm. The length of the nasopharynx is about 1.3

cm., and its width between the Eustachian openings is about 0.5 cm. The floor of the nose is quite straight and slopes downward slightly. The maxillary turbinate shows distinctly as a shelf-like process and touches the nasal floor lightly. The ethmoidal turbinates are well developed and are situated relatively more posteriorly in the nasal fossae, so that their anterior ends are about over the middle of the maxillary turbinates and their position

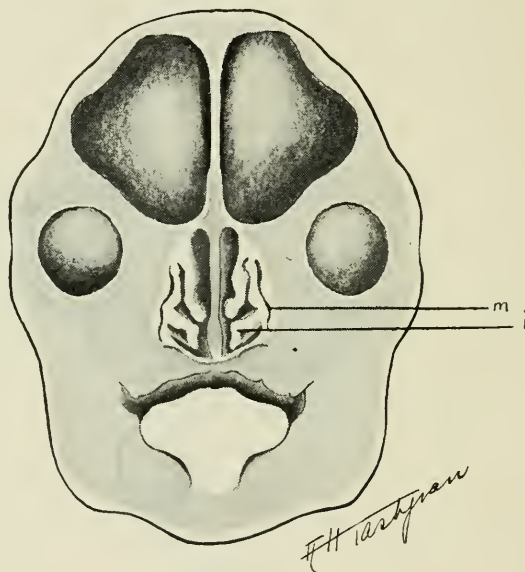


Fig. 4.

Transverse section through the head of a foetus six months old, showing both nasal fossae; the maxillary sinuses can be seen as narrow cavities with their walls almost in apposition (m) maxillary sinus, (i) inferior turbinate.

thus corresponds more closely to the position of these structures in some of the lower animals.

The choana is nearly round, its transverse diameter being slightly greater than the perpendicular. The nasopharynx extends downward and backward from the nose and is only very slightly curved. The opening of the Eustachian tube is elliptical and is nearly parallel with the floor of the nose. The larynx is relatively very high up, being about opposite the second vertebra.

The tongue is proportionately much thinner at its base than it is later. The width of each nasal fossa is relatively less than in the adult, because the septum in the foetus is much thicker.

*Foetus, sixth month, Figs. 3 and 4.*—In a foetus of the sixth month the turbinates are all more prominent and the meati are

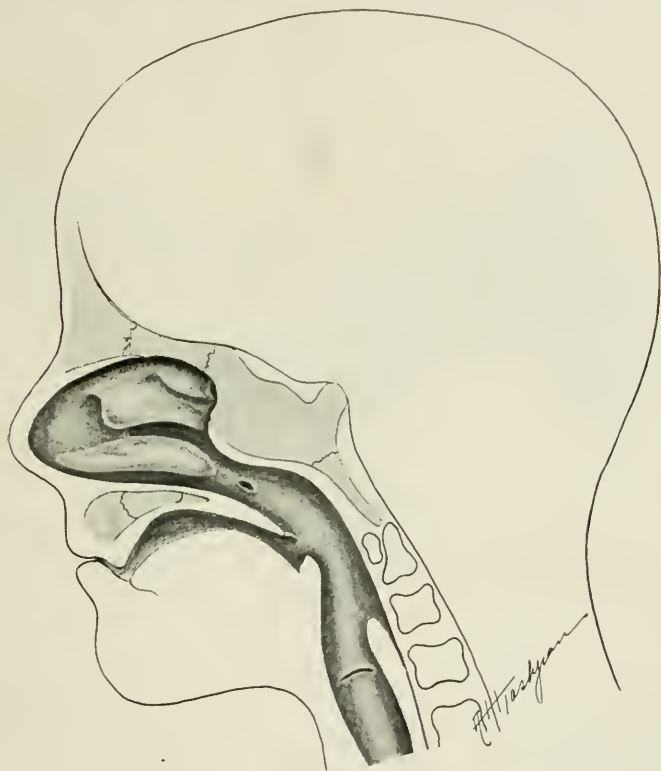


Fig. 5.

Section showing the right nasal fossa and pharynx of a foetus about eight months old. In this specimen only two ethmoidal turbinates are present; the nasopharynx is free from adenoid tissue; the elliptical opening of the Eustachian tube is nearly parallel with the floor of the nose.

well marked. The septum is proportionately somewhat thinner and the nasal fossae are consequently a little wider. The maxillary sinus shows distinctly as a narrow cavity, its lateral walls being almost in apposition. Very shallow depressions in the

frontal, ethmoidal and sphenoidal bones suggest the beginning of the sinuses in these regions. The nasopharynx is somewhat more sharply curved than it is in a younger foetus. Hypertrophied adenoid tissue may be present, and its relative position is much lower than it is in children and adults, so that its inferior portion may extend below the opening of the larynx. The larynx remains relatively high about opposite the third vertebra.

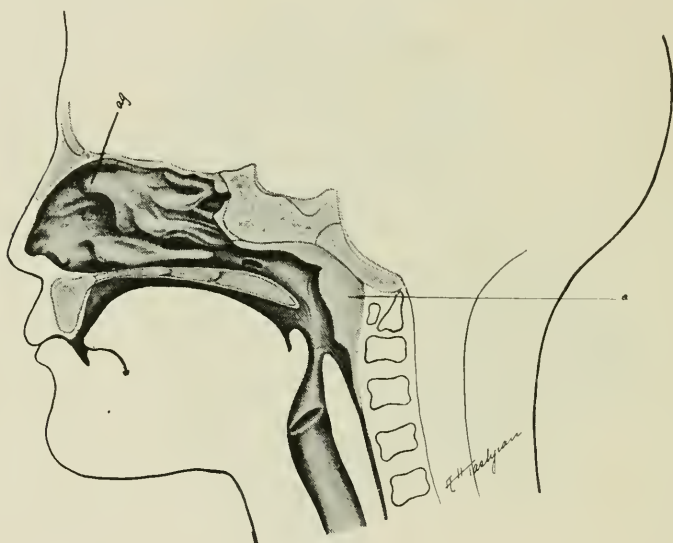


Fig. 6.

Longitudinal section, showing the right nasal fossa nasopharynx, pharynx and larynx of a child about six months old. The outline of the maxillary turbinate is about the same as in an adult. Four ethmoidal turbinates can be seen. The agger nasi shows distinctly as a rounded process extending forward from the anterior part of the ethmoidal turbinate. A small diverticulum extending into the sphenoid bone shows the beginning of the formation of the sphenoidal sinus. The long axis of the Eustachian tube is nearly parallel with the floor of the nose. The nasopharynx contains a rather large mass of adenoid tissue, which extends down below the opening of the larynx. The tongue is relatively thin posteriorly. The larynx is relatively high. (a.g.) agger nasi; (a) adenoid tissue.

*Foetus, eighth month, Fig. 5.*—In a foetus of the eighth month the length of each nasal fossa is about 3.0 cm.; the height about 1.4 cm.; the width about 0.5 cm. The length of the nasopharynx



is about 2.4 cm., and its width between the Eustachian openings 1.3 cm.

The turbinates and the meati are sharply defined. The floor of the nose and the soft palate are flat and slope downward slightly. The nasopharynx curves downward and backward and its posterior wall presents a smooth, regular outline, if it is free from adenoid tissue. The larynx is about on a level with the upper border of the fourth vertebra.

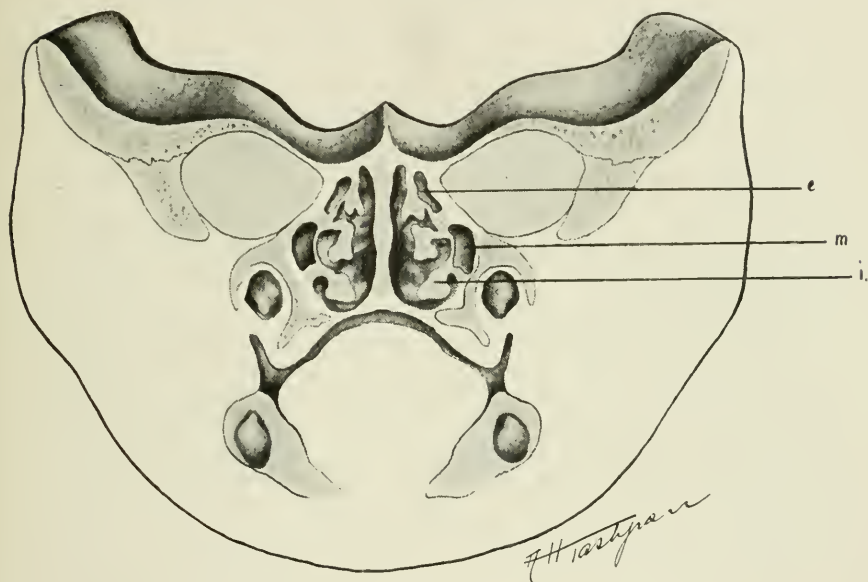


Fig. 7.

Transverse section through the head of an infant six months old, showing both nasal fossae. The maxillary sinuses show as rather oval cavities. Two ethmoidal cells show distinctly. (e) ethmoidal cell. (m) maxillary sinus. (i) inferior turbinate.

*Child, six months, Figs. 6 and 7.*—In a child about six months old the length of each nasal fossa is about 4 cm., the height is about 1.8 cm., and the width 0.7 cm. The width of the nasopharynx is about 1.6 cm., and its length 3 cm.

The general conformation and the relative position of the turbinates are nearly the same as in the adult. The palate is slightly



curved. The long axis of the Eustachian opening is nearly parallel with the floor of the nose. The posterior boundary of the nasopharynx is sharply curved. The larynx is about on a level with the fourth vertebra.

If there is much hypertrophy of the adenoid tissue it may obstruct not only the posterior nares, but also the larynx, for the nasopharynx is relatively low and the larynx is relatively high.

### *Summary.*

During foetal life and early infancy the relative proportions of the length and the height of the nasal fossae remain about the same—that is, the length is about twice as great as the height. After the second year the height increases more rapidly. On account of this increase in height of the fossae, the choanae, which are nearly round in infants, become decidedly elliptical and the perpendicular diameter of each choana becomes about twice as great as the transverse diameter.

The width of each nasal fossa is relatively less in an infant than it is in an adult, and hence any pathological lesion causing nasal obstruction in an infant is a more serious matter than it is in an adult. This is so not only on account of the relatively greater interference with respiration, but also because the nasal obstruction causes decided interference with the taking of nourishment.

The septum is relatively much thicker in the embryo and young infant than it is later in life. The general form of the maxillary turbinate remains very nearly the same during its whole development. The ethmoidal turbinates show many variations. Two are always present; there may be three, four, or occasionally even five ridges which correspond with the much more complicated development of these structures in many of the lower animals. The fourth and fifth ethmoidal turbinates usually disappear in early infancy. The third ethmoidal turbinate remains in about eighty per cent of cases.

The *ager nasi* is a slight elevation at the junction of the anterior end of the middle turbinate (first ethmoidal turbinate) with the

nasal process of the superior maxillary bone and is the rudiment of the nasal turbinate of the lower animals.

The maxillary sinus appears about the middle of the third foetal month. The frontal sinus begins as a slight depression extending upward from the nasal fossa in the third foetal month. It is, however, so small that it can hardly be called a sinus until about the seventh year when the true sinus is formed by the separation of the two tables of the skull.

The ethmoidal cells appear first during early foetal life as small depressions which grow by the absorption of the bone. The sphenoidal sinus is primarily a constriction of the primitive nasal fossa and begins to form in the third foetal month. The space is so rudimentary that not until the seventh year has there been sufficient absorption of the cancellous bone to make the sinus apparent.

The organ of Jacobson develops at a very early period and after the fifth foetal month it usually begins to disappear.

The hard palate at birth is about on a level with the junction of the sphenoidal bone and the basilar portion of the occipital bone. At three years it is opposite the middle part of the basilar portion and at six years it is about the same as in the adult, opposite the anterior edge of the foramen magnum.

The soft palate at birth is nearly horizontal and about on a level with the atlas. The tongue is relatively thinner at its base in an infant than it is in an adult.

The nasopharynx at birth is a tube-like structure extending downward and backward. It is relatively long and shallow.

Hypertrophied adenoid tissue may be congenital. If it is present in an infant, it may obstruct the nasopharynx and also the larynx on account of the high position of the latter. The obstruction and irritation of the larynx in this way is probably one of the chief factors in the causation of croup and other lesions of the larynx in children with adenoids. It seems probable also that the relatively low position of the adenoid tissue might make deglutition more difficult. It may be seen in some cases by direct inspection through the mouth if the soft palate is elevated and drawn slightly forward. On account of its relatively low position, it may be easily felt in a careful examination with the finger. The

advisability of its removal is self evident, regardless of the age of the child.

The openings of the Eustachian tubes are elliptical and the long axis at birth is nearly horizontal. The Eustachian prominences are only slightly raised above the surrounding tissue and hence are less liable to be injured in operations in the nasopharynx in infants.

On account of the small oral cavity and the shape of the nasopharynx in infants a curette with a straight handle and its blade set at an angle of fifty-five degrees to the handle will follow the posterior wall of the nasopharynx better and remove the hypertrophied adenoid tissue more completely than it will if the blade is more nearly perpendicular to the handle, as it is in many curettes. The bayonet curette of Fein was devised to permit greater latitude in the movement of the curette and thus allow its blade to follow the conformation of the nasopharynx. The width of the curette blade should be determined, of course, by the width of the nasopharynx. A curette 1.3 cm. in width with a blade 1 cm. in width is probably small enough for all infants.

The shape of the nasopharynx in infants makes it practically impossible to do a complete adenotomy with forceps.

### *Bibliography.*

1. The Development of the Human Body. J. F. McMurrick.
2. Text Book of Embryology. J. C. Heisler.
3. The Development of the Nose and the Pharynx and Its Derivations in Man. M. T. Sudler, *American Journal of Anatomy*, Vol. 1, p. 391.
4. The Premaxillary Wings and Deviations of the Septum. H. P. Mosher, *The Laryngoscope*, November, 1907.
5. Adenoids in Infants. Herman Jarecky, *New York Medical Journal*, Vol. 80 (1904), p. 309.
6. Adenoids in Infancy. J. L. Morse, *Journal American Medical Association*, Nov. 9, 1907, p. 1589.
7. Adenoide Vegetationen. Prof. E. J. Moure, *Allgemeine Wiener Medizinische Zeitung*, Dec. 26, 1905.
8. The Practice of Pediatrics. W. L. Carr (1906).
9. Zur Anatomie der Nase Menschlicher Embryonen. Gustav Killian, *Archiv für Laryngologie und Rhinologie*, Band III., p. 16.

10. Human Anatomy. George A. Piersol.
11. Quain. Elements of Anatomy.
12. Remarks on the Diagnosis of Adenoids in Infancy. W. F. Chappell, Transactions of the American Laryngological Association, 1901, p. 39.
13. Post-Nasal Adenoids; How Shall the Diagnosis Be Made in Young Children? C. C. Rice, Transactions of the American Laryngological Association, 1903, p. 198.
14. A. Kölleker. Neben das Jacobsonsche Organ des Menschen.
15. The Development of the Accessory Sinuses of the Nose. L. A. Coffin, American Journal of the Medical Sciences, February, 1905.
16. Comparative Anatomy of the Vertebrates. Wiedersheim and Parker.
17. Structure of Man. R. Wiedersheim.
18. Hand Atlas of Human Anatomy. W. Spalteholz.
19. Anatomie der Nasenhöhle. E. Zuckerkandl.
20. The Anatomy of the Middle Turbinate. H. W. Loeb, Journal American Medical Association, June, 1907.
21. A Contribution to the Knowledge of the Olfactory Apparatus in the Dog, Cat and Man. Effie Reed, American Journal of Anatomy, May, 1908.
22. Morphology and Embryology of the Nasal Fossae of Vertebrates. Leon Dienlafe, Annals of Otology, Rhinology and Laryngology, March, June and September, 1906.
23. Skeletlehre, Kopf. F. Graf von Spee.
24. Lehrbuch der Anatomie des Menschen. A. Rauber.
25. Die Abtragung der Rachenmandel mit dem Bajonettformigen Adenotom. Johann Fcm.

*Candidate's Thesis.*

## NASOPHARYNGEAL FIBROMATA.

BY ALBERT C. GETCHELL, M.D.

In the transactions of the American Laryngological Association for the year 1883 is a paper on Nasopharyngeal Fibromata by Dr. Rufus P. Lincoln. This paper passed in exhaustive review a series of 58 cases of nasopharyngeal tumors, including three cases of his own, two having been previously reported.<sup>1</sup> An analysis of these cases shows that they were not all true fibroma; indeed, several were unquestionably malignant, others were undefined, but enough were of this type to make the paper a distinct and valuable contribution to the subject. It was one of the first, if not the very first, considerable contributions to this subject by a throat specialist. This fact, added to the skill and success with which he removed the growths through the natural passages, seemed to mark a new epoch in the treatment of these troublesome growths.

The hopeful feeling shown in the discussion following the presentation of his paper was shared by others. In the second volume of his work on the Diseases of the Nose and Throat, bearing the date of 1884, Morrell Mackenzie<sup>2</sup> says:

"The method of dealing with these growths is likely to undergo a fundamental change. Until a comparatively recent period they had, as a rule, attained considerable dimensions before their true nature, or, in some cases, their very existence was discovered. Now, however, that the nose and nasopharyngeal region can be thoroughly examined by direct inspection, fibromata are sure to be observed at a stage when they are amenable to treatment of a tolerably mild nature. It is not improbable, therefore, that the severe 'preliminary operations,' presently to be described, may, after a time, become almost obsolete, and that the electric cauter-

---

<sup>1</sup>Transactions of the American Laryngological Association for 1879, p. 247.

<sup>2</sup>Diseases of the Nose and Throat, vol. ii., p. 501.

applied *per vias naturales* will, in a great measure, supersede all other methods."

Since that time cocaine and adrenalin have created new possibilities for intranasal surgery, which have been developed by a large number of resourceful and competent physicians. Even so in the *Journal of Laryngology, Rhinology and Otology* for January, 1909, page 28, a case of fibroma of the nasopharynx is given, and the operation thus described:

"Dr. J. W. Bond said that when he began the operation it promised to be easy, and after a preliminary laryngotomy he endeavored to remove the tumor by splitting the palate. But contrary to his hitherto invariable experience he failed to move the tumor, which was wedged into the posterior part of the nose and protruded but little into the nasopharynx. He then tried to dislodge the growth from the front by removing the ascending process of the superior maxilla and the anterior wall of the antrum, but this manoeuvre also failed. Finally the upper jaw had to be removed and the tumor peeled off the cribriform plate and the body of the sphenoid, which was nearly all destroyed by the tumor. It had been a very severe operation."

On the other hand, a few days ago, at the monthly clinic of the Throat Department of the Massachusetts General Hospital, Dr. H. P. Mosher showed a boy of about the same age, from whom he had removed a fibroma, with a cold wire snare, experiencing no trouble except the severe hemorrhage, which, as he said, usually accompanies these operations.

Such are the wide limits of ease and difficulty, of safety and danger, that the removal of these growths presents, in spite of all the developments of nasopharyngeal surgery in the twenty-six years since the publication of Dr. Lincoln's paper.

It is evident that the subject has not passed beyond the region of profitable discussion, and that in view of the admitted rarity of the growths, every new experience has its lessons. It so happens that in my practice I have had two cases, which fact, particularly, has prompted me to a study of the subject.

I have carefully gone over the literature since the date of Dr. Lincoln's paper, and find much confusion therein. The references I have followed up have led me to all sorts of growths, in all sorts of localities in the nose and nasopharynx, in people of all ages, both male and female.



In view of this, and in order to have clear ideas upon which to study the subject, it is necessary to define what nasopharyngeal fibroma is. I know of no better definition than that of Jonathan Wright<sup>3</sup>. In substance, it is this: Nasopharyngeal fibroma is histologically a benign growth, but owing to its situation gives rise to symptoms which, if unrelieved, are almost certain to result in death; and it demands operative treatment. It occurs almost exclusively in males between ten and twenty-five years of age. So marked is this influence of age, that not a few cases are recorded of spontaneous recession of the growth after this period, affording in this respect a marked resemblance to another nasopharyngeal growth, viz., lymphoid hypertrophy or adenoid vegetations. As to its point of origin, he says it springs from the dense fibrous tissue and periosteum which cover the under surface of the basilar process of the occipital bone, and the body of the sphenoid.

Morell Mackenzie,<sup>4</sup> Greville MacDonald<sup>5</sup> and H. Lambert Lack<sup>6</sup> make practically the same definition.

This definition lays emphasis upon the age and sex of the patient, and also upon the tendency to recession at or about the age of twenty-five. In classifying fibrous tumors of the nose and nasopharynx, these considerations should be observed. According to this idea nasopharyngeal fibroma is a disease of development.

Fibroma of the nose, on the other hand, appears to be a different disease. It occurs mostly in middle age and in either sex. Thus, Kelson<sup>7</sup> removed one from the skin of the vestibule of the nose. The patient was a man and had fibrous tumors in other parts of the body. Stewart<sup>8</sup> reports a fibroma removed from a patient, probably a man, between fifty and sixty years of age. This growth was the result of an injury received forty years before. It filled the nose and nasopharynx, but was found to be attached to the septum, from which it grew by a pedicle. Casselberry's<sup>9</sup> case was a woman thirty-nine years old. These and other

<sup>3</sup>American Text-book of Diseases of the Eye, Nose and Throat, p. 1091.

<sup>4</sup>Diseases of the Nose and Throat, ed. 1884, vol. ii., p. 493.

<sup>5</sup>Diseases of the Nose, p. 266.

<sup>6</sup>Diseases of the Nose, p. 239.

<sup>7</sup>Journal of Laryngology, 1902, vol. xvii., p. 28.

<sup>8</sup>Journal of Laryngology, 1896, vol. x., p. 56.

<sup>9</sup>Journal of the American Medical Association, April 21, 1888.



reported cases of fibroma of the nose, few in number, for the disease is very rare, seem to be, as it were, accidental. Knight's<sup>10</sup> case approaches more nearly the type we are considering. It occurred in a young man twenty-one years of age. It had never caused serious symptoms, like hemorrhage. It was pedunculated. It had the characteristics clinically of a mucus polyp, which had an unusual amount of fibrous tissue. It was easily removed with a cold snare, and was found to contain fibrous tissue only. It was attached to the posterior end of the middle turbinate. Might not this growth come under the head of nasopharyngeal fibroma, according to our definition? It occurred in a young man. It was a pedunculated, innocent affair. But for certain reasons impossible to state it may not have undergone the active growth of more typical ones, or it may have been discovered before these changes had occurred. The point of its origin is interesting. Apparently it was from the posterior end of the middle turbinate. Now, when one considers how near that is to the sphenoid, is it possible to say that its origin was not from the sphenoid instead of the middle turbinate, and that it grew forward instead of backward?

My second case I had looked upon as a nasal tumor. It was mostly within the nose, but so wide was its implantation that I cannot be sure that this sphenoid was not involved, as well as the middle turbinate. It certainly had all the clinical characteristics of nasopharyngeal fibroma, and I so consider it. I am inclined to think that the point or origin in most, perhaps all of these growths, is the sphenoid.

If a growth in this region is found to consist of fibrous tissue only or contains round cells, for some of them resemble sarcoma, and possesses the clinical characteristics of nasopharyngeal fibroma, whether it grows toward the nose or toward the nasopharynx, in my opinion is and should be called nasopharyngeal fibroma, although that term is inadequate.<sup>11</sup>

It is not necessary here to enter further into a description of the disease. There are questions of treatment, however, which should be considered:

First: Shall any operative treatment be attempted in view of

---

<sup>10</sup>Diseases of the Nose and Throat, p. 158.

<sup>11</sup>See Wright, American Text-book, p. 1081, foot note.

the well-founded belief in the recession of the growth about the age of twenty-five? It is not safe to act upon that expectation, for such may be the rapidity of the growth of the tumor that not only will there be great suffering, but a fatal issue may be reached before that time. Therefore, it is the duty of the surgeon to remove the growth as soon as it is discovered, in the hope of removing it entirely and curing the disease, or, if not, of keeping the morbid process within bounds until nature comes to the relief of the sufferer.

Second: If the operation is to be done, what shall it be? These cases usually come first to the laryngologist, and he must decide the question whether he will attempt the removal through the natural passages by methods with which he is familiar, or will ask the general surgeon to remove the growth by the external method. Every case must be decided on its own merits. But it must be borne in mind that if the external method is adopted the preliminary operation necessary before the growth is reached is in itself a distinct danger.

Thus, Mackenzie says:<sup>12</sup>

"These procedures are in themselves attended with considerable risk. Sédillot and Demarquay each lost a patient from hemorrhage in the course of the 'preliminary operation,' and in twenty-one cases collected by Lincoln in which a 'preliminary operation' was done, death took place on the table in three, while in a fourth the patient succumbed within a few hours."

So that if removal by the natural passages affords fair prospect of success, considerable risks may be taken, in view of the positive risks of the external operation.

I desire to report these two cases:

Case 1. Harry W., aged 18, presented himself at the Worcester City Hospital March 25, 1899. Except for typhoid fever in 1897 he had always been well. He came for the removal of an obstruction in the throat, an adenoid, it was thought. His trouble appeared to date from the attack of typhoid fever. Aside from the obstruction of breathing his other symptoms were a feeling of fulness in the left ear, impaired hearing and tinnitus. He had had epistaxis several times, once so severe that he fainted. Except for the local trouble in the nose, the boy appeared to be well.

---

<sup>12</sup>Diseases of the Nose and Throat, vol. ii., p. 509.

Examination of the nose showed in the left side an obstruction with a raw surface, which filled the whole of the lower meatus. In the nasopharynx was seen a mass red in color, about the size of an English walnut, attached by a sessile base, apparently to the basilar portion of the occipital bone, which sent prolongations into both sides of the nose. By feel it was very hard. As it was impossible to engage the growth with a snare, the patient was etherized and an attempt was made to draw it out with volsellum forceps, and remove it with scissors. This failing, it was removed piecemeal with a large adenoid forceps. It was exceedingly tough and required much force to tear it away. As it was impossible to reach the growths in the nose by this method they were left. A large hole was left by the operation, at the bottom of which bare bone could be felt. The operation lasted three-quarters of an hour. Bleeding was very profuse, but at no time alarming. The recovery from the operation was satisfactory. Seven days after the operation this note was made:

"Doing well, up and about the ward. Has been treated in the out-patient department, small fragments being removed from the nose with cold wire snare; one of these operations being followed by such severe hemorrhage as to require plugging."

Again, in June, I removed with the snare a remaining piece from the nose, and in November of the same year, there having been some bleeding, under ether I again operated on what remained in the nasopharynx with forceps and curette. I have not seen the patient since. He then left to live in a remote part of the State; indeed, he had gone there in the interval between the first operation and the later ones. Although I have not been able to get into direct communication with him, I learn from acquaintances that he was in the regular army during the Spanish war, and that he is apparently well now. There is no record of a microscopic examination of the growth.

Case 2. R. A., boy of seventeen, generally well. He gave a history of obstructed nose of two years' duration, with occasional epistaxis, especially on exertion, and severe. There was broadening of the face at the base of the nose. The septum was deviated so much to the right, the obstructed side, that the growth could not be seen there, but it could be seen projecting into the naso-

pharynx. Subsequently, coming in one cold day, the growth could be plainly seen anteriorly. It bled profusely on slight manipulation. An attempt to correct the deviated septum in order to get more room failed on account of severe bleeding.

Having decided to remove as much of the growth as possible with the cold wire snare, and to complete the removal by subsequent operations, January 30, 1907, I operated with cocaine anaesthesia. As it was impossible to pass a loop through the nose I brought it up from the nasopharynx in this manner. Threading a soft catheter with strong silk I passed it through the nose, drawing it out of the mouth. I then fastened the ends of the wire loop

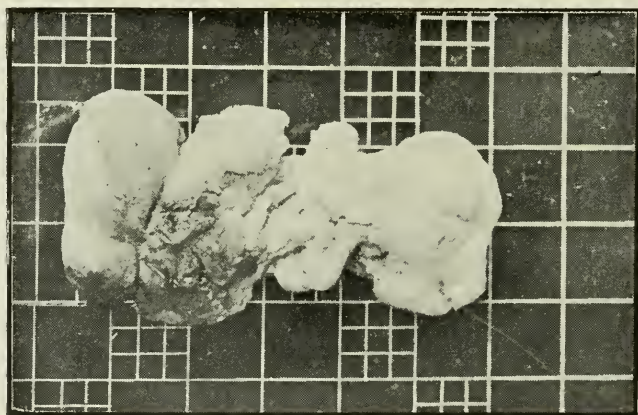


Fig. 1.

Nasopharyngeal fibroma. Dimension of large square, 1 centimeter.

to the silk and drew the wire back through the nose, engaging the loop over the mass with my finger in the nasopharynx. Then I passed the cannula of the snare over the wires. The snare was a strong one, but so tough was the growth that it was put out of order before the growth was cut through. I was compelled then either to abandon the operation or to remove the growth by evulsion. Thoroughly appreciating the dangers of the latter course, I did it. The growth came away entire. Hemorrhage was very profuse, but stopped of its own accord. The patient felt faint from the hemorrhage, but recovered after a few moments in the

recumbent position. The operation was done in my office, and the patient went to his home, only a short distance away. His recovery was uneventful, except that the next day he complained of the other side of the nose feeling more stopped than usual. On examination I found that in delivering the growth the septum had been pushed over, in which position, practically in the median line, it has since remained. I have seen him several times since. There has been no recurrence nor further trouble. I saw him last April 10, 1909.

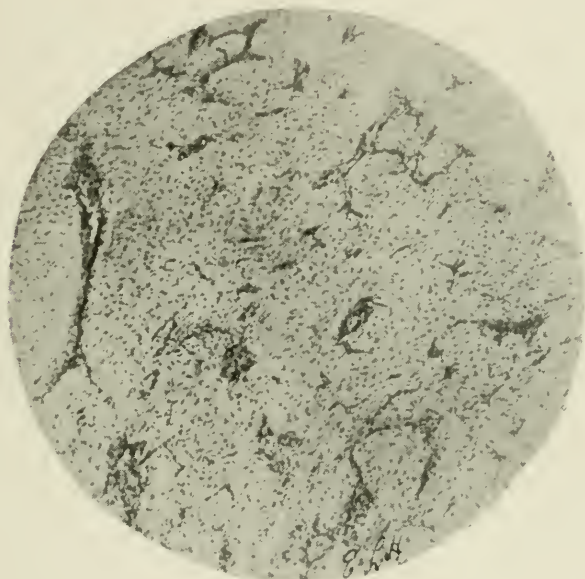


Fig. 2.

Section of nasopharyngeal fibroma.

Dr. Ernest L. Hunt, assistant pathologist to the Worcester City Hospital, made the photograph of the growth, also the microphotograph. Appended is his description of the microscopic section:

"Microscopical sections show a tissue of moderate density made up of spindle and stellate cells with large ovoid nuclei, and separated by a large amount of fibrillar intercellular substance. This structure is traversed by numerous clefts and channels, often



branching, and varying greatly in size. These are lined by a delicate endothelium, supported in the larger ones by two or three layers of spindle cells, generally longitudinally disposed. These spaces contain in their lumina granular coagula, sometimes round, and polynuclear cells and rarely red blood corpuscles; they are blood vessels and lymph channels and must have given to the growth something of an erectile character. Scattered through the tissue, most numerous near the vessels, are round cells and rarely polynuclear leucocytes.

“Diagnosis—Angio-fibroma.”



## THE ACTION OF THE RESPIRATORY MUSCLES IN THE PRODUCTION OF VOICE.

BY G. HUDSON MAKUEN, M. D.

At the last meeting of this association there was a hurried and somewhat unsatisfactory discussion of the action of the respiratory muscles in the production of voice, and as I was, in part at least, responsible for its precipitation, I welcome this opportunity of reopening the discussion in order that I may more fully set forth my views in the matter. The opening paper upon the subject, as you will recall, was entitled "The Essentials of Voice Production," and although it was presented by Prof. Mills, a physiologist and teacher of high repute, and contained many excellent things, it contained no reference whatsoever to what many consider to be one of the great essentials of voice production, namely, the action of the respiratory muscles.

I called attention, at the time, to the fact that, in his recent book on voice production, the author also dismisses the subject of breath control in a few words, presumably leaving this important phase of the subject to chance, or as Sam Weller would say, to the "taste and fancy" of the speaker. The same criticism may be made of nearly all the books on this subject, and if we were to look for a cause of the omission, I think we should find it in the fact that the exact use of the respiratory muscles in the production of voice is exceedingly hard to demonstrate and even to understand. It ought not to be difficult, however, for one who does understand it, to explain or demonstrate it to a body of men such as those to whom this paper is addressed.

I think I understand the action of these muscles in the production of voice, but I am not at all surprised when others seem to doubt it. A medical friend of mine in Philadelphia, who has made a special study of the abdominal and thoracic viscera, says that very little is actually known about the diaphragm in the liv-

ing subject and its action even in ordinary passive breathing, and when it comes to the more complicated action of this and related muscles in the production of voice, we have a still more difficult problem to solve. When I told him that my diaphragm is in strong contraction during the emission of a sustained tone he asked how I knew that it was thus in action. I said: "I can feel it contract," and that is how I know.

The kinesthetic sensations of muscle action are largely acquired, and they may be developed to a high degree. It is quite possible for one to learn to feel the sensations of muscle action and to call them into consciousness. Indeed, this forms a part of the education of every vocalist.

This kinesthetic faculty must be acquired especially by those who would overcome a faulty muscle action, whether it be in the production of voice or in the articulation of voice into speech, and it is for this reason that I make such a point of the precise action of these muscles, and that I teach it to those having vocal and speech defects.

The same principle is made use of in the teaching of the blind and deaf. Helen Keller, for instance, depends entirely upon the development of the kinesthetic areas of her brain for guidance in her vocalization and articulation. Indeed, she has no other senses to guide her. She cannot see the action of her muscles, nor can she hear the results of their action, but she feels and knows the sensations for every word and syllable which she utters.

In the teaching of the deaf, as you know, much attention is given to the exact use of the muscles of the lower jaw, the lips, the tongue and the palate, and in a similar manner we may teach the precise use of the abdominal muscles, the diaphragm and the large thoracic muscles, in the production of voice. We cannot see their action, but we can learn to hear and appreciate the results of their action, and to feel the sensations which arise from their use. The trained ear may even learn to tell which muscle or group of muscles is at fault from the particular character of voice that is being used, and this knowledge is very helpful in the treatment of defects of voice and speech.

There are two schools which seem to be diametrically opposed

in their thought as to the action of the diaphragm and abdominal muscles in the production of voice. The one school, and this is the one in which I was first educated, advocates a sinking or drawing in of the abdominal walls, and the other one, to which I now belong, advocates the protrusion of the abdominal walls during the emission of tones. The difference consists entirely in their notion as to the action of the diaphragm. Is it contracted or is it relaxed during the act of voice production? If it is relaxed, then the contraction of the abdominal muscles will tend to push the abdominal viscera and diaphragm, piston like, up into the base of the thoracic cavity, and there will be a sinking of the abdominal walls; but if, on the other hand, it is contracted, there will be a compression of the abdominal viscera and a slight protrusion of the abdominal walls, the extent of which will be governed by the amount of resistance given by the contraction of the abdominal muscles.

Those of the first school probably constructed their theory upon the commonly accepted views of physiologists with regard to the action of the diaphragm in ordinary respiration. The books tell us that the diaphragm is an inspiratory muscle, that it contracts during inspiration, thus elongating the thoracic cavity, and relaxes during expiration, when the thoracic cavity becomes shortened.

In the process of ordinary respiration, therefore, the act of inspiration may be considered as being active, while that of expiration is passive. In other words, inspiration is the result of the enlargement of the thoracic cavity by muscular contraction, and expiration is a result merely of a passive return of these muscles to their original condition of partial relaxation.

It is not difficult to understand, however, that this theory will not apply to the production of voice, which is a positive, and not a negative process. In other words, after drawing air into the lungs by muscular contraction, we do not then let it flow out for vocal purposes by muscular relaxation, but we control its outward movement in voice production by definite and powerful muscular contractions.

The action of the muscles in normal breathing, therefore, is not the same as the action of the muscles for vocalization, be-

cause the expiratory phase of the one is passive, while that of the other is active.

My attention was first called to the importance of breathing in relation to voice production when I was a student of the subject some years ago.

Among the authors which I have consulted on this subject was the late Dr. John Howard, whose book, now unfortunately out of print, is the very best of which I have any knowledge, and to him more than any one else am I indebted for my interest in the subject. I claim, therefore, no originality for the method, but I do claim to have given it a thorough trial, during nearly thirty years of practice and teaching of the voice and speech, with upward of five thousand pupil-patients.

The faulty method, to which I have referred, is the outgrowth of the notion that the breathing of voice production is alike in all respects to normal passive breathing, a proposition which is altogether untenable. The exhalation of the one form of breathing is passive, while the exhalation of artistic breathing is active, positive, definite and precise. The inhalation of artistic breathing is powerful and rapid, while the exhalation may be equally powerful, occasionally rapid, but sometimes very much prolonged. In this rapid and strong inhalation the diaphragm must take no part whatsoever, but in the artistic exhalation which follows it must take a more or less controlling part. In other words, for artistic purposes the diaphragm is not an inspiratory, but an expiratory muscle, and not only so, but the slightest action of the diaphragm interferes with forced inhalation by checking the full expansion of the thorax. This can be readily demonstrated by the following simple experiment: Place the hand upon the upper third of the abdomen, and, while taking a forced inhalation, push the abdominal wall forward, which, be it understood, can be done only by the contraction of the diaphragm. When the greatest possible amount of air has been inhaled by the combined action of the rib-raising muscles and the diaphragm, allow the abdomen to recede, which can be done only by the relaxation of the diaphragm, and note that an appreciable amount of additional air may be taken in, because the relaxation of the diaphragm permits of a further upward and outward movement of

the ribs. This little experiment, suggested by John Howard, which any one may make for himself, proves conclusively, I think, that any action of the diaphragm interferes with the full inhalation often requisite for artistic purposes.

Now, when the inhalation is completed the production of voice immediately follows, the very first part of the tone being the result of the natural recoil of the air cells of the expanded lungs and of the inspiratory muscles which have caused the expansion. As the tone proceeds the inspiratory muscles relax and the expiratory muscles contract with a force which is proportionate to the strength and volume of the tone; and that the diaphragm is an important factor in this expiratory effort is shown by the concomitant protrusion of the anterior abdominal walls.

As an inspiratory muscle, therefore, the diaphragm is not a success—at least for artistic purposes. Powers and others have shown that only about twenty-five cubic inches of air can be inhaled by any purely diaphragmatic effort. In forced inspiration the lateral walls of the thorax must expand to the fullest extent, because the lateral walls cover about five-sixths of the entire lung surface, while only the remaining one-sixth is contiguous to the diaphragm. Furthermore, it has been demonstrated that a pair of lungs, removed from the thorax and inflated, expand through the lateral and antero-posterior diameters far more than through their vertical diameters. Anything, therefore, that interferes with the enlargement of these diameters interferes with artistic breathing. That the contraction of the diaphragm does interfere with the upward and outward movement of the ribs is shown by the fact that a contraction of the diaphragm resulting from electric stimulation of the phrenic nerve actually pulls the ribs in.

Let us consider, briefly, first the mechanism of the inhalation for voice production, and, second, of the exhalation for voice production.

In the time at my disposal, it will be quite impossible to discuss the action of all the muscles employed in the production of voice; nor, indeed, is it necessary to do this, because many of them work in groups and may thus be disposed of.

A word as to the framework of the thorax seems to be neces-



sary at this point. As is well known, the ribs, while at rest, incline downward from their points of attachment to the spinal column, tending by their curved shape to increase this downward inclination, and it is evident therefore that the enlargement of the thorax can best be brought about by the outward rotation of the ribs and their elevation relative to the spinal column. As John Howard has pointed out, it is quite possible to elevate both the ribs and spinal column together, and thus get very little increased thoracic expansion. To get the best results, the ribs must be brought approximately to a position which shall be at right angles to the spinal column.

The inspiratory muscles may be divided into two classes, the fixation muscles and the actual rib-raising muscles. The fixed points to which the latter group is attached are three in number, namely, the spinal column, the head and the shoulder, on either side, composed of the clavicle, scapula and humerus. The spine is more or less fixed by the erector spinae, the head by the trapezius and complexus, and the shoulder bones (the clavicle, scapula and humerus) by the trapezius, the rhomboid, the levator anguli scapulae, the scaleni and the deltoid muscles. From these three more or less fixed points the rib-raising muscles descend to the ribs, their lower and movable points of attachment.

The chief of the rib-raising muscles are the serratus magnus, the latissimus dorsi, the pectoralis minor and to some extent also the pectoralis major. All the aforementioned must be regarded as inspiratory muscles because they either pull directly upon the ribs or hold in a fixed position the upper attachments of the rib-raising muscles.

This brings us to the muscles of exhalation for voice production, or the expiratory muscles. The erector spinae has been referred to as a fixation muscle for the spine in inspiration and it has a similar function in expiration. It must hold the spine erect against the forward and downward pulling of the diaphragm and abdominal muscles.

The abdominal muscles are attached to the movable ribs above, to the more or less fixed spinal column in the rear and the upper edge of the pelvic bone below. These muscles form the anterior



and lateral walls of the abdominal cavity, and they extend posteriorly to either side of the spinal column.

Obviously, the first result of the contraction of this network of muscles is to compress the abdominal viscera and to push them upward against the only other yielding portion of the abdominal walls, namely, the diaphragm. But this can have but little expiratory effect, because it merely pushes the diaphragm up into the thoracic cavity and does not, to any extent, at least, pull the ribs downward and inward, which must be their direction in forcible expiration. If, however, the diaphragm is contracted and thus made to resist the upward motion of the abdominal viscera, it helps to form a sort of fulcrum over which the abdominal muscles will pull downward and inward. On the other hand, when the ribs are pulled upward and outward by the inspiratory muscles, the contraction of the diaphragm pulling over the abdominal viscera, already compressed by the simultaneous contraction of the abdominal muscles, will tend to pull the ribs downward and inward with considerable force.

The points of fixation for the abdominal muscles are the crest of the ilium and the spine, and when the diaphragm contracts, preventing the inward and upward movement of the abdominal viscera, the recti muscles, with their tendinous aponeuroses, form a more or less fixed surface from which the other abdominal muscles, the external, internal and transverse, pull downward upon the ribs with great force. Likewise, when the ribs are drawn up nearly at right angles to the spine, as they are in the full inhalation required for voice production, the diaphragm tends to become flattened out like a large plate, and during the emission of tone its contraction over the resisting viscera, slightly compressed by the action of the abdominal muscles, will naturally result in a pulling of the ribs inward with considerable expiratory effect, the slight upward pulling of the ribs by the diaphragm being more than offset by the action of the abdominal muscles, the quadratus lumborum and the serratus posticus inferior.

The intercostals are usually given a prominent place among the respiratory muscles, but I fail to see how they can be more than subsidiary to those which I have already described. The distribution of the fibers of the external intercostals are such that

their contraction, unassisted by any fixation muscles, would merely pull the lower rib upward a little further than it would pull the upper rib downward, and the fibers of the internal intercostals being attached further from the spine above would pull the upper rib downward a little further than they would pull the lower rib upward. It is evident, therefore, that the intercostals of themselves can have but little respiratory action, but when the upper rib and clavicle are fixed, mainly by the scaleni muscles, their combined action is inspiratory, and when the lower ribs are fixed, mainly, by the abdominal muscles, their action is expiratory.

An effort has been made herein to describe briefly the action of the respiratory muscles in the production of voice, as this action is understood by the best exponents of both the theory and the practice of the subject. There will be, I think, no special controversy between the general and special physiologists except as to the action of the diaphragm. This muscle has been classed with the inspiratory muscles for so long a time that there will always be those who will oppose its removal from this class for any purpose whatsoever until absolute proof can be given of the necessity of doing so. With our present facilities and instruments of precision, this proof, it must be admitted, cannot now be given, nor does it seem to be forthcoming, although Röntgenography may yet come to our aid in this connection. Indeed, I made an attempt to have some pictures to show you at this time, but the efforts of Dr. C. L. Leonard, of Philadelphia, who has made some excellent Röntgenograms of the abdominal and thoracic viscera in which the position of the diaphragm is shown very clearly, were not altogether successful. We tried to get on the same plate a picture of the two positions of the diaphragm, the one in forced inspiration and the other in forced expiration, in order that we might make more satisfactory comparisons, but we were obliged to abandon the scheme temporarily because of some slight difficulties in the way of technique.

The picture which we attempted to make, however, even if we had been successful, would merely have shown the positions of my own diaphragm in forced inhalation and exhalation. It would merely have shown the action of the muscles which I had acquired for artistic purposes, and this of itself would not have proved

anything. To be of any scientific value, pictures of a large number of the best vocalists would have to be taken and a series of moving pictures would have to be made while the vocalists were in the very act of singing and speaking. That this may be done in the near future is well within the realm of possibility, and we shall probably have to wait until then for absolute proofs of the propositions advanced in this paper. In the meantime, we must accept the teachings of physiologists who have given special attention to this subject, among whom are Drs. John Howard, A. Ransome, Charles Benson, Hutchinson, Landois, Sibson and Rosenthal. It is true there are those also who oppose the theory which I have advanced, but they seem not to have made out a good case against it.

### *Summary.*

The most important thing in voice production is good and efficient breathing.

Good breath control is absolutely essential to good voice production.

There may be various methods of controlling the breath in voice production, but there is only one best method.

Breathing may be divided into two classes, passive and active breathing. Passive breathing is that which is used for all ordinary purposes, such as merely aerating the lungs, and active breathing is used for extraordinary purposes, such as singing and speaking.

In passive breathing the aeration of the blood is the chief purpose, whereas in active breathing it is of secondary consideration.

The inhalation of passive breathing is due to a slight contraction of certain muscles, including the diaphragm, while the exhalation is purely passive and due to a recoil of these muscles and of the air cells to their original condition.

The inhalation of active breathing is much more extensive, and consists in the wide expansion of the thoracic cavity by means of a more or less vigorous contraction of the rib-raising muscles.

In active inhalation the diaphragm takes no part whatsoever, because its contraction interferes with the upward and outward movement of the ribs.

The exhalation of voice production consists in the relaxation of the rib-raising muscles, and a more or less vigorous contraction of the rib-depressing muscles, the chief of which are the diaphragm and the abdominal muscles.

During the inhalation of voice production, the diaphragm and abdominal muscles should be entirely relaxed, so that at the point of fullest inhalation, the recti muscles, extending from the symphysis pubis to the ensiform cartilage, should form or approximate a straight line.

Any protrusion of the anterior abdominal walls during inhalation interferes with the expansion of the ribs, and therefore with the fullest breathing.

In the exhalation of voice production the diaphragm and abdominal muscles contract simultaneously and to a degree commensurate with the amount of breath pressure required. For strong and impassioned tones, the breath pressure is sometimes very great.

The action of the respiratory muscles in the production of voice is very important and it must be acquired by long practice properly directed.

Defects of voice and speech are due in large measure to faulty breathing, and successful voice culture or voice building depends almost altogether upon the accuracy and efficiency of breath control.

### *Conclusions.*

I. The action of the respiratory muscles in voice production differs in some important respects from their action in passive breathing.

II. While the function of the diaphragm is inspiratory in passive breathing, it must be expiratory in active or artistic breathing.

III. Although the diaphragm is generally classed among the involuntary muscles, its action, like that of so many other so-called involuntary muscles, may be brought entirely within the domain of the will.

IV. The proper use of the respiratory muscles for singing and speaking may be acquired by practice, and should be taught by the teachers of voice culture.

*Discussion.*

Dr. J. H. Lowman: I would like to ask Dr. Makuen if he has observed the Litten phenomenon during the breathing. In many people the diaphragm will be observed to move very distinctly and you cannot see the Litten phenomenon at all. You can see the diaphragm descend from an inch to an inch and a half. If you have a shaft of light across the chest and the patient takes a deep inspiration you can follow the movement of the diaphragm by a very slight shadow. The diaphragmatic phenomenon, as described by Litten, is a positive sign of the movement of the diaphragm and can be used as an aid to diagnosis under many circumstances.

Dr. J. Payson Clark: Has Dr. Makuen ever used the fluoroscope or radiograph in demonstrating this action of the diaphragm?

Dr. Makuen (in closing): I may say that I was obliged to omit a very important part of my paper in which I went into the skiagraphic work. My friend, Dr. Leonard, tried to make a Röntgenogram of my own diaphragm during forced inhalation and forced exhalation, trying to get both pictures on the same plate, but the result of our efforts was a failure, and Dr. Leonard thinks with our present technique it is impossible to get a satisfactory demonstration or proof of my theory with reference to this matter. I hope that some time we may be able to make moving pictures of the diaphragm during the production of tone in singing and speaking. Many pictures would have to be taken of good singers and speakers in order to get valuable data. There are various methods of breathing during voice production, and the question is which is the best method.

## A CASE OF PRIMARY CARCINOMA OF THE TRACHEA.

BY T. PASSMORE BERENS, M.D.

At the meeting of this association in 1906, Theisen read an exhaustive paper on the subject of "Primary Carcinoma of the Trachea." After excluding all doubtful cases, both as regards diagnosis and location, he gathered twenty-seven cases and reported one case from his own practice, making in all twenty-eight cases. In 1908, Nager (*Archiv für Laryngologie und Rhinologie*), in a lengthy article, quoted eight cases, including one of his own. Of these eight cases, one was Theisen's case, one was a case reported by Schroetter, Jr. (*Klinik der Bronchoskopie*, 1907), and the remaining six quoted by him had already been quoted by Theisen. The writer, after a somewhat arduous search through the literature, accepts Theisen's classification as correct, and has found to date but thirty cases of Primary Tracheal Carcinoma, to which number he would add the following report of a case from his own practice.

The patient, a man fifty-five years old, was seen in consultation with Dr. J. M. Bleyer, who gave the following history. The patient had always been healthy; there was no specific history, but a brother had recently died from carcinoma of the stomach. The patient had consulted the doctor about nine months before, because of a persistent cough. The cough grew worse, and attacks of dyspnoea had become a marked symptom, increasing in severity and frequency. A subglottic tumor had been seen by Dr. Bleyer. The patient was a large man, weighing 175 pounds, with a short, thick neck. Examination revealed both vocal cords reddened and slightly thickened. Beginning at the second ring of the trachea was a grayish-pink velvety-appearing mass, which occupied all sides of the trachea and diminished its lumen to about one-third of its natural size. The mass was higher and thicker on the right side, and apparently faded into what appeared to be thickened mucous membrane on to the left side, where the third



tracheal ring was visible. Dyspnoea was marked, and he was placed in the Manhattan Eye, Ear and Throat Hospital, where, the day following, under general anaesthesia, the following operation was performed: After division of the soft parts and ligation of the isthmus of the thyroid gland, the trachea was incised from the larynx to the sternal notch. A successful effort was made not to wound the mucous-membrane of the trachea until the rings had been divided. Adrenalin was then applied, and the mucous-membrane incised without bleeding. The larynx was likewise split without hemorrhage. The larynx was found to be free, but beginning at the second ring the walls of the trachea were occupied by an infiltrating fungoid-appearing growth that extended an inch below the sternal notch. The surface of this growth was velvety and of a grayish rose-pink color. Owing to its extension so deeply down the trachea, exsection of the latter was out of the question, so that an attempt was made to remove the mass by means of a sharp bone curette, and, apparently, the attempt was largely successful, for the result of the curettage left normal-appearing tissue. The growth was not adherent to the rings and did not extend beyond the limits of the trachea. A large and long tracheotomy tube was inserted and the wound stitched. The silver tube was not sufficiently long and a large rubber drainage tube was inserted through it. Although the operation consumed less than an hour and the loss of blood was insignificant, the patient suffered considerably from shock. There was but slight fever, at no time more than 101 degrees, but the patient did badly and died of pulmonary oedema and heart failure three weeks after the operation. Post-mortem examination was not allowed. Examination by Dr. Jonathan Wright of the tissue removed showed it to be a Columnar Epithelioma.

#### *Discussion.*

Dr. E. L. Shurly: Some fifteen years ago I encountered a similar case, the tissue of which was diagnosed by the pathologist as angioma. I lost this patient, very unfortunately, from hemorrhage. The man, when I was called to see him in consultation, was suffering very great dyspnoea, and I discovered a growth in the trachea, situated back of the sternum and about

seven or eight inches in extent. I made a tracheotomy, and upon cutting through the mucous membrane, met with a hemorrhage which was profuse, and the only way that I could control it was by stitching the edge of the wound and drawing it tight. It was my intention at that time to remove the growth with the curette, after the preliminary tracheotomy, but the man died from the effects of the loss of blood and the shock, on the third or fourth day. I reported this case some years ago, and I think if I should encounter another such case I should proceed more slowly and make more thorough provision against hemorrhage to be encountered.

## BACTERIOLOGY OF THE NORMAL NOSE.

BY FREDERIC C. COBB, M.D., AND E. V. NAGLE, M.D.

In order to properly understand the pathology of any organ, it is, of course, necessary that we should be properly conversant with its physiology and conditions under normal circumstances. This seems such a truism that it would be almost unnecessary to state it were it not that it is so often disregarded from a practical standpoint. Relatively, to the work done upon pathological conditions in the nose, the amount of labor expended in consideration of its normal condition, is small. As regards the bacterial status of the nose in health, opinions of various investigators differ widely.

In 1895 Jonathan Wright investigated this subject and found a mass of conflicting testimony as regards the presence or absence of bacteria in the nose. We need not repeat what Wright has so clearly set forth, except to refresh your minds as to the previous results of investigation.

In 1876 B. Fränkel, in an article on *Acute Coryza*, stated that he found a normal nose free from bacteria. In 1881, Herzog found numerous bacilli in normal secretions. In 1885 Loewenberg and Hajek, three years later, found very few bacilli in the normal nose. In 1887, Reisman found two kinds of bacilli. In 1888, Wright, in ten cases, found cultures in every one. Besser, a year later, in eighty cases, found large numbers of bacteria in the normal nose. Schubert finds the mycelium. Delette, four different kinds. Vibell, in 1887, and Paulson, in 1890, both got numerous bacilli. In 1893, Wurtz and Lemoyez tried to grow bacilli on the nasal secretions, and came to the conclusion that the action of the mucus obtained was inimical to their growth.

In 1895, Strauss found tubercle bacilli in the normal nose. In the same year Thompson and Hewlett wrote a paper calling attention to the fact that the vestibule, with its hairs, always contains bacteria of many kinds in large amounts. Two years later

Wright, in thirty-six cases, found bacilli in thirty cases; of the six sterile cases, in five the mucus was removed with a small platinum wire loop, and the amount of mucus was so small as to form a probable explanation of the negative results. Neuman found bacteria in the normal nose. Haslauer, in an analysis of the noses of garrison workers, got but eight sterile cases out of 111. Klemperer believes that the staphylococcus and streptococcus are always found in the nose. Shonsboe, quoted by Felix Eugen, found twenty-three noses free of bacteria. Thomson and Hewlett, as we have said, were the first to call attention to the vestibule as a source of bacteria. In all cultures of the nose they found bacteria in the vestibule, but the interior sterile in 80 per cent of the cases. Their method was to simply pass the speculum through a Bunsen flame and then introduce a platinum loop and touch the mucous membrane in the vicinity of the middle turbinate, taking great care to avoid the hairs of the vestibule. No disinfection of the vestibule itself was attempted. The possible sources of error here are, it seems to us, the absence of disinfection of the vestibule and the fact that a small loop, which might have failed to catch the bacteria, was used. From the bacteriological side, the fact that the authors made their cultures on agar (although they say that on other media the results were the same) and not on blood serum, agar and bouillon, and that some of the work appears to have been done by cover glass preparations stained as soon as removed from the nose, seems to us to impair the results obtained. The use of a small wire loop, as Wright has pointed out, may not pick up all the bacteria, and he attributes five out of his six sterile cultures to this procedure. Cover glass preparations might have allowed some bacillus to escape observation, which, if cultivated, might have given several colonies.

Thomson and Hewlett made no attempt to differentiate bacteria, their only object being to show sterility or its absence. On reading over the literature, their contention that the vestibule was the real source of bacterial contamination in cultures of the normal nose, was emphasized in our minds by the fact that Wright and others seem to have found less bacteria the more careful they were in regard to avoiding contamination by the vestibule. It seemed logical to assume that if greater care in cleaning the

vestibule produced less bacteria in the nasal cultures, then the greatest possible precautions in this respect might produce sterile ones. To test roughly the possibility of infection by the hairs of the vestibule, they were greased with black ointment and a white swab introduced through the vestibule with great care, but it was found that the gluing down of the hairs allowed manipulation, which would not correspond to the normal conditions. Therefore, the process was reversed and a swab, covered with lamp black, was introduced, after repowdering the hairs of the vestibule with chalk. It was found difficult and sometimes impossible to pass a small swab through the powdered vestibule without getting some of the white dust on the black swab. If the hairs were long and projected through the apertures in the open speculum, the procedure was quite often out of the question. A piece of thin rubber was then used to make a cot, which should protect the interior of the speculum against contamination by the hairs, but as the edges of the cot on passing through the vestibule might catch a few bacteria, the ends were folded in and the speculum closed, then sterilized and opened, umbrella-like, in the nose.

Before using this sterilized speculum and cot the vestibule was washed with soap and water and then soaked with peroxide of hydrogen for five minutes, and again with corrosive 1:1000 for the same length of time. The tip of the nose was also washed and sterilized as completely as possible. The speculum and cot were then introduced and the cot opened in the nose and a swab passed through it. The culture was taken from the middle turbinate region, as some drippings from the vestibule might have disinfected the floor of the nose. Three cultures were made of the nose, one on blood serum, one on agar, and the third (of the cot which lay in the vestibule) was grown in bouillon. In spite of the most minute care the cot almost always showed bacteria, not of all the kinds given by many authors, but only of the staphylococcus pyogenes albus and aureus. After every precaution and many cultures, we decided that the cause of failure to sterilize the vestibule must be the inability of corrosive or peroxide to kill the staphylococci, and on looking up the bacteriology of this organism we find abundant proof of this. Jordan, in his bacteriology, says, "the staphylococci can grow as low as 8 de-

grees centigrade. The thermal death point is not constant, different strains appearing to vary greatly in their resistance; some succumbing only after 30 minutes' exposure to a temperature of 80 centigrade, while others are destroyed at a lower temperature. Considerable resistance is displayed toward drying, experiments showing a retention of vitality for many days and months in cultures dried upon silk threads desiccated by calcium chloride. Toward the chemical substances ordinarily used as disinfectants staphylococci aureus also exhibit more than average resistance. It is the hardest to kill of all non-spore forming bacilli."

Hektoen and Reisman state that the staphylococcus pyogenes aureus abounds in cutaneous surfaces, especially in the ducts of the sweat glands and about the hair follicles. Delafield and Prudden say "it is quite tenacious of vitality, surviving long drying and degrees of heat and cold and exposure to chemical bactericides to which many bacteria readily yield." We therefore looked about for something stronger which could kill the staphylococci without producing too much irritation of the nose, and finally decided upon Harrington's solution, the comp. of which is as follows:

Corrosive sublimate.....	2 grams
Hydrochloric acid.....	150 grams
Alcohol (70%).....	2500 grams

The first few cultures were preceded by soap and water, but later we found that scrubbing and soaking the vestibule for three minutes in cotton saturated with Harrington's solution gave us sterile cots, so that we could either withdraw the cot and examine through the now aseptic vestibule, or, if preferred, through the cot itself. We have gone into these details so fully because no one, in our judgment, can hope to treat any bacterial disease of the nose unless he can eliminate all possibility of infection of the cultures by the vestibule. We have proved that this can be done in suppurative conditions of the nose as well as in healthy conditions. Our experiments may be catalogued according to variations in methods of disinfection of the vestibule. The media were made 1.5 per cent. acid to phenolphthalein (5 per cent. solution in 50 per cent. alcohol). The cultures were grown for four days at 37 C.



Series A numbers 12 cases. Here the vestibule was not disinfected, but care was exercised to prevent infection of cultures from the vestibule. The first few cultures were made by using a rubber cot to cover the speculum and prevent hairs from coming through its apertures to infect the swab when the speculum was opened. The end of the cot was sealed lightly with rubber cement and put in closed on the speculum after boiling both speculum and cot. The result of this culture was three sterile, one a few bacteria, while of the cots, two were negative and two contained large numbers of bacteria.

This was unsatisfactory because the cement would not break at the proper opening, and the edges, having then passed through the vestibule, were not sterile and might infect the swab so that in the next experiments the edges of the cot were folded into the lumen of the speculum and were spread out by sterile forceps when in place in the nose. The swab then passed over sterile rubber until beyond the vestibule. Eight cultures were taken in this way; one culture was negative and all the cots had a thick growth. The procedure does not seem to have improved the technique, but it will be noted that in two of the three sterile cases the vestibule was negative, while in other cases the growth on the cot was thick.

As our most sterile cases, therefore, showed sterile vestibules, it suggests further attempts to avoid contamination from this source.

The next series (Series B) consisted of 17 cases and were treated by disinfection of the vestibule with peroxide of hydrogen, leaving a cotton plug saturated with this disinfectant in the vestibule for three minutes. In the first four cases we relied on this and used no cot and found growths of staphylococcus every time. We now added the cot as before to the sterilized vestibule and got out of 13 cots only two sterile, while from the interior of the nose 4 sterile cultures resulted. The condition of the cots suggested that we had failed to disinfect the vestibule. In ten cases (Series C) we disinfected the vestibule by laying in it pledgets of cotton soaked with peroxide for five minutes, followed by the corrosive 1.1000 for the same length of time, after first washing the vestibule with soap and water.

In spite of this procedure, however, the cots showed only three sterile cases out of ten. We now tried Harrington's solution in the next series (Series D) consisting of sixty cases. The result of using this solution, applied carefully to the exterior of the nose as well as to the vestibule, the tampons being allowed to stay for three minutes, was interesting. In every case no bacteria were found to grow on the cot, although in the nose a few staphylococcus were found in five cases, while the rest were sterile. In two cases at least scabs and crusts of the vestibule cast some doubt on the diagnosis of the nose. Proper disinfecting of the vestibule has therefore given us 92 per cent of sterile noses.

To summarize briefly we find:

*First.*—That the principle source of bacteria in the normal nose is the vestibule.

*Second.*—That the disinfection with peroxide and corrosive sterilizes the vestibules for all germs except staphylococcus.

*Third.*—That the disinfection by Harrington's solution will sterilize the vestibule of all germs.

*Fourth.*—We believe that the remaining cases showing bacteria may be due to some as yet undiscovered fault in our technique.

*Fifth.*—That cultures in pathological cases should only be regarded as reliable when the cot in the vestibule is sterile, and that any form of staphylococcus should be treated with suspicion as the positive factor in any disease of the nose, owing to the difficulty of eliminating its presence from the normal nostril.

#### *Discussion.*

Dr. G. B. Wood: I would like to ask Dr. Cobb whether he believes that the interior of the nose, especially the posterior part, is sterile in the normal individual. I did not know that it was supposed to be absolutely sterile, but almost so. I know that the accessory sinuses are sterile.

Dr. Cobb: It is undoubtedly true that the profession believes that the nose is sterile, but it is equally true that the greatest number of observers in trying to bear out this opinion by bacteriological tests, have failed. The trouble has plainly been in the condition of the vestibule.

A CASE OF LARYNGEAL CARCINOMA UNDER  
OBSERVATION FOR THIRTEEN YEARS:  
ULTIMATE LARYNGECTOMY.

BY HARMON SMITH, M.D.

A report of this same case during its early observation was submitted to this body in 1896 by Dr. Gleitsmann, under the title: "A Case of Unusual Laryngeal Growth." The patient disappeared and only came under observation again August 22, 1907, twelve years subsequent to the first examination.

Interest in this case is emphasized by the long period of comparative comfort experienced by the patient with a malignant growth in the larynx; by the low order of malignancy of the tumor which apparently existed in an unstable state of equilibrium with almost equal probability of becoming benign or malignant, and by the final determination of its pathological character after numerous pieces had been submitted for microscopical examination.

The prognosis given in Dr. Gleitsmann's paper, that the patient would ultimately succumb to the disease, as the indications pointed to malignancy, came true in part, and only surgical intervention prevented its being true in entirety; but the malignant character was of such low order that it took thirteen years for the tumor to become alarming in its subjective symptoms. To present the course of this case in its sequence it is necessary to draw largely from Dr. Gleitsmann's report of 1896.

The patient, J. S., a Russian Jew, thirty-three years of age, came under the observation of Dr. Gleitsmann in the winter of 1895 and was presented to the Section on Laryngology of the New York Academy of Medicine. No previous history of disease was obtainable. He complained of a hoarseness extending over one year. He had not lost flesh, had had no pain, no cough, no dyspnoea, and had been able to continue his vocation.

His hoarseness remained unchanged during the period he remained under observation.

The larynx and adjacent regions externally were normal. No glands could be detected. The examination of the larynx showed the epiglottis standing erect and uninvolved. A large snow white mass could easily be seen extending horizontally the entire diameter of the larynx from the anterior commissure to the arytenoid cartilage. It was confined to the right side and appeared to be located between the false and the true cord, although nothing could now be seen of the true cord.

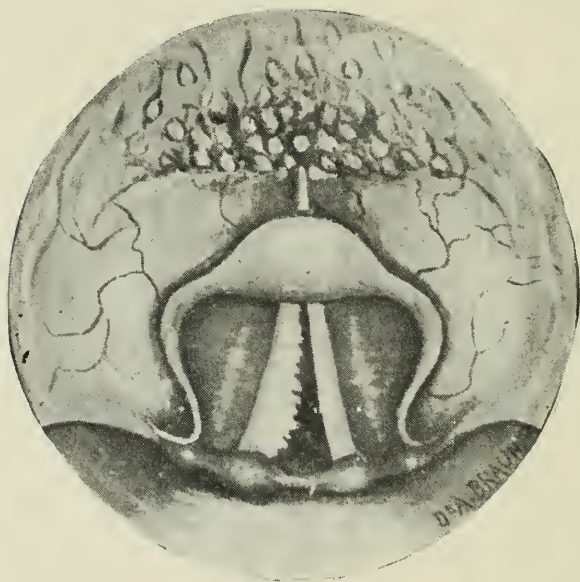

Fig. 1.

Appearance of larynx as noted by Dr. Gleitsmann in 1896. Reported in A. L. A. transactions of that year, p. 145.

The whiteness of the growth was homogeneous in its entire length, its surface very little corrugated and its free border slightly irregular. Movement of the involved side was apparently unimpaired, and adduction seemed perfect. The first piece removed for examination was not made sufficiently deep.

to show the real structure of the tumor, so a second piece was removed three weeks later.

The microscopical report of Dr. Schwyzer, to whom the specimen was given, is as follows: "The tumor may be defined as a papilloma durum laryngis. It is composed of proliferated papillary mucosa, covered by a thickened epithelial layer. The surface layer of epithelial cells presents itself as a horny covering; the underlying epithelial cells show marked proliferation, with a splitting up of the nuclei. The submucosa shows a small-celled infiltration in consequence of connective tissue proliferation. The epithelial layer shows a tendency to invasion of the sub-epithelial tissues, as in carcinoma.

"The glands at the margin of the new growth appear very much changed. The individual tubules or ducts should appear distinctly separate, one from another, instead of which, and at certain points, the cylindrical epithelium appears to merge from one duct to another. This condition also gives rise to a strong suspicion of malignancy, and justifies the following diagnosis: Papilloma durum, probably malignum, and perhaps carcinomatosum."

Dr. Gleitsmann expressed the opinion that if either the whole tumor could have been removed or the excision made from a deeper layer, the malignant character of the tumor would have been more firmly established.

The case then disappeared from observation until August, 1907, when he presented himself at my clinic at the Manhattan Eye, Ear and Throat Hospital. At the first examination I was inclined to believe the growth epitheliomatous or syphilitic, and placed him upon potassium iodide to eliminate syphilis from the diagnosis. The appearance had changed somewhat from the original picture and only certain areas of the white could be seen. The ventricular band was very much swollen and parts of the cord on the opposite side were hidden by some swelling of the ventricular band of that side.

When I called Dr. Wright's attention to the case he recognized it as the one reported in 1896 by Dr. Gleitsmann. I removed a piece of the growth and Dr. Wright reported it as probably *Pachydermia laryngis*. The patient had no pain, no enlarged



glands, and had lost no suspicious amount of weight. Was hoarse, and complained of difficulty in breathing at times. A second piece was removed September, 1907, and Dr. Wright reported as follows: "There is considerable hyperplasia, with cornification of the surface layers, but the epithelium is dipping down into the stroma in atypical fashion. There is apparently not enough hyperplastic epithelial growth to account for the tumor. There is considerable nuclear fragmentation, which, I

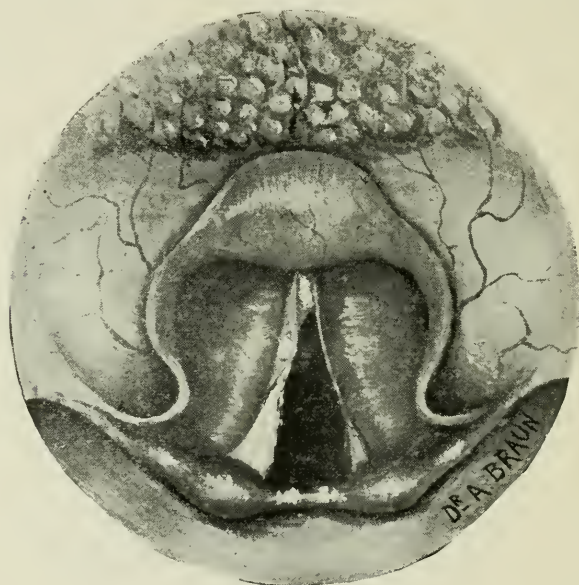


Fig. 2.

Appearance of larynx when first seen in clinic at Manhattan Eye, Ear and Throat Hospital, 1907.

suppose, may be attributed to the previous endolaryngeal operation."

After each removal the patient felt very much relieved, and would willingly have had me remove a piece at each clinic attendance. There was scarcely any hemorrhage or any reaction after each operation.

There were several more examinations made of pieces removed, and at each time there were changes which led me more strongly



to the belief that the tumor was not benign. The patient's condition began to get worse in January of 1908, and he gave evidence of general physical weakening. His hoarseness increased perceptibly and his breathing became more difficult, until he was anxious to have something done to relieve his dyspnoea. The examination of the last piece I removed at the clinic April 8, 1908, was reported upon by Dr. Wright as follows: "I cannot but feel that this growth is now assuming a malignant histological appearance.

"1. The separation between the stroma and epithelium is becoming lost in many places.

"2. The epithelial cells are becoming in such cases more atypical.

"3. There is more penetration of the leucocytes, whose nuclei are more fragmented.

"4. Cell inclusions, cancer cells, and 'whorls' are beginning to suggest themselves.

"5. The whole arrangement of stroma and glandular structure is more confused.

"6. The epithelial type varies more widely from typical columnar flat stickle cells, with many intervening atypical forms.

"7. There are several nuclei exhibiting markedly irregular karyokinesis. Altogether the evidence now points strongly to a malignant growth."

(Remark by Dr. Wright, after completing all the Sections: "It is evident that as the result of many examinations of tissue removed at different times, the changes here referred to must be accepted as changes in my own opinion as to the nature of the growth rather than as changes in the structure of the growth itself. It is in reality the result of a more extended acquaintance with the topography and with the separate features of the tumor—and the cumulative evidence of the tumor furnished by successive pieces—and not a change in the biogenic forces.")

The patient's general condition bore out the microscopical evidence of malignancy, though there had been no marked pain.

except a sensation as of a foreign body on the right side of the larynx. There was a small gland sensible to palpation just below the larynx. The patient was suffering from marked dyspnoea, and was willing to have any operation performed to relieve his distress. Previous to this distress no amount of persuasion could induce him to have a laryngectomy performed, although Dr. Gleitsmann had a patient, upon whom he had performed a successful laryngectomy, exercise his powers of persuasion objectively as well as verbally—but to no purpose.

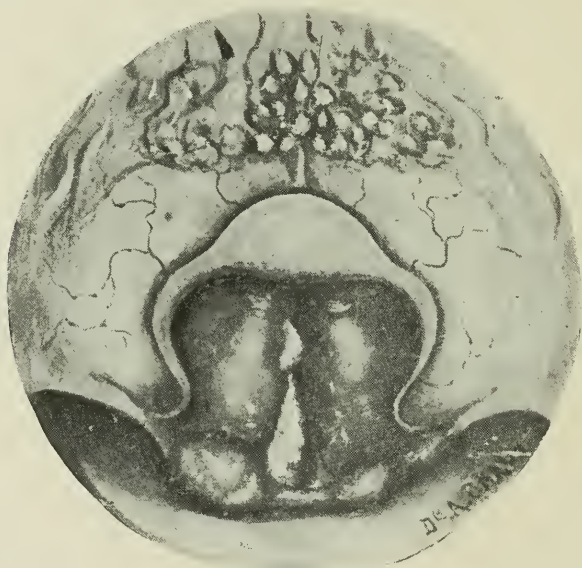

Fig. 3.

Appearance of larynx two weeks prior to operation, April, 1908.

I turned the case over to Dr. George E. Brewer, at Roosevelt Hospital, for surgical consideration. A low tracheotomy was performed, and after an interval of ten days the larynx was removed. Before the patient left the table a good-sized rubber tube was inserted into the stomach through the nose, and through this the patient was fed rather than per rectum. I believe this to be an advantage, as there was comparatively little depression

following the operation, and the patient made a quick and uneventful recovery.

The entire larynx was given to Dr. Wright for further examination, whose report is as follows:

"The larynx of the patient operated upon by Dr. Brewer and submitted to me for examination was completely filled with a sessile growth, plainly springing from nearly the whole of the

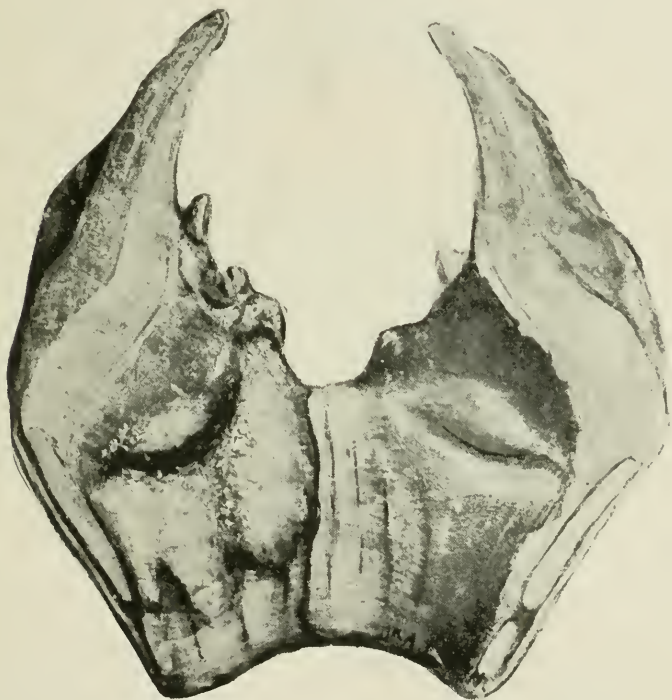


Fig. 4.

Appearance of larynx after removal; opened anteriorly.

internal structure of the right side, and apparently pretty well limited posteriorly and anteriorly by the middle line. It had a white papillary and irregular surface. Having been laid open by anterior incision through the cartilage, it was fixed in formalin and hardened 'en masse' in alcohol. The soft parts were then divided by vertical incision into five divisions; each of these

was separated from the cartilage, embedded in celloidin and mounted separately. A number of sections from each division were stained in eosin and haematoxylin and examined with care.

"Since the vertical incisions passed through the aryteno-epiglottic folds above and the extent of the mucous membrane below, involving tissue over 3 cm. long, and more than 5 mm.

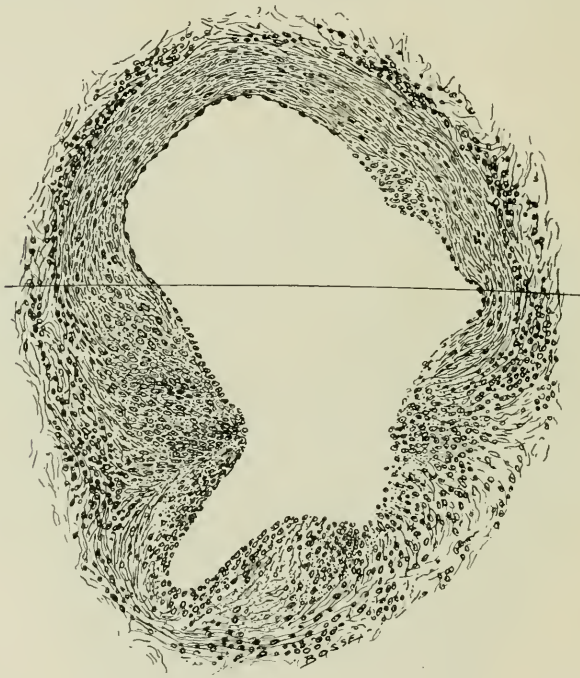


Fig. 5.

Showing infiltration of blood vessel wall below the horizontal line.

thick, the whole character of the growth could be appreciated,—which was far from being the case in the small pieces removed from time to time endolaryngeally, and the causes of the embarrassment in the attempts at microscopic diagnosis under these conditions were apparent.

"A glance through the sections of these divisions at once shows that the growth as a whole presents the characteristics of a flat-celled epithelioma, while in portions of it this nature is far from

apparent. In the great rarity of epithelial whorls so usually associated with this kind of epithelioma, in the rarity of marked irregularity in the karyokinesis, we note the absence of those special features in the diagnosis which often establishes it, even when the piece submitted is very small. The infiltration of the vessel walls with cancer cells, as shown in Fig. 5, occurs chiefly in the deeper tissues of the growth, untouched by the endolaryngeal forceps. There are many places where surface epithelium is so sharply differentiated from the stroma that a grasp of the forceps including only this would lead to the opinion that the

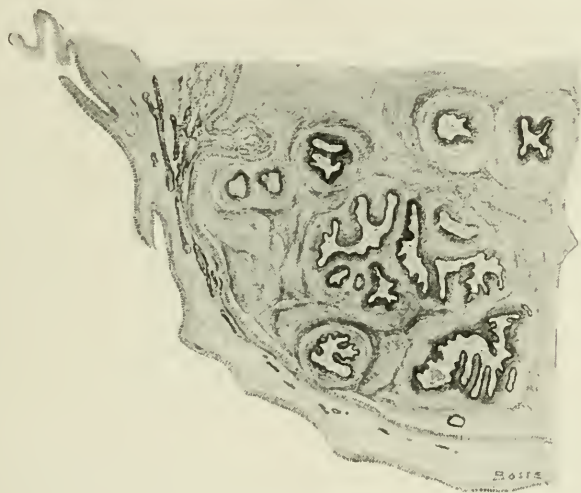

Fig. 6.

Low power drawing of section from anterior part of larynx.

growth might, indeed, be a pachydermia, which would be more in accord with the long duration of the clinical history. In other places, the stroma at the periphery of the growth occupied by a profuse proliferation of round cells with great fragmentation of the nuclei, thickened vessel walls, and structure sprung from the capillaries resembling giant cells, would warrant the suspicion that we had here to do with a syphilitic growth, if the forceps happened to excise that area, especially where the surface epithelium was not so thick. The cornification of the



epithelium, which gave it the pearly white appearance so prominent in the laryngoscope, and so elegantly shown in Dr. Gleitsmann's illustration, is not pathognomonic of malignant growth any more than of the pachydermia of the syphilitic patches, the smokers' plaques, and other benign epithelial hyperplasias.

"In the sections from the first or anterior division, one of which in a drawing from a low power magnification is reproduced in Fig. 6, it is plainly to be seen that the heterogeneous cells at this point are under but not connected with the surface epithelium. Neither is the growth itself of such a nature as to suggest its origin from the columnar cells of the racemose glands, or from those of the laryngeal ventricles. By the contrast here presented it is seen that the origin of the growth must have been elsewhere, probably in that part of the larynx covered by squamous epithelium, that is, the vocal cords.

"But it is also evident that the surface epithelium here has taken on itself a process of proliferation whereby the surface has become papilliform, such as is seen in the papillary adenomata of the nose. As in the nose, so here, it has arisen chiefly from an expansion of the ducts of the adjacent glands and a projection of the fundi of acini to the surface. The superficial glands have contributed to this process, but the deeper glands are not much involved. These sections have evidently fallen through the anterior portion of the fundus of the ventricle, the sub-mucous tissue of which has been invaded by the growth, while the surface tissue, answering to the irritative stimulus from below, has been thrown into this pseudo-adenomatous condition.

"Elsewhere the tissue structure presents the general appearance to which I have referred. Leucocytes and their fragmented nuclei are abundant in the cancer cells, especially in those areas of vicious epithelium where, below, the definition between epithelium and stroma is lost.

"In division 2 and division 3 the sections show the surface epithelium is co-terminous with that of the growth, and here we get the convincing evidence of the infiltration of the arterial walls, as shown in Fig. 5, and the cancer cells creeping along the lymph spaces, and the epithelial whorl, as shown in Fig. 7.

"Some of the subjacent stroma at a distance from the edge of



the growth contains 'Mast-zellen' and fibrous tissue of a low grade, and eosinophilous cells. The left side of the larynx, while to the naked eye presenting no appearance of disease, at least after the specimen had been hardened, showed one section that, at the anterior portion in the region of the cords and above them, a little of the growth has fairly passed the middle line, but only by a few millimetres.

"There is nothing especially exceptional about the histology of this growth. We call it an epithelioma. There is something exceptional about the history. Recognized fourteen years ago by two microscopists as being of a malignant nature, it evi-

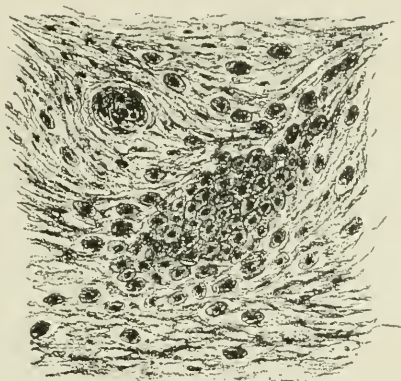


Fig. 7.

Cancerous infiltration of the stroma, and an epithelial whorl.

dently has not changed its structure since. Beyond occluding the breathway it has, as a matter of fact, run a comparatively benign course. No external gland involvement was found, in spite of the changes in the vessel walls I have indicated, and the future alone must declare if distant metastases have begun.

"Nothing could illustrate better than this case that *structure* is not always a satisfactory guide for prognosis. The remark may also be permitted that any operative procedure which eliminated this growth, or a portion of it, followed by twelve years of comparatively good health, would have been regarded as a triumph of surgical skill.

"I trust you will not find the few remarks I have to make on this case out of place. They are somewhat supplementary to the series of articles I have lately contributed to the *New York Medical Journal*, where I have referred to the declaration of Ehrlich and Apolant that 'the histological structure is the expression of clinical virulence.'

"This opinion of experimental observation of cancer is curiously contrasted with that of Lubarsch and Orth and others who have had such large experience in the histological diagnosis of cancer in man. As I have insisted, I cannot subscribe to the views of Ehrlich and Apolant, if they are to be applied to cancer in man as it is seen in practice. I cannot too strongly urge the significance of this case in the consideration of the points involved. Recognized fourteen years ago by many clinicians and microscopists as a malignant epithelial growth, it has never been radically extirpated, but in spite of considerable endolaryngeal interference it has remained practically quiescent during that time. For most of that term it had passed from the observation of experienced laryngologists. The patient again presenting himself, his laryngeal growth, changed somewhat in appearance, is again recognized by clinical observers as malignant.

"Many months elapsed before fragments removed for microscopic examination presented appearances confirmatory of the clinical diagnosis. A study of the series of sections from the whole growth as they exist in my slides, especially those from the middle of the larynx, cannot fail to reveal evidence of malignancy, as structure is usually interpreted, yet we see how comparatively benign has been the course of a growth in such a situation as the larynx, when in such a period of time it had not before reached dimensions and caused discomfort or suffering demanding its removal in a reluctant patient."

I last saw the patient in June, 1908, at which time he was in good health and could use his lips in speaking fairly well, but he seemed depressed mentally. I loaned him the amount of money he claimed was sufficient for his business purposes, and since that time the offer of a premium to the hospital orderly who could locate him has proved ineffective

The three most important points in this case are:

1. The long standing, slowly advancing malignancy of this tumor.
2. The almost positive belief in malignancy, and yet the presence of sufficient doubt to make one refrain from radical operative measures. I believe that in the early stages this tumor could have been removed by thyrotomy with a reasonable hope of non-recurrence.
3. The extremely small systemic manifestations for a malignant growth of such long standing.

### *Discussion.*

Dr. D. Bryson Delavan: I do not remember the history of a more interesting case than this one. While it may be rare, and while, also, some cases operated upon may find life prolonged after operation, it nevertheless suggests one thing to which I wish to call especial attention, namely, that the average duration of life in cancer of the larynx is a certain period now pretty well recognized. From the time that the tumor is discoverable in the larynx the patient will probably live two years, sometimes less, sometimes more. Two years is a conservative average. If operative interference will prolong the life of a few patients for three, four or five years, and if it will also kill a much larger proportion of cases, it becomes desirable that we study the arithmetic of these cases, as to whether such operations actually add to the sum total of life. In my belief these operations at the present time, done often by unskilled men, fail to prolong life. Again, a great many of our most distinguished surgeons refuse to operate for cancer of the larynx. I could name several among my own immediate acquaintance. In the last report of the Mayo Sanitarium, for example, there are given no statistics of operations on the larynx. With few exceptions those who do operate have always failed to help the progress of our knowledge in this matter by the publication of their statistics. We know nothing of the absolute value of operations for cancer of the larynx because the reports of unsuccessful cases are almost invariably withheld. A few European surgeons have concentrated their efforts and have honestly published their results, and a few in this country have done the same thing. I am much gratified to find that one of them is a member of this Association. I feel that a somewhat venture-some exploit of my own some fifteen years ago is being re-

warded. At a meeting of the British Medical Association held in London in 1895 I opened a discussion with Mr. Henry T. Butlin on this subject, and I stated that the best results would never be attained until men especially skilled and experienced should surround themselves with special facilities for operating, and should under the most highly favorable conditions demonstrate whether such operations were actually worth while or not. This proposition met with almost unanimous disapproval, not only apparent but vigorous. It was true, however, and I am glad that it has been recognized as the truth by at least a few.

You have all probably read the last report of Mr. Butlin on the subject of laryngectomy. His closing paragraph is extremely interesting. He says: "I began to perform the operation (for complete extirpation of the larynx) on account of Gluck's success, and of the excellent modification due to Solis-Cohen. I wish I had begun to perform it earlier. I am sure that several cases on which I performed thyrotomy were much better fitted for laryngectomy, and I cannot help thinking I might have saved one or two of the patients in whom recurrence took place if I had then removed the larynx. I think the glands ought to be removed in every case in which there is extensive carcinoma of the larynx, even if it be intrinsic, unless the disease is limited to the middle zone of the interior of the larynx. Even in these cases it would probably be a wise precaution to remove the glands. I have never removed the glands and the larynx at one sitting."

That is a remarkable statement as coming from Mr. Butlin, since it is in entire harmony with the views advanced a number of years ago by our distinguished fellow member, Dr. John N. Mackenzie.

Dr. Chevalier Jackson: This very interesting case shows the low degree of malignancy or slight vulnerability in some cases. No one has followed Dr. Delavan's work in laryngology more closely than I; it was my ideal when I started and still is. Still I lay no claim whatever to having fulfilled what he has laid down as the qualifications for doing the major operations upon the larynx. His teaching, I think, will be universally accepted. That these cases should be sent to a few men in each large centre who may thus have a collective experience. The work of Gluck, Semon, Butlin and others is only possible because they get a collective experience. The operable cases are extremely rare. If we put all these cases in the hands of a few men they can get results worthy of modern surgery. For instance, Dr. Brewer can get cures where a man could not who operates upon

a case every five or six years. I find there is quite a tendency throughout the country to say "this patient is going to die with cancer of the larynx and we might as well take it out for experience." It is a crime to laryngectomize such a case. The patient dies. Then these operators rush into print, and their mortality renders general statistics valueless because they have operated upon an inoperable case which should not be taken into consideration for one moment with work upon operable cases. If you take the statistics of a few men like Semon, Butlin, Gluck, Chiari and others who have narrowed their work down to operable cases only, we have statistics of value and the results are very gratifying. As Mr. Butlin says, in cancer of the tongue he operates upon every case where there is any hope of benefit. If this rule were applied to the larynx it would be murder, and the statistics would be worth nothing. The mortality in the cases I have seen, if operated upon, would have been 80 per cent. Operable cases are rare and they should, as Dr. Delavan said many years ago, be put in the hands of a few men, who, by the results of collective experience, could get results obtainable in no other way.

Dr. J. W. Gleitsmann: I am in full accord with what has been said by Drs. Jackson and Delavan. By the courtesy of Dr. Smith and Dr. Brewer I was invited to witness the laryngectomy made by the latter, and can only say words of praise for its efficient and skilful execution. Since I had the privilege of seeing my patient after many years in Dr. Wright's and Dr. Smith's clinic, and had observed the ultimate positive malignant nature of the growth, the most interesting problem in the case for me has been to form an opinion or to reach a definite conclusion as to the exact nature of the growth at its very inception.

When I read the history of the patient before the Association in 1896, I quoted a similar case reported by Felix Semon and had some correspondence with him when an abstract of my paper appeared in the *Internationales Centralblatt fuer Laryngologie*. Semon drew my attention to the observation that such whitish growths in the larynx had proven to be of a highly suspicious character, which was verified by the issue of the cases reported.

From the extensive collective investigation in the *Centralblatt* denying the occurrence of the transformation of a benign into a malignant growth we must assume that the growth in the larynx of this man bore the germ of malignancy already in 1896. Therefore the biologic question arises if there is a possibility that other growths may also carry the malignant type in their structure for years before their true cancerous nature becomes manifest or if such extended latency is only found in this special class of whitish tumors.



NERVE DISTRIBUTION IN RELATION TO NERVE  
REFLEXES SIMULATING LOCAL INFLAMMATION.

BY ARTHUR AMES BLISS, M.D.

The development of painful sensations within the upper respiratory tract and ear, as well as through the head, at points more or less distant from the site of an inflammation, produces a class of patients in whom diagnosis and treatment present many elements of doubt and uncertainty. Over this wide area reflex irritation depends largely upon the distribution and inter-communications of the Fifth and Eighth pair of cranial nerves, the Trifacial, Pneumogastric, Glosso-pharyngeal, and Spinal Accessory. There results a complicated network of sensory, motor, and sympathetic fibres, each one a possible track for short-circuiting or deflecting nerve impulses, by each fibre, in terms of its own function, to areas remote from the causative lesion. And the mere "reflex" alone in many cases is rendered more complicated by the intensity of the suffering produced and the need for relatively prompt relief. The Trifacial nerve, perhaps the chief offender, has four ganglia which form the whole of the cephalic portion of the sympathetic system. Its first and second divisions are sensory nerves, the Ophthalmic and Superior Maxillary, with the Ophthalmic and Spheno-Palatine ganglia. The third division, the Inferior Maxillary nerve, connects with the Optic and Submaxillary ganglia. The interlacing of fibres between these three divisions and the ganglia is direct, and their communication also with the sympathetic plexus of the Cavernous sinus and with the Carotid plexus. Emerging from the distal source of this great nerve, the Gasserian ganglion, fibres go to the tentorium cerebelli and the dura of the middle cranial fossa. Its Ophthalmic and Superior Maxillary divisions are closely associated by fibres which bring the Spheno-Palatine ganglion and Nasal nerve and Naso-Palatine nerve in intimate relation, by means of the Ciliary nerves, with the Iris and Ciliary muscles.



The Trifacial is the great sensory nerve of the cranium and face. By its Ophthalmic division it gives sensation and pain as well to the frontal sinus region, forehead and the scalp as far back as the occiput. The course of its three main branches lies between the ocular muscles and supply the Corrugator Supercilii, Occipito-frontalis and Orbicularis Palpabrum muscles with common sensation—too frequently with uncommon sensation. The Ophthalmic's nasal branch, the Nasal nerve, is distributed over the very area, on the side of the nose and inner angle of the orbit, external to the anterior ethmoidal cells, supplying also the conjunctiva, lachrymal sac and caruncle lachrymalis. The Superior Maxillary connects its anterior dental nerve with its Meckel's ganglion. This ganglion itself sends that most sensitive nerve of the nasal chambers, the Naso-Palatine, or nerve of Cotunnius, out below the opening of the Sphenoidal sinus and across the nasal septum within constant reach of the pressure of a swollen middle turbinated body.

The posterior branches of this Meckel's root of many nasal evils, this Spheno-Palatine ganglion, are the Vidian and Pterygo-Palatine nerves, connecting it with the naso-pharyngeal region and the Carotid plexus of the Sympathetic. Over this track pass the "reflexes" that produce asthma of strictly nasal origin. To make matters worse and more confusing, as stated before, Meckel's ganglion is in relation with the Ophthalmic ganglion. The Inferior Maxillary branch of this troublesome Fifth nerve is a nerve of three functions—sensory, motor and of special sense for the tongue. Its Optic ganglion brings it in close relation with the external auditory meatus and canal, by the auriculo-temporal nerve, and, with the chorda tympani, by fibres from the Gustatory and Lingual nerve, as well as from the Submaxillary ganglion. At several critical points this Trifacial nerve is in relation, by communicating branches, with the Facial nerve.

In a state of health it is proper, doubtless, to regard the Trifacial nerve with considerable admiration because of its ability to control so many and varied activities, but when the special poisons of Grippe establish their cycle of symptoms, this remark-

able nerve can become the originator of much suffering for the patient and perplexity for the physician.

I think that we are too apt to regard the very complex tangle of anatomy constituting the nasal chambers as a simple architectural structure of bony boxes, rather apart from the functional activities that are inherent in all vital tissue. We look at them from the standpoint of a mechanic and develop the habit of regarding morbid activities within them as prone to follow the very definite course of inflammation, hypersecretion and supuration. So when pain develops within the region which they control we tend to the belief that this pain is due always to the existence of occlusion or retained secretions. Therefore, resort must be had to methods of carpentry and plumbing. It is well to remember that a neuritis or neuralgia of the Fifth nerve and of its separate branches and ganglia can occur, as with any nerve, and may occur from any of the causes that produce neurones, elsewhere, from auto-intoxication or from direct inflammation, as in the complex of symptoms which we call Grippe.

With the onset of a rhinitis there develops at once a vicious circle, for irritation of sensory filaments of the Ophthalmic and Superior Maxillary nerves react on the Sympathetic plexuses and we have vaso-motor irregularities which in themselves increase the irritability of the sensory nerves. The Fifth nerve rises to the occasion and the whole area of its distribution may be involved in a general mass of misery. The streaming eyes avoid the light, and movements of the ocular muscles are painful. The head aches from the face to the back of the neck and the teeth are sore. The ears are sensitive and aching and the tensor of the drumhead and the stapedius muscles drum and vibrate in quivering, spasmodic movement. The region of the Frontal sinus is excessively tender to the touch; so also is the area over the anterior Ethmoid cells. There may be a contraction of the Orbicularis muscle forming a thickened body over the eyebrow which we may fancy to be a true swelling over the Frontal sinus, even finding a trace of suggestive edema about it. Of course these areas are painful under even light pressure and the bony box idea of the nasal chambers favors the happy thought that the Frontal sinus is full of pus. So, too,

must be the Ethmoid cells. The opinion is readily formed that "something is sort of stopped up inside that ought to come out." Resort must be had to drills, chisels and rongeurs.

Well, in the majority of attacks of an acute rhinitis there is no pus in these sinuses. It is very doubtful if any exudate exists there. I am convinced that more often than not the mucous lining is free from inflammation. The pain is a neuralgia or neuritis of the wretched Fifth nerve. The best results will come from the simplest and most gentle treatment of the nasal chambers and full attention to the patient's general condition, of which the nasal discomfort is merely a local expression. Then, too, in this class of cases it is not so very difficult to cause a real infection of the sinuses by over anxiety to probe into them. Once infected, of course you have a surgical state of things, and some aggressive minds would be delighted with a certainty, now, for the need of carpentry and plumbing.

I believe that a safe guide for the real need of surgical interference, is found, as in acute mastoiditis, in the temperature range, the duration and continuance of real pressure symptoms, and in the mental state of the patient. We cannot ignore the fact that the Ophthalmic vein and Cavernous sinus are related closely to the regions of the Frontal and Ethmoid cells. The lymph vessels also, may be carriers of infection to the meninges. In cases, even of true sinusitis, we have, also, the elements of neuritis of the associated nerve tracts. The wise physician must consider the data at his command, and, while not deceived by a nerve irritation, which, in most instances, is the gist of the situation, be on the alert for manifestations of what may be a grave condition within the nasal sinuses demanding surgical treatment. When a Grippe influenza complicates a case of chronic sinusitis of one or more of the nasal sinuses, there is less reason for giving too much weight to the question of nerve irritability alone, in a desire to avoid active surgical procedures. But, in these cases, the clinical conditions are more apt to be presented with a frankness that leaves little doubt of the true situation. In purely acute cases aggressive surgery is almost never needed. In chronic cases, with acute infections added, the

urgent need for it is not infrequent. In chronic cases alone, free from any acute exacerbation or infection, the question of operative treatment must be decided by a study of the conditions presented by each patient alone. No one can bluntly state that, as a rule, every case of chronic nasal sinusitis must be attacked by gouge, chisel and curette, or that, on the other hand, it must be treated only by irrigations and antiphlogistics.

The Glosso-Pharyngeal branch of the Eighth Cranial nerve, by its tympanic branch, Jacobson's nerve, from the Petrous ganglion, is distributed to the Fenestra Ovalis and Fenestra Rotunda. It has communication branches to the Greater and Lesser Petrosal nerves, and, by the latter, to the Otic ganglion. I saw a lady, on one occasion, who had been distressed for many months by a peculiar cough, dry, hacking, ineffective, of a character that should always excite suspicion of a "reflex." After a long course of fresh air and forced feeding treatment, the patient had been urged to try the climate of Southern California. No one had examined this patient's ears, as there was no noticeable disturbance with the hearing. In this case, the vocal cords and mucosa of the larynx were reddened in tint, doubtless from the long-continued irritation of the paroxysmal cough. This patient's external auditory canals were filled with impacted cerumen over a bed of hard, desquamated epithelium. While the canals were being freed from the cerumen and epithelial plugs, the patient had spasms of coughing, but the very simple matter of clearing the external auditory canals ended the long term of hacking cough, forced feeding and medication. The reflex irritation had gone over the tract of the Otic ganglion, Inferior Maxillary, Glosso-Pharyngeal and Pneumogastric nerves to the Pharynx, Larynx, and Trachea. This is an extreme case, of course, although the irritability of this special nerve tract should be considered always when a persistent cough cannot be explained by the usual causes. The existence of aural pain, simulating that of an acute Otitis Media, coincident with dental caries, eruption of the teeth and irritation of the dental nerves, is so well recognized as to need merely a passing notice. Less frequently noted is the persistence of discomfort, and even pain, over the mastoid region and

back of auricle, which has led to trephining of the mastoid cells, in the belief that the cause might be intracellular inflammation. The auricular branch of the Pneumogastric, Arnold's nerve, joined by filaments of the Glosso-Pharyngeal, reaches the surface between the mastoid process and the external auditory meatus. This distribution is well to remember in cases of vague mastoid pain where other evidences of mastoiditis are wanting. A case occurred in my practice during the epidemic of Grippe this winter, where the patient, a man of middle age, suffered intense pain within the ear, over the corresponding mastoid process, down the neck and over the temporal region of the same side. He had a persistent temperature, well above normal, lasting many days. The drumhead was quite pinkish, but without distension, reddened by the instillation of medicine to relieve pain. Hearing was normal. The pain was spasmodic, and was not developed by pressure of the mastoid process. It was a case suggestive of a possible Otitis Media with antral involvement, but the cycle of symptoms overreached itself in its efforts to deceive. The distribution of the painful areas, the character of the pain itself, all pointed to a neuralgia and yielded to Salicylates and Aspirin.

Reference has been made to "aural cough." There is, also, coughing that might be called "nasal." In some individuals any irritation along the course of the Naso-Palatine nerve, but especially opposite the posterior half of the middle turbinated body, will develop this reflex coughing. This may become a very annoying feature of attacks of Rhinitis, due to vaso-motor instability, or may be caused by pressure from structural defects in the nasal chambers. Such coughing is not laryngeal or tracheal. It is nasal in origin, and will not yield to medical sedatives. The Glosso-Pharyngeal nerve, by its pharyngeal branches, united with filaments of the Pneumogastric, goes to the pharyngeal plexus, uniting there with the external laryngeal and sympathetic nerves. It has a branch to the tonsils, going also to the soft palate, anastomosing with the palatine nerves. Elongated uvulae can produce coughing, not alone by tickling the larynx, but also by flapping about against the pharyngeal walls and tonsils. Inflammation of the tonsils, especially enlargements of these structures, with re-



tention of caseous substance, hyperplasia of fibrous bands, binding down such swollen tonsils, can all be productive of "reflex cough," which might excite the suspicion of laryngitis, tracheitis, or a bronchial catarrh. For many chests will give suggestions of abnormality in percussion and auscultation that is not due to any lesion, but rather to structural idiosyncrasies. Taken in connection with a cough not recognized as a "reflex," they can suggest to the examiner's mind a causative element, although harmless in themselves, thus producing uncertainty and errors in diagnosis.

The sensory nerve of the interior of the larynx, including the vocal cords, is the Pneumogastric's Superior Laryngeal nerve. Its course along the side of the pharynx, behind the internal carotid artery, brings it into association with the deep chain of cervical lymphatic glands, and pressure from an enlarged gland, even without suppuration or caseation, may induce reflex coughing. A child, eleven years old, with tuberculous glands of the left side of the neck, was annoyed by a persistent and very distressing cough, most noticeable at night. The patient had hypertrophied faucial and pharyngeal tonsils, but was free from any other lesions. I excised the tonsils and adenoids, thus obtaining entire relief from mouth-breathing. The cough continued, however, until the cervical lymphatic glands were completely removed by a very thorough dissection of the neck. They were found to be tuberculous. As the Superior Laryngeal nerve and the pharyngeal branches of the Pneumogastric are closely associated, as simple condition as hypertrophy of the mucous follicles in the pharynx, especially in the lateral chain, behind the posterior faucial pillars, can excite a "reflex" in the form of a so-called "laryngeal cough."

Pressure on the Recurrent Laryngeal nerve is more apt to be attended by changes in the patient's voice or interference with respiration rather than with reflex coughing. I note, in passing, the well-known fact that an aneurism at the aortic arch, or in the right subclavian artery, is revealed very often for the first time by the picture of a laryngeal paralysis reflected in the laryngeal mirror, and this is the case also when tumors exist in the mediastinum. Equally well known, in these days, is the development of right-sided laryngeal paralysis from an infiltration at the right



pulmonary apex, within the pleura or over-lying lymphatic glands. But the relation of laryngeal lesions with affections of this motor nerve of the vocal cords is too well developed in medical literature to justify a further discussion of the subject.

This outline sketch of the distribution of the fifth and eighth pair of cranial nerves may explain a puzzling class of patients, whose subjective symptoms are intensely distressing, and yet whose recovery is rapid, under very mild and non-heroic local treatment, together with internal medication. It may indicate, also, the need for care in arriving at an exact diagnosis, thus avoiding unnecessary surgical interference in this class of cases, especially in subjects where the pro and con is not clear as to the need for opening into any one or more of the nasal accessory sinuses. Exact diagnosis is of great importance in these cases, where it is often most difficult to make. The X-ray and transillumination are, indeed, most helpful, but are very far from being infallible guides. With all our modern mechanical aids we must depend still very largely on personal and direct observation, aided by clinical experience. Errors in these cases are made easily. Aggressive operators may be led astray by their surgical zeal and the apparent, although not real, reason for its exercise. Thus much unnecessary suffering may be inflicted by an undue surgical interference, the evil results of which, it is true, may not be revealed to any one, unless to the conscience of the operator.

### *Discussion.*

Dr. O. T. Freer: Dr. Bliss seems to me to have given the clearest and best presentation of this important but neglected subject which I have yet encountered, and it is one of those articles where one can agree with everything.

A most important reference in the paper is the one to supra-orbital pain, a phenomenon so often misinterpreted and one which is continually leading to needless and disfiguring external opening of healthy frontal sinuses. A case in illustration: A rhinologist had condemned a patient to a double Killian frontal sinus operation who had merely a supraorbital neuralgia, which healed promptly under galvanism. The rhinologist in question was one of those skilful manipulators whose knowledge of medicine was confined to his specialty and who had not learned in

general practice that there are other affections besides those of the nose, throat and ear.

More often than supraorbital neuralgia, in my experience, suppuration of the maxillary antrum is mistaken for frontal sinus suppuration because of reflected pain from the antrum felt in the forehead instead, as would naturally be expected, in the cheek. Dr. Charles A. Parker, of the London Throat Hospital; Dr. A. Logan Turner, in Edinburgh, and Dr. Brown Kelly, in Glasgow, all informed me that they regarded supraorbital pain as far more characteristic of empyema of the antrum than of frontal sinus inflammation. I know of healthy frontal sinuses whose opening has been suggested or performed because of supraorbital pain caused by suppuration of the maxillary antrum.

In reference to a rise in temperature in empyema of the sinuses, it has not been my experience to find it invariably present even in acute suppuration of these cavities.

The nasal cough spoken of I have so often encountered that I do not regard it as an unusual phenomenon. I have found it oftenest present in children and young persons and am usually able to excite the characteristic cough by lightly rubbing the nasal interior with a small swab, the lower turbinated bodies especially being a frequent source of this peculiar reflex. Children are often treated for chronic bronchitis because of a cough which is of nasal origin.

The term sinusitis is used by Dr. Bliss in his paper. This is the common usage in America. In Germany the term *sinuitis* is employed. Can it not be determined at this meeting which term is the correct one?

Dr. W. L. Ballenger: I want to speak about the word *sinuitis*. Before publishing my text-book I wanted to be sure on that point, so I asked Lea Brothers to write to Prof. Duane, and the latter replied that, although "*sinusitis*" has been long used and so has the sanction of that use, the proper word is "*sinuitis*."

## NASAL TUBERCULOSIS; TWO CASES, ONE INVOLVING RIGHT ETHMOID BONE, WITH RECOVERY AFTER OPERATION.

BY OTTO T. FREER, M.D., CHICAGO.

The account of my own cases is preceded in this paper by a short, composite description of nasal tuberculosis, obtained from its literature, articles on lupus, because of the proof of its tuberculous nature, being also considered. The writings to which I am most indebted are P. H. Gerber's clear and full description of nasal tuberculosis in Heymann's *Handbuch*, and Koschier's remarkable series of articles, including many case reports of his own observation, in the *Wiener Klinische Wochenschrift* in 1895. In addition to these two more detailed descriptions, Herzog's paper in the *American Journal of Medical Sciences*, in 1893, Gleitsmann's admirable article on tuberculosis of the accessory sinuses in the *Laryngoscope* for 1907 and a number of other articles mentioned in the literature list have proved of great value.

*Designation.*—Custom still retains the name lupus for the group of cases of nasal tuberculosis possessing special features which were thought to make them a distinct disease called lupus before the identity of tuberculosis and lupus was established. For the sake of a clear understanding of the matter, therefore, I have sought out from the literature what was regarded as the distinguishing characteristics of lupus and nasal tuberculosis proper.

Lupus is a form of nasal tuberculosis occurring commonly at the age of puberty in women, while ordinary nasal tuberculosis usually occurs between the ages of 25 and 60 and is at least as frequent in males as in females.

Lupus is a primary form of nasal tuberculosis of an exceedingly slow course, extending at times over decades. It may remain the only evidence of tuberculosis in the body, generally leading late, if at all, to secondary tuberculous deposits.

Nasal tuberculosis is more rapid and less benignant than lupus,

is often secondary to another tuberculous focus, especially pulmonary tuberculosis, and, if primary, is disposed to an earlier creation of other tuberculous affections than lupus.

Lupus appears in the form of granulations and diffuse infiltrations, which, instead of breaking down rapidly, have a tendency to cicatricial metamorphosis, so that the disease heals by scar formation in some places, while progressing in others. The tuberculous tissue in lupus advances superficially in the mucosa and invades cartilage and bone, if at all, late in its course.

In contradistinction to this, the granulation tissue of nasal tuberculosis, in most cases, breaks down early by cheesy degeneration and produces ulcerations of a more or less destructive character, which are disposed to attack cartilage and bone at an earlier stage than lupus, while cicatrization does not occur.

Granulation tumors, often of considerable size, are occasionally found in nasal tuberculosis, but are not found in lupus.

Lupus, even when at first intranasal, is very apt to extend to the skin of the external nose, lips and face. Nasal tuberculosis, on the other hand, commonly stays within the nasal interior.

Histologically the lupus nodule is a miliary tubercle, but usually, instead of disintegrating by cheesy degeneration, it disappears by cicatrization, while the tubercle of nasal tuberculosis undergoes the central caseation and destructive softening characteristic of the typical miliary tubercle.

To express the matter briefly, the term lupus may be used to designate the well-known type of mild, slow, cicatrizing tuberculosis, which resembles the fibrous type of pulmonary phthisis, and which is less apt to destroy the structure it invades than to replace it with connective tissue. In contradistinction to this ordinary nasal tuberculosis shows the tendency to caseation and breaking down without repair characteristic of the more virulent forms of tuberculosis. The large proportion of cases of the milder lupus form of tuberculosis in the nose indicates a vigorous resistance of its structure to tubercular infection.

So long as the disease remains intranasal it will always be difficult, because of the many cases showing mixed characteristics of both lupus and tuberculosis, to tell to which of the two disease groups a given case should be assigned. But as the affections are

etiologically one, and differ merely in respect to prognosis and pathological changes, the distinction is not of great importance.

*Etiology.*—The opinion prevails that the usual beginning of both lupus and nasal tuberculosis on the foremost part of the septum is an evidence that the tubercle bacillus finds lodgment in the nose as the result of direct inoculation, for the surface of the cartilaginous septum is especially subject to the impact of particles in the air current, to friction with the handkerchief, and to abrasions and eczematous conditions due to this friction and to picking the nose. In fact, Massei thinks that the establishment of the disease in the usual site at the front of the septum is often caused by direct inoculation of the mucosa with the fingernail contaminated with tubercle bacilli.

Haematogenous conveyance of the bacilli into the nasal tissues is thought possible in rare instances.

While the authorities concede that absolute proof that a tuberculous affection is primary is to be supplied only by an autopsy, it is, nevertheless, agreed that the course of almost all cases of lupus, and that of many cases of nasal tuberculosis, indicates a primary tuberculous lesion.

The rarity of tuberculosis of the nasal passages, in spite of their exposure to inhalation infection, is explained as due to the bactericidal qualities of the nasal mucus, the ejecting action of the ciliae of the epithelium and the protective presence of a subepithelial adenoid layer of cells—theoretical explanations without experimental basis, and hence liable to mislead.

*Appearances and Symptoms.*—Nasal tuberculosis is divided, according to its aspect, into four forms—the tuberculous ulcer, the tuberculous tumor or tuberculoma, the diffuse infiltration and the formation of granulation areas, the latter being the variety characteristic of lupus.

*The Tuberculous Ulcer.*—In this group of cases, to which belong most of those secondary to pulmonary or laryngeal phthisis, ulceration is the chief characteristic of the affection. The tuberculous infiltration which precedes the ulcer is rarely seen, as it creates no symptoms, the first thing ordinarily discovered being



the fully developed ulcer, which makes its presence known by producing obstructing scabs in the affected naris.

When cleansed of these scabs the ulcer, in its early stage, is usually found to be solitary and to be seated upon the anterior part of the cartilaginous septum. Its form is round, oval or irregularly gnawed out and scalloped. Its floor is rarely clean, being usually covered by a yellowish, thin, false membrane, out of which sprouting, fungous, pale granulations arise. The tissue surrounding the ulceration is seldom congested, may even be pale, and is commonly invaded and thickened by tuberculous infiltration of varying extent. The borders of the ulcer may be steep, but are usually shallow, and in almost all instances so ill-defined that it is impossible to tell exactly where, beyond the ulcer, the intact epithelium begins, so much is it fretted by minute ulcerations scattered about the ragged edge of the central one.

While small nodular collections of miliary tubercles studding the mucous membrane about the tuberculous ulcer are commonly described as a characteristic aspect, I could see nothing of the sort in my two cases of nasal tuberculosis, nor have I so often met with this condition in the neighborhood of tuberculous ulcers of mucous membranes elsewhere that it seems to me at all a usual feature, and I think that its description as typical represents rather a text-book tradition than actuality.

While the tuberculous ulcer is seldom rapidly destructive, and is usually slow to invade cartilage and bone, still, in the course of time, it produces perforations of the septum and caries of its skeleton.

In spreading beyond its usual site on the septum, the ulceration commonly progresses across the nasal floor to the inferior turbinated bodies.

*The Tuberculous Tumor.*—This is usually solitary, and, like the other forms of nasal tuberculosis, often appears upon the cartilaginous septum, and next in frequency upon the inferior turbinated body. It varies in size from the bulk of a pea to growths large enough to be mistaken for sarcoma, as occurred in a case which came to my knowledge. Herrmann Coenen describes a tuberculoma so large that it filled the right nasal fossa, forced over



the septum, infiltrated the hard palate, and required extensive resection of the bones of the nasal skeleton for its removal. After the operation the patient died of septic pneumonia, the autopsy showing primary nasal tuberculosis. Rueda also reports a large tuberculoma weighing thirty-five grammes.

Nasal tuberculoma may be spherical or lobulated, may have a papillomatous, smooth or irregular surface, and may be pedunculated, but it has usually a broad base. Its color is grayish red or dark red or whitish. Characteristic of tuberculous tumors are their friability and their tendency to ulcerate.

*The Tuberculous Infiltration.*—This variety, like the edematous form of laryngeal phthisis, with its deep-seated tuberculous infiltration of the submucosa and perichondrium of the larynx, produces diffuse swelling of the part in the nose attacked, which is usually the cartilaginous septum, the skeleton of this structure as well as the mucosa being invaded by the tuberculous granulations. Entering thus deeply into the framework of the septum, the disease expands it in the form of diffuse, pale pink, resistant swellings, whose surface may show sprouting granulations or ulceration in places, while remaining smooth in others. In marked cases the thickened septum may appear like a tumor filling both nares, and feel like a hard lump when the external nose is grasped. Later carious breaking down of the infiltration often leads to multiple perforations of the septum and extensive destruction of its skeleton. The disease is apt to advance into the external nose from underneath, causing it to thicken and broaden.

The tuberculous infiltration in its more superficial and less destructive forms approaches lupus in character. When actively progressing it is the most formidable variety of nasal tuberculosis.

*Proliferation of Granulations.*—The form of intranasal tuberculosis typical of lupus is the granulating area upon the mucous membrane. It commonly begins, as do the other varieties, upon the cartilaginous septum, and appears as a bed of grayish red granulations, producing a surface like that of a raspberry, commonly hidden by scabs. Later in the disease the granulations also appear upon the lower turbinated bodies.

This is the most benignant of the varieties of nasal tuberculosis.

While it may lead to perforations of the cartilaginous septum, it is not in its nature to enter deeply into the structure it occupies, and it progresses superficially over increasing areas of the mucosa, and commonly later also over the skin of the external nose. Its tendency to form cicatrices may narrow the external nostrils.

In addition to the typical forms described, Koschier mentions a case of nasal tuberculosis having an exceptional primary deep beginning in the bones of the septum and inferior turbinated bodies, invading the mucous membrane from beneath.

The symptoms caused by nasal tuberculosis are mainly scabbing, due to drying of the scanty secretions from ulcerated and granulating surfaces, and nasal obstruction.

*Pathological Histology.*—Microscopic sections of the tissues attacked and of the tumor formations show a diffuse infiltration of lymphoid and epithelioid cells traversed by connective tissue bands, with often so great a scarcity of typical miliary tubercles and isolated giant cells that many sections may need to be examined before these objects are discovered. Tubercle bacilli are commonly very rare, are most frequent in the deeper parts of the products of the disease, and are not to be discovered in tissue typically tuberculous.

*Diagnosis.*—While the most important means of establishing the diagnosis is a histologic examination of excised tissue, the microscopic findings may, nevertheless, be doubtful, because of the rarity of elements distinctly tuberculous in the specimen examined. Typical miliary tubercles with a centre of cheesy degeneration and giant cells may be regarded as pathognomonic, even if bacilli be not found, but, as shown by Max Goerke, giant cells alone do not prove the existence of tuberculosis, as they are also found in the products of tertiary syphilis, and as the result of the entrance of minute foreign bodies into the tissues. Both these conditions may, however, usually be excluded clinically, and the history of the case, its gross appearances and the finding of giant cells in fields of epithelioid and lymphoid cells establish the diagnosis with sufficient certainty, even if typical tubercles and bacilli be not found in the section.

The inoculation of suspected tissue into animals remains equiv-

ocal, even if they become tuberculous, as it is impossible to exclude contamination of the specimen employed with tubercle bacilli accidentally present in the nares.

The mere gross appearances may be very deceptive, as I found in the case of a young man, with extensive and obstinate ulcerations and large areas of granulations on the septum and left inferior turbinated body, the aspect of the affection being so much like tubercular ulceration that I was surprised when repeated microscopic examinations showed a nearly pure culture of influenza bacilli in false membrane removed from the surface of the ulcers, and simple inflammatory ulceration in the tissue examined microscopically. In spite of the comparatively innocent infection in this case, mild measures were of no avail, and the excision of the diseased mucosa on the septum and resection of the lower turbinate were needed to effect a cure.

Syphilitic ulceration and hyperplasia are usually attended with extensive necrosis of bone, the formation of large sequestra and putrid discharge. In contradistinction to this, when destruction of bone and cartilage occurs in nasal tuberculosis, it is by insensible softening and carious absorption by the advancing granulation tissue, without fetor or the formation of a sequestrum.

*Prognosis.*—Nasal tuberculosis is commonly a benignant and often primary form of tuberculosis in a tissue little susceptible to the disease and permitting but few bacilli to penetrate it. If, therefore, the tissue invaded can be completely removed, recovery without a relapse is a possibility. Even in lupus, and still more in common nasal tuberculosis, secondary deposits, in the form of pulmonary tuberculosis, tubercular meningitis, tubercular lymphomas, joint disease or some other forms of tuberculosis, are to be feared as long as the primary affection in the nose is not extirpated.

*Treatment.*—The structures forming the nasal cavity are not of vital or the highest functional importance and are comparatively accessible, and for this reason, as compared to its location in other organs, primary tubercular disease within the nose is somewhat favorably situated for the thorough surgical extirpation,

which its dangerous and obstinate nature demands as the treatment of choice, in case it be deemed feasible. As compared to surgical excision all of the other methods of treating nasal tuberculosis are far less certain in their results, some being but vaguely experimental, and they are only justifiable, where the extensions of the disease have gone so far that its surgical removal involves great disfigurement, such as a sacrifice of the external nose, or where these extensions have entered regions whence they can not be removed by operation with the preservation of life.

The best implements for the excision of the tuberculous products are those which cut them out as cleanly as possible; rounded knife blades, chisel-shaped blades, the punch forceps, and, merely as an adjuvant, the sharp spoon. The latter implement is often described as being the main reliance for the removal of the tuberculous tissue. Its action is, however, too circumscribed and inaccurate; it leaves torn shreds of flesh behind and cannot cut away the apparently healthy but suspicious zone about the tubercular granulations or ulcer, which it is absolutely necessary to remove to diminish the likelihood of recurrence. Even a careful excision will, of course, give no insurance against a reappearance of the disease somewhere in the nose, for the least remnant of tubercular tissue left will reproduce the disease, and in such instances, as in my first case, the tuberculous granulations must be followed up by secondary operations until they no longer return.

The measures, which may be employed when the disease is beyond operation, as it was in my second case, are the excision of obstructing masses of tuberculous tissue as far as possible, curettement followed by lactic acid, tuberculin, Hollander's destruction of tuberculous tissue by superheated air, the galvanocautery and the X-ray. Massei states that electrolysis has not become popular and that long trials of phototherapy have proved ineffective.

As mentioned by Massei, extensive operations on the bony skeleton of the facial nose, opening it widely, are often needlessly employed to make intranasal tuberculosis accessible for curettement or for its removal in other ways, when an operation through the nostrils would have given ample access.

Case 1. My first patient was a young woman of twenty, first seen on September 5, 1907. Her chief symptom was an odorless,

mucopurulent discharge, tending to dry into scabs and coming from the right nostril, which was constantly more or less obstructed since the condition began, in March, 1906.

Inspection showed the left naris to be normal. In the right one an elevated, cockscomb-like ledge of pale pink granulations could be seen upon the septum, beginning in front opposite the anterior end of the middle turbinated body and following the septum clear to its posterior border, where it could be seen by posterior rhinoscopy, projecting into the nasopharynx as an irregular superficially ulcerated, whitish tumor, of the size of a hazelnut. (Fig. 1). Back of its posterior third the middle turbinated body was involved in the disease, the granulations bridging and filling the space between it and the septum, as could be seen both by anterior and posterior rhinoscopy.

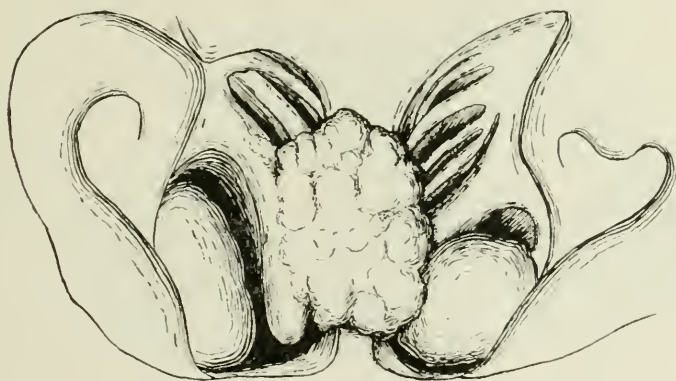


Fig. 1, Case 1.

View by posterior rhinoscopy of tubercular granulation tumor projecting from posterior border of vomer and uniting the vomer to the middle turbinated body.

On September 27, 1907, the diseased outgrowth was removed from the posterior border of the septum by an angular blade, which hooked behind it and cut up and down, while a probe in the left nostril pushed the mass over into the right one to steady it. The granulating area on the right side of the septum was then dissected off to the cartilage and bone by means of one of my sharp elevators used in the submucous resection. This procedure



radically extirpated the tubercular tissue from the septum, and no recurrence ever took place on this structure.

The middle turbinated body was then resected along its whole length with one of my septum knives, its tissue cutting readily, owing to carious absorption of the bone by the tubercular granulations. The stump was then trimmed with the Grünwald-Hartmann punch forceps until all the disease seemed removed.

Microscopic examination of the tissue showed abundant giant cells embedded in fields of epithelioid cells, but no tubercles or bacilli were found at this time.

The denuded area healed promptly, but scabbing began again

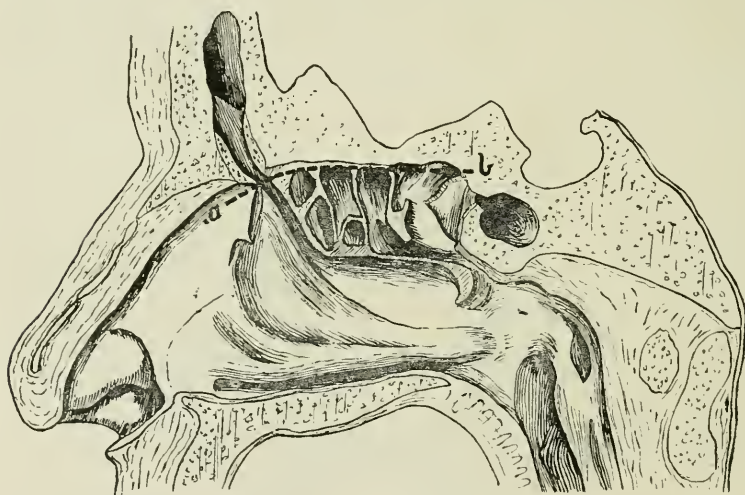


Fig. 2, Case 1.

View of lateral wall of right nasal fossa. The middle turbinated body has been excised and the ethmoidal cells uncovered by removal of the inner vertical plate of the right lateral mass of the ethmoid bone. The dotted line a....b indicates the path of the ethmoidal chisel in cutting through the attachment of the ethmoidal cells above.

after some weeks in the region of the stump of the middle turbinated body, from which pale polypoid granulations were seen to be again sprouting. On November 25, therefore, all but a posterior remnant of the stump of the middle turbinated body was extirpated with what tissue seemed to be tuberculous. Again the disease seemed eradicated until, in January, scabbing recom-



menced and fungus granulations could be seen growing along the attachment of the extirpated middle turbinated body, showing involvement of the ethmoid labyrinth underneath it. Therefore, as complete an intranasal extirpation as possible of the right ethmoidal cells was performed on January 31, 1908.

The first operations, done with cocaine anaesthesia, had been done hastily, because of the patient's unusual nervousness, which terminated in hysterical attacks. This time, therefore, chloroform was employed, the patient being kept in half narcosis in a half reclining position on a high operating chair, the operator standing at his work. The distinguished Danish rhinologist, Dr.

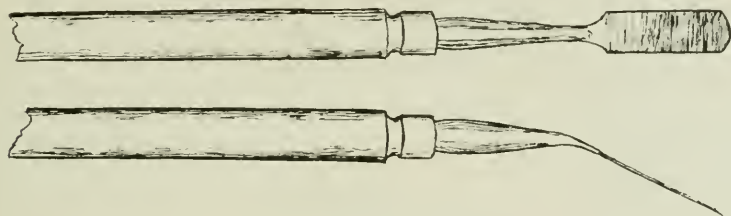


Fig. 3, Case 1.

Thin-bladed chisel bent on the flat; natural size.

N. Rh. Blegvad, of Copenhagen, who was visiting America at the time, honored me with his assistance on this occasion. The intranasal excision of the right lateral mass of the ethmoid bone was done in the following manner. A chisel-like instrument, with a thin blade, bent on the flat at an obtuse angle (Fig. 3) was pushed with the hand upward underneath the nasal bones and nasal spine of the frontal bone and backward under the cribriform plate (Fig. 2) in order to sever the anterior and upper surfaces of the lateral mass of ethmoid cells from its attachment to the cribriform plate and ethmoidal notch of the frontal bone as far outward as the os planum (lamina papyracea), the chisel following the direction of the upper and anterior attachment of the perpendicular ethmoidal plate. The mass of cells, thus cleanly detached in front and above, was then removed with the Grünwald-Hartmann punch forceps and Grünwald's set of nasal curettes. A diseased remnant of the middle turbinate was also found and cut away. The operation left a large hollow space, extending out-

ward from the septum to the os planum. No reaction followed beyond slight pain in the right orbit, when the eye was moved, and in the course of about two months the whole cavity left by the excision of the ethmoidal cells had healed over smoothly and has remained so ever since, no trace of tuberculous disease having

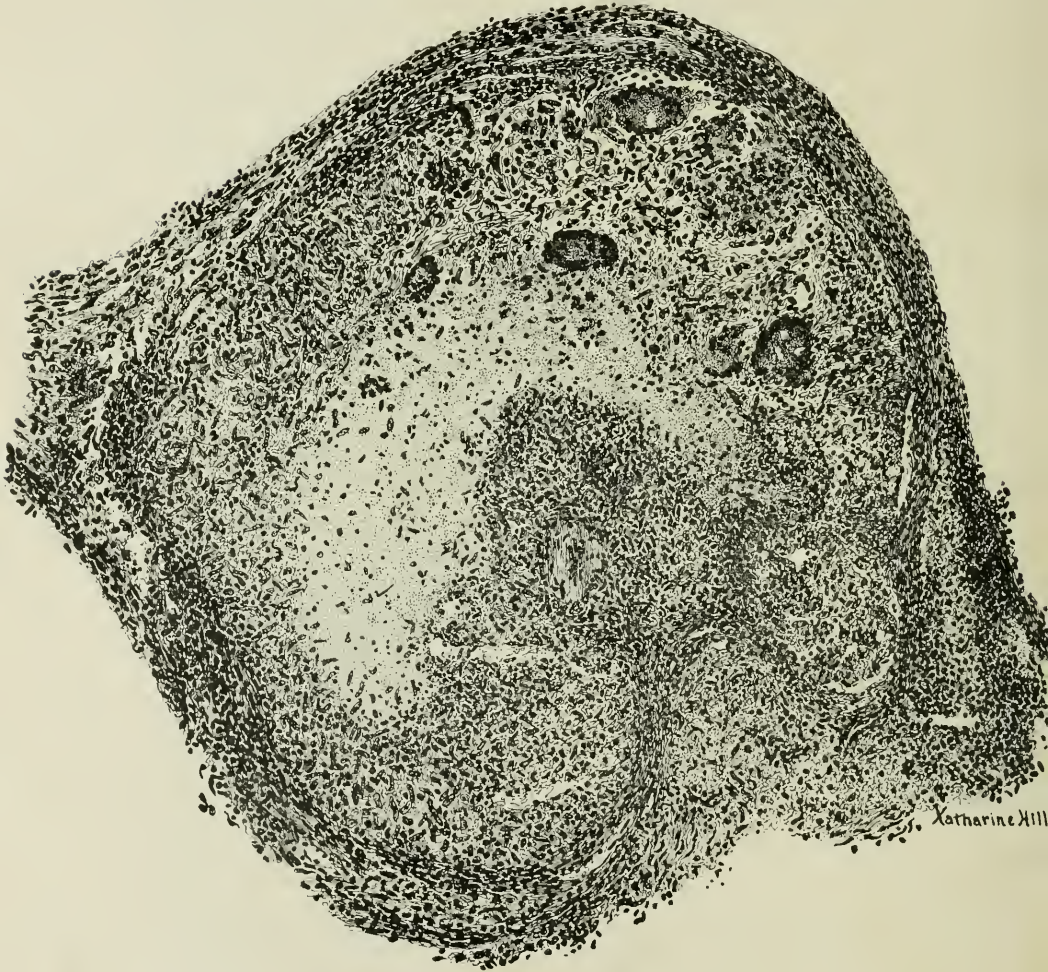

Fig. 4, Case 1.

Tubercle from ethmoid region showing caseation of centre and giant cells.

reappeared either on the septum or in the region of the extirpated ethmoidal cells at the last examination, January 18, 1909.

Examination of sections of the removed ethmoidal lateral mass showed the typical miliary tubercle shown in the drawing (Fig. 4) and some tubercle bacilli, thus making the diagnosis absolute.

The patient was nervous for some months after the operation and had marked asthenopia, being unable to read or sew without exciting pain in the eyes, especially the right. These symptoms have disappeared and she is now in health.

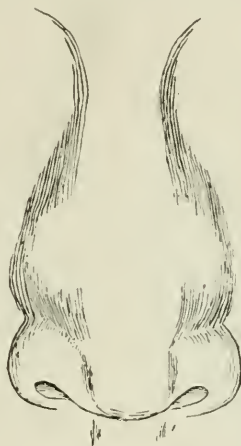


Fig. 5, Case 2.

Swelling of bridge of external nose due to tuberculosis of the cartilaginous septum and lateral cartilages of the external nose.

Case 2. My second patient was typical of a grave variety of infiltration nasal tuberculosis. She was a woman of fifty. No tuberculosis in the family and no luetic history. Her nasal affection began in June, 1908, the chief symptom being obstruction in both nostrils, which gradually increased until it had become absolute three weeks before she was first seen on September 7, 1908. In September she first noticed swelling of the external nose on either side of the bridge. There was no scabbing and only a slight watery discharge from the right nostril. No pulmonary involvement.

Examination showed a bulging swelling on either side of the nasal bridge, above the wings of the nose, as shown in the sketch (Fig. 5). This bulging was due to a great broadening of the

foremost part of the cartilaginous septum, where it blends with the triangular cartilages of the external nose, this broadening lifting the sides of the nose outward.

Rhinoscopy showed complete obstruction of both nares by the thickened septum, the thickening extending into the perpendicular plate above. The surface of the diseased septum on both sides was knobbed into irregular swellings and showed intact epithelium in some places, while in others it was covered with beds of pale pink, fungous granulations, upon which ill-defined superficial ulceration of a cheesy color could be seen. (Fig. 6) The ulcera-

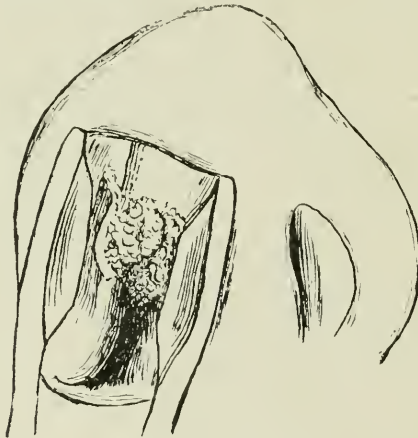


Fig. 6, Case 2.

View into the right naris showing granulating tubercular ulceration of the cartilaginous septum and right lower turbinated body.

tion also extended across to both lower turbinated bodies and the granulations had created adhesions between the left lower turbinate and septum. A contact ulcer also existed on the inner surface of the external nose on the left side, in the region of the limen nasi.

Sections from a piece excised from an ulcerated area on the right side of the septum were examined microscopically by Dr. Maximilian Herzog, who declared the tissue to be tuberculous, with a hypertrophic tendency and few infecting bacilli. The microscopic field showed epithelioid cells, lymphoid cells, polynuclear leucocytes and giant cells.



Because of the extensive involvement of the triangular cartilages of the external nose from beneath, the tuberculous infiltration of the thickness of the entire cartilaginous septum and the wide-spread areas of tubercular granulations in the nasal fossae, it was obviously impossible to radically excise the diseased tissue, and therefore only the obstructing hypertrophic masses were cut away on both sides of the septum, in order to permit free breathing. The nose remained open for two months, and during this period Dr. Herzog employed tuberculin injections, but without perceptible benefit. After this period the patient failed to return, so that there is no further history.

The complete recovery of the first of my two cases indicates the primary nature of her nasal tuberculosis and shows the value of surgical excision of the diseased tissue provided it can all be removed. The possibility of a practically complete intranasal extirpation of the ethmoid cells on one side is also demonstrated. Had the disease had time to deeply invade the infundibular region and the frontonasal duct or frontoethmoidal cells (infundibular cells of Heymann) surrounding it, a later external operation through the processus frontalis of the superior maxillary bone might have been needed to clear out this difficult region.

My second case is of interest as showing typically the deep-seated formidable infiltrative variety of nasal tuberculosis, which permeates the cartilaginous skeleton of the nasal septum, and of the external nose from beneath, and is similar to other cases of the kind, described in the literature.

#### *Literature Consulted.*

Hahn. Tuberculose der Nasenschleimhaut. Deutsche Medicinische Wochenschrift, 1890.

Hajek. Tuberculose der Nasenschleimhaut. Internationale Klinische Rundschau, Wien, 1892.

P. McBride. Primary lupus of palate and anterior nares. Edinburgh Medical Journal, July, 1893.

John W. Farlow. Two cases of nasal tuberculosis. New York Medical Journal, November 4, 1893.

Maximilian Herzog. American Journal of Medical Sciences. December, 1893. Tuberculosis of the nasal mucous membrane, with a report of ten new cases.

Simonin. Transactions of the Soc. Franc. de Lar., 1895.  
Pedunculated tubercular tumors of septum.

Koschier. Ueber Nasentuberculose. Wiener Klinische Wochenschrift, 1895.

Sachs. Tubercular tumor of cartilaginous septum. Deutsche Medicinische Wochenschrift, 1896.

Gaudier. Tumeur des fosses nasales, Nord. Med., March 15, 1897.

Sachs. Munchener Medicinische Wochenschrift, 1897. Tubercular tumors.

St. Clair Thompson. Primary tuberculosis of nasal cavities. British Medical Journal, October 30, 1897.

Heron. Lupus of the nose cured with the new tuberculin. British Medical Journal, March 5, 1898.

G. Prota. Tuberculosis vegetans of the nose. Congress of the Italian Laryngological Otological and Rhinological Society, October, 1899.

Hollander. Über den Nasenlupus. Berliner Klinische Wochenschrift, 1899.

M. Goerke. Archiv für Laryngologie und Rhinologie, 1899.

A. Jarisch. Graz. Nothnagel's Handbuch der Pathologie und Therapie, 1900.

L. Bar and V. Texier. Nasal tuberculosis, three cases. New York Medical Record, December 22, 1900.

V. Hinsberg. Über Augenerkrankungen bei Tuberculose der Nasenschleimhaut und die Milchsäurebehandlung derselben. Zeitschrift für Ohrenheilkunde. XXXIX., Heft 3, 1901.

Willard G. Reynolds. Tuberculosis of nose and pharynx. Brooklyn Medical Journal, October, 1901.

F. Rueda, Madrid. Riesentuberculom der Nasenhohlen. Archives Latinos, Laryngol. Otolog. No. 115, 1902.

Clement Thomas. Des tumeurs tuberculeux primitives des fosses nasales. These de Paris, 1902.

N. Calamida and S. Citelli. Endotelioma della fossa nasale con tubercolosi. Arch. Ital. di Otologie, July 13, 1902.

Coenen, Berlin. Primäre Tuberkelgeschwulst der Nasenhöhle. Archiv für Klin. Chir. Band 70, 1903.

Massei. Lupus du nez. Revue hebdomadaire de laryngologie, No. X., 1905.

Fein. Beitrag zur Lehre von der primären Tuberculose (Lupus) der Nasenschleimhaut. Berliner Klinische Wochenschrift, No. 48, 1906.

Senator. Ueber Schleimhautlupus der oberen Luftwege. Berliner Klinische Wochenschrift, No. 22, 1906.

B. Ranzer. Primäre Tuberculose der Nasenschleimhaut. Wiener Klinische Wochenschrift, No. 7, 1906.



Rossi Marselli. Tuberculoma nasi. Arch. Ital. di Laringologie, No. 11, 1906.

Cramer, Coburg. Zur Nasentuberkulose. Wiener Klinische Rundschau, No. 10, 1907.

Comas y Prio, Barcelona. Archivos de rinologie, laringologie y otologie. March-April, 1907. Lupus vegetans of the nose cured by X-ray.

J. W. Gleitsmann. Tuberculosis of the accessory sinuses of the nose. Laryngoscope, June, 1907.

## NASAL TUBERCULOSIS—A CASE AND REMARKS.

BY W. SCOTT RENNER, M.D.

The patient whose case I am about to report was a robust, healthy looking woman, twenty-eight years of age and weighing 180 pounds. She came to consult me on April 16, 1908, from a remote country district of western New York.

She complained of complete obstruction of both nostrils, which gave her great discomfort in breathing, interfered with her sleeping and produced a characteristic intonation of the voice. She stated that this condition had been coming on gradually for several months and was accompanied by a profuse malodorous discharge.

Upon examination I found both nasal fossae completely obstructed by a pyriform tumor occupying the position of the nasal septum. My first impression was that the tumor was probably an abscess of the nasal septum, but closer examination revealed the fact that the side of the tumor encroaching upon the lumen of the left nasal fossa, was a marked deflection of the septum to that side, and that the mucous membrane covering it was normal in character and directly in contact with the cartilaginous portion of the septum, where it belonged. The projection into the right nostril was a dark red and somewhat lobulated tumor, completely filling the fossa, whose surface had been more or less altered in appearance by two or three lines of electric cauterization. The tumor was elastic in character, not dense.

I made a provisional diagnosis of sarcoma, removed a specimen for microscopic examination, prescribed a placebo and requested the patient to return in about a week. The pathologist, Dr. Charles Bentz, of the University of Buffalo, returned a report of his examination, stating that the tumor was a characteristic tuberculous growth containing giant cells, etc., and that he had discovered tubercle bacilli in several of the microscopic slides from the specimen.

When the patient next visited me I removed the growth piecemeal, with snare and curette, until I reached the underlying cartilage and healthy mucous membrane, posteriorly and at the suture between the bony and the cartilaginous portion of the septum. When I had, in this manner, removed the growth from the septum, I discovered that the anterior portion of the lower turbinate of the same side was indurated and superficially ulcerated. The floor between the two tumors was likewise ulcerated.

The following day I removed most of the anterior portion of the inferior turbinate, with scissors and forceps, until no more evidence of disease was discernible. At this and at subsequent visits I thoroughly cauterized the wound surface on both the septum and the outer nasal wall with lactic acid. I also cauterized the edges of the wound, where the mucous membrane appeared normal, with an electric cautery. The wound surfaces were kept separate by packing with iodoform gauze until the wounds had healed.

This patient has a good family history, free from tuberculosis. She has an old scar in the cervical region, and gives a history of glandular abscess in childhood. She has four children, one of whom, she says, has "lung trouble." But I have never had an opportunity to examine this child.

I referred the patient to Dr. De Lancey Rochester, of Buffalo, for an examination of her chest. He reports as follows: "I find no disease of the lungs here. Heart is not very strong. There is history of old gland abscess in the neck, etc."

At no time, while under my care, did the patient have any rise of temperature. Since her recovery from the local lesion it has been impossible to carry out any systematic treatment of the case. However, I prescribed potassium iodide and recommended tonics and out-of-door life. Had she been able to visit the city, from time to time, I should have instituted tuberculin treatment.

Whether this should be considered a primary infection of the individual is questionable. As already mentioned, she has an old scar on the neck of a lesion which was probably active twenty years ago, and may or may not have been tuberculous. The nasal infection, I should judge, commenced as a tuberculoma of the nasal septum and subsequently infected the lower turbinate. The in-

fection may have started as a "contact infection" of an erosion of the concave cartilaginous portion of the septum and not by secretion from the patient's lungs. Or, she may have been infected by the secretions from her own child, seven years old, who may have tuberculosis.

This is reported as a typical case of nasal tuberculosis, which usually commences in the cartilaginous portion of the nasal septum, as a tuberculoma. The usual classification of the various forms of nasal tuberculosis is that suggested by Gerber in Heymann's Handbook and adopted by Prof. Gleitsmann in his report at Vienna last year. It includes tuberculous ulcer, diffuse infiltration, tuberculoma and lupus. A simpler division is: True tuberculosis of the nasal mucous membrane and lupus of the nasal mucous membrane.

Tuberculous infiltration and tuberculoma are identical in character. The latter is simply a greater elevation of the diseased tissue above the surface attacked by the infection. Both of these undergo some ulceration in time. These two forms are supposed to be primary in character, and differ in this respect from the tuberculous ulcer of the nasal mucous membrane, which is a secondary infection.

Although tuberculosis of the nose is a comparatively rare disease, a sufficient number of cases has been reported and critically studied during the past fifteen years to establish clinical characteristics and etiological factors. Up to the time that Prof. Chiari wrote his paper, in 1894, on "Tuberculoma of the Nasal Septum," only twenty-one cases, including six of his own, had been reported. Since that time the number of cases reported has rapidly increased and exhaustive articles have been written upon the subject by Gerber, Pasch, Caboche, Gerst, Katz and others.

Authors who come into contact principally with cases of pulmonary tuberculosis have, with very few exceptions, contributed very little to the literature on this subject, and the cases which they have reported have been those of simple ulceration without any perceptible proliferation of tissue. This is the form of tuberculosis which occurs in the nose in advanced pulmonary conditions, which is like that found in the pharynx in advanced phthisis. For instance, Karl von Ruck, in his report on the treatment of

pulmonary tuberculosis, in 1903-04, cited eight cases, and, in his report of 1905-06, he reported six cases, all of which were ulcerative in character. Caboche states that of twenty cases of tuberculous ulcers of the nasal mucous membrane, which he collected from the literature, eighteen appeared as the ultimate manifestation of pulmonary phthisis.

The proliferative form of nasal tuberculosis is considered to be primary, and most of its characteristics are illustrated by the history of the case just cited. It occurs usually in people of robust health, who have no other active tubercular lesions, although evidences of latent tuberculosis may be found in other organs. For instance, the patient whose case I have been considering has a scar on her neck, and may also have some undiscovered latent pulmonary lesion.

The tuberculous tumor, or tuberculoma, is of the type of so-called primary infection of the nasal septum. Its presence is discovered by the symptoms of nasal obstruction. Examination in such cases reveals a tumor of variable size, starting from the typical spot on the cartilaginous portion of the nasal septum and varying in color according to its vascularity from gray or pale red to dark red. This description may also apply to any tumor of the nasal septum. Tuberculoma, when not removed, may in time undergo coagulation necrosis and possibly become an ulcer. The process usually commences on the cartilaginous septum and other tuberculous lesions in the nose are the result of infection from it by contact and continuity of surface; it may thus extend to the floor of the nose, the turbinates, the ethmoid, frontal and maxillary sinuses. Infection may start in other parts of the nose, but rarely. It may also occur on the vomer and extend through the nasal duct to the conjunctiva.

Caboche claims that all primary infections of the nasal septum are lupic in character and that twenty-nine out of forty-four cases of tuberculoma of the nasal septum which he collected from the literature were undoubtedly lupus, and of twenty-one observations of tuberculous infiltration of the nasal mucosa, only four are probably lupus; all the others, seventeen in number, are absolutely lupus. He sums up by saying: "There are only two forms of nasal tuberculosis; miliary tuberculosis and lupus, which

comprises tuberculous tumors and the majority of tuberculous granulations."

Lupus of the nasal mucous membrane has all the histological characteristics of other forms of nasal tuberculosis and is distinguishable only by the clinical manifestations. Many authors believe that lupus of the face always commences in an internasal lesion from an infection of the nasal mucosa and that as the lesion produces no symptoms until the skin is attacked, it is first seen by the dermatologist who rarely pays much attention to the interior of the nose until destruction takes place.

The difference between primary tuberculosis and lupus is not always acknowledged by others than dermatologists. Much that is claimed to be lupus by some is called tuberculosis by others. Hajek, Michelson and Zarnico have entirely given up the classification into nasal tuberculosis and nasal lupus, and speak only of nasal tuberculosis. As we have already seen, Caboché and others claim that all primary internasal tuberculosis is lupic in character, while, on the other hand, Merotz, Schmidt, and many other authors, devote a separate chapter to lupus of the upper air passages.

Primary infection of the nasal mucus membrane is more rare than one would expect from its location, because the nose is protected by weapons of defense in the ciliary epithelium of the mucous membrane and the bactericidal qualities of the normal nasal secretion. Tubercle bacilli and other pathogenic germs have been found in the nasal cavities of healthy people by many investigators, especially in people such as nurses and attendants associated with tuberculous patients. Inoculation may then occur through defects in the epithelium through excoriations and erosions. This part of the nose is also subject to the insults of the scratching finger and to the use of the soiled handkerchief of some infected person. As has already been stated, the tuberculous ulcer is a secondary infection in patients with pulmonary phthisis.

Some authors claim that all nasal tuberculosis is a secondary ascending disease, yet some, on the other hand, assert that every case of facial lupus has its origin in the nasal mucosa. Many cases that are apparently primary in origin are in reality secondary to some latent lesion in the lungs or some other organ which



cannot be recognized by any means of physical diagnosis. Consequently it is almost impossible during life to make an absolute diagnosis of primary infection, for we know how often latent tuberculous lesions are found post-mortem. X-ray examination of the lungs is now being practiced and will probably bring to light many undiscovered lesions.

The tuberculous nasal ulcer is usually easily diagnosed from its characteristic appearance and from its association with pulmonary phthisis. The proliferative form can be absolutely diagnosed from histological findings only. It is usually unaccompanied by pain or fever. The diffuse infiltration may resemble a specific infiltration which is differentiated by the therapeutic test, although the two diseases may coexist.

Tuberculoma is not apt to be mistaken for syphilis. Syphilis rarely produces as large a tumor as tuberculosis. The tuberculous tumor may be confounded until examined histologically with papilloma, fibroma and sarcoma. Onodi, for instance, diagnosed a case as carcinoma of the nasal septum from the clinical picture and the microscopic examination of an excised portion. After radical removal of the tumor it proved to be a tuberculoma. Pasch and Gerst describe cases of infiltration of the nasal mucous membrane, which are not distinguishable from true hypertrophy of that membrane, producing neither defects nor prominences. As illustrative of this condition, Gerst describes, among others, a case of a woman fifty-eight years old, whose right lower turbinate was uniformly enlarged, posterior extremity much enlarged, with irregular surface and dark red in color. This turbinate only partially collapsed on application of cocaine and adrenalin, the posterior extremity remaining unchanged. The anterior part only partially collapsed and was anemic, showing dark red colored spots prominent and circumscribed. The left lower turbinated also appeared hypertrophied without the posterior extremity being especially enlarged, and it reacted pretty uniformly to the cocaine and adrenalin. After that the middle turbinates were visible and unchanged, septal mucous membrane normal. The excised posterior extremity of the right turbinated was found to be tuberculous. After discovering this the left lower turbinated and the mucous membrane on both sides of the septum were removed and

found to be tuberculous. The only rhinoscopic changes were in the right lower turbinated, yet the nasal mucous membrane was found to be extensively tuberculous.

In conclusion and by way of summary I would say that, clinically, nasal tuberculosis may be divided into three classes:

First, the tuberculous ulcer occurring in advanced phthisis, which is usually discovered by the specialist in that line, who adds to his pulmonary examination a systematic inspection of the upper air passage, as was cited in the cases of Von Ruck, who reported fourteen ulcerations of the nasal mucosa in five hundred and fifty-four cases of pulmonary tuberculosis.

Second, the tuberculous tumor and infiltration, for which the patient consults the rhinologist for nasal obstruction.

Third, lupus, cases, of which are usually diagnosed by the dermatologist after the tuberculous lesion of the mucosa has extended to the skin of the nose and face.

The last two are primary in origin and are more accurately termed tuberculosis rather than lupus. In my opinion the term "lupus" could with impunity be dropped from our nomenclature.

#### *Bibliography of Nasal Tuberculosis.*

1. Gerber, Dr. P. H., "Tuberculose und Lupus der Nase." "Handbuch der Laryngologie und Rhinologie," Bd. 3. S., 901-930.
2. Gleitsmann, Dr. J. W., "Behandlung der Tuberculose der Oberen Luftwege," Archiv für Laryngologie, Bd. 21, 1908, S. 111-119.
3. Chiari, O., "Über Tuberculome der Nasenschleimhaut," Archiv für Laryngologie, 1894, S. 121-134.
4. Pasch, Ernst, "Beitrag zur Klinik der Nasen Tuberkulose," Archiv für Laryngologie, Bd. 17, 1905, P. 454-483.
5. Caboche, Henri, "Contribution to the Study of Tuberculosis of the Nasal Mucosa," Archives of Otolaryngology and Rhinology, Vol. 17, 1908, P. 180-242.
6. Katz, Dr. Leo, "Die Tuberkulose der Nasenscheidewand," Die Krankheiten der Nasenscheidewand, S. 83-100.
7. Gerst, Dr. Ernst, "Zur Kenntniss der Einscheinungenformen der Nasentuberkulose," Archiv für Laryngologie, Bd., 1908, P. 309-324.

8. Von Ruck, Karl, and Von Ruck, Silvio, "A Clinical Study of 261 Cases of Pulmonary Tuberculosis," treated at the Win-yah Sanitarium, Asheville, N. C., 1905-6.
9. Same as above for years 1903-4.
10. Onodi, A., *Deutsch med. Woch.* 29, 1906.
11. Hajek, M., "Die Tuberkulose der Nasenschleimhaut," *Internationale Klinische Rundschau*, 1889.
12. Zarniko, Carl, "Die Krankheiten der Nase und des Nasenrachens."
13. Schmidt, Moritz, "Die Krankheiten der Oberen Luftwege."

*Discussion on the Papers of Dr. Freer and Dr. Renner.*

Dr. Emil Mayer: Neither of the speakers has mentioned whether there were any lesions on the skin, nor has anything been said as to whether there was any lesion existing in the larynx. I hope they will mention whether there was anything of the kind there. The statement made by the reader of the last paper that nasal tuberculosis appears late in pulmonary involvement does not always obtain. I have seen several cases of very insignificant looking deposits on the nasal mucous membrane which showed these to be tuberculous and of a most serious kind, the patient developing miliary tuberculosis within a very short time after the appearance of these lesions. In these cases both were examined very carefully by some of our very competent men, who were unable to make a diagnosis on the presence of anything like tuberculosis. That the size of the growth is any evidence as to whether it is specific or not cannot be maintained very seriously. I am not in accord with the final statement of the last speaker that the term lupus should be dropped. Notwithstanding that a few tubercle bacilli are found in lupus of the upper air passages those who have followed cases of lupus of the larynx will find that it comes very frequently as a surprise to the laryngologist that the patient has anything like a lesion in the larynx, yet there will be an advanced lesion with absence of symptoms. The older members of this association will recall a discussion on this subject some years ago when the late Dr. Asch presented a case of primary lupus of the larynx. This case it was my fortune to see and follow for a number of years. This patient lived for eighteen years after the first evidence of the disease showed itself, and finally succumbed to general tuberculosis. Lupus seems so distinct an entity to tuberculosis that we ought to keep these things distinctly apart in our nomenclature. I hope we will al-

ways keep the term of lupus as a differentiating mark to our patients and to ourselves. It means much to them if you can tell them they have a tuberculous lesion, with which they may live for a number of years. I have seen three or four cases of lupus of the larynx and have followed them for several years.

Dr. Freer: In reply to Dr. Mayer's question in respect to tuberculous lesions of the skin or larynx in my patients, I answer that there were none.

I do not regard the ulcerative type of nasal tuberculosis as pertaining especially to advanced pulmonary tuberculosis, for a review of the literature will show that ulcerative nasal tuberculosis is quite common irrespective of lung disease.

I agree with Dr. Mayer that the term lupus should be retained for the reason that lupus is, after all, a characteristic phase of tuberculosis, whose course has marked features of its own. In addition, in spite of opposition, custom retains the designation lupus.

Dr. Renner: In reply to Dr. Mayer I would say there were no laryngeal or skin lesions in my case. I do not dispute the clinical differences between lupus and other forms of nasal tuberculosis, but it seems we might better consider the histological nature in the nomenclature. I did not say that the ulcers were not found in cases which were not advanced, but that they usually occurred in the more advanced stages of pulmonary phthisis.

A NEW METHOD OF PACKING THE NOSTRIL, DESIGNED TO PREVENT POST-OPERATIVE HEMORRHAGE

AND

A NEW QUADRIVALVE SELF-RETAINING NASAL SPECULUM.

BY W. E. CASSELBERRY, M.D., CHICAGO.

The packing of the nostril in some manner, including the insertion of a plug in the posterior naris, is necessary at times; in order to control a dangerous degree of post-operative nasal hemorrhage, especially that which is liable to ensue after some hours, in consequence of a branch of the post-nasal artery having been severed, as, for instance, following a full length turbinectomy or the radical ethmoid operation. The fact that plugging the posterior naris will succeed in stopping such a hemorrhage, even though an anterior pack alone has failed, is due to the ring-like conformation of the choana, against the bony edge of which the main vascular stem as it emerges from the spheno-palatine foramen, together with its larger branches, is certain to be compressed by any plug which firmly fills the choana. But the painfulness of the customary method of packing with bare gauze, especially in connection with a posterior plug, the disposition of the gauze to adhere so intimately to the wound as to preclude its removal under forty-eight hours without a probability of causing hemorrhage anew, and the liability of the post nasal plug to favor infection leading to an abscess of the ear, have deterred many from using any sort of pack for the purpose only of preventing hemorrhage, and have deterred all from inserting a posterior tampon excepting to meet an urgent necessity. Feeling the risk and responsibility in this respect to be disproportionate to the minor character of most of the operations performed, I have sought to devise a simple, safe and effective method of packing the nostril and posterior naris, as it

is obvious that a preventive tampon which, while affording safety from hemorrhage, would be itself safe, and which, though inserted by the easier route from in front, would embrace the merits without the demerits of the posterior plug, would extend the benefits of nasal surgery and lessen the anxieties of the surgeon.

The new tampon, which I have used satisfactorily for three years, finding it to fulfill the requirements, is composed of a rubber finger cot or, preferably, as I have now perfected it in shape, of what might be called a club-finger cot (Fig. 1), which, after insertion into the nostril, is filled by means of an ordinary tubular gauze packer with a strip of sterile gauze  $1\frac{1}{4}$  inches in width by a yard or more in length. The finger cot and packer having been sterilized by boiling, the packer ready armed with gauze, is used first as a stem on which the rubber case, lubricated and held for



Fig. 1. (One-half size).

Casselberry's "club-finger cot" for use in packing the nostril.

the moment lengthwise on the stretch, is carried into place, extending from front to back in the nostril with the closed bulbous end just overlapping the choana into the nasopharynx. Both the packer and cot are then in a position (Fig. 2) to pass the gauze which at the start should be packed with special firmness in order to form the posterior plug by an over-distension of the expanded end of the finger cot where the rubber is reinforced to withstand the strain. The club-finger cot, with its bulbous closed extremity and proximal slight constriction of its calibre, is especially suitable for forming such a plug in and behind the posterior naris, although an ordinary finger cot of large size or one cut from a surgeon's rubber glove can be made to serve the purpose almost, but not quite, as well, by extra firmness, albeit gentleness, in packing the rear end.

Not only does the incasing of the gauze in rubber render the tampon comparatively free from the pushing and pulling re-



quirements of uncovered gauze during its insertion and withdrawal, but its smooth surface permits of a ready detachment from the wound as soon as its purpose is fulfilled, usually by the

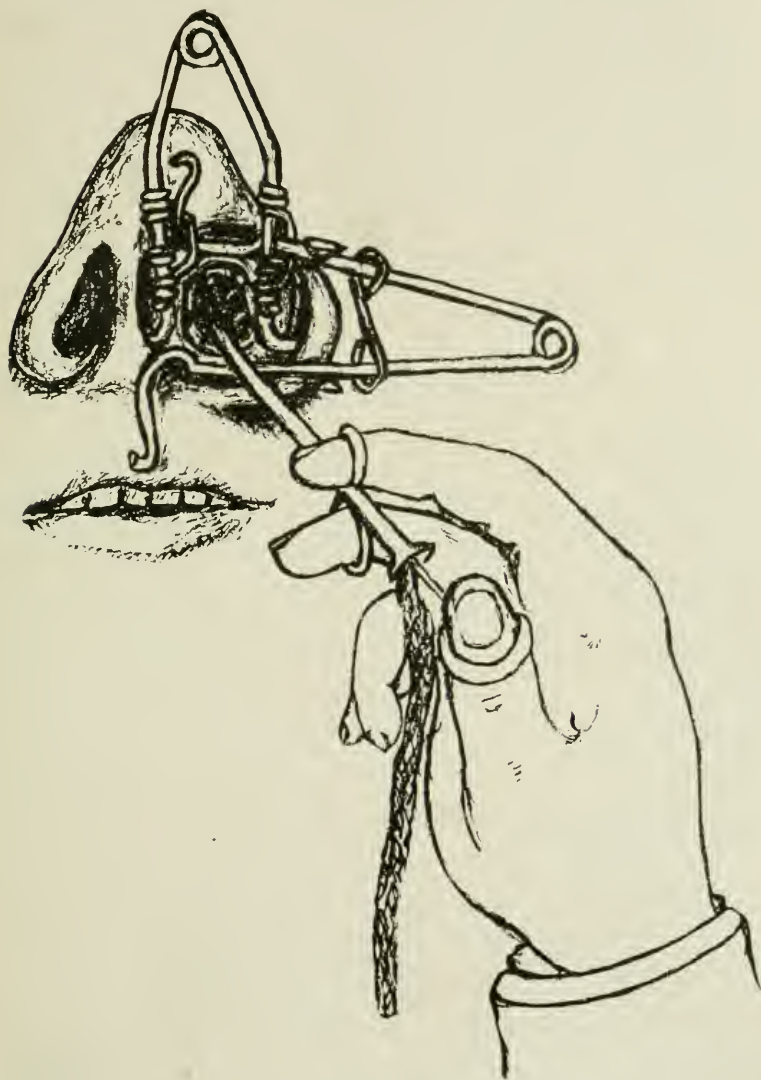


Fig. 2.

Representing Casselberry's club-finger cot in position and the gauze packing being inserted: Also the new quadrivalve speculum.

end of eighteen hours, instead of forty-eight, when by first withdrawing the gauze from the rubber the flaccid case will slip from the nostril. Any tampon left in the nose for a couple of days or more becomes a hardship and a menace, but the discomfort incidental to this one is usually well tolerated, being greatly lessened by the brevity of the period necessary for it to remain in place, and by the assurance to the patient of its early removal the next morning; and being for the most part nonabsorbent, it resists putrefactive changes, experience indicating that its use during this brief period is free from danger to the ear or nasal accessory sinuses.

Its efficiency, no doubt, will be found to vary, as with other tampons, in accordance with the degree of compactness and dexterity with which it is inserted. I have employed it in about seventy-five private cases, having adopted a routine of inserting it as a precautionary dressing immediately on the completion of intranasal operations of the sort which experience has taught are prone to a continuance or recurrence of hemorrhage during the first day and night. This number, composed of operations on the turbinals, septum, ethmoid and other accessory sinuses, ordinarily would have given occasion for several emergency calls to stop hemorrhages more or less severe, whereas only once did the tampon fail to fulfill its purpose, and then for the reason that in order to minimize the discomfort the gauze inside the cot had been too loosely inserted. The bleeding, which commenced about four hours after a full length inferior turbinectomy, was profuse and proceeded from far back in the nostril, having been, therefore, of that type which is best controlled by efficient pressure at the posterior naris. It was this incident which led me to perfect the plain finger cot, which I was then using, into the club-finger pattern, in order that its bulbous extremity when over-distended with gauze might compress the posterior vessels against the ring-like boundary of the choana in the same manner as a regular posterior plug. Its pressure, if the bulbous extremity be firmly and accurately applied with the choana as a vantage point, would seem to be adequate for the prevention of posterior bleeding, and, therefore, I regard the club-finger pattern of cot as especially valuable and suitable for inser-

tion, following the operations which render the patient liable to this particular type of hemorrhage. In submucous resection of the septum it acts also as a suitable supporting compress.

The primary purpose for which I devised this method of packing the nostril, and for which I now recommend it, is to serve as a preventive of hemorrhage rather than to control a copious bleeding when already in progress. Not being equal to free gauze in coaptability to a highly irregular surface, nor in extreme power of compression, one can see that it might not be capable of stemming the tide in full flow; nevertheless, I confidently expect that in the majority of cases experience will prove it to be capable of control as well as prevention.

#### A NEW SPECULUM.

Any speculum will answer for the insertion of the packing, but the new quadrivalve nasal dilator, shown in Fig. 2, is designed to facilitate both it and the preceding steps of the various operations, although I designed it especially to meet the requirement often felt when operating under general anesthesia, for a self-retaining dilator which would dilate efficiently and retain itself persistently despite the manipulations of the anesthetist and assistants. I believe it to be the first nasal speculum to be furnished with four connected blades, instead of two or three, one pair which opens vertically and another pair which opens horizontally, thus providing the greatest degree of expansion while causing the least discomfort. The two pairs are detachable, but before insertion and while in situ, they are securely linked together, which has the effect of each holding the other in place. Leverage on either one of the arms suffices to slant all four blades at once in any direction necessary for an unobstructed view through the nostril, but no amount of leverage will cause any blade to slip out of the nostril. The action of both springs can be moderated by the single controlling device on the horizontal spring. The blades are shaped to fit between each other when open, and to lock compactly together when closed for introduction. The mechanism, although puzzling in appearance at first, is simple once the combination is learned. The key to the device lies in the revolving

movement given the two connecting links attached to the arms of the vertical spring, and success in its use depends on the unequal turning of the links each to the site suitable for passing through it the corresponding connecting bar of the other pair of blades. The speculum is of bilateral usefulness, an advantage which is also due to the revolving movement of the links, but different sizes of it are required to fit accurately the varying dimensions of nostrils.

*Discussion.*

Dr. Emil Mayer: I wish simply to present for examination the self-retaining speculum of Yankauer.

## AN EMBRYOLOGICAL STUDY OF THE METAPLASIA OF THE EPITHELIUM OF THE TONSILLAR CRYPTS—A CONTRIBUTION TO THE ORIGIN OF LYMPHOCYTES.

(From the Laboratories of the Wistar Institute of Anatomy.)

BY GEORGE B. WOOD, M.D.

The object of this paper is to discuss the probability of the production of lymphocytes by metamorphosis from the epithelial cells of the tonsillar crypts. While it is not a new thought that the lymphocytes can be produced from epithelial cells, the majority of authorities believe that they are mesodermic in origin. It must be admitted, however, that the connective tissue origin of the lymphocyte has not been proven. According to Florence R. Sabin, the lymphocyte of the lymph nodes is first found in the fine reticulum surrounding the artery and its capillaries, but she says there is no proof that they are formed in this position, and it is certain that the lymphocytes develop independently from the lymph ducts.

Koelliker, in 1879, was probably the first to suggest that the thymus gland derived its lymphoid structure from the epithelial cells. His theory, however, was not accepted unconditionally by anatomists, and the question of the origin of the lymphoid cells in the thymus gland has been one of continual dispute. The close parallelism between the formation of the thymus and the tonsil, in that they both are essentially lymphoid structures in which the embryological anlage is epithelial, makes it worth while, perhaps, to enter more closely into this discussion. A few authors, chief among whom probably is Beard, hold that the thymus gland is the parent source of all leukocytes. The discussion, however, of this statement would carry us into another disputed field, namely, as to whether all leukocytes come from the lymphoid cells. For the sake of brevity I will not go into this question more than to say that I have not seen any reason to change my views as stated in an article on

"The Function of the Tonsils," published in 1904, in which I took the ground that the more recent evidence was strongly in favor of the view that all forms of leukocytes were derived by a continuous evolution from the lymphoid cell.

His in 1880, Stieda in 1881 and Dohrn in 1884, corroborated Koelliker's statement that the original anlage of the thymus is epithelial, but they did not believe that the lymphoid cells themselves are derived from the epithelium; rather, that they are mesodermic in origin, wandering in from the outside. Maurer in his earlier works also believed that the lymphoid cells of the thymus are mesodermic.

In 1887 Schultze states that the lymphocytes are epithelial in origin, but that the reticulum is mesodermic. In 1887 Herman et Tourneux found that in man and other mammals the original epithelial cells of the thymus are gradually converted into leukocytes and reticulum cells. He was not positive about all the reticulum cells being derived from the epithelium, because during the transformation prolongations of connective tissue containing blood vessels gradually grow into the anlage. In 1886 Maurer thought that in teleosts the lymphocytes come directly from the epithelium of an anlage, but in 1888, in a study of amphibians, he could not find any transitional forms, and was, therefore, unwilling to conclude that in these animals the lymphocytes are epithelial in origin.

In 1892 Capobianco took the ground that lymphoid tissue originates from cells which have immigrated from the outside into the primary rudiment, and that, therefore, the lymphatic structure of the thymus is acquired secondarily.

In a series of articles, dating from 1894 to 1900, Beard has published the results of a large amount of work in which he claims to have seen a direct conversion of the epithelial cells into lymphocytes, and has traced all the intermediate forms. He says that the first change seems to take place in the cytoplasm, which becomes more refractive, and in favorable sections takes on a somewhat brownish tinge. Later the nucleus becomes rounded and assumes an eccentric position. His claim is that the thymus is the parent source of all leukocytes, and that the



lymph glands and the spleen act simply as centres wherein a secondary division of already existing cells takes place.

Prenant in 1894, after a careful study of the development of the thymus in sheep, believed that there is a direct transformation of the epithelial cells into lymphocytes. He found all the transitions between the pale elliptical nuclei of clear reticular structure, and a small, deeply colored, rounded nuclei which takes the stain very strongly. These last cells, he said, are certainly lymphocytes, and constitute an immense majority of the cellular elements; and, further, that it is probable that a certain number of the epithelial cells exist as reticulum cells, even in fully formed organs. In 1899 Ver Eecke believed that in frogs the epithelial anlage is invaded by lymphocytes and connective tissue from the outside. His idea was very similar to that advanced by Retterer, that the connective tissue commingles with the epithelial cells, not destroying them, and forms what might be termed a lympho-epithelial tissue.

Maurer in 1899, after a careful study of lizards, stated that in these animals the original loose reticulum, and also the lymphocytes, are formed directly from the epithelial cells. Kollman in 1900 said that it was nonsense to believe that lymphocytes can be derived from the epithelium, and that leukocytes are developed from the mesoderm, both in embryo and in the foetus of the adult. Nusbaum and Prymak in 1901, in a series of studies of the *Salmo fario* L. and the young *Carassius vulgaris*, believed that the lymphoid element of the thymus is derived solely from the epithelium. After more continued study Nusbaum, associated with Machowski, found additional support for this theory. In 1902 Prymak, from a study of the teleosts reiterates very positively his belief that the large quantity of lymphoid tissue which is present in the later developmental stages of the thymus gland comes directly from the epithelial cells of the pharyngeal entoderm, and that it is never derived from the mesenchyma. He has never seen the wandering of leukocytes from outside the thymus body into its interior, but in its later stages large numbers of leukocytes pass from the interior to the outside.

In 1903 Stohr, while acknowledging that the small round

cells of the thymus were derived from the epithelium, made the statement that these small cells of the thymus, while closely resembling lymphocytes, were not lymphocytes, but still epithelial cells.

In 1905 a very elaborate work on the development of the thymus was published by E. T. Bell. His work was done entirely on embryos of pigs. He found that the thymus of the pig was developed entirely from the third branchial cleft. He said that by a gradual process of vacuolization and liquefaction of the cytoplasm, the epithelial syncytium of the thymic anlage is converted into a cellular reticulum. Three types of nuclei are present—large pale nuclei, small dark nuclei or lymphoblasts, and large dark intermediate forms. The lymphoblasts gradually work loose from the cellular reticulum, moving into spaces and forming lymphocytes. The lymphoblasts are present in the thymus long before lymphocytes are found anywhere in the neighborhood of the thymus. The cellular reticulum persists in a modified form as the reticulum of both cortex and medulla, so that practically all the reticulum of both cortex and medulla, as well as the lymphocytes, are of epithelial origin. In 1905 Hammar published an article which is a searching review of the literature and a very careful histologic study of the thymus in many animals. His conclusions were that the reticulum was certainly epithelial in origin, but that the evidence was not yet sufficient to decide the question of the origin of the lymphocytes.

Bryce, 1905, in looking over the preparations of Prof. Kerr, concludes that the thymus of the *Lepidosiren* has up to an advanced larval stage absolutely nothing to do with the formation of leukocytes. He admits, however, that his specimens were not of a sufficiently late stage to show the deposit of lymphoid tissue in the thymus anlage. After siding with Stohr in his general theories he calls attention to the fact that Stohr accepts the results of observers who describe a transformation of the original cellular elements into small lymphoid-like cells, but saves his theory of the origin of lymphoid tissue from the middle layer derivatives by denying to the thymus cells kindred with them.

In 1907 Hammar again comes to the front with strong evi-

dence contradicting this latest theory of Stohr's. From a careful study, both histological and biological, he concludes that the small cells of the thymus and lymphocytes are identical. His reasons for this belief are: First, the thymus lymphocytes resemble the lymphocytes of the blood in that they possess basophilic protoplasm. Second, the thymus lymphocytes possess amoeboid movement. Third, the uncommon sensitiveness of lymphocytes of the other portions of the body to the Roentgen rays is also seen when the rays are applied to the thymus lymphocytes. Fourth, when the lymphocytes of the thymus are destroyed by the Roentgen rays, the organ becomes a mass of epithelial cells.

In summarizing the evidence of this literature, we cannot help but notice that in late years those who have done the most careful research work are almost unanimous in their belief that the lymphoid element of the thymus is essentially epithelial in origin. Stohr has headed those who believed that the small cells of the thymus were connective tissue in origin. The reason for his belief was chiefly that he could not see how lymphocytes could be anything but connective tissue, and he has presented very little direct evidence to show that the lymphocytes of the thymus come from the mesoderm. On the other hand, those who claim that the lymphoid deposit of the thymus is epithelial in character, have presented such an abundance of direct evidence in support of their view, that Stohr himself had to recognize the facts as stated by them, but endeavors to save his idea of the connective tissue origin of the lymphoid cells by claiming that the small cells of the thymus were not true lymphocytes, but simply modified epithelial cells. With the appearance of Hammar's article in 1907, I believe that this idea has been now taken away from him, Hammar proving that morphologically and biologically the small cells of the thymus are identical with the lymphocytes of the blood. I believe, therefore, that we can conclude that the lymphoid tissue of the thymus is formed from the epithelial cells of the pharyngeal entoderm by a process of direct metamorphosis of one cell into the other.

I have gone over the literature of the thymus because the embryology of this organ has been worked out much more ex-

tensively than that of any other lymphatic tissue which is in close relation with the epithelium. The histogenesis of the lymphatic tissue of the gastrointestinal tract, including the Peyer's patches, the solitary follicles and the adenoid tissue of the appendix, has not received a great deal of attention. Retterer believed that the adenoid tissue of the intestinal tract developed from the epithelium in a manner similar to that which is described as taking place in the tonsil. Kollman and Stohr attacked his theory and the whole question is still in a very debatable state.

In 1904, as the result of a histologic study of the faucial tonsils, I published the statement that it seemed very probable that the epithelial cells of the tonsillar crypts were in part converted into lymphocytes. The following facts lead me to this belief: The cryptal epithelium is peculiar in that it shows a marked tendency to invade the parenchyma of the tonsil. The deeper ends of the crypts are split up into numerous prolongations which penetrate the parenchyma of the tonsil in all directions. Some of these branches are simply solid sprouts of epithelium, while others contain a horny cure, which later may be exfoliated. In that portion of the epithelium, which is in most intimate relation with the parenchyma, we find marked changes in the character of the epithelial cells. In some places there are cells exactly similar to lymphoid cells, either single or grouped, occupying spaces surrounded on all sides by true epithelial cells. Between this lymphoid cell and the epithelial cell we can trace all stages of the transition. In properly stained thin sections, occasional mitotic figures can be found in the epithelial cells. Where we find this cell metamorphosis, it will be noticed that the subepithelial connective tissue has disappeared, and the basement member has been obliterated. It is frequently impossible to determine the boundary line between the epithelial cells and the tonsillar parenchyma. The lumen of the crypts may or may not contain a few lymphoid cells, but more frequently we find there polymorphonuclear leukocytes.

The presence of the lymphoid cells in the epithelium can be explained only in two ways, either they have migrated there from the outside, or have been formed in situ as the result of

an epithelial metamorphosis. The presence of transitional stages speaks strongly against the infiltration theory and for metamorphosis. The fact of the epithelial growth, in spite of its apparent disintegration, is likewise against the theory of infiltration, and may readily be accounted for if we believe that certain of the epithelial cells are being converted into some other form, as then it would be necessary for growth in order that the epithelium may exist. The fact that the lumen is comparatively free from lymphocytes, while the entire epithelium is infiltrated with them, is strongly opposed to the theory that the lymphocytes are migrating from the tonsillar parenchyma into the crypts. Polymorphonuclear cells are more frequently seen in the cryptal lumens, yet are comparatively rare in the cryptal epithelium. In that part of the parenchyma of the tonsil most closely related to the epithelium, we are very apt to find greater or less variations in the form of the lymphocytes. This fact would seem to indicate that some of the transitional forms are separating from the epithelium before being fully developed into lymphocytes, and, of course, cannot be explained by the infiltrative theory.

This theory of the transformation of the epithelial cells of the tonsillar crypts into lymphocytes has met with much opposition, and it appeared to me so apparent that for the last few years I have endeavored to obtain further evidence by an embryologic study.

Those who have worked on the histogenesis of the tonsil nearly all agree that at first there is an invagination of a solid sprout of epithelium which penetrates into the mesoderm before there is any lymphoid deposit. The authors disagree, however, as to the origin of the lymphoid cells which accumulate around these epithelial sprouts.

Gulland says that the ingrowing epithelium is sufficiently irritating to cause the out wandering of leukocytes from the blood vessels in the immediate neighborhood, and that this diapedesis is probably helped by pressure from the ingrowth causing a certain amount of mechanical obstruction.

Stohr also believes that the lymphocytes of the adenoid tissue comes originally from the blood vessels, and also that this out



wandering from leukocytes of the blood vessels continues even after the formation of the germinating follicles.

Retterer's idea of the development of an angio-thelial tissue is rather interesting. He says that a portion of the epithelial ingrowth has become separated and that the germinating follicles are formed from this tissue. In a publication in 1900, while still insisting upon this theory, he recognizes, however, that the small cells found in the basal portion of the cryptal epithelium are formed from the superficial epithelial cells. He says that in these superficial cells numerous mitotic figures can be found and that the small lymphoid-like cells are the result of the division of the epithelial cells.

Kollman believes that not only the lymphocytes of the tonsil, but also the entire intestinal tract are mesodermic in character, and that it is impossible that they should be derived from epithelium. As far as the tonsil is concerned, he says that the subepithelial connective tissue can be found surrounding every portion of the cryptal epithelium.

Hammar has probably done the most thorough work in connection with development of the tonsils. He says that shortly after the epithelial sprouts have pushed into the mesoderm, cells closely resembling leukocytes begin to accumulate around them. He believes, however, that these cells result from a proliferation of the fixed connective tissue cells, and he is very positive that they do not come from the blood vessels. He calls attention to the peculiar infiltrative appearance of the epithelial sprouts, and has noticed the disappearance of the boundary line between the epithelium and the lymphoid tissue.

There is so much disagreement among these authors that little positive knowledge can be gained from their publications except that from the very earliest an epithelial ingrowth seems to play a very important part in the development of the tonsil.

On account of the large size of the tonsil in the hog, and the fact that embryos of this animal can be readily obtained at any slaughter house, the work which I have done myself has been limited to this animal. The tonsil of the hog is situated along the buccal surface of the soft palate and developed in two lateral portions. The tonsil is flat, does not project much beyond the



surface, and the crypts are simple invaginations with lateral prolongations. The histology of the adult tonsil resembles that of the human lingual tonsil very closely.

In the preparation of the tissue for examination, Zenker's solution was used for fixing, and paraffin for embedding. In the majority of instances long ribbons of serial sections were cut, though they were not all mounted. The methods of staining employed were hematoxylin and eosin, iron hematoxylin, Loeffler's methyl blue and eosin, and thionin and eosin. For the study of the form of the nucleus, its staining ability and the amount of cytoplasm, I found that the thionin preparations were far better than any others. Next to this was methyl blue, the iron hematoxylin preparations, and lastly hematoxylin with eosin. Hematoxylin preparations were not satisfactory for the study of the nuclei because of the even staining and lack of differentiation between the various types.

It was somewhat difficult at first to find in what size embryo the tonsil showed its beginning. I began with embryos 18 millimeters in length and worked upward. In the smaller embryos sections were made through the entire head, but it was found that before the tonsil was at all apparent, marked bone formation had taken place and the tonsillar region had to be removed and examined by itself.

#### DESCRIPTION OF THE ANATOMICAL FINDINGS IN PIG EMBRYOS.

The first sign of tonsillar formation in the pig occurs in embryos with the parieto-coccygeal length of fifteen centimeters. The degree of development of the tonsil differs somewhat in the different pigs of the same litter. In embryos twenty-two centimeters long the crypts and the tonsillar tissue in their immediate neighborhood are fairly well developed, but there are still no signs of the germinating follicles. Between these two stages we can trace the development and accumulation of lymphoid tissue around the epithelial anlage, as it was only the origin of these early lymphoid cells that I was studying, and I did not carry my investigations further than the twenty-two centimeter embryo.

Fifteen centimeter embryos.—The epithelial covering of the roof of the mouth and the soft palate at this stage is four to five cells in thickness, the peripheral cells being slightly flattened in shape, and the basal cells cuboidal, or slightly cylindrical. The nuclei of the peripheral cells are centrally placed, round or slightly oval in shape and stain very lightly. The

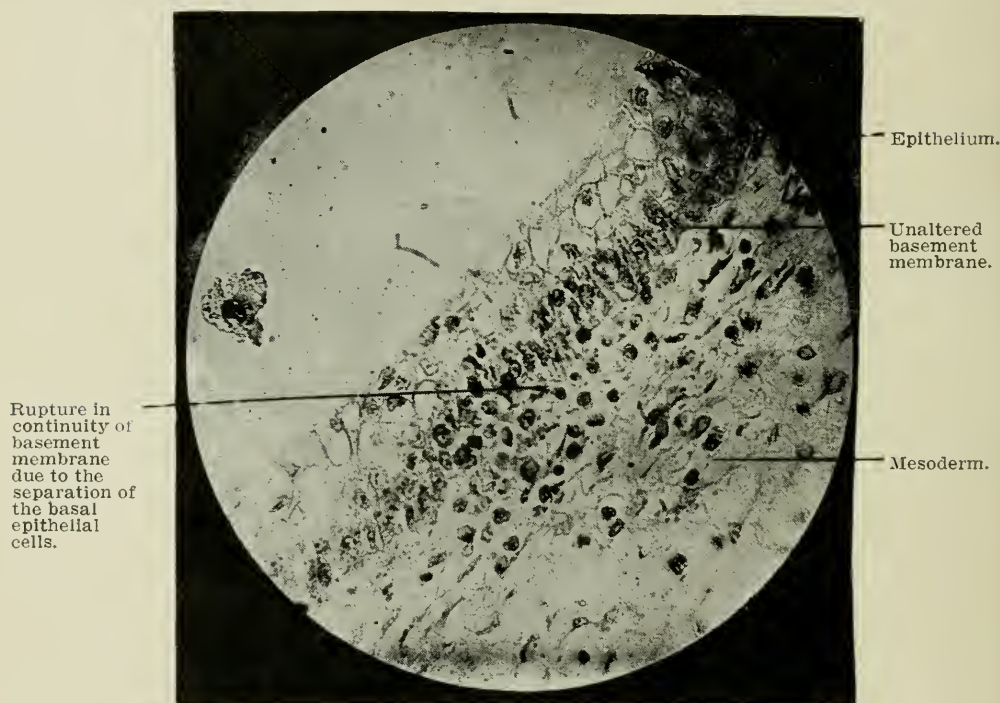


Fig. 1.

The earliest sign of the tonsil formation in a pig embryo 15 cm. in length.

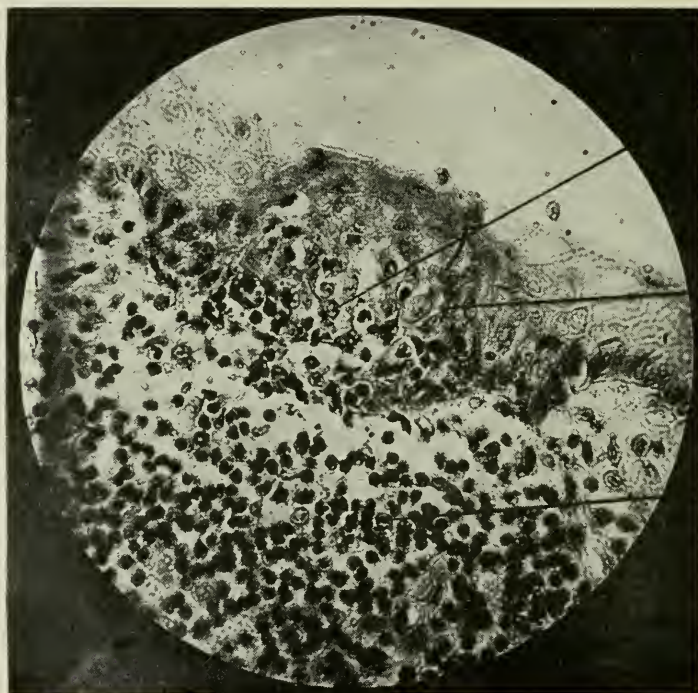
nuclei of the basal cells are more oval and stain more deeply, and are placed, as a rule, in the basal portion of the cell. There is a distinct basement membrane separating the epithelium from the mesoderm. There are a very few cells in the mesoderm, either stellate or fusiform in shape, while some of them possess long filaments. Capillary blood vessels may be seen and generally contain a few polymorphonuclear leucocytes.

In that portion of the soft palate, which later is transformed into the tonsil, there are at certain spots along the basal epithelium accumulations of a few polymorphonuclear cells, and also a few cells with large pale nuclei which are round or slightly oval in shape. At this point the basal membrane of the epithelium is broken, and the epithelial cells themselves are irregularly placed, some of them apparently protruding through the rupture in the basal membrane. This is the first indication of the location of a future tonsillar crypt. It has been impossible so far to determine with absolute certainty whether the change in the epithelium takes place first, or whether this is preceded by the coming together of a few polymorphonuclear cells just where the break in the epithelium is to occur. In some places it is possible to detect accumulations of cells without visible change in the epithelium, but serial sections would undoubtedly show the presence of some epithelial change in the immediate neighborhood. The cells accumulate around and on all sides of the epithelial break so that it would be impossible to obtain a section through the epithelial anlage without cutting through the zone of accumulated cells, while a section through the edge of the focus of accumulated cells would not necessarily touch the part of the epithelium which has undergone a change. On the other hand I have found slight thickening of the basal portion of the epithelium without rupture of the basement membrane and unaccompanied by the cell accumulation. This concentration, or thickening of the epithelium is not sufficient, however, to enable one to definitely state that at this point an anlage of the tonsil was beginning, though such seems very likely.

In other words, it seems probably that the beginning anlage of the tonsil is first manifest by a localized thickening of the epithelium lining the roof of the mouth, and is almost immediately followed by rupture of the basement membrane and by the accumulation of polymorphonuclear leucocytes, and also of cells resembling lymphocytes. (See Fig. 1.)

Fifteen and a half centimeter embryos. A distinct advance in the development of the tonsil can be seen. The epithelium shows numerous points of thickening and at some places slight invaginations. There are definite accumulations of polymorphonuclear

leucocytes mixed with cells resembling lymphocytes. The origin of the polymorphonuclear leucocytes is rather hard to explain, but it seems probable that they are chiefly derived by migration from the capillaries in the neighborhood of the tonsillar anlage. The capillaries contain fairly large numbers of these cells and they appear more numerous in the zone immediately surrounding



Cell showing transition between epithelial cell and lymphocyte losing its cytoplasm.

Epithelial anlage.

Surrounding zone of lymphocytes and polymorphonuclear leucocytes.

Fig. 2.

Epithelial anlage of a tonsil of a pig embryo, 15½ cm. in length, before definite crypt formation has taken place.

the capillary than in other portions of the mesoderm, except at the tonsillar anlage. On the other hand, occasionally polymorphonuclear cells can be found in between the cells of the epithelial anlage. Their presence in the anlage could easily be accounted for by migration, except that transitional stages between the epithelial cell and the polymorphonuclear can at times be dis-



tinctly made out. The transitional cells in embryos of this size are not so numerous or so distinct in their character as in the later stages or in the adult tonsil. The origin of the lymphoid cells which are found around the tonsillar anlage can be easily traced to the epithelium. The basement membrane of the epithelium is in places entirely destroyed, and some of the epi-

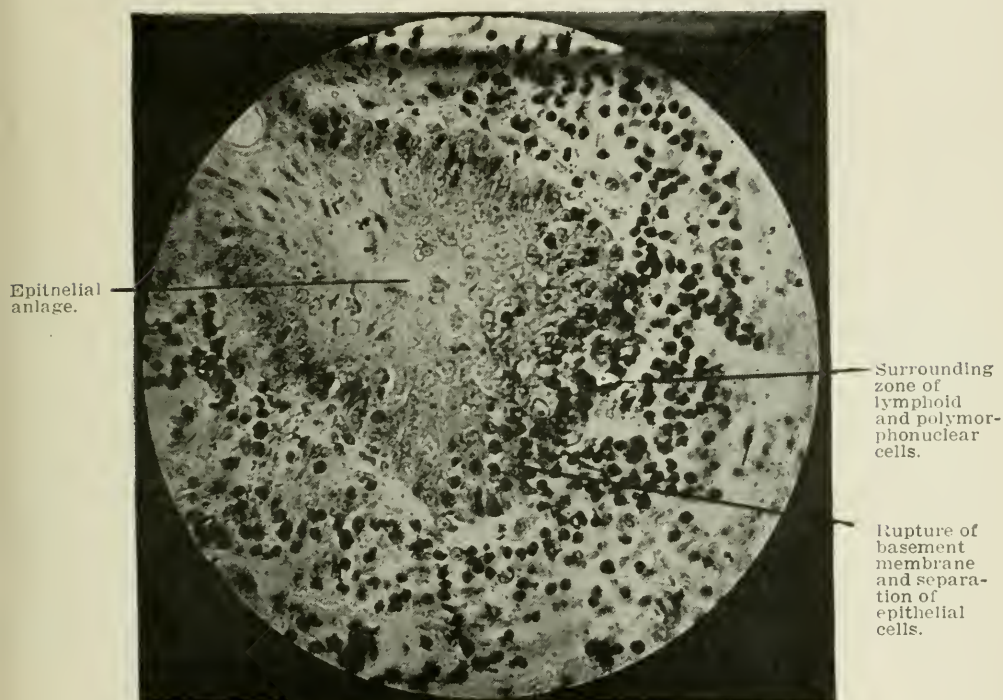


Fig. 3.

Epithelial anlage from a pig embryo 18 cm. in length.

thelial cells can be seen separating from each other, the nuclei becoming rounded, losing their oval shape, and surrounded by only a very small amount of protoplasm.

Less numerous are cells with elongated, pale nuclei and possessing prolongations of protoplasm. These latter cells are evidently fibroblasts and develop from the mesodermic elements. A cross section of one of these cells would give us a picture very

like that of a lymphocyte, and I believe this accounts for the presence of a few scattered cells closely resembling lymphocytes not in the immediate neighborhood of the tonsillar anlage.

Eighteen centimeter embryo. There is distinct crypt formation and beginning branching. The cellular elements have all increased in quantity, and we see more clearly the epithelial morphosis.

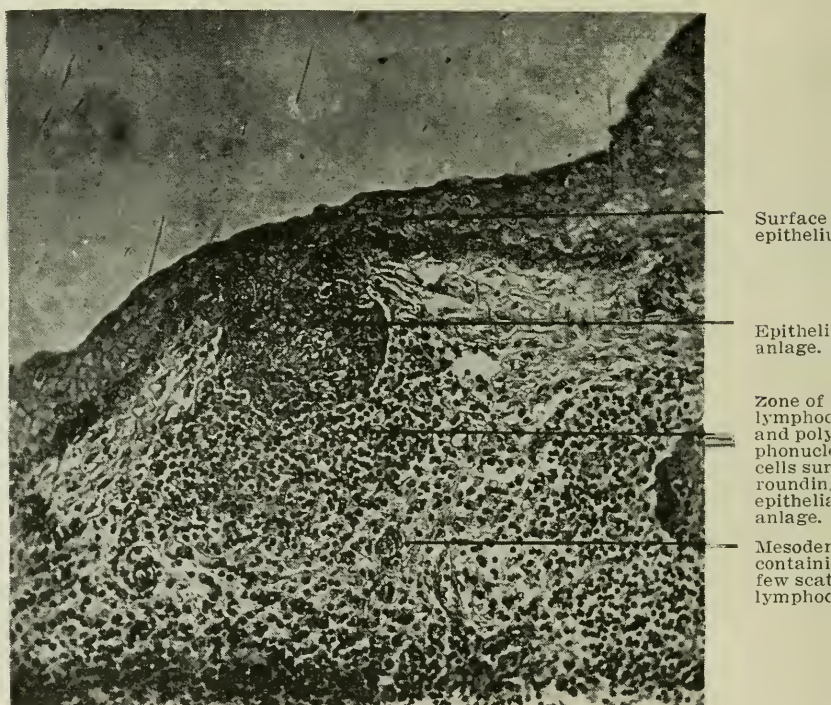


Fig. 4.

Tonsil of a pig embryo 18½ cm. in length.

Eighteen and a half centimeter embryos. The crypts are larger, deeper and the branching slightly more pronounced. In the anterior portion of the tonsillar region beginning crypts can still be found, and at some places there is apparent thickening of the epithelium without any special accumulation of the lymphoid



cells in the immediate neighborhood. This condition is very similar to that described in the 15 centimeter embryos.

Where the crypts are larger, we find that at the end of the epithelial invagination, the epithelial metamorphosis is, in some places, very marked and in other portions very slight, or even absent. It is apparent now that the whole epithelium of the crypt does not at the same time show this peculiar degeneration. In

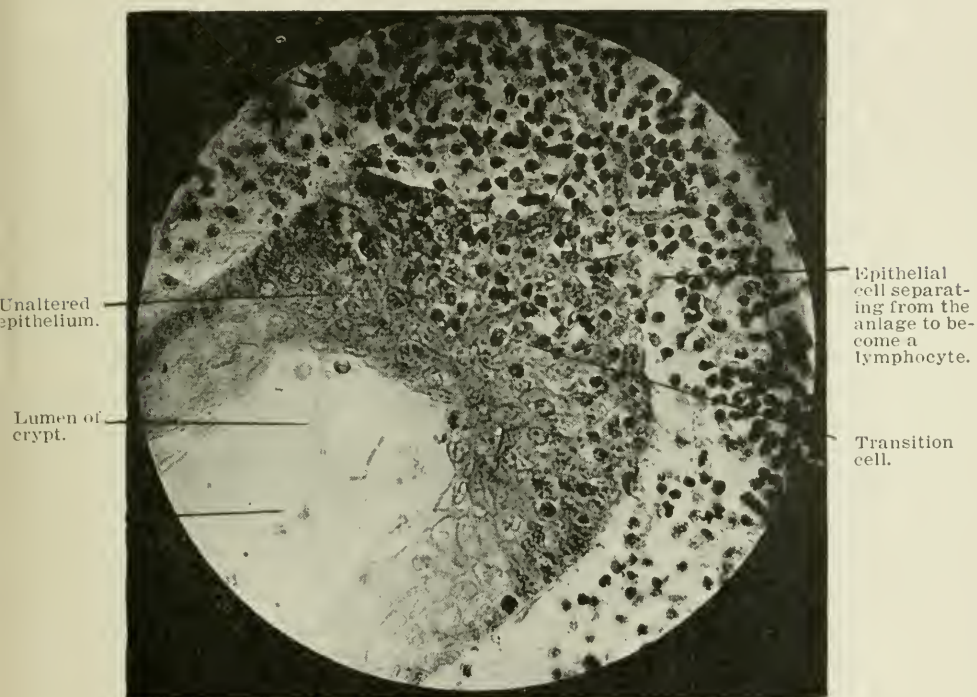


Fig. 5.

The mesodermal end of a crypt of a tonsil from a pig embryo 19½ cm. in length.

some portions there is absolutely no boundary line between the epithelium and the surrounding accumulation of round cells, and various transition stages can be seen, while in other places the epithelium remains practically unchanged. The branches from the main crypt show much more of the metamorphosis than the main crypt itself. The lymphoid cells which have developed in

the epithelium are generally surrounded by a small, clear space. The lumen of the crypt is perfectly free, containing no cells of any description except perhaps a few desquamated squamous epithelial cells. In some places there is evidently beginning hornification of the superficial cells in the interior of the crypt. In the mesoderm surrounding the epithelial invagination we find the usual accumulation of cells, but the lymphoid cells are now almost as numerous as the polymorphonuclear. Between the crypts there has apparently developed an area of tonsillar parenchyma, in which can be seen an increase in the connective tissue element and a deposition of lymphoid cells. It is not, however, so concentrated an area as far as lymphocytes are concerned as that in the immediate neighborhood of the crypt. In this area a very few mitotic figures can be seen, but I am uncertain as to the origin of the dividing cells.

Nineteen and a half centimeter embryos. The epithelial anlage has penetrated still more deeply into the mesoderm and the lateral epithelial prolongations are more marked. Just as in the 18½ centimeter embryos, the mesenchymal edge of the cryptal epithelium shows numerous places of rupture where the basement membrane is entirely wanting, and some of the epithelial cells can be seen undergoing separation from the rest of the anlage. The nuclei of the separating cells are generally oval, pale, and surrounded by little or no cytoplasm. Some of the nuclei, however, are darker, resembling more clearly lymphocytes. Where this breaking of the epithelium has occurred we may find a few polymorphonuclear leucocytes, and also cells which look like transitions between the dark staining polymorphonuclear cell and the pale epithelial nucleus. Surrounding the epithelial anlage we find the usual zone of cells, with the lymphoid element gradually gaining in preponderance.

In this embryo the epithelial origin of the lymphoid cells is still more apparent than in the younger ones. The transitional stages are more easily seen, and the characters of the different types of cells are more marked.

Twenty-two centimeter embryos. The whole tonsillar region has become more distinctly outlined and there is still more differentiation in the cell characters. The crypts are somewhat more

extended and the accumulation of adenoid tissue a little greater, otherwise the tonsil resembles very closely that of the 19½ centimeter embryo.

### *Summary.*

To summarize briefly the results of this study we note:

First, that in the adult tonsil there are certain phenomena which are very suggestive of the idea that the epithelial cells of the crypts undergo a metamorphosis, the result of which is the formation of cells morphologically similar to lymphoid cells.

Second, that in the embryo, the very earliest stages show a peculiar activity of the epithelium characterized by the separation of the basal epithelial cells, rupture of the basement membrane, and the presence, in the epithelium and in the neighborhood around this epithelial centre, of cells morphologically similar to lymphocytes.

Third, that the increased growth of this epithelial anlage is attended by the deposition in its immediate neighborhood of more lymphoid cells.

Fourth, that transition cells between the typical epithelial cell and the lymphoid cell may be found not only in the epithelium, but also in its immediate neighborhood. These transition cells are more easily studied and are in greater number in the later stages than in the very beginning.

Fifth, that the polymorphonuclear cells are comparatively more abundant in the early stages than later.

The appearance of polymorphonuclear cells in the early stages of the tonsil is difficult to explain. The presence of these cells in the neighboring blood vessels and in the tissues immediately surrounding the blood vessels would seem to indicate that they are derived from the circulation. On the other hand, the undoubted presence of transition types in the epithelium in the very early stages would seem to show that they have a common origin with the lymphocytes. That they gradually disappear as the tonsil develops would lead one to suppose that they are not an essential part of the adult tonsil. It may be that the early change in the epithelium acts as a chemotactic power, attracting the polymor-

phonuclear cells. It might be argued that these polymorphonuclear cells, coming from the blood, give rise to the lymphoid element, were it not for the peculiar metamorphosis of the cryptal epithelium. The origin and function of the polymorphonuclear leucocytes in the early tonsillar anlage needs much more study, but the fact of their presence does not, to my mind, in any way interfere with the theory of the epithelial origin of lymphocytes.

It seems practically proven, therefore, that some of the cells of the epithelium of the tonsillar crypt undergo a metamorphosis, being converted into cells which are indistinguishable from lymphocytes. We must also remember that, revolutionary as it may seem, the idea of an epithelial origin of lymphocytes is not a new one: that the work which has been done on the embryology of the thymus gland shows conclusively that the lymph tissue of the thymus is formed from the epithelium of the pharyngeal endoderm. Also, there is good reason to believe that the adenoid tissue throughout the gastro-intestinal tract results largely from an epithelial metamorphosis. Further, we must not be too positive in our acceptance of the doctrine that epithelium breeds only epithelium, that connective tissue breeds only connective tissue, and that endothelium breeds only endothelium. In 1901, His, Woedain and Dekhuisen all agreed that perhaps after all an interchange between the tissue types might under certain circumstances be possible. Krompecher, in 1905, after an elaborate study not only of a large number of embryologic and pathologic specimens, but also of a thorough review of the bibliography, stated that it is possible, under certain circumstances, for the epithelium to be converted into connective tissue, and that transitional stages can be positively shown to be present in certain forms of tumors, and in certain stages of embryonic life.

#### *Bibliography.*

- J. Beard. The Development and Probable Function of the Thymus. *Anat. Anz.*, Bd. ix., 1894.
- J. Beard. The True Function of the Thymus. *Lancet*, 1899.
- J. Beard. Concerning Leukocytes and the True Function of the Thymus. *Anatomischer Anzeiger*, 1900, vol. xix., p. 6.
- E. T. Bell. The Development of the Thymus. *Amer. Journ. of Anat.*, v., 1905-6.

- R. J. A. Berry and L. A. H. Lack. The Vermiform Appendix in Man and the Structural Changes therein coincident with Age. *Journ. of Anat. and Physiol.*, London, 1905-6, vol. xl., p. 247-256.
- T. H. Bryce. Note on the Development of the Thymus Gland in *Lepidosiren Paradoxa*. *Journ. of Anat. and Physiol.*, London, 1905-6, vol. xl., p. 91.
- Capobianco. Contribution a la Morphol du Thymus. *Arch. Ital. de Biol.*, vol. xvii., 1892.
- Deckhuisen. Discussion of W. His. 1901.
- Dohrn. Studien zur Urgeschichte des Wirbeltierkörpers. V. Mitteilungen aus d. Zool. Station in Neapel. Bd. 5, 1884.
- G. Lovell Gulland. The Development of Adenoid Tissue with Special Reference to the Tonsils and Thymus. Lab. Reports issued by the Royal College of Physicians, Edinburgh, 1891.
- J. A. Hammar. Zur Histogenese und Involution der Thymusdrüse. *Anatomischer Anzeiger*, Bd. 27, vol. xxvii., 1905, p. 23-30, p. 41-89.
- J. A. Hammar. Ueber die Natur der Kleinen Thymuszellen. *Archiv. für Anat. und Physiologie. Anatomische Abteilung*, 1907, p. 83-100.
- Herman et Toureux. Article Thymus, *Dict. Encycl. des Sciences Medicales Troisieme Serie*, p. 17, 1887.
- W. His. Beiträge zur Kenntnis der zum Lymphsystem Gehörigen Drüsen. *Zeitschr. f. Wissensch Zool.*, Bd. 10, u. 11, 1861-2.
- W. His. Anatomie Menschlicher Embryonen. Leipzig, 1880. S. 56.
- W. His. Ueber Syncytien, Epithelien und Endothelium. *Verh. Ges. Deutsch. Nat. Aerzte* 72. Vers. th. 2 Hälfte. 2p., 1901, p. 273-276.
- Koelliker. Koelliker Entwicklungsgeschichte. 2. Aufl. Leipzig, 1879.
- J. Kollman. Die Entwicklung der Lymphknochen in dem Blinddarm und in dem Processus Vermiformis. Die Entwicklung der Tonsillen und die Entwicklung der Milz. *Archiv. für Anatomie und Physiologie*, Jahrgang, 1900, p. 155.
- E. Krompecher. Über Verbindungen Übergänge und Umwandlungen Zwischen Epithel. Endothel und Bindegewebe bei Embryonen Niederen Wirbeltieren und Geschwulsten. *Beitr. z. Path. Anat. u. z. Allg. Path.*, Jena, 1904-5, vol. xxxvii., p. 28-134.
- Marcel Labbe et Ch. Levi-Sirugue. Recherches sur la Structure des Amygdales. *Soc. Anatom. de Paris*, Juli. 1899, p. 685.



- Maurer. Schilddrüse und Thymus der Teleostier. *Morph. Jahrb.*, Bd. II., 1885.
- Maurer. Schilddrüse, Thymus und Kiemenreste bei Urodelen und Anuren. *Ibidem.*, Bd. 13, 1887.
- Maurer. Die Derivate der Schlundspalten bei Eidechse. *Verhandl. Anat. Gesellsch.*, Bd. 12, Versamml. Kiel, 1898.
- Maurer. Die Schilddrüse, Thymus und Andere Schlundspaltenderivate bei der Eidechse. *Morphol. Jahrb.*, Bd. 27, 1899.
- Maurer. 1899, 2. Die Schlundspaltenderivate von Echidna. *Verhandl. Anat. Gesellsch. Tübingen.*
- Maurer. 1899, 3. Schilddrüse, Thymus und Sonstige Schlundspaltenderivate bei Echidna und ihre Beziehungen zu den Gleichen Organen bei Anderen Wirbeltieren. *Semons Forschungsreisen*, Bd. 3.
- Maurer. Die Entwicklung des Darmsystems. *Hertwigs Handb. d. vergl. u. exper. Entwicklungsgesch.*, Bd. 2, 1902.
- J. Nusbaum and J. Machowski. Die Bildung der Concn. Trischen Körperchen und die Phagocytotischen Vorgänge bei der Involution der Amphibienthymus Nebst Einige Bemerkung über die Kiemenreste und Epithelkörper der Amphibien. *Anatomischer Anzeiger*, 1902, Bd. xxi., p. 110.
- J. Nusbaum and T. Prymak. Zur Entwicklungsgeschichte der Lymphoiden Elemente der Thymus bei den Knochenfischen. *Anat. Anz.*, Bd., vol. xix., 1901.
- Prenant. *Développement Organique et Histologique du Thymus, de la Glande Thyroïde, et de la Glande Carotidienne. La Cellule*, Tome x., 1894.
- Teodor Prymak. Beiträge zur Kenntnis des feineren Baues der Involution der Thymusdrüse bei den Teleostiern. *Anatomischer Anzeiger Centralblatt für die Gesamte Wissenschaftliche Anatomie*. Bd., vol. xxi., 1902, p. 164-179.
- M. E. Retterer. *Evolution de L'Amygdale du Chien*. XIII. *Congres de Medicine*. Paris, 1900. *Anat. and Phys.*, p. 96-112.
- Florence R. Sabin. The Development of the Lymphatic Nodes in the Pig and Their Relation to the Lymph Hearts. *Amer. Journ. of Anat.*, vol. iv., No. 3, 1905, p. 386.
- Schultze. *Grundrisse der Entwicklungsgeschichte*, 1887. Leipzig.
- Stieda. Untersuchungen über die Entwicklung der Glandula Thymus, Gland. Thyreoidea und Gland. Carotica. Leipzig, Englemann, 1881.
- Philip Stohr. Ueber Mandeln und Balgdrüsen. *Virchow's Archiv.* 97, 1884.



- Philip Stohr. Die Entwicklung des Adenoiden Zellgewebes, der Zungenbalge und der Mandeln des Menschen. Festschr. z. Feier d. Karl. Wilhelm v. Nageli und Albert v. Koliker, etc., Zurich bei C. Meyer, 1891, 19-36, 1 pl.
- Philip Stohr. Ueber die Entwicklung der Darmlymph Knotchen und uber die Buckleidung von Darmdrusen. Archiv. fur Mikroskopische Anatomie, 1898, Bd., vol. li., p. 1-54.
- Philip Stohr. Ueber die Thymus. Sitzung-Berichte d. Physik-Med. Gesellschaft z. Wurzburg, 1903-5.
- Ver Eecke. Structure et Modifications Fonctionnelles du Thymus de la Grenouille. Bulletin de l'Academie Royale de Medicine de Belgique, 1899.
- F. Weidenreich. Ueber Speichelkorperchen; ein Uebergang von Lymphozyten in Neutrophile Leukozyten. Folia Haematol.; Leipzig, 1908, v., p. 1-7.
- Woedain. Discussion of W. His. 1901.

## THE TONSIL OF THE INFANT, THE CHILD AND THE ADULT.

BY HARRY A. BARNES, M.D.

*(By Invitation.)*

The lantern slides which I have to show were prepared for the purpose of demonstrating the differences in the histological struc-

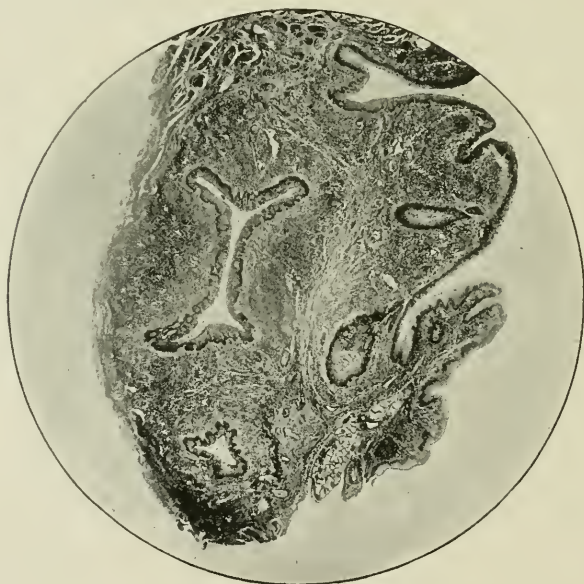

Fig. 1.

Cross-section of human tonsil, age six months; lymphoid tissue inactive; only slight suggestions of follicles may be seen near the crypts; cryptic epithelium intact; crypts on right of figure still in formative state.

ture of the tonsil at different ages, and the bearing that these differences have on the question of infection. (Fig. 1.)

From the histological standpoint, three types of tonsils may be distinguished, viz., those of the infant, of the child, and of the

adult, according to the activity of their lymphoid elements, and, secondarily, to the changes in the crypts and their epithelial lining brought about by this activity. As the tonsil is in many cases a scant respecter of chronology, we do not always find it falling into its proper group, according to age. Many tonsils of the adult have all the characteristics of the tonsil of childhood, and often the infant tonsil shows a lymphoid development which places it in the childhood group. The histological structure of

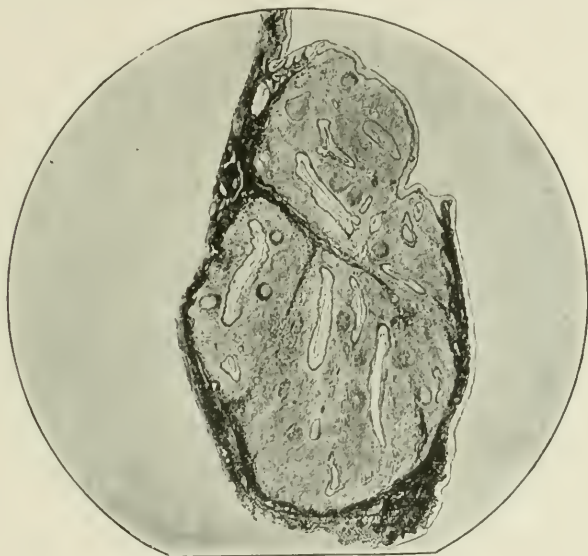


Fig. 2.

Cross-section of human tonsil; age eleven months; lymphoid tissue beginning to be active; numerous follicles are present; cryptic epithelium for the most part intact; in the lower right quadrant the lymphoid tissue is invading the epithelium of the crypts.

the average tonsil, however, corresponds to the age of the individual.

If we examine the tonsil of the infant at birth we find that it has very little lymphoid tissue. No follicles are present, consequently there are no germinal centres; the lymphoid tissue may be said to be inactive. The epithelium of the crypts is essentially like that of the surface, except that at this age many of the

crypts are still in the formative stage and show either as solid epithelial buds or as buds in which the central cells have formed a core which is ready to be expelled. Very few lymphocytes are passing through the epithelium into the cavity of the crypts. Partly owing to this and partly because the walls of the crypts are not pressed tightly together by rapidly growing lymphoid tissue, accumulation of cellular debris in the crypt is slight. Therefore bacterial growth within the crypts is probably not excessive. Conditions in such a tonsil are not favorable to infec-

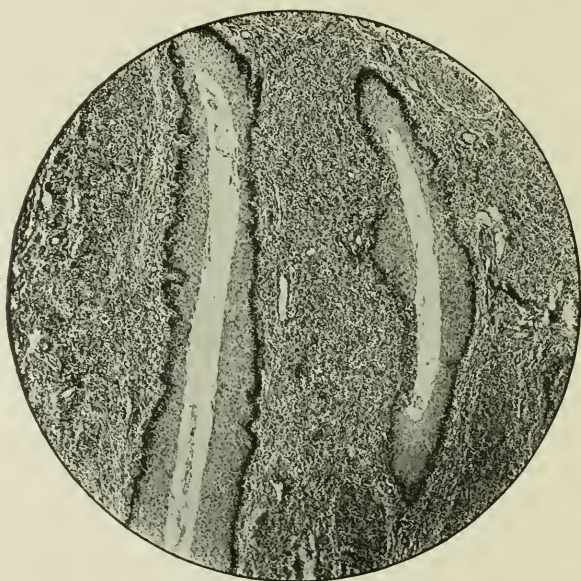

Fig. 3.

Field from right lower quadrant of Fig. 2 under high power; shows the disintegration of the cryptic epithelium by the invasion of lymphocytes.

tion, and although those changes which render infection more probable begin between the fourth and sixth months of infancy, they have, nevertheless, not attained a sufficient degree to have any marked influence in this regard until well into the second year. (Fig. 2.)

Between the fourth and sixth months of infancy the follicles with their germinal centres first begin to show distinctly, and with



their appearance the lymphoid tissue becomes very active. Large numbers of lymphocytes are produced which invade the epithelium of the crypts, disintegrate its lower layers, so that they appear as ragged strands of epithelium extending from the surface of the crypt into the lymphoid tissue below. Only a very thin film of intact epithelium is left lining the cryptic cavity. This disintegration of cryptic epithelium is probably produced, not by any inherent power of motion of the lymphocytes, but

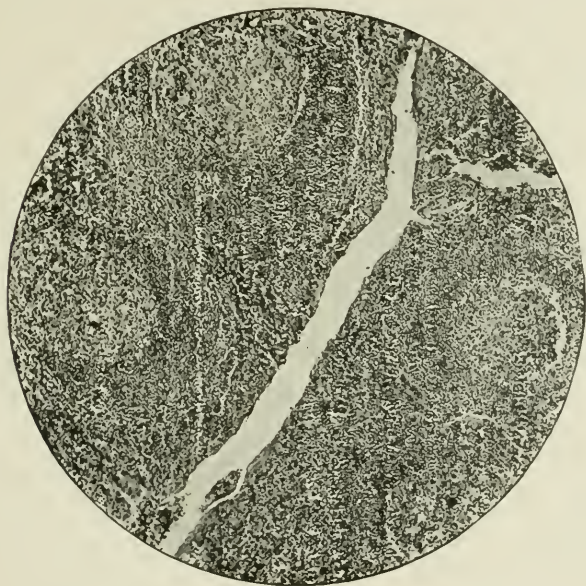

Fig. 4.

Typical section from tonsil of childhood; lymphoid tissue very active; numerous follicles with highly developed germinal centers; cryptic epithelium reduced to a thin film.

purely by the pressure of numbers. The surface epithelium does not suffer, as it is able to expand outwards. (Fig. 3.) This pressure brings about another important change in the crypt; viz., their walls are pressed tightly together so that drainage becomes obstructed and the large number of lymphocytes that are by this time passing through the epithelium into the cavity of the crypts are retained there and form the cheesy masses so com-

monly found in the tonsils of childhood. (Fig. 4.) After the first year and a half of life, therefore, we find conditions very favorable to infection—poorly draining crypts containing decomposing masses of cellular debris, which are perfect hotbeds for the cultivation of bacteria, and a cryptic epithelium which, from a mechanical standpoint, can make but a feeble defence should the other resisting powers of the individual be lowered. (Fig. 5.)

At about puberty the lymphoid tissues of the body begin to

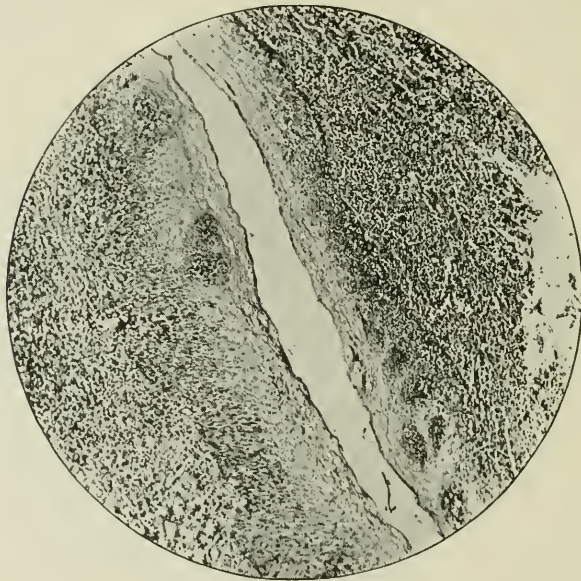


Fig. 5.

Typical field from regressive tonsil of the adult; lymphoid tissue inactive; cryptic epithelium fairly uniformly thick.

show a diminution in activity, and the tonsil shares in this retrogressive change. Its lymphoid follicles become less numerous and less active, the whole organ becomes smaller, pressure on the crypts is lessened, with the result that drainage is freer; the lymphoid cells recede from the epithelium of the crypts, its fragments fall together and a more or less general thickening takes place. It is almost never uniform, however, and in places often does not occur at all. But the average unhyertrophied tonsil



of the adult has a cryptic epithelium which nearly approaches the infantile or surface type. From the standpoint of the question of infection, the conditions here are not unlike those in the infant tonsil, except that pockets or dilatations of the crypts occurring in childhood may persist and give rise to trouble.

*Discussion on the Papers of Drs. Wood and Barnes.*

Dr. Leonard W. Williams (*by invitation*): Everyone must agree with Dr. Wood that the literature upon the origin of the lymphocytes is apparently only a mass of contradictory statements. A thorough embryological and histological study of the subject is greatly needed. A small beginning has actually been made, for we now know something of the origin of the lymphatic vessels and lymph glands in man, the pig and the rabbit. The lymphatic vessels are primarily outgrowths from the veins. They begin to form in human and rabbit embryos of about ten millimetres, and in pig embryos of twelve millimetres. As Dr. Wood has said, they do not contain either lymphocytes or red blood cells, and the lymph vessels are well formed before lymphocytes and lymphoid tissue appear.

Lymphoid tissue has been shown by Dr. Sabin to arise first in the tissue around the deep cervical lymph vessels of pig embryos of thirty-four millimetres. Dr. Lewis, in a paper in press, describes the earliest lymph glands in man and the rabbit. They arise on large superficial lymph vessels and the first lymphoid tissue appears in the mesenchyma lying around and between the large lymph and blood vessels. There is apparently a direct transformation of mesenchyma into lymphoid tissue, for there is a series of transitional cells which are apparently being converted into lymphocytes. There is not the slightest indication that the lymphoid tissue of the earliest lymph glands arises from epithelium. It is reasonable, therefore, to assume that lymphoid tissue arises from mesenchyma.

Lymphoid tissue exists in the embryo long before it appears in the tonsil, for in the pig it appears in the lymph glands before the embryo is forty millimetres long, whereas Dr. Wood finds it present in the tonsil only in embryos of 150 millimetres. It is not known, I believe, when the lymphocytes first appear in the blood and lymph vessels and we have no proof that they migrate from the blood vessels into the tonsil or that they arise, as has been asserted, from the connective tissue of the tonsil.

The two facts, namely, that lymphoid tissue almost certainly arises in the first instance from mesenchyma and that it appears

in the lymph glands much earlier than in the tonsil, make it probable that the lymphocytes of the tonsil either arise in it as in the lymph glands or migrate into it.

The evidence upon which Dr. Wood bases his belief that the lymphocytes of the tonsil, or certain of them, arise from the epithelium of the crypts is, it seems to me, insufficient, for, until we know the relation of the various types of lymphocytes to one another and to connective tissue, it is unsafe to base a far-reaching conclusion on the slender premise of the similarity between certain epithelial cells and lymphocytes. One cannot affirm that Dr. Wood's conception is right or wrong, but we are justified in asking for a much more extensive study of the origin and structure of lymphoid tissue and lymphocytes.

Dr. J. L. Goodale: I want to express my own thanks to Dr. Wood and to Dr. Barnes for their presentations, which represent a great deal of laborious work. The discussion of the paper was so admirably done by the last speaker that I have nothing to add, but I should like very much to talk later with Dr. Wood on this subject.

Dr. H. L. Swain: I did some of the work in Germany in the time that Dr. Stohr was working up his earlier observations on the migration of white cells, which were at that time all called leukocytes, with none of the sharp distinctions which now are made. We supposed this destruction of epithelium, which apparently takes place, was a real destruction, that there was an absolute erosion of which these specimens shown us by Dr. Barnes would practically be typical. Now, Dr. Wood would have us believe that this thinning out of the epithelium is more or less due to the active processes which the epithelial cells are undergoing in producing lymphocytes. That is an altogether novel view. But we have heard the experienced embryologist say to-day that he is not prepared to accept it. I believe that the tonsil is an active part of the lymphoid structure of the body, that it is in every sense of the word a lymph node, with just as much importance (and no more) in the economy than any other lymph node, except that it is a direct absorbent and recipient from all the matters coming into our mouths.

With the wide variation in viewpoint of Dr. Shurly and Dr. Casselberry with regard to the total removal of the tonsils, it is hard to tell where those of the coming generation who may read this discussion will place their ideas. What shall guide them in action? We are essentially kindergarten in our method of receiving ideas, accepting most easily those which are adroitly pictured to us. We do not stop to think that the tonsillar tissue was placed in the throats of our victims with a distinct purpose, and

that it is in fulfilling this physiological purpose in the normal body that it becomes larger than it ought to be. Just because we have a child under ether and are taking out an adenoid which is obstructive, I do not think we should always do a tonsillectomy any more than the surgeon who is working in the abdominal cavity is justified in taking out every appendix. I think that when the tonsil operation is so much to the forefront as it is at present, it is wise to seriously consider such statements as those made by so keen an observer as Dr. Shurly. Perhaps we might look upon the situation as does the surgeon in regard to lymph nodes of the neck—who does not remove them just because they are large, but only when he believes them to be tubercular. We might go a step further and say that tonsillectomy, which should be looked upon, as it is, as a major and serious operation, should only be done when the tonsils are believed to be seriously diseased or to be producing disease of the neighboring lymph nodes. With this view, one could not be too thorough or too painstaking. When the tonsil is merely too large and our object is merely to provide more space, an ordinary tonsillectomy, after thoroughly releasing the tonsil from its pillars, should be the operation of election.

Dr. D. Braden Kyle: Unfortunately, many laboratory workers and experimenters start out too frequently to prove a theory. While this is investigating, it is not exactly scientific investigating and is apt to lead one into error. The embryonic or transition stage of any cell, epithelial or connective, is very much like a small plant—we cannot tell whether it is going to grow into a beautiful flower or simply a weed. It is equally impossible to determine whether an embryonic cell is a connective or epithelial cell. However, when it becomes an adult cell, it is easy to determine to which variety of tissue it belongs. Connective tissue is the only independent structure. The epithelial tissue is dependent always on the connective tissue. We can have the connective tissue without epithelial, but we cannot have epithelial tissue without connective tissue. This makes the epithelium the dependent structure, and it must get its nourishment from the connective tissue.

The general trend of opinion based on histological investigation certainly tends to prove that tissue never changes type, and it certainly has never been clearly demonstrated that tissue does change type, and for that reason I think that Dr. Wood's statement will have to be more definitely proven before it can be an accepted fact.

Dr. Wood: I expected to be criticized for my attitude, but I have heard nothing that would change my views that epithelium

of the tonsil crypts is changed in cells morphologically similar to lymphoid cells. It has been proven and admitted by Stohr that the lymphoid cells of the thymus do come from the epithelial cells, and Hammar has lately shown that they are lymphoid cells. I am not an embryologist or anatomist, and my work on the tonsils was at first a routine procedure, as I was more or less interested in pathology, but I could not explain the infiltration theory of the epithelium as advanced by Stohr. Suddenly it came to me, as it were, out of the dark, that there was an epithelial metamorphosis in the tonsil. Dr. Peirsol, of the University of Pennsylvania, was as strong in his belief opposed to this theory as is Dr. Williams. After he spent two hours in going over these slides he told me in so many words that he thought these specimens absolutely proved to his mind that the lymphoids came from the epithelial cells. I did not say or intend to say that the first lymphocytes are formed in the tonsils. Beard held that they first appeared in the thymus, but I believe in the last four or five years they have been found in the suprarenal gland prior to their appearance in the thymus.

REPORT OF A FATAL CASE OF STATUS LYMPHATICUS OCCURRING IN A PATIENT OPERATED ON FOR TONSILLAR HYPERTROPHY UNDER COCAINE-ADRENALIN INFILTRATION.

BY THOMAS J. HARRIS, M.D.

I desire to report briefly a fatal case of tonsillectomy. Such accidents are, unfortunately, too frequent where a general anaesthetic is employed, but so far as we can learn they are exceedingly rare where, as in the present case, only a local anaesthetic was employed. The patient was a Russian Jew, aged thirty. He presented himself in my service in the Post-Graduate Hospital, complaining of repeated sore throats. Examination revealed large tonsils of the so-called submerged variety. According to the house surgeon's notes, he was admitted to the hospital at 11 a. m., April 22, 1909. His appearance was that of a short, muscular, working man. A fluid lunch was given and at 1:15, 1-60 of sulphate of strychnine was administered by the mouth. One-half hour later the patient was sent to the operating room and had a 1-5 of 1 per cent of cocaine hydrochlorate in a normal saline solution, containing two drachms of 1-1000 adrenalin-chloride injected into the tonsils. The solution was freshly prepared before the operation. The tonsils were very cryptic and the contents of the first syringe, containing 1 1-2 drachms, entirely escaped and was expectorated. The second syringe-full was injected. Of this, at the outside, not more than thirty minims could have been retained. There was, then, in all, approximately 1-12 of a grain of cocaine retained and from eight to ten minims of 1-1000 solution of adrenalin-chloride. After the first injection the patient complained of feeling badly and vomited and had a slight convulsive seizure, presenting the appearance that we often see where cocaine has been employed locally for a nasal operation. His head was lowered for a moment and he



sat up again and permitted the injection of the second syringe-full. Anaesthesia was prompt and I immediately without difficulty enucleated both tonsils with the cold wire snare. No bleeding followed. During the removal of the tonsils the patient's head was supported by an assistant. The operation could not have consumed more than two minutes. At the completion of the operation I was at once struck by the pallor of the patient and discovered that he was unconscious. He was at once placed upon the operating table with the head in the Trendelenberg position. At this time respiration was plainly visible, but I was unable to get any pulse at the wrist, although there was a peculiar fluttering or tremor at times. Morphine was administered hypodermically, followed by whiskey and strychnine, and oxygen and artificial respiration were employed for more than an hour before we desisted in our attempts at resuscitation. An autopsy was performed by the Coroner, assisted by the house staff, the same afternoon. Nothing abnormal was discovered in the lungs. When, however, the pericardium was opened it was found that the right auricle was swollen. The right auricular appendage was dilated with fluid blood until it was five times as large as the left. The right ventricle was also swollen, but not so much as the right auricle. The auricle showed a peculiar power of contractility, a wave of contraction passing over the entire auricle and sometimes returning when the auricle was stimulated by a blow of the instrument. The muscle wall of both sides of the heart looked normal. The left side of the heart was rather undersize in proportion to the size of the man. The coronaries were patent and normal. The valves were all normal except the tricuspid, which must have been opened, due to the dilation of the right side. The thymus gland weighed eighteen grammes and was bunched up in the top of the sternum. The distance from the sternum to the body of the vertebrae was one inch. The trachea and bronchia contained a little blood and mucus. The stomach contained dark colored mucus. The glands of the axilla and groin were slightly enlarged. The kidneys were normal. The pathologist of the hospital, Dr. H. T. Brooks, examined the thymus gland and reported that the most striking feature was that it showed no atrophy, which in a person of

this age is to be regarded as abnormal. The patient died, in all probability, of an over-dilated right ventricle, due to the enlarged thymus with its action on the trachea and recurring laryngeal with the cocaine-adrenalin injection acting as exciting cause.

During the last few years a great deal of interest has been taken in the subject of the thymus gland and recently a symposium was held in the New York Academy of Medicine on Status Lymphaticus. One of the most complete articles on the subject is to be found in "Osler's System of Medicine," by Alfred Scott Warthin, Ph. D., M. D., from which I take the liberty of quoting at some length.

"Atrophy of the lymphoid tissue, with its replacement by adipose and fibrous connective tissue, takes place gradually from the second year to the advent of puberty and more rapidly after this time, so that in the adult the thymus comes to be replaced by a mass of fibrous tissue and fat, containing small nodes of lymphoid tissue.

"Numerous cases occurring in the literature of the last several years have proved beyond all doubt that such a compression of the trachea does occur as the result of thymic enlargement, even when the increase in size does not far surpass the limits ordinarily regarded as normal.

"All thymic enlargement may be regarded as relative or absolute. The weight in different individuals varies greatly. In general it may be said that any thymus weighing fifteen grammes or more is hyperplastic. Increase in the thickness is of far greater importance than an increase in any of the other dimensions.

"Thymic enlargement occurs as apparently an independent condition or in association with status lymphaticus, tonsillar hyperplasia, adenoids, etc.

"In thymic death all symptoms point to suffocation resulting from tracheal stenosis and secondary laryngeal spasm as the chief if not the only cause of the fatal termination. *To a reflex spasm of the glottis may be added a reflex cardiac paralysis, or the latter may alone be the direct cause of death in those cases of sudden death in which all signs of tracheal compression or laryngeal stenosis are wanting.*

"The compression of the great vessels lying beneath the thymus may cause disturbance of blood pressure and cardiac dilatation. We must, therefore, conclude that the immediate cause of death varies in thymic enlargement, but the general picture is that of a convulsive attack of thymic asthma of the severest type. The muscular spasm closes, the face becomes ashy, then intensely cyanotic, reflex irritability is lost, there is rapid cardiac failure and death suddenly ensues. The reported cases of thymic death tend to show that its occurrence is often apparently induced by a number of factors that have no effect on the normal individual. Sudden death from fright or intense emotional excitement during trivial surgical operations has in too many instances been associated with enlarged thymus. It is probable that a large proportion of deaths occurring in surgical anaesthesia are due to this condition. An enlarged thymus has been found in many of the sudden deaths associated with slight operations, such as the removal of teeth or adenoids and tonsils."

The foregoing conforms very largely to the conditions in our case. The patient had an enlarged thymus, eighteen grammes, which, while not excessive, is sufficient to account for all the symptoms produced. There was the convulsion with pallor, followed by the intense cyanosis. There was, however, no tracheal stenosis, and the death, as shown by the autopsy, was undoubtedly of cardiac origin. How important a role the local anaesthesia played it is difficult to say. From what authorities on the subject say, the slightest agency, as fright or excitement, is sufficient to serve as an exciting cause. We cannot conceive that the small quantity of cocaine, 1-12 of 1 per cent, freshly prepared, contributed largely to the fatal result. Whether the amount of adrenalin (eight to ten minims of 1-1000 solution), with the possibility of more having been absorbed through the stomach from the first syringe-ful (although it is our firm belief that this was all expectorated), can be considered a more weighty factor is open to question. While it has been employed very largely in this form, we recognize that a number of warnings have been given regarding the possibility of accident, especially where there was a diseased condition of the heart or blood vessels, which, in our case, was not present. We have not had an opportunity to

thoroughly examine the literature, but in a hasty survey we have not been able to discover any reported case of death from cocaine-adrenalin infiltration. We have heard, however, of one such case occurring in Baltimore within the last few months, where a Schleich solution was introduced for the removal of the tonsils. Here, we were informed, the patient died three hours after the operation. Two cases have recently occurred in New York City, one where a strong solution of cocaine-adrenalin was introduced into the nose on cotton in a young, healthy adult, and the other where a strong solution was painted over the tonsils of a boy for tonsillectomy.

### *Discussion.*

Dr. Thomas Hubbard: I think that the case reported by Dr. Harris and one which I will describe should effectively open our eyes to the fact that in adrenalin chloride we have an unstable drug of great physiological activity. The variation in the strength alone should make us cautious. I know that there have been many instances in which alarming conditions were induced by adrenalin, and it is time that we speak plainly of the dangers, as it is such a popular and very useful drug. It is difficult to ascertain from the literature sent out by the manufacturers the precise dose for certain indications, but it is evident from the fact of acknowledged variation in strength and instability that the only safe way is to keep a big margin of safety. I believe from experience and information derived from patients using it for asthma and similar affections that the maximum dose for hypodermic or submucous injection, and especially in the vicinity of such venous sinuses as we have in the turbinates, is two or three minims. Some asthmatics acquire a tolerance that will allow a dose of fifteen minims. Three to five minims internally will promptly relieve an ordinary asthmatic attack.

As to the part that adrenalin played in causing the death reported by Dr. Harris, in consideration of the pathological condition found, there must be an element of doubt, but I feel it a duty to record a similar death occurring in the practice of a colleague for the details of which I depend on the report of the anesthetist read before the Academy of Medicine. A young man, healthy excepting that he was in a state bordering on nervous prostration due in part to obstructed nasal respiration caused by deflected septum and extensive adhesions, was prepared for operation and the usual mixture of chloroform and ether admin-

istered. The proper stage of anesthesia was attained without incident, all of the reflexes being in normal condition, when the anesthetic was temporarily stopped. A syringe containing about 15 minims of adrenalin 1:1000 was emptied into the turbinate, but as a part of it seemed to have escaped into the throat the syringe was again filled. A second injection was only partly given when the patient suddenly blanched, the heart fluttered briefly, and after a few vanishing respirations the patient was dead.

Dr. H. L. Swain: Dr. Harris may have some idea that the adrenalin was incompatible with the enlargement of the thymus gland. I know it is not, because I had a case of enlarged thymus where I thought of doing the Jackson operation and where the external application of adrenalin ointment not only caused shrinkage of the gland, but the patient was restored to comfortable breathing and passed through the danger period without operation. I think there is not the slightest doubt that Dr. Hubbard's planation is the correct one, namely, that the adrenalin got directly into a blood vessel and thus caused immediate and violent contraction of all the peripheral blood vessels, sending the blood directly and forcibly back to the right side of the heart.

Dr. J. O. Roe: I should hesitate to ascribe the fatal result in this case entirely to adrenalin, as the cocaine may have had something to do with it, notwithstanding the fact that it was used in such small quantities. Some people have a special susceptibility to the effects of cocaine, and I have seen many such cases. I have at the present time the case of a middle aged woman upon whom cocaine has this unusual effect. If I put a drop of a two per cent solution of cocaine in her nose she will almost immediately be seized with wild agitation of the heart, great dyspnoea, and depression so marked it would seem that a little larger quantity of cocaine might cause her to suffocate.

Adrenalin is, however, a very powerful drug, and the preparations that we get are often of such uncertain strength as to require great caution in its use, as illustrated by the interesting and instructive cases reported by Dr. Harris and Dr. Hubbard.

Dr. Harris: I feel my paper presents a fatality which may prove as a warning to you all. There has been a reckless use of adrenalin chloride, but I did not think I was reckless or indiscreet, but in the way Dr. Swain explains it the adrenalin chloride did play its role. I cannot believe that the cocaine had any part in the fatal result.



## ELONGATED STYLOID PROCESS.

BY CHARLES W. RICHARDSON, M.D.

The abnormal presentation of an elongated styloid process in the tonsillar region is rather an unusual occurrence, if we are to judge from the infrequency of the reported cases, especially when we take into consideration the enormous number of tonsils which are subject to operative intervention. My attention was directed to this subject first through the report of clinical cases by Drs. G. L. Richards and James E. Newcomb; again, when in 1907 there appeared in the *Annals of Surgery* a most interesting article by Dr. Thomas Dwight on Stylo-Hyoid Ossification. My interest was still further aroused by the presentation during March, 1908, at one of the regular meetings of the Clinico-Pathological Society of Washington, D. C., by Dr. L. W. Glazebrook, of a most rare specimen of complete stylo-hyoid ossification which he had accidentally discovered and removed from the body of a young man who committed suicide by cutting his throat. I regret to state that this specimen became misplaced and has never been rediscovered. A few months later the subject again presented itself to my consideration in a clinical way. In June, 1908, a young woman twenty-five years of age presented herself to me with the following history. She stated that for several years she had had quite an annoying post nasal catarrh, attended with crust formation. There was quite a degree of soreness and stuffiness in the tonsillar region. She had some difficulty in deglutition and soreness in the neck after much use of the voice. She stated that about a year ago she had consulted one of my colleagues who had located the trouble from which she suffered in the left tonsil, and, with her consent, had removed it. The removal of the tonsil had been attended with great difficulty on account of "long, slender piece of bone" which was contained in the tonsil. She stated that she had gained great relief from the operation. As the condition had recurred, she came to me for

the purpose of having the right tonsil removed. On examination of the faucial region, I found on the left side the evidences of a removed tonsil; on the right side a small flat tonsil which hardly projected beyond the pillars. Palpation demonstrated just within the anterior tonsillar fold, and parallel to its course, a narrow bony ridge. This bony process was slightly mobile. (Fig. 1.)



Fig. 1.

I recognized I had here to deal with an elongated and abnormally placed styloid process. It is quite probable that the same condition existed upon the left side. I was rather disinclined, at first, to remove the process, but, on finding it tender and painful on pressure, and at the earnest solicitation of the patient, I altered my opinion. In the operation, which I did under cocaine, I opened up the antrum fold its full length and thereby thoroughly exposed the process. The portion extending into the tonsillar

region was then removed in three successive bits with a curved bone forceps. (Fig. 2.) The wound healed kindly. In a letter received from the patient some four months later she stated that her throat gave her no trouble and that she never felt better.

In the normal state the styloid process has an average length of about two and one-half centimetres and is directed downward, forward and inward from the under surface of the petrous portion of the temporal bone. In order to reach the location in which the styloid extended in the above described case it must have been between five and six centimetres in length. It is therefore proper to state that the styloid process in this instance was abnormally long. Its course was also somewhat anterior to and directed



Fig. 2.

more internally than is usual for the stylo to follow. Dwight gives as the course followed by a bony rod which may extend from the styloid process to the hyoid bone as follows: "This rod passes between the carotid arteries and may interfere with operation for tying them and with those on the parotid gland, which it probably indents on the inner side. Passing by the internal pterygoid, to which it is attached by the fibrous envelope of that muscle, it lies against the outer side of the tonsil, which it may indent or displace." From the above reason and description of the usual course of the styloid, I should judge that we are correct in stating that the course of the styloid in this instance was abnormal.

*Discussion.*

Dr. H. P. Mosher: This specimen which I present is a bit unwieldy, but it is the nearest I could come to a live patient with a stylo-hyoid ossification. This was found in the course of dissection. On one side it shows complete ossification down to the hyoid bone and on the other side partial ossification.

Dr. B. Alexander Randall: This ossification of the stylo-hyoid ligament is a constant condition in the dog and other animals.

Dr. W. E. Casselberry: Judging from the number of anatomical specimens presented, prolongation of the styloid process reaching into the tonsil is more frequent than generally supposed from clinical observation. I fear we do not look closely enough for it. When the American Medical Association met in Atlanta in 1896, Dr. Stirling, of that city, stated before the Section on Laryngology that he had under observation at that time as many as three cases of "bone in the tonsil," without explaining what kind of bone. The statement was received with such skepticism that a committee, of whom I was one, was appointed to examine the cases, an opportunity to do so having been courteously tendered by Dr. Stirling. The explanation the committee arrived at was—prolongation of the styloid process. Digital examination in addition to inspection would readily expose any such condition in the tonsil, and it would be well, preceding operations on the tonsils, to exclude by palpation the possible presence of this or other complications, such as tonsillitis, foreign bodies, syphilitic or malignant induration and aneurysmal or anomalously located arteries.

Dr. G. L. Richards: The case of mine referred to was reported some years ago. I stumbled onto the case when attempting to do a tonsillotomy with a tonsillotome, and could not get through the tonsil on account of the obstruction. Digital examination revealed the same thing on the other side, though not so long. That tonsil was not touched. At the time of my report I wrote Dr. Wright in regard to it and reported his remarks on the subject.

Dr. R. C. Myles: I was also one of the committee mentioned by Dr. Casselberry, and after that experience I looked for this type of protruding styloid process and found many of them. One of the first I unfortunately told the patient about and she caused her physician endless trouble by her expressions of anxiety. Since that time, in trying to involute the tonsil with the dull forceps, I have engaged the styloid process on several occasions and have noticed that the tonsil rolls over the process during the act of contraction of the muscles of the throat.

Dr. J. E. Newcomb: My own case to which reference has been made in the paper just read, was discovered by the fact that I met with an obstruction in driving a blade of a Mackenzie tonsillotome through the tonsil, though the bone was not thick enough to prevent the blade from cutting it off. Palpation revealed the tip, but that was covered over with a sufficient amount of tonsillar tissue to give no further trouble.

Dr. J. O. Roe: I have no doubt these cases of elongated styloid processes occur much oftener than we suspect, as, during life, our attention is called to them only by accident or when the bone is causing trouble. I have seen two such cases and both were in females from twenty-five to thirty years of age. In one case the patient consulted me for a sore throat, stating that she felt as if a bone or some foreign body had become lodged in it. I carefully examined her throat and found no foreign substance nor general inflammatory condition, but on the left side of the fauces, just behind the tonsil, in the palato-pharyngeal fold, I observed a red spot, somewhat painful and very sensitive to pressure, which on feeling of it with my finger I discovered to be an elongated styloid process. The tonsil was not especially enlarged nor diseased. I made an incision over this styloid process, separated the tissues from it, and cut it off with a pair of bone cutters as high up as I could. It was nearly as long as the specimen which Dr. Richardson has shown. Unfortunately, I did not save it, as I did not regard it as anything very unusual, having seen a number of very long styloid processes in the dissecting room.

In the other case, a very long styloid process was found projecting into a diseased tonsil. On removing the tonsil with the snare, which I always use for this purpose, it came against a hard substance, making it impossible for the snare to cut entirely through the tonsil. On examination as to the cause of the difficulty I found a long styloid process which had to be cut off with bone forceps before I could remove the tonsil or even the snare. These are two interesting cases which might be added to the list.

Dr. J. Price-Brown: I have seen one somewhat similar case in a man thirty-five years of age, I found the right styloid process extending internally beyond the centre of the throat, but it passed by the side of, not through the tonsil, and produced no particular difficulty. The patient finally died of aneurism of the aorta without ever complaining of this abnormal condition in his throat.

Dr. Richardson: The most interesting feature to me in this styloid process was not that it was there, but the fact that it took such an abnormal course. In most reported cases the styloid has been in the back of the tonsillar mass. This styloid process was in the palato-glossal fold anterior to the tonsil entirely and ex-



tended almost down to the attachment of the tongue. Of course, I think this condition occurs much more frequently than would seem from the number of cases reported, and no doubt when we get to removing tonsils in the more rational way by the finger method we will necessarily palpate more tonsils and find more abnormally placed styloid processes.

REPORTS OF CASES ILLUSTRATING OUR PROGRESS  
IN THE SURGICAL TREATMENT OF CHRONIC  
STENOSIS OF THE LARYNX AND  
TRACHEA.

BY JOHN R. WINSLOW, M.D.

There is no more difficult chapter in the entire realm of laryngology than that on the treatment of chronic stenosis of the larynx and trachea. Many of these cases are excessively rebellious to treatment, requiring patience, persistence, self-sacrifice and skill on the part of the surgeon, and the endurance of discomfort or even suffering by the patient.

Despite these drawbacks, of such seriousness is the condition, and so imperative the necessity for its amelioration, that we are well compensated for making any sacrifice of time and energy that may be necessary for a successful outcome.

The modern treatment of laryngotracheal stenosis may be said to have begun with L. Von Schroetter, of Vienna, who in 1871 devised two methods of dilation, the one by means of metal olives after tracheotomy, the other by the use of hollow hard rubber tubes inserted through the mouth without preliminary tracheotomy; both of these methods have been successfully employed in many cases by numerous operators.

The next great advance in the treatment was the system of intubation invented in 1885 by O'Dwyer, of New York, and since then elaborated and universally adopted; this may be employed without tracheotomy, or with tracheotomy, either as simple intubation or associated with fixation of the tube through the fistula (Rogers).

Rapid dilation by means of divulsors (sometimes cutting) or of sounds, introduced through the mouth or tracheotomy wound, seldom gives permanent success, but the combination of divulsion with intubation (Egidi) has proven an invaluable method.

The large number of the older methods seems to be an indication of their inefficiency; when we examine the methods hitherto

employed we find that, despite their difficulty and tediousness, none of them guarantees a certain result nor against recurrence of the stricture.

Recently a new method of surgical treatment has been introduced which seems to offer more hope of certain and adequate results in these hitherto intractable conditions than any previous method. I refer to laryngotracheostomy, originated by Killian and developed by Sargnon and Barlatier of Lyons.

This may be defined as the median vertical fissuring of the larynx and trachea, with the maintenance of a temporary or permanent fistula for a long period. Associated with this is the employment of graduated dilation by means of soft rubber drainage tubes, introduced through the tracheotomy fistula.

My personal experience in the treatment of these cases dates back to the Winter of 1891, when I had the privilege in the clinic of Professor Schroetter, of familiarizing myself with his methods. Although I can definitely recall several cases of scleroma and of syphilis treated by me there, as well as a number subsequently at home, I can now find no record of such, and must abstract from a case previously reported (*Jour. Eye, Ear and Throat Dis.*, 1896).

Case 1.—A case of stenosis of the larynx with fibroma (?) following a razor cut. Cured by intubation with Schroetter's tubes.

A negress, twenty-five years of age, was seen by me at the Throat Dispensary of the University Hospital, August 6, 1892, complaining of and exhibiting marked dyspnoea; this was so aggravated when lying down that she could not sleep in that position. The voice was little affected. Externally there was a cicatrix in front of but not adherent to the larynx, which she stated was due to a razor slash received at the hands of her lover two and one-half months previously. This was found to have severed the thyroid cartilage and entered the larynx below the vocal cords.

Laryngoscopic examination was difficult owing to dyspnoea and general irritability of the patient, but under cocaine anesthesia I finally detected a subchordal stenosis, low down in the

larynx, but still exhibiting the thyroid angle; this seemed at first to be almost complete, but upon closer examination the centre was seen to be movable and follow the respiratory current. The apparent size of the growth was that of a small shoe button, fitting the laryngeal lumen like a valve.

The patient was put in the hospital and given spray treatment and iodide of potassium internally.

After several days, the urgent symptoms having lessened, I began dilation with Schroetter's bougies under 20 per cent cocaine anesthesia. The smallest size tube, about that of a large lead pencil, was first introduced and could only be tolerated a few moments. Gradually increasing the size of the tube by the 22d of September the patient was able to pass the tube herself without

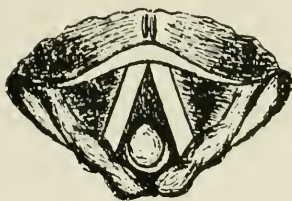


Fig. 1.

cocainization and retain it indefinitely. Examination at this time showed that the growth had shrunk considerably, was no longer movable and that its attachment was to the anterior laryngeal wall. The treatment was continued, and on October 6 (two months) the patient reported that she could "sleep well and run without losing her breath." Four months later she reported that she breathed easily except on running rapidly up stairs, and worked regularly at housework. Examination showed that the stenosis was much dilated and the growth had vanished. Altogether the patient was under observation about ten months, and has never reported for treatment subsequently.

Case 2—A case of laryngostenosis due to double adenofibroma, treated by laryngofissure and exsection of growths: cure.

Nathan G—, white, aged forty-two, was seen at the Presbyterian Eye, Ear and Throat Hospital, January, 1907.

Complains of hoarseness for past three weeks; has been subject to similar attacks each winter. During interval says that there is complete restoration of voice (?). Patient smokes cigars and works in a dusty atmosphere (freight handler).

*Diagnosis.*—Subacute laryngitis and faucitis. Ventricular bands swollen concealing remaining laryngeal structures. Treated with Ag. No. 3 mop and disappeared in a few days. After recovering from this condition patient was re-examined. Voice at this time was strained and almost stridulous; this he designated as its normal condition. Learned subsequently that he had been hoarse at least ten years. Laryngeal examination revealed a fusiform grayish tumor having a smooth surface attached by a broad base along each ventricular band. Notwithstanding this broad attachment the growths seemed somewhat movable, and on

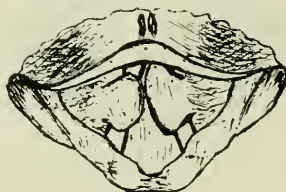


Fig. 2.

expiration came into close contact. Only the anterior and the posterior quarter of the *right* cord were visible, the *middle half* being concealed by the tumor. The posterior quarter of the *left* cord was visible, the anterior *three-quarters* being concealed. A typical picture of double so-called eversion of the laryngeal ventricles was presented.

I attempted removal per os with a Landgraf-Krause double curet, but found the tissue so dense that I could not obtain even a specimen for examination. A similar attempt with heavy forceps also failed. An examination of the patient by direct laryngoscopy (Ingals' Spatula) was made with the view of determining the feasibility of this method, but the irritability of the patient and the volume and density of the tumors led me to adopt thyrotomy as the most available operation.

The patient was placed in the University Hospital and this



operation performed May 20, 1907, under chloroform anesthesia. No tracheotomy was performed, but all preparations were made for same in case of emergency. A median vertical incision was made through the skin, extending from the hyoid bone to the cricoid cartilage. Beneath the skin an unusually large anterior jugular vein, the size of a goose quill, was encountered, extending obliquely across the thyroid cartilage. This was severed between ligatures. The thyroid cartilage was then exposed and denuded. The surface of the cartilage and thyrohyoid membrane was mopped with a solution of cocaine 10 per cent, Adrenalin 1-5000; the membrane was then incised and the interior of the larynx mopped with the same solution. A vertical incision was then made with a heavy knife through the cartilage, from the incisura thyroidea to the middle of the thyroid cartilage. A long stout silk ligature was passed through each wing, and the wound held open by an assistant, the field being illuminated with an electric head-light. Two fusiform tumors were then exposed resembling the nasal turbinals (polypoid or adrenalinized). These were amputated along their attachment with Struycken's Alligator Turbinal Scissors, and gave the sensation on section of turbinal tissue. The thyroid plates were secured with catgut, but were so dense that the insertion of the needle was difficult. The muscular layers were united with catgut, the skin with silk. The usual precautions in the after treatment of the respiratory organs were observed.

The temperature and pulse were practically normal until the fourth day after operation, when the temperature rose to 100 1-5; this was found to be due to an infection of the cervical tissues from a slight leakage of the laryngeal wound. The temperature promptly fell under hot applications and drainage, but from that time on we had to deal with a suppurating wound of the neck. The thyroid wound healed promptly and the patient was discharged from the hospital in two weeks and reported for dressing as indicated. Considerable difficulty was experienced from infected ligatures, which delayed the healing of the neck wound until about August 20 (three months).

The patient was seen and re-examined September 1, 1907. Both cords were then visible and their functions fair, despite

some paresis of the vocalis muscles. The voice, while raucous and disagreeable, was strong and intelligible. Notwithstanding the suppurative accidents and consequent repeated incisions, a great part of the wound healed per primam and the disfiguration is slight. The patient was last seen in the Fall of 1908. He was working and in good health; the voice was rough but strong. There was no evidence of recurrence of the growths.

#### NOTEWORTHY POINTS.

1. The tumors belonged to the unusual group of fibro-adenomata (Prof. Hirsh).
2. Unusually large anterior jugular vein across the thyroid, necessitating ligation.
3. Partial thyrotomy. No tracheotomy.
4. Unusual density of thyroid cartilage, making suturing difficult and rendering tight closure of the wound impossible; this resulted in leakage into the tissues of the neck, with neck and ligature infections.

We seem to be afraid of entering the larynx from without, and prefer inexact and incomplete work with the laryngeal mirror.

In many cases of benign tumors laryngofissure is the conservative and preferable method of removal. Subsequent experience proved that, owing to their extent and density, these tumors could not have been removed either by indirect (mirror) or direct laryngoscopy, and that thyrotomy was the appropriate and conservative method of operation.

Case 3.—A case of stenosis of the larynx diagnosed by direct laryngoscopy and successfully treated by tracheotomy, retrograde dilation and intubation: Incidental removal of a foreign body from the trachea by direct lower tracheoscopy.

On November 23, 1907, Mary M., an Italian school girl, aged 11 years, was sent into the University Hospital from the dispensary by my assistant, Dr. H. C. Davis, with the history of increasing dyspnoea for a month or more, and that for several winters she had had similar attacks. She was poorly nourished, underdeveloped and could not speak above a whisper. Decided dyspnoea and some cyanosis were present.

November 27, 1907, the patient was anesthetized without difficulty with chloroform. Every preparation was made for tracheotomy, but suspecting that a condition of laryngeal papilloma might be present, I first introduced the direct speculum through the mouth, and discovered that such was not the case, but that I was dealing with an obstructive condition of indeterminate character beneath the chords. This was shown by subsequent examination to be a fibrous ridge extending obliquely downward from beneath the left vocal chord.

The entire larynx and trachea were acutely inflamed, and dyspnoea became so alarming that immediate tracheotomy became necessary. The usual after treatment of tracheotomy was carried out, with normal progress until the evening of December 14, when the temperature suddenly rose to 102 degrees, pulse to 160, and respiration 30, with marked dyspnoea. This was found to be due to the improper insertion of the tracheotomy tube after cleansing, between the trachea and the skin, by an assistant. No further incident occurred prior to healing of the wound.

On December 8, 1907, the first intubation was done through the mouth, with a medium-sized tube, which was retained but two hours. This was repeated on the 12th, 13th, and subsequently at varying intervals, by myself or my assistant, Dr. Davis, until the discharge of the case on April 14, 1908.

The intubations were done mainly under cocaine. On two occasions intubation was performed through the direct speculum, which was probably one of the earliest uses of this method, but the usual method proved more practicable. During this period the tracheal cannula was frequently plugged, compelling the patient to breathe through the intubation tube or larynx. On January 9, 1908, the tracheal wound was enlarged and retrograde dilation performed, under ether, with male urethral sounds up to a No. 8 American, followed by intubation with tubes of increasing size. On February 18 dilation was repeated up to a No. 24 male urethral sound, followed by intubation with the largest size tube of the O'Dwyer's children's set. Early in the treatment of the case, on account of its chronic character, a hard-rubber fenestrated tracheotomy tube had been substituted for the metal one. At 2 o'clock in the afternoon of May 6, 1908, while

eating cake, the patient was seized with coughing and cyanosis. Upon examination it was found that the tracheal cannula had become unscrewed from its plate and dropped into the trachea. In my absence this was located at the tracheal bifurcation, and skillfully removed under chloroform through the tracheoscope by my assistant, Dr. R. H. Johnston. Further dilation was not found necessary, as the patient could breathe well with or without the intubation tube. The tracheotomy wound was allowed to close, and the patient discharged from the hospital April 14, 1908, after a stay of four months and twenty-one days. She was then in good health, and could run and play without dyspnoea. Her voice was raucous but strong. During her treatment at the hospital and subsequently she was put upon large doses of Syrup of Iodide of Iron and Iodide of Potassium, with a view to a possible syphilitic taint.

The patient reported at frequent intervals at the dispensary for examination, and was re-examined by me November 23, 1908, which happened to be the anniversary of her entrance into the hospital. At this time she was in good health, breathed well when at rest, and could run up and down a long hall without dyspnoea. Her laryngeal lumen was of good size, though somewhat constricted on the left side. It was of an elliptical shape over the posterior two-thirds, and into this a pyramidal mass projected from the inter-arytenoid space. The nature of this projection is conjectural, the patient having been saturated with iodide, and repeatedly examined negatively for tuberculosis during her stay in the hospital.

Case 4.—A case of post-typhoidal laryngotracheal stenosis, exfoliation of the arycartilages and collapse of the vocal chords, treated by laryngotracheostomy, hemichordectomy and prolonged intubation: incidental removal of a rubber dilator by direct lower tracheoscopy.

Fred L., white, aged 24 years, consulted me on July 24, 1908, with the history of having had typhoid fever three summers previously (Woodberry epidemic). During convalescence, extending over a period of eight weeks, in one of the city hospitals, he was suddenly seized with a coughing spell, and spat up two hard

conical objects, which were said by the resident in charge to be the arytenoid cartilages. Thirteen days later he had a severe attack of dyspnoea, necessitating emergency tracheotomy. Ever since that time he has been wearing a silver tracheotomy tube of medium size. While at rest he can stop up this tube for several hours, but he cannot dispense with it entirely. When active, he can keep the tube stopped for only a short time. He cleans the inner tube himself, but the outer tube has not been removed for two years. He can do no physical labor, is of poor physique, rather haggard, and subject to frequent bronchial colds. His voice is coarse and strained.

*Examination.*—A medium-size silver tracheotomy tube, with no fenestra, is inserted through a fistula above the third tracheal ring, well on the left side. A broad scar indicates a healing of the original wound by granulation.

Laryngeal examination was difficult, but under cocaine I was able to discover a double paresis, the cords being relaxed and degenerated, and exhibiting a scarcely appreciable abduction during inspiration. No arytenoid eminences were visible.

The nature and difficulties of the condition were explained to the patient, together with the hopelessness of its treatment by any ordinary measures, and he was allowed to ponder upon the same during my absence on my summer vacation.

Upon my return he put himself under my care, with full permission to do whatever I considered requisite.

I placed him in the University Hospital, and on October 12, 1908, I enlarged the tracheal fistula, and by means of the tracheoscope determined that there was no obstruction below that level. I also made a direct examination of the larynx from above with Jackson's tube-spatula, gaining no additional information beyond that afforded by the mirror.

October 29, 1908, under combined anesthesia (Scopolamin gr. 1-100, Morphin Sulph. gr. 1-8, Schleich infiltration) I split the larynx and trachea with a stout knife to the third tracheal ring. Then, after mopping the laryngotracheal mucous membrane with 10 per cent. cocaine solution in 1-1000 Adrenalin, I removed the left vocal cord in its entirety with Struycken's turbinal scissors. The cord was flabby, like a shred of meat.



In performing cordectomy, I was fully aware of the clinical and experimental observations of Citelli and of Fraenkel upon the recrudescence of extirpated vocal cords, but I considered that the recurrence could be removed as often as necessary through the tracheostomy fistula.

Behind the cricoid a narrow stricture, admitting a 3-16 inch

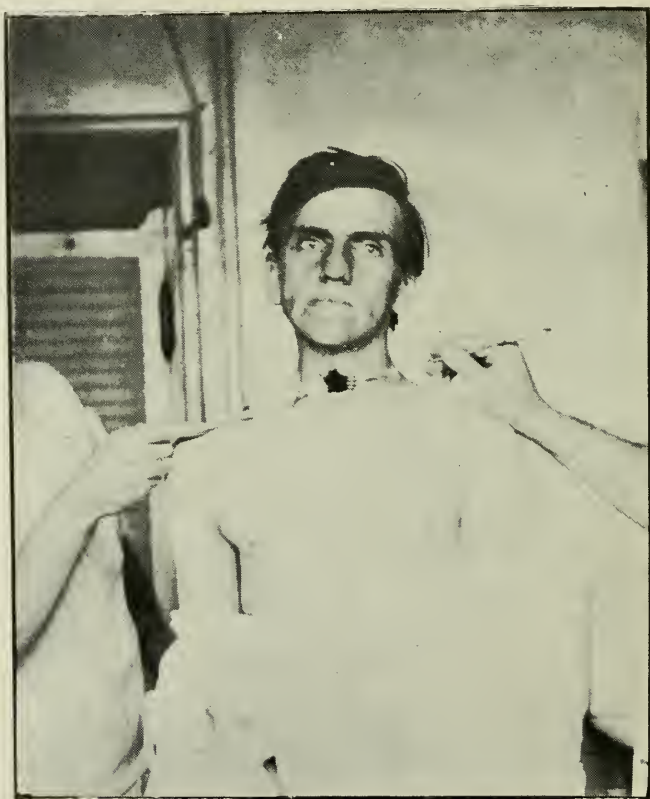


Fig. 3.

catheter, was found, which was not cicatricial, but was due to interstitial hyperplasia of the cartilage.

The mucous membrane of the larynx and most of the trachea was stitched to the skin, but that of the cricoid region was too atrophied and adherent to hold sutures.

The wound dressing and after treatment were according to the method of Sargnon and Barlatier, of Lyons, the details of which will be found in their original communications.

The period of sloughing lasted about six days, that of the subsequent dilation three months.

The first attempt at dilation was made on November 3, 1908. A piece of thick red rubber drainage tubing, bevelled at its lower end and stuffed with cotton, as devised by Sargnon, of Lyons,




Fig. 4.

was inserted through the laryngostomy fistula and attached by a ligature to the rings of the tracheal cannula. This tube measured  $1\frac{1}{2}$  inches in length and  $\frac{3}{16}$  of an inch in diameter; it had to be removed upon the following day on account of pain and irritation. A couple of days' rest was allowed, and on November 8 a second tube of the same length but  $\frac{5}{16}$  of an inch diameter was inserted. This was retained for thirty-six hours, then removed, cleansed and reinserted. On November 15 the diameter of the dilator was again increased to  $\frac{6}{16}$  of an inch.

With this tube in position, when the fistula was covered with gauze, the patient could breathe through the tube and the larynx. The retro-cricoid stenosis yielded with unexpected facility to the dilation, and within a short time a dilator  $\frac{1}{2}$  inch in diameter could be inserted. At this stage the type of tube was changed from that of Sargnon to that of Fournier, in which the tracheal cannula is inserted through the rubber dilator. A fenestra was then made in the tracheal cannula, so that the patient could breathe through it and the dilator at will, by occluding the mouth of the tracheotomy tube with a rubber cork.

On the night of November 14 the Fournier tube, though apparently tightly fixed, in some way slipped down the tracheal cannula into the trachea. As this caused no dyspnoea nor alarming symptoms, it was left until the following day, when I removed it under cocain anesthesia through the tracheoscope, with Lister's foreign body hook. This was accomplished with some difficulty, owing to the oscillation of the tube during respiration, between the bifurcation and the tracheal fistula.

The accidents which occurred in these two cases show the necessity for facility in bronchoscopic methods in any one who undertakes this work.

Dilation was continued at varying intervals, and for varying periods, according to circumstances, until about January 15, 1909. At this time a subcutaneous abscess developed at the upper angle of the wound over the right side of the thyroid, due to infection, which necessitated a suspension of the dilation, and the patient was transferred to the outdoor department February 2, to be dressed until the fistula had healed. Special difficulties encountered in the treatment of this case were excessive irritability of the mucous surfaces, even with the use of 20 per cent cocain, excessive mouth and laryngeal secretions, amounting at times almost to a flood running down the trachea, and an apparently unconquerable habit in the patient of handling the tubes and dressings, due to the protracted wearing of the tracheotomy tube previously.

*Second Period.*—Early in March, 1909, the patient returned for examination, with the abscess healed and the fistula nicely cicatrized. Examination of the larynx at this time showed that

the left vocal cord had been replaced by a cicatricial band, but that the laryngeal lumen was greater than before operation.

The patient re-entered the hospital, and on March 15, 1909, I dilated the larynx through the tracheostomy fistula, under cocain, with male sounds consecutively up to No. 28A.

Intubation was then attempted through the mouth, but the tube was not retained.

I then devised a special "T" tube of hard rubber for insertion through the tracheostomy fistula, which has been used ever since, in increasing sizes, and retained for progressively longer periods.

The latter part of April the patient was discharged from the hospital and has since been treated ambulatory. The tube is readily inserted with or without cocain, and he removes it himself whenever necessary, coming back to me for reinsertion. After wearing the tube he is able to breathe through the larynx without it for a variable time (three days longest time.)

I do not know whether he will ever be able to entirely dispense with an intubation tube. The present condition seems to be as much one of collapse of the laryngeal walls as of stenosis. The largest male sound may be introduced at any time, but the laryngeal lumen does not remain long open without the tube.

Prolonged intubation seems inevitable: fortunately the larynx will tolerate a rubber intubation tube almost indefinitely. Possibly, by forcibly keeping the cords apart by an intubation tube for a long period, they may become shaped so as to maintain a permanent space between them sufficient for breathing.

A repetition of chordectomy does not at present seem justifiable.

The voice, without the tube, is better than before operation; with the tube in situ it is forced and suppressed, but thoroughly intelligible.

The patient is still under treatment. He has gained in that he is no longer subject to frequent colds, that he is in better general health and is able to do light physical work (painting), and that he seems to feel more like a human being when breathing through the larynx, and has hope. This I share with him, although the case may have been an impossible one from the beginning, and its difficulties may prove to be insuperable.

A word in conclusion upon this new operation: While realizing thoroughly that a single case warrants few conclusions, and that even this one may not have been a fair test of the method, still, my experience in it convinces me that we have in Laryngo-tracheostomy an enormous advance in the treatment of intractable and hitherto often incurable stenosis in these regions. By means of it we can observe and control directly the area of necrosis caused by the pressure of the dilator, an advantage afforded by no other method.

The mortality is under 5 per cent., no greater than that of Laryngofissure, to which operation it is, in my opinion, preferable in all cases of grave stenosis.

*Bibliography of Laryngo-Tracheostomy.*

- Barlatier et Sargnon—Les Laryngostomies et les Tracheolaryngostomies. *Archives Int. de Laryng.*, 1907. Also *Jour. Laryng. Rhinol. and Otol.* (English), Vol. No. 23, 1908. Contributions a l'Etude de la Laryngostomie. *Revue Hebdom. de Laryng.* No. 44, 1908.
- Rabot, Sargnon et Barlatier—Stenoses du Larynx et de la Trachee. Consecutives au Tubage et la Tracheotomie. Maloine, Editeur, Paris, 1908.
- Fournier et Sargnon—Stenose Laryngee chez une Enfant Tubarde-cannularde-laryngostomie. *Revue Hebdom. de Laryng.* No. 22, 1908.
- R. Barlatier—La Laryngostomie dans le Traitement des Retrecissements du Larynx. Maloine, Ed., Paris, 1908.



## SOME OBSERVATIONS UPON THE COMPLETE EX-TIRPATION OF THE DISEASED FAUCIAL TONSIL.

BY JOSEPH S. GIBB, M.D.

A series of 100 cases of tonsillectomy in an institution in which the comforts and care of a private home were thrown around the patient gave an admirable opportunity for the observation of the after effects of this operation, and also to contrast it with previous operations of tonsillotomy in the same institution.

This institution, the Girard College, of Philadelphia, admits the pupils at the age of six years—and they remain until they are eighteen years of age. The boys are given a good education and it is the policy of the management to provide as nearly as is possible a home life for them. Under the will of Stephen Girard, the founder, boys who are orphans or half orphans (having lost a father) are eligible. Necessarily they are drawn from the lower classes.

Before admission the applicant must pass a physical examination, which includes an examination of the nose, naso-pharynx and pharynx. Cases which are believed to be affected with disease of the latter parts are set aside by the resident physician for a subsequent examination by myself. So that the cases selected for operation are typically healthy boys, save for the secondary conditions engendered by mouth breathing.

Incidentally, a fair idea of the prevalence of tonsillar and adenoid hypertrophies among this class of patients is obtained by this rigid entrance physical examination. In a recent class of applicants in 102 boys, 36 were found to have either hypertrophied tonsils or adenoids, or both. Only those cases were classed as necessitating operation in which (1) tonsils were so large as to be evident to a casual observer, (2) those in whom the tonsils were buried and covered by the pillars, (3) those in

whom the crypts and surrounding parts gave evidence of attacks of tonsillitis.

Of the 100 cases which serve as a basis for these observations, 65 were operated within one week, so that they were all in the infirmary at or about the same time—the remaining 35 were done within six weeks of each other and were practically consecutive. The cases are prepared for operation in the same manner as for a major surgical operation, admitted to the infirmary the day before operation, purgative the night before and the usual preparation for anaesthesia.

An anesthetic was administered in every case except in a few older boys with simple non-adherent hypertrophied tonsils. The method adopted for the removal of the tonsils is as follows: The tonsil is firmly grasped by a forceps—the forceps which has served me best, after trial of a number of varieties, is that sold in the shops as the Mikuliez broad ligament forceps—the tonsil is firmly pulled from its bed by an assistant and the attachment to the pillars severed by the Allis blunt dissector. In many cases the attachment is so firm as to cause considerable tension of the surrounding tissues. Rather than exert force to sever these firm adhesions, it has been found wise and expedient to effect separation by means of a sharp instrument, either a properly constructed scissors or tonsil knives. Having effected a thorough separation of the pillars, the finger is introduced and an endeavor made to break up the deeper adhesions and to leave the tonsil hanging, as it were, by a shred of tissue. The forceps still in place, a strong wire snare is passed over the handles, down over the tonsil, and around the shred of tissue, and slowly drawn home.

In most cases this method has been found to be exceedingly satisfactory, enucleating the tonsil from its bed, often with the capsule attached.

In some cases, however, and especially is this so in the so-called buried tonsil, the gland is so adherent to the surrounding parts, and its tissue so friable, as to make it difficult for the forceps to retain their hold. Many of these will yield, however by a proper amount of patience, but there are some which will not. In these latter, by affecting as free a separation as possible, it is

a comparatively simple matter to engage the tonsil within the bite of a good punch and complete the removal.

There are still other cases in which owing to frequent inflammatory attacks the tonsil is not only adherent, but so bound down by adhesions as to resist all efforts to separate by blunt dissectors. In these sharp separators are used and the punch employed to complete the operation. The results of these operations have been most gratifying. This method has been employed by me in a desultory way for several years, but no opportunity had arisen to study the effects in a consecutive series of cases until these now reported presented.

Every laryngologist has been disappointed at times in the use of the tonsillotome. We have all seen cases of so-called recurrences of the hypertrophy, which means that, in most instances, the operation was not a complete one—again we have realized what an ineffective instrument the tonsillotome was in the so-called buried tonsils. It seems to me apparent that if it becomes necessary to remove a tonsil at all only a complete extirpation is indicated.

We know that the crypts, which are the parts of the tonsil singularly subject to diseased conditions, extend down to or near the capsule. Therefore, if a piece is sliced off the tonsil, we effect only an increased breathing space in the fauces (and this at times only temporarily), while the crypts below the incision remain diseased and a possible source of infection. Whatever function the tonsil possesses is necessarily abrogated by the conditions already enumerated, and which we recognize as diseased conditions. Therefore, if it is necessary to remove a tonsil it should be done in as complete a manner as is possible. Of course, it is important that care should be exercised in the selection of cases. No tonsil should be removed unless it is diseased and ceases to be a functioning organ.

In my first cases by this method I was considerably chagrined by the severity of the reaction, but experience taught me to reduce this to a minimum. One of the first lessons learned was to employ as little force as possible. It is far better to employ a sharp instrument to sever refractory adhesions than to stretch the tissues until they break. By the latter is induced a cellu-

litis, with subsequent infection and prolongation of the post-operative effects. The same may be said of the too strenuous use of the finger in breaking up the adhesions. It is far better to snip the tissues with a curved scissors or depend upon the wire for the severance. Another important matter is that the pillars shall be entirely free and not included in the grasp of the snare when the final severance is effected. However, even where the greatest care is employed, the reaction is at times more pronounced than in the use of the tonsillotome.

Let us study the 100 cases: As an evidence of the unusual care given the boys in this institution, and not because of necessity, the operated cases were retained in the infirmary from two to seven days after operation—the average time was four days. This long stay afforded an exceptional opportunity to study each case. The efficient resident physician, Dr. Trinder, looked after the cases daily and kept careful notes of any departure from the normal. Again, even after the discharge from the infirmary, the boys remained in the institution and have all been seen from time to time since the operation. It is now a year since the first 65 cases were operated.

As to the temperature range: In 90 per cent of the cases the thermometer registered a temperature between  $98\frac{1}{2}$  and 101 degrees, and in the larger number of these did not rise above 99 degrees. In 9 cases the temperature mounted to 102 degrees and over. The first group, namely, those whose temperature remained below 101 degrees, were the type of case mainly with simple hypertrophied tonsil and slight attachment to the pillars. There were, however, quite a few in whom the tonsils were submerged and firmly adherent. In this group there was very little faucial disturbance. While the extent of removed tissue was observed by inspection to be more extensive than is usually seen after a tonsillotomy, the subjective symptoms were not thereby increased.

Later, when the effects of the traumatism had entirely disappeared and the boys were about their usual duties, an examination of the throat disclosed a perfectly normal fauces except that there was not a vestige of tonsil remaining.

The group of 9 cases with excessive temperature were those

in which the tonsils were firmly adherent to and submerged beneath the pillars. Most of them were cases in which the tonsil had been the site of repeated inflammatory attacks and its tissue was soft and friable, requiring much dissection and the use of the tonsil punch—hence unusual traumatism. In these cases there were, in addition to the systemic disturbance, both objectively and subjectively, marked faucial symptoms. The patients complained of much difficulty and pain in swallowing. In two there was regurgitation of fluids through the nose. The fauces were indurated in the region of the half arches, and the tonsillar wound was the site of a superficial ulcer covered by a slough.

All of these cases made a good, though tardy, recovery, and subsequent examination revealed normal fauces, except that the tonsil was absent. It is not at all unlikely that much of the disturbance noted in this last group of nine cases might have been avoided had recourse been made to sharper instruments to effect a separation of the adhesions. These were among the early cases and at that time the lesson had not been learned to avoid as much as possible undue traction on the surrounding tissues, which the use of dull dissectors and the finger is sure to produce in firmly adherent cases. Many cases as difficult have been operated since with no more disturbance than in the first group recorded.

In contrasting tonsillectomy by the method described, with previous operations, tonsillotomy, the first point to which I would direct attention is the thoroughness of the operation. Tonsillectomy leaves little to be desired so far as complete ablation of the tonsil is concerned.

Tonsillotomy, on the other hand, effects a complete extirpation only in those cases in which there are no adhesions or in which there is slight attachment to the pillars. In the large class of submerged or buried tonsils this operation effects in some cases only a partial removal, which is almost useless, and in others it is impossible of execution.

As to the after effects of the two operative procedures: It has been pointed out that in by far the larger number of cases—namely, 90 per cent—there is practically no severe symptoms



following the tonsillectomy—the fauces clear rapidly and cleanly and leave no permanent injury or disfigurement. This is as good a result as tonsillotomy shows. It is true that in nine cases there was unusual systemic disturbance and faucial ulceration and oedema succeeding the operation. These cases, however, were all of the deeply submerged, adherent type of case, requiring much dissection to free.

A type of case familiar to every laryngologist, in which it is necessary to grasp the tonsil firmly with the forceps and pull it from its bed to demonstrate the hypertrophy, and then frequently to find it surrounded by a tightly adherent, thinned-out pillar or fold. This, then, was the character of the cases in which excessive reaction followed the dissection and removal. No comparison can possibly be made between the two methods of operating in cases of this nature, for the reason that the tonsillotome is absolutely incapable of removing such hypertrophies, except the adhesions be first separated, the tonsil pulled from its bed and the tonsillotome used to cut off the remaining shred of tissue from the base. In which case it simply takes the place of the snare used in the latter part of the operation described, and is infinitely less satisfactory.

As to hemorrhage: Tonsillectomy has effected a great change in the operating room in these cases. It is rare to see profuse bleeding by this method for the removal of tonsils. In two cases of the group reported, there was an unusual amount of bleeding—both of which the cause was a spurting vessel, which clamping with a hemostat readily and quickly controlled. The amount of hemorrhage in a given case is largely under our own control—the more rapidly the snare is tightened the greater the liability to bleeding, for it then approaches a knife in incisive qualities—the more slowly it is drawn home the more crushing force it possesses and the mouths of the vessels are closed. It is only necessary to recall the many anxious moments every operator has experienced in the past, when he has successfully excised a large tonsil, to find the buccal cavity filled with blood and more blood welling up from a large bleeding area, and contrast it with the procedure under consideration, where only a little oozing follows the snare, to realize the tre-

menous advance in this one particular the modern method affords.

The contention then is, from a study of these cases—

(1) That tonsillectomy is the proper operation for the removal of diseased tonsils.

(2) That tonsillectomy in the majority of cases results in no more serious traumatism to the faucial tissues than does tonsillotomy.

(3) That in those cases in which marked systemic and faucial disturbance follows a tonsillectomy, it results because of the difficulty attending a separation of adhesions and that these latter cases are totally unsuited for the operation of tonsillotomy.

(4) That tonsillectomy is always a completed operation. Tonsillotomy is only occasionally completed.

(5) That hemorrhage after tonsillectomy is slight and largely under the control of the operator. In tonsillotomy, hemorrhage is often profuse, at times serious.

### *Discussion.*

Dr. E. L. Shurly: I congratulate Dr. Gibb for presenting this subject so finely. He states the truth regarding the technique of the operation. It seems to me this whole question revolves upon the point whether the tonsil is a necessary organ or not. I think no one will contend that a really diseased tonsil should not be removed, but there are many instances in which only a few of the crypts are diseased, and some cases where there is a general hypertrophy. The approximate results of tonsillectomy are very nice indeed, but we do not know always what the remote results may be. We do know that in the epoch when we began cutting off all sorts of things that were not considered dangerous to remove, we were in the habit of taking the uvula and tonsils off without reference to anything excepting a good operation, but we soon found out that some bad results followed, undoubtedly often due to a faulty or radical surgical operation. But after the dawn of laryngology and the special study of these parts, there were great improvements made in the technique, with immediate results that were illuminating. However, we have to stop and consider now, not only the immediate results of the operation, but the remote results of it—what trouble these people may have with the pharynx or stomach, or with contiguous or relative organs when the whole of the tonsil, which is endowed with an internal

secretion, is taken away. We do know that people may live with the spleen taken out, or a good deal of the thyroid gland taken away, but those persons, after all, are cripples, and show it sooner or later. In my little experience with operations upon tonsils, both by tonsillotomy and tonsillectomy, I do not know that I can give any statistical record; but I do know of some grown up people whom I have operated upon very thoroughly that I do not like to meet, to sit in the street car with. When they afterwards, as well as others, come to consult me about disease of the chest and stomach, etc., I then wonder whether I ought not to be punished or made to support them the rest of their lives for having taken out all their tonsillar tissues. Therefore, I think, while, perhaps in many instances, there may be no evil results, we should remember that the tonsils are necessary organs to the body—that they have an internal secretion *sui generis*, both efferent and afferent lymph vessels, and, although there may be deformed tissues or crypts, that we could take away these deformities while leaving enough of the organ to perform the proper function.

Dr. W. E. Casselberry: When the tonsils are diseased, in the sense either of obstructive enlargement or of being retainers of foul secretion and foci of infection, I favor, as an ideal, their complete enucleation by the operation now termed tonsillectomy in contradistinction to tonsillotomy, a name newly limited to mean only a partial removal. As stated in a publication some five years ago, I am convinced that the more nearly we can conform to this ideal, that is, within the limits of reasonable safety and expediency, the more satisfactory will be our results; but it is well that the qualification expressed by the words "within the limits of reasonable safety" should be emphasized. With this reservation always in mind, total tonsillectomy has been my practice for a period of years long antedating our present more exact technical methods, and I have recorded statistically, the immediate and ultimate results from a total of 600 double operations upon private patients, among whom are relatives, friends and acquaintances, who, together with patients re-examined years afterwards, form a considerable number in whom I have been able to ascertain that the last state of the patient is not worse than the first, a contingency alleged to be possible in the opinion of the last speaker, based on the fallacy that absence of faucial tonsils means absence of function, whereas other tonsillar tissues remain, adequate to take up the function.

I have yet to see in a single one of that number of cases any reason to regret that I made as thorough a tonsillectomy as I did at the time, my sole regret being that I did not make it more thorough in those cases in which a remnant of the tonsil eluded my grasp at the moment.

I agree with the contention of the essayist that the use of unnecessary violence in operating, as by blunt instruments, is of more detriment to the patient than the use of sharp instruments. I have never quite understood the suggestions made by a few operators, whom I know to be skillful, to extirpate the tonsil with the finger nail used as a blunt dissector. Very loosely connected tonsils may be so removed, but the majority are firmly enough attached to render this method tedious and inexact, if unassisted by sharp instruments. For the same reason, more soreness and delay in healing follow enucleation by the cold snare than follow enucleation (not decapitation) by a snare-like, to and fro, action of the blade of the author's tonsillotome. This instrument, which I adapted years ago from Mathieu's pattern, by omitting the transfixion fork and using as a substitute for the fork a tonsil vulsellum forceps, I have used satisfactorily as an enucleating instrument, first separating the pillars and velar lobe as if preparing for a snare, but less freely, hence quickening the operation. I do not use it customarily on adults, because by the cold snare one seeks to avoid serious hemorrhage in adults, but I do often use the tonsillotome with snare action in children under a general anesthetic. Inasmuch as in the literature already standing over my name I have recorded methods of technique differing from that which I now employ, I will tabulate my present routine now adopted:

1. "Nick," that is, make a short scissors cross-cut into the edge of the plica tonsillaris at its junction with the anterior pillar at the point where the pillar curves to join the velum, which serves to relax the tension at its edge of the fold enveloping the velar lobe of the tonsil. Don't "nick" into the muscular substance of the pillar.

2. Draw downward and inward the velar lobe by the author's forceps, insert through the "nick" a small spud knife, edge upwards, and work it upward and posteriorly between the superior border of the velar lobe of the tonsil and the velum, cutting mostly on the pull of the knife and by its pressure toward the surface.

3. Reintroduce the spud knife at the "nick," this time edge downward, and loosen the anterior border of the tonsil from the muscular substance of the anterior pillar, cutting on the pull through the plica tonsillaris, which is merely a fold of mucous membrane which binds the tonsil to the pillar. Let the plica adhere to and be removed with the tonsil, but avoid cutting any of the muscular substance of the pillar.

4. Lift the tonsil upward and inward and liberate its inferior border with the same knife, but not so freely, as a small vessel here, if cut, will delay the subsequent steps.

5. Pull the tonsil forward and loosen the posterior border. In

children this detail is often necessary only in part, and in adults this posterior dissection need not be so free as at the other borders. Either the same knife or a curved, sharp spud is used. It is the most difficult border to see perfectly while liberating it.

*Note.* Item 5 may be carried out before item 4, if deemed more convenient.

6. Envelop the base of the tonsil while making traction with forceps downward and inward away from its socket, and enucleate it, peeling the tonsil with its capsule from the underlying fascia, either by a cold snare or by a snare-like action of the author's tonsillotome.

Dr. O. T. Freer: I agree with Dr. Casselberry that tonsils should be removed by sharp dissection and regard the use of blunt implements which tear out the tonsil, including the wire snare, as a crude and timid substitute for the knife blade, a substitute suggested by the fear of hemorrhage, a fear which the use of keen cutting implements in tonsillectomy has shown me to be unfounded.

I have seen much damage done in rending and tearing the pillars and soft palate in the employment of the finger and blunt separators and I have seen such an operation, concluded with the wire snare, terminate in pyemia, ulcerative endocarditis and death, because of gangrenous pharyngitis, which had its beginning in the decomposing foul sloughs produced by the tearing of the tissues about the tonsil. This unfortunate result occurred to a colleague not at all unskillful.

At present I use for the removal of all tonsils, from the atrophic, hard, shriveled cicatricial one, which, buried in the tonsillar recess, leads to peritonsillar abscesses, to the large protuberant one, a knife dissection method, which I described recently in the *Journal of the American Medical Association* (Feb. 13, 1909, Vol. 52, pages 547-552). The entire operation is performed with knives of suitable form. A most important part of the excision is the cutting out of the velar lobe of Casselberry (the uppermost part of the tonsil where it lies in the soft palate beneath the fossa supratonsillaris), the circumcision of the velar lobe while traction is made on the tonsil is the key to the liberation of the tonsil from its bed, for, as soon as the velar lobe is free, the whole tonsil turns wrong side out like a pocket in a striking and characteristic manner. It is then cut off behind its base by a knife curved on the flat. The operation, including pillar liberation with the pillar knife, is so exact that even the delicate plica triangularis remains intact. Except in the rarest cases, there is only a short immediate hemorrhage. I have never seen delayed hemorrhage of consequence nor secondary hemorrhage at all.



The more serious forms of hemorrhage in tonsil removal are in my opinion nearly always due to cutting arteries ascending or descending in the faucial pillars and the precise technique of the method I describe confines the incisions strictly to the boundaries of the tonsil. The healing is rapid and without reaction, clean knife wounds always having this advantage over the bruised and torn ones created by blunt implements.

One of the greatest obstacles in removing tonsils bluntly is their adherence to their surroundings by reason of chronic peritonsillitis which binds down the fibrous covering of the tonsil to the glosso-palatine and pharyngo-palatine muscles and to other parts of the tonsillar recess. Such tonsils can only be removed by knife dissection. This chronic peritonsillitis, which I have often observed, seems to have received but little notice. It is usually evidenced by smooth thickening of the pillars, which bulge as rounded oedematous masses, their clean-cut delicate shape being lost. In two of my cases such peritonsillar inflammatory hypertrophies so resembled tubercular hyperplasia that portions had to be excised for histologic examination.

In conclusion, I repeat that all removal of the tonsils with blunt implements is timid surgery, is accompanied by excessive reaction and traumatism and should be replaced by knife dissection.

Dr. G. L. Richards: I rise to defend the use of the finger, which Dr. Casselberry says produces traumatism, and also states that with it it is impossible to get out cleanly the buried tonsil. If the finger is introduced just below the posterior superior angle or below the anterior superior angle, that is, in back or in front of the triangular fold, it is easy, as a rule, with the finger alone to make a clean separation between the pillar and the attachments of the tonsil. By continuing the pressure with the tip of the finger one easily completes the separation of the tonsil from its attachments to the fascia external to the superior constrictor muscle. The finger is then carried upward so as to separate the so-called velar lobe, and by continuing this movement backwards and forwards and using a degree of pressure in accordance with the need of the individual case, it is usually easy to roll the upper half or two-thirds of the tonsil entirely out, so as to leave it pedunculated and attached only at the base. The traction forceps, of whatever type desired, are then attached and any further dissection made with the aid of gentle traction. The finger has the advantage over the blunt instruments that one has always the sense of touch as an aid in the dissection. Whether one uses the finger or blunt instrument, with which the dissection can, of course, be made, it is necessary to make it entirely extra-capsular. As a rule, I do not use any traction at the moment of final enuclea-

tion with the instrument, and usually use the Casselberry tonsillotome instead of the snare, the tonsil being removed with capsule intact. Traction should be avoided at the base of the tongue, since sometimes large blood vessels appear at this point. Sometimes in the separation a few fibres of the superior constrictor muscle will be cut, but I have not found this to be productive of any harm.

We have, I think, used the words "tonsil adhesion" rather loosely for many years. As I understand the anatomy of the palato-glossus and palato-pharyngeal muscles, their free borders divide into two folds, the one going backward, becoming continuous with the capsule of the tonsil, and the other going forward, forming the mucous membrane of the tonsil. The plicae are reduplications of the mucous membrane attached to the anterior pillar. While these folds may vary in size, thickness and position, they are normal attachments and should not be given the name of "adhesions," the word adhesion being used in a pathological sense.

Dr. C. W. Richardson: I also wish to speak in defense of the finger dissection. I think it is one of the easiest and most admirable operations that can be done. You will be surprised when you become dexterous in this operation how few the disadvantages are, and how easily the tonsils come out. I think that with the finger dissection in the adult, with tonsils that have been the subject of frequent acute inflammation and quinsy, in whom we should expect adhesions almost impossible to break down, the tonsil frequently shells out better and better results are obtained than in children. As Dr. Richards has said, the main thing is breaking in between the pillar and the tonsil mass. After this is accomplished, it is easy to carry your work upward and separate the velar mass of the tonsil. It is usually wise to separate the velar lobe in the first part of the procedure, then you simply roll the tonsil down and it practically drops out. I often, instead of using any instrument whatever, snare or tonsillotome, grasp the tonsil, which is almost entirely enucleated, with a pair of forceps or haemostats, and, drawing it forward by carrying my finger backwards, take it off readily. In all the cases I have had I have never had any postoperative hemorrhage, and less hemorrhage primarily by the finger than by any other method.

Dr. J. F. Barnhill: It is evident from this discussion, as from those on the same subject in other societies, that a great many operators use different methods and each one succeeds to his own satisfaction. It must be, therefore, that there is something in personal technique. A tonsillectomy, to my mind, is usually very much superior to a tonsillotomy, and I desire to agree with the es-

sayist in this respect. I think that whatever function the tonsil may have, there is plenty other tissue left in the throat, very much like the tonsil, which will take care of that function, especially since the tonsil is diseased. The regret I have usually had in meeting any dissatisfied patients has been the same regret that Dr. Casselberry has experienced, that I have not removed a sufficient amount of the tonsil, and that the patient, therefore, still has a proportionate amount of his old trouble. I believe that when we do this operation for a definite purpose the tonsil ought to be removed completely in order to accomplish that purpose. The technique to me is a simple one. Three instruments are all I ordinarily use: A snare, some kind of tonsil knife and some kind of grasping forceps. I catch the tonsil deeply, draw it outward and forward, and loosen it thoroughly at its upper part; then to finish the removal I very much prefer the snare to any other instrument. The snare, in my hands, has caught the capsule invariably, and has, therefore, removed the tonsil thoroughly, provided dissection has been well done preceding the use of the snare. When other instruments have been used, I often find that some part of the capsule has been left. The wire, if the loop is properly arranged, the snare adjusted and the tonsil is well drawn out, has a tendency to follow the connective tissue line on the outer side of the capsule, whereas a knife or scissors cuts in a straight line and therefore has a tendency to cut through rather than follow outside. I was rather surprised to hear the essayist state that in his 100 cases all the throats looked normal afterwards, with the exception that the tonsil was absent, for there has been one result in many of the tonsils which I have myself removed, and in those which I have afterwards seen which have been removed by others, which, to some extent, occurs in a large majority of all enucleated cases. I refer to a filling-in of the tonsil pit after operation by granulation tissue, and in a certain number of these cases to adhesions occurring between the anterior and posterior pillars, and in a few instances I have seen these adhesions pile on the tongue and to a slight degree bind it down. It is instructive to hear Dr. Freer state that the pain is less when sharp instruments are used, for one of the most unfortunate results from this operation of complete removal of the tonsils is the severe after pain. There are few persons who do not complain of it rather bitterly. As a post-operative measure to prevent hemorrhage, whether after local anesthesia or otherwise, I make firm pressure for a few seconds on the operated area by means of a pillow of gauze which has been saturated with peroxide of hydrogen; then, when the tonsil bed is thoroughly dry, I paint it with Monsel's solution. I never use Monsel's solution on a bleeding area, always waiting until

the field is dry, in which case this styptic has proven very satisfactory.

Dr. C. G. Coakley: I wish to say that in most of my cases, healing is not completed in seven days; there is anywhere from two to four weeks afterwards a small mass of granulation tissue that can be seen and frequently best treated by either punching it out with forceps or touching it with nitrate of silver. I have rarely seen, following the complete excision of the tonsils by the methods described here, any tonsillar fossa left. There is only a smooth area on each side of the pharynx; occasionally there is little projection of the anterior pillar or a little projection of the posterior pillar, but it is usually pretty smooth in that region when the tonsil is completely removed. I have not infrequently noted an irregularity in the lower edge of the velum on two sides, not only in my own cases, but I have seen this same irregularity and obliteration of the tonsillar fossa in cases operated on by other and better operators than myself. I have wondered what effect this condition might have on those who are accustomed to use their voice. Certainly the lower arch of the velum is shortened for some months and this must produce some change in the singing voice.

Dr. G. H. Makuen: One thing which makes Dr. Gibb's paper valuable is the fact that he was able to study his cases for some time after the operation and observe the results. My own position in this respect has been somewhat unique, because many patients upon whom I have operated for tonsillectomy have had defects of speech, and I have seen them nearly every day for many months. Referring to the indications for the removal of tonsils, I think we must all agree that a diseased tonsil can do no good, but only harm, so that it all hinges upon the point as to what is a diseased tonsil. As to the desirability of taking out all of the diseased tonsil, I would say that I can see no reason for leaving any of it in, for such a procedure would be contrary to all the principles of surgery. I do not think it makes much difference how we do the operation so long as we do not injure the surrounding tissues, and so long as the patient is treated properly afterwards. I am not a believer in doing tonsillectomy, turning the patient loose and taking the chances of his getting well. The treatment should be followed up carefully until the wound is healed, and all tendencies toward the formation of pockets by cicatricial contractions and adhesions have passed. The palatal pillars must be left freely movable in order to preserve their functions in the production of voice and speech.

Dr. R. C. Myles: Mackenzie, in his remarkable book, has given the bibliography of the extirpation of the tonsils—since the first

century of the Christian era, and it would seem that we are adopting procedures which have been tried and abandoned at different periods during the past nineteen hundred years. It would be well if we could establish a sound and safe technique for all types of cases. During the past fifteen years I have been dissecting out the deeply imbedded tonsils, either with or without the capsules. The complete enucleation of the capsule is the ideal surgical operation. The after results in a few cases in group D of my classification were followed by cellulitis in the cervical and zygomatic regions.

I have seen a few cases where the tongue was more or less restricted in extension outward, but I do not know the ultimate effect upon singing or talking. I must state, judging from my experience, that, as we go on with experiments there are many little points which will be noticed in a series of cases, which I have not yet seen properly described in the many papers, little things which appear as after results, and I must also state that I observe too many of the sections of the superior constrictor muscles attached to the removed tonsils or capsules. I have had a great many cases of chronic peritonsillar abscesses where I have dissected through this region and quite frequently I have found a cavity between the basic capsule of the tonsil and the superior constrictor muscle, and it would seem to me that occasionally we might get into very serious trouble in this region, especially if we do not differentiate between the walls of the cavity and the capsule.

Dr. J. Price-Brown: In regard to the effect upon the voice I wish to give the opinion of a music teacher in my city. He advised his pupils never to have the tonsils removed. When I asked him why, he said that there were several instances in which his pupils, having promising voices, had them destroyed by a removal of the tonsils. This man had a professional experience as a teacher of voice culture for more than a quarter of a century. I do not agree with his view, but it is quite possible to be too radical in our treatment of tonsillar disease.

Dr. W. K. Simpson: I think, in view of what has been said this afternoon, Dr. Shurly has considerable truth in his statements. Based on what Drs. Barnhill and Coakley have said, are there not some remote difficulties with the complete removal of the tonsil? What harm about the small amount of tonsillar tissue that a good operator may leave in by the ordinary means of tonsillectomy? I think before we give in absolutely to this present way of tonsillectomy we would better bear the remote effects in mind. I think we are liable, at the present time, to base our results of the so-called tonsillectomy on the immediate results, but I think in a number of cases we may get just as much harm from the filling



up of this cavity with the cicatricial and connective tissue that will form there, interfering with the muscular action of the velum, as though a small portion of the tonsil had been left.

Dr. J. O. Roe: I hesitate to take up your time in extending this already lengthy discussion, but in view of what some of the speakers have said, I wish to emphasize the importance of tonsillectomy instead of tonsillotomy, so commonly done.

Nothing has been said in this discussion about the mischief caused by the septic absorption from diseased tonsils through their internal connection with the lymphatics of the neck, and the amount of general disturbance that may be caused by septic conditions of the tonsils, amounting in some cases to a general septicaemia. Dr. Goodale and others have called attention to this ready communication from and through the tonsils to the lymphatic and general system, a condition which should never be overlooked. I have, in a great many cases, seen more trouble, more lymphatic involvement and general disturbance caused by diseased tonsils after having been partially removed than were present before the operation. This is due to the opening up of the capsules and the liberation of septic material contained therein, leaving an open feeding ground for germs and germ propagation and infection, which does not take place if all these diseased structures are entirely removed. When the tonsil is diseased, it is diseased all the way through. The crypts go to the bottom of the tonsil, and if you leave a portion of these diseased tissues behind you have an increasing absorption of these septic products. I would, in the majority of cases, rather let tonsils alone than to remove a portion of them, as the septic absorption would be quite sure to be increased rather than diminished.

Regarding the technique of the operation, for the radical removal, every one has his own particular opinion and method concerning the operation, and each operator considers his method the best, and I believe it is, for him, for the personal equation has much to do in adapting him to certain methods and procedures. The operation of tonsillectomy should not be regarded as a trivial surgical operation, for it is an important one, not to be considered lightly, and the wound should be carefully looked after until the parts are healed. There is one point regarding the removal of the tonsils which should not be overlooked—it is the radical removal of the upper lobe of the tonsil, which so frequently is completely submerged and extends high up into the arch of the palate. If this is left behind it often becomes completely cut off from its external communication as healing takes place, and is thereby shut up in a pocket, so to speak, causing a great deal of mischief. I would rather leave behind a large part of the lower

portion of the tonsil than any part of this upper lobe, as much less disturbance would be caused thereby.

Dr. D. Bryson Delavan: The subject of tonsillotomy, although prehistoric, is always interesting and ever provocative of discussion. We have all heard of the various operations practised for the removal of the tonsils. There are few of them that are new. The paper to which we have just listened is well worthy of consideration, since it gives the results of observations made with unusual care and under particularly favorable conditions. I should like, however, to propose seriously and with a good deal of earnestness a study on the part of this Association of the methods for the prevention of those congestions of the lymphoid areas of the upper air passages which result in chronic hypertrophies. We are showing ourselves very much behind in medical progress that we allow so many of these cases to develop until operation is a necessity. A certain proportion of them, by proper dietetics and proper care, may, in my belief, be entirely avoided. It is time that more attention had been given to the prophylaxis of lymphoid hypertrophy.

Dr. J. O. Roe: Dr. Barnhill has spoken of the pain and soreness of the throat following operation on the tonsils, but nothing has been said during the discussion about methods of relieving it and making the patient more comfortable. I would therefore like to mention the use of orthoform for this purpose. Soon after the tonsils are excised and the bleeding is stopped, if a little of this powder is dusted over the raw surface with a powder blower, it will prevent the soreness and distress which so soon follow the operation, and by having a little applied or blown in every four or five hours it will keep the patient quite comfortable. If used just before the patient attempts to eat, the pain on swallowing is very much ameliorated.

Orthoform is something of an antiseptic in addition to its anodyne properties. It is also non-irritating and seems to assist the process of healing.

Dr. Emil Mayer: I think that the suggestion made by Dr. Delavan is an exceptionally good one, but there should be added to it the study of the results of our operations. If five years after operating we took a series of cases, as some of us are doing, give the report of the patients five years after operation, how many had a subsequent quinsy and peritonsillar abscess or equivalent thereto, I think it would be particularly advantageous. In regard to the operation in question, I have found the same difficulty as the essayist in the use of a blunt dissector, and having a very strong and radical objection to the use of a razor-sharp knife in the hands of any but a very skilled operator, I have

taken the blunt separator and have had its edges serrated so that it represents a file, but can be used as a knife if occasion requires. I object to the use of the finger as unsurgical, and the general surgeon is getting away from the use of the finger or hand; he always uses the rubber glove, which is impossible in this operation. The finger advocates will readily agree that we can do as well with sight as with touch, and the operation becomes more simple by the introduction of such an instrument as I speak of. Particularly do I agree with the last speaker, that the important part is the removal of the tonsil in the upper portion, and getting that part thoroughly enucleated will help us very materially in our results, and little harm can come to the patient if a little of the lower portion is left behind. Regarding the whole subject, it does seem to me that we have all made very light of this question. We are apt to make light of what may be a serious question, as this one of hemorrhage, and I feel we should be very careful in making statements, as they go broadcast through the land, and while it is possible for a man who is skilled and living in a large city to watch what is being advised, the average man in a small town in the country has not his facilities and we should therefore be very careful in recommending these radical measures.

Dr. G. H. Makuen: I think, while we are on this subject, there is one point which ought to be settled. For some years, as far back as I can remember, we have been getting up here and speaking of separating the tonsils from the pillars, and Dr. Myles invariably gets up afterwards and says he has never seen the tonsil adherent to the pillars. I saw a case the other day where it was quite impossible for me to tell where the edge of the anterior pillar ended and where the tonsil began, and I had to make my incision where I thought this line of separation should be.

Dr. Gibb: The criticism of Dr. Shurly as to remote results was answered so fully by Dr. Casselberry that I have not a great deal to say, except that in my paper I stated the class of patients were those with *diseased tonsils* between the ages of six and sixteen. The little known about the function of the tonsils has led me to believe that if it has a function it is in operation before or about the age of eight, and a tonsil that is diseased has no function at all. I therefore have no twinges of conscience that I will hear from these cases again. I fear that I have not presented my case in as clear a manner as I could from the discussion which has been produced. This is not a new operation, but the technique was given simply to show how the tonsillectomy was done in these 100 cases. It seemed a good opportunity to study 100 cases where one could see the patients for as many months or years as desired. From the discussion as to technique I find

myself in a middle position: some gentlemen advocate sharp, others blunt, dissectors, while in my method there was a combination of the two. The use of the finger for dissection has been rather fully gone into. In most of the cases of tonsillectomy it has not been possible to use the finger as a complete dissector. I always use the finger for separation as far as possible, but to use it to completion I find but few cases in which that can be done. If the finger is used in a rough manner it does more harm than good. Some remarks have been made regarding the appearance of the fauces after operation. I have seen granulation in many cases soon after operation, but in the cases reported I am giving the result after a year, and by this time these granulations have disappeared. I do not recall seeing any granulations later. I have noticed the appearance which Dr. Coakley spoke of, the shortening of the velum, but have observed no injurious effect on the patients because of it. Removal of the tonsils in singers I have done without a particle of effect on the voice. I know a young woman who is a very prominent singer, whose tonsils were removed without effect on her singing voice. With us some of the teachers advocate the removal as an improvement to the singing voice.

CAVERNOUS SINUS THROMBOSIS; TERATOMA OF  
THE SOFT PALATE. CASE REPORTS.

BY LEWIS A. COFFIN, M.D.

*A—Cavernous Sinus Thrombosis.*

While still at her country place, on the morning of October 4, 1908, Miss J. G., fifty-nine years of age, was seized with a sharp and violent pain in the right anterior aspect of her head. For four or five days following, beside the severe pain located about and in the right eye, there was nausea and vomiting and patient complained of a blowing or rushing noise. The nurse said she could hear the same noise with her ear at the patient's temple. About the fifth day after the onset of pain some bulging of the right eye was noticed and diplopia developed. The temperature during this time was never over  $99\frac{1}{2}$  degrees F., nor did it rise higher during the subsequent history of the case.

On October 12 patient was moved to the city and I, being asked over the phone to call, was told of the severe pain over, and bulging of the right eye. Wrong as it may seem, my diagnosis of disease of the nasal accessory sinuses was made, and I hastened to make the call, prepared to confirm the long-distance diagnosis. Found patient in condition described, but history was not gone into as minutely as should have been done. The right frontal sinus was darker on transillumination than the left, and very tender on percussion and pressure. No discharge was seen in the nose. Drainage, I believed, to be blocked, and the eye condition due to pressure. Septum was markedly deviated to the right and there was a broad ecchondroma on that side of the nose. Owing to this intra-nasal condition and the temperament of the patient, who declared she would consent to no operation except under general anaesthesia, I decided to do a radical Killian operation. I asked Dr. C. G. Coakley to see the case with me. He confirmed the diagnosis and agreed that a radical operation offered the best solution of the case, suggest-



ing, however, that we delay operation to obtain a radiograph of patient's head. Dr. Caldwell made the exposure on the afternoon of October 13, and on the morning of the 14th delivered an excellent negative, which showed cloudiness of both frontal and ethmoidal regions; greater cloudiness showing on the right side. A complete Killian operation was done in the afternoon. I was much surprised to find in the frontal sinus no pus, polypi nor granulations. The lining membrane was, however, very thick from congestion, as was the membrane lining the ethmoidal and sphenoidal cavities. Bleeding was very profuse, and although there may have been at some point a diseased cell or pus, I was not able to recognize it. Recovery from operation was uneventful, except for condition about the eye. Immediately the pain disappeared. The exophthalmus was reduced and continued steadily to improve, but there developed a marked chemosis of the lower lid. Sixteen days after the operation, the chemosis persisting, I asked Dr. Egbert Le Fevre to see the case. He gave as his opinion that we had been dealing with a thrombosis of the cavernous sinus, and said further that he believed that the operation had been of the greatest benefit, as by reducing the oedema about the tissues of the eye by the extensive bleeding we had probably saved the sight of the eye, if not the life of the patient. To reduce the coagulability of the blood, as well as to break up any existing thrombus or clot, large doses of lemonade were ordered. A slightly astringent wash and light pressure were applied to the eye. Improvement in the chemosis was immediate and steady, and patient was considered well on November 12. Her nurse left her on November 14, and I find this entrance on her chart. "Patient in A No. 1 condition."

Thrombophlebitis is of traumatic or septic origin. In the region under discussion thrombophlebitis from traumatism may be ruled out. Herbert Parsons<sup>1</sup> says: "Thrombosis of the cavernous sinus may arise from extension from the ophthalmic vein, the source of infection being wounds or septic infection of the skin, etc., or from the ear, nose and accessory sinuses, pharynx, tonsils, etc., or as a metastasis in infectious diseases or septic conditions."

<sup>1</sup>J. Herbert Parsons—*The Pathology of the Eye*, vol. IV, p. 1226.

Thrombophlebitis is a progressive and cumulative disease, as long as the source of infection persists, but the source removed, the disease is marked by retrogression and self-limitation. The last holds good, of course, only when the source of infection has been removed before the disease has progressed to a point beyond repair.

Siguard, H.,<sup>2</sup> says the prognosis of thrombophlebitis is very gloomy, and he is inclined to believe, with Parker, that thrombophlebitis of the cavernous sinus is equivalent to a death warrant. He cites seven cases, however, in which recovery from a condition diagnosed as thrombosis of the cavernous sinus followed operation on and about the mastoid.

In my own case it is probable that the source of infection was in some one of the accessory sinuses of the nose, that by the operation the source of infection was removed. Much of the oedema and pressure were removed immediately by the local blood letting. Liquefaction of the clot and a re-establishment of circulation through the sinus was probably hastened by the administration of the lemon juice. This question presents itself: Given a case of thrombosis of the cavernous sinus in which no trouble can be found about the ear or elsewhere which may be considered as the septic focus, would we be justified in doing a radical Killian operation in the hopes that the septic origin might be in some of the accessory sinuses of the nose? I do not hesitate to say that I believe we would.

#### *B.—Teratoma of the Soft Palate.*

In the latter part of October, 1908, Mrs. H. R. consulted me on account of a tickling in her throat and a constant desire to cough on lying down.

Mrs. R. is a lady sixty-six years of age, very large, of a nervous temperament, and has very large varicose veins about the sides and at the base of the tongue. For years she has had what she calls strangling spells, the tendency to which has been well controlled by cathartics and nitroglycerine. When told of the

---

<sup>2</sup>Siguard, H.—Thèse de Paris, 1904. Thrombo-Phlébite des Sinus Caverneux d'Origin Otitique.

tickling and cough I, not being in a condition at the time to examine the throat thoroughly, thought probably it was caused by the varicose condition at the base of the tongue and prescribed accordingly.

About ten days later, on the phone, I was told her condition was no better. The patient was asked to come to my office. With a small mirror in the back of the throat I discovered what seemed a small tumor lying just behind and above the uvula, and of the shape of the uvula. Hooking the velum forward and up with the mirror, a tumor as large as my thumb hung free in the pharynx. I stepped to the phone and asked Dr. Jonathan Wright to come to my office, as I wished him to see the growth *in situ*. Dr. Wright and myself both thought it to be a simple papillomatous growth. I snared off what I could of the growth through the mouth and gave it to Dr. Wright for microscopic study. His report was as follows: "This specimen is apparently primarily a teratoma; cells included in the tissue probably from embryonic life. They are apparently branchiogenetic cells. Unfortunately, there are areas where the endothelium of the blood vessels is so infiltrating the tissue as to leave little doubt in my mind that we have here an endotheliomatous growth of serious import. The surface epithelium is hyperplastic, assuming the form of a papilloma." Dr. Wright asked me to submit the slides to others for an opinion. Dr. Hodenpyle, of Columbia University, reports as follows:

"The tissue consists partly of a new growth and partly of the underlying normal tissue. This latter consists of mucous glands, a loose stroma with blood vessels, etc. The growth itself consists of two parts. The major portion is composed of intercommunicating strands of squamous epithelium, arranged in such a manner as to resemble a papilloma. On either border the growth is of different character. Here and originating in the columnar epithelium the growth is distinctly glandular in type. It gradually becomes atypical (i. e., bordering on carcinoma) and finally becomes merged into the papilloma.

"The growth is infiltrated with a moderate number of leucocytes, and careful research reveals but a very few leucocytes.

"I should regard the growth as a papillary adeno carcinoma,

and I think it took its origin just at the junction of squamous and columnar epithelium. From the specimen I gain the impression that the growth is not very malignant, at least, some of the signs of malignancy are wanting. Not knowing the history of the patient I am unable to speak definitely upon this point. However, I would suggest the advisability of removing any remaining traces of the growth if there be such. Yours sincerely,

"EUGENE HODENPYLE."

In accordance with the advice of Drs. Wright and Hodenpyle I operated for the removal of the base of this tumor, which was situated in the median line, just posterior to the septum, in the following manner:

Under cocaine anaesthesia a transverse incision from molar to molar was made through the tissues of the hard palate in a line parallel to, and just anterior to, its junction with the soft palate. The posterior flap thus made was dissected back until free of the hard palate, when the incision was carried through the soft palate into the nasao-pharynx. The soft palate was then separated into two layers, the posterior containing the growth was cut out as near the eustachian tubes as possible. The transverse incision was stitched up and healed by primary union, except for a small slough in the centre. The opening thus caused was completely filled by granulation and contraction in about one month. Bleeding during the operation was practically nil. Dr. Wright has given much study to this growth and has made it the subject of many consultations, and sends me the following report for this paper:

"DEAR DR. COFFIN—In going over the reports of the case of Mrs. R., which we made you from the laboratory without a view to their being incorporated in a report for publication, in looking over the sections, and in considering the various expressions of opinion as to the tumor by competent histologists to whom the sections were submitted, there is so much conflicting evidence that I am unable to say more than that it was regarded as an epithelial growth of a malignant nature. I was inclined at first sight of the piece removed for microscopic examination to think it a teratoma of branchiogenetic origin, with evidences of malig-

nant potentialities of a feeble character in certain cells, some of which were of endothelial appearance and some of an epithelial nature. On examining the whole tumor there can be no doubt that the fimbriated extremity from which we on inspection in the mirror made the diagnosis of a benign papilloma presented the structure microscopically which warranted it, but deeper down, closer to the base, were various appearances of graver import, which, when revealed by the microscope, justified the operative course pursued.

"Frankly, I do not know what name to give the growth, and a minute and exhaustive description of the objective appearances would extend this report beyond the limits suitable for your purpose.

JONATHAN WRIGHT."

The soft palate seems to be a favorite field for the development of trouble-making tumors—trouble for the pathologist as well as the possessor.

They are often diagnosed as mixed tumors, but in several instances have been classed as teratoma. Serapin<sup>3</sup>, in discussing these tumors, says:

(1) The mixed tumors of the palate form a group by themselves, from the pathological, anatomical and chemical point of view.

(2) They have a common origin with teratomata and teratoid tumors.

(3) From a clinical point of view, they are benign in character, easy to enucleate and not inclined to recurrence.

Garel<sup>4</sup> has reported a teratoma of the soft palate. Fullerton, R.<sup>5</sup>, has reported a teratoma arising from the right tonsillar region.

So far as I have been able to look the matter up, mixed tumors of this region have been reported by the following men:

<sup>3</sup>Serapin—Mixed tumors of the palate. *Russ. Archiv f. Chirurg*, Feb. 2, 1903.

<sup>4</sup>Serapin—Mixed tumors of the palate. *Russki Chirurg. Archiv*, 1903.

<sup>5</sup>Garel—Tumeur rare du voile du palais. (Teratoma of Soft Palate). *Bulletin de la Soc. Méd. des Hôpitaux de Lyon II*, 1903. Séance du 24 Fév., 1903.

<sup>6</sup>Fullerton, Robert—Teratoma arising from the right tonsillar region. *Brit. Med. Journal*, Oct. 12, 1907.



## Bibliography.

- Gevaert—Les tumeurs du voile du palais. *Belg. Méd.* V, 1898, p. 385.
- Cordes—Ein Fall von Endothelioma myxomatodes palati mollis. *Deutsche Med. Wochenschrift* 35, 1900.
- Halstead—Mixed tumor of the soft palate. *The Laryngoscope*, Sept., 1906.
- Leto (Luigi)—Tumore misto del palato. *Archiv Ital. di Laringologia* III, 1906.
- Chaput—Tumeur glandulaire (adeno-myxome) de la voûte palatine. *Bull. et Mém. de la Soc. Anat.*, No. 9, 1900.
- Gross, G.—Hoche, G.—Tumeur mixte du voile du palais. *Société de Médecine de Nancy*, Séance du 23 Juillet, 1902; *Revue Médicale de l'Est*, 1 Novembre, 1902.

## Discussion.

Dr. W. L. Ballenger: I heard nothing in the paper presenting the symptoms of cavernous sinus thrombosis. I have seen two cases myself of toxic origin, and I wish that Dr. Coffin had incorporated the symptoms. The second point I wish to make is that they used the skiagraph in the sinus disease. In my case, I was unable to tell by looking at the skiagraph whether the case was suppurative or simply a catarrhal congestion of the sinuses. The conditions look exactly alike, and the skiagraphs therefore have no value in differentiating between the two conditions. That is a point which I think should be brought out. I have made this observation a number of times. Because you get a clouded skiagraph is no reason you should not operate.

Dr. Thomas Hubbard: I had a similar case to that of Dr. Coffin, but I hesitated to classify it as cavernous sinus thrombosis. The patient had some distinct evidences of suppuration in accessory sinuses. The principal symptoms during the early stages were intense pain, extreme exophthalmos with the eyeball crowded to the outer angle of the orbit. The eye-ground was carefully studied by an ophthalmologist, and, as the treatment gave no relief and there were evidences of beginning disturbances of the optic nerve, it was thought best to operate. We decided to explore the orbit, and especially to separate the periosteum from the medial orbital wall, and see if there was a fistula from some of the deeper ethmoidal or sphenoidal cells. This pro-

cedure presents some advantages over that of Dr. Coffin's. Make the usual Killian incision, explore the periosteum as far back as is safe, and, finding no pus, do not open the accessory cells from the orbit. We found no pus and decided to go no further in that direction, only making a slight incision through the periosteum into the orbital cellular tissue in search for pus. The ethmoidal cells were cleaned out intranasally, which I believe is the better surgical procedure. There is always an additional risk in operating on the sinuses during the acute stage, and to go through even the lower portion of an uninfected frontal sinus is a very great risk. This is avoided by entering the ethmoid intranasally. There was in my case, as in Dr. Coffin's, immediate improvement and the result was satisfactory, with only transient disturbance of vision and no subsequent intranasal complications. I think Dr. Coffin's title sounds rather formidable. To be sure, all infectious progress through contiguous tissue is a process of septic phlebitis, but I believe that he ascribed too much importance to exophthalmos as a symptom. He may have had an orbital cellulitis, due to infection through a minor vein.

Dr. Coffin: Dr. Ballenger doubts the diagnosis because symptoms of thrombo-phlebitis have not been given in connection with the case. I would say that, aside from the symptoms given—namely, sudden pain in the head—the gradual development of exophthalmos, diplopia, chemosis and a bruit-like sound heard, both subjectively and objectively, I do not know the symptoms. Would like to have Dr. Ballenger state what the further symptoms are. Symptoms had persisted for eight days when operated. It is not necessary that the other sinus should become affected in order to prove the case. Herbert Parsons says this transference to the other side takes place in about 50 per cent. of the cases. Further, Dr. Ballenger evidently cannot have read Dr. Coakley's paper on "Skiagraphy of the Accessory Sinuses," as he showed that cloudiness will occur either from a bony cavity filled with fluid or lined by a thickened second membrane. In regard to Dr. Hubbard's not knowing whether he would classify his case as cavernous sinus thrombosis, I can say nothing. We were surprised at finding no pus in our case. When Dr. Lefevre said it was a case of cavernous sinus thrombosis it explained the case, and

we accepted the diagnosis. Dr. Hubbard was fortunate in his results. He opened the orbit and cleared the ethmoids and sphenoid intranasally. He skipped the frontal sinus, which might have been the source of infection. I should consider the risk in doing a radical Killian in an acute case less than that attending intranasal work, which can never be as cleanly, thorough or give the same amount of drainage.

SOME RECENT CASES OF NASAL SARCOMA; SUB-  
MITTED AS A COROLLARY TO A FORMER  
PAPER UPON THE SAME SUBJECT.

BY J. PRICE-BROWN, M.D.

It is acknowledged that in our professional life we should hold no secrets in the treatment of disease. Every method should be as open as the day. And if, after long experience, we have found faith in one method above all others, by which valuable lives have been saved, no matter how long and tedious may have been the path of the finding, it becomes our duty to proclaim it to others; and to continue to proclaim it, until our confreres not only give us a patient hearing, but also grant to the method a reasonable examination.

Six years ago I reported to this Association three cases of nasal sarcoma. All of them had exhibited the usual classical symptoms—continued obstructive growth, repeated hemorrhages, etc. All had been previously operated upon. All had been of long standing; and pathological examinations of sections taken from each individual case verified each diagnosis. Two were reported at that time to be cured; one was still under treatment.

Four years ago I submitted a further report upon the last of the three. At that time it still required, occasionally, operative treatment at the basic spot, at the juncture of the posterior naris with the vault.

This necessity is now over, and two and a quarter years have elapsed since the last cauterization was made.

To-day all three men are perfectly well, following their usual vocations as bread-winners for themselves and families. It is fourteen years since the first was last operated on; seven years the second, and over two years the third.

Case IV. In the December issue of the *Annals of Otology*, for 1906, I reported my next case, of which I offer a brief note. The patient was a butcher, aged 58. His father had died of cancer

of the stomach at the age of 72. On examination I found the left nasal passage from the anterior to the posterior naris filled with a dark, dense growth, which bled on being touched. After removing a section with a knife, microscopical examination by a pathologist proved it to be round-celled sarcoma. The treatment was on similar lines to that reported in the previous cases. In two weeks the growth was, seemingly, entirely removed and the nasal passage cleared of obstruction. The growth in this case was from the outer wall, the middle and inferior turbinals being involved and softened. The electro-cautery operations numbered seven or eight, being done at intervals of one or two days. At the expiration of the time mentioned there was complete restoration of normal breathing through that nostril. His temperature when he first presented himself was 99 2-5, and it continued more or less elevated throughout the treatment, running between 99 and 102 degrees. As the operative treatment drew to a close, septic symptoms developed. He lingered about two months and then succumbed to them. He died, I believe, from the absorption of toxins from the site of the original tumor. There was, however, no return of the sarcoma, nor of inflammatory vegetations; and both the patient and his friends were spared the horrible and unsightly disfigurement and distress which usually attends death from this disease.

Taking this as one fatal case out of four, 75 per cent. of recoveries have been the result of the electro-cautery method of treatment, which was adopted in all of these cases—a fairly good showing when we consider the far smaller percentage of recoveries which have followed the usual surgical methods of operation.

More than two years elapsed. Then, on April 1, 1909, Dr. Kerr, of Toronto, referred:

Case V. Mr. C. C., age 35. His general health had been good; also his family history. He was a bachelor, and a weaver by trade. For several months there had been gradually increasing stenosis of the left nasal passage, and for the past few weeks complete occlusion, affecting even the right side. Taste and smell were both gone, and the voice had a thick, nasal twang.

*Examination.*—Left nasal passage packed with a red, fleshy growth, which bled on being touched. On applying cocaine and adrenalin, the tumor was found to be widely sessile and attached chiefly to the triangular cartilage of the septum. It extended to, but not into, the naso-pharynx. A segment was at once removed



by knife and submitted for pathological examination. Drs. Carveth and Davis gave the following report:

"The specimen is for the most part composed of small, round cells, with deeply staining, round nuclei and but little cytoplasm. There is a small amount of interstitial reticulum. There are many blood vessels with undeveloped walls, some showing only the endothelial lining, and in some cases they seem to be blood spaces rather than vessels. The microscopical examination, together with the clinical history, incline us to believe that the growth is a small, round-celled sarcoma."

Electro-cautery operations were repeated almost daily for a period of two weeks, the sloughs presented being a portion of what was taken away during that period. By the time the growth was fully removed the nasal passage was quite free and breathing had become normal again. For the six succeeding weeks he has been under observation. The sense of smell has returned, and for more than a month he has been doing his regular work. There is no indication of the redevelopment of the sarcoma.

Case VI. April 9, Mr. W. S., age 20, was referred by Dr. Nicol, of Cookstown. For more than two years he had suffered from a constantly increasing growth in the right nasal passage. For the whole of this period he had lost the sense of taste and smell. Nine months ago the stenosis had become very severe, and, being referred to a surgeon, segments had been removed by one means or another from then until now, each one being attended by excessive hemorrhages. As the tumor continued to increase in size, he was finally brought by his family physician to the city and placed in the Toronto Western Hospital, under my care.

I found complete occlusion of the right nasal passage by a red, inflamed mass, which extended from the anterior naris backward into the post-nasal space. There it assumed a globular form and seemed to be attached to the right summit of the septum. It bore no resemblance either in attachment or appearance to adenoid tissue. The slightest touch caused bleeding; yet, notwithstanding this fact, the hardness within the nasal cavity was so dense that, on first examination, I considered the obstruction to be partly due to a cartilaginous and bony ridge of the septum; which, after a free application of cocaine and adrenalin, I attempted to remove

with a saw. But the instrument met with neither bony nor cartilaginous resistance. It simply removed a mass of tissue, which upon pathological examination proved to be a portion of an angio-sarcoma, as verified by Drs. Davis and Carveth. The bleeding was excessive, and nasal packing had to be resorted to.

"Examination of specimen from nostril, we find that this is an angio-sarcoma, composed of small, round cells in a fibrous reticulum, having in it large and numerous blood vessels with thin walls. Myxomatous degeneration is found in places.

"(Signed) L. A. DAVIS,  
"GEO. H. CARVETH."

On the 11th the tampons were removed, and electro-cautery operations were done on the 12th, 13th, 14th and 15th of April.

On the afternoon of the 15th he had a severe rigor, and in the evening, when sleeping, had a large involuntary movement of the bowels. Nasal operations were consequently suspended.

On the 18th the patient awoke in the morning with agonizing pain around the left ankle, the opposite side to that of the sarcoma. This was followed by swelling. The treatment at first was by fomentation and subsequently by poultices; but the leg was not opened until May 3, when a large amount of streptococcal pus was evacuated. Several days later a smaller abscess was operated on on the opposite side of the foot. Since then the leg has completely healed.

To return to the sarcoma. On the 19th, the day after the chill, the nose was cauterized, but not again until the 29th, after which the cautery operations were repeated almost daily until May 17, the rule being to cleanse the nasal cavity and anesthetize it with cocaine and adrenalin; then to cauterize as much of the growth as was deemed advisable each morning, and to follow this by an evening dressing.

By this time the nasal cavity was tolerably free from the growth all the way back to the naso-pharynx. So, on May 18, chloroform was administered and a large portion of the naso-pharyngeal portion of the tumor removed by means of a modified Lowenburg's forceps, and, as the growth had been fissured in several places by the intra-nasal operations, this lessened the hemorrhage.

The attachment was to the anterior part of the roof of the naso-pharynx, to the septum and also to the outer wall and to the upper side of the soft palate.

Subsequently I operated almost daily with the electro-cautery upon the fragments of the growth still remaining, and upon the base of the naso-pharyngeal pedicle. This could all be done by means of a strong light through the nasal cavity. These operations were continued until last Saturday, when the treatment was almost complete.

The nose is free, and practically all that remains of the tumor are a few disintegrating sloughs, which will soon cease to form. In this case, too, the sense of smell has returned. Still, when I return, I may find a few minor cauterizations necessary.

Case VII. On April 12, 1909, Mr. S. W., age 18, was referred to me by Dr. W. M. Brown, of Neustadt. The history in some respects was more severe than in the last-mentioned case. For several years the left nasal cavity had been filled with a similar growth, extending into the naso-pharynx, where it assumed a much larger size than in the case of Mr. S. During the last two years he had undergone very many operations by snare and forceps and cautery, each being attended by abundant hemorrhage.

On examination, I found nasal breathing on either side impossible. The left passage was filled by the growth swelling out in a roundish form to within half an inch of the nostril. The right side, while narrowed by the pressure from the opposite chamber, was filled with pus. In the post-pharynx was a large globular mass completely filling it. He was at once placed in the Western Hospital.

I need not detail the treatment in this case, as it was on similar lines to the preceding one, which resembled the method practised in all the cases I have reported.

In this, however, there were no preliminary operations of any kind to secure a section for pathological examination. That was deferred until later, the daily cautery operations being commenced at once. As the main object was to reduce the size of the tumor as speedily and as safely as possible, the attacks were made on the central part, leaving the shrinking shell as a protector to the normal tissues. Consequently, although the sittings were

long and tedious to the operator, they produced little pain in the patient. Little by little the heart was eaten out of the nasal portion of the tumor and the naso-pharynx was reached. In the meantime I had discovered that the attachment was to the middle turbinal and upper posterior end of the septum and naso-pharynx, and, like the former case, there was also an adhesion to the soft palate. Many sloughs were taken away during the first month of treatment, and the nasal cavity became quite free. Still, breathing through the nose was quite impossible owing to the presence of the post-nasal section of the growth, although several cautery cuts into it through the nasal passage had been made.

On the thirty-first day of treatment chloroform was administered and the body of the tumor removed, post-nasally, with cutting forceps. The bleeding was very severe—much more so than in the previous case just reported—and post-nasal packing had to be done. Two days later this was removed, when I discovered one piece of tumor still attached to the post-pharyngeal wall, low down and immediately behind the left posterior pillar. It presented the appearance of a hard, misplaced uvula. Another segment occupied the posterior part of the nasal cavity, and was attached to the middle turbinal and the summit of the septum. These were both removed by electro-cautery. Since then many other spots have required to be burned in the nose and post-nasal space, but all were done directly through the nasal cavity.

During the last week the improvement in every way has been very marked. There are now no vegetations of the growth to be seen anywhere—only sloughing spots from recent burnings, which are removed daily. Nasal respiration is perfectly free; the vault open to the fullest examination. The affected nostril is much wider than the other one all the way through, and the posterior choana at least three times the size of its corresponding fellow. The sense of smell, entirely absent for more than a year, has likewise returned. A noticeable feature, particularly marked in this case, is the ease with which any recrudescence of the disease could be attacked again *per vias naturales*.

In one respect the pathological examination in this case differed from the preceding two. The section taken was from the

centre of the mass removed in the major operation from the naso-pharynx. The report is here appended.

"Dr. Price-Brown, Carlton street, City.

"Dear Doctor—I have examined the specimen of tissue from the naso-pharynx, and consider the condition to be one of myxosarcoma. The myxomatous tissue, forming a considerable part of the growth, is exceedingly vascular, the vessels as a rule having poorly developed walls, and in different areas of the growth there are masses of small round cells, the individual cells being separated by very scant stroma, which in places contains thin-walled blood vessels. The condition, I believe, is one of sarcomatous transformation of a myxomatous tissue. Yours faithfully,

"(Signed) H. B. ANDERSON,

"Assoc. Prof. Clin. Med., Univ. of Toronto."

In reviewing these cases, it may be noted that the whole seven cases occurred in males; that the ages were respectively 18, 20, 21, 21, 35, 50, 58, and that two of them occurred in the right nasal passage and five in the left. Three out of the seven have permanently recovered; one died; the fifth had no return six weeks after healing, and in the last two the growths have been removed, the patients being still under treatment. They were all private patients.

In view of these facts, I think I am entitled to present this subject in the light of research work—not in pathology, but in operative treatment—and in doing so there are several points I would like to touch upon, basing them upon the history of these cases, with the fourteen years' experience which they have afforded, and the fact that the process and results have made me a stronger advocate of the treatment here outlined than ever.

1. In sarcoma of the nose the usual site of origin is in the soft tissues, and not in the bony framework which supports them.

2. That the origin is usually in the form of a pedicle, which rapidly becomes sessile.

3. That as the sarcomatous mass enlarges and presses upon the surrounding mucosa abrasions take place that are quickly transformed into adhesions. These in time may become almost co-extensive with the disease itself.



4. These adhesions never attain the vitality and virile power possessed by the pedicle. Hence, when once destroyed, they are not likely to reform again.

5. Recrudescence, however, may take place in the region of the pedicle; and, in view of this contingency, this region should be kept under regular observation and control.

6. Owing to the fact that in many cases of nasal sarcoma the affected cavity becomes entirely filled by the hemorrhagic growth, that its adhesions are extensive and that it is impossible at the time of examination to locate them, attempts at intra-nasal removal by the ordinary knife are inadvisable; but that gradual and systematic dissection out by the cautery knife, in suitable cases, is a method which is always available and should be encouraged.

### *Discussion.*

Dr. J. E. Logan: This is a very interesting subject to me, as I have had a number of just such cases as Dr. Brown reports. In 1893 I reported before the Pan-American Medical Congress, at Washington, the case of a man 54 years of age, upon whom nine previous operations had been performed for the removal of what proved to be a round-cell sarcoma in the post-nasal space. This growth was removed by the galvano-cautery knife, and it never recurred in the former location. Eight years after the patient died of sarcoma of the pancreas.

Another case was one of spindle-cell sarcoma operated upon before my class in 1906. A very large growth attached to the body of the sphenoid and occupying the entire left sinuses of the face. I attempted to remove this by galvano-cautery, but the results were so slow that I resorted to more radical measures. The common carotid was tied and the growth was removed from the nose by means of morcellation and the cold-wire snare. The growth was completely removed, but recurred in five months afterward. The patient applied to me for further treatment, but I refused to operate on the grounds of my fear of his death from hemorrhage upon the table. Dr. Fenger, of Chicago, diagnosed a fibroid tumor and placed the patient under a general anesthetic, and in less than five minutes after operation began the patient died.

Another very interesting case was that of a melano-sarcoma of the nose and naso-pharynx in a man 64 years of age. I removed a very large growth from the body of the right sphenoid by means

of the snare. This case repeatedly recurred, and I operated upon it a number of times. I could remove large masses exhibiting almost the entire contour of the nasal cavity. Also removed large masses from around the gums. The patient lived about a year and a half.

I desire to call attention to the case of a boy, aged 14, who came to me in consultation with his doctor. This case presented a well-defined spindle-cell sarcoma, filling the entire left nostril and naso-pharynx. I suggested the use of the electrolysis, and the procedure was carried out with success by his physician. There has been no recurrence, so far as I am able to learn, after five years.

I want to agree with Dr. Price-Brown in what he said regarding the use of electricity as a valuable means of removing these growths. I am inclined to favor electrolysis more than cauterization, believing it to be as effective in its destruction and more rapid in its use. However, in the skilled hands of Dr. Brown, I am sure his methods could not easily be improved.

Dr. E. L. Shurly: I wish to testify to the marvelous results in two of these cases of Dr. Brown's. I was quite sceptical about his success in removing the growths or stopping them in this way, but it is a fact that he did it, and when I saw these two cases subsequently I was surprised. I think we are sceptical because we have not been persistent enough, and also because the general surgeon has gotten cases out of our hands before we were through with them, and finally passed them on to the undertaker. I recall two cases in which I intended to follow Dr. Brown's example, but which before I had gone very far in the treatment died, subject to operation at the hands of surgeons. I also agree with the remarks of Dr. Logan regarding electrolysis. I believe it is the proper thing to do when you know that these cases invariably die from operations by the knife. It seems to me the general surgical treatment for sarcoma should stop.

Dr. Thomas Hubbard: I wish to congratulate Dr. Brown on his successful work and thank him for presenting this subject to the association. I have had one case remarkably similar to Dr. Logan's, that of sarcoma involving the inferior turbinate, in a man of fifty, completely filling the fossa and also the choana posteriorly. The growth was removed by the avulsion method, with forceps and snare. The report of the pathologist was sarcoma. Three years later the patient died of sarcoma of the pancreas without any recurrence in the nasal fossa.

Dr. H. L. Swain: With regard to sarcoma, I never feel quite safe until I have taken it all out, and I think that I have

been able to develop in a way a method whereby, without removing the whole superior maxilla; you can take out the lateral wall of the nose and the whole sarcoma with it with excellent results. The sarcomas which I have happened to see in the nose have, with but two exceptions, been of the middle, or inferior, turbinal region, hence the natural choice of the method stated. You are thus much safer than by any method whereby you leave the elements within which are liable to recur. For all malignant growths there is nothing so satisfactory as to completely remove them.

Dr. W. L. Ballenger: I have had some experience in removing sarcoma from the nose. One case I operated upon six years ago and the patient is still living. I did the so-called Ollier operation (turning the nose down over the mouth) after making numerous intra-nasal attempts to remove the growth. I got very good exposure and succeeded in removing the growth, which involved both sides of the nose and the septum, the septum being largely destroyed. Another case I operated upon a year ago was at the base of the sphenoid, and the report given by the hospital authorities was sarcoma. My personal diagnosis was soft-fibroma, and my reason was that it was a pedunculated growth. That brings me to a point in reference to Dr. Price-Brown's paper. He spoke of some of his cases being pedunculated in the early stages. Sarcoma is a sessile, not a pedunculated growth. I have had one case of pedunculated carcinoma of the larynx. Dr. Freer informs me he only knows of two other cases on record. There is a question in my mind as to the diagnosis of Dr. Brown's cases. I should look with suspicion on a pedunculated growth as being sarcomatous, although it might be. My case was diagnosed as sarcoma, but I do not believe it is and am going to submit it to other pathologists. Another point is as to the curability of these cases. Nasal sarcomata are not as malignant as is this disease in other parts of the body, and no matter what method you use you should get better results than in other portions of the body. This is a point to be borne in mind in comparing results here with those of sarcoma occurring elsewhere. You will also have greater longevity after operation here. I operated on a case two months ago as sarcoma of the nasal pharynx. I removed the growth as I would an adenoid, with adenoid forceps, and four weeks later the naso-pharyngeal space was filled with complete nasal stenosis. In the nose these growths are not so fully malignant, while in the naso-pharynx they are much more so.

Dr. F. C. Cobb: I think there is one point of importance as

regards diagnosis of sarcoma. Appearances caused by small round cell infiltration in tissue under microscopic examination are so easily like those of small round celled sarcoma as to be often mistaken for it. Two cases in my own practice have occurred, one in a septum, due to syphilis, and one in a case of polypi. Both patients are living and well at present and in both the diagnosis of sarcoma was made by a prominent microscopist.

Dr. O. T. Freer: In my experience, sarcomata histologically closely alike vary greatly in malignancy. I have seen a case of round-celled sarcoma of the right lower turbinated body which in five weeks involved the entire upper jaw and produced a hideous facial deformity. The condition was so hopeless that Nicholas Senn refused to operate. In the beginning I had removed the patient's lower turbinate, and two weeks later had found it necessary to already cut away the entire nasal wall of the antrum. Three weeks after this, the condition described was present.

In a second case, in which the growth histologically and microscopically hardly differed from the first, the entire nasal wall of the antrum, the inferior and middle turbinated body had been absorbed in the tumor, which filled the entire naso-pharynx with a stinking, gangrenous mass. In three operations, with my per-nasal forceps and the Grünwald-Hartmann forceps, I succeeded in radically extirpating this tumor.

Dr. J. Price-Brown: In Dr. Logan's second case, I think the difficulty was that he operated too much at one time. As soon as severe hemorrhage threatens I stop the operation. Slight packing for a moment will stop the hemorrhage; then the patient goes home and comes back the next day, and so, little by little, the growth is removed with practically little loss of blood. With reference to Dr. Swain's remarks regarding the external operation, I would say these cases do not require external measures, because you can do the whole thing, if you take the time, through the internal route. In answer to Dr. Ballenger's statement that "Sarcoma is a sessile, not a pedunculated growth," I may refer him to Dr. Harris's exhaustive paper upon 103 cases of nasal sarcoma, in which he says that it usually proceeds from a well-defined pedicle. In regard to the length of time: Of the former cases I reported all are well now, after fourteen years, seven years and two and a half years. From the appearance of the new cases now reported, they are in such condition that I consider recovery in each case probable. The growths in all my cases, except two, were all originally naso-pharyngeal; I judge that from the difficulty in getting the post-nasal portion away.

I think this method should be tested more than it has been, and if you can possibly save your patients any deformity it seems worthy of trial. We follow our methods according to our successes. I think every laryngologist, finding himself unsuccessful in a certain method, drops it and turns to something else. My results with this method have been better than those of others by other methods, and the longer I use it the more am I convinced that it is a scientific and successful method of treatment of a loathsome and malignant disease.



## CONTRIBUTION TO THE ETIOLOGY AND TREATMENT OF DENTIGENOUS CYSTS.

BY D. CROSBY GREENE, M.D.

The familiar occurrence of cysts in the upper jaw, which encroach in their growth to a greater or less extent on the cavity of the antrum, brings the subject in a practical way to our attention. In a recent case, the cavity of the antrum was found at operation to be practically obliterated by the cyst, so that the anterior and posterior walls of the antrum were in apposition. It was possible in this case to shell out the cyst, by blunt dissection, almost intact. The cavity had a smooth lining membrane, and contained no tooth, nor any part of a tooth. Examination of a section of the posterior wall of the cyst, which was also the anterior wall of the antrum, showed the following structure: A central thin plate of bone with periosteum on either side, covered on the antral side by the columnar epithelium of the antrum and on the cyst side by flat stratified epithelium. The tumor is in this instance, therefore, a simple fibro-epithelial cyst.

The question of the origin of an epithelial growth within the bone tissue of the upper jaw brings up the broader question of the origin of such tumors in general. It has been shown by numerous experiments of Ribbert and others that it is possible to make an artificial epithelial cyst by transplanting a bit of skin epithelium, with its supporting cutis, into the deeper tissues—as, for example, into the subcutaneous tissue or into the abdominal cavity. The epithelium, growing in its new location, spreads over the raw surface of the space into which it has been placed and makes a lining membrane of the space, with a small cavity within. Such an artificial cyst will continue to grow indefinitely. This gives the suggestion as to the origin of an epithelial growth in the bone of the jaw. It is the accepted view of pathologists that a tumor of any given type takes its origin from a normal tissue of the same type—connective tissue tumors from normal connec-

tive tissue—epithelial tumors from normal epithelial tissue. The formation of an epithelial tumor in the bone of the jaw can be rationally accounted for in accordance with this theory only in connection with the development of the teeth. The teeth are essentially epithelial structures, which are developed from an invagination of the epithelium of the jaw in the embryo, into the body of the jaw. Other elements enter into the final structure of the tooth, so that it is eventually a composite structure, made up in part of tissue derived from the epithelium and in part of tissue derived from the mesoderm. But the anlage of the tooth is an ingrowth of the epithelium of the jaw, designated by embryologists as the dental shelf. Now, it is easy to conceive of a bit of this ingrowing epithelium as becoming pinched off from the rest as an island of isolated epithelial tissue. The situation in this case is similar to that in the case of epithelial tissue artificially transplanted into the midst of connective tissue. The island of epithelial tissue, separate from the rest of the tooth germ, grows in an atypical way, with the resulting formation of a cyst. Other and more complicated types of cystic tumors of the jaw frequently occur whose origin can likewise be traced to an atypical growth of the tooth germ.

The treatment follows naturally on the histogenesis of these tumors. In order to insure against recrudescence it is necessary that all of the epithelial lining should be removed, since if any is left, the possibility of its growth and spread is evident. This may be done effectually in some cases by making a wide opening into the cavity, thoroughly curetting the entire inner surface and maintaining drainage. This treatment is satisfactory in many instances. There are, however, certain cases, particularly cysts of large size, in which this method results in extremely slow retrogression of the cavity. I have seen three such cases. In one of these, from which the accompanying skiagraph was taken, I removed the entire anterior wall of the cyst and thoroughly curetted the cavity, which was found to contain many fragments of wooden toothpicks, which the patient had forced up through a small sinus at the tip of a tooth socket. After curetting I packed the cavity with gauze and later systematically cleaned and drained it. The reduction

in the size of the cavity was extremely slow. A year after the operation it was about one-half its original size and causing some discomfort from the lodgment of food within it. The results in this case and in others which I have not had the opportunity of following so closely, suggested a method of dealing with large cysts, first mentioned to me by Dr. Mosher—namely, by drainage of the cavity into the nose and by way of the antrum, and closing off the mouth opening in order to avoid the annoyance and contamination caused by the latter.



Fig. 1.

Skiagraph of dentigenous cyst packed with bismuth gauze.

If this method is employed, together with a complete enucleation of the cyst, as was done in the case of the specimen exhibited, the cystic cavity can be permanently and effectually disposed of.

The following case illustrates the method, which was in this instance satisfactory as to results:

The patient, a young man of 21, had for the past five years been having more or less discomfort in the right upper jaw, with swelling at intervals. In the early part of his trouble the second molar tooth had been extracted and an opening made through the socket into a cavity said to have contained pus. Since that time the swelling and dental troubles had recurred at irregular intervals. Last fall an opening had been made through the canine fossa into a cavity of considerable size, which discharged a purulent fluid for two months, at the end of which time I first saw him in consultation with Dr. F. E. Garland.




Fig. 2.

Section of posterior wall of dentigenous cyst, showing epithelium of antrum and cyst, and thin lamella of bones undergoing absorption.

Examination showed a hard, smooth, rounded tumor of the upper jaw, corresponding to the anterior and outer wall of the right antrum. There was a bulging upward and inward of the outer part of the floor of the right nostril, and the right lower turbinate was pushed toward the median line. There was no intranasal evidence of inflammation in the antrum. The mucous

membrane in the vicinity of the ostium appeared normal. A probe, passed into the cavity through the mouth opening, showed that the cavity extended up close to the floor of the orbit and a considerable distance outward. (Fig. 1.) Transillumination was much brighter through the right antral region than through the left. On washing out through the mouth opening no fluid came through the nose. This evidence all tended to show that the cavity was a cyst, and was not the antrum. At operation I assisted Dr. Garland, who enucleated the cyst largely by blunt dissection. Inasmuch as the anterior wall of the antrum was closely incorporated with the posterior wall of the cyst, it was found that complete removal of the cyst wall made its cavity one with the antrum. (Fig. 2.) Again, the inner wall of the cyst being in close connection with the outer wall of the right nasal fossa, we found that in removing the cyst we had established communication between the nasal cavity and the antrum below the inferior turbinate. A gauze drain was placed through the nose and into the antral cavity, and the mouth opening closed off with silk sutures. By this method the large cyst has been effectually disposed of.

### *Discussion.*

Dr. G. B. Wood: Last fall I had a case of dentigenous cyst of the upper jaw almost as large as a hen's egg, taking the place of the floor of the nose, covered above by the nasal epithelium and below by the mucous membrane of the roof of the mouth. I was able to enucleate it completely, and the mucous membrane of the nose came in apposition with the mucous membrane of the mouth, almost obliterating the cavity, although the cyst reached almost two inches back from the canine teeth. The case healed up very quickly, though a small fistula remained for about two months.

Dr. W. E. Casselberry: Some years ago I reported two cases to this Association under a title adapted from recent German usage—"Serous Disease of the Antrum," a condition probably the same as that designated in the older English works as "Hydrops Antri." In my cases, the antrum contained a thin, straw-colored serum such as might be found in a cyst, but the conformation of the antrum was unchanged, and aspiration from every possible site, in one, yielded repeatedly during the course of several weeks the same sort of serum, while in the other case puncture tests yielded first a serum, but a week later pus. The first case had in conjunction polypoid hyperplasia of the middle



turbinal, which presumably stopped up the naso-antral opening. In diagnosis, the possibility of a cyst was carefully considered, and excluded in favor of chronic serous disease of the antral cavity itself. However, I would ask the essayist if his cases afforded any additional data which would tend to certify the diagnosis between these two conditions.

Dr. N. H. Pierce: Dentigenous cysts are divided histologically and pathologically into two divisions, one class arising from inflammation and the other from errors in embryology. The cysts that arise from inflammation of the peridental membrane are frequently removed at an early stage by the dentist. The tiny cyst is perched on the end of the root. This may go on to develop until it occupies the entire antrum, and causes what Dr. Casselberry calls serous disease, or hydrops of the antrum. In my opinion, which is supported by the work done by the dental clinic, hydrops or serous disease of the antrum cannot produce ectasis of the antrum or bulging of the wall. Whenever this does occur it is due to a dentigenous cyst. The difference between a serum due to hydrops ex vacuo, if ever occurring without inflammatory factors in the antrum, and the fluid contained in dentigenous cysts is that the latter contains cholesterin crystals. The other form, dentigenous cyst, due to errors in embryology, may take on the most remarkable and various shapes, but always has a bony wall. One case that I saw in the Illinois Eye and Ear Infirmary presented clinically a fistula which ran from the nasal bones opposite—about the middle of the left nasal bone—to the gum; projecting from the gum were insufficiently developed teeth which when removed showed other teeth back of them, and on operation, the cheek being laid open, not less than four teeth were found distributed over the upper and lower portion. This was also a dentigenous cyst; usually, however, there is but a single bony cavity containing a tooth. This form is differentiated from the other clinically by the fact that there is usually one tooth missing where the cyst develops, although rarely the cyst may develop from a supernumerary tooth.

Dr. J. H. Bryan: I do not agree with Dr. Pierce in regard to the non-existence of hydrops of the antrum. In many of these cases they are dentigenous cysts, and in one of my articles I stated that hydrops did not exist. Later I had a case which proved the contrary. In this case there was a closure of the maxillar opening and marked thinning of the antrum wall, and decided crepitation on palpation. I aspirated and drew off serous fluid, and on opening the sinus did not find connection with the teeth. I also stated that there was no such thing as hydrops of the frontal sinus, and Dr. Knapp, immediately on the publication of my article, said that statement was wrong, and he proved that the condition did exist.

Dr. J. Payson Clark: I wish Dr. Greene would clear up the confusion which exists in the use of the terms dentigerous and dentigenous.

Dr. D. Bryson Delavan: It would be interesting to know what relation these cysts bear to the expansions sometimes found in the ethmoid cells and middle turbinated body. One of the first papers I ever wrote was "On the Question of Hypertrophy of the Middle Turbinated Body," the hypertrophy referred to consisting of a bladder-like expansion of a very thin wall of bone surrounding a large cavity of cystic nature, as also described by Zuckerhandl. I would be glad to know what relation such cysts bear to those described in the paper.

Dr. H. L. Swain: I wish Dr. Greene would say what he noticed were the appearances in these cases when transilluminated by the ordinary methods.

Dr. D. Crosby Greene: I did not go into the question of the diagnosis and differentiation of these tumors, my subject being limited to a consideration of the etiology and treatment. In response to Dr. Casselberry, with reference to the diagnosis between a cyst and hydrops of the antrum, I think that puncture of the cyst through the mouth and washing out the cavity with fluid under considerable pressure would probably clear up the question. Unless the ostium were closed, in the case of hydrops, the fluid would come out through the nose; whereas in the case of a cyst no fluid would come through the nose. If there were doubt of the patency of the ostium, a puncture into the antrum could be made intranasally; then, on injecting fluid through the oral wall, the question whether the cavity were cyst or antrum would be settled.

In regard to Dr. Swain's question relative to transillumination: If the cyst has been emptied of fluid, transillumination on the affected side is much brighter than on the other, owing to the absorption of the bony anterior wall of the antrum. If the cyst is full of fluid, transillumination is darker on the affected side.

I would like to say in regard to the origin—a question which Dr. Pierce has brought up—that our pathological data in regard to cysts are quite insufficient. It is the stated opinion of many authors that some dentigenous cysts are of inflammatory origin, but satisfactory reports of histological examination are lacking. My chief object in presenting this communication was to show the very clear structure and origin of the cyst in the case exhibited. The correct name is, I think, *dentigenous*, rather than *dentigerous*. The former term means arising from teeth; the latter means tooth bearing. Another and perhaps better term is *Cystic Odontoma*.

## HEMOPHILIA, WITH REMARKS ON THE HEMORRHAGIC DIATHESIS—CASE REPORTS.

BY THOMAS HUBBARD, M.D.

Case 1. *Hemophiliac; Postoperative Bleeding.* M. G., a healthy, well nourished boy four years of age. During the previous winters had had several attacks of otitis, and was dull of hearing much of the time. In the fall of 1908 he had a severe cold and otitis media, and it was evident that he was drifting into a chronic catarrhal condition. Operation for removal of the large tonsils and adenoids was performed on the 31st of December, '08. The tonsils were completely extirpated, by blunt dissection and snare, and adenoids removed by curette and forceps. The bleeding was profuse, but it apparently ceased and the child slept most of the following four or five hours. He then vomited an unusually large amount of dark clotted blood. It was a peculiar feature in this case throughout that it was very difficult to determine when he was bleeding.

It is characteristic of this type of hemorrhage that the blood clotting is retarded and thus is formed the long ropelike clot hanging so far down into the oesophagus that the fresh blood trickles down without any effort at swallowing. This child bled for about seven hours before the condition was realized, and by that time he was quite exsanguinated. I located the seat of most active hemorrhage in the left tonsillar fossa, and applied digital compression. There was no evidence of bleeding for about 14 hours. Active persistent hemorrhage from the left tonsil was again detected, and I applied the tonsil compression forceps, using very firm pressure for 7 hours. During this period there was some bleeding from the naso-pharynx and nose which I attributed in part to the congestion incident to the firm compression of the larger veins, as evidenced by oedema of the left side of the face. Normal saline solution 4 oz. every 2 hours, and lactate of calcium 90 grains daily were given per rectum, and fortunately well retained. The urine became cloudy with phosphates in a short time as evidence of absorption of lime. Gelatin was administered

in every way possible, with the saline enemata and in milk and beef extract, to the extent of a pint or more daily. I should add that one of the important and difficult features of the management of such cases as this is in keeping the bowels free from decomposing blood clots and yet not draining the system by too free catharsis. So much depends on attention to these details, and it was only by the most competent nursing that this result was attained. On removal of compression haemostat and after resumption of liquid nourishment in 48 hours the condition improved. Evidence of subacute otitis supervened, and either as result of this or extreme exsanguination he became very deaf. The temperature was elevated one or two degrees and the pulse was almost constantly above 130. Blood mass, 1 gr., three times a day was begun on third day. On the fifth day there was nasopharyngeal hemorrhage, but on account of the otitis I did not think it best to make direct application of irritating styptics to the naso-pharynx, and it ceased temporarily.

During the night of the fifth day there was violent bleeding from the right tonsil. As in the left there was no distinct point of hemorrhage but a general free oozing, and again I had to apply the compression forceps. There was the same symptom of congestion and a more marked oedema of the face, and free nasopharyngeal and nasal hemorrhage at intervals during the seven hours of compression. It was astonishing how well the child tolerated the forceps. He seemed to have greater dread of the hemorrhage and would even sleep with the clumsy instrument in place. In seven hours it was removed and there was no more bleeding from the right tonsillar fossa.

The child seemed to have about reached his limit of recuperation. He was at this time extremely pale, pulse feeble and rapid, 130 to 150, and the blood as it escaped looked like pink serum. On two occasions we actually prepared for transfusion by the method of Crile, as the case seemed so desperate and hopeless, but the hemorrhage became less copious, and more easily controlled, and the operation was postponed. The tubal congestion gradually subsided and the hearing improved by the eighth day.

At this time the hemoglobin percentage was 28 (Dare) and it had probably been lower. From the eighth to the eleventh day

there were frequent hemorrhages from the naso-pharynx. By means of the Killian self-retaining palate retractor I could make direct compression for several minutes in the naso-pharynx, using Monsel's solution. It controlled the hemorrhage for 6 to 12 hours each time, and by vigilance we were able to prevent any considerable loss of blood. On the eleventh day the left tonsil again bled freely. This was ten days after removal of the hemostatic forceps, and it was indeed very discouraging. I controlled this by pressure and application of Monsel's solution. Every 6 or 12 hours blood would flow, the usual nervous excitement follow, and the higher pulse rate and tension increase the bleeding. Finally on the twelfth day I began the method of anticipating the hemorrhage. Every 6 hours firm pressure was made with swab saturated with Monsel's solution in the left tonsillar fossa and naso-pharynx. Instead of causing dread and excitement this routine seemed to give the child confidence and quiet his fears. The last bleeding was on the fourteenth day after operation, but the treatment was continued at longer intervals for some days. Convalescence was slow but complete.

I should add that adrenalin was tried during the first hemorrhages but seemed of no benefit. During the last stages, when the nasal and naso-pharyngeal bleeding was slight but persistent, I used pledgets saturated with 1:1000 solution in nares with good results as to nasal oozing. It seemed very useful in preventing slight hemorrhages but of little service in checking the flow when once established. (Drs. C. N. Smith and N. W. Brown were in frequent consultation and directed the general treatment.)

*Comments*—The operation was perfectly done, and there was no traumatic laceration in the epipharynx or tonsillar fossae. Concealment of the hemorrhage was one of the trying features throughout. This was in part due to the character of the blood in this diathesis. Clinical observation of such a case tends to confirm the theory of retarded coagulation. The clot was certainly of the ordinary consistency and the fibrin mass was firm and very tenaciously adherent to the oozing surface. One could see a firm clot almost decolorized near the fossa and hanging several inches into the esophagus and down which fresh blood was flowing.



Compression forceps were applied in all fourteen hours. It may have been longer than necessary, but the instrument was well tolerated and it was the proper procedure in this case.

One of the essentials in the use of any hemostatic appliance or coagulant is that the bleeding surface shall first be absolutely freed from fibrin clots. This was done by means of the curette forceps. I found the Monsel's solution very satisfactory. It does not form the firm, leathery, shrinking clot that is characteristic of the powdered persulphate or chloride of iron which conceals bleeding, and it is not so irritating but that it can be repeatedly applied.

Calcium lactate was given per rectum in thirty to ninety grains daily for more than two weeks, and gelatin to the amount of about a pint daily during the same period. The effect could not be definitely determined, but the end result justified their administration.

This case merits a brief consideration of surgical procedures other than those applied. It was evident that the bleeding was not from any particular vessel, and on my first inspection it was apparent that stitching the pillars together would not compress all of the bleeding surface. It came from the whole fossa. At this time I did not fully appreciate that the patient was a hemophilic and it was very fortunate that ligation of the external carotid was not attempted. Radical surgical procedures should not be resorted to prior to determination of the true nature of the hemorrhage.

*Heredity.* Parents healthy and the patient was the youngest by twelve years of the three children. A sister has exophthalmic goitre, and has undergone ligation of the arteries. The father had a severe epistaxis when about four or five years old, not traumatic, and it bled for several days until he was seriously prostrated. Maternal grandfather was called a "bleeder." He had a prolonged, severe hemorrhage from a tooth socket and while still a young man died of pulmonary hemorrhage supposed at the time to be caused by tuberculosis. The patient had several suggestive but not severe hemorrhages from an injury to the frenum of the upper lip when an infant. Other than this the

tendency to bleeding had not been observed. From this family record alone one is scarcely justified in calling him an hereditary hemophiliac, but the clinical history here narrated is quite typical, and temporarily, at least, he should be so classified, and it shows how very difficult it is for the surgeon to secure that information which would protect the patient and himself.

Case 2. *Scorbutus, Epistaxis.* M. C. This case illustrates the importance of the study of epistaxis as a symptom. It is not always a local lesion and the successful treatment must be general as well as local. The call was an urgent one, a case of epistaxis of three days' duration, several physicians having in vain attempted to check the hemorrhage. I found a young girl in a state of extreme exsanguination. During the examination syncope with complete loss of consciousness came on, no pulse perceptible, lasting about ten minutes. The blood-soaked condition of the bedding corroborated the statement of the parents that she had lost much blood, and, worse, she was still bleeding. Partial inversion and hot saline enemata aided in restoring to consciousness and permitted examination. There was a general oozing from the anterior third of the septum, and also from the turbinate, rather than a distinct arterial hemorrhage. I made the natural error of attempting to seal the vessels by the fused chromic acid method. She still bled. Adrenalin was inert. Only by packing firmly with gauze was it finally controlled.

The patient was carefully nourished and her appetite, ravenous after the fasting and drain of blood, was gratified in every way. But she still bled profusely at intervals during two weeks. I had labeled her an hemophiliac when I incidentally observed the condition of mouth and skin, and then I did what should have been done earlier; that is, study the case and search for the systemic cause. (General examination by Dr. N. W. Brown.) Patient a girl of ten aet., undersized, anaemic, skin dry and of dusky color, visceral examination negative. Gums swollen and spongy and frequent bleedings from the mouth for some months, and also hematuria. Tongue thick and dry and covered with small petechiae. The mucous membrane of the cheeks and pharynx showed small hemorrhagic areas. Conjunctivae normal but eyelids puffy. Indurated swellings were noted in the left popliteal space over the thigh and also over the sternum, all showing more

or less ecchymosis. Urine contained a trace of albumin and a few corpuscles. Blood: Red blood corpuscles, 3,412,000; leucocytes, 9,800; hemoglobin, 60 per cent. Coagulation period 6 to 7 min. The question of diagnosis involved hemophilia, purpura hemorrhagica and scorbutus. There had been no suggestive traumatic bleeding heretofore, nor hereditary evidences, and time of coagulation was not delayed. Purpura was excluded by absence of fever, the relative lymphocytosis and general character of the attacks.

The commonly observed etiological factors that aid in diagnosis of scorbutus as seen in infancy are difficult to determine in a child of this age, but a careful inquiry gave evidence that she had never had proper food and lived in wretched hygienic conditions. The history brought out the fact that she had been in the scorbutic state of malnutrition for many years; rheumatoid pains in the limbs, hyperesthesia, muscular soreness, transient edema of the skin, with or without ecchymosis, sore bleeding gums and epistaxis being the symptoms observed. The crucial test in the diagnosis of scorbutus is the response to proper dietetic treatment, but in adults with long existing lesions and perverted physiologic habits the improvement would naturally come more slowly. In this instance it was noticeable that she gained steadily, and gradually all of the symptoms vanished. The relatives, alarmed by the desperate condition as described, came to the rescue and she was well fed and lived as never before. The diet consisted of fruit juices, fresh vegetables, beef and milk. Iodide of iron was prescribed and the treatment of the mucous membranes was of cleansing healing character rather than the usual styptic or escharotic remedies to stop hemorrhages. She was free from all evidences of the diseased condition in a few months, and remained well for eighteen months when last seen.

#### *General Remarks on the Hemorrhagic Diathesis.*

The hemorrhagic diathesis can be divided into two classes, the pathologic and non-pathologic. To the former belong those diseases characterized by unaccountable hemorrhages into the skin, mucous membranes, joints, organs, etc., with or without peculiar

inflammatory conditions, such as scurvy, purpura hemorrhagica and allied diseases. The condition known as hemophilia alone represents the non-pathologic class. The modern teaching of pathology that such diseases as purpura and possibly scurvy are probably due to a micro-parasitic pathogenic agent still further emphasizes the necessity of such a distinguishing classification and further, purpura and scurvy exhibit none of the hereditary characteristics of hemophilia.

All of these manifestations of the bleeding tendency have apparently certain features in common. The most prominent is the frequent involvement of the joints such as rheumatic arthritis and hemorrhages into the joints. This similarity is due in part to a somewhat loose application of the term hemophilia. Hemophilia is not a pathologic process, but a permanent condition (Litten). It is intensely hereditary. It is probable that many of the cases of so-called acquired hemophilia are manifestations of the hemorrhagic diathesis of pathologic character. In females it is shown by the tendency to transmit, and in males it becomes manifest. Women from bleeder stock, but not bleeders, are called "conductors." Late statistics show, however, that the proportion of females to males who manifest the disease is somewhat higher than was formerly accepted, it being 1 female to 13 males. Males may be "conductors" of the disease, but comparatively rarely. The theories advanced to explain hemophilia present so many contradictions that pathologists have, as a last resort, declared that it is not due to a pathologic condition in the ordinary acceptance of the term. It is quite generally accepted that the time of coagulation is lengthened. The test should be made of the blood drawn from a fresh prick rather than taken from a bleeding wound, on account of the fact that in the normal subject hemorrhage shortens the time of coagulation, and especially at the point of bleeding. Statistics show that the anatomical regions most frequently manifesting the "love of bleeding" are those of particular interest to our special art. More than fifty per cent are nasal hemorrhages, and the most fatalities also, about twelve per cent are of the mouth, and five per cent of the lungs. Nineteen cases of hemorrhages from extraction of teeth proved fatal in six instances, and to still further clinch our interest it should

be mentioned that the period of pathological development of lymphadenoid tissue is the period when the tendency to bleeding is most liable to become manifest. The tendency to arthritic inflammation peculiar to hemophiliacs also calls attention to our anatomical preserve, the lymphadenoid ring, as the channel of infection.

For the protection of all concerned, surgeon and patient, a casual questioning will not always suffice to bring out the essential facts, as the absence of a "bleeder" in one generation engenders a false feeling of permanent security and the hereditary fault is forgotten. In the case reported in this connection I had made inquiry during the first three or four days of bleeding as to whether any of the family had shown this tendency, but it was not until the fifth day that the mother made the remark incidentally that her father was a "bleeder." Her immunity broke the continuity of heredity in her own mind. To facilitate a proper direction of inquiry before committing a surgical blunder the laws governing hereditary transmission are presented (Crile):

1. Daughters of a bleeder father are exempt, but may transmit to male offspring.
2. The sons of bleeder fathers are also as a rule exempt and do not transmit to their offspring.
3. The daughter of a bleeder father may transmit the disease to a single one, to several, or all of her offspring.
4. Where there are several daughters, the capability of transmission to offspring may be confined to one or all of the daughters may transmit it.
5. Occasionally there is direct transmission from father to son through several generations.
6. The disease does not appear in the issue of the sons of a bleeder family who are not themselves bleeders.
7. There is not always evidence of any hereditary influence so far as can be discovered by the record of ancestors.

The differential diagnosis between hemophilia, purpura hem-



orrhagica and scorbutus has an important bearing on treatment. Certain cases of hemophilia having no clear record of heredity may present symptoms, in so far as local hemorrhagic lesions are concerned, quite similar to purpura and scurvy, but a careful study of those general symptoms which characterize a disease caused by a micro-parasitic agency or one associated with mal-nutrition will usually aid in clearing up the diagnosis. Prostration, fever and relative lymphocytosis are not characteristic of hemophilia. In scurvy, as seen in children, all of these systemic symptoms are found, but the diagnosis can usually be determined by inspection of the mouth. Swollen, bleeding gums and mucous membrane petechiae are characteristic. Purpuric spots on the skin, spontaneous or caused by slight traumatism, and, above all, the evidences of mal-nutritional lack of development complete the clinical picture.

The true diagnostic test of scurvy is found in effect of treatment. Such patients respond quickly to a generous varied diet, including fresh meats, fruits, vegetables and orange and lemon juice.

*Hemorrhage.* Two or three per cent of body weight can be lost without materially altering blood pressure, but the blood pressure is maintained at the expense of increased action of vascular nervous energy and that individual cannot withstand shock as well as one whose vascular nervous function has not been overtaxed. In a child weighing 30 pounds, from 6-10 to 9-10 of a pound, or nearly a pint of blood, can be lost without materially altering blood pressure.

Crile calls particular attention to one very important point in the pathology and treatment of hemorrhage. The vital nerve centres will not stand a prolonged or considerable degree of anemia without permanent damage. In these cases of prolonged hemorrhage, as obtains in the hemophiliac, this point must be kept distinctly in mind in watching for approach to the danger line.

In nose and throat operations concealed hemorrhage is often the cause of serious degree of exsanguination. How much of the blood swallowed is digested is an important question. It must be that a considerable part of it is restored to circulation, especially

in prolonged bleedings. In the case reported this observation was made several times. A bleeding would occur as shown by bloody expectorations, and even during this bleeding he would take nourishment. An hour or so later the vomitus would contain dark, partially disintegrated clots, but no traces of the milk or gruel which had been recently swallowed. Blood clots in the stomach certainly did not stop digestion, and were partially digested.

*Systemic and local treatment considered from standpoint of laryngologist, and with special reference to post-operative bleeding following tonsillectomy and adenectomy and nasal operations.*

Calcium chloride is probably the most commonly used drug to increase blood coagulation. Calcium lactate has, to a considerable extent, superseded the chloride, as it is better tolerated. In children it should be given by rectum in half drachm doses two or three times a day and at longer intervals as the bleeding decreases. Iron or arsenic should be administered. These cases are usually long drawn out and every effort should be made to aid recuperation by maintaining nutrition. Exclusive milk diet, administered at short intervals, is considered to be of material benefit in increasing coagulability of the blood. Liquor thyroidei as well as adrenalin, are possibly useful in checking obstinate hemorrhage in certain individuals, but there are not definite indications, and we may consider both to be still on therapeutic trial. One cannot afford to tamper with physiologic functions in critical cases and only clear indications should be followed. Stimulating drugs should be avoided in hemorrhage at any stage. The first indication is to maintain the volume of circulating medium and the physiological solution of blood salts accomplishes this. The method of administration depends on the age and tolerance of patient and urgency of symptoms. If it be retained, enemata are the simplest and least disturbing. Small portions, 4 oz. given every 2 hours, is the best for children. If this fails, intracellular injections should be tried. Intravenous injections may be indicated, but only in emergency. In some cases it is advisable to maintain a steady sustaining supply of physiological saline solution by means of continuous rectal injection.

If there is no response to the saline injections the serum method

may be tried. Weil and others advise repeated small injections of fresh human or horse serum. Intravenously 10 to 20 C. C. or subcutaneously 20 to 30 C. C. should be given, and repeated in twenty-four hours if necessary. The difficulty is to obtain fresh serum, and this is essential, as the fibrin ferment, which aids in restoring coagulability to the blood of the recipient, is not permanent and disappears rapidly from the serum. Certain individuals are "sensitized" to horse serum. This danger can be, in a measure, safeguarded by giving a small dose, 1 C. C., and if no central or vasomotor disturbance be noted in fifteen or twenty minutes, the larger dose can be administered.

If fresh serum is not available, diphtheria antitoxin serum may be given in the same manner as above outlined, but it would be less efficacious in promoting coagulation.

K. Wirth, in Vienna Letter, N. Y. Med. Rec., May, 1909, reports eight cases treated with horse serum. One was a hemophiliac, tonsillotomy, epistaxis. All of the eight cases had been treated by usual methods without benefit, and responded favorably to 20 C. C. subcutaneous injections of horse serum.

The method is not without danger, and the practice of making test injections of 1 C. C., as mentioned above, is advised.

*Transfusion.* Carrel, Crile and others have demonstrated that direct transfusion of blood is a practical surgical procedure. It requires a refinement of surgical dexterity that is not given to every operator, but the chief difficulties have been overcome, and its field of usefulness outlined so that we may have a reasonable faith that in every hospital will soon be found the talent to apply it. It would seem that the true hemophiliac is an ideal subject for transfusion. Fortunately they are rare, but it would not be astonishing to find that there is a possibility of more or less permanently improving the blood is so far as coagulability is concerned, rescuing these doomed unfortunates from the dreaded fate that hangs over them. I have investigated one family of "bleeders" in which three sons of one generation died of traumatic hemorrhages. One of these I saw at the time when he suffered amputation of the arm after many futile attempts to check a bleeding of the hand which started from a slight cut. He recovered from this, but died soon after of another slight trau-

matic hemorrhage. Two sisters had sons who were bleeders. One lost three and the other two from hemorrhages; eight deaths in two generations. This seems, as stated, an ideal field for application of transfusion. I shall only refer you to Crile's admirable book on Hemorrhage and Transfusion, convinced that the study of this subject and his work in perfecting this operation is of peculiar importance to throat and nose surgeons.

CLINICAL EXPERIENCE WITH CALCIUM LACTATE  
IN HEMORRHAGES OF THE UPPER AIR TRACT.

BY WILLIAM K. SIMPSON, M.D.

The control or prevention of hemorrhage from whatever cause or wherever occurring is of such vital importance that any measures, which will be of assistance to us, should be at once recognized and eagerly pursued. We cannot have too many resources at our command to meet the emergency. The danger of a hemophilic tendency should be ever before us, not only in instances of spontaneous bleedings, but also in its bearing on operative procedures, and no operation should be undertaken until we have *fully* contemplated the question of hemorrhage both as to its effects and control. The question of hemorrhage in operations takes its place in importance alike with that of shock and sepsis, and although we may feel secure behind the many cases in which no hemorrhage has occurred, yet that one unlooked-for or unprevented fatal hemorrhage will always stand before us for daily contemplation.

The use of calcium salts for the control of hemorrhage has been employed for a sufficient length of time to make them a factor deserving profound consideration, their efficiency depending on the increase of the calcium content of the blood and consequent diminution of the period required for coagulation.

This subject was first brought to the attention of the profession by A. E. Wright, of London, in 1891 and 1893,<sup>1</sup> since which time it has received a great deal of merited consideration.

My interest in the employment of calcium lactate began in December, 1905, in conjunction with Dr. John W. Coe, of New York, in the treatment of a hemophilic patient, who had been the subject of severe attacks of epistaxis for many years. All the known means had been employed, including chloride of calcium, suprarenal extract, and other constitutional measures,



but, apparently, without any positive effect in controlling the hemorrhage for any length of time. I may here call attention to a most excellent article by Dr. Coe,<sup>2</sup> going at length into the treatment of a number of cases.

At this time we became familiar with the experiments of Wright and Paramore,<sup>3</sup> of London, and Boggs,<sup>4</sup> in the use of lactate of calcium, and decided to give it a trial in the treatment of our patient. The result of its use became at once so positive in the control of the hemorrhages, and so far exceeded the effect of any previous medication, that I determined to use it not only with this patient, but in all subsequent cases where the prevention or control of hemorrhage was necessary, especially in the upper respiratory tract.

As the result of an extended experience since that time I have come to the conclusion that we have at our command in the lactate of calcium a remedy which has a profound effect in many hemorrhagic conditions. I have employed it not only in non-operative hemorrhages, but also in hemorrhages associated with operations with an idea to their modification, if not prevention. The non-operative cases have been mostly those due to epistaxis, and one case to hemorrhage of the lower trachea. Although it is well known that severe cases of epistaxis may yield to various measures, or cease spontaneously, still in certain of the cases under my care there can be no doubt whatever but that the immediate and continued control of the hemorrhage was due to the use of lactate of calcium.

In the patient referred to above—who, by the way, is a physician of large practice and experience—the effect has been so marked that I think it deserves detailed notice.

Prior to the use of lactate of calcium, apparently nothing but local measures, such as cauterization of the bleeding points within the nose, had any effect, and this effect was but temporary, to be followed in very short order by frequently renewed and severe attacks of epistaxis. Since the use of the lactate, however, extending over a period of three and a half years, the hemorrhages are so controlled that they occur only at very long intervals, and then are due to some error in diet or accidental

cause. Not only have the hemorrhages been controlled, but the character of the mucous membrane of the nose has undergone a very marked improvement.

During the many years of his treatment for epistaxis the nasal mucous membrane was such that the slightest touch with a cotton applicator would bring on a profuse hemorrhage and greatly interfere with its control, but at the present time, when any necessity arises for manipulating the nasal mucosa, it can be done with comparative impunity, thereby assisting greatly in pressure control and in the cauterization of the hemorrhagic area, and the ordinary appearance of the nasal mucous membrane is much more healthy and normal. There can be no doubt but that the control of the hemorrhage in this instance is due to the hastening of the coagulation time. This was proven a number of times by Wright's tubes, wherein the period of coagulation was reduced from nine and a half minutes to five minutes and from nine to four minutes.

In another instance a young girl of sixteen, who was the subject of profuse nasal hemorrhages, and whose coagulation period was above normal, the use of the lactate produced a marked controlling effect and cessation of the attacks. With this patient also, complete blood examinations were made with the result of demonstrating the change in the coagulation period.

With a view of ascertaining whether lactate of calcium would control operative hemorrhages, I have made it a practice, where it is possible to do so, to administer it for three days prior to operation and three days or longer time after. The operations in which I have used the drug have been for nasal polypi, turbinectomy, various operations on the septum, and antrum operations—but mostly for the operations of tonsillectomy and for the removal of adenoids. In the intranasal operations we do not have such a good field for observation in the control of hemorrhages by general measures as the areas are immediately under direct control by pressure, but, in certain cases, where no post-operative packing has been employed, there appeared to be less tendency to after-hemorrhage than in

cases where the lactate was not used. In the operations on the tonsils and adenoid vegetations, however, the conditions are entirely different, and afford a most excellent opportunity for observation in the control of surface hemorrhage, and it was in this type of cases that my observations were concentrated.

As in cases of epistaxis, so also is the hemorrhage from adenoid operations and tonsillotomy a variable quantity, and it is difficult to get an exact basis for comparison, but from careful observations, extending over a large number of operations in clinic and private practice, one can make a comparison which is practical and conclusive. From the results of seventy-five cases of operation in private practice for the removal of tonsils and adenoids, in which the calcium lactate was given, I can say positively—if clinical observation amounts to anything—that there has been a controlling influence at the time of operation, but more especially in the *prevention* of secondary hemorrhages. Even more especially has this been observed in the cases under general anesthesia, where it is a recognized fact that hemorrhages at the time of operation are much more severe than when anesthesia is not employed. The opinion of assistants and others concerned in the conduct of the operations will confirm this opinion of control.

Acknowledging the comparative rarity of severe immediate or secondary hemorrhages, in these operations, it is a fact far stronger than coincidence that the *only* severe hemorrhages during the period under consideration that have come to my experience, in a very large number of cases, comprising private and *many* additional clinic cases, have been those in which the lactate of calcium was *not* given. These are five in number, one of which will serve as a marked illustration. The patient was a lad of fifteen, from the West Indies, upon whom the adenoids and tonsils were removed under ether. On the removal of the adenoids a most violent hemorrhage ensued, which, after diminishing somewhat, the tonsils were removed. This operation was followed by a still more alarming bleeding, reducing the patient to a very extreme condition, and necessitating very active measures for its immediate control. The hemorrhage from the

tonsils continued for several days, with variable severity, and it was during this time that observation was afforded for watching the coagulating effect of the lactate of calcium. As soon after the operation as possible, when hemorrhagic vomiting had ceased and medication could be retained, he was given an initial dose of sixty grains of the lactate, which was followed by thirty-grain doses, four times daily, for several days, and more often when it was deemed necessary; and many times during its administration the blood could be plainly seen to coagulate in distinct, firm masses, as it appeared on the surface of the tonsils. No blood examinations relative to the period of coagulation were made with this patient, but it was clinically evident that the lactate had a very controlling influence. It was subsequently learned that a sister of the patient had nearly "bled to death" a year previously from a similar operation, there being probably a family hemophilic tendency.

There is no doubt, in this case, but that the calcium lactate exerted a strong influence in the control of bleeding, and in the remaining cases of severe operative hemorrhages, in which it was not given till after the operation, there is every reason to believe that it modified greatly the subsequent course of the bleeding.

Relative to the dosage, I think it best, in all cases, to begin with an initial dose of sixty grains, especially in the adult, children in proportion, and then thirty grains twice during the first twenty-four hours. In the non-operative and hemophilic cases, the drachm doses may be continued every morning and then every other day until such time as there is improvement in either the bleeding or in the hastening of the coagulation, as determined by laboratory tests—the improvement to be maintained by occasional drachm doses. There are no hard and fast rules as to the amount to be given, but each case must be treated as conditions are indicated. In operative cases, especially for the removal of tonsils and adenoids, preliminary treatment should begin by administering the calcium lactate, where possible, three days previous to operation, and continued for three days after; as these operations occur mostly in children, the dosage

may be proportionately smaller, giving twenty grains, thrice daily, as an average.

There seems to be neither danger nor untoward symptoms arising from large or continued dosage. Coc<sup>4A</sup> cites an instance where, by mistake, a patient of thirty-three years was given sixty grains every three hours for six doses, with no ill effects, and our first-mentioned patient has continued with drachm doses almost daily, and sometimes twice daily, for nearly three and a half years. He, being a close observer, thinks that sixty grains is a maximum dose, and further states that in his own instance a better effect is maintained in controlling the coagulation by omitting one or two days after a maximum effect has been reached. I may say here in passing that at one time he discontinued its use for some while, taking up the serum injections in its stead, with the result of return to very severe hemorrhages, which were subsequently controlled by the resumption of the calcium lactate. It seems preferable to administer it when the stomach is free from food, *i. e.*, early morning and between meals. The lactate not being immediately soluble, the best means for its administration is to place the powder in a tumbler, adding a small quantity of warm water, stirring thoroughly, then adding cold water up to a half or full glass. The preparation which has given the most satisfaction is that made by Merck; attention has been called to some instances where the inferiority of the preparation has minimized the results, and I consider the purity of the preparation a very important factor.

The object of this contribution has been simply to relate my own clinical experience and impressions, and I have purposely refrained from discussing the theories and variations relative to the subject of coagulation, the various modes of determining the calcium content of the blood, the period of blood coagulability, or the conflicting opinions concerning the efficacy of the calcium salts in the control of hemorrhage. Still it is interesting to note, and, at the same time, somewhat difficult to understand, this diversity of opinion. Wright, in 1896,<sup>5</sup> showed that after the ingestion of calcium chloride or lactate the time of



coagulation was shortened in hemophilic as well as in normal cases, mentioning in the same article an instance of a hemophilic in which the result was negative, who failed to absorb the calcium, and the effect was not produced until a subcutaneous injection of the lactate was given, which finally controlled the hemorrhage from the gums, from which he suffered. A few days previously, however, an injection had proved inefficient. Wright advises against the subcutaneous injection of the chloride, and in reference to the lactate, it should not be injected in a stronger concentration than 1 to 20.

Wright and Paramore<sup>3</sup> state that calcium lactate causes increased rapidity of coagulation in twenty minutes and its maximum effect is reached within forty-five minutes, the effect being maintained from four to seventeen days, and also that the effect of four grammes, *i. e.*, about one drachm, is greater than a similar dose of the chloride.

Boggs<sup>4</sup> states that a distinct influence was noted on the coagulation after the taking of calcium lactate. In periods of three days in which the calcium was omitted, the time required for coagulation returned to its former period, and returned to the shortened period after the resumption of the calcium, and he concludes, as it displays its efficacy in those patients in whom the time of coagulation is physiologically diminished, it may be regarded as a valuable remedial agent.

In another paper Boggs, T. T.,<sup>6</sup> states: After the normal calcium content of the blood had been determined, the dogs used in the experiments were fed with calcium lactate, in doses of 2-4 grammes, twice daily, and after five days the animals were again bled and the calcium content determined. In both animals there was a marked and constant increase in the calcium content of the blood; coincident with this, there was an increase in the coagulability of the blood.

Hinman and Sladen,<sup>7</sup> on "Calcium Therapy," consider the lactate the best calcium salt, the chloride being too irritating; had never seen the lactate cause the slightest gastric disturbance; given either by mouth, rectum, subcutaneously or intravenously, it tends to shorten a delayed coagulation time. While it is requi-

site to always determine the coagulation time, there is no contra-indication in giving it in normal cases.

R. Kobert,<sup>8</sup> in considering calcium salts as styptics, states that gramme doses of calcium salts including the lactate given by mouth, enema, subcutaneous or intravenous injections, in a 1 per cent solution, cause immediate styptic effect in individual cases.

T. Addis<sup>9</sup> gives his general conclusions as a result of a number of experiments:

(1) The coagulation time of the blood is unaffected by the administration by the mouth of soluble calcium salts or of citric acid.

(2) The amount of calcium in the blood is increased by the giving of soluble calcium salts and diminished by citric acid, but the increase or decrease brought about is considerably less than the degree of variation in the calcium content which is necessary before any appreciable effect is produced in the coagulation time. As these results were at variance with Wright, of London, he gives a description of the apparatus used and discusses the difference between the two coagulometers, giving his reasons for relying on Blair Bell's calcimeter.

George W. Ross<sup>10</sup> speaks of the favorable results in the treatment of headaches, due to insufficient blood coagulation, by the use of calcium salts, preferring the lactate to the others, it being more palatable, less nauseating, and often better absorbed.

Arthur P. Luff,<sup>11</sup> on the basis of numerous favorable experiences, recommends the use of calcium salts, especially the lactate, in fresh solution, in all diseased conditions which are associated with a lessened coagulative condition of the blood, and thereby a tendency to increase transudation of plasma through the capillary wall, stating that condition occurring in frontal headache with slight oedema of face, eyelids, hands and feet, also in urticaria, chilblains and oedema of the feet and hands, not due to heart or kidney disease or venous obstruction.

In his summary of 121 cases treated, 78 per cent were cured, 9 per cent were considerably benefited, and in 13 per cent no good resulted from the treatment. In the 121 cases, no bad symptoms were produced by the administration of the lactate. Among a large number of other cases treated, not included in his paper,

were only three cases where any unpleasant symptoms supervened which necessitated the withdrawal of the calcium lactate. These symptoms, he states, certainly pointed to some commencing thrombosis. In one case there was a definite slight attack of venous thrombosis in the right calf, in the second, slight numbness of the arms and legs, associated with tingling, and in the third case, tinnitus and deafness were produced. In the three cases the unpleasant symptoms rapidly subsided after the withdrawal of the calcium salt.

This question of the danger of thrombosis from the use of calcium lactate is frequently raised, but I have never seen any instances of it.

F. C. Ard<sup>12</sup> reports a case of profuse hemorrhage following tonsillotomy in which lactate of calcium was used with most satisfactory results.

Opposing views as to the efficacy of the calcium lactate are held by Dahlgren.<sup>13</sup> In two cases, in which the lactate was administered by the mouth and by enema, there was a negative effect, both patients dying from post-operative secondary hemorrhage for acute appendicitis. He concludes that in hemophilia, bloody operations should not be performed unless necessary for the prolongation of life, but stating at the same time that a prophylactic treatment with serum, gelatin and the calcium salt may possibly prove of value.

Also W. E. Robertson, G. M. Ullman and A. A. Duncan<sup>14</sup> speak very strongly in opposition to the beneficial effects of calcium salts or any other means in controlling the period of blood coagulation. These observations were carried out mostly in cases of typhoid fever, and they present a table of cases in corroboration of their views. Their article was read at a meeting of the A. M. A., in 1907, and in the discussion (Section of Pharmacology and Therapeutics) Dr. Lowe said that in his investigations calcium salts were of little value in the coagulation of the blood. Dr. M. Solis Cohen states that Dr. Wright's statements seemed perfectly true till one investigated them. He (Cohen) tested the coagulability of the blood in fifty cases, and was unable to corroborate any of Wright's statements relative to the clotting time in diseased conditions. Dr. Robertson

pointed out that the chief value of work of their kind, if confirmed by others, serves to warn us of a false sense of security in giving the calcium salts. This article was made the basis for including the calcium salts among "Pharmacologic fetishisms" by Barton,<sup>15</sup> who considers their use as folly.

As the writer of this paper mentioned above, it is indeed difficult, in view of his own observations, to reconcile these diverse opinions.

The conclusions of the writer are:

1. Calcium lactate from a clinical experience has a controlling influence in hastening the coagulation of the blood.

2. Its efficacy is more marked in hemophilic cases where the coagulation is delayed than in normal cases of coagulation time.

3. In operations, especially on tonsils and adenoids, careful inquiry should be made relative to any hemophilic heredity or tendency.

4. In suspicious cases the coagulation period should be determined before operation.

5. It is questionable, if not positively contra-indicated, whether such operations should be undertaken in hemophilic cases other than under the most extreme urgency.

6. In all cases of operations for the removal of tonsils and adenoids, calcium lactate should be given for a period prior to and after the operation, both for its possible effect in diminishing the immediate hemorrhage and in preventing secondary surface hemorrhage.

7. Of the calcium salts, the lactate is more positive in its results, is more agreeable to administer, and less irritating to the stomach.

#### REFERENCES.

1. *British Medical Journal*, Dec. 19, 1891, and July 29, 1893.
2. *Jour. Am. Med. Assn.*, Oct. 6, 1906, John W. Coe.
3. *Lancet*, Oct. 14, 1905, p. 1096.
4. Ueber Beeinflussung der Gerinnungszeit des Blutes im lebenden Organismus. *Deutsches Archiv für klin. Med.*, March 15, 1904, p. 539.
- 4A J. W. Coe, Loc. cit.
5. *Lancet*, Jan. 18, 1896.
6. Variations in the calcium content of the blood following therapeutic measures. *Johns Hopkins Hospital Bulletin*, June-July, 1907.

7. Johns Hopkins Hospital Bulletin, June-July, 1907.
8. Lehrbuch der Pharmakotherapie, II Auflage. Stuttgart: 1908.
9. *Quarterly Journal of Medicine*, vol. 2, No. 6. January, 1909. The investigations were carried out in the Laboratory of Physiology, University of Edinburgh.
10. On the relief of certain headaches by the administration of one of the salts of calcium. *Lancet*, Jan. 20, 1906.
11. A lecture on the uses of the Calcium Salts in various Morbid Conditions. *British Med. Journal*, Jan. 30, 1909. A very exhaustive article.
12. Dangers Associated with Removal of the Tonsils and Adenoid Growths. *MEDICAL RECORD*, March 6, 1909.
13. "Hemophilia and Surgical Intervention in Hemophilies." *Beitrag zur klin. Chir.*, vol. 61, Feb. 3, 1909.
14. "Coagulation of the Blood." A summary with especial reference to the therapeutic efficacy of the alleged coagulants. *Journal Am. Med. Assn.*, May 16, 1908.
15. "Pharmacologic Fetishisms." *Jour. Am. Med. Assn.*

*Discussion on the Papers of Drs. Hubbard and Simpson.*

Dr. G. Hudson Makuen: I think there is nothing that excites our interest and anxiety more than hemorrhage, whether it comes during or after the operation. These papers are very timely in these days of radical operations, especially upon the tonsils. My experience has been that the more radical the operation, as a rule, the more copious the bleeding, although I believe some do not agree in that opinion. I have no special fear now of bleeding in the average case, when I have the patient under ether, because I have found that it is comparatively easy to catch the bleeding point and put a ligature around it or to pass a suture through the pillars, and thus control the hemorrhage at the time, and also prevent, in a great measure, the hemorrhage which may follow, especially if he be not a regular bleeder. I have come to the conclusion that for tonsillectomy our patients should always, even adult cases, be under a general anesthetic, because it is so much easier to control the hemorrhage primarily by ligature or by suturing the pillars. I had a case recently that impressed this opinion upon my mind. It was that of a man, nineteen years of age, fully developed. He did not appear to be a hemophilic, and I could get no history of the presence of this condition, but when I attempted the removal of the left faucial tonsil I had trouble. I loosened up the attachments and with the Richards forceps drew the tonsil out and removed it en masse with the ring tonsillotome. The bleeding immediately



became profuse, it caused my patient to cough, clear his throat, gag and to become very much excited, all of which did not tend to increase my own confidence in my ability to deal successfully with the conditions, but, fortunately, I had one of these clamp forceps in my armamentarium, exactly the same as that which has been passed around to-day. I had carried it for twenty years and boasted that I had had no occasion to use it. But in this case I needed it badly. I was entirely unable to see the bleeding point or to put a ligature around it, on account of the coughing and gagging of the patient. I succeeded in putting the clamp in and left it there for seven or eight hours. I sent him to the hospital, gave him chloride of calcium, and in three days he was up and all right. When the question of the other tonsil came up I removed it successfully without hemorrhage by means of the cautery knife, nor did I have any post-operative hemorrhage. But on the side upon which I had the bleeding I found a pocket, resulting, I suppose, from the pressure of the clamp forceps, and I thought I would open it up with the cautery knife, which I did, and in less than a week after that the patient was awakened with copious bleeding from that side; his physician stopped it easily with adrenalin solution. The same thing happened three times in the course of a week. It never bled at all in the daytime. Finally, I touched the little red bleeding point with a chromic acid solution, and he had no more trouble.

Dr. G. B. Wood: Not long ago I had a case of severe hemorrhages following a tonsil and adenoid operation and tried my usual method of stopping hemorrhage by sewing the pillars together with two or three stitches. The bleeding, however, persisted for about thirty-six hours, but gradually lessened as the child came under the influence of thyroid gland. This patient had a hemophilic history, as was found out after the operation. I have been so struck by the advantages of the use of thyroid in cases where the clotting time of the blood is lessened that I am now accustomed to give it two or three days prior to all my tonsil operations. I think it of absolute advantage. If we suspect hemophilia the patient should be sent to the laboratory and have the coagulation time determined.

Dr. G. L. Richards: I have been conducting some general investigations along these lines. I have 130 replies to my circular letters, and calcium lactate, when referred to at all, has been said to be advantageous. Reports as to tonsillar hemorrhages are most various. One gentleman said he had done 30,000 operations, and he had had but one case of hemorrhage, and that was in a hemophiliac, while others reported as high as five

to ten per cent. having troublesome hemorrhage after removal of the tonsil.

Dr. C. G. Coakley: In reference to calcium lactate, an adult came to me with a large adenoid, giving a history of having had an operation some years before, when they thought that she was a hemophiliac; some time later she underwent an abdominal operation. The abdomen was found filled with fluid after the second operation and gelatine was administered. I had arranged for the removal of the adenoid, when her physician called me up and advised me to use gelatine prior to operation. I did so, and also gave her 30 grains of calcium lactate every four hours for two days before operation. I removed the adenoid and there was no more bleeding than one usually gets in the case of an adult, and there was no subsequent hemorrhage.

Dr. N. H. Pierce: It seems to me that the fact is here emphasized that we should take very great care in our histories of tonsillar cases and endeavor to find out when hemophiliacs come along, as well as making a thorough examination of the urine, etc. I operated on a boy of eight years, in whose epipharyngeal space adenoids had recurred. When I saw him he was extremely anemic and I took a drop of blood from his ear and did the well known test; normally there will follow a coagulum about a minute after such a drop is drawn. In this case it did not follow for five minutes, therefore, I put the boy on calcium chloride for a week, and before operating repeated the blood experiment and found that the coagulum followed about a minute after it was drawn. He was operated on with even less hemorrhage than is usually found. Another case which would indicate that calcium is of benefit was a woman who had one tonsil removed some years before, and in whose other tonsil I suspected either an encysted abscess or something else which caused great irritation, so much so that she insisted upon its removal and was willing to run the risk of a hemorrhage, which was very alarming at the time of the first operation. I administered calcium chloride for ten days, and although the tonsil was fibrous there was very slight hemorrhage at the time of operation. I believe that calcium, either lactate or chloride, has a distinct influence in lessening the hemorrhage in tonsil and adenoid cases.

Dr. J. O. Roe: Long before calcium chloride was found to have hemostatic properties and brought forward as a remedy in cases of hemophilia, or other cases of persistent bleeding, I was in the habit of using chloride of sodium on the theory that in these cases we find a lowered specific gravity of the blood. By increasing the specific gravity of the blood we not only increase its coag-

ulability, but we thereby prevent osmosis. The efficiency of this treatment I have proved in a great many cases. I well remember the case of a bleeder that I was called to see by one of the surgeons of the City Hospital several years ago. The bleeding began as an epistaxis, which was followed by hemorrhage from the gums and from almost every mucous membrane, and had continued for about three days, until the patient was nearly exsanguinated. I advised the doctor to give the patient salt in teaspoonful doses, washed down by a glass of water, every hour until the bleeding stopped, which it did in about four hours, without recurrence. The action of calcium chloride and calcium lactate in these cases is, I believe, the same as that of sodium chloride, to increase the specific gravity of the blood, thereby increasing its coagulability and preventing exosmosis. In all these cases, however, there is associated a lowered vitality, and in some of them an alteration or degeneration of the walls of the vessels, as shown by the readiness with which the tissues slough after pressure, in cases of scorbutus and other allied conditions.

Regarding hemorrhage after tonsillectomy, in all these cases, if the bleeding does not promptly cease after the operation, I immediately suture the parts until I have tied up every portion that shows the slightest disposition to bleed. By so doing we avoid the annoyance and the danger of secondary hemorrhage and do not have to resort to such uncertain measures as styptics or pressure.

In the case of nasal hemorrhage, whether from injury or following operation, I have never failed to stop the hemorrhage by thorough packing, and I have seen a very large number of such cases, not only in my own work, but in consultation with others. These cases are extremely interesting and there is nothing that so frequently taxes the nerve of the doctor, nor so thoroughly frightens the patient, as hemorrhage.

Dr. Emil Mayer: In regard to the first paper, I wonder why the reader did not call his first case a true hemophiliac, while the second case, which seemed to me a case of scorbutic hemorrhage, was accepted by him as one of hemophilia. It is hoped that when the new nomenclature committee reports it will give satisfactory distinctions and definitions. In the reported cases, in which we have the true descent coming from the grandfather, missing the mother, we have clearly defined hemophilia. Unfortunately, statistics are in these instances absolutely wrong very often, for the reason that a post-operative bleeding is not necessarily due to hemophilia. You will find that you have left a portion of tonsil remaining, and, that tag being removed, there is no further post-operative hemorrhage. Much has been done of late in the way

of the various sera for treatment of those conditions. I am glad to hear the statement of Dr. Wood in favor of thyroid extract, and I believe we will eventually be able to so alter the coagulability of the blood in these cases that we will be able to relieve the distressing condition of hemophilia. I recall one case, in which the late Dr. Asch, Dr. C. H. Knight and myself spent hours in relays for twenty-four hours in digital compression in the case of a young man, a bleeder, who had his tonsil removed. Some two or three months later a very small aural polyp was removed and he again bled very profusely.

Dr. A. A. Bliss: I think Dr. Hubbard has very well drawn the distinction between true hemophilia and scorbutus and other conditions which produce bleeding, and at the same time it is a question in my mind whether we should attempt an operation for hypertrophied tonsils and adenoids where there is a distinct history of hemophilia. Calcium lactate and chloride may be of use, but I doubt if preliminary treatment would control the hemorrhage in a child, although perhaps in an adult, of the true hemophiliac diathesis. At the same time, it is most important to get the history of the case, and that is where the greatest difficulty lies. Intelligent people will tell you that this trait runs through their family, but in general hospital work you will find it very difficult to elicit an acknowledgment of the bleeding diathesis. The less intelligent classes seem to look upon it as a disgrace and are very apt to conceal it. I lost a case by such a condition of things. Eight hours after the operation a hemorrhage came, although we had had the usual amount of bleeding at the time of operation. The mother then acknowledged to me, although we had tried to find a history of bleeding, that her people were of that diathesis, and the child lived but three days. It is my opinion that, where we get a distinct history of hemophilia in a child, the minor operations, such as excision of the tonsils and adenoids, should not be attempted. I doubt very much if an adult will present himself for such an operation if he realizes his hemophiliac tendency. Those who do correspond more to the class of patients referred to by Dr. Mayer, in which there is accidental hemorrhage.

Dr. W. E. Casselberry: Although not wishing to controvert the scientific data offered in favor of calcium lactate or thyroid extract as agents for preventing and controlling copious bleeding, my clinical experience indicates that an over-reliance is being placed upon them. I have encountered several serious post-operative secondary hemorrhages, which persisted steadily over periods of time adequate to test the chloride of calcium given to the limit of tolerance. For instance, following an electro-cauterization, a separation of the slough on the seventh day opened a



branch of the post-nasal artery, which for three weeks thereafter would spurt copiously every time the packing was changed, despite the free administration of calcium chloride. In another case, following the removal of a polypoid middle turbinal, the duration was two weeks in which a firm pack had to be maintained, while calcium chloride given to the limit was powerless. To my mind there is a local influence to be counted on in these cases aside from hemophilia, scorbutus or other blood disorder. I have observed that practically all cases of serious tonsillar hemorrhage are really due to the persistent spurting of a small artery which fails to close as promptly as usual with arterial twigs. Such a vessel may bleed copiously from one tonsil and not from the other excised in the same general manner at the same time. In fact, tonsillar hemorrhages in bilateral operations are nearly always from only one side and from only one of the several small arteries of the one side. The same is true of post-operative nasal hemorrhages. Evidently, then, a local defect of the vessel or a chance variation in degree or kind of traumatism exerted upon the arterial coats in making the cut, leading to defective local contractile power of the severed end, is a more reasonable explanation in a preponderating number than lowered blood coagulability. I have looked upon such small red spots as that referred to by Dr. Makuen, from which bleeding recurred, as formed by unhealthy granulation tissue slower to cicatrize than usual, and as being additional evidence of a local defect in or around the bleeding vessel. I do not mean to exclude by this statement the influence of possible systemic conditions, only in the rather large number of cases I have seen the patients have been healthy people without hemophilia or scorbutus. What I wish to convey is that while not omitting calcium lactate, let us provide ourselves with every appliance and familiarize ourselves with every dexterous means to stop the bleeding artery at the wound.

Dr. H. L. Swain: There is one point in this discussion which has not been touched upon. We have heard a good deal upon the condition of the blood and we must admit that calcium has an influence in controlling insufficient coagulability. I am thoroughly of the belief that every hemophilic has a different variety of blood vessel from the ordinary person. I have found enough actual difference in studying the vessel walls in the nose to have become convinced that histological differences may exist in the make-up of the wall in some of these cases. If you have a case of hemophilia which is principally due to friability of the vessel wall, not alone to lack of coagulability of the blood, you can give calcium chloride without satisfactory results, while in the other cases like those mentioned by Dr. Simpson or Dr. Roe



there is an absolute effect from the administration of the drug.

Dr. R. C. Myles: I have encountered several different types of hemophilics, one of which I believe to be due to a condition brought about by extreme loss of blood. In other words, they become pseudo-hemophiliacs after they have lost a certain amount of blood. There is another type in which it seems the artery itself is at fault, whether due to the lack of power to contract or lack of proper coagulum one cannot readily always determine. I believe that the neglect of proper and early attempt to control the hemorrhage has been a large factor in causing the serious after-effects so often to be dealt with. I am a strong believer in the general surgeon's principles of arresting hemorrhage—first pressure, second the ligature. The ligature can be often applied, and the wisest way of using it in the throat is with the ordinary curved staphylorrhaphy needle, deeply or superficially as indicated.

Dr. Thomas Hubbard: I want to call particular attention to the fact that there is no pathological anatomy of hemophilia, it being considered simply an hereditary condition. I think that Dr. Simpson's case is not that of a true hemophiliac, and for my reason I refer you to the rules of heredity which will be published with my paper. We should encourage a proper use of the term "hemophilia." At present it is applied indiscriminately to all unusual hemorrhages, and as a result therapeutic measures advocated disappoint us when used in true hemophilia. A more careful study may bring out more of that group of the type of the scorbutic case mentioned.

It is reasonably clear that calcium lactate is indicated and Dr. Simpson has given excellent rules for administration. I believe that in another case similar to the one reported I should depend on fresh horse serum, theoretically, after having, of course, exhausted all of the ordinary and well-tried procedures.

Dr. Simpson: If Dr. Hubbard and myself have not contributed any positive data on the subject we have at least elicited a discussion which may be suggestive when we attend these conditions. I tried to confine my remarks to the subject in hand, the clinical experience with lactate of calcium, but I do not think it would be out of place to mention one opposite condition which occurs. In reading over the subject the question of citric acid was found mentioned as producing an opposite effect from the calcium salts, and I may say that this family, father and son, have found out that certain things which they eat will diminish their coagulation period and bring on hemorrhages, especially grape fruit, which I presume contains a certain amount of citric acid. I did not bring up lactate of calcium

as a panacea nor to meet all the types of hemorrhage which may ensue, but simply to emphasize the fact that we should in all these cases for operation go thoroughly into the history. We want to meet and prevent that one case (we may do the "30,000 without the one hemorrhage"), but that one hemorrhage when it does occur makes all our successful cases pale into insignificance, and it is for that case that we must look. I am positive if we go into the history of our cases, and, if necessary, take the laboratory test for coagulation, and in suspicious cases give the lactate of calcium or any of the other measures we have bearing on the coagulability of the blood, we will save ourselves trouble, or at least save our consciences.

THE CHOICE OF AN OPERATION FOR THE COR-  
RECTION OF OBSTRUCTIVE DEVIATIONS OF  
THE NASAL SEPTUM—A PERSONAL  
POINT OF VIEW.

BY WILLIAM L. BALLENGER, M.D.

I have been and am still an enthusiastic advocate of the submucous resection operation for the correction of obstructive deviations of the nasal septum. No other operation is as universally applicable, and in many instances the obstruction can only be completely overcome by this operation. While this is true, it is equally true that some obstructive lesions of the septum may be fully corrected by other methods of operating, which are much simpler in technique, more easily performed, and which are attended by less stress upon the patient. If this is true, it is obvious that the characteristics of each case should be studied and an operation elected that will most surely accomplish the desired result, with the least difficult technique, the least expenditure of time and the least risk to the patient. The submucous resection operation requires the most difficult technique and the greatest expenditure of time, and for these reasons is, in the hands of the average rhinologist, not always successfully executed.

My contention is, therefore, that while the submucous operation is the best, and, indeed, the only method by which many obstructive deviations of the septum can be completely removed, the technique is often difficult, and may require from one-half to three hours for its successful performance, even though the operator is an experienced and skillful surgeon. This being true the operation should be reserved for those cases which cannot be corrected by other and simpler operative procedures. Conversely, when an obstructive lesion of the septum can be corrected by a simple operative procedure, the simpler procedure should be adopted in preference to the more complex and difficult submucous operation.

The foregoing statement is made because the submucous resection of the septum has successfully "held the field" against all other operations for the past four or five years. I feel the more free to challenge its right to thus hold the field against all "comers," in view of the fact that I have had something to do with its development. I desire, moreover, to pay a just tribute to other operations (most of which were originated by Fellows of this association), which, in properly selected cases, are equally good in their results and much simpler in their technique. No bouquets will be thrown, no axes ground. On the contrary, I will endeavor to calmly and dispassionately, and I trust judiciously, discuss the place each operation should occupy in relation to the various types of obstructive deviation of the septum. Persons and personalities will not be given place in this critique. The operative procedures and their applications, and not the originators of the operations, will be discussed. Nor will the indications given by the authors of the various operations be considered. On the contrary, I have taken the liberty of expressing my personal opinion on this phase of the subject, as the only excuse I can offer for opening this discussion is that my points of view may, in some respects, differ from those held by the authors of the various operations.

*Fundamental Facts*—If a few well known fundamental facts are held in mind when a case of obstructive deviation of the septum is examined, the choice of an operation for its correction will be greatly facilitated. The following appear to me to be worthy of consideration:

*The tendency of cartilage to return to its former position*—Owing to the persistent resiliency of cartilage it tends to return to its former position after it has been displaced by an operative procedure. This fact has largely influenced operators to hesitate to attempt to correct deviations of the cartilaginous portion of the septum by the various flap operations, more especially the non-beveled flaps used in the Asch operation. This objection to the flap operations does not apply with equal force to the beveled flaps used in the Watson, Gleason and the Price-Brown operations, as they are in a measure self-retaining.

*Bone when fractured and placed in a new position has but*

*slight tendency to return to its former position.* This fact renders fracturing procedures feasible when the deviation is limited to the bony portion of the framework, as the perpendicular plate of the ethmoid and the vomer. Roe's crushing operation may therefore be chosen in those cases in which the obstructive lesion is limited to the perpendicular plate of the ethmoid bone, and the author's operation may be practiced when the obstructive deviation is limited to the vomer. The last named class of cases are also suitable for Bosworth's sawing operation.

*Non-beveled flaps which are not self-retaining*—Operation utilizing non-beveled flaps which are not self-retaining, as in the Asch operation, require the use of a nasal splint or tube for a period of from three to six weeks, otherwise the cartilaginous flaps return to their former position and defeat the object of the operation. The Kyle operation, which consists of the removal of the redundant tissue at the apices of the convexities, converts the septum into two or more parallel flaps, also requires the prolonged use of nasal splints. In my opinion any operation requiring the prolonged use of intranasal splints or tampons is objectionable and should not be chosen, especially in view of the fact that other operations which do not require the prolonged use of intranasal splints may be performed with entire satisfaction.

*Non-beveled flaps which are partially self-retaining*.—The ribbon flaps in Sluder's operation are self-retaining three or four days after the operation and may therefore be utilized in suitable cases, namely, in extreme angular deviations of childhood. These flaps become self-retaining in three or four days, or as soon as they become agglutinated by inflammatory adhesions. At the end of this time the nasal splint may be discontinued.

*Beveled flaps are self-retaining*.—A properly beveled flap of the cartilaginous portion of the septum when pushed toward the concave side of the septum, is retained in its new position by the beveled edges of the incised cartilage. Such flap operations are, therefore, rational procedures for the correction of obstructive deviations limited to the cartilaginous portion of the septum nasi. The beveled flap operations include the Watson, Gleason and the Price-Brown operations.



*Compound deviations involving the cartilaginous and the bony portions of the septum*—In these cases it is impossible to correct the obstructive deviation by either of the foregoing methods of operating. In some it would be possible to do so by two or more of them, though this is rarely advisable. It is in this class of cases that the submucous resection operation should be performed. This type of deviation is frequently present in adults, while the simple cartilaginous deviations are often found in children and occasionally in adults. It appears, therefore, that the submucous resection operation is the operation of choice in a majority of cases presenting themselves for operation.

### *Discussion.*

Dr. O. T. Freer: Further experience has but confirmed my opinion that there is but one operation for straightening the bent septum which possesses the correct principle for this purpose—the submucous resection. It alone is able not only to remove the deviation absolutely, but also to take away bodily what is often even more of an obstruction to nasal breathing, excessive thickness of the septum. The fracturing operations advocated by Dr. Ballenger leave this thickness. The submucous resection is the only operation which deliberately exposes and hence intelligently adapts itself to the endless variety of anatomical differences presented by the skeleton of the deviated septum. While the submucous resection thus accurately determines its indications during its progress, the fracturing operations must obviously be prearranged from the external aspect of the septum alone. This aspect, however, is deceptive and gives no clew whatever to the arrangement of the internal framework of deflections of the septum. In other words, one cannot look through the mucous membrane and discover what is underneath it, but the uplifting of this mucous membrane in the submucous resection plainly discloses the anatomical conditions to view. A deflection, which appears from its external appearance to be cartilaginous, may prove, as I have often found, to be mainly of bone, the perpendicular plate and the vomer filling the place normally occupied by the cartilage. On the other hand, before an extensive cartilage, the borders of these bones may recede out of the reach of fracture so that the attempt to infract portions of such a septum fails, be-

cause of the elasticity of the cartilage, as I found in my first resection, in which I concluded by cartilaginous resection by breaking or trying to break the bony deflection with the forceps of Roe, a piece of violent surgery that was often as harmful as it proved to be ineffective.

The fracturing operations therefore must always be haphazard. In addition to uncertainty of result and objectionable injury they, however, also possess dangerous features. When I performed submucous resections in Professor Fraankel's clinic in Berlin, both he and Professor Edmund Meyer told me of a patient who had become blind in one eye as the result of the breaking out of a portion of the vomer. Evidently a fissure had penetrated the optic foramen. Professor Hans Koschier in Vienna informed me of a case where the whole vomer was torn out in a fracturing operation. I have seen a double sphenoidal suppuration follow an Asch operation, due to fissures entering the sphenoidal sinus. In contrast to this the exact excision of bone employed in my method of the submucous resection has never been followed by evil consequences to my knowledge.

One of my patients, upon whom I did a submucous resection in this city, as a minor part of the removal of a thick, bony congenital closure of the right choana three years ago, died some days after the operation. This death, as the careful post-mortem made at the Massachusetts General Hospital proved, was due to status lymphaticus, had nothing to do with the operation, and was one of those unfortunate happenings which may succeed any surgical operation, no matter how well executed. I am, therefore, justified in saying that none of my 355 submucous resections was followed by any complications whatever. I wish to especially emphasize that I have never seen sinking of the nasal bridge after any of my operations.

With such mathematical precision does a properly performed submucous resection remove all deflections, of whatever nature, no matter how extreme, far back in the nares or how massively bony they may be, that I did not hesitate to perform sixteen resections by my method as a demonstration in the great clinics of Europe, on deflections selected for their difficulty, in strange surroundings and before critical audiences including such men as Sir Felix Semon, Bernard Frankel, Edmund Meyer, Holger Mygind, Dundas Grant, Charles A. Parker, Gustav Killian, Logan Turner, Brown Kelly, Hans Koschier and others. All of the results were perfect. The chief objection urged against my way of operating is that the procedure is rather lengthy. I personally take from one-half an hour to an hour for the average resection, where I am not delayed by demonstrating. Has the surgeon, however, a right to consider his time, provided, as is the case, the patient

suffers neither pain, shock nor danger from the duration of the operation and the extra time employed insures the most perfect result obtainable?

While I was developing my method with deliberate performance, an open operative field, complete excision of bone and keen dissection where needed as its principles, the essayist, without ever having seen me operate, tried to change the well-planned deliberate surgical operation which a submucous resection should be into a quick rhinological manipulation, including mechanical excision of cartilage and forcible fracture of bone, blunt elevation of the coverings of the septum being advocated as the main reliance. Now, here we stand to-day, he admitting that he finds it necessary to call to his aid the fracturing operations of haphazard and incorrect principle to help him in his endeavors to correct deflections, while I, with increasing satisfaction, find that the submucous resection gives such ideal results that I need no other method.

In conclusion I say that to help out the submucous resection by the fracturing operations is not, what to the uninitiated it may seem to be, judicious selection, but simply retrogression, a retrogression countenanced neither in Germany, England nor the Scandinavian countries, where the submucous resection alone is employed.

Dr. J. O. Roe: I am very glad to know that Dr. Ballenger recognizes the value of other operations for correcting deviations of the septum than the submucous operation. I am also sorry to hear Dr. Freer say that he uses no other method than the submucous operation in the correction of all deviations of the septum. Of course, it is quite natural that when an operator becomes proficient in one method, he considers it the method par excellence, but if Dr. Freer would take the trouble to become as proficient in the use of my fracturing method as he is in the submucous method, he would use the submucous method only in those cases where there is extensive thickening of the septum. There are many cases in which there is an osseous or cartilaginous thickening of the septum where submucous resection is the thing. I have done it in cases where there were no deviations of the septum whatever, the septum being so thick as to very seriously obstruct the nasal passages and where it was very much more rational or scientific to reduce the thickening of the septum than to cut away the turbinated bodies, when no other conditions demanded it. The fracturing operation, as Dr. Ballenger has stated and as I have previously pointed out, is especially serviceable where there is a deviation of the osseous and the osseocartilaginous portion, which comprise about 65 per cent of all deviated septa. There are, as we all know, a large number of different operations that have been devised and proposed for correcting the different deformities and malformations of the nasal

septum. In some cases certain of these operations are far better adapted for them than others, especially in deviations of the cartilaginous portion, but it will be found in nearly all these different operations that the fracturing of the osseo-cartilaginous portion of the septum is an indispensable adjunct to their success, and also in a great many of the cases where the submucous resection method is resorted to. I venture to say that every one who familiarizes himself with the fracturing method will soon appreciate its value as Dr. Ballenger has done.

Dr. Freer has spoken of the dangers of the fracturing method in producing meningeal complications. Such fears are entirely imaginary and groundless, for I have used this method in a very large number of cases with no such accident or complication whatsoever, which I am sure is more than Dr. Freer can say for his submucous method. I believe, at least I was so informed, that the patient on whom he did a submucous resection of the septum as a demonstration before the throat section of the recent Boston meeting of the A. M. A., at the Massachusetts General Hospital, succumbed shortly after to a meningeal complication.

Dr. J. Price-Brown: I am pleased that Dr. Ballenger mentioned my operation. In these cases my results have been usually successful, and I only wish it were possible for me to show some of them to you, after the H operation had done its work.

Dr. Ballenger: I would say that I did a number of Freer operations before I learned another method, but it was too slow for me, as it takes about two hours. I can do the submucous resection by the method I pursue in about twenty minutes. I agree that the Freer is one by which you can get the results if you have the time and if the patient has the endurance. There are a good many other things to think of, such as the prolonged shock, etc. You must not forget there have been deaths in connection with the submucous method to say nothing of blindness. I have had one case where sinking in of the nose resulted from this operation. In very young children we usually do the simpler operations, employing either the Gleason or Watson, the Price-Brown or the Sluder operations. After all, the submucous operation has the widest range of application, the other operations being reserved for those cases in which only the cartilage or only the bone is obstructive.

Dr. Freer's contention that the submucous operation should be performed is ill advised, as many cases can be completely corrected by other methods in five minutes. The surgeon should be resourceful and adapt his methods to the needs of the individual cases. The surgery should be made for the case and not the case for the surgery. His statement that only by the submucous operation can obstructive deviations be corrected does not accord with my experience, as I have had brilliant results by other methods.

**JOINT SESSION OF THE AMERICAN OTOLOGICAL  
SOCIETY AND THE AMERICAN LARYNGO-  
LOGICAL ASSOCIATION.**

---

SUBJECT FOR DISCUSSION—NASAL AND PHARYN-  
GEAL CONDITIONS AS CAUSATIVE FACTORS  
IN AURAL DISEASE.

*FIRST PAPER.*

BY GEORGE A. LELAND, M.D.

That the nose is the source of all our woes was once stated as the caption of an article in a New York daily paper. That the nose and naso-pharynx are the source of a great majority of aural woes can hardly be gainsaid. For when we come to inquire into those conditions of the ear which conduce to discomfort, to abolition of the sense of hearing, even to danger to life itself, it will be found that almost all have their morbid origin in this region. For with the exception of certain changes in the secretion of cerumen, which are said to be influenced by naso-pharyngeal circulation, whether exuberant or diminished; also of some markedly virulent cases of external otitis which may possibly pass through a thinned drumhead, and also of trauma, we can exclude largely external conditions as causative factors of middle ear disease.

So also as to invasions from the cerebral side. Trauma, as in fractures of the base may cause middle ear complications, and, aside from this may be mentioned that still rarer factor, cerebro-spinal meningitis, which may invade the tympanum through the labyrinth. Thus we are confined in our considerations to the protean forms of middle ear disease, which have their origin in



extension of inflammation and of infections from the nasopharynx. And the reason for this extension must be found in loss of the protection normally provided for the safety and the integrity of the conducting apparatus of the organ of audition.

Now the ear is both the most delicate organ of the body and the best protected. From without, it is fended from damage by a movable cushion, the auricle, set upon the hardest bone in the body, the M. T., its outer limit an inch and a quarter from the surface, approachable in the white races by a narrow curved canal, the inner two-fifths of which is of flinty hardness. From within it is protected by being at the outer end of a tube about one and one-half inches in length, whose inner mouth is about three inches from the outside. Thus, by its position is it guarded from changes of temperature as well as from other sources of injury. Now as most diseases come from the inside, a brief consideration of this protective mechanism may be opportune, and this may be arranged under two heads.

1. Structure of the Eustachian tube, its muscles and surroundings and their physiological movements.

2. The influence of normal respiration (respiratory movements of M. T.)

1. The Eustachian tube is a vertical slit in the side of the naso-pharynx, about one and one-quarter inches long and about one-quarter of an inch high, whose sides, except at the outer end as it emerges from the tympanum and at the inner opening in the pharynx, are when at rest in light contact. It is lined with columnar ciliated epithelia whose motion is downwards toward the pharynx. The posterior wall of the tube consists of a cartilage which curves over at the top so as to form a hook-like projection forward, below the anterior edge of which the anterior wall consists of a fibrous membrane or fascia which is attached to the anterior tip of the Eustachian cartilage continuous with its perichondrium, and extending downward becomes part of the tendon of the origin of the tensor palati muscle. This muscle is the dilator of the tube, and would have been called so if it had not been named before Rudinger described it and its action (Bezold). It has its origin from the anterior tip of the Eusta-

chian cartilage and from the fascia of the anterior wall and then narrows to pass around the hamular process.

Another muscle is the levator palati, which has its origin from the petrous portion of the temporal bone, and "its cylindrical belly runs along the floor of the cartilaginous tube" (Bezold) to be inserted into the soft palate.

Hovell describes a third muscle of the tube, the salpingopharyngeus or retractor of the tube, which, however, is not always present. It arises from the pharyngeal end of the cartilage and passes backward and downward into the muscles of the pharynx.

The action of these muscles is obvious. The tensor palati pulls forward the anterior movable fibrous wall of the tube, the levator palati by its contraction swells its rounded belly upward and pushes upward the floor of the tube and pushes backward the inner tip of the posterior cartilaginous wall. This action widens the pharyngeal mouth, assisted by the action of the tensor, which immediately follows. This pushing backwards of the tip of the cartilage is assisted by the third muscle, though a weak one.

In normal conditions, therefore, every act of swallowing, most acts of speaking and even those of respiration, as they cause movements of the very sensitive and flexible soft palate, also cause this continual opening of the inner mouth of the Eustachian tube.

We can conceive also when active contraction ceases and the sides of the tube fall together again to a state of rest, that the letting downward of the floor, as the belly of the levator relaxes, acts as pumping or sucking, to draw air and moisture out of the tube, assisted by the elasticity of the drumhead itself.

Now, the inner opening of the Eustachian tube is situated in the midst of the lateral extension of the adenoidal ring of His or Heryng, and in the anterior wall of the tube between the fascia and the mucous lining is a mass of lymph glands. It will be readily seen that when the naso-pharyngeal glands are hyperplastic and hypertrophied and the mucous membranes are swollen because of their presence, the normal movements of the E. T. will be curtailed and the circulation increased to even a pathological degree.

Hence the protection of the middle ear afforded by normal physiological ventilation and drainage will be lost. Hence will result rarefaction of the air in the middle ear spaces; depression of its only external movable part, the M. T.; the possible consequent effusions, serous or mucous or both, which may cause maceration of the inner walls, and so adhesions, which may take place without inflammation of a sthenic type, without pain or invasion of germs, but producing the insidious variety of adhesive catarrh, which leads to loss of hearing, sooner or later, becomes the O. M. C. C. of middle and later life, which is amenable to treatment at any time, but curable only in the earliest stages.

Moreover, if the tube is covered in and pressed upon by adenoidal masses or swollen mucous membranes, so that the action of the ciliae of the interior is in abeyance and the pumping motion lost, bacterial invasion may pass up the tube, with so-called extension of inflammation, and then may follow inflammatory conditions (O. M. A., O. M. P.; O. M. P. C.) with all the complications with which we are only too well acquainted.

Both the structure and physiology of these parts point out the rational method of treatment.

2. One of the greatest factors in the protection which should hedge about the organ of hearing may be found in proper normal respiration, and that means *nasal respiration*, first, last and all the time. An English writer said long ago that the Eustachian tube begins at the tip of the nose; that meant that the air passages in front of the Eustachian orifices should be free. And Mr. Mayo Collier, of London, has shown, in an interesting brochure published some ten years ago, the great influence of nasal respiration upon the integrity of the upper air passages. Others have written on this subject, but as Collier's arguments are especially lucid, they may be mentioned here. There has been much said as to how the accessory cavities of the nose are kept clean, since at least two of these have their only exits near the top of thin bony cavities (antrum of Highmore and sphenoid) and all of them have only very small exits. Collier shows that this is accomplished by alternate condensation and rarefaction of air, because the nasal orifices are very much smaller than the cavities to which they lead.

The air passages, including the nose, pharynx, trachea and lungs, contain a very large quantity of air, and this must be constantly renewed by alternate movements to and fro through the small nasal orifices. In normal quiet respiration, at rest, twenty cubic inches of air must pass through these orifices twenty times a minute. By exercise or exertion this may be increased to thirty cubic inches of air thirty times or more a minute. It is obvious that on inspiration there must occur a partial vacuum behind the introitus nasi, and that on expiration the air pressure must be increased. And it is this alternate variation of pressure which causes an interchange of air through the foramina leading into the accessory nasal sinuses, and keeps them clean. In this category may also be considered the middle ear cavity, for its ventilating tube is only somewhat longer than that of the frontal sinus.

That these respiratory movements actually take place was shown by Politzer in 1860, by the use of his manometer and has been shown by another European observer who was able to see these movements by covering the M. T. with an iridescent paint and using a magnifying glass for accurate observation.

The writer also had an experience which amply proved to his mind that these respiratory movements take place. Some years ago a laborer was admitted to the City Hospital with large exostoses of the external auditory canal. On account of pain and deafness caused by accumulation of epithelial debris which could not be removed through the occluded canal, the exostoses were chiselled away after the removal of the cartilaginous and cutaneous canal. There was a perforation through the M. T. and the wound became infected. One morning, on removal of the packing, a bubble was formed over the canal orifice which swelled out with expiration and was retracted with inspiration, which movements were constant till the bubble burst. His Eustachian tubes were apparently not abnormally open, but this observation and the experiments of others clearly show that there is a movement of air through the E. T., even though its walls are in apparent contact, and even though the force of the respiratory currents may not be very great.

From the foregoing may be deduced the rationale of treatment. Continuous nasal respiration is essential to the preservation of

proper passages through the nose; that is, by the proper circulation of air through this region, proper circulation of the blood and lymph fluid is maintained.

Upon this also depends the normal condition of the nasopharyngeal surfaces, and it is undoubted that the increase in the size of the lymphatic chain which surrounds the upper entrance to the body is largely caused by the lack of proper play of the air through the nose. Slight colds and carelessness of the medical attendants as well as of the parents allow the mouth to be used instead of the nose for respiration. Hence the space, not being needed, is filled up by hyperplastic lymph masses called adenoids. The proper movements of the Eustachian tubes are thus curtailed, and thus in earliest life is the foundation laid for deafness after the soft stage of life has passed; that is, after middle life. The time to cure, therefore, O. M. C. C. is *before* the initial earache has taken place or exudate has formed, which causes depression and probably subsequent adhesions in the middle ear, and, though in a very limited field, there is no part of preventive medicine that can have more far reaching individual importance than the prevention of these initial earaches in the very young.

To this end almost universal education must be promulgated to teach people that their children must not be allowed to have earaches, and the general indifference of the community to even a slight earache must be removed, for the middle ear never forgets it. Too many of us, and the writer speaks from personal experience, are suffering from this very neglect which took place in our earliest life, and it is a very serious question for the individual when he gets along in life to a position of some importance, at least to himself, if he finds that he is to be shut off from the activities and pleasures of life, more or less, by the inevitable encroachment of almost irremediable deafness which could have been prevented had it been taken in time.

Hence the earliest symptoms of the presence of these growths must be a warning to us for their removal. Slight colds which are frequent and last a considerable time should call attention to the ears, and if the drumheads are found to be dull and lustreless, the air in the middle ear having been diminished or lost, the nasopharynx, and especially the fossæ of Rosenmüller should be imme-



diately cleaned out and nasal respiration insisted upon. But supposing the earaches have already taken place. Delays are dangerous at this stage, not only for the present, but more so for the future, and from what has been said it seems deducible that the rational method of treatment even then is to clear out the naso-pharynx and fossae; that is, to hasten the mechanism of opening and shutting and pumping the E. T. To this end the sides of the naso-pharynx should be relieved of the growth which is inevitably present, for I am sure there is no child to be seen with earaches not caused by an injury where adenoids are not present, with the possible exception of the infections of the exanthemata and of influenza, and even here it is doubtful.

To possibly throw some light on this point, my assistant, Dr. Henry Tolman, Jr., examined last week 127 cases in the scarlet fever wards at the Contagious Department of the Boston City Hospital. It is well known that this disease often, if not always, causes an increase in size of these naso-pharyngeal lymph tissues. I was surprised to find that he found 43 cases without adenoids. There were 84 cases with adenoids, and of these it is again surprising that there were 72 without aural complications either past or present. Of the 12 cases with aural complications, acute or chronic, all had adenoids and of these only five had them generally distributed, and the other seven had them only in the fossae of Rosenmüller. This bears out my reiterated statement that children with earaches always have adenoid growths, and further emphasizes the importance of a clear fossa of Rosenmüller.

It has been the writer's privilege in numerous cases on the coming of earaches to scrape out the fossae of Rosenmüller and the sides of the naso-pharynx at the end of the E. tube, and to have others do it under his direction in the hospitals. In almost every instance (I recall no exceptions), drainage has been established, inflammation of the ear has gone down and perforation, pathological or artificial, was not necessary. Of course, this procedure, which looks barbarous, cannot be done in every instance; unfortunately we have to defer to the opinions, whims and prejudices of guardians and parents, but in those instances where I have been given permission to do it, or where the more formidable ether operation has been allowed, the immediate re-

removal of these growths from the naso-pharynx has been followed by an immediate subsidence of inflammation in the middle ear, both in children and adults.

Hence, with this etiology in view, the rhinologist evidently is the most natural aurist for the beginning of these cases. Now if these cases have been allowed to run on and the insidious variety of adhesive catarrh has commenced to take place, with or without adhesions, the most rational treatment is that aimed to establish the proper physiological movements of the pharyngeal mouth of the Eustachian tube. From what has been said it will be recalled that the mouth of this tube is never at rest; that its continuous movements tend to renew the air in the middle ear, but that if the side of the pharynx is swollen, and especially if there is present a mass of adenoidal tissue, the older the tougher, or of adhesive bands or cicatricial tissue *in the fossae of Rosenmüller*, the pushing back of the tip of the tube by the levator palatai, and the pulling back by the retractor of the tube cannot take place. Hence the proper movements are curtailed. Formerly the customary treatment in these cases was by inflation of the middle ear by the Politzer method, or by the use of the catheter; also, by means of tragus massage after Hommel's method, aiming thus to keep up the mobility of the drumhead. In most of these cases, permanent improvement did not take place, and could hardly be expected when these grosser methods of inflation were applied only once or twice a week, and it is a question whether the use of Politzer's bag is not injurious, because it is usually used with so much force and because these forceful methods produce an overstretching of the M. T. and middle ear structures.

The proper method, therefore, in the writer's opinion, is to establish the physiological movements and to this end must be restored the integrity of the region of the mouth of the Eustachian tube. The fossae of Rosenmüller must be kept clean and wide, so as to permit the proper excursions of the posterior lip of the tube. Therefore, it may be said that the operation for the removal of adenoidal vegetation, in whatever time of life it is performed, is far from complete, and, in fact, utterly useless where adenoids are removed only for the restoration of the respiratory space, and not for the restoration of proper movements at the

sides of the naso-pharynx, that is, utterly useless so far as the ear is concerned.

Moreover, one result of the operation in this fossa which is a sulcus narrowing at depth outwards, and which by the rhinoscope may appear but one-quarter of an inch deep, but which, by the use of the finger, may be found to be half an inch or more in depth, is to wound its surfaces. Hence as these surfaces are movable, there is a tendency for the production of adhesions so that sooner or later, after the operation, this fossa will be found to be occluded by fibrous tissue or by a reproduction of adenoids, which, it is a fact, are absolutely impossible of complete removal, especially in this locality. Hence, in order to keep these fossae clean so to insure their proper movements it is occasionally necessary to scrape them after the major operation, and to make application of astringents in them soon and perhaps frequently afterward to keep the adhesions from forming.

Now, it is evident that such subsequent treatment is difficult of accomplishment, but it is also evident that in many cases it will be necessary if the proper movements of this tube are to be established and hearing preserved; that it is, without doubt, much better to suffer a few weeks of uncomfortable treatment than that the rest of life after middle age or earlier should be compromised by increasing deafness.

Now the obliteration of this fossa, more or less complete, is not confined to early life. It frequently obtains also in adults with increasing deafness, and compromises the proper movements that establish ventilation of the middle ear. It seems to the writer much more rational to reestablish proper movements of these parts whereby the patient treats himself by the motions of swallowing and by movements of respiration 20 or 30 times a minute than it is to rely wholly on the use of the catheter or Politzer's bag. I beg to submit that this auto-treatment is much more effective where the middle ear has not been too firmly bound down by adhesions than any other treatment which can be artificially applied. To emphasize this position might be cited numerous cases which have been formerly under treatment for many years where the re-establishment of those palatal and respiratory movements has brought the ear back to a satisfactory degree of hearing and

given the patient much greater comfort and a brighter outlook on life.

In one case a man of sixty years of age, where a diagnosis had been made of ankylosis of the stapes and the patient after twenty-five years of treatment had been given over to that hopeless state where further treatment was considered useless, the establishing of these movements brought back hearing so that it was considered by his family that he had been restored to his normal condition.

Another case of fifty-eight years of age, after the same length of former treatment, had been given over to *occasional observation* without treatment, which was considered hopeless interference.

The hearing has been restored from one inch right ear and half inch left, to between one and three feet right and half to one foot left, for Politzer's accumulator; here general conversation at the table had been wholly lost, but now there is comfort at the table and in the office which had been unknown for years.

Another one, a man of sixty-four years of age, after forty years of ordinary methods of treatment, finally consented to have his nose restored, the swellings of his naso-pharynx reduced, and so was brought into a condition where intercourse with his fellow men has now become a comfort when formerly it was a trial.

The reason which may be given for this difference in these cases is deduced from what has been said above and here reiterated, that the proper respiratory and naso-pharyngeal movements are operative twenty-four hours in each day, twenty or more times a minute, and that these very gentle movements of the drumheads tend to stretch or make flexible the stiffened membranes, and even the adhesions, just as continual dropping of water may wear away the rock. In the writer's opinion, this rational method of treatment has given better results in cases of encroaching deafness than are produced in any other way, and that in many cases this treatment must be insisted on at the very beginning of life.

There is one form of disease in which, as yet, very little progress has been made; namely, oto-sclerosis. May it not be true that even this disease, started by inflammatory attacks in early

life, influenced by rheumatism and other dyscrasia, may be prevented, with all the rest, by rational treatment of the nasopharynx *before these inflammatory attacks are begun.*

Dependent on the nose and throat may be mentioned several isolated symptoms. And the first is pain. Many patients come to us complaining of earaches, where, after careful examination, there is no evidence of inflammatory mischief in the middle ear or its annexes. This pain is, therefore, reflex, and may come from various locations, even from the aryepiglottic folds or from the sides of the larynx, as was shown many years ago by our colleague, Dr. J. Orne Green. Most frequently it comes from the tonsils, radiating upward. It occasionally comes from swelling of the lateral pharyngeal lymphatic bands behind the posterior pillars of the fauces, which pass up around the region of the Eustachian tubes. It may come from a tooth, painful because of decay or improper striking; for any part of the tri-geminal, in its myriad branches, may have the cause of pain, which may be referred to any other part. Also, we may have pain in the ear from intra-nasal pressure, from suppuration of the sphenoid, and probably also from the ethmoid, but this only shows that in some cases the whole periphery or whole nervous supply must be overhauled to find the cause.

The second symptom of this nature is a feeling of fullness in the ear, as if there were a plug of cotton, the removal of which would clear up this condition of discomfort. I have found this pressure feeling to be only a lesser degree of that which means pain, and to be caused in a large number of cases by pressure of the corresponding second turbinal upon the top of the third, or on the outer wall. The removal of this pressure clears up the feeling of plugging, and it is utterly irrational to inflate the ear in these cases, for in most of them hearing tests will prove that, the ear being all right, there can be no cause for the sensation there.

The third symptom is tinnitus, and especially the low toned roar, often with pulsations, or, as the patient describes it, a hammering. In these cases there is frequently an effusion in the middle ear, but as often the tympanum is clear. That this variety is often due to hyperaemia of the lymphatic structures in the



sides of the naso-pharynx, and especially in the fossa of Rosenmüller has been abundantly proved by its almost immediate cessation after they have been cleared out and kept clean by astringent applications, often necessarily made with considerable force. So, also, the hissing variety of tinnitus, especially in late or even middle life, is often though less surely diminished or abolished by reduction of the circulation around and inside the mouth of the Eustachian tube. And to this end, for a result more or less permanent, let it again be reiterated that normal, unobstructed nasal respiration must be established, and, further, that most common cause of all nasal obstructions corrected; namely, the vicious habit of mouth breathing.

The fourth and last symptom is vertigo. The occlusion of the nose with its hypercirculation is occasionally responsible for this symptom, even without active aural lesions. An old habitue of the aural service many years ago is well remembered, who for several months came to the clinic led by his daughter because of staggering in the street. He was treated aurally by me three to four months with little relief; by my colleague for the next six months, and was still coming in the same way when the service was changed. Then it was discovered that his turbinates, lower and middle, were much engorged. On reduction of these bodies the vertigo ceased and hearing improved. This case has served good stead as a pointer to occasional cases of nasal vertigo.

In speaking of these functional movements, those produced by blowing the nose have not been mentioned, because it is considered, together with the Valsalvan experiment, a pernicious practice, resulting too often in over stretching of the membrana tympani and of the middle ear tendons and ligaments, and because proper treatment and proper use of the nose should make the use of the handkerchief unnecessary; for there is no doubt that this act increases congestion and intensifies most morbid conditions.

In closing, it must be conceded that the whole subject has by no means been touched upon in this paper—it is too large for the time allotted—that many of the diseases of the ear of inflammatory and infectious extensions have been only hinted at; but it has been attempted to call attention to certain principles which

have been of value as stimuli in practice, and to certain methods which have been followed by satisfactory results. Nor is it thought for a moment that anything new has been brought forward, anything outside of the practice or experience of most, if not all, of this audience of specialists; but only that this paper is a small part of this symposium, which, with its discussion, is to go out to do missionary work among the family physicians, and especially the pediatricists, and even the obstetricians who have to do with the youngest victims of these troubles, when treatment is most effective for the future as well as for the present; and also to make clear that treatment of the naso-pharynx, especially operative treatment, is in the province of the aural specialist, since its effect on the function of hearing is of the utmost importance.

## SECOND PAPER.

BY NORVAL H. PIERCE, M.D.

Aural disease may be caused by pathological conditions in the nose and pharynx, including the epipharynx, in three ways: First, mechanically, by pressure on or within the tube, or by interference with its ventilating mechanism. Second, indirectly, (a) by hyperemia and stasis, which by extension reaches the middle ear from the nose and pharynx; (b) by toxins formed elsewhere which are transported to the ear without the presence of micro-organisms; (c) reflexly, by way of the nervous mechanism, as in the otalgias accompanying tonsillar calculus, elongated styloid process, granular pharyngitis, etc. Third, directly, by the transportation of inflammatory incitants from foci established in the nose and throat.

The consideration of the subject may be approached from a pathologic, anatomic or clinical viewpoint. From the latter, the greatest importance attaches to hyperplasia of the lymphoid structures, constituting the upper portions of Waldeyer's ring. The

nature, anatomical relations, and symptomatology of these structures cannot be exhaustively studied in this paper for obvious reasons. It is sufficient for the present purpose to say that besides the large mass of lymphoid tissue situated on the posterior and upper wall of the epitympanic space known as adenoids, there are smaller groups of the same tissue situated in Rosenmüller's groove in the nasal chambers, especially along the floor, scattered over the soft palate and, most important, within the Eustachian tube itself. Not always is it the volume of adenoids alone that interferes with tubal ventilation, either by stopping up the tube or by pressure interfering with the ventilating apparatus; but this is, in large part, due to the large quantities of tenacious mucus which is extruded by these growths, probably the result of inflammatory action. The same may be said of these growths as they interfere with respiration. It is a well-known fact that the greatest annoyance in this regard occurs at night. During the daytime, respiration may be much more normal, because gravity assists in draining the mucus into the mouth and esophagus. At night, however, this is no more operative on account of the recumbent position; the tenacious mucus accumulates in the choanae and post-nasal spaces, and the individual is forced to breathe through the mouth. As deep sleep approaches the tongue sinks back in the mouth and is eventually aspirated against the soft palate. Respiration becomes impossible and the victim, awakened by suffocation, adjusts the tongue, sinks again to sleep, only to experience a repetition of the torment. No wonder these little sufferers are disturbed by fearful dreams, frequently accompanied by enuresis.

On account of the nasal stoppage, food is hastily taken and insufficiently masticated, for the mouth must be used for breath. Because of some subconscious impulse, perhaps, the very desire for food is lessened.

The poor suckling fares especially hard. He cannot nurse and breathe at the same time, and his puny protests at this unfair fate, as well as the cachectic condition into which he falls if not relieved, have been witnessed by us all. Children with adenoids and enlarged tonsils are under-nourished; they arise from their troubled sleep unrefreshed; they arrive at school already weary;

add to this defective hearing and the superimposed nervous strain by which they endeavor to overcome the defect, and we have an explanation of their mental backwardness that is at least as satisfactory as Guye's elaborate hypothesis of *aproxia nasalis*. You may regard this as an unwarranted digression, but I have thought it wise in order to emphasize the fact that these children are most liable not only to aural, but to all other infections.

Whether because of mucus in the Eustachian tube or because of the mechanical stoppage of the tube by the mass of adenoids in the epipharynx, or within the tube itself, or because of pressure on the cushion interfering with the ventilating apparatus, certain well-defined conditions result within the *cavum*. The tympanic membrane is displaced inward, and with it the ossicular chain. In consequence, the equilibrium of the conducting apparatus, which normally is capable of movements at the foot-plate of the stapes far beyond our present power of macroscopic measurement, is disturbed and a loss of audition results. The cause of this displacement is generally ascribed to a loss of atmospheric pressure in the *cavum*, the plus atmospheric pressure in the external auditory canal being exerted against the tympanic membrane, pressing it inward. To the writer's mind, however, this is not a closed question.

Bezold regards the *cavum* as a modified pulmonary vesicle which, while changed to the extent of containing a portion of the auditory apparatus, retains its ancient power of absorbing oxygen and throwing off carbon dioxide. This can hardly account for the great retraction of the tympanic membrane we find in some cases. The capillaries are incapable of absorbing so much oxygen. In the lung, four-fifths per volume remains after respiration. To account for the greater rarification, Koerner likens the process which occurs in the *cavum* to that which takes place in the resorption of a pneumothorax by the pleura, and ascribes to the lymph spaces in the epithelial cells of the mucosa the greater part of the absorption of the gases. When we recall how completely a pneumothorax may be absorbed and the pleural vacuum re-established, the latter hypothesis seems more reasonable. Whether or not contraction of the tensor tympani contributes to the retraction of the tympanic membrane in recent cases is, in the

writer's opinion, an unsettled question. Surely there are cases of short duration in which, even by forcible inflation with the catheter, the membrane does not resume its normal contour or position. The writer has advanced the theory that the plus carbon dioxide would tend to cause contraction of the muscle. Against this has been brought the fact that the tensor is isolated from the cavum in its canal, only the tendon projecting into the cavity of the drum, and that, further, it has its own blood supply. Still, it may be urged, if the plus carbonic acid gas is absorbed by the lymph spaces of the epithelium covering the tendon and about that portion of the muscle nearest the cavum, a sufficient plus quantity may be conveyed to the muscle itself to cause contraction.

Your Secretary, when he invited me to take part in this symposium, expressed the hope that I would be practical in my method of treating the subject. I fear, as he sits there listening, he must experience a sense of disappointment. But, at the expense of adding to this disappointment, I feel constrained to dwell upon another subject that must be regarded as unsettled. We must accept the clinical fact that the sinking-in of a drumhead is caused by insufficient ventilation, due to tubal obstruction; but it is a question whether the exudates that frequently accompany the same condition can be regarded as of purely mechanical origin. The condition as it occurs in the brain—*hydrops ex vacuo meningeus*—cannot be used as a comparison, as then the brain mass shrinks in a cavity with unyielding walls. It may better be compared to the exudative process as it occurs in *meningitis serosa* of aural disease. Every constriction within the nose, whether it or in pleural exudates. Years ago the writer proved that the serous aural exudates, especially as they occur in young children with tubal stoppage, were not only sterile, but were occasionally possessed of certain bactericidal power (*Jour. Amer. Med. Assoc.*, Dec. 9, 1906). Notwithstanding this, it is more in accord with general pathology to assume that serous exudates result from inflammatory agencies, if not directly, at least indirectly; if not from direct bacterial invasion of the tissues involved, at least indirectly from the action of bacterial toxins elaborated elsewhere, as in the case of two instances quoted for comparison. This has been proved in reference to same aural manifestations



as they occur in connection with the pharyngeal invasion of the bacillus diphtheriae.

If this view of the subject is accepted, then the term *hydrops ex vacuo* is no longer tenable and should be dropped from our nomenclature.

Tubal obstruction, as it occurs from hyperplasia and bacterial invasion of the adenoid tissue, pharynx and epipharynx, forms the keynote of a great part of aural pathology. If early operative assistance is extended to these cases the results are most brilliant and lasting, yet not a few require after-treatment by means of inflation, massage, local applications, etc. The neglected cases form no inconsiderable number of those instances of defective hearing in adult life where the changes in the aural apparatus are permanent. Among these may be mentioned malposition and malformation of the conducting apparatus, adhesions, atrophy of the membrana tympani, luxation of the long process of the anvil from the head of the stapes, stapes ankylosis, spontaneous rupture of the membrane with consecutive cholesteatoma formation. In not a few cases of chronic aural suppuration has the removal of hyperplastic tonsils and adenoids been followed by a cessation of the discharge.

Here I wish to state the belief that nasal obstructions *per se* do not cause aural disease, as witness those cases of congenital atresia of the choanae in which the auditory apparatus remained normal for years, or the cases of post-nasal fibroma, in which the ear is unaffected until pressure necrosis causes a breach in the surface continuity of the tumor and hemorrhage, accompanied by inflammatory phenomena, occurs, or cases of nasal polypi, in which the ears are quite normal.

I am reminded further of one of my guides in a recent hunting expedition in New Brunswick, whose hearing, in spite of a pronounced septal deviation, was much more acute than mine, although he was nearly twenty years my senior.

There must always be, in addition to the purely mechanical obstruction, inflammatory factors present to produce disease of the middle ear that is of nasal origin. In saying this I do not wish to be understood as underestimating the importance of nasal obstruction as an indirect and important factor in the production

of aural disease. Every constriction within the nose, whether it be bilateral or unilateral, may cause hyperemia and disturbance of nutrition in the tissue back of the constriction, by reason of the rarification of air which occurs there. Such constriction is caused by collapse of the alae of the nose, due to paresis of the levators, which occurs in mouth-breathers. Deflection of the septum acts in the same way as do hypertrophies and turgescences of the turbinated bodies, especially when accompanied by excesses in eating and drinking. These individuals are constantly "taking cold." The chronic hyperemia and the disturbances of nutrition behind these constrictions render the tissue less resistant to bacterial invasion, so that each acute exacerbation is liable to be followed by invasion per continuity of surface of the tube and cavum, as well as the accessory sinuses.

These sinuses are not infrequently unsuspected depots for the distribution of infectious material in aural disease. Everywhere, however, we see bacterial life playing the paramount rôle due, it may be in many cases, to the lowered resistance of the nasal mucosa, caused by nasal obstruction. But this leads me to say that not infrequently the same conditions may be brought about in the nasal mucosa which lead to affections of the ears by errors in living, excesses in drink, lack of fresh air and exercise, overwork, worry and the thousand unnatural shocks that our artificial life is heir to. And, further, clinical experience teaches that if the inflammatory factors are not super-added to nasal obstruction these may be most extensive and pronounced without the occurrence of aural disease.

In conclusion, I shall take this opportunity to raise a protesting voice against the widespread and irrational removal of slight irregularities of the septum and turgescient turbinated bodies, in the mistaken belief that such slight irregularities play a considerable part in the production of aural disease. The idea of nasal insufficiency has been carried to unwarranted extremes by many operators, and no little unnecessary suffering has been caused by their misguided enthusiasm. In not a few instances which have come to my observation have these operations been performed on patients whose conducting apparatus had been long before permanently injured by previous pathological processes, the results

of which are atrophy of the tympanic membrane, malformation of the malleus, dislocation, adhesions, etc. I have been especially impressed by the unnecessary nasal and pharyngeal operations undertaken with the vain hope of relieving cases of uncomplicated oto-sclerosis—a disease that has no etiological relationship with nasal obstructions. Let us remember that the anemic, overworked clerk may need fresh air, nutritious food and fair fields more than our turbinate scissors—the irritable neurasthenic other treatment than our nasal saws.

I wish to thank you for so patiently bearing with me in taking up so much of your time in discussing so well worn a subject.

### *THIRD PAPER.*

BY D. BRADEN KYLE, M.D.

In discussing this interesting subject, the natural course of procedure would be first to classify the causes. In the first place, experience teaches us that few aural conditions are primary, so the first natural classification of nasal conditions affecting the ear would be primary and secondary, or one which would be equally good would be direct and indirect. In considering this subject from any standpoint as to classification it is not my aim to take up any conditions other than those described by the title, as primary lesions of the ear, in no way associated with pharyngeal or nasopharyngeal conditions, certainly do not come under this heading.

Many nasal, nasopharyngeal and pharyngeal causes would be placed under the classifications mentioned above. Yet, different stages of different conditions might change the classification as to cause—an indirect might become direct, a secondary condition might really be a primary one, as far as the ear is concerned. An equally good classification would be a physiological one, where from physiological causes, nasal conditions causing obstruction to the passage of air might involve

the ear secondarily. Another excellent classification would be *mechanical*; for example, where there is inequality in the size of the nostril, or by the direction of the current of air, or by the presence of a foreign body, a mechanical irritation is set up and an ear lesion follows. Where malformations exist, such as narrow nasal orifices, malformation of the nasal bones, irregularity as to the formation of the structures, probably due to some physiological cause such as adenoids, nevertheless such conditions would be classed as an *anatomical* cause. Opposing the physiological classification would be the *pathological*, where, either by direct or indirect, by primary or secondary causes, physiological lesions develop in the mucous membrane of the upper respiratory tract and secondarily involve the ear. Again, another classification is the *constitutional* cause, where, from some condition of the circulation, some systemic condition involving the secretions, some systemic condition such as an infectious fever, some lesion of the heart, some lesion of the liver, intestinal tract, stomach, or, in fact, of any of the internal viscera, in a secondary way through the circulation and through the irritation of the mucous membrane, may be a primary causal factor in ear lesions. So that the classification of these nasal, nasopharyngeal and pharyngeal causes would depend entirely upon the standpoint from which the practitioner or specialist views these conditions.

Let us enumerate some of the conditions of these structures that will come under the above classifications. The anatomical cause—the narrow nasal orifice—or let it be an undeveloped orifice due to obstruction in the naso-pharynx so frequently seen in children with adenoids, it may be a malformation, it may be an anatomical malformation not due to the narrow orifice, but due to the fact that there is a malformation involving the accessory cavities, in fact, the entire nasal structure—such conditions would be important causal factors of aural diseases.

Irregularity in the size of the nostril is equally important. In fact, a wide open nostril or a nostril which admits of a large current of air, is equally as disastrous as a narrow nostril. The direction of the current of air, owing to the shape of the anatomical nasal structure, may be such that the current points directly

toward the Eustachian orifice. In such individuals, ear lesions will certainly result. The mouth-breather—whether it is due to nasal or nasopharyngeal obstruction—if it is a nasal obstruction the removal of the same before any damage is done to the ear or the nasopharyngeal structure may avert a resulting ear lesion. But the nasopharyngeal obstruction may be removed, and yet, on account of the bony development sufficient nasal capacity cannot be established and the individual remains a mouth-breather, setting up a constant irritation of the pharynx, thereby producing an inflamed condition of the nasopharyngeal structure and involving the Eustachian tube. These conditions come under several of the above classifications. The mucous membrane lining the nasal cavity may be overworked, due to irregularities in the size of the nostril. You may have the hyperplastic condition, causing nasal obstruction. The bone itself may be enlarged. These conditions, of course, would come under not only mechanical, but anatomical, pathological, or even physiological causes.

Traumatism is a mechanical cause, or even a pathological cause.

Atrophic rhinitis, with the shrinking of the mucous membrane, with the wide open nostril, with the formation of pus, with a certain amount of infection, with the direct or indirect current of air, or the current of air directed toward the Eustachian tube, certainly predisposes to ear lesions. The violent blowing of the nose, forcing material into the Eustachian tube, causes primary or secondary, direct or indirect, infectious or non-infectious, mechanical—in fact, could be classed under almost any of the above varieties as to cause. Any form of rhinitis—the simple catarrhal form—would be either a primary or a secondary, a direct or an indirect cause. The post-nasal inflammatory condition could be classed in exactly the same way. Take, for example, hay fever or any form of lithemic rhinitis, or the so-called rheumatic or gouty forms, where there is sudden congestion of the nasal mucous membrane, interfering with nasal breathing, and naturally an accumulation of mucus in the nasopharynx; these would be primary or secondary causes of the ear lesion, direct or indirect, infectious or non-infectious—simply classified according to the individual case.



Take the specific lesions, tuberculosis, syphilis—in fact, any of the specific granulomata, either from their primary infection or from a tertiary lesion, where the structure is actually involved—such conditions may occur either as primary or secondary, direct or indirect, pathological, mechanical, in fact, would come under any classifications except physiological.

Under constitutional or systemic causes, take lesions of any of the viscera—lungs, liver, spleen, kidney, stomach, intestinal tract—such constitutional conditions as lithemia, rheumatism, gout—while they are strictly classed under constitutional or systemic—they act as primary or secondary causes, direct or indirect, pathological and even mechanical causal factors.

Age is a factor. Every observing practitioner or specialist knows that at puberty, in both male and female, there is turbulence of the mucous membrane of the nose. This is a mechanical cause, and yet it is also a physiological one. There is no pathological condition of the mucous membrane—it is a purely physiological hyperemia; yet, from the fact that it interferes with nasal breathing, it may become a primary or secondary, a direct or indirect cause of aural lesion. The same condition would exist at the menopause period. Also in the old, where there is a shrinkage of the mucous membrane, here again you would have a physiological cause, a mechanical cause, a pathological cause, and also a direct or indirect, a primary or secondary.

Children with the sensitive intestinal tract, with their tendency to diseases of childhood, would form another classification as to causes. Intestinal conditions such as constipation, intestinal worms, diarrhoea, the infectious diseases of childhood, would all act as causal factors of nasal congestion, and the nasal congestion then would act as a causal factor of aural lesions. In fact, I think many of our pathological conditions of the ear start in childhood. One important feature in all these causal factors is this: That if the cause of the nasal obstruction, no matter under what classification you may place it, is removed before there has been set up in the Eustachian tube or ear any permanent pathological change, then the removal of the cause will be curative; but if the causal factor remains sufficiently long to produce within the ear area a permanent pathological change—or, in other words,

a chronic condition, a change in the tissues—then we certainly will have a permanent ear lesion. This illustrates the primary and secondary condition. Take, for example, tumors of any form—the adenoid tissue involving and blocking the Eustachian tube; nothing wrong originally with the Eustachian tube, nothing wrong with the ear, but through mechanical obstruction, through a direct or indirect cause, through a primary or secondary lesion, the ear is involved.

Take the infectious diseases of childhood, or infectious diseases of adults. In all these diseases there is an associated inflammatory condition of the mucous membrane and the entire respiratory tract. Besides, there is added to this an infection—each disease, of course, having its own specific infection, but nevertheless exposing the aural cavity to secondary infection. To be sure, this may travel by continuity of tissue and be a secondary involvement, or it may be a direct involvement owing to the violent blowing of the nose, forcing infectious material into the Eustachian tube. At the same time, there is a lowered physiological condition, a lowered resistance and a greater tendency to spread infection. Grippe, typhoid fever, pneumonia, either in children or in the adult, would also be a causal factor. Any infection, direct or indirect, primary or secondary, is an important etiological factor.

Foreign bodies, depending entirely on their size, location and position, would act in a number of ways, mechanical, pathological, primary, secondary—in fact, in every way but a physiological one.

Occupation is a factor. Individuals confined in close quarters, poor ventilation, dust, various occupations which produce what is known as pneumoconiosis, dry atmosphere, overheated air, sleeping in rooms illy ventilated—all causal factors indirectly to the ear through the irritation of the nasal mucous membrane and nasal obstruction to breathing, but primarily as far as the ear is concerned. In the case of boiler-makers, ironworkers and individuals employed in shops where they are subjected to deafening sounds at all time—here we have a slightly different condition. We have an internal primary cause on account of the irritation of the mucous membrane, due to the dust and constant change in temperature. Then, an external cause which does not come un-

der the title of this paper, would be the effect on the ear drum when the individual is working in confined spaces and subjected to such deafening noises. Occupation as a cause is well illustrated in engineers, automobile drivers, balloonists—any individual who is exposed to constant draughts and the necessary irritation produced by the rapid passage through the atmosphere.

Under amusements, I have seen children amusing themselves by blowing soap bubbles, forcing secretion into the ear, and setting up an acute ear condition. The violent blowing of the nose can also be classified under every known classification, even the physiological, because it is a physiological process.

Primary lesions of the eye, involving secondarily the nasal mucous membrane, and eventually the nasopharyngeal mucous membrane, may be casual factors of ear lesions. Sinus involvement, in which there is nothing wrong with the nasal cavity, but where infectious material is poured out into the nasal cavity, is also a casual feature.

Another physiological cause, or if I may be allowed to introduce another causal factor as to name, might be the esthetic cause. This refers to the individual who labors under the impression that each morning he must give his nasal mucous membrane a bath, so he promptly snuffs up quantities of water through the nostril, thereby setting up a resulting inflammatory condition and originating a mechanical, a direct or indirect, a primary or secondary cause of aural lesion.

Sudden changes in temperature, or the temperature cause, is another factor. The sudden change from heat to cold, or from cold to heat, will produce irritation of the mucous membrane, which irritation may produce some ear lesion.

The cleft palate is also a causal factor. This might be an anatomical one, or a physiological one, or a mechanical one, but we have all seen cleft palates in which the Eustachian orifice was directly exposed and the necessary irritation produced by this exposure to the passage of food, and the irregular passage of air, produced early in life an ear lesion. I have under my care now such an individual who is stone deaf, and his deafness began at the age of five. The mucous membrane around the Eustachian orifice is so thick and fibrous that it is almost impossible to locate

the orifice. This, as to cause, might come under almost any variety.

The enlarged and imbedded tonsil, let it be an adherent one or a congenital imbedded tonsil in which from its location it obstructs the Eustachian tube or forms a pocket back of the soft palate, keeping up a constant irritation, becomes an etiological factor in ear disease. The lateral pharyngitis, the simple tonsillitis, in fact any infection or any primary lesion involving the pharynx or any of the pharyngeal structures, may become a causal factor.

Another causal factor which may be secondary as far as the nasal structures are concerned is that nervous phenomenon which follows shock, grief, fright—in fact, any condition which lowers the tone of the nervous system, in which we get the local cyanotic congestion. The engorgement of the nasal mucous membrane would be then a direct and indirect cause of aural lesions. There would also be the direct effect on the ear of the lowered nerve tone. In fact, every otologist has seen the case of sudden deafness following shock and grief. While this does not strictly belong under nasal causes, at the same time the congestion of the nasal mucous membrane is a direct factor.

Hereditary cause is another possible classification. So frequently we hear from our patients the statement that they inherited the catarrh, that they inherited the deafness; but if we look into the matter we find that they have inherited the family nose, the narrow orifice, the high nasal arch, with the long, narrow, slit nasal passage, where the slightest irritation will cause obstruction to the free passage of air, causing early in life a nasopharyngitis and predisposing the individual to ear lesions.

It is very true, certain inflammatory conditions of the ear exist without any pre-existing nasal lesion, or at least any lesion that is discernible at the time the aural lesion is discovered; nevertheless, in the large per cent. of acute aural disease such nasal irregularity, either anatomical or pathological, exists.

The above causes bring us to this conclusion: That no matter what classification we may use as to cause, no matter what the obstruction may be, the first point for the practitioner to decide is this, first of all. Can this nasal causal factor be removed; and,

if so, has this nasal causal factor already produced permanent pathological lesions in the ear, or will the removal of the nasal obstruction remedy the ear lesion?

#### *FOURTH PAPER.*

### CHRONIC EPIPHARYNGEAL PERIADENITIS IN ADULTS.

BY JAMES E. LOGAN, M.D.

As its name implies, this is a disease of the tissues situated in the vault of the pharynx. The writer is not content with the term—periadenitis—as interpreted literally it would indicate that the structures surrounding the glands are alone involved, while it is intended to comprehend a pathological process extending throughout the glandular, muscular, vascular and connective tissues.

In 1903 I read before this Association a paper entitled, "Adenoid Growths, With Especial Reference to the Condition in Adults," in which I recited my experience in operating upon sixty-five cases in adults over twenty-five years of age. I shall attempt to give you further proof of the importance of recognizing this affection as a distinct disease which deserves a separate classification along with other inflammatory processes of the upper respiratory tract. Writers upon this subject generally considered this condition as an extension of inflammatory processes, either from the nose or from the pharynx into the nasopharynx, thus making it a secondary and not a primary affection.

In the light of our experience, we are convinced that in these structures are developed the etiology and pathology of many diseases which have baffled the efforts of our greatest men in the sphere of investigative research. We have been taught that after the age of puberty the lymphatic glands undergo atrophy



and ultimately disappear, and, within certain limitations, clinical facts bear out the truth of this statement. Whenever the age of childhood has passed without the establishment of pathologic processes of a chronic nature within these structures, then trophic changes take place that very soon obliterate their existence. But whenever chronic inflammation has occurred they seldom, if ever, disappear.

In entering upon the discussion of the pathology of this disease we shall not attempt to go into the details of the acute forms of this affection, leaving that to some future time.

In 1868 Luschka indefinitely described a chronic disease of the naso-pharyngeal bursa, to which he gave the name "Chronic Naso-pharyngeal Bursitis." Later, in 1885, Tornwaldt gave a more detailed account of this affection, to which many writers have ascribed the name "Tornwaldt's Disease." D. Braden Kyle, in the last edition of his work, refers to it as a suppuration of rare occurrence in the pharyngeal bursa, presenting symptoms very similar to those of empyema of the sphenoidal sinus. The latter condition he regards as occurring more frequently. Ballinger mentions it as a disease of the recessus medius, due to inflammatory adhesions of the median borders of the adenoid mass. Schwabach regarded it as a disease of congenital origin, situated in the remnant of the middle cleft.

In determining the actual pathology of this disease I have submitted a number of these growths to my friend, Dr. Frank J. Hall, of my city, who has spent much time investigating its characteristics, and I am indebted to him for valuable aid. I shall give you his report in detail:

"The tissue removed from the epipharyngeal region of Mr. D—— by you, and sent to me for microscopic examination, presents the following:

"The gross specimen is roughly circular, 3m. in diameter and 2m. thick. Sections made at right angles to the surface present the following: The epithelial covering is squamous epithelium, which is broken at one point by an ulcer whose floor is composed of polymorphonuclear leucocytes held in a reticulum of fibrin. At one other point the surface epithelium is being invaded by leucocytes and round cells. This area lies directly over a lymphoid deposit resembling tonsillar tissue.

"Beneath the epithelium at all points the submucosa is liberally infiltrated with round and polymorphonuclear cell exudate. Here and there is a deposit of lymphoid tissue, whose lymph sinuses are choked with inflammatory products. Deeper down, groups of mucous glands are encountered. The lumina of these glands are wide and filled with a liberal amount of secretion. About the glands just mentioned are considerable deposits of inflammatory round cells of the plasma of the small leucocyte type. In the planes of connective tissue at the level of the mucous glands is a noticeable amount of fibrin, almost sufficient to constitute a severance of the overlying sub-mucosa from the gland-bearing area. Still deeper, planes of voluntary muscles are encountered. Between the individual fibres of the muscles is a great quantity of inflammatory material, both cellular and fibrinous, constituting a real interstitial myositis.

"Throughout all the section, and particularly marked in the upper layer of submucosa, are many degenerated nuclei of the proper connective tissue. These degenerated nuclei are drawn out in the most bizarre fashion into clubs, strings, etc. No giant cells or other specific histological cell elements or arrangement of same is noticeable. Blood vessels are all the seat of thickening of the intima and media."

You will observe from Professor Hall's report that this disease does not alone involve the glandular structure, but extends to the muscular, vascular and connective tissue. We believe this to be of especial importance with reference to the muscles concerned in the function of hearing. The tensor tympani, tensor palati and the levator palati are to be mostly considered in this connection because of their attachments into and around the orifice of the tube, influencing, as they do, the action of the drum membrane, together with the effect upon the lumen of the tube by the opening and closing functions of the levator and tensor palati. These muscles originate in and around the orifice, and any inflammatory process in adjacent tissues undoubtedly involves these fibres and must of necessity interfere with their physiological action. This might serve to explain the yet unsettled theories of sclerosis of the middle ear. Chronic catarrhal inflammation of the middle ear has been the bugbear

of every pathologist. He has never been able to establish its identity. We know that these cases progressively increase in deafness, even when they are given the very best attention. In the light of these facts, it is clearly evident that either these conditions are irremediable or the etiology, pathology, and its elimination are yet unknown. Buck, in his third revised edition, page 41, says: "As yet we are unable to form any very accurate idea of the extent to which the impaired hearing in this class of cases (referring to chronic catarrhal deafness) is to be attributed to the abrogation of the functions of the tensor tympani and stapedius muscles. The sclerosing process invades both of them and to a greater or less extent paralyzes their action; and it is also conceivable that in certain cases a state of permanent contracture may be produced whereby the membrana tympani on the one hand and the stapedio-vestibular-annular ligament on the other are kept by these muscles permanently in an abnormal state of tension."

Retraction of the membrana tympani is more often dependent upon the lack of resiliency of the tensor tympani than upon any perceptible encroachment upon the lumen of the tube. This fact can be proven in a large proportion of cases by catheterization.

It can also be proven by the unimpeded introduction of the bougie through the tube. If the tube permits of the entrance of air, and also of the introduction of the bougie, then why does the membrane tympani remain retracted? The answer to this question seems to me to be found in the foregoing statement, viz., the lack of resiliency of the tensor tympani. Admitting that sclerosis (a process hard to define) does become established within the drum, then it must have a cause, and that cause in a great majority of cases is to be found in a diseased condition of the tissues of the epipharynx.

This disease may exist indefinitely without producing any disturbances in the function of the ear, though this is the most frequent complication.

Whenever the tissue in the vault has been the seat of repeated attacks of acute inflammation, supervening upon the chronic process, we have found these patients frequent victims of acute rhinitis and of epidemic influenza. The reason of this lies in the

productiveness of this soil for the cultivation of all forms of pathogenic bacteria. In forty-two cases of acute epidemic influenza in adults, in which were found the *diplococcus catarrhalis*, every one exhibited a greater or less amount of lymphoid and connective tissue hypertrophy in the vault. I desire to lay especial stress upon the question of the amount of this hypertrophied tissue. In my experience, the smallest amount of it is sufficient to furnish a field for the cultivation of infectious material.

We must realize that in adults the process of deterioration of this lymphoid structure can leave but little of the growth in all but exceptional cases; but the point we wish to bring out is that even the slightest amount may be the origin of widespread invasion. In the drawings presented for your inspection you will observe that in the cases of No. 1 and No. 2, as shown on the plates, there existed the smallest amount of hypertrophied tissue, yet the removal of it brought about good results. In the cases of No. 3 and No. 5 it is our purpose to show that the presence of this periadenitis was the determining pathological process of the chronic suppurative otitis media. The case of No. 4 is of special interest, as showing the effect of bacterial invasion into the right ear during measles in childhood, and the development of a chronic progressive deafness in the left at the age of twenty-eight.

*Diagnosis.*—Diagnosis of this disease is a matter of little difficulty. In the routine of all nasal, aural and pharyngeal examinations, we carefully inspect the vault in every instance. With rhinoscopic mirror we can in most cases determine fairly well the condition of the epipharynx, but we should always go farther and introduce the finger behind the soft palate. By this means we can not fail to discern every evidence of adventitious tissue in this space. I have presented the plate marked "Cross Section" in order to show that this upholstered mass may exist in considerable thickness without destroying the symmetry of the cavity. The obtuseness of the angle made at the juncture of the basilar process with the spinal column varies greatly in different skulls, consequently the mirror alone may lead to a mistaken idea of the amount, while the keen sensibility of a thoroughly clean finger is a never-failing indicator.

*Prognosis.*—The prognosis in these cases is usually favorable so far as the vault condition is concerned. So far as the disappearance of complications, this depends upon what organs and functions are involved, the age of the patient and the amount and character of the impairment.

I can express myself upon this question in no better way than by giving you the results of my experience. Within the last six years I have operated upon 652 cases of adenoids, both young and old, in my private practice. Of this number 386 were below the age of 25 years, and 284 were from 25 to 59 years. Of the 284 adults, 166 were between the ages of 25 and 35, 106 between the ages of 35 and 45 and 11 between the ages of 45 and 59. I have seen one case, 64 years of age, with large epipharyngeal growth, but was not allowed to operate. Of the 284 adults, 210 suffered from chronic progressive deafness in varying degrees of severity, 24 were victims of recurrent attacks of acute and subacute catarrhal otitis media, 17 had chronic otitis and 33 exhibited no ear complications of any moment. Of the 210 cases of progressive deafness, 182 showed noticeable improvement after operation. This number represents those who faithfully persisted in the after-treatment and whose conditions were not so disastrous as to preclude the possibility of some benefit. Twenty cases were of such long standing and of such a character that the after-treatment failed to bring about any appreciable improvement. These patients gave marked evidence of internal ear complications. The remaining eight cases were operated upon and little or no after-treatment was given. Of the 24 cases of recurrent acute and subacute otitis operated upon, 16 have had no recurrence of the discharge and the hearing has been improved. Five have had recurrent attacks. In three of these I have recently done the preliminary stripping and secondary removal, as in the first operation I failed to get rid of the hypertrophies about the orifice of the tubes. Two cases were operated upon and I have lost sight of them.

Of the seventeen cases of chronic suppuration of the middle ear, occurring in adults over 25 years of age, five have had no recurrence after the removal of the growth in the vault, eight required subsequent curettage of the necrosed tissues of the mid-



dle ear and four demanded the radical operation. Of the thirty-three cases operated upon showing no ear complications, all of them exhibited symptoms of nasal and epipharyngeal diseases of various kinds. Four were in patients who had recurrent hemorrhagic expectoration without evidence of lung complication, and so far have had no return of the trouble; five cases had active suppurative inflammation in the epipharynx, accompanying atrophic rhinitis; twenty-four were cases of various nasal and pharyngeal conditions, where the periadenitis seemed to be the predominant etiological factor. In more than 75 per cent. of these cases turbinal hypertrophies were present. Deflections of the septum existed in the usual proportion. Sinus complications were present in twenty-two, a little less than 10 per cent.

In summing up the question of prognosis, my experience leads me to say that whenever a case presents itself exhibiting any disease whatsoever of the nose or accessory sinuses, the middle ear, the pharynx or larynx, and at the same time there is evidence of the smallest amount of adventitious tissue in the epipharynx, the prompt removal of this mass adds greatly to the chances of permanent relief. If I may be pardoned for appearing extreme and over zealous, I will go still farther and say that permanent good is practically impossible if this fertile field of infection is not destroyed.

*Symptomatology.*—It is hardly necessary to dwell at length upon the symptoms of this disease, as to go into detail would involve the question of complications, which are so varied that your patience would cease to be a virtue. Just a few points I desire to bring to your attention. First, the general symptoms are those complained of by patients suffering from the ordinary phases of nasal inflammation—viz., repeated attacks of acute coryza, especially of the infectious influenza type; sensations of fulness in the vault and pharynx, and a more or less constant desire to hawk and expectorate, especially upon arising. Each morning the patient may remove a large mass of inspissated muco-pus, and during the day a large amount of mucus and muco-pus is secreted.

As heretofore stated, a very large majority of my cases were coexistent with hypertrophies of the nasal mucosa, and in many deflections of the septum were present. Consequent symptoms of

these conditions were present. The same may be said of those showing sinus complications.

Secondly, the invaluable aid given us by the mirror, enabling us to see the actual condition; and lastly, and by all means the most important, information revealed by the introduction of the thoroughly sterile finger behind the soft palate—all conspire to render plain the symptoms of this disease.

*Treatment.*—The treatment of this condition can be nothing less than a total extirpation of the diseased tissue. If allowed to remain, it will suffer repeated invasions of acute inflammations and render ultimate relief, even to the remotest complication, impossible. Situated as it is, high up in the vault and in the fossae on either side, it has been almost impossible to devise an instrument that will serve the purpose of total extirpation. Failing in so many instances to remove the tissue in the fossae and about the orifices of the tubes, I have resorted to the following method:

Thoroughly cleanse the epipharynx and nose with warm sterile normal salt solution, by means of the post-nasal syringe. Through the nose, by means of a long curved applicator wrapped with cotton, apply an eight or ten per cent. solution of cocaine several times for ten or fifteen minutes. In the intervals of this application I also apply a solution of superarenal extract, about twice through each nostril. Within this time the vault is well anesthetized. With thoroughly sterile hand, the right index finger, with long sharp nail, is introduced behind the palate. Beginning at the lower border of the left eustachian orifice, proceed to break up all the adhesions and upholstered mass within the vault; in other words, strip the growth away from its bed wherever it can be felt. The result of this preliminary operation is to free the tubes and the fossae of this resisting mass, which is almost impossible to remove by forceps or curette. An active inflammation follows this procedure, which renders the tissue brittle and susceptible of easy separation from the underlying structures. After an interval of forty-eight hours the secondary operation is performed. This is done by the use of the curette in a large proportion of cases. In well-trained throats, the Brandagee forceps may serve good purpose. In the selection of the curette, I prefer the Beckman pattern. After the operation the finger should be introduced be-

hind the palate to make sure that none of the growth remains. The size of the curette depends upon the width of the space between the tubal orifices. The No. 4 Beckman is the size I usually employ. Another important point is that the curette should be pushed high into the vault, following closely the posterior border of the septum, so as to engage the mass; then, changing the grasp of the instrument so that the dorsum of the hand is upward, firmly and quickly, with a wrist movement, cut backward and downward, following the under surface of the basilar and the anterior surface of the spinal column. This procedure, if done with a sharp instrument, will deliver the growth into the mouth, sometimes out into the lap of the patient, or upon the gown of the operator. I have performed this operation in this manner more than 200 times, and have not had occasion to use a general anaesthetic. In fact, I would hesitate a long time before giving ether or chloroform to an adult, first, because the operator is at a great disadvantage by reason of the lying-down position of the patient, and, secondly, there is much greater danger of hemorrhage.

The advantages of the primary and secondary operations are, first, the operator can break up all adhesions easily and strip the mass from its bed in the fossae of Rosenmüller, where it exists in greatest abundance. Second, this mass can not be removed in its entirety in these fossae without the greatest difficulty by the use of forceps or curette. Third, your finger will detect hypertrophies where the mirror will fail to reveal them. Fourth, the danger of severe hemorrhage is practically eliminated by the preliminary stripping of the mass. This procedure breaks up the continuity of the blood vessels, which undergo degeneration within forty-eight hours, at which time the growth is removed. In all my experience with this method, so far I have had but three cases of hemorrhage which required plugging.

#### *Historics.*

Case No. 1.—Miss Wharton, age twenty-eight, light eyes, brown hair, applied to me for treatment July 9, 1908.

During the Winter of 1906 she suffered an attack of double acute catarrhal otitis media which lasted some two or three months. Previous to that time had noticed that her hearing was

becoming impaired—especially during attacks of “colds”—since the attack of double otitis she realized that she was fast losing ground. Being a music teacher, she became greatly alarmed at this condition. Upon testing her ears found watch hearing R. E. 3 in., L. E. 4 in.—during attack of acute rhinitis hearing in both ears reduced to bare contact of watch. Bone conduction increased—drum membranes of both markedly retracted. Shrapnell’s membrane showed signs of previous acute inflammations. Catheterization showed both tubes open and the bougie passed readily into the middle ear.

Examination of nose revealed slight hypertrophies of both inferior turbinals—the epipharynx was the seat of some thickening in and about the orifices of both tubes—the left posterior lip bound down by three bands of adhesions to the posterior border of the fossae of Rosenmüller—only one small adhesion on right. As represented in the plate, you will observe that there showed but little evidence of thickening except in the fossae. With the finger I detected great depth to the fossae, which was filled to almost a level of the grooves with a mass of tissue. This mass was not observable through the mirror and would have been overlooked but for the use of the finger.

*Diagnosis.*—Chronic Epipharyngeal Periadenitis—complicated with partial loss of function of the tensor tympani and the levator and tensor palati muscles. She complained of great discomfort from what she termed her ears “clicking.” This symptom has practically disappeared. This “clicking” sensation I regard as an interference with the free action of the tensor tympani, levator and tensor palati muscles, rather than the interrupted entrance and exit of air.

Am reporting this case to illustrate the facts. First, the mirror alone did not reveal the true condition of the epipharynx. Second, air passed readily into the middle ear, yet the drum membranes remained constantly retracted—the bougie passed both tubes unobstructed.

Case No. 2.—Mrs. W. H. Jones, age fifty-four, married, one grown daughter, applied for treatment February 27, 1906.

Gave history of progressive deafness of more than thirty-five

years standing—had been treated more or less constantly for thirty years.

Right ear the seat of recurrent acute otitis in childhood—left ear had never been involved in any acute inflammation. Hearing tests—watch at hard contact in right ear—at bare contact in left. Bone conduction increased in left—tuning fork on vertex, forehead or teeth intensified in left. A perceptible negative Rinné in left—indefinite in right. Whisper heard in left at 2 inches—not at all in right. Drum membrane of right showed many scars and was deeply retracted—ossicles displaced high up in attic and bound by adhesions—left drum membrane slightly thickened above firmly—retracted—lower portion normal in color. Examination of the nose revealed turbinal hypertrophies of both inferior bodies. The epipharynx exhibited the picture shown in plate No. 2. I could see but slight ridge on left side, extending from the basilar down the posterior wall, blending with some hypertrophied tissue which began in the upper portion of the fossae of R. and disappeared under the posterior Eustachian lip of that tube. The right fossae of R. was more nearly filled with a mass of larger size—one small adhesion on left side—the finger confirmed the presence of a mass greater than the mirror showed. This patient complained of much annoyance from the “clicking” sensation in left ear. She complained of very occasional tinnitus.

*Diagnosis.*—Chronic Epipharyngeal Periadenitis—Fixation of tensor tympani and probable ossicular ankylosis in R. E.—Partial fixation of tensor tympani and palate muscles in left ear and vault.

This was a most unpromising case—the patient talked in such low voice as to be almost inaudible. She observed the movement of the lips in those conversing with her very closely. Prognosis very unfavorable so far as the hearing was concerned. I removed a mass of considerable size from the vault on March 25, 1906. She remained under my charge constantly for more than a year, during which time I catheterized both tubes and introduced bougie twice each week. She persistently complained of the “clicking” in left ear, which even now occasionally troubles her. She called on me May 27, 1909, at which time I found the following conditions:



Hearing R. E. watch  $\frac{1}{2}$  inch.

Hearing L. E. watch 2 inches.

Whisper test 6 feet—no tinnitus; hears ordinary conversation at 8 feet distinctly.

Case No. 3.—Mrs. Briggan, age thirty-four, German parentage, married, one child, light blue eyes, brown hair, strong, robust.

Applied to me for treatment November 15, 1905; had measles at seventeen years of age, followed by a suppurative otitis media in left ear that had never ceased discharging in seventeen years.

At the time of my examination found left ear excreting a very foul pus in great quantity. A large perforation existed, including almost the entire Schrapnell's membrane; the tip of the handle of the malleus was yet intact below the margin of the opening, incus was destroyed, large granulations protruding through opening. Mastoid had been involved, according to the patient's statement, but no evidence of trouble at the time of her visit to me.

Patient heard watch L. E. at bare contact when first examined—R. E. normal.

Examination of nose and epipharynx showed the presence of extensive inflammations. The vault was upholstered with a mass of hypertrophied tissue, which, under the microscope, proved to be an inflammation of the muscular, vascular and lymphoid structures.

This seemed a fit case for radical operation, though I felt warranted in postponing such action until the growth in the vault was removed and the granulation in the ear destroyed. I operated upon her November 20, 1905, removing the growth. Ten days later curetted out the granulations through the perforation in drum membrane—packed the canal with iodoform gauze. This treatment continued for three weeks after which time the discharge ceased and has not again recurred.

This case with that of No. 5 are exhibited here for the purpose of showing some of the different phases into which this periodontitis enters as determining etiological factor.

Case No. 4.—A. J. Dawson, age twenty-eight, single; clerk in dry goods store; dark eyes and hair, not robust, pale, anemic.

Applied to me for treatment January 27, 1909—threatened with

attack of acute otitis in left ear—severe pains in ear—some temperature, etc. This condition lasted but a few days then subsided. Examination of this case showed R. E. had been seat of suppurative otitis in childhood, following measles—almost total destruction of drum membrane and contents of middle ear. At present only slight discharge—hearing R. E. nil. Left ear soon regained its normal condition so far as any inflammatory process was concerned, the function, however, had been long since impaired. This loss of hearing became noticeable at about eighteen years of age. Following this acute attack, for which he visited me, L. E. showed watch at bare contact, which improved to 3 inches when all acute symptoms subsided—membrana tympani firmly retracted—some evidences of thickening.

Examination of nose showed prominent inferior tubinals—septal deflection to left side—epipharynx exhibited the condition shown in the plate No. 4. This patient was operated upon March 29, after a preliminary stripping done on the 27th, the growth removed was typical of periadenitis and is the last one examined by Dr. Hall, whose report I have submitted to you.

Case No. 5.—Mrs. Gilliam, age twenty-eight, light hair, blue eyes, anaemic, weight 105 pounds; family history good.

At twelve years of age patient suffered an attack of scarlet fever—right ear became seat of a destructive suppurative otitis media, which continued uninterruptedly for fifteen years; received treatment of various kinds with no permanent results up to the time of her coming to me. Upon examination of the right ear found hearing completely destroyed, and a very offensive discharge, consisting of pus with much desquamative epithelial cells becoming inspissated about the walls of external canal. The drum membrane exhibited a large perforation, including the entire posterior superior quadrant. Shrapnell's membrane was the seat of great inflammation, extending high into the attic. The incus had been destroyed, but the malleus and the stapes remained. Granulation tissue protruded through, especially over both inferior turbinates and a cartilaginous deflection of the septum to the right side of slight degree. This seemed to me a very unfavorable case and so informed the patient, telling her that I regarded

a radical operation necessary to a complete recovery. To this she demurred.

On July 9, 1908, I did the preliminary operation of stripping the vault tissue, and on the 11th, removed the mass exhibited to you. This patient made a rapid recovery, the discharge ceased in twenty-one days after the operation, and up to the present time there has been no recurrence.

### *FIFTH PAPER.*

## THE IMPORTANCE OF THE THOROUGH STUDY OF THE NASOPHARYNX IN TREATMENT OF DISEASES OF THE EAR.

BY FRANCIS R. PACKARD, M.D.

Although before a gathering such as this it may seem somewhat trite to present a paper with the title borne by mine, I feel that the subject is one of great importance and presents some aspects which are occasionally not sufficiently dwelt upon, and that, therefore, it would not be amiss to thresh over again some points with which, possibly, familiarity has bred contempt. There is a saying which has well nigh become a proverb amongst aurists and has been attributed to various distinguished laryngologists in the United States that, "some day the rhinologist will do away altogether with the necessity for the aurist," meaning thereby to imply the great frequency with which affections of the ear depend upon diseases of the upper respiratory tract.

The point I would particularly emphasize is the necessity for a thorough examination of the nasopharynx before undertaking the treatment of *any* aural condition. It seems to me that this examination is much too frequently either altogether neglected or carried out in such a manner as to be practically useless. In teaching in a post-graduate institution, I have frequently been struck with the fact that the physician-student in the aural clinic,

who has been told repeatedly to make an examination of the nasopharynx in every case of ear trouble, considers that he has carried out his directions when he has inserted the tongue depressor in the patient's mouth and examined what is revealed in that manner. As Politzer says in his text book: "Often, however, without the slightest visible changes on the posterior pharyngeal wall, affections of the mucous membrane of the nasopharynx may nevertheless be found which are very far advanced. The absence of changes on the posterior pharyngeal wall does not, therefore, render the examination of the postnasal space unnecessary."

Among some of the pathological conditions in the nasopharynx, besides the acute infectious diseases, which may give rise to disease of the ear are:

1. The presence of adenoid growths in the nasopharynx, which may act either as a mechanical obstruction, interfering with the ventilation of the Eustachian tubes or as a source of infection to the middle ear, because, as is well known, practically every adenoid mass is inhabited by numerous pathogenic micro-organisms which, under favorable circumstances, find easy access to the middle ear through the eustachian tube. Every aurist must be familiar with the frequency with which chronic suppuration of the middle ear completely ceases after the removal of a mass of adenoid tissue from the nasopharynx. This has occurred so frequently in my own work that it has become an automatic process with me to at once turn to the nasopharynx as a possible source for the continuation of a chronic discharge from the ear in almost every instance. I believe that in very many of these cases such nasopharyngeal examination is neglected, and the attention of the aurist is devoted almost solely to finding the origin of the trouble in some local condition within the ear, such as the presence of dead bone or suppuration within the mastoid.

2. So-called catarrhal infections of the nasopharynx are frequently a source of disease of the middle ear, chiefly by the mechanical occlusion of the Eustachian tube, which results from a swollen mucous membrane. Personally I feel that, in most instances, so-called nasopharyngeal catarrh is generally the result of some more serious condition in the nose or its accessory sinuses,

especially the sphenoid, but the term, "nasopharyngeal catarrh" is probably firmly fixed in rhinological literature, whether it is used to express a distinct entity or to signify the condition of the mucous membrane of the nasopharynx as the result of disease elsewhere in the nose or accessory sinuses.

3. The atrophic condition of the mucous membrane of the nasopharynx, which is usually seen in association with chronic atrophic rhinitis, leads to the accumulation of decomposing crusts in the nasopharynx, and under these circumstances the orifices of the Eustachian tubes are more patulous than normal, and it is quite common to see disease of the middle ear result from the patient's blowing or washing infective material into the tubes.

4. Tumors, other than adenoid growths, may occur in the nasopharynx. The author has personally seen a case in which a sarcoma protruded into the nasopharynx from the sphenoid region, first manifesting itself by aural symptoms, the patient complaining of increasing hardness of hearing and tinnitus.

5. The occurrence of adhesions in the nasopharynx, generally the result of previous operative work, is, I believe, a not uncommon and a frequently unlooked for source of disease of the Eustachian tubes and middle ear. Dr. J. W. Jervey, of Greenville, S. C., in a paper read before the South Carolina Medical Society, in 1906, and published in its Transactions, called attention to the frequency with which adhesions in the nasopharynx were sources of pathological conditions in the eustachian tubes and ear. Dr. Jervey stated that he had had his attention called to the subject by Dr. Brunk, of Birmingham, Ala., and Dr. Pyncheon, of Chicago. He reported a series of cases, all of which had been greatly improved by breaking up adhesions in the nasopharynx. Shortly after reading Dr. Jervey's paper, I had the opportunity of seeing a patient who had been under his care and had been treated by him, in whom he had broken up a number of adhesions which occluded her Eustachian tube orifices. This young woman was the daughter of one physician and the sister of another. She had had an adenoid growth removed from her nasopharynx and her tonsils taken out in childhood. Some years after the operation she began to notice that her hearing was impaired and that she also suffered from increasing tinnitus. She was placed by



her father and brother under the care of a distinguished aurist, and after his death was treated by several others. Her condition not improving, she went abroad, where she consulted aurists in several cities. Returning to this country she went for the Winter to Greenville, S. C., at which time Dr. Jervey saw her. He proceeded to destroy the adhesions which he found in her nasopharynx, by inserting his index finger and forcibly breaking up the bands, with the most gratifying results. Upon her return to Philadelphia in the early Spring of 1908, I saw her professionally for the first time. I had been a friend of her brother's and had known her and been aware of how very great was the deafness from which she suffered, although I had never treated her. When she entered my office I was struck with the great improvement which was immediately apparent in her hearing for ordinary conversation. I examined her nasopharynx and found it was quite free from any evidence of adhesions or any other abnormal conditions. She volunteered the statement to me that she had had absolutely no relief from the usual measures of treatment which had been employed by various physicians, until a careful examination of her nasopharynx had been made and the adhesions within it had been destroyed. From that time she said her hearing had shown progressive improvement. Dr. Jervey has since published an article in which he gives further details as to his method of work and its results. He also appends to his article a bibliography of the subject.<sup>1</sup>

Since my attention was drawn to the subject by Dr. Jervey's publications, I have had the opportunity of studying a number of cases in which ear trouble undoubtedly originated from the existence of adhesions in the fossa of Rosenmüller and the nasopharynx, the breaking up of which resulted in gratifying improvement in the aural condition. These cases presented almost identical histories, namely, prolonged Eustachian and middle ear trouble, with increasing deafness, without relief from the usual measures of treatment by Politzerization, massage, hot air, etc. Several of these cases had had adenoid operations in childhood. The method I pursued in the treatment was identical with that of Dr. Jervey, namely, after the nasopharynx is thoroughly cleansed

---

<sup>1</sup>Journal of the American Medical Association, May 16, 1908.

and cocainized, the index finger of the right hand is introduced and the adhesions forcibly torn across, after which silver nitrate solution or albuminate of silver is applied over the torn surfaces.

From the observations which are recorded above, we may draw the following conclusions:

1. That in every case of middle ear disease which presents itself for treatment, one of the most important measures to be employed is to make a thorough examination of the nasopharynx.

2. The examination of the nasopharynx should be made, not only with the mirror, but with the finger. The examination should be made, first, before cleansing the nasopharynx, and again after cleansing it. If the nasopharynx is examined while it is full of mucus or other discharges, important alterations within it may be concealed. On the other hand, a visual examination should be made, or, at any rate, attempted before cleansing it out, in order that we may ascertain whether there are accumulations of discharge or morbid materials within it. In the case of children and adults in whom it is impossible to use the mirror the nasopharynx should be cocainized through the nares and a digital examination made. The digital examination of the nasopharynx is, as a rule, so much disliked by patients that the rhinologist is very apt to neglect it. Of its great value, however, there is no doubt, and I believe that it should be made the routine practice in every case in which it is not possible to get a thorough view with the mirror.

3. Although the presence of obvious growths, such as tumors or adenoids, or the existence of inflammatory conditions in the nasopharynx has had the importance of their presence as a source of aural disease recognized for many years, the existence of adhesions in the nasopharynx as a cause of pathological conditions within the ear has been largely overlooked, chiefly because of the difficulty attendant upon the examination of the nasopharynx, which would lead to the discovery of their presence.

As my apology in presenting the foregoing remarks on a subject which must be regarded as somewhat commonplace by the majority of my hearers, I would state that my reason for doing so is that it seems to me that in most of the text books, and on the part of some of the teachers in our medical schools, there is a

noticeable laxity in directing the student's attention to the importance of a nasopharyngeal examination in the proper study of diseases of the ear.

### *General Discussion.*

Dr. E. A. Crockett (Otolological Society): I wish to emphasize particularly the one point brought out by Dr. Pierce, that is the fact that the nose is often operated upon for the relief of ear diseases, without any regard to the pathological conditions which appear in the ear, and the prognosis as given the patient in such cases is often entirely erroneous and unjustifiable. For instance, it seems to me to promise a patient that has a high grade of otosclerosis that any form of pharyngeal operation will improve his hearing to the slightest degree is unjustifiable. It seems to me that it is a matter which is perhaps too simple to need emphasis, and yet it has been my experience many times, in seeing cases in consultation, or in the hands of other practitioners, that it is a frequent error. Otosclerosis is not a disease which originates in the nasopharynx and is characterized by a high grade of deafness which is not going to be influenced in its course by any form of intranasal operation. It also seems to me that the operations upon the nasal septum and upon the anterior portions of the nasal turbinates and also upon the accessory sinuses, are not going to influence the patient's hearing at all. It is a matter of frequent experience to see patients with deafness with no septal deviation at all, and those with septal deviation with no deafness, and I have yet to see a case where operation upon the nasal septum has resulted in alteration of the hearing to any extent. If the nasal or pharyngeal conditions which exist do not influence the moving of the muscles of the Eustachian tube no improvement is to be expected from intranasal surgery. That brings me to a point particularly well covered in this symposium, the presence of the process in the fossa of Rosenmüller in the upper portion of the nasopharynx, where periadenitis and adenitis are of extremely common occurrence. This is the first meeting which I have had the pleasure of attending where this subject has been so thoroughly brought out. It is very common in this portion of the country to find patients on whom adenoid operations have been performed where the lateral portion of the pharynx has not been touched in the slightest. That is not done by good operators, but often occurs, and if you see a patient of that sort, after an adenoid operation has been performed with no influence on the hearing do not dismiss the patient without digital examination of the pharynx. There are cases of very large growth

in which you can see everything with the mirror, but this is not common. You should get your finger in with or without an anesthetic and feel carefully the vault, the upper portion of the postnasal space and the fossa of Rosenmüller on either side, and you will find adhesions, remains of adenoids, or periadenitis of very common occurrence, and by removing these remnants you may get a very distinct improvement in your patient. When it comes to the nose itself it is a matter of considerable infrequency to get improvement in hearing or cessation of a progressive deafness from intranasal surgery.

Dr. O. T. Freer: I wish to say a word in regard to the recessus pharyngeus medius, referred to by Dr. Logan, and the bursa pharyngea, often confused with it but regarded as not identical with the recessus by anatomists. The bursa is supposed to be of foetal origin and is a pocket which extends backward into the periosteum of the occipital bone in the nasopharynx. The recessus pharyngeus is the deep median sagittal fissure of the pharyngeal tonsil, which persists in some persons after atrophy of this structure. In these cases this median cleft forms a pouch which may be entered with the finger. Such pouches I have found in three patients, but never have met with a true bursa pharyngea.

In two of my patients hemorrhagic discharge from the nasopharynx, referred to by Dr. Logan, was the characteristic and alarming symptom. In each instance my index finger entered a median pouch in the vault of the pharynx whose entrance grasped the finger, the bleeding being brought on by the examination in both cases. A complete recovery resulted in each from cutting away the remains of adenoid tissue forming the walls of the pouch with my pernasal adenoid forceps, shown in this society three years ago. With this forceps it is also possible to thoroughly clean out the fossa of Rosenmüller without injury to the tube, and, in fact, to absolutely extirpate all adenoid remains in any part of the nasopharynx.

A third patient had symptoms to which Dr. Logan has referred—the formation of hard, shell-like, purulent scabs in the pharyngeal vault. This patient, although informed by me that his scabs were the result of a persisting median pharyngeal recess, nevertheless let himself be persuaded into a sphenoidal sinus operation by a German specialist, the result being sepsis and an abscess of the cervical glands. He has now recovered as the result of treatment of the nasopharynx.

Dr. Logan has called our attention to a most important condition in his reference to adenoid remains in adults as a cause of pharyngeal and aural symptoms.

Dr. W. L. Ballenger: I want to emphasize some facts which

have been brought out by the various papers, and perhaps more particularly that brought out by Dr. Pierce. Dr. Pierce made it plain to us that the simple obstructions in the nose are not the cause of middle ear disease very often, but that there must be an associated inflammatory condition, which I think is the correct view. In the past years one reason we failed to get results was because we operated upon the wrong portion of the nose. The obstruction lies high in the nose. Deviations of the septum produce infective conditions within the nose, and this extends to the epipharynx and into the middle ear and produces deafness. If we direct our attention to these conditions in the nose we would then find that, if we operate at an early enough period, the ear conditions would very often be relieved. I have found that there are a few conditions that generally have to do with the causation of middle ear deafness and inflammation. These conditions are, first, ethmoiditis and sphenoiditis, and, second, enlargement of the posterior ends of the middle turbinates, and associated with this we often find epipharyngitis; the third condition, which is a very fruitful source of deafness, is the presence of adenoids, which are almost universally associated with periadenitis. Hence I have been in the habit of teaching my students these three facts as being the main persistent cause of middle ear disease. The other causes enumerated are very numerous, but these three are very commonly present and are very fruitful sources of middle ear inflammation and deafness, and I have had numerous opportunities of watching the beneficial results following the proper attention to these three conditions. I had one case of chronic mastoiditis, on which I did a radical operation, in which there was a persistent discharge from the Eustachian tube. This young man had adenoids, which I removed, and the discharge from the Eustachian tube promptly ceased. There is another feature I wish to enlarge upon, namely, that middle ear suppurations apparently are almost always associated with one of these three conditions. Of course, there are some cases that come from acute infectious diseases without these conditions, but in the large percentage of the cases we have one of these three conditions present, and we all know that in children we find that the suppuration disappears after the removal of adenoids. If we would carry this same thought to adults, we would be surprised to see how many of them would be improved by the removal of adenoids, because adults having chronic ear discharge often have remnants of adenoids. Another point is that adenoids do not necessarily atrophy at the age of puberty. As a matter of fact, the mouth breathing ceases at this time; but the adenoids are just as large in adults as in children, the improved mouth breathing being due to the increased size of the epipharyngeal space.



Dr. G. L. Richards: This is a very important subject. We have been trying for years to get something to help us in the treatment of these cases of otitis media, and since, in the last two or three years, we have come to the study of the relations of the fossa of Rosenmüller, we are getting some help. I want to speak of two or three points. First, in reference to the examination you make of the patient in the office. Mention has been made of sterilizing the finger. If you have a box of very thin rubber finger cots in your office, which can be made perfectly sterile, you can examine the patient with all the facility of the bare finger and yet with more facility in introduction. That is a simple point, which makes the examination in the office quite a little easier.

In the operation for adenoids, most of the forceps or the curettes do not follow, in a great many cases, the anatomy beyond the fossa of Rosenmüller, because they are not long enough and are too wide. Vogel has devised an adenoid curette which is admirably adapted to follow the fossa of Rosenmüller. After you are through with the other part of the operation, and you want to be certain you have left nothing behind, this can readily be proved by the use of this curette. At the result of the removal of these remnants one is often agreeably surprised. The other day I removed the tonsils from an adult, under anesthesia, who had poor hearing in the right ear. As I was taking her from the table back to the ward it occurred to me that, as she was still under the anesthetic, I would feel in her nasopharynx and see what might be there. There was quite a band of adhesions, and I separated these with my finger, and, much to my delight, two weeks later the girl said she could hear much better. One other point. Dr. Packard referred to the work of Dr. Jervey, of South Carolina. I wish to say that we have in the audience to-day Dr. F. P. Emerson, whose work in this direction goes back quite as far as Dr. Jervey's.

Dr. Emil Mayer: I merely wish to call attention to an addition to our armamentarium in examining the pharynx presented here by Dr. Coakley, and which I am sure he would have mentioned in his paper had he been able to read it. The instrument is that known as the pharyngoscope, which is on the plan of a cystoscope, and enables us to make examinations and find the conditions even more readily than with any other method.

Dr. Percy Fridenberg, New York (Otological Society): In regard to the routine examination of the nasopharynx, to which a number of the gentlemen have referred, it seems we have in the Hays pharyngoscope a very valuable addition. The finger is undoubtedly a good probe, but you cannot keep it in the post-nares very long, and in many cases prolonged examination is

necessary. With the pharyngoscope in position you can study the very smallest growth in the post-pharyngeal space with no discomfort to the patient. I have tested the instrument for ten minutes, while making a careful drawing of the post-nares. Another great advantage is that you can study the various changes which take place in deglutition or coughing or gagging and see just what does happen to the muscles of the soft palate and muscular structures about the orifice of the tube. One of the gentlemen has called attention to the involvement of the muscular structures in the production of sclerotic disease of the middle ear. I confess my inability to understand the very beautiful drawings which were handed about. I do not see how we can detect interference with the muscles by examination from the outside. If you examine the post-nares with the pharyngoscope during swallowing you see, even in very marked cases of adenoid growth, a practically normal contraction of the soft palate and muscles around the tube. As far as obstruction is concerned, you see pressure from the outside in a few cases and none where there are adenoids in the fossa of Rosenmüller. I have examined in the last two months a large number of cases of adenoids in both children and adults, and in few cases was there compression during swallowing, but almost invariably solid masses of mucus were pushed between the soft palate into the Eustachian orifice and into the cavity of the pharynx. I want to allude again to the pharyngoscope which I demonstrated yesterday. I then mentioned that the great advantage of the instrument would be that it will enable us to control with the eye the introduction of a catheter into the Eustachian tube for our own purposes of performing that operation, and it will be found a very valuable teaching adjunct.

Dr. G. E. Shambaugh: We must not forget our pathology in this discussion of the therapeutics of middle ear trouble. We can all of us agree that middle ear disease very often has its origin in disease of the nose and throat. But while this is true, we must be cautious how we express ourselves as regards the relief of all forms of middle ear troubles by operations upon the nose or throat. Everyone is familiar with the enormous benefit to tubal catarrh, of adenoid origin, when these growths are removed. On the other hand, there are certain forms of middle ear troubles, or, perhaps better, stages of these conditions, that cannot be influenced in the least by operations upon the co-existing conditions in the nose or throat. We are familiar with the improvement in cases of chronic suppurative otitis media when an existing adenoid growth is removed. On the other hand, if this same patient consults us later in life because

of deafness as the result of scar tissue in the tympanum, none of us would expect to improve his hearing by operating upon conditions that may be found in the nose or throat.

What is true of suppurative otitis media applies also to the chronic tubal catarrh. These conditions are frequently caused by enlarged tonsils or adenoids. Yet the time to get an improvement of the ear condition by operating upon the throat is chiefly during the early or secretive stages of the middle ear catarrh. If these same cases consult us in middle life on account of deafness we will often find that the tubes are wide open and no operation in the nose or throat can offer much chance of improving the condition in the ear. We have here a pathological condition similar to scar tissue remaining after a chronic suppurative otitis media. These fundamental facts in the pathology of the middle ear diseases are too frequently lost sight of, and countless unnecessary operations are performed for slight anatomical variations found in the nasal chambers, with the hope of relieving defects in the hearing due to pathological changes in the tympanum that cannot in the least be influenced by these operations.

There is another point that should be emphasized, and that is we should make a sharp distinction between cases of middle ear disease and cases of ankylosis of the stapes, due to otosclerosis.

Again, there are many cases of defective hearing associated with evidences of previously existing middle ear trouble, which are, however, not diseases of the middle ear at all, but diseases of the labyrinth. The severer forms of defective hearing are always associated with labyrinthine trouble, and, of course, no improvement in these advanced cases can be effected by treatment applied to the middle ear.

Dr. Kyle spoke about the different forms of occupation deafness in a way that we might infer that occupation deafness was due to middle ear trouble. By occupation deafness we usually mean, of course, degenerative changes in the labyrinth of the ear.

Dr. Emil Gruening (Otolological Society): I wish to record that the name of the inventor of the pharyngoscope is Dr. Harold Hays, of New York. I have heard no mention of this fact in the remarks upon the instrument.

Dr. W. K. Simpson: I wish to ask Dr. Logan if he has had any experience in producing an atrophic condition of the nasopharynx in the removal of the thickening in adolescents and in adults? I have seen a number of instances where a certain amount of so-called hypertrophied tissue in the nasopharynx

has been removed and a very marked condition of atrophy has been produced.

Dr. J. F. Barnhill: Concerning the adhesions of the Eustachian tube, I wish to say a word and to have some explanation from those who have brought the subject forward. I have read the several articles that have appeared on the subject, and have tried to act on them. The result in most instances has been disappointing for the reasons that have just been advanced by Dr. Shambaugh, namely, that most of these cases are ones we should have been treating ten, twenty or thirty years ago, for ankylosis of the stapes has already taken place to a greater or less extent, retraction of the drum membrane and adhesions have already occurred, and it is therefore unreasonable to expect the mere breaking up of adhesions at the pharyngeal end of the Eustachian tube, at this late date, to do much good. Nevertheless, if it will do good we want to find it out. In my hands it has not been very successful, and I cannot see why it should be. These adhesions are almost invariably attached to the posterior lobe of the Eustachian os. Most of these tubes are already open, as may be shown by Eustachian catheterization. Breaking up these adhesions and the other operative procedures about the nasopharynx have done some good in other ways. In the first place, we get a certain amount of hemorrhage, and hemorrhage in some of these cases does a certain amount of temporary good in that the tinnitus will often be relieved, and, second, there is a psychic element entering into the case. In the class of cases under discussion there is nearly always a predisposition to local infection of the remnant of adenoid tissue, which is handed down from childhood. These are invariably cases that are better or worse according to whether or not an acute exacerbation of the nasopharyngeal disease is present, because each attack of nasopharyngitis enables a new infection to take place, with resulting damage to the ear. Such operations as Dr. Logan has described will prevent such acute attacks, and in this way help to make the individual better. I do not condemn anything that Dr. Logan has said, but I believe we ought not to give the impression that the cure of these old chronic middle-ear diseases can be effected very often by removing a nasopharyngeal cause in the form of an old adenoid with adhesions, especially when such cause has been active for many years, and when serious and permanent damage has already been done to the conductive or perceptive hearing apparatus.

Dr. G. H. Makuen: Some years ago I had a little experience in my own person which impressed me with the fact that intranasal lesions do have a very direct influence upon middle-ear conditions. I had a slight nasal spur, with intranasal pressure



and recurrent attacks of fulness in the corresponding ear, and a tendency toward vertigo. The spur was removed, pressure relieved, and for fifteen years I have had absolutely no return of either of these distressing symptoms. I want to say also that my experience coincides entirely with that of Dr. Logan in regard to post-nasal adhesions. Recently I operated upon a patient for another purpose, and incidentally I put my finger in the vault and broke up some adhesions between the pharyngeal walls and the Eustachian orifices, and the hardness of hearing which had distressed this man for many years was greatly relieved. His hearing was at least 25 per cent. better than it had been for years. I would like to mention also in this connection a little plan that I have adopted in all my adenectomies of recent years, and that is to put my finger into the vault, before the adenoid is removed, and thoroughly curette the fossae of Rosenmüller. Adhesions can be removed more thoroughly at this time, and after the procedure the adenoid itself comes away more easily.

Dr. J. P. Clark: I was very much interested in Dr. Logan's paper. It seems to me, as I understand him, that he advocates an operation for removal of lymphoid tissue from the pharynx in all cases of adults or children where there is simply an inflammation of lymphoid tissue, without any definite hypertrophy. I consider that procedure very radical. It seems to me there are a great many cases of inflammation of lymphoid tissue in which a great deal can be done by medicinal applications, and I am sure that I have had a great many such cases that have been cured by these means. I may have misunderstood Dr. Logan, and if so my remarks are not in order. One other point in regard to the pharyngeal bursa. I have been taught that the embryologists now consider this a depression left by the separation during foetal life of the hypophysis cerebri or pituitary body from the ectoderm. This depression may vary in depth from a shallow dimple to a cavity large enough to be called a pouch.

Dr. F. P. Emerson (by invitation): After listening to this very able and instructive symposium, I do not think that any of us would assign one cause as accountable for all conditions of the middle ear. I am exceedingly gratified, however, at the emphasis that has been laid upon the relation of the fossae of Rosenmüller to otitis media. We have all recognized this fact in children, and I think that if you would take adult cases, without regard to age, in chronic secretory and suppurative otitis media, you would be surprised to find, not as Dr. Barnhill suggests, simple bands connecting the fossae with the Eustachian eminence, but a large amount of degenerate tissue. Those cases in which it is always present, without regard to age, are characterized by unilateral deafness, accompanied by low pitched tinnitus, a feeling of stuffi-



ness in the ear, and are affected by climatic changes. After examining systematically several hundred cases during the last five years, I find that you can predict the ear involved by the condition of the corresponding fossa. This seems a very strong point in showing the relationship that this degenerate tissue in the fossa bears to the middle-ear disease. These patients complain not so much of the absolute deafness as of fluctuations in hearing and the low-pitched tinnitus. The tinnitus, if low pitched, is improved and sometimes cured by cleaning out the fossae. The depth of Rosenmüller's fossae is in some cases very marked, and the amount of soft, friable tissue considerable. This has been overlooked in adults because in a large proportion of cases it cannot be seen with a posterior mirror, and we have not been in the habit of making a digital examination. I believe very strongly in the point emphasized by Dr. Leland, that when the fossae of Rosenmüller are free, so that the physiological action of the palatine muscles can be normally exerted in opening and closing the Eustachian tubes, that it has a marked influence in improving the hearing in adults, and that the catheter has been much abused. One other point of practical importance is that, in our nasal work and in freeing the fossae, we should follow the case until there is no danger from adhesions and the inflammation has subsided.

Dr. B. A. Randall: There are one or two points which I wish to touch upon. This matter of the hysterical action of the muscles does not need to be further emphasized, except that it is constantly forgotten. In these cases physical massage and gymnastics by gargling are of an importance which cannot be too much emphasized, particularly when it is so easily carried out in any place by anybody, unless hard to those who are the most in need of it. Then, we must ever bear in mind, in relation to nasal respiration, the course of the inspired and expired air, which is through the vault of the nose. Small amounts of protrusion here can have so much obstructive effect, while spurs below can have so little, in spite of all that is written by authorities as to eddies and vacuum behind the spurs in the lower portion of the nasal chamber. It is impossible, in my view, to have adenoid removal at all permanent, however far reaching the operation—even cutting down to the muscle or underlying fascia, if you have a stuffed nose in front of it. I was very fortunate in having been brought up under the teaching of Harrison Allen, when some of these matters which are being constantly rediscovered, like the importance of the Rosenmüller fossa, were drilled into me twenty-five years ago. I think that this matter deserves considerable consideration, although I have never yet seen any brilliant results from the clearing out of this fossa. We find conditions there which improve

under treatment, and I have seen many cases where very shrunken adenoid masses in the vault, although no longer mechanically obstructing, have been removed with marked improvement. I must confess there is some advantage in being adapted to one's environment. Philadelphia is called exceedingly slow, and some of my patients are old-fashioned enough to find their "otosclerosis" improving under treatment of middle-ear disease.

Dr. Leland: I wish only to add, as was said in my paper, that adhesions which occur in the middle ear, when too firm, probably cannot be influenced by these physiological movements, but when they are not too great, then the continual action of these movements does produce some effect. It is often the case that improvement in hearing takes a shorter time than the coming on of deafness. That is another point in my argument—that these lesions should be stopped at the beginning. It has been said that the tubes may be easily inflated by condensed air through the Politzer bag, and otherwise. That is true enough; but this does not mean that they are freely enough open to be influenced by these continuous gentle physiological movements. I believe that the membrana tympani can be made flexible, and the adhesions also in many cases, by the natural movements described.

Dr. Pierce: I have nothing to add regarding this special subject, but I am going to say something about a matter which came up in the first meeting of the Laryngological Association, namely, whether a case of hydrops of the antrum can cause ectasis of the walls of the maxillary sinus, or whether whenever we have a bulging of the maxillary sinus do we invariably have a dentigenous cyst? Now, in the case of insufficient ventilation of the middle ear, we have a partial vacuum and a plus atmospheric pressure in the external auditory canal. We can have this go on for a considerable length of time; in fact, until the pressure atrophy of the tympanic membrane caused by this plus pressure may bring about complete attenuation of the tympanic membrane, so that almost every nook and cranny of the cavum will be obliterated without serous exudate in the middle ear. This exudate does occur if the tympanic membrane is sufficiently resistant and there are added toxins formed elsewhere and conveyed to the cavum. Hydrops of the antrum occurs from a like cause—*i. e.*, insufficient ventilation, either from congenital or inflammatory closure of the ostium. The air is absorbed and a partial vacuum is established from the absorption of oxygen by the capillary or lymph spaces in the epithelium, and the existence of the tissue is overcome and the serum sucked out into the cavity of the antrum. I ask now whether it is reasonable to think that this hydrops, which is caused by a partial vacuum, could be produced to such an extent as to dilate the maxillary sinus?

Dr. Logan: I agree with Dr. Crockett's remarks in toto, and believe their importance is clearly recognized.

Dr. Richard's use of the finger cap I find objectionable. I cannot feel as sensitively with it as without it. The finger can be made absolutely clean and no more objectionable than would be the finger stall.

In answer to Dr. Fridenberg's remarks, would say that the plates exhibited here are applicable only to the report of cases which I have prepared, but not read because of the lack of time. They are intended to serve only in explanation of a few very interesting cases. By these plates I have attempted to show that even the smallest amount of hypertrophy existing in the fossae of Rosenmüller may produce a great amount of pressure trouble around the orifice of the Eustachian canal, and that this pressure must be relieved before we can release the tension upon the tensor-tympani, levator and tensor-palati muscles.

I agree with Dr. Shambaugh in what he has said, and also endorse Dr. Emerson's remarks regarding the differentiation between otosclerosis and sclerosis. The operation that I have recommended is a simple but radical means of clearing away all hypertrophies of the nasopharyngeal space, thereby removing the cause of most of the diseases of the middle ear, as well as many of the diseases of the upper respiratory tract. The removal of the hypertrophy is but the beginning of a long course of after-treatment.

In reply to Dr. Simpson's question, will say that I never yet have had any atrophy in the cases so far operated upon.

I was glad to hear Dr. Makuen report his case, in which the hearing was improved after breaking up the adhesions binding the post-pharyngeal wall to the Eustachian lip.

I only wish time permitted me to report some of the more interesting cases I have operated upon, showing the different types of the disease attributed to initial lesions in the vault. I have in my report two cases giving every sign and symptom of oto-sclerosis, that have been greatly relieved by the removal of a small amount of hypertrophied tissue within the fossae of Rosenmüller. I certainly believe that in a very large number of these cases we are able to prevent a further loss of hearing power, and most cases will be greatly benefited if we persist in the necessary after-treatment.

Dr. Packard: I think we are all practically agreed upon the most important points. I do not think any one would claim he could cure middle-ear diseases by the removal of conditions in the nasopharynx. My remarks are merely intended to emphasize the fact that the nasopharynx is the most important site of origin of middle-ear disease, and that its examination is very frequently overlooked or is not properly carried out.

*Candidate's Thesis.*

THE ANATOMICAL AND CLINICAL RELATIONS OF  
THE SPHENOPALATINE (MECKEL'S) GANGLION  
TO THE NOSE AND ITS ACCESSORY SINUSES.

BY GREENFIELD SLUDER, M.D.

*Anatomical Relations.*—The treatises on anatomy describe the sphenopalatine (Meckel's) ganglion "as lying in the pterygopalatine fossa close to the sphenopalatine foramen." (Quain, Bardeleben, Piersol, Sabotta and others.)

The pterygopalatine fossa is described as "formed above by the under surface of the body of the sphenoid and the orbital process of the palate bone; in front, by the superior maxillary bone; behind, by the anterior surface of the base of the pterygoid process and lower part of the anterior surface of the great wing of the sphenoid; internally, by the vertical plate of the palate."<sup>1</sup>

Neither this description nor any found in other textbooks on anatomy suggests any close relation of Meckel's ganglion to the nose or its accessory sinuses; nor do the special treatises upon the nose make mention of such relation. As a fact, however, Meckel's ganglion lies very close to the external bony wall of the nose, in which the sphenopalatine foramen occurs as a small deficiency at its upper posterior part. By actual measurement, Meckel's ganglion frequently lies as close as one or two millimeters from the nasal mucous membrane; it may lie as deep as seven or even nine millimeters.

The current descriptions of the pterygopalatine fossa give the impression of its being surrounded by solid bones. This also is misleading. More comprehensively, the description "formed above by the under surface of the body of the sphenoid and the orbital process of the palate bone" means that it is bounded above

---

<sup>1</sup>This description is taken from Gray's Anatomy, 1896.

by the walls of the sphenoidal sinus, including the pterygoid process of the palate bone closing it, and that the separating wall is a thin one. The description "in front, by the superior maxillary bone," means that it is bounded in front by the wall of the maxillary sinus, and that this wall, too, is of thin bone. The description "behind, by the anterior surface of the base of the pterygoid process and lower part of the anterior surface of the great wing of the sphenoid," means that this wall also is, in some cases, only a thin plate separating the fossa from a downward prolongation of the sphenoidal sinus into the pterygoid process and into the great wing, a condition which is not uncommon, although in the great majority of cases the pterygoid process is of solid bone.

The outer aspect of the pterygopalatine fossa is then the only one that is not in intimate association with the cavity of the nose or its accessory sinuses.

It seems essential that in any comprehensive description of these parts especial emphasis should be laid upon their intimate relations to the nose and its accessory sinuses; and this is certainly true if the anatomy is to lead the way to clinical application or investigation.

The variations of the accessory sinuses ought also to be studied in detail:

The sphenoidal sinus may form the entire upper boundary of the pterygopalatine fossa (Figs. A and B).

The sphenoidal sinus may also form the posterior boundary of the pterygopalatine fossa as a result of its being prolonged downward into the pterygoid process and great wing (Fig. C).

A post-ethmoidal cell may bound the anterior half of the upper part of fossa (Fig. C).

The wall of the nose may curve so sharply outward as to form a part of the anterior boundary of the fossa.

Meckel's ganglion lies high up in the pterygopalatine fossa. It is apparently prolonged backward into the vidian (pterygoid) nerve. (Quain, 1897.) There is usually a marking upon the bone corresponding to this—a well-modelled funneling at the anterior end of the canal.



RELATIONS OF MECKEL'S GANGLION IN THE PTERYGOPALATINE  
FOSSA.

The ganglion lies close to the top of the pterygopalatine fossa. (All text-books are agreed upon this point.)

In front the ganglion is in relation with the arteria palatina descendens and arteria sphenopalatina and with the corresponding veins. These vessels, with some surrounding connective tissue, form a separation of 3 or 4 mm. from the wall of the maxillary sinus—the anterior boundary of the fossa.

THE RELATIONS OF MECKEL'S GANGLION TO THE WALLS OF THE  
ACCESSORY SINUSES OF THE NOSE.

When the upper boundary of the fossa is made wholly by the sphenoidal sinus (Fig. A) the ganglion lies in close relation to the sphenoidal sinus above.

When the upper boundary of the fossa is made by the sphenoidal sinus in its posterior half and by a post-ethmoidal cell in its anterior half (Fig. C) the ganglion lies in close relation to both.

When the sphenoidal sinus is prolonged downward into the pterygoid process (Fig. C) the ganglion will then lie posteriorly in close relation to the sphenoidal sinus.

Anteriorly the fossa is formed by the wall of the maxillary sinus. But the ganglion can never lie in close relationship to this wall because of the pad formed by the arteria palatina descendens and the arteria sphenopalatina with their accompanying veins and surrounding connective tissue. (See above.)

THE RELATION OF MECKEL'S GANGLION TO THE COMMON WALL  
OF THE NOSE.

The sphenopalatine foramen seems to be accurately placed at a point just posterior to and immediately above the posterior tip of the middle turbinate. All authorities are agreed that the ganglion lies close to the plane of this foramen.

The ganglion, however, does not always show the same relation to the foramen. I have found it as close as one or two millimeters from the general membrane of the nose, and as far as nine

millimeters. I believe the variation in the position of the ganglion, whether higher or lower, to be very slight. It varies more as to whether deeper or shallower in relation to the membrane of the nose.

The pterygopalatine fossa, considered from the above point of view, is seen to resemble an accessory sinus of the nose. It is, however, not closed externally or below by nasal tissues, and is filled by the above-mentioned structures with their accompanying connective tissue instead of air.

*Clinical Relations.*—With such intimate anatomical association, clinical manifestations from the extension of inflammation or its products would seem of almost necessary occurrence. Meckel's ganglion is, in fact, in quite as close relation to the nose and its accessory sinuses as is the optic nerve. It has long been recognized that inflammatory processes in the sphenoidal, post-ethmoidal and maxillary sinuses extend to the optic nerve, and the fact has been demonstrated post-mortem (Birsch-Hirschfeld). It is, therefore, altogether reasonable to assume that these processes also pass over to Meckel's ganglion, although the clinical picture is very much less striking than the blindness produced by involvement of the optic nerve.

According to my observations, characteristic disturbances have followed post-ethmoidal and sphenoidal suppurative inflammations which cannot be explained otherwise than by assuming that Meckel's ganglion has become involved by extension; some of these disturbances have been transitory, and some have persisted for many years. In other cases the conviction has been equally positive that the extension has been from the nose proper; thus far I have not seen anything that I could interpret as an extension from the maxillary sinus. From the anatomical relations of Meckel's ganglion to the anterior boundary of the pterygopalatine fossa, *i. e.*, to the posterior wall of the maxillary sinus (see Fig. A), I do not believe that it is very likely to be involved by extension of an inflammatory process from that sinus, inasmuch as the arteria palatina descendens and the arteria sphenopalatina, together with their accompanying veins and the surrounding connective tissue, lie between the ganglion behind and the wall of the maxillary sinus in front. This relation appears to be constant;

and I believe explains why clinical manifestations referable to the ganglion do not ordinarily follow inflammatory processes in the maxillary sinus.

During 1907 I saw a number of cases of acute suppurative inflammation, of gripe origin, in the sphenoidal and post-ethmoidal cells. They got well in from three to four weeks, but left behind them pains which seemed neuralgic in nature. Usually the neuralgic manifestations arose a few days after the inflammatory onset. The pain of the suppurating sphenoid referred to the occiput, or of the post-ethmoidal cells referred to the parietal eminence, usually preceded these neuralgic symptoms. I have seen, however, similar neuralgic phenomena in an ordinary corhyza of moderate severity without suppurative involvement of any of the sinuses.

In a preliminary report<sup>1</sup>, based on ten cases, I have already described certain of these manifestations; now, after an observation of forty-seven cases, it is possible to draw a more complete clinical picture.

The typical picture of these neuralgic phenomena (or at least the picture oftenest presented) is of pain which begins at the root of the nose, extends downward over the maxilla, and backward on the mastoid, to become severest about 5 cm. posterior to its tip; thence extending backward to take in the entire occiput, and downward into the neck, shoulder blade, shoulder, and sometimes into the axilla. With the severest attacks it extends down into the arm, forearm, hand, and even to the fingers! According to my observations this pain very rarely invades the upper part of the head. When very severe it may extend a little way into the brow, or somewhat above the line of the zygoma. I have seen this picture complicated by or associated with other headaches; but the distinctive "neuralgic phenomena" as outlined above, and which have proved uniformly amenable to treatment (cocainization from the nose), have not extended to the upper part of the head. I have observed also concurrent salivation and perversion of the sense of taste (described as metallic), referred to the af-

---

<sup>1</sup>The role of the sphenopalatine (or Meckel's) ganglion in nasal headaches. By Greenfield Sluder, M. D., *New York Medical Journal*, May 23, 1908.

tected side, and, not infrequently, earache, toothache or pain behind the eye.

I have observed also, in some cases, a sore throat, described as on the affected side, of which no visible explanation was found in the throat, and in which prompt relief was afforded by the application of cocaine in the neighborhood of the sphenopalatine foramen.

I have on four occasions thought I detected motor disturbances in the soft palate, but of this I am not sufficiently sure to permit a positive statement.

I have never seen trophic changes. By way of experiment I anaesthetized the ganglion in a case of convulsive motor tic, and in one of sensory tic, without result.

I herewith submit some reports of cases, each of which seems illustrative in its way:

Miss S., 27 years old, consulted me June 13, 1906. For many years, "off and on," she had suffered from pain in the head which she described as paroxysmal, beginning at the root of the nose, involving the upper jaw and teeth (occasionally also the lower jaw and teeth), extending backward to the tip of the mastoid, and becoming intensest about 5 cm. posterior to this point.

These paroxysms recurred sometimes two or three times a week; and, when at her best, at intervals of two or three months. Examination of the nose was negative in every particular. She made the observation, however, during an attack, that the cocaine which had been sprayed into the nose, 4 per cent. sol., had helped the pain.

In the absence of a definite diagnosis, but continuing the spraying of the nose with cocaine, it was found that each application appreciably mitigated the pain. Under this treatment, in apparently much improved condition, she passed from observation. About three months later she returned for treatment of a severe corhyza, which in two days localized itself in a suppurating inflammation of the post-ethmoidal and sphenoidal sinuses of both sides; almost simultaneously the old pain reappeared, on the left side, involving the root of the nose, the cheek, the mastoid tip and a little behind it, the neck, shoulder blade, shoulder and arm—all in great severity.

Remembering the position of Meckel's ganglion, in close prox-

imity to these sinuses, and the widespread distribution of its branches and connections, I felt that this distribution of pain was possibly due to the inflammation or its products extending to or acting upon the ganglion; and, if this were true, that cocain applied (soaked) over the sphenopalatine foramen might probably prove effective in at least mitigating the pain.

The experiment was tried, and succeeded even beyond expectation. Since then I have applied the cocain for her at the same site in severe recurrent attacks, probably twenty times, always relieving the pain and usually aborting the attack.

I have also done some experimenting in these cases, but particularly in this case. During an attack an application of a single drop of dilute solution 4 per cent. cocaine, through the nose to the region overlying the ganglion, was followed by only the faintest relief. This dilute solution was then replaced by a drop of 10 per cent. cocaine, with more relief. A drop of 20 per cent. solution was then applied, with further lessening of the pain. A drop of saturated solution (about 67 per cent.) was then applied, when the relief would usually become complete. Applications to other areas gave negative results. In very severe attacks the pain would stop except at the point 5 cm. posterior to the tip of the mastoid, where, although greatly mitigated, it never quite disappeared; a very slight pain always remained here. The applications were allowed to remain twenty minutes in position. This patient suffered greatly from repeated attacks until December 1, 1908, when I began injections of alcohol; making the attempt to put the alcohol in direct contact with the ganglion. A straight needle, directed upward and outward under the posterior fourth of the middle turbinate, will reach the sphenopalatine fossa, just where the ganglion lies. The needle must, however, be passed obliquely through the lateral wall of the nose, which in this case was so hard as to make the procedure impossible. I thereupon drilled through the bone, thus removing the obstacle to the passage of the needle into the pterygopalatine fossa and opening an easy route for subsequent injections. The injection of the alcohol aggravates the characteristic pain already described, but the exacerbation is transitory, and is followed by relief.

After a course of ten injections the relief seemed complete;



but, after somewhat more than three weeks of freedom from pain, the patient contracted another severe coryza, with suppurative inflammation of the post-ethmoidal and sphenoidal cells of both sides, rekindling the old pain now for the first time also on the right side, although with less severity than on the left side. One application of saturated cocaine solution on the right side, posterior to and slightly above the posterior tip of the middle turbinate, stopped the pain, and it did not recur. On the left side relief was more tardy.

Miss S. has recently had another "explosion," which was relieved by one drop of saturated cocaine solution to the ganglion with the exception of a rather severe pain which persisted in the shoulder blade of that side. On the next day the cocaine application was repeated, with complete relief of the pain.

Mr. B., 35 years old, came to me September 24, 1907, with a high-grade deflection of the septum, which I resected. The operation was in every way uneventful and satisfactory. May 14, 1908, he returned with an acute suppurative inflammation of the post-ethmoidal and sphenoidal cells of both sides, accompanied by a headache referred to the parietal eminence and occiput of both sides, which lasted seven days. Three days later he developed a pain, which he described as beginning in the root of the nose, taking in the maxilla, extending backward into the occiput, and downward into the neck and shoulder blade. It improved under applications of 0.4 per cent. formaldehyde over the sphenopalatine foramen, was completely well June 23, 1908, and has remained so.

Mr. S., 45 years old, came to me November 23, 1903. For ten years he had suffered much from headache which incapacitated him for business two or three days of almost every week.

Nothing in his general health or life was at fault. He defined the distribution of the pain as beginning at the root of the nose on the right side, taking in the upper jaw, and extending backward to become emphasized at the tip of the mastoid and for a distance of 5 cm. posterior to it. The attacks were not always of equal severity. During a milder attack he could continue his business. In severe attacks the pain extended to the neck, shoulder and shoulder blade of the same side, and was so intense as to

compel him to go to bed. It was accompanied by vomiting. These severer attacks lasted from twelve to twenty-four hours.

Examination of the nose showed a dusky red swollen area in the right olfactory fissure about 1.5 cm. in diameter, roughly circular, beginning on the anterior wall of the sphenoidal cells and extending forward.

Applications of 2 per cent. nitrate of silver solution were made to the affected area two or three days a week for about three months. It finally became normal in appearance. With the improving appearance of this area went hand in hand a lessening of the frequency and severity of the attacks of pain, until they ceased. Since that time he has enjoyed freedom from painful attacks except at the time of a coryza. Coryzas of medium severity are accompanied by a moderately severe attack of pain, as above described. He had one severe coryza which was accompanied by great pain.

After I had learned to associate these neuralgic manifestations with Meckel's ganglion, and to apply the anesthetic in its immediate neighborhood (October, 1907), I was always able to stop the pain during coryzas. With this patient, anesthetizing the ganglion aborts the attack.

Mrs. N., sister of Mr. S., whom I had seen many times in acute coryzas, came, February, 1909, with what appeared to be a coryza of ordinary severity; she complained, however, of pain as in a typical case of Meckel's ganglion neuralgia. One application of cocaine afforded complete relief, and there has been no recurrence of pain. The coryza was otherwise commonplace and uneventful.

Mrs. L., 42 years old, came to me August 3, 1908, complaining of pain behind the right eye and in the upper jaw (all sinuses normal).

She described the pain as constant. She stated that she had for thirty years been subject to violent headaches, ending in vomiting. This was diagnosed as migraine by Dr. F. R. Fry, who sent her to me. A little later I saw her in one of her "bad spells." The pain was very great; it took in the entire half of the right side of the head and ran down into the neck, shoulder, shoulder blade, axilla, arm, forearm and hand. A drop of saturated solu-

tion of cocaine (67 per cent.) was then soaked into the site of the sphenopalatine foramen with marked relief except of the pain in the upper half of the head. A second application was then

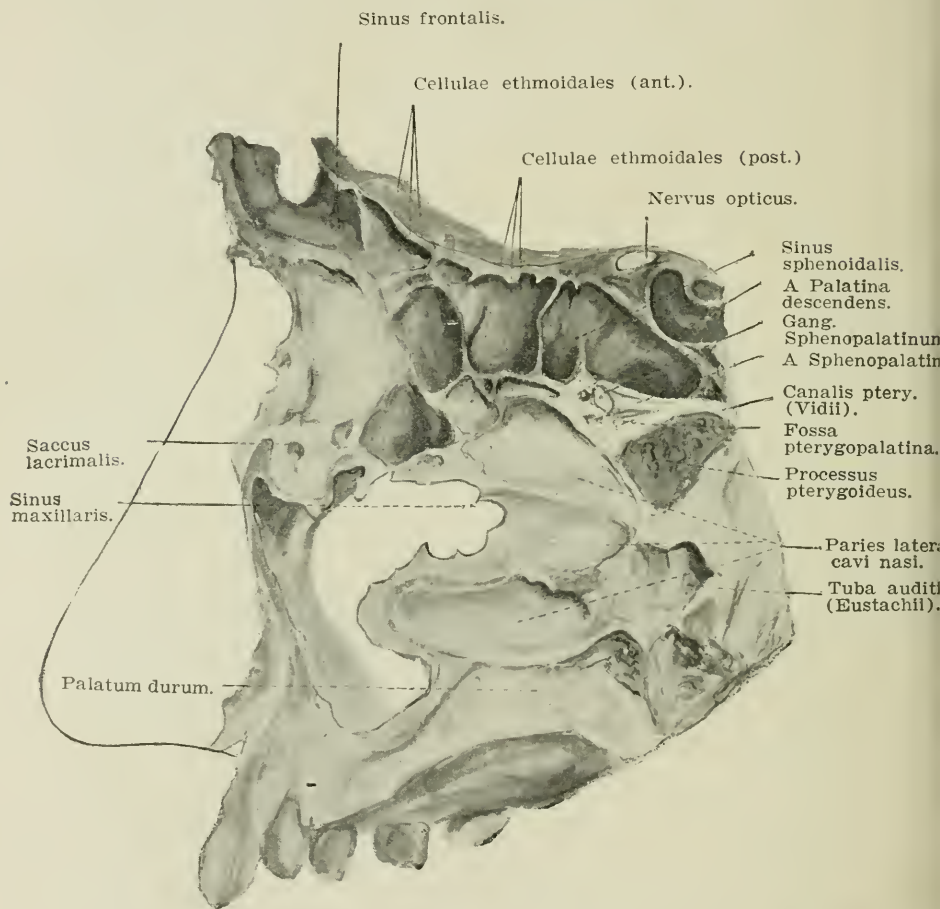


Fig. A.

Sagittal section 3 mm. lateral to the sphenopalatine foramen, showing a dissection of the pterygopalatine fossa.

made with complete relief of all the pain except that of the upper half of the head, which remained unchanged. The relief afforded in this attack lasted about one hour, at the end of which time the

pain had returned just as it had been. I saw her in two more "bad spells," the histories of which are identical with that above. Each time cocainizing over the ganglion stopped all the pain ex-

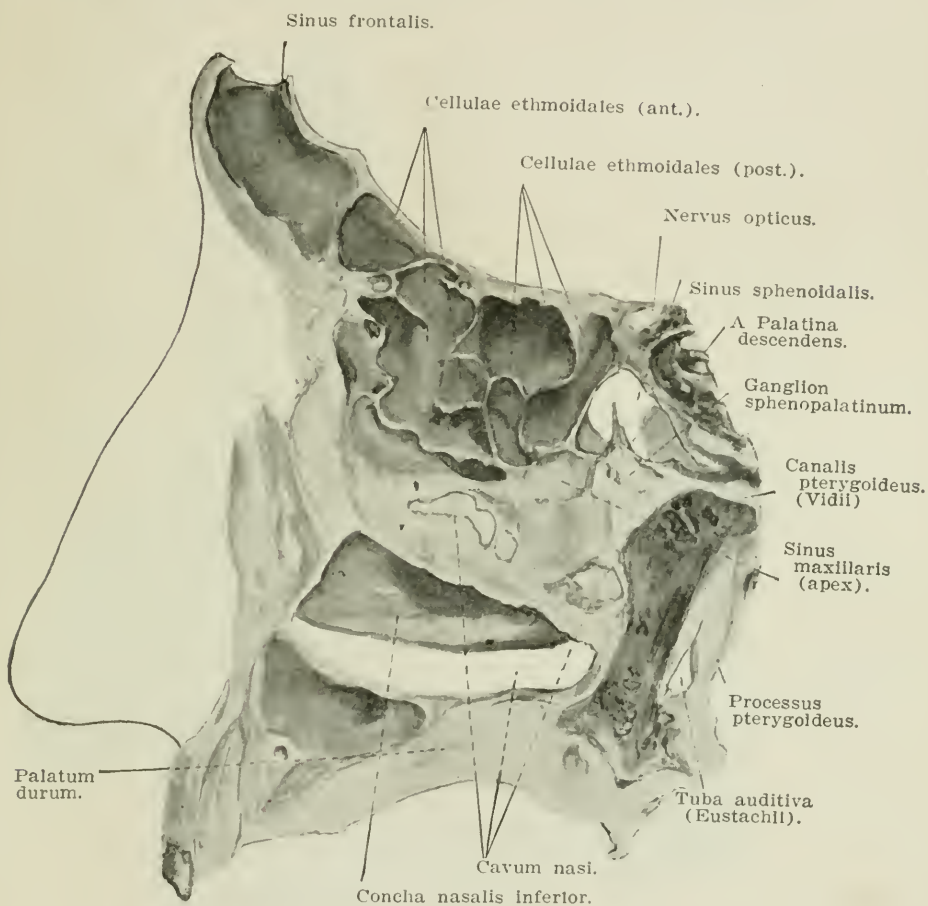


Fig. B.

Sagittal section 5 mm. lateral to the sphenopalatine foramen.

cept that of the upper half of the head, and the relief lasted about an hour.

Applications of one-half per cent. formaldehyde were continued over a period of four months; the pain behind the eye and

in the jaw having stopped at the end of four weeks, for the most part. It occasionally returned in a lesser degree. The intervals between the "bad spells" became longer and their severity lessened.

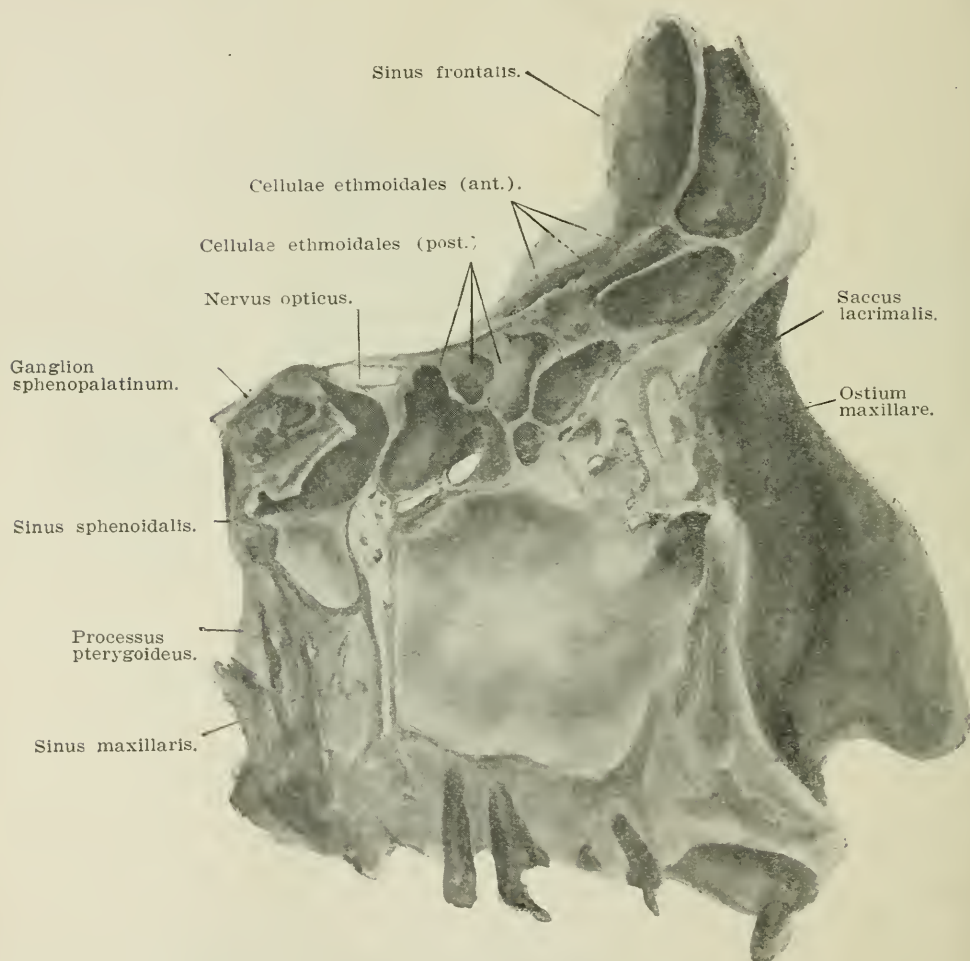


Fig. C.

Sagittal section 7 mm. lateral to the sphenopalatine foramen.

In addition to the above cited cases, I desire to call special attention to a case of an acute access of glaucoma reported by Dr.



A. E. Ewing.<sup>1</sup> In this case the area of the sphenopalatine foramen was inflamed. One application of 50 per cent. cocaine (one drop) to the sphenopalatine foramen stopped the violent pain. It did not return. The attack aborted.

Applications of one-half per cent. formaldehyde were continued daily in conjunction with the proper eye treatment for three months. Four months have now elapsed since the onset with no return of pain.

In this case the other eye had been lost by glaucoma three years previously. The pain had been relieved only by iridectomy. But despite this there had lingered always a little pain in this eye. An injection of alcohol into Meckel's ganglion aroused this pain to great severity, which lasted about three hours, and then began to subside, requiring a week to stop altogether. But when the reaction was finally over, the old pain had stopped. Two months have now elapsed with no return. (The idea of associating glaucoma with Meckel's ganglion was Dr. Ewing's. This case was treated throughout in accordance with his ideas and instructions.)

---

<sup>1</sup>"Pain of Acute Glaucoma Relieved by Cocaine Applied to Meckel's Ganglion." By A. E. Ewing, M. D., St. Louis, Mo., U. S. A. *American Journal of Ophthalmology*, December, 1908.

SYMPOSIUM ON THE SURGERY OF THE  
ESOPHAGUS.*FIRST PAPER.*FROM THE STANDPOINT OF THE GENERAL  
SURGEON.

BY SAMUEL J. MIXTER, M.D.

*(By invitation.)*

The reasons why I present this paper before your association, in a city where such splendid esophageal work has been done by members of your society are, first, the invitation of your president, with whom I have seen a large number of esophageal cases, and, second, on account of the great interest that this class of cases has for me—an interest that has steadily increased ever since, twenty years ago, I first tried to do something to relieve those patients that it seemed to me were neglected, and who were only treated by the passage of the probang.

Let us first mention the troubles for whose relief patients generally consult us. They are:

First—Spasmodic stricture, so called.

Second—Cicatricial stricture from burns, syphilis, peptic, or even typhoid ulcer near the cardiac opening.

Third—Malignant disease in any part of the esophagus.

Fourth—Esophageal pouch, either congenital or acquired.

Fifth—Congenital malformation, such as double esophagus, etc.

Foreign bodies should also be mentioned, and may be dismissed with the remark that unless ulceration and perforation have taken place they should be removed by the aid of the esophagoscope if possible, otherwise by esophagotomy.

True spasmodic stricture is easily cured by the passage of a large probang.

The history of the case is of the greatest importance in arriving at a correct diagnosis. A gradually increasing dysphagia without cause, in a person beyond middle life, with little or no regurgitation of food at first, generally means malignant disease, and the finding of a definite stricture confirms the diagnosis. An esophageal pouch generally has a long history of dysphagia, and especially of regurgitation, often of large amounts, and frequently of food swallowed hours, or even days, before. In some cases that I have seen, the inability to swallow the saliva during sleep has been one of the most distressing symptoms, the bed and body clothing being so soaked as to require changing during the night.

The method of examination without the use of the esophagoscope or anesthesia is simple. A probang shows us where the hitch is, and in long-standing cases that is generally all, as there is almost always a dilation of the esophagus above the stricture, and the opening is seldom in the middle, but more often to one side, and well above the point reached by the probang. Next, a straight flexible bougie is used, and if that refuses to engage, one with a tip woven so that it is bent like a *coudé*, or *bi-coudé* catheter, is tried, and except in very difficult cases the opening may be found by exploring the sides of the esophagus. Should a small bougie thus pass into the stomach, a measure of the stricture may be taken by passing other bougies alongside of the first one, or passing over it one or more perforated bulbs. Should a large bulb pass freely, we may be sure that we have neither malignant disease nor cicatrix.

For getting past the "spur" of a pouch high up, I have found the *coudé*, or *bi-coudé* web catheter, with funnel-shaped top most useful. Strong silk threads may be passed through the top of the funnel, and into it may be fitted the tip of a large bougie, both instruments being then pushed in and withdrawn together.

In case no instrument will pass after several sittings, we must try another method—and here let me say that too prolonged search for the opening should not be made, as the manipulation, however gentle, may cause swelling of the mucous membrane sufficient to render swallowing still more difficult, with consequent discouragement of the patient. I have found that the use

of cocaine is rather a disadvantage, as the attempts at regurgitation are rather an aid to the passage of the instrument than otherwise.

When Dunham devised the method of using a string as a guide, and showed that a thread would go through any opening however tortuous that allowed water to pass, he greatly simplified the matter of passing difficult obstructions. He used this method in cases where a gastrostomy had previously been done, the thread being fished out of the opening in the stomach and kept taut by being held above and below. I soon modified this method by having the patient without a gastrostomy swallow a considerable quantity of string, which passes down into, or even through, the intestinal tract, thus giving a firm hold to the lower end of the string. This method is perfectly harmless, and a patient may go about with a thread throughout the length of his intestine for days or weeks if care is taken to leave slack string to be taken up as the peristalsis of the intestine carries it on.

I have never seen a case where water would pass through the esophagus where I have been unable to get a string through after patient trial. Perhaps it would not go the first time or the tenth, but eventually it will go, and then in all cases of stricture, and often in cases of pouch, the relief of the symptoms is a matter of time.

Bear in mind also that a small instrument finds the opening much more easily from the stomach end than from above, and it may be possible in cases where gastrostomy has been done to pass a ureteral catheter through a curved tube introduced into the lower end of the esophagus, up through the stricture. It might even be possible in such a case, if the stricture were not too tight, to carry the thread from the stomach through the esophagus by means of small doses of apomorphia, or other suitable emetic. When once we have a string through the stricture as a guide, there is no difficulty in following it with suitable instruments, and this is true whether there is or is not a gastrostomy opening, and the great advantage of the method is that it is done with flexible instruments and never requires anesthesia.

Malignant disease brings us far more cases of esophageal trouble than all other causes combined, and its treatment must

always be largely palliative. Excision of cancer of the esophagus, except in the neck, where it is most seldom seen, is a most severe and anatomically difficult operation, and one that I have had little personal experience with. In the neck even the glands and surrounding tissues, including the larynx, are generally involved, and, though in exceptionally favorable early cases we may remove the local disease, the end result is generally the same.

What palliative measures then should we adopt? Dilation for a long time was the only thing suggested, and this still holds good as long as it can be done easily and without too much pain or hemorrhage. For this purpose I like best the olive pointed bougies that I get from Luèr. In many cases the patient can be kept fairly comfortable by more or less frequent dilatation, but generally there comes a time when the passage of good-sized instruments is more or less difficult, and we must do something else.

In a great many cases the use of the Symonds tube is most useful. The stricture must not be too high, or the tube will irritate the larynx, and will not be tolerated. In low strictures that can be passed by a small bougie, a Symonds tube, open at the end, may be passed over the bougie, by an instrument that I have made, with little discomfort to the patient, and, if proper liquid food is taken, may be worn two weeks, or even more, without changing. If the tube dilates the stricture and the funnel-shaped top passes through it and cannot be withdrawn—do not be alarmed, but cut the string and let it go, and it will pass through the intestinal tract in time.

I have had patients wear these tubes for months, and finally die of the disease without having had the slightest trouble in swallowing liquids.

Cutting or curetting of malignant stricture should, I feel sure, never be done.

In case dilatation or the Symonds tube fails to give relief, an esophagostomy or gastrostomy should be done at once.

Esophagostomy, of course, can only be done when the disease is in the very upper end of the esophagus, but when possible, it is much to be preferred to a gastrostomy. The patient feeds himself easily and there is generally no leaking.

Gastrostomy by any of the so-called valve methods works well



and does not leak if the opening into the stomach be high up and near the cardiac end.

Cicatricial strictures require infinite patience and often a string for their treatment; with these two you rarely fail. First of all, if the patient is thoroughly starved and weak, do a primary gastrostomy and get him, especially if it is a child, in good condition before touching the esophagus. In many cases dilatation alone will work a cure, and this can be done by means of bulbs on a string if there is a gastrostomy, or by some form of esophagus dilator, such as that perfected by Mosher. Personally I prefer the bougie or bulb. In other cases dilation must be supplemented by some cutting operation, and I am firmly convinced that the string-sawing method of Abbe is the safest and most effectual. Any number of strictures may be cut at a sitting, and they are apt to be multiple. Only the tissue is divided that should be, namely, the cicatrix. Dr. Abbe has recently sent me an instrument for string cutting from above, but I have not had a chance to try it, as it is so small that it passes through strictures that have been somewhat dilated. I mean to try the larger sizes.

And now I come to a subject that has been more interesting to me than all other phases of esophageal surgery put together, namely, the treatment of esophageal pouch. When, years ago, I reported a case of excision and cure to the American Surgical Association, it was, I believe, the first one reported in the country. Since that time I have seen a large number of such cases, yet have been compelled to operate on but two others. The operation is a fascinating one to do, and all three of my cases were perfectly successful, but I feel much more pleased at the results I have obtained in the cases that I have relieved without cutting.

Remember the anatomy of the esophageal pouch. Its opening is generally fairly high in the esophagus, while its lower end, if it is a large one, may reach to the second or third rib. There is absolutely no narrowing of the esophagus and, the way once formed, the largest bougie passes readily. Obstruction to swallowing is caused simply by the crescentic lower edge of the opening that acts as a valve closing against the opposite wall of the esophagus, which is pushed to one side by the pressure of the dilated pouch. A straight instrument always fails to find the

opening of the esophagus, and goes to the bottom of the sac. A bent bougie generally, and a string always, can be made to go through, and with either of these as a guide the largest instruments may be safely passed. I can only say that in many cases the forcible stretching of this spur, or flapper, has given perfect relief, even in pouches of considerable size. The passage of an instrument is constantly easier until, in a large number of cases, the patient can do it himself, the muscular wall of the pouch has a chance to contract, swallowing becomes easy, and regurgitation nearly or wholly ceases.

This has been the history of the great majority of these cases, but there have been two on which I have been forced to operate, and I have one other still under observation where I seem to have come to a standstill, and shall operate if the annoyance of slight regurgitation, now her only symptom, makes her demand operation.

Now, gentlemen, I am sure there is a chance for you to do brilliant work in these cases. All that interferes with swallowing and drainage of the pouch is the "spur." This once removed, the pouch is taken up or rendered innocuous. I proposed to your president that in the patient last referred to, he cut this spur or put a thread or elastic band through it, and so divide it as we divide "spurs" in cases of intestinal fistulae. He agreed to do it if I could assure him that there were no important structures between its folds. This I was unable to do, though I feel sure that there would be no harm done by the operation, judging from the anatomy as I have seen it in the living. Should I have occasion to operate on such a case in future, I shall try to study the anatomy more thoroughly, and if the proceeding is a safe one I shall lose the pleasure of future operations of this sort.

Cardia spasm has of late been much talked about. The condition may be relieved by forced dilation with inflated bag or other suitable dilator.

I need only mention congenital malformations. They are most difficult to diagnosticate, and some are not easy to treat successfully. One child of ten that died of starvation at the Massachusetts General Hospital soon after entrance, a few hours after I had performed a gastrostomy with cocaine, had a double esopha-

gus, one-half beginning at the pharynx and ending in a blind pouch near the stomach, the other with a good cardiac orifice at the stomach and ending in a blind sack near the pharynx. Between these two was only a pin-hole opening through which the child had been able to swallow enough liquid food to keep him alive. Had he been seen earlier, I feel sure that a thread and dilatation would have saved his life.

My excuse, gentlemen, for troubling you with all these details, most of which are, of course, familiar to all of you, is to prove that good results may be obtained in the treatment of esophageal troubles without the aid of direct vision. I do not claim that the esophascope should be neglected any more than the microscope, but I do claim that in certain cases we can make a correct diagnosis and treat the patient in a proper manner even without its use. Those of your members who are familiar with my work know that I try to work with them and seek their aid whenever I find a case where there is doubt. I have never, for several years, performed an esophagotomy for foreign body unless attempts to remove with the esophagoscope had failed, or operated on a pouch unless it had been seen by a laryngologist.

I am sure that in many cases I can get a thread past an obstruction with greater ease and less discomfort and danger to a patient than can be done by inspection of the esophagus, and my plea is that you try certain of these methods before condemning them as unscientific and old fashioned.

## *SECOND PAPER.*

### FROM THE STANDPOINT OF THE LARYNGOLOGIST.

BY CHEVALIER JACKSON, M.D.

Anterior and posterior transthoracic esophagotomy, dorsal mediastinotomy and other procedures for the resection of the thoracic esophagus, concern the laryngologist only in so far as he may with the esophagoscope render aid to the general surgeon,

or with the bronchoscope assist in passing oxygen to the lung to prevent pneumothorax.

Diseases of the esophagus may be classified into stenotic and non-stenotic, the stenotic being of spastic, cicatricial, compressive, neoplastic and acute inflammatory forms. Surgery of the esophagus is chiefly of aid in the stenotic diseases associated with stricture, and neoplasms. Diverticulum is a non-stenotic disease, but is usually caused by a subdiverticular stricture, through which the musculature of the esophagus endeavors to propel the esophageal contents. This pressure causes dilatation above the stricture. Another form of stricture is due to traction, as by an adhesion, externally on a circumscribed portion of the esophageal wall. Therefore our subject narrows itself to the surgery of strictures, diverticula and neoplasms.

The surgery of foreign bodies in the esophagus is not within the scope of the present symposium, but I wish to say that since the development of esophagoscopy external surgery has no place unless the foreign body has escaped, in which event it is no longer a case of foreign body in the esophagus. In all other cases the foreign body, no matter how large, if it has gone in by the natural passages, can be brought out by the same route. This is not a criticism of the past skilful work which had its place then, but has not now. It is a note of progress.

#### PRELIMINARIES TO ESOPHAGEAL SURGERY.

Rest of the esophagus to reduce the ever-present esophagitis is an essential operative preliminary. Absolutely nothing but water, milk, ice cream and consomme should be allowed, and bismuth subnitrate should be swallowed dry. If the patient is emaciated and feeble he should, when possible, be improved in condition before operation. No dependence should be placed upon rectal alimentation. Thirst can be quenched, but starvation cannot be prevented by rectal feeding. It is better to have the patient gastrostomized early in any case, and always before resection of the esophagus. The stomach should be empty of food (it is never completely empty of secretions), and the bowels should be freely emptied by enemata. I find a disposition of the profession to dis-

regard this common pre-operative precaution in patients who have been unable to swallow any food for several days. Before any operation upon the esophagus, it is imperative to use every precaution to exclude aneurysm, which often produces a compression stenosis simulating stricture. If the diagnosis of aneurysm can be made by radiography or fluoroscopy and physical methods, it is better not to pass an esophagoscope; for, while the careful and proper use of an esophagoscope passed without an obturator under ocular guidance will in no way hasten the rupture of an aneurysm, the rupture, when it ultimately does occur, will be blamed upon the esophagoscopy, and thus unjust criticism attach to a useful method. In such cases of aneurysm as cannot be otherwise excluded, the careful esophagoscopist will detect the lesion. The blind passage of an esophageal sound in an esophagoscopically unexplored gullet is a dangerous procedure rarely justifiable. Three deaths from its use have come to the writer's knowledge within a year. It is necessary also to exclude ulcerative and inflammatory disease, endo-muro- and peri-esophageal malignancy, and all forms of compression stenosis. It is necessary to bear in mind that the history of stricture from accident does not exclude malignancy, as evidenced in a case referred to the author by Dr. L. W. Swope. A stricture following the swallowing of lye afterward became the site of an epithelioma (specimen examined by Dr. Joseph H. Barach). Another patient with stricture following the swallowing of lye was admitted to the Western Pennsylvania Hospital in a dying condition. The imminent starvation demanded immediate gastrostomy, which was rapidly done by Dr. J. Hartley Anderson. Esophagoscopy later by the writer showed a varicosity above the stricture which would have rendered string cutting or even dilatation extremely dangerous. Had the stricture been operated upon blindly, as has been done in hospitals where there is no esophagoscopy practiced, serious and probably fatal hemorrhage would have occurred.

#### STRICTURE OF THE ESOPHAGUS.

Mechanical or operative treatment of strictures is indicated whenever the stenosis is either dilatogenic or sufficient to interfere seriously with nutrition. It is associated with little risk when



done with discretion. Of course, it must be remembered that the esophagus is one of the most intolerant organs we have to deal with surgically. Shock is out of all proportion to the extent of the work, or of the lesion, as shown in ordinary acute esophagitis.

Stricture of the esophagus has been, in my experience, amenable to four methods of treatment:

First—Bonginage per tubam.

Second—Dilatation with esophagoscopically placed laminaria tents.

Third—Esophagoscopic string-cutting dilatation.

Fourth—Abbe's retrograde string-cutting method.

Bonginage is dangerous when practised blindly with a sound. There have been numerous cases, a few recorded, many unrecorded, where fatal mediastinitis has resulted from the perforation of the esophageal wall weakened by malignancy, or by the erosions that occasionally occur as the result of the acute or chronic esophagitis, which is always present above, never below, the stricture.

Bouginage per tubam is a very safe and often efficient procedure, when practiced with Bunt's double olive bougies, which I have adapted to endoscopic work. The distance between the olives permits the following of the piloting olive on the tip by one on the stem large enough safely to do a valuable amount of dilating, the stem between the two serving as a guide to the second bulb.

The first bougie is followed by a larger and a still larger one until the limit of safety has been reached. Nothing but the sense of resistance communicated to the finger will determine this limit. Dilatation is repeated at the next seance two days later until sufficient dilatation has been obtained, when, if the esophageal wall is free from weakness, the ordinary soft flexible silk-and-wax bougie may be used, and the patient trained to pass it himself, so that he may retain the dilatation obtained. The method is safe in careful hands and in properly selected cases. It yields good results in cases where the entire circumference of the esophagus is not cicatricial. In the class of cases where the entire

circumference of the esophagus is involved in the stricture or strictures, the string-cutting method of Abbe, modified for esophagoscopic use, is best, in my opinion. The original operation was done by an assistant holding the ends of a string as one would a Gigli saw, one end coming out the mouth, the other out a gastrostomic opening. Tension is made on the string by the assistant,



Fig. 1.

Tent carrier attachment operated by the author's endoscopic forceps.

while the operator makes a pressure upon the dilating bougie. The string is introduced by retrograde bouginage very easily, as the esophagus below the stricture leads directly to the stricture without dilatation or diverticulum. Subsequently Abbe modified this for working from above only, by a string-cutting esophago-

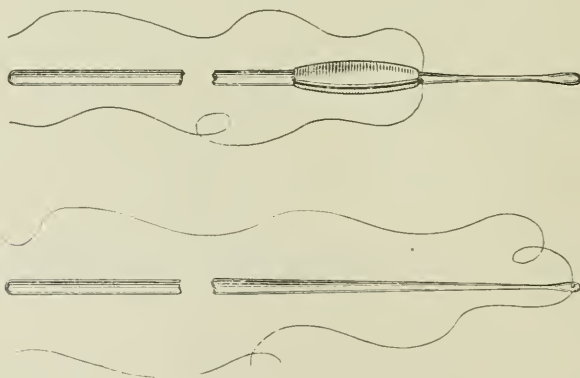


Fig. 2.

String-cutting esophagotome for esophagoscopic use.

tome, the bight of the string being carried down by a dilating metal guide to the face of the stricture, which is rapidly worn through by the to-and-fro travel of the string worked by the assistant, while the operator makes prudent pressure upon the stem of the dilating esophagotome. In cases where the string-bearing end of the instrument could find the lumen of the stric-

ture this method proved quite feasible in the hands of Dr. Abbe. But a very large percentage of the long-standing cases have a dilatation, or even a diverticulum, above the stricture, and the lumen of the stricture is of pin-hole size, so that it is impossible by blind groping to find the strictured passage or to be sure of it when found. It is here that the esophagoscope serves as a speculum, enabling the surgeon to see what he is doing. The instrument that I have used (shown in Fig. 2) has the thread exposed on one side only. This side is turned toward the cicatricial side in strictures which do not occupy the entire circumference of the esophagus. The great danger of operating blindly is understood



Fig. 3.

Esophageal intubation tube. (A) Anti-deglutition swell. (B) Anti-regurgitation swell. (C) Thickened edge to prevent mucosol erosion.

when we realize that the string may be wearing away the normal esophageal wall in a partial stricture of this kind. As said before, most of these partial strictures will yield to bouginage.

Tent dilatation I have elsewhere described, and I need here only show the instruments (Fig. 1) and state briefly that the tent is inserted through the esophagoscope. After five hours the tent is removed and the double olive bougies are passed thereafter about twice weekly for a few weeks. After that, if the esophageal wall is free from weakness, the patient is taught to pass upon himself the ordinary sound daily.

*Cervical esophagotomy* for the removal of foreign bodies is, I think, rarely if ever justifiable in these days, for reasons already herein given. Cervical esophagotomy is of value as a step to esophagostomy and for the extirpation of malignancy. Cervical esophagotomy is closely associated with laryngectomy, in which operation is very frequently included a greater or lesser resection of the esophagus. In some instances malignant disease of the esophageal aspect of the laryngeal framework will be involved in the growth, while the interior of the larynx is free from evidence of disease unless there is a paralysis from recurrent involvement. Except in the latter instance the symptoms will be entirely deglutitory, yet the larynx in whole or in part will have to be removed on the general principle that the entire growth with an area of healthy tissue must be extirpated, or any operation whatever is absolutely contraindicated. In some cases of this




Fig. 4.

Flexible bougie for inserting esophageal intubation tube. The lower illustration shows the tube in position for the insertion of the bougie. After the point of bougie has passed the stricture the tube is run down upon the bougie, into position.

kind hemicricarytenoidectomy, either lateral or posterior, will be sufficient. If so, a portion of the larynx that will be useful for breathing may be saved, and thus the patient will have a whispered voice. But it must be remembered that any operation interfering with epiglottic closure will almost certainly result in septic pneumonia, unless the entire larynx be removed and the trachea be brought forward and stitched to the skin.

*Lateral cervical esophagotomy* without opening the larynx is occasionally necessary for esophageal resection, chiefly for malignancy. It is rarely if ever the procedure of choice in stricture or for feeding. Its mortality is high.

*Subhyoid pharyngotomy* gives access to the introitus esophagi, and subhyoid pharyngo-laryngotomy is useful where there is involvement of the upper posterior part of the larynx as well as the

esophagus. In these procedures the rule above expressed in regard to epiglottic damage should be borne in mind. The slide speculum, and the open speculum of Dickinson or of Ingalls all enable operation by natural passages, which is the method of choice for all benign diseases of the hypopharynx and mouth of the esophagus. In malignant disease their only use is to facilitate the taking of a specimen.

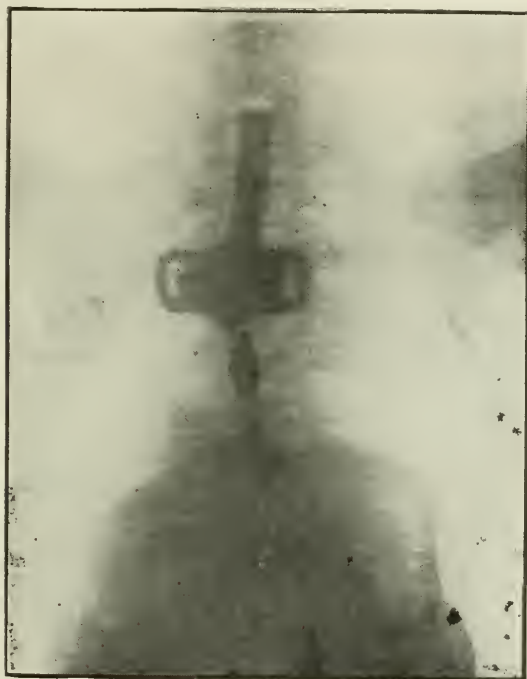

Fig. 5.

Esophageal intubation tube seen in position above and posterior to the tracheal cannula. Cicatricial stenosis of the introitus esophageal in a man 60 years of age. Radiograph from the living patient by Dr. Russell H. Boggs.

*Esophageal intubation.* In three cases of stricture and two of inoperable malignancy I have inserted a tube (Fig. 3) into the stenosed lumen, and enabled the patient to swallow liquids and



raw and soft-boiled eggs. The strictured case should more properly be called an impermeable esophagus from luetic sloughing and ulceration. The slide speculum enabled me to make an opening through the cicatricial web into the esophagus, the opening being maintained by the tube shown in Fig. 3. In this instance, replacement of the tube was done every second day, by the aid of the slide speculum. In one of the cases of malignant disease the tube was introduced by means of the flexible bougie shown in Fig. 4, which was first passed and then the tube was run down upon it. This blind passing of the bougie I consider safe in the



Fig. 6.

Autoplasmic repair of the anterior pharyngo-esophageal wall after resection for malignancy.

cervical portion of the esophagus, provided the esophageal wall is known by previous inspection to be free from weakness. The tube is shown in position in the radiograph (Fig. 5) taken by Dr. Russel H. Boggs. In the other case of malignancy the growth was in the thoracic esophagus, and the tube was placed through the esophagoscope.

#### AUTOPLASTIC REPAIR OF THE ESOPHAGUS.

Esophageal resection of limited extent is repairable by approximation of the edges. Those of greater extent will be followed by stricture if, indeed, there is not failure of union from sloughing out of the sutures because of too great tension. The most frequent repairable post-operative esophageal deficiency is that associated with laryngectomy for malignancy of the anterior esophageal wall, either primary or secondary to extrinsic laryngeal malig-

nant extension. It is often associated with deficiency of the pharynx also. In this class of cases, good results follow the plas-



Fig. 7.

Double olive bougie. Adapted by the author for endoscopic use. Originally used by Bunt without the aid of vision. The stem is thin and flexible and soon loses its straightness, which is an advantage in use.

tic operation by submental flaps (Fig. 6), which is readily understood from the illustration.

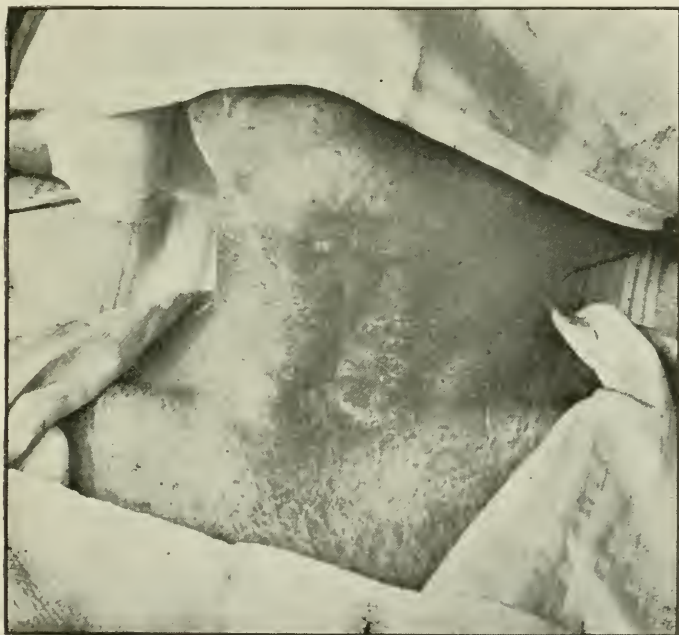

Fig. 8.

Photograph of patient six months after total laryngectomy, with resection of esophagus and pharynx for carcinoma. The lower opening is the tracheal orifice united to the skin. The upper opening is the esophageal opening ready for plastic closure. Patient could talk well by placing a colostomy pad over the two openings.

The epidermal surface of the submental flaps is turned inward, and the flaps are sutured in place, after which the fresh surface

of the flaps is covered, and the entire wound closed by the large cervical flap. A little wick of gauze drainage is usually necessary, but would be better omitted if possible. The epidermal surface in a sense takes on the duties of a mucous membrane, acquires a slippery surface, and deglutition is usually good.

*Conclusions.*

1. In no case of dysphagia should any esophageal procedure precede esophagoscopy.

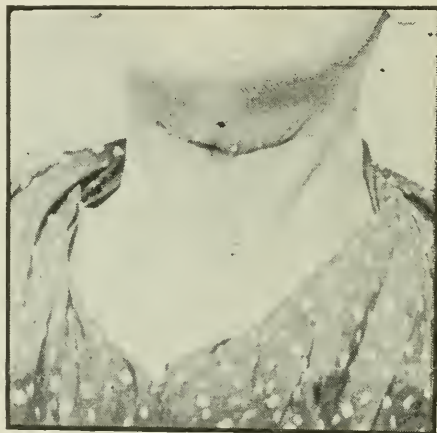

Fig. 9.

Photograph of a woman 70 years of age from whom the author removed a large scirrhous carcinoma of the upper end of the esophagus. Patient referred by Dr. George Feldstein.

2. In every instance every means to exclude aneurysm should be employed prior to esophagoscopy.

3. Esophagoscopy examination should be used to exclude neoplastic, spastic, compressive and inflammatory stenosis, as well as ulcerations and varicosities.

4. External esophagostomy for foreign bodies is rarely if ever justifiable.

5. The treatment of strictures is best carried out by one or more of five procedures. In the order of preference these are:

(a) Bouginage per tubam, using a double olive bougie passed by sight through the esophagoscope.

(b) Dilatation by an esophagoscopically placed laminaria tent.

(c) Esophagoscopy string-cutting dilatation.

(d) Prolonged intubation.

(e) Abbe's retrograde string-cutting method.

6. Resection of the upper portion of the esophagus, if it interferes with glottic closure, is so certain to be followed by septic pneumonia, that it is safer to close off the larynx, or to extirpate it and bring the trachea forward and stitch it to the skin.

7. In all operations upon the esophagus the strictest watch over the operating room organization is necessary. Nurses and internes are apt to be led into carelessness by the fact that the field of operation cannot be sterilized. They often fail to remember that while the patient is more or less immune to the organisms he himself harbors, he is not immune to organisms, even of identical kinds, introduced from other sources.

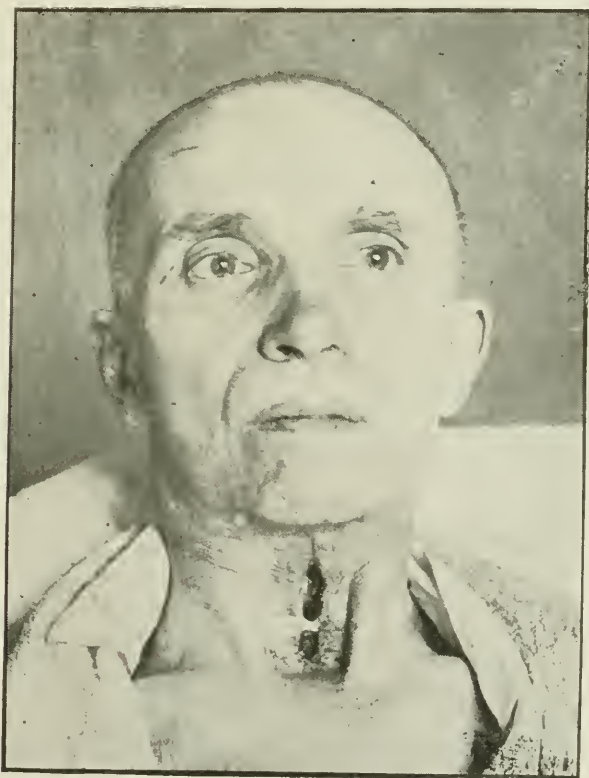


Fig. 10.

Photograph of a man 70 years of age, taken one years after total laryngectomy, with resection of the upper 5 c. m. of the esophagus for endo-thelioma originating in the larynx. Patient referred by Dr. Jacob Wolf.

*THIRD PAPER.*

## THREE ESOPHAGEAL CASES.

BY HARRIS P. MOSHER, M.D.

I wish to present three cases, two cases of stricture of the esophagus with dilatation and one case of diverticulum. Then I wish to discuss briefly the treatment of strictures, and in so doing to dwell somewhat on instruments and instrumentation, and to demonstrate on preparations and models the major facts of the applied anatomy of the esophagus.

Case No. 1.—A boy two years old swallowed a caustic solution, and three months later developed marked difficulty in swallowing. Milk became his only food. One day a part of the milk he took would stay down, the next day the greater part would be regurgitated soon after it was swallowed.

Under ether a stricture was found at the cardiac end of the esophagus and a moderate dilatation above it. The stricture proved to be about an inch long. It dilated readily with soft bougies to 20 F. From this point the dilatation was carried to 32 F. with the mechanical dilator. It was impossible to pass even a small bougie into the boy's stomach before etherization, but after etherization a No. 32 bougie could be passed readily. Since the dilatation, which occurred about a year ago, the 32 F. bougie has been passed once a week by the family physician. To-day the boy is as well nourished and rosy as one could wish. He still has trouble in swallowing meat.



Case No. 2.—Through the kindness of Dr. Horace D. Arnold and Dr. R. C. Larrabee about two months ago a young woman of 30 was referred to me for difficulty in swallowing, of fifteen years' duration. She gave a rather doubtful history of having swallowed a fish bone during her childhood.

At the time of this accident the father pushed his finger down the child's throat, and was supposed to have removed the bone. During the past fifteen years the patient has had numerous consultations with physicians, and at least once during this time has had bougies passed at regular intervals for a month, and has been fed by stomach tube for an equal period. The chief symptom always has been regurgitation of food within an hour after it was taken. Associated with this was great evidence of malnutrition. The normal weight of the patient is 130 pounds; when I saw her she weighed 75 pounds, and was fast becoming a walking skeleton. There never has been any pain, only a sensation of fullness after eating, the feeling of fullness and distention starting in the epigastrium and extending into the neck as far as the larynx. The regurgitation of food was associated with no nausea and seemed to be in a great measure under the patient's control. Whenever she felt discomfort and wished to do so she could bring up the food she had taken. As Dr. Arnold put it, "On request she would bow politely and present you with her last meal." The essential points in the physical examination were as follows: The patient was much emaciated. For the full width and the entire length of the sternum there was a tympanitic area. No stomach tympany could be made out. A test meal was returned undigested.

I have never had the pleasure of working for a more willing or a braver patient. She submitted without a murmur to a two-hour fluoroscopic examination, during which she was fed bismuth, and at the end had an X-ray plate taken. The conclusions drawn from these two methods of examination were that there was a stricture at the cardiac end of the esophagus, with an elongated dilatation of the esophagus above it. The dilatation swung to the right of the median line, so that the tip of a bougie struck the bottom of the dilatation, but did not enter the stomach, the cardiac opening being more to the left and slightly higher.

## THE ETHER EXAMINATION.

Under ether the esophagus was easily entered with a large oval tube. The lumen of the esophagus was found to be dilated all the way down, the dilatation increasing and reaching its maximum at the lower part behind the heart. Everywhere the esophagus appeared to be normal. There were no scars. The posterior wall of the heart could be seen for its full length, pulsating strongly into the dilated esophagus from the front and from the left. The opening into the stomach was found readily. It lay to the extreme left of the bottom of the pouch and on a somewhat higher level. When the esophagus was ballooned the dilatation appeared as a large black cavern which the light of the tube failed to illuminate. The opening into the stomach readily took a good-sized bougie. The bougie was followed by the mechanical dilator, and the opening spread to 45 F. before the resistance became marked. At this point the dilatation was discontinued, and a small metal bullet was wound with flax thread and carried with forceps into the stomach and left there. The upper end of the thread was brought out of the patient's mouth and fixed to the cheek with adhesive plaster.

## THE AFTER TREATMENT.

The after treatment was as simple and as satisfactory as the examination. For twenty-four hours the patient was nourished by rectum, then small quantities of milk were allowed by mouth. The greater part of this was retained. All that was given and all that was returned were measured and compared. A food chart showed the nutritive value of the food taken, so that we had the satisfaction of knowing accurately at any given moment how much the patient really took and how nearly this amount approximated the normal amount of food reckoned in calories which this patient's normal weight called for. Needless to say, this scientific sureness of feeding was not due to me, but was the result of work previously done in this line by Dr. Arnold. It was throughout a great comfort to me. I had the feeling which a surgical man seldom has nowadays—that the medical part of my case was thoroughly up to date and scientific.

On the second day the olive bougies were passed on the thread, starting with the small one and then using the two largest. All the bougies passed easily. After the third and fourth day the patient ceased to regurgitate, and at the end of a week was gaining weight. At ten days the patient was eating everything, her meat being minced. She no longer had the feeling of fullness after eating. At times she was conscious that the food entered the stomach slowly, but the former distress did not come back.

I saw the patient about ten days ago. She is putting on weight all the time. She now weighs 90 pounds instead of 75, her weight when she entered the hospital.

I will speak of the third case and then give what I have to say on the treatment of the three cases altogether.

Case No. 3.—A woman of middle age was sent to me because she had had for a few years symptoms suggesting a pouch, and because the attempt to pass a stomach tube, which was necessary on account of a fermentative condition, had failed at the last attempt, although it had passed easily at a number of previous trials. The tube seemed to halt just below the cricoid cartilage. The patient was examined under ether, the object of the examination being, of course, to find out whether or not there was a diverticulum, but especially to determine the presence or the absence of beginning cancer.

#### THE ETHER EXAMINATION.

The large oval tube halted about an inch and a half below the cricoid cartilage, and no lumen could be seen ahead. A tube the size of the gastroscope passed readily into the stomach. The esophagus was apparently normal. Remembering how easy it is to miss pathology with the small tube, I went back to the large oval one. Again the tube halted in a blind pocket about an inch and a half below the cricoid cartilage. At this point the window plug was put in place, and the lumen of the esophagus dilated. At once it was seen that the end of the tube was in a pouch. At each contraction of the hand bulb which controlled the air pressure the walls of the pouch expanded, so that the whole of the pouch could be distinctly seen. On withdrawing the tube slowly, and all the time forcing air into the esophagus, at a point about an inch below the level of the cricoid cartilage, suddenly two

openings were seen. Both openings dilated with each pressure on the bulb. One opening was in the lower left quadrant of the field of vision, and the other in the upper right-hand quadrant. A probe passed into the lower opening entered a pouch about three-quarters of an inch long, and a bougie passed into the upper one slipped easily into the stomach. Once the openings were found, it was easy to pass the end of the large oval tube at will into either, to go to the bottom of the pouch or to go into the stomach. Before the esophagus was ballooned the large tube missed the opening of the esophagus and the small tube missed the opening of the pouch; both openings were found only after the esophagus was distended with air. In this case, therefore, the practice of ballooning the esophagus demonstrated its usefulness and its possibilities.

#### INSTRUMENTATION AND METHODS OF EXAMINATION.

In a paper soon to be published I have gone at some length into the methods of making esophageal examinations, so that I will refer at this time only to a few points which I wish to bring before you, because some of them, I am convinced, will be of service. In esophageal examinations it is a great convenience to have the examining table placed upon a platform while the examiner stands on the floor. In this way the old sprawling method of conducting the examination is done away with, and the procedure assumes a more surgical aspect. Whatever instrument is used, occasionally strong pressure is put upon the teeth. This is especially true if the operator uses the open speculum. Indeed, for a time I exposed myself to the good-natured ridicule of my associates at the hospital by loosening and occasionally extracting teeth. Now I use in all cases a thin dental impression tray, and the teeth, good or bad, give me no further trouble. In my opinion it is essential to use as large a tube as the esophagus under examination can be made to take.

The lateral position, the dental tray and the open speculum make it possible to start the introduction of very large tubes, and such tubes once beyond the obstacle offered by the cricoid cartilage proceed downward with ease.

The lumen of the esophagus is very much larger than we are

accustomed to think that it is, both in the infant and in the adult. At one year the esophagus will pass a flat mother-of-pearl button one inch in diameter. Between two and three years of age the upper part of the esophagus will easily take the end of the Jackson tube spatula. In the adult the general surgeons have for years passed bougies in old stricture cases, where the stricture has been dilated and is being kept at its maximum dilatation, which are at least an inch in both diameters. It is repeatedly stated that three-quarters of an inch is the safe limit for dilatation in stricture cases. This measurement is manifestly too small.

The objection usually made to the use of large tubes in the esophagus is that they cannot be used without ether. To me this is not an objection. It is only the exceptional case which I wish to examine without ether. A negative examination under cocaine with a small tube amounts to nothing, whereas a negative examination under ether with large tubes affords data upon which some reliance can be placed.

I consider that it is settled that strictures of the esophagus are best diagnosed and best treated by means of the esophagoscope and instruments used through it. Nothing could be more satisfactory than the finding of a stricture by this means, and determining its location, nature and extent. Opening the stomach for the relief of non-malignant strictures ought to become a rare operation. Opening the esophagus from the side of the neck for the removal of smooth foreign bodies is obsolete surgery. The ballooning of the esophagus promises to be a help in locating the lumen of tight strictures, and the direct method of carrying a gelatine capsule filled with thread through the stricture into the stomach is much better than feeding the thread to the patient. The perforated metal olive bougies of Mixer, which run down the thread as a guide are of great service in pouch cases and in cases of tortuous or tight strictures. The thread keeps the bougie from going wrong. After a while the small guide can be used without the thread and the olives passed on the guide. The metal guide often finds the way better than the larger elastic bougie. When the metal guide is in place the large olives can be run down on it with the greatest confidence.

All strictures cannot be dilated. Some will need to be cut.



This is now being done. The instruments for accomplishing this are much the same as those used in the urethra. Certain strictures are ideal for treatment by cutting. I remember one case which I saw together with Dr. Coolidge. The patient was a child. In this case there were three or four falciform folds partially encircling the lumen of the esophagus at different levels. The folds gradually became smaller until the main stricture was reached. These partial strictures could be readily slit outward to the esophageal wall. When there is a firm ring-like stricture, cutting still can be done, but it should be employed with the greatest caution. The esophageal wall must never be cut through. There are too many major relationships about the esophagus to permit the slightest slip in this matter of cutting the stricture. Look at these specimens for a moment and see for yourselves. For perhaps two inches in the upper part of the esophagus it is safe to cut backward and risk perforating the esophageal wall. Everywhere else the esophagus is surrounded with the most important structures. Take the relationships in order. From behind, there are the thoracic branches of the aorta, the thoracic duct, the azygos vein, and the descending aorta. Anteriorly, first the posterior membranous wall of the trachea, then the arch of the aorta, then the heart itself. On the right side, in the neck, the recurrent laryngeal nerve, then in the chest, the right innominate vein, the right azygos vein, and finally the inferior vena cava. On the left side, again in the neck, the recurrent laryngeal nerve; in the thorax the arch of the aorta once more, and finally the whole of the thoracic course of the descending aorta. This is surely a discouraging outlook for cutting, when considered from the anatomical standpoint. The case is not hopeless, however, because, although it may not be anatomically permissible to cut through the walls of the esophagus on any side, the clinical fact remains that in the majority of cases so much cutting is probably not necessary. We can cut the stricture and nothing else. And this we shall learn to do. I believe that the cases are few where it will again be necessary to open the stomach and saw through the stricture with a string. This method has done good service, but we now have a better one.

What is the lesson which these three cases teach? The first case illustrates the most modern and so far the best treatment for strictures of the esophagus. The stricture was found with the tube and dilated through the tube. This case needs to be dilated again. Perhaps the stricture may come to cutting.

The third case, to take the last case next and out of order, was a pretty example of the help which ballooning the lumen of the esophagus affords in finding a diverticulum. This procedure should be resorted to whenever the lumen of the esophagus does not stand out clearly ahead of the advancing tube.

The second case is the most recent, and the one which still, in a measure, surprises me. Here was a history of trouble with swallowing for fifteen years. For one month during this time bougies were passed and for an equal period the patient was fed by the stomach tube. The fluoroscope and the X-ray taken after bismuth was swallowed showed a marked dilatation of the esophagus, the dilatation being especially prominent in the lower part, near the opening into the stomach. From the X-ray it seemed probable that the opening into the stomach from the pouch-like dilatation was to be found on the left. I expected a hard examination and a long after-treatment. All my expectations, happily, were disappointed. The examination was most easy, the dilatation pouch was readily made out, and the opening from it into the stomach was found at once and found to be easily dilatable. Within a week, with daily passing of the metal olives, all regurgitation stopped, in a week and a half the patient was eating practically everything and eating it in the natural way, with the exception that the meat was minced. It is now about two months since the examination, and the patient eats everything, taking only the precaution to out-Fletcher Fletcher in chewing her food. Meat she feels goes into the stomach slowly, but a swallow of fluid at once sends it along. The esophagus, which was stretched for fifteen years, has retained its elasticity sufficiently to contract. This was a surprise to me. In fact, the whole case from the beginning to the end has surprised me from its extreme ease and simplicity. If such cases can be duplicated, and I believe they can, a certain number of esophageal cases, which hitherto have been sent from pillar to post, which have been put down

as due to nervousness one day and the next subjected to repeated attempts at the blind passing of bougies, and all the time have remained half starved, will be relieved as other surgical cases, are now relieved in a reasonable time by direct examination and direct treatment.

At the risk of making an anti-climax, I cannot refrain from mentioning two other happenings in this case. One was somewhat ludicrous, the other anything but amusing. I will take the disagreeable happening first. I saw the patient last, one week ago. Since she has been out of the hospital, perhaps a little over two weeks, her family physician has been passing the metal olives on the metal guide. The last two or three times the olives were passed, they stuck on the return behind the larynx so that the physician told the patient that he thought there was narrowing in this place. The stricture at the cardiac opening gave no trouble either to the passage or to the return of the olives. I found on passing the olives that there was no resistance anywhere on going down, but when the olives reached the region of the larynx they stuck firmly. After trying a few times and failing completely to get the olives up, I used almost enough force to lift the patient from the chair, but still the bougie failed to come. I had visions of giving the patient ether to release the olives. Just as I was beginning to get a little excited, I thought of the probable explanation of the trouble. The olives were caught below the larynx and were tipping it out of line. I had the patient firmly caught, like a fish on a hook. As soon as I thought of this I pushed the larynx downward and forward, with my finger in the mouth, and up came the olives. Needless to say I shall not soon forget his manoeuvre.

This happening distressed both the patient and me. The other happening distressed only the patient. The day before she left the hospital, she asked, like a true New Englander, if when she went home she could eat beans. She said her mother told her she couldn't, and asked for my decision in the matter. I told her that she could and she did. Her stomach had not been used to beans in quantity for fifteen years and they, true to their usual custom, liberated a great quantity of gas, so that she became acutely distended. She tried to get the beans up, but failed. Had

they been in the esophagus she could have accomplished this easily by her old habit of regurgitation. Now, however, she could not get them again, as she had lost the power to vomit. For an hour or two, therefore, she prayed to go back to the old order of things, until finally her distressing meal passed onward.

### *General Discussion.*

Dr. Emil Mayer: I am sure we are very much indebted to the gentlemen for their presentation of so vitally interesting a subject, and, above all, that attention is called to the existence of these things, so that we may be able to make our diagnoses earlier than we have been in the habit of doing. I presented twenty years ago the history of a case of a child with congenital stricture of the esophagus, which was at that time the third case in the world's literature. This child had lived to be ten years of age without being able to swallow a morsel of solid food, taking liquids only by the tablespoonful. She would oftentimes lie on the sofa, with her feet where her head should be, trying to get food into her stomach; it seemed easy from this to make a diagnosis of congenital stricture, although no diagnosis had been previously made, and she required but the passing of a single large-sized bougie under anesthesia to be able to swallow food, which she has done from that time on with no recurrence of the trouble, showing that the thing was under no circumstances of an hysterical nature, but that it was due entirely to obstruction. She swallowed food immediately after etherization and the passage of the bougie, and has remained well ever since. I saw her fifteen years later; she came to me from time to time just for the passage of a soft bougie into her esophagus to see that it was all right. The next case, one which came to me very recently, was a clergyman, who presents an interesting history. No diagnosis had been made before he came to see me; he had been told that he had a neurosis, and that there was nothing wrong with him; yet, on the introduction of the bougie, it was arrested nine inches from the teeth and it was quite impossible to pass it further. The question arose whether we had to deal with a diverticulum or not, and here I would like to say one word in connection with the examination of these patients with the X-ray. It is a question in my mind whether the swallowing of bismuth is as safe a thing as it would appear to be. I feel very much afraid we will get a metallic substance in the pouch, which would be very difficult to remove and lay ourselves open to subsequent blame. In this patient, having this thought in mind, I took a soft piece of tubing, filled it with

shot, introduced that into the pouch and took an X-ray picture, which showed it beautifully. I was very glad to hear Dr. Mixer say that these patients would do very well under dilatation. I shall make it a point to see what I can do with this patient, who is not suffering very much. He has studied medicine and knew something of the symptoms, and said he had an obstruction in his esophagus. He had noticed twenty years ago on eating grapes and on leaning forward that the grape came out as he had swallowed it. Recently, on introducing a bougie, I brought up a piece of bacon he had eaten for his breakfast four hours before. It was certainly, therefore, in a pouch of the esophagus. The more modern methods of examination with the instruments we have, and the work which has been done by our colleagues are being watched and followed very closely.

Dr. J. O. Roe: In 1882 I had the honor to report two cases of internal esophagotomy, the first cases that had been reported in this country. I also wrote up the subject and collected all the cases that had been reported up to that time. This was, I think, not only the first article written on this subject in this country, but in the English language. Sir Morell Mackenzie had shortly before reported one case, which he showed before the International Medical Congress of London in 1881, but all the other cases had been in continental Europe; eight in France, three in Germany, and one in Denmark, making a total of fifteen cases up to that time.

Of my two cases, one was a boy about eight years of age, the stricture having resulted from swallowing lye six months before. The opening through the stricture was so small that I could pass but a small filiform bougie. I could dilate it by using bougies of gradually increased size, but the contraction would soon return so that he could swallow no better than before. As the stricture was undoubtedly of a membranous character, I decided on the feasibility of internal esophagotomy. Having seen Sir Morell Mackenzie's successful case the year before, in London, I wrote Sir Morell, requesting him to have his instrument makers, Mayer & Meltzer, send me one of his esophagotomes, such as he used in his case, which he very kindly did. With this instrument I succeeded in cutting the stricture so that after dilatation the passage remained permanently free. In order to determine the extent of the stricture and the side on which the constriction projected the most, I devised a half round bulbous bougie with which, by turning it in different directions, would very readily determine these points. I could thus determine the side on which to make the incision and also the depth to which I wished to cut, the instrument being so regulated that the blade could be thrown out the



desired distance when cutting through the stricture. The several incisions were made at different sittings, followed each time by dilatation until ample room was afforded for deglutition. Dilatation of the stricture was also continued at frequent intervals for a time afterward until there was no further tendency to contraction. The boy remained perfectly well during the following five years, during which time I used to see him frequently. Since that time I have lost track of him.

The second case occurred in a woman about thirty-five years of age, caused, she thought, by the lodgment of a piece of chicken bone in the upper part of the esophagus. The stricture in this case resembled somewhat that of the previous case, being evidently composed of an elastic membrane, somewhat limited in extent. I operated in this case very much the same as in the previous case and the result was equally satisfactory, as the stricture did not return, and the patient was well when I last saw her, several years after the operation.

At that time we had to examine the esophagus blindly, governed mainly by the sense of touch. With the modern esophagoscopes and illuminating instruments which have been developed since that time, we can be more accurate in our methods.

At the present time I have an interesting case of a pouch of the esophagus in a woman sixty-five years of age. On exploring her esophagus with a bougie I discovered the pouch, which is very similar to the one that Dr. Mixer has illustrated, and which was confirmed with the esophagoscope. In order to dilate the opening through the esophagus, which was nearly closed at the site of the pouch, I used a long, slender aluminum bougie as a guide, and over this bougie I passed a large, cone-pointed, soft rubber perforated bougie, in size nearly as large as the lumen of the esophagus. In a woman of her age I did not think it quite safe to do any cutting operation in her esophagus, for, by occasionally dilating it, she gets on very comfortably and avoids the danger of surgical interference. I report this case as being an interesting one which illustrates the value of dilating the esophagus in the case of a pouch as recommended and practiced by Dr. Mixer.

Dr. G. L. Richards: Dr. Mosher's last remarks about the difficulty of getting at the pouch recalls an experience with an instrument now almost obsolete. I refer to the coin catcher. One of my colleagues in the hospital one day had a child two or three years of age with a coin in the esophagus, so he used the coin catcher, and, after catching the cent and trying to remove the catcher, found it an impossibility on account of the danger of suffocation. He had to do a tracheotomy first, and was then

able, but with difficulty, to remove the catcher. I suppose the coin catcher was caught under the thyroid cartilage, and the expedient suggested by Dr. Mosher was not thought of.

Dr. D. Bryson Delavan: It is unnecessary for me to speak in appreciation of these papers in general. I would like to say, however, with regard to the last paragraph of Dr. Jackson's paper, that the more earnestly we consider what he said the better we will realize the import of it, and the more we lend our efforts to carrying it out the greater will be the advance of surgery in this country, which to-day is seriously threatened because of too general operating, in cases requiring special skill, by men not specially qualified for it. I am glad that Dr. Jackson has had the wisdom and the courage to give us that paragraph.

Dr. A. Coolidge, Jr.: While listening to these papers it struck me that in the diagnosis and treatment of the esophagus the general surgeon and the laryngologist are rapidly coming together. As we learn each other's methods we shall solve the problems in the same, not in different ways. The surgeon looks upon the laryngologist as the expert with the head mirror. Dr. Jackson has discarded the head mirror.

Dr. Jackson considers it unsafe for anyone except the experienced and skillful man to pass even a bougie without previously seeing his way with the esophagoscope. I am not sure that this is good doctrine to teach the unskillful man. I should myself much prefer to have such a man try to pass a bougie rather than an esophagoscope if I were the patient.

Dr. Jackson: I have nothing to add except to thank the gentlemen, Dr. Mixter and Dr. Mosher particularly, for I have learned a great deal from what they have said. I also wish to thank Dr. Delavan for his remarks.

In regard to the coin catcher which Dr. Richards mentioned, I am sorry to say it is not an obsolete instrument. A patient was brought to the Eye and Ear Hospital a few weeks ago with a penny in his esophagus. A coin catcher had been previously passed down to take out the penny, the position of which was demonstrated by a radiograph, but the coin catcher entered the trachea, and on being drawn out had torn out the inside of the larynx. The child is in a very serious condition. It took but a moment to remove the penny safely and easily by esophagoscopy.

### *Presentation of Instruments and Specimens.*

In connection with the various papers the following instruments and specimens were presented:

By Dr. Ballenger, a knife for the removal of the ethmoid cells en masse, and for the removal of the middle turbinates; also drawings illustrating the use of these instruments.

By Dr. Casselberry, a headlight for use in tonsil operations and a new model of a "quad" self-retaining nasal speculum.

By Dr. Coakley, a Hays pharyngoscope.

By Dr. Farlow, the original laryngoscope devised in 1859 by Dr. Ephraim Cutter, a former member of this Association.

By Dr. Freer, a raspatory for use in submucous resection of the nasal septum, bone forceps (Casselberry model), and tonsil knives.

By Dr. Ingersoll, model of a curette for the infantile nasopharynx and a wooden model showing the naso-pharyngeal curves.

By Dr. Mayer, a Yankauer self-retaining nasal speculum.

By Dr. Makuen, framework specimen of the human chest, showing the diaphragm in position.

By Dr. Mixer, various esophageal bougies.

By Dr. Mosher, various laryngeal instruments for examination, a dental plate for use in esophagoscopy and various specimens and exhibits from the collections of the Harvard Medical School.

By Dr. Richards, various instruments for the removal of tonsils.

By Dr. Richardson, specimen of elongated styloid process.

## AMERICAN LARYNGOLOGICAL ASSOCIATION.

*Business Meeting.*

The Thirty-first Annual Congress of the American Laryngological Association met at the Harvard Medical School, Boston, under the Presidency of Dr. A. Coolidge, Jr., of that city, on Monday, May 31, 1909, at 10 A. M. During the sessions of the Congress the following Active Fellows were in attendance:

Dr. A. Coolidge, Jr., Boston, Mass., President.

Dr. Emil Mayer, New York City, First Vice-President.

Dr. Francis R. Packard, Philadelphia, Second Vice-President.

Dr. James E. Newcomb, New York City, Sec'y and Treas.

Dr. Joseph H. Bryan, Washington, D. C., Librarian.

Dr. Joseph W. Gleitsmann, New York City, Member of Council.

Dr. Herbert S. Birkett, Montreal, Canada, Member of Council.

And in addition:

Dr. William L. Ballenger, Chicago, Ill.

Dr. John F. Barnhill, Indianapolis, Ind.

Dr. T. Passmore Berens, New York City.

Dr. Arthur A. Bliss, Philadelphia, Pa.

Dr. J. Price-Brown, Toronto, Canada.

Dr. William E. Casselberry, Chicago, Ill.

Dr. J. Payson Clark, Boston, Mass.

Dr. Cornelius G. Coakley, New York City.

Dr. Frederic C. Cobb, Boston, Mass.

Dr. Lewis A. Coffin, New York City.

Dr. D. Bryson Delavan, New York City.

Dr. John W. Farlow, Boston, Mass.

Dr. Otto T. Freer, Chicago, Ill.

Dr. Richard Frothingham, New York City.

Dr. Albert C. Getchell, Worcester, Mass.

Dr. Joseph S. Gibb, Philadelphia, Pa.  
 Dr. Joseph L. Goodale, Boston, Mass.  
 Dr. Charles P. Grayson, Philadelphia, Pa.  
 Dr. D. Crosby Greene, Jr., Boston, Mass.  
 Dr. Thomas H. Halsted, Syracuse, N. Y.  
 Dr. Thomas J. Harris, New York City.  
 Dr. Frederick E. Hopkins, Springfield, Mass.  
 Dr. Thomas Hubbard, Toledo, O.  
 Dr. John M. Ingersoll, Cleveland, O.  
 Dr. Chevalier Jackson, Pittsburg, Pa.  
 Dr. D. Braden Kyle, Philadelphia, Pa.  
 Dr. Samuel W. Langmaid, Boston, Mass.  
 Dr. George A. Leland, Boston, Mass.  
 Dr. James E. Logan, Kansas City, Mo.  
 Dr. John H. Lowman, Cleveland, O.  
 Dr. G. Hudson Makuen, Philadelphia, Pa.  
 Dr. James F. McKernon, New York City.  
 Dr. Harris P. Mosher, Boston, Mass.  
 Dr. Robert C. Myles, New York City.  
 Dr. Norval H. Pierce, Chicago, Ill.  
 Dr. B. Alex. Randall, Philadelphia, Pa.  
 Dr. W. Scott Renner, Buffalo, N. Y.  
 Dr. George L. Richards, Fall River, Mass.  
 Dr. Charles W. Richardson, Washington, D. C.  
 Dr. John O. Roe, Rochester, N. Y.  
 Dr. George E. Shambaugh, Chicago, Ill.  
 Dr. Burt R. Shurly, Detroit, Mich.  
 Dr. Ernest L. Shurly, Detroit, Mich.  
 Dr. William K. Simpson, New York City.  
 Dr. Greenfield Sluder, St. Louis, Mo.  
 Dr. Harmon Smith, New York City.  
 Dr. Henry L. Swain, New Haven, Conn.  
 Dr. George B. Wood, Philadelphia, Pa. Total, 55.

Following the roll call the Annual Address was delivered by the President, Dr. Coolidge. The scientific program was then followed as far as time permitted. At 12.45 P. M. the Association went into executive session. The first order of business was election of Fellows. The candidates were as follows: For trans-



ference from the Corresponding to the Honorary list, Sir Felix Semon, of London, and Prof. Dr. B. Fraenkel, of Berlin. For Active Fellows: Dr. Albert C. Getchell, Worcester, Mass., proposed by Drs. Goodale and Clark. Thesis, "Naso-Pharyngeal Fibromata." Dr. Burt R. Shurly, Detroit, Mich., proposed by Drs. Barnhill and de Roaldes. Thesis, "An Investigation of Post-Operative Conditions Five to Ten Years After Intubation." Dr. Greenfield Sluder, St. Louis, Mo., proposed by Drs. Leland and Delavan. Thesis: "The Anatomical and Clinical Relations of the Sphenopalatine (or Meckel's) Ganglion to the Nose and its Accessory Sinuses."

The election resulted in the choice of all the candidates named, Drs. Richardson and Freer acting as tellers.

Drs. Grayson and Halsted were appointed by the President as Auditing Committee of the books and accounts of the Treasurer.

An election of a Committee of Five to nominate officers for the ensuing year resulted as follows: Dr. Delavan, Chairman; Drs. Halsted, Casselbury, Pierce and Swain.

At 1 P. M. the Congress adjourned and with their ladies enjoyed a lunch tendered by the Boston Fellows and served under a tent just outside the building. At 3 P. M. they reconvened and listened to a symposium on Diseases of the Esophagus. At the conclusion of this, the program was resumed until 6 P. M. At this hour the Congress adjourned.

In the evening a reception was held by Dr. and Mrs. Coolidge at the Hotel Tuileries, No. 230 Commonwealth avenue. In connection with this an interesting musical and literary program was given by various artists under the direction of Dr. Greene.

On Tuesday, June 1, the Association met at 9.30 in executive session. The following matters of business were considered.

### *Secretary's Report.*

During the year just elapsed Dr. Urban G. Hitchcock resigned from Active Fellowship on account of ill health and Dr. Frederic I. Knight died. Including the candidates elected at the present Congress, our classes of Fellows now number as follows: Honorary 2, with 13 vacancies; Corresponding, 27, with 3 vacancies, and Active, 89, with 11 vacancies.

The Constitution requires the formal presentation of a copy of the Transactions of the last Congress. The volume was the most expensive one we have ever published, the net cost being \$3.34. Somewhat over 200 copies were distributed to Fellows and to libraries. A small number were sold at an advance over cost to cover the expense of distribution.

During the year the twenty-fifth anniversary of the establishment of the *International Centralblatt für Laryngologie* was celebrated and a congratulatory letter was sent to and acknowledged by its editor, our Corresponding, now Honorary Fellow, Sir Felix Semon. Copies of the letters follow:

To Sir Felix Semon, the Council of the American Laryngological Association extends its hearty congratulations on the occasion of the Twenty-fifth Anniversary of the establishment of the "*Internationales Centralblatt für Laryngologie, Rhinologie und verwandte Wissenschaften*."

The successful conduct for a quarter of a century of this treasure house of information in these departments of scientific medicine is alone an achievement which will confer imperishable renown upon its editor.

To no body of physicians have the results of his labors been more helpful than to the Fellows of this Association, who recall with grateful recollections his visit to this country. To them, when in his own city, he has always shown a gracious hospitality which has been cordially appreciated, and they appreciate also the honor conferred upon their body by his Corresponding Fellowship, dating back almost to the beginnings of their history.

On the occasion of this Silver Jubilee, they renew their pledge of hearty support and tender their best wishes.

By order of the Council,

(Signed) A. COOLIDGE, JR., President.  
J. E. NEWCOMB, Clerk.

Dear Sirs: Pray submit to the American Laryngological Association, one of the oldest Corresponding Fellows, of which I am proud to call myself, my most sincere thanks for their extremely kind message on the occasion of the twenty-fifth anniversary of

the establishment of the "Internationales Centralblatt für Laryngologie, etc."

It makes me happy and proud to hear that the endeavors of my dear contributors and of myself have succeeded in making the journal, as you graciously call it, "a treasure house of information," and from the international tokens of good will which I have received on this occasion I am glad to see that I have succeeded in realizing the ideal which I had before me when founding the journal, viz., to make it a truly international one.

I am particularly touched by the kind reference to my visit to America, the memories of which I, too, still cherish, and shall always cherish. May the Centralblatt forever fulfil the purposes for which it was founded, and may it be worthy of the support of my American confreres. Sincerely yours,

(Signed) FELIX SEMON.

To the President and Council of the American Laryngological Association.

The sixtieth anniversary of the birth of our Corresponding Fellow Prof. Dr. Paul Heymann, of Berlin, was also celebrated during the year and the following letter was sent:

New York, Jan. 27, 1909.

The Council and Fellows of the American Laryngological Association beg to tender their heartiest congratulations to their Corresponding Fellow, Prof. Dr. Paul Heymann, of Berlin, on the occasion of his sixtieth birthday.

His many labors in the common field of nose and throat diseases and the editorship of his monumental handbook have distinguished him as an industrious clinician, an accomplished scholar and a scientific worker of the highest order.

That his life may long be spared for a continuance of his many useful activities is their earnest wish.

(Signed) A. COOLIDGE, JR., President.

J. E. NEWCOMB, Clerk.

During the year one meeting of the Council has been held and the minutes will now be read.

This report is respectfully submitted.

JAMES E. NEWCOMB, Secretary.

*Treasurer's Report.*

## RECEIPTS.

Balance from old account .....	\$567.17
Sale of dinner tickets, 1908 .....	135.00
Loan, Corn Exchange Bank .....	400.00
Received from candidates on account of illustrations for theses .....	18.42
Received from Fellows on account Assessment of Tri- ennial Congress, 1907 .....	40.00
Arrears of dues .....	90.00
Dues for current year .....	820.00
Exchange on check .....	.15
Sale of Transactions .....	34.55
<hr/>	
Total .....	\$2,105.29

## EXPENSES.

Annual dinner, 1908 .....	\$145.00
Stenographer, 1908 .....	100.00
Publishing Transactions, 1908 .....	835.55
Repayment bank loan .....	400.00
Interest on loan .....	6.89
W. H. Carmalt, Secretary Triennial Congress, 1907....	40.00
Programs and distribution, 1909 .....	31.00
Printing and stationery .....	37.50
Expenses of office of Secretary and Treasurer .....	45.97
<hr/>	
Total .....	\$1,641.91
Balance to new account (bank balance) .....	463.38
<hr/>	

\$2,105.29

## STATEMENT OF ASSETS AND LIABILITIES.

## ASSETS.

Invested—de Roaldes Prize Fund, Jan. 1, 1909, per account No. 202,169 Franklin Savings Bank, New York City, in name of Treasurer .....	\$530.60
Current—Unpaid dues .....	\$90.00
Postage in office .....	2.16
Bank balance .....	463.38—\$555.54

## LIABILITIES, NONE.

Respectfully submitted,

JAMES E. NEWCOMB, Treasurer.

Boston, May 31, 1909.

Audited and found correct,

(Signed) C. P. GRAYSON,

T. H. HALSTED.

Auditing Committee.

*Report of the Librarian.*

Since the last meeting 8 bound volumes and 101 pamphlets have been received by the Librarian and have been deposited in the library of the Surgeon-General U. S. A. at Washington.

Respectfully submitted,

J. H. BRYAN, Librarian.

The Committee on Nominations, through its Chairman, Dr. Delavan, made the following report:

For President, Dr. James E. Logan, Kansas City, Mo.

For First Vice-President, Dr. Cornelius G. Coakley, New York City.

For Second Vice-President, Dr. Harris P. Mosher, Boston, Mass.

For Secretary and Treasurer, Dr. James E. Newcomb, New York City.

For Librarian, Dr. Joseph H. Bryan, Washington, D. C.

For Member of the Council (to serve for four years), Dr. A. Coolidge, Jr., Boston, Mass.

The next meeting will be held in Washington, May 3, 4 and 5, 1910, in connection with the Triennial Congress of the Association of American Physicians and Surgeons. This report was received and action thereon deferred till the next day.

Under the heading of miscellaneous business the Committee appointed at the last Congress, consisting of the Council together with Dr. E. Fletcher Ingals, to consider the matter of establishing a journal in connection with other special societies reported through Drs. Ingals and Richardson as follows:



Chicago, April 14, 1909.

The American Laryngological Association.

Gentlemen: At the annual meeting of the A. L. R. & O. Society for 1907, a committee was appointed consisting of Dr. E. B. Dench, of New York; Dr. C. W. Richardson, of Washington, and Dr. E. Fletcher Ingals, of Chicago, to consider the expediency of publishing a Journal on Laryngology and Otology under the joint auspices of the Am. L. R. & O. Society, the Am. L. Association and Am. O. Society. This committee investigated the matter carefully and at the annual meeting of the Am. L. Association in 1908, Dr. Ingals presented a report similar to that that was made to the A. L. R. & O. Society. The Am. L. Association appointed a committee, consisting of the Council and Dr. Ingals to further consider the subject. As a final result of the investigations of the original committee it was found that such a journal could not be published without a deficit of \$2,500 annually. The subject was taken up by the Council of this Association at its January meeting, and it was decided that it was inadvisable to undertake such a publication.

(Signed) E. FLETCHER INGALS,  
CHARLES W. RICHARDSON.

The Committee on Nomenclature, consisting of Drs. Kyle, Coolidge and McKernon, presented, through Dr. Kyle, its report. The following vote was passed: Resolved, that if this report shall be accepted by the following bodies, viz., the American Otological Society, the American Laryngological, Rhinological and Otological Society, and the Section on Laryngology of the American Medical Association, it shall be adopted by this Association, in so far as it relates to diseases of the nose and throat, and that such portion shall be published in the Transactions for permanent reference.

Voted, that the Committee be discharged with the hearty thanks of the Association.

The Committee on the award of the de Roaldes prize, Dr. Farlow, chairman, Drs. Casselberry and King, reported progress, submitting a design for a medal and stating that an expense of

\$25.00 had already been incurred in connection with the procuring of a design for a medal. A prolonged discussion concerning the whole matter then ensued, and it was finally laid on the table till the day following. The following vote was passed: Resolved, that the Treasurer be and hereby is authorized to pay to the Prize Committee the sum of \$25 for expenses already incurred.

A letter was read by the Secretary from Dr. W. H. Carmalt, of New Haven, Secretary of the Congress of American Physicians, stating that the program for the Triennial Congress of 1910 was being arranged and containing the following statements:

CONGRESS OF AMERICAN PHYSICIANS AND SURGEONS.

Secretary's Office,

87 Elm street, New Haven, May 20, 1909.

Dr. James E. Newcomb,

Secretary American Laryngological Association.

My Dear Doctor: The program for the Congress of 1910, so far as it affects the component Associations, has been arranged as follows, viz.:

First. The Congress will be held on May 3 and 4, 1910.

Second. There will be a general session of the Congress on the afternoon of Tuesday, May 3, from 2.30 to 5 o'clock, during which time no sessions of the component Associations will be held.

Third. The subject of Artificial Immunization will be considered at that time, the speakers being, as usual, selected by the Committee on the Program.

Fourth. The component Associations are requested to consider at their several meetings on Wednesday afternoon, May 4, the second day of the Congress, the cognate subject of Vaccine Therapy, each from its own point of view by writers selected by the Association itself—the papers to be published as a part of the Transactions of the Congress. It is understood that if two (or more) Associations wish to unite in a discussion they are at liberty to do so. You will therefore kindly bring this to the notice of your Association at its next meeting, or otherwise, accor-

ding as your organization is constituted, and have the writers appointed as mentioned, notifying me as soon as possible in order that I may get out the preliminary program of the Congress without delay. I am very truly yours,

(Signed) W. H. CARMALT.

It was voted that the Secretary be authorized to confer with the Secretary of the American Otological Society with reference to the holding of a joint session and that the President and Secretary of this Association be authorized to select the readers of the papers to be presented as our contribution to the discussion of the joint session.

Following the executive session, the Congress proceeded with its scientific program, and the first order was an exhibition of instruments and specimens. After this the reading of papers was continued till 1.15 P. M., when adjournment was taken for lunch, which was provided by the Boston members of the American Otological Society and of this Association to the visiting members of both organizations, and was served under the tent as on the day preceding.

The Congress reassembled at 3 P. M. and finished and discussed the rest of the papers assigned for the afternoon. Adjournment took place at 6 P. M.

In the evening the annual dinner was held at the University Club, No. 270 Beacon street. Forty-four Fellows were in attendance. At the close of the dinner those present sang some songs written for the occasion by Dr. Mosher.

On the last morning, Wednesday, June 2, the Association met at 10 A. M. in joint session with the American Otological Society and listened to a symposium on Nasal and Pharyngeal Conditions as Causative Factors in Aural Disease. The scientific session closed at 12.45 P. M., and the Association went into executive session. The report of the Committee on the de Roaldes Prize Fund was taken from the table and discussed. It was finally voted that the committee confer with Dr. de Roaldes and report at the next Congress. It was voted "that a sufficient sum may be taken from the capital account of the fund for the preparation of the die for the medal if the prize shall take this form,

and that the future income not required for the reproduction from the die and other necessary expenses be added to the capital account until the amount borrowed shall be replaced.

The Treasurer was authorized to borrow funds not to exceed \$600 to defray the expense of publication of the Transactions of the present Congress.

The report of the Nominating Committee was again read, and the Secretary was directed to cast an affirmative ballot for the ticket as read. This was done and the nominees were declared elected. Drs. Shurly and Roe were appointed a committee to escort the President-elect, Dr. Logan, to the chair. On taking the chair, Dr. Logan expressed his thanks for the honor conferred by his election, and trusted that there would be a large attendance at the meeting in 1910.

The following resolutions were adopted:

*Resolved*, that the thanks of the Association are due to the retiring officers, and especially to the President and his Boston colleagues for their untiring efforts to make the present Congress successful. The retiring President, Dr. Coolidge, responded for himself and his associates, and congratulated the members on the large amount of work done during the last three days.

*Resolved*, that the thanks of this Association be extended to the authorities of the Harvard Medical School for the courtesies received during the present Congress.

Adjourned at 1.15 P. M.

JAMES E. NEWCOMB, M.D., Secretary.

**DR. FREDERICK IRVING KNIGHT.**

The subject of this memorial was born in Newburyport, Mass., May 18, 1841. He was a son of Frederick Knight and Anne Goodwin, his wife. His early education was received at the Newburyport High School. He entered Yale College in 1858, became a member of D. K. E. and of the senior society, "Scroll and Key," and after a particularly praiseworthy career was graduated in 1862. As an undergraduate he gave the impression to his classmates of a genial, earnest, high-minded young man, fond of his friends, a fair scholar, but not yet having come visibly to his own. Apparently he had already begun to look toward his profession, for it is said of him that he showed unusual interest in the Soldiers' Hospital—it was during the Civil War—and spent so much time in helping to watch and nurse the patients there that he was often spoken of as "Doctor" Knight. In 1866 Yale gave him the degree of A. M. Having finished his academic course at New Haven, he entered the Harvard Medical School, from which he was graduated in 1866. He then entered the City Hospital, of Boston, where he passed the usual time as interne, and upon graduating went to New York City. There he associated himself with the late Professor Austin Flint, with whom he remained and studied for one year. At this time his real nature became apparent, for when it came to the acquirement of an education in medicine he was most earnest and serious minded. The attachment between Dr. Flint and himself was a particularly cordial one, so much so that Dr. Knight was strongly urged to continue his association with Dr. Flint and to remain permanently in New York. The prospect of a brilliant career thus opened to him in the metropolis, and under the patronage of one of the ablest and strongest men of his time, must have offered a temptation difficult to resist. Dr. Knight's parents, however, were still living and at Newburyport, and this tie together with the acquaintanceships and associations which he had already made in New England, induced him finally to decline Dr. Flint's proposition



and he decided to return to Boston. This he did and at once became the assistant of the late Dr. Henry I. Bowditch (Harvard, 1828), which partnership was continued for twelve years.

Meanwhile in 1871-1872 Dr. Knight spent a year abroad at Vienna, Berlin and London, under the personal instruction of the best masters of the day. Thus, it will be seen that his education was broad and liberal and that few specialists of his time entered the field equipped with a better knowledge of general medicine or a more accurate idea of the detail work of his department, gained from such masters as Bowditch, Flint, von Schroetter and others, from among the most accomplished and distinguished authorities then living.

From the beginning he had devoted his attention to diseases of the chest and the upper air passages, and having perfected his knowledge of these subjects as far as was possible he returned to Boston and entered upon their active practice.

The story of Dr. Knight's professional career is essentially the history of our specialty in New England. Laryngology was first taught in the Harvard Medical School as a part of clinical medicine. It was taught as a special subject first in 1866 by Dr. H. K. Oliver, one of the visiting physicians of the Massachusetts General Hospital. In 1872 Dr. F. I. Knight, while in Europe, was made "Instructor in Percussion, Auscultation and Laryngoscopy," and on his return established a clinic in New England to include Laryngology. Instruction in this branch was largely limited to teaching the methods of examination. Diseased conditions received attention only incidentally. Daily sessions of the class were held for two weeks. There was no examination. Courses for graduates were added the next year. In 1879, after seven years of such instruction, Percussion and Auscultation were separated from Laryngology and the title of the Teacher became that of Instructor in Laryngology. In 1880 Harvard established a voluntary fourth year. Dr. Knight gave a course to the class of that year, consisting of three exercises a week for two months. The instruction was both clinical and didactic, and was followed by a written examination. In 1882 he was made Assistant Professor and in 1886 Clinical Professor. Associated with him as instructor was Dr. Franklin H. Hooper. By this time not only were

the methods of examination taught, but the whole field of diseases was covered by systematic lectures, by demonstrations and by the clinical use of patients.

Although in the full prime of life and at a period when his mental and physical powers were in every respect at their best, he resigned this position in 1892 in order to allow of the appointment to it of his friend, Dr. Franklin H. Hooper, who had for some time aspired to attain it.

In the experience of the writer the high-minded unselfishness of this act stands without a parallel. Dr. Hooper in reality was hopelessly ill. It was not likely that his life would be prolonged sufficiently for him to occupy the place for any great length of time. It was equally probable that if Dr. Knight resigned the position he would not take it up again. Under the circumstances then the relinquishment of it meant everything to him. It was a final test of friendship and in it was shown the greatness of heart and of mind which distinguished the man whose whole life was filled with a series of just such evidences of genuine nobility of character.

Dr. Knight was connected at various times with the Boston City Hospital, the Boston Dispensary and the Carney Hospital, but resigned these positions in 1872 to establish a special clinic in laryngoscopy at the Massachusetts General Hospital. He was also Consulting Physician to the Massachusetts General Hospital, the Free Home for Consumptives and the Sharon Sanatorium.

While abroad he was married in Berlin, October 15, 1871, to Miss Louisa Armistead Appleton, daughter of William Stuart Appleton, formerly of Baltimore, Maryland. He is survived by one child, Theodora Knight, now Mrs. G. K. B. Wade, of New York City, and by a granddaughter, Miss Ruth Wade.

Dr. Knight was one of the founders of the American Laryngological Association, and he was present at the meeting in Buffalo held June 3, 1878, at which the Association was organized. From the earliest moment of the inception of the Association he was a leading spirit and throughout his long connection with it one of its most enthusiastic and valuable members. He was rarely absent from its meetings, but whether present or not his influence was always powerful and salutary.

At the first annual meeting of the Association held in New York City, June 10, 1879, the first scientific contribution presented was the paper of Dr. Knight on "Retro-Pharyngeal Sarcoma." The first committee appointed by the Association included him as a member. The object of the committee was the furtherance of a more definite organization of the Society and the establishing of a scientific nomenclature for the diseases of the upper air passages. At this meeting he was also appointed a member of the first nominating committee and for many years afterward was re-elected to the same position. During the temporary absence of Dr. Elsberg, the first President, Dr. Knight was appointed Temporary Chairman.

His contributions to its discussions evinced the highest order of scientific excellence and were therefore always welcomed. They were wise and scholarly and were offered with a modesty fully appreciative of the value of the views of others, but with a dignity born of experience and careful thought.

In the councils of the Association he was invaluable. Indeed, during that period of his career when the diverse elements which had united in its formation had not yet become thoroughly amalgamated and when conflicting interests and ambitions at times assumed proportions which threatened the Society's welfare, much of the success of the Association was due to Dr. Knight, through whom, more than through any other one man, wise policies were adopted and order maintained.

Dr. Knight was elected third president of the Association and the meeting was held in Boston, beginning June 12th, 1882. His presidential address dealt with the subject of instruction of students in the department of laryngology. In reading it over to-day, one cannot help being impressed by the wisdom of its suggestions, which now, after thirty years, have remained practically unchallenged.

In 1880 was founded the *Archives of Laryngology*, a magazine devoted to the study of diseases of the upper air passages. The editorial staff was composed of four of the leading laryngologists of the time, namely, Louis Elsberg, J. Solis-Cohen, George M. Lefferts and Frederick I. Knight. Among its collaborators were

such men as Morell Mackenzie, *facile princeps*, Krishaber, Vololini, Labus, Burow, Foulis, Oertel and Zawerthal. While this journal was so far in advance of the times that its career was terminated at the end of four years, it remains to-day the most elegant and best edited periodical on laryngology that has ever appeared. Under such management as controlled it and with the vastly increased number of specialists in the field there is no doubt that to-day it would be an acknowledged success.

Dr. Knight was a pioneer in the movement against tuberculosis. Fifteen years ago he became deeply interested in the subject and devoted much time and energy to its furtherance, especially through the medium of the American Climatological Association. His services to and through this society constitute an important contribution, and it is probable that they have been richly productive of valuable and lasting results.

When Governor Greenhalg was considering the establishment of a State Institution for the treatment of consumption in Massachusetts, he consulted Dr. Knight, and it was largely through his advice that Rutland was established. In fact, with this, as with other philanthropic interests, he was always ready and willing to give his counsel and assistance towards the advancement of the public good. He was constantly engaged in the warfare against tuberculosis, both in his own city and State and throughout the country. One of his last contributions to the literature of this subject was a paper read by him at the International Congress on Tuberculosis, held in Washington last September. This, like all of his papers, attracted much attention for its sound common sense and conservative judgments.

Dr. Knight was a member of the American Academy of Arts and Sciences, ex-president of the American Laryngological Association and of the American Climatological Association and also of the Boston Society for Medical Improvement. He was a member of the Massachusetts Medical Society and also of the St. Botolph and University Clubs.

Personally, Dr. Knight was by nature, as well as by lifelong training and association, a man of distinct superiority. Every attribute which he possessed, whether physical, mental or moral,

indicated that superior quality of good breeding which seems only to come to those whose forebears have been gently reared, of stainless integrity and capable of successfully accepting the responsibilities and the honors of high social and professional life. Osler might have made him his model in writing "Æquimitas." Knowing the man himself, it would not surprise us to find that in following back his ancestral line his name had originated not in any matter of fancy, but in veritable and substantial fact.

Physically he was a man of distinguished presence, bright, attractive countenance, with well-chiselled features. His expression was radiant with intelligence and geniality, clearly reflecting the purity of his heart and the frank honesty of his purpose. Few have better deserved the confidence and appreciation of wisely discriminating friends, and few, indeed, have been more widely and heartily accorded it. From the beginning of his career Dr. Knight was everywhere welcomed among those whose good opinions were most worth having and whose social standing was actually the best.

With him every additional talent, every accession of influence was but another instrument with which to increase his efficiency in those fields of philanthropic work, which, up to the very end, he so unselfishly and so earnestly cultivated.

Devoted to the interests of those individuals who sought his advice and care, he was no less generous with his energy and time to the general medical and charitable interests of the State. In these he was an able leader, a counsellor of ripe experience and of sound judgment.

His career seems to have been one of singular evenness. As far as one may judge, no overwhelming misfortune, temptation or trial ever fell to his lot. On the contrary, he was able to work out a high degree of success under conditions that appeared ideal. No one acquainted with him was ever other than his staunch friend.

Thus, in brief, we have traced the outlines of a life well endowed with rare personal qualities, replete with opportunity for the betterment of humanity promptly recognized and vigorously



embraced, full of those traits which cause us to love and honor the possessor and to regard him as truly great.

His life was like the story of a day in June, for its atmosphere was throughout genial, its hours perfection and not until its matchless sunset came the end, an end peaceful, beautiful, gentle, the exquisite finish of a perfectly rounded career.

D. B. D.

**PUBLICATIONS OF FREDERICK IRVING KNIGHT**

(NOT INCLUDED IN THE TRANSACTIONS OF THE A. L. A.).

Case of Graves disease with autopsy; Boston Med. & Surg. Jour.....	1868
Remarks on cases of thoracic disease; Boston Med. & Surg. Jour....	1868
Two cases of paralysis of intrinsic muscles of larynx; Boston Med. & Surg. Jour.....	1869
An addition to Cammann's binaural stethoscope; Boston Med. & Surg. Jour. ....	1869
Recovery from pneumothorax in a case of incipient pthisis without pleuritic effusion; Boston Med. & Surg. Jour.....	1869
Is the safety-valve function of the right ventricle sometimes the cause of transient systolic murmur? Boston Med. & Surg. Jour.....	1869
Bilateral paralysis of abductors of the vocal cords in a case of syphilis; case; Boston Med. & Surg. Jour.....	1869
Report of diseases of the throat; Boston Med. & Surg. Jour.....	1872-83
Clinical lecture on diseases of the throat; Boston Med. & Surg. Jour..	1873
Methods of removing growths from the larynx; Boston Med. & Surg. Jour. ....	1873
Case of complete paralysis of recurrent and partial of the other, etc.; Arch. of Elect. & Neurol., Vol. I.....	
Reports on diseases of the chest; Boston Med. & Surg. Jour....	1874-1883
Action of the soft palate in speaking and swallowing; Boston Med. & Surg. Jour. ....	1874
A remarkable complication of so-called catarrhal pneumonia; Boston Med. & Surg. Jour.....	1875
Laryngoscopic clinic at the Massachusetts General Hospital; Boston Med. & Surg. Jour.....	1875
Case of anaemia following a blow on the occiput; Boston Med. & Surg. Jour. ....	1877
Foreign body in the base of the tongue; Boston Med. & Surg. Jour..	1878
Aneurism of the aorta; Boston Med. & Surg. Jour.....	1878
Lymphosarcoma of the neck involving the lung; Boston Med. & Surg. Jour. ....	1878
Abscess of the liver opening into the lung; recovery; Boston Med. & Surg. Jour. ....	1879
The dangers of thoracentesis and injections into the pleural cavity; Boston Med. & Surg. Jour.....	1880
Chorea of the hyo-thyroid muscles; Arch. of Laryn.....	1880
Acute idiopathic inflammation of the thyroid gland; Arch. of Laryn..	1880
Treatment of posterior hypertrophy of inferior turbinates; Phila. Med. News .....	1882
Opening address at the first annual meeting American Clinical Association; N. Y. Med. Jour.....	1884

Three cases of lupus of pharynx and larynx; Arch. of Laryn.....	1881
Case of rheumatic (?) paralysis of the right vocal cord, gradual recovery; nine years later paralysis of the left cord, gradual recovery; Arch. of Laryn.....	1883
Disappearance of trachoma of vocal cord without treatment; Arch. of Laryn. ....	1883
Traumatic paralysis of the posterior arytenoid muscle; Arch. of Laryn. ....	1883
Chronic nasal catarrh; removal of hypertrophied tissue; Boston Med. & Surg. Jour.....	1884
Laryngeal complications of pulmonary phthisis; Boston Med. & Surg. Jour. ....	1884
Cocaine hydrochlorate in the larynx; Boston Med. & Surg. Jour....	1884
Recent methods of treating hay fever; Boston Med. & Surg. Jour....	1885
Is tuberculosis of the lungs contagious? Boston Med. & Surg. Jour....	1887
On the selection of a climate for patients with pulmonary tuberculosis; Boston Med. & Surg. Jour.....	1888
Case of bronchial asthma apparently caused by foreign body in the lung; Boston Med. & Surg. Jour.....	1889
The climatic treatment of bronchial asthma; Phila. Med. News.....	1889
The rational treatment of bronchial asthma; Boston Med. & Surg. Jour. ....	1890
Two cases of suspected aneurism of aorta; autopsies; Boston Med. & Surg. Jour.....	1891
On the return of cured tuberculosis patients from high altitude; The Sanatorium ....	1891
Presidential address, Am. Clim. Ass'n; Trans. Am. Clim. Ass'n.....	1891
Altitude in affections of the heart; Trans. Am. Clim. Ass'n.....	1892
Legal control of tuberculosis; Trans. Am. Clim. Ass'n.....	1894
Choice of a summer residence in New England; Trans. Am. Clim. Ass'n ....	1897
Common errors of general practitioners in dealing with cases of pulmonary tuberculosis; Boston M. & S. J., CXXXIX., 485, 496.....	1898
Common errors of general practitioners in dealing with cases of pulmonary tuberculosis; Trans. Am. Clim. Ass'n.....	1898
Exhibition of specimen of polyp of cord; Boston M. & S. J., CXXXVIII., 8 .....	1898
Climate in pulmonary tuberculosis; Boston M. & S. J., CXLIV., 52-53..	1901
What shall we do with patients having pulmonary tuberculosis? Boston M. & S. J., CLI., 257-259.....	1901
What shall we do with patients having pulmonary tuberculosis? Trans. Am. Clim. Ass'n, XX., 360-363.....	1904
Municipal care of the consumptive poor; Boston Med. & Surg. Jour., CXLIV., 499-500 .....	1901
Climate a factor in the treatment of tuberculosis; Boston Med. & Surg. Jour. ....	1906
Importance of supervision of apparently cured tuberculosis patients after they leave sanatoria; J. Am. Med. Assoc., XLIV., 328.....	1907
Comparative importance of treatment in sanatoria near at hand and entire change of climate: Trans. International Tuberculosis Congress, Washington, D. C., September.....	1908

As nearly as has been ascertained the aggregate of Dr. Knight's publications was as follows:

1868-69, 7 papers; 1870-80, 17 papers; 1880-85, 14 papers; 1885-89, 7 papers; 1890-1907, 14 papers; about 70 in all.

**DR. EDGAR HOLDEN.**

After many years of suffering from attacks of angina pectoris, Dr. Edgar Holden died from sequelae, following an attack of supposed ptomaine poisoning, on July 18, 1909, in the seventy-first year of his age, at his summer home in Chatham, N. J. He attended to his office duties until within a few days of his end.

He was born at Hingham, Mass., on November 3, 1838, and came of a distinguished Colonial ancestry. His early education was received at the Hingham Academy and later at Hunter's School, Jamaica, L. I. He prepared for Princeton University at the Pingry School, in Newark, entering the university in his sophomore year and received therefrom the degree of A. B. in 1859; later that of A. M., and still later, in 1872, that of Ph. D. from the same institution.

On leaving Princeton he began the study of medicine at the New York College of Physicians and Surgeons (now Columbia), and graduated therefrom in 1861. He became an interne in the Kings County (N. Y.) Hospital, and then entered, in 1861, the regular medical service of the United States Navy, serving in his professional capacity till the close of the Civil War. In the famous fight between the Monitor and the Merrimac he was on duty as Assistant Surgeon on the U. S. S. Minnesota. After the conflict he was placed in charge of the work of caring for the wounded, not only from the Minnesota, but also those from the Congress and the Cumberland.

He continued in the service, being present at many notable engagements, including that against the Confederate ram Albemarle, serving at the time on the Sassacus. In 1864, owing to ill-health, he resigned from the navy and accepted a commission as surgeon in the United States Army Volunteer Service, becoming a member of the staff of the Ward Hospital, in Newark, N. J.

At the close of the war he established himself in civil practice in Newark and soon became one of the leading medical men in New Jersey. In 1867 he became identified with the medical de-

partment of the Mutual Benefit Life Insurance Company, of Newark, being elected in 1870 president of the Medical Board, which office he held the remainder of his life. In 1891 failing health compelled him to curtail his professional activities and he retired as an active practitioner.

At a meeting of this Association held in New York, June 10, 1879, his name, together with those of ten others, was added to the list of original Fellows who organized in Buffalo in June, 1878. He was elected a Vice-President in 1889. In 1894 he signified his desire to resign from the Association and his name was transferred to the corresponding list on May 30 of that year. Our Transactions contain the following contributions from his pen: Chorea Laryngis, 1884, 128. Gummatous Disease of the Larynx, 1886, 142. A Possible Substitute for Tracheotomy and Intubation in Certain Cases, 1888, 30. A Flexible Curette, 1890, 126.

He was a voluminous contributor to various medical and other scientific journals. His essay on "The Sphygmograph" received the Stevens Triennial Prize of his medical alma mater, the College of Physicians and Surgeons, and was subsequently published in book form. Other contributions (place and date of publication not obtainable) include the following:

- "Use of the Sphygmograph."
- "Potential Factors in the Spread of Tuberculosis."
- "Ostracism for Consumptives."
- "Contribution to the Study of Chorea Laryngis."
- "Unison Resonance in Auscultation."
- "Pharyngeal Neurosis Due to Uterine Disease."
- "Relation of Cancer and Tuberculosis."
- "Is Consumption Contagious?"
- "Health and Mortality of Newark for Twenty Years."
- "Selection of Lives for Insurance."
- "House Heating, Sanitary and Unsanitary."

His naval life furnished the incidents for the following articles:

- "Cruise of the Monitor Passaic."
- "Cruise of the Sassacus."
- "Chapter on the Coolie Trade."
- "Battle With the Ram, Albemarle," and others.

He also wrote the following books :

"Refra."

"E. Stella."

"The Atlantid."

"The Waif of Minot's Ledge."

"The Wreck of the Cohasset Train."

"The Ghost of Nantasket Beach."

In the days of his professional activity he was consulting surgeon to St. Michael's and St. Barnabas's Hospitals and the Eye and Ear Infirmary, of Newark. At the time of his death he was a member of the following organizations: Association of Medical Directors of Life Insurance Companies, New Jersey State Medical Society, Essex County (N. J.) Medical Society, Newark Medical and Surgical Society, New Jersey Academy of Medicine, New Jersey Microscopical Society, New Jersey Historical Society, American Medical Association, American Laryngological Association, American Authors' Guild, Military Society of the Loyal Legion; was an hereditary member of the Society of the Cincinnati, and a member of the Grand Army of the Republic—  
Marcus L. Ward Post.

Dr. Holden was twice married. His first wife was Miss Katharine Hedden, of East Orange, N. J., whom he married in 1862. She died in 1870, and in 1873 he married Miss Helen Stewart Burgess, of Orange. The latter, with two sons and three daughters, survive him.

J. E. N.

### DR. CARLO LABUS.

Announcement is made of the death of Dr. Carlo Labus, who died recently in Milan from acute perityphlitis. He was the son of a famous sculptor and the nephew of a distinguished archaeologist. At the age of twenty-one he received his medical degree at the medical school in Pavia; he served in the war between Italy and Austria, returning to Milan, where he speedily took a leading part in all matters relative to public health and medical education. He was a pioneer in laryngology in his native land, and in 1878 was recognized as docent in the University of Pavia. In 1880 he took the initial steps which resulted in the first International Congress of Laryngology ever assembled. He was a member of many scientific societies, being chosen in 1881 a Cor-



responding Fellow of our own Association. In literature he was the Nestor of Italian Laryngology. In the *Archivio Italiano di Otologia, Rinologia e Laringologia*, vol. xx, 5 fascicolo 1909, is a list of his writings from 1871 to 1901 containing 37 titles. Failing health since the latter year had circumscribed his activities, but his mind remained clear and active to the last, and he was keenly appreciative of the advances of modern laryngology.

J. E. N.

## ACTIVE FELLOWS.

1910.

1906. BALLENGER, WILLIAM L., Columbus Memorial Building,  
Chicago, Ill.
1908. BARNHILL, JOHN F., 323 North Delaware St., Indianapo-  
lis, Ind.
1880. BEAN, C. E., Germania Life Bldg., St. Paul, Minn.
1904. BERENS, T. PASSMORE, 35 Park Ave., New York.
1893. BIRKETT, HERBERT S., 252 Mountain St., Montreal.
1893. BLISS, ARTHUR AMES, 117 South 20th St., Philadelphia,  
Pa.
1878. BOSWORTH, FRANCKE H., 41 Park Ave., New York.
1901. BROWN, J. PRICE, 37 Carlton St., Toronto, Can.
1892. BROWN, MOREAU R., 34 Washington St., Chicago, Ill.
1891. BRYAN, JOSEPH H., 818 17th St., Washington, D. C.
1889. CASSELBERRY, WILLIAM E., 34 Washington St., Chicago,  
Ill.
1896. CHAPPELL, WALTER F., 7 East 55th St., New York.
1897. CLARK, J. PAYSON, 71 Marlborough St., Boston, Mass.
1902. COAKLEY, CORNELIUS G., 53 West 56th St., New York.
1899. COBB, FREDERIC C., 11 Marlborough St., Boston, Mass.
1905. COFFIN, LEWIS A., 156 West 58th St., New York.
1878. COHEN, J. SOLIS, 1824 Chestnut St., Philadelphia, Pa.
1893. COOLIDGE, ALGERNON, JR., 613 Beacon St., Boston, Mass.
1882. DEBLOIS, THOMAS AMORY, 48 Gloucester St., Boston,  
Mass.
1881. DELAVAN, D. BRYSON, 1 East 33d St., New York.
1892. FARLOW, JOHN W., 234 Clarendon St., Boston, Mass.
1901. FREEMAN, WALTER J., 1832 Spruce St., Philadelphia, Pa.
1905. FREER, OTTO T., 34 Washington St., Chicago, Ill.
1879. FRENCH, THOMAS R., 150 Joralemon St., Brooklyn, N. Y.

1897. FROTHINGHAM, RICHARD, Sydenham Bldg., Madison Ave., and 58th St., New York.
1909. GETCHELL, ALFRED C., 6 Linden St., Worcester, Mass.
1907. GIBB, JOSEPH S., 1907 Chestnut St, Philadelphia, Pa.
1880. GLEITSMANN, JOSEPH W., Sydenham Building, Madison Ave. and 58th St., New York.
1898. GOODALE, JOSEPH L., 258 Beacon St., Boston, Mass.
1905. GRAYSON, CHARLES P., 251 South 16th St., Philadelphia, Pa.
1906. GREENE, D. CROSBY, JR., 483 Beacon St., Boston, Mass.
1905. HALSTED, THOMAS H., 831 University Block, Syracuse, N. Y.
1896. HARDIE, T. MELVILLE, 34 Washington St., Chicago, Ill.
1903. HARRIS, THOMAS J., 117 East 40th St., New York.
1878. HARTMAN, JACOB H., 5 West Franklin St., Baltimore, Md.
1888. HINKEL, F. WHITEHILL, 581 Delaware Ave., Buffalo, N. Y.
1907. HOLMES, CHRISTIAN R., 8 East 8th St., Cincinnati, Ohio.
1893. HOPE, GEORGE B., 133 West 72d St., New York.
1895. HOPKINS, FREDERICK E., 25 Harrison Ave., Springfield, Mass.
1895. HUBBARD, THOMAS, 541 Nicholas Building, Toledo, Ohio.
1901. HYATT, FRANCK, 1022 14th St., N. W., Washington, D. C.
1878. INGALS, E. FLETCHER, 36 Washington St., Chicago, Ill.
1904. INGERSOLL, JOHN M., 318 Euclid Ave., S. E., Cleveland, Ohio.
1882. IVES, FRANK L., 117 East 30th St., New York.
1907. JACKSON, CHEVALIER, 1018 Westinghouse Building, Pittsburgh, Pa.
1878. JOHNSTON, SAMUEL, 204 West Monument St., Baltimore, Md.
1901. KING, GORDON, 624 Gravier St., New Orleans, La.
1885. KNIGHT, CHARLES H., the St. Hubert, 120 West 57th St., New York.
1898. KYLE, D. BRADEN, 1517 Walnut St., Philadelphia, Pa.
1880. LANGMAID, SAMUEL W., 277 Dartmouth St., Boston, Mass.
1878. LEFFERTS, GEORGE MOREWOOD, 212 Madison Ave., New York.

1894. LELAND, GEORGE A., 354 Commonwealth Ave., Boston, Mass.
1903. LINCOLN, WILLIAM, 210 Lennox Bldg., Cleveland, Ohio.
1897. LOGAN, JAMES E., 1208 Wyandotte St., Kansas City, Mo.
1888. LOWMAN, JOHN H., 1807 Prospect Ave., S. E., Cleveland, Ohio.
1886. MACCOY, ALEXANDER W., 216 South 15th St., Philadelphia, Pa.
1883. MACKENZIE, JOHN N., 605 Washington Place, Baltimore, Md.
1898. MAKUEN, G. HUDSON, 1627 Walnut St., Philadelphia, Pa.
1896. MAYER, EMIL, 25 East 77th St., New York.
1899. MCKERNON, JAMES F., 62 West 52d St., New York.
1904. MOSHER, HARRIS P., 828 Beacon St., Boston, Mass.
1901. MYLES, ROBERT C., 46 West 38th St., New York.
1893. NEWCOMB, JAMES E., 118 West 69th St., New York.
1903. PACKARD, FRANCIS R., 304 South 19th St., Philadelphia, Pa.
1906. PIERCE, NORVAL H., 31 Washington St., Chicago, Ill.
1878. PORTER, WILLIAM, 3886 Washington Ave., St. Louis, Mo.
1908. RANDALL, B. ALEXANDER, 1717 Locust St., Philadelphia, Pa.
1903. RENNER, W. SCOTT, 361 Pearl St., Buffalo, N. Y.
1897. RHODES, J. EDWIN, 100 State St., Chicago, Ill.
1884. RICE, CLARENCE C., 123 East 19th St., New York.
1905. RICHARDS, GEORGE L., 84 North Main St., Fall River, Mass.
1902. RICHARDSON, CHARLES W., 1317 Connecticut Ave., Washington, D. C.
1893. ROALDES, ARTHUR W. DE, 624 Gravier St., New Orleans, La.
1879. ROE, JOHN O., 44 Clinton Ave. South, Rochester, N. Y.
1907. SHAMBAUGH, GEORGE E., 100 State St., Chicago, Ill.
1909. SHURLY, BURT R., 32 Adams Ave. W., Detroit, Mich.
1878. SHURLY, ERNEST L., 32 Adams Ave. W., Detroit, Mich.
1909. SLUDER, GREENFIELD, 3542 Washington Ave., St. Louis, Mo.

1892. SIMPSON, WILLIAM K., 952 Lexington Ave., New York.  
1908. SMITH, HARMON, 44 West 49th St., New York.  
1889. SWAIN, HENRY L., 232 York St., New Haven, Conn.  
1903. THEISEN, CLEMENT F., 172 Washington Ave., Albany,  
N. Y.  
1892. THRASHER, ALLEN B., The Groton, 7th and Race Sts.,  
Cincinnati, Ohio.  
1892. WAGNER, HENRY L., Pacific Union Club, San Francisco,  
Cal.  
1892. WATSON, ARTHUR W., 126 South 18th St., Philadelphia,  
Pa.  
1908. WILSON, J. GORDON, Dept. Anatomy, University of Chi-  
cago, Chicago, Ill.  
1906. WINSLOW, JOHN R., 114 West Franklin St., Baltimore,  
Md.  
1905. WOOD, GEORGE B., 129 South 18th St., Philadelphia, Pa.  
1890. WRIGHT, JONATHAN, 44 West 49th St., New York.

#### HONORARY FELLOWS.

1909. FRAENKEL, PROF. B., Lenne'strasse 5, Berlin W. 9, Ger-  
many.  
1909. SEMON, SIR FELIX, 39 Wimpole St., Cavendish Square,  
London W., England.

#### CORRESPONDING FELLOWS.

1880. BRUNS, PAUL, Tübingen, Württemberg, Germany.  
1896. CHIARI, OTTO KAR, Bellariastrasse 12, Vienna, Austria.  
1901. COLLIER, MAYO, 145 Harley St., Cavendish Square, Lon-  
don W., England.  
1890. DE LA SOTA Y LASTRA, R., 7 Calle de Torqueros, Seville,  
Spain.  
1893. DESVERNINE, C. M., Cuba 52, Havana, Cuba.  
1901. GRANT, DUNDAS, 18 Cavendish Square, London W., Eng-  
land.  
1902. HEYMAN, PAUL, 60 Lützowstrasse, Berlin W., Germany.



1908. KILLIAN, GUSTAV, Freiburg-im-Breisgau, Germany.  
1892. KRAUSE, H., San Remo, Italy.  
1902. LERMOYEZ, MARCEL, 20 Rue de la Boetie, Paris, France.  
1897. LUC, H., 54 Rue de Varenne, Paris, France.  
1903. MCBRIDE, P., 16 Chester St., Edinburgh, Scotland.  
1896. MACDONALD, GREVILLE, 85 Harley St., Cavendish Square,  
London W., England.  
1894. MACINTYRE, JOHN, 179 Bath St., Glasgow, Scotland.  
1892. MASSEI, F., 4 Piazza Municipio, Naples, Italy.  
1887. MOURE, E. J., 25 Cours du Jardin-Public, Bordeaux,  
France.  
1896. MYGIND, HOLGER, 31 Havnegade, Copenhagen, Denmark.  
1901. NATIER, MARCEL, 12 Rue Caumartin, Paris, France.  
1903. ONODI, A., o'Uctza 12, Buda-Pesth, Hungary.  
1894. SAJOUS, C. E., 2043 Walnut St., Philadelphia, Pa.  
1896. SCHMIEGELOW, ERNEST, 18 Nørregade, Copenhagen, Den-  
mark.  
1902. THOMSON, ST. CLAIR, 28 Queen Anne St., Cavendish  
Square, London W., England.  
1903. TILLEY, HERBERT, 72 Harley St., Cavendish Square, Lon-  
don W., England.  
1901. WINGRAVE, WYATT, 11 Devonshire St., Portland Place,  
London W., England.  
1894. WOLFENDEN, R. NORRIS, 76 Wimpole St., Cavendish  
Square, London W., England.

## PAST OFFICERS.

*Presidents.*

(Year of Election.)

1879.	Louis Elsberg.	1894.	J. O. Roe.
1880.	J. Solis-Cohen.	1895.	W. H. Daly.
1881.	F. I. Knight.	1896.	C. H. Knight.
1882.	G. M. Lefferts.	1897.	T. R. French.
1883.	F. H. Bosworth.	1898.	W. E. Casselberry.
1884.	E. L. Shurly.	1899.	Samuel Johnston.
1885.	Harrison Allen.	1900.	H. L. Swain.
1886.	E. Fletcher Ingals.	1901.	J. W. Farlow.
1887.	R. P. Lincoln.	1902.	J. H. Bryan.
1888.	E. C. Morgan.	1903.	J. H. Hartman.
1889.	J. N. Mackenzie.	1904.	C. C. Rice.
1890.	W. C. Glasgow.	1905.	J. W. Gleitsmann.
1891.	S. W. Langmaid.	1906.	A. W. de Roaldes.
1892.	M. J. Asch.	1907.	H. S. Birkett.
1893.	D. B. Delavan.	1908.	A. Coolidge, Jr.

*Vice-Presidents.*

1879.	F. H. Davis.
1880.	W. C. Glasgow, J. O. Roe.
1881.	E. L. Shurly, W. Porter.
1882.	C. Seiler, E. F. Ingals.
1883.	S. W. Langmaid, S. Johnston.
1884.	J. H. Hartman, W. H. Daly.
1885.	H. A. Johnson, G. W. Major.
1886.	E. C. Morgan, J. N. Mackenzie.
1887.	J. N. Mackenzie, S. W. Langmaid.
1888.	W. C. Glasgow, C. E. Sajous.
1889.	E. Holden, C. E. Bean.
1890.	J. O. Roe, J. H. Hartman.

1891. M. J. Asch, S. Johnston.  
1892. S. Johnston, J. C. Mulhall.  
1893. J. C. Mulhall, W. E. Casselberry.  
1894. C. C. Rice, S. H. Chapman.  
1895. J. Wright, A. W. de Roaldes.  
1896. T. M. Murray, D. N. Rankin.  
1897. A. W. MacCoy, H. S. Birkett.  
1898. J. W. Farlow, F. W. Hinkel.  
1899. T. A. DeBlois, M. R. Brown.  
1900. H. L. Wagner, A. A. Bliss.  
1901. J. W. Gleitsmann, D. Braden Kyle.  
1902. G. A. Leland, T. Melville Hardie.  
1903. J. H. Lowman, W. Peyre Porcher.  
1904. Thomas Hubbard, W. J. Freeman.  
1905. J. L. Goodale, C. W. Richardson.  
1906. G. H. Makuen, A. B. Thrasher.  
1907. J. P. Clark, J. E. Rhodes.  
1908. E. Mayer, F. R. Packard.

*Secretaries and Treasurers.*

- |                       |                     |
|-----------------------|---------------------|
| 1879. G. M. Lefferts. | 1889. C. H. Knight. |
| 1882. D. B. Delavan.  | 1895. H. L. Swain.  |
| 1900. J. E. Newcomb.  |                     |

*Librarians.*

- |                       |                     |
|-----------------------|---------------------|
| 1879. F. H. Bosworth. | 1883. T. R. French. |
| 1903. J. H. Bryan.    |                     |

## PAST MEMBERS.

*Honorary Fellows.*

- \*1880. Senor Manuel Garcia, London, England.
- \*1883. Sir Morell Mackenzie, London, England.
- \*1907. Leopold von Schroetter, Vienna, Austria.

*Corresponding Fellows.*

- \*1892. Lennox Browne, London, England.
- †1904. B. Fraenkel, Berlin, Germany.
- \*1887. A. Gouguenheim, Paris, France.
- \*1894. Edgar Holden, Newark, N. J.
- \*1881. Carlo Labus, Milan, Italy.
- \*1880. Wilhelm Meyer, Copenhagen, Denmark.
- \*1901. Schmidt, Moritz, Frankfort-a-Main, Germany.
- †\*1881. Schroetter, Leopold von, Germany.
- †1881. Sir Felix Semon, London, England.
- \*1881. Pugin Thorton, London, England.
- \*1881. R. Voltolini, Breslau, Germany.
- \*1880. W. McNeil Whistler, London, England.

*Active Fellows.*

- \*1880. Harrison Allen, Philadelphia, Pa.
- \*1878. Morris J. Asch, New York.
- 1895. J. E. Boylan, Cincinnati, Ohio.
- \*1883. C. W. Chamberlain, Hartford, Conn.
- \*1882. S. Hartwell Chapman, New Haven, Conn.
- 1884. S. Solis-Cohen, Philadelphia, Pa.
- 1880. E. W. Cushing, Boston, Mass.
- 1878. Ephraim Cutter, West Falmouth, Mass.
- \*1880. W. H. Daly, Pittsburg, Pa.
- \*1878. F. H. Davis, Chicago, Ill.
- \*1901. E. T. Dickerman, Chicago, Ill.
- \*1878. Frank Donaldson, Baltimore, Md.

- \*1886. Frank Donaldson, Jr., Baltimore, Md.
- \*1879. J. H. Douglas, New York City.
- \*1879. W. F. Duncan, New York City.
- \*1878. Louis Elsberg, New York City.
- \*1878. William Carr Glasgow, St. Louis, Mo.
- 1881. Urban G. Hitchcock, Poughkeepsie, N. Y.
- †\*1879. Edgar Holden, Newark, N. J.
- \*1882. Franklin H. Hooper, Boston, Mass.
- \*1878. Hosmer A. Johnson, Chicago, Ill.
- \*1879. Woolsey Johnson, New York City.
- \*1880. William C. Jarvis, New York City.
- 1879. R. H. Kealhofer, St. Louis, Mo.
- \*1878. Frederick I. Knight, Boston, Mass.
- \*1878. Rufus P. Lincoln, New York City.
- 1881. G. W. Major, Montreal, Canada.
- 1879. Charles McBurney, New York City.
- 1885. H. Clinton McSherry, Baltimore, Md.
- \*1881. E. C. Morgan, Washington, D. C.
- \*1886. J. C. Mulhall, St. Louis, Mo.
- 1892. T. Morris Murray, Washington, D. C.
- \*1881. H. Mynter, Buffalo, N. Y.
- \*1895. J. E. H. Nichols, New York City.
- 1879. H. K. C. Oliver, Boston, Mass.
- 1894. William H. Park, New York City.
- 1892. W. Peyre Porcher, Charleston, S. C.
- \*1880. D. N. Rankin, Allegheny, Pa.
- 1881. J. M. Robertson, Detroit, Mich.
- 1878. Beverly Robinson, New York City.
- \*1878. T. F. Rumbold, St. Louis, Mo.
- †1880. Charles E. Sajous, Paris, France.
- \*1879. Carl Seiler, Scranton, Pa.
- \*1893. Charles M. Shields, Richmond, Va.
- 1879. Andrew H. Smith, Geneva, N. Y.
- 1879. Bernhard Tauber, Cincinnati, Ohio.
- \*1899. Max Thorner, Cincinnati, Ohio.
- 1888. S. O. Van der Poel, New York City.
- 1878. Clinton Wagner, New York City.



1896. Marshall R. Ward, Pittsburg, Pa.

1879. Whitfield Ward, New York City.

\*1886. Benjamin F. Westbrook, Brooklyn, N. Y.

1896. Greene V. Woollen, Indianapolis, Ind.

---

\*Deceased. †Corresponding Fellow. ‡Honorary Fellow.











RF            American Laryngological  
l            Association  
A5           Transactions of the  
v.31        annual meeting  
Biological  
& Medical  
Serials

PLEASE DO NOT REMOVE  
CARDS OR SLIPS FROM THIS POCKET

---

UNIVERSITY OF TORONTO LIBRARY

---

STORAGE

