


---

This is a reproduction of a library book that was digitized by Google as part of an ongoing effort to preserve the information in books and make it universally accessible.

Google<sup>TM</sup> books

<https://books.google.com>





S. R. C.











# TRANSACTIONS

OF THE

## Thirty-fourth Annual Meeting

OF THE

## American Laryngological Association

HELD AT

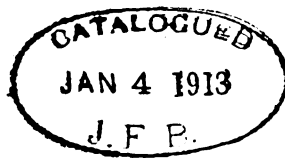
ATLANTIC CITY, N. J.

*May 9th, 10th and 11th, 1912*


NEW YORK

PUBLISHED BY THE ASSOCIATION

1912



THE McCONNELL PRINTING CO.  
230-242 WILLIAM STREET, NEW YORK



## OFFICERS

(ELECTED MAY 31, 1911.)

*PRESIDENT,*  
JAMES E. NEWCOMB, M.D.

*FIRST VICE-PRESIDENT,*  
F. E. COBB, M.D.

*SECOND VICE-PRESIDENT,*  
B. R. SHURLY, M.D.

*SECRETARY AND TREASURER,*  
HARMON SMITH, M.D.

*LIBRARIAN,*  
JOSEPH H. BRYAN, M.D.

*COUNCIL.*

THE ABOVE EX-OFFICIO AND

HERBERT S. BIRKETT, M.D., MONTREAL, CANADA.  
ALGERNON COOLIDGE, JR., M.D., BOSTON, MASS.  
JAMES E. LOGAN, M.D., KANSAS CITY, MO.  
D. BRADEN KYLE, M.D., PHILADELPHIA, PA.

## TABLE OF CONTENTS

---

	PAGE.
President's Address. JAMES E. NEWCOMB, M.D. . . . .	I


### *Papers:*

I. "Orbital Abscess from Infection Through the Ethmoid."	
JOHN O. ROE, M.D. . . . .	12
II. "Anatomy and Surgery of Ethmoidal Labyrinth." HARRIS	
P. MOSHER, M.D. . . . .	25
III. "Some Anatomical and Clinical Relations of the Cavernous Sinus and the Third, Fourth, Fifth, Sixth and Vidian Nerves." GREENFIELD SLUDER, M.D. . . . .	46
IV. "The Anatomy of Deflections of the Nasal Septum."	
OTTO FREER, M.D. . . . .	71
V. "Anæsthesia for Peroral Endoscopy." CHEVALIER JACKSON, M.D. . . . .	88
VI. "The Aphthous Ulceration in Tuberculosis of the Upper Air Passages." JOHN N. MACKENZIE, M.D. . . . .	101
VII. "Traumatic Paralysis of the Right Recurrent Laryngeal Nerve. Report of Two Cases." D. BRYSON DELAVAN, M. D. . . . .	114
VIII. "When Should Singers Having Vocal Disability Be Allowed to Resume Work?" CLARENCE C. RICE, M.D. . . . .	119
IX. "Salvarsan in Tertiary Syphilis of the Nose and Throat." JOSEPH L. GOODALE, M.D. . . . .	127
X. "Salvarsan in Syphilis of the Nose and Throat." DRs. POST, COBB and KNOWLES. . . . .	143

	PAGE
XI. "The Upright Position in Ether Operations Upon the Nose, Throat and Other Portions of the Head, with Demonstration of a New Method for Attaining the Position with Expedition, Ease and Safety." THOMAS R. FRENCH, M.D. . . . .	148
XII. "Complications of Tonsillectomy." CHARLES W. RICHARDSON, M.D. . . . .	170
XIII. "The Middle Turbinated Body: Indications for Its Treatment or Removal." W. SCOTT RENNER, M.D. . . . .	198
XIV. "Vincent's Angina: Its Frequency and the Importance of Its Diagnosis." THOMAS H. HALSTED, M.D. . . . .	216
XV. "Morphological Changes in the Nose and Face, Due to the Development of the Brain." (Lantern pictures.) JOHN M. INGERSOLL, M.D. . . . .	232
XVI. "The Question of Post-operative Nasal Packing in the Light of Additional Experience with the Author's Rubber Tampon." WILLIAM E. CASSELBERRY, M.D. . . . .	244
XVII. "The Ozena Investigation in the United States." EMIL MAYER, M.D. . . . .	250
XVIII. "Coryza and Respiratory Gymnastics." MARCEL NATIER, M.D. . . . .	256
XIX. "Contribution to the Pathogenesis of Bronchial Asthma." HENRY L. WAGNER, M.D. . . . .	265
XX. "Malignant Diseases of the Upper Air Passages, with Notes Upon Two Cases of Epithelioma." J. PRICE BROWN, M.D. . . . .	268
XXI. "Report of a Case of (a) Hæmophilia Successfully Treated by Transfusion; (b) Nasal Sarcoma." WALTER F. CHAPPELL, M.D. . . . .	282
XXII. "Report of a Case of Bronchoscopy for Multiple Foreign Bodies (almond shell and pulp) in a Child Two Years of Age with Some Observations Upon Bronchoscopy in Infants and Young Children." JOHN R. WINSLOW, M.D. . . . .	290
XXIII. "A Case of Myxo-fibroma of the Naso-pharynx." JOSEPH H. BRYAN, M.D. . . . .	302



	PAGE
XXIV. "Report of a Case of Rhino-pharyngeal Fibroma." JOSEPH H. GIBB, M.D. . . . .	306
XXV. "Two Cases of Exudative Laryngeal Growths: (a) Malignant, (b) Tubercular." W. KELLY SIMPSON, M.D.	318
XXVI. "Report of a Case of Carcinoma of the Larynx, Re- moved by Operation." FRANCIS R. PACKARD, M.D. .	329
Report of the Secretary . . . . .	332



TRANSACTIONS OF THE THIRTY-FOURTH ANNUAL  
MEETING OF THE AMERICAN LARYN-  
GOLOGICAL ASSOCIATION,

HELD AT ATLANTIC CITY, N. J.,

MAY 9TH, 10TH AND 11TH, 1912.

---

THE PRESIDENT'S ADDRESS.

BY JAMES E. NEWCOMB.

*Fellows of the American Laryngological Association:*

For the third time in our history, the council has seen fit to meet here in this city by the sea. On this, the occasion of our thirty-fourth annual meeting, it is my pleasure to greet you with great cordiality. As an association we have passed the limit of age allotted to one generation of men. Our series of annual scientific gatherings, as attested by our published transactions, has been unbroken. Our limit of active fellowship has gradually risen from thirty to one hundred, and many still knock at our door.

It cannot be said that during the year just elapsed there have been any startlingly new discoveries in our branch of the medical field; rather has there been a steady clearing up of ground already occupied. Another international congress in our special field has been held, and the association was formally represented by Dr. Simpson, who will report to us at the present session. In addition, four other members were present. One action taken at the congress calls for special mention. A motion made by Dr. Alexander, of Berlin, called for a collective investigation, along national lines, of the subject of ozena. It was felt by some of us Americans present, that this was not essentially an American disease. Yet we

thought that the committee in Berlin which had sent out a call for an American opinion, and had appointed our colleague, Dr. Emil Mayer, the American representative on the committee, deserved a courteous response. Accordingly, after consultation with Dr. Mayer, I appointed Dr. Robert C. Myles and Dr. Harmon Smith to act as a committee with Dr. Mayer to represent the association in any work that might be undertaken. I presume that Dr. Mayer's paper, scheduled for our closing session, will acquaint us with the present status of the question.

At the outset, the Association, in Emersonian phrase, "hitched its wagon to a star." It has never lost sight of its high ideal. In 1879 Elsberg enumerated twenty-five men who might be looked upon as the laryngologists of the United States. Of these, two taught laryngology exclusively. All the others included some other branch, generally the ear or chest, in connection therewith. In his opening annual address, Elsberg stated the goal of the proposed new organization as follows: 1st, a more intimate personal acquaintance among the fellows; 2d, stated meetings for scientific discussion; 3d, the establishment of the then sadly-needed desideratum of a proper nomenclature of the various structures embraced in our specialty, and for the various diseases to which they are subject; 4th, the offering of a prize for original research; 5th, the preparation of official reports on important topics taken up by itself, or referred to it for the information of the general medical profession; 6th, the appointment of a committee to prepare a digest of the progress of laryngology reflected by the publications pertaining to our department; 7th, the collection of a special library; 8th, the endeavor to create an influence which should secure instruction in our department by thoroughly competent men in all schools of medicine, men whose whole study and practice are devoted to it.

Elsberg was certainly a man of broad vision, a wide outlook and painstaking spirit in all he set out to do. As Dr. E. L. Shurly wrote of him in his address, as President of the association, a quarter of a century ago: "Although of genial yet enthusiastic temperament, he was sharp and incisive in debate, with an insight so critical as to be able to detect the slightest inconsistency

or defect in the statement or work of a colleague, and with a mind powerful or courageous enough to broaden such defects into chapters of instruction." A noble tribute of one large-hearted man to another. Some of you knew Dr. Elsberg personally. To those of us of a later day, his name, though cherished and his work, though enormous and epoch-making, are merely historical. Let us see to it, gentlemen, that we are worthy of the heritage he has left us.

It remains for us to ask how his original and ambitious aims have been carried out as the years have flown by. Let me answer seriatim. The intimacy of acquaintance has been by universal testimony, ideal. Sessions for scientific discussion have been held in unbroken annual sequence. After a lapse of some years, a committee on nomenclature has been appointed and has submitted its report. Its universal acceptance awaits co-ordinate action by sister societies. It is difficult to make it entirely satisfactory to the United States Government officials, who conduct the Bureau of Vital Statistics, for they take cognizance only of diseases which may prove fatal, which is not the case with many of the maladies which fall to our lot.

A prize fund has been received from Dr. Roaldes, and arrangements made for the award of the prizes. I would call your attention to the fact that the fate of our sister society in finding essays worthy of the receipt of prizes offered by it, has not been at all encouraging. The preparation of official reports on professional topics coming before us has been practically provided for by the annual publication of our Transactions. The great growth of current literature, particularly of the abstract departments in the various journals, has rendered the appointment of a committee to report on the progress of laryngology needless. A library has been established, and, after various migrations, is securely housed with the Surgeon-General of the Army at Washington, accessible to our members. I would suggest the advisability of the publication of an inexpensive catalogue, with annual additions. The last catalogue was issued by Dr. French, the then librarian, in 1886-87. Lastly, no reputable medical school is without special instructors. If we allow for the change between conditions of to-

day and those of thirty-four years ago, I think we can well say that the ambitious projects of Elsberg have been well fulfilled and that we have been reasonably faithful to our trust.

The motto of the association is "Docendo discimus" (We learn by teaching). The unique peculiarity of our fellowship is that we are practically all teachers, either in the stall or at the bedside. The spirit of this motto has always been made much of by us. The oldest of national societies devoted to the study of throat and nose diseases properly chose a motto implying appreciation of its duties and obligations to the general medical profession. Various of my predecessors in the presidential office have spoken at length expressing sympathy with this view. In 1882, the late Dr. F. I. Knight thus wrote: "If the student neglects to acquire some practical familiarity in the use of the laryngoscope while attending the hospital he will probably never make the loss good afterward." Quoting again from Dr. Knight, "Our special concern is to consider how we can promote the teaching of laryngology in the schools in a sufficient amount for the general practitioner." I think it is well for us to emphasize this point, as each fall we come into relation with a new class of students. We shall not unduly magnify our office by so doing.

As near as I can learn, those actually present when the Association was founded numbered twenty-one. To them were added the names of eleven other gentlemen, and at the first annual meeting, June 12th, 1879, a motion was carried "that every Fellow of the American Laryngological Association at this date, be declared a founder." By the constitution, the Active fellowship was limited to fifty. Later it was increased to sixty; still later to seventy-five, and finally to one hundred, its present limit. It now is eighty-seven. Of the original founders seven are yet with us, and we hope they will long continue with us. As a matter of fact, they are all eligible for the new class of Retired Fellows, provided for in the new constitution. As far as I have been able to learn, there is no demand on the part of the present fellowship for an increased limit of the Active list above the present number. It is true that a former President has said, "It seems a question whether we have a right to exclude from our membership, what-

ever be its limit, any one who by the character of his work has shown his fitness to be one of our Fellows." But this opens a large question. Of the present eighty-seven Active Fellows, twenty-one are eligible for the retired list, and under the provision of Article X of the proposed new by-law, are exempt from discipline of the council if they do not attend or furnish a paper for three successive meetings, i. e., their exemption being based upon their twenty years' standing as Fellows. Hence the Association must depend for its working force upon eighty-seven, less twenty-one, or sixty-six men. During the years since 1900 the council has been lenient in enforcing this provision of the by-laws. Of course, the number of contributions varies from year to year, although we have always had an attractive program, but from an experience as secretary, which, through your recurring courtesy, has been nearly twice as long as that of any of my predecessors, I have remarked a growing reluctance on the part of some to contribute to the program, though they are regular in attendance and cheerfully take part in our discussions, yet, when approached on the subject of papers, get that familiar clinical condition known as "cold feet." They say, and we know, that their interest in the Association and its work has not waned, but realize that they have simply become less active in all their society activities.

Almost every one of my predecessors in the presidential office has referred to the fact that we are the oldest national body devoted to the study of nose and throat diseases. In estimating the relative position the Association holds to-day among kindred bodies, the changed condition of affairs between 1878 and 1912 must be taken into account, and looked squarely in the face. As long as the association had the field to itself, it went on with its initial velocity and enthusiasm, but it cannot live on alone, or rely on that for continued existence and activity. Gentlemen, we cannot live on our pedigree, pure though the strain may be. In every organization as old as ours, stagnation inevitably ensues unless new blood is from time to time infused. Where shall that new blood be found? The incorporation of the ear and its diseases into the field covered by so many laryngologists, renders it the exception

and not the rule to find any new man eligible, in the judgment of the council, who is not already a member of some national organization whose work is akin to ours. The establishment of the American Otological Society antedates our own. Yet you may be surprised to learn that no less than twenty-four of our Active Fellows are affiliated with it. In 1896 the American Laryngological, Rhinological and Otological Society was formed on the same general plan as our own, but having Eastern, Middle, Southern and Western sectional meetings, in addition to its annual convention, with an unlimited membership, and selecting, unfortunately for us, a name in some respects strongly suggestive of our own, as, indeed, they have a perfect right to do. As you will recall, we all were courteously invited to join. At the present date very nearly half our number belong to both organizations. Then there is the American Academy of Ophthalmology and Oto-Laryngology, originated in the West, on whose list of members I am told, although I have not seen it, we have a generous representation. Finally, there is the section of Laryngology and Otology of the American Medical Association with its unlimited membership. These various organizations offer between them a national forum for every one. We all of us agree that there are too many societies. Some of us are getting to a time of life when the tendency is to lighten rather than increase the burdens of society memberships. It is, I repeat, getting hard to find a new candidate with proper credentials, who is not already a member of some society kindred to our own. We cannot expect him to absolve himself from all his old obligations simply because he assumes new ones when invited to come with us. As the members of the council of the last eleven years well know, I have frequently expressed my conviction, when the question of candidates was before us, that a man's standing and excellence as an otologist are not the necessary credentials for the American Laryngological Association. Union of our association with any other I would strongly deprecate, although realizing that joint sessions may be, and in fact have been held with mutual profit. Our aim embraces the consideration and promotion of all that concerns the diseases of the upper air passages. Surely an aim broad enough to call

for our best efforts and most assiduous zeal. Many problems which we have often considered, and perhaps partially solved, yet confound us. The Association was christened the American Laryngological Association. It has met annually for thirty-five years without a break. The same number of printed volumes of Transactions lies upon the shelves of our libraries. The future historian of laryngology in America, must resort to its records for authentic facts, especially of the early days, for they are found nowhere else. The 757 papers already presented to it, embrace practically all the important discoveries that have been made in our own field. Indeed, in no small number of instances, particular papers have been chosen by their authors, as the medium of giving out new truths to the general profession. They may be read by us all with profit. Let us cherish them. Let the name bestowed upon us by our god-parents at our birth, be kept inviolate. Let there be one Laryngological Association devoted to nothing else.

It is a matter of mutual thanksgiving that our Active number has been unbroken by death during the year now closing. We chronicle the lamented demise of two of our former Active Fellows, Drs. Ives and Van der Poel. Dr. Frank Linsly Ives was elected in 1882 and died March 23 of the present year. He resigned on account of ill health in 1910, and gradually withdrew from all professional activities. His name will be remembered in our Transactions by a single paper, submitted in 1885, on "Submucous Laryngeal Hemorrhage Complicated with Cyst." At one time he was a member of the clinical staff of the New York Eye and Ear Infirmary. He was a good clinician and courteous gentleman, and will be greatly missed by his many friends. Of recent years he had rarely attended the annual meetings of the Association. Dr. Samuel Oakley Van der Poel was elected in 1888, resigned in 1905 and died April 23d of the current year. Of late years he had become the senior medical director of the New York Life Insurance Company, and had become engrossed with the laborious duties of that responsible position. Our index of Transactions shows him to have contributed two papers: one on "A Case of Myxoma of the Epiglottis," in 1890, and one on "Some Observa-



tions on Laryngeal Tuberculosis," in 1896. For some years of his active laryngological life, he was connected with the Manhattan Eye and Ear Hospital, in New York City. Since 1895 he had not met with the Association. We have also lost one Honorary Fellow, the courtly man, the skilled scientist and the learned professor, Bernard Fraenkel, of Berlin. Little did those who saw him in Berlin, presiding so vigorously at the International Congress in August last, anticipate his so speedy demise. He had had an illness just before the opening of the congress, and for a while, it was feared that he would be unable to preside over its sessions. He rallied, however, opened the congress as per appointment, attended all of its sessions and the day social meetings, was in firm voice and apparently fully recovered. In a call on him at his residence two days after the congress, I spent a delightful hour. He spoke with great pride of the conclusion of the twenty-fifth volume of his *Archiv für Laryngologie*, the final pages of copy of which he had sent within a few days to the printer. It is too soon after his death for us to appreciate properly his standing as a scientific man. He was born in 1836 and graduated from the University of Berlin in 1859. Ten years later he made, in association with Cohnheim, in Virchow's Pathological Institute, valuable studies on tuberculosis. At the close of the Franco-Prussian war, in which he took part, he returned to Berlin and became a Privat-Docent in Rhino-Laryngology. In 1873 he established a private clinic which he continued till 1887, when, upon the establishment of a Government clinic in those branches, he was appointed its director. In 1873 he had become connected with the medical service of the Augusta Hospital. He thus laid a solid foundation for the special work of his later years, an ideal course for the specialist. His professional activities continued till the close of his life. He bulks so large in our minds as an editor, and as one associated with public hygienic movements, that we are apt to forget the valuable laboratory work of his earlier years. He has also the credit of being the first to cure, permanently, a case of laryngeal cancer, by endo-laryngeal operation, and many important discoveries in tuberculosis. It is a pleasing thought he has been succeeded in his university chair by another of our Corresponding

Fellows, Professor Gustav Killian, called from Freiburg-im-Breisgau, from whom, in his new position of larger opportunities and greater usefulness, we may expect a continuation of that marvelous mechanical ingenuity and scientific skill, which have already solved for us some of the intricate problems of the clinical surgery of the upper air passages. To Fraenkel, the words of Cato to his friend Scipio and Laelius, as recorded by Cicero's "*De Senectute*," are well applicable: "As I love to see the fire of youth somewhat tempered by the gravity of age, so am I equally pleased when I see the phlegm of age somewhat enlivened by the vivacity of youth, and whoever unites these qualities in his character may indeed have the mark of years in his body, but will never discover the same in his mind."

The principal item of executive business before us at the present session is the adoption of a new constitution and by-laws. At the congress of 1910, a committee of Drs. Coakley, Coolidge and Swain was appointed to consider the question. They submitted a report last year in Philadelphia, but the President of that year, Dr. Kyle, ruled that permanent action thereon must be deferred till this year. In the meantime, copies of the proposed document have been ordered printed and submitted to you. Presumably you have read them and we are now ready for final action. The Association has been incorporated. Articles of incorporation are printed in the Transactions of 1911. It is now empowered to hold funds. It is to be hoped that the generous example of Dr. Johnston may meet with many imitations, and that among the legatees of your respective estates there may appear the name of the Laryngological Association. Already the council has been advised of one generous bequest. The establishment of a new class of fellows has already been referred to, otherwise there are no notable changes. The numbering of the various paragraphs in the new document, renders reference to its provisions legible and easy. Too much detail in regard to matters of associational conduct has been, and in my own judgment, very wisely avoided. It has rightly been judged that in special instances, the same common sense which has guided us wisely in the past will so guide us in time to come, as more particular interpretation may become

necessary. The treasurer has been made a separate officer. I have examined the draft with much care. Let us spend no time in quibbling over mere verbiage, but let us adopt the document promptly. In my judgment it covers every point which a secretarial experience of eleven years has shown to be necessary.

I may mention one point with reference, to which the council agrees, that an ideal method of procedure is yet to be found; I refer to the nomination of candidates for Active fellowship. It is frankly admitted by us all, that the present plan does not fulfill all inclinations. The fellowship at large prefer, apparently, to leave the matter in the hands of the council, because we get answers from less than one-half the present Fellows. It was felt that the list of candidates sent out this year for scrutiny was far from satisfactory. It was felt by the council, that there were cast against each man thereon, sufficient ballots to render it inadvisable to nominate him for Active fellowship. In two instances, the criticism was such that the names could in no wise be considered. I seriously call your attention as to the proper course to be followed in this dilemma; either it seems to be necessary that you shall all vote in the annual informal ballot, or else shall leave the matter entirely to the council, thus making of it a virtual committee on membership. This is obviously open to objection, as it offers opportunity for electioneering. If Fellows would pay attention to the informal ballot, consider carefully the names on it, disregard personal feeling and bear in mind only the welfare of the Association, I believe that the results would be satisfactory. But kindly remember that following the precedent of the ruling by the chair last year, no change can be made in the draft you propose to adopt, unless it lies over until the next annual congress.

I hope and trust that in its present form it will meet with your approval also. Such action as we propose is always somewhat of a critical time in a society like ours. Our records are free from the history of any controversy. Let the harmony remain unbroken.

I wish in your presence to express my personal obligation to our deserving secretary, Dr. Smith. He has carried on the work

of his office wisely and well. Year by year this work has grown and the activities of the office have expanded. During the first year, from unfamiliarity, the task is especially hard, but from what he has already done I vouchsafe for him a long and successful tenure of office.

And now, gentlemen, I have but a brief closing word. In the year 1900 you deemed my name worthy to be coupled in our history with those of Lefferts, Delavan, C. H. Knight and Swain as the custodian of your records and the guardian of your funds. When I felt compelled, from physical reasons, to retire last year from that office, you conferred upon me the highest honor in your power, and in my judgment the highest honor in the power of American laryngologists to bestow. For your unvarying kindness and loyal support during these dozen years I thank you from the bottom of my heart. I am humbly your debtor, and shall never minimize, still less forget, the friendships formed and the obligations I am under. As president I succeed a long line of sterling men of choice souls. May I, in some feeble way at least, measure up to their standard.

I now declare the Thirty-fourth Annual Congress of the Association open and ready for business.

## ORBITAL ABSCESS FROM INFECTION THROUGH THE ETHMOID

BY JOHN O. ROE, M. D., ROCHESTER, N. Y.

The intimate and important relations existing between disease of the ethmoid labyrinth and the orbital cavity are well illustrated in the following cases of orbital abscess resulting as an acute extension of ethmoid infection. This intimate relation is also shown in the frequent disturbances of vision resulting from nerve irritation, reflected from the nose to the retina, this irritation being caused by intranasal pressure and various diseased conditions.

Onodi in his book, "The Optic Nerve and Accessory Sinuses of the Nose," and also in an article on "Disturbances of Vision Induced by Disease of the Posterior Accessory Sinuses of the Nose," very clearly has shown how this takes place through the anatomical connections of the two parts. Coffin, in the Transactions of the American Laryngological Association, 1910; Harmon Smith, N. Y. Medical Journal, April 5, 1911; Halsted, in Transactions of Am. Laryng., Rhin. and Otol. Soc., 1901; Holmes, Ohio State Med. Jrl., Feb., 1906, and Hanau Loeb, Annals of Otol., Rhinol. and Laryngol., June, 1909, have given us excellent papers on this subject and cite many interesting cases from their clinical experience.

The first case I report is especially important as illustrating the readiness with which the orbital cavity can be reached and abscess of this region opened by the nasal route, giving immediate and complete relief.

Case 1—Stanley Gilmore, aged seventeen, was brought to my office on the morning of August 10, 1911, by Dr. Carpenter, of Pittsford, N. Y. The young man was suffering from a very much swollen condition of the right side of the face and bulging

of the right eye, so much so that he was unable to see out of it. The history of the case is as follows:

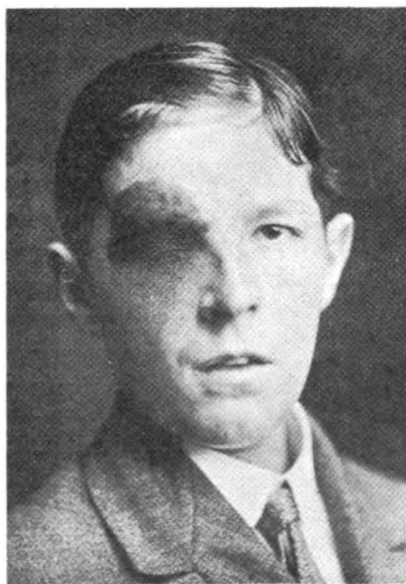On July 16 Dr. Carpenter was called to see the boy and found him suffering from a sore throat and cold in the head. He continued to grow worse and soon began to have some swelling about the right eye. From July 20 to August 6 he remained in much the same condition, excepting that the swelling about the eye increased so much as to amount to a general cellulitis. The swelling spread more or less over the whole side of the face, but was more pronounced about the eyeball, causing a well marked bulging of the eye. The upper eyelid and the parts immediately above the eye were most swollen, so much so as to completely close the eye, he being able to see clearly with this eye only when the eyelid was raised. When the eye was opened he could see dimly, although he said the sight seemed very much blurred. There being no oculist at hand no ophthalmological examination was made. The case being urgent, however, and the temperature having increased to 103, I decided to operate at once.

As the pain and swelling was most intense directly back and above the eye, this condition at first appeared to be a complication of acute frontal sinusitis, producing what appeared to be a subperiosteal abscess, involving the orbit and the supraorbital region. On examining the nose, however, the turbinates and other parts were found markedly swollen with a muco-purulent discharge coming from the ethmoid region. It was quite evident, therefore, that the orbital infection had come from the nasal infection, also manifested in the sore throat that he had been having for several days previous to the ocular involvement.

In order, however, to settle the question regarding the presence of a subperiosteal abscess above the orbit, I made a deep incision with a slender knife down to the bone, just to the right of the supraorbital notch. As no pus was found in this region, it was clearly evident that we had to deal with a complication of the rhinitis and ethmoiditis only, as there were no indications, after careful examination, that the other accessory sinuses were involved.

As the ethmoid cells were unquestionably the source of the

orbital infection and abscess, the logical method for opening this abscess was through these infected cells by the nasal route. Cocaine was applied to the interior of the nose and by the use of a small amount of chloroform the pain of the operation was avoided. After removing the anterior portion of the large middle turbinate, I went through the posterior ethmoid cells and the posterior portion of the orbital plate, using an angular pair of cutting forceps, especially designed for operations on the ethmoid cells. Very little resistance was encountered, as the osseus



structures in this region had become necrotic and very much softened. As soon as the abscess cavity was reached, pus began to flow into the nose. I immediately enlarged the opening sufficiently to give free vent to the pus, and by pressing gently over the eye the pus flowed out in quite a stream, until we estimated that fully an ounce had escaped. After getting out all the pus obtainable, I irrigated the nasal cavity with a warm saline bichloride and boric acid solution, 1-5000, and the nostril was

packed loosely with iodoform gauze. A mild pressure with a bandage was made and maintained over the orbital region to gently force out whatever pus remained or might continue to accumulate from the disintegrated tissues. The cellulitis, orbital infiltration and swelling quite rapidly subsided, and at the end of ten days were almost gone and the boy made a complete and uneventful recovery.

Case 2. Another exceedingly interesting case came under my observation about three months later. On Oct. 20 I was called on the phone to come to Clifton Springs to see a young man nineteen years old who had an enormous swelling of both eyes and was becoming more or less delirious. When I reached there I found the young man in a semi-comatose condition with evidently a septic cellulitis of the orbital region on both sides. The history of the case was that the young man about ten days before had injured his hand with a rusty nail, the wound becoming immediately infected. Directly afterwards he began to have a cold in the head, evidently the result of inoculating himself by picking his nose, which he had previously done a great deal with the infected hand, causing an acute infection of the ethmoid cells. He grew rapidly worse up to the morning I saw him, when he was becoming delirious and more or less comatose. The marked bulging of the eyes, the cellulitis and discoloration of the orbital tissues very much resembled the condition in the case previously described. The temperature at this time was 103, but we were undecided as to whether the brain disturbance was due to pressure from orbital infiltration and probable abscesses, or from a meningitis. If due to a meningitis there was absolutely no hope of his recovery, but if due to pressure from the orbital infiltration there was some hope for him. Therefore, in order to give him the benefit of this doubt and every possible chance, I at once proceeded to open into both orbits through the posterior ethmoid cells in about the same manner as in the previous case. A more or less bloody pus came, but not in any considerable quantity, as in the previous case. The young man, however, did not rally as we hoped after the removal of this apparent orbital pressure, but continued to grow rapidly worse and died the



latter part of the afternoon of the same day. An examination was made shortly after by Dr. Webb, the Pathologist of Clifton Springs Sanitarium, who found this orbital phlegmon and infectious ethmoiditis to be associated with a general streptococcus infection, as we believed to be the cause when no relief was obtained from the operation.

While such cases are more or less rarely met with, they are sufficiently frequent to emphasize the importance of giving careful attention to the ethmoid labyrinth in all cases of orbital abscess. In the first place the infection was entirely local, while in the second case the streptococcic infection was general, although the meningeal involvement was probably secondary (through the cribriform plate) to the same infection that developed the orbital phlegmon.

In some of these cases there also may be involvement of the other accessory sinuses.

Villeneuve Clin., Chir. Par., 1891, reports a case in which not only the ethmoidal and frontal sinuses were involved in association with the orbital abscess, but the phlegmon extended to the meninges. The frontal sinus was opened and the opening continued through into the cranial cavity. The cranial abscess was drained through this opening and the patient recovered. Gruening, Mt. Sinai Hosp. Rep., N. Y., 1903, III., 487, reported a similar case in which the patient died. Wilson, Laryngoscope, St. Louis, 1906, XVI., reports a case of empyema of the frontal, ethmoidal and sphenoidal cells, associated with abscess of the orbit and followed by serous meningitis, optic neuritis and otitis media. The abscess was opened by a Killian operation and the patient recovered. In this case the drainage was maintained through the wound, although he states that pus was exuding into the nostril through a hole about the size of a dime in the orbital plate.

Harlan, Philadelphia Medical Journal, 1901, VII., 932, reports a case of abscess of the orbit with disease of the ethmoid. In this case Jansen's operation for empyema of the frontal and ethmoidal sinus was employed, except that instead of packing

the cavity with gauze as Jansen does, drainage through the nostril was used and the wound sutured.

Oliver and Wood, *Am. Jour. Med. Sci.*, Phila., 1902, CXXIV., 92, reports a case of orbital abscess associated with antral and ethmoidal disease. The case was that of a girl, thirteen years old, and the obscurity of the different conditions giving rise to the trouble made the diagnosis difficult and of long delay. In this case the abscess was opened by an external incision through the lower eyelid and the antral abscess through the canine fossa, drainage being instituted through the external wound.

Roy, *Brit. Med. Jour.*, Lond., 1906, II., 1864, reports a case of orbital abscess simulating a malignant growth, but on attempting to remove the supposedly sarcomatous eye, an orbital abscess was revealed by a gush of pus through the preliminary opening made for the removal of the eye.

In nearly all of the cases reported, the orbital abscess has been opened through an external incision, either a Killian or a Jansen operation, whereas the logical way of opening the abscess, particularly when uncomplicated with infection of the other sinuses, is by the nasal route. This is accounted for by the fact that nearly all these cases come under the observation of the oculist. In the case of orbital abscess reported by Posey, *Penn. Med. Jour.*, Pittsburgh, 1902-3, VI., 414, he referred the case of an examination to Dr. Packard, the consulting rhinologist of the hospital, who readily evacuated the orbital abscess through the posterior ethmoid cells.

In considering the comparative advantages, disadvantages and dangers of the operation for the opening of orbital abscess by the external and internal route, certain points in the technique must be considered. By the external route, the operator has the advantage of direct ocular inspection of the work as he goes along, is enabled to follow the course of the diseased process in whichever direction he may find it leading him, and can also directly control any hemorrhage that he may encounter. On the other hand, the disadvantages of the external route are the external disfigurement, which, more or less, fol-

lows such operations, sometimes amounting to a considerable deformity.

The advantages of the internal route are that the direct opening is made into the portion of the orbit where the abscess and phlegmon are generally most concentrated. This is particularly true in all those cases in which the orbital abscess has resulted from infection through the ethmoid. We are also following the disease from its source and at the same time removing or eliminating the source of the infection in the ethmoid cells. There is also entire freedom from danger of disfigurement or deformity; and we are giving drainage to the abscess through the most direct outlet. The relief is speedy and the complications of the external wound are avoided. In those cases in which the frontal sinus is involved, even if this is not discovered until after the opening through the ethmoid has been made, it does not preclude a direct opening into the frontal sinus externally if it is found necessary, but on the contrary affords a more direct and effectual drainage.

The comparative danger attending the two operations depends entirely upon the technique of the operator., In either case, a bungling operator may do irreparable damage, when in proximity to the cranial cavity, but with a skillful technique and a thorough knowledge of the anatomy of the parts, the internal operation can be made as safely as the external.

I will not attempt to mention any points of the external operation so commonly done and quite familiar to you all, but I will mention some of the points that I have found most important to observe in an operation for entering through the posterior ethmoid cells. On beginning the operation, the first and most important thing is to locate the posterior wall of the nasal cavity, throughout its entire extent, from the cribriform plate to the basilar process. Unless this is carefully and accurately done, so that the exact depth of the nasal chamber at every point is known, no operator should attempt to open the posterior ethmoid cells, because he would be uncertain as to whether he was penetrating an ethmoid cell or the cranial cavity.

In examining a skull the cranial cavity is always found rounded

at this region so that the cranial contents lie posterior to a line drawn at right angles to the posterior nasal wall. Therefore, by locating the posterior nasal wall accurately and going in laterally at right angles to the anterior plane of this wall, the posterior ethmoid cells can be opened with the utmost ease and accuracy; and with entire freedom from danger of penetrating the cranial wall, whereas by penetrating these cells antero-posteriorly, we have no certainty as to when we have reached the last posterior cell, or the anterior cranial wall.

The instrument which I mainly use in penetrating these cells is a forceps cutting at right angles, such as I show you here, made right and left for the respective sides, and I use for locating the posterior nasal wall a slender, thin, flat steel probe, which will much more readily pass obstructions and with which the posterior wall can be more accurately outlined than with the slender, round, silver probe, so commonly used. This little instrument, which is most serviceable in all nasal work, I have designated as my long finger with an eye in the end of it, as it indicates to me the exact location and condition of the different parts of the nasal chamber, and is a very material aid to direct or indirect inspection.

It may be considered that there is danger of increased infection following through this opening into the orbital cavity, but this is more imaginary than real, for we are removing rather than spreading the infection already present. In other cases in which I have been very desirous of removing all infected ethmoid cells and where the os-planum happened to be unusually thin, I have opened into the orbit, but in no instance have I ever had any ill effects resulting.

Therefore it is readily seen that with a thorough knowledge of the anatomy and the particular configuration of the nasal chamber and its posterior wall, ascertained so accurately by the method which I have described, the opening of the orbital abscess by the internal route is easily, accurately and safely made. It is also free from all dangers of disfigurement, and that is the most direct, the most logical and the most desirable method for

opening orbital abscesses in cases where the infection has entered through or extended from the ethmoid cells.

### *Discussion.*

Dr. H. P. Mosher, Boston: I have had the good fortune to meet three or four cases of orbital abscess, and in all cases it was secondary to trouble in the frontal sinus, and the cases were treated by the external route. I do not see how Dr. Roe excludes trouble in the frontal sinus in his first case. If the trouble originates there the labyrinth becomes involved secondarily.

Dr. C. G. Coakley, New York City: This is a very interesting question and one in which there probably is not time to go into as fully as it deserves. These cases of orbital infection are of two kinds, one where there is actual pus in the orbit, and one where there is only very moderate oedema of the orbital periosteum and of the orbital contents. I have had a number of cases verifying the last condition; in fact I have had two cases this past Winter. One was the case of a child 17 months old who had an attack of measles and had the ordinary rhinitis which accompanies this disease. The physician in charge noticed a sudden acceleration in temperature with marked swelling around the left upper lid. Within twenty-four hours the eye was closed, both lids swollen, and there was distinct injection of the conjunctiva, so that the conjunctiva of the lower lid protruded between the lids, and there was an ecchymosis. There was an external and forward protrusion of the globe of the eye. The case was transferred, being a case of measles, to the public hospital for these diseases, and I was invited to go there and operate, which I did. We went in by the external route, and all we found was an enormous hyper-vascularity of the tissues with oedema and a polypoid condition, but not a drop of pus could be found anywhere through the ethmoidal and sphenoidal regions. However, cultures were made from the wound at the time and these showed a pure streptococcus involvement. In other words, this case was operated on in forty-eight hours from the inception of the orbital swelling and there was a condition which I would regard very much like the indurated condition one sees in a cellulitis of an erythematous character. The temperature, which had been 104° to 105°, dropped after thirty-six hours, and on the second day an erythema developed which extended up over the scalp and down over the shoulder and left side. There was some rise in temperature. The child went along very well. I saw it only two or three times after the operation, and my last report was nine days after the operation, when the child was in excellent physical con-

dition, and the temperature nearly normal. The following morning I was very much surprised to get a report of the death of the child. There was a sudden embarrassment in respiration, the child became cyanotic, and died. We were very fortunate in getting an autopsy. The cranium was opened. There was absolutely no evidence of a meningitis, but the blood vessels were rather overfilled. There was slight increase in amount of cerebro-spinal fluid, which both microscopically and bacteriologically was found sterile, and there was a very slight increase in the cell elements. The operative field showed that all of the ethmoidal cells had been taken away. There was one small area of slight vascularization of the dura over the posterior portion of the ethmoid where a localized thickening and redness was apparent, but there was nothing in the pia in that region. The other side was investigated, but normal conditions found. In the lungs we found a small area of consolidation at the left base, but not sufficient to cause death. We were at a loss to account for the death. The autopsy was continued, and when the trachea and larynx were opened it was found that the child had an exudate in the larynx and trachea, which on culture was found to be diphtheritic. The solution of the problem was this: the child was sent into this contagious hospital with measles, had accidentally become infected there with diphtheria, and died with a laryngeal and tracheal diphtheria without its being recognized. This case had no pus at all, simply an enormous oedema of the orbital contents. I fully expected to find a small amount of pus. I do not believe any intranasal operation in such a condition would have been of very much value in so young a child.

Two weeks ago I saw another case in an adult where an attempt was made to remove the middle turbinal and open the ethmoidal cells for the relief of swelling, pain and temperature, which had steadily increased, but after thirty-six hours all the symptoms had increased, and I decided to go in externally, but found no pus. Again I think intranasal operation would not have been of much value.

In these extreme oedema cases, where the infection is more like erythema, not a typical abscess, which one runs across occasionally, you cannot tell the true condition except by operation, and I do not think intranasal operation is the rational method.

In answer to the question just asked by Dr. Renner, I would say that the diagnosis in my case lay between an orbital cellulitis and disease of the cavernous sinus. The cavernous sinus and all the sinuses were opened and there was no clot or any evidence of involvement, and a portion of the left cavernous sinus was microscopically examined. It was decided positively that it was not a case of cavernous sinus disease.

Dr. W. E. Casselberry, Chicago: Clinically it is important to distinguish between abscess of the orbit, cellulitis without pus and passive oedema, although pathologically they may be but stages of the same process. My experience has been with cellulitis and oedema. A foreigner, in a hospital, able to give but little history, had protrusion of one eye of an acutely inflammatory nature, very painful, which had not been relieved by middle turbinectomy with opening of the anterior ethmoid cells. Exploratory punctures by an ophthalmologist into the orbit having failed to locate pus, I made a Killian operation, but found no pus in the frontal sinus or frontal cells, only a slight oedematous state of their lining membrane. Persistent hemorrhage from the inflamed tissue so prolonged the operation that I was obliged to defer extending it as intended into the spheno-post-ethmoid cells. The patient for the next ten days resisted further operating. Then he had a convulsion and Dr. Pierce, in my absence from the city, opened the spheno-post-ethmoid cells, but found only a small amount of purulent fluid, which was not under pressure nor adequate to displace the eyeball. Evidently it was an orbital cellulitis in conjunction with cerebral venous thromboses, terminating in fatal meningitis, although the infection had started probably in the nasal sinuses.

The prognosis is more favorable and the condition more amenable to intranasal surgical treatment when a passive oedema rather than active inflammation of the orbital cellular tissue exists, as was exemplified by a young woman with multiple nasal sinus suppuration, in whom great protrusion of one eyeball had gradually developed in the course of months, but unaccompanied by pain or acute inflammation. There was a distended, copiously suppurating nasal agar cell which encroached on the frontal sinus and somewhat on the orbit. Intranasal surgical drainage of this and other sinuses resulted, not in any sudden recession of the eye as one might expect were the displacement consequent upon mere pressure by an abscess, but in a gradual withdrawal of the eyeball into its proper place in the orbit.

Dr. J. Price-Brown, Toronto, Canada: I would like to report a case somewhat similar to that mentioned by Dr. Roe. A few weeks ago a girl twenty years of age was put in the hospital under my care suffering from headache. She was extremely plethoric, but had never had a headache in her life until this one came on. It gradually increased in severity, the right eyelid swelled, diplopia set in, and there was hemorrhage from the right side of the nose. She had been in the hands of a specialist, who referred her to me, saying it was acute sinus disease. On examination I found

an enlarged right middle turbinal, about the size of a plum; on touching this there was bleeding, but no purulent discharge. Under an anesthetic I removed the middle turbinal, expecting a gush of pus, but none came. As the growth was very large I did not think it necessary to go further into the ethmoid cells, but tried to pass a probe into the fronto-nasal duct, but did not succeed. I directed that she be given boric acid irrigations every four hours, which was done for a certain length of time. There was gradual improvement. There was no discharge from the nose at any time, excepting during irrigation, when a purulent slough came away. The eye symptoms passed away, and the headache almost entirely, but the diplopia continued for some time. In looking to the left side from the right eye she could see single—then, as she looked forward, the diplopia came on. This condition cleared up about three weeks after the operation.

Dr. Norval H. Pierce, Chicago: This appeals to me as being a very important subject. To be brief and to the point, I believe that it is the best surgery to resort to an external operation whenever the orbit or brain is threatened. The Winter before last I knew of two cases, one under my personal observation in consultation, where the anterior ethmoids were opened during an acute attack of inflammation. Both patients died of meningitis a week after the operation. I do not believe you can properly investigate these cases by an internal operation. I believe that it is difficult, even with an external operation, to thoroughly explore this septic field, but it gives us much more chance to be thorough when we have an external wound than when working in a closed cavity.

Then, in the cases described as cellulitis, which is probably the preputular condition of the same thing which eventuates in an abscess, we have a chance of controlling hemorrhage better in an external than in an internal operation. I have known of cases where an internal operation has been attempted, and where hemorrhage has brought the operation to a close at an early stage, it being impossible to control it long enough to make any further operative progress. Therefore, I think it is a well-defined rule that when the orbit is threatened or there are symptoms of meningitis to begin immediately with an external operation, and I believe the frontal sinus should be opened in all these cases, whether you find external evidence or not, because we cannot afford to temporize or lose any time whatever in supposing one way or the other. Whenever a meningitis originates in these cases the prognosis is very bad, much worse than in meningitis connected with the ear, either in chronic or acute cases.



Dr. W. Scott Renner, Buffalo: I would like to ask if in Dr. Coakley's case the cavernous sinus was opened at the autopsy to see if there was any trouble there.

Dr. John O. Roe: I take no issue with those who believe in the external operation when all the different accessory sinuses on one side are involved at the same time, associated with an orbital abscess, and especially in those cases in which the frontal sinus is implicated. No one would be warranted in attempting to open the frontal sinus from the nasal side in such cases, but when we have an orbital phlegmon, associated only with an ethmoid disease from which the orbit has become infected and sufficient time has elapsed for pus formation, the indications are then, to my mind, to open through the ethmoids. The operation is also a perfectly safe one if the operator exercises due care in exploring the nasal cavity and locating the exact position of the posterior wall. He can then go in through the posterior cells laterally without danger, as I have pointed out in my paper. In this manner he follows along the line of the infection rather than opening up other areas of infection. Perfect drainage of the abscess is also thus obtained, and the scars and facial deformity resulting from external operations are thereby avoided. In the case I have reported this result was most gratifying.

I would not, however, advise this operation in any case of orbital cellulitis, unless sufficient time had elapsed for the formation of pus, and we were certain that pus was present. In most of the cases of orbital abscess that have been reported the trouble had existed for several weeks. In the second case that I have reported we were in some doubt as to the question of finding pus, as there had been scarcely time for very much breaking down of tissue. The operation was, therefore, done largely as an exploratory measure, as there was some doubt then as to whether the increasing comatose condition was due to the orbital pressure or to meningitis. There was no question as to a beginning abscess formation from the moderate amount of serous pus that came away, but the meningeal involvement was due to a streptococcic infection. In the second case reported by Dr. Coakley, thirty-six hours only having elapsed, he could not expect to find pus in that length of time, but only marked cellulitis, as there was no time for the breaking down of tissue and formation of pus. These cases are exceedingly interesting, both from the oculist and rhinologist point of view, and it is only after a considerable study of this subject and experience in dealing with such cases that we can come at once to the correct conclusion in every case.

THE APPLIED ANATOMY AND THE INTRA-NASAL  
SURGERY OF THE ETHMOIDAL LABYRINTH.

BY HARRIS PEYTON MOSHER, M.D., BOSTON.

During the last year I have passed through a revelation in connection with intra-nasal ethmoidal operating. The surgical application of a well known relationship of one of the anterior ethmoidal cells caused me to look at the labyrinth in a new light and completely changed my operative technique. The suddenness and sharpness of the new conception were startling. Whether you will find the procedure novel in any way I do not know. Neither do I know whether it has been described in the literature. Some of my associates and friends have been kind enough to say that it was new to them, also some of them have had to a certain extent the same operative awakening which occurred to me. I do not mean to give the impression that I am now suddenly thoroughly happy and altogether efficient when working in the ethmoidal labyrinth. I am not, and never shall be; but I can keep my feet better than ever before, and my operative manipulations have changed from a blind opening of cell after cell into a definite and systematic procedure.

An increase of my knowledge of the relationships of the agger nasi cell, the lowest and the most anterior of the cells grouped about the upper part of the unciform groove, led to my operative awakening. In certain animals a turbinate, called the naso-turbinal, runs along beneath the nasal bone and above the maxillo or inferior turbinal. Anteriorly it is attached to the inner surface of the ascending process of the superior maxilla. In monkeys and man this turbinate is wanting, but a ridge remains to mark its former attachment. In man, about a third of the distance down the unciform groove and in front of it, over the ridge called the agger nasi, there is very frequently an anterior ethmoidal cell, called from its position the cell of the agger nasi.

This cell drains backward into the unciform groove. Not rarely two cells are found at this point. This cell is under the cover of the extreme upper part of the middle turbinate where this bridges across the unciform groove. When this cell is of any size the mound which it makes on the inside of the ascending process of the superior maxilla is readily made out on looking into the nose of the living subject. For years this cell has stared me in the face in anatomical preparations. This year it occurred to me to begin the opening of the ethmoidal labyrinth by passing a curette into it. I did so, and found that the head of the curette was at once in a sizable cavity. A probe carried into this entered the frontal sinus with great ease. The same thing happened in other specimens and kept on happening during the next few excited weeks until the procedure had proved successful for catheterizing the frontal sinus in fifty out of fifty-three heads. As the frontal sinus cannot be catheterized by the anatomical route in any such proportion of cases, and as the usual operative procedures for catheterizing the sinus are not successful in anything like this percentage, I began to try this manipulation on the living. The results were almost as successful as they were on the dead. It was soon found that this procedure was an easy and sure way of exenterating the anterior ethmoidal cells, and that a slight and natural extension of it accomplished the same thing in regard to the posterior cells.

The foregoing somewhat long and personal paragraph will serve, with your permission, as an introduction to this paper. The purpose of the article, then, is to review the applied anatomy of the ethmoidal cells, to describe the position and the form of the naso-frontal duct, and then to outline a definite and systematic plan of exenterating the ethmoidal labyrinth by the intra-nasal route. Throughout this article I shall dwell only on the anatomical points which bear upon the purpose of the paper.

#### *The Position of the Ethmoidal Labyrinth.*

The ethmoidal labyrinth is situated outside of the cribriform plate and rises an eighth of an inch above it. Posteriorly, the labyrinth is in part free in the nasal cavity and in part united to

the front face of the sphenoidal sinus. Anteriorly the labyrinth is bounded by the posterior and inner surface of the ascending process of the superior maxilla and by the posterior surface of the internal angular process of the frontal bone. Its position in relation to the orbit, the antrum, and the nasal cavity is too well known to call for review.

#### *The Classification of the Ethmoidal Cells.*

The ethmoidal cells are divided into two groups by the attachment of the middle turbinate. The cells placed in front of this are classed as anterior, and those back of it as posterior cells. The important anterior cells are those which cluster about the upper part of the unciform groove, and are on a level with the superior turbinate. The anterior attachment of the middle turbinate continues in front of the unciform groove, roughly, about a third of the distance down the groove, and in the region of the ridge of the ascending process of the superior maxilla called the *agger nasi*. After bridging across the unciform groove the attachment of the middle turbinate slants directly downward, making an angle of forty-five degrees with the front face of the sphenoidal sinus. The upper third of the unciform groove is covered by the extreme upper part of the middle turbinate. The essential anterior cells are on this level.

#### *The Grouping and the Size of the Ethmoidal Cells.*

Three or four small cells radiate from the upper part of the unciform groove under cover of the extreme upper part of the middle turbinate. They suggest in their arrangement the tail fins of a lobster. A third of the distance down the unciform groove in front, and in the region of the *agger nasi* there is another cell, the *agger nasi* cell. There may be two cells in this locality. The posterior boundary of the unciform groove is the oblong sausage-like swelling of the ethmoidal bulla. This consists, as a rule, of two cells, an upper and a lower one. The first or the upper cell is in close relationship with the cells which crown the unciform groove. This cell opens posteriorly into the

groove of the ethmoidal bulla. The lower of the two cells in the bulla in most cases pierces the attachment of the middle turbinate and drains into the middle of the third meatus.

The third meatus in one-half of the cases is the highest and therefore the supreme meatus. It has three openings in it classed as upper, middle and lower. The middle opening, as has just been said, in most cases leads to a cell which makes the inferior part of the ethmoidal bulla. The upper opening leads to a cell which runs outward and expands upon the os planum for its base and then runs upward to the roof of the ethmoidal labyrinth. The inferior opening leads to a cell which, like the upper cell, runs outward to the os planum and there expands and makes its base. Then, like the upper cell, it runs to the roof of the labyrinth and then extends backward to the front wall of the sphenoidal sinus, with the outer part of the anterior wall of which it unites; the outer part of the front face of the sphenoidal sinus and the posterior part of the ethmoidal labyrinth having in this way a common wall.

When a fourth meatus is present there is usually but one cell leading from it. This cell may monopolize the whole of the common wall with the sphenoidal sinus, or it may take a part and leave the rest for the lower cell of the third meatus. The posterior cell, which is in relationship with the front wall of the sphenoidal sinus, often sends a prolongation backward to the outside of the sinus, and at times this is larger than the sinus itself. There are some seven anterior cells, and they are small; there are three or four posterior cells, and they are much larger, especially the most posterior cell, than the anterior cells. It is not unusual to find one or two large posterior cells making up the whole posterior half of the labyrinth. The anterior and the posterior groups of cells are generally distinct, and the partition between them, the attachment of the middle turbinate, is thin and easily broken. I have met with two instances in the dissecting room and one instance in the living, a case which I saw with Dr. F. P. Emerson, in which the attachment of the middle turbinate was so strong that no force which one

would be justified in using on the living would force a curette through it.

The most posterior ethmoidal cell is in relation not only with the front wall of the sphenoidal sinus, but with the optic nerve and the large veins from the orbit which empty into the cavernous sinus. For practical purposes this makes it in relation with the cavernous sinus itself.

#### *The Naso-Frontal Duct.*

The conception which I had of the naso-frontal duct was that it consisted of a tube-like canal half an inch long, which left the posterior internal angle of the frontal sinus an eighth to a quarter of an inch from the median septum, and then ran down through the sponge-like anterior ethmoidal cells to the inside of the lachrymal bone, to end in the unciform groove in a quarter of the cases, or in half of the cases to end under cover of the middle turbinate above and distinct from the unciform groove, the unciform groove in such cases ending in an anterior ethmoidal cell. The canal was surrounded by ethmoidal cells, which separated to make the duct, and as they surrounded it they could, and often did, mound into it and narrow and distort it. On examining the form of the duct I was surprised to find that in very many cases—I do not give the figures, because as yet my series is not large—there is no tube-like duct at all. The only place where it has this form is at the beginning, where it is made by the internal angular process of the frontal bone. At this point there is a definite bony ring. This at once, however, gives way to an antro-posterior slit, which is more like an ethmoidal cell or an irregular meatus. Other ethmoidal cells, and not only the frontal sinus, often empty into it at its lowest part. In those cases in which there is an anterior ethmoidal cell in front of the duct and making its anterior wall the duct, is tubular. Such a cell is not uncommon, running up in front of the duct as its anterior wall and mounding forward into the inner side of the upper extremity of the ascending process of the superior maxilla, or extending still further upward into the frontal sinus

in front and to the inside of the duct to end beneath the middle partition which divides the two frontal sinuses, causing the posterior inferior portion of the middle partition to balloon outward. Such a formation narrows the duct anatomically, but makes it possible to widen it easily surgically.

Where an anterior ethmoidal cell does not make the anterior wall of the duct, the duct, as I said, is slit-like, and more comparable to a cell or a meatus than to a duct. When this cell-like formation is present the inner wall of this is the anterior end of the extreme upper part of the middle turbinate. As far as my specimens show, up to the present time, it is commoner to find an ethmoidal cell placed to the outside of the duct than in front of it. There may be two cells on the outside of the duct. It is less usual to find a cell on the inside of the duct, although this does occur. As a rule the duct is nearer the middle turbinate than the lachrymal bone. However surrounded and related to the cells about it the duct may be, it tends to slant inward and to come into relationship with the inner surface on the anterior end of the middle turbinate. The duct, therefore, is easier to reach from the nose than from the orbit.

*Catheterizing the Frontal Sinus and Exenterating the Anterior Ethmoidal Cells.*

The chin of the patient is tipped up forcibly so that the operator can see the anterior end of the middle turbinate and as much as possible of the superior turbinate. If the septum is deviated and obstructs the view it is forced to the middle line with a short Killian speculum. The point of attack is the agger nasi cell, if it is present and its mound can be recognized; if not, the anterior end of the middle turbinate on a level with the superior turbinate. The external guide to this point is the inner canthus of the eye. In the beginning it is useful to lay the curette on the side of the patient's nose and to measure off on it the distance from the inner canthus of the eye to the lower edge of the ala cartilage at the posterior end of the vestibule. A mastoid curette, with a long handle and a bowl about half of a centimetre wide, is the most convenient instru-

ment to work with. Having located the mound of the agger nasi cell, or if it is not present having brought into view the anterior end of the middle turbinate at the level of the superior turbinate, the curette is pushed upward into the olfactory cleft with the cutting edge outward and aimed and then pressed toward the lachrymal bone. If the curette is in the right place it easily enters the ethmoidal labyrinth. If it does not, it should be carried higher and a little further backward. The common mistake is not to go high enough. The curette has an allowable outward excursion varying with the labyrinth of a half of a centimetre to a centimetre and a half. If the curette is carried too far it enters the orbit. No harm results from this, except a slight black eye which lasts a few days. If the operator puts the tip of his finger over the inner canthus he can readily detect the approach of the curette, and if the manipulation is carried out delicately the resistance of the lachrymal bone can be felt. After the initial outward plunge the handle of the curette is brought into the median line and the head of the curette brought into line with the antro-posterior axis of the labyrinth. With the bowl up and the cutting edge downward the curette is carried backward and downward until the bulla has been entered and destroyed. This means a backward excursion of about half of an inch. These manipulations leave the anterior end of the middle turbinate in shreds and dangling. This loose part is now cut off with a conchotome. When this has been done the anterior portion of the labyrinth stands open before the operator. The cutting surface of the curette is now turned forward and a little outward and brought forward until the flint-like posterior edge of the ascending process of the superior maxilla is encountered. A few strokes of the curette leave this bare.

Experiments on the cadaver have shown that these manipulations are easily and quickly executed and that they exenterate the anterior ethmoidal cells and obliterate the naso-frontal duct, except for the bony ring where it leaves the frontal sinus. In the roof of the operative cavity thus made is the opening of the naso-frontal duct. Usually it is placed anteriorly and ex-



ternally. The best guide to it is the posterior surface of the ascending process of the superior maxilla. If a probe carried upward and outward along the posterior surface of the ascending process of the superior maxilla does not drop into the frontal sinus, the probe should be carried further backward and then brought forward still pointing outward. This procedure is necessary when an anterior ethmoidal cell makes the front wall of the naso-frontal duct. When present such a cell is often broken down by the forward curetting. In a few cases it is necessary in order to find the duct to turn the end of the probe inward. If the probe is turned inward at the start there is danger of getting it caught in a cell on the inside of the tip of the ascending process of the superior maxilla, or in a similar cell placed a little higher up and mounding into the posterior part of the median partition of the frontal sinuses.

In order to enlarge the duct the head of the curette is carried upward behind the ascending process of the superior maxilla until it brings up against the roof of the ethmoidal labyrinth, or if the duct is wide, against the posterior wall of the frontal sinus, where this slopes downward and backward over the orbit. A small curette will enter the posterior part of the sinus, and to carry it upward until it strikes the sloping roof of the sinus posteriorly produces a most uncanny feeling. A lateral X-ray plate gives the operator confidence in this matter, because from this by measurements he can get an idea of the slope and the height of the posterior wall of the sinus. In order to enlarge the duct, therefore, after the curette has been carried upward and it meets the resistance of the posterior wall of the sinus, the bowl is turned outward toward the orbit and brought forward and downward until it brings up against the ascending process of the superior maxilla.

If the purpose of the operator is simply to catheterize the frontal sinus and not to exenterate the anterior cells the initial puncture is made through the extreme upper part of the middle turbinate and then the curette is brought forward until the posterior surface of the superior process of the superior maxilla is curetted free. Then the catheter is introduced. If the open-

ing of the sinus is not readily found all the anterior cells must be exenterated.

Long before this time some of you are wondering about the cribriform plate. The cribriform plate is the roof of the olfactory slit and is to the inside of the middle and superior turbinates. All of the manipulations are carried on to the outside of the cribriform plate and inside the ethmoidal labyrinth. The roof of the labyrinth is above and distinct from the cribriform plate.

In what way does this procedure differ from the customary one employed in catheterizing the frontal sinus? The plan which I have ordinarily followed has been to remove the anterior end of the middle turbinate and then to fish upward and outward with a probe for the opening of the sinus. If this did not succeed I took a conchotome and bit away more or less at random the anterior cells which presented, and then tried with the probe again. It should be remembered that removing the anterior end of the middle turbinate does not open the labyrinth. Opening a few of the anterior and internal cells does not effectively open the labyrinth. In order to do this the extreme upper part of the middle turbinate must be entered and the curette carried outward and behind the ascending process of the superior maxilla. Not to do this is simply to scratch the inner surface of the labyrinth, not to open it.

#### *The Exenteration of the Posterior Ethmoidal Cells.*

After the exenteration of the anterior ethmoidal cells it is only necessary to continue the curetting backward through the attachment of the middle turbinate in order to enter the posterior part of the labyrinth. Before the procedure is attempted it is of the greatest importance to bring the head of the patient downward until the roof of the ethmoidal labyrinth is level. During the manipulation upon the anterior cells the head of the patient has been tipped strongly upward and backward. There is a tendency on the part of the operator to leave the head in this position. To do this causes the operator to lose his orientation, and may, as has happened once, lead to disaster. Therefore, the moment the opera-

tor starts to enter the posterior part of the labyrinth the head of the patient is brought level, and care is taken to keep it in this position for the rest of the operation.

Having, then, the head level the operator plunges the curette through the attachment of the middle turbinate and works slowly backward and downward, keeping always to the outside of the middle turbinate. In a majority of cases the moment the attachment of the middle turbinate is pierced the head of the curette enters a sizable cavity. This is due to the fact that the posterior cells are much larger than the anterior cells, and that one or two cells not infrequently comprise the whole posterior portion of the labyrinth. By this formation Nature has left but little for the curette to do. So roomy is the cavity into which the curette enters that the operator, feeling no bottom, fears to carry the instrument onward. After the first case or two, when he has come to realize the large size of the posterior cells, he loses his natural timidity and quickly carries the curette backward to the posterior wall of the labyrinth. The relief that one experiences when the curette brings up against the posterior wall is much like the feeling that a tired and frightened swimmer has when he reaches near enough to the shore to feel his feet strike bottom.

The next step in the operation is the removal of the middle turbinate—that is, what is left of it, and the removal as well of the lower half of the superior turbinate. This is accomplished most easily by cutting straight backward as high above the middle turbinate as the scissor punch can be made to engage. One blade is placed in the exenterated labyrinth and the other follows backward in the olfactory slit. When the scissor punch has cut its way back to the front wall of the sphenoidal sinus, the middle turbinate and the lower part of the superior turbinate are removed with a snare, or they are twisted out with a pair of small Luc forceps. If the operator prefers, the remaining portion of the middle turbinate and the required amount of the superior turbinate can be removed with a conchotome.

The final step in the operation is the complete uncovering of the front wall of the sphenoidal sinus and the recognition of the

posterior ethmoidal cell. The hardest part of the operation is to recognize the limits of this cell. It is in this cell that he can get into the most trouble. Working in this cell, especially in its posterior upper outer angle, is the most dangerous part of the whole procedure. Experience has proved that it can be easily fatal to the patient if the operator loses his bearings in this locality. By carrying the curette backward to the outside of the middle turbinate it must of necessity bring up in this posterior cell. The trouble comes when the head of the patient is not held level so that the curette strikes the posterior wall at its extreme upper part. If it strikes not only the upper part of this cell, but strikes it at the outer superior and posterior angle, it is easy to enter the cranial cavity, especially if the cell walls have been softened by polypi or pus. When, however, the head of the patient has been kept in the proper position, that is, level, the curette meets first the lower part of the posterior wall of this posterior cell. Owing to the bulging inward of the posterior part of the inner wall of the labyrinth, the front face of the sphenoidal sinus, where it is free in the upper and posterior part of the nasal cavity, is obscured until the posterior part of the superior turbinate has been removed flush with the face of the sinus. As soon as this important manipulation has been executed a very definite and characteristic picture is obtained. To the inside is the septum. Just outside of this comes the nasal face of the sphenoidal sinus. This is recognized by the presence of the ostium. Further out and limiting the nasal face of the sinus is the ridge which represents the attachment of the superior turbinate. Lastly, to the outside of this there is a depression made by the remaining portion of the posterior ethmoidal cell. Once this picture is obtained it is necessary to follow the removal of the superior turbinate absolutely to the front wall of the sinus. If the operator loses his orientation he can regain it, and he should regain it or abandon the operation, by finding the upper border of the choana and then advancing with a probe upward close to the septum. No matter how narrow the nasal wall of the sphenoidal sinus may be this procedure will locate it. The wider the posterior cell the

narrower is the free or nasal part of the front wall of the sinus. The inclination of the operator is to work too high and too far outward, and so to mistake the posterior wall of the posterior ethmoidal cell for the free wall of the sinus. Having made out the extent of the free wall of the sinus and the extent of the posterior wall of the posterior ethmoidal cell, which is a wall common to the posterior cell and the outer half of the front face of the sinus, the operator selects the inner half of the front face and forces the curette through the ostium of the sinus into the cavity of the sphenoid. If the location of the ostium is not clear the operator finds the upper rim of the choana and proceeds with his curette up the front wall of the sphenoid close to the septum. Presently the curette finds a thin place and enters the sinus. It seems to me dangerous to enter the sinus through the posterior wall of the posterior ethmoidal cell. When the ostium has been found and the cavity of the sinus has been entered a probe bent at a right angle is introduced into the sinus and turned outward and brought forward against the external part of the front face of the sinus and its extent is thus ascertained. With this information in mind the operator introduces a small, right angular punch into the sinus and bites outward, and downward, and inward, until all the thin bone of the front face of the sphenoidal sinus has been removed. The steps of the operation have now been completed. All that remains is to remove tags wherever they are found. It is not well to curette the superior outer angle of the posterior cell. The probe is even more dangerous in this region than the curette, because the wall of the cell is thin at this point. There has been one fatality from a probe entering the cranial cavity at this place. Not only can the probe enter the anterior fossa if used at this point, but it may encounter the ophthalmic veins as they merge with the cavernous sinus. Hitting these veins is practically the same thing as puncturing the sinus itself. As a finishing touch to the operation the curette is carried outward to the os planum posteriorly and then brought forward along its inner surface. In my experience, the os planum is fairly resistant.

*Summary.*

The anterior boundary of the ethmoidal labyrinth is made by the internal angular process of the frontal bone and the posterior surface of the ascending process of the superior maxilla. The labyrinth cannot be entered effectively unless the curette is carried outward behind the ascending process of the superior maxilla toward the lachrymal bone. Removing the anterior end of the middle turbinate and curetting upward, and not outward, does not open the labyrinth to any extent. The internal angular process of the frontal bone makes two-thirds, or the whole, of the bony ring, which is the first part of the naso-frontal duct. The best guide to the duct is the posterior surface of the ascending process of the superior maxilla. In a large number of cases the naso-frontal duct is not a tubular canal, but consists rather of a bony ring at the beginning, and then becomes a triangular antro-posterior slit. This is more like an ethmoidal cell, or an irregular meatus, than a duct. The naso-frontal duct tends to run from without inward and to come into relationship with the anterior end of the superior turbinate. When the drainage canal has the cell form the anterior end of the superior turbinate makes its inner boundary. The duct, therefore, is reached most easily through the nose, and through the anterior end of the extreme upper part of the middle turbinate. A curette introduced at this point and carried outward toward the lachrymal bone and then withdrawn a little and carried straight backward and downward, enters the anterior part of the labyrinth behind the ascending process of the superior maxilla and breaks down the cells through which the naso-frontal duct runs, destroying both the cells and the duct. Very little curetting is required to convert the anterior part of the labyrinth into a single cavity. In the roof of this chamber, usually in the anterior outer angle, the opening of the naso-frontal duct is placed.

If it is the wish of the operator to clean out all the cells, the posterior half of the labyrinth is entered by piercing the attachment of the middle turbinate and by curetting still further backward, using all the while the outer side of the

middle turbinate as a guide. If the head of the patient is held level, the middle turbinate guides the curette backward into the posterior ethmoidal cell. Often the posterior half of the labyrinth is a large cavity, made up of only one or two cells. This portion of the labyrinth has been exenterated by nature. When the curette brings up against the back wall of the labyrinth the remaining part of the middle turbinate and the lower half of the superior turbinate are removed. Then the posterior part of the superior turbinate is taken away, flush with the front face of the sphenoidal sinus. The operator now recognizes the inner part of the front face of the sphenoidal sinus, which is free in the nasal cavity, and the outer part which has a common wall with the posterior ethmoidal cell. The posterior upper outer angle of the posterior ethmoidal cell is dangerous to curette or to probe. It is of the utmost importance that the operator should be sure of his landmarks in this locality. He orientates himself by finding the upper rim of the choana and then by differentiating the nasal face of the sphenoidal sinus by proceeding upward from the rim of the choana close to the septum. Having made out the extent of the free or nasal face of the sinus, the width of the common wall between the sphenoidal sinus and the posterior ethmoidal cell is determined. The dividing line between the two parts of the anterior face of the sphenoidal sinus is made by the obliquely vertical line, which is the attachment of the superior turbinate.

The usual mistake made by the operator is to get lost in the posterior ethmoidal cell—that is, he goes too high and too far outward, and considers the posterior wall of the posterior ethmoidal cell as the whole of the front face of the sphenoidal sinus. This mistake, if persisted in, will carry him into the brain. Insufficient removal of the posterior part of the superior turbinate and allowing the head to become tipped upward, are the chief causes of this confusion. After the landmarks of the front face of the sphenoidal sinus have been cleared and recognized, the sinus is entered near the septum—if possible, through the ostium—and the whole of the anterior wall removed.

The mishaps of the operation are entering the orbit through

the lachrymal bone and entering the posterior part of the anterior fossa of the cranial cavity at the apex of the orbit. The first accident is trivial; the second is fatal.

Puncture of the anterior end of the superior turbinate for catheterizing the frontal sinus or exenteration of the anterior ethmoidal cells is readily accomplished under cocaine anaesthesia. For the complete removal of the anterior and posterior cells, especially if this is to be accomplished at one sitting, it is more satisfactory to use a general anaesthetic.

In beginning this paper I used the word "revelation" in regard to my recent increase of knowledge of the ethmoidal labyrinth. I do not expect that the manipulations here described will have any such effect upon you. Many of the points are already known, and many of the manipulations have been—in part, at least—practised by you. This is a report of individual, though perhaps belated, progress. My ethmoidal operating has lacked definite plan, and I easily became confused as to where I was, and I was always in doubt as to how much had been accomplished at any given moment. The anatomy of the naso-frontal duct was especially hazy.

The operative procedure which has just been described has been tried on the living some ten times. The results have been satisfactory, and immeasurably better than any I have secured before.

### *Discussion*

Dr. C. G. Coakley, New York City: I think we all should be extremely thankful to Dr. Mosher for showing us the situation of the anterior group of ethmoidal cells. They, to my mind, have been the hardest things to properly manipulate by intra-nasal work, the hardest things to clean out, and I am very glad to get Dr. Mosher's beautiful demonstration of a far better way of doing this than I have been following. All that I have been doing has been to remove, piecemeal, this group of cells at repeated operations, not doing it in the regular and scientific way which Dr. Mosher has shown can be easily done at one or two sittings.

I wish also to add my voice to what he has said about the difficulty of probing frontal sinuses that are only acutely inflamed or that are not extensively diseased. It is impossible or rare to be able to demonstrate on a normal nose or a nose not



extensively diseased, so far as the frontal and anterior group of ethmoids is concerned, the probing of the frontal sinus; on the other hand, in a chronically diseased frontal sinus, especially those with polypoid formations, it is extremely easy, as a rule, to be able to probe that frontal, because Nature has broken down many of the anterior group of ethmoidal cells, making it comparatively easy to get in. So far as the naso-frontal canal is concerned, perhaps Dr. Mosher means to ring out this point, that the irregularity and tortuosity of the canal is due to the encroachment upon it by this anterior group of ethmoidal cells. The naso-frontal canal, as you see it when opening into the frontal sinus, as we have done so many times when entering from below, is frequently a tortuous canal owing to the bulging into it of some of these anterior ethmoidal cells. One of these anterior groups is so large that it is not difficult for one to pass a probe into that anterior ethmoidal cell and have it go up so far that you feel quite certain from the position of your probe that you are in the frontal sinus when you are not in it at all. There still remains a difficulty in all of this intra-nasal work that we have, namely, that if the ethmoidal labyrinth is cuboidal in shape and runs in a straightforward and backward direction, it is easy to exenterate the ethmoidal labyrinth at one or more sittings, but if the ethmoidal cells branch out over the roof of the orbit it is extremely difficult to get at all these ethmoidal cells through any intra-nasal operation. The only operation likely to reach all the ramifications of this unusual development is one which takes off all the outer wall of the ethmoidal labyrinth, or the inner wall of the orbit, so that you can behold the contents of the orbit externally. That work cannot be safely done intra-nasally. After doing all these intra-nasal operations there will still be a certain number of cases not cured.

Dr. Mosher speaks of the use of the curette. Its use is important to break into a cell, but I do not know of any curette that will remove the fragments of these ethmoidal cells. A curette is a good probe, but to get rid of these fragments you must use a sharp cutting forceps, straight, bent, or suitably angulated.

Dr. Henry L. Swain, New Haven, Conn.: I want to add my personal vote of thanks to Dr. Mosher for his beautiful exposé of the relationship of this anatomically complicated part. We have all had our difficulties, and his first preliminary communication in one of the journals gave me a clue to explain what had happened to me on one previous occasion when I had blundered into the agar cell. I have since then seen the patient and have gone up into the frontal sinus through that cavity, and I.

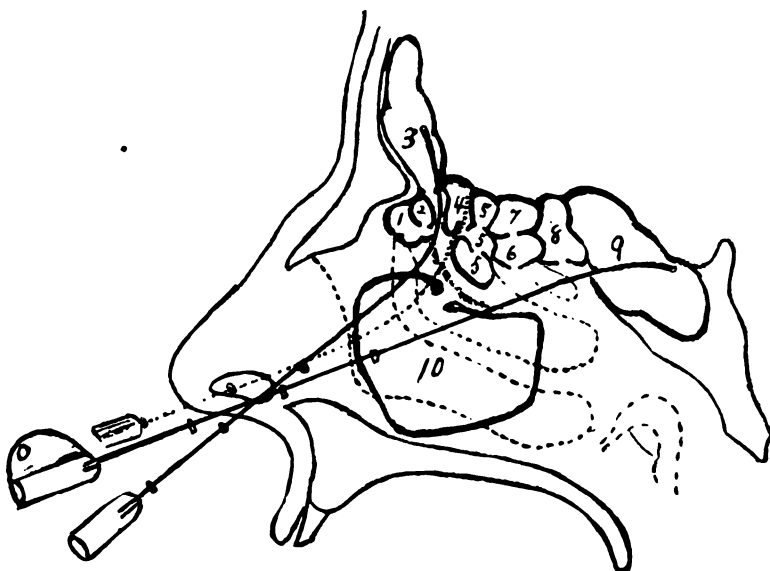
appreciate now what the possibilities of Dr. Mosher's ideas are. I am delighted he has made it all so graphic.

Dr. E. Fletcher Ingals, Chicago: I have been greatly interested in this paper, which seems to me to clear up many difficulties encountered in getting into the frontal sinus. Dr. Coakley said it is possible in practically all chronic cases to probe the frontal sinus; I should have said in 95%; but in acute cases it is usually difficult and often impossible. With Dr. Mosher's explanation, we ought to find it much easier to open the frontal sinus properly and to clear out the ethmoidal cells. As a result, I feel that the extensive operation which has heretofore been considered so important will be much less frequently done and that our patients will be much better off. The naso-frontal furrow, instead of duct, that the author has shown to exist in a large number of cases, has been a source of much difficulty. The difficulty with the probe catching in one of the fronto-ethmoidal cells has been frequently experienced. In some instances where I have had difficulty in passing a probe into a frontal sinus in doing my operation for intranasal drainage I have passed the probe up to the top of one of these cells and have then introduced the burr and cut away some of the partitions, after which it was easy to pass the probe into the frontal sinus and complete the operation. The arrangement of these cells clearly demonstrates the reasons for this procedure.

Dr. W. E. Casselberry, Chicago: Having opened the agar cell at first for other reasons and found entrance to the sinus, I have since utilized it in a tentative way when passage through the naso-frontal duct was impracticable, but Dr. Mosher's demonstration on the anatomic relations now gives it accredited standing, as a favorable alternate route to the frontal sinus. I have found but one disadvantage with it, in that, having made a roomy channel expecting to reintroduce the cannula on occasion without difficulty, I have found it shut off a couple of weeks later by eversion of the recontracted orifice, through the formation of cicatricial bands which in the agar region seem especially prone to radiate across the rim of the opened cell. This, doubtless, will be minimized through the freest excision, as described by the essayist, of the "overhang" and cellular septa, but my rule of safety, to cease operating whenever precise landmarks are lost to sight and touch, has sometimes limited the "clearing of the way." Dr. Mosher's systematized directions tend, moreover, to prevent obscuration of the view so that his operative procedure should represent a decided advance in the intranasal treatment of cases of pronounced fronto-ethmoidal suppuration. In mild and

semi-latent cases, however, one may well heed, as a principle, the conservation of the tubal mucosa in avoidance of a tubal stenosis, inasmuch as, in this class, the mere removal of obstructing hypertrophies from the vicinity of the outlet of the naso-frontal duct may suffice to restore its patency.

As depicted by Killian the frontal sinus, which typically should develop from the frontal recess, at the top of the naso-frontal duct, and so should conduce to a direct open connection between



THE NASAL SINUSES.

1, 2, 3, if none forsakes,  
Frontal cells, as Killian states,  
3 mayhap the sinus makes,  
4 the frontal probe mistakes,  
5 the bulla, sections three,  
All belong to A. E. C.

6 the lower P. E. C.,  
7 ascending cell may be,  
8 the cell of highest meatus,  
9 the sphenoid (hawking screatus),  
10 the antrum, first and greatest.

sinus and duct, often develops, instead, from the third frontal cell, in which event the naso-frontal duct (infundibulum) is apt to terminate in a persistent frontal recess or small blind expansion of its own upper end, through a rift in the side of which the channel must then make a jog to form but an indirect connection with the sinus. This jog, for the probe, is eliminated in the route through the agar cell which corresponds to one or both

of Killian's first and second frontal cells. The fourth frontal cell, which borders the naso-frontal duct behind and into which the frontal sinus probe is prone to slip, also is avoidable by the agar route.

The labyrinthine arrangement has seemed less confusing since the renaming of the middle ethmoid cells as sections merely of one compound cell—the bulla ethmoidalis, the familiar bulging section of which serves as a conspicuous reminder of the other two, higher up, the tier of three being grouped with the frontals, as anterior ethmoid cells (A. E. C.) Behind the bulla, above, usually appears another, broader but less prominent bulge, that of the whole group of posterior ethmoid cells (P. E. C.) which I identify the more readily through the suggestiveness of naming it the back-bulla. Also to promote identification of the wide variations in contour of the individual cells, by reference, intuitively, to the conventional scheme, I find it helpful to fix and recall to mind the typical order by the rote of rhyme.

Dr. Greenfield Sluder, St. Louis: The ethmoidal labyrinth has been of interest to me for a long time, as it has been to all of us, and I have known one or two points in this connection. It has been my habit to remove the middle turbinate by a little knife which cuts outward and downward on the pull and on the pressure. I preferred that to all other means, because it may be gotten under the middle turbinate with its angle so placed as to cut precisely the proper line upward and inward until you meet the internal angular process of the frontal bone. With regard to one of Dr. Mosher's drawings, I do not remember to ever have seen a turbinal running in attachment to the internal angular process of the frontal. I make this cut then forward, which will bring a piece of bone out. The cut may be placed in that way above almost to the cribriform plate of the ethmoid, in fact it may be placed within  $\frac{1}{8}$  or 1-16 of an inch of the cribriform plate. When such a cut has been made it throws the infundibulum wide open. Dr. Mosher has turned the descriptive anatomy of the infundibulum into a piece of most valuable applied anatomy and it is for that I thank him.

I have been conscious of the agar cell by the fact that I opened it in my upward and forward cut, but of its precise relation to the other cells I did not give the right value. That such a cut enters the frontal satisfactorily I believe is true, for I have measured my patients two years after the operative work and found they will average  $\frac{1}{4}$ -inch antero-posteriorly,  $\frac{1}{8}$  of an inch play laterally.

I also want to thank Dr. Mosher for giving us the new term

"the overhang of the ethmoid," to describe that portion of the internal wall of the capsule of the ethmoid which is limited by the cribriform plate above, by the uncinate process of the frontal bone in front, and by the anterior notch of the upper meatus, behind.

Dr. Otto T. Freer, Chicago: Dr. Mosher has presented to us one of those rare original researches that mark a great anatomical and surgical advance. The method of intranasally entering the frontal sinus, shown us by Dr. Mosher, is developed from the anatomy of the region considered, and for this reason I think that it will in time become the classic one.

I wish to call attention to the method of removing the ethmoidal cells, which I described in the transactions of this association in an article on nasal tuberculosis in 1909. An especial thin-bladed, angular chisel, pushed by hand, is used to cut away the lateral mass of ethmoidal cells from their attachment to the cribriform plate above. The blade of the chisel, following the direction of the nasal surface of the nasal bones and groove of the nasal spine of the frontal bone, readily enters into the plane of the attachment of the ethmoidal cells to the cribriform plate and but slight force is needed to sever them from their superior attachment and to drop them toward the nasal floor. The blade also cuts the ethmoidal cells away from the orbital plate by being pushed backward parallel to it. The partly severed lateral mass of ethmoidal cells is then removed with the punch forceps and Grünwald's curettes.

Dr. J. M. Ingersoll, Cleveland: Dr. Mosher spoke of his orientation in the region of the sphenoid cavity. One of the difficulties I find is that the posterior ethmoidal cells sometimes encroach upon the cavity and it is then difficult to differentiate the anterior wall of the sphenoid cavity from the posterior wall of an ethmoidal cell that is encroaching upon the sphenoidal cavity.

Dr. Harris P. Mosher, Boston (in closing): One point which Dr. Coakley brought up is the relation of the posterior ethmoidal cell, and he said he thought the external operation was the only operation which would deal with this. I have never, in the external operation, taken off the whole of the os planum, but have been content with removing three-fourths of it. Up to the present time I have been very much in favor of the external operation. I am beginning to vary a little bit now, and I find, after the operation as now done by me, I am able to keep my orientation better than by the external route. With regard to this pos-

terior cell, it is very hard sometimes to tell where you are in relation to it. If you will get the posterior part of the superior turbinate off you can recognize the two parts of the anterior wall of the sphenoid, and can orientate yourself with relation to the posterior cell.

Some of the speakers have spoken of using this procedure more or less unconsciously for entering the frontal sinus. Some of the men in Boston have told me of similar experiences. In operating they fell into a cavity and that cavity led them into a frontal sinus. I have tried to make this a conscious rather than an unconscious procedure.

As to the arrangement of the anterior ethmoidal cells, it seems to me my method is simpler and easier than that followed by Dr. Casselberry.

SOME ANATOMICAL AND CLINICAL RELATIONS OF  
THE SPHENOID SINUS TO THE CAVERNOUS  
SINUS AND THE THIRD, FOURTH, FIFTH,  
SIXTH AND VIDIAN NERVES.

BY GREENFIELD SLUDER, M.D.

The body of the sphenoid bone is usually hollowed out by the sphenoidal sinus. This cell may, however (rarely), be rudimentary and occupy a very small space in the lower anterior part of the body, which is otherwise hollowed out by a post-ethmoidal cell. It is of the cell which hollows the body of the sphenoid that I speak, regardless of whether it be the sphenoidal sinus proper or a post-ethmoidal cell.

The body of the sphenoid is covered above and laterally by the dura mater, with the cavernous sinus between its external and internal surfaces (in it), occupying a position for the most part above and lateral to the body. Within the cavernous sinus are found the internal carotid artery and the third, fourth and sixth cranial nerves, with the first division of the fifth lying in the lower part of its lateral wall. The impression given in the treatises on anatomy is, usually, that these nerves are rather widely separated from the sphenoid sinus, as shown in Fig. 1. The second and third divisions of the fifth and the Vidian are also usually represented as well removed from this cell—that is, separated by a considerable thickness of bone. Fig. 1. The fact is the sixth and the third division of the fifth are the only ones of these nerves that are not at times in close association with this cell—that is, separated from it by a very thin layer of bone; and even the third division of the fifth is sometimes also in rather close association with it. Fig. 2i, 2ii. The sixth, so far as I have found, is uniformly placed on the lateral aspect of the carotid and always removed from this

bony wall. Thus far I have been speaking of a sphenoid sinus which is limited to the body of the sphenoid. Should it be extended into the greater wings the sixth nerve may come into close association with it in the sphenoidal fissure below.

The fact which determines the relations of these nerve trunks to the sphenoid sinus is the size of the cavernous sinus rather more than the size of the sphenoid sinus. If the cavern-

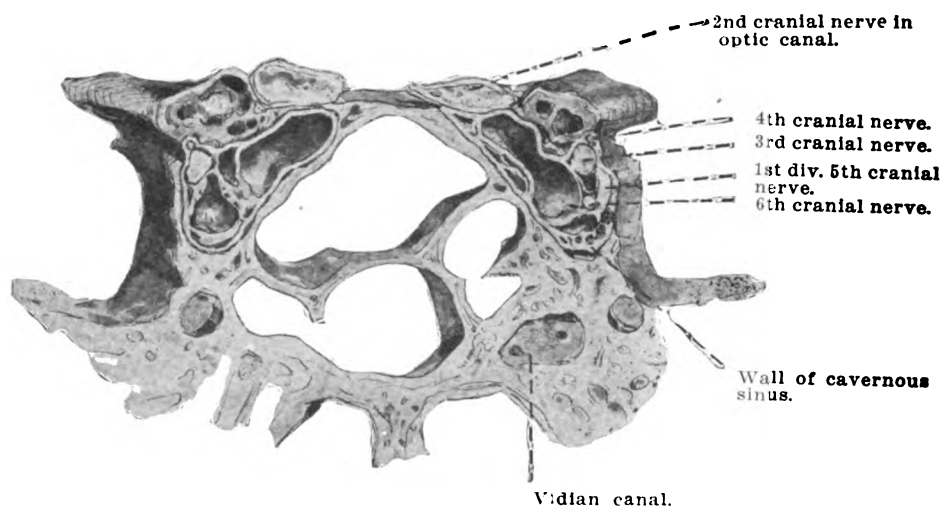


Fig. 1.

Cross section of a cavernous sinus of large length and breadth, at a point far forward, as indicated by the section through the optic nerves and anterior clinoid processes seen from behind, showing all nerve trunks well separated from sphenoidal sinus. This section shows only the right sphenoidal sinus.

ous sinus be large in length and cross section, these nerve trunks will usually be far removed from contact with a sphenoid sinus of any size. On the other hand, if the cavernous sinus be small in length or cross section these nerve trunks may be closely associated with a sphenoid sinus limited to the body of the sphenoid bone. Of course a small sphenoid sinus in the center of the body of the sphenoid bone will be widely removed from contact with these nerve trunks regardless of



whether the cavernous sinus be large or small. A sphenoid sinus of large extent—prolonged backward and outward—may readily closely approach the third division of the fifth in the foramen ovale (Fig. 2i, 2ii), and Dr. H. P. Mosher has shown me two specimens in which the sinus extended to a close association with

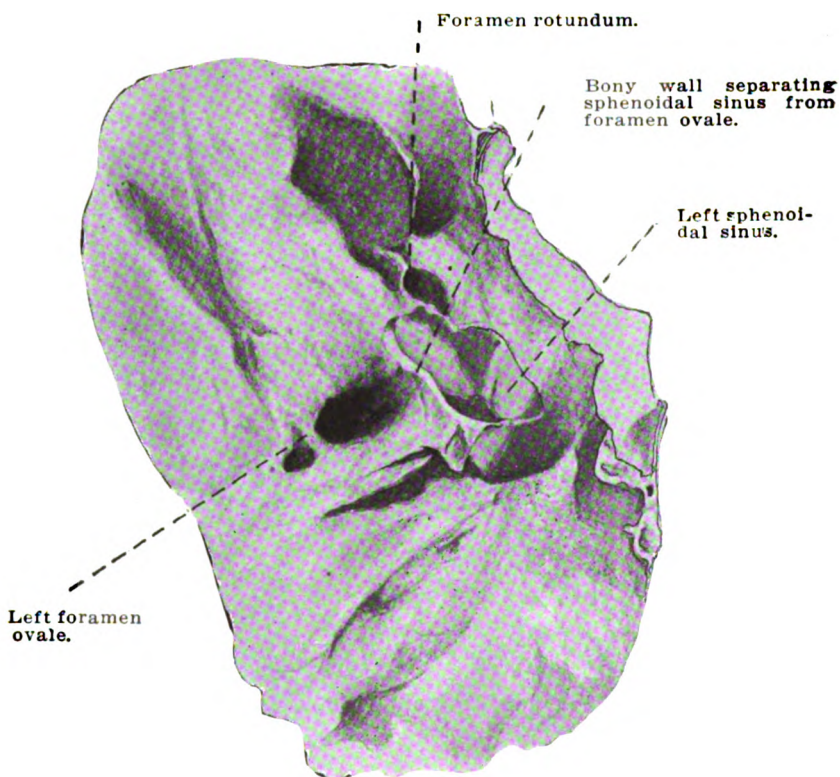


Fig. 2i.

Left sphenoidal sinus and foramen ovale seen from a point above and to the left.

the Gasserian ganglion. In these two specimens the internal carotid rising out of the foramen lacerum medium was surrounded on the internal half of its circumference by the sphenoidal sinus, the wall of which was less than the thickness of a hen's egg-shell at

this place. Fig. 4ii. A sinus extended downward soon approaches the Vidian nerve. In fact, the upper side of the bony case of the Vidian canal is often partly deficient under these circumstances. Fig. 2ii, 3, 4. The excavation may also extend below the level of the canal and leave it stalking through the sphenoid sinus like an ancient aqueduct, over the plain, connected with the bone below by a paper-like support. Fig. 3. Or it may be protected on one

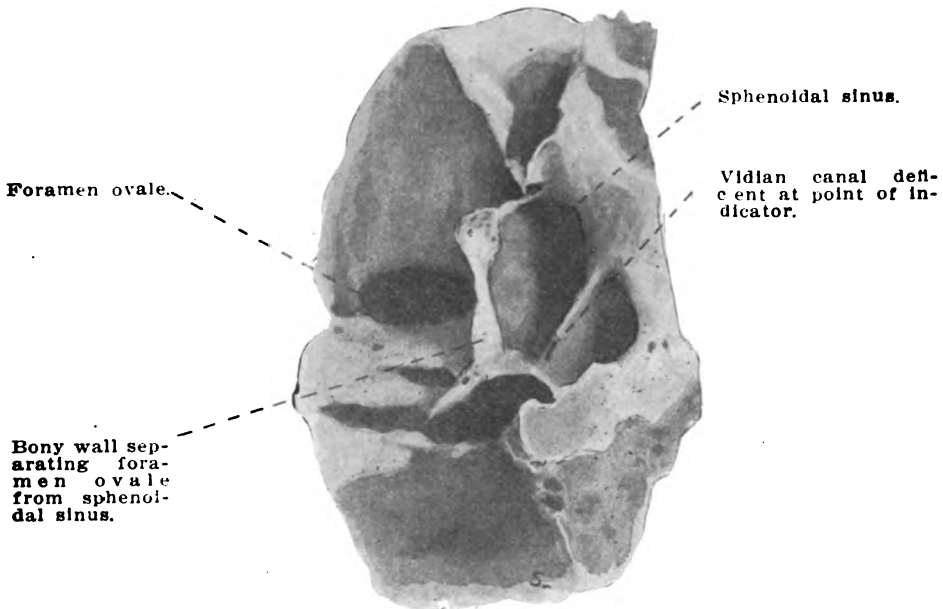


Fig. 2ii.

The same specimen as shown in Fig. 2i. Seen from a point above and to the right.

side of, and exposed on the floor of the sinus of the other side of the skull. Fig. 4. The sphenoid sinus extended laterally soon reaches the foramen rotundum and may then environ one-half of its circumference, bringing the second division of the fifth at this point and for some distance posterior to it in very close association with it. Fig. 5. The third and fourth nerves are in close association with the anterior clinoid process or lesser

wing of the sphenoid, which are not infrequently hollowed out by a prolongation of the sphenoid sinus or (from in front) by an extension from a post-ethmoidal cell, thereby bringing these nerves also into close association with these cells. Fig. 6. The first division of the fifth comes into close association with the sphenoid sinus anteriorly if the cavernous sinus be small in either direction. Figs. 7, 8.

Clinically the inflammatory diseases of the accessory sinuses of the nose vary greatly. Each has, however, some semblance of constancy in its behavior, at least as far as symptoms with signs go, with the exception of the sphenoid. As is known to

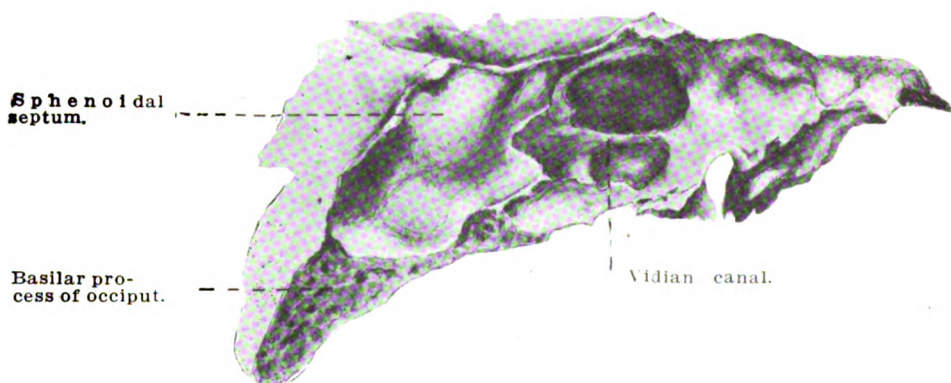


Fig. 3.

Interior of left sphenoidal sinus showing Vidian canal supported by thin bone with the sinus cavity above and below it. The canal is open on top.

us, it is no uncommon thing to see a sphenoidal empyema give rise not only to its own characteristic symptoms, but to simulate the pains produced by all the other sinuses. Pain of a frontal sinus inflammation may be simulated by a sphenoidal inflammation—the differential diagnosis being made by the absence of pus from the frontal, with no tenderness of its floor, as well as a negative finding on the Roentgen ray picture. The pain of a maxillary antrum inflammation may be differentiated by a negative antrum puncture as well as a negative Roentgen ray picture. Absence of pus in or from the ethmoid



would exclude the ethmoidal cells. These symptoms, when produced by the sphenoid, are, however, more apt to be nocturnal than diurnal.

It seems to me there are two pictures produced by inflam-

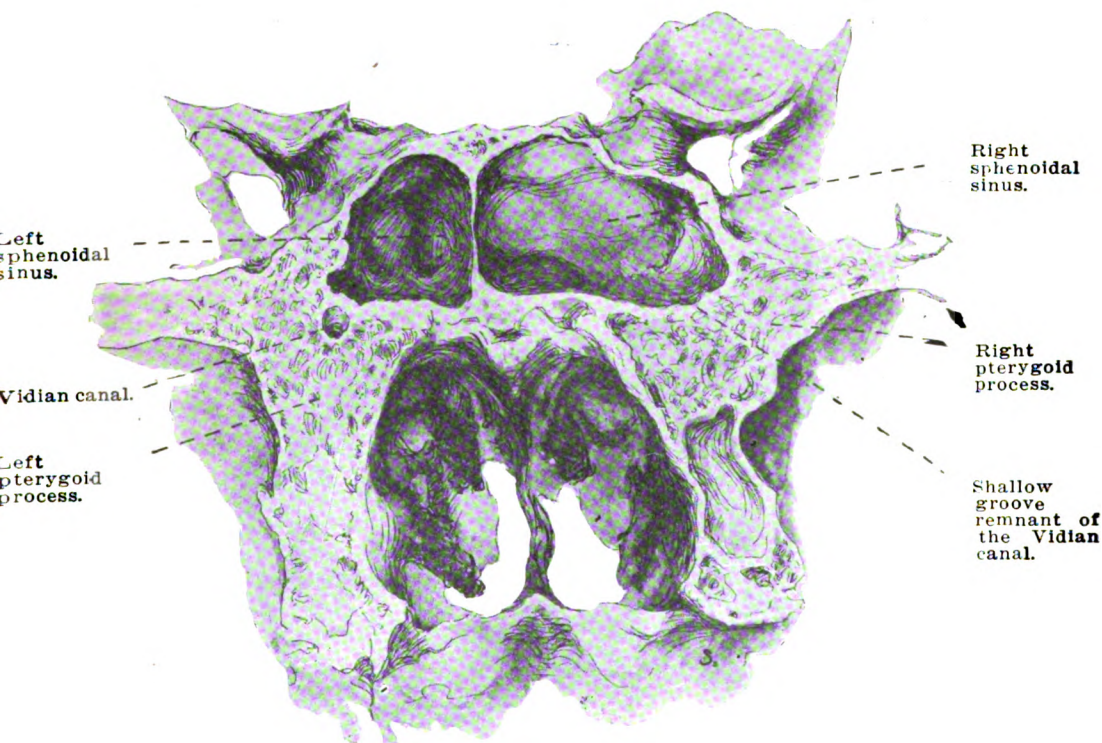


Fig. 4.

Cross section of a skull through the pterygoid processes. Seen from behind showing the Vidian canal of left side well imbedded in the bone; and that of the right side exposed in the sphenoidal sinus.

matory disease of the sphenoid sinus. The primary simple one being that produced by pressure from an obstructed out-flow of pus. I have construed this as the explanation of the somewhat "dull," "heavy" pain in the back of the head described by these patients. The more complex one, simulating

the pains which are ordinarily produced by the other sinus, can only be explained by assuming that the associated nerve trunks have become involved either by the inflammatory process or by its toxins. This assumption applied to the third nerve explains also the dilated pupil seen in some of these cases, when the ophthalmologist or neurologist can assign no reason

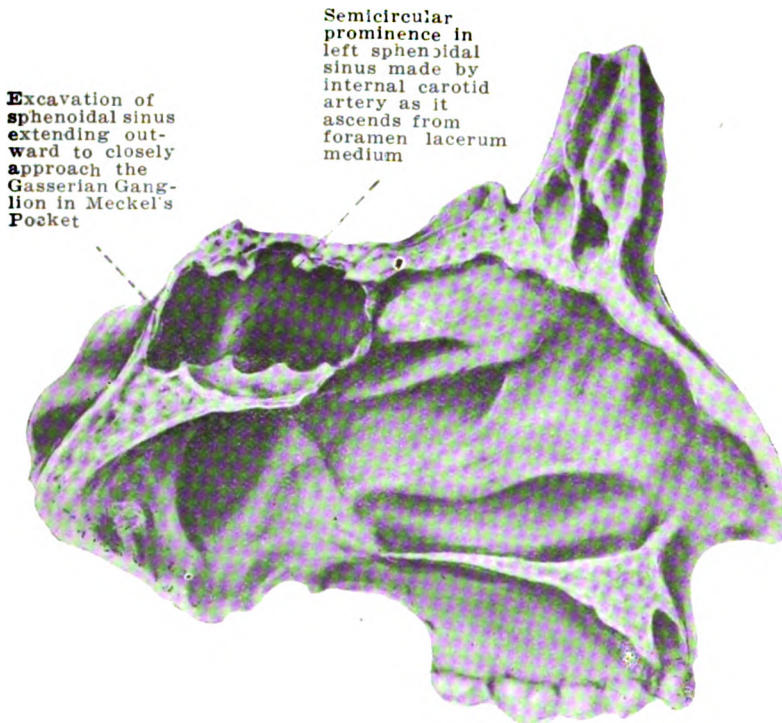


Fig. 4ii.

Picture of specimen loaned me by Dr. H. P. Mosher.

for it, and the asthenopia that is sometimes met with when no reason may be found in the eye or nose, otherwise. Some of these cases show a paresis of the superior oblique.

From the above sketched anatomy it would seem possible with the arrangements cited, by which the sphenoid sinus is

separated from the nerve trunks by thin divisions of bone that such an extension of inflammation might easily occur. In an effort to prove the accessibility of these nerve trunks I have ten times painted the cavity of the sphenoid in a stripe from above downward and outward with a very small applicator bearing about one-half drop saturated water solution of cocaine and paralyzed the three divisions of the fifth

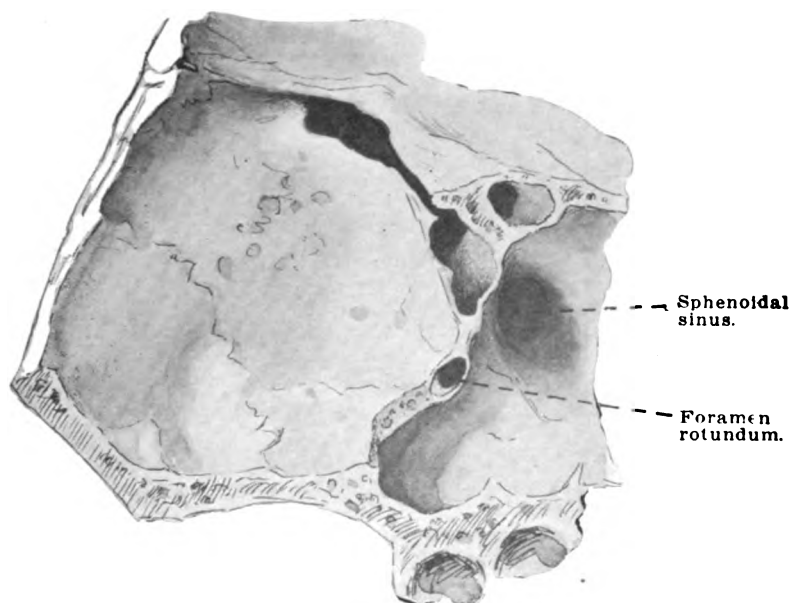


Fig. 5.

Middle fossa of skull showing foramen rotundum separated from sphenoidal sinus by thin film of bone.

for tactile sensation and pain, accompanied by a marked sense of stiffness of the lower jaw on that side. A needle passed through the skin supplied by these nerves failed to evoke sensation. In these cases the separating wall must have been a very thin one, thereby permitting the cocaine to pass quickly and easily through to the nerve trunks. I have also for therapeutic purposes filled the sphenoid with oil solutions—1 per



cent phenol, 2 per cent menthol, 5 per cent and 10 per cent oil wintergreen and 1 per cent cocaine alkaloid—and found that they all produce a well defined analgesia of the first and second and often the third division of the fifth, accompanied by very little or no tactile anesthesia. It therefore seems to me reasonable to assume, when the diagnosis is sphenoid empyema and the symptom is pain in the brow, that it is inflammation or

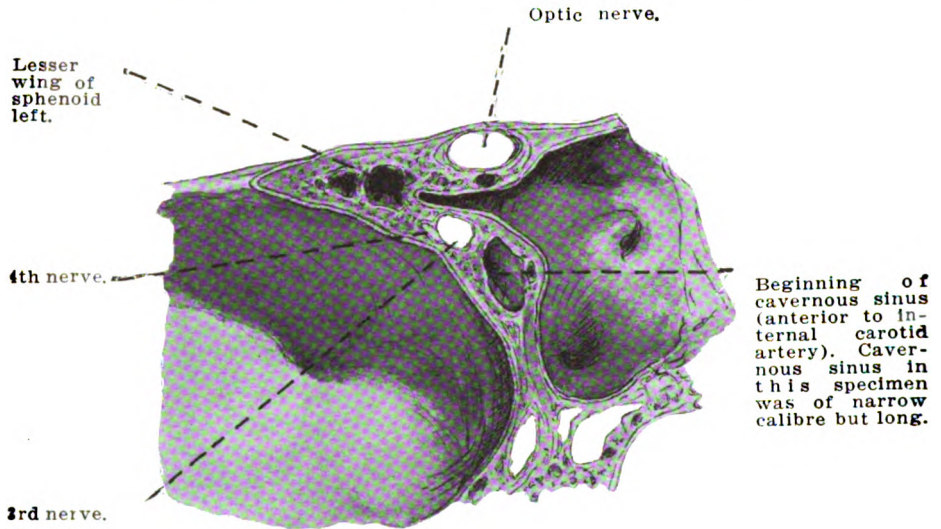


Fig. 6.

Left sphenoidal sinus seen from behind showing a prolongation into lesser wing of sphenoid, bringing 3rd nerve in close association with it.

irritation of the first division of the fifth by the process within the sinus which makes the symptom. When the symptom is pain in the upper jaw and teeth it seems reasonable to assume the second division of the fifth has become involved. When the symptom is pain in the lower jaw and teeth, accompanied by a sense of stiffness in the jaw on that side, it may be assumed that the third division has become involved and that probably in the foramen ovale.

The behavior of certain sphenoid empyemata has interested me much for several (5) years. These are cases in which the pains

and aches have continued unchanged despite wide opening of the cavities and cessation of all pus or signs of local disease. It is my habit to perform the Hajek "Radical Post-Ethmoidal Sphenoidal Operation." It seems to me the most comprehensive treatment. Some of these cases, however, although recovering from the suppurative inflammation, and later from all signs and symptoms, have frequently subsequently developed headache and behaved as cases of migraine. Dr. M. A. Bliss has seen a number of these cases in consultation and has sent some of them to me and has

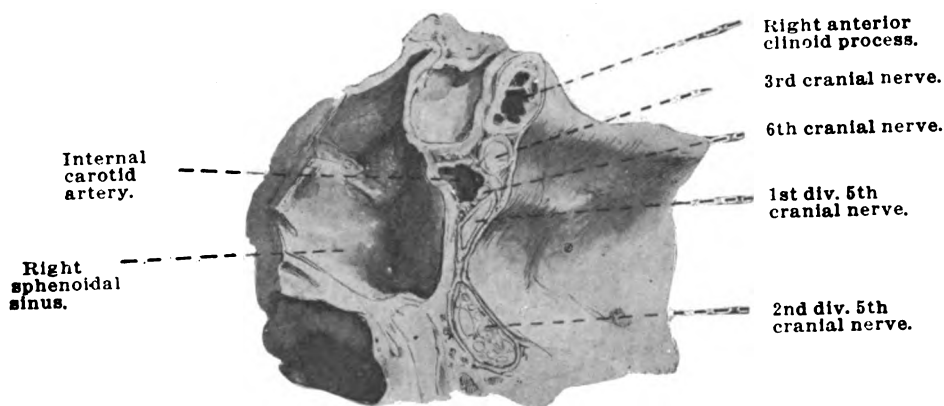


Fig. 7.

Cross section of right cavernous sinus (long and narrow), seen from behind, showing 1st division of 5th nerve in close association with sphenoidal sinus.

agreed in the diagnosis of migraine. We have felt that in at least this class of cases which have simulated and borne the name of migraine that the origin of the pain was a local one. These are of similar symptom complex to those of toxic origin. The distribution of the pain has been that suggesting as its origin the first division of the fifth, as, or well as, the second division, sometimes, or the third division, and combined at times with the posterior pain, which I have attributed to the irritation of the Vidian. In a recent paper<sup>1</sup> I mentioned that in the injection of

<sup>1</sup>"The Syndrome of Sphenopalatine Ganglion Neurosis," by Greenfield Sluder, American Journal of the Medical Sciences, December, 1910; also Trans. Am. Laryng. Assn., 1910.



the sphenopalatine ganglion with alcohol, that when the needle was placed too far internal the pain produced by the alcohol was projected backward and into the shoulder, etc., and when placed too far external the pain was referred to the upper jaw—that is, when the side of the ganglion upon which the Vidian enters it was injected the pain was referred posteriorly, whereas when the side upon which the second division entered it the pain was re-

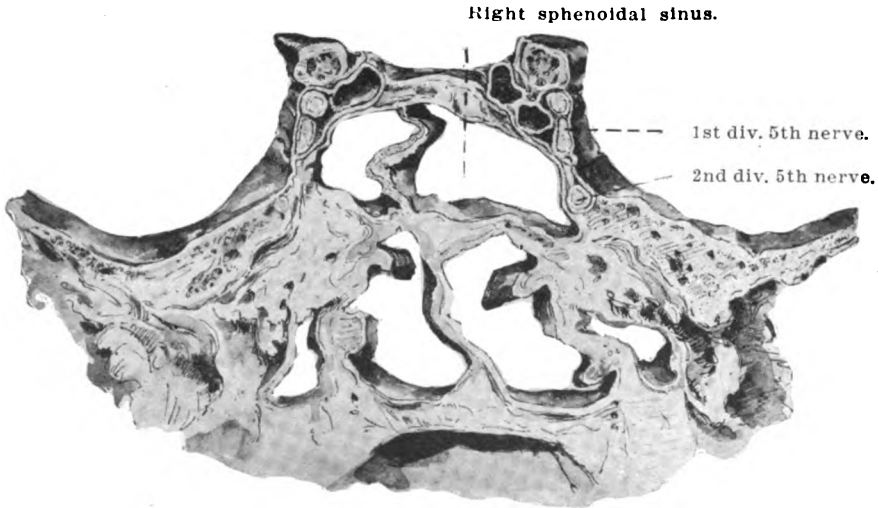


Fig. 8.

Cross section of sphenoidal sinus and anterior clinoid processes showing 1st and 2nd divisions of 5th nerve separated from sphenoidal sinus by thin bone.

ferred to the upper jaw. When the alcohol was placed in the ganglion direct the pain was referred in both directions. (The relative position of the Vidian and second division of the fifth is shown in Fig. 9, which portrays the foramina through which they pass at these points.)

These cases of recent origin (six months to two years approximately) when well of the suppuration were usually well of all symptoms and remained so until a coryza infected the general nasal cavity, when they again developed their pains, often with-

out suppuration of the sphenoidal and post-ethmoidal sinuses. The membrane of the sphenoidal sinus, however, usually showed under these circumstances a swollen, oedematous condition (even polypoid) analagous to that shown by the anterior ethmoidal region in hyperplastic ethmoiditis under similar inflammatory influences. In the recovery the swelling and oedema would subside, but more or less of the pain would continue, and at a time later begin a cyclical reappearance, with no visible disturbance in

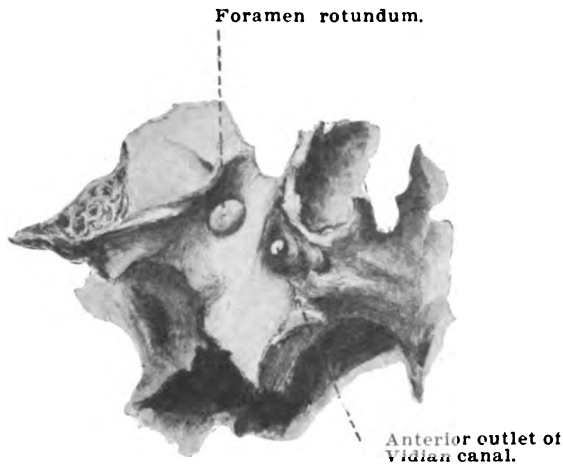
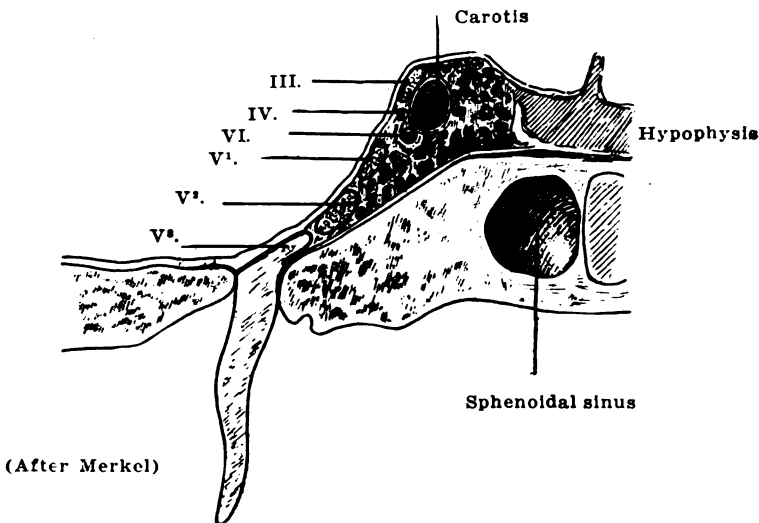


Fig. 9.

Anterior aspect of base of right pterygoid process, seen from in front.

the sphenoid sinus even when its anterior wall had a permanent opening in it large enough to permit a good view of its interior. I have observed a similar behavior of the sphenopalatine ganglion, i. e., intermittent reappearance of the neuralgia. I have also observed in these cases a picture identical with the neuralgia which starts in the sphenopalatine ganglion. This is not surprising—on the contrary, would be expected when one proves the accessibility of these nerve trunks. The entire nerve supply of that ganglion—namely, the second division of the fifth and the Vidian nerve—being so closely associated with the sphenoid sinus, the picture of the ganglion neuralgia is readily reproduced under inflammatory conditions within the sinus. The differential diag-

nosis, it seems to me, is made by the facts—that cocainezation of the ganglion stops the pain when it is originated in the ganglion, but fails to stop it when it is originated in the sphenoid, because the ganglion is peripheral to that point of origin; and that cocaine solution applied within the sphenoid sinus does stop the pain. In the case of ganglion neuralgia the membrane covering the sphenopalatine foramen is often, but not always, congested. This appearance is absent in the case where the pain is started in the nerve trunks from within the sinus.



(After Merkel)

Showing cavernous sinus and 3rd, 4th and 1st, 2nd and 3rd div. of the 5th and 6th nerves, hypophysis, sphenoidal sinus and carotid artery.

I have seen this class of sphenoidal cases behave as vaso-motor rhinitis or rhinorrhoea or "hay fever," as the patients call that form of paroxysmal sneezing accompanied by profuse watery discharge and by asthma. In these cases all therapeutical measures applied peripherally (intranasal) were of no avail. The cases yielded to intra-sphenoidal applications. The one so far most usually acceptable has been a 2 per cent to 5 per cent solution of sodium salicylate.

The history of one of these cases bearing on this phase of their behavior I herewith relate:

Case 1. Miss M. M., 37 years old, February 26, 1908, consulted me for general headache with great morning sneezing. There was swelling of the cavernous tissues in the nose with profuse general watery secretion; but no pus or visible evidence of sphenoidal inflammation. In the effort to control this syndrome the anterior nasal nerves were injected with alcohol (Stein) and trichloroacetic acid applied to the tubercle of the septum (Francis) and middle turbinate, finally the galvano-cautery to lower turbinates and tubercle, November 6, 1908; December 26, 1908. The nose was opened for air, but the sneezing continued. All efforts failed. She had to abandon a busy and very useful life for an indefinite period of rest. Dr. D. B. Delavan, who saw her in consultation, advised rest in the mountains. After six months in the mountains of the South she returned to St. Louis, well, and remained so for one year. At this time, March 17, 1910, she returned for treatment because of a "bad cold and headache," as she expressed it. She showed a bilateral post-ethmoidal-sphenoidal suppuration, for which I eventually operated, both sides (April 21, October 27, 1910). On January 10, 1911 she returned to me for an acute coryza with general headache and almost insufferable sneezing (sneezing to exhaustion) without evidences of post-ethmoidal-sphenoidal suppuration, for which she was again compelled to retire to the mountains. June 12, 1911, she again reported to me well. October 12, 1911, she consulted me because of intractable sneezing and general headache with intense burning, stinging sensation in the nose ensuing upon a coryza. This time I began the intra-sphenoidal applications of 1 per cent cocaine in oil, with 1 per cent phenol in oil, which controlled the sneezing and headache fairly well. A little later I began applications of 2-5 per cent sodium salicylate water solutions, which proved much more satisfactory—the sneezing and headache stopped in about six days. February 17, 1912, a coryza again made general headache and sneezing. This time, knowing that salicylate of methyl was a more potent remedy than the soda salt, and that it was usually tolerated, I filled the sphenoid with a 5 per cent solution synthetic methyl-salicylate solution in oil. To my surprise and disappointment it aggravated the entire syndrome in great severity, and in addition produced asthma lasting five days. A little later, after applications of the sodium salt, she became comfortable; and this in a much shorter time than in the preceding attacks. Locally this case behaves like a hyperplastic ethmoiditis. In the inflammatory stage the membrane becomes

oedematous with polyp formations, which subside when the attack is over.

That post-ethmoidal-sphenoidal inflammation may give rise to a periodic headache, which is usually spoken of as migraine, is illustrated by the following history :

Case 2. J. H. A., 37 years old, strong, healthy man, had never had a headache in his life that he remembered ; consulted me May 27, 1910, because of a severe left-sided headache which had lasted three weeks. He showed a left sphenoidal post-ethmoidal suppuration. His pain was parietal and occipital, for the most part, and irregular in severity, sometimes stopping. When severe it was combined with pain in brow and upper jaw. He was melancholic. Treatment was not satisfactory. (He was compelled to be out of the city five days of every week). On October 12, 1910, he took the proposed operation. The reaction was severe. He was free of symptoms in three months. March 4, 1911, he consulted me because of a coryza with pus which recovered spontaneously. January 6, 1912, he returned because of a coryza with headache, which did not recover spontaneously. At that time he did not show pus in the sphenoid. He had suffered greatly from intermittent general left side headache. Believing that the anaesthetic qualities of carbolic acid could be soaked into the nerve trunks in juxtaposition to the sphenoid, I filled the cavity with 1 per cent solution in oil, which stopped the pain in six hours. The cavity was filled once a week for three weeks, when he seemed well, and remained so until the next coryza, six weeks later, which was controlled by 1 per cent carbolic acid in oil. The left pupil is larger than the right during his attacks, and use of his eye is somewhat difficult at those times. He says his pupils were always equal before his headache began and are so now in the intervals between coryzas when he is well of headache. This case has so far not behaved as a hyperplastic ethmoiditis. In the inflammatory attack it shows only redress with little swelling, and sometimes pus.

Case 3. Mrs. Buc., aged 40 years, consulted the Nose and Throat Clinic, O'Fallon Dispensary, Washington University Medical Department, for severe headache, worse on left side, extending to neck and shoulders. All examination was negative. After considerable effort I determined a post-ethmoidal-sphenoidal inflammation R. and L., and later, February-July, 1910, opened both sides. The reaction was severe. After some months she was better, and finally became comfortable. A coryza without suppuration later re-established the pain, which on the

right side was stopped by intrasphenoidal applications of 10 per cent salicylate of methyl, and much improved on the left side. Applications of cocaine inside the left sinus quickly produced total anaesthesia and analgesia of the areas supplied by all the divisions of the fifth nerve, with a marked sense of stiffness of the lower jaw of that side, which I took to be the effect of the cocaine upon the motor function in the third division. Dr. D. E. Jackson, of the Pharmacological Department, Washington University, agrees with me in this conclusion. The right side ceased to be painful six months ago, which is shortly after the applications of methyl salicylate were begun. The left continues to be intermittently painful to a considerable degree, but is markedly helped by methyl salicylate, and remains vastly better than before this treatment was begun. She frequently complains of stiffness of the lower jaw on that side. Only once did this case show a tendency toward oedema with polyp formation at the time of acute inflammatory attack, and then only slight.

Case 4. Miss A. McM., 38 years old, consulted me March 20, 1911, because of intermittent headache from which she had suffered years. At this time it had been coming much oftener and has been rapidly growing more severe, then requiring  $2\frac{1}{2}$  grains of morphine sulphate subcutaneously administered by her physician to control the pain. She never took morphine herself. The pain was worse in left temple; but in the height of the attack it seemed to extend over the entire head. And very rarely it came on the right side alone or would be much worse on that side. A post-ethmoidal-sphenoidal inflammation was found on the left side, which was operated two months later. The reaction was intense. She improved little or none during the next four months under a treatment of simple cleansing of the cavities. At this time (October, 1911), intra-sphenoidal applications of 10 per cent methyl salicylate were begun with the idea of soaking the medicament into the environing fifth nerve. Since then the general improvement in her suffering has been very considerable. Much of the time she is free of pain and a large part of the remaining time she suffers only slightly. The recurrence of the intensely severe attacks is less frequent and intense. She recognizes two kinds of pain—one that I can stop by filling the sphenoid sinus with cocaine methyl salicylate or menthol solutions and another distributed over the same area which I have tried in vain to stop by these measures. When this attack begins it progresses despite all efforts to stop it; but it has become less

severe and less frequent under this treatment, and the last attack April 1, 1912, was on the right side only.

This case has never in any way suggested by its clinical behavior a similar condition to that of hyperplastic ethmoiditis. It has always appeared a simple inflammatory condition of low grade with once a suppurative stage also of low grade. Since the primary appearance disappeared this district of the nose has appeared normal.

Case 5. Mrs. C. Siek, aged 25 years, consulted me February 20, 1903, for an acute pan-sinus suppuration with general headache. Prior to this attack she had very rarely in her life been sick in any way. She did not remember to have ever had a bad headache, and had always been strong. She has done hard work (shoe machine) since her nineteenth year. Since this attack she has had, up to the present time (nine years), a recurrent headache that seldom skips more than ten days. Much of the time it is frontal, sometimes maxillary, and often intense combined with occipital pain. It is worse at night and during menstruation. Meanwhile I have opened the frontal sinuses and antra and ethmoids and sphenoids, and done everything known to possibly help (contacts, etc.). I have from time to time put her in charge of specialists in all the departments of medicine, who have found her normal, save hyperopic astigmatism, for which she wears glasses. November, 1911, I proved that her trigeminus was easily accessible (intra-sphenoidal) on both sides. Since then I have filled the sphenoid once in ten days with 1 per cent phenol in oil. She says that this is the first medication to help her pain.

All characteristics of a nose case disappeared from this patient by the end of the first three months.

I could report another case similar to this, of four years' standing, in which there has been a recurrent sphenoidal suppurative inflammation at long intervals with great exacerbation at these times.

Case 6. Mrs. M. D. A., 48 years old, consulted me June 11, 1910, because of right side recurrent sphenopalatine ganglion neuralgia, or, at least, what seemed to be such. It had lasted twenty-four years. It was stopped by cocainization of the sphenopalatine ganglion and controlled for one year by carbolization<sup>2</sup> of the ganglion, at the end of which time she suffered

<sup>2</sup>"A Phenol (Carbolic Acid) Injection Treatment for Sphenopalatine Ganglion Neuralgia," by Greenfield Sluder, *Journal of the American Medical Association*, December 30, 1911, Vol. LVII., p. 2137.

some kind of an explosion which took in her entire head, upper and lower part, on both sides, which confined her to her bed for four weeks despite acetphenetidin, aspirin, codeine and morphine. I did not see her during this illness. After this attack, however, she came to see me, but showed no local changes. She continued to suffer very greatly, and frequently from what seemed, from its distribution, a trigeminal neuralgia with pain in her occiput and neck almost altogether on the right side. After a careful explanation of her case to her, describing the local conditions and telling of a possible benefit from intra-sphenoidal medication, Dr. Bliss and I advised her to submit to the opening of her sphenoid, despite the fact that no sphenoidal inflammation betrayed itself. She accepted the proposal. Twice prior to the Hajek Radical Post-Ethmoidal Sphenoidal operation I injected a drop of 5 per cent solution carbolic acid<sup>3</sup> in 95 per cent ethyl alcohol into the sphenopalatine ganglion, each being allowed to rest five days with the idea of benumbing it and thereby reducing the reactionary shock. The pain of the operation under cocaine and the succeeding depression and pain were, in this case, astoundingly little. Subsequent filling of the sphenoid sinus with 2 per cent sodium salicylate water solution has been accompanied by a decided betterment, both in severity and frequency of the pain on the right side.

Case 7. Miss M. R., 21 years, consulted me March 24, 1912, because of a mild posterior headache with dilatation of the pupil on the right side, accompanied by discomfort in use of her eyes, of one week's standing. Ophthalmological examination was negative. An upright rod appeared to her bifurcate below, which, I understand, indicates a paresis of the superior oblique. The anterior wall of the right half of the sphenoid was reddened and bathed in serum. The effort was made to fill the sinus with 1½% sodium salicylate water solution. This was repeated three times in nine days, when she was free of all signs and symptoms, and remained so ten days, when she had a "sick headache" (in which I did not see her) and again had a dilated pupil which became normal when the headache stopped. No discernible cause could be assigned for the sick headache.

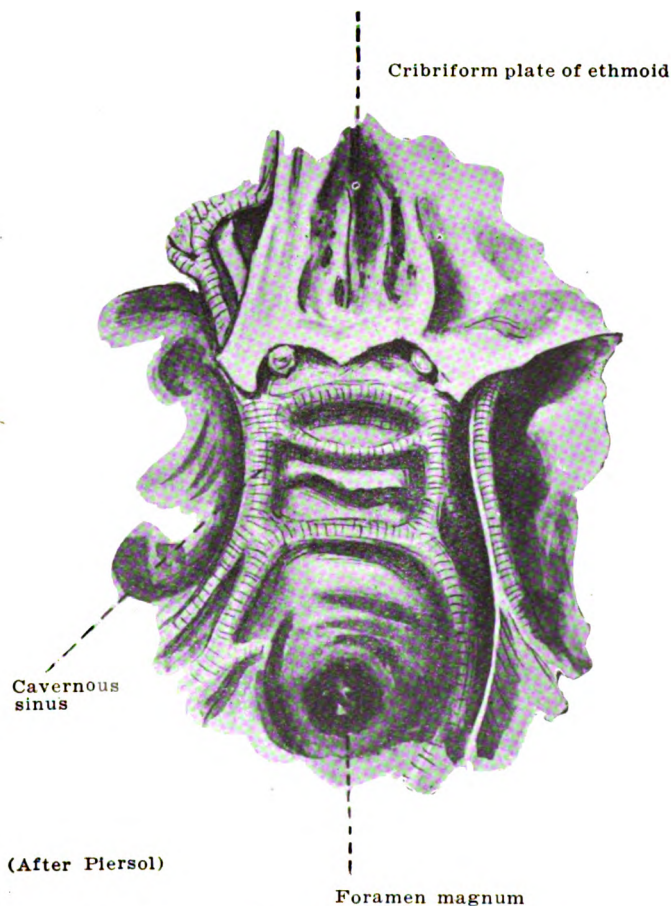
The difficulties that beset some of these diagnoses need not be considered by me. They were emphasized by Dr. Casselberry in his paper before this Association last year. I have selected a series of cases which pass by graded stages from the most evi-

---

<sup>3</sup>L. C.



dent to the least evident, if indeed Case 6 be admitted to the company of sphenoidal cases. These cases are not unique. They have been selected from a considerable number. Many times have I seen the same features in other cases, with the exception



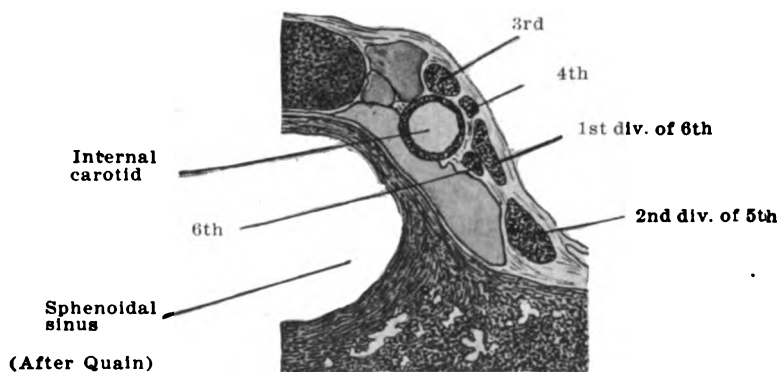
Showing venous formation of cavernous sinus.

of Mrs. M. D. A., Case 6, in whom I opened the sphenoid, which appeared normal, in order to permit of intra-sphenoidal medication in the effort to soak the remedies through bony walls directly

into the nerve trunks. It has been of apparent benefit under extreme circumstances; but the result is not of sufficient time standing to admit of conclusions. In the effort to forestall the shock and subsequent reaction and pain of Hajek's Radical Post-Ethmoidal Sphenoidal Operation I have five times carbolized the sphenopalatine ganglion with marked success.

Some of the other cases have had optic atrophy. The vision would diminish under coryzas. Pain lasted much of the time.

In the observation of these cases I am led to the belief that a large number of the frequently recurring headaches, of whatever length of time standing, that usually bear the name "migraine,"



Showing cavernous sinus and 3rd, 4th and 1st and 2nd div. of the 5th and 6th nerves, hypophysis, sphenoidal sinus, and carotid artery.

that are met with in the general practice of medicine, that have defied diagnosis and treatment, are sphenoidal inflammations existent; or were *started* as such. They may have lost all the evidences of local disease, which some months before were easily recognizable. I believe that the nerve trunks have become diseased from juxtaposition, just as the optic is known to do. Disease of the nerve trunks under these circumstances is in nowise different in its clinical behavior from that which is started further toward the periphery, as, for instance, from an antrum of Highmore sup-puration or a diseased tooth, which after the cure of the local disorder continues painful at intervals or becomes a *tic-douloureux*.

The second division of the fifth in the foramen rotundum is in almost as close association with the sphenoid sinus as is the optic nerve in the optic canal, and under identical setting, namely, surrounded completely by a firm, bony ring. This is true of the third division of the fifth also; but it is not, as a rule, so closely associated with the sphenoid sinus. Optic nerve disease, secondary to the sinus diseases, is too well known and proven to require argument from me. I see no reason why we may not assume as much for the other nerve trunks, in close association with these sinuses, with the difference between motor and sensory nerves.

This sphenoidal area being central to the place of injection of alcohol into the branches of the fifth nerve, from under the zygoma, may explain some of the cases that have not been relieved by that treatment. Also, for the same reason can we understand that when the Gasserian ganglion proper has become involved and gives rise to the pain, intra-sphenoidal applications will fail to relieve.

The involvement of the nerve trunks in the sphenoidal district producing the sneezing cited in Case 1 explains why the injection of the branches in the neighborhood of the sphenopalatine foramen (Stein), combined with the same treatment of the anterior nerves, has failed to influence the sneezing in some cases, the sphenoidal area being central to the other nerves.

It would appear from Case 2 that whatever may be the lesion of the nerves it is rather easily remediable in its earlier stages by intrasphenoidal medication. How far such patients as cases 5 and 6 may be helped by intrasphenoidal medication remains to be learned.

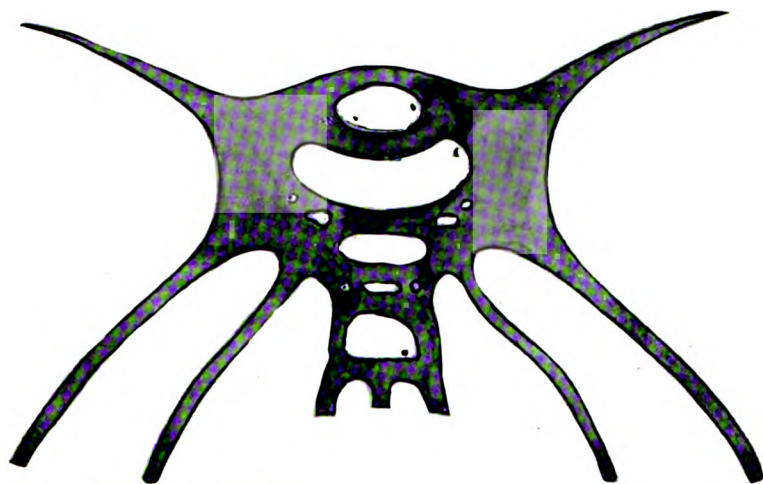
I have not thus far been able to secure any post-mortem material bearing on the above question.

The various medicaments mentioned above have been distinctly advantageous in the treatment of some hitherto irremediable cases (at least in my hands). There is, however much to be desired—many remedies remain untried. (In many respects this paper must be considered a preliminary report).

That the cavernous sinuses may become infected and thrombotic, secondary to sphenoidal infection, is well known. In these

considerations the cavernous sinus, however, plays only an anatomical part.

I have cited in the records of some of these cases that they behaved as a hyperplastic ethmoiditis, and that some did not. So far as I have been able to learn there is no post-mortem histological proof of a hyperplastic process in the sphenoid such as has



(After Rauber and Kopsch)

Showing venous formation of cavernous sinus.

been proven in the ethmoid. This possible condition has been thought to exist and reasoned out by Hajek in his third edition. He also laments the absence of post-mortem material.

#### *Discussion.*

Dr. Joseph H. Bryan, Washington, D. C.: This paper throws a great deal of light upon the post-operative pains in relation to suppurative diseases of the posterior sinuses. I have had a case that has given me much trouble; Dr. Mosher has seen this case once for me, and he can also tell you it has been one of great trial. This is a suppurating sinusitis of progressive nature starting in on the left side; it now involves all the sinuses of the head, all having been operated upon. In December, a year ago, I did the radical operation on this patient with a view of relieving in-

tense pain on movement of the eyeball on the right side, and on that occasion found the middle and posterior ethmoidal cells very decidedly involved, and I also opened up what we were not able to find through intranasal operations, a sphenoidal sinus which dipped down through the pterygoid process. This operation was followed by great relief so far as the movements of the eyeball were concerned, but she has never been free from pain, and she has suffered for ten or twelve years. Recently her condition has been growing worse. She is of a highly neurotic type, and has had four convulsions of an epileptiform nature, one the day before yesterday and one about two weeks ago. Her condition is evidently becoming of such a serious nature that something must be done more than we are now doing. As far as I am able to determine there is no sphenoidal cavity now on the right side, but I believe there is an injury to the Vidian, or some involvement of the nerves in that region, which is accountable for the pain keeping up. I believe what Dr. Sluder has said will throw some light on her condition.

Dr. H. P. Mosher, Boston: I had the pleasure of reading Dr. Sluder's paper before he presented it. I consider this pioneer work and work which has very great possibilities, therapeutically. Being pioneer work, it is very hard to discuss adequately, but it is not hard to praise, and I want to praise it heartily and to urge Dr. Sluder to persevere in it. Anatomically, I have followed him to quite an extent, and I can bear out certain of his findings; that is, very often, that the Vidian nerve runs through the sphenoidal sinus like a live wire, and the outward prolongation of the sphenoidal sinus, which tends to bring the sinus into relation with the Gasserian ganglion, is very common.

There are three points in the paper which especially interested me. First, the possibility of anesthetizing through the sphenoidal sinus, the various branches of the fifth nerve. I can see a large future for the use of this technique. Second, that there can be violent and protracted symptoms of neuralgia without any pus in the posterior ethmoidal cells or in the sphenoid. And the last point, which is even more interesting, is that you can avoid the severe shock which follows in certain operations on the posterior ethmoidal cells by preliminary cocaineization of Meckel's ganglion.

Dr. John O. Roe, Rochester, N. Y.: I have seen a very large number of cases of headache due to intranasal pressure, in which the patient was entirely relieved of the headache by eliminating this pressure. Many years ago I published an article which I had read before our State Medical Society on Nasal Headaches. This was before we had cocaine to assist us

in our work, but since that time, with the aid of cocaine, the relations between the headaches and the nasal pressure can readily be demonstrated before any operative procedure is undertaken. In nearly all of these cases I have found the pressure to be mainly in the ethmoid region and against the septum, and the pain referred to the occipital, the vertex or the frontal region, according to the exact location of the pressure. In many of these cases where the pressure is due to a large middle turbinate I find an inflated condition of the turbinal cells, which Turner so clearly describes. In some cases the anterior ethmoid cells are found much enlarged, causing pressure against the septum, and in other cases the posterior ethmoid cells. I might mention as an illustrative case that of a lady with intense headaches that I had entirely relieved by the removal of the intranasal pressure, caused by inflated turbinal cells. She came back three months later with a return of the headaches. On examination I found some granular tissue not larger than a pea pressing against the septum at the site of the former pressure. I removed this granular tissue and the headaches disappeared, as if by magic. I also recall the case of a lady who had suffered from the tic douloureux, in which I found the cause of the disturbance to be a diseased condition of the sphenoid, which, on opening, I found full of myxomatous tissue. Curettement of this tissue, thereby removing the pressure, relieved the disturbance.

I would like to ask Dr. Sluder what has been his experience with relation to this complication.

Dr. Emil Mayer, New York City: I would like to ask Dr. Sluder, in closing the discussion, to tell us briefly how he makes the application of an anesthetic to the sphenoidal sinus; how much is necessary to use in the majority of cases; how long a time he waits after the application before he operates.

Dr. Greenfield Sluder, St. Louis (in closing): I believe that Dr. Bryan's case is one of those which I have attempted to describe. Dr. Roe has mentioned contacts. In all of these cases there have been no contacts, most of them having the middle turbinates removed and pain still continuing. Some of them have had the ethmoidal labyrinth cut out in addition.

In answer to Dr. Mayer's question, the sphenoid must be opened to make it accessible, usually. The shock has been very great, as has also the post-operative reaction, until the last five cases, in which I carbolyzed the sphenopalatine ganglion. These cases are of somewhat recent execution, and it is difficult to pass on them, and there are a number of reasons why this should

be considered a preliminary report. In the intrasphenoidal medication some experimentation must be resorted to, to find which medicine will be borne. In one case I provoked the condition into severity by menthol. In the application to anesthetize the nerve trunks I have used a thin copper wire, tipped with cotton, with a small amount of cocaine, about half a drop, and that is curled with as wide a curl, approximately a right angle, as can be introduced into the sinus, and then turned for its cotton tip to stroke the outer wall from above downward and outward.

Just before leaving home I had two cases of tic douloureux associated with this sphenoidal condition, one corresponding to the second case cited by Dr. Roe, where there was a hyperplastic state of things in the sphenoidal district, but this is too recent for me to speak of conclusively.

I appreciate greatly Dr. Mosher's kindly criticism of the anatomical work.

## THE ANATOMY OF DEFLECTIONS OF THE NASAL SEPTUM.

BY OTTO FREER, M.D.

Of far more surgical consequence than the external form of deflections is their internal structure, my knowledge of which, taught me by my submucous resections by my open or flap method, virtual dissections upon the living, is here set forth. The insight into the distorted anatomy of the deflected septum so gained has also shown me how deflections come to be and the propriety, denied by me in my earlier experience, of grouping them into traumatic deflections and those due to faulty growth. I have also been convinced of the correctness of the conclusion reached in 1767 by Morgagni, attributing non-traumatic deflections to excess of growth of the septum as compared to that of the upper jaw, a conclusion shared by Chassaignac, Schech, Rethi, Schaus, H. P. Mosher and so many of the later observers that it may be regarded as nearly universally accepted to-day.

*Deflections from Growth.*

The Horizontal Crest Shaped Deflection.—This is the commonest type of deflection and is the one so often in part sawed away as a crest or ledge. When the septum grows too fast for the space allotted to it in the skull, either because it develops too rapidly for the nasal cavity containing it or because the nasal cavity lags in its growth, as in the case of a high arched palate, the resisted growth expansion subjects the septum to chronic pressure, which causes it to bend into one or the other naris or both nares. The growth-pressure may be merely horizontal between the sphenoid body and the nasal bones, or vertical between the base of the skull and the hard palate, or else be both vertical and horizontal. The horizontal pressure is the least effective, as it directly involves only the part of the septum between the



sphenoid body and the nasal bones, which can escape forward to form a Roman nose. The effect of the horizontal pressure is usually the formation of a vertical bowed or obtuse angled de-

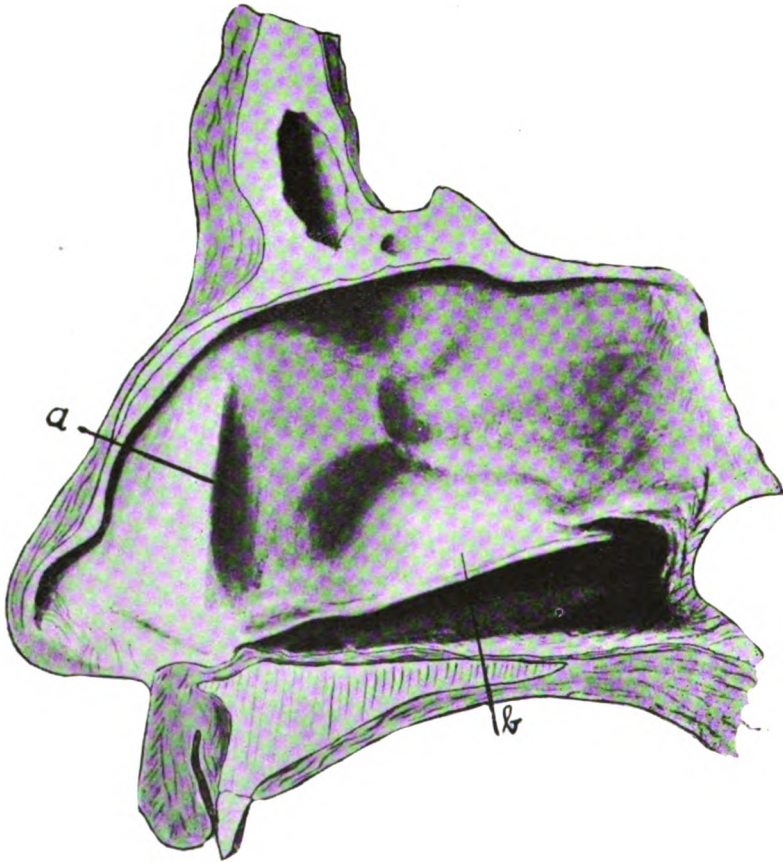


Fig. 1.

Side view of a vertical and crest (double-angled) deflection of the septum from growth; a, vertical (cartilaginous) angle of deflection; b, horizontal angle of deflection, or crest deflection extending upward and backward towards the body of the sphenoid bone.

flection in the cartilage, which extends more or less upward into the perpendicular plate of the ethmoid bone. (Fig. 1, a.)

The vertical pressure, taking place between the unyielding hard

palate and the base of the skull, includes the entire septum, and hence produces profound changes in both the bony and cartilaginous septum which result in the well-known crest or ledge (*crista lateralis* of Welcker), or, as I have termed it, crest deflection or horizontal angle of deflection, which, ascending from the incisor (premaxillary) crest (premaxillary wings of Mosher), follows the anterior border of the vomer upward and backward to a variable distance, sometimes as far as the body of the sphenoid bone. (Fig. 1.)

In the following description of the anatomy of the crest deflection I have tried to give a composite picture of what is typical, admitting that there are many variations from it.

The growing cartilage, pressing unduly down from above upon the anterior border of the vomer, and the growing vomer pressing upward from below against the posterior inferior border of the quadrangular cartilage, finally cause the cartilage to travel down upon and override the side of the vomer and drive before it that flange or wing of the vomeral groove which gives away most easily. At the same time the pressure bends over the entire vomer in the form of a half arch over the nasal floor, the bone proving plastic, as bone always does under chronic pressure. Thus there is no true dislocation of the posterior inferior border of the cartilage from its groove in the anterior border of the vomer, as has been alleged, for the cartilage, in overriding the vomer, carries the entire articulation down with it, broadening it and spreading it in varying degree over the side of the vomer (Fig. 2, Fig. 3, B, a—a), the articulation, normally a narrowed channelled surface that looks upward (Fig. 3, A, a—a), becoming a broad one that looks laterally and is indented to receive the projections of the roughened under surface of the cartilage. The posterior inferior border of the septal cartilage, thus carried down upon the side of the vomer, grows out into the thick, often sharp edged, cartilaginous crest (Fig. 2, a) so familiar to all and which rests upon the bony ledge into which the downward displaced wing of the vomeral groove hypertrophies. For this reason sawed off bony crests have a strip of cartilage upon them. The arched over vomer below and the overriding cartilage above, ending in

the crest just described, form the anterior osseo-cartilaginous part of the convexity of the crest deflection. It is continued posteriorly by the bony part formed by the union of the over-

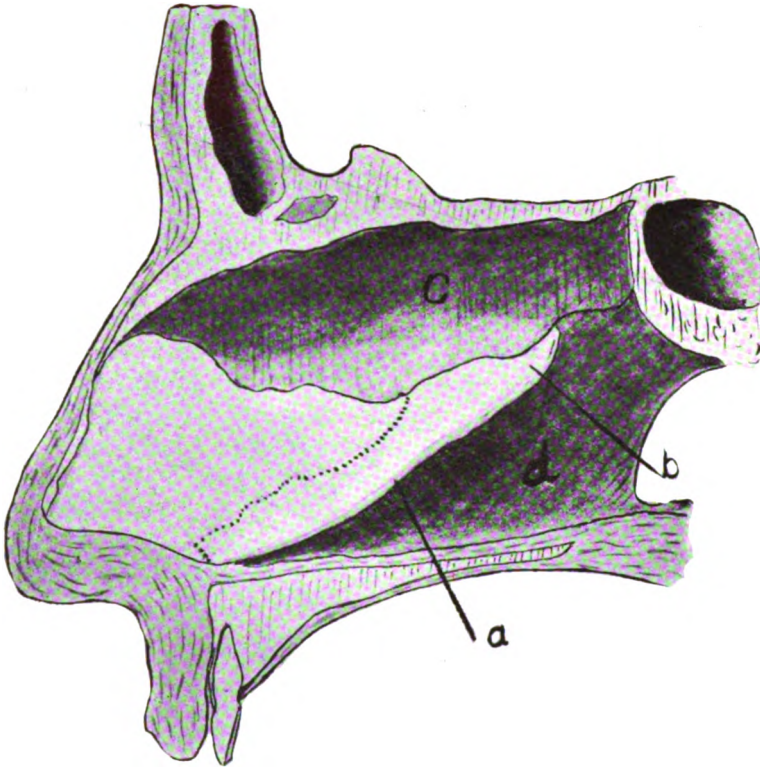


Fig. 2.

Side view of a crest deflection, showing overlapping of the vomer and incisive crest by the cartilage; a, posterior inferior border of the septal cartilage forming the well-known cartilaginous crest; b, posterior extension of the septal cartilage (processus sphenoidalis septi cartilaginei) normally within the vomero-ethmoidal joint, but here escaped from the laterally opened joint and applied to the side of the vomer; c, perpendicular plate of the ethmoid bone; d, vomer.

arching vomer with the posterior inferior border of the perpendicular plate, the two bones as seen after the removal of the cartilage forming an angle like a capital V (Fig. 4, Fig. 3, E, F)

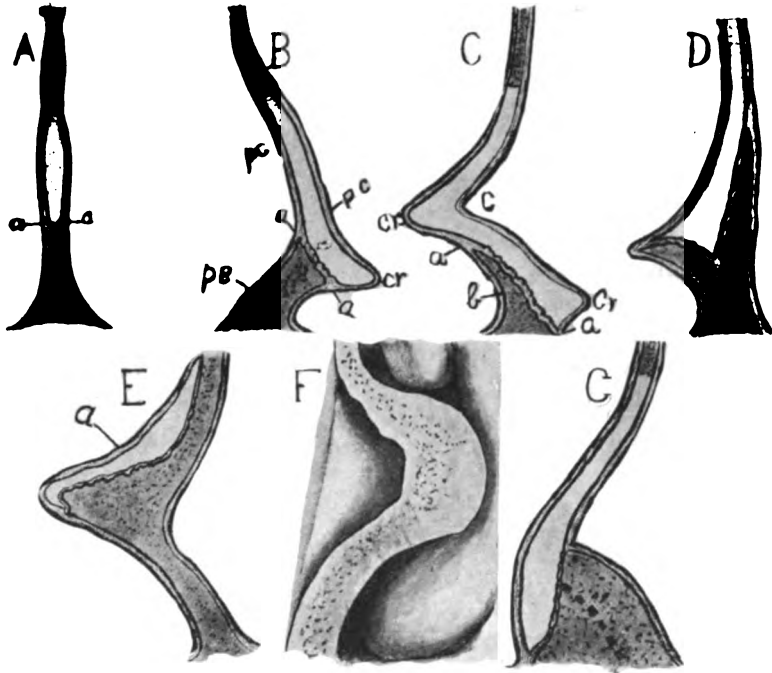


Fig. 3.

A, normal septum in vertical section showing perpendicular plate, cartilage and vomer. a—a, vomero-cartilaginous articulation showing crossing of blended periosteum and perichondrium from naris to naris; B, crest deflection in vertical section. a—a, displaced vomero-cartilaginous articulation slanting into naris of convexity; cr, cartilaginous crest; pc, perichondrium, pe, periosteum blending and crossing from naris to naris in the plane of the articulation a—a; C, type of crest deflection with slanting of the vomero-cartilaginous articulation into the naris of the concavity, with the formation of two crests and angular bending of the cartilage on itself to form a knee; c, concavity of the deflection; cr-cr, the two cartilaginous crests; a—a, line of vomero-cartilaginous articulation with crossing of blended periosteum and perichondrium. b, vomer. D, unusual case where flanges of vomer were wedged open by the downward pressure of the growing cartilage to form a crotch; E, the junction of the vomer and perpendicular plate to form the bony V; a, processus sphenoidalis septi cartilaginei (caudal prolongation of Mosher), escaped from laterally opened joint and applied to side of vomer and perpendicular plate. F, a very massive deflection without overhang of vomer, producing a nearly straight septum in the narrowed naris with typical concavity in the other. Dotted line shows where the thick, wedge-shaped vomer would ordinarily overarch the nasal floor. Such septa seem not to be in the median line, but really are so.

lying on its side, and for this reason I call this part of the deflection of the bony V. On the side of the vomero-ethmoidal joint facing the concavity of the V the edges of the perpendicular plate and vomer are firmly pressed together and united into one bone, but along the apex of the V the edges of the joint are correspondingly open, permitting the prolongation of the cartilage of the septum in the joint called the processus sphenoidalis septi cartilaginei (the so-called caudal prolongation) to escape and grow broadly upon the upper surface of the convexity of the V in the form of a long cartilaginous crest or strip (Fig. 2, b; Fig. 3, E a; Fig. 4, a), which continues backward the overlapping of

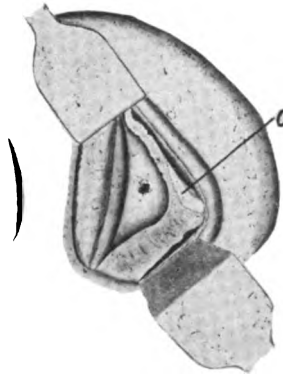


Fig. 4.

A typical bony V formed by the junction of the vomer and perpendicular plate, showing the hollow of the bony cavity and the covering of the opposite naris detached from the bone. The cartilaginous deflection has been removed; a, escaped processus sphenoidalis septi cartilaginei (caudal prolongation) of the septal cartilage, applied to side of vomer and perpendicular plate.

the septal cartilage over the vomer and may reach almost to the posterior border of the vomer.

In the naris opposite to the one containing the convexity of the crest deflection is seen the often deep and acute angled groove of its concavity, also ascending horizontally towards the sphenoid body. The bottom of the groove corresponds to the anterior border of the vomer, and the uppermost wing of the laterally

tilted and broadened vomero-cartilaginous and vomero-ethmoidal articulation, while the sharp edge of the crest in the naris of the convexity indicates the downward displaced wing, so that, in most crest deflections, the bottom of the groove of the concavity lies higher than the apex of the crest in the naris of the convexity and between the two extends the plane of the vomero-cartilaginous articulation whose situation is thus determined. (Fig. 3, B a—a.)

The lower surface of the groove of the concavity is therefore bony and is formed by the vomer arching over into the other naris, while the upper surface of the groove is cartilaginous in front and bony behind the junction of the perpendicular plate with the vomer.

The arrangement of the periosteum and perichondrium on the vomer and cartilage is important. The periosteum, ascending over the vomer in the naris of the convexity after passing under the cartilage and over the plane of the tilted articulation (Fig. 3, B, pe), descends into the other naris over the anterior border of the vomer, which, as stated, follows the line of the bottom of the groove of the concavity. The perichondrium (Fig. 3, B, pc), descending over the cartilage on the side of the convexity, passes around its thickened inferior border, indicated, as described by the cartilaginous crest (Fig. 3, B, cr), and, blending with the periosteum over the articulation, ascends into the other naris. Thus, in the two lines marking the borders of the tilted vomero-cartilaginous articulation, a periosteal bridge unites the coverings of both sides of the septum by passing through the articulation, and until, in the course of the denudation of the deflection, this bridge is divided by a sharp blade, the detachment of the coverings cannot progress below it. While the usually easily detached perichondrium is above the bridge, below it is the periosteum, grown firmly to the vomer and incisor crest.

Less frequently, instead of the typical crest deflection just described, the vertical pressure produces a variety of it in which the vomero-cartilaginous articulation instead of being tilted into the naris of the convexity slants into that of the concavity (Fig. 3, C, c and a—a), the cartilage overriding the vomer in this nostril. In this case two crests are formed, one at a higher level, in the naris of the convexity, formed by the bent out and hypertrophied

uppermost flange or wing of the vomeral channel, the other lying near the bottom of the septum in the naris of the concavity corresponding to the flange which has been carried downward into the naris by the overriding cartilage (Fig. 3, C, cr-cr) ; between these two crests extends the plane of the broadened and displaced articulation. The cartilage, in these cases, instead of merely applying itself flatly to one side of the vomer, as in the typical crest deflection, is bent at a horizontal angle upon itself (Fig. 3, C), in order to follow the tilting of the articulation into the other naris. In this variety of crest deflection the operator finds in the naris of the convexity the high, bony wall of the vomer between him and the overlapping cartilage in the other nostril.

In some unusual, but surgically important cases, in the typical crest deflection, the hollow under the arching vomer is filled with bone, the so-called ridge (a convenient, but inaccurate term used to describe the blending of the incisor crest, superior maxillary crest and vomer) having a wedge form with a very broad base (Fig. 3, G). In these cases the septum appears as if not standing in the median line, and seems fairly straight in the naris narrowed by its apparent displacement, while the other naris shows the usual groove of the concavity, which thus explains the condition. The chiseling away from the narrowed naris of a broad ridge of this kind places the septum in the mid line and so gives ample breathing space.

As the result of combined horizontal and vertical compression during growth a deflection results which, in addition to the usual crest shaped horizontal angle of deflection just described, possesses the usually rounded vertical angle in the cartilage mentioned as caused by horizontal growth compression, such angles often extending upward from the horizontal angle into the perpendicular plate. (Fig. 1, a.) When both the vertical and the horizontal angle are in the same naris I have called such deflections double angled. (Fig. 1.) Where the vertical and horizontal angle are in opposite nares, a horizontally sigmoid deflection is formed. Vertically sigmoid deflections occur when the upper surface of a crest deflection is concave in the naris of the convexity, the perpendicular plate and cartilage

in these cases bulging strongly into the other naris. I have not found such deflections common.

Very common are the deflections due to overgrowth of the anterior inferior portion of the septal cartilage (so-called columnar cartilage) ending below in the anterior inferior free border, which is driven downward by the excess of growth of the cartilage and so becomes displaced from its seat over the cutaneous septum, slipping down beside it and projecting into one or the other nostril. (Fig. 5.) These deflections may be

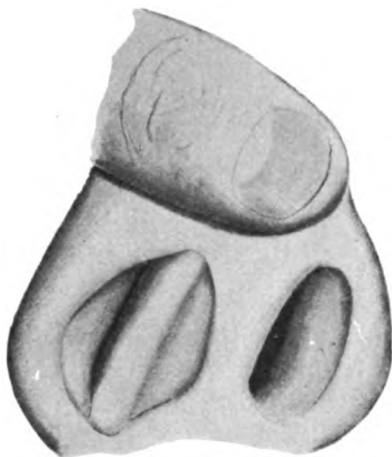


Fig. 5.

Dislocation of the free (anterior inferior) border of the septal cartilage from its seat above the membranous septum into the right naris, completely closing it.

limited to the columnar cartilage, or may be the continuation forward of the overriding of the cartilage in a crest deflection, the free border in this case projecting into the same naris as the crest, or else the deflected columnar cartilage forms the base of the anterior plane of a marked vertical angle of deflection in the cartilage, the free border in these cases lying transversely across both nares (Fig. 6), so that it protrudes obstructively into the one opposite to the angular deflection. This condition is especially characteristic of the extreme vertical angular deflections due to trauma, and is very often seen.



Where a displaced anterior inferior border protrudes as a white ridge into an external nostril its presence as a source of obstruction is obvious. Often, however, the deflected columnar cartilage applies itself so closely to the floor of the nasal vestibule and the side of the incisor crest and nasal spine that all that is noticed to indicate the condition is narrowing of the nostril to a slit, with consequent suction upon and collapse of the nasal wing concerned. (Fig. 7.) Feeling with a probe discovers the displaced free border along the foremost part of the base of the septum and the resection of the obstructing

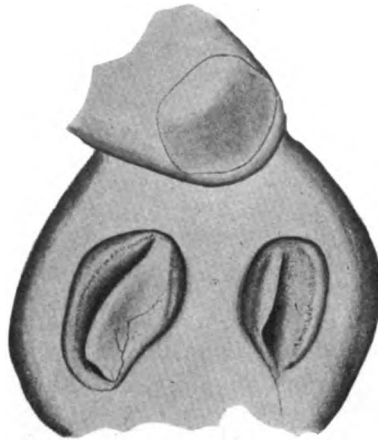


Fig. 6.

A typical traumatic vertical deflection with the anterior inferior border of the cartilage, forming the lower border of the anterior fragment, lying across both nostrils.

cartilage at once transforms the slit nostril into a wide one with cessation of the alar collapse.

Traumatic deflections.—As explained by E. von Bergmann, the bony part of the nasal septum is well protected against fracture, because of its sheltered position within the strong bones forming the nasal cavity, external force being only indirectly transmitted to it through the cartilage, in whose elastic substance it is lost before it can break the bony part of the

septum. While the vomer is quite beyond the reach of fracture the perpendicular plate may be broken in crushing injuries which drive in the upper half of the nasal bones, but transverse fractures at or below the middle of the nasal bones do not affect the perpendicular plate, whose articulation with them does not descend so far. For these reasons traumatic deflections are nearly all confined to the cartilage.

Von Bergmann describes luxation of the posterior inferior border of the cartilage from the vomer as an occurrence due to trauma. I have never seen it, and I think that the carrying over of the entire vomero-cartilaginous articulation by the overriding cartilage in crest deflections from growth, as described,

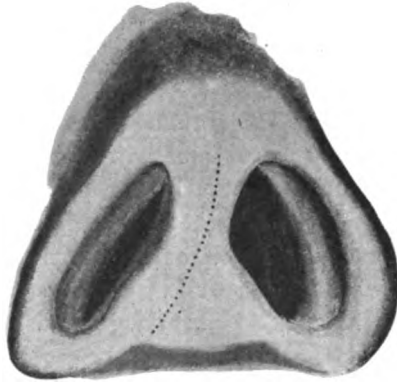


Fig. 7.

Concealed displacement of the anterior inferior free portion of the septal cartilage from its normal seat above the incisor crest to an attachment to its side, thus causing a slit nostril with collapsing ala. The collapse ceases when the free border of the septal cartilage is excised.

has been mistaken for a luxation. In a luxation the cartilage would not be firmly attached to the vomer, as I have always found it, but would be contained in its own capsule of perichondrium. Nor have I any reason to think that a blow upon the nose can cause the caudal prolongation of the septal cartilage to act as a wedge to disrupt the articulation between the vomer and perpendicular plate and cause the latter to break a wing of the vomeral groove, as described by Mosher.

The usual effect of fracture of the septum, as shown me in my resections, has been the production of a vertical angle in the cartilage (Fig. 6), usually placed well forward in or just behind the nasal vestibule and often so extreme and sharp that it presses against the external wall of the naris. The anterior plane of the angle may recede, lie transversely across the naris or both nares, or it may even form, with the posterior plane of the deflection, an acute angle whose apex advances toward the observer. The posterior plane usually forms a longer slant than the anterior before it reaches the mid line (Fig. 8, b), but usually does so before the bony septum is reached. The anterior plane of the vertical angle of deflection is bounded below by the anterior inferior free border of the septal cartilage, which thus, as described above, is often made to lie across both external nostrils and so to project into the one of the concavity. (Fig. 6).

The apex of the angle of a traumatic deflection indicates the line of fracture, and I have usually found the fragments in merely fibrous union, a fibrous bridge passing from naris to naris between them through the fissure left by the ununited fracture. Thus each fragment has its own perichondrial envelope. In denuding a deflection of this kind the dull elevator can not pass over the apex of the angle, because arrested by this fibrous bridge, and the bridge must be severed and the envelope of the posterior fragment must be split before its denudation can be accomplished.

The concavity of the angle of the traumatic deflection is often very deep and pointed. It is partly filled with a tongue of mucous membrane, which, after the removal of the cartilaginous angle (Fig. 8, a), retains the angular form in the mucosa like a cast of the concavity of the angle. This tongue must be carefully dissected from the hollow of the angle, for, if it is cut through, a large perforation results.

In a number of traumatic deviations the sharpness of the angle is much reduced by partial overlapping of the fragments. (Fig. 8, c.) This condition is to be suspected when the anterior part of a traumatically deflected septum is very thick.

In some cases of comminution of the cartilage even three overriding fragments may be found side by side, each in its own dense perichondrium.

A traumatic deflection moderate at the start may, through the changes of growth, gradually become extreme, and in some cases may even bend out portions of the bone.

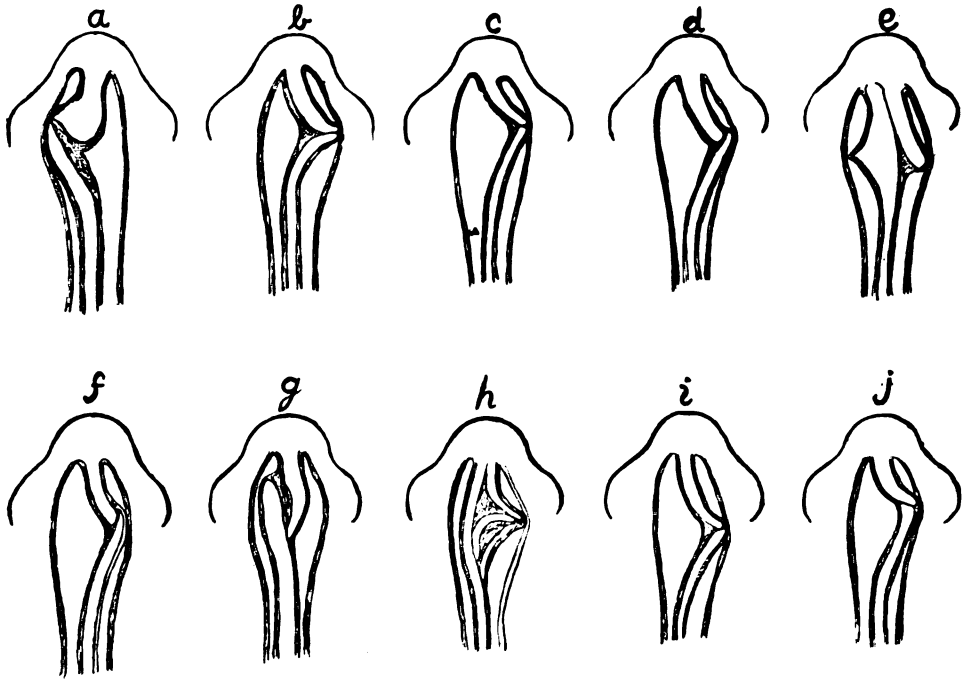


Fig. 8.

Series of horizontal sections through traumatic deflections; a, shows characteristic tongue of mucosa and perichondrium entering between fragments; b, d, e, f, g, h, show overlapping of fragments. All the deflections show fracture, each fragment in its own perichondrium.

As the result of the fracture, the coverings of traumatic deflections are often found to be thickened, fibrous and firmly adherent, so that such deflections often have to be dissected from their coverings with a keen blade.

Deflections of all kinds obstruct not only by reason of their

projection from the normal plane of the septum, but also because of the thickening of the septum which accompanies them. Thus the overriding of the cartilage in the crest deflection doubles the width of the septum, as does also the overlapping of the fragments from fracture. In addition, deflected bone is often greatly thickened, as if hypertrophied, to resist the pressure of abnormal growth. As an instance, I have found maxillary ridges from three-eighths to one-half of an inch thick, perpendicular plates from one-fourth to three-eighths of an inch thick, and the bony V may be very massive, even when set in thin bone. The mere thickness of a slight deflection may therefore indicate resection, and the gain in breathing space so secured by the thinning will be far greater than that obtained by the straightening. In contradistinction to this, the straightening of a deflection by fracture may help but little, because of the thickening of bone and cartilage remaining.

#### *Discussion.*

Dr. C. G. Coakley, New York City: I think we are all very much indebted to Dr. Freer for his very excellent description of these deformities, and especially for his description of the traumatic cases. I agree with him that these are the most difficult with which we have to deal, and sometimes when we least expect it to be so. A thickened septum, apparently presenting no great difficulty, and you begin to operate with the idea of completing the operation in the average amount of time, only to find that it takes from an hour to an hour and a half to get through to the part where the cartilage peels easily. The time spent in going through such a region carefully, however, is well worth while. If you attempt to hurry you will surely have a perforation.

Dr. B. R. Shurly, Detroit: Dr. Freer is certainly to be congratulated on the splendid classification and definite way in which he has outlined these anatomic principles, which have given us more or less difficulty in this operation. Recently I had an exceedingly interesting case, illustrating the difficulties and the erroneous idea which some of us get, perhaps from work of this kind involving the relief of a deflection of the anterior portion of the cartilage. The case was very similar to one shown by the author. A sub-mucous resection was done by one of our very competent operators, and a portion of this

anterior cartilage was left, the reason being given to the patient that if this cartilage were removed the nose would sag. The resection was done, and a perforation the size of a thumb-nail remained, with a considerable amount of obstruction on account of not completely removing the anterior piece of cartilage. The patient came to me suffering from the aesthetic appearances and from a whistling sound through the perforation. It seemed to me that it was possible to relieve both conditions with one operation, which I performed, taking out an anterior piece sufficiently large enough to relieve the nasal obstruction, dissecting the mucous membrane from either side back to the perforation, making a slit to slip in the piece of cartilage over the perforation, which I did, putting in a very carefully adjusted rubber cut splint on either side, packing it carefully, and the case healed most beautifully. The perforation and obstruction were both relieved; the patient was made happy. This was also an absolute demonstration of the erroneous view of the previous operator.

Dr. D. Bryson Delavan, New York City: It has been my privilege to see the patient referred to by Dr. Shurly within the past two weeks. His nose was in perfect condition, healing almost entirely complete, with every evidence of permanent closure of the opening. I am glad Dr. Shurly has reported the case, because it illustrates a procedure new and valuable in these unpleasant cases, where openings have been left and may otherwise remain.

Dr. E. Fletcher Ingals, Chicago: I have been greatly interested in Dr. Freer's excellent description of the anatomical conditions. I am fully in accord with his statement that these deflections are due partly to overgrowth and partly to traumatism. This has been my view for many years. I recall a priest with a spur in his nose who once came to me after having seen one of our former members. The patient inquired the cause of the condition, and the doctor, who favored the theory of traumatic origin, asked if he had ever had a blow on his nose. The patient replied: "Yes, and I have never known a boy with any spirit grow to manhood without at some time getting a blow on his nose."

Dr. W. L. Ballenger, Chicago: I have been very much interested in this illustrated anatomical exposition of deformities of the septum, and feel greatly indebted to Dr. Freer.

I would like information on one point. In my second edition and my third edition of my textbook I have given credit to Dr.

Neumann which I fear should have been given to Dr. Freer. He states in working in Dr. Neumann's clinic he first demonstrated this particular point that where the bone meets bone in the formation of the septum the periosteum grows continuously across, but where bone meets cartilage the periosteum does not continue upward, but turns down on the other side and goes to the floor of the nose and there forms adhesions which it is difficult to elevate. I was informed by one of Neumann's assistants that this had been shown by him, and to him I gave the credit. I did not speak to him last Summer about it and have no statement directly from him to this effect.

In taking a lateral view of the septum, when we get to the groove we have great difficulty in elevation, and there is the same difficulty on the concave side. We can elevate to a certain point and then have to stop on account of the deviation. In illustrating this I have shown that if we make an incision through the back of the lifted membrane along the crest of the vomer after the juncture forward, that we could easily lift after that by the use of the instrument, where before making this incision it would be impossible to do so without tearing the membrane.

As to the operation performed by Dr. Shurly, if I understood him, it was as follows: He elevates the mucous membrane around the perforation, inserts a piece of fresh cartilage, and all the margins of the mucous membrane overlap the cartilage and hold it in place, and the edges of the cartilage are freshened so that the perforation heals over by granulation, and the cartilage, after being absorbed, leaves only a fibrous connection between. This was demonstrated a few years ago by Dr. Goldsmith, of Toronto, and to him I have given the credit. He wrote an article a few years ago upon the subject, reporting a number of cases with perfect result. I have myself performed the operation once or twice with very satisfactory results.

Dr. Otto T. Freer, Chicago (in closing): The agreement of Dr. Coakley's experience with mine in regard to the difficulty of the excision of the imbedded fragments of a traumatic cartilaginous deflection shows the need of a cautious entrance into the intricate anatomy of deflections. Those authors, such as Killian, who have misled the inexperienced by describing the submucous resection as a simple little manipulation to be done in a few minutes, with half sharp, or dull instruments, have greatly injured the operation. In these gnarled traumatic deflections the surgeon is sure to encounter surprises, and needs time, the keen blade and sharp vision in order to avoid disaster.

Dr. Ballenger refers to a claim which was made for, not by,

Dr. Neumann, by Dr. Fletcher, of Chicago, assigning the discovery of the crossing of the periosteum and perichondrium from naris to naris to Dr. Neumann. Dr. Fletcher was in Vienna in 1908, when, after I had demonstrated this matter in London and in Berlin, I showed it in Dr. Neumann's school, and it was at this time that, according to Dr. Fletcher, Dr. Neumann described the periosteal crossing as his. In 1906, two years before this, I wrote a description of the crossing of the periosteum and perichondrium in a paper which was published in April, 1907, in the *Journal of Ophthalmology and Otolaryngology*. This article appeared in booklet form and long before Dr. Fletcher made his claim for Dr. Neumann.

The first description of the crossing of the periosteum and perichondrium from naris to naris was therefore made by me, and is my property. I am pleased to learn from Dr. Ballenger that he will assign the credit for the description to me in future editions of his book.



## ANESTHESIA FOR PERORAL ENDOSCOPY.

BY CHEVALIER JACKSON, M.D., PITTSBURGH, PA.

While it is impossible to lay down any hard and fast rules for anesthesia in tube work, yet I believe the time has arrived when we may formulate a few general principles from which deviation can be made to suit the particular case or the operator's personal equation. The herein given rules are respectfully submitted for discussion without any claim to either originality or finality.

Total abolition of the cough reflex should only be for short periods. The facile operator will do good work in many cases in spite of a moderate degree of cough. After a short period of tubal contact in bronchoscopy, coughing lessens and often practically ceases, especially in infants. Following the general rule in surgery, an anesthetic should never be used at all unless necessary; never in greater quantity than the needed minimum. In general surgery, anesthesia is required for three purposes: (1) The obtunding of pain (really analgesia); (2) the abolition of reflexes (relaxation), and (3) for psychic effect (mainly abolition of apprehension). For peroral endoscopy, analgesia is not required, for the pain in careful work is exceedingly slight; but anesthesia for the lessening of the reflexes, and for the lessening of the apprehension which intensifies the reflexes, is necessary under certain circumstances. These reflexes are manifested by spasmodic action of certain muscular systems, chiefly those of vomituration and coughing. In so far as these may be excited by mucosal contact they may be controlled by local anesthesia alone; for, of course, local anesthesia is purely and simply mucosal anesthesia. Muscular contractions, as well as pain, resulting from psychic mechanism, or traction upon tissues remote from the mucosa, can only be controlled by deep general anesthesia, and to a less degree, by the control of

the patient's mental state by the personality of the operator. The degree of this control varies widely with the personal equation of the operator as well as of the patient. The operator who can keep his patient free from apprehension and who can keep his patient's mind fixed on the task of breathing slowly, deeply and regularly will get along without any anesthetic and do better work than another operator under profound general anesthesia. As Brunings has pointed out, the operator who is not sufficiently practised to pass the tubes without general anesthesia is not justified in using general anesthesia to overcome faults in technic.

### *Esophagoscopy.*

1. For foreign bodies, no anesthetic is needed in either adults or children, except in case of very large and sharp foreign bodies, wherein the relaxation of the esophageal musculature, by deep general anesthesia, will obviate the trauma incident to the withdrawal of the intruder through a spasmodically constricted lumen.

2. In case of a sharp foreign body threatening perforation, especially open safety pins and fish hooks, it is safer to abolish antiperistalsis by deep general anesthesia.

3. In cases of suspected esophagismus and cardiospasm, the spasmodic element can be entirely eliminated by deep general anesthesia.

4. In cases of large foreign bodies, general anesthesia adds enormously to the danger of respiratory arrest from pressure of the foreign body on the trachea and on the peripheral nervous respiratory mechanism.

5. The use of a general anesthetic will greatly lessen the need for skill in the introduction of the esophagoscope; but such use is utterly unjustifiable.

6. Local anesthesia is needless for esophagoscopy. If used at all, it should be applied only to the laryngo-pharynx, never to the esophagus.

*Pharyngo-Laryngoscopy.*

For pharyngo-laryngoscopy or naso-pharyngoscopy with the Hays or Beck pharyngoscope or similar instruments, no anesthesia is required, except in relatively rare instances, when the local application of a 4 per cent cocaine solution to the fauces is sufficient.

*Direct Laryngoscopy.*

1. For diagnosis. In infants and children, no anesthetic whatever in any case. In adults who tolerate indirect laryngoscopy well, no anesthetic, general or local, is needed.

2. Foreign bodies. In infants and children, no anesthesia, general or local.

3. For the removal of foreign bodies from the larynx, both local and general anesthesia should be avoided, lest their application lead to dislodgment of the intruder.

4. For papillomata in children, no anesthetic, general or local, is needed. In adults, local anesthesia is usually necessary for accurate work, in removing specimens or entire neoplasms of any kind.

5. In a few adults, intolerant and uncontrollable general excitability, and in some cases of hysteria a general anesthetic may be necessary for accurate work in the removal of laryngeal neoplasms; but such cases are exceedingly rare.

*Tracheo-Bronchoscopy.*

1. For diagnosis, in children, no anesthesia, general or local; in adults, local anesthesia of the larynx in some cases; none at all in others. Rarely, local anesthesia of the trachea and bronchi, as well as of the larynx, will be needed.

2. For foreign bodies in the trachea and bronchi of infants and small children no anesthetic, general or local, is needed, except possibly in very complicated removals, such as in case of open safety pins. Foreign bodies in the trachea and bronchi of adults can often be removed without any anesthesia, general or local; but in many cases local anesthesia is needed. General

anesthesia is only needed in complicated cases where there is a stricture to dilate to reach the foreign body, or where the mechanical problem of removal is complex.

3. For the after treatment of stricture local anesthesia is sufficient, and in some cases none is needed, because tolerance to manipulation becomes established after repeated passage of the instruments.

#### *Lower Bronchoscopy.*

Tracheotomy.—If lower bronchoscopy is ever justifiable, it is only so in cases with extremely severe dyspnoea, and even in such cases the facile operator will slip in a bronchoscope, through which, with the aid of amyl nitrate and oxygen, artificial respiratory aid can be supplied with greater facility than through a tracheotomy wound. The occasional bronchoscopist will prefer tracheotomy, which never need be done under general anesthesia, and in a dyspnoeic case general anesthesia is utterly unjustifiable because as soon as anesthesia begins, respiration ceases, owing to the loss of the aid of the accessory respiratory musculature. The personal preference of the author, as between upper and lower bronchoscopy for any and all purposes, is in absolutely all cases for upper bronchoscopy, even if a tracheotomy shall have been already done.

#### *General Rules for Local Anesthesia.*

Anesthetic adjuncts, such as adrenalin, antipyrin and various synthetic compounds, the author has never used, consequently he cannot formulate any rules, even in a suggestive way, and he is compelled to rely upon Drs. Ingals, Coolidge, Mayer, Mosher, Winslow, Yankauer, Casselberry and other eminent co-workers to supply the deficiency. Doubtless, adrenalin by the ischemia which it induces, increases anesthesia and also prolongs it by slowing the carrying away of the cocaine by the blood. Bromides in large doses, some hours beforehand, as suggested to the author by Dr. Frank D. Sanger, of Baltimore, have a marked effect in lessening cough reflex, and lessening the amount of cocaine needed. Morphine has also, but its use is objectionable because

of after nausea, and in cases where repeated sittings are necessary, there is risk of drug habit. Heroin is an adjunct useful in some cases. None of these antitussives should be used in such large doses as to abolish the cough reflex for a long time because, as the author has frequently pointed out, the cough reflex is the watchdog of the lungs, quickly ridding the lungs of irritative and infective materials.

For esophagoscopy, local anesthesia is needless. If used at all, its application should be limited to the epiglottis and laryngopharynx (not hypo-pharynx). The esophagus is insensitive, as anyone may determine for himself by swallowing very hot coffee. After the pharynx is passed the burning sensation ceases, though sometimes it is felt again slightly when the stomach is reached. The following rules apply to the use of cocaine in the air passages:

- (1) Cocaine should never be used in infants or small children.
- (2) Its use should be avoided, if possible, in all cases, such as cases of papillomata, in which frequent sittings are necessary.
- (3) The patient should never know the name of the drug.
- (4) The amount used should be the minimum as to
  - (a) Strength of solution.
  - (b) Quantity of solution.
  - (c) Mucosal area touched.

Hence, only certain highly sensitive areas should be touched with the stronger solutions; the less sensitive areas receiving only the weaker solutions, either by direct application or by the incidental flow over the moist mucosal surface following the application of the stronger solutions to the highly sensitive areas.

- (5) Solutions may be applied by
  - (a) Spray.
  - (b) Syringe.
  - (c) Painting syringe (Brünings').
  - (d) Applicator carrying cotton or gauze saturated, but not dripping, with solution.

Preference should be given to either or both of the last two methods as being more precise. The spray is useful, if the operator desires to use any anesthetic at all in cases of foreign body in the larynx, as a spray is much less liable to displace the in-

truder than a swab; but for this very reason any form of anesthesia had better be omitted in cases of laryngeally lodged foreign bodies.

(6) The stomach should always be empty, not only because the tendency to vomituration and vomiting are thus lessened, but because, as proven by Brünings' absorption of cocaine, is thus lessened.

### *The Author's Technic.*

The author has two porcelain jars, thick and heavy, though small (about 2 c.c.), carried with the instrumentarium. In one, an 8 per cent cocaine solution is freshly prepared, and in the other a 20 per cent solution. The latter is known by a red band around the jar, burned into the porcelain. This solution is used only with extreme caution and in small quantity. In no case are the jars refilled, hence the total quantity is always limited; and, of course, most of it is thrown away in the swabs and escapes with the secretions, so that only a very small portion of the solutions is absorbed by the patient. Used in this way, the author has never had a serious symptom. This method was adopted after the death of a child in rhythmic, symmetrical convulsions one hour after the removal of a papilloma of the larynx under cocaine anesthesia. He has never, however, used cocaine in children since, and never will. All of his endoscopy on children under about seven years of age is done without any anesthetic, general or local, except in a very few cases of complicated foreign body extractions, such as the closure of safety pins. The author's method of application for local anesthesia is as follows: With a dossil of cotton held in a Sajous laryngeal forceps, the laryngopharynx is swabbed with an 8 per cent solution of cocaine, by sense of touch, without a mirror. After two minutes' wait, the slide speculum is introduced, and the posterior surface of the epiglottis is painted with a small gauze sponge saturated with the 20 per cent cocaine solution and carried in with a Coolidge applicator. A fresh sponge is saturated and carried through the glottis and down the trachea. After a two minutes' wait, the bronchoscope is introduced if necessary; deeper applications made as necessary. The posterior tracheal wall and the neighborhood of the

bifurcation are the sources of much reflex cough; and the bronchus to be entered may need an application; but the skilful operator will often dispense with local anesthesia after the first application, as the cough reflex in many instances soon ceases to be troublesome, and a certain amount of cough need not interfere with work. In case of impacted foreign bodies, it is of advantage to hold the swab in contact with the surrounding tissues for about ten or fifteen seconds.

### *Technic of General Anesthesia.*

For esophagoscopy and gastroscopy, ether or chloroform may be started by the usual method and continued by dropping upon a folded bit of gauze several layers thick laid over the mouth after the tube is introduced. Undoubtedly, there is a remote risk from the inflammability of ether, which is too often forgotten.

For tracheo-bronchoscopy, ether or chloroform may be started in the usual way and continued by holding a gauze sponge with a hemostat in front of the tube, though this means frequent interruption of the work as well as of the anesthetic. So far as interruptions of the anesthetic are concerned, they are, in the author's opinion, factors of safety, if care be taken to avoid excessively deepening the anesthesia to prolong the interval. Or, after starting in the usual way, chloroform and ether may be continued by means of the Buchanan attachment directly to the bronchoscopic tube, care being taken carefully to time the insufflations properly in relation to inspiration. The author prefers starting with ether, and continuing with chloroform, which is relatively quite safe after the stimulant effects of ether are established.

In conclusion, I beg to urge that every effort be made to work without any anesthesia at all. My work in this direction has convinced me that anesthesia, general or local, is relatively rarely needed for peroral endoscopy.

### *Discussion.*

Dr. E. Fletcher Ingals, Chicago: I have not seen the criticism referring to my use of atrophine, but I hardly think it

needs any defense. Atrophine is used in general surgery very commonly to prevent excessive secretion when administering ether. I have used it frequently and have no reason to regret it.

I formerly thought that bronchoscopy without an anesthetic would be unnecessarily painful, but shortly after learning Dr. Jackson's method I tried bronchoscopy without an anesthetic on a little child, for a nut in the bronchus, and it worked admirably. I think he is correct in his statement that it is not necessary to anesthetize these little patients. What he says about adults is also correct.

I do not see much, if any, objection to the use of cocaine in small quantities if employed in connection with adrenalin. Cocaine alone will give very severe constitutional symptoms and undoubtedly might cause death in some cases, but with adrenalin it may be used in considerable quantities and in strong solution with safety. Apparently the stronger the solution the better, according to Dr. Freer's experience. I understand that he takes a 1-1000 solution of adrenalin, with which he saturates a swab, which is then dipped into the crystals of cocaine, and this is applied thoroughly to the naris. Anesthesia is produced quickly and he claims not to get toxic effects. I thought he would kill some of his patients in this way, but I have not heard of any bad results. I have used this method often and have never seen any constitutional symptoms from the cocaine. I commonly use strong solutions of cocaine, but always with adrenalin, which prevents the constitutional symptoms, probably by retarding absorption. I generally use a 20 per cent. cocaine solution if used with adrenalin, without any ill effects, but I often got toxic effects when I employed only a 4 per cent. solution without the adrenalin.

I understood Dr. Jackson to say that lower bronchoscopy was never needed, but we must remember that probably he has more facility with the bronchoscope than anyone else. I admire his skill very much. I have always favored upper bronchoscopy first, excepting in cases with dangerous dyspnoea, but I cannot always succeed in this way. The plan that I advocate is to try upper bronchoscopy, and, if it does not succeed in a short time, at the same time or at a subsequent operation I do a tracheotomy and lower bronchoscopy.

Dr. Algernon Coolidge, Jr., Boston: I admire the amount of work that Dr. Jackson can do without anesthesia. Of course, any anesthetic, whether general or local, is in itself a possible source of danger. But anesthesia removes other



dangers and makes possible what we otherwise would not be able to do. Dr. Jackson has shown that for certain things anesthesia is necessary. For other things, although it is not necessary for him, it may still be impossible for most of us to do the work in hand without it. When it is possible to dispense with anesthesia the operator is forced to a careful manipulation which in itself is an advantage both to the patient and to the surgeon. We are again indebted to Dr. Jackson for his warning against reckless and unnecessary use both of general and local anesthetics.

Dr. H. L. Swain, New Haven: I agree with Dr. Coolidge that when we have a patron saint we should live up to the principles he lays down, and I have been able to believe that it was right for me to use the esophagoscope and do direct laryngoscopy without an anesthetic, but I did believe that it was not right for me to undertake the removal of a foreign body from the bronchus without a general anesthetic—I trembled at the idea. This last summer I did my first removal without anesthesia of a foreign body, half of a peanut meat, from way down in the right bronchus, in a child 11 months old, and I succeeded fairly well. I admit that I was forced into this because the gentleman who called me in consultation had twice tried with a general anesthetic to get into the trachea, but the child had taken the anesthetic so poorly that after about five minutes they had to stop, therefore they implored me not to attempt it in that way. For that reason, and because of my faith in Dr. Jackson, I undertook the matter and succeeded much more easily in the use of the instruments and the removal of the foreign body than I thought possible. I had to go in three or four times before I got the foreign body, but there was no trouble afterwards other than the extreme prostration from which the little patient suffered during early July because of the heat. I must add, however, that my faith was not quite strong enough so that I could do the thing without some local anesthetic, so I applied 20 per cent. cocaine and 1-1000 adrenalin to the interior of the larynx, and I believe this facilitated my getting the tubes back and forth very much. When Dr. Jackson once gets his tube in he does not remove it until he is through, but I am not yet so adept, and for me I think it is the safer plan when the struggling or dyspnoea becomes very marked to remove the tube and insert it later.

Dr. Otto T. Freer, Chicago, Illinois: My method of applying cocaine has been mentioned. I call the mixture used cocaine n.ud. In my experience, cocaine not only increases in efficiency

with the concentration employed, but out of all proportion to it. For instance, in full strength cocaine is more than ten times as active as in a ten per cent. solution. For this reason a smaller quantity of concentrated cocaine will give the same local insensibility as a larger amount of the diluted drug, while the chance of intoxication is proportionately lessened. I have never seen any alarming toxic effect from cocaine, but I have noticed that, in hysterical persons, cocaine may bring on an hysterical condition.

With regard to foreign bodies in the larynx, and the attempt to remove them without a local anesthetic. Local anesthesia diminishes laryngeal spasm, and the laryngeal spasm is one of the great obstacles to the removal of foreign bodies from the larynx. Sharp bodies are wedged in more tightly by the spasm, are hidden by the convulsively contracted laryngeal muscles, and can therefore be neither so easily seen nor so easily grasped as when the larynx is put at rest with cocaine.

As for lower direct bronchoscopy, it has this advantage, that a shorter tube is used, and, therefore, the leverage and possibility of injury done by the end of the tube reduced. To my thinking, lower direct bronchoscopy gives a better control of the situation, and, because of the preliminary tracheotomy, eliminates the danger of suffocation from possible laryngeal edema following the manipulations.

Dr. W. E. Casselberry, Chicago: I cannot see that the principles underlying the giving of anesthetics differ in bronchoscopy from those discussed so many times in connection with tonsil and adenoid operations, or from those of general surgical practice. Anesthesia is now customarily employed in a vast range of operations in which, though not impossible, it is inexpedient to dispense with it, and it is our part to use the anesthetic skillfully and with regard to the least danger rather than to withhold it altogether. I regard bronchoscopy as a subject in point; though the passage of the tube is possible, sometimes even easy, without anesthesia, for a specially skilled operator, it must be terrifying to the child and very disquieting to the parents, which are good reasons in my mind for anesthesia. That anesthesia *per se* involves some risk we agree, but inasmuch as it lessens spasm and facilitates, for most bronchoscopists, the passage of the tube, lessening the number of times it must be introduced and withdrawn, I doubt if the danger, in sum total, be greater in the hands of an average operator. However, local anesthesia is usually preferable for laryngoscopy, which often must be

repeated at short intervals. Cocaine alone may be inadequate and bromides help but little, but morphine given half an hour previously is a satisfactory adjuvant. I believe the danger of cocaine is overestimated if it be used with ordinary care. I have seen very few toxic symptoms since observing the routine of telling patients to expectorate any excess and not to swallow it, as it is chiefly that swallowed which is absorbed. The reason it has so little toxic effect when applied, concentrated, by Freer's method, is that there is no excess or overflow to be swallowed.

Dr. Emil Mayer, New York City: I want to agree most heartily with every statement that Dr. Jackson has made, and especially that lower bronchoscopy should be very, very rarely attempted. I am a little surprised that some may find it necessary to withdraw the tube once it has been placed in a bronchus; I have never had occasion to do this. Once I have inserted the tube I have never found the condition so serious as to withdraw it on account of the breathing; perhaps if the patient coughs very severely a mild spray of 2 per cent cocaine with 1-1000 adrenalin will relieve it in a few minutes. I think applications made to the larynx in the case of foreign bodies should be only from a mild spray, and the smaller the quantity and the smaller the dose the better for the patient.

None of us can equal entirely the skill of Dr. Jackson, though we try to follow him carefully, and each and every one of us agrees that he has laid down rules for us all to follow. Certainly for an intralaryngeal examination of the youngest child no anesthesia is absolutely necessary.

Dr. G. Hudson Makuen, Philadelphia: I welcome any suggestion which seems to do away with the necessity of extensive local anesthesia. I have come to be as much afraid of it as of general anesthesia, because I have recently had one or two somewhat alarming experiences with it. I have a patient now in whom I dare not try the submucous operation under cocaine on account of my previous scare with her in another nasal operation. She collapsed so profoundly that I feared she would not recover. Moreover, I do not use enough cocaine to cause dripping in the pharynx, and I use the adrenalin chloride with powdered cocaine, as suggested by Dr. Freer.

I read two or three days ago that the infusion of coffee with a hyperdermatic injection of a small dose of morphia absolutely prevents cocaine poisoning, and if this is true it would seem to me to be an important discovery.

Dr. Chevalier Jackson, Pittsburg (in closing): I hope I have not been misunderstood. I would be the last one in the world to

say that tracheotomy is never necessary; it is occasionally absolutely necessary for dyspnoea, but it is absolutely never necessary for bronchoscopy. I feel sure lower bronchoscopy is simply a relic of the days of poor illumination, when it was very difficult to get the light to the lower end of a long tube, but in these days, whether with a distal or a proximal lamp, you get plenty of light at the lower end of the tube. Illumination to-day is not what it was when Killian first created bronchoscopy. With modern illumination, distal or proximal, it is impossible to determine by looking through the tube whether the tube is long or short. The instruction is given in all the text books, and probably will be for years to come. "If you cannot succeed by the upper method, try the lower." This is a mistake. The lower is no easier. I had a Marathon racer for three hours under no anesthetic at all in removing a lump of coal from the bronchus. Had I stopped at the end of the first hour and used lower bronchoscopy I would have gotten it out, but no sooner, yet the success would have been credited to the lower route. If we will only keep on trying success will follow, and if we use a small tube the larynx will not be injured by a prolonged upper bronchoscopy.

Dr. Swain illustrates very clearly a very important point in regard to anesthesia. Circumstances arose which prevented his using the general and he used the local anesthetic and succeeded. We all of us have been using a general anesthetic where a local anesthetic would have been sufficient. We did not know it because we did not try.

Dr. Coolidge's suggestion that we try first with no anesthetic, then if necessary use the local, and if this still is unsatisfactory then resort to a general anesthesia, appeals strongly to me.

Dr. Freer's contention with regard to spasm, that any attempt at removal of a foreign body may cause spasm which will dislodge the intruder, I quite agree with, but the application of an anesthetic, either local or general, may do the very same thing. Therefore a spray seems best, as it excites a minimum amount of spasm.

Perhaps another misconception of conditions is in regard to what Dr. Freer said of the advantages of the lower bronchoscopy, which is, in my opinion, erroneous from a mechanical point of view. The upper thoracic aperture is the fulcrum which cannot be changed, and simple mechanics will show that you will gain as great latitude of motion by moving the patient's head and neck to the opposite side as can possibly be gained through a tracheotomy wound.

With regard to Dr. Casselberry's remarks, one general difference between our work and that of the general surgeon is that we are dealing with the air passages. That makes the problem very different; most of the surgeon's work is remote from the air passages. Where the anesthetic is introduced is where we are working, for in almost all cases the anesthetic, whether local or general, is introduced through the air passages.

I was delighted to hear Dr. Mayer's opinion regarding anesthesia in direct bronchoscopy, for he has had abundant experience.

In conclusion I would like to ask you all to test the matter and see if you cannot agree with me that in adults general anesthesia is often used where local would suffice, and that in small children no anesthetic at all is needed.

## APHTHOUS ULCERATION OF THE UPPER AIR-PASSAGES IN PULMONARY TUBERCULOSIS.

## A Retrospect and a Review.

BY JOHN N. MACKENZIE, M.D.,

There is perhaps no subject in the whole domain of laryngeal pathology which has excited such universal interest and awakened so much animated discussion as the pathological conception of laryngo-tracheal phthisis. The association of ulcerative disease of the upper air passages with pulmonary consumption has been recognized from an early time, and, although over a century has elapsed since the publication of Petit's little classic,<sup>1</sup> the most divergent opinions prevailed concerning the correct interpretation of their reciprocal relationship. The older writers described only one form of ulceration, and busied themselves with the question of a laryngeal phthisis, in the generic sense of the term, without making those finer histological distinctions which pathological anatomy later developed. The existence of true tubercle as the chief etiological factor in the production of what is commonly known as phthisis laryngea cannot be gainsaid, in the light of pathological investigation, and it now only remains to be decided whether all forms of ulceration of the upper air passages which are encountered in the course of pulmonary tuberculosis are to be referred directly to the tubercle bacillus as their primary cause, or whether, on the other hand, there are not some which may be regarded as owing their origin to influences associated with, but not necessarily dependent upon, the true tubercular process.

I propose in this paper to consider a variety of ulceration which has an important bearing on this question, and which,

---

<sup>1</sup>De phthisi laryngea, Monspeteer, 1790.

on account of its more frequent localization in the lower portion of the trachea and bronchi, and its usual occurrence in the later stages of pulmonary phthisis, comes more within the notice of the pathological anatomist than under the eye of the clinical observer. It is probably due mainly to this fact that it has been overlooked by many of the leading writers on diseases of the throat, notably in England and America, and its existence lost sight of in the discussion of more pressing and therefore more engrossing questions.

This, the so-called aphthous erosion of the older writers, was first depicted in the atlases of Cruveilhier<sup>2</sup> and Albers,<sup>3</sup> and clearly distinguished from tubercular ulceration by Rokitansky.<sup>4</sup> In his *Lehrbuch der pathologischen Anatomie*, Rokitansky calls attention to round or oval erosions of the mucous membrane, surrounded by a scarlet border and covered with a yellowish slough, which are found, during the course of pulmonary phthisis, in great numbers in the trachea, and which, after the extrusion of the slough, coalesce and lend to the membrane a sieve-like worm-eaten appearance. These, which are not to be confounded with tubercular ulceration, are found, according to this distinguished observer, in greatest number on the side of the trachea corresponding to the lung whose disorganization is the more pronounced.

Föster,<sup>5</sup> who also clearly recognized this peculiar form of ulceration, whilst admitting its aphthous nature and pointing significantly to the fact that it may resemble tubercular ulceration so closely as to render an appeal to the microscope necessary to differentiate them, asserts as the result of his observations that the majority of the so-called aphthous erosions of the trachea are in reality tubercular. On the other hand, many authors look upon these ulcers as catarrhal (Louis,<sup>6</sup> Trou-

---

<sup>2</sup>Livre 35, Pl. 4, Fig. 3.

<sup>3</sup>II., Tafel 13, Fig. 4.

<sup>4</sup>*Lehrbuch d. path. Anatomie*, Wien, 1861, Bd. III., S. 19.

<sup>5</sup>*Lehrbuch d. path. Anatomie*, Jena, 1864, p. 312.

<sup>6</sup>*Recherches sur la phthisie*, Paris, 1825.

seau,<sup>7</sup> Andral,<sup>8</sup> Hasse,<sup>9</sup> Rheine,<sup>10</sup> Rühle,<sup>11</sup> Heinze,<sup>12</sup> and others), or, as Rindfleisch recently has done, refer them to follicular ulceration; whilst their tubercular nature is maintained by Isambert,<sup>13</sup> Ziegler,<sup>14</sup> Eppinger,<sup>15</sup> and others. Eppinger, who describes them as *tubercular arrosions*, held in the absence of absolute histological proof of direct tubercular infiltration, that they are, notwithstanding, specific tubercular products, and suggested that they may be evoked through the operation of the *monas tuberculosis* of Klebs.

Many years ago I examined the respiratory organs of all patients dead of tuberculosis in the Rudolph and Jewish hospitals of Vienna during a period extending over five months, and published the results of the examination of this abundant material in the *Monatsschrift für Ohrenheilkunde*<sup>16</sup> in Berlin.<sup>17</sup> I wish to-day to present to you a description of this aphthous erosion, based upon an analysis of these cases, and to attempt to define, as accurately as possible, the relations between it and pulmonary tuberculosis.

*Microscopical Appearances.*—Aphthous ulceration appears as small, for the most part superficial, irregularly round or oval erosions of the mucous membrane, which vary in size from a pin's head to a small pea, and which, separate and distinct, stud the surface of the membrane, or, coalescing, form a large ulcer, which spreads in an irregular manner over the mucous surface. Commencing as superficial erosions of the mucous membrane, with tolerably defined margins, they assume later a more characteristic appearance; their walls become sharp.

<sup>7</sup>Traite de la phthisie, laryngée, Paris, 1827.

<sup>8</sup>Clinique medicale, Paris, 1820, Tome II.

<sup>9</sup>Spec. path. Anatomie, Leipzig, 1841, Bd. I.

<sup>10</sup>Virchow's Archiv., 1853, No. V.

<sup>11</sup>Die Kehlkopfkrankheiten, Berlin, 1861.

<sup>12</sup>Die Kehlkopfschwindtsucht, Leipzig, 1870.

<sup>13</sup>Lehrbuch d. path. Gewebelehre, IV. Auflage, Leipzig, 1875.

<sup>14</sup>Annales des Maladies de l'oreille, etc., II., 3, p. 162, 1875.

<sup>15</sup>Volkmann's Vorlesungen, VI. Serie., S. 1305.

<sup>16</sup>Path. Anatomie des Larynx u. der Trachea, Berlin, 1880.

<sup>17</sup>No. 9, 1881. Ueber die sogenannten Substanzverluste auf der Schleimhaute des Larynx, der Trachea u. der Bronchen bei tuberculöser Lungen phthisie. See also a paper in the Transactions of the Medical and Chirurgical Faculty of Maryland, 1882. "Diphtheritic Ulceration of the Upper Air Passages and Its Relation to Pulmonary Phthisis."



irregular, and somewhat elevated, and vary in color from a light reddish shade to a pronounced livid hue. The base is either smooth and red in color, or presents a rough, uneven appearance. It is generally covered with a yellow slough, or with a more or less orange-colored exudation. The ulcers are surrounded with a brilliant scarlet border, and the mucous membrane between them is slightly swollen and deeply hyperaemic, thus forming a pathological picture of great beauty. These ulcers, which are always multiple and never single, are most frequently met with, and are by far more abundant in the lower portion of the trachea and bronchi; in the former the posterior wall seems to be their most frequent seat, though the whole mucous membrane may be covered with them. I have seen the trachea in its entire length and circumference, together with the bronchi of both sides, almost completely destroyed and its mucous membrane converted into a necrotic mass. In my experience they are *never* found in the bronchi of the unaffected lung, but where both lungs are disorganized the bronchi of both sides are studded with them, and in most cases they can be traced directly into the cavities themselves. They are met with less frequently in the larynx and the pharynx. In the former they select the laryngeal aspect of the epiglottis, the anterior surface of the arytenoid cartilages and the inter-arytenoid fold as their favorite seats. In the pharynx I have seen them most frequently in the pyriform sinuses, where they sometimes assume a considerable size. Their occurrence here is most probably explained by the accumulation in these cavities of the irritant sputa. In the larynx they lose to a great extent their characteristic appearances and approach more closely the type of simple catarrhal ulceration. They are sometimes found associated with or in the neighborhood of tubercular ulcers, and I have seen them more frequently than tubercular ulceration in the trachea.

The sections presented in general the typical picture of circumscribed necrosis of the mucous membrane. At those situations where sloughs were present the epithelium and upper layers of the mucosa were converted into a finely granular de-

tritus, and the neighboring connective tissue of the mucosa, and also, to a great extent, the submucosa, highly infiltrated with lymphoid cells. This round-cell infiltration invaded the tissues between the mucous follicles, without, however, involving them in a marked degree in the inflammatory process. The spots where ulceration had already occurred presented in the base and edges of the ulcer likewise a granular detritus, and the surrounding tissues were also the seat of a high grade round-cell infiltration. Here and there it was possible to recognize transition stages of both the above-described processes; viz., nodules, so to speak, of necrobiotic tissue, in which the slough had already begun to separate, although adhering closely at several points. The examination of a great many sections showed that the first stage of the aphthous process consisted in a high grade round-celled infiltration of the mucous membrane in its upper layers, with cloudy swelling of the superimposed epithelium. Distinct miliary tubercles were nowhere to be seen, neither within nor in the neighborhood of the necrobiotic nodules. Sometimes individual nodules coalesced, and especially was this true of the bronchi, so that the membrane over a considerable area presented the above described sloughing of the upper layers of the mucosa. The above anatomical appearances, therefore, leave no room for doubt that these ulcerated areas are the result of a circumscribed superficial mycotic or septic inflammation of the mucous membrane—that is to say, an infiltration of its tissues with so rich and rapid cell-proliferation as to eventuate in necrosis and sloughing of the superficial layers.

In view, then, of this interpretation of their nature, what practical conclusions can be drawn concerning the etiology of these lesions? Are they related to the tubercular process in the lungs, and, if so, what is the nature of the relationship? The first question I must answer decidedly in the affirmative, since they are most frequently found in connection with well pronounced tubercular changes in the lungs, and in regard to the second, it seems impossible to resist the conclusion that the foul contents of the pulmonary caverns, lingering in the bronchi and lower trachea, so irritate the mucous membrane as to cause it to react with tissue necrosis.

It may be here remarked that in years gone by two opinions prevailed concerning the part which the sputa play in the production of laryngeal phthisis. Following Louis,<sup>18</sup> the advocates of the one affirmed that the sputa and ulcers stand to each other in the relation of cause and effect, although they differed widely as to the nature of the ulcerative process, some maintaining it to be a simple catarrhal erosion, while others regarded it as tubercular, evoked through the invasion or infection, as it were, of the superficial layers of the mucosa by the micrococci in the expectorated matter (Ziegler, Eppinger). The champions of the other and perhaps more popular idea were equally confirmed in their belief that the sputa played no role whatsoever in the destructive changes, and some even went so far as to deny the possibility of corrosion of an intact mucous membrane by the contents of the pulmonary caverns (Heinze).

Passing then to a summary of the evidence upon which the co-relationship between aphthous as contradistinguished from tubercular ulceration of the air passages and the corrosive action of the sputum rests, the following facts present themselves in favor of the view expressed above:

a. The predilection of the ulcers for those places which are in constant contact with the sputa, viz., the trachea and the bronchi, and especially the posterior wall of the former and the laryngeal surface of the epiglottis.

b. The fact that they increase in number as the lungs are approached, and that they are much less common in the upper portion of the trachea and larynx. It was these familiar facts that suggested to Louis the hypothesis which bears his name.

c. That they may be traced from the bifurcation of the trachea to the division of the bronchial tubes where in all cases they become visible only in one tube, which is that leading to a cavity. This remarkable distribution of the ulceration in pulmonary tuberculosis, which I have repeatedly verified by

---

<sup>18</sup>Op. cit. This popular view was advanced over a century before the time of Louis by Sylvius. *Opera Medica*. Trap. ad Rheum., 1695, p. 692. Vide Virchow, *Die Krankhaften Geschwülste*, II., S. 644-645.

dissection, did not escape the observation of Stokes, who advanced it in favor of Louis' hypothesis.

d. Their absence in the bronchi of lungs which are not the seat of cavities or advanced tubercular change. This, at least, has been my observation, and I am unaware that they have been seen by others when the lungs were not the seat of pronounced disorganization.

e. Their occasional presence in the oesophagus, stomach and intestines from swallowing the sputa. In one of my cases ulceration was found in the oesophagus and small intestine macro and microscopically identical with the aphthous ulcer in the larynx.

Tubercle was present only in the lungs.

f. Finally, their occasional appearance in suppurative pneumonia (Wunderlich<sup>19</sup>) and gangrene of the lung.

These lesions, therefore, may be regarded as the result of an inoculation, so to speak, of the mucous membrane with the detritus from the broken down pulmonary tissue, leading to the formation of a loss of substance pathologically distinct from, but possessing some of the characteristics of, the tubercular ulcer. Notwithstanding, however, that these nodules owe their existence to the disintegration in the lung, it does not seem to me justifiable to look upon them, as Eppinger has done, as specific tubercular products, for the following reasons:

First. That they differ histologically in no respect from the circumscribed mycotic or septic ulceration of the mucous membranes of individuals in whom no evidence of tuberculosis exists; an important point in their differentiation from the well-defined and characteristic anatomical changes of tubercular infiltration and ulceration. In this connection, it may be added that the tubercular process, as shown by Heinze, commences under the epithelium, whereas in the ulcers under review that structure is always first affected.

Second. That well pronounced circumscribed inflammatory infiltration resulting from necrobiosis and sloughing and

<sup>19</sup>Handbuch d. pathologie u. Therapie, III., 2, Stuttgart, 1856. p. 96.

histologically identical with these aphthous lesions is found, although not as frequently and as abundantly, in the mucous membranes of the air passages, and particularly in that of the trachea, as a secondary complication in diseases other than pulmonary phthisis. Thus, in circumscribed gangrene of the lung, or as the result of perforation into the trachea of broken down, sloughing bronchial glands, small, round "aphthous" erosions may be detected in the mucous membrane of the trachea and bronchi, which are the histological analogues of those described above.

Third. That on other mucous membranes of the body, under similar conditions, namely, as the result of a neighboring long-standing gangrenous process, or the constant passage over them of an ichorous discharge, ulceration is found, identical in every respect with that described above. This is true, for instance, of the mucous membrane of the vagina in gangrenous conditions of the uterus. In one of my cases of this kind the vagina was studded with these small aphthous erosions, the result of gangrene of the *portio vaginalis uteri* from an unknown cause.

The great number of the ulcers, their absence in intense, acute and chronic simple catarrh of the pharyngo-bronchial membrane, their characteristic microscopical appearances, especially their often elevated, livid, irregular edges and sloughing base, and the picture which the microscope reveals, are sufficient to exclude the idea of their catarrhal nature, and strongly militate against the hypothesis which should regulate them to the simple inflammatory condition of the mucous membrane which often ushers in or accompanies the tubercular process in the air passages.

I think, therefore, in conclusion, that my observations go to show that aphthous ulceration of the larynx, trachea and bronchi occurring in the course of pulmonary tuberculosis is related to the affection in the lung in so far as it is produced by the corrosive action of the sputa; but that in the present state of our knowledge (1880) it is impossible to affirm its specific tubercular nature.

At the time these observations were made our study of the

subject was rendered infinitely more difficult than it is at present by our comparatively scant knowledge of its bacteriology, and the technique of examination then in use was ridiculously primitive when compared with the methods of precision and exactness of modern scientific research. Moreover, the darkness surrounding the investigation of the disease had not been illumined by the isolation of the tubercle bacillus, and we had therefore to work out the problem without the light of that great discovery.

For these reasons, it is not surprising that in days gone by there should have been so much divergence of opinion in regard to the ulceration under consideration. But even with modern histological and bacteriological methods of investigation there was still no consensus of opinion among authorities on the subject until the atmosphere of the question was cleared by the painstaking and interesting researches of Ziba in the Pathological Institute at Strassburg.

Before referring to this important work permit me to pass briefly in retrospect and review the opinions of some of those who have specially investigated the subject histologically during the past thirty years, and who from the carefulness of their studies are entitled to eminent respect.

While Virchow<sup>20</sup> admitted the possibility of "erosive" ulceration of the larynx and trachea in tuberculosis, B. Fraenkel,<sup>21</sup> on the other hand, maintained, from the presence of tubercle bacilli in the secretion obtained from them, that the erosions in question were true tubercular products. Schech,<sup>22</sup> while acknowledging that he was repeatedly unable to find either tubercle or bacilli in the walls and base of the ulcer, nevertheless declared that it is a specific tubercular lesion and sought to explain the frequent absence of characteristic structure and bacillus on the ground that at the time of the examination the tubercles had already been cast off or were lost to sight in the overwhelming multitude of the lymphoid cells of the secretion. Heryng,<sup>23</sup> as the result of numerous bacteriological examinations, agrees with Schottelius

<sup>20</sup>Berliner klin. Wochenschrift, 1883, pp. 109, 135.

<sup>21</sup>Berliner klin. Wochenschrift, 1883, No. 4, p. 523.

<sup>22</sup>Volkman's Sammlung, series 8, 230, 1883. See also article on "Tuberculosis of the Larynx" in Heymann's Handbuch der Laryngologie u. Rhinologie, 1898.

<sup>23</sup>Die Heilbarkeit der Larynxphthisie u. ihre Chirug. Behandlung, 1887.

that simple erosions of the mucous membrane of the larynx may exist which are due to the secretion from the lung, and which may occur quite apart from infection by the tubercle bacillus, but which can subsequently be secondarily infected with tuberculosis.

Orth<sup>24</sup> believes that the vast majority of the so-called "aphthous," "erosive" or "corrosive" losses of substance are true tubercular ulcers. At the same time he calls attention to the fact that the sputa of the cavities contain, often in considerable number, bacteria other than the tubercle bacillus, and that, furthermore, chemical changes may occur in the secretion which may exert a corrosive or septic or necrotic influence quite aside from that produced by the specific poison of tuberculosis.

Eugen Fraenkel<sup>25</sup> concludes from his histological and bacteriological researches that all destructive lesions of the larynx occurring during pulmonary tuberculosis are due to the operation of the tubercle bacillus, which invades the tissues through the epithelium, and is often assisted in its destructive action by pyogenic organisms. This observer admits, however, that there are some cases of ulceration which cannot be regarded as specific tubercular products, since they show neither the characteristic anatomical changes of the disease nor the presence of the bacillus. He would set these cases aside as examples of mycotic epithelium necrosis due to invasion of pathogenic cocci through the surface. This view of Fraenkel that the overwhelming majority of larynx ulcers in consumption are true tubercular in origin is shared by most pathologists and laryngologists, with the exception perhaps of Gottstein, who regards the so-called aphthous ulcer as the result of simple necrotic sloughing of the epithelium.

In talking the matter over with Professor Hans Chiari in the Autumn of 1910, when he was in this country to deliver the Herter lectures at the Johns Hopkins University, he was very positive in his opinion that the work done by me over thirty years ago was good to-day; but that it would have to be gone over again with modern methods of examination, and in the light

<sup>24</sup>*Lehrbuch der Spez-Pathologie*, 1887, Bd. I.

<sup>25</sup>*Virchow's Archiv*, 1890, No. 121.

of the discovery of the tubercle bacillus; and he furthermore said that on his return to Strassburg he would have it done.

The following Spring the work of Ziba,<sup>26</sup> inspired by Chiari, appeared, which, I venture to think, has shed much light upon the subject, and which is important from the fact that the author has approached the question in a different and more comprehensive and liberal way than that pursued by some other observers. For a detailed account of his observations and methods I must refer to the original publication, and content myself simply with a summary of his conclusions.

As the result of his histological and bacteriological researches he believes with me in the existence of the aphthous ulcer of the larynx and trachea in pulmonary tuberculosis, as contradistinguished from the true tubercular ulcer. He has found that the aphthous ulcer is caused by streptococci in the sputa from the lung cavities—that infection takes place from the inner surface of the mucosa and produces an inflammatory process which is associated with tissue necrosis, and which leads to the formation of the aphthous ulcer—the latter may later become tubercular, but in the aphthous ulcer originally there is neither in its base nor walls any trace of miliary tubercle. This conception of its nature is, furthermore, supported by bacteriological examination. Only in those ulcers in which miliary tubercle was discovered microscopically were tubercle bacilli found and solely in the region of the miliary tubercle itself. In all these cases both miliary tubercle and tubercle bacilli were absent. Even in those cases in which tubercle bacilli were found in the secretion which covered the mucous membrane both characteristic structure and bacillus were wanting.

Aphthous ulceration of the larynx and trachea produced by streptococci may invite the development of tubercular ulceration. This is all the more probable when it is remembered that it appears in greatest numbers in the last stages of pulmonary tuberculosis. At this period the great majority of the ulcers are simply

---

<sup>26</sup>Archiv für Laryngologie u. Rhinologie, 1911 (3) Bd. XXIV., Heft 3.



strepto-mycotic in character and secondary tuberculosis only develops in them here and there.

I have brought this question before you for discussion reluctantly and with much diffidence on account of my personal interest in the matter. But, quite apart from any such consideration, the subject is deserving of attention in view of the fact that it is overlooked by nearly all English-speaking authors on tuberculosis of the upper air passages.

#### *Discussion.*

Dr. Norval H. Pierce, Chicago: I hesitatingly get up to discuss this paper, as I am thoroughly ignorant regarding the pathology of this condition. It is the first time I have heard that there is such an interesting subject, yet I cannot help but congratulate Dr. Mackenzie and the society on the historical connection between one phase of medicine and another which we regard as very much more enlightened to-day. The aphthous ulcers that we have in the throats of those suffering from acute streptococcus infections are well known, and I know that the histological findings in these aphthous ulcers, as they occur in tuberculosis, are identical with the histological character of the streptococcic ulcerations. This winter in Chicago we have had a remarkable epidemic that has caused some deaths from sepsis and meningitis, the original focus of infection apparently being in the pharynx. It was characterized by very slight local symptoms. The tonsils were but very slightly enlarged or swollen; the crypts not filled with the ordinary hard, fibrous exudate, as in acute tonsillitis, but an exudate which resembled a rather thick pus. However, associated with this I have noticed in several cases with these aphthous ulcers, superficially well-defined ulcers, occupying the anterior folds of the pharynx especially, and giving, on bacteriological examination, a pure streptococcus culture, which varied from the ordinary streptococcus in that it possessed a very thick capsule.

Dr. Henry L. Swain, New Haven: Years ago, when we used to hear in these meetings a great deal said about tuberculosis of the larynx and tuberculous ulcerations in the trachea, and had brought to our attention remedy after remedy that had been successful in their treatment, we all too little realized these aphthous ulcerations, and we took the clinical evidence that an ulcer healed was a tuberculous ulcer because occurring in conjunction with a known focus of tuberculosis. Half of these ulcers which healed were the simple superficial streptococcus erosions which

would get well with anything that will stimulate sufficiently to cause repair and death of the germ. Thus, unconsciously, many of us treated the same conditions to which Dr. Mackenzie has referred. I have certainly seen them, at autopsy, many times going away down into the bronchial tubes.

Dr. B. R. Shurly, Detroit: The modern trend of the care and treatment of pulmonary tuberculosis in the last decade has been to take away from the laryngologist, very largely, the observation of cases of this type that have innumerable conditions connected with the nose, throat and larynx, but which are now put in charge of men who are specialists in tuberculosis, pure and simple. If you look over the various sanatoria of the country, I think you will find that, very largely, they are without the care of the laryngologist. In other words, the training is that of internal medicine with the special training of laryngology left out. It seems to me that perhaps this explains why we have fewer contributions to the literature of conditions of this kind in connection with pulmonary tuberculosis. The cases of laryngeal tuberculosis and ulceration of the various types that are found in these advanced conditions of tuberculosis are especially interesting, and have been considered for the most part a rather hopeless proposition, from the standpoint of therapeutics, and consequently our interest in that, scientifically, has waned to a certain degree.

The treatment of these ulcers Dr. Mackenzie did not mention, but it seems to me that ulcers of these various types have a modern treatment in the use of formalin and fulguration, which have considerable value in hurrying along the healing process. We almost never, now, see a case of laryngeal tuberculosis in its primary form; I can scarcely recall one in a large experience in pulmonary tuberculosis in sanitarium work. It is almost always the fact that there is some greater or less lesion to be found elsewhere.

Dr. J. N. Mackenzie, Baltimore: The term "aphthous," as applied to the ulcers under review, is a rather unfortunate one, as it may lead, as has happened in this discussion, to their confusion with the simple aphthous erosions so commonly seen on the mucous membrane. I have retained the term simply in deference to long and common usage. I need scarcely say that the one is a simple affair yielding readily to treatment, while the other is one of the deadliest forms of ulceration, occurring most frequently in the last stages of tuberculosis, when the patient is beyond the reach of recovery.

## PARALYSIS OF THE RIGHT RECURRENT LARYNGEAL NERVE FROM ACCIDENTAL TRAUMA—TWO CASES.

BY D. BRYSON DELAVAN, M.D., NEW YORK.

Paralysis of the recurrent laryngeal nerve due to various kinds of injuries of the neck is not very uncommon. Thus, in the course of operations upon the thyroid gland and of other surgical procedures in its vicinity the recurrent has more than once been so injured that its function has been permanently destroyed. From whatever cause such an accident has taken place, however, the victim has usually been a person in adult life and it has not been possible to follow the history of the case for any considerable length of time. With regard to the cases here reported, the injuries were received early in life, before the larynx had matured and in patients whose history subsequent to the injury was easily obtained. In both cases the ultimate effects of the loss of function of the nerve have had abundant time to be completely developed. The histories therefore are uncommon.

Case I. Elizabeth X. Aged 23. Patient otherwise healthy; speaks in a hoarse tone of voice of peculiar quality; this is worse in bad weather, when she is fatigued or when she has a cold. States that when 12 years of age and fairly well grown, she tripped in crossing a railway track and fell, striking her throat upon the inner edge of the opposite rail. The fall was hard and the shock severe. Upon striking the rail she uttered a loud cry, but in attempting to speak immediately thereafter found that she had lost her voice. Subsequently she had been treated at various times and places, but principally at the Massachusetts General Hospital. Applications had been made to her throat in great variety and the use of electricity employed for considerable lengths of time. No good result had followed any attempt at relieving her.

Eleven years after the accident patient was examined by the writer. She appeared normally developed, well nourished and healthy. She occupied the position of waitress in a summer hotel

and filled her place satisfactorily. Laryngoscopic examination showed the right side of the larynx fixed, with the vocal band drawn a little to one side of the median line. The length of the right vocal band was distinctly shortened, to the extent of about one-third, as compared with its fellow of the opposite side. Fixation was absolute. The cord was slightly hyperaemic and the whole of that side of the larynx appeared contracted. The left side of the larynx was in every respect normal, both as to appearance and physiological function.

It seemed evident that at the time of the injury to the larynx the right recurrent laryngeal nerve had been completely paralyzed.

The patient was advised of the importance of avoiding laryngitis and it was suggested to her that she report back to the Massachusetts General Hospital for periodical examination of the throat at intervals of not more than a year, so that the history of the case might be kept in mind and that she herself might be under the supervision of some competent specialist.

Case II. Mr. Y. Aged 50, of excellent family history, but of delicate constitution and highly nervous temperament. Voice is somewhat hoarse and its tone feeble. Finds difficulty in phonation, especially when in poor physical condition. His vocal defects are evidently accentuated by highly faulty use of the breath. Has never suffered from any marked indications of dyspnoea.

Patient states that he has been hoarse and has had difficulty in speaking since childhood, and attributes this to one of three possible causes, namely: An attack of diphtheria, one of whooping cough and a possible traumatism. The latter was acquired in the following way:

When a small child he attempted to climb a tree, but when part way up lost his hold and fell in such a way that his neck was pinioned in the crotch between two limbs, where he hung for a few moments before being rescued. No accurate observations or examinations were made at that time, but following the accident changes in the voice occurred, as mentioned above.

At the present time examination reveals a complete paralysis of abduction on the right side of the larynx. The vocal band on this side is shorter than its fellow and in every respect less well

developed. Immobility seems complete, the vocal band resting a little to the right of the median line, but apparently not quite as far outward as in the so-called cadaveric position. The movements of the left side of the larynx are normal and the left vocal band is fully developed. It is not likely that this condition could have resulted either from diphtheria or whooping cough. On the other hand, such a traumatism as that described might easily be supposed to have inflicted an injury upon the right recurrent laryngeal nerve so severe as to cause complete loss of its function. The fact that it was the right recurrent which suffered may have been purely accidental. Nevertheless, it is possible to suppose that with equal opportunity for injury on both sides the position of the right would render it more liable to injury from external violence than the left. Instruction in the proper use of the voice, especially with regard to breathing, has resulted in distinct improvement in tone quality and control.

The prognosis in these cases as to recovery is absolutely bad. There is no reason, however, why the patient should not enter upon any of the ordinary avocations of life with success, the great point being to avoid all sources of irritation to the larynx, and in case of the occurrence of a laryngitis of the simplest type to resort to proper measures for its relief at the earliest moment, as a laryngitis from any cause may so reduce the lumen of the g'ottis as to produce dyspnoea.

#### *Discussion.*

Dr. Otto T. Freer, Chicago: The prognosis in traumatic paralysis of the recurrent laryngeal nerve is not always bad. I recall a case where total paralysis of a recurrent laryngeal nerve followed exposure of this nerve in the removal of a thyroid gland. The paralysis entirely disappeared in some weeks. In another case seen by me permanent paralysis of the nerve resulted from the excision of carotid lymphatic glands.

Dr. Norval H. Pierce, Chicago: I would like to put on record a similar case of goitre operated on in St. Luke's Hospital—one lying low, below the notch. The man had almost complete paralysis, quite a breathy voice and, upon laryngoscopic examination, the right cord scarcely moved at all in phonation. It was red, and slightly swollen. In eighteen months the man speaks

nearly as well as ever, although there is still some muscular paralysis. There is constant improvement. This nerve was probably pinched in the course of dissection. I examined this man before the operation, and at that time the larynx was working properly.

Dr. Emil Mayer, New York City: It might be well if all surgeons who are in the habit of operating rather frequently on various forms of diseases of the neck—goitre, etc.—would make it a rule to always have a laryngoscopic examination made before operation, to see if in some cases there would not be a pre-existing disease of the recurrent laryngeal nerve.

Dr. John O. Roe, Rochester, N. Y.: In connection with Dr. Delavan's interesting paper I would like to mention a case of traumatic paralysis of the left side of the larynx from a stab wound in the neck that came under my observation a number of years ago. It was the case of a medical student, who was attempting to collect a bill for his preceptor, when the patient resented his intrusion by stabbing him in the neck with a sharp knife. The hemorrhage that immediately followed was so profuse that the young man fainted before assistance could reach him. Dr. E. M. Moore, Sr., of Rochester, was summoned, who promptly arrested the hemorrhage by acupuncture. The doctor believed the internal jugular had been opened, and controlled it by the introduction of two needles in such a manner as to bring firm pressure on the jugular. This injury was attended with immediate loss of voice and considerable dyspnoea, although not sufficient to require tracheotomy. After recovery from the stab wound I examined the young man's larynx, and found it completely paralyzed on the left side, and he was completely aphonic. After a few weeks he began to recover his voice, and it was interesting to watch the progress of the case. There was, however, no restoration of function on the left side of the larynx, the side on which he received the injury, but on the other the vocal cord came over and approximated the lame cord, thereby compensating for this lack of mobility on the opposite side. His voice continued to grow stronger, until, at the end of two and a half or three years, his hoarseness had disappeared and his voice had become perfectly normal in tone.

Dr. Clarence C. Rice, New York City: It is remarkable how good the singing voice is in some cases of paralysis. I recall the case of a church singer, who did quartette work very satisfactorily, and he had absolutely no motion of the left vocal cord. I do not remember the cause of this paralysis. I think the prognosis as to the return of the voice is better when the left recurrent

is injured than when the right, because the right seems to have greater compensating power. I have found, too, that the voice seems to make greater recovery in the cases of short vocal cords—that is, in sopranos and tenors—than where the cords are longer, for the reason that the shorter the cord the more easily is it drawn to the median line.

Dr. C. G. Coakley, New York City: It has been my privilege to see three cases of traumatic lesion of the recurrent laryngeal nerve where I have had the opportunity of seeing them in the early stage and following up the subsequent history. One of these cases was where the recurrent nerve was injured or cut as a result of thyroidectomy. The second was the case of a patient who had a malignant growth of the gland at the bifurcation of the cricoid and the removal of that malignant growth resulted in paralysis. The third was a gunshot injury case. The thing which surprised me in all acute cases was the marked edema of the arytenoid, the ventricular band, and the distress from a feeling of a lump in the throat, and examination showed marked swelling and edema. The prognosis has been invariably bad. There has been no case which has recovered the function of the cord. In the early stages the voice is practically that of a whisper, but after a while by the action of muscles they have a fair speaking voice, provided they use it only moderately, but they have only occasional control over it.

Dr. D. Bryson Delavan, New York City (in closing): I perhaps should have more correctly entitled these cases as accidental trauma. Of course, we know that in the course of various operations and diseases in the neighborhood of the neck the recurrent laryngeal nerve may be destroyed. Those occurring from accident, however, are somewhat unusual. A great many years ago Dr. Lefferts reported a case of stab wound of the neck in which the recurrent was severed. Dr. Roe's reference to the fact that the unaffected side seems to overdevelop in his case as a compensatory effort seems to have been exemplified in both my cases. Certainly the larynges of these two cases which I have reported bear many points of similarity. The voices in these patients are not absolutely bad; they are not aphonic, but there is enough hoarseness to make the tone quality different from the normal—and different in a peculiar way.

## WHEN SHOULD SINGERS HAVING VOCAL DISABILITY BE ALLOWED TO RESUME WORK?

BY C. C. RICE, M.D.

The responsibility upon the attending laryngologist of allowing a singer, and I mean one of reputation, to continue working when the vocal apparatus is abnormal, is sometimes a grave one. It might seem at first that the degree of responsibility was in direct relation to the value of the voice, and by that I mean its earning power, but this can hardly be true, for the voice which may command but a small salary may be the sole asset in supporting a family. And again it is true that the inferior voice may be longer and more seriously injured than that of the noted singer, because the greater the artist, the better is the general stamina of the vocal organs; the muscles are stronger, the chords are wider and, consequently, greater is the resistance to injury which may be caused by a robust use of voice when the performer is not entirely right.

In deciding whether to say yes or no to the patient who asks your opinion, it is well to consider our subject from several aspects: First—We should have clearly in mind the usual or best condition of the particular larynx we are studying—that is, of the patient in hand. What sort of a larynx is it? Is it the type easily seen to be that of a “professional”—that is, one that has had long and proper use—or is the vocal apparatus that of an “amateur”?

It is most important to determine this point, because the frail larynx is easily injured, whereas the stronger one will bear the brunt of an evening's hard singing without harm. A word as to the difference between these two types; but first I should say that not all professionals have a professional working organ. The singer who is fortunate enough to possess a white, fibrous larynx, hard, well rounded—aryte-



noids, side ligaments from epiglottis to arytenoids, which are not thin and frail, but powerful; wide vocal bands, with liberal concavity above them, and a larynx, as a whole, free from soft, spongy tissue—the owner of such a larynx not only does not get out of voice easily, but can generally stand the wear and tear of singing with success.

It requires years of patient and intelligent vocal work to convert the spongy larynx of an amateur into one of professional quality. I remember but two singers of first-class reputation who have very narrow vocal chords and a generally spongy larynx, and they get out of voice easily.

The laryngologist can more easily tell when it is safe to resume work in the case of the stronger larynx, for he can more accurately determine the degree of laryngeal strength which is present. It is often very difficult to ascertain when the power of the vocal adductors has returned, for the voice is often unsatisfactory, even when pathological conditions have disappeared. This trouble in determining whether a singer can safely resume an engagement is greatest when the larynx is, as has already been stated, of the amateur type, with thin, narrow bands, soggy arytenoids, frail ligaments and spongy side walls.

No one can determine without a singing demonstration whether such a person is in good voice or not; or, if they remain good during a five minutes' trial, whether they will last for an evening, or whether an evening's work will so tire the muscles as to produce another week's hoarseness, or perhaps a nodule on the border of the chord. An opinion based on a careful inspection of the chords with a laryngeal mirror is not a safe one, and it is dangerous to arrive at a conclusion even after a single trial of the voice, except—and I again repeat it—in the well seasoned larynx.

There are other points to consider in addition to the local condition of the larynx, such as the general health of the patient; the mental stamina, the confidence in themselves, or, as we express it, their "nerve," their previous record as to failures or successes in singing, and the condition of the respiratory tract generally, that is, whether catarrhal or not.

The difficulty of determining whether a singer should be allowed to work may be appreciated, when it can be truthfully stated that some people can get through a large singing part, with a larynx which is far from normal, whereas others with a vocal apparatus apparently right, can go but a short distance, and that with difficulty. Whether this is due to lack of courage or real muscular weakness, it is sometimes hard to say, where there is apparently very little in sight that is wrong. Our opinion here must be based on the record of past performances.

A few weeks ago a grand opera tenor came to me for what he considered slight huskiness. His speaking voice was only moderately affected. He had sung a heavy role two days before, and had been singing two and three times a week for three or four months. He was a happy-go-lucky style of man. I found his larynx was generally congested, edges of chords uneven, and one arytenoid considerably larger than the other. The merest novice in throat practice could have told him he ought not sing; but he would not seriously consider my advice "to rest for a week." On the contrary, he took his role that night, and so on to the close of the season, which ended two weeks after my examination. Of course, he was not in good voice, and it was only possible to get a satisfactory tone by over-exertion, which is always acquired at too great expense of nerve and muscular power. But this example demonstrates what can be accomplished by the courage of a person who knows how to sing. The probability is that all pathological conditions in his case will disappear after a six weeks' rest, and that his voice will not be permanently injured, although it probably has been shop-worn for some time. Such abusive treatment must necessarily shorten the duration of the large earning value of a voice.

A decidedly different condition of affairs is seen, and often in first-class artists, who are nearly frightened to death with the first night's performance, and who, although the larynx looks normal enough, persuade themselves and almost persuade the physician that they are sadly out of condition. The voice breaks repeatedly because of no other reason than fright. Here it is difficult for the laryngologist to advise, because the performance

may not be satisfactory and he will be blamed. Again the past record of the singer will help as to the kind of advice to give.

Not long ago I had under my care a singer of good reputation. She came to me with an acute nodule on the band; had not sung for two weeks, and the opening performance had been postponed for a week longer. The larynx finally appeared normal. She was extremely nervous. She tried her full voice several times and reported it satisfactory; said she could get notes which had not been in her voice for a year. She was very anxious that I should attend her at the theatre at the first performance. When I arrived there, prepared to assist her, she declined all help from me, would have nothing done and I found that she had a Christian Science healer ministering to her wants. She did not get through her work acceptably.

I have known two women, one a very great singer, the other less distinguished, to get through an evening's performance without great difficulty, and they were both suffering from acute follicular tonsillitis, with high temperature. Neither of them injured their voices. Both, against all persuasion, had determined to sing. In one instance the singer's fee was very large and in the other the artiste did not wish to disappoint the management.

The larynx has wonderful inherent restorative power. I once saw in a noted singer actual loss of tissue midway in the length of the chord, where I was told a growth had been removed by forceps. Such a condition in one of my patients would have given me great anxiety. I don't know the method of recovery in this case, or the present condition of the vocal bands, but I do know that the season has been a successful one for him. Perhaps a larynx, made remarkably strong by robust singing of the best kind, has larger recuperative power than has the throat of the ordinary individual.

I have sometimes thought that the increase in muscular and fibrous striation, seen in strong professional larynges, dissipated the periperal circulation, and, consequently, greatly diminished the tendency to congestion and swelling.

In considering the condition of the larynx in a disabled singer

I think it a good classification to place simple disorders under two heads, catarrhal and "traumatic" laryngitis, giving the latter name to the variety in which the pathological conditions have been caused by over-singing or a bad method of singing, or both combined.

I need not say that where an acute or chronic catarrhal condition exists, the traumatic effects of singing follow with much greater frequency than in the normal throat. It is unnecessary for me to describe to this Association the different appearances that exist in the catarrhal and traumatic varieties of laryngitis, because you are all quite familiar with them. The lesions of "singers' " or "traumatic" laryngitis may very briefly be stated as usually unilateral and localized, while catarrhal changes are general in appearance.

After an attack of simple, general catarrhal laryngitis a singer may resume work when the chords approximate strongly, when their edges are smooth, and when the arytenoids are of normal size. He need not necessarily wait until all congestion of bands has disappeared, because some chords are never white. Strong, even approximation and smoothness of borders are very essential. There is very little encouragement to permit a singer to continue who has any degree of thickening along the edges of the chords, because if the work is hard and continuous—that is, nightly—singing will increase the size of the nodule and eventually congest the entire side of the larynx.

I saw an actress, playing a rather hard speaking role, produce a nodule by a single night's performance. She had a weak larynx and always "talked in her throat"—because the public thought her quality of voice very attractive and she didn't wish to have it changed. I found that another actress, who is very popular and whose queer, husky breathiness makes her a great favorite for imitators, possessed vocal chords always apart during phonation, apparently because of lack of adducting power. She considered this voice a valuable trade mark and wanted no strengthening of muscles, if thereby the voice would be changed.

This amount of adducting power and laryngeal strength is a very subtle matter; oftentimes apparently at low ebb, as demon-

strated by bad voice, although the bands seem to come together satisfactorily; and, again, sufficiently strong to furnish an adequate voice, when the laryngeal muscular outfit seems much impaired; so that in many instances the singer must show what he can do before we give our consent to resume work.

If we only possessed some instrument which could measure the muscular power of each of the several muscular adductors, and their combined force as well, it would furnish a valuable working basis to the laryngologist.

It is most important to *know our patient* well when advising to sing or not to sing. Unfortunately there are many who, either incapable of doing good work or not having the nerve to make proper effort, are apt to place the burden of their failure on the physician. If we were obliged to treat only honorable people we could give advice with little hesitation.

#### *Discussion.*

Dr. A. B. Thrasher, Cincinnati: This is a very interesting paper, and is instructive to all of us who have much occasion to treat singers. I remember, in confirmation of the statement in reference to the effect of tonsilitis on the singing voice, one of the most prominent voices, the best known of our sopranos, was to appear in Lohengrin, not many years ago, and her manager called me up to see her in the middle of the afternoon, and I found a peritonsillar abscess, which I promptly opened, and said she should not sing that evening. Much to my surprise, on attending the opera I found her singing, and you could hardly tell from the way she handled her voice that she had anything wrong with her throat. A great difficulty is often found in cases in which the adventitious organs are affected, instead of those directly concerned with the voice itself. Her tone was very good, and also her resonance. I know, also, a very good basso singer, of rather light tone, who has a complete paralysis of the left vocal cord. He has made a fair living for himself by singing, and, at one time when a little hoarse, he called at my office, and I suggested he stop singing for a while, and he refused, saying he sang as well as usual. I found a permanent paralysis. He is still singing—in fact, has charge of a singing school in New York. You would think a man would not be able to sing under such conditions. That was another case in which the left vocal cord was not of as much importance in vocalization as the right one.

Dr. Norval H. Pierce, Chicago: I wish to express my pleasure at hearing Dr. Rice's paper; it shows a man who is intimately connected with this anomaly known as a singer. I think they may be divided into two classes, real singers and those who are willing to sing. The real singer can overcome the most stupendous obstacles, and the willing singer is the greatest bore on the face of the earth to the laryngologist. Full of imagination, full of fear—knowing in their subconscious mind that they never can sing and yet having the desire to sing—and so they come complaining of all sorts of conditions, not being able to take the middle notes or the upper notes or the lower ones; and yet there is no pathological change in the larynx at any time. It is the faulty singing, perhaps, but these people study diligently and hard, but take their notes differently every day. They cannot control the musculature of the larynx, and that is the cause, I think, of a large majority of these complaints. On the other hand, the real singer can overcome the greatest obstacles. I have seen our leading tenor come into my office with vocal cords nearly as red as flannel, associated with a tonsilitis, and tell me he had to sing Faust the following night and needed a little treatment! I did not think he could sing anything at all, by the looks of his throat, so I told him perhaps he had better not have it treated but rest for a month or the balance of the season, but he said he would be out too much money; so I touched up something or other, and he sang most gloriously the next night.

There is a lady who is noted for her very high notes; she can take notes of about 36,000 double vibrations a second, I think, and there is a tradition in the profession that she takes them with her tonsils, not vocal cords at all—but, of course, this is foolish. She may take these notes with her tonsils, because they are large, and when she does take a high note they almost meet in the middle line.

It is a great question as to the treatment of these people. Another tenor, and a good one, who has a varicosity on one vocal cord, sang Tristan for the first time in Chicago. It is a very trying part, and, to my horror, the next day he had an ecchymosis of that cord almost occupying the upper portion of the cord, yet his singing voice was scarcely influenced at all.

Dr. Clarence C. Rice, New York City (in closing): It seems to me that Dr. Thrasher's case and my own must be about the same. I am obliged to Dr. Pierce for his classification, which I think is splendid. What he has said will make a valuable addition to my paper.

This matter of ecchymosis of a vocal band occurring after

singing I have seen several times. The voice is better the first twenty-four hours after the congestion takes place than it is later on.

As to the treatment of enlarged tonsils in singers, our methods should be most conservative. Where a voice is perfectly satisfactory we cannot hope to improve it by any operative work on the tonsils, but the pharynx should be kept in a sanitary condition by proper treatment. When the patient suffers from frequent attacks of tonsillitis, predisposed to by a very unsanitary condition of the tonsils, we may safely reduce congestion and swelling somewhat, and empty the crypts of the tonsils of cheesy, calcareous material.

## SALVARSAN IN SYPHILIS OF THE NOSE AND THROAT.

BY DR. ABNER POST AND DR. FREDERIC C. COBB.

In the treatment of syphilitic lesions a few words as to the nature of the disease may not be out of place. According to Browning and MacKenzie on the diagnosis and treatment of syphilis, "It is important to keep in view the morbid anatomy of the disease, and the distribution of the spirochaetes in the body. Were syphilis a blood infection like relapsing fever, we could predict with practical certainty the complete sterility of the tissue and subsequent cure of the disease by means of Salvarsan, so marked are its spiricidal properties. But this is not the case. Syphilis is essentially a tissue disease, though the spirochaetes are also carried by the blood stream. The organisms have special preference for dense connective tissue structures and embedded in these or at the margin of the caseous lesions they may remain alive though inactive for years. If these points be kept in view the difficulty of bringing the drug efficiently in relation with the spirochaetes will be readily appreciated, especially when it is borne in mind that probably the drug, as indicated by arsenical excretion in the urine, has disappeared from the blood stream within three or four days after intravenous injections." This explanation is, it seems to me, of great value in showing not only the lack of reliability of a negative Wasserman reaction, but also the necessity for several injections of Salvarsan in rebellious cases. The same authors state that ninety-five per cent of syphilis in the secondary stage can be cured, whereas of the tertiary only seventy-five are cured. In order to estimate the value of Salvarsan, as compared to other methods of treatment, we must determine whether or not its effects are more rapid, more permanent, and whether it is less dangerous. As regards rapidity, it is impossible in clinical cases, which differ so much as to conditions and extent of the lesions, to give an accurate description of the



relative rapidity of healing under mercury as contrasted with Salvarsan. Certainly the impression produced is that the action of Salvarsan far exceeds that of all other forms of treatment in its apparent prompt effect. The patient's symptoms disappear in a surprising manner. From a clinical standpoint the results seem to me far ahead of those achieved by mercury. The question of permanency can only be determined by time and by a constant negative Wasserman reaction made at long intervals. As to the dangers involved in the use of Salvarsan Ehrlich says that the fatalities are represented by one in one thousand patients treated, and, moreover, that such fatalities occurred in severe infections of the nervous system almost exclusively. The literature relating to the action of Salvarsan as applied to the lesions of the nose and throat, while satisfactory from a therapeutical standpoint, lacks technical accuracy from a laryngological one. The contra-indications as given by Martindale and Westcott are:

- I. Severe non-syphilitic retinal and optic disease.
- II. Severe heart and vascular disease.
- III. Severe lung affections.
- IV. Severe non-syphilitic kidney affections.
- V. Advanced and degenerative process of the central nervous system.
- VI. Those suffering from Angina or fever.

The following cases observed at the Boston Dispensary and reported as briefly as possible may serve to show the rapidity of effect of Salvarsan. These may be divided into two groups—Secondary and tertiary cases:

*Secondaries.*

- E. F. B.—Male; showed mucous patches on both tonsils; slight shallow ulceration over supra-tonsillar fossa. Received 606 April 15. Two days after, great improvement noticed. Six days later, a small spot on left tonsil remained and some redness of posterior pillar. Eight days after, throat apparently normal; no spirilla could be found.
- L. T.—Female; April 9; had a line of redness extending from uvula over palate to left side. Wasserman and Noguchi positive; Salvarsan; four days later nothing abnormal could be seen in throat. May 1, throat still absolutely normal.

- M. J.—Complaining of nasal obstruction, had ulceration of cartilaginous septum with much scabbing and crusting. Deep ulceration of salpingo-pharyngeal fold. Wasserman positive; received 606 April 23. Three days after, symptoms disappeared. Six days after, injection ulceration of throat entirely healed, but that of the nose had improved, but was not well. After ten days, ulceration of the nose still present, but almost healed.
- A. D.—Female; mucous patches on tonsils; larynx and nose normal. Spirochaetes found. March 19, 606. Ten days after, no spirochaetes found; throat normal.
- O. J.—Female; red areolar extending over pillars about three-quarters of an inch around the soft palate with an even, deep-red color and very sharply defined. April 16, 606. Four days after, throat no longer sore; redness still visible, but very faint. Eight days later, throat apparently normal. All the subjective symptoms relieved in three days.

*Tertiary:*

- J. G.—A patient kindly referred to me by Dr. Smith for examination; infected ten years ago; very hoarse for two or three years. Showed, on first examination three months ago, a very great swelling of the epiglottis and right arytenoid with ulceration of true cords. Examination by Dr. Otis showed no tubercular condition of lungs and a negative tuberculin reaction. Had 606 on January 27. February 28 second dose, April 4 the third dose. Seen on March 30, after second dose. Nose and pharynx normal. Larynx showed swollen epiglottis on right arytenoid very large on same side; ulceration of true cords. Apparently active ulceration of false cord on right side. Dr. Holmes, who had been watching the patient, said that the conditions had materially decreased in the last three months. After the third injection there was some diminution in size of epiglottis, and arytenoids. The cords remained unchanged, but the ulceration of the false cords was evidently healing. On April 17, fourth injection given with further improvement to arytenoid and epiglottis, and ulceration of false cords almost healed; voice clearer. April 20, condition unchanged. May 3, no marked change. In this case considerable doubt as to the diagnosis existed; neither Wasserman nor tuberculin test being positive. The improvement, however, seems to indicate that the diagnosis of syphilis was correct.

J. B.—Specific of tongue. Tongue was covered with whitish, irregular patches on its upper surface, alternating with red glazed spots, due to loss of epithelium. Scars on soft palate. Has tried mercury and potassium iodide with only temporary relief. April 2, 606. April 8, tongue very much less swollen; patches less prominent. April 26, swelling of tongue has entirely subsided. Patches of reddish epithelium have almost disappeared, but raised appearance still persists.

---

### SYPHILITIC STENOSIS OF LARYNX TREATED WITH SALVARSAN AND INTUBATION WITH SUCCESSIVELY LARGER TUBES.

KINDLY REPORTED BY DR. KNOWLES, OF BOSTON.

Elizabeth L.—Married; thirty-five years old; was admitted to Massachusetts Charitable Eye and Ear Infirmary March 29, 1911, with marked difficulty in breathing, which had been increasing for the last few weeks. There was a purulent discharge from both nostrils, due to the removal of nasal polypi some days before by her family physician. On the posterior wall of the pharynx was a shallow punched-out ulceration with thickened edges. Upper part of larynx markedly swollen, almost obliterating vocal cords. The arytenoids swollen and flattened. The dyspnoea was so great that I performed tracheotomy in the ward, without having her moved from the bed. April 14, Wassermann positive. Patient was given full dose of "606" intramuscularly. April 19, tracheotomy tube was removed. April 24, patient was given a second dose of "606." May 29, the third dose of "606," given this time intravenously. July 1, tracheotomy was done again on account of the increasing dyspnoea. Two weeks later tracheotomy tube removed and intubation tube put in and since then the patient has worn intubation tubes each larger than the preceding; tubes being held in place by the method suggested by Drs. Rogers and Delavan some years ago. February 1, 1912, patient was given fourth dose of "606," this time intravenously. February 28, 1912, Wassermann was negative. May 6, patient is now wearing an extra large size intubation tube on account of the sub-glottic infiltration, which is, however, less and less at each change of the intubation tube, occurring about every six weeks.

- F. D. P.—Syphilis, which was quite severe for two years, treated by mercury by mouth and intro-muscular injections. During the third year there appeared on various parts of the body a few small circumscribed nodules evidently gummata, which ulcerated and remained long as open sores. At the same time there appeared on one side of the tongue a circumscribed swelling, limited to one side, which ulcerated and, in spite of mercury and iodide and local treatment, remained for about a year. It was extremely painful, caused some little difficulty in eating and made speech at times difficult. Mercury and iodide had no effect. After one injection of 0.4 gr. Salvarsan the ulcer of the tongue and the swelling greatly diminished. A second injection given after an interval of a month was followed by a complete disappearance of the swelling. The Wassermann reaction, taken a month after the second injection, was negative.

#### *Conclusions.*

The cases have been taken at random from both the author's clinics at the Boston Dispensary since the President's request for this paper was sent. They by no means represent all cases treated, but only those we have seen together since that time. Many patients have failed to return for observation. None of the cases reported has shown severe reaction. Whatever may be the final outcome of the disease, the lesions in the throat have healed with remarkable rapidity under the influence of the new drug, although most of them had resisted treatment by the older methods. Laryngeal syphilis has shown less marked improvement perhaps owing to ulceration, scar tissue, ankylosis of the arytenoids, etc. The permanency of the cure can only be determined by the experience of years.

## THE INDICATIONS FOR THE USE OF SALVARSAN IN SYPHILIS OF THE NOSE AND THROAT.

BY J. L. GOODALE, M.D.

My experience covers a series of thirty cases at the Massachusetts General Hospital, and six cases in private practice. The majority of these were in the secondary stage, and showed the ordinary forms of mucous patches in the throat and mouth. One case occurred of primary syphilis of the tonsils. Six cases were seen of tertiary lesions.

In the presentation of these cases I shall group them according to the reason for administering salvarsan. The efficiency of the preparation is now sufficiently established, and further proof of this statement does not seem required. It is not, however, always easy to decide whether a given case of syphilis shall receive it, or whether mercury and iodine shall be given in the time-honored manner, or whether finally a combination treatment is preferable. I hope that a description of certain typical conditions will bring out in the discussion the views of our members with especial reference to rendering more precise our views regarding the indications for its administration.

A word should be first said in regard to the method employed at the Massachusetts General Hospital. It is given either in a full dose of six decagrams or in a half dose of three decagrams. In the first instance the patient is admitted to the wards, and remains there for one or two days after his treatment. In the second case a half dose is given in the Out-Patient Department, and the patient is kept there for about six hours in a recumbent position. Intravenous injection is done into the arm with aseptic precautions. No ill-effects have so far been noted, although after a full dose chilly sensations and nausea sometimes occur during the following night.

Mercury is usually given in alternating months for a year

afterward, usually by inunction. Where inunction is not possible or desirable for social reasons, as in private practice, intramuscular injections of a soluble salt, such as the bichloride of mercury, are given, and are preferred to the administration of mercury by mouth. If a half dose of salvarsan is given in ambulatory practice, a second one is given usually in from two to six weeks, and in refractory instances a third is necessary a few weeks later.

During the past year the safety of salvarsan has become increasingly manifest, and the tendency correspondingly apparent at the hospital to employ it more and more as a routine measure.

Certain conditions, however, have seemed to me especially to require salvarsan in preference to entire reliance upon the former methods. These conditions are the following:

1. Where a prompt removal of infectiveness is important on social or conjugal grounds. Of this class the following case is typical. A young man, married about a year, came to me in March, 1912, with a typical chancre of the tonsils, acquired from a source alleged to be unknown to him. The wife was free from infection so far as could be determined. Wassermann was strongly positive, and a beginning roseola was present on the skin. The right tonsil was much enlarged with an indurated, flat, ulcerated surface, covered with necrotic debris. It was manifestly extremely important to remove the infection as promptly as possible. A full dose of salvarsan was given intravenously. Within a week the tonsil had cleaned up strikingly, and at the end of a fortnight the induration and ulcerated appearance had nearly disappeared. Inunction was then begun and will be continued for alternating months for a year. Wassermann is now negative.

A second class of cases is represented by those with persistent mucous patches in the mouth, where mercury is badly borne. Here we encounter stomatitis, at least in part mercurial, and often difficult to control, requiring the iodides with local applications of dilute chromic acid, and continually recurring in spite of all our efforts. This type is illustrated by a

man coming February 24, 1911, with mucous patches on the tonsils, and pyorrhoea alveolaris. Under mercury, the throat lesions promptly disappeared, but mercurial stomatitis appeared, requiring omission of the mercury. In January, 1912, Wassermann was positive, and a half dose of salvarsan was given. Mercury was again given with recurrence of stomatitis. In March he received another half dose. Wassermann is now negative, but the pyorrhoea persists.

In a third class, especially in out-patient work, lesions continually recur, whether from especial severity of the disease, or from neglect of treatment. As an instance, a man came in April, 1911, with syphilis of five years' duration, having had treatment intermittently, and still showing mucous patches of the tongue, with smooth atrophy at the base. Mercury and iodide of potassium were given at the hospital, but on January 27, 1912, the Wassermann test was still positive. Salvarsan was then given, and repeated in a month. On April 1 Wassermann was negative, and the throat normal, except for the smooth atrophy, which will, of course, remain.

In a fourth class, we wish to use salvarsan for the purpose of ascertaining the nature of a given lesion. We may, for instance, know that an individual has syphilis, and yet we are confronted with a swelling or a new growth in the throat or nose, where we cannot exclude the possibility of a sarcoma or carcinoma, or even simple hypertrophy. The excision of a specimen for microscopical examination may not be desirable or even practicable. The element of time may also be important. In a swelling of the septum or of the nasal bones a few days may make all the difference between control of a gumma and its caseation, with ensuing deformity. Further, the therapeutic test with mercury and the iodides may leave us in doubt, or their efficiency may not be sufficient to cope with rapidly advancing infiltration. These various conditions are represented by the following case of tertiary syphilis, referred to me by Dr. F. C. Shattuck: A woman, the wife of a sea captain, came November 17, 1911, complaining of severe pain over the right eye of six weeks' duration, with a numbness for two days below the eye, extending

over the cheek. The septum showed a symmetrical, firm thickening at the junction of the quadrangular cartilage and the ethmoid plate, covered by smooth, pale mucous membrane. The right middle turbinate was much enlarged, and showed considerable oedema. The region of the cheek supplied by the infra-orbital nerve was anesthetic to the touch. The patient stated that she had taken, five years before, some medicine in drops for a periostitis of the left upper jaw with recovery. She was now given sajodin  $7\frac{1}{2}$  grains and protoiodide of mercury 1-6 grain three times a day. On December 1 the ethmoidal and septal swelling had much diminished, and the numbness and pain had disappeared. On January 2, 1912, she reported, stating that she had been doing well until ten days previously, when severe general headache appeared, together with a return of the numbness over a smaller area. There was now no supraorbital pain. The right middle turbinate showed now general disorganization, with beginning necrosis of the bone. The septal swelling was manifest but slight. Four days later a diffuse periosteal swelling appeared over the left cheek. A full dose of salvarsan was then given. Within a week her headache had disappeared, and there was less thickening evident over the left antrum. The right middle turbinate showed a marked diminution in size, with a clean, moderately oedematous surface. A month later, numbness was present below the right eye, but otherwise the patient felt entirely well.

A fifth condition indicating salvarsan is found in certain types of tertiary syphilis. While the ordinary gumma usually yields a prompt response to the iodides, yet we find at times on the dorsum of the tongue, in the larynx and on the septal cartilage more superficial tertiary lesions, relatively slow in development, and exhibiting a protracted course. These cases appear analogous to the slow-moving superficial serpiginous gummata of the skin. The following is a typical instance: A man came to the clinic August 17, 1911, with a history of syphilis acquired two years previously, and showing papules on the skin and patches on the tongue. Mercury was given by inunction, but on October 21 the Wassermann was positive, although the lesions on the skin



and tongue had improved. Inunctions were continued, and by November 25 all the lesions had disappeared, with the exception of a sore ulcerated area on the tongue, which had invaded the submucous tissue, and had the aspect of a superficial aggregation of gummata. In spite of continued mercurial treatment and chromic acid applications, no improvement was noted in the ulceration. On January 4, 1912, a half dose of salvarsan was given. The sore was persistent through the following month, and on March 14 a second injection was made. Healing now began rapidly, and in twelve days was complete. Examination on April 24 showed a scar on the tongue corresponding to the ulceration, but otherwise nothing abnormal.

The clinical results following the use of salvarsan appear to me comparable to those following the intramuscular injection of mercury, but more immediate and much more powerful and lasting. While with mercury we may count with reasonable probability upon the melting away of active syphilitic lesions, with salvarsan, on the other hand, the elements of doubt and delayed response appears eliminated. Particularly in the indolent tertiary types, and in the malignant forms of syphilis, salvarsan shows its most brilliant results, and occupies a position far superior to the older modes of treatment. As to its power to effect a cure, opinions are not yet unanimous, but the weight of evidence justifies the statement that salvarsan in repeated doses and in association with mercury offers the best hope of attaining this result.

#### *Discussion.*

Dr. J. M. Ingersoll, Cleveland: I have comparatively little to say on this subject, because the experience I have had from the use of Salvarsan and the opinions I have drawn agree so closely with those expressed in the papers.

Personally I have never administered Salvarsan nor made a Wassermann test. In cases in which I make a diagnosis of syphilis I refer the patients to the men who are doing this work in Cleveland. We have, of course, worked together in the dispensary and private work, and our results and opinions coincide very closely with those of Dr. Goodale and Dr. Cobb. I have come to the conclusion that divided doses give better results than a single large dose, extending the period according

to the results and the Wassermann reaction. The general results have been almost universally good.

This treatment is not a specific, as there are cases where the old line of treatment works better. The majority of cases clear up quicker with Salvarsan, however. I never have used Salvarsan as a test as we use mercury and potassium iodide. If the Wassermann reaction is negative and there are no decided clinical evidences of syphilis we do not use Salvarsan.

Dr. Goodale spoke of the possibility of differentiating the beginning of a gumma of the posterior part of the septum without other physical lesions. In such a case we would make scrapings from the septum and make repeated Wassermann tests, and if they were all negative we would not administer Salvarsan. We also alternate this treatment with mercury.

Recently I had a case of secondary lesions of the mouth in which mercury was given first on account of the patient's preference, but it apparently had no effect whatever. The diagnosis was absolutely positive although the man did not know when he had the primary syphilitic lesion. Scrapings from the ulcers and the Wassermann reaction were both positive, and with the failure of result from mercury we gave Salvarsan in divided doses, and the results were all one could desire, the thing clearing up rapidly, much to the patient's relief.

There is just one thing I would like to call attention to, and that is the effect of Salvarsan on the auditory nerve. I make it a practice to test the hearing of my patients after making the diagnosis of syphilis before giving Salvarsan. If they have a lesion of the auditory nerve I always use mercury in preference, because any existing lesion of the auditory nerve may be made materially worse by the use of Salvarsan. Last Summer in Vienna I saw at least twelve cases which had been carefully worked up in which the deafness had been made decidedly worse, and in two cases the deafness was absolute. I think it wise, therefore, whether doing ear work or not, to examine the ears and test them before the administration of Salvarsan.

Dr. B. R. Shurly, Detroit: My experience with Salvarsan has also been comparatively limited. We received a rather early assignment of this remedy in Detroit, and as soon as it arrived our chemist made up the solution for intramuscular administration and I administered it personally to the cases under observation that were malignant and those that had

not responded to the ordinary mercurial method of treatment. It struck me at the time that this remedy was something very much like diphtheritic antitoxin in the early days when it first came under my observation, when it was my pleasure and privilege to test it clinically for one of the large manufacturing establishments. It was the first specific remedy in which one could see from hour to hour and from day to day the actual effects and trace them by the naked eye. It seemed to me Salvarsan was of that type, and so it proved in the first case we had under observation. The effect was so marvellous that it was a pleasure to observe the lesions fade away, especially as this patient had been under observation for six years and mercurial remedies of every sort had been tried, without much effect. There were still in this case skin lesions and deep lesions of the tongue and mucous membrane in various localities in the throat and mouth. After administering .6 gram intramuscularly the lesions cleared up marvelously by the end of two weeks. That was more than a year ago, and I saw the patient recently, and the one dose in this case seemed absolutely sufficient to bring about practically a perfect recovery.

There is no question that the preparation of Salvarsan is an exceedingly important matter. There are comparatively few chemists that know how to prepare it as it should be done. There are three distinct methods for preparing the material. The intravenous injection of a very dilute alkaline solution, subcutaneous or intramuscular injection of a concentrated alkaline solution and the intramuscular injection of a neutral substance. Of course, the intravenous method is the one in greatest favor now, and is undoubtedly the method which will stand as the favorite from the fact that the patient need only remain in the hospital a short time, where the injection can be given, whereas the intramuscular administration is very painful and frequently patients will not submit to more than one dose administered in this way. The fact that 95 per cent of these cases are cured, as stated by Dr. Cobb, in the secondary forms, 75 per cent in the tertiary, carries out the analogy to diphtheria antitoxin, which, I believe, has about 5 per cent mortality.

The differential diagnosis of syphilis by the use of Salvarsan I have not used. The old method of biniodide of mercury with potassium iodide has always been satisfactory and so extremely useful to the laryngologist in the vast majority of cases that it seems to be the consensus of opinion that it is best to use mercury in addition to Salvarsan in the malignant

cases and in those which do not respond promptly to the use of 606.

The contraindications to the use of Salvarsan are very important as touched upon by Dr. Ingersoll in speaking of the auditory nerve. Then there is the effect on the heart, lungs, kidneys, retina and optic nerve, which should be familiar to us. I always tell a patient before administering this drug of its possible dangers. While we have had no fatal cases in Detroit up to the present time, the fact that the mortality is one in a thousand shows we have a remedy that is an exceedingly dangerous agent and one which should be thoroughly understood by the patient before its administration.

Dr. Henry L. Swain, New Haven: I think, as Dr. Cobb suggested in the beginning of his remarks, we have to remember the fact that we, as specialists, devoting our labors to the disease of one small part of the body, are touching upon a general disease affecting the whole body. We are reaching it at a tangent, and only touching a part of the circumference. I have always felt that we, as a profession, were lamentably weak in the treatment of syphilis. We are supposed to have a specific, but almost never properly use it. You and I come into contact with cases taking mercury, and in a haphazard, unsystematic way outline the treatment. As a result the patients get half way better or slip back, as the case may be, and thus get into a state where no amount of mercury given in the ordinary way has any influence. We hoped when Salvarsan was brought to our attention, as Dunbar hoped when he brought out his treatment for hay fever, that there would be a remedy which would always cure the disease. We are again doomed to disappointment, because Salvarsan alone will not cure these cases. We must give mercury in addition. So that it has already passed to the stage of being an adjunct in the treatment. As a perfectly proper means for making a diagnosis in obscure cases, if for no other purpose, it would, however, be worthy of our best consideration, even if it did no good therapeutically.

One of the cases in our hospital demonstrated the last fact in a most interesting way. I had observed a case clinically which came to the office, and I made up my mind it was syphilitic, and gave anti-syphilitic treatment. It did not respond well, and I consulted a friend and colleague. He presented it as a case of tuberculosis to a society. I was greatly astonished, but he said he based his statements upon the following grounds: First, it had been treated indefinitely with mercury, without the lesion being cured; second, it did not present all

the characteristics of a syphilitic lesion, and had absolutely no history; thirdly, he had recently given test doses of tuberculin with a beautiful reaction, and, therefore, felt satisfied in presenting it to the meeting with this diagnosis. I said I had thought it syphilis, had given anti-syphilitic treatment; it had begun to improve, but I deferred to the tuberculin test. We put the case in the hospital and treated it there for a while, and the ulcer steadily spread. The uvula went in the course of a week, and I suggested that I would give it Salvarsan for diagnostic purposes. This was done, intravenously, and inside of five days there was no lesion to control. In this case Salvarsan was a splendid diagnostic means, and now mercury is being given to produce absolute remission of all symptoms. If mercury is kept up for a year, and then a year follows in which there are no manifestations, you can consider it a cure. This case is particularly instructive, because of the fact that tuberculin was positive; it had had two negative Wassermanns, one negative Noguchi, and, therefore, certainly suggested the diagnosis of tuberculosis. After we had given the first Salvarsan injection (the patient has had two) the Wassermann came very clearly into evidence, the most pronounced effect coming about ten days later. When the second dose of Salvarsan was given the Wassermann again disappeared, with complete abeyance of all symptoms. That gave a pretty demonstration of the general relation of the Wassermann and other means of diagnosis to Salvarsan.

Another case for diagnosis was an obscure condition in the nose. There was a form of polypoid enlargement of the anterior end of the middle turbinal in both nostrils, with very little nasty purulent discharge coming into the nose, with very marked pain, and thickening of the mucous membrane in the frontal sinus, as shown by transillumination, and yet, as I looked at that case, I could not believe it required external operation. I removed some of the growths, examined them microscopically, and there was a small cell infiltration in a mass of myxomatous tissue. It was not the ordinary form of edematous fibroma, and I thought it possibly gummatous, although nothing positively diagnostic was found about the material. Here, again, I suggested that Salvarsan might prove useful. Two Wassermanns were negative. Salvarsan was given, and immediately all symptoms improved. The patient was better than he had been in a year and a half. Here, please remember, there was an absolutely negative history and two negative Wassermanns.

While considering these facts regarding the injection of

Salvarsan, we ought to consider the manner of giving it. Interesting data are brought out by the work of Parke in the injection of diphtheria antitoxins. The intravenous injection gives a maximum effect immediately and then quickly recedes. Intramuscularly, the effect comes on gradually, reaches its maximum after a longer period and recedes very slowly, as in both instances to be expected. But the thought obtrudes itself as to whether it would not be well to sometimes use one way and in some cases the other.

Dr. Emil Mayer, New York: I think we should have our attention directed to the fact that Ehrlich has now presented a new preparation of Salvarsan, which is supposed to be less harmful in its uses than the former preparations known as Salvarsan. Dr. Swain has mentioned the use of an injection of Salvarsan followed by a positive Wassermann reaction. Some observers have already called attention to that, and to speak of the injection of Salvarsan as a provocative injection, really bringing out the effect of the Wassermann reaction and thus making it positive. This is an observation which Dr. Swain had probably made independently.

An important question we should help decide is, how soon after an injection of Salvarsan has been given may we propose to do a repair operation for the destruction occasioned by syphilitic disease? I have occasion to see all the throat cases coming to Mt. Sinai Hospital for Salvarsan treatment, and I am asked occasionally to advise how soon we may be able to take care of the cicatricial bands and remove existing cicatrices. I would like some light thrown on that subject. My own opinion has been to wait until the patient has gone a length of time with a negative Wassermann.

Dr. H. S. Birkett, Montreal, Canada: During the past two years I have had an opportunity to collect a number of cases, in which one was able to form certain opinions in the use of this remedy—Salvarsan—in the treatment of syphilis. There is one very striking feature—that in the cases under my care the secondary, as well as the tertiary manifestations in the acquired conditions, have responded very promptly; but what has struck me with greater force is the use of this same remedy in the inherited form of syphilis, and that was shown very remarkably in a child seven years of age, who presented himself with his mother, showing an extensive ulceration of the posterior wall of the pharynx and perforation of the hard palate, extending directly into the nose. The child was given minimum doses of Salvarsan intravenously, and within ten days the ulceration had healed, the perforation closed, and the picture was one of great difficulty in which to find anything

wrong with the throat. This child went through the usual tests—the Wassermann reaction, the examination not only of the organs of hearing, but also of sight, so that we knew exactly where we stood before the treatment was begun.

Dr. J. H. Hartman, Baltimore: I saw a most interesting case of syphilis of the larynx on March 29th, 1911, in which Salvarsan was used. There was a large gumma on the right side of the larynx and a mucous patch on the left velum, in other words, the secondary and tertiary symptoms both apparent. A Wassermann test was made a few days after admission to the hospital and reaction was positive. On April 10, 1911, Salvarsan was injected intravenously. On May 3 the entire gumma had disappeared, but one could make out the original site. The patient was put on mercurial treatment with instructions to report from time to time, which instructions he failed to carry out, disappearing entirely. On February 15, of this year, he reported again, complaining of hoarseness and there were two large nodules on his forehead. Salvarsan was again administered on February 29th. On March 6 he was much improved, on April 9 Wassermann comparatively negative, and on May 4 another Wassermann was made and was absolutely negative. This case shows the very rapid improvement possible under Salvarsan.

Dr. A. B. Thrasher, Cincinnati: This discussion brings to my mind a case which may be of some interest in this connection, in which there was an ulcer of the nose in a patient treated for two years by injections of mercury and by the exhibition of potassium internally without any attempt to heal. It was continually extending, until it was thought it might be malignant in character. The administration of Salvarsan in the minimum dose intravenously injected cleared up this ulceration entirely in two weeks. This was accompanied by entire disappearance of reaction to the Wassermann test. In the course of two months the Wassermann was again made, and in accordance with the remarks made by Dr. Cobb it was found to give nearly as violent a reaction as before the injection of the Salvarsan. Another injection of the remedy was followed by a negative Wassermann. Whether it will again recur I cannot say. This disappearance of the Wassermann reaction within a short time, three or four weeks after the injection of Salvarsan, has been almost a universal experience, but in three cases the Wassermann has again returned in from two to three months, necessitating a second injection of Salvarsan.

I would not be satisfied with the single use of Salvarsan in these cases, but consider we should still use mercury and

potassium in addition. One interesting point about the case above reported was the complete failure of relief from the older methods of treatment alone, but this treatment was continued after the injection of Salvarsan and I believe had a part in the rapid improvement.

Dr. T. H. Halsted, Syracuse: I should like to report a case which may possibly suggest one contra-indication in certain ulcerations of the throat. A boy twelve years of age was sent to the hospital with a tertiary ulceration of the posterior wall of the pharynx. This was early in the days of Salvarsan, when it was first brought to this country, and he was given an injection. A week later he was exhibited at a medical society where I saw him. The ulcer was healing rapidly and bade fair to be entirely healed in a short time. I did not see him again until six months later, when he came to my office for the relief of deafness. I found the anterior wall of the soft palate and the posterior wall of the pharynx absolutely and completely united, the mucous membrane looking perfectly normal. The boy was very deaf, the bone tests were normal, but the drums were tremendously retracted. I think I have never seen this more marked. It was a case practically of middle ear disease. Now the question is whether in such a case it would not have been better to have given the patient iodide of potash and mercury, allowing the healing to take place more slowly and possibly preventing the formation of adhesions. I have since had a similar case of tertiary ulceration in the pharynx and soft palate in which I have refused to use Salvarsan for this reason.

Dr. J. M. Ingersoll, Cleveland: First, I would take issue with Dr. Cobb and Dr. Halsted, for one of the advantages of Salvarsan is the rapid combating of the poison and prevention of scar tissue. I think it is more rapid and satisfactory than any other known method. I believe the case of deafness reported by Dr. Halsted would have been worse had Salvarsan not been used.

Salvarsan has practically no effect on the middle ear. The idea I meant to give was that arsenic has a peculiar selective effect on the auditory nerve. If the lesion in the auditory nerve antedates the syphilitic infection Salvarsan should not be used, because the nerve is less resistant than an ordinary nerve. If the lesion, however, is due to syphilitic infection, then the use of Salvarsan is not contra-indicated.

Dr. Otto T. Freer, Chicago: Dr. Arthur Geiger, of Chicago, informed me that when he was in Vienna he saw some twenty cases of total deafness of the acoustic nerve in one or both ears following the use of Salvarsan, and I should like to know if any one present has seen bad results of this nature.



Dr. H. L. Wagner, San Francisco: Last year after the Laryngological Congress in Berlin I had the opportunity to visit a number of hospitals in Europe and study the results obtained with Salvarsan, and I learned that primary and secondary affections are greatly benefited, but less good results are obtained in tertiary conditions. I then had occasion to observe a few cases of lues, where marked symptoms of serum disease followed not the first, but the second or third injection of Salvarsan, and it may be possible that the disturbances of the retina, of the optic nerve, of the vestibular apparatus within the ear and a few recorded deaths are principally due to anaphylaxis. This has been substantiated by a Russian author, whose publication appeared in the *Muenchner med. Wochenschrift* a few weeks ago. Of interest may it be that stomatitis or mercurial poisoning takes place less often and to less intense degree when Salvarsan has preceded the administration of a mercurial treatment.

Dr. E. Fletcher Ingals, Chicago: Regarding the administration of Salvarsan, it is interesting to recall that Dr. Brainerd in 1849 demonstrated that various substances could be injected directly into the veins, without harm, that would cause an eschar if injected into arteries, muscle or areolar tissue. It may be for this reason that Salvarsan is better injected into the veins than intramuscularly.

Dr. J. R. Winslow, Baltimore: I have seen three cases which illustrate the great value of this remedy in what may be termed malignant cases, in saving important structures. One was the case of Dr. Hartman's, in which he did not bring out this point, namely, that the infiltrated ventricular band presented a soft appearance and seemed ready to ulcerate, probably in forty-eight hours it would have ulcerated, but the single injection of Salvarsan cleared up this condition.

Another case was that of a young woman with ulceration of the soft palate, which was fairly melting away with syphilitic, tertiary ulceration, and this was saved by a single injection of Salvarsan.

A third case, of which I did not see the termination, but which I had the opportunity of observing in 1910 in Berlin, was gumma of the right bronchus in a most dangerous situation. I am told that this yielded promptly to the injection of Salvarsan, which I saw administered.

These three cases, therefore, illustrate the great value of the remedy in saving dangerous situations and avoiding destruction of valuable tissues.

Dr. Harmon Smith, New York City: There were a number

of cases of syphilis treated with Salvarsan in my clinic at the Manhattan Eye, Ear and Throat Hospital, the results of which were given in a paper read by my assistant, Dr. Francis White, before the Section on Laryngology, New York Academy of Medicine, February 28th, 1912.

One case, however, occurred before the series was taken up, and consisted in multiple, syphilitic papillomata of the larynx, in an Italian boy, nine years old. The microscopical examination and the Wassermann reaction were both positive. The boy remained in the hospital for several weeks after the injection of Salvarsan and showed marked improvement both locally and constitutionally. At the expiration of about two months the papillomata had disappeared, but the cords were thickened and his voice remained somewhat husky. He remained away from the clinic for three months and then returned with a well-developed jaundice, upon which treatment had no effect, and death ensued one week later. An autopsy was not permitted, but I have since wondered if Salvarsan could have in any way induced the jaundice.

Dr. W. K. Simpson, New York City: As Dr. Swain has said, we are considering a subject with a general application, but we have a right to consider our own specialty.

In line with what Dr. Goodale said, I have had experience with a very indolent type of tertiary syphilis within the nose, and I may say here that in spite of the denial on the part of the patient that anything syphilitic had ever happened to him there was a scar in the pharynx which to my mind was nothing more or less than a tertiary cicatrix. On the strength of that I determined that the condition within his nose was syphilitic. It varied greatly in appearance and location from the ordinary syphilitic lesion and was of an indolent type. There was no gumma, and the ulceration was at an unusual location on the inferior turbinal bone. I had a Wassermann made and it was very markedly positive. I placed the patient on iodide, but he could not take it well, and I changed to mercury and still he did not do well. Then he was given an intramuscular injection of Salvarsan in conjunction with the mercury, and still he did not do as well as I had hoped he would. Subsequently another injection was given intravenously and he responded very well, so that the condition practically cleared up.

There are several instructive points in this case, the indolent nature of the lesion, and the fact, on which I lay great stress, namely, that the pharyngeal cavity is an excellent place to make a diagnosis of late syphilis, and the fact that mercury and iodide alone or even after the first injection of Salvarsan did not work

well, but that after the second injection of Salvarsan intravenously the patient responded to this remedy.

Dr. George C. Stout, Philadelphia: I was very much pleased with Dr. Simpson's remarks. In my own personal work I find Salvarsan of more use in indolent cases of ethmoiditis with dry, hard scabs in the posterior nares and pharynx than in the more marked specific lesion, which usually responds promptly enough to hypodermic injection of mercury or inunctions and large doses of iodide of potassium.

I would like to ask Dr. Winslow if mercury and iodide of potassium were used in the three cases he reported before the resort was made to Salvarsan.

Dr. Frederick C. Cobb (in closing): Dr. Ingersoll's remarks relative to nerve lesions resulting from the use of Salvarsan have interested me very much. So far I have personally seen no such effects and I think that the truth can only be ascertained by comparing notes in a large number of aural cases. As to Salvarsan not being a cure, that, as I have said in my paper, seems to be a question for time to decide. The Wassermann test repeated at rather long intervals, perhaps two or three times a year, appears to be our only guide. As regards Dr. Mayer's question as to how soon after these injections operations may be performed with safety, I can only say that I do not know. Personally I should feel that after several Wassermann negative reactions one could operate with comparative safety.

Dr. J. L. Goodale, Boston (in closing): Several of the speakers have called attention to the use of Salvarsan in ethmoiditis, and I want to emphasize the importance of that point by mentioning briefly a case. A man with a history of syphilis acquired a number of years ago came with a large cystic middle turbinate on one side and severe headache of several months' duration. A Wassermann was made and the reaction was positive. His family physician put him on iodide of potassium for several months, but without effect. I then considered the headache due to pressure of the turbinal and prepared to remove it. Before operating the family physician asked permission to have Salvarsan given; this was done, and the headache cleared up so promptly, and without recurrence, that I cannot help believing it was due to syphilis rather than to pressure from the turbinal.

With reference to the explanation of possible ill effects of Salvarsan in nerve lesions of the ear and eye it has been shown that in such conditions an edema occurs in the sheath of the nerve, the resulting pressure bringing about a destruc-

tion of the nerve. In this connection I would mention a case under observation for a number of months with low indolent syphilitic ulceration of the larynx who developed in ten days paralysis of the abductor fibres in the eye on one side. The question now arises whether it would be safe to use Salvarsan on this patient, with the probable prospect of having the paralysis recur, or would it not be safer to run this risk of sudden recurring edema and sudden but transitory paralysis rather than to allow him to continue in his present condition. I came to the conclusion this was the least dangerous of the two evils and he has, therefore, had it but too recently to give a report. Dr. Ingersoll said that the intravenous injection was more apt to cause this nerve irritation than was the intramuscular or subcutaneous injection.

At the Massachusetts General Hospital our method is to have two flasks, one of the physiological salt solution, the other containing a solution of Salvarsan. The trocar is connected with two rubber tubes and each of these has a bivalve with rubber bulb; it is easy to draw up first from the bottle of salt solution the salt solution into the trocar, and when the air is driven out this is introduced into the vein; that bivalve is then closed and that leading into the Salvarsan is drawn up and pushed into the vein immediately following the salt solution. When the injections have been completed we then again open the valve to the salt solution and infuse an ounce after the Salvarsan, which insures a complete introduction of the Salvarsan into the veins and leaves none in contact with the skin.

THE UPRIGHT POSITION IN ETHER OPERATIONS  
UPON THE NOSE, THROAT AND OTHER POR-  
TIONS OF THE HEAD, WITH DEMONSTRA-  
TION OF A NEW METHOD FOR ATTAIN-  
ING THE POSITION WITH EXPEDI-  
TION, EASE AND SAFETY.

BY THOMAS R. FRENCH, M.D.

Twelve years ago the writer prepared a paper for presentation to this distinguished body, the title of which was somewhat like that of the one now being read. In the paper of earlier date the upright position was extolled and the belief expressed that it was of greater value in ether operations than other positions. So far as we are aware the contribution did not make much of an impression, and we like to think the apparent lack of impressiveness was, at least in part, due to the writer's inability to be present to emphasize his convictions and demonstrate his method. The method for securing and maintaining the upright position, which was described at that time, consisted in anesthetizing the patient upon a table, from which, when partly anesthetized, he was lifted into a specially designed chair tilted well backward, and after the body was strapped to the chair so that it was practically one with it, it was brought slowly from the recumbent to the upright position. Our experience with the method since then has taught us many things, and we have come before you again to present the results of such teaching.

In the communication just referred to, we said: "A search through surgical literature reveals the existence of an almost universal fear among surgeons of performing ether operations upon the nose and throat while the patient is in the upright position. The fear seems to be due mainly to the supposed danger of blood flowing into the windpipe. \* \* \* It is alleged that disaster is courted when operations are performed when the body is in such a position, and if blood flows into the lower air passages

while the cough reflex is abolished, one has only himself to blame if either pneumonia or violent bronchitis occurs afterwards." When one takes into consideration the superiority of the display of the interior of the mouth and the fauces, and also the interior of the nasal cavities, when the patient is in the upright position, it would be difficult to understand why it would not always be the position of choice in ether operations, if it could be demonstrated that, while employing it, the patient's interests would not be jeopardized by an added risk in the administration of an anesthetic, and by the dreaded, but largely mythical, inspiration of blood into the windpipe; and also that neither extra time nor trouble need be taken to attain and maintain the upright position. In the hope of being able to help in proving that such dangers and difficulties can be readily avoided and the position be made as safe and easy as any other, an outline of the results of our experiences in this field are presented for your consideration.

In the time which has passed since this matter was, to us, quite satisfactorily settled, it became apparent that there must be something seriously wrong with the older method of attaining the upright position, for anesthetists, especially hospital internes, not infrequently showed a decided reluctance to preparing patients for it. Such reluctance, it would seem, has in part been due to the more or less frequent occurrence of trouble in maintaining respiration until the patient was fully anesthetized and safely placed in the position for operating. In the hands of an expert anesthetist, thoroughly trained in the various steps of the procedure necessary to placing the patient in the desired position, there is no greater difficulty or danger with the older method than with the new, but it is unquestionably a fact that when a large number of patients are to be operated upon at one time, the older method is much more tiring even to the expert anesthetist. Because of the difficulties and objections just mentioned, a new method has been evolved from the old to make the position safe in the hands of relatively inexpert anesthetists, and also to make the anesthetizing and operative work easier and more expeditious in any hands.

While the older method has proved to be satisfactory when one or a few operations have been done at a time, especially when

the anesthetic has been given by an expert, it has nearly or quite broken down in hospital work when many operations are scheduled for a single session. Indeed, in one hospital the internes practically struck because of the added labor required of them to bring the patients to the upright position in long operative clinics. This brought us to a realization of the situation and we set to work to reduce the difficulties and make the method feasible and easy for all operative sessions. The outcome of an evolutionary process of development, occupying a considerable length of time, is what we regard as a satisfactory surgical device and a satisfying




Fig. 1.

The chair table shown as table; the height in this adjustment is a little less than that of the regulation operating table; it can be raised higher.

method. Described in a word, the method consists in placing the patient upon a table for anesthetization in the recumbent position, and when the stage of excitement has passed, in converting the table into a chair and bringing the body to the sitting posture; or, for that matter, placing it in almost any other position except one with the face downward.

The designation of this piece of surgical apparatus as a *chair table* (Fig. 1)\* will, we believe, convey a fair idea of its character. When viewed as a table the top is seen to be made in three sec-

---

\*We are indebted to Dr. Nathan T. Beers for taking the excellent flash-light photographs which illustrate this paper. The exposures were made in the operating room department of the Long Island College Hospital.

tions, the longer end section being the chair back, the middle section the seat and the other end section the footrest. The long end section is made of three parts, telescopic in character, which makes it possible to lengthen or shorten the back to fit the back of any patient. The extreme outer end of this section is fashioned into a solid headrest. The table top can be made to occupy a level as high as, or considerably lower than, that of the regulation operat-

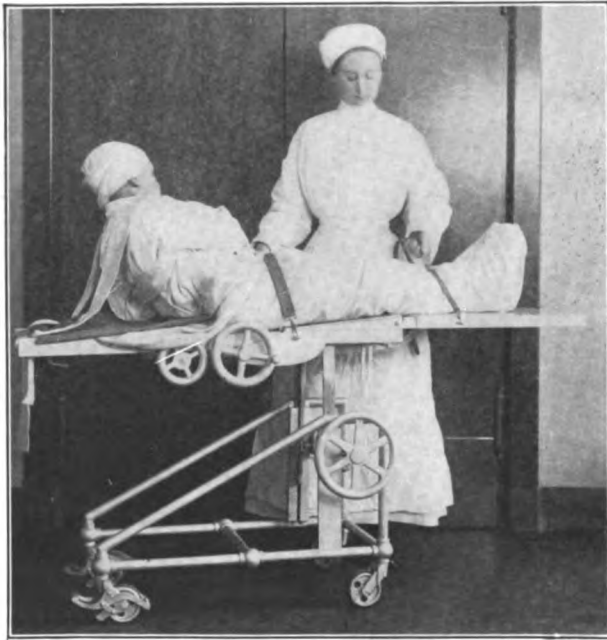

Fig. 2.

Strapping the patient to the table top before anesthetization.

ing table. The top is balanced upon and is attached to the frame of the table by a mechanism similar to the Trendelenburg device, which, with other mechanical aids, makes it possible for us to do many things with the chair. Footbrakes are attached to the rear casters to hold the chair firmly to the floor during operations.

By placing a patient upon the table we will be better able to follow the various movements. Before the patient is wrapped in



a blanket, a stout four-inch bandage is made to encircle the upper part of his back, the ends being drawn up under the axillae and over the front of the shoulders, and for the moment the ends are allowed to hang in the recesses on either side of the headrest (Fig. 2). After the patient has been wrapped in a blanket the leather straps attached to the seat are fastened rather loosely around the hips, and the legs below the knees are fastened to the footrest (also shown in Fig. 2). When the patient is nearly anesthetized the anesthetist turns the wheel at the junction of the back of the chair with the seat and the body is thus raised slowly

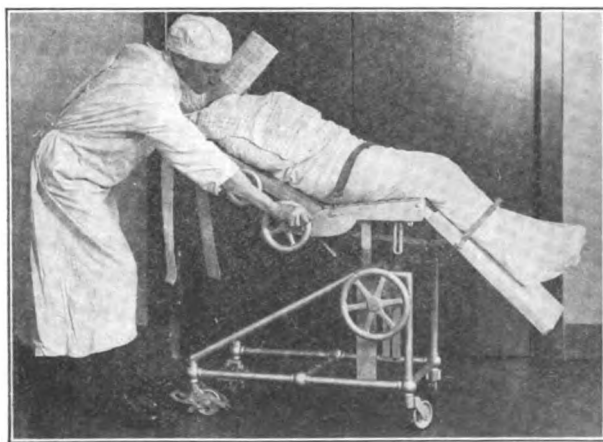


Fig. 3.

Anesthetist raising patient to the sitting posture. This is accomplished by means of the wheel at the junction of the back of the chair with the seat.

forward (Fig. 3) to the upright position, the mechanism being so constructed that as the back ascends the footrest descends. The seat, which is a trifle higher in front than at the back, is covered with a mat of corrugated rubber which checks largely, if not entirely, the tendency of the body to slide toward the foot of the table or chair. While the upward movement is taking place the headrest is adjusted to the patient's head by means of the smaller wheel on the side of the back section (Fig. 4), and

this is accomplished, whether the patient is a child or a tall adult, with such ease and accuracy that the position of the head for the proper administration of the anesthetic and the desired display of the field of operation can be readily maintained. At the same time the shoulder bandage is adjusted by drawing the ends around the headrest when they are caught under, and tied to a hook on the back of the chair. The patient has now reached the upright

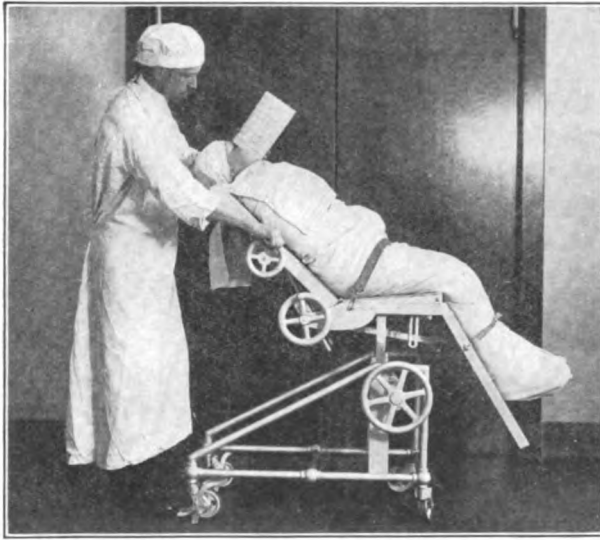


Fig. 4.

When the patient's body is part way up the headrest is adjusted to the head by means of the wheel on the side of the chair back. Foot brakes applied.

position and is ready for operation. If the surgeon desires to operate while standing, the chair part of the mechanism can be raised (by means of the large wheel in the frame of the base) sufficiently to bring the head of the patient opposite his own (Fig 5). If, however, he desires to operate while sitting, the chair can be lowered, if necessary, as far as the base (Fig. 6); and these movements are made with surprising ease, even if the patient's body is of great weight. Figures 5 and 6 also show the

anesthetist standing inside the rear part of the frame of the base, in which position he administers the anesthetic and controls the mechanism of the chair. If respiratory or circulatory troubles arise, and it is desired to lower the patient's head, this can be

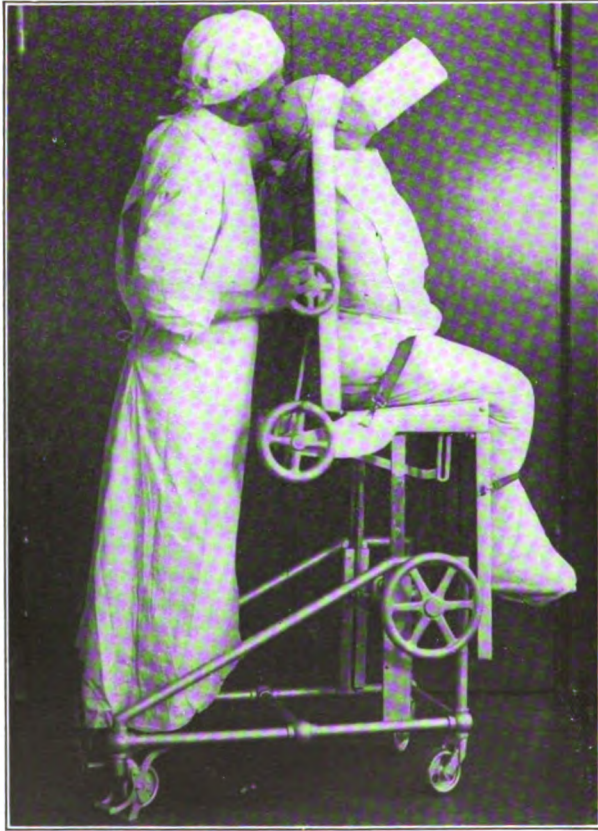


Fig. 5.

Shows the patient in the upright position and ready for operation. The chair is elevated to permit the surgeon to operate while standing.

quickly done by tilting the chair backward (Fig. 7), and then by wheel action converting the chair into a table top in the Trendelenburg position (Fig. 8).

The special chair exhibited before this association twelve years ago is now being remodeled and, we believe, greatly improved. It will be light in weight and collapsible, and therefore easy to carry about. We have reason to think it will be well adapted for

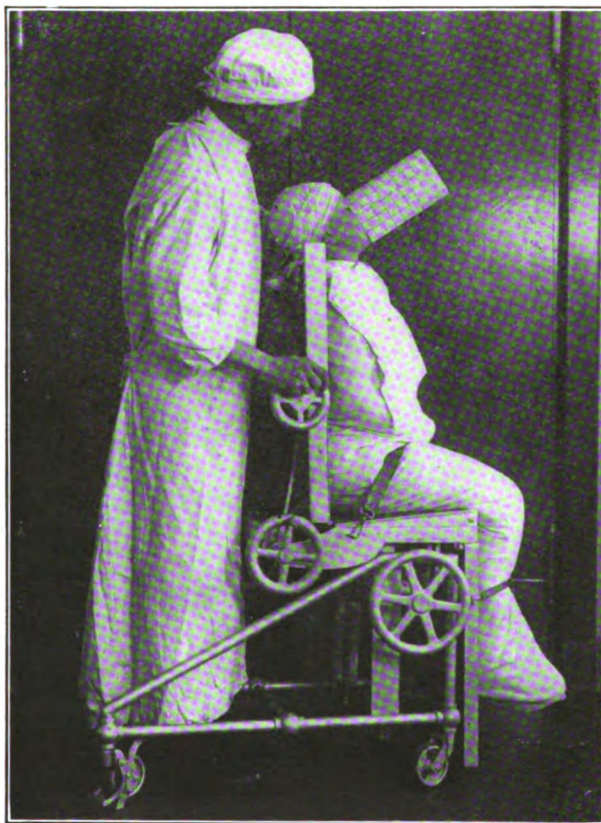


Fig. 6.

The same as Fig. 5 except that chair is at lowest level to permit the surgeon to operate while sitting. The elevating and lowering movements are made with the large wheel in the frame of the base.

operative work in patients' homes. The chair table is perhaps a trifle too heavy for use except in permanent operating rooms.

While we are not without hope that the members of this asso-



ciation from Boston and its vicinity may find something of use to them in the particular method which we are describing, we have, of course, no thought of the need of impressing them with the *value* of the upright position. A young laryngologist from "up New England way," while in New York a few weeks ago, was asked what position he employed in operating upon adenoid growths and faucial tonsils, and he replied: "Why, the chair posi-

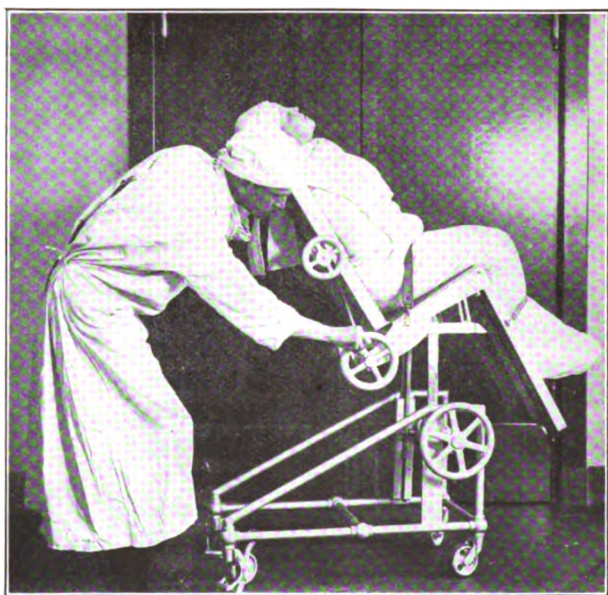


Fig. 7.

Chair tilted backward; this is the first movement necessary to reach the Trendelenburg position.

tion, of course! Is there any other worth the while?" My deeply lamented friend, Dr. Franklin H. Hooper, brought the idea from England and taught it so well in Harvard that, in this particular, practically all of New England is upright to-day.

It is, we believe, the almost invariable custom of writers of text books and monographs, when dealing with operations within the upper air passages, to advise the upright position when local

anesthesia is to be employed, and the recumbent position when the patient is to be placed under the influence of a general anesthetic. The proper interpretation of the latter piece of advice is, no doubt, that although the upright position is regarded as nearly always preferable, a concession must be made to the horizontal position because of the supposed danger of blood flowing into the wind-pipe, as well as the danger from the anesthetic, in the upright

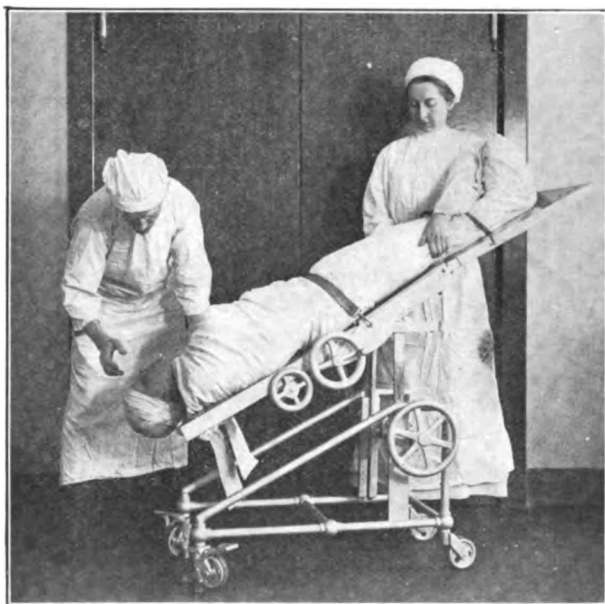

Fig. 8.

Trendelenburg position.

position. We believe every one of our auditors will agree to the statement that, with very few exceptions, every operation upon the nose and throat can be done more skilfully, and therefore more satisfactorily, when the patient is in the upright position, a position which enables us to occupy the same topographical relationship with our patients as that to which we are accustomed in everyday office practise. If this proposition is agreed to, then is not the whole question reduced to the following: Is there

greater danger from a general anesthetic, and is there greater danger from blood flowing into the windpipe in ordinary operations, when the patient is without voluntary control, in the upright position than under similar conditions in the recumbent position? Our experience of many years, in which we have rarely operated upon a patient under the influence of a general anesthetic except in the upright position, enables us to say that neither the one nor the other is more likely to trouble us in the upright than in the hanging-head position, provided that the operator and assistants are alive to the needs in the administration of the anesthetic and the manner of disposing of the stream of blood. In reviewing our experiences with this method, we can scarcely wonder that some of the surgeons witnessing such operations should have been deterred from adopting the position because of the temporary embarrassment to respiration occasioned by, or resulting from the incapability of the anesthetist. With an ordinary chair, or even with the special chair as previously constructed, it has been at times very difficult to place and keep the head of the patient in the required position for the proper administration of the anesthetic and for easy access to the field of operation. With the new method this difficulty has been eliminated, and even the inexperienced interne or newly graduated medical man can, under instruction, bring the patient to and maintain him in the upright position with perfect ease and safety. This is accomplished partly by means of wheel devices, the slightest turn of which either raise or lower the upper portion or the whole of the body or elevate or depress the headrest, and that too without further need of attention than is required in turning them.

The secret of a safe and an uninterrupted administration of an anesthetic in the upright position, is in keeping the neck somewhat stretched and the head moderately extended over the headrest. It is, we believe, the not infrequent stiff working of the sliding back of the chair and the lack of a wheel action, quickly to elevate, or more often depress the headrest, which has made the upright position in the hands of relatively inexpert anesthetists, at least in our section of the country, seem unsafe and

the administration of an anesthetic difficult. We feel confident, however, that when the piece of surgical furniture described in this paper is used, there need be no added risk in the administration of the anesthetic, provided, always, that the body is not bent or raised from the recumbent to the upright position too rapidly. The last statement leads us to say again what we have already said on this subject—that a sudden change from the horizontal to the upright position, while the patient is under ether narcosis, is apt to occasion a too rapid development of cerebral anemia and a consequent loss of cardiac balance. In our earlier operations with this method we experienced considerable difficulty because of the too hasty elevation of the head, but, as since then the upward movement has been made a more deliberate one, utilizing the two minutes just before the patient is sufficiently anesthetized for operation (the time when the face and field of operation are cleansed and prepared) we have not observed disturbances which could be attributed to the change in position.

Our experience would seem to show that the danger of blood flowing into the trachea is no greater, during the routine operations which we are wont to perform in the nose and throat, when the body is upright than when in the Rose position. In both of these positions, and in all other positions, it is possible for a small quantity of blood to be aspirated into the larynx, and when this has occurred in our patients while in the upright position it has not caused the loss of more than a few seconds of time. Immediately after extensive incisions have been made, we are in the habit of having the patient's head bent quickly forward to allow the excess of blood to flow from the nose or mouth. But even when this movement of the head is omitted, evidences of blood in the larynx are very rarely present. The immunity of the larynx is, no doubt, due to the pharyngeal gutters which conduct the stream of blood escaping the sponges around the laryngeal orifice (which stands up in the throat like the curb of a well) into the esophageal opening. And we may say, in passing, that the blood thus flowing into the gastrointestinal tract has never, in our experience, made its presence manifest by untoward disturbances in that canal. Our results, in the consid-



erable number of patients upon whom we have operated in the upright position, have led us to the conviction that the fear of blood flowing into the air passages is based upon theory and not upon fact. If from the laying open of a large artery the gush of blood should overflow the well-curb of the laryngeal outlet, the air passages might (if the head was not bent forward) be flooded, but such an occurrence would be an inundation and so exceptional that, so far as we know, it will have to be recorded in the future, if at all. While for the proper safeguarding of the gastrointestinal tract it is desirable to catch as much blood as possible in sponges, or divert it through the nares or mouth, it is quite safe to say that in routine operations, even without alertness in sponging or without bending the head forward, embarrassment from blood flowing into the larynx or trachea does not occur.

But why, it may be asked, has all this trouble been taken to devise a means for getting the patient easily into, and safely maintaining him in, the upright position for ether operations? We have already said it must be generally conceded that in the upright position, which is the natural position in which to view the parts, we can do everything better because we are accustomed to having the patient's body upright in our everyday practice. We gave this as one reason for preferring the upright position in our last communication on this subject to this association. Exception was taken to it by various observers who thought there was little need of it, as we did most of our work, more especially upon adenoid growths and faucial tonsils, by the sense of touch alone. Well, in ten or twelve years the aspect of many affairs is changed, and judging from the discussion of Dr. Swain's admirable paper, read before this association a year ago, we must infer that a good portion of the members taking part in it would not only be unwilling to operate for the removal of faucial tonsils by the sense of touch alone, but believing as they did, in tonsil enucleation, they must of necessity require the best view obtainable. In these days of clearing vision, whether it be a tonsil enucleation, a complete tonsillotomy, a staphylorrhaphy or any other operative procedure in the nose or

throat, we are obliged to see the whole of the field of operation where possible, and to see it as well as may be. While in the recumbent position a good view of the fauces can be obtained by the forceful use of the tongue spatula, the display is not, as a rule, comparable to the display obtained from the use of the spatula in the upright position, aided, as it is, by the gravitation of the tongue and the soft parts of the neck. And is it not also reasonable to assume that a straightaway, right side up view of the nasal cavities is conducive to better surgical work in that part of the body?

Still another word can be said for the upright position. There is less shock and less disturbance in other ways to the patient after operation, because less ether is required to maintain narcosis when the sitting posture has been attained. This, no doubt, is due to the diminished blood pressure in the vessels of the head when the body is in the upright position and under the influence of a general anesthetic. The difference between the flushed face in the recumbent position and its relatively pale appearance in the upright position is at times very marked. The difference in the quantity of the anesthetic required is, we believe, due to the difference in the amount of blood in the brain in the two positions. But whatever the true explanation may be, the fact remains that less ether is needed when the body is upright than when in other positions, and under certain conditions and in certain cases this is a consideration of self-evident importance.

With the presentation of one more reason for preferring the upright position, we will have finished this little story. We refer to the relatively small amount of blood lost while the patient is in that position. We revert again to our earlier remarks on this feature of our subject, which run as follows. "When the body is upright there is less blood pressure in the vessels of the head than when the body is supine. This is especially true when the subject is under the influence of a general anesthetic. The amount of blood which can be withdrawn from the body without harm varies in different individuals. A moderate amount of bleeding will do no harm in the comparatively healthy, but the very young, the aged, the feeble, the cachectic do not bear well the loss of much blood. The

abstraction of a considerable quantity of blood from an anemic child adds to the cachexia, diminishes its rallying powers and reduces the bodily resistance in the event of the onset of any special disorder. Shock is felt more by the child than the adult, and although the child recovers from shock more rapidly the ultimate recovery will be retarded if a considerable amount of blood has been lost." As a rule children in a fair state of health before operation sustain the loss of a relatively large quantity of blood in a very remarkable way, and in time recover their usual, if not better, health, but they do not always do so without concurrent disturbances, and how often these are due directly or indirectly to the loss of blood it may be difficult to say. We doubt, however, if there can be two minds about the desirability of reducing the shock of an operation and in securing the retention of as much blood as possible in the bodies of anemic, delicately constructed children with lowered vitality and a weakened power of resistance.

The practical realization of our conception of the device described in this paper was made possible by the mechanical skill, ingenuity, highly intelligent co-operation and unvarying courtesy of several of the members of the staff of the Kny-Scheerer Company, of New York, to whom our thanks are due and are cordially given.

### *Discussion*

Dr. W. E. Casselberry, Chicago: For many years I used the upright position for adenoid and tonsil operations on children under ether anesthesia, the patient being held on the lap of an assistant with the head resting on the assistant's shoulder, but tilted forward during bleeding intervals. This, however, was in the period of dispensary and residence operating, and usually with no better illumination than daylight and a head-reflector, a gas flame being inadmissible with ether anesthesia and electric illumination being then not generally available. I found it a safe position, the easiest for the operator, and one affording the best view of the field of operation to himself and assistants. I relinquished it reluctantly, but would not wish to return to it, despite the advantage of Dr. French's well adapted table-chair, inasmuch as the modern electric headlamp enables one to view

the field of operation equally well in any position, and as general anesthesia cases now commonly enter hospital, where recumbency is the established routine, I have adopted the right side semi-ventral position as uniformly practical for both of the tonsils and the adenoid, and for both children and adults.

I would think that with minor changes in its general height, and in the length of its back and head rests, Dr. French's table-chair would be splendidly adapted for nasal and sinus operations on adults with local cocaine anesthesia, there being still an urgent need of a simple mechanism instantly changeable between table and chair and adjustable for the upright support of the shoulders and head of tall or short persons.

Dr. Charles W. Richardson, Washington, D. C.: I am somewhat like Dr. Casselberry, a renegade. From the earliest time of my operating on the throat and nose I used this favorite upright position, but I also had to contend with the same difficulties that others have, and for the fact that I was the only one in my vicinity using this position I was constantly having it called to my attention that I would kill some one by this position sooner or later. The opposition of my colleagues and assistants caused me to resort to the recumbent position, and for the last eight or nine years I have done all this work in the recumbent position, but I wish to state that every contention that Dr. French has made for this position is absolutely correct. There is no question that the vision is better because the light is thrown more correctly and can be maintained in the erect position in a correct manner. The bleeding has given me more trouble in the recumbent position than in the upright position. I mean the blood getting into the larynx. I do not remember a single instance when I was operating in the upright position where I was troubled by blood in the air passages. Since using the recumbent position I have had numbers of cases in which the operation has had to be temporarily suspended to get the blood out of the larynx. The bleeding certainly is much less in the upright position than in the recumbent.

I have noticed over and over again, as Dr. French said, the marked difference, a suffused and congested face in the recumbent position, and an almost anemic appearance in the upright. This table is the solving of the question. I think it is the most admirable mechanical device for the purpose intended, and I think it will be the means of leading some of us back to the operations in the upright position. There is no reason in the world why we should not operate on adenoids, tonsils and various nasal conditions in the upright position under general anesthesia if done in a safe and sound way, as this table gives us.

Dr. H. P. Mosher, Boston: As a member from New England, I think I should thank Dr. French for his kindly reference to the uprightness of the New England men. I appreciate it very much.

Dr. Casselberry surprised me a little by his reference to the inflexibility of hospital routine. I had a shock last year in connection with the meeting of the Triological Society. A member from New York while a guest in Boston made some very uncomplimentary remarks about us, saying that we operated in a kitchen chair, and that our methods corresponded in mediaevalism to our operative furniture. They may, but we have managed something which has not been managed, evidently, in some of the other cities, and I am surprised it should not be managed in Chicago. We do have a flexible hospital routine. We find no difficulty in having the men who help us do what we ask them, and it is no trouble to have them join in and carry out the upright position.

In regard to this table, anything which helps the change from the prone to the upright position and makes it more safe is a gain. I have held that any mechanical device which restricted the movements of the patient in the upright position was a disadvantage. The safety of the upright position is the ability of the operator to change the position of the patient at any moment and quickly. It is important to change not only the head, but also the shoulders. If this table does not allow this to be easily accomplished, to me it would be a disadvantage, and I should still prefer the primitive "kitchen chair."

Dr. A. A. Bliss, Philadelphia: Many years ago Dr. French exhibited a table for the upright position which pleased me very much. I suppose he has long given up using it, as he has this perfect table now, the great advantage of which is that the patient can be etherized in the recumbent position. The old chair was an upright chair, with the disadvantage of not being able to put the patient in the recumbent position. I have always used the upright position in operating and have never had reason to regret it. The work is made much more simple. In our hospital we use the Chappel chair, the patient being tied in by a 6 inch bandage, many yards long, rolled from each end, the rolls meeting in the centre. The patient is etherized on an ordinary operating table, if quickly fixed in the chair and in less than a minute the bandage is tied. That secures the patient perfectly so that he is immovable, except for neck and head. The position requires only one assistant, which is also a great advantage, and it also enables one to make use of what Dr. Mosher mentions, which I

am sure does not apply only to the New England hospitals, the use of a kitchen chair. Any chair that has a square top and a reasonably narrow back is quite available for the purpose. This instrument of Dr. French is so perfect, however, that most of us will try to have it installed in our hospitals.

Dr. Otto T. Freer, Chicago: I would like to ask Dr. French if it is possible to raise this chair high enough to make it applicable for rhinological operations and bronchoscopy?

Dr. A. B. Thrasher, Cincinnati: I would like to accentuate a remark already made with reference to the rather slow dropping of the head. It seems to me in this chair there may be a time when you would desire rapidly to place the head below the level of the body, and from the manipulation shown here to-day that is the only objection I see to this apparatus. The elevation is quite perfect. I personally never would operate on a patient in that position, but for any one who might desire to do so this is a perfect instrument with the exception mentioned.

Dr. D. Bryson Delavan, New York City: The paper and the demonstration to which we have just listened are the outcome of many years of earnest study and wide experience. An intimate personal knowledge of the practical work of the reader of the paper has impressed me with his pre-eminent caution, thoroughness, knowledge and technical skill. I have known of no wiser physician nor more expert surgeon. This operating chair upon which Dr. French has been experimenting for so many years represents an accumulation of knowledge gained from his own experience and from his observation of other contrivances used in departments of surgery outside of our own, which should command for it our very respectful consideration. Many of its valuable points have already been alluded to and need not be further dwelt upon. There is one feature of it, however, to which attention should be called, namely, the emphasis which it places upon the surgical importance of operations for the removal of adenoids and tonsils. Your experiences have doubtless been like mine with regard to the relative importance which these procedures have come to be held in the public mind. The work of operating upon adenoids and tonsils has been so widely diffused throughout the medical profession as to have caused it to be considered as far more simple and free from risk than is really the case. Even in some of our best hospitals such cases are entrusted to young assistants in general surgery who have had no special experience and whose work

in consequence is often crude and unsafe. The same criticism applies to the major nasal operations. Thus the best interests of the patients are not subserved and discredit is thrown upon the specialty itself. Dr. French's operating chair actually gives us an aid far superior to any other of its kind. In addition to this it forcibly demonstrates the many and great advantages of thoroughly scientific methods in the performance of the operations for which it is intended to be used. With it facility, thoroughness and speed in operating are secured in the highest degree, while the safety of the patient with regard to all of the possibilities of accident which may attend the operation, whether from bleeding, from the anesthesia or from any other causes, are better forestalled, or, if actually present, are more easily and successfully met than by the use of any other method. I have seen Dr. French operate on a number of occasions and upon many patients. I shall adopt his methods in my clinics as soon as the necessary apparatus can be secured, for among all of the good methods that have as yet been suggested I regard his as undoubtedly the best.

Dr. H. S. Birkett, Montreal, Canada: This table interests me very much, because six months ago I had a table constructed by the same firm very much on these principles, but there is one thing contained in this table which is also included in mine—that is, the main support of the table. It has always been a question in my mind if you had a patient weighing 200 or 300 pounds whether or not that support would be strong enough to bear his weight. The movements of Dr. French's table are better controlled than are mine, because it has the wheel movement.

Dr. G. Hudson Makuen, Philadelphia: The history of the development of this table has interested me very much. I was in doubt at first whether Dr. French desired to have us infer that the table was originally intended to bring patients into the upright position for operation or whether it was to bring the New England people into a position of uprightness. Dr. Bliss has told you that Philadelphia has maintained this position for all the years since it was first suggested by Dr. French.

There are two things which appeal to me in connection with the table in addition to the convenience of operating in the upright position, and they are that a minimum amount of the anesthetic is required in this position and that there is less bleeding. If these two things are true they are exceedingly interesting, and I think they are true for the reasons given by Dr. French.

Dr. Thomas R. French, Brooklyn (in closing): The discussion has been very gratifying, but a method like this has to be tested, has to be tried, before its worth can be proved, and I hope that if any of you make use of it you will find it as pleasing as I have found it.

Dr. Casselberry's method of supporting the patient's head on the shoulder of a nurse would, perhaps, not work very well if the patient were a youth or adult. It seems to me to be better to have an apparatus, such as the table just exhibited, to hold and control all sizes and weights of individuals.

Dr. Richardson's experiences have been similar to my own. The sitting posture has been generally avoided because of fear and not because of danger. In times past many surgeons have evidently believed, and have not infrequently dropped the remark, that we would kill some one in the upright position some day; that the patient would be strangled by the blood which they believed *must* flow into the windpipe or that pneumonia would develop later for the same reason. "You'd better look out!" has been the implied advice from many sources for many years past. Well, we have "looked out," and in a long and reasonably large experience have seen nothing but good while looking. This is a *bogey* which was created long ago and which still exists to some extent. The objectors seemed to think their fears were well grounded even though the thing they so greatly feared had never happened. It requires infinite patience to maintain an unrealized fear indefinitely. Dr. Richardson's statement in regard to the aspiration of blood into the trachea while the patient is in the hanging head position should go far to clarify the existing confusion of ideas on this part of our subject.

The simplicity and strength and yet apparent delicacy of the table, referred to by Dr. Birkett, is in large part due to the fact that the apparatus is built by a manufacturer capable of refinement in this kind of work, namely, the Kny-Scheerer Company, of New York.

Dr. Freer's suggestion that the table might be made so that it could be raised higher to permit of its use in submucous resection work can be readily met by placing the base upon a platform such as that used in operating in the Trendelenburg position. A mechanism in the table which would permit a higher level being attained would, if necessary, be at the expense of the movement in the opposite direction, and the low level now obtainable is needed for operating upon long-backed adults in the upright position.

When Dr. Mackuen tests the method, which I infer from his



remarks he intends to do, it will not take very long to demonstrate the accuracy of the observations recorded in the paper.

I believe Dr. Mosher will find the device capable of affording all necessary mobility of the hips and lower portions of the body. Indeed it may be said that the slanting shape of the seat and its ribbed rubber surface secures for the body a more natural and easy pose than when it is dropped into a tilted chair with the thighs at a right angle with the trunk.

In this connection it may be well for me to add a word to that which was said in the paper about strapping. The object in waiting until the body is partly raised before drawing in the shoulder straps is to make sure that the trunk and thighs have settled solidly upon the seat so that traction upon the shoulder straps will not literally hang the patient by the axillae. When care is not taken in this particular the circulation in the arms may be materially interfered with. Our habit is to adjust the shoulder bandage by moderate traction when the body is about half way up, and if the shoulders are not sufficiently flattened against the back of the chair when the upright position has been reached the bandage should be readjusted by making further traction. A little experience with this adjustment will enable one to make it properly. It is also desirable to apply the hip straps loosely. An inch or two of the slack is taken up in the upward movement which it is best to make allowance for. As, however, the straps do not cross the abdomen above the pelvis no injury to the abdominal contents can be caused by them even when too tightly applied.

With small children the straps on the footrest should not be used at all, for unless the thighs of the patient are as long as the seat the calves of the legs will be drawn sharply against the front edge of the seat when the footrest is lowered and the straps are too tightly bound about the ankles. In order, however, to prevent the possibility of serious injury being done when these directions are not followed and the footrest straps are tightly applied over the ankles of small children, a spiral spring has been inserted into each of the footrest straps. We think it only fair to have such *safety valves* permanently attached even if with large children and adults it may permit considerable play of the feet when the patients are only partly anesthetized. Moreover, it must be remembered that the strapping of the legs is not essential to the securing of the body to the table or chair but is done simply to keep the feet out of the way of the operator; and it may be said that the straps thus fitted with the spiral springs work in a most satisfactory way. It is, nevertheless, advisable to omit the use of the straps on the footrest entirely except with youths and adults, and, even with them, because of

the changing angles of the knees in relation to the chair as the footrest descends, it is best to wait until the sitting posture has been attained before applying them.

Dr. Delavan is my friend. He is right, however, in his suggestion that we should aim at distinction in our work, and to the extent in which we attain it will we, as experts in our chosen field, come into our own. We should aim, by virtue of our necessarily superior ability, to do many things differently and better than is now being done by the men we turn out of our medical colleges each year. The device just demonstrated to you is not intended as an operating table for adenoid growths and faucial tonsils only but is fitted for practically all operative procedures in the upper air passages. With the back section slightly elevated it is admirably adapted to bronchoscopic work, the movable headrest and adjustable end of the table relieving the second assistant of much of his arduous labors.

If I have to any extent succeeded, or if ultimately I shall succeed, in advancing the interests of the upright position in operating under ether narcosis, which my friend, Dr. Hooper, believed in and advocated, I shall feel well rewarded.

## COMPLICATIONS OF THE OPERATION FOR REMOVAL OF TONSILS.

BY CHARLES W. RICHARDSON, WASHINGTON, D. C.

I have given my paper the above title in order to embrace all the procedures that are employed in the excision of diseased or enlarged tonsils. The removal of tonsils has become such an every day matter of fact operation that the general profession and the laity have grown to look upon tonsillectomy as a trivial affair, a simple procedure that has no danger, and that may be performed by any one. It seems, therefore, that it is adequate time for us to be considering our bearings and inquire if this operation be so simple as many seem to consider it, and whether it be devoid of serious danger to the welfare and life of the patient. It seems to me that it is wise for us at this time to turn our attention from the technique and the favorable issue of excision of the tonsils to the consideration of its complications and ascertain, if possible, the method to avoid them. We are all more inclined to narrate and publish our own successful issue in medicine and surgery than our unfavorable ones, which fact, no doubt, accounts for the small number of complications of tonsillectomy reported in the literature. When one sees, hears, and occasionally reads of the unfortunate complications which ensue subsequent to the excision of tonsils, we wish it was considered the duty of every operator to report the complications which occur in his tonsillar surgery. In a careful review of this subject, one is impressed with the small number of complications, other than hemorrhage, that are reported. Several excellent papers have been published on the complications of tonsillectomy, most of them treating of one particular type of complication and referring to others. It will be my aim in this paper to collate all types of complications that may arise in connection with this operation that have been reported in the literature which has been accessible to my research, and report in detail some of the

complications which it has been my misfortune to encounter. Those cases in which complications ensue in conjoint tonsillar and adenoid operations are not reported, as frequently the complication is probably as much the result of the adenotomy as the tonsillectomy. Neither should we consider the rather too frequent death from local or general anesthesia during tonsillectomy as a complication of this operation.

*Hemorrhage.*—The most frequent and most dreaded complication of tonsillectomy is post-operative hemorrhage. Hemorrhage following tonsillectomy may be immediate or post-operative. Lindley Sewell<sup>1</sup> reports fifty cases of serious hemorrhage, with nineteen deaths. As this report is the most recent one on this complication that I have read and his number of cases tallies with the numbers reported by others, I take it for granted that it probably summarizes all the extremely serious bleedings and deaths reported in previous papers. We all know from personal experience and from the experience of our immediate colleagues that this is by far an inadequate report of the serious hemorrhage resulting from tonsillectomy. I feel that technique and accident are more frequently the cause of this complication than the haemophilia. To minimize the danger of this complication in tonsillectomy, I would suggest the employment of finger enucleation. The freedom from post-operative hemorrhage in finger enucleation is the strongest and most favorable argument for the general adoption of this method of operating.

*Hyperpyrexia.*—Hyperpyrexia, without known cause, is a rare complication of this operation. Hyperpyrexia, with fatal termination occurring after operations of minor importance, is one of the unpleasant sequelae met with in general surgery, so we should not be unprepared for its occasional occurrence in our field of labor. An interesting case of this type is reported by Dr. J. B. G. Wishart<sup>2</sup>. The patient was a girl eighteen years old, presenting no symptoms other than those of enlarged tonsils and adenoids. The tonsils were slightly inflamed, coated with secretion, and the follicles were filled with cheesy detritus. The operation was done under general anesthesia, being attended with

<sup>1</sup>Medical Chronicle, Manchester, July, 1911, p. 212.

<sup>2</sup>Laryngoscope, February, 1909.

only moderate hemorrhage. Shortly after the operation the temperature rapidly rose a degree per hour until it reached 107°, and the patient died twelve hours after the completion of the operation. Post-mortem gave no indication of cause of death.

It has been my unpleasant experience to have had almost an identical case with that reported by Dr. Wishart. During March, 1909, I operated upon a child four years of age for enlarged tonsils and adenoids. When the child was brought to the operating room I was told that the patient had a temperature of 99.4. I refused to operate and proceeded with several other operations upon other patients. After finishing my clinic, I visited the patient in its room and there was won over by the parents, who were anxious to have the operation done, to proceed with the operation. The operation was a remarkably easy and almost bloodless one and the patient was sent to its room in good condition. At four o'clock I was notified that the temperature was 102° and, from that time, its temperature rose steadily until it registered 107.2 at ten P. M. The child died at eleven-fifteen P. M. None of the treatment instituted influenced the upward tendency of the temperature. An autopsy was made in the early afternoon of the day following its death by Dr. L. W. Glazebrook. There was no blood in the stomach or intestinal tract and all organs of the body presented an absolutely normal microscopic appearance. We were quite surprised at the findings and embarrassed at our inability to ascertain the cause of death.

*Infarct of the Lung.*—I have heard several cases of this character spoken of, but find none reported as such in the literature. When one considers the large cavity left between the pillars after the excision of the tonsil, with more or less bruised tissue which must slough away, it is rather surprising that this complication does not occur more frequently. I have had two cases of this character to develop under my care. Two years ago in June I operated upon a vigorous, rather large, man of forty-five years of age for the removal of both tonsils. The operation and convalescence were slow. A moderate fever continued for six days. On the seventh day the patient returned to his home and was lost sight of by me for nearly ten days, although under the constant care of his family physician. When I saw him again in consulta-

tion, I found the patient a very ill man. He was running a septic temperature, coughing constantly, complaining of great pain in the base of his right lung, and presenting a very anxious and distressed countenance. A slight area of dulness, with some moist rales, could be made out over base of the right lung posteriorly. The patient was taken to his home in a distant State, when, several weeks later, the full evidence of an abscess of the lung developed, which was later operated upon and drained, with a favorable issue.

I have also had another case of the same character this winter. In December I operated upon a young married woman, twenty-four years of age, for hypertrophied tonsils. The case was simple in operation and attended with very little hemorrhage. The patient's throat was very sore for several days and the convalescence was slow. Ten days after the operation she developed a severe and harassing cough; the temperature had a moderate septic curve. Physical signs were negative over chest. On the thirteenth day the cough was more annoying and was frequently of a paroxysmal character. She now began to expectorate a large quantity of purulent, very offensive secretion, and complained greatly of an intensely offensive odor whenever she coughed. Examination of the sputum, which was very offensive in odor, demonstrated it to be made up largely of pus cells. The infecting organism was found to be a streptococcus. Physical examination demonstrated a small consolidation between the second and fourth ribs on the right side, with small mucous rales. On the fifteenth and sixteenth days she had great pain in upper portion of right lung. This pain recurred again on the twentieth day of illness. The patient was put on urotropin, and, in the course of three weeks, made a complete recovery, attended by a gradual and complete subsidence of all symptoms.

La Play<sup>3</sup> reports an exceedingly interesting case, when a child who had a double tonsillotomy done some eight days before being brought under his observation was thought to have diphtheria, and antitoxine was administered. Culture examination proved the case to be of a non-diphtheritic character. Subsequently the child, a patient of eight years, developed pulmonary

<sup>3</sup>Archives Gen. O. Med., Vol. II, p. 3280, 1905.

symptoms. Physical examination showed in the left lung distinct dullness, with an expiratory egophonic souffle. A pleurotomy was done and an abscess cavity drained. Culture of the pus demonstrated the presence of pneumococci. This case appears to be of embolic origin.

*General Sepsis.*—Mild sepsis, enduring for a few days, is a frequent complication of tonsillectomy, but the more severe types of general sepsis are seemingly quite infrequent, if one is to judge from the number of cases reported. It is not strange that sepsis follows such an operation when we consider the fact that such large open wounds are constantly bathed in such an abundant flora as is contained in the buccal cavity, but rather strange that it does not occur much more frequently in its severer forms.

A. Sonntag<sup>4</sup> reports the following case: A boy, seven years old, was operated upon. Two days after the operation the patient felt sick and showed torticollis toward the left side. On the third day there was vomiting, headache and delirium, in the evening spasms; temperature 39.6°. On the seventh day there was swelling of knee and right wrist; somnolence increased and temperature rose to 40°. Death occurred on the eleventh day from severe general infection. Dr. L. W. Dean,<sup>5</sup> in an excellent article in the *Laryngoscope*, narrates three cases of sepsis following tonsillotomy and tonsillectomy. In his article Dean gives a full resume of all reported cases of sepsis as a complication of excision of the tonsils. The first case reported by Dean was a death from general sepsis following tonsillectomy occurring in the practice of Dr. L. L. Smead, of Newton, Iowa. The patient was not in a good general physical condition at the time of the operation. All care was employed at the time of the operation to insure as aseptic an operation as possible. The operation was done under local anesthesia. The right tonsil was enucleated and the greater portion of the left. The operation on left tonsil was incomplete on account of hemorrhage. The wound surface and adjacent tissue, as well as glands of neck, were greatly inflamed the day after the operation. The temperature ran between 102°

<sup>4</sup>A. Sonntag, *Zeitschrift für Laryngologie*, Würzburg, 1908-9, Vol. I. p. 756.

<sup>5</sup>L. W. Dean, *The Laryngoscope*, Vol. XX, No. 7, p. 738.

and 103°. There was great difficulty in swallowing and breathing. On the third day there was delirium, dimness of vision, and slight vomiting. The amount of urine eliminated became progressively less. On the sixth day all lymphatic glands of body were enlarged; delirium was more pronounced. The patient died on the evening of the sixth day. Dr. Dean's second reported case was one occurring in his own practice of cerebral thrombo-sinusitis, following tonsillotomy, with recovery. The patient, a boy of fourteen years of age, was operated upon under local anesthesia at the clinic. He did not remain in hospital after the operation, as directed, and Dr. Dean did not see him again until a week after the operation. The following is the condition of the patient as reported on the seventh day: "The remains of the tonsils were somewhat swollen and reddened. The cut surfaces were covered with a fibrous exudate. The pharynx was also inflamed. The condition of the throat was not bad. The temperature was 105°. It had been intermittent. There had been a series of chills. Pulse was 100°, very weak. Patient was delirious. Along the anterior border of the sterno-cleido mastoid muscle a cord-like swelling could be very easily felt. On the left side was exophthalmos with panophthalmitis. On the right side was a well-marked optic neuritis. The ear and mastoid seemed normal. Dr. Kimbell's physical examination was negative. A diagnosis of septic phlebitis, involving the internal jugular and extending along the cerebral sinuses to the orbital veins, accompanied by thrombosis of the orbital veins on the left and perhaps of the left cavernous sinus. A very bad prognosis was made." The patient recovered. The third case was one of gangrene of muscle of neck following tonsillectomy, with recovery. The condition narrated did not manifest itself until fifteen days after the operation. The case was one of extensive infection of the glands and tissues of the neck. The condition was met by free incisions and use of bichloride washing and drainage.

Ballinger<sup>6</sup> reports two severe cases of streptococcus infection.

Pierce<sup>7</sup> reports a serious case of infection resulting in a permanent torticollis following a tonsillectomy.

---

<sup>6</sup>Diseases of Nose, Throat and Ear, p. 416.

<sup>7</sup>Transactions of Section of Laryngology and Otology, A. M. A., 1909.



Dr. C. E. Deane<sup>8</sup> reports two cases of severe sepsis occurring in his practice.

*Emphysema.*—Subcutaneous surgical emphysema is fortunately a rare complication of tonsillectomy. An interesting case of this character, in which the emphysema was very extensive, is reported by Dr. Benjamin D. Parrish<sup>9</sup>, of Philadelphia. He does not give the name of the operator in his article or the hospital in which the operation was performed. He states the patient left the operating room in good condition. The operation was attended with a little more bleeding than is usual in such operations. He states that the tonsils were quite adherent, and in freeing them a small buttonhole was made in the lower part of the posterior pillar on the left side. "The orderly and nurse noticed on the elevator that the patient seemed to be struggling for breath and also that his neck and face were swelling rapidly." He states that, when he reached the patient, the breathing was rapid and shallow, the face was livid, and the lips cyanosed. The entire neck was puffed out so that the line of the jaw was completely obliterated. The emphysema affected the face and right eyelid and emphysematous crackling extended over the anterior portion of chest as far down as the last rib. By flexing the neck and opening the mouth the breathing was restored and further extension of the emphysema prevented. The patient made a good recovery, with gradual absorption of the emphysema.

I had a mild emphysema to occur in my practice, also in a male adult. The emphysema followed after a double tonsillectomy, and involved only the right side of the neck. In this case the emphysema was noted about an hour after the operation, and extended on the right side of the neck almost to the line of the clavicle. There was only moderate swelling, but very distinct crackling. It subsided completely within forty-eight hours.

*Infection of the Lungs and Serous Membranes.*—The occur-

---

<sup>8</sup>California State Journal of Medicine, 1909, p. 92.

<sup>9</sup>The Laryngoscope, November, 1910, p. 1046.

rence of pneumonia and pleurisy as sequelae of tonsillectomy is not usually reported, but there is a sufficient number of cases incidentally reported that indicates that this is not an infrequent complication. In my own practice, covering now some years, I have had two cases of pleurisy, both of which recovered, and one case of pneumonia, which was fatal in its termination.

Coley, as quoted by F. C. Ard, reports three cases of septic infection of the serous membranes under his observation, and Putnam as having seen two cases of meningitis following the operation.

In a recent article, Eugene A. Crockett<sup>10</sup> states that in the Massachusetts Charitable Eye and Ear Infirmary, within the past few years, there had been two cases of ether pneumonia, one of which died.

*Disturbances in Relationship to the Nervous System.*—Complications in connection with the nervous system are more apt to occur in those of a hysterical temperament. I found two cases of this character to report.

E. Bergh<sup>11</sup> reports a case in which nervous disturbances developed after tonsillectomy in a female child seven years old. Immediately after the operation the little patient had an attack of strangulation, followed by spasmodic contraction of the thighs on the abdomen. Patient had at decreasing frequency subsequent attacks of strangulation, followed by muscular contractions. Patient finally recovered under treatment. Bergh states that the patient was of a nervous temperament, but the nervous attacks were doubtless due to the tonsillectomy.

Pfingst<sup>12</sup> reports quite an interesting case of hysterical hemiplegia coming on a week after a tonsillectomy. This patient was a robust young woman, eighteen years of age, with a personal history of an hysterical temperament. She manifested a number of symptoms during her illness, all of which partook

<sup>10</sup>Boston Medical and Surgical Journal, March 23, 1911, p. 414.

<sup>11</sup>E. Bergh, Monatschrift für Ohrenheilkunde, Berlin, 1904, Vol. XXXVIII, p. 549.

<sup>12</sup>A. O. Pfingst, The Laryngoscope, July, 1911, Vol. XXI, p. 798.

of the hysterical type. The patient remained in this condition for a period of three months, when gradual improvement set in. The last symptom to disappear was the hemiplegia, which entirely disappeared four months after the tonsillectomy.

*Status Lymphaticus.*—Dr. F. R. Packard<sup>13</sup> gives the report of a case upon which he performed the operation of tonsillectomy which resulted in death, apparently due to a status lymphaticus. The operation was done without incident of any kind whatever upon a female child of three and a half years of age. He states: "The child was apparently a perfectly normal little girl, of the average size and healthy appearance, except for a somewhat sallow complexion." Immediately after the operation, nor at any subsequent period, was there any bleeding. When coming out from under the ether, she vomited a small quantity of blood. The operation was done at 1 P. M.—at 4:30, 5:30 and 6:30 the child was examined and no bleeding noted. About 6:20 the little one's condition became very serious, temperature 100, respiration 36, and pulse rate 156. At 7 P. M. the child stopped breathing, for which no relief came, although tracheotomy was done. No autopsy was obtained. Packard states: "This case presents features which, to my mind, render it practically certain that the fatal result was due to the condition known as status lymphaticus. The child's death was certainly not due to hemorrhage, nor could it be attributed to the method of administering the anesthetic or the quantity used. As to status lymphaticus, so little is really known about it that, unless an autopsy had been obtained and an enlarged thymus gland found, it would be impossible to state positively that this condition had been the cause of the child's death."

Dr. T. J. Harris<sup>14</sup> reports a case of death from status lymphaticus. In Dr. Harris's case the operation was done under cocaine adrenalin infiltration. Two injections of the local anesthetic were administered, as it was thought that all of the first given was lost through escape from the follicles of the diseased tonsils. The patient was profoundly impressed

<sup>13</sup>American Journal of the Medical Sciences, September, 1910, p. 399.

<sup>14</sup>Annals of Otology, Rhinology and Laryngology, 1909.

after the first injection. "Complained of feeling bad, vomited and had a slight convulsive seizure, presenting the appearance we often see when cocaine has been employed locally for a nasal operation." It was necessary to support the patient during the operation. After the completion of the operation Dr. Harris states he was struck by the pallor of the patient, and discovered he was unconscious. All efforts at resuscitation, employed for over an hour, failed. An autopsy was performed and nothing abnormal discovered except that the right auricle was swollen and the right auricular appendage was dilated with fluid blood until it was five times as large as the left; the right ventricle was also swollen, and the thymus gland was hypertrophied and weighed eighteen grammes. The examination of the thymus gland demonstrated that it showed no atrophy. Dr. Harris states that "The patient died, in all probability, of an over-dilated right ventricle, due to the enlarged thymus, with its action on the trachea and recurring laryngeal, with the cocaine-adrenalin injection acting as an exciting cause."

*Amygdalotomy Rash*—This complication occurs rarely as a sequela to the removal of the tonsils and is of no consequence, except for the anxiety it may cause. It usually appears from two to three days after the operation and appears either in a roseola, papular or erythematous form. It makes its initial appearance usually on the chest, abdomen or limbs. It may or may not be attended by itching. It attains its maximum of intensity in a day or two and then rapidly disappears. It is usually attended by a slight elevation of the temperature. Dr. Wyatt Wingrave reports thirty-four cases of the rash. Dr. Edgar Forsyth<sup>15</sup> also reports cases, in an excellent paper. I have had this rash to appear in four cases upon which I have operated. Dr. S. S. Adams reported it as occurring in a case upon which I operated while the patient was under his observation. This condition is no doubt due to auto-intoxication from the blood which is swallowed during the operation. A brisk purgative the day after the operation should prevent the occurrence of the complication.

---

<sup>15</sup>New York Medical Journal, December 21, 1901, p. 1144.

*Diphtheria*—A case of diphtheria following tonsillotomy is reported by August Caille<sup>16</sup>. This complication can only result in operating upon a patient who is a carrier. For this reason it would be wise to make cultures of the faucial secretions of all children upon whom the operation is to be done.

Oswald Levenstein<sup>17</sup>, after an extensive review of the subject of diphtheria in connection with tonsillotomy, makes the statement that the mucous membranes of the mouth and nose lodge a considerable number of cocci spirilla and bacilli of many varieties; among the latter may sometimes be found virulent Klebs-Loeffler bacilli. He gives reports of cases of diphtheria ensuing after tonsillotomy. Lichtwitz<sup>18</sup>, in two different articles appearing in 1896 and 1900, discusses the diphtheritic phase of tonsillar complications.

F. Kobrak<sup>19</sup> reports a case of excision of the tonsils in a female child. Within three days after she showed severe symptoms of angina, with the formation of a membrane which proved to be diphtheritic. To this was added an eruption of scarlatina. The child died.

*Local Disturbances as Sequelae of Tonsillar Operations*—There are a few cases reported of injury about the faucial region, less probably by far than actually occur, as many of these result from accident during operation and from faulty technique; therefore, the operator hesitates to report them.

Dr. Lindley Sewell in his paper reports two cases of tracheotomy which were necessitated on account of prolonged glottis spasm with collapse and cyanosis. Without giving authority he also reports a case of torticollis and a case of retro-pharyngeal abscess. Bauchecourt and Martin, as quoted by Dean, report three cases of edema of the pharynx and the glottis, one of which was fatal.

Dr. I. Lederman<sup>20</sup> reports a unique complication in the

<sup>16</sup>Pediatrics, September 15, 1899, Vol. VIII, p. 254.

<sup>17</sup>Archive Internat de Laryngol d'Otol et du Rhinology, January, February, 1910.

<sup>18</sup>Lichtwitz, Gazette hebdom. de Sciences, Med. de Bordeaux, 1896, Vol. XVI, p. 125; Gazette hebdom. de Sciences, Medd. de Bordeaux, 1900, Vol. XXI, p. 534.

<sup>19</sup>F. Kobrak, Archiv für Laryngology, Berlin, 1906-7, Vol. XIX, p. 330.

<sup>20</sup>Kentucky Medical Journal, December 15, 1911, p. 959.

formation of a haematoma in the fauces following a tonsillectomy. Dr. Lederman states that, shortly after the removal of the tonsil, blood began to extravasate under the mucous membrane until a large mass nearly the size of a hen's egg was found in the tissue of the palatine arch.

Dr. Francis Huber<sup>21</sup> reports a case of lateral pharyngeal abscess occurring in a child two years old, following a tonsillectomy. Dr. D. Van D. Hedges, of Plainfield, New Jersey, reported by Dr. F. C. Ard, has observed two cases of torticollis following tonsillectomy. The condition lasted two months in one patient, and one month in the other. Condition ascribed to sepsis.

Injury to the pillars and accidental removal of the uvula are not uncommon results of operative work for removal of the faucial tonsils. Cicatrices forming in the palatine arch, which more or less impair the movement of the vela curtain and adhesion of the anterior and posterior pillars to each other in the process of repair, are possible occurrences. These results are not of any serious moment to the speaking voice, unless the injury is great, but are of decided moment to the singing voice or to the voice used for elocution purposes.

Dr. Hudson Makuen<sup>22</sup> writes, in no hesitating terms, in regard to these conditions, as follows:

"Seeing, as I do, many children having defects of voice and speech day after day for many successive weeks, I have, perhaps, a somewhat unusual opportunity for studying the local, as well as the general, effects of the operation under discussion, and I confess to you that I have been amazed at the apparent disregard for the surrounding structures with which much of this work is done. The sacrifice of one or more pillars of the palate and of the uvula seems not to give some operators any concern whatsoever and the results upon the voice and speech have been, in some cases, not only disastrous, but altogether irreparable."

Infection of the middle ear as a complication of tonsillectomy is an occasional occurrence, as all operators are aware, but I find only a few reports of such infection. To be sure, this complica-

---

<sup>21</sup>Archives of Pediatrics, 1894 p. 655.

<sup>22</sup>Transactions of the American Laryngological Association, 1911, p. 223.

tion is more apt to occur after operation for adenoids than tonsillectomy. Infection of the cervical glands is also another type of complication which is occasionally manifested, but, as it is looked upon by operators as only an incident in the cases, they are not usually reported.

*Unclassified.*—A case of gangrene, with death, is reported by Terkenle in a child of seven years, eight days after a tonsillectomy, as quoted by Dr. S. M. Bourak.<sup>23</sup>

In Crockett's article, previously referred to, he states: "The occurrence of twelve deaths in this city (Boston) and its suburbs in the last year and a half or two, following upon the removal of tonsils, as well as the occurrence of a large number of very considerable hemorrhages, also fatal unless checked by experienced hands, would prove to my mind that it is not wise to advise such removal except on sufficient symptoms." Evidently these twelve cases of death referred to by Crockett have not been reported by the operators; neither can they be classified, as the reporter does not refer to the causes of death.

Also, as unclassified may be mentioned the case reported by Schuchardt,<sup>24</sup> of a case of a sudden death following excision of tonsils due, according to the findings of the court, to either hemorrhage, strangulation or shock. The patient was a child of thirteen years of age, of the lymphatic, chlorotic constitution, who died immediately after the removal of the right tonsil, the left having been previously operated upon. All methods of restoration were adopted, including tracheotomy.

If anything can be gleaned from the reports which I have enumerated above, it would seem to be that tonsillectomy may be at times attended by most serious, even fatal, complications. It behooves us, therefore, to be most careful in our technique and most cautious in our post-operative attention to our patients. Tonsillectomy, therefore, should be considered a major operation, and the patient should be prepared and surrounded with all the post-operative attention, as in any major operation.

With such knowledge, is it proper and wise to suggest this

---

<sup>23</sup>Archiv für Laryngologie and Rhinologie, B. 22, H. 2.

<sup>24</sup>Aertzliche Sachverständigen Zeitung, No. 7, 1900.

operation, as is so often done by the internist, with insufficient and inaccurate data from a local standpoint, as a prophylactic measure? I believe that this point of view, as an overwhelming demand for the removal of the tonsils, is too often presented to the reluctant patient. I believe that a few general conditions probably have their portal of entry into the general system through the tonsils, but I would demand that, in every individual case, the tonsil be first proved to be guilty before it is sacrificed. One must hold steadfastly in mind the fact when suggesting such a procedure under such conditions that we by this operation are placing the patient in danger of his life—probably a greater danger to his life than the probable remote infection.

#### *Discussion.*

Dr. Joseph H. Bryan, Washington, D. C.: This is a subject I have felt very strongly about for a good many years, particularly since doing the radical operation on the tonsils. I think it is time that something was being done to educate the public in regard to the dangers of this operation. Nine out of ten persons probably think, or have been taught, to believe that it is a trivial matter; some think that it can be done in the house, and that in the course of forty-eight hours the parts are healed. I have always informed my patients that it is a major operation, and should only be done by a qualified surgeon and only in the hospital. The consequence is that many of the cases have refused to accept my views of this kind of an operation, and have gone to men who consider it less seriously, and in a number of instances have met with serious results, which have proven that these things should not be considered as trivial matters. I hope that this paper will be published and broadly disseminated, and it is high time this association took a decided stand regarding this matter. We are continually having this operation done by men not qualified. Only qualified surgeons should do it, and those capable of doing a ligation of major vessels and sewing up the pillars, etc., and I believe this paper is going to have a tremendous influence on the manner and the character of the men doing this operation in the future, and I believe that the laity should be put in a position where they can understand this is not a trivial matter, but one which must be taken under serious consideration before the operation is done.



Dr. Otto T. Freer, Chicago: Most operators have so great and needless a fear of hemorrhage after tonsillectomy that, to avoid it, they incur the greater danger of sepsis and pyaemia by tearing out the tonsil with the finger and blunt instruments where they should use the keen blade. Two deaths from pyaemia as the result of blunt dissection and the crushing cut of the snare have come to my knowledge, while I have never seen a death from hemorrhage after knife-tonsillectomy.

The disposition of the pharynx to gangrene and septic inflammation is well known. They are positively invited by the devitalization of the tissues produced by forcible tearing and rending from its bed of the tonsil, so notorious for its septic contents. Even the laity knows how poorly a torn wound heals as compared to a cleanly cut one. In addition, chronic peritonsillitis often adds to the danger of septic inflammation from blunt evulsion of the tonsil.

Manifold injury to the palate also may result. I have seen adherent tonsils, enucleated with the finger, to which large pieces of muscular tissue remained attached. Tonsils completely removed in this manner are often shown as proof of a perfect operation. What is important is not so much the aspect of the removed tonsil as the condition of the throat from which it came. I have seen the results of operations by other surgeons who practise dull enucleation, where the palato-pharyngeus muscle was torn apart, the posterior pillar torn away, the tonsillar fossa and its surroundings reduced to a putrid, sloughing mass and other mutilations produced. The snare, too, is notoriously liable to ensnare and cut off the uvula and portions of the palate.

For many years I have dissected tonsils out with keen blades, as described in my paper in the *Journal of the American Medical Association* in 1909. Post-operative bleeding has occurred after this method, as it may after any; but it was never dangerous, as the walls of the tonsillar fossa were not injured. The clean-cut cavity remaining after knife-tonsillectomy heals without reaction, even the delicate plica tonsillaris being preserved and serving to line the tonsillar fossa in the healing process. There is no injury to the palate, and no tearing of the pillars such as occurs in blunt enucleation, which takes no account of the frequent adhesion of chronically inflamed tonsils to their bed.

Dr. D. Bryson Delavan, New York City: This association placed itself on record last year with regard to the surgical treatment of the tonsil. Not long ago, at a meeting of an important

medical society, a pediatricist stated that he always excised a swollen tonsil in a child and that he had operated in over 800 cases. A man who fails to discriminate between the varieties of enlargement of the tonsil, operating upon every case he sees, certainly does not understand the subject as he should, and, in certain phases of tonsillar enlargement, errs in resorting immediately to surgery.

We are under obligation to the writer of this paper because, in view of such misconceptions as above quoted, the subject cannot be too widely exploited.

With regard to hemorrhage, some years ago I had occasion to study the question carefully, and in the literature and from my own experience found it to be unusual for bleeding to occur before the eighteenth year, nearly all serious cases, excepting in haemophilic subjects, occurring after that age. A most important point to be considered is the risk of operating under conditions which may be septic. No such condition have I found more serious than grippe. Children operated upon while recovering from influenza, even after convalescence has seemed well established, have, in numerous instances, developed severe inflammatory conditions of the throat and ear. The removal of the tonsil under any circumstances in which the throat is in a septic condition is distinctly apt to be followed by severe and even dangerous reaction.

Dr. W. E. Casselberry, Chicago: If one were to view the essayist's report of fatalities following tonsillectomy as representing an average experience it would indeed be appalling, but I look upon it rather as a collection of contingencies presented on the principle that to be forewarned is to be forearmed. In rebuttal, may be mentioned that a group of us here, representing at least a few thousand tonsil operations, find on mutual inquiry that none has ever had a fatality. Nevertheless, one cannot but fear the ever present liability, for granting that some of those reported might possibly have been avoided, there were others in which naught now understood would have so availed, and it would be a corresponding relief were the discussion to develop additional practical means of prevention.

Regarding hemorrhage, true haemophilia is rare, although persistent dangerous tonsillar hemorrhage is not uncommon after tonsillectomy as well as after tonsillotomy, but in the absence of haemophilia, it has always been controllable, in my experience, by mechanical means. The compressor, cautery, artery forces, ligature and suture have each served well on occasion. None should operate without them, nor without skill and illumination

adequate for their prompt application before the panic and collapse which come with exsanguination, interfere with their use. The so-called "venous ooze" is a deceptive myth, for on wiping off the clot and searching behind the pillars I have always found a small spurting artery. Another source of deception lies in the swallowing of the blood, young children requiring the test position, face downward, to disclose hemorrhage. To operate on acutely inflamed tonsils or in a state of pyrexia is to court hemorrhage and other complications.

With regard to hemorrhagic infarct, the author did not specify whether they were cases of true hemorrhagic infarct from embolism, as by a clot arising in the systemic venous system, propelled through the heart and lodged in a small pulmonary artery, or instances of insufflation pneumonia by blood drawn into the bronchial tubes during the operation. The infarct is a recognized contingency in external surgery of the neck, but unfamiliar in tonsil operations; whereas, insufflation of blood, though surprisingly infrequent, calls for finesse in bleeding periods both during and after a tonsil operation in order to guard against it. But insufflated vomited matter is more liable than blood to cause pulmonary infection. How often does the neophyte nurse, instead of turning the nauseated, unconscious patient merely raise his head and flex the neck, bringing chin on chest, a position which tends to prevent expulsion of the vomited matter; and a like disregard, by the orderly, for insuring freedom of the air passages while moving the patient from table to bed, has been responsible for emphysema.

Regarding sepsis, the only phase of it familiar to me is that which takes the form of a tonsillitis in the other tonsil when one is removed or in the pharyngeal follicles when both tonsils are removed, being characterized by like symptoms, local aspect and temperature range, and liable exceptionally to like complications. It is more rare after total tonsillectomy and adenectomy than after partial operations, hence the best safeguard is a complete operation. I have seen no approach to fatal hyperpyrexia, but feel that it and the chance of accident under anesthesia, even though remote with ether, together with other remote contingencies, constitute the bare chance which must be taken if one would profit by this or any other surgical operation.

Dr. W. L. Ballenger, Chicago: I wish to express my impressions of the paper. To me it was a most alarming presentation, something out of proportion to the true situation. As Dr. Beck has directed your attention, the fact that many of these complications were years ago before the technique was as careful as it

now is should be taken into consideration. With the Sluder operation, which injures the musculature less than any other and which may be done without a shred of muscle being removed, yet notwithstanding that fact and theories I advanced previous to this in which, from experience, I must say there are hemorrhages just as severe following this operation as with the older dissections with the finger or knife. Just as many hemorrhages as before and just as severe in my practice. To my mind the safest operation is by partial dissection and then following this with the snare. I do not believe any method of dissection is absolutely free from the danger of hemorrhage. I do not, however, know how to explain the hemorrhages following the Sluder operation. I am not familiar with Dr. Beck's technique of the Sluder method, and, therefore, can only accept his statement that there is no hemorrhage, but whether he can repeat this statement in the next ten years we shall have to wait and see. I had the most severe hemorrhage I have ever had with the snare. I have never had a death, however. The severest complication followed an operation upon a brother specialist, of Chicago, of general septicemia. Following the operation he was laid up for five or six months. This case is one that should be instructive to us. He came to me; I made no examination, taking for granted that he knew what he needed and what should be done. He said afterwards he had a feeling of a splinter in his throat. An infection followed this operation by sharp knife dissection and he had a most violent reaction with very unfortunate results. He has, however, recovered with no after effects.

Dr. Richardson enumerates thirteen complications or sequelae to the operation and some unclassified ones, and I think if the impression goes out from this meeting that this operation is as dangerous as this paper seems to me, it would not be exactly fair, yet I recognize that this paper is to warn the inexperienced man from doing his imperfect work without proper preparation. As Dr. Casselberry has so well said, many complications arise in the practice of experienced men. While we all recognize the tonsil operation is not simple, I must personally say there are many refinements of technique to-day which make it much more safe than it was formerly. The advent of the Sluder method has removed many of my terrors, but my terror of hemorrhage still remains. Before using the Sluder method I rarely used ether. About the time I took up this method I began to use ether extensively, and it is to the ether I attribute most of my hemorrhages, from the high blood pressure. With local anesthetics in older patients I never see any serious hemorrhages.

In conclusion, I do not believe the general impression given

by this paper that this is a tremendously serious operation is a well taken one, yet I think we should all feel we have, however, a problem to consider in this connection which should make us all exceedingly careful in our preparation and handling of these cases.

Dr. John O. Roe, Rochester, N. Y.: There is one sequela of this operation which Dr. Richardson has not mentioned, which is not serious to life or attended by hemorrhage. It is the impairment of the voice that follows the mutilation of the throat by the inexperienced man. Dr. Makuen last year before this society called attention to the serious effect on the singing voice of the cutting away of the pillars of the fauces in the operation of tonsillectomy. This subject should receive much more attention than it has received in the past. Among the many cases of mutilated throats in attempts at tonsil removal, I have two cases of complete adhesion of the soft palate to the pharynx as the result of such mutilation. In both of these cases the operations were done under ether anaesthesia, and in both the tonsils were left behind, while the soft palate and posterior pillars were so removed or so badly mutilated that complete adhesion was the result. One of these cases I have reported in my article on "Palato-Pharyngeal Adhesions," for which I was obliged to devise a new flap operation to remedy the defect. The second case is a recent one, on which I have not yet operated. It is the result of the attempt of a young general practitioner to do the operation himself rather than send the patient to a specialist.

Dr. Richardson and Dr. Bryan have observed that this operation can no longer be considered the minor operation that people were led to believe when tonsillotomy—the shaving off of a portion of the tonsil—was generally practised, but that, when it is properly performed, it must be classed as a major operation. It is, however, the fact that profuse hemorrhage was more frequently encountered during those times when tonsillotomy was practised, for the reason that the pillars of the fauces were very commonly contained within the grasp of the tonsillotome, and consequently there was wounding of the arteries lying along the edges of the pillars, from which the most profuse bleeding occurs. With reference to cases of fatal hemorrhage after tonsillectomy I have, notwithstanding my very large experience in this operation, but one case to report. It was that of a girl eighteen years of age, sent to me by her family physician from a neighboring city for the removal of her diseased tonsils and adenoids. I removed the tonsils with the snare—my usual method—after

freely separating the tonsil from the pillars, and the adenoids with the curette, and nothing unusual attended the operation. In a short time, however, she began to bleed slightly, the blood oozing from every portion of the wound, and this continued, in spite of everything that could be done, and steadily increased. I sutured the pillars of the fauces, applied styptics and pressure; gave saline injections subcutaneously, and packed the posterior nares, but all to no avail, and she finally succumbed to the loss of blood about six hours later. It was very gratifying that the father was present at the operation and afterwards and realized himself the hopelessness of the situation. I was also gratified to receive a few days later a letter from the family physician telling me that four or five years previous the mother of the girl had died from hemorrhage in a very similar manner, after a uterine curettement, as I remember, and that he also believed they were a family of haemophiliacs.

Dr. J. Price-Brown, Toronto: In speaking of this paper I would like to sound a word of warning regarding operation on the tonsil in cases of chronic rheumatism. In the early part of this year a man was referred to the Orthopedic Hospital of Toronto suffering from chronic rheumatism to such an extent that he could not stand. As he had very large tonsils, Dr. McKenzie thought possibly the rheumatism might be a result, and desired their removal, to which, on examination, I agreed. The tonsils were very large, but the pillars quite free. He was lifted from his chair to the operating chair. Under cocaine and adrenalin I removed the tonsils completely. There was but slight hemorrhage at the time, but on account of the rheumatic tendency of the man I stayed with him about an hour. He was put back to bed and I then left him. I was absent from my office for several hours and on my return a telephone message awaited me that the man was bleeding to death. I went immediately and found they had raised the foot of the bed one foot and the young surgeon had his finger in the patient's throat and the man was almost unconscious. The pulse was 150. There would have been a fatal result in another quarter of an hour. I examined the throat; found bleeding from an artery in the lower part of the right tonsil. The pillars were perfectly free and by digital pressure on this spot for about one hour the hemorrhage ceased. The patient made a slow but good recovery. It was two weeks before he rallied from the shock. The cause of the hemorrhage was the arterial sclerosis which existed. He was about fifty years of age. After his recovery from the loss of blood his rheumatic symptoms indicated marked improvement.

Dr. Greenfield Sluder, St. Louis: My name has been mentioned in connection with a method I described two years ago, so I feel called upon to say a word in its behalf. From the beginning it has been criticized as a bleeding method. In the description I put out at that time I emphasized the use of a dull blade guillotine. I have now attached a snare to the guillotine, because the instrument maker insisted on serving it with a sharp blade. I do not use this instrument and I object very strongly to its use. It is, however, the instrument now on the market and I am helpless to prevent it, all due to the fact that I cannot get the instrument maker to realize that the blade should be dull and not sharp.

It happens that I have measured the amount of blood in 300 children varying from 15 years to probably  $2\frac{1}{2}$  to 3 years. The average bleeding in my hands has been 70 cc. (4 2-3 table-spoonfuls). That does not seem to me to be an immense amount for both tonsils and adenoids.

It was Dr. Beck's criticism that my guillotine blade was terrible; that he substituted a ring with a snare sliding in it and pulls it up, according to the description, under the jaw. He says that by the snare they do not bleed. Putting my combination snare and guillotine into use it just happens that out of these 300 children the only ones that had to be attended for secondary hemorrhage were those who had been snared. This may be a coincidence, and I think it is.

In the way of precaution, in the St. Louis Children's Hospital we have approximately ten children every Friday. A blood test is made beforehand to ascertain the time of clotting. The puncture is made at the same point in the lobe of the ear by the same instrument, and the same means of computing the clot are used. I emphasize the use of the same instrument and same site, because the estimation of the amount of blood which will exude from a like point from the same instrument may be taken as an index not only of the clot that we estimate later, but as an index of the resilience of the vessels in that particular individual. Last Summer a child was brought to me, five years of age, whose mother said she wanted his tonsils and adenoids removed. His blood would not clot under five minutes, and from the prick he bled ten times the amount of the ordinary child. I gave him calcium lactate for a month, but could not raise the clotting time to less than two minutes and a half. I decline to operate with a clotting time beyond a minute and a half. I therefore refused to operate on this child. The mother promptly went to another laryngologist in the city, who promptly went into it and the

child was all but lost. It bled until turned upside down, injected with serum, transfused, given hypodermoclysis, and, in fact, everything was done for it. I believe eventually its life was saved. I believe the precautions used in our hospital have something to do with the fact that, except once, we have had no serious hemorrhage, and that was in a case of scarlatina. The shock of this operation was out of all proportion to the customary, and the child continued to bleed, collapsed, but was not lost. Since that time no child is accepted for operation with a temperature of more than 99.2 degrees, and then the question is put to the mother, "Does this child seem to you to be absolutely normal?" and when she answers "yes" we proceed.

Dr. J. R. Winslow, Baltimore: The ill effects following tonsillectomy are dependent in some measure on the method of operation, in a larger measure on the operator; some are avoidable and some are unavoidable. Take the subject of hemorrhage: I think the sooner we accept it as a fact that there is no *method* of operation that is going to protect our cases for us the sooner we will get down to a definite method of proper treatment in these cases. Sooner or later every method is followed by hemorrhage, unless the primary operation is treated from the surgical standpoint in the beginning. I cannot understand why a man who does not hesitate to open up the mastoid, the labyrinth, or do a laryngotomy should shy at the subject of tonsillar hemorrhage. The only protection is the man himself. He must be a surgeon, look at the matter from a surgical viewpoint, and meet hemorrhage by usual surgical means. The method of removal of the tonsil makes no difference; I usually do it by sharp dissection and under general anesthesia, but this is the point: I pick up and ligate every bleeding vessel and every bleeding portion of muscle, and dismiss the patient from the table in a dry condition. I would consider myself unsurgical if I allowed my patient to go to his room with a so-called oozing wound. The abdominal surgeon does not do this, and we should not. It is the rarest thing to have secondary hemorrhage if we ligate our bleeding tissues and vessels at the primary operation. This is my view and the view of my colleagues at the Baltimore Eye, Ear and Throat Hospital in regard to the subject of tonsillar hemorrhage.

With regard to sepsis, if we do not injure the tissues we lessen very materially the possibilities of infection, absorption and sepsis. Here again, in large measure, we have this question under our control. If you operate by the methods attended with the smallest degree of injury to the tissues you will not only lessen sepsis, but the ordinary reaction following tonsillectomy.



I also had intended to allude to Dr. Makuen's article regarding the effect upon voice speech of mutilation of the throat, but that has already been mentioned. There are other minor disorders following tonsillectomy, such as paralysis of the palate following the use of the snare. Another trying sequence, a remote one, is a sensation of dryness in the throat for which I am unable to account, and which I cannot relieve. I tell the patients they will outgrow this; most of them do, but some do not. I would like to know if this has been the experience of others.

Dr. Henry L. Wagner, San Francisco: That we cannot be too careful in our preparatory examinations of our patients to be operated upon teaches the following case: A lad whose history revealed diphtheria a few years ago, but in whose mouth no Klebs-Loeffler germs were found, had his tonsils removed and developed 36 hours later a recurrent diphtheria in the wounds of the operation. Months later after the patient was entirely well and the throat showed no diphtheria germ any more, a small area of necrosis—as large as a pinhead—was discovered in the middle turbinal of his nose, which space harbored still some active bacteria. It is very probable that this focus of infection had existed before the operation; therefore, it is necessary not only to examine the secretions of the throat, but also of the nose. Referring to hemorrhages: The time of the coagulation of blood should also be made a part of the preliminary examination, although I remember a patient whose blood was found normal, and at the time of operation an arterial and venous hemorrhage demanded not only the ligation of several smaller vessels and sewing the pillars together, but also the use of serum—in this case diphtheria serum—checked the profuse oozing. Thrombokinase has been favorably spoken of in these conditions.

Dr. Norval H. Pierce, Chicago: It is a matter of care and precaution as to whether this is a dangerous operation or not. A death occurred in Chicago last Winter which will illustrate the lack of care. A strong, full-blooded man went to see his physician—a nose and throat man—on account of some trouble with his throat. The doctor told him he ought to have his tonsils out and the patient asked when could he do it. "Any time," the doctor said; and so the patient said: "Come around to my house to-night." "Very well." The patient went to a hotel, had a full luncheon, back to his office, then again to the hotel and had a heavy dinner, with several cocktails and an abundance of wine; then excused himself, saying he had to go and have his tonsils out. About nine o'clock this was done. He bled to death that night. That illustrates what may happen when absolutely no precautions

are taken. Under proper precautions it is practically devoid of danger by men who are used to operating in this region.

Dr. Harmon Smith, New York City: I do not wish to depreciate the gravity of the statements made by Dr. Richardson which advocate bringing before the medical profession the importance and proper consideration of the operation of tonsillectomy, yet at the same time, if we compare the number of cases reported of fatalities, amounting to possibly 41 or 42, to the thousands of cases that have been operated upon, it shows a very small per cent. of mortality. We get a greater mortality in any other surgical operation employing ether. The importance of bringing the operation into proper surgical hands is undeniable, and also the importance of having the people recognize it as a major surgical operation, but I think we are probably laying too much stress upon the resulting mortality.

Dr. Wagner spoke of thrombokinase. This is made in the laboratory of the Manhattan Eye, Ear and Throat Hospital and has been successfully employed for the stoppage of oozing. It can be obtained from the hospital, which will gladly furnish it on request. It acts on the fibrin ferment of the blood and forms a clot within the intima of the vessel. Adrenalin acts upon the outer muscular coat; thrombokinase will only control oozing and not profuse hemorrhage. I have employed it successfully in the control of hemorrhage following the removal of the middle turbinate and operations upon the ethmoids, sub-mucous resections and in tonsillar oozing.

Dr. B. R. Shurly, Detroit: There have been many points of interest brought out. There is a terrific apprehension regarding hemorrhage, which is peculiar to certain geographic centres, according to individual experience. There are two of our operators in Detroit who have had so many serious cases of hemorrhage that now, as a routine, they ligate the pillars at each operation in the region of the supratonsillar fossa. In a very large series of cases it has been my fortune to have but one very serious hemorrhage. I returned from one of our national meetings where some one read a paper on the value of calcium lactate in 15-grain doses, and I administered this dosage to a patient. Dr. Freer's knives were used. I am now threatened with a suit for damages for a tonsil hemorrhage, the greatest and most terrible I have ever seen.

Dr. D. J. Gibb Wishart, Toronto (by invitation): I thank the association most heartily for their kindness in allowing me to discuss this excellent paper by Dr. Richardson. The case to which

he referred was an exceedingly interesting one and I have not either before or since met with one like it, nor have I read or heard of any until that of Dr. Richardson's, which was of a similar character. The rapidity with which the apparently innocent condition of affairs at the time of operation became changed, the climbing of the temperature, and the absolute failure of any measure which could be thought of to avert the fatal termination, made a very great impression upon me.

With reference to other accidents in connection with tonsillectomy, I have been fortunate enough not to lose any cases through hemorrhage. I have an idea that hemorrhage is not abundant except where there is a considerable amount of tearing of the musculature around the tonsil. Where you stick closely to the capsule in removal you get very little hemorrhage. That has been my experience and I think it is borne out by my observations on the cases of my confreres in my city. Of course, one always does meet with a few cases of hemorrhage occurring some time afterward, but these, as a rule, have not been serious in my experience.

I wish something could be done by this association and by others to carry out that with which Dr. Richardson so ably concluded in his paper—that removal of the tonsil is a major and not a minor operation, as it was formerly considered. It is time that something definite was done with regard to this point. Even our surgeons consider it a minor operation, and where they set the example of course the ordinary public may be pardoned if they follow suit.

I am greatly indebted to Dr. Richardson for this paper. He has gone into the different sequelae of tonsillectomy so thoroughly that I shall read his paper when it is published with pleasure and keep it as a matter of reference.

Dr. W. E. Chenery, Boston (by invitation): I would like to add my experience in a recent case. This was a young man of thirty-five, who had been operated on under ether in a hospital. He had been kept there for observation for five days and then sent home. Twelve hours afterward he began to spit blood; his specialist was sent for, but could not be found, and a general physician was called in to stop the hemorrhage. He proceeded to take a cotton ball and wipe it round the back of the throat, which only increased the hemorrhage. After two hours I was sent for, and found the man exsanguinated, thready pulse, marked pallor and sweating, and in a very serious condition. To put the head up only a foot caused him to faint away, so I kept him on the bed and searched for the bleeding point, and succeeded, after wiping

away the clots, in stopping the hemorrhage at the lowest portion of the right tonsil by means of nitrate of silver fused on the end of a probe. I think this case is an important one, because the patient was an alcoholic, and the hemorrhage occurred five days after operation, and under the best conditions. I think we should always consider the alcoholic subject in operating. I have had a little experience in using rabbits' serum in stopping hemorrhage, and consider it worth while. We should never operate on acute tonsils.

Regarding the minor accidents, if you use the snare you must be very careful not to include the uvula.

Dr. Beck, Chicago (by invitation): I first wish to express my thanks to the Association for allowing me this privilege. I have listened to all the papers with a great deal of pleasure and profit.

I had planned, if called upon, to enumerate some of the complications that were mentioned by Dr. Richardson, but I am glad that I cannot do that. I have had, like most men, of course, cases of considerable bleeding. Within the last year or two the technique has been so much improved that at least complications can be left out of the possible occurrences.

I would like especially to mention the operation I am employing at the present time where the question of hemorrhage, or even free bleeding, is something I do not see very much—and that is making a very broad statement, but it is true absolutely, as I have frequently demonstrated. With the method employed by Dr. Sluder of lifting out the tonsil and then snaring it off slowly, neither hemorrhage nor traumatism follows this procedure, for there is no possibility of including the pillars, the uvula or anything else that should not be. I saw in consultation a case of abscess of the lung which seemed to have followed so close upon enucleation of the tonsil that I will gladly describe it to Dr. Richardson to include in his report, if he so desires, as it has additional features to those described by him. The abscess was operated on, and the patient is still wearing a tube in the chest, although he made quite a successful recovery.

Another case which may belong among the amygdalar scarletiform rashes is one I saw in the isolation ward of the Cook County Hospital, admitted for scarlet fever. This patient had his tonsils removed a week before, then, becoming infected with diphtheria, required tracheotomy. He never peeled, it never being scarlet rash, and I mention it so that some one may be blamed for making a diagnosis of scarlet. The intern-

ists and pediatricists should know of this complication, which may sometimes occur after operation for tonsillectomy.

Dr. Charles W. Richardson, Washington, D. C. (in closing): I wish to thank the gentlemen for the kindly manner in which they have discussed my paper.

There is one point that surprised me, and not noted until mentioned by Dr. Roe, and that was my neglect to report the injuries resulting from this operation. On looking my paper over I found that my stenographer had left out the pages giving these and other examples, but it will appear in printed form later. In the portion referred to I quoted Dr. Makuen's paper in which he stated that he was amazed at the number of injuries to the palate, to the fauces, the vault and the soft palate itself, which he had observed in persons operated on for tonsillectomy or tonsillotomy, and the impairment or direct injury to the singing or speaking voice. Of course, most of these injuries or the cicatrices produced, which are sometimes worse than injuries, are a serious matter to a public speaker or singer.

With regard to the method by which this septic infarct gained entrance to the lung I cannot say. I suppose it was taken up by the vessels or lymphatics at the time of operation or shortly afterward, although it may have been produced by the entrance of blood into the lungs direct.

Dr. Freer referred to the sepsis probably being due to rough handling, bad technique, etc. Most of the cases which report sepsis are not due to rough or bad technique, but usually due to the use of sharp knives. Three cases of infection resulted from instrumentation, and not from the use of the finger. So we see that the method of operation is not responsible for the infection directly.

Dr. Winslow has made an excellent point. We should always treat these cases in a thorough surgical manner. We do not think of turning other cases back to the wards without guarding against hemorrhage, and we should take the same precautions in tonsillar cases.

Dr. Sluder made the suggestion about operating on these cases without temperature, or only 99.2 degrees. That is good as a general point. I have made almost a hard and fast rule not to operate on any case showing temperature. But this Spring I have had two cases, one a child running a temperature for over six months up to 101 and 101.5 every day. The child had been to several physicians, who said the tonsils were the cause of the fever and that they should come out. There was no interval when the child was free from abnormal

temperature; so after considering the situation I decided to and removed the tonsils. In four days this child was free of temperature, and has had none since. You, therefore, cannot lay down a hard and fast rule to which you will always adhere. If the temperature is due to infection in the tonsils, then remove the tonsils. Otherwise, with inflamed or diseased tonsils, or in individuals that have infection of any kind, do not operate until the condition has subsided.

Dr. Smith has well stated that this is a very small mortality as compared to the number of tonsil operations done. Nevertheless, this does not cover all the unreported cases. How many are there like those reported by Dr. Crockett. These fatal cases are not usually reported, but may be found all over the country. My paper was written simply to show the complications that occur in connection with tonsil operations and to impress upon us the importance of looking carefully after the patient in the post-operative period and cautioning us as to the importance of doing this operation in a thorough surgical manner, and in preventing the general practitioner and the patient looking upon this as a minor operation.

## THE MIDDLE TURBINATED BODY: SOME INDICATIONS FOR ITS REMOVAL.

BY W. SCOTT RENNER, M.D., BUFFALO.

The association of pathological conditions of the middle turbinated bone with nasal reflexes, nasal polypi and suppuration of the nasal accessory sinuses has been recognized and discussed by innumerable writers on rhinology during the past twenty-five or thirty years. And in 1907 a most valuable symposium on the subject was presented here in Atlantic City before the Section of Laryngology and Otology of the American Medical Association.

Oculists of to-day refer many patients to rhinologists for nasal examination when symptoms are found which lead them to suspect internasal or nasal accessory sinus trouble. The recent literature has led them to believe that their patient is suffering from some sinus trouble. Many of these have no involvement of the sinuses, but conditions are often found in the region of the middle turbinate which produce reflex eye strain, headache, etc. These are cases which would not come under the observation of the rhinologist were it not for the interest that oculists are showing in the nasal cavity as a causative factor of abnormal conditions of the eye.

I do not wish to dwell upon the cases of chronic sinusitis and nasal polypi in which the enlarged turbinate requires removal as a part of more radical operations, but to speak of the importance of the middle turbinate in producing many of the reflex neuroses and the necessity of its removal for the proper ventilation and drainage of the nasal accessory sinuses, especially those of the anterior group, and thereby preventing the occurrence of the chronic sinusitis.

The turbinated bone becomes important clinically, first, by increased volume of its mucous membrane; second, by its varie-

ties of shape, and, third, on account of its relation to other portions of the ethmoid bone, such as the bulla ethmoidalis, the unciform process and the perpendicular plate of the ethmoid.

The middle turbinated bone varies in type, whether diseased or not. The free anterior border may be so removed from the external wall of the nose that the whole extent of the hiatus semilunaris can be made out by rhinoscopic examination, or it may by its position completely hide the hiatus, or it may be in opposition with the nasal septum.

It may be broad anteriorly and small posteriorly, or it may narrow in front and extend far back and be broad posteriorly, or it may be large in the whole of its extent. It may contain a large or several small cells which open into the anterior or posterior ethmoid cells, or it may have a hiatus of its own. Besides these differences in the shape of the bone itself, its surroundings may by their anomalous positions press upon it. The septum may be pressing upon it, when it is often small in front or throughout its extent. The hiatus semilunaris may be narrow or broad, according to the relative positions of the uncinate process and the bulla ethmoidalis. Both of these processes may contain cells which vary in size. At either side of the uncinate process are the anterior and posterior fontanelles, which have some influence on the appearance of these parts. But the uncinate process and the bulla ethmoidalis may be large or enlarged so as to overlap the middle turbinated bone and be mistaken for it, or have the appearance of a double middle turbinate. The middle turbinate and its coverings, therefore, from its position and relation to the neighboring parts, may or may not prevent free drainage of the hiatus semilunaris and the anterior group of nasal sinuses, or from pressure upon the septum or bulla ethmoidalis may produce pressure symptoms, eye symptoms and other reflex neuroses. Early attention to the condition of the middle turbinates should prevent most cases of sinusitis of the anterior group of cells.

Of the various reflex neuroses attributed to intranasal pressure and hyperaesthesia of the nasal mucous membrane the most common are eye strain, accompanied by headache or neuralgia;



"paroxysmal sneezing" and reflex cough, accompanied at times by asthma, vertigo, twitching and spasm of the eye muscles. Pressure may also produce passive congestion in neighboring parts; pressure on the ethmoid cells, and especially on the bulla ethmoidalis, by an enlarged middle turbinate may produce eye symptoms due to congestion.

The greatest number of cases of reflex disturbance are those in which the patient complains of headache, eye strain, etc., in which the ophthalmologist is unable to find any refractive error or in which the correction of a refractive error does not relieve the symptoms. The discomfort and ocular pain are increased by use of the eye.

The following cases are illustrative:

Miss C——, 29 years of age, consulted me on November 9th, 1911. She had had eye trouble all her life and complained of eye strain, headache and nasal obstruction. I found the right middle turbinate especially enlarged, the left less so. Both lower turbinated bones were covered with pale hypertrophic tissue. I removed both middle turbinates and the posterior hypertrophies from both lower turbinates between November 13th and December 9th. Treatment was followed by relief of symptoms.

Dr. R. R. Satterlee, an ophthalmologist, examined this case and reported as follows:

"Miss C. came to me November 11th, 1911. I found right fundus veins swollen, nasal side of disk fuzzy. Left disk normal, but veins swollen and tortuous. Vision: each eye slightly subnormal with any correction. Weak interni. Reported again January 11th, 1912. A month after the operation fundi cleared up, veins about normal in size, no tortuosity, better muscular balance. Vision normal with proper correction prescribed."

Miss W., 31 years old, a nurse, consulted me August 26th, 1911. She complained of excruciating headaches and eye strain. I found the left middle turbinate especially enlarged and recommended its removal, which was done a few days later and which gave great relief for a few days, when she came back with a return of the pain. An interval of a couple of weeks passed before I removed the other turbinate.

This patient had seen several ophthalmologists and had had a gall-bladder operation for the relief of the headache, etc.,

without any benefit. The symptoms disappeared a short time after the operation.

The ophthalmologist reported in this case as follows: "Miss W. came to me September 5th, 1911. I found on examination intense ciliary spasm, engorged veins of both fundi, vision sub-normal, abnormally strong interni, severe headache. Was to be operated on, so increased the glasses she was wearing and told her to report in one month. September 28th, 1911, veins less swollen, vision more nearly normal with correction. In December gave full correction, fundi normal, muscular balance about normal. Saw her a month later, headaches all gone, eyes normal in every way."

Other cases quite similar to these have recently come under my observation where the findings of the ophthalmologist before and after operation were practically the same. These, however, are only a few of the many cases which we all see where the patient has complained of headache and eye strain, especially on constant use of the eye, where the relief from the removal of the middle turbinated bone has been great, but unfortunately no ophthalmoscopic examination had been made in most cases of this class until recently.

The effects of pressure of the middle turbinated upon the anterior ethmoid cells in the production of congestion of the conjunctiva and lachrymal ducts are illustrated by the following cases:

Mrs. W. C. M., 35 years of age, came to me on November 4th, 1911, at the request of Dr. Satterlee, for what appeared to be obstruction of the left tear duct, swelling at the inner canthus, excessive lachrymation with redness of the conjunctiva. She said that she also suffered from nasal obstruction and frontal headache. She had been treated by several oculists, who failed to relieve her symptoms. On examination of the nose I found that the left middle turbinate was large, that the bulla ethmoidalis was large on that side, and the mucous membrane over the lower turbinates on both sides was hypertrophied. At the first seance I removed the left middle turbinate and the anterior wall of the bulla ethmoidalis, which contained a very large cell. The eye symptoms were greatly improved in twenty-four hours. I subsequently removed the

posterior hypertrophies from both lower turbinates. She has been perfectly free from nasal obstruction, headache and lachrymal irritation since the completion of her treatment.

A similar case is that of Mrs. S., 44 years of age, who for some time had been troubled with excessive lachrymation of the right eye, especially on exposure to cold air. She has had nasal trouble for years, and eighteen years ago I removed posterior hypertrophies, but had not at that time considered her middle turbinated of importance. She came to consult me March 11th, 1911, upon the recommendation of an oculist. I found the right middle turbinated very broad, long and thick throughout its extent. Removal of the turbinated was followed by a gradual disappearance of the eye symptoms and she has had no return of them up to the present time. These are not cases of obstruction of the tear duct such as we expect to meet where the lower turbinated obstructs the nasal end of the duct, but they are of more frequent occurrence in my practice.

At certain seasons of the year patients consult us for acute ethmoid and frontal sinus trouble. This may be the first attack, but most of them have had one or two attacks of this kind in the spring of the year which disappear under treatment and the patient remains perfectly well until the following year. If these attacks in former years have not taken on the form of a purulent ethmoiditis or frontal sinus trouble, the patient has been subject to repeated attacks of cold in the head coming on after exposure, etc. Most of these cases are found to have large middle turbinated bones on the side of the inflammation.

All cases of acute sinus and ethmoid trouble, when not complicated by the presence of polypi and ethmoiditis of long standing, probably may be prevented from either recurring or becoming chronic by the removal of the middle turbinated bone. An acute attack should, if possible, be carried through the acute stage before the bone is removed. The patient should be kept in bed and all general toxic condition eliminated by free catharsis, alkalines and light diet. Before the discharge has commenced cold applications should be made externally, and hot applications after the discharge has been established.

The hiatus may be kept open by the insertion of pledgets of cocaine and adrenalin if tolerated by the patient. Adrenalin, however, even when much diluted is an irritant to many mucous membranes. I more and more incline to depend upon the rest in bed, catharsis and heat externally for the relief of these inflammations during the acute stage and feel that my cases do better when no medication of the hiatus is attempted. The inferior meatus may be irrigated with warm normal salt solution, especially where there is much pus coming down from the upper part of the nose. The very severe pains which occur for a few hours each day should be relieved by the hypodermic use of anodynes such as codeine. The passage of a probe into the frontal sinus or the irrigation of the sinus are contra-indicated. When it is possible to irrigate a sinus, rest and heat will cure the acute inflammation in a very short time.

Unless heat and rest relieve the pain and tenderness in from three to six days I remove the whole of the middle turbinated bone of the corresponding side under cocaine or general anaesthesia and continue the rest treatment without irrigation of the nose. Should this fail (which must occur very rarely in acute cases) I would resort to an external operation. Of course, if there were much involvement of the ethmoid cells of a chronic character, or if there were any polypi found in the hiatus at the time of the removal of the middle turbinated bone, I should remove them at the same time.

I would like to report the following case in connection with the above:

Mrs. H., now 35 years old, first came under my observation nine years ago, when she said she was subject to repeated colds. Removal of the posterior hypertrophies was followed by a rather severe hemorrhage, which prevented her from consenting to any radical treatment, and each attack of coryza was accompanied by severe headache and sneezing. At such times the right middle turbinated bone was acutely inflamed, or, at least, hyperemic and swollen. The condition was never accompanied by a purulent discharge. The advisability of the removal of the middle turbinated bone was often discussed, but the patient never consented.

On the 1st of February, 1912, she developed an acute sinus

trouble, purulent discharge with great tenderness and excruciating pain, which did not yield to any treatment, such as external applications of moist heat, salines and anodynes. On the 9th of February I removed the right middle turbinate under a general anaesthesia, and after another ten days the pain had practically disappeared and the discharge stopped. The patient has not had any return of her recurring coryza, has been free from headache at the menstrual period and is well satisfied. The patient had a great deal of infraorbital pain during each attack of acute coryza, which was always relieved by the application of cocaine to the anterior end of the middle turbinated bone. Such cases are very numerous, but are always relieved in this way, and it must be but rarely that a case of frontal sinus trouble would become chronic if the middle turbinate were removed.

Severe pain in the frontal region, even when there is much tenderness, does not indicate necessarily that the suppuration is in the frontal sinus. Many of these are ethmoidal with reflected pain. The tenderness may be over an ethmoidal cell, situated high up and bulging into the frontal sinus.

The following cases illustrate the benefit of early removal of the turbinated bone in antrum cases:

Miss U. came with her physician to consult me for what was considered an acute antrum trouble on the right side. She had nasal discharge between the middle and lower turbinates. The right middle turbinate had a very large globular anterior end which did not press upon the septum, but could have easily directed a flow of pus into the antrum. She had pain and tenderness in the region of the infraorbital nerve. Transillumination etc., showed that the antrum was clear. I directed the patient to have hot applications externally, and recommended the removal of the middle turbinate as soon as acute symptoms subsided. I felt that she had no antrum trouble. She recovered, but had a similar attack one year later. As she was very anxious to attend to her work I removed the middle turbinate, which contained a large anterior cell. She was completely relieved of all her symptoms in twenty-four hours and has remained free from trouble since that time.

Mr. C. W. F., 53 years old, came to consult me on September 25th, 1910, upon the recommendation of his oculist, Dr. Elmer Starr, for a pain in the head which he thought due to his eyes. Correction of his vision had not helped him. The right middle turbinate was found to be very large, especially at its anterior

end, and any examination of the hiatus, even after adrenalinization, was not possible. The patient would not consent to removal of the bone, but one year later he presented himself with a well-established case of antrum trouble, which was completely relieved by irrigation in about three weeks; the middle turbinate was then removed and has been followed by the disappearance of the headache and no return of the antrum trouble.

Many similar cases will occur to *you*. These cases have been mentioned to show how an acute antrum trouble may follow an acute ethmoiditis, the antrum simply acting as a receptacle for the pus until an inflammation of the antral mucous membrane is set up.

Among my records of cases of "chronic paroxysmal" sneezing I recall several in which the condition was completely relieved by the removal of the middle turbinated bone. The first is that of Miss T., from whom I removed both turbinated bones more than ten years ago for the relief of hyperesthetic rhinitis and asthma, and for which she received no other treatment. She has had no return of her symptoms.

Another case is that of Mrs. E. G., who consulted me at the suggestion of an ophthalmologist for eye strain and headache. She also complained of nasal obstruction with paroxysmal sneezing. She had been sent previously to a rhinologist, who had said that her symptoms were not due to sinus trouble. I considered her middle turbinated bones large enough to be the cause of them. I removed them both, with complete relief of all symptoms.

Another case is that of a school girl, fourteen years old, who suffered from enlarged glands, nasal obstruction, attacks of colds in the head, hay fever-like attacks accompanied by asthma. The tonsils and adenoids were removed, which was followed by an improvement of the condition of the cervical glands. Later, posterior hypertrophies were removed, affording no relief to the nasal symptoms. Although this girl was quiet young, I decided to remove the middle turbinated bones. Since having this done she has been completely well and finds it easier to do her school work.

These cases seem to demonstrate that there are many in which it is not necessary to look for and treat hyperesthetic spots after

the real disturbing lesion has been removed. In all these cases the nasal mucous membrane has, during the sneezing attack, the sodden, pale appearance found in true hay fever.

In marked contrast to these cases is that of a young man who came under my observation through the kindness of the late Dr. A. A. Hubbell in 1894. At that time he had every six or seven days attacks of excruciating headache, coryza and excessive lachrymation. There was no sneezing; the whole interior of the nose was excessively sensitive and the patient was unable to open his eyes in bright light. The first attack occurred in March, 1888, just after he had apprenticed himself to a photographer; the second attack eight or nine months later, after which the intervals decreased in length down to once a month and finally once in six or seven days. This condition I completely relieved by cauterizing the interior of the nose with dilute chromic acid 20 grains to the ounce. I cauterized especially the surface of the middle turbinated bone and sensitive spots which I found on the septum. This condition, however, returned after a few years, and from time to time since, relief being gained by a similar line of treatment until four months ago, when I removed the right middle turbinated, which was followed by a complete disappearance of the symptoms until a couple of days before the writing of this paper, when he returned with an attack confined to the right side: that is, only the right eye and right nasal fossa were affected. This attack followed the general house-cleaning and sweeping of his photographic studio. I have always felt that his attacks were caused by some chemical which he used in his work.

It is, however, very different from the paroxysmal sneezing, hay fever and other reflexes produced by external irritants.

When asthma is produced reflexly in nasal trouble, it occurs in one of two forms: The first form is acute in character. It is seen as a sudden attack of dyspnoea which may last from a few hours to two or three days. In the intervals between the attacks, all obstruction to breathing disappears. Patients who have been the victims of "sneezing-catarrh" and hay fever often develop this condition.

In the chronic form of the asthmatic attacks, the patient has more or less difficulty in breathing which is increased at night, and in which you hear, as well as in the acute form, snoring and whistling sounds in the chest. This is often diagnosed as chronic bronchial asthma, but it is not, for it disappears quickly after a change of climate, or after removal of the cause; such rapid disappearance of the physical signs would not occur in true bronchitis.

Although bronchial asthma is sometimes due to nasal trouble, we frequently have asthma associated with nasal trouble where there is no etiological relation between the nasal and bronchial conditions; in such cases, the removal of the nasal trouble makes the asthmatic more comfortable, for it is a great relief even in asthmatic attacks to have the nasal passage free. When asthma is due to internasal conditions painting of the nasal mucous membrane with a solution of hydrochlorate of cocaine will generally relieve the asthmatic attack. No asthmatic should be treated for a nasal complication without excluding all serious causes of asthma, such as diseases of the kidneys, however much trouble there may be in the nose. In this connection I wish to speak briefly of a case of asthma in the wife of a prominent dentist whom I treated many years ago. She had sufficient trouble in both nasal fossae to produce any amount of reflex disturbance; both were filled with polypi. The application of but a small amount of cocaine to her nose during the first call had a decidedly bad effect on the action of her heart. I sent her at once to an internist, their family physician, who found that she was suffering from Bright's disease, of which she died in less than a month's time.

There are such a variety of possible causes for vertigo that a thorough examination of the patient should be made before a case is considered due to any internasal lesion. The following case, however, which recently came to my notice seems to be one of this sort:

Mr. R——, 21 years of age, about a year ago consulted an internist for nausea, headache and eye strain. After washing out and examining the contents of the stomach he referred



him to an ophthalmologist who failed to give any relief by correction of the refractive error. The case was then referred to me for nasal examination. I found both middle turbinated bones enlarged and pressing upon the septum. I removed both middle turbinated bones and the patient has remained free from his symptoms since the operation several months ago.

During the discussion of this subject in 1907, Dr. Frederick Cobb mentioned a series of cases in which a large, long middle turbinated bone seemed to be the cause of progressive deafness. I saw in 1908 a lady who complained of deafness, tinnitus and otalgia. She was relieved of these symptoms by the removal of a long turbinated bone which contained a large anterior cell. A few such cases have come under my observation.

Among about three hundred cases of large middle turbinated bones which I have treated during the last six years, frontal headache and eye strain have occurred most frequently. The second in frequency were cases of paroxysmal sneezing. (I do not include among these cases of true hay-fever.)

The third in order of frequency are the cases of acute frontal sinus and ethmoid trouble. Many of the middle turbinated bones have more or less hypertrophy of their mucous covering. Many of them contain one or more cells, and when they are large, they do not necessarily touch the septum in order to produce reflex disturbance. All of the offending turbinateds seem to be simply a latent state preceding one or the other of the two forms of ethmoiditis, i. e., the suppurative form, or that form accompanied by nasal polypi.

The shape of the turbinated seems to cause the flow of pus from the anterior nasal cells into the antrum. And most cases of antrum trouble not originating from decayed teeth are, in my opinion, the sequel of acute frontal or ethmoid trouble. All or any of the symptoms enumerated should direct our attention to this region and encourage the early removal of anything preventing drainage and ventilation of the hiatus.

Many of these conditions are associated with deflections of the upper portion of the nasal septum, which may need correction either before or after the removal of the middle turbinate.

The upper part of the septum may be deflected independently of the rest of it. This is a portion which is difficult to correct without going close to the roof of the nose. The advisability of such an operation will vary with the case, and in the judgment of the surgeon.

When the deflection is confined to the upper portion of the septum, I prefer to remove the turbinated first, if it can be gotten at. If it is hidden by the septum, then it is necessary to correct the septal deflection first.

Where there is a polypoid thickening of the mucous membrane it is generally sufficient to remove that without touching the bone itself. When the bone is very large or broad anteriorly, or when it contains a cell, I remove the whole of the bone with a snare. The wire used in the snare should be stiff enough to grasp the bone and not slide over it. When I fail to remove a sufficient amount of the bone in this manner I finish the operation with cutting forceps. Should polypi or pus containing cells be found, they should be removed.

Cysts or cells of the middle turbinated, unless their openings are obstructed or unless they contain pus, do not have any influence upon the symptoms through the increase of the volume of the bone in which they are situated.

In making an examination of the nose the whole of the mucous membrane should be thoroughly adrenalized and cocainized, except in the case of acute sinus trouble. The extent of the bone and the relation of the parts are made out much more easily in this manner, and while we are looking for an established sinus trouble we may find some condition the correction of which will prevent the development of sinus disease.

The middle turbinated is usually removed as a part of the examination, where we suspect suppuration of the sphenoidal or posterior ethmoidal cells, in a serious case of eye trouble, such as optic neuritis.

The removal of the middle turbinated prevents almost always a return of the acute trouble and prevents the existing attack from becoming chronic, and usually prevents the necessity of performing an external operation.

The diseased middle turbinated interferes with the nasal respiration and should receive attention before the lower turbinated and as early and as frequent as the septum. It is more in the route of the inspired air than the lower turbinated. It should be removed to relieve pressure reflexes such as eye strain, headaches, paroxysmal sneezing, and especially to ventilate and prevent the obstruction of the flow of secretion from any of the anterior set of cells.

Other symptoms, such as vertigo, cough, twitching of the eye muscles and lachrymal irritation, which are likewise due to the pressure of such turbinals, are always associated with one or the other of the two groups of reflexes, eye strain and headache, or "paroxysmal sneezing." One must not, however, attribute all these symptoms to the condition of the nasal mucous membrane alone, for many over-fed, obese and lithemic patients will not yield to any treatment until their habits are corrected. Furthermore, many neurasthenic patients have been uselessly operated upon until the interior of their nose is one continuous cicatricial surface.

We must especially be careful not to consider all the cases sent to us by ophthalmologists as necessarily due to a condition within the nose or its neighboring sinuses, for all the symptoms enumerated are likely to arise from some condition in other parts of the body. Vertigo especially has such a variety of causes that the real cause may be easily overlooked.

### *Discussion.*

Dr. Greenfield Sluder, St. Louis: Dr. Renner has described a number of clinical conditions, and you have heard them in their centering about the middle turbinate. Concerning his first classification of general asthenopia, as I construe it without ophthalmological explanation, he has referred to pressure contact from the middle turbinated body, and says that the eye symptoms have been relieved after the removal of such a turbinate. This class of cases has been of great interest to me for a long time, and I described them in 1900, in conjunction with Ewing, of St. Louis, in two papers read before the American Ophthalmological Society. In that paper, and in my present idea of the condition, I disagree with Dr. Renner in the philosophy. I consider these cases as closure of the frontal sinus, in which the middle turbin-

ate plays a part directly or indirectly, or may play no part at all. I recall the production of this clinical picture in six ways. First, the middle turbinate may be hypertrophied and occupy the space between the septum and the lateral wall, and thereby close the hiatus semilunaris, the outlet of the frontal sinus, and permit an absorption of the oxygen content of the air with negative pressure, which will bring about a low grade congestion and a degree of sensitiveness; second, the frontal sinus may be closed by the simple pushing down upon the lateral wall, happening for what reason I do not know, but nevertheless seen a certain number of times without hypertrophy. A more potent thing in the production of the picture is the tubercle of the septum, which has become thickened and pushes laterally to close both middle meati, or, deviated slightly with some thickening to one side or the other, closes very effectively by pressing the middle turbinate to the lateral wall.

Another classification is with an absolutely normal nose, the turbinate swinging over, but in which experience has seemed to justify removal because of the tender point on the orbit, the point at which the superior oblique is attached, with the unending difficulty in the use of the eyes, asthenopia, which makes the patient almost helpless. Such turbinates when removed reveal the bulla of the ethmoid approximated to the uncinate process. The same condition arises from an acute coryza, and can close the outlet by a soft swelling. Such a condition may exist for a long time after the coryza and may be relieved by a simple treatment for a few days continuously.

I take the view that these are vacuum headaches, and are not produced by contact or pressure within the nose, for many times I have left the pressure which existed and opened the anterior district, to let air into the frontal sinus, and relieved the condition. The tenderness of the upper angle of the orbit disappears, and the eyes become relieved. I thought I was original in the idea of a vacuum headache, and published my paper stating such an opinion, but last year I found that Dr. MacBride, of Edinburgh, in 1884 mentions a possible vacuum headache, although in no wise connected with these clinical issues.

Dr. J. Price-Brown, Toronto: In connection with Dr. Renner's paper I want to report one case of intense facial neuralgia in a lady thirty years of age, the pain extending up the side of the nose, around the temporal bone and down the cheek bone over the antrum. The pain was almost continuous, and the relief given by medicine was nil. Under observation, all I could find in examining the nose was pressure from the middle turbinate, which, however, seemed normal in size, against the

upper portion of the septum. I anesthetized her and removed the middle turbinate, with complete relief of all headache.

Dr. Charles W. Richardson, Washington, D. C.: There are a few points in this interesting paper that I want to take a slight exception to, particularly in reference to those cases in which the asthmatic and the paroxysmal sneezing is supposed to be produced by hypertrophy of the turbinate. There is no doubt in many cases of this character that we do find the turbinate more or less congested from time to time, and tender upon pressure, but that condition is only transitory, although it may be of perennial type. In many of these cases we find constitutional disturbances are responsible for the local condition in the nasal chambers, and a proper appreciation of this relationship will often save a great deal of surgery about this region and give more proper and rational relief to the patient. Personal sensations are worth a great deal in all of this kind of work, and one who has had this perennial type of disturbance and who can connect so closely a transitory obstruction of the nose, the sneezing, cough and asthma, with some general exciting cause, can realize how important the general conditions are in causing these disturbances. I think if we would look a little outside of our nasal chambers for the causes we would do less internal surgical work in this type of cases and give greater satisfaction to our patients and to ourselves.

Dr. Emil Mayer, New York City: Indorsing entirely what Dr. Richardson has just said, I recall an instance of a man who had periodic headaches, suffering very intensely from an enlarged middle turbinate, and the removal of this relieved him somewhat, but a closer investigation showed that the headache was of an exactly periodic nature. He would get up in the morning and feel comfortable, but usually at eleven o'clock on a given day he would get his headache, which would be so severe as to compel him to give up work. It occurred with such certain regularity that it showed itself to be malarial in origin, and a couple of doses of ergot associated with quinine cured him completely.

Dr. W. L. Ballenger, Chicago: I want to confirm in large measure the general trend of the statements made in the paper. I have had the opportunity in the last few years of examining about 200 cases sent to me by one doctor, a man engaged in the fitting of glasses, cases in which he was unable to give satisfactory glasses for the relief of the asthenopia. In discussing this subject he said one of the symptoms was a pocketful of glasses, since these patients usually went from doctor to doctor trying to get satisfaction from the glasses prescribed. In about

twenty-five or thirty-five of these cases sent by this physician I have had the opportunity of attempting to relieve the nasal condition causing the symptoms, and without exception have given them relief.

The lesions described by Dr. Renner agree in general with those that I have found. We have three conditions of the middle turbinate, one of thickening of the mucous membrane, hyperplastic changes in the mucous membrane of the middle turbinated body, sometimes eventuating in the polypoid condition; another, the papillomatous enlargement of the middle turbinated body, large cells in the anterior portion particularly, and then we have the enlarged bulla ethmoidalis, the overhang, the hiatus semilunaris and high deviations of the septum, etc. We also have cells in the uncinat process itself which may occlude the opening. The philosophy advanced by Dr. Sluder strikes me as a possible explanation for these cases, although I have always attributed it to contact, but as I think of it more and more it occurs to me that probably this may also be one explanation, that there is obstruction and consequent congestion, a catarrhal or suppurating infection of the frontal and anterior ethmoidal cells. I want to endorse most heartily the idea that in this region we very frequently have eye difficulties and the difficulty of getting proper vision, and it is a field in which we can easily relieve our patients, if we will give it the proper attention. I also want to emphasize the etiological relationship of this region in causing not only the acute but more particularly the chronic affections of the ethmoid, of the frontal sinus, and of the antrum of Highmore. I do not believe Dr. Renner has said that the antrum of Highmore is usually a reservoir, but I believe the same explanation can be given to the cause of antrum disease as to the ethmoidal and frontal; namely, that there is chronic obstruction to the drainage through the infundibulum, which receives the drainage from the frontal sinus in many cases and the part of the anterior ethmoidal cells, and all from the antrum of Highmore, except where there are accessory openings higher up; hence, obstruction here blocks all these three sinuses. Being a chronic obstruction there is a chronic cause of lowered vitality of the mucous membrane within these sinuses, and they are subject to infection from time to time, and hence chronic suppuration or inflammation is established.

Dr. W. E. Casselberry, Chicago: Judging from the trend of the discussion, the essayist regards infection of the antrum as usually secondary, in consequence of the antrum acting the part of a reservoir for pus from above, and ascribes the hyperplasia of the middle turbinal to the fronto-ethmoidal infection. Doubt-

less this is the order at times, but I have been impressed with the frequency of a reversed sequence—a multiple sinus infection involving the frontal which had commenced in the antrum and extended upwards, the fundamental cause of the suppuration in the antrum having been diseased teeth, especially dead and decayed roots which modern dentistry so diligently conserves to be gold crowned and elaborately built upon and then neglected. Disease of the teeth, of course, is a well known cause of antrum suppuration, but it is not so well known that commencing in the antrum it often spreads upward to the frontal sinus and that sinus infections including but not united to the antrum surely have multiplied in recent years in pace with gold crowns.

Dr. Norval H. Pierce, Chicago: Of course, we talk now of cases that show no pus and no particular polypoid hypertrophies or changes in the region of the middle turbinated body and the outer wall of the nose and septum. We are asked to pass our judgment on cases of this kind as to whether the turbinates should be removed, the frontal sinus opened or the anterior ethmoidal cells reamed out. I think if we are wrong it is a very serious question if we operate in these ways. Is it not all an hypothesis unsupported? Talking about the vacuum headaches, to my mind it has not been proved in any way that such a vacuum headache can take place in a sinus. The theory that the oxygen is absorbed from the ear by the capillaries, and that  $\text{CO}_2$  is given off originated, I believe, with Besault, who regarded the middle ear as a modified alveolus of the lung, modified to the extent that it contains the conducting apparatus for heating, but retaining its unusual ability to absorb oxygen and give off  $\text{CO}_2$ . This hypothesis was manufactured for the purpose of explaining the sinking in of the tympanic membrane in insufficient ventilation, due to closure of the Eustachian tube. As a matter of fact, while this has been generally accepted, it has not been altogether universally accepted. There are other explanations—for instance, that the  $\text{CO}_2$  gas acts on the tensor tympani muscle, causing it to contract and drawing in the tympanic membrane. Or, as in other cases, they regard this sinking in of the tympanic membrane as due to some other gas operating on the muscle. It has never been proved that it is caused by a vacuum, so far as I know. This theory was applied to the sinuses to explain various pathological conditions occurring there, serous accumulations in the antrum, for instance. Now that we know this same condition occurs in the tympanic cavity, we have a serous non-bacterial exudate. We also have the same condition in the pleural cavity, and modern

pathology believes that it is usually not due to a vacuum, because the pleura is quite accustomed to a vacuum, but to the action of toxins without the presence of living micro-organisms, and probably this is what occurs in the antrum and in the membrana tympani. The whole thing seems pure hypothesis, and we should be extremely slow in building up this hypothesis, especially as these cases of eye difficulties and headache occur almost invariably in neurotics.

Dr. Frederick C. Cobb, Boston: Dr. Renner's paper has interested me very much. Cases are constantly sent to a laryngologist by the oculist to determine whether or not there is middle turbinate pressure which might affect the eyes. How is the laryngologist to decide this point? To say that the turbinate is large and in contact with the septum is unsatisfactory, for this may be the case at the moment of investigation, while an hour later the turbinate may have shrunk away, giving plenty of room. Should the operation only be done where there is marked degeneration of the turbinate as in cystic cases or should it be performed in any case of large middle turbinate which at the time of examination rests upon the septum? How much of the element of suggestion is there in these cases? The ultimate decision must rest, not with the laryngologist, but with the oculist who follows the cases through a period of years.

Dr. W. Scott Renner, Buffalo (in closing): I reported these cases because I thought the symptoms were especially due to the condition in the middle turbinated body. It is often difficult to say when it is due to the middle turbinate, but if you eliminate every other cause you have a right to suspect this. If applying cocaine relieves the pain some think it proves our case. I do not believe this. The only thing to do is to take off the bone. I do not know whether these symptoms are caused by a vacuum or not.



VINCENT'S ANGINA: ITS FREQUENCY AND THE  
IMPORTANCE OF ITS RECOGNITION—(WITH  
REPORTS OF TWO FATAL CASES.)

BY THOMAS H. HALSTED, M.D., SYRACUSE, N. Y.

Since the discovery of the cause of Vincent's Angina, there has been much difference of opinion among bacteriologists as to whether the specific organisms, the fusiform bacillus and the accompanying spirochete or spirillum, were in reality two distinct organisms living in symbiosis, or simply one, the fusiform bacillus, the spirochete or spirillum being merely evolutionary forms of the former, but always found present with the bacillus. The latter view seems to have been definitely proven by Tunnicliffe, Wright and others.

This bacillus, producing a pseudo-membranous ulceration of the throat and mouth, is not limited in its field of activity, however, to these parts. While it is the infective organism in Vincent's Angina, and in noma, it has also been found as the specific cause of reported cases of laryngitis, bronchitis, bronchopneumonia, pneumonia, and mastoiditis. It causes hospital gangrene, and has been found as the etiological factor in phagedenic ulcers of the penis and genitalia, in abscesses of the lung and spleen, and in a case recently reported by Tunnicliffe,<sup>1</sup> the fusiform bacillus was the pathogenic agent throughout in a case of general pyaemia, with multiple abscesses in various parts and organs of the body, following an appendicitis. It is quite apparent, therefore, that Vincent's Angina is merely the local manifestation in the upper respiratory tract of the pathogenic activity of a specific organism which is frequently active in all parts of the body.

The fusiform bacillus, as well as the spirochete form, is anaerobic, but occurs in association nearly always with aerobic bacteria—the streptococcus, staphylococcus, pneumococcus, bacil-

<sup>1</sup>Tunnicliffe.—*Jour. Infectious Dis.*, January, 1912.

lus of diphtheria, and other pathogenic or non-pathogenic organisms. Like the other organisms with which it is found associated, it occurs in healthy mouths, but perhaps more particularly in mouths and throats in which there is some unhealthy condition, such as diseased tonsils, decaying teeth, and inflamed gums. Its habitat is especially about and around bad, unclean teeth. It rarely produces disease when the tonsils, teeth and mucous membranes are in a normal condition, but occurs secondarily to some pre-existing pathological condition of these parts, or when the individual's general health is such that his resistance is greatly lowered.

The typical lesion produced on a mucous membrane by the fusiform bacillus when it causes disease is a pseudo-membranous ulceration. A pseudo-membrane in the throat is produced not only by the fusiform bacillus, but by the diphtheria bacillus, the streptococcus, staphylococcus, pneumococcus micrococcus catarrhalis, bacillus coli, and other organisms, and in nearly every pseudo-membranous inflammation there are two or more of these organisms present—a mixed infection being nearly always the rule. Consequently we have Vincent's Angina present with diphtheria, in scarlet fever, in measles, or with syphilitic lesions of the throat, or with other non-diphtheritic pseudo-membranous inflammations produced by the streptococcus, the staphylococcus, or other organisms. In the majority of such cases of mixed infection the organisms of Vincent's Angina, while they might be the predominating ones, and the actual cause of the disease, are usually entirely overlooked, because they do not grow on the ordinary culture media used in examination for the pathogenic organisms. They are discovered only by direct examination of the smear made from the swab or curettage of the ulcer or membrane. In other words, to discover which of these various pseudo-membrane producing germs is the predominating one and the cause of the disease, it is necessary to examine the smear from the swab, as well as the culture—otherwise Vincent's Angina will be entirely overlooked by the bacteriologist. The usual method of bacteriological examination for suspected diphtheria in American municipal laboratories is to examine the culture

only, not the smear. Hence the reported rarity of Vincent's Angina.

Errors in the diagnosis are constantly made by competent physicians, the error consisting in mistaking Vincent's Angina for diphtheria, or in mistaking an ulceration of Vincent's Angina for a mucous patch, a gummatous ulceration, or even a chancre of the tonsil. A third error that is frequently made is in not recognizing the deep and sometimes gangrenous ulcerations of the tonsil and mouth that occur in the late stages of scarlet fever and diphtheria, as due to the fusiform bacillus of Vincent's Angina rather than to the streptococcus or the Klebs-Loeffler bacillus of the original disease.

Vincent's Angina has been regarded as a comparatively rare disease, as compared with other pseudo-membranous inflammations of the throat. Rolleston<sup>2</sup> says that of 18,187 cases of suspected diphtheria admitted to the Metropolitan Asylums Board Hospital (London) during the years 1905-7, 3,047 were proven, after admission, not to be diphtheria. Of these latter non-diphtheritic cases ninety-five only were Vincent's Angina; i. e., this disease was present in but 0.5% of all forms of membranous anginas, and in but 3.1% of the non-diphtheritic anginas. At the Grove Hospital (Contagious Diseases) Vincent's Angina was present in 0.9% of all membranous anginas and in 4.9% of the non-diphtheritic cases. Vincent found it present in 2.2% of all cases, while A. Meyer, out of 15,000 cases of ear and throat diseases at Heymann's Clinic in Berlin, saw but thirty cases. On the other hand, Lublowitz found the organism in six out of thirty-eight cases of ulcerative stomatitis, Beitzke in five out of fifty-eight cases of suspected diphtheria, while Rodella found the organisms in about one-third of the pseudo-membranous anginas which he examined. Of the last 2,500 cases of all kinds of ear, nose and throat diseases, seen in private practice by the writer, twenty, or one in 125, have been cases of Vincent's Angina, the diagnosis being confirmed by bacteriological (smear) examination, and of these cases the majority have been of the type in which the lesion resembles syphilis rather than diphtheria.

<sup>2</sup>Rolleston.—Br. Jour. Children Dis. Vol. VII. 1910.

That the type of Vincent's Angina, resembling diphtheria clinically, is altogether more common than the foregoing statistics would indicate, seems to be shown by statistics from the Michigan State Board of Health Bacteriological Laboratory. Dr. M. L. Holm<sup>3</sup>, their bacteriologist, reports that in 1909-10, out of 687 swabs sent in by physicians for examination for suspected diphtheria, 242 cases, or 28%, were proven bacteriologically to be diphtheria, and 178, or 25%, were proven to be Vincent's Angina. Diphtheria was absent in 445 cases. Of these latter, non-diphtheritic anginas, 178, or 40%, were shown to be Vincent's Angina bacteriologically; i. e., in this number the fusiform bacilli with the spirilla were the predominating organisms, the other organisms, in the order of their predominance, being the staphylococcus, the streptococcus and the pneumococcus. Of the 687 swabs sent in for examination a positive clinical diagnosis of diphtheria had been made in 224 cases, but the bacteriological examination proved the presence of diphtheria in but 120 of these cases, or in 53%, the clinical diagnosis was correct, 47% incorrect. Forty-six, or 20%, of these clinically diagnosed diphtheria cases were proven to be Vincent's Angina; i. e., of each five cases diagnosed clinically as diphtheria, one of them was Vincent's Angina. Other species of organisms were always found associated with the fusiform bacillus, but in all these cases it was the organism found to predominate. In all these cases examinations were made directly from the swab on smears, and from the swab on cultures, the fusiform bacillus being found only in the smears, never in the cultures, as they do not grow on the ordinary diphtheria culture media. This latter fact accounts for their being so often overlooked.

There are two distinct clinical types of the disease. In the first type, the disease is to be differentiated from diphtheria and other non-diphtheritic pseudo-membranous anginas. The local symptoms are much more severe than the constitutional. There is much pain in swallowing, with a pronounced fetor to the breath. The temperature is normal or slightly elevated. On examination there is a pseudo-membrane covering an ul-

<sup>3</sup>Holm.—Quarterly Bulletin North West Med. Sch., December, 1909.

ceration of one or both tonsils, it may extend up the pillar to the uvula and cover the soft palate. The membrane quickly re-forms. As a rule there is an accompanying membranous stomatitis, especially of the alveolus. The membrane is grayish, or yellowish gray in color, more friable than that of diphtheria, perhaps, but is often entirely indistinguishable to the eye from that of diphtheria. Oedema of the soft palate and uvula is often present. There is a marked tendency to necrosis and destruction of parts as, for instance, the tonsils and uvula, and unlike diphtheria, cicatrization is likely to follow healing. The writer had one such case where the uvula was completely destroyed, a deforming cicatrization of the velum palati following. The pseudomembrane continues for from a few days to several weeks, the average being in thirty-two cases reported by Rolleston eighteen days. Dr. Woody, of the Philadelphia Hospital for Contagious Diseases, says that Vincent's Angina is especially severe as a secondary affection, following diphtheria, scarlet fever and especially measles. He says, as reported in an excellent article by E. H. Place<sup>4</sup>: "The disease in secondary cases is characterized by little elevation of temperature, but with rapid, feeble pulse, profound prostration, excited nervous system, irritability, wakefulness, tremor and frequently in later stages with the Hippocratic facies and death in a brief period from toxæmia or exhaustion. The odor is characteristic, with salivation, and moderate cervical entumescence, and the spongy, friable and readily bleeding gums are almost invariably present, in some cases simulating scurvy. In severe cases necrosis is very rapid, tissues melting away, destroying large areas in an incredibly short time." Such cases, I am sure, every practitioner of many years' experience has certainly seen duplicated in the scarlet fever and late diphtherias. Had such cases been examined bacteriologically they would have been discovered to be Vincent's Angina, secondary to the scarlet fever and diphtheria. That is to say, these deep necrosing ulcerations were not due to the streptococcus and the staphylococcus which was present in the scarlet fever, but to the fusiform bacillus and the spirochetes.

During the past winter the writer saw in consultation the fol-

---

<sup>4</sup>Place.—Boston Med. and Surg. Jour., November 9, 1911.

lowing case, which closely resembled diphtheria, and terminated fatally:

Mrs. H——, age 41, pregnant 8 mos. Her physician, Dr. Chase, of East Syracuse, was called to see her first on January 2, 1912, for what appeared to be bleeding hemorrhoids. No examination was made, but there was a bloody discharge from the rectum. An adrenalin suppository was prescribed and the bleeding soon ceased. He did not see the patient again for two weeks, when he was called because of a supposed quinsy, of which she was subject to recurrent attacks. There was much pain in swallowing and also tenderness at the angle of the jaw. The neck was swollen on both sides. Temp. 101 degrees Fahrenheit. In a few days the quinsy ruptured spontaneously, the discharge being very profuse and accompanied by an unusually foul odor. On February 9 Dr. Chase called me in consultation. The patient was very weak, semi-conscious, difficult to arouse, pulse rapid, skin of a peculiar saffron color; she could hardly speak or swallow, and was suffering from some dyspnoea, due in part to her eight months' pregnancy. The odor of the breath was very fetid and offensive—temperature normal. On examination with reflected light a thick, grayish-yellow membrane completely covered the tonsils, soft palate and uvula, the buccal mucous membrane on both sides, around the margins of the teeth and gums and inside the lips. A more extensive pseudo-membrane I had never seen. There was a pseudo-membrane in the vagina, which disappeared a week later. I gave it as my opinion that the disease was diphtheria, remarking, however, on the possibility of it being Vincent's Angina. A culture was made. Antitoxin was advised, and later in the day it was given by Dr. Chase. The City Laboratory reported next morning that the culture was negative. On the following day Dr. Chase made another culture, and on my suggestion a swab for smear for Vincent's Angina. Both were reported negative. Cultures were made on the two following days, all reported negative for diphtheria. On the fourth day after my first consultation I saw the patient for the second time, taking with me Dr. Waldorf, pathological interne at the Women's and Children's Hospital. The patient was in practically the same condition as on the previous visit. I curetted gently the mucous membrane under the edge of the pseudo-membrane, making several smears, which were later in the day examined by Drs. Groat and Waldorf, who found that the fusiform bacilli and spirochetes of Vincent's Angina were the predominating organisms, and were present in large numbers. A

positive diagnosis of Vincent's Angina was made. The patient had received 28,000 units antitoxin and 40 cc. anti-streptococcic serum—without local effect on the membrane—though she always felt better after the injections. Locally tr. iodine was applied, the mouth cleansed with a boric acid solution and orthoform tablets to relieve pain were used—all without appreciable effect. Strychnine and other tonic treatment were given throughout. I did not see the patient after my second visit on February 12, 1912, but Dr. Chase reports that on several occasions the membrane nearly disappeared, only to recur, that the odor became steadily more offensive, and her general condition weaker, with increasing difficulty in taking nourishment. On March 2, about six weeks after her first throat symptoms, labor began, and fifteen minutes later, as the head reached the perineum, she suddenly collapsed and died before delivery could be accomplished. The prominent symptoms were the general toxic condition of the patient, which was very great; extreme prostration, foul fetid odor, peculiar saffron color and greenish cast of the skin, together with the great pain in swallowing, interfering with nourishment and sleep; the extensive pseudo-membrane covering the mucous membrane of mouth, tongue, throat, and its rapid reformation after removal.

In the second type of Vincent's Angina a purely local and quite limited ulcer or ulceration simulating very closely the throat lesions of syphilis is present. The ulcers, covered with a pseudo-membrane, may be single or multiple, superficial or deep, resembling either the mucous patch or the tertiary ulcer, and occur most commonly on the tonsil, one or both. The writer had a case in which the ulcer resembled the primary lesion of syphilis. In one case there were ulcerations on the post pharyngeal wall and in the larynx. Necrosis followed by cicatrization occurs. The glands are likely to be tender and swollen. Pain is generally quite marked, and the breath is bad. The general health may not be much impaired. A history of previous similar attacks is often obtained. A positive diagnosis can be made only by a bacteriological examination of the smear, although the clinical diagnosis in this type of the disease is similar to the type resembling diphtheria. There was in many of the cases a similar ulceration along the posterior alveolar borders, along the edges of the teeth, some of which were usually decayed, the cavities filled with a foul, thick mass of cheesy pus. In one case improvement of the

tonsillar ulceration only took place after the teeth and the alveolar ulcerations were thoroughly cleansed and treated, and some of the teeth extracted. This class of cases does not resemble diphtheria, but the diagnosis is to be made from syphilis, secondary or tertiary. Unless one is careful an error in diagnosis will be made if one rely too much on a history of syphilis in the individual, because Vincent's Angina may occur in a syphilitic. Indeed, a differential diagnosis may even have to be made from a chancre, as, for instance, a chancre of a tonsil which is usually accompanied with great swelling and induration of the cervical gland. In these mild cases simulating syphilis, recurrence is, in the writer's limited experience, a very marked characteristic. A cicatrix or scar in the soft palate or throat is no more presumptive evidence of previous syphilitic diseases than it is of previous Vincent's Angina.

As to age and sex.—These cases apparently occur equally in both sexes and at all ages. Most frequently, perhaps, under eighteen years of age, in the type most closely resembling diphtheria; whereas in the other type where local ulcerations resembling syphilis are seen, the age is rather that of adult life.

There does not appear to be any question but that the disease is contagious, although perhaps mildly so. Several epidemics occurring in institutions have been reported. The disease is usually conveyed through drinking utensils, the common use of a pipe, and possibly through surgical or dental instruments.

The previous life of the patient has doubtless a bearing on the development of the disease. An impairment of the general health predisposes one who is harboring the disease bacilli in the mouth to local infection. The presence of decaying teeth and a general oral sepsis or diseased tonsils would predispose to attack.

There is every reason to believe that fatalities are not so rare as reports of cases might indicate. That the disease has been almost entirely overlooked in differentiating it from diphtheria has been pretty conclusively proven by Holm, as referred to earlier in this paper. Without doubt many of the fatalities due to so-called membranous croup or pseudo-diphtheritic laryngitis in children, in whom the Klebs-Loeffler bacillus was not discovered, were caused



by Vincent's Angina involving the larynx. In other words, the fusiform bacillus must be considered in a differential diagnosis of membranous croup or laryngitis. Vincent's Angina of the tonsils is usually not a grave disease, but the same disease invading the larynx, causing a false membrane, becomes immediately a menace to life, particularly in young children. In such a case it is interesting to note that Watson Williams, in his book on "Diseases of the Respiratory Tract," published eleven years ago, shows a cast of the trachea and bronchus expectorated by a child at the Bristol Infirmary, in which Klebs-Loeffler bacilli were absent, but the Vincent's organism, spirillae and spirochetes were present and were the cause of the false membrane. Rothwell<sup>5</sup> has reported several cases of bronchitis in which the infective organism was the fusiform bacillus. Among other causes of fatalities in this disease have been three deaths reported by Bruce, one due to toxic absorption from the local lesion and two to suppurative broncho-pneumonia following laryngeal involvement. Pneumonia was the cause of death in DeCarli's case. In Gilberti's case osteo-myelitis of the lower jaw following an ulcero-membranous stomatitis and angina caused death. Meyer reports a case of pernicious anaemia, disposing to an infection of Vincent's Angina, and terminating fatally. The writer has recently seen a case somewhat similar to this last, also terminating fatally, and reports it briefly as follows:

Miss —, single, age 33, domestic, was admitted to the medical service of St. Joseph's Hospital on August 30, 1911. Two days before admission had a fainting spell. She was very weak, semi-conscious, hard to arouse into conversation, complained of being very tired and wanting to sleep, no appetite, and with a great deal of aching of the bones. Heart and lungs were normal, liver and spleen normal. Tongue dry, red and glazed, gums and mucous surfaces of the lips covered with a thin pseudo-membranous exudate. Teeth poor and dirty. Skin dry and of a lemon yellow color. Peculiar odor about the body. Blood examination, hemoglobin 60 plus. Color index .75, erythrocytes 3,420,000, leucocytes 4,200. Urine pale, spec. grav. 1020 acid, no albumen, no sugar. Respiration 18, pulse 66, temperature 98 F. She gave a history of

<sup>5</sup>Rothwell.—*Jour. Am. Med. Ass'n.* Vol. LIV. 1910.

not menstruating for ten years, i. e., since twenty-three years old, but of attacks of epistaxis every month or two. Moro test negative. There was a history of syphilis dating back ten years. During the first eight days after admission the patient was restless, more or less listless, without appetite, refusing food some of the time, sleeping a great deal and complaining much of difficulty in swallowing. Temperature varied from 98 F. to 98.4 F. Pulse from 66 to 100, and respiration about 22. She was given strychnia, peptomangan and Baer's Sedative. She went on in this condition, steadily growing weaker and losing weight, with involuntary stools, no appetite, finally taking no nourishment whatever. On September, 11, thirteen days after admission, I was asked to see her because of the difficulty in swallowing, foul odor of the breath and ulceration of the gums. I found her greatly emaciated, anaemic, skin dry and lemon tint, difficult to arouse, breath very fetid. Resisted all efforts to use a tongue depressor or open the mouth, complaining of great pain. On examination there was very extensive stomatitis, involving the alveolar and buccal mucous membranes, which were swollen and covered with a dirty yellowish gray friable pseudo-membrane; the gums about the dental margins swollen and bled easily; tongue covered with yellowish exudate. Unable to get satisfactory view of the tonsils or pharynx; submaxillary glands enlarged. Making a tentative diagnosis of Vincent's Angina, prescribed orthoform powder for relief of pain, tincture iodine locally, and a wash of permanganate of potassium. A smear was made at the same time, from a gentle curetting of the alveolar pseudo-membrane, and submitted to Dr. Meader for examination. His report was positive for the fusiform bacillus and spirilla of the Vincent's Angina. A blood examination was also made and showed hemoglobin 60 plus, color index 1.2, erythrocytes 2,624,000, leucocytes 6,800. The patient continued to grow weaker, became delirious and died two days later. An autopsy by Dr. Weiskotten showed a chronic interstitial nephritis, arterio-sclerosis of abdominal and thoracic aorta, arterio-sclerotic endocarditis of the mitral valve, a bilateral chronic salpingitis, oedema of the brain, ulceration of the mouth, larynx, trachea and esophagus without lesions. Bacteriological examination from smears from ulcers in mouth made before death was fusiform bacillus and spirochetes of Vincent's Angina.

Treatment is satisfactory in the mild cases, most unsatisfactory in the serious ones accompanied by toxæmia, prostration and mechanical obstruction to breathing. In the mild cases, those in

which the ulcer resembles syphilitic lesions, the writer has derived best results from the use of trichloracetic acid. The membrane is first removed by peroxide of hydrogen and wiping off with cotton swab. A 10 per cent. solution of cocaine anesthetizes the ulcer, after which in a few minutes trichloracetic acid is applied. Three or four applications, at intervals of two or three days, are sufficient—sometimes but one. Tincture of iodine, in the writer's experience, is not so efficacious as the trichloracetic acid, but in an extensive ulceration involving much surface it would be preferable. Orthoform relieves the pain. The teeth must be cared for, and no progress will be made so long as carious teeth and ulcerations around them remain. The general condition of the patient must be improved. In the more serious cases, such as the two reported in this paper, local treatment is not satisfactory. It is hoped that a specific antitoxin may yet be produced, or possibly salvarsan might be efficacious against this spirochete, as it is against that of syphilis, and the writer intends employing it in the next serious case unless something better is found.

#### *Discussion.*

Dr. Greenfield Sluder, St. Louis: I have been listening carefully to see if Dr. Halsted would mention the anilin dyes or if any of the gentlemen discussing this paper would refer to their use, for the reason that they might assign the credit of this therapeutic measure to whom it may belong. It is not original with me at all events. I have never seen the fatal cases that the writer has described. I have seen the stubborn ulcerative cases about the mouth and gums lasting months clear up with marvelous rapidity and without discomfort under applications of methylene blue, either a saturated solution in alcohol or in powder, and not having methylene blue on one occasion I used methyl violet with equally satisfactory results.

Dr. C. G. Coakley, New York City: I think we are indebted to Dr. Halstead for this excellent presentation. The pseudo-membranous forms I do not know, the reason being that I have seen almost no cases of diphtheria, possibly one a year, and comparatively few of acute affections, these being treated more by the general practitioner. With the deep ulcerative type of Vincent's I am perfectly familiar, and know how stubborn some of these are to treatment. Within a month we lost a case at Bellevue Hospital, a stout woman, who gave a history of ulcera-

tion in the tonsil supposedly a peritonsillar abscess, which was opened without finding pus. There was a gangrenous inflammation of the tonsil extending over the velum with a destructive ulceration of the whole velum on the left side and uvula, and extending down into the pharynx, with beginning edema of the arytenoids but not of the larynx. When she came to the hospital the diagnosis lay between gumma, noma or Vincent's. I suggested that to save time we give her an injection of Salvarsan; this was done and immediately a smear taken and Vincent's found. No attempt at cleanliness could be made. The process extended, edema of the larynx developed six days later, tracheotomy was done, and the patient died of septic pneumonia.

I have under treatment a case where there is most extensive ulceration of the tongue near the anterior portion, and a second ulceration at the posterior portion which had the clinical appearances of gumma or tuberculosis, but examination showed neither to exist. Wassermann was negative, the same as in the first case reported. The Vincent bacillus was found and the patient is getting along very nicely. I find the greatest difficulty in getting the deep ulcerative processes to heal until all superficial slough is curetted away. The applications of 50 per cent chromic acid do not seem to go deep enough into the tissue to reach the healthy part, and the quickest way to start this to surface, although it bleeds very freely. Not until we get rid of the necrosed tissue in which the bacilli lie can we expect satisfactory results. Some apparently heal only to suddenly break down again.

Dr. E. Fletcher Ingals, Chicago: I have not had a great deal of experience with Vincent's angina, but with three or four cases during the last year I found, as the author has stated, that nitrate of silver and carbolic acid did not seem effective in checking the ulceration or in stopping the disease, besides they were quite disagreeable. None of the patients died, but the cases were all tedious. I was at a meeting of the Southern Section of the Laryngological, Rhinological and Otological Association in New Orleans in February and heard one of the gentlemen make the statement that treatment by formalin was most satisfactory. I think he said that he used it as strong as the patient could bear (probably 1 to 2 per cent), and that all cases would heal in two or three days. I have not had an opportunity to try it, but his statement was very positive and he seemed reliable.

Dr. B. R. Shurly, Detroit: The fact that those of us who are so familiar with different lesions in the throat should be often puzzled over the early diagnosis of this condition perhaps

explains why so many of these cases go by the general practitioner so far as the diagnosis is concerned. The majority of them are unrecognized bacteriologically as Dr. Halsted has brought out, from the fact that almost all differentiations in diagnosis of pseudomembranous conditions made by the general practitioner are the differentiations by culture, and not by examination of the swab smear directly. It seems to me that is a special point which will be of great value, even beyond all others, to have it thoroughly understood that this is a diagnosis by swab and not by culture, and this method may also apply to the Klebs-Loeffler bacillus. We can often make a direct swab examination and absolutely determine the earliest diagnosis of the diphtheritic condition by way of differentiation and gain at least twelve to twenty-four hours in the treatment of our case. The unusual soreness of the throat is perhaps one of the remarkably characteristic things of this pseudomembranous form, and its persistence and the difficulty of handling it by the ordinary methods of treatment is also prominent. I would like to ask if Dr. Halsted has used vaccines for any of these cases after they have run a course? It seems to me as though these should be of value.

Dr. Henry L. Swain, New Haven: It has been evident to those of us who follow the history of Vincent's angina that in general the fusiform bacillus is an organism of low resistance, and a great many remedies are proposed, all giving good results. I myself have been guilty of recommending zinc chloride. In one of my first cases, having no other suitable solution at hand, I used 10 per cent zinc chloride; the patient got well with remarkable ease and quickness and I have used the remedy ever since with most satisfactory results. Some of the deep-seated cases, as Dr. Coakley has said, need to be cleared out and the solution applied in a thorough manner, but usually the case gets well, I having had but one exception, which I have reported fully in another place.

Last Winter in New York I heard a most interesting paper concerning an epidemic taking place in a children's hospital, which was interesting in showing how under proper circumstances the bacillus is transferred from one to another, and in conversation with the author afterwards I came to the conclusion that the common drinking cup was the cause here. Generally these cases come up sporadically, and it was most interesting to hear this paper, which spoke of fifty or sixty cases.

Dr. C. F. Theisen, Albany: I would like to add a fatal case of Vincent's angina to those reported by Dr. Halsted and Dr.

Coakley. The patient was brought into the hospital in a semi-conscious condition and had developed the worst necrotic type with pseudomembranous condition on both tonsils, soft palate and posterior wall. The odor was so bad that you could hardly remain in the room more than a few minutes. There was great difficulty in examining him due to the difficulty in separating the jaws, and, as I said, he was in a semi-conscious condition. An interesting complication was what occurred just before his death; *i. e.*, multiple hemorrhages from the mucous membranes of mouth and rectum, and under the skin. We gave him normal horse serum in large quantities without effect. In this case, too, the typical fusiform bacillus and the spirillum of Vincent were obtained in smears from the swab, but not from culture, and that has also been my experience in other cases. The mistakes in diagnosis are made in early and simple cases of Vincent's angina that often originate in a carious last molar tooth. I recall a case I saw many years ago which later fell into the hands of Dr. Emil Mayer, and which I diagnosed as syphilis, putting the patient on antisyphilitic treatment. Later Dr. Mayer wrote me the true nature of the case, and ever since I have been on the lookout for such cases.

Dr. Henry L. Wagner, San Francisco: Referring to the diagnosis by the microscope, it is necessary to obtain by means of a scoop some serum from the infected area of the throat, the same as in primary luetic infections. Regarding treatment, all cases I have seen have been most stubborn; I have found that alcohol 60 to 70 per cent will do just as well as anything else, especially if one injects it into the fossa supra-tonsillaris.

Dr. Norval H. Pierce, Chicago: I wish to accentuate the point made by Dr. Wagner. It is very important not to depend upon swabs but upon curettements in our differential diagnoses, and to instruct the laboratory men not only to say whether it is Vincent's angina, but also to look for the spirillum of syphilis as well. That is really very important. We can get these germs at the base of the ulceration better than superficially. Another point regarding the treatment. Dr. Coakley suggests that he gave his people salvarsan immediately, and I think it a wise precaution. We cannot differentiate between syphilis and Vincent's angina always by inspection; it is difficult in the laboratory to differentiate it, because the two germs are frequently and possibly invariably associated. I have known of one case where extensive ulceration resulted in permanent deformity of the soft palate in a young married woman, where the Vincent's 'spirillum' was

found and the Wassermann was negative, where there had been several healthy children, where there was no history of syphilis, but which healed up immediately on anti-syphilitic treatment. Therefore, in the beginning of a process which threatens permanent destruction and deformity I believe it is best to proceed immediately with anti-syphilitic treatment, and, again, in Vincent's angina potassium iodide in large doses has a decided effect. Regarding the local treatment, as I can with a swab saturated in hydrogen peroxide; possibly the oxygen has some effect on the germ, since it is anaerobic. Next, I have used formalin solution as high as 1 to 30, limiting it to the membranous exudate.

Dr. J. M. Ingersoll, Cleveland: I have had a couple of cases in which differentiation was difficult, but scrapings from the ulceration itself helped to make the diagnosis clear where cultures did not make the diagnosis positive. I do not agree with Dr. Pierce's recommendation to give such patients anti-syphilitic treatment. It seems to me if our cultures are negative and our scrapings are negative and the Wassermann is negative, then we should treat the case as one of Vincent's angina rather than as syphilis.

Dr. Thos. H. Halsted, Syracuse (in closing): The bacteriological differences between Vincent's Angina and syphilis are so great that no error could be made in a bacteriological diagnosis.

It is important in making a smear for examination to get the smear by gently curetting under the pseudo-membrane. A swab from the surface might fail to disclose the organism, as was evidenced in one of my fatal cases reported in the paper. Dr. Shurley has suggested the probable value of vaccine therapy, and it seems to me that it may be the ultimate treatment for the disease. At present the practical difficulty exists in growing the organism on a culture medium, but I have been told that a well-known bacteriologist is now working on this and has already succeeded, or soon expects to succeed, in growing the fusiform bacillus on culture. When this is done, the therapy of the disease, in these severe cases, may offer a different outlook. The treatment of the cases which resemble syphilis in appearance, and are localized, is generally very satisfactory, but it is important to have the gums and carious teeth attended to. After using most of the local applications advised by different authors, I have had most success in the use of trichloroacetic acid, the application being preceded by cleansing the ulcer and applying a cocaine solution. In the cases with extensive pseudo-membrane resembling diphtheria, I have seen no benefit from local applications.

A case which I did not report, but referred to, is an important one. I had a patient with a small ulcer, which proved to be Vincent's Angina on one tonsil; it healed in a week. She had enlarged tonsils and adenoids and I advised removal. A month later, unfortunately, without making any further examination for Vincent's Angina, and there was no evidence, locally, of it, I removed the tonsils and adenoids, following which she had a severe sore throat with pseudo-membrane. I saw her ten days later, at which time the membrane covered the faucial surfaces where the tonsils had been and extended up the soft palate to the posterior pharyngeal wall. She could not even swallow liquids, and was very sick indeed. To make a long story short, the uvula sloughed and a cicatricial deformity of the soft palate resulted from this deep ulceration.



## THE MORPHOLOGICAL CHANGES IN THE NOSE AND FACE DUE TO THE DEVELOPMENT OF THE BRAIN.

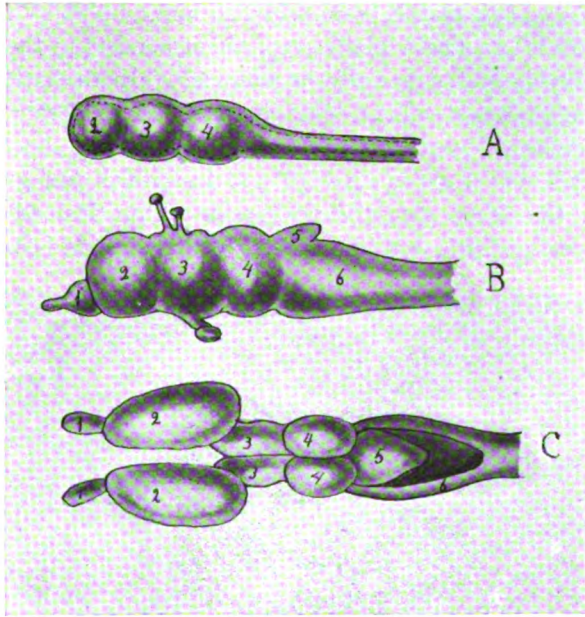
BY J. M. INGERSOLL, M.D.

The central nervous system consists of two parts, the encephalon, or brain, and the spinal cord. The first indication of the central nervous system is a longitudinal furrow, called the medullary groove, on the dorsal side of the embryo. This groove is gradually converted into a tube, by the uniting of its edges, but before the groove is entirely closed, its anterior, expanded end presents three swellings known as the primary fore-brain (prosencephalon), mid-brain (mesencephalon) and hind-brain (rhombencephalon) or the anterior, middle and posterior cerebral vesicles.

The primary fore-brain and hind-brain each divide into two parts and thus five divisions of the brain are formed. From before backward these divisions are called the telencephalon (secondary fore-brain); the diencephalon (primary fore-brain); the mesencephalon (mid-brain); the metencephalon or cerebellum; the myelencephalon or medulla oblongata. The cerebral hemispheres of the brain develop from the telencephalon and the olfactory lobes spring from the base of the cerebral hemispheres.

The peripheral part of the telencephalon is called the mantle or pallium. The relative development and differentiation of this part of the brain is closely related to the mental development of the animal and reaches its highest development in mammals, especially in man.

At first all of the vesicles lie in the same horizontal plane, but in the course of development a cerebral flexure occurs and the axis of the vesicles is bent downward so that the mid-brain forms



Figs. A, B and C.

#### DIAGRAMMATIC DRAWINGS OF THE DEVELOPMENT OF THE BRAIN IN A FISH.

Figure A represents the expanded end of the medullary groove, with its three divisions.

2. Fore-brain or anterior vesicle.
3. Mid-brain or middle vesicle.
4. Hind-brain or posterior vesicle.

Figure B shows the second stage in the development of the brain, in which the primary fore-brain and hind-brain have each divided into two parts and the olfactory lobes have formed.

1. Olfactory lobe.
2. Telencephalon or cerebrum.
3. Diencephalon, with the pineal body and the pineal eye above and the pituitary body below.
4. Mesencephalon, from which the optic lobes arise.
5. Metencephalon or cerebellum.
6. Myelencephalon or medulla oblongata.

Figure C. Dorsal view of the fully developed brain.

1. Olfactory lobes.
2. Cerebral hemispheres.
3. Diencephalon.
4. Optic lobes.
5. Cerebellum.
6. Medulla oblongata.

the apparent apex of the brain. In fish and amphibia the cerebral flexure is practically obliterated, but it persists in the higher types of vertebrates, especially in mammals. In the latter class the original relation of the different parts of the brain is still more complicated by the remarkable development of the cerebral hemispheres which grow forward and backward and gradually cover all the other parts of the brain. Thus instead of the various portions of the brain being situated one behind the

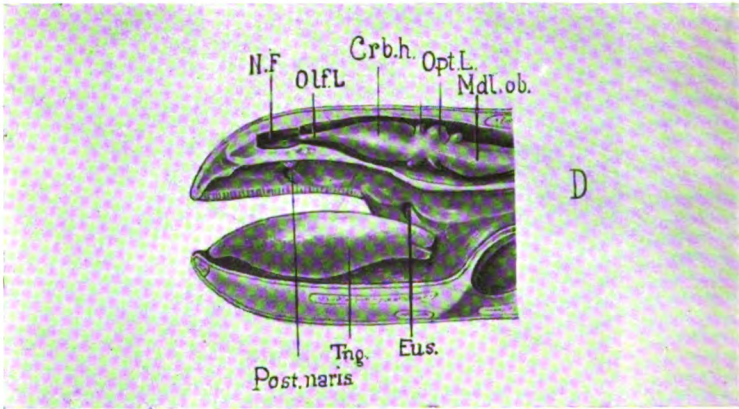


Fig. D.

#### LONGITUDINAL SECTION THROUGH A FROG'S HEAD.

N. F.—Nasal fossa, exposed by removing the septum.

Olf. L.—Olfactory lobe of the brain.

Crb. H.—Cerebral hemisphere.

Opt. L.—Optic lobe.

Mdl. Ob.—Medulla oblongata.

Post. naris.—Posterior naris, which opens into the anterior part of the oral cavity.

Tng.—Tongue.

Eus.—Pharyngeal opening of the Eustachian tube.

The different parts of the brain are all in about the same plane. The brain surface is smooth, without convolutions or sulci.

other they develop so that eventually they lie above one another. This condition attains its greatest perfection in man.

*Fish.*—In some fish the fore-brain remains undivided, but in most cases it divides and forms the two cerebral hemispheres. Each hemisphere gives off a forward prolongation which forms the olfactory lobe. In most fish the brain does not fill the cranial

cavity, but is separated from the roof of the skull by a gelatinous fluid. The pallium is a simple, epithelial structure.

The olfactory organs are sack-like structures situated well forward in the snout with one or two openings externally. The mucous membrane in the nose is always raised up in more or less complicated folds in which the olfactory nerve is distributed.

*Amphibia*.—The brain of amphibia has large cerebral hemispheres and olfactory lobes. The pallium is a little more highly

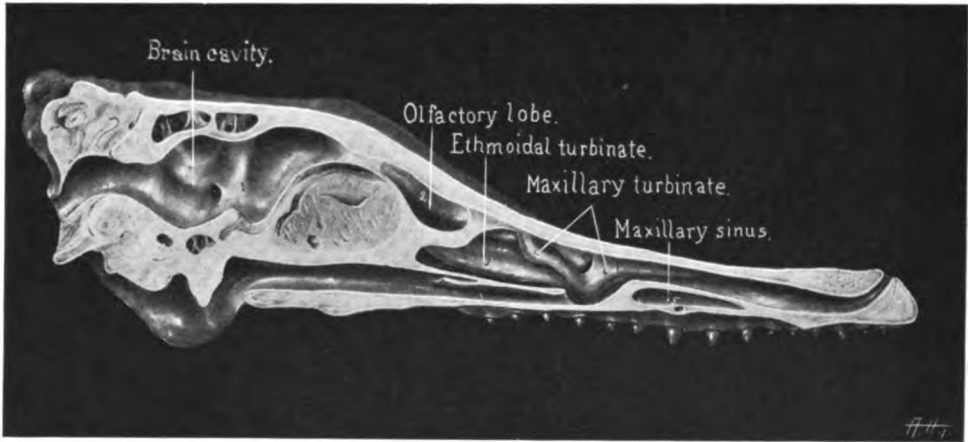


Fig. E.

LONGITUDINAL SECTION THROUGH THE HEAD OF AN ALLIGATOR.

1. Brain cavity.
2. Cavity which contains the olfactory lobe. The olfactory lobe becomes very much constricted at first as it extends forward from the cerebrum, but it expands considerably at its anterior end and divides into numerous branches which pass through the cribriform plate to the olfactory portion of the nasal fossae.
3. Ethmoidal turbinate.
4. Maxillary turbinate.
5. Maxillary sinus.

developed than it is in fish. The cerebellum is very small. The brain of the frog shows a somewhat higher degree of development than the brain of the fish. The different parts of the brain are all in about the same plane and the brain surface is smooth. The olfactory bulbs are fused in the median line. The olfactory cavities each have two openings, the external nostrils or anterior

nares and the posterior nares which open into the anterior part of the mouth.

On account of the changed method of respiration, the nasal fossae become differentiated into an olfactory and a respiratory portion. The turbinates are simple prominences on the floor and side walls of the fossae.

*Reptiles.*—The brain of reptiles is more highly organized than that of the amphibia. The brain substance shows a distinct differentiation between the gray matter or cortex, derived from the pallium, and the white medulla. The cerebral hemispheres are well developed, but the cerebellum remains comparatively small.

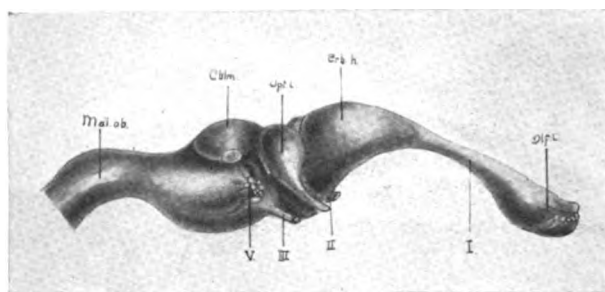


Fig. F.

#### THE BRAIN OF AN ALLIGATOR.

Olf. L.—Olfactory lobe. At its extreme anterior part, the severed ends of the olfactory nerve are shown.

Crb. H.—Cerebral hemisphere.

Opt. L.—Optic lobe.

Cblm.—Cerebellum.

Mdl. Ob.—Medulla Oblongata.

I, II, III and V.—Cranial nerves.

The whole brain shows a higher degree of development and the subdivisions are more distinctly marked than they are in the amphibia, but the brain surface does not show any convolutions.

The olfactory lobes are well developed and extend forward toward the nasal fossae. Their anterior ends are expanded to form the olfactory bulbs from which the olfactory nerves arise and are distributed in the mucous membrane of the posterior superior part (olfactory portion) of each nasal fossae.

In alligators and crocodiles the extent of the nasal fossae is much increased anteriorly by the growth forward of the facial



region and posteriorly by the formation of the hard palate which prolongs the nasal fossae backward under the brain and the base of the skull.

Each fossae is divided posteriorly into two super-imposed cavities. The superior cavity is the olfactory portion of the nose and is lined with olfactory mucous membrane. The rest of the cavity comprises the respiratory portion of the nose. The turbinates are all rather simple structures.

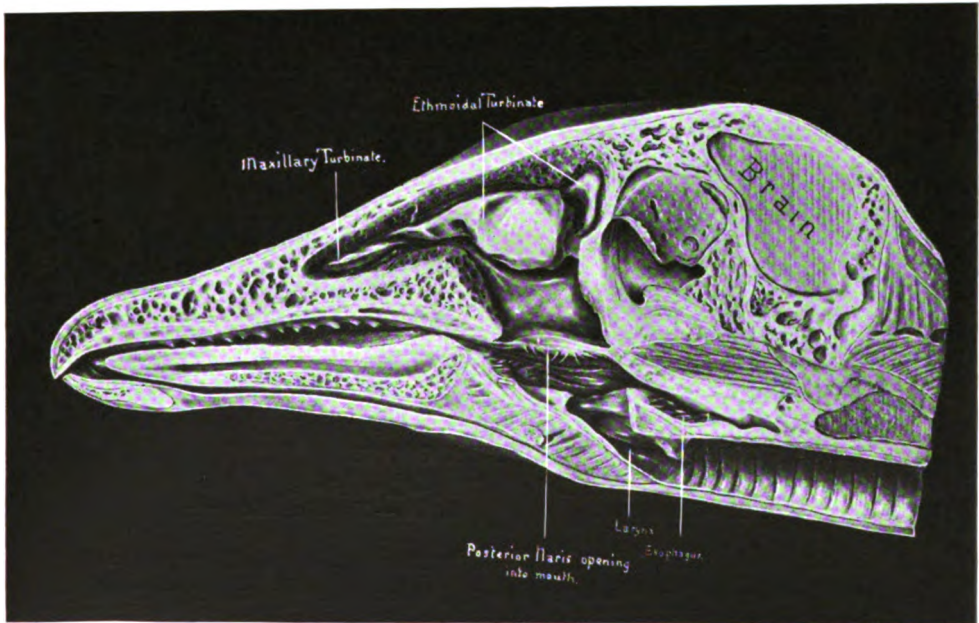


Fig. G.

#### LONGITUDINAL SECTION THROUGH THE HEAD OF A GOOSE.

The large air cells in all the bones are characteristic of the bony structure of birds, and make the skeleton lighter. The maxillary turbinate is a T-shaped structure attached to the superior lateral wall of the nasal fossa. In a longitudinal section only the median surface of the two arms of the T can be seen, and the support of this turbinate is entirely covered so that it looks like an irregular projection from the lateral wall. The external opening of the nose is at the anterior end of this turbinate. The anterior ethmoidal turbinate is a double coil. One branch coils upward and makes one complete turn; the other branch coils downward and makes two and one-half turns. The median surface of this turbinate also gives no suggestion of its complicated structure. The posterior ethmoidal turbinate is simply a ridge-like structure and contains air cells.

In fish and amphibia the nasal fossae are directly anterior to the brain and on about the same horizontal plane. The olfactory nerves extend forward from the olfactory lobes into the nasal fossae and there is practically no cerebral flexure. In reptiles the brain extends over the nasal fossae somewhat and the cerebral flexure begins to be evident.

*Birds.*—In birds the brain fills the cranial cavity and is shorter, broader and more rounded in form than in reptiles. The cerebellum is comparatively large and has two small lateral lobes and one large median lobe. The median lobe is marked by shallow radiating grooves which extend down into the cerebellum and carry the gray matter with them, thus increasing its extent. The medulla oblongata has a well marked flexure. The cerebral hemi-

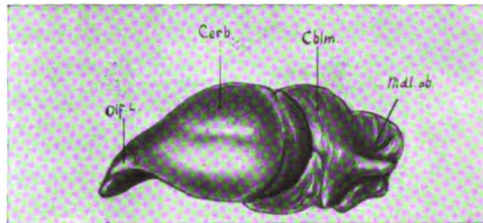


Fig. H.

BRAIN OF A GOOSE.

Olf. L.—Olfactory Lobe.      Cblm.—Cerebellum.  
Cerb.—Cerebrum.          Mdl. Ob.—Medulla oblongata.

spheres are quite large. They extend backward to meet the cerebellum and forward as far as the extreme posterior part of the nasal fossae. The olfactory bulbs are extremely small and the nasal fossae show a moderate degree of development. Each fossa in most birds contains three turbinates. The anterior one is shaped like an inverted T, and is covered with stratified epithelium. The two posterior turbinates are scroll shaped and are covered with olfactory mucous membrane.

*Mammals.*—In the lowest types of mammals, the cerebral hemispheres are relatively small, their surfaces are smooth and do not extend over the cerebellum. In the higher types the relative development of the hemispheres is remarkable. They extend backward and completely cover the rest of the brain. The surfaces

of the hemispheres are divided into numerous complicated convolutions by deep sulci, and in this way the extent of the gray matter is tremendously increased. This development of the cerebral hemispheres reaches its maximum in man.

The optic lobes are relatively small. The olfactory lobes vary considerably in different types of mammals, and their development corresponds with the development of the olfactory organ. In the animals which have an acute sense of smell, with well de-

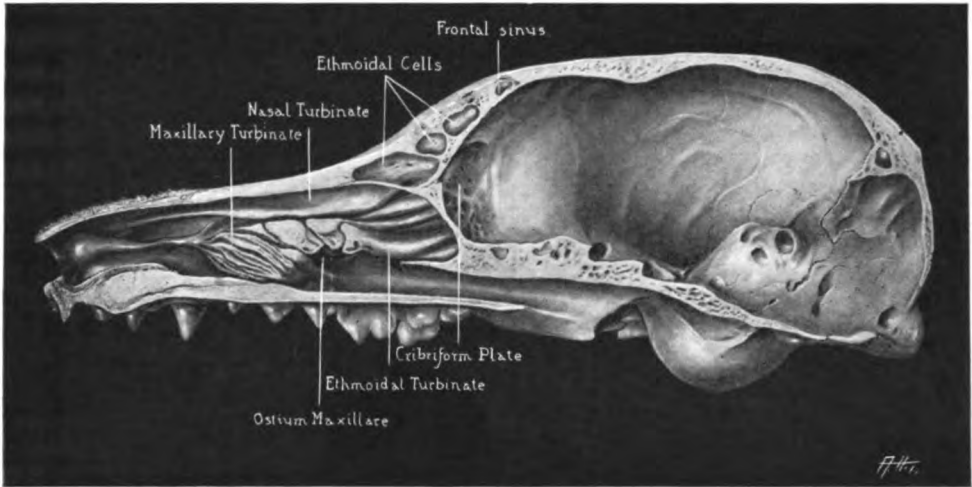


Fig. I.

#### SECTION THROUGH THE HEAD OF A DOG.

The maxillary turbinate is a complicated structure with many branches. Its anterior end has a cartilaginous prolongation which extends forward to the extreme anterior part of the nose. In sniffing, this prolongation partially closes the respiratory portion of the nose and directs the inspired air through the olfactory portion. The ethmoidal turbinates are delicate structures with numerous fine divisions. All of the accessory sinuses contain some branches of the ethmoidal turbinates.

veloped ethmoidal turbinates, the olfactory lobes are relatively large.

This condition is well shown in the dog. The olfactory lobes are large and form the anterior portion of the cerebrum. The greater part of the anterior boundary of the brain cavity is formed by the cribriform plate of the ethmoidal bone, which is hemispherical in shape and contains numerous perforations through



which the branches of the olfactory nerves pass and are distributed over the ethmoidal turbinates. The marked development of the cerebral hemispheres in the dog carries them forward as well as backward, so that they extend over part of the nasal fossae anteriorly and over the cerebellum posteriorly.

The monkey's brain shows a high degree of development, which is only surpassed by the development of the brain in man. The difference between the human and anthropoid brain is less than the difference between any other two vertebrate groups.

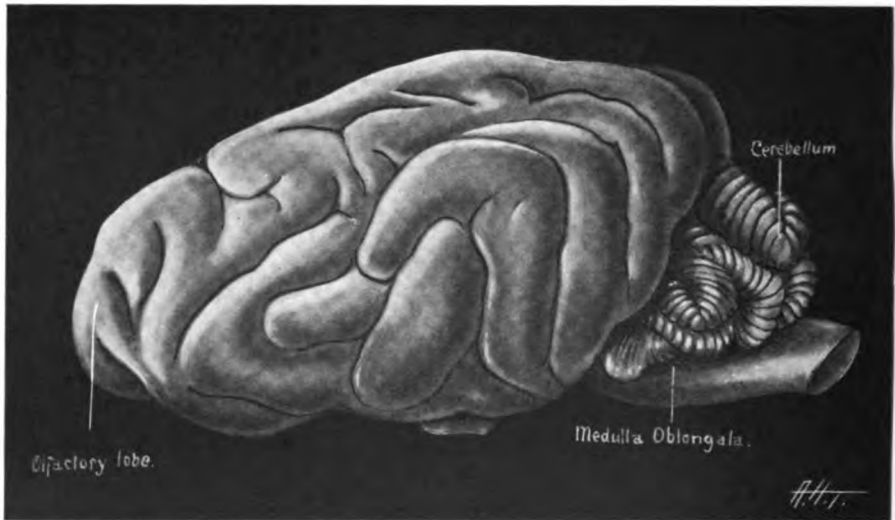


Fig. J.  
THE BRAIN OF A DOG.

The cerebral hemispheres show a very high degree of development, with well marked convolutions and sulci. The olfactory lobes are relatively large and form the entire anterior portions of the cerebrum. The cerebellum is comparatively small and is partially covered by the cerebrum.

The human brain, in the course of its development in the embryo and in early life, passes through, in regular order, conditions characteristic of some of the lower vertebrates. The brain of a two-year-old child resembles very closely the brain of an ape. There is, however, a very great difference between an adult human brain and the brain of an ape. In the human brain all of the lobes are relatively much larger, the sulci are deeper and

the convolutions are more intricate, and thus the amount of gray matter is tremendously increased.

The skull and features of a young ape resemble very closely those of the human foetus, but the adult skulls in each case show very marked differences. The cranial cavity of the ape is small and the jaws are large and protruding, but in man the cranial

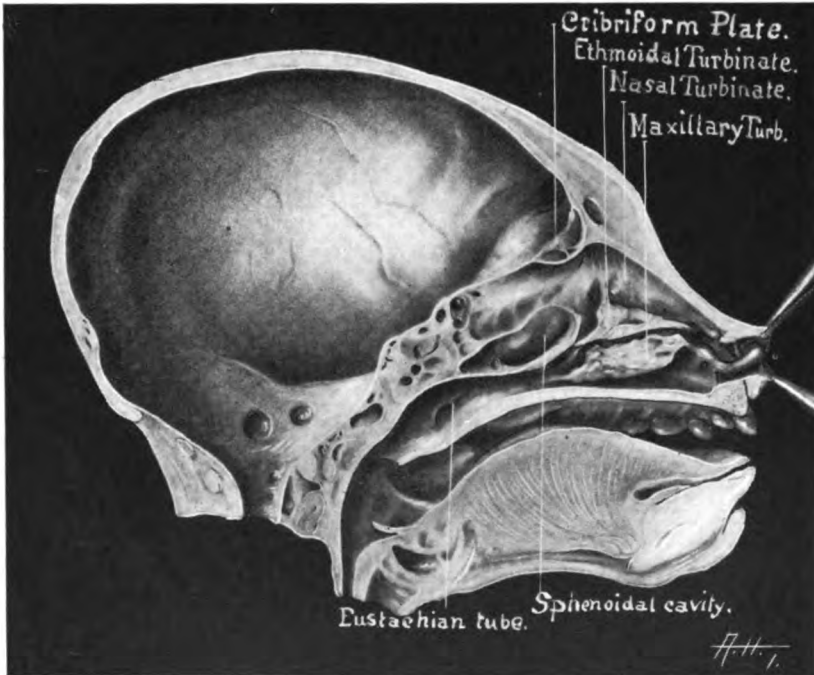


Fig. K.

#### BRAIN OF A MONKEY (CEBUS).

The brain cavity extends over the posterior half of the nasal fossae, and the cribriform plate forms the roof of the nose. The maxillary turbinate has a double coil. There is only one ethmoidal turbinate. The nasal turbinate is rudimentary.

cavity is actually and relatively very large, while the jaws and face are small and subordinate to the cranium. The principal cause of this difference between the human skull and the skull of an ape is found in the greater development of the human brain, which

continues to grow until man reaches adult life, while the brain of an ape reaches its full development very early in life.

The tremendous development of the human brain carries it forward so that it extends over the nasal cavity and changes the facial angle. The nose lies almost directly under the brain instead of being anterior to it, and the cribriform plate forms the roof of the nose in man, whereas in most other vertebrates it forms the posterior boundary. The olfactory organ in apes, and especially in man, is a decidedly degenerated structure. The turbinates are small and the olfactory sense is not acute, but this degeneration

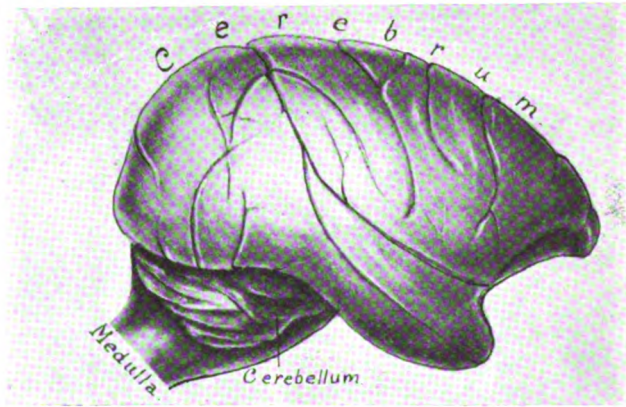


Fig. L.

BRAIN OF AN ADULT MONKEY (CEBUS).

The cerebrum is large and completely covers the cerebellum. The sulci and convolutions are quite similar to those of the human brain, but less intricate.

is more than compensated by the wonderful development of the brain.

By comparing the cranial and facial axes and planes we see that in fishes and amphibia there is no cerebral flexure. The nasal fossae are directly anterior to the brain and on the same plane. In reptiles and birds the brain, as it develops, extends forward over the nasal fossae and shows some flexure and there is a slight facial angle.

In mammals, as we ascend the scale, we see a continuous development and increase in the size of the cerebral hemispheres

and a marked cerebral flexure. The facial angle increases from 0 to 90 degrees, and the form and position of the nose and face are completely changed.

#### Discussion.

Dr. H. P. Mosher, Boston: I would like to ask Dr. Ingersoll about the size of the sphenoidal sinus in the monkey; how often is it large and how often small, and whether or not there are any prolongations. One of the slides suggests a prolongation.

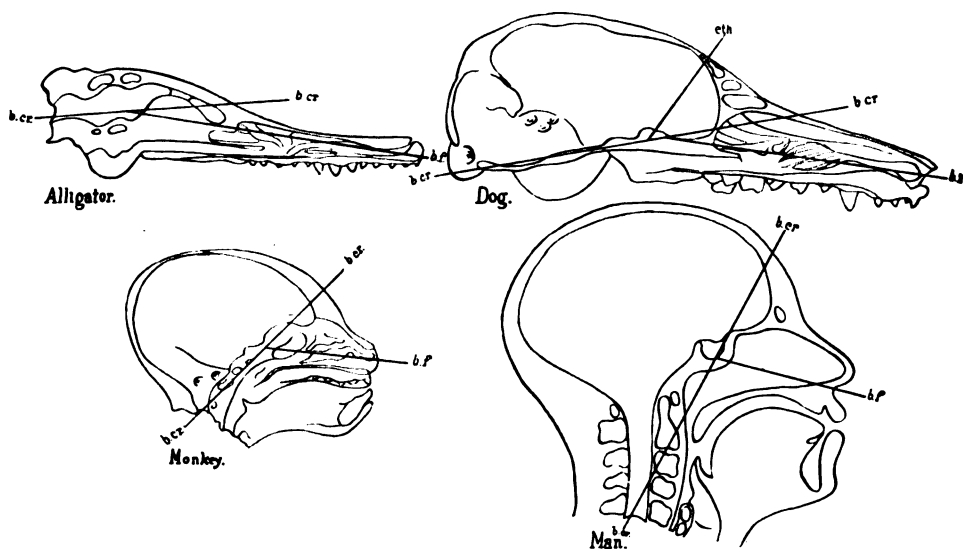


Fig. M.

b. cr.—Basi-cranial axis.  
b. f.—Basi-facial axis.  
eth.—Ethmoidal axis.

Dr. J. M. Ingersoll, Cleveland (in closing): The frontal sinus varies more in the monkey than in man—if that is possible. The chimpanzee is the only one with a definite frontal sinus; in the others it is crowded out by the orbit. The dipping in of the sphenoidal sinus is very marked in one of the pictures of the ape shown, and suggests why in some human skulls we find the dipping in so far. In other monkeys the sphenoidal sinuses are fairly regular, and have no prolongations. It is evidently a rudiment of earlier days, and the orang-outang is the only one I know of that has it. The bear, also, has a decided prolongation outward of the sphenoidal sinus.

THE QUESTION OF POST-OPERATIVE NASAL PACK-  
ING IN THE LIGHT OF ADDITIONAL EX-  
PERIENCE WITH THE AUTHOR'S  
RUBBER TAMPON.

BY W. E. CASSELBERRY, M.D.,

When in 1909, under the title, "A New Method of Packing the Nostril Designed to Prevent Post-Operative Hemorrhage," I described a combination nasal and post-nasal aseptic tampon consisting chiefly of a soft rubber tubular case with a bulbous expansion at its closed end, it was stated that the painfulness of the customary method of packing with bare gauze, the disposition of the gauze to adhere to the wound and cause hemorrhage anew if withdrawn in less than two days, when less than one day should suffice, and its liability, being so long retained, to induce infection of the ear, had deterred many from using any sort of pack for the purpose alone of preventing hemorrhage and had deterred all from packing the posterior nares excepting to meet an urgent necessity. Experience, however, has taught that a posterior pack of some sort must at times be inserted in order to control a dangerous degree of post-operative hemorrhage, especially that liable to ensue some hours after the severing of a principal branch of the post-nasal artery, as in turbinectomy and the speno-ethmoid operation. As these are the operations and this the pathway, for the intranasal surgical drainage of the speno-postethmoid group of accessory sinuses which, as I essayed to show last year, harbor the infections fundamental to a whole range of serious post-nasal diseases, long resistant to simpler methods, the severing, in trunk or branch, of this particular artery now so often confronts us that a satisfactory safeguard against subsequent hemorrhage has a very practical bearing on the extent to which this much needed surgical treatment is likely to be utilized.

I had twice experienced, under vital circumstances, the fact that plugging the posterior naris will succeed in stopping such a hemorrhage even though a well placed anterior pack has failed, and had found this fact to be due not, as generally supposed, to damming up the blood in the nasal fossa, but due to the ring-like conformation of the choana, against the bony edge of which the trunk of the post-nasal artery as it emerges from the sphenopalatine foramen, together with its principal branches, is necessarily compressed by any plug which fits snugly into the choana or is held against it by forward traction. A preventive tampon, therefore, competent to prevent hemorrhage at this site, must possess a post-nasal feature, an advantage imparted to the rubber tampon by a bulbous expansion of its distal end, which, being distended by the gauze packer, assumes the form and effectiveness of the ordinary post-nasal plug whilst free from its various disadvantages. Without a bulbous expansion, in the form of a plain finger cot, which I first tried for the purpose, the tampon failed to control posterior hemorrhage, but since then, in its present form with a bulbous expansion it has not once failed to fulfill its purpose. Neither is the discomfort occasioned by the tampon, during the single night it remains in position, more than very moderate in degree compared with that by uncovered gauze; so that I have, for the last five years, utilized the rubber tampon as a primary dressing, inserting it at the close of all operations reputed to be liable to secondary hemorrhage, numbering some 175 private cases. Moreover, as it has proven to be a safeguard against hemorrhage even without quietude in bed, and to be itself safe, it has enabled me to extend the benefit of nasal surgery to many more persons in need of it than would have accepted an exclusively hospital procedure.

Hence the main purpose of my theme is to review the question of post-operative nasal packing from the standpoint of a non-absorbent, smooth-surfaced, aseptic tampon, and to suggest a revision of our antipathies to nasal packing *per se* in so far as the opposition is still based upon experience with the old-time, necessarily septic tampon of uncovered gauze, about which there is no question in my mind but that packing with it should be

wholly abandoned. Authorities whose last editions are otherwise up to date are found lagging in recognition of this change of base from a septic to an aseptic tampon and consequently in perception of the multiplication of beneficiaries from nasal surgery to be expected from the change. One author phrases his negative advice substantially as follows: "Never pack; they do not often bleed, and if they do, why, let them bleed; it is far better than to use a tampon excepting in extreme emergency, especially a post-nasal tampon, the most dangerous of all." Obviously, he refers to the absorbent or septic tampon, whereas, if he had in view the non-absorbent aseptic tampon, he might, with more regard for the exact truth, have advised in the affirmative substantially in this way: "Always pack; if not, they nearly always bleed to an extent alarming to the patient, frequently to an extent disquieting to the surgeon and occasionally to an extent menacing to health or life." Why is it not repugnant to good surgical sense to leave unsecured vessels competent so to bleed, on the chance that they may be secured amidst the panic of an emergency, although perhaps not in time to prevent days or weeks of enfeeblement consequent upon loss of blood?

In another negative opinion that "tampons cause sepsis, the more gauze the more sepsis; also meningitis and frequently otitis," and in the oft reiterated dictum: "Don't pack in sinus disease"—septic tampons of unsheathed gauze are, of course, implied; but although based on the septic tampon the antipathy thus expressed is reflected against all tampons and is that of which I speak as in need of revision; for it impedes the advance of surgical relief by alleging treachery against a much needed safeguard. Sinus disease is abroad in the land ravishing sight, hearing, breathing and thinking; its evil works, in large part, are yet uncovered, for it issues in disguise from hidden lairs in the darkness of night and destroys by silent throttling and slow poison. It is in no trifling cause, therefore, that I bespeak for the rubber tampon exemption from reflection of the charge of treason, for in this contest in the capacity of rear guard, as it were, it has served me well.

It is not meant that a mild form of autoinfection never occurred

which, independently of tamponning, may manifest itself as tonsillitis in a small percentage of operations on the turbinals, including electro-cauterization, in which a tampon is never employed. But it is meant that in not a single instance of my series, which embraced many cases of sphenoid and other sinus suppurations, did it induce or contribute to infection of the ear, meninges, sinuses or any septic condition.

But why, it may be asked, does not the mere obstruction to drainage promote absorption of pus even though the rubber tampon cannot harbor in itself the organisms of infection? In part, because capillary attraction proceeds between the approximated mucous and rubber surfaces which provides a vent in the form of liberal oozing, but principally because of the brevity of time during which the obstruction endures. In all cases the tampon has been withdrawn in from fifteen to eighteen hours and in not over five per cent has it been necessary to re-insert it for another period of equal brevity.

Is it always effective? In order to obviate the only uncertain element I have recently added an anchoring cord within the rubber to the post-nasal bulb, by which any relaxation or shifting of it from the position of the vessels to be compressed in the choana may be prevented. A single strong black silk thread is tied to the first few inches of gauze, enfolded into a small knot, just as it emerges from the distal end of the packer, before the rubber is slipped over it. The string, therefore, during insertion of the tampon, leads forward along the outside of the packer but inside of the rubber case, being held taut till completion of the gauze-packing, by the same hand that holds the packer, when by gently pulling the string and affixing it to the front end of the pack by a few turns around a fold of gauze or cotton, the post-nasal bulb is drawn snugly into the choana and held against its ring-like bony edge in the same manner and with equal efficiency as an ordinary post-nasal plug, but with the advantage that both gauze and string are incased in rubber. Even the anterior end of the rubber tampon could be closed and sealed if desired, but this is unnecessary and would, moreover, interfere with an easy regulation of the tightness of the pack which is one



of its conveniences; for, if after several hours the pack seems unnecessarily tight and there is no bleeding, one can answer a telephone complaint by permission to withdraw a small portion of the gauze or if too loose and bleeding occurs one can give directions, to first find the black string and while holding it taut to tighten the pack in front by crowding in more gauze and then to tighten it behind by simply pulling forward on the black string.

### *Discussion.*

Dr. A. A. Bliss, Philadelphia: It is surprising how quickly wounds of the mucous membrane heal under pressure by clean rubber. Several years ago I wrote a paper on pressure against the septum in cases operated on by the Watson method. In place of using hard rubber splints I took a drainage tube in proportion to the size of the nostril and cutting each end packed it with gauze and placed it in position to act as a splint. That could be left in for many days. I could take the packing out and replace it if necessary, and the wound which was made against the septum by the operation would heal very nicely under pressure by the clean rubber. So I can easily see that Dr. Casselberry's method must be as nearly aseptic as any dressing put in the nose can be.

Dr. E. Fletcher Ingals, Chicago: I have utilized this method of packing many times, and, although I have not employed the thread for pulling the wad of gauze into the posterior naris, but have drawn on the rubber itself; but I can appreciate the advantages of the thread. I have never had bleeding of any consequence since using it, and have found the method very satisfactory. The patients complained of some pain when it was taken out, but it does not compare with that caused if the naris is packed without the rubber cut. I have found that the packing can all be removed painlessly by pulling out the gauze slowly and gently, and by moistening it when it sticks by irrigation inside of the rubber.

Dr. J. Price-Brown, Toronto, Canada: I have used rubber packing for a good many years, and appreciate fully what Dr. Casselberry has said, but I have not used it in his form. My rubber is chiefly for operations in the anterior portion of the nasal cavity, and I have used soft, pure rubber cut to suit the case, and in no case have I had hemorrhage of alarming character. My cases, however, have not been those in which I re-

quired to use the rubber for the back end of the passage; but I will do so in future, if the conditions call for it.

Dr. W. E. Casselberry, Chicago (in closing): Regarding pain in the removal of the rubber pack, the gauze comes out very easily until that which formed the bulbous expansion at the back end is drawn upon, when it is apt to require coaxing. If then a little cocaine be applied outside the rubber case, after a few minutes, the case and remnant of gauze will slip out together without pain. Also since using the anchoring thread for the purpose of drawing taut the back end of the pack, I have found the thread to serve incidentally as a running line along which the gauze unfolds during withdrawal without tangling at the rear end. It is worth the addition of the anchoring thread, even if it served no greater purpose, to prevent resistance by knotting of the gauze on withdrawal. But the real purpose of the anchoring thread is to increase and insure the efficiency of the postnasal feature of the pack, an addition which makes the rubber pack equal to any other in preventing and arresting nasal hemorrhage, while superior in freedom from infection and ease of application.

## THE OZENA INVESTIGATION IN THE UNITED STATES.

BY EMIL MAYER, M. D.

At the meeting of the Third International Laryngological Congress, held in Berlin, in 1911, it was unanimously resolved that a collective investigation of a statistical nature should be held on ozena, and that this investigation should embrace the whole civilized world. A general committee composed of Professor Grabauer, Professor Rosenberg and Professor Alexander, all of Berlin, was appointed to institute the same, reporting its findings at the next International Laryngological Congress in Copenhagen in 1915. This committee at once undertook the Herculean task of appointing a chairman for each country, appealing for the financial aid such an investigation requires, notifying the profession at large of its existence and purpose as also the general public through the press, and finally requesting permission of its government to make the needed examination of school children and inmates of homes, asylums, reformatories and prisons.

At the request of this committee and at the earnest solicitation of one of our members, the writer agreed to assume charge of the investigation for the United States, as far as our complete lack of means for this purpose would permit. This latter statement was quite essential, as the idea seemed to have gone forth that we had but to mention the character of the disease which we wished to investigate when ample funds from some of our philanthropic multi-millionaires would not only be forthcoming for our own needs, but some might even drift the way of the general committee. With a clear knowledge then on their part of an absence of any funds and of our inability to gather the same, the appointment was accepted. The chairman at once formed an executive committee, after conferring with the officers of our three large laryngological

associations. This executive committee consists of Dr. Joseph W. Gleitsmann, Dr. Robert C. Myles, Dr. Harmon Smith, representing the American Laryngological Association; Dr. Thomas J. Harris, Dr. Wolff Freudenthal, Dr. H. Holbrook Curtis, representing the American Laryngological, Rhinological and Otological Society, and Dr. Sidney Yankauer, representing the American Academy of Ophthalmology and Otolaryngology.

The first meeting of this committee was held on March 9, and it was resolved that for the purpose of this investigation the term "ozena" is meant to indicate a disease of the nasal interior, beginning as a rule in childhood, which is characterized by degeneration of the nasal mucous membrane and bony atrophy without ulceration and which in its further course gives rise to a disagreeable odor perceptible at a distance. A second classification was made to be known as "ozena suspects," that is, having the same conditions without odor where some other member of the family has ozena.

From the lists of membership of our American associations this committee selected the names of those who were to be invited to assume charge of the investigation for the various States of the Union, and up to the present time the following men have accepted, and their names appear with the name of the State for which they act as chairman:

Dr. J. H. Allen, Portland, Me.  
Dr. H. L. Swain, New Haven, Conn.  
Dr. W. B. Johnson, Paterson, N. J.  
Dr. G. B. Wood, Philadelphia, Pa.  
Dr. C. W. Richardson, Washington, D. C.  
Dr. S. R. Rosenheim, Baltimore, Md.  
Dr. D. A. Kuyk, Richmond, Va.  
Dr. W. B. Goff, Clarksburg, W. Va.  
Dr. H. A. Briggs, Asheville, N. C.  
Dr. E. F. Parker, Charleston, S. C.  
Dr. Dunbar Roy, Atlanta, Ga.  
Dr. Richmond McKinney, Memphis, Tenn.  
Dr. Otto Joachim, New Orleans, La.  
Dr. J. O. McReynolds, Dallas, Tex.

Dr. H. B. Hitz, Milwaukee, Wis.  
Dr. W. L. Ballinger, Chicago, Ill.  
Dr. J. B. Barnhill, Indianapolis, Ind.  
Dr. H. B. Lemere, Omaha, Neb.  
Dr. L. W. Dean, Iowa City, Ia.  
Dr. James E. Logan, Kansas City, Mo.  
Dr. Robert Levy, Denver, Col.  
Dr. J. M. Ingersoll, Cleveland, O.  
Dr. B. R. Shurly, Detroit, Mich.  
Dr. J. B. Parsons, Sioux Falls, S. D.  
Dr. A. M. MacWhinnie, Seattle, Wash.  
Dr. C. A. Thigpen, Montgomery, Ala.  
Dr. Hill Hastings, Los Angeles, Cal.  
Dr. John J. MacCoy, New York, N. Y.  
Dr. Frederick C. Cobb, Boston, Mass.  
Dr. John A. Donovan, Butte, Mont.

Each chairman is privileged to appoint as many assistants as he desires, to inform the profession of the purpose of the investigation, to secure the examination of school children, inmates of asylums, homes and public institutions, and to supervise the collection of the histories of cases thus obtained, and in some appropriate way to have the general public notified of the investigation and its purport.

For the prompt acceptance of the onerous duties the committee expresses its thanks and its gratification at the feeling of loyalty shown. The chairman was also authorized to confer with the Surgeon-General of the Public Health and Marine Hospital Service in order to secure the valuable co-operation of that body. The reply of the Surgeon-General states that "it is the purpose of the bureau to keep in touch with and to assist in so far as practicable in those investigations and measures relating to public health subjects. Limitations of our force and the stress of other work connected with investigations which must be carried on have to be borne in mind in considering any new movements, but I should be pleased to meet with you should my duties take me to New York in the near future." Replying to this, the chairman sent a letter to the Surgeon-General asking for such valuable assistance as

his department could give in making this investigation and promising him the co-operation of the chairmen of the various States already appointed by this committee. No answer to this has as yet been received, but in view of the fact that it is part of the duty of the Department of Public Health and Marine Hospital Service to take up such investigations, the writer feels that we may in some way still be able to secure the needed co-operation.

The general committee in Berlin has in addition to securing permission from the authorities to examine all children in the schools, established an ozena clinic in the larger cities so that once a week cases of ozena assemble at this chosen place, and several rhinologists agree to be present to confirm the diagnosis and note the development of these cases.

We are to ascertain the number of cases of ozena existing in the United States, whether ozena occurs in the native born or among foreigners and the relative frequency of the same, also is it at all common among the negroes? It has been deemed advisable to have a rather complete history taken of ozena occurring in children, and for this purpose a history blank has been prepared by the general committee, as follows:

1. Full name. Sex. Religion. Age. Date of birth. Residence. City and country. School. Class. Place of birth. Nationality. How long in the United States (if foreign). Birthplace of parents. Occupation.

2. History. How long has the nose condition existed? Was there any ophthalmia? When? Diseased conditions directly after birth? Diseases of childhood, especially infectious diseases? Was the child breast or bottle fed? General condition of the residence, size, cleanliness, etc.? Nutritive conditions of the family and child, clothing, care of body and teeth?

3. General bodily conditions. General appearance, size, development, form of chest. Conditions of the circulation, respiration (if tuberculosis is suspected), nervous system. Condition of bones (rachitis, tuberculosis of bones). Skin, eczema, etc. Constitutional conditions, especially syphilis. Glandular infiltration, otitis, etc. Enlarged thyroids. Examination of the urine, blood, secretion of the nose. Wassermann reaction.

4. Local conditions. Examination of the nose, both sides, space, appearance of turbinates, of the mucous membrane of the septum, sensibility of the nasal mucosa, sense of smell,

crusts, intensity of the odor before and after removal of crusts. External nose, appearance of the skin, superior maxilla, hard palate, teeth, pharynx, appearance of the mucous membrane, pharyngeal and lingual tonsils. Naso-pharynx, condition of the mucous membrane, adenoid, larynx and trachea. Photograph, full and profile, measurements of the skull, length of the septum.

5. Complications on the part of the lachrymal canal, and the middle ear, accessory sinuses. Special examinations, transillumination. Roentgen rays photograph.

6. Hereditary or infectious. Patient is the (4th, 5th, etc.) child with ..... brothers and sisters, of whom ..... are living. Patient is an only child. Diseases and causes of death of parents or brothers and sisters. Have children occupied the same bed and up to what time?

If death should occur in an ozena subject, autopsy is to be held.

With the co-operation of the rhinologists who have so graciously accepted and that of the Department of Public Health and Marine Hospital Service of our Government, which we hope to interest in our behalf, the writer earnestly believes that the final report, made two years hence from the United States, will in no way be behind that of other countries.

#### *Discussion.*

Dr. Frederick C. Cobb, Boston: This investigation seems to me a matter of great difficulty. Such statistics as the author needs involve a very long, painstaking investigation all over the country. When it is finished we shall have made some measurements, perhaps found out some points in regard to the contagiousness of the disease, but shall have achieved little in its prevention or cure. Would not the same energy be better directed to the investigation of the cause of Ozena, now that Abel's bacillus has given us a clue of the etiology? By the method which Dr. Mayer proposes we shall only get the florid cases of the disease which are almost incurable. The real hope for the prevention of the spread of atrophic rhinitis seems to me to lie in the treatment of the early cases. I can, however, agree with Dr. Mayer in so far that it seems to me most important that this subject should be called to the attention of all school physicians and others interested in children.

Dr. Emil Mayer, New York City (in closing): I am afraid

Dr. Cobb has misunderstood the situation. A resolution was passed by the laryngologists, assembled from all over the world, that they wanted to find out just how frequently ozena occurs in the various countries. It is stated, for instance, that in Spain every third patient who appears in the clinics for nose and throat work has bad ozena. It is all important to determine whether ozena is at all common among our native Americans, or whether foreigners have it more, and it is for that particular purpose that the collective investigation is being made.

I am merely acting as an agent for those appointed by the last Congress to limit the investigation to the lines along which the resolution is worded. Nevertheless, there is no restriction to any individual using the material which he has as he chooses. If you will recall in looking over the list of States, the Southern ones are very well represented, and I am sure we will be able to present some original work as to the presence or absence of this disease among the negroes. The State of Massachusetts is the only big State which so far has no representative, and I am sure I voice the sentiments of the whole committee if a man like Dr. Cobb would accept that chairmanship and use the material for any purpose he desires, and I am sure this association would be delighted to hear a paper on such material, so that he could report on 400 instead of on 40 cases. If Dr. Cobb would accept, I am sure I could offer him the chairmanship of the Massachusetts committee. The representatives from the association are Drs. Gleitsmann, Myles, Harmon Smith and myself.



## CORYZA AND RESPIRATORY GYMNASTICS.

BY MARCEL NATIER, M. D.

## I.

Physicians, Alphonse Karr has said, have devised nothing since the time of Moliere, except that of calling a cold in the head *coryza* and of reducing its duration to a month, which before was thirty days. That sally is easily understood. Coryza—perhaps one is too unmindful of it—is not by any manner of means a mark of entity, an affection *sui generis*—it is always a symptom associated, it is true, with eminently differing maladies.

It does not come within the province of this paper that I should mention all the maladies capable of provoking coryza. I desire simply to relate the positive influence of bad general health upon its appearance and thereupon the persistence of this functional disorder. It is particularly often connected with respiratory incapacity. But the same exercises which overcome the latter at the same time bring about the disappearance of that resultant which now concerns us—namely, coryza. For proof take the following case:

## II.

CASE UNDER OBSERVANCE—Young girl, born at Paris, Sept. 15, 1896.

*Personal Antecedents*—Father 54 years old, medium height; temperate, general health good but nervous; commenced to lose his hair early and displays at present decided baldness. Mother 48 years old; ruddy complexion; middle-sized; equally nervous; no blood relationship between the two parents.

*Personal Antecedents*—Fifteen days before birth, and after an uncomplicated pregnancy, the mother had rheumatic pains. Began at the knee joint; lasted six months. Birth fifteen days ahead of time. Infant well formed; weight, 3 kilos. Immediately after birth a double purulent ophthalmia, which abated at the end of two months owing to the care of a trained nurse, whose surveillance had been exercised night and day. The mother gave a thirty-five-day trial of breast feeding, in spite of a fever of 40 degrees Celsius. Slight progress. After this delay resorted to the exclu-

sive use of sterilized milk. No digestive disorders. Normal development. Final weaning at 14 months; no discomfiture followed.

Child absolutely normal at nine months. Walked at 11 months. Talked earlier than usual.

At 3 years, mild whooping cough without complications, followed almost immediately by very light chicken pox.

At 3½, light bronchitis with angina.

At 8 years, February, 1904, scarlet fever of moderate intensity. Indoors forty days; no complications, no trace of albumin. Rapid convalescence.

At 9 years, April, 1905, first touch of appendicitis. Sudden convulsion in the morning, immediately after rising. In bed fifteen days; intense pains. All milk diet; daily enemas. For six months daily dose of castor oil. No troublesome after-effects apparent from this long indisposition.

At 11½ years, mild measles without complications.

In 1909, in the month of December, colicky pains in the appendix, followed by a bad attack of appendicitis. Suffering very intense for three weeks. Operation, Jan. 20, 1910; results favorable; returned home 20 days later. Following that there was decided loss of weight and marked anaemia, which persisted up to the time of leaving Paris. Stay at the seaside during August and September; quick recuperation; complete transformation at the time of return.

In December, 1910, an attack of grippe with angina, epistaxis, headache, vomiting spells and colic. Severe pains in the left ear. Three weeks in bed. Result: Additional great loss in weight, anaemia and exhaustion.

No trace of menstrual periods till now; but, since about a year, each month, pains in the lower part of the abdomen.

For the past eighteen months at rather long intervals the lower gums bleed very easily. Hemorrhages occasionally profuse; in one instance the mouth was filled with blood. Daily applications of tincture of iodine, continued for six weeks, finally overcame these losses of blood.

At Paris, confined existence, whether at home or at school, where space is so restricted that there is not even a court in which to play. Each year since the age of two a two months' stay at the seashore or in the country, whence the child returns generally in excellent condition.

Frequent pains in the face, especially of the eyes. Retained up to the age of 4 the habit of sucking her thumb and of pulling at her ear.

Always inferior for her age in mental development; seeks in preference the society of children younger than she and takes a real pleasure in sharing their sports. Even now she indulges in the outbursts of a little girl, demands caresses and throws herself upon the neck of those for whom she cares in order to make them embrace her. Of variable humor, she passes with equal ease from anger to joy and from laughter to tears.

Put in school at 6 years 3 months. Average scholar. Works easily enough; lacks application; rebels at the mastering of certain subjects, such as orthography and mathematics. General knowledge limited.

*Headaches*—Almost daily for the past two years.

*Sleep*—Exceedingly restless since earliest childhood. She has had dreams constantly, and talks and laughs and cries during her sleep. For the first and only time some months ago she rose up in her bed and proceeded to call her father. She has never been a sleep walker. Now and then somewhat prolonged attacks of insomnia, followed by great lassitude in the morning. It is worthy of mention that mother and daughter occupy the same bed in a rather small room whose window is never opened at night, making too little ventilation and impure air.

*Respiratory System*—Constant tendency toward colds for the last three

years. During certain winters as many as eight or ten colds, one following the other. By no means rare during the summer. Average duration, from three to four days or of a week. After the nose the throat and chest becomes affected; all slightly.

Persistent sensation of the nose being stopped up, with the habit of regularly breathing through the mouth while awake as well as asleep. Snores at night.

Outside of the periods of coryzas, nasal secretions very infrequent.

*Digestive System*—Excessively choice in the selection of food; is rarely hungry; very difficult to feed. Digestion bad. Decided tendency to constipation since infancy; often goes two days without a passage, necessitating frequent recourse to purgatives. Yawning and belching after meals.

*Circulatory System*—Has cold feet always.

*Urinary System*—Urination frequent, but little urine.

*Capillary System*—Short hair, fine and light, dry and brittle.

Summoned for the first time to the patient at the occasion of the trouble with her ears following the attack of grippe, in January, 1911, I was profoundly impressed with her appearance. There was nothing to be done so far as the ear was concerned; on the other hand, her general health needed serious attention. Already the doctor in charge had prescribed "tonics" and cinchona in particular. I succeeded without difficulty in convincing the parents of the need of entrusting their daughter to my charge, as she gave ample evidence of insufficient respiratory capacity.

*Jan. 31, 1911. Actual Condition*—Child beyond medium size. Keen eye; excessively thin face, accentuating markedly the prominence of her nose.

*Nasal Passages*—Normal dimensions. Discolored mucus. No hypertrophy.

*Post-nasal Passages*—No trace of adenoid growths.

*Mouth and Pharynx*—Nothing to note.

*Larynx*—Slight stiffness of the vocal cords.

*Voice*—Slightly muffled.

*Skin*—Grayish yellow, dry and harsh to the touch. No perspiration. For two years a permanent acneiform eruption, exclusively localized on the face.

*Head and Neck*—Thin, inclined forward.

*Chest, Front View*—Projection of the clavicles, accentuating the depth of the supra and infra claviclar fossae. Projection of the sides, especially of the lower part.

*Side View*—Flattening of the chest; exaggeration of the curve of the lumbar section. Prominence of the head of the humerus.

*Posterior View*—Exaggerated projection of the shoulderblades and of the spinous processes of the spinal column.

*The Glutei*—Noticeably reduced in size.

*Limbs*—Spindly.

*Respiration*—Too scant. Vesicular murmur hardly perceptible, especially at the apex.

The patient has for four months been submitted to respiratory gymnastics. No drugs. She has shown herself most docile and punctual. The unflagging and intelligent co-operation given by her mother very rightly deserves praise in addition. The results have been rapid and encouraging, as the reading of the following notes will witness:

*Feb. 14th.* Obligated to-day to wear a new corset waist, the others having become too tight.

*Feb. 20th.* Vomited twice in the morning the day before yesterday. Slight indisposition to-day with nausea. Headache. Illness like that of just a month ago. That makes one think of the coming of the menstrual period.

*March 30th.* It is the universal opinion of those who have not seen the patient for a definite time that she is literally transformed. It is also the opinion of her teacher, who, dominated by her professional ideas, could not prevent herself from insinuating that suspension of studies would engender habits of laziness.

*May 13th.* Appearance the day before yesterday of the first menses. Not abundant and already stopped

*June 2nd.* Definite cessation of treatment.

*Headaches*—None.

*Sleep*—Better. Fewer dreams. No longer cries out. Sleeps longer. Rested upon awakening.

*Respiratory System.* Mucus of normal color. Breathing deep and regular; nose constantly clear. Not the faintest trace of coryza; neither sneezing nor coughing.

*Digestive System*—Appetite in all respects excellent. Constipation since the beginning of the cure has completely given way through the practice of respiratory exercises.

*Circulatory System*—No longer cold feet.

*Urinary System*—Urine more abundant, more regular and clearer.

*Cutaneous System*—Complexion—Color better. Skin rosier, finer in grain, softer and more pleasing to the touch. Lobes of the ears less yellow; eyes more sparkling. Always a little acne upon the face (forehead) and the anterior portion of the thorax.

*Capillary System*—Hair thicker and less brittle.

*Nervous System*—Less excitable than formerly.

A little more taste for intellectual occupation.

*June 9th.* At the school, where she has been back four days, the change in her has surprised all of her companions. Alas, she did not find from her teacher the support which she had expected. The former, always a little vexed at the interruption of her studies, lost no opportunity of expressing her displeasure. For example: "It is not worth the trouble of having become fatter and of having become so large, if you can not succeed in doing this or that."

*September 29th.* Having returned for the second time at Easter, the menses stopped until September. They then reappeared and have not stopped until this time (April, 1912).

Has just passed two months at the seaside; took a great number of baths, and these, joined to the excessive heat of the summer, have made her lose in weight. More nervous. Has lost 2 kil. 500 since the cessation of treatment; but yet has grown from 0 m. to 020 m. taller.

The comparison of the photographs (1, 2, 3) taken at the beginning of the treatment with those (4, 5, 6) taken at the close is superior to all comments. It permits, in fact, obtaining a clear idea of the surprising bodily changes which have taken place.

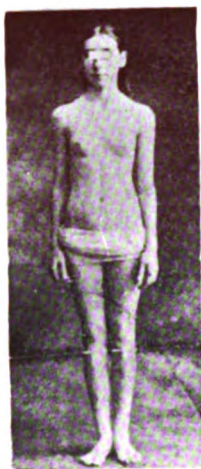

Fig. 1.

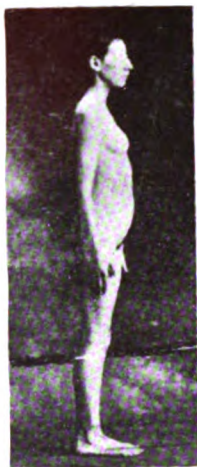

Fig. 2.



Fig. 3.



Fig. 4.

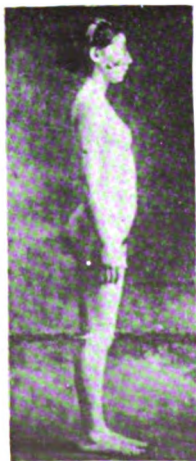

Fig. 5.

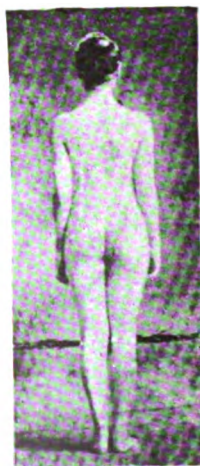

Fig. 6.

- (1) Photograph of the front.  
(2) Of the side.  
(3) Of the back before the treatment; and (4, 5, 6) corresponding photographs of the same child after four months of respiratory exercises.

In addition, the figures below, extracts from a tabulation kept regularly daily, make appreciable the precise advance of progress made:

## A.—HEIGHT.

January 23, 1911.....	I m. 550	May 3, 1911.....	I m. 576
February 9, 1911.....	I m. 562	May 18, 1911.....	I m. 579
February 28, 1911.....	I m. 564	June 2, 1911.....	I m. 581
March 28, 1911.....	I m. 570	September 29, 1911.....	I m. 600

B.—CHEST.<sup>1</sup>

	A.	M.	D.
January 23, 1911.....	68—69	69—70	60—62
February 9, 1911.....	69—72	70—72	61—64
February 28, 1911.....	71—74	72—75	62—67
March 28, 1911.....	73—76	73—77	62—68
May 3, 1911.....	74—78	74—79	63—69
June 2, 1911.....	78—81	77—80	65—70

C—WEIGHT.<sup>2</sup>

January 23, 1911.....	36 k. 870	April 8, 1911.....	43 k. 300
February 9, 1911.....	37 k. 610	April 15, 1911.....	43 k. 940
February 17, 1911.....	38 k. 510	May 3, 1911.....	45 k. 230
February 28, 1911.....	38 k. 930	May 18, 1911.....	46 k. 330
March 16, 1911.....	40 k. 340	June 2, 1911.....	46 k. 250
March 28, 1911.....	41 k. 900		

So in reality the gains after four months were:

- (a) Height—o m. 031.
- (b) Chest—10—12; 8—10; 5—8.
- (c) Weight—9 k. 460.

<sup>1</sup>The measuring was done at three different heights—right beneath the arms (A), the breasts (M) and the diaphragm (D); whence the three groups of figures. In each of these the first number (68) represents the thoracic perimeter of the chest in repose; the second (69) indicates the development attained in the inhalation of a deep breath.

<sup>2</sup>The weight was always taken at the same hour, the patient being entirely nude.

## III.

As in all observation, minutely taken, with the unceasing endeavor of bringing to light methodically, patiently and without prejudice even apparently the most insignificant details, the interest in the fact which has just been expounded is decidedly enhanced by recognition of details. These, by their sequence, permit not only of tracing back to the origin of coryza, but also they make us understand its chronicity, its nature and they aid us in determining with exactness its importance.

From its hereditary antecedents the child naturally should have had a nervous temperament. But this last could not

have escaped being unfavorably influenced by the series of successive illnesses which made their appearance during the course of her early years. The attacks of appendicitis, the operation necessitated by them, lessened her general resistance. Finally, the kind of life led regularly by this patient rather than lessening, increased still more the pernicious action of these varied morbid factors.

One is struck by the degenerate condition of many of the organs. The functional derangements exhibited by the latter when viewed separately and superficially seem of little moment, on the other hand grouped together and viewed as a whole, they acquire importance and they bring to the light of day the pathology, otherwise obscure, of coryza.

In each of the branches of the organism concerned we notice indirect specific derangements. But whether it has to do with headaches or with permanent coldness of the lower extremities, with hemorrhages of the gums or delayed menstruation, of oligurie or of polakurie, with discoloration of the cutaneous and mucous membranes, with troubles in sleeping, with neuralgias, with instability of character, with constipation, or even with coryza, one is forced to recognize in all these symptoms, at first view so different, a closely correlated and common cause. All are overcome and relieved, I shall not hesitate to say, by insufficient respiration, the pernicious effect of which it is now my task to demonstrate.

*To explain*—Reduced in frequency and amplitude, respiration no longer guarantees complete haematosis. The blood, progressively impoverished, becomes more and more unfit in its task of nutrition. The entire system suffers simultaneously a similar attack. As a result the central and peripheral nervous system, motor and sensory, is altered in different degrees in its functions.

We pause for a moment with those difficulties which have to do with the secretions. These will be, according to the character and the duration of the respiratory insufficiency, increased or diminished, accelerated or retarded. This hypothesis, exclusively based upon physiology, makes us immediately seize upon the working of all the secretory disorders, be they

of a general nature or be they limited to the sections classified as the mucous membranes (respiratory, digestive, genital). The same reasoning and for precisely identical causes is applicable to the skin.

In addition to which does not the treatment furnish counter verification? As one refers to the results obtained, one notes that the close subordination among the well-verified symptoms bears obvious witness to insufficiency of respiration. In proportion, indeed, as the respiratory insufficiency is overcome the symptoms disappear proportionately, even for the most part giving way entirely.

*To sum up*—Coryza is never an illness in itself, well defined and always exactly comparable to itself. It is simply and most unfailingly one of the many manifestations of a change, either temporary or lasting, light or serious, in the general health.

Such a pathogenic conception greatly facilitates the explanation of the numerous forms of coryza. In fact, all reduces itself from that to a question of degree in the action of the cause, the etiological principle remaining invariable, as much for the slightest cold in the head as for ozena itself, and taking in thereby all intermediary stages.

According to type, coryza will be accompanied by variable changes in the composition of the tissues of the nasal passages, being able to pass from congestion with simple hypertrophy to atrophy affecting the bony framework itself.

Insufficient respiration plays an indispensable role in the genesis of coryza. To the proofs already provided elsewhere<sup>1</sup> let those brought forward to-day be added.

The chronicity of coryza in a child ought to be looked upon with particular suspicion. For its future is then endangered. If it points toward respiratory exercises the length of the treatment will often provoke simultaneously the hesitation of both parents and teachers. One will seek to enlighten both as to their real duties. In case of need one cannot but by insistence at once gentle and firm endeavor to obtain in the

---

<sup>1</sup>Marcel Natier. (a) Ozena and Respiratory Gymnastics (Transactions of the 32d Annual Meeting of the A. L. Assn., 1910). (b) Ozena Nutrition and Respiration. Etiology and Pathology. (Ibid., 1911).



fully comprehended interests of the young patient unanimous co-operation.

As analogous effects follow upon the action of identical causes, the better way to forestall against the possible return of coryza would be to avoid the causes which have brought about its appearance. It must happen that the repetition of the cure in each instance will be followed by no less favorable results.

Considered in its origin and also as to its progress, coryza ought then, without exception, to be kept within the province of general pathology. Also specialists and ordinary practitioners ought never to lose sight of this essential point in their therapeutic endeavors.

## A CONTRIBUTION TO THE PATHOGENESIS OF BRONCHIAL ASTHMA.

BY HENRY LEWIS WAGNER, SAN FRANCISCO.

In an able paper presented at the annual meeting of the Association of American Physicians in 1910, S. J. Meltzer\* took the position that bronchial asthma could be interpreted as resulting from an anaphylaxis, analogous to that which obtains in hay fever asthma—that the sufferer is sensitized to a specific substance, and that the asthmatic attack results from the toxic action of this substance (a specific proteid), even though this substance be incorporated in very minute quantities. A further interesting point made by the author was that bronchial asthma, arising from stenosis of the bronchioli, was of peripheral and not of central origin.

Meltzer based his conclusions on a series of experiments made upon animals by Auer and Lewis\*\* of the Department of Pharmacology and Physiology of the Rockefeller Institute. The results of these experiments were subsequently confirmed by Anderson and Schultz, and still later by Biedl and Krauss.\*\*\*

Confirmatory evidence of this "primary idiosyncrasy" or, as Friedberger† has termed it, "Constitutional hypersensitiveness," has recently come under my own observation in two cases of bronchial recurring asthma. One of these cases occurred in my own, the other in consultation practice. As both cases presented practically the same features I shall embody the history of both in one report.

Both patients were men of about middle age, one a lawyer and the other a laryngologist. Both were of nervous tem-

---

\*S. J. Meltzer: *Bronchial Asthma as a Phenomenon of Anaphylaxis.*—*Journal American Medical Association*, 1911, No. 12, Page 1021.

\*\*Anderson and Schultz: *Proc. Soc. exp. Biol. and Med.*, 1910, 7, 32.

\*\*\*Biedl and Krauss: *Wien. Klin. W.*, 1910, 385.

†Friedberger: *Deutsche Med. W.*, 1911, 4.

perament, though otherwise in good bodily health. Inquiry developed the fact that in neither case were the parents of either patient afflicted with asthma.

Both patients had, years ago, been freed of bronchial asthma through rhinological interference combined with general treatment. In both instances the treatment had proved effective. The one had enjoyed immunity from asthmatic attacks for some fourteen years, the other throughout a period of eight years. Diphtheria occurring in both their families about this time, each of the patients was given, as a prophylactic measure, an intramuscular abdominal injection of diphtheria antitoxin of 500 and 2,000 units respectively.

The effect in both cases was similar and noteworthy. Some four or six hours after the injection great restlessness and uneasiness was observed. There was a marked increase in both pulse rate and respiration. The temperature of the body was slightly elevated. The urine analysis gave normal results. In the case of one of the subjects blood pressure was taken and found to be lower than normal. This general picture lasted for about eight hours, and was followed by a seeming return to the normal. Between three and four days later, however, other symptoms of serum disease occurred, such as urticaria, similar eruptions near the place of the intramuscular injection, swelling of the inguinal glands, pains in the various joints of the body, and, in the case of one, a small quantity of albumen was detected in the urine along with some hyaline casts. In both cases there ensued a sudden onset of paroxysmal sneezing, followed in an hour or two by an acute attack of asthma.

The sequence of stages marking the progress of the attack in both cases seems to me to point inevitably to typical anaphylaxis in connection with bronchial asthma.

The period of incubation of the serum disease was comparatively short. Nothing abnormal was found in the mouth, pharynx or larynx, but in the nose an immense swelling of lower and middle turbinal was observed, which subsided on the application of novocain and suprarenalin solution. Coinci-

dent with this subsidence the asthma disappeared—but only for the time being:

We have here a diffuse sub-acute oedema within the nasal passages. Accepting Martin Fischer's view, this pathological process we may account for as follows: A poison introduced into the system had created a deficiency of oxygen, followed by an excessive production of acid, especially lactic acid. This increased amount of acid within the system caused the oedema by increased imbibition (*quellbarkeit*) of the tissues within the turbinals.

The progress of improvement in the various accompanying disorders was slow. The pains in the joints disappeared after four or five days. Subsequently the urticaria-like eruption with the glandular swellings of the groin subsided. But it was not until six or eight weeks of nasal treatment that the asthmatic attacks ceased.

I found nasal symptomatic treatment far more efficient than general treatment (i. e., than the use of atropin, iodides, heroin, etc.). This point is emphasized here because Auer and Lewis found that anaphylaxis could be prevented in animals by a preliminary injection of atropin.

The question also arises: Is there a state of "anti-anaphylaxis," of absolute "unsensitiveness" (*"unempfindlichkeit"*) after complete recovery from asthma, and if so, how long does it continue? Unfortunately the results of animal experiments shed no light on this important question. We know merely that the state of "unsensitiveness" (*unempfindlichkeit*) may at any moment pass into that of "hyper-sensitiveness." For this reason we should constantly be on our guard and extremely cautious in the use of antitoxins with persons whose history discloses asthma. Even a long period of freedom from attacks gives no indication or complete immunity. In cases that come within this category we should use Friedberger's method of slow injections or adopt the passive immunization process I dwelt on at our last meeting.\*

---

\*American Laryngol. Assoc. Transactions, 1911.

MALIGNANT DISEASES OF THE UPPER AIR PAS-  
SAGES, WITH NOTES UPON TWO CASES  
OF EPITHELIOMA.

BY J. PRICE-BROWN, M.D.

I present the subjects of this paper with diffidence, for already on three different occasions I have expressed my views and related my experience in the treatment of malignant diseases of the nose and throat to this association. I was beginning to think it was too old and trite a story to be inflicted upon you again. Still I had nothing else to write about, and when our President, in the exceeding goodness of his heart, intimated to me that an article upon any subject would be welcome, I concluded to try your patience once more.

I was encouraged, too, in choosing this subject by the strong advocacy of Voltolini's views, so forcibly presented and supported by Bryson-Delavan last year in his paper upon naso-pharyngeal fibroma. And particularly so when such men as Bosworth and Lincoln, Ruprecht and Tomassi, Woods and Doyen all give expression to the view that these growths should be removed by internal, not external, operations—electrical methods of one kind or other always having the preference when at all possible.

My argument is, judging from personal experience only, that the treatment so advocated for fibroma is equally applicable to sarcoma, and to a limited extent to epithelioma also, and that of all methods electrical treatment is the best. It may be by electrolysis, the cautery-snare or the electro-cautery knife, one or two or all three combined, but however arranged, in the hands of a skilled, careful and persistent operator, the success which will attend his efforts by these means will far exceed the beneficial results which he can obtain by any other method up to the present time evolved.

If you can do away with the preliminary external operation in naso-pharyngeal fibroma you can just as effectually do away

with a similar operation in naso-pharyngeal sarcoma. They grow alike, have a like origin in the soft tissues of the vault, and the injury to bony structures is more frequently that of pressure absorption than of malignancy within the bone itself. These remarks do not refer to malignancy within the antrum, which, of course, is an involvement of the bony walls and only amenable when practical at all to external operative treatment.

For twenty years I have advocated these views, and in the ten cases that I shall refer to each one has been treated solely by internal methods. Of course, I do not claim originality in the plan of operation, but I do claim to be the first to have carried out this method of treatment for such a prolonged period in so many cases and with such gratifying results.

Twenty-five years ago Bosworth and Lincoln both strongly advocated the use of the electro-cautery ecraseur in both fibroma and sarcoma of the naso-pharynx. Fourteen collated cases of fibroma are given in which eleven were cured and three recurred.

Of sarcoma of the nose treated in the same way the following are reported:

Rabetsch I. Removed with galvano-cautery snare. No subsequent report.

Lincoln I. In which two operations had been previously done, followed each time by recurrence. Lincoln then resorted to the electro-cautery loop and subsequently the electro-cautery knife, with complete success.

Schmiegelow I. Removed by electro-cautery snare. No return in seven months.

Major I. Galvano-cautery. No return in four months.

Bosworth I. Galvano-cautery knife. No return in a year. Also one removed digitally and by curette. No return in six months.

In naso-pharynx—

Lincoln I. Removed by galvano-cautery snare. No subsequent report.

Massei I. Galvano-cautery snare. No subsequent report.

Bosworth I. Cured by oft-repeated use of the galvano-cautery knife and forceps piecemeal. No return in seven years.

My first case, one of nasal sarcoma, came to me twenty years

ago, when Bosworth's elaborate treatise was new in my hands. I need not dwell upon it now, as I reported it to this association in my first paper upon the subject, except to say that the growth was very large, was located in the right nasal passage, that the treatment consisted in the alternate use of electrolysis and the galvano-cautery, that it took more than six months to remove it. There has been no return, and the man is still in the enjoyment of excellent health.

Ten years elapsed. Then cases two and three came almost together. During that period the trend toward radical operation had developed. Fortunately my experience in case one had given me faith, and I tried it again; chiefly the galvano-cautery part. Case two recovered as the result of three months' treatment.

Case three required electro-cauterization upon the site of the original growth, to be repeated at intervals for six years, before the tendency to return was conquered. But it is now four years since he last received treatment. And both of these men are well to-day.

Five years later case four was placed under my care. The growth was removed in similar fashion. The freedom of the nasal passage was restored, and there was no perceptible recurrence, but the patient died two months later from septicemia, induced partially by chronic suppuration of the antrum.

Next came cases five, six and seven, reported at our meeting in Boston three years ago. Case five was cured in a very few weeks by successive electro-cauterizations. The only deformity left was an internal one—the destruction of a large portion of the septum, to which the growth was attached. The external nose is normal, and the man is in the enjoyment of excellent health.

In case six vegetations at the site of origin of the tumor continued to recur, but these were very thoroughly burned away by electro-cautery each time that they appeared. I presume now that the vitality of the neoplasm has been conquered, for there has been no return whatever during the last nine months.

Case seven was the one in which the common carotid was tied one year after commencing treatment, on account of excessive hemorrhage. This is two years ago now. Although the tying of the artery saved the man's life at the time, it did not put an end

to the redevelopment of the sarcoma, for it still persisted in showing itself at the junction of the posterior choanae with the vault of the pharynx, calling for renewal of the cauterizations. The last, however, was done three and a half months ago, and at the present time there is no sign of redevelopment. Both these young men are now the pictures of robust health, as their appearance in the last issue of the Transactions indicated a year ago. All these cases presented the usual classical signs. All but one had been operated upon by other surgeons before coming to me. All, without exception, were pronounced cases of sarcoma by competent pathologists after careful microscopical examination, thus verifying the clinical diagnosis.

I now come to case eight, sarcoma of the larynx, which I reported to the association last year. To be brief, two weeks after our meeting in Philadelphia in June, 1911, the man was well enough to return to his regular occupation as lithographer, and to continue at it for the ensuing five months. During all this period, however, I was required to repeat the destructive operations once or twice a week. If a longer interval was allowed to elapse, the vegetations would increase so rapidly within and without the left side of the larynx that respiration would be seriously impaired. Still, during all this time, he enjoyed fairly good health, had a normal appetite and easy deglutition.

On January 2 last he had a deeper cauterization than usual in the region of the left ventricular band, above the vocal cords, and also external to the left aryepiglottic fold. On the following day, while at work, he had a severe chill, compelling him to leave the shop and return home. The temperature, which had all along been about normal, ran up quickly to 104.5. He became very ill. Impending suffocation followed. The breath became foul and the neck on the affected side became tender, red, brawny and swollen up level with the jaw. It looked like a severe case of localized erysipelas, with rapid extension of the disease. I considered the case at last to be hopeless, and expected a speedy euthanasia.

But a change came. In a couple of days the fever abated. The swelling commenced to go down and the patient spat off successive pieces of putrid tissue. Deglutition and respiration im-



proved, and two weeks later the patient returned to my office in good spirits.

On examination I found that large masses of sarcomatous tissue had sloughed away. The affected surfaces looked clean and healthy and but little of the tumor was visible. The neck was much smaller and the glands had shrunk. I kept the case under observation, and for another two weeks there was no reaccession of growth. It looked as though the erysipelatous inflammation—*bacillus prodigiosus* like—had made a finishing case of the disease.

But it was not so. For five weeks there were no burnings. Then the life buds of the degenerate appeared again. Once more the gland commenced to enlarge. And from then until now burnings have been resumed.

Three weeks ago, as a last resort, I concluded to try the effect of radium once more. This time as an adjunct to the cautery treatment. The patient has had during this period twenty milligrams of bromide of radium strapped on his neck over the enlarged gland for a period in all of seventy-two hours, at the rate of about five hours a day. During the same time he has had one cauterization of the laryngeal growth per week.

I can only say that the conditions are encouraging, but it is too soon to hazard an opinion on the probable result. Physically the man continues well and hopeful.

The new cases, nine and ten, are both epitheliomata.

Case nine, M, F, plasterer, age 72, was referred to me at the Western Hospital on November 16, 1911, complaining of a large growth in the left side of the throat, which produced difficulty in swallowing and was attended by pains shooting up into the ear.

On examination I found an ulcerated tumor occupying the place of the left faucial tonsil, including both anterior and posterior pillars, and attached to the side of the tongue and part of the posterior wall of the pharynx as far down as the back of the thyroid. The growth appeared first about a year ago, but during the last few months it has grown rapidly. As the external glands were only slightly swollen and the patient physically was in a fair condition of health, I considered it a better case for combined internal operation than for a radical external one.

The first operation was on the 19th, three days after admission. It was divided into three stages. First, under ether, at my request, Dr. Beatty tied the common carotid in order to control subsequent hemorrhage. Second, while the patient was still unconscious, chloroform was substituted for ether, and I dissected out as much of the tumor through the mouth as I could. Third, I cauterized the base of the growth with the electro-cautery at a white heat. It was impossible to remove every portion of the growth at this operation. Still it cleared the way widely for future effort. There was much hemorrhage notwithstanding the ligation of the artery. The patient came out of the anesthetic well, suffered little pain and expressed himself as more comfortable than he had been for weeks. Soft food was readily taken and he slept well.

During the next two months there were a number of cauterizations with the electro-cautery, all under cocaine, the intervals between the treatments gradually increasing in length. The last was done on January 19, exactly two months after the first operation, the intention being to destroy all reforming epitheliomatous granulations.

Three days after the last cauterization an event similar to the one recorded of case eight occurred. The external throat condition became almost identical, while deglutition and respiration remained almost unimpaired. My impression was that the deep tissues of the neck, which could not be reached by operation, had become involved, and as swallowing and breathing could be carried on the best thing the patient could do would be to return to his home in the country and under the care of his physician await the end.

Six weeks later his doctor wrote me that the neck finally broke and discharged very freely, thereby relieving the patient. He was in other respects much the same, although he said that the tumor in the throat was again reforming. The patient himself wrote me that he was coming down soon to see me. Since then he has grown rapidly worse. The end is near.

The pathologist pronounced the disease epithelioma.

Case ten, the last of the series, is a particularly interesting one.

On January 31, 1912, Mrs. W. J. L., aged 52, a lady of culture and means, formerly a distinguished vocalist who had been a throat patient of mine off and on for twenty years, consulted me about a growth in her right nostril. It had been coming on for a number of weeks. It was much inflamed, occluding the passage and attended by stinging pains which shot up into the ear and side of the face.

On examination I found the central portion of the inner aspect of the right alar and lateral cartilages covered by a reddish, irritable growth, the thickness of a quarter of an inch, and coated with muco-pus. On cleaning the part and applying cocaine and adrenalin the growth became clearly defined. It was circumscribed and flat, leaving a clear margin of mucous membrane above and below and backwards between it and the anterior margin of the nasal bone. The nostrils of the lady were clearly defined and delicately formed, but this wing of the nose was altogether more than three times the thickness of the other in its central portion. The redness extended all over the ala of the nose outside as well as in, and even the external skin was tender.

I decided, as it was growing rapidly, to operate the next day. Chloroform was administered. I then excised the growth with a scalpel. Bleeding was quite free. As soon as this abated, the patient, still under the anesthetic, I applied the electro-cautery very freely over the inner surface and destroyed every portion of suspicious-looking tissue.

The pathologist made a very careful examination of the growth and pronounced it a case of undoubted epithelioma.

On coming out of the anesthetic the patient was fairly comfortable and declared herself completely relieved of the stinging pains. The only application was simple white vaseline.

A few days later the patient came to my office, and as suspicious granulations had formed I cauterized two or three under cocaine. Six days later this was repeated. No further development occurred for thirty-two days, when spots were cauterized again. Two weeks later there was a more visible return of the growth in the form of a small ulcer on the top of an inflamed central area. So I decided to remove it again under chloroform

the next day. But when twenty-four hours had passed it had trebled in size. Again it was removed by electro-cautery. In three more days there was another return, with a slight extension to the very margin of the nostril. Again the chloroform and again the cautery to each portion more effectually than ever.

Notwithstanding all these severe burnings no part of the cuticle had been sacrificed, neither had any portion of the normal cartilage been destroyed. The contour of the nose would still be perfect if the regrowth could only be arrested. But I began to realize that while the growth could be positively destroyed with the electro-cautery, it was very doubtful if by its use alone redevelopment could be prevented.

So I decided to call in the assistance of the radiologist. Dr. Aikins kindly came to my aid at once, and before the granulations had time to form again he applied twenty milligrams of the bromide externally and a tube in the passage. I need not enter into the particulars of his treatment. But I may say that for the past six weeks the patient has been under our mutual control, and by the careful and painstaking management no suspicious granulations whatever have formed during that period. It looks at last like a cure, but no doubt careful watching will be required for some time yet to insure so favorable a result.

It may be asked why, in this last case, did I not resort to the use of radium at the very first? My answer is that I feared any delay might be disastrous. The delicate tissues of the nostril were so deeply involved that immediate destruction of the malignant growth became imperative, and the action of the cautery would be positively quicker than the action of radium. This, I believe firmly, while at the same time it is equally clear, from the history of this case, that the judicious use of radium has prevented the reformation of the malignant granulations.

The amount of radium used might be estimated at one centigramme for twenty-four hours. The total number of applications being five—a cross-fire being induced by a plaque of the bromide of radium being placed outside and a tube within the nasal passage.

*Reports of Ten Cases Treated with Galvano-Cautery.*

No.	Sex	Age	Duration When First Seen	Diagnosis from Path. Reports, Etc.	Period When Oper's Were Done	How Long Since Last Oper.	Present Condition if Alive	Result	Remarks
1	M	23	4 Years	Sarcoma of Nose	6 Mths	19 Yrs	Excellent	Cure	Strong Well
2	M	50	2 Years	Nasal Sarcoma	2 Mths	10 Yrs	Fair	Cure	General Break Up of System Old Age
3	M	21	3 Years	Nasal Sarcoma	6 Years	4 Years	Very Good	Cure	Strong Stout Well
4	M	58	A Year	Sarcoma of Nose	6 Weeks	Lived 2 Mths After		Death	No Return of Growth Died of Septicem
5	M	35	9 Mths	Nasal Sarcoma	2 Mths	2¼ Yrs	Good	Cure	Ordinary Health
6	M	21	Several Years	Sarcoma of Nose and Naso-Phar	2¼ Yrs	9 Mths	Very Good	Not Yet Cert.	Too Soon to be Sure
7	M	18	Several Years	Sarcoma of Naso-Phar. and Nose	2¼ Yrs	3 Mths	Very Good	Not Yet Cert.	Too Soon to be Sure
8	M	21	3 Mths	Sarcoma of Larynx	15 Mths	3 Days	Fair	Doubtful.	Not Much Hope
9	M	72	Nearly a Year	Epith. of Pharynx	2 Mths	4 Mths	Unfavorable	Prognosis Hopeless	Treatment Prolonged Life
10	F	52	A Few Weeks	Epith. of Nose	3 Mths 2 Caut. and 1 Rad.	Still Treated by Rad.	Good health	Prog. Good	Caut. Des. Growth. Rad. Prev. Return

*Discussion.*

Dr. C. G. Coakley, New York City: These cases are certainly most interesting and instructive, and from my experience with malignant cases the question has divided itself into sarcoma and epithelioma. Sarcomata vary greatly in malignancy and are difficult to diagnose, and we are frequently led to make these diagnoses when we have to do with a granuloma from some other source. This has been my experience more than once. Only recently we had occasion to see a case of sarcoma of the tonsil which had been treated by cauterization in one of the Southern States and the real condition was not recognized until a piece had been examined and a diagnosis of sarcoma made by the pathologist. I saw the case in conjunction with Dr. Erdman; then the

left tonsil had a large crevice filled with grayish material where apparently operation had been done; there was moderate enlargement in the glands of the neck, loss of weight, and gastric disturbance. Dr. Erdman, although he could feel nothing on abdominal palpation, felt that any work in the neck was useless unless we could be sure there was no metastasis in the abdomen. Exploratory laparotomy disclosed a mass about 3 inches in diameter on the posterior wall of the stomach, but unfortunately no section was taken. There were numerous enlarged glands, several of which were removed. Some of these glands were as large as a horse-chestnut. One of the smaller ones he opened and found to be cheesy. We gave this to the pathologist, and to our surprise the report came back tuberculous gland, not sarcoma at all. The patient recovered from this operation, went South, and returned to us in six weeks. The tonsil was smaller, the glands in the neck were very much smaller, but he had a metastasis in the stomach and died in a few weeks. In this particular case the diagnosis from the pathologist at autopsy was sarcoma. I took out a section of the tumor for examination, submitted it to a pathologist who did not know what it was, not being sure whether it was malignant or not, but considered it suspicious; three well known pathologists in New York examined it and two finally came to the conclusion of sarcoma, and one of them said it was not sarcoma, but endothelioma. I simply recount this case as an illustration of the difficulty of getting an absolutely correct pathological report.

I had another case of what to my mind was sarcoma, an enormous mass of glands in the neck with enlargement of the tonsil projecting into the pharynx. I suggested taking out the tonsil as a means of finding out the true condition. I removed it under cocaine, and the pathological report was simply an enormous increase of lymph cells in the tonsil. The glands in the neck were taken out "en masse" two or three months later, and were sarcomatous. Later on there was metastasis in the stump of the tonsil, which was unquestionably sarcomatous.

I have another case of sarcoma in a comparatively young woman in whom Jonathan Wright made a diagnosis of sarcoma of some tissue removed ten or twelve years ago. There were two recurrences within two or three years, then she went along until last year, when there was a small recurrence at the tip of the velum which was removed by a cold wire snare, and she has been perfectly comfortable since.

Sarcoma is much more amenable to treatment than is epithelioma. In the author's case, aged 52 years, my prognosis would be grave in spite of the use of radium, for I think it is only of

service in superficial skin epitheliomata and the hard, chronic, slow growing types, where anything taking away the growth in the rapidly growing types in young people.

Dr. John O. Roe, Rochester, N. Y.: The use of the galvano-cautery is, in my opinion, the ideal method of removing malignant growths, for the reason that the cautery destroys all the malignant tissues that it comes in contact with as it goes along, and seals up the tissues and thereby prevents further infection, whereas by use of the knife you liberate any infection that may be present and by opening up the tissues facilitate its further spread. During the past year I have had two cases of epithelioma of the tonsils which I removed with the galvano-cautery. In both cases it was the right tonsil that was the seat of the disease. In one case the surrounding faucial tissues were so extensively involved, including the base of the tongue, that an operation with the knife was not regarded as warrantable. In this case there was much pain on that side of the neck, although little or no glandular involvement, and the scalp was so sensitive on the right side that the patient was obliged to wear a skull cap as a protection from draughts. In this case I removed, with the cautery knife at the first sitting, all the diseased tissue that I could readily get out; afterwards, at different sittings, whenever I discovered any reformation of the growth, I removed it as completely as possible, until finally the parts healed, leaving no evidence of the disease in the throat.

Examination of the growth by the pathologist showed it to be an epithelioma. The man remained well for a year, when there was a recurrence in the deeper glands of the neck. These were immediately removed, but the operation was a difficult one, owing to their proximity to the carotid artery, jugular vein and pneumogastric nerve, but every gland was removed that could be found. The wound healed nicely and the patient was quite well for three or four months, when the disease recurred in the deep cervical and mediastinal glands, and the patient succumbed a few months afterwards. The fact, however, that the patient remained well for about a year and a half after the original removal of the growth in the throat by the galvano-cautery shows its value in the treatment of such cases.

The second case was quite similar to this one, and the parts behaved about the same after the radical removal with the cautery. The disease, however, recurred in the glands of the neck, about nine months afterwards. When the throat had become healed after the removal of the growth with the

cautery the patient disappeared, and when I saw him again the entire neck on that side was so extensively involved that further operative treatment was out of the question. In both cases I felt morally certain that had I seen the patient at the beginning of the disease, when it was comparatively localized in the tonsil, that the radical removal with the galvano-cautery would have effected a permanent cure.

I want to congratulate Dr. Brown upon the excellent results he has had in the cases he has reported, demonstrating that the use of the galvano-cautery in these cases has given him better results than he could hope to obtain in any other way.

Dr. Harmon Smith, New York City: I think some of the beneficial results reported at times in sarcoma are probably due to the errors of an inexperienced pathologist, in so far that the pathologist, who is not accustomed to the examination of small pieces of tissue from the lymphoid region, will mistake frequently the condition which exists. No lesser authority than Dr. Jonathan Wright has made such a mistake, and has pronounced as sarcoma a tumor which has gotten well under anti-syphilitic treatment. Syphilitic tumors, microscopically, resemble sarcoma very closely. I had a case recently sent to me from the South for operation. Six weeks previously the pathologist had pronounced the specimen a hyperplastic lymphoid growth of the right nasal chamber. On removing a piece of this growth on my first examination the pathologist at the Manhattan Eye, Ear and Throat Hospital pronounced it small, round, cell sarcoma. Dr. Jonathan Wright, who consulted in the case, said it was not typical, although of a corresponding character. Consultants have agreed that it has gone beyond operative measures. The specialist referring this case to me is one of unquestioned ability in the South, and had had several specimens examined, but the small sections examined did not go to the base of the growth, or the pathologist was unaccustomed to making reports on a small piece of lymphoid tissue.

Dr. D. Bryson Delavan, New York City: These remarks illustrate the great importance of accurate and fine diagnosis in the recognition of new growths in this part of the body. Sarcomas vary in malignancy, as do epitheliomas, but to a much greater degree. There are on record, and doubtless have occurred in all our experiences, cases of sarcoma recovering after various treatments. I can myself recall numerous instances, and they are to be found commonly in the literature. Certain types may be cured, and remain so permanently. At the present moment, in view of our knowledge of the treat-



ment of epitheliomas, they are not curable. Yet they vary in activity and in importance. About twenty years ago I had a patient twelve years of age who had an angiosarcoma of the nose. I turned him over to a distinguished operator, who removed the growth, which promptly recurred. Again, the same operator removed the superior maxilla, with apparently the removal of all the diseased tissue, but the disease again recurred. At this period there was nothing left to remove, and the case seemed hopeless, but we put him in the hands of Dr. Coley, and, to make a long story short, he underwent a very active and persistent course of treatment by the toxins of erysipelas and streptococcus prodigiosus, which was attended by great reaction. It resulted, however, in the cure of the patient. He was in my office the other day—a middle-aged man of family and absolutely well. The use of the toxins in that case undoubtedly seemed to have a curative effect. This case was treated before Dr. Coley had accumulated the experience which twenty years have now given him. At the present time he has fifty or sixty such cases to his credit.

With regard to the use of radium, I will not refer to it at the present time, except to say that in my own experience in epitheliomata it has been absolutely useless, however valuable in other forms of tumor.

With regard to epithelioma I would like to allude to a certain case. Ten years ago Dr. Mayer sent to me a gentleman with a nodular area on the tip of the epiglottis, about one-quarter of an inch in diameter. This patient went abroad and had the growth removed, including one-third of the epiglottis. Every vestige of the growth was excised. For nine years the patient remained well. Then recurrence took place in the neck. Without going further into the history, this case brings up the following question: Was that original nodule a purely local condition, or was it the result of some general condition which never was done away with by the removal of the local manifestation, but still remained in his system, to break out years later into a violent and rapidly increasing epithelial disease?

Dr. J. Price-Brown, Toronto, Canada (in closing): With regard to Dr. Coakley's remarks on the diagnosis of sarcoma I would say that the cases I mention could not be cases of tuberculosis. There is certainly in some cases great difficulty in diagnosing sarcoma. We cannot always be sure of our pathological reports. However, if we combine the findings of the pathologist with the clinical history of the case, we can generally arrive at a fairly safe conclusion. With regard to that case of epithelioma of the nose, I want to impress that one

point, namely, that I had to use the cautery over and over again, and yet as soon as the radium was employed there appeared an abeyance of symptoms, for there has been no return of granulations. The mucous membrane is smooth and the nostril is perfectly clear. I have sufficient faith to believe this case may get well. Some physicians, particularly our French confrere, say epithelioma of the skin can be cured by radium, but this is so near the skin, the wall of the nostril being only one-eighth of an inch thick, that if radium has any effect it should be good in this position.

I am glad Dr. Roe supported the electric cautery methods. The fact that by their use you destroy any possibility of auto-infection is a great thing, and you also control blood vessels, so that the hemorrhage following operation is practically nil.

In regard to syphilis, it is the one thing that sarcomatous cases are supposed to be mistaken for. In all these cases I have reported, not a case has been treated anti-syphilitically. We know syphilis cannot be cured by local operations, and the patients have given the history recorded. With regard to the use of Coley's toxin, I used it once, but not in any of these cases; it was in a case of sarcoma of the antrum, and had no effect.

(a) HAEMOPHILIA SUCCESSFULLY TREATED BY  
TRANSFUSION.

(b) NASAL SARCOMA.

BY WALTER F. CHAPPELL.

The patient whose history I am presenting may not be classed as a true haemophilic, as there is no hereditary influence discoverable in his family, but some have described these cases as temporary bleeders.

Fred Killian, Bohemian, 18 years old, eight months in the United States. His parents are alive and well, and there is no history of haemophilia in parents, grandparents or brothers and sisters. He has three brothers and two sisters, all of whom are alive and well.

*Previous History*—He had measles in childhood, also diphtheria.

*Present History*—During the past six years he has had repeated attacks of nose bleed every two, three or four months, principally from the left nostril. After the bleeding had continued for some time the blood also came out of the right nostril. The bleeding usually lasted three or four hours, and it was generally necessary for him to go to a physician's office, who often had considerable difficulty in controlling it.

On February 5, 1912, he came to the Manhattan Eye, Ear and Throat Hospital and was admitted to my service under care of Dr. Gerhard H. Cocks. He was bleeding profusely from the left nostril, and stated that it had continued for one month every second or third day, and for a period of ten or twelve hours. This time his nose had been bleeding continuously for thirty-two hours.

He was extremely pale, and his face was almost as white as a sheet. Pulse, 120.

*Examination of the Nose*—The nose showed a long, ridged spur along the floor of the left nostril. There was a continuous oozing from the whole anterior portion of the septum and from a spot on the anterior end of the inferior turbinate about the size

of a ten cent piece. There was apparently a third spot further back on the floor of the nose, where there was also oozing. There was no special bleeding vessel to be seen. The left nostril was packed with gauze, saturated with fresh human blood serum. This controlled the bleeding in about one-fourth of an hour. 20 c. c. of the freshly prepared blood serum of the brother was also injected into the patient's arm, intravenously.

The blood pressure on admission was 110, the haemoglobin was 35 per cent and the red blood cells 2,784,000.



Fig. 1—F. K. After transfusion.

February 6—The packing, which had been in the nose for almost twenty-four hours, was removed and three hours later the patient began to bleed again. At 6 o'clock P. M. 18 c. c. of human serum was injected, intravenously, and the nose was again packed with gauze, thus controlling the hemorrhage.

February 7.—The packing was removed, and an hour later the nose began to bleed. He was then given 18 c. c. of fresh rabbit serum, intravenously, twice a day.

February 8, 9 and 10—He was given 20 c. c. of fresh rabbit serum, intravenously, twice a day.

February 8—There was a slight oozing.

February 9—There was practically no bleeding, except a few large clots were removed from the nose.

February 10—Bleeding practically ceased. As the patient had had blood serum, intravenously, almost continuously for six days, part of that time as much as 40 c. c. a day, it was not thought advisable to continue this method of treatment any longer.

February 12—At 4.00 A. M. the patient began to bleed very profusely from the left nostril. Dr. Stuckey partially controlled the hemorrhage with gauze soaked in blood serum. The doctor said that the blood welled out of the left nostril as fast as he could wipe it away. At 11.00 A. M., as the oozing still continued, 30 grains of lactate of calcium was ordered by mouth, and 15 grains of the same drug were given twice a day for two days.

February 13, 14 and 15—Practically no bleeding.

On February 16 the nose was examined, and clots removed from both nostrils; there was some oozing from a small vessel at the anterior part of the septum of the left nostril, which was controlled by actual cautery. This was the only time while the patient was under observation that there was any bleeding vessel seen, and this vessel was very small. The bleeding was always an oozing, and from almost the entire septum and sometimes the inferior turbinate.

On the 17th, during the night, there was a profuse bleeding from the whole left side of the septum. This was controlled by peroxide and plain gauze packing, after which plain gauze packing was inserted. In spite of packing the oozing continued.

On the 18th there was no bleeding.

On the 19th there was a slight oozing again, and on the 20th there was a very profuse hemorrhage, and it was necessary to pack the nose twice before the bleeding could be controlled.

On the 20th there was another profuse hemorrhage, which was partially controlled by gauze packing.

On the 21st the oozing continued, the nose was repacked with

cotton, moistened with peroxide. In addition to the nasal hemorrhage there was a slight bleeding from gums and lips, and it was now realized that the patient's condition was becoming desperate, and that the measures heretofore tried were not sufficient to control the bleeding. It was therefore decided to transfuse the patient with the brother's blood.

On February 22 this operation (transfusion) was performed by the consulting surgeon, Dr. Brewer, assisted by Dr. Phelps. The blood was run in from the exposed artery to the patient's vein for twenty-eight minutes. Before operation the patient's haemoglobin was 30 per cent; after operation it was 65 per cent. At the conclusion of the operation the change for the better in the patient's condition was most noticeable. The color came back into his lips, cheeks and ears. Before the patient was sent back to the ward the nose was packed with gauze, and this packing was allowed to remain in the nose four or five days. A slight oozing from the lips and gums persisted for three or four days after the operation, and on February 24 he had some bleeding from the nose, and also on the 25th. On February 28 there was a profuse bleeding from the arm, which was with difficulty controlled by adrenalin and thrombokinase and with pressure by a gauze pad. He developed a large haematoma on the arm.

On February 29 there was again some bleeding from the mouth and from the nose, making it necessary to pack again. Patient had no more hemorrhage until March 8, when there was a slight oozing. He was discharged from the hospital on March 30 practically cured, and up to the present time has remained perfectly well. (A photograph showing his robust condition is passed.) Now and then he has a slight oozing from the nose, which he himself has learned to control by putting a little piece of cotton in the nose. At the present writing it is over a month since the patient returned to his home. In the first week or two after he went home he had one or two minor hemorrhages, but since these occurred he has been perfectly well.

Blood transfusion has been recommended for many different diseases, but was not very generally employed, as so many deaths followed its use. In view of the modern blood tests before trans-

fusion, it has now become a reasonably safe method of saving life. Some years ago a prominent young man of New York City died from hemorrhage of the nasal passage. All the known remedies and methods were tried with no avail. Transfusion was suggested but rejected by several surgeons on the ground that it would surely prove fatal. I have not been able to find a case where it has been used for severe nasal bleeding, but in view of our blood tests for hemolysis and agglutination it certainly may be of great service in a desperate case.

(b) *Nasal Sarcoma.*

John Alden, age 11, was admitted to the Manhattan Eye, Ear and Throat Hospital September 18, 1911.

*Family History*—Father and mother living. Grandmother, on maternal side, died of cancer; grandfather, on paternal side, died of "rapid" consumption.

*Previous History*—Had measles at three years of age, and has never been strong.

*Present History*—About two years ago began to have trouble in nasal breathing, but nothing was done about it until a year ago, when the parents consulted a doctor, who gave a spray. The mouth breathing increased and a moderate muco-purulent discharge appeared. A few weeks before entering the hospital he had a number of nasal hemorrhages, and just before entering had two severe ones. These, together with the nasal obstruction, caused the boy to be sent to the hospital. There has been no pain.

*Condition on Admission*—Pale and of slight build. He was septic, and looked very ill. Temperature, 104; pulse, 152; R 32. The left malar region was more prominent than the right, and slight protrusion of the left eye was noticed, and tears had overflowed on to the cheek for past months. A muco-purulent discharge came from the left anterior nares. On examination the left nasal passage was found filled with a soft, grayish white mass, covered with considerable necrotic tissue, which extended from the floor of the nose to the ethmoid region. It bled profusely on touching with a probe, and in the lower part of the growth pulsa-

tions could be seen. The site of origin could not be definitely determined, but seemed to be located on the antral side of the nasal passage. The portion next to the septum was slightly movable. The nasal septum deviated to the right and infringed on the turbinates.

There was complete lack of nasal breathing on the left side, and a very slight amount on the right. On pressure a small amount of tenderness was present over the left malar region,



Fig. 2.—J. H.—Nasal sarcoma. Appearance in quiescent stage following operation and use of Coley's serum.

frontal sinus and nasal bones. The nasal bones were slightly separated. No view of the posterior nares could be obtained. Adenoids and tonsils were present. There was no bulging of the palate.

*Course of Disease*—On September 22, 1911, Dr. Jonathan Wright reported that a section which had been removed was a "granuloma syphilitic," but did not feel definite about it. Another section, taken a week later, was accompanied by a severe hemorrhage, and Dr. Wright reported it as "a malignant connective



tissue growth, probably a fibro-sarcoma." On admission the patient was put to bed and placed on a liquid diet. Hot normal saline irrigations, followed by five drops of adrenalin in the nose, were ordered three times a day. The temperature dropped from 104, on admission, to 99 at the end of forty-eight hours.

September 21—Three minims of Coley's serum were given at 6.30 P. M. The temperature was then 100 F. It dropped to 98, and then rose to 105 at the end of thirty hours. No chill was present, but the patient complained of his arm being stiff and sore. The temperature did not reach normal until the evening of the 25th. The serum was again given—three minims—on the 29th. No reaction.

September 26—Radiograph taken. No. 375-376. Dr. Law reports: "Frontal sinus involved—right ethmoid. Inner border of left orbit destroyed—left antrum involved."

September 30—A Wassermann reaction was negative, but the mixed treatment was prescribed, and applications of monochloroacetic acid made and continued until October 15, when the general condition was considered better and the growth seemed to have decreased in size, so that a small amount of air could be drawn through the left nasal passage.

October 15—Another section was taken from the tumor, accompanied by hemorrhage. Dr. Strong reported it as a case of "fibro-sarcoma of slight grade of activity." The Coley's serum was continued every second day; five minims each dose.

October 18—Another radiograph taken. No. 426-427. Dr. Law's report shows "lessening of trouble in left antrum and slight lessening in frontals. There seems to be slight difference in nasal condition, the bony septum showing clearer."

By the middle of November the serum had been increased to eleven minims, and during this time the general condition had improved and the patient was able to walk around the ward. After the slight initial improvement the nasal growth began to enlarge, and had now reached such a size that it projected from the anterior nares and appeared a freely movable tuft one-fourth inch wide and three-fourths in length.

The eleven minims of serum caused some reaction, so it was reduced to ten and discontinued on November 21. On the morn-

ing of the 19th of November the patient complained of earache in the right ear and temperature rose to 102. He was referred to Dr. Duel's service for treatment of the aural condition. Hot irrigations were used and the ear soon began to discharge. An acute mastoiditis developed and on November 22, he was operated upon for that condition by Dr. Duel. During the induction of the anaesthetic there was a severe epistaxis, which required packing both nasal passages anteriorly and posteriorly. The usual post auricular incision was used. Cortex removed and also tip of mastoid. The cells were filled with a peculiar firm yellowish matter, not unlike granulation tissue. Dr. Strong reported that the smear showed culture of streptococci. The antrum was roughly cleaned out, as the patient was in a bad condition. No sutures were used and moist dressings applied. Patient returned to ward in critical condition, P. 170, R. 34. Following this the boy made an uneventful recovery, as far as the mastoid wound was concerned.

Immediately after the mastoid was opened, the condition of the nasal tumor began to improve and seemed to melt away. By the middle of December he had good nasal breathing on both sides, and by January 15, 1912, the tumor had seemingly disappeared, but on careful examination a small, smooth tumor could be seen on the external wall of the passage at the junction of the middle and posterior third.

This mass was smooth and had every appearance of being a fibrous mass. The boy grew, took on weight, looked and seemed as strong as any boy of his age. The photograph shows his condition the latter part of April. The partial disappearance of this large fibro-sarcoma and the boy's restoration to apparently a normal state was somewhat of a mystery to me, but it has been suggested that during his attack of suppurative mastoiditis a vaccine was manufactured which, in part, destroyed the growth. Some two weeks ago it was thought best to remove the tonsils and adenoids. Since the operation the boy has not seemed quite so well and it is suspected that the fibrous mass in the left nasal passage has increased in size. It is possible that the operation in the nasopharynx may have stimulated a return of the growth. I am indebted to the junior surgeon of my clinic, Dr. Edgar H. Farr, for the notes in the case.

REPORT OF A CASE OF BRONCHOSCOPY FOR MULTIPLE FOREIGN BODIES (ALMOND SHELL AND PULP) IN A CHILD TWO YEARS OF AGE, WITH SOME OBSERVATIONS UPON BRONCHOSCOPY IN INFANTS AND YOUNG CHILDREN.

BY JOHN R. WINSLOW, M.D.

On January 5, 1911, at 2 p. m., in accordance with a telegraphic appointment, I met Dr. F. G. Wright, of Chambersburg, Pa., at the University Hospital in consultation upon the case whose history follows:

Iona B., aged 2 years, was playing upon the floor two days previously, when her mother's attention was attracted by her crying, and she noticed that the child was blue in the face and breathing badly. She immediately held the child up by its feet, slapped her back and running her finger down the throat removed a large amount of almond shell and pulp; this resulted in greatly improved respiration, and the mother supposed that the nut had all been removed.

Since this time, however, the child has at times exhibited embarrassed respiration and occasionally cyanosis.

Examination:

Respiratory movements much shallower on left side and respiratory sounds lost below the second rib, no rales present; temp., 98 2-5; pulse, 118; resp., 28. Slight supra-clavicular retraction on left. Right lung normal.

The patient was admitted to the University Hospital and the larynx examined under cocaine with the direct Jackson's speculum. Nothing was seen in the glottic or subglottic space, and realizing the impossibility of passing a bronchoscope through a larynx of such size without undue force, tracheotomy was determined upon.

Meanwhile a radiograph was obtained, which, as was to be expected from the nature of the object (nut), revealed no foreign body, but only enlarged peribronchial glands.

On January 6, 1911, at 3 P. M., I performed a low tracheotomy, assisted by Dr. F. G. Wright, under chloroform anesthesia.

Immediately afterwards, with Dr. H. C. Davis in charge of the patient's head and the bronchoscopes, I passed a 7 m. m. Jackson's tube into the left lower lobe bronchus, which was systematically examined; the tube was, however, too large to enter the upper lobe bronchus. A considerable amount of milky pulp was found in the bronchus and removed with mops; no shell could be discovered.

I had expected to employ suction with Killian's aspirator, in the hope of aspirating the material from the smaller bronchus, but the patient became cyanotic, the pulse weak, and oxygen and amyl nitrate had to be administered.

The bronchoscopic examination was of necessity discontinued, having occupied about thirty minutes.

The tracheotomy wound was left open, long sutures were inserted in the lips, and the nurse instructed to pull the wound open should the patient cough.

The following day (January 7) the temperature shot up to 103.4° F., respiration 140. Embarrassed respiration, diminished resonance with loss of inspiratory and expiratory murmur below the second rib were present on left side; tubular breathing was heard at left apex.

Subsequently marked cough with expectoration developed. In short, the patient manifested well marked pneumonia.

At this period Dr. C. W. McElfresh was called in consultation and placed in charge of the medical treatment of the case.

From the 9th to the 15th the patient went through the varying phases of a typical pneumonia.

On January 13 the tracheotomy tube, which had been inserted the day following the operation, was permanently removed and the patient was able to breathe through the mouth readily.

On January 17, the thirteenth day, the patient was discharged from the hospital to return home; temperature 97.3°, pulse 110, respiration 24. Tracheotomy wound nearly closed, general condition much improved. The subsequent history of the case is derived from two letters sent by Dr. Wright. The first, dated February 16, 1911, reports:

Dear Doctor:—The child is still alive, but very ill. When she first came home she was very well, except a running ear and a solid patch a little larger than a silver dollar in the left apex. It seemed as though the trouble would subside and the foreign body become encapsulated, but she developed an influenza (every one here has it) and after a week of coughing developed a pneumonia involving at least the whole of the upper left lobe. After having the pneumonia one week the scar in the trachea opened spontaneously and I opened the skin, allowing a free discharge. The next day she coughed up an oval piece of almond kernel about 6x3 m.m. That is four or five days ago, and she is slightly improving. If she gets well will send full data.

WRIGHT.

An extract from the second letter, dated February 29, 1912, gives the final outcome of the case:

Dr. John Winslow.

Dear Doctor:—To-day I examined Iona B. Sorry we did not report earlier, but they had moved. Have only lately located them. The child is apparently *perfectly well*, with no signs to show where the trouble in the chest was.

The scar in the neck is rather broad, but the trachea seems solid. After a slow convalescence she recovered fully.

Very truly yours,

FAIRFAX G. WRIGHT.

A more unfavorable case could scarcely be imagined than this one, presenting many difficulties.

1. The child's age (2 years) and under-development.
2. The nature of the foreign body, a pulpified nut, furnishing multiple particles which were splattered all over the lung surface, and doubtless entered every bronchiole.

3. The bronchus involved, the left, the most difficult to examine.

I have hesitated whether to call this a successful or an unsuccessful case; while technically I did not succeed in removing all of the foreign body by bronchoscopic methods, yet I am firmly convinced that had the nut-pulp not been removed from the main bronchus, tracheotomy alone would not have enabled the child to clear its lung and survive the first pneumonia.

From a life-saving standpoint the case was most successful, and one in whose outcome every one concerned has reason to feel gratified.

The pathologic condition in such a case is well illustrated in that reported by F. E. Hopkins (Trans. Am. Lar. Ass'n 1911).

A female child 4 years of age inhaled a peanut; careful bronchoscopic examination at two sittings failed to reveal a foreign body and the child died on the second day.

"Autopsy showed many (24) small fragments of nuts scattered throughout the lungs and around each a pneumonic area.

"Instead of a single nut occluding the trachea or larger bronchi, the many fragments of the well-chewed nut were shot into the smaller bronchi."

Thomas Hubbard reports similar autopsy findings (*ibid*) in a peanut case, in his practice.

Cases of foreign bodies in the lungs of young children and infants (say of four years and under) are coming under our care in increasing numbers, because through the writings of Killian, Jackson, Ingals, Coolidge, Halsted, Mosher, Hubbard and other masters of bronchoscopy, the general profession is being educated to recognize these conditions and their proper method of treatment.

These cases constitute the most difficult in the whole field of bronchoscopy, both on account of the small size of the respiratory passages at this period of life and the difficulties of instrumental manipulation, as well as the nature of the objects usually encountered.

While a young child is liable to place almost anything in the mouth and inhale it, owing to the small size of the glottis (6 mm. infants, Jackson—7 mm. 3 yrs., Killian) large objects cannot pass through into the lower passages, therefore many of the foreign bodies commonest in adults are rarely found in the lungs of very young children (pieces of bone), while those encountered belong to the class most difficult of removal, small or multiple objects (nut shells, pulp, beads, pins, beans, pebbles, etc.).

The younger the child the greater the difficulty and urgency, and the mortality is high, despite successful removal. So that it has seemed to me that these cases constitute a group of themselves well worthy of the discussion of this representative body, and for this purpose I have brought the subject before you.

What is our best course of procedure in this class of cases? Should we tracheotomize at once, as the primary procedure, or has the advent of bronchoscopy largely abolished the necessity for this operation?

The desirability of upper bronchoscopy (without tracheotomy) is obvious, and it should be the routine method were there no disadvantages associated with it.

In pre-bronchoscopic days tracheotomy was the method of choice, whose success is attested, among numerous others, by the remarkable series of four cases of foreign bodies in the bronchi of small children under two and one-half years of age, reported by our fellow T. H. Halsted (Trans. Am. L. R. O. Soc., 1902).

In these young children upper bronchoscopy has serious objections attached to it. The anatomical structures are small, rendering the manipulation of instruments difficult and resulting in loss of time and irritation of tissues.

A study of the cases reported shows that while upper bronchoscopy has been frequently attempted for the removal of foreign bodies in infants, in a large percentage, if not the ma-

jority of the cases, tracheotomy has become ultimately necessary for successful removal.

Now, if such be the situation, why not tracheotomize at once and operate by the easier and more certain route (lower bronchoscopy)?

In a recent article (*Deutsch. Med. Wochenschrift*, June 29, 1911) G. Killian has made a most valuable contribution, in which he calls attention to another aspect of this subject, namely, the frequency with which tracheotomy or intubation becomes necessary after upper bronchoscopy, even when successful, reporting a series of nineteen cases under seven years of age, some of them personal and some derived from literature. He also cites a series of thirty-five cases reported by Schneider, of Moscow, of which five required intubation or tracheotomy. He concludes that these procedures stand in a causal relation to upper bronchoscopy, inasmuch as the changes necessitating them occur within a relatively short period (6-37 hours) afterward; that the site of the change is the subglottic space, as evidenced by the stridor and the results of intubation or tracheotomy, and in a few cases by direct or indirect laryngeal examination.

We know from both clinical experience and post-mortem evidence that inflammatory swellings are prone to occur in the subglottic space. Children from the seventh, and especially from the fourth, year downwards are especially liable to such swellings after upper bronchoscopy. In this connection the relation of the calibre of the tube to the width of the subglottic space becomes of paramount importance. No reliable measurements have hitherto existed. In order to furnish such data, Killian undertook the measurement of twenty-two children's larynges in fresh cadavers. For this purpose he employed a series of semi-circular metal sounds of increasing size, observing which one passed the cricoid region easily, which with difficulty, which not at all. In this way he determined that the width of the subglottic space stands in no especial relation to the sex of the child, and in but little to the age, the



most important and hitherto neglected moment being the *bodily development*.

Upon this basis he has constructed the following table: ,

Body length.	Diameter of subglottic space measured with calibrated metal sounds.	Calculated periphery of the lumen.	Age.
45 c. m.	3.5 m. m. (4 not)	10.99 m. m.	8 mos.
50 "	4.5 m. m. (5 not)	14.13 "	4 "
52 "	5 m. m.	15.7 "	3.5 "
53 "	4.5 m. m. (5 not)	14.13 "	3 "
53 "	5.5 m. m.	17.27 "	new born
53 "	4.5 m. m. (5 not)	14.13 "	" "
56 "	4.75 m. m.	14.91 "	?
58 "	5 m. m. (5.5 with pressure)	15.7 "	2.5 mos.
58 "	5.5 m. m.	17.27 "	4 "
60 "	5.5 m. m.	17.27 "	9.5 "
62 "	5.5 m. m. (6 with difficulty)	17.27 "	6 "
62 "	6 m. m. (6.5 not)	18.84 "	18 "
63 "	5.5 m. m.	17.27 "	9 "
64 "	5.5 m. m.	17.27 "	13 "
65 "	6.5 m. m. (7 not)	20.41 "	8 "
70 "	5 m. m.	15.7 "	16 "
80 "	6.5 m. m. (scarcely)	20.41 "	12 "
80 "	6.5 m. m. (7 not)	20.41 "	24 "
86 "	7.5 m. m. (8 not)	23.44 "	48 "
94 "	7 m. m. (7.5 not)	21.98 "	36 "
120 "	8 m. m.	25.12 "	7 yrs.
?	9.5 m. m.	20.83 "	10 "

A study of this table shows that the subglottic space is much narrower than is commonly supposed; that it increases gradually with the body length, but not commensurately, and is subject to great variations. Comparison of these measurements with the age of the child, in the series collected, shows that in some of the cases the bronchoscopic tube was too large for the subglottic space, and must have caused trauma.

Killian observes that we still require a great deal of information as to the anatomic relations of the child's larynx at different ages and different grades of bodily development, and promises to take this up for future research.

The selection of method must be individual, depending upon a number of considerations.

1. Age of the patient: as Killian has demonstrated that it is more a matter of physical development than of age: nationality

also may have a bearing, at least my intubation experiences have shown me that in certain nationalities (Italian) the larynx is smaller than the corresponding age.

Some years ago Ingals announced that he had rarely found upper bronchoscopy satisfactory in children under 3 years of age.

Recently Finder, apropos to an unsuccessful case of a piece of bone in the right bronchus of an 11 months old child, reported to the Berlin Laryngological Society, stated that henceforth he will resort to inferior bronchoscopy in all children in the *first year* of life.

In discussing this case E. Mayer went still further and considers inferior bronchoscopy preferable in children *six years* of age and under. Brünings advises it in all children under *two years* of age, as a *routine procedure*.

Nehrkorn recommends low bronchoscopy in *all young* children.

Jackson, however, regards tracheotomy as being "unnecessary 9 times out of 10, and believes that it should be limited to dyspnoeic cases." I should like to know whether he intends this to apply to these very young children.

2. The *nature* of the foreign body is of great importance in determining this question:

Objects which are liable to swell so that they cannot be withdrawn through the subglottic space (beans) should be removed by the lower route (Nehrkorn, Killian).

Likewise brittle objects which are liable to be broken into several fragments, or multiple objects necessitating a great deal of manipulation; objects which are irritating in themselves and certain to be followed by pulmonary inflammation (peanut shells, pepper corns) should be removed without irritation of the subglottic space by instruments.

3. The *duration* of the condition is of a determining moment: the presence of a foreign body rapidly produces a catarrhal condition of the air passages in children, increasing the vulnerability of the mucous membrane to instrumental manipulation; therefore when the foreign body has remained for a long time tracheotomy is indicated (E. Mayer, Killian).

4 The *side* affected must be considered, for it is much more

difficult to remove a foreign body from the *left* bronchus, especially by upper bronchoscopy. Among 13 cases in children collected by Killian, in nearly two-thirds the foreign body was found in the left bronchus.

5. The condition of the *subglottic space* is of paramount importance: this should always be determined by direct or indirect laryngeal examination before undertaking upper bronchoscopy.

Any outspoken subglottic swelling constitutes a contra-indication to upper bronchoscopy.

The passage of the bronchoscopic tube will inevitably result in the necessity for tracheotomy; it is therefore better to perform this operation primarily and employ lower bronchoscopy.

In conclusion, it seems to me that the *present* situation with regard to foreign bodies in the lungs of *young children* has been well summarized in the advice of Hubbard, "When in doubt do tracheotomy."

### *References.*

- Halsted, T. H., Trans. Am. Lar. Rhin. & Otol. Soc., 1902.  
Killian, G., Trans. Am. Lar. Rhin. & Otol. Soc., 1907.  
Killian, G., Deutsch Med. Woch., June 29th, 1911.  
Brünings, W., Zeitschr. für Ohrenheilk., Dec., 1910.  
Finder, Verhandl. der Laryng. Gesellsch. zu Berlin, 1911.  
Mayer, E., Verhandl. der Laryng. Gesellsch. zu Berlin, 1911.  
Hubbard, Thos., Trans. Am. Laryng. Ass'n, 1911  
Jackson, Chevalier, Trans. Am. Laryng. Ass'n, 1911 (discussion).  
Hopkins, F. E., Trans. Am. Laryng. Ass'n, 1911.

### *Discussion.*

Dr. Chevalier Jackson, Pittsburgh: This paper opens up no end of questions that nobody has ever yet decided, except each individual for himself as the case arose, and I am not just sure but that is as good a way as any to leave it, because the personal equation of the operator is the chief factor. It is a question in many cases whether he will work through an extremely minute tube. If an operator wishes to use a 7 mm. tube, internal diameter, the outside being 8 mm., it will be necessary

in any child under one year of age to do a tracheotomy, 5 mm. being the limit through the larynx of such a child. If you use a larger one you will have to do a tracheotomy. The over distension of the subglottic tissue will result, especially if the tube is long in position, in a post-operative edema, which will require an after tracheotomy. But if you can work through a 4 or 5 mm. tube (internal diameter) tracheotomy is absolutely unnecessary for any purpose other than dyspnoea. Laryngeal trauma in introduction and over-distension from too large a tube are the two factors causing after edema. It is not caused by prolonged work.

Another point regarding tracheotomy after operation. Recently I have obviated the after tracheotomy in four cases by putting down a bronchoscope and pumping out a thick viscid secretion, accumulating within twenty-four hours after bronchoscopy. This is a peculiarity found only in children. In the adult expectoration is far from a perfect process, but an infant practically cannot expectorate at all and will drown in his own secretions if you do not pump out that post-operative thick viscid secretion. The patient will have all the symptoms of a laryngeal dyspnoea, completely relieved by such pumping. Before tracheotomy I would beseech you all to pump out this secretion and see if this is not sufficient. It will be found so in a great many cases, I am sure. It is particularly necessary in cases of multiple foreign bodies, such as comminuted kernels of nuts, especially peanuts.

Another interesting point is in regard to what the parent did in Dr. Winslow's case in trying to remove the object with her finger. A great many of the foreign bodies gain entrance to the air passages by the aid of the parent's finger. I consider this case of Dr. Winslow a very successful one, indeed, and I compliment and congratulate him.

Dr. B. R. Shurly, Detroit: Within the last two months a very interesting case came under my observation, in which there was a screw in the left bronchus, and it brought into prominence many of the difficulties of which Dr. Winslow has spoken. Dr. Hickey and I were unsuccessful in removing this screw by upper bronchoscopy, and almost immediately a severe subglottic edema came on. The child was two years of age, and it was necessary to perform intubation, which gave immediate relief. We found that the accumulation of this viscid secretion was quite rapid, as Dr. Jackson has said, and yet with the intubation tube in place there was a certain amount of drainage which relieved the condition.

It seems to me that, just as in our old intubation experience, many of these cases are divided very abruptly, according to age. Those under three years are decidedly more serious and more difficult from every standpoint than those over three years of age. In fact, in our old intubation statistics the mortality from broncho-pneumonias and other complications was always greater in children under three years of age. The subglottic edema is certainly brought on, just as in our retained intubation tubes, many times from trauma of this region. In our case we passed a tube which was decidedly too large.

Nationality has a great deal to do with the size of the larynx, as we have found from our study of the fitting of intubation tubes. The Italian children have a particularly small larynx. The study of intubation tubes is a very appropriate one in connection with the passing of the bronchoscopic tube in very young children and infants.

Dr. W. K. Simpson, New York City: Dr. O'Dwyer, in his early experience with intubation tubes, made a study of the measurements of the subglottic space, and I think the guide to the use of his intubation tubes is the finding of these measurements. He also devised a set of graduated cylindrical tubes (based on these measurements) for the expulsion of foreign bodies.

Dr. Emil Mayer, New York City: I have had two cases of peanut lodged in the bronchi successfully removed, one in a boy of four and the other in a child of three years. In each instance the peanut was removed in the main part, but not entirely, I believe, also by upper bronchoscopy. In the second case, happening quite recently, that of a little girl, I removed the larger portion of the peanut and some of the shell under general anesthesia, the patient developing a low degree of pneumonia after the removal and having a perfect recovery.

It seems to me, however, that in the case presented by Dr. Winslow we have a different proposition, because the very smallest of our tubes have to be used, and our instruments are exceedingly small, and the space is small. In all probability, therefore, I do not think we are justified in making a hard and fast rule of upper bronchoscopy in these small children.

Dr. John R. Winslow (in closing): My sole object in bringing this paper before you was for the discussion it might excite.

With regard to the dyspnoea following upper bronchoscopy being due to secretion, I have no doubt whatever that such is the case in some, but certainly not in all instances. Killian reported

two cases in his own practice, which he had examined, one by direct laryngoscopy and the other post mortem, in which there was a marked condition of edema, and the post-operative obstruction was not due to accumulated secretion.

I was very much interested to hear from Dr. Simpson of the measurements made by Dr. O'Dwyer of the dimensions of the subglottic space, but it seems to me they are not available directly for this work. Intubation tubes are put in with a great deal of force and pressure, whereas bronchoscopy tubes are not. The relation between size of subglottic space, age and development of child, and calibre of the bronschoscopes, is a field which needs re-investigation by some one qualified who has the opportunity of examining the larynges of many children.

## REPORT OF A CASE OF MYXO-FIBROMA OF THE NASO-PHARYNX.

BY J. H. BRYAN, M.D.

The report of this case is interesting from the fact that benign growths of this character in the naso-pharynx in children are not very common.

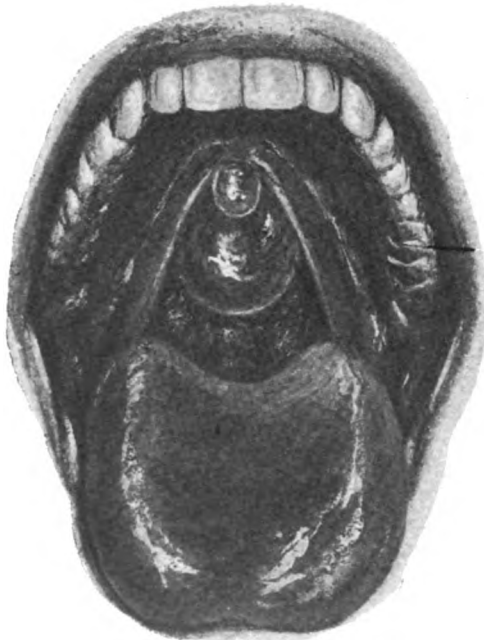
Maggie C., an undeveloped and anaemic girl, 12 years of age, came under my observation during March of this year, complaining of occlusion of both sides of the nose, headache, noisy respiration, and at times difficulty in swallowing.

Examination of the nose showed the left side quite free, but no air could be drawn through it into the naso-pharynx. The right side was so filled with thick mucous secretion that no satisfactory view of the interior could be obtained. After clearing the nose of mucous I could not get any view of the growth. Examination of the mouth showed a large pinkish growth hanging in and filling the naso-pharynx almost completely. The growth extended into the pharynx about 1-16 of an inch below the free margin of the soft palate. The accompanying illustration shows the growth presenting in the pharynx and its relation to the velum palati.

Owing to the great timidity of the child, it was impossible to remove the growth without the aid of a general anaesthetic, so she was placed under ether anaesthesia, and a wire snare was passed well up into the naso-pharynx, the growth seized and firm traction made, then withdrawn. The hemorrhage following was quite severe for a few moments, but gradually subsided after firm compression by means of a gauze compress passed well up into the naso-pharynx. The growth after removal was found to be pinkish in color, quite firm to the touch, and measured three inches in length.

Several days after its removal, on posterior rhinoscopic examination, an excellent view of the naso-pharynx was obtained,

and there were two points which showed an ecchymotic state, either of which might have been the seat of attachment; one in the roof of the naso-pharynx which contained some adenoid tissue, and the other in the right posterior nares just above the posterior extremity of the middle turbinal. The latter was probably the point of attachment. The following is a report of the microscopic examination made by Dr. J. B. Nichols: The tumor is covered with stratified columnar epithelium, and is made up



Myxo-fibroma appearing in naso-pharynx of child.

of myxo-fibromatous and soft fibromatous tissue, containing massive extravasations of blood and fibrin, small blood vessels are plentiful, gland structure nearly absent. Scattered through the substance of the tumor, in places in more or less dense collections, are an abundance of polymorphonuclear leucocytes, small lymphocytes, plasma cells, and pigmented phagocytes. It is impossible to estimate the frequency with which these neoplasms



occur, owing to the fact that many cases are not reported, but, judging from the number of reported cases, they cannot be considered to be very common.

Myxo-fibromas may be considered of nasal origin and generally spring from the upper part of the posterior nares, where the nasal mucous membrane is continuous with that lining the naso-pharynx, while fibroma, a much more serious affection, has its origin in the naso-pharynx. The former may therefore be said to partake of the characteristics of both nasal and naso-pharyngeal growths, which may be explained by the fact that they spring from the junction of the two cavities, the lining membrane of the two cavities being quite distinct histologically.

#### *Discussion.*

Dr. C. G. Coakley, New York City: I can recall having seen two similar cases, both in female children, one about 12 years of age, which came to us at the clinic and had just such masses removed about every six to eight months for three or four successive removals, extending over a period of more than two years. In one case the mass extended down lower than shown in the drawing of Dr. Bryan's case, and that patient was only cured by opening up the antrum, which was completely filled with the same sort of material, and exenterating the ethmoids. The other case was in a child of six years, from whom a man in Paterson had removed what was considered to be a polypoid growth, but of which a later diagnosis of sarcoma was made. The father of the child was told that there would undoubtedly be a fatal result. When the child was brought to me I could see nothing of a sarcomatous nature, and after again removing the mass, both intra and post-nasally, it promptly recurred. The antrum was subsequently opened and found to be filled with polypi, the ethmoid cells showed polypoid degeneration, all of which was removed. Since then there has been no recurrence.

Dr. W. E. Casselberry, Chicago: I have seen in a child of 11 years a similar growth, not so large as to descend into view through the mouth, but large enough to pack the rear part of the nostril and fill the corresponding side of the naso-pharynx. It was bilobular but not multiple, broadly pedunculated, attached in or near the spheno-ethmoid sulcus, and had the general appearance of what Jonathan Wright describes as oedematous

fibroma. It was associated with suppuration in the sphenopostethmoid group of cells, whether as cause or effect being uncertain, as usual. I would ask if there were any indications of sinus suppuration in the essayist's case.

Dr. Henry L. Swain, New Haven: These remarks remind me of a case in which there was a recurrence of a growth on two previous occasions. The patient had difficulty in chewing and from gagging, and wished me to relieve her. On examination I found what proved to be a myxofibroma, or edematous fibroma, of the naso-pharynx, which had come down by a long pedicle and hung in front of the palate, and lay with its posterior surface on the tonsil of that side. With a snare I pulled away the polyp very readily, and then it was discovered that the pedicle was not in the naso-pharynx at all, but came from the posterior superior attachment of the middle turbinate. The growth as it occurred in the back of the mouth was as large as a pigeon's egg and produced a great amount of retching at times.

Dr. Joseph Bryan, Washington, D. C. (in closing): In reference to the implication of the sinuses, particularly the maxillary sinus, I took that into consideration, and at first supposed that it might be the source of this from the character of the secretion in the nose. That cleared up within a few days after removal of the growth, the nose being perfectly free of all secretion which would lead you to feel the sinuses involved.

Several years ago I had three cases of myxomatous growths springing from the maxillary sinus, and they frequently recurred; but in this case the point of attachment was just above the posterior extremity of the middle turbinal. I looked for the maxillary sinus, however, as being the probable seat of the trouble. I cannot say positively that it was not, but I believe the seat was just about as I have stated. If there is a recurrence in this case I will make a later report on it.

## REPORT OF A CASE OF RHINO-PHARYNGEAL FIBROMA.

BY JOSEPH S. GIBB, M.D.

The report of this case seems to be warranted because of the comparative infrequency of the condition, and for the need of accurate records of individual cases.

Fibroma of the naso-pharynx fully developed is such a formidable disease and presents so many difficulties in its management that, as pointed out by Norval Pierce<sup>1</sup>, there is great need of early diagnosis. Perhaps in no other condition in this region are the demands for early diagnosis more urgent. The record of the case here presented will show that the removal of the growth in the early stages is not so serious, while we all know the great difficulties and unparalleled dangers that attend the removal of growths by surgical means when they have formed deep-seated attachments and thrown out prolongations into the nasal chambers.

### *History of the Case.*

I. C., aet. 13. Previous history good. Since the Spring of 1909 has had increasing difficulty in breathing through nose. He sleeps with his mouth open and snores. He has occasional attacks of epistaxis. His general health has not been impaired, though his mother thinks he has lost flesh.

The patient was brought by his physician for examination October 27, 1909, the latter stating that he had made a digital examination of the naso-pharynx and detected a mass which seemed to be everywhere attached, and especially so at the vault and to the posterior edge of the septum. The examination gave rise to very considerable bleeding. His appearance

---

<sup>1</sup>Pierce, Trans. American Laryngological Association, 1911.

at this time indicated a marked interference with nasal respiration—an exaggerated adenoid facies.

The rhinoscope revealed a reddish vascular looking mass occupying the entire naso-pharynx. There was no evidence of the growth within the nasal chamber. Digital examination detected a hard mass, which seemed everywhere adherent to the surrounding tissues. There was no semblance of a pedicle. The mass seemed to have its origin from the vault, probably from the basilar process of the occipital bone, and there were firm adhesions to the posterior edge of the nasal septum. It gave the impression to the finger of a deep-seated immovable attachment over a broad surface and that the mucous membrane and all the superficial tissues were stretched over its rounded surface. The examination gave rise to considerable bleeding. With the exception of an unusually large thyroid gland, the boy seemed healthy.

Operation, November 3, 1909. An anaesthetic (ether) was given, a digital examination was again made and further effort made to more clearly outline the growth. The result of the previous examinations was confirmed. The growth was found to be hard and unyielding and everywhere attached. The point of origin seemed to be at the vault. There was no pedicle. The mass pushed forward the mucous membrane and superficial tissues overlying its surface. Again there was very considerable bleeding from examination.

It was decided at this time to make an attempt to remove the growth. In consequence of the free bleeding and the consequent embarrassment to respiration this might occasion, it was deemed prudent to do a preliminary tracheotomy. Considerable difficulty attended the operation because of the enlarged thyroid, and it was only after the left lobe and middle section had been dissected free and lifted up out of the way that a point extremely low in the trachea could be found and entered.

The anaesthetic, heated, was now given through the tracheal tube. First an attempt was made to remove the growth by snare. A heavy wire was passed through the nasal chamber,

and it was hoped by grasping the growth and pulling it forward that the snare might be made to encircle its base. This was entirely unsuccessful and was abandoned. A strong post-nasal adenoid forceps was now used to grasp the growth, and while alternate twisting, tearing and traction was made by these forceps, the finger of the other hand was used in an attempt to separate it from its attachments. By these combined efforts we were successful in separating it entirely from its attachments and finally removing it intact.

During these manipulations there was a very considerable hemorrhage, and at the final removal a sudden outpouring of blood, but this ceased very quickly. Aseptic gauze was packed up in the vault, but it was not deemed necessary to replace it, as there was very little oozing upon its removal. On examination of the vault, after the removal of the growth, a deep cavity was found at the bottom of which could be detected bare spiculae of bone. While doubtless the removal of this growth could have been accomplished without the preliminary tracheotomy, this latter gave the operator a sense of security which facilitated the operation. The patient stood the operation well. The tube was allowed to remain for a day. The recovery was without incident. More than two years have passed since the operation. There has been no recurrence, and the patient has remained well. The growth was submitted to the Polyclinic Laboratory for examination and the following report obtained:

Microscopic examination of portion of growth shows it to consist of well developed bands of fibrous tissue throughout structure, showing well developed blood vessels and the surface covered with clot and detritus. No evidence of malignancy.

The early diagnosis of nasal fibromata should not be difficult, the symptoms presented being similar to nasal obstructions from adenoids, the diagnosis from which may be readily cleared by the mirror and touch. The early recognition of this condition, however, usually rests not so much with the laryngologist as with the family physician or the patient himself.

It may be difficult to impress upon the general practitioner or

the patient the importance of such symptoms as nasal obstruction when they see frequent evidences of this in the large number of adenoid cases. However, an effort in the right direction will have been made if it is generally inculcated that nasal obstruction plus epistaxis or the expectoration of blood are symptoms demanding careful attention.

In the study of the literature of naso-pharyngeal fibromata one is impressed by the formidable operative measures advocated for their removal. Before the days of laryngology and rhinology these cases fell into the hands of the general surgeon, who rarely saw or at least diagnosed the case until the growth was well developed and encroached on the nasal chambers and the adjoining spaces. It is little wonder that the surgeon, with no knowledge of the snare or electrical methods, and realizing the small amount of space offered by the natural passages, should devise some external operation whereby the space through which the growth was to be removed might be increased. These preliminary measures were separations of the external nose, splitting of the palate and other equally formidable operations, and were in themselves severe and subjected the patient to danger from hemorrhage, shock and sepsis.

That the formidable nature of the procedures was fully recognized by the surgeon is evident. Dieffenbach<sup>2</sup> wrote "that great courage is required to undertake this operation because the surgeon is almost compelled to choose between one of three conditions, choking to death of the patient during the operation, bleeding to death at the time of the operation as a result of tearing or cutting them out, or not finishing the operation."

In more recent years there is a disposition on the part of the surgeon to abandon these preliminary operations and to secure removal through the natural passages. Doyen has done much of this work and says he has never seen a naso-pharyngeal fibroma that could not be removed through the natural passages.

Since the rhinologist has studied these growths his efforts have been directed to their removal through the natural passages. He has brought to his aid both the cold and hot wire

---

<sup>2</sup>Dieffenbach, quoted by Holmes, *Journal of Laryngology*, XVII.

snare and the influence of the electric current upon the growth by electrolysis and cauterization. Voltolini and Lincoln<sup>3</sup> have demonstrated that much may be accomplished by electricity, and that the mortality of the disease may be much decreased by careful application of these methods. Delavan<sup>4</sup> in a number of able articles has pointed out the advantages of these measures, and deplors the fact that notwithstanding these advantages over the former severe measures there is a singular lack of recourse to them.

Both the general surgeon and rhinologist realize that the greatest danger in the removal of a naso-pharyngeal fibroma arises from hemorrhage. It has been observed that hemorrhage is much more severe in an incomplete operation—i. e., where a portion of the growth has been removed, and during the manipulative procedures. If the growth is removed quickly and from its attachments, the hemorrhage while profuse ceases quickly.

To accomplish a quick and complete separation of the growth from its periosteal attachment, Doyen has devised a number of raspatories. It is by rapid operative measures and complete severance of the growth from its origin that this latter surgeon has attained his remarkable success.

Gordon King<sup>5</sup> with this same idea in view devised strong scissors which were passed through the nasal chambers and an effort made to sever the growth at its attachment. There is no record of King's method having been used in any other than the frightful case which came under his care from Swain.<sup>6</sup> In this case, while King was able to complete the operation, the hemorrhage was appalling.

It would seem from the knowledge we have of the methods used in separating the growth by means of instruments that some other method were necessary. It was with this idea in view that Voltolini and Lincoln suggested and successfully employed the hot wire snare.

The difficulty in the way of the use of either the cold snare

---

<sup>3</sup>Lincoln, *Trans. American Laryngological Assn.*, 1883.

<sup>4</sup>Delavan, *Trans. American Laryngological Assn.*, 1901-'03-'11.

<sup>5</sup>Gordon King, *Trans. American Laryngological Assn.*, 1903.

<sup>6</sup>Swain, *Trans. American Laryngological Assn.*, 1909.

or the snare to be heated by the electrical current is the broad attachment of the growth. It is so seldom there is a pedicle. Usually the base is broad and firmly adherent.

Possibly by the use of the forceps designed by Ingals,<sup>7</sup> which grips the growth firmly, and with which powerful traction may be made, the growth may be sufficiently separated from its attachments to enable a wire to be thrown around the base and heated by the current. It would seem, however, that the powerful traction necessary to separate the growth from its attachments would itself induce such bleeding that it were better to complete the avulsion rather than waste time in an effort to pass a wire over the neck secured by the severance of the attachment, and it would also seem not unlikely that the profuse flow of blood would nullify the power of the current to sufficiently heat the wire. But I confess to no practical knowledge of this method of securing a neck for the wire.

The treatment of fibroma of the naso-pharynx depends largely on the size of the growth. At an early stage, but one unfortunately rarely seen by the rhinologist, there are two methods open to the surgeon, depending upon the attachment of the growth. Should there be a well marked pedicle, a condition in my experience very uncommon, it is a simple matter to engage the growth in either a strong cold wire snare or one heated by the electric current, and remove it at the base. Should the growth, however, be a sessile one, the base extending over a broad surface, the method of avulsion, while not unattended by danger from hemorrhage, offers a rapid and effectual treatment.

In the hands of a Voltolini and Lincoln it may be possible to adjust the loop of an electric wire over a hard, unyielding, and usually superficially smooth mass, but certainly in the hands of the average operator such a course is not feasible. To waste time by the electrolytic method in these small growths would seem unnecessary. At a later stage, when prolongations have been thrown into the nasal chamber, cheek and other contiguous tissue, the management of the case is very different. Each case must be treated on its merits.

---

<sup>7</sup>Ingals, Trans. American Laryngological Assn., 1903.



Certainly, thanks to the work of Voltolini and Lincoln, ably championed by Delavan, there must be a decreasing necessity for preliminary operation and an increasing use of the electrical. Hence, while it may not always be possible to at once remove the growth from its base, a consummation to be desired, such may ultimately be attained by a combination of snaring, electrolysis and cauterization. By one or the other or all of the measures room will ultimately be secured in the nose and also naso-pharynx sufficient to enable us to encircle the growth with a wire and remove it from its attachment.

The important point in the removal of the growths is to attack them at the base. Growths so removed are much less likely to recur, and the hemorrhage, while profuse at the time, ceases quickly. The treatment must ever be influenced by the age of the patient. We know that the tendency is for growths of this kind to undergo a process of absorption at about the twenty-fifth year of life. Literature contains many cases in which remarkable cures have occurred by what may be called Nature's method, where recovery seemed hopeless.

On the other hand, there are any number of cases in literature in which the first appearance of the growth occurred after the twenty-fifth year. Therefore, while we should be mindful of the fact that Nature may come to our aid at or about this age, and should be conservative, yet this method of relief should not be depended upon.

#### *Discussion.*

Dr. D. Bryson Delavan, New York City: Dr. Gibb has done well to bring this neglected subject before us, as we do not hear a great deal of it in our time, and there seems to be a widespread and deep ignorance in the minds of most practitioners with regard to it. There are more surgical crimes which can be laid against the treatment of this particular disease than almost any other, crimes which relate to the various radical operations, so-called, done for the removal of naso-pharyngeal fibroma. There are really three classes of operations, operations done after preliminary operation of extensive nature, operations done after what is known in general as the method of Doyen, because he happens to have exploited the procedure, and the methods of

treatment advocated by Voltolini and Lincoln. The methods by preliminary operation may be dismissed without a word, except to say that they are absolutely unjustifiable. Some of the most trying recollections of my student days were the pictures of patients being carried out of the operating rooms after attempts by the old-fashioned methods at removal of these growths. In regard to the Doyen method, in other words, the method in general by avulsion, something is to be said in its favor. I remember that our late fellow member, Andrew H. Smith, was once operating on a large fibroma of the pharynx by means of an ecraseur when the mechanical part broke and he was unable to detach the loop. Using great force he tore away the growth and with its base came a considerable number of spiculae from the base of the skull. The result of the operation was very successful as the tumor never recurred. While the Doyen operation and the use of the cold snare offer about equal advantages with regard to successful result they are both attended with very considerable hemorrhage. The use of the cold snare is almost certain to provoke violent hemorrhage. With regard to the electrical methods, the galvano-caustic loop does not cause bleeding, and therefore even if not more effective in its results than the cold snare it would still be far superior. The objection which the reader of the paper has made to this method, namely, the difficulty of fixing the snare about the base of a sessile growth, is undoubtedly to be considered. There are not many cases, however, in which some form of the electrical treatment cannot be employed. It would be possible to surround the base of the growth with the snare even if the cauterant action of the loop did not succeed in taking away all of the base of the growth from the base of the skull, for the effects of the cautery are such as to destroy the remaining tissue, so that very little is left. What may be left can be easily treated by the various forms of cautery. But far the best method is the electrolytic method. The only objection to this is that in some cases the pain caused by the use of the needle is pretty severe. First reducing the size of the growth by electrolysis by cutting off a certain amount of the blood supply as near as possible at its base, the use of the galvano-cautery loop is often possible in cases where before the employment of the electrolytic method it was not. The method is devoid of loss of blood, of shock, or of any of the dangers attending the other methods. The trouble with this method is that it requires a great deal of skill.

Dr. E. Fletcher Ingals, Chicago: I have removed a number of these growths, but the cold snare has not been satisfactory because I have never had one strong enough to cut off the

fibroid growth. By the electrolytic wire I have removed several and with very little bleeding and not much pain. The wire being made to encircle the growth I turn on the current for a second or two, until the patient begins to wince, then cut it off for a few seconds, and repeat this operation over and over, cutting into the growth about  $\frac{1}{8}$  of an inch at a time and constantly tightening the wire until the whole base is cut off. There is usually a spurt of blood at the end but not enough to amount to anything. There is much difficulty in getting the wire around the base of sessile growths, but there is usually a place where it will hold. I have devised a strong clamp which is a great aid in these operations. This clamp is insulated with ivory along the back of each blade so as not to short circuit the current. With it I grasp the growth at its base and then there is no difficulty in running the loop up back of the clamp and tightening the wire so that it cuts off the growth absolutely at the base. I have used this two or three times with great satisfaction.

I operated on such a case last Summer when I was recovering from typhoid fever. I knew that because of weakness it was impossible for me to take time to get the growth out by the hot wire, therefore I employed the ordinary Lowenberg adenoid forceps and had a big fellow assist me who had a hand like that of Providence and muscles to go with it. With my finger back of the palate to direct the forceps I seized the growth and had him grasp over my hand to close the blades and wrench and pull it out. I think there would be danger of tearing out the base of the skull in some of these cases, therefore, I do not like to employ the necessary force for this kind of operation, but in this particular case where the growth was only about three-quarters fibrous, I succeeded in clearing it out very thoroughly. Had it been entirely fibrous I should not have attempted its removal in this way.

In injection of these growths, when they recur, I have used lactic acid from 20 per cent to 35 per cent strong. I first draw into the hypodermic syringe, used for the operation, about fifteen minims of this solution, then two or three minims of carbolic acid, and then five minims of a four per cent solution of cocaine, in such a manner that they are not mixed. I then insert the needle into the growth and force in five minims supposed to contain the cocaine. I then wait a few minutes for it to take effect, and then slowly inject the remainder of the contents of the syringe. The carbolic acid is used to prevent the after pain. I would now make a solution of the cocaine in a 1-2000 solution of epinephrin. This method has been very successful in getting rid of the tumor a little at a time, apparently in masses the size

of a large pea. I believe that a half of one per cent solution of quinia-urea-hydrochlorate would be a good anaesthetic for this purpose, as it promises the great advantage of causing prolonged anesthesia without danger to the patient.

Dr. Harmon Smith, New York City: I think whereas the surgical and electrical methods are most feasible in these cases we should not entirely disregard other methods. In two cases where the fibroma filled the entire postnasal space I have with 14 to 17 injections of monochloracetic acid seen the growth disappear, and three years later there has been no recurrence.

I want to disclaim any originality for this method of treatment, since I only constructed a syringe for the easier injection of the acid.

Dr. Algernon Coolidge, Jr., Boston: In dealing with this tumor we must bear in mind that its development is divided into three periods—in the first it grows more or less rapidly; in the second it grows slowly, or is stationary; in the third it shrinks in size and disappears. From beginning to end it runs its course in a few years. It begins generally between the ages of eight and eighteen, and the earlier it begins the earlier it disappears. In its growth it displaces and destroys neighboring structures. The problem is to prevent it, so far as possible, from doing this until its period of growth has stopped. The dangers from operating are injury to surrounding parts and hemorrhage, both at the time of operating and secondary to it. Where it is possible to do it, I believe that the safest method is to encircle as much of the tumor with a stout, cold wire and cut it through very slowly with an *ecraseur*. Where this is not possible cutting forceps or careful avulsion may be necessary. Subsequent operations are indicated whenever the recurrent growth threatens other structures. When the period of slow growth has been reached it is often possible to do very little operating; it may be sufficient to keep the patient under careful observation to see that the tumor is within bounds. In the first stage, therefore, active complete radical operating is necessary; in the second stage careful observation, and in the third stage nothing at all.

Dr. Norval H. Pierce, Chicago: The blood supply of these tumors is the most interesting thing in the whole subject. No matter what methods one may use, whether the hot wire or the cold wire, avulsion or whatnot, you are liable to have a hemorrhage, which may be fatal during the operation. There has been reported a case in which the artery in the base of the tumor was the size of the internal maxillary artery. In every

case the blood supply is the keynote of the whole situation. In the formative stage the blood supply is much richer than at any other time; the involution of these tumors is probably produced by the cutting off of this blood supply. Therefore, it seems to me that the electrolysis or the injection method recommended by Dr. Smith and others is the very best, at least until the formation of fibrous tissue has taken place and its contraction occurs, which will strangle off the blood vessels, as in the natural process of involution. It is at the formative stage that we have the greatest hemorrhage. In the quiescent stage the connective tissue formation begins, and the blood vessels are scarcely ever as large as in the beginning. When a tumor has invaded the neighboring cavities, the zygomatic fossa, the orbit or the brain, we may always be consoled by the fact that none of these processes receives blood from the surroundings—that the blood supply comes only from the base, and I have seen a case in my own practise of a young lady where the side of the face was greatly deformed by the invasion of the zygomatic fossa, in which the tumor was treated by electrolysis, the loop being carried well up over the base. After each application you could really see the tumor within the zygomatic fossa and outside in the face recede, showing that the place to attack the tumor is at its base, for here you can get at the root of the blood supply.

Dr. Harris P. Mosher, Boston: It is a great comfort to me in dealing with these cases to have the injection method to come back to, as advocated by Dr. Smith. I have usually detached such tumors either by the cold wire snare or by avulsion. After the first operation, which is sometimes simple and easy and sometimes hard and horrible, it is very distressing to have the return of the tumor stare you in the face in a few weeks. I have one case now which was treated by the cold wire snare and avulsion, where everything was as hard as possible, but the patient survived. The boy is around 18 or 19 years of age and is now being carried along by the reduction and control of the tumor by the use of the thermocautery through the nose. Since Dr. Smith called our attention to his method I approach these cases with more hope, because I know that in spite of as thorough operation as I can perform I am liable to have to go through the same performance again in a short time unless I make use of injections. This is very hard for the surgeon, but much harder for the patient.

Dr. Joseph S. Gibb, of Philadelphia (in closing): The case was of special interest, for the reason that it was seen early in its course. In the operation the finger of the left hand palpated

the growth continuously during the efforts of traction and torsion, and it seemed that the growth did not yield to the efforts until the finger had torn through the mucous membrane, and, perhaps, the periosteum, and reached the base of the growth.

It seems to me, from my experience in this case, that growths which are small may be removed by avulsion with little danger. I believe the secret of success in the operation, so far as recurrence is concerned, lies in the removal of the growth entirely from its attachment at the base. The origin is doubtless from the periosteum over the basilar process of the occipital bone or contiguous structures at the base of the skull. The growth must be removed entirely from these sites to insure permanent results.

By a preliminary tracheotomy the danger of the hemorrhage overwhelming respiration is practically eliminated, and it does not complicate the operation. It gives the operator a sense of security which is very comforting.

While it is feasible to accomplish—by avulsion—these results where the growth is small the case is very different in those cases where the growth fills the naso-pharynx and encroaches upon the nasal chambers. In such cases the method of avulsion is fraught with severe danger, and, perhaps, had better not be thought of.

In these latter the methods of Voltolini and Lincoln had best be resorted to. The difficulty has always been, in my hands, to surround the growth by the wire at its base. Dr. Delavan spoke of the possibility of accomplishing this in skilful hands. It is doubtless true that much experience in this work is more likely to bring success. My observation, however, of cases removed by the wire snare is that they are rarely removed at the base. At the same time, I entirely agree with Dr. Delavan that in these large growths this method offers the best means we possess.

The same criticism as to the entire removal of the growth I would give as to the ingenious forceps of Dr. Ingals. These forceps would seem to facilitate the application of the wire, but I believe that force sufficient to enable the tumor to permit a wire encircling its base would give rise to such hemorrhage as to nullify the action of the current in heating the wire. I have had no experience with monochloroacetic acid, suggested by Dr. Harmon Smith.

I quite agree with Dr. Coolidge that age has a very important bearing on the question of operation. If a case is seen at or about the time these growths show a tendency to become absorbed it were better to stay our hand unless symptoms of danger or urgency arise.

TWO CASES OF WHITE EXUDATIVE GROWTHS  
OF THE LARYNX.

(a) Malignant.

(b) Tuberculosis.

BY WILLIAM KELLY SIMPSON, MD.

*Case No. 1—Malignant.*

Male patient, age 57 years, physician; seen by me in consultation with our president, Dr. Newcomb, in October, 1909, at which time this history begins. He gave a history of impairment of voice, variable in extent, but always noticeable, which had existed for seven years, coming on very suddenly while on an ocean steamer in June, 1902. This sudden onset was preceded by some clearing of the throat; the hoarseness was very marked and lasted for about two months, when it abated somewhat, and since then, as stated above, had been variable, patient sometimes having quite a clear voice.

*Previous History*—Twelve years ago had an attack of grippe which resulted in partial loss of the sight of one eye—the right. (Iriodocyclitis.) Five years ago had another attack of grippe, resulting in an empyema of the ethmoid and frontal sinuses, a purulent nasal discharge still existing. One year ago had an attack of bronchitis, lasting about a month, the cough remaining about two months. He has had some cough at intervals since then. No specific history. Has been an abstainer from alcohol for twenty-four years; has always been a heavy smoker until one month ago, generally inhaling as he smoked. His sputum has been examined, but no tubercle bacilli found. There has been no pain in the throat, nor loss of bodily weight; his general health is excellent, and he has the appearance of a hearty and robust man.

Previous to the beginning of this history, and while under Dr. Newcomb's care, he had been seen by other laryngolo-

gists, both in this country and abroad, but owing to a peculiar anatomical throat formation no satisfactory examination of his larynx had been made, and the direct cause of his hoarseness had remained unsolved. My first attempt at laryngeal examination by the usual method at once demonstrated its difficulty, and only a small portion of the larynx could be seen. The direct method was then attempted under cocaine, but was so irksome that it had to be abandoned. A day or so later I used the Hays pharyngoscope, and at once an easy and complete view of the entire larynx was obtained. I wish to state in this connection that seldom have I experienced such satisfaction in the use of an instrument as in the case mentioned, and in the subsequent examinations of this patient's larynx, which were very many, the instrument proved invaluable, rendering the examination a simple matter in the subsequent progress of the case.

The first examination with the pharyngoscope defined a small sessile growth, occupying the anterior fourth of the right vocal cord, impinging on the commissure. The growth was about as large as a fair-sized pea, somewhat flattened, and its color was slightly reddened. The most striking feature of the growth was that its surface was dotted with a well-marked, distinctive, follicular exudate, resembling very closely the appearance of a chronic folliculitis of a small portion of the tonsil. During the entire observation of the case the exudative character of the growth was prominent, at times punctate as well as more or less diffuse. Despite the length of time the growth had existed—viz., seven years—one could not, owing to the age of the patient, divest himself of the idea of malignancy, and at the same time it strongly suggested some form of mycosis. With an idea of determining this latter condition two swabbings were taken from the surface of the growth—one in November, 1909, and the other in December, 1909—and in both instances there were found pure cultures of *micrococcus catarrhalis*. No evidence of mycosis was found. It was suggested that an autogenous vaccine be made from the cultures, and that hypodermic injections of these vaccines be given. This was done, both in December, 1909, and January, 1910. The patient reacted to the vaccines



constitutionally, but it cannot be said that any direct or positive action was shown as regards the local appearance of the growth, either in diminution of size or change in the character or amount of exudate. Frequent and detailed examinations of the larynx were made, and noted, and conditions remained in statu quo, the patient's general health remaining excellent, and he pursued his professional duties undisturbed till March 20, 1910, when he was seized with a sudden exacerbation of hoarseness; examination showed also an acute inflammatory swelling of the entire right side of the interior of the larynx, including the right arytenoid, and considerable oedema in this region. This all subsided in a short while, leaving no visible change in the laryngeal picture. This exacerbation was supposedly due to an unusual use of the voice in conversation, against the noise of the street, on a cold and rainy day. The patient took his usual Summer trip to Europe, and while there was examined by one of our German confreres—by the direct method—but the ordeal was so severe that he refused to submit to a second examination, which was asked for, in order to better determine the nature of the growth. So little change had taken place in the appearance of the growth since first seen that its malignant nature was coming to be doubted, and from its quiescent condition and inaccessibility it was thought unwise to interfere for purposes of microscopical examination. The patient, in the meantime, suffered no increase in hoarseness or decline in general health. In the latter part of January, 1911, signs of increase in the growth began to show, spreading posteriorly on the vocal cord, and at the same time hoarseness increased with paroxysmal coughing and some slight interference with breathing. It was decided to do a thyrotomy, which was performed by Dr. George E. Brewer, of New York, on February 20, 1911. On excision of the growth it was found to be much more extensive than was supposed, and its scirrhus nature on section at once suggested malignancy, which was confirmed by immediate microscopical examination—being a typical epithelioma. This was further confirmed by subsequent examinations. The following day a tube of radium was inserted through the thyrotomy

wound, being held in place against the site of the operation for forty-five minutes. This resulted in producing a great deal of cough and irritation, and was followed after a few days by the appearance of granulations about the surface of the external laryngeal wound. The patient made an apparently good recovery from the operation, with the exception of an irritative cough, some pain, which seemed to be external, and some tendency to external swelling of the opposite thyroid cartilage. However, his condition seemed good enough to allow him to go abroad in May, 1911. While abroad the symptoms of perichondritis developed, with external redness and swelling about the thyroid region and the apparent presence of suppuration. This combination persisted to the extent of producing marked laryngeal stridor, which necessitated a tracheotomy for its relief. This was done in London, July 6, 1911, by our distinguished corresponding fellow, Dr. St. Clair Thomson, in the presence of Dr. Newcomb and myself. At that time there was swelling, with redness and tension, over and about the laryngeal region, and the first skin incision evacuated considerable pus. There was some difficulty in reaching the median line of the trachea, as it was considerably displaced by the deeper swelling. The tracheotomy tube was left in situ, and the patient returned to this country a month later—August 6—and on September 5 a complete laryngectomy was performed by Dr. Brewer, and there was found distinct malignant recurrence in the larynx. The patient is still living.

Inasmuch as the object of this paper is mainly to record the exudative and somewhat unusual nature of these two growths, I will not go into the subsequent history of this case since the laryngectomy. This probably will be done at a later period.

#### *Case No. 2—Tuberculous.*

Miss B., age 25. Russian Jewess, Stenographer, through the courtesy of Dr. M. Schulman, of New York, first consulted me January 1, 1911, on account of hoarseness, which was very marked, approaching complete aphonia, of three months' duration, and growing gradually worse. There was some cough,

mostly at night and morning, but very little during the day; some expectoration, in which no tubercle bacilli could be found. There was slight pain in the throat, and a small bilateral goitre.

*Family History*—Negative, except that a sister had some type of growth burnt from her throat, the exact nature and location not being definitely known. The patient gave a history of pleurisy with effusion four years previously, but no subsequent pulmonary symptoms, except a cough from time to time, physical examinations being negative other than some dullness at site of the old pleurisy. There was, however, a positive von Pirquet skin reaction. No specific history could be obtained. She had had quite a severe gastric attack about a year previously, supposedly due to ptomaine poisoning while in the country, and which she associated in some manner with her present throat trouble. Her general condition and spirits were excellent, suggesting no bodily illness.

Examination of the larynx revealed a most unusual picture. The right side of the larynx, at the site of the vocal cord, was occupied by a broad and somewhat rounded, snow-white growth, extending the entire length of the cord and for a considerable distance above and below, as shown in the accompanying painting from life by Dr. Braun. It had all the appearance of a small tuft of cotton, and, from its marked similarity, immediately called to my mind the rare type of similar laryngeal growth reported by our colleagues, Drs. Gleitsmann<sup>1</sup> and Harmon Smith<sup>2</sup>.

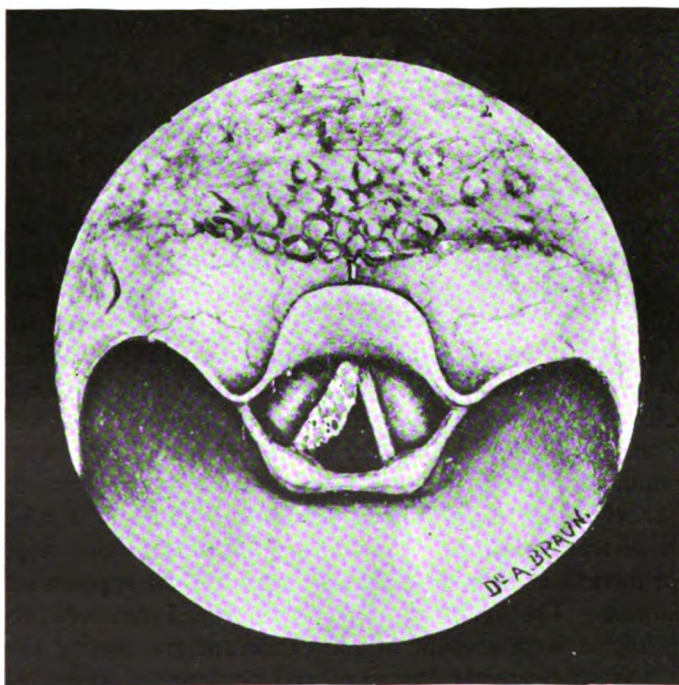
A number of our New York members examined the patient, and various opinions were held as to the nature of the tumor, and, notwithstanding the patient's age, and her probable tuberculous condition, the growth was generally supposed to be malignant, this opinion being strengthened by the point brought out in Dr. Gleitsmann's article (loc. cit.) "That snow-white tumors generally point to malignancy."

The sense imparted by the touch of the laryngeal sound was that of underlying hardness, and the white portion seemed to penetrate quite deeply and was quite difficult of removal by the scraping curette. Examinations of the scrapings revealed nothing definite, either by the microscope or straining process. The

<sup>1</sup>J. W. Gleitsmann, *Trans. Am. Laryng. Ass'n*, 1896, p. 145.

<sup>2</sup>Harmon Smith, *Trans. Am. Laryng. Ass'n*, 1909, p. 79.

patient was placed on general sustaining treatment, and iodide of potash, with local applications of lactic acid of varying strength, and kept under observation. The treatment was of no avail, the growth increased in size, the voice becoming more aphonic and the breathing somewhat embarrassed. It was considered unwise to attempt to excise any of the growth for microscopical purposes, as it was very evident that any such excision



Appearance of right vocal cord before operation.

would have to be made deeply into the growth, and in any event it would be necessary to remove the entire growth, whatever might be the findings, so it was decided to do a thyrotomy and excise the whole growth with the underlying mucous membrane down to the cartilage. This was done by Dr. George E. Brewer at the Roosevelt Hospital, on March 10, 1911. A frozen section was immediately made and examined by the pathologist, who reported it to be an epithelioma. On the strength of this re-

port a tube of radium was held for fifteen minutes in the wound cavity through the separated thyroid, while the patient was still under the anaesthetic, with the idea that the immediate irritation would be thus lessened, and with the remote expectation, as was hoped for in case No. 1, of preventing any recurrence.

The immediate post-operative interval was accompanied with considerable cough, throat irritation and some pain, which seemed to be referred more to the unoperated side—and there was also some pain on pressure, and slight swelling over the thyroid on that side.

The first post-operative opportunity for examining the larynx occurred on March 28th, eighteen days following the operation, and resulted in finding the wound cavity partially filled with sloughing and granulating tissue.

There was also some of the same type of tissue at the site of the median thyroid incision. A second examination was made on April 6th. She had complained of some difficulty in breathing and pain on the left side; the breathing at the time was somewhat stridulous and the cough dry and croupy. The lumen of the larynx was considerably reduced by sub-cordal swelling on the left side, as well as by some whitish slough in the wound cavity and median incision line, and in addition there was an exuberant amount of granulation tissue springing from these same areas and extending down into the trachea. The whitish slough above mentioned resembled quite closely the original type of growth and the granulating tissue had the appearance of papillomata. The following day, April 7th, I removed endolaryngeally a large amount of the exuberant granulating tissue, which was subsequently examined and pronounced to be tuberculous in nature. This was confirmed by other examinations. In view of these findings the original specimen was re-examined more closely with a final decision of its being non-malignant. On April 24th there was still some stridor and considerable pain on the left side and inspection showed remaining granulations as above noted and also left sided swelling, and it was decided to reopen the larynx by a secondary thyrotomy, the original wound having entirely closed. This was done by Dr. Brewer, May 16th, and resulted in removing a large amount of granulation

tissue generally distributed in the larynx and extending down in the trachea, also the discovery and opening of an abscess under the mucous membrane of the left thyroid. This abscess accounted for the pain of which the patient had complained, as well as for the swelling of the mucous membrane of that side and the condition of the left vocal cord, which was quite reddened, flabby and pulpy with somewhat the appearance of extrusion of the ventricle. The subsequent history is one of clearing up of the larynx so that no further operative interference has been necessary. The patient has spent the past autumn and winter in the country and has gained much in weight and general health, and if it were not for her loss of voice, would give little or no indication of illness. Laryngeal examination at the present time of writing, April 28th, 1912, thirteen months after the first operation, reveals the following: Voice aphonic, and will probably so remain indefinitely; some cough, which has been quite a feature and is of an irritating nature, having its origin in the sensitiveness of the larynx or trachea. The cavity of the original excision on the right side is entirely smooth and filled with what appears to be cicatricial tissue. It is immobile and there is nothing either here or elsewhere in the larynx which suggests recurrence. The left side is very movable but somewhat distorted and it is difficult to exactly define the left vocal cord. The general color is rather paler than otherwise and there is ample lumen.

*Abstract of Pathological Report.*

*Miss B.*

*Specimen:*

March 4th, 1911.

Tissue from tumor of vocal cord. Sections from different portions of tissue.

*Microscopic Examination:*

Frozen sections reported epithelioma.

Frozen sections show surface epithelium sending into submucous tissues finger-like projections.

There are as well in deeper tissue isolated islands of epithelium. Definite pearls also present.

Tissue is everywhere invaded by polynuclear, but no area of ulceration made out. Mitotic figures present in fair number.

*Diagnosis:*

Epithelioma.

*Abstract of Pathological Report.*

*Miss B.*

*Specimen:*

March 4th, 1911.

Scar tissue, granulation tissue, cartilage.

*Gross Examination:*

I. Two small strips of rough grayish white scar tissue.

II. Several small pieces of soft exuberant vascular tissue (has the gross appearance of granulation tissue) to which a few fragments of hyaline cartilage are attached.

*Microscopic Examination:*

I. Section of tissue with intact epithelium on the surface showing but few down growths. In the lowest portion of the section far below the epithelium there is definite tubercle formation with an increase in fibrous tissue, a surrounding zone of round cells and an inner zone of fibroblasts and epithelioid cells with large giant cells about the periphery and beginning necrosis in the central areas.

II. Section of granulation tissue—showing a very extensive tuberculous process, the whole section being infiltrated with round cells and multiple tubercles with giant cells and some necrosis of central areas. There is epithelium present.

*Abstract of Pathological Report.*

*Diagnosis.*

May 16th, 1911.

*Tuberculous Inflammation.*

(In view of the fact that these sections show the presence of a tuberculous inflammation, the previous diagnosis of epithelioma on the first growth excised should not be considered as such, but merely a hyperplasia due to the inflammatory stimulation which was acting before that time.)

In reviewing these two cases I cannot refrain from mentioning (aside from their features of rarity) the points which seem to be emphasized in common. First the difficulty which attends a positive early diagnosis and, second, the similarity in the immediate post operative intra laryngeal irritation, shown in the beginning by cough and exuberant granulation and subsequently by condral abscesses; and in seeking a cause for this similarity of action we cannot ignore the irritating effect of the radium. It was the consensus of opinion of those who were closely concerned that the radium was a very strong factor; and the experience of these two cases, though too small to establish a fact with certainty, suggests caution in placing such a strong force as radium in the healthy mucous membrane of the larynx. The destructive force of radium in a pathological mass is one thing, but in healthy underlying tissue after an operation is quite another.

#### *Discussion.*

Dr. Emil Mayer, New York City: These cases are extremely instructive and well worth thinking over. I especially refer to the second case that I had the honor to see at the request of Dr. Simpson, and it recalled, as Dr. Simpson has mentioned, the other case of a white, cottony mass, apparently lying within the body of the larynx. That case was shown by Dr. Gleitsmann, and eventually reported so well by Dr. Harmon Smith. In the case we were all puzzled what to call this mass, and felt rather inclined to believe it of a malignant nature, which it eventuated to be after thirteen years. So that it would seem that our present knowledge of such deposits within the larynx would be that we would have to call them malignant; of a slow, growing character. This girl's condition has not had time to show what may eventually occur, and we are also confronted with this difference between the cases—that in the first case presented by Dr. Gleitsmann the patient would not permit of any operation. In the case of Dr. Simpson's, an operation has been performed which may be worth a tremendous lot to the girl subsequently.

Dr. Clarence C. Rice, New York City: I have seen the effect of radium in two cases of epithelioma of the larynx. I have had the assistance of Dr. Robert Abbe, and I think he is very uncertain as to the exact effect of radium upon epithe-



lioma of the larynx. The first case was that of a man of sixty-five, who had epithelioma at the border of one vocal cord, and we, after cocainizing the larynx, suspended the bottle of radium in the larynx for forty minutes. There was no effect for two or three days. Then the growth began to crumble away, and we were very much encouraged to feel that we had effected a cure. After a week the larynx had the peculiar appearance of having been varnished with a brush. There was a good deal of general swelling, with considerable laryngeal dyspnoea, for a couple of weeks, and then there began a return of the growth. We were encouraged to feel that a second trial with radium would finish the cure, but there was so much laryngeal swelling that the patient had to have a preliminary tracheotomy. He died of pneumonia. The other case occurred in a younger person, and we applied the radium in about the same way. The result was much less satisfactory. The growth sloughed; there was a great deal of inflammation; tracheotomy was done, and the patient went to a hospital, where, I believe, she eventually died. I think we know very little about the exact effect of radium, and I doubt if it has the same effect in different individuals, even when applied in exactly the same way. It certainly produces a wonderful reaction in superficial cancerous ulcerations. First, after a few days an increased hyperaemia is apparent; later, sloughing of the overgrowth, and, finally, in the successful cases a healthful ulceration and healing. Radium should certainly be employed in superficial epithelioma of the pharynx and larynx.

Dr. Henry L. Swain, New Haven: I hope Dr. Simpson will later give us the full history of these two cases, that they may be properly filed with these two reports.

Dr. W. K. Simpson, New York City (inclosing): I am glad Dr. Rice brought up the subject of the use of radium. In these two cases we thought there was a most excellent opportunity for its use. Here we had the thyroid cartilage opened and the larynx exposed to view, and all that there was to do was to apply the radium directly to the site of the wound, and this was done. In speaking with the physician in charge of the first case he said the irritation was severe, and there is no question in my mind but that it was the cause of the subsequent unusual type of reaction. In the second case it was the general opinion that the subsequent irritation was also due to the radium.

THE REPORT OF A CASE OF MALIGNANT GROWTH  
OF THE LARYNX REMOVED BY OPERATION.

BY FRANCIS R. PACKARD, M.D.

The case which I wish to report presents the following history:

Male, white, aged 50 years, a peddler by occupation, calling out his wares on the street. He presented himself at the Out-Patient Department of the Pennsylvania Hospital in November, 1910, with the history of having had a choking sensation in his throat for a year, with increasing huskiness of voice and a dry cough. He had suffered no pain at any time.

Upon examination with the laryngeal mirror, a growth was seen with a smooth, shiny surface, presenting itself below the vocal cords, in the anterior portion of the glottis. The patient's family history was entirely negative as regards any tumors or other growths, or tuberculosis. He denied specific history, and the Wassermann test was negative. He admitted the excessive use of tobacco. A portion of the growth was removed, and a microscopic examination made at the laboratory of the Pennsylvania Hospital reported that it was carcinomatous. Subsequent to this, in the month of December, a direct laryngeal speculum was introduced and a much larger piece removed, the examination of which, at the same laboratory, resulted in another report that it was of a carcinomatous nature.

He was admitted to the Pennsylvania Hospital, and on the 18th of February, 1911, he was etherized and Dr. Robert G. Le Conte made a median incision in the anterior surface of the throat, extending from above the thyroid cartilage almost down to the suprasternal notch. A large number of smooth, fatty masses and small glands presented themselves in the subcutaneous tissues. Dr. Le Conte removed these thoroughly, ligating from time to time the very numerous small veins which were unusually distended. I then assisted him in the performance of

a tracheotomy, after which the larynx was opened through its median line, anteriorly, and the growth enucleated from the surface to which it was attached. The attachment was almost altogether on the right side of the inner surface of the thyroid cartilage. After the removal of the growth, the larynx was sutured and the tracheotomy tube allowed to remain in situ.

On the 22d of February, four days after the operation, the tracheotomy tube was removed, and on the 26th, eight days subsequent to the operation, the sutures were removed from the external wound. On the 28th, the patient was out of bed, and was discharged from the hospital on March 6th.

The growth was the size of a very large walnut. After removal, a microscopic examination of the tissues taken from various parts of the growth all showed marked carcinomatous characteristics.

The patient has had no recurrence up to the present time (May 6, 1912). He has a voice which, although not useful for the purpose of peddling things in the street, is good for ordinary purposes. His general health is excellent. He weighs 160 pounds and complains of no discomfort whatever in his throat.

My reasons for presenting this patient's history are as follows:

1st. I do not believe it would have been possible to have removed a growth of this size completely by any intralaryngeal operative procedure.

2d. The great advantage which was given throughout the operation by the performance of a preliminary tracheotomy. All the subsequent steps of the operation were continued without the slightest danger of suffocation, the ether being given entirely through a tube.

3d. I believe that one feature which has so far favored a good result in this case was the complete way in which Dr. Le Conte was enabled to dissect out the glandular tissue in the neck, which was, at the microscopic examination subsequent to removal, found to be also carcinomatous. The necessity for such a prolonged and extensive dissection is my reason for having the co-operation of a general surgeon in any operation of this character.

Of course, a year and four months is much too short a period

to venture to predict that there will be no recurrence of the growth in the throat or elsewhere. Nevertheless, the man has had a year and four months of great comfort, and at the present time presents no symptoms of what was undoubtedly a malignant growth in a dangerous region.

## AMERICAN LARYNGOLOGICAL ASSOCIATION.

*Business Meeting.*

The Thirty-fourth Annual Congress of the American Laryngological Association met at the Hotel Chelsea, Atlantic City, under the presidency of Dr. James E. Newcomb, on Thursday, May 9, 1912. During the progress of the meeting the following Active Fellows were in attendance:

Dr. W. L. Ballinger, Chicago.  
Dr. T. P. Berens, New York.  
Dr. H. S. Birkett, Montreal.  
Dr. A. A. Bliss, Philadelphia.  
Dr. J. P. Brown, Toronto.  
Dr. J. H. Bryan, Washington.  
Dr. W. E. Casselberry, Chicago.  
Dr. W. F. Chappell, New York.  
Dr. F. C. Cobb, Boston.  
Dr. C. G. Coakley, New York.  
Dr. L. A. Coffin, New York.  
Dr. Algernon Coolidge, Jr., Boston.  
Dr. D. Bryson Delavan, New York.  
Dr. O. T. Freer, Chicago.  
Dr. T. R. French, Brooklyn.  
Dr. J. S. Gibb, Philadelphia.  
Dr. J. L. Goodale, Boston.  
Dr. T. H. Halsted, Syracuse.  
Dr. J. H. Hartman, Baltimore.  
Dr. F. E. Hopkins, Springfield.  
Dr. E. Fletcher Ingals, Chicago.  
Dr. J. M. Ingersoll, Cleveland.  
Dr. Chevalier Jackson, Pittsburgh.  
Dr. Samuel Johnston, Baltimore.  
Dr. J. N. Mackenzie, Baltimore.

Dr. G. Hudson Makuen, Philadelphia.  
Dr. Emil Mayer, New York.  
Dr. H. P. Mosher, Boston.  
Dr. J. E. Newcomb, New York.  
Dr. N. H. Pierce, Chicago.  
Dr. W. Scott Renner, Buffalo.  
Dr. C. C. Rice, New York.  
Dr. C. W. Richardson, Washington.  
Dr. J. O. Roe, Rochester.  
Dr. B. R. Shurly, Detroit.  
Dr. W. K. Simpson, New York.  
Dr. Greenfield Sluder, St. Louis.  
Dr. Harmon Smith, New York.  
Dr. G. C. Stout, Philadelphia.  
Dr. H. L. Swain, New Haven.  
Dr. C. F. Theisen, Albany.  
Dr. A. B. Thrasher, Cincinnati.  
Dr. H. L. Wagner, San Francisco.  
Dr. J. R. Winslow, Baltimore.  
Dr. G. B. Wood, Philadelphia.

President's Address, by Dr. James E. Newcomb, was followed by the regular

*Scientific Session.*

"The Exenteration of the Ethmoidal Labyrinth by the Intra-Nasal Route," by Dr. Harris P. Mosher. Discussed by Drs. Coakley, Swain, Ingals, Casselberry, Sluder, Freer, Ingersoll and in closing by Dr. Mosher.

"Report of a Case of Primary Carcinoma of Cushion of Eustachian Tube," by Dr. Norval H. Pierce. No discussion.

"A Case of Myxo-fibroma of the Naso-pharynx," by Dr. Joseph H. Bryan. Discussed by Drs. Casselberry, Coakley, Swain, and in closing by Dr. Bryan.

"Report of a Case of Rhino-pharyngeal Fibroma," by Dr. Joseph S. Gibb. Discussed by Drs. Delavan, Ingals, Smith, Coolidge, Pierce, Mosher, and in closing by Dr. Gibb.

*Presentation of Instruments and Specimens.*

Dr. C. F. Theisen presented a piece of glass removed from the larynx.

Dr. Samuel Johnston presented a cast of the anterior nares.

Dr. Henry L. Swain presented an esophagoscope (Ochs) showing a method whereby the esophagus can be inflated for removal of foreign bodies.

Dr. Algernoon Coolidge, Jr., presented an esophagoscope.

Dr. Harris P. Mosher presented an esophagoscope and open speculum.

Dr. Cornelius G. Coakley presented a modification of the Myles antrum trocar.

Dr. Greenfield Sluder presented a combination guillotine and snare (not original).

Dr. John O. Roe presented a laryngeal curette.

*Executive Session.*

The Chair appointed Drs. Swain and Sluder as members of the Auditing Committee.

It was moved that the Constitution as presented and furnished to the Members of the Association by the Secretary be adopted. Seconded and carried.

On motion, Dr. Simpson's Report on the Berlin Congress was deferred until a later session.

Nominating Committee was appointed as follows: Dr. Ingals, chairman; Dr. Delavan, Dr. Shurly, Dr. Hartman and Dr. Sluder.

## AFTERNOON SESSION.

*Scientific Session.*

"Aphthous Ulceration of the Upper Air Passages in Pulmonary Tuberculosis. A Retrospect and a Review," by Dr. John N. Mackenzie. Discussed by Drs. Pierce, Swain, Shurly, Price-Brown, and in closing by Dr. Mackenzie.

## Reading of Dr. Simpson's Report on Meeting in Berlin:

## THIRD INTERNATIONAL LARYNGOLOGICAL-RHINOLOGICAL CONGRESS HELD AT BERLIN, AUGUST 30 TO SEPTEMBER 2, 1911.

Having been a delegate from this association, I have been asked by our president, Dr. Newcomb, to say a few words by way of report of the International Congress of Laryngology and Rhinology held at Berlin, August 30, to September 2, 1911. If I were to present all my impressions or attempt to record the great value emanating from the congress to the laryngological world, I would indeed give myself a very long, but at the same time, a very pleasant task. I find much has been written about the congress, and refer the members of our association to the article by Dr. Goldstein in the September, 1911, number of *The Laryngoscope*, wherein he has given an excellent account. I hardly feel it necessary, in view of the article referred to, and others as well, to go into much detail. This scientific matter has been fully recorded in the extensive volume of transactions of the congress, which has lately been received in this country, and which, I presume, is in the hands of most of us. From the fact that the major number of dissertations were presented in languages foreign to our own, it was a matter of some difficulty to those of our tongue to follow them as well as we would like to have done. Those who could follow them were well repaid. It would be hard to imagine any improvement in the way in which the congress was conducted. The thorough system of registration, the distribution of the daily programs and the various cards of invitation to the social events, rendered it an easy matter for the "stranger within the gates." The building in which the congress was held, viz., the Herrenhaus of the German Parliament, was spacious and adequate, both as regards the session halls and the space allotted to the exhibition of specimens, apparatus, instruments and demonstrations. This department of the congress was most interesting, and received very close attention from those present, and afforded an excellent opportunity to exercise an interest for those who could not follow the various discussions. It seemed as if every nose and throat instrument necessary, and some unnecessary, were on exhibition, rather confirming the somewhat general impression that the Germans are a surgical nation.



Certainly the exhibition emphasized the modern trend of surgical ingenuity and interference in things laryngological and rhinological. I have often thought that this tendency of multiplication of instruments, though laudable as far as ingenuity is concerned, sometimes detracts from our efficiency. One of the most interesting exhibitions was the one showing the development of the instruments used in modern tracheoscopy, bronchoscopy and oesophagoscopy. In this connection I may mention the disappointment felt by the American members in the absence of our fellow member, Dr. Jackson, who was to take part in the discussion on the above subjects, and who was detained at home on account of family illness. The social side of the congress was most elaborate and endless, both as shown to the members and to the visiting ladies and guests, and one could only admire and wonder at German hospitality. It was overwhelming, and at the same time extremely cordial. Aside from the official entertaining, there were many individual side shows, so to speak; for, as the world knows, Berlin is a very entertaining town. It was hard work to keep up with the procession, but every one seemed to be on hand the next morning as if it were an ordinary home routine day. The members of our own association who were in attendance, as far as I can recall, were our president, Dr. Newcomb. Drs. Birkett, Wagner, Holmes and myself. There were a number of other American laryngologists present, but the total number was not as large as I should like to have seen. There was a goodly representation from Great Britain, among them names which are familiar to us all. The various continental nations were more or less represented, as well as far-away Japan. From the number present, the character of the work accomplished, the great interest manifested, one must admit laryngology has made wonderful progress. In closing these few words, I cannot but think that one of the most pleasant and lasting impressions of a congress of this kind, is to have met these men whose names are so familiar in the literature and uplift of our specialty. We see their names in print and often wonder what manner of men they are—their personality—and it is at these meetings that we meet them face to face. At this particular congress it was a great pleasure to meet the president, Dr. Fraenkel, whose name has

been so conspicuous since the incipency of our work, and the honor thus bestowed on him by the congress, seemed a most fitting close to a life's work so nobly done.

WILLIAM KELLY SIMPSON, M.D.

Symposium on "The Effects of Salvarsan."

"Indications for the Use of Salvarsan in Syphilis of the Nose and Throat," by Dr. Joseph L. Goodale.

"Salvarsan in Syphilis of the Nose and Throat," by Drs. Post and Cobb.

Discussion on Symposium by Drs. Ingersoll, Shurly, Swain, Mayer, Birkett, Hartman, Thrasher, Halsted, Freer, Wagner, Ingals, Smith, Winslow, Simpson, Stout, and in closing Drs. Cobb and Goodale.

On motion the meeting adjourned.

## SECOND DAY, MAY 10—MORNING SESSION.

### *Executive Session.*

Reading of telegrams from Drs. Kyle and Wilson.

Report of the Secretary and Treasurer. Moved, seconded and carried that this report be adopted as read.

### *Secretary's Annual Report.*

This is my first opportunity to thank you, gentlemen, for the honor you have so graciously conferred upon me. I desire also to emphasize the fact that in the eleven years you have been so faithfully and efficiently served by Dr. Newcomb, you have had the essence of secretary ability and that my one year's experience has demonstrated, beyond question, that I can never hope to attain his proficiency.

The promptness of secretary work depends largely upon the Fellows making immediate replies to all communications, and in

reducing the necessity for more than one appeal for each object. The Transactions may be issued early in the autumn, if those having taken part in the discussion will correct their proof and return to the secretary before going on their summer's vacation.

During the year there have been no deaths in the Active Fellowship of the Association, but we have lost our most distinguished and highly esteemed Honorary Fellow, B. Fraenkel, of Berlin. The council sent a letter of condolence to his daughters, from whom an appreciative reply was received.

We are regretful of losing by resignation, Drs. Bosworth, Knight and Lincoln, which leaves the membership of Active Fellows eighty-four, with sixteen vacancies; Honorary Fellows, four, with eleven vacancies; Corresponding Fellows, twenty-four, with six vacancies.

At the meeting of the council, held at the Hotel Manhattan, January 13, 1912, it was voted that each Fellow receive notice of the fact that the New Constitution would be acted upon at the next annual meeting, and that a receipt be obtained from him of the reception of a copy of the New Constitution and of the Certificate of Incorporation.

The Secretary complied with this motion, and now has on file each Fellow's acknowledgment that he received both of these documents one month prior to this meeting.

It was moved that the resolution relative to tonsils, adopted at the 1911 annual meeting, be referred back to the originator of the motion for elucidation and simplification and to be brought before the 1912 annual meeting, which has also been complied with.

At the second council meeting, May 9, 1912, it was moved that each Active Fellow sending in his resignation, should be notified of the meaning of the new honorary position of Retired Fellow, and asked if he will consent to become such.

Also moved that these Fellows be made acquainted with the policy of the Association adversely relative to electing an American Fellow to the position of Honorary Fellow.

*Treasurer's Annual Statement.*

## RECEIPTS.

Balance from old account.....	\$371.85
Dues collected .....	860.00
Sale of transactions.....	20.00
	<hr/>
Total .....	\$1,251.85

## EXPENDITURES.

Stenographer, 1911 .....	\$102.50
Transactions and mailing, 1911.....	636.58
Printing and stationery .....	64.44
Programmes and distribution (800).....	41.50
Express charges, J. E. Newcomb.....	2.00
Exchange on checks .....	.66
Express on books to Librarian.....	.60
Office expenses of Secretary and Treasurer.....	20.00
Letter circulars, McConnell & Co.....	475
	<hr/>
Total expenditures .....	\$873.03
By balance in bank.....	378.82
	<hr/>
Total .....	\$1,251.85

## ASSETS OF ASSOCIATION.

*Invested.*

De Roaldes Fund .....	\$500.00	
Accrued interest .....	91.64	
	<hr/>	
	\$591.64	\$591.64

*Current.*

Unpaid dues .....	\$150.00	
Postage in office .....	2.20	
Bank balance .....	378.82	
	<hr/>	
	\$531.02	531.02
Total .....	\$1,122.66	

LIABILITIES—None.

Respectfully submitted,  
HARMON SMITH,  
Treasurer.

Atlantic City, May 9, 1912.

Audited and approved.

H. L. SWAIN,  
GREENFIELD SLUDER,  
Auditing Committee.

Report of Librarian.

Report of Nominating Committee read by Dr. Ingals as follows:

President—Dr. George A. Leland, of Boston.

First Vice-President—Dr. Arthur W. Watson, of Philadelphia.

Second Vice-President—Dr. W. Scott Renner, of Buffalo.

Treasurer—Dr. J. Payson Clark, of Boston.

Secretary—Dr. Harmon Smith, of New York City.

Librarian—Dr. Joseph H. Bryan, of Washington, D. C.

For the ten Directors required by the incorporation of the Association:

Dr. Herbert S. Birkett.	Dr. Thomas H. Halsted.
Dr. Joseph H. Bryan.	Dr. Christian R. Holmes.
Dr. Cornelius G. Coakley.	Dr. Samuel Johnston.
Dr. D. Bryson Delavan.	Dr. D. Braden Kyle.
Dr. Thomas R. French.	Dr. Harmon Smith.
For Councillor—Dr. James E. Newcomb.	

Action on Report of Nominating Committee deferred, until last Executive Session.

Report of Roakles Fund Committee, by Dr. Delavan: "The Committee reports that the die for the making of the medal has been cut by Tiffany, of New York, and that as far as that is concerned, the preparations are completed for the striking of the medal at any time that the prize may be awarded; the funds of the prize are in such condition that the award may be made during the coming year, and therefore it would seem proper to announce the prize and call for theses."

Dr. Newcomb: "You will recall that at the meeting last year it was voted that the Committee be authorized to draw on the Treasurer for the necessary amount, \$175.00, to pay for the making of the die, and the idea of that motion was that the annual income of the Prize should be added to the principal until it reached its original amount, \$500.00. What is your wish in this matter?"

Moved that this be accepted. Seconded and carried.

Dr. Ingals broached the subject of the publication of a journal of Laryngology and Otology, saying: "Several years ago I with others was appointed on the Committee with reference to a Journal of Laryngology and Otology. I was appointed both from this and the other society, and made the report which showed that the journal could not be published as was contemplated at that time without a deficit of \$2,500.00 per year. Since that time the Journal of the American Medical Association has taken up the publication of some special journals, and I have reason to believe a journal of Laryngology would be taken up by it, if the special societies cared to have it done, without any expense to the societies. The plan adopted by the pediatrists would probably be the better one, that is, a certain number of editors were selected by the society and part by the trustees of the Journal, although I am not sure of the manner of election. Then the Journal received contributions from the various societies but reserved to itself the right of excluding any contribution they did not consider worthy. It seems to me if this association and the Association of Laryngology, Rhinology and Otology and the Association of Otology were to ask for the publication of such a journal, it would be taken up by the Trustees of the American Medical Association and probably acted upon favorably, and then they can publish a good journal on our special subjects without expense to us. Our Transactions could be published in connection with this at much less expense than at present. It occurs to me that we could furnish one of these journals to each member from the annual dues which are now paid."

Dr. Delavan: "The only possible comment or criticism that could be made on this would be as to the management of the

journal. If the composition of the journal board were established satisfactorily to all three of the interests represented I think it would be an admirable proposition. If any one society were to acquire a preponderance of influence in the management of the magazine it might not work well."

Dr. Ingals: "With reference to that very matter from my last conversation on the subject with the authorities of the American Medical Association, I felt convinced that the trustees of the Journal of the American Medical Association would appoint the editors and they would claim a free hand in doing it, but they would be glad to consider nominations from the societies, although they would not be willing to undertake the publication and give the societies the absolute right of appointing the editorial staff. Therefore, I think the journal staff would be well managed."

Dr. Coakley: "I move that a committee of three be appointed by the Chair to investigate this subject and bring in a definite written report at the next meeting, this committee not in any way to commit this society to any definite arrangement with regard to this matter."

Dr. Ingals: "I would like to say that a committee would get nowhere unless it was authorized to request the trustees of the Journal to publish such a journal with the provision that this request could be withdrawn."

Dr. Coakley: "My object would be to request the other societies to join with us, and let the three societies take action on this matter and get something absolutely tangible to work on."

Dr. Shurly: "I would like to amend Dr. Coakley's motion, that this matter be brought before the Board of Directors at their annual meeting and let them give final action on it, which would save six months if the matter is considered feasible."

Motion with amendment seconded and carried.

#### *Scientific Session.*

"Anesthesia for Peroral Endoscopy," by Dr. Chevalier Jackson; discussion by Drs. Ingals, Coolidge, Swain, Freer, Casselberry, Mayer, Makuen and, in closing, Dr. Jackson.

"The Upright Position in Ether Operations Upon the Nose, Throat and Other Portions of the Head, with Demonstration of a New Method for Attaining the Position with Expedition, Ease and Safety," by Dr. Thomas R. French. Discussed by Drs. Casselberry, Richardson, Mosher, Bliss, Freer, Thrasher, Delavan, Birkett, Makuen and, in closing, Dr. French.

"Malignant Disease of the Upper Air Passages, with Notes upon Two Cases of Epithelioma," by Dr. J. Price-Brown. Discussed by Drs. Coakley, Roe, Smith, Delavan and, in closing, Dr. Price-Brown.

"Report of a Case of Bronchoscopy for Multiple Foreign Bodies, (almond shell and pulp) in a Child Two Years of Age; with Some Observations Upon Bronchoscopy in Infants and Young Children," by Dr. John R. Winslow. Discussed by Drs. Jackson, Shurley, Simpson, Mayer and, in closing, Dr. Winslow. On motion adjourned.

#### AFTERNOON SESSION.

##### *Scientific Session.*

"Orbital Abscess From Infection Through the Ethmoid," by Dr. John O. Roe. Discussion by Drs. Mosher, Coakley, Casselberry, Price-Brown, Pierce, Renner and, in closing, Dr. Roe.

"Some Anatomical and Clinical Relations of the Sphenoid Sinus to the Cavernous Sinus and the Third, Fourth, Fifth, Sixth and Vidian Nerves," by Dr. Greenfield Sluder. Discussion by Drs. Bryan, Mosher, Roe, Mayer and, in closing, Dr. Sluder.

"Morphological Changes in the Nose and Face, due to the Development of the Brain," by Dr. J. M. Ingersoll. Discussion by Dr. Mosher and, in closing, by Dr. Ingersoll.

"Traumatic Paralysis of the Right Recurrent Laryngeal Nerve. Report of Two Cases." By Dr. D. Bryson Delavan. Discussion by Drs. Coakley, Freer, Pierce, Mayer, Roe, Rice and, in closing, Dr. Delavan.

"When Should Singers Having Vocal Disability be Allowed to Resume Work?" by Dr. Clarence C. Rice. Discussion by Drs. Thrasher, Pierce and, in closing, Dr. Rice.



"The Question of Post-operative Nasal Packing in the Light of Additional Experience with the Author's Rubber Tampon," by Dr. W. E. Casselberry. Discussion by Drs. Bliss, Ingals, Price-Brown and, in closing, Dr. Casselberry.

"Two cases of Exudative Laryngeal Growths: (a) Malignant, (b) Tubercular," by Dr. W. K. Simpson. Discussion by Drs. Mayer, Rice, Swain and, in closing, Dr. Simpson.

On motion adjourned.

### THIRD DAY, MAY 11—MORNING SESSION.

#### *Scientific Session.*

"The Ozena Investigation in the United States," by Dr. Emil Mayer. Discussion by Dr. Cobb and, in closing, Dr. Mayer.

"The Anatomy of Deflections of the Nasal Septum," by Dr. Otto T. Freer. Discussion by Drs. Cobb, Coakley, Shurly, Delavan, Ingals, Ballenger and, in closing, Dr. Freer.

"The Middle Turbinated Body: Indications for Its Removal," by Dr. W. Scott Renner. Discussion by Drs. Sluder, Price-Brown, Richardson, Mayer, Ballenger, Casselberry, Cobb, Pierce and, in closing, Dr. Renner.

"Vincent's Angina: Its Frequency and the Importance of Its Diagnosis. With Reports of Two Fatal Cases," by Dr. Thomas H. Halsted. Discussion by Drs. Coakley, Ingals, Shurly, Sluder, Swain, Theisen, Wagner, Pierce, Cobb, Ingersoll and in closing, Dr. Halsted.

"Complications of the Operations for the Removal of Tonsils," by Dr. Charles W. Richardson.

Discussion by invitation: Drs. Wishart, Beck, Cheney. Drs. Bryan, Delavan, Ballenger, Sluder, Freer, Casselberry, Roe, Wagner, Brown, Pierce, Winslow, Smith, Shurly and in closing, Richardson.

### AFTERNOON SESSION.

#### *Scientific Session.*

"Contribution to the Pathogenesis of Bronchial Asthma," by Dr. Henry L. Wagner. No discussion.

"Report of a Case of (a) Haemophilia Successfully Treated by Transfusion; (b) Nasal Sarcoma, by Dr. Walker F. Chappell. No discussion.

*Papers Read by Title.*

"A Study of Sinus Headaches," by Dr. Walter J. Freeman.  
"The Effects of Salvarsan on Syphilitic Lesions of the Upper Respiratory Tract," by Dr. Lewis A. Coffin.

"Salvarsan in the Treatment of Syphilis of the Upper Respiratory Tract," by Prof. Ferd Massei.

"Coryza and Respiratory Gymnastics," by Dr. Marcel Natier.

"Report of a Case of Carcinoma of the Larynx, Removed by Operation," by Dr. Francis R. Packard.

*Executive Session.*

The Chair appointed Drs. Shambaugh, Coolidge and Kyle to act on the committee for the publication of a journal.

Resolution of Dr. Richards read, as follows:

Resolved, That the president appoint a committee of three to make a collective investigation on the physiology and pathology of the tonsil, and its relation to the rest of the body.

This committee to appoint three sub-committees. Sub-committee No. 1, to study the physiology of the tonsil; Sub-committee No. 2, to study the pathology of the tonsil and its relation to general bodily conditions and systemic disorders; such as rheumatism and the like. Also to consider the question of treatment, but not operative technique. Sub-committee No. 3, to study the operated tonsil, the results of tonsillotomy and tonsillectomy, including the technique and the sequelae.

No case to be presented in which the history cannot be given for at least three years after the first observation, or after operation.

All of this information to be sought from the members of special societies throughout the world, and from leading general practitioners and surgeons. Five to ten complete case histories to be obtained from each person contributing.

The original committee to make its report in two years, and this report when published to include all the tonsil problems, and be published as a monograph on the tonsil by the Association, and for general sale.

The Chair appointed Drs. Richards, Clark and Swain to act as a Committee for the Collective Investigation on Tonsil Work.

Report of Nominating Committee (read for first time on Second Day) :

President—Dr. George A. Leland.

First Vice-President—Dr. Arthur W. Watson.

Second Vice-President—Dr. W. Scott Renner.

Secretary—Dr. Harmon Smith.

Treasurer—Dr. J. Payson Clark.

Librarian—Dr. Joseph H. Bryan.

Member of Council—Dr. James E. Newcomb.

Ballot cast in favor of the nominations as read.

Officers duly elected.

Dr. Wm. Kelly Simpson was chosen as the delegate to represent the Association at the next Congress of the American Physicians and Surgeons in Washington City.

Dr. Christian R. Holmes, of Cincinnati, was chosen as the delegate to represent the Association at the next International Rhinology-Laryngological Congress in 1914.

Dr. Renner, second vice-president-elect, being the only one of the newly elected officers present, thanked the Association for the honor conferred upon himself and the other members of the society.

On motion, a vote of thanks was tendered to the retiring president, Dr. James E. Newcomb, for the very good and scientific meeting prepared, and for the tact and dignity displayed by him at the meetings.

On motion, the meeting adjourned to meet in Washington, D. C., in 1913.

---

**DR. JAMES E. NEWCOMB.**

It is with profound sorrow that the secretary is obliged to announce that since our last meeting our honored and loved comrade who presided at it has passed away. He died on August 27, 1912, at his summer home at Lake Kushaqua, in the Adirondacks.

Dr. James Edward Newcomb was born in New London, Conn., on August 27, 1857; he therefore died on his 55th birthday. He was educated in the public schools of that city, graduating as valedictorian of the first class at the Bulkeley High School. He graduated at Yale College in the class of 1880. He studied for three years at the College of Physicians and Surgeons, now the medical department of Columbia College, in New York City, and graduated among the first ten in the very large class of the year 1883.

By competitive examination he became an interne for eighteen months at the Roosevelt Hospital. Shortly after his retirement from this position he began general practice and very soon became interested in laryngology. He began his work in this specialty at the Demilt Dispensary and in the Out Patient Department of Roosevelt Hospital. Later he became consulting laryngologist to the hospital. He remained connected with it until his death, having completed a service of thirty years in that institution.

For several years he was Lecturer on Laryngology at Columbia University, and was Professor of Laryngology at Cornell Medical College at the time of his death. He was successful in general practice, and gradually acquired the same result when he devoted his attention more exclusively to the diseases of the nose and throat. He became a member of this Association in 1893, and for eleven years he was our beloved and honored secretary. He was a member of many other medical and philanthropic associations, and his general standing among his professional and private companions was of the very highest.

He was married in 1887 to Miss Elizabeth Wilmot, of New York, and assisted her in the building up of the very successful establishment of the Stony Wold Sanatorium for phthisical patients at Lake Kushaquaa, New York.

Dr. Newcomb, as we know, was a frequent contributor to laryngological literature. He was the editor of the American edition of "Grünwald's Atlas of the Diseases of the Mouth, Pharynx and Nose." In collaboration with Dr. Burnett and our associate, Dr. Ingals, he was the author of a text book on the diseases of the nose and throat.

It would be superfluous to say more than we have of the high esteem and personal affection in which he was held by all of us. His geniality, his conscientiousness and devotion to duty, his love for this Association, and his appreciation of the honor which it did him in electing him president, are fresh in our minds. The latter is evidenced by the desire of presiding at our last meeting, although he knew he was at the very gates of death. We all of us appreciate deeply his sterling worth, and we mourn his loss.

---

## LIST OF ACTIVE FELLOWS.

1913.

- 1906. BALLENGER, WILLIAM L., Columbus Memorial Building,  
Chicago, Ill.
- 1908. BARNHILL, JOHN F., 328 Delaware St., Indianapolis, Ind.
- 1880. BEAN, C. E., Germania Life Bldg., St. Paul, Minn.
- 1904. BERENS, T. PASSMORE, 35 Park Ave., New York.
- 1893. BIRKETT, HERBERT S. 252 Mountain St., Montreal.
- 1893. BLISS, ARTHUR AMES, 117 South 20th St., Philadelphia,  
Pa.
- 1901. BROWN, J. PRICE, 28 College St., Toronto, Can.
- 1892. BROWN, MOREAU R., 34 Washington St., Chicago, Ill.
- 1891. BRYAN, JOSEPH H., 818 17th St., Washington, D. C.
- 1889. CASSELBERRY, WILLIAM E., 34 Washington St., Chicago,  
Ill.
- 1896. CHAPPELL, WALTER F., 7 East 55th St., New York.
- 1897. CLARK, J. PAYSON, 71 Marlborough St., Boston, Mass.
- 1902. COAKLEY, CORNELIUS G., 53 West 56th St., New York.
- 1899. COBB, FREDERIC C., 11 Marlborough St., Boston, Mass.
- 1905. COFFIN, LEWIS A., 156 West 58th St., New York.
- 1878. COHEN, J. SOLIS-, 1824 Chestnut St., Philadelphia, Pa.
- 1893. COOLIDGE, ALGERNON, JR., 613 Beacon St., Boston, Mass.
- 1882. DEBLOIS, THOMAS AMORY, 48 Gloucester St., Boston,  
Mass.
- 1881. DELAVAN, D. BRYSON, 40 East 41st St., New York.
- 1892. FARLOW, JOHN W., 234 Clarendon St., Boston, Mass.
- 1901. FREEMAN, WALTER J., 1832 Spruce St., Philadelphia, Pa.
- 1905. FREER, OTTO T., 34 Washington St., Chicago, Ill.
- 1879. FRENCH, THOMAS R., 150 Joralemon St., Brooklyn, N. Y.
- 1879. FROTHINGHAM, RICHARD, 616 Madison Ave., New York.
- 1909. GETCHELL, ALBERT C., 6 Linden St., Worcester, Mass.
- 1907. GIBB, JOSEPH S., 1907 Chestnut St., Philadelphia, Pa.
- 1880. GLEITSMANN, JOSEPH W. 616 Madison Ave., New York.

1898. GOODALE, JOSEPH L., 258 Beacon St., Boston, Mass.  
1905. GRAYSON, CHARLES P., 251 South 16th St., Philadelphia, Pa.  
1906. GREENE, D. CROSBY, JR., 483 Beacon St., Boston, Mass.  
1905. HALSTEAD, THOMAS H., 831 University Block, Syracuse, N. Y.  
1896. HARDIE, T. MELVILLE, 34 Washington St., Chicago, Ill.  
1903. HARRIS, THOMAS J., 117 East 40th St., New York.  
1878. HARTMAN, JACOB H., 5 West Franklin St., Baltimore, Md.  
1888. HINKEL, F. WHITEHILL, 581 Delaware Ave., Buffalo, N. Y.  
1907. HOLMES, CHRISTIAN R., 8 East 8th St., Cincinnati, Ohio.  
1893. HOPE, GEORGE B., 159 West 72d St., New York.  
1895. HOPKINS, FREDERICK E., 25 Harrison Ave., Springfield, Mass.  
1895. HUBBARD, THOMAS, 544 Nicholas Building, Toledo, Ohio.  
1878. INGALS, E. FLETCHER, 15 E. Washington St., Chicago, Ill.  
1904. INGERSOLL, JOHN M., 318 Euclid Ave., Cleveland, Ohio.  
1907. JACKSON, CHEVALIER, 1018 Westinghouse Building, Pittsburgh, Pa.  
1878. JOHNSTON, SAMUEL, 204 West Monument St., Baltimore, Md.  
1898. KYLE, D. BRADEN, 1517 Walnut St., Philadelphia, Pa.  
1880. LANGMAID, SAMUEL W., 143 Newbury St., Boston, Mass.  
1894. LELAND, GEORGE A., 354 Commonwealth Ave., Boston, Mass.  
1897. LOGAN, JAMES E., 1208 Wyandotte St., Kansas City, Mo.  
1888. LOWMAN, JOHN H., 1807 Prospect Ave., S. E., Cleveland, Ohio  
1911. LOCKARD, LORENZO B., Metropolitan Bldg., Denver, Col.  
1886. MACCOY, ALEXANDER W., 216 South 15th St., Philadelphia, Pa.  
1883. MACKENZIE, JOHN N., 605 Washington Place, Baltimore, Md.  
1898. MAKUEN, G. HUDSON, 1627 Walnut St., Philadelphia, Pa.  
1896. MAYER, EMIL, 40 East 41st St., New York.  
1899. MCKERNON, JAMES F., 62 West 52d St., New York.  
1904. MOSHER, HARRIS P., 828 Beacon St., Boston, Mass.

1901. MYLES, ROBERT C., 46 West 38th St. New York.  
1903. PACKARD, FRANCIS R., 304 South 19th St., Philadelphia, Pa.  
1906. PIERCE, NORVAL H., 31 Washington St., Chicago, Ill.  
1878. PORTER, WILLIAM, 3886 Washington Ave. St. Louis, Mo.  
1908. RANDALL, B. ALEXANDER, 1717 Locust St., Philadelphia, Pa.  
1903. RENNER, W. SCOTT, 341 Linwood Ave., Buffalo, N. Y.  
1897. RHODES, J. EDWIN, 100 State St., Chicago, Ill.  
1884. RICE, CLARENCE C., 123 East 19th St., New York.  
1905. RICHARDS, GEORGE L., 84 North Main St., Fall River, Mass.  
1902. RICHARDSON, CHARLES W., 1317 Connecticut Ave., Washington, D. C.  
1893. ROALDES, ARTHUR W. DE, 1328 Jackson Ave., New Orleans, La.  
1879. ROE, JOHN O., 44 Clinton Ave. South, Rochester, N. Y.  
1907. SHAMBAUGH, GEORGE E., 100 State St., Chicago, Ill.  
1909. SHURLY, BURT R., 32 Adams Ave. W., Detroit, Mich.  
1878. SHURLY, ERNEST L., 32 Adams Ave. W., Detroit, Mich.  
1909. SLUDER, GREENFIELD, 3542 Washington Ave., St. Louis, Mo.  
1892. SIMPSON, WILLIAM K., 952 Lexington Ave., New York.  
1908. SMITH, HARMON, 44 West 49th St., New York.  
1911. STOUT, GEORGE C., 1611 Walnut St., Philadelphia, Pa.  
1889. SWAIN, HENRY L., 232 York St., New Haven, Conn.  
1903. THEISEN, CLEMENT F., 172 Washington Ave., Albany, N. Y.  
1892. THRASHER, ALLEN B., The Groton, 7th and Race Sts., Cincinnati, Ohio.  
1892. WAGNER, HENRY L., 2303 Bush St., San Francisco, Cal.  
1892. WATSON, ARTHUR W., 126 South 18th St., Philadelphia, Pa.  
1908. WILSON, J. GORDON, 5221 Hibbard Ave., Chicago, Ill.  
1906. WINSLOW, JOHN R., The Latrobe, Charles and Reade Sts., Baltimore, Md.  
1905. WOOD, GEORGE B., 129 South 18th St., Philadelphia, Pa.  
1890. WRIGHT, JONATHAN, N. Y. Post Grad. Med. School, 20th St. and 2d Ave., New York.



## HONORARY FELLOWS.

- 1910. CHIARI, OTTOKAR, Bellariastrasse 12, Vienna, Austria.
- 1910. MASSEI, F., 4 Piazza Municipio, Naples, Italy.
- 1910. MOURE, E. J., 25 Cours du Jardin Public, Bordeaux, France.
- 1909. SEMON, FELIX, Rignall, Great Missenden, Bucks, England.

## CORRESPONDING FELLOWS.

- 1880. BRUNS, PAUL, Tübingen, Wurtemberg, Germany.
- 1901. COLLIER, MAYO, 145 Marley St., Cavendish Square, London W., England.
- 1890. DE LA SOTA Y LASTRA, R., 7 Calle de Torqueros, Seville, Spain.
- 1893. DESVERNINE, C. M., Cuba 52, Havana, Cuba.
- 1901. GRANT, DUNDAS, 18 Cavendish Square, London W., England.
- 1902. HEYMANN, PAUL, 60 Lützowstrasse, Berlin W., Germany.
- 1908. KILLIAN, GUSTAV, Friedburg-im-Breisgau, Germany.
- 1892. KRAUSE, H., San Remo, Italy.
- 1902. LERMOYEZ, MARCEL, 20 Rue de la Boetie, Paris, France.
- 1897. LUC, H., 54 Rue de Varenne, Paris, France.
- 1903. MCBRIDE, P., 16 Chester St., Edinburgh, Scotland.
- 1896. MACDONALD, GREVILLE, 85 Harley St., Cavendish Square, London W., England.
- 1894. MACINTYRE, JOHN, 179 Bath St., Glasgow, Scotland.
- 1896. MYGIND, HOLGER, 31 Havnegade, Copenhagen, Denmark.
- 1901. NATIER, MARCAL, 12 Rue Caumartin, Paris, France.
- 1910. NAVRATIL, EMERICH VON, IV Yaaczi-utcza 40, Buda-Pesth, Hungary.
- 1903. ONODI, A., o'Uctza 12, Buda-Pesth, Hungary.
- 1910. RETHI, LEOPOLD, IX Garnisongasse 7, Vienna, Austria.
- 1894. SAJOUS, C. E., 2043 Walnut St., Philadelphia, Pa.
- 1896. SCHMIEGELOW, ERNEST, 18 Nørregade, Copenhagen, Denmark.

- 1902. THOMSON, ST. CLAIR, 28 Queen Anne St., Cavendish Square, London W., England.
- 1903. TILLEY, HERBERT, 72 Harley St., Cavendish Square, London W., England.
- 1901. WINGRAVE, WYATT, 11 Devonshire St., Portland, Place, London W., England.
- 1894. WOLFENDEN, R. NORRIS, 76 Wimpole St., Cavendish Square, London W., England.

RETIRED FELLOWS.

- 1878. BOSWORTH, FRANCKE H., 41 Park Ave., New York.
- 1885. KNIGHT, CHARLES H., 55 East 93d St., New York.
- 1903. LINCOLN, WILLIAM, 210 Lenox Bld., Cleveland, O.

## PAST OFFICERS.

*Presidents.*

(Year of Election.)

1879. Louis Elsberg.	1896. C. H. Knight.
1880. J. Solis-Cohen.	1897. T. R. French.
1881. F. I. Knight.	1898. W. E. Casselberry.
1882. G. M. Lefferts.	1899. Samuel Johnston.
1883. F. H. Bosworth.	1900. H. L. Swain.
1884. E. L. Shurly.	1901. J. W. Farlow.
1885. Harrison Allen.	1902. J. H. Bryan.
1886. E. Fletcher Ingals.	1903. J. H. Hartman.
1887. R. P. Lincoln.	1904. C. C. Rice.
1888. E. C. Morgan.	1905. J. W. Gleitsmann.
1889. J. N. Mackenzie.	1906. A. W. de Roaldes.
1890. W. C. Glasgow.	1907. H. S. Birkett.
1891. S. W. Langmaid.	1908. A. Coolidge, Jr.
1892. M. J. Asch.	1909. J. E. Logan.
1893. D. B. Delavan.	1910. D. Braden Kyle.
1894. J. O. Roe.	1911. James E. Newcomb.
1895. W. H. Daly.	1912. George A. Leland.

*Vice-Presidents.*

1879. F. H. Davis.
1880. W. C. Glasgow, J. O. Roe.
1881. E. L. Shurly, W. Porter.
1882. C. Seiler, E. F. Ingals.
1883. S. W. Langmaid, S. Johnston.
1884. J. H. Hartman, W. H. Daly.
1885. H. A. Johnson, G. W. Major.
1886. E. C. Morgan, J. N. Mackenzie.
1887. J. N. Mackenzie, S. W. Langmaid.

1888. W. C. Glasgow, C. E. Sajous.  
1889. E. Holden, C. E. Bean.  
1890. J. O. Roe, J. H. Hartman.  
1891. M. J. Asch, S. Johnston.  
1892. S. Johnston, J. C. Mulhall.  
1893. J. C. Mulhall, W. E. Casselberry.  
1894. C. C. Rice, S. H. Chapman.  
1895. J. Wright, A. W. de Roaldes.  
1896. T. M. Murray, D. N. Rankin.  
1897. A. W. MacCoy, H. S. Birkett.  
1898. J. W. Farlow, F. W. Hinkel.  
1899. T. A. DeBlois, M. R. Brown.  
1900. H. L. Wagner, A. A. Bliss.  
1901. J. W. Gleitsmann, D. Braden Kyle.  
1902. G. A. Leland, T. Melville Hardie.  
1903. J. H. Lowman, W. Peyre Porcher.  
1904. Thomas Hubbard, W. J. Freeman.  
1905. J. L. Goodale, C. W. Richardson.  
1906. G. H. Makuen, A. B. Thrasher.  
1907. J. P. Clark, J. E. Rhodes.  
1908. E. Mayer, F. R. Packard.  
1909. C. G. Coakley, H. P. Mosher.  
1910. Robert C. Myles, J. M. Ingersoll.  
1911. F. C. Cobb, B. R. Shurly.  
1912. A. W. Watson, W. Scott Renner.

*Secretaries and Treasurers.*

- |                      |                      |
|----------------------|----------------------|
| 1879. G. M. Lefferts | 1895. H. L. Swain.   |
| 1882. D. B. Delavan. | 1900. J. E. Newcomb. |
| 1889. C. H. Knight.  | 1911. Harmon Smith.  |

*Treasurer.*

1912. J. Payson Clark.

*Librarians.*

- |                       |                     |
|-----------------------|---------------------|
| 1879. F. H. Bosworth. | 1883. T. R. French. |
| 1903. J. H. Bryan.    |                     |

## PAST MEMBERS.

*Honorary Fellows.*

- \*1880. Senor Manuel Garcia, London, England.
- \*1883. Sir Morell Mackenzie, London, England.
- \*1907. Leopold von Schroetter, Vienna, Austria.
- \*1904. B. Fraenkel, Berlin, Germany.

*Corresponding Fellows.*

- \*1892. Lennox Browne, London, England.
- \*1887. A. Gouguenheim, Paris, France.
- \*1894. Edgar Holden, Newark, N. J.
- \*1881. Carlo Labus, Milan, Italy.
- \*1880. Wilhelm Meyer, Copenhagen, Denmark.
- \*1901. Moritz Schmidt, Frankfort-a-Main, Germany.
- \*1881. Pugin Thornton, London, England.
- \*1881. R. Voltolini, Breslau, Germany.
- \*1880. W. McNeil Whistler, London, England.
- †1881. Sir Felix Semon, Bucks Co., England.
- †1887. E. J. Moure, Bordeaux, France.
- †1892. F. Massei, Naples, Italy.
- †1896. Ottokar Chiari, Vienna, Austria.

*Active Fellows.*

- \*1880. Harrison Allen, Philadelphia, Pa.
- \*1878. Morris J. Asch, New York.
- 1895. J. E. Boylan, Cincinnati, Ohio.
- \*1883. C. W. Chamberlain, Hartford, Conn.
- \*1882. S. Hartwell Chapman, New Haven, Conn.
- 1884. S. Solis-Cohen, Philadelphia, Pa.
- 1880. E. W. Cushing, Boston, Mass.
- 1878. Ephraim Cutter, West Falmouth, Mass.
- \*1880. W. H. Daly, Pittsburgh, Pa.
- \*1878. F. H. Davis, Chicago, Ill.

- \*1901. E. T. Dickerman, Chicago, Ill.
- \*1878. Frank Donaldson, Baltimore, Md.
- \*1878. William Carr Glasgow, St. Louis, Mo.
- †1879. Edgar Holden, Newark, N. J.
- \*1882. Franklin H. Hooper, Boston, Mass.
- 1882. Frank L. Ives, New York City.
- \*1878. Hosmer A. Johnson, Chicago, Ill.
- \*1879. Woolsey Johnson, New York City.
- \*1880. William C. Jarvis, New York City.
- 1879. R. H. Kealhofer, St. Louis, Mo.
- \*1901. Gordon King, New Orleans, La.
- \*1878. Rufus P. Lincoln, New York City.
- 1881. G. W. Major, Montreal, Canada.
- 1879. Charles McBurney, New York City.
- 1885. H. Clinton McSherry, Baltimore, Md.
- \*1881. E. C. Morgan, Washington, D. C.
- \*1886. J. C. Mulhall, St. Louis, Mo.
- 1892. T. Morris Murray, Washington, D. C.
- \*1881. H. Mynter, Buffalo, N. Y.
- \*1893. James E. Newcomb, New York City.
- \*1895. J. E. H. Nichols, New York City.
- 1879. H. K. C. Oliver, Boston, Mass.
- 1894. William H. Park, New York City.
- 1892. W. Peyre Porcher, Charleston, S. C.
- \*1880. D. N. Rankin, Allegheny, Pa.
- 1881. J. M. Robertson, Detroit, Mich.
- 1878. Beverly Robinson, New York City.
- \*1878. T. F. Rumbold, St. Louis, Mo.
- †1880. Charles E. Sajous, Paris, France.
- \*1879. Carl Seiler, Scranton, Pa.
- \*1893. Charles M. Shields, Richmond, Va.
- 1879. Andrew H. Smith, Geneva, N. Y.
- 1879. Bernhard Tauber, Cincinnati, Ohio.
- \*1899. Max Thorner, Cincinnati, Ohio.
- 1888. S. O. Van der Poel, New York City.
- 1878. Clinton Wagner, New York City.
- 1896. Marshall R. Ward, Pittsburgh, Pa.
- 1879. Whitfield Ward, New York City.

- \*1886. Benjamin F. Westbrook, Brooklyn, N. Y.
- 1896. Green V. Woollen, Indianapolis, Ind.
- 1878. George M. Lefferts, New York City.
- 1901. Frank Hyatt, Washington, D. C.

---

\*Deceased. †Corresponding Fellow. ‡Honorary Fellow.











4113  
16+

[



3 2044 102 960 382