# Transactions
# American Laryngological Association

Forty-fifth Volume

# TRANSACTIONS

OF THE

## FORTY-FIFTH ANNUAL MEETING

OF THE

# American Laryngological Association

HELD AT ATLANTIC CITY, N. J.

MAY 16, 17 AND 18, 1923

---

PHILADELPHIA

PUBLISHED BY THE ASSOCIATION

1923

# CONTENTS.

List of Officers . . . . . vii
Registration . . . . . 17
Address of the President. Emil Mayer, M.D. . . . . 19
Acute Laryngeal Edema. Clement F. Theisen, M.D. . . . . 28
Some Observations on the Cases of Laryngeal Cancer Seen During the Past Year, with Microscopical Findings in Three Incipient Cases. J. E. Mackenty, M.D. . . . . 45
Anatomical and Clinical Observations on the Lower End of the Esophagus and the Diaphragm. Harris P. Mosher, M.D. . . . . 58
The Relation of Sinusitis to Arthritis Deformans. E. Ross Faulkner, M.D. . . . . 101
Tonsillar Pathology in Relation to Systemic Infection. George B. Wood, M.D. . . . . 108
Chronic Infections of the Upper Respiratory Tract and Their Relation to General Disease. Francis P. Emerson, M.D. . . . . 119
The Effect of Dental Infection on the Rest of the Body. Kurt H. Thoma, D.M.D. . . . . 132
The Nature of the Influence of Focal Infection and the Means Necessary to Meet It. Ralph Pemberton, M.D. . . . . 141
Glossopharyngeal Neuralgia from the Standpoint of the Rhinolaryngologist. Harold I. Lillie, M.D. . . . . 162
Further Experience in the Use of Tissue Juices in Tonsillectomy. Joseph B. Greene, M.D. . . . . 172
Stenosis of the Larynx and the Trachea. Treatment Shown by Moving Pictures. Francis W. White, M.D. . . . . 181
Brain Abscess of Paranasal Sinus Origin. Gordon Berry, M.D. . . 186
Nasopharyngeal Fibroma: A Clinical and Pathological Study. Perry G. Goldsmith, C.B.E., M.D., C.M. . . . . 198
A Case of Epithelioma of the Esophagus, with Some Unusual Features. S. McCullagh, M.D. . . . . 211
Glossodynia, with Lingual Tonsillitis as Its Etiology, and Its Control Through the Nasal (Sphenopalatine, Meckel's) Ganglion: Report of a Case. Greenfield Sluder, M.D. . . . . 215
Notes on Fourteen Cases Operated on for Intrinsic Cancer of the Larynx. J. S. Fraser, M.D., Ch.B., F.R.C.S. (Edin.) . . . . . 223
Radical Operation for Extrinsic Carcinoma of the Larynx. V. P. Blair, M.D. . . . . 228

The Reaction of the Paratonsillar Tissues to Tonsillectomy: A Study in the Etiology of Posttonsillectomy Pulmonary Abscess. George Fetterolf, M.D., and Herbert Fox, M.D. . . . . 252
A Study of the Retropharyngeal Abscess (Candidate's Thesis). James A. Babbitt, M.D. . . . . 282
Presentation of Instruments. Robert C. Myles, M.D. . . . . 289
Memorial:
Ramon de la Sota y Lastra, M.D., Ph.D., Litt.D. . . . . 293

---

List of Fellows, 1923:
Active Fellows . . . . . 297
Associate Fellows . . . . . 300
Honorary Fellows . . . . . 301
Corresponding Fellows . . . . . 301
Emeritus Fellows . . . . . 302
Past Officers . . . . . 303
Past Members . . . . . 305

## OFFICERS FOR 1922–1923

PRESIDENT

EMIL MAYER, M.D.

FIRST VICE-PRESIDENT

GEORGE FETTEROLF, M.D.

SECOND VICE-PRESIDENT

LORENZO B. LOCKARD, M.D.

SECRETARY

GEORGE MORRISON COATES, M.D.

TREASURER

J. PAYSON CLARK, M.D.

LIBRARIAN

JOSEPH H. BRYAN, M.D.

COUNCIL

The above Ex-officio and
CORNELIUS G. COAKLEY, M.D.
NORVAL H. PIERCE, M.D.
HARRIS P. MOSHER, M.D.
HARMON SMITH, M.D.

TRANSACTIONS OF THE FORTY-FIFTH
ANNUAL CONGRESS

OF THE

# AMERICAN LARYNGOLOGICAL ASSOCIATION

HELD AT

ATLANTIC CITY, N. J., MAY 16, 17 AND 18, 1923

---

## REGISTRATION

The Forty-fifth Annual Congress of the American Laryngological Association was called to order, Wednesday, May 16, 1923, at 10 A.M., by the President, Dr. Emil Mayer, at the Hotel Ambassador, Atlantic City, N. J. The following Fellows enrolled during the session:

BABBITT, JAMES A.
BARLOW, ROY ALEXANDER
BERRY, GORDON
BIRKETT, HERBERT S.
BLAIR, VILRAY P.
BRYAN, JOSEPH H.
BUTLER, RALPH
CLARK, J. PAYSON
COAKLEY, CORNELIUS G.
COATES, GEORGE M.
COFFIN, LEWIS A.
DEAN, LEE WALLACE
DELAVAN, D. BRYSON
EMERSON, FRANCIS P.
FAULKNER, E. ROSS
FENTON, RALPH ALBERT
FETTEROLF, GEORGE
GOLDSMITH, PERRY G.
GOODALE, JOSEPH L.
GREENE, D. CROSBY, JR.
GREENE, JOSEPH B.
HALSTEAD, THOMAS H.
HURD, LEE MAIDMENT
INGERSOLL, JOHN M.
JACKSON, CHEVALIER
JOHNSTON, SAMUEL
LEWIS, FIELDING OTIS
LILLIE, HAROLD I.

Loeb, Hanau W.
Logan, James E.
Lynch, Robert C.
Mackenty, John E.
Mayer, Emil
McCullagh, Samuel
McKinney, Richmond
Mosher, Harris P.
Mullin, William V.
Myles, Robert C.
Newhart, Horace
Packard, Francis R.
Pierce, Norval H.
Randall, B. Alex.
Richardson, Charles W.
Roy, Dunbar
Sauer, Wm. Emil
Shambaugh, George E.
Skillern, Ross H.
Sluder, Greenfield
Smith, Harmon
Spencer, Frank R.
Stout, George C.
Swain, Henry L.
Theisen, Clement F.
Watson, Arthur W.
White, Francis W.
Winslow, John R.
Wood, George B.

# ADDRESS OF THE PRESIDENT

EMIL MAYER, M.D.

It is with great pleasure that I welcome you to this forty-fifth Congress of the American Laryngological Association. This year marks also the fiftieth anniversary of the founding of the New York Laryngological Society, the first association of throat specialists in the world.

To commemorate this event, Dr. D. Bryson Delavan has kindly brought photographs of those pioneers in laryngology and has arranged them in due order for exhibition.

In our own organization many of you have been comrades and associates of mine in this body for more than a quarter of a century, others for the duration of your membership, and I recall the many occasions on which we have met, each reunion strengthening the bond of friendship, never once marred by even the slightest misunderstanding, striving always for the highest aims of scientific physicians, loyal to our Association and to our country, whose name comes before our chosen specialty, whose representatives we are. It is with pardonable pride that I extend most cordial greetings to you, my true and sincere friends, as your President, grateful that our ranks have not been diminished by the grim destroyer during my term of office, bespeaking your cordial coöperation, candid criticism and kind indulgence for any errors into which my zeal may lead me.

To you, associate Fellows, thrice welcome, the honor of your selection by the Council as being worthy thereof is a great one, and one that I know you appreciate. Remember that you are among friends, free to prepare any papers for future meetings, free to discuss any scientific questions now, and above all free to come and go, to learn to know us and to let us know you. You are entitled to be present at all our meetings, scientific, executive

and social. I can add for myself the sincere wish that I may be permitted to greet all of you in the near future as Fellows.

To all our guests a cordial welcome. Our scientific sessions are open to you, and you are invited to participate in our discussions.

The honor of membership in the American Laryngological Association is only secondary to one other thing, and that is the expression of your confidence in granting the greatest office in your gift, the Presidency, to one of your members. How sincerely I appreciate your selection of myself to be your standard-bearer for the year, to be listed forever afterward as a Past President in association with the names of men famous as founders in American laryngology, I find difficult to express in terms fitting for so great an honor. After all, thank you is the best I can say, coupled with every honest endeavor to give to our Association the best service possible on my part now and hereafter.

As a member of this illustrious body one is conversant with the traditions and scientific work of this Association, but only when the honor of the Presidency is conferred does one get to study carefully the practical application of its working rules. A thorough survey of these reveals what seem to be inequalities here and there, for which the remedy proposed will, I am confident, be sufficient to readjust.

At the outset I can only express the greatest admiration of the farsightedness of the founders of this Association in making the requisites for admission to membership so high that in this forty-fifth year of its existence the membership list contains the names of practically every teacher of laryngology in medical colleges known as Class A in this country, in addition to those who have given freely of their best in the theory and practice of laryngology in our leading hospitals as well as in the literature of our speciality. During my term of office the presiding officer of each of the six leading special societies similar to our own in this country has been a member of this Association.

Forty-five years make a vast increase in the number of men interested in any specialty. When our constitution was framed the few laryngologists were known to our Council. With the growth of the work so many have been attracted to our special

field of endeavor that thousands are coworkers now where there were hundreds at the founding of this Association. This growth was recognized years ago by the Council, resulting in the formation of a committee on new members, and from this grew the recommendation to have Associate Members, who were to be selected because of the promise that their present scientific attainments seem to give, with the intention of making them full members if they proved worthy within the five-year term of their membership. Ten such Associate Members have been elected this year. While the Council may at any time propse these to full membership, there is no by-law stating who shall take the initiative in their promotion, obviously not the Council, who are in the position of judges.

There is a by-law to the effect that members on the active list must read a paper at least once in three years. This is not possible of accomplishment, as the number of papers on any program is much less than one-third of our membership. It is probably for this reason that the rule has never been enforced. A change in the by-law is advisable. Instead of the rule as to papers it should be changed to read: "Members must be present at least once in three consecutive years. Such absence, without excuse satisfactory to two-thirds of the Council at its annual meeting, shall be sufficient for dismissal, the action to be reported by the Council to the Association." This rule might be placed on each program.

A schedule of attendance at meetings during the last four years has been drawn up and shows a lack of interest on the part of a few of our active members. If with the publication of our *Transactions* we would print with our membership list the years of attendance during the last five years, with some distinguishing mark to indicate papers read, we could readily see who were neglectful, some credit would be given for faithful attendance as well as cordial coöperation and the limelight of publicity would be effective.

The meetings of the Council are held at stated times and the amount of business performed is always great and often under pressure because of limited time. Questions of policy and the like arise that would be the better for previous careful consideration.

For some years prize awards have been offered and the committees in charge report that no thesis worthy of a prize has been presented. I question seriously whether this form of stimulus to scientific workers has not outlived its usefulness. I am informed that a prize was awarded by a fellow society for original work a few years ago, and that those who awarded the prize now regret their decision and would withdraw it if they could.

Laboratory study is quite well endowed nowadays, and it would seem best to use funds destined for prizes to aid individuals to complete work begun, either to pay for the actual expenses incurred in an investigation or for the illustration and publication of work completed. If such a proposition prevailed the work would naturally bear this endorsement: "The publication (or investigation) of this work has been made possible by the grant of the American Laryngological Association, and the Casselberry (or the De Roaldes) Fund." That this is a practical scheme I can affirm from personal experience.

It is the yearly custom to arrange the time and place of meeting by our Council mainly on the advice of our President, except at the triennal sessions, which are held as part of the Congress of American Physicians and Surgeons. For practical purposes, securing the greatest scientific value as well as convenience to our members, it has hitherto been wisely determined to confer with other national societies, so that our meetings should be held at convenient places as close together as possible. In arranging for the time of this year's meeting we were met with a statement that the Council of the Otological Society was desirious of holding sessions two full days after ours, and because so many of our members were members of their society they were most anxious not to have any overlapping, so that no papers could be missed. Hence they proposed that we hold a two-day session first. Your Council felt that the three-day meeting was of vital importance to our organization and that our time could not be curtailed. But realizing that in the past the Otological Society had often yielded to our requests, in the spirit of true camaraderie, we changed our meeting days to Wednesday, Thursday and Friday, leaving the Monday and Tuesday previous, two full days, to them, to their evident satisfaction. Thus the three national societies

have eight days of meeting this year at the same place, one following the other. There is no question whatever that similar arrangements can be made each year, aside from the Congress year, giving each society a chance for priority. That this would be agreeable to the other societies, I have ascertained from conference with their responsible officers.

The correction of these omissions and errors is entirely possible without altering our Constitution by having a by-law, creating a Committee on Welfare, to be appointed annually by the President; this Committee on Welfare to consist of five Fellows, with the addition of the President and the Secretary *ex-officio*. This committee shall act as a lower house to the Council and have its report in the hands of the Secretary of the Association at least two weeks before the meetings of the Council, and shall only have power to recommend to the Council. It shall prepare a list of Honorary or Corresponding Fellows, new Fellows and Associate Fellows, including the advancement of the latter to full Fellowship for election. It shall prepare a list of attendance of members at each annual meeting, beginning with the year 1919, and also of papers read, and this list shall be published in connection with the list of names and addresses of members in the *Transactions*, thus "Bronson, Edward (city and address), 1920, **21**, 23." (The black figures mean paper read.) It shall call the attention of Associate Fellows to the rules of the Association as to attendance and reading of papers and advise them if in their opinion such should be necessary. It shall act upon any communication sent to it by the President or Secretary, reporting its recommendations to the Council at least two weeks before the meetings of the latter. It shall consult with any chairman of standing committees at the request of the Secretary. It shall confer in the selection of a meeting place and time with officials of other organizations and report to the President before the meeting of the Council. If these recommendations meet your approval and this new committee be created the value of membership will, in my opinion, be greatly enhanced, the power of our Association increased, a dead-letter By-law repealed, the labors of a frequently overworked Secretary decidedly diminished and the Council free to act in the judicial capacity that the Constitution calls for.

Following illustrious precedents, after thus calling attention to certain needed changes in the rules of our Association, permit me to add a brief contribution on—

## The Toxic Effects of Local Anesthesia

For the past four years it has been my privilege to conduct an investigation into the toxic effects following local anesthetics: For the first two years assisted by able committees, all, with one exception, members of this Association, and for the last two years by a committee of representative men from various other branches of medicine. Two reports have been published covering the first two years and solely from laryngologists. The report from this representative committee is to follow. Without in any way anticipating this latter report, I bring this subject to your attention, as we are seeking the widest publicity in order to secure the greatest possible coöperation from our friends in the profession.

The investigation had its origin in the Therapeutic Research Committee of the Council on Pharmacy and Chemistry of the American Medical Association, as it believed there must be many more deaths following the use of local anesthetics than were published in the medical journals. As a result of a communication sent by this body to the section on Laryngology and Otology of the American Medical Association, in 1919, I was asked to assume charge of the investigation and accepted.

The plan and scope of the investigation was drawn by myself and the work assigned to the members of the committee, who assisted loyally and enthusiastically. It was soon ascertained that physicians paid no attention to requests published in medical journals, and a questionnaire was sent to selected members of our specialty. This had the merit of brevity, as there were but three questions. Believing that we might throw some light on the behavior of morphia and local anesthetics when used at the same time, animal experimentation was undertaken and fully described in the first report.

The results of our questionnaire were startling and impressive. We learned that the suspicions of the Therapeutic Research Committee were well founded and were able to disclose the

histories of 20 cases, only a very few of which had been published, and of these were recorded 5 deaths as "Mistakes of the Nurse" (a substitution of one drug for another). We then requested a continuance of our work, questions to be sent to a larger number of fellow specialists, and this was endorsed. Again we recorded 22 deaths, making 42 in all, and the same proportion of the avoidable and shocking deaths in those marked "Mistakes of the Nurse," etc.

We found that a drug would be stated as causing a death when other drugs had been used at the same time, so we changed the nomenclature in our reported cases. Thus if a death were attributed to novocaine only, and we learned that cocaine was also used, we changed it to a cocaine-novocaine death. How important this is will appear.

Very noteworthy in our report was the similarity of symptoms, both as to time of appearance and character. They were practically always the same—a sudden onset, convulsions and death on the table.

Our studies led us to the following queries, requiring elucidation; If in a limited field of medicine a relatively large number of deaths were to be found, how would it be in other fields of medicine? Was there a greater sensitiveness in one part of the body to these anesthetics than another? Did the presence of adrenalin add to the dangers from these drugs? Did deaths occur among the dentists, the genito-urinary specialists or among the general surgeons as frequently as they did among the nose and throat specialists? Did the position of the patient, practically always sitting up, with little or no side support, have any influence? What methods of resuscitation were used from the onset of symptoms? What light did autopsies throw on this important subject?

To answer these as fully as possible a new committee was formed by the Therapeutic Research Committee of the Council on Pharmacy and Chemistry of the American Medical Association, who requested that I preside, consisting of members representing internal medicine, surgery, urology, pathology, stomatology, laryngology and pharmacology. A questionnaire was sent to members of the Association in the sections represented, the

answers to go to their representative and thence forwarded to the chairman of the committee for compilation and final consideration by the full committee. The actual expenses of this committee were borne by the Association.

The responses from members of the profession varied. Some answered promptly, some after repeated questioning and some not at all. In some instances we could get information by writing to some member in the home town of the delinquent, but this was rarely possible, as information sent to us was strictly confidential and we could not press the inquiry without a breach of honor. Thus one colleague reported a death under local anesthesia that happened in his own practice, but when asked for the simplest details claimed to have forgotten everything about it, and we could not press for information. While much material has come to hand, it seems amazing that the ordinary courtesy of a reply should not be forthcoming from members of the profession on a matter so important, so vital and coming from a committee appointed by and acting under the auspices of the American Medical Association. The Medical Examiners of New York City and the City of Chicago have responded splendidly and with scientific enthusiasm, realizing the value of their contributions. The Medical Examiner for Boston, on the other hand, has paid no attention to repeated requests in writing, by telephone or in person for reports of casualties that he may have and evidences a woeful lack of that willingness to assist that one would confidently expect from a representative of a city where one always finds the highest intellect, courtesy, coöperation and eagerness for scientific investigation.

From the reports of the general committee received we may state that the sudden onset of symptoms and the rapidly fatal ending without any premonitory symptoms are the same in other parts of the body as in those previously recorded by me. The same preportion of absolutely avoidable deaths, "The Mistakes," also exist.

Two cases of special interest were reported showing how careful one should be in stating the name of the drug responsible for the cause of death. One was previously included in my report as a death from novocaine. Information has since come that the

coroner's jury brought in a verdict of death from cocaine. The second, an external operation of the chest, injected with 1 per cent procaine, convulsions and death on the table.

Some of the fluid used and injected was submitted to analysis and the report was that it contained 15 per cent cocaine.

When our final report is drafted we hope to reach conclusions that will be commensurate with the importance of the subject and the amount of labor that four years' study of this subject has entailed. We are still hopeful of the hearty coöperation of the profession in bringing to us the histories of any toxic effects they know of, each case being a study in itself, and we feel that we are rendering a service to humanity and to medicine in emphasizing the occurrence of avoidable deaths, for some one's mistake has been the means of unspeakable distress and unhappiness. What has happened time and again may occur to one of you. May I entreat you to bear this in mind and to surround yourselves with every protection against these mistakes? In this connection, and in conclusion, permit me to quote from Thackeray, who in speaking of the Doctor says:

"One can fancy how awful the responsibility must be to a conscientious man; how cruel the feeling that he has given the wrong remedy, or that it might have been possible to do better; how harassing the sympathy with the survivors, if the case is unfortunate—how immense the delight of Victory."

By virtue of the authority you have vested in me, I hereby declare the forty-fifth Congress of the American Laryngological Association open for scientific and business purposes.

# ACUTE LARYNGEAL EDEMA

CLEMENT F. THEISEN, M.D.

THERE are few conditions that are of such interest to the laryngologist, and even fewer that at times make him work faster, if the life of the patient is to be saved, than acute edemas of the larynx. I do not know of anything more startling or distressing to the patient than an edema developing rapidly, with few and, sometimes no preliminary symptoms. From an etiological standpoint the subject is of particular interest, because cases differ so widely in the way they appear to originate. It is difficult to satisfactorily explain the etiology in cases that develop so rapidly that in this repect they simulate angioneurotic edema, which occasionally develops very suddenly in the larynx. There is a class of cases that comes on with such rapidity that it is impossible to put one's finger on any one etiological factor. I have seen a few patients belonging to this class who apparently had the laryngeal edema habit, and the sudden development of the edema without preliminary symptoms makes a differential diagnosis from angioneurotic edema difficult. Cases have come under the writer's observation when, during a slight cold without temperature and negative pharyngeal findings, a laryngeal edema developed which in two or three instances caused alarming difficulty in breathing in a very few minutes from the beginning of the attack. In several cases of this kind, one of which will be reported in my paper, the pharynx was normal, with the exception of a slight redness of the mucosa, and there was no evidence of any infection of lymphoid tissue anywhere in the pharynx, nor was there any inflammation of the epiglottis. With proper treatment—an ice-coil, iced adrenalin spray and incisions into the edematous infiltrated laryngeal mucosa—the edema in this class of cases subsides about as rapidly as it develops. The writer

has only had to perform tracheotomy a few times in this form of laryngeal edema. This type is similar also to the edema that sometimes suddenly develops after the continued administration of potassium iodide. I have no doubt that most if not all the members of this Association have had hurry calls in cases of this kind. This form is quite as alarming at times as the other types, and on one occasion the writer had to do a very rapid tracheotomy to relieve the extreme difficulty in breathing. This patient, a man, aged thirty-one years, had been taking small doses of iodide of potash for a long time. The edema developed very rapidly, and by the time I got to the patient's house, cyanosis was so extreme that an immediate tracheotomy was performed. After the patient quieted down a laryngeal examination was made. The edema was so extensive that the glottis was almost completely closed. Apparently all of the laryngeal mucosa was involved. Free incisions, followed by the escape of a large amount of a clear, serous fluid, were made and an ice-cold adrenalin spray (1 to 5000) was used, at frequent intervals, the first twenty-four hours. The potassium iodide was of course stopped and was not given again for several weeks, and then only for short periods. The patient's larynx was practically normal in three or four days, so that the tracheal tube could be removed. There was no further trouble and no return of the edema.

A few individuals have come under the observation of the writer who seem to be susceptible to attacks of acute laryngeal edema of a rather mild form and of short duration. This form may perhaps be properly classified under the neurotic edemas. The cases observed by the writer invariably occurred in intensely nervous high-strung individuals.

These attacks, in neurotic individuals, are perhaps allied to the frequent attacks of vasomotor rhinitis, with intense congestion and edema of the nasal mucous membrane or edema of the uvula, coming on with a slight cold, in individuals of the same nervous type.

In the experience of the writer, acute edemas occurring in patients of this type are not, as a rule, serious if prompt measures for the relief of the condition are started at once, and they usually subside very rapidly. I do not think I have ever had to perform

tracheotomy in this form of edema. Free incisions, an ice-coil, ice in the mouth and a cold adrenalin spray in the majority of the cases causes a prompt disappearance of the edema. In this form, particularly if accompanied, as it sometimes is, by a vasomotor rhinitis, we may have a complicating reflex asthma or true bronchial asthma. This is also promptly relieved by the adrenalin spray, supplemented in bad cases by the hypodermic use of adrenalin.

There is another form of edema, not quite as rapid in development as the forms described, which is secondary to abscess formation in various parts of the pharynx. It sometimes also accompanies laryngeal abscess, and the edema in such cases is similar to the edema of the soft palate and surrounding parts in a peritonsillar abscess.

In infections of lymphoid tissue low down in the pharynx, with or without the presence of pus, and in acute inflammations or cysts of the epiglottis, the edema that sometimes goes with such conditions may extend into the larynx, so that the etiology may be explained in that way.

The inhalation of sharp, foreign bodies remaining in the larynx for a while before removal may cause temporary secondary edemas.

An acute laryngeal edema developing in an apparently well person, or in one with a slight cold, with a slightly reddened but otherwise normal pharynx and epiglottis, is rather hard to explain. It is, of course, a well-known fact that apparently slight colds, with more or less negative throat findings, are sometimes attended by sudden and serious complications, depending largely upon the organism responsible for the trouble.

It is also a recognized fact that streptococcus infections particularly may skip the pharynx and cause localized or general edemas of the laryngeal mucosa.

The writer has always believed that the type of laryngeal edema coming apparently out of "a clear sky," and developing so rapidly that alarming difficulty in breathing comes on almost at once, without a definite preliminary infection somewhere in the throat, as an etiological factor, is frequently neurotic. There is rarely any temperature. The patient is perfectly well and in fifteen to twenty minutes is struggling for air.

There have been a number of cases of sudden death in this form of neurotic or angioneurotic edema recorded. It is possible that some of these cases of sudden death may have been due to localized cerebral edemas involving the respiratory or cardiac centers. This form, while fortunately not very common, is, in the opinion of the writer, rather more frequent than is generally supposed. Two cases have come under the writer's observation during the past winter and will be reported in this paper. One case was undoubtedly angioneurotic. There is some doubt about the origin of the other case.

It must not be forgotten, in considering the etiology of laryngeal edema, that edema of the aryepiglottic folds particularly is an occasional complication of nephritis. Fauvel and Schrötter claimed that edema of the larynx is sometimes an early symptom of nephritis. This must be a fairly infrequent occurrence, however, as the writer cannot recall other references to it in the literature except Lori's report of 2 cases. Such edema when it occurs is probably due to a venous stasis.

Angioneurotic edema is, unfortunately, often confused with urticaria. The same underlying causes are responsible for both conditions, and they may occur together. For example, the asthma, probably caused by an edema of the bronchial mucous membrane, occurs sometimes with the skin lesions, but the term "urticaria" should not be used to include angioneurotic edema of the respiratory tract.

Halsted's review of the subject is one of the most comprehensive I have found, and he has reported some interesting cases.

Inherited nervous conditions are important etiological factors in all these cases. If a careful family history is obtained it will be found that some members of the patient's family had had some form of the disease, caused by a vasomotor neurosis.

A case has been reported by Osler, for example, in which the disease occurred in five generations. Of 39 members of the family 19 had angioneurotic edema, 2 dying of edema of the larynx. Attacks of neurotic edema, in susceptible subjects, may be brought on by autointoxication caused by some toxin in the intestinal tract, and in a certain percentage of the cases the larynx is the first part of the body attacked. There is no doubt that vaso-

motor neuroses are primarily responsible for such conditions in susceptible individuals, the frequent attacks of vasomotor rhinitis with almost complete and persistent occlusion of the nose, and attacks of edema of the uvula, without definite colds, also pointing conclusively to the vasomotor origin. The edema of the laryngeal mucosa is caused, first, by a contraction of the bloodvessels, then a secondary dilatation and stasis, with a serous exudation into the mucosa and submucosa.

The following cases are reported to show the different types of the disease. In the first case the etiology was rather obscure, because of the history of the inhalation of a foreign body, which could not be verified by direct examination, and the reported exposure to diphtheria.

Case I.—Four-year-old child. The writer was asked to see her in July, last year, by the family physician. About a month before I was asked to see her, the child apparently aspirated a piece of peanut shell, which the mother said she had in her mouth. Immediately after there was a violent paroxysm of coughing, some difficulty in breathing and slight cyanosis. About the same time the child had been exposed to diphtheria, but several throat cultures were negative. An immunizing dose of antitoxin was given, followed in a short time by greatly increased difficulty in breathing. The child was brought to my office breathing with some difficulty, although not alarmingly so. There was some cyanosis. It was impossible to make a laryngeal examination, so a little ethyl chloride was given, and a direct laryngeal examination was made. No foreign body could be seen in the larynx or trachea, but some edema of the aryepiglottic folds. The child was sent home and two days afterward I received a hurry call to the hospital, where the child had been taken. I found her breathing with great difficulty and told the family doctor that I thought a tracheotomy would be necessary. He was anxious to have another direct laryngeal and tracheal examination first, which was done under ethyl chloride. A small Jackson tube was passed, and again the edema was present in the same place, but much more marked. No foreign body could be seen anywhere in the air passages. After this attack the child improved, but six weeks later, during my absence from the city, she was again exposed to diphtheria, a sister or brother developing the disease. She was given a large dose of antitoxin and died several hours later. In all probability this case belongs to the

class of cases in which a greatly increased edema and death may have been brought on by the injection of antitoxin.

It is a well-established fact that antitoxin injections will cause both urticaria and edema in the throat, just as it will cause urticaria of the skin. I have seen this a number of times. A number of sudden deaths have been reported following the use of antitoxin, but I will not review them in this paper. Some of them have been reported by Halsted in the paper before referred to.[1]

Without doubt, many of the cases of reported deaths from antitoxin have been in susceptible subjects, that is, individuals subject to attacks of neurotic edema, vasomotor rhinitis, asthma or erythematous skin lesions.

Case II.—This was an undoubted case of angioneurotic edema of the larynx. The patient, a man, aged thirty-four years, has been under my care from time to time, for several years, for the treatment of frequent attacks of vasomotor rhinitis, sudden attacks of edema of the uvula and localized edemas of the base of the tongue. He is an extremely nervous man—in fact, belongs to a very nervous family. Two other members of the family have been hayfever victims for years, and these same members (sisters), he said, have been subject to frequent attacks of urticaria, particularly after eating strawberries or shell-fish. The attacks of edema of the uvula and tongue, for which I had treated him in the past, always developed very suddenly, and when he was apparently free from cold. The uvula very quickly became tremendously edematous, but the swelling always subsided quickly under the use of a cold adrenalin spray. Occasionally it had been necessary to incise the edematous membrane. The same treatment was always effective for the circumscribed edemas of the tongue. The attack, the first one involving the larynx, came on very acutely in December, 1922. He was about to dress for breakfast, when he said he had a "choking spell." Within fifteen to twenty minutes the difficulty in breathing started, but had subsided by the time the family doctor arrived, possibly a half-hour later. About 10.30, as I was about to leave my office, I received an urgent phone call to come to the patient's house at once. By the time I reached his house, perhaps five or six minutes, he was sitting in a chair breathing with great difficulty, and was very cyanotic. I

[1] Transactions of American Laryngological Association, 1905.

at once sprayed his throat with cocain and adrenalin, in the meantime assuring him that he was not going to die, although I was far from feeling that way about it myself. Laryngeal examination showed such a great general edema of the mucosa that the glottis was practically occluded. I made several deep incisions with the Schrötter guarded laryngeal knife, than which I have still to find a better instrument, and in a few minutes his breathing was fairly quiet. The edema developed again later in the afternoon, requiring the same treatment, after which, with rest in bed for a few days and a thorough cleaning out of his intestinal canal, there was no further trouble. In my experience the cold adrenalin spray, with an ice-coil around the neck, gives more rapid relief than any method of treatment I have used.

It helps these patients a good deal, also, if you do not let them see that you are worried about them. I have been in the habit of telling them that their trouble was not at all unusual—in fact, did not amount to much. It really does as much good, perhaps more, than medicine.

Case III.—The etiology of the last case I will report is also a little doubtful, although it also suggested, in some respects, a neurotic edema.

This patient I did not see until called to his home by his doctor. The patient was a short, stout man, forty-three years old. He had had a slight cold for twenty-four hours, but no temperature, at least not above 99°, no sore throat, and a very slight coryza, with little discharge. His breathing was not as bad as in Case II, so I was able to make a fairly careful examination of the throat before treating him. His pharynx was unusually free of lymphoid tissue—no visible tonsil tissue, no hyperplasia of the lymphoid tissue at the base of the tongue—in fact, nothing could be seen but a slight general redness of the pharyngeal mucous membrane. No edema or inflammation of the epiglottis. There was considerable edema of the laryngeal mucosa, involving mainly the ventricular bands and arytenoids. Incisions and the same treatment as in Case II relieved him very promptly, and I only saw him once or twice after that. Cultures taken from his larynx showed the Streptococcus viridans as the main organism—in fact, the laboratory reported an almost pure culture of this organism.

One or two points brought out in the patient's history made me think that this case also belonged to the neurotic class. The patient said his brother had had similar attacks to his own, and that he himself had an occasional attack of "hives," after eating too much, which he occasionally did. I found a rather sluggish condition of the bowels, which in the neurotic cases is a rather important point. Overwork, mental depression or worry are also of great importance in the cases in which the laryngeal edema comes on very suddenly.

In conclusion, a word about the use of antitoxin in patients subject to angioneurotic edema of the air passages, or skin or asthma of the same nature. We will all agree, I think, that there is perhaps no one medical discovery of modern times that has saved as many lives as antitoxin, and it should, of course, be promptly used even in cases susceptible to angioneurotic edema if they really have diphtheria—I mean bacteriological diphtheria.

On the other hand, when the really considerable number of deaths following almost immediately injections of antitoxin in individuals with inherited vasomotor neurosis, neurotic edema particularly, are taken into consideration, immunizing injections of antitoxin should never be used. It is far safer to wait and see if the patient, who has been exposed to diphtheria, really develops the disease.

Another point of importance in the treatment is attention to the patient's intestinal condition. Neurotic subjects sometimes have a good deal of stomach and intestinal trouble, and the diet should be carefully regulated, avoiding articles of food that are known to cause urticaria and reactions in the mouth.

The longer we are in practice the more we realize, I think, that laxatives, proper diet and plenty of aqua pura will cure many of the ills that flesh is heir to.

For the rapid relief of the immediate difficulty in breathing a spray of adrenalin, about 1 to 10,000 or 1 to 5000, used cold, to which, if necessary, a little cocain may be added, seems to be about as good as anything.

Other methods of treatment have been given in the report of the writer's cases.

## Discussion

Dr. Henry L. Swain, New Haven, Conn.

[Dr. Swain explained that, having some slides already made, he had suggested to Dr. Theisen that if it was agreeable to him the slides could be used to open the discussion of his paper, and he had received a request to do so by all means. Dr. Swain then remarked as follows while the pictures were being shown.]

This is one of the simplest forms of acute edema of the aryepiglottic folds, and in this case had no serious significance except that it occurred as practically angioneurotic edema. You have all had them begin on one side, and by virtue of therapeutic measures used had the swelling go away in good order, only to have it appear the next day on the other side. There may not be an antecedent acute inflammation. It has always been a query in my mind why we should have edema down here in the aryepiglottic fold, for example, from pressure from above. We have two notions regarding edema, and one is that it is produced by pressure, or lymphatic retropressure, damming back the outflow, and that it is lymphatic in origin. I fail to see how pressure up above in the tonsil would make edema down here where it is supplied by vessels of an entirely different origin. The vessels under pressure by the quinsy above have nothing to do with the vessels supplying this part. You all have had cases where the epiglottis alone was markedly edematous, where it did not go down under your first measures, where it appeared to organize and become in a way more or less permanent. Again, and this illustrates a point of anatomy once more, I will show you the picture of a case that came to autopsy where edema was down in the larynx and trachea and yet the tonsils, enormously enlarged, were apparently the cause. The only explanation is that it is due to the local acidosis, which is the explanation sometimes given for edemas in other situations, and may happen here. Just before coming down here I had a case of edema involving the whole epiglottis on the left side, and the cause of it was pressure at the base of the tongue, and that may explain some of our cases. This patient had an abscess in this tonsil, occurring in the situation which is usually the point of election. This abscess promptly broke during my first application to try to take care of the edema. Having found an abscess, as you have all observed, the moment it is opened the edema goes. I did nothing for the edema, which went down in twenty-four hours, merely

because this lingual tonsil abscess was evacuated. In a recent number of the *Journal of Laryngology* there was a very pretty reproduction of the sacculus in the larynx. I had nearly forgotten that there was such a thing as the sacculus. These drawings came to me as a revelation. I have wondered when the epiglottis swells on one side enormously, as I have seen it do, and then subsequently goes down rapidly with the evacuation of a large amount of greenish colored mucus, whether it may not have been this same sacculus which you see dissected out. You see how it comes down into the ventricle from in front, how it lies above, how it is lined with mucous membrane and has definite secretive possibilities, and has a definite, narrow opening. You see what an enormous thing this sacculus is. I had no idea how big it was until I saw these dissections, looking not unlike a protruding gall-bladder, the illusion heightened by the prominence of the racemose mucous glands. Why could not the opening become occluded and the congestion and swelling cause edema or enlargement of the epiglottis? It is merely a notion of mine, but here is the opening beautifully shown. I can show you a picture of ulceration with breaking down of the wall and you can see in the ventricle that this same opening is involved.

Next is a picture showing edema produced by enormous swelling of the tissues in a thirteen-year-old child. You see how the lymph glands are involved. The case did not live long enough after it came into the hospital to let us make much of a research into it, and the diagnosis was of edema; but when we looked down the laryngoscope we saw no edema. Tracheotomy was promptly done, but here is where we found edema away down in the larynx and inside of the trachea. Even the lingual tonsil, which is not largely developed in a thirteen-year-old child, was distinctly swollen. This accounts for some of our failures. One might even do a tracheotomy and fail to relieve the case, because the edema lies far below the glottis. Here is a beautiful example of edema of the glottis made from a photograph of an actual specimen. You see the specimen illustrates most beautifully what you perhaps have felt when you attempted to intubate these cases; your finger slumps into a soggy, wet mass, and if you are wise you will not attempt to do an intubation in such a case, for it is obvious that the swelling would override the mouth of the intubation tube. In this case one would have failed if he had tracheotomized. This was a young child, practically moribund, taken from the ambulance into the operating room, who died before we could do anything. Edema went entirely down through the whole length of the

trachea, and lungs already had edema there. Of course, nothing there could have saved the case. This was a kidney case. This plate shows edema itself under the microscope. This is a low power, and then the next one is higher, and the next one is higher still, showing how even the racemose mucous glands have edema, which also extends even into the muscle fibers.

Here is the type of edema that becomes superimposed upon a chronic inflammation, and this was added to a tubercular ulceration, as you see here. There is a still different type which is incident to disease of the cartilages themselves. This plate is from a case which came in as a simple edema and was put into our hospital in the diphtheritic ward and we could find nothing about the cause, and after death we found these ulcerations. The edema had evidently become organized. Not merely the exudation of simple lymph, but colloid substance, with infiltration all the way down to the cartilage itself. Here is one of the same type and here is another, which I think shows you pretty definitely that we may at least possibly explain as one of those cases of stopping up of outlet of the sacculus and conditions following upon it. This plate is from a post-typhoid, and the trouble suddenly began with difficulty in breathing, although the pharynx was clear. I made the diagnosis of paralysis of the cricoarytenoideus posticus, and as there was also considerable edema, we did tracheotomy. The man lived three weeks, dying of hemorrhage. This shows a necrotic, sloughing cricoid cartilage. You have all seen such cases.

This plate show influenzal laryngitis (we must take notice of influenza as a cause of edema), and this extends away down into the trachea, with denuded areas, as shown here. Particularly do I wish to speak of this on account of reference made in papers before the Otological about the fate of the ciliated epithelium. In these influenza cases we find the same desquamative tracheitis and the pictures are the same microscopically and macroscopically as occur with gas. In war-gas tracheitis this would be a typical picture, and we can put the tissues under the microscope, when caused by gas, and you cannot tell the difference between them, and both will often begin with edema of the glottis.

Dr. Chevalier Jackson, Philadelphia:

I have very seldom had the opportunity of obtaining so much food for thought in such a very few minutes as this morning from this paper by Dr. Theisen, together with the beautiful lantern demonstration by Dr. Swain. Time permits of discussion of only two or three points.

I was delighted to see Dr. Swain bring up the matter of influenza. Subglottic edema occurring in influenza simulates diphtheria so closely that quite a good many patients have been sent off to municipal hospitals under an erroneous diagnosis. The croupy cough and the clinical symptoms with a doubtful bacteriologic diagnosis justify giving antitoxin, but a direct laryngoscopy would enable a diagnosis free from doubt. In regard to treatment of the influenzal type of edema, I have always thought that it is better, as a rule, to do a tracheotomy, a low tracheotomy, than to intubate; but a very remarkable instance to the contrary was that of a son of a physician who was in the Service. The case was in the care of Dr. George B. Wood and Dr. H. C. Carpenter, who had intubated the child for acute influenzal edema. Perfect recovery followed without tracheotomy. The points brought up by Dr. Swain in regard to extension of edema downward, it seems to me, are a further indication for a low tracheotomy done under local anesthesia as the measure of choice in most cases. This does not apply to the diphtheritic edema in which intubation is often preferable. The typhoid case brings to mind the hundreds of cases of laryngeal perichondritis in Pittsburg, many of them complicated with necrosis of the cricoid cartilage and always associated with edema, sometimes complicated with fixation of the cords, sometimes with true paralysis. Dr. Theisen mentioned one point on which I think emphasis should be placed, namely, quieting the patient's fears. If the patient is extremely anxious to get in much air quickly he will get very little. The floor of the ventricle is not horizontal but inclines upward and inward, so that on sudden deep inspiratory effort it shuts down like a pair of old-fashioned cellar-doors. If the patient can be induced to breathe slowly he can take in more air. This is very important in laryngeal dyspnea of other kinds also. Dr. Swain illustrated one case with a large edematous mass above the glottis. If such a patient takes a sudden deep inspiration he gets less air and may even asphyxiate. If you quiet him and tell him to breathe through his nose he will give you a little time to do your tracheotomy. As advised by Dr. Theisen many years ago, tracheotomy in dyspneic cases should be done under local anesthesia. In regard to the subglottic type to which children are especially subject, it seems to me that an intubation tube put right in contact with the inflammatory tissue is less desirable than a tracheotomy done very low and far away from the inflammatory area. Low tracheotomy is the only kind that ought to be done in any case. In regard to Dr. Theisen's case of edema with the history of choking on a peanut kernel, the

patient had choking and gagging, followed by wheezing, coughing, dyspnea and subglottic edema. These are absolutely diagnostic symptoms, and it seems likely that a kernel got in at that time. Probably it was coughed up and probably the diphtheria was an intercurrent condition. Dr. Tucker, my assistant, has had two cases in which, after he removed the peanut kernel, the children developed diphtheria, with positive cultures and masses of membrane requiring removal. The diphtheria was purely intercurrent. I do not mean to say that there was a peanut kernel which Dr. Theisen did not remove. It is likely the peanut was coughed out before the case came to Dr. Theisen.

Dr. Joseph H. Bryan, Washington:

In the few remarks I have to make, I wish to direct attention to the etiology of these conditions, and leaving aside the traumatic variety, angioneurotic edemas do occur, but I believe they are much less frequent, however, than the infectious type. I believe in most cases these infections are latent and suddenly spring up and produce this edematous state. The tonsils, both lingual and faucial, are the seat where most of these organisms are carried.

This is well illustrated in a case I had some time ago in a high-ranking officer of the army, who came into my office casually with another officer I was treating and said, "I wish you would examine my throat." He gave a history of previous attacks of laryngitis and a condition at this time of stiffness of neck and shoulder. Examination showed nothing wrong with the throat, no inflammatory condition, tonsils insignificant on inspection. Gentle pressure, however, produced slight exudate, rather creamy. I washed the tonsils out and made a culture. The report came back, Streptococcus viridans. He came in the next day with acute laryngitis, on the third day he was critically ill with edematous laryngitis of the streptococcus variety. When I first liberated the infectious material the culture showed it was of the milder type, but when the deeper secretions had been liberated, he got up this very acute infectious condition. This man was very critically ill.

I find if cultures are made of the tonsils in the beginning without attempting to cleanse with any antiseptic or detergent sprays or washes that we will get a stronger type of infectious organism. I believe in the majority of cases of infectious laryngitis the causes will be found in the tonsils.

Dr. Thomas H. Halsted, Syracuse, N. Y.:

The excellent paper of Dr. Theisen followed by the clear demonstration of Dr. Swain make a splendid contribution to this subject. Some eighteen years ago I took as my thesis, on entrance to this society, the subject of angioneurotic edema of the respiratory tract. I looked into the literature very thoroughly and was much impressed by the fact that so many sudden deaths followed the injection of antitoxin. Since that time a great many more cases have been reported, and it would seem that there can be no question but that in susceptible persons the antitoxin of diphtheria and probably the protein toxins are responsible for very many of these so-called angioneurotic edemas of the larynx as well as of other parts and organs.

I saw recently a patient in whom an acute edema of the larynx followed an external injury in the neck. This man while working in a sawmill was hit in the neck in the region of the larynx by a sliver of board flying off the rotating saw. He immediately developed dyspnea and was taken to the hospital, where I saw him within half an hour of the accident. There was no external evidence of injury to the larynx or to the skin, no erosion, no edema, swelling or scratching of the skin of the neck, but yet the dyspnea was so great that he was taken to the operating room immediately. On examining the larynx it was seen that there was a tremendously large, black-and-blue swelling of the epiglottis and larynx. He evidently had a hematoma and edema. We did not do a tracheotomy, as I expected to do, but instead incised the mucous membrane, relieving almost immediately the dyspnea. Within two or three days the swelling had entirely subsided.

Another case, rather unusual and under observation from time to time, is a very nervous business man who has learned to fear any sudden mental disturbance. This man at times develops a sudden laryngeal or pharyngeal edema on very slight provocation, such as a disturbing conversation over the telephone. I have seen him during two or three such occasions when that appeared to be the cause, the difficulty apparently brought on purely by emotion. I have regarded the attacks as angioneurotic.

Dr. Perry G. Goldsmith, Toronto, Ontario:

I address myself to angina associated with marked edema of the fauces, in incising which you get little or no pus. There is some edema spreading down the lateral wall of the pharynx and you fear laryngeal edema—possibly some swelling of the neck that may be incised. That patient is suffering from septicemia and he dies, and the majority

of these cases do die, but not from streptococcic infection. They die not from inspiratory dyspnea, but from cardiac failure. It is a type very distinct from the type of edema with obstruction. There is edema, but the obstruction is more apparent than real.

Dr. Cornelius G. Coakley, New York City:

I am very much interested in this paper of Dr. Theisen's. In the first place, I must confess I have never seen the angioneurotic type of edema that I could not explain on some ground other than that. We see a great many of these cases: at Bellevue Hospital there is scarcely a week that we do not have one or more cases of laryngeal edema admitted. Many of these are inflammations, due to severe sepsis, and we must distinguish between those due to general and those due to local conditions. Now I find it is absolutely useless to examine these cases by the indirect method. It does not show where the trouble is. You have edematous aryepiglottic folds which, if you examine most cases by the direct method, laryngoscope or esophagoscope, will very frequently show you a small area of localized inflammation down in the pyriform fossa, and the evacuation of a small abscess in that region clears the thing up, as spoken of here earlier. In these cases that are at all inflammatory, or that I feel are inflammatory, I dislike to use knife scarification with the idea of lessening edema. I am very much afraid that in the septic process this introduces a new focus of infection in that region. I prefer to put on applications outside the neck, and, if that does not control, then use an external incision and get at your edematous area there, and then tracheotomize if necessary. In these inflammatory septic cases, where a tracheotomy is necessary, you will find they almost all die. The external incision has been very much more valuable than a tracheotomy. There is another thing: we do not always find pus in these cases. Quite a number of these cases, perhaps three or four a year, which show only a general redness and edema when looked at by the direct method, will in the course of the next twenty-four hours have definite erysipelatous inflammation down the side of the neck or even on the cheek. Most of those of erysipelatous type of inflammation occurring in the skin do not go on to suppuration and do not need tracheotomy, but cold applications. I do feel there is a great element of septicemia in these cases, as the last speaker suggested. In some the edema gives considerable distress, but they go on through that sepsis and die from the cardiac effect.

Dr. Robert C. Lynch, New Orleans:

I want to place another case on record similar to Dr. Jackson's, namely, a child who was supposed to have inhaled a piece of charcoal. When we examined the throat we found both tonsils covered with plastic exudate, which proved diphtheritic in origin. We gave large doses of antitoxin to counteract diphtheria, then bronchoscopy, and removed the charcoal. We see quite a number of cases in New Orleans —in July, August and the first part of September—of acute laryngeal edema occurring in 'longshoremen, working in the refrigerating plant, in unloading ships, going down in the holds of ships where the temperature is very high, and after the day's work they usually come up on the wharf, and the wharf is fixed with big planks with big cracks between, and the negroes particularly will lie down on the wharf and sleep for two or three hours and wake up with this sudden edema, and are brought into the hospital, as a rule, in a hurry, choking. It seems to be due either to the relaxation from the day's work, followed by the change in temperature from heat plus exhaustion, the cooling-off process during sleep, that gives them edema. They have no history of any infection previously or condition of that kind. Then we see it, too, in the men who work in the refrigeration plant, the outside temperature being anywhere from 98° to 100°, and they are in the refrigeration plant, which is down to 2° below zero, especially for the keeping of some of the meats and vegetables, and then they come out into the high temperature again and will be taken with a sudden edematous laryngitis. Most of these cases are put at rest and treated locally and clear up without anything further being done. We have not made it a rule to incise edematous areas, simply giving them adrenalin spray and ice-packs, and the edema subsides in thirty-six to forty-eight hours. On two occasions we had to do tracheotomy for them. Then we see acute edema occur in engineers on movable engines, where they jump off the train at an eating station, rush in and get a cup of boiling-hot coffee; these people are fond of coffee, and they jump off their engines and gobble it down—not sipping it—and so they have a true burn of the upper portion of the larynx, and we have had 15 to 20 cases of edema of the larynx with this etiology. Then we have had a few cases of protein toxemia from antitoxin injection to patients who were sensitive, and some of these cases have yielded to mild alkaline medication and the introduction of bicarbonate of soda into the system as fast and freely as we can get it. Then we have had 2 cases of intralaryngeal edema from traumatism. A child was slapped in the throat by a teacher in school; the edema there was from fracture of the hyoid

bone. The acute edema came on rapidly and tracheotomy had to be done in that case.

Dr. D. Bryson Delavan, New York City:

Dr. Theisen has made a valuable contribution to this subject.

The progress of our knowledge of the diagnosis and treatment of laryngeal edema may be divided into three periods, the first of which should not be forgotten. Many years before the time of Prof. Schrötter, of Vienna, in 1846, the late Dr. Gurdon Buck, of New York City, one of the most eminent surgeons of his day, became interested in the subject of laryngeal edema, from which, at that time, many lives were lost and no resource was applied but tracheotomy. The laryngoscope had not yet been invented. Dr. Buck learned to diagnose edema of the larynx by palpation. He then invented his celebrated double-edged, curved laryngeal knife and the method of applying it for the purpose of scarifying the edematous tissues. By means of this scarification, together with inhalations, applications and general medication, he was able to secure hitherto unattainable results. In the absence of other means his method is too valuable to be ignored.

The second period was inaugurated by O'Dwyer. By his system of intubation, dyspnea is at once relieved and pressure is brought to bear upon the edematous tissues, in itself an agency of marked remedial effect.

The third resource in this condition is the application of some one of the new agents which, like adrenalin or procaine, act by constricting the engorged tissues and which, in some of the less urgent cases, carefully watched, are productive of efficient relief.

Without question the urgency of some cases may be such as to demand tracheotomy. But, at its best, tracheotomy is uncomfortable, and the conspicuous scar which it leaves upon one of the most attractive regions of the human body should not be inflicted if intubation will answer a better purpose.

A few years ago the art of intubation was understood by many practitioners. Now it is less often heard of. It would not seem unreasonable to expect that every considerable hospital should be furnished with a proper O'Dwyer outfit and with men qualified in its use. The skilful application of the O'Dwyer tube in these cases is less difficult, more expeditious and more satisfactory than is tracheotomy. It is well that the value of the O'Dwyer tube should not be forgotten. And where, in emergency, neither tracheotomy nor intubation is available, be it remembered that scarification, as suggested by Buck, has saved many lives.

# SOME OBSERVATIONS ON THE CASES OF LARYNGEAL CANCER SEEN DURING THE PAST YEAR WITH MICROSCOPICAL FINDINGS IN THREE INCIPIENT CASES

J. E. MACKENTY, M.D.

SINCE my last report to this Association, one year ago, on laryngeal cancer, 43 cases of this disease have been examined by

FIG. 1.—Case I. Mr. McC. Incipient, no loss of motility. Posterior view of the inner surface of larynx showing tumor of right vocal cord: *a*, squamous celled epithelioma showing location of section (see Fig. 3); *b*, location of section from anterior end of vocal cord (see Fig. 7); *c*, location of section from posterior end of vocal cord (see Fig. 9).

me in the clinic and in private practice; 42 were males. They came from Canada, the United States, Cuba and 1 from South America. The point of origin of the disease was as follows: On one or other vocal cord, 40; on the edge of the pyriform fossa,

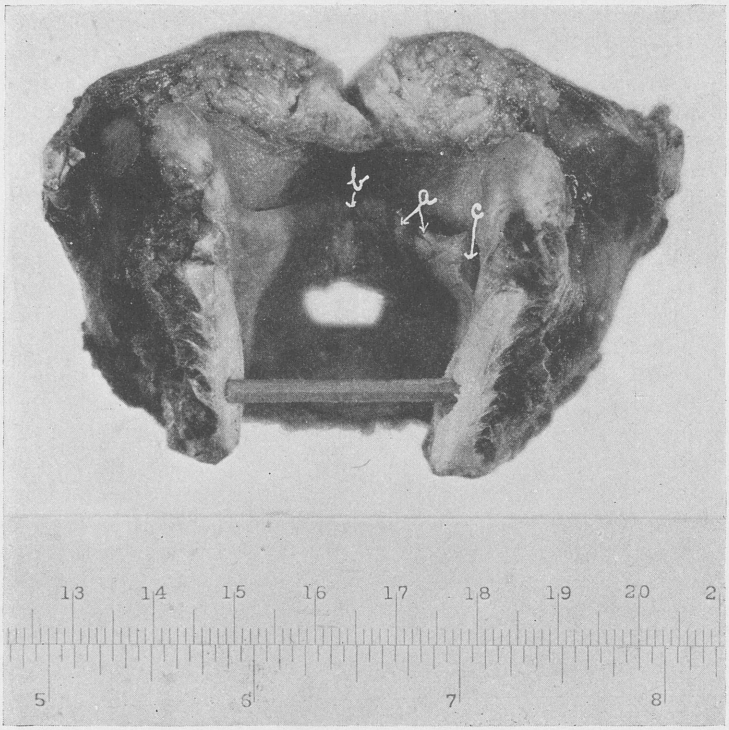


FIG. 2.—Case II. Mr. M. Extremely incipient, no loss of cord motility. Posterior view of inner surface of larynx showing small tumor mass upon right vocal cord: *a*, squamous celled epithelioma (see Figs. 4 and 6); *b*, location of section from anterior end of vocal cord (see Fig. 8); *c*, location of section posterior end of vocal cord (see Fig. 10).

2; in the pyriform fossa, 1; 21 of these cases appeared to be intrinsic and operable; 17 submitted to operation. The others elected to try radium. One very early intrinsic case, seen in June, 1922, could not be dissuaded from radium and died one month ago of carcinoma. In 2, apparently late intrinsic cases, the disease had

extended through the thyroid cartilage, the arytenoids and mouth of the esophagus being free from disease both macro- and microscopically.

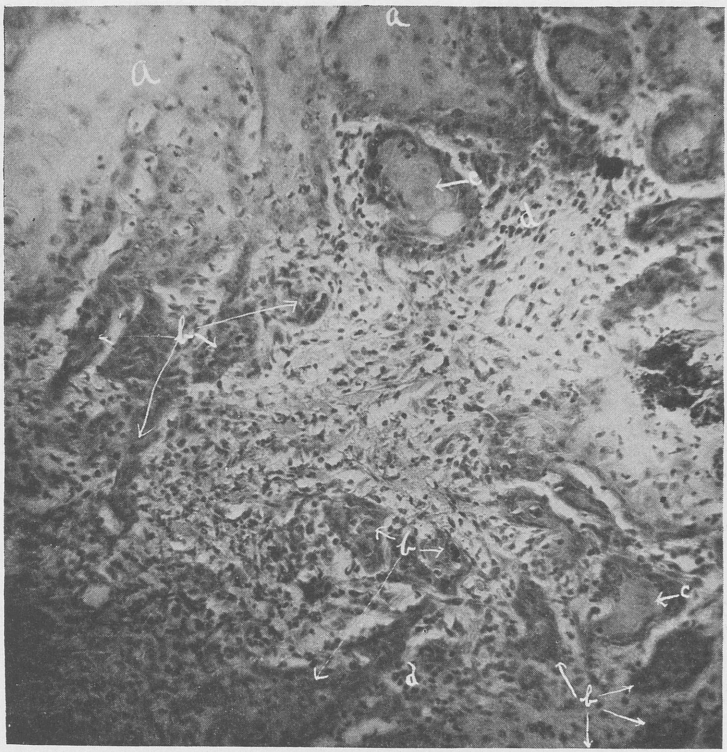


FIG. 3.—Case I. Mr. McC. (see Fig. 1, Case I). Section of main tumor: *a*, epithelial papillæ greatly hyperplastic extending into submucosa; *b*, segregated masses of epithelial cells in submucosa; *c*, epithelial pearl formation; *d*, mononuclear inflammatory reaction around tumor cells.

One death occurred three months after operation from some mediastinal condition, probably carcinoma (no autopsy). This case proved to be extrinsic at operation, for which a block dissection of one side of the neck was done. The operation was a mistake and should not have been attempted. This is the only death in my series since 1916–1917. In the operative and post-

operative technic now developed the surgical mortality has become almost *nil*. Two unusual complications arose in these recent cases. One was almost asphyxiated two weeks after his operation, when he was apparently out of danger, from a plug of inspissated secretion at the tracheal bifurcation. This was

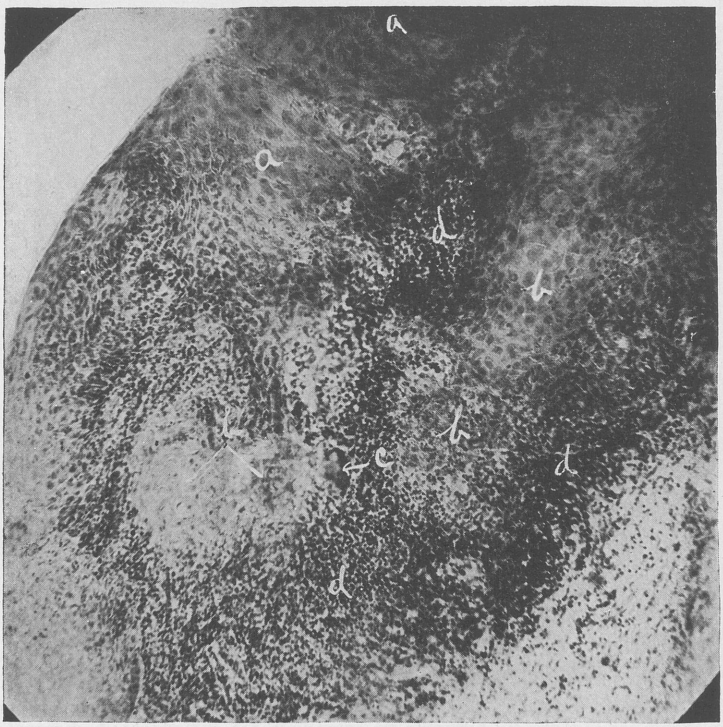


FIG. 4.—Case II. Mr. M. (see Fig. 2, Case II). Section of main tumor showing epithelial invasion of submucosa with epithelial pearl formation: *a*, hyperplastic epithelial papillæ; *b*, areas of epithelial cells in submucosa; *c*, multinucleated epithelial giant-cells; *d*, mononuclear inflammatory reaction adjacent to tumor.

removed by the aid of a bronchoscope. The other case during the healing granulating period had repeated and severe hemorrhages from the granulation tissue. Fractional transfusions failed to control these bleeding spells. They occurred about every four or five hours and generally from a different area of the

wound each time. The bleeding area was small, but the flow was very active. The only means of control was the removal of the exhuberant granulations and pressure. Total laryngectomy was done in the 17 cases notwithstanding the fact that 3 of them were apparently incipient. A careful microscopical study was made of these 3 cases.

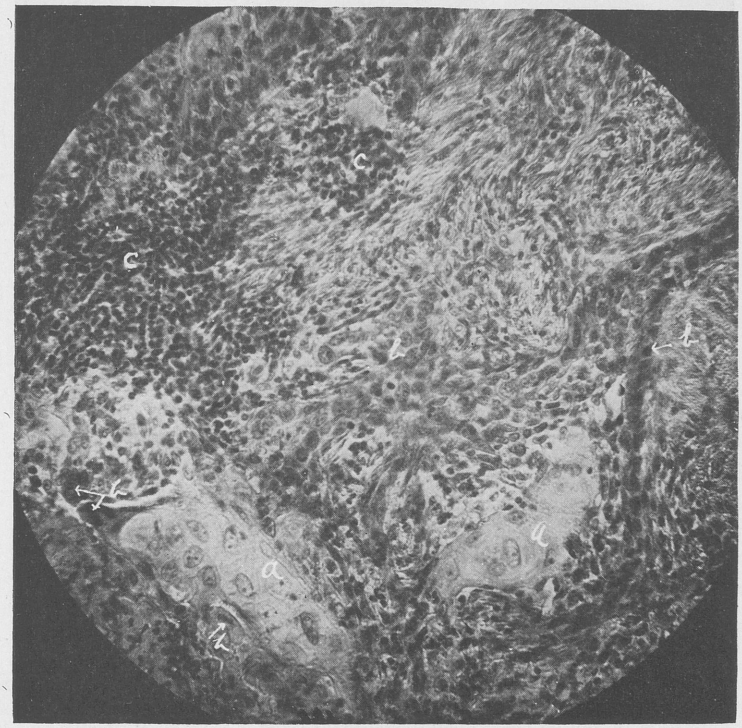


FIG. 5.—Case I. Mr. McC. (see Fig. 1, Case I). High magnification of areas of epithelioma cells in submucosa: *a*, areas of cells showing hyalinization and epithelial pearl formation; *b*, mitotic epithelial cells; *c*, mononuclear inflammatory reaction adjacent to tumor cells.

This study was undertaken in order to prove or disprove a belief long held by me that incipient intrinsic cancer of the larynx was often much more extensive than the surface outcropping would indicate. That these 3 cases selected for microscopical

study were incipient, was evidenced by a short history of voice change, a small nodule occupying only a fraction of the cord surface and the presence of but slight or no interference with cord motility. In these cases the entire larynx was removed. The

FIG. 6.—Case II. Mr. M. (see Fig. 2, Case II). High magnification of papillæ and isolated epithelial cells in main tumor: *a*, epithelial papillæ with excessive hyalinization; *b*, multinucleated epithelial giant-cells; *c*, isolated epithelial cells in submucosa; *d*, mononuclear inflammatory reaction adjacent to tumor.

patients readily consented to the more radical operation when the facts, as they appeared to me, were placed before them. They were told that a partial operation gave no assurance of a permanent cure, but that a complete laryngectomy did. No biopsy was done, the diagnosis being made on the clinical evidence alone.

The type was squamous-celled carcinoma. The growth occupied one-third or less of the cord length, normal-appearing tissue being visible both in front and behind the neoplasm.

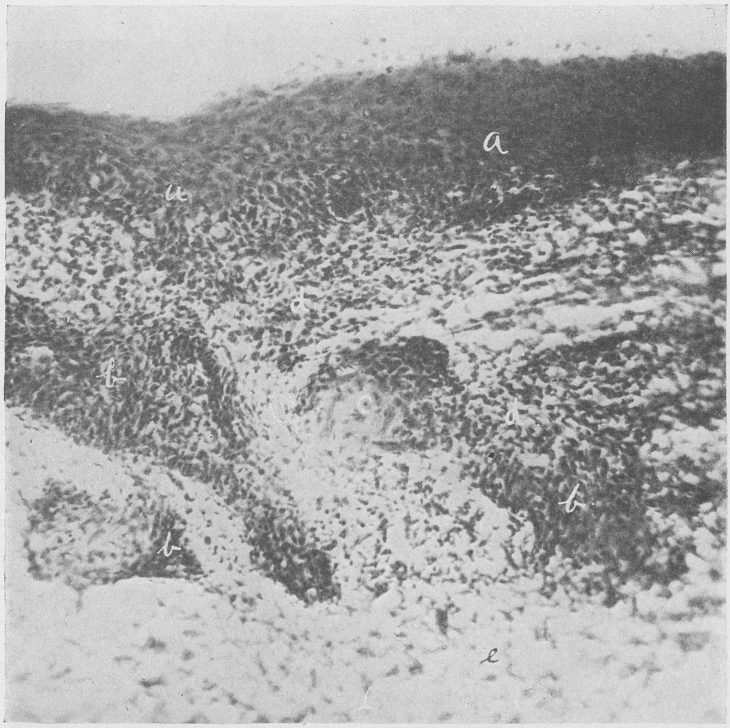


FIG. 7.—Case I. Mr. McC. (see Fig. 1, Case I). Section from anterior end of vocal cord showing extension of tumor anteriorly: *a*, slightly hypertrophied surface epithelium; *b b b*, areas of tumor cells in submucosa; *c*, hyalinized tumor cells in submucosa with beginning pearl formation; *d*, mononuclear inflammatory reaction beneath surface epithelium and around areas of tumor cells; *e*, subepithelial fat.

In cases of this extent thyrotomy with exenteration or window resection is the usual procedure. Multiple sections were made forward up to and into the anterior commissure and backward into the arytenoids. They all showed subsurface extensions of carcinomatous tissue well forward and well backward or in both

directions. I will show 1 case in particular sectioned and examined for me by Dr. Eggston at the Manhattan Hospital Laboratory. In this case the growth was so early that I left the choice of the operation to the patient, explaining the proba-

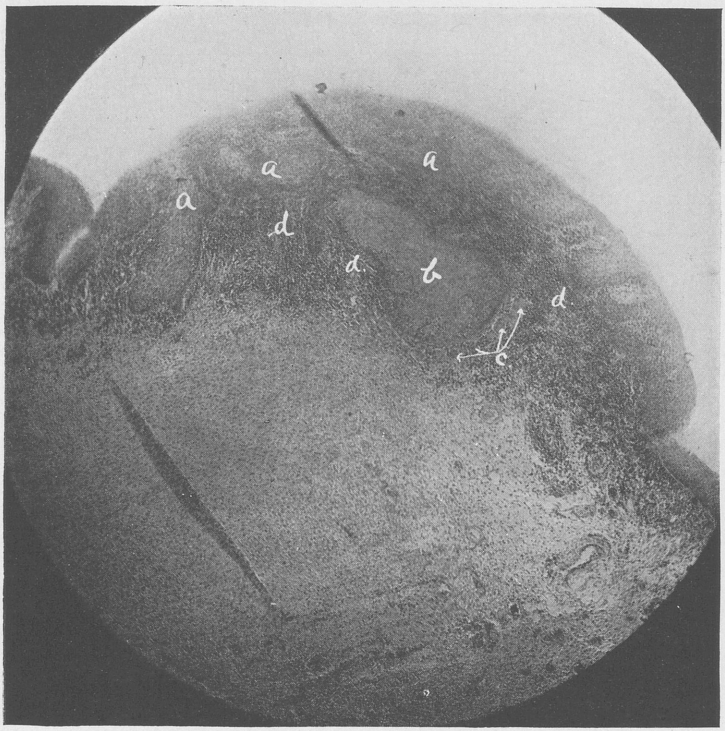


FIG. 8.—Case II. Mr. M. (see Fig. 2, Case II). Showing extreme forward extension. Section taken at anterior end of vocal cord showing extension of tumor anteriorly: *a*, hyperplastic surface epithelium showing papillæ and subepithelial inflammatory reaction; *b*, area of epithelial cells in submucosa; *c*, multinucleated epithelial giant-cells adjacent to *b*. Note similarity of these cells to those of main tumor (see Figs. 4 and 6); *d*, mononuclear inflammatory reaction adjacent to tumor areas.

bilities in either event. Total laryngectomy was urged. Fortunately for both of us he selected to have the latter done.

The multiple section showed no extension backward. From the growth, which was at the junction of the middle and posterior

thirds of the cord, up and into the angle of the anterior commissure subsurface lines and areas of malignancy were found. These lines and areas diminished in size as the distance increased from the original growth.

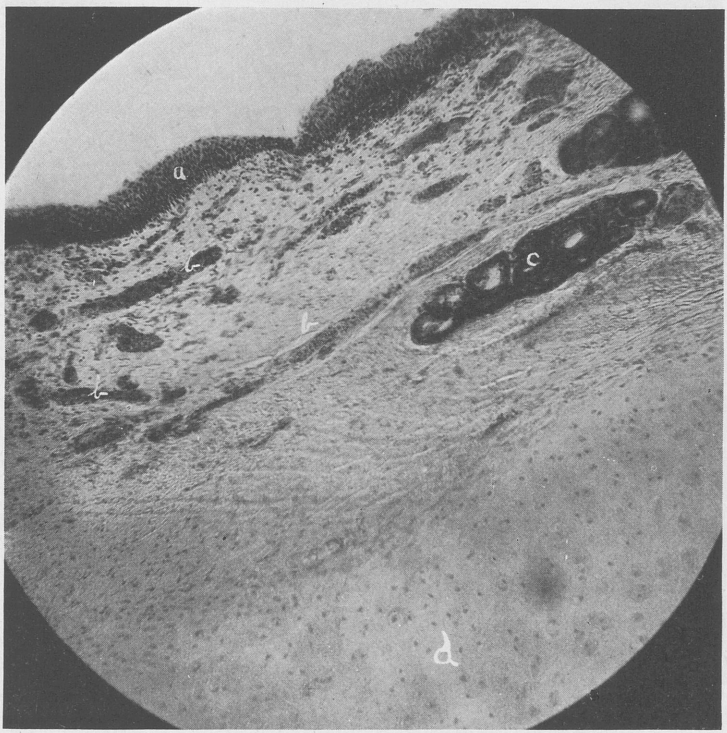


FIG. 9.—Case I. Mr. McC. (see Fig. 1, Case I). Section from posterior end of vocal cord showing normal structures: *a*, normal surface epithelium; *b*, blood and lymph vessels; *c*, normal mucous glands; *d*, cartilage.

The second case, slightly more advanced, showed even more subsurface extension. There was no backward extension.

The third case showed subsurface extension in all directions, but stopping just short of the anterior commissure and of the arytenoid.

The convincing conclusion to be drawn from these observations is that a partial resection of the larynx would probably not have saved these victims from a recurrence. And here a question

FIG. 10.—Case II. Mr. M. (see Fig. 2, Case II). Showing no backward extension. *a*, normal surface epithelium; *b*, cross-section of normal epithelial papillæ; *c*, bloodvessel; *d*, cartilage.

arises: When is a partial operation justifiable, and how can we be sure of circumventing the disease by other than a total extirpation of the larynx?

## Discussion

Dr. J. S. Fraser, Edinburgh, Scotland:

If I understand Dr. Mackenty aright, he advocates removal of the entire larynx in all cases of malignant disease, including those of early epithelioma affecting one vocal cord. I must confess that it seems to me to be hardly justifiable to remove the larynx from a patient who has only got a surface growth on one vocal cord, the cord itself being freely movable. There can surely be no doubt but that laryngectomy is a serious mutilation of a patient. I believe that this operation is only called for in intrinsic cases which have passed the limits suitable for thyrotomy. Though my proportion of recoveries after thyrotomy only amounts to 50 per cent, I know that Sir St. Clair Thomson and Dr. Chevalier Jackson have from 78 to 80 per cent of recoveries, so that, in well-chosen cases, we have no reason to be dissatisfied.

Dr. Fielding O. Lewis, Philadelphia:

I should like to refer to the complications Dr. Mackenty has just mentioned. Out of 13 laryngectomized cases I have had two similar complications, that is, thick inspissated blood was found blocking both bronchi. In each case it was necessary to perform ten bronchoscopies to save the patient's lives. I assume from what Dr. Mackenty has said, he does not believe much in radium as a treatment for these cases. I am of the same opinion, but am inclined to believe that as a preoperative and postoperative measure it is sometimes advisable.

Dr. Robert C. Lynch, New Orleans:

I would like to place on record an observation I have made in the last two years relative to the diagnosis of carcinomas. I have had 5 cases which have been referred to me as truly intrinsic carcinomas when by every means at my disposal, that is with the indirect method and with the direct method, apparently they were intrinsic carcinomas. In view of the situation which I had about five years ago in doing a laryngectomy and having the patient die within six months from an esophageal metastasis quite low down and apparently not in any association with the larynx, I began a more careful general study of these cases, and in the few cases which make up this report, 4 of these apparently intrinsic carcinomas limited to the whole or a part of one vocal cord, in 4 of these I have found a large metastasis in the lung. I am yet unable to determine just what the association between the

two situations is: Whether the larynx tumor is the primary source, whether the individual has two foci or whether the lung is secondary. It is safe to say that in this situation any type of larynx operation is contraindicated. In the other case, a man was seen after an operation on the larynx because of the intrinsic carcinoma of the larynx with some hoarseness of about six months' duration. There was no doubt about the diagnosis. In none of these cases were there any palpable lymphatic glands. There was no limitation of motion into the larynx, and by no means could we see that we had to deal with a tumor that was any other than an intrinsic carcinoma. As usual, we sent this man to an internist and for *x*-ray pictures and went over him generally, physically, as carefully as we could, and found no secondary involvement, and I was about ready to do an operative procedure for him, and preliminary to the operation I put down an esophagoscope and found an esophagus tumor from which I removed a section, which proved to be carcinoma. There were then two foci in this case—one in the larynx, intrinsic, from which he was complaining on account of hoarseness of voice, and the other of tumor of the esophagus, which as yet had given him no trouble at all, and yet an operative procedure on his larynx would surely have been followed by a waking up of the process in the esophagus and would have resulted fatally or subjected him to an unnecessary operation.

Dr. Mackenty (in closing):

Dr. Fraser's remarks on the question were to the effect that if I had my way I would do away with thyrotomy. Perhaps we are not agreed upon the classification of incipient cancer. Perhaps these cases I have shown are not incipient. All I can say in answer to Dr. Fraser is the microscope speaks for itself. Here we have a case of no limitation of motion and a small wart on one cord, yet the microscope shows extension lines up to and into the anterior commissure. How are we to know that beforehand? The microscopic work was done by an excellent man. I do not think there can be a mistake about that. I have done a great many thyrotomies, but I have not been rewarded by the brilliant results spoken of by Dr. Thomson and others. I cannot show 70 per cent cures. I think 20 per cent is nearer the truth. I believe my thyrotomies and window resections are extensive and as carefully done, but I get no startling results. Many of these patients die of recurrence. I think there is a wrong conception on the part of men who have not done a lot of this work in regard to the mental and speech condition of the patient after total laryngectomy. I would

like very much if these meetings were not so far from the source of supply to bring some of these cases down here and show how well they can communicate with their families and associates. I received a letter from one of them yesterday, and in it he said, "This letter I am dictating to my stenographer." So these patients, after a while, become so proficient that they can dictate their work to their stenographers. He is not the only one. They are not cast down and are not in such miserable mental condition as you might imagine. About radium: I have not seen a cured case from radium. As to postoperative treatment, it might be good. I do not believe I would advocate it before, because it might interfere considerably with tissue-healing. Dr. Lynch's metastasis: I have never seen anything of that kind. I thought cancer extended through the lymphatics to neighboring glands and not by metastasis. I have had one case of sarcoma of the larynx. This may extend by metastasis. Dr. Lynch's cases are extremely interesting. I wish he would put them in form and report them.

# ANATOMICAL AND CLINICAL OBSERVATIONS ON THE LOWER END OF THE ESOPHAGUS AND THE DIAPHRAGM*

HARRIS P. MOSHER, M.D.

SUMMARY. The cone of the diaphragm acts as a sleeve to support the terminal part of the esophagus. When the cone is obliterated by a permanent falling of the diaphragm the terminal part of the esophagus is set afloat and turns and twists in its attempt to keep in line with the hiatus.

The terminal portion of the esophagus consists of a vertical and a horizontal arm. Where the two arms meet, the esophagus twists on itself and turns to the left. At the turn the vertical arm comes to a point. The horizontal arm has the thick left crus of the diaphragm behind and the edge of the left lobe of the liver in front. Backward pressure on the liver tends to close the horizontal arm; downward pressure on the liver opens it.

The posterior basal tips of the lower lobes of the lungs extend to the apex of the cone of the diaphragm and are in relation with the esophagus on both sides until it passes through the hiatus.

The fluoroscope shows that when the diaphragm is up the esophagus is momentarily closed. The point of closure is at the junction of the vertical and horizontal arms, where the turn to the left occurs. When the diaphragm is down the horizontal arm is carried downward and comes into line with the esophagus above. As it swings toward the median line the esophagus opens.

* The writer is deeply indebted to Dr. A. S. Macmillan, who is in charge of the *X*-ray Department of the Massachusetts Charitable Eye and Ear Infirmary, for the great majority of the *x*-ray plates which illustrate this paper.

In the interpretation of all the points brought out by the plates the writer has relied upon Dr. Macmillan, for without his help the paper could not have been written. In many respects the article, therefore, is a joint paper.

The illustrations were drawn by the writer.

In the majority of cases of stricture of the terminal portion of the esophagus the "reversed phenomenon" has been present—that is, the esophagus is momentarily closed when the diaphragm starts downward. This is due to the pressure on the esophagus of the expanded lung tips.

The ligaments from the basal tips of the lungs are attached to the esophagus and the diaphragm on the rim of the hiatus. From below, where the horizontal arm enters the stomach, a suspensory ligament runs upward to the diaphragm. From the fissure in the liver which lodges the obliterated ductus venosus a ligament runs upward to the diaphragm over the front face of the terminal portion of the horizontal arm of the esophagus. Deformity of these ligaments would tend to deform the hiatus.

Three out of 7 recent cases of stricture of the terminal part of the esophagus—so-called cardiospasm—showed old or recent tuberculosis. Tuberculosis of the lungs involving the basal tips is the probable cause of a certain number of strictures or of a general narrowing of the terminal portion of the esophagus. A twist of the terminal part of the esophagus on its vertical axis can cause an esophageal obstruction. The pernicious vomiting associated with some cases of stricture of the terminal portion of the esophagus is due to acidosis. This should be corrected before the ether examination of the esophagus.

Conclusions. 1. The posterior median basal tips of the lungs as they expand within the cone of the diaphragm momentarily occlude the esophagus.

2. Tuberculosis of the posterior median basal tips of the lungs is the probable cause of a certain number of cases of stricture of the terminal portion of the esophagus or of its general narrowing.

3. A twist of the terminal portion of the esophagus on its vertical axis causes esophageal obstruction.

4. As the esophagus is an intrathoracic organ, much of its pathology originates in the thorax.

The Cone of the Diaphragm. The two halves of the diaphragm meet in the midline and in front of the spine dip down in a cone, the tip of which is made by the crura. Through this cone runs the terminal part of the esophagus and the cone intervenes between the esophagus and the liver. The cone of the diaphragm

is packed with loose connective tissue. It binds the esophagus more firmly on the front and sides than behind. The cone of the diaphragm acts as a sleeve, which keeps the terminal part of the esophagus in line. With falling of the diaphragm the cone of the diaphragm opens and flattens out. When this happens the terminal part of the esophagus is set afloat. The esophagus then turns and twists and bobs about aimlessly on the flattened diaphragm.

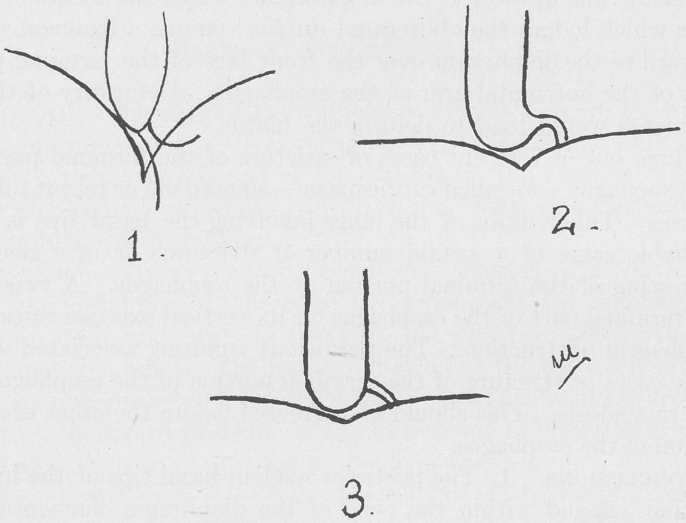


FIG. 1.—Diagrammatic drawings to show the twisting of the terminal portion of esophagus when the diaphragm falls and the support of the cone of the diaphragm is withdrawn from the esophagus.

Drawing No. 1.—The normal cone of the diaphragm with the esophagus ending in the physiological point.

Drawing No. 2.—The diaphragm is flat and the terminal portion of the esophagus becomes a trap.

Drawing No. 3.—The diagram is flat. The terminal portion of the esophagus has swung round so that a twist has been added to the trap. See Case III.

THE LIVER TUNNEL. The terminal part of the esophagus is not only surrounded by the cone of the diaphragm, but it passes through a tunnel of surrounding liver. Between the esophagus and the liver, the cone of the diaphragm and the crura which make the point of the cone intervene.

The liver is chiefly responsible for the shape of the lower end of

the esophagus. According to the closeness of the investing liver the terminal part of the esophagus either flares like a trumpet or narrows into a cone. The lower end of the esophagus has liver

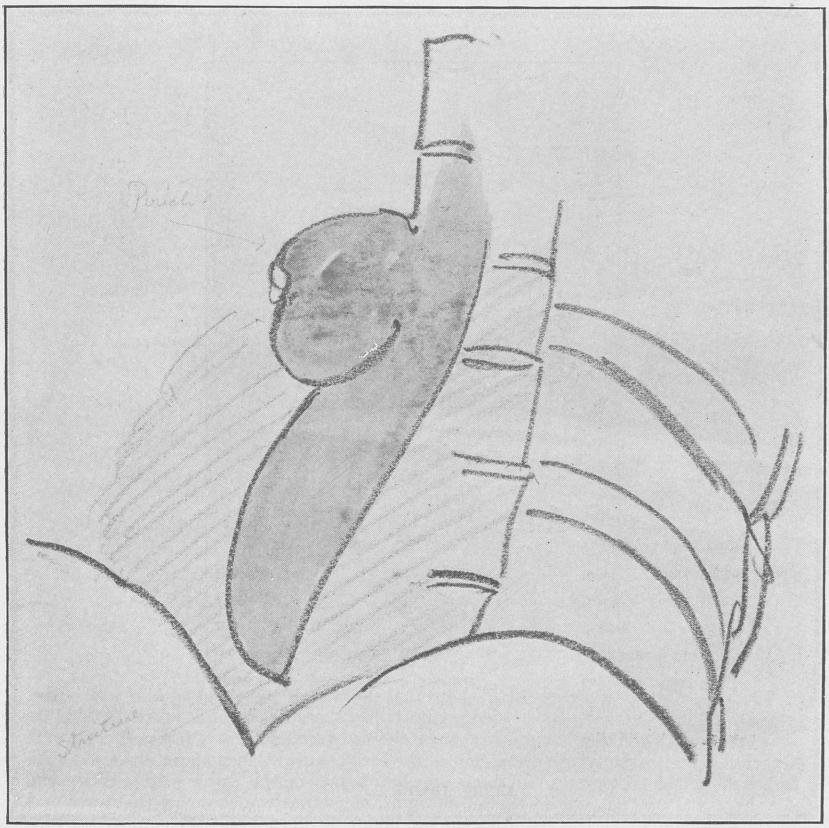

FIG. 2.—Tracing from an *x*-ray film of the esophagus of a man aged fifty years. The esophagus shows a pouch springing from the right side just below the bifurcation of the trachea. There was an annular stricture of the terminal portion of the esophagus. This was dilated under ether. The plate is put in at this point because it shows the cone of the diaphragm well. (See Case III.)

on the right, in front, and in many cases a thin tongue of liver hooks round its left edge like a sickle. Behind the esophagus is the descending aorta, which separates it from the vertebral column.

The dimensions of the liver tunnel, as studied on the cadaver, vary greatly in different subjects. Owing to the extreme size of the liver at birth the liver tunnel in the baby is much longer and wider than in the adult.

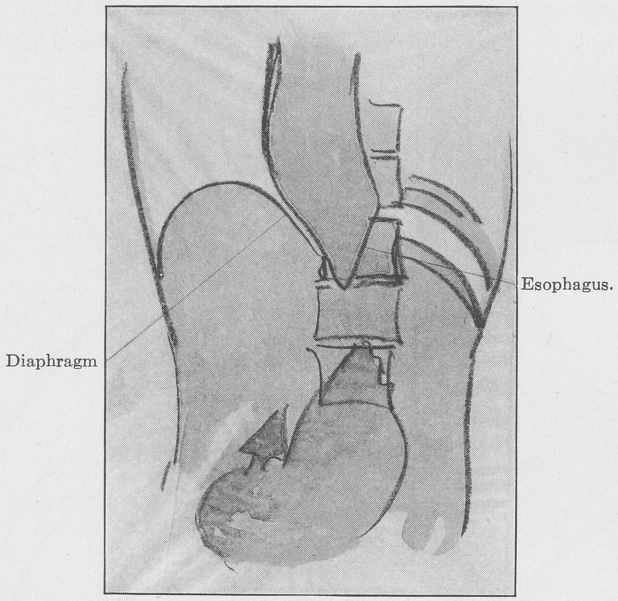


FIG. 3.—Case of stricture of the terminal portion of the esophagus of four years standing. Female, aged thirty-two years. Old tuberculosis of left apex. The plate was taken with the diaphragm up. Only the right half shows. Notice the support which it gives to the terminal portion of the esophagus. Other plates show that the left half of the diaphragm supports the esophagus in the same way. When the diaphragm is up the cone of the diaphragm determines the shape of the lower end of the esophagus. In this instance the esophagus is dilated and the cone of the diaphragm is wider than normal.

THE LOWER END OF THE ESOPHAGUS AS SEEN IN FROZEN SECTIONS. In frozen sections the esophagus is seen to end in a point or in a slit in the middle of the diaphragmatic cone. The slit has the position characteristic of the hiatus—that is, it slants upward and to the left. When the esophagus ends in a round opening instead of a slit, the opening is to the right of the center.

A Reconstruction of the Lower End of the Esophagus from Frozen Sections. This shows that the terminal portion consists of a vertical part and a horizontal part. Where the two arms join, the esophagus twists on itself and turns to the left. Where the turn comes the esophagus may even actually kink on itself. At the turn the esophagus ends in a point.

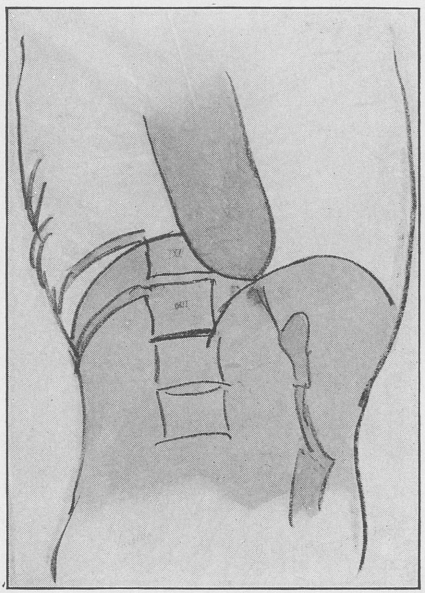

Fig. 4.—Same patient as Fig. 3. The diaphragm is down. When the diaphragm is down the cone of the diaphragm opens up and the terminal portion of the esophagus looses its support. Notice the change in the shape of the terminal portion of the esophagus.

The left crus crosses behind the esophagus on a slant, running from the left above to the right below. The slanting edge of the left crus mounds into the esophagus and makes the chief boundary of the slit usually called the hiatus.

The Horizontal Arm of the Terminal Part of the Esophagus. This is imprisoned between the left crus behind and the edge of the posterior surface of the left lobe of the liver in front. The right crus comes in between the liver and the horizontal arm

in front, but the right crus is thin and does not leave its impression on the esophagus as does the left crus. Frozen sections show that the horizontal arm of the esophagus is flat and practically closed. Backward pressure on the liver will actually close the lumen of the horizontal arm, whereas pulling the liver forward or downward

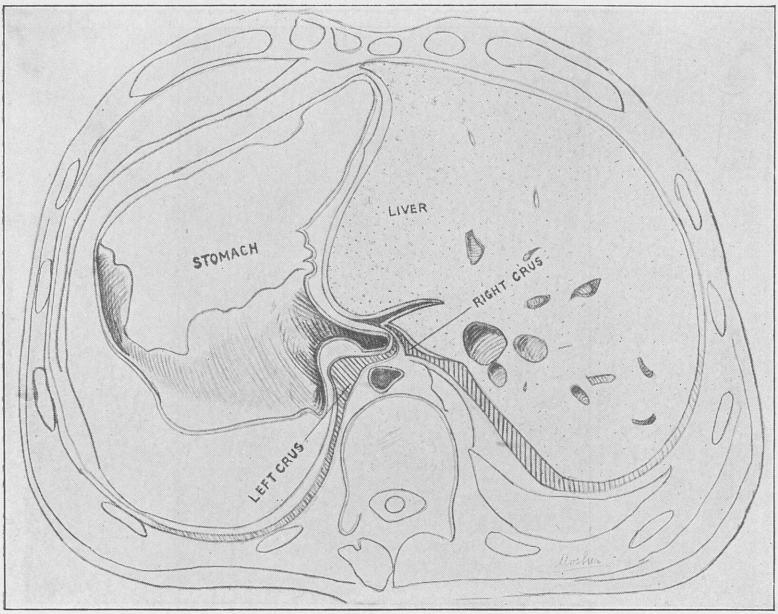


FIG. 5.—Drawing from a frozen section of an adult cadaver. The section passes through the horizontal arm of the terminal portion of the esophagus. Notice that the left or posterior crus lies behind the horizontal arm and that the posterior surface of the left lobe of the liver lies in front. The anterior or right crus in this specimen is not in relation with the anterior surface of the horizontal arm. The drawing shows how backward pressure from the left lobe of the liver can close the horizontal arm.

opens it. Tipping the liver forward and its posterior surface backward also closes the horizontal arm. As we study the anatomy of the esophagus on the dead, the patency of the horizontal arm is seemingly controlled by the position of the liver (Fig. 7).

In frozen sections when the esophagus is taken out of the diaphragmatic cone a large and roughly oval hole is left in which the

left crus and the aorta figure prominently posteriorly, the thin right crus anteriorly. Between the anterior edge of the left crus and the left edge of the anterior crus there is a membranous area

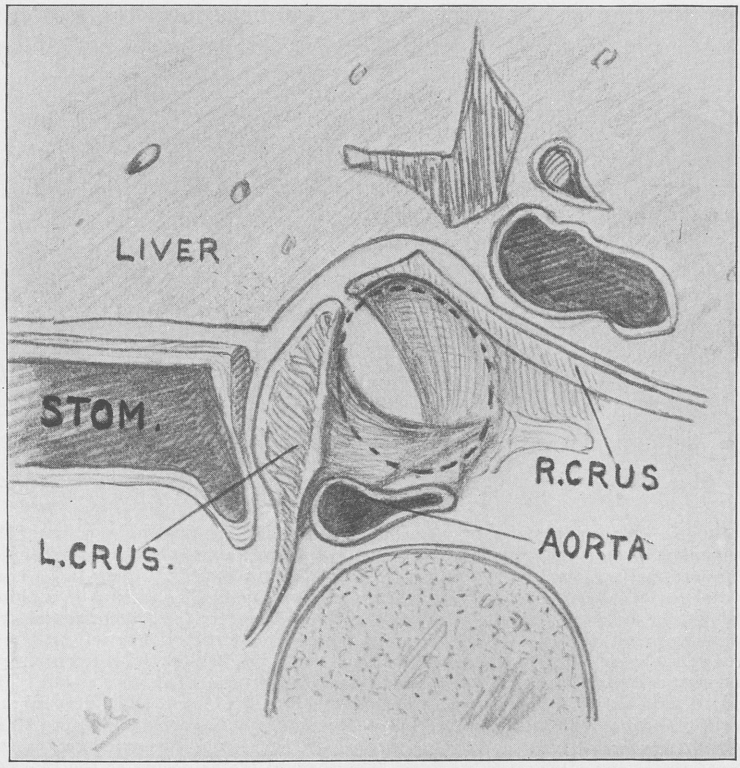


FIG. 6.—Drawing from a frozen section of an adult cadaver. The terminal portion of the esophagus has been removed in order to show the crura. The dotted line indicates the esophagus. Notice how much thicker the posterior crus is than the anterior crus. The drawing shows how the left crus passes obliquely behind the esophagus and between the esophagus and the aorta. The posterior surface of the left lobe of the liver is seen overlying the anterior surfaces of both crura.

through which the horizontal arm reaches the stomach. This membranous area is overlain by the liver. Between the right edge of the aorta and the posterior surface of the right or anterior crus there is another membranous area. It is only when the esophagus

is put back in place and resumes its natural bend to the left that anything approaching a hiatus is found. (See Fig. 6.)

Applied Anatomy. The esophagus ends in a point or slit. The terminal part turns to the left and partially twists on itself. The pointing of the esophagus is accentuated by the left crus

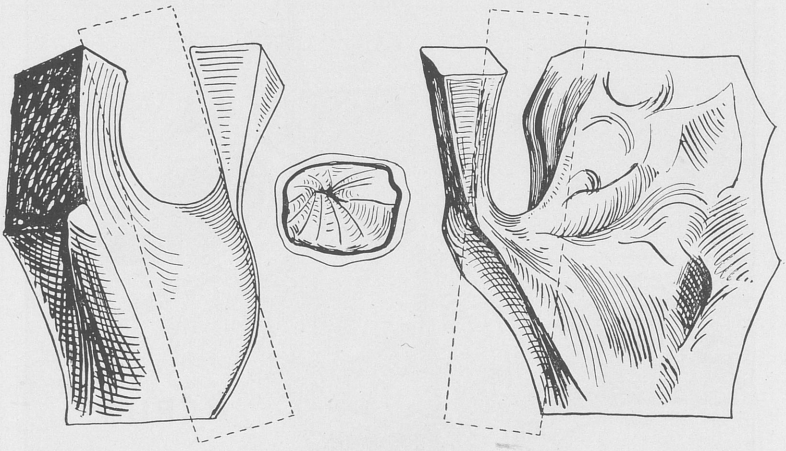

Fig. 7.—Wax reconstruction from frozen sections of the terminal portion of the esophagus of an adult cadaver. The first cut shows the esophagus from behind. The terminal portions of the esophagus is divided into a vertical part and a horizontal part. The vertical part or arm is pyramidal in shape and ends in a point. Below this the esophagus turns on itself to the left and makes the horizontal arm of the terminal portion. The dotted lines represent the posterior or left crus as it crosses the esophagus from behind. Notice that it lies behind the horizontal arm and that where it crosses the esophagus the vertical arm comes to a point. The second large cut shows the same reconstruction from the front. The vertical and horizontal arms of the terminal portion of the esophagus are shown as before. The dotted lines again show the position of the posterior crus. The small central cut shows the lumen of the vertical arm. The surgical hiatus occurs at the junction of the vertical and the horizontal arms of the terminal portion of the esophagus. When the horizontal arm of the esophagus is closed the surgical hiatus appears as a small round central opening. When the horizontal arm is open the hiatus becomes an oblique slit which follows the direction of the left crus and into the lumen of which the left crus often makes a distinct mound.

passing obliquely behind the esophagus and by the pressure of the liver on the front face of the horizontal arm. The edge of the posterior surface of the left lobe of the liver is parallel with the edge of the left crus. The anterior crus is so thin that it plays but a minor part in the opening and closing of the horizontal arm.

Cadaver Experiments in the Adult. If backward pressure is made on the left lobe of the liver, the abdominal wall being flaccid, and the lumen of the esophagus is watched through the esophagoscope a crescentic mound appears in the right quadrant of the field. Very strong pressure will practically close the esophagus. This mounding into the field of the esophagoscope is caused

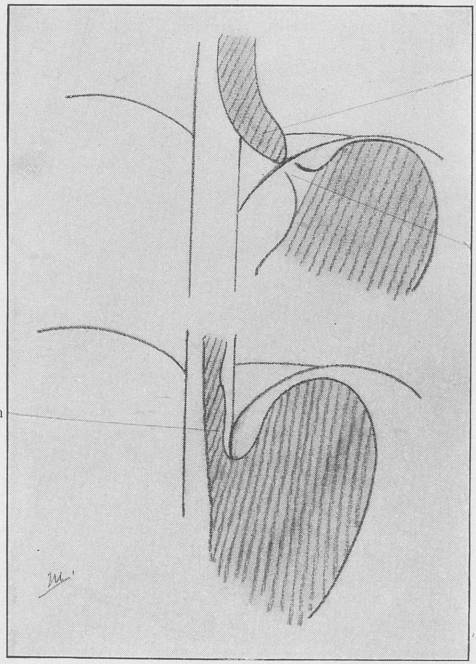


Fig. 8.—Diagrammatic drawing to show the changes in the horizontal arm of the terminal portion of the esophagus, as the position of the diaphragm changes.
Upper drawing.—Diaphragm up, esophagus closed.
Lower drawing.—Diaphragm down, esophagus open.

by the liver. Anatomically it may be either the upper edge of the left lobe or the edge of the Spigelian lobe where this fits into the lesser curvature of the stomach and bounds the terminal portion of the esophagus on the right. If downward traction is made on the liver the lumen of the esophagus increases in size.

Fluoroscopic and *X*-ray Findings in Normal Swallowing. In normal individuals when the diaphragm is up there is a momen-

FIG. 9.—Drawing copied from Testut to show the relation between the lungs and the terminal portion of the esophagus.

tary delay in swallowing. The esophagus comes to a nipple-like point in the middle of the cone of the diaphragm. When the diaphragm and the liver go down the terminal part of the esophagus opens and the contents of the esophagus move freely into the stomach. This observation—which I admit was just the opposite of what I expected—has been abundantly verified. It should be remembered that the above happens in the normal esophagus. In

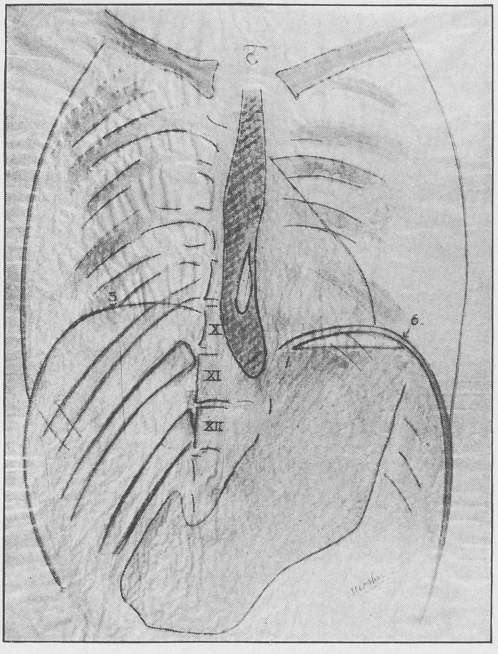


FIG. 10.—Tracing from an *x*-ray film of a normal adult male to show the relation of the esophagus to the spine.

certain cases of cardiospasm a reversed finding occurs—that is, the esophagus is closed momentarily when the liver is down and opens when the liver is up.

The esophageal nipple in normal cases occurs in the middle of the cone of the diaphragm at the junction of the vertical and the horizontal arms of the terminal part of the esophagus. Frozen sections show that the vertical portion normally comes to a point.

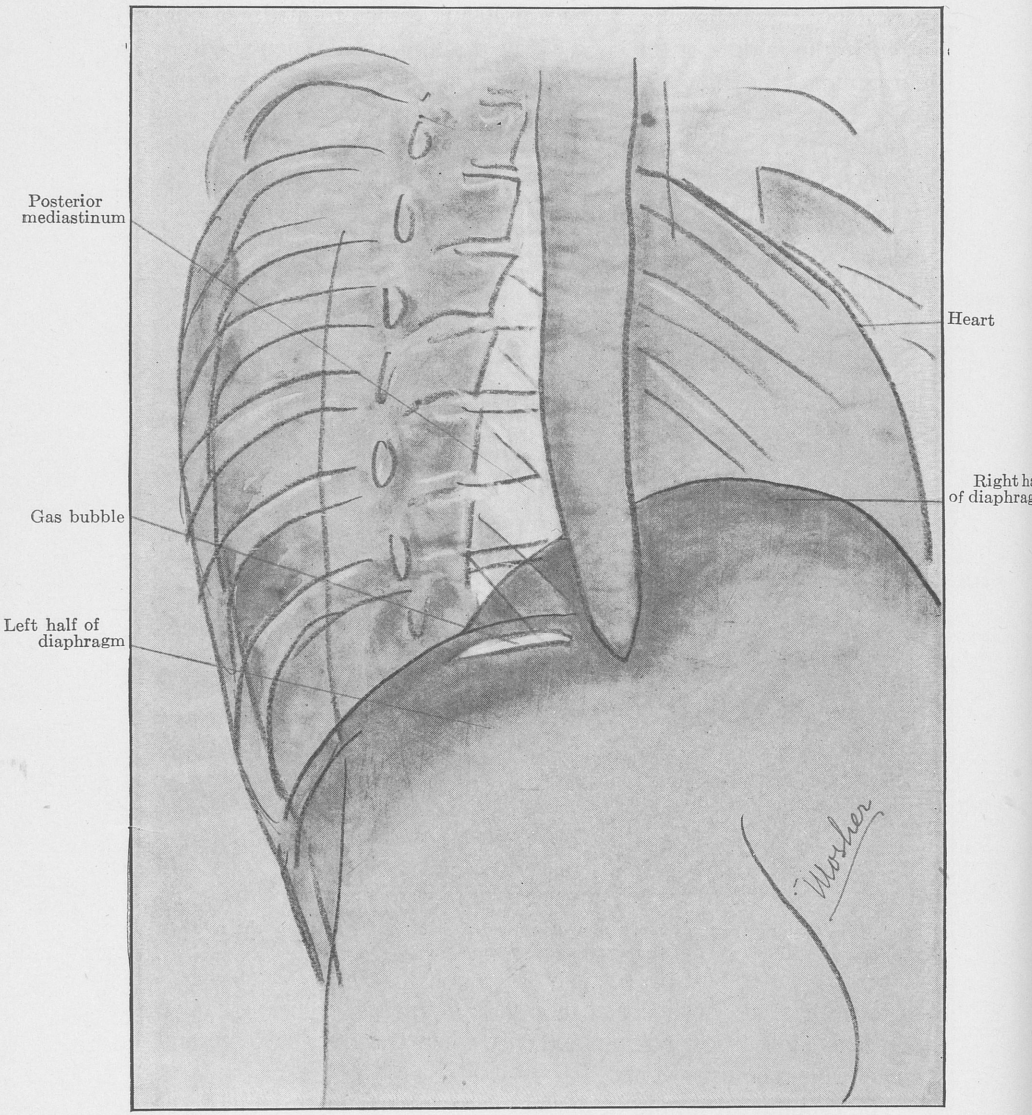


FIG. 11.—Tracing of an *x*-ray film of the esophagus of an adult male. The posterior mediastinum—the space between the esophagus and the vertebral column—when normal shows on the film as a light vertical streak. Pathology in the posterior mediastinum shows as a dark area. Invasion of the posterior mediastinum is very common in malignant disease of the esophagus. The esophagus is shown momentarily closed in the center of the cone of the diaphragm. This as has been shown is normal.

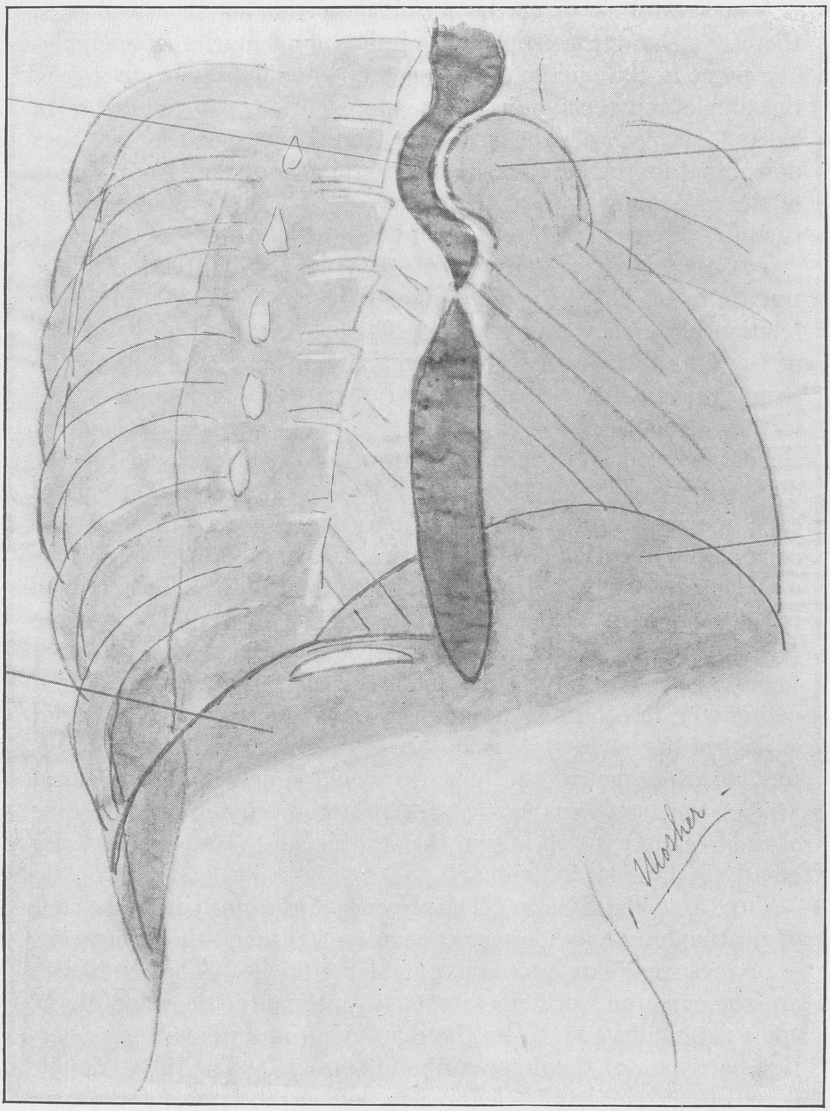


FIG. 12.—Tracing of an *x*-ray film of the esophagus. It shows the compression of the esophagus by the arch of the aorta. The crescentic form which the barium takes opposite the arch of the aorta—the aortic crescent—is normal. It is more marked, of course, when the arch of the aorta is enlarged.

A successful *x*-ray of the terminal portion of the esophagus, therefore, shows the esophagus, closing momentarily in a nipple-like point in the middle of the cone of the diaphragm. Between the nipple and the fundus of the stomach is a gap unfilled with barium. This gap is the closed horizontal arm. As the liver goes down, and its pressure on the horizontal arm of the terminal part of the esophagus is released, the horizontal arm opens and a continuous stream of barium flows into the stomach.

The Basal Tips of the Lungs. From the bifurcation of the trachea to the tip of the diaphragmatic cone the lungs are in close relationship with the esophagus. The posterior median basal tips of the lungs fill the cone of the diaphragm on either side of the esophagus and the aorta. The basal tips of the left lobe extend farther down than the tip of the right lobe. Each tip sends a slender ligament downward and inward to become attached to the diaphragm close to the esophagus. The diaphragmatic end of each ligament blends with the connective tissue, which packs the cone of the diaphragm and surrounds the terminal portion of the esophagus. A study of frozen sections shows that the lung tip is in relationship with the posterior surface of the horizontal arm of the terminal portion of the esophagus—the diaphragm intervening—for a varying distance. In some cases the relationship is only a centimeter, in others it extends the whole length of the posterior surface of the horizontal arm. Where the relationship is extensive, forcible expansion of the lung tip would squeeze the horizontal arm of the esophagus against the posterior edge of the left lobe of the liver. It is well known that the size of the basal tips varies greatly in different individuals.

The Lung Triangles. The presence of the lung tips in the cone of the diaphragm divides the cone as seen through the fluoroscope or on the *x*-ray plate into a right and left triangle. The boundaries are the same on both sides, namely, internally, the edge of the spine externally and below the diaphragm and above the projection backward of the dome of the diaphragm. The right triangle is indistinct, the left is clear. The left is the larger of the two, as there is more lung substance in it. The lung triangle can be made out in the direct anteroposterior position, especially the left triangle. The right oblique position, however, brings out the left triangle the best. (See Figs. 13 to 22.)

The external and lower boundary of the left triangle is especially distinct as the line of the diaphragm is reinforced by the upper edge of the posterior face of the left lobe of the liver. Frozen sections show that this edge coincides with the line made by the projection of the dome of the diaphragm.

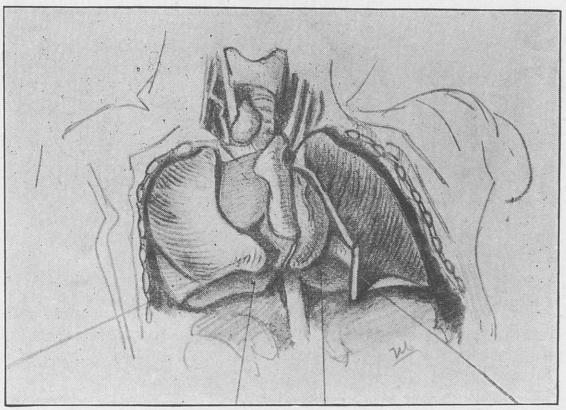


FIG. 13.—Drawing of the open thorax of a baby dead at birth. The drawing shows the basal tips of the lungs. Only the posterior basal tips come into relationship with the terminal portion of the esophagus.

THE REVERSED PHENOMENON. Up to now I have been unable to explain the clinical observation that in some cases when the diaphragm was down the lumen of the esophagus instead of opening as it does in the majority of normal cases became momentarily closed. This I called in a recent paper the "reversed phenomenon." Four recent cases of terminal stricture of the esophagus have all shown it. In each case the fluoroscope showed that in full inspiration the left lung triangle brightened and increased in size markedly. At the same time the esophagus in the lung triangle appeared as if cut off with a string, and the point of occlusion retracted upward a quarter to half an inch. The occlusion lasted for only a second or two and then gave way to an opening of the esophagus as the diaphragm reached the limit of its downward excursion. In one of the 4 cases both the right and the left lung tips could be seen to inflate and strangle the esophagus. In the other 3 cases the left lung tip was the only one which could be made out plainly.

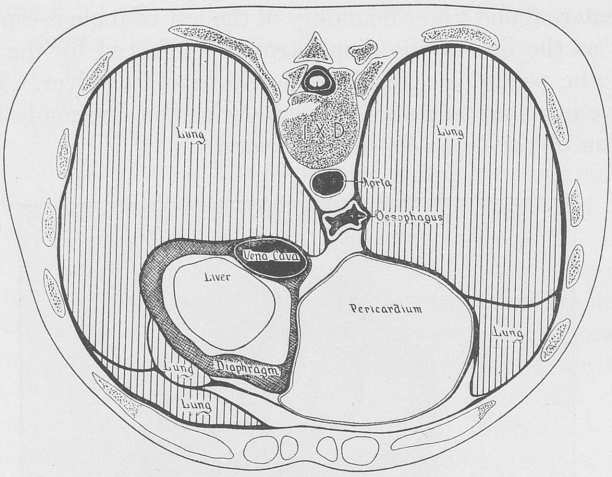


FIG. 14.—Drawing from a tracing of a frozen section of an adult cadaver through the ninth dorsal vertebra. The drawing shows the intimate relationship between the lungs and the esophagus at this level.

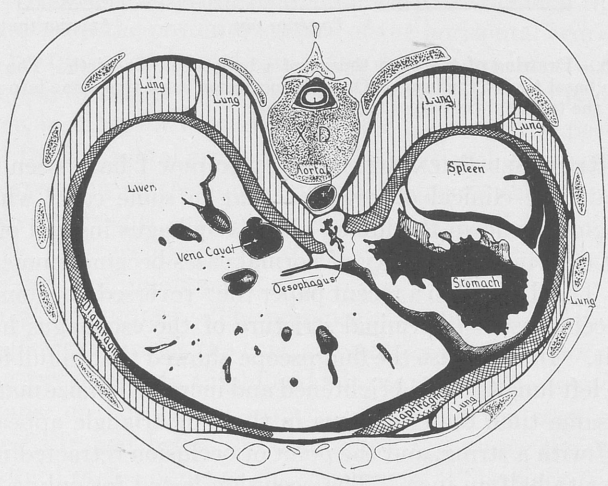


FIG. 15.—Drawing from a frozen section of the same cadaver shown in Fig. 14. The section is made a vertebra lower down. The drawing shows the intimate relationship between posterior basal lung tips and the esophagus. Notice how the long axis of the esophagus has become antro-posterior, instead of transverse as in the section above. This the writer believes is due to the pressure of the expanded lung tips.

These observations show that the terminal portion of the esophagus in the cone of the diaphragm is hard put to it. When the diaphragm is up the liver edge shuts it off. When the lung tips expand it is again shut off.

Fluoroscopic observation of pouch cases shows that during swallowing the larynx and the hyoid bone move upward. This is accompanied by an upward movement of the esophagus of about two inches. By the same means it can be seen that when the diaphragm ascends even in normal cases—but more marked in

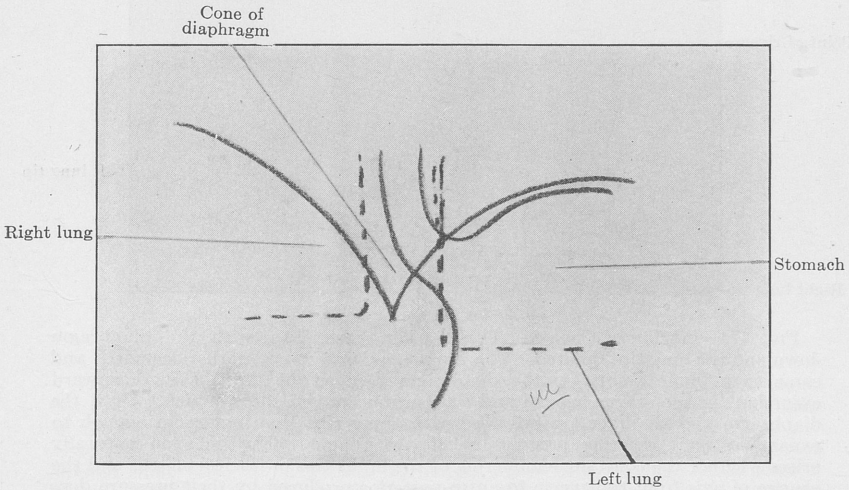


FIG. 16.—Diagrammatic drawing to show the relationship of the posterior basal tips of the lungs to the terminal portion of the esophagus. Notice that the left tip extends further down than the right.

cases of terminal stricture of the esophagus—the lower end of the esophagus is carried upward at least an inch and bends distinctly to the right. It would seem, therefore, that there is constant mobilization of the lower end of the esophagus, and that the extreme displacement of the esophagus to the right and the accompanying bend which are found in long-standing cases of stricture of the terminal portion of the esophagus are but an exaggeration of a natural tendency of the esophagus. Apparently this is one of the few false moves made by Nature as a routine. (See Fig. 29.)

The presence of the lung tips in the cone of the diaphragm opens another field of speculation. The more I think the matter over, the more I feel that pathology of the lung tips—adhesions after a pleurisy or a frank tuberculosis—can be the starting-point of pathology in the adjacent esophagus. After infection the connective tissue in the cone of the diaphragm about the esophagus should be a splendid place for adhesions to form. The ligaments from the basal tips of the lungs to the diaphragm by contraction

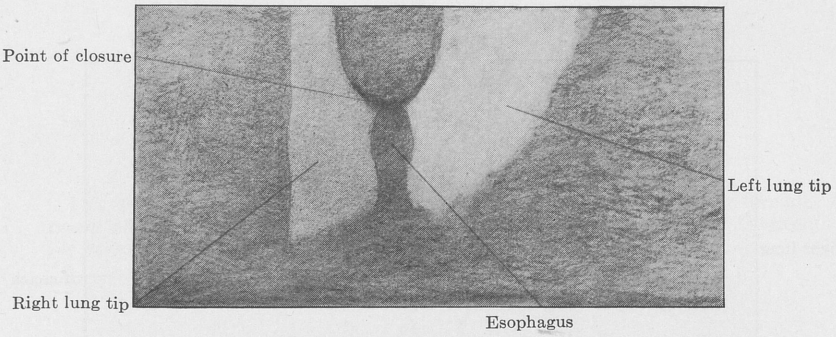


FIG. 17.—Tracing of Case I. The tracing was taken with the diaphragm down and the lung tips inflated. The esophagus was momentarily occluded and came to a blunt point. As the diaphragm reached the limit of its downward excursion the esophagus opened and the barium entered the stomach. Until the diaphragm and the liver are fully down the lung tips have not room enough to expand without exerting pressure on the esophagus. The question naturally arises whether the constant hammering of the lungs tips on the esophagus and the change of axis from transverse to antro-posterior produced by their pressure does not tend to mobilize the lower end of the esophagus or even twist it on its vertical axis.

would deform the opening in the diaphragm through which the esophagus passes. Fuse the end of the lung ligament with the strands of connective tissue in the cone and a string-like band is formed across the face of the esophagus. Last year I stated that lower thoracic disease and upper abdominal infection, especially infection about the lesser omentum, were both causes of obstruction in the terminal part of the esophagus. For the moment and in this paper I am featuring lower thoracic disease.

THE DIAPHRAGM. Next to the heart the diaphragm is the hardest-worked muscle in the body. It is an odd muscle in that

it is made up of a number of large segments. The heart lies on its upper surface and the liver hangs from its under surface. Its downward movement is due to the contraction of its muscular fibers. The upward movement is caused by the upward surge of the abdominal contents and the negative pressure in the thorax. Its upward excursion is done for it; the downward movement it does for itself. There is no reason why its musculature should not at times become played out the same as the heart muscle. Considering everything, it is no wonder that occasionally it weakens and sags and responds poorly.

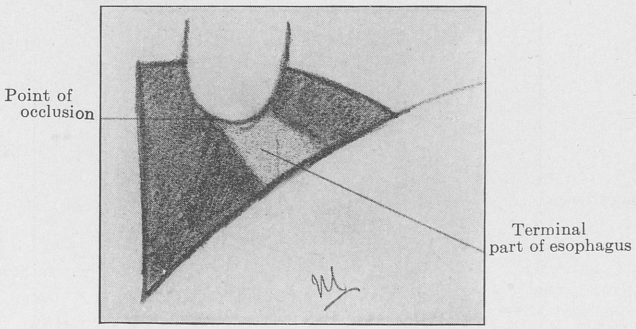


FIG. 18.—Tracing of the left lung triangle with the lung tip inflated. The esophagus was seen to be momentarily occluded and to end in a blunt point in the middle of the lung triangle. The shutting off was not absolute because there is a faint shadow in the esophagus below the point of constriction. This patient has been dilated under ether and a No. 38*a* F. bougie passes easily. Three other cases of stricture of the terminal portion of the esophagus show the same phenomenon after dilatation of the strictured esophagus under ether. In these 3 cases also, a large bougie can be passed easily.

In quiet breathing, the combined upward and downward excursion of the diaphragm is about half an inch. With a forced inspiration it sinks an inch below the low level of quiet breathing and with a forced expiration it rises an inch.

In chest-breathing, room for the full lung is gained mainly by expansion of the chest walls The tracing in such cases shows that the diaphragm has its greatest excursion upward. The downward movement is slight. In the abdominal type of breathing the diaphragm on forced inspiration moves actively downward, and on forced expiration has an equal extension upward.

The ptotic or fallen diaphragm on forced inspiration moves down but little or not at all, because it is already down about as far as it will go. The upward movement in which the diaphragm is a passive agent is normal in extent.

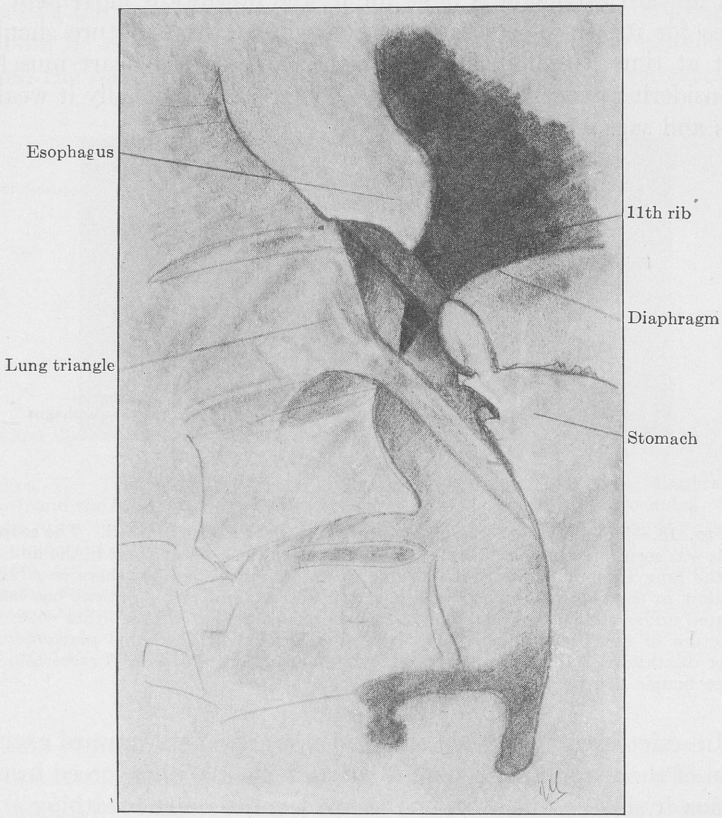


FIG. 19.—Tracing of an *x*-ray plate of stricture of the terminal portion of the esophagus. Female, aged thirty-two years. The diaphragm is down and the lung tips expanded. There is a gap in the esophagus which corresponds accurately to the dark lung triangle.

Unless the patient coöperates intelligently it is rather hard to get accurate tracings of the movements of the diaphragm.

Deformities of the Diaphragm. At the sides where the diaphragm joins the ribs—that is, in the costodiaphragmatic angle—semilunar webs are often found. These are adhesions left by a former pleurisy.

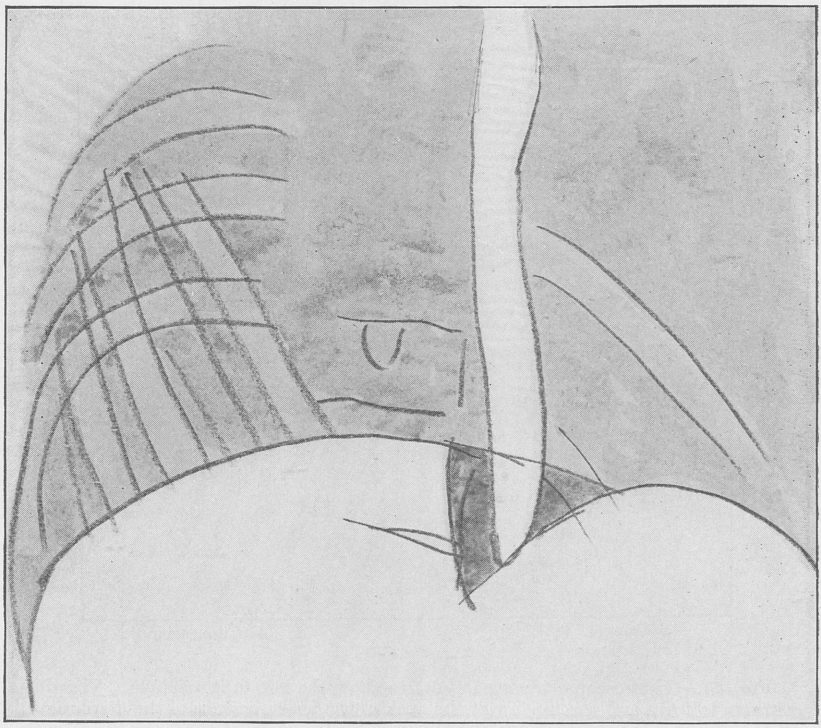

Fig. 20.—Tracing from an *x*-ray film of a boy of seventeen who had an annular stricture of the terminal portion of the esophagus. The film shows the left half of the cone of the diaphragm and the left lung triangle. The dark area is due to the lung tip. This is a typical picture of a case of so-called cardiospasm. (See Case V.)

Adhesions between the diaphragm and the pleura appear as saw-toothed projections from the upper face of the diaphragm.

One or both halves of the diaphragm may have a wavy outline. This irregularity has usually been ascribed to unequal contraction of the various muscular segments of the diaphragm. Recently,

I found in a dissecting-room subject that it may be due also to a contraction of the diaphragm associated with tuberculosis of the lung.

Congenital hernia of the diaphragm has long been known and is not a great rarity. In such cases the stomach or a part of it usually protrudes into the thorax through the esophageal opening.

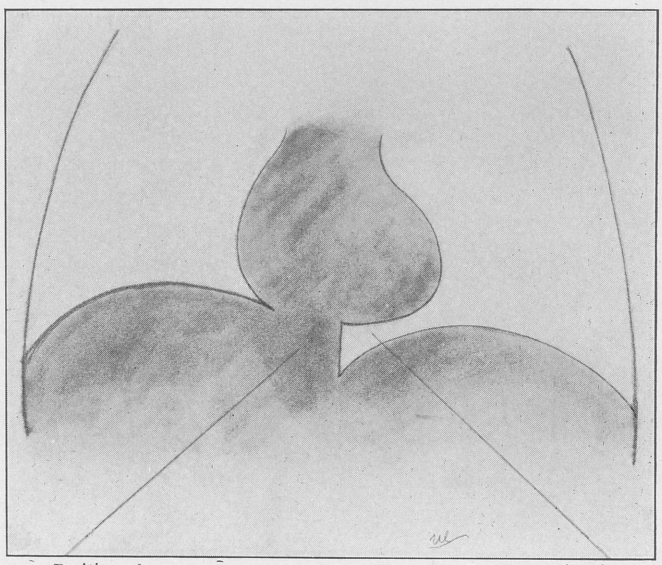


FIG. 21.—Fluoroscopic tracing (adult) to show the left lung triangle. The diaphragm is down and the shadow of the apex of the heart is clear of the diaphragm. When the diaphragm is up the shadow cast by the apex of the heart fuses with that of the left half of the diaphragm. The right lung triangle does not show. Its position, however, is indicated by the pointer.

Morrison recently reported a series of 16 cases of small herniæ of the stomach through the esophageal opening. They appear only when the patient is lying down and simulate a pouch springing from the lower end of the esophagus.

I have two tracings in which the right half of the diaphragm, instead of bowing down to meet the spine, rises as if carried upward by adhesions. One of these patients was a tuberculous case.

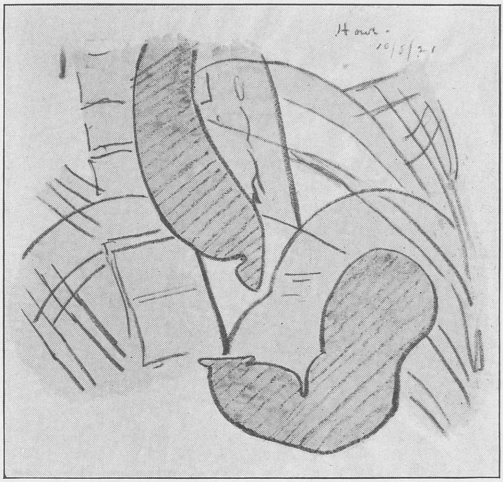

FIG. 22.—Tracing of an *x*-ray plate of a case of stricture of the terminal portion of the esophagus. Male, aged fifty years. The tracing shows a large left lung triangle. The esophagus is dilated and bent to the right.

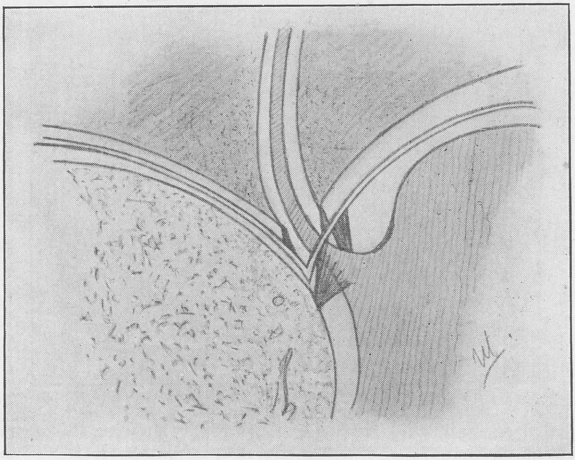

FIG. 23.—Diagrammatic drawing to show the ligaments from the basal tips of the lungs to the diaphragm at the rim of the hiatus, the suspensory ligament from the terminal portion of the esophagus and the ligament from the obliterated ductus venosus of the liver.

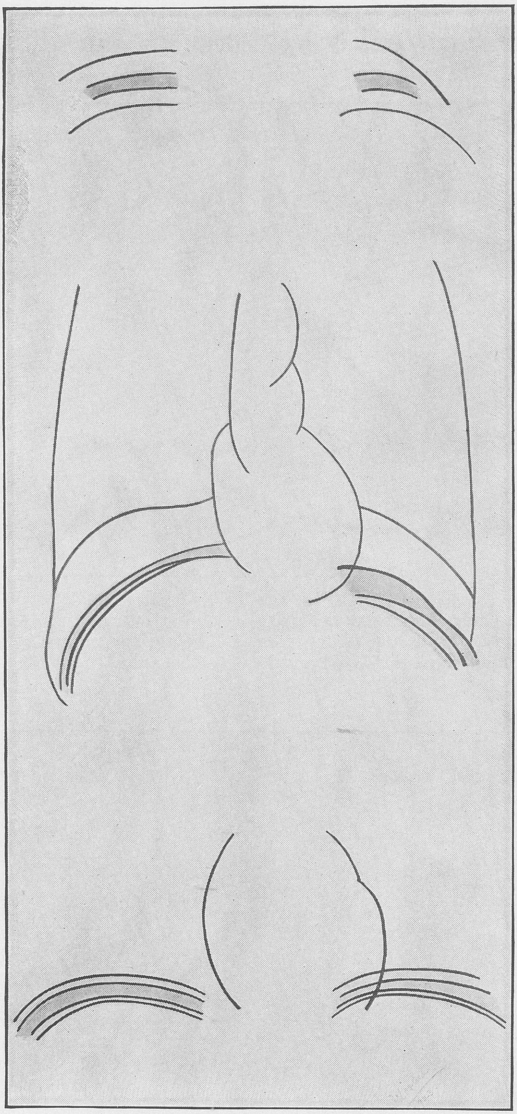

FIG. 24.—Upper drawing.—Tracing from *x*-ray film showing the normal excursion of the diaphragm.

Middle drawing.—Tracing from *x*-ray film showing a very extensive three-inch-upward excursion of the diaphragm. The downward excursion was limited. The patient was a tall man with a thin long chest.

Lower drawing.—Tracing from *x*-ray film showing a limited upward-and-downward excursion of the diaphragm. The diaphragm is of the ptotic type.

In all three drawings the shaded area shows the excursion of the diaphragm during quiet breathing. The top and bottom lines indicate the limits of forced expiration and inspiration.

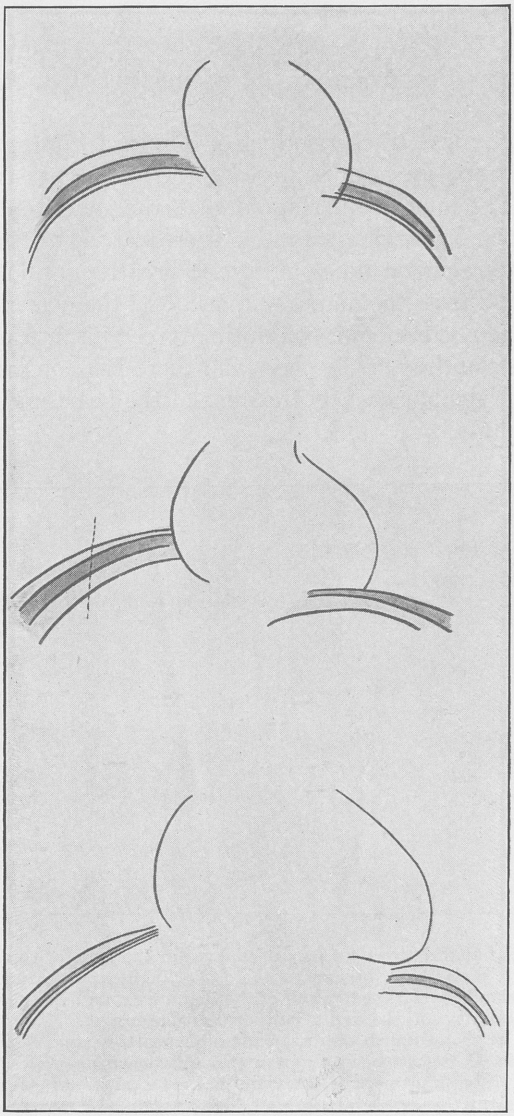

FIG. 25.—Upper drawing.—Tracing from an *x*-ray film showing a limited downward excursion of the diaphragm and a fair upward excursion on forced breathing This is a common type of tracing in patients where the diaphragm is ptotic. A. the diaphragm is low its contraction produces little or no downward excursions The upward excursion of the diaphragm is a passive affair brought about by the upward surge of the abdominal contents and negative pressure within the thorax. Therefore the upward excursion of the diaphragm is interfered with less.

Middle drawing.—Tracing of an *x*-ray film in which the right half of the diaphragm is higher than normal. To the inside of the vertical dotted line the diaphragm moved very little. This suggests adhesions. On the left the line for the forced upward excursion of the diaphragm was lost.

Lower drawing.—Tracing from an *x*-ray film showing an enlarged heart and a nearly motionless and low diaphragm. The patient had suffered from an uncompensated heart for a year.

One of the last tracings which I obtained interested me very much: The patient had suffered for over a year from cardiac asthma. The fluoroscope showed that the much enlarged heart was squatting on the diaphragm. There was very little movement of the diaphragm on quiet or forced breathing. The weight of the heart had tired the diaphragm out. In the normal case, when the diaphragm is carried down during forced inspiration, the heart is seen to swing free in the chest and there is a considerable space between the shadow cast by the apex of the heart and the shadow of the diaphragm.



FIG. 26.—Diagrammatic drawing to show changes in the form of the diaphragm. First figure, upper row. Web like adhesions in the costo-diaphragmatic angle. Second figure, upper row. Adhesion between the left half of the diaphragm and the pleura. Third figure, upper row. Irregularity of the right half of the diaphragm. First figure, lower row. Congenital hernia of the stomach through the esophageal opening. Second figure, lower row. Small hernia of the stomach through the esophageal opening (Morrison). Third figure, lower row. The inner part of the right half of the diaphragm runs upward as if displaced by adhesions.

## LIST OF CASES

CASE I.—Mrs. M., aged fifty years.

The chief points in this case are as follows: For two years there had been moderate difficulty in swallowing. There was no discoverable etiology. A year ago, in her home city, the esophagus was dilated for cardiospasm, with some relief.

In the Brigham Hospital she was given atropin to saturation, with slight relief for a few days. Through the courtesy of the surgeons there she was transferred to me.

I found that a No. 22 bougie passed readily into the stomach. On beginning a meal she almost always strangled. The fluoroscopic examination of the esophagus, three hours after a meal showed it two-thirds full of fluid. It was observed also, that the lung tips on inflation closed the esophagus.

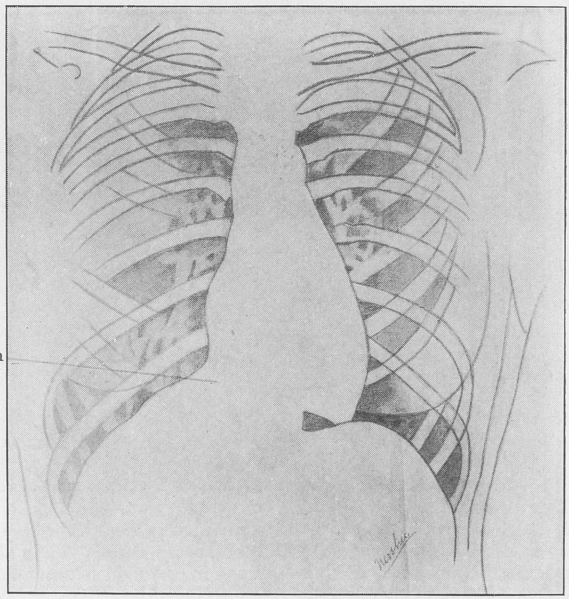


FIG. 27.—Tracing of *x*-ray plate of a case of terminal stricture of the esophagus. The right half of the diaphragm has an irregular wavy outline. The inner end of the right half of the diaphragm instead of curving downward runs upward suggesting a dislocation upward from adhesions.

Under ether the full-sized esophagoscope, after the initial halt at the central narrowing, passed readily into the stomach. The pictures obtained on the way through the terminal portion of the esophagus are shown in the drawing opposite the place where they were obtained. These pictures are explained to a nicety by a reference to the reconstruction of the terminal part of the esophagus from frozen sections. It is a great comfort to have them, as it is so hard to be sure of what

you see at the end of a twenty-inch tube, where everything is seen end-on and the picture is a composite of pictures from various depths.

Two other points stand out in this case: The first is that there was a proven element of spasm, because atropin gave slight transitory betterment. The second is that the esophagus was constantly full of fluid, probably accumulated saliva. The choking at the beginning of the meal was due to the fact that the entrance of food into the full esophagus splashed some of the fluid into the larynx and trachea.



FIG. 28.—Tracing from a lantern slide from an *x*-ray film of the chest of an adult male with resolving pneumonia in the right half of the chest. The right half of the diaphragm is pulled upward. This is common in cases of pneumonia. It is found also in massive collapse of the lung due to an occluded bronchus.

In 2 other cases I have found the esophagus two-thirds full of fluid some hours after the last meal. The patient just mentioned was 90 per cent relieved by the passing of the large esophagoscope. She now has bougies passed periodically and the relief continues.

CASE II.—Male, aged fifty-five years.

This patient had been living on fluids for months. The *x*-ray plate showed a pouch springing from the right side of the esophagus just below the bifurcation of the trachea. There was extensive fibrosis of the right lung about the pouch. This infiltration extended into the right half of the cone of the diaphragm, the right lung triangle

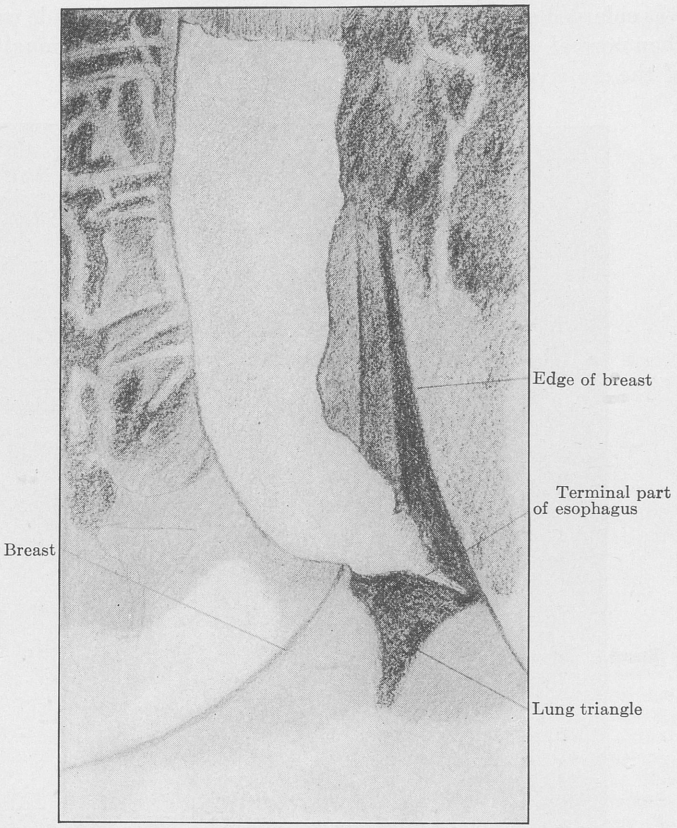


FIG. 29 A.—Tracing from an *x*-ray plate of a case of stricture of the terminal portion of the esophagus. Symptoms for three years. Mrs. C., aged fifty years. The diaphragm is up and there is a marked bend of the esophagus to the right. There is a large lung triangle. Under ether a central narrowing was found with a crescentic mounding into the right quadrant. Dilatation up to 30 F. was accomplished with bougies. A metal olive on a metal staff could not be passed, neither could the mechanical dilator. The patient came to the hospital with pernicious vomiting associated with acidosis. Since the examination a flexible bougie cannot be passed. The patient left the hospital swallowing normally and continues to do so after a period of four months. The next figure shows that the terminal portion of the esophagus is reduced to a narrow ribbon. Under ether the flexible bougies followed the bend of the narrow esophagus, the metal instrument would not. Without ether even flexible bougies will not follow it. As the patient is swallowing normally it would seem as if the antero-posterior diameter of the ribbon-like narrowing was greater than the vertical. It is possible that this narrowing is due in part to the pressure of the lung tips, because if the shadow of the breast is excluded it is seen that there is a very large lung triangle.

was enlarged and the inner half of the diaphragm on this side was lower than normal. In addition there was a stricture of the terminal portion of the esophagus.

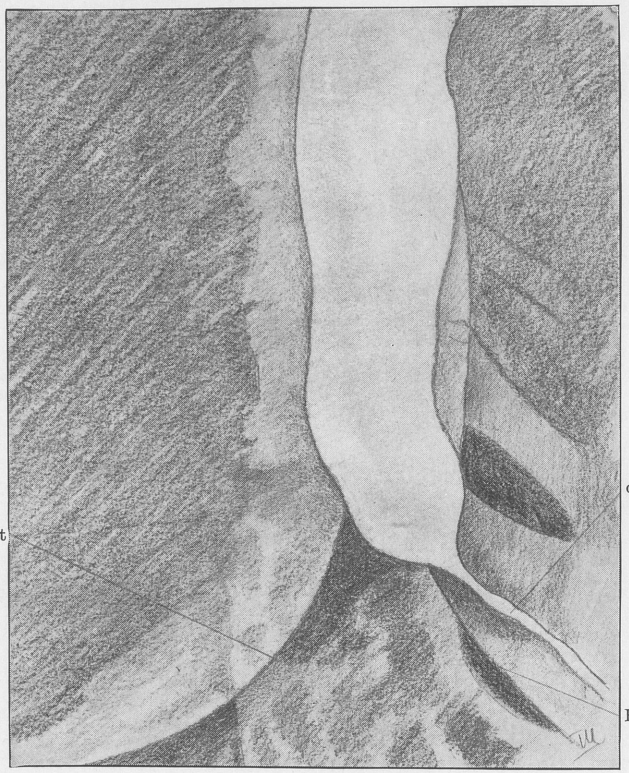


FIG. 29 B.—This plate is from the same patient as Fig. 29 A. The diaphragm is down. The terminal portion of the esophagus is, at least in the antero-posterior position a narrow ribbon. See description accompanying Fig. No. 29 A.

According to Turner, pouches springing from the middle portion of the esophagus have been proved by autopsy to be generally tubercular. The lung in this case gives every evidence of an old tubercular process. To my mind both the pouch and the stricture are of tubercular origin.

The stricture readily dilated under ether and the man left the hospital swallowing normally.



FIG. 30.—Case I. Stricture of the terminal portion of the esophagus. Female, aged fifty years. Tracing of an *x*-ray plate. Diaphragm down. The oval drawings are the tube pictures obtained during the examination under ether. In order to make them legable they are drawn out of scale and slightly larger than actual size. Each oval drawing has a pointer leading to the portion of the esophagus where it was obtained. First tube picture, counting from above downward. The esophagus shows a small central opening. On the right there is a crescentic mounding into the lumen of the tube. This mounding into the tube is very common. It is usually found below the central narrowing. See Fig. 37. Anatomically this may be caused by the pressure of the edge of the left lobe of the liver or by the edge of the Spigelian lobe. It can be due also to the inward folding of the right quadrant of the esophagus. In some cases this mounding acts like a true web comparable to the webs found in the pyriform sinus. There is still another possible explanation of this mounding into the right quadrant. The horizontal arm of the terminal portion of the esophagus turns sharply to the left. At the beginning of the turn backward pressure would tend to fold the right quadrant inward. This folding can be imitated by approximating the thumb to the first finger. The fold between the base of the thumb and the index finger behaves like the folding of the right quandrant of the horizontal arm.

Second tube picture.—The second tube picture shows the esophagus narrowed to a small central opening.

Third tube picture.—The central opening has given way to an antero-posterior slit. The long axis of the esophagus which previously has been transverse has become antro-posterior owing to the pressure of the lung tips on the sides. See Fig. 9.

Fourth tube picture.—The fourth tube picture was obtained by advancing the esophagoscope into the horizontal arm and then on into the stomach. On withdrawing the tube a small slit was seen in the mucous membrane of the esophagus in the middle line posteriorly. This slit I take to be due to the breaking of a web or the ungluing of a vertical fold. One or two slits in the mucous membrane are common after the dilatation of a stricture of the terminal portion of the esophagus by the gradual advance of the large esophagoscope.

Out of 7 recent cases of terminal obstruction of the esophagus 3 of the patients had old or recent tuberculosis.

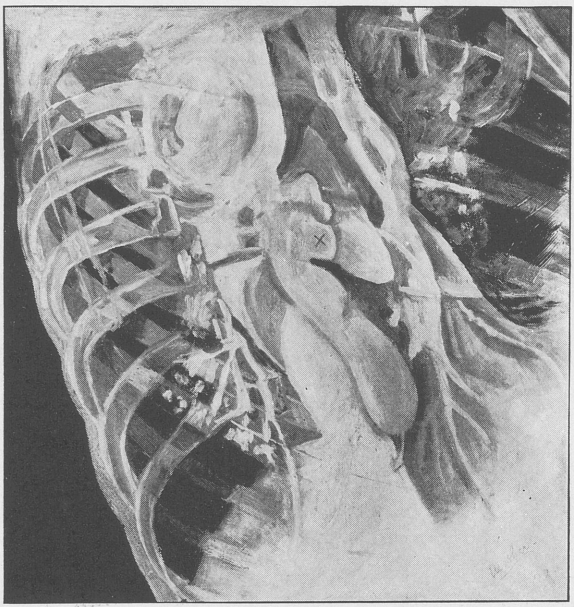

FIG. 31.—Case II. Male, aged about forty-five years. Difficulty in swallowing for four years. Plate taken from the back. The whole right half of the median portion of the chest shows old fibrosis from tuberculosis. This extends to the diaphragm, and the right half of the diaphragm is pulled upward into a blunt point. There is a pouch springing from the right side of the esophagus just below the bifurcation of the trachea. The pouch is marked with an X. The terminal portion of the esophagus shows a ribbon-like narrowing an inch long. At the ether examination the pouch was easily found, explored and passed. The terminal portion of the esophagus was narrowed to a small central opening. This dilated readily with bougies and the mechanical dilator to 35F. The patient came to the hospital swallowing only liquids and soft solids. He was discharged eating normally. He has continued to eat normally for the past seven months. For the first two months a No. 30F. bougie was passed at intervals. An occasional feeling of pressure in the center of of the chest was the only symptom which could be referred to the pouch. The ether examination showed that it opened widely into the esophagus. (See also Fig. 2.)*

CASE III.—Male, aged fifty-five years.

The patient had worked in a marble quarry in Vermont for many years. Five years ago he came to me after a period of treatment in New York. Under ether the typical central narrowing was found. This dilated easily. Large bougies were passed periodically for a

* This case was kindly referred by Dr. P. F. Butler.

time and all went well until last year, when there were symptoms of returning obstruction. I was about to examine him under ether

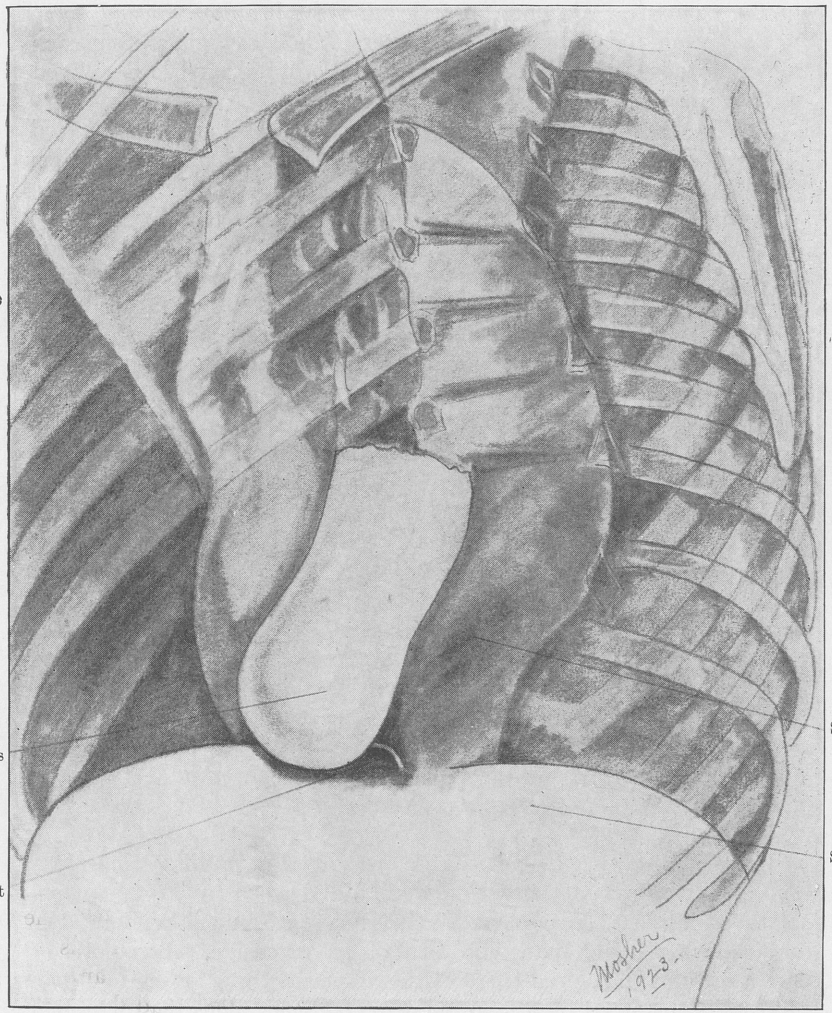


FIG. 32.—Case III. Retouched tracing of an *x*-ray film of the esophagus of a man of fifty-five years. (See Case III.) The esophagus is much dilated and the terminal portion twists on the upper part in an attempt to find the hiatus in the fallen and flat diaphragm. The terminal portion of the esophagus is also very narrow.

again, but delayed a few days in order to attend a meeting of this Association. In my absence the man vomited a quart of blood. The esophageal examination was given up, and instead a tube was placed in the stomach. The man after leaving the hospital, wasted away to a skeleton and died six months later. His family gave permission for an autopsy before the patient left the hospital, and loyally lived up to their word.

The fluoroscopic and *x*-ray examination of the esophagus showed a much dilated esophagus with the usual bend to the right. The diaphragm was low and practically motionless. Dr. Macmillan, on examining the plates, suggested that they seemed to show that the esophagus was twisted on itself at the point where the constriction began. Whatever caused the obstruction was a permanent affair, because even after the insertion of the tube into the stomach nothing would pass from the esophagus into the stomach. I never dared to pass a bougie after the hemorrhage. The case was catalogued in my mind as one of lower esophageal obstruction, due to a fallen diaphragm, with associated mobilization of the esophagus, with trap formation and perhaps a twist. The autopsy showed the usual dilatation of the lower part of the esophagus. There was no stricture anywhere. No adhesions were demonstrated. In the lower part of the middle lobe of the right lung there was an old tuberculous nodule with a few areas of fresh tuberculosis about it.

The trap accounts for the obstruction and the fact that for several years a good-sized bougie could be passed. The patient was accustomed to pass a No. 36 bougie on himself at intervals for years. The trap was finally complicated by a twist, which made a permanent obstruction. I have a growing suspicion that the tuberculosis was at the bottom of the whole affair. The fresh area of tuberculosis found at autopsy explained the hemorrhage which brought my investigation of the esophagus to an abrupt close.

Case IV.—This was not a case actually but a dissecting-room subject, to whom my attention was kindly called by Prof. Warren, of the Anatomy Department of the Harvard Medical School. The subject was an old man who died of an extensive tuberculosis of the right lung. The right half of the diaphragm was lowered an inch and was contracted by a large semicircular scar. This had deformed the liver by cutting a groove in its upper right border nearly an inch deep. The left half of the diaphragm was four inches higher than the right half. The esophagus was slightly constricted at the point where

it passed through the diaphragm. The diaphragm was drawn into a band in front of the hiatus and this band was continuous with the semicircular scar on the right.

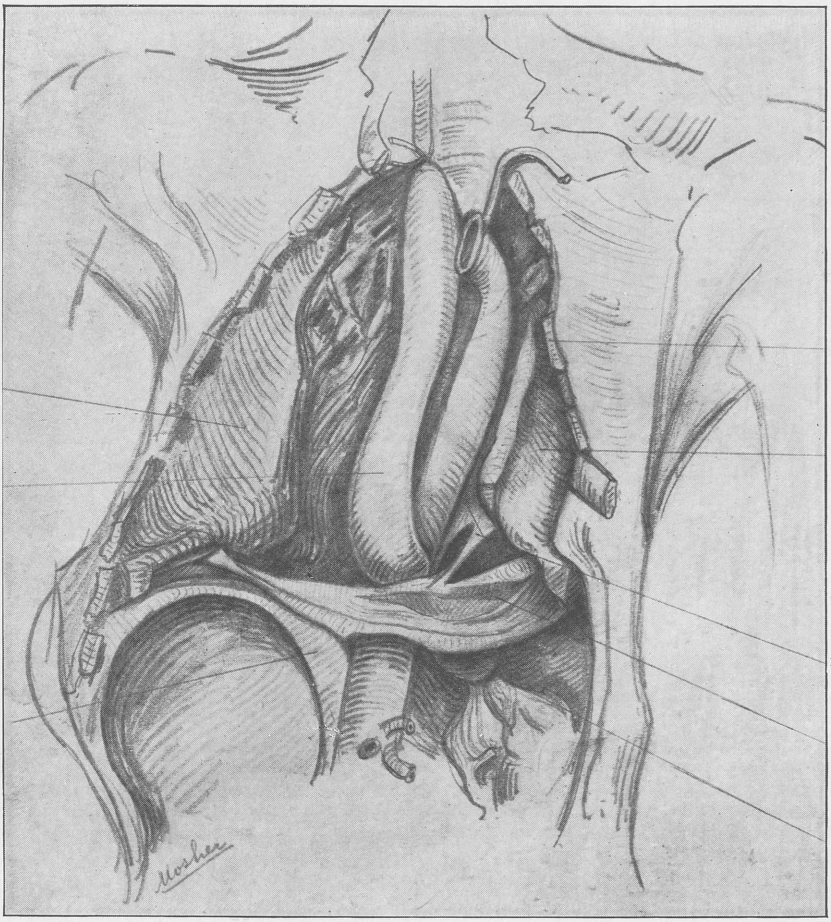


FIG. 33.—Case IV. Drawing from a dissecting room subject, old male, who died with extensive tuberculosis of the right lung. (See Case IV.) The right half of the diaphragm is deformed by a very extensive semicircular rib-like adhesion, which had pulled the diaphragm down an inch and had cut a deep groove in the upper surface of the liver.

This case is of interest as showing what tuberculosis of the lungs can do to the diaphragm. The right half of the cone of the diaphragm was obliterated. This case would have been perfect for my present purposes if there had been more obstruction of the esophagus. I can, of course, take refuge in the statement that no one knows how the esophagus functioned when the patient was alive.

The case features the point that tuberculosis can deform the diaphragm extensively.

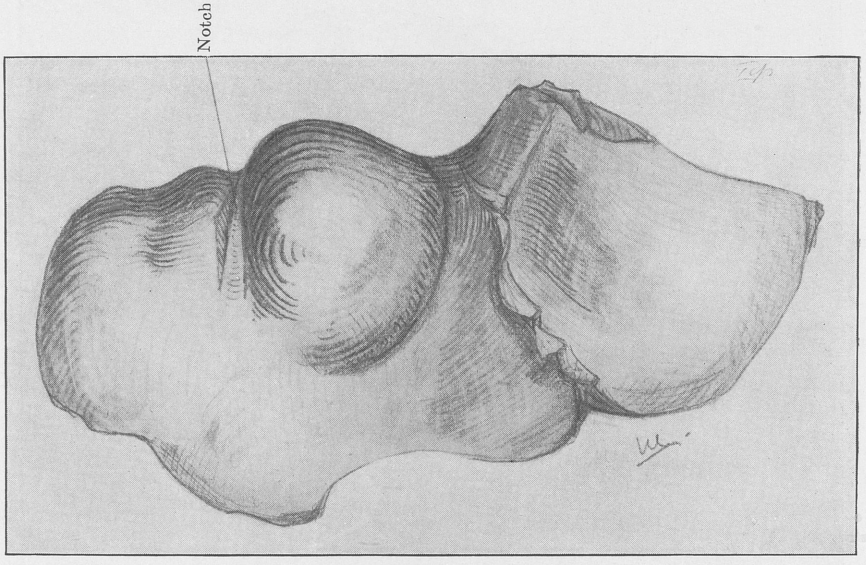


FIG. 34.—Case IV. Deformity of the liver caused by contraction of the right half of the diaphragm associated with tuberculosis of the whole of the right lung. The line of the diaphragm would follow the outline of the liver and so in this case would be a series of waves. A similar irregularity, but of lesser extent has usually been classed as due to irregular contraction of the different muscular segments of the diaphragm. This case shows that it may be due to tuberculosis. (See Fig. No. 33.)

CASE V.—This patient was a boy, aged seventeen years. He had had trouble with swallowing for two years. No etiology could be found for the condition, except that five years before he had been thrown from his pony and the pony stepped on his chest. I have wondered for some time whether trauma to the chest could not mobilize the esophagus. I have another case—in fact, the case which follows this one—in which the patient was in an electric-car accident and was

thrown forward so that her chest struck violently on the back of the seat in front of her. The boy now under discussion had been living on fluids for months. He had short periods when he could swallow normally. Under ether the usual central narrowing was found, and

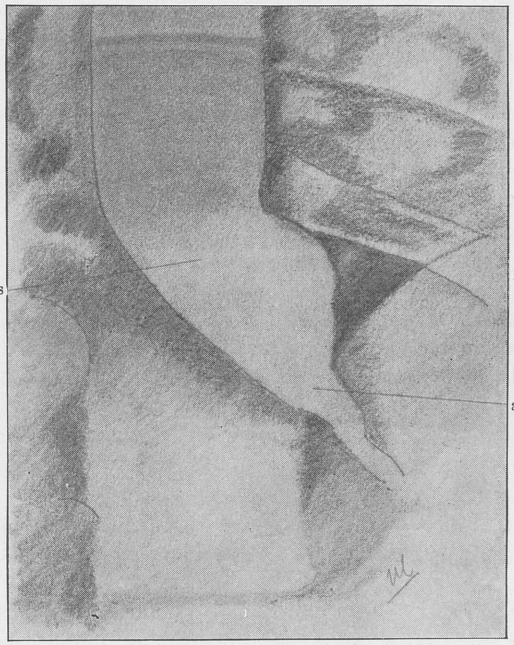


FIG. 35.—Case V. Male, seventeen years. The diaphragm is up. The esophagus is moderately dilated. With the ascent of the diaphragm the terminal portion of the esophagus has been carried up and to the left, producing a bend of the esophagus to the right. This happens normally, but where there is a stricture of the terminal portion of the esophagus or the esophagus is dilated the bend is more marked. An excessive bend of the esophagus to the right with trap formation is but an exaggeration of this normal happening. The plate shows the right lung triangle well. The ether examination showed a central narrowing of the terminal portion of the esophagus, below which was the customary crescentic mound into the right quadrant. Dilatation was accomplished readily. The boy passes a No. 40F. bougie on himself twice a week, on passing the bougie it halts slightly just before it enters the stomach.

below this on the right a crescentic web or a folding together of the right half of the esophagus or a mounding of the liver into the esophagus at this point. The large esophagoscope was worked by gradual pressure through the central narrowing into the stomach.

After this the mechanical dilator was used. Following the ether dilatation a large bougie was passed at intervals and now the boy passes on himself a No. 38 bougie two or three times a week.

This young man has been very coöperative and I have fluoroscoped him repeatedly, as much for my benefit as for his. On passing a No. 40 bougie a slight resistance is felt just before the bougie enters the stomach. The boy is on full diet. Whenever he eats anything he feels it halt at the lower end of the esophagus. Then he takes a drink of water, feels some gas come up from the stomach into the esophagus and the food in the esophagus goes down.

At each examination with the fluoroscope the esophagus was found to be two-thirds full of fluid. The barium milk halts at the esophageal nipple in the cone of the diaphragm. When the patient takes a drink of water the contents of the esophagus shoot at once into the stomach.

The first plate of this patient shows the esophagus pulled up by the ascent of the diaphragm and bent to the right. In the second plate the esophagus has become straight with the descent of the diaphragm and the terminal portion appears to be twisted on its vertical axis. It was from this case that I got the idea of the possibility of a vertical twist of the terminal portion of the esophagus as a cause of intermittent obstruction of the esophagus. The twist explains nicely the present symptoms in the case. The original stricture in the case was done away with by the dilatation under ether. The vertical twist of the terminal portion of the esophagus persists. Owing to the twist the esophagus retains fluid all of the time. When the patient takes a drink of water the weight of the extra fluid is sufficient to start the untwisting and the upward flow of gas from the gas bubble in the stomach finishes the opening. The passage of a bougie, of course, untwists the twist. I have tried not to draw on my imagination too much in interpreting the *x*-ray plate.

There is ample chance for the esophagus to twist on its vertical axis should the right conditions occur. The stomach follows the upward and downward movements of the diaphragm. As the diaphragm goes down the fundus of the stomach approaches the middle line of the body and the horizontal arm of the terminal portion of the esophagus (which turns sharply to the left when the diaphragm is up), is straightened out and becomes a straight line with the upper part of the esophagus. This is part of the mechanism by which the esophagus opens and discharges its contents into the stomach.

Any rotation of the stomach on its vertical axis would cause the same sort of a rotation of the terminal portion of the esophagus.

CASE VI.—This case was a woman in the late forties. For three years she had had increasing trouble in swallowing. For a year at least she had lived on liquids. For two weeks before she came into

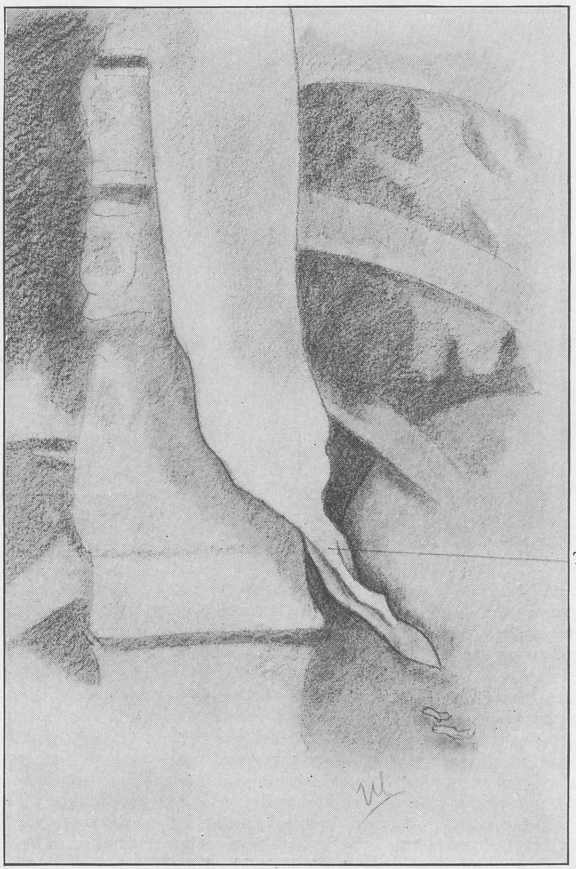


FIG. 36.—Case V. See Fig. 16. Male, aged 17 years. The diaphragm is down and the bend of the esophagus which was present when the diaphragm was up has straightened out. The terminal portion of the esophagus appears to be twisted on its vertical axis. Notice the lung triangle.

the hospital she had vomited everything taken by mouth and was practically starving. There was no obtainable etiology for the esophageal obstruction except trauma to the chest in an electric-car acci-

dent. Examination of the urine disclosed a marked acidosis. The patient was fed by rectum for four or five days, and glucose was

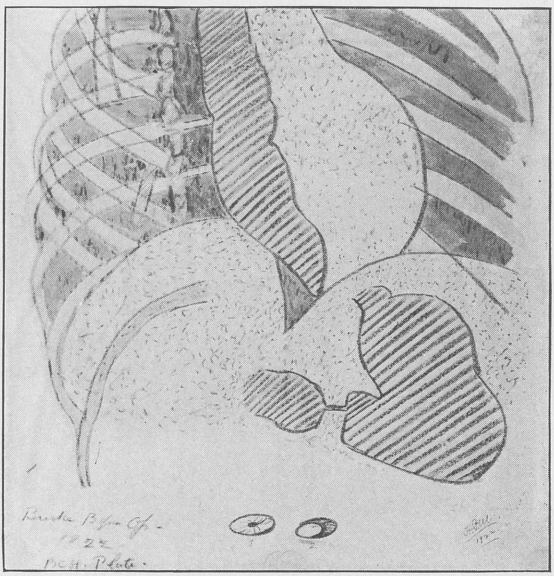

FIG. 37.—Case VI. Tracing from an *x*-ray plate of a typical case of stricture of the terminal portion of the esophagus. Female, aged fifty years. Symptoms of obstruction for three years. The plate is taken slightly from the side-right oblique. The diaphragm is up. The left lung triangle shows clearly. The esophagus is dilated and bends slightly to the right. The esophagus tapers to the typical nipple. It appears to touch the diaphragm. This is due to the rotation of the body to the right. The nipple is really a little above the diaphragm. The horizontal arm is closed and is represented by a gap between the nipple of the esophagus and the fundus of the stomach. Under ether a central narrowing of the esophagus was found at the level of the esophageal nipple and below this there was a crescentic web or fold mounding into the right quadrant of the esophagus. The narrowed esophagus dilated easily. A large bougie can now be passed readily. The patient came to the hospital starving. She went home eating normally. The tube pictures are shown in the small diagrams at the bottom of the plate. The advocates of the spasm theory would maintain that the central narrowing was due to spasm. It persists, however, under ether and a large esophagoscope is halted by the narrowing and has to be coaxed through slowly by steady pressure. In most instances the withdrawal of the large tube discloses one or two breaks in the mucous membrane of the esophagus in the region of the central narrowing giving the observer the feeling that an actual gluing of the esophagus was present at this point or that a web was present which was broken by the passing of the esophagoscope. If a small tube is used for the examination and this is followed by dilatation with the water bag or the mechanical dilator no accurate idea can be gained of the actual condition. Even when the esophagus is put on the stretch by as large a tube as can be safely introduced it is not easy to interpret correctly the tube picture.

given the same way and by subpectoral injection. The acidosis promptly cleared up and the vomiting stopped. Within two months of this case I had a similar one. The patient, also a woman, had had

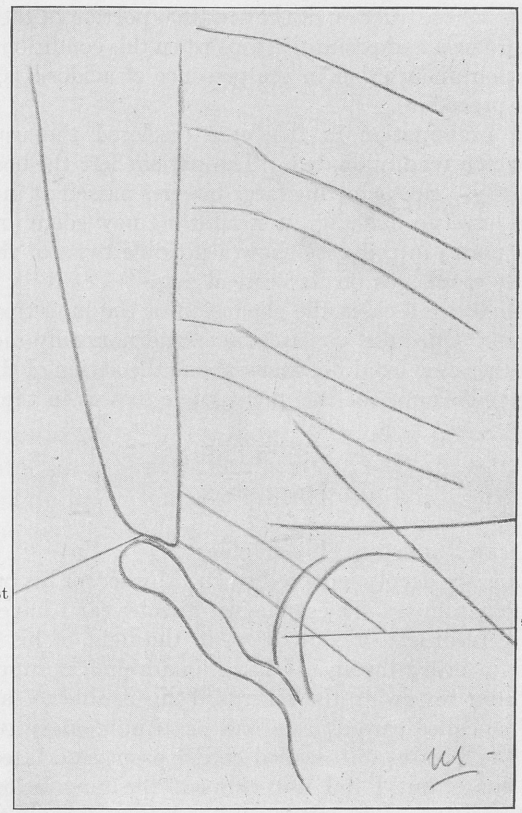


FIG. 38.—Case VI. See Fig. 33. This case gave the typical plate and the typical findings under ether, that is, a central narrowing with a crescentic mounding into the right quadrant below it. The figure is from an *x*-ray plate taken after operation. It suggests the possibility of a twist of the esophagus on its vertical axis at the level of the beginning of the cone of the diaphragm. The patient came to the hospital starving, and with pernicious vomiting associated with acidosis.

trouble with swallowing for three years. She was reduced to liquids. For three weeks she had vomited everything and was sent into the hospital as an emergency case. She also had a marked acidosis. The

condition cleared up under treatment similar to the treatment of the first case. When the acidosis cleared both cases were examined under ether.

These 2 cases show that the pernicious vomiting which occasionally occurs in cases of obstruction of the terminal portion of the esophagus is due to acetonuria and promptly stops when this condition is relieved. An examination under ether in the presence of acidosis is, of course, a hazardous procedure.

The ether examination in this case disclosed the usual central narrowing, which readily dilated. The patient left the hospital swallowing normally. She is having large bougies passed at intervals and continues to have no difficulty in swallowing now some four months.

The *x*-ray plates in this case show a possible twist of the terminal portion of the esophagus on its vertical axis.

In 4 of the above 6 cases the expansion of the lung tips closed off the esophagus. One case was a cadaver and naturally did not show it. In the other case I did not know about the action of the lung tips and so did not examine for this point while he was in the hospital.

---

## Discussion

Dr. Chevalier Jackson, Philadelphia:

All clinicians are deeply indebted to Dr. Mosher for his fundamental work on the anatomy of the esophagus. Each year I have gone back over my case records to review them in the light of his anatomical findings and in every instance I have found clinical support for his views. Without reviewing the records, I am unable to say if any of my cases of so-called cardiospasm had basal pulmonary tuberculosis. I do recall 3 or 4 cases of so-called cardiospasm associated with disease of the lungs, but I did not connect the lung lesion with the esophageal condition. The whole subject brings strongly to mind the fact that the lower end of the esophagus is subject to a great many different diseases that have heretofore been considered as one disease under the erroneous name cardiospasm. Cardiospasm is not spasmodic and is not at the cardia. It seems to me we need a name for the syndrome common to all these diseases in which there is non-malignant stenosis at the terminal portion of the esophagus with suprajacent dilatation. I have had the temerity to suggest preventricular stenosis, or, better, preventriculosis, which leaves out all considerations of etiology and pathologic mechanism.

# THE RELATION OF SINUSITIS TO ARTHRITIS DEFORMANS

E. ROSS FAULKNER, M.D.

THE attempt to establish a true relationship in pathological phenomena requires long, patient and careful observation, and the little presentation of evidence which I will submit to you today is a very small part of a great synthesis which will perhaps some day confirm a general assumption into an established truth. Thus our case reports and our case presentations help us by slow gradations to discover the common factors in our clinical experience which, when attested to by many witnesses, become constituted and accepted as a part of knowledge.

One cannot find a better way to realize how gradual the progress of medicine has been than by consulting a series of textbooks covering a period of twenty to twenty-five years. There is a slow and steady elimination of the less probable notions in favor of the theories which are better sustained by evidence, and the evolution of methods for acquiring such evidence seems to be the sphere wherein progress is most noted.

I have indulged in this pleasant little bit of retrospecting before writing this paper, and it is quite surprising to realize how much our views have changed in the past ten years in regard to many of the most common diseases. Thus it is only within the last ten to twelve years that the great subject of focal infection has come under discussion, and yet how much this idea of causation of disease has changed our notions of many everyday ailments. So our views keep changing, and probably the next ten years will produce as great alterations in our opinions as the past has done. When we have learned a little more we will no doubt eliminate the word "neurosis" entirely, and may also use the term "toxemia" as an expression of a hiatus in our knowledge.

I have been constrained to make the above reflections from a recent study on the disease "arthritis deformans." I find that up to ten years ago this was described in text-books as a disease of unknown etiology, some claiming that it was due to a specific infection while others considered it a so-called neurosis. As this disease had been known to exist for five thousand years and had been the subject of much investigation, its morbid anatomy had been quite thoroughly determined; but the idea of a focal infection being the main factor in its causation was first mentioned in text-books about ten years ago. It was diagnosed as a distinct entity in arthritis and was differentiated from chronic rheumatism, gout, Charcot's disease, chronic pulmonary osteoarthropathy, and Still's disease. The last named was a joint affection closely resembling arthritis deformans, except that it occurred in children, whereas the true arthritis deformans was supposed to be a disease of middle age. Now, since we know a little more of the etiology of all these affections, we can reduce our classification to a simple basis, and, accepting gout as a generic name for the joint disorders, due to metabolic dysfunction, we can enlist all the others under the term of rheumatism, due to focal infection; and the word rheumatism should only bear significance as the name of a symptom.

Any badly drained pus cavity can produce rheumatic manifestations, whether that be the nasal sinuses, the tonsils, a tooth socket, the middle ear, the lung, the gall-bladder, the appendix, the uterus and vagina, the pelvis of the kidney, the bladder or the urethra; and according to the joint structures attacked, do we get the variations in morbid anatomy. Thus gonococci are more prone to attack the fibrous structures about the joint. Some streptococci affect the synovial membranes and some affect the cartilages, and it is when the latter are attacked that we get the changes characteristic of arthritis deformans. The variation in tissue involvement is determined by the predilection of organisms for certain tissues and is not a matter which can be estimated by the morphology of the organism. Thus, as has been noted, several members of the same family may acquire the same infection with its inherent predilection, and hence the disease in these individuals runs nearly the same course. There is besides a certain vulner-

ability of tissue in some people which predisposes that tissue to morbid changes, and that vulnerability may be inherent or acquired by disordered metabolism. This is noticeably so in joint diseases, and a case of arthritis deformans may have a focal infection as the exciting cause with the disordered metabolic function producing a lowered resistance, both generally and locally.

These combined factors must be remembered in the treatment, and if they were, we might find reason for a more optimistic attitude than has prevailed hitherto. Even text-books of the present day regard arthritis deformans, once established, as an incurable disease; but I am sure there is ground for a more hopeful view if the focus of infection is entirely eliminated.

The first important step in treatment is the discovery of the focus, and here the coördination of several specialists may be necessary. Of all the possible foci, I am persuaded that intranasal sinus disease has been the one most frequently overlooked, or rather disregarded. In the cases which I am going to report there was an abundant purulent discharge from the nose, and yet it had been quite unsuspected for years as a cause of the joint trouble. In two other cases which I have not treated there is a profuse nasal discharge, but as these cases are very old, and have been crippled for years, they are not anxious to venture on any new treatment. There has probably been a hesitant attitude in attempting sinus treatment in many of these cases. It is a long-drawn-out process and must be entirely finished before one can get results from the joint lesions. I would commend a more aggressive attitude toward eradicating this focus, where it is the cause of progressive joint disease, and if you are successful in saving them from years of suffering and helplessness, you will be doing something which will give an increased prestige to the work of the rhinologist and will enlarge his sphere of influence in the treatment of general disease.

Though it may appear a little irrelevant to the subject of my paper, I wish to say something in regard to the treatment of sinusitis when it is found associated with progressive joint disease. Now, the general principles are, of course, the same as one would exercise in treating sinusitis without complications, but in these

cases it is imperative to remove the entire focus, and from past experience I would urge that this be done as rapidly as possible. The patients should be put on the same regimen as a tuberculous patient—rest in bed out-of-doors with as much good food as they can take. Vaccines should be given a trial. The local treatment from the start will demand the establishing of free drainage by operative measures. If the tonsils have not been removed this should be done at once, paying great attention to the infected tissue at the base of the tongue, the importance of which has been very wisely emphasized by Dr. French. I believe the first step in treating sinusitis should be the removal of the tonsils, and in many instances this will have a very beneficial effect on the sinusitis. If there is obvious antrum involvement these may be opened at the same time. If there is no steady improvement in the joints, open up the other sinuses by the intranasal route, and if good frontal drainage cannot be established this way and the arthritis is continuing, do a radical frontal. Keep up the after-treatment until there is no more pus in the nose, and if you succeed in accomplishing this I think you will see the end of the joint trouble.

I will now give you some details of 3 cases which I have had in the past five years. They were many times very discouraging, but the final results have been very gratifying both to the patients and to me.

Case I.—I first saw this patient in 1918. She was then forty-six years of age. Her joint trouble had started seven years before and was so rapidly progressive that for the previous four years she had been bedridden, with almost every joint in the body involved, and most of the time the joints were swollen and painful. On examination of the upper respiratory tract I found obviously infected tonsils, with a great deal of purulent discharge from both nostrils. I removed the tonsils first with great difficulty, as she had involvement of the temporomaxillary joint and could open her mouth only about $\frac{3}{4}$ of an inch. She showed slight improvement. I next opened both antra through the inferior meatus. She improved a little from this, but the old symptoms returned, so I did an intranasal ethmoid operation, opening the sphenoids and establishing frontal drainage. Both frontals and sphenoids were very small. Improvement followed for

a time, but in about a year she seemed as bad off as ever, in spite of all the local measures.

At her own request I did a radical operation on the right side in January, 1922, and succeeded in getting this side clean. She was much better from this, but still had some pus on the left side; so she insisted on having a radical on the left side. This was done in November, 1922. Her nose has been free of pus ever since, and her joints have been free of any acute manifestations, so she is able to sit up every day and sleeps all night without pain. Of course, there has been very slight return of movement in the joints, as they had lost their function long before. With what she has gained in comfort life has become a much more tolerable thing to her.

Case II.—A woman, aged fifty years, with joint trouble for five years, involving mostly the hands, shoulders and knees. The trouble first began after an attack of influenza and a severe nervous strain. She had had bad tonsils for years, but no evidence of sinus trouble, as far as she can remember, until two years after the joint trouble started. She then began having a great deal of purulent discharge from the nose. The tonsils were taken out with no improvement in any way. I saw her two years ago and started to treat the nose. I first did a submucous and opened the antra, but got no cessation in either the nasal discharge or the arthritis in spite of constant treatment for months. I then did a complete intranasal sinus operation and seemed to get satisfactory drainage of all the cavities; but still a great deal of pus came from her nose. Vaccines were tried and seemed to do more harm than good. About six months later she was suffering so much that I was considering doing a radical operation on her. However, her drainage seemed so perfect that I thought surely the discharge would improve. I began injecting collene into the cavities and her physician began giving her a capsule containing thyroid, salol and luminol. She began to improve very fast. The discharge entirely disappeared from her nose, and coincident with that her joint symptoms have disappeared. Her general treatment has been very carefully managed by Dr. Wheelwright, and her great improvement in general health has been no doubt a greater factor in curing her sinus infection than the injections which I have practised.

Case III.—A woman, aged forty years, a stenographer, who had reached the stage where locomotion was becoming almost impossible, and her only prospects were to spend the remainder of her life in bed.

She had had her tonsils out five years before, and had improved for a time, but relapsed. Three years ago she had a Caldwell-Luc done on her right antrum, and although she improved after this for a time, she began getting steadily worse and had a considerable discharge of pus from both nostrils and from the back of the throat. When I saw her six months ago she had involvement of all the sinuses with a small cavity in the right antrum. Apparently the cavity had become partially obliterated but considerable pus came from the remaining cavity. I attempted an intranasal drainage operation on all the sinuses, but was unable to establish drainage from the right frontal into the nose; so I opened over this from the outside and took off enough bone to get a clear view of the inside. There was pus in the cavity, but the lining membrane looked as if it might recover on drainage alone, so I inserted a soft-rubber catheter from the sinus into the nose. I attached a thread of silk to the end in the sinus and brought it out through the skin, level with the eyebrow. I pulled the catheter out a little way each time I saw her and pulled it back by the thread. This worked very well. The thread never caused any infection and I kept up draining the sinus in this way for six weeks. I thought then that a drainage track would be established, but in a few weeks after I left the catheter out the track closed entirely and the frontal blew up with pain and external swelling. I was obliged to operate again and obliterate the sinus. After each operation, all of which were done under a general anesthetic, there was complete cessation of all joint symptoms. Red, painful joints looked quite normal in twenty-four hours, but in ten days all the symptoms would return. She kept on coming to the office with difficulty and having all the pus cleaned out of her nose. For a period of a few hours afterward the pain would be much better, but there were no signs of permanent recovery. I started her on an autogenous vaccine. She had quite an acute exacerbation in her sinuses after the first dose, but the arthritis almost disappeared. I have continued the vaccine and the joint symptoms are practically gone. How long they will stay away I do not know, but she has gained in weight and has gone back to work. The joints in her feet had become partially ankylosed, but they are now free from pain, and she is able to walk comfortably.

## Discussion

Dr. John E. Mackenty, New York:

There is no doubt that the failure to cure the results of focal infections in the general system is due to incomplete work on the focus. There is no field in the whole of surgery so difficult as the sinus field. There is no field in which incomplete work is more often done. These cases are highly sensitized to their own infection. The leaving of even one infected cell will keep up the infection indefinitely. I think if we had some way of absolutely curing this sinus infection we would get a different story in the end-results. I have observed in rheumatic cases that they are always greatly relieved after anesthesia. This often raises false hopes in the inexperienced. It is just so with epilepsy, which is often temporarily relieved by even the most minor surgical procedure.

# TONSILLAR PATHOLOGY IN RELATION TO SYSTEMIC INFECTION

GEORGE B. WOOD, M.D.

THE size of the faucial tonsil and the fact that it is so frequently the seat of pathological conditions demanding its removal have made it the chief lymphoid deposit of the throat for study and investigation. However we must remember that all the lymphoid tissue of the pharynx and of the gastrointestinal tract is similar in structure and probably possesses similar physiological properties, and, perhaps, to a lesser degree, similar morbid tendencies.

The faucial tonsil is separated from neighboring structures by a fibrous capsule, from which trabeculæ pass into the parenchyma of the tonsil, carrying the bloodvessels, nerves and efferent lymphatics. There are no afferent lymphatics. Between the trabeculæ is the parenchyma proper of the tonsil, consisting of the germinating follicles and the interfollicular tissue. Into the parenchyma is projected, from the free surface of the tonsil, ingrowths of epithelium which, being hollowed out by a desquamation of the central cells, form the crypts. The epithelium covering the surface of the tonsil is of the squamous, stratified type, with a distinct basement membrane, and beneath this is a definite layer of fibrous tissue. As soon as the epithelium dips inward to form the crypt the subepithelial fibrous layer disappears, and also the greater part of the basement membrane, so that the basal cells of the epithelium become intimately associated with the interfollicular tissue. The cryptal epithelium is so infiltrated with lymphoid cells that usually there are only one or two layers of intact epithelial cells separating the cryptal lumen from the parenchyma.

The histology of the tonsil presents many very interesting cytological phenomena which will reward the student or investigator for any amount of detailed study. It is not my purpose,

however, at this time to delve deeply into this side of the question, though I want to briefly discuss certain structures which are often supposed to be of pathological significance, but are found so frequently in the tonsil that considerable debate has arisen as to their true import.

The plasma cell is found in varying numbers in practically all tonsils in individuals over two or three weeks of age. David J. Davis says that they are not found in the fetus or newborn and are more numerous in hypertrophied tonsils than in supposedly normal ones. He believes that their presence probably indicates a chronic infection of the tonsillar crypts. Goodale found them abundantly in acute tonsillitis, and, oddly enough, more numerous in the parenchymatous type of the disease than in the suppurative. J. Gordon Wilson has made a very careful study of these cells and is not at all certain that a bacterial irritation is necessary for their appearance. He feels rather that they are the manifestation of some metabolic activity and that they have an important function to perform, namely, to combat certain toxic bodies, which bodies may be of katabolic origin as well as bacterial. However, it would seem probable that their presence in unusual numbers is an evidence of an unusual toxic attack, most plausibly of bacterial origin.

Eosinophile cells are occasionally found in tonsils just beneath the epithelium. According to my own observations they are apt to be very abundant in acute inflammations of the tonsil, but the significance of their presence is not known. The presence of a few scattered eosinophile cells I do not believe could be interpreted as an indication of a morbid condition.

In practically every tonsil that is examined histologically we will find polymorphonuclear cells. Their presence in any great numbers or in concentration, must be accepted as an indication of some toxic irritation due to bacteria, but if we would call every tonsil diseased in which they are found, we must then call every tonsil pathologic.

The amount of fibrous tissue in a tonsil varies considerably according to the age and also individually. While a marked fibrosis must be considered as evidence of previous inflammation, it is very difficult to know just where one should draw the line

between a physiological fibrosis and a pathological one. It must be left to the opinion of the examining pathologist. We should remember, however, that fibrosis is a scar of past trouble and not an indication of present active disease.

Cartilage and bone are frequently found in the capsule and trabeculæ, but there is considerable dispute as to their pathological significance. A number of observers, among whom are J. Forman, H. Albert and M. G. Douglas, believe that the cartilage and bone are the result of a metaplasia, and as such are evidence of a chronic inflammation. On the other hand, H. Mantchik asserts that the cartilage is the result of a defective retrogression of the primitive cartilaginous skeleton of the tonsillar region. In this view he is supported by Grosvenor, who says that the condition is not one of metaplastic change but is probably a development of the matrix of unused or displaced embryonic cells derived from the second branchial cleft. E. G. Carey also believes that the cartilage is an embryonic derivative. Imhofer says that this cartilage results from both causes, *i. e.*, it may be embryologic or it may be due to an inflammatory metaplasia. In a series of 696 tonsils reported by four different observers, these cartilaginous deposits were found 87 times. They have been found during embryonic life and may occur in tonsils which are otherwise free from inflammatory evidence. The structure is usually that of embryonic cartilage. The bony tissue which is frequently found in association with this cartilage is most plausibly the result of a physiological process of ossification.

The life-cycle of the tonsil does not correspond with the life-cycle of the invidual. The tonsil reaches its full tide of functional activity at a very early age and then tends to undergo a type of involution. At the time of the highest functional activity there is no doubt that the cryptal epithelium is in a state of growth. The basal cells are apparently penetrating deeper and deeper into the interfollicular substance and the surface cells desquamating. This desquamation of the epithelium gives rise to a type of lacunar plug which, at least in the deep terminal portions of the crypts, must be considered a normal formation, but with possibilities of pathology which we will discuss when we consider positive diseased conditions.

There have been several attempts to classify by name the chronic pathological conditions of the tonsil, some of them based on the clinical appearances only and others on the pathological examination. Except for a few well-recognized conditions, such as tuberculosis and hyperkeratosis, it is exceedingly difficult to do this because of the variety of lesions that may be found in one tonsil. The classification, originally suggested by Semon and Williams, and quoted by J. J. Moore, has been followed by a number of men, but it is not entirely satisfactory. In this there is distinguished first a chronic cryptic or lacunar tonsillitis; second, a chronic interstitial tonsillitis; and third, a chronic peritonsillitis.

Under chronic lacunar tonsillitis are placed all tonsils that show changes of the lining, size and contents of the crypts such as irregular outline of the epithelium, desquamation and keratinization of the superficial cells, dilatation of the crypts from the accumulation of desquamated epithelium and the presence in the crypts of cholesterin crystals, polymorphonuclear leukocytes, hyaline material and bacteria.

The term chronic interstitial tonsillitis includes all of the tonsils which show a pathological increase in connective tissue or the presence of cartilage and bone in the connective-tissue stroma, and the author has for some reason associated with this group the hypertrophic tonsil.

Under chronic peritonsillitis are those tonsils which show an increase in the thickness of the capsule or a deposit of fibrous tissue in the peritonsillar region as a result of a previous peritonsillar infection.

While such a terminology is of some value for the purposes of classification, it helps little in defining the condition which had been determined by the pathological examination and of rating its possible influence on the general health. The chronic interstitial tonsillitis and the chronic peritonsillitis do not represent active pathological conditions, as they are simply scars of a previous inflammation. Because the hypertrophied tonsil was supposed to later on develop an excessive amount of fibrous tissue, they have been placed in the chronic interstitial group. I do not feel that this point is well taken, because even if we admit that a hypertrophic tonsil is a diseased condition, it is the parenchyma

that is involved, and further, I have not seen any evidence to indicate that a hypertrophied tonsil will develop a greater percentage of fibrous tissue than a small tonsil. I might say here that to call a tonsil hypertrophied has to my mind little significance, except to indicate that the tonsil examined is larger than the average. Under the term of chronic lacunar tonsillitis there are included certain conditions which are undoubtedly physiological and normal, and others the presence of which is of no pathological significance.

From our present knowledge of the pathology of tonsillar infection, it would appear impossible to present a definite terminology which would adequately describe the pathological findings in a given tonsil. It would be far better if a pathologist in reporting on a tonsil condition were simply to note the conditions found without attempting classification. Happily this is what the majority of our pathologists are doing today.

In considering the various lesions which may be found in the tonsillar structures, it is evident that they must be placed in two groups:

In one group, which might be called the cryptal, the pathology is peculiar to the tonsil itself, because the anatomy of the tonsil makes possible certain conditions that can be found only where this type of anatomy exists. The crypt of the tonsil, with deep penetrations, with a peculiarly disintegrated epithelium, makes for the production of pathological conditions which, while really external to the body structure, produce an influence on both regional and distal body tissues.

In the other group, which might be called the parenchymatous, the lesions are beneath the cryptal epithelium and affect the tissues locally and distally in the same way and manner as similar lesions would in other portions of the body. There is this difference, however: The tonsil parenchyma is more easily reached by outside influence than any other subdermal structure, and this because the epithelium of the crypt does not offer as great a mechanical barrier to the penetration of toxin and its progenitor, the bacterium, as does other surface epithelium.

The contents of the tonsillar crypts vary exceedingly both in amount and character, and this variation is applicable not only

to the different crypts but also for the individual crypt at different times. While the debris found often possesses pathological potentiality, yet the keratinized cells which frequently fill the lumen of the deep terminal portions of the crypts must be regarded as a normal condition. Extensive accumulation of desquamated cells is often sufficient to cause quite a marked dilatation of the crypt. These masses closely resemble cholesteatoma and the picture is made more perfect by the finding of cholesterin crystals. This condition in a sense is pathological, but it has no influence on the health of the tonsil or of the individual until it becomes infected by bacteria from the mouth. An evidence of such infection is the presence of polymorphonuclear cells. If the contents of the crypt show large numbers of polymorphonuclear cells, and they can be seen passing through the epithelium, then I would assume that the bacteria of the crypt are elaborating toxic material which is being absorbed through the epithelium. On the other hand the mere presence in the crypt of various forms of bacteria cannot be looked upon as a pathological condition, as they are frequently found with no evidence of reaction in the tonsil. I further believe that large plugs of desquamated epithelium may undergo putrefaction in the tonsil crypt without inducing pathology, the infecting organism being saprophytic instead of pathogenic or of a pathogenesis to which that particular tonsil is immune.

Bacteria in the lumen of the tonsillar crypt can produce lesions of the tonsil, and consequently systemic reactions, either by their toxins being absorbed through the cryptal walls or by the bacteria themselves gaining entrance to the tonsil parenchyma. For instance, the early enlargement of the tonsil in acute tonsillitis is due to cell proliferation, which cell proliferation is the result of tissue reaction to the toxins absorbed from the crypt. Later on, after necrosis of the cryptal epithelium has taken place, the bacteria gain entrance and cause suppuration, which, as has been shown by Goodale, invariably starts in the germinating follicles. It is possible that, under proper conditions, certain of the pathogenic bacteria may pass in from the crypts through the normal epithelium. This has been proven by experimental research, but a careful observance of a large number of tonsils has led me

to feel that in the great majority of cases the bacteria will not pass beyond the first layer of epithelial cells as long as these cells retain their vitality.

It has been reported by several observers that the cryptal epithelium often shows complete breaks in its continuity, but I believe that the majority of the so-called breaks are artefacts, either produced during the removal of the tonsil or during the hardening, embedding and cutting of the specimen. On the other hand, small localized areas of acute inflammation, unrecognized clinically, are frequently found in the course of the regular routine tonsil study. In these small localized areas we have a counterpart of conditions found in acute tonsillitis. The crypt is filled with epithelial debris, polymorphonuclear leukocytes, fibrin and bacteria, and there is, perhaps, necrosis of the epithelial cells. When this latter takes place, we do have an open gate-way for the bacteria to enter the tonsillar structures.

The accumulation of debris in the tonsillar crypts, the foundation of the debris being desquamated epithelial cells, is due either to poor drainage of the crypt or to an excessive growth of the epithelium. It is easy to understand how the anatomical variation of the individual crypt, or the shape of the tonsil as a whole, may interfere with the drainage. It is not so easy to explain why the epithelium at times tends to desquamate and at other times is entirely free from such tendency, but that such variation of growth of the epithelium does happen there is no doubt. For instance, in acute tonsillitis we notice an increase in the penetration of the basal cells into the interfollicular tissue, and we can find under these circumstances mitotic figures showing strong evidence of growth activity. Again, in the condition called hyperkeratosis a portion of the cryptal epithelium gives rise to the formation of cornified cells, the accumulation of which produces a horny projection from the crypt mouth, which is the pathological peculiarity of this condition. It would not seem unreasonable to believe that under certain circumstances a lacunar plug is the result of some stimulation that has been imparted to the epithelium of that crypt by bacterial toxins. Arguing from this standpoint, one would be justified in regarding any great cryptal accumulation as pathological. However, I believe that unless polynuclear

cells are present, either in the surrounding epithelium or in the lumen of the crypt, the lacunar plug is not a menace to the health of the individual.

Sometimes the lumen of the crypt external to the accumulation becomes absolutely occluded, giving rise to a so-called retention cyst. If this cyst contains living pathogenic organisms, there is, of course, more chance for absorption of toxic products than if the crypt were open. In fact, we would expect, and it often does happen, that an acutely infected occluded crypt produces so much reaction that we have an extension of the suppurative process with definite abscess formation. On the other hand, these occlusion cysts often show little evidence of any inflammatory reaction, and if they have existed long enough to be placed in the category of chronic lesions are apt to be sterile, the bacteria probably having succumbed to the phagocytic action of the polymorphonuclear leukocytes.

An interesting anatomical freak is the occasional occurrence of mucous glands in the capsule of the tonsil, the ducts of which glands open into the deep end of one of the tonsillar crypts. The secretion from these glands would, of course, have a direct influence on the cryptal contents, though the condition cannot be classed as a pathological one, as I have noted certain writers do.

There are very few chronic pathological entities of the true parenchyma of the tonsils that can be recognized. Primary tuberculosis has been found to exist in about 5 per cent of all tonsils that were examined after operation. The importance of these lesions to the general health has been variously estimated by different observers. They are, of course, no more apt to lead to a general tuberculosis or a pulmonary involvement than are tuberculous glands of the neck.

Occasionally follicular abscesses are found in what are supposed to be chronic tonsillar conditions. D. J. Davis has four times seen small abscesses deep in the tonsillar tissue, near the capsule and surrounded by a dense fibrous wall. Hambrecht and Nuzum state that minute subepithelial abscesses are quite common, but I have never seen them. The reason that we do not see more evidence of chronic inflammation in the parenchyma of the tonsil is probably, in part at least, due to the lymph current that

undoubtedly exists in the interfollicular tissues, preventing the stagnation of any toxic material. Toxins which have entered the parenchyma from the crypts are either absorbed by the venous capillaries or else removed by way of the efferent lymphatics. It is very important that we realize the possibility of soluble toxins being absorbed from the tonsil directly into the blood-stream. If this takes place, and I am convinced it does, there can be a systemic effect without a preliminary involvement of the lymph nodes. The very great general intoxication which occurs so early in an attack of tonsillitis can only be explained by this assumption. Bacteria, on the other hand, are probably removed entirely by way of the lymph vessels, though a few very unusual organisms, such as the anthrax bacilli, do penetrate the bloodvessel walls. The fact that they are seldom found in the interfollicular tissues and that the abscesses found in acute tonsillitis always originate in the follicles is evidence that bacteria do not accumulate or stagnate in the interfollicular tissues, at least for a sufficient length of time to produce necrotic changes. In my studies with the anthrax bacillus the organisms were found surrounding the follicles and filling the efferent lymphatics of the trabecula, but seldom in the interfollicular tissue.

It is very probable that a certain type of enlargement of the tonsil is due to proliferation of lymphoid elements, which proliferation may be the result of reaction to toxins absorbed from the crypt. How far this proliferation is responsible for chronically enlarged tonsils is problematical. While there is no doubt that some tonsils are normally larger than others, a distinct depreciation in the size of the tonsil can frequently be brought about by treatment directed toward the crypts. The shrinkage following such treatment, however, is always limited.

The frequency of occurrence of distinct pathological lesions in the tonsil is a most difficult question to answer with accuracy. Hambrecht and Nuzum made a careful study of the tonsils from 218 patients and claimed to have found definite pathological changes in 93 per cent. They used the classification of Moore and found chronic lacunar tonsillitis in 42 per cent; chronic interstitial tonsillitis in 21 per cent; chronic peritonsillitis in 6 per cent; abscesses (their location not being mentioned) in 10 per cent;

lymphatic hyperplasia in 14 per cent; mucous glands in the capsule, 7 per cent; and cartilage in the capsule, 3 per cent. It is evident that a large number of these cases were not pathological in the sense that the condition found was a menace to the individual, such as mucous glands and cartilage in the capsule or of a hyperplasia of the connective tissue. Further, we must remember that the tonsils so examined were from individuals who had supposedly presented clinical symptoms sufficient to warrant tonsillectomy.

In closing, I would like to call attention to a peculiarity of the tonsil that has frequently impressed itself upon me, and this is its tendency to rapid repair and its comparatively high degree of resistance against morbid processes. In experimental work with tuberculosis I noticed that the disease progressed much more rapidly in the lymph nodes of the neck than it did in the tonsillar structures. Also, a characteristic feature of primary tuberculosis of the tonsil is the absence of caseation. In acute tonsillitis the rapidity with which a tonsil riddled with suppurative foci becomes normal in size and color when immunity has once been established is rather remarkable. That it is able to withstand the almost constant insults that are heaped upon it by the flora of the crypts is further evidence of its disease-resisting ability.

Yet we must remember that because of the deep cryptal pockets and the peculiarity of its epithelium the tonsil does present, under some circumstances, a comparatively open gate-way for infection to reach the interior of the body.

## Bibliography

1. Goodale, J. L.: Pathology of Acute Tonsillitis, Jour. Boston Soc. Med. Sci., January, 1899.

2. Babbitt, James A.: Pathology of the Faucial Tonsil, Trans. Am. Laryngol., Rhinol. and Otol. Soc., 1907, p. 189.

3. Davis, D. J.: Bacteriology and Pathology of the Tonsils, with Especial Reference, etc., 1912, x, 148.

4. Grosvenor, L. N.: The Tonsil: Some Pathologic Reasons for Their Removal, Journal-Lancet, 1913, xxxiii, 653.

5. Imhofer: Zur Pathologic der Gaumen Mandeln, Präg. med. Wchnschr., 1913, xxxviii, 411.

6. Hett, S.: The Anatomy and Comparative Anatomy of the Palatine Tonsil, etc., British Med. Jour., 1913, ii, 743.

7. Shambaugh, G. E.: Tonsil and General Infection, Trans. Am. Laryngol., Rhinol. and Otol. Soc., 1914, p. 307.

8. Leopold, R. S.: The Faucial Tonsils; Pathology and Bacteriology, Jour. Ophthol., Otol. and Laryngol., 1915, xxii, 575.

9. Carmody, T. E.: Histopathology of the Faucial Tonsil, Laryngoscope, 1915, xxv, 272.

10. Carey, E. G.: Cartilaginous and Bony Nodules in the Tonsils, Proc. New York Path. Soc., 1916, xvi, 173.

11. Albert, H., and Douglas, Minnie G.: Ann. Otol., Rhinol. and Laryngol., 1917, xxvi, 909.

12. Moore, J. J.: Chronic Tonsil Infections, Jour. Lab. and Clin. Med., 1917–1918, iii, 283.

13. Mink, P. J.: The Pathology and Therapy of the Tonsils in the Light of Their Physiologic Function, Laryngoscope, 1918, xxviii, 437.

14. Forman, J.: The Occurrence of Nodules of Cartilage in the Tonsil, Ann. Otol., Rhinol. and Laryngol., 1918, xxvii, 137.

15. Tunnicliff, Ruth: The Microscopic Appearance in Ulceromembranous Tonsillitis, Jour. Infect. Dis., 1919, xxv, 132.

16. Turley, L.: Relation of the Bacteriology to the Pathology of the Tonsils, etc., and to Symptomatology, Ann. Med., 1920, i, 41.

17. Shambaugh, G. E.: The Tonsils as Foci of Systemic Infection, Illinois Med. Jour., 1921, xxix, 531.

18. Keiper, G. F.: The Tonsil Question up to Date, Laryngoscope, 1921, xxxi, 777.

19. Gill and Graves: Tonsil from a Clinical and Pathologic Standpoint, South. Med. Jour., 1921, xiv, 498.

20. Anderson, Mann and Sharpe: Chronic Tonsillar Infections, Canadian Med. and Surg. Jour., 1921, xlix, 8.

21. Hambrecht and Nuzum: A Correlated Study of the Indications for Tonsillectomy and of the Pathology and Bacteriology of the Excised Tonsils Arch. Int. Med., 1922, xxix, 635.

# CHRONIC INFECTIONS OF THE UPPER RESPIRATORY TRACT AND THEIR RELATION TO GENERAL DISEASE

FRANCIS P. EMERSON, M.D.

In discussing the relation of focal infections to general diseases, it is my purpose to try and point out in what way we determine that such a relationship exists, how it acts and what means are necessary to cure or arrest its progress. In other words, to endeavor to establish general principles applicable to an increasing number of general systemic manifestations, rather than enumerate a list of diseases that may be benefited or otherwise by removal of the original focus depending on the pathology or tissue changes that exist at the time of the surgical intervention.

Dr. William J. Mayo, in a recent article on the significance of lymphatic involvement in infections, quotes a clinician of great experience as saying that if he could choose between an infection disseminated through the blood-stream and one spread by way of the lymphatics he would choose the former, giving as a reason that when a noxious agent enters the blood the whole force of the organism acts on it quickly, with the reasonable chance that it will be carried to some portions of the body with sufficient resistance to develop immunity; whereas, if it enters the lymphatics and is not overcome in the lymph nodes the toxic agent may be permitted to enter the blood more or less continually and will perhaps eventually lead to an incurable infection. He further quotes Cohnheim's original observation that the source of a given infection can be located.

To the rhinologist dealing particularly with chronic infections of the upper respiratory tract these observations are significant. They form, in fact, the basic principle which, in a given case, leads us to decide between radical surgery and palliative measures, topical applications or drainage and ventilation, the shrinkage of tissue or the removal of all infected areas that cannot be restored

to a normal function. In other words, it is a question of hyperplasia or secondary infection.

So long as we have hyperplasia alone in the mucous membrane or connective tissue, whether of the sinuses or nasopharynx, removal of redundant tissue, drainage and topical applications are indicated; but when a secondary infection has produced changes in the deeper structures, notably the connective tissue and periosteum, by long-continued suppuration, so that a return to the normal is not probable, then anything less than radical removal converts a chronic process into a latent one or leaves tissue of such low vitality that reinfection is sure to occur.

If the exacerbation or reinfection were a local phenomenon unattended by general systemic poisoning through the lymphatics it would not be a serious matter. Many observers believe, however, that such chronic foci for which the patient has lost all immunity are among the most serious problems with which we have to deal in their immediate and remote effects. In other words, that such foci, having become chronic in the lymphoid tissue and having once overcome the local barrier, rarely clear up but are subject to acute exacerbations throughout life, and whether the patient dies from a kidney, heart or some other secondary lesion, that it is the chronic toxemia which is primarily accountable for death.

Whether this acts by lowering the resistance of the host, by causing hyperplasia, followed in later life by degenerative changes or by direct toxemia, is an unimportant distinction. Whether the effect on the individual be to lower his vitality or to cause chronic invalidism depends on the virulence of the infecting organism and the resistance of the host. The frequency of the lymphatic invasion may be influenced by out-of-door life, rest and careful medical supervision, but when the lymph nodes cease to offer a barrier to the toxin of a chronic focus, lowered resistance from overwork or any other cause is one of the most potent causes of an acute manifestation.

Heredity may endow the individual with more resistance to a given infection, but the protection is only comparative and not absolute. Raymond Pearl, in his Lowell Institute Lectures for 1920, says that longevity is affected by the rate of metabolism

as influenced by temperature. Many of the chronic cases of focal infection who complain of tiring easily, who lack initiative and never feel at their best, even though there may not be acute exacerbations or marked remote tissue changes, carry an afternoon temperature of 99° to 99½° for months or years. Some are diagnosed as latent tuberculosis. Many have enlarged mediastinal glands or fibroid changes in the lungs as well as enlarged cervical glands. Myositis can frequently be diagnosed by palpation. In other words, there is a general lowered resistance, and functional as well as organic manifestations are common. This is not confined to any one class, but rich and poor are both victims. Following a fresh lymphatic invasion without any local phenomena there may develop a serious myocardial weakness, a pyelitis, cholecystitis, appendicitis, etc. Wherever there is any lymphatic connection the toxic invasion may manifest itself. In adults it is one of the most serious problems. Much has been done in dealing with similar conditions in childhood and adolescence, but the condition is as common and as serious in adults. During the last four years the writer has operated more cases between forty and sixty for chronic infections than at any other age, and no work has been more satisfactory. All being chronic cases of years' standing, there is a definite relation between the operative interference and the result.

Diagnosis. If we assume a focal infection in the lymphoid tissue, how do we determine whether it is a local process or that it has a direct relation to some general systemic disease? For instance, visual examination cannot tell us whether a tonsil should be removed or not, even if pus be present. The pyogenic focus may be walled off or it may menace the life of the individual by causing remote tissue changes either as an acute or chronic general systemic toxemia.

To make a diagnosis three things are essential, the macroscopical changes in the lymphoid tissue itself or the presence or absence of pus being the least important: First of all is a careful history of the patient, dating back to childhood. Second is the enlargement of the tonsillar gland under the angle of the jaw, which becomes tender to palpation at the time of the acute exacerbation. Third is the presence of a probable local cause.

| Case. | No. | Age. | Referred for | Diagnosis. | Operation. | Result. local. | Result, general. |
|---|---|---|---|---|---|---|---|
| F. R. | 1 | 35 | Asthma | Rt. pansinusitis of dental origin | Rt. modified Killian; rt. radical antrum; extraction of 3 teeth | No symptoms | No asthma. |
| H. T. | 2 | 22 | Asthma | Chronic empyema of both max. sinuses; chronic tonsillitis | Double radical antrum; tonsillectomy | No symptoms | No asthma. |
| A. W. | 3 | 52 | Asthma; deafness | Empyema of left max. sinus with secondary atrophy; deviated septum; chronic tonsillitis; infected teeth | Left radical antrum; submucous resection; tonsillectomy; extraction of teeth | No symptoms | No asthma. |
| F. T. | 4 | 64 | Asthma; vertigo | Empyema of right max. sinus; deviated septum | Right radical antrum; submucous resection | No symptoms | No symptoms, except with colds possibly once a year. |
| I. P. | 5 | ? | Asthma | Double ethmoiditis, with polypoid degeneration; chronic tonsillitis | Double ethmoid exenteration; tonsillectomy | No symptoms | No asthma. |
| M. H. | 6 | 35 | Asthma | Chronic empyema of right max. sinus; chronic tonsillitis | Right radical antrum; tonsillectomy | No symptoms | No asthma since January. |
| E. D. | 7 | 15 | Asthma; bronchitis | Empyema of left max. sinus | Left radical antrum | No symptoms | No symptoms. |
| F. C. | 8 | 56 | Myositis; hair-follicle infections | Empyema of right max. sinus; chronic tonsillitis; abscessed tooth | Rt. radical antrum; tooth extracted; tonsillectomy | Slight mucous discharge in A.M. | No symptoms. |
| R. N. | 9 | 43 | Myositis; gastric ulcer; frequent colds | Empyema of right max. sinus; several abscessed teeth | Right radical antrum; infected teeth extracted | No discharge | No symptoms. |
| W. C. | 10 | 56 | History of rheumatic fever; postnasal discharge | Empyema of left max. sinus secondary to abscessed tooth | Left radical antrum; extraction of infected tooth | No discharge | No symptoms. |
| F. C. | 11 | ? | Arthritis (helpless for seven years) | Empyema of right max. sinus; many infected teeth | Right radical antrum; extraction of infected teeth | No discharge | Not relieved. |
| A. S. | 12 | 30 | Myositis for fourteen years; endocarditis, postnasal discharge | Empyema of left max. sinus; deviated septum; chronic tonsillitis; several abscessed teeth | Left radical antrum; neg.; tonsillectomy; extraction of infected teeth | No symptoms | No symptoms. |

| | | | | | | | |
|---|---|---|---|---|---|---|---|
| F. C. | 13 | 52 | Chronic frontal sinusitis — 3 previous ops.; myositis; pressure symptoms | Pansinusitis; incapacitated | Left modified Killian; left radical antrum | Free from symptoms on left side | Improved—to have the other side done. |
| A. N. | 14 | 57 | Myositis; deafness; postnasal discharge | Chronic empyema of right max. sinus; deviated septum; double ethmoiditis; several abscessed teeth | Right radical antrum; submucous resection; extraction of infected teeth; double ethmoid exenteration | Could not be cleared up at one sitting and never had second op. | Improved—but subject to acute exacerbations. |
| E. G. | 15 | 64 | Neuritis; myositis | Empyema of right max. sinus; chronic cryptic tonsillar disease | Right radical antrum; tonsillectomy | No symptoms | No symptoms. |
| J. R. | 16 | 65 | Occipital headaches; myositis; physical condition bad | Empyema of left max. sinus; left ethmoiditis; diseased tooth | Left radical antrum; extraction of a diseased tooth; left ethmoid exenteration | No symptoms | No symptoms. |
| J. J. | 17 | 69 | Myositis; obstructed breathing | Empyema of both max. sinuses; hyperplastic ethmoiditis; chronic tonsillitis | Double radical antrum; double ethmoid exenteration; tonsillectomy | Mild tracheitis | No symptoms. |
| F. C. | 18 | 50 | Myositis; headaches; postnasal discharge | Chronic empyema of left max. sinus; chronic tonsillitis; many diseased teeth | Left radical antrum op.; extraction of diseased teeth; tonsillectomy | Slight mucoid discharge at times | No symptoms. |
| R. M. | 19 | 24 | Myositis; repeated erysipelas | Double suppurative ethmoiditis; chronic empyema of left max. sinus; cryptic tonsilar disease | Double radical antrum; tonsillectomy | ..... | Chronic erysipelas not relieved |
| M. C. | 20 | 47 | Arthritis—27 years; hayfever | Deviated septum; chronic tonsillitis | Submucous resection; tonsillectomy | No symptoms | No symptoms. |
| J. S. | 21 | 27 | Arthritis | Deviated septum; chronic tonsillitis; infected teeth | Submucous resection; tonsillectomy; extr. teeth | No symptoms | No symptoms. |
| G. W. | 22 | 65 | Myositis; enteritis | Infected teeth, 8; chronic tonsillitis | Extraction of diseased teeth; tonsillectomy | No symptoms | No symptoms. |
| W. B. | 23 | 56 | Rheumatic fever as youth; myositis; cardial murmur | Infected teeth; chronic tonsillitis | Extraction of diseased teeth; tonsillectomy | No symptoms | No symptoms. |
| D. T. | 24 | 32 | Myositis; postnasal discharge | Empyema of right max. sinus; ethmoiditis; deviated septum; chronic tonsillitis | Right radical antrum (reoperated later); submucous resection; right ethmoid exenteration | Has had several reinfections | No symptoms. |

| Case. | No. | Age. | Referred for | Diagnosis. | Operation. | Result, local. | Result, general. |
|---|---|---|---|---|---|---|---|
| A. L. | 25 | 63 | Chronic arthritis—10 years | Infected teeth; chronic tonsillitis | Extraction of teeth; tonsillectomy | No symptoms | Much improved. |
| J. W. | 26 | 51 | Myositis; deafness | Empyema of both max. sinuses; double suppurative ethmoiditis | Double radical antrum; double ethmoid exenteration | Slight mucous discharge with colds | No symptoms. |
| C. W. | 27 | 24 | Deafness with intermittent discharge | Chronic empyema of right max. sinus; chronic tonsillitis; chronic sclerosed right mastoid | Right radical antrum op.; removal of granulations of right ear; tonsillectomy | ..... | No reply. |
| E. A. | 28 | 64 | Deafness | Chronic empyema of left max. sinus; chronic tonsillitis | Left radical antrum op.; tonsillectomy | No symptoms | No symptoms. |
| G. D. | 29 | 50 | Deafness (A. S.); bronchitis | Chronic empyema of both max. sinuses; chronic tonsillitis; many infected teeth | Double radical antrum op; tonsillectomy; extraction of infected teeth | No symptoms | No symptoms. |
| R. D. | 30 | 53 | Deafness; postnasal discharge | Chronic empyema of both max. sinuses | Double radical antrum op. | No symptoms | No symptoms. |
| W. M. | 31 | 46 | Deafness | Chronic empyema of left max. sinus; chronic tonsillitis | Left radical antrum op.; removal of posterior end of lower turbinate; tonsillectomy | No symptoms | No symptoms. |
| R. R. | 32 | 30 | Deafness | Chronic empyema of both max. sinuses; chronic tonsillitis | Double radical antrum op.; tonsillectomy | Occasional reinfections | No symptoms. |
| C. B. | 33 | 30 | Deafness; frontal headaches | Empyema of both max. sinuses; many diseased teeth; chronic tonsillitis | Double radical antrum; tonsillectomy; extraction of diseased teeth | | |
| M. C. | 34 | 35 | Headaches since childhood | Chronic empyema of right max. sinus; right ethmoiditis | Right radical antrum op.; exenteration of right ethmoid cells | Occasional reinfections | No symptoms. |
| A. R. | 35 | 48 | Headaches since 14 years of age | Empyema of left max. sinus; left ethmoiditis; chronic tonsillitis; many infected teeth | Left radical antrum op.; tonsillectomy; extraction infected teeth; removal of ant. end of left middle turbinate | ..... | Not relieved from the headaches; still has infection in the ant. ethmoid. |
| G. C. | 36 | 37 | Persistent headaches | Empyema of right max. sinus; several infected teeth; ethmoiditis | Right radical antrum op.; extraction of teeth; ethmoid exenteration; mod. Killian | No symptoms | Headaches not relieved until Killian op. was done. |

| | | | | | | | |
|---|---|---|---|---|---|---|---|
| W. W. | 37 | 42 | Frontal headaches | Empyema of left max. sinus; left ethmoiditis | Left radical antrum op.; left ethmoid exenteration | Discharge; pain persisted | Double modified Killian later; no symptoms. |
| J. C. | 38 | 30 | Parietal headaches; otalgia | Empyema of left max. sinus | Left radical antrum op. | Scanty mucoid discharge | No symptoms. |
| A. C. | 39 | 37 | Frontal headaches; postnasal discharge | Empyema of right max. sinus | Right radical antrum op.; 1913; reoperated 1921 | Purulent discharge | Fair. |
| R. MP. | 40 | 26 | Vertex-occipital and supraorbital headaches | Empyema of right max. sinus (dental origin); infected teeth; chronic tonsillitis | Right radical antrum op.; extraction of all upper teeth; tonsillectomy | Mucous disch. with colds | No symptoms. |
| B. G. | 41 | 39 | Left frontal headaches; pain in left antrum with colds | Empyema of left max. sinus; double ethmoiditis | Left radical antrum op.; double ethmoid exenteration | Occasional reinfections | No symptoms. |
| H. T. | 42 | 29 | Headaches; postnasal discharge | Empyema of right max. sinus (dental origin) | Right radical antrum op. | No symptoms | No symptoms. |
| G. C. | 43 | ? | Left frontal headaches; pain in left ant. | Empyema of left max. sinus (dental origin); left suppur. ethmoiditis | Left radical antrum op.; left ethmoid exenteration | No symptoms | No symptoms. |
| C. J. | 44 | 23 | Pyelitis | Empyema of left max. sinus; polypoid degen. of left ethmoid; chronic tonsillitis | Left radical antrum op.; ethmoid exenteration; tonsillectomy; root amputation | No symptoms | No symptoms. |
| M. S. | 45 | 35 | Pyelitis; postnasal discharge | Chronic empyema of both max. sinuses | Double radical antrum op. | No symptoms | No symptoms. |
| C. W. | 46 | 36 | Gastric ulcer | Deviated septum; chronic tonsillitis; one infected tooth; ? max. sinus inf. | Submucous resection; T. and A; sinuses negative | ..... | No symptoms for one year. |
| W. H. | 47 | 22 | Frequent colds with frontal headaches; mentality of 14-yr. child | Depressed nasal fracture; chronic tonsillitis; right max. sinus empyema | S. M. R.; tonsillectomy; right max. sinus washed out | No symptoms | No symptoms; gained 21 lbs.; 90 per cent stable mentality. |
| M. P. | 48 | 64 | Right nasal obst.; gen. debility | Empyema of right max. sinus; double ethmoiditis; chronic foll. tonsillitis; many infected teeth | Right radical antrum op.; right ethmoid exenteration; extraction of teeth | Complete blocking up of nose one year later with polypi | Complete relief following second operation. |
| D. S. | 49 | 32 | Postnasal discharge | Empyema of left max. sinus (dental origin) | Right radical antrum op.; extraction of tooth | No symptoms | No symptoms. |
| H. B. | 50 | 26 | Acute exacerbation of chr. left antrum | Empyema of left max. sinus; deviated septum | Left radical antrum op.; S. M. R. | No symptoms | No symptoms. |

| Case. | No. | Age. | Referred for | Diagnosis. | Operation. | Result, local. | Result, general. |
|---|---|---|---|---|---|---|---|
| B. C. | 51 | 56 | Endocarditis | Chronic empyema of right max. sinus; ethmoiditis; chronic tonsillitis | Right radical antrum op.; ethmoid exenteration; tonsillectomy | No symptoms | No symptoms. |
| E. T. | 52 | 51 | Bronchitis; vertigo | Empyema of left max. sinus (dental origin); chronic tonsillitis | Left radical antrum op.; extraction of diseased teeth; T. and A. | Mucous disch. at times | No symptoms. |
| F. H. | 53 | 48 | Tuberculosis (arrested); acute exacerbation of right ant. | Empyema of right max. sinus; right ethmoiditis; chronic tonsillitis | Right radical antrum op.; ethmoid exenteration; T. and A. (tuberculosis found in right) | Slight mucoid discharge | Improved gen. condition. |
| R. N. | 54 | 35 | Hoarseness; discharge a. d. | Chronic empyema of right max. sinus; pharyngitis sicca; deviated septum; ethmoiditis; sphenoiditis | Right radical antrum op.; S. M. R.; left ethmoid, sphenoid exenteration | Pharynx functionally well | No symptoms. |
| J. A. | 55 | 38 | Vertigo; tinnitis | Chronic empyema of right max. sinus, with secondary atrophy; ethmoiditis; infectious eighth nerve deafness | Right radical antrum op. | No symptoms | Slight vertigo. |
| J. J. | 56 | 20 | Odor; crusting in nose | Ozena with secondary atrophy; empyema of right max. sinus | Right radical antrum op. | No symptoms | No symptoms. |
| G. C. | 57 | 23 | Crusting in nose | Ozena with secondary atrophy; pansinusitis; chronic tonsillitis; deviated septum | Right radical antrum op. (twice): T. and A.; S. M. R.; right mod. Killian op. performed twice act. incomplete drainage | ..... | No relief. |
| V. M. | 58 | 65 | Severe colds; loss of smell and taste | Chronic empyema of left max. sinus; ethmoiditis | Left radical antrum op.; left ethmoid exenteration | Pus and crusting; pain in frontal region; mod. Killian should have been done | |
| T. B. | 59 | 33 | Chronic rhinitis | Left ethmoiditis; empyema of left max. sinus | Exploration 1; antrum rad.; postethmoid cells opened; ant. face sphenoid removed | No relief until mod. Killian was done | No symptoms. |
| H. G. | 60 | 44 | Sudden choking spells | Chronic empyema of left max. sinus; chronic tonsillitis; deviated septum | Left radical antrum reoperated; S. M. R.; tonsillectomy | No symptoms | No symptoms. |

ETIOLOGY. Whether the focus be primarily in the faucial tonsil, sinuses, teeth or some other tissue, its invasion is through the lymphatics after the lymph nodes have ceased to protect the individual from the toxin resulting from the acute or the exacerbation of the chronic infection whose presence can be diagnosed as outlined. In the experience of the writer, the lymphoid tissue is usually first infected, invasion of the other tissues or cavities following hyperplasia as a secondary infection. If the cavities are primarily involved, such an infection is prone to clear up unless hyperplasia has interfered with drainage. The invasion of the lymphoid tissue usually follows measles, scarlet fever, diphtheria or grippe, the frequency being in the order named. Follicular tonsillitis is a common cause, especially in childhood. In adults the teeth must always be considered. Buccal infections, sinusitis, chronic mastoiditis, etc., occur as secondary infections, causing acute exacerbations of the lymphoid focus whenever drainage is impaired or the resistance of the host becomes lowered. Infections of large masses of lymphoid tissue always involve the adjacent lymph follicles and mucous membrane, the extent of the area depending on the virulence of the infecting organism, and is manifest either as hyperplasia or as secondary pyogenic foci. Whether the blood-stream is invaded at the same time depends on the integrity of the lymph nodes. The invasion of the sinuses is the result of a secondary infection. In the frontal sinus there may be not only a previous hyperplasia in the middle fossa obstructing drainage, but anatomical variations like an orbital prolongation of the ethmoid that predispose it to chronic infection. The relation of the antrum to the teeth will be ably covered by Dr. Thoma.

In an analysis of the preceding cases of chronic infections of the upper respiratory tract, a tabulated list is appended showing the complaint for which the patient was referred—the diagnosis, operation and the local and general results. While there were 64 cases of chronic sinusitis, most of them also had teeth extracted, tonsils removed, ethmoids exenterated or all of these procedures at once. The routine consisted in having the operating dentist present, and following the extraction of infected teeth and the removal of carious bone in the mandible the other sources of infection were dealt with surgically.

The amount of work done at one sitting was limited only by time, on the principle that it is safer to remove all the infection, as far as possible, than to remove part and activate the rest. This applies particularly to the lymphoid tissue, for experience teaches that any sinus operation is apt to be followed by follicular tonsillitis unless the tonsils have first been removed. While many adult cases had an antrum and ethmoid operation with removal of tonsils or a double radical antrum and removal of tonsils without any serious consequences, yet this should never be recommended unless it can be done within a well-defined time limit. Where a radical antrum operation is referred to, it means an opening 2 x 2½ cm. through the canine fossa with removal of the lining membrane and of the antronasal wall to the floor of the nose, leaving the inferior turbinate intact.

Perhaps the surgical treatment of no chronic infection of the upper respiratory tract admits of so much difference of opinion as that of the maxillary sinus. From the viewpoint of systemic infection the same surgical principle holds good here, as previously pointed out. If there has been a long-continued secondary pyogenic infection of the sinus, whether it has been followed by atrophy or not, a radical operation through the canine fossa is indicated with thorough removal of all the lining membrane. If atrophy has not taken place the *x*-ray will show thickening of the periosteum showing that the deeper structures are chronically involved. If secondary atrophy has been followed by polypoid degeneration a window resection of the antronasal wall without removal of the lining membrane will only convert a chronic process into a latent one. Any exacerbation of this latent process may be followed by serious systemic consequences. In two of the writer's cases such an exacerbation was followed by albumin and blood cells in the urine in cases of twenty years' duration. Because there are so many cases where atrophy has taken place, the *x*-ray is of less help here than in any other chronic sinus infection unless it be the sphenoid. Many chronic antra are overlooked because of the abscence of pus where polypoid degeneration has taken place. Such antra, however, can keep up a lateral pharyngitis, infect the Eustachian tube or cause vasomotor symptoms such as chronic asthma.

When an ethmoid exenteration is referred to it means by the Mosher method.

A radical frontal sinus operation was done by the Mosher modified Killian method without obliteration in all cases showing an ethmoid prolongation. All the cases reported showed such an anatomical development and all intranasal methods had proved failures. One case of pansinusitis on the right side had atrophy and crusting in the upper vestibule of the nose before operation, and still has it. Another case that should have had a Killian operation could not be reoperated and is not cured. One case of double antra with a pure culture of staphylococcus still has discharge. Two Killian operations healed so completely as to interfere with drainage and are not free from symptoms.

RESULTS. *Sinuses.* The appended list tells its own story. The old saying, "Once a sinus, always a sinus," has not proved true. All were old cases of many years' standing and some had had two or three previous operations. In several there was atrophy and crusting. These were operated on the assumption that all such cases are due to infection and insufficient drainage and never to too much space or any other cause. All failures, in the opinion of the writer, could be attributed to so-called conservative methods and lack of thorough exenteration. These conclusions are not in accord with accepted belief but seem warranted by results. Cases of ethmoid exenteration with polypoid degeneration were watched at intervals after operation until the lining membrane became healthy. A follow-up treatment was also carried out with the antrum and frontal sinus cases until the infection was cleared up. All operated sinuses are subject to reinfection, but after the first year the resistance of the tissues has increased so that with improved drainage they should readily respond to treatment.

*General Diseases.* It is difficult to draw exact conclusions in regard to general systemic disease, as so much depends on selecting cases before secondary foci have taken place that would keep up the remote manifestations.

*Myositis.* These cases did uniformly well. This group included 17 cases.

*Asthma.* Those cases in which there was an anaphylactic reaction to some definite organism, and in which there was definite pathology, did well. This group comprised 7 cases. All are free from symptoms, 1 for four years, 1 for two years, 3 for one year and 1 since January. Two had atrophic changes in the antrum and the asthma symptoms had existed for years. As a rule, patients are not free from symptoms following operative interference for approximately six months.

*Pyelitis.* Two cases followed the acute exacerbation of chronic antra of twenty years' duration. One clearing up without immediate operation and one following operation.

*Arthritis.* Here the result must depend on whether there are secondary foci. One case, in a patient aged sixty-seven years, where the carpal and metacarpal joints were so deformed that she could not hold a plate securely, cleared up so that she has worked hard for three years and the swelling of the joints is hardly noticeable. There were too few cases in this group to draw any conclusions.

*Bronchitis.* The writer has under treatment now a patient, aged seventy-three years, who has been subject to bronchitis all his life. He definitely feels a soreness in the right throat before each attack. The next day there is roughness of the throat and the following day a bronchitis. Last year he had broncho-pneumonia and this year a bronchitis. There are only two or three follicles on that side containing cheesy material.

A doctor's wife had a similar experience each time, added to fibroid changes in the base of the right lung confirmed by an internist and by *x*-ray. She lost ground steadily for ten years and when aged sixty-four years the tonsils were removed and several teeth with apical abscesses. There has been no further trouble for the last five years. Many similar cases could be cited.

It is obvious, if we admit a blood-stream infection by way of the lymphatics, where the lymph nodes fail to act as a barrier and the patient is subject to acute exacerbations without any immunity, that the situation is very serious. The lymphatic connection exposes any organ to repeated infection and the site of the clinical manifestations seems to depend on some particular strain of bacteria that acts and reacts on that tissue indefinitely.

Whether this causes hyperplastic changes or secondary foci the retrograde changes in later life are of serious import to the patient. Secondary anemia always exists and the normal resistance is lowered for combating the acute invasion of any disease.

CONCLUSIONS. 1. In determining the relation of a focal pyogenic infection to a general disease three things are necessary:

(*a*) A detailed history dating from childhood is the most important.

(*b*) The enlargement or enlargement and tenderness of the sentinal gland during the acute phase.

(*c*) Local conditions showing a probable cause.

2. Partial or incomplete removal of a chronic focus is inadequate from the viewpoint of systemic infection.

3. In those cases showing bone infection in the mandible it is necessary to know that this has been removed surgically and completely.

4. If the whole surgical procedure is not carried out at one sitting the lymphoid infection should be removed first.

5. The writer has not found any way of removing lymphoid infection except by surgery.

6. Adult cases of focal infection showing a blood-stream invasion are among the most serious with which we have to deal and should be examined as carefully as we examine for any general disease.

# THE EFFECT OF DENTAL INFECTION ON THE REST OF THE BODY

KURT H. THOMA, D.M.D.

WHEN discussing the subject of the relation of dental infection to the rest of the body before men whose work is just as highly specialized as that of the dentist, it is but natural that I should start by pointing out the close relation between your profession and mine. Not only are infections in the nose and throat and in the teeth and jaws equally prominent as a cause for focal infection, but there is also so intimate a connection between the two specialties that for diagnostic and operative procedures a close cooperation is required. To support this statement, it is only necessary to remind you of the spreading of infection from the teeth to the throat by continuity, the formation of retropharyngeal abscesses from infected, partly erupted third molars, the vicious circle of narrow arches and adenoids.

The dental factor in maxillary sinus disease, however, is a topic which I should like to discuss more in detail.

THE RELATION OF DENTAL DISEASE TO DISEASE OF THE MAXILLARY SINUS. It is a well-known fact that careless instrumentation in connection with dental operations is quite frequently the cause of acute maxillary sinusitis.

The symptoms of this condition are well marked and the disease therefore seldom escapes notice. It is different, however, with the chronic infection, and I believe that the dentist in general practice does not always realize that the patient with chronic infections on the upper bicuspids and molars may also have a diseased maxillary sinus.

The dental cause, however, is not always evident, not even if a roentgen examination of the teeth is made. The offending tooth may have been previously extracted without detecting

sinus disease or because the sinus may have become infected during a dental operation. It should be remembered, when reading a roentgen picture of the teeth, that a small shadow around the root does not necessarily mean that the dental condition is negligible, because in cases where the roots are protruding into the maxillary sinus there is not enough bone to allow the formation of a large abscess cavity. These cases, with little indication of bone destruction, are more liable to cause sinus infection than those with an extensive abscess cavity well removed from the sinus. This is illustrated in the following case, which happened in my own mouth:

Some years ago the pulp of the right upper bicuspid had to be removed because it was accidentally exposed when preparing the tooth for filling. There was no infection at that time and the tooth was treated and the root canal filled by the best known method. About two years ago I had a roentgen picture taken which showed a very slight infection around the apex of this tooth. I again had the tooth treated experimentally by the various modern methods and then filled under strict asepsis. Some time later a bridge was attached to it which was perfectly comfortable and useful. Many months after that the bicuspid started to become slightly tender, and one morning I felt a fulness and throbbing sensation in the region of the maxillary sinus and a small amount of discharge of a gelatinous substance from the right nostril. I had a roentgen picture taken at once and the sinus transilluminated; both showed that it was abnormally dense. The tooth was extracted at once and a probe passed into the alveolar socket, which showed, however, that there was no opening into the antrum. No further treatment was resorted to, the symptoms disappeared and a roentgen picture taken seven weeks afterward showed no signs of infection. Another picture, taken a year later, also shows the maxillary sinus normal.

This teaches us that it is not necessary for the dental infection to have direct communication with the sinus. The infection may spread through the Haversian canals.

*Dental Cysts Invading the Maxillary Sinus.* Other forms of dental disease affecting the maxillary sinus are the dentigerous and peridental cysts.

The dentigerous cyst is formed by the abnormal development

of a tooth germ and generally contains an unerupted cuspid, bicuspid or molar. Such a case is illustrated in the next slide.

The peridental cyst is of infectious origin and develops from a chronic abscess or granuloma at the root end of a tooth. When occurring on the posterior teeth of the upper jaw it is often encroaching on the maxillary sinus, sometimes filling the entire cavity. These dental cysts should be distinguished from cysts of nasal origin. The dental cyst is usually formed from the floor of the sinus while the nasal cyst may be formed from other walls.

*Treatment of the Dental Condition in Maxillary Sinus Disease.* In the treatment of maxillary sinus disease of dental origin it is my firm belief that it is to the best interest of the patient to have the rhinologist and dental surgeon cooperate. The diseased teeth, infectious granulations in the floor of the antrum or infected bone should be removed. In cases of radical operation of the maxillary sinus the dental surgeon should operate at the same time with the rhinologist, and I believe that after the dental cause is removed the alveolar wound should be closed by suture, which ends the work of the dental surgeon and prevents the formation of a permanent opening into the mouth, which is not only extremely bothersome to the patient but sometimes very difficult to close later on.

There has been some discussion about injury to the dental organs caused by radical operation of the maxillary sinus. While I have seen some cases where some of the teeth felt numb after the operation, I have failed to see so far a single case where the pulp of a normal tooth became diseased subsequent to this procedure. The arteries and nerves which supply the teeth are contained, as you know, in small canals in the wall of the maxillary sinus. Generally there are three canals, the posterior, middle and anterior superior alveolar canals, but the middle one is in quite a number of cases absent. I believe that the numbness in teeth may be due to injury of one of these canals when making the opening into the canine fossa and not to curettement of the membrane or polypoid degenerations in the sinus. While such an injury may cause disturbance in the innervation of the tooth, I do not believe it influences its nutrition because of the extensive anastomosis of the various branches of the infraorbital artery in the upper jaw.

*Diagnosis of Maxillary Sinus Disease in Cases of Dental and Focal Infection.* Owing to the fact that patients may be unaware of existing chronic maxillary sinusitis, it is desirable that dentists make an examination or advise the patient to consult a rhinologist when conditions are found on the teeth which are liable to be an etiological factor in chronic disease of the antrum. On the other hand, it would be to the advantage of the rhinologist to have an expert dental consultant pass on the dental condition, with the fact in mind that the teeth may not only be the etiological factor, but that coexisting dental disease in maxillary sinusitis from nasal origin may be an important contributory factor in preventing a complete recovery.

*General Diseases Caused by Dental Infection.* The fact that until recently dentistry has been looked upon as a profession apart from medicine is probably the reason why, for a long time, it was thought that infections connected with the teeth had no effect on the rest of the body. On the other hand, since the discovery of focal infection, many teeth have been ruthlessly sacrificed on the evidence of a careless diagnosis. It is a mistake to spread the impression that diseases of the mouth and teeth always play a predominant part. In a patient suffering from a disease which has nothing to do with oral infection such a condition may become, nevertheless, a considerable burden on the body. The continuous fighting of the infection and elimination of the poisons produced must be a great tax on the organs whose function it is to combat disease. Therefore, for this reason alone, it is important to search for and eliminate diseased conditions in the mouth in order to raise the resistance and improve the patient's general health.

The various dental lesions which may cause disease in other parts of the body may be divided into those which discharge pus into the mouth and those where there is no outlet, and the mode of transportation of bacteria or toxins is that of metastatic infection.

Among the first group belong periapical infections with fistulæ discharging pus, oral sepsis from all kinds of unsanitary conditions, especially those connected with poorly fitted crowns and bridges, and pyorrhea pockets from which pus flows into the mouth.

The second group includes such conditions as the blind abscess or dental granuloma, pulp infection, the less frequent extensive bone infections and infectious cysts.

Proof that these latent conditions unnoticed generally by the patient are of infectious origin is brought out by the fact that if the general resistance becomes lowered by debilitating diseases, poor physical condition, pregnancy or malnutrition, acute exacerbations may occur. I have also observed several cases where such a latent abscess without clinical evidence, and only discovered by roentgen examination, developed into an acute suppurative stage from nothing but repeated roentgen exposure, a dose of *x*-ray known as a stimulating dose, showing that only a change of conditions is necessary to produce formation of pus to such an extent that the protecting forces which take care of these conditions are no longer able to cope with the infection.

*The Effect of the Pus Discharging into the Mouth on the Rest of the Body.* The pus mingling with the saliva and food during mastication is not only liable to cause infection in the throat, but reaches the stomach and intestines, giving rise to the diseases of the mucosa of the alimentary canal. For a long time the acids of the stomach have been looked upon as destructive to such bacteria, but Smithies,[1] in a microscopical examination of gastric extracts from 2406 different individuals with "stomach complaint," showed that, irrespective of the acidity of such gastric extracts, bacteria were present in 87 per cent. Hunter[1] says there is a limit to the power of the stomach to destroy such organisms. Even in health it is never complete and is solely due to the presence of free hydrochloric acid. This power, however, becomes progressively weakened when, through any cause, an increased and continuous flow of pus organisms is associated with a diminished and continually lessening acidity of the gastric juice.

*The Effect of Pus Absorption from Enclosed Infection.* The most common dental lesions, those which have been mentioned in the second group, have no outlet into the mouth. The pus or toxins are absorbed and give rise to metastatic infection. The reverse of the condition I have also observed in several cases, namely, that focal infection in other parts of the body can cause infectious lesions on the otherwise perfectly normal teeth with no filling and no history of injury. In 3 cases which I have care-

[1] Mayo, C. H.: Mouth Infection as a Source of Systemic Disease, Jour. Am. Med. Assn., December, 1914, lxiii, 2025.

fully studied, a metastatic infection of streptococcic origin started on teeth which were perfectly normal and where there was no bone infection on any neighboring teeth. Two of these cases later started to suppurate, proving an infectious nature. This also was verified by bacteriological examination.

The enclosed dental infections may give rise to a variety of special and general diseases; the commonest are those otherwise unexplainable obscure symptoms of toxemia, such as fatigue disproportionate to the slight exertion occasioning it, inability to do mentally or physically the accustomed day's work, benumbed mental activity, requirement of an abnormal amount of rest, loss of weight, grayish or sallow skin and a rise of temperature in the afternoon or evening. A person suffering from such an infection is always running the danger of some systemic involvement. The lowering of body temperature by cold or wet may precipitate it and give rise to more or less rheumatic symptoms such as myositis, arthritis or neuritis. Cases of acute multiple arthritis from dental infection are not uncommon and generally improve rapidly after removal of the focus. The following is an illustrative case:

The patient, Mr. D. G., says that five weeks ago he started to have rheumatic swellings and pains in the knees. The shoulders were next attacked and in a short time all the large joints became involved. He took electric baths, but without result. When he came for examination of the mouth, he was walking on crutches and was in great pain. Roentgen examination showed a chronic infection on a maxillary incisor and first molar. A sinus plate was taken in routine examination and showed that the maxillary sinus connected with the infected molar was involved. After the extraction of the teeth and treatment of the maxillary sinus the patient first suffered exacerbation and had to stay in bed for a few days, but later improved rapidly, and after seven weeks was entirely rid of his arthritic symptoms.

In chronic infections, especially arthritis of long standing, the results are, however, not always so gratifying. The joints may present tissue changes which are beyond repair, but in all cases of

so-called rheumatic attacks without tissue changes very gratifying results can be obtained by removal of the focus. A case of this type is that of Mr. G., a chauffeur.

The patient had been having pain in the back and shoulders which incapacitated him for his work. Roentgen examination of the back and spine revealed no bony changes. Careful clinical examination made by his physician showed no cause for the condition. A roentgen examination of the teeth showed many infections in the jaw. Seven teeth were extracted for the removal of foci. Bacteriological examination showed Streptococcus viridans and hemolytic streptococci. The patient improved rapidly, so that he was able to go to work. He is now driving a truck and has been free from symptoms ever since the operation, three years ago.

A case of toxemia is that of Mr. T. R., a middle-aged man who had been in the best of health for several years, but complained that recently he had had symptoms which manifested themselves in benumbed mental activity, a feeling of grogginess upon arising; smoking made him ill where before he had been able to smoke a great deal. He had been carefully examined and was otherwise in good, physical condition. Roentgen examination of the teeth, however, showed three which were infected, and after the removal of these foci the patient got permanent relief.

Children are also frequently victims of focal infection, causing great and sometimes irremediable conditions such as endocarditis and nephritis, and in these diseases it is important to remove all oral infection, although it may not be the original cause.

Cervical lymphadenitis is a common occurrence in the young, which is often caused by infected teeth.

A typical case is that of Miss P., a young college student, who consulted me about a tooth which had been treated. She complained of a tired feeling and frequent intermittent fever. The condition had lasted for three months and there were no other symptoms discernible except a swelling of the submaxillary lymph gland. Roentgen examination showed two teeth with a large shadow at the apices, indicating bone infection. After extraction of the teeth and the removal of the chronic granulation tissue the patient recovered and the temperature remained normal.

In a symposium entitled "The Teeth in Relation to the Specialties in Medicine," David Wells[1] stated that the committee for investigating the cause of iritis and iridocyclitis of the Academy of Ophthalmology and Otolaryngology reported at the last meeting, after two years' work, the collection of 90 cases, 40 of which had been examined with sufficient detail to meet the requirements. Of these about 20 per cent were found to be due to focal infection from teeth and tonsils. Benedict, of the Mayo Clinic, says the method of transmission may be due to direct extension through bone, to direct extension along the periosteum or through transfer of organisms from the focus through the blood stream, which possibility is well demonstrated by the laboratory experiments of E. C. Rosenow.[2]

F. Gorham Brigham,[3] who presented the relation of internal medicine to the teeth in the same symposium, states that diseases of the cardiovascular system, including the large group of arteriosclerosis, are greatly benefited by the curing of oral disease, in many cases rapidly progressing conditions being checked almost as by magic.

Examination and Treatment. In searching for foci of infection in the mouth, it is of the greatest importance to have a complete examination because a departure from a thorough examination often leads to regrettable oversights. It is necessary not only to examine the patient clinically, but also to make a complete roentgen examination of all the teeth, including the spaces where teeth have been lost and where broken roots, bone abscesses or cysts quite often occur. If any of the teeth connected with the maxillary sinus are infected the nasal and accessory cavities should be roentgenographed.

In patients suffering from some chronic disease or whose resistance is lowered, radical treatment is generally indicated. It is perfectly justifiable to be radical in such cases, not only with diseased but with suspicious teeth, although they may not be the direct cause of the condition.

[1] Teeth in Relation to Diseases of the Eye, Dental Cosmos, May, 1922, lxiv, 524.

[2] Studies on Elective Localization: Focal Infection, with Special Reference to Oral Sepsis, Jour. Dent. Research, 1919, i, 204 and 251.

[3] Teeth in Relation to Internal Medicine, Dental Cosmos, 1922, lxiv, 540.

F. H. McCrudden[1] states that in chronic disease the hopeful therapeutic measure lies in improving the functional efficiency of the body and building up the general health. To further this end, it is important to remove all necrotic tissue, because the organs whose function it is to combat disease must be freed from any additional burden.

In cases of focal infection, and especially where the patient's resistance is lowered, proper judgment should be used in determining the number of teeth that are to be removed at one time. It is not only the shock of the operation which must be considered, but also the fact that new channels are opened for absorption of bacteria and toxins. The removal of a large number of infected teeth at one time is known to cause, under certain circumstances, very alarming constitutional symptoms, while extraction at intervals, which should be six to eight days, not only decreases this danger, but, on the other hand, is of a certain therapeutic value in producing a similar effect as that of repeated vaccine treatment.

The elimination of foci in the nose, throat and mouth is certainly very desirable for safeguarding the health of the patient, and I believe a great deal can be accomplished by proper cooperation between the rhinologist and dentist who see patients perhaps more than the general practitioner, and not only discover existing infection by careful examination but can impress upon the patient the importance of their removal.

[1] The Treatment of Chronic Disease is a Problem of Applied Physiology, Boston Med. and Surg. Jour., No. 2, vol. clxxv.

# THE NATURE OF THE INFLUENCE OF FOCAL INFECTION AND THE MEANS NECESSARY TO MEET IT

RALPH PEMBERTON, M.D.

I AM very sensible of the compliment you pay me in giving me an opportunity to talk to you today on the subject of focal infection. I believe, as an internist, that we internists as a group have given too little philosophical consideration to the large syndrome which arises from this cause and to the nature of the pathology behind it. I feel that the work that you gentlemen have been doing, and also that the orthopedists have been doing, especially in relation to arthritis, has been of great value in bringing before us some of the more important phases of this topic. I think we will agree that the study and treatment of focal infection is at last analysis the study of the symptoms it produces, unless we are willing at the present state of pathological knowledge to regard the matter from the standpoint, for example, of round-cell infiltration and gross morbid anatomy alone. Therefore, we have been driven to the necessity, in studying this topic, of considering some of the many conditions which focal infection brings about. As long ago as the '80s, Charcot called attention to a large group of cases which come under this general heading, such as neurasthenia, optic disturbances, diseases of the skin, arthritis and so on. Much of what I have to say today will be grouped around one of these topics, particularly arthritis; but I do not want you to believe, if you please, that I am discussing arthritis alone, because I think nothing is more sure than that focal infection produces many conditions and that arthritis is only one of them. Indeed, many of these conditions may occur coincidentally in the same individual. Because of its external manifestations, however, arthritis lends itself better than the others to analysis and treatment.

In taking this question up, it will be necessary, from the standpoint of the internist and biochemist, to refer to technical matters, but I will try to be as brief as possible. I will have a good deal to say this afternoon about focal infection, and I have been exceedingly interested in the papers that have gone before. I shall have a great deal to say both pro and con, and I want to make clear that I believe focal infection to be a cause of disease, and indeed the cause of a great many kinds of diseases. As a matter of fact, all of our cases of neurasthenia, arthritis, etc., were studied routinely by specialists in genito-urinary and nose and throat line, dentistry or any other which seemed pertinent. However, it is important to realize, in the first place, that removal of focal infection, as some of the speakers have remarked, does not always cure the disease in question. In the second place, it is important to realize that some cases of neurasthenia, arthritis, etc., are apparently favorably influenced by other factors, and lastly, it is important to try to find out just what it is that focal infection does after all. We have learned, heretofore, little or nothing on this point. During the War I was fortunate in being in charge of the intensive study and treatment of arthritis in this country for the Army, and we had the opportunity of studying a great many cases, a larger number indeed than had ever been studied before under anything approaching controlled conditions. In this connection I want to call your attention to these charts, which portray certain outstanding facts that our studies developed.

We had 400 cases of chronic arthritis, and it was a great surprise to us, a matter of great interest to us, to find when we analyzed them for the apparently exciting factor that exposure stood at the top of the list by markedly predominating figures (Table I).

TABLE I

| | Number of cases. | Per cent. |
|---|---|---|
| Exposure | 232 | 58.00 |
| Dysentery | 33 | 8.25 |
| Injury | 30 | 7.50 |
| "Flu" | 28 | 7.00 |
| "Gas" | 23 | 5.75 |
| Drilling and hiking | 15 | 3.75 |
| Tonsillitis | 13 | 3.25 |
| Pneumonia | 6 | 1.50 |
| Neisserian infection | 4 | 1.00 |

Nearly 60 per cent of the cases were referable to immediately preceding exposure of some kind, either in water or from sleeping on damp ground, on stone floors or in other ways. Dysentery came next, though much lower, and it was interesting to note that tonsillitis was pretty well down the list—3 per cent only. These cases were all analyzed from every standpoint that the internist could bring to bear. They all had complete physical examinations, blood counts, Wassermanns, etc. Twenty-seven per cent of cases had apparently contracted arthritis in the absence of demonstrable surgical foci. It is, of course, difficult to say that a case is absolutely free of foci of infection. However, on the other hand, 73 per cent, or 293 cases, showed definite demonstrable surgical foci either in the teeth, tonsils, genito-urinary tract, sinuses or a combination of these, and I think there is very small room for error on this side. If anything, the number was probably higher rather than lower. Of 208 cases, 52 per cent of the entire series showed tonsillar infection; 134 (33 per cent) showed dental infection; 12 per cent showed genito-urinary; 20 per cent showed a combination of these. Now the point which I think will perhaps interest you most, as it did us, and was indeed very surprising to us, is brought out in the following figures: 23 per cent, 92 cases, recovered in the apparent absence of any surgical focus. Nearly one-half of the entire series, however, 184 cases, or 46 per cent, recovered in the presence of a demonstrable focus of infection (Table II). This means that a great many men came into the

TABLE II

| Number of cases. | Per cent. | Remarks. |
|---|---|---|
| 92 | 23.00 | Recovered in the apparent absence of a demonstrable focus. |
| 184 | 46.00 | Recovered in the presence of a demonstrable focus. |
| 34 | 8.50 | Recovered after the removal of foci. |
| 31 | 7.75 | Were improved after removal of foci. |
| 28 | 7.00 | Were unimproved after removal of foci. |
| 310 | 77.50 | Recovered "by whatever means." |
| 74 | 18.5 | Improved "by whatever means." |
| 16 | 4.00 | Were unimproved "by whatever means." |

hospital well or they came in convalescent and got well, or they came in and recovered after treatment other than operative. But

at all events nearly one-half got well in the presence of a definite surgical focus. Tonsillectomy was one of the most frequent procedures carried out in the way of removing focal infection, and about 16 per cent improved or got well as the result of removing surgical foci in the seven months that we had opportunity to observe these men. So that in the last analysis, looking at the matter dispassionately and desiring simply to get facts, the outstanding deduction is that an overwhelming proportion got well in the presence of demonstrable surgical infection and relatively few got well as the result of removing foci. It is perfectly true that these cases were nearly all in young men between the ages of twenty to thirty-two and they were more or less selected subjects. Their disabilities had been developed under war conditions and constituted almost a laboratory experiment, so it is not fair to regard these men as comparable in all respects to cases in civil life. Nevertheless, the lesson forced upon us is that great emphasis must be given to the fact that these men got well in the presence of definite foci of various kinds.

We endeavored to study this topic of arthritis, or rather the whole syndrome, from a number of different angles, and among other things we took up the subject of basal metabolism. I do not mean to take up your time with technical matters, but some brief references will be necessary. By basal metabolism we mean the amount of heat generated by a unit of body surface per unit of time, or, in other words, the intensity of the sum total of the chemical processes of the body. We found a slight reduction below normal in 20 per cent of these cases.

We also studied the urea of the blood and the normal values found give no color to the conception that the nitrogenous metabolism is disturbed and that the widely practised avoidance of "red meat" has any justification is fact. We found some increase in the blood creatin of half the cases studied. The importance of this is that it has some relation to the carbohydrate metabolism. *Apropos* of the carbohydrate metabolism, we came across some other facts of rather more interest. I do not know whether you gentlemen are familiar with the so-called glucose tolerance test. Like most new measures introduced into medicine, it has been carried often to extremes, but it reveals part of the pathology

back of a number of conditions. There is nothing specific about it, however, even for diabetes, where it has its widest application. One gives 100 grams of glucose by mouth and examines the sugar in the blood; before the glucose is ingested the sugar in the blood will be found at a certain fixed normal level. If the blood is examined again half an hour after ingestion of the glucose,

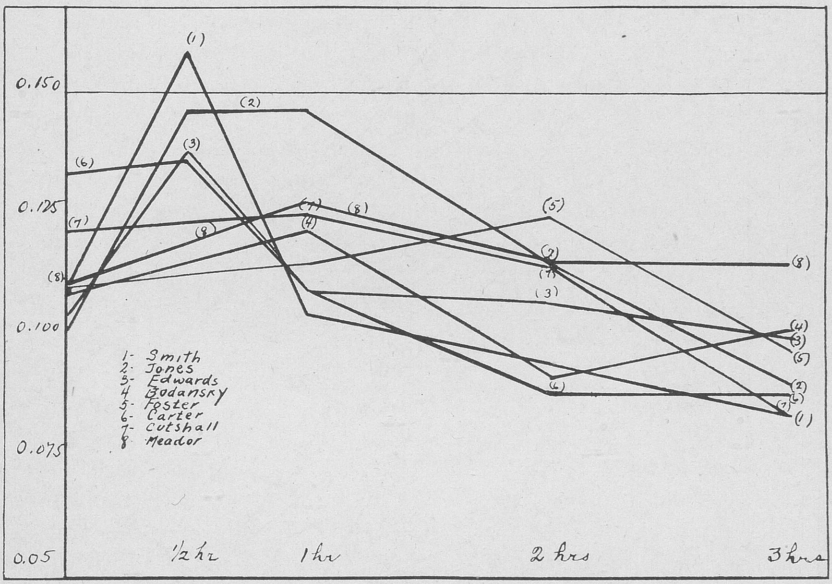


CHART I.—The curves of sugar-tolerance in 8 normal individuals. The ordinates are percentage concentrations of blood sugar, the abscissæ are time-periods of one-half, one, two and three hours, respectively. The black transverse line in this and the following charts corresponds to a percentage sugar concentration and is at the approximate upper limit of normality after feeding 100 gm. of glucose. The glucose was ingested immediately after determination of the first point on each curve. The second point was determined one-half or one hour, generally one-half hour, after the first.

the glucose will be found to have risen to a certain amount, and an hour later it will have probably returned to about its former level. One gets then a curve of which these various curves are representative. Merged into one they will go about like this (Chart I).

If one studies the group of arthritics, however, one finds a different picture. Using the same base line here for both groups

the curves for the arthritics go very much higher (Chart II). In other words, the glucose in the blood is not removed as quickly

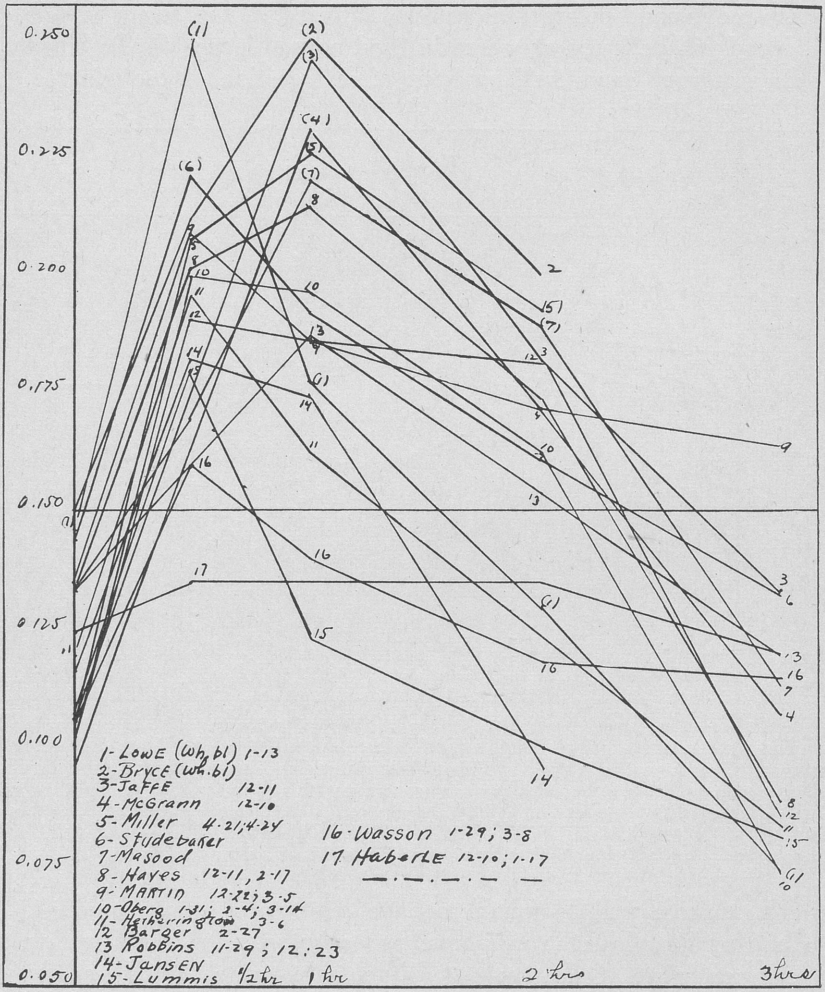


CHART II.—The lowered sugar-tolerance in severe arthritis.

as it should be. It may reach very high figures, almost diabetic. It is obvious that something is going on that we do not completely

understand which interferes with the normal removal or utilization of the ingested sugar. This abnormality is not a specific disease-condition *per se*, but some interesting things can be developed from it. I want to call attention to this chart (Chart III) of a boy, aged nineteen years, with severe arthritis of the hip, who had been sick

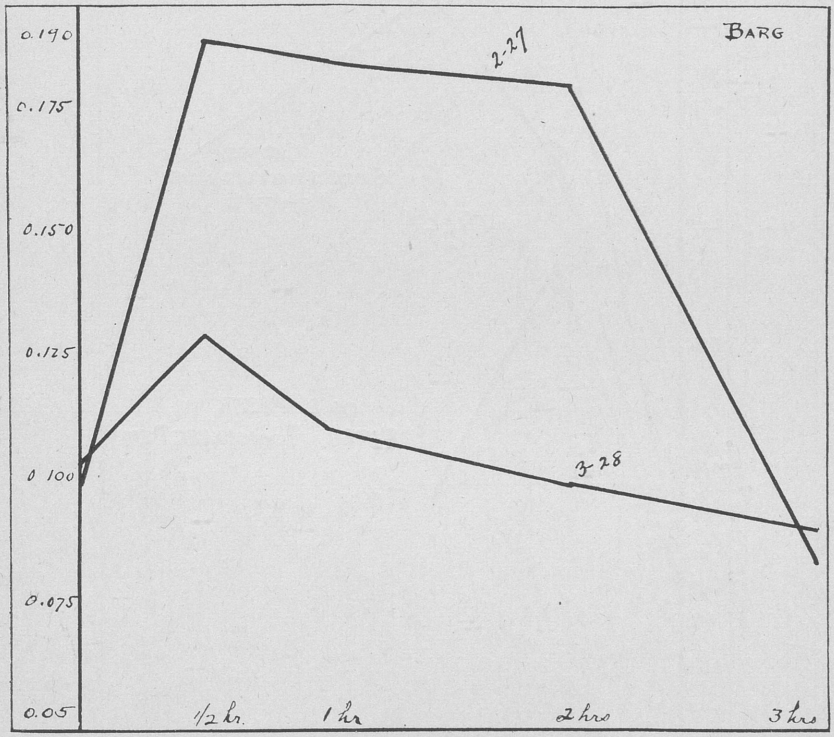


CHART III.—The striking contrast after fourteen days in the sugar-tolerance of a severe arthritic who made an abrupt convalescence following tonsillectomy on March 14, 1919.

nine months. He had a very bad pair of tonsils. We determined his sugar tolerance when he came into the hospital and we found the curve resulting was about like this, very high. He tolerated sugar poorly and hence had a high curve. We removed his tonsils two weeks after admission; two weeks later he was

entirely free from all arthritis and his sugar tolerance was at a normal level which you see here.

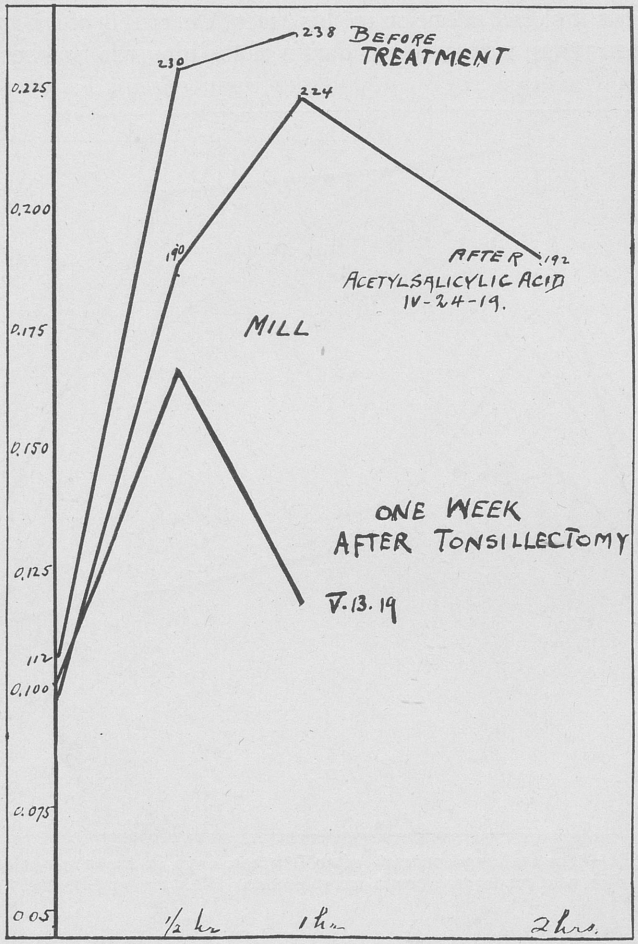


CHART IV.—The slight effect of acetylsalicylic acid and the marked effect of tonsillectomy in a severe case which recovered.

This chart (Chart IV) illustrates the same sequence of events in a soldier presenting acute arthritis of wrists and knees and ankles. It portrays a marked elevation of the glucose tolerance curve

and also the fact that it is not modified by doses of salicylates even though they controlled the symptoms. The difference in the curves is practically negligible. This man had his tonsils removed and two weeks later his tolerance was down almost to normal. Here is the case (Chart V) of a man who had no focal infection, at least any such had been removed long before we saw

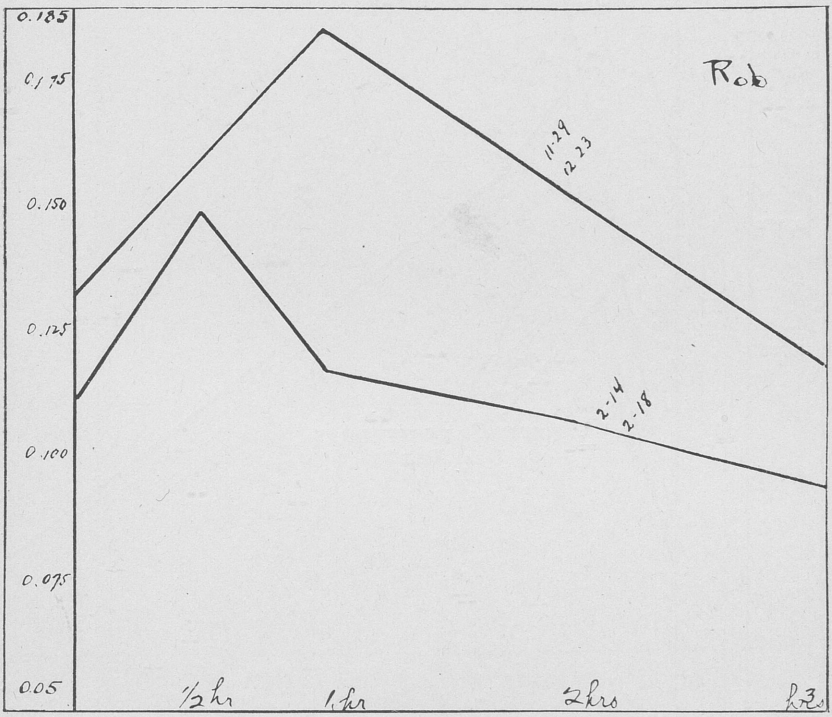


CHART V.—The contrast in sugar-tolerance before and after convalescence on a restricted diet.

him, though he was exceedingly sick and confined to bed. He made a recovery from arthritis along different lines, dietetic lines, and it is of interest to see that while he had a lowered sugar tolerance during the height of illness, when definitely convalescent it again came down precisely as after removal of the tonsils in the other cases.

This chart (Chart VI) is that of a man, with severe spondylitis, in whom the sugar tolerance returned toward normal after the removal of six infected teeth. Here is a case (Chart VII) in which recovery and a return to normal of a lowered sugar tolerance were brought about by repeated injections of non-specific protein, the

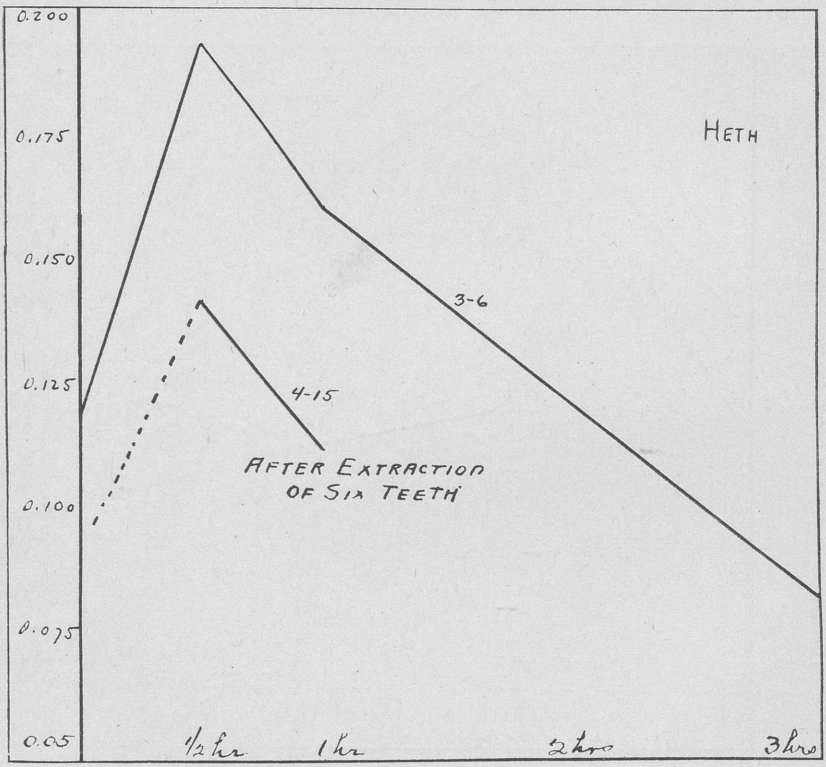


CHART VI.—The contrast in sugar-tolerance of a spondylitis patient who recovered after the extraction of six teeth.

man having no focal infection. This chart (Chart VIII) finally, is the chart of three individuals who had enlarged tonsils without symptoms and were apparently active, healthy men. Two of them gave normal curves, a third slightly elevated. They had no systemic symptoms. The man who had a high curve had

previously given a slightly high curve in other hands. Something evidently was going wrong in his systemic metabolism.

Consideration of these general findings led us to wonder what was going on to produce these results. The work of the English physiologists and, subsequently, the American has drawn attention to the blood gases and the respiratory functions of the blood. For a number of reasons, which I will not take your time to

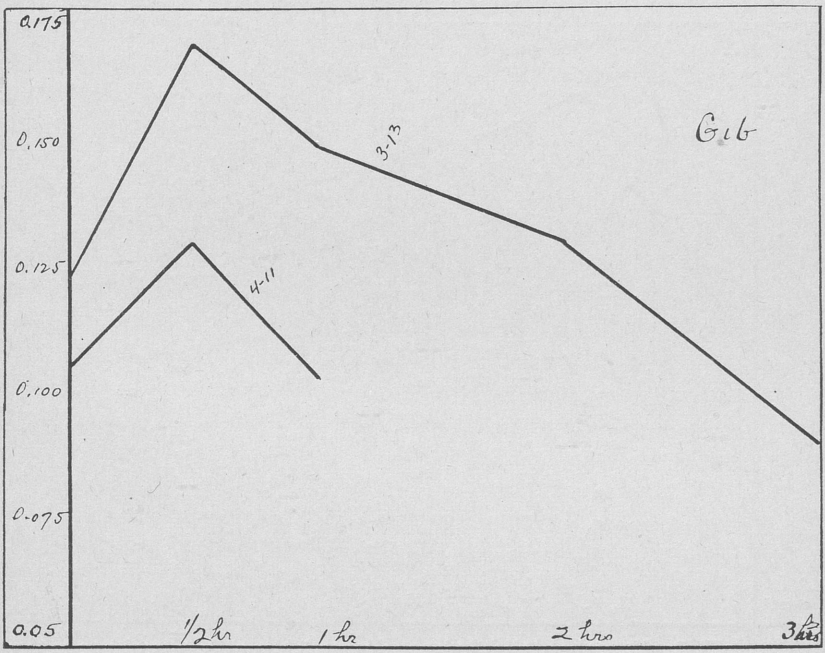


CHART VII.—The contrast before and after treatment by non-specific protein injections.

consider, we took up the study of the blood gases in this syndrome of which arthritis is one expression. We found that if the blood gases of a vein of a normal arm were studied by a given technic which we used, one got figures for the oxygen percentage saturation of the blood corresponding to about 42, but if we studied the arthritics we found somewhat higher figures which were roughly in the neighborhood of 54, some much higher. This means that apparently as the blood comes back from the periphery there is

under the conditions of these observations a tendency for the blood to contain more oxygen than is the case in a normal individual. For some reason or other it is apparently not removed, as it normally is, possibly because the tissues cannot utilize it, but more probably for another reason which I will come to later. It is also interesting to note (and this is rather corroboratory evidence) that if one studies the blood during the conduction of a test reveal-

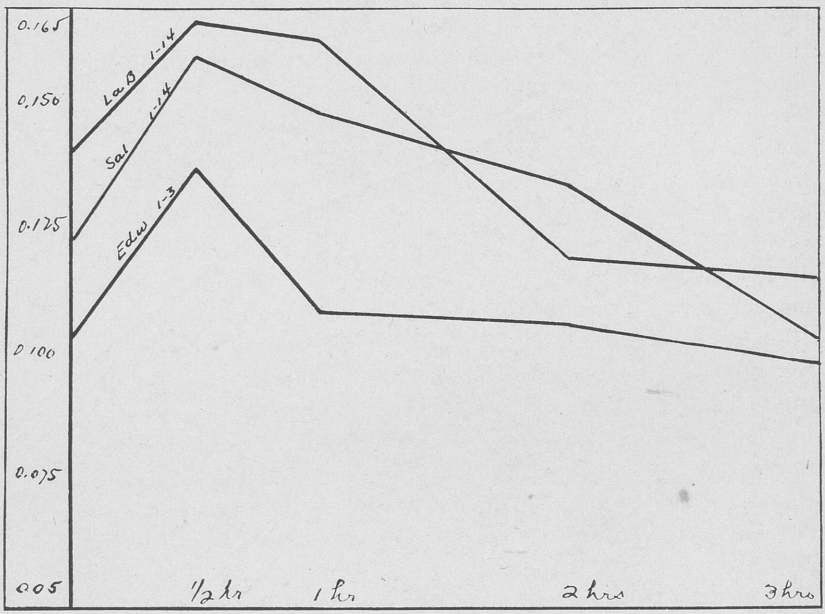


CHART VIII.—Normal and slightly lowered sugar tolerance in normal men with enlarged tonsils, but no systemic symptoms.

ing a lowered sugar tolerance one finds an increase in the percentage saturation of oxygen parallel with the rise in the concentration of sugar, and yet these changes do not seem to be due to the same mechanism. Sometimes the blood gases change more evidently than does the sugar tolerance during this test. We tried to explain the matter on a chemical basis. We could not find, however, that the blood held on to its oxygen more than it should in a strictly chemical sense. We were therefore driven to a con-

sideration of the possibility that the blood went by the tissues so fast or in such a way that the oxygen could not be removed. It is well known that in conditions of hyperemia this is the case. If one studies persons during hydrotherapy or an electric bake the oxygen of the peripheral blood shows the same changes, and it is well known that blood is going by faster under these conditions. This led us into a further study of bakes, hydrotherapy and the application of heat at large, and we have found some rather interesting results. I want to take time to call your attention to them because these measures are used widely in medicine. They are as old as Hippocrates and are employed by many different groups of physicians, such as neurologists, surgeons, ophthalmologists and internists. They have wide application in the treatment of nephritis, arthritis and the insanities. We have found if one studies the sweat under these circumstances that some interesting changes take place. The sweat normally is about neutral, though it may be actually acid or slightly alkaline; but whatever it be, during the process of hydrotherapy or the application of external heat of any kind, the sweat changes its reaction. If it started acid it becomes neutral; exceptionally it may swing all the way from markedly acid to markedly alkaline, but it never stays the same, always changing toward the alkaline range. Ninety-nine per cent of cases and all normals undergo this very definite change. A few cases of marked arthritis have not changed in their figures at all, remaining acid throughout. Now carrying this further, we have also found that a good many other things take place during the course of one of these treatments, though there is not time to go into the chemistry in detail, much as I would like to. Dr. Cajori and Miss Crouter, working in my laboratory, have found and recently reported the fact that there is a change in the carbon dioxide dissociation curve of the blood. There is also a change in what we call the hydrogen-ion concentration or the reaction of the blood which becomes more alkaline during this procedure than it was before. This is entirely in keeping with the change which the sweat shows, and it is also accompanied by changes of a parallel nature in many cases in the urine. So there is apparently something in the nature of an alkaline wave during these procedures. It is interesting to note

during the study of these individuals that if one puts a rubber bag around the arm and the individual is subjected to a "bake," the air in the bag will be found to increase in its carbon dioxide content. There is undoubtedly a loss of carbon dioxide through the sweat, especially excessive sweating, and it is probable that this plays a very important rôle in the blood changes to which I referred. It is important to remember that carbon dioxide is an end-product of metabolism.

Because of the fact that we cannot explain all of the above changes in the blood entirely on chemical grounds, we were driven to study the question of blood flow, making use of the hand calorimeter. This is a jar or box containing water, into which the hand was put with the aim of ascertaining the increase in temperature of the water produced by the blood. We were able to show that the arthritic tends to have a little less rapid blood flow than the normal individual. That led us again to consider the question of the capillaries, to which a great deal of attention has recently been drawn, and it is possible to demonstrate in some cases of arthritis the fact that in certain regions such as the finger they are finer and less conspicuous than in normals. The evidence on this point is not final, but it is at least suggestive and fits in with what I have already mentioned to you.

In other words, there seems to be evidence to indicate that in this syndrome there is a disturbance of metabolism, and that it is a little below normal; that there is an impairment of oxidation in a local and possibly a systemic sense, and that this disturbance arises from the way in which the blood passes through the tissue.

This is a very cursory survey of the facts relating to the dynamic pathology of this condition as we see it, and I mean to refer later to some other phases, but I want now to go on to the question of treatment.

It is of interest to note in studying arthritis that the agents of value in meeting the symptoms are those that improve the local or systemic metabolism or the local or systemic blood flow, and it has further been of interest to correlate this fact with the findings we have obtained in our work. Much has been said today about the removal of focal infection, and I am entirely in accord with the view which advocates the removal of focal infections of various

kinds when this can be done without too great and extensive damage to the individual and in suitable cases. Sometimes, however, the results do not follow which we anticipate, and I think it is of the highest importance to bring out the fact that treatment of the arthritic or other member of the group under discussion is not necessarily complete with removal of a surgical focus of infection. A great many cases hang fire after that point. If one regards them as referable only to this cause and disregards the subsequent pathological disturbances which may arise, the individual may remain in poor health for a long period of time, whereas if one takes a broader standpoint it is frequently possible to bring the individual back to health in a much shorter period of time. There is a more or less permanent dislocation of some physiological functions, as can be shown by these charts. In some cases with a marked dislocation of the sugar curve this could be shown to come down progressively as they convalesce, and it is obvious that if two, three, four or six weeks are required to bring it down, by the same token as many months may be required for the return, and sometimes it does not return at all. Now some of the agents which in general are of value in this condition toward improving metabolism are the following: Arsenic, potassium iodide, thyroid extract; and it is of interest to note that Kendall, the discoverer of thyroxin, states that it acts by virtue of $CO_2$, which it picks up and carries out of the body. Radium has an analogous effect. Of course the so-called radium waters and emanators commercially exploited are in general of small use because there is very little radium in them. *X*-ray has the same influence. Massage is also of value, as is exercise in general. The value of non-specific protein in this condition is probably almost solely due to the fact that a tremendous increase of metabolism arises from its use, accompanied by fever and some other phenomena. The use of vaccines I shall not refer to because you are all familiar with them. They have no specific value or action upon the resultant arthritis, or neurasthenia *per se*, so far as I am aware. I think it is important in considering this general question and the operation of focal infection to appreciate also the other factors which bring about the same syndrome and produce analogous results. The gastrointestinal tract is a field which

is productive of a great deal of damage, and attention has been very properly drawn, by the Boston School of Orthopedists in particular, to ptosis, malfunction and other disturbances which undoubtedly contribute to absorbable toxins. I would like, then, to present to you the thought that arthritis and this general syndrome may be regarded as part of a sort of metabolic equation. On the one hand we have the elements or factors which make for a diminution in metabolism and a variety of clinical symptoms. On the other hand we have a variety of agents which improve metabolism, and if these two sides of the equation can be properly equilibrated or balanced against each other, one may have absence of symptoms, and that is precisely what is often taking place in the individual during health. A lot of people have focal infections, possibly many people here today have them, and are not sick. It is important to note that this general relation has been known for generations and is the real *raison d'être* for the spaas and "kurorts" to which patients flock by the hundreds of thousands. Many individuals go to these places and get well. I think, as a matter of fact, that we are most of us to blame for not realizing that there are many ways of relieving this disturbed physiology. By removing or replacing the first link, a focal infection, say, we do not necessarily restore the chain in its entirety. This is the reason why these institutions succeed. I am sure you have all had illustrations that it is possible to effect great improvement in the clinical condition of these sufferers by reason simply of the improvement in their general physiological processes, and I mean by that that something more specific than outdoor air, good food and early retiring. I mean such measures as massage, sweating, exercise, certain drugs and so on. Before leaving this question of the general "balance of health" and the factors that make for ill health or improvement, I want to call attention to some interesting observations that were made by the English physiologist Barcroft, who found that at great altitudes some of the symptoms arise which the arthritic and neurasthenic suffer from peculiarly; for instance, headache and fatigue. There are even certain changes in the ends of the fingers which resemble hypertrophic pulmonary osteoarthropathy. In some of these conditions the

actual bone is concerned. The relation of oxygen want to these conditions is clearly proven.

I have spoken of the gastrointestinal tract, and the fact that if the anatomy or physiology is wrong, various consequences arise. They arise, in part at least, from the fact that the food is not properly taken care of and toxins are formed, probably from retention. There is another way, however, in which the food intake may operate in a more specific sense. If it is true that there is a difficulty in arthritis in completing some phases of the oxidative metabolism, and if it is true that agents which improve this metabolism are helpful, then it should follow that measures designed to lighten the load on that metabolism should be of value. This is indeed apparently the case. If one reduces the food intake in these individuals to a point considerably below what they have been accustomed to and gives the body less to metabolize, brilliant consequences sometimes follow. For example, one of these sugar-tolerance charts (Chart V) is that of an officer who got well along dietetic lines. He was eating 3500 calories a day and lying in bed all day. That is a large amount of food which only soldiers in service or workers in the Maine woods can utilize. We put him on 2100 calories on the basis of the thought that we could spare his metabolism an unnecessary burden. A very interesting result followed. In a few days he was able to get out of bed, in a very few days more he dispensed with crutches and he eventually left the hospital, symptomatically well.

I merely mention this because it is illustrative and rather graphically of the improvement which may take place when one considers the metabolism of these cases. I may say that this work has recently been corroborated by Fletcher, of Toronto. In a large series of 150 cases he found that about 40 per cent of unselected cases showed improvement from these measures without regard to whether or no they presented focal infections.

I do not want to be interpreted as advocating the rash use of dietetics. The real lesson to be deduced is that these cases should be regarded as open to treatment from a number of different angles, and if we combine these forms of treatment we will sometimes get results we could not get otherwise.

Now this dietetic form of therapy sometimes forms a very useful basis for other types of treatment. It is no panacea, and so far as I know there is no panacea in arthritis or in the syndrome we are discussing; perhaps there is none in medicine. Some cases do not get well along this line. The cases to be so treated should be very carefully and critically chosen, but such therapy can often successfully be made the basis of other forms of treatment. One man, for example, in the service made a 50 per cent improvement on diet and then hung fire. He had had his tonsils out some weeks before without improvement. We then gave him hydrotherapy in addition and he made a complete convalescence and was symptomatically well when he left the hospital. In other words, it is possible to regard this general syndrome as one in which various factors may be operative, and if we employ one measure alone we do not necessarily influence the situation as a whole. There is another phase of the dietetic treatment of these conditions which was brought out by Mendel, of Yale, some years ago, and by Howe in Boston, working in the Forsythe Dental Infirmary, that in a deficiency disease such as scurvy, where the diet is unbalanced, infection may arise as a result and not as the cause of the systemic disorder. This is well illustrated in the dental caries which these cases show.

I want to bring out one other fact, and that is that sometimes infections which are started by the tonsils or teeth may be perpetuated by the intestinal tract and can be reached sometimes only by diet in the way I have tried to describe.

In closing, gentlemen, I would like very much to leave with you the conception that we try to regard the syndrome precipitated by focal infection from a broad standpoint. We believe that focal infection does a great many things, that it produces a variety of diseases; but we also feel that the extreme view is nearly always a dangerous view and that it is easy to lose one's balance in this field. I do not believe myself that there is any single panacea for the general syndrome which results so often from focal infection, among other causes, and until we lose such undue enthusiasms as we are all subject to along these lines, we will continue to meet with many failures. I am sure that with inadequate effort to include the various measures at our disposal, failures are much

more likely to result. Only by a consideration of all these factors do we reach a really rounded viewpoint of the whole subject.

---

## Discussion on the Papers of Drs. Wood, Emerson, Thoma and Pemberton

Dr. James E. Logan, Kansas City, Mo.:

I want to express my appreciation of the interesting paper of Dr. Pemberton. No one could have been more interested in all of the points brought out by Dr. Pemberton than myself. As laryngologists and rhinologists, I think we have all been prone to centralize our efforts upon the regions included within the scope of our activity and have neglected to take into consideration the general systemic conditions which undoubtedly do enter into the etiology, pathology and treatment of many of the diseases of the upper respiratory tract. In my student days I can remember that when the general practitioners found difficulty in making a diagnosis of an obscure case they usually ascribed the condition as due to "malaria." At the present time those patients presenting a complex symptomatology are usually referred either to the rhinologist for some sinus infection or tonsil enucleation or to the dentist for partial or complete removal of teeth. The entire responsibility is thus transferred from the internist to one or both of the other special surgeons. Foci of infection undoubtedly do exist in nasal sinuses, adenoids, tonsils and teeth; but Dr. Pemberton has issued a word of warning when he tells us that faulty metabolism, diseased gall-bladders and numerous other pathologic conditions must be considered as important factors in diagnosis. Again, let me express my very high appreciation of this paper.

Dr. Frank R. Spencer, Boulder, Colo.:

I should like to ask if any relationship has been found between the site of the primary and secondary foci. A few years ago in more than 50 per cent of the cases the primary focus was on the same side of the body as the secondary focus. For instance, if the primary focus were found about the roots of the teeth on the right, the ear, sinus or eye being the secondary focus, would in more than 50 per cent of the cases be on the right side too.

Dr. J. Payson Clark, Boston:

I think the valuable papers this afternoon have given us all food for thought. Dr. Wood brought out the fact that—and I suppose it

has been proven—the tonsils have no afferent lymphatics. If this is so, the observation of some writers that the tonsils swell during the eruption of the first teeth is difficult to account for. This could not be the case, it seems to me, if there are no afferent lymphatics to the tonsils. I would like to ask Dr. Wood if I understood him correctly.

Dr. Dunbar Roy, Atlanta, Ga.:

I have not heard a paper in a long time that has interested me more than this one from Dr. Pemberton. I feel that papers along this line will be exceedingly valuable. We have heard so much about the tonsil question and about the teeth as causes for focal infection and so little along the line that Dr. Pemberton has given this afternoon that it is really refreshing. When men send cases to me with a note that they wish tonsils to be removed, I often feel that I would like to send these cases back to them and ask them if they will not tell me if there are no other conditions of metabolism in the body which cause this condition rather than the tonsil, and what I suffer most from in my own city is to find internists who will give time to these things instead of being led into the idea that the teeth and tonsils are supposed to be all the foci of infection. They overlook the conditions Dr. Pemberton has told us of, and I for one appreciate this paper, and have got very much valuable information from it.

Dr. Wood (in closing):

I used the faucial tonsil for pathological studies simply because it was easier to obtain in bulk than other pharyngeal lymphoid tissue. We must recognize, however, that diseased conditions of the tonsils may be duplicated, though to a lesser degree, by the lymphoid tissue of the throat, wherever found, and there is no reason why an infection might not rise in the pharyngeal as well as the faucial tonsils. The question concerning the lymphatics of the tonsil has, in my opinion, been practically settled, namely, that they have no afferent lymphatics. The surface mucous membrane of the tonsil will show a network of lymphatic vessels continuous with those of the surface mucous membrane of the mouth, but these are superficial mucous membrane lymph vessels and do not arise from or run to the deeper structures of the tonsils. The results obtained by Henk, in which he claimed to be able to inject the tonsils from the nose, have been absolutely disproven by Karl Amersbach. The fault of Henk's technic was that he did not take precautions to prevent surface inoculation of the tonsil.

DR. EMERSON (in closing):

I, personally, never have supposed that in removing a focus of infection I was doing anything more than initiating treatment. All of these cases of chronic toxemia show marked anemia and all such cases are referred to competent medical men who are trained to follow up this line of work. Our one trouble was that we were not always able to refer people to men doing the type of work that Dr. Pemberton has outlined to us this afternoon. These cases all temporarily improve by rest and anything which increases their resistance. Conversely, they are always in danger of acute exacerbations whenever they get tired or their resistance is lowered by any depressing influence until the original cause has been removed and their bodily resistance built up.

DR. THOMA (in closing):

I would like to say a word in regard to the question of tonsil infection from erupting teeth. I believe in all these cases in which teeth are erupting the infection and absorption is a surface absorption, just as Dr. Wood said. The infection does not occur until the permanent tooth is ready to erupt, and it is generally the thin layer of mucous membrane overlying the surface of the tooth which gets infected, and therefore the infection very probably would spread through the lymphatic vessels of the mucous membrane of the mouth.

DR. PEMBERTON (in closing):

Just a word of emphasis. I am afraid some of my remarks may be misunderstood and I do not want anyone to think that I am not in favor of the removal of focal infection as a broad principle. No one can be the better for carrying abscessed teeth and diseased tonsils. My remarks were directed chiefly to the physiology back of this condition. Inasmuch as wide disturbances of health may be brought about by focal infection, sometimes we add to that disbalance of health rather than relieve it by the removal of foci at the wrong time. I think that is particularly the case in severe conditions. Some of my colleagues at the Presbyterian Hospital have, I am afraid, at my own instigation, operated on patients at ill-chosen times and I have sometimes seen their condition much aggravated by such procedures. That is not to be interpreted as leaving in focal infection when it can be easily removed. I merely want to bring out the fact that operation may contribute to the pathology instead of relieving it.

# GLOSSOPHARYNGEAL NEURALGIA FROM THE STANDPOINT OF THE RHINOLARYNGOLOGIST

HAROLD I. LILLIE, M.D.

PAIN around the head in contradistinction to headaches, complained of by patients presenting themselves to the rhinolaryngologist, may offer great difficulties in the diagnosis of the causative factors. No other symptoms seem so important from the patient's standpoint, and it is for this pain in particular that they seek relief. So much has been written concerning the major trifacial neuralgias that all are quite familiar with the syndromes which are recognized as definite clinical entities. The diagnosis is relatively easy in a large number of the cases, while in a few of the less keenly-cut cases it is somewhat more difficult. The same may be said of the nasal ganglion pain syndrome of Sluder.

Three cases observed on the service in the section on Otolaryngology and Rhinology of the Mayo Clinic, during the spring of 1922, were looked on at first as major trifacial neuralgias, and it was only through exclusion by Doyle, in the Section on Neurology, that they were classified as glossopharyngeal neuralgias. Doyle investigated the literature and found that this syndrome had been described by Sicard and Robineau in 1920 and by Harris in 1921. The first 2 cases of Sicard and Robineau were seen in the French Army in 1916 and 1917 respectively. In one case the pain was on the right side and in the other on the left. In neither case could a cause be established. There was no antecedent history of syphilis, and the condition did not respond to treatment for syphilis, to sedatives or to physical agents. In both cases the pain had persisted for several years; it was not continuous, but it often recurred day and night in extremely acute paroxysms on the least movement of mastication, deglutition or speech. Occasionally the paroxysm occurred spontaneously. The patients

developed suicidal tendencies on account of the apparent incurability of the condition. The treatment in these 2 cases consisted in sectioning the glossopharyngeal nerve and the pharyngeal branches of the vagus, with ablation of the superior cervical sympathetic ganglion. The operation was performed by surgeons unaccustomed to operating on the neck. In one the ninth nerve was cut, the sympathetic ganglion was removed and the trunk of the vagus severed; in the other, the ninth and twelfth nerves and the pharyngeal branches of the tenth nerve were cut and the sympathetic ganglion was removed. Both of the patients convalesced rapidly. The first patient later developed unilateral palsy of the vocal cord; the second, hemiatrophy of the tongue. The third case was that of a woman, aged fifty years, in whom he successfully cut the ninth nerve and the pharyngeal branches of the tenth, and ablated the superior cervical sympathetic ganglion. During the operation the trunk of the vagus was pulled, resulting in paresis of the hemolateral vocal cord; this condition, however, steadily improved. As in the first 2 cases all pain disappeared immediately after operation. The first patient has been completely relieved for four years and the second for three.

Harris has recently described 2 cases of a rare form of chronic paroxysmal neuralgia which he terms glossopharyngeal neuralgia. The pain, according to him, characteristically starts in the throat in the region of the tonsil and anterior pillar and radiates to the ear and upper part of the neck. The first case was that of a man, aged forty years, whom he had first seen ten years before, when he successfully injected the third division on the affected side without influencing the pain. The second patient was a woman, aged eighty-seven years, who had suffered from the condition for ten years. Harris was convinced of the involvement of the ninth nerve in these cases; he had seen a man with similar pain and intense hyperesthesia of the side of the neck following a recurrence of epithelioma of the tonsil seven years after extirpation of a malignant vocal cord.

That there is a definite basis, from a neurological standpoint, for the seat of this pain may be seen by turning to anatomical descriptions of the glossopharyngeal nerve, its connections, communications and distributions. It is seen that the petrosal

ganglion enters into the picture and thereby complicates our conception as to the real origin of the pain if the Gasserian and nasal ganglion syndromes are to be used as comparisons. It has long been felt that there is no definite etiological factor for the major trifacial neuralgia syndromes, because no definite pathological change has been demonstrated on section. Reference to the illustration will show the distribution and connections of the glossopharyngeal nerves plainly.

Case I (A386270).—W. H. L., a man, aged sixty-four years, presented himself at the Clinic, March 14, 1922, complaining of severe paroxysmal stabbing pain in the ear and throat on the right side when he swallowed. He had noticed the trouble three years before while drinking cold water. Five years before he had had a similar attack. His tonsils were removed and he had had no further trouble until one year before, when he was relieved by having his teeth cared for. He had been well until three weeks before, when pain began in the right faucial region, radiating laterally to the area anterior and posterior to the right ear, and lasting from thirty to ninety seconds; the pain was definitely increased by talking and chewing, and was more constant during the day.

*Examination.* Findings in ears, nose and throat did not account for the patient's trouble. The physical examination was negative except for slight arteriosclerosis and moderate enlargement of the prostate. The systolic blood-pressure was 118 and the diastolic 80. Vision was 6/6 (with correction) in both eyes. Both pupils were slightly irregular. Reflexes and fields were normal. Both fundi were negative, except for slight choroidal sclerosis. A few peripheral lenticular opacities were noted. The Wassermann reaction, the urinalysis, the blood counts and the stereoscopic roentgenograms of the head were negative. A trigger area was discovered deep in the hypopharyngeal region. The only neurological findings were a slight to moderate diminution in perception of vibration and slight incoordination of both lower extremities. The neurologists diagnosed trifacial neuralgia, involving the auriculotemporal branch of the right mandibular division.

*Treatment and Course.* March 23, 1922, the sensory root of the right Gasserian ganglion was cut, the motor root being preserved. The patient was greatly relieved. April 8, there was complete anesthesia for tactile, pain and temperature senses over the area of dis-

tribution of the right trigeminal nerve. Sensation to touch and pain was normal in the external auditory canals and over the external aspects of both tympanic membranes. April 14, the patient returned to the Clinic. The pain had been constant for the last forty-eight hours. During examination the paroxysms were almost continuous. Morphin, hypodermically, gave but slight relief. April 25, the glossopharyngeal nerve was evulsed and the pharyngeal branch of the vagus cut. The patient has not had recurrence of the pain. For a few days after operation he complained of a sense of fulness in the right side of the pharynx with slight dysphagia. He has complete anesthesia to pain, temperature and touch over the area of cutaneous distribution of the right trigeminal nerve, over the mucous membrane of the right half of the buccal cavity, the right half of the alveolar processes, the tongue and hard palate and the anterior half of the right nasal cavity. Touch and pain are normally perceived over the entire surface of both external auditory canals, the external aspect of both tympanic membranes and both auricles. There is complete anesthesia to pain, temperature and tactile sensations over the entire right half of the inferior aspect of the soft palate. On its upper aspect the right half of the soft palate is completely anesthetic for 1.5 cm. anterior to its posterior border. All of the right half of the pharynx lying between the level of the hard palate above and the pyriform fossa below is completely anesthetic to pain, temperature and tactile stimulation. Pain, temperature and touch are normally appreciated over the posterior half of the nasal cavity and all of the nasopharynx above the level of a line drawn through the hard palate. Sensation is normal over the epiglottis and the upper aspect of the larynx. Taste is absent for salt, sweet, bitter and sour over the entire right half of the tongue. There is paresis, Grade 2 to 3, of the right masseter and temporal muscles; the right pterygoid muscles are normal. The right half of the soft palate and the right superior, middle and inferior constrictors of the pharynx are totally paralyzed. There is loss of tone of about Grade 2, without actual loss of power, in the right half of the tongue.

Case II (A118335).—Mrs E. M., aged fifty-seven years, came to the Clinic, May 2, 1922, complaining of pain in the throat. With the exception of typhoid at fifteen years and pneumonia at eighteen she had never been seriously ill. She had had ptosis of the right eyelid as long as she could remember. She had been perfectly well until the summer of 1921, when she developed occasional mild, sharp,

paroxysmal pain, lasting a second or two, originating in the right side of the throat and radiating to the region around the angle of the right mandible. Gradually the paroxysms increased in severity, but they never came in series. After recurring several times daily for six or eight weeks the pain ceased as mysteriously as it had begun. April 10, 1922, after she had taken a drink of cold water, the trouble she had had during the summer of 1921 recurred suddenly. Now, however, the paroxysms continued in series over a period of three or four minutes. April 17, she had a recurrence of paroxysms, and they have recurred at intervals of about twice a week. A choking sensation has accompanied all of the attacks. She did not become cyanotic or really dyspneic.

*Examination.* The patient was well preserved, moderately developed and fairly well nourished. Her blood-pressure on two occasions was 195 systolic and 120 diastolic; her pulse was 76. The blood Wassermann reaction was negative. The ear, nose and throat findings were negative. Vision was 6/12 and 6/6 in the right and left eyes, respectively (with correction). The right pupil was slightly larger than the left; the reflexes were normal. Except for slight reduction in the caliber of the retinal arteries the fundi were negative. Neurological examination was negative except for slight reduction in hearing in the left ear and ptosis, Grade 1 to 2, of the right upper eyelid. During the examination she had numerous paroxysms of severe pain. Unfortunately, this patient left the Clinic without treatment.

Case III (A388607).—J. H., a man, aged sixty-one years, presented himself at the Clinic, April 10, 1922, complaining of pain in the region of the left external auditory meatus. As a child he had had "spotted fever," which resulted in the loss of the right eye. During adolescence he had had repeated attacks of suppurative otitis media; he had had a discharge from the left ear for ten years. From childhood until the age of fifty years he had suffered from migraine. Nine years before he had become aware of repeated twinges of pain in the region immediately inferior and posterior to the left external auditory meatus. At first the pain was slight to moderate in severity; within thirty-six to forty-eight hours it became excruciating and the attacks recurred at intervals of ten to thirty minutes. After eight to ten days the seizures diminished in frequency and by degrees ceased. Six years before, he had had a second attack lasting eight or ten days; morphin alone gave relief. A third attack, not so severe or persistent, had occurred four

years before and had lasted two or three weeks. For two weeks, in the latter part of January, 1922, and the first part of February, exceedingly severe attacks occurred at short intervals. The pain was sharp, stabbing and stinging; it came on suddenly in the area posterior and inferior to the left external auditory meatus, radiating down to the region of the angle of the left mandible. The first attacks lasted only two or three seconds; the fourth and last attacks persisted from thirty to fifty seconds. The pain never occurred in series of more than two or three paroxysms. Sudden movements of the head and neck, talking, drinking and fright seemed to induce paroxysms. Swallowing, especially of hot or cold fluids, was most likely to start the pain.

*Examination.* The patient appeared old beyond his years. He had a glass eye in the right socket, severe pyorrhea, systolic blood-pressure 220, diastolic 110, pulse 72 and arteriosclerosis, Grade 3. The Wassermann reaction was negative. Vision of the left eye was 6/20 (with correction). The pupil was small and irregular; the reflexes were normal. The field was normal to rough test. The iris was atrophic; the globe was rather soft and the pupil did not dilate. The fundus was seen with difficulty; there were no definite vascular changes. Atrophic tonsils, normal nasopharynx and larynx, a glazed appearance of the surface of the mucous membrane of the pharynx and slight irregularity of the nasal septum were observed. A definite trigger area was not found. When inspissated cerumen has been removed from the right external auditory canal the tympanic membrane was found thickened. The left external canal was filled in its internal two-thirds with fibrous and mucous polyps and muco-purulent discharge. Stereoscopical roentgenograms of the left mastoid disclosed cloudiness, Grade 3, while three biopsies on the polyps proved them to be myxomatous. The Barany test revealed loss of function of the left vertical canal.

*Treatment and Course.* As the patient was not a good operative risk, the polyps were removed and radical operation deferred. May 21, the pain returned and the patient was seen in the Section on Neurology, where the only additional findings on complete examination were static and movement tremors of moderate severity and slight incoordination of the extremities. There was no loss of sensation to touch, pain or temperature in the tongue, pharynx, hypopharynx, nasopharynx, soft palate, pillars, tonsils and external auditory canals. Taste was preserved anteriorly and posteriorly over both sides of the tongue. During examination, May 24, a sudden attack of excruci-

atingly severe pain lasted about thirty seconds; it appeared and disappeared suddenly. During the paroxysm the patient coughed in a hacking manner every two or three seconds. Afterward he continued to hack, though less often, to relieve a sense of irritation in the left lateral pharyngeal region.

SUMMARY. The distribution of the pain in these cases was considered atypical, but the paroxysms were exactly like those of trifacial neuralgia. The paroxysmal character differentiated the type of pain from otalgia. When the pain recurred after section of the sensory root of the Gasserian ganglion in the first patient, it became apparent to the neurologist that the condition was similar to trifacial neuralgia, but that a nerve other than the trigeminal was involved. Harris' study of glossopharyngeal neuralgia convinced Doyle that these particular patients suffered from this disturbance.

It may be noted that the patients in this series were beyond middle life, and that in Cases II and III, there was definite hypertension. In Case III, the man was old beyond his age, with severe arteriosclerosis and with renal function greatly reduced; he was, in fact, such a bad surgical risk that the internist felt that he should not be operated on. It is an interesting fact that in Case I this same type of pain was relieved by removal of the tonsils, and subsequently by the care of the teeth. At the time of the examination, however, there were no discernible foci of infection, although there was a definite trigger area in the hypopharynx. In Case III, as will be recalled, there were many foci. The middle ear was filled with polyps and any probing or instrumentation here acted as a trigger. Patients often complain of parietal pain of a neuralgic type following instrumentation in certain cases of chronic suppurative otitis media. However, the pain is not constantly neuralgic as in glossopharyngeal neuralgia. In Cases I and II, besides paroxysms of pain, there were symptoms suggestive of irritation of the vagus. In Case II the patient had choking sensations and in Case III a non-productive cough. It will be recalled that the patients were not relieved by cocainization of the nasal ganglion, sedatives and palliative measures, and that in the first case section of the posterior root of the

Gasserian ganglion did not afford relief, whereas evulsion of the glossopharyngeal nerve has given permanent relief thus far.

It is a question of whether or not the syndrome arises from the petrosal ganglion. However, these cases presented the same clinical pain syndrome which was not relieved by procedures other than evulsion of the glossopharyngeal nerve in the first case. I believe that a glossopharyngeal neuralgia syndrome exists as a definite clinical entity.

The incidence of the glossopharyngeal neuralgia syndrome is not high, but it is definite.

S. B.—Since the preparation of this paper, one other patient has been studied and relieved of pain.

### Bibliography

1. Doyle, J. B.: A Study of Four Cases of Glossopharyngeal Neuralgia, Arch. Neurol. and Psychiat., 1923, ix, 34.

2. Harris, W.: Persistent Pain in Lesions of the Peripheral and Central Nervous System, Brain, 1921, xliv, 557.

3. Sicard, R., and Robineau: Algie vélo-pharyngée essentielle. Traitement Chirurgical, Rev. neurol., 1920, xxxvi, 256.

---

### Discussion

Dr. Greenfield Sluder, St. Louis, Mo.:

I am personally delighted to have heard this paper. It deals with the question of pain in the head and the neck. Anyone who works with these cases in any number is constantly confounded with the complexity of the presentation. Dr. Lillie spoke of the confusion with a trigeminal major neuralgia. There is a larger number of such cases than I believe appears. Dr. Adson has spoken of them and I think Dr. Blair knows something about them. They cannot be classified. They are not relieved by extensive root resection of the trigeminus, they are not nasal ganglion cases and I am perfectly delighted to learn that glossopharyngeal neuralgia of the tic variety can exist. I have never seen such a case, certainly did not recognize it at all, and it will be a definite help in the classification of these pains.

Dr. Roy A. Barlow, South Bend, Indiana:

The predominating symptom of this glossopharyngeal syndrome is pain. It was my privilege a short time ago to see in my office a

patient with the above-described clinical picture, a patient in middle life, well preserved, throat and nose negative except for a slight lowering of the bone conduction, a finding to which I attached very little significance. His own history and conversation were decidedly disjointed because of the frequent flashes of pain brought on by talking. I was also able to produce this same paroxysm of pain by having him drink cold water. Also, there was a decided flushing of the left side of the face with each attack of pain. He had been suffering in this way for nine weeks, and because of the painful swallowing and eating had lost considerable weight. As a matter of personal interest, I cocainized his nasal ganglion with 20 per cent cocain with no relief; swabbing the pharynx was likewise fruitless. I was unable to demonstrate a "trigger" area. The sensory roots of the glossopharyngeal nerves were evulsed and the patient has been completely relieved. A second case presented itself to me just before I came to this meeting. A man, aged forty-two years, who had his tonsils removed one year ago, followed by persistent irritative cough, most marked during eating or talking. He had had all forms of local treatment with no relief. The throat examination was negative, a very satisfactory tonsillectomy having been performed. Drinking cold or hot liquids would bring on an attack. Cocainization gave no relief. I have not had time to follow this case up, but I feel that this may also fall in the above classification with a modification of the vagus neuron. Having once seen this clinical picture, one never forgets the excruciating agony of which these patients are subject.

Dr. Richmond McKinney, Memphis, Tenn.:

I have seen several cases of apparent glossopharyngeal neuralgia following tonsillectomy. Recently, I saw a young woman who had had her tonsils removed five years ago. She has had constant pain in the right glossopharyngeal region ever since. I thought perhaps it was due to contraction of scar tissue. At the risk of throwing a controversial bomb into this meeting, I may say these have all been after the dissection and snare method, not after the Sluder method.

The President:

The Chair would like to ask Dr. Lillie to state whether in these cases there was not anything at all of a return of the attacks of pain at certain specific times? Whether these patients would run along for months entirely free and then begin to get attacks with any sort of regularity? Did he notice a periodicity that would show an old chronic condition of a malarial type?

Dr. Vilray P. Blair, St. Louis:

I wish only to confirm Dr. Sluder's statement that one who observes many of these typical trifacial neuralgia cases will find some that vary in their symptoms. I am a bit disappointed to look back and see how lacking I was in not recognizing 2 cases of the syndrome Dr. Lillie has described. Possibly I was misled by the fact that I have seen 1 case of typical trifacial neuralgia with a concurrent pain in the outside of the whole right thigh which was cured by the treatment of the affected fifth nerve. When I saw the cases with the pain centered in and about the ear, I thought of J. Ramsey Hunt's explanation that it could come through the great superficial petrosal nerve. In these 2 cases I cut this nerve as well as a root of the fifth, but the results were not satisfactory.

Dr. Lillie (closing):

The paroxysmal type of this pain is characteristic. It will be recalled that these patients have had several attacks of this paroxysmal pain, lasting over varying periods. The second case was relieved by the removal of surgical foci of infection. The possibility of malaria as a causative factor did not occur to us. The patients did not come from malarial districts. Until about eighteen months ago this neurological pain syndrome was not recognized in our clinic, but it is now recognized as a definite clinical entity and falls in the category of major facial neuralgia.

# FURTHER EXPERIENCE IN THE USE OF TISSUE JUICES IN TONSILLECTOMY

JOSEPH B. GREENE, M.D.

In the removal of the faucial tonsils there are three chief considerations aside from the anesthetic which should ever be borne in mind:

1. The prevention of hemorrhage.
2. The lessening of trauma.
3. The avoidance of infection.

It is my opinion that infection is largely due to hemorrhage and trauma, and these causes can be greatly reduced by a technic, which I shall describe later.

The clotting of blood is a very interesting and complex phenomenon, and we should make use in a larger way of this physiological process in our surgical operations. The control of bleeding in tonsil surgery is a bit different from that which usually confronts the general surgeon in that the gland is surrounded by delicate and important structures and the region also is none too easy of access for the usual surgical measures. In throat surgery there is also the added hazard of inspiration of blood into the lower respiratory tract with the danger of a complicating pneumonia or lung abscess. These factors and others make it imperative that bleeding be prevented and controlled as accurately as possible.

The development of tonsil surgery has made wonderful strides within the memory of most of us. In the beginning the surgeon was quite satisfied with the removal of the presenting portion of the hypertrophied tonsil, the submerged or inconspicious looking gland not being disturbed. This was in the days of the tonsillotome. In the next step of development of tonsil surgery we find the operator quite satisfied and sometimes boastful when

he had succeeded in dissecting the tonsil in its entirety, though the fossa should show evidence of marked trauma and shreds of muscle tissue be attached to the gland. This marked the era of the early dissecting operation. Thanks to the urging of the late Hudson Makuen,[1] Kenyon[2] and others the technic of tonsil surgery has been so perfected that we now have a feeling of disappointment, if not embarrassment, when injury has been done to adjacent structures. This statement has no reference to the technic of tonsil removal, whether by dissection or other methods.

It has occurred to me that at the present time more heed might well be paid to the two important factors of hemorrhage and trauma. Possibly the introduction of the suction apparatus has been in a measure responsible for this seeming indifference to the loss of blood, in that it can by this measure be so readily removed from the field of operation and the amount of hemorrhage be not fully appreciated. Although not wishing to enter into a discussion as to the advisability of the use of the suction apparatus, for it has been too generally accepted by our profession, yet I am of the opinion that its use tends to encourage bleeding rather than to favor clotting in the open vessels. While it is not my intention to discuss with you all the theories which have been offered to explain the clotting of blood, yet it seems desirable to recall with you some of the principles concerned in this important physiological process. In the first place, as you well know, blood does not clot in the body during life, though the important elements thrombogen (prothrombin), calcium and fibrinogen are present. According to Morawitz[3] the element thrombokinase is lacking in the circulating blood, though it is present in shed blood being derived from the disintegrating white cells, particularly the blood platelets and the injured tissue cells. It is thought that the thrombokinase of shed blood acting on the prothrombin in the presence of calcium converts it into thrombin, and this thrombin acting on fibrinogen forms fibrin. Howell[4] terms this product, which accelerates the clotting of blood and which is found in the injured tissues and in the broken-down, white cells, "thromboplastic substance." It has been noted that blood obtained without passing through injured tissue clots much more slowly than when brought into contact with wounded tissue or the tissue

juices (tissue fibrinogen) of the body. The clotting of blood which concerns the surgeon is the normal clotting which takes place in accidental injuries to tissue or in surgical wounds. Brain surgeons (Cushing, Dowman[5] and others) have long made use of the application of muscle tissue to facilitate clotting in troublesome bleeding, and we have already at hand, on removal of the tonsils, these coagulant elements of the tissue juices at the very place where most needed. Tissues of the body vary greatly in the activity of their clotting elements, and it has been proven that the lungs, brain, kidney and skin contain this tissue fibrinogen in the greatest abundance. Recently, Mills[6] has succeeded in making an extract of lung tissue which is more powerful than that obtained from the brain and other tissues of the body. It possesses such strong clotting qualities that 1 cc injected into the vein of a rabbit caused death from general thrombosis in less than a minute. This same extract when mixed with blood plasma in proper proportions caused clotting within ten seconds. Tissue extracts which are on the market under various names, as thromboplastin (Squibb), hemolitic serum (Mulford) and hemogulin (Lilly), are obtained from calves' brains, while coagulin ciba (Fonio) and coagulose (Parke Davis & Co.) are prepared from blood platelets. Although my experience with these preparations has been too limited to express an opinion as to their value, yet from a theoretical standpoint they might be at times useful.

Due to the kindness of Dr. C. A. Mills, of the biochemical laboratory of the University of Cincinnati, I am able to give the activity of the clotting elements of the tonsils. The tonsils were taken from an adult, though Mills says children's tonsil tissue possesses practically the same degree of activity as does that of an adult. He says, further, in his report: "The yield (extract) was 0.9 per cent of the weight of fresh tissue, or about one-third the yield from lung tissue, which is the most active tissue in the body in this respect. This should rate the clotting activity of the tonsillar tissue as about equal to that of the kidney, testes and brain. I think you will find that it is the injured tonsil tissue itself that aids in the control of hemorrhage." The result of the test follows:

1 cc citrated horse blood + 0.35 cc 1 per cent $CaCl_2$ clotted in 13 min.
1 cc " " " + 1.0 cc tonsil extract + 0.35 cc 1 per cent $CaCl_2$ clotted in 55 sec.
1 cc " " " + 0.5 cc " " + 0.35 cc 1 " " " in 1 m. 10 "
1 cc " " " + 0.3 cc " " + 0.35 cc 1 " " " in 1 m. 20 "
1 cc " " " + 0.2 cc " " + 0.35 cc 1 " " " in 1 m. 35 "
1 cc " " " + 0.1 cc " " + 0.35 cc 1 " " " in 2 m. 0 "

I am indebted to Drs. Anderson and Leonard, of Squibb's biological laboratory, for carefully extracting the clotting elements of the tissues of a pair of tonsils despatched to them a short time ago. The tonsils from a child, aged six years, were removed with almost no bleeding. The clotting time of his blood was eight minutes. "The capsule was removed from the tonsils as carefully as possible and an extract made from this tissue as well as that of the gland itself. Tests were then made with sheep plasma, using varying dilutions of the tissue extracts to determine the clotting time of the glandular portion and the capsular portion compared with thromboplastin (Squibb.) The normal clotting time of the sheep plasma without the addition of any coagulant was eighteen minutes and five seconds. All dilutions were made by adding physiologic salt solution to the tissue juice extract. (All tests were made in duplicate.) The test was made after adding two drops of the varying dilutions of the extract to the sheep plasma." The result of the test follows:

| C = capsular portion. | | | G = glandular portion. | | | S = thromboplastin, local (Squibb). | | |
|---|---|---|---|---|---|---|---|---|
| C undiluted | 1 min. | 35 sec. | G undiluted | 0 min. | 53 sec. | S undiluted | 0 min. | 50 sec. |
| | 1 " | 38 " | | 0 " | 58 " | | 0 " | 53 " |
| C 1 in | 5 dil. | 1 min. 10 sec. | G 1 in | 5 dil. | 1 min. 10 sec. | S 1 in | 5 dil. | 0 min. 50 sec. |
| | | 1 " 25 " | | | 1 " 10 " | | | 0 " 47 " |
| C 1 in | 10 " | 2 " 20 " | G 1 in | 10 " | 1 " 30 " | S 1 in | 10 " | 1 " 10 " |
| | | 2 " 25 " | | | 1 " 35 " | | | 1 " 15 " |
| C 1 in | 100 " | 4 " 15 " | G 1 in | 100 " | 1 " 40 " | S 1 in | 100 " | 1 " 30 " |
| | | 5 " 35 " | | | 1 " 35 " | | | 1 " 40 " |
| C 1 in | 500 " | 7 " 35 " | G 1 in | 500 " | 3 " 5 " | S 1 in | 500 " | 3 " 30 " |
| | | 8 " 0 " | | | 3 " 40 " | | | 3 " 20 " |
| C 1 in | 1,000 " | 13 " 5 " | G 1 in | 1,000 " | 6 " 20 " | S 1 in | 1,000 " | 6 " 10 " |
| | | 13 " 25 " | | | 6 " 35 " | | | 7 " 0 " |
| C 1 in | 5,000 " | 19 " 10 " | G 1 in | 5,000 " | 11 " 5 " | S 1 in | 5,000 " | 12 " 1 " |
| | | 19 " 25 " | | | 11 " 55 " | | | 10 " 40 " |
| C 1 in | 10,000 " | 26 " 20 " | G 1 in | 10,000 " | 17 " 5 " | S 1 in | 10,000 " | 18 " 10 " |
| | | 27 " 2 " | | | 18 " 10 " | | | 18 " 40 " |

It may be of interest to quote from Mills,[7] who has done a large amount of work on the clotting of blood. He says: "The circulating blood contains very little tissue fibrinogen, so that it is able to remain fluid and still contain soluble calcium salts and blood fibrinogen. However, in event of tissue injury with rupture of bloodvessels the escaping blood is immediately mixed with tissue juices and clotting induced. It has been found that those tissues in which hemorrhage is most dangerous possess the richest store of tissue fibrinogen, so that bleeding there is most quickly controlled. Such tissues are the brain, lungs, kidney and the endothelium of the bloodvessels. Not only does the escaping blood clot quicken when mixed with the juices from the tissues, but the amount of fibrin formed is much greater and the texture more firm. The additional strength thus imparted to the fibrin plug filling in the opening renders subsequent rupture less likely."

In my original paper, published in 1916,[8] I made use of the tonsil as a means of preventing hemorrhage and lessening trauma only during the first stage of the dissection of the gland. However, during the last several years I have extended the use of this technic until now I rely largely on the application of the tonsil to the fossa for the control of bleeding during the entire process of dissection and after removal. In my experience it accomplishes this purpose far better than a gauze sponge, in that it supplies the clotting elements of the tonsils and the wounded tissues to the mouths of the open vessels, thus forming a firm and abundant clot. In the technic of holding the tonsil firmly in the fossa before bleeding takes place, the tissue juices are applied in the most effective way, for the reason that these coagulant elements are not diluted nor are they washed away by the first rush of blood. Leaving out of consideration for the moment the action the tissue juices in causing clotting, there is no sponge which would give such accurate pressure with so little trauma as the tonsil itself. Furthermore, surgical sponges by their absorptive action on the tissue juices tend rather to lessen the clotting tendency of the blood, though they are effective as a means of applying pressure. In this connection it may be of interest to quote from a personal communication of Prof. Howell, of the Johns Hopkins University.

He says: "Your procedure can certainly be depended on, on *a priori* grounds, as introducing a favorable condition for clotting. The point is, the clotting of blood is much favored by tissue juice, the so-called thromboplastic action of the tissues. In dissecting off the tonsils there is much wounding of the tissues, but by your procedure of laying back the tonsil you add something to this exposure of the oozing blood to the tissue juice of the lacerated tissue and thus help the process of clotting." The technic in brief, is as follows: The tonsil is seized with forceps and the upper third is carefully dissected, using by preference sharp or semi-sharp instruments. Should vessels of any importance be encountered during this stage of the operation the tonsil is at once pushed back into its fossa and held firmly until bleeding is controlled. When the upper part of the tonsil has been sufficiently dissected the wire loop is slipped over the tonsil and its removal accomplished by slow action of the wire snare. The time required for this step is about one minute for each tonsil. The last and most important step in the operation after its complete severance is the holding of the tonsil firmly and accurately in its fossa for a period of about two minutes. This may be done by the assistant, and it should be borne in mind that the gland is at no time taken from its position in the fossa until about two minutes have elapsed to ensure the closure of the mouths of the vessels with a firm clot. As a rule, though of course there are exceptions, it is not necessary on removal of the tonsil to sponge the fossa to control any immediate postoperative bleeding, and rarely is it necessary to catch a bleeding vessel. The avoidance of sponging and the use of forceps in the wound will greatly lessen trauma. The element of shock, though still not thoroughly understood, yet it is a recognized fact that hemorrhage and trauma are important factors in its production. In this connection it may be well to mention the occurrence of shock in varying degrees of intensity. While all the underlying causes are not thoroughly understood, still it is recognized that hemorrhage and trauma are important factors in its production. It is well known that young children, and those of all ages whose health is below par, withstand the loss of blood badly. The fact that so many of our patients requiring operation come within this class makes it desirable to emphasize the importance of conserving all blood possible.

The objection which might be offered to this method of the control of bleeding is the possible danger of introducing the infection present in the tonsils into an open wound. This danger appears to me very remote, for the reason that the severed side of the tonsil is not the infected area of the gland. There is quite as much danger of carrying infection with a sugical sponge, for the reason that the mouth is a natural habitat of various infectious organisms.

In conclusion, I wish to emphasize the following points:

1. The application of the tonsil itself to the open vessels of the fossa controls bleeding more effectually than the usual method of sponging.

2. This technic conserves the patient's blood, and at the same time lessens trauma.

3. In the reduction of hemorrhage and trauma, the danger of infection becomes less and convalescence is hastened.

### Bibliography

1. Makuen, G. Hudson: New York Med. Jour., August, 1911.
2. Kenyon, E. L.: Illinois Med. Jour., June, 1916.
3. Morawitz: Beitr. chem. Physiol. u. Path., 1904, v, 171.
4. Howell: Physiology.
5. Dowman, C. E.: Surg., Gynec. and Obst., September, 1914.
6. Mills, C. A.: Jour. Biol. Chem., December, 1919.
7. Mills, C. A.: Med. Record, January, 1922.
8. Greene, Joseph B.: Laryngoscope, October, 1916.

---

### Discussion

Dr. George B. Wood, Philadelphia:

The idea of using fresh tissue substance for increasing the coagulability of the blood is, of course, not a new one, and it is probable that the majority of us have at times conceived the idea of checking a tonsillar hemorrhage with either the tonsil itself or of pressing one portion of the raw wound against the other. We are indebted, however, to Dr. Greene for his scientific study and for the working out of a practical technic which enables one to employ the removed tonsil for hemostatic purposes. The important part of Dr. Greene's technic is the immediate placing of the tonsil in the wound after it has been

severed by the snare and not removing it from the mouth. The chief difficulty in bringing hemostatic substances in contact with the bleeding vessel is the hemorrhage itself, and I can readily see that the immediate pressing of the tonsil into the wound gives the hemostatic action of the tonsil substance a better chance to come in contact with the bleeding vessels. However, I do not believe that severe hemorrhages can be controlled by any substance which has simply an action on the coagulability of the blood. In these cases we must use mechanical measures such as surface ligation or the placing of sutures.

Dr. Lee M. Hurd, New York:

I would like to ask Dr. Greene two questions: First, how many times has he done the procedure for comparison with the same number of cases without this, as we know the percentages of primary and secondary hemorrhages? Second, in resection of the tonsil he must have the capsule invaginated, and he is getting his tonsillar surface against the tonsillar fossa and not the capsule, due to the fact that the tonsillar fossa, from retraction by the muscle about the fossa, is larger after the tonsil is removed. I have tried to put the tonsil back, but it would not fit the hole by one-third. The tonsil juice method seems to be on the right track, as we know that the tissue juices are an important element in coagulation of the blood. I am working on phosphorized lipoids from the lower animals at the present time, on which I will report later.

Dr. Frank R. Spencer, Boulder, Colo.:

I have not had any personal experience in replacing the tonsil to control hemorrhage, but I believe this is based on a very sound principle. My chief, Dr. Robert Levy, in the department of otolaryngology, has been using this method of replacing the tonsil, but I am not familiar with the results he has obtained. We have been in the habit of doing most of our tonsil operations under general anesthesia and putting in a sponge for a few minutes to control the hemorrhage. We ligate the bleeding vessels with catgut if a sponge does not stop the hemorrhage and have the throat absolutely dry before the patient is put to bed. We have not used a needle to stitch the vessels, but we tie a piece of plain catgut over the end of a hemostat.

We have used suction for seven years. It has two advantages: (1) It gives a clear field. (2) It prevents aspiration of blood. It is is said to have two or three disadvantages. It may remove clots from the vessels. Perhaps by using Dr. Greene's method we may have less use for the vacuum bottle.

We have used most of the commercial products for controlling hemorrhage, such as thromboplastin (Squibb), coagulose (Parke, Davis & Co.) and recently Lilly's product called hemagulin. I have had too limited an experience to make any statement concerning hemagulin. I am watching with interest to see what results Dr. Greene will get from the use of these. We feel we get definite results from thromboplastin when there is oozing from delayed primary tonsillar hemorrhage.

Dr. Greene (in closing):

I appreciate very much the discussion of my paper, and would like to say that in the face of troublesome bleeding one would not, of course, temporize by using the tonsil for its hemostatic qualities. The use of the artery forceps to catch the bleeding vessel and hold for a few minutes is usually sufficient. It may be stated, however, that the use of artery forceps in this way takes advantage of the clotting elements contained in the tissues of the vessel walls. It has seemed to me that if one dissects the tonsil accurately in its capsule that there is little danger of encountering the large vessels which have been recently described by Dr. Schaeffer. In answer to Dr. Hurd's question as to the number of cases on which it has been tried, I will say that I have no accurate record as to the number, though I have made use of this method of preventing hemorrhage in tonsillectomy for a period of about one and a half years. This method has a very striking advantage over the previous method of the use of the gauze sponge. In conclusion, I would like to say that at times it is necessary to supplement the use of the tonsil with the application of a sponge to the tonsil itself in order to secure more accurate coaptation of the cut surfaces of the fossa. This measure also gives added pressure which should prevent the difficulties experienced by both Dr. Wood and Dr. Hurd.

# STENOSIS OF THE LARYNX AND THE TRACHEA. TREATMENT SHOWN BY MOVING PICTURES.

BY FRANCIS W. WHITE, M.D.

FOUR years ago this patient attempted suicide by cutting his throat. He was rushed to a hospital and a primary suturing of the wound was performed after the introduction of a tracheotomy tube. The tube remained in place three days. The patient remained in the hospital three weeks, after which time he was sent home and returned to work. He suffered from difficult breathing, and at the end of about a week was suddenly attacked with severe dyspnea and fell to the sidewalk unconscious. He was again taken to a hospital, where tracheotomy was performed under local anesthesia. He remained in this institution ten weeks. He was then discharged with the tracheotomy tube still in place. There developed a mucopurulent discharge from the tracheotomy wound and the same material was expectorated in large quantities. Later this discharge became markedly blood tinged. He was admitted to the Manhattan Eye, Ear and Throat Hospital and placed on Dr. Harmon Smith's service, put to bed and treated expectantly, while the suppurative process slowly ceased.

A larygngotomy was performed and a considerable amount of fibrous and granulation tissue in the trachea and larynx was removed. The anterior portion of a number of the cartilaginous rings of the trachea above the tracheotomy wound were missing, thus allowing a sucking-in of the structures upon inspiration when the tracheotomy tube was not in place, due, no doubt, to the frequent trauma and subsequent suppuration. No attempt was made to suture the thyroid cartilage, as it was hoped that a pseudo, false or fibrous joint might be formed simply by suturing the musculature and skin, leaving ample space for the large-size tracheotomy tube to be inserted. As soon as the inflammatory reaction

had subsided, dilatation of the larynx and trachea was instituted. At first dilatation was begun by means of an ordinary laryngeal applicator, and then by graduated intubation tubes, and also by means of a double piece of a No. 16 French catheter. This was left in place for three days at a time; later a similar piece of No. 18 was introduced. Subsequently a low tracheotomy was performed to allow closure of the high tracheotomy wound and to allow lengthening of the dilating tubing in the larynx and trachea.

(Moving Picture.)

---

## Discussion

Dr. Henry L. Swain, New Haven, Conn.:

Seeing the pictures reminded me of a case I had years ago where a man had been thrown through an automobile wind shield and had cut his larynx across diagonally, cutting the cartilages in a very sad sort of way. When rushed to the hospital the general surgeon attended to him, sewed the wound up and the man made apparently an uneventful recovery, only to have the same thing happen as in Dr. White's case. He was out on the street one day and fell down and nearly passed away on account of obstruction to breathing. He was quickly rushed to the hospital; there a low tracheotomy was done, *in extremis* almost, and he was subsequently brought down to the New Haven Hospital. We became interested in what had happened and found in looking down through the Killian tubes a large mass in the larynx composed of displaced pieces of cartilage, the white cartilages showing uncovered in three places. I do not know what I removed, but these objectionable pieces of cartilage that came into the larynx lumen I pinched off with biting forceps by a series of endeavors, and by the end of about a month restored a lumen to the larynx which was satisfactory to him. He acquired pretty good voice and subsequently, two years later, he came into my office and said, "You do not remember me?" I said, "No." He talked in a fairly clear voice, "Do you not remember me?" "No, I do not remember you." "Well," he said, "I was the man who had a fractured, lacerated larynx." Then it was interesting to see by indirect laryngoscopy what he had in the way of vocal cords. He had two fairly well-developed white cicatrices, or scar bands, that gave him very good voice, just as we see after thyrotomy or hemi-

laryngectomy. Evidently the false vocal cords came away in the melée and we do not know what happened to them. The man had a useful larynx and I felt very well satisfied with the work done through the Killian tube.

Dr. Harmon Smith, New York City:

I think Dr. White is to be commended for his long and tedious procedure and for the very successful outcome of the case. I had a case, some years ago, of an attempted suicide where the patient had cut his throat transversely and obliquely across the thyroid cartilage, severing one vocal cord at its anterior attachment. The surgeons in a Southern city had tried to close the outer wound without regard to the laryngeal mechanism within. After six months he came under my care with a fistulous opening in the thyroid and with scarcely any voice. I did a laryngo-fissure, stitched the flapping cord into place and closed the outer wound by a plastic operation. In due course of time his voice returned and likewise the motility of the severed side. Whether the recurrent laryngeal nerve reëstablished its function or whether it had never been severed is a question of conjecture; but, nevertheless, the patient recovered his voice, his fistulous tract ultimately closed and he was able to resume his occupation. This case, as well as others I have reported, shows conclusively that the larynx will stand an unusual amount of trauma without permanent injury.

Dr. Samuel McCullagh, New York City:

I had the privilege of seeing this patient about a week ago, and though I did not have an opportunity to examine the larynx, I tested out his voice roughly and it can very readily be heard at sixty to seventy-five feet. The voice is not a clear one, but the man is very happy, very comfortable and apparently suffers no ill effects from what he has gone through.

Dr. Emil Mayer, New York City:

I would like to ask whether the original attempt at suicide was in the hospital?

Dr. White:

No, not in a hospital.

Dr. Mayer:

I am particularly interested because of an almost similar case that I had occasion to see, that is worth while recording briefly. A man

was admitted to Mt. Sinai Hospital suffering for a long time with terrific pains in his legs, so much so that the diagnosis had been made of an incurable condition, and learning that his condition was incurable, he went into the toilet of the hospital and cut his throat with a razor that he had secreted. Help was immediately at hand; he had severed the larynx and trachea pretty thoroughly, but bleeding was promptly stopped and a tracheotomy tube was inserted directly into the wound he had made. He made a good recovery. A few days later I was asked to see the man and see what could be done with him toward closing the wound and eliminating the tracheotomy tube. He had slashed into things very thoroughly, severing the thyroid from the epiglottis and making a terrible gash. However, he was placed in my care and dilatation was practised and the parts coapted, and we began to feel some hope for him. Desirous as he had been of "shuffling off this mortal coil," he now became extremely desirous of living. The long time required for his treatment prevented his remaining in that hospital, and he then went into a hospital for chronic diseases. The last I saw of him was that he was extremely anxious to be without his tracheotomy tube.

I thought from the description of Dr. White's case that it was this same individual. From a large experience of similar cases I endorse what Dr. Smith has said as to the extreme tolerance of the larynx to severe manipulations, and how gratifying the results eventually are if you only have patience, and Dr. White has certainly evidenced this. One thing more in connection with this presentation: I would like, officially, to thank Dr. Law for coming to this meeting and assisting Dr. White in making this fine demonstration.

Dr. White (in closing):

I wish to express my appreciation to Dr. Law for his kindness in coming here and presenting the picture for us and also for his invaluable aid in helping me last winter in the photography of the larynx.

There seems to be a peculiar psychology associated with attempted suicide by throat-cutting. Whether it is a *bona fide* attempt or an act to gain sympathy it is difficult to say. Most frequently the attempt is carried out while gazing into a mirror, with the head tilted well back, thus pushing the larynx and trachea forward, and at the same time removing the vital structures in a posterior direction, such as the large vessels of the neck. It is for this reason that the cutting of the throat is so rarely fatal. In the particular case under discussion I do not believe the patient really wanted to die.

The remarks of Dr. Swain and Dr. Mayer are decidedly *a propos*. The first or emergency treatment of this class of cases is very important and should come under the immediate care of the laryngologist. I know of an occurrence in which the general surgeon introduced a tracheotomy tube into the original gash and sewed it up, but unfortunately the tracheotomy tube was in the larynx, not in the trachea, and it was followed by an abscess with fatal termination. Under the best of circumstances these cases are discouraging to treat. In the case I have reported the patient was under my care in the ward for six months. I am very sorry indeed that he is not here, but his non-appearance is not due to any throat condition. His voice at the present time is very good, but when presenting him at the New York Academy of Medicine I had an experience similar to Dr. Smith's, for although in good voice he developed stage fright and gave visible rather than auditory signs of speaking.

I remember Dr. Smith's case very well, as I assisted him at the operation, and not so many months after was somewhat astonished to hear audible, intelligible, if not elegant, speech emanating from a patient who previously could not be heard or understood.

# BRAIN ABSCESS OF PARANASAL SINUS ORIGIN

GORDON BERRY, M.D.

THE following two cases of brain abscess of paranasal sinus origin presented unusual features which were not entirely cleared until autopsy. The first case had a chronic temporosphenoidal abscess of sphenoidal origin but giving no trouble until two weeks before his admission to the hospital in a semiconscious condition. Operative interference failed to properly drain the abscess, and death ensued six weeks later. The second case had an acute frontal lobe abscess of ethmoidal origin. Operative interference succeeded, the patient lived four years and died of a recurrence. With this postmortem evidence let us review the outstanding features of each case in their chronological development.

CASE I (F. C.).—A strong, vigorous, white male, aged forty-four years, was admitted to the Worcester Memorial Hospital on November 1, 1922, in a semiconscious condition. Healthy until two weeks previous, he then began to have severe headaches accompanied by a blurred and double vision. He grew rapidly worse. During the first three days of his stay in the hospital he had several spastic convulsions accompanied by jaw fixation and unconsciousness. The history told of a "sunstroke" seven years previously and of a gradual failing of the left hearing a little later while working in an army boiler factory. He gave a history of no eye trouble, no ear or nose infection, but an occasional sore throat and once or twice a "quinsy" sore throat with the escape of foul pus. Now his severe parietal headaches, more marked on the left, a choked disc of four diopters and retinal hemorrhages on the left, a blurring of vision, a greater spasticity of the right side during the convulsions, all pointed to some tumor process of the left base or left temporosphenoidal lobe. The pulse was bounding, the temperature around 99°. A decompression operation was decided upon, when the nurse noticed a coughing up of some thick, foul pus with an almost immediate relief of his brain-

pressure symptoms. At this time the writer first saw the case. In addition to the above localizing signs he noted a tactile partial anesthesia of the left nasal mucous membrane and of the left cheek (nerve V, divisions 1 and 2). The tongue pointed a little to the right (nerve XII). The left cochlea and labyrinth were dead, showing no response to stimuli, while the right side was normal (nerve VIII). There was outward past-pointing to the left. The Wassermann test was negative and the left acoustic paralysis was provisionally ascribed to his work in a boiler shop. There was some congestion of the fundus and some visual blurring on the right (nerve I). The diagnosis was thus made that we had an abscess in the middle fossa, near the optic chiasm, on the left, probably near the pituitary, and periodically draining into the sphenoid with consequent cranial pressure relief. There was, however, no especial clouding of the sinuses in the *x*-ray films, and locally there was only a little mucoid discharge from both upper nares, suggesting a slight acute "cold." If anything, the left sinuses were a little more involved, both clinically and in the picture. There was no sinus pain or tenderness.

*Operation.*—Under local anesthesia the left middle turbinate was removed and the posterior ethmoidal cells and the sphenoidal sinus freely entered and exposed. No diseased condition of the bone, no granulation tissue, no pus was noted. That portion of the posterior wall of the sphenoid and ethmoid represented by the anterior face of the sella turcica and the roof of the sphenoid and ethmoids were clearly seen and probed. The bone was solid, the membrane appeared healthy. Then part of the right middle turbinate was removed in order to permit free inspection of the right posterior nares. Neither now nor later did more than a congestive mucoid secretion show on this side. The right ethmoidal nerves were much more sensitive than those on the left, and working on the right put him into a spastic convulsion.

The next week showed improvement. He continued to cough up thick, foul pus about every morning. His mind was usually lucid and fairly active. The vision and fundi became better—almost normal on the right. The postoperative nasal congestion made examination of the sphenoid unsatisfactory, and I was never able to clearly demonstrate the source of this expectorated pus until autopsy. It came at rare intervals, and all at once. On the eighth day, when he began to show more brain-pressure symptoms, I did a low left-sided decompression operation, and Dr. B. T. Burley (the neurologist) explored for a brain abscess. Repeated tappings into the frontal and

temporosphenoidal lobe failed to reach the pus. Twice we obtained the clear fluid of the lateral ventricle. We could not go deeper than this, for to reach an abscess through a lateral ventricle is to invite a prompt general meningitis. Two days later we injected 30 cc of air into the left lateral ventricle, bringing on a temporary coma. An *x*-ray of the head was immediately taken and the air distention found almost all in the right lateral ventricle. The left ventricle was collapsed because of the near-by abscess. The periodical coughing up of pus continued; the patient seemed to rally. It was hoped that the brain abscess would work to the surface. Then he became more delirious and succeeded in getting his finger under his bandage. The wound became slightly pussy and the brain herniated a little. This discouraged the second tapping of the brain we were contemplating. From then on there was a slow, steady decline. The temperature, with one day's exception, remained between 99° and 100° for five and a half weeks after the operation, then rose in a typicalmeningitis curve with death seven weeks after admission.

Autopsy showed a large abscess of the left temporosphenoidal lobe below the lateral ventricle into which it had ruptured. It was just ready to evacuate itself at our decompression site when meningitis and death intervened. Its lateral extent posteriorly accounts for his acoustic and labyrinthine paralysis far better than his boiler-maker's occupation seven years previously, and we may even question the "sunstroke" at about the same time. An anterior internal lobulation of the abscess reached to the pituitary fossa, and in the floor of this was found a necrotic opening directly into the left sphenoidal sinus.

*Comment.*—If the writer's reasoning is correct, the process started in the sphenoid. How else can we account for the dehiscence in its roof? Then the sphenoid cleared and remained so, for it looked normal at the time of operation. At that time I failed to find the break in the roof which brings out so important an anatomical point that it will be discussed separately at the end.

Case II (Miss G. V.).—A well-developed Armenian woman, aged twenty-two years, was admitted to the hospital December 24, 1915, in a partial stupor and mentally unresponsive, with a history of acute left ethmoidal and frontal sinusitis, five weeks previously, and a temperature of 102° to 103°. The temperature had returned to

normal, the pain had gone and the profuse nasal discharge was clearing when a severe, almost fatal epitleptiform convulsion had come on ten days previous to admission, followed by headache, nausea, intermittent vomiting, a slow pulse (66), no fever and an increasing mental indifference to her surroundings. There was a left-sided exophthalmos, a suggestion of a left optic neuritis and a paralysis of the left external rectus.

Her personal history gives a turbinotomy for nasal obstruction five years previously and an early adenotonsillectomy. She had been otherwise healthy. Her father died of a shock, the mother had had convulsive attacks, two brothers had had psychoneuroses, for which one had been in an insane hospital. All the children were ambitious, educated and musically talented. There was absolutely no history of any specific involvement and repeated Wassermann tests of the blood and spinal fluid proved negative. We could find no tuberculosis.

On the first day a bony sequestrum, apparently the posterior half of the middle turbinate, was removed from the left ethmoidal region. A little pus was escaping and the patient's condition bettered with this improved drainage. Three days later, by the intranasal route, the left ethmoidal labyrinth was thoroughly exenterated and the frontal and sphenoid sinuses freely entered. She began at once to improve. The ethmoidal roof was not disturbed until three weeks later, when an attempt was made to punch away some granulation tissue which was crowding down from above. This proved to be a brain abscess projecting through an opening in the posterior ethmoidal roof, and the nasal punch removed the abscess floor with a consequent gush of about 2 drams of thick pus, followed by a hemorrhage which required temporary packing of the upper naris. An *x*-ray at this time showed the abscess cavity filled with air; a large oval area with clearly defined edges, placed vertically in the middle of the left frontal lobe. She had improved much during these three weeks, and now with minor temporary setbacks and no more convulsions she continued to improve until March 17, 1916, after a hospital stay of almost four months, when it was deemed safe to send her home. She had been up and around daily; the eyes had returned to normal; the left nasal discharge had almost ceased; there were no convulsions; she seemed normal.

It later proved that menstruation commenced the morning of her discharge. She felt so well that she started home on the trolley and stopped on the way to visit some friends. On reaching home she found more friends to greet her. She retired at ten. At midnight

her mother found her in a convulsion. Five more occurred during the next three hours. She vomited several times and was semiconscious the next day. That evening the convulsions came in rapid succession until she was readmitted to the hospital and 35 cc of neg-

CHART I.—Tracing of *x*-ray in Case II. Positive picture. Side view. Taken after operative evacuation of frontal lobe abscess.

ative spinal fluid removed by lumbar puncture, when she vomited, then fell into a quiet sleep. On waking her mind seemed clear but she could not say the proper word—for instance, she called everyone by her nurse's name. In spite of morphine subcutaneously and chloral and bromides by rectum she had thirty-five more convulsions the next night, relieved by the withdrawal of 30 cc more of negative fluid under pressure. For the first time the white count was now excessively high (31,500) and the urine showed albumin and casts. The convulsions ceased. The next ten days found her out of bed and her mind nearly normal, though her memory of what happened during the acute attack was very vague. She left for home in two and a half weeks (on April 17, 1916). She returned to the hospital a little over a month later (on May 28), when she had another series of convulsions lasting twelve hours and clearing under large doses of bromides and morphine, permitting her discharge on June 16. The following month there was a series of twelve convulsions. In November, 1916, she was so well that I felt justified in removing a diseased tonsil stump and some adenoid tissue. In January, 1917, she returned to the hospital, where she had about thirty-five more seizures.

Each convulsion began with a slight cry, the mouth opened wide and with a contorted facial expression, the eyes rolled upward, then the mouth closed, clonic convulsions of the extremities set in, with a laryngeal spasm and consequent extreme cyanosis. The attacks lasted from one to five minutes, and were at times so severe as to suggest their proving promptly fatal. A little ether would occasionally stop the attack, but usually the ether had to be pushed to an extreme narcosis before it would stop the rapidly succeeding convulsions. After an attack she went into a relaxed comatose state, from which she gradually wakened if another attack did not supervene. Scopolamine given in heavy doses was more effective than morphine. At first the attack was followed by mental aberration, later there developed a tendency to a rebellious obstinacy, which was quite contrary to her natural sweet disposition.

Then for three years she was free of these seizures. At times there would be a dull headache with slight mental aberrations which her physician, Dr. R. J. Ward, was able to clear by prompt catharsis, rest in bed and a controlled diet. Thyroid and pituitary extracts were tried. She filled acceptably a responsible position as stenographer and bookkeeper during the day and studied with her piano or gave music lessons in the evening. It was hoped that we had won through. Then, after a little initial deafness (the first ear complication

experienced) she had a violent left frontal headache and vomited bile on February 2, 1920. Two days later the neck was stiff and the bowels distended with gas. The temperature rose to 104°. There was no convulsive seizure this time. The meningitis was well advanced when she entered the hospital on February 9, and death followed on February 18, 1920, sixteen days after the onset.

The postmortem examination showed a large oval abscess in the left frontal lobe similar to that we found four years previously, with a generalized meningitis resulting from its rupture at the base.

*Final Comment.* The abscess in the first case was correctly diagnosed, but we could not reach it. The abscess in the second case was suspected, but the strong neurotic element with insanity in the family made us think of possible hysterical or epileptiform seizures, with the suppurative ethmoiditis as an irritant. Here a kindly chance helped and we successfully drained the frontal brain abscess. But the convulsions did not cease for a year. Some were so severe as to almost kill her. Operative entrance through the frontal table of bone and exploration for a reformed frontal abscess was repeatedly considered. But it was pointed out in consultation that the former abscess might have left contracting scar tissue which might account for the epileptiform seizures. Operative interference was therefore not undertaken. After over one hundred of these convulsions she apparently got well and remained so for three years of a busy, happy life. Then came the rupture of the dormant brain abscess and death from a rapidly fulminating meningitis.

Anatomically it is interesting to note that the two abscesses went through two of the thinnest points in the roof of the nose. The floor of the pituitary fossa is often thinner than the anterior face in the large type sphenoidal sinus while the roof of the anterior part of this cavity and of the extreme posterior ethmoidal cells is covered by the thicker bone of the lesser wing. In front of this begins the widest part of the cribriform plate and the neighboring thin bone of the horizontal plate of the frontal where the second case broke through. With lues and tuberculosis apparently ruled out in both of these cases, it makes an interesting conjecture as to the nature of the infection which caused the bony necrosis

and the suppurative extension into the brain. In each case Staphylococcus aureus was recovered from the culture.

The first case offers two interesting anatomical points, a more intimate realization of which might possibly have helped. They were forcibly brought out by my failure to reach the abscess. First, an abscess of sphenoidal origin involving the temporosphenoidal lobe must necessarily be internal to the lateral ventricle anteriorly. To tap this abscess, we had three chances. One was through the ventricle, which would have drained the pus into the ventricle and caused meningitis at once. We tried the straight approach and stopped when we reached the ventricle. We tried going above the ventricle, but the abscess was not so high. We tried going below the ventricle anteriorly, but this carried us below the abscess. In theory, a curved trocar passed under the ventricle would have reached it, our second chance. This abscess six weeks later was found at autopsy to extend from the pituitary fossa backward and outward under the ventricle, so that posteriorly it was situated in the temporosphenoidal lobe external to the ventricle. If it was in this position when we tried to tap it, a straight trocar passed backward near the floor of the temporosphenoidal lobe would have succeeded. This was a blind third chance it is true, but the writer will bear it carefully in mind if he ever has a similar case.

The second anatomical lesson is learned from the writer's failure to find any break in the roof of the sphenoid until autopsy. During the intranasal sphenoid operation he took away so much of the anterior sphenoidal sinus wall that the neurologist, looking over the operator's shoulder could see clearly the posterior sphenoidal wall. The membrane was clear and normal. The bone was solid. There was no pus, and no granulation tissue was seen. The writer naturally decided against going through this normal bone in his search for an abscess. A study of the lateral *x*-ray picture of this patient's sphenoid shows a deep pituitary fossa and a sinus which extends not only below this fossa but far back into the body of the sphenoid bone. It was the floor of this fossa which was found necrosed through at autopsy. If we draw a straight line from the nasal vestibule through an imaginary large operative opening in the anterior sphenoidal sinus wall this

line will indicate the visual operative field. We now discover that the opening in the floor of the pituitary fossa was below the operator's line of vision. Only with an S-shaped probe could the

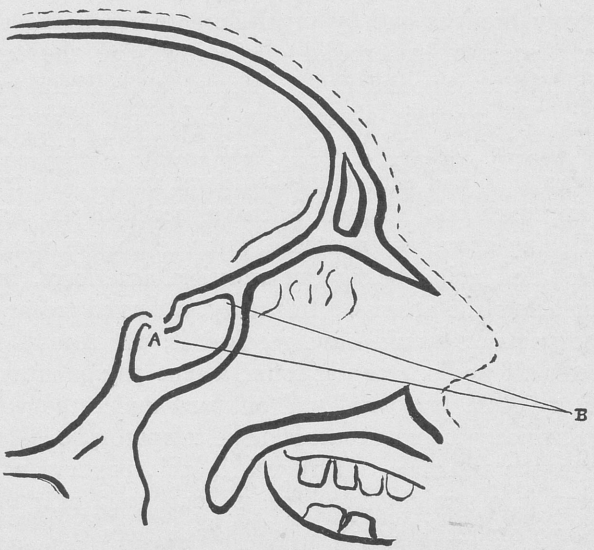


CHART II.—Diagrammatic tracing of *x*-ray in Case I. *A* is the necrotic opening through the floor of the pituitary fossa as revealed at autopsy. *B* shows the visual exposure of the sphenoidal sinus through an intranasal operative opening.

writer have reached around this double corner. Especially when operating by the intranasal route, much of a large sphenoidal sinus is below the line of vision. In this extreme case, that portion of the roof which was beneath the pituitary fossa was out of sight.

---

## DISCUSSION

DR. ROSS H. SKILLERN, Philadelphia:

Brain abscesses, a sequel to accessory sinus infection, come so seldom in one's life, in so far as I am concerned, at least, that I always have to read up between each case to know how I shall treat the new one. Brain abscess does occur from the various sinuses, as we all know, but to all intents and purpose it is fatal except when confined to the frontal lobe and probably from the frontal sinus. It

has also been my experience that unless these abscesses form very slowly there is very little hope for recovery. One very important factor is the type of infection. If we have a streptococcic infection I think we might just as well discontinue active treatment. If we have staphylococcus, particularly the aureus variety, then that does give us some hope and some chance. I also neglected to state that basal abscess outside of the brain lobe, in my experience, is invariably fatal, and it would seem that should a case of that sort occur it offers very little hope for recovery. The deeper the abscess the less chance there is for ultimate recovery; but while it may seem that I am pessimistic along these lines, nevertheless operation does offer us some chance for cure. It is curious that if we look over the statistics, I think we will be very much impressed to note the number of cures apparently occurring after operation. Of course without operation the mortality is 100 per cent. After operation, however, as far as I can gather from the literature, the cures would seem to be—I will have to quote widely here—between 20 and 30 per cent. However, this is very misleading, because you do not know that everybody who has ever operated on a frontal sinus successfully has reported the cure. How many of us have operated, with death, that we did not report? So that it is exceedingly misleading to say that the mortality is between 20 and 30 per cent. From my own experience and from what I can gather mostly outside of the meetings, talking out in the halls and antechambers, I would say that the percentage of cure is a good deal closer to possibly 5 or 10 per cent than anywhere nearly approaching 30 per cent. The mortality, of course, being inversely to that, or 90 to 95 per cent rather than 70 per cent. When we do have a brain abscess and primarily recognize it as such, which we practically never do, it always comes out later, from the history, that the case was operated on several times and finally brain abscess was found. I do not recall a case where the operator opened up the frontal sinus and drained an abscess—I mean a blind brain abscess in the frontal lobes—that was diagnosed primarily. I think the crux of the entire situation in the healing of these purulent collections lies in the wide-open method of packing and going very slowly in the way of doing any radical work and permitting Nature to take its course after we have done all we can in the evacuation of the abscess.

Dr. John M. Ingersoll, Cleveland, Ohio:

I have seen one case similar to Dr. Berry's sphenoidal case. The man had syphilis, and when I saw him he had symptoms pointing

distinctly toward involvement of the sphenoidal sinus on the right side. The sinus was opened and after the acute reaction from the operation cleared up, I was able to feel necrotic bone on the posterior wall of the sphenoid just under the sella. I thought the necrosis due to syphilis and, as he had had very few head symptoms, pushed the antisyphilitic treatment. He improved temporarily and then began to get worse and had distinct symptoms of brain irritation and brain abscess. My report is not as complete as Dr. Berry's because my patient refused further operative interference and died, I think, from a brain abscess. I was unable to secure an autopsy. My thought here is that he did have a syphilitic necrosis and then a secondary brain abscess from the necrosis of the sphenoid.

Dr. Henry L. Swain, New Haven, Conn.:

We all have found it very confusing, as Dr. Berry did in his sphenoid case, when the patient goes so long with intercurrent abscess after one's first endeavors, so that sometimes one is tempted to regard a case as cured when in reality it is not. In conjunction with that, I think we ought to take into consideration an experience I once had in treating an otitic abscess, namely, that there was more than one abscess. In this case I was draining very successfully an epidural abscess, and thought surely I was going to cure my case, when death suddenly occurred at a dressing, with the incidence of Cheyne-Stokes respiration. The case was being dressed and I happened to come into the ward at the time. We went ahead to finish the dressing, and just as we thought we were about through the patient had a most curious attack. He had the most beautiful development of Cheyne-Stokes respiration I have ever seen, and in ten minutes he was dead. We succeeded in getting an autopsy, and we found three abscesses, one directly connecting with the epidural abscess, one neighboring this and a third quite far up near the island of Reil. These three abscesses were entirely disconnected. There was no apparent passage from one to the other; the patient had had a rupture of the middle one of these abscesses into the third ventricle, and that is the way the case terminated. I think other points of interest are that these abscesses had probably existed for five years and that his particular pastime was in brawling. He would get into a fight on any occasion whatever, when in his cups, and then his favorite mode of attack was to topple his opponent over by head plunges at the solar plexus of his victim. He was brought into the hospital comatose in the original reception of the patient as a result of one of these brawls,

in which the man was wise to his method of attack and met his head with a foot and put him out on the first round.

DR. HARRIS P. MOSHER, Boston, Mass.:

I would like to ask Dr. Berry about the quinsy. Was that a typical quinsy or a retropharyngeal abscess? Could you answer that now? After you answer I want to say something else.

DR. BERRY:

All that I have is the patient's history. He said he had an attack of quinsy.

DR. MOSHER:

My wonder is whether it was not the discharge of the abscess in the retropharyngeal space. The longer I live the more I feel the retropharyngeal space is a bit neglected. In ear conditions such as mastoiditis you occasionally have pus discharged from the mastoid into the retropharyngeal space and below. I feel that you can get infections of the retropharyngeal space from many sources. I am wondering whether this may not have been a discharge from the middle fossa into the retropharyngeal space.

DR. BERRY (in closing):

Thank you, gentlemen, for your discussion. Dr. Skillern's remarks about the prognosis of frontal conditions over against other sinus infections is illuminating. Certainly my cases, the first of sphenoidal and the second of ethmoidal infection, were both fatal. In cultures from these patients, once we obtained streptococci, but usually there was only the Staphylococcus aureus. Dr. Ingersoll spoke about a sphenoidal case. He was more fortunate than I was, for he saw his necrosis. An interesting point Dr. Swain brought out was the Cheyne-Stokes respiration. Both of these cases, long before death, at times developed Cheyne-Stokes respiration. I am inclined to regard it as significant. Dr. Mosher kindly calls attention to what I consider a flaw in the history sequence. That quinsy sore throat may possibly have been a posterior sphenoiditis, or a retropharyngeal abscess or some infection in that region.

# NASO-PHARYNGEAL FIBROMA: A CLINICAL AND PATHOLOGICAL STUDY

PERRY G. GOLDSMITH, C.B.E., M.D., C.M.

A TUMOR formation, histologically non-malignant but pursuing clinically a malignant course, occurring almost entirely in the young male and definitely retrogressing about the age of twenty-three, is unique among tissue growths, and is found alone in the nasopharynx. Females are not, however, immune, since Pluyette, in 1887, was able to record 9 cases.

Tilley[1] says the origin of these tumors when confined to the nasal cavity is in the sphenothemoidal recess, and, quoting Jacques,[2] says they may have a more extensive origin and involve the arch of the choana, base of the vomer and pterygoid process, fossa of Rossenmüller, ethmoid and sphenoidal sinus or even the maxillary antrum. Tilley[3] records 1 case growing from the antrum. The most common seat of origin is from the fibrous tissue of the mucoperiosteum covering the basilar process of the occipital bone, body of the sphenoid and the anterior surface of the cervical vertebræ; that is to say, they are of periosteal origin and tend to cease growth when active periosteal growth has terminated and the skull has ceased development. Sir St. Clair Thomson[4] and Parker and Colledge[5] find them most often on one side of the middle line, while Escat finds the left side more often the common site. Ferreir,[6] while admitting the possibility of tumors springing directly from the vomer and choanal regions, believes the origin is due to an anomaly in the development of the functions of the hypophyseal system and a deviation in function to the pharyngeal tonsil. This he explains by assuming (*a*) that at a certain moment epithelial germs may regain their power of proliferation; (*b*) the chromophilic cells, to which glandular characteristics are attributed, increase their secreting action and

stimulate the periosteum of the roof of the pharynx to produce tumors resembling nasopharyngeal fibromas.

It is not always easy to define the original point of origin, since in rare instances they have been found to grow from the lateral wall of the pharynx and the internal pterygoid process of the sphenoid. Secondary attachments are not uncommon, due to a tissue necrosis from pressure or friction. The surface of the tumor is covered by mucous membrane under which are found large ramifying bloodvessels, but there is no dense envelope to which the term capsule might be applied. The mass is made up of dense fibrous tissue and agglomerated cells, pedunculated or sessile in shape and containing large venous channels most abundant in the peripheral portions. Walshame[7] says: "It is impossible to say beforehand that the tumor is a pure fibroma or that it will not recur after removal, since in many cases round cells are found which resemble fusiform or embryonic sarcoma."

Jonathan Wright[8] says: "Just insofar as the cellular richness is marked the question of the differential histological diagnosis of sarcoma arises."

When the venous channels within the mass are large, thin-walled and numerous the term fibroangioma has been fittingly applied. In such cases, on section, the growth has a spongy appearance and the walls may be formed by simple embryonic elements. The microscopical appearance of the growth is pink, dark red or purple, according to the vessel formation of the covering mucosa.

The attachment varies in size according to its seat or origin. The more anterior the seat of origin the smaller the pedicle, the less dense the fibrous masses, and the greater the edema. In several specimens of pedunculated growths in St. Bartholomew's Hospital Museum the peduncle is short and measures as much as an inch or more in diameter.

Coates[9] has reported a case in which there was present a nasal and a nasaopharyngeal fibroma. He quotes Getchell, who says the nasal fibroma occurs in either sex and more often in those past middle life.

Pierce's[10] assertion that they are never multiple is controverted by one of my cases, in which I found one large and two small fibromas.

Two varieties of tumors occur, according to Ferrier:[11] The true vascular fibromas show a nucleus of homogeneous structure which imitates that of periosteum; they are surrounded by an extremely vascular covering which springs from the aponeurosis of the spheno-occipital recess. Tumors *however*, growing from the edge of the choana and tending to grow forward into the nose show a different structure with varying degrees of malignant degeneration and more rapid growth.

When the growth arises from well within the choanal arch, from the Schneiderian membrane, the amount of fibrous tissue may be very slight and closely approach the character of an ordinary nasal polypus, and this too applies to choanal polypus, the attachment of which is generally found just within the maxillary antrum. It is difficult in reviewing the literature, as Coates has so thoroughly done before this society, to make sure that the cases reported as fibroma have really the right to be classed as such.

Thomas Guthrie[12] says: "The so-called choanal polypus has no affinity either in structure origin or clinical features to true fibroma, yet they are often reported as such. A microscopical examination shows this to be essentially a polypus with a large amount of fibrous tissue development."

In an analysis of a series of cases published prior to 1898, Walshame[13] was unable to satisfy himself as to the frequency of recurrence after removal, but in none of the cases described as pure fibromas was a recurrence reported.

The tumors with which this paper deals are those consisting largely of hard, dense, fibrous masses without sarcomatous elements or connected with preëxisting adenoids (Wright's fibro-lymphoid tumors). They do not produce secondary enlargements of neighboring lymphatic glands, nor does metastasis occur. In their enlargement destruction of adjacent structures is by pressure and not by infiltration, as in malignancy. They must not be confounded with the soft, gelatinous, freely movable masses frequently invading the nasopharynx from the nose.

The amount of destruction following gradual enlargement of the mass may be astonishing. The nasopharynx may be greatly widened laterally, causing occlusion of the Eustachian orifice and middle-ear involvement. The nasal septum may be pushed to

the outer nasal wall with loss of all its osseous and cartilaginous structure. The sphenoidal sinuses and posterior ethmoidal labyrinth may be filled with prolongations of the growth, causing optic atrophy, proptosis and even basal meningitis. The nose may be widened, maxilla separated and the antra filled, giving the patient a frog-face appearance.

The pressure necrosis may involve large vessels, leading to rapid and fatal hemorrhage. Extensive sloughing of the tumor itself or the surrounding tissue may lead to sepsis, pyemia or septic pneumonia. The secondary anemia from repeated hemorrhages, together with the result of chronic septic absorption, readily induces the appearance of cancerous cachexia. Occasionally these masses have been known to slough away or undergo calcareous or cartilaginous degeneration.

Dan MacKenzie[14] speaks of the possibility of the round-cell sarcoma of the upper ethmoidal region and nasopharyngeal fibroma being fundamentally akin, in spite of the fact that the former does not cease growth or undergo involution. Clinically they are similar in that there is unrestrained local growth, tendency to erode bone and form connections as it spreads and readiness to bleed profusely.

The tumors are rare, many specialists pass through a long, active career without encountering one, while others see but few. Sir James Paget, quoted by Grenville MacDonald,[15] has never seen a fresh specimen. Ingles[16], in 6500 records of private cases, cites but 5. From the number reported in continental literature, Coakley[17] thinks they must be more numerous in Europe, but Dighton[18] suggests this may be fallacious, owing to the readiness with which some countries report their cases. Lennox Browne[19] quotes Bosworth as having been able to hunt up only 40 recorded cases.

Treatment. Operative removal is necessary to prevent continuation of the growth with all its disastrous possibilities. If the tumor is small it may readily lend itself to removal with forceps, or a periosteal elevator insinuated under the periosteum of the basisphenoid or the basi-occiput removes the mass along with the periosteum.

Large tumors may necessitate Moure's lateral rhinotomy or

splitting the palate to permit better access to the base. Preliminary laryngotomy may be advisable to prevent blood getting into the trachea. Occasionally a wire loop may be passed around the mass and rapid removal be effected. The greater the extension of the growth, its vascularily and its basal attachment the more dangerous the operation. Shock both from hemorrhage and possibly cardiac inhibition, due to vagus irritation, are serious problems. The type of surgical risk the patient presents may well awe the surgeon.

Chevalier Jackson[20] has operated on 8 cases with preliminary ligation of the external carotid. Thomas Guthrie[21] reports that in none of the severe cases coming under his observation could any approach to complete removal be effected by cold wire or thermocautery snare. Harmon Smith[22] advises in some cases the use of injection of monochloratic acid directly into the tumor. Lincoln and Voltolini[23] long since advocated the use of electrolysis followed by the galvanocautery snare, and Delevan[24] recalled this to the memory of the Fellows in this Assocation in 1911. Diathermy and the use of radium will probably replace the extensive surgical procedures still in vogue. Daubney[25] records a case considered inoperable from severe and repeated hemorrhage that was cured by one application of radium. New and others have had similar experiences.

I give you the clinical features of 2 cases, 1 showing how a large mass and 2 smaller ones were removed by snare and forceps easily and with little or no anxiety, the other a more formidable procedure with a fatal outcome due largely, I think, to error of surgical judgment.

Case I. A Case of Multiple Fibroma of the Nasopharynx.—Boy, aged seventeen years, born in England, referred to me for removal of adenoids in 1921. His family history was unimportant. He had been operated on before for adenoids, but was not improved. The patient had a typical adenoid facies, overlapping teeth and highly arched palate. Rhinoscopy showed an engorgement of the mucosa on both inferior turbinates and an excessive mucous secretion such as one sees in postnasal obstruction. The middle and superior meati were clear, no structural abnormality was present and there was no evidence of any sinus involvement. Transillumination was equally

clear and *x*-ray examination was negative. No facial enlargement was present. The voice was toneless; the soft palate bulged downward and forward, but was not paretic. The faucial tonsils were moderate in size, freely movable in their fossa, soft to palpation and expression did not bring out unusual secretion. There were no enlarged cervical glands nor any evidence of toxic activity of the tonsils.

The postnasal mirror showed a bluish-gray, smooth, rounded tumor, almost filling the nasopharynx. It was of moderately firm consistence and attached to the center of the posterior pharyngeal wall in one place, but above its attachment appeared to be at the outer side of the right choanal arch.

*Diagnosis.* Nasopharyngeal fibroma.

*Operation.* General anesthesia, ether. Head slightly lower than thorax and a pillow under the shoulders. As excessive hemorrhage was to be feared, special efforts were made to combat it. Twenty cubic centimeters of normal horse serum was injected one-half hour before the operation began. Two rubber catheters were passed through the nose and the ends drawn out of the mouth. To each end was attached a stout silk ligature. The catheters were then drawn through the nose so that the ligature could be thrown over the forehead and caught with artery forceps. The other ends, which were holding a gauze pad quadrilateral in shape, were also thrown over the forehead. Pulling on the ligatures held by the forceps would then pull the gauze within each choanal arch and pressure would be better in the vault than if only one were used, which would press only firmly on the side through which it was originally passed in the nose. A cold wire snare was then passed through the nose into the nasopharynx, but I was unable to encircle the growth well because of the attachment on the postpharyngeal wall. This attachment was easily broken down and the wire firmly and slowly withdrawn. Bleeding became now rather free, so grasping the mass with a pair of postnasal forceps and drawing the wire home, the forceps rapidly removed the tumor through the mouth. The hemorrhage was copious but not alarming. Palpation then revealed two other small masses attached to the base of the sphenoid, and it was then found that the attachment of the main tumor was on the internal pterygoid plate. A Löwenburg forceps rapidly removed the small masses and the postnasal plug was rapidly and firmly passed into the vault. The bleeding stopped at once and did not return on removal in twenty-four hours. The nasopharynx was much dilated by the pressure of the tumor, but did not produce any aural complaint, nor was any deafness found

before the operation. The patient made a rapid and uneventful recovery. Microscopical examination of the tumor was made.

*Microscopical Examination (Gross Specimen).* Specimen consists of three tumors: The largest of these is almost as large as a walnut flattened; it is smooth in outline except for the base, about a half inch in diameter, which looks rather like the surface of the tongue; just behind this is a strand of tissue looking somewhat like a nerve. The tumor as a whole is whitish in color, smooth in outline and fairly soft. On section it is found to consist of a light pinkish material of an even consistency and an even texture. The other masses are each the size of a large bean, have a peduncle, and are composed of the same kind of tissue as the larger mass. The large mass weighs 14 grams.

*Microscopical Findings.* The tumor is made up of fairly loose fibrous tissue with a great number of thin-walled bloodvessels. The surface is covered with columnar epithelium and shows some lymphocytic infiltration. There is no evidence of malignancy.

*Diagnosis.* Polypoid fibroma (Department of Pathology, University of Toronto).

Case II.—Boy, aged thirteen years, Canadian. Referred to me for advice regarding frequently recurring severe nasal hemorrhage, which occurred at several weeks interval over a period of two or three years. Laterally the loss of blood has been very severe and on numerous occasions. Owing to the persistence and freedom of the bleeding it was thought he could not recover.

On examination nasal obstruction was bilateral, complete and permanent. The soft palate was prominent, rounded and restricted in its movements. The naso-pharynx was filled with a mass described below. Owing to its size I was unable to determine its attachments by either sight or palpation. A provisional diagnosis of malignancy was made and operative measures considered.

I undertook the decision as to the best method of treatment with great mental reservation and fear. The seriousness of an operation involving the removal of a large tumor from the base of the skull was always in my mind. The operation was postponed on one occasion in order that I might assure myself that surgical measures leading to removal *en masse* was the correct procedure, but I could not arrive at any decision unless the patient was under an anesthetic, when he could be more thoroughly studied. This was carried out under skilled ether anesthesia. Owing to both size and density of

the mass no conclusion could be reached from palpation of the pharynx. The finger could not be inserted far enough to identify even the chief attachment.

To gain more room and in order to secure a direct view the soft palate was split in the middle line, but it required the removal of some of the hard palate before one was able to secure a satisfactory examination. It was then found that the tumor was attached by a broad base to the upper part of the cervical aponeurosis. This attachment could be encircled by a probe but not by the finger. A constriction was present in the tumor mass leading to another large irregular fixed mass in the left choana and passed forward into the nose, pushing the septum, which from pressure was membranous only, tightly against the outer wall of the right nasal cavity. The decision now had to be made as to the advisability of attempting the removal of the growth, as removal seemed to be quite feasible by dividing the anterior constriction so as to separate the two main bodies. Hemorrhage up to the time was slight and removed by suction The patient's condition was good, and having in view the grave responsibility in leaving it alone or trusting to measures still on trial, such as radium and *x*-ray, I decided to continue the surgical measures already begun. This was an error of surgical judgment as a continuation of the narrative shows. The anterior constriction, was severed with scissors and knife, with seemingly comparatively little hemorrhage, but on attempting to remove the nasal part of the mass it was found very firmly attached in several areas. I succeeded, however, in clearing the nose with heavy forceps and torsion. The bleeding was not bothersome, but I think was, for this patient, too severe. The suction apparatus was helpful and also deceptive. On examination the nose, now free from the growth, showed the attachment to have been on the outer nasal wall—ethmoid, antrum and sphenoid: These sinuses were unduly open to finger palpation. So little of the ethmoid remained that I could palpate the cribriform area and nasal floor of the frontal sinus. The front face of the sphenoid was almost entirely destroyed.

I was tempted now to desist and leave the main body in the naso-pharynx for further consideration, but the accessibility of the pedicle to surgical measures and the natural desire to complete the operation led to another error of judgment. On attempting to remove the mass I found it impossible to get it away by torsion or snare, or by rocking it, after the manner of Stuckey. Attempts to do so, and they were vigorous, failed. I was then forced to punch out bits with

a large tonsil punch, and using curved scissors with traction I ultimately removed the growth. This left an enormous dome, but the bleeding in the walls was not severe and was easily controlled by gauze packing. The patient had already been given saline, owing to feeble heart action. The amount of blood lost was considerably more than I thought, and here too the suction apparatus, though useful, was deceiving. As the collapse became more severe no attempt was made to close up the roof of the mouth. Furthermore, it was thought that the case was probably malignant and the use of radium would be facilitated if the vault were more accessible. The patient was removed to the ward and an intravenous given, but he died without regaining consciousness.

*Microscopical Examination (Gross Specimen).* Two irregular masses of tissue, which originally formed one mass about the size of a blood orange, grayish-white in color, somewhat putty-like in consistency, with occasional firmer area. Here and there we find spicules of bone are adherent. One part of the tumor seems to have a definite capsule, the other part is broken and torn up and the skin cannot be made out. Cut surface shows numerous fine pin-point areas looking like bloodvessels. All spicules of bone seem to be on the external surface of the tumor, not on the internal.

*Microscopical Findings.* This tumor is made up of loose connective-tissue type of cell, which is rather edematous. The cells are well differentiated; large numbers of thin-walled bloodvessels, which are quite large in size. There are no mitotic figures present and no evidence of malignancy.

*Diagnosis.* Edematous fibroma (Department of Pathology, University of Toronto).

I am impressed with the thought that the shock due to hemorrhage may not find its sole result from the excessive loss of blood. What is the effect on the cardio-inhibiting fibers of the vagus? I intended showing charts exhibiting the effect on the blood-pressure produced from severe crushing in the nasopharynx of animals. Prof. McLeod, of the department of physiology of Toronto University, to whom I applied for assistance, thought very deceptive information would likely follow, since animals vary so much in their response to vagus irritation, and this too might apply to human beings. For this reason no animal experimentation has been performed.

I trust the recitation of a surgical catastrophe as my first contribution to the proceedings of this society will at least emphasize the importance of culturing the grace of humility. Sir Berkeley Moynihan,[26] in his Hunterian lectures of the present year, says: "To review our own work is a very stern and salutary discipline. It will make clear the need to correct the impressions, often vague and sometimes very treacherous, which have been gained rather from the occasional dramatic occurrence than from the tranquil observance of a daily and placid routine; it may confirm our faith in convictions that have slowly grown and strengthened almost imperceptibly; it will lead us to test again an opinion not quite so impregnable as we had thought. When those who are responsible for much of our modern surgical and medical literature will act for these truths, less ink will be spilled and more truth told."

## References

1. Tilley, Herbert: Diseases of the Nose and Throat, 4th edition, p. 325.
2. Jacques (Nancy): Arch. Int. d. Laryngol., Otol. and Rhinol., December, 1911.
3. Tilley, Herbert: Jour. Laryngol., 1911, p. 213.
4. Thomson, Sir St. Clair: Diseases of Nose and Throat, 2d edition.
5. Parker and Colledge: The Nose and Throat and Their Treatment, 2d edition.
6. Ferrier: Monatschr. Ohrenlike in Laryngo-Rhinol., Berlin, Suppl. 1, 1921.
7. Walshame: Nasal Obstruction, 1898, p. 139.
8. Wright and Smith: Diseases of Nose and Throat, 1915, p. 440.
9. Coates: Ann. Otol., Rhinol. and Laryngol., March, 1918.
10. Pierce: Trans. Am. Laryngol. Assn., 1911.
11. Ferrier: Monatschr. Ohrenlike in Laryngo-Rhinol., Berlin, Suppl. 1, 1921.
12. Guthrie, Thomas: Jour. Laryngol., 1915.
13. Walshame: Nasal Obstructions, 1898.
14. MacKenzie, Dan: Diseases of Nose and Throat.
15. MacDonald, Grenville: Diseases of Nose and Throat.
16. Ingles, Fletcher: Diseases of Nose, Throat and Nasal Cavity, 4th edition.
17. Coakley: Diseases of Nose and Throat, 4th edition.
18. Dighton, Adair: Diseases of Nasopharynx, 1912, p. 41.
19. Browne, Lennox: Diseases of Nose and Throat, 1915.
20. Jackson, Chevalier: New York Med. Jour., August 17, 1907.
21. Guthrie, Thomas: Jour. Laryngol., 1915, xxx, 427.

22. Wright and Smith: Diseases of Nose and Throat, 1915.
23. Trans. Am. Laryngol. Assn., 1883.
24. Trans. Am. Laryngol. Assn., 1911.
25. Daubney: Kentucky Med. Jour., July, 1922.
26. Moynihan, Sir Berkeley: Hunterian Lectures, Lancet, 1923.

---

## Discussion

Dr. George M. Coates, Philadelphia:

How long has it been since the operation on this case? The reason I ask this question is, in a case I reported before this Association in 1917, I said that I had hoped for cure by thorough removal of a multiple growth. The case only remained tentatively cured for about six months, then recurred, and that case I operated on at least twice more. The third time he had a very considerable hemorrhage, although at none of the preceding operations did I have any trouble from this source by using the avulsion and cold snare method. I lost track of him finally and am afraid I did not obtain a cure, as the usual history is that they recur for a number of years at any rate. I saw one other case that died on the table during operation, from respiratory failure. The heart action continued for many minutes after the respiration ceased, and in spite of heroic efforts this patient could not be carried through. I was not assisting at the operation.

Dr. James E. Logan, Kansas City, Mo.:

Dr. Goldsmith is to be commended for presenting this paper. It would be well if all of us would report our failures as well as our successes. In reference to these growths: The question of diagnosis is important. Many unilateral single large tumors are found in the posterior nares which seem to be benign fibroid tumors. A careful microscopical examination of a part of the growth taken as deep into the center of the tumor as possible often reveals the fact that we are dealing with a malignant instead of a benign condition. This has happened to me more than once. I realize the difficulty encountered in controlling the hemorrhage following this procedure. However, this seems to me to be the proper course to pursue if we are to avoid the mistakes which must result in failure. I have successfully removed two postnasal tumors by means of electrolysis with no recurrence in either case. Our gradually increasing knowledge of the use of radium may prove it to be a successful method of treatment.

Dr. J. S. Fraser, Edinburgh, Scotland:

I think Dr. Goldsmith is to be congratulated not only on the successful result of his first case, but also, and even more, on his honesty and candor in telling us about his second case. It has always seemed to me unfortunate that contributions to medical literature are so largely concerned with recounting successful operations. I once said, at a meeting of the Scottish Society of Laryngology and Otology, that no man should be allowed to report a successful case unless he at the same time stated the number of such cases he had operated upon and the mortality associated with the operation in his hands. If we look over isolated cases in medical periodicals we get an entirely erroneous idea of the mortality of various operations; for instance, if we looked up individual cases of cerebellar abscess reported in the journals, I feel sure that we would come to the conclusion that some 70 per cent resulted in recovery. We know, however, that when a writer records the results in a consecutive series of cases extending over many years the real percentage is only from 20 to 50.

Dr. D. Crosby Greene, Jr., Boston:

Dr. Goldsmith has alluded to the use of radium in this condition. Most of the cases I have seen at the Massachusetts General Hospital have been treated by the method of avulsion, and in spite of very pronounced hemorrhage the cases have recovered. In reference to radium, I wish to report one case in which recurrence occurred after extensive operation by Moure's rhinotomy route. A year later the growth had recurred and come forward and completely filled the left nostril. The surgeon attempted to reoperate by the same route and encountered such hemorrhage that he sent the patient to the Huntington Hospital for treatment by radium. Treatment by radium will not only cause shrinkage of the growth but diminish the tendency to hemorrhage, I believe. The first radium treatment by the insertion of seeds into the growth was promptly followed by severe bleeding at the point of insertion. The dosage was between 4 and 6 mc. The bleeding stopped and in the course of six months, during which the treatment was repeated three or four times, the tumor practically shrank away so that now there is no obstruction to breathing on that side. I mention this to emphasize the effect of radium on bleeding in these tumors. This effect is seen in cases of malignant disease of excessive vascularity within the nose and accessory sinuses. Radiation in proper dosage produces a decided lessening of the bleeding tendency in these cases. I believe that treatment by radium seeds will be found

to be successful in cases of nasopharyngeal fibroma, although my own experience in this line has as yet been too limited for me to speak positively.

Dr. George Fetterolf, Philadelphia:

Perhaps we would have a little additional light on the syncope and sudden death that sometimes occur in nose and throat operations if we recall what has been described as a trigemino-cardio-inhibitory reflex. This reflex was called to my attention some years ago during an external frontal sinus operation. The curious feature of this operation was that every time the sinus wall was curetted the patient became cyanotic. In looking over the literature an article by Brodie and Russell was found in the *Journal of Physiology,* 1900–1901, in which this trigemino-cardio-inhibitory reflex is described as having been demonstrated in the laboratory. Among their statements is this: "Stimulation of the nasal mucous membrane at once arrested the heart." If we note the number of septum, sinus and turbinate operations in which the patient becomes faint after the local anesthesia has been completed, an occurrence which cannot be ascribed to the anesthetic, and also recall the number of deaths that have occurred in dental chairs during the extraction of teeth—if we think of these accidents in terms of this cardioinhibitory reflex we may find an explanation of at least some of these sudden catastrophies.

Dr. Goldsmith (in closing):

As to the remarks of Dr. Coates, the operation was done two and a half years ago. I heard of this patient recently and he was quite well. Dr. Fraser was good enough to speak of my candor in reporting unsuccessful operations. I thought it would be much more fitting from a junior member as a confession of faith. I did several things wrongly. I did not start out to do the operation completely. I did not use radium because I had not arranged for it. I succumbed to the temptation to take the thing out because it looked easy, and I failed. A recent session of the Surgical Section of the Royal Society of Medicine was entirely taken up with the recitation of failures and mistakes in surgical practice. The papers were not reported in the proceedings of the society, but all were agreed that much more could be learned from the records of mistakes than by brilliant successes.

# A CASE OF EPITHELIOMA OF THE ESOPHAGUS, WITH SOME UNUSUAL FEATURES

S. MC CULLAGH, M.D.

T. P., aged fifty-seven years, consulted me March 28, 1923, with the following history: About a year ago he first noticed a feeling as though there was an obstruction in his throat which interfered with swallowing. There was no pain, tenderness—or interference with breathing. About nine months later he commenced to cough and raise thick, tenacious mucus. About a month later blood appeared in the mucus in small amounts. This hemoptysis persisted for about a month, but was entirely eliminated by treatment. No history of hematemesis or regurgitation of food.

His principal complaint was the cough, which was exhausting on account of the tenacity of the discharge and the consequent difficulty in raising it. There was no pain on swallowing, though the difficulty persisted. On quiet breathing a distinct rattling was audible and marked dyspnea occurred on slight exertion. Has had a Wassermann test which was negative. The sputum has been examined several times, but no tubercle bacilli have been found. Has lost about fifty pounds in weight. An *x*-ray of the chest taken about a month ago was negative.

Examination of the larynx showed a complete paralysis of the left cord, which was fixed, and a partial paralysis of the right cord, which on abduction reached the cadaveric position. The whole larynx was congested, but there was no evidence of new growth or ulceration. There was no marked adenopathy, though some enlarged glands could be felt below the larynx.

Dr. J. B. Solley, Jr., who examined his chest, reported:

"The examination of the chest on account of the stenosis is difficult. Percussion note is fair all over; there is no marked dulness or flatness. No rales. He coughed up a large 'gob' of thick, yellow

mucopus; there is therefore a raw surface somewhere in the bronchi or the alveolar spaces."

Dr. J. M. McKinney went over him from a neurological standpoint and reported:

"The neurological examination, with the exception of the throat conditions and a bilateral diminution of hearing, is negative. There is apparently a mass in the upper right mediastinum and some enlarged glands at the base of the neck. Pressure from this on the trachea might account for his breathing, but whether or not it will explain the laryngeal paralysis, I do not know."

Fluoroscopical examination with barium mixture showed some slight interference just above the clavicle, which apparently was confirmed by a plate, though this was very poor and the interpretation was only made definite after the postmortem examination.

On April 6 the patient's wife telephoned that he was "choking to death," and he was ordered sent to the Manhattan Eye, Ear and Throat Hospital, where an emergency tracheotomy was performed by Dr. Robert Buckley. On opening the trachea two masses of tumor were coughed out, the larger piece being about 5 mm. by 3 mm., and the smaller about 3 mm. by 2 mm. A ragged tumor, which bled very easily, was seen on the posterior wall. The lumen of the trachea was so obstructed by this mass that Dr. Buckley inserted a piece of rubber tubing, as the tracheotomy tube that could be used was not long enough to go below the mass.

I saw the patient about an hour later, and though his condition had greatly improved, respiration was still much embarrassed. He was again taken to the operating room, where I removed the rubber tubing and inserted a metal tube, after establishing the lower limit of the tumor by means of a bronchoscope introduced through the tracheotomy wound. The patient sank rapidly and died the next day.

Permission for a postmortem was limited to enlarging the incision. Following is the report submitted by Dr. A. A. Eggston, pathologist at the Manhattan Eye, Ear and Throat Hospital:

"The body is that of a well-developed but poorly nourished white man. In the anterior midline of the neck below the thyroid cartilage is an incised tracheotomy wound.

"In dissecting the tissues of the lower neck and upper mediastinum a dense infiltrating tumor mass is encountered. This mass lies between the esophagus and trachea and extends laterally, filling the entire upper mediastinum. The bronchial and mediastinal lymph nodes are enlarged and very firm and involved by the tumor mass. The esophagus, trachea and tumor mass are removed *in toto*.

"Upon opening the esophagus the entire upper one-third is indurated and shows an ulcerated area 10 x 6 mm. and covered with friable masses. In the lower part of the esophagus there are several tumor metastases upon the mucosa.

"Upon opening the trachea there is found a sessile oval tumor, 4 x 2 cm., attached to the posterior wall. This mass is friable and hemorrhagic. The mass is 3 cm. above the bifurcation of the trachea. The tumor mass between the esophagus and trachea is very firm and measures 11 x 5 cm. The mediastinal nodes are likewise indurated.

"Microscopical examination of the esophagus and tracheal tumors and of the tumor proper shows irregular areas and masses of rather large epithelial cells. The cells form no normal histological structures and many show active mitosis. Many areas of necrosis are present in the epithelial cells. These sections are similar to the ones made from the tissue which was expelled by coughing before death.

"Diagnosis: Medullary carcinoma."

The points of particular interest to me are: (1) The friability of the tumor, the detachment of at least one of the fragments expelled at the time of the tracheotomy undoubtedly having been responsible for the sudden attack of asphyxia, and (2) the slight subjective symptoms until just prior to the end.

---

## Discussion

Dr. Harmon Smith, New York City:

The doctor has mentioned paralysis of the recurrent laryngeal nerve. I have emphasized this point on a number of occasions and have had occasion to demonstrate it to my clinical co-workers in several cases. Any patient of cancerous age with partial laryngeal paralysis and with a frothy accumulation in the pyriform sinuses is very apt to be a case of esophageal cancer. A number of these cases will come to the throat clinic because of loss of voice, and one should be especially careful not to suspicion a tumor of the throat or in the tract of the vagus nerve when examining these cases.

Dr. Justin N. Waugh, Cleveland:

I would like to confirm what Dr. Smith has just said. A man was sent in with a diagnosis of possible malignancy of the epiglottis. I do not know how the man arrived at that conclusion, because the epiglottis was normal. He had paralysis of one vocal cord, with considerable mucus in the pyriform sinus. The larynx was otherwise normal. Direct examination showed a small malignancy of the esophagus, and I felt quite sure of what would be found there by direct examination. The man had some dysphagia at the time he presented himself.

Dr. Henry L. Swain, New Haven, Conn.:

I have here slides of a case of perforating cancer of the esophagus where it opened through into the trachea similar to that of Dr. McCullagh's, and one of the reasons why I take the liberty of bringing them down to present to you is the fact that I hoped they could be shown with the lantern, but they can be seen very well in this way if passed around. Not only are they interesting because of the perforation which took place, but two points are brought out: (1) This scar was low down and he had no trouble with the vocal cords at all; (2) the metastasis took place into the cervical lymph nodes at and above the angle of the jaw, showing how irregular the absorption into lymph glands may be in any given case. The carcinoma was at the bifurcation of the trachea where the arch of the aorta narrows the esophagus, and practically no other glands were involved. It is a point rather interesting to bear in mind, when doing laryngectomies or trying to remove malignant disease from the throat, that we cannot be sure we have done so merely because we have removed glands immediately adjacent to the tumor itself. I think Dr. Greene brought that out in one of his papers, showing how in some instances the draining lymph nodes lay above rather than below the laryngeal cancer.

Dr. Harris P. Mosher, Boston, Mass.:

When you consider the common wall between the trachea and esophagus, it is curious that we do not have more fistulæ. They are by no means an every day occurrence. The usual procedure is to have a frank fistula, which is very distressing, because whenever the patient takes food he floods his trachea and nearly chokes to death at the time of taking his nourishment. The unusual feature in Dr. McCullagh's case was that the cancer for years was a bit kindly—it plugged the opening, and it was kindly by killing the patient quickly at the end.

Dr. McCullagh (in closing):

I do not think there is anything to add. The interesting point to me in this is not so much the rarity of the condition as the extreme friability of the tumor mass.

# GLOSSODYNIA, WITH LINGUAL TONSILLITIS AS ITS ETIOLOGY, AND ITS CONTROL THROUGH THE NASAL (SPHENOPALATINE, MECKEL'S) GANGLION: REPORT OF A CASE

GREENFIELD SLUDER, M.D.

In 1918, I reported an observation to the effect that glossodynia was often secondary to lingual tonsillitis. In 1921, Lee Wallace Dean[1] recorded that glossodynia was controllable through the nasal ganglion. I know that glossodynia may be an isolated manifestation of a nasal ganglion lesion. Many times, however, I have seen it secondary to lingual tonsillitis.

The report of this case seems to me of interest in bringing out lingual tonsillitis, as the etiology of glossodynia and showing that although after it was established in this way it persisted after the lingual tonsillitis, and proved controllable through the nasal ganglion.

Case History.—Miss. L. B., aged thirty-two years, consulted me October 20, 1919, because of a chronic faucial tonsillitis, for which I did a tonsillectomy on October 28. The result was satisfactory: her general condition improved and her throat became comfortable.

February 10, 1921, she consulted me because of an acute follicular lingual tonsillitis. The acute symptoms subsided in ten days, but there remained considerable swelling of the lingual tonsil with a desire to clear her throat.

April 30. I did a galvanocautery destruction of a large part of the lingual tonsil. The result was diminution in bulk, cessation of the desire to clear her throat and a general better feeling in her throat.

October 16, 1922. She again consulted me, for an acute inflammatory trouble in the remnant of the lingual tonsil, this time, however,

[1] Trans. Southern Med. Assn., 1921.

accompanied by pain in the left side of the tongue as far forward as the tip. There was a reddened patch just anterior to the palato-glossal junction and an enlarged red papilla at that place. Inasmuch as I had often seen this phenomenon with acute lingual tonsillitis, and seen it subside in the wake of the attack, I assumed that this time it would also. I was disappointed, however. Applications of nitrate of silver solutions in small quantities (50 per cent) to the reddened patch anterior to the papilla were followed by disappearance of the redness and return to normal. The pain in the side of the tongue, however, continued. When it became evident that the pain lasted after the acute process in the lingual tonsil and that it resisted further treatment, I anesthetized the nasal ganglion, following Dr. Dean's experience. This was followed by immediate relief of the pain and it did not return for two weeks, when I again anesthetized the ganglion, with the same result. This time, however, the pain remained absent for one month, when the cocainization was again repeated. Since that time she has remained comfortable.

I have had 6 other cases of resistant glossodynias, for which I have injected the nasal ganglion. The results of these injections, according to my experience, have followed the routine for that procedure. Some of the cases were apparently cured by one injection, another required two injections, and I have on hand another case that is unsatisfactory after the second injection, some of the pain still remaining. I intend to inject this case again. One of these cases is an intractable sphenoid disease that has never come to a state of comfort. She has a persistent glossodynia, for which I injected the nasal ganglion three months ago, but without benefit. That this case should remain a failure is not surprising when one recalls that the sphenoid remains in more or less pernicious activity. It will be recalled that the nerve supply of the nasal ganglion on its central side passes through the body of the sphenoid, to wit: the Vidian in the floor of the sphenoid; the maxillary just lateral to it in the foramen rotundum which is separated from the sphenoidal cavity, usually by eggshell thickness bone. I have often mentioned that a sphenoidal case may give rise to a complete "lower-half headache," which I first described as the syndrome of nasal ganglion neurosis.

Clinicians who have dealt with glossodynias will welcome any

addition that may prove effective in its treatment. They continue on, month after month, despite all possible treatment. The patient almost always believes he has cancer of the tongue, and it is with much difficulty and a long lapse of time that he is dissuaded from this idea. The best description of glossodynia that I know of is in Sir Henry Butlin's *Diseases of the Tongue.*

## The Anatomy of the Sphenoidal Fissure

In 1914,[1] I injected the nasal (sphenopalatine, Meckel's) ganglion and paralyzed the abducens nerve. The abducens palsy recovered in three months. All diplopia vanished. I accepted this as the logical sequence of such an accident according to the accepted anatomical understanding of the anatomy of the sphenoidal fissure, *i. e.,* that the alcohol passed upward and outward from the pterygomaxillary fossa and reached the sphenoidal fissure, meeting there the lowermost nerve—the abducens. The tissues were very loose in this case. The alcohol met with no resistance.

Five years ago, Dr. Joseph C. Beck injected the nasal ganglion and paralyzed the oculomotor nerve, in a patient who later consulted me. This led me to think that the anatomy of the sphenoid fissure was subject to variations.

The accompanying drawings of dissections of the sphenoidal fissure show that the positions of the nerves are not constant. The abducens is probably oftenest the lowermost. Sometimes, however, the oculomotor, if not in its full trunk, certainly in some of its branches, is lowermost, which accounts for the clinical phenomena just mentioned.

[1] Ewing, A. E., and Sluder, Greenfield: Abducens Palsy Following Nasal-Trauma and Nasal Infection, Am. Jour. Ophthal., December, 1914.

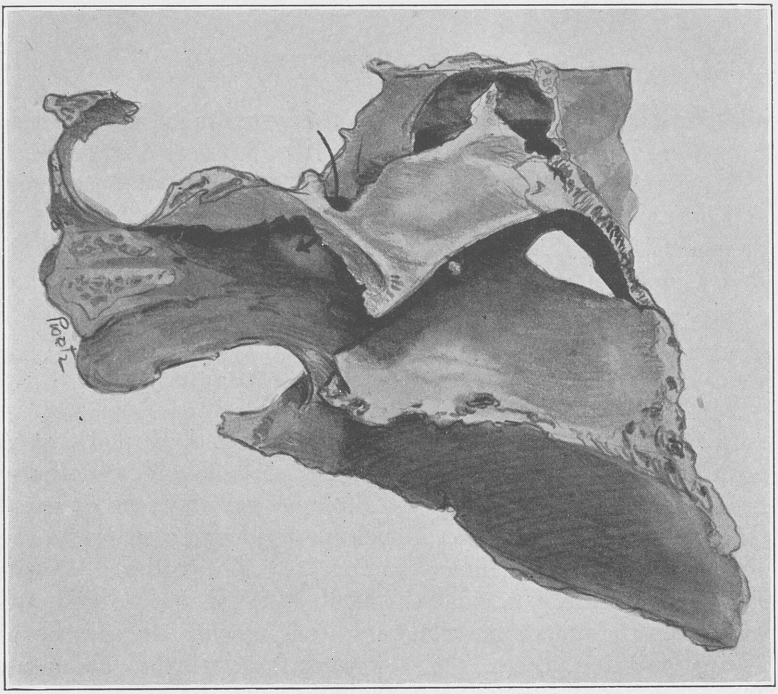

FIG. 1

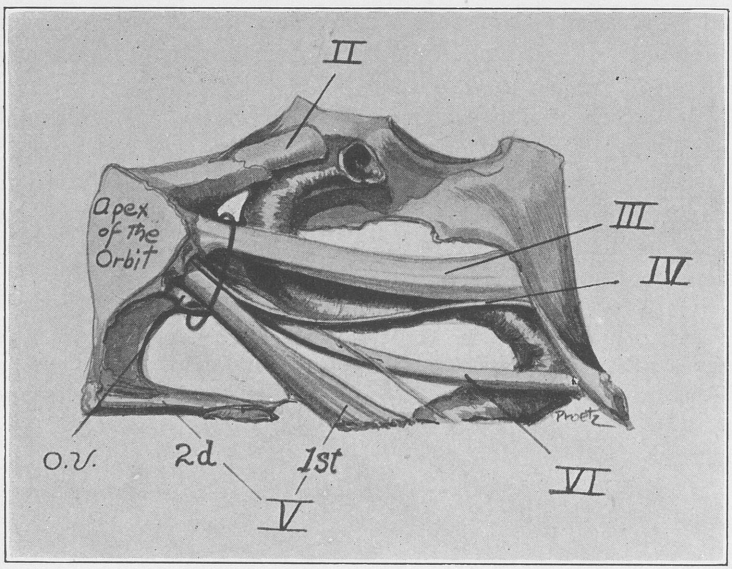


FIG. 2

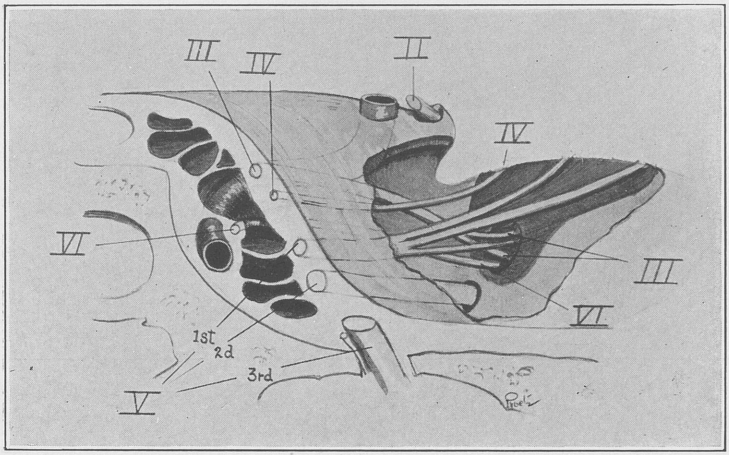


FIG. 3

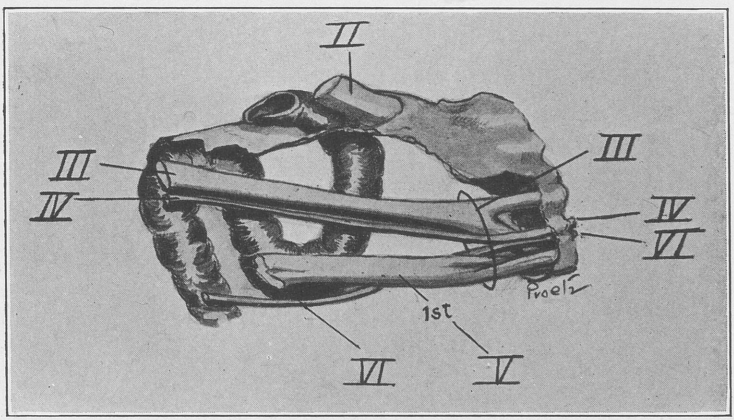


FIG. 4

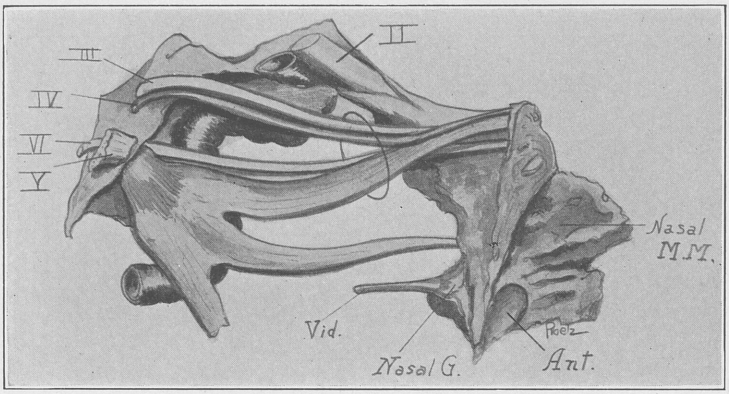
III
II
IV
VI
V
Nasal
M.M.
Vid.
Nasal G.
Ant.

FIG. 5

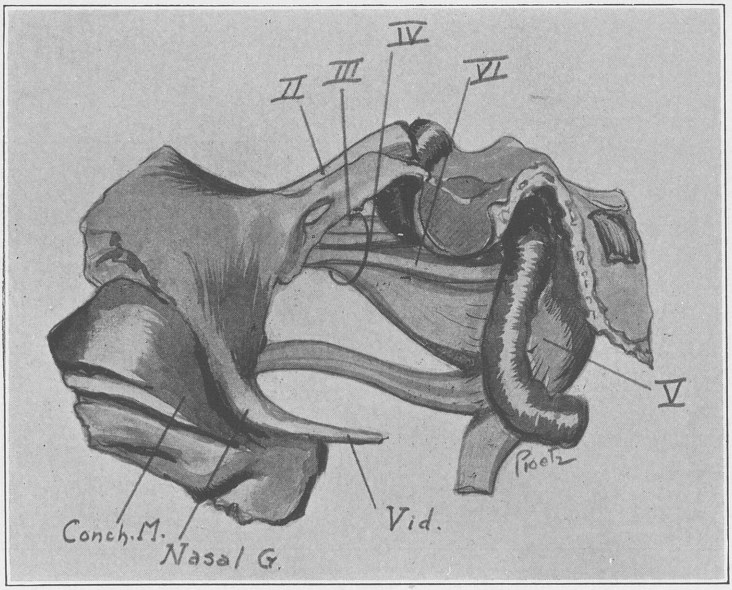
IV
II
III
VI
V
Conch. M.
Nasal G.
Vid.

FIG. 6

## Discussion

Dr. Henry L. Swain, New Haven, Conn.:

I shall be very glad to be one of those who Dr. Sluder said would probably welcome the knowledge which he gave us that application to the ganglion will probably be of some service in these cases. I shall take great pleasure in listening if he will speak further on this line. I have not removed the lingual tonsil in the way suggested, but have given treatment with solutions and caustics, and I hope it will be as beneficial to my patients as the treatment by Dr. Sluder was to his.

Dr. Perry G. Goldsmith, Toronto, Ont.:

It should not be surprising that glossodynia should be associated with lingual tonsillitis, as it has been shown by Mr. Shattock in the *Proceedings of the Royal Society of Medicine* that the fifth nerve has a very definite connection with the sensory nerve supply of the tongue. This would explain why local treatment to the sphenopalatine ganglion relieves the pain in the tongue.

Dr. George Fetterolf, Philadelphia:

Glossodynia is described as occasionally being one of the earliest symptoms of pernicious anemia. I would like to ask Dr. Sluder if he has observed this association in any of his cases.

Dr. Lewis A. Coffin, New York City:

I would like to ask Dr. Sluder if he considers that the removal of the lingual tonsil is best accomplished by the galvanocautery, and I would like to know why he did not eradicate the sphenoid disease.

Dr. Sluder (closing):

I have never seen pernicious anemia associated with glossodynia or glossodynia associated with pernicious anemia. Dr. Coffin asks if galvanocautery would be best in reducing the lingual tonsil. If you can get hold of the lingual tonsil with some cutting instrument I believe that is a better disposition of it. There are many lingual tonsils, however, that do not admit of any bite of the instrument. They are flat and they may be very considerably enlarged and a source of pharyngeal annoyance, but they cannot be grasped by any cutting instrument. A certain number of years ago a member of the society removed them by means of a snare which included the capsule

in the lingual tonsil mass. If possible to grab, the snare would be best. Dr. Myles's cutting forceps serves admirably. Some tonsils are so flat that they cannot be grasped by any grasping instrument. The galvanocautery under these circumstances can destroy the mass.

DR. COFFIN:

Yes. How about that sphenoid?

DR. SLUDER:

Dr. Coffin asks what is the matter with that sphenoid; why I do not cure it? Somebody answer that for me and state, I cannot. With the ramifications of the sphenoidal sinus in certain individuals, the cavity is prolonged upward in the lesser and down and out into the greater wings beyond the primary opening of the sphenoid.

# NOTES ON FOURTEEN CASES OPERATED ON FOR INTRINSIC CANCER OF THE LARYNX

J. S. FRASER, M.D., CH.B., F.R.C.S. (EDIN.)

THE cases reported on in this paper were seen between the years 1916 and 1922. Of the 14 cases, 6 were private and 8 were hospital patients. We may mention that in Edinburgh the rule is that at least 80 per cent of our patients are hospital cases.

SEX. Of the 14 cases only 2 were females.

AGE. The age of the patients varied from thirty-six to seventy-six years. The oldest patient made a good recovery and is alive and well four years after the operation. The youngest patient, a man, aged thirty-six years, died of recurrence of the growth. We think there is some reason for supposing that cancer appearing in a comparatively young person is likely to be of a markedly rapid and malignant type.

SYMPTOMS. The main symptom, of course, was hoarseness, the duration of which varied from one month to two years. In 6 cases the hoarseness had lasted for three months or less; in the other 6 from four to nine months; in the remaining 2 cases for two years. It is noteworthy that these last 2 cases were the only 2 females: both recovered: 1 after thyrotomy and the other, in which the cancer had spread round the glottic chink, after laryngectomy.

More or less pain was complained of by 3 patients and dyspnea in the bilateral case.

*Side Affected.* Of the 14 cases the right cord was the seat of the growth in 10, the left in 3, while in 1 case, as we have just said, both cords were involved. These numbers are, of course, too small to draw conclusions. Other operators have found the cords equally affected.

*General Condition.* Six of the 12 male patients showed marked pyorrhea alveolaris, necessitating extraction of all teeth before

operation on the larynx. At least 2 had arteriosclerosis, the blood-pressure in 1 being 260. This patient died of apoplexy one month after he returned home.

*Local Appearances.* Two of the 13 patients on whom thyrotomy was originally performed showed a papillomatous variety of growth, *i. e.*, the cancer formed a marked fringe which projected into the lumen of the glottis. In 1 other case the affected cord showed a condition of hyperkeratosis with the formation of white desquamating masses. In 8 cases the appearances were those of a grayish-pink, sessile, warty growth which in 3 instances reached the anterior commissure and in 1 case involved the extreme anterior end of the opposite cord. In the remaining 2 cases the growth had invaded deeply with marked ulceration; thyrotomy was performed in the first place and laryngectomy later, after recurrence of the tumor. Both died shortly after the latter procedure.

With regard to the mobility of the affected cord, in the above 13 cases treated by thyrotomy, we find that in 8 cases the cord moved more or less freely; in 3 the movement of the cord was very limited. One of these, a female, with a history of two years hoarseness, recovered after thyrotomy and is still alive and well six years later. The other 2 patients died—1 a few days after operation and the other some months later of recurrence. In the 2 remaining cases the cord was fixed: both died of recurrence in spite of laryngectomy.

*Diagnosis.* This seldom presents any difficulty on indirect laryngoscopy alone, but in every case, after the patient's consent to operation had been obtained, a piece was removed by direct laryngoscopy with Pfau's double cutting forceps. In all but 1 case the report was "squamous epithelioma." In 1 case, however, the pathologist stated that apparently only hyperkeratosis was present. After consultation with Dr. Logan Turner it was decided to proceed with laryngofissure and subsequent microscopical examination revealed some invasion of the deeper tissue.

We are sure it is unnecessary to call attention here to the importance of a thorough medical examination of the patient before operation. We do so, however, because in 2 of the 7 fatal

cases an efficient examination would have shown that operation was not advisable. In both of them the patients were reported by the physician as fit for operation, but in 1 case a mediastinal growth was apparently present while the other had chronic lung trouble with clubbing of the fingers; both died from pneumonia a few days after thyrotomy. In 2 other fatal cases no blame attached to the physician or to myself in regard to faulty medical examination. We knew that 1 of these patients, aged sixty-nine years, had marked arteriosclerosis, as already mentioned, and yet we decided on operation after measures had been taken to reduce the blood-pressure. In the other case we knew that tertiary syphilis was present and the Wassermann positive. The venereal disease expert, however, held that efficient treatment would take too long and advised me to "go ahead." The patient died of pulmonary complications six weeks after operation, and at autopsy a cavity, presumably a broken-down gumma, was found in the lung with empyema. In the remaining 3 fatal cases death was due to recurrence of the growth after thyrotomy. In 2 of these laryngectomy was performed and the remaining case refused this procedure.

Operation. In no case was an attempt made by endolaryngeal methods to remove the tumor, though in 1 case, in which the patient had only suffered from hoarseness for one month the growth was limited to the middle third of the cord and appeared very superficial. The direct method might have been sufficient.

The technic of laryngofissure is here briefly described. Heroine ($\frac{1}{12}$ gr.) and atropine ($\frac{1}{100}$ gr.) were given and the larynx sprayed with 10 per cent cocaine and adrenalin by indirect method before operation. General anesthesia. Midline incision from hyoid to episternal notch; median tracheotomy; anesthesia was carried on with Franke's apparatus; incision of cricothyroid membrane with knife and division of thyroid cartilage with Wagget's shears; halves of thyroid cartilage held apart with retractors and gauze packed on to the upper surface of the tracheotomy tube through the thyrotomy opening; affected cord separated with elevator from inner surface of thyroid cartilage; cord and surrounding healthy tissue excised with scissors, a small curved pair being used to make the posterior cut, which usually went through the

vocal process of the arytenoids. In early and very limited growths we do not think it is necessary to remove a piece of the false cord. In 3 cases part of the thyroid cartilage was removed along with the attached cord, following the method of Lambert Lack. In 3 instances the anterior end of the "other" cord was also removed as the growth reached, if it did not transgress upon the midline. After bleeding had ceased the gauze packing in the trachea was removed and a long tracheotomy tube substituted for the one used at operation. A fresh, but longer strip of gauze was now inserted so that not only the upper part of the trachea but also the lower part of the laryngeal cavity was packed. The end of the gauze strip was brought out between the thyroid and cricoid cartilages. The soft parts over the thyroid were then stitched with catgut and the wound closed with silkworm gut. At the end of the first twenty-four hours the gauze-packing and the tracheotomy tube were removed.

PROGRESS. In 6 cases there was some dysphagia after operation, but in 5 of these it was very slight; only in 1 case was there return of fluid through the tracheotomy opening. This patient, as already mentioned, was syphilitic. Death was due to pulmonary complication.

In 2 cases the gauze-packing left in the larynx gave rise to trouble, as some of it was inspired or drawn into the trachea alongside of the tracheotomy tube and had to be removed quickly to prevent choking. We confess that we are doubtful of the wisdom of packing the larynx at the end of the operation.

There was no trouble with hemorrhage in the 13 cases, a fact which may be attributed to the gauze-packing.

A granuloma formed in 5 cases and was removed by the direct method and microscopically examined.

*Results.* As has already been stated, 7 of the 14 cases recovered and 7 died. Taking the recoveries first, I find that 1 patient was alive and well seven years after the operation. She died this year of cancer of the cervix uteri, but I think I am entitled to regard her as a "recovery," as far as the larynx is concerned. One patient is well six years, 2 at a period of four years, 2 at two years and 1 at a period of only one year after operation.

As regards the 7 fatal cases, 1 died of apoplexy, 3 of pulmonary

complication following operation and 3 of recurrence of the local disease.

I am only too well aware that my 50 per cent recovery-rate compares badly with the 80 per cent rate of Dr. Chevalier Jackson and Sir St. Clair Thomson. I hope, however, that in future my results may improve.

Conclusions. If I may venture to draw conclusions from such a small experience, I would say that thyrotomy is a suitable operation for the cure of cancer of the larynx in a comparatively small group of cases. Patients suffering from marked arteriosclerosis, from chronic pulmonary affections or from syphilis should not be operated on, at least if the surgeon is one who thinks about his "batting average," as they say in cricket. Further, thyrotomy is only indicated if the growth in the vocal cord is a limited one, *i. e.*, if it does not transgress the anterior commissure or reach the vocal process, and if the cord itself is fairly movable.

In view of the brilliant results obtained by Tapia, of Madrid, my feeling is that in cases in which the growth has extended deeply and the cord moves very little or not at all the proper procedure is laryngectomy if the patient will consent to it. As you have seen from the lantern slides, the cancer tends to infiltrate between the thyroid and cricoid cartilages, so that removal even of a large piece of the thyroid cartilage may not be sufficient to prevent recurrence.

I do not need here to emphasize the importance of hoarseness as a symptom, but I would like to see a notice sent in large type to all general practitioners as follows:

"Every case of hoarseness which lasts more than a few days should have the larynx examined. If you cannot do it yourself, send the patient to someone who can. This warning applies with treble force to the case of male patients over forty years of age."

# RADICAL OPERATION FOR EXTRINSIC CARCINOMA OF THE LARYNX

V. P. BLAIR, M.D.

THE following observations are concurrent with the experience gained while treating, by a specified plan, 8 cases of cancer of the larynx in which it was either clearly evident or there was reason to believe the growth had become extrinsic:

(*a*) Even after a carcinoma has extended beyond the confines of the larynx, either directly or into the lymphatic nodes of the neck, it might still be curable by appropriate surgery.

(*b*) Light, thorough packing of the resulting wound is a much safer procedure than primary suture with free multiple drainage.

(*c*) Packing of the wound and the upper end of the trachea should be carefully maintained until the wound has healed spontaneously or the fistula is closed by secondary suture.

(*d*) Postoperative radiation may have been a contributory factor in the successful cases.

This small series contains several deaths, but it is believed that the few positive results can be taken as an indication of the possibilities of this plan of treatment and that the high mortality was incidental to the development of a technic rather than a logical sequence of the plan of operation. The plan had for its object the removal of the involved tissue in one mass and in such a manner that the subsequent closure of the external opening would be either spontaneous or require but a simple secondary operation. The extent and details of the operation varied with the requirements of the individual case; the general plan followed has remained the same, but certain unfortunate results suggested a radical change in the treatment of the wound from that followed in the earlier cases. By this I believe the mortality of the operation can be brought within an acceptable figure.

Intrinsic cancer of the larynx has long been recognized as among the least malignant manifestations of this disease. Obser-

FIG. 1.—Case I. Showing carcinoma invading lymph gland.

vation of neglected cases led to the conclusion that even after it had gone beyond the confines of the larynx it still averaged less

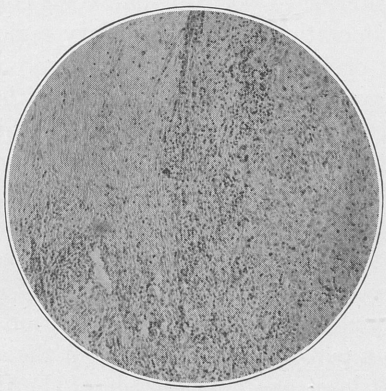

FIG. 2.—Case VIII. Showing carcinoma invading tissue anterior to the trachea.

malignant than neck invasions arising from within the mouth, and with these latter we have had some very gratifying results.

Preliminary tracheotomy was necessary in almost every one of these cases. In each instance a rather low opening was made some days or weeks before the radical operation and the trachea isolated by an iodoform gauze pack after the plan of Crile.

The general plan of operation is as follows: Approach to the larynx is made by a U-shaped incision starting external to the angle of the jaw and running down the anterior border of one sternomastoid muscle to below the cricoid ring, crossing the trachea and ascending the other side. The skin and the platysma are raised as a curtain flap with its base at the hyoid bone, or higher if need be. Prolongations of the original incisions downward and outward to the clavicle, on one or both sides, may be added to facilitate the lower neck dissection—a modification of the Gluck flap.

If the diagnosis has not been confirmed the larynx is now split in the midline, and if need be a microscopical examination is made while the neck dissection is in progress. Usually the demand for a complete neck dissection is much more evident on one side than on the other. In the advanced case it is better to do a thorough neck dissection on one side than a partial on both sides, but the nodes anterior to both jugular veins should be included. At the primary operation the submaxillary region is not invaded at this stage out of respect to the blood supply of the flap. The attack on the larynx itself varies somewhat with the location and extent of the disease. If the involvement is high, extending to the tongue or pharynx, the excision is made from below upward; if the thyroid gland or the muscles are involved, it is best begun above. In making the removal it is to be remembered that in the neck the only absolutely sacred structures are the spinal column, the carotid arteries, one phrenic and one vagus nerve. One can occasionally get by with the ligation of one common carotid artery in a person of cancer age, but the average mortality is very high. At least one inferior pole of the thyroid gland was preserved in each of these cases and in no neck dissection have I ever removed both internal jugular veins at the same sitting. At first, when necessary, later as routine, the ribbon muscles were removed with the larynx. This facilitates the subsequent care of the wound and their loss seems not noticeable.

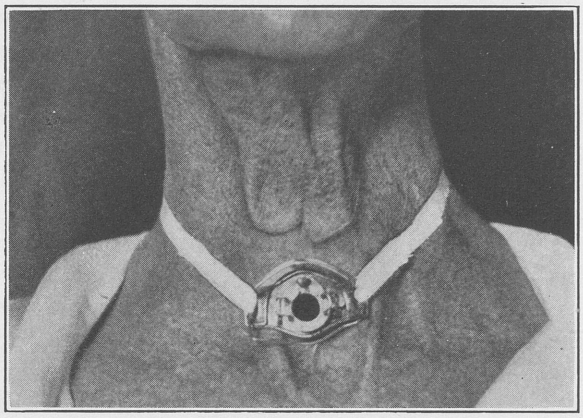

FIG. 3.—Shows final condition in Case III. Owing to scar contraction the curtain flap is apparently much smaller than it was originally made and the tracheotomy opening is higher. Examined, July, 1923, and has no sign of return of the disease.

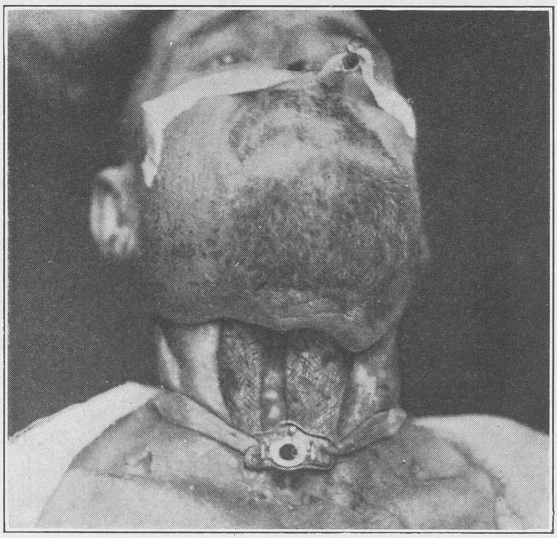

FIG. 4.—Shows condition of neck in Case V about a week after operation, when patient was apparently making an uninterrupted recovery. The central shiny line is the open pharynx; the two outside vertical masses are the sternomastoid muscles, and on each side of the pharynx, between it and the sternomastoid muscles, can be seen the deep gauze packing. In this case the feeding tube protrudes from the mouth.

I have attempted, but not succeeded, in permanently attaching the upper end of the trachea to the skin at the preliminary tracheotomy. If in making the excision the trachea is divided above the tube opening the part of the trachea above the tube is packed with a piece of vaselined iodoform gauze large enough not to slip in along the side of the tube. A Mikulicz pack will obviate this difficulty. The tent is made of one thickness of fine mesh gauze, care being taken to push enough of the tent into the trachea to permit of filling the upper cavity with a long, narrow strip of packing. At subsequent packings it will be found convenient to feed in the packing strip between the blades of a nasal speculum. The pharynx is lightly whipped together with running catgut, no attempt being made at a real surgical closure. The lower part of either lateral pocket behind the sternomastoids is drained through a stab wound, but a drainage tube should not touch the great vessels. Next, the whole wound is lightly but thoroughly packed with iodoform gauze and the curtain flap is tacked down with a few sutures to keep it stretched rather than to get primary union.

In our earlier cases the pharynx and the skin flap were both carefully sutured with free drainage, but the wound always became infected and we have learned that in an infected neck wound in which a large artery has been tied it is safer to pack than to simply drain. Billroth learned this many years ago. If well applied this primary deep dressing can be left undisturbed for seven or nine days and each time it is reapplied the gauze should be led to every part of the depth of the wound.

Before the wound is packed a feeding catheter or duodenal tube is placed in the esophagus through the rent in the pharynx and anchored to a piece of adhesive plaster attached to the neck. In the cases in which primary closure was attempted the feeding catheter was introduced through the nose. The feeding tube is a necessity, and with the aid of a meat-grinder and a syringe any kind of food can be administered, but it has several inherent dangers. The needs and desires of the patient should be considered in the selection of the food, and it should be administered slowly as in natural swallowing. After each feeding water is given to wash out the tube.

The wound may entirely close spontaneously or granulate down to a fistula that will require secondary operation. When indicated, subsequent operations may also be done to complete the gland dissection of the whole neck.

FIG. 5.—Is a somewhat diagrammatic representation of the condition of Case VIII immediately after operation, before the packing was inserted. The trachea was cut off at the level of, and has dropped down behind the sternum. On either side, just above the sternum, can be seen the two lower poles of the thyroid gland. Above is the hyoid bone, with the cut ends of the ribbon muscles attached. Lower down is the pharynx; the curtain-like structure hanging forward is that part of the pharynx that covered the posterior wall of the cricoid cartilage. On either side of the pharynx can be seen the great vessels bared by the gland dissection, and outside of these the edges of the sternomastoid muscles are visible. On either side of the neck protrude the drains leading from the pockets behind the sternomastoid muscles.

Of these 8 cancer cases, 4 were operated more than three years ago. The first was operated April 15, 1916, for a growth in the upper part of the larynx which involved the right arytenoid fold and which had two large broken-down cancerous masses in the right side of the neck. At the time of the laryngectomy the right

side of the neck was dissected and subsequently the left side, and the submaxillary regions were cleaned out. Subsequent *x*-ray treatment was given for a year. He is still free of recurrence and informs me that he has been granted a large policy by one of the older standard life insurance companies.

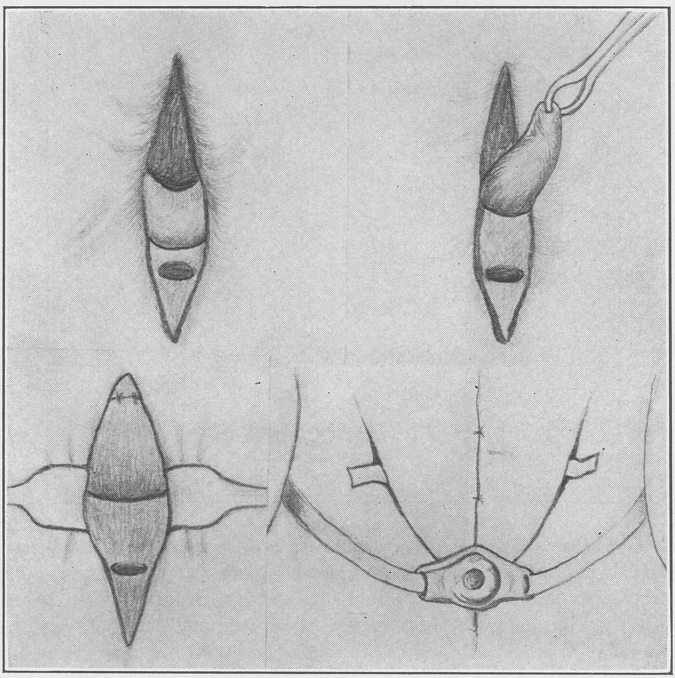

FIG. 6.—The upper left small figure shows the size of the opening just before it was finally closed by operation. The upper right small figure shows the cricoid part of the pharyngeal wall dissected up ready to be sutured into its proper place. Lower left, the pharynx closed; lower right, lateral skin flaps drawn over the pharynx and the deep space drained.

The second case was operated March 29, 1917. The larynx was almost completely closed with growth in the lower part which had perforated into the thyroid gland. A very radical operation was done at one sitting and the fistula closed at a subsequent operation. This man was kept under observation and died of

acute tracheitis and bronchopneumonia April 1, 1923, with no symptoms of recurrence. He had been in charge of a hoisting engine in a quarry and developed a loud, disagreeable coarse speech.

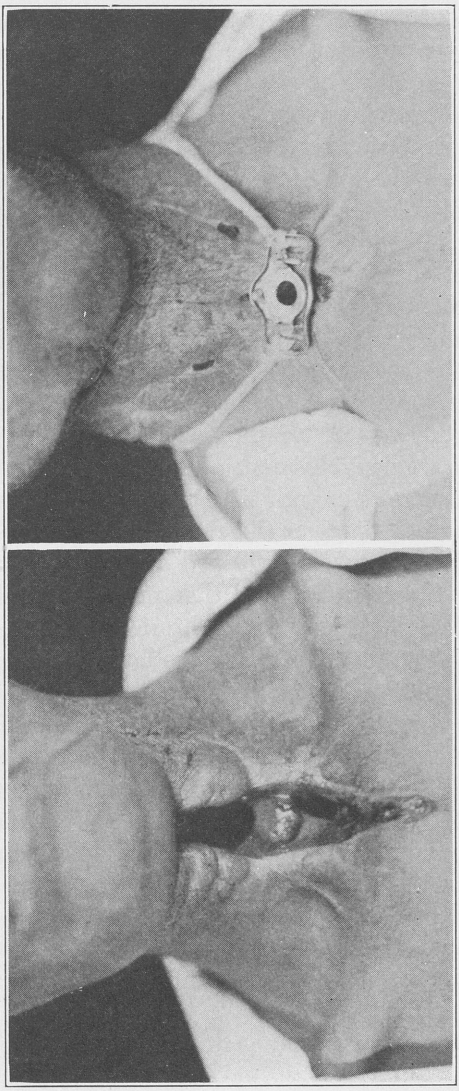

FIG. 7.—Photographs. Shows Case VIII some time before secondary closure operation was done and after final healing had taken place. The extreme vertical length of this wound is due to the fact that at the laryngectomy the whole of the original tracheotomy wound was included in the excision. The reason for doing this was that the tracheotomy wound was made through cancerous tissue. The photograph, to the right, shows condition at the time of his discharge from the hospital. The sites of the drains put in at the secondary closure operation are still visible.

Then came the War.

The third case had a less extensive involvement and was operated on May 18, 1920, and is still well. Prophylactic radium and *x*-ray treatments were given subsequently.

The fourth case, operated on January 22, 1921, had an almost complete obstruction of both larynx and pharynx from a growth starting in the upper larynx. Of the 5 that survived operation this is the only one so far to have a recurrence of the disease, and this occurred in the tracheal wound, not at the original site of the disease. He died in December, 1921. This incidentally is the second case in which the question of a possible implantation at the tracheotomy site has arisen. Preliminary radiation might obviate this danger.

The next 3 cases terminated fatally in the hospital following operation, each from a particular cause, but in all, I believe, there was some relation to the post war disorganization that occurred both in the house staff and in my own personal work, but in each proper wound and tracheal packing well maintained might have avoided the fatal termination.

The fifth case was an involvement of the larynx and pharynx with enlarged gland masses in both sides of the neck. The wound was packed open and the patient did well for about three weeks, after which bronchopneumonia developed and it was found that packing was not well maintained and that pus was trickling into the trachea. He died of the pneumonia March 23, 1921.

The sixth case had an involvement of the larynx, epiglottis and the base of the tongue on the left side, with a large, apparently fixed gland mass extending from the mastoid to the clavicle on the left side. A complete gland dissection was done October 10, 1921, on the left side, with removal of immediately contiguous nodes on the right and the larynx. The left half of the hyoid, the base of the left side of the tongue and the larynx were removed with a cautery. The wound was closed with free drainage. He apparently did well for nine days, when hemorrhage proved fatal in less than five minutes. Postmortem examination showed infection hidden under the curtain flap and that the lingual artery had sloughed off at its origin.

The seventh case was an elderly gentleman with long-standing

hoarseness, laryngeal obstruction and enlarged neck glands. Two attempts had failed to procure cancer tissue for microscopical examination by intralaryngeal biting forceps. Under 2 per cent novocaine block of the second and third cervical nerves on each side and 0.5 per cent novocaine infiltration locally the usual operation was done. The larynx was exposed and split before removal. A submucous growth completely surrounding the lower part of the larynx was found. The larynx, ribbon muscles and adjacent lymph nodes were removed in one mass. At first he carried fairly well, following a blood transfusion, but he was very feeble and tube-feeding was, I now believe, pushed with more diligence than discretion. He regurgitated a feeding, some of which went into the trachea.

The eighth case noted hoarseness one and a half years before admission to the hospital, when considerable perilaryngeal thickening was evident by palpation. While doing a preliminary tracheotomy it was found that carcinoma had invaded the ribbon muscles anterior to the larynx. A laryngectomy was done on December 12, 1922, along with a removal of the upper half of the thyroid gland and all overlying tissue save the skin. The glands in front of the bifurcation of the carotid were removed on both sides. On the right side a chain of glands running down the outer side of the jugular vein were excised. Following the operation 650 cc of blood were given.

To sum up, there are 2 patients (25 per cent) with extensive extralaryngeal involvement who lived six years or more after the operation without recurrence. One patient has been free for more than three years.

There has been one death from recurrence, but this may have been an implantation into the tracheotomy wound. There have been 3 postoperative deaths, but these might have been preventable.

## Discussion on the Papers of Drs. Fraser and Blair

Dr. Lee M. Hurd, New York City:

Dr. Fraser spoke of spraying the larynx with 4 per cent cocain solution before doing a thyrotomy. It is much simpler and more

satisfactory to use the solution in a hypodermic syringe and, as soon as the larynx is exposed, plunge the needle through the thyrohyoid membrane and inject a few drops directly into the lumen of the larynx, which will give a perfect anesthesia. This is also applicable in tracheotomy and will prevent the reflex cough. I have one thyrotomy of thirteen years' standing and he has a very resonant voice. I saw him last winter and he has largely replaced the removed cord with a fibrous band. He is now seventy years old. In regard to the postoperative feeding tube, I have abandoned the nasal feeding tube and now bring out the feeding tube through the wound, suturing the esophagus up to the tube, though I have yet to have primary union in the esophagus. The feeding tube coming out through the wound and through the dressing is infinitely more comfortable for the patient and easier for the nurse to take care of. I use a 22-caliber French soft-rubber feeding tube.

Regarding the one- or two-stage operation, I take it that Dr. Blair has been doing the two-stage. I feel much more secure if a low tracheotomy has been done a week or ten days before the larynx is removed and the mediastinum has been walled off with granulation tissue about the trachea. In this interval the teeth, nose and mouth can be made as clean as possible, so that when you do the laryngectomy there is less liability of infection. Of course, they have to wear the tracheotomy tube the rest of their life, but this apparently is no discomfort, as they soon learn to take care of their own tube, to clean and change it without the attention of the physician.

I would like to ask about life insurance. I do not see how any reputable life insurance company could insure any of these cases.

Laryngectomies can be done perfectly well under local anesthesia; in fact, the last one I did only required 20 cc of 0.5 per cent novocain subsequent to a hyoscin and morphine injection. He went back to bed and said he felt fine, and seemed no more shocked than if he had had a tonsillectomy under local anesthesia.

In regard to either local or general anesthesia, we have to be very careful not to tug on the vagi nerves, as it will bring on cough and inhibit respiration.

One man had a papilloma in the notch of the trachea. I took it off. He came back several years later with a malignant larynx which I took out, and eight months later he had a transplant in the tracheotomy wound. He died later of recurrence about the sternum.

In regard to extrinsic cancer, I am glad to hear they get well. I had one in which I removed everything, and he lasted six months and had a recurrence. I lost my courage and let him go.

Dr. Fielding O. Lewis, Philadelphia:

I think Dr. Blair is to be congratulated upon the results which he has obtained in these extrinsic cases of cancer of the larynx. Many cases such as he has described often have metastasis in the mediastinum or in the lungs. I should like to ask if he would operate if the rays show metastasis in these regions?

Dr. D. B. Delavan, New York:

This subject was extensively considered at our meeting of last year, on which occasion I expressed several opinions not necessary to be repeated here. Remembering that the operation of laryngectomy was first performed more than seventy-five years ago, that it has since been experimented with in many countries by large numbers of operators upon innumerable patients, the amount of reliable statistical material now accumulated should be very great. Unfortunately, this is far from being the case. Records of all cases operated upon have seldom been kept, only the favorable results having been published. Many years ago I urged that, as far as possible, all cases of laryngeal cancer be placed in the hands of men especially proficient in this department, who should operate with the help of skilled assistance in hospitals especially equipped for the purpose. Also, that careful records be kept and particular care taken to secure end-results. The cases should be studied and treated scientifically, in an effort to evolve some positive knowledge. Cases diffused among a large number of desultory operators have thus far taught us little. The papers we have listened to today give hopeful evidence of progress. It is from work of this kind that actual advance may be expected.

Referring to the three principal methods of treatment: While a few unusual cases in which malignant growths removed intralaryngeally have resulted in the prolongation of the patient's life, the failures have been so numerous as to be prohibitive.

Thyrotomy and partial laryngectomy in properly selected cases have been successful in the hands of several of the most distinguished diagnosticians and operators of our time, especially in England, where such men as Sir Henry Butlin, Sir St. Clair Thomson, and others elsewhere, have reported many favorable results.

Complete laryngectomy in early intrinsic cases is now recommended by a large number of authorities. It is only fair for me to say that I have seen several instances in which complete removal where the disease had become extrinsic has been followed by recovery with marked prolongation of life. I therefore agree with Dr. Fraser and

Dr. Blair that extrinsic cases are not invariably hopeless. I also believe with them, as with our distinguished Japanese guest of last year, that it is necessary to recognize the type of the growth. Upon this must depend the prognosis and the method of treatment to be pursued, since no single method can be equally applicable to all.

At our meeting last year I reported 9 cases of intralaryngeal carcinoma treated with radium and apparently arrested: 7 were cases of squamous epithelioma, 4 of which were so proved by microscopical examination; 2 were granulomas. None of these cases now show signs of recurrence, although more than a year has passed since the above report. In such cases opinions as to the actual results, based upon usual operation, are purely conjectural and lack scientific value. Time is the great test. How long these 9 cases may continue apparently well cannot be foretold. Certainly our experience thus far with them is encouraging and sufficient to warrant continuance of this method of treatment in selected cases, at least until it has been proved unsatisfactory.

For proof, either for or against, a long period of time will be required, in the course of which not so much will be accomplished by blind and unintelligent opposition as by open-minded, judicial observation. Thus far in our experience it seems that for the treatment of certain types of intralaryngeal cancer radium is possessed of decided merit.

Dr. John E. Mackenty, New York City:

The statistics shown about males and females correspond pretty closely with my own. I had 3 females in present 87 cases. The hyperkeratosis cases are the most favorable so far as I can determine. I had a few such cases which eventually became malignant. I had to operate finally, as the disease took on a more rapid growth. I removed the larynx and found malignancy was beginning to invade the deeper tissues. Personally, I am very much opposed to biopsy if it can possibly be avoided. In the 87 cases 3 biopsies were done to verify the diagnosis. If done it should be done close to the operation. I believe it tends to spread the disease. The number of squamous-cell cancers in Dr. Fraser's statistics are practically the same as in our own; practically all the cases are of squamous-cell variety. They do not yield to radium. I will mention only one instance to prove this: A case of incipient squamous cancer was treated by radium, a male, fifty years old. The emanations were injected into the tissues, not planted in tubes or pearls. He got up a terrific radium reaction which necessitated later a tracheotomy. He was brought to the hospital in a septic

condition. There we kept him, expecting he would die. He got down to 105 pounds from over 200, and finally he was in such misery that I decided to remove the larynx, expecting he might have some septic focus which was giving temperature and absorption. We found the larynx was an abscess cavity. The point I wish to emphasize is that in spite of an intense and locally lethal dose of radium the microscopical examination of the abscess walls showed actively growing cancer cells. Here radium surely had a chance to cure, but it absolutely failed. I have seen no squamous cancers cured by radium. I wish those who contend for radium would bring to the New York Academy a case cured by radium. The general surgeon's method of treating cancer in any other part of the body is pretty radical. I removed breasts, when I was a general surgeon, wide of the disease; in spite of that I had many recurrences. A quarter of an inch from active cancer growth is very little leeway to build a hope of no recurrence on. In the operation of total removal and partial removal the plugging of the trachea is extremely essential in order to keep secretions out of the lungs. I began that method twenty years ago and later published a method on how to pack the upper end of the trachea. The feeding tube, of course, is essential. When I started doing this work, a great many years ago, nobody seemed to know how long the feeding tube could be retained without getting esophagitis. With some trepidation I kept it in several cases for from four to eight weeks, with no ill effects. The mortality quoted in Dr. Fraser's operation I think is too high. I believe the reason to be this: The effort is made in doing this operation to get a very nice, neat-looking, sewed-up wound. When dealing with surgery of the mouth you do not dare put in many stitches: you put in as few stitches as possible; you pack the wound so that every crack and corner of that wound is open, and that is the way we treat our cases. If we aimed at primary union we would not save many of them from a septic death. We treat them with the idea that they are going to have infection and lay our barriers accordingly. I was very much interested in Dr. Blair's paper because I think he has presented to us more cures from extensive cancer of the neck than we have seen or heard of before. In my own experience, although I did extensive neck resection repeatedly, I have not had one cure—they all eventually died of cancer. I have even taken the esophagus out down to the sternum, including the larynx and everything that could be spared without killing the case, and yet they eventually died of cancer. He is to be congratulated on his results. I think if you only save one case of this kind in one hundred it is worth trying. His

discovery that the sewing up of the wound was the cause of death I think was timely, because you cannot safely close these wounds. The trachea does not drop back into the chest if it is anchored to the skin by silver wire. There is one point I do not think I have made very clear to men doing this operation, and that is the way of closing the trachea to prevent wound secretion getting in. The tracheal tube is very large and around the tracheal tube is wound some gauze which is saturated with vaseline and bismuth. This is formed into a cone shape. It fits the trachea like a cork does a bottle. This tracheal plug, which I devised years ago and have employed in all cases, has, I am convinced, saved many cases from secondary pneumonia due to gravitation of secretions into the lung. In extensive sloughing of the neck which sometimes occurs I cannot see how the case can be treated without this barrier between the wound and the lung.

Dr. Justin M. Waugh, Cleveland, Ohio:

I have been very much interested in these papers and I think that there have been some really very valuable things brought out. I believe the observation of Dr. Fraser, that malignancy in comparatively young adults is very fatal despite any surgical measures that are taken, is correct. I think that has been borne out by men who have done surgery for malignant growths in various parts of the world. I have wondered, as Dr. Fraser went on and described his cases and the mortality rate, if I gathered correctly from what he said that he did the laryngectomy after he had first done a window operation or partial resection. I wondered if the end-results in his percentage would not have been better if in all of these cases he had done a total laryngectomy first. I do not believe you can tell in many of these cases how much extension there is, and as we make more careful clinical observations and there are more accurate observations made with the microscope, I believe we will find that a larger percentage of cases have more wide extensions than we think they have. These cases shown here pathologically by Dr. Fraser are undoubtedly accurate, but I think cases are judged to be limited more than they really are. Dr. Blair is certainly to be congratulated if he has cured as many cases of extrinsic cancer as it appears. I believe that men who have very wide surgical experience with laryngectomy, such as Dr. Crile, have been inclined to side-step laryngectomy more and more in extrinsic cancer. Perhaps that has grown up somewhat from their willingness to let the *x*-ray man and the radio man show what he could do on these cases. The two-stage operation of Dr. Crile, I think, is

very valuable because he does exactly what you do by your packing and other methods—you put up a protective barrier. The great mortality rate in these cases comes from two causes, aspiration pneumonia and mediastinitis, and it is to avoid the mediastinitis that this preliminary stage of packing down well along the trachea and larynx a day or two ahead of time, to start a protective process upon the part of Nature, is done. That, I think, gives protection to the patient. Certainly we approve of the value of extensive tracheotomies and I think that is a feature that has been much neglected. As to the feeding tube: We use an ordinary duodenal tube. You can give the patient ample nourishment, and it is so small that it is not as inconvenient as the larger type of tube that is sometimes used. There is an additional thing I wish to speak of, that is, the matter of blood transfusion, which is carefully given and prepared for ahead of time. as this class of surgery calls for every nicety and every assistance that can be given the patient, and that is an invariable routine in Dr. Crile's operating in laryngectomy. His patients are also getting postoperative doses of *x*-ray and therapeutic single doses for some little time. I do not know the exact time they have decided, whether immediately or just as soon as they feel the patient can have it. There are undoubtedly cells (or transplants) that are set loose at the time of operation which have not much vitality and which may be killed by the *x*-ray. While we are all interested in the study of the cure of laryngeal cancer, I think we must all grow more and more interested in the precancerous stages of the larynx, and everything that is brought out that will help us to recognize the danger that, in certain types of laryngeal conditions, we see as premonitory of the possibility of cancer will be of great value. There is one other thing: I was impressed in a case of my own that the presentation of this problem to a patient, when the patient comes to you and you have made the diagnosis of cancer of the larynx, is a very serious matter. The manner in which you take it up with the patient is important, and I believe you must size up—if I may use that expression—the patient very carefully and make your statements accordingly. Recently I saw a man, about sixty-four years of age, who had an intrinsic cancer. He, unfortunately, had been going about for fifteen months, having various types of treatment from various men, and after making the diagnosis I went in another room and sat down a moment to think just how to present the situation to this man. He was a rather phlegmatic, well-balanced man apparently, and I took a great deal of pains to tell him, in as gentle and kindly a way as I could, the situation that he faced, and put just as optomistic a view

on the future as I possibly could. He accepted the thing and thanked me very much for the pains I had taken to present the situation to him. He lived a few miles away and got on the train that afternoon, apparently thought the thing over from another angle, and when he got home, having decided that the burden which his family must carry and the handicap he would be was too much, he blew his head off.

Dr. Perry G. Goldsmith, Toronto, Ont.:

In regard to the incidence of cancer in Great Britain, my recollection is that there was much more cancer reported in Great Britain than in any other decade. I would ask Dr. Fraser if that is also true in Scotland. When one thinks in the medical profession of Great Britain of the very definite endeavor to educate the people to the fact that hoarseness may be a very serious thing to a patient and should always be investigated and cancer eliminated, and also in regard to the fact that Edinburgh is the filter for all the bad cases in Scotland, one wonders why no more bad cases are in Dr. Fraser's experience. My impression is that cancer of the larynx is not as frequent in Scotland; the proportion of cases which Dr. Fraser seems to have recorded is rather small. Dr. Mackenty does not seem to favor microscopical examination. I would hate to have my larynx operated on by anybody's clinical diagnosis. You may have specific disease and cancer together. Cancer is of very slow growth; cases have been reported fifteen to twenty years. A man may be a very splendid pathologist, but may not be quite familiar with the malignancy of the mucosa of the upper respiratory tract or the variations from the normal. A patient not so long ago consulted me; he was hoarse, very hoarse, and the hoarseness had existed two months; he had diabetes and was not at all well; he was thin. He had seen two or three men who had pronounced his disease undoubtedly malignant. He had a papillomatous mass on the front part of the cord which extended into the glottis. Leading into this mass were noticeable bloodvessels, and there was a definite lack of movement of that cord. Clinically this man had malignant disease of the larynx. I endeavored to take a piece off by suspension. I failed, but succeeded, with MacKenzie's forceps, by the indirect method. It proved to be angiofibroma. The patient completely recovered, the cord regained its movement and he spoke quite well. I cite it because clinically it was malignant and one would have been justified in taking the larynx out on clinical grounds alone. Angiofibromata are infiltrating growths; hence the lack of cord motion.

DR. HARMON SMITH, New York City:

I expected to emphasize the very point that Dr. Goldsmith has so effectively done; hence it is superfluous to do so now.

We are all fallible in regard to diagnosis and prognosis of laryngeal cancer. I have now under consideration a man from Trinidad who ten years ago came to me for a tumor of the larynx and whose father died of cancer of the tongue. Several of my confrères pronounced it cancer, one of whom is present, and advised operation. Rest of voice and change of vocation (he was a lawyer at the time) seemed to overcome his condition. From time to time, however, he has returned to New York for radium treatment and apparently has benefited therefrom.

Another case, a man from Bolivar, was likewise diagnosed cancer and advised to have his larynx removed, but radium has at least enabled him to live for five years without the necessity of total laryngectomy, as was advocated by one of my consultants.

There are other factors in diagnosis which we have got to modify from the old cardinal points laid down as essentials in the diagnosis of laryngeal cancer. Position is one. The majority of intrinsic cancer has not occurred on the posterior part of the cord, as I was led to believe by the older text-books. Immobility of the cord does not occur in all cases of cancer upon the cord. I have a case now in a man, seventy years of age, where the growth was on the middle third of the cord; there was no immobility and nothing to indicate cancer except hoarseness and advanced age. Examination of the piece removed showed it to be squamous-celled carcinoma. I take issue with those who advocate either laryngofissure or laryngectomy upon a diagnosis made only from symptoms and macroscopical observation. A section removed either by indirect or direct method and diagnosis confirmed either from a frozen or hardened section is, to my mind, the only justifiable cause for either laryngofissure or laryngectomy. I was recently one of a number of consultants upon a case of neoplasm of the larynx in a man presenting all the symptoms of laryngeal cancer. There were only two conditions present which prompted me to urge the removal of a piece for microscopical examination before operative measures were instituted. The first was that the cord moved too freely for the size of the growth if malignant, and, secondly, the blood supply at the base of the tumor was too insignificant. I was overruled in my opinion and a laryngofissure was performed, with the subsequent revelation that the growth was a papilloma. For a positive diagnosis, even from microscopical examination, it is first essential

to remove a piece well below the surface evidence, and, secondly, to have a microscopist who is familiar with evidences of cancer derived from small bits of tissue.

Dr. D. Crosby Greene, Jr., Boston:

I reported, ten years ago, a series of 11 cases in which the percentage of cures was 60 per cent to 70 per cent; of that number there were three physicians. I think this is an important point to bring up in connection with the discussion of the cancer question in any locality, that the essential factor in the favorable result of our surgical treatment is the early diagnosis. If we can get these cases when they are operable and operable by thyrotomy, which I think is the safe and practical method of treating most of the early cases, it seems to me that there is no question that the percentage of cures will be very high. In regard to the question of radiation: I have 3 cases in which radiation played, I think, a very important part in the favorable result which was eventually obtained. One of these was a case of adenocarcinoma which was treated by radium as a palliative measure, and after a very stormy reaction from radium, eventually became well three years ago and has remained well. The tumor, the size of a walnut, was in the upper portion of the larynx. That was a case of undoubted malignancy which recovered under radium treatment. The other 2 cases were isolated cases among a large number of unfavorable results. A total laryngectomy was not done in either case. They were both squamous-cell carcinoma, and radium was applied to the region of the larynx after partial laryngectomy; one was done three years ago and is perfectly well today and the other was done two and a half years ago and is apparently well. So that there are some cases that are undoubtedly benefited by radium. I think there is absolutely no question that radium will destroy all tumor tissue that comes within the area of radiation. The difficulty in the application of radiotherapy comes in the inability to recognize the limits of the growth and also in restricting the destructive effects to tumor tissue.

Dr. John E. Mackenty, New York City:

In reference to biopsy, I mean taking away a piece of growth and examining it at your leisure, I did not say that I objected to a section just preceding operation. I am only against taking tissue away and waiting two or three weeks before you do your major operation. I do not object to frozen sections done at the time operation is done, and I have done this a few times. My objection to biopsy is backed by the experience of the general surgeon, who avoids it when he can.

The method generally employed of taking sections from the larynx is extremely objectionable in my opinion. A pinching or crushing instrument is used, which squeezes the cancer cells into the lymphatic channels. If a specimen must be taken, sharp cutting instruments should be used.

THE PRESIDENT:

The chair realizes that perhaps we have gone a little beyond the original idea of the papers in our discussion, and yet it is the most important subject before any body; and if any one decision can be gained from the discussion, it ought to be welcomed as coming from a body like the American Laryngological Association. Individually he is very much in accord with the remarks made by Dr. Harmon Smith and Dr. Waugh. The case Dr. Harmon Smith spoke of was a patient of Dr. Mayer: he was fifty-five years old; he was hoarse, with localized growth; there was every reason to believe that a thing coming so suddenly in a man of that age was in all probability malignant. The question was then, Was it malignant? We decided it might not be, but, nevertheless, a specimen should be examined, with the understanding that, if it proved malignant, operation should be immediately performed. The patient was an intelligent man; his physician his warm personal friend. We three considered every plan and the patient said, "I would prefer to submit to thyrotomy, so in case the disease shows itself to be non-malignant I will feel that it has been quite thoroughly removed." Thyrotomy was done under local anesthesia; a competent pathologist reported it was papilloma. The patient is absolutely content and so are all of us. The speaker felt that if he had removed a portion of that growth and the pathologist said it was a papilloma, would always to his dying day have the fear that he had not removed all that growth. As it was, he is satisfied.

Another instance: A patient was brought to him with the statement that at least six laryngologists had told him he had cancer of the larynx, that the only thing was complete extirpation, and he had an appointment for operation the day he came to my office. The speaker could not feel that it was malignant and that operation should be performed of an extensive nature. His larynx was split and the growth proved to be tuberculous and not malignant. Under these circumstances, as long as we are not sure through the results of our inspection and study of the history of the case, we should go very slowly before submitting patients to drastic operation.

Dr. Greenfield Sluder, St. Louis:

The question of the diagnosis of cancer of the larynx has been raised and I do not think I can add very much to it; but I would like to recite the story of a case: Twenty years ago I had a patient that presented what looked like a fibroma in the middle of the cord, the right side. It was of short standing. I explained what it was and by the indirect method I bit it off, and bit it off perfectly smooth and clean. It was so clearly fibroma by appearance that the question of cancer did not occur to me at all, but, as a matter of interest to see what the little thing was, I submitted it to a pathologist who is today one of the foremost pathologists in the country, elaborately trained for his work. I had submitted many specimens to him; he never made a mistake. To my astonishment and chagrin he reported this to be a cancer. I had bitten it off so mooth and clean that I thought I would wait for a trace of further activity before I said anything more about it. In the meantime I put the slides away and still have them. From that day to this there has been no activity in the cord; it is perfectly smooth; you cannot see that any surgery had ever been done on it, and I wondered if the pathologist had not been mistaken in his diagnosis. When Dr. Eugene L. Opie came to St. Louis (I fancy Dr. Opie's name is familiar to practically everyone present), I knew Dr. Opie's reputation, and one of the first things after forming his acquaintance I took out these slides and asked him to look at them, and he said it was cancer. I said I had removed it ten years before and there had been no further development, and he then remarked it must be a papilloma. I still have the slides, and if anyone is sufficiently interested I will bring them on next year. One of the cases that Dr. Blair spoke of was one that I sent to him, a swelling of the right cord, immobilization of the arytenoid cartilage, and I looked at that many times before I could come to anything like a conclusion. The man was in good health apparently—an elderly man. I thought, of course, it was syphilis. I gave him some iodide and mercury without effect. There was absolutely no break in the surface, no reason whatsoever to think it might be tuberculosis, and I concluded specifically in my own mind that it was not tuberculosis; it could not be, and still here was this perfectly smooth swelling of that side. It did not look awfully bad: there was nothing vicious looking about it, but it had been there for some time; so I concluded I would go in and bite a piece of it out. I felt that I could bite it by the indirect method. I got some of it out and submitted it for examination, and it was said to be normal tissue. I doubted this and so I set him up again for operation. This time I

bit an inch and a half below where I bit the first and again it was declared normal tissue. I sent the case to Dr. Blair, with all of this report, and with this suggestion, that it be considered a cancer of the larynx until it could be proved to be otherwise. He proved it cancer.

DR. BLAIR:
I raised the curtain and stripped the larynx and took a piece out.

DR. SLUDER:
Was it laryngofissure?

DR. BLAIR:
Part of the operation.

DR. SLUDER:
There was laryngofissure and no intralaryngeal surgery would have gone sufficiently far down to have gotten malignant tissue. Dr. Blair determined the fact that my judgment was right about it; he did the operation. It was one of the fatal cases, unfortunately; not from the surgery but from subsequent mishaps.

DR. FRASER (in closing):
In regard to what Dr. Hurd said concerning puncture of the anterior wall of the trachea and injection of cocain, I can only say that I have tried this method and believe that the one I have used is just as good or better. Spraying the larynx before operation has certainly one advantage, *i. e.*, the surgeon has not to wait until the cocain injection has had time to act. Perhaps it should depend upon one's mental make-up which method is more suitable. I personally do not care to wait and therefore prefer the method of spraying the larynx and upper part of the trachea beforehand.

I agree with Dr. Delavan that it would be a very good thing if certain men were told off to take up this line of work on cancer of the larynx and had all such cases handed over to them, so that they might really become experts on the subject. I should be quite prepared to take this line in Edinburgh. I agree that in several of my recorded cases thyrotomy should not have been performed; the larynx should have been extirpated. I refer, of course, to those cases in which the vocal cord was fixed or the movement greatly limited. In future I should perform laryngectomy under such conditions.

With regard to biopsy, I am very doubtful about there being any

danger to the patient in the removal of a piece of growth from the edge of one vocal cord for report by the rapid method within twenty-four hours. I do not feel so certain of my clinical diagnosis that I should like to perform even thyrotomy, much less extirpation of the larynx, without the confirmation of the pathologist.

I am glad to hear about the method of securing the packing in the upper part of the trachea and shall certainly adopt it in future. I quite agree with Dr. Harmon Smith that these intrinsic growths on the vocal cord occur most frequently in the anterior or ligamentous part of the cord. I am sorry I cannot answer Dr. Goldsmith, who asked about an increase of cancer in Great Britain.

I have never attempted to operate in extensive cases of cancer of the larynx with secondary enlargement of the cervical glands. In Edinburgh we send such cases to the general surgeon, but find that, as a rule, he also refuses to operate. As we are also discussing the subject of laryngectomy, perhaps I may call your attention to the cases demonstrated in Paris last July by Prof. Tapia, of Madrid, who showed some 19 patients on whom he had performed the operation of laryngectomy. Prof. Tapia gave a very interesting demonstration of the artificial larynx he employs. We could hear these Spaniards speaking in all parts of the large lecture hall.

Dr. Blair (in closing):

I really feel that something may have been gained by radiation in the first case, and believe that both radium and *x*-ray might be advantageous adjuncts. I think there is some advantage in the two-stage operation, although there is the objection that the patient usually has to wear a tracheotomy tube afterward. In my second case this was not so. The gland-bearing areas above the clavicle should be removed. I would not do a radical operation on the larynx where I was sure the *x*-ray showed involvement of the lung, but I am sometimes skeptical of the *x*-ray diagnosis. I think if one is going to do a biopsy sometime before the operation, preliminary *x*-ray treatment might help to prevent diffusion. When it comes to a question of diagnosis I do not believe there is any one means at our disposal that will always give 100 per cent correct diagnosis. I thought I could make a diagnosis of certain mouth lesions. Within the last year a man came with an ulcer on the cheek that had a number of signs that suggested epithelioma; there was a history of a growth having been removed some years previously; there was ulceration, induration and wartlike outgrowth at the edge, and I had no doubt that it was cancer. Some

distance off on the velum there was a small ulcer that I did not understand and thought it might be a combination of syphilis and cancer. Removal of a section previous to the intended operation proved that the whole thing was a tuberculous ulcer. When one cannot always make a diagnosis of a lesion in plain view on the cheek I think it might be difficult at times to do so down in the larynx. It is of interest that Dr. Bloodgood, in reviewing the microscopical sections of supposed cases of cancer of the breast that had survived five years after a local operation, was inclined to believe that the microscopical diagnosis was incorrect rather than that the local operation might have cured the cancer.

# THE REACTION OF THE PARATONSILLAR TISSUES TO TONSILLECTOMY: A STUDY IN THE ETIOLOGY OF POSTTONSILLECTOMY PULMONARY ABSCESS[1]

RECIPIENT OF THE CASSELBERRY PRIZE FUND AWARD, 1923.

GEORGE FETTEROLF, M.D.

AND

HERBERT FOX, M.D.

INTRODUCTION. Since the appearance, eleven years ago, of Richardson's[1] paper there has developed, especially in the last few years, a deep interest in the incidence of lung abscess as a sequel to tonsillectomy. A recent comprehensive study of the situation, based on a widely circulated questionnaire, has been made by Moore,[2] who gathered reports of 202 cases. Among his conclusions are the following:

"The vast majority of cases are of inspiratory origin because of (*a*) time of development and (*b*) involvement of the lower lobes of the lung in 60 per cent of the cases (right lower, 41 per cent; left lower, 19 per cent), being almost the same relative incidence as in cases of inspired foreign bodies."

"Blood-stream transmission of infected material, causing pulmonary abscess, occurs, but in a relatively small number of cases. Lymphatic extension is a rare mode of infection."

POSSIBLE PATHWAYS OF INFECTION. With this dire sequel occurring so frequently, and it cannot be questioned that it happens oftener than even Moore's paper would lead us to think, the thoughts of all interested must turn toward the reason or reasons for its occurrence and the adoption of methods of prevention.

The infection must reach the lung either (*a*) by way of the

[1] From the William Pepper Laboratory of Clinical Medicine of the University of Pennsylvania.

trachea and bronchi (bronchogenic), (*b*) by way of the venous system (hematogenic) or (*c*) by way of the lymph channel (lymphogenic). The writers of this paper instituted this study with no preconceived theory as to which pathway is the preponderating one, but they were of the opinion that the likelihood of the inhalation method of infection has been taken too much for granted. The fact that in Moore's series of 202 cases 39 (approximately 20 per cent) were secondary to operation under local anesthesia strengthened this view.

Influence of Complete Tonsillectomy upon the Incidence of Lung Abscess. It was in 1912 that attention first was drawn to lung abscess as a sequel to tonsillectomy. And it was about that time that the so-called "tonsillotomy" was being discarded in favor of complete removal, including the capsule. Possibly this is not a pure coincidence. Dean[3] says, "In my experience the infections have been much more frequent and severe since I have been performing tonsillectomy and not tonsillotomy." The infections he refers to are those in the immediate region of or adjacent to the tonsil. The incomplete tonsil operation, whether performed by guillotine, punch or what not, invariably left behind a mass of tonsil tissue walled off from the throat by a very firm and capable capsule. The raw surface left after operation was composed only of tonsil tissue with its associated vessels. No injury had been inflicted or infection implanted upon the muscle or other deeper structures of the pharynx, and no vessels of the tonsillar and pharyngeal region were traumatized or severed. In those days the use of a general anesthetic was universal and no suction appliance was in use, and yet posttonsillectomy lung complications were neither noted nor reported.

Lung Infection of Bronchogenic Origin. Let us consider for a moment the question of air-route infection. A fair fundamental question would be this: Is the lung very susceptible to infection through the air passages? The answer is, It is quite probable that the lung possesses inherently a highly protective margin of safety. This is evidenced by the fact that many injurious objects, notably bacteria, are daily being inspired under many and varying conditions with no deleterious result. General anesthesia offers a good opportunity for plugs of mucus and clumps

of bacteria to enter the respiratory spaces, thousands of cases with dirty mouths are being etherized, but postoperative pneumonia is not as common as the possibilities thus afforded would lead us to anticipate. For example, in Cutler and Hunt's[4] 1920 series of 1604 operations there were but 7 cases of bronchopneumonia and 1 of lobar pneumonia occurring as complications. In these 8 cases local anesthesia was used once (in the lobar pneumonia case), gas-oxygen four times and ether three times.

Moreover, the production of experimental pneumonia by the atomizing of bacteria into the trachea has proved very difficult of attainment. It has succeeded regularly only when very large doses or highly virulent organisms have been used and when they have been introduced by puncturing the trachea through the skin of the neck.

The question might be put more broadly: Are unbroken or even broken mucous membranes reasonably subject to septic invasion? For example, is an abscess of the nasal septum not a very rare condition? How many rhinologists have seen an abscess of a turbinated body, and this even considering the abrasions and open pathways for infection caused by the common habit of finger removal of crusts from the nose? How many cases of foreign body in the bronchial tree, the esophagus, the eye, the urethra or the intestines are followed by abscess? Very few! Of course, the bronchial and pulmonary mucosa may be less tough than that in the other locations mentioned; but even granting this, when a lung inhales some septic material in which are microörganisms to which the individual is probably partly immune, why should we necessarily assume that this inspired material is the cause of an abscess to the exclusion of other possible sources of infection?

Lung Infection of Hematogenic Origin. On the other hand, postoperative pulmonary embolism, following surgical procedures in the abdomen and elsewhere, is a common condition. Many of these cases are badly shocked and die promptly, because the embolus comes from a large vessel and blocks off a large branch of the pulmonary artery and a large area of lung. Even if the embolus is a septic one, death in such cases usually occurs before an abscess has time to form.

In the field of general surgery the thoughts of investigators are turning decidedly toward the embolic nature of postoperative lung complications. A careful and exhaustive study recently has been made by Cutler and Hunt[5] of a year's cases in the surgical wards of the Peter Bent Brigham Hospital, where a specially careful watch has been kept for the appearance of postoperative lung lesions. As the result of improved methods of case-watching and study, the percentages of such complications found has more than doubled in five years. Along with this naturally has come a drop in mortality percentage, because many small lesions have been discovered, lesions which appeared and disappeared with but few symptoms.

During 1920, 1604 cases were operated upon, and "63 of these patients developed a pulmonary complication that might be attributable to the operative intervention or to the anesthetic. There were 5 deaths among these 63 cases. Thus in 3.93 per cent of the cases (1 in 26) a complication developed and 0.3 per cent (1 in 321) patients died from one of the complications."

In this group of 63 there occurred 1 case of lobar pneumonia, 7 of bronchopneumonia, 16 of bronchitis, 2 of exacerbation of tuberculosis, 2 of pleurisy, 1 of empyema, 32 *of pulmonary infarction* (italics ours) and 2 of pulmonary embolism. Thus, even in a general surgical clinic approximately 1 case in 50 was complicated by an infarction of the lung, which shows that this form of pathological lesion occurs more frequently than is generally thought.

Among their conclusions are the following:

"Irritation and aspiration due to inhalation anesthesia may be the cause of a small percentage of postoperative pulmonary complications.

"The fact that these complications occur with local anesthesia, with inhalation anesthesia in the most expert hands and in a definite relation to the mobility of the operative field, is taken as evidence against the importance of the irritation of inhalation anesthesia in the production of these lesions."

W. J. Mayo[6] states that septic embolism from the operative field is a common cause of secondary pulmonary complications. He laments that these complications are too frequently attributed

to the anesthetic, and says that they are quite as frequently found in cases in which local anesthesia is employed. Many other surgeons could be quoted to the same effect.

Among otolaryngologists the possibility that these lung lesions are of embolic origin is not entirely a new one. Of those who might be quoted in this respect are Richardson, Porter, and Simpson and Noah.

Richardson[7] in his 1912 report describes 2 cases under the title of "Septic Infarct of the Lung."

Porter[8] says: "There exists a complicated network of veins, the plexus tonsillaris and the plexus pharyngeus, which cover the outer walls of the pharynx and the tonsillar cavities, receiving blood from the tonsils, tonsillar pillars and pharyngeal walls. These vessels are exposed and always injured even in the gentlest operative work. This too is a field impossible to protect from germ-laden saliva and pus. It is therefore not difficult to believe that infected emboli could be dislodged from veins, thrombotic from trauma and infection, located in an area active in every attempt at speech and swallowing. I feel that there can be no doubt that infected emboli travel direct to the lungs and cause certain cases of pulmonary abscess."

Simpson and Noah[9] state, "The writers believe that aspiration does not account for the production of lung abscess in the 2 cases reported." They conclude: "1. During or following operation septic material enters the veins, passes through the right heart to the lungs and there finds, in the presence of a tuberculous lesion, suitable soil for the production of an abscess.

"2. The possibility of aspiration of infected material as a cause of pulmonary abscess is not to be denied, yet we believe that more cases occur as a result of hematogenous infection than is generally supposed."

Answers to Arguments Favoring Bronchogenic Origin. A common argument in favor of the aspiration of infected matter as a cause of lung abscesses is that in location (preponderatingly on the right side and in the lower lobes) they correspond quite closely to that of foreign bodies. We believe this argument is not as definitive as appears on the surface, for the following reasons:

1. Foreign bodies have no monopoly of localization in the right

lung and its lower lobe. Pulmonary emboli, especially massive ones, seek the right side to even a greater degree than do foreign bodies. An abstract[10] of an article by Capelle[11] states that: "Pulmonary infarction and embolism (*massive*—authors) was stated to have occurred in 15 among 10,000 operations, but many cases called postoperative pneumonia are really instances of small pulmonary infarctions. A distinguishing sign is the bright-colored blood expectorated as compared with the rusty sputa of pneumonia."

Then follows a sentence having marked bearing on the question we are discussing: "13 presented changes in the back and front of the lower pulmonary lobes, and in only 2 were the signs restricted to the left lung." 13 out of 15 were in the right lung and all of them in the lower lobe! Does this not cast doubt upon the location of lung abscesses proving their inhalation etiology? So much for *large* emboli.

In searching the literature for data as to the localization of *small* infarcts we were unable to find definite figures. A letter of inquiry to Dr. Elliott C. Cutler[12] brought a generous and prompt response, and we are able to give his unpublished figures on this point. We herewith desire to express our deep appreciation of his kindness. His table is as follows:

DISTRIBUTION OF POSTOPERATIVE PULMONARY INFARCTION

| | 1920 cases. | 1921 cases. |
|---|---|---|
| Right upper lobe | 0 | 2 |
| Right middle lobe | 2 | 1 |
| Right lower lobe | 14 | 7 |
| Left upper lobe | 0 | 0 |
| Left lower lobe | 5 | 4 |
| Both lower lobes | 2 | 1 |
| Right upper and middle lobes | 1 | 0 |
| Left upper and lower lobes | 1 | 0 |
| Totals | 25 | 15 |

Cutler had accurate data on 40 of his cases. Of these 21 were in the right lower lobe only and 9 were in the left lower lobe only (21 to 9); 30 of the cases involving more than one lobe were located in the right lung and 13 in the left lung (30 to 13).

Welch[13] states that: "The course followed by an embolus in its travels is determined by purely mechanical factors, of which the most important are the size, form and weight of the plug; the direction, volume and energy of the carrying blood stream; the size of branches and the angles at which they are given off, and the position of the body and its members. In accord with these principles we find emboli in the lower lobes of the left lungs oftener than in the upper, and in the right lung oftener than in the left, the right pulmonary artery being larger than the left."

The size of the right pulmonary artery and right lung is to that of the left pulmonary artery and left lung as 4 is to 3. Therefore, an embolus leaving the right heart, other things being equal, would have 4 chances of going to the right lung to 3 of going to the left, or in 100 cases 57 would go to the right and 43 to the left.

2. Another factor could be the course of the two pulmonary arteries as and after they leave the pulmonary aorta. Possibly the right pulmonary artery is in more direct line with the pulmonary aorta than is the left. We are at present studying this piece of anatomy, but are not yet ready to report.

3. The inhalation of bloody throat secretions during tonsillectomy is, in our belief, not precisely comparable to the dropping or inhaling of a foreign body into a bronchus. In the great majority of cases foreign bodies enter while their host is in an erect posture, and in dropping down the trachea they naturally would tend to enter the wider and more vertical right bronchus. On the other hand, during tonsillectomy, under ether, with the exception of certain parts of New England, the patient usually is in a recumbent position and gravity could have little or no bearing on the problem. Whatever enters the trachea is drawn in during inspiration and consists of frothy, bloody mucus and tonsil crypt contents. It moves up and down the larynx and trachea during respiration, and when a collection of this material reaches the tracheal bifurcation it is almost as likely to be inspired into the left lung as into the right.

4. A final argument against the general acceptance of the respiratory theory of these lesions is the fact that so many are reported as being sequential to operation under local anesthesia.

With these facts in mind it is at least conceivable that the

inhalation theory, based upon a wider right bronchus with a more direct course in relation to the trachea, should be relegated to a less important place than it hitherto has occupied in the minds of otolaryngologists.

Reason for and Plan of Present Communication. With these thoughts as a working basis, it occurred to us that a minute study of the pharyngeal and cervical region following tonsillectomy would tell us exactly what happens there as a result of the operation. We hoped that examination of the peritonsillar tissues, and especially of those venous and lymphatic tissues which drain the tonsil area, might afford information as to the probable location of the *fons et origo* of lung abscess. We felt that we would be studying a region into which septic tonsil contents are squeezed during operation, which would be traumatized during operation, into which needle-borne septic sutures frequently are carried during operation and which is wide open to constant microörganismal infection after operation. Such conditions are ideal for the formation of septic thrombi which later could become detached and pass down the internal jugular vein into the right heart and thence into the lung. We felt also that there is hardly any place in the body where thrombi would be more likely to become detached, because the contraction of the tongue and throat muscles during swallowing certainly would promote the loosening of vein clots and the starting of them on their way down the jugular, through the heart and into the lung.

The present communication is based upon the results obtained from operations upon animals. Our experiments were as follows: One animal we devoted solely to the identification of the tonsil lymph node, using Gerota's technic, as employed by Wood[14] in his study of the same structure in man. The others were tonsillectomized. In one of them we removed one tonsil and left the other undisturbed, so that the tissues of the two sides subsequently could be compared. In the remainder both tonsils were removed: On one side two sutures were introduced and tied, while on the other an attempt was made to infect the raw surface by swabbing with bacteria. Before the sutures were passed they were soaked in a suspension of bacteria, these being actively hemolytic staphylococci and streptococci, the former having been isolated from the

blood of a case of staphylococcus septicemia and the latter from a case of acute pharyngitis.

Intratracheal ether anesthesia was used in each operation, and, in order to secure conditions well removed from the ideal, no antiseptic cleansing of the throat was done before operation and no sterilizing of hands, instruments or gauze was attempted. Two of the animals were killed at the end of two days and the third after a lapse of four days. Various blocks of tissue were removed and studied histologically as well as for bacteria.

This part of the work was done in the Laboratory of Surgical Research of the University of Pennsylvania, and we are greatly indebted to Dr. J. Edwin Sweet for his helpful coöperation.

Results of Present Investigations. Study of our material, both gross and microscopical, has elicited the following facts:

*The Tonsil.* The position of the tonsil in a narrow recess between and almost covered by the pillars, as depicted by Sisson,[15] was confirmed.

*The Tonsil Lymph Node.* The large lymph node lying under the occipitomandibularis muscle lateral to the pharyngeal wall and anterior to the sternomastoid was (Fig. 1) identified as the drainage node next in series to the tonsil. Turpentine-ether solution of Berlin blue injected into the tonsil was found to have drained rapidly (well under one-half hour) into this node. Lymph vessels were found, visible to the naked eye, connecting the lateral pharyngeal wall with this node. Dissection (Fig. 2) and microscopy of the tonsil revealed globules of the stain in the sinuses and along the cords of the tonsil, and also in the loose peritonsillar connective tissue. In the lymph node (to be called hereinafter the "tonsil lymph node") it was found to some extent under the capsule, but mainly along the cords within the node.

*Local Postoperative Effects of a Purely Traumatic Nature.* The first effect of tonsillectomy, that of trauma, was found in our material principally as hemorrhage. There was a pouring out of blood (Fig. 3) not only into the tissues immediately subjacent to the operative field, but also in those lateral to it, under the intact epithelium, and extending well beyond the pillars of the tonsil (Fig. 4). In addition, hemorrhage was found in the adjacent salivary gland with resultant degeneration from pressure and

impaired nutrition. Further reaction to the operative procedure was found in the form of round-cell and polynuclear infiltration, followed later by fibrinocellular exudation, the latter varying with the infection (Fig 5). This cellular infiltration reached the lateral and deep tissues, and among its sinister possibilities is destruction of these tissues, as happened to the salivary gland in these experiments.

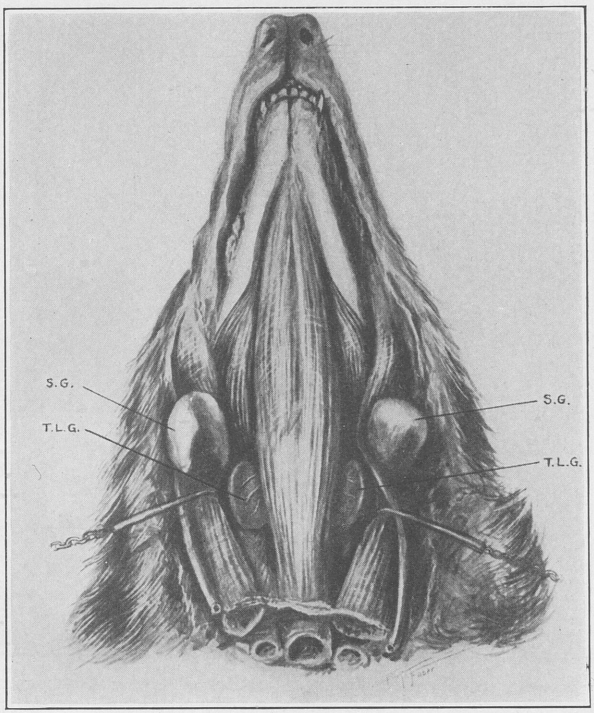


FIG. 1.—Author's drawing of a dissection of the neck, made after the tonsil region had been injected with a turpentine-ether solution of Berlin blue. The tonsil lymph node is shown, with its afferent lymph vessels. These vessels were traced back to the peritonsillar connective tissue. *TLG*, tonsil lymph node; *SG*, salivary gland.

Over the operation field a fibrinocellular sheet was found, the superficial layers of which are progressively cast off, just as false (Fig. 10) membrane loosens, until the healing area beneath it is completely exposed.

*The Effect of Tonsillectomy upon the Tonsil Lymph Node without any Attempt Having been Made to Infect the Operation Wound.*

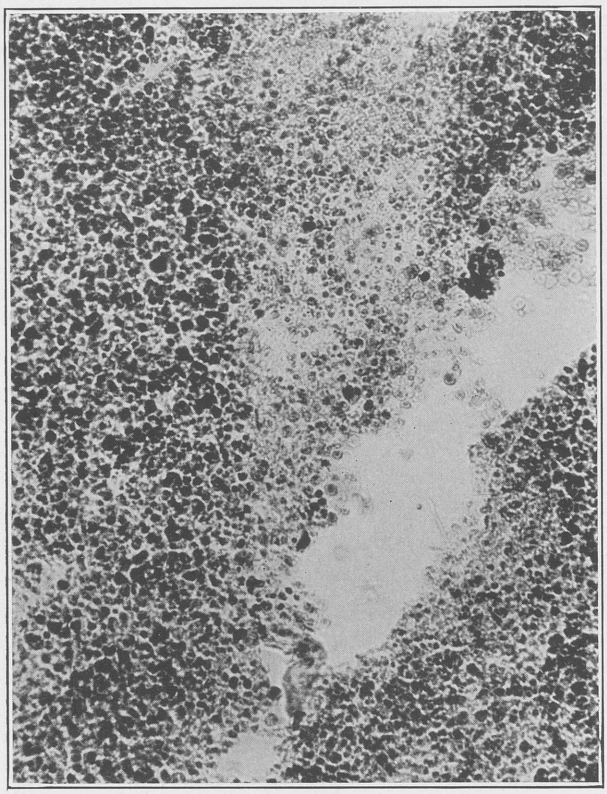

FIG. 2.—Tonsil lymph node, showing globules of pigment along cords. This specimen was taken from an animal which was killed one-half hour after the tonsil region had been injected with a turpentine-ether solution of Berlin blue. This was done to determine and identify the lymph node, which is next in series with the tonsil. It demonstrates how rapidly absorption from the tonsil into the lymph node takes place. The small globules of dye can be seen as innumerable black spots following the distribution of the lymphatic cords. No tissue stain has been used in this section.

Two days after operation blood was present in the tonsil lymph node. The node was swollen and, when sectioned, was found to be so full of fluid (Fig. 6) that the cut surface was wet and greatly

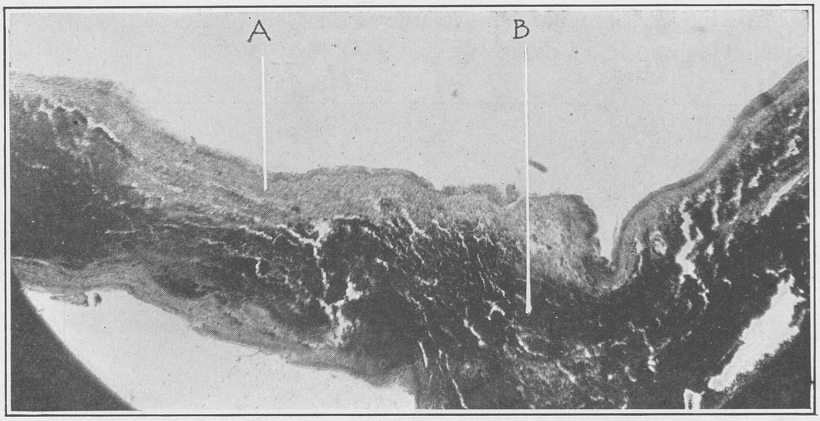


FIG. 3.—Tonsil pillar, showing submucous tissue distended with recent blood clot, two days after operation. This photograph illustrates one of the results of operative trauma on the tissue immediately adjacent to the tonsil. *A*, faucial mucosa and submucosa; *B*, muscular and fibrous tissue infiltrated with blood.

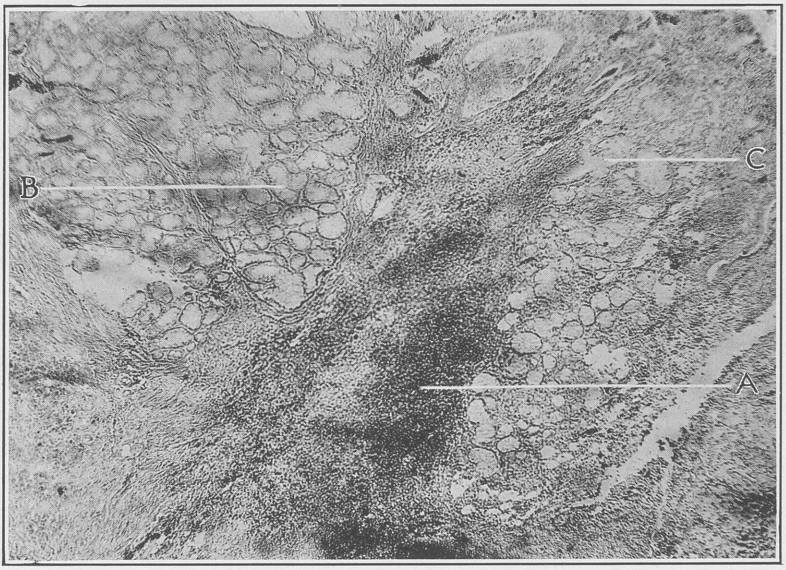


FIG. 4.—Salivary gland adjoining operation area. This specimen demonstrates hemorrhage into the gland as seen two days after operation. The hemorrhage shows as the dark structureless areas in the center and spreading out between the tubules. The pressure of the hemorrhage and the deprivation of blood supply have caused the gland cells to degenerate and the acini to lose identity; incidentally all parts lose contrast. *A*, hemorrhage; *B*, degenerating salivary gland, but some identity retained; *C*, more seriously destroyed salivary gland.

congested. The node on the unoperated side was pale pink or yellowish and less wet.

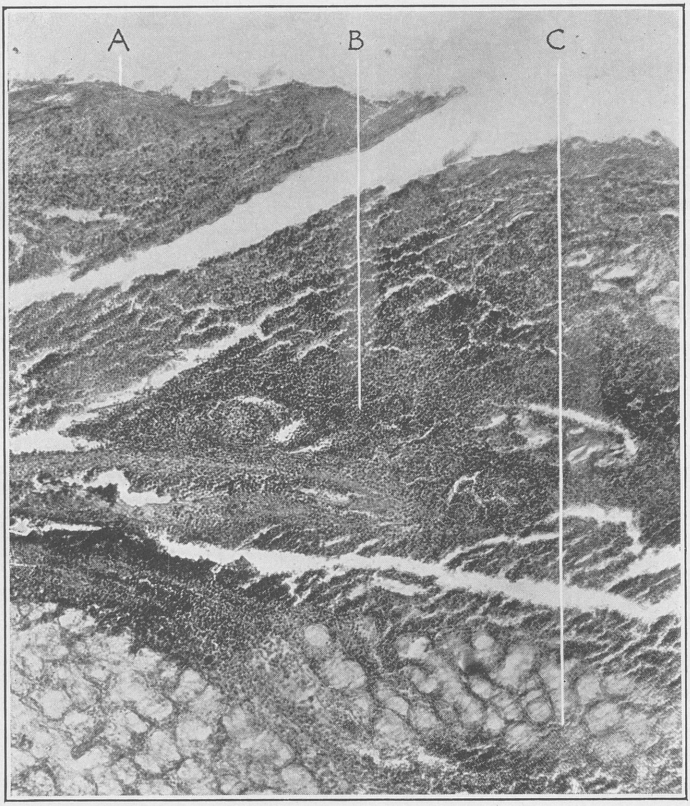


FIG. 5.—Operation field near salivary gland two days after operation. This picture shows hemorrhage and dense polynuclear and round-cell infiltration into the muscle tissue under the operation site and into the near-by salivary gland. *A*, raw operation field; *B*, muscle tissue with marked inflammatory cellular invasion; *C*, salivary gland with similar cellular invasion.

Under microscopical study the node on the operated side was seen (Fig. 8) to be full of blood cells and their fragments, the sinuses especially being widely dilated. The lymphoid tissue itself was active in proliferation, but the follicular areas were not emphasized, there being instead a diffuse lymphocyte increase of all parts.

FIG. 6

On the unoperated side the node was found to be active in its (Fig. 7) follicular areas, but otherwise normal.

*The Peritonsillar Results of Tonsillectomy Which Are Not Purely Traumatic and Which Were Found When the Wound Had Been Artificially Infected.* At the area of operation there was found, two days after operation, a well-developed fibrinocellular exudate

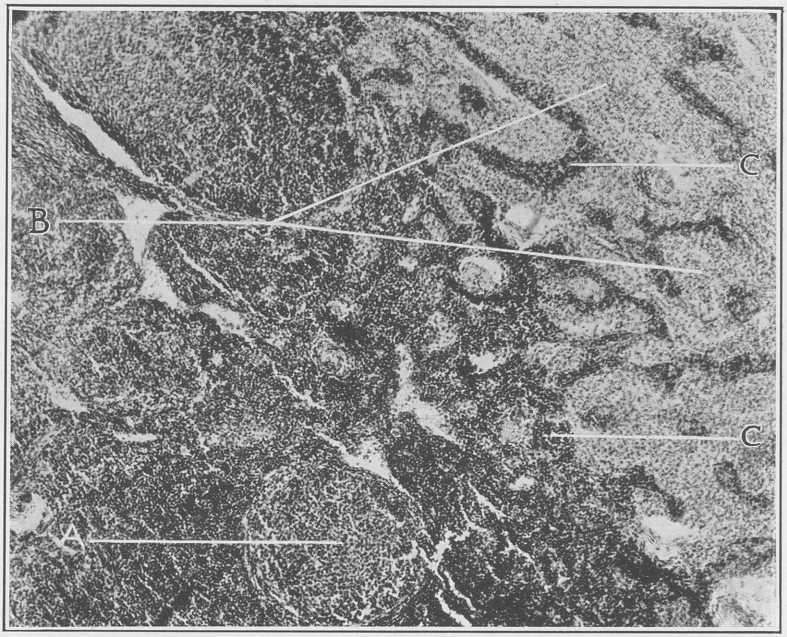


FIG. 7.—Section of the tonsil lymph node depicted in Fig. 6, *a*. The tonsil on this side of the body had not been removed. Specimen was removed two days after operation. While this node shows moderate activity in the follicles, all proportions are correct and the sinuses and cords are practically normal. *A*, follicle; *B*, sinuses; *C*, small normal cords.

(Fig. 9). This not only covered the raw surface, but also extended laterally to overlie the edge of the adjacent epithelium. This exudate formed a barrier (Fig. 12) to the extending of the epithelium over the raw surface. In addition, when infection was present the stratified layers of epithelium were seen to be thickly beset with polynuclears (Fig. 13) and in a state of active inflammation, this decreasing as the distance from the operation

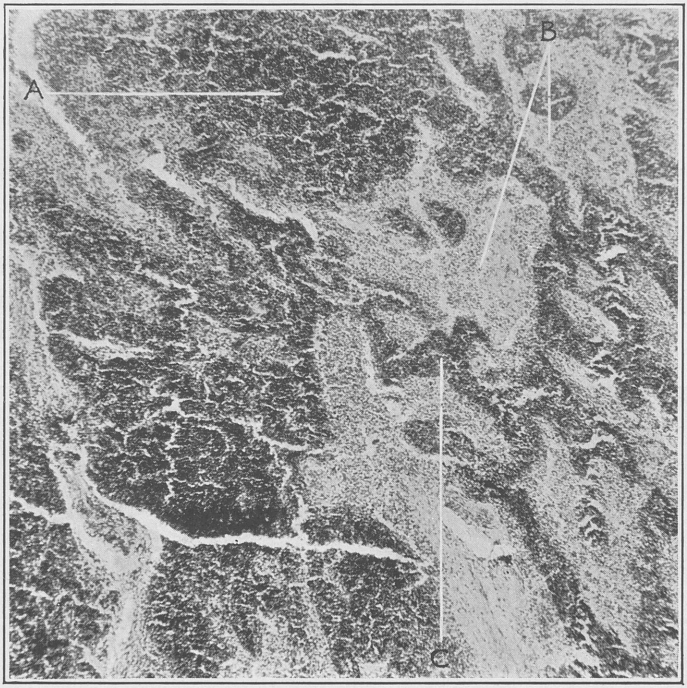


FIG. 8.—Section of the tonsil lymph node depicted in Fig. 6, *b*. The tonsil on this side of the body had been removed. Specimen removed two days after operation. The lymphoid tissue is very active and the markings are obscure, there being for instance no germ center in the two follicles in the picture. The sinuses are distended with blood, and the cords are wider than in Fig. 9. *A*, follicle showing activity; *B*, blood-filled lymph sinuses; *C*, cords.




FIG. 9.—Edge of the operation site, showing postoperative exudate overlying the edge of the epithelium two days after operation. *A*, end of the epithelium at the edge of the operative field; *B*, edge of the postoperative exudate overlying, but here artificially separated from, the epithelium; *C*, blood under the epithelium at the site of the operated area.

site increased (Fig. 10). The exudate lay upon a tissue base characterized by a reactive cellular inflammation.

A noteworthy finding in this inflamed part was the congestion of all varieties of vessels and the frequency of thrombi, both near the surface and deep in the tissues (Figs. 14 and 15). These

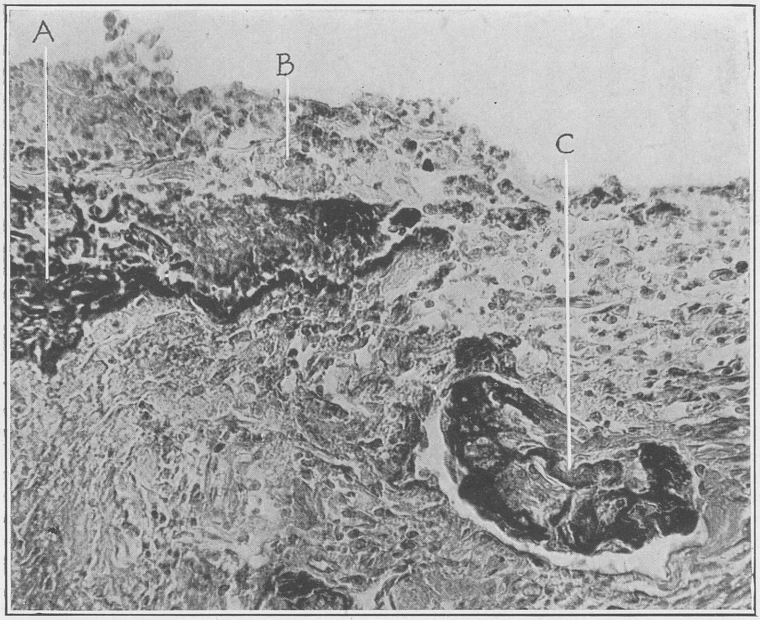


FIG. 10.—A portion of the operation field four days after operation, with the tissues stained for fibrin. The dark parts are fibrin. On the surface is an exudate consisting of two layers, a superficial light and a deep dark one. The former represents the actively degenerating part of the exudate, while the latter is the firm fibrinous exudate itself. The latter lies upon the healing operation base, and will itself later degenerate and be cast off. A well-formed thrombus lies in a vein just below operation area. *A*, fibrinous exudate; *B*, degenerated part of the exudate; *C*, thrombus.

thrombi were attached to the vessel wall and were well developed by the end of the second day. No signs of softening were observed in any of them.

Study of the deeper tissues of the tonsillectomy area showed the inflammation to be similar to that near the surface, including a feature already noted, viz., the involvement of the salivary

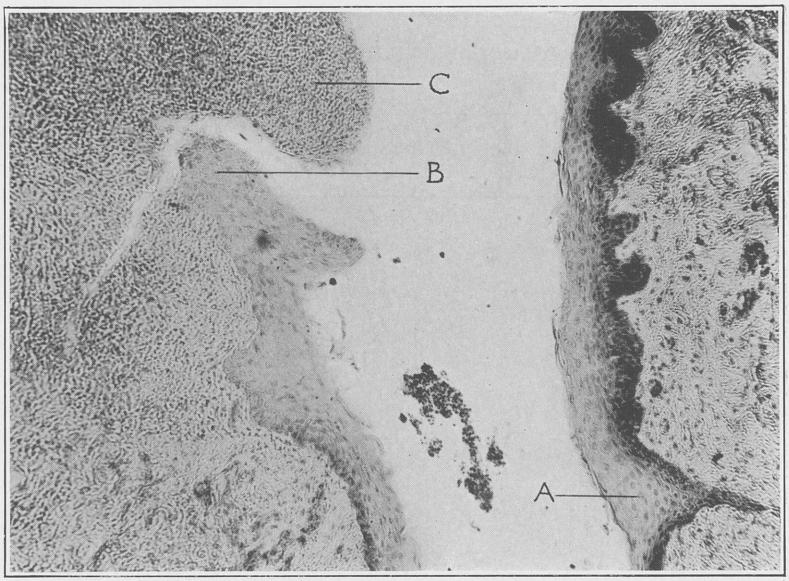


FIG. 11.—Tissue at the edge of the operation area, two days after operation. This figure shows the two lips of the wound, the one with undisturbed epithelium, the other at the cut edge where the epithelium is trying to spread but meets the exudate at the operation site. The epithelium is attempting to cover the raw surface but the exudate overlaps the proliferating surface cells. *A*, normal epithelium; *B*, inflamed epithelium at the edge of the wound; *C*, edge of the exudate overlying *B*.

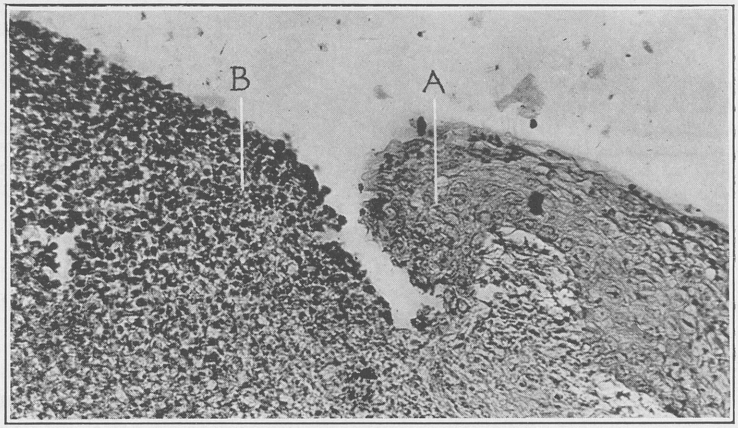


FIG. 12.—Edge of the tonsillectomy area, two days after operation. This figure shows the edge of the epithelium unable to make headway against the infected actively inflamed base of the operation site. *A*, edge of the epithelium; *B*, inflamed tissue showing the fibrino-cellular exudate developed at the operation site.

gland (Fig. 16). In addition the fibrinocellular exudate was seen to extend well into the muscle tissue (Fig. 15) and many small thrombotic veins were here encountered.

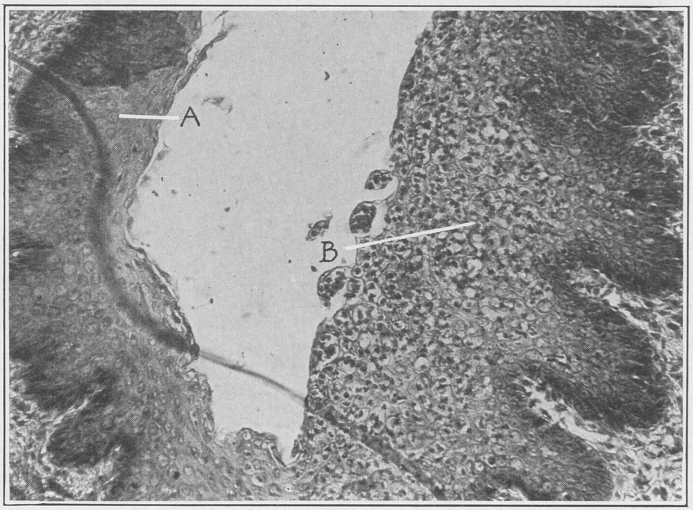


FIG. 13.—Fold in the mucous membrane adjoining the edge of the operation area, two days after operation. Normal epithelium at a distance from the wound. Actively inflamed epithelium adjoining the edge of the wound. *A*, normal epithelium distant from the wound; *B*, epithelium near the wound, showing active inflammation with many polymorphonuclears.

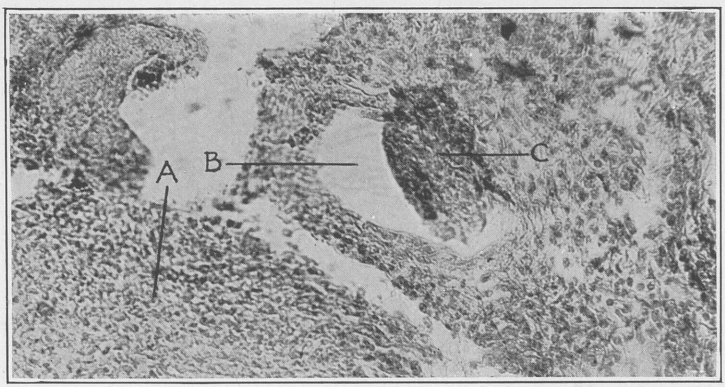


FIG. 14.—Base of operation site, two days after operation. This specimen shows dense infiltration, edema and a thrombosed vein. *A*, dense infiltration of round and polynuclear cells and much edema; *B*, thrombosed vein; *C*, thrombus artificially detached.

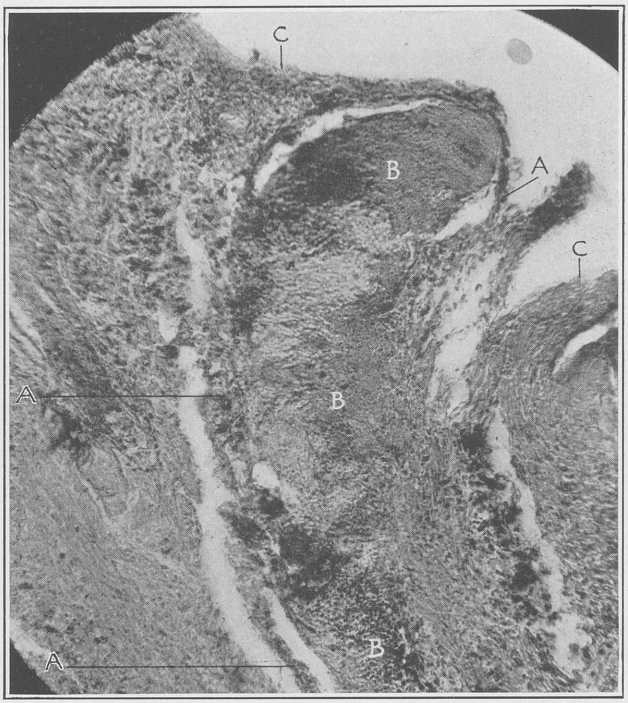


FIG. 15.—Thrombus in a vein just under the operation site, two days after operation. At several points the thrombus will be seen to be quite free from the lining of the vein, but at most of its periphery it will be seen to be closely attached. *A*,*A*,*A*, wall of vein; *B*,*B*,*B*, thrombus; *C*,*C*, raw operation field.

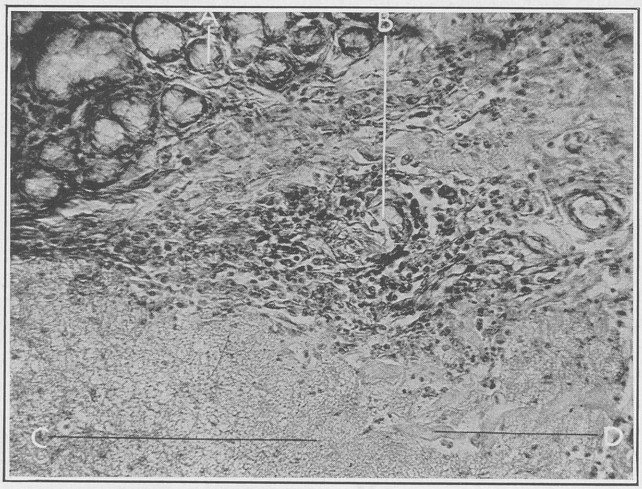


FIG. 16.—Deep tissue beneath the operation site, two days after operation. This specimen shows vacuolated salivary gland cells, and separation with destruction of a small piece of salivary gland by cellular infiltration. It also shows edema and degeneration of a large area of muscle, small strands of which are recognizable. *A*, salivary gland with vacuolated cells; *B*, isolated island of salivary gland surrounded by cells and edema; *C*, degenerated muscle, strand remnants of which are seen at *D*.

FIG. 17.—Silk stitch and adjacent area, under low magnification, four days after operation. Most of the stitch fibers have fallen out of the section. This picture shows a healthy reactive area around the stitch, with some degeneration of muscle and salivary gland tissue. *A*, fibers of the suture; *B*, degenerated muscle; *C*, degenerated salivary gland.

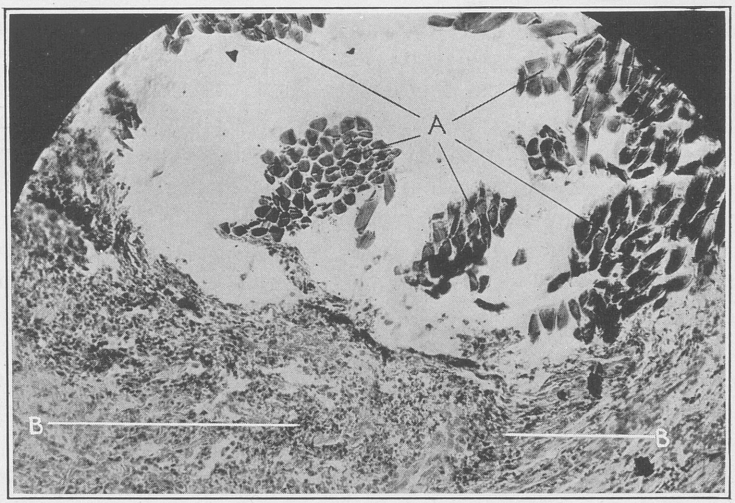


FIG. 18.—This picture shows the stitch and its adjacent tissue, under high magnification, four days after operation. *A*, strands of the stitch; *B,B*, healthy reaction to the stitch, some round-cell infiltration in small groups, but no abscesses.

*The Local Effect of Sutures.* The suture tracks were found to be surrounded by a mild fibrinocellular reaction, highly cellular at the end of two days (Fig. 17), and showed signs of healing at the end of four days. The tissue caught by the stitch was compressed and degenerated, particularly the muscle and salivary gland tissue (Fig. 18). Small patulous capillaries were found in the healing area, but the large veins usually were thrombotic.

*The Tonsil Lymph Node After Operation Plus Artificial Infection of the Operation Wound.* The tonsil nodes after an infected operation were very large, soft, wet and irregularly congested, especially at the capsule (Fig. 19). Under magnification a very marked hyperplasia was found, differing greatly from conditions depicted in Figs. 9 and 10. The follicles showed large germ centers and the cords were crowded with mononuclears. The sinuses were compressed almost to extinction by the lymphoid increase or were filled with large and small mononuclears (Fig. 21), as well as with endothelioid and polynuclear cells. This last change was best seen near the hylum of the node. In addition, the increased size of the lymph vessels was quite notable. They were greatly dilated and were almost completely filled with a hyaline postmortem lymph clot (Fig. 20), this being especially notable in the capsule. Bacteria were found in or near the lining of these vessels.

It should be stated in this connection that a superior mediastinal lymph node of one animal showed a similar hyperplasia. There were present also dilated lymph vessels, small hemorrhages and very marked degeneration of the follicular centers. Bacteria were not surely found.

*Bacterial Distribution.* Bacteria in those cases which were artificially infected were found with ease in the stitches and in the area immediately surrounding them (Fig. 22). As distance from the stitch region increased the microörganisms became fewer and fewer. They were traced along one tissue split directly into a muscle area (Fig. 23), and also were found in a salivary gland.

In the tonsil lymph node bacteria were present in pairs and in small clumps. They were found in the dilated capsular lymph vessels (Fig. 24), in the subcapsular (the so-called "marginal") sinus and in the interior sinuses near the edges of the cords.

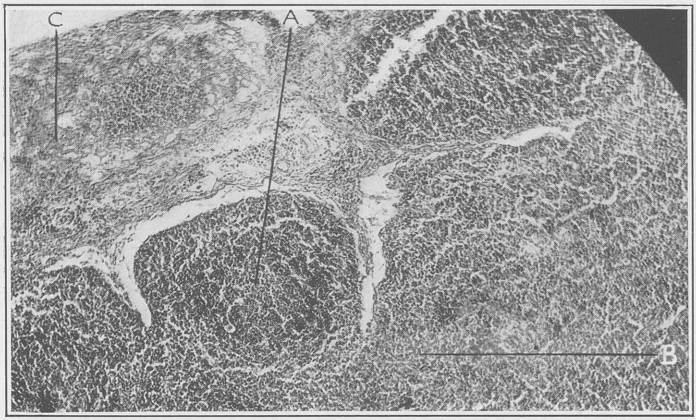


FIG. 19.—Tonsil lymph node, two days after operation, on the side of which infected stitches were used to close the wound of tonsillectomy. This node shows a very active hyperplasia, as indicated by the size and solidity of the follicles, a degree of compactness of the intervening lymphoid tissue great enough to obliterate the sinuses. In addition, there are congestion of the capsular vessels and distention of the lymph ducts. In certain of the capsular lymph channels some swelling and degeneration of the lining were found. Bacteria were found in these lymph ducts. *A*, hyperplastic follicle; *B*, solid cordal area without visible sinuses; *C*, swollen, congested and edematous capsule.

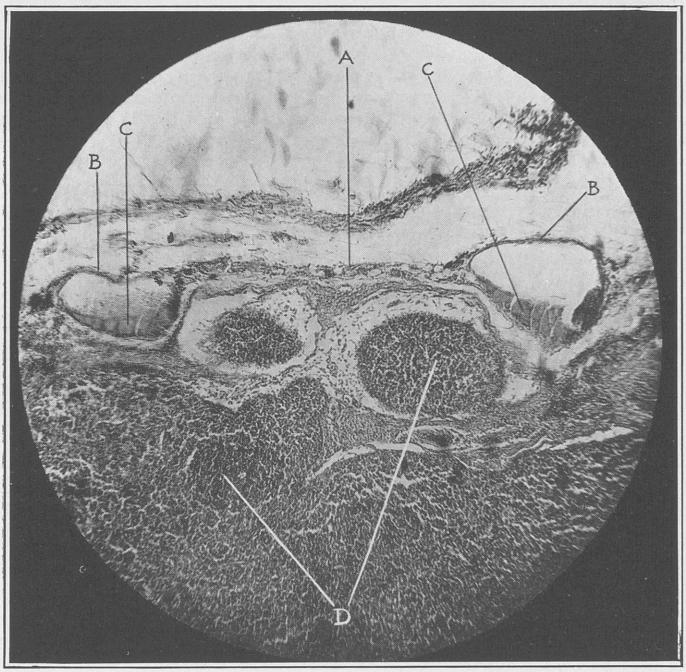


FIG. 20.—The same lymph node as that from which section shown in Figs. 19 and 21 were taken. It shows dilated lymph vessels with postmortem clots. A small group of bacteria was found in one of these clots near the lining of the vessel. Solid hyperplastic follicles of the node lie under the capsule. *A*, capsule of the lymph node; *B,B*, lymph vessels; *C,C*, coagula; *D*, follicle.

They were not found with unequivocal certainty in the thrombosed vessels.

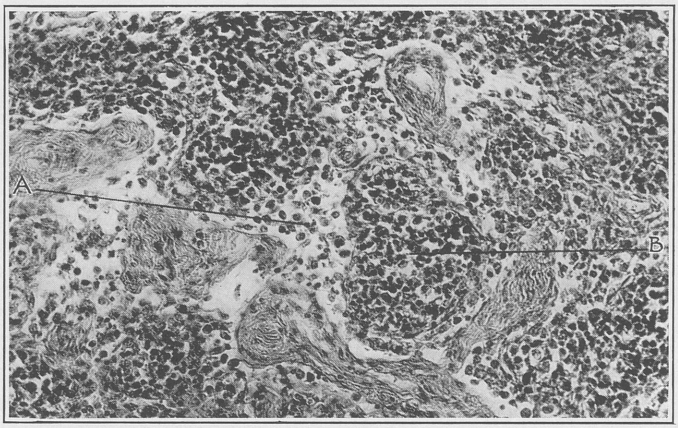


FIG. 21.—The same lymph node as that from which sections shown in Figs. 19 and 20 were taken. Central area of the node under high magnification. This specimen shows the cellular richness of the central sinuses. Numerous lymphoid cells of all varieties, polymorphonuclears and large mononuclears of endothelioid proportions were found in the well-crowded spaces. The cords are very thin at this point. *A*, a crowded sinus; *B*, the end of a small cord.

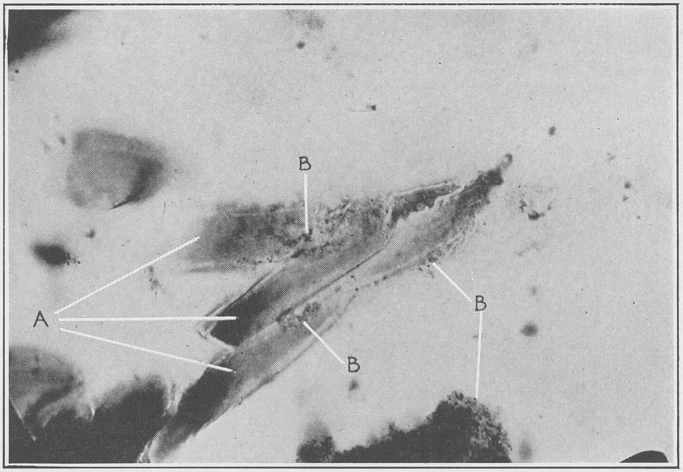


FIG. 22.—A strand of stitch with bacteria in it, four days after operation. (Oil immersion exposure.) *A*, fibers of silk; *B,B,B*, bacteria.

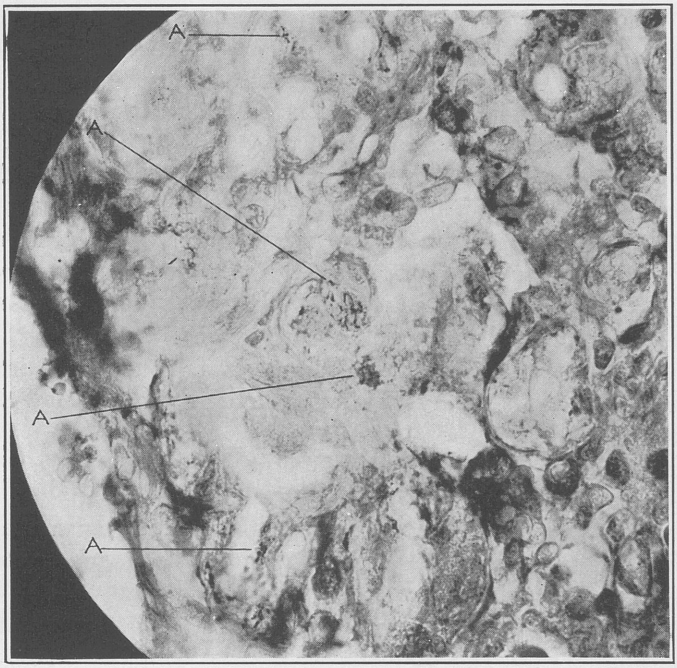


FIG. 23.—The salivary gland from animal artificially infected by stitches soaked in cultures, four days after operation. This photograph shows bacteria singly and in groups. *A*,*A*,*A*,*A*, bacteria.

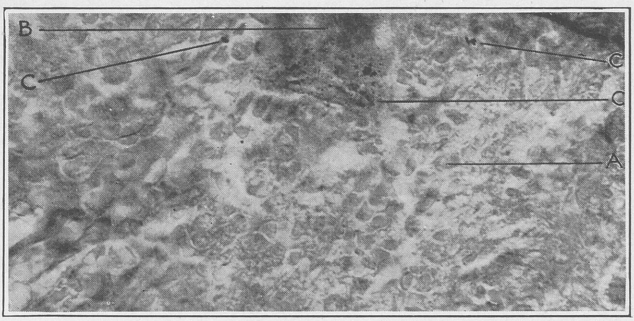


FIG. 24.—The tonsil lymph node from animal artificially infected by stitches soaked in cultures, four days after operation. This section shows bacteria on the edge of a cord and in a necrosis at the edge of a cord. *A*, cord; *B*, necrosing area; *C*,*C*,*C*, bacteria.

SUMMARY OF RESULTS. Injected material found its way from the tonsil to the first drainage lymph node in half an hour or less.

Tonsillectomy traumatism was manifested not only at the immediate operation site, but also in the collateral tissue in the form of hemorrhage and cellular infiltration.

The surface of the wound was covered with a fibrinous exudate, the outer layers of which were progressively cast off.

The tissue reaction at the site of operation was degenerative and fibrinocellular, the former appearing at once, the latter being in part the result of traumatism and in part the natural successor to degeneration, and therefore the early stage of repair.

Exudate of a fibrinocellular character was found deep in the tissues, with resultant degeneration of muscle and salivary gland tissue.

Many venous thromboses were found both near the surface and deeper.

The tonsil lymph node reacted to moderately clean operation procedures by caring for the extravasated blood and by mild hyperplasia.

To a purposely infected operation the reaction of the lymphatic tissue was very marked, so much so that the lymph current probably was obstructed.

Each attempt at artificial infection succeeded, and important structures, such as muscles and glands, were found to have been invaded by the microörganisms.

Bacteria were found easily in the surface exudate and in the vicinity of infected stitches. They also were found in the salivary glands and in the tonsil lymph nodes.

When bacteria-soaked stitches were introduced the infected, or at least inflamed, area was thereby made deeper, while important tissues were compressed and distorted.

While not certainly demonstrated in the thrombi near the operation wound, we believe that bacteria surely must be there. The fibrin was so dense (having taken the same stain as did the bacteria) that their definite identity was obscured.

* * * *

We have shown graphically what happens around a tonsillectomy wound. In a word, there are present hemorrhages, thrombi,

necroses and bacteria. Hemorrhage causes rifts in the tissues, opens pathways for infection and destroys tissue. Trauma and disturbed blood supply result in necrosis. Injured bloodvessels are closed by coagula which may become infected and loosened. Bacteria are carried into the tissues by physical force or are permitted to penetrate by the opening up of tissue clefts, especially when there has been some devitalization. These are present in an area which never can be put at rest, which constantly is open to reinfection and which is subjected to a great deal of constrictor muscle action.

What might be the consequences? Should a sterile thrombus be dislodged into the blood the result would be a small sterile pulmonary infarct which, however, later may become infected and give rise to pneumonia or an abscess. Should a septic thrombus be dislodged a lung abscess would be the probable result. Should a thrombus, either sterile or septic, reach a previously diseased area of the lung, such as a tuberculous focus, the lesion might be activated.

As yet there has been no postoperative study of tonsil cases in which the lungs have been carefully watched for small lesions. Lung infarctions after tonsil operations naturally would be small on account of the size of the peritonsillar veins, and it is perfectly possible that many a lung infarct caused by a non-septic embolus has escaped notice. *We would like to emphasize the following point:* One of the early signs of pulmonary infarction is the spitting of bright red blood, and it is quite possible that at times some of the blood-spitting in the early days following tonsillectomy is due to an overlooked infarction and not to oozing from the operation field. In our clinical work it might be well to keep this in mind and let this sign be a signal to examine the larynx and trachea as well as the tonsil fossæ, and also to have the chest examined and *x*-rayed.

Conclusions. 1. The peritonsillar region as depicted in our specimens constitutes a postoperative field studded with thrombi, which may be either sterile or septic.

2. We believe that as trauma, sepsis and muscular action are the principal factors in the formation and dislodgement of thrombi, the actively muscular pharynx is a particularly favorable region

for the dislodgement of such thrombi into the superior caval circulation.

3. We believe that many cases of pulmonary embolism escape notice on account of their small size, their sterile character and their prompt resolution.

4. It goes without saying that the performance of tonsil operations should be attended with every possible surgical device for promoting asepsis. We suggest, in the furtherance of this principle, that the routine use of needle-carried sutures for tying bleeding vessels be abolished and that surface ties be used instead.[16] The former are never surgically clean and we believe that their use carries with it possibilities of infection of at least the tissues adjacent to them.

5. While realizing that posttonsillectomy lung complications may at times be of inspiratory origin, we believe that such origin is not as common as has been thought.

6. While the infected condition of the lymphatic tissue found in our study must cause consideration to be given to a lymphatic origin for lung infections, we consider such origin to be rare.

7. Finally, it is possible that, in view of such studies as the present one, ideas in regard to the capsule of the tonsil may undergo a change. Instead of aiming to remove it, we may decide that it forms too good a bulwark to the peritonsillar tissues to allow of its being taken away. And we believe it to be entirely possible that some day the operation, called by Makuen[17] "intracapsular tonsillectomy," will be so demanded by the highest ideals of safety that in a perfected form it will be the operation performed by all of us.

## References

1. Richardson, C. W.: Tonsillectomy, with Consideration of its Complications, Washington Med. Ann., 1912, xi, 85.

2. Moore, Wm. F.: Pulmonary Abscess: An Analysis of Two Hundred and Two Cases following Operative Work about the Upper Respiratory Passages, Jour. Am. Med. Assn., April 29, 1922, lxxviii, 1279.

3. Dean, L. W.: Severe Sepsis following Tonsil Operation, Laryngoscope, March, 1919, p. 739.

4. Cutler, Elliott C., and Hunt, Alice M.: Postoperative Pulmonary Complications, Arch. Int. Med., 1922, xxix, 449.

5. Cutler, Elliott C., and Hunt, Alice M.: Loc. cit.

6. Mayo, W. J.: Mortality and End-results in Surgery, Surg., Gynec. and Obst., 1921, xxxii, 97.

7. Richardson, C. W.: Loc. cit.

8. Porter, W. B.: Pulmonary Abscess following Tonsillectomy under Local Anesthesia, Virginia Med. Month., 1921, xlvii, 12, 606.

9. Simpson and Noah: Report of Two Cases of Lung Abscess following Tonsillectomy under Local Anesthesia in Tubercular Subjects, Pennsylvania Med. Jour., 1920, xlix, 332.

10. Med. Sci. Abst. and Revs., 1921, v, 37.

11. Capelle: Einges zur Frage der Postoperativen Thrombenembolie, Beitr. z. klin. Chir., 1920, cxix, 485.

12. Cutler, Elliott C.: Personal communication.

13. Welch, Wm. H.: Allbutt's System of Medicine, 1899, vi, 230.

14. Wood, George B.: The Lymphatic Drainage of the Faucial Tonsils, Trans. Am. Laryngol. Assn., 1905, p. 269.

15. Sisson, Septimus: The Anatomy of the Domestic Animals, 1917, p. 492.

16. Fetterolf, George: The Safeguarding of the Tonsil and Adenoid Operation, Am. Jour. Med. Sci., 1922, clxiv, 884.

17. Makuen, G. Hudson: The Anatomy of the So-called Capsule of the Faucial Tonsil, Trans. Am. Laryngol. Assn., 1915, xxxvii, 117.

## Discussion

Dr. Norval H. Pierce, Chicago:

This is a careful scientific study of an important subject. It would have been more complete had Dr. Fetterolf, in his experiments, demonstrated that the thrombi do really carry from the operative field into the lungs. They only suggest the possibility of that occurring, and I think we are all convinced that that possibility has to be taken into consideration. At least there is very good reason for believing that the pulmonary symptoms arising after tonsillectomies, which I agree with the writer occur with greater frequency than is believed, are not all due to inhalation of septic material. It is a type of paper that elicits our admiration, and it is the hope of the older men that you younger men will indulge more frequently in this very pleasant and interesting mode of research. Now, regarding the practical proposition as to whether it is more dangerous to use a needle in anchoring a ligature than merely tying off the bloodvessel, that is rather a question, in my mind, perhaps more academic than anything else. If we have a bleeding bloodvessel we must tie it some way; that is a surgical fact. Whether the danger is greater from anchoring that ligature in the tissues or merely tying it off is a question. You are going to produce

necrosis in both cases. It is easier for me to anchor the suture than merely tie it off, and you will all agree, I think, that an anchored suture stays better than one that is merely thrown around the vessel. I congratulate Dr. Fetterolf and Dr. Fox on their most excellent work.

Dr. R. C. Myles, New York:

This is probably the best, the most original and scientific paper that has been presented on the subject of the tonsils since we began our crusade, about twenty years ago. The speaker had a lot to do at one time in trying to remove the tonsillar tissue without removing the capsule. After removal of the protruding tonsil with a MacKenzie tonsillotome the capsule was involuted and held with grasping forceps, and all visible tonsil tissue was removed with snare and punch forceps. This operation was employed to avoid the risks of paratonsillar sepsis after tonsillectomy. The occasional recurrence of tonsillar growth on the capsule wall and certain cicatricial scar pockets caused him to decide in favor of tonsillectomy. The speaker has observed that in nearly every case of tonsillotomy done under general anesthesia, blood and infected mucus are drawn into the trachea and bronchi.

Dr. James A. Babbitt, Philadelphia:

I feel that I would like to talk on this paper in view of the strain we are under these days to search for focal relations in more or less obscure general conditions. Physicians who themselves are keen in removing every point of infection are sending us patients, and after our surgery we are still at a loss to handle subsequent continuance of infection from isolated points of lymphoidal tissues on the posterior lateral wall and at the base of the plica which probably still release a certain amount of infective material. Sometimes our operative surgery seems to stir up greater trouble.

I feel this contribution is going to modify some of the tonsil work which I am connected with. For twenty years I have had a very large tonsil connection in two of the children's hospitals. I cannot recall a single loss by death through pulmonary abscess. That matter is negligible. I have felt very keenly the fact that we failed, in a considerable number of cases, in entirely clearing away focal infection. I am very much interested in this question of policy as to tonsillar capsule and in what our writer has said and demonstrated by slides in regard to hemorrhage. In watching work at the hospital and following cases that have been carried on in cities, it seems we have more hemorrhage

today when we take so much pains to avoid it than we had before, and I wonder sometimes if we are failing now to give Nature a fair chance to stop hemorrhage, if tearing up the tissues and retying and burrowing deep we are not making hemorrhage worse? I feel, personally, that this paper is a splendidly practical one and very helpful to me.

DR. FETTEROLF (in closing):

The point raised by Dr. Pierce, about our not having established the fact that the thrombi formed in the neck do pass into the lung, can be answered in general by the well-established fact that small emboli (and large ones) do pass from operation fields to the lungs. But, as a matter of fact, one of the things we had decided on in our future work was in some of our animals, after a certain number of days, when thrombi have become fully formed, to so compress the tissues of the throat that we might possibly be able to dislodge some of the thrombi and later on study the lung to see whether or not we had succeeded in driving them down. In regard to sutures, that is one of the points about which we feel most strongly, and in this connection it was very interesting today to hear the men who were discussing laryngectomy speak of the frequency with which their sutures became infected. If surface ties are used the only necrosis we get is superficial and is shut off from the circulation. If needle-borne stitches are put into the pharyngeal tissues, microorganisms are carried in and enclosed there. A third point was raised in connection with the thought of an intracapsular operation. The great desideratum of any tonsillar operation is to get rid of all the lymphoid tissue. At the present time, in order to completely remove this tissue, we have to take all the capsule out. To my mind the ideal procedure would be to take away all the lymphoid tissue of the tonsil but leave the capsule in place. Whether such a complete lymphectomy (if I may use that term) of the tonsil can ever be carried out without taking out the capsule we do not know. That at least is the ideal which we believe should be striven for.

# A STUDY OF THE RETROPHARYNGEAL ABSCESS

(*Candidate's Thesis.*)

JAMES A. BABBITT, M.D.

From the standpoint of basic pathology the retropharyngeal abscess presents little complexity. Its etiological significance, however, and its so frequently fatal sequence impress both laryngologist and pediatrician.

Its study is primarily the study of lymphatic nodes and channels, and chiefly concerns that period when such structures are most significant, hence its correlation includes the period of thymus activity, the possibly functioning epoch of the Waldeyer ring and the embryonic contribution in tympanic infection. The significance of the status lymphaticus is somewhat uncertain in this connection. It indicates, as stated by Cocks, referring to Paltauf, a general hyperplasia of tonsillar ring, lymph nodes, lymphatic elements of the spleen, arterial system, digestive tract and bone-marrow, including persistence or hyperplasia of the thymus and disposition to death from trivial causes.

Strauss, discussing the intimate lymphatics of the trachea, cites the early discovery by von Recklinghausen that lymph spaces and lymph vessels were lined with endothelial cells.

General anatomical description of lymphatic vessels in the head and neck shows their termination in the deep cervical chain along the carotid artery and internal jugular. Tributary channels come from orbit, temporal and zygomatic fossæ, entire naso-pharyngeal tract and even cerebral and meningeal lymphatics.

As stated by Wood, the retropharyngeal group of lymph nodes consists generally of two glands, back of the posterior pharyngeal wall near the outer edge and in close relation externally with the sheath of the great vessels of the neck. Suppuration leads to retropharyngeal abscess. These are in direct communication

with the deep cervical nodes. The loose investment of the pharyngeal mucous membrane over an area so directly in the lymphatic path offers an immediate reservoir for purulent collection and readily explains its frequent pathologic adoption.

Correlating the above facts, a lymphatic system structurally favoring toxic absorption, markedly hyperplastic in all its elements at the age period most susceptible to retropharyngeal infection, a network of channels linking the cranium, tympanic cavity and nasopharynx with superficial collar and deep cervical nodes, and leading beside the great vessel route into the mediastinal space; and finally a sequence history punctuated by frequent and unexplainable sudden death, assigned asphyxia, inspiration, pneumonia or toxemia—the invitation to pathology is complete. The toll of case reports however seems relatively low.

Etiologically, otitic infections extending downward beside the tensor tympani muscle, metastasis from accessory sinus disease and focal infections in the nasopharynx, seem to have predilection in inciting retropharyngeal sequence—this, of course, excluding fundamental types of luetic and tubercular origin.

Calvin Rush has classified infecting sources as: (1) Caries of the upper cervical vertebræ, usually tuberculous; (2) suppurative otitis media; (3) carotid abscess extension; (4) infected retropharyngeal lymph nodes.

Extensions downward along the Eustachian tube or from accessory sinuses are the frequent sequelæ of the exanthematous diseases and traumatic pharyngeal injury.

Dean and Armstrong have enlightened us much as to nasal sinus disease in young children. Levy, in discussion of the origin of nasopharyngeal polyps, and Beck, in histological examination of lateral pharyngeal masses, have added possible etiological significance.

The suppurative diseases of the middle ear in infancy have absorbed much recent attention, even in such remote conditions as when amniotic fluid is forced up the Eustachian tube at birth and the Rivinian segment is deficient. Infective ear conditions from remote thoracic and gastrointestinal disturbance, even these may be related to the latent, tardily recognized retropharyngeal collections. The course of these burrowing extensions from the ear into the lateral neck and postpharyngeal wall have been

analyzed by Oscar Beck, who also cites the possibility of extradural and subdural suppurations in posterior fossa producing burrowing abscesses, settling behind the wall of the larynx; peribulbar suppurations with usually thrombosis of the eyeball, extending along the base of the skull, and also retropharyngeal abscess.

The sequence in delayed evacuation would be extension downward into the mediastinal area through openings for the passage of vessels, through blood and lymph streams to meningeal and intercranial involvement, and with the rich vascular field of the carotid and its tributaries and proximity of venous channels, serious hemorrhage from erosion may result.

Unusual complicating sequelæ of retropharyngeal abscess have been reported, such as the thrombosis of the internal jugular vein with pyemia, by Mosher, and many cases of unexplained sudden asphyxia, probably from inspiration after sudden rupture.

The diagnosis is not always simple and incision without reaching pus is both embarrassing and sometimes dangerous. In older patients, fibromata, lymphosarcoma in the nasopharynx, as cited by Chamberlin, Hall, Fernandez, Stein, Buchmann and others, may simulate the diagnostic signs of postpharyngeal abscess. In children, with contracted pharyngeal aperture, and either lateral, epipharyngeal or hypopharyngeal displacement, the decision becomes almost empirical and in the last analysis guided by the facies and duck-like cry.

One personal case of interest may be cited:

Case I.—Pauline B., twelve weeks old, admitted to the Mary Drexel Hospital in an emaciated condition. Respiration and deglutition difficult, with swelling in the pretracheal region appearing shortly after birth and gradually increasing in size. Primary indications pointed to retropharyngeal mass as the anterior mass was not yet prominent. Digital examination in the throat indicated a hard mass on the right side, variously diagnosed as abscess, displaced hyoid bone, etc. While awaiting developments the anterior mass, occupying a position apparently between the diverging thyroid cartilage alæ, protruded more in front and with apparent fluctuation. This was needled, then opened and several cubic centimeters of creamy pus evacuated. Culture diagnosis was streptococcus, not

typed. A probe passed obliquely down two inches or more—clearly a patulous branchial tube—one could realize the consequence here of pharyngeal surgery.

Investigation of Special Series. With the assistance of Dr. Campbell, 50 cases of retropharyngeal abscess occurring in the Children's Hospital and the Mary Drexel Home, in Philadelphia, since 1908, have been carefully reviewed. In this series, 66 per cent occurred in the first year of infancy. Brown has reported in his series 50 per cent as occurring during the second six months and Freedman 33 per cent under one year.

In our series of 50 cases, 8 occurred in the first six months, 25 in the second six months, 13 in the second year, 1 each at two and a half, four, six and ten years respectively; 36 were in boys and 14 in girls. A rather marked difference, but probably not significant. Only 10 of the group occurred in colored children, and this is somewhat surprising in view of the tubercular susceptibility of the latter; 6 cases had definite otitis media at the time of pharyngeal involvement and 11 marked purulent rhinitis; 11 had hypertrophied cryptic tonsils and 14 cervical adenitis. Anemia and malnutrition were apparently definite antecedents in 13 cases; rachitic conditions in but 3. Complications recorded included: Premature birth (etiological); pertussis, 2; ischio-rectal abscess, 1; multiple abscess, 1; gastroenteritis, 2; cellulitis (erysipelas), 1; hereditary syphilis, 1; lobar or bronchopneumonia, 6. Spontaneous rupture of abscess occurred in 3 cases, of which 1 died. Total deaths recorded were 5 (10 per cent); 1 of these was the immediate result of hemorrhage.

In practical significance, possibly the justification of prompt and radical care of tonsils, otitis media and purulent rhinitis is the most important. One has the feeling that the investigation of paranasal sinuses has been insufficient. The basis of malnutrition cited by so many authors cannot be overestimated in causative importance. One is impressed, both in review of personal cases and those recorded in literature, with the importance of the relation of retropharyngeal abscess to cervical adenitis, and the careful judgment required in surgical procedure. Many cases in our review should obviously have been opened through

the neck externally and behind the sternomastoid, when the anesthetic could have been safely administered and the abscess contents neither swallowed nor inspired.

The death-rate would seem large, but this included 2 or 3 cases entered in serious condition and 1 case of spontaneous rupture, discussed below.

Spontaneous Rupture. Frank, discussing the results if abscess is left to itself, cites these as possible drainage into the pharynx, burrowing into the posterior lateral triangle of the neck rarely following down beneath the clavicle and into the axilla guided by prevertebral fascia (usually cold abscess of the cervical —Potts), traveling downward behind the esophagus into the posterior mediastinum, spreading by blood and lymph streams into the meningeal area with general septicemia, hemorrhage by erosion of great vessels in the neck and producing pressure on the epiglottis and the larynx with edema, perhaps rupturing and causing aspiration of the infecting contents with pneumonia, lung abscess or sudden asphyxia. Brown quotes Koplik as never having seen a fatal result in retropharyngeal abscess which has gone on to rupture spontaneously, but Bokai, Henock, Goldstein, Peirson and Muerhaff, as having called attention to similar cases, resulting in death.

The above citations are given as a preamble to a case reported in the conclusion of this paper:

Case II.—John H., aged seven years, sent into Mary Drexel Hospital, April 9, by Dr. Yeager, with glandular mass on the left side of the neck and a history of vomiting blood. Dr. Yeager reports that the boy was brought to his office on March 14, with a lump on the left side of the neck, about the level of the fifth cervical vertebra, which had appeared several days previously. Complained of slight cough more than a week.

March 22. Cough better, lump the same.

March 29. No change.

April 3. Swollen left tonsil.

April 5. Mother noticed blood on the pillow and stools, black.

April 9. Mother noticed more blood and black vomitus. No temperature and heart, lungs and kidneys normal. Patient now moved to Mary Drexel Hospital and placed under my care. Child

appeared quiet. No temperature nor undue rapidity of pulse. Gland in neck much swollen, suggestion of fluctuation. In nasopharynx much fibrinated clotted material felt, scarcely to be differentiated from adenoid tissue. Found considerable cavity extending beneath soft palate toward left angle of jaw. As child was quiet and apparently little bleeding, decided to leave until morning and await glandular developments. Two hours later the resident physician examined him. Everything appeared favorable. Ten minutes afterward the doctor was recalled. Patient had vomited considerable blood and died immediately. Dr. Reimann performed a partial autopsy the following day to determine cause of death. Found large abscess cavity extending from cervical gland up and out to angle of jaw. Examining probe and finger passed into a second large cavity anterior to this, not communicating and retropharyngeal. A third purulent pocket or channel had extended down along the sternocleidomastoid to and beneath the clavicle. Carotid and jugular not ruptured, but some of large tributaries evidently ruptured interiorly and behind tonsil area. Patient apparently died from asphyxia or some form of thoracic pressure.

Conclusions. 1. In infants under two years of age, retropharyngeal abscess should be more frequently suspected.

2. In suspected retropharyngeal involvement, paranasal sinuses and middle ears should be promptly investigated.

3. The paranasal sinuses have apparently been given too little attention in purulent rhinitis.

4. The external route should be more frequently employed in evacuating retropharyngeal abscesses, complicated with cervical adenitis.

5. The source and route of infection are often impossibly obscure.

6. It cannot be considered a safe procedure to permit a retropharyngeal abscess to continue on to spontaneous termination.

Bibliography

1. Cocks: A Contribution to the Pathology and Clinical Diagnosis of Status Lymphaticus, Proc. Am. Laryngol., Rhinol. and Otol., 1912, p. 338.

2. Paltauf: Wien. klin. Wchnschr., 1889, p. 887.

3. Strauss: Proc. Am. Laryngol, Rhinol. and Otol., 1922, p. 35.

4. Von Recklinghausen: Die Lymphgefässe und ihre Beziehung zum Bindegewebe, Berlin, 1862.

5. Wood: Article in Loeb's Operative Surgery of Nose, Throat and Ear.
6. Rush: Jour. Am. Med. Assn., 1918, lxxi, 174.
7. Dean and Armstrong: Proc. Am. Laryngol., Rhinol. and Otol., 1919, p. 33.
8. Levy: Proc. Am. Laryngol., Rhinol. and Otol., 1914, p. 314.
9. Beck, J. C.: Proc. Am. Laryngol., Rhinol. and Otol., 1911, p. 368.
10. Beck, Oscar: Monatschr. f. Ohrenhlk. u. Laryngol. u. Rhinol., Berlin, Suppl. 1, 1921, lv, 966.
11. Chamberlin: Proc. Am. Laryngol., Rhinol. and Otol., 1911, p. 51.
12. Hall: Kentucky Med. Jour., 1921, xix, 110.
13. Fernandez: Bull. d. Otol., Rhinol., Laryngol. et d. Broncho. Esoph., Paris, 1921, xix, 561.
14. Stein: Proc. Am. Laryngol., Rhinol. and Otol., 1911.
15. Buchmann: Schweiz. med. Wchnschr., Basel, 1922, lii, 492.
16. Mosher: Laryngoscope, 1919, xxix, 638.
17. Brown: Laryngoscope, 1919, xxix, 9.
18. Freedman: New York Med. Jour., 1921, cxiii, 604.
19. Frank: Jour. Am. Med. Assn., August 13, 1921.

# PRESENTATION OF INSTRUMENTS

ROBERT C. MYLES, M.D.

THE instrument which I wish to present to you has stood the test of use and time. The most important parts of this instrument are backward-cutting gouges. It is to be used with a hammer. In years gone by I have presented many modifications of it in chisels and gouges. These two types of models, in my opinion, are the best. They are the most useful and effective for enlarging the nasofrontal duct and the normal opening of the sphenoid cavity.

Before this instrument is used a preliminary operation is always necessary. In cases of acute retention or chronic mucopurulent diseases the preliminary operation is performed by the removal of the middle turbinal ends, followed by the exenteration of the anterior ethmoidal and nasofrontal cells. The initial penetration is then made by the smaller of the two gouges. A way is thereby made by backward-cutting for the employment of the larger gouge. When the sphenoidal opening is made large enough to admit some form of biting forceps it is advisable to finish with the latter instrument.

In many cases when an external operation seemed to be indicated the speaker has been able to relieve and cure the cases by the use of these two instruments, and he commends them to you for trial. It is advisable, however, not to attempt a removal of too large a piece of bone when using the bigger instrument. Should the gouge engage with too firm a resistance, it is best to loosen it by moving the handle in a semicircular manner.

The instrument was originally made by Ford. At the present time it is manufactured by Tiemann & Co., of West Twenty-eighth Street, New York.

# Memorial



RAMON DE LA SOTA Y LASTRA

# MEMORIAL

## Ramon de la Sota Y Lastra, M.D., Ph.D., Ltt.D.

Professor Ramon de la Sota Y Lastra died in his native city, Seville, Spain, in 1914. The disturbances of the World War have obscured the announcement of this fact, and it is only within a few months that definite information has been secured regarding it. This brief memorial must be largely the outcome of personal recollections, gained through a long-continued correspondence and by various meetings in the past.

Professor de la Sota Y Lastra was for a generation Spain's most distinguished representative of laryngology. An ardent pupil of Czermak and of Tuerck, he derived from those early masters an inspiration which placed him in the first rank of the teachers and practitioners of his time, among whom, by reason of his acknowledged professional eminence as well as of his fine personal character and broad culture he was held in highest esteem.

Devoted to his profession and actively useful in its scientific as well as in its practical aspects, he was at the same time an accomplished student of general literature and a patron of the arts. The descendent of an excellent family, he was a man of delightful personality, possessed of a somewhat large and commanding figure, a fine countenance and a courtly dignity which distinguished him at once and gained for him the consideration which was rightfully his.

The degrees which he had obtained sufficiently indicate the scholarly trend of his mind. These were: the Doctorates of Medicine and of Surgery; of Philosophy; and of Letters. The positions which he held were as follows:

Director and Professor of Surgical Pathology in the Medical School of Seville; Director and Fellow at the Academy of Belles-

Lettres of Seville; Corresponding Fellow of the Royal Academy of Medicine of Madrid; Corresponding Fellow of the American Laryngological Association.

In 1886 Dr. de la Sota Y Lastra contributed a thesis on "Lupus of the Larynx" to the eighth meeting of the American Laryngological Association, and in 1890 he was elected to its Corresponding Fellowship. His contributions to the literature of Laryngology were many and valuable while his *manuel theorico y practico de las enfermedades de la boca, nariz y garganta,* published in Seville in 1902, became the standard text-book of diseases of the upper air-passages in Spain.

He was an occasional attendant at the international medical congresses, where his distinguished personality and acknowledged intellectual accomplishments easily placed him among the foremost leaders of his time. My own association with him, continued for many years, proved him to be one of that most delightful of all the types of well-bred, cultured men, a Spanish gentleman.

D. B. D.

# List of Fellows
# 1923

# LIST OF FELLOWS

## 1923

### *Active Fellows*

1917. Arrowsmith, Hubert, 170 Clinton Street, Brooklyn, New York.
1923. Babbitt, James A., 2117 Chestnut Street, Philadelphia, Pennsylvania.
1915. Barnes, Harry Aldrich, 520 Commonwealth Avenue, Boston, Massachusetts.
1908. Barnhill, John F., 408 Penway Building, Indianapolis, Indiana.
1904. Berens, T. Passmore, 31 Park Avenue, New York.
1921. Berry, Gordon, 19 Elm Street, Worcester, Massachusetts.
1893. Birkett, Herbert S., 252 Mountain Street, Montreal, Canada.
1891. Bryan, Joseph H., 818 17th Street, Washington, D. C.
1913. Butler, Ralph, 2007 Chestnut Street, Philadelphia, Pennsylvania.
1915. Canfield, R. Bishop, Ann Arbor, Michigan.
1917. Chamberlin, William B., Osborn Building, Cleveland, Ohio.
1897. Clark, J. Payson, 71 Marlborough Street, Boston, Massachusetts.
1902. Coakley, Cornelius G., 53 West 56th Street, New York.
1917. Coates, George Morrison, 1811 Spruce Street, Philadelphia, Pennsylvania.
1905. Coffin, Lewis A., 114 East 54th Street, New York.
1913. Coffin, Rockwell A., 350 Commonwealth Ave., Boston, Massachusetts.
1893. Coolidge, Algernon, Jr., 613 Beacon Street, Boston, Massachusetts.
1913. Dabney, Virginius, 1633 Connecticut Avenue, Washington, D. C.
1917. Dean, Lee Wallace, Iowa City, Iowa.
1881. Delavan, D. Bryson, 40 East 41st Street, New York.

1921. Emerson, Francis P., 520 Commonwealth Avenue, Boston, Massachusetts.
1919. Faulkner, E. Ross, 101 East 58th Street, New York.
1914. Fetterolf, George, 2010 Spruce Street, Philadelphia, Pennsylvania.
1922. Forbes, Henry Hall, 40 E. 41st Street, New York.
1905. Freer, Otto T., 81 East Elm Street, Chicago, Illinois.
1879. French, Thomas R., 150 Joralemon Street, Brooklyn, New York.
1897. Frothingham, Richard, 616 Madison Avenue, New York.
1922. Goldsmith, Perry G., 84 Carlton Street, Toronto, Ontario.
1913. Goldstein, Max A., 3858 Westminster Place, St. Louis, Missouri.
1898. Goodale, Joseph L., 258 Beacon Street, Boston, Massachusetts.
1905. Grayson, Charles P., 262 South 15th Street, Philadelphia, Pennsylvania.
1906. Greene, D. Crosby, Jr., 23 Bay State Road, Boston, Massachusetts.
1917. Greene, Joseph B., Asheville, North Carolina.
1905. Halsted, Thomas H., 405 Fayette Park, Syracuse, New York.
1896. Hardie, T. Melville, 30 North Michigan Boulevard, Chicago, Illinois.
1903. Harris, Thomas J., 104 East 40th Street, New York.
1915. Hastings, Hill, 924 Trust & Savings Bldg., Los Angeles, California.
1895. Hopkins, Frederick E., 25 Harrison Avenue, Springfield, Massachusetts.
1895. Hubbard, Thomas, 234 Michigan Street, Toledo, Ohio.
1919. Hurd, Lee Maidment, 39 East 50th Street, New York.
1920. Imperatori, Charles Johnstone, 17 East 38th Street, New York.
1904. Ingersoll, John M., 1021 Prospect Avenue, Cleveland, Ohio.
1907. Jackson, Chevalier, 128 South 10th Street, Philadelphia, Pennsylvania.
1878. Johnston, Samuel, Greenway Apartments, Baltimore, Maryland.
1918. Kenyon, Elmer L., 104 South Michigan Boulevard, Chicago, Illinois.
1921. Kernan, John D., Jr., 156 East 79th Street, New York.
1914. Levy, Robert, Metropolitan Building, Denver, Colorado.

1918. Lewis, Fielding Otis, 259 South 17th Street, Philadelphia, Pennsylvania.
1911. Lockard, Lorenzo B., Metropolitan Building, Denver, Colorado.
1913. Loeb, Hanau W., 537 North Grand Avenue, St. Louis, Missouri.
1897. Logan, James E., 1208 Wyandotte Street, Kansas City, Missouri.
1915. Lynch, Robert Clyde, 632 Maison Blanche Building, New Orleans, Louisiana.
1921. McCullagh, Samuel, 17 East 38th Street, New York.
1913. McKimmie, Oscar A. M., 1330 Massachusetts Avenue, N. W., Washington, D. C.
1914. Mackenty, John E., 43 West 54th Street, New York.
1896. Mayer, Emil, 40 East 41st Street, New York.
1904. Mosher, Harris P., 828 Beacon Street, Boston, Massachusetts.
1914. Munger, Carl E., 81 North Main Street, Waterbury, Connecticut.
1901. Myles, Robert C., 25 West 51st Street, New York.
1922. New, Gordon B., Mayo Clinic, Rochester, Minnesota.
1903. Packard, Francis R., 302 South 19th Street, Philadelphia, Pennsylvania.
1906. Pierce, Norval H., 22 E. Washington Street, Chicago, Illinois.
1908. Randall, B. Alexander, 2009 Spruce Street, Philadelphia, Pennsylvania.
1903. Renner, W. Scott, 341 Linwood Avenue, Buffalo, New York.
1897. Rhodes, John Edwin, People's Gas Building, Chicago, Illinois.
1884. Rice, Clarence C., 52 Park Avenue, New York.
1905. Richards, George L., 124 Franklin Street, Fall River, Massachusetts.
1902. Richardson, Charles W., 1317 Connecticut Avenue, Washington, D. C.
1913. Roy, Dunbar, Grand Opera House, Atlanta, Georgia.
1921. Sauer, William E., 537 North Grand Avenue, St. Louis, Missouri.
1923. Sewall, Edward Cecil, 3515 Pacific Avenue, San Francisco, California.
1907. Shambaugh, George E., 122 South Michigan Boulevard, Chicago, Illinois.
1909. Shurly, Burt R., 62 Adams Avenue W., Detroit, Michigan,

1919. Skillern, Ross H., 1928 Chestnut Street, Philadelphia, Pennsylvania.
1909. Sluder, Greenfield, 3542 Washington Avenue, St. Louis, Missouri.
1908. Smith, Harmon, 44 West 49th Street, New York.
1911. Stout, George C., 2015 Walnut Street, Philadelphia, Pennsylvania.
1889. Swain, Henry L., Colonial Building, 197 Church Street, New Haven, Connecticut.
1903. Theisen, Clement F., 172 Washington Avenue, Albany, New York.
1892. Thrasher, Allen B., The Groton, 7th and Race Streets, Cincinnati, Ohio.
1892. Wagner, Henry L., 518 Sutter Street, San Francisco, California.
1892. Watson, Arthur W., 126 South 18th Street, Philadelphia, Pennsylvania.
1908. Wilson, J. Gordon, 5755 Kenwood Avenue, Chicago, Illinois.
1906. Winslow, John R., The Latrobe, Charles and Reade Streets, Baltimore, Maryland.
1922. Wishart, David J. G., 47 Grosvenor Street, Toronto, Canada.
1905. Wood, George B., 1830 Spruce Street, Philadelphia, Pennsylvania.

*Associate Fellows*

1923. Barlow, Roy Alexander, 122 North Lafayette Street, South Bend, Indiana.
1922. Blair, Vilray P., 400 Metropolitan Building, St. Louis, Missouri.
1923. Dennis, Frank Lowndes, Ferguson Building, Colorado Springs, Colorado.
1923. Fenton, Ralph Albert, 616 Journal Building, Portland, Oregon.
1923. Large, Secord Herbert, 536 Rose Building, Cleveland, Ohio.
1922. Lillie, Harold I., Mayo Clinic, Rochester, Minn.
1923. McKinney, Richmond, Bank of Commerce Building, Memphis, Tennessee.
1922. Monroe, Otho Lee, 24 East 48th Street, New York City, N. Y.
1923. Mullin, William Valentine, Ferguson Building, Colorado Springs, Colorado.

1923. Newhart, Horace, Donaldson Building, Minneapolis, Minnesota.
1923. Spencer, Frank Robert, Physicians' Building, Boulder, Colorado.
1922. White, Francis W., 174 West 58th Street, New York City, N. Y.

*Honorary Fellows*

1915. Bosworth, Francke H., 1 West 54th Street, New York.
1914. Cohen, J. Solis, 1833 Pine Street, Philadelphia, Pennsylvania.
1922. MacKenzie, John N., 879 Park Avenue, Baltimore, Maryland.
1910. Moure, E. J., 25 Cours du Jardin Public, Bordeaux, France.
1914. Thomson, Sir St. Clair, 65 Wimpole Street, W., London, England.
1921. Wright, Jonathan, Windy Rock, Pleasantville, New York.

*Corresponding Fellows*

1901. Collier, Mayo, Kearsney Abbey, Kent, England.
1893. Desvernine, Carlos M., 52 Cuba Street, Havana, Cuba.
1920. Ferreri, Gherardo, University di Roma, Rome, Italy.
1901. Grant, Sir James Dundas, K.B.E., 148 Harley Street, London, W 1, England.
1919. Kelly, Adam Brown, 26 Blythswood Square, Glasgow, Scotland.
1921. Le Maitre, Fernand, Avenue Victor Hugo, 120 (XVI), Paris, France.
1902. Lermoyez, Marcel, 20 Rue de la Boetie, viie, Paris, France.
1897. Luc, H., 15 Rue de Varenne, Paris, France.
1903. McBride, P., 20 South Drive, Harrowgate, England.
1919. McKernon, James F., 62 West 52nd Street, New York.
1896. Macdonald, Grevill, 85 Harley Street, Cavendish Square, London, W., England.
1894. MacIntyre, John, 179 Bath Street, Glasgow, Scotland.
1920. MacKenzie, Dan, 61 Wimpole Street, Cavendish Square, London, W 1, England.
1896. Mygind, Holger, 31 Havnegade, Copenhagen, Denmark.
1919. Paterson, Donald Rose, 15 St. Andrew's Crescent, Cardiff, Wales.

1919. Rogers, John, Jr., 177 East 71st Street, New York.
1894. Sajous, C. E., 2043 Walnut Street, Philadelphia, Pennsylvania.
1896. Schmiegelow, Ernest, 18 Norregade, Copenhagen, Denmark.
1903. Tilley, Herbert, 72 Harley Street, Cavendish Square, London, W., England.
1913. Turner, Logan, 27 Walker Street, Edinburgh, Scotland.
1901. Wingrave, Wyatt, 11 Devonshire Street, Portland Place, London, W., England.
1894. Wolfenden, R. Norris, The Grange, Kent, England.

*Emeritus Fellows*

1914. Brown, J. Price, 106 South Drive, Toronto, Canada.
1922. Cobb, Frederick C., 11 Marlborough Street, Boston, Massachusetts.
1918. Farlow, John W., 127 Bay State Road, Boston, Massachusetts.
1918. Hinkel, F. Whitehall, 581 Delaware Avenue, Buffalo, New York.
1923. Leland, George A., 354 Commonwealth Avenue, Boston, Massachusetts.
1912. Lincoln, William, 1054 Rose Building, Cleveland, Ohio.
1922. MacCoy, Alexander W., Haverford Court, Haverford, Pennsylvania.
1914. Robinson, Beverley, 42 West 37th Street, New York.

## PAST OFFICERS

### *Presidents*

(Year of Election)

1879. Louis Elsberg
1880. J. Solis-Cohen
1881. F. I. Knight
1882. G. M. Lefferts
1883. F. H. Bosworth
1884. E. L. Shurly
1885. Harrison Allen
1886. E. Fletcher Ingals
1887. R. P. Lincoln
1888. E. C. Morgan
1889. J. N. Mackenzie
1890. W. C. Glasgow
1891. S. W. Langmaid
1892. M. J. Asch
1893. D. B. Delavan
1894. J. O. Roe
1895. W. H. Daly
1896. C. H. Knight
1897. T. R. French
1898. W. E. Casselberry
1899. Samuel Johnston
1900. H. L. Swain
1901. J. W. Farlow
1902. J. H. Bryan
1903. J. H. Hartman
1904. C. C. Rice
1905. J. W. Gleitsmann
1906. A. W. de Roaldes
1907. H. S. Birkett
1908. A. Coolidge, Jr.
1909. J. E. Logan
1910. D. Braden Kyle
1911. James E. Newcomb
1912. George A. Leland
1913. Thomas Hubbard
1914. Alexander W. MacCoy
1915. G. Hudson Makuen
1916. Joseph L. Goodale
1917. Thomas H. Halsted
1918. Cornelius G. Coakley
1919. Norval H. Pierce
1920. Harris P. Mosher
1921. Harmon Smith
1922. Emil Mayer
1923. J. Payson Clark

### *Vice-Presidents*

| | | |
|---|---|---|
| 1879. | F. H. Davis | |
| 1880. | W. C. Glasgow | J. O. Roe |
| 1881. | E. L. Shurly | W. Porter |
| 1882. | C. Seiler | E. F. Ingals |
| 1883. | S. W. Langmaid | S. Johnston |
| 1884. | J. H. Hartman | W. H. Daly |
| 1885. | H. A. Johnson | G. W. Major |
| 1886. | E. C. Morgan | J. N. Mackenzie |
| 1887. | J. N. Mackenzie | S. W. Langmaid |
| 1888. | W. C. Glasgow | C. E. Sajous |
| 1889. | E. Holden | C. E. Bean |
| 1890. | J. O. Roe | J. H. Hartman |
| 1891. | M. J. Asch | S. Johnston |
| 1892. | S. Johnston | J. C. Mulhall |
| 1893. | J. C. Mulhall | W. E. Casselberry |

| | | |
|---|---|---|
| 1894. | C. C. Rice | S. H. Chapman |
| 1895. | J. Wright | A. W. de Roaldes |
| 1896. | T. M. Murray | D. N. Rankin |
| 1897. | A. W. MacCoy | H. S. Birkett |
| 1898. | J. W. Farlow | F. W. Hinkel |
| 1899. | T. A. DeBlois | M. R. Brown |
| 1900. | H. L. Wagner | A. A. Bliss |
| 1901. | J. W. Gleitsmann | D. Braden Kyle |
| 1902. | G. A. Leland | T. Melville Hardie |
| 1903. | J. H. Lowman | W. Peyre Porcher |
| 1904. | Thomas Hubbard | W. J. Freeman |
| 1905. | J. L. Goodale | C. W. Richardson |
| 1906. | G. H. Makuen | A. B. Thrasher |
| 1907. | J. P. Clark | J. E. Rhodes |
| 1908. | E. Mayer | F. R. Packard |
| 1909. | C. G. Coakley | H. P. Mosher |
| 1910. | Robert C. Myles | J. M. Ingersoll |
| 1911. | F. C. Cobb | B. R. Shurly |
| 1912. | A. W. Watson | W. Scott Renner |
| 1913. | F. E. Hopkins | Geo. E. Shambaugh |
| 1914. | Clement F. Thiesen | Lewis A. Coffin |
| 1915. | J. Gordon Wilson | Christian R. Holmes |
| 1916. | Thomas H. Halsted | Greenfield Sluder |
| 1917. | John Edwin Rhodes | D. Crosby Greene |
| 1918. | G. E. Shambaugh | John R. Winslow |
| 1919. | Francis R. Packard | Harmon Smith |
| 1920. | Harmon Smith | W. B. Chamberlin |
| 1921. | Dunbar Roy | Robert C. Lynch |
| 1922. | George Fetterolf | Lorenzo B. Lockard |
| 1923. | Hubert Arrowsmith | Joseph B. Greene |

*Secretaries and Treasurers*

| | | | |
|---|---|---|---|
| 1879. | G. M. Lefferts | 1895. | H. L. Swain |
| 1882. | D. B. Delavan | 1900. | J. E. Newcomb |
| 1889. | C. H. Knight | 1911. | Harmon Smith |

*Secretaries*

| | | | |
|---|---|---|---|
| 1912. | Harmon Smith | 1919. | J. M. Ingersoll |
| 1918. | D. B. Delavan | 1920. | George M. Coates |

*Treasurers*

| | | | |
|---|---|---|---|
| 1912. | J. Payson Clark | 1923. | George Fetterolf |

*Librarians*

| | | | |
|---|---|---|---|
| 1879. | F. H. Bosworth | 1903. | J. H. Bryan |
| 1883. | T. R. French | | |

## PAST MEMBERS

**Deceased*

### *Honorary Fellows*

*1893. De Roaldes, Arthur, New Orleans, La.
*1914. De La Sota Y Lastra, Ramon, Seville, Spain.
*1880. Garcia, Senor Manuel, London, England.
*1914. Lefferts, George Morewood, Katona, N. Y.
*1883. Mackenzie, Sir Morell, London, England.
*1910. Massei, Ferdinand, Naples, Italy.
*1879. Oliver, H. K., Boston, Mass.
*1909. Semon, Sir Felix, Great Missenden, England.
*1914. Wagner, Clinton, New York City.

### *Corresponding Fellows*

*1892. Browne, Lennox, London, England.
*1887. Gouguenheim, A., Paris, France.
*1894. Holden, Edgar, Newark, N. J.
*1881. Labus, Carlo, Milan, Italy.
*1880. Meyer, Wilhelm, Copenhagen, Denmark.
*1881. Thornton, Pugin, London, England.
*1880. Whistler, W. McNeil, London, England.

### *Emeritus Fellows*

1914. Brown, J. Price, Cranbrook Lodge, Wycombe, Ontario, Canada.
*1914. De Blois, Thomas Amory, Boston, Mass.
1892. Farlow, John W., Boston, Mass.
*1914. Gleitsmann, Joseph W., New York City.
1888. Hinkel, F. Whitehill, Buffalo, N. Y.
*1912. Knight, Charles H., New York City.
1912. Lincoln, William, Cleveland, Ohio.
*1914. Porter, William, Ocean Springs, Miss.
1914. Robinson, Beverley, New York City.

*Active Fellows*

*1880. Allen, Harrison, Philadelphia, Pa.
*1878. Asch, Morris J., New York.
*1880. Bean, C. E., St. Paul, Minn.
*1893. Bliss, Arthur Ames, Philadelphia, Pa.
*1895. Boylan, J. E., Cincinnati, Ohio.
*1892. Brown, Moreau R., Chicago, Ill.
*1889. Casselberry, William E., Chicago, Ill.
*1883. Chamberlain, C. W., Hartford, Conn.
*1896. Chappell, W. F., New York.
*1882. Chapman, S. Hartwell, New Haven, Conn.
1918. Cox, Gerard H. New York.
1880. Cushing, E. W., Boston, Mass.
*1878. Cutter, Ephraim, West Falmouth, Mass.
*1880. Daly, W. H., Pittsburgh, Pa.
*1878. Davis, F. H., Chicago, Ill.
*1901. Dickerman, E. T., Chicago, Ill.
*1878. Donaldson, Frank, Baltimore, Md.
*1901. Freeman, Walter J. Philadelphia, Pa.
*1917. Friedberg, Stanton A., Chicago, Ill.
1901. Getchell, Albert C., Worcester, Mass.
*1907. Gibb, Joseph S., Philadelphia, Pa.
*1878. Glasgow, William Carr, St. Louis, Mo.
*1878. Hartman, Jacob H., Baltimore, Md.
*1879. Holden, Edgar, Newark, N. J.
*1907. Holmes, Christian R., Cincinnati, Ohio.
*1882. Hooper, Franklin H., Boston, Mass.
1893. Hope, George B., New York City.
*1901. Hyatt, Frank, Washington, D. C.
*1882. Ives, Frank L., New York City.
*1878. Ingals, E. Fletcher, Chicago, Ill.
*1880. Jarvis, William C., New York City.
*1878. Johnson, Hosmer A., Chicago, Ill.
*1879. Johnson, Woolsey, New York City.
*1879. Kealhofer, R. H., St. Louis, Mo.
*1901. King, Gordon, New Orleans, La.
*1885. Knight, Charles H., New York City.
*1878. Knight, Frederick Irving, Boston, Mass.
*1898. Kyle, D. Braden, Philadelphia, Pa.
*1880. Langmaid, Samuel W., Boston, Mass.

*1878. Lincoln, Rufus P., New York City.
*1888. Lowman, John H., Cleveland, Ohio.
*1919. Lynah, Henry L., New York.
*1879. McBurney, Charles, New York City.
*1885. McSherry, H. Clinton, Baltimore, Md.
*1898. Makuen, G. Hudson, Philadelphia, Pa.
*1881. Major, G. W., Montreal, Canada.
*1881. Morgan, E. C., Washington, D. C.
*1886. Mulhall, J. C., St. Louis, Mo.
1892. Murray, T. Morris, Washington, D. C.
*1881. Mynter, H., Buffalo, N. Y.
*1893. Newcomb, James E., New York City.
*1895. Nichols, J. E. H., New York City.
1894. Park, William H., New York City.
1892. Porcher, W. Peyre, Charleston, S. C.
*1880. Rankin, D. N., Allegheny, Pa.
*1879. Roe, John O., Rochester. N. Y.
1881. Robertson, J. M., Detroit, Mich.
*1878. Rumbold, T. F., St. Louis, Mo.
*1879. Seiler, Carl, Philadelphia, Pa.
*1893. Shields, Charles M., Richmond, Va.
*1878. Shurley, E. L., Detroit, Mich.
*1879. Smith, Andrew H., Geneva, N. Y.
*1892. Simpson, William Kelly, New York City.
*1879. Tauber, Bernhard, Cincinnati, Ohio.
*1899. Thorner, Max, Cincinnati, Ohio.
*1888. Van der Poel, S. O., New York City.
1896. Ward, Marshall R., Pittsburgh, Pa.
1879. Ward, Whitfield, New York City.
*1886. Westbrook, Benjamin F., Brooklyn, N. Y.
1896. Woolen, Green V., Indianapolis, Ind.