Transactions
American Laryngological Association

Forty-seventh Volume

TRANSACTIONS

OF THE

FORTY-SEVENTH ANNUAL MEETING

OF THE

American Laryngological Association

HELD AT WASHINGTON, D. C.

MAY 4, 5 AND 6, 1925

PHILADELPHIA

PUBLISHED BY THE ASSOCIATION

1925

CONTENTS

List of Officers vii
Registration 17
Address of the President. Lee Wallace Dean, M.D. 19
Cysts in the Floor of the Mouth. Otto J. Stein, M.D. 26
Problems in Olfactometry. II. "Fractional Fatigue" of the Olfactory Apparatus. Arthur W. Proetz, M.D. 45
Pemphigus from the Laryngologist's Standpoint. Gordon B. New, M.D. 52
Otolaryngology in Relation to General and Medicolegal Medicine. With a Special Report of Cases of Scurvy and Bronchiectasis. Burt R. Shurly, M.D. 62
A Case Report of Laryngeal Carcinoma; Nonreturn at the End of Three and a Half Years. Radium Treatment; Interesting After-result. Henry Hall Forbes, M.D., F.A.C.S. 75
Plexiform Neuroma of the Pharynx. Henry Hall Forbes, M.D., F.A.C.S. 77
A Case of Rhinoscleroma in an American-born Patient. George B. Wood, M.D. 87
The Significance of the Science of Speech Correction. Max A. Goldstein, M.D. 94
Sinusitis and Swimming: Further Observations of Etiologic Factors, with Special Emphasis on Man's Lack of Adaptation to Aquatic Habits. H. Marshall Taylor, M.D. 99
Cicatricial Stenosis of the Trachea, with a Report of Three Cases. Charles J. Imperatori, M.D. 116
Empyema of the Frontal Sinus with Absence of Symptoms Other Than Headache and Local Tenderness. Report of Two Cases. Horace Newhart, M.D. 121
The Importance to the Pediatrist of Infections of the Paranasal Sinuses in Infants and Young Children. Philip C. Jeans, M.D. 131
A Plea for the One-stage Operation in Total Laryngectomy with a Discussion of the Important Points in Its Management. Demonstration of a New Artificial Larynx. J. E. Mackenty, M.D. . . . 145
Lung Abscess; an Occasional Sequel of Tonsillectomy. Edwin McGinnis, M.D. 156
Pachydermia Laryngis, with Report of an Unusual Case. Fielding O. Lewis, M.D. 167
Stenosis of the Larynx in Laryngeal Tuberculosis. Frank L. Dennis, M.D. 171

Vaccines from Hemolytic Cocci in Spheno-ethmoidal Disease. Ralph A. Fenton, A.B., M.D., F.A.C.S. 189
The Retracted Nose. V. P. Blair, M.D. 209
Blastomycosis of the Larynx. Chevalier Jackson, M.D., Sc.D. . . 220
The Value of the Roentgen-ray in Rhinologic Diagnosis, with an Elaboration of the Oblique Method of Rhese. W. P. Wherry, M.D. . 231
Presentation of Cases:
Osteomyelitis of the Skull. Joseph H. Bryan, M.D. 254
Gunshot Wound Through the Superior Maxilla into the Posterior Wall of the Nasopharynx. Burt R. Shurly, M.D. 256
Memorials:
Beverley Robinson, A.M., M.D. 261
Alexander Watt MacCoy, M.D. 269

List of Fellows, 1925:
Active Fellows 273
Associate Fellows 277
Honorary Fellows 278
Corresponding Fellows 278
Emeritus Fellows 279
Past Officers 280
Past Members 282

OFFICERS FOR 1924–1925

PRESIDENT

LEE WALLACE DEAN, M.D.

FIRST VICE-PRESIDENT

ROSS H. SKILLERN, M.D.

SECOND VICE-PRESIDENT

GORDON BERRY, M.D.

SECRETARY

GEORGE MORRISON COATES, M.D.

TREASURER

GEORGE FETTEROLF, M.D.

LIBRARIAN

JOSEPH H. BRYAN, M.D.

COUNCIL

The above Ex-officio and

HARRIS P. MOSHER, M.D.

HARMON SMITH, M.D.

EMIL MAYER, M.D.

J. PAYSON CLARK, M.D.

TRANSACTIONS OF THE FORTY-SEVENTH ANNUAL CONGRESS

OF THE

AMERICAN LARYNGOLOGICAL ASSOCIATION

HELD AT

WASHINGTON, D. C., MAY 4, 5 AND 6, 1925

REGISTRATION

THE Forty-seventh Annual Congress of the American Laryngological Association was called to order Monday, May 4, 1925, at 10 A.M., by the President, Dr. Lee Wallace Dean, at the Hotel Raleigh, Washington, D. C. The following Fellows enrolled during the session:

ARROWSMITH, HUBERT
BABBIT, JAMES A.
BERRY, GORDON
BIRKETT, H. S.
BLAIR, VILRAY P.
BRYAN, J. H.
COAKLEY, CORNELIUS G.
COATES, GEORGE M.
COFFIN, LEWIS A.
DABNEY, VIRGINIUS
DEAN, LEE WALLACE
DELAVAN, D. BRYSON
DENNIS, FRANK L.
FAULKNER, E. ROSS
FENTON, RALPH A.
FETTEROLF, GEORGE
FORBES, HENRY HALL
GOLDSTEIN, MAX A.
GREENE, D. CROSBY, JR.
HALSTED, THOMAS H.
HARRIS, THOMAS J.
HURD, LEE M.
IMPERATORI, CHARLES J.
INGERSOLL, JOHN M.
JACKSON, CHEVALIER
KERNAN, JOHN D., JR.
KING, JAMES J.
LARGE, SECORD H.

Lewis, Fielding O.
Lillie, Harold I.
Loeb, Hanau W.
Mackenty, John E.
McGinnis, Edwin
McCullagh, Samuel
McKimmie, Oscar A. M.
Mosher, Harris P.
Mullin, William V.
Myles, Robert C.
New, Gordon B.
Newhart, Horace
Packard, Francis R.
Pierce, Norval H.
Proetz, Arthur W.
Randall, B. Alexander
Richardson, Charles W.
Sauer, Wm. Emil
Shurly, Burt R.
Skillern, Ross H.
Sluder, Greenfield
Smith, Harmon
Stein, Otto J.
Stout, George C.
Swain, Henry L.
Taylor, Hermon M.
Tucker, Gabriel
Watson, Arthur W.
Wherry, William P.
White, Francis W.
Winslow, John R.
Wilson, J. Gordon
Wood, George B.

ADDRESS OF THE PRESIDENT

LEE WALLACE DEAN, M.D.

It is with a proper feeling of pride that I convene the Forty-seventh Annual Congress of the American Laryngological Association. It is a sufficient honor to be a fellow of this august body. This society has done more than any other association to advance modern laryngology. It has done so because of the particular type of men composing this group. They are men with practical laryngological ability. They have the firm foundation of internal medicine and pathology. Each has the research type of mind. It is impossible for this Association to be other than a research body. To be chosen president by such a group of men is the greatest honor that has or will come to me.

A careful study of the discussions of the last few annual meetings of the Association of American Medical Colleges will convince us that the curricula of the various medical schools today are not satisfactory. I am positive that no faculty is satisfied with the work it is doing. Most schools have the course of study in process of revision. We have been guided by regulations of the College Association, the Council on Education of the A. M. A. and the Federation of State Boards of Health. Their regulations, by eliminating certain schools and stimulating others to meet the course as outlined, have served a most beneficial purpose. The time has now come when the faculties of the various medical schools are studying their own particular problems and meeting the exigencies of the situation as they deem best.

During this period of reconstruction, laryngology, with the other medical sciences, will be studied with regards to its use in the undergraduate medical curriculum. I do not believe one person in this room can definitely say that laryngology will or will not be dropped as a required study for graduation.

As to whether or not it will remain a required study rests, I believe, with the members of this Association. If it is proven

that internal medicine, neurology, pediatrics and surgery can be taught best by association with work in laryngology it will not be dropped. A knowledge of internal medicine, pediatrics, neurology, general surgery and obstetrics will be the goal of most undergraduate medical faculties. Time to accomplish this will be so difficult to find that nonessentials will be discontinued. We know laryngology is an essential undergraduate study. The professors of internal medicine, neurology, pediatrics, surgery and obstetrics, who will be most influential in arranging the clinical part of the curriculum, must be convinced of this if they do not already hold this view. I have tried making laryngology so essential to the teaching of internal medicine, neurology, pediatrics and general surgery that the heads of these various departments would feel that it was essential to the undergraduate teaching of their particular subject. I believe in this I have been successful.

In teaching undergraduate laryngology there are certain things purely laryngological that must be taught. For the most part, however, we should confine our teaching to the laryngological side of general medicine, pediatrics, neurology and general surgery. We must teach not only the science of laryngology but the art of laryngology. The art cannot be practised without the knowledge. The art of laryngology I would define as the method of applying the fundamental facts of laryngology to the relief of the sick person. It depends upon the development of thought and judgment in the individual. A century ago the art of medicine was taught in the undergraduate medical schools at the expense of the science. Today a just criticism of undergraduate medical education would be that the teaching of the art of medicine was neglected. Let us convince our students that every patient is a human being psychologically influenced by his disease. Science permits us to diagnose an incurable malignancy. Art permits us, with perfect truthfulness, to encourage the individual to carry on his hopeless fight in the best possible way. By convincing him and his family that everything possible is being done, a most beneficial thing has been accomplished. When science stands helpless, art lends the supporting arm. The older laryngologists are far more proficient in the art of laryngology than the younger. The members of this Association are particularly qualified to instruct both

in the art and the science of laryngology. It was my good fortune and pleasure last winter to be present while one of our members consulted with one hopeless case of malignancy after another. Nothing could be more beautiful than the satisfaction the patient and members of his immediate family derived from the conference. This is the thing that is being overlooked in modern education.

Laryngology as a science is no different from internal medicine. Its development depends upon the same things as does the development of internal medicine. In short, it is just as integral a part of internal medicine as is the science of gastrointestinal disease. Its progress depends upon a knowledge of general physiology, metabolism, pathology, dietetics and epidemiology. It is a wholesome thing to find metabolism, biochemistry, biophysics, epidemiology and dietetics entering the laryngological field.

Teachers of undergraduate laryngology should be clinicians and research men. They must devote the same time and energy to the teaching of and research in laryngology as the teaching staff in internal medicine gives to internal medicine. If we give this time and energy to development of and the teaching of the laryngology of internal medicine, pediatrics and general surgery, medical educators will be influenced to give laryngology more time in the undergraduate curriculum rather than less.

At all pathological and clinical conferences where the representatives of the often so-called major teaching departments are present the laryngological staff should be in attendance. By entering into discussions they keep alive the importance of laryngology to the proper understanding of the pathology of general disease. They bring up questions for discussion which the general man and the general pathologist would overlook: What can be more important in such conferences than the laryngological side of sudden deaths following operations on the thyroid? The question of laryngeal death without manifest clinical evidence of laryngeal obstruction must be considered; the symptomatology of gradual paresis of one vocal cord may enter the discussion; the ability of the pathologist at autopsy to detect the presence of or absence of preoperation paralysis of one vocal cord might be considered. These things are strictly laryngological, but general surgery and internal medicine cannot make satisfactory progress

in the study of goiter without the assistance of the laryngologist. I remember a case where blastomycosis of the bone of the leg was said to be secondary to blastomycosis of the larynx. A proper presentation of the subject of blastomycosis of the larynx by the laryngologist ruled out the larynx as a primary focus. In every hospital for the teaching of undergraduate medicine, team-work on the part of the staff is a most essential thing. The laryngologist is a most important member of the team and he should be present on all occasions and do his share of the work.

It is axiomatic that the laryngological budget should comparatively approximate the other teaching budgets. The budget is the constant bugbear of medical college executives, and there may be financial reasons for giving laryngology a less permanent part in undergraduate teaching than is best for the undergraduate student. In every teaching hospital laryngology must have its proportionate share of beds; the exigencies of the teaching of the undergraduate student and the necessity for the laryngological care of the patients demand this. Undergraduate medical students should have laryngological house cases assigned to them for study. They should examine and keep a complete clinical chart of the cases. They should have ready access to the laryngological wards at all times in order to carefully observe their cases and record their findings. In short, they should do their work in laryngology the same as in internal medicine. Naturally they must always be under the careful supervision of an instructor. I feel it is better if the laryngological out-clinic is in intimate connection with the out-services of internal medicine, pediatrics and general surgery. Further, the laryngological house cases should be under the same roof as those of internal medicine, general surgery and pediatrics.

At Iowa the laryngological service is housed in the same building as internal medicine, general surgery and neurology. Their out-clinics are close together. Pediatrics is housed in a separate building. The housing of pediatrics in a separate building is a constant handicap to rendering the very best laryngological service to pediatrics and to the undergraduate teaching of the laryngology of pediatrics. It is almost impossible to get the close coöperation which is so essential and which is secured best by close contact of both out-clinic and house services.

Certain things strictly laryngological must be taught the undergraduate. He must be taught the technic of examination, otherwise he will be unable to apply his knowledge. Quinsies, inflammations of the larynx, common colds and many other strictly laryngological subjects must be considered. Nevertheless, the bulk of the teaching should be the laryngological side of internal medicine, general surgery, pediatrics and neurology. Perhaps you will say that all these matters are strictly laryngological. I would not be inclined to debate this, because a knowledge of general medicine is the essential foundation for laryngology, and we are all first physicians and second laryngologists.

Laryngology—including as it does bronchoscopy, esophagoscopy, certain parts of brain surgery, the plastic surgery of the throat and nose—is such a tremendous subject that the undergraduate medical student must invade its realm in order to be able to grasp the science of internal medicine. However, undergraduate medical students cannot be taught all of general medicine and surgery. With the time at our disposal we must teach those things a knowledge of which will benefit them most as general practitioners.

Requisition cases or transfer cases from the general services of the hospital furnish excellent material for teaching, because they are cases which go primarily to the general practitioner. From the medical, pediatric and general surgical wards alone we secure an abundance of teaching material. Certainly most cases of headache should be studied from the laryngological side. Then come the cough cases, the goiter cases, infants with hoarse crying and adults with hoarseness, the cases with hemorrhages from the upper respiratory tract, the multitude where a focus of infection is to be sought for, the cases of difficult swallowing and the lung abscesses. Infants with fever without apparent cause or with gastrointestinal upsets furnish a very large number of instructive cases. At times, during inclement weather, it seems as if every infant in the pediatric service was a laryngological case. In every teaching hospital there should be a large number of requisition and transfer cases from the general service to the laryngological service. If this is not true, undergraduate medicine is not being taught in the best way. This material is the very best for teaching laryngology to the undergraduate student. By diagnosing and

treating these cases, by assisting the general men in diagnosis, by helping in the teaching of general medicine, pediatrics and surgery, by becoming an integral part of the teaching hospital laryngology becomes indespensible to the undergraduate medical school.

The teaching of graduate laryngology in America is on a very satisfactory basis. The efforts of the committee on the teaching of laryngology representing The American Laryngological Association, The American Otological Society, The American Laryngological, Rhinological and Otological Society, The American Academy of Ophthalmology, Otology and Rhinolaryngology and the Otolaryngological Section of the A. M. A., has had much to do with bringing about this condition. This committee had the moral support of all these societies and exerted a decided beneficial influence on standardizing not only the required course, but the requirements for admission to graduate work in larygology. Most of the short courses looking forward to the production of laryngologists have disappeared. Their places have been taken by courses created by members of this Association who have made use of the facilities at their disposal and produced excellent courses for the teaching of graduate laryngology. We have convinced most of the universities and medical schools that the graduate instruction in laryngology was just as much the function of the university as the graduate study of pathology or any other medical subject.

Money and clinical facilities for the work have been granted by many of these schools. The result has been the creation of well-balanced courses in graduate laryngology. In this connection we must not forget the influence exerted by the work that is being done by the American Board of Otolaryngology. I have been surprised by the influence that it has on the development of laryngology in the Middle West. Every young laryngologist I know is preparing himself for his examination before this board, if he has not already taken it. The older laryngologists should secure a certificate from this board in order to help them in their work.

Laryngology today covers a broad field. In teaching graduate laryngology it is advisable to cover the whole field thoroughly. The curriculum must include courses in bronchoscopy, esophagoscopy, the plastic surgery of the nose and mouth, the lesions

of the tongue and buccal cavity, the tumors of the jaws: the diagnosis of lesions in the neck and its surgery must be considered; certain parts of neurology and a knowledge of certain phases of brain surgery are essential. Just as in general surgery there are certain men who are outstanding as goiter men, orthopedic surgeons, neurological surgeons, etc., so in laryngology there will always be laryngologists who will be outstanding men as bronchoscopists, plastic surgeons, operators in the larynx or specialists in voice, etc. It is not advisable for these subdivisions to become separate specialties and I do not believe they ever will. Too much specialization is a bad thing; the practice of laryngology argues against the universal carrying out of such subdivisions; the exigencies of its practice prevent it. Certainly it is of great benefit to laryngology for a few laryngologists, because of particular ability along certain lines, to limit their activities to a particular subdivision and by carrying on intensive work and research in their particular subdivision to advance it materially and benefit laryngology as a whole. Such men are of particular service in handling the very difficult cases in their particular line of work. Most of us, as we grow older, limit our activities and our interest to particular lines of work. We find our capacity for work diminishing; the financial reward may not be longer needed. It is a fine thing to forward the cause of a particular subdivision of laryngology rather than to retire and rob laryngology of the particular expert service.

The teaching of graduate laryngology must be done by each of us as we think we can best accomplish the desired end. In its final analysis it is nothing more or less than imparting to the student the laryngological knowledge that has accumulated during the ages of civilization. If the student possesses creative thought to a marked degree, he, during his lifetime, will add to this knowledge. One of the functions of the graduate teacher of laryngology should be that of detecting the few individuals with this rare ability and directing them along proper channels. The mass of laryngologists will not help in increasing this knowledge. Creative intelligence is confined to a few.

No greater compliment could be paid to any man than to be made president of this association, each member of which possesses this rare ability.

CYSTS IN THE FLOOR OF THE MOUTH

OTTO J. STEIN, M.D.

RARELY are cysts involving the floor of the mouth a subject for report or discussion by laryngologists, but usually the cases that have been seen and studied are those of the general and the oral surgeons. Nevertheless, cysts in this region are not infrequently seen by the laryngologist, and because of this, as well as their general interest, the subject may warrant a presentation.

Considering the present advanced state of medicine it surprises the reflective mind how little is known, by many, of the true character of these tumors, and also how meagerly the subject is treated, if at all, by most of the text-books and books of references.

There is quite a variety of these cysts, including ranula, dermoid, thyroglossal, branchial, multilocular, mucous and echinococcus, but a satisfactory classification for a basis of study has not been found. This has been due partly to the manner in which cases have been reported and partly to the incomplete study given to the origin of the growth. A more comprehensive understanding of their true character might best be obtained if greater consideration were given to the kind of tissue from which they originate, with a minute examination of their saclike walls; in other words, a gross anatomical and a histological or histopathological study must be made instead of a report on the cyst contents alone. In determining the parentage of such cysts, not only must the anatomical structures composing the floor of the mouth be considered, but the neighboring structures that occasionally invade or encroach upon this territory must be thought of: such is the origin of the branchiogenetic, the thyroglossal and the jaw-bone cysts.

The floor of the mouth is not a large territory, but owing to the movability of the tongue and the elasticity of the soft tissues it is often remarkable what size such cysts may attain, occasionally approaching that of a small fist or even larger. The tongue,

forced against the roof of the mouth, may limit the upward growth, but they may present well below the chin and even into the neck. Usually they are much smaller than this—from walnut to hen's egg size—while some of the mucous cysts may not be larger than a filbert or pea. In general, they are smooth, globular, glistening and centrally or laterally located, easily movable or displaced if not too large, tense to palpation, as a rule painless, and inconvenience chiefly from their size and are not accompanied by neighboring adenitis. Their growth is slow and they occur in male and female alike and at all ages.

The most important cysts will be discussed in detail and in the order of their frequency.

RANULA. Although mentioned by our very earliest confrères, ranula was little understood until recent years. Many of the cysts found in this region were generally called ranula, and, though some considerable study had been given to their origin, diversity of opinion existed that far from clarified the situation. It was customary to believe, and the general understanding seemed to be, that a ranula was any cyst in the floor of the mouth containing mucus or saliva, the result of a retention caused by the closure of the duct of a mucous or a salivary gland. The failure of the secretion to escape from the orifice of the duct was attributed either to an inflammation of its lining membrane, with subsequent swelling and obstruction, or to an increase in the viscosity of the fluid. In some instances precipitation of the salts and the formation of a calculus was thought to bring about the closure. Any thing that might cause a stricture of the duct or a plugging of its outlet, like a cicatrix resulting from an incision or injury or an ulcer, or pressure from a tumor or mass upon the duct and occluding it, was assumed to result in retention of its secreting fluid with consequent dilatation and cyst formation.

Diemerbrock[1] was the earliest observer who attempted to show that ranula resulted from the retention of saliva in the *duct* of the *submaxillary gland.* Much later, Dupuytren[2] explained their presence as a result of mucus retained in the mucous glands of the mouth. Fleischmann[3] confined their origin to an obstruction to the flow of mucus from a certain follicle that he discovered on the floor of the mouth. Neumann[4] thought the gland tubules

of Bochdoleck was the seat of origin. Pauli[5] described a most interesting observation, wherein a stenosis of Wharton's duct produced a dilation of the same until the thin wall ruptured, allowing the retained saliva to extravisate into the neighboring connective tissue, creating a ptyalectasia, and several of these uniting formed a ptyalocele. There is a cluster of mucous glands beneath the tip of the tongue called the Blandin-Nuhn gland. Von Recklinghausen[6] expressed his belief that obstruction to the duct of this gland resulted in a retention mucus cyst known as ranula.

The sublingual salivary gland has many small ducts, called Rivini, besides the main large one called the duct of Bartholin. The smaller ones open on a ridge alongside of the frenum of the tongue, while the duct of Bartholin opens into the floor of the mouth near the frenum, either separately as a small papilla, or, as is more usual, in common with the duct from the submaxillary salivary gland, known as the duct of Wharton. Obstruction in any of these ducts resulting in retention of saliva was thought by others to be the only cause of this condition. As late as 1904, Deaver[7] states that obstruction and dilatation of one of the several ducts opening at the side of the lingual frenum will occasion a cystic swelling known as ranula; also it may be due to an obstructed mucous follicle.

Suzanne[8] and Hippel[9] appear to be the first to recognize the sublingual gland as the site of this cyst. Hippel, more than any one else, championed this view, and his studies of the histopathology brought conclusive evidence as proof of his position. The experimental work of DeClosmadene, Cl. Bernard, Cornil, Ranvier and Suzanne demonstrated that no cyst resulted following ligature or cautery of any of these ducts; on the contrary, atrophy and cessation of all gland secretion resulted, with no ranula. Hippel's investigation then demonstrated a chronic interstitial inflammation of the gland with subsequent closure of the ducts. The lining epithelium in these ducts proliferate, then desquamate. The accumulated salivary secretion, plus the transudated capillary secretion, produces a pressure atrophy of the gland tissue, causing it to disappear, eventually being replaced by connective tissue. Hippel's findings are based on the histopathological study

of 7 cases. All of these showed the inner wall of each cyst made up of two different layers of cells, mostly spindle form, and in between large round cells and a few small round cells. Besides these were other large, round protoplasmic cells arranged in irregular manner. There was neither basement membrane nor epithelial cells of any description present.

Thompson[10] recognizes a cyst of the submaxillary gland and a cyst of the sublingual, but claims a direct relationship exists between these and a branchiogenetic cyst. In other words, they are compound cysts arising from a persistent cervical sinus and arriving in the submaxillary area by migration, the result of muscle action.

Although the term ranula is applied by many to a large variety of cysts, including the parotid and even the pancreatic duct, its definition should be confined to a degenerative cyst formation of the salivary glands in the sublingual region. Its histopathology shows it to be the result of a degenerative process of a salivary gland. Its chronicity, the absence of a mechanical obstruction of its orifices, its tendency to recur and its usual position to one side of the frenum help to differentiate it.

Hygromas that result from the occlusion of the ducts or orifices of mucous glands found in this region of the mouth, as the glandula incisiva, the gland of Blandin-Nuhn beneath the tip of the tongue, Fleischmann's bursa, etc., have a different pathology. These cysts are *in* the mucous membrane, while ranulæ are *beneath* the mucous membrane. The wall of the mucous cyst is lined with epithelium and contains lymph structures. They are true retention cysts, usually the size of a pea or bean, and occur single or multiple in any part of the mucous membrane of the mouth.

A condition described as acute ranula is occasionally seen. It occurs rather suddenly, probably while masticating. There is sudden pain and the appearance of a swelling under the tongue. The flow of saliva called forth by the act of mastication is suddenly checked by an obstruction to the salivary gland, usually by a small calculus or fishbone or other foreign substance, resulting in dilatation of the duct from the oncoming flood of saliva. When the calculus escapes or retreats toward the gland immediate relief and disappearance of the swelling are experienced.

Diagnosis. Ranula takes its name from frog belly, just why I cannot see, as it it bears little resemblance to that animal's abdominal region. Dermoids in this region resemble much more the appearance of a frog's belly than do ranula. The former presents a bluish cast; a smooth, velvety appearance; not as tense to the touch as a dermoid; somewhat fluctuating; usually located laterally to the frenum, although when large it may present in the median line as well, but then it occasionally is bilobed in appearance from pressure of the frenum. It is confined usually to the region of the mouth beneath the tongue and only occasionally presents below the chin into the neck, as do dermoids. This is on account of the superficial position of the gland. Its development is fairly rapid, much more so than dermoids; but it never attains to great size, differing in this from a dermoid. Its contents is a glairy or mucoid fluid; as a rule, clear, at times floculent, and may even be turbid from contamination. The orifice and main duct are usually patent. On account of lack of resistance met by its growth, it but slightly interferes with the function of the mouth unless it is acutely inflamed or very large. Sex or age appear to be no important etiological factor, occurring in male and female alike, children and old age.

Treatment. I have seen a number of true ranula and they were treated by various methods, including incision with evacuation, followed by the application of tincture of iodine, nitrate of silver or trichloracetic acid and gauze packing. These cases never did well. The incision closed prematurely, there was a reaccumulation of fluid and at times infection. A partial excision of the cyst wall with topical applications brought the case to healing, after a long time and much discomfort to the patient. These cysts are difficult to handle surgically, per orum, owing to the adherence of the growth, the interference of the tongue, the bleeding and mouth secretions, and the danger of infection and aspiration. Where this method is followed, the following procedure is advised: Linear incision of mucous membrane only; careful dissection of same from the sac as far as possible without puncturing; placing a fine wire in a snare-holder around the remainder; remove as much of the cyst as possible. After thorough toilet the remaining cyst wall may be sutured to the mucous membrane edges.

In 2 cases I followed the advice of Von Hippel,[11] using the neck incision; following the lower border of the mandible about 6 cm.; dissecting down to the submaxillary gland and displacing it downward and the digastric, geniohyoid and genioglossus muscles forward; then through the mylohyoid to the cyst in the sublingual gland. This gland is supplied by the submental and sublingual arteries and veins and these have to be ligatured. A through-and-through rubber-gauze drain is applied for several days, then removed, and in a week or ten ten days the wound is healed. This method of handling ranula is much preferred to any per oral surgery. Especially where a former attempt by incision had been made.

Cysts of the mucous glands more readily respond to the incision or resection method per orum than do ranula, although total excision is at times the only permanent relief.

The epithelial-lined cysts include the mucous, dermoid, thyroglossal, colli congenita and the multilocular or adamantinoma. Some of these are simple retention cysts resulting from a closure of the ducts orifice or obstruction within the duct. Some are inclusion cysts resulting from trauma. Others are congenital in origin, as fetal inclusions in foreign soil or fetal rests derived from embryological clefts, fissures and ducts.

Dermoids of the mouth have received special attention from Gueterbock,[12] Robinson,[13] Fendt,[14] Klapp,[15] Rocha,[16] Schubmehl[17] and Trumper.[18] Cumston,[19] in reviewing the literature in 1902, found 42 cases. Since then quite a number have been reported. The first recorded case found by Schubmehl was from Jourdain ("Maladres de la bonche," 1761), and is of special interest because he attempted to differentiate it from ranula.

My personal observation comprises 3 cases. A brief note of each case is as follows:

Case I.—A. K., female, Lithuanian, aged nineteen years, mail-order clerk, presented herself on account of difficulty of speech and swallowing. She is the second child in a family of four children, three of whom are brothers, all well. Patient had measles and whooping-cough only. Examination showed a large symmetrical smooth and yellowish-like tumor occupying the entire floor of the mouth. Its size was such as to push the tongue against the roof of the mouth and

to bulge as a globular mass into the neck below the chin. It appeared the size of a small orange. It had a tense but elastic feeling, and was easily movable with the tongue or finger, but not in the least painful. There was no interference with normal breathing, no choking attacks, but some complaint because of difficulty in eating and in talking. It was first noticed when a little girl, aged five years, as a slight swelling below the tongue. Of late it appeared to grow more rapidly, at least it caused greater discomfort from its size, and therefore she presented herself for the first time for examination.

Operation. Cocaine locally, then a 1 per cent procaine solution submucously. Incision of mucous membrane of mouth to left of frenum, avoiding the salivary ducts. The wall of the cyst was grasped by two forceps and the cyst incised. A mass of pasty clay-colored material was disclosed, which proved to be sebaceous. About one-half the contents was easily removed with a large spoon curet, which permitted the removal of the sac containing the remainder through the incision. With slight traction and blunt dissection the entire cyst was easily liberated, until the pedicle attachment to the hyoid was reached. Scissors were then used to cut this. Two sutures and a drain completed the operation. No complications. Microscopic examination of cyst wall showed connective tissue, pavement epithelium, cylindrical cells, few bloodvessels, sebaceous glands, sweat glands and few muscle fibers.

Case II.—A. N., female, colored, married, aged twenty-one years, housewife, complained of a swelling in the mouth and neck that inconvenienced her in eating and talking and somewhat in breathing. Had been present and slowly growing for many years. At times she had choking attacks. On examination there presented a large, smooth, round mass, filling the mouth and pushing the tongue upward and bulging below into the neck behind the chin. It appeared and proved to be the size of a small orange. It was elastic to the touch, movable and caused no pain. Skin and membrane normal. The latter had a light-yellow color with a few blue veins across the surface. There was no inflammation of the membrane or adenitis present.

Operation. Cocaine locally and 1 per cent solution procaine submucously. A horizontal incision through membrane in floor of mouth to left of frenum; the sac was grasped with forceps, then incised and its contents, a yellowish, cheesy mass, removed partly by a large spoon curet and the cyst wall then readily peeled from the surrounding tissue with no bleeding. The firm, fibrous pedicle attached to the hyoid was severed with scissors and the cyst removed completely.

Two sutures and drain. No complications, excepting a slight delay in healing from accumulation of fluid. Microscopic examination: The contents was sebaceous material; the walls, connective tissue, pavement epithelium, papilla, sebaceous and sweat glands and few bloodvessels.

CASE III.—Man, aged twenty years, presented himself with a history of having a cyst under his tongue for three years. It had been operated on twice by incision only, but as promptly recurred. It was the size of a marble and caused no special inconvenience. The mucous membrane showed scars of the former incision over a bulging near the frenum linguæ.

Operation. Under cocaine and procaine anesthesia, and grasping the tumor with two forceps, after incision of the mucous membrane, the cyst was dissected free with scissors and knife and removed. On opening it contained a light brownish mucoid material and many hairs. Microscopic examination: Fibrous tissue, hair follicles, a few sweat glands and pavement epithelium.

DERMOIDS are misplaced fetal inclusions that take on activity and form cysts. The sebaceous and teratoid are the two varieties. These are not the same as the acquired type of inclusion cysts arising from traumatic implants, the result of burns, injuries or operations around the mouth. This defect in the orderly embryological closure of the branchial arches results in retention of the epithelial germs after the ectoderm closes in, and is the reason given by some for the fibrous adhesions to the hyoid and symphysis as indicating the point of entrance. Gerard-Marchant speaks of two kinds—the adgenien and the adhyoidien—according to their adhesions. In the former the fibrous attachment is to the symphysis of the lower jaw, while in the latter it is the hyoid bone. Rarely are they found free from such anchorage.

Dermoids commence shortly after birth, but on account of their slow and painless growth attract little attention until early youth or adolescence, unless there should be interference with nursing. They project into the floor of the mouth or into the neck behind the chin or both places. At times they attain the size of an orange. Only rarely is there deformity of the jaw or irregular teeth with faulty occlusion. Both the skin and mucous membrane coverings are healthy and normal. They have a pale-yellowish cast; feel

soft, smooth and elastic; globular in appearance and centrally located. On rare occasions the cyst has been found to the side. Gueterbock reports one found in the left side of the mouth and Klapp found one on the right side. In both instances they were mistaken for ranula. Their lining membrane consists of connective tissue, squamous or pavement epithelium, sebaceous glands, hair follicles and even sweat glands. Those of epiblastic origin may contain sebaceous substance, hair, epithelial cells and cholesterin. Those originating from hypoplasm contain mucoid fluid and have a connective tissue lining membrane containing cubical and columnar epithelium. In the differential diagnosis, consideration should be given to the possibility of—

Ranula
Abscess
Angioma
Hematoma
Aneurysm
Suprahyoid bursal cyst
Hydatid
Gumma
Lipoma
Lymphadenitis
Mikulicz's disease.

Methods of Operating. Total extirpation of the cyst is the only method to be entertained. This can be carried out under local anesthesia per orum. The sac peels quite readily from its bed and only its pedicle attachment may cause some delay. This method offers no such difficulties as the removal of a ranula per orum. If desired, a horizontal incision in the neck back of the chin may be employed, but it is much more of a dissection than the per oral route.

Thyroglossal Cyst. The work of His[20] demonstrated the thyroid gland as developing from three independent parts: the two lateral lobes and a median tubular part from the ventral wall of the pharynx, which becomes the isthmus as well as the pyramidal lobe. The tubular is divided into an upper and lower part. The upper is called the lingual duct and extends from the foramen cecum at the base of the tongue to the hyoid bone. The lower is known as the thyroid duct and extends from the hyoid to the isthmus of the thyroid. This small-caliber epithelial-lined embryological structure, known as the thyroglossal duct, can be demon-

strated in the embryo of four weeks, after which time it begins to disappear. By the time the hyoid cartilage has developed, in the fifth week, the duct is obliterated. Should any part remain patent, and not disappear, a fistula and even a cyst, or both, may appear later. In certain invertebrates, as the crab and scorpion, it persists—the thyroid being a sex gland and its duct empties into the genital tract. In man a persistence of a portion of the tract is much more frequently found in the infrahyoid segment, either in part or as a whole. C. F. Marshall[21] found it in 43 per cent of subjects examined, or 60 children from a few weeks up to ten years. The suprahyoid segment usually obliterates entirely, although Marshall[22] has shown a continuous tract from the foramen cecum to the hyoid. J. E. Frazer[23] thinks some of the cells of the duct may remain and regenerate, although the remainder of the tract had entirely disappeared. A sudden activity after years of quiescence has been attributed to bacterial invasion of neighboring lymph adenoid tissue.[24]

Cysts and fistulæ of this tract are not rare occurrences. Out of 86,000 consecutive patients examined in the Mayo Clinic, 31 cases were found.[25] Out of 117 cases compiled from the records of the London Hospital, Bailey reports 75 occurred in women. Twelve cases have come under my own observation; 6 were operated on. Two of the 6 operated on were associated with sublingual cysts. In 2 of the fistulas the duct was closed at the hyoid and communication existed only in the throat at the foramen cecum. In the remaining 10 cases a fistula in the anterior median neck existed. These external openings result from the rupture of the cyst and they may be near the thyroid isthmus or in the hyoid region.

The youngest of my patients was four years and the oldest sixty years of age; 7 were female and 5 males. At times several members of a family may present similar defects. In one instance 3 of the children presented sinuses from incomplete cleft closures. All of them had sinuses in front of the tragus. In 1 there was in addition a sinus in the carotid area and in another an added thyroglossal fistula with cyst formation. I will briefly mention the 2 operated cases of sublingual thyroglossal cysts because of their interest.

CASE I.—Man, aged thirty years, complained of a "lump" in the mouth that at times became most annoying, because of the limited motion of the tongue interfering with talking and swallowing. On one occasion it was much larger than at any time, creating alarm because of embarrassment of breathing. It was then opened in the mouth by an incision as an emergency measure. The fistula was dry when he first presented himself. A skin scar covered the opening. The size of the "lump," as he called it, varied as to the patency and discharge of a fistulous opening just superior to the body of the hyoid bone. The floor of the mouth showed a smooth, firm swelling near the center about the size of a pecan. The mucous membrane was not so thin or bluish in color as a ranula or as yellowish as a sebaceous cyst. There was slight speech defect, as if he had a wad of tobacco in his mouth, and attacks of laryngeal irritation with a hacking cough which at times caused apprehension for fear of suffocation. It could be felt below the chin by firm pressure in the mouth. No inflammation, no pain. Attempts to establish drainage through the neck fistula by aid of a probe was partially successful, but similar procedure *via* the foramen cecum brought no result. The injection of methylene-blue to determine a patency at this place only caused great pain to the patient and no discoloration in the mouth. An operation under ether anesthesia was performed, using a short collar incision and encircling the fistulous opening. By grasping the fistula, in which a probe had been introduced, in the jaws of a large dressings forceps, and making slight traction, I dissected toward the hyoid, using chiefly a stripping method and occasionally a Mayo dissecting scissors. In this way I readily reached the body of the hyoid. At this point it was difficult to determine whether the fistula passed in front of or behind the bone. It has been reported as passing through the hyoid. Frazer has shown the relationship of the complete infrathyroid tract to the hyoid. The retrohyoid portion is carried into its position by folding around the lower edge of the bone, giving the appearance of passing through the bone. On this account he believes that division of the hyoid is seldom necessary. I separated the median raphe of the mylohyoid and genihyoid, and, at a place where a bulging presented resulting from a finger exerting pressure within the mouth, the sac was uncovered and dissected free by stripping. Its contents was mucoid and its inner wall was mucous membrane epithelium. No thyroid gland tissue was found.

CASE II.—Woman, aged thirty-three years. Since childhood, or about ten years of age, developed a large lump beneath the chin. This

very gradually grew larger until one time she put her finger in her mouth and felt the same mass distinctly. Later on, she relates, a fistula established itself anterior in the neck and the swelling disappeared. Since then it has been discharging. She was under local treatment by several physicians, but the only result was an inflamed skin about the orifice with destruction of the normal skin to the size of a thumb-nail and the fistula discharging pus. The opening was near the cricoid and just to the left of the median line. A probe entered 2 inches, upward, inward and toward the right. Injection of a solution of mercurochrome caused pain and swelling. Neither this or methylene-blue passed to the mouth. She was operated on in a similar way as the one just recited. The fistula and sac extending up behind the hyoid were removed *in toto* and measured $2\frac{3}{4}$ inches. Its lining was mucous-membrane epithelium.

Differential Diagnosis. This cyst must be differentiated from a sublingual dermoid, an abscess of a suprahyoid lymph gland, a suppurating infrahyoid bursa and from accessory thyroid substance. The ingestion of food has been observed to create an increase in the amount of discharge from a fistula or an increase in the size of the cyst.[26, 27] On protrusion of the tongue the cyst is pulled upward, receding as the tongue is withdrawn.

Branchial Fistulæ. Under colli congenital or branchial fistulæ one understands an embryological deficiency of development in the neck the result of a persistent cervical sinus. They show themselves in three places: Along the outer side of the neck, anywhere from the mastoid tip down to the head of the sternum; the other two places are in the throat, in the region of the tonsil and in the region of the sinus pyriformis. Where the branchial cleft closes both internally and externally, but an intermediate portion remains unobliterated, the lining epithelium may proliferate and by other changes create a cyst. These cysts usually occupy the submaxillary region and rarely involve the floor of the mouth. Occasionally such a cyst may grow so as to encroach upon the floor of the mouth from below the mandible, as is shown in a patient, who came under my observation. My patient was aged fifty-five years, well-proportioned and healthy otherwise, the only complaint being the unsightliness of a large swelling in upper angle of right neck. It was first noticed by patient thirty years

before. Its growth was slow and painless. On examination it was the size of a large hen's egg, immovable in the neck, but a swelling in the floor of the mouth of the same side could be depressed with the finger and showed to be part of the neck lesion. There was neither skin nor mucous-membrane changes, no pain, no inflammation and no adenitis. The dissection necessary for its removal extended into the sublingual field, the specimen proving to be a compound cyst involving the cervical sinus and the submaxillary gland.

J. E. Thompson has observed several such compound cysts and he believes direct relationship exists between ranula and branchiogenetic cysts.

Multilocular Cysts. The multilocular cyst of the jaw-bone is one of the least frequent of all. It is known as cystic adenoma or adamantinoma. It is easily confused with sarcoma, although benign in nature. Malassez describes it originating as epithelial rests derived during fetal life from (1) mucous membrane of the jaw; (2) from epithelial cord of enamel organ; (3) from epithelial membrane of enamel organ. It encroaches on the floor of the mouth by an extension inward from the mandible. It can scarcely be confused in diagnosis with any other variety of cysts found in the mouth, first, because of the deformity of the jaw; second, because it is integral with the jaw itself and hence immovable; and, third, because of its firm, bony feel.

Echinococcus Cysts. The echinococcus cyst, although of common occurrence elsewhere in the body, only rarely is found in the mouth. It presents as a chronic cystic enlargement, causing mechanical inconvenience alone, and no pain unless it should become infected and suppurate. When in the mouth they are usually of the tongue.

Summary and Conclusion. Laryngologists occasionally encounter cystic formations in the floor of the mouth that require a differential diagnosis because of the different methods of procedure followed in their removal.

Several varieties of cysts occur in this region, among which are ranula, dermoid, thyroglossal, mucous, branchial, multilocular and ecinococcus.

A histopathological study of their walls has given an accurate

understanding of their origin and structure, and this knowledge has lent itself to the construction of a symptomatology and clinical picture which permits of a correct diagnosis and method of operating.

The laryngologist is now equipped with the information necessary to handle these cases successfully, and he should develop his ability to a greater extent so as to successfully cope with this class of surgery by eliminating infections and lessening complications and recurrences.

Bibliography

1. Diemerbrock: Opera Omnia, 1685.
2. Dupuytren: Leçons d. Cliniq. Chir., 1833.
3. Fleischmann: Norimbergæ, 1843.
4. Neumann: Langenbeck's Arch. 20, 1877.
5. Pauli: Langenbeck Arch. 2, 1862.
6. Von Recklinghausen: Virchows Arch. 84, 1881.
7. Deaver: Surgical Anat. Head and Neck, 1904.
8. Suzanne: Arch. Phys. Norm. et Path., 1887.
9. Hippel: Langenbeck Arch. 55, 1897.
10. Thompson: Annals of Surgery, 1920.
11. Hippel: Arch. Klin. Chirg., 1897.
12. Gueterbock: Arch. Klin. Chir., 1878.
13. Robinson: St. Thomas Hospital, 1888.
14. Fendt: Freiberg, 1898.
15. Klapp: Beitrag z. Klin. Chirg., 19, 1897.
16. Rocha: Halle, 1898.
17. Schubmehl: Freiberg, 1901.
18. Trumper: Wien. Klin. Runds., 1911.
19. Cumston: Am. Jour. Med. Sci., 1902, cxiii.
20. His: Anat. Mensch. Embry., 1885.
21. Marshall: Jour. Anat. and Phys., 1895.
22. Marshall: Jour. Anat. and Phys., 1891.
23. Frazer: British Jour. Surg., 1925.
24. Bailey: British Jour. Surg., 1925.
25. Sistrunk: Annals of Surgery, 1920.
26. Bertwistle: British Jour. Surg., 1925.
27. Spencer: Lancet, 1914.
28. Ozenne: Arch. Gen. d. Med., 1883.
29. Tillaux: Chirg. Clinique, 1883–5.
30. Dardignac: Rev. d. Chirg., 1884.
31. Richard: Beiträge Klin. Chirg., 1887.
32. Gerard-Marchant: Bull. d. l'Soc. Anat., 1888.

33. Reclus: Gaz. d. Hôp., 1888.
34. Spencer: Path. Soc. London, 1889.
35. Strephard: Montreal Med.-Chir. Soc., 1889.
36. Schnitzler: 1890.
37. Monod: La Modern Med., 1891.
38. Gussenbauer: Beit. Chirg., 1892.
39. Hildebrand: Langenbeck Arch., 1894.
40. Hildebrand: Arch. Klin. Chirg., 1894–5.
41. Konig: Langenbeck Arch., 1895.
42. His: Arch. Anat. Phys., 1891.
43. Marshall: Jour. Anat. and Phys., 1892.
44. Konig: Arch. Klin. Chir., 1895.
45. Johnson: Lancet, 1890.
46. Kostanecki and Mielecki: Virchows Arch., 1891, vol. cxx.
47. Kanthack: Jour. Anat. and Phys., 1891.
48. Gueterbock: Arch. Klin. Chirg., 1878, Bd. 22.
49. Naumann: Arch. Klin. Chirg., Bd. 33.
50. Goris: Rev. Int. R. O. L., 1892, ii.
51. Morestin: Bull. Soc. Anat. de Paris, 1898, lxxiii.
52. Andre: Rev. Med. de l'est, Nancy, 1897, xxix.
53. LeFort: Bull. Soc. centr. de Med. du nord Lille, 1902.
54. Grimond and Clermont: Toulouse Med., 1905, vii.
55. Dujarier: Bull et Mem. Soc. Anat. de Paris, 1905, lxxx.
56. Cignozzi: Policlin., Rome, 1910, xvii.
57. Gilman: Surg., Gynec. and Obst., 1916, xxii.
58. Federspeil: Dental Cosmos, 1917, lix.
59. Freer: Trans. Am. Laryng. Assn., 1918.
60. Stengel: Anat. Anzeiger, August, 1921.
61. Keller: Anat. Anzeiger, April, 1922.
62. Mouchet and Peltier: Soc. Anatomique, Paris, March, 1922.
63. Blair and Ivy: Oral Surgery, 1923.
64. Blair: Annals of Surgery, June, 1923.
65. New: Surg. Clin. North Am., 1924.

Discussion

Dr. Gordon Berry, Worcester, Mass.:

I have very much enjoyed hearing this paper, as I know we all have. In my rather limited experience with thyroglossal duct operative work I have gained much help and confidence by the preliminary injection of methylene blue. This stains the duct throughout its length and makes it easy to follow.

By this means interesting anatomical observations may be made.

The duct is lined with firm fibrous tissue as far as the hyoid. There it may go either in front of or behind the hyoid bone, (immediately against it in the latter case), or it may divide and go to both sides. As it enters the tongue it begins to lose its fibrous lining and becomes a thin, membranous duct which is easily torn. Near the hyoid bone one or two blind, short branches may make off laterally. Then the main stalk passes up into the substance of the tongue. As it nears the pharynx it branches. In 1 case I chased it as far as three branches and in another I found five branches. These I tied off rather than go into the pharynx.

The same use of methylene blue permitted my following the duct of a branchial cyst up the side of the neck clear to the tonsillar capsule, where it ended. This was then an embryological remnant of the second branchial cleft.

Dr. E. Ross Faulkner, New York City:

My experience has been fairly limited in this thing, but I wanted to say a word about the operative procedure in cases such as the thyroglossal duct and dermoid cyst. I remember a number of years ago operating on a thyroglossal cyst about the size of an orange and I got into difficulty. I did not get my incision quite big enough at the start, an accident prone to happen to men not doing surgery every day, and dissection was very difficult. I was embarrassing the patient's breathing, and while I did dissect back to the base of the tongue, I found it a very difficult operation and felt after I got through that anybody looking on would consider it rather a muffed sort of a job.

I made up my mind then, and so remarked in the operating room, that the next time I operated on one of these cases I was going to try putting in a laryngoscope as a support.

About a year afterward, when Dr. Dean made a little visit to New York—an occasion which we all look forward to and are always pleased to see him—he came up to the Manhattan Hospital where I had a private case for operation. I asked him to come in, as I was going to try using the laryngoscope. I found a thyroglossal cyst about 1½ to 2 inches long and I separated around it quite easily. The house surgeon put in a laryngoscope, pressed it forward and the cyst popped out of the wound. I do not believe I was over twenty minutes doing the whole thing. Dr. Dean said, "Your had better report that before any one else does." It makes a difficult procedure a simple one. When you do that, you will be astonished how easily it will go. The cyst pops right out of the wound. You can cut off the pedicle without any dissection at all. If you put your finger in, you will

feel the laryngoscope very near your finger. The muscles seem to flatten out; there does not seem to be ¼ of an inch of tissue between. That is true of operating on the side also. The laryngoscope is an excellent instrument to be used as a support.

The only dermoid cyst I can recall is a case I had diagnosed as a thyroglossal cyst. The dermoid has no pedicle extending back, and this one I operated on, I was surprised to find, had no pedicle. It did not give me any trouble, however. Suppuration in any of these cysts may occur and produce a menacing condition. The little experience I have had with them indicates that they quickly produce embarrassment of the respiration from edema. They are easily operated on. You inject novocain in the center line and there is no bleeding at all. When you make the incision, leave in a large drainage tube. One of the assistants in my clinic was operating on one and a large quantity of pus came out. He packed it with gauze and the house surgeon had to do a tracheotomy that night. A large drainage tube would have obviated the necessity for that.

I never mentioned the use of the laryngoscope before. I have since met a man who said he had been doing the same thing for years. Whether he had priority or not, I do not care; but it is a useful instrument in facilitating that operation.

Dr. J. E. Mackenty, New York City:

I would like to ask Dr. Stein a question with regard to the cutting of the hyoid body. On two or three occasions I have removed these thyroglossal cysts and removed the center portion of the hyoid bone with the cyst. It saved time and there seemed to be no objection to it. I saw no ill-effects following the operation.

As to the embarrassment of respiration which Dr. Faulkner speaks of, I have used an ordinary breathing flat tube, used by anesthetists. It holds the tongue in position and gives a hard background against which to operate.

Dr. G. B. New, Rochester, Minn.:

In listening to Dr. Stein's paper there are several points that I thought might be of interest.

Dermoids are usually in the midline in the mouth and are filled with putty-like material, so that they pit on pressure. The diagnosis in some cases of thyroglossal duct cysts is interesting. I examined one boy who had had many previous operations elsewhere for thyroglossal duct cyst, and ultimately the opening outside the neck was closed. He was a very neurotic chap and still complained of secretion

getting into his throat. Upon examination I found the foramen cecum patent and injected this with thin bismuth paste by means of a specially curved-tip syringe. The *x*-ray showed the bismuth extending from the foramen cecum downward outside the hyoid bone and just to the skin of the neck.

In the surgical treatment of the thryoglossal duct cysts Dr. Sistrunk has made a valuable contribution in urging the dissection of a finger-like tract upward and backward at an angle of 45 degrees from the hyoid bone, instead of trying to dissect out the tract itself. In addition to this, a finger is passed in the mouth down to the foramen cecum, so that this point is held up into the wound, making the dissection much simpler.

In hygroma cystica we feel that radium is the treatment of choice in most cases in children, rather than surgery. Sometimes a small, thickened nodule, or what remains of the tumor, may have to be removed surgically, but in most of these cases the greater part can be removed with radium.

Dr. John D. Kernan, New York City:

I was interested in Dr. Stein's method of a collar incision. I had occasion some years ago to take care of one of these thyroglossal cysts or ducts, one that had been done a couple of times before and had recurred. Dr. Francis White used to call it my "annual." He always came up to the operating room when I did it. The only way I ever got rid of it was by removing the body of the hyoid bone in the manner Dr. Mackenty has suggested. I found in using a midline incision, as most men were doing at that time, that it left an ugly scar along the midline of the neck even when the operation was successful in getting rid of the duct.

I have often thought if the collar incision or a tongue-shaped incision were used to keep the scar tissue of the incision away from the scar tissue of the dissection tract, it would do away with the pencil-like mass of scar tissue.

Dr. Stein (in closing):

While the injection of methylene blue or similar coloring material is the method pursued by a great many for operative assistance, and probably has some value, I never could see the advantage of using colored material for such purpose, although we have tried it in order to demonstrate the patency of the thyroglossal fistula from the neck into the mouth. I do not believe it facilitates the removal or dissection of the cyst or the fistula.

Regarding Dr. Mackenty's question as to the excision of the central portion of the hyoid. Of course that was the method used for a long time where they wanted to reach the foramen cecum; they went through the body of the hyoid and there is no objection to it. But the recent work of Frazer, only done in the last year, has shown beautifully that it is not necessary always to do this. He found the infrahyoid segment passing from in front around the lower edge of the hyoid, extending behind it and coming down again. It gives the appearance of going through, but it does not. One can dissect it without the necessity of excising the central portion, although there is no particular harm in doing so that I can see.

PROBLEMS IN OLFACTOMETRY. II. "FRACTIONAL FATIGUE" OF THE OLFACTORY APPARATUS.[1]

ARTHUR W. PROETZ, M.D.

Two great obstacles which confront the investigator of the olfactory function are, strangely enough, the complexity of the central apparatus and the simplicity of the end-organ. The anatomy of the first cranial nerve and its central tracts and pathways has been minutely described. Concerning their separate functions, which in the aggregate produce those mental impressions which we interpret as smell, we are in total ignorance.

Tedious and inconclusive experiments were at one time performed upon animals in an attempt to fasten certain smell impressions upon given tracts and centers, but the results were so uncertain as to be of little value.

Although the central apparatus consists of a score of nuclei, tracts and fasciculi, which is hardly surprising when one takes into account the complexity of smell impressions, still the peripheral organ in the nose, which records these impressions, is bafflingly simple. Unlike the perception apparatuses of eye and ear the specific sensory epithelium in the nose is extremely primitive. The olfactory cell is a simple, elongated, fusiform, neuroepithelial cell supported by columnar, nonciliated, epithelial cells. The cytoplasm of these latter usually, though not invariably, contains a yellow pigment.

Considering the great delicacy of the sense of smell (man, though a microsmatic animal, distinguishes six or eight parts in a million), the infinite variety of impressions which it differentiates and the complexity of its central pathways, one must be impressed by the possibilities it should afford for diagnosis. If the functions of the individual tracts were understood, this knowledge would offer material aid in localizing central lesions.

[1] From the Department of Otolaryngology, Washington University School of Medicine, St. Louis.

Three years ago the writer began a study of the problem, not unconscious of its difficulties, but encouraged by an observation, made in 1908 by Read, that the terminal fibers in the nasal mucous membrane, supposed until then to form a plexus, are in reality not a plexus at all, but a closely interwoven mass of individual and discrete neurons proceeding separately to their terminations in the olfactory bulb. This appeared to open up at least a likelihood of the diversity of function extending into the end-organ.

The problems encountered are somewhat as follows:

1. The accurate measurement of olfactive acuity.

2. A demonstration of the separability, from a physiological standpoint, of the smell complex into its components.

3. A correlation of these components with anatomical structures in the brain.

The first problem, a system of making and recording observations of olfactory acuity, is the subject of a previous contribution by the writer. Briefly, the apparatus consists of a collection of one hundred bottles containing odorous solutions which the patient is given to smell under controlled conditions. These are arranged in ten rows, ten bottles in a row. Each row represents one test substance; each bottle in the row a different concentration of that substance.

Accepting the probability that odor is directly or indirectly based upon the chemical composition of the odorivector, the test substances were classified according to their chemical groupings, the simplest in row one, the most complex in row ten. Certain requisites were essential, such as freedom from oxidation, solubility in oil to prevent evaporation, and other characteristics of a purely practical nature considered particularly for the purpose of maintaining the solutions standard over a fairly long period of time.

By experimenting with finely graduated concentrations of these substances upon several hundred apparently normal noses, a minimum perceptible concentration was determined for each of the substances. This concentration was arbitrarily termed "one olfact," and was expressed in grams per liter—the substance and the solvent being stated in each case thus: 1 phenol-petrolatum olfact = gm. 0.01921. Two, three, four olfacts, and so on, represent two, three, and four times this number of grams. The

expressions of olfacts in grams per liter was adhered to, in spite of some apparent discrepancies in the progression of smell-intensity, because it offered the only easily controlled and definitely measurable comparison. Following is a list of test substances employed in the olfactometer together with the value of one olfact in each case:

Substance.	Grams per liter.	Parts per million.
Iodoform	0.00250	2.5
Methyl salicylate	0.00297	2.9
Amyl alcohol	0.00275	2.7
Xylol	0.01730	17.3
Nitrobenzol	0.03050	30.5
Phenol	0.01921	19.2
Guaiacol	0.00302	3.0
Cinnamon	0.00106	1.0
Eugenol	0.00053	0.5
Coumarin	0.00077	0.7
Oil theobroma	0.03621	36.2
Menthol	0.00524	5.2
Vanillin	0.00041	0.4
Allyl sulphocyanate	0.00305	3.0
Benzaldehyd	0.00033	0.3

The last five substances were determined, but are not now a part of the olfactometer.

This constituted the first step in the investigation. Brain lesions involving the olfactory areas are rare, and more data will be required before any light can be shed upon the third problem, the actual localizing of olfactory brain functions.

The second problem is fundamental: Can olfactory impressions be separated, for purposes of study, in such a manner that various odors may be employed to test individually the functional acuity of tracts involved? In other words, can we demonstrate physiologically that the tracts which have been mapped out by the anatomist play separate and distinct parts in the smell complex?

Obviously it is impossible to block certain of the peripheral fibers of the olfactory nerve by ordinary means without blocking the rest. The uncertainty of picking out certain central pathways for destruction in animals has been mentioned. Still it seems of utmost importance, to demonstrate, before attempting any differentiating tests, that the whole smell apparatus from beginning to end is not concerned with each and every smell impression.

The appended chart for conveniently recording observations, has been devised since the publication of the method.

OLFACTOMETRIC CHART

Age Ref.

Preop. Diag:

Postop. Diag:

Note:

R. L.

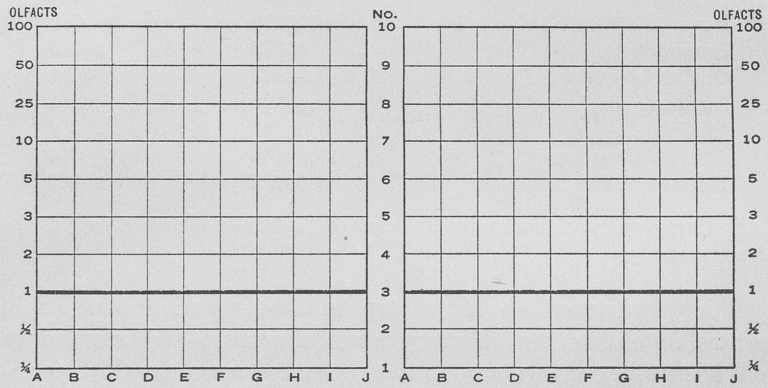

After some unfruitful experiments along other lines, the idea finally occurred to me of utilizing the well-known phenomenon of fatigue for this purpose.

It was observed long ago that the olfactive apparatus, at least in man, is peculiarly prone to fatigue. Zwaardemaker, by whom few phases of the physiology of smell were overlooked, plotted fatigue curves (Ermüdungscurven) for several odors.

In the use of the olfactometer, this tendency to fatigue has sometimes been very annoying. One fact, however, is apparent: That fatigue to one odor does not necessarily impair acuity to other odors. The following experiment was accordingly performed:

Two solutions were prepared in suitable, wide-mouthed bottles.

The first was a strong solution of an odorous substance, *A*. The second was a similar solution of *A*, to which a small amount of another test substance, *B*, was added. The proportion of *A* in the solution completely overpowered *B* so that *B* could not be detected by smelling. Accordingly both bottles smelled wholly of *A* although bottle No. 2 contained some *B*.

Bottle No. 1 (pure *A*) was now applied to the nose and smelled for three to eight minutes in order to fatigue the nerve to odor *A*.

It was found that when at the end of this time, bottle No. 2 was again smelled, the odor of *B* was quite apparent, in a few instances approaching *A* in intensity.

This strengthens a small but important observation, namely, that in some way the smell apparatus deals separately with various odors. Whether certain tracts become fatigued or whether specific components of the olfactory pigment cells become exhausted, we do not know. Exponents of the "undulatory theory" which credits the pigment with an important part in the smell function, will adhere to the latter view. Until the exact nature of olfaction is understood, the causes of the fatigue phenomena must remain a mystery. What concerns us here, however, is the fact that certain elements of the smell apparatus can be individually fatigued and thus physiologically separated from other elements.

It has been noted that the experiment may be reversed by interchanging the concentrations of *A* and *B*, using *B* as the exhaustor.

Furthermore the phenomenon is much more pronounced with some substances than with others, among them, aromatic volatile oils, such as peppermint, anise, clove, and cinnamon. It can be produced as well by tasting the solutions (gustatory odors). Thus far attempts to determine optimum concentrations and combinations have failed as they vary widely between individuals and at different times in the same individual.

Abstractly these observations of "fractional fatigue," if one may coin that term, are unimportant. They are introduced, for the present, merely as stepping-stones along a seldom trodden path on which our foothold at best is none too secure.

The third problem lies ahead. It is to be hoped that rhinologists and brain surgeons may unite forces and by recording and corre-

lating their respective findings may eventually bring to light the latent possibilities of the first nerve as a diagnostic aid.

References

Aronsohn, E.: Experimentelle Untersuchungen zur Physiologie des Geruches, 1886.

Bawden, H. Heath: Bibliography of the Literature on the Organ and Sense of Smell (846 references), Jour. Comp. Neurol., 1901, xi, 1.

Bechterew, W. V.: Leitungsbahnen im Gehirn, etc., 2d edition, Leipzig, 1899.

Heyninx, A.: Essai d'Olfactique Physiologique, Brussels, 1919.

McKenzie, Dan.: Aromatics and the Soul: A Study of Smells, New York, 1924.

Proetz, Arthur W.: A System of Exact Olfactometry, Annals of Otol., Rhinol. and Laryngol., September, 1924, xxxiii, 746.

Read, Effie A.: Contributions to the Knowledge of the Olfactory Apparatus in Dog, Cat and Man, Am. Jour. Anat., 1908, viii, 17.

Sachs, Ernest: Relationship between Central and Peripheral Involvement of the Cranial Nerves, Am. Jour. Med. Sci., 1922, clxiv, 727.

Schaeffer, J. P.: The Nose and the Olfactory Organ, etc., Philadelphia, 1920.

Zwaardemaker, H.: Physiologie des Geruches, Leipzig, 1895.

Discussion

Dr. Otto Stein, Chicago:

I consider this a very excellent contribution to this line of work because of the possibilities for use in differential diagnosis.

There is just one question I would like to ask: I cannot quite understand how patients can differentiate these different odors when they are ignorant of what they are. The doctor has a method for detection and one for differentiation. How can a patient not familiar with the odor describe that particular odor?

Dr. Greenfield Sluder, St. Louis, Mo.:

I cannot add a single thing to Dr. Proetz's paper. I am familiar with the work he has done in an effort to localize brain lesions. It seems to me the point he has made, the matter of fractional fatigue, is not merely very interesting but ought to be helpful in the differentiation. I am sure that some of the gentlemen who are busy with

brain surgery will welcome this and possibly add something for our instruction to it.

Dr. Harris P. Mosher, Boston, Mass.:

I cannot discuss the paper. I wish, however, to add my praise to that of Dr. Sluder for a paper of this kind. To me there are great possibilities in the subject as brought out by the reader.

Dr. Hanau W. Loeb, St. Louis, Mo.:

I want to add also a word of commendation. I have been familiar with the work of my fellow-townsman, Dr. Proetz, and I feel before very long he will be able to give us something of practical value on this experimental work. I hope we will all help him as much as we can.

Dr. Proetz (in closing):

In reply to Dr. Stein, I wish to explain that we employ a sort of jargon when we do these tests. If a patient is given nitrobenzol to smell, he usually says: "That's shoe-polish." Coumarin is "sweet clover," and so on. He may have his own terms for what he smells, but the odors are so distinctive as to leave little doubt. If there is a doubt we go on to another odor, and return later to the one in question. If we used only smells easily recognized, certain important chemical groups would go unrepresented.

Much has been written on the sense of smell, more than is generally supposed; but little of it has lived. A few years ago the *Journal of Comparative Neurology* published a list of eight hundred and forty-six titles of articles, most of them written between 1850 and 1900. It will be seen that in spite of much thought given the subject it has advanced but slowly.

PEMPHIGUS FROM THE LARYNGOLOGIST'S STANDPOINT

GORDON B. NEW, M.D.

PEMPHIGUS is a disease characterized by the development of bullæ of the skin and mucous membranes, remissions, and usually progressive failure and death. Most physicians believe it to be a dermatosis which occasionally affects the throat and mouth, but only if the lesion has existed on the skin for some time or if the disease has become generalized. It is our purpose to emphasize the characteristics of the early lesions of the mucous membrane of the throat and mouth so that, with a dermatologic examination, an early diagnosis may be made.

During the last five years, from 1919 to 1924, inclusive, we have examined at the Mayo Clinic 29 patients with pemphigus. Of these, 19 (more than 65 per cent) came primarily on account of the lesions of the mouth and throat. Some of the patients had no other lesions on the body at the time of the original examination or they were so slight as not to be recognized by the patient. A diagnosis or a tentative diagnosis was made from the lesions of the mouth or throat, which was later corroborated by dermatologic examination and the further progress of the disease. If the disease is primarily of the skin the laryngologist is not consulted, as the dermatologist expects the involvement of the mouth and throat. The early diagnosis of the disease is essential on account of the usual fatal outcome, which may occur within a few months.

ETIOLOGY. The cause of pemphigus is not definitely known, although it has been attributed to may different organisms. Eberson's recent work has not been completely confirmed. The Bacillus pyocyaneus has been obtained from the exfoliative type of the disease by several investigators. Evidence favoring a bacteriologic cause continues to accumulate and undoubtedly will eventually be demonstrated by further study. It has been

noticed that in a large percentage of this series of 29 cases the onset of the disease was in the summer months, especially August. This may serve as a starting-point in the determination of the cause of the disease.

Types. Pemphigus is usually classified in four types: (1) Pemphigus acutus; (2) pemphigus chronicus; (3) pemphigus foliaceous, and (4) pemphigus vegetans. While this classification has little bearing on the present discussion, it might be said that the pemphigus acutus is a fulminating type of the disease ending in death within a few weeks or months. Occasionally, however, the acute symptoms subside and the patient recovers completely or the disease takes on a chronic form. Pemphigus chronicus, or vulgaris, is the most common type, the name of which is self-explanatory. Pemphigus foliaceous is characterized by the formation of bullæ, followed by generalized exfoliation. The mucous membrane in this type is affected usually late in the disease. Pemphigus vegetans is the rarest of the four types, usually found primarily on the mucous membrane, lesions on the skin appearing later and differing from the chronic pemphigus in that the base of the bulla becomes papillomatous or condylomatous around the genital, crural and axillary regions. The benign type of pemphigus may last for a period of years.

Age, Sex, Nationality and the Duration of Disease. The age varied from twenty to seventy-six years. Most of the patients were about middle age. There were 18 females and 11 males. It has been previously emphasized that there is a high percentage of Russian Jews with this disease. In our series there were 6, a high percentage as compared with the percentage of patients of this nationality coming to the clinic. The disease had existed for from two weeks to seven years before the patient was examined at the clinic, the average duration being eighteen and a half months.

Symptoms and Previous Treatment. Patients usually complain of a sore throat or mouth, difficulty in swallowing and increased salivation. They have usually consulted several physicians, have had various diagnoses and much treatment. The treatment has consisted of vaccine with streptococcus, staphylo-

coccus and diphtheria serum; silver nitrate, chromic acid, radium and copper sulphate have been applied; tonsillectomy and dental extractions have been performed; Fowler's solution by mouth, and routine treatment for tuberculosis given.

Type and Location of the Lesions. Of the 19 patients who came for examination primarily because of lesions of the mouth and throat, the condition was eventually diagnosed as pemphigus acutus in 1 patient, pemphigus vegetans in 8 patients, pemphigus chronicus in 6, and mixed in 4. The mouth was affected in 19, the pharynx in 14, the larynx in 11, the esophagus in 1, the nasopharynx in 1, and the nose in 1. Although the vegetans type is usually considered the rarest, 8 of the series were of this type.

Five of the 19 patients had no cutaneous involvement. In 1 the conjunctivæ; in 6 the skin; in 3 the conjunctivæ and skin; in 2 the conjunctival, vaginal and rectal mucous membranes; and in 2 the conjunctival and vaginal mucous membrane and skin were involved.

Character of the Lesions of the Mucous Membrane. The lesions of the mucous membrane in the various types of pemphigus all present similar pictures. The type of pemphigus cannot be distinguished from the early lesions of the mouth and throat. All lesions of a bullous character are not pemphigus. It has been noted that the first lesions on the mucous membranes of the mouth and pharynx are rarely seen in the bullous stage without other dermatologic findings. We have been so fortunate as to recognize many cases in which this was the only lesion, and later the diagnosis was corroborated by the course of the disease.

Patients frequently describe their lesion as "a small blister the size of a pea," which later ruptures. Several bullæ may appear in a crop; as many as eight have been observed at one time. They may be of various sizes and round or oval. During the first few months of the disease bullæ may last twenty-four hours, but as the disease becomes more chronic the bullæ may appear and break within an hour. The lesions appear on healthy mucous membrane. Bullæ may not at first be apparent on the mucous membrane, but there is a fibrinous exudate, and the bullæ are found later only on careful examination. The possibility of the formation of bullæ

that rupture early should be considered as a cause of the fibrinous exudate. It has been necessary in some cases to observe the lesions several times a day in order to recognize a bulla before it ruptured. After it ruptures the remaining pellicle may be observed hanging loosely or collapsed on the mucous membrane, particularly around the lips. The resulting erosion of a solitary bulla is usually superficial and may heal in from three or four days, while if the lesions are numerous the ulceration may extend over a considerable area or there may be multiple ulcerated patches.

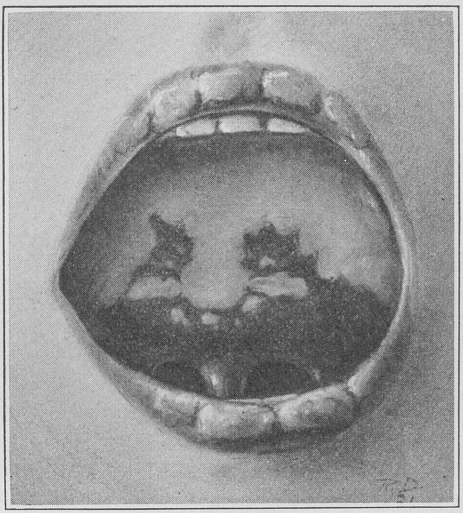

FIG. 1.—Ulcerations with irregular margins over the soft palate, and involvement of the lips.

In the severe cases the mucous membrane of the mouth, pharynx and larynx may, to a great extent, be covered with a beefy-red ulceration and fibrinous exudate. A slight inflammatory reaction occurs around the lesions, which is usually irregular, with projections or islands of the normal mucous membrane extending into the ulcerated or eroded areas. A fetor typical of the disease is present and the secretion of saliva is usually markedly increased. In the mouth and throat the absence of scarring, as a rule, is con-

spicuous, although it may occur and may cause laryngeal obstruction; however, on the conjunctivæ it occurs frequently. With ulceration of the mouth and throat, often with the fibrinous exudate and increased saliva, pemphigus should be suspected at the time of the primary examination and the patient immediately referred to a dermatologist for further investigation. After repeated examinations a bulla may be found on the mucous membrane. Of the patients who came primarily on account of the condition of their mouth and throat, and later developed lesions of the skin, the interval between the appearance on the mucous membrane and

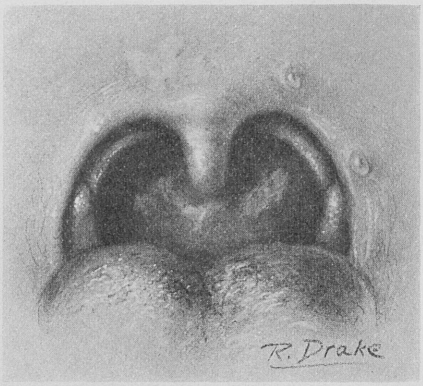

FIG. 2.—Areas of exudate over the posterior pharyngeal wall and palate, and two blebs on the soft palate and anterior pillar.

skin was from a few weeks to three years. It is believed that the more rapid the appearance of the cutaneous manifestations following lesions of the mouth and throat the more virulent and rapid the course of the disease (Figs. 1, 2 and 3).

DIAGNOSIS. The diagnosis of pemphigus from the laryngologist's standpoint must depend on the history, the finding of the lesions of the mouth or throat that makes one suspect the disease, and after repeated observations the finding of bullæ on the mucous membrane. In all such cases a dermatologist should be consulted. Lesions in the mouth and throat that simulate pemphigus are erythema multiforma and sprue. Other diseases, such as syphilis,

Vincent's angina and ulcerative and aphthous stomatitis, are usually included in the differential diagnosis, but as a rule would not be considered by an experienced laryngologist. The progress of the disease, with involvement of the skin or other mucous membranes, is often confirmatory evidence.

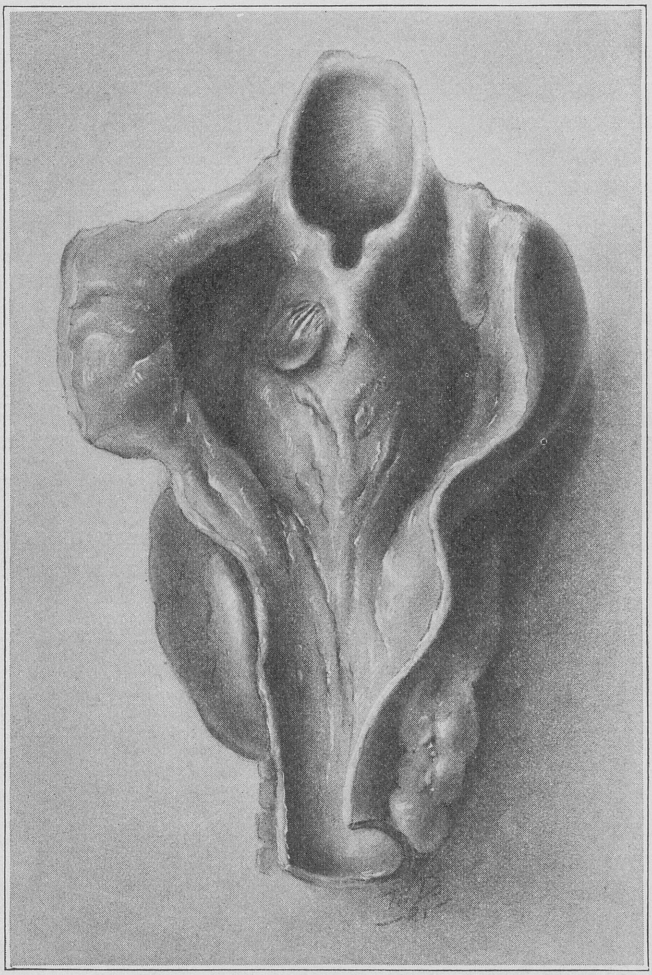

FIG. 3.—Postmortem specimen. Bleb on the outer surface of the larynx.

TREATMENT. Present methods of treatment of the various types of pemphigus are not satisfactory. The use of coagulen and iron cacodylate, as suggested by Davis and Davis, has apparently been attended with varying degrees of success. Wende reports that 9 patients were definitely benefited by this method, but in our experience there has been practically no improvement. The occasional brilliant result, however, justifies further trial of the method. The use of immune serum made from the bacterium of pemphigus (Eberson) has not met with encouragement. The intravenous injection of mercurochrome and gentian violet and many other preparations have not been beneficial.

Treatment of the lesions of the mouth and throat is likewise unsatisfactory as a rule. The lesions of the mucous membrane usually run a parallel course with the lesions of the skin. A few cases have been observed in which the former cleared up while the latter persisted to a fatal termination. In the vegetative type of the disease the lesions of the mucous membrane are more pronounced, persistent and troublesome. All foci had usually been thoroughly eliminated before the patient presented himself for examination. In the cases in which the teeth or tonsils were cared for under our supervision it has seemed that this has only aggravated the disease.

CONCLUSIONS. 1. Contrary to the usual opinion, patients with pemphigus, as a rule, consult a laryngologist primarily on account of trouble in the mouth and throat.

2. Many patients with pemphigus are given much treatment without a definite diagnosis.

3. The rapidity with which the cutaneous manifestations follow lesions of the mouth and throat is an index to the virulence of the disease and the length of life.

4. Early diagnosis of pemphigus is essential, in order that relatives may be given a prognosis and to obtain for the patient early institutional treatment.

BIBLIOGRAPHY

1. Davis, R. H. and Davis, W. D.: A Contribution to the Treatment of Pemphigus, Arch. Dermat. and Syph., 1923, viii, 627–638.

2. Eberson, Frederick: Studies on the Etiology of Pemphigus. I. Bacteriologic Findings in a Group of Cases of Pemphigus, Arch. Dermat. and Syph., 1923, viii, 204–232.

3. Wende, G. W.: Pemphigus; experience with Davis treatment, Arch. Dermat. and Syph., 1925, xi, 783–788.

Discussion

Dr. Cornelius G. Coakley, New York City:

In the very large dematological clinic of Dr. Fordyce, at the Vanderbilt Clinic, we see these cases of pemphigus, but I have never had the privilege of seeing one in our outpatient department before the skin lesions have appeared. They have always been cases of skin lesions fairly definite, and sent in simply for an examination as to the extent of the lesions in the mouth, occasionally in the nose and in the lower parts of the pharynx. I have never seen one in the larynx. Of course, these patients complain most bitterly of sore throat and are referred to us with a view of finding some way to ameliorate the symptoms. No treatment has given the patient any great amount of relief. All these cases have gone on to a fatal termination sooner or later, dependent upon the extent and rapidity of the skin lesions. The cases vary from comparative youth to middle age, with occasionally one in well-advanced years.

Dr. Harmon Smith, New York:

I remember 2 cases coming under my observation a number of years ago when I was chief of clinic under the late Dr. Walter F. Chappell at the Manhattan Eye, Ear and Throat Hospital. Both were women, and they presented no skin lesions for a long while after the throat observation.

The ulcerated area presented a perfect symmetry, and radiated from an apex on the hard palate to divergent extremities on the soft palate near to the tonsils. It was some weeks ere any of us were able to see the blebs, which when erupted gave the appearance of a mucus patch and which led us to treat these cases as suspected syphilis.

The pain was the one factor which argued against syphilis, and as it was before the days of the Wassermann test we were tempted to administer antisyphilitic treatment.

In due course of time a definite diagnosis was made from seeing the bleb formation and from the skin lesions. Both patients ultimately died from intestinal complications.

Dr. Henry L. Swain, New Haven, Conn.:

I never had the opportunity to give much thought to this particular form of trouble except on one or two occasions.

In the first pandemic of grippe, in the early nineties, an elderly lady came to me with throat trouble. She had distinct blebs, located almost exactly as in the first picture put on the screen. She lived ten years afterward, and as she did not have any generalization I had thought of it as being a peculiar manifestation of the grippe of that period. Then the idea occurred to me whether there could be any connection between herpes as we see it in the mouth and pemphigus as you have described it today.

Dr. G. B. Wood, Philadelphia:

I would like to ask Dr. New if he has ever used the intravenous injection of mercurochrome in these cases, as I have seen some improvement from its use in certain cases in Philadelphia. The improvement, however, was only temporary and after a while they failed to yield to its use.

Dr. Lewis A. Coffin, New York:

We should be thankful that Dr. New has brought this subject to our attention. When a man of Dr. Coakley's experience says he has never seen an early case we may knew how rare this condition is, and this well-presented paper will greatly add to our preparedness for diagnosis. I have seen two cases. The first case made a deep impression on me, because no one on the staff of the Manhattan Eye, Ear and Throat Hospital was able to make a diagnosis until Dr. Jonathan Wright was called in consultation, he being our pathologist at the time. Dr. Wright diagnosed it at once. This was probably twenty or twenty-five years ago. I have forgotten now what was the length of time before the skin lesions developed, but they did develop and death ensued.

Dr. Harris P. Mosher, Boston:

I have been in occasional touch with a case which I suppose to be pemphigus of the mouth and pharynx. The patient is a woman of middle age, who dated the beginning of her trouble, as quite a number of people do, to a trip West and the eating of certain food—corn, I think. I wonder whether or not there is anything in the food basis for these cases? Dr. New said most or many of his cases were Russian Jews. Did they all come from the same locality?

Dr. New spoke of using vaccine as one method of treatment. In looking up the literature to find help for this case of mine, I came across an article advising transfusion. I would like to ask Dr. New what he knows about transfusion in these cases.

Dr. H. H. Forbes, New York City:

I would like to ask Dr. New the exact lesion that he found in the esophagus, bringing up the question raised by Dr. Mosher of the possibility of a protein element causing these cases.

The only case I have seen, where the lesions were of the chronic type, involving the skin and the mouth, came into the hospital as an emergency with an acute obstruction of the esophagus. A bismuth picture showed a complete obstruction. Fortunately at that time the suggestion was made of the possibility of pemphigus being a protein poisoning and having the effect of a local edema. One injection of adrenalin cleared up the obstruction in the esophagus and the patient was able to swallow as well as would be expected. I examined this patient within twenty-four hours with an esophagoscope. There was neither an erosion nor a pemphigus lesion in the esophagus that I could discover.

I believe, as set forth in the literature given to me by the dermatological department, that the protein idea certainly has some warrant for us to consider it as a causative factor.

Dr. Greenfield Sluder, St. Louis, Mo.:

I would like to ask Dr. New if he has seen the lesions in the nose?

Dr. New (in closing):

Regarding the etiology of pemphigus, the only point we thought might be a factor was that the disease started in August in many cases, so that possibly the food factor Dr. Mosher has brought out may be an important one.

Answering Dr. Swain's question regarding the possibility of herpes, I would say that the disease does not act like the other types of herpes that we see, and I would be surprised if it proved to be that type of lesion.

Regarding the use of mercurochrome, we have used it on some cases, but the end-results have always been the same. Bad cases who are going to die go on and die in spite of the treatment, while the chronic cases continue along with exacerbations no matter what you do for them.

We have used transfusions several years ago with a similar result.

OTOLARYNGOLOGY IN RELATION TO GENERAL AND MEDICOLEGAL MEDICINE

WITH A SPECIAL REPORT OF CASES OF SCURVY AND BRONCHIECTASIS

BURT R. SHURLY, M.D.

THE modern trend of the highly developed differentiation of effort in specialism has produced a finer line of demarcation between the general surgeon, the internist, the public health specialist and the pediatrist. Medical education has been standardized so elaborately that its departments and heads, usually twenty in number, lead to great difficulties in practical teaching and management. Border-line surgery and medicine should not become matters of rule, but should be governed by scientific qualification, choice and interest.

There is danger in the development of otolaryngology to an ultra-specialty that ignores the study of systemic disease. It must not be forgotten that many conditions of the upper respiratory tract are wholly systemic in origin and must be treated on a broad and liberal basis.

The Association of Medical Colleges has issued a new edict—that the faculty shall be grouped under four divisions—surgery, medicine, public health, and gynecology and obstetrics, and all departments be merged under these divisions.

The close interrelationship of pulmonary abscess and tonsillectomy (Hedbloom reports 54 such cases operated on), of laryngeal tuberculosis and the pulmonary variety of hyperthyroidism and tonsillar-ring infection, of mediastinal disease and laryngeal paralysis, of tonsillar infection and rheumatism, of psychoneuroses and focal infection, call for renewed interest in general medical diagnosis.

With the passing of the general practitioner, with the increased intelligence of the patient, with the diminution of referred cases,

there must come to the specialist a greater interest in general medical diagnosis and therapeutics.

Along this line of thought, I beg to submit the following 5 cases associated with general and medicolegal medicine for your consideration:

CASE I.—G. K., aged twenty-eight years, male; well nourished; admitted to the Detroit Eye, Ear, Nose and Throat Hospital, January 3, 1925, with the following history: Father died of cerebral hemorrhage; mother, three brothers and two sisters, living and well; no history of hemophilia; wife and daughter living and well. Past history: Diphtheria at four years, with good recovery; rheumatism at sixteen years without complications. Had frequent colds and sore throat until 1919, when tonsillectomy completely relieved this tendency. Three years ago patient suffered from abdominal pain and distention with constipation; *nine months ago* consulted a surgeon who diagnosed appendicitis and advised a rigid diet free from fresh vegetables and fresh fruits. This typewritten diet, consisting of five meals per day, was followed absolutely during a period of nine months. When this diet was ordered by the surgeon, March 24, 1924, the blood count was hemoglobin, 80 per cent; red cells, 4,810,000; white cells, 9200; lymphocytes, 7 per cent. Urine negative. On January 3, 1925, the blood count was hemoglobin, 40 per cent; red, 1,840,00; white cells, 7350; index, 1.1; differential polymorphonuclears, 61; lymphocytes, 32 per cent; transitional, 4 per cent; eosinophiles, 2 per cent; basophiles, 1 per cent. No nucleated or stippled red blood cells. Coagulation began at nine minutes; fragile at fifteen minutes and very little firmer at twenty minutes. *X*-ray showed no bone involvement. On this date, January 3, the patient entered the Detroit Eye, Ear, Nose and Throat Hospital, as a stretcher case, with the following symptoms and findings:

Marked hemorrhage from time to time from ears, nose and throat; bleeding gums; pain and swelling of right knee, later left knee, followed by pain in the lumbar region—too painful to sit up; hemorrhage areas over right knee and internal aspect of both legs and thighs; urine, highly colored but no albumin or sugar found; specific gravity, 1026. *X*-ray and clinical examination of chest negative. Basal metabolism, 44.12, with 39.5 as normal; blood-pressure, 132; calcium content, from estimation on blood plasma, 10.8, with normal 9 to 11. Examination of the feces was negative. The alarming blood picture, pending a diagnosis, was met with intravenous calcium and iron and a full diet of fruit and fresh vegetables.

We gave consideration to the following differential facts for diagnosis. Examination of the nose and throat and ears was negative; the temperature range was from 103° to 99°. The question of differential diagnosis brought into consideration hemophylia, purpura hemorrhagica, pernicious anemia, anemia with parasites in the blood, relapsing fever, lymphatic anemia or scurvy. Three outstanding features were negative: Family history; no foreign residence, and lack of sufficient red-cell destruction or increased eosinophiles ruled out hemophilia, relapsing fever or parasitic anemia, such as malaria, filariasis or trypanosomes. It was not classified as splenomedullary leukemia because there was no hypertrophy of the spleen or an increase in the number of leukocytes. It was not lymphatic anemia because there was no lymphatic enlargement, large spleen, increased leukocytes or small lymphocytes in the differential count. In pernicious anemia the color index is usually above 1 and nucleated red cells may be seen.

The blood picture made three days later, following forced feeding of fresh vegetables, fruit juices, intravenous iron and calcium with Blaud's pills, showed a striking improvement. Hemorrhages ceased; the edema in the tissues rapidly subsided; joint and muscles pains faded.

The blood report on January 6 (three days later) was red cells, 3,496,000 leukocytes, 5100; hemoglobin, 60; color index, 85; polymorphonuclears, 75; lymphocytes, 14; large mononuclears, 2; transitionals, 6; eosinophiles, 1. Coagulation time, five and a half minutes; firm clot, nine minutes.

The patient steadily and rapidly improved, and on January 9 the blood count was: red cells, 4,420,000; leukocytes, 6500; hemoglobin, 70; color index, 9; polymorphonuclears 64; lymphocytes, 31; transitionals, 3; eosinophiles, 1; basophiles, 1. The red cells show a moderate variation in size, shape and staining quality. No stippled or nulceated red cells seen. Coagulation time, five minutes, with a firm clot in eight minutes. Pain had subsided entirely. No fresh hemorrhage occurred and the purpuric areas had faded. The patient was discharged from the hospital in eight days on full house diet with an excess fruit of juices.

A complete count January 13, showed red cells, 4,080,000; leukocytes, 7350; hemoglobin, 80; color index, 1; polymorphonuclears, 62; lymphocytes, 27; large mononuclears, 2; transitionals, 7; eosinophiles, 1; basophiles, 1; coagulation time, four minutes; firm clot, five minutes.

This case exhibited the factors of faulty diet, weakness, mental depression, hemorrhage from the gums, ears and nose, with purpura and subperiosteal hemorrhage and tenderness. The diagnosis was confirmed by the series of blood counts and the rapid recovery with iron and calcium, intravenously and by mouth, together with an abundant diet of meat, fresh fruits and vegetables. The antiscorbutic vitamin water soluble C., found particularly in oranges, lemons, limes, and tomatoes, with vitamin D., in red bone-marrow, with a tonic rich in calcium and containing malt, pulverized ossis, lactic acid, pancreatin and pepsin, was continued for some months. At the present time the patient is well.

Case II.—Bronchiectasis, while strictly belonging to the internist, becomes of otolaryngologic interest from the fact that many cases are primarily sinus infection and that three distinct measures for relief fall directly into our special field. The condition is frequently overlooked clinically. Eighty-four per cent of the cases, according to Moore, may be definitely diagnosed with the *x*-ray. In my own cases the picture of dilated tubes and saccules filled with pus over the lower lobes could be seen to empty with cough and expectoration. Moore distinguishes three varieties: The infiltratic, the cylindrical and the sacculated. The characteristic profuse sputum, without tubercle bacilli, the violent paroxysmal morning cough, the offensive odor, the physical signs of cavernous breathing, bronchophony and whispering pectoriloquy, with coarse and metalic râles, temperature 99° to 100°, give suggestive evidence confirmed by the fluoroscope. These symptoms and findings were present in Mrs. C., aged twenty-two years, housewife, who consulted me October 6, 1924. Former physician diagnosed pulmonary tuberculosis. Following tonsillectomy, one and a half years ago, patient lost weight; cough and expectoration increased and temperature developed.

Examination and X-ray. The hilus density markedly increased and contains numerous dilated bronchi. Both bases show an irregular diffuse infiltration, through which are evident the honeycomb-like structures, probably the result of dilated bronchi. The apices are clear and the lung fields clear with the exception noted. Frequent sputum examinations showed staphylococcus, pneumococcus and streptococcus. Examination of nose and throat showed bilateral antrum infection.

In this type of case, otolaryngology has three therapeutic aids to offer over that of the internist, that is, puncture, irrigation

and drainage of the sinuses; intratracheal medication with guaiacol and camphor to facilitate drainage of the bronchial tubes, and bronchial lavage with the proper bronchoscopic tubes and irrigating apparatus. Under this procedure the patient obtained great relief. The temperature returned to normal, the cough was greatly improved and the odor subsided. Irrigation has been continued at intervals until the present time.

The interrelation of medicolegal medicine and otolaryngology has become more intimate since the war, and the report of three cases of personal experience may prove of interest. During the last few years one in every one hundred doctors in Michigan has been sued for malpractice.

CASE I.—C. T., a girl, aged twenty-one years, sued Dr. H. of central Michigan. The charge in this case was that in the removal of the plaintiff's tonsils, the doctor improperly and negligently attempted to remove the tonsils, and in so doing removed the uvula, the palate, the posterior and anterior pillars in the plaintiff's throat, cut and tore the walls of the pharynx and the muscles of the throat, which resulted in a complete atresia of the nasopharynx. The plaintiff had formerly (according to her statement) a splendid voice and as a result of this injury she was incapacitated from carrying on a musical education. The patient, after commencing suit, came to the Detroit Eye, Ear, Nose and Throat Hospital with a complete atresia of the nasopharynx, traumatic in origin. I operated and secured an opening an inch in diameter. A dentist manufactured a holding device that was attached to the molar teeth. This was imperfect, however; scar tissue formed, and after seven years the contraction has been so great that the nasopharyngeal opening will only admit a probe the caliber of a lead-pencil.

At the trial there was no question about the damage, but in order that the plaintiff might have her case submitted to a jury, it was necessary to procure some medical witness familiar with the practice in the community or similar communities in which Dr. H. practised, to testify that in the performance of the operation the doctor used some method not in accordance with the usual, ordinary practice in that community, and that as a result of his failure to use that ordinary method the damage probably followed (it is safe to say that it probably followed), or that he omitted to

do something which was ordinarily done by physicians practising in that and similar communities, and that as a result of the omission the damage probably resulted. It was the theory of the defense that some blood condition existed, and, while the charge was not openly made, plaintiff took it up as an open challenge and a Wassermann test resulted in negative findings.

At the first trial the case was submitted to the jury on the testimony of an *x*-ray specialist, who formerly had been in general practice, regarding the faulty position in which plaintiff was placed at the time of the operation. The jury disagreed, even though the doctor had offered to pay $6000 in settlement.

At the first trial I refused to appear on account of family sickness, and as the attorney for the plaintiff was unable to subpoena me it was agreed that a written statement would be admitted.

At the second trial a subpoena was served upon me and I was forced to appear. I was on the stand for an entire day. The attorney for the plaintiff tried to get a statement from me which would carry the case to a jury, and it looked as if the judge was going to direct a verdict of no cause for action; but he felt so sorry for the girl that he asked Mr. Barbour, attorney for the defendant, to try and get the doctor to pay something and that he would endeavor to get the plaintiff's father, the plaintiff and the attorneys for the plaintiff to accept it, and, eventually $1000 was paid to the girl, $250 to the attorneys, the doctor's bills were paid and the case was settled.

Case II.—The second case was C. F., *vs.* Dr. J. P. T.: Dr. T. was more of a physician than surgeon, but had considerable experience in the removal of tonsils. He was called upon in the course of his practice to remove the tonsils of the plaintiff. In removing them he left a considerable portion of each tonsil, and the plaintiff claimed she continued to suffer from neuritis and rheumatism as she suffered before the operation until I removed the remaining portion of the tonsil some months afterward, at the request of Dr. T.; she subsequently became perfectly well.

There is no doubt but that Dr. T., left a considerable portion of both tonsils. I was called as a witness by the attorney for the plaintiff to establish negligence. On being questioned, it was

stated that in my opinion the average physician might easily remove only a portion of the tonsil, and even a specialist might do so if the hemorrhage was especially great, and that it might be better to remove the remaining portion at a later time. It was stated that if I were sued for all the pieces of tonsil I had left in the last thirty years the Wayne County Circuit Court would have little else to do. Every effort was made to call out statements that the average practitioner in this community would be guilty of negligence if he left a portion of the tonsil and that such portion of the tonsil would probably cause a continuance of the neuritis and rheumatism. The court directed a verdict in favor of the doctor of no cause for action.

The next case to which I wish to call your attention, in which I was the defendant, may be considered as strictly falling within the domain of otolaryngology, since it was a case of death occurring during the administration of an anesthetic and I never proceeded as far as the tonsillectomy itself. Inasmuch, however, as the administration of the anesthetic may be correctly termed a necessary part of the operation, and since some useful information may be derived from my experience in this case, I have decided to bring it to your attention.

Case III.—In August, 1922, Mrs. E. B., widow, in company with a woman friend who claimed to be a practical nurse, consulted me with reference to performing a tonsillectomy upon her son and removing his adenoids. The son did not accompany her. He was physically a fine-appearing young fellow, nineteen years old, six feet tall and weighed 175 pounds. According to her statement, he had been attending a military institute in Ohio, had been suffering from tonsillitis and had been advised by the resident physician of the institute to have his adenoids and tonsils removed. An appointment was made for him for the following morning and he appeared with the nurse at the appointed hour and was examined.

In accordance with our general routine, where not otherwise arranged for, preparations had been made for a general anesthetic. He was preceded upon the operating table by a woman patient from Morenci, Michigan, to whom a half of 1 per cent solution of procaine had been administered, and who, as she was leaving

the operating room said in the presence and hearing of the young man (who was outside the operating room awaiting his turn) that she was feeling fine and that her operation had been a splendid success. He entered the operating room in my absence, my anesthetician and a surgical nurse being the only other persons present at the time. Upon entering the room he inquired what anesthetic the preceding patient had had and was informed that it was a local anesthetic; whereupon, he asked why he couldn't have the same thing and was told that he could, and he then expressed his desire to have the same anesthetic administered to him that the preceding patient had received. In accordance with this request, the anesthetician, who is a graduate surgeon, proceeded to administer the same solution of procaine and had injected 2 drachms into the posterior pillar when the patient suddenly collapsed and, after about an hour spent in unavailing efforts to revive him, died. The mother was sent for and, of course, asked how the death had occurred. Relying upon the information received from the anesthetician and surgical nurse, I informed her that, while *procaine* was being administered as the anesthetic, he had collapsed and died.

Some time thereafter I was sued for malpractice by the mother as the boy's administratrix, she claiming $50,000 in the name of his estate. She had employed a firm of very skilful lawyers who, I am informed by my counsel, departed from the usual practice of attorneys in malpractice cases, and, instead of suing, as the lawyers term it, "in tort" or, in common language, for the negligence or malpractice of the physician, claimed that she had told me of having been warned by her family physician (conveniently dead) never under any circumstances to permit *cocaine* to be administered to him. She claimed that I had agreed not to administer *cocaine* or any of its derivatives; that I had administered *cocaine* or one of its derivatives, and that I had told her that I forgot to tell the anesthetician to administer a general anesthetic and not *cocaine* or other local anesthetic, and that the *cocaine* had caused his death; and, instead of claiming, as is usual, damages for the negligence, she claimed damages for this claimed breach of contract.

My counsel informed me that this was a very cunning device, inasmuch as it might cut off my right to demand that she prove the

malpractice by the testimony of surgeons, as is the rule of law in ordinary malpractice cases, and that it would leave the case to be presented to the jury on this phase of the case merely upon the testimony of lay witnesses whom the jury might believe as against my uncorroborated denial of the fact that any such agreement had been made by me. Counsel said, however, that this would still leave the case in such condition that plaintiff must produce such medical testimony to the effect that the death did really result from the administration of *cocaine* as would warrant the jury in finding that to have been the fact, and that, if she did not present that testimony, we would still have the right to demand that the judge direct a verdict in my favor because she had failed to prove that fact.

It will be quite apparent, I think, to you, that, as it was claimed by my lawyers, plaintiff's claim was founded upon the similarity of the two words "*procaine*" and "*cocaine.*" I did, in fact, tell her that "*procaine*" had been administered; but not being familiar with the name of that drug, she probably understood me to say "*cocaine*" and she must have stated that fact to her lawyers. There was no medical testimony produced by plaintiff tending to prove that the boy's death was, in fact, caused by the administration of *cocaine,* and none that cocaine was, in fact, administered; but the able judge who presided at the trial held that sufficient testimony had been developed by her own and her companion's testimony that I had admitted the use of *cocaine* (which was untrue), together with other testimony, to warrant submitting the case to the jury. The trial occupied a week and the jury promptly returned a unanimous verdict in my favor.

One very interesting point of law was developed when the trial judge held that the boy, although still a minor and under his mother's guardianship, had arrived at such a stage of mental development as to give him the right to choose what anesthetic should be administered to him, and the case was submitted to the jury upon that basis.

Under all the circumstances, it was very clear that this was a case of thymic death, and my associate, Dr. Gaines, and Drs. J. B. Kennedy and Frank T. F. Stephenson, as well as I, myself, testified to that effect in response to hypothetical questions covering the

proven facts of the case. No postmortem was held. The coroner gave the cause of death as paralysis of the phrenic nerve. No one knows the real cause of death, however, which is greatly to my advantage legally.

Aside from the medical and surgical facts involved here, my counsel have made these suggestions as to the legal aspects of the case:

1. In all your cases be very careful that at least one physician besides yourself is present at the interview where arrangements for an operation are made.

2. Wherever possible have the details in writing. This can be done in the manner of taking a history, jotting down the points in the presence of the person or persons with whom the arrangements are made and finishing the memorandum with a full statement of the details of the anesthetic operation, perhaps the price, or confirming the arrangement by letter in some other way.

I should say that this case is not yet finally settled legally, since the plaintiff has appealed to the Supreme Court from the judgment in my favor.

Under the law, as I am informed by my counsel, no new testimony is to be taken and the verdict of the jury and the judgment based upon it must stand unless it can be successfully demonstrated to the Supreme Court that the trial judge committed some substantial legal prejudicial error either in the admission or exclusion of evidence or the substance of the instructions or charge which he gave to the jury.

In my opinion, and that of my counsel, this case was what is called a "frame-up." One of the proofs that it was such is apparent in the claim that the word "*cocaine*" was used. For ten years "*procaine*" has been so commonly used as my local anesthetic in tonsillectomies that it has become a matter of routine with me and my assistants, and I could not, therefore, have used the word "*cocaine.*"

Another proof that it was a "frame-up" is furnished by the fact that, about a year after the boy's death and while the suit against me was pending, I received word that an out-of-town physician had agreed to hold an autopsy upon the body. My counsel and I and several other surgeons were present at the time and place

secretly arranged for the autopsy. We waited a long time before any one else appeared. Finally, some one did appear who, immediately upon seeing us there, backed out of the room, waited on the outside for his companions to appear, held a whispered conversation with them and apparently communicated with the plaintiff.

After we had waited nearly four hours the undertaker said that the mother had telephoned, and was then on the telephone, and had given strict orders that no autopsy should be held so long as I was present. This statement was confirmed to me over the telephone by the mother herself.

This experience serves to emphasize the great care necessary in taking all possible precautions in dealing with strangers.

Discussion

Dr. Thomas H. Halsted, Syracuse:

I have had only one threatened suit for malpractice, but this one extended over a period of ten years, with several threats from different lawyers and several intermissions of some years, all of which kept me in somewhat of a perturbed frame of mind for ten years whenever I happened to think of it. The case never came into court, nor was there any settlement.

It was a case of intubation for diptheria in a child two years of age, in which the tube descended below the cords into the trachea, requiring, six days later, tracheotomy for removal. Then the tracheal cannula could not be dispensed with, granulations and cicatrization occurring low down. This was in the prebronchoscopic age, twenty or more years ago. Another surgeon in another city, a few years later, did a laryngotomy, the result being worse than ever, with almost complete occlusion of the larynx following his operation. I attempted, when the child was about twelve years old and following the other surgeon's operation, to overcome the laryngeal obstruction by inserting a T-shaped cannula, but at the end of a week had to remove it and be content with a tracheotomy. The patient has worn the tracheal cannula ever since, is now a mother herself, and when I last saw her, three or four years ago, was in excellent general health, her lack of clear voice being the chief complaint. Being an infant at time

of the original operation, the parents had themselves appointed guardians for the purpose of bringing an action and were in a position to sue me at any time until she became of age. However, at the time of my attempted repair operation, when she was about twelve years old, they signed away all intention of holding me responsible for the result of the original intubation, much to my relief, although I was entirely blameless. The proper tube for a child of her age had been inserted, but she evidently had an unusually large glottis, permitting the tube to drop down into the trachea as the pseudomembrane and diphtheritic swelling subsided. Their complaint was that I did not leave the string attached, which was, of course, not the usual practice.

Another case, which however had no legal complication, but might have had had the outcome been different, is brought to my mind by Dr. Shurly's case. A married woman, sister of a lawyer, arranged to have her tonsils removed by me under a local anesthetic. At the time of operation the lawyer brother was present. I was delayed, and instructed my assistant, a capable laryngologist, to inject the pillars with a $\frac{1}{5}$ per cent solution of cocaine with a few drops of adrenalin, while I was preparing myself in the scrub-up room. While I was scrubbing he came in hurriedly and whispered in my ear that he had accidentally injected one side with a 10 per cent cocaine solution. I immediately went into the operating room and did the quickest dissection tonsillectomy I have ever done, first on the anesthetized side, then on the unprepared side, which latter, she said afterward, hurt. The tonsil was removed probably within two minutes of its injection and while the tissues were still edematous from the solution, and there was some bleeding, which was helpful. She was taken at once to her room and soon signs of cocaine poisoning occurred, among other things opisthotonos lasting two or three hours. One or the other of us, together with an internist, remained with her for about four hours, at the end of which time she quieted down and went on to an uneventful recovery, neither she nor her lawyer brother ever learning that anything unusual had occurred. Only the quick removal of the tonsil and the prompt drainage of the tissues saved the patient, and saved us from an unpleasant subsequent explanation, perhaps in the courts. The mistake in the solutions occurred in having both the $\frac{1}{5}$ and the 10 per cent put in glass cups that were identical in appearance, and was a fault of the operating-room technic, but one which has not occurred since. Three years ago, while abroad, I was invited by one of the most eminent laryngologists in Europe to be present next morning at a thyrotomy which he was to do under local anesthesia for epithelioma of one cord. I arrived at about the same time that he

did. The hospital intern injected a 10 per cent solution of cocaine into the skin while the operator was scrubbing up, but unfortunately did not discover the mistake, which occurred precisely in the same manner as mine had, until perhaps after ten minutes had elapsed, and too late to bring about recovery. There have, without doubt, been other similar mishaps, in which a stronger solution than intended has been used with unfortunate result; so many, indeed, that the operator himself should make certain, before injection, that the solution is the one ordered. My own preference is general anesthesia for tonsil operations, and I always employ it unless there are special reasons for doing otherwise.

A CASE REPORT OF LARYNGEAL CARCINOMA; NONRETURN AT THE END OF THREE AND A HALF YEARS. RADIUM TREATMENT; INTERESTING AFTER-RESULT

HENRY HALL FORBES, M.D., F.A.C.S.

CASE REPORT.—An interesting case of destruction of the posterior laryngeal wall in part. Nonrecurrent carcinoma of the larynx treated by radium.

Female, aged forty-five years, born in U. S. On August 20, 1921, the patient was referred to me by Dr. Thompson Sweeney. On examination there was found a laryngeal newgrowth involving the left half of the larynx, intrinsic in type. There was present a loss of voice and dyspnea. A previous history of the removal of a growth several years before this was given to me, and the patient was told it was a papilloma. Under a direct laryngoscopy the picture was most confusing. The mass involved the left aryepiglottic fold and the left false cord, as well as the interarytenoid space; smooth, nonulcerative. My diagnosis at the time was a papilloma, which was confirmed on removal, a few days later, by the laboratory.

On September 20, 1921, the growth had extended down the posterior wall of the larynx. The laboratory report (three specimens) showed chronic inflammation. About this time a tracheotomy was necessary, owing to dyspnea. On November 28, 1921, a specimen removed resulted in the following report from our laboratory.

Nature of Specimen. Tissue from larynx.

Result of Examination. Gross: Specimen measures 5 x 5 x 3 mm. It presents a somewhat wrinkled mucous surface; it is only moderately firm; on section it is brown in color.

Microscopic: Serial sections were prepared of the entire specimen. Many of these sections reveal no further information. In some of them however, there occur areas in which solid groups of epithelial cells are found deeply situated in the fibrous stroma. These cell groups are without lumen and show no recognizable tendency to cornification. Mitotic figures are very scarce. At one spot there is a small ulcer over such an area. The adjacent stroma is rich in inflam-

matory cells. By examination of the series of sections one is assured that these cell groups are not merely infoldings of the epithelium but represent an actual abnormal location.

Diagnosis. Basal-cell carcinoma.

(Signature) W. J. MacNeal, M.D.

The report of this case, I hope, will be of interest to the association, for it brings to us forcibly the question of biopsy, which was brought out at our last annual meeting and freely discussed by many members who responded to Dr. Mullin's paper, "Diagnostic Limitations in Laryngology."

The following are the additional points I wish to bring to your attention (and please note the removal of a newgrowth several years before the patient came to me): The noncharacteristic picture of the laryngeal growth; the number of specimens removed before one was found showing malignancy; the elapsed time, now three and a half years, with a nonrecurrence of the growth, which after the diagnosis of malignancy was treated by radium; finally, the very important point to the patient, and for which I seek your advise and aid, is the loss of tissue involving the right lateral and posterior wall of the larynx to the level of the true cords, the cicatricial contraction involving the true and false cords giving an almost complete stricture of the larynx. Attempt to dilate this contraction, in order to remove the tracheotomy tube, is followed by a part of her food, especially liquids, finding its way into the trachea.

My present experience and reading of the literature teaches me that biopsy is necessary in all doubtful cases. Permission of the patient to operate if the specimen is found malignant, is wise and a safeguard to the patient and to the laryngologist.

During the time of treatment, Dr. T. J. Harris was in consultation and has seen the case recently. Other members of the Association have examined the case: April, 1923, Dr. Emil Meyer; June, 1923, Dr. D. Bryson Delavan; July, 1923, Dr. Chevalier Jackson.

I am unable to obtain the detailed report of the amounts of radium used in the case.

PLEXIFORM NEUROMA OF THE PHARYNX

HENRY HALL FORBES, M.D., F.A.C.S.

CASE REPORT.—Girl, aged fourteen years. The patient was admitted to the Post-Graduate Hospital in New York City in October, 1924, with a history of increasing dysphagia and nasal obstruction. The general condition was fair. Examination of the neck showed a few cervical glands, right, slightly enlarged. The nose was negative: oral examination showed a large, irregularly smooth mass occupying practically half of the faucial pharynx and involving the tonsillar pillar, right portion. The left half of the pharynx was not involved. A specimen taken at this time was reported as a nerve tumor of embryonic origin. The tonsil was removed on the right side and the posterior part was found to be involved in the newgrowth. Later an attempt was made to remove the growth. Under a general anesthetic the greater part of the tumor was removed. The recovery was excellent.

PATHOLOGICAL REPORT. October 29, 1924. Nature of specimen, pharyngeal tumor.

Result of Examination. Gross: There are nine pieces of tissue, the largest measuring 30 x 23 x 8 mm., and the smallest 10 x 5 x 4 mm. All are irregular, pale-pink tissue, semisoft and resilient for the most part and loose in structure, with coarse papillary projections on the free surface. On section there are white and translucent streaks throughout, suggesting fine, twisted, nerve trunks.

Microscopic: Sections from all pieces show the same structure. There is a partial covering of stratified squamous epithelium. Beneath this there is a stroma of loose connective tissue for the most part and in part dense fibrous tissue. Embedded in this are mucous glands and abundant striated muscle fibers. The most abundant tissue, however, is cross-sections of nerves. These appear throughout in various shapes as round, oval or elongated and tortuous. They show highly cellular fibers in parallel arrangement with central denser compressed portions and peripheral sheath. These react to specific stains as nerves react and indicate a remarkable hyperphasia of nerves.

Diagnosis. Plexiform neuroma. Very rare in this location. *Note.* These recur locally.

(Signature) L. H. MEEKER, M.D.

The radium report is as follows: November 12, 1924, $\frac{3}{5}$ mg. needles in growth; $\frac{2}{10}$ mg. needles, 100 mg. hours, in pharynx four hours; December 30, 1924, $\frac{3}{50}$ mg. tubes with 1 mg. block, 3000 mg. hours, outside pharynx, 4 spaces every five hours.

(Signature) G. ALLEN ROBINSON, M.D.

The case I find from our pathologist, Dr. Meeker, to be of decided interest and a report of the pathological findings is being made by the doctor at the meeting of the Pathologists and Bacteriologists being held at the Army Medical Museum, Tuesday afternoon, May 5. Examination on March 11, 1925 showed the pharynx negative.

NOTE BY DR. MEEKER. Clinically this is a plexiform neuroma, but microscopically this is a true ganglion neuroma. The tumor tissue examined in the microscope consisted almost wholly of tortuous nerve trunks of various sizes. These appeared under the epithelium among the mucous glands, invaded the muscle bundles, and were present in the deepest parts of the excised tissue. Nerve fibers and ganglion cells are very numerous and there is no evidence of degeneration.

Dr. Meeker's research failed to find the report of another ganglionic neuroma in this location.

DISCUSSION

DR. WARD J. MACNEAL, New York City:

I wish to thank you for the privilege of the floor and to show some slides. (While showing the slides, Dr. MacNeal made the following remarks.)

Slide I: These sections of the laryngeal tissue from Dr. Forbes' case show that the growth is not a highly malignant thing such as we commonly think of a cancer. If it were in an accessible part of the body a single dose of radiation would probably eliminate it. The interest here, of course, is in the location of the lesion, where it is not by any means easily accessible. Because of the physical difficulty of application it is with much less assurance that one applies radium or *x*-ray to a locality of this sort. The patient seems to be doing very well, but it must be kept in mind that the tumor is of a slowly growing type and as yet it is too soon to be certain of its eradication.

Slide II: This particular pathological specimen is of peculiar interest because it shows the embryonic type of neuroma in which we have elements of nerve fibers and also ganglion cells in an embryonic stage, suggesting the possibility of this tissue developing in either direction. A specimen of this sort indicates that the peripheral nerve tumors are essentially of one group and not distinctly separated into ganglionic neuromas and neurofibromas.

Dr. George B. Wood, Philadelphia:

I want to briefly mention an extremely unfortunate accident that occurred to me just recently. I had a patient with inoperable carcinoma of the larynx, the diagnosis being confirmed by Dr. Fielding O. Lewis. There was a large mass in the right side of the larynx, with more or less edema above it and absolute fixation of the vocal cord on this side. The mass had extended up into the pyriform sinus. There was marked cervical adenitis. On account of some inspiratory dyspnea a tracheotomy was done, from which he recovered, after a few days of reaction, very well; in fact, there seemed to be less edema of the throat, less swelling of the glands and less pain after the tracheotomy had been done.

Without hope of final cure, but more for the sake of doing something, *x*-ray treatment was started. The night after the second dose he developed a chill, followed by a rise in temperature, which soon took on a septic type. The glands of his neck enlarged, first on the right side and then on the left, until in two days the neck was swollen out beyond the chin line. There was marked increase in the edema of the esophagus, so that he was swallowing with difficulty. Deep incisions into the neck by a general surgeon found nothing but edematus tissue. He died on the fifth day after the last treatment, with a temperature of 107°.

I believe that in this case there was an unrecognized periesophagitis as the result of perforating ulceration of the esophageal wall by the carcinoma, and that this infection, started into great activity by the *x*-ray treatment, produced a deep esophageal abcess, though we were never able to reach it by our external incision.

Dr. D. Crosby Greene, Boston:

Our experience at the Huntington Memorial Hospital in Boston has not been favorable as regards the cure of laryngeal carcinoma by radium. We have had beneficial results in a considerable number of cases in the way of palliation and retardation of the growth, but I

know of only 3 cases out of the total number seen at the clinic in the past ten years in which the treatment has apparently been curative.

One of these was a large adenocarcinoma, arising from the right arytenoid region, which obstructed the respiration so seriously that a tracheotomy was done before any other treatment was considered. Subsequently a biopsy was done, and the tumor radiated by heavy doses of radium emanation seeds inserted into the center of the growth. After a stormy and prolonged reaction the tumor disappeared, and today, five years after the treatment, there is still no sign of recurrence. The pathological diagnosis was made by Dr. J. Homer Wright, of the Massachusetts General Hospital.

In the second case in which radiation was effective a partial excision had been done and the patient was sent to our clinic with the cavity of the larynx exposed by a thyrotomy incision through which the growth could be seen involving the posterior part of the larynx. In this case screened tubes of emanation were applied to the surface of the growth in a series of treatments extending over three or four months. It is now more than five years since the treatment was given and the patient still shows no recurrence. The pathological diagnosis in this case was squamous-cell carcinoma.

A third case, which might not legitimately be classed as laryngeal, was that of a large squamous-cell cancer growing from the lateral wall of the hypopharynx and projecting over the larynx so as to completely hide the laryngeal cavity from inspection with the laryngoscopic mirror. This case was apparently also cured by the method of seed insertions and has remained without evidence of recurrence for three and a half years.

These cases, however, represent a very small percentage of the total number treated, perhaps 2 or 3 per cent, in which the large proportion fail to show cures or even marked benefit. Many cases are slowed up and lives prolonged by means of radiation, but in operable cases we always advise operation rather than radium.

When it comes to the question of what cases are operable or inoperable there is room for a considerable variation in judgment, and this is also true as to the type of operation in a given case.

I feel that operation, as contrasted with radium treatment, is the only thing to be tried in operable cases.

Dr. William V. Mullin, Colorado Springs:

Dr. Forbes kindly referred to my paper before this Society last year and to the discussion brought out at that time. I am sorry Dr. Wood has not the pathological report of his case. If it were

available, we might make some comparison as to the degree of malignancy existing between the two cases. In one we have undoubtedly a case of low-grade malignancy, and probably in the other one a very high grade of malignancy, and that, it seems to me, must be the solution of the problem. In this respect the work of Dr. Broder, of Rochester, Minnesota, seems to be getting more valuable to us all the time, and that is in the grading and cell differentiation of the epithelial mass.

I believe Dr. Forbes believes in biopsy in all cases. Then, if one takes that stand, you must play it on the law of averages. I believe if one does that and plays it that way, by the law of averages, he will lose out. The harm from biopsy, unless you operate immediately, may offset the good that is derived in the occasional case from it.

I believe the teachings of Dr. Bloodgood where he says that the one to do the biopsy is the surgeon who is prepared to do the operation immediately, otherwise it may lead to a rapid spread. This may have applied to Dr. Wood's case. The reaction from the *x*-rays may have caused flaring up of this patient's condition.

I was most interested in the plexiform neuroma because I have recently had occasion to comb the literature for information on neoplasms of the oropharynx, and this is the first time I knew such a tumor existed.

Dr. Fielding O. Lewis, Philadelphia:

I was glad to hear Dr. Greene say what he did about the treatment of laryngeal carcinoma. My feeling is that so soon as we can convince the general practitioner, as well as the specialist, that the only form of treatment of laryngeal carcinoma is surgery, when it is operable, the more cases we will be able to save.

We have a very active service in the Radiological Clinic of the Philadelphia General Hospital, and the vast majority of cases of laryngeal carcinoma who report for examination are found to be inoperable. The histories of these cases reveal that many months of valuable time are lost by temporizing with antileutic treatment, radium, *x*-ray and other measures.

As to biopsy, I am of the opinion that it should be made in all cases. Many cases which I have seen, that clinically were malignant, were found to be otherwise by biopsy and I have seen just the reverse. Our method is to get consent of the patient for operative treatment, perform a biopsy, and if malignant, operate immediately.

Dr. Gordon B. New, Rochester, Minn.:

While I have one patient, a man, seventy-two years of age, who was not in a condition for any operative treatment, who is well now four years and three months after the use of radium for a squamous-cell epithelioma, grade III, involving one side of the larynx, I feel that this is an exceptional case, and all patients with cancer of the larynx in which the condition is surgical should be operated on, either by thyrotomy and excision of the growth in very early cases, or by a laryngectomy in the more advanced ones.

Dr. John E. Mackenty, New York City:

I might say that the longer I treat cancer the more radical I become, because things come up once in a while that do change one. I did a thyrotomy seven years ago and the man is dying of cancer of the larynx now. I believe that if the cancer is on the surface of the cord, not deeply situated and occupying a small section of the cord, a thyrotomy should be done, though you cannot promise a patient a cure. In several incipient cases I have found subsurface extensions backward and forward to points beyond the probable limit of thyrotomy operation. That scared me a good deal on thyrotomy.

Of course, there are cures for cancer by radium that are very interesting, but they have the effect of making people think that radium should be tried in all cases. I have had the same experience as Dr. Lewis in seeing a great many cases of cancer of the larynx. Unfortunately most of them are inoperable. They come too late. Many come with the history of treatment by radium and sometimes multiple biopsies.

Dr. Charles J. Imperatori, New York City:

I would like to ask Dr. MacNeal whether or not he has been able to correlate the degree of malignancy with the clinical and pathological findings.

Dr. Vilray P. Blair, St. Louis:

What is the opinion of this Association in regard to the treatment of cancer of the larynx by radiation from the outside? Personally, I do not believe it is rational. I believe it has been determined by radiologists that the larynx cartilage is more susceptible to the radiation than is the carcinoma, and this seems to be borne out by clinical observation. In some cases the cancer seems to have been stimulated by the radiation; in others the patient has had an abscess and a lot of trouble; sudden death from asphyxiation has followed the radiation.

I believe we will never be in a position to discard biopsy; but in many cases it is preferable to do it by laryngeal fissure, to be immediately followed by surgical removal or radium if indicated.

There is one type of carcinoma of the larynx which we do not think is worth while operating on under any circumstances. Then it is our belief it is a good place to use radium. This may also be true of basal-cell carcinoma.

Not only is biopsy at times necessary to confirm the diagnosis, but it is often desirable to know the histologic characteristics of the individual growth before deciding on the type of treatment.

Dr. Lee W. Dean, Iowa City:

I am glad that the question of performing a biopsy has entered into this discussion. In my judgment this is far more important than the question of the use of radium in the larynx. In the University Hospital, as soon as a patient suffering from a tumor of the nose, jaw, pharynx or larynx enters our service and we feel that the patient is going to be guided by our advice as to operation or treatment, if there is a probability of the tumor being malignant, usually we perform a biopsy, cauterizing the wound at the time of the removal of the piece. We have been impressed by the work of Broder, and feel that before we can properly advise the patient as to the particular type of therapy needed in his case it is necessary for us to have not only a knowledge as to the kind of growth that we are dealing with, but of the malignancy of the growth.

I have not seen a bad result from biopsy and I think the dangers of biopsy are exaggerated. Unless we are certain as to the type of tumor that we have in the larynx we perform a biopsy. If the pathologist returns a diagnosis of a malignant growth the information is of value. If, on the other hand, the pathologist returns the opinion that the growth is not malignant, and clinically it is malignant, we disregard the pathological report. In other words, a positive report is of great value and a negative report should not be depended upon.

Dr. Henry L. Swain, New Haven, Conn.:

Dr. Wood says in some of these cases that we think we do the best for, we sometimes err. From an error I once made, as well as from hearing the discussion today, there is no doubt in my mind as to how I should feel about treating cases with radium. I had a case of what seemed to be very operable epithelioma of the larynx. The surgeon at my suggestion did a very nice hemilaryngectomy, removing all the cancerous mass. In order to make sure that everything was done

to ensure success I felt we ought to radiate the region. We got no end of reaction in the cartilage and the patient died from no earthly reason other than that I tried so hard to do for him the best thing possible. If he had been allowed to heal up naturally I think he would have been all right.

Yet when one sees how much radium can accomplish, one cannot help but have the lively hope arise that sometime we are going to know how to use radium so that we can apply it and have it help us in the final healing up of our cases.

Dr. Forbes did succeed splendidly, but he must now get rid of the contracting adhesions and that may be almost as hard work as the removal of the original growth.

Regarding the plexiform neuroma, like Dr. Mullin, I have gone over a great many case histories, but I have never known there was such a thing and am delighted to be so clearly informed.

Dr. Harmon Smith, New York City:

The question of biopsy having been brought up, I beg the privilege of saying a few words upon this subject.

Within the week I have had occasion to see a man of about fifty, a traveling salesman, who gave a history of hoarseness for five years, but not of serious import to him until about a month previously. Examination showed a warty growth of one cord, no fixation, no pain, no glandular involvement and with no evidence of malignancy other than prolonged hoarseness. I firmly believed it to be only a papilloma, but advised biopsy. The specimen was unquestionably epithelioma, diagnosed as such by Drs. Eggston and Jonathan Wright. Since then Dr. Mackenty has removed the larynx. Here biopsy was positive, though the clinical evidence was in question.

Another instance, in a man, eighty years of age, came to me a month ago, with a similar history of hoarseness for six years. Examination of a specimen showed it to be carcinoma, and as high blood-pressure, partial paralysis and other conditions argued against operative procedure, I turned him over to the radium expert for treatment.

I believe that biopsy should be resorted to in all cases ere operative measures are employed, for unquestionably there will come a time when a larynx will be removed for a benign tumor irrespective of the ability of the laryngologist to diagnose tumors of the larynx. Whether the examination of the specimen is made at the time of the operation or preceding it, there should be corroborative evidence of the microscope to uphold the clinical diagnosis of the observer.

DR. MACNEAL:

In regard to the question asked, I would say that from our own cases we have no analysis to present at all. It is very well known that the carcinoma of the larynx is of a slow-growing type which metastasizes late in the disease, if at all. The danger to life is local rather than general. As I tried to bring out, such a type of carcinoma in an accessible part of the body, such as the skin, we would treat with confidence by radiation.

In general the malignant tumor of the larynx is of low-grade malignancy. This particular one which Dr. Forbes is presenting is of unusually low-grade malignancy because there was not even cornification found in the little masses of cells down beneath the basement membrane. It corresponds more nearly to the relatively benign basal-cell carcinoma.

The question of biopsy interests me a little bit. I should say that those men who do not practise biopsy would do well to submit their surgical specimens to a pathological examination as a check upon their precision in diagnosis.

On the question of radium, if I may say a word about that, I am by no means convinced that it is the beneficent agent which the public imagine. I have contributed one article to the literature indicating that radium occasionally gives rise to serious consequences.

The attitude toward radium expressed by some of the gentlemen here resembles in a way the attitude of the laity in their fear of surgery. The layman realizes that the knife is dangerous in the hands of the injudicious and unskilled. Radium is in the same way dangerous in unskilled hands.

DR. FORBES (in closing):

In closing the discussion, first we will pass over the plexiform neuroma, as this seems to be the only one on record. I wish to thank Dr. McNeal, the director of our laboratories, for the presentation of the pathological specimens in connection with the two cases.

I thank all who contributed to the discussion of the carcinoma of the larynx. The first point I wanted to bring out was the fact that under careful observation and after consultation with other members of the staff, biopsy having been performed, having agreed that we were dealing with a papilloma (from the laboratory report) and having treated its recurrence, a subsequent specimen was taken, getting the diseased as well as the normal tissue, and there was a negative diagnosis. Finally, when the growth had increased and at the time the diagnosis of carcinoma was made, we had an inoperable case, the

growth at this time extending down the posterior wall of the larynx into the pyriform sinus, involving the soft tissues in the pyriform sinus and extending into the esophagus. I certainly at that time considered it an inoperable case and so we used the radium.

The other point, where no one has seemed to help me, is that we have a woman whose larynx is partially destroyed by disease. I would like to take the tracheotomy tube out so she can go back to her vocation which was selling goods in a shop. Several men have seen the case. I sent it over to Dr. Jackson in Philadelphia, Dr. Harris has reviewed the case at various times and all have advised me to wait for at least four years. It is now three and a half years since I undertook this case and the woman is getting impatient. I really would like a suggestion in reference to how I can build up her larynx, have it act normally and allow the removal of the tracheotomy tube.

I think that some of the members have heard one or two papers that I have read on the use of radium, and realize that, like most others, I take the position that radical surgery in early cases is wise. In the question of the use of radium as a general proposition, I feel that we must still experiment with it in our inoperable cases, but I have no enthusiasm for its use in operable cases.

I favor biopsy in all cases where permission to operate has been obtained. Some years ago a patient who had a new-growth on the right cord came to my office. The case had passed three excellent men in New York City, who had failed to make a biopsy and had given a diagnosis of nonmalignancy. The case came to me and I suggested that a specimen be taken, and it proved to be malignant. Dr. Mackenty performed a hemilaryngectomy, which was followed by two or three postoperative radium applications.

The impression I created of advocating radium in cases of carcinoma of the larynx reminds me of a paper I read on lung abscess at the Tenth International Congress in Paris, and gave statistics at the time of some 68 cases of lung abscess following tonsillectomy gathered in the United States. After I read the paper, on either that day or the next, an Englishman came to me and seemed to have a great deal of sympathy for me. He said, "I am sorry, Dr. Forbes, it seems impossible that one man, and apparently one with experience, should have had 68 abscesses of the lungs following your tonsil operations."

So please do not think that I believe in using radium alone. I advocate surgery when possible, but in later cases where surgery is contraindicated I feel that the patient should be given the benefit of radium.

A CASE OF RHINOSCLEROMA IN AN AMERICAN-BORN PATIENT

GEORGE B. WOOD, M.D.

ALTHOUGH a fairly large literature on rhinoscleroma has been published, especially in foreign countries, since the first description of this disease by Hebra in 1870, it is for us in America one of the least common of the specific diseases of the nose and throat. It is seen more frequently in Central Europe, especially in those countries neighboring on the Baltic and Black seas, and it is probable that the disease has spread from this area by emigration to other portions of the world.

Walter J. Freeman, in 1900, said that before 1895, 23 cases had been reported in Central America and only 6 in North America, and up to the time of the publication of his paper had never been seen in a native American. Wright and Smith state that it has been found, so far as is known, exclusively among those of foreign birth. Herman Goodman, however, states that some cases have been reported in native Americans and 1 case of scleroma of the larynx as occurring in a native American negro.

Rhinoscleroma is very insidious in its onset and for years the patient may be unaware of any serious condition, bothered perhaps only by an excess of nasal discharge and crust formations. The initial lesion usually starts deep in the nose and slowly spreads both anteriorly and posteriorly, gradually involving the pharynx and larynx, as well as the external nose. There is little pain until ulceration of the pharynx causes more or less sore throat or fissuring of the vestibule of the nose gives rise to considerable discomfort. Sooner or later the characteristic deformity with intense hardness of the external nose brings the patient to realize that he is afflicted with something more than ordinary "catarrh."

In the early stages the histopathology of rhinoscleroma is somewhat similar to that of the granulomata. The stroma of the fibrous

tissue is infiltrated with lymphocytes and plasma cells, and the elastic tissue more or less completely destroyed. The collagen fibers are increased and thickened, and the gradual development of firm fibrous tissue gives the characteristic hardness to the diseased structures. The pathologic diagnosis is usually easily made because of the presence of the so-called foam cells, the cells of Mikulicz. These peculiar cells are frequently crowded with the rhinoscleroma bacillus, though the bacillus is also seen extracellular. Hyaline bodies are more frequently met with than in other forms of granulomata and possess the usual characteristics of the so-called Russell bodies.

The importance of the bacillus of Frisch as an etiologic factor has apparently not as yet been positively proven. This organism is a Gram-negative, encapsulated bacillus, closely related to Friedländer's and the Mucosus capsulatus, from which it is distinguished only by its ability to break up sugar with gas formation.

In 1870, Perkins, after considerable animal experimentation, failed to produce any condition resembling rhinoscleroma and came to the conclusion that this bacillus had no etiologic relation to the disease and was only a secondary invader. As far as I have been able to ascertain, the disease has not been reproduced experimentally in any animal or by accident in any human being.

On the other hand, Goldzieber and Neuber, Gali-Valerio and other observers have demonstrated a positive compliment-fixation, and C. H. Bailey, after a careful serologic study of a case of rhinoscleroma, demonstrated conclusively that the blood serum of his patient contained compliment-fixation antibodies, not only for its own strain of the bacillus, but also for the rhinoscleroma bacilli of other patients. Bailey also showed that this compliment-fixation could be demonstrated with Friedländer bacillus, but not to so high a degree as with the rhinoscleroma bacillus. Also that, coincident with a clinical improvement under roentgen-ray and radium, there was a diminution in the complement-fixing power, so that he very strongly favored the view that the rhinoscleroma bacillus was the etiologic factor in this disease.

Certain it is that the confirmation of our diagnosis, when a biopsy cannot be obtained, depends largely upon the finding of the

bacillus of Frisch in the blood coming from an incision in the diseased tissue.

Report of Case.—M. J. S., male, aged twenty-four years, Trenton, N. J., presented himself for examination on October 18, 1924. His father and mother were born in Austria, but came to this country before the birth of the patient. There was no history of tuberculosis or cancer in the family, nor any condition resembling that from which the patient was suffering.

The patient's general health had been, on the whole, good. He had had scarlet fever and pneumonia, but no operations or serious accidents. About five years ago he first noticed trouble with his nose, consisting chiefly in the formation of hard crusts in the left side. Two or three years later a similar condition developed on the right side. During this time he had had no sore throat. Gradually he began to have difficulty in breathing through his nose, increasing until nasal respiration was practically impossible. About five or six months previous to the examination, he began to develop sore throat and hoarseness, with distinct tenderness of the external nose. His general health, except that he has lost about 12 pounds in the last three months, had been good. There was no history of venereal disease.

Examination. The general appearance of the patient was that of a healthy-looking young man, with no outward signs of disease except that immediately surrounding his nose. The lungs were normal, with fair equal expansion, no râles or areas of percussion dulness and good vesicular breathing throughout. His heart was normal in position and there were no murmurs. His abdomen was negative. There was a slight blepharitis marginalis.

The whole of the nose below the nasal bones was slightly swollen, normal in color, with an unusually smooth surface. On touch it was hard, giving a resistance like that of cartilage, and was distinctly tender. Both nostrils were contracted, the margins thickened and the slight crusting from the fissuring completely excluded both openings. Just above the margin of the left ala was a small, elevated, somewhat reddened, slightly nodular growth about the size of a split pea. The rigidity of the nostrils was so great that it was impossible to examine the interior of the nose. The hardness of the tissues extended down into the upper lip for a half inch and gave the feeling to palpating fingers as though the lower parts of the nostrils were surrounded by a ring of bone. There were no lesions to be found in the mouth.

The appearance of the posterior pharyngeal wall and fauces is

difficult to describe. There was apparently superficial ulceration, without much destruction of tissue covering the right side of the posterior pharyngeal wall just back and below the edge of the velum palati. There was distinct distortion of the posterior pillars of the fauces, especially on the right side, though the tonsils themselves did not seem to be involved. The edge of the soft palate was thin and unusually tense and only a small stump of the uvula was present. The pharyngeal wall was covered to a considerable extent with inspissated mucopurulent secretion which was apparently coming from the back of the nose. As far as could be seen, this condition extended up into the nasopharynx. Below the eroded area the mucous membrane was thickened and drawn into ridges by scar tissue.

The epiglottis was greatly distorted, being thickened anteroposteriorly and drawn backward and downward over the laryngeal opening, making it impossible to see the interior of the larynx. A glimpse of the arytenoid bodies could be obtained on each side of the contracted epiglottis and they seemed to move freely on phonation.

His temperature was normal or subnormal. The urine examination was negative. The red blood cells were 3,860,000; hemoglobin, 90 per cent; white blood cells, 8200.

Cultures made from the nose showed staphylococcus, pneumococcus and a bacillus of the mucosis capsulatus group, which was probably Frisch's organism. Examination for lepra bacilli was negative. The blood Wassermann was negative.

The pathologic report of the piece of tissue removed from the floor of the left nostril was as follows: The specimen examined is composed principally of fibrous tissue with a small round-cell infiltration. There was a noted absence of elastic tissue and the general appearanc suggested old-scar tissue. The fibrous tissue, however, was arranged in bands separating the infiltrated areolar tissue into islands. In these islands were many small round cells, and scattered throughout were large vacuolated cells of the Mikulicz type, containing a short Gram-negative rod-shaped organism arranged around the periphery of the cell. None of the so-called Russell bodies were seen. The pathologic diagnosis is rhinoscleroma. The specimen was first examined by Dr. Paul, pathologist to the Howard Hospital, and later by Prof. Allan J. Smith, of the University of Pennsylvania.

Note. The diagnosis of this case at first was uncertain until it was cleared up by the biopsy. Syphilis was ruled out by his history and a negative Wassermann, and by the fact that he had been treated for this disease before coming into my care. Leprosy was thought of, but

not considered seriously, and excluded when the bacillus could not be found. For a while the condition was supposed to be lupus vulgaris, chiefly because the dermatologist said it was.

Treatment. An attempt was made to restore the patulency of the nostrils by removing a piece of tissue from the base of the left nostril and placing in each nostril rubber drainage tubes which were kept *in situ* for several weeks. The nose was cleansed with weak Dakin solution, followed by dichloramin-T in oil. He had two *x*-ray treatments, and then, at the suggestion of my assistant, Dr. Hunter, he was put on antimonium potassium tartrate, injected intravenously. A 1 per cent solution was used and 5 cc. given daily for twenty-three days, the dose being increased a drop a day until he was taking 10 cc. Following the last injection, on November 28, 1924, he became nauseated, showed considerable reaction and the injections were stopped. At this time there was distinct evidence of improvement. The nodule on the left ala had almost disappeared, the soreness of the nose was much less, the nostrils were sufficiently open for nasal breathing when kept free of crusts, and the throat condition was giving him very little discomfort, though appearances were only slightly altered. The very slight inspiratory dyspnea which occasionally bothered the patient at night when he first came into the hospital, had almost entirely disappeared. He left the hospital after almost two months' stay, the discharge note of the resident being "patient very much improved."

On February 19, he was readmitted into the Howard Hospital for further antimony treatment. His condition at this time was about the same as when he left the hospital, except that the reddened area above the left nostril had extended somewhat downward toward the tip of the nose. This time we used a preparation of antimony put up by Hynson, Westcott & Dunning for intravenous use, called antimonythioglycoamid. This was given intravenously, starting with a dose of 10 cc.; two days later, 15 cc. He returned home to Trenton to continue the injections by his home physician.

On April 7 his condition was about the same as it was two months ago. He did not feel that the injections were helping him, and he is now undergoing *x*-ray radiation at two- or three-week intervals.

When I first started to report this case I believed that the rather marked improvement in his condition that occurred during his first stay in the hospital was due to the antimony injections, but at present I am somewhat skeptical. The only reported success in the treatment of these cases has been with radium and *x*-ray. G. M. McKee makes a rather positive statement that the *x*-ray and radium offer the best

and perhaps the only means of curing this disease, and he says, furthermore, that the cure is absolute and permanent. Bailey also mentions the fact that in the case which he reported there was clinical improvement under the use of *x*-ray and radium. It may, therefore, very well be that the improvement which we noted when this patient was first in the hospital resulted from his *x*-ray treatment and not from the antimony injection.

Bibliography

1. Freeman, Walter J.: A Case of Rhinoscleroma, Ann. of Otol., Rhinol., and Laryngol., May, 1900.

2. Wright and Smith: Text-book of the Diseases of the Nose and Throat, 1914.

3. Goodman, Herman: Rhinoscleroma, New York Med. Jour., 1922, cxvi, 391.

4. Perkins, J.: Infect. Dis., 1907, iv, 5.

5. Goldzieber and Neuber: Centralbl. f. Bakteriol. 1st abth. orig., 1909, li, 121, and Gali-Valerio, Ibid., 1910, liii, 477.

6. Bailey, C. H.: Serologic Reactions in a Case of Rhinoscleroma, Jour. Cutan. Dis., 1919, xxxvii, 447.

7. McKee, G. M.: Rhinoscleroma and the Roentgen-ray, Am. Jour. Roentg., 1917, iv, 180.

Discussion

Dr. Harmon Smith, New York City:

In my clinic and that of Dr. Jonathan Wright, at the Manhattan Eye, Ear and Throat Hospital, about the years 1908 to 1909, there were 5 cases of rhinoscleroma. These were all verified by the microscope. We both turned over these cases to Dr. J. H. Güntzer for experimental purposes. He made a vaccine from the combined bacilli of Friedländer, Frisch and Abel, and administered it to these patients without apparent results. *X*-rays and other medications had also been employed. However, 1 case to whom the vaccine had been given went out West for a number of years, I believe five, and when he again presented himself for examination there had not only been no progress in the nose and larynx, but apparently an inhibition of the disease. The other cases were lost sight of. As this disease is ordinarily a progressive one, it is reasonable to suppose that some benefit had resulted from the vaccine.

When Wright and Smith was published, in 1914, there had been

reported no definite case of schleroma occurring in those born in America. All authenticated cases had occurred in those from the regions mentioned by the author and gave a family history leading to the belief that inheritance played a part.

DR. WOOD (in closing):

I have nothing further to add except that I understand, not from my own experience but from reading of the experiences of others, that the prognosis in this case is not absolutely hopeless. Some do spontaneously recover or remain in *status quo* for a very long time. This case certainly did show very marked improvement while it was under the antimony treatment; whether it was *x*-ray or antimony, I do not know.

THE SIGNIFICANCE OF THE SCIENCE OF SPEECH CORRECTION

MAX A. GOLDSTEIN, M.D.

SPEECH correction, handicapped and distorted by charlatans, commercialized stammering institutes and inadequately qualified teachers of voice, has at last reached the dignity of a science, due largely to the earnest and untiring efforts of such medical pioneers as Kussmaul and Gutzmann, Flatau and Avellis, Zwaardemaker and Mygind abroad, and Bluemel and Blanton, Martin and Greene and our own colleagues, Kenyon and the late George Hudson Makuen, in America.

From the time that Demosthenes, the silver-tongued orator of Greece, cured himself of stammering by juggling handfuls of pebbles in his mouth, to almost our own era, when Dieppenbach, in 1841, proposed an operation for resection of the tongue for the radical correction of stuttering, literature and history have jumbled facts and fancies associated with these human imperfections into a chaotic mass. The stammerer and the aphasic have stumbled through the ages, beset by accusations of witchcraft and mysticism, suffering as the scapegoats of ignorance and fanaticism and ostracised from social intercourse by the mental impotence and helplessness of their fellows to devise ways and means for overcoming such defects.

As knowledge was unfolded in anatomy and physiology of the speech mechanism, in neurology and the significance of cerebral localization, in psychology and the relation of mental to physical stimuli, the fundamental principles were created for the establishment of a new science—the study, classification and correction of defects in speech.

It is not the purpose of this paper to trace the evolution of this comparatively young science through its period of struggle and misunderstanding. Let us rather view it today as a healthy young

structure, built by sincere workers in medicine and pedagogic science of a substantial mass composed of anatomy, physiology, neurology, psychology, the physics of sound, the art of expression and the philosophy of language.

It still remains for laryngology, when convinced that correction of defects in speech has actually attained the scientific dignity which we claim for it, to adopt this young offspring of the older sciences as one of its own working forces. Here is a real and almost made-to-order instrument to add to the armamentarium of the laryngologist which, when well used and properly directed, will accomplish much for humanity. More than 5 per cent of all school children in the United States have some form of defect in speech, including stammering, stuttering, lisping, lolling, "baby-talk" and various aphasias. This field of operation is numerically larger than perhaps all other activities in laryngology combined. Yet American laryngologists who have actively interested themselves in this cause are few in number. The correction of defects in speech is as legitimately a field in laryngology as are aphonias due to paralysis of the recurrens or nasal obstructions due to deflections of the septum. These speech defects are as tangible as laryngeal neoplasms and are as amenable to correction. Stammering, defined as a speech inability due to spasmodic or incoördinate action of the muscles of respiration, phonation or articulation, is largely a laryngological problem.

We seriously study the pathology of the recurrent laryngeal nerve in tabes, but disregard the same nerve impulses when they produce a stammerer. We operate plastically and beautifully for harelip and cleft-palate and discharge our obligation when our surgery has been successfully completed, overlooking the important utilitarian needs of the child to acquire motility of the palate, proper resonanace and tone-displacement in voice-production throughout his school period. We punctiliously inform the parent of a child from whom masses of adenoids and tonsils have been removed that the patient is now free of mouth-breathing causes, mushiness of speech and local foci of infection, but we utterly disregard the psychology of the stammerer who has the same right to an education and who, with his speech handicap, hesitates to recite his lessons, to speak to his fellow-pupils and his friends and

whose mental and psychological nature constantly undergoes depressions and tortures, and who, reprimanded by teacher and parent, discouraged by poor scholarship, frequently shuns the schoolroom and becomes a charge of the truancy courts.

Every laryngologist has had occasion, in his own experience, to see many cases of "baby-talk." Intelligent mothers, when their attention is directed to this early defective and unintelligible form of speech, will remark, "Oh! Doctor, isn't it cute?" Instances have been brought to my attention where experienced laryngologists have replied to this remark with a graceful gesture and a look of wisdom: "Don't worry, madam, the child will outgrow it."

Last year two Czecho-slovakian children, a girl, aged nine years and her younger brother, aged seven years, were referred to me and reported as congenitally deaf. On first examination this seemed apparent, but on more careful study it was found that these children heard practically everything that was said to them, but were unable to produce what they heard in speech. We made the diagnosis of "word-deafness," a condition somewhat analagous to color-blindness and explained theoretically by the fact that the Wernicke center in the cortex (speech-hearing center) and the Broca center (speech-producing center) were both intact, but that the connecting tract or fibers between these centers were undeveloped or imperfectly stimulated. After one year of intensive pedagogic training similar to that applied by speech-methods to the congenitally-deaf child, these children have acquired a working vocabulary, speak spontaneously, and in another year or two, will be sent back to the normal schoolroom.

The more profound field of the laryngologist includes laryngectomy. With the total extirpation of the larynx, we might conclude that all possibility of speech in such a case had been forever lost. I cite a laryngectomized case referred to us by Dr. Vilray P. Blair one year after operation. Six months of special pedagogy enabled this man to speak *with voice*, and *without any artificial means whatever*, so that he could be heard across a twenty-foot room.

In the reconstruction work after the war many unusual and interesting cases came to our attention, and it is gratifying to report that a wide field of practice and usefulness was developed in the

rehabilitation of soldiers who had been shell-shocked, shell-concussed, shrapnelled in the speech areas of the head, in the jaws, in the mouth and in the larynx, and who, by the painstaking care of well-trained teachers and guidance of the laryngologist experienced in this work, can be restored to a practical and utilitarian status.

These instances should suffice to substantiate my plea that the correction of defects in speech affords even the most ambitious among us every facility for profound and dignified research and a practical application of many experiences which we have gleaned in general laryngology. This science is worthy of every support and upbuilding which laryngology can offer; its best interests have been served by a few; let the laryngologist in every community interest himself in the segregation, in the classification, in the pedagogy and in the uplift of the large group of cases of defects in speech to be found everywhere, so that laryngology may share in the glory and development of this splendid and useful young science.

Discussion

Dr. John E. Mackenty, New York City:

I cannot let this paper go by without some comment on the work Dr. Goldstein is doing. I have some acquaintance with the speech-defect work in New York City and I must say that the men who are doing this work conscientiously and effectively, as Dr. Goldstein is doing, are uplifting a lot of derelicts from a terrible life.

I do not think any body who has not seen these people before and after realizes just what an uplift they get. I could quote dozens of cases where patients have been down and out without means of support, young people of very good and sometimes very high intelligence, who have been cured of the speech defect and taken responsible positions where they have earned large salaries. Some of them have come up from being anarchistic in their tendencies. Their hatred of mankind was cured by the curing of their speech defects.

In regard to persons having acquired speech after a laryngectomy, I have three who have acquired stomach speech and one other who is beginning to acquire speech. They can talk audibly, that is,

make themselves heard, in a room as big as this and larger. They do not need any artificial aid. I shall show you the best of the four tomorrow. This man taught himself. His example has affected the others so that other men have taken it up and have now acquired very good speech. One of these can count up to twenty on one stomach full of air without refilling. If we had others who would make a business of training these people as Dr. Goldstein is doing, we might make a lot of them speak without the use of the artificial larynx.

SINUSITIS AND SWIMMING: FURTHER OBSERVATIONS OF ETIOLOGIC FACTORS, WITH SPECIAL EMPHASIS ON MAN'S LACK OF ADAPTATION TO AQUATIC HABITS

H. MARSHALL TAYLOR, M.D.

In recent years the advances in medicine along bacteriological and immunological lines have opened up such tremendous fields for research that they have to some extent overshadowed some other branches of medicine of paramount importance and tended to relegate them to the background. Biology, the fundamental study of all phenomena of life and its manifold relations, is one of the branches of science that cannot be ignored. We must always bear in mind, as Dendy[1] has said: "Man derives his existence from the same ultimate sources and is subject to the same natural laws as all the other living things with which he shares the earth." The literature dealing with the subject of infections of the upper respiratory passages caused by swimming has, to a large extent, ignored the fact that man has few structural adaptations for an aquatic environment, but has in a large measure dealt with only the one etiologic factor, that of contaminated water.

My interest in other causative factors of sinusitis from swimming has been increased in the last few summers when I learned that a number of my patients had only been patronizing a pool which was fed by a spring having a flow of three thousand gallons a minute, while other cases gave histories of only using a pool which had a flow of thirty thousand gallons a minute. Chemicals, which are often alleged to be irritants to the nasal mucous membrane, were not used in either one of these pools on account of the low bacterial counts found after repeated examinations by the Florida State Board of Health. Bacterial examinations of samples collected from both of these pools on heavy bathing days did not show more than 150 bacteria per cubic centimeter, and showed no evidence

of contamination. In other words, the cases coming under my observation bathed in relatively pure spring water, having a temperature of 71° F.

My purpose in mentioning these two pools, specifying the large amount and quality of water supplied and its relative degree of purity, is primarily to emphasize that factors other than contaminated water play a significant rôle.

Fenton[2] states: "Swimmers and divers introduce the following factors which interfere with the protective mechanism of the nasal mucous membrane: Destructive action of plain water upon cells, by osmosis drawing out saline elements, causing edema and acidosis of cells, loss of ciliary activity and eventual cell death. This 'irritative action of water' causes lowered local resistance. The specific protective substance of the sinus secretion is diminished and eventually lost by being forcibly washed away and later inhibited by the edema and chemical degeneration of the secretory cells."

The experiences of others, as well as my own, have aroused my interest in etiologic factors other than contaminated water—one in particular, man's lack of adaptation to aquatic habits. My review of the subject has taken on many and varied aspects and has brought to light several questions which seem to the writer worthy of consideration. It is not my present purpose to set forth any new discoveries, but merely to summarize certain structural adaptations found among the animals whose normal habitat is water, with a view toward a better understanding of the condition in man.

It has occurred to the writer that sinus infections secondary to swimming evidently come from one or both of the following sources: Either foreign bacteria may gain entrance to the deeper portions of the nasal apparatus and conjoined structures; or bacteria normally and constantly present in this region may be allowed, by a lowered resistance on the part of the individual, to multiply to pathological proportions.

Keeping these possibilities in mind, another question arises which originally led us to the investigations which we will summarize in this paper. Why is man so suceptible to sinus diseases, while lower animals breathing air as man does and living constantly

in the water do not encounter these same difficulties? What have air-breathing aquatic animals to protect them from sinus infection, which man is so likely to contract when he places himself in their normal environment and practises their activities?

The plan of respiration for all air-breathing animals is fundamentally the same, there being no essential difference in the epithelium lining their respiratory tracts. It is the usual stratiform flat epithelium lining the nasal vestibule which gradually assumes the structure of true respiratory mucous membrane, that is, the stratiform ciliated cylindrical epithelium. The latter, a specialized type, is designed to keep moist the tracts through which a current of air is constantly passing, to warm the air, to secrete a mucus which is inhibitory to bacterial growth or bactericidal, and in which the bacteria are enmeshed and are carried by the wavelike motion of the ciliated epithelium to the pharynx and esophagus to be disposed of.

We cannot look for the difference between man and the aquatic animals here. The difference lies in the fact that those animals, which are highly modified to live in the water, can at their will or involuntarily close their anterior nares and in this way protect their respiratory epithelium from the destructive action of the water.

Wiedersheim[3] in his text on the comparative anatomy of vertebrates, says the diving mammals are provided with a complicated musculature which forms a sphincter in connection with a special valvular apparatus for closing the nostrils.

Zoölogists are far from knowing the anatomy and physiology of all animals. Neither are they agreed on the relative importance of a great number of modifications of structures which animals present. The information I have gained on the comparative anatomy of aquatic animals, aside from personal observation, has been scattered through many books and periodicals, and I find also that there remains much yet to be ascertained.

Let us here review some of the anatomy of various animals who are modified for life in the water. For interest's sake we will start with the alligator, the highest form of reptilian life. The anatomic feature which is relevant to this paper is that the muscles of the anterior nares are so arranged as to entirely close the nostrils at

the will of the animal, and this is always done when the head is submerged.

Also, according to Reese,[4] the posterior margin of the tongue of the alligator is elevated as a transverse fold that meets a corresponding fold, the velum palaitinum, from the lower side of the palate and completely shuts off the mouth from the opening of the trachea and gullet. Also, into this hinder chamber open the posterior nares, so the animal can open its mouth under the water without water coming in contact with the respiratory mucous membrane. To test the efficiency of this means of protecting the nasal mucous membrane from water, the writer recently sectioned the head of an alligator immediately after submerging in an aqueous

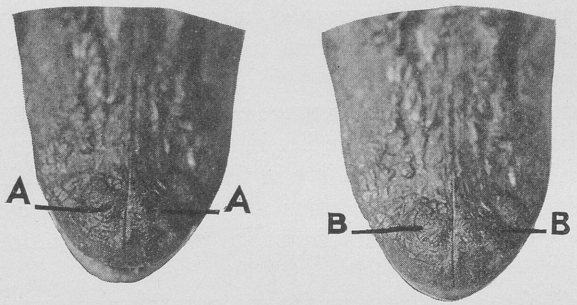

FIG. 1.—Anterosuperior portion of head of alligator Mississippiensis, showing external nares open as during respiration. *a*. Open external nares. *b*. Closed nares.

solution of methylene blue, and no evidence of staining of the respiratory mucous membrane could be detected.

In the aquatic birds we find a wide variation in the means they have of protecting the respiratory mucous membrane, yet all are more or less on the same principle. The booby, a bird which dives from some distance above the water to catch its prey, has no external nostrils. Its tongue is small, elongated and set up on a sort of narrow stalk. It can be plugged directly and tightly into the internal nares. The true opening of the trachea has a padded margin of muscle and connective tissue, called the rima glottidis, capable of being tightly closed. A crest or projection on the thyroid cartilages, itself cartilaginous, called the ligula laryngis,

serves as a support for this valvular arrangement. The cormorant and the snake bird are similar. They have no external

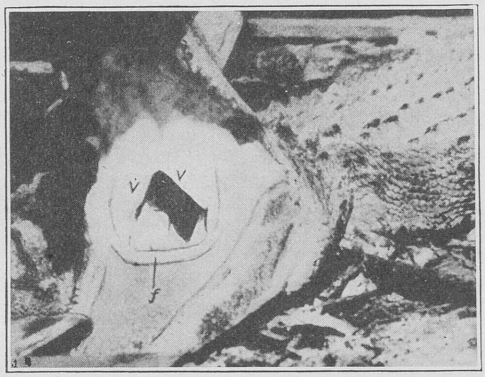

FIG. 2.—Interior of the mouth of alligator Mississippiensis (after Reese). *f*. Transverse fold at the base of the tongue. *v. v.* Velum palatinum.

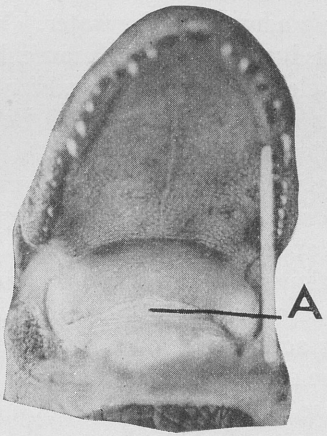

FIG. 3.—Interior of mouth of alligator Mississippiensis. *a*. Transverse fold at base of the tongue in contact with velum palatinum as while submerged.

nostrils. The diving petrel has external nostrils, but they may be closed very tightly by an arrangement similar to that in the alligator. The penguin has very minute hairlike slits for external

nostrils, and arrangements in the glottis and internal nostrils similar to those of other birds. The frigate bird is rather transitional. It has a scalelike membrane entirely closing the external nostrils, but indicating that they were formerly open. Though the external nares of some of the aquatic birds cannot be closed, water, in no instance, in the species I have reviewed, is allowed to come in contact with the parts lined by respiratory epithelium.

In many of the mammalian groups there have arisen forms modified for life in the water in that they too have a musculature by which their nostrils are closed at the will of the animal and which protects their stratiform ciliated epithelium from water. This is true in the beaver, the hippopotamus, the seal, the walrus, the manatee and dugong. This arrangement of the anterior nares we also find to exist in the cetaceans, who are modified to a higher degree to life in the water than are any of the aquatic mammals.

From biology we learn that every species of animal life is adapted to its environment and that all of its organs are fitted to its functions and all of its functions to its environment. Now, let us briefly discuss man's adaptation for water. What has he, or has he anything which is homologous to the musculature which aquatic mammals have for closing the nostrils and for keeping water from their nasal cavities and appurtenances? Eckley,[5] in describing the compressor narium of man, states it is "a small muscle arising from the superior maxilla and is inserted by an aponeurosis across the bridge of the nose into its fellow of the opposite side." "This is a small muscle at best and very hard to demonstrate." In describing its functions and that of the dilator nares anterior and the dilator nares posterior, which oppose the compressor narium, he says, "By their action they confer on the human face, facial expression." These comparative anatomic features of the aquatic animals and man are in line with the assertions of the students of comparative anatomy and biology that man is now far, far removed from being an aquatic animal and has not the adaptation for an aquatic environment. Time will not permit of a discussion of the phases of inheritance of acquired characteristics or of the degenerating effect of disuse upon an organ.

It is well to recall here that when man assumed the upright position he also lost the gravity drainage of his maxillary and sphenoidal

sinuses; which means that the drainage of these sinuses is solely dependent upon the wavelike cilia of his ciliated epithelium. Hence the drainage of the sinuses of man is not as complete as it is in the aquatic animals, in whom the ostia are so situate that gravity drainage is a material factor.

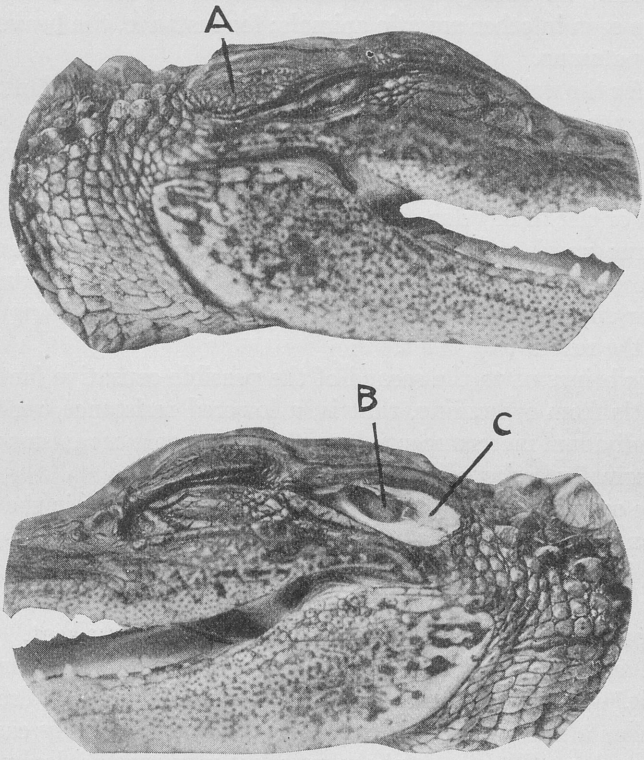

FIG. 4.—Lateral view of head of alligator Mississippiensis, showing cornified flap protecting membrana tympani. *a*. Cornified flap covering and protecting membrana tympani. *b*. Membrana tympani exposed. *c*. Area where cornified flap has been detached.

It is not the purpose of this paper to describe the anatomy and physiology of the ear of the aquatic animals, but it is germane to our subject to briefly refer to some of their modifications to show how thoroughly nature has endowed them with organs necessary

for aquatic life, and to also note the conspicuous absence of these modifications in man. For instance, in the alligator, immediately behind the eye is a hinged cornified flap constituting an ear covering which is closed tightly as the reptile goes beneath the water, and this prevents water from coming in contact with the membrana tympani. An analogous modification which has the same function can be seen in other aquatic animals; for instance, the beaver and hippopotamus.

So far the writer has endeavored to show some of the adaptations which the aquatic animals have to the circumstances in which they live, particularly in reference to keeping water from gaining entrance to their nasal cavities, whereby infections might be introduced or else injury done to the respiratory epithelium which lines the true nasal cavity and the paranasal sinuses. It is evident that these adaptations are sufficient for their mode of living and are far superior to any means which man has for keeping water from the respiratory tract.

This brings us to the second of the possible causative factors of sinusitis from swimming, that is, a lowered resistance, rendering the individual more susceptible to the pathogenic organisms which are normally harbored in the upper air passages.

The question of the duration of time one can remain in the water without reducing the body temperature and lowering one's resistance is a matter of paramount importance. We know that cold water has a veritable appetite for heat, and all authorities agree that prolonged cold baths cause a rapid loss of body heat.

We are all familiar with the investigations of Pasteur[6] and Durck,[7] who have found that chilling lowers resistance. Trommsdorf[8] has also shown that prolonged chilling of the body causes a decreased motility and phagocytic activity of the leukocytes. The work recently done by Mudd, Goldman[9] and Grant is also interesting in this connection. In a most exhaustive study they have reported that chilling of the body surfaces causes a fall in the temperature of the nasal and pharyngeal mucous membrane, and conclude by saying that chilling of the nasal mucous membrane and change in vasomotor tone may so disturb the equilibrium between the host and the bacteria of the nose as to favor infection.

During the past summer the writer became interested in the

question of lowered resistance from chilling, particularly in reference to sinusitis from swimming, and had the temperatures taken of 250 children under thirteen years of age, both before and after they had been swimming for forty-five minutes in an indoor swimming pool, water temperature 73° F. Of the 250 children, only 30 maintained a normal temperature, while the other 220 showed a reduction of temperature, many as low as 95° F.

Now, let us briefly consider the adaptations which some of the warm-blooded aquatic animals have for their environment and their means of maintaining their body temperature. For instance, the cetaceans. These mammals are the most highly adapted of any of the warm-blooded animals for aquatic life. They live their entire lives in cold water and many of them maintain a higher normal temperature than man. The function of keeping their bodies warm is performed by a thick layer of blubber, a nonconductive material, a dense kind of fat placed immediately beneath the integument. Other aquatic animals who live in cold climates, such as the seal, walrus and sea-lion, have a heavy coat of fur as well as the fatty layer. It all seems to point to the fact that they are highly adapted mechanically to their normal habitat, which even without natural physiological immunity would adequately protect them.

Now let us see how evident it is that man is not so modified to maintain his normal temperature in water which is of a lower temperature than his own. Fox[10] states that in a bath with a temperature of 70° F., of from fifteen to twenty minutes' duration, the loss of heat may be increased to fivefold that of the normal basal rate. In strong normal persons this loss of bodily heat does not result in immediate lowering of the body temperature, but if the bath is prolonged the production of heat fails to keep pace with the loss and the temperature of the body falls. This observation in itself is sufficient evidence of the fact that man is lacking in the adaptation to maintain his body temperature for more than a brief period in water temperature lower than his own.

SUMMARY. In the foregoing statements the writer has endeavored to show the modifications which the aquatic animals have for their environment and the striking absence of such adaptations in man. He has noted the means which nature has endowed the

aquatic animals for preventing water from gaining entrance to the respiratory tract, the means which they have of maintaining their body temperature in cold water and the absence of these provisions in man.

Conclusion. In conclusion, we can but reiterate: Man is essentially a terrestrial being, and his anatomy and physiology are not modified for a water environment. When man is out of his normal sphere he must understand what limitations nature has placed upon him, and not ignore the fundamental laws that regulate his own being.

Bibliography

1. Dendy, A.: Outlines of Evolutionary Biology, 1913, p. 7.
2. Fenton, R. A.: Annals of Otology, Rhinology and Laryngology, June, 1923.
3. Wiedersheim, R.: Comparative Anatomy of Vertebrates, p. 265.
4. Reese, A. M.: The Alligator and Its Allies, 1915, p. 151.
5. Eckley, W. T.: Practical Anatomy, 1899, p. 34.
6. Pasteur: Reference by Dawson Williams in Allbutt's System of Medicine, Vol. 11, Part II.
7. Durck: Studien über die Aetiologie d. Pneumonie, Separatabdr. Arch. f. klin. Med., 1897.
8. Trommsdorf: Arch. f. Hyg., 1906, lix, 1.
9. Mudd, S., Goldman, A., and Grant, S.: Reaction of the Nasal Cavity and Postnasal Space to Chilling of the Body Surfaces, Jour. Exper. Med., 1921, xxxiv, 11.
10. Fox, R. F.: The Influence of Heat and Cold upon the Human Body, ibid, 1915, xliv, 353.

Discussion

Dr. Ralph A. Fenton, Portland, Ore.:

Dr. Taylor's active work along this line for a good many years deserves recognition and great commendation not only because he reminds us of the biological shortcomings of human beings in this respect (and that is something we need reminding of, with the number of swimming tanks in constant use throughout the Nation), but it also reminds us that we should place the knowledge of these limitations before the public; herein the profession is perhaps remiss.

We have, I think, under the stimulus of contributions from Dr. Taylor, largely given up the idea that infection in swimming tanks is mainly the cause of the infection of the sinuses. With that in mind we should perhaps turn our attention to methods of prophylaxis against further injury to these structures, which are not protected in any measure as they are in aquatic animals. For instance, certain swimmers (as we may recall from Dr. Mayer's delightful exhibition at Atlantic City), provide themselves with a thin coating of oil before they go into the water. Similar protection to the sinuses should be remembered by individuals who want to swim and have narrow nasal openings; if the nose is filled up with oil before such a person enters the water, he will be protected from some of the consequences of his indiscretion. People with narrow nasal cavities should not be permitted to go into the water at all, or at least not be permitted to dive.

The average swimming teacher does not know anything about that and he is not watching people; he is teaching. Many people are advised to inhale with the head down in the Australian crawl stroke. If they do, they are pretty sure to get water up under the turbinates and invite serious trouble.

Another most important contribution which Dr. Taylor has made is the intensive study of the matter of chill. This has been studied by the bacteriologists, but ignored by a great many of us, and should point, of course, to another factor in prophylaxis—getting out of the swimming tank within a reasonable length of time.

Dr. Harmon Smith, New York City:

I think unquestionably sinus trouble is on the increase, particularly since women as well as men are beginning to compete in swimming contests. That is one factor.

The second is the method of swimming as mentioned by the last speaker, which conduces more to sinus trouble, possibly by infection or by lowered resistance, than the old forms such as the overstroke method, where the head was kept out of the water.

Dr. Jonathan Wright, before Dr. Mudd took up the subject, undertook to demonstrate surface tension and biochemical conditions of the surface mucous membrane as a factor in infection. We have reason to believe that the sinuses remain sterile until bacteria gain entrance therein. We carry in the nose and pharynx innumerable bacteria. If the surface tension or biochemical change or biochemical equilibrium is lessened, the bacteria in the nose will gain entrance. Whether that be due to the lessening of the function of the epithelium

by the presence of water—water does irritate the nose—or is lowered by the chilling, is immaterial. I believe the infection in the pools plays a part less than the lowered tension, allowing the infection in the nose to gain entrance into the sinuses.

The doctor is to be commended for bringing the subject before us. The number of young girls taking swimming lessons having sinus trouble has led me recently to think of some method by which the nares might be shut off while they dive and swim, and thereby lessen this disturbance.

There is one point that does not seem to jibe with the doctor's statement unless, perchance, those in the South Seas have established an immunity to infection. Possibly they carry less infection within their nares or have adopted aquatic habits from being in the water all the time, which lessens their susceptibility. In the South Sea Islands they are in the water as much as they are on land. They dive and carry on continuously all aquatic sports, and from the little experience and observation I had a few years ago in the Hawaiian Islands, I did not notice any unusual evidence of sinus trouble. I do not know what that means exactly, unless it means they have established an immunity.

Dr. Ross H. Skillern, Philadelphia:

There has hitherto been a great deal of confusion as to the exact etiological factor of sinusitis in swimming. I was under the impression that the cilia played an important rôle and bacteria likewise. Just exactly as to the relation between the two, I was somewhat at sea. I think Dr. Taylor's paper has cleared this up to a greater or lesser extent. In the first place, it shows conclusively to my mind that the cilia or the action of the cilia is the crux of the situation. The bacterial content of the pool, of course, plays an important part, as shown by Dr. Fenton several years ago. You will immediately say: "Well very true; but how do these cilia lose their function?"

There are several things. All of us swim. We all have jumped into the water and we all know when we jumped into the water from a height, the water rushed up the nose and one's head ached with intense pain. That is why a great many hold their noses when they jump. Then the chilling of the body, certainly, as Dr. Taylor has shown us, lowers the resistance. Anything that lowers the resistance is going to retard the action of the cilia. If we have this, plus traumatic action on the mucosa, with the lowered resistance, one can see how readily bacteria can get access to the nasal mucosa and finally into the sinuses.

That brings us to contamination of the pools. We will say here are two pools, one contaminated and one not contaminated. We will also say that the contaminated one is 10° higher, at a temperature of 70°. The pool not contaminated has a temperature of 10° lower, or 60°. Suppose individuals go into those two pools and stay for a short time in the contaminated pool and a greater length of time in the noncontaminated pool; who will have the sinus infection and who will not? The ones who remain in the noncontaminated pool the greater length of time, because in addition to the chilling they contaminate themselves. They have contamination in their own noses.

You all understand how on getting into the water, we get water in our mouths, spit it out again and not only contaminate ourselves but others also.

The conditions in the natatorium one goes in today are totally different from what they used to be. Years ago, one undressed and plunged in. Nowadays, when one disrobes, the first thing insisted upon is a shower before going into the pool.

If these proprietors of the natatoriums and swimming places will recognize these things and we also will recognize them, I think by our gradual education of the laity, as we have in a great many things—smallpox many years ago and later tuberculosis—we will bring them to see and appreciate the dangers which lurk in these places and take the necessary precautions.

Dr. George B. Wood, Philadelphia:

This very instructive and interesting paper by Dr. Taylor reminds me of a remark I heard Dr. Pohlmann make in Philadelphia the other day when he was talking about the audiometer. He said, "Since I have been doing this scientific work, I have come to the conclusion we do not know anything about how we hear."

Sometimes scientific investigation proves that our beliefs of by-gone days are simply thoughts and theories and not facts. For instance, we do not really know very much about the causation of colds in the head. We do not know what the bacteriology of the common cold is. We do not know whether it is a filterable virus, a coccus, or whether the germs we find in the nose after the second or third day are primary or secondary invaders. We know very little about it.

As to the matter of chilling the body, I have been up in the Maine woods away from the contaminating germs of civilization and I have been both chilled and physically exhausted but never caught a cold. The same experience follows through the history of the camping

of troops out in the West. When you are free from contamination, you can expose the body *ad libitum* and you will not catch cold.

My feeling is one of thankfulness for one more paper that helps possibly to teach us that we do not know as much as we thought we did.

Dr. John M. Ingersoll, Cleveland, Ohio:

The work Dr. Taylor has been doing interests me very much because I have done a little work myself at various times in comparative anatomy.

All the birds, I think, are provided with some method of closing off the nasopharynx. The posterior part of the nares has finger-like projections which interlace and close the nose posteriorly. If the nose is open anteriorly, it is closed posteriorly, so that the water cannot circulate through.

In pretty nearly all the mammals I know anything about, the maxillary ostium is a slit which extends down to the floor of the sinus. In man the sinuses are rudimentary structures and the maxillary opening is high up above the floor, so that fluid in the maxillary sinus tends to stay there.

Good divers go in head first; if any go in feet first they usually hold their noses. Going in head first, with their mouths closed, some water gets into the anterior nares, and if it is contaminated it is a source of danger. When they come up, they simply let the water run out of the nose. They do not snort, as do inexperienced swimmers. I think that is one reason why the professional diver is somewhat less open to attack than the average diver.

The matter of drainage is another reason why the sinuses are more liable to be affected in man than they are in the lower mammals. Almost all of the mammals, the dog for instance, can close the exterior nares when they go under water, so that little or no water enters the nose.

There is one other thing, I think, that makes some people more susceptible than others. You all know that in a certain percentage of maxillary sinuses there is an accessory opening. Such a sinus is more liable to have water enter it. If the sinuses are filled with air, and some water enters the nose, the air acts as a cushion and probably very little water gets into the sinuses unless a man jumps in feet first.

Dr. Harris P. Mosher, Boston:

The flavor of this paper was extremely agreeable to me. It almost

gave me courage enough to try a paper on the comparative anatomy of the larynx before this Association. I was interested in what was said about chilling.

It is notorious that women are very much better swimmers than men. They can stay in the water longer. I would like to ask Dr. Taylor whether he observed in children that the girls presented a less loss of heat than the boys. It seems to be the general opinion that it is the infection of the water, rather than the water itself, which causes the trouble, although I do not think Dr. Taylor agrees with that.

Dr. Bryson Delavan, New York City:

I would suggest that the reader of this admirable paper summarize his remarks which relate to the practical side of the subject and make a popular document of them. It would be very helpful to the public in general if his ideas could be promulgated. The public may not be as deeply interested in comparative anatomy as we are, but they are interested in preventing the serious troubles which so frequently arise from injudicious bathing.

Dr. Henry L. Swain, New Haven, Conn.:

I have for a good many years past been up against the problems brought out today in connection with the college community with which I am connected. In winter boys go in swimming in the tank and they have their sinusitis. The general public goes in bathing in the salt water of New Haven harbor in the summer. The influx of sinus cases will somewhat correspond to these two swimming seasons, in my own practice.

When the tanks first came into use we had contamination of the water, but did not know it. We have now better-managed pools and general arrangements and we certainly have much fewer bad results from the swimming than we had in the old days. However, it is interesting to note that the boys who indulge in water polo have much more trouble with the ears and they get a higher percentage of colds and sinusitis than those who simply go in to swim and come out again. They are scrimmaging together in the water with the ball, tossing it around, swimming under water and have a high percentage of sinusitis and drum ruptures.

The public who in summer time bathe in salt water have a much smaller percentage of colds and sinusitis than the people who go bathing in pools. I think the evidence is straight there, whether

salt water has less liability to produce trouble in the nose than fresh water, which acts in a derivative way upon the epithelium, we have not determined.

As just previously mentioned we often have in the water-polo group the external injury to the drum from blows or pressure which force the column of water with which the canal of the ear is filled into the middle ear through the drum. We have a much higher percentage of ruptures of the drums in this group of boys than otherwise. There is no doubt also that those who go in swimming with colds have a great percentage of sinus affection. This is true of winter and summer alike.

I agree heartily with Dr. Delavan's suggestion that we popularize whatever information we can for the help of the public, and that we ought to caution the public that when they have acute rhinitis they should not go in swimming.

Dr. Cornelius G. Coakley, New York City:

This paper of Dr. Taylor's has been very instructive to me as explaining the type of case that I meet in the summer near the seashore where the water is cold and where there is a great deal of surf bathing. I am called upon more frequently than I would like to be in my vacation time to assist people who have infections of the sinuses and especially of the ears.

The furunculosis we see in these cases of surf bathing is one of the most difficult to handle. There we have no question of contaminated water. The water is clear, it is free from the sewage that the sea near New York contains and yet we have a great deal of sinus and ear infections in the ocean bathing.

Quite a number of the children who cannot stand the buffeting of the surf go into the bay, which is only a couple of miles away, and we see very much less of infection in these children who bathe in warmer, quieter water than where we have ocean bathing.

It seems to me that the explanation Dr. Taylor has given has made my understanding of these infections very much better. In the first place, our water is cold. There is almost always a breeze blowing. They come out and lie on the sand, with the cold air evaporating the water in their bathing suits. They get chilled, go in again, stay in a long time and then the sand that is in the breakers near shore bruises the external auditory canal. We do find sand in the external canals and softening of the epithelium of the walls of the external ear. The abrasion by the sand makes it easy for them to develop very bad furunculosis.

Salt water in the ocean does the same thing as the fresh water which Dr. Taylor is dealing with. You get too high a salt content there as compared with the water in the bay. So we have the destructive action on the epithelium by strong salt water in the same way we would in fresh water and we have chilling of the surface and the mechanical action of the sand that is in the water, all tending to make autoinfection without contamination of the water an important feature in these cases.

Dr. Taylor (in closing):

In reply to Dr. Smith's question as to sinusitis among the South Sea islanders, I cannot speak authoritatively as to the frequency of the condition among these people. In the warm waters of the tropical seas it stands to reason that you do not have the chilling of the body surfaces that you have in the colder waters of the temperate zone. It would be interesting to study these people, who are such expert divers, with the idea of determining the frequency of these infections. It may be that through succeeding generations they may have acquired some degree of immunity.

In reply to the question Dr. Mosher has asked relative to the ratio of sinus infection in the male and female, I will state that I have not collected statistics on this phase of the subject.

Regarding Dr. Coakley's discussion, will state that the paper is confined entirely to the etiology of infections of the sinuses from swimming. The fact that aquatic air-breathing animals protect their columnar ciliated epithelium from water would seem to be of more than academic interest, when we know of the destructive action of water upon the protective mechanism of the nose in man.

Dr. Delevan has spoken of the importance of giving this matter publicity. The American Public Health Association of the various state boards of health has written much on the subject of sanitation of the water and bathing premises, but little attention has been given to chilling of the body surfaces by prolonged bathing lowering one's resistance and making the individual more susceptible to either the bacteria in the water or those which are always harbored in the upper respiratory passages.

The question of man's lack of adaptation to an aquatic environment has received little attention, but the whole subject is of vital importance to the rhinologist and otologist as well as the sanitarian.

CICATRICIAL STENOSIS OF THE TRACHEA, WITH A REPORT OF THREE CASES

CHARLES J. IMPERATORI, M.D.

THE usual cause of cicatricial stenosis of the trachea is an injury or wound of sufficient depth to destroy the submucosa. Typhoid fever, diphtheria or any disease-producing ulceration of the mucosa is undoubtedly the cause of those so-called idiopathic cases. Gunshot or high-explosive wounds of the trachea must have caused many during the World War, but none from these causes have been seen by the writer. Poorly performed tracheotomies and repeated and prolonged intubation for diphtheritic stenosis appear to be the most common causes.

In order that these cicatrices or webs shall form there must, necessarily, have been considerable destruction of the mucosa, particularly in the transverse diameter of the trachea. The loss in continuity of the mucosa is replaced in the normal process of repair by a callus, which in turn becomes covered by the adjacent mucous membrane. A cross-section of a web will show two layers of epithelial cells and between them a stroma of connective tissue, with fibrous tissue of increasing density as the tracheal wall is approached. It is the contraction of the callus that produces these thin, weblike structures stretching around the lumen of the trachea from each end of the wound. The general outline of these cicatrices is irregularly falciform, with the thin edge directed toward the lumen of the trachea.

CASE I.—Mrs. A., aged forty-two years, was operated upon for a papilloma of the vocal cords about fifteen years ago. Two days following the laryngeal operation, because of marked and increasing dyspnea, it became necessary to do an emergency tracheotomy. She wore a tube for four and a half years and was decannulated by the late Dr. Janeway. Since that time she has had some treatments and the application of radium by a physician who is not a laryngologist, and,

as far as can be ascertained, these treatments seem to have been in the nature of dilatations.

The patient was first seen in August, 1924, having been referred by Dr. Alfred A. Schwartz. At this time the patient complained of considerable dyspnea, accompanied by a marked stridor. Each inspiratory effort was such that there was marked depression of the episternal notch, and it was evident that there was considerable interference in the larynx or trachea. The general appearance was that of one suffering from increasing air-hunger. She had no speaking voice and was of an ashen-gray appearance. The slightest exertion produced increasing dyspnea. Externally, over the cricoid and extending slightly diagonally, was a puckered scar rather irregular in outline, the mute evidence of a hurried tracheotomy done high up, mostly through the cricoid and first ring of the trachea. A laryngoscopic examination showed a rather dense infiltration of the right aryepiglottic fold and a considerable degree of laryngeal stenosis, especially in the anterior commissure.

The patient was hospitalized to ascertain by direct examination whether there was any tracheal stenosis, for it did not seem that the laryngeal stenosis was sufficient to cause the marked dyspnea. Under local anesthesia it was with some difficulty that a 7-mm. Jackson bronchoscope was passed through the glottis. A little over 3 cm. below the vocal cords a falciform web was seen extending around the trachea and occluding over two-thirds of the lumen. With a punch forceps this web was easily excised, with immediate cessation of the dyspnea. The patient rapidly improved and was in such good condition within two days that she was permitted to leave the hospital.

A week later she was dilated with a 24-Fr. Lynah laryngeal dilator, and at intervals of a week for four weeks was dilated with increasing sizes, so that at the fourth dilatation, five weeks after the excision of the cicatrix, a number 30-Fr. size was passed. She has been dilated four times since, the last interval having been three months. In all, seven dilatations have been done. The dilatations were done under what has been facetiously termed "vocal anesthesia," through a Jackson laryngoscope and using the Lynah dilators. A very short interval of time is required to pass two or three of these dilators.

Generally, this patient has improved remarkably, and while she has not a good speaking voice, it is for all practical purposes very satisfactory. The infiltration of the aryepiglottic fold still remains. The vocal bands move freely but there is an ankylosis of the arytenoid joint on the right side. The patient experiences no dyspnea, even on extraordinary exertion.

CASE II.—Baby M., aged three years, was referred to me by Dr. George Berry, of Brooklyn, N. Y., in December, 1922. Three months previously she had had a severe laryngitis. The child was treated as a case of diphtheria and, because of the marked laryngeal stenosis, was intubated. The tube was frequently coughed out and she was reintubated several times. About three weeks previous to the time that I saw her a tracheal web was seen by a colleague, who divulsed it, using a bronchoscope. Within a few weeks, however, there was a recurrence of the tracheal obstruction and marked cyanosis.

Examination through a child's size Jackson laryngoscope showed a falciform web about 1 cm. below the glottis and attached to over two-thirds of the circumference of the tube. It occluded over half of the lumen of the trachea.

Using a punch forceps, the cicatrix was partially removed and a two years' O'Dwyer intubation tube was introduced. This was left in for four days, when it was removed. The trachea was dilated subsequently eight times, getting up to 26 Fr. each time, the dilatations extending over a period of one year. Results were immediate, and within a few weeks the child began to gain in weight. One year after the excision of the cicatrix a tracheoscopic examination, using a 5-mm. Jackson bronchoscope, showed no evidence of the site of the web. Two years after the operation the child was again examined and with the before mentioned results.

It would seem that the mere breaking-up of the web was not sufficient, and that as much as possible should have been removed in order to lead to such conclusive results.

CASE III.—While a member of the attending staff of the Otolaryngological service of Bellevue Hospital, and through the courtesy of Dr. Coakley, D. E., female, aged thirty-five years, was referred to me for endoscopic examination. This was in April, 1921. The patient had been attacked and slashed with a razor in July, 1912. She was taken to Bellevue Hospital, in an unconscious condition and with considerable emphysema of the neck and chest. The razor slash had opened the trachea at the second ring. The wound was immediately sutured, no tracheotomy tube having been inserted.

Since that time she had complained of increasing dyspnea on exertion, and at times she had had severe smothering attacks. She was treated by her physician and, unfortunately, was given heroin in increasing doses until she became a drug addict, and when seen she was confined to the prison ward of the hospital.

Examination per bronchoscope, using a 7-mm. Jackson, revealed a falciform web stretching around the trachea and occluding the lumen almost three-quarters. It was situated 2 cm. below the glottis, was rather flaccid and moved with each respiratory movement.

Through the bronchoscope the web was excised, using the punch forceps. Afterward she was dilated through the laryngoscope, using a Lynah 26 Fr. There were three subsequent dilatations. This patient never complained of any urgent dyspnea but was somewhat cyanosed.

Following the excision and dilatation she improved rapidly, stopped taking the heroin, but unfortunately substituted cocaine for it. However, up to two years ago, when she was lost track of, she was free from any respiratory obstruction.

SUMMARY. The etiological factors were as follows: In Case I the cause was a poorly performed tracheotomy, following a laryngeal operation; in Case II diphtheritic erosion and repeated and prolonged intubation was the cause of the cicatricial stenosis while in Case III the resultant scar followed a razor-slash.

All these webs were located mostly on the anterior wall of the trachea. The distance from the glottis was 3 cm., 1 cm. and 2 cm. respectively. The predominating shape was irregularly crescentic with the concavity directed posteriorly.

The most prominent symptom was increasing dyspnea and some hoarseness. In the first patient the hoarseness was of long standing and was due to the ankylosis of the crico-arytenoid joint on one side, while in the other 2 cases there was a chronic catarrhal laryngitis. Cyanosis was marked up to the time of operation.

All were operated upon by the direct method, using a laryngoscope or bronchoscope, a Struycken's punch forceps, and the treatment was continued by graded dilatations.

Case III was under observation two years after the excision and completed dilatation. During that time she had remained free from any respiratory difficulty. The other 2 patients have been observed for two and a half years, in the child, and nearly a year in Case I. Both of these patients are free from complaint relative to tracheal obstruction. All have a good-speaking voice, excepting Case I, who has an ankylosis of the right arytenoid joint.

Careful inspection of these patients fails to show the site of the cicatricial webs.

It would seem that it is better practice to excise the web and then to continue treatment by graded dilatations after epithelization of the remains of the web has occurred. This would appear to be the method of choice and would seem to lead to more permanent results.

These cases will be further observed and reported upon at some future date, for one cannot be unmindful of the case reported by Drs. Keen and Jackson—a tracheal web that was excised by Dr. Keen some twenty years previous to the dilatations done by Dr. Jackson.

It would almost seem that these patients may be classified with those of cicatricial stricture of the esophagus and conclude that at least some of them will be potential patients for dilatation the rest of their lives.

Discussion

Dr. Gordon Berry, Worcester, Mass.:

My experience with laryngeal and tracheal stenoses has been chiefly in army work, where we were dealing with gunshot wounds. These seemed to have more firm fibrous deposits than those Dr. Imperatori so interestingly describes.

The French, particularly Moure of Bordeaux, advocated radical laryngofissure for these cases, with the excision of the web-scar and the formation of a tracheal trough which could be closed after six months to a year, when all scar contraction had ceased. This might have been the shortest way to cure some of our protracted cases. We, however, employed cutting, electrocautery and dilatation, and the wearing of soft rubber tubes in the stenoses, with ultimate success in all but one case. In this I finally did a thyrotomy with scar excision, and, rather than leave it wide open as a trough to epidermatize, I inserted a skin-graft on a stent. This took well and I sent the boy home for a rest and change. I hope he will some day return for closure of the tracheotomy tube wound, which was left patent to ensure his breathing if the laryngeal stenosis should gradually reform.

EMPYEMA OF THE FRONTAL SINUS, WITH ABSENCE OF SYMPTOMS OTHER THAN HEADACHE AND LOCAL TENDERNESS. REPORT OF TWO CASES

HORACE NEWHART, M.D.

THE purpose of this paper is to call attention to the occurrence of cases of empyema of the frontal sinus in which only frontal headache and local tenderness on pressure are present, other diagnostic evidence being wanting.

In examining our standard text-books on rhinology one finds very little material or comment to warn the unwary of the possibility of encountering such cases in practice. Our own comparatively recent experience with 2 cases of this atypical form suggests the probability that cases of this kind are more frequent than is indicated by the small number of reported cases. A careful search of the accessible literature, published chiefly since 1910, discloses the fact that very few such cases have been published. Those which we have been able to find have been reported primarily because of other features or complications and not because of the conspicuous absence of the classic symptoms other than headache and tenderness. Guisez, in 1911, reported a case of closed frontal sinusitis operated in coma. Hudler, in 1912, reported a case with persistent headaches in which the frontal sinus was completely isolated from the nasal cavity through absence of the nasofrontal duct; the headaches disappeared after a radical operation. Skillern, in 1913, in a paper on the "Untoward Results Following the External Frontal Sinus Operation," with a critical review of 20 cases, mentioned absence of nasal discharge in 2 cases. In October, 1923, in a personal conversation with the writer, Dr. Skillern related his then recent experience with a case with absence of endonasal symptoms similar to the cases herewith reported. Avellis, 1902, in a paper on the differential diagnosis between simple neuralgia of the supraorbital nerve and the pain of inflammatory

frontal sinus disease, enumerated fourteen different diagnostic points and stated that cases exist which require for a positive diagnosis an external exploratory operation. Weleminski, writing in 1921, on the etiology of headache in acute empyema of the nasal sinuses, refered to the fact that headache and neuralgic pains may be due to involvement of the maxillary sinus or to inflammatory swelling of the middle turbinate, the pain being caused reflexly by irritation of the posterior superior branch of the nasal nerve. Richards, in 1912, reviewing 81 cases of inflammation of the frontal sinus, made no reference to cases of the closed type—that is, without the discharge of pus into the nasal cavity. Literature having a direct bearing upon the subject of this paper is conspicuously scarce.

By far the most prominent symptom of frontal sinusitis is the headache and local tenderness on pressure. The absence of other symptoms is to be explained upon the basis of anatomical variations known to every rhinologist. Zuckerkandl, Hajek, Gerber, Onodi, Mosher, Sluder, Schaeffer and others, including members of this Association, have pointed out the great variations in the anatomic structure of the frontal sinus and the ductus nasofrontalis. These variations in themselves, including the occurrence in the floor of one or both frontal sinuses of a large encroaching anterior ethmoidal cell, causing tortuosity and narrowing of the passageway leading from the sinus, together with even slight pathological thickening of the mucosa, account for the absence of pus in the middle meatus, with retention in the sinus. They also explain the absence of other endonasal signs.

The unreliability of transillumination of the frontals and the not infrequent failure of the roentgen-ray to give absolutely dependable information as to the true conditions of the frontal sinus is well known. The report of Onodi, who in examining 1200 heads found the greatest discrepancy between the results of transillumination and the roentgen-ray findings, well illustrates this point. The absence of a sufficient leukocytosis to point positively to pus formation is to be expected in all cases of sinus inflammation before the occurrence of complications or extension to neighboring soft parts. We have been unable to find in the literature anything of significant value regarding the white blood

count in inflammatory diseases of the sinuses. Likewise, we find nothing of special diagnostic helpfulness in the temperature, so far as uncomplicated cases of paranasal sinus disease is concerned.

Case Reports

Case I.—J. W., aged eighteen years, male, student, was first seen February 20, 1920, complaining of pain in the left frontal region, with tenderness most acute at the supraorbital notch. Family history negative, except that the mother had undergone numerous operations for involvement of the paranasal sinuses.

The patient for several years had been susceptible to head colds with a tendency to persistent nasal discharge, which however entirely ceased between attacks. One year ago he had an attack of frontal headache with involvement of the left maxillary sinus. This cleared up under intranasal treatment.

The present attack of pain had lasted about one week, following a cold in the head. The pain was periodic in type, being at its worst between 11 A.M. and 2 P.M. It seriously interferred with his capacity to study. Examination showed a marked high deflection of the nasal septum to the left, the middle turbinate was slightly edematous; there was a small amount of pus in the middle meatus of both nostrils but no edema. Transillumination was negative. Roentgen-ray examination, anteroposterior plate, showed slight haziness of the left maxillary sinus. The frontal sinuses were reported clear, but showed well-defined septa, apparently dividing the frontal region into three cavities. Shrinking of the middle turbinate with cocaine and adrenalin, followed by suction and inflation, produced no appreciable amount of pus in the middle meatus. The symptoms rapidly subsided under conservative treatment and in a few days the patient returned to school to report soon for a submucous resection. This was performed March 20, 1920. At the same time the anterior end of the left middle turbinate, which was large and moderately cystic, was resected. Even after these operations it was impossible to pass a probe into the left frontal sinus, which out of curiosity we tried to do.

The patient was not seen again until September 6, 1921, when he complained of recurrence of the headaches, following a cold in the head acquired two weeks previously. There was no nasal discharge and no edema of the nasal mucosa. Shrinkage of the mucosa of the middle meatus, followed by suction, gave negative results. The pain and tenderness on pressure over the left frontal sinus increased from

day to day. Transillumination was negative, temperature normal, no edema of frontal region or eyelids. The roentgenogram was reported as showing an apparently normal condition of the frontal sinuses, with septa as in the previous film. The urine, blood and leukocyte count were all normal. The patient was in great distress during the attacks. In spite of liberal doses of opiates the pains persisted for two or three hours and appeared daily with regular periodicity and increasing severity. Several attempts to pass a probe into the nasofrontal duct failed. Since the intranasal findings were entirely negative and the pain became unbearably intense, we advised exploratory opening of the left frontal sinus through the anterior frontal wall. A roentgenogram taken at this time, previous to operation, showed for the first time a cloudiness of the left frontal sinus and of the space between the two frontal sinuses.

September 8, 1921, operation under gas-ether. A two centimeter opening through the anterior wall revealed a large amount of thick greenish pus under pressure. The pus contained pneumococci. The mucosa was moderately thickened with some granulations; there was no exposed or necrotic bone. The nasofrontal duct could not be found. Accordingly a wide opening was made from the floor of the sinus into the nasal cavity. The external wound healed rapidly after a few days of irrigation and there was very free drainage into the nasal cavity. At this time all thought of conservative measures should have been abandoned, but because the patient felt that he must leave town to attend an eastern college within a few days, he was referred for consultation, observation and treatment to Dr. Harris P. Mosher. He was also attended by Dr. Swain at New Haven. After eight weeks, because of a reaccumulation of pus through closure of the intranasal opening, Dr. Mosher kindly referred the patient back to me for further surgical care.

On December 4, 1921 we performed a Killian operation. This revealed the true anatomical condition which was responsible for our previous findings or rather lack of other signs. At this time it was found that an erosion had taken place in the median wall of the left sinus, leading into a large cavity between the two frontal sinuses. This proved to be a large fronto-ethmoidal cell projecting into the frontal bone between the two frontal sinuses, thus obstructing the nasofrontal duct. The two cavities—that is, the left frontal sinus and the large ethmoidal cell—were made into one by the complete removal of this septum. The usual Killian operation was completed. The patient made an uninterrupted recovery, without complications and

with a fairly satisfactory cosmetic result. A year later there was a slight reinfection of the unobliterated cavity, but this soon subsided.

Case II.—Mr. W. F. McL., banker, aged fifty years, on April 26, 1923, was first seen by my associate, Dr. W. E. Camp. The patient complained of very severe pains in the right frontal region and in the eyeball, first noticed two days previously. He could assign no cause except that several weeks before, he had an attack of influenza with slight nasal symptoms. Two years ago he had a submucous resection for deviation of the nasal septum to the right. Examination by my associate showed a distinct tenderness of the supraorbital region. Intranasal examination showed no pus in the middle meatus and no edema of the middle turbinate. Shrinking of the turbinate and suction yielded no pus. Transillumination was negative. The patient was asked to return in a day or two if his condition did not improve. This he did not do, but for relief for his increasing discomfort he placed himself in the hands of Dr. George Head, an able internist, who sent him, on May 2, to the Abbott Hospital for detailed neurological and general study. Here all findings were negative, but the headache became more severe. May 4, the writer was asked to see the patient in consultation.

Examination, May 4, 1923 showed no pus in the middle meatus, and the middle turbinate and nasal mucosa appeared normal. There was marked tenderness over the right frontal region and in the floor of the orbit, but no external edema. Shrinking the turbinate, posture, and suction produced no pus. The blood count, urine, pulse, temperature, and transillumination were all negative. *X*-ray, May 3, showed moderate-sized frontal sinuses, which were reported normally clear, but deeply lobulated, with well-defined septa. The other sinuses were clear. Ocular and neurological examination gave negative results.

The patient described his pain as deep, boring, and increased by stooping and on making physical effort, coming on with great regularity at the same time each forenoon, but increasing daily in severity. He showed great restlessness at times, marked irritability and depression and complained of great prostration. Morphine gave only very temporary relief. Although a second roentgenogram, made May 5, was reported entirely negative, and there were no external or intranasal signs, fearing the possibility of meningitis or a frontal-lobe abscess we advised an exploratory external operation. Under general anesthesia the right sinus was opened by removal of a portion of the frontal wall. On first opening the sinus, to my great chagrin

and disappointment, it appeared empty. There was a distinct bubbling from gas under pressure, followed almost immediately by an abundant flow of thick green pus from the floor of the sinus. This contained pneumococci and long-chain streptococci.

The anterior sinus wall was resected sufficiently to explore the cavity, when the posterior wall was found to be intact. The median wall, however, showed a small fistulous opening with rough edges, leading into a large medially situated cell, about $1\frac{1}{2}$ cm. in diameter. It was impossible to pass a fine probe into the nasofrontal duct. The case being an acute one it was decided to attempt no further operative work, but provide adequate drainage by tubes through the external opening, leaving any needed radical procedures until a later time. For nearly a week the patient complained of pain, depression and restlessness. The wound was irrigated for three weeks, when it healed with no further disturbance up to the present. Last month he had an acute right maxillary sinusitis which yielded promptly to irrigation, but no frontal pain.

The earlier plates in Case I were made in the glass age of roentgenology and through unfortunate breakage I have only a fragment to illustrate the appearance of the frontal sinuses before operation. The films of Case II are unsatisfactory. They were reported negative before drying. As I look at them now, in the light of a larger experience, I should say that there was a suggestion of haziness between the two frontal sinuses. A well-made stereoscopic plate would probably have been of great help in making a preoperative diagnosis.

COMMENT. Admitting the possibility of error from more or less faulty technic and interpretation of the findings, we have in these cases, as an outstanding feature, the fact that a positive diagnosis was not made before operation because of a notable absence of the usual symptoms of pus in the middle meatus, edema of the mucosa of the middle turbinate, a definite shadow on transillumination and a positive indication of pathology showing in the earlier roentgenograms.

In both cases some of these symptoms would probably have appeared soon had there not been surgical interference, which was urgently demanded by the severity of the pain. In both cases we have examples of structural variations, with the encroachment into

the frontal sinus of a large anterior ethmoidal cell, with consequent interference with drainage. In fact, they might be regarded as cases of frontal sinusitis secondary to inflammation in an occluded anterior ethmoidal cell lying within the frontal sinus. It is probable, especially in Case II, that the infection was first localized in the ethmoidal cell. In this case the frontal sinus when first opened contained but little pus, being largely filled with serum and air under pressure. Case I undoubtedly had had previous attacks of sinusitis, with long periods of latency, which when he was first observed had left no change demonstrable by the roentgenogram. It was undoubtedly a mistake of judgment to have allowed this patient to go after the first operation without some form of radical procedure.

Case II was subject to occasional severe frontal headaches previous to the submucous resection. The severity of his general symptoms before and after operation was probably due to an underlying toxic and neurasthenic state.

Conclusions. 1. Empyema of the frontal sinus should be suspected in all cases of severe frontal pain and local tenderness after the exclusion of all other possible causes, including the vacuum headache of Dr. Sluder, eye disease and maxillary sinusitis, even though intranasal examination, transillumination and the roentgen-ray give negative findings.

2. In such cases a prompt exploratory operation through the frontal wall is justifiable for the sake of a positive diagnosis, to give the patient speedy relief and to permit examination of the sinus in order to determine the possible presence of caries of the posterior wall and other complications.

Literature Consulted

Avellis, George: Unterscheidungsmerkmale zwischen der reinen Supra-orbitalneuralgie und dem entzündlichen Stirnhöhlenschmerz, Verhand. der Süddeutscher Rhinologen, 1902, p. 532.

Ballenger, W. L.: Diseases of the Nose, Throat, and Ear, 1914.

Beck, J. C.: Applied Pathology in Diseases of the Nose, Throat and Ear, 1913, p. 144.

Boenninghaus: Die operationen an den Nebenhöhlen der Nase, Handbuch der speciellen Chirurgie des Ohres und der oberen Luftwege, Wurtzburg, 1913, vol. iii.

Bruck, Alfred: Die Krankheiten der Nase und Mundhöhle, etc., 1912, p. 129.

Denker und Brünings: Lehrbuch der Krankheiten des Ohres und der Luftwege, Jena, 1923.

von Eicken: Zur Diagnose der Stirnhöhlen Erkrankungen, Verhandlungen des Vereins Süddeutscher Laryngologen, 1906, p. 264.

Eschweiler: Roentgen Photographie bei Stirnhöhlenempyem, Detusch. Med. Wchnschr., 1909, p. 326.

Gerber, P. H.: Die Komplicationen der Stirnhöhlenentzündungen, Berlin, 1909.

Guisez: Closed Frontal Sinus Operated During Coma. Reported February 10, 1911, Proceedings of Parisien Society of Laryngology, Otology, and Rhinology, Abstract, Jour. of Laryngol., Rhin. and Otol., 1913, xxviii, 213.

Hajek, M.: Pathologie und Therapie der entzündlichen Erkrankungen der Nebenhöhlen der Nase, 4th Edition, 1915.

Hudler, W.: Ueber einen Fall volkommenen Abschlusses der Stirnhöhle von der Nasenhöhle und Fehlen des Ausführungsganges, Fränkels Archiv. 1912, xxvi, 3.

Kuttner, A.: Die Roentgendiagnostik bei Erkrankungen der Nebenhöhlen, Handbuch der speciellen Chirurgie des Orhes, und der oberen Luftwege, vol. xii.

Kuttner, A.: Die entzündlichen Nebenhöhlenerkrankungen der Nase in Roentgenbild, 1908.

Kyle, Braden, D.: Diseases of the Nose and Throat, Philadelphia, 1914.

Loeb, H. W.: Operative Surgery of the Nasal Cavities, Operative Surgery of the Nose, Throat and Ear, 1917.

McKenzie, Dan: Diseases of the Throat, Nose and Ear., St. Louis, 1921.

Mackenty, John E.: Frontal Sinusitis with Toxic Manifestations, Laryngoscope, 1918, xxvii, 1472.

Naegeli, Otto: Blutkrankheiten und Blutdiagnostik, Berlin, Julius Springer, 1923.

Onodi, A.: Die topographische Anatomie der Nasenhöhle und ihrer Nebenhöhlen, Handbuch der Speciellen Chirurgie des Ohres und der Oberen Luft wege, vol. xi.

Onodi: Demonstration of Preparations of Paranasal Sinuses at Meeting of Society Italiano di Laryngologia e di Rhinologia, Turin, 1908. Abstract of Transactions in Internationales Centralblatt für Laryngologie, Rhinologie und verwandte Wissenschaften, vol. lxxvi, p. 89.

Phillips, W. C.: Diseases of the Nose and Throat, Philadelphia, 1923.

Richards, George L.: A Review of Eighty-one Cases of Inflammation of the Frontal Sinus. A Comparative Study, Laryngoscope, 1912, p. 100.

Schaeffer, J. Parsons: The Nose, Paranasal Sinuses, Nasolacrimal Passageways, and Oldfactory Organ in Man, Philadelphia, 1920.

Skillern, Ross H.: The Accessory Sinuses of the Nose, 1923.

Skillern, Ross H.: Untoward Results Following the External Operation on the Frontal Sinus. A Critical Review of Twenty Cases, Laryngoscope, 1913, xxiii, 163.

Sluder, Greenfield: Headaches and Eye Diseases of Nasal Origin, St. Louis, 1918.

Tilly, Herbert: Diseases of the Nose and Throat, New York, 1920.

Thompson, St. Claire: Diseases of the Nose and Throat, New York, 1920.

Vohsen, Karl: Wert der Durchleuchtung bei Erkrankungen der Stirnhöhle, Verhandlungen des Vereins Süddeutscher Laryngologen, 1907, p. 361.

Weleminsky, J.: Zur Aetiologie des Kopfschmerzen bei akutem Nebenhöhlenempyema, Monatschrift für Ohrenheilkunde, 1921, p. 1723.

Wright, Jonathan and Smith, Harmon: Diseases of the Nose and Throat, Philadelphia, 1914.

Zarnicko, Karl: Die Krankheiten der Nase und des Nasenrachens, Berlin, 1910.

Zwaluwenberg, James G.: The *X*-ray Diagnosis of Accessory Sinusitis, Am. Jour. Roentgol., vol. ix, p. 1.

Discussion

Dr. Lee M. Hurd, New York City:

It strikes me that most of these cases are due first to the occlusion and expansion of ethmoidal cells. I have seen several of them where there was no frontal sinus.

Dr. Henry L. Swain, New Haven, Conn.:

I had the pleasure of seeing this case after Dr. Mosher. There is no doubt the skill of the operator was beyond criticism. Nevertheless the opening from the frontal sinus into the nose closed up. He kept on having attacks of pus formation which compelled us to reopen the wound. He tried two winters to come to New Haven, but in spite of every care relapsed and had to go home early. This winter he is spending in New Mexico trying to pass one winter without a recurrence. He is hoping to come back and get a Yale degree, which splendid persistence ought to be rewarded.

Dr. John E. Mackenty, New York City:

A patient who came under my observation five years ago fits in with what Dr. Newhart has given us in his excellent paper. This woman had been for many years suffering from intense pain in her frontal region, coming in periods and having remissions. She had tenderness over both frontal areas, but in the nose there was no evidence whatever of sinus disease. The ethmoid and other sinuses were normal in appearance, radiographically and otherwise. The

suffering became so intense that we decided to open her frontal sinuses. The *x*-ray did not help us very much. The evidence when we got into the sinus showed that the *x*-ray could not help us, as she had a deformity of the sinuses. Her frontal sinuses extended up to the hair line and were not deeper than $\frac{1}{4}$ cm. in the deepest portion. There was no pus in either sinus. They were both filled with granulations and the pathological evidence showed an obliterating process.

An interesting part of the whole thing was that on the floor of the sinus, where you expect to find the frontonasal duct, there was no evidence of such a passage. It had disappeared and there was a deep area of solid bone. The ducts had been obliterated, shutting off drainage into the nose. We removed the entire anterior wall and obliterated the area, causing a slight deformity, with complete cure of her headache. This was the only case of the kind I have ever seen.

Dr. Harris P. Mosher, Boston, Mass.:

We all know that it is not essential in acute sinusitis to have pus in the nose.

It is well known, also, that where there is an accessory frontal sinus, the involvement is mostly confined to that; such cases are hard to handle. Both of the reader's cases evidently fall into this class.

I do not quite understand why Dr. Newhart proceeded to the external operation without first doing more in the nose. In other words, the procedure which would have been my routine, for what it is worth, would have been to remove the anterior ethmoidal cells thoroughly before proceeding to the external operation, in the hope that I would have obtained drainage.

The ordinary pain of acute frontal sinusitis is severe, but I have lately seen a case where the pain was more severe than usual and was in fact so excruciating that it stood out as the most prominent thing. This case turned out to have early involvement of the bone. I have it pigeonholed in my mind to watch in the future. If there is this pain, plus more tenderness than is usual for the time the case has been going on, it is beginning necrosis of the bone, which usually is a late affair rather than an early one.

Dr. Newhart (in closing):

As the hour is very late I will add nothing more to the thought brought out in my paper, except to answer Dr. Mosher's question. The symptoms in both cases were so acute that we felt any endonasal work might cause dangerous and unwarranted delay. From the severity of the symptoms we feared meningitis.

THE IMPORTANCE TO THE PEDIATRIST OF INFECTIONS OF THE PARANASAL SINUSES IN INFANTS AND YOUNG CHILDREN[1]

PHILIP C. JEANS, M.D.

A VERY large part of the work of the pediatrician concerns infections, even in the field of infant nutrition. A large proportion of these infections consists of, or results from, upper respiratory inflammation. For many years the importance of diseased tonsils and adenoids has been realized, both in their direct and indirect effects. That paranasal sinus infection is of equal importance is realized but incompletely. This is due to the more recent recognition of the rôle of sinus disease and to the fact that the knowledge of its importance has not been disseminated sufficiently.

That sinus disease occurs with considerable frequency in certain parts of this country has been shown by a number of observers.(1–11) The opinion is encountered that there is a tendency to overemphasize its importance in children, because it is a new idea and therefore a new panacea, and that it can only take its proper place after it has withstood the test of time. To some extent this may be true. It is also possible that this opinion arises chiefly in those sections where sinus infection is uncommon for climatological reasons. To one working in a region in which sinus disease is common and in association with a rhinologist who recognizes sinusitis readily, it seems difficult to exaggerate its importance. Improvement following the treatment of sinusitis in many instances has been so definite and marked as to be convincing as to the rôle this infection had played. To see a child with deforming arthritis associated with severe bouts of fever become comfortable and afebrile and to see function gradually restored as a result of treat-

[1] From the Department of Pediatrics, College of Medicine, State University of Iowa.

ment of sinus disease is impressive, especially when in former years one has been accustomed to see all efforts unavailing and the disease become progressively worse.

The local and general effects of sinusitis have been described[1–18] in our current and recent medical literature. To consider them here in any detail would be tedious. That part of these descriptions concerning the remote effects of sinusitis might be summarized in part by stating that any condition which may result from a focus of infection may result from sinus disease. Among such conditions may be included the following: Cardiopathies, rheumatic fever, chorea, nephritis, pyelitis, certain cases of cyclic vomiting, deforming periarthritis, anemia, anorexia, malnutrition and chronic digestive disturbance. To these also may be added certain cases of neuritis and possibly erythredema (acrodynia).

Certain remote effects seem more or less peculiar to sinus disease. Several writers have emphasized the relationship between sinusitis and subacute laryngitis, bronchitis, bronchiectasis, some pneumonias and certain cases of asthma.

The possible symptoms and more or less local effects may be enumerated as follows: Nasal discharge, nasal obstruction, epistaxis, sneezing, constant colds, pharyngitis, otitis, mastoiditis, catarrhal deafness, dizziness, cervical adenitis, chronic cough without lung pathology, headache, pains in the face and teeth, occult and recurrent fever, orbital cellulitis, retrobulbar neuritis, corneal ulcer, uveitis, epiphora, cavernous sinus phlebitis, meningitis, brain abscess, poor general health, sallow complexion, irritability, lethargy, lack of initiative, depression of cerebration and memory, poor school progress, hypersensitiveness, nervousness and inordinate fear of examination. The above enumeration represents a compilation from the literature to which reference has been made. Surely this is an imposing array. Of course, but few of these conditions will be found in any one patient, though they are to be found in almost any combination. The conditions here listed do not represent an overstatement of fact. With the exception of the eye and intracranial complications, the majority of the named conditions has been observed in our children's hospital during the past winter in association with sinusitis, and the conditions have been traceable more or less directly to this infection.

It is not possible in such a paper as this to consider all of these phases of sinus disease. A few outstanding features only can be discussed.

An important manifestation which has been touched upon but lightly in the literature is an acute illness in infancy with symptoms referable chiefly to the gastrointestinal tract and of such severity that death results if the condition is not relieved. In order to clarify the discussion of this condition I wish to digress for a moment to refer to a group of cases observed in our clinic and falling under the head of masked mastoiditis.[19] In the course of the past winter we have seen several infants who suddenly developed symptoms of "cholera infantum" with diarrhea, fever, dehydration, intoxication and sudden marked weight-loss, and who were proven to have acute mastoiditis, though the local signs by which mastoiditis might be diagnosed were insignificant or almost totally lacking. In those instances in which the mastoids were operated upon and in which recovery took place the convalescence was rapid, and within a few hours of the operation very definite and marked improvement could be noted.

W. F. M. was an infant, two months of age, at the time she developed symptoms exactly similar to those just related and recovered equally promptly upon treatment of acute paranasal sinusitis.

It is not sufficiently appreciated that confined infection in infancy may cause such an acute disturbance with symptoms almost wholly referable to the gastrointestinal tract and frequently leading to death if the infection is not found and treated adequately. Nor is it appreciated that such infection usually is located in connection with the upper respiratory tract. Dean[16] has reported several instances in which death in infancy seemed to be due to sinus infection exclusively.

The above-named patient, W. F. M., at a later time illustrated the effect of chronic paranasal sinus infection upon nutrition in infancy. After being at home for a time her infection recurred subacutely and she was returned with stationary weight, refusing or regurgitating much of her food and apparently feeling miserable. Without any essential change in her diet all of the symptoms were relieved by treatment of the sinus infection.

In the publications mentioning gastrointestinal disturbance in relation to sinusitis, the prevailing conception is that the digestive trouble is due chiefly to swallowed secretion. This scarcely seems a suitable explanation. In the mastoiditis cases referred to, swallowed secretion could not have been a factor. Infection alone probably is the chief factor in the sinus cases as well, whether it be acute, subacute or chronic.

In the presence of rheumatic fever, chorea and heart disease, we are in the habit of thinking first of the lymphoid tissue of the throat as the site of an infectious focus. Nevertheless, everyone is familiar with the failure of tonsillectomy to prevent recurrence in many instances. Numerous examples might be cited indicating that upon sinusitis also rests some of the responsibility. Two such examples will suffice.

D. S., aged nine years, had chorea of four months' duration. She had had a complete tonsillectomy and adenoidectomy at seven years of age. In addition to chorea, she was found to have a moderate secondary anemia and to be 10 pounds underweight. As foci of infection, every paranasal sinus was found filled with pus, so thick in the maxillary sinuses that it was aspirated with difficulty.

G. Y., aged seven years had chorea. The tonsils had been removed, some small stumps remaining. In addition to the chorea there was a very moderate mitral insufficiency, well compensated and apparently inactive. She was markedly underweight and had a secondary anemia. Chronic ethmoiditis was diagnosed. In about a month she had recovered completely from the chorea and seemed to be in excellent condition. The tonsil stumps were then removed. It was expected that the sinus disease would clear. She seemed to be quite well for two months, when she began to have fever and cough. After ten days of illness she was seen again and found to have acute endocarditis. No possible focus was found except the sinus disease which had persisted. Convalescence was rapid following active treatment of this infection.

In 1923 Marriott and Clausen[20] pointed out the relationship between sinus infection and parenchymatous nephritis (nephrosis). All of the nephrosis patients studied had sinusitis and the causative

organism was found to be a staphylococcus. The interrelationship was shown by the prompt disappearance of albuminuria and edema upon free drainage of the sinuses. In February of this year Aldrich[21] reported 3 cases of nephrosis, in all of which patients sinusitis was found and prompt recovery followed free drainage. In 2 of these patients Staphylococcus albus was found in the pus. Apparently the third was not cultured. During the past winter we have dealt with 3 cases of nephrosis; in all 3 maxillary sinusitis was found; in 2 cases the pus was quite thick; the third case, definitely convalescent, showed but flakes of pus, though staphylococci were found to be present. For some reason pus from the first case produced no growth in culture; staphylococci were grown in the second case. The first patient died from streptococcus septicemia. The other 2 have been operated upon so recently that no further statement concerning them can be given.

The interrelationship between hemorrhagic nephritis and infection is undisputed. The infectious agent probably is a streptococcus in all instances and its source is usually the tonsils. However, several writers have reported cases in which the sinuses seemed responsible and the following case will serve to illustrate this same point:

H. B., a boy, aged ten years, admitted to the hospital December 8 with acute hemorrhagic nephritis, of which the first symptoms were noted November 19. A uremic attack occurred November 30. Upon admission the urine was bloody and contained many casts. He improved with bed-rest and dietary care, and on February 10, when all evidence of nephritis had disappeared, he was submitted to tonsillectomy, chronic tonsillitis having been diagnosed. Immediately following the operation signs of nephritis reappeared. These all disappeared in two weeks and after two weeks of freedom from signs he was allowed to go home. He returned for observation April 8, at which time many red cells were present in the urine and it was quite evident that the nephritis was active. The urine became negative within a few days. On April 18, at operation, he was found to have pansinusitis. The operative procedure was followed by another mild exacerbation. Within a week all evidence of nephritis had disappeared and the boy has remained well until the present time. It cannot be said that this boy's troubles are over, but it is evident that

a focus of infection existed after a clean removal of the tonsils and adenoids and that foci were found in the sinuses.

Many writers have reported instances of headache due to sinus infection. The following case may serve to emphasize this point:

J. W., a boy, aged eight years, complained of headache and loss of appetite and he was suspectedof having tuberculosis. The complaints were of one year's duration. At first the headaches had been about once a week. They increased in frequency until they were occurring daily. After three weeks of study and observation he was permitted to go home undiagnosed and untreated. He returned two months later at our request, at which time chronic suppurative disease of the ethmoid and sphenoid sinuses was diagnosed. The tonsils and adenoids had been removed at five years of age. Temperature at times between 100° and 101° F. was a feature of both periods of observation. Following active treatment of the sinus infection he was dismissed. A communication, six weeks later, states that he has been entirely free from headaches since going home and that he is improving physically.

Although asthma has been studied intensively by a considerable number of investigators, our information concerning this condition is still in an unsatisfactory state. Without entering into the details and merits of the arguments concerning the etiology of asthma, it may be stated that a relationship exists between nasal infection and asthma in some cases and that this is attested by a considerable number of trustworthy observers. Our own experience supports such a conclusion. During the past winter in several cases of long-standing and frequently recurring asthma the patients have been relieved by drainage of the paranasal sinuses and at the last report were free from attacks. One of these has been free since September and another since December.

In the cases here reported the rhinological diagnoses were made and the operative treatment carried out by Dr. L. W. Dean. Numerous other instances of the effects of sinus infection might be cited from our records, but this would be largely a repetition in different combinations of the various conditions and symptoms already noted. Nothing original is claimed for any of the observations presented, but if this review serves to attract a little more attention to this phase of focal infection in childhood, it has served a useful purpose.

References

1. Dean, L. W.: Infections of the Paranasal Sinuses in Infants and Young Children, with Special References to Adenoids and Chronic Tonsillitis as Etiologic Factors, Ann. Otol., Rhinol. and Laryngol., 1918, xxvii, 534.

2. Dean, L. W., and Armstrong, M.: Nasal Sinus Disease in Infants and Young Children, Including Bacteriologic Study, Ann. Otol., Rhinol. and Laryngol., 1919, xxviii, 452.

3. Oppenheimer, S.: Accessory Nasal Sinuses of Children, Jour. Am. Med. Assn., 1919, lxxiii, 656.

4. White, F. W.: Pathologic Nasal Accessory Sinuses in Children, Ann. Otol., Rhinol and Laryngol., 1921, xxx, 221.

5. Cleminson, F. J.: Nasal Sinusitis in Children, Jour. Laryngol. and Otol., 1921, xxxvi, 505.

6. Mitchell, E. C., and Shea, J. J.: Nasal Sinus Disease in Children, Arch. Pediat., 1922, xxxix, 230.

7. Dean, L. W.: Paranasal Sinus Disease in Infants and Young Children, Southern Med. Jour., 1922, xv, 846.

8. Arbuckle, M. F.: Systemic Manifestations of Suppurative Disease in Paranasal Sinuses, Jour. Am. Med. Assn., 1923, lxxxi, 741.

9. Strachan, J. G.: Chronic Sinusitis in Children, Canadian Med. Jour., 1923, xiii, 807.

10. Jones, A. C.: Accessory Sinus Disease in Children, Northwest Med., 1923, xxii, 339.

11. Dean, L. W.: The Diseases of the Nose and Paranasal Sinuses, Abt's Pediatrics, Philadelphia, W. B. Saunders Company, 1924, iii, 728.

12. Byfield, A. H.: Systemic Manifestations of Chronic Nasal Sinus Infections in Childhood, Jour. Am. Med. Assn., 1918, lxxi, 511.

13. Webb, G. B., and Gilbert, G. B.: Bronchiectasis and Bronchitis Associated with Accessory Sinus Disease, Jour. Am. Med. Assn., 1921, lxxvi, 714.

14. Mullin, W. V.: The Accessory Sinuses as an Etiologic Factor in Bronchiectasis, Ann. Otol., Rhinol. and Laryngol., 1921, xxx, 683.

15. Lemere, H. B.: The Diagnosis of Nasal Sinus Disease in Children, Arch. Pediat., 1922, xxxi, 601.

16. Dean, L. W.: Complications of Paranasal Sinus Disease in Infants and Young Children, Ann. Otol., Rhinol. and Laryngol., 1923, xxxii, 285.

17. Byfield, A. H.: Systemic Effects of Chronic Infection of the Upper Respiratory Tract, Abt's Pediatrics, Philadelphia, W. B. Saunders Company, 1924, iii, 778.

18. Coakeley, C. G.: Paroxysmal Cough, a Frequent Symptom of Infection of the Paranasal Sinuses in Children, Southern Med. Jour., 1924, xvii, 38.

19. Floyd, M. L.: Masked Mastoiditis in Infants, Arch. Otolaryngol., April, 1925, vol. 1.

20. Marriott, W. McKim, and Clausen, S. W.: Intoxications Associated with Alterations in the Physico-Chemical Equilibria of the Body Cells and Fluids, Trans. Am. Pediat. Soc., 1923, xxxv, 205.

21. Aldrich, C. A.: A Study of the Clinical Course of Generalized Edema, Jour. Am. Med. Assn., 1925, lxxxiv, 481.

Discussion

Dr. McKim Marriott, St. Louis, Mo.:

About six years ago, at a meeting of the Journal Club of the St. Louis Children's Hospital, Dr. Jeans reviewed an article by Dr. Dean on the subject of sinus infections in childhood. Up until that time we, like other pediatricians, had an idea that sinus infections were rare in children and that when they did occur the symptoms were entirely local and easily recognized. Dr. Dean's paper emphasized the frequency of sinus infections and the general constitutional effects of such infections. It was evident that we had been overlooking many of them. We asked Dr. Sluder to examine a number of patients then in the wards who presented some of the constitutional symptoms that we now know are frequently associated with sinus disease. He found the sinuses infected in a number of these children, and since that time either Dr. Sluder or some one of his associates has examined all children presenting symptoms which might even remotely be occasioned by infections of the paranasal sinuses. For some time past almost one-half of the patients in the medical wards of the Children's Hospital have been under treatment for some form of sinus infection.

Dr. Jeans mentioned acute nephritis as being one of the diseases caused by sinus infection. We have come to recognize that there are two different forms of nephritis which are common in childhood, and these two conditions are so different as regards etiology and pathology as to constitute practically separate diseases.

One form is acute parenchymatous or tubular nephritis, or "nephrosis," as it is sometimes called. It is accompanied by marked edema, diminished urinary output and albuminuria, but without any change in the blood-pressure and no retention of nitrogen in the blood. This form of nephritis in children is more frequently associated with staphylococcus infections of the nasal accessory sinuses, especially the maxillary sinuses, than any other condition. It has been shown by Clausen that the blood of these patients contains a substance capable of changing the surface tension and that this same substance is excreted in the urine. It appears that this surface-active substance brings about the appearance of edema. When the staphylococcus infections of the nasal sinuses are cleared up by drainage or irrigation the surface-active substance disappears completely from the blood and urine and at the same time all of the symptoms of nephritis, including the edema and albuminuria, also disappear. As far as can be made out

the children become entirely normal again, and remain so unless subsequent attacks of sinusitis occur.

We do not know why staphylococcus infections of the nasal sinuses are more likely to cause nephritis than staphylococcus infections elsewhere. The toxic substance responsible for the edema and the nephritis seems to be produced through the action of the staphylococcus on the body tissues rather than by any product of growth of the staphylococcus itself. Clausen has shown that the serum of patients suffering from edema due to this form of nephritis differs in its physical properties from the serum taken from patients suffering from edema due to other causes. The test consists in determining the weight of a few drops of the serum obtained under standard conditions.

The second form of nephritis is the glomerular or hemorrhagic nephritis. This is the result of streptotoccus infections which, may be in the sinuses, but are more likely to be in the tonsils, adenoids or middle ear or mastoid. In this form of nephritis there is blood in the urine, a high blood-pressure and retention of nonprotein nitrogen. Edema is rarely marked. The blood serum has a normal surface tension. There is a change in the capillaries throughout the body and the condition may often be diagnosed, even without examination of the urine, if the skin capillaries at the base of the nail are observed under the microscope. These capillaries show characteristic changes. Whenever we see these changes a search is made for streptococcus infection and the infection is likely to be found somewhere in the mouth, nose or throat.

Besides nephritis there are many other conditions in children which may be attributed to sinus infection. Indeed, so frequently are the sinuses an important factor in producing disease during childhood that it has become our custom almost as a routine to ask the rhinologist to examine the sinuses of children presenting themselves for medical treatment. A very frequent type of case is the child who is pale and undernourished, has slight evening temperature and occasionally a cough. These children often come in with a diagnosis of tuberculosis and occasionally of malaria. Sinus infections are usually found and when treated the symptoms rapidly disappear.

Many infants with so-called feeding difficulties, who have been tried on all sorts of milk formulas and patent foods, are really suffering from infections in the nose, throat or ears. Many of these infants have infections of the mastoid antrum and cannot be satisfactorily treated until these infections are cleared up by operative measures. In

general, we have come to realize that the pediatrician cannot practice successfully now-a-days without the aid of the otolaryngologist. We now send for the laryngologist as soon as the child comes in with almost any condition. This is a great change from the days when we spent our time feeling pulses and looking at diapers.

Dr. Lewis A. Coffin, New York City:

This is one time when I am unable to sit still until some one else has spoken. The study of sinusitis in children was forced on me many years ago when my daughter, aged ten, fell ill of a disease accompanied by chills and fever. A good pediatrician was called and diagnosed the disease as malaria, and antimalarial treatment was instituted. The treatments had no effect on the disease. I noticed that she was blowing her nose very frequently. Getting my head mirror and looking into the nose I was shocked to see a stream of pure white pus coming from the middle meatus. Dr. McKernon, Dr. Charles H. Knight and Dr. Robert C. Myles were called in consultation. Diagnosis was not altogether agreed upon. Dr. McKernon suggested that if it were his child he should want somebody to explore the head for the source of the pus. I attempted it myself. Under cocaine anesthesia I attacked the middle turbinal, but accomplished little in the way of removal on account of the reaction of the little patient. I constructed a tent into which was thrown steam medicated with benzoine. The nose was sprayed frequently with weak solutions of cocaine and adrenalin. Marked relief was apparent at once and complete recovery soon followed.

About the same time there came into my clinic two boys, about nine years of age, both suffering from intense headache, proptosed eyes and nasal discharge. I did complete Killian operations, except for the fact that no bridge was saved. I was criticised when rather boastfully telling how I had entered the sphenoid of a boy nine years of age through an external incision. I was told that it could not be, because children of that age had no sphenoids. I down hard; and accordingly, after obtaining permission to work at the city morgue, I dissected about twenty heads of children from intrauterine life to the age of puberty to find that they did have sinuses, as set forth in a paper read at Chicago in 1904, in which I was able to publish the first pictures ever shown of children's sinuses. I felt I had something of importance to present to the pediatricians and got myself invited to read a paper before the Section of Pediatrics of the New York Academy of Medicine, showing by slides pictures of my anatomical findings

and pictures of the two boys before and after operation. There was absolutely no discussion of the paper. I felt a bit downhearted and discouraged; but I was somewhat bucked up in spirit when, coming down in the elevator, I heard Dr. La Fetra, whom I saw before me, say that he had learned a great deal and thought now he was able to understand many headaches that he had been unable to explain; but the message seemed to have fallen by the wayside, and there seemed to me for a long time little growth of interest. I found a short time ago, in looking over some old papers, that I had said in one "that I hoped in time that the signs and symptoms of sinusitis in children would become so well known that a wayfaring man, though a pediatrician, would be able to make a diagnosis," and now it is most gratifying to hear these eminent pediatricians giving such evidence as to the importance to the pediatrician of a knowledge of disease of the paranasal sinuses in children.

About three years ago a pediatrician of good repute in New York had under his care a girl, ten years of age, who had been sick for something over one year, during which time she had suffered at frequent intervals with severe headaches, delirium, vomiting and convulsions. During that year penumonia had been diagnosed two or three times. At one time there was a sudden hemorrhage from the nose, accompanied by a foul discharge. During that year she was in three hospitals, one being the Neurological Insitute, for study and diagnosis. The chest was *x*-rayed, but never the head. Finally, a small fluctuating tumor appeared on the side of the nose near the inner canthus of the eye. At this time she was brought to my clinic at the Manhattan Eye, Ear and Throat Hospital and a diagnosis of pansinusitis was made. Complete recovery followed the treatment of the sinuses. There has never been a recurrence of the sinus trouble, and in fact the little girl is perfectly well up to the present time. I have cited this case as showing how important and timely has been this paper of Dr. Jeans', and, gentlemen, this paper has been like music to my ears.

Dr. Cornelius G. Coakley, New York City:

I am very glad to know the pediatricians are alert to these sinus infections. We see a lot of them. I know sometimes it is difficult to make a diagnosis in the very young children. I should be very glad to have the President give us enlightenment in the matter of diagnosis.

Dr. Edwin McGinnis, Chicago:

It is certainly refreshing to listen to a discussion by pediatricians of nasal sinus infection, because it makes for coöperation and progress. Dr. Marriott's work with nephrosis and nephritis corroborates some experimental work I have done with bacteria isolated from the nasal cells of asthmatic and kidney cases. The Staphylococcus aureus hemolyticus recovered from the nasal cells does not produce abscesses, but stimulates a round-cell infiltration.

Dr. John Ruhräh, Baltimore, Md.:

I have listened to this discussion with a great deal of pleasure. Those of us in active pediatric practice realize that in seeking the cause of many symptoms we have to look much further than the region where the trouble is located by the patient. The association of kidney disease with infected tonsils and sinuses is well known and the relief afforded by removing the infection through surgical methods is one of the most striking things in infantile therapeutics. Recurring abdominal pain in children is one of the most puzzling conditions with which we have to deal and I was very glad to hear what Dr. Jeans and Dr. Marriott had to say on this subject.

Dr. John E. Mackenty, New York City:

Will the doctor please tell us exactly what operation was done on some of these cases reported in the paper? I would like to know how extensive the sinus disease was and how much was done; whether or not the disease was mostly in the maxillary sinus or in all the sinuses and what operative procedure was followed out in some of the cases mentioned.

Dr. Harris P. Mosher, Boston, Mass.:

I wish to express my own appreciation, and I take it upon myself to go a bit further and express the appreciation of the members of the society to the two gentlemen who have come here today and given us these papers, which I know are illuminating to all of us.

The first speaker said that there was an impression abroad that the question of sinus disease in children had been perhaps overemphasized. The second speaker left me with the impression that there was no possibility of overemphasizing the importance of this condition. Somehow, I rather agree with the first speaker.

Frankly, when Dr. Dean began this work, I could not bring myself to believe that the ordinary dirty nose of an undernourished child

could be responsible for all the ills laid to it. We have today the larger of the sinuses, the maxillary, dwelt upon, with actual demonstrable pus coming from it, and it appears to me that we have cause and effect in such cases better than when we have the ordinary condition that we used to call "dirty nose."

It has been suggested that the incidence of sinus disease may be different in different parts of the country. That may be the reason that in my part of the country we have not found this condition with its complications as frequently as they have been found in the West. That is an easy explanation and I cannot help feeling that there is something in it, but it would be worth while for some one to look up the epidemiology of sinus disease.

The first speaker referred to a masked mastoiditis. The second speaker referred also to mastoiditis. What is a masked mastoiditis? How do they detect it? The results given by our two invited guests were very striking, especially the results given by the second speaker; in other words, the cases of nephritis.

Dr. Henry L. Swain, New Haven, Conn.:

It has been delightful to have listened to Dr. Coffin's brilliant remarks, having thus heard from the grandfather of sinus diseases in children with his co-workers sitting in the chair and around the room. It would seem that the chairman ought to have something to say before we close this discussion.

I rise to ask the foolish question of Dr. Marriott whether this substance that he finds in the blood of the staphylococci-infected individuals, which makes it drip differently from normal blood, is capable of detection by a wayfaring man, though not a pediatrician?

President Dean:

It has been a great pleasure for me to listen to the discussions of Dr. Jeans and Dr. Marriott.

Dr. Mosher asked Dr. Jeans how mastoiditis in certain infants was diagnosed. I would answer Dr. Mosher's question for Dr. Jeans by citing an incident that has occurred in the last month and a half. Dr. Jeans telephoned me, saying: "One of the juniors on your staff has examined an infant that we thought had infection about the head, probably mastoiditis. He reported that there was no sinus or ear infection present." Dr. Jeans asked: "Would you mind operating on the ears in the absence of evidence of acute infection? We think this gastrointestinal upset is the result of some infection about the ear or upper respiratory tract." Following this conversation with

Dr. Jeans, I examined the infant and found a slight bulging of the posterior superior wall in each external auditory canal. The drumhead was quite negative. The infant was operated on. A bilateral acute suppurative mastoiditis was found. The gastrointestinal upset disappeared and the child got well.

Many of the diagnoses of sinus and ear infection in our service are made because the pediatrists insist that the cause of the trouble is in the otolaryngological field.

Dr. Marriott:

The means of detecting these substances in the blood are a specially constructed dropping apparatus and a chemical balance. The procedure is very simple and requires only three or four drops of serum.

The substance seems to be a protein derivative. It is soluble in alcohol and in water, but insoluble in ether or chloroform. Its exact nature is only of academic interest, as it is not necessary to isolate it in pure form in order to make a diagnosis, and furthermore the substance disappears when the sinus infections are cleared up.

There is just one other condition I would mention. Recently we have had two patients in the hospital who presented all of the symptoms of encephalitis lethargica. They were sent in with that diagnosis. One had a paralysis and a ptosis, and the other a partial hemiplegia. Both were found to have sinus suppuration and all of the symptoms disappeared following active treatment of the sinuses.

In the diagnosis of sinus or mastoid antrum infection we go on the general symptoms. We have often asked the otologist to open the mastoid antrum in infants. He has asked: "Which antrum?" and we do not know, but tell him: "If it is not one it is bound to be the other," and to open which ever one he thinks is most likely to be involved.

Dr. Jeans (in closing):

The details as to which sinuses were involved in the reported cases are noted in the case reports. In the nephrosis cases the maxillary sinuses were affected. The important point, probably, is the type of infection rather than the location of the sinusitis. Pansinusitis was present in the reported case of hemorrhagic nephritis.

Dr. Dean and Dr. Marriott have answered the question in regard to the diagnosis of masked mastoiditis. I might add that, in the beginning, the association of acute diarrhea and mastoiditis was recognized by necropsies. As a result of such observations the occurrence of the clinical picture described became an indication for drainage of the mastoid antra.

A PLEA FOR THE ONE-STAGE OPERATION IN TOTAL LARYNGECTOMY, WITH A DISCUSSION OF THE IMPORTANT POINTS IN ITS MANAGEMENT. DEMONSTRATION OF A NEW ARTIFICIAL LARYNX

J. E. MACKENTY, M.D.

In 1908 I took up the study of laryngeal cancer from a surgical standpoint. Gluck's classical work influenced my selection of the one-stage operation, to which I have steadfastly adhered ever since. My several years' experience in general surgery made Gluck's procedure seem the most logical, since the tendency in general surgery, then as well as now, was and is toward dealing with any given disease by one single effort. The older members of this Association may recall the reverse of this in our own specialty twenty years ago, when weeks were consumed in removing polypi, when tonsils were taken out piecemeal and the submucous on the septal cartilage was a procedure of some magnitude and a surgical entity. Now the entire sinus field may be attacked in one operation, the submucous being only a step in securing a better approach.

Going back into more ancient history, cancer of the larynx, from being nibbled at by the indirect method, was more boldly attacked by laryngofissure, and finally, on this pyramid of experience, laryngectomy came forth as a fixed procedure in the majority of cases and on a par in every respect with the best general surgical effort of the time. The one-stage operation seemed to be fixed and well established until it became apparent that the operative mortality was out of proportion to that obtained in major surgical procedures in other fields. To obviate this the multiple operation, in two or more stages, was created and has justified to some degree its existence in lowering the excessive mortality.

In reviewing the literature of this subject it becomes apparent that there was a great discrepancy in the mortality of the one-

stage operation in the hands of different operators. Gluck was so successful with the one-stage operation that he strongly advocated it and reported a considerable number of consecutive cases without a single surgical mortality. After a long experience with this operation I became convinced that the essential points in its technic and postoperative management were never completely worked out and its dangers overcome. Gluck perhaps came closer to solving the problem than anyone in his time or for a long time after.

In the cases with obstruction a two-stage operation is inevitable, since a preliminary trachectomy must be done in order to restore the patient's equilibrium in general and his pulmonary circulation in particular. No surgeon would be so rash as to do an immediate one-stage operation on a patient with embarrassed respiration. This preliminary trachectomy is, however, not a two-stage operation, as I understand it. In my own obstructed cases a medium trachectomy is done with the idea of excising with the larynx the tracheal area through which the cannula passes, thus reverting to the one-stage operation in practically all its details. The object aimed at is the securing of a fresh, healthy tracheal stump for union with the skin.

This skin-trachea union is of paramount importance to the patient during the remainder of his life, obviating as it does in nearly all cases the necessity of wearing a tracheal cannula. The avoidance of a permanent cannula and of the misery to the victim of multiple operations are two sufficient reasons for the one-stage operation, providing we can establish that its safety is on a par with the multiple-stage operation. Ninety one-stage total laryngectomies have been done by the author with 2 mortalities in the first 13, giving 77 consecutive cases without a surgical death. The 2 mortalities were in diabetics. Added to those 2 is a third, a syphilitic diabetic who died of embolism when the wound was almost healed. I feel in justice to the operation that this case should be excluded from the mortality list.

The low mortality compared with that of ten or more years ago is, I feel, a distinct triumph for surgery in this dangerous field and justifies the surgical principles which have grown out of the careful study of many operated cases.

These surgical principles I shall now enumerate and shall elaborate:

1. A careful study of the patient's general condition and of the metabolism, especially as shown in the blood chemistry. Patients with pronounced and irremediable metabolic imbalance are rejected.

2. Digitalization just prior to the operation in all cases in which cardiovascular degeneration is suspected.

3. Careful dieting and colonic lavage for at least one week preceding the operation.

4. Mouth hygiene. The extraction of all diseased teeth and the treatment of diseased gums. Practically all mouths are unclean at the age at which cancer occurs. The entire absence of teeth is a distinct advantage.

5. The combination of local and general anesthesia; the latter not to exceed one-half hour in time.

6. The absolute exclusion of blood from the trachea during operation and of wound drainage after operation.

7. The placement of wound drainage so as to block extension of infection into the planes of the neck and the careful management of this drainage during the convalescent period.

8. The anchoring of the trachea in the lower angle of the wound and the corking of the trachea to exclude wound drainage during the whole convalescent period.

9. The use of suction for wound cleansing and for clearing the trachea of secretion. Inspicated secretions sometimes lodge at the tracheal bifurcation causing serious embarrassment to respiration. These should be removed with the bronchoscope.

10. The use of the naso-esophageal feeding tube extending only half way down the esophagus. This secures a liberal diet from the start.

11. The dressing and care of the wound by the surgeon himself, and not by an assistant or staff doctor probably untrained in this work. All one's experience in the handling of infected wounds is required in forstalling a serious septic invasion. The surgeon must be at least one jump ahead of the infection else he loses out in the struggle.

The surgical principles, five, six, seven and eight, need some elaboration.

Five. A very satisfactory regional anesthesia can be secured with a 0.5 to 1 per cent. novocaine and adrenalin (♏x to the ounce). About one ounce or less is required. The injection is made over and around the site of operation. Paravertebral anesthesia gives an extensive complete and lasting anesthesia when successfully applied, but its dangers offset its advantages. It is possible to complete the operation without resorting to general anesthesia by either the paravertebral or regional methods. Here the tremendous nervous strain, even in the entire absence of pain, is in itself a grave depressant which has a much more serious consequence than the effect of a short period of general anesthesia. Hence I am a strong advocate of the beneficent effect of complete unconsciousness from the moment the trachea is severed from the larynx until the hypopharynx is closed. The patient remains in a somnolent condition during the completion of the operation without the further administration of ether. The combination of local and general anesthesia, I am convinced from actual experience, minimizes shock.

Six. Blood in the lungs with the larynx out and expulsive cough abolished, acts like a septic foreign body. Hence not a drop should be allowed to enter. Under local anesthesia, the operation is carried to the stage where the trachea is severed from the larynx. Then a rubber-tube extension is fitted into the trachea and the general anesthesia given. A set of such tubes, graduated in size is used. They are made slightly conical at the inserted end, so that a tight fit between trachea and tube is secured.

Seven. Four vulnerable points are drained: Two lateral to the hypopharyngeal closure and two lateral and diagonally outward from the tracheal stump. A small, fairly rigid double tube, open at the distal end and with four perforations close to this end is wound with gauze to the size of a large pencil. Four such drains are placed in the four pockets mentioned above. In the earlier cases these areas or pockets were drained in the ordinary way. In two or three days the drains became foul and had to be replaced. This replacement occurred during the local reaction period when the tissues of the neck were swollen. When the drain was removed

the pocket immediately closed, making replacement almost impossible. The consequence was infection beyond the end of the drain. To obviate this the drains are now left in until the reaction period is over (five to seven days), and are kept active and clean by washing the tubes and gauze with a saline solution forced through by gravitation and brought out by suction. By closing one of the double tubes with a clamp and forcing the saline through the other tube, the gauze surrounding the tubes is cleansed and restored to activity. This is done as often as indicated, from two to three times in twenty-four hours. The cleansing of the drains is begun on the third day.

Eighth. The trachea must be tightly corked so long as there is any secretion coming from the wound or until the wound has closed. Bismuth vaseline gauze is wound about a large cannula so as to form a cone with the small end downward. Later, paraffin gauze is substituted, since it has been observed in a few instances that bismuth causes tracheal irritation when its use is continued for a long period.

The artificial larynx here exhibited was worked out with the assistance of the Western Electric Company's laboratories. Great difficulty was experienced in producing a voice approaching the human in pitch and quality. This we have done. Some patients using it have even succeeded in giving the tone a degree of modulation. The apparatus is simple in construction and in operation and practically indestructible. I am hopeful that it may bring more of these doomed victims of cancer to see the radical cure in a more favorable light.

None of the complications attributed to the one-stage operation have occurred in the author's series, since the 2 deaths mentioned. These complications are septic bronchopneumonia, lobar pneumonia, general sepsis, mediastinal infection and pneumogastric block.

The advantages of this method are that the patient has but one ordeal to face and that a tracheal opening is secured, with skin and mucous membrane in union—contraction of the opening is thus minimized. In 80 per cent of the cases no tracheal cannula is worn after the third month.

Discussion

Dr. John E. Mackenty, New York City:

I would like to demonstrate to you two types of voice restoration which we have in these two laryngectomized cases. One is a man whom I operated on ten years ago for the removal of his larynx for an extensive carcinoma which fortunately did not recur, due, perhaps, to the excessive sloughing which occurred in his neck following operation. Two or three years after the operation he began to develop a voice and surprised me one day by telephoning me, telling me who he was.

There is a feeling among some men that these patients are derelicts and do not want to live. I failed to find one who was not content to live. This man uses this apparatus very well. He can speak in an ordinary-sized room. He carries on a wholesale business in New York, in which he has to use the telephone, and he talks to a lot of people every day. He is very well content with the result of the speech he has. He has a low whisper without the larynx and uses the whisper with his family.

Dr. D. Bryson Delavan, New York City:

The demonstration just submitted to us possesses rare interest for me. The points to be discussed in connection with it are so numerous that one is embarrassed to know where to begin. Since Watson, in 1868, performed the first operation for complete laryngectomy, large numbers of patients have been subjected to it, at the hands of many surgeons, in different parts of the world. In many instances the operation has been undertaken with little or no previous experience on the part of the surgeon, with the assistance of attendants often inexperienced in that class of work. Where in the hands of one man, few cases have been operated upon, the results have often been so unsatisfactory as to cause the surgeon to cease further efforts.

A number of years ago I called attention to the evil results of such desultory work. Undoubtedly some cases were successful and life was prolonged; but, estimating the duration of life in a case of laryngeal carcinoma to average two years from the early appearance of the disease, it seemed probable that, on the whole, the number of cases in which life had been actually shortened through the results of operation was in excess of those prolonged. Thirty years ago, in a symposium before the Laryngological Section of the British Medical Association, in London, contributed to by Sir Henry T. Butlin, Felix Semon,

Dundas Grant, John N. Mackenzie and others, I advanced the following proposition, namely, that capital operations upon the larynx are difficult and peculiar, and that they require special knowledge, skill and experience. The reason why little progress had been made up to that time was because every one and any one operated upon anything that came in his way. Proper records were seldom kept, and the reports of unsuccessful cases were seldom published. It was, therefore, impossible to secure reliable statistics. I asserted that the matter had reached a point which placed it almost beyond the pale of individual ambition, for such patients were usually too poor to appeal to the acquisitive man and the operation had been so often performed that to lose a patient or two for the sake of having done it had long ceased to bring anything but discredit. The majority could well afford, therefore, to exercise a fair amount of self-denial if by so doing the general good might be promoted. I strongly urged that, for a time at least, both the welfare of the patients operated upon as well as the interests of science demanded that the indiscriminate performance of capital operations upon the larynx should cease. In most great centers there were individual surgeons or groups of operators who were especially well fitted, both as to personal qualifications and hospital facilities, for the successful performance of this work, as had been proved in several cases by the records which they had already made. Let such men surround themselves with the proper assistance; let them systematize their efforts and use all diligence in the perfecting of appliances and methods and in the study of the cases under them; let them keep careful and accurate records of everything pertaining to the history of their work, following it to the end. Then resign to them temporarily the care of as many cases of laryngeal cancer as possible. When a sufficient amount of material has been collected, let them place it upon a substantial scientific basis, recording one advance after another as made. When satisfactory knowledge has been established, let them give to the public the results. Under this system we would soon learn whether the radical extirpation of laryngeal epithelioma was on the whole unjustifiable, or whether, as we had the best reasons for hoping, it had already proved a substantial success. Such an example in a limited way had already been set in London. It would be fortunate, indeed, if it could be followed in other parts of the world.

Since these statements were made, in 1895, the first one to seriously take the matter in hand was Gluck, of Berlin. About twenty years ago he began to devote a great amount of care and effort to the

subject of total laryngectomy and operated upon a great many cases. At first his results were unsatisfactory. Moreover, he did not publish his statistics. To this his confrères offered serious objection, believing his results were very unfavorable. Later, however, with improved technic and greater experience he met with better success. He adopted in the main the principles utilized by Solis-Cohen in his celebrated case, the first of its kind operated upon in this country, in 1884, the patient surviving eleven years and dying without recurrence.

For many years it was my ardent hope that the example of Gluck would be followed by others. Today Dr. Mackenty has brought about this very thing. He has specialized upon the surgery of the larynx, has worked with greatest energy and intelligence in developing the best procedures, and has shown a high degree of self-sacrifice, as any surgeon must, in personally assuming the after-care of these very harassing cases. The large number of cases which he has observed, almost one hundred, at once places his statistics in a position of importance. They speak for themselves. Whether or not we may agree with all the details of his operative methods, he certainly has achieved an exploit for which we owe a debt of gratitude. It is to be hoped that the example of thus centralizing the work may be extensively followed.

Like other complicated and dangerous surgical operations in general, laryngectomy is no work for the tyro. In all other departments of life careful preparation is required before grave responsibilities are allowed to be assumed. One who wishes to undertake such operations should become thoroughly grounded in them, best of all, as assistant to an operator of acknowledged skill, according to the principle universally carried out in the best clinics of the world.

With regard to the apparatus for reproducing the voice: At the International Medical Congress held at Budapest in 1909, Professor Gluck presented a number of cases upon which he had performed complete laryngectomy and showed a curious apparatus intended to provide tone. It was a small, boxlike affair, somewhat resembling a miniature hand-organ, furnished with a crank, which on being turned caused the instrument to make a very ineffective sound. It impressed one as being unsatisfactory. Dr. Mackenty modestly expresses the hope that his apparatus is but the beginning of something better, leaving room for improvement until a very perfect tone effect is produced. The advance which he has made upon the apparatus of Gluck proves that he has progressed many stages forward.

Until the prevention and cure of cancer by other means than surgery

has been discovered, it would seem that the exhibition this afternoon gives better hope than anything we have ever had before.

Dr. Fielding O. Lewis, Philadelphia:

I always enjoy hearing Dr. Mackenty speak of laryngectomy because I too am interested in this subject. My experience of course does not compare with Dr. Mackenty's. I might say that I follow practically his technic. I have had two mediastinal infections; one in which the patient developed a staphylococcic infection, in which both clavicles sloughed out, and he finally died after a month's struggle. The other case developed abscess in the mediastinum and got well. I have had 51 total laryngectomies and only 2 had infection of that type.

We are fond of using rectal anesthesia, instead of local anesthesia followed by chloroform anesthesia which Dr. Mackenty uses. Rectal anesthesia, given by some one who understands it and is experienced, makes the operation less troublesome to the operator as well as the anesthetist, and so far we have had no difficulties.

The dressings which we use differ somewhat from those of Dr. Mackenty's inasmuch as renewal of dressings starts on the second day, as well as renewal of the drains. Sometimes, of course, it is necessary to renew the dressings two or three times during the day.

I have also enjoyed seeing this artificial larynx. It seems to me much is to be expected from it.

Dr. Vilray P. Blair, St. Louis, Mo.:

I just want to rise to pay a perfectly complete and total tribute to Dr. Mackenty's technic as he has worked it out. I think there is no place in surgery where you are going to live or die by your technic, both operative and postoperative, as you do in laryngectomy.

I have in the past felt that the preliminary tracheotomy and two-stage operation should be the safest plan. I am beginning to feel that its drawbacks may equal its advantages. Some bad experiences with the two-stage operation have brought me in complete accord with Dr. Mackenty's plan. We operate on any case that offers any sort of a fighting chance; therefore our operative death-rate is fairly high, but we have some "cures" on these very advanced cases.

I believe that if you can teach a patient to give a prolonged noisy belch you can teach him to speak without the use of the artificial larynx. Some cannot master the trick.

Dr. Lee M. Hurd, New York City:

I did not hear all of Dr. Mackenty's paper, but I have seen quite a change in the last few years. These cases do get well and do not have recurrence. It is a question of technic. I am still sticking to two-stage operations.

One thing I did want to speak about is the buccal voice: The fundamental point of the buccal voice is that a person has to learn to hold the diaphragm absolutely still while he talks. Unless he does that, he will not have a buccal voice you can hear. Teach him to hold his breath. He will get so that he can use his esophagus. One of the easiest ways is to get a person who smokes and put him back at smoking and have him pull. Then start him off on the fundamentals—a, e, i, o, u—and he will get all the sounds but soft "h" and one or two that do not count. The greatest trouble comes from the question of age. These patients are not willing to take up something new and learn it. They will not try. I had one in the office a week ago and he heaved so hard you could not hear his buccal voice. He simply will not try. That is the trouble with most of them. But I have one who conducts a business over the telephone and has no difficulty except with one or two sounds which he can avoid.

Dr. Mackenty (in closing):

The pictures which I showed you were not a complete exposition of technic; they were shown to prove certain important points.

I am greatly flattered at Dr. Delavan's remarks. Coming as they do from a man of his standing and enormous experience, his praise is most encouraging. I am sure that he overestimates my contribution. I feel grateful to him for his friendship.

The voice without the larynx I think is produced by opening the esophagus. This man I had here gets a stomach full of air, because when his stomach is full of food he can count only to ten, but when it is empty he can count to twenty on one stomach full of air. He fills his stomach with air, as well as the esophagus, and talks on a long belch.

I think that Gluck was much maligned in his time. I think he was ahead of his time. He was the great pioneer that put this work on the map. We owe him a great debt of gratitude for his pioneer work. I saw Gluck operate and I know how expert he was, particularly with his assistant, Sorenson. Their work was wonderfully well done.

I have 4 cases of buccal or stomach speech now, and this man

here presented is the best of the 4. I have another one who speaks louder but not so well. There are two others coming along very satisfactorily.

Dr. Lewis is too modest. He has done some wonderful work in this field. The question of drainage, I think, is of great importance. The method shown makes it possible to leave the drains *in situ* for a week without changing them. Changing the drains during the reaction period tends to spread infection.

This year I got a primary union in a man aged seventy-four years. He was out of the hospital eighteen days after his larynx was removed. He healed without the slightest infection.

I do not know how to control a rectal anesthesia. Perhaps they have a more expert man in Philadelphia, but I think it must be in the hands of a great expert before it is safe.

I want to thank Dr. Blair for his kind remarks and for his support of some of the leading points in the technic which I demonstrated.

Leakage into the trachea is one of the things to be avoided. Instead of leaving the wound wide open, we bring the angles of the incision together under the chin. These two angles must be kept intact. If they break away they must be restored by silver wire in order to prevent a fistula. Therefore, that point must be kept intact during the whole period of convalescence. Of paramount importance is the question of the patient's tissue reaction. This can be fairly well estimated by a blood chemical test. A patient with diebetes, for instance, will never stand the operation. The reason we have had good results is that we have picked the cases carefully and refused a lot of bad risks. If we had taken them as they came along we would have had a great many more deaths.

LUNG ABSCESS; AN OCCASIONAL SEQUEL OF TONSILLECTOMY

EDWIN MC GINNIS, M.D.

TONSILLECTOMY is a very valuable prophylactic and efficient remedial measure, and to its safeguarding we should direct a good deal of our efforts. There are certain accidents and complications that may occur either during the operation or postoperatively, and one among these, namely, lung abscess, is certainly deserving of our attention.

The first medical man to call attention to the possibility of abscess of the lung as a sequel to operation upon the upper respiratory tract appears to have been Charles W. Richardson, of Washington, D. C., who stated in a paper read before his local medical society on March 20, 1912, that he had had several cases of septic infarcts of the lungs following tonsillectomy reported to him verbally, but had found none in literature. He reported, on his own account, 2 such cases; in 1 of these, a man, aged forty-five years, the abscess was successfully opened and drained; in the other, a woman, aged twenty-four years, the patient expectorated a great quantity of foul sputum, from which the streptococcus was cultivated. Both patients eventually recovered.

The following year, 1913, in his thesis presented for the doctorate in medicine at the University of Paris, C. Georges Bassin took a case report from the practice of P. Mortier, of a little girl, aged five years, who developed an intrathoracic abscess following removal of the tonsils and adenoid.

Scudder, the well-known Boston surgeon, in reviewing lung abscesses operated upon at the Massachusetts General Hospital up to the year 1914, remarked: "Attention is attracted to lung abscess following tonsillectomy."

The next year, 1915, Morris Manges, of Mount Sinai Hospital, New York, reported a case of lung abscess which ended fatally

twelve days after the operation. The next year he reported 8 additional cases. He seemed to think that the abscesses were due to carelessness and confined wholly to dispensary and clinic patients.

Shortly after the appearance of the latter paper, Coakley, of New York, took exception to the statement that lung abscess occurred only in clinic practice, for he knew of cases occurring in patients who had the best care.

In 1917, Dr. Ira Frank, of Chicago, presented an extensive paper on this subject.

Following Frank's report, cases appeared in the literature with increasing frequency. The cases were similar and were never reported by the one who had done the operation.

Harry Wessler, in a series of 100 cases of gangrene and suppuration of the lung, reported 21 cases following tonsillectomy. In this same year, 1919, Lilienthal, of New York, reported a brilliant success of extirpation of the greater part of the right lung damaged by posttonsillectomy abscess.

Clendening and Flagg, in 1920, discussed the motor-driven anesthesia apparatus as a causative factor; Clendening condemning it, while Flagg upheld it.

W. F. Moore, Philadelphia, collected a total of 202 cases. In 60 per cent the abscess was located in the right or left lower lobe, thus approximating Jackson's percentage for foreign bodies aspirated into the lungs as finding location also in the right or left lower lobe.

Lambert and Miller tried to produce lung abscess experimentally, but apparently were unsuccessful.

In 91 cases listed as lung abscess in the records of the Presbyterian Hospital, Chicago, 7 cases bear on the subject at hand: 1 case entered the hospital with a diagnosis of lung abscess and the tonsils were removed as a remedial measure—there was some change for the better following the operation; 2 cases followed teeth extractions—1 with a gas anesthesia, the other after tooth extraction and cavity curettage with local anesthesia; the remaining 4 cases followed tonsillectomy with general anesthesia. None of the tonsillectomies were done by staff members. One of the 4 cases lived nineteen days after the operation, which was performed at

another hospital, and died on the day she entered the Presbyterian hospital without any special effort having been made to alleviate the condition; the other 3 cases had external drainage done by means of rib resection and they all had protracted treatment. As to the end result, 2 died; 1 after the lapse of one year and the other four years later. This last one had a long illness with attempts at drainage by three different surgeons. The fourth patient, who is still under treatment, had the tonsillectomy done March, 1922, and rib resection for external drainage, July, 1922. This was done outside of Chicago. She entered the Presbyterian Hospital February 12, 1923. The old incision was opened and rubber drainage tubes inserted February 15, 1923. The wound was still draining March, 1925.

After this somewhat sketchy review of some of the literature, I am led to the report of the following case which I saw as a consultant:

CASE REPORT.—Female, aged about forty years, was admitted to the hospital December 15, 1924, in the evening, preparatory to a tonsillectomy. The following morning, December 16, under gas-ether anesthesia administered by a well-known anesthetist, the operation was performed by a skilled general surgeon with ample assistants. Suction was used. The Sluder technic was employed. As there was a good deal of bleeding, a gauze pack was placed in both fossæ and retained by sutures. The next day sutures and packs were removed, to be replaced because of bleeding. Coagulose was used. Five days later, patient had a severe cough and headache; temperature, 101.4° F. Six days after the operation patient was discharged from the hospital.

January 1, 1925 the cough was more marked and evening rise of temperature was present.

January 7, 1925, patient reëntered the hospital. Chest notes: No thoracic dulness. Tactile fremitus increased over the left side. Temperature, 99.4°; pulse, 90; respiration, 20. No excess sputum.

January 28, 1925. Patient had a chill during the night. Cough nonproductive, but severe. Pain, left side of chest, posteriorly.

January 30, 1925, I searched the tracheobronchial tract, first passing the tube into the right main bronchus, which was found to be dry and odorless. On passing the tube over into the left bronchus a saprophytic odor was observed, but no excess secretion seen. Further

search revealed the lower main bronchus completely occluded by blood-clot. This was broken up with forceps and most of it removed with suction. The next day a considerable amount of mucopurulent sputum was coughed up. Temperature, 101.° F; pulse, 92; respirations, 22. Bacteriological report of material aspirated: No tubercle bacilli, but pneumococci, short chain streptococci, fusiform bacilli present. No attempt made to find mouth spirochetes.

February 18, 1925. An artificial pneumothorax, left side, was produced at the suggestion of another consultant. One week later a more extensive pneumothorax produced so much compression that the chest contents were crowded against the right chest wall and coughing was very severe.

This case is still under treatment and at some future date I shall report the end-result. The conditions were difficult, but very often we have to make the best of a bad situation.

The consensus of opinion as to the etiology of lung abscess appears to be that infected material is aspirated into the depths of the air passages. Davis and Pilot, in extensive studies of the cheesy masses from tonsillar crypts, tartar from the teeth, also discharge from chronically infected ethmoid cells, and lastly coughed-up material from lung abscess cases, found that mouth-spirochetes and fusiform bacilli were present in large numbers. Koessler has confirmed this study. This is essentially a mucous membrane involvement and follows the bronchial branches out to the air cells, and there is very little destruction of lung tissue; hence no large cavity formation. The affected area is softened, and swollen and this was verified in a similar case reported recently by Dr. John Cavanaugh, of Chicago, to the Chicago Laryngological Society in his description of the findings at external operation. Hence, the term abscess denoting large cavity is usually a misnomer.

In my reported case, tonsils were noted to be full of cheesy masses, rather prolonged ether anesthesia, probable aspiration of some of the cheesy material, occlusion of the lower main bronchus with a blood-clot, and the conditions favorable to anaërobic growth were present.

Dr. Carl A. Hedblom has recommended thoracotomy drainage for all cases of solitary abscess not centrally located. For centrally

located abscesses pneumothorax collapse is urged as promoting drainage and lessening absorption and the tendency to extension of the process. It is contraindicated in peripheral abscesses because pleural adhesions may prevent the collapse.

Dr. Lukens, of the Bronchoscopic Clinic, Philadelphia, working with Chevalier Jackson, advocated bronchoscopic aspiration followed by topical applications. Drs. Davis, Koessler and Pilot urge the use of an arsenical intravenously. It seems to me that a combination of the two methods would give an added assurance.

Last, an early chest examination in this case would have revealed some signs of an occluded bronchus, and no doubt there was evidence early. By this means a suspicion of something in the bronchus would have been sensed, for at my examination, six weeks later, there was an entire absence of breath and voice sounds over the left lower lobe. No râles or other adventitious sounds were present. This would have suggested early bronchoscopic intervention to the material benefit of this patient.

Literature Cited

Bassim, C. Georges: Les complications broncho-pulmonaires consécutive á l'adénoidectomie et á l'amygdalectomie, Thèse de Paris, 1913, No. 181.

Chipman, C. N.: Relation of Anesthetic to Pulmonary Abscess Following Nose and Throat Surgery, Jour. Am. Med. Assn., 1922, lxxix, 539.

Clayton, T. A.: Lung Abscess Following Operations on the Nose and Throat, Internat. Clinics, 26th series, 1916, xi, 73.

Clendening, Logan: The Cause of Abscess of the Lung After Tonsillectomy, Jour. Am. Med. Assn., 1920, lxxiv, 941.

Coakley, C. G.: Lung Abscess Following Tonsillectomy, Ibid., p. 1008.

Daland and Judson: Lung Abscess following Tonsillectomy, Tr. Am. Acad. of Ophthal. and Oto-Laryngol, xxi, 1924.

Fisher, L. and Cohen, A. J.: Pulmonary Abscess in Adults Following Tonsillectomy Under General Anesthesia, Jour. Am. Med. Assn., 1921, lxxvii, 1313.

Flagg, P. J.: The Cause of Abscess of the Lung after Tonsillectomy, Jour. Am. Med. Assn., 1920, lxxiv, 1183.

Frank, Ira: On Lung Abscess as a Sequel to Tonsillectomy, Laryngoscope, 1917, xxvii, 474.

Gwathmey, J. T.: The Avoidance of Pulmonary Abscess with General Anesthesia in Nose and Throat Surgery, New York State Jour. Med., 1922, vol. xxii.

Hedblom, C. A.: The Surgical Treatment of Acute Pulmonary Abscess and Chronic Pulmonary Suppuration, with Especial Reference to the Post-tonsillectomy Type, Jour. Am. Med. Assn., 1924, lxxxiii, 1577.

Heuer, G. J. and MacCready, P. M.: Lung Abscess, Arch. Surg., 1923, vi, 337.

Lambert, A. V. S. and Miller, J. A.: Abscess of the Lung, Arch. Surg., 1924, viii, 446.

Lewis, D.: Lung Abscess Following Tonsillectomy, Internat. Clinics, 28th series, 1918, xi, 84.

Lilienthal, Howard: Resection of the Lung for Posttonsillectomy Abscess, Surg., Gynec. and Obst., 1919, xxix, 443.

Lukens, Robert M.: Pulmonary Abscess Following Tonsillectomy. A Cure by Bronchoscopic Drainage, Surg. Clinics North America, 1924, iv, 70.

Manges, Morris: Nontuberculous Pulmonary Suppurations; Their Medical and Surgical Relations, Jour. Am. Med. Assn., 1915, lxiv, 1554. The Occurrence of Abscess of the Lung after Tonsillectomy; with a Report of Nine Cases in Adults, Am. Jour. Surg., 1916, xxx, 78.

Moore, W. F.: Pulmonary Abscess: An Analysis of 202 Cases Following Operative Work About the Upper Respiratory Passages, Jour. Am. Med. Assn., 1922, lxxviii, 1279.

Richardson, C. W.: Abscess of the Lungs Following Operation on the Tonsils and Upper Air Tract, Laryngoscope, 1916, xxvi, 1001.

Richardson, C. W.: Tonsillectomy, with Consideration of its Complications, Washington Med. Ann., 1912, xi, 85.

Scudder, C. L.: Report of the Cases of Lung Abscess at the Massachusetts General Hospital Clinic, Boston Med. and Surg. Jour., 1914, clxxi, 523.

Slyfield, F.: Lung Abscess Following Operation on the Upper Respiratory Tract, Nat. Tuberc. Assn. Trans., 1919, xv, 252.

Weinstein, J.: Lung Abscess Following Tonsillectomy, Med. Rev. of Rev., 1917, xxiii, 589.

Discussion

Dr. Greenfield Sluder, St. Louis, Mo.:

I think that the development of lung abscess after tonsillectomy is dependent to a great extent upon the anesthetic. In St. Louis we have used gas since 1910. We can account for 25,000 cases in which the first 20,000 ran without a lung abscess. Since that time, 2 abscesses have developed, fortunately not fatal. These operations have been done with the guillotine, which permits of rapid execution. The majority of them were done in twenty seconds. The gas anesthetic is so short, consciousness returns quickly, and I believe that to be a definite factor in running as large a number as this with so few complications. No morphine was administered beforehand.

Recently, I was very much interested to see that some gentleman in New York City, whose name just for the minute I cannot recall,

inspected the larynx and windpipe of tonsillectomy patients and found the trachea was uniformly more or less full of blood and that fifteen minutes later all traces of blood had disappeared. Those patients were under ether anesthesia and permitted obviously and readily such an inspection; with gas anesthesia it would be very much more difficult, if not impossible. When I saw this article I thought that we too would like to see what happened. It does not seem to be a feasible investigation.

Dr. Loeb, of St. Louis, has collected statistics. I believe he began four years ago. He sent out a circular letter to a great many of our special workers. I do not know whether the circulation of that letter was limited to laryngologists or not, but he got a great many replies.

To me it was surprising to find the great number of lung abscesses that developed from all sorts of surgery in the upper respiratory tract. It was not at all limited to tonsillectomy, nor was it limited to any special technic.

I can remember clearly that Dr. Coakley described a case as a perfect tonsillectomy under local anesthetic in which there was no possible aspiration and yet which developed a lung abscess. That raises the question, what is the route by which the infection travels?

From Dr. Loeb's responses it would seem that certainly a great deal is carried by the blood stream and follows the local anesthetic. The insertion of the needle for the injection of the anesthetic in all probability carried the infection. Again I desire to emphasize, according to Dr. Loeb's information, the technic of the tonsillectomy apparently played no part. The number has run in St. Louis to 25,000 with 2 abscesses. I do not believe this was due to the fact that these were guillotine operations, I would like very much to think so, but I do not.

Dr. Coakley's case is familiar to all of you present. I wish he were here to give the details about it.

Dr. Lee M. Hurd, New York City:

This winter a man came to me. His family doctor had told him he had chronic bronchitis. He was losing weight. The family physician advised him to have his teeth cleaned and his tonsils out. He came to me with this history and loss of weight. He was coughing up a little more expectoration than he ought to. He had a pair of nasty tonsils and I made arrangements to have them removed. I gave him ether and took out his tonsils. I saw him the second day after and he complained of excessive expectoration. I found he had

an abscess in the right upper lobe of the lung, which he had had two months. The ether made no difference to him. We put him to bed and in five weeks the abscess was well. The abscess cavity was an inch and a half in diameter with a fluid level.

Dr. Harold I. Lillie, Rochester, Minn.:

I am in accord with what Dr. Sluder has said. We hear much, nowadays, about aspiration following tonsillectomy causing lung abscesses. Metastasis of infected thrombi from the peritonsillar vessels producing infarction in the lung must not be overlooked as a causal factor. Fetterolf presented the investigative work along this line last year at the meeting of the American Laryngological Association. I have observed 4 cases of lung infarctions; 1 followed tonsillectomy and adenoidectomy under general anesthesia, and 3 followed tonsillectomy under local anesthesia. In 1 case an abscess resulted, but the patient recovered by natural reparative processes. The symptoms begin in three or four days, initiated by severe sharp pain in the chest. The physical examination, roentgenograms and the fluoroscope will reveal the part of the lung involved. I have never seen an abscess from aspiration, although I know they occur.

Dr. William V. Mullin, Colorado Springs, Colo.:

I am of the same opinion as Dr. Sluder and Dr. Lillie. Dr. Lilienthal analyzed, I forget how many, cases of posttonsillectomy lung abscesses, and there was something magical about the abscess developing between the eleventh and thirteenth day. Dr. McGinnis passed a bronchoscope on his case six weeks after the first symptom. I believe, had this been due to blood or infected material being aspirated, that it would have broken down long before that time. The mass of material he got out through the bronchoscope might have been due to the breaking down of a localized penumonic condition in the lung as the result of an embolus.

I have under my care now a man I am treating by bronchoscopic aspiration, whose lung abscess followed an appendectomy done under ether anesthesia. I know of another case that followed a gastroenterostomy.

One thing about the treatment: Dr. McGinnis spoke about artificial pneumothorax. Some cases have a spontaneous evacuation and drain and heal, others may be amenable to external surgical drainage, and others may be benefited by bronchoscopic aspiration and postural drainage. As the abscess develops into the chronic state there is a

gradual thickening of the abscess wall, and when artificial pneumothorax is instituted, what is quite likely to happen is a collapse of the healthy lung tissue all around the abscess, with the abscess wall resisting the collapse. Therefore, I do not believe this form of treatment helps many cases.

Dr. D. Bryson Delavan, New York City:

Until a few years ago I never heard of lung abscess following removal of the tonsils. I have never had such a case in my own practice, and I never heard of one in the practice of my predecessors and older associates in medicine. Dr. Lefferts, Sir Morell Mackenzie, and the others who removed large numbers of tonsils in their time, never seemed to have experienced this accident. The removal of tonsils in those days may not have been as thorough as it is now; the buried tonsil was not recognized as it is with us; but many tonsils that were evidently diseased were amenable to removal by the guillotine or by the snare, and in those cases the operation brought the same success that attends it today, namely, the relief of present symptoms and the removal or the prevention of the troubles following long-continued persistence of large tonsils. Long before the methods which we now use were employed, I substituted the snare for the guillotine, usually operating under general anesthesia.

One of the questions which arises under this discussion is whether it is necessary to use the very radical measures now employed in all cases where tonsils require removal. There are some tonsils which are easily and effectively removed by means of the snare or the guillotine. I have never been an advocate of the removal of the capsule of the tonsil, believing that no useful purpose is gained by so doing, and that its presence is intended by Nature to be a valuable protection to the pharyngeal wall. It seems possible that some of the accidents now met with might be avoided if the capsule were left intact. Formerly, general anesthesia was not used: local anesthetics were unknown, yet there were far fewer accidents and the final results were good.

Do not misunderstand me as ignoring the value of the more radical procedures of the present when the conditions may require them, as in the case of the buried tonsil and in the prolongation of the tonsillar tissue downward and upon the base of the tongue, as described by French. The recognition of these conditions has marked an advance of incalculable value. Not all cases of tonsillar enlargement, however, are of this class.

Dr. John E. Mackenty, New York City:

I think that Dr. Sluder has covered a very important point in regard to the avoidance of lung abscess by his quick method of operating. There is no doubt the method he uses of getting the tonsils out in a hurry before the patients have lost their reflexes as completely as they do under general anesthesia, must have something to do with the enormous number of cases he has done without lung abscess.

In the slower operations, in which we use a deeper anesthesia, the patient is not given morphine, which is a great mistake before any operation. It retards the return of the protective reflexes which preside over cough and deglutition, allowing the entrance of mouth and wound secretions into the trachea.

The technic which we have used in these operations aims at the prevention of blood from entering the trachea. We use two suction apparatuses. One is held by the anesthetist, who keeps the blood from the posterior wall of the pharynx at all times. The operative area is thoroughly exposed and kept exposed by the anesthetist holding down the tongue with the other hand. The assistant, with another suction tube, keeps the blood away from the point of attack. The patient is kept on the table with the throat exposed and under inspection until the reflexes are reëstablished. All secretions from the mouth and wound are sucked out, so that nothing gets into the trachea until the patient is able to swallow. The patient is put back in bed on the side, not on the back. Morphine is not used before the operation, but is given after reaction from anesthesia has taken place.

I think there is some times something inherent in the patient which predisposes to lung abscess and which the traumatism of the operation may bring out. Otherwise, we would have more lung abscesses by the methods used in taking out tonsils.

Dr. George M. Coates, Philadelphia:

Not all the lung abscesses that develop are attributable to tonsillectomy. The only case I have seen was a case done in another hospital some two months before it came under my observation. I saw it then with the general surgeon, who proposed to do external drainage. The case had a lung abscess and had had the tonsils removed a couple of months before. The lung was satisfactorily drained externally and the person made a good recovery, remaining well until one year later, when he developed another lung abscess on the opposite side without having had any further operative interference in the meanwhile.

Dr. McGinnis (in closing):

In closing the discussion I should like to say that my reason for reporting this case was that it was very unique to me. I felt as some of the members have felt that blood aspirated into the tracheobronchial tree would have been broken down and coughed up long before the six weeks which the facts show in this case. It was very surprising to look down through the bronchoscope and see this plug in the lower end of the bronchus.

I hope Dr. Sluder does not take to heart the fact that I mentioned that Sluder's technic was used in this case. The man who did this operation was a man I had trained in the Sluder method.

I have had the same experience as Dr. Sluder with tonsillectomies with the Sluder operative technic, and have long been an admirer of Dr. Sluder and one of the early ones to take up the Sluder operation. I use two Sluder instruments for the one operation. In that way there is no bleeding until we get rid of both tonsils.

With regard to Dr. Hurd's remarks, I have 1 case in this report of a patient with a lung abscess before the operation. There were 25 cases of lung abscess that had developed spontaneously in this series in the Presbyterian Hospital. They followed acute colds or some lowering of resistance and lung suppuration followed.

Dr. Lillie mentions the fact that you can get an abscess from other means than aspiration.

In answer to Dr. Mackenty, this patient no doubt has had an infection in the nasal accessory sinuses. This may have something to do with this lung abscess in that she may have aspired some of the infected material from the nose at the same time as the tonsillectomy.

Dr. Coates had a similar experience that had nothing to do with the operation.

PACHYDERMIA LARYNGIS WITH REPORT OF AN UNUSUAL CASE

FIELDING O. LEWIS, M.D.

MANY reported cases of pachydermia laryngis are to be found in the literature and its pathology is well estalbished, but in no instance have I been able to find a case with such extensive and aggressive involvement, symptoms so alarming and treatment deemed so radical as the one herewith recorded.

Virchow, in 1887, was first to apply the term pachydermia laryngis to this characteristic white or grayish-white thickening of the epithelium and subepithelial tissue of the vocal cords and other parts of the larynx.

Two distinct varieties are found, presenting a totally different clinical picture as well as different symptoms: (1) pachydermia laryngis verrucosa, so-called from its wartlike appearance; and (2) pachydermis laryngis diffusa, a more extensive and uniform hypertrophy of the mucosa.

The verrucosa type is usually found on the posterior extremity of the vocal cords in the region of the vocal processes. The laryngoscopic image reveals on one cord an oval thickening, grayish in color with a central depression; while on the opposite cord there is a warty-like hypertrophy the apex of which during phonation fits into the cupped depression of the opposite cord. It was formally thought that the hypertrophy on one side produced a depression on the opposite cord, but careful examination will usually reveal a depression on both sides, due no doubt to the closer attachment of the mucous membrane at that point to the subjacent cartilage, as suggested by St. Clair Thomson. Ulceration and inflammatory changes are absent. Similar conditions have been described as occurring on the anterior surface of the arytenoids. The interarytenoid space is another frequent site for the development of this type of pachydermia. In my experience I have seen

one pronounced case in this location, occurring in a singer, where it was necessary to apply the electric cautery on two occasions to control spontaneous bleeding. The etiology of this disease is somewhat obscure.

Virchow, on the postmortem table, found it more prevalent in alcoholics. It is usually found after the age of forty. Males are affected more frequently than the females. Vocal abuse, excessive smoking, syphilis and suppurative condition of the upper respiratory tract are mentioned as contributing causes by some. Other observers look upon it as being a precancerous condition and by them it is so treated. Hoarseness is the predominating symptom in this form of the disease, occasional blood spitting is noted, if desquamation occurs. Excessive secretion is the rule. Treatment other than surgical has been useless.

"The diffuse type," says W. T. Horne, "is of equal or greater importance clinically, as it is liable to stimulate or to be a part and parcel of the more serious disease, epithelioma of the larynx." It extends over a greater surface of mucous membrane, involving the whole cord, both cords or entire surface of the larynx. The symptoms, therefore, are dependent upon the location and extent of the involvement. Hoarseness, dry brassy cough with occassional expectorations of dirty gray crusts and laryngeal dyspnea of varing intensity produced by the formation of crusts are the symptoms usually noted.

Case Report.—G. W. K., male, aged fifty-two years, American born, for ten years working at steaming tallow. Was referred to me by Dr. George B. Jobson, of Franklin, Pa., in June, 1924, with the following history:

Chief Complaint. Chronic hoarseness and laryngeal dyspnea.

Family History. Father died at the age of fifty-eight years, of dropsy; mother living, but in ill health. Has had some throat trouble for the past three years. One brother and three sisters living and well. Wife living, and four children living and in good health. Negative family history as to cancer or tuberculosis.

Personal History. Always enjoyed good health. Does not use alcoholic beverages and is a moderate smoker. Had usual diseases of childhood and several attacks of bronchitis. Denies venereal infection. Has had an occasional sore throat and so-called rheumatic pains in the knees.

Present Illness. Began two years ago. First manifestation was the coughing-up of necrotic looking masses; later followed by continuous hoarseness, and during the last few months the inspissated crusts have increased in amount, with frequent and alarmng attacks of laryngeal dyspnea. Local treatment afforded only temporary relief.

General physical examination showed nothing of note other than an obesity, he weighing 275 pounds. Blood Wassermann was negative.

Direct Laryngoscopic Examination. The entire larynx from the ventricular bands down to well beyond the level of the vocal cords was covered with a thin grayish membrane which could not readily be separated. There was no apparent ulceration. There was marked infiltration of the ventricular bands, vocal cords and the subglottic and interarytenoid tissue. A small specimen was removed from the left side for biopsy, but no evidence of malignancy was found. In consultation with Dr. Chevalier Jackson it was thought best that inasmuch as the patient's symptoms were increasing with alarming rapidity, in view of the extensive involvement and the possibility of its becoming malignant, a total laryngectomy should be advised. The patient readily consented and a total extirpation of the larynx was performed on July 12, 1924. The pathological report as submitted by Dr. B. L. Crawford of Jefferson Hospital is as follows:

"Specimen consists of a larynx and epiglottis, which has been sectioned. Entire mucosa of the larynx and base of the epiglottis is roughened, granular, dry and wrinkled, and of a dirty, yellowish-gray, color. Both above and below the line of demarcation between the lesion and the normal mucosa is sharply defined.

"On section the mucosa is thickened, but there is very little fibrosis of the submucosa tissue; however, the surface of the underlying cartilage is roughened and calcified in places. No ulceration was observed. Formalin fixation."

Histology. Section from the affected portion of the laryngeal mucosa shows a marked thickening of the epithelial layer and marked hyperkeratosis. There is marked hyperplasia of the epithelium with long papillæ extending deep into the submucous tissue, but the basal layer of the epithelium is regular and definite evidence of infiltration by the epithelium is not observed.

The submucous tissue is extensively infiltrated by mononuclear leukocytes. At the margin of the lesion there is a very abrupt change from the hyperplastic epithelial layer to the normal mucosa.

Diagnosis.—Pachydermia laryngis.

It is not the purpose of this paper to advocate laryngectomy as the treatment for pachydermia laryngis but it seemed to the writer it was the only method of treatment which would eradicate the disease and which would prolong the life of this particular patient.

The patient has made a complete recovery, has a good buccal voice and is perfectly happy and contented.

Discussion

Dr. Henry L. Swain, New Haven, Conn.:

I do not think any of us supposed that because the discoverer of this disease was a German that sauerkraut would be necessary in order to learn to talk buccally. Those of you who remember back a great many years may have had, in common with myself and others, the suspicion that Virchow discovered this term "Pachydermia" in trying to help the Crown Prince, as he was about to become Kaiser. The exact synchronization of "Pachydermia" and the condition of the Crown Prince at that time seemed almost too adjacent not to be cause and effect.

After we had our eyes, so to speak, open for such a possibility most of us saw cases of pachydermia. I know I had one which I would not previously have thought to classify as such. Section of a piece removed showed a picture similar to the one the doctor has shown —an enormous thickening of the epithelial layer. This pursued a chronic benign course and never really became malignant. I know he did not die for years and years after this hard mass of pachydermic tissue formed itself in the interarytenoid space. Of late years, it seemed as though I had not seen any such cases.

Dr. Gordon B. New, Rochester, Minn.:

I was fortunate enough to see this patient about six months before Dr. Lewis operated on him. I think the etiology is particularly interesting, as undoubtedly it was due to the fact that the man worked steaming tallow for some ten years.

Dr. Cornelius G. Coakley, New York City:

I have not seen a pachydermia of the larynx for some little time, but it seemed to me from the pathology of this case that it would be very interesting to know what radium could do in cases of this kind with that kind of epidermis. If I had such a case as that I think I would perform a tracheotomy and use radium, to see what it would do, before proceeding to the extent that was done in this particular case.

STENOSIS OF THE LARYNX IN LARYNGEAL TUBERCULOSIS

FRANK L. DENNIS, M.D.

WHILE stenosis is not a frequent complication of laryngeal tuberculosis, it is still sufficiently common to merit careful consideration of the methods of relief by those who treat this disease. It is not the purpose in this paper to deal with those acute cases due to edema, but to discuss the more chronic forms of obstruction caused by:

1. Tuberculoma.
2. Widespread and extensive infiltration.
3. Paralysis of the abductors and ankylosis of the crico-arytenoid joint.
4. Web formation.
5. Amyloid disease.

Several instances of blocking from large tuberculomata are found in the literature. Jaehne[1] reports a typical one, the tuberculoma springing from the right ventricle of Morgagni and extending across to the opposite side, almost completely obstructing the glottic orifice (Fig. 1).

The only symptom was hoarseness and, strangely enough, the respiration was not labored nor quickened. Removal was followed by a spreading of the local tuberculous process and a lighting up of the lung lesion. Douglass[2] observed a large tuberculoma entirely closing the rima glottis; no opening into the larynx could be discovered.

Fetterolf's case,[3] in which the vocal cords were united at their anterior halves, leaving a small round glottic opening, is like Case III of my series. Von Lénárt[4] saw a similar case, in which the adhesions followed three weeks after surgical removal of tuberculous granulations. The case was treated by laryngofissure and excision and the application of a Thiersch graft.

The cases of stenosis due to extensive infiltration are frequently

associated with fixation of the arytenoid or with posticus paralysis. The two latter conditions may be combined. Following a perichondritis, one arytenoid becomes fixed in the midline; later, abductor paralysis develops on the opposite side. There is less and less outward movement of the cord on inspiration; increasing dyspnea and, eventually, suffocative attacks supervene. Death by suffocation is inevitable unless the danger is removed by tracheotomy. A confrère saw such a case one afternoon and advised immediate tracheotomy, but the patient elected to wait until the next day and was found dead in bed the following morning. Pressure on the recurrent laryngeal nerve by enlarged lymph nodes lying along the trachea may cause paralysis and, according to Moritz Schmidt,[5] both sides may be affected simultaneously.

Web formations, following healing of the tuberculous lesions, are interesting because of their rarity, although they are not uncommon after syphilitic ulcerations in the larynx. They represent an end-result in the process of healing, analogous to fibrosis of the lung in long-standing pulmonary tuberculosis. I have seen two such cases, in both of which the scar lay above the cords and had its origin in the ventricular bands.

Amyloid tumor of the larynx is a very rare disease. Pugnat[6] saw a case in 1918 which he says is the twenty-eighth reported. He says they occur in middle and old age, usually in males, most often in the conjunctiva and next in frequency in the larynx. He describes them as being of a "vitreous translucent appearance." Swershewski[7] and Willimann[8] each report one case. The diagnosis in both was confirmed by histological examination; one was cured by roentgen-rays and the other by removal. These amyloid tumors must be pathologically different from the condition of so-called amyloid disease. The latter accompanies prolonged suppuration, tuberculous empyema, bone tuberculosis and other wasting diseases and affects the liver, spleen, kidneys and intestines. It is invariably and rapidly fatal. The former is usually described as a benign tumor, lasting for several years, and is apparently not a part of a generalized degeneration[9] In one of my cases who died of general amyloid disease the stenosis was apparently due to a fibrous web and, as no microscopic examination was made, amyloid degeneration locally was not confirmed.

TREATMENT. Surgical relief of some sort is required in all cases when the respiration begins to be embarrassed. It is important to not delay the tracheotomy too long. One should not wait until these patients have become exhausted by their efforts to breathe or until they suffer from oxygen starvation. Besides promoting the general wellbeing of the patient and improving the lung tuberculosis, early tracheotomy has a particularly favorable influence on the tuberculous disease of the larynx. Schmidt[10] recommends tracheotomy as a therapeutic measure in laryngeal tuberculosis, even in the absence of stenosis. It is not uncommon to see an early and comparatively rapid improvement locally. If the stenosis be due solely to the infiltrative process, the tube may be removed as soon as this disappears, which often happens within a few months.

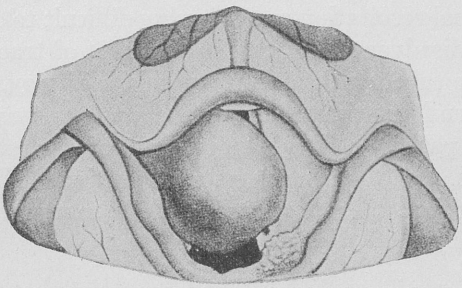

FIG. 1.—Jaehne's case of tuberculoma. (Taken from Ztsch. f. Ohrenh.)

Laryngectomy, as advocated by Onodi,[11] seems to be an unnecessarily severe remedy.

The paralytic cases frequently require hurried tracheotomy because of the tendency of these patients to refuse consent to early operation.

In cases complicated by web formation and paralysis or ankylosis, even though the infiltration may have disappeared, glottic respiration is, naturally, still impossible. It is very desirable to decannulize them as soon as may be, but due regard must be had also to the danger of setting up renewed activity of the tuberculous process. One should wait several months or a year until this has become thoroughly quiescent; then, as soon as it is safe to do so, the hindrance to respiration should be removed. This is difficult

to do because of the tendency to a return of the scar. Sometimes incision and forcible intubation may succeed. Delavan,[12] Rogers[13] and Imperatori[14] report success with this method, although they were not dealing with tuberculosis. In one of the writer's patients it was temporarily beneficial. Most cases will need laryngofissure and removal of the obstruction, followed by prolonged dilatation. Dilatation by doubled rubber tubing has been advocated by Iglauer[15] and Schmieglow; and recently a careful method of treatment by dilatation has been worked out in Dr. Chevalier Jackson's Clinic.[16] Irwin Moore[17] suggests an ingenious operation for transplanting the anterior ends of the cords laterally in patients with abductor paralysis. The sequelæ of the tuberculous lesion might defeat the aim of this operation in the cases under discussion.

If the tube be worn too long, these patients seem to lose the knack of normal respiration and it is very difficult to dispense with it. Another disadvantage is the development of tracheal spurs at the end of the tube which interfere with the airway. One of my cases when seen four years after the tracheotomy, was still wearing his tube. A patient of Dr. Mullin, my partner, still wears his tube at night, ten years after its introduction. His lesion was very advanced but has now been healed for many years.

Case Reports

Case I.—Miss W., aged twenty-five years, was first seen in June, 1908, with a history of pulmonary tuberculosis for a year; hoarse for seven months; no laryngeal pain.

Examination revealed tuberculous infiltration of both arytenoids, posterior wall and both vocal bands; reddening of the right vocal band (Fig. 2).

Under local treatment the infiltration diminished and the voice became clear. The throat lesion remained quiescent until May, 1911, a period of fifteen months, when there was renewed activity, indicated by infiltration and ulceration involving the right ventricular band and and vocal band and increased infiltration of both arytenoids (Fig. 3). The condition grew slowly worse, and five months later suffocative attacks occurred at intervals, due to narrowing of the glottis from paralysis and ankylosis. After two months more the stenosis was so great that a tracheotomy became necessary. The cords lay close together and there was no movement on inspiration (Fig. 4).

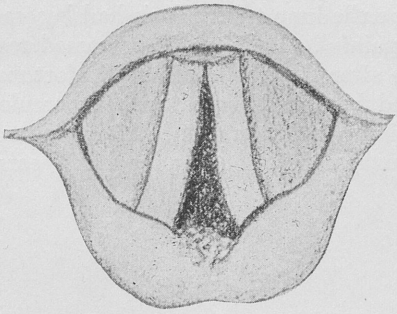

FIG. 2.—Case I. Illustrating the condition at first examination.

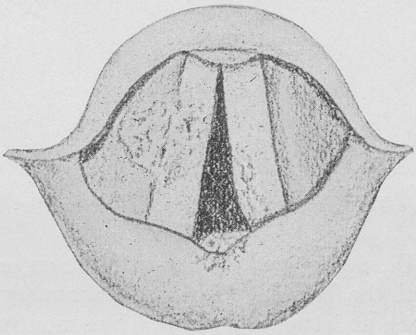

FIG. 3.—Case I. Almost three years later. Note ulceration on right ventricular and vocal bands; increased infiltration.

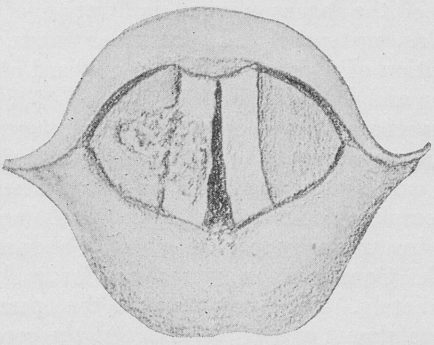

FIG. 4.—Case I. Larynx at time tracheotomy was done. Note position of cord.

In the meantime the lung tuberculosis had become active and the throat was very painful. Relief to embarrassed respiration was, of course, immediate after the tracheotomy. Unfortunately, the tissues around the wound became infected with tuberculosis, resulting in extensive undermining and ulceration. After nine months of misery, death finally brought relief, four and a half years after the first examination.

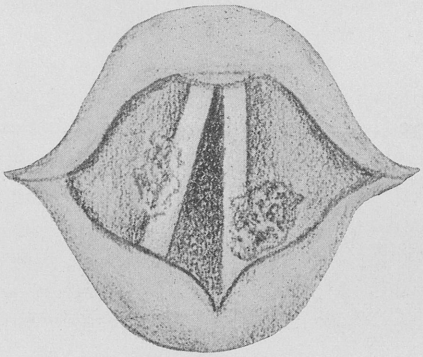

FIG. 5.—Case II. First examination. Note fixation of left cord.

CASE II.—A. H., male, aged twenty-three years, consulted me on May 10, 1908, with the following history: Pulmonary tuberculosis for three years. Since an attack of "grip," five months ago, has been failing; aphonia during the past winter; hoarse for two months; no pain. For three nights has not been able to sleep on account of difficult breathing.

Examination of the larynx showed infiltration of the epiglottis, aryepiglottic folds, arytenoids and ventricular bands. The left cord fixed in the position of phonation; motion outward of the right cord limited. Stridor and dyspnea (Fig. 5).

Immediate tracheotomy was urged but was refused. During the next month there were repeated suffocative attacks; finally, he had a very severe one and almost died. When seen the next morning the cords were in complete adduction, with practically no motion of the right one, it having gradually lost the power of abduction during the preceding month. Consent was now obtained for tracheotomy, which was done immediately. Three months after the operation the lesion in the larynx was almost entirely healed, but the cords were still in adduction. One year later there was complete healing of the tuberculous process in the larynx and the lung lesion was quiescent. The

patient disappeared from view for three and a half years, at the end of which time he was again examined. There was no change in the position of the cords. He was not able to breathe through the larynx and still wore his tube, four and a half years after its introduction (Fig. 6).

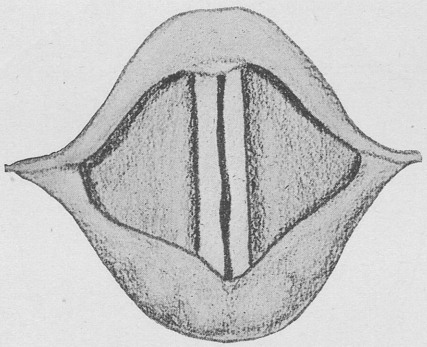

FIG. 6.—Case II. Four and a half years later. Almost complete stenosis; both cords in the median line; ulcers healed.

COMMENT. These two cases represent, in my opinion, instances of ankylosis and paralysis combined. If the first patient had been more assiduous in following advice it is probable that her original laryngitis would have remained healed. Both cases had suffocative attacks at night which are always very dangerous and apt to prove suddenly fatal. The second case is a good example of the curative effect of rest to the larynx and of increased oxygenation afforded by tracheotomy.

CASE III.—Ella M., aged seventeen years, was first seen on April 2 1909, complaining of pain in the throat and hoarseness. She has extensive active pulmonary tuberculosis. The throat symptoms have existed for two months.

Examination. Extensive tuberculous infiltration and ulceration involving the epiglottis, both ventricular bands, aryepiglottic folds, arytenoids, posterior commissure and vocal bands (Fig. 7).

In five months, under general and local treatment, the ulcerations healed. However, four months afterward there developed a narrowing of the glottis from scar tissue and the movements of the arytenoids were hindered by ankylosis. The anterior halves of the cords were

apparently adherent to each other, leaving only a small space posteriorly for respiration (Fig. 8). Two months later, owing to increasing

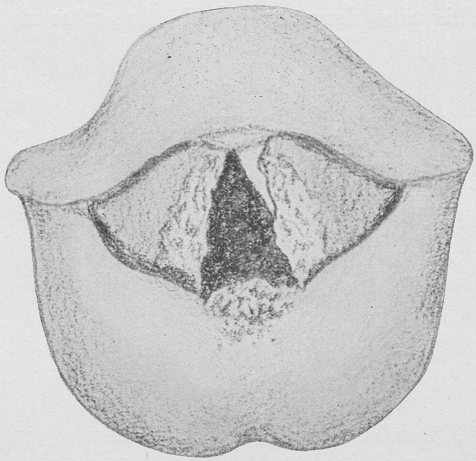

FIG. 7.—Case III. First examination. Note widespread involvement.

dyspnea, measures for relief were imperative. The available space for respiration consisted of a round opening through a weblike scar which

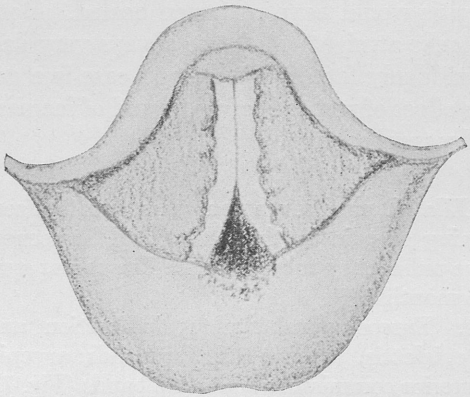

FIG. 8.—Case III. Nine months later. Cords adherent to each other.

extended from the epiglottis backward, embracing the ventricular bands and blending with the infiltrated arytenoids. Through this

opening could be seen the immovable cords, fixed in a position between phonation and inspiration (Fig. 9). The opening in the web was enlarged with biting forceps and an O'Dwyer tube inserted, which gave relief to the embarrassed respiration. Quantities of viscid sputum were brought up through the tube, causing some difficulty in keeping it free. After some preliminary improvement the lung tuberculosis became more active and the patient failed rapidly. Amyloid degeneration of the kidneys, liver and intestines was discovered, which ended fatally, ten weeks after intubation.

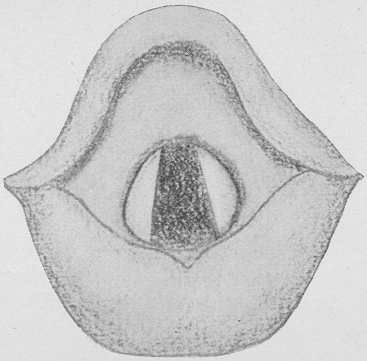

FIG. 9.—Case III. Stenosis from web at time of operation and intubation.

COMMENT. This case is interesting because of the widespread involvement of the larynx; the remarkable improvement during the first eight months under active treatment, which included the inoculation of live tubercle bacilli by her physician; the rapid development of scar tissue following the initial healing of the ulcerations, and the final development of amyloid disease. In order to relieve the dyspnea portions of the obstruction were removed on one or two occasions before the use of the intubation tube, but with only temporary benefit. It is probable that these measures made matters worse and it would have been better to resort to tracheotomy at once and then wait for the arrest of the tuberculosis before attempting removal of the laryngeal obstruction. Moritz Schmidt[18] says, "stenosis in consequence of healed tuberculous ulceration should be left alone if there is no pressing need for relief, because of the danger of setting up renewed ulceration. One should wait at least a year."

CASE IV.—Miss E. P., aged twenty-five years, consulted me on March 24, 1915. She has had pulmonary tuberculosis for several months, during which time she has had "trouble" with her throat—worse for the past four weeks. She has pain occasionally and is hoarse; strangles when drinking.

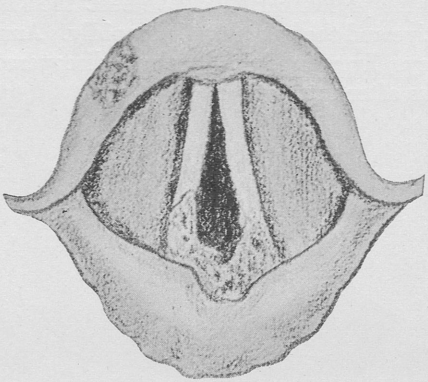

FIG. 10.—Case IV. First examination. Showing ulceration on epiglottis, both cords and posterior wall.

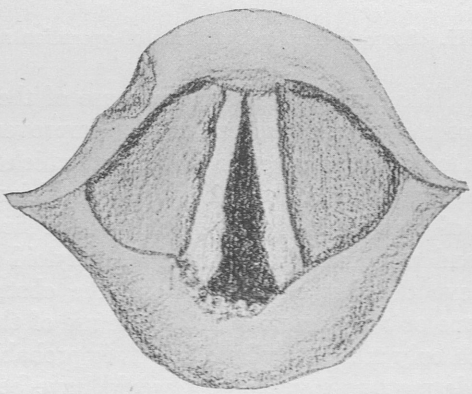

FIG. 11.—Case IV. Ulcer on epiglottis healed; infiltration lessened.

Examination. Small ulceration on the right edge of the epiglottis, ulceration on the posterior ends of both cords extending across the posterior commissure, arytenoids infiltrated, worse on the right (Fig. 10).

She was treated for a year with galvanocautery and trichloracetic acid with some improvement, viz., healing of the ulcer on the epiglottis and a diminution of the infiltration of the arytenoids (Fig. 11). A recrudescence occurred six months later, with edema of the arytenoids

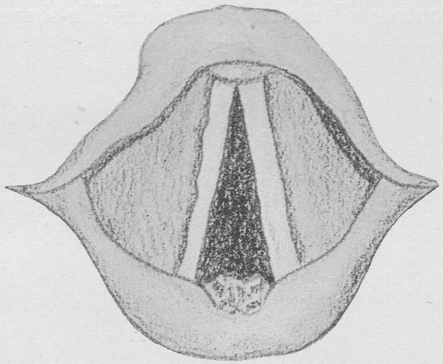

FIG. 12.—Case IV. Ulcers healed; infiltration in posterior commissure.

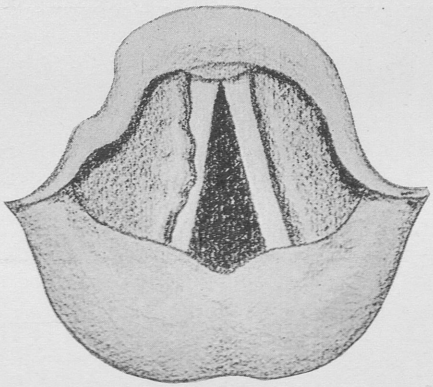

FIG. 13.—Case IV. Renewed activity; infiltration of arytenoid region and right ventricular band.

and infiltration of the right ventricular band. This gradually improved and six months afterward the findings were: epiglottis distorted by scar and loss of tissue; arytenoids almost normal in appearance; ulcers on both vocal bands and posterior wall healed; right ventricular band moderately infiltrated (Fig. 12). Five months after

this observation she made a visit to her home and renewed activity in the larynx occurred, indicated by infiltration of the right ventricular band and the arytenoids (Fig. 13). During the following six months the throat improved greatly. The exigencies of war prevented my seeing the patient for fifteen months, at which time the following findings were noted: all ulcers healed; a sickle-shaped scar extends

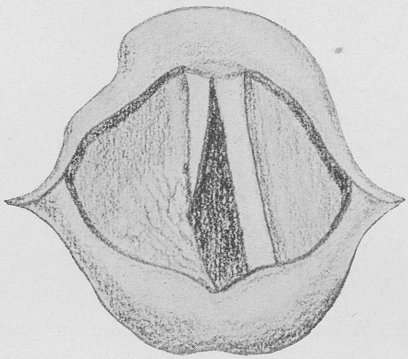

FIG. 14.—Case IV. (Respiration.) Showing beginning of scar formation.

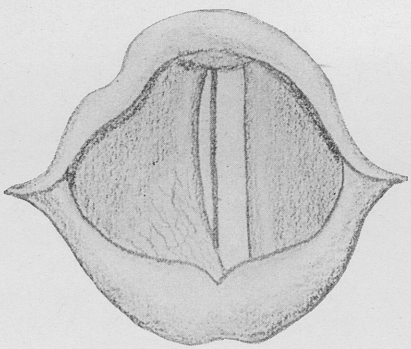

FIG. 15.—Case IV. (Phonation.) Sketched at same time as Fig. 14.

from the right ventricular band to the arytenoid and posterior wall as far as the midline; the arytenoids are slightly enlarged and pale (Figs. 14 and 15). The larynx remained quiescent for three years, at which time she complained of dyspnea on exertion, noisy respiration and poor voice. Her general condition was good. There was fixation of the left cord in a position midway between phonation and

inspiration; the web has extended a little farther to the left, compromising the breathing space (Fig. 16). In May, 1924, diseased tonsils were removed on account of arthritis. Since then she insists that her breathing is easier and she certainly has a better voice. No treatment for the relief of the stenosis has been instituted. The condition on February 23, 1925, is illustrated in Fig. 17. The left cord is still immovable; the shape of the scar seems somewhat altered by contraction.

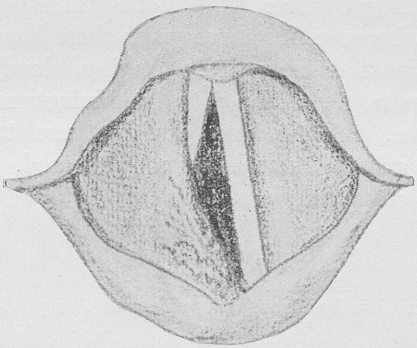

FIG. 16.—Case IV. Compare with Fig. 14. Note extension of scar.

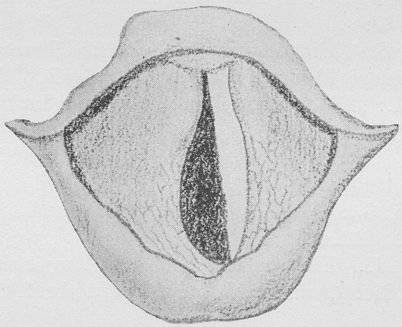

FIG. 17.—Case IV. Condition on February 23, 1925, Note retraction of scar on right and beginning scar formation on left.

COMMENT. This case is an example of unremitting fighting against an insidious and implacable foe, extending over a period of ten years, during the first four years of which the treatment was practically continuous. The net result is an individual who

is able to enjoy a fairly normal, if limited existence, with a larynx which has healed—in fact, too well healed. Undoubtedly, this web is an end process in the healing. The larynx is distorted and crippled in function by the scarring and the left cord is fixed, but fortunately not in the phonation position. But, in spite of it all, the voice is clear although low in pitch. Whether this woman will have again a lighting up of the focus in her larynx or whether the stenosis will get worse, time alone will show: I am inclined to believe not, because, for three years there has been no relapse and these patients do sometimes develop, slowly and painfully through the years, a resistance to their infection which prevents a recrudescence, and because, during these three years, the dyspnea is less and the stenosis has not increased. Her pulmonary tuberculosis is completely arrested.

Bibliography

1. Jaehne, A.: Ein Fall von Tuberculom des Larynx, Ztschr. f. Ohrenh., 1912, lxvi, 8.

2. Douglass, Beaman: An Unusual Case of Tuberculosis of the Larynx, Laryngoscope, 1922, xxxii, 236.

3. Fetterolf, George: The Larynx in Pulmonary Tuberculosis, Laryngoscope, 1916, xxvi, 37.

4. Von Lénárt, Z.: Mittelst Laryngofission und Transplantation geheilter Fall von Larynxstenose, Ztschr. f. Ohrenh., 1913, lxviii, 277.

5. Schmidt, M.: Die Krankheiten der oberer Luftwege, Berlin, 1903, ed. 3, p. 392.

6. Pugnat, A.: Jour. de Laryngologie etc. Abstracted in Jour. Laryngol., Rhinol. and Otol., 1919, xxxiv, 32.

7. Swershewski, L.: Lokales Amyloid des Kehlkopfes, abstracted in Ztschr. f. Ohrenh., 1911, lxii, 274.

8. Willimann, M.: Ein weiterer Fall von Amyloidtumor des Larynx, Arch. f. Laryngol. No. 2, vol. 26; abstracted in Ztschr. f. Ohrenh., 1913, lxviii, 249.

9. Wright, J. and Smith, H.: Diseases of the Nose and Throat, Philadelphia, Lea & Febiger, 1914, p. 496.

10. Schmidt, M.: Idem, p. 426.

11. Onodi, A.: Totale Kehlkopfextirpation bei Kehlkopftuberculose, Ztschr. f. Ohrenh., 1914, lxx, 9. This operation was done by Gluck, who had done 34 cases with healing in 11. In the case reported, "healing was complete," but the patient died two months later with acute lung inflammation.

12. Delavan, D. Bryson: Treatment of Cicatricial Stenosis of the Larynx, etc., Jour. Laryngol., Rhinol. and Otol., 1909, xxiv, 42.

13. Rogers, John: Articles in Am. Jour. Med. Sci., November, 1905, and April, 1908.

14. Imperatori, C. J.: Chronic Stenosis of the Larynx, Laryngoscope, 1917, xxvii, 172.

15. Iglauer, S.: Treatment of Laryngeal Stenosis, Ann. Otol., Rhinol. and Laryngol., 1918, xxvii, 1233.

16. Tucker, Gabriel: Laryngostomy for Laryngeal Stenosis, Arch. Otolaryngol., 1925, i, 157.

17. Moore, Irwin: Operative Procedures in the Treatment of Stenosis of the Larynx Caused by Bilateral Paralysis of the Abductor Muscles, Jour. Laryngol. and Otol., 1923, xxxviii, 236.

18. Schmidt, M.: Idem, p. 605.

Discussion

Dr. George Fetterolf, Philadelphia:

I have had 5 of these cases, 1 of which should be put on record because of a very interesting factor connected with it.

This man I first saw eighteen years ago at a sanitarium in White Haven. My attention was called to him because of obstructive dyspnea. Examination showed a condition in the larynx similar to the one Dr. Dennis showed in Fig. 2: decided adduction of the cords, with a broad papillomatous projection from the posterior wall, some thickening of the arytenoid cartilages and some roughness of the cords. He was taken to Philadelphia and a low tracheotomy was done. The breathing was, of course, immediately relieved. He was a very intelligent man, a priest, and his coöperation straight through was most valuable.

In the attempt to cure the tuberculous disease of his larynx, first the papillomatous growth was removed. It proved to be a simple papilloma, a nontuberculous hyperplasia. Then the arytenoids were cauterized and they shrank to normal size. All the granulations on the cords then disappeared and the latter became smooth. He was able to use his voice if he took a lung full of air and put his finger on the tracheotomy tube.

The thought occurred that a valve could be put on the tracheotomy tube which would open during inspiration and close during expiration. A ball-valve arrangement was made and hooked on to his tracheotomy tube by a bayonet catch. The valve consisted of a hollow steel ball which would close the opening during expiration and pull up and open during inspiration. He found he did not like this very well for

two reasons: The steel ball was rather heavy and required distinct muscular effort to fill the lungs, and then, too, there was a distinct, audible click and at each breath people nearby would look around to find where the click came from.

In place of the steel ball a cork ball was tried, with a couple of wires behind the ball to keep it from going down the tracheotomy tube and into the trachea. This arrangement has continued in use for years with great comfort and he is now able to fulfil all the functions of a priest, preaching in a large church, intoning services, etc.

Dr. D. Bryson Delavan, New York City:

This very valuable paper recalls to my mind one of the most dramatic incidents of a lifetime. While lecturing one day in the College of Physicians and Surgeons, I was called in haste to the Sloane Maternity Hospital nearby with the statement that a woman in labor was strangling. I responded, carrying with me my laryngoscope, instruments for tracheotomy and a set of O'Dwyer tubes.

I found the patient, a small peasant woman, suffering from pulmonary tuberculosis, in the second stage of labor, cyanotic and gasping for breath. I was able to get a very fair laryngoscopic picture of the larynx, the cavity of which was nearly filled with a mass of tuberculous infiltration which had nearly closed the rima glottidis and extended upward to the superior limit of the larynx, displaying a very unfavorable condition for a tracheotomy. The patient was naturally very restless, unrestrained in her activities and violently throwing herself about. The labor pains were coming on rapidly and the situation was critical. I inserted with much difficulty an O'Dwyer tube as large as was possible to pass the obstruction. It was quickly coughed out. Incidentally, in inserting the tube, it seemed evident that the infiltration which composed the obstruction was a ring made up of a dense mass of tissue which contained a great deal of fibrous element.

A larger tube was inserted, but also was soon coughed out. The situation was growing desperate. I chose the largest tube it seemed possible to insert into the larynx and, with the help of Dr. W. K. Simpson, who was present, we managed by the exercise of great force to urge that tube through the obstruction, at the imminent risk of tearing the larynx to pieces: but the tube was successfully placed and retained. In about ten minutes news came that the baby was delivered, a fine-looking, healthy boy, and that the condition of the patient was excellent. And so it continued throughout the confinement. The subsequent history I have never learned. I have seldom passed

through more exciting or anxious minutes than were consumed in the insertion of that tube.

Dr. Gordon B. New, Rochester, Minn.:

I would like to ask whether there was any amyloid degeneration in the larynx in the case Dr. Dennis referred to with generalized amyloidosis.

Dr. James A. Babbitt, Philadelphia:

A case was referred to me after operation for a severe malignant abdominal condition and obstinate nausea following the use of the stomach tube. Thirty-six hours after the previous operation a marked laryngitis had developed, with infection and edema of the arytenoids and ventricular cavities, constant dyspnea and aphonia. One evening the patient coughed up one arytenoid, as identified by two or three anatomical people, and several days later the other. In spite of their absence, cicatricial repair occurred and the voice measurably returned, though the patient died six months later from the above-mentioned abdominal condition. This case is interesting because of its relation to the reparative changes in the larynx presented so clearly by the speaker.

Dr. William V. Mullin, Colorado Springs, Colo.:

The problem of dealing with such conditions in the tuberculous as Dr. Dennis has presented here today is a very perplexing one. One hardly realizes how slowly everything moves in tuberculosis. These people may be indiscreet in some way and not suffer the effects of it for four, five or six months. As Dr. Dennis has shown, none of his series have been acute cases. They are all chronic, which naturally come on very slowly, often through a healing process; an overproduction of fibrous tissue filling in the larynx or preventing motion of the crico-arytenoid joint, and these patients actually pay a penalty for having obtained a healed tuberculous larynx.

Tracheotomy is inevitable in most cases, and yet one hates to advise it because one cannot offer them a very good outlook for getting rid of the tube. Sometimes, when tracheotomy is put off too long and there is much embarrassment to respiration, the effect on the general condition is bad and they go down very quickly.

Of course, you always have the general as well as the local condition to consider in tuberculosis. When laryngeal obstruction goes on

for a short time there is usually a blocking of secretion in the bronchi and lungs, and then, as soon as tracheotomy is done, this seems to release quantities of this secretion with a possibility of the wound becoming infected around the tube.

I had one case similar to Dr. Delavan's—a woman going through labor and a tracheotomy had to be done. She went through the labor nicely and the child lived, but the mother paid the penalty.

I think you would be interested to know that the illustrations Dr. Dennis used in his paper were done by his son.

DR. DENNIS (in closing):

I have only one or two words to say and I think they may be summed up in substantiating the points Dr. Mullin has brought out. These cases, in the majority of instances, are always slowly developed and it is a long story. We have not devised any instrument in the tracheotomy tube to permit these people to use their voices except the closing up of the tube mouth by a finger. In this case of Dr. Mullin's which I showed, the man gets along well in the day when he wants to talk by slipping his finger over his wound. When night comes he finds he cannot breathe properly without the tube and he slips the tube in and spends the night that way.

The point of the whole business is to let these people alone, so far as the larynx is concerned, until we have a quiescent period of the process. I think it is a great mistake to interfere surgically with these obstructions until they are thoroughly quiet. So far as the effect of a tracheotomy is concerned, the effect is very, very good on the laryngeal infection as a rule. Sometimes we do get infection around the wound in the neck, as happened in one of my cases.

With regard to the amyloid case Dr. New spoke of, I do not know whether there was any amyloid degeneration in the larynx or not. This was a case of acute pulmonary and laryngeal tuberculosis from the beginning. The development of the obstruction in the larynx was very rapid. As I mentioned, the mistake was made in this case of doing too much in the larynx. I think if this patient had been tracheotomized and then the larynx had been let alone, she would have got along better, although, of course, none of this had any relation to the fatal issue, because she died of amyloid degeneration.

VACCINES FROM HEMOLYTIC COCCI IN SPHENO-ETHMOIDAL DISEASE*

RALPH A. FENTON, A.B., M.D., F.A.C.S.

FOLLOWING the false dawn of vaccine therapy, in 1895[1] and the temporary and unauthorized excitement over Marmorek's work with the streptococcus, a veritable sunburst of enthusiasm for vaccines again occurred about twenty years ago. Hasty proponents of the new serological vocabulary were busy with papers and case reports; and the pharmaceutical houses, with biological departments and detail salesmen, gave practical emphasis to Shakespeare's

> "Our remedies oft in ourselves do lie!"
> (*All's Well that Ends Well*, Act. I, sc. 1).

This Association was among the first to take note of the trend toward bacteriologic investigation and therapy of the accessory sinuses, following Boucheron's pioneer case in 1897.[2] The admirable essay of Hinkel,[3] in 1902, on chronic sphenoiditis, mentions the continued menace of mucopurulent pharyngeal discharge, but does not suggest vaccine treatment. Not until 1910 did the Association invite general discussion of this method. Birkett and Meakins[4] then claimed that, with vaccines based mostly upon the staphylococcus aureus, they had been able to sterilize the accessory sinuses; their recommendation was mainly for subacute or chronic cases, following operative procedures. Coakley and Kendall[5] took a contrary view, stating that the opsonic index and the vaccines were useless in their cases, save for one sphenoid and one antrum infection of streptococcic origin. Cobb and Nagel[6] had negative results. The following year, Casselberry[7] entirely omitted vaccines from his treatment for suppurative sphenoiditis. But Coffin,[8] in 1915, voiced a certain discontent with results even

* From the Departments of Otolaryngology and Pathology, University of Oregon Medical School, Portland.

after the most thorough and radical operations; he counseled autogenous vaccines, along with suction and oily antiseptics. First mention of the hemolytic streptococcus was made by Halsted,[9] in 1917, discussing cases of general infection of accessory sinus and tonsillar origin.

In other societies similar discussions prevailed; enthusiasm at first, then general use of autogenous or stock vaccines, and a waning interest after two or three years, relegating vaccines to the cloistered retirement of a few "selected cases." Coates[10] was among the earliest to emphasize that vaccines had no place until necessary surgery had been done, and,[11] in 1917, pointed out the fallacies in missing true toxic agents, due to faulty cultural methods. His results were good in preventing recurrences. Levy[12] had postulated, in 1909, that all obstinate cases in which other methods had failed should have the benefit of vaccine; he reported 6 cures, 6 improved, 3 unchanged. Patterson,[13] in 1910, did not mention hemolytic organisms, nor did he employ the streptococcus. Brawley's[14] best results were in cases not over a year's standing. Graef and Wynkoop,[15] in the same year, reported a brilliant cure of streptococcic meningitis after a septum operation, by autogenous vaccine. Dabney's[16] vaccines, in 1912, were made up in the proportion of one part streptococci to ten of staphylococci, without hemolytic differentiation. Haskin,[17] in 1916, was first to use an autogenous vaccine from streptococcus hemolyticus in a case of nasal and oral pemphigus.

In spite of wide interest throughout the country in these results,[18-24] and more recently abroad,[25-34] and in spite of the propaganda of stock-vaccine salesmen, rhinology has turned away from the use of vaccines. Skillern has well stated the prevailing pessimism, not only in his treatise,[35] but more recently in his masterly review of the history of the sinuses.[36] Mosher,[37] nevertheless, directs attention to the probability that toxins may be elaborated in the sinuses without apparent pus and even without appreciable bacterial growth.

Addressing ourselves to the bacterial side of the question, we are reminded that vast changes have come into the culture and identification of bacteria during thirty years; and in corollary thereto, that the entire theory of cell-chemistry and of protein-sensitization and therapy is now under active revision.

Stock vaccines, as well as polyvalent autogenous vaccines, may well be dismissed from present consideration. Their value, because of multiple protein content, can scarcely be specific in any case, and probably depends upon the stimulant action of foreign protein upon the blood and its defensive mechanisms.

It is folly to assume that casual swabbing or washing from any nose or throat will even approximate the percentage of pathogenic germs existing thereafter. Only pure or highly preponderant cultures should be considered. Here again is room for fallacy; on certain media weedlike growths of nonpathogenic germs speedily obliterate the dangerous species. Skilled differential culture is needed. Such cultures should be repeated at intervals during the course of each case. Growth upon the subject's own blood is favored by Solis-Cohen.[58]

Injection of alien protein, either milk (conceded by many to owe its revulsive value to its variable content of bacteria), or diphtheria antitoxin,[38] or typhoid vaccine,[39] or bacillus coli vaccine,[40] or plain horse serum, has been employed for some years against chronic ocular inflammations. Duke[40] uses it in asthma and hayfever. Rather violent temperature and skin reactions accompany the leukocytic increase in the blood after use of these agents, whose discomforts and dangers are not to be ignored.

Infestation of the population with streptococci and other hemolytic organisms has been a noteworthy problem in epidemiology during recent years. Bacteriologists have discovered a considerable proportion of hemolytic germs in cultures from the nose and tonsils.[41-45] Some observers have inclined to the belief that filterable virus from unrecoverable organisms is to blame for acute colds, and for lighting up chronic disturbances. Others depend upon improved cultural methods, animal inoculation and clinical experiment for determination of specific infective agents.

Every rhinologist will admit that he sees certain cases of sphenoethmoidal disease which seem to resist every type of treatment; cases which too often wander from one man to another, while we invoke

> " . . . . . a kind of hope
> Which craves as desperate an execution
> As that is desperate which we would prevent."
> (*Romeo and Juliet*, Act I., sc. 2).

Here are found the asthmatic types—protein allergies of course excepted—sphenopalatine neuralgias; relapses after complete operations; inoperable cases: pregnant women, marantic children, the aged; diabetics, albuminurics; the high anemias and hemophilia, septicemia; heart cases; the tuberculous. Free pus is often not found;[37-58] telltale lymphatic reddening behind the posterior pillars, or burning sensations with dry, intractable cough, may be the only sign. The roentgen-ray will show clear sinuses; and if opened their walls will often show but slight congestion, and a little pale mucus which is sterile to ordinary culture media.[37]

Methods of obtaining material for the fine differential technic of the bacteriologist have often been excessively crude. Brawley[14] used irrigation and aspiration. Skillern[35] advises a sterile sound inserted into the sinus: a difficult problem sometimes unless much preliminary surgery be done. Ordinary cotton swabs pick up a freight of vestibular mucus coming and going, although much work has been done in this way.[44-58] The West tube, passing into the mouth behind the soft palate, is complex and easily contaminated, although recommended by Pilot and Pearlman.[45] These investigators have accurately studied the shortcomings of cotton-swab cultures. Others are making use of washings from various sinuses, notably antrums and frontals.

For our investigation, cultures were made with a long platinum loop set in a glass rod, inserted through a long-bladed speculum after preliminary vestibular cleansing, flatwise across the middle turbinate into the spheno-ethmoidal recess. Loop and rod are flamed clean after each loopful is inoculated.

Under the advice and direction of Dr. Robert L. Benson, head of the Department of Pathology, University of Oregon Medical School, two sorts of media were inoculated from each nostril of each case. Without Dr. Benson's special and painstaking skill, this study would have been impossible, because of the faulty technic which impairs the accuracy of ordinary clinical laboratories. The first medium was 1 per cent dextrose beef-infusion agar, to which citrated human blood was added in the proportion of 1 cc. to the ordinary agar slant. The second medium was 1 per cent dextrose beef-infusion broth, to which 1 cc. citrated human blood was added as each culture went into the incubator. Plating

out of the organisms was also done on human blood agar. Final determination in cases of doubtful hemolysis was in all cases made on blood infusion agar without dextrose.

A few experimental cultures convinced us of the frequency of hemolytic organisms in the spheno-ethmoidal region of such uncured or inoperable cases as were mentioned. This important factor in pathogenicity, the power of a given organism to attack and disintegrate the red blood corpuscle, discoloring and destroying hemoglobin and with it the power of oxygen fixation, was first mentioned by Marmorek for streptococci in 1895[1] and by Kraus[46] in 1900 for staphylococci. Hemolysins are filterable substances, "produced in quantities roughly proportionate to the virulence of the particular microörganism." "Absolutely avirulent races do not, so far as we know, produce hemolysins." (Zinsser.[47])

Several types of hemolysis have been worked out, following the work of Smith and Brown[48] and of Benson and Sears[49, 50] on streptococci isolated from milk-borne epidemic tonsillitis. With streptococci, the alpha type has feeble, indefinitely outlined, 1 to 2 mm. zones of discoloration about each colony. Type alpha has a sharply marked discolored zone resembling the clear transparent completely hemolyzed colorless 2 to 4 mm. zone of type beta. The former is never pathogenic, however;[51] the beta type practically always so. For the purposes of our clinical series, no hemolysis either streptococcic or staphylococcic was considered unless it conformed to the beta type. Following is a table of all such organisms found in thirty of a total of 50 cases:

TABLE I

	Times found.	Per cent.
Streptococcus hemolyticus, long chain . . .	5	10
Streptococcus hemolyticus, short chain . . .	7	14
Staphylococcus albus (hemolytic)	14	28
Staphylococcus aureus (hemolytic)	24	48
Streptococcus viridans (green pigment) . . .	2	

Two highly anemic cases showed the Streptococcus viridans, which is feebly hemolytic with formation of a green methemoglobin pigment. Nearly half of our hemolytic cases showed Staphylococcus aureus, an interesting parallel to the work of Birkett[4] in 1910.

We have felt that hemolysis, when found in relatively pure culture organisms, would afford us a notable criterion of general damage which might be suffered by the individual so infested. Cognizance of this fact has recently been taken not only by workers on the rôle of soluble filtrates in epidemiology, and other bacteriologists,[47-54] but also by internists considering the etiology of pernicious anemia,[55] as well as of visceral disease.[58]

Cultures taken in our series of 50 persons presenting the various indications already stated were positive for hemolytic organisms in the spheno-ethmoidal region in thirty individuals, or 60 per cent. In 8 cases, 16 per cent, it was necessary to repeat the culture once, and in 2 cases, or 4 per cent, twice, to secure a practically pure or heavily predominant culture of the suspected organism. In one-sided lesions the predominant organism was isolated from the affected side in over 90 per cent, but in only about 60 per cent of simultaneous cultures from the uninvolved side—a point suggestive of the tissue resistance inherent in undamaged mucosal surfaces.

The average age of these patients was thirty-one years and five months; of 6 children under twelve, the youngest was seven; of 4 adults past forty-five, the oldest was seventy-one. There were 19 males and 24 females in the series treated by vaccines or proteins.

Ten cases, 20 per cent, disclosed a predominant nonhemolytic streptococcus from which vaccines were prepared, and used as controls. Three cases, 6 per cent, presented asthmatic symptoms without hemolytic organisms; these 3 were treated as controls, with typhoid vaccine. The remaining 7 cases, 14 per cent, presented neither streptococci nor hemolytic organisms, and were not considered further for vaccine treatment.

All cases were private, insuring more accurate control of dosage, reactions, and details of results.

Vaccines were prepared in the concentration of two billion killed organisms to the cubic centimeter, and preserved in a cold place. Contrary to the practice of ten years ago, when 0.5 cc. was the usual starting dose for a vaccine containing four to six kinds of killed bacteria,[10] we began with an average dose of 0.1 cc., and in some cases, as children or prostrated invalids, used as little as

0.05 cc. to start. Table II shows the initial reaction to each type of vaccine, by percentages.

TABLE II.—INITIAL REACTION TO VACCINES

Kind of vaccine.	Slight, per cent.	Moderate, per cent.	Severe, per cent.	Excessive, per cent.
Hemolytic	28	28	42	2
Nonhemolytic streptococcus	10	30	60	
Typhoid	25	..	75	

Such vaccines were given every four days, injected subcutaneously, preferably in the back or over the shoulder blade, after alcohol sterilization. Subsequent doses increase 0.1 cc. each time unless considerable general reaction occurs, in which case the previous dose is repeated. On reaching the tolerance limit, usually 0.3 cc. in children, rarely over 0.5 cc. in adults, injection is made weekly. Local reaction was noted but twice, an indurated wheal which disappeared before the next hemolytic injection date. Two of the cases of typhoid vaccine control had large painful lumps after 0.5 cc. injections; these disappeared slowly, as commonly with this agent. One case, apparently cured by vaccine of a rather severe recurrent nasal erysipelas, was exposed to typhoid through milk, and received the usual typhoid vaccine prophylactic from his family doctor. Terrific temperature reaction was immediately followed by a most violent erysipelas of the whole face and scalp. This case is highly suggestive of the rôle played by alien proteins, whether pollens or food allergies, or animal exudates, in lowering the threshold of resistance to organisms previously well tolerated in the nose and throat.

Because the nasopharyngeal flora changes rapidly during the process of immunization, repeat cultures were taken in many cases, so that 47 hemolytic vaccines were used in the 30 cases analyzed. Dr. Benson properly insists that success in the use of these vaccines can only be reached by keeping the vaccine abreast of the nasal infestation at any given time. Bacteriology is constantly developing new variants in the growth, affinities, preferences and metamorphoses of various strains of the cocci. It may readily be assumed that an immunized individual may develop high resistance against one type of organism, thus permitting another to crop out and be isolated at subsequent culture dates. The fallacy of stock-vaccine therapy, save as it is used as

a somewhat unstandardized method of alien protein injection, is too apparent to demand refutation at this time. Even as alien protein, stock vaccines have many of the objections incurred by whole-milk injections—multiple protein content, and unknown proportions of organisms of varying serological potency. Typhoid vaccine, containing but one well-studied organism, affords an accurate standard for control work on alien protein; and it does not contain the soluble filterable hemolysins which might assist the action of a mixed-coccus vaccine.

Table III shows the clinical diagnoses in the series:

TABLE III.—CLINICAL DIAGNOSES IN FIFTY CASES

Diagnosis.	Hemolytic cases.	Nonhemolytic streptococcic.	Typhoid.
Ethmoiditis one side	7	1	
Ethmoiditis both sides	23	9	3
Sphenoiditis one side	2		
Spenoiditis both sides	3	2	1
Maxillary one side	4	2	1
Frontal one side	1		

Operative procedures which had preceded the use of vaccines were as follows:

TABLE IV.—PREVIOUS OPERATIONS IN FIFTY CASES

Operation.	Hemolytic cases.	Nonhemolytic streptococcic.	Typhoid.
Middle turbinate one	1		
Middle turbinate both	2		
Ethmoid, partial one	3		
Ethmoid, partial both	4		
Ethmoid, complete one	3		
Ethmoid, complete both	4	2	
Sphenoid one	3		
Sphenoid both	3	2	
Maxillary one	2	1	
Septum, partial	1		
Septum, complete	6	3	2
Tonsil	16	3	2
Adenoid	9		
Frontal, internal	2		

It should be noted that sphenoid, ethmoid, turbinate or septum operations had been done on 24 of the 30 hemolytic cases, and on 5 of the 10 nonhemolytic streptococcus controls. Most of these

results were excellent as to improvement of drainage; a few had small foci which required attention before vaccines could be considered. Most of the surgery had preceded vaccine work by periods ranging from several months to ten years. Recurrence of former symptoms was usually the reason why operated cases sought further treatment. In most instances strong objection was made to any more operative procedures; occasionally operative procedures were blamed for exacerbation of symptoms. Our conservatism regarding surgery in such cases was strengthened by the views of Mithoefer,[56] who decries operation in the presence of hemolytic organisms; and of Shambaugh,[57] who is averse to operation on purely neuralgic indications, especially where true suppuration is undemonstrable.

Five of the 30 hemolytic cases were highly sensitized to a large number of proteins; as also were one each of the nonhemolytic streptococcus group of 10 and the typhoid control group of 3.

The degree of anemia in these persons was as follows:

TABLE V.—ANEMIA AS AN INITIAL FACTOR IN FIFTY CASES

Type of cases.	Anemia Marked, per cent.	Moderate, per cent.	Slight, per cent.
Hemolytic cases	21	45	34
Nonhemolytic controls	20	20	60
Typhoid controls	33	67	

Complications of these cases included the following conditions:

TABLE VI.—COMPLICATIONS EXISTING IN FIFTY CASES

Condition.	Hemolytic cases.	Nonhemolytic streptococcic.	Typhoid.
Pregnancy	2		
Dysmenorrhea	3	..	1
Metrorrhagia	3		
Arteriosclerosis	3		
Hemophilia	1		
Mitral regurgitation	2		
Mitral stenosis	1		
Myocarditis	2		
Septicemia (positive culture)	2		
Asthma	10	1	3
Bronchitis chronic	2	1	2
Mucous colitis	2	..	1
Arthritis acute	1	1	
Arthritis chronic	3	1	

Following is an analysis of symptomatic results in cases treated with hemolytic vaccines:

TABLE VII.—SYMPTOMATIC RESULTS, THIRTY HEMOLYTIC CASES

Symptoms complained of.	Cured.	Improved.	Relapsed.	Unchanged.
Asthenia	3	4		
Nasal discharge	10	3	1	2
Nasal obstruction	8	..	1	
Dry burning throat	3	1	..	1
Intractable cough	6	2	..	1
Asthma	7	1	..	2
Low fever (99°–100.6°)	6	1	1	
Headache, frontoparietal	3	..	1	1
Headache, occipitomastoid	8	1	..	1
Recurrent colds	5	2		
Recurrent erysipelas	1			

Obviously certain of these cases were unfit for further operative procedures, aside from their personal objections to methods tried before and found wanting. Most remarkable were the symptomatic results in two children thought to have whooping-cough because of the character of the paroxysms. Cessation of cough after one or two injections was a surprise alike to us and the attending pediatricians. One case of malignant endocarditis at the mitral, bedfast for months with a fever from 100° to 101°, who had previously had an extensive ethmoid well done on the affected side, was after two injections free from fever, and in a month able to sit up and even move about her room. Most of the cases required long-continued and careful work, however.

In the following list, the disappearance of all symptoms for four months or more following cessation of the use of vaccines is reported as cure. Prolonged freedom from more than half of the symptoms is reported as improvement. Two-thirds of the hemolytic series have been well for periods ranging from six to eighteen months; the rest have maintained cures or improvement in spite of severe winter conditions. It is of course impossible to say whether some may not relapse, and records will be kept to check all these results. Numerical list of cases is appended to the paper.

TABLE VIII.—GENERAL RESULTS OF VACCINES

Vaccine used.	No. of cases.	Immediate cure, per cent.	Cure in 4 weeks, per cent.	Late cure, per cent.	Improved, per cent.	Unchanged, per cent.
Hemolytic (47 vaccines)	30	13	37	23	17	10
Nonhemolytic streptococcic	10	..	20	10	40	30
Typhoid	3	..	..	..	..	100

The original infective agent was found to have disappeared in every case where final culture was made in the hemolytic series. Several cured cases returned at the beginning of their second winter and requested cultures so as to be protected by vaccine against recurrence; and in a few cases hemolytic organisms were found in small numbers in these persons, and prophylactic vaccines were made.

CONCLUSIONS. 1. Mixed vaccines with numerous organisms, used in spheno-ethmoidal disease, depend largely upon somatic reaction to alien protein for such value as they may possess. Their effects are likely to be dangerous and are undefinable in proportion to their dosage of different bacteria, each with its own coefficient of protein reaction.

2. Alien protein injections, if used, should be made with some highly-standardized product, such as typhoid vaccine. This product was found to have no beneficial effect in 3 control cases of our series.

3. Autogenous vaccines from hemolytic cocci secured by loop inoculation on human-blood media were found curative in 73 per cent of cases of obstinate spheno-ethmoidal disease.

4. Autogenous vaccines from nonhemolytic streptococci secured by loop culture on human-blood media were found curative in 30 per cent of cases of obstinate spheno-ethmoidal disease.

5. Injection of vaccines based on hemolytic cocci is recommended and was tried only upon such cases as were unsuitable for, or had failed to respond to, the established procedures of surgical and anitseptic treatment.

Grateful acknowledgement is made to Dr. Ross H. Skillern for suggestions regarding this study; to Dr. Robert L. Benson, for invaluable assistance and advice, in preparation of the whole series of vaccines; and to my associate, Dr. Irving M. Lupton, for data on numerous control cases.

APPENDIX: NUMERICAL LIST OF CASES

No.	Name.	Age.	Sex.	Diagnosis.	Organisms found.	Vaccine begun.	Dose, maximum cc. dose.	Vaccine ended.	Result.
					HEMOLYTIC SERIES				
1	M. N. J.	32	F.	Eth. and sph. B. Opt. atroph. R., streptococcemia Hemophilia	1. strep. short ch.	11/27/22	0.1–0.4	1/27/23	Improved.
					2. staph. aureus	1/28/24	0.1–0.5	3/14/24	Cure.
2	H. G. P.	56	M.	Eth. L., recur. erysipelas (recurrence after typh. vacc. 4/24	1. strep. long ch., and staph. aureus	10/29/23	0.1–1.0	12/11/23	Improved.
					2. strep. long ch.	12/14/23	0.1–0.4	12/29/23	Improved.
					3. staph. aureus.	8/ 6/24	0.1–0.5	10/18/24	Cure.
3	G. H.	16	M.	Eth. B., acne, glossitis	1. strep. long ch., strep. short ch., staph. aureus	1/ 7/24	0.1–0.5	2/ 5/24	Improved.
					2. staph. albus	2/19/24	0.1–0.5	6/10/24	Cure.
4	T. B.	7	M.	Eth. B asthma (cough)	1. strep. short ch., staph. albus	12/27/23	0.1–0.5	1/31/24	Cure.
					2. staph. albus	2/ 8/24	0.1–0.3	6/ 3/24	Cure.
5	A. C.	8	M.	Eth. B many prot. allergies (cough)	1. strep. long ch.	12/ 3/23	0.05–0.5	1/28/24	Improved.
					2. strep. viridans, staph. albus	2/11/24	0.1–0.5	5/12/24	Improved.
					3. staph. aureus (prophyl.)	10/11/24	0.1–0.4	12/ 8/24	Cure.
					4. staph. aureus (prophyl.)	12/30/24	0.1–0.4	3/15/25	Cure.
6	G. H. C.	36	F.	Eth. L, pregnant, muc. colitis	1. strep. short ch.	12/ 3/23	0.05–0.5	5/6 /24	Cure.
					2. strep. long ch. (prophyl.)	12/15/24	0.1–0.5	3/15/25	Cure.
7	L. R.	34	M.	Eth. B asthma	1. staph. aureus	12/29/23	0.2–0.5	1/30/24	Improved.
					2. staph. aureus	2/11/24	0.1–1.4	4/30/24	Cure.
8	W. R. L.	71	M.	Eth. B, asthma, bronchitis	1. staph. albus	1/16/24	0.1–0.5	3/10/24	Cure.
9	M. W.	34	F.	Eth. R, sphen. R, max. R	1. staph. albus, and staph. aureus	1/19/24	0.1–0.2	1/27/24	Unchanged.
10	G. P. A.	39	F.	Eth. B, asthma, Mitral sten.	1. staph. aureus	1/24/24	0.1–0.2	1/10/24	Unchanged.
					2. staph. aureus	3/15/24	0.1–0.4	4/16/24	Cure.
11	F. C.	9	M.	Eth. B, chr. bronch. (cough)	1. staph. aureus	1/28/24	0.1–0.5	2/29/24	Improved.
12	J. B. C.	65	M.	Eth. L asthma, myocarditis, arteriosclerosis	1. staph. aureus and strep. short ch.	1/31/24	0.1–0.5	2/16/24	Improved.
					2. duplicate used at home; traveling, spoiled,	2/23/24	0.1–0.4	3/ 5/24	Discontinued because severe reaction
					3. staph. aureus	7/24/24	0.1–0.3	7/30/24	Discontinued for same reason as (2); Impr.
13	M. E. T.	62	F.	Eth. B, sphen. B, chr. bronchit. asthma, myocarditis	1. staph. aureus	2/ 5/24	0.1–0.5	3/13/25	Cure (of asthma and cough).

14	C. C. W.	36	F.	Eth. B, sphen. B, sphenopal neuralg.	1. staph. aureus	2/ 8/24	0.1–0.5	3/27/24	Improved (marked).
15	J. P.	8	M.	Eth. B, asthma (cough)	1. staph. aureus	2/ 8/24	0.1–0.5	5/16/24	Cure.
16	M. McD.	18	F.	Eth. B, front. R	1. staph. aureus	2/11/24	0.1–0.5	3/24/24	Cure.
17	K. C. R.	32	F.	Eth. B, sphen. B, front. R sphenopal. neuralg.	1. staph. aureus	1/17/24	0.1–0.5	4/23/24	Improved.
						Severe reaction on 0.5 cc.			
					2. duplicate	5/ 2/24	0.2–0.4	6/23/24	Improved.
18	C. D.	11	M.	Eth. B, (severe cough and discharge)	1. staph. albus and staph. aureus	2/ 9/24	0.1–0.4	5/ 3/24	Cure.
19	A. J. C.	34	F.	Eth. L, OMS. L, sphen. L, pregnant	1. staph. aureus (prophylactic against eclampsia)	2/27/24	0.1–0.4	9/10/24	Cure.
20	A. W.	39	F.	Eth. B streptococcemia, chr. arthritis	1. strep. short ch.	2/29/24	0.1–0.3	7/ 7/24	Improved.
					2. strep. short ch.	12/ 2/24	0.05–0.1	3/15/25	Improved.
21	A. W. S.	34	F.	Eth. B asthma (allergic)	1. staph. albus	4/22/24	0.2–1.0	6/24/24	Improved.
					2. staph. albus	10/13/24	0.1–0.3	11/10/24	Unchanged.
22	J. S.	39	M.	Max. L, eth. L	1. strep. viridans and staph. albus	8/ 9/24	0.1–0.5	9/13/24	Improved.
					2. staph. albus	9/23/24	0.1–0.5	11/15/24	Cure.
23	C. McN.	28	F.	Eth. B, beg. ozena	1. staph. albus	9/ 2/24	0.1–0.5	11/25/24	Improved.
24	H. C.	11	M.	Eth. B, (cough)	1. strep. long ch.	10/11/24	0.1–0.4	12/ 8/24	Improved.
					2. staph. aureus	1/30/25	0.1–0.4	3/15/25	Cure.
25	S. A. S.	31	F.	Eth. B, (allergic)	1. staph. aureus	12/ 9/24	0.1–0.5	3/14/25	Cure.
26	D. McD.	27	F.	Eth. B	1. staph. albus	12/23/24	0.1–0.5	3/ 7/25	Cure.
27	L. H.	35	M.	Eth. B, sph. L, arthrit. chr.	1. strep. short ch.	12/ 4/24	0.1–0.5	12/28/24	Unchanged.
28	E. J.	17	F.	Eth. L, mitral regurg. (fever)	1. staph. aureus	1/20/25	0.05–0.1	3/20/25	Impr. (marked).
29	D. P. S.	45	M.	Eth. B	1. staph. aureus	12/26/24	0.1–0.5	3/15/25	Cure.
30	F. E.	10	M.	Eth. B, arthrit. (cough)	1. staph. albus	1/16/25	0.1–0.5	3/ 2/25	Cure.
					NONHEMOLYTIC STREPTOCOCCIC CONTROL CASES				
1	W. W.	36	F.	Eth. B, sphen. B, sphenopal. neuralgia	1. nonhem. strep.	9/ 3/24	0.1–0.4	12/13/24	Improved.
2	C. H.	18	F.	Eth. B	1. nonhem. strep.	9/ 1/24	0.1–0.5	10/11/24	Improved.
3	C. R. E.	30	M.	Eth. B	1. nonhem. strep.	9/13/24	0.1–0.5	9/30/24	Unchanged.
4	A. F. C.	30	F.	Eth. R, max. R	1. nonhem. strep.	9/18/24	0.1–0.5	2/20/25	Improved.
5	A. M.	26	F.	Eth. B, front. R	1. nonhem. strep.	10/11/24	0.1–0.5	12/22/24	Cure.
6	M. N.	32	F.	Eth. B, max. R	1. nonhem. strep.	10/15/24	0.1–0.5	12/ 1/24	Improved.
7	D. W. R.	26	M.	Eth. B	1. nonhem. strep.	11/ 1/24	0.1–0.5	3/ 4/25	Unchanged.
8	M. L.	34	F.	Eth. B, sph. B	1. nonhem. strep.	12/28/24	0.1–0.5	3/10/25	Cure.
9	F. L. R.	28	F.	Eth. B	1. nonhem. strep.	1/30/25	0.1–0.5	2/25/25	Unchanged.
10	E. B. S.	41	M.	Eth. B, asthma	1. nonhem. strep.	1/28/25	0.1–0.5	3/13/25	Cure.
					TYPHOID VACCINE CONTROL CASES				
1	E. S.	36	F.	Eth. B, sphen. B, asthma	1. typhoid vaccine	7/25/24	0.1–0.5	8/20/24	Improved.
					2. typhoid vaccine	9/29/24	0.2–0.5	12/27/24	Unchanged.
2	T. McE.	44		Eth. B, asthma	1. typhoid vaccine	11/17/24	0.1–0.5	12/ 5/24	Unchanged.
3	F. R.	39	..	Eth. B, max. L, asthma	1. typhoid vaccine	11/18/24	0.1–0.3	12/ 9/24	Unchanged.

May I express the hope that this preliminary report, based on 50 cases observed from 1922 until the present, but requiring confirmation of results over a period of years, may persuade others with greater clinical opportunities to assist in the ultimate decision on the value of hemolysis as a criterion for the clinical usefulness of vaccines? To quote from Marmorek's classic study of the streptococcus:[1] "Nous n'ignorons pas combien la prudence est nécessaire quand il s'agit de juger un remède nouveau. Nous nous garderons donc de toute conclusion hâtive." (We have not forgotten how necessary prudence becomes when the question of judging a new remedy arises. We shall therefore be guarded against all hasty conclusions.)

Bibliography

1. Marmorek, A.: Le streptocoque et le sérum antistreptococcique, Ann de l'Inst. Pasteur, 1895, ix, 593.
2. Boucheron: Sérum antistrep. dans la sinusite maxillaire aigue, Compt. rend. Soc. de Biol., 1897, 10 s., iv, 218.
3. Hinkel, F. W.: Symptoms and Treatment of Chronic Empyema of the Sphenoidal Sinus, Trans. Am. Laryngol. Assn., 1902, p. 93.
4. Birkett and Meakins: Value of Vaccine Treatment of Chronic Inflammations of the Accessory Sinuses (Symposium), Trans. Am. Laryngol. Assn., 1910, p. 94.
5. Coakley and Kendall: Trans. Am. Laryngol. Assn., 1910, p. 105.
6. Cobb and Nagel: Trans. Am. Laryngol. Assn., 1910, p. 112.
7. Casselberry, W. E.: Attenuated Types of Suppurative Sphenoiditis, Trans. Am. Laryngol. Assn., 1911, p. 92.
8. Coffin, Lewis A.: Nonoperative Treatment of the Accessory Sinuses, Trans. Am. Laryngol. Assn., 1915, p. 138.
9. Halsted, T. H.: General Streptococcic Infection through the Accessory Sinuses and Tonsils, Trans. Am. Laryngol. Assn., 1917, p. 78.
10. Coates, Geo. M.: Vaccine Therapy in Diseases of the Nose, Throat and Ear., New York Med. Jour., 1915, cii, 71.
11. Coates, Geo. M : Clinical Experience with Vaccines in Diseases of the Ear, Nose and Throat, Jour. Am. Med. Assn., 1917, lxviii, 162.
12. Levy, Robert: Vaccine Therapy in Rhinology and Otolaryngology, Trans. Am. Laryngol., Rhinol. and Otol., Soc. 1909, p. 530.
13. Patterson: Present Status of Vaccine Therapy in Diseases of the Nose, Throat and Ear, Laryngoscope, 1910, xx, 871.
14. Brawley, Frank: Auto-vaccines in Nasal Accessory Sinus Infections, Laryngoscope, 1910, xx, 877.
15. Graef and Wynkoop: Case of Streptococcic Meningitis Cured by Autogenous Vaccine, New York Med. Jour., 1910, xcii, 74.

16. Dabney, V.: Vaccine Therapy in Treatment of Diseases of Ear, Nose and Throat, New York Med. Jour., 1912, xcv, 273.

17. Haskin, W. H.: Pemphigus of Nose and Throat Due to Streptococcus Hemolyticus, Laryngoscope, 1916, xxvi, 984.

18. Irvin: Vaccines in Treatment of Eye, Ear, Nose and Throat, Bull. El Paso County Med. Soc., 1914, vi, 16.

19. Lewis: Otologic and Rhinologic Aspects of Vaccine Therapy, Iowa Med. Jour., 1907, xiv, 274.

20. Sperry: Present Status of Vaccines in Nose, Throat and Ear Diseases, Proc. Conn. Med. Soc., 1912, p. 162.

21. Haughey: Preliminary Report of Commission on Vaccines, Jour. Michigan Med. Society, 1916, xv, 65.

22. Campbell: Vaccines in Ear, Nose, Throat, Jour. Michigan Med. Society, 1916, xv, 109.

23. Moss: Vaccines in Infectious Diseases of the Ear, Nose and Throat, Texas State Jour. Med., 1915–1916, xi, 648.

24. Fox: Autogenous Vaccines in Treatment of Diseases of the Ear, Nose and Throat, Jour. Florida Med. Assn., 1918, iv, 360.

25. Portmann: Les stock-vaccines en oto-rhino-laryngologie, Arch. Int. de laryng., 1922, xxviii, 67.

26. Portmann: La vaccinotherapie, Rev. de laryngol., 1922, xliii, 49.

27. Caulet: Auto-vaccinotherapie en oto-rhino-laryngologie, Bull. d'oto-rhino-laryngologie, 1923, xx, 236.

28. Worms and Delater: De l'auto-vaccinotherapie en oto-rhino-laryngologie, Bull. d'oto-rhino-laryngologie, 1922, xx, 236.

29. Calicete: Efficacia dell'autovaccinoterapia (caso dello streptococco), Boll. d. Mal. orec. gol. nas., 1922, xl, 121.

30. Worms and Delater: Autovaccinotherapie en oto-rhino-laryngologie, Rev. de lar., 1923, xliv, 307.

31. Retrouvez and Cantorné: Vaccinotherapie en otorhinolar. chez les enfants, Jour. de méd. de Bordeaux, 1924, liii, 633.

32. Given: Use of Anticatarrh Vaccine, Jour. Roy. Nav. Med., 1921, vii, 330.

33. Moreaux: Vaccin de Delbet en oto-rhino-laryngologie, Rev. méd. de l'est, 1922, l, 57.

34. Seifert: Zeit. f. inn. Med., 1921, xlii, 465.

35. Skillern: The Accessory Sinuses, 1923, 4th ed., p. 91.

36. Skillern, R. H.: History of the Sinuses, Trans. Am. Laryngol., Rhinol. and Otol. Soc., 1924, p. 327.

37. Mosher, H. P.: Unsolved Problems of Otolaryngology, Trans. Am. Laryngol., Rhinol. and Otol. Soc., 1924, p. 354.

38. Key, B. W.: Ocular Infections, Trans. Ophth. Sec., Am. Med. Assn., 1923, p. 158.

39. Wilder, Wm. H.: Discussion, Trans. Ophth. Sec. Am. Med. Assn., 1923, p. 165.

40. Duke: Treatment of Hay Fever and Asthma, Am. Jour. Med. Sci., 1923, clxvi, 659.

41. Kruse, W.: Die Erreger von Husten und Schnupfen, München. Med. Wchnschr., 1914, lxi, 1547.

42. Bloomfield, A. L.: Serial Quantitative Culture in Study of Respiratory Disease, Jour. Am. Med. Assn., 1921, lxxvii, 187.

42-*a*. Bloomfield, A. L.: Variations in Bacterial Flora of Upper Air Passages, Bull. Johns Hopkins Hosp., 1921, xxxii, 12.

43. Foster, G. B.: Filterable Virus in Acute Colds, Jour. Am. Med. Assn., 1916, lxvi, 1180.

44. Goldman, Mudd and Grant: Bacteriology of the Nose and Throat; Reactions to Chilling, Jour. Inf. Dis., 1921, xxix, 151.

45. Pilot and Pearlman: Bacterial Studies of the Upper Air Passages, Jour. Inf. Dis., 1921, xxix, 47.

46. Kraus: (Quoted by Hiss and Zinsser infra), Wien. klin. Wchnschr., 1900, v, 3.

47. Hiss and Zinsser: Text-book of Bacteriology, 5th edition, 1922, p. 393.

48. Smith and Brown: Streptococci Isolated from Milk-borne Epidemics of Tonsillitis, Jour. Med. Res., 1914, xxxi, 455.

49. Benson and Sears: Milk-borne Septic Sore Throat, Jour. Am. Med. Assn., 1923, lxxx, 1608.

50. Sears and Benson: Pathogenic Streptococci and Milk Sterilization, Am. Jour. Pub. Health, 1923, xiii, 937.

51. Bloomfield and Felty: Dissemination of Hemolytic Streptococci Among Healthy People, Johns Hopkins Hosp. Bull., 1923, xxxiv, 414.

52. Young and Crooks: The Blood Plate as an Aid to Diagnosis, Jour. Lab. and Clin. Med., 1923–1924, ix, 409.

53. Russel, F. F.: Streptococcus Carriers, Ann. Otol., Rhino. and Laryngol. 1919, xxviii, 374.

54. Smillie, W. A.: Studies of the Beta-hemolytic Streptococcus, Jour. Inf. Dis., 1917, xx, 45.

55. Smithies, F. (Chicago): Pernicious Anemia, Annual Lecture, Portland (Ore.) Acad. of Medicine, January, 1925.

56. Mithoefer: Causes of Failure in Surgery of the Nasal Accessory Sinuses, Trans. Am. Acad. Ophth., Otolar., 1921, p. 374.

57. Shambaugh, Geo. E.: Recent Problems in Rhinology, Minnesota Med., 1924, vii, 496.

58. Solis-Cohen, M.: Visceral Disease Due to Bacterial Infection of Apparently Normal Upper Respiratory Tract, Jour. Am. Med. Assn., 1924, lxxxiii, 824.

Discussion

Dr. Ross H. Skillern, Philadelphia:

During the reading of this paper Dr. Fenton was good enough to quote me in regard to the attempt to introduce a sound into the sinuses

for the purposes of culture taking. My paper was written in 1913, so that that method at the present time is about as obsolete as Noah's ark.

We have been using, as everybody has for perhaps a decade, the long platinum loop on a glass rod. First of all, it is introduced in the sphenoid without cleansing. Then the nose is wiped out. Suction is applied (and I think that is an important part) and again a culture is taken of the spheno-ethmoidal region. It is interesting to note the differences which the culture brings out between the time of the investigation before the washing and after the suction.

Regarding his conclusions, they are most illuminating. In conclusion No. 3 he says: "Autogenous vaccines from hemolytic cocci secured by loop inoculation on human-blood media were found curative in 73 per cent of cases of obstinate spheno-ethmoidal disease." Seventy-three per cent! Three cases out of four! That was remarkable. Just think what it means to us in these old cases of obstinate spheno-ethmoidal disease.

In paragraph No. 4, he says: "Autogenous vaccines from non-hemolytic streptococci secured by loop culture on human blood media were found curative in 30 per cent of cases of obstinate spheno-ethmoidal disease."

No. 5, which I think is the most important of all, says that "the injection of vaccines based on hemolytic cocci is recommended and was tried only upon such cases as were unsuited for or had failed to respond to the established procedures of surgical and antiseptic treatment."

In my humble judgment the author has shown infinite capacity for taking pains, and if his results are corroborated by future observations (which there is every reason to believe they will be) he will indeed have conferred a boon on humanity and given his colleagues a new lease on life and incidentally have gone a long way toward solving the so-called ethmoidal problem.

Dr. George M. Coates, Philadelphia:

My interest in vaccine therapy dates to the time when I heard Sir Almroth Wright read one of his first papers on the opsonic index, which seemed to offer a great deal of promise but did not prove to be of as much value as it was thought at the time that it might. His further observations on prospects of cure of various diseases by vaccine therapy, we are also familiar with.

This interest has been stimulated by such papers as we have had in

the past and particularly such as Dr. Fenton has just read before us, presenting a most admirable study of this whole question; particularly, as Dr. Skillern has just said, his remarkable results in these old chronic cases that have for the most part defied every other method of cure.

Vaccine therapy, a chance to cure these old cases that have defied everything else, offers us an alluring field to work in. Our main trouble in the past has been to isolate the true infective agent in each case. We have tried various methods of skin reactions with rather indifferent success. If we can assume, then, that the majority of these cases are caused by hemolytic organisms and that the vaccines made from these hemolytic organisms offer a better chance for cure, we have gone a long way toward solving the problem of what strain of organism to use.

In my early attempts at vaccine therapy in accessory sinus disease, I was impressed with the fact that we could get results at certain times in cases that resisted other methods of treatment. I tried vaccine, first, on cases that later proved to be operative cases or that I thought at the time were operative cases. I thought vaccine therapy might obviate the necessity of operative interference. In all these cases, as Dr. Fenton has quoted, we had failures. But it seemed to me at the time that these cases that had had previous administration of vaccines did better after operation. We had more prompt cure after drainage and ventilation were established.

We found in a certain proportion of cases that a cure could be obtained by vaccine therapy following the operative procedure. We also found, I think to our satisfaction, that when we did get a cure there was less danger of relapse, as is only too common in these cases from repeated inter-current infections later on.

Dr. Fenton stresses the need of taking repeated cultures and taking them carefully. I think this is of extreme importance. We recognize the necessity of taking a culture carefully; there is no discussion about that. But the vaccine must be made carefully by an expert, and the laboratory and the clinician must work in close coöperation here just as Dr. Wherry insisted upon in his *x*-ray work.

An unskilled preparer of vaccine can spoil your vaccine or, as in one case of mine, send you back a live vaccine which may be disastrous. In this particular case, which I have put on record, the vaccine sent back from the laboratory was injected and there resulted therefrom a streptococcic abscess in the upper arm. Nothing happened except that the case was cured of old, long-standing ear suppuration from the one injection. She was cured, and stayed cured, by a live vaccine.

That opens up possibilities. If we could use live vaccines carefully, maybe we might get better results.

The necessity of taking repeated cultures is evident from Dr. Fenton's work. We find that one particular type of organism will disappear after a certain amount of vaccine therapy and another take its place. Immunity is established for one and that allows another type of organism to grow.

Thus we have found, in our work, that it is necessary to take repeated cultures and to make repeated vaccines, for the second and third cultures may come out entirely different from the original one.

Also we have had trouble in the past in getting what we thought was the specific organism and occasionally I have thrown out from the first vaccine an organism which we did not consider to be pathogenic but which later on proved to be so. In some early work on the ear, I uniformly discarded all Bacilli pyocyaneus; but later on, when the treatment was not successful, I returned this organism to the vaccine, with the result that the cases were promptly relieved.

Dr. Greenfield Sluder, St. Louis, Mo.:

I cannot express my gratitude to Dr. Fenton for opening my mind on this issue, which has been closed for a good many years. I have repeatedly tried vaccines, but I know nothing about bacteriology and therefore cannot criticize the bacteriological methods employed. I had of necessity to trust that side to two men, each of whom is recognized as an accomplished bacteriologist. I got the vaccines all right and I administered them, but I uniformly failed. Possibly I did not understand getting the cultures well enough. They left me at my wit's end absolutely in these almost-abandoned old cases. There were headaches and they were nearly wild, they suffered so frightfully. They and I would resort to anything as an experiment that held out any prospect of relief.

That I should have failed uniformly with vaccines is to me somewhat surprising and I have always been perfectly willing to admit the fault was mine, but I really do not know where it lay.

I am going to start over again and see if I cannot help some of these sufferers.

Dr. Fenton (in closing):

Mr. President, I cannot express my gratitude to the Fellows who have been so gracious to me, and especially to Dr. Skillern. I feel that this is but a humble step on the pathway; it is something in

which I feel we owe much to the stimulating influence of the internists who have gone along with the bacteriologists ahead of us. Many of us have followed the surgical line somewhat exclusively and have perhaps not been reasoning along serological lines very much. I know I speak for myself in this connection. I know Dr. Mosher and Dr. Skillern have been reasoning along these lines for a great many years.

In this regard I might speak of the work of Dr. Meyer Solis-Cohen, of Philadelphia, to which I referred briefly. Solis-Cohen has an interesting variant of this same thing. Our arrangement is to take human blood from some standard citrated supply kept in the laboratory. Solis-Cohen takes from the arm a syringeful of the patient's blood and squirts that into an empty tube which has previously been inoculated by a swab from the affected ethmoid. He selects whatever germ is hemolytic to that patient's own blood. He has investigated this from the standpoint of visceral diseases. We have made a few tests along this line and are going to make more. Some of the vaccines we found from this source are very helpful in connection with cardiac diseases and rheumatism.

THE RETRACTED NOSE[1]

V. P. BLAIR, M.D.

RETRACTION of that part of the maxillæ which forms the foundation of the cartilaginous nose and related part of the upper lip, may cause changes in the human face that may vary from not pleasing to hideous deformity. The abnormality is more evident when viewed in profile.

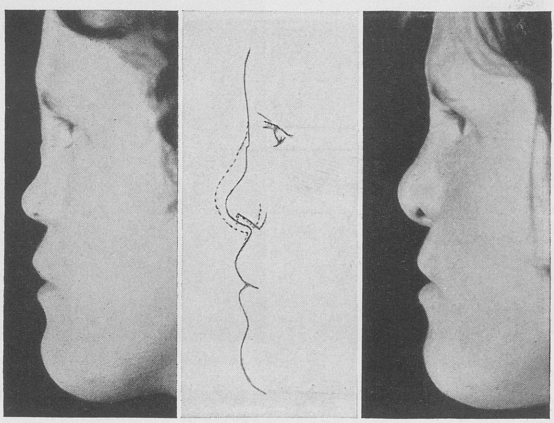

a *c* *b*

FIG. 1, *a*.—A young girl who originally had a saddle nose in conjunction with a moderate amount of flattening of the maxillary bone in the neighborhood of the anterior nares and proportionate anteroposterior shortening of the septum. She had been previously treated by the implantations of cartilage into the upper part of the dorsum, which accounts for the prominence of the bridge. *b*, The result of the implantation of a triangular-shaped piece of the right eighth costal cartilage through an incision within the nostril after removing one of the original transplants. At a later operation another strip of cartilage was implanted upon this triangular piece to raise the tip further. By these operations the dorsum, the alæ and tip of the nose, the cheeks and upper lip have been brought forward. The amount of this forward movement is more easily seen in Fig. 1, *c*. *c*, Superimposed tracings made from profile negatives, taken when the girl first came to us and after the completion of our second operation. This is a somewhat simple but usually not the most satisfactory plan of treating such cases. If there is much strain the cartilage is apt to bend and we have had to remove it in 2 cases. Bone is more rigid, but if rib is used it may not give sufficient body. (See Fig. 2, *a*.)

[1] From the Surgical Department of the Washington University Medical School based on cases treated in association with Dr. Ellis Fischel, Dr. Earl Padgett and the resident staffs of the Barnes Hospital, the St. Louis Children's Hospital and the St. Louis Mullanphy Hospital.

The cases observed by the writer have fallen into the following etiological groups:

1. Those of apparently natural occurrence.
2. Those due to an actual loss of bony foundation of the lip, nose or both, from trauma or disease.
3. Those in which the retraction has followed repair of a single or double congenital cleft of the lip and palate.

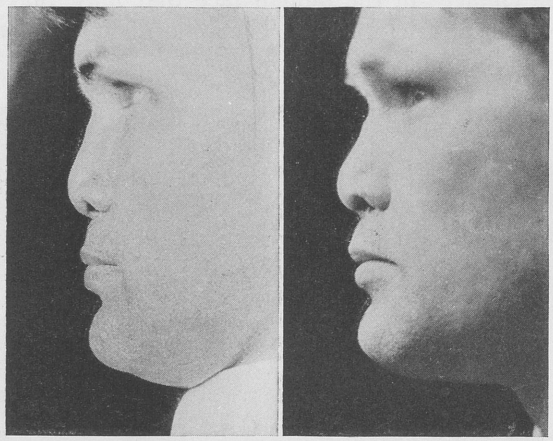

a *b*

FIG. 2, *a*.—If, in a case similar to that presented under Fig. 1, the attempted correction is made by the insertion of a straight piece of bone such as might be obtained from a rib, unless some plan is adopted to hold forward the lower end of the graft until bony union occurs, the tip of the nose will still lack prominence. This illustrates such a condition with a rib graft solidly united to the dorsal surface of the bony bridge. *b*, The result showed was obtained by lengthening the columella by means of a strip slid from the central part of the lip, and at the same time chiseling the nasal bones free from their attachments to the maxillary and frontal bones and the nasal septum. The nose was then pried forward and held in a more desirable position until union occurred. This was done by means of a metal bar, which had a dental anchorage below and passed up into the right nostril between the lip and the maxillary bone. This complicated and not overly satisfactory splint was ingeniously contrived by Dr. J. A. Brown, D.D.S., to meet the patient's objection to the long detention from his business that an external splint would have caused. The latter would have given greater final prominence to the tip of the nose. Fig. 2, *b*, does not do full justice to the result because it is not a true profile.

Among those of the first group the lack of maxillary prominence is most marked about the lower and lateral boundaries of the anterior nares and is accompanied by an anteroposterior shortening of the septum. The whole maxilla may be contracted in size, but

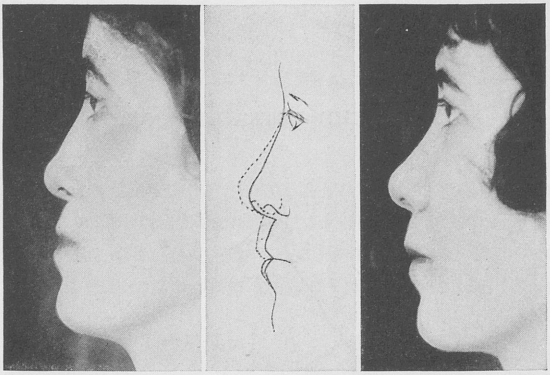

a *b* *c*

FIG. 3.—If the retraction is limited to the lip and lower part of the nose it is not practicable to correct it by the implantation of either bone or cartilage unless one is willing to chisel away the prominence of the bridge before inserting the implant.

A young woman with a well-developed nasal bridge in whom the retraction was limited to the tissues bordering the anterior nares. In this case, as in the immediately preceding one, the columella was very short, the anterior portion of each ala recurving backward to join it. The mesial crus of the lower lateral cartilage appeared to extend into the substance of the upper lip. In this type of case much improvement can be obtained by stepping forward the cheeks, upper lip, and lower part of the nose. This is done by freeing the lip and alæ with the adjacent parts of the cheeks, from the maxillæ, through an incision in the upper fornix which extends from one first molar tooth to its opposite fellow; this is continued up into the nose and forward along the lower border of the septum. The cheeks and lip can now be sutured in a forward position on the maxilla, which will correct the retraction about the anterior nares, and the columella can be stepped forward on the lower border of the septum which will give a forward tilt to the tip of the nose. The hæmorrhage following the freeing of these tissues is quite sharp and we have controlled it by gauze packing and, maybe, ten minutes of finger pressure before attempting to suture. Just before suturing, a curved, semisharp elevator is passed between the skin of the dorsum and the cartilaginous bony framework of the nose. In 1 case of this kind, to give greater mobility, the writer made a circumferential division of the lining skin of the vestibule which was followed by a stricture. This subsequently required an intranasal skin graft for its relief. *a* and *c*, A case which was treated in the manner described under Fig. 3. In this particular instance a vertical wedge of tissue was removed from the under surface of the middle part of the lip, which allowed the skin to fold forward to compensate for the shortness of the columella. *b*, tracings made from the negatives of photographs *a* and *c* show how much was accomplished. A photograph sent by the patient one year later shows no appreciable recurrence of the retraction.

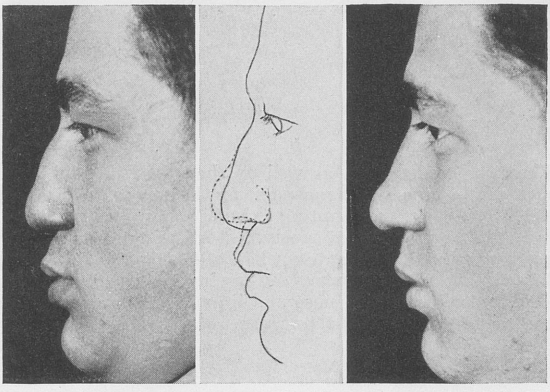

a *b* *c*

FIG. 4, *a*, *b* and *c*.—The same type as that shown in Fig. 3 but more pronounced. The same type of operation was used in both cases.

FIG. 5.—Superimposed tracings of a case similar to that shown in Fig. 3. In this case two pieces each 3 cm. long taken one from the eighth and one from the ninth right costal cartilage were inserted into a tract made just in front of the maxillary bone between the floor of the vestibule and the mucosa of the upper fornix; an external incision was made on each side in the ala labial fold which was immediately sutured.

This was not considered sufficient improvement and the operation described under Fig. 3, *a* and *b*, was subsequently done in addition.

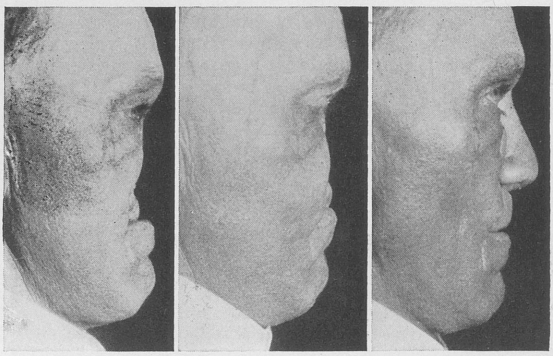

a *b* *c*

FIG. 6.—When the foundations as well as the upper lip and nose have been destroyed, much can be gained by transplanting the cheeks forward, after the plan described under Fig. 4, before attempting to build the lip and nose. *a*, Profile of a man who had, a number of years previously, lost from an ulceration the whole nose, part of his cheeks and lip and the anterior half of the palate and alveolar processes of the maxillæ. *b*, The result obtained by freeing the cheeks and suturing them forward. *c*, Final result after the nose and lip were made from a bald scalp flap and a cartilage was implanted into the bridge.

in many instances the palate and alveolar process are absolutely normal in size and in their relations to the mandible.

Heredity or the atavism will no doubt account for many of the cases that would fall in the first group. In some the mucous lining

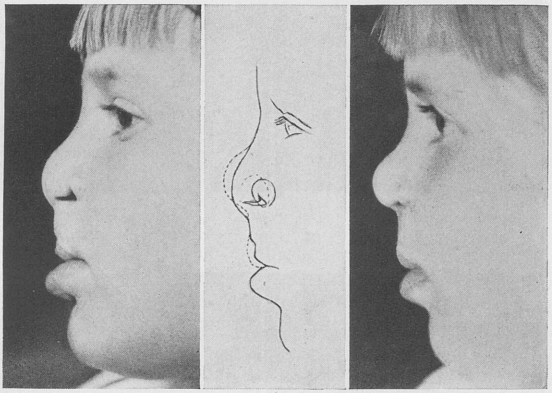

a *b* *c*

FIG. 7, *a*.—A common deformity that may follow a harelip operation in which the premaxilla was moved back, is a lateral spreading of the nostrils, an extremely short columella, and snubbed nose. *b* and *c*, Shows such a case treated after the plan detailed under Fig. 3, plus the excision of a diamond-shaped piece of skin and subcutaneous tissue from the base of the columella and upper part of the lip.

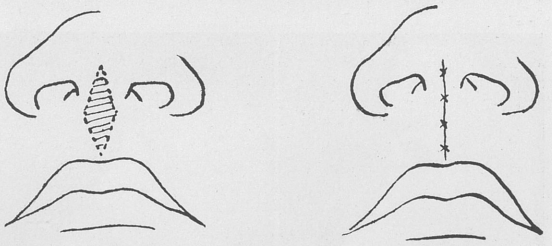

FIG. 7, *d*.—The diamond-shaped piece of skin and subcutaneous tissue was excised from the base of the columella and upper part of the lip. This latter step decreased the septolabial angle. The excessively long lip will be shortened at a subsequent operation.

of the nasal passages is markedly shortened from before backward, which has suggested the thought that possibly early inflammations and scarring of this mucosa from infantile "snuffles" or other infections may have had a causative influence.

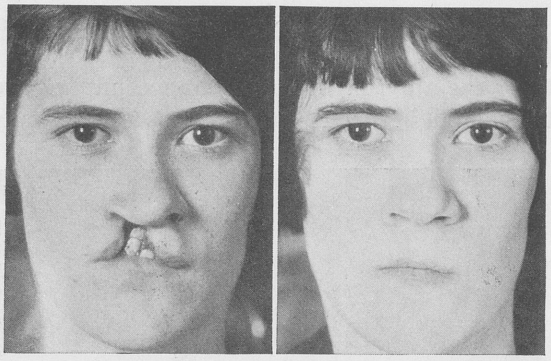

a *b*

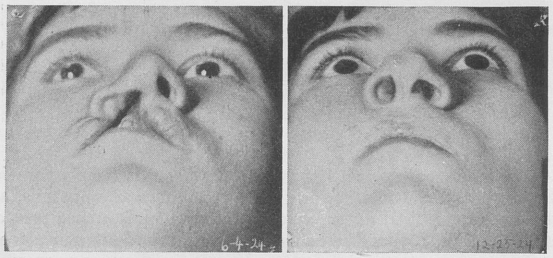

c *d*

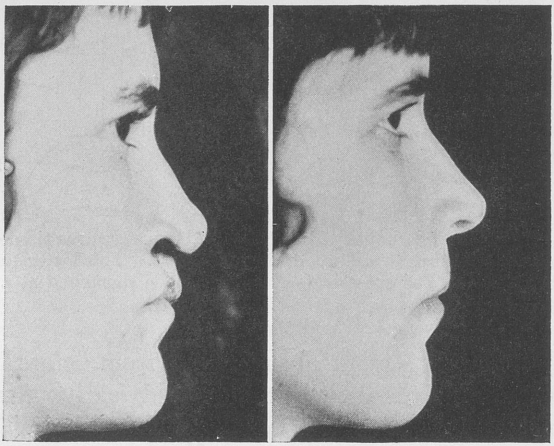

e *f*

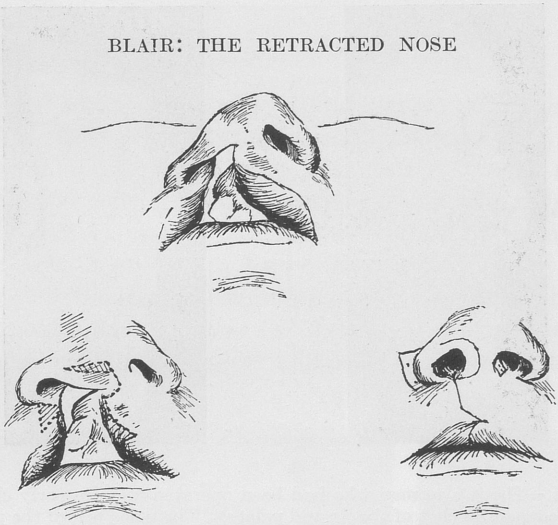

g

FIG. 8, *a*, *b*, *c*, *d*, *e*, *f* and *g*.—If a single harelip remains unoperated upon for some years or if the operation does not establish a proper relation between the base of the columella and the ala on the affected side, then with growth there will develop a characteristic variation which consists primarily of a unilateral retraction of the lip and nose and when pronounced can be satisfactorily relieved only by stepping forward the lip, cheek and columella of the affected side. This necessitates the splitting of the columella in the midline and usually the removal of a "V" under the lip to allow one-half the columella to be stepped forward. *a* and *b*, show the front and side views of such a case before and after operation and Fig. 8, *g*, shows the plan of the operation.

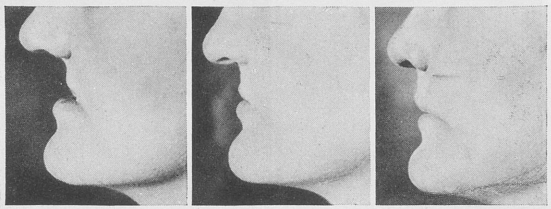

a *b* *c*

FIG. 9.—If there is much retraction of the anterior part of the maxilla, the lip may have to be held forward, either by orthodontic treatment or by a prosthesis. This shows the result of a previous correction after the loss of the anterior one-half of the palate and alveolar processes of the maxillæ and part of the upper lip from trauma. The lip is adherent to the bone. The later treatment of the case consisted in first freeing the lip from the maxilla to well above the attachment of the alæ, and lining the new sulcus with Thiersch grafts. This required two operations. Later a full-thickness triangular flap was turned from the lower into the upper lip at the site of the greatest loss. *b*, Shows the result of these operations before insertion of the prosthesis. *c*, Shows patient's appearance when wearing an upper dental plate which is so planned as to compensate for the lost part of the maxillæ.

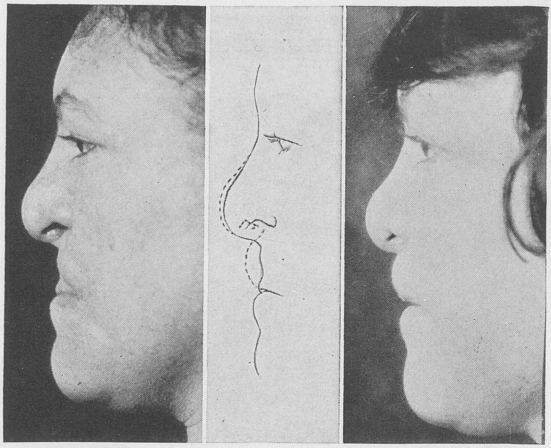

a *b* *c*

FIG. 10, *a*.—Shows a woman who had been operated upon in early childhood for a complete congenital cleft of the lip and palate. There is a loss of the premaxillary bone and the lip is very thin, much scarred and bound down to the maxillæ. The first step in the treatment was to liberate the lip, base of columella and alæ by incision and Thiersch graft as described in Fig. 9. Next the whole outer surface of the lip was replaced with a flap from the forehead giving the result shown in Fig. 10, *c*. *b*, Shows tracings for comparison. Note how much the alæ septolabial angle and the lip have been brought forward, but the tip of the nose has been moved very little. The case could still be improved very materially by transplanting the columella forward in the septum with corresponding forward movement of the tip. The new lip is still thick from recent operation.

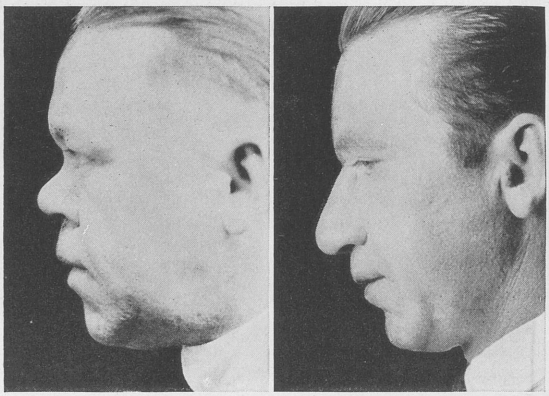

a *b*

FIG. 11, *a* and *b*.—The retraction may be complicated by a very short mucous lining of the nasal fossa which will have to be lengthened before the tip of the nose can be brought forward. This was accomplished by piecing out the covering as well as the lining. After freeing the soft parts of the nose from the maxillæ and nasal bones through a crescent incision across the bridge which completely divided the septum and the lining mucosa, the nose was drawn forward and the gap in the lining was pieced out by means of a forehead flap let in through the external incision. After this tissue had healed in place, the pedicle was cut and part of the remaining flap was used to lengthen the external surface of the nose.

Besides direct trauma and ulceration, the injudicious use of radium was the cause in 1 case included in Group 2.

Following a repair of a congenital cleft of the lip and palate there may be considerable retraction, which will vary with the type of repair employed. Usually it is most pronounced in the alveolar part, permitting a backward displacement of the upper lip with or without some snubbing of the nose; but where a "V" has been cut from the lower free border of the septum, to move back the premaxilla, the nasal snubbing may be the most noticeable feature.

a *b* *c*

FIG. 12, *a*.—In this case the soft parts were freed from the bones through an incision in the upper labial fornix and the cut mucous lining was pieced out by means of a flap from the arm let in through an incision in the upper fornix. *b*, The final result obtained by this operation and the subsequent implantation of a rib cartilage into the dorsum. *c*, The condition immediately after the first operation was completed and the pedicle of the flap returned to the arm.

The common characteristic of these cases is a receding upper lip or the tip of the nose or both; but the abnormal anatomy producing this retraction varies in different cases both in kind and degree, and must be considered in seeking the most appropriate plan of correction in each instance. In general there are two surgical plans applicable to the correction of this condition: One is to build out the deficient maxillary foundation, thus pushing forward the retracted soft tissues; the other is to draw them forward and fix them in this position. A combination of these two plans will often give the best results.

The retracted maxilla may be built out or supplemented in a number of ways.

When seen early, orthodontic treatment will give very great help in some cases.

The plans we have used to build up the bone about the orifice of the anterior nares have been the implantation of cartilage; the use of a dental prosthesis after liberating the soft tissues from the periosteum of the maxillary bone and lining the sulcus with "Thiersch" grafts; by liberating the cheeks from the maxillæ and suturing them in a forward position; by lengthening the lining of the nasal tube with a flap from the forehead, arm or the mucosa of the mouth. The soft tissues have been drawn forward and suspended in this position, either by the implantation of cartilage or bone between the skin and framework of the dorsum of the nose, or by suturing the liberated columella in a forward position on the lower border of the septum.

There is a type of retracted nose in which the septum and the columella are both short, part of the cartilage of the latter being buried in the lip. The columella is also short in the complete double congenital cleft of lip and palate. In these cases the columella will have to be lengthened in order to bring the nose forward. In some cases the external nose was so small that it was necessary to piece out the covering as well as the lining in order to obtain a desirable result.

Discussion

Dr. Gordon B. New, Rochester, Minn.:

I think we all know Dr. Blair and his wonderful work so well that it almost seems superfluous to congratulate him on his excellent results.

I wish to show lantern slides of two patients in which the retracted nose was treated by the use of full-thickness skin grafts. One a syphilitic deformity in which the entire inside of the nose was lined with a full-thickness skin graft, inserted through an incision inside the mouth between the cuspid teeth, and held in place with dental compound attached to a splint on the anterior teeth. Dr. Gillies has reported a similar case in which he used a Thiersch graft. I feel that the full-thickness skin grafts are more satisfactory.

The second case was a pugilist with complete closure of the anterior part of his left nostril. The scar was incised and the anterior two-

thirds of the nose lined by means of a thin full-thickness skin graft held in place with dental compound.

Dr. D. Bryson Delavan, New York City:

This fine exposition carries me back to the days when as resident, house officer in the Presbyterian Hospital, New York, I used to assist at the operations of Dr. Gurdon Buck, our famous surgeon, he who devised "Buck's extension" and who contributed to surgery so many other admirable original ideas, especially in the plastic surgery of the face. I wish he could be with us this afternoon to see the progress that has been made in this department which he labored so earnestly to advance, especially in the field of rhinoplasty.

Dr. Thomas A. Sabine, of New York City, many years ago attempted to restore the nose of a well-built, handsome young man whose external nasal organ had been completely destroyed. Dr. Sabine attempted to remedy this by affixing to the face the middle finger of the patient. Surgically, his effort was a complete success. The finger was attached to the face, and severed from the hand of the patient with complete recovery. Later, when the patient appeared in public the attention of everyone was attracted by the weird spectacle of a fine, human countenance surmounted by a large, perfectly evident finger in the place of a normal nose. Dr. Blair has wisely referred to the importance of the psychology of these cases. Chagrined at his disfigurement the man promptly shot himself.

BLASTOMYCOSIS OF THE LARYNX

CHEVALIER JACKSON, M.D., SC.D.

BLASTOMYCOSIS of the larynx is a rare disease, though probably not as rare as the paucity of literature on the subject would indicate. It is hoped that its recognition as a diagnostic possibility by the laryngeal text-books of the future will lead not only to its more frequent detection, but to the early diagnosis that may result in cure of the otherwise fatal disease.

REPORT OF CASE. Male, aged forty-eight years, a clerk in a general store by occupation was referred by Dr. J. D. Brewer to the Bronchoscopic Clinic for diagnosis as to the cause of laryngeal stenosis and aphonia and for cure and decannulation. He was wearing a tracheotomy tube which had been inserted eight months previously.

About two years before admission the patient developed hoarseness, which became progressively worse. Dyspnea on exertion developed within a few months of the onset of hoarseness. A diagnosis of pulmonary and laryngeal tuberculosis had been made and also a diagnosis of asthma. These conditions were treated by climate. The dyspnea increasing, the opinion had drifted more strongly to asthma, and adrenalin was used. This did not improve the dyspnea. Falling into the hands of other physicians, a tracheotomy was done. After tracheotomy the laryngeal stenosis apparently was relieved and the cannula was abandoned. The patient struggled along with more or less dyspnea for three or four months, at the end of this time he visited a large clinic where a second tracheotomy was done and a specimen was taken which did not confirm the clinical diagnosis of malignant disease of the larynx. After the removal of the specimen the patient's voice was said to have improved, but no diagnosis was made. The patient then came under the observation of Dr. Brewer who referred him to us.

Symptoms. There was a subjective sensation of burning and "soreness" of the skin of the neck around the tracheotomic wound, and to a less extent in the larynx and trachea. There was slight cough, and a small amount of mucopurulent secretion was expelled from the cannula.

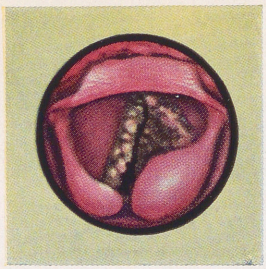

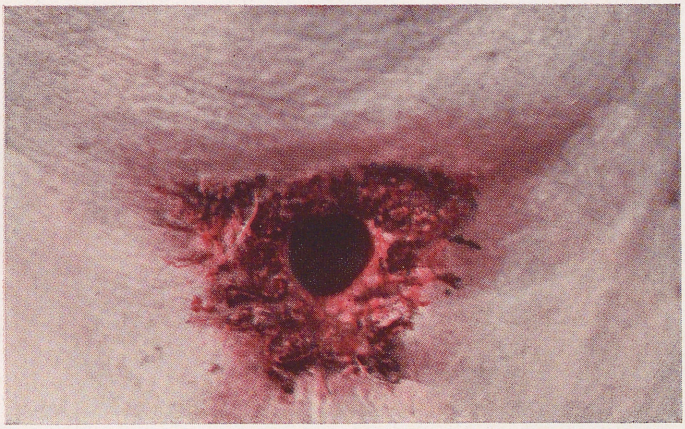

The upper illustration shows a mirror view of the stenotic laryngeal lesion in a case of primary blastomycosis of the larynx. From an oil color drawing by Chevalier Jackson.

The lower illustration is a tinted photograph of the front of the neck, showing the butterfly-shaped dermal lesion, the result of extension by continuity from the larynx after tracheotomy performed for blastomycotic laryngeal stenosis.

There was no history of fever, chills, great loss of strength or other general symptoms.

Mirror Laryngoscopy. Showed an infiltrative process involving the left side, part of the right side of the larynx and the inter-arytenoid space. The left cord and left ventricular band were not distinguishable, because of the presence of a grayish mass, quite granular below, whitish above, as if brushed with silver nitrate. The infiltrated area was covered with a whitish exudate that was cleared away partially by semi-cough. The left arytenoid was fixed, and the arytenoid half of the epiglottic fold was swollen about twice the normal size. On the right side the cord was replaced by a nodular mass extending from the anterior to the posterior commissure, the mass being covered with shining nodules having the appearance of frog spawn. There was slight motility of the right arytenoid. The right aryepiglottic fold looked inflammatory but was not noticeably enlarged.

Direct Laryngoscopy. The findings of the mirror were confirmed and in addition the subglottic region was explored. A good view of the right ventricular floor was obtained; the entire floor was covered with whitish nodular excrescences which extended out over the region where the cord should be and thence down into the trachea. This grayish exudate was continuous with a similar exudate covering the entire tracheal wall and extending down below the tracheotomic cannula. A specimen was taken for biopsy. The tissue cut easily with the biting forceps, but did not come away without resistance as in cases of cancer or papillomata.

Neck. Examination of the neck showed the fistula and tracheotomic cannula in foul condition, evidently not having had proper care. The cannula had not been removed for many weeks and was corroded and roughened.

Surrounding the fistula was a deep purplish red, nodular, intensely inflammatory rash extending irregularly but symmetrically for a maximum radius of about 3 cm. The general outline was somewhat in the form of a butterfly. The nodules were glistening, some deep crimson, others whitish, others slightly yellowish. Most of them were less than 3 mm. in diameter, many were pinpoint-sized. The general surface looked raw but not ulcerated; it was covered with a scanty seropurulent secretion with a slight tendency to crusting. The three most striking things about the rash as compared to the ordinary dermatitis around a neglected tracheotomic cannulated fistula were; (1) The dark, intensely red, almost purplish color; (2) the tiny nodules; (3) the sharp limitation of the external margin. A specimen was taken from this dermal lesion for biopsy.

The following is a report on the histologic examination of tissue by Dr. B. C. Crowell and Dr. B. L. Crawford:

Histology. The sections from the larynx show a markedly inflamed and ulcerated mucosa with considerable hyperplasia of the epithelium, and in the submucous tissue there is also extensive inflammatory reaction and fibrosis and numerous small foci containing giant cells, giving it somewhat the appearance of tuberculous lesion. The inflammatory reaction also involves the cartilage. Sections were examined from the two specimens removed and histologically the lesion is the same.

Sections from the margin of the tracheotomy wound show a marked hyperplasia of the squamous epithelium and extensive inflammatory reaction involving the epithelial layer and also the subcutaneous tissue. The foci in the skin are composed of polynuclear leukocytes in which there are many giant cells. In these foci numerous blastomyces were demonstrated. The fungus was also demonstrated in the sections from the larynx.

The sections were stained for tubercle bacilli but none was found. A portion of the tissue was macerated and injected into the groin of a guinea-pig, but there was no local evidence of infection and the pig remained well two months. At autopsy of this pig no lesion of any kind was found.

Histologic Diagnosis. Blastomycosis involving the larynx and tracheotomy wound. The blastomyces were demonstrated by Dr. Crowell.

Bacteriological Report of Dr. Bowman C. Crowell. Cultures were made from scrapings from the skin about the tracheotomy wound, where the organisms were found abundantly in the sections of the tissue. Cultures were made on glycerin-agar, Sabouraud's agar and in maltose broth. All were grown at room temperature and all tubes gave a growth. On the solid media the colonies are confluent, moist, whitish and pasty. The colonies in broth sink and form no pellicle.

Smears from the cultures show round to oval organisms, the larger ones with a well-developed hyaline, double, outer membrane. There is a moderate development of mycelium, but no asci are seen. Hyphæ are septate. Some budding is seen. The action of the organism on other culture media has not yet been studied, but the organism seems to comply with the description of *Cryptococcus dermatitidis*, Gilchrist and Stokes, 1898. (Synonym, *Cryptococcus gilchristi* Vuillemin.)

Progress. Consultation with Dr. Frank C. Knowles developed the fact that the dermatologist obtains very satisfactory results from the internal administration of potassium iodide in blastomycotic

lesions of the skin. The patient was placed upon twenty drops of a saturated aqueous solution of potassium iodide thrice daily.

Now at the end of five weeks of treatment the nodules have disappeared from the skin except for a few grouped around the margin of the tracheotomic fistula. The discoloration is less intense, though still a rather deep red. The larynx is almost free from the nodules in most of the supraglottic region. The subglottic region still shows a grayish granular, infiltrated area.

COMMENT. The skin lesion in this patient did not appear until after the tracheotomy, and was evidently an extension by continuity. That the disease was primary in the larynx is clearly evident from the history of absence of lesions or symptoms anywhere else. At the incipiency of the disease the patient was thoroughly examined for a long period of time by a competent group of men in another city and no lesion other than that in the larynx was found, though the nature of the laryngeal lesion was not evident to the histologist in the group. What led us to question the tuberculous diagnosis was the intense, deep-crimson mucosa with the gray, nodular and especially the peculiar "frog-spawn" appearance of portions of the interior of the larynx. This appearance we had never seen before and is the last thing to expect in laryngeal tuberculosis. Furthermore, the lungs were entirely negative and the man presented none of the general characteristics of advanced laryngeal tuberculosis. Had he had an advanced blastomycotic lesion of the lung it is probable that we would not have taken a specimen, because of an inferential diagnosis of pulmonary tuberculosis.

LITERATURE. Search of eighteen laryngea text-books failed to find mention of blastomycosis of the larynx.

Frank L. Dennis,[2] reporting the same case as Downing,[2] found reports of 3 cases of blastomycosis in which the larynx was found at autopsy to be secondarily involved. There was no record of laryngeal appearances during life.

I am indebted to Major George E. Pariseau, M.C., U. S. A., retired, for finding 2 cases reported in the periodical literature, 1 by E. D. Downing and the other by Sartory, Petgè and Claoue. Allotting numbers 1 and 2 to these cases, respectively, and number 3 to my own, I have prepared an analysis of the features presented,

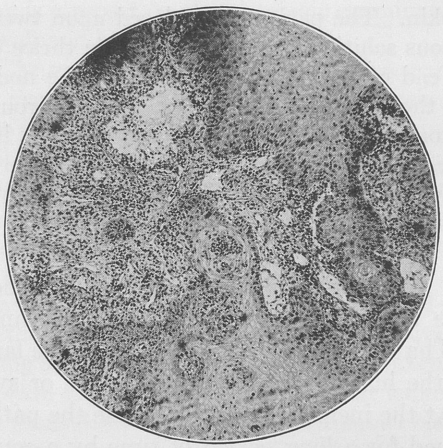

FIG. 1.—Photomicrograph, showing under low magnification, the histology of the laryngeal lesion in a case of blastomycosis primary in the larynx. The dipping downward of the epithelium is rather suggestive of epithelioma. Near the central portion of the field there is shown a tendency to abscess formation (B. C. Crowell).

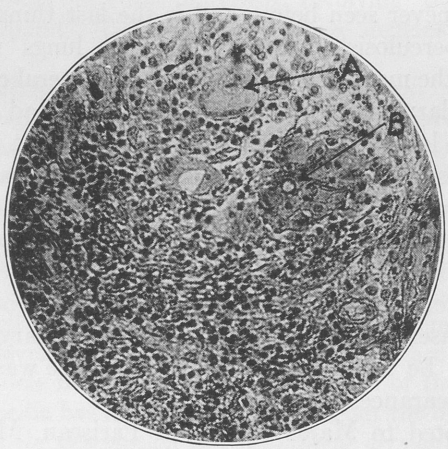

FIG. 2.—Photomicrograph, showing the histology of the lesion in the case of blastomycosis primary in the larynx. The giant cells, *A*, *B*, are suggestive of tuberculosis. In giant cell *B* is shown the blastomyces, probably dead before the specimen was taken. No mycelia were found in the tissues. (B. C. Crowell.)

and hope that the giving of a place to this disease by future textbook writers will result in prevention of the fatal overlooking of the malady in its curable stage.

CHARACTERISTICS PRESENTED BY BLASTOMYCOSIS OF THE LARYNX. *Sex.* All three patients were males.

Age. All three patients were adults, the respective ages being thirty-seven, sixty and forty-eight years.

Occupation. Laborer in a grain elevator; poultry huckster; clerk in a general store. The latter patient gave a history of having a cough and "sore throat" while on a farm threshing grain; but this occurred seven years before what seemed to be the onset of the disease, and the interval was subjectively symptomless. He had also been in a corn-mill frequently, but not for seven years before the apparent onset.

Etiology. Special exposure is fairly clear in the histories of at least 2 of the 3 cases: Case I gave a clear history of having cleaned out old wood from the bottom of a grain elevator a few days previous to onset of initial symptoms; Case II was probably exposed almost to constantly fermenting starchy foods in his occupation as poultry huckster; Case III was a credit clerk in a general store, but had to make trips out on farms at frequent intervals. Previous exposures mentioned in the preceding paragraph seem too remote to be etiologic. Local predisposing factors could not be elicited in 2 cases. In Case II, however, there was the vocal abuse of huckstering. General predisposing factors were not evident except in Case II, in which there was overwork.

Symptomatology. Initial symptoms in all 3 cases were hoarseness and cough, at first nonproductive, later there were limited amounts of expectoration, even in the 1 (Case I) in which there was pulmonary involvement. In 1 case the sputum contained membranous shreds. The cough was severe and paroxysmal in all cases. The onset in 1 case was similar to a "cold" that "settled" in the larynx. Dyspnea was present in all 3 cases; 2 required tracheotomy. Dysphagia was present in 2 of the 3 cases. Progressive loss of bodily strength and weight were present in all 3 cases. The temperature was only slightly elevated in 2 of the cases, probably, so in all 3. Local subjective sensations of pricking and burning in the region of the larynx and trachea were present in 2 cases.

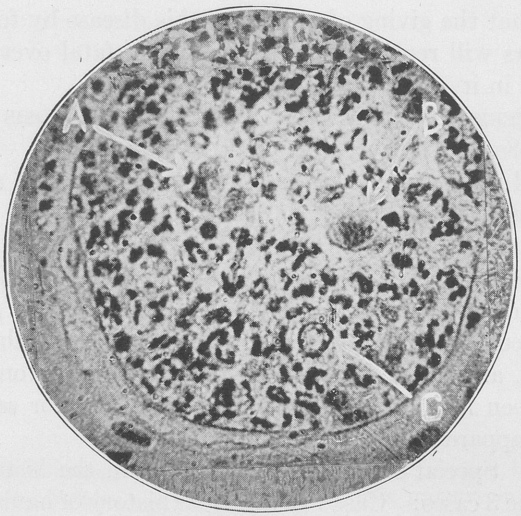

FIG. 3.—Photomicrograph showing the histology in a case of primary blastomycosis of the larynx. At *A* are shown large cells at a stage of the progress toward becoming giant cells. At *C* a blastomycotic organism (*Cryptococcus dermatitidis*) is seen. No mycelia were demonstrated in the tissue but they developed in the cultures. (B. C. Crowell.)

FIG. 4.—Photomicrograph magnification showing at *A*, under high power, the blastomycotic organism within a giant cell. Nuclei are numerous around the giant cell except below it (*B*), where they are absent. (B. C. Crowell.)

Pathology. No necropsy was done in the only fatal 1 of the 3 cases. The regions involved besides the larynx were the pharynx, tonsil, trachea and lungs. The skin was involved only in 1 case (Case III) and this was a secondary extension after tracheotomy. Leukocytosis was evident in 1 case, the count being 19,000. This was the Case I, in which the pulmonary involvement was fatal. Minute abscesses are characteristic of the blastomycotic lesions. In the larynx those of the abscesses that are superficial rupture on the surface, leaving an ulcerated spot among other as yet unruptured nodules.

FIG. 5.—Photograph of the front of the neck of a patient showing a blastomycotic dermatitis, the result of extension by continuity from a similar lesion in the larynx. Tracheotomy had been done because of laryngeal stenosis due to primary blastomycosis of the larynx. The butterfly-shaped lesion was an intense dark purplish red and had a moist surface.

Histology. The histologic picture was suggestive of tuberculosis in all 3 cases. Inflammatory infiltration, proliferation of the epithelium, giant cells and minute abscesses were present. The characteristic in all the 3 cases was the presence of spherical, encapsulated parasitic cells. They were demonstrated in the tissues in all 3 cases. Mycelia were not present in the tissues.

Bacteriology. The sputum was scanty in all 3 cases, but the blastomyces were demonstrated in smears of sputum or secretions. Mycelia were demonstrated in the sputum of 2 of the cases. Sartory, Petgè and Claoue (Case II) believe the organism found to be a new one, to which they gave the name Cryptococcus laryngitides, N. Sp. They describe the organism as spherical or slightly ovoid, 4 to 8Y in diameter. In some instances the contents were homogenous, in others a vacuole with a brilliant granule was noted. They cultured the organism on carrots, potatoes, bouillon, gelatine, agar and Roulin's fluid. Carrots gave a luxuriant growth, white, glossy and moist, soon extending over the entire surface. The best temperature was found to be 28° to 32° C. Subdermal and peritoneal inoculations in the guinea-pig produced a local lesion, the two pigs peritoneally injected died in thirty-eight and forty-two days respectively, with pulmonary lesions in which the parasite was found. In Case I an overgrowth of other organisms prevented culturing the blastomyces. In Case III growth on Sabouraud's medium, on glycerine gelatine and in maltose broth gave an appearance similar in all respects to *Cryptococcus dermatitidis,* Gilchrist and Stokes, 1898. Guinea-pigs were refractory to inoculation.

Laryngoscopic Appearances. The appearances in the mirror in all 3 cases were similar in being inflammatory with a grayish, minutely nodular surface in some portions of the lesion, with a few minute, isolated, yellowish nodules. In all cases there was in some portion of the lesion an appearance as after an application of argentic nitrate, and some of this membrane came away on coughing, leaving a red, inflammatory, eroded and, in small spots, ulcerated surface. In 2 cases the epiglottis was involved, in 1 of them there was a V-shaped ulceration on the free margin the lesion extending onto the tongue. The cords were nodular in only 1 case (Case III), but glottic stenosis was marked in 2 cases (Case I and Case III), requiring tracheotomy.

In considering laryngoscopic appearance it may be well to remember that the stage of the lesion, or part of the lesion, is important. In the early stages it may be flat; the nodules and yellow or grayish points are minute, superficial abscesses. When the abscesses rupture the lesion flattens at that point. Exudate

may cover considerable areas of the lesion. In my case (Case III) the opaline "frog-spawn" appearance of the tiny nodules was quite unlike anything else I have ever seen in the larynx. The mucosa that was not covered with grayish nodules was deep crimson, the intense redness being in marked contrast to the pallor so often seen in the pale type of laryngeal tuberculosis.

Diagnosis.—The diagnosis can be made with certainty by biopsy, and bacteriologic examination.

Complications. Pulmonary involvement was slight in 1 case and fatal in 1. Extension to the skin surface was present in 1 case (Case III). Palpable lymph nodes were absent in 1 case (Case III), not noted in the others.

Prognosis. One patient of the 3 died of the disease, 1 recovered, 1 is still under treatment, progressing favorably.

Treatment. The unfavorable results from surgical treatment of blastomycosis of the skin evidently influenced the three observers against surgery in their respective cases. The extension along the tracheotomic fistula in Case III seems to furnish support for this view. The good results obtained by the dermatologists with potassium iodid in blastomycotic determal lesions point to treatment by this drug as the method of choice. The selective effect of potassium iodid on the laryngeal mucosa strengthens the indication for its use. The results in Cases II and III confirm this theoretical consideration. This remedy, however, failed to arrest the progress of the disease in Case I, the patient dying of what was probably blastomycosis of the lung. Early diagnosis and treatment might forestall pulmonary extension.

Conclusions. 1. Blastomycosis of the larynx is a rare disease, but may not be quite so rare as the paucity of case reports and the absence of mention in the laryngologic text-books would seem to indicate.

2. The clinical and even the histologic resemblance of this disease to laryngeal tuberculosis would seem to urge the necessity of the exclusion of blastomycosis in every case of laryngeal tuberculosis in which tubercle bacilli are not found. Concurrent pulmonary blastomycosis may make the clinical picture identical with that of laryngeal tuberculosis in every respect. Blastomycosis is not mentioned in connection with the differential diagnosis of

laryngeal tuberculosis in any text-book on laryngeal disease accessible to the author.

3. The diagnosis cannot be made positively otherwise than histologically. The structural changes are not conclusive; but fortunately the blastomycotic organisms are easily demonstrated if the possibility of their presence is kept in mind; otherwise they are almost certain to be overlooked. Dr. Crowell tells me they are easiest seen in an unstained specimen; which may account for overlooking them, because of the routine staining of tissue sections in the laboratory.

BIBLIOGRAPHY.

1. Sartory, Petgè and Claoue: Laryngite Chronique Pseudo-tuberculeuse d'Origine Mycosique Due a Une Levure Nouvelle, Compte rend. Soc. de biol., Paris, 1923, **89**, 179.

2. Downing, E. D.: A Case of Blastomycosis with Laryngeal Involvement, Jour. Amer. Med. Assn., 1918 (January 12), **70**, 85.

3. Dennis, Frank L.: Blastomycosis of the Upper Respiratory Tract, with Report of a Case Primary in the Larynx, Annals of Otology, Rhinology and Laryngology, June, 1918.

THE VALUE OF THE ROENTGEN-RAY IN RHINOLOGIC DIAGNOSIS, WITH AN ELABORATION OF THE OBLIQUE METHOD OF RHESE

W. P. WHERRY, M.D.

In 1916, before the Detroit meeting of the American Medical Association, Iglauer presented a résumé of his experience in the use of the oblique position of Rhese, a position designed to show to the best advantage the ethmoid and sphenoid sinuses in roentgenograms. My interest was aroused at the time, and since this meeting I have used the method routinely. The advantage of the oblique position lies in the fact that it presents the sinuses in their anteroposterior dimensions, which allows a study of the separate cells and readily identifies the structures in question. Further, since the exposure is made through tissues of lesser density than is ordinarily the case, types of tissue changes, suppurative and nonsuppurative, are more easily recognized. This is especially true in stereoscopic exposures.

The oblique method requires unusual accuracy in the placing of the patient and the timing of the exposure. An error of a few degrees in position causes an overlapping of parts to such an extent that the entire region cannot be seen through the orbit. Stereoscopic roentgenograms are essential to careful diagnosis.

The oblique position observed in Fig. 1 should show the sphenoethmoid labyrinth and the ethmofrontal region in their anteroposterior dimensions. The shadow of this region is thrown into the opposite orbital cavity, distorted to a very slight degree because of the oblique direction of the ray through the parts. The optic foramen being the posterior landmark, should seemingly rest on the orbital rim with the ethmoid roof line directed slightly downward, then upward, as it progresses forward toward the ethmofrontal region, the anterior landmark.

Fig. 2 shows a normal ethmosphenoidal field and is from a

patient, aged twenty-four years, who came complaining of headaches and distal focal symptoms, which were disposed of through the use of glasses and tonsillectomy. In this case the normal findings in the film, confirming those of the intranasal examination, excluded the sinuses from the clinical problem.

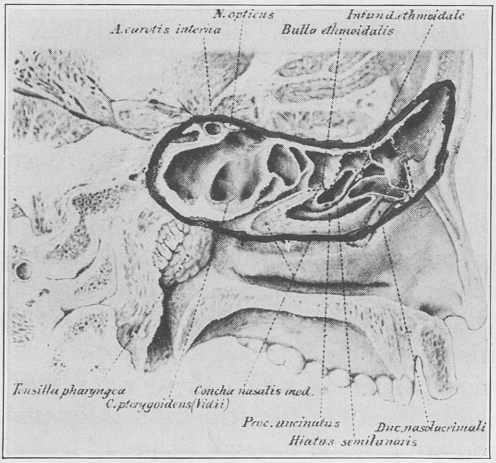

FIG. 1

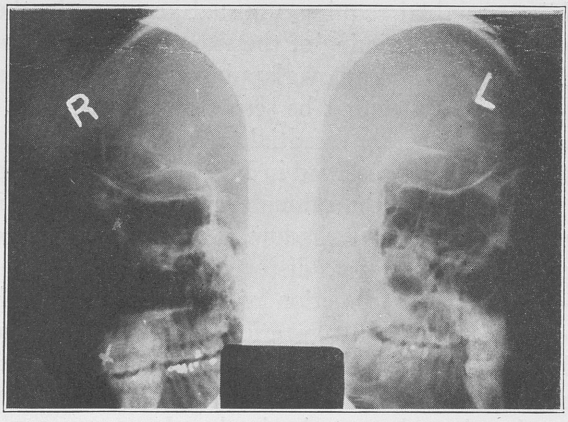

FIG. 2

The two white circular patches observed in the lower and posterior parts of each field are the overlapping petrous portions of the opposite temporal bone.

There is a haziness around the agger nasi of each side which in the flat roentgenogram would be suspicious, but which stereoscopically observed proved to be the zygoma of the same side.

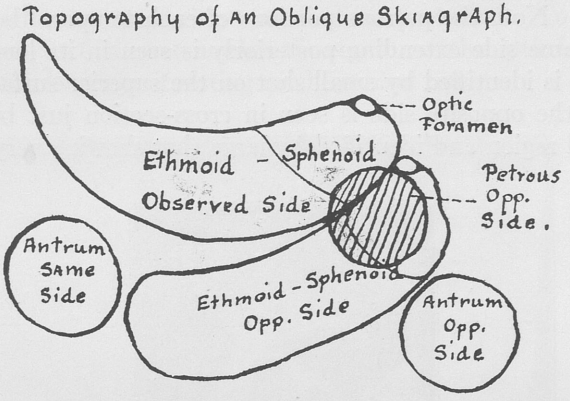

FIG. 3

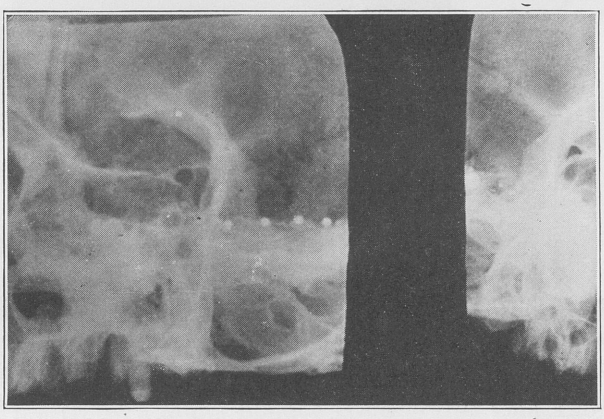

FIG. 4

The topography of the various structures appearing on the oblique roentgenogram should, if the placement is correct, be as shown in Fig. 3.

The next few roentgenograms, taken of dissected skulls in some instances, are shown to illustrate the difficulties in accurate interpretation when the placement of the head is incorrect.

In Fig. 4, the head has been turned a few degrees to displace the optic foramen forward. As a result, the ethmoid field is brought out in relief, but the ethmofrontal has been covered over by the nasal bones and the frontal processes of the superior maxillæ. Note the petrous portions of each temporal bone; that of the same side extending posteriorly is seen in its longitudinal axis and is identified by small shot on the superior surface, while that of the opposite side is seen in cross-section just below the sphenoid region and identified by large shot showing very faintly.

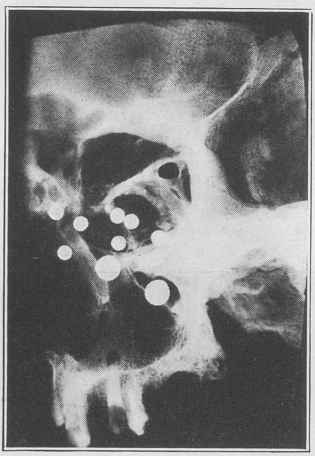

FIG. 5

The roentgenogram (Fig. 5) illustrates another faulty position with the head tilted too much downward. The superior surface of the body of the sphenoid forming the roof of the sinus has been accentuated with barium paste to show how the shadow cast could be mistaken for tissue alteration within the sphenoid.

I am positively convinced of the necessity of stereoscopic roentgenograms to place accurately this annoying overlap in the study of the region *in vivo*.

The small shot outline the ethmoid—the larger shot mark, as nearly as possible, the floor of this sinus. Observe the thick petrous portion extending backward. Had the other half of the skull been used when this picture was taken, the petrous portion of that half would have completely blotted out the area we wished to show.

This roentgenogram (Fig. 6) shows how, when the placement is correct, the flat surface of the superior wall of the sphenoid sinus is prevented from interfering with the interpretation. To do this it is necessary to distort somewhat the contour of the optic foramen, as well as to place it as if resting on the orbital rim.

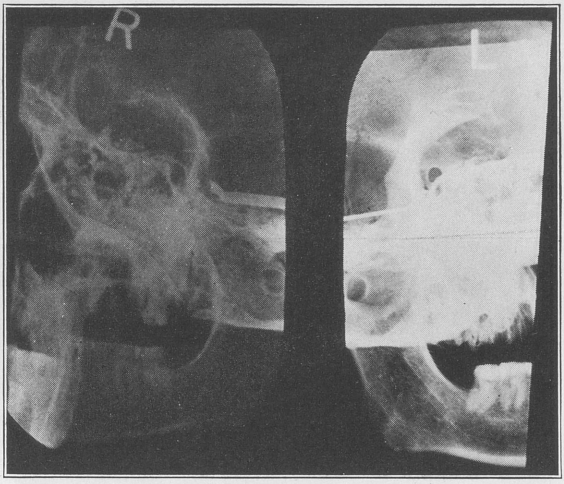

FIG. 6

Barium paste of different percentages has been used in an attempt to simulate the shadows of living tissue changes in the ethmosphenoidal field. In this flat picture the observation is difficult, but stereoscopically seen, the opacities of these different pastes become apparent.

Fig. 7 illustrates a faulty oblique position that comes to us frequently from those who are not familiar with the proper angles of placement or who seem to be of the opinion that the oblique is a modified straight lateral.

Here the small shot identify the right side of the skull; the wire

marks the left side. Observe that the desired field is a conglomerate mass of petrous portions and both ethmoids.

Two large shot are placed on the floor of each antrum. It will be noted how they overlap. I will show later how the two antrums appear when the placement is correct.

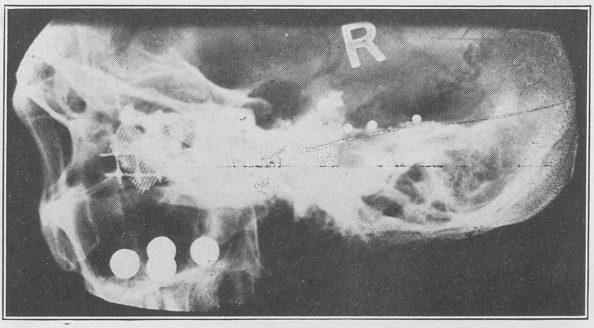

FIG. 7

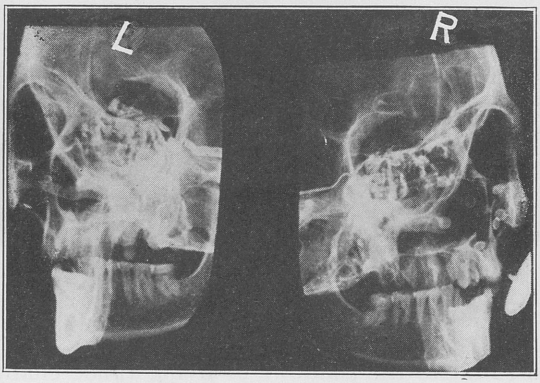

FIG. 8

My point in this figure is to show the annoying handicap developed to correct interpretation when the placement has been carelessly made or the technic incorrect.

As contrasted to the faulty placement just shown, another roentgenogram (Fig. 8) is the better, although even here the tilting forward of the head borders on error.

Barium paste is used to show the ethmoid and sphenoid; while the petrous portions are identified by strips of tin pasted on their superior surfaces, small on the left and larger on the right; circular platelets are used to mark the several boundaries of each antrum and the sphenoid septum.

The antrum of the same side is placed forward as if in the tip of the nose with the malar bone and the nasal border of the superior maxilla overlapping, while the antrum of the opposite side is posterior and down behind the petrous block.

FIG. 9

We have been looking for tooth projections into the antral floor from this position, but have been disappointed so far. This roentgenogram does present a tooth projecting into each antrum.

The roentgenogram (Fig. 9) from a living subject exemplifies the type that is often sent to me for interpretation, and in which proper technical care has not been exercised in placement. An accurate reading regionally and otherwise is impossible in this sort of placement.

I have two reasons for showing Fig. 10. First, because in the correct position as shown in the right, both sphenoids, right and left are sometimes brought out in comparative relief, one below the other. Incidentally, this right side is a normal sinus roentgeno-

gram. The second reason is to show what sometimes happens in case of a careless placement, since the left position is thrown forward only a slight degree, yet enough to put it out of line with the right. This technical error, slight as it may be, could interfere with interpretative accuracy were only flat pictures used, but taken stereoscopically this difficulty becomes negligible.

Several of the following illustrations show the material assistance rendered by the roentgen-ray in a diagnosis.

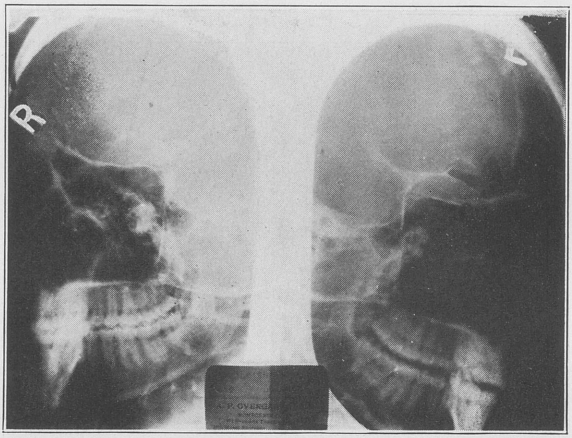

FIG. 10

Fig. 11 exhibits an unusually large sphenoid with a low-grade chronic hyperplastic process in both the sphenoid and posterior ethmoid, left side.

The patient, aged forty-six years, came complaining of most violent periodic headaches, especially for the last few years. Drainage of the sphenoid did not entirely relieve the symptoms. I suggested it might be the impacted third molars, evidenced in the roentgenogram. The patient was in doubt, because his dentist had just advised him that the teeth were not a factor. The dentist in turn was surprised to note the status of the third molars. They were extracted and the headaches disappeared. The end-result in this case emphasizes the value of roentgenograms in arriving at a complete diagnosis.

Fig. 12 is from a case of chronic suppurative sphenoditis, left, with a certain tissue change around the nasofrontal region as well as a chronic hyperplastic ethmoiditis, both sides. The diagnosis was confirmed by the operative findings.

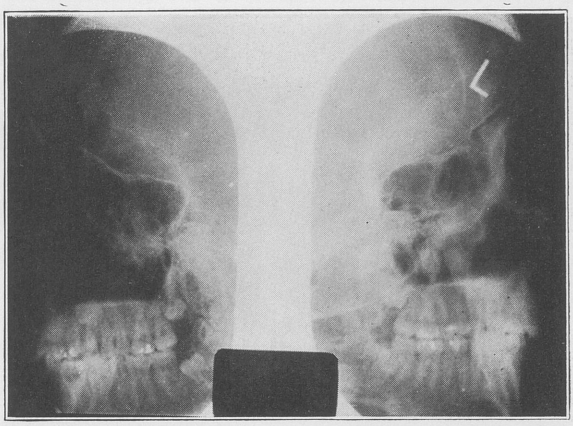

FIG. 11

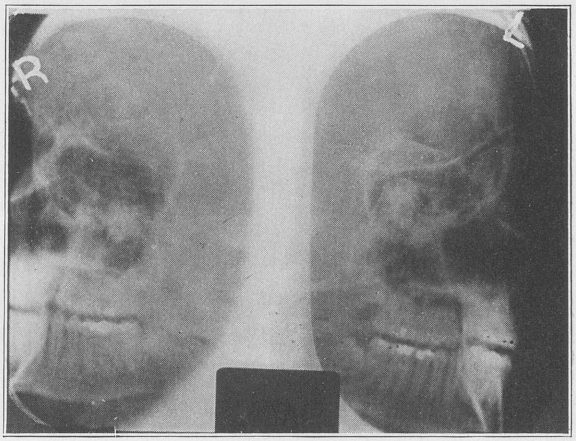

FIG. 12

Fig. 13 illustrates a chronic posterior ethmoiditis, right, with some changes around the nasofrontal region, also a low-grade hyperplastic ethmoiditis on the left side.

The petrous portion on the left has been placed to overlap the lower part of the sphenoid, and in flat pictures might prove annoying to the interpreter, but when stereoscopically taken can be observed properly.

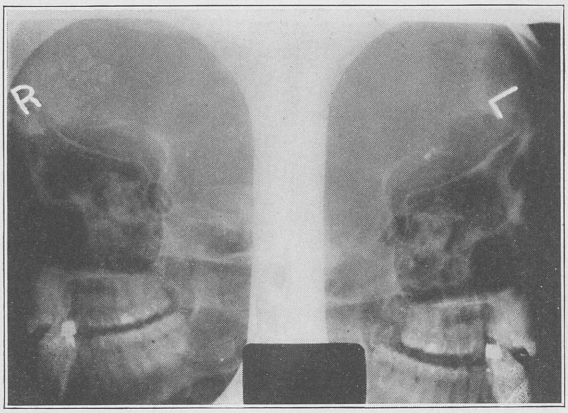

FIG. 13

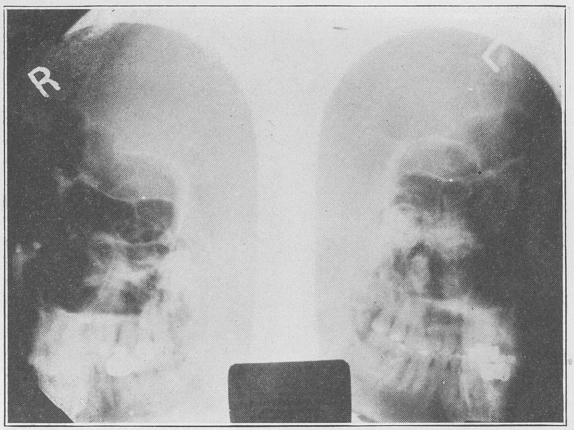

FIG. 14

Fig. 14 shows a normal right side. A chronic nonsuppurative hyperplasia exists in the sphenoethmoid field, left side. The

patient, aged forty-two years, complained of distal focal symptoms. Nasal examination was doubtful, yet surgical interference on the left side stopped the arthritis.

Since the acceptance of the focal infection syndrome, cases such as this, borderline so far as diagnosis, have become sufficiently frequent that an accurate use of the roentgen-ray is imperative for a diagnosis.

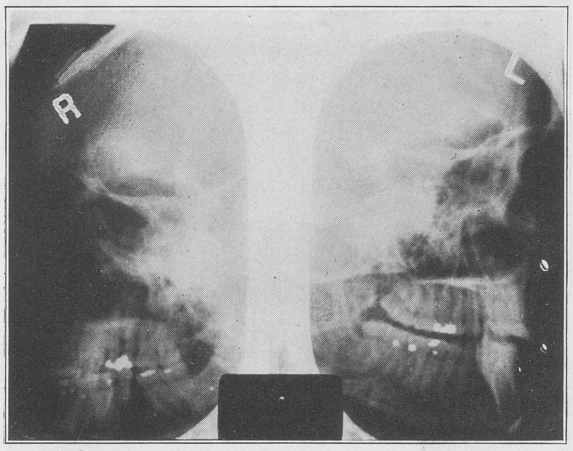

FIG. 15

This roentgenogram (Fig. 15) is from a patient, aged forty-nine years, who had headaches, with the characteristic syndrome of chronic ethmoiditis. It is so easy from a good roentgenogram taken in this position to know that the sphenoid must be drained along with the ethmoid.

Operative interference demonstrated the accuracy of the roentgenogram and my point is just that accuracy.

Chronic sphenoiditis on both sides, the left more especially, with spotted ethmoiditis, spotted so far as determining the areas of greatest involvement rather than as to typing the ethmoiditis, and a chronic suppurative process in the frontals are shown in Fig. 16. The operative findings supported the diagnosis in all instances.

The frontal sinuses were drained intranasally without satisfactory results and will soon be drained externally, since the symp-

toms now are confined definitely to that sinus, those incident to the sphenoid having subsided postoperatively.

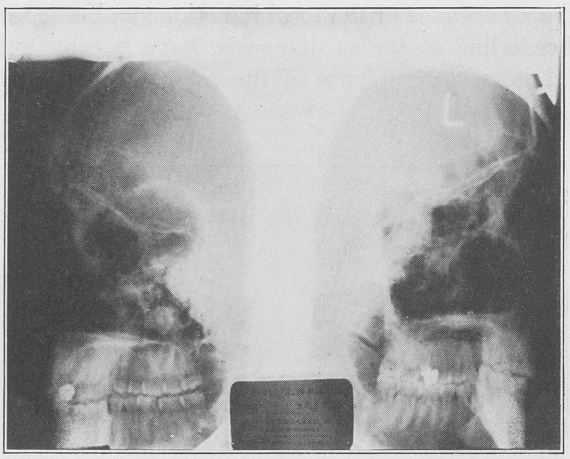

FIG. 16

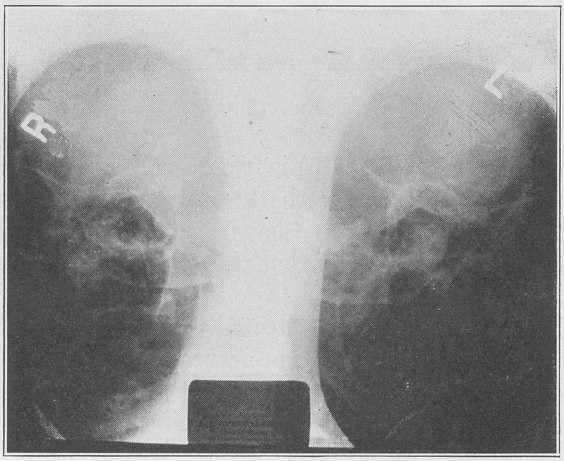

FIG. 17

Diagnostic accuracy with proper placement is the point in evidence.

Fig. 17 is of a woman, aged sixty-eight years, and shows a chronic posterior ethmoiditis. The patient complained of scotomas and a varying degree of visual interference. Intranasal examination did not present any evidence of tissue alteration, and the Waters' position for the antrums on this patient did not reveal the pathologic condition of the ethmoid.

Unfortunately, the ethmoid pathology was discovered too late to correct the ocular complex, although its progress was stopped through nasal surgery.

The next two illustrations are given because of their real merit in completing a surgical picture before operation.

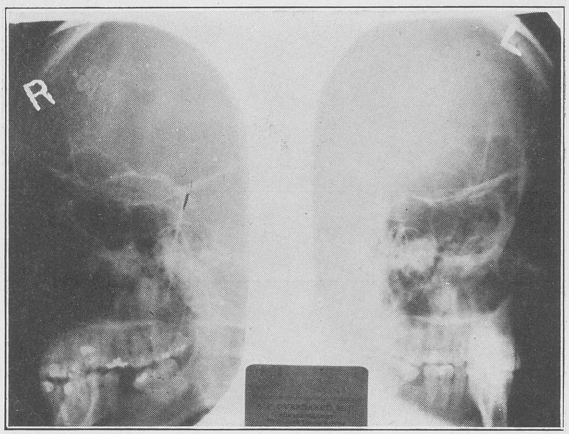

FIG. 18

In cases of chronic suppurative maxillary sinusitis, the upper nasal stratum of the affected side is always blocked from the swollen muscosa created through the constant flow of pus over it. At times it is exceedingly difficult to know whether to exenterate the ethmoid sinus when the radical antrum surgery is done. To do this in every case would be empiricism while not to operate in the necessary instance would minimize the desired result in the antrums

One roentgenogram (Fig. 18) is of a woman with such a process in the left maxillary sinus. From its interpretation conservative surgery was advised. The results proved the value of the judgment exercised in avoiding operation on the ethmoid labyrinth.

My point here is diagnostic accuracy.

The next roentgenogram (Fig. 19) is from another patient, a woman with a similar antral process and a similar appearance in

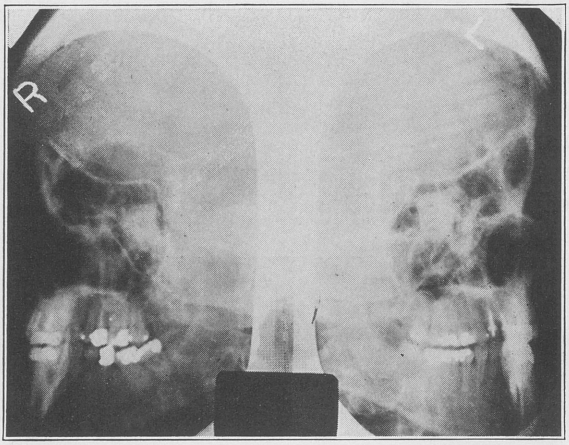

FIG. 19

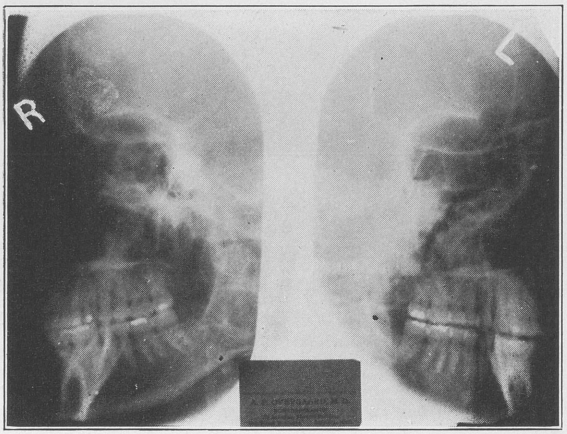

FIG. 20

the upper nasal stratum. Here exenteration of the ethmoid was indicated. Findings at operation proved that the course adopted was correct.

Fig. 20 is of a most interesting, and at the same time a most perplexing, case. It shows a chronic right sphenoiditis. This is the third picture of this patient. The sphenoid was drained six years ago and has continued to drain, notwithstanding the removal of as much of the anterior sphenoid wall as allowable. The sphenoid sinus can be seen dipping far down and back.

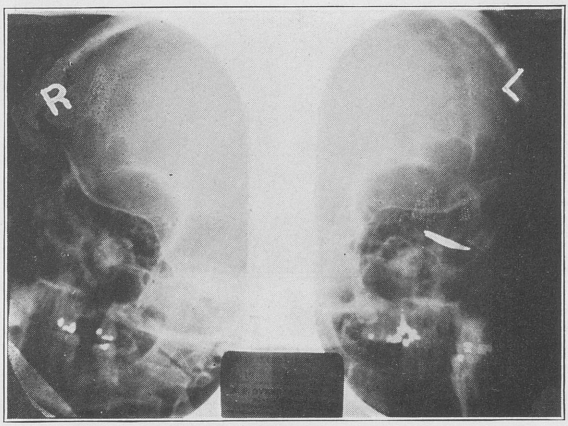

FIG. 21

Fig. 21 is a roentgenogram of another interesting case. The patient had a definite history of left antrum disease with an indefinite nasal discharge. Waters' position seemed to show the left antrum normal, but this oblique position exhibits an unerupted left upper third molar that was seemingly projecting into the antrum. We had overlooked the tooth in our early examination of the roentgenogram, but after several washings and an intranasal antrum operation for drainage had brought no relief, another inspection of the film revealed it. Its removal relieved the symptoms and demonstrated the root projection into the antrum. I should like to emphasize here the need of care in interpretation.

Fig. 22 shows a chronic hyperplastic ethmoditis and sphenoiditis of both sides, more especially of the right. It further shows beautifully the dipping down of the left sphenoid and the line of demarcation between this cavity and the posterior ethmoid cells.

This patient has not consented to operative interference, wishing to try lavage and other home treatments first. It will not only be

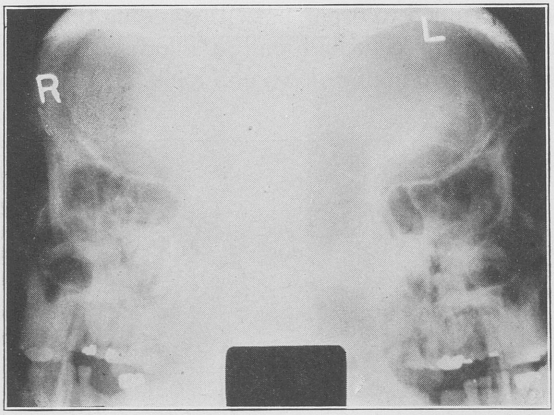

FIG. 22

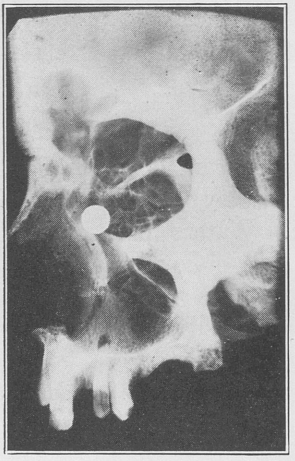

FIG. 23

interesting at a later date to compare a roentgenogram taken at that time, but also, if no change is apparent at the second sitting, the convincing value of the roentgenogram will be immense.

My experience has been that patients can readily appreciate the reading of a film taken in the oblique position, but seem confused when attempting to decipher the ethmosphenoidal field from the usual Waters' position.

I have had a desire to identify the sphenopalatine foramen, and this illustration (Fig. 23) shows an unusually large foramen discovered in one of the skulls.

The field was placed downward because in this particular roentgenogram we were attempting to work out relations in the antral floor.

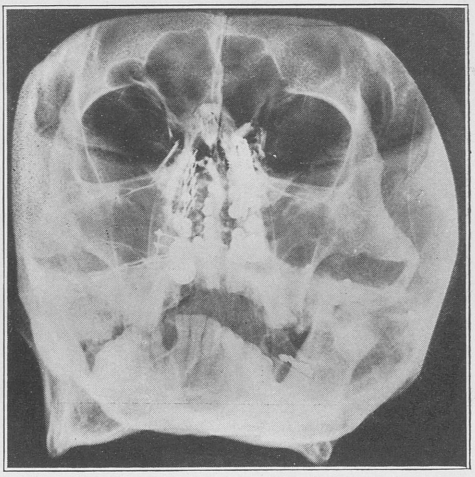

FIG. 24

The large round shot identifies the agger nasi, while the patch of barium paste behind the malar bone marks the sphenopalatine foramen.

So far, we have had no success in identifying the foramen in live subjects.

The next roentgenogram (Fig. 24) represents the usual Waters' position and, with the few slides that follow, is shown for comparative purposes. We use the Waters' position for the study of the maxillary and frontal sinuses.

The shot and wires identify the ethmoid and sphenoid, the larger shot being in the posterior ethmoid and sphenoid. This dissection was pictured obliquely and the identification of parts, especially of overlapping structures, became much easier.

The particular reason for showing this roentgenogram is to demonstrate the overlapping petrous portions on the antral fields, identified by means of the shot and wires.

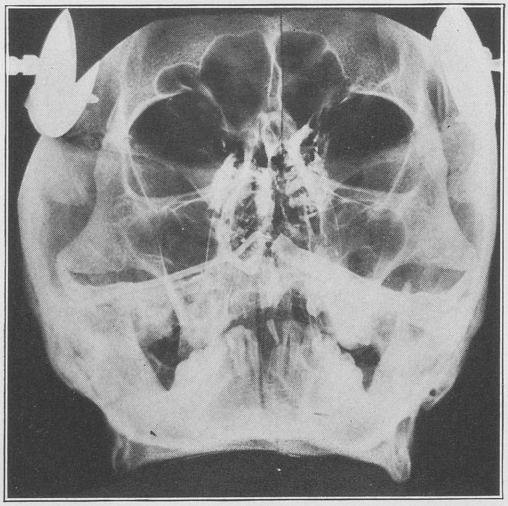

FIG. 25

Fig. 25 shows the usual Waters' position again. The ethmoid sinuses are outlined with barium paste. Note the overlapping petrous portions in the lower antral field identified by strips of tin on their superior surfaces. Circular platelets of tin identify the lower portion of each antrum to indicate the degree of overlapping which in this instance is nearly one-half. This, to me, warrants, the assumption that stereoscopic plates are imperative if accuracy in interpretation is to be maintained.

Do not misinterpret my thought. I have seen many roentgenograms in which the petrous block was out of the field, but an analysis of the last 200 cases shows 91 per cent with this overlap,

rendering proper interpretation difficult or impossible and emphasizing the necessity for stereoscopic pictures.

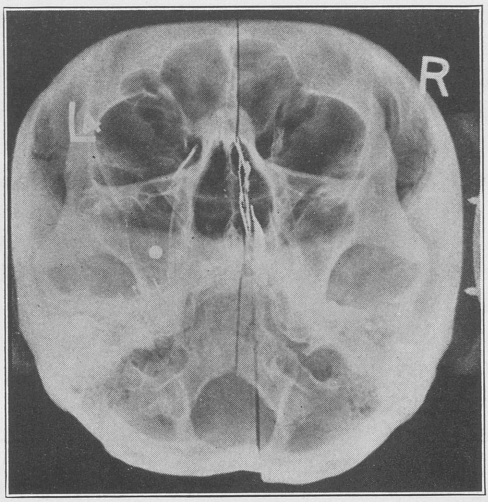

FIG. 26

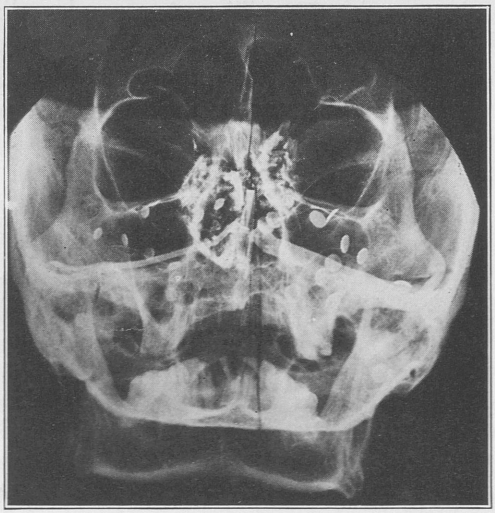

FIG. 27

Another roentgenogram (Fig. 26) illustrates another difficulty in antrum diagnosis. The greater and lesser wings of the sphenoid in this skull were unusually thick, and though the petrous portions were materially out of the field, yet from flat roentgenograms an error in diagnosis surely would have been possible.

Fig. 27 shows another usual Waters' position with a different skull, showing the overlapping petrous portions on the antral fields.

Those who do antrum surgery fully realize why the surgeon is so anxious to determine carefully the lower part of the antral field. In most instances the greatest area, and sometimes essentially the only area, of bony change is in this part of the field.

The circular piece of tin in the midline marks where the sphenoid septum should be.

This illustration is given as an additional evidence of the necessity of stereoscopic roentgenograms.

I have asked Dr. Overgaard, who has done most of the roentgenographic work involved, to give details of the position, which are as follows:

TECHNIC. We use four 8 by 10 duplitized films which are placed with double intensifying screens mounted in cassettes. We use a 5-inch spark gap with 20 milliampères, and a distance of 23 inches for the Waters' position and 33 inches for the oblique position.

The Waters' position is made with the patient prone on the table with a heavy pillow under the chest, chin resting on an 8 by 10 plate changer, which is raised 2 inches from the table. The nose is about 1 inch from the plate changer. The roentgen-ray tube is centered 23 inches above the head and stereoscopic views are taken.

The oblique position is made in the same manner with the patient prone, and the chest resting on a firm pillow. The head is placed so that the left side rests on the superior angle of orbit, and the prominence of the left malar bone. The tip of the nose touches the plate changer and a $\frac{5}{8}$-inch block of wood is placed under the chin. Stereoscopic views are taken, the position is changed and the procedure repeated on the right side. The distance in this instance is 33 inches. Both right and left oblique

views can be placed on an 8 by 10 film by having a mat made with 5 inches of lead on one side and on the other an oval shape made of aluminum. This is an advantage, as both sides can be studied at the same time.

COMMENT. In my hands the oblique method of Rhese affords the best comparative study of the ethmoid and sphenoid sinuses of any methods I have tried. Most of the other positions present the individual sinus isolated from its adjacent structures or overlapped by other parts, and do not convey the comparative information so necessary for proper orientation.

I am desirous of expressing my appreciation to Dr. Overgaard, a roentgenologist, Drs. Poynter and Scarda of the Anatomical Department of the University of Nebraska, and to my associates, Drs. Haney and Hansen, for their assistance in the preparation of this paper.

DISCUSSION

DR. HARRIS P. MOSHER, Boston, Mass.:

I have been very much impressed by what the reader has said about the oblique position and its possibilities of interpreting pathology of the ethmoid and sphenoid. I shall ask our roentgenologist to check up on this position.

The Waters' position has been a favorite of mine for determining the relation of the frontal sinus to the frontal ethmoidal cells, as I feel that many of our failures in the operation on the frontal sinus have been due to failure to recognize such a cell in series with the frontal sinus. We do not depend on the Waters' position for interpretation of pathology of the antrum.

Now about the stereoscopic plates, I have been worried because we do not use them more than we do. Some time ago, Dr. Ingersoll said he had had great success with stereoscopic plates, and that he could determine the presence of a brain abscess with them. We have not been able to accomplish this.

The question of stereoscopic plates came up the other night at the medical school and our *x*-ray man was asked to speak to this point. He surprised me by saying that stereoscopic plates failed in the interpretation of pathological conditions. A stereoscopic plate will give the configuration of the sinuses, but the minute pathology of the mucous membrane disappears. He prefers, therefore, to make his interpretation from the flat plate.

Dr. Ross H. Skillern, Philadelphia:

There is one word that I would like to say regarding the oblique method or method of Rhese.

To use the vernacular of today, I was never sold on this particular method for a number of reasons that Dr. Wherry has brought out: The improbability of getting a fine plate and the great difficulty in reading that plate. The difficulty of interpreting that plate after you get it is quite astonishing. This plate will sometimes produce bizarre effects and to orientate yourself with it, as far as I am concerned, is not only difficult but absolutely impossible.

Therefore, I venture to prophesy that this method, except perhaps in those cases where the liaison between the *x*-ray man and the roentgenologist is close or in other words when they are working side by side, will not be of much assistance and I doubt if it will be popular.

Regarding personal interpretation, that is one of the important points of the whole affair and it is the entire gist of the thing. It was not long ago that one of our interns said to me (he had *x*-rays of the teeth and sinuses): "Why, I look at the *x*-ray plates and draw my own conclusions. If it coincides with my impression, well and good." I thought his idea of his own importance was rather high; but why should not he, with his observations, learn and teach himself to read those and interpret them as well as the *x*-ray man? We must remember the *x*-ray man embraces everything, from the top of the head to the toe. This is a specialty of a specialty. Why cannot we learn to discern and interpret those pictures quite as well as any one else?

Here is an illustration of how that came into play. There was a case I had which was most curious to me. There were two apparent cysts coming up from the sinuses. I punctured both of them and not a thing was in either one. Here were these opaque, roundish, cysts-appearing shadows on the floor of both maxillaries. The *x*-ray man interpreted them as bone cysts. There were no symptoms of cysts and never had been.

Going to bed at night, I thought and thought of that case and finally it occurred to me what that might have been. In that particular case, it happened that it was an anteroposterior exposure and the body of the atlas had come up and bulged into the floor of both antrums. Now you see how we could be confused in a thing of that sort. Therefore, why should not we teach ourselves to interpret these things and, as this intern I spoke of, use our judgment regarding them, comparing them with the roentgenologist's report?

Practically speaking, I have been very much disappointed in the ability of stereoscopic plates to tell me anything. I thought at first

that we had something that was perfect. Theoretically that is true, but, as Dr. Mosher has said, they failed me miserably except in one instance. When I can get a fine stereoscopic image of the ethmoid, I learn things that otherwise remain obscure. We know how many cases of these there are, those old chronic ethmoid conditions which make us unhappy and bring us to our wit's end to know what to do. Sometimes the plates will bring out little hypertrophies there and maybe one cell will have a little more shadow than another that will finally give us a clue to work on and result ultimately in bringing about as much of a cure as is possible under those circumstances.

DR. WHERRY (in closing):

I appreciate very much the discussion of Dr. Mosher and Dr. Skillern. When I first started on this work I had a similar thought as to stereoscopic interpretation. As experience developed, the same comments of doubt were expressed by many roentgenologists; but as progress was made, especially when in returning to our film and attempting to criticize our original interpretation and policy, the overwhelming evidence supported the fact that the stereoscopic roentgenograms were the more accurate.

Oftentimes in interpretating flat pictures we were in doubt as to whether there was present an overlapping block. This element of uncertainty, in our judgment, is quite accurately disposed of through the stereoscopic exposure.

PRESENTATION OF CASES

Osteomyelitis of the Skull

JOSEPH H. BRYAN, M.D.

I HAVE here a specimen taken from a young girl I operated on for osteomyelitis of the skull following a sinus operation performed in Nashua, N. H.

Last summer, this child, fifteen or sixteen years of age, left Washington to attend one of the girl's camps in New Hampshire in perfect health. She indulged in bathing in the lake and was seized with an intense headache. In the course of twenty-four hours there was marked swelling over the right frontal and partial closing of the eye by the swelling of the corresponding lid. The operator, I believe, did not see this case after the operation. She made a slow recovery under the attendance she was receiving there, and finally, when she reached Washington, there was a swelling over the frontal and this portion of the nose, through which large quantities of pus were discharging. The swelling of the lid was very marked. She could not raise it sufficiently to get any vision.

When I saw this case I decided it was a case for immediate operation. I made an incision extending from the outer angle of the orbit down to past the middle of the nose, elevated the periosteum, and found an enormous quantity of diseased bone, as this specimen will show.

This specimen of osteomyelitis extended beyond and pretty well up toward the eminence. A large quantity of bone was taken away, the whole orbital roof was removed *en masse* as well as the inner portion of the infraorbital ridge and the ethmoid and sphenoid were exenterated. She made a very good recovery.

She had an attack of influenza during the latter part of February, and I had to reopen the sinus through the opening that I had previously made and found there was considerable pus in the region of the obliterated sinus. Fortunately, I did not find any further diseased bone.

This case was treated with mercurochrome, and apparently has made a good recovery, as far as we can tell. The parts are all healed and there is no trouble, with as minimum a scar as you could expect after a cicatrix resulting from an operation done during the period of the first infection.

You cannot tell when this might break out again, but at the opening of the cavity at the second operation the bone was in normal condition.

GUNSHOT WOUND THROUGH THE SUPERIOR MAXILLA INTO THE POSTERIOR WALL OF THE NASOPHARYNX

BURT R. SHURLY, M.D.

T. H., male, aged thirty-eight years, entered the Detroit, Eye, Ear, Nose and Throat Hospital, February 11, 1925. His previous history was negative except for enucleation of the left eye, in 1920, for a foreign body.

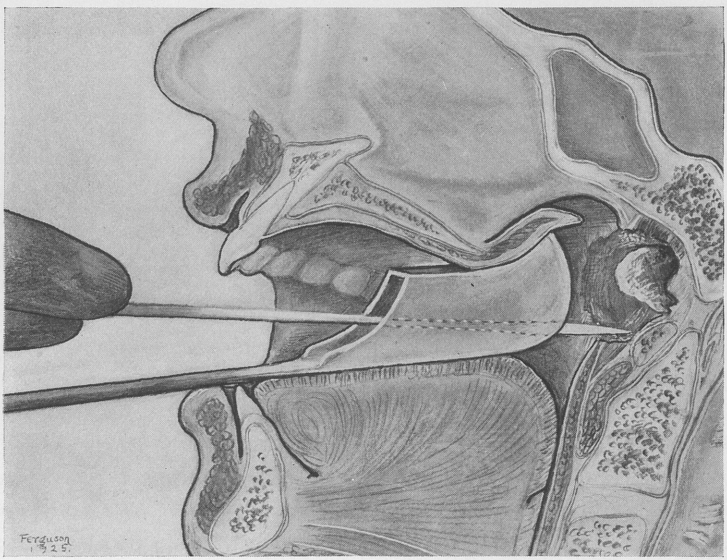

On February 8, at 9 P.M., patient was held up by a negro, who without warning fired a revolver at close range within 3 inches of his nose. The gun was pointed downward and slightly inward, the bullet striking 1 inch below the inner canthus of the right eye.

The path followed through the superior maxilla and nasal passage to the vomer, where it was reflected and passed into the soft tissue directly opposite the body of the second cervical vertebra, close to the median line. Profuse hemorrhage was arrested at the receiving hospital and the patient was transferred to our hospital three days later.

On account of the nervous condition of the patient, ether was administered. With a well-localized *x*-ray report and picture, a Kelly nasopharyngoscope, a long quinzy knife and long Jackson tonsil-forceps modified with a gentle curve, a 32-caliber deformed bullet was quickly removed through a small incision. The patient made an uneventful recovery with slight nasal obstruction.

Memorials

BEVERLEY ROBINSON, M.D.

MEMORIALS

BEVERLEY ROBINSON, A.M., M.D.

1844–1924

Beverley Robinson was one of those men, great in the early days of laryngology, whose names will remain for all time illustrious in the history of this Association, for he was of that notable company by whom it was founded, now nearly fifty years ago. The names of the founders may be recalled to you. Let me rehearse them:

J. Solis-Cohen, of Philadelphia; Clinton Wagner, Beverley Robinson, Frank H. Bosworth, George M. Lefferts, Rufus P. Lincoln, Louis Elsberg, of New York; Frank H. Davis, E. Fletcher Ingals, Hosmer A. Johnson, of Chicago; Samuel Johnston and J. A. Hartman, of Baltimore; Frederick Irving Knight, of Boston; William C. Glasgow and Thomas F. Rumbold, of St. Louis; and Ernest L. Shurly, of Detroit.

Of these, three are now living: Dr. Solis-Cohen, Dr. Samuel Johnston, and Dr. Frank H. Bosworth.

The founding of the American Laryngological Association, in 1878, was in an important degree inspired by the successful career of the New York Laryngological Society, organized in 1873 by Dr. Clinton Wagner.

Ably representing the new science of laryngology in what were at that time the established medical centers of the United States, no country in the world has ever gathered together such a notable assembly. Of strong character, splendid personal integrity and culture and highly trained professional ability, it was these

men whose wisdom, foresight and unselfish devotion created the American Laryngological Association and established for it the high ethical and scientific standards under which it has flourished preëminently for nearly fifty years.

Of this group Beverley Robinson was a worthy member. He was born in Philadelphia, Pa., March 22, 1844. Distinguished as to his ancestry, he was one of the sons of the late Moncure Robinson, Esq., a civil engineer of eminence and a maternal greatgrandson of Edmund Randolph, first attorney-general of the United States. The social standing of the Robinson family was of the highest. The brothers of Dr. Robinson, and there were several of them, were men of influence in their various positions in life.

Dr. Robinson's early education was gained in the schools of Philadelphia. Upon graduating from the University of Pennsylvania, in 1862, he joined the Pennsylvania state militia and fought with it in the Gettysburg and other campaigns. At the close of the Civil War he entered upon the study of medicine and, following the ambition of many students of his time, went to Paris, where he was one of the first Americans to be graduated, receiving his degree with honors in 1872. In 1873 he entered upon the practice of medicine in New York City. Here his social qualities and professional ability were quickly recognized, and he was soon appointed attending physician and later consultant to several of the leading hospitals. Chief among these was St. Luke's Hospital, with which he was connected for more than forty years. He was for many years professor of clinical medicine at Bellevue Hospital Medical College. He was a founder of the Association of American Physicians and a former president of the American Climatological Association. During the World War he was one of six American physicians to receive an honorary medal from the Faculty of Medicine of Paris.

One of the most interesting phases of Dr. Robinson's career was his connection with the New York Laryngological Society. Although not a charter member with Wagner, Bosworth, Lefferts, Asch, Woolsey Johnson, Kinnicutt, Mann, McBurney and Weir, he was one of the earliest to be elected to it and was an important contributor to its history in the days when it was exerting such extraordinary influence in the development of our specialty.

The story of the founding of the New York society should be familiar to all of us, but it is not, because of the inaccuracies of statement made by those of a later generation who, borrowing from one another, have alluded to it in their publications. Even Jonathan Wright, in his *History of Laryngology*, dismisses it as a society which had a brief existence and was soon lost sight of. (Birkett, in his masterly address upon "Laryngology in America," quoting from an article by Gleitsmann in a German publication issued many years ago, speaks to the same effect.) No one of us should be willing to thrust the matter aside so cavalierly, for the New York society was the first society of laryngologists in history. Organized in 1873, it was the birthplace of the scientific rhinology of the world and the cradle of laryngology in the United States. The formation of this society was suggested by Dr. Clinton Wagner, who called to his house one evening in the early autumn of that year a group of young men, all of whom had received practical instruction abroad and who represented the very best element of the profession of the time. Before the close of the evening, according to Dr. Wagner, they had "decided to organize a society, not only for mutual improvement and the advancement and enlargement of their limited knowledge of the nose and throat, but also with the view of establishing on a solid footing with the medical profession the specialty of laryngology in this country, for the reason that many of the physicians of the time looked askance at all specialties." Following that memorable evening, monthly meetings were held regularly at the houses of members of the society for nearly ten years. The membership was gradually increased, the meetings were well attended and much enthusiasm was shown in the advancement of the infant science. Familiar with their character and purpose I cannot recall the memory of them without a thrill of pride. Many of the members were inaugurating the pioneer work which made them famous, and it was at the modest meetings of the society that their epoch-making ideas were first exploited and discussed.

Thus, in 1873, Clinton Wagner founded the Metropolitan Throat Hospital, modeled after the throat hospital of Dr. Morell Mackenzie at Golden Square, London. This was the first special hospital for diseases of the throat in the Western Hemisphere.

There he began the first systematic courses of postgraduate instruction in laryngology in the United States. In this year, also, Lefferts initiated his courses of instruction for undergraduates at the College of Physicians and Surgeons, and developed them to a perfection never since equalled either in this country or in Europe. Bosworth called the attention of the world to the relief afforded by the removal of nasal obstructions. The striking benefits derived from the application of the new idea led at once to a lively interest in the investigation of nasal conditions in general, and soon the long-neglected study of the anatomy and pathology of the nose and its sinuses was receiving widespread and enthusiastic attention. Jarvis, investigating abnormal conditions of the turbinated bodies, demonstrated their influence upon nasal respiration, upon the ear and the function of hearing, and upon the nervous system. To Bosworth and Jarvis is due the credit of the greatest advance made in the history of nasal obstruction and its sequels. Roe, the pioneer of intranasal surgery, inaugurated the submucous removal of redundant hard tissue and performed miracles of original work in the restoration of deformities of the nose long before it was dreamed of in Europe. Asch proved the value of the principle of the reëstablishment of the displaced septum to its normal vertical position without the removal of any of its parts. Lincoln developed methods for the cure of nasopharyngeal fibroma which were far in advance of anything done before and have never been equalled since. Among the noteworthy members of the society was Beverley Robinson. Always an acknowledged authority in matters medical, to him belongs the credit of many valuable suggestions in the therapeutics of laryngology. With such men, and others like them, young, brilliant and filled with enthusiasm for the new art, it is not strange that the contributions of their genius and the discussions of them should have made the meetings of the New York Laryngological Society well worthy of an honorable place and a permanent record in the history of medicine.

Dr. Robinson's connection with the department of laryngology was one of the most interesting phases of his career. During his student days in Paris he placed himself under the instruction of several of the most eminent specialists in Europe. Particularly he interested himself in the study of diseases of the throat and

chest, always from the medical point of view. Surgery had little attraction for him. With ample clinical opportunity the passing years brought ever-increasing experience in the broader fields of general medicine, and this, in turn, added vastly to his value as a specialist. He wrote much and upon many subjects. Many of his earlier publications related to the throat and chest. In them he manifested excellent knowledge, soundness of judgment and practical wisdom. The list of his medical writings contains many articles valuable today.

To those who made the acquaintance of Dr. Robinson through his writings and his expressions of opinion on the various public matters which interested him, the mellowness and deliberation of his feelings and utterances were their most impressive trait. Outside of medicine, he interested himself especially in prison reform, to the services of which he devoted his pen and his influence. He was a firm believer in the powerful effects of high personal character in the individual, and believed that cultivation of integrity of purpose, common sense and honor would bring to an end many of the evil and reckless controversies of the day. He was of a deeply religious nature, believing that religion should consist not merely in forms and ceremonies but in everyday life and devotion to the principles of Christianity. In his professional eminence and private life he was a figure to inspire admiration for the rapidly disappearing general practitioner in medicine.

My own personal acquaintance with Dr. Robinson began in the first year that I entered practice. By a kind act of fate I found myself his next door neighbor, and was soon favored with a call from him, at the suggestion of mutual friends. Not every man has been found willing to advance the interests of a young stranger who may become a possible rival. The kindness and unselfishness of Dr. Robinson's nature was strikingly illustrated in his friendliness to me, for he invited me to his house, introduced me to his most influential neighbors and manifested a substantial interest in my professional advancement. Later, on the occasion of visits to Philadelphia, his introductions to leading members of the profession were of important advantage in my career. As he was to me in that early day, fifty years ago, so he was throughout his life to every young man toward whom he felt justified in

reposing confidence. I have never known him to lose an opportunity to further the interests of those to whom his influence could be helpful; and with his wide acquaintance among the best circles, both medical and social, and the unlimited respect and esteem in which he was universally held, his influence was of decided importance.

Nervous in manner, always ready to take part in conversation or debate, or to express himself upon matters of public interest in the secular journals, his opinions were well-grounded and positive, sometimes highly original, and, given with great earnestness and with the best of good nature, always interesting. In the various circles in which he moved, invariably of the best, he was regarded as an oracle. Gentle, but fearless, he could carry his point leaving his opponent a firmer friend than ever. For one of such strong personality, his most remarkable trait was the warm friendship which he inspired throughout his lifetime in the hearts of all.

Dr. Robinson was married in 1875, to Miss Anna E. Foster, of New York City. Of their four children, three are living: Beverley R. Robinson, a successful lawyer of New York; Mrs. Arthur W. Butler and Miss Pauline Robinson. Mrs. Robinson died, after a long period of illness, in 1921. Dr. Robinson died of heart disease at his home in New York City, June 21, 1924.

ALEXANDER WATT MACCOY, M.D.

ALEXANDER WATT MacCOY, M.D.

1847–1924

Alexander Watt MacCoy was born in Mercersburg, Franklin County, Pennsylvania, in the year 1847. During his early life the family removed to Springfield, Ohio, where his boyhood was spent and where he gained his education, graduating from Wittenburg College in 1866 with the usual A.B., and three years later receiving from it the title A.M. Having graduated in medicine, from the University of Pennsylvania in 1870, he served as intern at the Philadelphia (Blockley) Hospital. Having taken up the study and practice of laryngology and rhinology he became lecturer on those subjects at the Woman's Medical College of Philadelphia, and later professor of the same at the Philadelphia Polyclinic and College for Graduates in Medicine.

Among the dispensaries and hospitals he was connected with may be mentioned the Mercer Hospital, Pittsburgh, Pa., the Polyclinic Hospital of Philadelphia, and the Out-Patient Department of the Pennsylvania Hospital. He was a member of his county and state medical societies, of the American Medical Association and of the College of Physicians of Philadelphia. He was elected a Fellow of the American Laryngological Association in 1896 and became its President in 1914, presiding at its annual meeting held in Atlantic City in that year.

Dr. MacCoy was not a prolific writer, but his publications were of distinct value. Among them may be mentioned a paper upon the subject, "Painless Surgery of the Nasal Passages," another entitled, "Note on Osteophytes in the Nasal Chambers." One of his most interesting contributions, published in 1899, was the article "Observations on Laryngeal Paralysis Dangerous to Life, Occurring During the Progress of Typhoid Fever."

He was married at the age of thirty to Miss Emma M. Logan and was among the first of those who selected for his family residence a place in the suburbs of the city. Although having his office in the town, his life was eminently domestic. His confrères saw little of him. He was a man of quiet demeanor, tall, slender, of extremely light complexion and delicate appearance, and great gentleness of disposition, one who made for himself a useful place in the world and filled it with dignity.

He died at his home in Haverford, on November 19, 1924.

List of Fellows
1925

LIST OF FELLOWS

1925

Attendance during last five years shown by figures following each name.
Asterisk (*) indicates year paper was read.

Active Fellows

1917. Arrowsmith, Hubert, 170 Clinton Street, Brooklyn, New York, 1921, '22, '24, '25.

1923. Babbitt, James A., 2117 Chestnut Street, Philadelphia, Pennsylvania, 1923, '24, '25.

1915. Barnes, Harry Aldrich, 520 Commonwealth Avenue, Boston, Massachusetts, 1920, '24.

1908. Barnhill, John F., 408 Penway Building, Indianapolis, Indiana, 1922, '24.

1921. Berry, Gordon, 19 Elm Street, Worcester, Massachusetts, 1921*, '22, '23, '24, '25.

1893. Birkett, Herbert S., 252 Mountain Street, Montreal, Canada, 1920, '21, '22*, '23, '25.

1925. Blair, Vilray P., 400 Metropolitan Building, St. Louis, Missouri, 1922, 23*, 25*.

1891. Bryan, Joseph H., 303 Stoneleigh Court, Washington, D. C., 1920*, '21, '22, '23, '24, '25.

1913. Butler, Ralph, 2007 Chestnut Street, Philadelphia, Pennsylvania, 1920*, '21, '23, '24.

1915. Canfield, R. Bishop, Ann Arbor, Michigan, 1921, '22.

1917. Chamberlin, William B., Osborn Building, Cleveland, Ohio, 1920, '21*, '22.

1897. Clark, J. Payson, 71 Marlborough Street, Boston, Massachusetts, 1920*, '21, '22, '23, '24*.

1902. Coakley, Cornelius G., 20 East Fifty-third Street, New York, 1920, '21, '22*, '23, '24, '25.

1917. Coates, George Morrison, 1811 Spruce Street, Philadelphia, Pennsylvania, 1920, '21, '22, '23, '24, '25.

1905. Coffin, Lewis A., 114 East Fifty-fourth Street, New York, 1920, '21, '22, '23, '25.

1913. Coffin, Rockwell A., 350 Commonwealth Avenue, Boston, Massachusetts, 1920, '21, '22*, '24.

1893. Coolidge, Algernon, Jr., 198 Beacon Street, Boston, Massachusetts, 1920, '21, '24.

1913. Dabney, Virginius, 1633 Connecticut Avenue, Washington, D. C., 1921*, '22, '24*, '25.

1918. Dean, Lee Wallace, Iowa City, Iowa, 1920*, '21*, 22, '23, '24, '25.

1881. Delavan, D. Bryson, 40 East Forty-first Street, New York, 1920*, '21*, '22, '23, '25.

1921. Emerson, Francis P., 520 Commonwealth Avenue, Boston, Massachusetts, 1921, '22, '23*, '24.

1919. Faulkner, E. Ross, 101 East Fifty-eighth Street, New York, 1920, '21, '22, '23*, '25.

1914. Fetterolf, George, 2010 Spruce Street, Philadelphia, Pennsylvania, 1920, '21, '22, '23*, '24, '25.

1922. Forbes, Henry Hall, 40 East Forty-first Street, New York, 1922, '25*.

1879. French, Thomas R., 469 Clinton Avenue, Brooklyn, New York, 1920*.

1897. Frothingham, Richard, 666 Madison Avenue, New York.

1922. Goldsmith, Perry G., 84 Carlton Street, Toronto, Ontario, 1922*, 23*, '24.

1913. Goldstein, Max A., 3858 Westminster Place, St. Louis, Missouri, 1920, '21, '22, '25*

1898. Goodale, Joseph L., 258 Beacon Street, Boston, Massachusetts, 1920, '21, '22*, 23, '24.

1905. Grayson, Charles P., 262 South Fifteenth Street, Philadelphia, Pennsylvania, 1921.

1906. Greene, D. Crosby, Jr., 23 Bay State Road, Boston, Massachusetts, 1920*, '21*, '22, '23, '24*, '25.

1917. Greene, Joseph B., 305 Haywood Building, Asheville, North Carolina, 1921, '22, '23*, '24.

1905. Halsted, Thomas H., 405 Fayette Park, Syracuse, New York, 1920, '21, '23, '24, '25.

1896. Hardie, T. Melville, 30 North Michigan Boulevard, Chicago, Illinois.

1903. Harris, Thomas J., 104 East Fortieth Street, New York, 1921, '22' ,24*, '25.

1915. Hastings, Hill, 306 Medical Office Building, 1136 West Sixth Street, Los Angeles, California, 1921*, '24.

1895. Hopkins, Frederick E., 146 Chestnut Street, Springfield, Massachusetts, 1920*, '22.

1895. Hubbard, Thomas, 234 Michigan Street, Toledo, Ohio, 1920*, '22*, '24*.

1919. Hurd, Lee Maidment, 39 East Fiftieth Street, New York, 1921, '23, '25.

1925. Iglauer, Samuel, 400 Pearl Market Bank Building, Cincinnati, Ohio.

1920. Imperatori, Charles Johnstone, 17 East Thirty-eighth Street, New York, 1921*, '22, '24*, '25*.

1904. Ingersoll, John M., 1020 Huron Road, Cleveland, Ohio, 1920, '21, '22, '23, '24, '25.

1907. Jackson, Chevalier, 128 South Tenth Street, Philadelphia, Pennsylvania, 1921*, '22*, '23, '24*, '25*.

1918. Kenyon, Elmer L., 104 South Michigan Boulevard, Chicago, Illinois, 1922, '24*.

1921. Kernan, John D., Jr., 156 East Seventy-ninth Street, New York, 1921*, '22, '25.

1914. Levy, Robert, Metropolitan Building, Denver, Colorado.

1918. Lewis, Fielding Otis, 259 South Seventeenth Street, Philadelphia, Pennsylvania, 1921*, '22*, '23, '25*.

1925. Lillie, Harold I., Mayo Clinic, Rochester, Minnesota, 1923*, '24*, '25.

1911. Lockard, Lorenzo B., Metropolitan Building, Denver, Colorado.

1913. Loeb, Hanau W., 537 North Grand Avenue, St. Louis, Missouri, 1920, '21, '22, '23, '25.

1897. Logan, James E., 1208 Wyandotte Street, Kansas City, Missouri, 1920, '21, '22, '23.

1915. Lynch, Robert Clyde, 632 Maison Blanche Building, New Orleans, Louisiana, 1920*, '21, '22, '23, '24*.

1921. McCullagh, Samuel, 71 Park Avenue, New York, 1921*, 22, '23*, '25.

1913. McKimmie, Oscar A. M., 1301 Massachusetts Avenue, N. W., Washington, D. C., 1921*, '22, '25.

1914. Mackenty, John E., 111 East Sixty-first Street, New York, 1920*, '21, '22*, '23*, '25*.

1896. Mayer, Emil, 875 West End Avenue, New York, 1921, '22, '23, '24.

1904. Mosher, Harris P., 828 Beacon Street, Boston, Massachusetts, 1920, '21*, '22, '23*, '24, '25.

1925. Mullin, Wm. V., Ferguson Building, Colorado Springs, Colorado, 1923, '24*, '25.
1914. Munger, Carl E., 81 North Main Street, Waterbury, Connecticut, 1921.
1901. Myles, Robert C., 25 West Fifty-first Street, New York, 1923, '25.
1922. New, Gordon B., Mayo Clinic, Rochester, Minnesota, 1922, '24, '25*.
1903. Packard, Francis R., 302 South Nineteenth Street, Philadelphia, Pennsylvania, 1920, '21, '22, '23, '24. '25.
1906. Pierce, Norval H., 22 East Washington Street, Chicago, Illinois, 1920*, '21, '22, '23, '24, '25.
1908. Randall, B. Alexander, 2009 Spruce Street, Philadelphia, Pennsylvania, 1920*, '21, '22, '23, '25.
1903. Renner, W. Scott, 341 Linwood Avenue, Buffalo, New York, 1920, '22, '24.
1884. Rice, Clarence C., 52 Park Avenue, New York.
1905. Richards, George L., 124 Franklin Street, Fall River, Massachusetts, 1920, '21, '24.
1902. Richardson, Charles W., 1337 Connecticut Avenue, Washington, D. C., 1920*, '21, '22*, '23, '25.
1913. Roy, Dunbar, Grand Opera House Block, Atlanta, Georgia, 1921*, '22, '23.
1921. Sauer, William E., 537 North Grand Avenue, St. Louis, Missouri, 1921, '23, '25.
1923. Sewall, Edward Cecil, 3515 Pacific Avenue, San Francisco, California, 1924.
1907. Shambaugh, George E., 122 South Michigan Boulevard, Chicago, Illinois, 1920*, '22, '23, '24.
1909. Shurly, Burt R., 62 Adams Avenue W., Detroit, Michigan, 1920, '21*, '22, '24, '25*.
1919. Skillern, Ross H., 1928 Chestnut Street, Philadelphia, Pennsylvania, 1920*, '21*, '22*, '23, '24, '25.
1909. Sluder, Greenfield, 3542 Washington Avenue, St. Louis, Missouri, 1920*, '21, '22*, '23*, '25.
1908. Smith, Harmon, 44 West Forty-ninth Street, New York, 1920, '21, '22*, '23, '25.
1924. Stein, Otto J., 30 North Michigan Avenue, Chicago, Ill., '25*.
1911. Stout, George C., 2015 Walnut Street, Philadelphia, Pennsylvania, 1922, '23, '25.
1889. Swain, Henry L., Colonial Building, 197 Church Street, New Haven, Connecticut, 1920, '21*, '22, '23, '24, '25.

1903. Theisen, Clement F., 172 Washington Avenue, Albany, New York, 1920*, '23*, '24*.
1892. Thrasher, Allen B., The Groton, Seventh and Race Streets, Cincinnati, Ohio.
1892. Wagner, Henry L., 518 Sutter Street, San Francisco, California.
1892. Watson, Arthur, W., 2013 Locust Street, Philadelphia, Pennsylvania, 1921, '23, '25.
1925. White, Francis W., 74 West Fifty-eighth Street, New York City, New York, 1922, '23*, '25.
1924. White, Leon E., 390 Commonwealth Avenue, Boston, Massachusetts, 1924.*
1908. Wilson, J. Gordon, 5755 Kenwood Avenue, Chicago, Illinois, 1920, '21, '22, '24, '25.
1906. Winslow, John R., The Latrobe, Charles and Reade Streets, Baltimore, Maryland, 1921*, '22, '23, '25.
1922. Wishart, David J. G., 47 Grosvenor Street, Toronto, Canada.
1905. Wood, George B., Suite 504, Physicians' Building, Northeast corner Twentieth and Chestnut Streets, Philadelphia, Pennsylvania, 1921, '22*, '23*, '25*.

Associate Fellows

1923. Barlow, Roy Alexander, care of Jackson Clinic, Madison, Wisconsin, 1923, '24*.
1924. Carmody, Thomas E., 806 Metropolitan Building, Denver, Colorado, 1924.
1923. Dennis, Frank Lowndes, Ferguson Building, Colorado Springs, Colorado, '25*.
1923. Fenton, Ralph Albert, 616 Journal Building, Portland, Oregon, 1923, '25*.
1925. King, James Joseph, 40 East Forty-first Street, New York, New York, 1925.
1923. Large, Secord Herbert, 2323 Prospect Avenue, Cleveland, Ohio, 1924*, '25.
1924. McGinnis, Edwin, 104 South Michigan Boulevard, Chicago, Illinois, 1924, '25*.
1923. McKinney, Richmond, Bank of Commerce Building, Memphis, Tennessee, 1923, '24*.
1922. Monroe, Otho Lee, 24 East Forty-eighth Street, New York City, New York, 1922, '24.

1923. Newhart, Horace, Donaldson Building, Minneapolis, Minnesota, 1923, '25*.
1924. Proetz, Arthur Walter, 234 University Club Building, St. Louis, Missouri, 1924, '25*.
1923. Spencer, Frank Robert, Physicians' Building, Boulder, Colorado, 1923, '24*.
1924. Taylor, Hermon Marshall, 111 West Adams Street, Jacksonville, Florida, 1924, '25*.
1925. Tucker, Gabriel, 335 Trevor Lane, Cynwyd, Pennsylvania, 1925.
1924. Wherry, William P., 620 Bankers' Reserve Life Building, Omaha, Nebraska, 1924, '25*.

Honorary Fellows

1915. Bosworth, Francke H., 1 West Fifty-fourth Street, New York.
1914. Cohen, J. Solis-, 1833 Pine Street, Philadelphia, Pennsylvania.
1910. Moure, E. J., 25 Cours du Jardin Public, Bordeaux, France.
1914. Thomson, Sir St. Clair, 65 Wimpole Street, W., London, England.
1921. Wright, Jonathan, Windy Rock, Pleasantville, New York.

Corresponding Fellows

1901. Collier, Mayo, Kearsney Abbey, Kent, England.
1893. Desvernine, Carlos M., 52 Cuba Street, Havana Cuba.
1920. Ferreri, Gherardo, University di Roma, Rome, Italy.
1901. Grant, Sir James Dundas, K.B.E., 148 Harley Street, London, W 1, England.
1919. Kelly, Adam Brown, 26 Blythewood Square, Glasgow, Scotland.
1921. Le Maitre, Fernand, Avenue Victor Hugo, 120 (XVI), Paris, France.
1902. Lermoye, Marcel, 20 Rue de la Boetie, viie, Paris, France.
1897. Luc, H., 8 Rue de Chanaleilles, Paris, France.
1903. McBride, P., 20 South Drive, Harrowgate, England.
1919. McKernon, James F., 62 West Fifty-second Street, New York.
1896. MacDonald, Greville, Wildwood, Haslemere, England.
1894. MacIntyre, John, 179 Bath Street, Glasgow, Scotland.
1920. MacKenzie, Dan, 61 Wimpole Street, Cavendish Square, London, W 1, England.

1896. Mygind, Holger, 31 Havnegade, Copenhagen, Denmark.
1919. Paterson, Donald Rose, 15 St. Andrew's Crescent, Cardiff, Wales.
1919. Rogers, John, Jr., 177 East Seventy-first Street, New York.
1894. Sajous, C. E. DeM., 2043 Walnut Street, Philadelphia, Pennsylvania.
1924. Schaeffer, J. Parsons, Jefferson Medical College, Philadelphia.
1896. Schmiegelow, Ernst, 18 Norregade, Copenhagen, Denmark.
1903. Tilley, Herbert, 72 Harley Street, Cavendish Square, London, W., England.
1913. Turner, Logan, 27 Walker Street, Edinburgh, Scotland.
1901. Wingrave, Wyatt, 11 Devonshire Street, Portland Place, London, W., England.
1894. Wolfenden, R. Norris, The Grange, Kent, England.

Emeritus Fellows

1914. Brown, J. Price, 106 South Drive, Toronto, Canada.
1922. Cobb, Frederick C., Riverview, Gloucester, Massachusetts.
1918. Farlow, John W., 127 Bay State Road, Boston, Massachusetts.
1924. Freer, Otto T., 81 East Elm Street, Chicago, Illinois.
1918. Hinkel, F. Whitehall, 581 Delaware Avenue, Buffalo, New York.
1912. Lincoln, William, 1054 Rose Building, Cleveland, Ohio.
1924. Rhodes, John Edwin, Peoples' Gas Building, Chicago, Illinois.

PAST OFFICERS

Presidents

(Year of Election)

1879. Louis Elsberg
1880. J. Solis-Cohen
1881. F. I. Knight
1882. G. M. Lefferts
1883. F. H. Bosworth
1884. E. L. Shurly
1885. Harrison Allen
1886. E. Fletcher Ingals
1887. R. P. Lincoln
1888. E. C. Morgan
1889. J. N. Mackenzie
1890. W. C. Glasgow
1891. S. W. Langmaid
1892. M. J. Asch
1893. D. B. Delavan
1894. J. O. Roe
1895. W. H. Daly
1896. C. H. Knight
1897. T. R. French
1898. W. E. Casselberry
1899. Samuel Johnston
1900. H. L. Swain
1901. J. W. Farlow
1902. J. H. Bryan
1903. J. H. Hartman
1904. C. C. Rice
1905. J. W. Gleitsmann
1906. A. W. de Roaldes
1907. H. S. Birkett
1908. A. Coolidge, Jr.
1909. J. E. Logan
1910. D. Braden Kyle
1911. James E. Newcomb
1912. George A. Leland
1913. Thomas Hubbard
1914. Alexander W. MacCoy
1915. G. Hudson Makuen
1916. Joseph L. Goodale
1917. Thomas H. Halsted
1918. Cornelius G. Coakley
1919. Norval H. Pierce
1920. Harris P. Mosher
1921. Harmon Smith
1922. Emil Mayer
1923. J. Payson Clark
1924. Lee Wallace Dean
1925. Greenfield Sluder

Vice-Presidents

1879.	F. H. Davis	
1880.	W. C. Glasgow	J. O. Roe
1881.	E. L. Shurly	W. Porter
1882.	C. Seiler	E. F. Ingals
1883.	S. W. Langmaid	S. Johnston
1884.	J. H. Hartman	W. H. Daly
1885.	H. A. Johnson	G. W. Major
1886.	E. C. Morgan	J. N. Mackenzie
1887.	J. N. Mackenzie	S. W. Langmaid
1888.	W. C. Glasgow	C. E. DeM. Sajous
1889.	E. Holden	C. E. Bean
1890.	J. O. Roe	J. H. Hartman
1891.	M. J. Asch	S. Johnston
1892.	S. Johnston	J. C. Mulhall
1893.	J. C. Mulhall	W. E. Casselberry

1894.	C. C. Rice	S. H. Chapman
1895.	J. Wright	A. W. de Roaldes
1896.	T. M. Murray	D. N. Rankin
1897.	A. W. MacCoy	H. S. Birkett
1898.	J. W. Farlow	F. W. Hinkel
1899.	T. A. DeBlois	M. R. Brown
1900.	H. L. Wagner	A. A. Bliss
1901.	J. W. Gleitsmann	D. Braden Kyle
1902.	G. A. Leland	T. Melville Hardie
1903.	J. H. Lowman	W. Peyre Porcher
1904.	Thomas Hubbard	W. J. Freeman
1905.	J. L. Goodale	C. W. Richardson
1906.	G. H. Makuen	A. B. Thrasher
1907.	J. P. Clark	J. E. Rhodes
1908.	E. Mayer	F. R. Packard
1909.	C. G. Coakley	H. P. Mosher
1910.	Robert C. Myles	J. M. Ingersoll
1911.	F. C. Cobb	B. R. Shurly
1912.	A. W. Watson	W. Scott Renner
1913.	F. E. Hopkins	Geo. E. Shambaugh
1914.	Clement F. Thiesen	Lewis A. Coffin
1915.	J. Gordon Wilson	Christian R. Holmes
1916.	Thomas H. Halsted	Greenfield Sluder
1917.	John Edwin Rhodes	D. Crosby Greene
1918.	G. E. Shambaugh	John R. Winslow
1919.	Francis R. Packard	Harmon Smith
1920.	Harmon Smith	W. B. Chamberlin
1921.	Dunbar Roy	Robert C. Lynch
1922.	George Fetterolf	Lorenzo B. Lockard
1923.	Hubert Arrowsmith	Joseph B. Greene
1924.	Ross H. Skillern	Gordon Berry
1925.	John E. Mackenty	Robert Levy

Secretaries and Treasurers

1879.	G. M. Lefferts	1895.	H. L. Swain
1882.	D. B. Delavan	1900.	J. E. Newcomb
1889.	C. H. Knight	1911.	Harmon Smith

Secretaries

1912.	Harmon Smith	1919.	J. M. Ingersoll
1918.	D. B. Delavan	1920.	George M. Coates

Treasurers

1912.	J. Payson Clark	1923.	George Fetterolf

Librarians

1879.	F. H. Bosworth	1903.	J. H. Bryan
1883.	T. R. French		

PAST MEMBERS

**Deceased*

Honorary Fellows

*1893. De Roaldes, Arthur, New Orleans, La.
*1914. De La Sota Y Lastra, Ramon, Seville, Spain.
*1880. Garcia, Senor Manuel, London, England.
*1878. Johnston, Samuel, Baltimore, Md.
*1914. Lefferts, George Morewood, Katona, N. Y.
*1883. MacKenzie, John N., Baltimore, Md.
*1883. Mackenzie, Sir Morell, London, England.
*1910. Massei, Ferdinand, Naples, Italy.
*1879. Oliver, H. K., Boston, Mass.
*1909. Semon, Sir Felix, Great Missenden, England.
*1914. Wagner, Clinton, New York City.

Corresponding Fellows

*1892. Browne, Lennox, London, England.
*1887. Gouguenheim, A., Paris, France.
*1894. Holden, Edgar, Newark, N. J.
*1881. Labus, Carlo, Milan, Italy.
*1880. Meyer, Wilhelm. Copenhagen, Denmark.
*1881. Thornton, Pugin, London, England.
*1880. Whistler, W. McNeil, London, England.

Emeritus Fellows

*1914. De Blois, Thomas Amory, Boston, Mass.
*1914. Gleitsmann, Joseph W., New York City.
*1912. Knight, Charles H., New York City.
*1923. Leland, George A., Boston, Massachusetts.
*1922. MacCoy, Alexander W., Philadelphia, Pa.
*1914. Porter, William, Ocean Springs, Miss.
*1914. Robinson, Beverley, New York City.

Active Fellows

*1880. Allen, Harrison, Philadelphia, Pa.
*1878. Asch, Morris J., New York.

*1880. Bean, C. E., St. Paul, Minn.
*1904. Berens, T. Passmore, New York City.
*1924. Bigelow, Nolton, Providence, R. I.
*1893. Bliss, Arthur Ames, Philadelphia, Pa.
*1895. Boylan, J. E., Cincinnati, Ohio.
*1892. Brown, Moreau R., Chicago, Ill.
*1889. Casselberry, William E., Chicago, Ill.
*1883. Chamberlain, C. W., Hartford, Conn.
*1896. Chappell, W. F., New York.
*1882. Chapman, S. Hartwell, New Haven, Conn.
1918. Cox, Gerard H., New York.
1880. Cushing, E. W., Boston, Mass.
*1878. Cutter, Ephraim, West Falmouth, Mass.
*1880. Daly, W. H., Pittsburgh, Pa.
*1878. Davis, F. H., Chicago, Ill.
*1901. Dickerman, E. T., Chicago, Ill.
*1878. Donaldson, Frank, Baltimore, Md.
*1901. Freeman, Walter J., Philadelphia, Pa.
*1917. Friedberg, Stanton A., Chicago, Ill.
1901. Getchell, Albert C., Worcester, Mass.
*1907. Gibb, Joseph S., Philadelphia, Pa.
*1878. Glasgow, William Carr, St. Louis, Mo.
*1878. Hartman, Jacob H., Baltimore, Md.
*1879. Holden, Edgar, Newark, N. J.
*1907. Holmes, Christian R., Cincinnati, Ohio.
*1882. Hooper, Franklin H., Boston, Mass.
1893. Hope, George B., New York City.
*1901. Hyatt, Frank, Washington, D. C.
*1882. Ives, Frank L., New York City.
*1878. Ingals, E. Fletcher, Chicago, Ill.
*1880. Jarvis, William C., New York City.
*1878. Johnson, Hosmer A., Chicago, Ill.
*1879. Johnson, Woolsey, New York City.
*1879. Kealhofer, R. H., St. Louis, Mo.
*1901. King, Gordon, New Orleans, La.
*1885. Knight, Charles H., New York City.
*1878. Knight, Frederick Irving, Boston, Mass.
*1898. Kyle, D. Braden, Philadelphia, Pa.
*1880. Langmaid, Samuel W., Boston, Mass.
*1878. Lincoln, Rufus P., New York City.
*1888. Lowman, John H., Cleveland, Ohio.
*1919. Lynah, Henry L., New York City.

*1879. McBurney, Charles, New York City.
*1885. McSherry, H. Clinton, Baltimore, Md.
*1898. Makuen, G. Hudson, Philadelphia, Pa.
*1881. Major, G. W., Montreal, Canada.
*1881. Morgan, E. C., Washington, D. C.
*1886. Mulhall, J. C., St. Louis, Mo.
1892. Murray, T. Morris, Washington, D. C.
*1881. Mynter, H., Buffalo, N. Y.
*1893. Newcomb, James E., New York City.
*1895. Nichols, J. E. H., New York City.
1894. Park, William H., New York City.
1892. Porcher, W. Peyre, Charleston, S. C.
*1880. Rankin, D. N., Allegheny, Pa.
*1879. Roe, John O., Rochester, N. Y.
1881. Robertson, J. M., Detroit, Mich.
*1878. Rumbold, T. F., St. Louis, Mo.
*1879. Seiler, Carl, Philadelphia, Pa.
*1893. Shields, Charles M., Richmond, Va.
*1878. Shurley, E. L., Detroit, Mich.
*1879. Smith, Andrew H., Geneva, N. Y.
*1892. Simpson, William Kelly, New York City.
*1879. Tauber, Bernhard, Cincinnati, Ohio.
*1899. Thorner, Max, Cincinnati, Ohio.
*1888. Van der Poel, S. O., New York City.
1896. Ward, Marshall R., Pittsburgh, Pa.
1879. Ward, Whitfield, New York City.
*1886. Westbrook, Benjamin F., Brooklyn, N. Y.
1896. Woolen, Green V., Indianapolis, Ind.