

Transactions
American Laryngological Association

Fifty-fifth Volume

TRANSACTIONS
OF THE
FIFTY-FIFTH ANNUAL MEETING
OF THE
American
Laryngological Association

HELD AT WASHINGTON, D. C.

MAY 8, 9 AND 10, 1933

PHILADELPHIA
PUBLISHED BY THE ASSOCIATION
1933

CONTENTS

List of Officers	vii
Registration	17
Chairman's Address. GORDON BERRY, M.D.	19
The Radicular Cyst Which Invades the Bones of the Face. ARTHUR M. ALDEN, A.M., M.D.	23
Speech Movements in Action. R. H. STETSON, Ph.D.	29
Permanent Enlargement of the Lips and Face, Secondary to Recurring Swellings and Associated with Facial Paralysis: A Clinical Entity. GORDON B. NEW, M.D.	43
Some Clinical Observations on Nasal Hemorrhage. DUNBAR ROY, M.D.	51
Mucocele as a Cause of Proptosis. Report of Six Cases. WILLIAM B. CHAMBERLIN, M.D., and THAYER L. PARRY, M.D.	59
Cysts of the Larynx. MERVIN C. MYERSON, M.D.	71
Bronchial Disinfection and Immunization. JOHN A. KOLMER, M.D.	83
Fracture of the Styloid Process and Its Tonsil Fossa Complications. Report of Case. JAMES A. BABBITT, M.D.	114
The Minute Anatomy of the Sphenoid Ostium. ARTHUR W. PROETZ, M.D.	125
A Clinical and Pathological Study of Tumors of the Nose, Pharynx and Mouth of Teratological Origin. A. C. FURSTENBERG, M.D.	128
Rhabdomyoma of the Larynx. Report of a Case. CHARLES J. IMPERA- TORI, M.D.	139
Fibrolipoma of the Larynx. Report of a Case. CHARLES J. IMPERATORI, M.D.	143
Contact Ulcer of the Larynx. Report of a Case. CHARLES J. IMPERA- TORI, M.D.	149
Fibroepithelial Tumors of the Nose (Papilloma) and Their Relationship to Carcinoma. ERNEST M. SEYDELL, M.D.	158
A Discussion of Cardiac, Pulmonary and Other General Conditions Secondary to Chronic Nasal Sinus Infection. JOHN B. POTTS, M.D.	180
Plaster Casts Showing the Relationship of the Structures of the Neck Following Strangulation—Homicidal or Suicidal. HENRY BOYLAN ORTON, M.D.	195

An Eye Retractor and a Suture-carrier-knot-tyer for the External Pan- sinus Operation. ROMEO A. LUONGO, M.D.	205
Parotid Gland Tissue in the Tonsillar Fossa. Case Report. ERNEST M. SEYDELL, M.D.	208
A Simple Maneuver to Increase the Visibility of a Salivary Calculus in the Roentgenogram. SAMUEL IGLAUER, M.D.	210
Presentation of Instrument. JOHN B. POTTS, M.D.	211
Presentation of Instrument. ARTHUR M. ALDEN, M.D.	212
Memorials:	
GEORGE FETTEROLF	215
CLEMENT FRANK THEISEN	223
Executive Sessions and Reports of Officers and Committees, 1933 . . .	225

List of Fellows, 1933:

Active Fellows	251
Associate Fellows	256
Honorary Fellows	256
Corresponding Fellows	256
Emeritus Fellows	257
Past Officers	259
Past Members	262

OFFICERS FOR 1932-1933

PRESIDENT

GEORGE FETTEROLF, M.D.

FIRST VICE-PRESIDENT

GORDON BERRY, M.D.

SECOND VICE-PRESIDENT

FRANK R. SPENCER, M.D.

SECRETARY

GEORGE M. COATES, M.D.

TREASURER

WILLIAM V. MULLIN, M.D.

LIBRARIAN

JOHN F. BARNHILL, M.D.

COUNCIL

The above Ex-officio and

HERBERT S. BIRKETT, M.D.

FRANCIS R. PACKARD, M.D.

HENRY L. SWAIN, M.D.

GEORGE E. SHAMBAUGH, M.D.

TRANSACTIONS OF THE FIFTY-FIFTH ANNUAL CONGRESS
OF THE
AMERICAN LARYNGOLOGICAL ASSOCIATION

HELD AT
WASHINGTON, D. C., MAY 8 AND 9, 1933

DR. GORDON BERRY, First Vice-President of the American Laryngological Association, called the Fifty-fifth Annual Congress to order at The Raleigh Hotel, Washington, D. C., at 10 A.M., May 8, 1933.

REGISTRATION

Registration for the entire meeting was as follows:

ALDEN, ARTHUR MAXWELL
BABBITT, JAMES A.
BARNHILL, JOHN F.
BECK, JOSEPH C.
BERRY, GORDON
BLAIR, VILRAY P.
BRYAN, JOSEPH H.
CAMPBELL, EDWARD H.
CHAMBERLIN, WILLIAM B.
CLERF, LOUIS H.
COATES, GEORGE M.
DABNEY, VIRGINIUS
DEAN, LEE WALLACE
FAULKNER, E. ROSS
FURSTENBERG, ALBERT
CARL
GOODYEAR, HENRY M.
GREENE, JOSEPH B.
HALSTED, THOMAS H.
HARRIS, THOMAS J.

HILL, FREDERICK T.
HOUSER, KARL MUSSER
IGLAUER, SAMUEL
IMPERATORI, CHARLES J.
JACKSON, CHEVALIER
JARVIS, DEFOREST C.
LEWIS, FIELDING O.
LIERLE, DEAN M.
MACPHERSON, DUNCAN
MCKINNEY, RICHMOND
MKNALLY, WM. JAMES
MOSHER, HARRIS P.
MULLIN, WILLIAM V.
MYERSON, MERVIN C.
NEW, GORDON B.
NEWHART, HORACE
ORTON, HENRY B.
PACKARD, FRANCIS R.
PIERCE, NORVAL H.
POTTS, JOHN B.

PROETZ, ARTHUR W.
RIDPATH, ROBERT F.
ROY, DUNBAR
SEYDELL, ERNEST M.
SHEA, JOHN J.
SHURLY, BURT R.
SMYTH, DUNCAN

SONNENSCHN, ROBERT
SWAIN, HENRY L.
TUCKER, GABRIEL
WANAMAKER, ALLISON T.
WHERRY, WM. P.
WILSON, J. GORDON
WOOD, GEORGE B.

CHAIRMAN'S ADDRESS

GORDON BERRY, M.D.

WHEN on the seventh of January, at the behest of your Council, I received this highly prized gavel from Mrs. George Fetterolf, I told her that I accepted it as the symbol of a temporary trust, a trust which her husband had so enjoyed planning for but which his physical powers at the last had been unable to bear; and that I would endeavor to carry on in his stead and "keep the faith" for us, his laryngological brothers, for him and for her. To this end your Council has instructed me to call this, our fifty-fifth annual conference, and our efficient and esteemed secretary has prepared this program. Thanks to his help and to that of those participating, I feel sure we will wish it said to our beloved president who conceived and initiated the arrangements: "Well done good and faithful servant." But we shall miss him sorely, also Dr. Clement F. Theisen. Later in our deliberations our historian, Dr. Delavan, has arranged for the presentation of fitting memorials for these two loyal Fellows.

Had his waning strength permitted, Dr. Fetterolf would have addressed you in accordance with the time-honored custom of our Society. Knowing his intense love for our Association and his high pride both in its traditions and in its future, I venture that he would have happily dwelt on how the Association can develop and build, from the solid foundations our laryngological fathers have laid, the beautiful and enduring structure that best can serve our professional sons and grandsons. A review of the early days after Dr. Frank H. Davis of Chicago called together 21 men in Buffalo in 1878 and, with 11 others, founded the oldest laryngological group in the world, and of our subsequent growth and enthusiasm, points out with clarity the recurring idea that these were the chosen who should lay the lasting foundations. Through succeeding years our presidents urged these men to prove worthy of their unique privilege and high calling: laryngology was at stake, it would enter into its unique mission if our

members were faithful and true; our Association was the agency through which their leadership would be made articulate.

As the years passed, we grew in physical stature. Our membership was increased from 50 to 75, to 100; then an associate membership was added. Also, our mental stature has continued great. We find Dr. Bryson Delavan rejoicing in what he calls the Giants of the Past: Solis-Cohen, Allen and Sajous in Philadelphia; Oliver, Knight and Hooper in Boston; Wagner, Lefferts, Bosworth and Elsborg in New York; French in Brooklyn; John MacKenzie in Baltimore; Shurley in Detroit; Ingals in Chicago; Glasgow in St. Louis; deRoaldes in New Orleans; Logan in Kansas City. These pioneers placed laryngology in the vanguard among the specialties. In 1906 Dr. Joseph W. Gleitsman glories that our teaching activities and hospital facilities and clinics have surpassed those of our European brethren. Much later, this spirit of responsibility for the standards and for the advancement of laryngology finds its expression in the American Board of Otolaryngology where such members as Drs. Mosher, Loeb, Shambaugh, Beck, Wherry, Fenton, Coates, Spencer (to name a few) have taken so self-sacrificing and prominent a part. Thus has our Association fulfilled its high mission to promote and establish laryngology in the United States.

While this task has been carried forward to happy fruition, the conception as to our Association seems to have altered. First, it is simply an assembly of the leaders. Later, it becomes a scientific body whose yearly pronouncements carry weight and dignity. At present do we not think of it as our Laryngological Alma Mater? She elected to do us honor; we render her our homage and love her; year after year we bring the best fruits of our labors and ask her to accept them. The American Laryngological Association then has been changing, and from a group of separate individuals we have now become a living, self-perpetuating unit: a unit or body surrounded with traditions, and claiming and receiving the constant devotion of its proud members.

If Dr. Fetterolf should come back like Abou Ben Adhem's angel, would he enter our names in the Laryngological Book of Gold? Are we as individuals, or collectively, doing our part to make the record fair and fine? I think we are. Review with me the programs of the last decade and realize afresh the many staunch

standard-bearers, a loyal "host that has not yet bent the knee to Baal." Somewhat in chronological order we find: cardiospasm by Mosher; bronchoscopy by Jackson, Tucker, Clerf, Imperatori and Myerson; laryngeal cancer, with Mackenty, Lynch, New and Orton; laryngeal tuberculosis, with Spencer, Carmody and Mullin; sinus complications from swimming by Taylor; sinusitis in children by Coakley and Dean; the displacement method in sinus diagnosis by Proetz; sphenopalatine neuroses by Sluder; radical sinus surgery by Lynch, Skillern, Lewis, Faulkner and Sewell; diet deficiencies, with Dean, Shurley and Barlow; Casselberry prize anatomical researches by Fetterolf and Campbell; studies in olfaction by Proetz and Seydell; allergy by Hastings and Tobey; color changes in the septum by Jarvis; researches in living cell pathology by Mosher, Fenton and Proetz. And this is a partial list. When we consider that most of these subjects were new when presented, or were discussed from a fresh angle, we realize with assurance and pride that this race of "giants" is not vanishing from our midst. Are there stalwart sons in the offing imbued with the same consuming purpose for our laryngological Alma Mater? If I read the membership of our younger Fellows aright, there need be no concern for the future.

As a means toward higher accomplishment, Dr. Norval H. Pierce, in his presidential address of 1920, proposed a Program Committee with a rotating five-year membership, to carefully discuss, select and assign subjects for investigation and research. Relieving somewhat our overburdened secretary, it would serve as a clearing-house for all our scientific and clinical contributions. It would encourage individual research workers, and would seek and stimulate the donation of funds to finance their efforts. It was shortly after this proposal that our sister society conceived its otosclerosis program, which has been carried forward so energetically and which has so redounded to the benefit of the American Otological Society and to the enthusiasm of its members. Have we a constructive plan and a far-seeing purpose? We come here for the rare fellowship; we come here to do homage to our Association; but the Book of Gold cannot find that "Lo, our name leads all the rest" unless we contribute as well as receive.

A chance turn of fortune's wheel has cast on my willing but inexperienced shoulders the mantle of a prophet among us. Thus

empowered and imbued with his zeal, proud of our past, mindful of our future, I present for the consideration of our Elder Statesmen this idea that we would yet more successfully serve our Association if we should take careful thought for the morrow. Unlike "the lilies of the field," toil we must and spin, if we are to serve this Alma Mater. Can we "build for her yet statelier mansions"? Could some of the less burdened members of our Council, for instance, or others duly elected, be assigned to such a continuing committee as Dr. Pierce outlined? Through them, individuals who are competent to carry forward research work would be encouraged. By them, funds to help could be secured, perhaps through university affiliations, perhaps through direct gifts. The endorsement of such an authoritative committee would imbue each task with added dignity and merit, as well as stimulate the individual to his best effort. Can we do more? Other and more beautifully vaulted chambers can appear in the architectural plan. Perhaps competition for recognition by our Casselberry and other awards can be keener. Our desire as well as our duty will urge us to save our best contributions for the American Laryngological Association and we will jealously insist that these papers be heard first by these peers, who in turn will add to our earnest efforts their helpful criticism and their constructive benediction. Interwoven with these phases of our plan will be those concerned with the seeking and the securing of the finest of the oncoming leaders in our specialty. And in and through it all, as the golden thread in the woof and fabric of the tapestry, will continue the rare spirit of fellowship which Dr. Delavan envisions.

This thought of an increasing and controlling purpose finds happy expression in the echoing verses of Tennyson's Locksley Hall. I like to think that George Fetterolf is quoting them.

"Yet I doubt not through the ages one increasing purpose runs,
And the thoughts of men are widened with the process of the suns.
Knowledge comes, but wisdom lingers, and I linger on the shore,
And the individual withers, and the world is more and more.
Not in vain the distance beacons. Forward, forward let us range,
Let the great world spin forever down the ringing grooves of change."

With this tribute to our revered President whose "increasing purpose" so advanced the interests of our society, and in his behalf, I now have the honor to open the fifty-fifth annual meeting of the American Laryngological Association.

THE RADICULAR CYST WHICH INVADES THE BONES OF THE FACE

ARTHUR M. ALDEN, A.M., M.D.

THERE are four types of dental cysts which are to be found in the upper jaw: the median anterior maxillary cyst, the multilocular adamantinoma, the follicular cyst, and the radicular cyst. The two latter ones are of special interest to the rhinologist because of the fact that each of these, in its growth, at times invades the cavities in the maxilla. The follicular, often called dentigerous cyst, develops from a malformed tooth and always contains in its periphery one or more normal or embryonic teeth. It is most frequently seen in young persons between the ages of twelve and eighteen years. The radicular cyst develops secondary to an apical granuloma and occurs in older individuals, usually during the early or middle part of adult life.

Becker,¹ who has perhaps done more work on the histopathology of this latter condition than anyone else, believes that the radicular cyst is an outgrowth from an apical granuloma secondary to hemorrhage into the pericemental membrane. This hemorrhage is due to infection or trauma. However, only those granulomas which contain epithelial rests are capable of developing into true radicular cysts. Not every granuloma contains epithelial rests and therefore not every granuloma can develop into a cyst. He considers that these epithelial rests of Malassez are remnants of Hertwig's sheath and, therefore, are probably postembryonic cells. The radicular cyst developing from them is benign, while the multilocular cyst develops from the anlage, which is made up of embryonic cells and is, therefore, on the borderline toward malignancy.² Given an infectious granuloma with a few of these epithelial cells, it only remains for the irritation incident to the infection to start a proliferation of these cells which rapidly forms the epithelial lining for the future cyst. The desquamation of cells lining the cyst, and the collection of epithelial débris which is in every way analogous to the cholesteatomatous masses seen

in the ear, is the primary reason for the growth of the cyst into the surrounding tissues. While this type of cyst is seen in both the upper and lower jaws, only those which occur in the maxilla are of particular interest to us as rhinologists.

In the majority of cases radicular cysts are first seen by the dentist, or particularly the exodontist. If careful roentgen-rays of the teeth are taken, the diagnosis is, as a rule, not difficult to make. If the cyst is not large, the removal of the involved tooth and the complete shelling out of the cyst wall from the bony cavity is all that is necessary to produce a complete cure of the condition. When, however, the cyst is of long duration and has grown upward and invaded the cavity of the maxillary sinus, particularly if the cyst has become infected, the differential diagnosis between a cyst and a true maxillary sinusitis is very frequently missed. This type of cyst grows slowly and when it invades the antral cavity it, as a rule, pushes the lining wall of the sinus ahead of it and never actually invades the mucosal cavity of the sinus except where secondary infection of the cyst has taken place with necrosis of the soft tissue wall of both the cyst and the sinus. I am sure that many cases of what has been diagnosed as chronic suppurative maxillary sinusitis with necrosis of the alveolar process are in reality radicular cysts which have invaded the maxillary sinus and have become secondarily infected.

In the average case, the differential diagnosis between a radicular cyst which has invaded the maxillary sinus and a maxillary sinusitis *per se* is not difficult to make. These cases are most often referred to the rhinologist by the dentist because of the roentgen-ray picture showing cloudiness in the antrum above the apex of a suspicious tooth or because the dentist has removed the tooth and found that the apex penetrated the antral cavity and lavage through the alveolar process brought down purulent secretion or epithelial debris. In the first type of case, that is, an uninfected radicular cyst occupying the antrum, if the antrum can be entered through the normal ostium and lipiodol injected, the opaque fluid in the antral cavity will be seen to occupy a small space, usually close to the inner and upper wall of the sinus, and the cyst itself will be clearly outlined by the filling defect extending from below

upward. In the other type of case, that is, where the cyst is opened and infected, lavage of the cyst cavity usually brings out purulent secretion or epithelial débris, while inspection of the nose shows, as a rule, no evidence of a suppurative involvement of the mucosal cavity of the maxillary sinus. If lipiodol is injected into this cyst cavity and radiographs taken, it will usually be seen that the cyst does not communicate with the mucosal cavity of the sinus. In such cases, particularly where the cyst is a large one and of long standing, it will also be noted that the cyst cavity is not always in conformation with the normal shape of the maxillary sinus, but is much more extensive and may involve the entire floor of the nose, even across to and sometimes entering the maxillary sinus cavity on the other side. In the presence of such a picture the diagnosis is certain.

The mechanism by which it is possible for such a growth to slowly destroy the bone of the maxilla, often to a very marked degree, is a very interesting one. In the older literature it was thought that this bony destruction was due to pressure. I am sure that this is not the true explanation, for I have seen several cases where the bone of the canine fossa, which forms, of course, the external wall of a cyst which occupies the maxillary sinus, was as thin as paper and yet showed no evidence of rupture. In 2 of these cases, although the external bony plate was thin as an eggshell, the cyst had invaded and destroyed a large amount of hard bone underneath the floor of the nose. If pressure were the sole factor leading to the destruction of bone, rupture of the cyst into the mucosal cavity of the sinus and discharge of its contents through the normal ostium would be much more common. I have never observed this phenomenon.

In studying the microscopic anatomy of these cyst walls we found open spaces in almost all of them which looked as though they had contained crystals. In an effort to decide this point we sent the untreated membranous wall of some of these cysts to the chemist and he reported that in every case the cholesterol content was very high; in several of them as much as 15 per cent. We know from our experience with the cholesteatomatous masses which we see in the temporal bone, that a cholesterol-containing growth

has the ability to destroy and invade even the most compact type of bone, and for this reason I am sure that the method by which these tumors progress is not a mechanical one due to pressure, but a chemical one secondary to the action of the cholesterol content in their capsule upon the underlying bony matrix.

The treatment of this condition is, of course, entirely surgical, and consists in the complete removal of the cyst from its underlying bony wall. As a rule, a line of cleavage between the cyst and bone is easily established, and in the majority of cases it is possible to shell out the radicular cyst as an intact sac. Where the cyst has invaded and occupies only a portion of the maxillary sinus, and where there is no infection present, it is usually best to remove the cyst and allow the mucosal lining of the sinus to drop back into its normal position. In such cases the incision is closed and, as a rule, heals by primary union. In those cases where there has been infection and a communication between the cyst and mucosal cavity of the sinus is present, a typical Caldwell-Luc procedure should be carried out with complete exenteration of the lining wall of the sinus and cyst and a large opening made underneath the inferior turbinate. The healing here takes place in the same way as occurs following the radical antrum operation. Where the cyst is an extensive one and has eroded a considerable portion of the alveolar process, or where it is necessary to remove two or more teeth, the mucosal incision instead of being made in the usual location, that is, in the apex of the gingivolabial fold, should be made along the gingival margin, both lingual and labial sides, and the approach to the antrum carried out through the alveolus. In such cases a typical radical antrum operation, with removal of all involved alveolar tissue and closure of the two mucosal flaps, usually brings about a very good result and a satisfactory bed for a subsequent dental prosthesis.

BIBLIOGRAPHY

1. Becker, Erich: Radicular Cysts, No. 2, Meusser Collection, 1920, quoted from Theodor Blum, Jour. Am. Dent. Assn., April, 1929.
2. Kruse: Development of Cystic Tumors of the Lower Jaw, Virchow's Arch. f. path. Anat., vol. 124.

DISCUSSION

DR. HARRIS P. MOSHER, Boston, Mass.:

This is a very clearly written paper.

What bothers me a little is the apparent recommendation of treating some of these cysts through the alveolar process and letting them granulate up. That has never appealed to me. The few times I have seen it tried by the dental profession, the results were long delayed and not good. I have had the feeling that the direct way of getting at these and getting a quick result was to do the ordinary Caldwell-Luc operation.

Now about the new etiology of cholesterol crystals acting as absorbents for bone. I have always supposed it was pressure of the cyst contents. The fact the bone was thin over the external wall of the cyst in Dr. Alden's case did not convince me, but when I saw his slides I was convinced. What happens in the frontal sinus when you get the same sort of a performance? Are we going to find cholesterol crystals acting there, or is the bone absorption due to old-fashioned pressure?

DR. JOHN J. SHEA, Memphis, Tenn.:

The development of the antrum is very closely related to the descent of the permanent molars. The buds of the upper molars are stacked behind the youthful antrum, and as it develops downward and backward, the six year, the twelve year molar and then the wisdom tooth are forced into their position in the alveolar process. An arrested development of the antrum leaves these future molars in cancellous bone, depending upon the stage of development at which time the arrest occurred.

Cysts readily form in this diploic bone about these improperly erupted teeth.

Two slides were demonstrated. One of a cyst, which started about the root of a lateral incisor and migrated into the antrum, devitalizing the teeth in its passage.

The second slide was of a cyst surrounding the left eye tooth in a child of pre-school age, which was thought at first to be a tumor, but proven to be cystic by filling it with radio-pathe oil.

DR. ARTHUR W. PROETZ, St. Louis, Mo.:

I should like to ask Dr. Alden whether he regards cholesterol as being the agent which produces the growth and the spread of these

cysts, or whether it may not be simply a by-product of the spread. We find cholesterol everywhere that epithelial tissue breaks down, whether there is cyst formation or not. I wondered whether cholesterol may not be a part of the broken down tissues found in the cyst.

DR. GORDON B. NEW, Rochester, Minn.:

I would like to ask Dr. Alden one question about his theory of development, the stimuli of the epithelial débris. In my experience most of the cysts of this type have a flat epithelial lining, while the epithelium of the basal layer of the enamel organ are columnar in type.

DR. E. ROSS FAULKNER, New York City:

I would be inclined to agree with Dr. Alden that the erosion of the bone is not due to pressure only. Pressure effect on bone occurs in aneurysms, and if you look through the pathological museums, you will find specimens of eroded vertebra from aneurysms. It produces almost a smooth surface, which has not the typical carious appearance you get associated with these cysts. I do not think you see the same effect as you see in cases of pure pressure of bone.

DR. ALDEN (in closing):

First, in answer to Dr. Mosher's question relative to the line of approach to the cyst which invades the maxillary sinus.

We have found that in most of our cases due to the fact that the origin of the cyst involved one or more of the teeth underlying the sinus, an incision along the gingival margin and elevation of the soft tissues upward gives us a better view of the entire process than the typical Caldwell-Luc incision which I usually make in the apex of the gingivolabial fold.

Aside from this change in the position of the incision, the operation is carried out in exactly the same way as the Caldwell-Luc procedure is ordinarily done.

In answer to Dr. Proetz's questions, I am sure that the production of cholesterol crystals in the lining mucosa of these cysts is secondary to the chemical change which takes place in the collection of epithelial débris. This is the same mechanism that operates in the formation of a cholesteatomatous tumor in the temporal bone. The action of cholesterol on bone is always a destructive one and I feel that the ability of these cysts to destroy and invade hard bone is probably due much more to the presence of these crystals in the lining wall than to the pressure factor which has hitherto been described as the reason for their invasive properties.

SPEECH MOVEMENTS IN ACTION

R. H. STETSON, PH.D.

THE basic movement of speech is the pulse which produces the syllable: The syllable is a puff of air through the glottis made audible by the vocal cords in speaking aloud, especially in the vowels, and stopped and started by the articulatory movements of the consonants. The larynx itself does not initiate the syllable nor control the process of articulation; this is quite apparent in the case of speech with an artificial larynx. The larynx makes possible the tone of speech. In just one thing is it a prime mover: it determines the pitch of the tone. The principal problems of the speech process lie above and below the larynx.

A familiar way of treating speech divides the physiological apparatus into resonators, reed and bellows. But the bellows is not of the organ type furnishing air under pressure to the glottis. Negus's statement that the larynx is a valve is easily misunderstood; only in the case of the glottal catch, which does not occur in normal English, does the larynx figure as a valve in speech. The chest-abdomen is like a bellows for blowing the fire, in which the volume increases when it is inflated but the pressure is at zero.

The boards of the fire-bellows are held in position by the larger muscles of the arms. Quick little puffs can be made by the muscles of the hands. When the hand muscles produce a single puff from the nozzle, the arm muscles maintain the posture, and with each puff adjust the boards of the bellows to the slightly reduced volume, but do not keep the air under pressure.

When the hands make a series of rapid puffs through the nozzle, the arms make a continuous movement to "support" the puffs and maintain the proper position of the boards during the group of puffs. If one of the puffs is more vigorous than the rest, the culmination of the arm movement reinforces the stroke of the hands. Thus it is possible to group and to accent the series of puffs from the fire-bellows; the puffs are made by the hand movements, and they are grouped and accented by the arm movements.

In speech also there are two fundamental groups of muscles:

1. The abdominal muscles opposed by the diaphragm (+ chest) which maintain the posture and the slowly changing adjustment (Fig. 1, D-R). The larger muscles of the rib-cage fixate the attachment of the diaphragm. The pressure from the abdominal muscles is transmitted through the viscera to the diaphragm.

2. The internal intercostals opposed by the external intercostals make the syllable by a momentary pressure-pulse. (Fig. 1, I.I.-E.I.) The internal intercostals draw the ribs down, deflating the chest; they are the muscles of expiration which produce the puff. The external intercostals draw the ribs up, opposing the internal intercostals, and terminate the syllable puff.

As the hand muscles produce single puffs from the nozzle of the fire-bellows, while the arm muscles maintain the position of the boards and with each puff adjust the boards to the slightly reduced volume but do not keep the air under pressure, so the intercostals make the single syllable puffs through the glottis, while the abdominal muscles and the diaphragm maintain the posture and adjust to the slightly reduced volume of the chest but do not maintain pressure in the chest.

When the intercostals make a rapid series of syllable puffs, the abdominal muscles make a single movement for the group of syllables against the opposing diaphragm. This constitutes the "breath group." The main accent of the group is produced by the culmination of this abdominal movement.

Thus the intercostals make a rapid series of syllable puffs at rates as rapid as 8 to 10 per second, and the larger movements of the abdominal-thoracic musculature group and accentuate the syllables. These groups may follow each other at the rate of 3 to 4 per second.

Kymographic evidence of the two musculatures (D-R and I.I.-E.I., Fig. 1) is given in Fig. 2. The pulses produced by the intercostals and the abdominal muscles have been recorded in different ways. By means of a negative pressure apparatus it is possible to record the pulse of the intercostals as it comes through the body wall. In the case of tracheotomized subjects it is possible to record directly the variations of pressure produced by the chest and abdominal muscles.

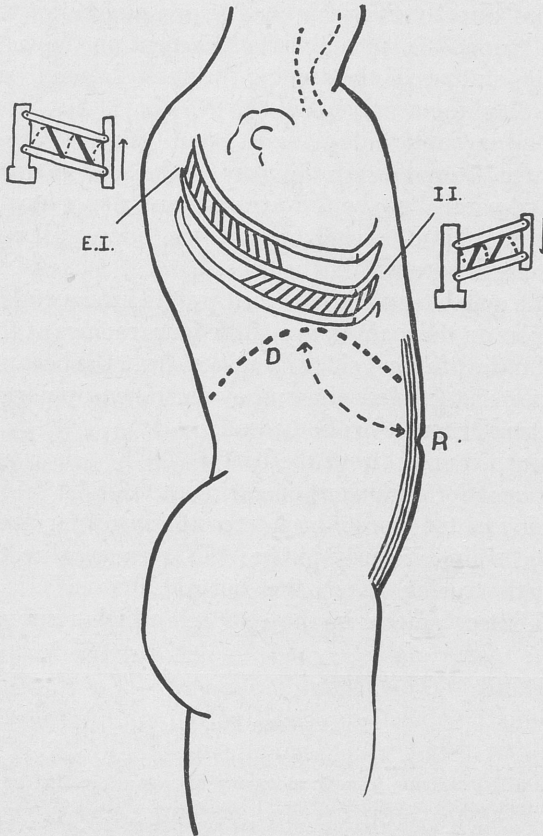


FIG. 1.—The two fundamental musculatures of speech. A, The reciprocating muscles which produce the syllable pulse. Ribs exposed to show the two layers of intercostal muscles. I.I., internal intercostals, more pronounced toward the sternum, which draw the ribs downward, expelling air in the syllable puff. Muscles of expiration. E.I., external intercostals, more pronounced toward the spine, which draw the ribs upward arresting the flow of air in the syllable puff. Muscles of inspiration.

B, The reciprocating muscles which support the posture, and group and accentuate the syllable puffs. R, rectus abdominis, leading muscle of the abdominal group. Muscles of expiration. The viscera transmit pressure from the abdominal muscles to the diaphragm. D, diaphragm in cross-section. When the larger muscles of the chest fixate the rib cage to the edges of which the diaphragm is attached, the contraction of the diaphragm enlarges the chest and forces out the abdominal muscles. Muscle of inspiration.

The first and third tracings from the bottom in Fig. 2 ("Subglot") record directly the variations of pressure below the glottis. The word "aladad" is spoken with the accent on the last syllable. The general contour of the tracing for each "aladad" shows the abdominal-diaphragm movement (D-R, Fig. 1) but it is divided into two sub-groups, "ala-" and "-dad" since the abdominal muscles make *two* pulses for the word. The second tracing (CR) was recorded parallel to the third tracing and shows how faithfully the negative pressure tracing through the body wall records the variations of pressure within the chest.

The single syllable pulses produced by the intercostals are to be seen as ripples on the main waves of the four tracings at the bottom of Fig. 2. In the fifth and eighth tracings (from the bottom, "CN") only the intercostal pulses show; they are taken by negative pressure apparatus through the body wall.

The seventh tracing (from the bottom, "CE") show an abdominal adjustment for each word occurring at least 0.2 second before the beginning of the word; the intercostal pulses for the syllables are recorded simultaneously in the "CN" tracing directly above.

The fourth tracing (from the bottom, "Stom") is obtained from an inflated balloon in the stomach which responds to the

LEGEND FOR FIG. 2.

FIG. 2.—Orig. 15 by 24 cm. The word "aladad;" tracings of the chest and abdominal movements. T, tracing from the tongue. The bulges in the curve show the tongue in contact with the palate for the "l" and "d." Just beneath is a time line giving fifths of seconds. AO, tracing of the air-pressure as the air leaves the mouth. It is to be noted that the liquid "l" as well as the occlusive "d" interrupts the air flow. CN, separate chest pulses for each syllable; accent on the first and last syllables. CE, simultaneous with CN above. Abdominal movement anticipating the chest pulses by two-tenths second or more. Main accent from the abdominal muscles is on the first syllable. CE, from a second subject. Abdominal movement with pronounced accent on the last syllable. In words 4 and 5 it is obvious second syllable tends to fuse with third (to "al'dad"). CN, simultaneous tracing from this second subject showing merely the chest pulses. Stom, from a third subject. Tracings of the pressures from balloon in stomach, showing the same pattern of air-pressure in the chest. Subglot, from a fourth subject. Tracing of the pressures from the tracheotomy tube. CR, simultaneous tracing from this fourth subject, from body wall with negative-pressure apparatus; the same forms as that of the tracheal pressures directly above. Subglot, from this fourth subject; tracing from the tracheotomy tube showing same forms. CN, CE, CR, are tracings of the pressures taken through the body wall with negative-pressure apparatus. The vertical lines connect the syllable pulses of the various tracings.

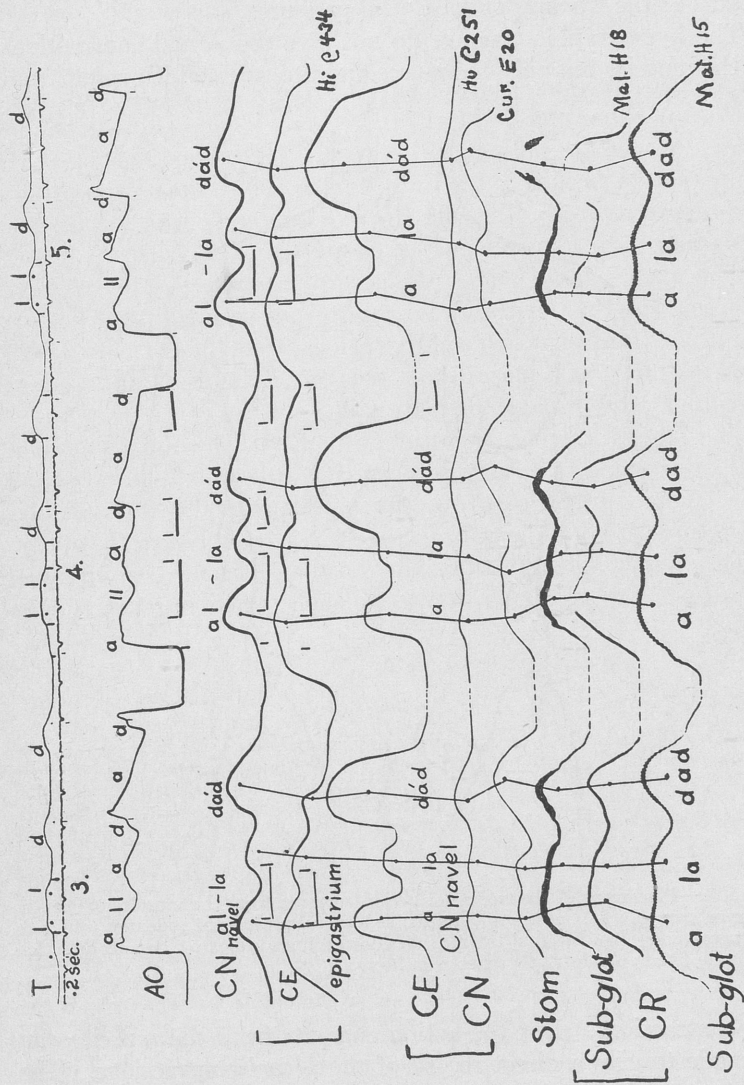


FIG. 2.

thoracic pressures of speech and gives the same contours and details as the tracings of subglottal pressures.

The kymographic tracings do not give the actual contractions of the muscles but only the pulses and pressures which result from

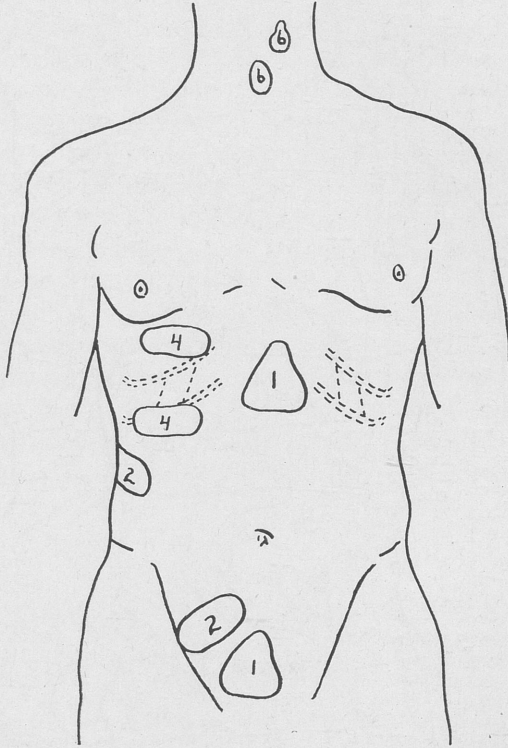


FIG. 3.—Placement of electrodes for action currents from the muscles of speech. Anterior groups. 1-1, rectus abdominis; 2-2 lateral muscles of abdomen (obliques and transverse); 4-4 internal intercostals; dotted lines indicate ribs and direction of muscle fibers; 6-6 intrinsic muscles of larynx.

the contractions. But the action currents from the muscles can be made to give a direct record of the actual contractions. The placement of the electrodes for simultaneous recording of the muscles involved in speech is shown in Figs. 3 and 4. With proper amplification it is possible to get simultaneous oscillographic

records of the contractions of these muscles, although there is always some leakage from adjacent muscles.

In Fig. 5 the top line "Mic." gives the microphone record of the syllable "pup" said slowly. It is apparent in Figs. 5 and 6 that first the rectus abdominis and second the laterals of the

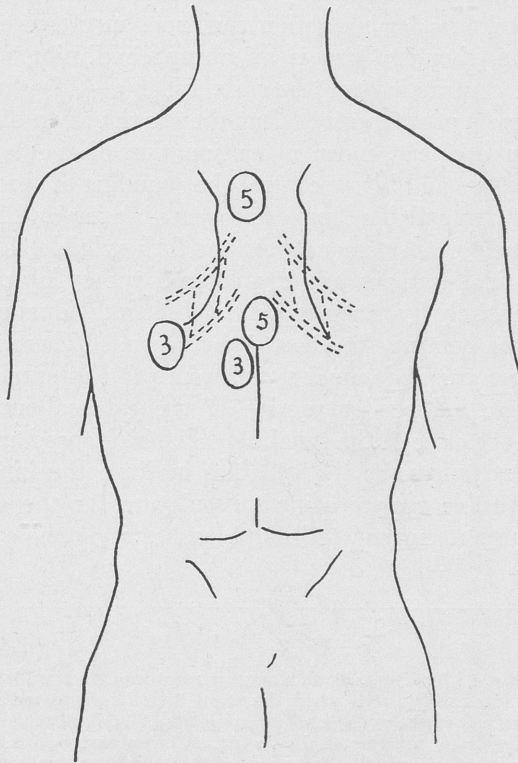


FIG. 4.—Placement of electrodes for action currents from the muscles of speech. Posterior groups. 3-3, diaphragm; 5-5, external intercostals; dotted lines indicate ribs and direction of muscle fibers.

abdomen lead in the contraction for the syllable. It is possible that the diaphragm contracts with the abdominal muscles which initiate the syllable—there are some indications—but there is extensive leakage from the lateral abdominals and the intercostals. The independent action of the diaphragm is between the syllables

which it arrests (with the external intercostals not shown). It is to be noted that the internal intercostals come in later than the abdominal muscles in initiating the chest pulse for "pup."

The contraction of the intrinsic larynx muscles "L" begins later than that of the intercostals producing the puff, but the larynx muscles contract considerably earlier than the actual sounding of the vowel; the larynx action continues until some time after the syllable, though there is an abrupt inhibition immediately before the contraction for the next syllable—this shows also in Fig. 6. One must remember that the continuation of the larynx contraction does not mean a continuation of the tone; the air pressures above and below control the sounding of the tone.

In Fig. 6 the syllable "pup" is repeated faster and faster, from 2 per second to 7 per second. At the fifth syllable, 4 per second, the abdominal muscles are fixated and the syllable pulses are produced entirely by the intercostals. The individual contractions of the larynx continue to about 5 per second. There is extensive leakage from the abdominal muscles into the external intercostal line, but the independent action of the external intercostals is evident at the close of the syllables. The high speed and precision of the chest pulses for the syllables indicate the intercostals as the one possible reciprocating musculature for the chest pulse. And the action current technique makes it possible to demonstrate it.

LEGEND FOR FIG. 5.

FIG. 5.—Orig. 18 by 25 cm. Action-current records of the simultaneous contraction of the muscles of speech when the word "pup" is repeated slowly. Mic., microphone record of the syllables "pup, pup, pup," spoken at the rate of 2 per second. L, intrinsic muscles of the larynx. Contraction begins later than the abdominal and thoracic muscles, but much earlier than the actual vowel. II, internal intercostals which contract vigorously at the beginning of the puff of air for the syllable and also maintain some contraction in opposition to the diaphragm and to the external intercostals (not shown) at the close of the syllable puff. D, diaphragm; apparent opposition to the internal intercostals and to abdominal muscles is in part leakage; the independent contraction of the diaphragm shows between syllables. LA, lateral muscles of the abdomen which anticipate the contraction of the intercostals but are relaxed during part of the syllable and between syllables. RA, rectus abdominis which leads the contraction of all the muscles for the syllable, but is quite relaxed during part of the syllable and between syllables. The relaxation of the abdominal muscles, LA, RA, between the syllables shows that each syllable is separate. They constitute one-syllable groups. Time lines top and bottom give one-sixtieth second.




FIG. 5.

In one form of stammering there is a clutch between the abdominal muscles and the diaphragm (+ rib cage) D-R, Fig. 1. The vocal canal including the glottis is open and the subject often exhales some air in an effort to release the heavy fixation.

"Dyssynchrony," when the chest and abdominal muscles move in opposite phase—is not the mark of a speech defect but occurs in any emphatic or forced utterance, and in staccato singing.

The coördinations in normal legato singing are like those of speech; the chest sinks slowly during the phrase and the abdominal muscles adjust to the decreasing volume.

In training the deaf (-mutes) to speak it is important to begin with the syllable and with groups of syllables; "sounds" do not occur alone. The deaf child should learn first the fundamental coördinations as does the normal child. And in lip-reading also, the grouping and the rhythm of the syllables gives the basic structure of the phrase with its articulations.

The vowels are modifications of the larynx tone; they are due to the varying shape of the cavities above the larynx but the vocal canal is open and the vowels do not interfere with the flow of air of the syllable puff.

On the other hand the consonants do affect the flow of air and have a part to play in the formation of the syllable puff. The

LEGEND FOR FIG. 6.

FIG. 6.—Orig. 18 by 25 cm. Action-current records of the simultaneous contractions of the muscles of speech when the word "pup" is repeated faster and faster. Mic., microphone record of the syllable "pup" at rate 2-7 per second. As the speed increases the tone extends through the consonants although the pulse of the syllable is marked. L, intrinsic muscles of the larynx; much less amplification than in larynx record of Fig. 5. Action of the larynx muscles apparent up to 5 per second. II, internal intercostals; contraction for each syllable throughout the record; dots have been placed above the pulses at high speed; EI, external intercostals. Probably some leakage from internal intercostals at slow speed. Essential contraction of EI at the close of syllable to arrest chest pulse shows clearly at both low and high speed. Dots have been placed above these functional contractions. At low speed both intercostals tend to relax completely just before the beginning contraction of the syllable. At high speed the continuous contraction of both the internal and external intercostals, upon which the pulses for starting and stopping the syllable supervene, is characteristic of all rapidly reciprocating musculatures. It appears in the rapid tapping of the hand. LA, lateral muscles of the abdomen follow the lead of the rectus abdominis; RA, rectus abdominis leads the contractions at the beginning of the syllable. At 0.4 per second the abdominal muscles fixate. The first four syllables are grouped separately; thereafter the syllables constitute one long group. Time lines top and bottom give one-sixtieth second.




FIG. 6.

vowel merely colors the syllable puff but the consonant functions in releasing and arresting the syllable puff.

The consonants constrict the vocal tube partially or completely, with or without closure of the velum. At the beginning of the syllable puff the consonant closure builds up and then *releases* the momentary pressure of the syllable puff. At the close of the syllable puff the consonant closure *arrests* the momentary flow of the syllable puff, and as the pressure backs up assists in stopping the syllable movement in the chest. The releasing consonant movement acts with the internal intercostals in starting the syllable pulse; the arresting consonant movement acts with the external intercostals in stopping the syllable pulse.

Some of the consonants, the "occlusives," close the vocal canal completely (p/b, t/d, k/g) while some, the "continuants," (f/v, s/z, r, l, etc.) are leaky closures which function, however, like the complete closures.

It is possible, of course, to make syllables without consonants, in which case the chest muscles release and arrest the syllable pulse without help from the consonant movements. Such syllables are said to consist of vowels. But the releasing consonant helps to make the syllable movement definite, and the arresting consonant is important for a heavily accented syllable. Only languages with arresting consonants develop the characteristic rhythms of a heavy word accent.

Most stammering involves a clutch between the articulatory movement and the chest movement.

The velum is closed in speech except for the nasal sounds (m, n, ng in English). Insufficient action of the velum may be due to scar tissue or other mechanical interference. Learning to control the velum is one of the fundamental problems after plastic surgery for cleft palate, and in teaching speech to the deaf. It is easy to connect nostril plugs ("olives") with a Marey tambour-and-lever so that the subject may see when he does and does not close the velum while practising selected combinations; with such practice one can get rapid improvement.

Most subjects do not find it difficult to learn speech with a satisfactory model of artificial larynx. The subject and the teacher

should understand that the air-pressure—as well as the sound—must be led into the mouth *behind* the articulations. The mouth tube must be long enough to reach the k/g articulation at about the juncture between the palate and the velum; a silver tube of proper length, flattened at the end and curved slightly toward the median line of the palate is better than the rubber tubes in use.

If it can be learned, the better form of speech after laryngectomy involves drawing a few cubic centimeters of air into the upper esophagus by the action of the chest muscles as in ordinary speech. This very small supply of air is constantly renewed as in staccato singing, and the subject uses the normal coördinations between chest and articulatory movements. The result is a “voice” like that of a severe laryngitis, but the speech is fluent and natural. It must be learned early, while the muscles about the upper esophagus are relaxed and before the “buccal whisper” supervenes.

DISCUSSION

DR. W. B. CHAMBERLIN, Cleveland, Ohio:

I have been familiar with Dr. Stetson's work for a great many years and when I tell him I do not know anything about it, he replies by telling me it is something which, as a laryngologist, I ought to know something about. I still feel that the subject is decidedly over my head; but I thought it would be of interest to have Dr. Stetson come here and present his work before the American Laryngological Association in order to show the type of work which is being done in an allied field. So it was at my suggestion he came here this afternoon to give this paper which, if we can not entirely understand, we can appreciate. It can also inspire us to work along the same line.

DR. HENRY L. SWAIN, New Haven, Conn.:

I think we ought to say something after having heard such a wonderful paper. I did not get in at the first, so I do not know what Dr. Stetson told us at the beginning. I know at one time they were taking and reading tracings from phonographic cylinders. Scripture, in my town, took great interest in it. One could see “I killed cock-robin,” and it was extremely interesting. Has that work been given up entirely?

Another thing, it has often occurred to me, when we were speaking, how the breath came out. It seems to me the old-fashioned bagpipe idea fitted in with your bellows idea.

I have enjoyed you this afternoon and I hope you can tell us more even than you have, at the close.

PRESIDENT BERRY:

I am wondering whether, in closing, Professor Stetson would be willing to tell us a little of the applicability of this method for teaching the deaf, that is, the mechanics of using it to teach the deaf.

PERMANENT ENLARGEMENT OF THE LIPS AND FACE, SECONDARY TO RECURRING SWELLINGS AND ASSOCIATED WITH FACIAL PARALYSIS: A CLINICAL ENTITY

GORDON B. NEW, M.D.

IN the last twenty-two years, 67 patients presenting chronic, noninflammatory, permanent enlargement of the lips and face have been observed in The Mayo Clinic. This condition has followed repeated swellings, and has been associated with facial paralysis in 13 cases. The condition comes on suddenly in a manner similar to angioneurotic edema, and then, with recurrence of attacks, increasing enlargement is a residue. The condition is apparently a clinical entity, but we have been able to find only slight mention of it in the literature. The results of treatment of the condition have been satisfactory.

LITERATURE. The acute, circumscribed swelling described by Quincke in 1882 corresponds with the onset of the condition, but Quincke did not mention the residual enlargement. In Quincke's edema, although the swelling has a preference for certain regions, such as the eyelids, cheeks, lips and hands, it does not always recur in the same area. Melkersson reported a case of recurring facial paralysis associated with angioneurotic edema of the upper lip, with residual swelling of the lip. Rosenthal described 4 patients who had bilateral facial palsy associated with acute, recurring edema of the face. Although he mentioned slight residual swelling in 2 cases, he thought it of little importance, and did not suggest treatment. Literature of inflammatory enlargements due to erysipelas and lymphangitis is not given.

PRESENT INVESTIGATION. *History.* The ages of the patients at the occurrence of the first swelling ranged from four to fifty-four years. Twenty-nine of the patients were less than twenty years of age, and 50 were less than thirty years of age. In more detail the incidence by decades of life was as follows: one to ten years, 3 cases; eleven to twenty years, 26 cases; twenty-one to

thirty years, 21 cases; thirty-one to forty years, 10 cases; forty-one to fifty years, 5 cases, and fifty-one to sixty years, 2 cases. There were 46 males and 21 females.

The patients gave fairly uniform histories of swelling of the lips and face, coming on rather suddenly, with no signs of local inflammation or premonitory symptoms. In the first attack, the patient might awaken in the morning with the upper and lower lip, or both, three or four times normal size. In a few cases, the attacks were preceded by a cold and indisposition, and in others there was a relationship to migraine or menstruation. One patient stated that the attacks were preceded by headache and migraine. Seven patients gave histories of migraine. Seasickness, influenza, overwork, loss of sleep, trauma and exposure to cold were causes that were given for the swelling of the lips and face. Three patients gave histories of trauma to the upper lip; 1 patient stated that a brother had the same condition. There was no history of relationship to the eating of any particular food, other than that one patient stated that the attacks followed eating strawberries. No seasonal relationship was noted.

The patients had no discomfort, except from enlargement of the part and a feeling of fullness. There was no swelling of any part of the body other than the face, mouth and throat. In a few hours to two days the maximal enlargement occurred, and then gradually receded. The condition might last only a few hours or might continue for three weeks. Regions first involved by swelling were as follows: upper lip, 38 cases; cheeks, 11 cases; lower lip, 9 cases; nose, 4 cases; eyelids, 3 cases, and upper alveolar process, 2 cases. After the first attack, the lips and face usually returned to their normal appearance, but a slight residual swelling might be left even after the first attack. Repetition of this swelling occurred three weeks to six months later, affecting the same portions or spreading to other parts of the face. Usually, after the second or third attack, swelling remained, and after each succeeding attack, enlargement of the region increased. One patient, however, stated that he had had the recurring swelling of the lips and face for twenty-five years, and that no residual swelling had appeared until two years previous to his examination.

Facial palsy might accompany the swelling or might antedate

it by many years. One patient, aged thirty-one years, stated that the first attack of facial palsy occurred when she was aged four years, twenty-two years before the swelling of her face had been noted, and she had had five attacks of facial palsy involving each side of the face. Facial palsy occurred twenty-five years before the swelling in 1 case, sixteen years before it in 1 case, ten years before it in 1 case, six years before it in 2 cases, five years before it in 2 cases, three years before it in 1 case, and six months before it in 1 case.

Findings. A soft, nonpitting, smooth, diffuse enlargement, usually involving the lips was noted. The regions involved by swelling, more than one region in most cases, were as follows: upper lip, 52 cases; cheeks, 35 cases; lower lip, 30 cases; nose, 7 cases; tongue, 6 cases; eyelids, 5 cases; upper alveolar process, 2 cases, and larynx, forehead, and soft palate, each 1 case. The lips might be found three or four times their normal size. The skin over the involved region appeared normal, did not pit on pressure, and there was no change in the temperature of the region. In the lips, most of the swelling seemed to occur inside, rolling the lips outward. The lips might be chapped and fissured from the enlargement.

Peripheral facial paralysis occurred in 13 cases, and in 3 of these, the affection was bilateral. This condition is apparently caused by swelling about the nerve. The facial paralysis might clear completely, as in Bell's palsy, or it might leave some motor disturbance due to faulty regeneration.

Specimens of tissue were taken for biopsy in a few cases before treatment, but nothing was found other than edematous tissue containing lymphocytes. After the patients had received repeated treatment, biopsy disclosed fibrous and inflammatory changes in the tissue, as would be expected. General examination in these cases revealed nothing of note that might bear any relationship to the condition. In the cases in which tests for allergy were made, metabolic rates were determined, and the state of the sinuses was investigated, the findings were negative.

ETIOLOGY. The cause of the condition is not known. Its similarity, in some respects, to angioneurotic edema, has been mentioned. However, angioneurotic edema occurs elsewhere in

the body than the face, at the same time that the face is affected, but in this group of cases only the face, mouth and throat were affected. The question of lymphangitis or recurring erysipelas can be excluded in this series although the enlargements of the face secondary to these conditions is well known.

In 7 cases, enlargement was associated with a cold or exposure to cold, or followed attacks of influenza. The usual condition that is thought of as edema causes tenseness of the skin and pitting on pressure, but the residual swelling in these cases is soft and elastic. There is no change in the skin itself. The fact that 13 of the 67 patients gave histories of facial paralysis, or had facial paralysis at the time of examination, would indicate a common cause for the recurring swelling and the paralysis.

Suggestions concerning the causative factors of this condition are purely theoretical. Just what produces the increased amount of lymph in the part is indeterminate. One must consider (1) a disturbance of trophic, vasomotor, or motor nerves; (2) alteration in the metabolism or state of nutrition of the tissues, changing the power of the cell to attract, give off or retain fluid; (3) some chemical disturbance in the cell, of a complicated nature, that changes the fluid balance, and (4) a possible so-called vital secretory activity of the endothelial cells.

TREATMENT. Treatment of this condition has consisted of injection of boiling water into the involved parts, and irradiation externally over the face. The patient is anesthetized with nitrous oxide, and the face is then covered with a thick coating of petrolatum, so that any drops of boiling water which fall cannot burn the skin. A metal syringe is used, and a few cubic centimeters of the boiling water are injected into many portions of the involved region. Boiling water is not used about the skin of the nose or the eyelids. This treatment causes considerable local reaction, so that the following day the part is markedly swollen. In a few days the swelling begins to reduce, and gradually clears. Treatment with radium is given over the involved region, using 3000 to 4000 mg. hours with 2 mm. of lead and 1 inch of wood screening. The patient is then allowed to return home, and is instructed to come back in three months for observation.

In some cases one treatment accomplished a great deal in pre-

venting recurrence of the swelling, but in others four or five treatments were necessary. When there is no tendency to recurrence of the swelling for a period of six months, then the superfluous tissue of the lips or cheeks may be excised, in order to shape up the part to its original size. We have seen patients who have undergone excision of tissue without the tendency of the condition to recur being stopped before operation; permanent enlargement of the parts has been much greater than before operation was performed. It is essential to eliminate the recurring swelling before attempting operation. Just how the treatment stops the swelling is indeterminate. It may be that production of fibrosis in the lymph structures or change in the cells themselves prevents swelling of the tissues. The results of treatment have been satisfactory.

BIBLIOGRAPHY

1. Melkersson, E.: A Case of Recurrent Facial Paralysis with Angioneurotic Edema, *Hygiea*, 1928, **90**, 737.
2. Quinke, H.: Über akutes umschriebenes Hautödem, *Monatschr. f. prakt. Dermatol.*, 1882, **1**, 129.
3. Rosenthal, Curt: Gemeinsames Auftreten von (rezidivierender familiärer) Facialislähmung, angioneurotischem Gesichtsoedem und Lingua plicata in Arthritismus-Familien, *Ztschr. f. d. ges. Neurol. u. Psychiat.*, 1931, **131**, 475.

DISCUSSION

DR. JOSEPH C. BECK, Chicago, Ill.:

I have seen 3 of these cases. I saw 1 of them here again, among the collection of these cases shown by Dr. New in which the facial paralysis was present. In 2 of the 3 cases that I had, there was facial paralysis, and 1 of these had a bilateral facial paralysis. All 3 cases recovered with a considerable thickening of the swollen tissues or from the treatment. The differential diagnosis was brought out by Dr. New, and he said this is a pathologic entity because there are two distinct changes present, namely, in the alveolar tissue and the presence of facial paralysis. Professor Wyeth, of Philadelphia, years ago, in connection with true angioma and lymphangioma in which boiling water was first used, had made some studies as to whether the changes were due to the use of boiling water or not.

The interesting point to me particularly is the facial paralysis in these cases. Perhaps Dr. New has made observation in the other

departments connected with his clinic in regard to whether this is a peripheral facial paralysis or of that portion of the facial nerve located within the middle ear.

In 2 of the 3 cases I have observed in which paralysis was present, the function of audition was absolutely normal. In this one case of bilateral facial paralysis and swelling of the upper lip, this condition occurred during measles. Within the course of the disease and abatement of the eruption, this swelling of the upper lid and facial paralysis appeared. A quick recovery took place. I employed large doses of calcium lactate and whether that had anything to do with the course I do not know.

DR. THOMAS H. HALSTED, Syracuse, N. Y.:

I presented in 1907, at the meeting of the American Laryngological, Rhinological and Otological Society in New York, a young woman about thirty years of age, with infiltration of the soft palate and larynx, and it created a good deal of interest at the time, being examined by Professor Killian of Freiburg, Germany, who was the guest of the Society and many local members.

Dr. Killian did not hazard a definite diagnosis but inclined to the view that it was syphilitic. Dr. Prince Morrow, an eminent dermatologist and syphilologist of New York City also examined her. The following year, 1908, I again reported the case, before the same Society. This time as a "Case of Probable Persistent Angioneurotic Edema of the Larynx and Soft Palate," and it will be found in the *Transactions* of that Society for 1908.

The patient had this edema covering a period of about five years in that the infiltration was pale and leathery, without pain or dyspnea, excepting at times there was slight difficulty in breathing. In the face there were five or six attacks of what looked like erysipelas but which did not terminate as erysipelas does, and I, together with different physicians who saw her, came to the conclusion that this disease was an angioneurotic edema as was the case of the soft palate and larynx.

DR. J. GORDON WILSON, Chicago, Ill.:

This paper of Dr. New's well illustrates that rare form of facial disfigurement called by various names (chronic edema, elephantoid hypertrophy, etc.). In my experience it is a malady more likely to come to the attention of the dermatologist than of the rhinologist.

I can recall 4 cases of such persistent solid edema of the face; however, none was associated with facial paralysis, but otherwise

each presented the same clinical history and appearance. Of one of these I show a photograph, a typical picture. You will note that the solid edema is symmetrical, confined to the upper and lower lips, though extending slightly on to the cheeks on both sides. The origin of it the patient traced to a redness and swelling in this locality which appeared several years previously and which was considered to be erysipelas. There were repeated attacks of the swelling without any obvious cause, not accompanied by redness, leading to the gradual increase and great disfigurement.

Another case in the same position was that of a farm laborer in which a swelling appeared without apparent cause (exposure to wind?) over three years before I saw him. While under observation there were exacerbations with no marked redness in which the increased swelling, which occurred at that time, would only partly subside. The third case appeared as a swelling of the cheeks on each side of the nose, not involving the eyes. There were exacerbations at irregular intervals without obvious cause, leaving a marked disfigurement. A fourth case involved the lower lids, less marked but otherwise comparable to the one shown by Dr. New.

Chronic edema was clearly described by Sir Jonathan Hutchinson in 1883 (Jonathan Hutchinson: "On Certain Diseases Allied to Erysipelas," *Medical Journal and Gazette*, 1883, 1, 4; also "Solid and Persisting Edema of Face," *The Illustrated Medical News*, October, 1888, p. 82). One at least of his photographs (swelling of lower lids) is an exact reduplication of that shown by Dr. New. Mr. Hutchinson says, "Of this malady I have seen many examples, and in both sexes. The history is always nearly the same. At some former period, perhaps years ago, an attack occurred which was called erysipelas, and which was attended by sharp illness, and all the usual conditions of the idiopathic form. The swelling on the first occasion probably showed a tendency to spread. . . . Subsequent attacks very probably have not been attended by any tendency to spread. . . . After each successive attack the edema subsides only imperfectly." He defines erysipelas as "a special form of inflammation of lymphatic spaces, attended with much edema and of very transitory duration."

Confining oneself to laryngological literature one finds that Dr. James Adams (*British Medical Journal*, 1909, vol. ii) described 2 cases and the treatment he found satisfactory, laying emphasis on a peripheral lesion as the cause. Dr. Herbert Tilley (*Journal of Laryngology, Rhinology and Otology*, 1907, 22, 60) showed a case before the Laryngological Society in London. In the discussion it was apparent that

several of the members had seen similar cases and various opinions were expressed regarding the etiology. While one may hesitate to accept the facial paralysis as more than a coincidence, one has no hesitation in saying that the results of treatment at The Mayo Clinic appear most satisfactory.

DR. WILLIAM B. CHAMBERLIN, Cleveland, Ohio:

I would like to ask Dr. New if the sections of tissue he removed showed anything characteristic at all.

DR. NEW (in closing):

I appreciate very much the discussion, as it has tended to bring out a great deal in the differentiated diagnosis. I think we must differentiate clearly between the group of inflammatory conditions, the group secondary to erysipelas or lymphangitis and the group I have described. The group Sir Hutchinson reported are secondary to lymphangitis and erysipelas, and facial palsy is not present in any of them. Our cases come on like angioneurotic edema, sometimes lasting only an hour or two and completely disappearing. It is difficult to see how one could confuse this with lymphangitis or erysipelas.

The differential diagnosis of those groups is very important because the treatment is just as different. The results of the treatment of the group I am talking about have been satisfactory, due to the hot water injection, the radiation and excision, whereas the results with the erysipelas and lymphangitis group have not been satisfactory.

Dr. Beck's cases, with 2 patients with facial paralysis in 3 cases, is interesting because it is a very high average.

The case Dr. Halsted reported is of this group, coming on like angioneurotic edema. These patients have no fever, the thing may last only an hour or two, and it is difficult to think how erysipelas could act that way.

Regarding Dr. Chamberlin's question, the tissue showed nothing except lymph in between the cells, nothing suggesting anything of an inflammatory condition in any of the cases.

SOME CLINICAL OBSERVATIONS ON NASAL HEMORRHAGE

DUNBAR ROY, M.D.

NASAL hemorrhage is not a myth. In the active practice of the rhinologist, it is one of the frequent and by no means trivial occurrences in his routine work. It seems absurd to present a paper before this Association on such a trite subject, and yet to the older men in the practice of rhinology the writer knows of no subject which has brought more disturbing memories than the many hours in their past clinical life which were spent in attempting to relieve a patient suffering from nasal hemorrhage. Like Banquo's ghost, a severe epistaxis frequently occurs during the dreamy hours of night, when man's slumber should not be disturbed by such a rude awakening as a call to stop a severe nasal hemorrhage. But all of us have had our troubles, and it is just the commonplace things in life which give us the most concern.

Several years ago, the writer reported a case of uncontrollable nasal hemorrhage followed by death as the result of an intranasal ethmoidectomy, where the many sleepless hours engendered through our attempts to relieve this condition brought more than one wrinkled furrow to a once placid countenance.

A complete clinical and bibliographical discussion of this subject is beyond the scope of my paper, but the writer wishes to call attention to a very satisfactory and simple procedure which he has used for years in the relief of the ordinary spontaneous nasal hemorrhages and especially those arising from the anterior part of the nasal septum.

Traumatic nasal hemorrhages and such as follow intranasal operations are not as a rule difficult to manage, because we anticipate that such may occur, and we take precaution to tampon the bleeding area. Even then, in a subject having a tendency to bleed, the oozing which sometimes follows is often quite difficult to control.

The other class of nasal hemorrhages which give us the most trouble are those which occur in elderly people where the presence of an arteriosclerosis is a contributing and exciting cause for this

condition. How frequently one hears it said that a nasal hemorrhage in this class of people probably saved them from an intracranial hemorrhage, and for that reason it was probably a life-saver for that individual. However, this is a small comfort to the rhinologist who is called in to stop the hemorrhage and whose ability to accomplish the necessary results is taxed to its utmost. Packing of the nasal cavities in these cases is a hazardous procedure. Hazardous, not in the actual packing, but the troublesome hemorrhage when the packing is removed. This occurs in spite of the packing being saturated with some oleaginous material. Hemorrhage in these cases arrested without any packing is a far more desirable procedure.

In the writer's experience, the majority of nasal hemorrhages in elderly people and those with arteriosclerosis arise from the neighborhood of the middle turbinate and the attic of the nose. Rest in bed, especially where hypertension is present, is absolutely necessary in these cases. Temporary adrenalin packs and a spray of the same solution, together with horse serum or even the intravenous injection of the patient's own blood has, in the writer's experience, proved to be the best line of procedure. Such cases must necessarily be under the strict supervision of the internist.

At the International Congress of Otolaryngology, held in Copenhagen in 1929, a very practical article was presented by Dr. Aspisoff, of Tiflis, in which he described his operation for the cure of nasal hemorrhage when the same occurred at the usual bleeding point on the anterior end of the nasal septum. His procedure was as follows:

After cocainizing and adrenalizing the nasal mucous membrane, an oval incision about 1 cm. from the bleeding point is made posterior and above, down to the cartilage, in order to cut through the bleeding vessels. The bleeding surface is now covered with a sterile gauze tampon, saturated with peroxide of hydrogen and allowed to remain for twenty-four hours. After healing, there remains a fine, hardly perceptible scar at the point of incision, while the bloodvessels below gradually shrink and disappear. The bleeding disappears immediately, and remains permanent.

Aspisoff has used this method for many years with unusually good results. The present writer has tried this method in a few cases, but cannot say that it has been universally successful.

According to Aspisoff, two-thirds of the cases of nasal bleeding occurred from the anterior part of the nasal septum, 10 per cent from the floor of the nose and 15 per cent from the posterior part of the nasal cavities. I am entirely in accord with this writer when he says that the most difficult cases of epistaxis to manage are those occurring in elderly people with arteriosclerosis. Nasal packing in these cases is to be avoided if possible on account of recurrent bleeding when the packing is removed. Every abrasion will start a new point of bleeding. Long nasal packing is apt to produce infection which may extend to the sinuses or middle ear.

Any simple procedure is certainly to be welcomed, especially if it is efficacious.

A number of French and German rhinologists have reported good results from the use of electrocoagulation in all kinds of nasal hemorrhage. The writer has also used this method. My objection to it is the fact that the cartilage is frequently injured and is sometimes followed by scabs and even perforation.

In 1902 Dr. Charles H. Cargyle, in conjunction with Johnson & Johnson, and with the aid also of Dr. Robert T. Morris, of New York, and Dr. John B. Deaver, of Philadelphia, succeeded in producing an animal membrane which has since been known as the Cargyle membrane.

The membrane finally selected was made from the peritoneum of the ox. This membrane is sterilized and placed in hermetically sealed envelopes. It was found that this membrane, placed in contact with the tissue surface, became adherent at once upon an abraded surface. It was not easily displaced, forming a protective that would prevent adhesions and itself be absorbed in a varying course of time. Consequently, it has been used in intestinal operations, skin grafting, burns and to considerable extent in brain surgery.

Six years ago, the writer started the use of this membrane in those cases of denuded membrane with scabs so often seen on the anterior portion of the septum, and from which the large majority of nasal hemorrhages occur.

The method of using this membrane in such cases is as follows: After controlling the bleeding by tampons of adrenalin or peroxide of hydrogen, the point or points of bleeding are touched with a 4 per cent solution of nitrate of silver. Over this is spread a layer

of Cargyle animal membrane just large enough to cover this area. The membrane will adhere perfectly to the septum surface, and if not, flexible collodion can be used. The patient is told not to blow the nose for twenty-four hours. At the end of this time, if the membrane is loose or has disappeared, another layer is put in the same position. This must be repeated perhaps several times.

In addition to the use of this membrane in those cases of hemorrhage from the septum where there is no perforation, the writer has found its use most valuable in those cases which are sometimes seen accompanied by large perforation of the septum and considerable scabbing and bleeding from the exposed edges. We mean, of course, in those cases where the perforations are large and where it is almost impossible to rectify the same by surgery. It is here that the membrane can cover the edges and obtain comfort for the patient where all other methods have failed. The same procedure is adopted as one uses it in the milder forms of bleeding, thus preventing a further disintegration of the cartilaginous septum. Just what is the biochemical action of the Cargyle membrane in these cases is difficult to say, but certain it is that it aids very materially in the regeneration of the matrix cells, both in the mucous membrane and the cartilage itself. In all of my cases there has been no return of the bleeding, and this has extended over a period of several years.

In other portions of the nasal cavity, the same procedure can be used with the exception that it is more difficult to place the animal membrane over surfaces which are not quite so accessible. However, tampons can be made of the same membrane and used just as readily as any other material. In those cases of hemorrhage due to arteriosclerosis, these membranes are far superior to other packings in that one need never be concerned about their removal. Hurd, of New York, is a strong advocate of placing strips of fat pork in the nasal cavities for arresting any intractable hemorrhage in that region. However, in a few cases of mine where it was used, the results were not so satisfactory as one might desire.

In hemorrhage from the posterior portion of the nasal cavity, where it is impossible to see the bleeding points, we must resort to the postnasal tampon to obtain immediate results. In addition, however, the animal membrane placed as a tampon more anteriorly is a most excellent adjuvant.

DISCUSSION

DR. JAMES A. BABBITT, Philadelphia, Pa.:

I am very much interested in this presentation of Dr. Roy. Most of us who have little bleeding think it inconsequential, but when the uncontrollable bleeding comes appreciate its seriousness.

I have had two serious bleeding cases in the postnasal region. In one, after working one full night and parts of several days, finally controlled the bleeding by using strips of vaselined packing in which was rubbed Squibb's alum powder—not a very pleasant sort of thing to use. The other was not stopped until a surgeon tied off the external carotid.

Some years ago in Cincinnati and again by Dr. Green of Asheville, we were taught the idea of using the tonsil itself as a hemostat after tonsillectomy. After varied changes we are still using this. There is at least sufficient hemorrhage control to leave a favorable impression.

During this past winter we had a nasal hemorrhage case in an old man with a varied general pathology, who bled almost continuously for six days and from both sides of the nose. He was packed first in the dispensary and then sent in to the ward to us, continuously bleeding. We packed and repacked anteriorly and posteriorly and even pressures of the ligatures passing through the nose to the post-nasal pack caused fresh bleeding. We have seldom seen a man bleed so much, and yet it did not seem to affect him seriously. He even returned three months later with a brief repetition of the bleeding.

Observation of this case leads to the thought that perhaps we overestimate the actual amount of bleeding when it comes from an area which is so exposed and open.

May I suggest a point about the control of nasal ulcerations in the anterior part of the nasal septum? Dr. Randall once taught us the valuable use of 25 per cent trichloroacetic in the nose. Its reaction is less painful and less prolonged than that of silver nitrate. A 25 per cent solution of trichloroacetic hurts for two or three minutes and then it is over. The silver nitrate would pain for several hours. Dr. Randall called attention to the fact that the after-result of the trichloroacetic was to leave a stimulated healing surface and silver a more eroded one.

Dr. Roy's method is very unique and we shall try it. Did I understand him to say that he used collodion to make it adhere? In presence of moisture, I find its adhering qualities impaired.

DR. ROY: The collodion will stick perfectly.

DR. HENRY L. SWAIN, New Haven, Conn.:

After such picturesque cases, I, with some temerity, rise. These are frequent cases and we all have our own way of dealing with them. The invariable rule with us is to spray them out, when they come in, with cocain and adrenalin, directing the spray in front on the septum. I have a hand atomizer on the desk all the time, ready for emergency. Then, if bleeding is still active, put a small wisp of cotton dipped in adrenalin, and lay it on the bleeding area. In the majority of cases so treated, bleeding has readily stopped. In my own individual practice, as the bleeding usually comes from the anterior part of the septum, I take a welt of cotton, light as possible, dipped in a solution of ferropyrin, having it rest on the spot indicated by bleeding or plainly visible varices. When it is taken off the region is covered with adrenalin ointment, and a lightly placed bit of cotton inserted just to keep air from going into the nose until the patient gets home. The patient is told to lie with his head high at night, and to do nothing which sends blood to his head.

The majority of those patients do not come back. You have them cured if they will keep their fingers off that area in cleansing the nose for a period of time, every morning, noon and night, will cover the surface with adrenalin ointment. First, the greasy substance prevents the accumulation of mucus on the area; second, the thing is healing; third, the action of the adrenalin, ever-present in the nose all the time the ointment is there, tends to keep the bloodvessels contracted.

I suppose that has been the invariable first treatment of all cases when they come in, for the last twenty years, and I think it is an effective way of taking care of them if only the patient will learn to keep the fingers or the handkerchief out of contact with the bleeding area. I have had physicians themselves, seated in the chair, press the wing of the nose in against the bleeding area. There is a scab formed there which is moved, and that starts the bleeding the next time they stoop over to tie their shoestring or they wake in the night after deep sleep.

I am quite sure that this exceedingly simple method has been helpful to me and I hope it will be to someone else.

DR. E. ROSS FAULKNER, New York City:

Any suggestion to help us out in this troublesome phenomenon is always very welcome. I have never heard of this method Dr. Roy has spoken about this afternoon.

I remember a friend of mine told me that, at a casualty station during

the war, they always took a little piece of muscle and found it the best hemostat they could get. It probably acts the same as the animal membrane. I have never tried the method suggested here but I would be glad to try it in the future.

The harrowing experience most of us have had with nasal hemorrhage is the thing that has done more to make us grow old in the practice of medicine than anything else. I think I have had more than my share, and the worst ones I have ever seen have come from the antrum operation through the inferior meatus. I have never been certain what vessels it came from.

In certain dissections at one time, we thought it might be the posterior palatine, but in the serious cases I have had of that kind, it was not. They are usually secondary hemorrhages and the blood clot is released every fourth or fifth day. The secondary hemorrhages are in infected noses and your packing cannot be left in very long without serious danger to your patient. An ordinary vaseline gauze packing is not satisfactory. You may control your bleeding with it but you cannot leave it in beyond twenty-four hours without some danger.

This thing occurred to me in a serious case of hemorrhage. Recurrence came every day as soon as I took out the packing. I was transfusing her every other day to make up the loss of blood. I decided to use the old solution of castor oil and balsam of Peru and I have used it ever since. I take ordinary vaseline gauze and dip it in the solution and wipe off the excess. It will pack tighter than any vaseline gauze and control the bleeding much better. You can leave it in there two days with absolute impunity and with no odor or much discomfort to the patient.

I was talking to a pathologist about this and he said there was nothing that would destroy parasitic germs like castor oil. In using a postnasal plug, soak it in a 25 per cent solution of castor oil and balsam of Peru and it makes it nice and soft; you can then pack that in so tight that you can stop Niagara Falls with it. If you can keep your patient comfortable you can leave it in there forty-eight hours and not likely get any recurrence of bleeding when you take it out.

I would like to speak of a case I had a year ago last June. I was called to New London one night last spring to see a terrific hemorrhage; they had been working on him for hours—a man aged about sixty years, with blood-pressure over 200, bleeding all day and no form of packing they used would completely control it. The bleeding came from the anterior palatine and I could not stop it without using

strong pressure with my thumb back of the incisor teeth and then packing on it. Without the pressure of your thumb, you could put the packing in and watch the pulsation gradually lift it. Holding it awhile, I could completely control it and it would stay controlled for an hour. I worked from 6 to 12 o'clock and the case was getting more and more desperate with no prospect of controlling it by packing alone, so we decided to tie his external carotid. Thinking discretion the better part of valor, as I was quite exhausted, I did not attempt to tie the carotid myself. I called in a general surgeon to do the operation, and after that he was all right and made a good recovery.

DR. ROY (in closing):

The object of the paper was not in reference to traumatic hemorrhages or hemorrhages of posterior packings, but those 8 or 9 cases where there is a little scabbing on the anterior part of the septum. Those are the cases that come in frequently and are quite annoying. I used to use the galvanocautery and desiccation by means of an electric spark. I tried all of those things. The great trouble with those is, when you have a scabby condition and you use those remedies, they not only destroy the vessels but they frequently destroy the cartilage, and you have continued scabby condition which adds more to the trouble than what you originally had.

My idea was to get away from all that and see if I could not remedy that scabby condition we all see just inside of the nose, and that I have accomplished by means of the animal membrane by simply cleaning it off and getting all the scabby conditions eliminated, smoothing it out and putting a graft of that membrane right over it. It sticks perfectly and the mucus on the mucous surface sticks. Rarely do I use collodion. It stays in there for twenty-four to forty-eight hours. I tell the patient not to blow his nose. If there should be the slightest bit of raw surface I put it in again. I have been wonderfully pleased with the results from putting this membrane over the bleeding surfaces in those simple cases of chronic nosebleed and those cases of perforation of the septum where there is a large perforation you cannot close. The patient bleeds, scab forms and a great amount of discomfort is experienced by the patient. If you will cleanse all of that surface off and take small particles, like a skin graft, and lay them over the edge, you will get results. Just what the biochemical action is, I do not know. Certainly there is some action by which there seems to be a regeneration of the cells and the relief of the patient. In my hands, it is far better than anything I have ever tried.

MUCOCELE AS A CAUSE OF PROPTOSIS

REPORT OF SIX CASES

WILLIAM B. CHAMBERLIN, M.D.

AND

THAYER L. PARRY, M.D.

(From the Division of Otolaryngology of the Department of Surgery, Lakeside Hospital, Western Reserve University)

As Vail¹ has pointed out, Rollet in 1896 first suggested the term "mucocoele" as applicable to a condition in which there is an accumulation of and a retention within a sinus of a mucoid secretion owing to a continuous or periodic closure of its ostium. As a result, there is a gradual thinning, distention or actual erosion of one or more of the sinus walls.

In 1921, Dabney² collected 74 reported cases of mucocoele of the accessory sinuses of the nose. Since then, Thomson and McIlraith³ reported a case of mucocoele of the frontal sinus in 1923. This was followed by Garretson's⁴ case in 1927, Heatly's⁵ 2 cases in 1928 and Vail's⁶ case in 1930.

Occlusion of the ostium from chronic inflammatory changes within the sinus or from pressure of a tumor, such as an osteoma, constitute the main etiological factors, although trauma, as in cases reported by Howarth⁷ and Garretson, may be a factor.

The main clinical features are illustrated by the following 6 cases which have been treated at Lakeside Hospital during the past seven years:

CASE I.—J. B., a man aged thirty-eight years, came to the eye clinic July 6, 1932, complaining of a swelling above the left eye, which had displaced his eye. Following a head cold in November, 1931, he had noted a non-tender swelling at the inner portion of the left upper lid which had displaced his eye slightly. There was no increase in the size of the swelling and he was free from symptoms until June 1, 1932, when, following another head cold, the swelling increased and the eye became more markedly displaced. He had blurring of

vision in the left eye and excessive tearing. At varying periods of time he had dull pain in the region of the left eye. The past history was negative except for intermittent colds.

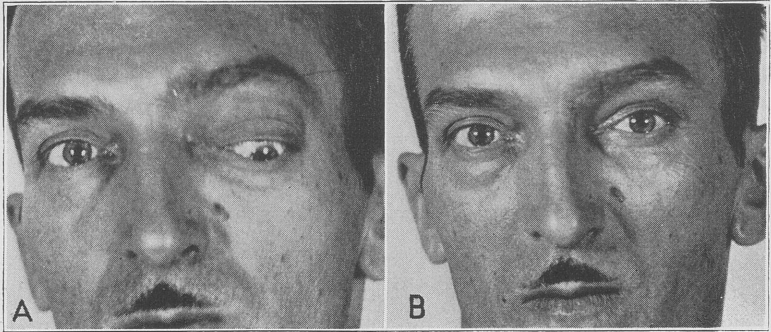


FIG. 1.—Case I. A, appearance before operation, showing the typical displacement of the eyeball; B, appearance after operation.

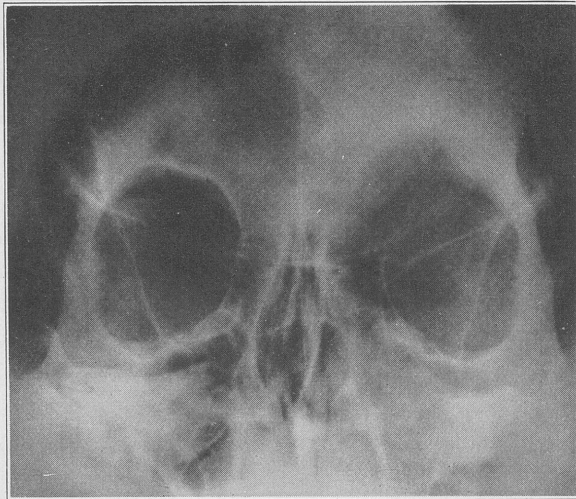


FIG. 2.—Case I. Roentgenogram of the mucocoele of the left frontal sinus, showing cloudiness and erosion of the floor of the sinus.

Examination by Dr. M. Paul Motto was as follows: V.O.D., 6/6; V.O.S., 6/60. There was marked swelling and ptosis of the left upper

lid and forward, downward and outward displacement of the left eye. There was limitation of motion of the internal, superior and external recti muscles. A moderately firm, fluctuant, slightly movable mass was seen, downward and outward from the inner and upper orbital margin. The mass was only slightly tender. There was some engorgement of the vessels and hyperemia of the left disk. The patient was referred to the otolaryngological service, where examination revealed some mucopurulent discharge in the left middle meatus and hypertrophy of the left middle turbinal. The white blood cells were 12,400, of which 78 per cent were polymorphonuclear cells. A roentgen-ray examination showed destruction of the roof of the left orbit and a cloudiness of the left frontal, ethmoid and maxillary sinuses.

A left external frontal operation was performed July 15, 1932, by T. L. Parry. A soft, fluctuant tumor mass was found extending through the necrotic floor of the frontal sinus into the upper and inner part of the orbit. Aspiration gave a thick, tenacious, mucopurulent material, culture of which showed *staphylococcus albus*. The walls of the cyst were thick and were continuous with the sinus mucosa, which showed moderate uniform thickening. The cyst, together with the sinus mucosa, was removed. The remaining necrotic bone was removed and a large opening made into the nasal cavity, through which a heavy rubber drainage tube was placed. The periosteum and skin were closed tightly. The drainage tube was removed on the third postoperative day and the patient discharged on the sixth. There was a rapid disappearance of the swelling following operation. Examination on August 25, 1932, by Dr. Motto, showed the eye to be back to its normal position. He no longer had blurring of vision or epiphora and the muscle actions were normal.

CASE II.—F. D., a man aged thirty-two years, came to the eye department of the Lakeside Outpatient Department on April 20, 1932, complaining of a swelling in the region of the right upper eyelid, which had begun one year previously and gradually increased in size, thereby displacing the right eye. He had had neither pain nor visual disturbance. The past history was not remarkable.

Examination by M. Paul Motto was as follows: V.O.D., 6/75; V.O.S., 6/6. Muscle movements were normal. There was a moderately firm, nontender, fluctuant mass arising from the region of the roof of the orbit, which had displaced the eyeball outward, forward and downward. The conjunctiva and fundus were normal. The exophthalmometer reading was O.D., 22 min.; O.S., 15 min. The patient was referred to the department of otolaryngology, where nasal

examination revealed no obstruction or discharge. A roentgen-ray examination showed destruction of the upper orbital margin and definite depression of the orbital roof. The white blood count was 8100.

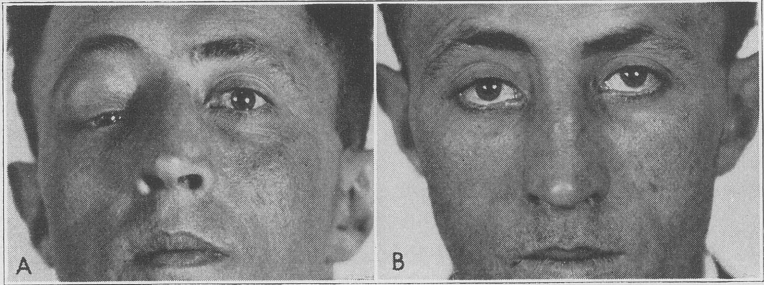


FIG. 3.—Case II. *A*, appearance before operation, showing the typical prolapse of the eyeball; *B*, appearance after operation.

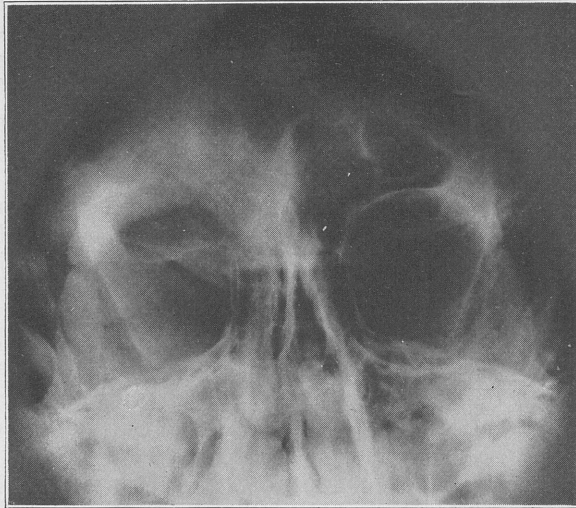


FIG. 4.—Case II. Roentgenogram of the mucocoele of the right frontal sinus, showing cloudiness and erosion of the floor of the frontal sinus on the right.

Operation was advised. This was at first refused but later accepted, and on June 3, 1932, a right external front operation was performed

by T. L. Parry. The inner part of the floor of the frontal sinus was found to be necrotic and a soft, fluctuant mass seen arising from within the sinus and extending into the upper part of the orbit. The mass contained a thick, tenacious, viscid, brownish fluid, which yielded staphylococcus albus upon culture. The walls of the cyst were thick and were continuous with the sinus mucosa, which was somewhat thinner. The cyst, sinus mucosa and necrotic bone were removed and a large opening made into the nasal cavity. Cigarette drains were passed from the frontal sinus into the nasal cavity and the periosteum and skin closed tightly. The patient was discharged on the sixth postoperative day.

There was a rapid disappearance of the swelling following operation and when the patient was discharged from the Outpatient Department on September 27, 1932, the eye had returned to its normal position.

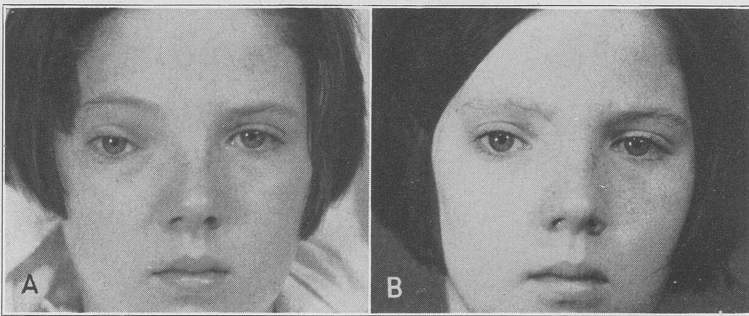

FIG. 5.—Case III. A, appearance before operation, showing mucocoele of the right frontal and ethmoid sinuses, with typical widening of the nasal dorsum opposite the inner canthus; B, appearance after operation.

CASE III.—M. N., a girl, aged twelve years, was admitted to the hospital June 22, 1930, complaining of a swelling above the right eye. This was accompanied by displacement of the eye, as well as excessive tearing. The swelling had first appeared following scarlatina nine years previously and had gradually increased in size. There had been no pain or visual disturbance.

Examination of the right eye revealed some limitation of motion upward, as well as displacement outward, downward and slightly forward by a nonmovable, nontender, fluctuant mass above the inner canthus. Nasal examination revealed a marked increase in size of the right middle turbinal. Roentgen-ray examination showed

destruction of the upper border of the right orbit and an increase in size of the right frontal and ethmoid regions, accompanied by increased density.

An external frontal operation was performed by W. B. Chamberlin, and a large mucocele involving the frontal and ethmoid sinuses found. This had eroded the orbital plate of the frontal bone. The mucocele was removed and a large opening made into the nasal cavity. Culture of the material in the mucocele gave no growth. The patient was discharged on the tenth postoperative day.

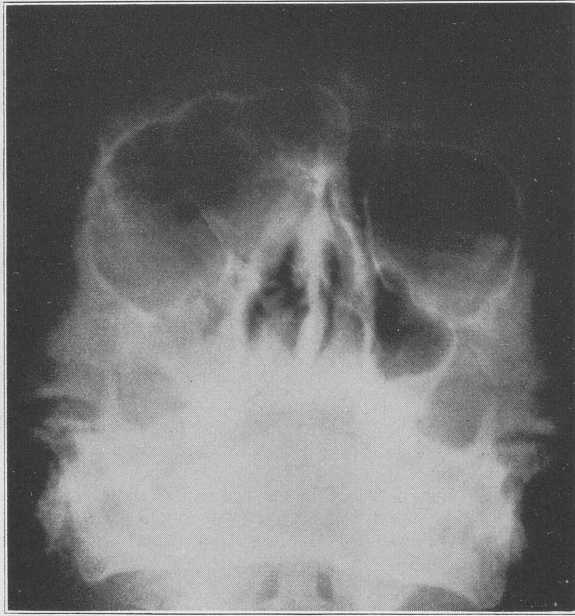


FIG. 6.—Case III. Roentgenogram showing cloudiness of the right frontal and ethmoid sinuses, with dehiscence of the floor of the frontal sinus.

The swelling disappeared rapidly and when last seen on October 20, 1930, the eye had practically returned to its normal position and function. There remained but slight widening between the bridge of the nose and the right internal canthus.

CASE IV.—G. M., a colored female, aged forty-three years, came to the eye clinic February 5, 1927, complaining of an injury to the left

eye and left side of her forehead as the result of a fall six weeks previously. She admitted, however, that she had first noticed that the left eye was more prominent than the right one year previous to the injury. The displacement of the eye had gradually become more marked since the injury and she had had sharp and more or less continuous pain in the region of the left eye. There was no nasal discharge and no visual disturbance.

Examination showed the left eye to be displaced downward, forward and outward. Muscle movements were slightly limited in all directions. The vision was O.D., 6/6-2; O.S., 6/6-4. The left pupil was also smaller than the right. A soft, fluctuant nontender mass extended beneath the entire upper orbital margin. Roentgen-ray examination showed destruction of the entire orbital roof.

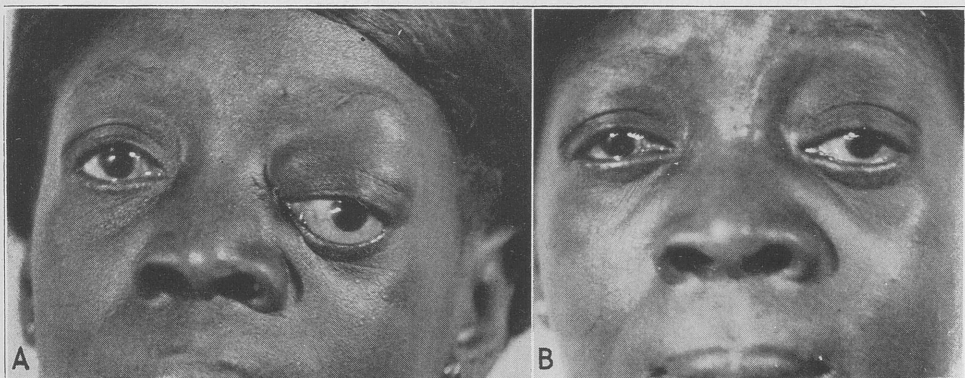


FIG. 7.—Case IV. *A*, mucocoele of the left frontal sinus before operation, showing the typical and marked displacement of the eyeball; *B*, after operation.

A left external frontal operation was performed by I. F. Weidlein, and a large mucocoele was found, which had eroded the floor of the frontal sinus. The same procedure was carried out as described in the previous cases. The patient was discharged on the seventh postoperative day.

The swelling rapidly subsided and examination on April 7, 1927, showed that the eye had returned to its normal position and normal mobility.

CASE V.—J. W., a male, aged thirty-two years, came to the eye clinic on October 11, 1926, giving a history of his left eye having been displaced by a swelling above it. He had first noticed this

nine months before admission. The swelling had gradually increased since that time and had seemed to increase more rapidly with each successive cold.

Examination showed the left eye to be displaced outward and forward. The muscle movements were normal, as were both fundi. Vision was O.D. 6/7.5; O.S., 6/7.5. He had no diplopia. There was a small tumor mass presenting above the inner canthus of the left eye. Nasal examination was negative except for a left deviation of the septum. Roentgen-ray examination showed an area of increased density about the left frontal sinus, as well as a cloudiness of the left ethmoid and maxillary sinuses.

A left external frontal operation was performed by I. F. Weidlein, and a large mucocele of the frontal sinus uncovered. This had eroded the internal and superior orbital walls. The mucocele and necrotic bone were removed and an opening made into the nasal cavity. The patient was discharged on the fifth postoperative day.

The swelling diminished and the displacement of the eye became less, but the patient did not return as requested, so that the final result was not noted.

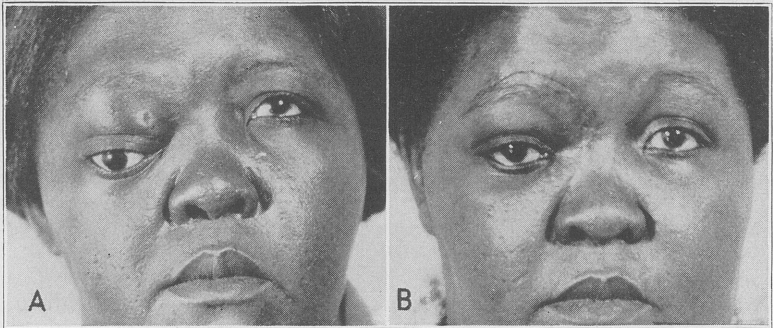


FIG. 8.—Case VI. A, the appearance before operation, showing the tumor and marked displacement of the eyeball; B, after operation, showing the return of the eyeball to a seminormal position.

CASE VI.—M. K., a colored female, aged thirty-eight years, came to the eye clinic on July 28, 1925 because of a swelling above the right eye which had caused displacement of the eyeball. She had first noticed this swelling five years previously. Since that time the swelling had gradually increased in size and had displaced the eye to a more marked degree. At times she had dull pains in the right orbital

region. Previous to the onset she had a continuous nasal discharge but had noted none since then.

Examination showed a soft, fluctuant swelling above the right eye, which had displaced the eyeball outward, forward and downward. There was slight tenderness but no evidence of acute inflammation. The eye movements were limited in the upward and inward directions. Exophthalmometer reading was O.D., 29; O.S., 20. The fundi were normal. There was no discharge in the nose. A diagnostic aspiration showed the contents to consist of a thick, tenacious, mucoid material. Vision was O.D., 6/30-1; O.S., 6/6-1. Roentgen ray examination revealed destruction of the supraorbital bony margin.

A right external frontal operation was performed by W. B. Chamberlin, and a large mucocoele, which had eroded the orbital plate of the frontal bone, disclosed. The mucocoele and necrotic bone were removed and an opening made into the nasal cavity. The patient was discharged on the thirteenth day.

Two months after operation there was a complete return of the eye to its normal position and vision was O.D., 6/9; O.S., 6/6-1. Following this, the patient had an acute head cold and began to have pain and slight swelling above the right eye. Nasal examination showed the presence of granulations in the region of the opening into the frontal sinus and a purulent discharge in the right middle meatus. She refused any intranasal operation and the swelling subsided under local treatment.

By suitable correction with glasses following refraction on November 3, 1925, the vision was brought to O.D., 6/6-1 and O.S., 6/5.

COMMENT. An analysis of the cases will show that these patients usually come first to the eye clinic on account of the displacement of the eye. This displacement is the result of pressure from the mucocoele which has eroded through the orbital roof. Mucocoele usually occurs during middle adult life but may start early in childhood, as in Case III. The duration of the external swelling varied in the above cases from eight months to nine years, which is indicative of the very slow growth, as well as the characteristic minimal amount of pain accompanying this condition. The eye displacement downward, forward and outward may or may not be accompanied by visual disturbances. Limitation of mobility varies according to the extent of the orbital involvement. The lack of evidence of acute inflammation, the fluctuant character of the mass, the absence of any evidence of secretion or diminution

in size upon compression, together with evidence of bony destruction as shown by roentgen-ray, should help establish the diagnosis.

Dermoid cysts, as a rule, are less freely movable and are congenital. Meningoceles, likewise, are congenital. Furthermore, they are usually found in the midline. The presence of fluctuation and the roentgen-ray appearance help to differentiate mucocoele from osteoma and fibrosarcoma. Aspiration may be used as an additional diagnostic aid, but is seldom necessary. Mucocoeles causing proptosis most often originate in the frontal sinus, but may arise from both the frontal and ethmoid, as in Case III, or from the ethmoid alone. The sphenoid sinus has been the site of origin rarely. Only two such cases have been reported.

So-called mucocoele of the antrum of Highmore in those cases so far reported contained only a thin serous fluid and not the thick, gelatinous and tenacious fluid which is characteristic of mucocoele of the frontal sinuses and ethmoid. The tendency to cystic degeneration in the maxillary sinus makes it probable, in the opinion of Skillern, that the reported cases accordingly are not true mucocoeles but only cysts of the antrum.

The differential diagnosis between mucocoele and pyocoele presents, as a rule, no difficulties. We can conceive, however, of a mucocoele being subject to an acute inflammatory process. Skillern gives the following diagnostic points in the differential diagnosis:

<i>Mucocoele</i>	<i>Pyocoele</i>
Growth extremely slow	Growth rapid
No inflammatory symptoms	Inflammatory symptoms predominate
Tenderness absent	Tenderness marked
Firmness on palpation	Fluctuation
Mild orbital complications	Severe orbital complications
Puncture shows mucoid substance	Puncture shows pus
Secretion sterile	Secretion infected

The absence of conjunctival edema and prolapse might also be added; such a condition was not observed in any of the reported cases. The presence or absence of fever would be an additional point in the differential diagnosis.

The external frontal operation is the treatment of choice in all cases of mucocoele. The operation should include the removal of the tumor mass, together with all sinus mucosa and necrotic bone. Above all, the establishment of a large drainage opening into the nasal cavity is a *sine qua non* if recurrence is to be avoided and

prevented. After the operation there is, as a rule, disappearance of the swelling, with a return of the eye to its normal position. There is also a restoration of the impaired vision and mobility to normal. Subsequent external deformity is limited to that produced by the healing of the surgical incision and is usually inconspicuous. It is a matter of interest that all of the above cases occurred in dispensary cases and none in private practice.

CONCLUSIONS. 1. Displacement of the eyeball downward, outward and forward occurs as a result of erosion of the orbital roof and pressure from a mucocele of the frontal sinus or ethmoid.

2. Symptoms referable to the eye vary according to the extent of the orbital involvement.

3. Treatment should consist of external operation with removal of the mucocele, together with all sinus mucosa and necrotic bone. The establishment of a large opening into the nasal cavity is most important.

4. As a rule, the swelling rapidly disappears after operation and the eye returns to its normal position. Eye symptoms caused by the orbital involvement subside rapidly after the operation.

5. The surgical scar is usually inconspicuous and in these cases practically no external deformity results.

REFERENCES

1. Vail, D. T., Jr.: Orbital Complications in Sinus Disease, *Am. Jour. Ophthalmol.*, 1931, **14**, 202.
2. Dabney, V.: Mucocele of the Nasal Accessory Sinuses: Two Cases of Pansinus Involvement with Recovery After Internal Operations. *New York Med. Jour.*, 1921, **114**, 619.
3. Thomson, St. Clair, and McIlraith, C. H.: Mucocele of the Frontal Sinus, *Jour. Laryngol. and Otol.*, 1923, **38**, 365.
4. Garretson, W. T.: Mucocele of the Frontal Sinus, with the Report of a Case, *Laryngoscope*, 1927, **37**, 350.
5. Heatly, C. A.: Mucocele of the Accessory Nasal Sinuses, *Arch. Otol.*, 1928, **7**, 150.
6. Vail, D. T., Jr.: Proptosis in Sinus Disease, *Ohio State Med. Jour.*, 1930, **26**, 403.
7. Howarth, W. G.: Mucocele and Pyocele of the Nasal Accessory Sinuses, *Lancet*, London, 1921, **2**, 744.
8. Skillern.: Accessory Sinuses of the Nose, 2d ed., pp. 51, 136, 258, 342.
9. Hajek.: *Nebenhoelen der Nase*, 3d ed., pp. 173, 201, 258, 282.
10. Thomson, Sir St. Clair: *Diseases of the Nose and Throat*, 3d ed., pp. 324, 326, 327.
11. Zarniko.: *Krankheiten der Nase*, 2d ed., pp. 618, 628, 671, 696, 697, 707.

DISCUSSION

DR. D. C. SMYTH, Boston, Mass.

As to the necessity of removing of mucocoeles entirely, oftentimes it is impossible to remove the lining, due to the fact that it is sometimes attached to the dura. My results have been good by simply leaving the lining *in situ*, especially in those cases of mucocoeles of the frontal sinus that involve the ethmoid. I like to compare the mucocoele in its shape to the Politzer bag. The bulk of the mass is in the frontal sinus with the neck in the ethmoid. All a mucocoele of this type is waiting for is to have its head knocked off, that is, the part of it which involves the ethmoid. This leaves a perfectly lined nasal duct which cannot be improved upon. Those which involve the ethmoid alone can be removed in the same way by an ethmoid operation. In those cases where we have to open up the frontal sinus I think it better to leave the lining in place, and this practice has worked out well in my cases.

DR. CHAMBERLIN (in closing):

I think Dr. Smyth's point is probably well taken. None of these cases on which we operated, apparently, came in contact with the dura, as the posterior wall of the sinus had not been eroded, so we did not have this problem to face.

CYSTS OF THE LARYNX

MERVIN C. MYERSON, M.D.

CYSTS of the larynx occur less frequently than the literature of thirty or forty years ago would indicate. There is no doubt that polypi of various kinds were included when cysts were considered at that time. One can appreciate this, for even at the present time the classification of benign neoplasms of the larynx is not well understood. Cysts do, however, occur more frequently than text-books and current literature would lead one to believe.

The first cyst of a larynx was encountered by Verneuil²⁶ in the cadaver of an infant, in 1852. Durham⁵ was probably the first to observe a cyst in a living person. In 1863 he operated upon a large cyst which sprang from the laryngeal surface of the epiglottis in a boy, aged eleven years. Gibb⁹ removed a cystic growth from the vocal cord of a patient in the same year. Of 693 laryngeal tumors, which Beschorner² reviewed in 1877, 45 were cystic tumors. The first large series of cysts of the larynx, 117 in number, were collected by Moure¹⁵ in 1881. Ullrich²⁵ included 156 cases in his paper a few years later. Since then there have been several fine articles on this subject, notably those of Salomon,²¹ Glas,¹⁰ Schneider,²² Marx¹³ and New.¹⁶ Instructive case reports and short articles have been written by several laryngologists. Some have seen many, while many others have seen a few.

Cysts of the larynx are of four types: Retention, embryonal or congenital, lymph or blood, traumatic or implantation.

A great majority of the cysts which have been reported are retention cysts. These cysts are formed by the closing off of the duct of a gland so that there is obstruction to the outflow of the glandular contents. A retaining sac is thus created, which forms the cyst. It is the same mechanism which is responsible for the production of salivary and sebaceous cysts. Most retention cysts are to be found in the region of the epiglottis.

Congenital or embryonal cysts are distinguished by the fact that they contain both endodermal and mesodermal structures.

When, however, there is no intermixture of the products of the embryonal layers it is difficult, in fact impossible, to distinguish between a retention and a congenital cyst. A combination of the products of the various germinal layers is seen in tumors laterally placed in the neck, the so-called mixed or teratoid tumors. The first embryonal cyst of the larynx was recorded by Louys. He removed a cyst of the larynx by means of thyrotomy after a preliminary tracheotomy. At operation the cyst, which appeared to be situated upon the right false cord and in the right ventricle, was found to extend upward to the right greater cornu of the hyoid bone with whose periosteum it was found to be firmly united. The outer wall of the cyst contained cell aggregations and islands of cartilage.

It is claimed by Kahler¹² and others that cystic swellings of the epiglottis are due to faulty union of the bilateral anlage of the epiglottis at the point of coalescence of its two segments. Glas believes that cysts form where the columnar epithelium of the respiratory tract meets the squamous epithelium of the digestive tract. New considers this as untenable because the epithelium of both comes from the endoderm. He agrees with Schneider that the embryonic cysts are very likely caused by a pinching off of the appendix of the ventricle. The location, form, size and epithelial lining do not assist in the determination that a cyst is of congenital or embryonal origin. When examination does not reveal mesodermal structure the possibility of it being a retention cyst must be considered.

Lymph or blood cysts are formed by a localized collection of lymph or blood in the subepithelial tissues. This type is caused by a coalescence of lymph spaces in some cases. This type of cyst is extremely rare.

Traumatic or implantation cysts are of relatively infrequent occurrence. These are caused by the implantation of epithelial tissue into the submucous region. Glas, and Dean and Gregg,⁴ encountered such a cyst. The cyst of Dean and Gregg was located in the interarytenoid region. It appeared several weeks after the curettage of a tuberculous larynx.

It is difficult to estimate the relative frequency of the various types of cysts because of the difficulty of differentiating between

the embryonal and retention types. Cysts may have a lining of squamous, cuboidal or columnar epithelium. If the cyst is tense and lasts long the pressure will either flatten the epithelium or may even cause it to disappear, as occurred in one of New's cases.

The age, physical characteristics, symptomatology, diagnosis and treatment are important.

Cysts occur at all periods from birth to old age. Oppikofer¹⁷ reported a cyst of the epiglottis in a patient aged eighty-nine years. They are round or ovoid and may be sessile or pedunculated. Most are sessile in their attachment. Their size varies from a pinhead to a large hen's egg. Very large cysts are not frequently seen, but that of New and of Schousboe²³ were unusual for their size. Schousboe's cyst measured 6 by 3 cm. and filled the left pyriform fossa so as to immobilize that size of the larynx. The smaller cysts are most frequently found on the vocal cords, while the larger ones are most often attached to the epiglottis. They may be very small and cause no symptoms, but they may grow rapidly so that an acute condition or a foreign body would be suspected.

These cysts are thin-walled or thick, soft or firm, fluctuant or solid, and are frequently streaked with small bloodvessels. They contain a fluid that may be thin and serous, or thick and gelatinous or colloidal in nature. Blood has been found in some. These cysts are colorless or translucent, grayish, yellowish, pinkish or light reddish in appearance.

The relative frequency of the various locations of laryngeal cysts have been given as follows:

	Moure	Ullrich
Epiglottis	50	60
Vocal cords	45	50
Ventricle	8	8
Arytenoid	4	8
Aryepiglottic fold	4	
Ventricular band	2	
Not indicated	4	
<i>Epiglottic Cysts—According to Mishkin¹⁴</i>		
Lingual aspect		49
Laryngeal		10
Rim		17

The traumatic cyst reported by Dean and Gregg appears to be the only cyst that was located in the interarytenoid region. Four-

teen of Beschorner's series of 45 laryngeal cysts originated from the epiglottis. A majority spring from the anterior aspect of the epiglottis, while a few originate from the laryngeal side and a still smaller number from the rim of this structure. The vocal cords are next in the order of frequency as the site of origin of these cysts.

SYMPTOMATOLOGY. The symptoms caused by cysts of the larynx bear a direct relation to the location and size of the offending tumor. Hoarseness or change of voice occurs where the perfect approximation of the vocal cords is interfered with. When located on the vocal cord, ventricular band, in the ventricle or the aryepiglottic fold, varying degrees of hoarseness will result.

Varying degrees of interference with respiration have been encountered in these cases; from mild dyspnea to extreme asphyxia. The dyspnea is in direct proportion to the amount of airway which is occupied by the growth. Inspiratory stridor may be a very prominent symptom in the obstructive type of case. Dysphagia is occasionally seen when the cyst obstructs the introitus of the hypopharynx. In one of New's cases an epiglottic cyst filled the approach to the hypopharynx so thoroughly that fluid was regurgitated through the nose. In addition, adults complain of a sensation of a foreign body. This is seen more especially in the epiglottic cysts.

DIAGNOSIS. The cystic appearance of the new growth, its location, its fluctuancy, translucency, size, shape and color will assist in establishing the diagnosis of cyst of the larynx. This condition should not be confounded with that of a prolapse of the ventricle, in which the prolapsed tissue can be replaced, while the cyst cannot be forced out of position. In infants an erroneous diagnosis of enlarged thymus or congenital stridor is frequently made. In older children papilloma, diphtheria, asthma and foreign body have been diagnosed. Of course, examination of the larynx, by which ever means is dictated by the age of the patient, will readily establish the diagnosis.

PROGNOSIS. The prognosis is grave in the very young. Because of the small size of their structures and the delicacy of their tissues, the management of these growths in infants is extremely difficult. Many cases have occurred in which it was learned that

the infant had a cyst of the larynx only after death by asphyxiation. Reports of infants found dead under such circumstances have been made as follows:

Author	Age of infant
Stoerck ²⁴	5 days
Salomon	28 days
Edis ⁶	2 days
Porak and Theuveny ¹⁸	24 hours
Punder ¹⁹	2½ months
Esch ⁷	Less than a month
Rosenberger ²⁰	6 weeks

The prognosis may be grave in older individuals when the cyst suddenly increases in size. Davis saved the life of his patient who was asphyxiating by rupturing a cyst with his finger. In a great majority of older children and adults the prognosis would appear to be good. There have been, however, several cases in which adults asphyxiated before they could be helped. Laryngeal obstruction from cysts, as from any cause, is always a serious condition.

TREATMENT. The treatment will vary according to the size and location of the cyst. The age of the patient must also be considered. Simple incision or cautery puncture does not seem to be of value. The growth recurred even after Beck burned a hole through the wall of a cyst in a five-year old child. In the case of a young infant it would appear that the simplest and best temporary measure would be the production of a hole in the cyst wall by the cautery. This would keep the cyst more or less empty until such a time as the infant was able to withstand removal of the cyst. Total removal is the only certain means of cure. The method by which this will be accomplished will depend a great deal upon the location of the cyst and its size.

New used a snare to remove the cysts in his cases and cauterized the stump which remained with the cautery tip, by the indirect method. Thyrotomy has been used extensively for the removal of cysts of the larynx. Imperatori¹¹ employed this type of exposure in the removal of a multilocular cyst of the aryepiglottic region. Suspension laryngoscopy has been used to good advantage in the total extirpation of these growths. Chamberlin,³ Freudenthal⁸ and others have used this method. Some have been able to remove

cysts by means of punch forceps. Pharyngotomy has been employed by some where it was felt that the growth could not be removed through the mouth.

CASE REPORTS. CASE I.—Baby J.,* aged two days, was admitted to the hospital because of audible respiratory stridor, transient cyanosis and difficulty in swallowing since birth. Direct laryngoscopy revealed a reddish translucent mass involving the right aryepiglottic fold and extending in front of the same side of the epiglottis. The larynx was markedly displaced to the left. Incision into the cyst wall caused the escape of a thick, glairy mucus, as a result of which the cyst became smaller. After this the baby cried better. The inspiratory stridor returned in forty-eight hours and continued for seventeen days. The infant died of a bronchopneumonia at the age of twenty days.

Postmortem Examination of the Larynx. In the region of the right pyriform sinus and effacing the right aryepiglottic fold, extending upward to the lateral portion of the right vallecula and downward to about the middle of the inferior cornu of the thyroid cartilage, there was a globular, fluctuant mass the size of a large pea, about 1 cm. in diameter. It had a glistening white, smooth surface and displaced the larynx to the left, at the same time occluding the lumen of the oropharynx anteriorly. The epiglottis was not involved in the mass. The glottis could not be seen from above and behind.

CASE II.—M. K., female, aged three years, was brought into the hospital in extreme dyspnea and in asphyxia. Tracheotomy was performed at once. She had had a harsh inspiratory stridor since birth and had been seen by many physicians. She was treated at various times for enlarged thymus, asthma, congenital laryngeal stridor, diphtheria, papilloma. Two weeks before admission her condition became worse. There was an increase in the dyspnea and the stridor was more marked. A nonproductive cough, which caused vomiting, had persisted until the time of admission. During the past three days the condition of the child had become alarming. Retraction of the chest in every direction was noted. Direct laryngoscopy revealed a large, ovoid mass attached to the left aryepiglottic fold filling the brim of the larynx and encroaching upon the glottis. Tracheotomy was performed with the bronchoscope in place. Three weeks later, under chloroform anesthesia induced through the tracheal tube by Dr. Branower, a suspension laryngoscopy was performed and the

* This patient was seen and treated by Dr. Kramer, on service at the time.

ovoid mass excised with scissors and knife. There was a severe reaction twenty-four hours later; the temperature rose to 105° F. and the respirations were 50 to the minute. This reaction soon subsided and, except for some difficulty in swallowing liquids, the convalescence was uneventful. A week after operation direct laryngoscopy revealed considerable loose slough in the left aryepiglottic region. Two weeks after operation the wound was observed to be healthy and granulating. The child was discharged as fully recovered one month after operation.

CASE III.—A male child, aged three years, was admitted to the hospital September 22, 1932. He had had stridulous breathing since birth and had been hoarse during the same time. His breathing became more embarrassed following an attack of whooping cough a year before and his stridor had increased during the past two months. Tracheotomy was performed. One week later direct laryngoscopy revealed a globular swelling occupying the infraglottic region of the left side. It appeared to be in close relation to the inferior surface of the vocal cord and to the vocal process of the arytenoid. The globular swelling was removed with punch forceps. The tissue submitted for microscopic study was reported as cyst wall containing columnar epithelium. Although subsequent direct examination of the larynx proved that the cyst was no longer present, we were surprised to find that the tracheal tube could not be removed. Bronchoscopy revealed a cystic swelling of the right upper tracheal wall. Thyrotomy and fissure of the upper trachea were, therefore, performed on November 14. A cystic swelling was found, extending along the right side from the inferior border of the cricoid cartilage to about the third or fourth tracheal ring. The globular swelling previously noted was no longer present. The tracheal swelling was aspirated, but no fluid was obtained. The cystic mass was excised and submitted to the laboratory. The pathologist reported that the specimen consisted of a cyst wall lined by columnar epithelium, infiltrated with lymphocytes and containing mucous glands. The tracheal tube was removed on December 28. There was no hoarseness and the child was breathing well. About six weeks after he was discharged the boy began to have some difficulty in breathing. His mother thought that he had a "cold" and paid no particular attention to his dyspnea until it became alarming a few days later. He was seen by a laryngologist who advised that he be sent to the hospital. The family delayed until the following day, when he was rushed to a local hospital where he expired before I could perform a bronchoscopy or tracheotomy. A broncho-

scope was passed and artificial respiration with the bronchoscope in place was of no avail. On opening the trachea I was surprised to find a tumor mass lying unattached in the trachea. The description of Dr. Antopol, the examining pathologist, follows:

"The specimen consists of an irregular ovoid mass, 8 by 8 by 6 mm. The surface is smooth except for the region of the pedicle, which is about 1 mm. in diameter. The cut section is very edematous in appearance and discloses numerous small vessels coursing radially toward the surface. Microscopic study reveals a markedly edematous tissue, the edema being most pronounced at the periphery. Epithelium is not seen on most of the specimen except near the pedicle where a stratified squamous epithelium with slight cornification is seen. This fades gradually into an edematous and necrotic type of tissue. There is a diffuse round-cell and plasma-cell infiltration which is most pronounced in the edematous area. Throughout the mass are seen blood channels which converge toward the pedicle. At this point, instead of the edematous stroma of the periphery, there is a denser stroma made up of the fibroblastic type of cells. Van Gieson stain shows numerous strands of connective tissue which are separated from each other in the peripheral portion and become much closer at the pedicle.

"Impression. Vascular and edematous granuloma."

COMMENT. It is reasonable to deduce from the history and circumstances of each case that the cysts had been present since birth. In each case only an inferential diagnosis was possible until a direct examination of the larynx was carried out. The third case has several unusual features. The presence of two cystic tumors, one of which was situated entirely in the trachea, is very unusual. The second cyst which was removed by a fissure of the larynx and upper trachea, and the unfortunate asphyxiation of the child from what proved to be a pedunculated growth which, no doubt, sprang from the anterior commissure of the larynx or from the line of fissure of the cricoid or upper trachea, are unusual. The granulomatous and vascular nature of the growth would indicate that it was of relatively recent origin. This tumor mass is of the same type that we frequently see in adults following thyrotomy. The histologic study of this mass is given in detail because thyrotomy is performed infrequently in young children and because it is thought that the age and delicacy of the structures

might influence the type of granuloma which would follow this operation. The relatively small size of a child's air passages should lead us to anticipate the formation of a tumor mass following thyrotomy. We would then be able to forestall discomfort, distress or death from encroachment upon the airway.

Cysts obstructing the laryngeal passage probably account for some of the cases of asphyxia of the newborn. Recently, within a period of two weeks, a local pathologist encountered two such cysts at autopsy, in infants one day old and two weeks old, respectively. The first case would have been pronounced as a case of asphyxia neonatorum if it were not for the autopsy. It is a fact that this condition is overlooked, not only in the newborn but also in older infants and young children.

This paper represents a review of the subject of cysts of the larynx and stresses some of its practical considerations. Three cases are recorded, in one of which there were cystic masses in both the larynx and trachea.

BIBLIOGRAPHY

1. Beck, Joseph C.: Cyst of Epiglottis, *Laryngoscope*, 1923, **38**, 9.
2. Beschornier: Ueber Epiglottis-Cysten, *Berlin. klin. Wehnschr.*, 1877, **14**, 620.
3. Chamberlin, W. B.: Cyst of the Larynx, *Laryngoscope*, 1917, **27**, 622.
4. Dean, L. W., and Gregg, J. B.: Cyst of the Larynx, *Laryngoscope*, 1918, **28**, 74.
5. Durham: Mentioned by Gibb,⁹ p. 76.
6. Edis, A. W.: Cyst in the Larynx of an Infant, *Trans. Obst. Soc. London*, 1876, **18**, 2.
7. Esch, A.: Zysten in der ersten Lebensmonaten, *Int. Zentr. f. Ohrenh.*, 1920, **18**, 1.
8. Freudenthal, W.: Cysts of the Larynx Removed by Suspension Laryngoscopy, *New York Med. Jour.*, 1920, **11**, 1080.
9. Gibb, G. D.: *Throat and Windpipe*, 2d ed., 1864, p. 76; *Diseases of the Throat*, 2d ed., 1863, p. 154.
10. Glas, Emil: Ueber Larynxzysten, *Arch. f. Laryn. u. Rhinol.*, 1907, **19**, 285.
11. Imperatori, Charles J.: Brachiogenetic Cyst of the Larynx Removed by Thyrotomy, *Laryngoscope*, 1929, **39**, 679.
12. Kahler, Otto: Ein Beitrag zur Genese der Epiglottiszysten, *Arch. f. Laryn. u. Rhinol.*, 1905, **17**, 8.
13. Marx, H.: Angeborene Kehlkopfeysten, *Ztschr. f. Hals-, Nasen- und Ohrenh.*, 1928, **21**, 376.
14. Mishkin: Über Epiglottiszysten, *Inaug. Diss., Königsberg*, 1912, p. 808.
15. Moure, E. J.: Étude sur les kystes du larynx, Paris, Delahaye et Cie, 1881.

16. New, Gordon B.: Cysts of the Larynx, *Journal-Lancet*, 1917, **37**, 99.
17. Oppikofer: Quoted by Denker and Kahler.
18. Porak and Theuveny: Kyste du larynx, *Compt. rend. Soc. d. obst., de gynéc. et de pédiat. de Paris*, 1902, **4**, 150.
19. Punder, Anna: Larynxstenose durch angeborene Kehlkopfzyste, *Jahrb. f. Kinderh.*, 1918, **87**, Pt. 1, 65.
20. Rosenberger, R. C.: Cyst of Larynx and Lobus Azygos of Lung, *Laryngoscope*, 1927, **37**, 360.
21. Salomon, Walter: Ueber Larynxcysten, *Ztschr. f. Ohrenh.*, 1910-1911, **62**, 49.
22. Schneider, P.: Zur Genese der Kongenitalen Larynxcysten, *Ztschr. f. Ohrenh.*, 1911-1912, **64**, 358.
23. Schousboe, H. L.: Ein Fall von sehr grosser Larynxzyste, *Acta Otolaryn.*, 1918-1919, **1**, Pt. 2, 408.
24. Stoerck, Oskar: Über einen Fall kongenitaler Larynxstenose, *Frankf. Ztschr. f. Pathol.*, 1916, **19**, 149.
25. Ullrich (Quoted by Marx¹³): Ueber Kehlkopfeysten, *Inaug. Diss.*, Würzburg, 1887.
26. Verneuil: No title—Report of case included in *Bull. Soc. anat. de Paris*, 1852, p. 103; *Bull. Soc. anat. de Paris*, 1853, p. 8.
27. Benjamins, C. E.: Two Cases of Cysts of the Larynx, *Nederl. Tijdschr. v. Geneesk.*, 1924, **1**, 542.
28. Davis, E. D. D.: Cysts of the Larynx, *Jour. Laryngol.*, 1923, **38**, 9, 473.
29. Denker, A., and Kahler, O.: Cysten des Kehlkopfes, *Handb. der Hals-, Nasen- u. Ohrenh.*, vol. **5**, p. 393.
30. Henke, F., and Lubarsch, O.: *Handb. d. spez. path. Anat. u. Histol.*, vol. **3**, Pt. 1, p. 455.
31. Mason, W. B.: Laryngeal Cysts, *Ann. Laryn. Rhinol. and Otol.*, 1926, **35**, 873.
32. Sanvanero-Roselli, G.: Cysts of the Larynx, *Ann. di laring. ed oto., rh., e. far.* 1928, **29**, 84.

DISCUSSION

DR. CHEVALIER JACKSON, Philadelphia, Pa.:

Nothing but commendation can be said of the paper as a whole. There are one or two points, perhaps, which require a little emphasis: first, that the modern, up-to-date obstetrician is now recognizing the fact that the blue baby may have something else wrong besides persistent patent foramen ovale. Now the obstetrician calls upon the laryngologist to look at the larynx. It is not so many years since a great many laryngologists could not look at the infant larynx. The advent of direct laryngoscopy without anesthesia, general or local, has changed all this and now a laryngologist is being called in in cases of blue baby. The reader of the paper should not criticize himself for having overridden that growth in the trachea. After the breathing has stopped, the overriding of a foreign body is the only thing to do.

You have not time to deal with the obstruction; you must go past it to get air down into the lungs before the heart stops.

DR. JOSEPH C. BECK, Chicago, Ill.:

Dr. Myerson referred to a case of a cyst of the larynx that I reported. I wish he had said it was reported more than twenty-five years ago. It was on a child aged five years, and I had made a probable diagnosis of a cyst or tumor of the epiglottis. The diagnosis was made by the indirect method, which is a most difficult examination in a child. There was another difficulty not reported, and that was the child was an Italian. Those of you who have had experience in large cities with Italian clientele, know that in operating on such a child, if something should happen, such as a fatality, in an operating room, one would not feel so calm. We did not have the modern method of electrocoagulation, so when I discovered it was a cyst I employed electrocautery. We used chloroform a great deal in those days and this fact enabled me to use electrocautery in this case. I burned right through the cyst. There was a reoccurrence, but it never returned as a cyst nor did it interfere with respiration. The child wore a tracheal tube for three years because I feared something would happen, and being that it was an Italian child I preferred to leave the tube in longer.

DR. GORDON B. NEW, Mayo Clinic:

Dr. Myerson referred to a case of mine. I have two or three slides to show of 3 interesting cases of laryngeal cysts.

(Slide.) The first one was found on routine examination, showing two cysts of the epiglottis.

(Slide.) The next one was a cyst that filled the pharynx and attached to the anterior wall of the epiglottis. This I ruptured to get exposure and then removed the tumor with a snare and cauterized the base. No further trouble.

(Slide.) This is a woman, aged thirty-five years, whom I saw within a year. Whether this is a congenital cyst or secondary to the appendage of the ventricle of the larynx I do not know, but the latter is probably the most likely because of the particular type of cyst. Nothing was done in this case because the cyst would have required removal from the outside due to the fact that the base of the tongue and arytenoid were involved. I could not be sure that the voice would be satisfactory after removal.

DR. CHARLES J. IMPERATORI, New York City:

I have seen two branchial cysts of the larynx that I removed by thyrotomy. Shortly, there will be formed in New York City a Society

in which Dr. Jackson is very much interested, the object of which is the prevention of asphyxial death, particularly in the newborn and in all other cases where asphyxia is impending. Dr. Flagg, the anesthesiologist, is the organizer of this Society. It is up to the laryngologist, particularly those who understand direct laryngology, to stress the necessity that all laryngologists be able to examine a child's larynx and, if necessary, pass one of these flexible tubes or a bronchoscope so that an infant may be resuscitated and asphyxial death prevented.

DR. MYERSON (in closing):

I want to thank the gentlemen for enhancing the value of the paper by their discussion. I have nothing to add.

BRONCHIAL DISINFECTION AND IMMUNIZATION

JOHN A. KOLMER, M.D.

UNDER this heading I refer to the therapeutic possibilities of direct or topical applications of chemical disinfectants and biologic agents in the treatment of the chronic intractable bronchitides, early cases of bronchiectasis, selected cases of lung abscess and other nontuberculous suppurative infections of the bronchi and lungs, commonly grouped under the designation of "suppurative pneumonitis." Their frequency, along with the well-established fact that ordinary medicinal treatment possesses little or no real value, renders this relatively large group of pulmonary infections worthy of further investigation in relation to both etiology and treatment, with special reference to bronchiectasis.

I doubt if any method of treatment will prove curative in well-advanced congenital or acquired bronchiectasis, although chemical disinfection may prove helpful in reducing the amount of suppuration and its attending purulent secretions, and thereby afford a gratifying relief from some of the annoying symptoms; but I am impressed with the possibilities of treatment along these lines in *chronic bronchitis, early bronchiectasis*, before the structural changes become advanced, and in some cases of pulmonary abscess, providing a way and means are found for *the frequent and thorough removal of the secretions and the application of bactericidal and biological agents*.

Before discussing the principles involved, as I understand them at present, it is first necessary to briefly consider some factors in etiology and pathology, as these considerations are of fundamental importance in the choice of chemotherapeutic agents. Needless to state an enormous literature has accumulated upon these subjects, and, insofar as bronchiectasis is concerned, has been splendidly summarized in a recent series of articles by Ballou, Singer and Graham,¹ well worthy of being thoroughly studied by all students of this disease.

ETIOLOGICAL CONSIDERATIONS

Aside from those cases due to probable congenital deficiencies in the bronchi and foreign bodies, it is my opinion that the majority is due to bacterial infection, and especially to streptococci and staphylococci. At least this is the impression gained during the past six years as a result of the opportunity of conducting bacteriological examinations of a very large number of specimens collected by bronchoscopy and submitted for examination by Dr. Chevalier Jackson and Dr. Gabriel Tucker.

In my experience, streptococcus infections are by all odds the most frequent and important, and appear to be the prevailing infection in both early and late cases of purulent bronchitis and bronchiectasis. Indeed they have not infrequently been present in pure cultures, and considering the fact that they have been collected under conditions greatly minimizing or entirely removing the chances of contamination with saliva with reasonable certainty, I have the conviction at present that they bear a very important etiological relationship to these infections. Staphylococci, pneumococci, various Gram-negative diplococci, including *M. catarrhalis*, *diphtheroid bacilli*, *B. pyocyaneus*, *B. friedländer*, etc., are also encountered in chronic infections as would be expected, but streptococci, staphylococci and pneumococci would appear to be the more important in relation to the primary infection.

Spirochetes are sometimes seen in direct smears and more especially by dark-field examination, but not in my experience with the frequency suggested by Smith² and others. In view of the numerous species to be found in the saliva and gingival secretions, especially in adults, it is to be expected that they may reach the bronchi in chronic infections and constitute secondary infection. However, it is possible, in some cases at least, that they may possess the etiological importance assigned to them by Smith in producing primary infection of the bronchial walls and favoring the development of pockets analogous to the rôle of *Spirochæta pallida* in the production of aneurysms; but I hesitate to accept this view in individual cases unless relatively large numbers are found in the secretions or until microscopic examination of tissues removed at autopsy more definitely establish this relationship.

Furthermore, it would appear that *Spirochæta vincenti* and *B. fusiformis* may produce a type of Vincent's infection of the pulmonary tissues; but in the large majority of the chronic bronchitides and bronchiectasia my findings assign a more frequent and important rôle to the bacteria, with special reference to the streptococci.

Various molds and yeasts are sometimes recovered in cultures of secretions from chronic bronchial infections, but so far these have been almost entirely of the various *Aspergilli* and *Penicillia* commonly found in the dusts of the house and factory. It is to be expected that molds of these and other species may have some bearing upon the production of allergic asthma; but, with the exception of such pathogenic species as the *astinomyces*, their rôle and importance as etiological agents in suppurative pneumonitis are as yet to be determined.

THE PRINCIPLES OF CHEMOTHERAPY APPLIED TO BRONCHIAL DISINFECTION

While sanitarium regimen, *frequent postural drainage, elimination of mouth and sinus infection, bronchoscopic removal of foreign bodies and secretions* and various surgical measures are logical measures of value in the treatment of suppurative pneumonitis, as recently emphasized by Alexander and Brickingham,³ yet it would appear that the possibilities of local disinfection by chemotherapeutic agents applied by bronchoscopy, bronchial lavage or bronchoclysis are worthy of serious attention.

Castex and Heidenreich⁴ have reported favorably upon intra-bronchial injections of neoarsphenamine in the treatment of spirochetic infections, and Stiehm,⁵ the Ballons,⁶ Blumberg⁷ and others refer to the possible curative effects of intrabronchial injections of iodized oil (lipiodol), although the bactericidal activity of the latter is so low that it is possible that the benefit observed was due to other factors. Gomenol has been applied by Jackson, Tucker and others through the bronchoscope and apparently with some benefit, which is to be expected, since this oil possesses some bactericidal activity as I shall discuss later on, but otherwise no systematic attempts at local disinfection appear to have been made, although a number of antiseptics have been tried.

Naturally a relatively large list of bactericidal agents is available for the choice of compounds to be employed, but it would appear that substances selected for attempted bronchial disinfection should possess the following essential properties:

1. A reasonably high degree of parasitidal activity *in the presence of pus* and especially for streptococci and staphylococci, as likewise for other bacteria, spirochetes and fungi.

2. Be rapidly parasitidal, because the time of contact must be necessarily brief.

3. Preferably stain the tissues in order to prolong antiseptic or bacteriostatic action.

4. Free of destructive effects for the bronchial cilia in order not to reduce or destroy their activity in the removal of secretions.

5. Possess the maximum degree of penetrability in order to reach and destroy microorganisms entrenched in cells and tissues, including the rich bronchopulmonary lymphatics.

6. Be free of injurious effects upon phagocytes in order not to interfere with phagocytosis, which doubtless exerts a very important rôle in the mechanism of resistance and recovery.

7. Be free of injurious effects upon the pulmonary tissues. That is, the chosen antiseptic should not exert excessive hyperemia or inflammatory changes, abolish the cough reflex or interfere with ciliary action and bronchial peristalsis.

8. Be sufficiently low in toxicity to spare the kidneys, liver and other organ injuries. Injurious effects following absorption from the lungs.

9. Furthermore, the solution employed for irrigating the bronchi and preparing solutions of the chosen antiseptic should not favor the development of edema and especially since the tissues are already injured by infection.

Since the exudates in suppurative pneumonitis are usually plastic and so rich in coagulating principles as to coagulate solid or almost so in the Tucker, Clerf and other collectors employed in bronchoscopic drainage, it would appear advisable to employ a fluid possessing liquefying or digestive properties. For this reason the alkaline antiseptics, like Dakin's solution, command special attention, but unfortunately some chemical antiseptics are precipitated by alkalis and the pulmonary tissues greatly

irritated by concentrations sufficient for liquefaction of the exudates. It may be that proteolytic enzymes may be of service in this direction, but, so far, we have not been able to work out a satisfactory solution of them for irrigating purposes.

PRINCIPLES OF APPLICATION

But even if the above requirements are fulfilled, and I believe they may by some antiseptics as discussed later on, *the important problem of adequate application to the infected tissues must be solved.* This refers not only to sufficiently wide distribution in the infected areas of the lungs along with adequate drainage of the secretions, but also, and more importantly, *to sufficient frequency of application.*

Thus antiseptics may successfully reduce the number of pathogenic bacteria to some extent and otherwise fulfil these essential requirements, but bacteria escaping destruction soon begin to multiply under the favorable conditions of the lungs and the original state is soon restored unless a way and means for sufficiently frequent applications is worked out.

In other words, *it would appear that but little or no benefit may result from an occasional application of a bactericidal agent*, for example once a week, by bronchoscopic application. Bronchoscopy is doubtless of great value in removing plugs of secretions and foreign bodies and required occasionally for these purposes in the majority of cases, but it is necessary to employ a method permitting applications at frequent intervals, even daily, for a while at least, with the minimum of discomfort and expense to the patient. For this reason I am greatly interested in the possibilities of bronchial lavage as developed by Stitt,⁸ Iglaue⁹ and others, and especially in the method of bronchoeclysis for prolonged intrapulmonary therapy devised by Mandelbaum,¹⁰ because they may afford a means of not only removing and washing out the purulent secretions, but provide a method of instilling relatively large amounts of bacteriostatic or bactericidal solutions for reaching areas beyond direct application through the bronchoscope. In other words, it would appear that but little is to be expected from the application of antiseptics on gauze pads through the bronchoscope, because but small areas can be reached thereby, and the

time of contact with the infected tissues too brief, whereas if it were possible to introduce and leave relatively large amounts of antiseptic solution at frequent intervals a wider distribution and more prolonged contact may be secured, with possible greater therapeutic benefit, providing the procedure was found entirely safe and feasible.

Of course, the intravenous or intramuscular injection of chemotherapeutic agents of curative value would be the ideal in treatment, but there is nothing of proven value to employ by these routes of administration except neoarsphenamine or bismarsen¹¹ for the treatment of Vincent's or other spirochetic infections of the lungs.

DANGERS AND CONTRAINDICATIONS TO BRONCHIAL DISINFECTION

No doubt certain dangers may attend attempts at bronchial disinfection by the direct application and instillation of antiseptics by bronchoscopy or bronchial lavage and Mandelbaum states that broncholysis should not be used during the early or acute febrile stage of bronchopulmonary disease, although he has found it to be a form of intrapulmonary therapy practically innocuous in thousands of instances in which his method has been used in human subjects. But it has already been shown by Stitt and others that 15 cc. of solution may be introduced with each inspiration. The cough reflex expels the solution along with the thick, ropy secretions, so that as much as 250 cc. may be used for cleansing purposes. Under the conditions at least some of the antiseptic remains for a while in contact with the infected tissues and according to my experimental work it is possible and safe to leave a portion of the last instillation for more prolonged bactericidal and bacteriostatic action without local and general injury.

The question of spreading the infection to healthy portions of the lung is very important in this connection, but if bactericidal solutions are employed it would appear that this possible or theoretical danger is greatly minimized.

Likewise the danger of forcing or permitting the antiseptic solution to reach the terminal alveoli, with the production of infection and pneumonitis, is of importance, but I believe that it is possible to determine this danger by suitable experiments upon rabbits.

Advanced cardiovascular-renal disease and pulmonary malignancies may be accepted as contraindication, and likewise pulmonary tuberculosis, but yet it is not unreasonable to hope and expect that these methods may find a safe and useful field of application in the treatment of some cases of the latter if the results of suitable experiments upon the lower animals shows that bronchial lavage and instillation of carefully selected bactericidal agents is a safe procedure.

EXPERIMENTAL INVESTIGATIONS

With these considerations in mind, the main purpose of my investigation¹² was to select a number of the more promising bactericidal agents most nearly meeting the requirements for bronchial disinfection as outlined above and determine the tolerance of the lungs of rabbits for them by repeated intrabronchial injection.

For these purposes a large number of chemical agents were tested for rapidity of bactericidal activity in the presence of protein and a number of them injected intratracheally into rabbits every two or three days, in doses as high as 1 cc. per kg. of weight of dilutions proving completely bactericidal *in vitro* in five minutes or less.

After 6 to 24 instillations under ether anesthesia, the trachea, lungs and kidneys of each animal were examined macroscopically and microscopically to determine the degree of toxicity and tolerance of the tissues for each antiseptic with special reference to the bronchi. In this manner I hoped to determine whether or not it is safe not only to irrigate the lungs with bactericidal solutions, but more importantly to leave relatively large amounts in the lungs without producing irritation or inflammation of the tissues. Also to determine whether or not the absorption of the antiseptic from the lungs produced evidences of general toxicity with special reference to possible injury of the kidneys.

BACTERICIDAL AND SPIROCHETICIDAL ACTIVITY OF VARIOUS CHEMICAL AGENTS IN RELATION TO BRONCHIAL DISINFECTION

The preliminary bactericidal tests were conducted with a strain of hemolytic streptococcus and *Staphylococcus aureus*. While the value of these tests is limited, yet by conducting them in a men-

struum rich in protein at body temperature, the results are not without significance in the selection of compounds for intrabronchial disinfection.

The technique employed was very simple, as follows: (1) To 90 cc. of sterile ascites fluid was added 10 cc. of a twenty-four-hour broth culture of the test organism and 2 cc. amounts placed in sterile test-tubes. (2) Solutions of each chemical compound were prepared in physiological saline solution and varying dilutions added in amounts of 2 cc. each. Under these conditions the bactericidal action of each compound was determined for relatively large numbers of the organisms in a 50 per cent dilution of ascites fluid representing a large amount of protein approximating the conditions of inflammatory exudates. (3) These mixtures were kept in a water-bath at 37° C. and subcultured at the end of five minutes in order to select substances on the basis of fairly rapid bactericidal action.

The substances tested and the approximately highest dilutions completely bactericidal for the two organisms at the end of *five minutes* are shown in Table 1.

TABLE 1.—BACTERICIDAL TESTS

Compound	Highest bactericidal dilution in five minutes	
	For Streptococcus hemolyticus	For Staphylococcus aureus
Gentian violet	1:6000	1:4000
Neutral acriflavine	1:6000	1:3000
Equal parts of gentian violet and acriflavine	1:6000	1:4000
Rivanol	1:3000	1:1500
Merodicein	1:10,000	1:5000
Mercurochrome	1:200	1:100
Mercuraphen	1:20,000	1:15,000
Metaphen	1:30,000	1:60,000
S.T. 37 (1 to 1000 hexylresorcinol)	1:3	1:2
Potassium permanganate	1:175	1:75
Argyrol	1:100	1:20
Gomenol	1:60	1:8
1 per cent iodine in 25 per cent alcohol	1:75	1:75
Dakin's solution	1:30	1:4
Chloramine-T	1:600	1:400
Dichloramine-T	1:300	1:75
Lipiodol (iodized oil)	None	None
Neorsphenamine	1:50	1:30

Since spirochetes are not infrequently found in the exudates of chronic bronchitis, bronchiectasis and other types of suppurative

pneumonitis, it was necessary to inquire into the spirocheticidal activity of at least some of the bactericidal agents listed in Table 1 in relation to bronchial disinfection, even though the exact etiological status of these organisms is as yet unsettled, except in some instances of pulmonary spirochetosis where such enormous numbers of spirochetes are found in the profuse exudates as to leave little or no doubt of their etiological significance.

As shown in Table 1 neoarsphenamine was completely bactericidal for *Streptococcus hemolyticus* and *Staphylococcus aureus* in dilutions of about 1 to 50. Mixtures of equal parts of 1 to 25 solution and bronchial secretions containing large numbers of various spirochetes (final dilution 1 to 50) showed complete loss of motility within five minutes, as determined by dark-field examination. Of course, this does not necessarily imply the death of the organisms, but it is likely that under the conditions the majority at least were crippled and probably destroyed.

TABLE 2.—SPIROCHETICIDAL TESTS

Compound	Approximate concentration sufficient to cause loss of motility in five minutes
Gentian violet	1:100
Neutral acriflavine	1:300
Rivanol	1:300
Merodicein	1:25
Mercurochrome	1:50
Mercurophen	1:1000
Metaphen	1:1000
S.T. 37 (1 to 1000 hexylresorcinol)	Undiluted
Potassium permanganate	1:25
Argyrol	1:10
Gomenol	1:10
1 per cent iodine in 25 per cent alcohol	1:5
Chloramine-T in water	1:5
Neoarsphenamine	1:50

Additional tests with other chemical agents are shown in Table 2. As a general rule the finer spirochetes (*presumably Sp. microdentium*) were more easily destroyed than the larger and coarser ones like *Sp. macrodentium*. It was surprising, however, that the final concentrations of various agents required to cause complete loss of motility of spirochetes in purulent secretions within five minutes were many times greater than required for bactericidal activity by the method employed. For example, gentian violet, acriflavine and rivanol were spirocheticidal in 1 to 100 to 1 to 300,

but bactericidal in 1 to 3000 to 1 to 6000; merodicein was bactericidal in 1 to 5000 to 1 to 10,000 but spirocheticidal in only 1 to 25; mercurophen and metaphen were bactericidal in 1 to 15,000 to 1 to 60,000, but spirocheticidal in only 1 to 1000 etc.

These and numerous other experiments, summarized by Kolmer,¹³ have shown that neoarsphenamine and probably other bactericidal agents possess well-defined spirocheticidal properties *in vitro* by local application, and it is expected that lavage of the lungs in the various types of "suppurative pneumonitis" with bactericidal solutions will likewise result in the destruction of at least some of those spirochetes with which the solutions come in direct contact.

THE TOXICITY OF VARIOUS CHEMICAL COMPOUNDS FOR RABBITS BY INTRABRONCHIAL INJECTION

Upon the completion of these bactericidal and spirocheticidal tests, I approached the more important part of the study in relation to bronchial disinfection, namely, the toxicity of the various agents employed for rabbits when injected intratracheally.

Preliminary experiments with lipiodol (iodized oil) showed that the injection of 1 cc. per kg. of weight into the trachea resulted in a widespread distribution in the bronchi as determined by roentgen-ray examination within a few minutes after the injection.

Normal adult rabbits were employed and under ether anesthesia solutions of the various compounds were injected directly into the trachea exposed by incision in a dose corresponding to 1 cc. per kg. of weight. As a general rule the solutions of each compound corresponded approximately to those proving bactericidal for *Staphylococcus aureus* and *Streptococcus hemolyticus* in five minutes. It is true that the amount injected was very large, since it corresponded to as much as 60 cc. for an adult weighing approximately 135 pounds, but I purposely wished to make the tests reasonably severe even though it was realized that, if chemical disinfection were to be used in the treatment of human beings, probably only 15 cc. would be introduced at one time followed by removal until about 250 cc. had been used for lavage, and leaving only from 5 to 15 cc. in the bronchi for more prolonged disinfection.

The injections were given every two days. As a general rule,

several rabbits were employed for each solution, and with many of the compounds solutions were tried many times stronger than their bactericidal dilutions in order to intensify the toxic effects.

Upon the death of the animals, or after 6 to 24 injections had been given, autopsies were conducted with an inspection of the trachea, bronchi, lungs, etc., and sections were removed at different levels for histological examination.

Insofar as the *maximum tolerated doses* of the various compounds employed are concerned, it would appear that the following represent the approximate dilutions in dose of 1 cc. per kg. of weight every two days for 6 to 24 injections:

Gentian violet	1 to 2000
Neutral acriflavine	1 to 2000
Equal parts of these	1 to 2000
Rivanol	1 to 2000
Merodicein	1 to 800
Mercurochrome	1 to 300
Mercurophen	1 to 5000
Metaphen	1 to 5000
S.T. 37 (1 to 1000 hexylresorcinol)	1 to 2
Potassium permanganate	1 to 1000
Argyrol	1 to 20
Gomenol	1 to 10
1 per cent iodine in 25 per cent alcohol	1 to 25
Dakin's solution	Undiluted
Chloramine-T in water	1 to 300
Dichloramine-T in chlorozan	1 to 200
Lipiodol (iodized oil)	Undiluted
Neoarsphenamine	1 to 50

By reference to Table 1 it is observed that these maximum tolerated dilutions were bactericidal for the streptococcus and staphylococcus with the exception of S.T. 37, potassium permanganate and lipiodol. With several, however, the maximum tolerated dilutions were but slightly higher than the bactericidal dilutions as in the case of the dyes (gentian violet, acriflavine and rivanol), mercurochrome, argyrol, gomenol, Dakin's solution, chloramine-T, dischloramine-T and neoarsphenamine, whereas merodicein, mercurophen, metaphen and the iodine solution were tolerated in dilutions 3 to 12 times stronger than their bactericidal dilutions (Table 3). From this standpoint the last-mentioned would appear to be preferred for bronchial disinfection, but a final decision upon the choice of compounds was based upon gross and histological examinations for possible evidences of pulmonary irritation.

TABLE 3.—TOXICITY OF VARIOUS COMPOUNDS FOR RABBITS BY INTRAPULMONARY INJECTION

Compound	Dose, 1 cc. per kilo of:	No. of injections	Results
Gentian violet	1:2000	6	Survived
Neutral acriflavine	1:2000	12	Survived
Equal parts of gentian violet and acriflavine	1:2000	6	Survived
Equal parts of gentian violet and acriflavine	1:1000	3 to 10	Died
Rivanol	1:2000	12	Survived
Rivanol	1:1000	10 to 17	Died
Merodicein	1:800	12	Survived
Mercurochrome	1:300	24	Survived
Mercurochrome	1:200	6 to 10	Died
Mercuraphen	1:5000	12	Survived
Mercuraphen	1:1000	5 to 7	Died
Metaphen	1:5000	6 to 24	Survived
S.T. 37 (1 to 1000 hexylresorcinol)	1:2	12	Survived
S.T. 37 (1 to 1000 hexylresorcinol)	Undiluted	3 to 9	Died
Potassium permanganate	1:1000	24	Survived
Potassium permanganate	1:500	3	Died
Argyrol	1:20	12	Survived
Gomenol	1:10	6	Survived
Gomenol	Undiluted	2	Died
1% iodine in 25% alcohol	1:25	12	Survived
1% iodine in 25% alcohol	Undiluted	3	Died
Dakin's solution	Undiluted	6	Survived
Chloramine-T in water	1:200	2	Died
Chloramine-T in water	1:300	6	Survived
Dichloramine-T in chlorozan	1:20	2	Died
Dichloramine-T in chlorozan	1:200	6	Survived
Lipiodol (iodized oil)	Undiluted	12	Survived
Neoarsphenamine	1:50	8	Survived
Martin-Bledsoe saline (control)	Control	12	Survived
Paraffin oil (control)	Control	12	Survived
Olive oil (control)	Control	12	Survived
Chlorozan solution (control)	Control	12	Survived

PATHOLOGICAL CHANGES PRODUCED BY INTRATRACHEAL INJECTIONS OF VARIOUS COMPOUNDS

Therefore, I have determined with particular care the tolerance of the trachea, bronchi and lungs of rabbits for the various disinfectants employed in this study, administered by intratracheal injection, and by means of macroscopic and microscopic examination of these tissues have sought to determine their irritating properties, since it is quite evident that any agent chosen for bronchial disinfection should be without any pronounced injurious effects. At the same time, sections of the kidneys of all animals were examined for evidences of renal injury as a measure of possible

systemic toxic effects resulting from the absorption of the compounds from the lungs.

For this purpose autopsies were conducted on all animals either immediately after death or twenty-four hours after receiving the last intratracheal injection of solutions of each compound.

At least 3 to 6 rabbits were used for each compound and the examinations conducted after injecting intratracheally from two to twenty-four doses of 1 cc. per kg. of weight.

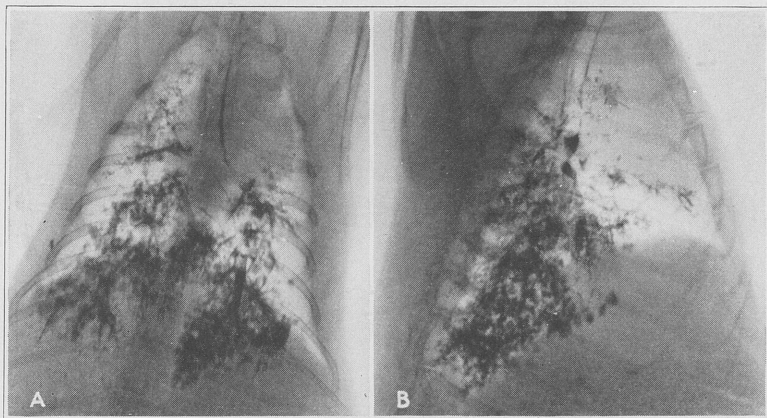


FIG. 1.—A, front view of the lungs of a rabbit; the roentgenogram was taken immediately after the intratracheal injection of iodized oil in dose of 1 cc. per kilogram of weight. B, lateral view of the lungs of the same rabbit.

Sections of the trachea were made just above the bifurcation into the primary bronchi. Sections of the lungs were selected from areas showing the maximum macroscopic changes, and sections were also made of both kidneys.

Marked Variations Were Observed in Individual Animals. For example an animal receiving 3 injections sometimes showed more pronounced histological changes in the trachea, bronchi and lungs than a second animal receiving 12 injections of the same substance at the same time and in the same dosage. Furthermore, the changes produced in the lungs were more or less localized rather than diffused; as a general rule, the greater changes occurred in the right lungs, especially around the primary bronchus and in the

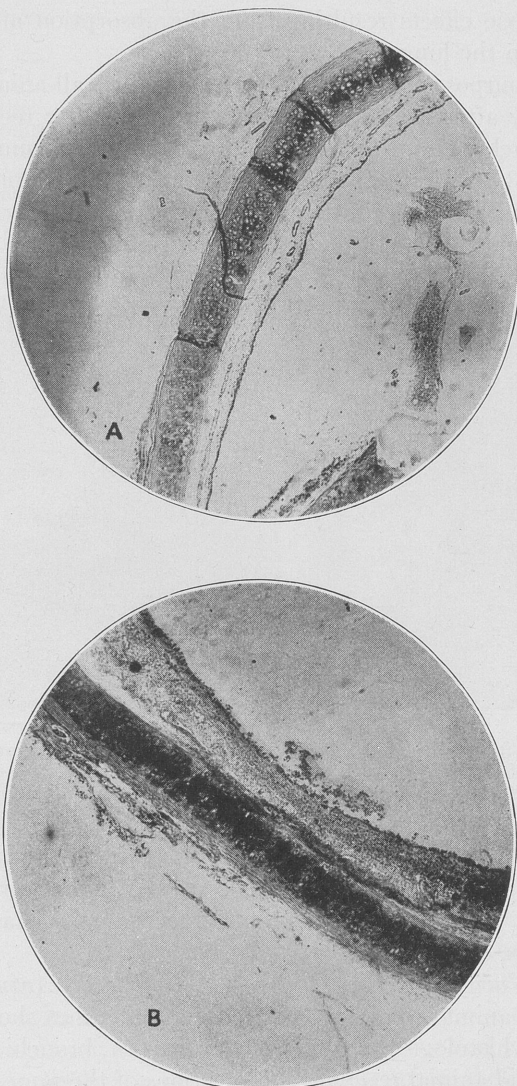
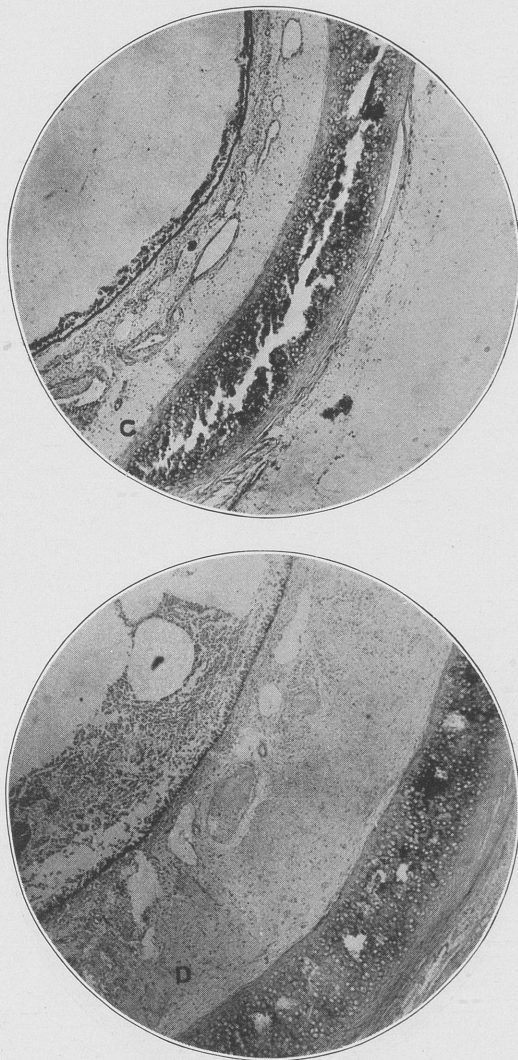


FIG. 2.—A, photomicrograph of a section of trachea. No changes were seen; the section was taken from the rabbit twenty-four hours after six intratracheal injections of 1 to 2000 solution of acriflavine base in dose of 1 cc. per kilogram. B, section of trachea showing congestion, edema and hemorrhagic extravasations in the submucosa with exfoliation of the mucosa, taken from a rabbit twenty-four hours after 6 intratracheal injections of 1 to 2000 solution of gentian violet in dose



of 1 cc. per kilogram. *C*, section of trachea showing moderately severe tracheitis with extensive edema, taken from a rabbit twenty-four hours after 4 intratracheal injections of S.T. 37 (1 to 1000) in dose of 1 cc. per kilogram. *D*, section of trachea showing very severe tracheitis with extensive congestion, edema and leukocytic infiltration with inflammatory exudate on the mucosa, taken from a rabbit twenty-four hours after 6 intratracheal injections of dichloramine-T in water (1 to 100) in dose of 1 cc. per kilogram.

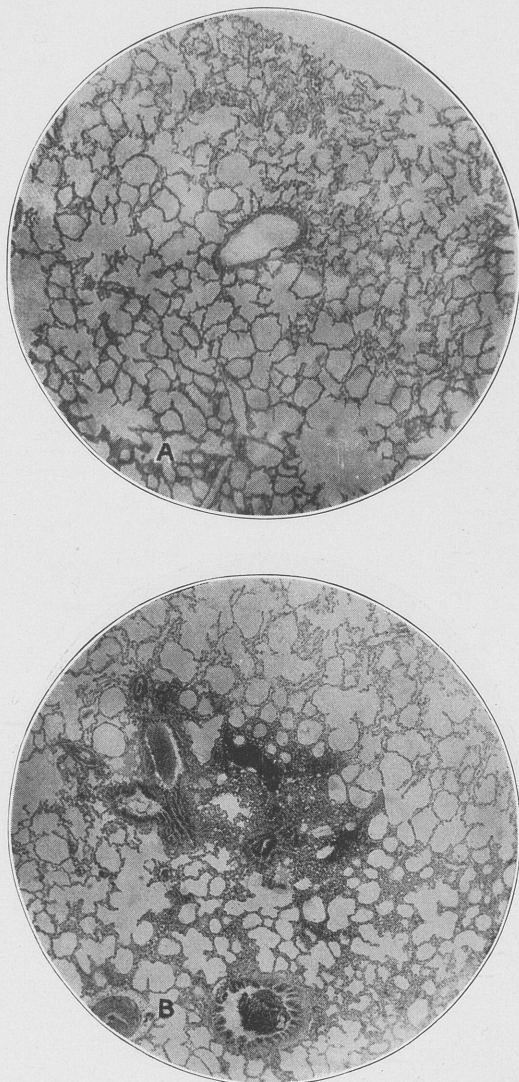
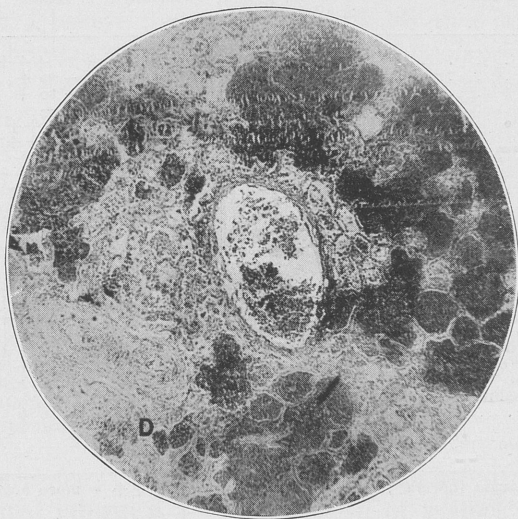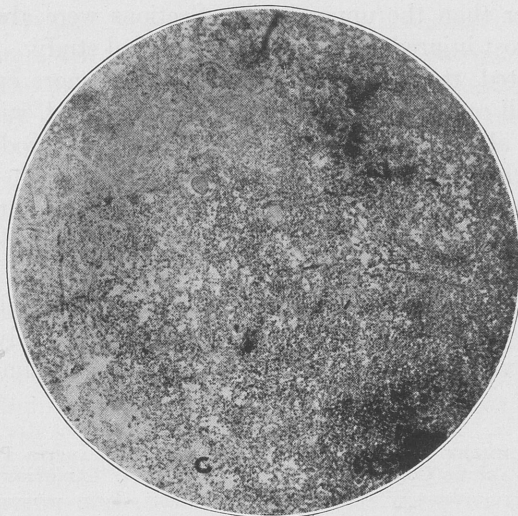


FIG. 3.—A, photomicrograph of a section of lung. No changes were seen; the section was taken from the lung of a rabbit twenty-four hours after 4 intratracheal injections of solution of acriflavine base 1 to 2000 in dose of 1 cc. per kilogram. B, section of lung showing hemorrhagic exudate in the bronchi with slight hemorrhagic and leukocytic infiltration of the peribronchial alveolar spaces, taken from the lung of a rabbit twenty-four hours after 6 intratracheal injections of a 1 to 2000



solution of acriflavine in dose of 1 cc. per kilogram. *C*, section of lung showing acute diffuse hemorrhagic pneumonitis, taken from the lung of a rabbit twenty-four hours after 6 intratracheal injections of a 1 to 1000 solution of gentian violet in dose of 1 cc. per kilogram. *D*, section of lung showing very severe suppurative pneumonitis with abscesses and liquefaction necrosis, taken from the lung of a rabbit twenty-four hours after 4 intratracheal injections of a 1 to 200 solution of mercurochrome in dose of 1 cc. per kilogram.

lower rather than the upper lobes. Sections were always taken from the most injured portions for histological study.

As expected, the bronchi have shown much more evidences of injury by all compounds than the trachea. Indeed, with but few exceptions, all of the compounds employed have produced some injury of the lungs, although in this connection it should be emphasized that the doses were quite large and amounted to 1 cc. per kg. every two days, corresponding to as much as 60 to 70 cc. for an adult human of average weight. Furthermore, it is to be remembered that all was left in the lungs after each injection rather than only a small portion. But I have purposely made the conditions very severe in order to elicit the maximum injury (Table 4).

TABLE 4.—SUMMARY OF PATHOLOGICAL CHANGES IN RABBITS PRODUCED BY VARIOUS COMPOUNDS BY INTRAPULMONARY INJECTION

Compound	Dilution 1 cc. per kilo	No. of doses	Trachea	Lungs	Kidneys
Gentian violet	1:1000	3 to 10	- to ++	+ to +++	-*
Gentian violet	1:2000	6 to 12	- to +	- to +	-
Acriflavine	1:1000	6 to 12	- to +	- to +	-
Acriflavine	1:2000	6 to 12	-	-	-
Rivanol	1:1000	6 to 17	-	+ to ++	-
Rivanol	1:2000	6 to 12	-	+ to ++	-
Merodicein	1:2000	6 to 12	-	- to +	-
Merurochrome	1:200	6 to 24	-	- to +++	- to +
Merurophen	1:5000	6 to 12	-	-	-
Metaphen	1:5000	6 to 24	-	- to ++	-
S.T. 37 (1:1000 hexylresorcinol)	Undiluted	3 to 9	- to +++	- to +++	- to +++
S.T. 37 (1:1000 hexylresorcinol)	1:2	6 to 12	-	- to +	-
Potassium permanganate	1:500	3 to 9	- to +	- to ++	-
Argyrol	1:20	3 to 11	-	- to +	-
Gomenol	1:10	4 to 12	-	- to +	-
1% iodine in 25% alcohol	1:25	6 to 12	- to +	+ to +++	-
Dakin's solution	Undiluted	3 to 8	-	+ to +++	++
Chloramine-T in water	1:200	2 to 8	-	- to +	- to +
Dichloramine-T in chlorozan	1:100	2 to 8	+	+ to +++	+
Lipiodol (iodized oil)	Undiluted	6 to 10	-	- to +	-
Neoarsphenamine	1:50	6 to 18	- to ++	- to +	- to +
Martin-Bledsoe saline solution	Control	6 to 24	-	-	-
Paraffin oil	Control	6 to 10	-	- to +	-
Olive oil	Control	6	-	-	-
Chlorozan solution	Control	6	-	-	-

* - = no changes (normal); + = very slight changes; ++ = more marked inflammatory changes, etc.

With few exceptions, all of the compounds were well borne by the trachea, although the majority produced irritation of the bronchi and especially the smaller branches; this was especially true in the case of those rabbits receiving 6 to 24 injections at

two-day intervals. As a general rule these bronchial changes were of mild degree and largely in the nature of hyperemia with some edema of the submucosa, although in some instances bronchial exudates of fibrin and polymorphonuclear leukocytes were produced.

As expected, the predominant lung changes were in the form of peribronchial areas of hyperemia, edema and slight leukocytic infiltrations of the alveoli. Indeed, practically all compounds produced such lesions, and especially in the case of those animals receiving more than 6 injections at two-day intervals. In some instances, however, these changes were quite severe, with relatively large areas of pneumonitis and multiple abscesses as in the case of a large number of injections of mercurochrome, hexylresorcinol, iodine and the chlorine compounds.

As a general rule there were none or but slight evidences of renal irritation, and such as were found occurred only among rabbits receiving 6 or more injections.

However, I believe that it is entirely likely that lavage of the bronchi of humans with 15 cc. amounts of the following solutions for a total of 250 cc., and leaving the last 15 cc. in for prolonged disinfection, would be without injurious effects at the rate of a treatment every two days or twice a week:

Gentian violet	1 to 2000	
Acriflavine	1 to 2000	(less irritating than gentian violet)
Merodicein	1 to 2000	
Mercurophen or metaphen	1 to 5000	
S.T. 37	1 to 2000	(equal parts of S.T. 37 solution and saline)
Potassium permanganate	1 to 500 to 1 to 1000	
Argyrol	1 to 20	
Gomenol	1 to 10	
Chloramine-T	1 to 300	
Neoarsphenamine	1 to 50	

Mercurochrome (1 to 200) is apparently too irritating and may produce renal injury; a 1 to 25 dilution of a stock 1 per cent solution of iodine in 25 per cent alcohol also produced pulmonary changes, as was likewise true of Dakin's solution. It is to be observed that lipiodol (iodized oil) was well tolerated in confirmation of the work of Stiehm and the Ballons, but is too low in bactericidal activity to be used for bronchial disinfection.

DISCUSSION AND PRACTICAL APPLICATIONS

It would appear, therefore, that bronchial disinfection may be attempted in the treatment of bronchiectasis and other types of "suppurative pneumonitis" by lavage or bronchoclysis with disinfectant solutions. If lavage is employed, 15 cc. amounts may be slowly passed through into the main bronchus coincident with each inspiration followed by expulsion of the solution together with the thick, ropy secretions by the cough reflex, until as much as 100 to 250 cc. have been used for lavage according to the principles of the Stitt-Wooding method. Following the last lavage, I believe that it will be safe to leave 15 cc. in the bronchi for wider distribution and more prolonged bactericidal action.

Since frequency of application is undoubtedly a matter of primary importance, I hope that it will be possible to apply the treatment at daily intervals in some instances for several days at least, followed by subsequent treatments every two days or several times a week, according to conditions. This is a matter, however, to be determined by clinical experience; all that I have hoped to show by the work summarized in this paper is that it would appear possible to safely employ a number of compounds in solutions of sufficient bactericidal activity in the presence of exudates to offer some hope of bactericidal and bacteriostatic activity along with the removal of purulent exudates by lavage as part of a program for the treatment of at least some cases of "suppurative pneumonitis."

From the standpoint of choice of compound no one has stood out predominantly in those employed in this study. But it would appear that the following are worthy of trial from the standpoint of bactericidal and spirocheticidal activity and freedom from toxic effects, although their influence upon bronchial cilia has not yet been determined:

(a) Equal parts of 1 to 200 gentian violet and 1 to 2000 acriflavine.

(b) Mercurophen or metaphen, 1 to 5000.

(c) Merodicein, 1 to 2000.

(d) Equal parts of hexylresorcinol solution 1 to 2000 (S.T. 37) and saline solution.

(e) Argyrol, 1 to 20.

(f) Chloramine-T, 1 to 300.

(g) Neoarsphenamine, 1 to 100, for spirochetic infections.

Each compound may be prepared with saline solution and the chosen solution should be warmed to about 40° C. before administration.

According to my results, these compounds in the strengths mentioned are bactericidal in the presence of pus, do not destroy leukocytes or retard phagocytosis, appear to otherwise fulfil most of the requirements of an ideal antiseptic as previously outlined, and will probably be well borne by humans, although the latter must be determined by clinical experience, as likewise a final choice of the compound to employ.

If the method is given clinical trial the results may be judged not only by the condition and progress of the patient with special reference to the character and quantity of expectoration but, likewise, by qualitative and quantitative bacteriological examinations of the bronchial secretions. That is to say, it is readily possible to determine quantitatively with approximate accuracy the influence of treatment upon the numbers of viable bacteria in the secretions by plating methods. Where spirochetes greatly predominate it would appear possible to use intrabronchial lavage and injections of neoarsphenamine in 1 to 50 or 1 to 100 dilution and study the effects by examination of direct smears of the secretions supplemented by dark-field examinations.

BIOLOGIC THERAPY APPLIED TO BRONCHIAL DISINFECTION

Therefore, while bronchial disinfection by intrabronchial lavage with various chemotherapeutic agents would appear to be both possible and safe and worthy of clinical trial in the treatment of bronchiectasis and other types of chronic suppurative pneumonitis, local immunization and disinfection of the bronchi by intrabronchial injections of vaccines, antiviral and bacteriophage may offer even greater therapeutic possibilities, and also prove worthy of clinical trial in the treatment of bronchiectasis and other types of pulmonary suppuration.¹⁶

Undoubtedly subcutaneous and intracutaneous injections of properly prepared autogenous vaccines are sometimes of therapeutic value in certain cases of chronic bronchitis, especially those

associated with allergic asthma, but vaccine therapy has generally failed to be of any particular value in the treatment of bronchiectasis.

Phagocytosis is undoubtedly the chief mechanism of defense against bronchial infection and likewise the chief and possibly the sole mechanism of recovery. Therefore, anything that may safely be done to increase phagocytosis of the organisms productive of chronic bronchitis and bronchiectasis, and especially of streptococci and staphylococci, may be expected to have therapeutic value.

In this connection I refer not only to phagocytosis of organisms by microphages (the polymorphonuclear leukocytes), but likewise, and possibly more importantly, to phagocytosis by macrophages with special reference to clasmatoocytes. At least the cells of the macrophage system appear to be more phagocytic in chronic infections.

VACCINES BY INTRABRONCHIAL ADMINISTRATION

As shown by Gay and Morrison, the intrapleural injection of sterile broth, 1 per cent egg-white, 1 per cent peptone solution, acacia broth and other substances into the pleural cavities of rabbits has resulted in a great increase in these clasmatoocytes in the exudates and pleural tissues, and after seventy-two hours the changes resulted in greatly increased resistance to intrapleural injections of virulent streptococci. According to these investigators, however, the results were not due as much to what was injected as to the time element, and it has occurred to me that intrabronchial injections of vaccines made of heat-killed broth cultures of streptococci and other organisms may serve equally well in producing a local mobilization of these and other phagocytic cells.

Furthermore, it may be that a vaccine administered in this manner may cause increased production of antibodies, with special reference to opsonins, by the local tissues (bronchi and parenchyma of the lungs), since it would appear that some evidence has accumulated to show that antibodies are produced primarily and principally by the tissues directly infected and antigenically stimulated. And since opsonins bear an important and essential relationship to the mechanism of phagocytosis, it has occurred to me that

intrabronchial injections of autogenous vaccines prepared with broth may serve the dual purpose of increasing the macrophages of the exudates and tissues with special reference to clasmatocytes, along with an increased production of specific opsonins so vitally concerned in both microphagic and macrophagic phagocytosis.

In this connection it is also pertinent to inquire into the possible therapeutic value of intrabronchial injections of Besredka's antiviral virus in the treatment of chronic bronchitis and bronchiectasis, since this may be related in some respects to the artificial stimulation of clasmatocytic phagocytosis.

Antivirus is prepared by cultivating the organism in a suitable broth medium for from eight to ten days followed by Berkefeld filtration. The filtrate is designated as "antivirus," and according to Besredka contains something which is specifically bacteriostatic and bactericidal for the organism. That is to say, if the organism is replanted in the filtrate it either fails to grow or grows but sparsely, whereas other organisms grow almost as luxuriantly as in the control broth medium. Besredka stated that the inhibiting substance is specific, thermostable and atoxic, and for the want of a better term has called it "antivirus."

Personally, I am inclined at present to the view that antivirus owes its therapeutic properties to stimulation of both microphagic and macrophagic phagocytosis along with local antibody production; but it may contain a principle directly destructive for the organism, as Besredka maintains. If this is true, there may be a relationship between antivirus and bacteriophage, and in all events it would appear profitable likewise to inquire into the possible therapeutic benefit to be derived from intrabronchial injections of bacteriophage in the treatment of chronic bronchitis and bronchiectasis.

At the outset, however, it was realized that bacteriophage therapy involved considerable technical difficulty, especially in the preparation of suitable and potent bacteriophage for the streptococci recovered in cultures of bronchial secretions. Staphylococcus bacteriophage is easier to prepare, and that which is commercially available is frequently lytic for the staphylococci occurring in purulent bronchial exudates, but the preparation of phage for pneumococci has met with no success, so far, in my laboratory.

TOXICITY OF VACCINES, ANTIVIRUS AND BACTERIOPHAGE FOR RABBITS BY INTRABRONCHIAL INJECTION

Vaccines of *Staphylococcus aureus* and hemolytic streptococci recovered in cultures of bronchial secretions, containing approximately 1 billion heat-killed cocci per cubic centimeter and preserved with 0.3 per cent cresol, were extremely well borne by rabbits receiving as much as 1 cc. per kg. of weight every two or three days for as many as 24 consecutive intrabronchial injections. In every instance the animals survived, maintained their weight and showed no demonstrable ill effects to either vaccine.

The same was true of a second series of rabbits receiving from 6 to 24 intratracheal injections of antiviruses of the same strains prepared by cultivating the organisms in a broth medium for ten days, followed by Berkefeld filtration. As much as 1 cc. per kg. of weight was injected every two or three days, and all animals survived without demonstrable ill effects.

Similar results were observed with bacteriophages for both strains injected intratracheally in a similar dose of 1 cc. per kg. of weight every two or three days for a total of from 6 to 24 consecutive injections, so that it may be stated that these substances were well borne by normal rabbits by this route of administration, despite the fact that the doses were purposely made extremely large according to body weight. It is true that the injections were sometimes followed in a few hours by a temporary elevation of rectal temperature along with slight but definite leukocytosis, especially in those animals receiving intrabronchial injections of the two vaccines, but these changes were usually observed only after the first 1 to 3 injections, following which it appeared that the animals rapidly acquired a tolerance for all three products of each organism.

Furthermore, the injections did not appear to produce more than slight amounts of bronchial exudates. Autopsy was performed several days after the last of 6, 12 and 24 injections of each product, and the lower portion of the trachea and the bronchi were carefully inspected along with the preparation of smears from numerous locations for cytological examination, but in no instance were there any macroscopic evidences of pronounced bronchitis resulting from irritation due to any of the products administered.

The smaller bronchi, however, frequently contained more exudate than was found in untreated controls and especially in those rabbits receiving intrabronchial injections of the two vaccines; smears stained with methylene blue (methylthionine chloride, U. S. P.), hematoxylin and eosin and neutral red showed the presence of increased numbers of not only polymorphonuclear leukocytes but likewise of the larger cells corresponding to descriptions of the morphological and staining characteristics of clasmatocytes. These cytological changes were most marked, however, in smears of secretions from rabbits receiving injections of the vaccines and antiviruses, but were practically absent or much less in evidence in smears taken from animals receiving the injections of the two bacteriophages.

Furthermore, the results have clearly shown that intrabronchial injections of staphylococcus and streptococcus vaccines, antiviruses and bacteriophages result in the production of specific opsonins and agglutinins in normal rabbits.

Additional experiments were now conducted in an attempt to determine if intrabronchial injections of vaccines and antiviruses of virulent *Staphylococcus aureus*, a hemolytic streptococcus and a Type I pneumococcus afforded any protection against intrabronchial injections of broth cultures of these organisms.

Especially definite evidence of acquired immunity to the Type I pneumococcus was observed after as few as 3 intrabronchial injections of the pneumococcus vaccine and antiviral. For example, the intratracheal injection of 0.5 cc. of ten-hour hormone broth cultures of this pneumococcus into control rabbits resulted in a fatal septicemia in all, with positive cultures of the heart blood within forty-eight hours after inoculation. The same was true of rabbits inoculated intratracheally after receiving from 2 to 3 intrabronchial injections of sterile broth, indicating that the broth alone was without demonstrable protective value against this highly virulent pneumococcus by intratracheal injection. But all of the animals receiving the intrabronchial injections of the vaccine survived when given injections with the virulent pneumococcus, as was likewise true of all animals receiving 3 injections of the antiviral. These results, therefore, afforded definite evidence of the fact that intrabronchial injections of Type I pneumococcus vaccine and antiviral resulted in immunization against fatal infec-

tion by intratracheal inoculation with the organism, and since intrabronchial injections of sterile broth were without these effects it is apparent that the presence of the pneumococcus and its products in the vaccine and antiviral produced specific effects.

Less definite evidence, however, was secured in the case of the staphylococcus and streptococcus, owing to the fact that both organisms were much less virulent for rabbits by intratracheal inoculation.

Only from 20 to 50 per cent of the controls inoculated intratracheally with large amounts of twenty-four-hour hormone-broth cultures (2 cc.) succumbed to septicemia, as was likewise true of controls receiving 3 preliminary intrabronchial injections of sterile broth for nonspecific mobilization of microphagic and macrophagic phagocytes, including clasmotocytes. However, all animals receiving 3 preliminary intrabronchial injections of the staphylococcus and streptococcus vaccines and antiviruses survived when inoculated intratracheally with 2 cc. amounts of twenty-four-hour hormone-broth cultures of the respective organisms and thereby indicated some degree of acquired immunity; but since some of the controls likewise survived, the results were not as definite as those observed with the Type I pneumococcus.

However, it was apparent that as few as 3 intrabronchial injections of vaccines and antiviruses of *Staphylococcus aureus*, a hemolytic streptococcus and a Type I pneumococcus resulted in engendering demonstrable degrees of acquired immunity to the three organisms which were especially well marked in the case of the pneumococcus.

I am convinced, therefore, that it is both safe and feasible to try intrabronchial injections of autogenous vaccines, antiviruses and bacteriophages in the treatment of the chronic intractable bronchitides, bronchiectasia and other types of suppurative pneumonitis of man.

DISCUSSION AND PRACTICAL APPLICATIONS

Certainly it would appear from these experiments with rabbits that all three substances are extremely well borne by intrabronchial injection and that their administration by this route may be of therapeutic benefit.

Autogenous vaccines and antiviruses are especially interesting in this connection because of the ease of preparation in the large amounts likely to be required. The preparation of bacteriophage is much more difficult and indeed may be impossible for some of the bacteria secured in cultures of bronchial secretions. Staphylococcus bacteriophage is ordinarily readily prepared and may be obtained commercially, but the preparation of streptococcus and pneumococcus bacteriophages may be difficult and indeed impossible so far as the preparation of the large amounts of actively lytic products are concerned. Furthermore, bacteriophages should not be tried until actual preliminary tests have shown that they are actively lytic in the test-tube for the organisms against which they are to be employed. I believe that intrabronchial injections of actively lytic phages may be of therapeutic benefit, but the technical difficulties of preparation may constitute an objection to their use on a large scale.

Autogenous vaccines, however, are readily prepared in large amounts, and for this purpose I suggest that bronchial secretions be secured bronchoscopically in the Tucker, Clerf or other collectors, and cultured in flasks of hormone-broth medium suitable for the cultivation of streptococci. These may be incubated for about five days, at the end of which time fairly heavy growths will be observed. In many instances these are almost pure cultures of streptococci, but in the majority of such cultures staphylococci, pneumococci and various Gram-positive and Gram-negative organisms also occur, with streptococci predominating. The mixed culture, however, should be used and may be diluted with sterile saline solution to give a total concentration of about 1 billion organisms per cubic centimeter. Cresol may be now added to give a total concentration of 0.5 per cent (10 cc. of a stock 5 per cent solution to each 100 cc. of vaccine), well mixed and incubated at 37° C. for twenty-four hours, when subcultures are made for sterility. This type of vaccine contains the broth and approximately 1 billion chemically killed organisms per cubic centimeter along with their exogenous toxins and, in my opinion, is to be preferred to the usual heat-killed suspensions in saline solution in order to secure the effects of the broth alone in the mobilization of both microphages and macrophages with special reference to

clasmatoocytes in both the bronchial exudates and bronchial tissues for purposes of phagocytosis.

Antivirus may be prepared in exactly the same manner, except that the culture of bronchial secretions in broth is cultivated at 37° C. for ten days, followed by Berkefeld filtration. The clear filtrate should be then cultured for sterility and put up in sterile vials or flasks in the amounts required for treatment without the addition of a preservative.

Only future clinical trial can determine the relative therapeutic effectiveness of vaccine and antivirus; personally, I expect results from both, and especially from the latter.

The method of administration and dosage must be likewise determined by clinical trial and experience, but I would suggest that the ropy, mucoid secretions be first removed by lavage before introducing vaccine, antivirus or bacteriophage. According to this method, 15 cc. of saline solution is slowly forced through a catheter into the bronchi coincident with each inspiration, followed by expulsion along with the thick, ropy secretions until as much as 250 cc. is used. Following the last washing, the vaccine, antivirus or bacteriophage may be introduced.

The initial dose may be about 5 cc. in order to have it retained with as wide distribution as possible. If well borne, the treatments may be given about twice a week and the doses gradually increased. Larger doses are particularly indicated if bacteriophage is employed. It may be that the doses of vaccine and antivirus must vary for individual cases according to the amounts of toxin present, since it is likely that both contain variable amounts of toxins which will vary with different cultures, especially in the cases of streptococci and staphylococci.

When vaccine or antivirus are employed there may be an added advantage in using one of the chemical disinfectants for lavage as suggested above instead of the plain saline solution. Indeed, this would appear to be the better procedure in order to secure the possible benefit of chemical disinfection, especially since the disinfectants and solutions recommended are without injurious effects on the bronchi and phagocytes; but if bacteriophage is employed, the disinfectants should be omitted in the lavage because they may destroy the phage if the latter is indeed a living virus.

BIBLIOGRAPHY

1. Ballon, R. H., Singer, J. J., and Graham, E. A.: Bronchiectasis, *Jour. Thorac. Surg.*, 1931, **1**, 154; *Ibid.*, 1932, **1**, 296, 397, 485.
2. Smith, D. T.: Oral Spirochetes and Related Organisms in Fuso-spirochetal Disease, Baltimore, Williams & Wilkins Company, 1932.
3. Alexander, J., and Buckingham, W. W.: Treatment of Non-tuberculous Suppurative Pneumonitis, Abscess and Bronchiectasis, *Jour. Am. Med. Assn.*, 1930, **95**, 1478.
4. Castex, M. R., Heidenreich, A. J., and Repetto, R. L.: Le Salvarsan par voie tracheale dans le traitement des processus fétides de l'appareil respiratoire, *Bull. Acad. d. méd.*, 1926, **95**, 131.
5. Stiehm, R. H.: Treatment of Bronchiectasis with Lipiodol, with Report of Nineteen Cases, *Wisconsin Med. Jour.*, 1930, **29**, 556.
6. Ballon, R. H., and Ballon, H. C.: The Value of Bronchoscopic Injections of Lipiodol in the Diagnosis and Treatment of Bronchiectasis, *Jour. Laryngol. and Otol.*, 1929, **44**, 153.
7. Blumberg, Nathan: Personal communication.
8. Stitt, H. L.: Bronchial Aspiration and Irrigation with a Hypertonic Saline Solution, *Jour. Med.*, May, 1927, 1.
9. Iglauer, S.: Advantages of Intubation Method of Introducing Iodized Oil for Bronchography in Children, *Jour. Am. Med. Assn.*, 1931, **97**, 1517.
10. Mandelbaum, M. J.: Bronchoelysis. An Original Method for Prolonged Intrapulmonary Therapy, *Arch. Phys. Ther., X-ray and Rad.*, 1932, **13**, 373.
11. Kolmer, J. A.: Bismuth Sulphonate (Bismarsen) in the Treatment of Syphilis and Other Spirochetic Infections, *Arch. Dermat. and Syph.*, 1930, **21**, 394.
12. Kolmer, J. A.: The Effects in Rabbits of Intrabronchial Injections of Various Chemical Disinfectants, *Arch. Int. Med.*, 1933, **51**, 346.
13. Kolmer, J. A.: Principles and Practice of Chemotherapy with Special Reference to the Treatment of Syphilis, Philadelphia, W. B. Saunders Company, 1926, p. 342.

DISCUSSION

DR. CHEVALIER JACKSON, Philadelphia, Pa.:

Dr. Kolmer touched very lightly on the subject of the etiology of bronchiectasis. Undoubtedly, that is a very complex problem and there are many, many phases.

There is one phase that I believe has not received the attention that it deserves, and that is what might be called the mechanical phase, in relation to the consistency of the secretion. Bronchoscopically, when we go down to empty the bronchiectatic patient, we encounter first some secretion, and as we go down further, thicker secretion. What the patient coughs up is very much thinner than anything we get through the bronchoscope. Reasoning from that, it

seems the secretions, the exudate, are exceedingly thick and gummy. It is very difficult for the patient to cough it up. The patient will cough and cough and get up a great deal of pus, but when we go down with the bronchoscope we find a great deal he did not get up. This is thick and tenacious, viscid to an intense degree.

It seems we have a parallel here to what the sanitary engineers call a septic tank—a tank into which sewage and all sorts of material, chiefly infective, are run and where the character is changed as to bacterial content and physical state, enabling the sanitary engineer to get rid of it by drainage methods.

Now then, we have in the bronchiectatic septic tank Nature's method to change the gummy, tenacious pus into a material easily expelled by a process which is the equivalent of rotting. The putrid pus the bronchiectatic patient gets up is the pus that has undergone those bacterial, chemical and physical changes that enable him to get it up.

If we take that patient with the bronchiectatic septic tank to the bronchoscopic clinic and get that pus out before it can rot, the odor disappears, the patient becomes a useful member of society; he is no longer ostracized. We have eliminated the bronchiectatic septic tank. Another method of drainage that is very little understood is the tussive squeeze of the lungs; it is the most important factor in the drainage of the lung. The bechic blast of air forced up by the lungs through the air passage drives out whatever may be in the larger bronchi; but the peripheral pus, whether an abscess or a collection in the natural passages, is forced up into the larger bronchi in the same way you would squeeze a sponge filled with water.

Just to illustrate how little these things are understood, it has been said in quite a number of journals, "How can bronchoscopy be efficient when you cannot get into the small peripheral bronchi or around the corner into the upper lobe?" You do not need to get into them, nor into an abscess cavity; you go down with the bronchoscope and aspirate the pus in the larger bronchi. Suppose the upper lobe is affected, you aspirate all the pus in that right portion of the tracheal-bronchial tree. The patient coughs, if he is not anesthetized (and he should not be, either locally or generally) and we see quantities of pus appear from coughing. He has squeezed that upper lobe and has squeezed the pus out into the larger bronchi; that is why bronchoscopic aspiration is efficient; it is the coöperation of the tussive squeeze.

While I agree with Dr. Kolmer that if you are going to put in chemical agents, to do any good they should be repeated frequently, I do not believe it would be wise to keep on dumping the bactericidal

and spirocheticidal remedies in on top of a pool of pus. I believe we should combine it with bronchoscopic aspiration at intervals to lessen stagnation.

He has suggested patients should be treated by antiviruses every day or more than once a day. I think that is very good, but at intervals we ought to empty the bronchiectatic septic tank, get the surfaces cleared off; as a surgeon would in any accessible region, for the action of those agents.

In conclusion, I want to call your attention to a beautiful piece of work. Laboratory men are prone to ignore the fact that for a clinician to take up anything new, for instance the introduction of chemical and other powerful agents into the lungs, he wants to know beforehand that it is not going to injure his patient. The laboratory man is apt to ignore the fact that while the cat has nine lives the baby has only one; it is necessary to go, very, very carefully when you introduce substances into the lung. Dr. Kolmer has worked out with the utmost care just that particular phase of the question; in other words, he has made such tests that he can assure us positively that certain remedies introduced into the lung will not injure the patient's tissues.

DR. ERNEST M. SEYDELL, Wichita, Kan.:

I would like to ask Dr. Kolmer in reference to the menstruum he uses for injecting these drugs into the trachea and bronchi. I injected a camphor and menthol oily spray into a patient's trachea about a year ago from which she developed a pneumonia. I have found similar cases reported in the literature and wonder if he has had any like experience.

DR. KOLMER (in closing):

In answer to the first inquiry, I beg to state that the bactericidal tests were conducted with a menstruum prepared of equal parts of sterile serum and broth, or equal parts of sterile ascitic fluid and broth, carrying a large amount of protein in the menstruum.

As far as lipiodol is concerned, we, too, found in some of our rabbits areas of bronchopneumonia following its injection, although in the majority of instances it would appear that rabbits have stood anywhere from 3 to 6 injections in doses of 1 cc. per kilogram of body weight without demonstrable pulmonary injury.

FRACTURE OF THE STYLOID PROCESS AND ITS TONSIL FOSSA COMPLICATIONS

REPORT OF CASE

JAMES A. BABBITT, M.D.

SPONTANEOUS fracture of the styloid process of the temporal bone, perhaps better termed fracture without obvious relation to traumatism, is apparently of rare occurrence. Without doubt many cases have not been reported, and distorted positions of the process in the tonsil fossa may have represented unrecognized fractures. This could readily happen with the difficulty in adequate roentgen-ray demonstration. In the special case cited below, the plate of an examination made almost immediately after removal of the distal portion showed the fragment apparently intact in the original position. Careful subsequent roentgen-ray studies proved the first to have been due to an exact alignment of the opposite styloid process, obscuring the picture on the operated side. Fractures coincident with some crushing injury to the skull are relatively frequent but do not belong in this category.

From a survey of the available literature, barely a half dozen cases, including the one here reported, appear to be chronicled as true spontaneous, or nontraumatic fractures, and the etiology is ascribed in three of them to a massive effort of swallowing or severe fit of coughing. The complex arrangement of muscles comprising the hyoid apparatus, with the hyoid bone acting as fixed base, and the binding down of adjacent fascia, would afford, in unusual or complicated movements, and especially in strained position, an opportunity for displacement of the process. The possibility of pathological fracture in these cases must not be overlooked. Deficiency in calcium content and delayed union of the two ossification segments should likewise be important. The first case was reported by Pfahler¹ of Philadelphia in 1911, under the caption, "Technique for the Isolated Roentgenogram of the Processus Styloideus." Though reported in a German journal,

the patient consulted La Place in the Medico-Chirurgical Hospital in Philadelphia in 1908 for examination of a tumor-like induration in the tonsillar region, which interfered with singing and caused painful swallowing. The roentgenogram showed fracture of the styloid process, with the proximal portion of the distal fragment drawn backward into tonsillar area. There was an unusually long process on the opposite side. A difficult tooth extraction under gas six months before may have had some etiological bearing in this case.

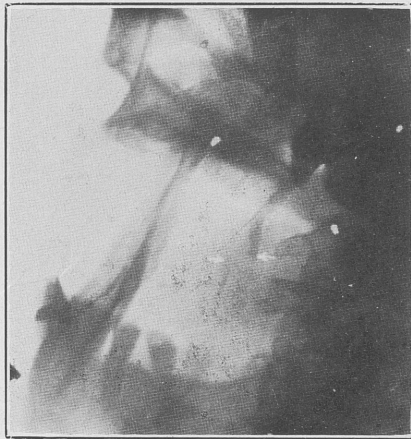

FIG. 1.—Fracture of styloid process. Case reported by Dr. Pfahler.

Goris,² in Belgium, reported 2 cases in 1900, one occurring suddenly in an effort of swallowing, during which the patient was taken with a fit of laughter, and the second during a violent fit of coughing. Swallowing in each case aggravated the pain, and diagnosis was confirmed by digital examination.

Karl Specht,³ in Germany, reported a similar case, also occurring during mastication. In his somewhat extended monograph, which included studies in the anatomy, physiology and development of the hyoid apparatus and discussion of the fracture mechanism, he states that his search of the literature revealed but 2 similar cases, those above credited to Goris. We are indebted to Harburger,⁴ in Paris, for the most extensive study which has been

published. In the fourth section of his paper, that on the normal and abnormal styloid, he presents 49 references, including 8 of his own, in which the styloid-hyoid apparatus was studied. In one of these a spontaneous type of fracture is suggested and ascribed to external pressure.

The final case of the group is the subject of the special case report concluding this paper. A radical mastoid operation per-

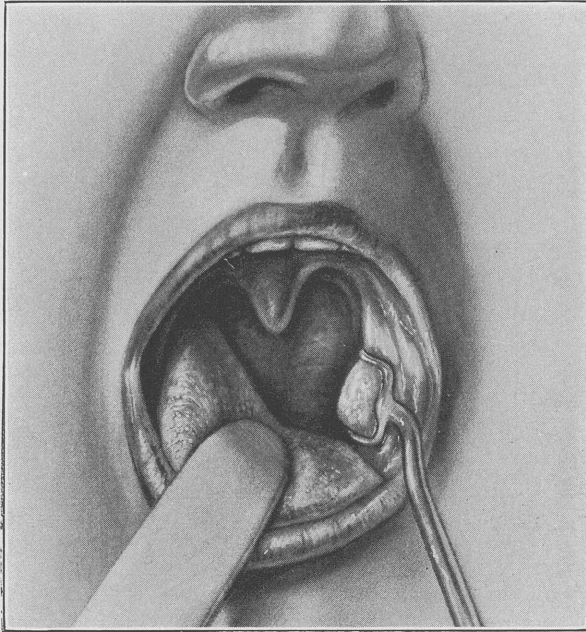


FIG. 2.—Protrusion of styloid fragment in the tonsil fossa.

formed thirteen years before, and the roentgenographic evidence of softened adjacent bone are the only known contributing factors. The only injury the patient could recall which might have any traumatic relation occurred about twelve years ago. While riding in an automobile her head was bumped against the top of the car. This occurred so long ago that it presents little significance in the recent situation.

In addition to this group, Patterson⁵ suggests a possible fracture

of the process during an epileptic attack in one of his patients, but it was not fully demonstrated.

Many references have been made to styloid disturbance in the tonsil and adjacent pharyngeal region due to elongation and malposition of the process, both before and after tonsil removal, with dysphagia the predominant symptom. In the search for relief, suspicious middle turbinates have been removed and adjacent glands scrutinized and operated upon.

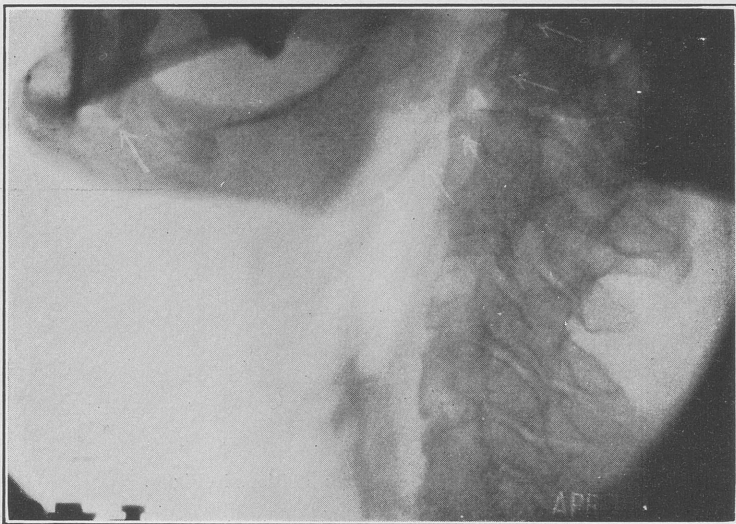


FIG. 3.—Fracture of the left styloid process. Proximal end dropped downward.

In a study of the etiological background, the same group of factors would seem to apply to fracture and malposition of the process without fracture. The principal ones are suggested: (1) The complexity of muscular and fascial pull in the anatomical makeup of the hyoidean apparatus; (2) imperfect ossification in the styloid process itself; (3) unrecognized traumatism, both intrinsic and extrinsic. Any combinations of these factors may be present in producing the discomfort and malposition which suggest the diagnosis. The hyoid bone represents a fairly fixed base. The suprahyoid muscles connecting with the mandible, tongue and cranium, the middle constrictor of the pharynx, and in an asso-

ciated degree the infrahyoid group, link with the stylohyoid and styloglossus in a most complex muscular action—such as occurs in forceful swallowing, choking or severe coughing. If these be inadvertently combined or interrupted by laughter, sneezing or other surprise movement, and especially in the presence of an elongated or maldeveloped process, the stage for displacement or fracture is complete.

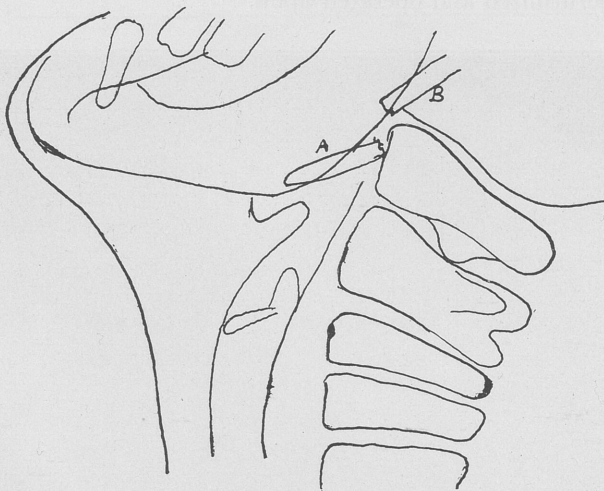


FIG. 4.—Diagram illustrating positions in Fig. 3.

Much has been published in this and other countries on the throat complications, particularly from an elongation of the styloid process. According to Kulvin,⁶ Marchetis first refers to the ossification of the stylohyoid ligament in 1652, and Wemlicher of Vienna, in 1872, reported the first removal of the elongated process. Kulvin reviews the clinical significance of this condition: (1) In the difficulty of diagnosis from sensation standpoint between this and the presence of foreign body; (2) in the possible complications during tonsillectomy, incising of peritonsillar abscess or insertion of needle for suturing bleeding point; (3) in its occasional snug position between the carotids when ligation of the latter be necessary.

The normal styloid process is about 30 mm. in length ($1\frac{1}{4}$ inches).

Guthrie⁷ quotes Gruber's results in the examination of 2000 skulls in which only 11 styloid processes measured over $1\frac{1}{2}$ inches, and only 1 over 3 inches. The styloid process is a part of the hyoid bar of the second visceral arch of the embryo and consists of two parts of which the first joins the petrous at or about the time of birth. From the cartilage of this second gill-arch are formed the stapes, styloid process, stylohyoid ligament, lesser cornu and part of the body of the hyoid bone. The second part, according to

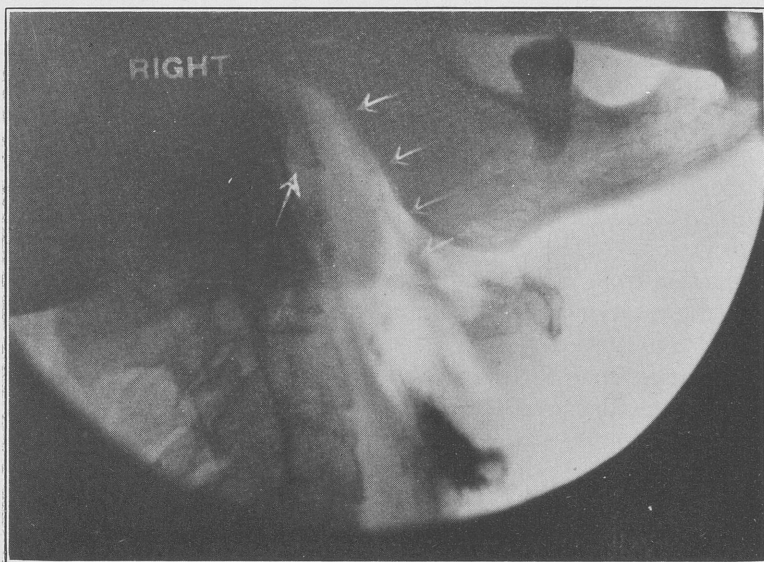


FIG. 5.—Stump of styloid process after removal of fragment. Process on the opposite side also seen.

Alexander,⁸ represents all but the base as an ossification of the stylohyoid ligament and does not join the first part until puberty or later. An unduly long styloid process is the result of the ossification of this stylohyoid ligament. According to Kohler,⁹ defective ossification of the styloid process, or rather of its two portions, is frequent, though complete ossification of the stylohyoid ligament sometimes occurs. Such an ossified stylohyoid ligament has often been mistaken by surgeons for a swallowed denture with operation for removal. Sir William Turner¹⁰ reported a hyoid

apparatus in man in which a separate epihyal bone was developed—the right styloid process 31 mm. in length, two or three times the normal thickness, instead of terminating in a point expanded and formed an articulation with a bar of bone 56 mm. long, which passed down to articulate with the lesser cornu of the hyoid bone. The place of the right stylohyoid ligament was taken by this epihyal bone.

There does not seem to have been great difficulty in recognizing either an elongated or misplaced styloid process. Palpation upon localized area of tenderness should be sufficient, even without roentgen examination. In treatment the removal of the tip has been easily accomplished, but has often been left undisturbed in the reported group. Rather curiously convalescence without removal has usually occurred. Bacher,¹¹ who reported 16 cases of elongation complicating tonsillectomy, found in the literature up to 1922, including 2 of his own, made this valuable diagnostic observation. "The characteristic movements of the styloid, in distinction from other possible bony substances, are a movement with the rotation of the head and movement with nodding of the head."

Operation upon the process may open up infective pathways in the retrotonsillar area. A classic example is that of Von Eiken,¹² in which infection of the petrous bone followed removal of a portion of the styloid process. A bony sequestrum was subsequently removed on continuance of symptoms. This was followed by middle ear complications, incision of tympanic membrane and, finally, involvement of the facial canal and petrous tip, requiring major surgery.

REPORT OF SPECIAL CASE. This patient, Miss A. W., aged fifty-three years, tall, rather thin, with a poor physical background, including suggestion of former pulmonary lesion, came to the office in 1916 because of a chronic discharge of the left ear. Her tonsils had been well removed by another physician some months previous. As it was impossible to pass a eustachian catheter upon the side of the offending ear, on account of septal deviation, a submucous resection was done. She returned for further treatment in August, 1919 and in January, 1920, a simple mastoid operation was done, and patient was discharged after a normal period. By midsummer there was a marked recurrence of mastoid symptoms with breaking down of the

postauricular wound. This was accompanied by vertigo, discharge from the canal and behind the ear, with marked swelling and edema of tissues about the ear. A very extensive radical mastoid was performed in August, 1920, with unfavorable results. There was marked increase of labyrinthine symptoms and a temporary facial palsy. The bony structures about the ear were softened and carious, almost osteomyelitic in type, and a very extensive removal was required. Inadvertently a portion of the lower anterior wall was grasped and crumbled away—exposing the parotid area. This is quoted because of its possible etiologic bearing upon the subsequent fracture of the styloid process. An argument against this is the fact that the fracture was not at the base of the styloid—a very appreciable fragment will be noted in the slide—yet there may have been septic entrance into the styloid area, weakening the bony structure.

In the roentgenograms recently taken the softened condition of surrounding bone structure may be noted. This patient has been under occasional routine observation during the interim since the radical operation. Although she had a middle ear abscess on the right (opposite) side with resultant intermittent discharge and also required right ethmoid drainage some years after this radical mastoid, she had made a fairly complete recovery—vertigo and palsy disappeared, the ear was dry, and she carried on her duties in a responsible position in a department store.

In 1929, ten years after the last mastoidectomy, she complained of increasingly annoying throat symptoms in the left tonsillar fossa. This appeared to be more in the lingual tonsil or at the junction line of the base of the tongue. This was watched for two or three years, and small masses of lymphoid tissue were cauterized or removed. The pain, however, persisted and a slight protrusion in the left tonsillar fossa was noticed. Roentgen-ray films were taken by Dr. Pfahler demonstrating the fracture of the styloid near the base. He has courteously furnished two other slides, one showing a definite fracture of the left styloid process (Case I) and the other showing congenital failure in the ossification of the styloid ligament. On April 28, 1932, with the coöperative assistance of a general surgeon, Dr. Knox, the distal fragment was removed. This did not prove to be as simple as indicated in published cases, and consumed, partly because of ether complications, nearly two hours of excavation in the tonsil fossa. The segments of bone which show how small this styloid projection was, are presented for inspection of the Society. This patient made a slow but uneventful recovery. The large aperture in the tonsil fossa is completely closed, there is no drainage nor referred ear symp-

tomatology. She still, however, complains of occasional periods of local soreness, rather neuralgic in type, but the throat appears normal.

CONCLUSIONS. 1. The group of published cases of fracture of the styloid process without obvious traumatic etiology is so small that it suggests a much larger unreported list.

2. The symptomatology in cases of fracture of the styloid process closely resembles that of simple protrusion of an elongated process.

3. Faulty ossification may readily account for the occurrence of both of these complicating disturbances.

4. It is of interest to note that removal of the offending tip has not always appeared necessary. The procedure in removal should not be attended with danger.

5. The complicated mechanism of the stylohyoid apparatus should readily permit the malposition of an elongated process. A minor deviation from the normal might explain long-continued discomfort in deglutition customarily assigned to other causes.

BIBLIOGRAPHY

1. Pfahler, G. E.: Die isolierte Aufnahme einer Oberkieferhälfte und die isolierte Aufnahme des Processus styloideus, *Fortschr. a. d. Geb. der Röntgenstrahlen*, 1911, **17**, No. 6, 369.
2. Goris: Deux cas de fractures spontaines de l'apophyse styloïde, *Ann. de la Soc. Belge de chir.*, 1900, **8**, 233.
3. Specht, Karl: Fracture of Styloid Process of Temporal Bone, *Deutsch. med. Wehnschr.*, 1925, **51**, 2074.
4. Harburger, Adrien: Étude anatomique clinique et radiologique de l'appareil hyoïdien, normal et anormal, chez l'homme, *Arch. internat. de laryn., otol., rhinol., et bronchoscophagoscope*, N.S. IV, 1925, pp. 933, 1074.
5. Patterson, Norman: Abnormality of Right Tonsil, *Lancet*, 1909, **2**, 1668.
6. Kulvin, Mas M.: Elongated Styloid Processes, Formation and Clinical Significance, *Laryngoscope*, 1930, **40**, 906.
7. Guthrie, Douglas: Styloid Process of the Temporal Bone, Its Variations and Their Surgical Significance, *Edinburgh Med. Jour.*, July, 1924, vol. **31**.
8. Alexander, G. J.: A Very Long Styloid Process with Throat Symptoms, *Jour. Ophthalmol., Otol. and Laryngol.*, May, 1917.
9. Kohler, A.: The Borderlands of the Normal and Early Pathological Skiagrams, English translation of the fifth German edition, 1928, p. 299.
10. Turner, Sir William: Hyoid Apparatus in Man in Which a Separate Epiphyal Bone was Developed, *Jour. Anat. and Physiol.*, 1902, **36**, 162.
11. Bacher, J. A.: Styloid Process in Tonsillectomy, *California State Med. Jour.*, 1922, vol. **20**.
12. Von Eiken, C.: Infection of Petrous Bone After Removal of Styloid Process, *Ztschr. f. Laryngol. u. Rhinol.*, 1931, **21**, 96.

DISCUSSION

DR. JOHN F. BARNHILL, Indianapolis, Ind.:

I have never seen an instance of fracture of the styloid process such as Dr. Babbitt has described, but have often recorded anomalies and the numerous disturbances that arise therefrom.

I recall once finding a much elongated styloid process in a most unusual environment. The patient had a deforming enlargement of the neck, which on palpation was of the size and hardness of a billiard ball, lying near and overlapping the hyoid bone. There was no thought of this tumor being connected with the styloid process, but on removing it the styloid process was encountered, was exposed backward toward its attachment, and removed. The tumor had developed about the tip of the styloid and when all was removed looked not unlike an "all-day sucker," the styloid process serving as a handle.

Much elongated styloid processes are not uncommon. I have often found them in the living, and likewise in the anatomical laboratory. Recently, in 16 cadavers examined in respect to the styloid process, 6 were greatly elongated.

The point in the paper which interested me most, but which I did not clearly understand, was Dr. Babbitt's method of removing the necrosed fragment. The impression I got was that the operation was performed through the mouth, was tedious and required two hours. I would, of course, offer no criticism of the method in this particular case since the operator with conditions before him must have chosen the best plan, but as the operator narrated his difficulties, I wondered if another, more open method might not have proved easier and speedier. I refer to the mode of entrance through the pharyngomaxillary fossa, described by Mosher. This space in the neck is not difficult to find and, when entered, the styloid process will be found deeply at the bottom.

The technique in brief consists in exposing the submaxillary salivary gland, turning the gland out of its bed and upward over the mandible, and inserting the finger upward and backward into the fossa. The finger usually encounters the styloid process rather deeply, and should necrosis of its tip be present, the same might be removed externally. Such mode of entrance would at least have the merit of giving best possible drainage while healing takes place. Would Dr. Babbitt choose an external route if operating again for a similar reason?

DR. BABBITT (in closing):

As far as could be observed in gross examination this tissue showed no necrotic change. The difficulty in getting the portions of the styloid process out through the tonsil fossa was almost amusing. The process seemed right under the finger, reachable with ordinary hemostatic forceps, but it constantly slipped, one and another piece was broken off and we finally lost track of the base. We closed our work in the neighborhood of the temporal bone, but with only a moderate amount of bleeding.

This patient took the anesthetic very badly and with the difficulty in retaining the hold on the styloid process the operation was much delayed. Probably the muscles of mastication threw the fragment out of position.

THE MINUTE ANATOMY OF THE SPHENOID OSTIUM

ARTHUR W. PROETZ, M.D.

THE minute anatomy of the nasal mucosa and that of the sinus has been frequently recorded, but a careful search of the available literature has failed to reveal any description of the microscopic structure at the ostium itself. This study was accordingly undertaken to determine whether or not the mechanical arrangements at the ostium and the relations of nerves and vascular structures to one another, and to the sharp bone edge, might be a factor in the production of pain. It seemed important surgically also to determine whether at operation there might be any advantage in avoiding injury to the ostium, or possibly in eradicating it. The sphenoid ostium was chosen partly because of the relative simplicity of preparing sections, but chiefly because of the headaches arising in its vicinity and the obscurity of their cause.

The sphenoid mucosa is characteristically thin, its tunica composed chiefly of parallel elastic elements laid closely together and bound firmly to the underlying bone. (Fig. 1, *S*.) It contains very few glands. The nasal mucosa, on the other hand, is many times thicker and is permeated with vascular channels and glandular elements (*N*).

It is seen on the most casual inspection that the two sheets of mucosa do not lose their identity at the ostium, and do not merge, but lie definitely side by side until they reach the edge of the ostium, the only tissue which passes uninterrupted through the ostium being the epithelial layer. The underlying bone comes to a sharp edge, around which no structure can be seen to pass from nose to sinus (or the reverse), and against which no structure can impinge in case of swelling.

The tunica propria of the sinus can scarcely be said to enter into the formation of the ostium at all, as it terminates abruptly somewhat short of the margin. The ostium lining is thus a part of the nasal mucosa which exhibits two or three small folds just at the opening, and which is here supplied with more than the

usual number of mucous glands and venous spaces. The connective tissue elements are loosely arranged.

No nerve elements of any consequence were found. A few fibers were encountered, usually in close relation to the arterioles,

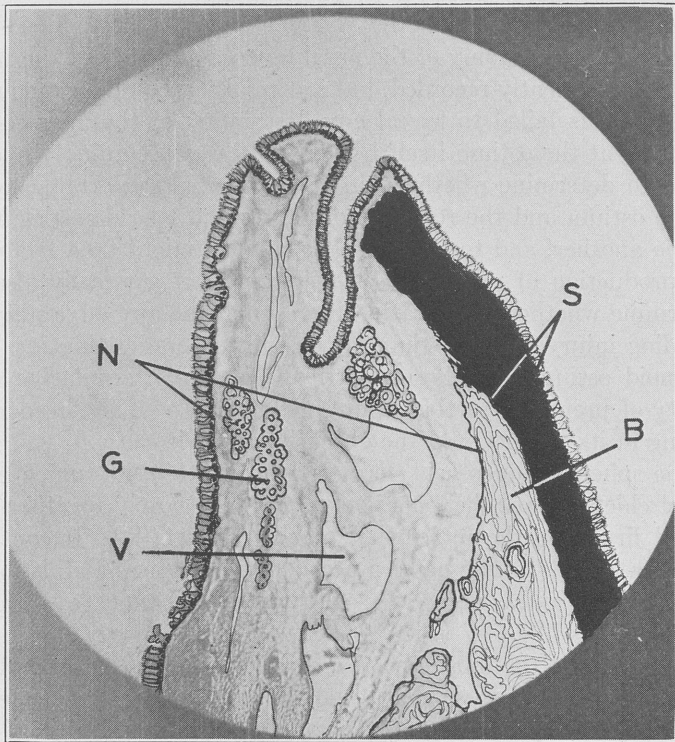


FIG. 1.—Diagrammatic representation of a cross-section of the margin of the sphenoid ostium at its widest part. *N* is the relatively thick nasal membrane; the black strips indicate the tunica propria of the sinus mucosa; *G*, gland; *V*, venous spaces; *B*, bone.

but in no case were they large enough or so placed that engorgement of the vessels or edema of the tissues could have brought them under pressure against bone, especially against the bone margin of the ostium.

Insofar as one may be permitted to deduce functions from

structures, the following suggest themselves with a reasonable degree of likelihood, in the case of the sphenoid.

1. The connective tissue stroma and the intercellular spaces are so arranged that swellings probably take place into the nose and into the sinus respectively, and that only extreme tension can cause the tissues to encroach upon the ostium in such a way as to close it.

2. That in case of inflammation the nasal side of the ostium expands much more than the sinus side because of (a) the loose arrangement of tissues, (b) the disposition of the blood spaces and (c) the location of the folds and furrows in the mucosa.

3. That considerable engorgement or actual hyperplasia is required to close the ostium completely.

4. That the ostium, as such, is probably not involved in the causation of headache.

5. That the surgical protection of the ostium is unimportant.

6. That since the ostium is composed chiefly of nasal, and not sinus, elements and is supplied chiefly by nasal arteries, application of constrictors, such as ephedrine, to the neighborhood of the ostium should suffice to open it.

A CLINICAL AND PATHOLOGICAL STUDY OF TUMORS OF THE NOSE, PHARYNX AND MOUTH OF TERATOLOGICAL ORIGIN

A. C. FURSTENBERG, M.D.

THERE is, perhaps, no chapter in the study of pathology more interesting than that which treats of the tumors of teratological origin. The occurrence of these lesions in various organs of the body, as the result of congenital disturbances of development or the misplacement of embryonal cells, is a common example of a few of the mysterious factors pertaining to the genesis of neoplastic growth. In one instance we may be dealing with a tumor which develops from a mass of tissue misplaced during the development of the embryo; in another, the neoplasm is more logically explained as a proliferation of aberrant cell collections. Both formations give rise to an extensive group of heterologous tumors, varying from the simple cysts to the larger, more complex teratoid growths which may contain a collection of widely differentiated cells from many organs of the body.

Many notable examples of neoplasms of this nature have been observed in the nose, pharynx and mouth. Their precise origin, whether from embryonal rests, aberrant structures or superfluous collections of cells, and the influences which initiate and encourage their growth, are phenomena of the teratoid tumors which do not often yield to scientific explanation. Why, for example, may a mixed salivary gland tumor arise within the ethmoidal labyrinth and develop to proportions which destroy life? What influences are at work to produce a cartilaginous growth in some part of the body where normally cartilage is not found? What are the factors giving rise to the complex teratomas of the neck containing muscle, cartilage, bone, teeth, hair and a large variety of connective tissue cells? Theories to account for these pathological changes are numerous, although chiefly of a speculative nature and usually devoid of scientific proof. They ultimately give recognition to the mechanical hypothesis which, in a broad sense,

ascribes the derivation of many of the teratomas to some disturbance or irregularity of the mechanics of embryonic development.

A typical example of such an anomaly is found in the common odontoma or dentigerous cyst. We may speak of them as similar lesions, for their modes of origin are so intimately related that they may be properly classified as such. The tumor is derived from a dental follicle which may represent a supernumerary structure or occur as a misplaced anlage usually within the lower jaw and more rarely in the superior maxilla in close proximity to the tissues of the orbit. Not infrequently one may find as suggestive evidence of a misplaced follicle the absence of one or more molar teeth which are found to be an integral part of the tumor mass. In many instances all of the elements of the tooth, the pulp, dentin, and enamel, participate in varying degrees in a proliferation which gives rise to a tumor mass frequently found within the wall of an epithelial cyst.

Those cases coming to our attention in the clinic have presented clinically more or less deformity of the affected parts. A firm, painless swelling of the mandible or the superior maxilla encroaching upon the oral cavity, the nose, or the nasal accessory sinuses is the usual clinical picture. To this we add a well-directed roentgenogram casting a circumscribed shadow of varying degrees of transparency or opacity, and containing one or more teeth or the rudiments of teeth, and the true identity of the lesion is clearly revealed.

The successful treatment of these lesions calls for at least one important surgical principle, namely, the complete enucleation of the tumor mass together with its cystic wall. Every rudiment of the wall of the cyst should be carefully removed and this can often be greatly facilitated by exposing the lining membrane to a sponge saturated with 5 per cent picric acid in 30 per cent acetone for several moments when it will be found that the softened capsule strips with greater ease. Enough bone is removed to permit of easy access to the tumor and its contents, and, when feasible, the osseous wound is cauterized to allow partial, and in some instances, nearly complete obliteration of the cavity by the adjacent soft tissues of the mouth and cheeks.

Closely related to this type of lesion, but occasionally malignant

in character, is the adamantinoma occurring within the mandible or involving the superior maxilla. It is a neoplasm which originates from the paradental epithelial débris. It appears as a solid or cystic tumor growing slowly within the alveolar processes, eroding the bone in which it lies, and dilating the neighboring tissues until it becomes circumscribed by a thin osseous capsule which, on pressure, gives the feeling of crepitation. The lesion may grow to large proportions, encroaching upon the oral cavity or extending into the nose and nasopharynx, the nasal accessory, sinuses or the orbit. Ewing reports that the tumors are usually observed in adult life and that the growth may be prolonged over a period of many years. He points to the fact that the cystic tumors are usually found in the mandible, while the solid and more malignant type of lesion usually arises within the upper jaw. The incidence in women is greater than in men.

A microscopic section of the growth reveals a thin, bony capsule surrounding a cystic or solid tumor. The architecture varies from a group of small cysts intermingled with fibrous connective tissue trabeculae to the more cellular variety with an abundance of stroma closely resembling a sarcomatous change. The small cysts may be lined by a variety of epithelial cells ranging from stratified squamous epithelium to columnar enameloblasts.

Because of the malignant potencies of adamantinoma, treatment calls for the radical extirpation of the entire growth. In the deeply ramifying multilocular cysts it may be necessary to sacrifice a large part of the mandible or the greater portion of the superior maxilla. Every vestige of the new growth must be excised in order to avoid recurrences and the tendency to malignant degeneration. Cases are on record where the latter have been followed by metastasis to the cervical lymphatics and to the lungs.

A large group of congenital anomalies derived from irregularities in the closure of the clefts of the face and neck, are found in the nose, pharynx and mouth. There occur at the location of the different clefts a variety of abnormalities ranging from dermoid cysts and patent ducts to solid tumors of a malignant character. The histopathology of these lesions presents the structures of the layers of the embryo which are involved in their development. Thus we may observe in a true dermoid of the nose resulting

from some embryonal disturbance within the nasomaxillary cleft the elements of the ectoderm, including epidermis, dermis, glands of the skin and hair. In the larger cysts, derived from the branchial clefts, both embryonal layers, the ectoderm and entoderm may participate in their formation. The cyst may be lined by epidermis or it may reveal a squamous epithelium of mucous membrane or a ciliated columnar epithelium of entodermal origin. Many of these cysts lie in close relation to the lateral pharyngeal wall, although they seldom produce symptoms referable to this region unless they become involved in a carcinomatous degeneration.

A striking example of a cyst arising from a congenital disturbance of development is that which takes its origin from the thyroglossal duct. The latter is a vestigial structure which passes as a canal from the foramen cecum to the isthmus of the thyroid gland. If a part of the duct remains patent, a cyst is formed which is lined by ciliated columnar epithelium. These cysts, which often reach a large size, are open to infection from the pharynx and are often the seat of repeated inflammatory changes with abscess formation and general reactive symptoms. Such a process must invariably occupy the midline of the neck. In one of our patients the cyst, which had reached the size of an orange and was prone to frequent acute infections, projected through the base of the tongue and appeared in the oral cavity as a tumor which gave rise to dysphagia, a localized inflammatory edema and a cervical lymphadenitis.

PATHOLOGY. The wall of the midline cysts is composed of fibrous connective tissue which occasionally contains scattered patches of lymphoid structure. The latter probably tends to furnish a fertile soil for the growth of infection which rapidly distends the cyst until it ruptures spontaneously through the skin of the neck. In the external perforation thus produced an epithelial lining is formed. This gives rise to a permanent fistula through which there is a flow of mucus or the products of inflammation. The epithelial lining of the cyst may be squamous, ciliated or mixed.

TREATMENT. A successful operation for the removal of neck cysts and fistulæ calls for the total removal of the epithelial structures which line their walls. Sistrunk has clearly described the technical requirements for extirpation of a thyroglossal cyst.

He stresses the importance of removing a portion of the hyoid bone to which the duct is attached. Without attempting to identify the fine pedicle of fibrous tissue which forms a continuation of the duct from the hyoid bone to the dorsum of the tongue, the surrounding tissues are cored out through the mylohyoid, geniohyoid and genioglossus muscles up to and sometimes including the structures about the foramen cecum. Skilful dissections which follow these essentials of technique are not unlikely to be followed by recurrence of these troublesome lesions.

It is difficult, if not impossible, to properly classify the large variety of swellings which develop within the floor of the mouth. The term *ranula* has been employed in a loose sense to include a wide range of cystic swellings in connection with the sublingual, submaxillary and mucous glands or those derived from some disturbance in the closure of the second branchial cleft. The *ranula*, which implies a thin, glistening, cystic swelling of glandular origin, does not belong to the teratomas. It is an acquired change in which the pathological process is probably a myxomatous degeneration of one of the numerous glands in the floor of the mouth, following occlusion of its duct. (In support of this view, Fitzwilliams has reported cases to show that Blandin's gland, the submaxillary and sublingual glands, and the simple mucous glands may give rise to the typical *ranula*.)

Not all cysts found in this region are derived from this source. Some are undoubtedly of teratological origin and represent heterotopias or dystopias of pharyngeal mucosa as observed in the branchial cysts. In this type one may find a clinical feature of considerable diagnostic significance, namely, the presence of an open duct through which, upon pressure over the tumor, a mucoid secretion appears. In the simple *ranula* a similar structure cannot be found, and compression of the gland fails to elicit a discharge or diminish its size and shape.

If a section through the wall of a simple *ranula* is examined microscopically, mucous membrane will be found. In the congenital *ranula*, arising from the second branchial cleft, we observe a characteristic admixture of stratified and columnar epithelium which is peculiar to these cysts. It is probable that some of the large bilocular *ranulae* which ramify over the face and neck in an extraordinary manner are deep cysts of this type.

ANGIOMA. In the human blood and lymphatic systems we may find evidences of irregular influences in embryonal growth represented by the occurrence of congenital angiomata. The hemangioma, composed of bloodvessels, and the lymphangioma, consisting of lymph vessels, are occasionally found in the lips, tongue, buccal mucosæ and in the mucous membranes of the nose.

In explanation of the origin of the hemangioma, Ewing refers to them as a "developmental anomaly in the structure of certain vascular segments which do not fit into the circulatory system and which retain embryonal characters." Ribbert, in a careful study of the origin of the simple angioma, observed that the tumor develops in a portion of a bloodvessel wall and from that point produces a proliferation of new-formed vessels which invade the neighboring tissues but do not connect with any of the normal bloodvessels in the surrounding structures. All of the bloodvessels, therefore, in the part affected do not participate in the growth of the neoplasm.

PATHOLOGY. Microscopic examination of a section shows many new-formed bloodvessels, with a proliferation of endothelial cells. The latter may grow so profusely that the bloodvessels become obliterated, or they may be found in dense masses scattered throughout the sections. In the cavernous angioma a group of large blood spaces lined by endothelium is seen. Such a lesion may extend deeply into the surrounding tissues and, in rare instances, metastasize to other parts of the body.

The origin of the lymphangioma is probably similar to that suggested for the tumors composed of bloodvessels. Here again it is assumed that an isolated lymph vessel which has been improperly developed takes on the behavior of neoplastic tissue and by slow proliferation forms a network of new lymph channels. The congenital lymphangioma may be found in many parts of the body, both superficial and deep. It has been observed in the mucous membranes of the lips and tongue, and in the areolar tissues and muscles of the neck may grow to amazing proportions.

Microscopically the lesion consists of a network of dilated and thickened lymph vessels associated with many new-formed bloodvessels which, in some parts of the tumor, give it the structure of a hemangioma. There may be more or less hyperplasia of the endothelium and here and there lymphoid tissue may be found.

TREATMENT. Positive methods for the management of these lesions cannot be dogmatically prescribed. Complete excision, destruction with cautery, electrocoagulation and radium have all been advocated, and each appears to have logical values in a given case. The hemangioma may be successfully destroyed with some form of cauterization or by the application of radium. The action of radiation on vascular endothelium produces an obliteration of the bloodvessels and this effect is satisfactorily obtained in many of the mucous membrane lesions. The response of the lymphangioma to radiant energy is not so satisfactory. Its growth may be controlled by the use of radium but it is seldom possible to eradicate the tumor by this means alone. Those lesions of this character which have come to my attention have been exceedingly resistant to radium therapy and have yielded only to surgical measures of a radical nature. Excision appears to be the treatment of choice, particularly in the extensive tumors of the neck, where formidable dissections are occasionally required.

SCHWANNOMA

There appears to be much confusion concerning the terms applied to the encapsulated tumors of the peripheral nerves. They have been variously described as perineurial fibroma, perineurial fibroblastoma, solitary neurofibroma. Schwannoma, peripheral glioma and a host of other names have been given to them. This profusion of terms is probably the result of the controversial opinions of pathologists in reference to the fundamental constituents of these tumors. One group expresses the belief that the neoplasm is composed of the mesodermal fibroblast, while another school holds that a neurectodermal structure, the cells of Schwann, are the proliferating elements responsible for the new growth. Although the precise derivatives of these lesions have not yet been clearly identified, it must be conceded that the occurrence of these lesions in the mouth and pharynx is probably of teratological origin.

Figi has recently reported the first case of solitary neurofibroma primary in the pharynx, and a similar tumor developing in the floor of the mouth in an infant has recently been seen in our

clinic. These tumors occur more frequently in the acoustic nerve or in the spinal nerve roots and more rarely appear as a round or lobulated firm mass along the course of one of the cranial nerves.

The microscopic appearance of the tumor which came to our attention was similar to that described by Figi. The characteristic architecture was a mass of long, thin fibers with elongated nuclei appearing in parallel arrangement, or like a palisade. In other parts of the tumor the nuclei were massed in the form of whorls or eddies.

TREATMENT. Treatment calls for radical excision of the new growth. The tumor is malignant by position and of grave importance when it involves the acoustic nerve or one of the roots of the spinal nerves. It appears to be exceedingly resistant to radiant energy, but does not tend to recur if completely removed through surgical intervention.

MIXED SALIVARY GLAND TUMORS

The precise derivation of the mixed salivary gland tumors so frequently found in the oral-facial region is not clearly understood. Their occurrence in the nose, sinuses, mouth and tongue is evidence of some irregularity in the mechanics of embryonal growth, probably in the nature of cell misplacements, although their histogenesis remains an unsolved problem.

From a clinical standpoint they are most vicious in their manifestations. Appearing in an insidious manner in a comparatively benign form they gradually undergo malignant evolution, with slow but certain destruction of the tissues involved and the life of the victim. Complete removal of the entire tumor is exceedingly difficult, and years after what was considered a successful operation the lesion returns with features of advanced malignancy. With each successive recurrence there is a tendency to depart further and further from the myxomatous and cartilaginous structures which characterized the original growth.

The microscopic structure is varied and bizarre, which accounts for the term mixed tumor applied to these neoplasms. It may arise as a myxochondroma, composed of myxomatous material which stains like cartilage, groups of epithelial cells often assuming a glandular architecture, fibrillar connective tissue with mucin,

and occasionally lymphoid tissue and bone. As the tumor develops, frank carcinomatous alterations occur which reveal, on successive examinations, a transition from a chondromatous tumor to an epithelial neoplasm of a highly malignant nature.

The prognosis is exceedingly grave. Dr. C. V. Weller has frequently said, "It is my own conviction that the fate of the patient lies in the hands of the first surgeon. Hope of a cure rests with the man who performs the first operation. If he can successfully eradicate every part of the lesion there is, of course, little danger of a recurrence. This is seldom accomplished. We continue to attack these tumors with knife, cautery and radiation, but our numerous failures give proof to the belief that modern treatment of these neoplasms remains a provoking and unsettled problem."

In the Clinic of Otolaryngology, where several hundred thousand patients have been examined in the past thirty-five years, only 2 cases of a tumor of pituitary origin occurring in the nose and nasopharynx have been seen. I regard them as neoplasms of great rarity, for a diligent search of the literature has thus far failed to disclose a record of a tumor of similar nature. Meeker states that pituitary tumors may arise in the nasopharynx but are very rare. Baily suggests the possibility of such a lesion in acromegaly, but has never observed the tumor. Haberfeld has discovered the pituitary gland in the nasopharynx of man but has not found it undergoing neoplastic growth. A record of these cases is as follows:

CASE I.—Mrs. O., aged forty years. Chief complaint, hoarseness and difficult breathing. Enormous tumor of posterior wall of nasopharynx and oral pharynx which was first noticed by the patient six weeks ago. Lateral soft tissue plates show a large swelling of the retropharyngeal tissues encroaching upon both the nasal and oral pharynx, extending down beyond the limits of the palate to the level of the fourth cervical vertebra. Material taken for biopsy. Patient refused operation and returned to her home, where it is said she died of suffocation.

CASE II.—Mrs. A. H., aged forty-five years. Chief complaint, difficult nasal respiration and pain in the right eye, which began two years ago. Right eye has slowly become prominent. Repeated intra-

nasal operations for the removal of a growth followed by many severe hemorrhages. Tumor in right nares with proptosis of right eye. Tissue obtained for microscopic study. Patient returned to her home and died of hemorrhage.

These two tumors present a similar pathological picture, so that they may be properly described as one. They are soft, elastic tumors without capsules and appear to infiltrate the neighboring tissues. Both present an alveolar grouping, the alveoli being separated by fibrous septa. The structure of these growths is cystic and there appears to be a tendency to form the reticulated structure of the adamantinoma. In one of the tumors colloid can be seen within the cystic spaces; in the other, ductlike structures with evidence of side branches suggestive of hypophyseal remains are clearly demonstrated.

In the embryological development of the hypophysis a stalk is formed which connects Rathke's pouch with the oral cavity. This stalk separates from the gland and its epithelial remains are found throughout life somewhere between the sphenoid bone and the epithelium of the nasopharynx. This vestigial remnant of the epithelial tract which forms the anlage of the anterior pituitary lobe has been termed the pharyngeal hypophysis.

It seems logical to assume that both of these tumors were of teratological origin, developing from the remnants of the hypophyseal duct. Their close relation to the pituitary gland and their histopathological structure seem to properly refer them to a group of hypophyseal tumors which are sometimes called crineopharyngeomas, but heretofore have been found within or above the sella turcica.

DISCUSSION

DR. GORDON B. NEW, Rochester, Minn.:

Dr. Furstenberg has given such an excellent paper, I do not know when I enjoyed one as much. There is no question but that the tumors he described are exceedingly rare. The so-called mixed tumors referred to are an interesting group. The results of the treatment, as he has brought out, depends entirely on the first surgeon to see the patient. I have never seen one that was completely removed

without rupture that ever recurred. I have seen many that have been repeatedly cut into and partially removed that have recurred locally and metastasized to the spine and pelvis. I have never seen one recur that was completely removed at the primary operation.

Regarding the cysts of the neck that he referred to, we have found that in infants and children the multilocular cysts, or the hygroma cystica, may be completely removed using radium externally, and by repeated treatments are cleared up. I do not think it necessary to use surgery in these cases, except to remove a fibrous area of tissue that sometimes remains.

I want to congratulate Dr. Furstenberg on his excellent paper.

DR. FURSTENBERG (in closing):

In conclusion I wish to thank the members of the Association for their kind attention and to express my gratitude to Dr. New for his courtesy in discussing my paper.

RHABDOMYOMA OF THE LARYNX

REPORT OF A CASE

CHARLES J. IMPERATORI, M.D.

RHABDOMYOMA of the larynx is of very rare occurrence, for no cases have been reported in the literature and practically no atten-

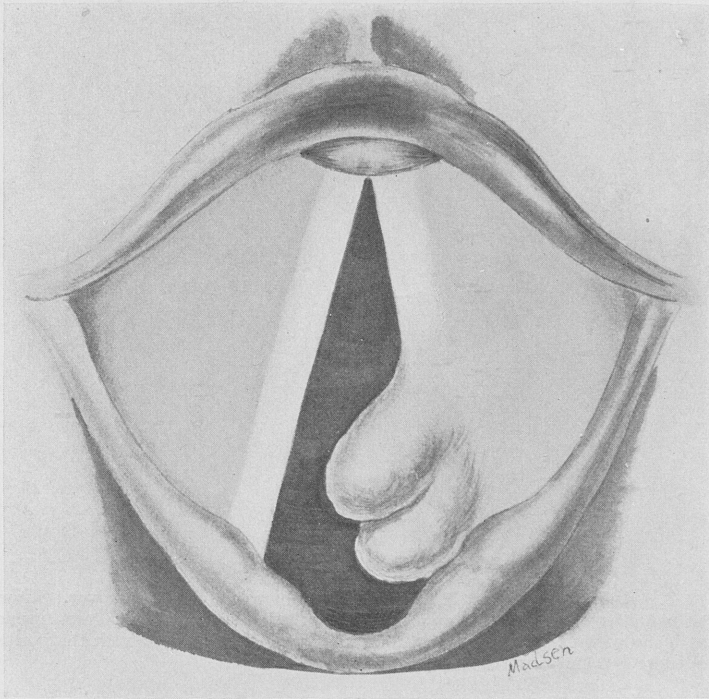


FIG. 1.—Rhabdomyoma of the larynx. Lobulated growth attached to the posterior part of the right cord.

tion is given to this type of connective-tissue tumor in the textbooks on laryngology or pathology. The report of the occurrence of such a tumor in the larynx of a young man may be of interest.

H. S. MacD., aged twenty-three years, premedical student, born in Nova Scotia. Up to one year ago his history relative to his larynx was negative. There is no history of voice trauma and he smoked very moderately. Ten months previous to the first examination, September

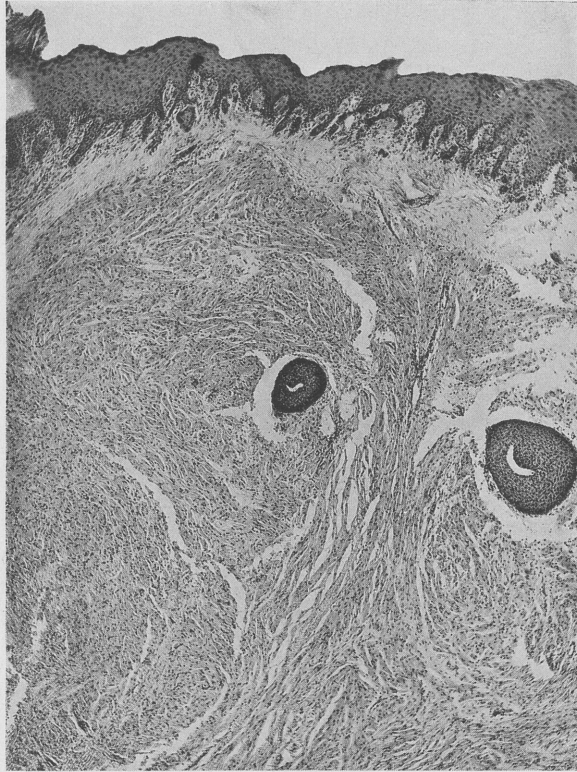


FIG. 2.—Rhabdomyoma of the larynx. Photomicrograph. Low power. Showing an epithelial covering and a stroma beneath it of spindle cells that, on being specially stained, show that they are striated muscle fibers. Intermingled with these muscle fibers there is a small amount of fibrous tissue.

13, 1932, he gradually became hoarse. This increased in amount. He was seen by Dr. E. R. Faulkner, who referred him to me for excision of what appeared to be an atypical fibrous growth of the left vocal cord.

Physical examination was negative other than a lobular, sessile growth that was attached to the posterior third of the left cord on its

superior surface. There was no appearance of infiltration. The growth was about the size of two green peas and light red in color. There was considerable air wasting on phonation and the voice was hoarse. The right cord appeared to be normal.

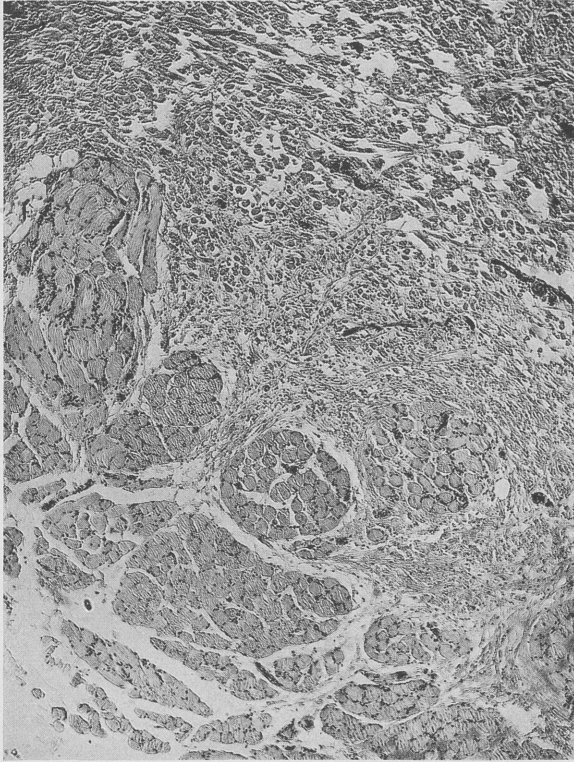


FIG. 3.—Photomicrograph. High power. Showing muscle bundles and fibrous tissue stroma. The nuclei of the muscle fibers are easily seen.

Under local anesthesia, and using a Jackson laryngostat, the growth was removed on September 14, 1932, using a cup type of forceps and removing the remaining tags with a biting forceps. The pathological report is as follows:

Size 15 by 7 by 6 mm. Coarsely papillary and firm. Cut surface is pale yellow and homogeneous.

Microscopic: All of the tissue was sent through and sectioned. There is a covering of stratified squamous epithelium that shows

irregular thickening with irregular prolongations at the base. At one point the epithelium shows transition to the columnar type. Several ducts of mucous glands show metaplasia of the epithelial lining, from columnar to squamous in type. The stroma beneath the epithelium is formed chiefly of spindle cells which seem to represent muscle fibers. With special staining these spindle cells are further identified as striated muscle fibers. They vary in size and shape. Some of them are embryonal in type, some of them are multinucleated and still others show communicating branches with central nuclei as in heart muscle. Mitotic figures are not found. Intermingled with the muscle fibers there is a small amount of fibrous tissue, especially beneath the epithelium.

Diagnosis: Rhabdomyoma.

Under date of January 13, 1933, Dr. A. E. Doull, of Halifax, states that there is no recurrence of the growth and the patient's voice is of normal volume and quality.

FIBROLIPOMA OF THE LARYNX

REPORT OF A CASE

CHARLES J. IMPERATORI, M.D.

(From the Laryngological Service of the New York Post-Graduate Medical School and Hospital, Columbia University)

THE patient from whom this growth was removed was a Mrs. A. Z., a widow, aged sixty-one years, and a Bohemian by birth. She was

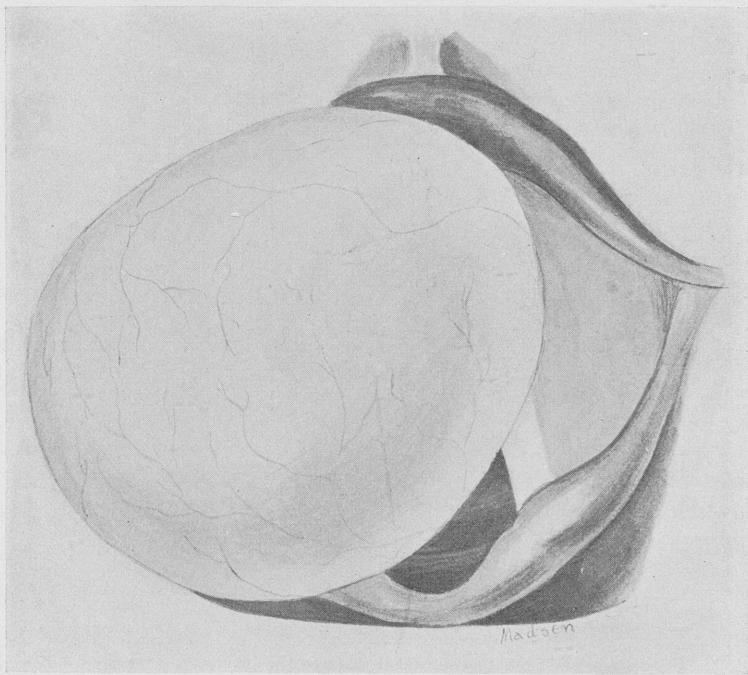


FIG. 1.—Fibrolipoma. Encroaching on the vestibule of the larynx, so that there is a very small airway, posteriorly. The upper part of the growth is in the lower pharynx.

admitted to the New York Post-Graduate Hospital, complaining of dyspnea, particularly on exertion, and dysphagia. The date of admission was April 7, 1932.

General examination showed that she had a moderate degree of cardiovascular disease, diabetes mellitus and a considerable degree of laryngeal obstruction.

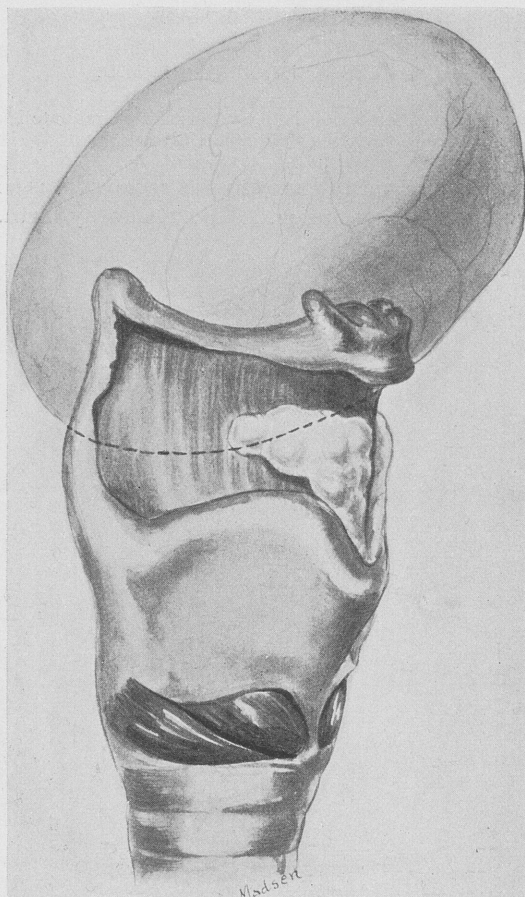


FIG. 2.—Diagrammatic view of the fibrolipoma in the larynx and laryngopharynx.

Laryngeal examination revealed a large pinkish tumor, rather pyriform in shape and attached by a broad but narrow pedicle to the right arytenoid and aryepiglottic fold. The pedicle, which was very short, seemed to be part of the aryepiglottic fold. The tumor was partly situated in the pharynx, but most of it was in the vestibule of the larynx and practically occluded the entrance of the larynx, with

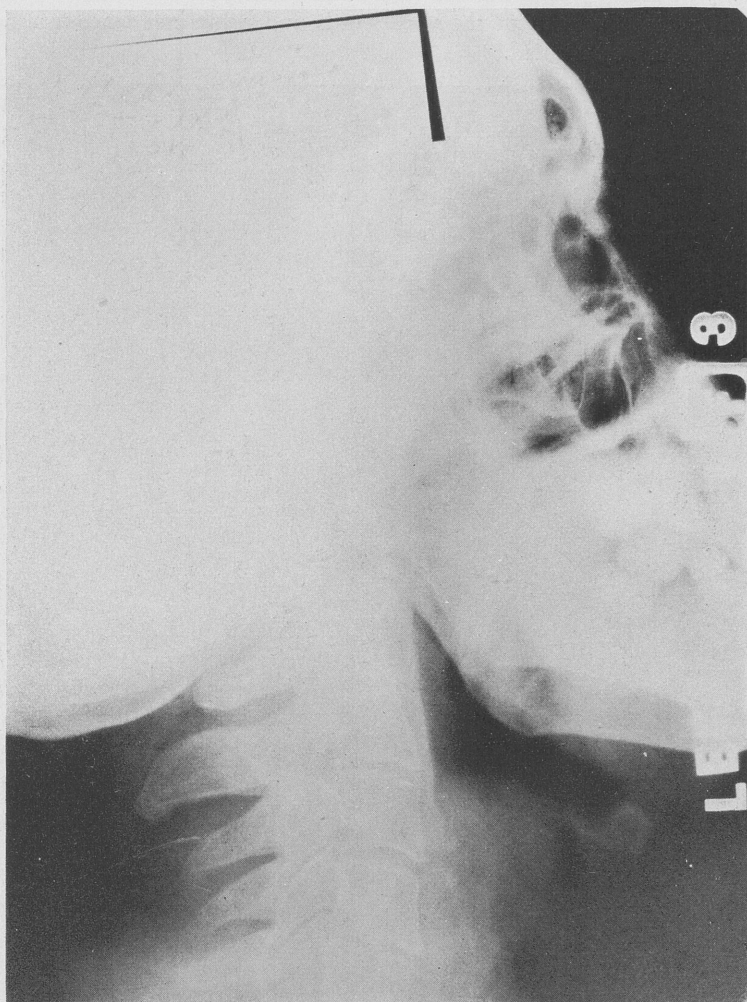


FIG. 3.—Roentgenogram showing lateral view. The growth is seen in outline below the hyoid bone. The vestibule of the larynx is considerably obstructed, but because of the angle that the film was taken the growth appears to be situated posteriorly.

the exception of the posterior commissure. The vocal cords could only be seen by grasping the tumor and pulling it to the side. There was no involvement of the vocal cords and, while her voice was not hoarse, it was muffled.

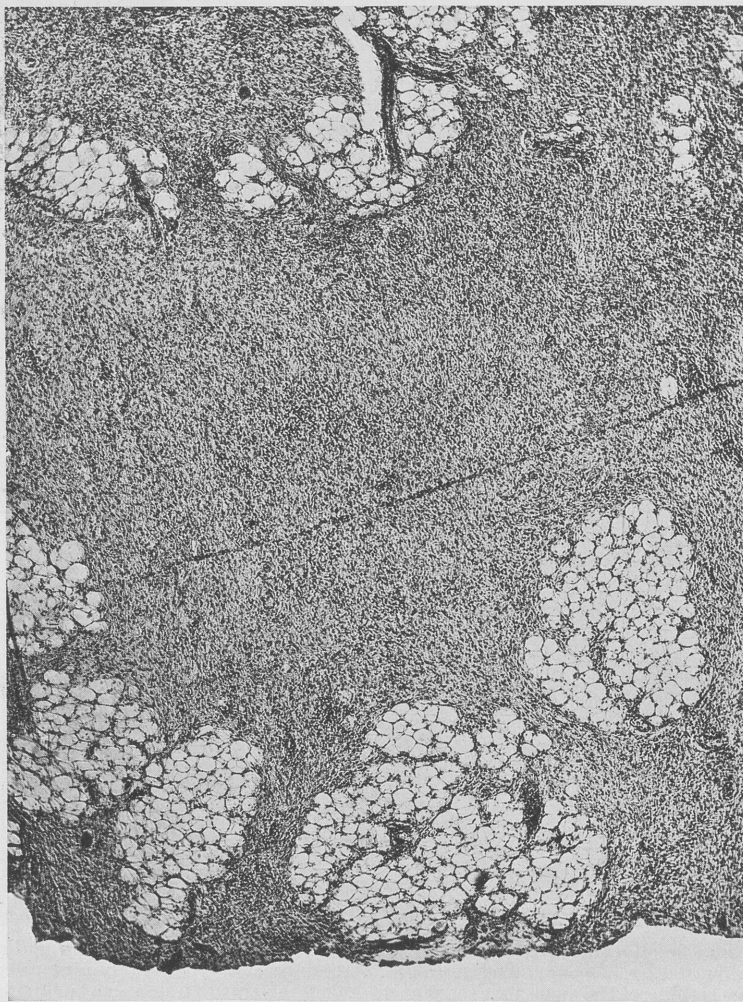


FIG. 4.—Photomicrograph showing fibromatous stroma with fat cells scattered in groups.

Laboratory findings showed 0.86 per cent sugar in the urine and a 3+ protein and acetone. Blood sugar was 200.

Medical treatment improved the patient's condition so rapidly that within four days the laboratory reports showed that the urine was free from sugar, albumin and acetone. Her blood sugar was 150.

A preliminary tracheotomy was done April 9, 1932, under local anesthesia, and also a biopsy. The report from the pathologist was that the tissue submitted was that of a fibrolipoma.

On April 15, 1932, under ether anesthesia and in the suspension laryngoscope, it was seen that the tumor was attached to the aryepiglottic fold, right arytenoid and down on the posterior surface of the larynx to the cricoid cartilage. The tumor was grasped with a uterine volsellum forceps. An incision was made on each side of the pedicle and a partial dissection with scissors was done. Then a large wire loop in a Moseley snare was passed over the growth and the mass removed almost in its entirety. Several tags were removed with large biting forceps. The tumor measured 7 by 6.6 by 4.7 cm. A feeding tube was placed in the esophagus. She was fed a special diet, because of her diabetes. Insulin was also given. There was comparatively little reaction, and on the third day postoperative the feeding tube was removed and on the fifth day the tracheotomy tube.

The report of the pathologist is that of a fibrolipoma.

Tumors in this location and of this size are not common; I have seen 3 others. One was carcinomatous and operated upon, considering that it was a cyst. However, there was no recurrence and the patient lived for twelve years after removal, dying from pneumonia. The other 2 were branchiogenetic in character. One of these has recurred. All of these patients were females and the location similar. In 1 of the patients with the branchiogenetic growth, removal was by thyrotomy.¹ The other 3 patients were operated upon in the suspension laryngoscope.

Lipoma may be fibromata that undergo fatty degeneration and they show a tendency to recur.

St. Clair Thompson² reports less than 25 cases. Chappell reported a similar case before this Association in 1907. J. Solis-Cohen³ reports a few similar cases. Several of these growths were removed by ligation and strangulation. Jackson⁴ reports 7 cases of lipoma of the larynx seen in an experience of forty years. Hinkel reported, in 1898, before this Association, a lipoma that repeatedly recurred. Jonathan Wright examined the tissues

microscopically. Max Goldstein, in the September, 1909, number of *The Laryngoscope*, reported a similar case and 12 others from the literature.

My patient was seen recently and there has been no recurrence.

BIBLIOGRAPHY

1. Imperatori, Charles J.: Branchiogenetic Cyst of the Larynx, Removed by Thyrotomy, *Laryngoscope*, 1929.
2. Thompson, St. Clair: Diseases of the Nose and Throat, 3d ed., p. 544.
3. Solis-Cohen, J.: Diseases of the Throat, William Wood & Co., 1872, p. 227.
4. Jackson, C., and Coates, G. M.: Nose, Throat and Ear and Their Diseases, Philadelphia, W. B. Saunders Company, p. 900.

CONTACT ULCER OF THE LARYNX

REPORT OF A CASE

CHARLES J. IMPERATORI, M.D.

THE title, "contact ulcer,"¹ is one given by Chevalier Jackson to a superficial ulceration on one or both sides of the larynx posteriorly, the ulcerated surface coming in contact, on phonation, with that of its fellow of the opposite side, the latter being ulcerated or not, according to whether the ulcer is monolateral or bilateral. These ulcer's are of comparatively rare occurrence.

Pathologically, they present the usual characteristics of chronic inflammation with ulceration. Usually, a chronic productive inflammation with recent edema and congestion, or exuberant granulation tissue with ulceration of the surface, is what is found on microscopic examination.

There do not seem to be any specific histological characteristics. The location of the lesions is at the vocal processes and posterior to them. Very little has been done on the bacteriology as an etiological factor, although Jackson suggested the possibility of Vincent's organism.

Symptoms are usually slight to occasional hoarseness. Occasional sharp, stabbing pains in the larynx and occasional awakening at night with a choking sensation that is probably caused by an overflow of saliva into the larynx. Because of the chronicity of the lesion, tuberculosis and cancer must be differentiated.

The patient who has this lesion is a healthy professional man, aged forty-four years. Family history and past history negative in so far as this present condition is concerned. Has never had attacks of laryngitis and has had few colds in the head. While there is no history of voice trauma, he used his voice a great deal and at times excessively. Does not use tobacco and is very moderate in the use of alcohol.

He was first seen in October, 1931, and gave a history of having had an acute attack of pain in the left ear and neck while touring about a week previously, and this was followed by hoarseness and

some amount of coughing. Two weeks previously had had a severe head cold and profuse nasal discharge. The night before he came to see me he had had a severe attack of coughing coming on during sleep. There was a slight amount of mucoid secretion expectorated.

Physical examination of his nose, throat, ears and chest was negative excepting that on the superior surface of the left arytenoid there was a small bleb and on the vocal process there was a small, glistening elevation about 3 or 4 mm. in diameter, with a slightly infiltrated base.

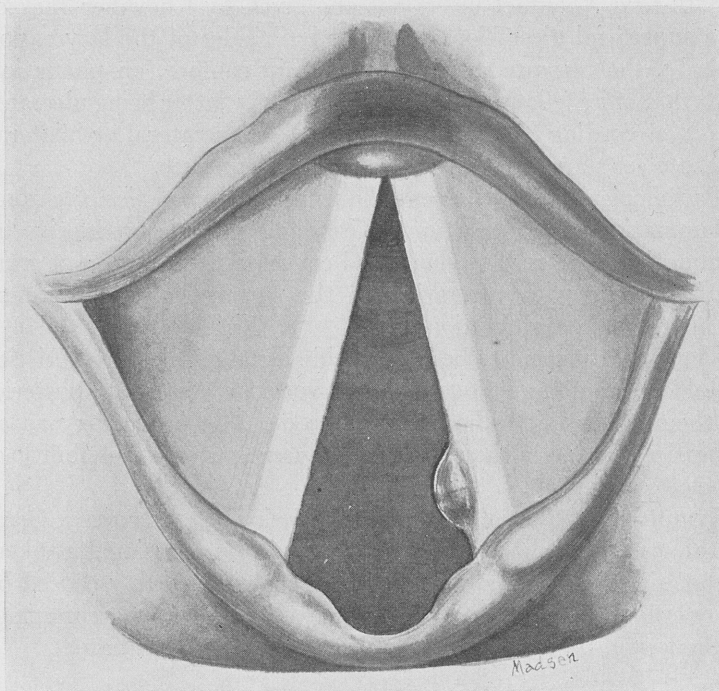


FIG. 1.—The vesicular lesion seen at the vocal process, before rupture. There is no degree of infiltration of the adjacent tissue.

There was edema of the uvula. This last was attributed to the severe coughing of the night before.

Within a few days the bleb on the arytenoid disappeared, but the one at the vocal process ruptured and within another few days presented a typical ulceration, but not of any depth. Within a month there were granulations surrounding the site of the ulceration and giving it a cup-shaped appearance.

The vocal cord anterior to the vocal process was not injected to any degree. The right cord was normal. Wassermann reaction and roentgen-ray of his chest were negative. His sinuses were negative. There was no sputum obtainable for examination.

The laryngoscopic picture remained essentially the same, excepting that there was a gradual lessening of the size of the ulceration and a

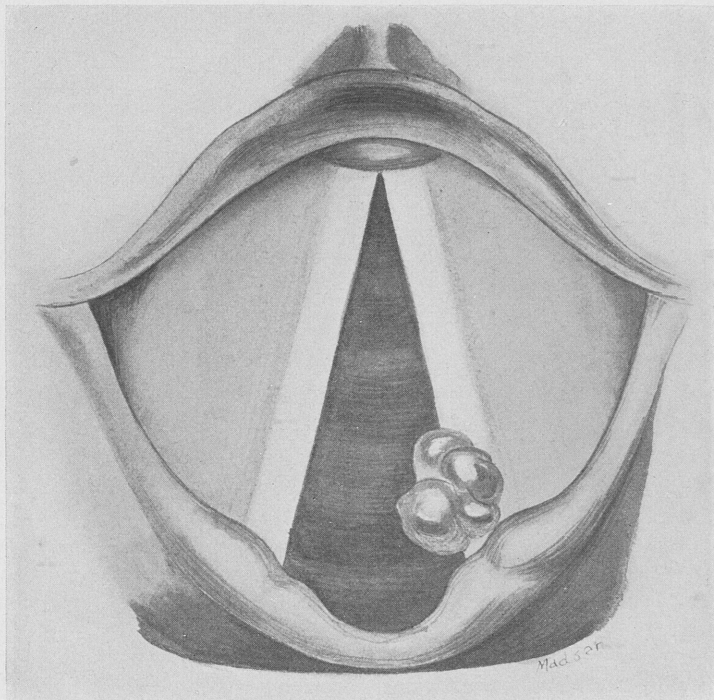


FIG. 2.—Granulation tissue at site of vesicle after rupture and ulceration.

gradual building up of the granulations, so that by the latter part of March, 1931, five months after onset, there was a polypoid mass about 4 mm. in diameter, located at the vocal process.

Voice rest and occasional inhalations had been used. At this time the patient was seen by Dr. C. G. Coakley, who felt that the condition was possibly a papilloma and agreed that it might be granulation tissue. He advised removal, microscopic examination and complete voice rest. His advice was followed and the laboratory report was that the specimen was granulation tissue.

Within a month, April 24, 1932, there was about the same laryngeal picture and a beginning of a cupping on the vocal process of the right cord, so that the granulations on the left cord fitted into it. Cauterization with electric cautery was done at this time and the granulations destroyed. The small ulceration on the right cord disappeared but the granulations on the left cord reappeared, and consul-

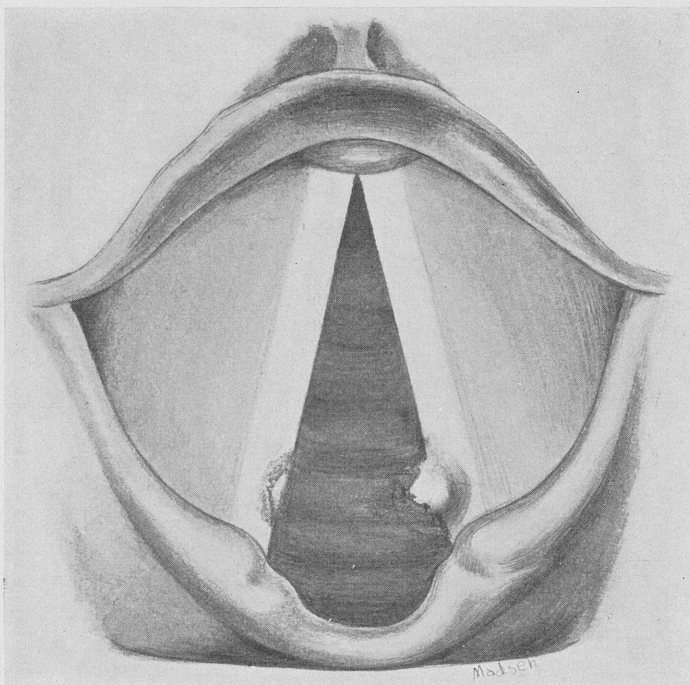


FIG. 3.—Appearance of a bilateral lesion with granulations on the left side and superficial ulceration on the right. On phonation these lesions fit into each other.

tation with Dr. Jackson was had in the early part of June, 1932. His diagnosis was contact ulcer. Wassermann and roentgen-ray of the chest were done by Dr. Jackson. He advised complete voice rest and removal of the granulations when indicated.

The treatment advised was carried out. However, by the end of August, 1932, the granulations on the left cord were about 8 mm. in diameter. These were removed and microscopic examination showed the tissue to be exuberant granulations and no evidence of any new growth.

During the next three months there was a very small ulceration on the left vocal process and a very small granulation on the right cord that fitted into the ulceration on the left cord. During this period, for about one month, applications of 1 per cent silver nitrate were used and, not appearing to be of any benefit, were discontinued. A 0.5 per cent solution of zinc chloride was used twice daily for several weeks, but this did not appear to make any difference and so was discontinued. Voice rest was continued. The lesions remained about the same in size, and for a period of two weeks previous to December

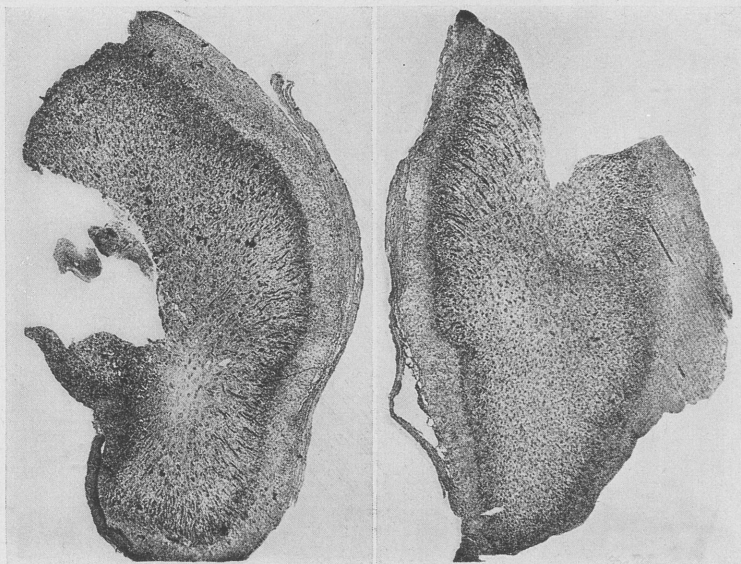


FIG. 4.—Photomicrograph showing granulation tissue with necrotic capsule.

17, 1932, he was allowed moderate use of his voice. His voice was fairly clear and only occasionally was it husky.

At this time he was again seen by Dr. Jackson. Diagnosis, contact ulcer, with the advice that further study be given the tissues removed. Laryngoscopic picture remained about the same. On December 19, 1932, the lesions were removed from both sides and part of the tissue, after proper preparation, injected into a guinea-pig. One month later Koch's old tuberculin was injected into the pig.

Later the pig was killed and the lymph nodes examined, but there was no evidence of tuberculosis.

Patient went to Florida and remained there until February 10, 1933, when he returned to New York. Laryngeal examination showed the left cord to be entirely healed and no evidence of any ulceration.

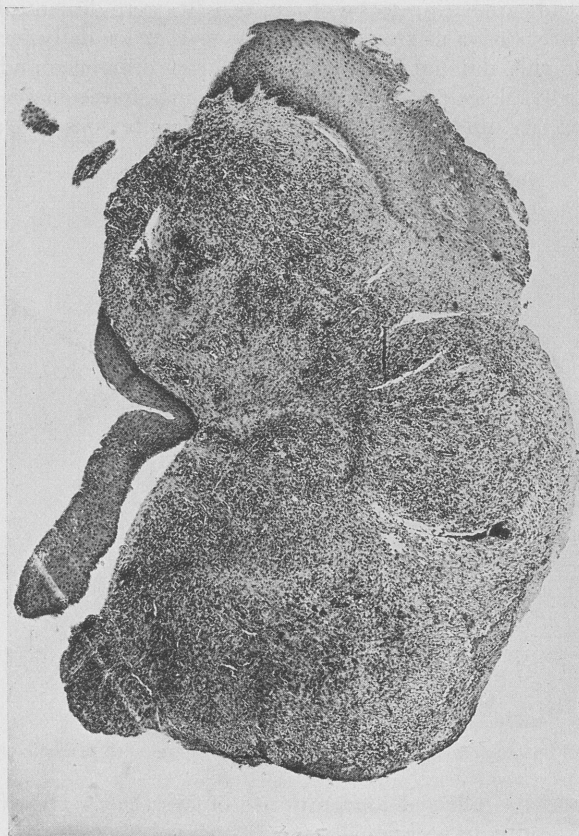


FIG. 5.—Photomicrograph showing chronic productive inflammation with edema and congestion. This is an exuberant granulation. In one corner of the preparation there is a partial epithelial capsule.

On the right cord there was a small granulomatous mass about 3 mm. in diameter. This was removed and the microscopic examination showed severe chronic productive inflammation, with atypical cell proliferation. Bacteriological studies were inconclusive.

The patient then returned to Florida and was again seen on March 27, 1933. Laryngoscopic examination at this time showed the left cord entirely healed. The right cord at the site of the ulceration showed a small elevation of about 2 mm. in diameter. No infiltration of the surrounding tissue and normal movement of arytenoids and cords. Voice practically normal.

The mass of granulation tissue with its ulceration was removed on March 30, 1933. Microscopic examination showed chronic inflammation and no cells of atypical growth present.

This area where the ulceration was removed has epithelized and the patient was seen recently and remains cured.

Both cords appear to be normal as regards movement and size.

The voice is normal. There does not appear to be any scar at the site of the ulcerations, probably because of the superficial nature of this condition.

It would seem that the condition spoken of as contact ulcer is what has been described by Virchow² from postmortem findings and by Fränkel from clinical observations as pachydermia laryngis. From the location and macroscopic appearance they would seem to be similar conditions.

Microscopically the contact ulcer is of a simple, inflammatory nature and, when changes occur in the blood supply, eventually ulcerates but ultimately heals. Pachydermia laryngis is a proliferation of the epithelium and a great multiplication of the papillæ. Ulceration occurs occasionally. This condition is usually induced by a sinusitis or any other irritation caused by a chronic infection above the larynx. The growth is usually of some size and the common location is in the interarytenoid space, although the vocal processes and the cords may be the site. Contact ulcer is superficial and is always located at or behind the vocal process, and commonly the growth is accompanied by a similar condition on the opposite cord, excepting that one is an elevation and the other is an excavation.

BIBLIOGRAPHY

1. Jackson, C., and Coates, G. M.: *The Nose, Throat and Ear and Their Diseases*, Philadelphia, W. B. Saunders Company, 1929, p. 807.
2. Turner, L.: *Nose, Throat and Ear*, William Wood & Co., 1924, p. 177.

DISCUSSION

DR. CHEVALIER JACKSON, Philadelphia, Pa.:

This very interesting contribution to the subject of contact ulcer is particularly important because it is carried out in every detail, including the histologic examination. We have lacked the opportunity for autopsic study because it is not a fatal disease. We have never discovered a subject in the morgue showing a contact ulcer, but my friend and pupil, Dr. Achille Peroni, in the Pathologic Institute at Milan, Italy, has in two instances discovered contact ulcers in the course of a general and complete autopsy. Both cases demonstrated the conditions shown in Dr. Imperatori's sections and, in addition, necrosis of the tip of the vocal process of the arytenoid. This necrosis has seemed to me to be one of the etiologic factors or at least a perpetuating factor.

The repair of cartilage is poor everywhere in infected areas. While it is true we can successfully transplant cartilage in an aseptic wound and it will produce no reaction, it is equally true that denuded cartilage anywhere exposed to infection, as it is in the larynx, will keep on granulating and pushing out granulomata almost indefinitely. This seems to be one of the perpetuating factors in contact ulcer.

In our biopsies, we have nipped off the tip of the vocal process when we believed it to be necrotic, and in every case we have found it so.

The treatment depends upon whether it is flat or fungating. We avoid all cauterant applications and give the flat ulcer a chance to heal under vocal rest, as Dr. Imperatori advised. Applications of silver nitrate act harmfully. If it is of the fungating type, we follow the course pursued by Dr. Imperatori in this case. These granulomata springing up from the ulcer are not the hyperplasia that comes in pachydermia—that is an entirely different thing. Contact ulcer is not the ulcer that comes posteriorly in tuberculosis. The ulcer is of the simple, not specific type. When I speak about removal, I mean careful precise work such as Dr. Imperatori used in this case. The abnormal tissue should be superficially scalped off with no damage whatever to the normal remaining tissues.

DR. WILLIAM B. CHAMBERLIN, Cleveland, Ohio:

This second case Dr. Imperatori presented suggests one on which I operated a number of years ago. I thought that this was a fibroma—firm, dense and resistant to touch. I removed it by the indirect method with a snare. It proved to be a microscopic tuberculoma on examination. I never saw one before and I have never come across one since. It was extremely dense, suggesting a fibroma, and was about 2 cm. in diameter.

DR. M. C. MYERSON, Brooklyn, N. Y.:

I had one of the men in the laboratory look up the literature on rhabdomyoma of the larynx, and there is absolutely nothing in the foreign literature about rhabdomyoma of the larynx.

I would like to present for consideration a theory, if you will, of the causation and production of the lesion which we call contact ulcer.

My understanding is that, in the first place, we must have a cartilaginous base upon which this lesion is superimposed. In the second place, we must have a break in the continuity of the superimposed lining of the mucous membrane. If you will recall, every one of us has seen thyrotomies in which well-formed granulomata appear within a period of weeks or months after the operation. My feeling is that perhaps, for some reason or other, we get a break in the continuity of the mucous membrane lining. With this cartilaginous background, the process of regeneration evidences itself in the form of granulomatous tissue. In the anterior commissure, the function of the larynx permits the formation of a well-defined granuloma. In the posterior commissure you have your joint asserting itself due to the muscles attached to it. We have motion and that motion would account, of course, for the ulceration on the opposite side and for the histologic changes which one sees in this type of lesion over a period of time.

I suggest that as a possibility of explanation of this lesion.

DR. JACKSON:

In regard to etiology, it has seemed to us to be the hammer and the anvil, traumatic action from the striking of one vocal process against the other. This is the initial trauma and the perpetuating factor as well; the hammering together of the two sides of the cartilaginous glottis, with every word the patient says, prevents healing.

DR. IMPERATORI (in closing):

The various speculations on the cause of contact ulcer are very interesting. On this particular patient I have operated seven times. Twice on the introduction of the laryngostat and before it was inserted all the way, what Dr. Jackson said about the hammer and anvil occurred, for both the arytenoids would snap at each other, just as though one were snapping the thumb and finger. I feel that Dr. Jackson's idea and contention is absolutely correct, plus infection of a type we have not been able to determine. We have felt that the spirillum of Vincent was the cause. Careful smears and cultures taken from the ulcer were negative.

FIBROEPITHELIAL TUMORS OF THE NOSE (PAPILLOMA) AND THEIR RELATIONSHIP TO CARCINOMA

ERNEST M. SEYDELL, M.D.

THERE is so much confusion in reference to the classification of papillomas that, when this term is used in the literature, it is extremely difficult to indicate to just what pathological picture one is referring.

The term papilloma has been applied rather generally to benign fibroepithelial tumors of the epidermis and of the mucous membrane of the nose, bladder and other organs. Due to the aforementioned confusion of terms and because of the clinical and prognostic relationship of the fibroepithelial tumors of the nose, in this paper, the terms papilloma and fibroepithelial tumor will be used synonymously.

It has been stated that papillomas of the nasal cavities and paranasal sinuses occur so rarely that each case should be reported, in hope that from these reports, the accumulated data will help to solve some of the perplexing phases of this problem.

FREQUENCY AND LOCALIZATION. Of 180,000 patients examined in Koffers¹ surgical clinic, only 3 had papilloma of the nose. Moritz Schmidt² found 1500 nasal tumors in 33,600 patients; of these growths, 6 were papillomas. In 1929 Eckbert Möbius³ made a survey of the literature and found that 60 cases of papilloma had been reported. The majority of these tumors were the wartlike papillomas of the vestibule and the truly neoplastic papillomas of the deeper portions of the nose.

The scarcity of case reports is, at least in part, due to the fact that papillomas are frequently mistaken for polypi or other benign growths or, because of their malignant clinical manifestations, for carcinoma.

Fibroepithelial growths arise as either solitary or multiple tumors varying greatly in size, form and consistency. They occur in greatest frequency in the vestibule of the nose, especially on the

anterior portion of the septum. Here they spring from the transitional epithelium which lines this portion of the nose. Out of the 32 cases of papilloma of the nose which Hasslauer⁴ found in the literature, 20 arose from the anterior portion of the septum. Papillomas also may arise in the posterior or superior portions of the nasal cavities, especially from the middle turbinate and ethmoid regions. They occur very rarely as primary growths in the paranasal sinuses. The following case reports are found in the literature: Herxheimer,⁵ Holmgren,⁶ Saxen,⁷ Neumayer,⁸ and Ewing.⁹ (Seydell, Case V.)

Papillomas are found more frequently in the male, usually between the fourth and fifth decade, but may occur at any age.

CLASSIFICATION. In all these growths we are dealing with structures composed of both epithelium and vascular connective tissue, the supporting tissue being sharply demarcated from the epithelium covering it. It is, therefore, consistent to name them fibroepithelial tumors. It will be noted that the quantitative relation between the epithelium and connective tissue varies considerably. In these fibroepithelial (papillomatous) growths there remains in the tumor a definite type of structure, similar to the formation found in normal skin, *i. e.*, a connective tissue stroma containing vessels and glands covered with epithelium.

There is no unanimity of opinion in reference either to the clinical or histological character of the papillomas. Some authors classify them with the malignant tumors, naming them papillary carcinoma, adenoma malignum and adenocarcinoma; others hold that they are benign and name them adenoma, fibroma, fibroepithelioma papillare and papilloma durum.

This diversity of opinion is due largely to the fact that the infrequency of these growths has made it impossible to make a comprehensive study of their histopathological characteristics. In some instances fibroepithelial tumors of a papillary type lose some of their benign characteristics. In these cases it is extremely difficult to determine by a histological examination whether the growth is benign or malignant. This fact will be referred to again later in the paper.

Papillary growths were formerly classified, according to the type of their epithelial covering, into hard and soft papillomas, the

hard type having a surface membrane composed of stratified squamous epithelium, the soft type being covered with columnar epithelium.

It has been shown that this classification is not consistent with the facts, inasmuch as the squamous-cell papillomas are frequently soft in consistency, while those covered with columnar epithelium may be hard. The degree of firmness of the tumor depends upon the degree of development of the connective tissue, and not upon the character of its covering membrane. It has been shown further that in some papillomas ciliated columnar epithelium may be found in immediate contact with stratified squamous.

ETIOLOGY. In view of the fact that most modern investigators consider nasal papillomas as being on the border between benign and malignant growths, the etiology of these tumors will be discussed, including some of the causative factors that are common to both papilloma and carcinoma. The results of some recent investigations on the etiology of carcinoma will also be included.

It has been rather generally accepted that the essence of tumor formation and that of malignancy is within the tumor cell. The four theories most frequently accepted are:

1. Many neoplasms originate from misplaced embryonal cell rests, *i. e.*, teratoma, neuroblastoma of the retina and sympathetic system, some of the angioma, etc.

2. There are undoubtedly many acquired tumors which have no relationship to embryonal cell rests. It has long been recognized that many new growths arise under the action of irritative factors. Usually this irritative factor is a prolonged one and may be of a mechanical or a chemical nature. Malignancies also develop on the basis of chronic infectious processes and in old scars.

3. "It has been realized that the irritation theory of malignancy is inadequate. Many neoplasms arise where no history or evidence of trauma can be determined. In others the etiology is known, as in roentgen-ray burns, and in these the removal of the causative factor does not stop the tumor formation. It has also been shown that a more or less prolonged period of time must elapse between the primary irritation and the formation of the new growth, which in turn signifies the presence of a continuous irritative process." (Fischer Wassels.¹⁰)

This investigator holds that the regeneration theory explains the development of these types of neoplasms.

The difference between the irritation and regeneration theories lies in the fact that neoplastic cells originate from normal cells through pathological regeneration and that there is no direct connection between the external trauma and the formation of the tumor.

Further, Wassels believes that there must be two factors operating in conjunction to produce a malignant growth, *i. e.*, the regeneration process and a constitutional factor. The nature of this constitutional factor is unknown. Also, it seems quite conceivable that this constitutional factor is essential in the development of those neoplasms which originate from misplaced embryonal cell rests. Although Wassels theory has not been generally accepted by pathologists, many notable investigators support it in a general way and it seems to be gaining steadily in adherents.

Animal Experiments. Fischer Wassels cites the following animal experiments to support his contentions: He experimented with mice by painting their skin surfaces with tar. In these animals no skin lesions were produced; but when a small area of skin that had not been previously treated with tar was burned, papilloma and squamous-cell carcinoma developed. He also found that when a saturated solution of scarlet red was inoculated into the ears of rabbits, atypical epidermoid growths were produced, resembling a precancerous lesion but never becoming malignant unless, for a considerable period of time, the animal received small doses of arsenic. It was found necessary to continue the arsenic for from four to seven months before papillomas developed, and from seven to eleven months before these tumors became malignant.

Clara Lynch¹¹ found that mice were very susceptible to spontaneous malignant tumors of the lung, varying in frequency with the strain of mice. When these mice were treated with tar, the malignancies increased from 7 per cent to 22 per cent in one strain and from 37 per cent to 85 per cent in another. Scabad¹² had similar results and, in addition, found that in the offspring of mice whose ancestors had been treated with tar, the percentage of spontaneous carcinomas increased to a maximum of 74.3 per cent.

The presence of this so-called constitutional factor may explain

why so many patients have embryonal rests, regenerative processes, papillomas and other benign growths, burns and scars, yet relatively few have cancers. It may also be the determining factor in those cases of papilloma which remain quiescent for years and then suddenly burst into malignancy.

A number of authors have investigated the possibility that some endogenous poison might be this so-called constitutional factor. Wassels administered indol to a group of animals and carefully observed their reactions. This experiment was carried on for a period of three years. The blood-building organs of these animals became involved and a severe anemia with atrophy of the bone-marrow resulted. Most of the animals died of an acute anemia. In those that lived, a reduction of the dosage produced regenerative processes followed by a late anemia. The survivors were now given still smaller doses of indol and developed aleukemic leukemia, lymphadenoma and myeloma; and some, metastasizing lymphosarcoma. Finally, those which did not succumb to these diseases developed a myelogenous leukemia.

4. Deelman, Lubarsch and others advance another etiological theory which must be considered. They believe that tumors, especially the papillomas, which present for an indefinite period of time benign histological characteristics and only later manifest malignant changes, do not undergo malignant degeneration or pathological regeneration, but actually possess, from the beginning, latent malignant properties.

In reference to the specific etiology of intranasal growths, we find in the literature infections and irritations listed as causative factors. It seems probable that they are only indirectly the cause of these tumors since many of the cases reported in the literature have not given a history of a discharge from the nose.

Many of the neoplasms spring from the deeper portions of the nose and from the nasal sinuses, a fact which in turn would seem to exclude direct irritation as a causative factor. To explain the cause of neoplastic growths, it would seem that here, as elsewhere in the body, one must choose between many theories and a few facts.

PATHOLOGY. 1. *Macroscopic Pathology.* The fibroepithelial growths of the nose may resemble ordinary polypi with the differ-

ence that the former are of a deeper red color and have a firmer consistency.

In other cases the growth appears as a series of deep folds in the mucous membrane (Case V). Still others, and these have been termed the true papillomas or neoplastic growths, have a cauliflower appearance. These in turn may be divided into two classes—those arising in the deeper portions of the nose or nasal sinuses and those found in the region of the vestibule. The latter are much firmer and have a pale appearance resembling closely the ordinary wart.

There is still a difference of opinion as to whether in these tumors the primary hyperplasia begins in the epithelium or in the connective tissue stroma. It seems reasonable to suppose, as stated by Borst,¹³ that in those tumors in which connective tissue predominates and there is a probability that they are of inflammatory origin, the primary development takes place in the connective tissue. On the other hand, where the epithelium in the tumor predominates, the primary hyperplasia more than likely occurred in the epithelium.

2. *Microscopic Pathology.* Under low-power magnification the non-neoplastic fibroepithelial tumors present a papillary appearance in which the papillæ vary both in height and breadth. The epithelium covering the connective tissue stroma may be composed of stratified squamous or columnar cells. In some tumors both types of cells may be found in the same section. Finally, the epithelium may be of the undifferentiated or atypical type. The epithelium is sharply demarcated from the connective tissue stroma and at no place should it penetrate the basement membrane. A varying amount of round-cell infiltration is usually present. In these tumors the stroma exceeds the epithelial covering.

The cauliflower type presents slender stalks or budlike projections of vascular connective tissue stroma, varying in size and shape. The epithelium covering these projections is disproportionately massive and may even reach 1 cm. in thickness. Here, again, we may find every variety of epithelial cells. "A few true papillomas have been reported whose covering epithelial cells consisted of a single layer of ciliated columnar cells." (Schmidtman.¹⁴) These finger-like projections extend deeply into the connective

tissue stroma but are sharply demarcated from it by a basement membrane. In some sections we may find that there has been a hyperplasia of the basal layer of cells which penetrates into the stroma, probably by pushing downward the basement membrane. Under low power one will find cross-sections of these strands of cells as well as of every type of oblique section, depending upon the way in which the tissue has been cut.

Since many nasal papillomas are covered with squamous epithelium, it is natural to inquire how this epithelium originates in these locations. Its presence in the region of the vestibule has been explained by the theory that in areas where mucous membrane and skin come in contact, a transitional epithelium occurs in which the cells are not completely differentiated. In this area the cells, therefore, may develop into either the squamous or the cylindrical type. Where squamous epithelium is found in the deeper portions of the nose or nasal sinuses we must look for some other explanation.

Herxheimer⁵ has shown that many papillomas which were formerly thought to be of the stratified squamous type are in reality clothed with columnar cells which, in his opinion, have undergone changes in shape, due to pressure caused by the rapid proliferation of the epithelium. In these growths the microscope reveals that the upper layer of the epithelium is composed of closely packed cells resembling stratified squamous epithelium. The deeper layers contain cells which appear quite flat. They can, however, be differentiated from squamous cells by special staining methods. In addition, careful examination usually shows that in some of the valleys between the papillæ normal areas of ciliated columnar epithelium can be found.

Some authors believe that squamous epithelium when found in the deeper portions of the nose is the result of embryonic cell rests. The presence of both ciliated columnar and stratified squamous epithelium in close apposition in the same section would make this theory unsatisfactory. This leaves one other explanation, *i. e.*, metaplasia.

H. Renys,¹⁵ who has made a thorough study of this question, thinks that pressure is not the causative factor in changing cylindrical to squamous epithelium, but strongly favors the metaplastic theory.

It long has been recognized that epithelium may undergo metaplastic change and it is more or less accepted that squamous-cell carcinomas of the nose, bladder, bronchi and other organs develop on the basis of metaplastic epithelium. Listed among the causes of metaplasia are irritative factors, mechanical and chemical irritations, and chronic inflammatory processes.

Walback and Howe¹⁶ found that metaplastic changes in the epithelium occurred when white rats and guinea-pigs were fed a diet lacking in vitamin A. These changes were not confined to the eye, where avitaminosis produces xerophthalmia, but appeared in various organs. In the respiratory tract metaplastic changes occurred in the nose, nasal sinuses, trachea and bronchi. Similar changes were found in infants afflicted with avitaminosis.

CLINICAL SYMPTOMS. Fibroepithelial growths rarely produce severe symptoms. Nasal breathing gradually may become impaired, though years may elapse before complete nasal obstruction takes place. Secondary sinus infections occur when considerable nasal obstruction is present. Nasal hemorrhages are infrequent. Broadening of the root of the nose, due to distention or destruction of the nasal bones, has been reported in a number of cases. (See Case I.)

DIAGNOSIS. A diagnosis of nasal papillomas cannot be made on the basis of their macroscopic appearance. When destruction of tissue has taken place, papillomas easily may be confused with malignant neoplasms. Again, they may resemble very closely the ordinary polypi.

Slow growth, or absence of symptoms and of metastases, points toward the benign character of the growth but cannot be relied upon as a diagnostic criterion. This is true, especially since nasal carcinoma may remain quiescent for a long time without producing local or general symptoms, cachexia or metastases.

It is therefore essential to make a microscopic examination of a portion of the tumor. There should not be much difficulty in making a diagnosis by biopsy in typical fibroepithelial tumors, or if frank malignancy is present. Nevertheless, we must take into consideration the shortcomings of this method of diagnosis.

According to Reimann,¹⁷ the microscopic diagnosis of malignancy does not seem to rest upon a broad scientific foundation inasmuch as pathological interpretation of tissue is composed of 90 per

cent of art and 10 per cent of science. Fischer Wassels¹⁰ and others emphasize that empiricism plays the principal rôle in diagnosis by biopsy. Virchow's opinion that it is impossible to recognize a malignant tumor cell under the microscope still holds today. (Dietrich, Borst, Lubarsch, Sternberg, Maresch and Hertzler.¹⁷)

It is unfortunate that in regions of the body where skin and mucous membrane come in contact, tumors arise which may present an atypical epithelial arrangement. Under these circumstances, especially where it is possible only to remove a small portion of the growth, the histological picture may be such that it is impossible to be certain whether the tumor is benign or malignant.

Another difficulty which arises to make the histological examination uncertain is the possibility that a primary malignancy may be associated with benign growths, or that a carcinoma may for a time present a papillomatous appearance.

The simultaneous presence of a papilloma and carcinoma may be accounted for in several ways: (1) Coincidence; (2) both growths may have a common etiological factor; (3) a carcinoma may develop from a benign growth, as in the case of Bayer,¹⁸ in which a polyp had undergone malignant degeneration at its distal end, the pedicle being free from malignant changes.

Renys¹⁵ reported a case in which a fibroepithelial growth had been removed from the nose. The microscopic picture was definitely benign. Three months later there was a recurrence. When it was again sectioned, portions of it were found still benign while other parts were definitely malignant.

It is also true that no morphological method has been devised whereby a conclusion may be reached as to whether a noncarcinomatous atypical cell proliferation will actually develop into a malignancy or will prove to be harmless. The deciding factor when such a lesion results in a malignant tumor may be an individual predisposition, the nature of which is utterly unknown.

Atypical papillary tumors are so numerous that the question of the advisability of the use of the terms precancerous, or beginning cancer, is rather important. It seems that the use of these terms as a histological diagnosis is condemned by many of our best pathologists. "Ewing's writings indicate that he favors the the-

oretical conception of a precancerous stage of epithelial proliferation passing by insensible gradations from normal cells to fully developed cancer, but in practice he regards changes without definite signs of malignancy as benign and does not permit including 'precancerous lesions' in the statistics of cured cancer." (Helwig.¹⁷)

PROGNOSIS. When not interfered with, fibroepithelial tumors slowly increase in size. Some develop into large tumors, while others spread over a considerable portion of the nostril without forming a large tumor mass (author's Case III). Destruction of tissue and bone has been frequently observed and in a number of cases the papilloma has invaded one of the sinuses; thus the dura may be laid bare with meningitis resulting.

In a general way, the prognosis is more favorable if the tumor is solitary and if located in the anterior half of the nose. When the tumors are removed with a snare or punch, they recur in the majority of cases, frequently within a few months, the secondary growth often attaining a much larger size than the parent growth. These recurrences if removed will likewise return. Cases have been reported in the literature where recurrences have been removed over a period of twelve years without producing symptoms or becoming malignant.

It is unfortunate that we not able always to be certain of the prognosis of papillomas. It is a well-known fact that in papillomas of the bladder, which occur more frequently and which have been more thoroughly investigated than those which occur in the nose, malignancy frequently develops in histologically benign papillomas. This malignant change also occurs in papillomas of the nose.

"We are able to diagnose a fully developed carcinoma, but it is impossible to state that a benign-appearing papilloma will not become malignant. The study of experimentally produced tar papillomas has shown that it is impossible to determine by morphological methods which of a number of tar papillomas will later become malignant. In other words, a papilloma may be morphologically benign but biologically malignant." (Deelman.¹⁹)

Nasal papillomas which later have become malignant have been reported by Saxen,⁷ Ewing,⁹ Kesselbach-Hellman,²⁰ Pold,²¹ Renys¹⁵ and others.

TREATMENT. In view of the fact that fibroepithelial tumors of the nose are considered to be on the border between benign and malignant growths, it is essential that their treatment should not be too conservative.

When solitary tumors are found, removal of the growth with as much of its base as possible should be carried out. As an additional precaution against recurrences, the tissues from which the tumor sprang should be destroyed with a galvano-cautery or diathermy.

Roentgen-ray and radium have proved to be of great value in the treatment of all papillomas of the nose. Schiebe²² effected a cure in a case of papilloma of the nose by using twelve exposures of roentgen-ray of one-fourth erythemia dosage, in the course of eight months, supplemented with arsenic internally. With similar treatment, Professor Brock²³ caused papillomatous masses in the nose to disappear. After fifteen years an examination showed that this patient had developed an atrophic rhinitis, but there were no recurrences.

A case reported by Renys¹⁵ is very instructive. Histologically, the tumor presented large, branching processes covered with ciliated epithelium. On July 5, 1928, the tumor was removed and treated by roentgen-ray radiation. In December, 1928, there was no recurrence of the growth. In April and again in June, 1929, small recurrences were removed. In these the epithelium had changed to a stratified, nondifferentiated type without cilia and, in addition, the branching processes were much shorter. Toward the end of 1929 the epithelium had again returned to the original columnar, ciliated type. In January, 1930, it was found that the tumor had invaded the frontal sinus. Here large branching processes with ciliated epithelium were found. A radical frontal sinus operation followed by roentgen-ray therapy every month for three months effected a cure. There were no recurrences within a year.

In multiple tumors all pathological tissue should be removed to the bone or cartilage, followed by roentgen-ray or radium therapy. If the sinuses are involved, external radical sinus surgery is indicated.

In the atypical or questionable cases it is advisable to destroy the tumor by diathermy, followed by roentgen-ray or radium radiations.

CASE I.—Mr. O. J. G., aged forty-eight years. This patient came under the author's observation in July, 1926, on account of an external nasal enlargement associated with complete nasal obstruction. The enlargement had been noticed for about six years and was gradually increasing in size. Both nostrils had been completely obstructed for about four years. A nasal discharge had been present for sixteen years. Seven years prior to the author's examination some nasal growths had been removed on account of impaired breathing. There



FIG. 1.—Case I. Showing external nasal enlargement.

was no history of pain or severe headaches. Laboratory tests, including a Wassermann reaction, were negative. A roentgen-ray examination did not give the impression of tumor formation in the sinuses, although they were generally cloudy.

The examination revealed that the patient's nasal bones had been separated and pushed apart, the root of his nose being about $1\frac{1}{2}$ inches wide. The bone was completely absorbed in several places. The skin covering the nose was of a deep red color and had a pitted appearance. The facial appearance created was what the Germans term a *Froschgesicht* (frog face). Both nostrils were filled with firm, reddish-colored polypoid tumors. A large number of these were removed and

the patient was instructed to return for observation but failed to do so. A letter of inquiry to his local physician in February, 1933, brought the following reply:

"Mr. G. is apparently well, his nose is still enlarged on both sides. I do not think it is more than one-third as large as it was, neither is it pitted and red as it was formerly." He further stated that the patient had had no trouble for about two years after the removal of the growths, but at the expiration of this time his nose gradually began to fill up again.

The report of the pathologist follows: "This section reveals marked proliferative changes in the epithelial lining. While in most areas the surface epithelium consists of 4 to 6 layers of high columnar cells with deeply stained, slender nuclei, there is one area with deep infoldings of the epithelium, covering a formation of plump papillæ. These are lined with 8 to 12 layers of plump cells with round or oval nuclei. The latter are lightly stained, vesicular, and have definite nucleoli. Only the basal layer consists of low columnar cells. These are well oriented and do not penetrate through the basement membrane. The majority of the cells in the papillary area are transitional. No prickle cells are found and no tendency to hornification is noticed. The stroma is a loose connective tissue with a few spindle- and star-shaped cells. There is marked edema and infiltration with eosinophiles, leukocytes, lymphocytes and plasma cells. The mucous glands are hyperplastic.

"*Diagnosis.* Adenofibroma edematodes (Ewing) with papillary proliferation of the transitional epithelium." Dr. Helwig.

CASE II.—Mr. O. C. E., aged sixty-four years, was examined on March 31, 1924. His chief complaint was impaired hearing. In the examination of his nose a papillary tumor was found which sprang from the lower turbinate on the right side and extended across the floor of the nose to the septum. The growth was removed by snare and punch but no histological examination was made. The patient did not come under our observation again until he was asked to return to the office for examination on October 10, 1932, when it was found that the growth had recurred. It presented a picture similar to that at the time of his operation in 1924. The papillary tumor was again removed and sections were made. The report on the histological examination follows:

"The stroma of this section consists of connective tissue, which varies in its consistency in different portions of the growth. In places it is loose and myxomatous in type, in other parts it is densely fibrous.

It contains numerous well-formed bloodvessels of various sizes. Imbedded in the stroma are numerous glands which are typical of the mucous membrane of the nose. The papillary projections on its surface are broad and lined with stratified cylindrical epithelium of various thicknesses whose cilia have been lost in portions of the tumor. Here and there is found a proliferation of the deeper cell layers with consequent penetration into the stroma. In these places the epithelium loses its columnar shape and resembles the stratified squamous type.

"Diagnosis. Fibroepithelial tumor." Dr. Jager.

COMMENT. The clinical term which has been applied to this tumor is papillary hypertrophy. The author believes, inasmuch as this tumor recurred after removal, it should be treated on the same basis as a true papilloma.

CASE III.—Mr. T., aged seventy-two years. This patient was brought to the office in June, 1931, by Dr. H. P. Knowles for a nasal examination. The patient complained of impaired nasal breathing and a sensation of pressure across the bridge of his nose.

In his left ethmoid region was found a cauliflower-like tumor mass which had destroyed most of his middle turbinate and ethmoid cells. The tumor was soft and bled freely when disturbed. A clinical diagnosis of malignancy was made and a portion of the growth removed for biopsy. The histologic findings and diagnosis were as follows:

"The growth has an exquisitely papillary structure and presents budlike projections of vascular connective tissue stroma. The epithelium covering this growth is of the stratified squamous type, the outer layer of which is more or less cornified. The stroma is more or less infiltrated with lymphocytes and leukocytes. The epithelium is everywhere sharply demarcated from the stroma.

"Diagnosis. Papilloma." Dr. Jager.

The patient refused to submit to radical surgery. He was asked to return for examination in October, 1932. At this time it was found that there was an extension of the growth in the ethmoid region and an involvement of the upper portion of the septum. His breathing was impaired but he complained of no other symptoms. There was no change in the histological picture.

COMMENT. The author classifies this tumor as neoplastic papilloma. Its location prevents removal by radical surgical means, roentgen-ray or radium-ray treatment being the method of choice.

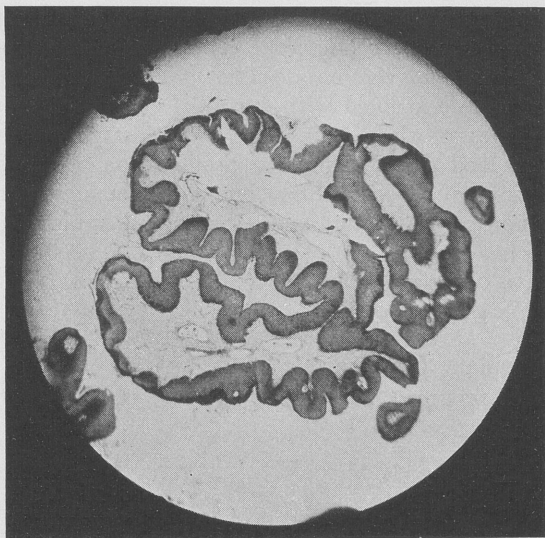


FIG. 2.—Case III. Neoplastic papilloma of the nose covered with stratified squamous epithelium.

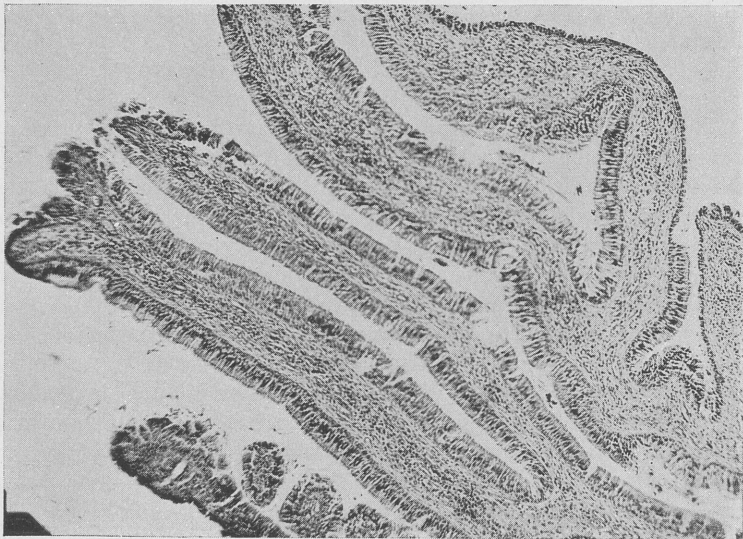

FIG. 3.—Case IV. Neoplastic papilloma of the antrum covered with stratified columnar epithelium.

CASE IV.—Mr. R. C., aged eighteen years. The patient complained of impaired breathing through his left nostril. Some growths had been removed from this nostril about one year ago.

Examination. Pus was found in both middle fossæ. A large polypoid growth protruded from beneath the left middle turbinate. Both antra and the left frontal sinus were flat on transillumination. This patient was kept under observation for a short period of time and was then advised to have a double radical antrum operation. This was carried out on March 29, 1921.

The tissue which was removed from the antra was not examined until March, 1933.

The pathologist's report follows: "The tumor is a papillary growth. Slender stalks of loose connective tissue of considerable height are covered with several layers of columnar cells. The cilia of the uppermost cells are well preserved. The slender cells are lying in from two to five rows. They are of uniform size and staining reaction. No mitotic figures are found. The basement membrane is well preserved and nowhere can there be noticed an invasion of epithelial elements through the basement membrane.

"A few areas of the tumor have a smooth surface without definite papillæ, the epithelium being much lower in these areas. A group of acini with mucus-filled cells are found in one area. The stroma is loose, edematous and large spindle- and star-shaped cells are scanty. There is diffuse infiltration with lymphocytes, plasma cells, and a few eosinophiles.

"*Diagnosis.* Papillary fibroepithelioma of the antra." Dr. Helwig.

COMMENT. This tumor is a primary papilloma of the antrum.

CASE V.—Mr. C. B. R., aged thirty-one years. On November 16, 1932, the patient came in on account of a severe head cold. In his left nostril a growth was found which was about $\frac{1}{4}$ inch in diameter and slightly more in length. Its surface was smooth and the tumor fluctuated. After the nasal infection had subsided, the growth was punctured and found to contain pus and granulation tissue. The latter was removed with a curet and sent to the pathologist, who reported as follows: "The section shows granulation tissue which is very necrotic, it stains poorly, there are no tubercles." By January 15, 1933, the growth had flattened to a papillar mass with a fistulous opening from which I could express a few drops of bloody, purulent fluid. So much of the tumor as was possible was removed and a section of the tissue was submitted to a number of pathologists

of international reputation. One reported, "The slide is a Grade 1 adenocarcinoma of the mixed tumor type." Another stated, "The tumor stroma consisted of edematous connective tissue in which are found many large dilated blood sinuses. This tissue is covered by an irregular papillar growth of somewhat atypical nasal epithelium. This epithelial layer is very irregular and has some of the features of carcinoma, but I do not find any definite infiltration. It is possible that the whole process began as a localized cavernous angioma over which the epithelium has become disordered by infection. I am unwilling to make a diagnosis of carcinoma on this material. I think if the bleeding area were cauterized or removed by diathermy, a cure would probably result, but I would watch the patient carefully for possible carcinoma. There is a definite possibility that this is an early superficial carcinoma."

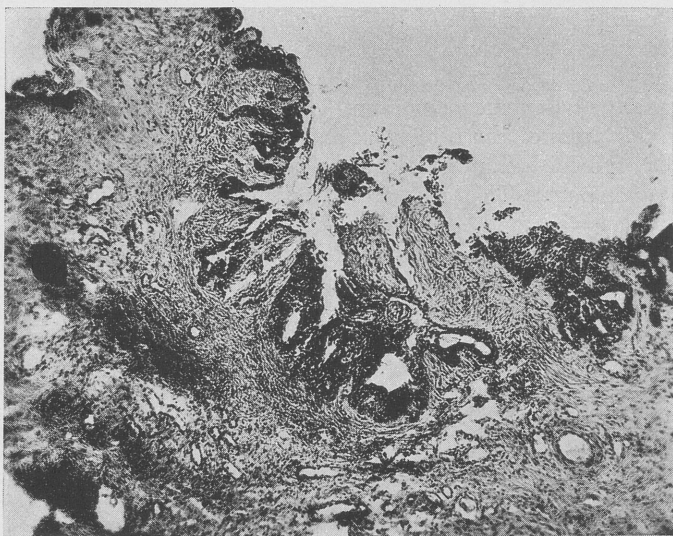


FIG. 4.—Case V. Papillary nasal tumor covered with atypical epithelium.

COMMENT. This growth is the type referred to in the paper as an atypical fibroepithelial tumor. This patient has been under close observation since the removal of the growth. The wound has healed completely and there is no evidence of recurrence. The author has hopes that the tumor is benign, but will keep the patient under close observation.

CASE VI.—Mr. G. R. E., aged forty-one years, came to the office in February, 1932, on account of impaired hearing and tinnitus. On examining his nose, the author found a papillary growth on the anterior end of the left side of his septum.

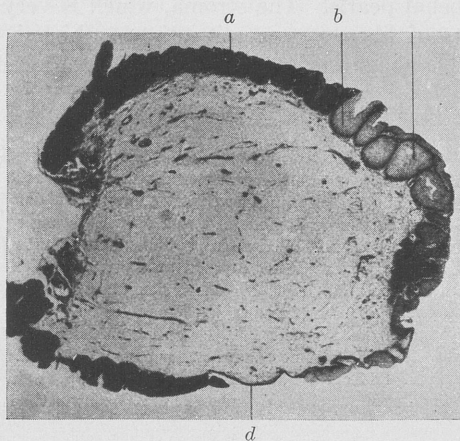


FIG. 5.—Benign fibroepithelial tumor showing: *a*, stratified transitional epithelium, cilia being present in some areas; *b*, stratified squamous epithelium; *d*, stratified columnar ciliated epithelium. (Case of H. Reny's.)

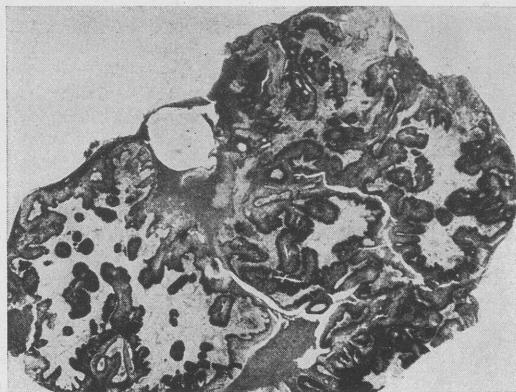


FIG. 6.—Both the papillary carcinoma and the benign fibroepithelial tumor shown in Fig. 5 were removed during the same operation. (Case of H. Reny's.)

This tumor was hard and wartlike in appearance and, while the patient was conscious of its presence, he was not inconvenienced by it in any way.

The pathologist's report was as follows: "The tumor presented for histological examination showed almost exclusively an epithelial structure of the squamous type, with atypical proliferation of the epithelium and marked cornification of the cells. It also contains numerous epithelial pearls. The stroma, which is very scant in this section, consists of fibrous connective tissue which is more or less degenerated. The diagnosis is epithelioma." Dr. Jager.

COMMENT. This growth is a neoplastic papilloma arising from the transitional epithelium of the vestibule. Although there is no evidence of malignancy from a clinical standpoint, the pathologist's diagnosis of epithelioma compels the author to regard the growth as belonging to those referred to previously as atypical, and he has treated the case accordingly.




FIG. 7.—At the left is shown a typical skin papilloma which developed four weeks after the investigator had burned the skin of a mouse previously treated with tar for eleven months. On the right is an epithelioma in the same mouse. This developed four weeks after he burned the skin area, the mouse having been treated with tar for thirteen months. (Case of Fischer Wassel's.)

CASE VII.—Mr. H. R., aged fifty-four years. This patient came to the author's office on December 17, 1932, complaining of severe pain over the left side of his head, frequent nasal hemorrhages, inability to breathe through his left nostril and a continual discharge from this side of his nose. The pain of which he complained had been gradually increasing over a period of eight months. The obstruction in his left nostril had been present for a much longer time. The patient was uncertain when it began.

The examination revealed a papillary growth which arose from the posterior one-third of his left lower turbinate and extended into and involved the upper portion of the nasopharynx. The histologic examination was as follows: "The tumor shows definite papillary projections. The epithelium covering the papillæ is of the squamous type and presents marked atypical proliferation. The cells are hypochromatic and some are multinuclear.

"*Diagnosis.* Papillary carcinoma." Dr. Jager.

COMMENT. This case has been included to demonstrate a typical papillary carcinoma of the nose. As this patient had not been examined prior to the time the carcinoma was found, there is no evidence to show that the growth originated from a nasal papilloma.

CONCLUSIONS. 1. The infrequency of nasal papillomas is due in part to the lack of histological examination of nasal tumor tissue.

2. Many investigators have associated ordinary polypi with the development of nasal malignancy. It seems probable that many of these cases have been papillomas which subsequently developed into malignant tumors.

3. It is not difficult to differentiate microscopically between typical polypi, papillomas, and malignant tumors of the nose. At times the structure of these growths may gradually merge, making it impossible to diagnose by morphological methods the true nature of the tumor.

4. Papillary fibroepithelial tumors of the nose, especially the so-called neoplastic papilloma, should be considered on the border between benign and malignant growths. Clinically, therefore, they must be regarded with suspicion. Their treatment must not be too conservative.

BIBLIOGRAPHY

1. Kofler: Monatsschr. f. Ohrenheilk. u. Laryngorhinol., vol. 55, Festschr. Hajek, p. 1407.
2. Schmidt, Moritz: Lehrb. d. Krankh. d. oberen Luftwege. Julius Springer, 4th edition.
3. Möbius, Eckbert: Handb. d. Hals-, Nasen- und Ohrenheilk., Denker & Kahler, vol. 5, p. 164.
4. Hasslauer: Arch. f. Laryngol., 1900, 10, 66.
5. Herxheimer: Über das sog. harte Papillom der Nase, Ztschr. Laryngol., 1912, 4, 249.
6. Holmgren: Papillom i Antrum Highmori, Hygiea, Stockholm, 1924, 87, 482.

7. Saxen: Über die pathologische Anatomie der von der Nasenkavität und der Kieferhöhle ausgehenden Karzinome und Papillome, *Acta otolaryngol.*, 1924, **6**, 542.
8. Neumayer: *Handb. der Hals-, Nasen- und Ohrenheilk.*, Denker & Kahler, vol. **5**, p. 165.
9. Ewing: *Neoplastic Diseases*, 3d ed. p. 764.
10. Wassels, Fischer: *Regenerationstheorie der Geschwulstbildung*, *Klin. Wehnschr.*, 1932, Nos. 47, 48.
11. Lynch, Clara: Quoted by Fischer Wassels (see 10).
12. Scabad: Quoted by Fischer Wassels (see 10).
13. Borst: *Die Lehre von den Geschwülsten*.
14. Schmidtman: *Das Papillom*, *Handb. der spec. path. Anat. und Hist.*, Henke und Lubarsch, vol. **3**, Pt I, p. 204.
15. Renys: *Ztschr. f. Hals-, Nasen- und Ohrenheilk.*, 1932, **30**, 421.
16. Walback and Howe: *Tissue Changes Following Deprivation of Fat Soluble A Vitamin*, *Jour. Exp. Med.*, 1925, **42**, 753.
17. Quoted by Helwig, C. Alex: *The Scientific Basis of Biopsy in Tumors*, *Arch. Path.*, 1932, **14**, 517.
18. Bayer: *Krebsige Entartung von Polypen*, *Deutsch. med. Wehnschr.*, 1887, p. 174.
19. Deelman: Über die Beziehung zwischen gutartigen und bösartigen Geschwülsten, *Ztschr. f. Krebsf.*, 1932, **37**, 3.
20. Hellman: *Papilloma durum der Nasen und Nasenhöhenschleimhaut, Übergang in Carcinoma*, *Arch. f. Laryngol.*, 1897, **6**, 171.
21. Pold: Quoted by Eckbert Möbius (see 3).
22. Schiebe: *Zur Behandlung der Papillome und papillomatösen Carcinome in der Nase*, *Arch. f. Laryngol.*, 1920, **33**, 501.
23. Brock: *Papilloma der Nase*, *Arch. f. Laryngol.*, 1912, **26**, 49.

DISCUSSION

DR. J. C. BECK, Chicago, Ill.:

It is so late, I do not want to take up any of your time, but Dr. Seydell's paper showed the great deal of work that has been done in this study and it should have some discussion. I would rather put my discussion in the form of questions:

As to the discussion of cylindromas and the cancroids and differentiation in these tumors, these have an important relationship in the etiology of carcinomas, possible development of carcinomas or regression of them into fibrous elements. The biopsy is necessary and will show the newer ideas in classifying tumors as to the adult type of tumors and those that are of the rapidly growing type, particularly the transitional type of epithelial tumors. One finds that type particularly in finger-like processes, more on the order of cylindromas. Rapidly will the process develop into malignancy. If there

is a great deal of adult tissue, as was shown in one of those slides, it is well known those rarely develop into malignancy. Again, the biopsy is important. One way of treating it is by using irradiation, particularly in the modern way with radium or deep roentgen-ray by fractional doses, and the other would be thorough excision with the electrothermic method.

DR. CHEVALIER JACKSON, Philadelphia, Pa.:

I should like to ask Dr. Seydell if he has had any experience with the treatment of malignant type of tumor in the nose by the Coutard technique.

DR. SEYDELL (in closing):

In answer to Dr. Beck, I did not wish to give the impression that I was opposed to removing tumor tissue for biopsy. In fact, I favor this procedure in any case where the pathology of the growth is in doubt. I do wish to stress that there are limits to our present morphologic diagnostic methods and that our leading pathologists frequently disagree in their diagnosis of borderline cases. I wish to agree with Dr. Beck in his statement that the histological examination of tissue is a great aid in assisting the surgeon to decide whether surgery, roentgen-ray, or radium should be used in the treatment of a given case.

In answering Dr. Jackson's question, I must state that I have, until recently, been unprepared to deal properly with the malignancies of the head and neck. I have not had any experience with the Coutard method of using the roentgen-ray.

DR. BECK:

I wish Dr. Jackson would briefly outline to us the Coutard idea. It is not as Dr. Seydell indicates, at least, that is not my understanding of what the Coutard treatment means.

DR. JACKSON:

Omitting details such as hardness of tube, wave-length and screening which concern the roentgenologist, it means giving the maximum dosage of deep roentgen radiation, 5 or 6 erythema doses, in smaller daily amounts, within a period of about thirty days. It is usually not repeated.

A DISCUSSION OF CARDIAC, PULMONARY AND OTHER GENERAL CONDITIONS SECONDARY TO CHRONIC NASAL SINUS INFECTION

JOHN B. POTTS, M.D.

(From the Department of Experimental Medicine, University of Nebraska College of Medicine)

THE serious general effects of acute and chronic infection of the nasal accessory sinuses are not appreciated by the laity and by but a very small part of our profession. In fact in recent years there has been a wide tendency by the general profession to disparage the rhinologist and his work. Undoubtedly some of the criticism is justified, and we are partially to blame for much of that criticism. The fundamental basis of our trouble is that no regulations have been made providing for the qualifications and special preparations necessary before beginning the practice of a specialty and until we are equipped as a specialty to render the expert service required of us, we will not command the confidence of the profession and public. At present too many diagnoses are missed and too much treatment is misdirected or inadequate, consequently not giving relief, or the surgery is often meddlesome and should not have been done. Therefore we have not rendered the profession the service that is expected, and hence it follows that many lives have been sacrificed, and misery and suffering that could have been relieved have and do exist. As an illustration of the feeling that does exist, I call to your attention an article by Dr. C. M. Anderson, an internist in one of our great clinics (Suppuration in Paranasal Sinuses as a Factor in Focal Infections: Review of 400 Cases, *Jour. Am. Med. Assn.*, 1930, 94, 1889), in which he seems to conclude that infection of the nasal accessory sinuses plays a very small rôle as a causative factor in focal infections. This view is all too common, and while many others recognize the importance of infection, they are doubtful of our ability to relieve it.

For a number of years I have been working in close affiliation with the Department of Clinical Research of the University of

Nebraska College of Medicine. Our work has led us to the conclusion that infection of the nasal accessory sinuses plays a very important part in general systemic diseases. Indeed, there is scarcely an organ in the body that we have not found affected.

The general appearance of patients often marks them. They look worn and tired, they have lost their snap and life has lost its zest. Their eyes look tired, the lids puffy, the skin has lost its healthy glow and they are mentally fagged; their shoulders are drooped and they walk flat-footed; they are easily irritated and find it difficult to concentrate. The diagnosis from a rhinological standpoint presents many difficulties. I think it is quite important to have a general working classification, and for my own use I have the following:

1. Acute.
2. Chronic purulent with frank pus in the sinuses but little thickening of the mucous membrane.
3. Chronic hyperplastic with or without polypi and a very sticky secretion, often only scanty in amount.
4. Mucocele.

I will not discuss Types 1 and 4. In Type 2 the turbinate bones adjacent to the infected sinuses are usually tumefied and more or less block the nares. Purulent secretion can usually be seen. Radiographs show the affected sinuses diffusely dense and frequently a fluid level, but usually not much thickening of the mucous membrane lining the sinuses. Type 3 shows a wide variety of pathology of the nasal structures. The turbinates range from no visible pathology to polypoid degeneration. The color of the mucous membrane varies from pink to almost white, seldom red. Polypi may or may not be present.

Proetz's method of displacement with opaque oil is a most important aid in diagnosis, as it will usually show the presence of hyperplastic membrane.¹ The maxillary sinuses, in our experience, are most satisfactorily filled by catheterization of the ostium. Diagnosis of the hyperplastic type is most essential, as it is the one that generally requires a radical operation. The other classes often respond quite satisfactorily to treatment or intranasal operation.

¹ Trans. Am. Laryn. Assn., 1930, 52, 121.

It has further been our experience that hyperplastic sinusitis is frequently made worse by intranasal surgery. This is especially true of the maxillary sinuses. We have also found that a large opening below the inferior turbinate does not allow the membrane of the sinuses to return to normal. We have repeatedly found this sinus with a free opening which has been present for months

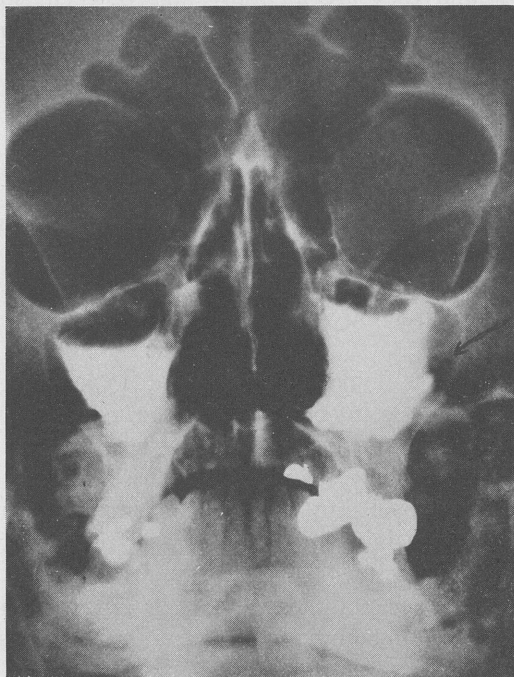

FIG. 1.—Case No. 32. Lipiodol injection. Waters position. Note thickened membrane and discrete abscess in membrane of lateral wall of left antrum.

or years, and still the membrane contains multiple abscesses with both grossly and microscopically the same evidence of infection as though no such opening existed. In many such sinuses it is possible to see these abscesses before operation by means of a pharyngoscope. It is this hyperplastic type that is most frequently associated with systemic diseases, especially with asthma.

As pointed out by Proetz and others, there is a chance for error in diagnosis when opaque oil is used in the sinuses due to an acute edema, allergic swelling of the mucous membrane, acute exacerbation or any acute inflammation. This must be kept in mind, and if there is any doubt as to the diagnosis, the true condition can usually be established by further investigation of the history, radiographs, tests for allergy and time.

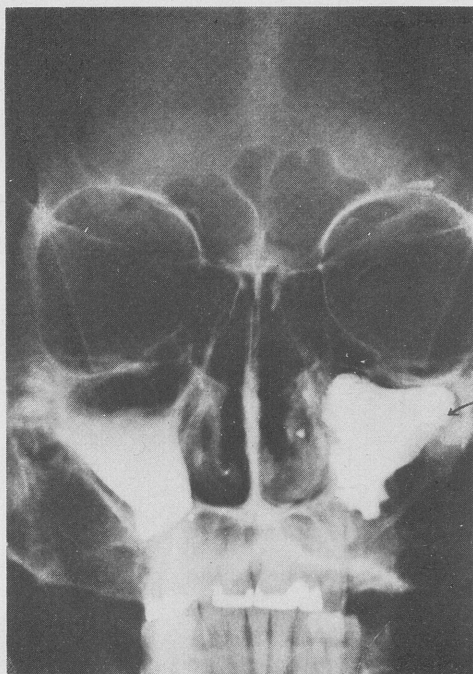


FIG. 2.—Case No. 101. Lipiodol injection of maxillary sinuses. Note thickening and polypoid changes in the membrane.

Grossly these membranes are thickened, usually ranging from 20 to 40 mm. in thickness. Polypi are frequently present, sometimes large and almost filling the cavity and at other times they are small, resembling a carpet of softly rounded masses. The deeper portions of the membrane are tough. Very frequently discrete abscesses, from the size of a pinhead to that of a bean, are

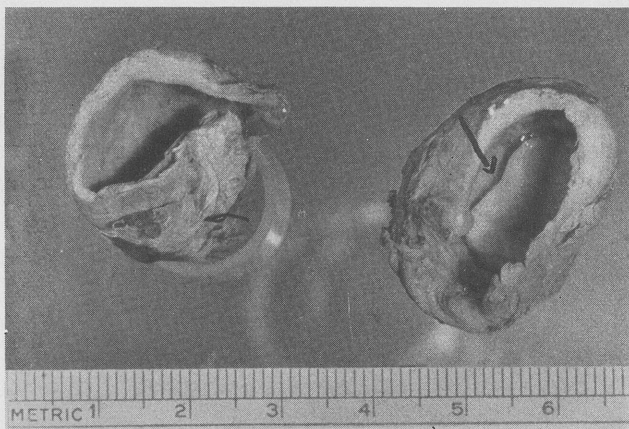


FIG. 3.—Case No. 32. *En masse* exenteration of both maxillary sinus membranes. Coronal section. The material has been removed in one piece and the membrane is complete except for the usual tearing along the medial wall near the ostium. Note the abscess in the left antrum, Fig. 1.

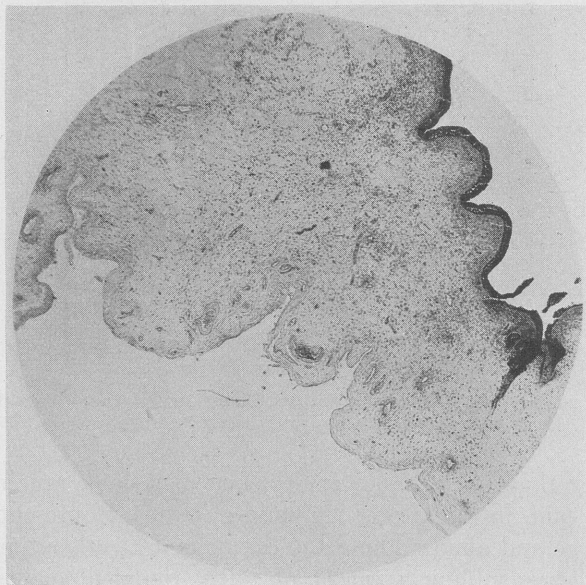


FIG. 4.—Case No. 101. Low-power of portion of maxillary sinus membrane, showing fibrosis of submucosal layers and thickened bloodvessels in lower left portion, while in upper portion there is acute swelling.

scattered throughout the membrane. These are quite as liable to be found on the upper outer wall as in the floor. Occasionally one is seen that contains 30 min. or more of pus. Intranasal drainage of such a sinus will not reach these abscesses. The secretions or fluid present in these sinuses are usually very thick and sticky, almost like raw rubber. A diagnostic puncture with irrigations frequently will not remove this secretion.

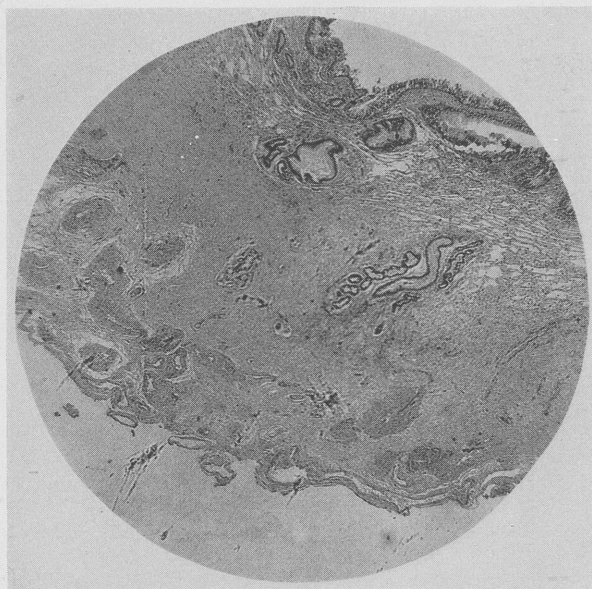


FIG. 5.—Case No. 8. Low-power of portion of maxillary sinus membrane illustrating the variety of pathological processes which may be present in a single field.

Microscopically the membrane shows a tough base, rather dense and containing many connective-tissue cells, fairly numerous bloodvessels and, as we go to the surface, the cells are less numerous and there is a greater amount of fluid space. But this is not constant, and areas of fresh proliferation are shot through the whole membrane. The more chronic the condition, usually the more hyperplasia of cells. In acute swellings the tissue is very edematous and tender. (The bone in old chronic hyperplasia is usually softened.)

Most important of all is the presence of bacteria all through the membrane. These can be shown in section by special staining methods. This, then, is the kernel of the whole problem. The infection, as shown by the abscesses and bacteria in the membrane itself, explains why our former efforts at drainage and incomplete removal were unsuccessful in relieving metastatic infection. They also make plain the necessity of complete removal of the infected

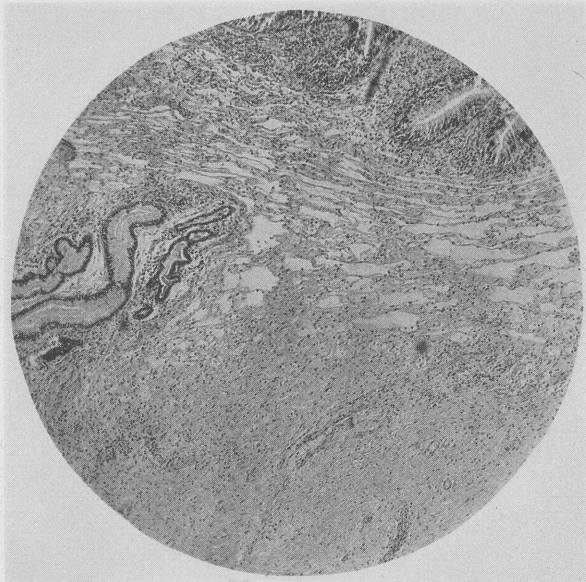


FIG. 6.—Case No. 8. Higher power showing the hydrops and epithelial proliferation, together with the inflammatory infiltration.

membrane. This is most effectively done in the maxillary sinuses, and hence to date our results have been best when the infection was confined to them.

Fortunately the membrane on the septum and the turbinate bones seem to escape this degeneration or are able to return to normal after the sinuses are relieved of their infection. The frontal lend themselves to operation almost equally well, but the ethmoid and sphenoid are more difficult. Still they can be very effectively dealt with due to their better natural advantage of

drainage and, in most cases, give very satisfactory results. As a source of infection the secretion found in this type of sinus is, I think, relatively unimportant, as the infection is a true bacteriemia from the infection in the sinus membrane, with the toxins

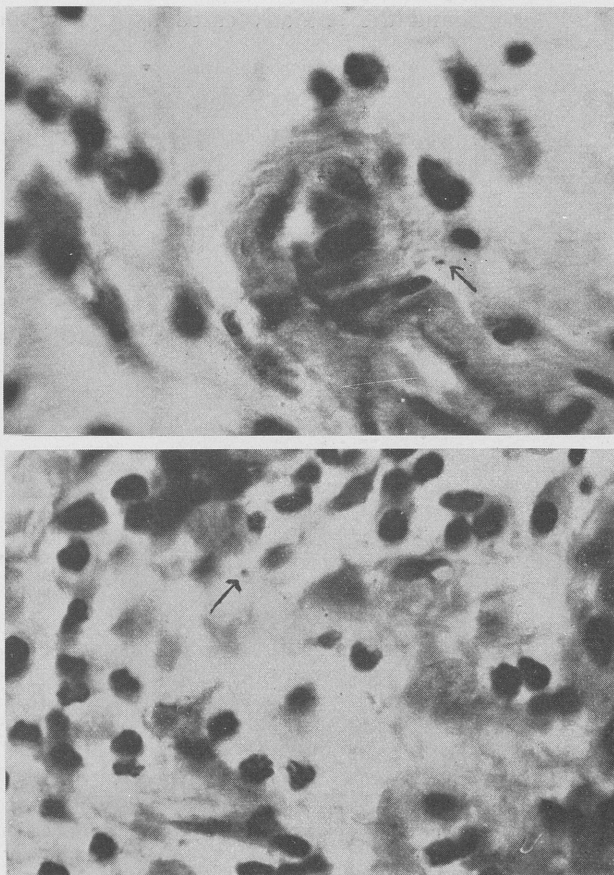


FIG. 7.—Diplococci indicated by arrows. Gram-Weigert stain.

and bacteria entering the system by the blood stream and lymph channels directly from the membrane and not by being absorbed from its surface. Hence again the futility of irrigation or drainage.

I use local anesthetics for all my operations, a nerve block pre-

ceded by morphine and scopolamine. In five years of this practice I have had no serious complication. A few patients have had an excitement state lasting from two to eight hours following the operation.

For the radical type of operation on the frontals, ethmoid and sphenoid, I have found the one advocated by Lynch the most

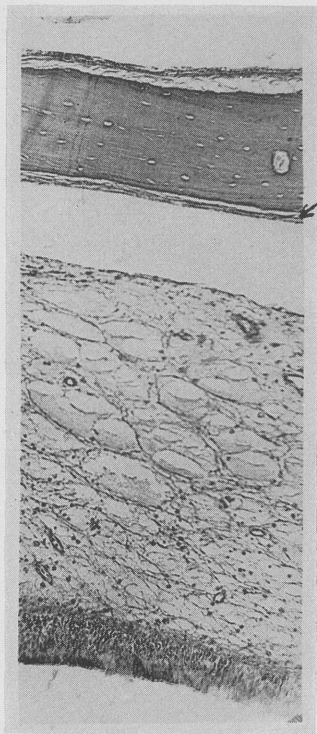


FIG. 8.—Case No. 93. Maxillary sinus membrane removed with portion of bone attached, and showing a natural plane of cleavage in the basal layers in which a thin layer of tissue remains attached to the bone.

satisfactory. For the maxillary sinus, the Caldwell-Luc with some modification. The incision should not extend anteriorly beyond the second bicuspid tooth and should be made sufficiently low so that the periosteum can be elevated without exposing the fat in the cheek. This prevents discoloration and swelling of the

cheek and lessens the chance of infection of the soft tissues to a minimum. In removing the membrane of the maxillary sinus, I lay particular stress upon removing it *en masse* by very careful dissection with blunt elevators, avoiding entirely the use of curettes. This seems to be important as sections made of the bone so denuded show a very thin layer of vascular tissue left over the bone. This, I feel, assists in the healing and may at least in part be responsible for my not having had to date any cases of osteitis. Gentleness in the dissection and handling of all the tissues is one of the most important factors in the success of the operation. The operation is greatly facilitated by having a suction apparatus which can be regulated to about 3 to 4 pounds vacuum, and a small suction tip. (I use Walker's submucous elevator and dissector.) This tip is kept back of the mucous membrane and keeps the field clean. If forcible suction is used it is liable to damage the specimen and spoil the dissection. No sponging is used in the sinus during the operation or afterward, no antiseptics and no packing. The ethmoid cells around the ostium should be carefully examined, and any that are degenerated, removed.

Postoperative care—ice over the operated sinus for one day and, following this, all the heat possible for seven to ten days. No nasal treatment except albolene, sprayed or dropped into the nares frequently. No irrigation except occasionally one or two to wash out a clot from the maxillary sinus on the fifth to the seventh day. Operate only those cases that have undergone extensive chronic degenerative changes. *Strive for accurate, clean, gentle en masse enucleation of the sinus membrane.*

The following case reports illustrate some of the different conditions, apparently secondary to chronic accessory nasal sinus infection.

CASE I.—Mr. C. W. H., aged sixty-five years, consulted me April 15, 1930. Had been home for a few days with a bad cold but now back at his business. Feels tired and irritable, cannot concentrate, eyes puffy, has no headaches. General examination negative. Purulent left maxillary sinusitis. Recovered rapidly under local treatment.

CASE II.—Mr. M. A. H., aged sixty-nine years, came in December 1, 1930, with the history that for the past two years he had suffered with

nasal obstruction. Has had previous intranasal operations without relief. One week ago he had a sudden attack of aphasia, in bed six weeks. Physical condition remained much below par, unable to attend to business, and mentally disturbed. Now has definite cardiac decompensation and myocardia. Radiograph with opaque oil: maxillary sinuses, marked thickening of the membrane; ethmoids dense; frontal sinuses apparently not involved. Exenteration of antral mucous membrane and ethmoid cells around the ostium on December 3, 1930. This was followed by a fairly rapid recovery. He was able to resume his practice of law in two months and has remained well and active to the present time.

CASE III.—Mr. C. W., aged fifty-seven years, seen in consultation on September 21, 1932. He was very much depressed with delusions of self-unworthiness and paranoidal ideas that someone was going to harm him. During his stay in the hospital he showed marked mental confusion that suggested a serious organic type of dementia. Radiograph, chronic hyperplastic sinusitis. Following a Caldwell-Luc operation on September 26th, his mental condition cleared fairly rapidly. He left the hospital October 27th with his mental condition relieved, and has remained in good condition to the present time.

CASE IV.—Mr. R. O. C., aged forty-six years, has had asthma for several years. On entering the hospital his asthma was so severe that he was unable to lie down day or night. Condition desperate, cardiac involvement and very cyanotic. Treated in hospital for two weeks, during which time he received large doses of epinephrin from four to eight times daily, sometimes with morphine. Complete radical operation, bilateral, on January 23, 1933. Considerable discomfort for the first twenty-four hours. Since his operation he has had no more severe asthmatic spasms, has not required any epinephrin or morphine, and has gone back to his position as drug clerk.

CASE V.—Mrs. G. O. M., aged twenty-two years, October 23, 1931, has had asthma since twelve years of age. Had several operations for removal of polypi and intranasal drainage of antra. Now has both nares filled with polypi. Free opening into antra below inferior turbinates, antra filled with polypi. On November 3, 1931, radical operation of the right frontal, ethmoid, sphenoid and maxillary sinuses. Some weeks later, the same on the left side. Since then has only had a slight return of an attack of asthma for a few nights when she had an acute cold. Nose now free from infection, no scabbing or secretion, no polypi.

CASE VI.—Mrs. D. P., aged twenty-three years, August 3, 1929, has had very severe asthma for the past six months which completely incapacitated her. First attack of asthma in fall of 1926. Is subject to frequent colds. Turbinates all tumefied, some postnasal mucoid discharge. Radiograph: antra marked shading, other sinuses clear. Bilateral exenteration of antral mucous membrane. This was thick and very fibrous. The asthma cleared up rapidly. Our last report from her on January 30, 1932, stated that she had not had any bad attacks of asthma and was feeling better than she had for years.

CASE VII.—Mrs. O. C. (widow), aged forty-six years, July, 1930, since attack of influenza in 1928 has never been well. Has been subject to some chronic nasal catarrh for several years. She was very thin, pale, listless and depressed. Had been hospitalized for diagnosis and treatment three times in the past two years. Complained of weakness, pain in abdomen, constipation, some headache, sensation of fulness and ringing in ears. Has been diagnosed as a neurasthenic. Examination of nose: no gross pathology, mucous membrane rather pale. Radiograph: both maxillary sinuses, mucous membrane very thick; ethmoids doubtful; frontals and sphenoids clear. Bilateral exenteration of antral mucous membrane, July 7, 1930. This was thick and tough, contained multiple small abscesses and one large abscess in the upper outer portion of left sinus. Four months later she had recovered her normal health and remained well until the midsummer of 1932. In the meantime she had gained 40 pounds. During August, 1932, she contracted a very severe cold, and following this had some of her old symptoms—stopped-up head, bronchial cough and mental lethargy. In March, 1933, she again reported for examination. She now had definite evidence of infection of the ethmoids. I did an intranasal ethmoidotomy on April 18, 1933, and following this she made a good recovery.

SUMMARY. Our experience has been that bronchial conditions usually respond well.

Arthritis, neuritis and allied conditions, except multiple arthritis and arthritis deformans, usually respond favorably.

Cardiac response is good.

Facial neuralgia, chronic headache, tinnitus, vertigo and ocular infections often are completely relieved.

Patience and study in this field of medicine yield many satisfactory results to both the rhinologist and his patient.

CONCLUSIONS. 1. In chronic hyperplastic sinusitis the infection lies in the membrane itself.

2. The secretion in these sinuses is relatively unimportant for diagnosis or therapeutic effect on local and general systemic disease.

3. The complete *en masse* removal of the membrane is the rational surgical procedure.

4. Gentleness of manipulation is essential to avoid complications.

I wish to thank Drs. A. D. Dunn, Lowell Dunn, Frederick Niehaus, Miss Helen Strothers and Miss Mildred Braden for their collaboration.

DISCUSSION

DR. M. C. MYERSON, Brooklyn, N. Y.:

This paper is one that gives food for thought and it is of great value because it demonstrates that results can be obtained in cases that many of us frequently think are more or less hopeless.

There is, however, a possible fallacy, if I might make so bold as to use that word, in Dr. Potts' presentation. Perhaps, I might say a possible overoptimism. When we deal with an operative procedure that may or may not influence favorably a disease that has a very definite functional aspect, we must be very careful in evaluating our end results, particularly when we are considering such a disease as asthma.

We all know, from our own experiences, that we have gotten cures of asthmatics with a submucous resection, a turbinectomy and even with pink pills, so that when we remove a thickened membrane from an antrum, we must be very certain that the thickened membrane is the cause of the patient's asthma.

I would ask Dr. Potts if he would not please let us know a year or two from now how the patient with asthma, operated upon in January, is doing. My own feeling is that the patient may come back with his asthma and require more operative procedure for temporary relief.

We all know of patients with depressive psychoses in whom we cannot demonstrate the presence of focal infection of any type. They have periods of lucidity and periods of entire freedom from their mental symptoms. Therefore, I do not feel that we can be too sure of the fact that the operation upon the antrum is the cause of the cure because this individual has recovered. If the recovery is permanent, perhaps we might consider it more seriously.

I might cite an experience of mine which has impressed me with the fact that asthmatics deserve special consideration when we contemplate operation. A lady, aged twenty-eight years, had been referred to me for bronchoscopy. Everything had been done for her and no results obtained. She was very noncoöperative. I did not succeed in passing the bronchoscope farther than the hypopharynx; not even to the vocal cords. I did make a lot of noise and rattled the forceps in the bronchoscope and asked her to hold still. I told her she was not to speak for twenty-four hours. That lady was bronchosoped six years ago and she is still cured of her asthma.

DR. A. W. PROETZ, St. Louis, Mo.:

I am glad to hear Dr. Potts lay emphasis again on the causation of remote disease from the sinuses because, although the literature has been full lately of statistics which show the tonsils and teeth are the primary causes, with still other things secondary, and that sinuses are only the tertiary causes, I have always felt that was not so.

This was brought to my attention again last fall by Dr. Le Mée, in Paris, when he showed me films of sinuses into which he had injected lipiodol and which did not empty themselves. After a week or two, another film showed the lipiodol not only remaining in the antra but distributed in the neck in a triangular formation down to the shoulder blades.

Another thing, he tells me lipiodol injected in the sinuses will be eliminated in the urine for a longer period and in greater quantities than when administered by mouth.

DR. E. ROSS FAULKNER, New York City:

I enjoyed Dr. Potts' paper very much and was glad to hear of those results he got, but I have a little feeling like Dr. Myerson about the time period in estimating results in some of these asthmatic cases. I have seen some cured by simple means apparently, and others, where I thought the results were going to be good, in the end were a disappointment.

I always feel I want to square myself with this Association regarding a report I made of a number of cases I operated on and reported years ago. They were all cases of rheumatoid arthritis and had been bed-ridden and, after their sinus operations, they had made temporary recovery and were going about their business. Every one of those cases relapsed afterward. I was never able to do anything more to influence them. An enormous number of these rheumatoid arthritis cases have head infections and osteitis in the walls of the sinuses.

Unless the operation is done fairly early, it is almost impossible to do. I have operated on them where the antrum wall would be very thick and the antrum cavity very small. The ethmoid would be extremely hard and the accomplishment of surgery would be almost *nil*.

DR. POTTS (in closing):

I extend my thanks to the gentlemen who discussed my paper. Your criticisms are well taken. I feel that this is a part of medicine that we as rhinologists are responsible for. There, certainly, are things that can be done for invalids and we are the ones who are and should be equipped to render this assistance. This Association in particular has members who can.

The remarks made as to the technical difficulties of the external ethmoid and sphenoid operation with removal of the membrane from these cells is greater than the difficulty encountered in most major surgery. There may be necrosis of the bone over the dura, necrosis of both the bone and dura, exposure of the carotid artery or optic nerve. Injury to any of these structures would be a most serious accident. Therefore, it is quite apparent that it is very important that we should insist on the training of the younger men so that they are equipped in their anatomical knowledge and technical training to do these operative procedures and do them well.

In regard to asthma, I am aware that there are many cases of asthma that have recovered with more or less bizarre forms of treatment. However, I have endeavored to present only those cases of long standing which have been thoroughly studied by competent internists and allergists, usually in the hospital, and I feel sure that the results I have recorded can be ascribed to the surgical removal of the infected tissue in the nose as the relief was prompt.

Arthritis deformans was purposely omitted from the report, as personally, my results have been disappointing in this condition. On the other hand a good many cases of arthritis of the large joints, neuritis, myositis, etc., do respond to the removal of the foci of infection from the nasal accessory sinuses.

PLASTER CASTS SHOWING THE RELATIONSHIP OF THE STRUCTURES OF THE NECK FOLLOWING STRAN- GULATION—HOMICIDAL OR SUICIDAL

HENRY BOYLAN ORTON, M.D.

I WISH to take this opportunity to express my sincere thanks to Dr. Harris P. Mosher for his instruction to me in the making of casts; also, to Dr. Harrison S. Martland, medical examiner of Essex County, Newark, New Jersey, to whom I am deeply indebted for the material from which these casts were made. I had hoped to have Dr. Martland present this subject jointly with me, but, due to unforeseen circumstances, he has been unable to give his version from a medical-legal aspect at this time, but has permitted me, however, to present these models before this Society at this time.

Much confusion has existed concerning the mode of death in manual strangulation, throttling by other means, and in suicidal, accidental and homicidal hanging.

Observations in these types of strangulation show that the main factor is asphyxiation, due to shutting off of the air passages, and that all other factors are practically always of secondary or contributory importance.

I shall attempt to prove this contention by plaster models showing the anatomical relationship of the structures in the mouth, nasopharynx and glottis.

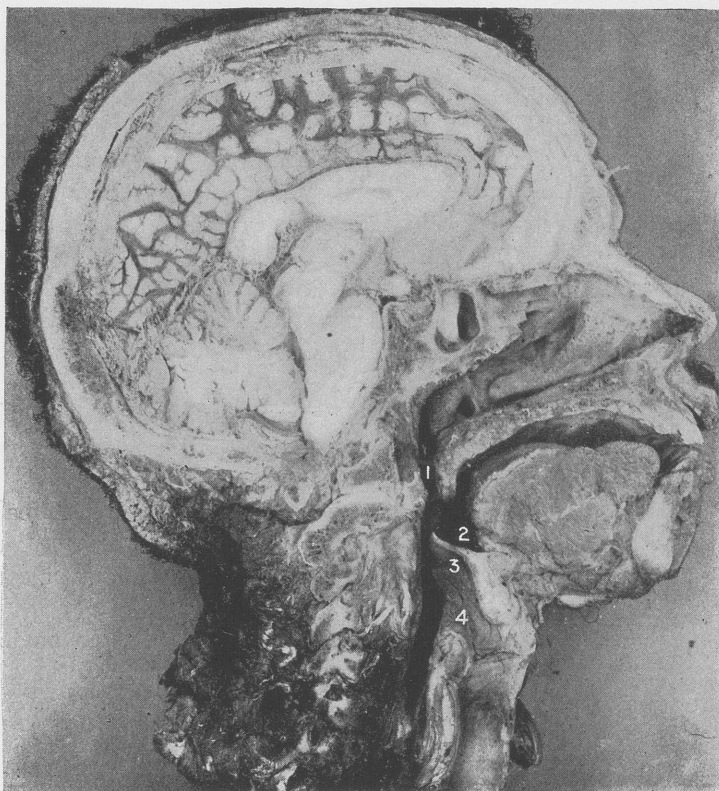


FIG. 1.

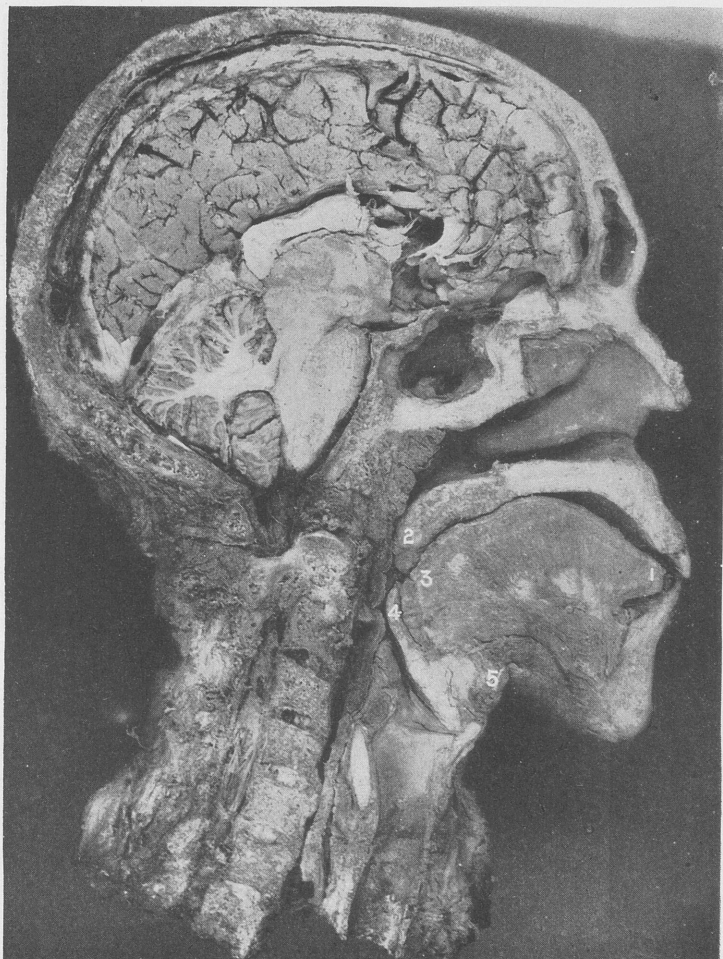


FIG. 2.

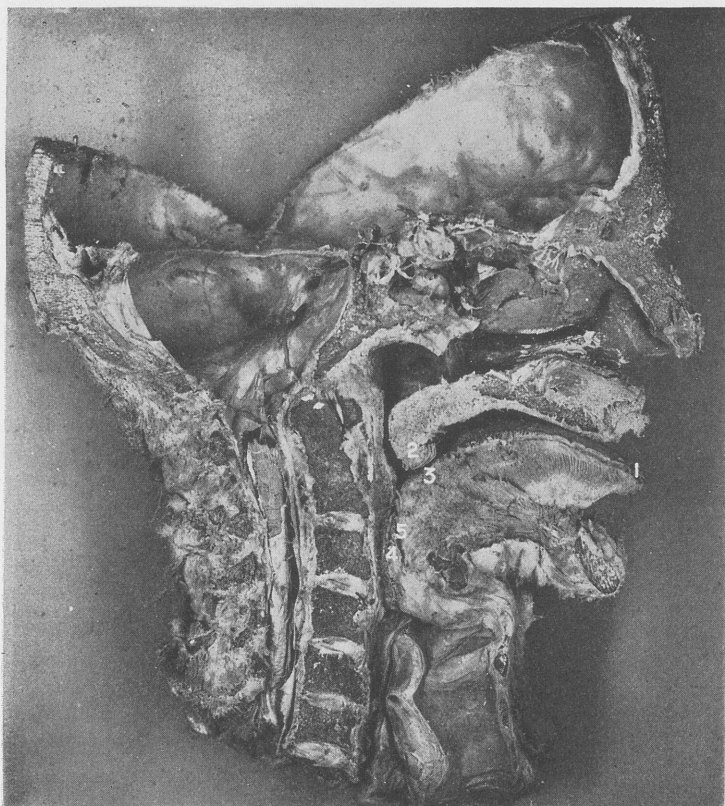


FIG. 3.

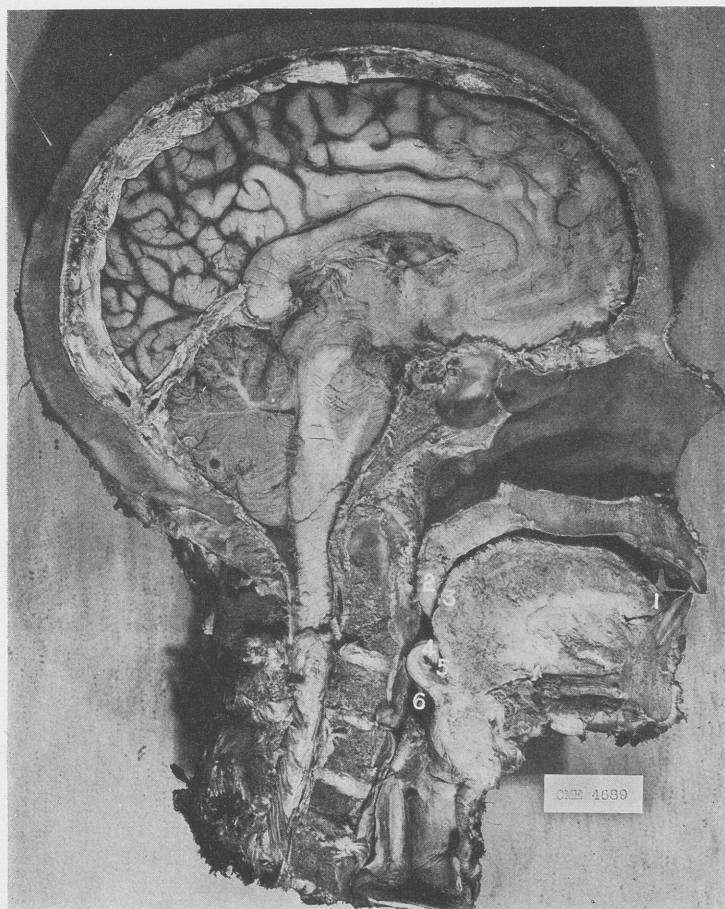


FIG. 4.

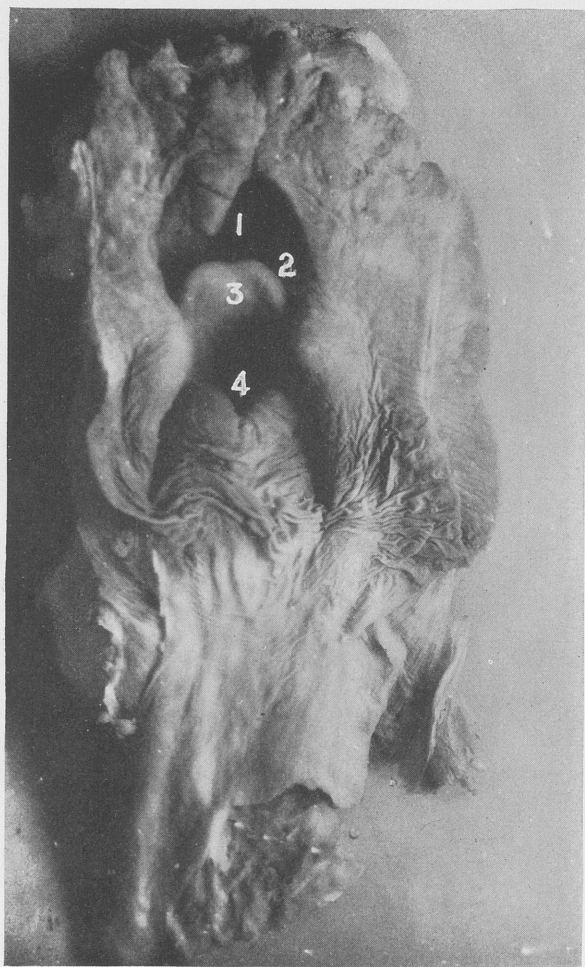


FIG. 5.

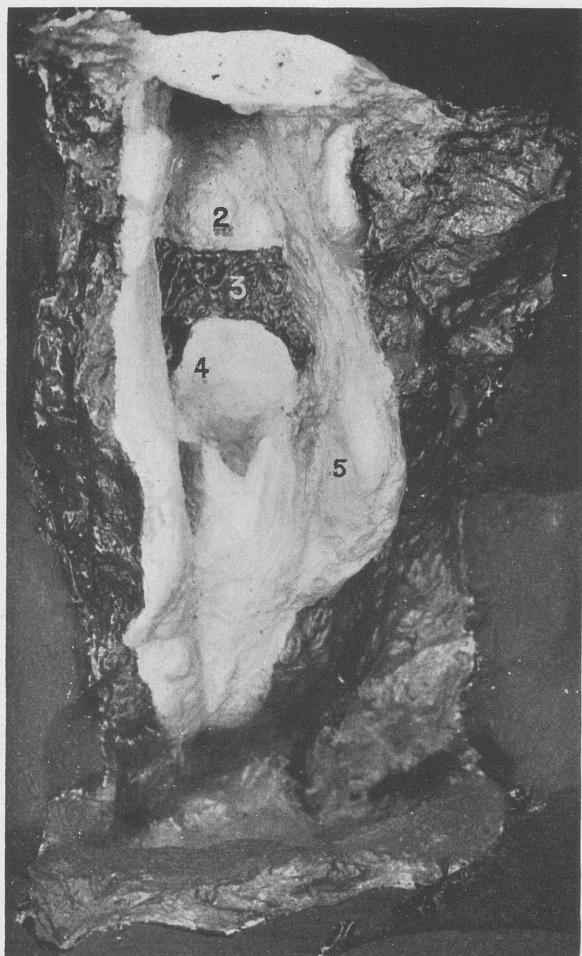


FIG. 6.

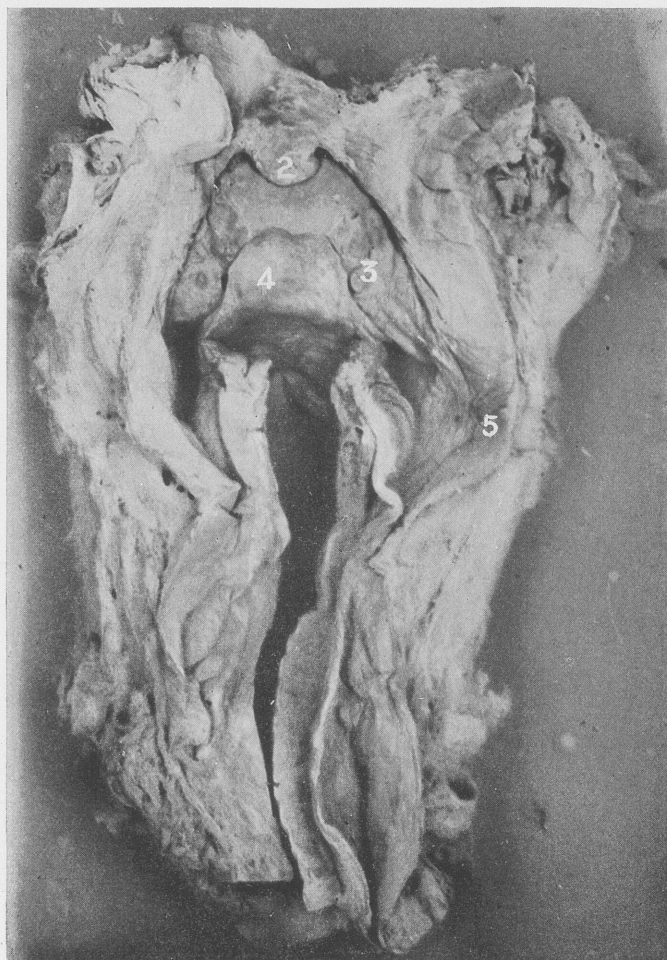


FIG. 7.

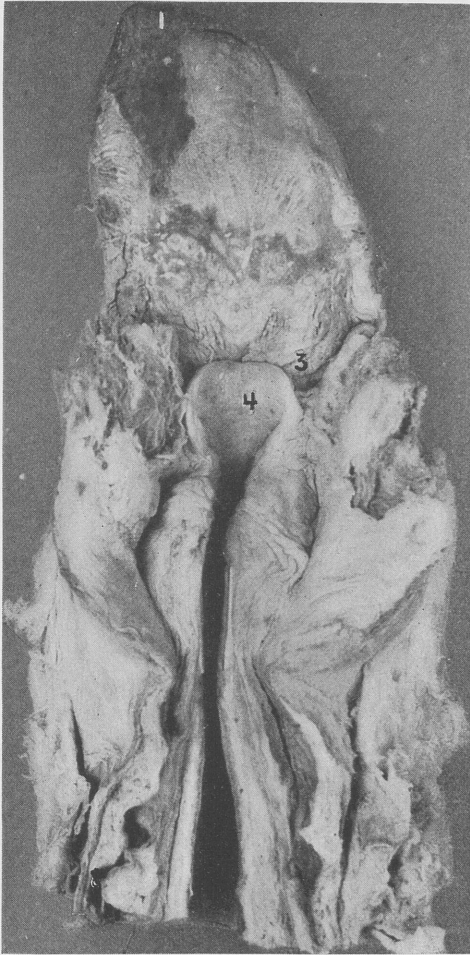


FIG. 8.

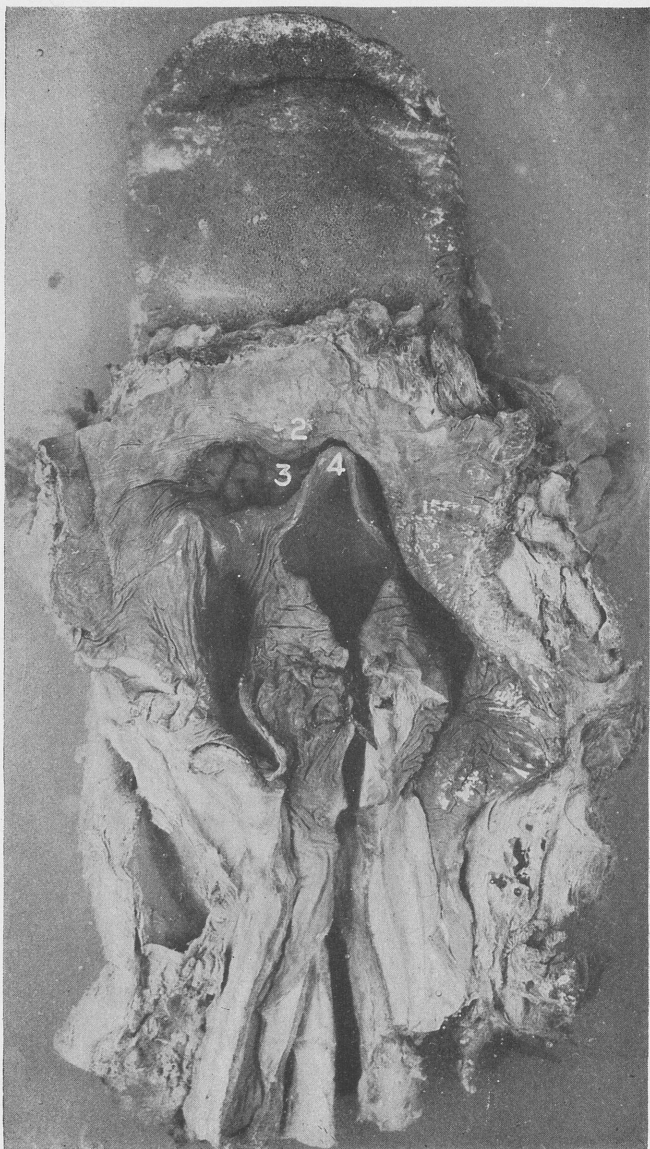


FIG. 9.

AN EYE RETRACTOR AND A SUTURE-CARRIER-KNOT-TYER FOR THE EXTERNAL PANSINUS OPERATION

ROMEO A. LUONGO, M.D.

THE EYE RETRACTOR

THIS instrument is a modification of the Ferris-Smith retractor, used for the external operation on the ethmo-sphenoid-frontal group of sinuses with the ligation of the anterior ethmoidal artery as described by Sewall¹ and Ferris-Smith.²

This retractor can be made to fit both on the right and left side by switching the arms around and reversing the teeth (Fig. 1).

Each blade has an eye shield which will protect the eye, making the stitching of the eyelids unnecessary. There are four blades: two slotted and two plain; the slotted ones are used for the ligation

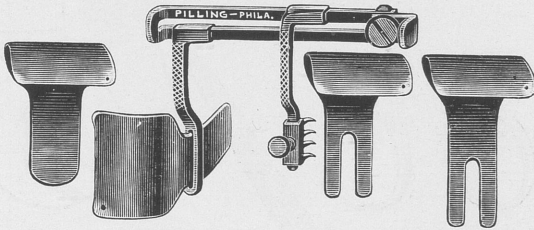


FIG. 1.—The retractor and the 4 blades. The arm to the left has a slot for the blades and the arm to the right ends in a square piece on which a sleevelike appliance with the teeth is slipped on and fixed with a setscrew. To reverse: Take the blade out, slide the left arm to the right and the right arm to the left and turn the teeth around.

of the artery and the plain ones for a better protection of the orbital contents. If the orbital periosteum is accidentally injured, exposing the orbital fat, the solid blade will keep this fat out of the field and it will prevent the infected material from the nose and sinuses from coming in immediate contact with the eye contents through the periosteal opening. After the ligation of the artery, I change from the slotted to the solid blade in order to protect the ligated stump of the artery, which often will persistently protrude through the slot, interfering with the view and being exposed to a possible injury by the instruments during the operation.

Prying with the point of a hemostat inserted in between the arms will facilitate the opening of the instrument. A hemostat can also be helpful in the closing of the instrument.

In opening and closing the instrument, use the force as near as possible to the transverse bars on which the arms slide.



FIG. 2.—The suture-carrier-knot-tyer.

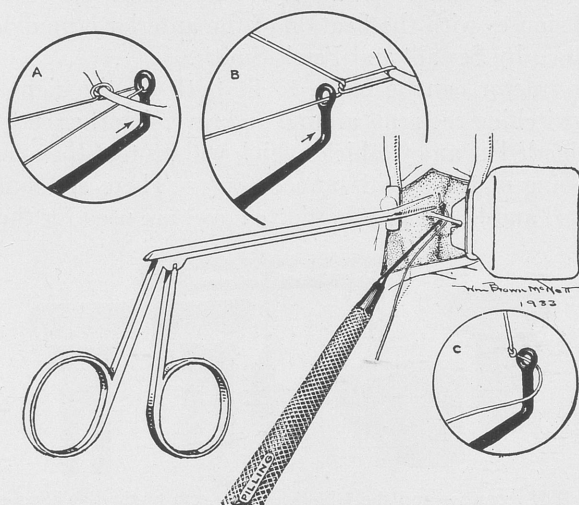


FIG. 3.—The tying of the anterior ethmoidal artery with the suture-carrier-knot-tyer. *Diag. C:* Threaded instrument, showing the knot and the free end of the catgut above it (the knot will become engaged into the ring by pulling on the other end of the catgut). *Central figure:* The instrument is in place, around the artery, with the free end of the catgut (beyond the knot which is already engaged into the ring) ready to be grasped by a Hartmann alligator forceps. *Diag. B:* Pushing the knot towards the artery. *Diag. A:* Tightening the knot around the artery.

THE SUTURE-CARRIER-KNOT-TYER

The ligation of the anterior ethmoidal artery can be done with this instrument alone. The catgut is threaded through the small ring at the end of the instrument and then a knot is made at about $\frac{1}{4}$ inch from the end of the catgut. (See Fig. 3, *Diag. C.*) By stretching the catgut, the knot will become engaged into the ring and the stiffness of the catgut will keep the free end (beyond the knot) in such a position that it can be easily grasped with a small

hemostat or forceps. The knotted end of the catgut is then pulled out while the instrument is kept in place (the ring will protect the artery from the sawlike motion of the catgut against the artery during this pulling). Without unthreading it, the instrument is

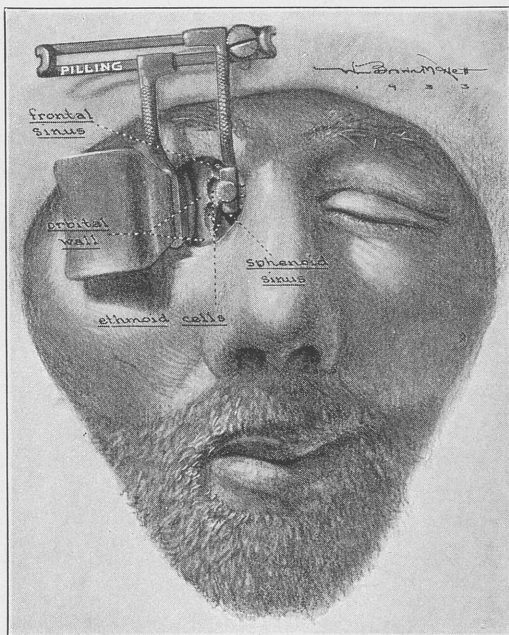


FIG. 4.—The retractor in place.

then withdrawn and a knot is made between the ring and the artery. This knot is then pushed towards the artery and tightened as illustrated in Diags. B and A of Fig. 3. Subsequent knots are made and tied in the same manner.

This instrument can also be used as a probe for intranasal as well as for extranasal work.

The making of these instruments has been made possible by the kind and generous coöperation of G. P. Pilling Company.

BIBLIOGRAPHY

1. Sewall, E. C.: External Operation on the Ethmosphenoid Frontal Group of Sinuses Under Local Anesthesia, *Arch. Otolaryngol.*, 1926, 4, 377.
2. Smith, Ferris: Chronic Sinus Disease, *Jour. Am. Med. Assn.*, 1933, 100, 402.

PAROTID GLAND TISSUE IN THE TONSILLAR FOSSA

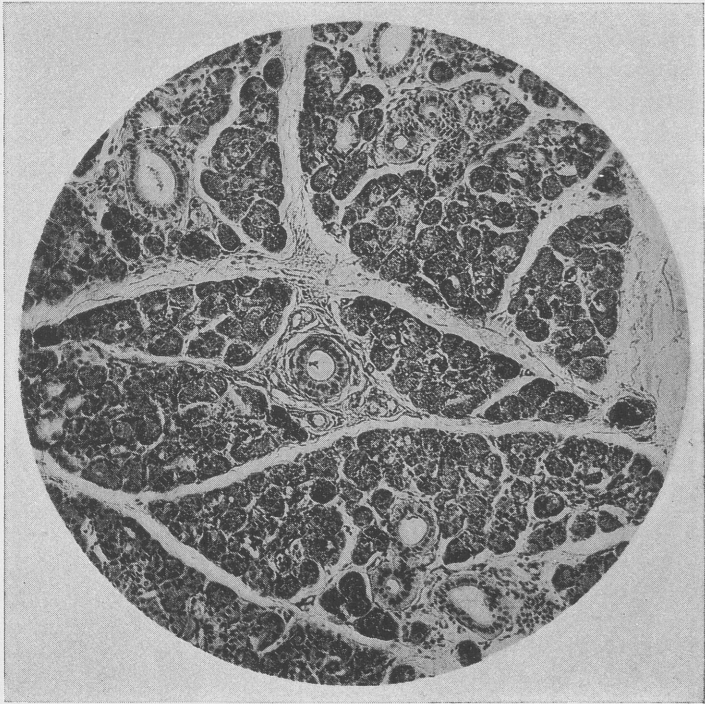
CASE REPORT

ERNEST M. SEYDELL, M.D.

BILLIE S., aged five years. This patient was referred to me because of recurring attacks of tonsillitis, frequent head colds and enlargement of the cervical lymph glands. He was also a mouth-breather. His physical examination was negative. The tonsils were hypertrophied and cryptic. The anterior pillars were injected and the cervical glands enlarged. His adenoid was hypertrophied.

The patient's tonsils and adenoid were removed under gas-ether anesthesia. After their removal I noticed a small growth in the region of the lower pole of the right tonsil. My first impression was that I failed to remove completely all of the tonsil tissue. After the excision of a portion of this tissue I realized that it bore no relation to the tonsil. It was yellowish in color and had a soft consistency. A careful examination of the tonsil fossa revealed that it contained more of the same tissue, which extended outward and downward into the neck. No attempt was made to remove it.

A microscopic examination of the mass removed showed that it was parotid gland tissue.



A SIMPLE MANEUVER TO INCREASE THE VISIBILITY OF A SALIVARY CALCULUS IN THE ROENTGENOGRAM

SAMUEL IGLAUER, M.D.

It is often difficult to obtain a roentgenogram of a calculus in the submaxillary gland or duct because the shadow of the stone is obscured by the body of the mandible. However, if the roentgenologist places his finger in the patient's mouth and pushes down the floor, the submaxillary gland and duct can be depressed

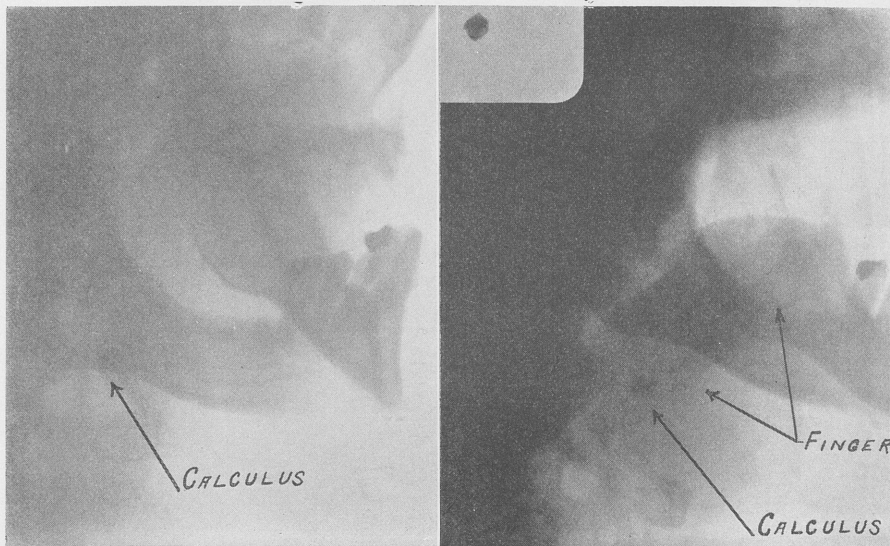

FIG. 1.

FIG. 2.

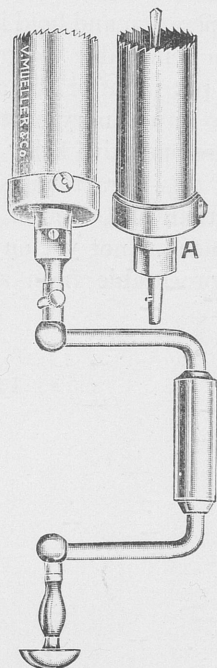
below the jaw bone and the calculus can then be brought clearly into view.

Fig. 1 shows a calculus near the angle of the jaw in a roentgenogram taken in the ordinary way. In Fig. 2 the same calculus can be seen to much better advantage below the mandible, and the shadow of the finger in the mouth is also visible. The small insert in Fig. 2 gives an roentgen-ray picture of the same calculus after it had been removed. (Roentgen-ray films by Dr. S. Brown.)

PRESENTATION OF INSTRUMENT

JOHN B. POTTS, M.D.

I WISH to present a new instrument designed by Dr. F. Lowell Dunn of Omaha, Nebraska, for securing specimens at autopsy of the nasal accessory sinuses. It consists of a coredrill, which can be placed on the floor of the cranium, and with an ordi-



nary brace to turn it remove a specimen which takes in practically the entire ethmoid and sphenoid region with part of the maxillary sinuses.

The instrument is made in two sizes and can be secured from the V. Mueller and Company, Chicago, Illinois.

PRESENTATION OF INSTRUMENT

ARTHUR M. ALDEN, M.D.

I HAVE been dissatisfied with all of the retractors designed for the Caldwell-Luc procedure. This one has been devised with the idea of its being an improvement on the old instruments. It comes in two sizes. It has a handle that is comfortable so the assistant can hold it during the operation and hold it quiet. We have added to it another feature, a removable electric illuminator, which is sterilizable and can be put on after the antrum is opened. This light can be attached to an ordinary battery and gives a brilliant illumination to the entire operative field.

We have found that this retractor is suitable for many operative procedures other than the one for which it was originally designed. This instrument is not yet on the market, but I hope that it will soon be procurable from some of our instrument manufacturers.

Memorials



GEORGE FETTEROLF

GEORGE FETTEROLF, A.B., M.D., Sc.D.

1869-1932

It is difficult to realize that Dr. Fetterolf, our President for this year, has passed from our midst. By his death this Association has lost one of its most loyal and enthusiastic fellows and we, its members, a loved and gracious friend.

Dr. Fetterolf died on December 29, 1932, from cerebral thrombosis. In December, 1928, he was operated on for cholelithiasis and although, after several months convalescence, he went back to active practice, he never regained his former robust health. In December, 1931, he had what was apparently a slight cerebral thrombosis, but from this he made an almost complete recovery. In the summer of 1932 he had another attack, this time more severe, so that he was not able to resume active practice. During the past fall, although he realized that there was little likelihood of his return to active work and was bothered a good deal by mental confusion, he did see a few patients and was delighted to see and talk with his friends. On Christmas Eve, after dinner, as the symptoms of his last illness began to develop, he said to his brother: "I think I am getting a stroke," and apparently knew that this was the end. The symptoms of extensive thrombosis gradually developed and he passed away peacefully on the following Thursday morning.

He is survived by his widow, Mrs. Lila Prosser Fetterolf, and a brother, Mr. Edwin H. Fetterolf. There were no children.

Dr. Fetterolf was born in Collegeville, Montgomery County, Pa., on March 31, 1869. His father was Adam H. Fetterolf, A.M., Ph.D., and his mother, Annie H. Fetterolf. For a while his father conducted a private school for boys at Andalusia near Philadelphia, and here Dr. Fetterolf received his early education. His mother died in 1877. In 1880 his father was elected vice-president of Girard College, Philadelphia, and president in 1883.

Dr. Fetterolf prepared for college at the Episcopal Academy in Philadelphia. He matured rapidly and was a brilliant scholar,

entering college at fourteen years of age. From childhood his ambition was always to study medicine. He graduated from the College Department of the University of Pennsylvania in 1887, as a preparation for his medical studies and spent the next year as demonstrator of histology and embryology, in the Biological School, at the University of Pennsylvania. Entering the Medical Department in 1888, he graduated in 1891.

His internship was spent at St. Luke's Hospital, Bethlehem, Pa. He early attached himself to the anatomical department at the University of Pennsylvania, and became prosector in applied anatomy in 1893. He advanced through the various offices connected with the anatomical department, teaching in the dissecting room and writing numerous anatomical articles, and in 1912 was made assistant professor of anatomy, which office he held until 1921. This association with the anatomical department gave him his profound knowledge of anatomy which stood him in such good stead in his chosen specialty of otolaryngology.

In "Famous Men who have Held the Chair of Anatomy," by George E. de Schweinitz, published in the *Pennsylvania Gazette*, January 28, 1927, we find the following passage:

"It is only necessary to mention a few of these men whose surgical and operative ability were so largely the outcome of their anatomical studies and dissecting-room experiences: William Hunt, D. Hayes Agnew, Charles Hunter, Charles B. Nancrede, H. Lenox Hodge, John B. Deaver, Richard Harte and George Fetterolf."

As soon as he had finished his internship at St. Luke's Hospital, he began to specialize in otolaryngology, though for years a large part of his time was taken up with his duties in the anatomical department of the University. He studied under Dr. Arthur Ames Bliss and was for a while assistant to Dr. D. Braden Kyle. His early clinical experience was gained at the Philadelphia Polyclinic, where he was assistant laryngologist until 1896. After this, and up to 1906, he was assistant laryngologist to the Methodist Episcopal Hospital of Philadelphia. His training in laryngeal tuberculosis was obtained at the Henry Phipps Institute, to which he was elected as laryngologist in 1905, and in 1906 was appointed laryngologist to the White Haven Sanatorium. As a consulting

laryngologist he served on the staffs of the Eaglesville Sanatorium, the Phoenixville Hospital, the Eastern Pennsylvania Institute for Feeble Minded and Epileptics, the Kensington Hospital and Dispensary for Tuberculosis, and the Shriners' Hospital of Philadelphia. Ursinus College gave him the honorary degree of Sc.D. in 1911.

In 1924 he was elected professor of otolaryngology at the University of Pennsylvania. Prior to his election there were two separate chairs of otology and laryngology, and when the authorities at the University of Pennsylvania decided to unify these two chairs they selected George Fetterolf as preëminently fitted to take charge of this department, and the subsequent development of this department more than justified their selection.

Dr. Fetterolf belonged to the Beta Theta Pi College Fraternity, the Phi Alpha Sigma Medical Fraternity, the Alpha Omega Alpha (Honorary Medical Society), the Theta Nu Epsilon Sophomore Society, and Lodge 51 of the Free and Accepted Masons. In 1910 he was elected to the Sigma Xi Society. The 1929 "Scope," a year-book published by the graduating medical class at the University of Pennsylvania, was dedicated to him. This was an honor that he appreciated very greatly.

For many years he was a member of the Union League of Philadelphia and, for even a longer time of the Art Club. Also, he was a member of the Merion Cricket Club, where his golfing enthusiasm found its chief outlet. His membership in the Swiftwater Preserve, a trout fishing club in the Pocono Mountains, was one of his greatest joys.

His professional society memberships included The American Association of Anatomists; The American Laryngological, Rhinological and Otolological Society; The American Medical Association and its associated state and county societies; The Philadelphia Pathological Society; The John Morgan Society; The College of Physicians of Philadelphia, where he was a member of the Mütter Museum Committee from 1913 to 1924, chairman of the section of otology and laryngology from 1923 to 1924, and a member of the Council from 1927 to 1929.

He was elected to fellowship in the American Laryngological Association in 1914 and, since his election, was intensely inter-

ested in the activities of our Association, valuing it above all his other professional societies. He was a member on the committee on tonsil investigation from 1918-1923 and its chairman for the last two of these years. He was first vice-president in 1922. In 1923 he was elected treasurer and served the Society with a fidelity and efficiency that cannot be overestimated. In recognition of his services as treasurer and as an appreciation of his ability in his chosen specialty, and because of the love which we have toward him as a man, this Association elected him its president in 1932, bestowing upon him the highest honor in American laryngology.

During the World War he was commissioned major in the medical corps of the Army on May 21, 1918, and served as chief of the department of otolaryngology, first, at Camp Sevier and, later, at Camp Hancock. He received his discharge on February 12, 1919.

In reviewing Dr. Fetterolf's contributions to medical literature, we are impressed not only by the meticulous care in the collection of material and preparation of data, but also by the unusually clear representation of facts and the detail of his published articles. Some of his most important anatomical contributions were based on the use of carefully made frozen sections through the body to demonstrate the relation of the various organs of the chest both in normal and pathologic conditions. Many of these articles were written in collaboration with such distinguished clinicians as H. R. M. Landis, George William Norris and J. Claxton Gittings, and their value depended upon the furnishing of an anatomical explanation of certain well-known clinical phenomena. For example: "The Anatomic Explanation of the Greater Amount of Vocal Fremitus and Vocal Resonance Normally Found at the Apex of the Right Lung;" again, "Some Anatomic Features of the Child's Thorax and Their Practical Application in Physical Diagnosis," and "The Anatomical Explanation of the Paralysis of the Left Recurrent Laryngeal Nerve Found in Certain Cases of Mitral Stenosis." It was probably the excellence of these studies that first brought the value of the man to the attention of Philadelphia medicine.

His writings on otolaryngology showed the same careful prep-

aration and planning. His article on "The Anatomy and Relations of the Tonsil in the Hardened Body, etc.," has been quoted in many of our American text-books. "The Reaction of the Paratonsillar Tissues to Tonsillectomy: A Study in the Etiology of Post-tonsillectomy Pulmonary Abscess," written in collaboration with Dr. Herbert Fox, was awarded the Casselberry Prize of the American Laryngological Association in 1923. This was an important contribution to the etiology of pulmonary abscess, and as such has received wide recognition. He published several articles on laryngeal tuberculosis and was an advocate of the importance of the galvanocautery in the treatment of this disease. He was one of the first, if not the first, among laryngologists to use ephedrine, and his published clinical experiences with this drug brought its importance to the attention of other laryngologists. His study of vagotonia and the relation of the upper respiratory tract to bronchial asthma were real contribution to laryngology.

In the reorganization of the editorial staff of the *Annals of Otolaryngology, Rhinology and Laryngology*, he was put on the Editorial Board and in 1929 was elected by the trustees of the American Medical Association as a member of the editorial board of the *Archives of Otolaryngology*.

Although Dr. Fetterolf was not a prolific writer, and wrote only when he had something to say, his publications, based on carefully worked-out data and written in a clear and convincing manner, have truly added to the sum of medical knowledge.

Dr. Fetterolf owed his success in the field of otolaryngology not to unusual opportunities but to his own ability. He had a rather remarkable manual dexterity and his gentleness of manipulation was a source of much satisfaction to his office patients. In his operative work he combined this technical skill and accurate knowledge of anatomy with the cautiousness of a conservative temperament. He was not a radical enthusiast, preferring to avoid major surgery when such could be avoided, but willing and able to do major surgery when it was indicated. His attention to details and an intense realization of his responsibility for the individual patient made him avoid many of the so-called accidents that happen to some of us who, perhaps, at times take too much for granted.

He was never jealous of the success of others, but accepted with apparent pleasure improvements in technique or new ideas that came to him through contact with those whose opinions he respected. This, with him, was not an evidence of vacillation or lack of conviction. It was necessary to convince his really intellectual grasp of any proposition, but when once convinced it became a pleasure for him to act on that conviction. He was generous in granting to others credit for achievement and had a singularly happy manner of expressing his approval.

He excelled as a teacher, possessing an orderly mind and an unusual ability to express his thoughts. He was, in his earliest days, one of the most popular and efficient instructors in anatomy that the University of Pennsylvania has ever had. When elected professor of otolaryngology he not only stood out as a teacher both in the clinic and on the platform, but also showed a rather unusual ability as an organizer.

He associated with himself an especially earnest and efficient group of assistants, which, coupled with his careful and detailed planning, made it possible for the work of otolaryngology at the University to be carried on smoothly and efficiently even when his increasing poor health of the last year or so necessitated frequent absences.

In 1903 Dr. Fetterolf married Miss Eleanor R. Walter, of Penn Yann, New York. They were divorced in 1913. In 1915 he married Miss Lila C. Prosser, daughter of Dr. W. O. Prosser, of Eugene, Oregon, a graduate of McGill University and at one time house physician to Sir Morell Mackenzie. In this marriage he found real domestic happiness, and these years of his second marriage were filled with a mutual sympathy and understanding that was idyllic. Their home radiated geniality and friendship and it became a Mecca for friends.

For his friends Dr. Fetterolf had a sympathy and understanding that made confidence natural. His apt and terse remarks about things and persons were at times perfectly delightful and his frankness often became contagious.

All his life he was exceedingly fond of music. From his college days when he led the banjo club and throughout the years of grand opera and symphony orchestra, music was to him not only an enjoyment but almost a passion.

His literary tastes were evidenced by the completeness of his library and the collection of many first editions, and his artistic appreciation by a complete set of Bishop's etchings.

His adaptability to the moods of others, his wide reading and his interest in art and music, and, above all, his delicious sense of humor made him a most pleasing companion. He was one of those rather rare conversationalists who stimulated but did not dominate. One might become provoked or even angry with him but never bored.

He enjoyed the great out-of-doors. He played a good game of golf but in his later years found his greatest relaxation in the wilder places. For years, he went regularly to the woods of Maine and, like all good fishermen, thrilled over new tackle and appurtenances.

As the fall of a great tree leaves an open scar in the forest, so the passing of George Fetterolf leaves a vacancy in the ranks of laryngologists and a lasting emptiness in the hearts of his friends.

By his ability and effort he made for himself an important place in Philadelphia medicine and won a national reputation as an anatomist and as a laryngologist. By his personal charm he won the devotion of friends and patients. We, members of the American Laryngological Association, will remember him for his zealous loyalty to our society, and still more for his outspoken friendship, his geniality and his happy companionship with us, his brother Fellows.



CLEMENT FRANK THEISEN

CLEMENT FRANK THEISEN, M.D.

1871-1932

DR. CLEMENT FRANK THEISEN was born in the city of Albany, New York, April 13, 1871. His father, J. L. Theisen, born in Denmark of Dutch parentage, was a merchant. His mother, of Alsace originally, was of French extraction.

Dr. Theisen's early life was passed in Albany, where he attended private school and the Albany High School. He graduated in medicine from the Albany Medical College in 1892 and became extern at Roosevelt Hospital in all departments, during 1892-1893. In the fall of 1893 he began the study of laryngology at Vienna, having as his instructors Professor von Schroetter, Chiari and Hajek.

Returning home in course of time he became connected with the Troy Hospital, the Childs' Hospital and the South End Dispensary, all of Albany, and has since been connected with St. Peter's and the Childs' Hospital of Albany and with the Troy Hospital, resigning from the Troy Hospital after five years service and also from the South End Dispensary.

His last associations were with the St. Peter's Hospital, the Childs' Hospital, the Maternity Hospital and the Infants' Home.

During the last eighteen months of the World War he was in charge of the nose, throat and ear department of the Draft Board of the five counties adjacent to Albany.

For twenty-nine years he was clinical professor in the department of nose and throat at the Albany Medical College.

He was admitted to Fellowship in the American Laryngological Association in 1903 and had held the office of Vice-President. He was also a member of the American Rhinological, Laryngological and Otological Societies, the American Therapeutic Society and of the National State and County Medical Society.

Some of his numerous philanthropic interests were the American Red Cross, the Young Men's Christian Association, the Young Women's Christian Association, the Boy Scouts, and the Guild for

the Sick. He was a devoted Episcopalian and a pillar of All Saints Cathedral.

A staunch Republican in politics, his secular associations were numerous. Among them the Albany Country Club, the Fort Orange Club, the Tidesco Country Club of Swampscott, Mass., and the Thousand Islands Yacht and Country Clubs of the St. Lawrence.

A man of numerous diversions, Dr. Theisen was especially cultured in music and drawing. He was also fond of golf and an expert at tennis.

In 1897 he was married to Miss Anna Alida Cain, of Schenectady, New York, a daughter of Nicholas Cain and his wife Alida Cromme. Of the two children left by them, the daughter, Alida Winne, is now Mrs. J. Morton Hoogue, and a son, Clement F. Theisen, Jr.

Of his contributions to medical science, one of the most important, related to experiments in coagulation time in blood of bleeders following injections of blood serum before operative procedures, was carried on at the Childs' Hospital, 1910-1911.

He died at his residence, 172 Washington Avenue, Albany, July 27, 1932.

The loss of Dr. Theisen is a marked event in the history of this Association, for in character, general attainment and professional skill he was unusual, a man of singular charm of person and quiet force of personality; he was without question for many years the most accomplished and reliable of specialist in his department between New York City and Montreal, just as a greatly beloved representative of the Association has been and is the best of his kind between here and Boston. Leading a life of absolute devotion to those about him, both at home and far and wide, his career was as praiseworthy as he himself.

**Executive Sessions
1933**

FIRST EXECUTIVE SESSION

MONDAY, MAY 8, 1933

THE First Executive Session of the Fifty-fifth Annual Congress was called to order by Dr. Gordon Berry, Vice-President of the Association, immediately following the first scientific session.

The following Active Fellows were elected to the Emeritus list, having received the recommendation of the Council: Dr. George E. Shambaugh, Chicago, Ill.; Dr. John M. Ingersoll, Miami Beach, Florida; and Dr. Thomas H. Halsted, Syracuse, N. Y.

The following were elected Active Fellows of the Association: Dr. John H. Foster, Houston, Texas; Dr. Edward H. Campbell, Philadelphia; Dr. Thomas Roy Gittins, Sioux City, Iowa; Dr. Karl Musser Houser, Philadelphia; Dr. DeForest Clinton Jarvis, Barre, Vermont; Dr. Ernest M. Seydell, Wichita, Kan.; Dr. Allison T. Wanamaker, Seattle, Wash.

Dr. William B. Chamberlin, Dr. Louis H. Clerf and Dr. Frederick T. Hill served as Tellers at the election.

The Chair appointed Drs. Richmond McKinney and Joseph B. Greene members of the Auditing Committee.

The Nominating Committee as elected by the members of the Association was composed as follows: Dr. Harris P. Mosher, Chairman, Dr. Chevalier Jackson, Dr. Charles J. Imperatori, Dr. William P. Wherry and Dr. Henry L. Swain.

There being no further business, the meeting adjourned.

ANNUAL BUSINESS MEETING

TUESDAY, MAY 9, 1933

THE Annual Business Meeting of the Association was held at 10 o'clock in the Raleigh Hotel with Dr. Gordon Berry in the Chair.

THE REPORT OF THE SECRETARY

The Fifty-fourth Annual Congress of the Association was held at the Hotel Chelsea, Atlantic City, N. J., on May 19, 20 and 21, 1932, Dr. George E. Shambaugh being President.

The Secretary has the sad duty of announcing the following deaths since the last Annual Congress: Dr. George Fetterolf, elected Active Fellow in 1914, elected President of the Association in May, 1932, died December 29, 1932; Dr. Clement F. Theisen, elected Active Fellow in 1903, died July 27, 1932.

The Association has now: Honorary Fellows, 2; Corresponding Fellows, 20; Emeritus Fellows, 16; Active Fellows, 91; Associate Fellows, 14.

The Annual Meeting of the Council was held at the home of the Secretary in Philadelphia on January 14, 1933, the following members being present: Drs. Berry, Mullin, Birkett, Swain, Packard and Coates. Dr. Gordon Berry, First Vice-President, presided.

The Hotel Raleigh was designated as headquarters for the Annual Congress, to be held in Washington on May 8, 9 and 10, 1933, in connection with the sessions of the Congress of American Physicians and Surgeons. The date for the banquet was left to the discretion of the Vice-President and the Secretary to be arranged so as to cause the least conflict with the affairs of the American Otological Society. Subsequently the Council agreed, in the interest of economy, to hold this year a joint banquet with the American Otological Society on Tuesday evening, May 9.

Dr. Charles J. Imperatori was reelected Abstract Editor for the ensuing year. Professors John A. Kolmer and R. H. Stetson were invited to be the guests of the Association at the Annual Meeting.

The resignation of Dr. Rockwell A. Coffin was accepted with regret.

The Council recommended the following proposed amendment to the Constitution, offered by Dr. Packard: To Amend Article 6, Section 11, by the omission of the words "and a Librarian" so that the Section will read:

"The Council shall meet immediately on their election, and

organize by electing from among their number: A President; A Vice-President; A Second Vice-President; A Secretary; A Treasurer; who shall perform the usual duties of such officers for both the Council and the Association."

This amendment was offered because the Council feels that in the absence of a Library, the position of Librarian is superfluous.

The Council recommended to the Association for election to Active Fellowship the following: Dr. John H. Foster, Houston, Texas; Dr. Edward Hastings Campbell, Philadelphia, Pa.; Dr. Thomas Roy Gittins, Sioux City, Iowa; Dr. Karl Musser Houser, Philadelphia, Pa.; Dr. DeForest Clinton Jarvis, Barre, Vermont; Dr. Ernest M. Seydell, Wichita, Kan., Dr. Allison T. Wanamaker, Seattle, Wash..

The Council elected as Associate Fellows the following: Dr. Robert Buckley, New York, N. Y.; Dr. Gordon Follette Harkness, Davenport, Iowa; Dr. Dean M. Lierle, Iowa City, Iowa; Dr. Bernard J. McMahon, St. Louis, Mo.; Dr. Porter Stiles, Birmingham, Ala.

The Second Meeting of the Council was held at the Hotel Raleigh, Washington, D. C., May 7, 1933. President: Dr. Gordon Berry in the Chair, Drs. Swain, Barnhill, Mullin and Coates.

The resignation of Dr. Perry Goldsmith was accepted.

Drs. Shambaugh, Ingersoll and Halsted were recommended, at their own request, for Emeritus Fellowship.

The Council decided that no award of the Casselberry Prize be made this year.

The Council directed the Treasurer to withdraw \$1000 from the surplus of the Casselberry Fund and \$1000 from the surplus of the Johnston Fund, to be invested as capital, the investment to be in government bonds or similar and equally safe security.

Respectfully submitted,

GEORGE M. COATES,

Secretary.

The Secretary's report was on motion made and seconded, accepted and placed on file.

The Auditing Committee reported through Dr. Richmond McKinney that it had examined the books of the Treasurer of the Association and found them correct in every respect. The Committee complimented the Treasurer on the careful manner in which his accounts had been kept.

TREASURER'S REPORT

THE following report covers the financial transactions of the Association for the fiscal year ended April 30, 1933.

Cash in bank at the close of the year amounted to \$2,103.90 as compared to \$2,965.36 at the end of last year (1932), a net decrease of \$861.46. The major cause of this decrease in surplus cash is due to non-payment of dues before the closing of the 1933 accounts. Sales of *Transactions* decreased in the amount of \$130.00, which, together with \$685.00 of unpaid dues, practically accounts for the decrease in surplus. It is earnestly requested that all members who have not paid their current or past dues please do so when possible.

After I took over the office of Treasurer from Dr. Fetterolf, I received boxes containing many volumes of *Transactions* for years past. There are as many as 116 volumes for one year. The question arises, would it not be wise to advertise these for sale at a somewhat reduced rate. If so, I would request this authority. Also it is a question if some greater effort should not be made to sell more numbers of the current transactions.

During the month of January, 1933, the Fidelity-Philadelphia Trust Company served notice to the effect that on and after February 1, 1933, and until further notice interest allowed on balances carried in Savings Fund Accounts would be at the rate of two and one-half per cent ($2\frac{1}{2}\%$) per annum, instead of three per cent (3%) as heretofore. This change in interest rates will effect the income on the Casselberry and Johnston Funds which are carried by the Fidelity-Philadelphia Trust in Savings Accounts. The De Roaldes Fund is carried in Cleveland, Ohio, with The Cleveland Trust Company. Three per cent (3%) interest is being allowed on this fund.

On the whole the finances of the Society are in a reasonably good condition. I express some concern over the condition and outlook of the investment held by the Casselberry Fund in that of the 1708 Chancellor Street Bonds.

I desire to express the great personal loss of Dr. Fetterolf, and my appreciation of his great coöperation and kindness to me in getting me started with my new duties.

Respectfully submitted,

WM. V. MULLIN,
Treasurer.

CLEVELAND, OHIO,
APRIL 30, 1933

TREASURER'S REPORT FOR YEAR ENDED APRIL 30, 1933

GENERAL FUND

Receipts

Dues, 1931:		
1 Active Fellow	\$20.00	
Dues, 1932:		
17 Active Fellows	340.00	
3 Associate Fellows	45.00	
Dues, 1933:		
60 Active Fellows	1,200.00	
12 Associate Fellows	180.00	
1 Associate Fellow, cash advance by Dr. Fetterolf	30.00	
	<hr/>	
Total Receipts from Dues	\$1,815.00	
	<hr/>	
Sale of <i>Transactions</i>	\$233.15	
Miscellaneous:		
Check collection fees	\$1.50	
Canadian Exchange	5.26	
Interest Receipts: on General Fund:		
Fidelity-Philadelphia Trust Company (previous to transfer)	16.06	
The Cleveland Trust Company	5.50	
Refund unexpired premium on Treas- urer's Bond (Dr. Fetterolf)	28.16	
	<hr/>	
	56.50	
	<hr/>	
Gross Receipts, General Fund	\$2,104.65	

Expenditures

Dinner expense, 1932 Meeting, Hotel Chelsea, 61.85	\$61.85	
Less: Refund Account overcharge	10.00	
	<hr/>	
Net	\$51.85	
Refund covering amount paid by Dr. Fetterolf ac- count of dues and protest fees:		
Dr. French K. Hansel	\$33.41	
Stereopticon 1932 Meeting	60.00	
	<hr/>	
Carried forward	\$145.26	

Brought forward	\$145.26	
Treasurer's surety bond (Dr. Mullin)	42.50	
Traveling expenses to Annual Meeting Council		
Members	118.64	
Stenographic service, 1932 Meeting	205.97	
Refreshments, annual dinner	45.00	
Multigraphing, stationery and printing	227.95	
Transfer and express charges on <i>Transactions</i>	42.00	
Printing and mailing <i>Transactions</i> , 1932	1,632.95	
Honorarium: Secretary, George M. Coates	300.00	
Treasurer, William V. Mullin	100.00	
Abstract Editor, Chas. J. Imperatori	50.00	
Wreath to funeral of Dr. Fetterolf	15.00	
Articles of Incorporation (500)	38.50	
Federal Tax checks issued46	
Canadian Exchange paid	1.88	
		<hr/>
		\$2,966.11

Amount of excess expense over receipts for year ended April	
30, 1933	\$861.46

FINANCIAL STATEMENT, APRIL 30, 1933

Assets

General Fund:

Cash in bank	\$2,103.90	
Accounts Receivable: Unpaid dues:		
1 Active Fellow, 1931	\$20.00	
1 Active Fellow, 1932	20.00	
27 Active Fellows, 1933	540.00	
		<hr/>
Total	\$580.00	
7 Associate Fellows, 1933	105.00	
		<hr/>
Total accounts receivable	\$685.00	
		<hr/>
Total Assets, General Fund		\$2,788.90
Casselberry Fund:		
Securities (at book value)	\$5,000.00	
Cash in bank	1,737.58	
		<hr/>
Total Assets, Casselberry Fund		\$6,737.58
		<hr/>
Carried forward		\$9,526.48

Brought forward	\$9,526.48
De Roaldes Fund:	
Cash in bank	\$815.91
Johnston Fund:	
Securities (at book value)	\$5,000.00
Cash in bank	1,322.17
	<hr/>
Total Assets, Johnston Fund	\$6,322.17
	<hr/>
Total assets (book values) April 30, 1933	\$16,664.56
<i>Liabilities</i>	
Unpaid bills	None

CASH ACCOUNT—GENERAL FUND

Balance in Bank at beginning of year, as per last report	\$2,965.36
Receipts, deposited during year	2,104.65
	<hr/>
Total	\$5,070.01
Checks issued, Nos. 233 and 234* account Fidelity-Philadelphia Trust Company	\$63.73
Nos. 1 to 30 inclusive account, The Cleveland Trust Company	2,902.38
	<hr/>
Total amount of checks issued	\$2,966.11
	<hr/>
Balance in bank April 30, 1933	\$2,103.90
Accounts transacted by Dr. Fetterolf:	

Accumulated receipts and expenses during this period were as follows:

Receipts

Dues Active Fellows	\$180.00
Dues Associate Fellows	60.00
Sale of <i>Transactions</i>	10.00
Miscellaneous	30.90
Balance of cash, April 30, 1932, as reported by Dr. Fetterolf	2,965.36
	<hr/>
Carried forward	\$3,246.26

* Check number 234 was issued in the amount of \$3,182.53 and covered transfer of funds from the Fidelity-Philadelphia Trust Company to The Cleveland Trust Company.

During the period, April 30 to May 23, 1932, the commercial checking account was carried at the Fidelity-Philadelphia Trust Company.

Brought forward	\$3,246.26
Less expenses:	
Hotel Chelsea, Dinner	\$61.85
Canadian Exchange	1.88
	<hr/>
	\$63.73
	<hr/>
Amount transferred to The Cleveland Trust Com- pany	\$3,182.53

The Casselberry Fund

The original capital of this fund was a legacy left to the Association by Dr. Casselberry in the amount of \$5000. From accumulated income and an additional \$1000 received from the Association, the Fund has increased in book value to \$7737.58 as at April 30, 1933.

Investments

2000, 1500 Walnut Street, Building, 1st Mortgage 6 per cent Gold Bonds, due April 1, 1947, cost	\$2,000.00
3000, William K. Randt, 1708 Chancellor St., Philadel- phia, Pa., 1 st Mortgage, Series "A", 6 per cent, due September 1, 1932, cost	\$3,000.00
1000, Pennsylvania Railroad Company, 40 year, secured 5 per cent, due November 1, 1964	\$1,000.00
	<hr/>
Total cost	\$6,000.00

Two thousand 1500 Walnut Street Building Bonds were issued by E. H. Rollins & Sons, and the purchase was recommended by the Philadelphia office of this concern. The last interest payment was made October 1, 1931. Coupons covering interest due April 1, 1932, and October 1, 1932, were sold at face value in the amount of \$120.00 on December 2, 1932.

As stated in the annual report of the Treasurer for the year ending April 30, 1932, these bonds are in default and were taken over by a Bondholders' Protective Committee. Since date of default in interest payment, the company's earnings have been only sufficient to pay October 1, 1931, coupons and the Protective

Committee has bought all subsequent coupons as they fell due. The current market is quoted around \$26 to \$35 per hundred flat, which indicates a value of approximately \$600. There is nothing further to be done at present as the Association's interests are being cared for by the Bondholders' Protective Committee on the choice of the Associations Fiscal Agent—The Fidelity-Philadelphia Trust Company. It is your Treasurer's opinion that it is wise to continue with this committee.

Three thousand William K. Randt, 1708 Chancellor Street Bonds. The total amount of the original issue of these bonds was \$400,000, of which by serial payments have been reduced to the present amount of \$383,500, which are now outstanding, and are secured by a first mortgage on a garage leased to The Penn-Warwick Garage Company. The property was appraised in 1928 at about \$625,000. The building is a steel frame, brick and concrete structure, six stories and basement. Approximate capacity, 470 cars. The lease to The Pen-Warwick Garage Company runs to February 28, 1938.

Bankers Bond and Mortgage Company advises that their business has met with ruinous competition from open-air garages, and that the property is now leased at a low rental compared with that which was received several years ago. It is stated that a plan of readjustment or refinancing will be submitted to the bondholders as soon as feasible.

Income and Expense statements covering the earnings are not available, although the estimated annual minimum rental would amount to about 1.87 times the annual interest charges on the bonds. The current market is quoted around \$22 indicating a value of approximately \$660.00.

One thousand Pennsylvania Railroad Secured 5's. This bond is a direct obligation of the Pennsylvania Railroad Company and is secured by a pledge of stocks of certain companies leased by the Pennsylvania Railroad.

The present indication is, that the company will be able to meet fixed charges of interest and taxes and have approximately \$13,000,000 over. At the current recent price of \$79 the value of this bond is \$790.00.

This your Treasurer believes to be a good investment.

Receipts: Cash

Balance in bank as per last report	\$1,441.73
Interest on bonds: Receipts	\$140.00
Interest credited to account No. 15892	43.65
Proceeds from sale of coupons	120.00
	<hr/>
	303.65
	<hr/>
	\$1,745.38
Less, Commission at 3 per cent charged by Fidelity Trust Company, Fiscal Agent	7.80
	<hr/>
Net cash balance April 30, 1933*	\$1,737.58

Johnston Fund

The original capital of this Fund amounting to \$5000 has been invested in 5000 par value of the 1500 Walnut Street, Philadelphia, Pa., bonds.

Receipts: Cash

Balance in bank as per last report	\$1,001.14
Proceeds from sale of interest coupons of 5000, 1500 Walnut Street, Philadelphia Bonds	300.00
Interest credited to account by the Fidelity-Philadelphia Trust Company	30.03
	<hr/>
	\$1,331.17
Less Commission at 3 per cent, charged by Fidelity-Phila- delphia Trust Company, Fiscal Agent	9.00
	<hr/>
Net cash balance April 30, 1933*	\$1,322.17

De Roaldes Fund

The original capital of this fund amounting to \$500.00 was deposited in a savings account with the Fidelity-Philadelphia Trust Company at 3 per cent interest.

* Two weeks' notice is now being required before withdrawal of cash from bank.

During the month of June, 1932, this fund was transferred to The Cleveland Trust Company of Cleveland, Ohio, and is now drawing interest at 3 per cent and is kept in savings account No. 79612 with the Euclid-E. 105th Office of the Trust Company.

Summary of Account

Balance in The Fidelity-Philadelphia Trust Company as at	
April 30, 1932	\$793.95
Interest credited by Fidelity Trust Company, for period ended	
June 1, 1932	9.92
	<hr/>
Amount transferred to The Cleveland Trust Company . . .	\$803.87
Interest credited by the Cleveland Trust Company for period	
ended December 31, 1932	12.04
	<hr/>
	\$815.91
Less expenditures	None
Balance in bank, April 30, 1933	\$815.91
	<hr/>

REPORT OF THE LIBRARIAN.

Mr. President, I feel somewhat in a curious position. I am librarian of something that doesn't exist, and, in so far as I am able to make out, has not existed for a long time.

When you gentlemen elected me to this position, some two years ago. I had no knowledge as to what we had but I did come immediately to Washington to find out, because it has always been stated that the library of the Surgeon-General's office was the repository for our books. When I met the said librarian and those who had in management this book affair, I spent an hour with them, learning that if they had any books there that were in our name, the librarian didn't know it. Certain books had been sent but they had been absorbed. Nobody had ever taken any interest in the said books.

However, Mr. Chairman, I think it is proper to say that the librarian was very receptive, very kindly and he wished to do us good. He wished that, if we desired, all the books or any of the books of the Surgeon-General's office be used by our people. He recommends that.

About that time, several gentlemen of this Society said to me they had been to St. Louis and that there was an opportunity in St. Louis of establishing a central library and these gentlemen thought it was probably a wise thing to do to go there and get the help of the St. Louis people. I therefore made a visit to St. Louis for the sole purpose of learning what might be in their minds. I visited Dr. Dean (and I might say in passing, he has a wonderful building there and a room that would be splendidly fitted for the purpose which we have in mind) and we saw the dean of the Medical School. He said that room could, at that time, be given us. Since that time I have heard nothing from St. Louis. I have talked to Dr. Dean and he said at the present time there is no chance of getting any money which, two years ago, he believed could have been had in pretty liberal amounts.

It is also estimated it would cost us \$10,000 to begin with in St. Louis and \$5000 each year to maintain a library. From such conversations as I have had with our members, it is our view we would not at the present time be in any position to take over any library that would cost that amount of money.

Making my whole report as short and brief as I can, Mr. President, I would, therefore, say that if we are to have a library, that I would recommend after two years' investigation that we affiliate, in such way as is best suited to the purpose of the Surgeon-General's library and our needs, with the Surgeon-General's library; that the Association give such assistance to the library as the librarian may request; and that, if there should be some moderate expense connected with this, that we should bear it; that a brochure, containing instructions to our members and to the members of such other National Associations as may affiliate with us in this enterprise explaining how to get books, reprints, transactions and the help they may need in the preparation of their work, be issued, and that this booklet also contain a catalog of all the books and such pamphlets as are there; that our members be urged when they write articles or textbooks, to send copies to the Surgeon-General's library, that our annual reports and transactions also be sent, so they may see that we are interested in this work and what they proposed doing for us; in fact, that we offer them such help as we are abundantly able to give.

I should say, in going through this library yesterday with Dr. Beck and Dr. Shurly, we saw on the shelves of that library a great many books in our department. There are a great many pamphlets stored away. These books have been very largely written by the men who sit before me and by their predecessors in this Association and in other National Associations. In other words, that library down there is a little child of the various Associations of America and we ought to take care of that child. It seems to me we ought to be interested in its growth because I understand, Mr. Chairman, that very soon there will be a new building erected in this city to carry it on in a new and better way than has ever been done before. The library already has 310,000 volumes on medicine and the librarian assures me it is the greatest library of its kind in the world, the greatest in number of books and pamphlets of help to the medical profession.

I submit this brief report and hope you will do something about it.

On motion by Dr. Jackson, seconded by Dr. Mosher, this report was accepted and filed.

Dr. Jackson moved that the Association approve the action of the Council in authorizing the Treasurer to fix a lower price for the sale of extra copies of the *Transactions*. This motion was seconded and carried.

JOHN F. BARNHILL,
Librarian.

DR. SHURLY: The problem of a library for ear, nose and throat research is more than just a problem of the American Laryngological Society; it seems to me it is a problem that should greatly interest every specialist along this line and those who are coming into the specialty, those that are developing their scientific work for the future.

With that in mind, I was very much interested a few years ago in trying to gather together representatives from each of the various six Societies of national interest and a committee was appointed with a representative from each Society with the idea of establishing a central library where it would be coöperative; one that would include everybody, should be located in some central place.

As Dr. Barnhill has said, we talked over the question of St. Louis which is now an impossible situation on account of finances at the present time but it seems to me the American Laryngological Society should enter into this greater coöperative idea and the Surgeon-General's library is undoubtedly the place for it. The opportunities are all there and the question of having your work translated is all possible in the Surgeon-General's Library. These thirty-five years have gone by without having anything to show from this Society and it seems to me sort of a calamity. It simply means our concentration of effort along that line has meant very little. In future, if this Society would work together with the representatives who will meet at Milwaukee, the representatives of this larger library committee, at that time we hope to make some very definite arrangements with the Surgeon-General of the Army and have a genuine and definite idea crystallized so that the opportunities of our younger men who wish to write articles and books may have a highly concentrated effort crystallized.

It seems to me that the American Laryngological Association which has always been the leader in the greater development of scientific interest and work along out special line, should help to lead the way. I believe it possible, by authority, to bring about this consummated effort which is the hope of the future in keeping our literature together and in allowing it to grow and become useful.

The Surgeon-General's library, with all there, should be properly classified. Our men have the opportunity to know what is there already and what will be there from time to time in looseleaf reports. The small amount of money spent along that line would be quite worth while as a stimulus to our young men to write and to read which, in my opinion, they sorely need.

DR. JACKSON: Mr. Chairman, it seems to me that the remarks that Dr. Shurly made are very apropos and, incidentally, it indicates we still need a librarian as liaison officer to work with the Surgeon-General's office.

DR. MULLIN: I referred, in my report, to these *Transactions*. Dr. Fetterolf carried them in his house and carried insurance on them. Fortunately, I am able to carry them in a fireproof vault, so I have not taken out insurance but I feel guilty about the fact that so many volumes are just stored up there. There are as

many as 116 from one year and, for many years, there are fifty or sixty. The thought occurred to me, in some of the teaching places, where they do postgraduate teaching, while we could not fill out a complete set, we could very nearly do it back as far, at least, as 1882, they might be very glad to have them available for their postgraduate students. The heads of departments carrying on postgraduate teaching might make application to this Society for as complete a set as we could make up of these *Transactions* and we might let them have them so they would be available to the students. It is true, a great many of the teachers have almost complete sets of *Transactions* but they don't feel like putting them on the shelf for any and every one to take them down and carry off. In that way, these *Transactions* would do far more good than at the present time, being stored in boxes.

DR. WHERRY: I have had much experience in the Academy with our *Transactions*. We have accumulated, I suspect, some eight or ten thousand volumes now. A few years ago we reduced our price and advertised and we have been delighted with the number of *Transactions* we have sold. Particularly is that true of the new members coming in, those who have ambition to go back and fill up their sets. If the volumes are standing on the shelves, they are no good to any one. They represent a certain frozen value. Personally, I think it is only proper procedure to loosen up and give them to those who so desire them, at almost anything we can get out of them. I think it is only good, sound, economic and logical judgment to dispose of them. We are selling them now at \$5.00 a volume for the more recent ones, two years back, \$2.50 for those between the two- and five-year interval, and \$1.00 a volume for those that have gone before.

Just the other day, before I left Omaha, we had an offer from one of the younger men for fifteen volumes. We were unable to supply all of the set. It represented just that much money we could use to advantage. The volumes become dirty and I think it is absurd to hold them.

DR. ROY: We have been discussing this along that line and that has been referred to the Council, according to the motion made by Dr. Jackson, but it seems to me we should crystallize

something and not go on talking year after year. I think Dr. Shurly has put forward the only thing that is of any concrete form.

I would like to amend that motion to read that the librarian should try to unite with some member librarians of other Societies and take this matter up say, at the Milwaukee meeting and see if something could not be done in getting a unified library for all the Societies and keep it in the Surgeon-General's office where the book would be available to everybody.

DR. CHAMBERLIN: I would like to ask how many complete sets the Treasurer has.

DR. MULLIN: None complete. Dr. Delavan has one and so has Dr. Swain, but the Society has not one complete set of the *Transactions*.

DR. JACKSON: My recollection is that somewhere in the minutes there is recorded a motion recommending that a complete set be acquired.

DR. SHURLY: I have a complete set—Dr. E. L. Shurly's *Transactions*.

It was moved by Dr. Jackson, seconded by Dr. Shurly that the report of the Librarian be accepted and filed.

REPORT OF THE ABSTRACT EDITOR

The Abstract Editor has the honor to report that all of the abstracted papers and discussions of the Fifty-fourth Annual Congress of the American Laryngological Association were sent to the Editor-in-Chief of the *Archives of Oto-Laryngology*, June 17, 1932, and were published in the August number of that journal.

These abstracted transactions of the Association, were published in the *Eye, Ear, Nose and Throat Monthly*, and in part in the *Annals of Otology, Rhinology and Laryngology*.

The experiment of publishing the abstracts of the papers so that they would be available for the meeting, met with such success in the past two years that it was decided to send these abstracted papers to the members before the meeting, this year.

The honorarium of \$50 was received from the Treasurer and the necessary expenses paid.

Respectfully submitted,
CHARLES J. IMPERATORI,
Abstract Editor.

Motion to accept the report was put to a vote and carried. Dr. Jackson moved that the recommendation of the Council that the Constitution be so amended that the office of the Librarian be abolished, be not enacted. Seconded by Dr. Roy. In support of this motion, Dr. Jackson said that from the discussion of the Librarian's report, it seemed very clear that the Association still needs the services of a Librarian. The motion of Dr. Jackson was put to a vote and carried.

Dr. Chamberlin moved that the suggestion given by Dr. Barnhill in his report in regard to the duties of a Librarian, as well as the suggestions of Dr. Shurly, be referred to the Librarian. This motion was seconded and carried.

ACTIVITIES OF THE AMERICAN SOCIETY FOR THE CONTROL OF CANCER FOR THE PAST YEAR.

The work of the American Society for the Control of Cancer has been carried on actively during the past year. It is difficult to report tangible progress in a field of action which necessarily entails a long time and a well organized program. The field representatives of the Society, however, report that the matter of cancer control is being studied carefully by an increasing number of state and local medical societies and that our advice is being sought in a much wider territory than a year ago.

The state medical societies in a number of the Southern states have entered into an extensive five-year program in which each local medical society is receiving programs, literature, lantern slides and other material for presentation to its members. Although this material is being furnished by the American Society for the Control of Cancer, the actual program is fostered and carried out by the Cancer Committee of the state medical society. During the year 1933 it is expected that approximately 640 county or local medical societies in the Southern states will devote one or more meetings to the subject of cancer of the breast. The following year cancer of the uterus will be presented in a like manner, and cancer in other sites is planned for the succeeding years.

State wide surveys of the present available facilities for cancer treatment have been made by the Society at the request of the state medical societies in Wisconsin, Missouri, Utah and Oregon.

The Society's field representatives visit the hospitals in these states, ascertain the present facilities and then, on the basis of the data collected, suggest to the state medical societies a well rounded out program which will be possible of attainment in the particular state involved. In each instance the part the Society can play in the program is clearly stated.

The decentralization of the Society's activities is being continued, and the field representatives in each section are working directly with the state and local medical societies. Coöperation with the American College of Surgeons and the American Medical Association has continued.

The Society has extended its plan of exhibits at the various professional meetings and conventions. The material presented is less statistical in nature and more in the line of clinical material. An extensive exhibit on cancer of the buccal cavity, consisting of wax models showing various types of malignant and benign conditions, with accompanying case histories, has been developed and shown at a number of the state dental society meetings. These exhibits are helping to make the dentist cancer-conscious, and a number of dental societies are having special programs devoted to neoplastic growths.

An extensive series of wax models of the breast, covering all the common conditions found in tumor growths, has been developed during the past year. These, with very brief accompanying case histories, are being shown at the state medical society meetings. It is expected later to develop extensive series of wax models showing clinical conditions for other sites in the body. The purpose of these models is to acquaint the physician with the clinical aspects of the more common cancerous conditions.

The *Bulletin* of the Society has continued its monthly publications. Articles of general interest are reprinted, and special articles written for the *Bulletin* by members of the Board of Directors and others are featured each month. News notes about happenings in the cancer field are also presented.

The distribution of literature has been continued on the same basis as before. Some of this is distributed to professional groups at the various conventions where exhibits are presented. A large amount is sent out by the main office to organizations and indi-

viduals for local distribution. Many requests for literature for the individual's own information are received daily in the mail and these are responded to promptly, often with an accompanying letter giving the specific information desired for procedure in securing examination or treatment for a cancerous condition.

The investigation work of the Society is being continued. Studies on buccal cavity cancer, cancer in children, and the relationship of castration to mammary gland cancer are being carried on.

The main office of the Society is being moved to Rockefeller Center, 1250 Sixth Avenue, New York, on May first.

The Society plans to carry on its activities this coming year with the same general program as during the past few years, developing its contacts with state medical societies, and ready to assist in any constructive, well coördinated program.

Signed,

D. BRYSON DELAVAN,
Chairman Cancer Committee.

This report was accepted and ordered placed on file.

Report of the Committee on the Control of Cancer. This report was read by the Secretary in the absence of Dr. Delavan.

This report was accepted with the thanks of the Association to Dr. Delavan.

REPORT OF THE NOMINATING COMMITTEE

The report of the Nominating Committee was presented by Dr. Mosher. The following names for the Board of Directors of the Association were announced:

- Dr. George M. Coates, Philadelphia, Pa.
- Dr. E. Ross Faulkner, New York.
- Dr. Thomas E. Carmody, Denver, Colo.
- Dr. Wm. V. Mullin, Cleveland, Ohio.
- Dr. James A. Babbitt, Philadelphia, Pa.
- Dr. John F. Barnhill, Indianapolis, Ind.
- Dr. Henry L. Swain, New Haven, Conn.
- Dr. Francis R. Packard, Philadelphia, Pa.
- Dr. Gordon Berry, Worcester, Mass.
- Dr. Dunbar Roy, Atlanta, Ga.

The report of the Nominating Committee was, on motion duly made and seconded, accepted.

Dr. Mosher presented the report of the Examining Board in Otolaryngology. He described the work of the Board during the current year.

The Report of the Biographer and Historian will be found under the title of Memorials.

It was moved by Dr. Mosher, seconded by Dr. Chamberlin, and carried, that the Secretary be instructed to send a telegram to Dr. Delavan expressing the affection of the members of the Association and their regret at his absence from the meeting.

The report of the Committee on the National Conference of Nomenclature of Diseases was presented by the Secretary.

The Committee on the Conference of Nomenclature of Diseases held several meetings at which Dr. Logie, the executive secretary of the conference, was present. Each term used to designate any disease in the realm of our speciality was carefully considered. It was found necessary in order to bring all these terms into line with the general plan of classification to eliminate many that are old and familiar. This undoubtedly will cause some confusion at first in the use of the classification. The advantages, however, of the new system are so many and obvious that your Committee hopes that it will find immediate adoption and widespread use among the members of this Association.

Respectfully submitted,
JOHN D. KERNAN,
E. ROSS FAULKNER.

FINAL EXECUTIVE SESSION

TUESDAY, MAY 9, 1933

The Final Executive Session was held at the end of the scientific program on Tuesday, May 9th.

The Board of Directors, put in nomination by the Committee on Nominations at the earlier business session, was balloted upon, Drs. Shea, Seydell and New acting as Tellers. The entire list of Directors was unanimously elected, and after withdrawing for the purpose of organization, the Board announced the election of the following officers for the ensuing year:

Dr. George M. Coates, President,
Dr. E. Ross Faulkner, First Vice-President,
Dr. Thos. E. Carmody, Second Vice-President,
Dr. William V. Mullin, Secretary,
Dr. James A. Babbitt, Treasurer,
Dr. John F. Barnhill, Librarian,

and as additional members of the Council; Drs. Henry L. Swain, Francis R. Packard, Gordon Berry and Dunbar Roy.

Dr. Jackson asked that the following Resolution be passed:

Resolved, That the American Laryngological Association desires unanimously to express its utmost appreciation for the loyal and efficient services of Dr. George M. Coates during his thirteen years' Secretaryship of this Association.

This resolution was adopted by a rising vote and Dr. Swain and Dr. Shurly were appointed by Dr. Berry to escort Dr. Coates to the Chair, where he was presented with the gavel of the Association. In accepting the gavel, Dr. Coates said: Dr. George Wood said this morning that the position of President of the American Laryngological Association is the highest honor in the Laryngological world, and it is with very deep humility and a very great feeling of my unworthiness that I accept this position. You may, of course, be sure I shall be your loyal and humble servant and have always the best interests of the Association deeply at heart—its interests and its traditions.

I have served, as Dr. Jackson said, a long time as Secretary and one of the pleasantest things that has ever happened to me in my life has been the opportunity for contact with the Fellows—their loyalty and help have been a great pleasure to me. It has been no burden because of the coöperation I have received from every Fellow of the Association. May I bespeak your continued loyalty to my successor, Dr. Mullin, who will prove a better Secretary than I have ever been.

I thank you for this honor from the very depths of my heart.

Dr. Jackson then moved a rising vote of thanks to Dr. Berry for conducting the meeting in a most masterful way in the absence of our dear friend, Dr. Fetterolf. This vote was unanimously carried.

As there was no further business, the meeting was declared adjourned.

**List of Fellows
1933**

LIST OF FELLOWS

1933

Attendance during last ten years shown by figures following each name.

Asterisk (*) indicates year paper was read.

Active Fellows

1923. BABBITT, JAMES A., 1912 Spruce Street, Philadelphia, Pennsylvania, 1923, '24*, '25, '26, '27, '28, '29*, '30, '31, '32, '33*.
1929. BARLOW, ROY ALEXANDER, 403 Medical Arts Building, Rochester, New York, 1923, '24*, '28, '29*, '30*.
1915. BARNES, HARRY ALDRICH, 520 Commonwealth Avenue, Boston, Massachusetts, 1920, '24, '27*, '28, '30.
1908. BARNHILL, JOHN F., 408 Pennway Building, Indianapolis, Indiana, 1922, '24, '27, '28, '29, '30, '31, '33.
1928. BECK, JOSEPH C., 185 North Wabash Avenue, Chicago, Illinois, 1928, '30, '31, '32, '33.
1921. BERRY, GORDON, 36 Pleasant Street, Worcester, Massachusetts, 1921*, '22, '23, '24, '25, '26, '27, '28*, '29*, '30, '31, '32, '33.
1893. BIRKETT, HERBERT S., 1190 Mountain Street, Montreal, Canada, 1920, '21, '22*, '23, '25, '26, '27, '28*, '29, '30, '31, '32.
1925. BLAIR, VILRAY P., 400 Metropolitan Building, St. Louis, Missouri, 1922, '23*, '25*, '28*, '31*, '33.
1932. BROWN, JOHN MACKENZIE, 1136 West Sixth Street, Los Angeles, California.
1891. BRYAN, JOSEPH H., 303 Stoneleigh Court, Washington, D. C., 1920*, '21, '22, '23, '24, '25, '26, '27*, '28, '29, '30, '32*, '33.
1913. BUTLER, RALPH, 1930 Chestnut Street, Philadelphia, Pennsylvania, 1920*, '21, '23, '24, '27, '29, '31, '32.
1933. CAMPBELL, EDWARD HASTINGS, 1904 Spruce Street, Philadelphia, Pa., 1930, '31*, '32*, '33.
1927. CARMODY, THOMAS E., 806 Metropolitan Building, Denver, Colorado, 1924, '26*, '27, '28, '30, '32*.
1917. CHAMBERLIN, WILLIAM B., The Carnegie Medical Building, Cleveland, Ohio, 1920, '21*, '22, '26, '27*, '28, '29, '30*, '31, '32, '33*.
1897. CLARK, J. PAYSON, 71 Marlborough Street, Boston, Massachusetts, 1920*, '21, '22, '23, '24*, '26, '28, '32.

1929. CLERF, LOUIS H., 1530 Locust Street, Philadelphia, Pennsylvania, 1925, '27*, '28, '29*, '30*, '32, '33.
1902. COAKLEY, CORNELIUS G., 20 East Fifty-third Street, New York, 1920, '21, '22*, '23, '24, '25, '27, '29, '30, '31.
1917. COATES, GEORGE MORRISON, 1721 Pine Street, Philadelphia, Pennsylvania, 1920, '21, '22, '23, '24, '25, '26, '27, '28, '29, '30*, '31, '32, '33.
1913. DABNEY, VIRGINIUS, 1633 Connecticut Avenue, Washington, D. C., 1921*, '22, '24*, '25, '27*, '28*, '31*, '33.
1918. DEAN, LEE WALLACE, School of Medicine, Washington University, St. Louis, Missouri, 1920*, '21*, '22, '23, '24, '25*, '26, '27*, '28, '29*, '31, '32.
1881. DELAVAN, D. BRYSON, 30 East Sixtieth Street, New York, 1920*, '21*, '22*, '23*, '25*, '26*, '27*, '28*, '29*, '31, '32*.
1926. DENNIS, FRANK LOWNDES, Colorado Springs, Colo., 1925*, '26, '27, '28, '30.
1919. FAULKNER, E. ROSS, 101 East Fifty-eighth Street, New York, 1920, '21, '22, '23*, '25, '27, '28, '30, '32, '33.
1926. FENTON, RALPH ALBERT, 806 Medical Arts Building, Tenth and Taylor Streets, Portland, Oregon, 1923, '25*, '26, '28, '30, '32*.
1922. FORBES, HENRY HALL, 40 East Sixty-first Street, New York, 1922, '25*, '27, '28, '29, '31, '32.
1933. FOSTER, JOHN H., 1304 Walker Avenue, Houston, Texas.
1897. FROTHINGHAM, RICHARD, 666 Madison Avenue, New York.
1933. GITTINS, THOMAS ROY, 408 Davidson Building, Sioux City, Iowa, 1928, '31, '32*.
1913. GOLDSTEIN, MAX A., 3858 Westminster Place, St. Louis, Missouri, 1920, '21, '22, '25*, '26, '27, '28, '29, '30, '32*.
1898. GOODALE, JOSEPH L., 258 Beacon Street, Boston, Massachusetts, 1920, '21, '22*, '23, '24, '26.
1932. GOODYEAR, HENRY M., 556 Doctors' Building, Cincinnati, Ohio, 1928, '29, '30*, '31, '32, '33.
1932. GRAHAM, HARRINGTON B., 4900 Post Street, San Francisco, California, 1932.
1905. GRAYSON, CHARLES P., 262 South Fifteenth Street, Philadelphia, Pennsylvania, 1921.
1906. GREENE, D. CROSBY, JR., 23 Bay State Road, Boston, Massachusetts, 1920*, '21*, '22, '23, '24*, '25, '26, '27.
1917. GREENE, JOSEPH B., 305 Haywood Building, Asheville, North Carolina, 1921, '22, '23*, '24, '26, '27, '28, '29*, '31, '32, '33.

1915. HASTINGS, HILL, 306 Medical Office Building, 1136 West Sixth Street, Los Angeles, California, 1921*, '24, '27*, '28, '30*.
1931. HILL, FREDERICK THAYER, Professional Building, Waterville, Maine, 1928, '29*, '30*, '31, '32, '33.
1933. HOUSER, KARL MUSSER, 2010 Spruce Street, Philadelphia, Pa., 1930, '32*, '33.
1919. HURD, LEE MAIDMENT, 39 East Fiftieth Street, New York, 1921, '23, '25, '26*, '28, '32*.
1925. IGLAUER, SAMUEL, 400 Pearl Market Bank Building, Cincinnati, Ohio, 1926, '27, '30, '32, '33*.
1920. IMPERATORI, CHARLES JOHNSTONE, 108 East Thirty-eighth Street, New York, 1921*, '22, '24*, '25*, '26*, '27*, '28, '31, '32, '33*.
1907. JACKSON, CHEVALIER, 3432 North Broad Street, Philadelphia, Pennsylvania, 1921*, '22*, '23, '24*, '25*, '27*, '28, '29, '30, '31, '32, '33.
1933. JARVIS, DEFOREST CLINTON, Room 7, Quarry Bank Building, Barre, Vt., 1928, '30, '32*, '33.
1918. KENYON, ELMER L., 104 South Michigan Boulevard, Chicago, Illinois, 1922, '24*, '28.
1921. KERNAN, JOHN D., JR., 120 East Seventy-fifth Street, New York, 1921*, '22, '25, '26, '27, '29, '31.
1929. KISTNER, FRANK B., 600 Mayer Building, Portland, Oregon, 1930.
1927. LARGE, SECORD HERBERT, 2323 Prospect Avenue, Cleveland, Ohio, 1924*, '25, '26, '31.
1914. LEVY, ROBERT, Metropolitan Building, Denver, Colorado.
1918. LEWIS, FIELDING OTIS, 259 South Seventeenth Street, Philadelphia, Pennsylvania, 1921*, '22*, '23, '25*, '28, '29, '31 '32, '33.
1925. LILLIE, HAROLD I., Mayo Clinic, Rochester, Minnesota, 1923*, '24*, '25, '26*, '28, '31*.
1911. LOCKARD, LORENZO B., Metropolitan Building, Denver, Colorado.
1932. LUKENS, ROBERT M., 1923 Spruce Street, Philadelphia, Pennsylvania, 1927, '28, '31*, '32.
1928. MACPHERSON, DUNCAN, 140 East Fifty-fourth Street, New York, 1928, '29, '30, '31, '33.
1921. McCULLAGH, SAMUEL, 2 East Fifty-fourth Street, New York, 1921*, '22, '23*, '25, '26*, '27, '28, '31.
1927. McGINNIS, EDWIN, 104 South Michigan Boulevard, Chicago, Illinois, 1924, '25*, '26, '27, '28, '29, '30*, '31, '32.

1913. McKIMMIE, OSCAR A. M., 1301 Massachusetts Avenue, N. W., Washington, D. C., 1921*, '22, '25, '28, '33.
1929. McKINNEY, RICHMOND, 899 Madison Avenue, Memphis, Tennessee, 1923, '24*, '26*, '27, '29, '31, '32, '33.
1904. MOSHER, HARRIS P., 828 Beacon Street, Boston, Massachusetts, 1920, '21*, '22, '23*, '24, '25, '26, '27, '28*, '29, '30, '31*, '32*, '33.
1925. MULLIN, WILLIAM V., Cleveland Clinic, Euclid Avenue at Ninety-third Street, Cleveland, Ohio, 1923, '24*, '25, '26, '27, '28*, '30, '31, '32*, '33.
1932. MYERSON, MERVIN C., 198 Lincoln Place, Brooklyn, New York, 1927, '28*, '29, '30, '31*, '32*, '33*.
1922. NEW, GORDON B., Mayo Clinic, Rochester, Minnesota, 1922, '24, '25*, '26*, '28*, '31*, '33*.
1926. NEWHART, HORACE, 527 Medical Arts Building, Minneapolis, Minnesota, 1923, '25*, '26, '28, '30, '33.
1931. ORTON, HENRY BOYLAN, 24 Commerce Street, Newark, N. J., 1927, '28, '29, '30*, '31, '32, '33*.
1903. PACKARD, FRANCIS R., 302 South Nineteenth Street, Philadelphia, Pennsylvania, 1920, '21, '22, '23, '24, '25, '26, '29, '30, '31*, '32, '33.
1906. PIERCE, NORVAL H., Del Mar, San Diego Co., California, 1920*, '21, '22, '23, '24, '25, '26*, '27*, '28, '30, '33.
1932. PORTER, CHARLES TERRELL, 520 Commonwealth Avenue, Boston, Massachusetts, 1927, '28, '30, '31*, '32.
1931. POTTS, JOHN B., 1620 Medical Arts Building, Omaha, Nebraska, 1931, '33*.
1927. PROETZ, ARTHUR WALTER, Beaumont Building, St. Louis, Missouri, 1924, '25*, '26*, '27, '28, '29, '30*, '31, '32*, '33*.
1903. RENNER, W. SCOTT, 341 Linwood Avenue, Buffalo, New York, 1920, '22, '24, '26, '28.
1884. RICE, CLARENCE C., 52 Park Avenue, New York.
1930. RIDPATH, ROBERT F., Central Medical Building, Eighteenth and Chestnut Streets, Philadelphia, Pennsylvania, 1930, '31, '33.
1913. ROY, DUNBAR, Grand Opera House Block, Atlanta, Georgia, 1921*, '22, '23, '26, '28, '31, '32, '33*.
1921. SAUER, WILLIAM E., 3720 Washington Boulevard, St. Louis, Missouri, 1921, '23, '25, '28, '31, '32.
1923. SEWALL, EDWARD CECIL, 3515 Pacific Avenue, San Francisco, California, 1924, '26*, '28*.

1933. SEYDELL, ERNEST M., First National Bank Building, Wichita, Kan., 1930, '31*, '33*.
1932. SHEA, JOHN JOSEPH, 1018 Madison Avenue, Memphis, Tennessee, 1928, '29, '30*, '31, '32*, '33.
1909. SHURLY, BURT R., 62 Adams Avenue W., Detroit, Michigan, 1920, '21*, '22, '24, '25*, '26, '27*, '28, '29*, '30, '31, '33.
1908. SMITH HARMON, 150 East Sixty-second Street, New York, 1920, '21, '22*, '23, '25, '26, '28.
1932. SMYTH, DUNCAN CAMPBELL, 375 Commonwealth Avenue, Boston, Massachusetts, 1932, '33.
1928. SONNENSCHN, ROBERT, 180 North Michigan Avenue, Chicago, Illinois, 1928, '29*, '30, '31, '32, '33.
1926. SPENCER, FRANK ROBERT, Physicians' Building, Boulder, Colorado, 1923, '24*, '26, '27*, '28, '30, '32*.
1889. SWAIN, HENRY L., Colonial Building, 195 Church Street, New Haven, Connecticut, 1920, '21*, '22, '23, '24, '25, '26, '27, '28, '29, '30*, '31, '32, '33.
1928. TAYLOR, HERMON MARSHALL, 111 West Adams Street, Jacksonville, Florida, 1924, '25*, '26, '27, '28, '31.
1931. TOBEY, HAROLD G., 270 Commonwealth Avenue, Boston, Massachusetts, 1927, '29*, '30*, '31, '32.
1929. TUCKER, GABRIEL, 326 South Nineteenth Street, Philadelphia, Pennsylvania, 1925, '26*, '27*, '29, '30, '31, '32, '33.
1892. WAGNER, HENRY L., 518 Sutter Street, San Francisco, California, 1926.
1933. WANAMAKER, ALLISON T., 817 Summit Avenue, Seattle, Wash., 1933.
1892. WATSON, ARTHUR W., 2013 Locust Street, Philadelphia, Pennsylvania, 1921, '23, '25, '27, '31, '32.
1928. WHERRY, WILLIAM P., 1500 Medical Arts Building, Omaha, Nebraska, 1924, '25*, '26, '27, '28, '29, '30, '31, '33.
1925. WHITE, FRANCIS W., 174 West Fifty-eighth Street, New York City, New York, 1922, '23*, '25, '26, '27, '28, '29, '31, '32.
1908. WILSON, J. GORDON, 5755 Kenwood Avenue, Chicago, Illinois, 1920, '21, '22, '24, '25, '26, '28, '29, '30, '31*, '32, '33.
1905. WOOD, GEORGE B., Suite 504, Physicians' Building, Northeast corner Twentieth and Chestnut Streets, Philadelphia, Pennsylvania, 1921, '22*, '23*, '25*, '28, '29, '31*, '32, '33.

Associate Fellows

- 1929. ALDEN, ARTHUR MAXWELL, 537 Frisco Building, St. Louis, Missouri, 1930, '31, '32*, '33*.
- 1929. ARBUCKLE, MILLARD F., 1011 Beaumont Medical Building, St. Louis, Missouri, 1929, '32*.
- 1932. ATKINS, RICHARD TRAVIS, 4 West Fifty-third Street, New York City, New York.
- 1932. BAUM, HARRY LESTER, 510 Republic Building, Denver, Colorado.
- 1933. BUCKLEY, ROBERT E., 829 Park Avenue, New York, N. Y.
- 1930. FIGI, FREDERICK A., Mayo Clinic, Rochester, Minnesota, 1930. '32*.
- 1932. FURSTENBERG, ALBERT CARL, 330 South State Street, Ann Arbor, Michigan, 1933*.
- 1933. HARKNESS, GORDON FOLLETTE, 2410 River Drive, Davenport, Iowa.
- 1933. LIERLE, DEAN M., University Hospital, Iowa City, Iowa, 1933.
- 1929. LYMAN, HARRY WEBSTER, 700 Carleton Building, St. Louis, Missouri, 1929, '31.
- 1933. McMAHON, BERNARD I., Missouri Theatre Building, St. Louis, Mo.
- 1931. McNALLY, WILLIAM JAMES, 1538 Sherbrooke Street, West Montreal, Canada, 1931, '33.
- 1932. SCHALL, LE ROY ALLEN, 270 Commonwealth Avenue, Boston, Massachusetts.
- 1933. STILES, PORTER, 501 Medical Arts Building, Birmingham, Ala.

Honorary Fellows

- 1910. MOURE, E. J., 25 bis Cours de Verdun, Bordeaux, France.
- 1914. THOMSON, SIR ST. CLAIR, 64 Wimpole Street, W., London, England.

Corresponding Fellows

- 1901. COLLIER, MAYO, Kearsney Abbey, Kent, England.
- 1893. DESVERNINE, CARLOS M., 52 Cuba Street, Havana, Cuba.
- 1930. EMERSON, FRANCIS P., Franklin, Massachusetts.
- 1901. GRANT, SIR JAMES DUNDAS, K.B.E., 148 Harley Street, London, W 1, England.
- 1919. KELLY, ADAM BROWN, 26 Blythswood Square, Glasgow, Scotland.

1931. LASAGNA, PROFESSOR FRANCESCO, Royal University of Parma, Parma, Italy.
1926. LAW, FREDERICK M., 140 East Fifty-fourth Street, New York City, New York.
1921. LE MAITRE, FERNAND, Avenue Victor Hugo, 120 (XVI), Paris, France.
1903. McBRIDE, P., 20 South Drive, Harrowgate, England.
1919. McKERNON, JAMES F., 636 Fifth Avenue, New York.
1896. MACDONALD, GREVILLE, Wildwood, Haslemere, England.
1920. MACKENZIE, DAN, 9 Weymouth Street, Portland Place, London, W 1, England.
1930. NEGUS, VICTOR E., 133 Harley Street, London, W 1, England.
1919. PATERSON, DONALD ROSE, 15 St. Andrew's Crescent, Cardiff, Wales.
1919. ROGERS, JOHN, JR., 177 East Seventy-first Street, New York.
1924. SCHAEFFER, J. PARSONS, Jefferson Medical College, Philadelphia.
1896. SCHMIEGELOW, ERNST, 18 Norregade, Copenhagen, Denmark.
1903. TILLEY, HERBERT, 72 Harley Street, Cavendish Square, London, W., England.
1913. TURNER, LOGAN, 27 Walker Street, Edinburgh, Scotland.
1901. WINGRAVE, WYATT, Lyme Regis, Dorset, England.

Emeritus Fellows

1914. BROWN, J. PRICE, 29 Edgewood Crescent, Rosedale, Toronto, Canada.
1922. COBB, FREDERICK C., Riverview, Gloucester, Massachusetts.
1931. COFFIN, LEWIS A., 114 East Fifty-fourth Street, New York.
1928. COOLIDGE, ALGERNON, 198 Beacon Street, Boston, Massachusetts.
1918. FARLOW, JOHN W., 127 Bay State Road, Boston, Massachusetts.
1927. HARDIE, T. MELVILLE, 30 N. Michigan Boulevard, Chicago, Illinois.
1933. HALSTED, THOMAS H., 906 Chimes Building, Syracuse, N. Y.
1932. HARRIS, THOMAS J., 104 East Fortieth Street, New York City, New York.
1918. HINKEL, F. WHITEHALL, 28 Norwood Avenue, Buffalo, New York.
1926. HOPKINS, FREDERICK E., 146 Chestnut Street, Springfield, Massachusetts.
1927. HUBBARD, THOMAS, 234 Michigan Street, Toledo, Ohio.

1933. INGERSOLL, JOHN M., Aladdin Building, Miami Beach, Fla.
1912. LINCOLN, WILLIAM, Wade Park Manor, Cleveland, Ohio.
1931. MYLES, ROBERT C., 1075 Park Avenue, New York.
1932. RICHARDS, GEORGE L., South Yarmouth, Massachusetts.
1933. SHAMBAUGH, GEORGE E., 122 S. Michigan Avenue, Chicago,
Ill.

Recipients of the De Roaldes Award

1928. DR. CHEVALIER JACKSON.
1931. DR. D. BRYSON DELAVAN.

Recipients of the Casselberry Award

1923. DR. GEORGE FETTEROLF and DR. HERBERT FOX.
1928. DR. RALPH A. FENTON and DR. O. LARSELL.
1929. DR. RICHARD A. KERN and DR. HARRY P. SCHENCK.
1929. DR. EDWARD H. CAMPBELL.
1931. DR. ARTHUR W. PROETZ.

Benefactors

DR. ARTHUR W. DE ROALDES.
DR. WILLIAM E. CASSELBERRY.
DR. SAMUEL JOHNSTON.

PAST OFFICERS

Presidents

(Year of Election)

1879. Louis Elsberg	1906. A. W. de Roaldes
1880. J. Solis-Cohen	1907. H. S. Birkett
1881. F. I. Knight	1908. A. Coolidge, Jr.
1882. G. M. Lefferts	1909. J. E. Logan
1883. F. H. Bosworth	1910. D. Braden Kyle
1884. E. L. Shurly	1911. James E. Newcomb
1885. Harrison Allen	1912. George A. Leland
1886. E. Fletcher Ingals	1913. Thomas Hubbard
1887. R. P. Lincoln	1914. Alexander W. MacCoy
1888. E. C. Morgan	1915. G. Hudson Makuen
1889. J. N. Mackenzie	1916. Joseph L. Goodale
1890. W. C. Glasgow	1917. Thomas H. Halsted
1891. S. W. Langmaid	1918. Cornelius G. Coakley
1892. M. J. Asch	1919. Norval H. Pierce
1893. D. B. Delavan	1920. Harris P. Mosher
1894. J. O. Roe	1921. Harmon Smith
1895. W. H. Daly	1922. Emil Mayer
1896. C. H. Knight	1923. J. Payson Clark
1897. T. R. French	1924. Lee Wallace Dean
1898. W. E. Casselberry	1925. Greenfield Sluder
1899. Samuel Johnston	1926. Chevalier Jackson
1900. H. L. Swain	1927. D. Bryson Delavan
1901. J. W. Farlow	1928. Charles W. Richardson
1902. J. H. Bryan	1929. Lewis A. Coffin
1903. J. H. Hartman	1930. Francis R. Packard
1904. C. C. Rice	1931. George E. Shambaugh
1905. J. W. Gleitsmann	1932. George Fetterolf

Vice-Presidents

1879. F. H. Davis	J. O. Roe
1880. W. C. Glasgow	W. Porter
1881. E. L. Shurly	E. F. Ingals
1882. C. Seiler	S. Johnston
1883. S. W. Langmaid	W. H. Daly
1884. J. H. Hartman	G. W. Major
1885. H. A. Johnson	J. N. Mackenzie
1886. E. C. Morgan	S. W. Langmaid
1887. J. N. Mackenzie	C. E. DeM. Sajous
1888. W. C. Glasgow	

1889.	E. Holden	C. E. Bean
1890.	J. O. Roe	J. H. Hartman
1891.	M. J. Asch	S. Johnston
1892.	S. Johnston	J. C. Mulhall
1893.	J. C. Mulhall	W. E. Casselberry
1894.	C. C. Rice	S. H. Chapman
1895.	J. Wright	A. W. de Roaldes
1896.	T. M. Murray	D. N. Rankin
1897.	A. W. MacCoy	H. S. Birkett
1898.	J. W. Farlow	F. W. Hinkel
1899.	T. A. De Blois	M. R. Brown
1900.	H. L. Wagner	A. A. Bliss
1901.	J. W. Gleitsmann	D. Braden Kyle
1902.	G. A. Leland	T. Melville Hardie
1903.	J. H. Lowman	W. Peyre Porcher
1904.	Thomas Hubbard	W. J. Freeman
1905.	J. L. Goodale	C. W. Richardson
1906.	G. H. Makuen	A. B. Thrasher
1907.	J. P. Clark	J. E. Rhodes
1908.	E. Mayer	F. R. Packard
1909.	C. G. Coakley	H. P. Mosher
1910.	Robert C. Myles	J. M. Ingersoll
1911.	F. C. Cobb	B. R. Shurly
1912.	A. W. Watson	W. Scott Renner
1913.	F. E. Hopkins	Geo. E. Shambaugh
1914.	Clement F. Thiesen	Lewis A. Coffin
1915.	J. Gordon Wilson	Christian R. Holmes
1916.	Thomas H. Halsted	Greenfield Sluder
1917.	John Edwin Rhodes	D. Crosby Greene
1918.	G. E. Shambaugh	John R. Winslow
1919.	Francis R. Packard	Harmon Smith
1920.	Harmon Smith	W. B. Chamberlin
1921.	Dunbar Roy	Robert C. Lynch
1922.	George Fetterolf	Lorenzo B. Lockard
1923.	Hubert Arrowsmith	Joseph B. Greene
1924.	Ross H. Skillern	Gordon Berry
1925.	John E. Mackenty	Robert Levy
1926.	Lewis A. Coffin	William V. Mullin
1927.	Charles W. Richardson	Hill Hastings
1928.	Robert Clyde Lynch	Francis P. Emerson
1929.	William B. Chamberlin	Ralph Albert Fenton
1930.	Harris P. Mosher	James A. Babbitt
1931.	Joseph B. Greene	Ross E. Faulkner
1932.	Gordon Berry	Frank R. Spencer

Secretaries and Treasurers

1879.	G. M. Lefferts	1895.	H. L. Swain
1882.	D. B. Delavan	1900.	J. E. Newcomb
1889.	C. H. Knight	1911.	Harmon Smith

Secretaries

1912.	Harmon Smith	1919.	J. M. Ingersoll
1918.	D. B. Delavan	1920.	George M. Coates

Treasurers

1912.	J. Payson Clark	1923.	George Fetterolf
	1932.	William V. Mullin	

Librarians

1879.	F. H. Bosworth	1903.	J. H. Bryan
1883.	T. R. French	1930.	John F. Barnhill

PAST MEMBERS

DeceasedHonorary Fellows*

- *1915. Bosworth, Francke H., New York City.
- *1914. Cohen, J. Solis-, Philadelphia, Pa.
- *1893. De Roaldes, Arthur W., New Orleans, La.
- *1914. De La Sota Y Lastra, Ramon, Seville, Spain.
- *1880. Garcia, Senor Manuel, London, England.
- *1928. French, Thomas R., Brooklyn, N. Y.
- *1924. Johnston, Samuel, Baltimore, Md.
- *1914. Lefferts, George Morewood, Katona, N. Y.
- *1922. MacKenzie, John N., Baltimore, Md.
- *1883. Mackenzie, Sir Morell, London, England.
- *1910. Massei, Ferdinand, Naples, Italy.
- *1879. Oliver, H. K., Boston, Mass.
- *1909. Semon, Sir Felix, Great Missenden, England.
- *1914. Wagner, Clinton, New York City.
- *1921. Wright, Jonathan, Pleasantville, N. Y.

Corresponding Fellows

- *1892. Browne, Lennox, London, England.
- *1887. Gouguenheim, A., Paris, France.
- *1894. Holden, Edgar, Newark, N. J.
- *1881. Labus, Carlo, Milan, Italy.
- *1902. Lermoye, Marcel, Paris, France.
- *1897. Luc, H., Paris, France.
- *1894. MacIntyre, John, Glasgow, Scotland.
- *1880. Meyer, Wilhelm, Copenhagen, Denmark.
- *1896. Mygind, Holger, Copenhagen, Denmark.
- *1894. Sajous, C. E. DeM., Philadelphia, Pa.
- *1881. Thornton, Pugin, London, England.
- *1880. Whistler, W. McNeil, London, England.
- *1894. Wolfenden, R. Norris, Kent, England.

Emeritus Fellows

- *1914. De Blois, Thomas Amory, Boston, Mass.
- *1924. Freer, Otto T., Chicago, Ill.
- *1914. Gleitsmann, Joseph W., New York City.
- *1912. Knight, Charles H., New York City.
- *1923. Leland, George A., Boston, Mass.
- *1922. MacCoy, Alexander W., Philadelphia, Pa.

931. Mayer, Emil, New York City.
914. Porter, William, Ocean Springs, Miss.
924. Rhodes, John Edwin, Chicago, Ill.
914. Robinson, Beverley, New York City.

Active Fellows

880. Allen, Harrison, Philadelphia, Pa.
917. Arrowsmith, Hubert, Brooklyn, N. Y.
878. Asch, Morris J., New York.
880. Bean, C. E., St. Paul, Minn.
904. Berens, T. Passmore, New York City.
924. Bigelow, Nolton, Providence, R. I.
893. Bliss, Arthur Ames, Philadelphia, Pa.
895. Boylan, J. E., Cincinnati, Ohio.
892. Brown, Moreau R., Chicago, Ill.
915. Canfield, R. Bishop, Ann Arbor, Mich.
889. Casselberry, William E., Chicago, Ill.
883. Chamberlain, C. W., Hartford, Conn.
896. Chappell, W. F., New York.
882. Chapman, S. Hartwell, New Haven, Conn.
913. Coffin, Rockwell C., Boston, Mass.
918. Cox, Gerard H., New York.
880. Cushing, E. W., Boston, Mass.
878. Cutter, Ephraim, West Falmouth, Mass.
880. Daly, W. H., Pittsburgh, Pa.
878. Davis, F. H., Chicago, Ill.
901. Dickerman, E. T., Chicago, Ill.
878. Donaldson, Frank, Baltimore, Md.
914. Fetterolf, George, Philadelphia, Pa.
901. Freeman, Walter J., Philadelphia, Pa.
917. Friedberg, Stanton A., Chicago, Ill.
901. Getchell, Albert C., Worcester, Mass.
907. Gibb, Joseph S., Philadelphia, Pa.
878. Glasgow, William Carr, St. Louis, Mo.
922. Goldsmith, Perry G., Toronto, Ont.
878. Hartman, Jacob H., Baltimore, Md.
879. Holden, Edgar, Newark, N. J.
907. Holmes, Christian R., Cincinnati, Ohio.
882. Hooper, Franklin H., Boston, Mass.
893. Hope, George B., New York City.
901. Hyatt, Frank, Washington, D. C.
882. Ives, Frank L., New York City.

- *1878. Ingals, E. Fletcher, Chicago, Ill.
- *1880. Jarvis, William C., New York City.
- *1878. Johnson, Hosmer A., Chicago, Ill.
- *1879. Johnson, Woolsey, New York City.
- *1879. Kealhofer, R. H., St. Louis, Mo.
- *1901. King, Gordon, New Orleans, La.
- *1885. Knight, Charles H., New York City.
- *1878. Knight, Frederick Irving, Boston, Mass.
- *1898. Kyle, D. Braden, Philadelphia, Pa.
- *1880. Langmaid, Samuel W., Boston, Mass.
- *1878. Lincoln, Rufus P., New York City.
- *1913. Loeb, Hanau W., St. Louis, Mo.
- *1897. Logan, James E., Kansas City, Mo.
- *1888. Lowman, John H., Cleveland, Ohio.
- *1919. Lynah, Henry L., New York City.
- *1915. Lynch, Robert Clyde, New Orleans, La.
- *1879. McBurney, Charles, New York City.
- *1885. McSherry, H. Clinton, Baltimore, Md.
- *1914. Mackenty, John E., New York City.
- *1898. Makuen, G. Hudson, Philadelphia, Pa.
- *1881. Major, G. W., Montreal, Canada.
- *1881. Morgan, E. C., Washington, D. C.
- *1886. Mulhall, J. C., St. Louis, Mo.
- 1901. Munger, Carl E., Waterbury, Conn.
- *1892. Murray, T. Morris, Washington, D. C.
- *1881. Mynter, H., Buffalo, N. Y.
- *1893. Newcomb, James E., New York City.
- *1895. Nichols, J. E. H., New York City.
- 1894. Park, William H., New York City.
- *1892. Porcher, W. Peyre, Charleston, S. C.
- *1908. Randall, B. Alexander, Philadelphia, Pa.
- *1880. Rankin, D. N., Allegheny, Pa.
- *1902. Richardson, Charles W., Washington, D. C.
- *1879. Roe, John O., Rochester, N. Y.
- *1881. Robertson, J. M., Detroit, Mich.
- *1878. Rumbold, T. F., St. Louis, Mo.
- *1879. Seiler, Carl, Philadelphia, Pa.
- *1893. Shields, Charles M., Richmond, Va.
- *1878. Shurley, E. L., Detroit, Mich.
- *1919. Skillern, Ross H., Philadelphia, Pa.
- *1909. Sluder, Greenfield, St. Louis, Mo.
- *1879. Smith, Andrew H., Geneva, N. Y.

- *1892. Simpson, William Kelly, New York City.
- 1924. Stein, Otto J., Chicago, Ill.
- *1911. Stout, George C., Philadelphia, Pa.
- *1879. Tauber, Bernhard, Cincinnati, Ohio.
- 1903. Theisen, Clement F., Albany, N. Y.
- *1899. Thorner, Max, Cincinnati, Ohio.
- *1892. Thrasher, Allen B., Cincinnati, Ohio.
- *1888. Van der Poel, S. O., New York City.
- 1896. Ward, Marshall R., Pittsburgh, Pa.
- *1879. Ward, Whitfield, New York City.
- *1886. Westbrook, Benjamin F., Brooklyn, N. Y.
- *1924. White, Leon E., Boston, Mass.
- 1922. Wishart, David J. G., Toronto, Ontario.
- *1896. Woolen, Green V., Indianapolis, Ind.

Associate Fellows

- *1932. Atkins, Richard Travis, New York, N. Y.
- 1930. Hansel, French K., St. Louis, Mo.
- 1925. King, James Joseph, New York, N. Y.
- 1922. Monroe, Otho Lee, New York, N. Y.

