


Transactions
American Laryngological Association

Fifty-seventh Volume



TRANSACTIONS

OF THE

FIFTY-SEVENTH ANNUAL MEETING

OF THE

American
Laryngological Association


HELD AT TORONTO, CANADA

MAY 29, 30, 31, 1935

PHILADELPHIA

PUBLISHED BY THE ASSOCIATION

1935



CONTENTS.

List of Officers	7
Registration	9
President's Address. DUNBAR ROY, M.D.	11
Various Research Problems Carried on in the Detroit Public School System. BURT R. SHURLY, M.D.	18
A Syndrome of Pain and Paralysis Arising From Inflammations of the Prevertebral Space. ARTHUR W. PROETZ, M.D.	27
Branchial and Thyroglossal Duct Cysts and Fistulas. JOHN MACKENZIE BROWN, M.D.	39
Some Observations on Surgery of the Neck as it Concerns the Otolaryngologist. Branchial Cysts and Fistulae. NORMAN PATTERSON, F.R.C.S.	53
Paralysis of the Larynx. A Suggested Explanation of the So-called Continued Median Position of the Vocal Cords in Bilateral Paralysis: A Consideration of Semon's Law. CHARLES J. IMPERATORI, M.D.	77
Ossification of the Cartilages of the Larynx and Its Possible Relationship to Some Types of Laryngeal Disease. H. MARSHALL TAYLOR, M.D.	86
Further Study of the Effects of Drugs on Ciliary Activity. A New Method of Observation in the Living Animal. D. M. LIERLE, M.D., and P. M. MOORE, M.D.	110
The Response of Allergic Phenomena to Ionization. ARTHUR M. ALDEN, A.M., M.D., F.A.C.S.	125
Sinusitis, Allergy and the "Common Cold." A Conception of Their Relationship. EDWARD CECIL SEWALL	143
Obliterative Frontal Sinusitis. SAMUEL R. SKILLERN, JR., M.D.	158
Rhinoscleroma—Is It an Indigenous Disease? WM. B. CHAMBERLIN, M.D.	180
The Sphenoid Sinus and the Sphenopalatine Ganglion as Factors in So-called Atypical Trigeminal Neuralgia. H. W. LYMAN, M.D.	195
Cancer of the Epiglottis; Total Extirpation of the Epiglottis by the Laryngofissure Route. GABRIEL TUCKER, M.D.	216
Xanthoma of the Pharynx and Larynx. GORDON B. NEW, M.D.	224

A New Procedure in the Treatment of Webs in the Larynx, With Report of a Case. SAMUEL IGLAUER, M.D.	228
Bilateral Abductor Paralysis of the Larynx Caused by the Injection of Antitetanus Serum and Its Subsequent Stenosis Due to Perichondritis. Case Presentation. CHARLES J. IMPERATORI, M.D. . . .	240
A Case of a Malignant Laryngeal Growth Implanted on Tissues, the Deeper Layers of Which were Infected With Trichini. Case Report. CHARLES J. IMPERATORI, M.D.	242
Treatment of a Series of Cases of So-called Carcinoid Tumors of the Bronchi by Diathermy. A Report of Ten Cases. JOHN DEVEREUX KERNAN, M.D.	243
Memorials:	
WILLIAM SCOTT RENNER	281
CORNELIUS GODFREY COAKLEY	285
HARMON SMITH	291
DAVID JAMES GIBB WISHART	301
JOHN WALTER CARMACK	305
JOSEPH HAMMOND BRYAN	309
WILLIAM VALENTINE MULLIN	317
WILLIAM REYNOLDS LINCOLN	323
THOMAS MORRIS MURRAY	325
MAYO COLLIER	327
List of Fellows, 1935:	
Active Fellows	331
Associate Fellows	335
Honorary Fellows	336
Corresponding Fellows	336
Emeritus Fellows	337
Recipients of DeRoaldes and Casselberry Awards	338
Past Officers	339
Past Members	342

OFFICERS FOR 1934-1935

PRESIDENT

DUNBAR ROY, M.D.

FIRST VICE-PRESIDENT

GORDON B. NEW, M.D.

SECOND VICE-PRESIDENT

SAMUEL McCULLAGH, M.D.

SECRETARY

WILLIAM V. MULLIN, M.D.

TREASURER

JAMES A. BABBITT, M.D.

LIBRARIAN

BURT R. SHURLY, M.D.

COUNCIL

The above Ex-officio and
FRANCIS R. PACKARD, M.D.
JOSEPH B. GREENE, M.D.
GORDON BERRY, M.D.
GEORGE M. COATES, M.D.

TRANSACTIONS OF THE FIFTY-SEVENTH ANNUAL
CONGRESS
OF THE
AMERICAN LARYNGOLOGICAL ASSOCIATION

HELD AT
TORONTO, CANADA, MAY 29, 30, 31, 1935

DR. DUNBAR ROY, President of the American Laryngological Association, called the Fifty-seventh Annual Congress to order at the Royal York Hotel, Toronto, Canada, at 2 P.M., May 29, 1935.

REGISTRATION

Registration for the meeting was as follows:

ALDEN, ARTHUR M.	GOLDSMITH, PERRY G.
BABBITT, JAMES A.	GOODYEAR, HENRY M.
BARNHILL, JOHN F.	GRAHAM, HARRINGTON B.
BECK, JOSEPH C.	GREENE, D. CROSBY, JR.
BERRY, GORDON	GREENE, JOSEPH B.
BIRKETT, HERBERT S.	GROVE, WILLIAM E.
BROWN, J. MACKENZIE	HARKNESS, GORDON F.
BUCKLEY, ROBERT E.	HASTINGS, HILL
CAMPBELL, EDWARD H.	HILL, FREDERICK T.
CARMODY, THOMAS E.	HOURN, GEORGE E.
CHAMBERLIN, WILLIAM B.	IGLAUER, SAMUEL
CLERF, LOUIS H.	IMPERATORI, CHARLES J.
COATES, GEORGE M.	JACKSON, CHEVALIER
DEAN, LEE WALLACE	JACKSON, CHEVALIER L.
EVES, CURTIS C.	JARVIS, DEFORREST C.
FAULKNER, E. ROSS	KERNAN, JOHN D.
FENTON, RALPH ALBERT	KISTNER, FRANK B.
FIGI, FREDERICK A.	LARGE, SECORD H.
FORBES, HENRY HALL	LAW, FREDERICK M.
FOSTER, JOHN H.	LIERLE, DEAN M.

LILLIE, HAROLD I.
LOOPER, EDWARD A.
LYMAN, HARRY W.
LUKENS, ROBERT M.
McCULLAGH, SAMUEL
McMAHON, BERNARD J.
MOSHER, HARRIS P.
MYERSON, MERVIN E.
NEW, GORDON B.
NEWHART, HORACE
ORTON, HENRY B.
PACKARD, FRANCIS R.
PORTER, CHARLES T.
PROETZ, ARTHUR W.
RICHARDS, LYMAN G.
ROY, DUNBAR
SAUER, WILLIAM E.

SCHALL, LeROY A.
SCHENCK, HARRY P.
SEWALL, EDWARD C.
SEYDELL, ERNEST M.
SHEA, JOHN J.
SHURLY, BURT R.
SKILLERN, SAMUEL R., JR.
SMYTH, DUNCAN C.
SONNENSCHN, ROBERT
SPENCER, FRANK R.
TAYLOR, H. MARSHALL
TOBEY, HAROLD G.
TUCKER, GABRIEL
WHERRY, WILLIAM P.
WILSON, J. GORDON
WOODWARD, FLETCHER D.

PRESIDENT'S ADDRESS

DUNBAR ROY, M.D.

FELLOW MEMBERS AND COLLEAGUES:

"May I be permitted to say a few words in reference to our deceased Secretary, Dr. William V. Mullin, or, as he was better known to all of us, 'Bill' Mullin? It was only a week before his death that I saw him in Roanoke, Virginia. At that time I never saw anyone looking better physically or in better spirits, and I well remember the last time I saw him, the night before he was to leave. He waved to me as he said, 'Goodbye, Dunbar! I'll see you in Toronto.'

"Death at any time is an untimely thing, but it was especially so in the case of Dr. Mullin, because he was a splendid Secretary and his work was such that it endeared him to all the members of this Association, and in the second place, he was just on the eve of sending out the final program of this meeting. But more will be said of Dr. Mullin later on in the meeting.

"I want to take this occasion to say to the members of our Council who so promptly offered their services as Secretary for the interim, that it made me feel, know and realize that this was not only a society for scientific production, but it was a membership of loyal, devoted friends. My good friend, Dr. Coates, kindly consented to act as Secretary until a new one was elected and thus he is occupying this position today. He is thoroughly familiar, as we all know, with this position. So I want to congratulate our Association on having Dr. Coates to take over the work of Dr. Mullin at the beginning of this meeting.

"I have a letter that I have just received and which I take the liberty of reading:

DEAR DR. ROY:

'Will you convey to the members of the American Laryngological Association my very deep appreciation of their expressions of sympathy in sending a lovely wreath of red roses?

'Most sincerely,

'LAURA N. MULLIN.'

"I also have the pleasure of introducing to you Mr. Norman Patterson, of London, who is our guest on this occasion."

I AM sure that I but voice the sentiments of our membership when I say that our meeting today within the borders of our sister Republic is one of extreme pleasure. This exemplifies the warm feelings which we hold for our Canadian confrères. Twice before, once in 1915, just across the border at Niagara Falls, and once in Montreal, in 1926, has the American Laryngological Association held its annual meetings in this country.

An invisible boundary line separates the two great republics, but there is not even the semblance of a line which separates the good relationship between the members of this organization and that of our Canadian colleagues. This is well exemplified in the coming joint meeting within a few weeks of the American Medical Association and that of the Canadian Medical Association in Atlantic City.

To enumerate the scientific and clinical advancements in rhinolaryngology which have been made during the last year, or even to present to you a long and tedious address on some obscure phase of our specialty, is not the object of these remarks, for in looking back upon those who have occupied this high office we will find not only the history of rhinolaryngology, but also the scientific advances which have been added to this specialty. Such an opportunity will be amply afforded when listening to the many excellent papers which will be presented at this meeting.

Allow me to express to this Society my deep appreciation for the honor which I hold today as your presiding officer. The incident of my election was one of the most unexpected in my professional career, for I had long ago realized that now is the age of youth, and little did I expect that the honor of being President of this Association would be extended to one whose professional contributions have not been commensurate with many of those who constitute the membership of this organization. My remarks today shall be brief.

In looking back upon the *Transactions* of this Society and reading over the addresses which have been delivered by many of your past Presidents, there has been forcibly impressed upon me many of the suggestions which have been previously made.

Drs. Delavan and McCoy have given you the history of this honored Society with its interesting associations, reading as it does almost like the biography of a family tree.

Mosher and Dean have told you of the uncertainties which beset the undergraduate of today and how the teaching of rhinolaryngology will be best accomplished in all the medical schools of the future.

Packard and Shambaugh have given to us some of the problems which must be faced by those who are now practising in the field of laryngology.

Norval Pierce has told you of the advanced requirements which should be demanded from those seeking a membership in our special societies, especially those seeking entrance into our own specialty.

Coakley has given you an outline for the teaching of rhinolaryngology, while Coates has instilled into us the ideals which should permeate the membership of the American Laryngological Society. In fact, every past President of this Association has discussed with you the clinical and scientific advancements which have been made in our specialty, have given you historical data of our past record, indulged in sentiments of professional loyalty and imbued you with those traditional instincts which are the very elements of our success.

In that delightful book of Walter Pitkin, entitled *Life Begins at Forty*, the author would have us believe that only at this age do our minds become mature and that we are enabled to adjust our mentality to the increasing problems of life. Certain it is that at this age, we begin to correlate our own experiences in whatever branch of medicine we are engaged, and we are far more able to use our experienced judgment in obtaining the best results.

One cannot but feel reminiscent when he contemplates his membership in an old and honored society, such as has always constituted the personnel of this organization.

Twenty-two years ago when I became a member, well do I remember that Chesterfieldian quartet, John McKenzie, Samuel Johnson, John Hartman and D. Bryson Delavan, who constituted the *esprit de corps* of those finer qualities which constituted the membership of the American Laryngological Association. Such men as these laid the foundation for the future type of our membership. They worked for the best interests of this Society, and by their yearly attendance they made us feel that such a member-

ship was worth a thousand sacrifices to build up the standards and influence of this organization.

But we are compelled to remember that the mantle must fall upon the younger members of today, and it is to them that we must look for the future strength and scientific standing of this Society, revering, however, the memories of those men who largely brought it to its present high standard.

Some of you gentlemen will no doubt remember that historical meeting in 1918, called the Fortieth Anniversary of this Society, when Dr. Solis-Cohen was elected as Honorary President. He began his address with these words, which I have always considered most suitable as characterizing the qualities of our membership:

"The American Laryngological Society was conceived in the arms of brotherly love, was born in the lap of professional comradeship, was nourished in the milk of emulatory kindness and has grown to vigorous maturity in a communal regard of its entire fellowship, its useful work in the cause of laryngology, medical progress in general and the interests of humanity."

These last words compel us to realize that this Society cannot be separated as a specialty from the general field of medicine, for we are compelled to know that rhino-laryngology is an integral part of medicine in general. Those economic conditions and changes which affect the one must also affect the other.

There is no distinct specialty in medicine, for we must all recognize the fact that every organ of our body is dependent upon the harmonious working of the whole human system.

Endocrine disturbances and allergy in its various forms are now in its infancy. What rôle they will play in the future study of rhino-laryngology are problems yet unsolved. Every day in our practice do we see the influences which must be attributed to these mysterious glands. Radical surgery is becoming less frequent, while hygiene and diet are rapidly asserting their importance.

Dr. Crile, in his address before this Society last year, forcibly brought to our attention the close relationship of the cerebral nerves of our body to the autonomic nerves of the endocrine system, with special reference to the thyroid as the telephone center of our body. What does all of this teach us? That the

diseases of rhino-laryngology are not distinct entities, but that each day we find their dependence and relationship closely united to every remote function of our body.

The man who looks upon the practice of rhino-laryngology as a specialty by itself can never make the successful laryngologist. For this reason those men who are now beginning the practice of laryngology will have more to learn in reference to the human body relationships than we who started the practice of medicine many years ago.

Along with the economic upheavals which have been disturbing the whole world, we cannot expect the medical profession to be free from these disturbances. Individual initiative seems to be giving away to governmental interference.

Just how far these social disturbances will affect our profession it is difficult to say. Never before has it been more important than the present for the whole medical profession to stand united on some bulwark which will counteract these proposed changes whose object it is to undermine the practice of our profession.

Some of us may not agree with the ideas as expressed recently by the American Medical Association. Others may be more in accord with the resolutions as advocated by the American College of Surgeons in reference to socialized practice of medicine, but all of us must admit that some change will ultimately occur which will leave the practice of medicine far different from what it was in that golden period of some twenty years ago. It is going to take courage to face the new issues, but let us lend our assistance for the establishment of those changes which will least affect the individual standards of the medical profession.

As I have said before, every specialty is an integral part of general medicine, and it is just as much our duty to uphold the integrity of our profession as it is for the internist, the general surgeon, the gynecologist, the pathologist, or any other branch of the medical science. Changes are obliged to come, but let us not lower the standards of this Society.

During the last year death has laid a heavy hand upon our membership, including some of those who have been outstanding in their labors for this Society.

As Longfellow has truthfully said:

"Death never takes one alone but two,
Whenever he enters in at a door,
He always leaves it upon the latch,
And comes again ere the year is o'er,
Never one of a household only."

These ranks must be filled, and it is to the younger men that we must look for that spirit which permeated the founders of our Society.

There will be presented for your consideration at this meeting the subject of a Memorial Fund for the Scientific Advancement of Laryngology. The origin and purpose of this fund will be fully discussed so that some definite action can be taken in order to show the wishes of this Association. Your President is heartily in favor of such a Memorial Fund, believing that the widows or members of the family would gladly add something to this object as a memorial to those who once belonged to this Society.

In this utilitarian age how seldom do we remember those whose genial smile and cheery words added much to the success of our meetings.

Reading sometime ago one of Freude's essays, in which he recalled to the minds of his countrymen the glorious deeds of Blake, of Raleigh, and Sir Richard Granville, it seems to me that we can do no better than to adopt the title of this essay as a reminder of all the past members of this Society, whose work completed, have passed into the "Land of Mystery." Its title was "Our Forgotten Worthies."

Every people has its heroes, all perilous callings have theirs, in our profession they are unnumbered. So many who die today obscure with their fame, the dead of yesterday. No towering shaft or storied window proclaims to posterity their deeds. But let not the departed members be forgotten. Their names are familiar to all of us. The record of their deeds is sealed in books never to be opened save by ourselves and by many of their fellow-men whom they served in life. By these they will and must not be forgotten, but by many their deeds will remain unknown.

In that delightful book, *The Story of San Michel*, in that chapter in which its author extols the qualities which should be the heritage

of every physician, there occurs this never-to-be-forgotten sentence "Those things which we keep, we lose. Those which we give away, we keep forever."

Nothing is truer than these words in their application to the medical profession. It is what we have given away as our clinical experiences which will make us live forever in the *Transactions* of this Society and in the memory of our fellow members.

None of our members can afford not to make some contribution to our annual meetings.

To become a member of the American Laryngological Society and then be satisfied with its reflected light is not the purpose of this organization.

The success of any society depends upon the interest and individual work of its constituent members.

No laryngologist can ever be benefited by his membership if he does not attend the meetings and take part in the discussions. It is one of our obligations to aid in furthering not only the ideals of this Society, but to elevate its standards in the medical world by adding our clinical and scientific experience to these yearly programs.

In conclusion allow me to say that this short address, though rambling in character, is neither a valedictory nor a swan song, for by associating with the members of the American Laryngological Association, one's life will be prolonged and by much the more if he attends these yearly meetings. After all has been said and done, a happy, complete and a long life should be the aim of every member of this organization.

I now declare the fifty-seventh annual meeting of the American Laryngological Association open for its annual program.

VARIOUS RESEARCH PROBLEMS CARRIED ON IN THE DETROIT PUBLIC SCHOOL SYSTEM

BURT R. SHURLY, M.D.

MR. PRESIDENT, Mr. Patterson, and Fellows of the American Laryngological Association: The story that I have to tell you is a story of coöperation, of organization, and the wonderful leadership in laryngology that came to me as an inspiration forty years ago, and that inspiration was no other than my wonderful colleague, my marvelous friend, and my grand and glorious uncle, Dr. E. L. Shurly. To him the inspiration of forty years of service always is present, and those words that we have just heard from the President, those words of J. Solis-Cohen, that now "echo and reëcho down through the corridors of time," are the words of laryngology expressed in its broader work and semblance, for laryngology leads the way, and in coöperation with general medicine it comes and goes and reaches far afield into the byways and into the pathways of science, and of art, and of education.

(Slide.) In Detroit there is a close coöperation between hospital clinics, the schools, and the Board of Health. Aëration is given the greatest possible consideration because of the effect on school adjustment.

(Slide.) Here we have the old medical school, the Detroit College of Medicine, where Dr. E. L. Shurly brought to Detroit and Michigan the first laryngoscope, and where the students of that institution for sixty-seven years have had the opportunity of developing and learning those necessary things that have to do with specialism and with general medicine, and for sixty-seven years Dr. Shurly or myself has been the head of that department.

We have watched it grow from a proprietary school and go down into a B class school, and so one day it was put upon the market, and I had the rare and almost unique experience of buying that medical school and owning it myself, and we reorganized it, developed a very fine faculty, and put it in the A class, and built new laboratories, fine laboratories and complied with all the requirements of the Council of Medical Education.

Laryngology led the way there toward making a research laboratory, and it is some of the story of that research laboratory and its development that I should like to call your attention to as quickly as may be possible.

(Slide.) We have here the laboratory buildings, first the old and original one, and now the new one, because this Detroit College of Medicine is again unique, because it is the only municipal medical school in the world, and I want you to have that picture, that it is a municipal medical school, under the Board of Education of the city of Detroit, controlled by it, guided by it, and furnished with plenty of money by the Board of Education funds, and so we have very good laboratories and the research laboratory is there, for which our mayor gave us \$25,000 to start, and since has kept us well supplied.

(Slide.) Here is one of the laboratory rooms, which is familiar to all of you.

(Slide.) Another one of the laboratory rooms, and here are some of the research problems that we have spoken of before, that have been worked out quite extensively—those of the Vitamin A Division. You have heard about halibut-liver oil which is now going all over the country. It was worked out here in this laboratory and promptly stolen by some of our proprietary firms who are now making several million dollars off the product.

(Slide.) And so a series of some twenty problems have been worked upon and some of them have been quite valuable, and others, as all research work must necessarily develop, not so successful. I might mention the use of carotene as an equivalent of halibut-liver oil. One drop of halibut-liver oil is equivalent to 3 teaspoonfuls of cod-liver oil. You are all familiar with it, and carotene we find quite equivalent; and the bacteriology of these conditions in animals in the ear, nose and throat has been studied extensively.

(Slide.) Just another room.

(Slide.) One of the teaching rooms—senior class.

(Slide.) Another one of the teaching rooms.

It is the broadening out of the research laboratory that has carried us into other fields. The school system has 256,000 children. Sixteen thousand and more are handicapped children, and

it seems to me that one of the grandest things the medical profession can do, and our specialty in particular, is to link up and gather together some of the scientific work that is necessary among these handicapped children.

We found first of all that 417 children in the school system had epilepsy. They were having convulsive seizures in the various school rooms, and were not obtaining an education, and they had practically all their tonsils out, but none of them were better. We thought we had better go a little farther with the problem. The parents are contacted by the school nurse before the doctor sees the patient.

Those able to do so attend the Schulze School, where the work is highly individualized. Boys remain from monday morning to friday afternoon, eating and sleeping at the school. The nurse gives the treatments and takes care of the boys with seizures. Many of the boys have hereditary epilepsy of the grand-mal type and some mild, petit-mal cases.

This is the first and only epileptic school in any school system in the country, we are told, and we just received \$15,000 from the State Legislature to conduct this, and \$20,000 for next year. The work is under the direction of Dr. Kimball, of Cleveland, who has made a very special study of it, and we find that in these children, under observation, where you can absolutely control their diet, and where you take away from them all the patent epileptic cures, where you take away the sedatives and luminal, and all that sort of thing, and give them a hypodermic of a lipoid substance of the brain of sheep, following the formula of Metchnikoff's laboratory, the number of seizures is cut down. Thus we have many of them improved.

(Slide.) This is a picture of the school child.

(Slide.) Some of the boys.

(Slide.) This is a study room.

(Slide.) This is the lunch room where we prepare under the dietitian with the most careful possible study in vitamins and calories, their proper food, and there is the room where this is done.

(Slide.) There is a room where they are taken if they have a seizure.

(Slide.) Those are three of the boys who have not had any

seizures for some months under this hypodermic treatment, which is purely experimental.

(Slide.) There is another one who has gone for months without a seizure.

(Slide.) Another one.

(Slide.) Another one.

(Slide.) Another one. In all the forty years I have operated on epileptics of various sorts for tonsils and adenoids, I have only 1 case, removing a large adenoid, where the child has had no seizure for the last ten or fifteen years. I have observed him. That is the only one I ever knew in whom it did any good to do any throat or nose work in the way of a lasting result.

We have developed a speech defect department which is distinctly connected with laryngology, and we have the elementary, intermediate, and high schools, with 6934 pupils enrolled for speech defects.

The pupils use mirrors for checking each other on lisping and lingual protrusion, and other devices are used to improve the speech. A bubble test teaches the child how it feels to give a sound correctly. Pupils are assigned to the classes after consultation with the teachers and supervisor.

All these handicapped children have been through the medical profession for the most part. We have a card index of every child upon which the family physician's name is placed, if the child has a family physician. I want to mention that, because our work is decidedly a coöperative work and it is under the Board of Education and not the Board of Health.

(Slide.) These speech defect classes are perhaps familiar to all of you, something of them, but the enormous number of speech defects in a school system is quite surprising—6900 children, all under special education, and the work is very interesting, and very valuable.

(Slide.) Therefore these particulars are dealt with: facial tics and blinking tics, and then there are these mirror drills. That is a list of words up there of various kinds, difficult to say.

(Slide.) That is just one department of special education. It belongs with laryngology and rhinology.

(Slide.) We have a glandular clinic which is part of the research

fund that I mentioned. Dr. Marinus has charge of it, and we take all those children who need treatment. The parents bring their children to the clinic once a month for a check-up of height, weight, pulse-rate and general conditions, until a tolerance dosage has been established. When necessary, basal metabolism is taken by the nurse.

Gland cases include: Congenital hypothyroidism with gonadal insufficiency; hypothyroidism of the cretinoid type; congenital hypothyroidism and mongolism; congenital goiter with moderate thyroid deficiency; pituitary overactivity of acromegalic type, with marked enlargement of face, hands and feet; thyroid-pituitary deficiency; congenital hypothyroidism of *forme fruste* type; colloid goiter with hypopituitary dysfunction; mongolian idiocy with complicated thyroid deficiency; microcephalic hypothyroidism; congenital hypothyroidism of the cretinoid type.

(Slide.) We find that many of the retarded children need a diagnostic examination—(Slide)—and we have here the various types that we have mentioned.

(Slide.) These retarded children are carefully gone over in the psychologic clinic, and we find that one real discovery—(Slide)—of which the medical profession was apparently not aware—(Slide)—although it is very simple—(Slide)—is that a very wonderful piece of work can be done with the—(Slide)—unborn child by treating the mother with thyroid and iodine—(Slide)—and this the obstetrician and the pediatrician have become quite well aware of very recently. This clinic found that out about five years ago. They are most interesting studies, and the I.Q. of a considerable number of these children has been greatly increased.

The relationship of the nose and throat with thyroid disease is a real and genuine thing, and the endocrine problem in general is so closely associated with it that—

(Slide.) This is one of the lunch-rooms.

(Slide.) The deaf school, and hard-of-hearing children. We have a very splendid deaf school, where there is a clinic.

(Slide.) This is a picture of it—Dr. Emil Amberg has charge of it, and here we have the various forms of oral teaching of the department.

(Slide.) Those children are referred from all the grades.

(Slide.) Some of them after lip-reading, can carry on through the higher grades.

(Slide.) The rhythm work and the music work you are familiar with.

(Slide.) And here is the ear clinic where various kinds of deafness are classified and referred back to the family doctor or the treatment outlined.

(Slide.) The sight-saving classes, and the completely blind. We have 55 pupils completely blind. Work is all carried on for them, and a special study is made of each individual. An individual study is made of them, with a special teacher. Of course, this work is rather expensive for the taxpayer, but if we can prevent these children, by proper vocational training, from being county and city charges, they can earn their own way and the money soon returns to the city.

(Slide.) We have twelve open-air schools, 1408 pupils, 52 open window classes, 1485 pupils. Typical open-air schools of Detroit have a capacity of 140 pupils, and include four class-rooms, dining-rooms, clinic, showers, kitchen and a large sun-room for the rest period. Assignments are made through the Board of Health.

One of the great pieces of work that has been done was to link up our own tuberculosis sanatoria, where we find 15 per cent of tuberculous laryngitis, and take those children who were contacts and who have been exposed to tuberculosis, but not active cases, and put them in these open-air schools. Then through the summer our Christmas Seal money provides a Christmas Seal camp for those that need it the most, and they are kept in the open air, the fresh air, and given all the chance in the world to develop a resistance to tuberculosis.

(Slide.) This is an open-air school. Toronto has copied this school building. That school, as you will see, is named after Dr. E. L. Shurly, and it was one of the first. We have 12 of these, and that study alone of open-air schools and the work that it does for those children in them, and the marvelous meals that are served to them through this depression, when many of our people have not had enough to eat, gives a story in itself of what a splendid work this is, the building up of the physical development of our children.

(Slide.) There is a lunch-room in the open-air school. They have the very best of food, with all the calories and vitamins that are possible, figured out, and the food is prepared with the best of cooking, and at a very low expense because it is bought in great quantities.

The study of these epileptic boys and girls in blood chemistry is interesting. We worked out the cholesterol problem in the blood and the lipoid chemistry, and we find that just before a seizure, these cases develop a sudden rise of cholesterol, and that after the seizure it goes down. I mention this for what it may be worth.

Now, one of the pieces of work that is going on in these schools is the use of Christmas Seal money to tuberculin test every child in the high schools; to those that are positive are given roentgen-rays of the chest and, if they have active tuberculosis, they are hospitalized by the county, and in that way our records in Detroit show the very best health record in the country, and one of the best for the decrease of tuberculosis, and this is being done now, I think, all over the country, because it is the real way to reach tuberculosis.

(Slide.) These are interesting, because we have the childhood type of tuberculosis, we have the adult type, we have the active type, which we pick right out of the study room—one girl, for example, with two large cavities, one in each lung, and around this child in the study room, 5 active cases of tuberculosis. Now if we are going to “swat the fly” and in other ways prevent tuberculosis, we must do it in a scientific way.

(Slide.) We have this problem alone of the prevention of tuberculosis by tuberculin-testing, roentgen-ray, hospitalization for all active cases, and this is one grand scientific achievement of the present day in the school system. We have carried this out with Christmas Seal money. It is expensive, but the Board of Health has not had money to do it. It has been done under our own auspices with Christmas Seal money.

The psychologic clinic and behavior classes I will just mention. The psychologic clinic, of course, is the sifting department, where you work out the whole problem for the child, all these various tests, and we have carried that on, and with it we have a large

vocational system whereby each child is sent where we believe it best to send him, and in this way we have a liaison system, where we can take care of it by an arrangement such as we would have in a hospital in war time, where we send a case where it belongs. So, the system is very extensive.

We have over 1000 records of probable criminals in this psychology clinic, in fact, a whole lot of our Purple Gang are children who were probably criminals according to their testing, and we now have, instead of the spanking system of the old days, the behavior school, where those mentally retarded and those who are behavior problems are especially taught and specially taken care of.

We have the parental home, whence they are sent with a guardian to school and brought back again from school, because they are all truants. We have the whole problem of the prevention of crime wrapped up in this school system, because 5280 boys were arrested in one year and sent to the detention home, and of that number, 85 sent were between thirteen and sixteen years of age, and 50 per cent of them were first offenders. This is the place to stop the trouble in this country.

I thank you for your patience.

DISCUSSION

DR. SECORD HERBERT LARGE, Cleveland, Ohio:

The Western Reserve Medical College has been carrying some experiments with their medical students.

During their first and second years the positive reaction is over 50 per cent and when these reach their final year becomes 100 per cent.

I should like to ask Dr. Shurly what were their findings in their tuberculin tests.

DR. FRANK ROBERT SPENCER, Boulder, Colo.:

I understood you to say something about laryngeal tuberculosis, and I wonder if you will repeat the percentage. I understood you to say 15, but that must be too high.

DR. BURT R. SHURLY (in closing):

Answering Dr. Large, we find one out of every 450 high school children has active tuberculosis, in Detroit, and that the high school girls' increase has not been stopped. The colored population brings it up quite a bit. We have 110,000 colored out of 1,500,000 population, almost one out of every 10, and the tuberculosis problem of activity is brought up and increased. Hospitalization has been necessary and there is a welfare problem connected with tuberculosis which has been very acute. One out of every 450 high school children is the activity. That is reported.

Answering Dr. Spencer, sometimes I say what I mean, and sometimes I say what I remember, but I am sure I said what I meant, and that is, the statistics of this hospital, which is from advanced cases, was 15 per cent through a period of ten years, because I happened to look it up after reading your book.

A SYNDROME OF PAIN AND PARALYSIS ARISING FROM INFLAMMATIONS OF THE PREVERTEBRAL SPACE*

ARTHUR W. PROETZ, M.D.

THERE is a train of symptoms, encountered particularly during the inclement months, which center chiefly about a deep shoulder pain, usually impossible to locate by external palpation.

In a certain proportion of cases, one sign occurs which has drawn attention to the prevertebral space as the source of the trouble, namely, a sore spot so located that a bolus of food passing down the esophagus aggravates the pain.

Before presenting the evidence which incriminates the prevertebral space, it may be well to enumerate these related symptoms. They are:

1. Deep pain, as of a muscle spasm, an inch to one side of the spinous processes anywhere between the seventh cervical and the third thoracic vertebræ.
2. Futile attempts to hold the head in some position which will relieve the deep cervical-thoracic tension; partial relief on lying supine.
3. Radiation of the pain to the arm, involving any or all of the branches of the brachial plexus.
4. Weakness and paralyses of various muscles attributable to brachial neuritis.
5. Occipital pain and tenderness.
6. A sore spot in such proximity to the esophagus that a bolus of food, passing down the tube, increases the pain.
7. Inflammation of the pharyngeal lymph tissues (or history of recent acute infection of these tissues).
8. Absence of fever or other severe systemic effects.

Between the posterior pharyngeal wall and the bodies of the cervical vertebræ are two layers of fascia. Behind the first lies the retropharyngeal space; between the second and the vertebral bodies is the prevertebral space.

* From the Department of Otolaryngology, Oscar Johnson Institute, Washington University.

The first of these potential rather than actual compartments has been the subject of numerous studies.^{1,3,5,6,7} The second, with which we are concerned, has received little attention beyond

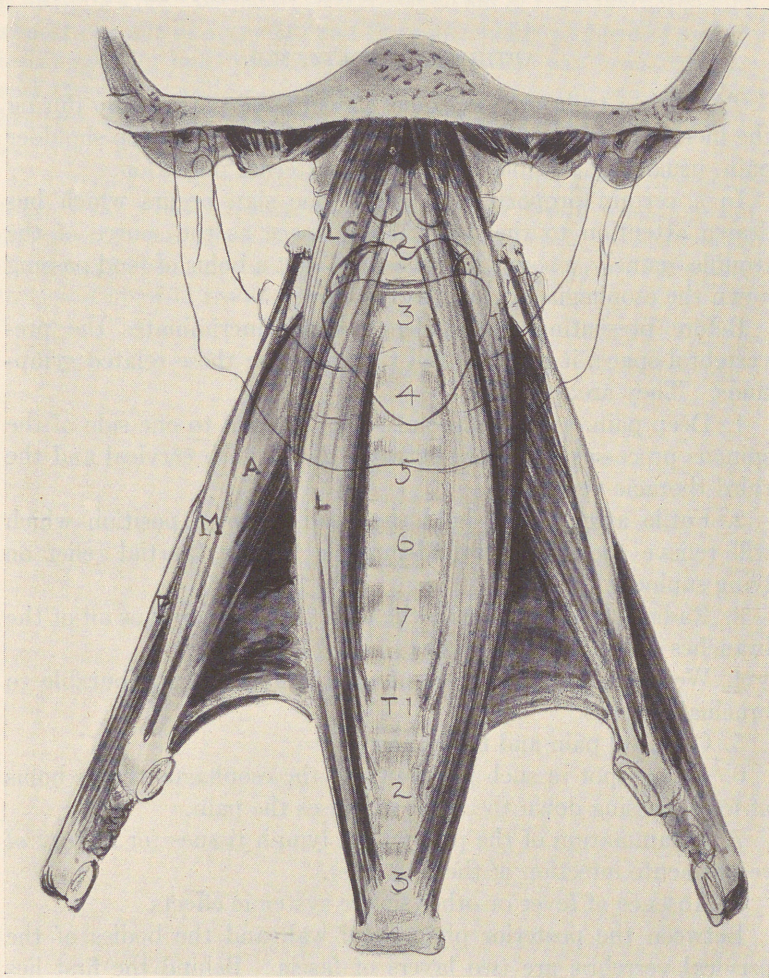


FIG. 1.—Semidiagrammatic representation of the prevertebral space, showing its relation to the spinal column, the longus colli muscles and the open mouth and pharynx. (Based upon an illustration from Spalteholz.) *L*, longus colli muscle; *LC*, longus capitis muscle; *A*, anterior scalene muscle; *M*, median scalene muscle; *P*, posterior scalene muscle.

the bare descriptions by the anatomists. Most of the standard texts fail even to differentiate it clearly from the retropharyngeal space, although a dissection of the region, especially a sectional

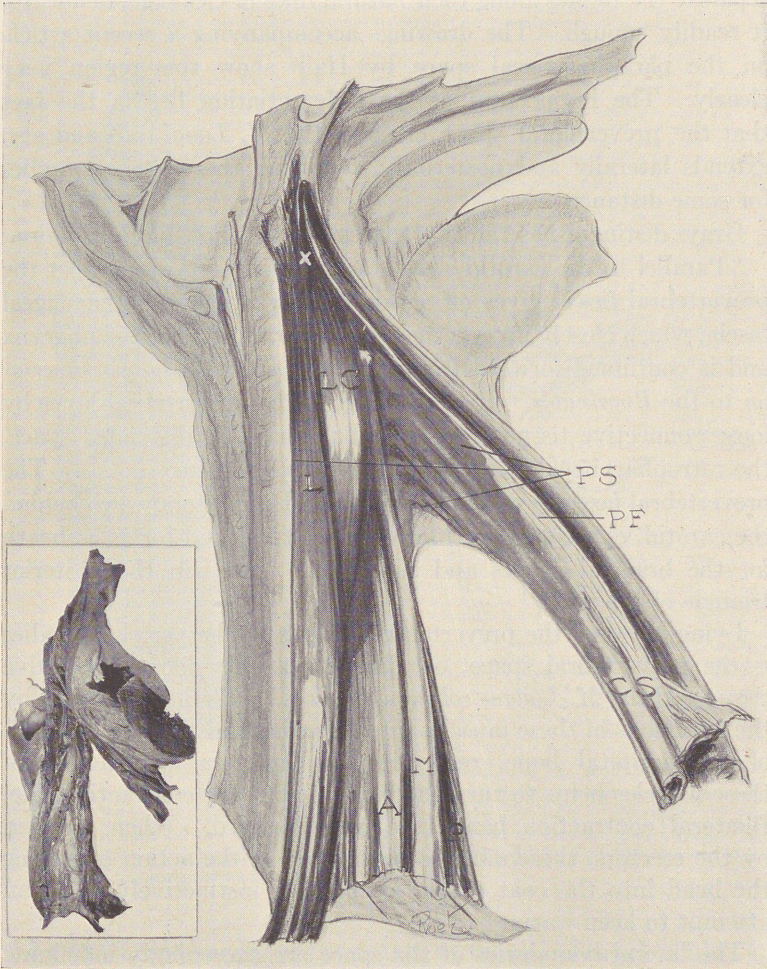


FIG. 2.—Diagram of a dissection of the deep muscles of the neck, showing the distribution of Chicago blue solution injected into the upper end of the prevertebral space. Inset, a photograph of the dissection. *L*, longus colli muscle; *LC*, longus capitis muscle; *A*, anterior scalene muscle; *M*, median scalene muscle; *P*, posterior scalene muscle; *PS*, prevertebral space; *PF*, prevertebral fascia; *CS*, carotid sheath.

study, makes the distinction apparent. Actually the prevertebral fascia, though quite thin, is constant and definite; a jet of compressed air projected against its edge in sagittal section, so as to separate the tissues along their natural lines of cleavage, delineates it readily enough. The drawings accompanying a recent article on the parapharyngeal space by Hall⁵ show this region very clearly. The importance of the differentiation lies in the fact that the prevertebral space encloses the *M. Longi colli* and also extends laterally and posteriorly, following the vertebral bodies for some distance.

Gray⁴ distinguishes the two spaces in the following description:

"Parallel to the carotid sheath and along its medial aspect the prevertebral fascia gives off a thin lamina, the bucco-pharyngeal fascia, which closely invests the constrictor muscles of the pharynx and is continued forward from the *Constrictor pharyngis superior* on to the *Buccinator*. It is attached to the prevertebral layer by loose connective tissue only, and thus an easily distended space, the retropharyngeal space, is formed between them . . . The prevertebral fascia is prolonged downward and lateralward, behind the carotid vessels and in front of the *Scaleni* and forms a sheath for the brachial nerves and subclavian vessels in the posterior triangle of the neck."

Lying between the prevertebral fascia and the vertebral bodies is the prevertebral space, occupied by a very loose connective tissue and the *M. Longus colli* and *capitis*. It is limited above by the insertions of these muscles into the atlas and the *pars basilaris* of the occipital bone, respectively. Unilateral contraction of these muscles helps to turn the head toward the contracting side. Bilateral contraction bends the neck forward. When opposed by the erectors, these muscles participate in the action of pulling the head into the coat collar, as one will instinctively do in an attempt to keep warm.

The lateral boundaries of the space are exceedingly indefinite. The prevertebral fascia extends laterally behind the carotid sheath to cover the *M. Scaleni*, and the space behind it is gradually obliterated between these muscles and the vertebral bodies in close proximity to the cervical nerves, as they emerge from their

foramina. Below, the space extends behind the upper esophagus into the posterior mediastinum.

Of clinical importance in the present instance is its contiguity above to the posterior pharyngeal wall and its lymphatic structures,

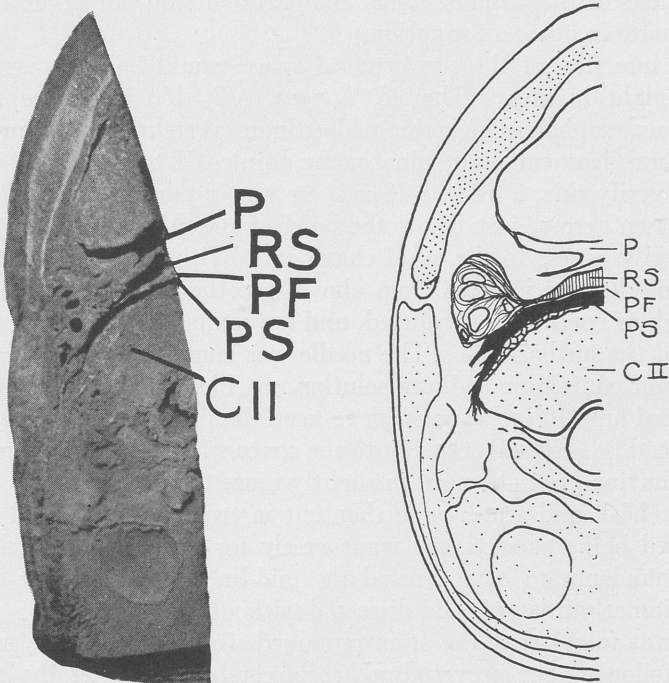


FIG. 3.—Photograph and diagram of a cross-section of the neck at the level of the *C II* vertebra, showing the relations of the retropharyngeal space, the prevertebral fascia and the prevertebral space. Note the lateral extension of the space to the side of the vertebra in the neighborhood of the cervical nerves. *P*, pharynx; *RS*, retropharyngeal space; *PF*, prevertebral fascia; *PS*, prevertebral space; *C II*, second cervical vertebra.

the pharyngeal tonsil and the lateral bands, through which it may be exposed to infection. There is little doubt that the pharyngeal lymphatics provide an efficient barrier to infection and that bacterial penetration through the fascial layers is infrequent; but it does occur, as evidenced by the formation of retro-

pharyngeal abscesses, and it is only a short step from the retro-pharyngeal to the prevertebral space.

Few reports are to be found^{8,9,10} of experimental work in regard to bacterial invasiveness of various types of tissue, but there can be no doubt that nonpus-producing invasions do occur and that infections of the various fascial compartments do not necessarily eventuate in abscess formation.

An infection of the prevertebral space would have access to, and might involve: The *M. Longus colli*, *M. Longus capitis*, pharynx, esophagus, posterior mediastinum, vertebral bodies, intervertebral ligaments and spinal nerve trunks CI to TIII.

To verify this, a fresh, soft cadaver was obtained and the head was sawn across, just below the level of the cribriform plate, so as to give access to the nasal chambers. With the body erect, a long needle was inserted from above into the prevertebral space as high as conditions permitted, and approximately $\frac{1}{2}$ inch to one side of the median line. The needle was connected with a small reservoir containing a dilute solution of Chicago blue, which was elevated only 10 inches in order to keep the fluid stream at a very low head. The fluid seeped into the space with comparative ease, 6 cc. having been absorbed in slightly more than two hours.

The head and trunk were then cut in two, sagittally, and the injected half was sectioned transversely for study. As the fluid was found not to have crossed the mid-line, the remaining half was similarly injected, and dissected without sectioning.

It was found that the stain remained well lateral to the mid-line, following the prevertebral fascia caudad and laterally, and staining the structures enumerated above, with the exception of the posterior mediastinum and the spinal nerve trunks, which it approached but did not reach.

It was demonstrated also by an injection beneath the mucosa of the face of the sphenoid that no direct continuity exists between this and the prevertebral space, the thick muscle insertions of the *M. Longus colli* and *capitis*, forming a barrier at least 1 inch wide.

Le Gros Clark² dropped a 10 per cent solution of potassium ferrocyanide and iron ammonium citrate in the nasal cavities of rabbits which he killed at intervals of one, two and three hours, washed and fixed in formalin. In one of his rabbits, killed one hour

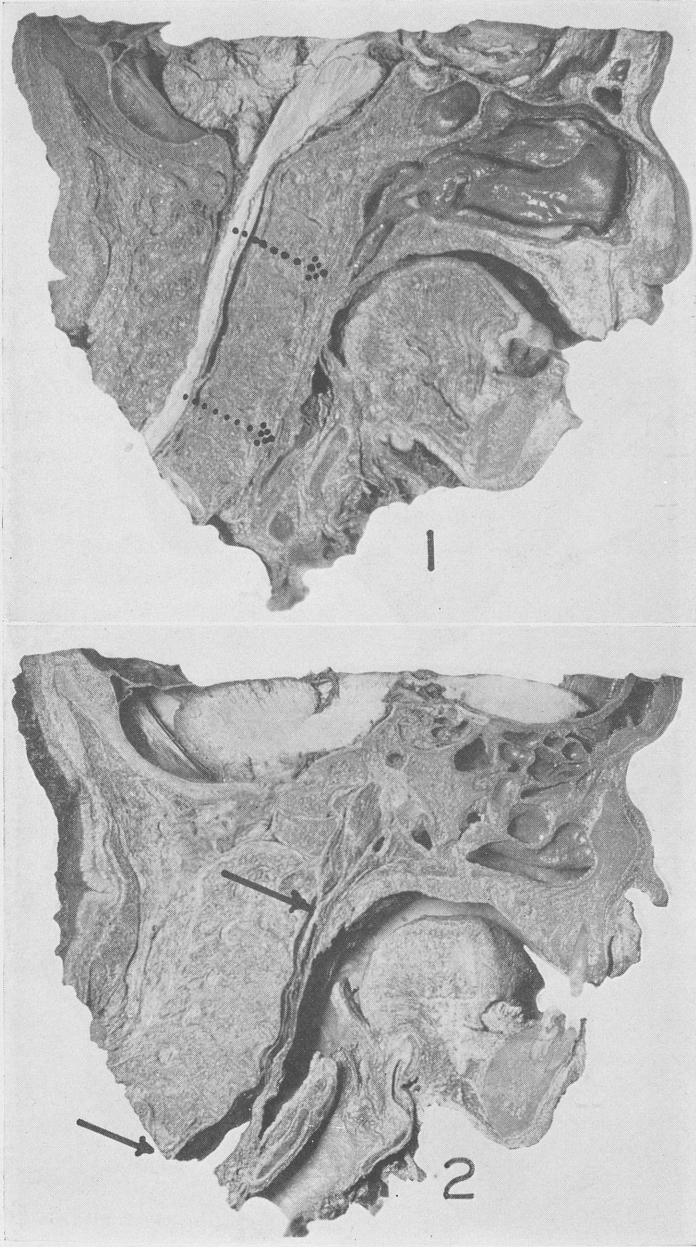


FIG. 4.—Sections showing the relations of the prevertebral space. Section 1, midline, showing obliteration of this space in the midline. Sections 2 and 3, more laterally, showing relations of vertebrae and prevertebral space. Note the disappearance of the retropharyngeal space in 3. Section 4 shows the space extending lateral to the bodies of the vertebrae. The tissues in these sections were separated by means of a jet of compressed air, which reveals the natural lines of cleavage.

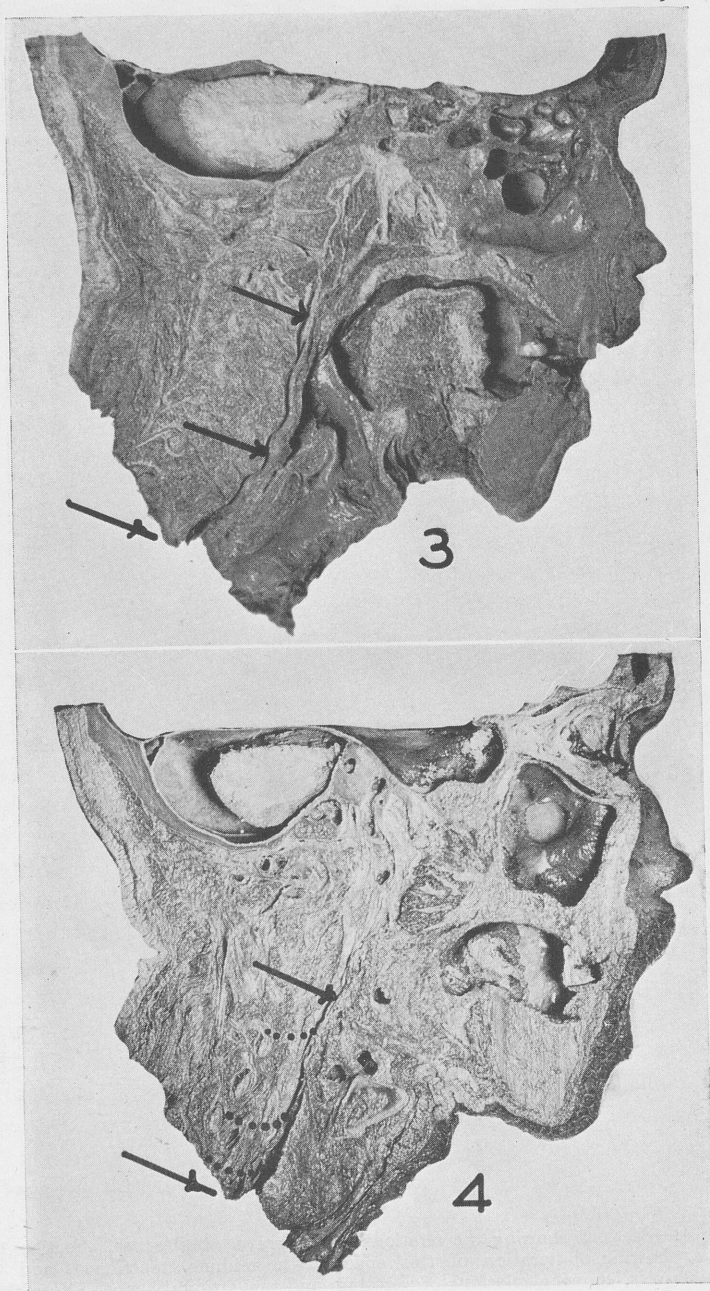


FIG. 5

after treatment, the solution was found to have reached, among other things "the deeper tissues in the orbit and the cellular tissue among the nuchal muscles, even extending on to the occipital aspect."

It would not be unreasonable to regard this avenue of infection as a possible source of the "nodular headaches" described by Sluder,¹¹ of which he says: "Nodules would appear under the skin of the neck, sometimes under the scalp, usually at the height of the pain. Their appearance followed the distribution of the lymphatic glands as given by Bartels . . . the nodules lasted twelve hours, to disappear only as the attack subsided which was the usual course. In other cases I failed to get such a response (*i. e.*, through cocainization of the nasal ganglion). They subsided only as the patient in general became better. The nature of these nodules is not known."

The spinal nerves whose roots correspond to the lateral limits of the prevertebral space, namely the CI to the TIII, are distributed over wide areas to structures too numerous to tabulate here. Some of them are the sites of pain for which it is commonly difficult to account. Such, for example, are the occipital regions supplied by the second, arising at the level of the pharynx, the muscles of the neck supplied by the third and fourth and the various groups of shoulder, arm and hand muscles supplied through the brachial plexus.

In a series of 22 cases, the complaints were similar and the central pain did not vary in its character and location. Only two of them presented the complete syndrome. The remaining 20 presented all but one or two, sufficiently definitely to include them in this group.

The most constant symptom is the deep pain in the region of the *M. Longus colli*, characterized by the inability of the patient to localize it, or the examiner to elicit it on external palpation. Like most cervical myositis, changes in position afford little relief.

The exacerbation of pain, when a bolus of food traverses the esophagus is sometimes not present, but it is extremely suggestive when it does occur.

Sensory disturbances of the branchial nerve branches are usually present. Motor paralyses are more rare. In three cases these were

pronounced, practically incapacitating the hand for a period of three to six weeks. In one case, definite burning sensations were described in the skin distribution of the posterior brachial cutaneous branch of the axillary nerve (origin, fifth and sixth cervical).

The reaction of inflammation of the pharyngeal tissues is apt to be slight and the local lymph nodes are not much swollen.

Thus far no cases of bilateral involvement have been encountered.

The condition is apt to recur with a repetition of symptoms characteristic of the individual case.

In only one case was it possible to observe an infection of this region at autopsy. In this case the infection, beginning in the left mastoid, perforated deep in the neck, crossed far down in the prevertebral space to the opposite side, dissected its way upward, finally penetrating the spinal canal with the vertebral artery beneath the oblique ligament of the atlas and eventuating in an extradural abscess at this point.

COMMENT. The evidence for the foregoing is admittedly circumstantial. Since the condition seldom leads to fatal results, postmortem verification must be rare. In view of the close adherence of the symptoms to the anatomical background and to the findings in the cadaver after injection, it seems justifiable to associate them with the prevertebral space. While an inflammation of the retropharyngeal space might cause some of the symptoms, it could not involve the *M. Longi colli* nor could it reach the spinal nerve roots.

REFERENCES

1. Beck, A. L.: A Study of Twenty-four Cases of Neck Infection, *Ann. Otol., Rhinol. and Laryngol.*, **42**, 741, 1933.
2. Clark, W. E. le Gros: Anatomical Investigation Into the Routes by Which Infections May Pass From the Nasal Cavities Into the Brain, Reports on Public Health and Medical Subjects, No. 54, London, p. 13, 1929.
3. Dean, L. W.: The Proper Procedure for External Drainage of Retropharyngeal Abscess Secondary to Caries of the Vertebrae, *Ann. Otol. and Laryngol.*, **28**, 566, 1919.
4. Gray, H.: Anatomy of the Human Body, 22d ed., Philadelphia, Lea & Febiger, 1930.
5. Hall, C.: The Parapharyngeal Space: An Anatomical and Clinical Study, *Ann. Otol., Rhinol. and Laryngol.*, **43**, 793, 1934.
6. Mosher, H. P.: Deep Cervical Abscess and Thrombosis in the Internal Jugular Vein, *Laryngoscope*, **30**, 365, 1920.

7. Mosher, H. P.: The Submaxillary Fossa Approach to Deep Pus in the Neck, *Trans. Am. Acad. Ophth. and Otolaryngol.*, p. 19, 1929.
8. Mudd, S.: The Penetration of Bacteria Through Capillary Spaces: I. The Motility and Size as Influencing Filterability Through Berkefeld Candles, *Jour. Bacteriol.*, **8**, 459, 1923.
9. Mudd, S., and Warren, S.: The Penetration of Bacteria Through Capillary Spaces: II. Migration Through Sand, *Jour. Bacteriol.*, **9**, 143, 1924.
10. Mudd, S., and Mudd, E. B. H.: The Penetration of Bacteria Through Capillary Spaces: III. Transport Through Berkefeld Filters by Electro-osmotic Streaming, *Jour. Bacteriol.*, **9**, 151, 1924.
11. Sluder, G.: *Nasal Neurology, Headaches and Eye Disorders*, St. Louis, C. V. Mosby Company, p. 289, 1927.

DISCUSSION

DR. JOHN F. BARNHILL, Indianapolis, Ind.:

It seems to me it would be rather unfortunate to let this paper go by without discussion. I have very little knowledge of the clinical side of it. I must admit that I have seen very few cases such as the doctor has described, unless we are willing to admit that the many cases we see of stiff neck, such as we are commonly in the habit of calling rheumatic, should be classed along with such cases as the doctor has described.

I wish to say a few words about the fascia of this region. I wish to commend Dr. Proetz for his anatomical work along this line. I have been convinced in certain studies which I have been making of this region, for many years, that we, as laryngologists, have not given the attention to the anatomy of the neck which it deserves. I am convinced that we cannot explain many of the phenomena of the accumulation of pus and its behavior in this particular region unless we are entirely familiar with the fascia of the neck.

It is clear to anyone who makes and studies cross-sections such as Dr. Proetz has exhibited here, that there are a few regions only along which pus and inflammation can readily travel.

I fancy that you noted that Dr. Proetz separated the layers of tissue he showed in the pictures with, as I understood, a small air-pressure apparatus, which proves how easy it is for fluids of any kind to form or travel as he described them in the prevertebral space, and to disseminate to the regions he described.

Over and over again I have cross-sections of the neck and in some of them, when they come to me, the connective tissue which holds together the structures of the neck has already fallen apart in certain places, they are so loosely attached to each other.

The most beautiful connective tissue that I know of in all the body lies in that particular region which the doctor described, and I mention that for the reason that the fact demonstrates how clearly and how easy it is for suppurative products to find their way in the direction Dr. Proetz has mentioned.

Instead of using the air pressure to separate the tissues one may use the finger which almost falls into the spaces which the doctor has spoken of, falls in, so loosely are the structures bound together in the areas described, and especially that one lying in front of the vertebræ commonly known as the prevertebral space.

DR. BURT R. SHURLY: Did you use diathermy?

DR. PROETZ: No. I am not prepared to say anything about diathermy. At present I am applying heat and gentle massage as recommended by the orthopedist, who admits heat is probably not any more effectual than anything else he can suggest.

DR. A. W. PROETZ (in closing):

I should like to thank Dr. Barnhill for his discussion and say when one begins to look for this syndrome, it is a little bit more frequent than he imagines, especially the symptom of pain on swallowing. Usually the patient comes in with a sore throat and tenderness or severe pain between the shoulder blades. The situation is usually this: You put your finger there and he says it is an inch higher and put your finger an inch higher, and he says, it is out a little bit, and you go out a little bit and it is not there. Sometimes he even complains of pain on pressure in the front, and, if you question him, without leading too much, you will find out he has an ulnar neuritis with it, which lasts from two to four or six weeks.

BRANCHIAL AND THYROGLOSSAL DUCT CYSTS AND FISTULAS

JOHN MACKENZIE BROWN, M.D.

THE presentation of this subject is prompted by the fact that, although laryngologists are consulted as frequently as anyone in our profession for the treatment of these conditions, there is very little to be found on the subject in laryngological literature. Therefore, I consider it not untimely to bring the matter to the attention of the members of this Association and present these few cases for your consideration.

DEVELOPMENT. A knowledge of the transformation of the embryonic to the adult pharynx is of practical importance. As expressed by Sir Arthur Keith,¹ it aids us in understanding the origin of these cysts and fistulas in the neck, and throws more light on the nature and anomalies of the thymus, thyroid and tonsil.

During the first two weeks of embryonic life, five branchial arches are formed in the neck of the embryo. These produce ridges, separated by grooves, which are found on the external lateral surfaces of the embryonic neck. They correspond to the gill arches of fishes, but in these lower animals the arches are separated by actual clefts, through which respiratory water flows. In man they never develop such a respiratory function, but are modified and take part in the formation of various structures in the mouth, pharynx and larynx. There are, then, definitely developed during the sixth and seventh week, four external grooves, with four internal pouches lying opposite on the inside of the pharynx, and an arch or supporting skeletal element on either side of each pouch. The first two arches are much larger than the other three, so overlap and obscure them, and the second arch becomes attached to the thoracic wall of the embryo. Thus, beneath is produced a sinus which becomes closed off, and under normal conditions the epithelial lining of the sinus is absorbed. Sometimes, however, the epithelial lining persists and the embry-

onic cervical sinus or a part of it (particularly that related to the second cleft) forms the cervical cyst of the adult. Likewise, a pinching-off and nonabsorption of the entodermal lining of the pharyngeal pouches on the inside of the embryonic neck may produce internal cysts. Further, if the thin wall intervening between the embryonic pouch internally and the groove externally breaks through, another interesting pathological condition results in the adult, a cervical fistula, opening directly from the pharynx to the outside.

While the tonsils, the thymus and parathyroid glands develop from the lining membrane of the side walls of the embryonic pharynx, the thyroid gland is formed from tissue found originally in the floor of this cavity. During the third week a dimple appears in the floor of the pharynx at the level of the first pouch. This dimple enlarges until a sac is formed, attached to the point of origin by an elongated neck. Around this point of origin there develops in the floor of the pharynx, the tongue, and the original point of origin of the thyroid gland remains marked in this organ, as the foramen cecum. The thyroid grows downward in front of the anterior wall of the pharynx, and its elongated neck becomes the thyroglossal duct. During the sixth week of embryonic life this duct usually loses its lumen and atrophies, the only portion of the duct persisting in the adult being its lower portion, which forms the pyramidal lobe of the thyroid gland. Failure in atrophy of portions of the thyroglossal duct results in accessory thyroids, cysts or fistulas, occurring usually in the mid-line of the neck and anywhere from the foramen cecum of the tongue down to the pyramidal lobe of the thyroid gland at the level of the thyroid cartilage.

PATHOLOGY. Theories concerning the origin of cysts and fistulas may be outlined as ascribed to the following:

1. Rupture of the embryonic membrane separating the branchial clefts.
2. Failure of malformed clefts to unite or fuse properly.
3. Incomplete retrogression of the branchial apparatus.
4. Anomalous development of the vestigial remnants of a branchial cleft.
5. The persistence of a cervical sinus.

6. Remnants of the thymic duct.

7. And, in the case of a true thyroglossal duct cyst, its lumen may not become obliterated and it becomes either an enclosed cyst or an open secreting sinus.

The cysts derived from the ectoderm contain squamous epithelium and a grumous putty-like substance. Those from the entoderm contain columnar epithelium and a mucoid substance containing cholesterin. However, some cysts contain both types of epithelium. When the cyst becomes degenerated from irritation or infection, the walls become infiltrated with the elements of chronic inflammation and firmly adherent to the surrounding structures, making dissection very difficult. Thyroglossal duct cysts and fistulas are usually lined with squamous epithelium and the content is grumous, and when infected, purulent.

CLASSIFICATION. The classification of these cysts and fistulas has been given by Andrews² as follows:

1. Cysts with no internal or external openings.
2. Cysts and fistulas opening internally.
3. Cysts and fistulas opening externally.
4. Fistulas with internal and external openings.

They are classified by Bailey³ according to position, as superficial or deep; auricular, parotid, sublingual, submaxillary, pharyngeal or tracheal; and by others, as to the cleft giving origin, as to the contents and the type of lining epithelium (Hyndman and Light⁴).

CLINICAL ASPECTS. *Cysts Without a Fistulous Tract.* The first complaint of the patient is usually of a soft swelling in the neck with practically no other symptoms. As the cyst increases in size, however, it may press upon various structures, causing hoarseness, coughing or difficulty in breathing and swallowing, depending upon the direction of growth. Carp⁵ reports a case with persistent hacking cough, due to pressure on the vagus, the symptoms subsiding after excision of the fistula. Thomson⁶ reports a case of fixation of the left vocal cord in which at operation the cyst was found attached to the left side of the larynx. Pain and tenderness are infrequent symptoms and usually due to infection.

Cysts, other than those preauricular, are all anterior to or under the sternomastoid muscle. They have never been reported as bilateral.

Cysts with a fistulous tract draining internally may present any of the foregoing symptoms, but with this type there is always a history of intermittent variations in the size of the tumor. This is due to the emptying of the cyst through its fistulous tract. In one of my cases, following tonsillectomy, the tumor decreased in size, probably the result of opening the fistulous tract. A common history in this type is that the patient had a discharge in the throat, and on careful inspection, a secretion may be found coming from the mouth of the tract, usually in the supra- or infratonsillar fossa. They are seldom noticed unless they are of sufficient size to drain habitually. This condition is frequently precipitated by tonsillectomy (Hyndman and Light⁴).

Cysts with fistulous tracts draining externally likewise have fluctuations in the size of the tumor. The outstanding complaint of those *with external openings* is periodic drainage which may be clear, tenacious, mucous or purulent. Coplin⁷ stated that stimulation of the salivary secretion by mastication sometimes excites secretion from the sinus even when it does not communicate with the alimentary canal. The external orifice is frequently pigmented and may present a dimpling or a tab of skin containing cartilage. Virchow,⁸ in 1861, reported 1 case of multiple openings at the junction of the sternomastoid muscle with the clavicle. Nearly all cysts with fistulas, whether internal or external, are infected to a varying degree.

Complete branchial fistulas with internal and external openings are uncommon. Six cases are reported by Kleinert⁹ from the Massachusetts General Hospital. They may be unilateral or bilateral. In Hyndman and Light's⁴ series, 16.8 per cent were bilateral.

A thyroglossal duct cyst without a fistulous tract may be located at any position along the former course of the embryonic thyroglossal duct. Its symptoms are those of swelling or pressure, or both, as evinced by difficulty in swallowing, coughing, hoarseness, breathing, and in fact all of the symptoms seen in a branchial cleft cyst. These cysts are practically always in the mid-line and seldom above the hyoid. However, Klingenstein and Colp¹⁰, reported a case in which the cyst was so far lateral to the median line that a thyroglossal duct cyst was not entertained.

A thyroglossal duct cyst with a fistulous tract either opens internally at the foramen cecum or externally in the mid-line of the neck, between the hyoid bone and the suprasternal notch, though the opening may be lateral. The symptoms are also similar to those of branchial cleft cysts with fistulas draining internally or externally. Infection is the rule in this type.

DIAGNOSIS. Differential diagnosis involves the following:

1. *Adenitis*, which is usually bilateral and associated with some focus of infection. *Tuberculous* adenitis in children must be determined by the history, the tuberculin test and bacteriological examination of the contents. Injection of lipiodol and subsequent roentgen-ray examination is of considerable value in differentiation, as tuberculous glands of the neck present an irregular outline after injection, as stated by Wagensteen.¹¹

2. *Cystic hygromata*, which are allied with lymph cysts, are translucent and usually situated in the lower half of the neck.

3. *Venous hemangiomas* decrease in size on pressure.

4. *Lipomata*. The contents cannot be aspirated but may strongly simulate the cyst otherwise.

5. *Sublingual epithelial cysts* are usually congenital. The symptoms are the same as branchial cysts and can only be differentiated by the pathologist. Dr. John B. Hitz¹² reports an interesting case of this type.

6. *Dermoid cysts*, ranulas and tumors of the thyroid must be differentiated from thyroglossal duct cysts. This can be done by lipiodol injection and roentgen-ray examination, together with microscopic examination of the contents of the cyst. Frequently, the noninfected cysts are mistaken for abscesses; Baumgartner¹³ reports 4 such cases.

CASE REPORTS. The following 7 cases are reported in the order of their location:

CASE 1.—J. V., male, aged ten years, gave a history of having an intermittent draining sinus in front of the left ear for five years, with resulting swelling, pain and tenderness upon cessation of the discharge. Examination revealed a fistulous tract, about 1 cm. deep anterior to the left tragus, which was discharging pus. Further physical and laboratory examinations were negative. A diagnosis of infected branchial cyst was made. On October 26, 1934, at the Los Angeles

County General Hospital, the patient was operated upon, and a cyst, $1\frac{1}{2}$ by 2 cm. in size, with four small blind fistulous diverticulæ leading from it, were found and dissected out. Pathological examination showed squamous epithelial lining with muscle and connective tissue in the outer part of the wall. Pathological diagnosis: branchial cyst. Recovery was uneventful.

CASE 2.—J. C., female, aged twenty-seven years, gave a history of swelling in front of the left ear, slightly over the tragus, which had been present since birth. There had been intermittent drainage from the opening for several years. *The patient stated that her mother and brother had similar openings in the pre-auricular region but they had never shown other symptoms.* Examination showed a red, semifirm, pre-auricular swelling just above the tragus in the center of which was a small dimple-like formation in the skin. Further physical and laboratory examinations were negative. A diagnosis of branchial fistula was made. At operation, on April 4, 1935, at the Los Angeles County General Hospital, the sac containing three pockets was dissected out. Pathological diagnosis: branchial fistula. The patient was discharged from the hospital in three days and a discharge from the wound occurred for ten days.

CASE 3.—J. B., female, aged sixty-three years, gave a history of a swelling of three or four months' duration, beginning back of the right mandible, under the lobe of the ear. The swelling increased in size and pushed forward in front of the ear and over the mandible. One month prior to my examination, this cyst had been opened by a surgeon, and a large amount of serous fluid obtained. The mass completely disappeared for a short time, then began to increase in size, causing pain over the entire side of the face. Examination revealed a swelling about 8 by 5 cm. It was firm and tender only at the margins, non-fluctuating, freely movable, with no attachment to the angle of the mandible. It displaced the lobe of the ear upward. Other physical and laboratory examinations were negative. A diagnosis of branchial cyst was made.

On November 5, 1934, at St. Vincent's Hospital, an incision was made parallel to the zygoma, back to the lobule of the ear, then downward over the tumor to the neck. The lower and anterior borders of the tumor were located and the tumor shelled out. *A pedicle was found going around back of the mandible, which was traced almost to the pharynx.* Pathological examination showed a thin and fibrous-walled cyst with an opaque, velvety inner surface, 5 cm. in

diameter, containing yellow purulent fluid. The inner surface of this fibrous wall was densely infiltrated by an inflammatory exudate and covered by stratified epithelium. Pathological diagnosis: branchial cyst. The patient was discharged eleven days after operation with a healed incision.

CASE 4.—L. B., male, aged twenty-eight years, gave the history of a recent sore throat, more pronounced on the right side, with accompanying enlargement of the cervical glands on that side. On examination, purulent material could be freely expressed from a large tonsil tag at the base of the right fossa. Externally, there was a smooth swelling, the size of a walnut on the same side in front of the sternomastoid muscle, which was thought to be a gland, as several glands of the anterior group were enlarged. Further physical and laboratory examinations were negative. The tonsil tag was removed, after which the smaller glands disappeared and the larger one reduced in size. Two weeks later it began to enlarge and took on the characteristics of a cyst. A diagnosis of branchial cyst was now made.

In August 22, 1934, at St. Vincent's Hospital, an incision was made over the tumor which lay anterior to the sternomastoid. The tumor was shelled out from its bed. *A pedicle which was attached to it was traced to the infratonsillar fossa.* Pathological examination showed a unilocular cyst, 4.5 by 6 cm. in diameter, containing a viscid, opaque, yellow fluid, with a wall, 2 to 3 mm. in thickness. The lining of the wall was of stratified, squamous epithelium beneath which were deposited many nodules of hyperplastic lymphoid tissue. Pathological diagnosis: branchial cyst. The patient was discharged four days later. Recovery was uneventful.

CASE 5.—M. N., female, aged thirty-five years, gave a history of a small swelling on the left side of the neck of several weeks' duration, not preceded or accompanied by a cold or sore throat, and not painful or tender. Examination disclosed a swelling, 3 by 5 cm., in the left anterior cervical region in front of the sternomastoid muscle. Other physical and laboratory examinations were negative. During an observation period of eight weeks, the size of the swelling gradually increased. A diagnosis of branchial cyst was made.

On March 15, 1935, at St. Vincent's Hospital, a transverse incision was made through the skin and platysma muscle; the cyst was easily located just anterior to and under the sternomastoid, and a pedicle was found which ran toward and almost reached the pharyngeal wall. The cyst was enucleated, the pedicle ligated with catgut very close

to the pharynx and the wound closed without drainage. Pathological examination showed a unilocular cyst with a white, opaque lining, with a fine, granular surface. Microscopically, the cyst was composed of a fibrous layer covered by squamous epithelium internally, with considerable degeneration and multinucleated phagocytes present on the surface and infiltrating the fibrous stroma. Pathological diagnosis: branchial cyst. Recovery was uneventful.

CASE 6.—R. B., male, aged five years. Four years ago the boy's mother first noticed a small hard lump in the mid-line of the neck under the chin. This lump was lanced by a physician and discharged a mucoid material. Three surgical attempts to remove the draining area were unsuccessful. Examination showed a small opening in the mid-line, 2 cm. below the chin, 1 mm. in diameter, draining a viscid material. Further physical and laboratory examinations were negative. A diagnosis of thyroglossal cyst was made. On December 13, 1934, at the Hospital of the Good Samaritan, the fistulous tract was dissected to the hyoid bone, the central section of the hyoid bone removed and the fistula followed to the base of the tongue. The wound discharged for three weeks and then healed completely.

CASE 7.—L. E., female, aged nine years, was admitted to the Los Angeles County General Hospital, on April 8, 1935, complaining of having a painful tumor in the mid-line of the neck just before the larynx. Her parents stated that she had had a small dimple in that region since birth, which intermittently would become swollen, and discharge a thin, serous fluid. On physical examination a tumor mass was found in the mid-line of the neck, just below the hyoid cartilage, measuring about $1\frac{1}{2}$ by 3 cm. It was fluctuant and slightly tender on palpation. Other physical and laboratory examinations were negative. A large aspirating needle was inserted with the view of aspirating the fluid and injecting lipiodol for roentgen-ray examination. The content of the cyst was so thick, however, that it could not be aspirated. A diagnosis of thyroglossal cyst and fistula was made.

At operation, on April 10, 1935, the cyst was found to contain a thick, yellow mucoid substance and the lining was extremely thick. The cyst and fistulous tract were dissected out. The wound discharged for two weeks, after which it healed, and the patient was discharged from the hospital.

In a series of 20 cases recorded at St. Vincent's Hospital, Los Angeles, during the past ten years, 13 were diagnosed as originating from the branchial apparatus and 7 from the thyroglossal duct.

The occurrence in the sexes was equal and the age incidence was from three and a half to sixty-three years. Those of branchial origin showed no predilection for either side of the neck. Ten were cysts without fistulas; 2 were cysts with internal openings and 1 a cyst with an external opening. Three had had previous surgery; 90 per cent were diagnosed before operation.

TREATMENT. It is generally conceded that complete surgical resection of the entire cyst and its fistulous tract, if it has one, is the only method of treatment that has proven satisfactory. Fistulas must also be removed in their entirety. McNeill Love¹⁴ advocates in this type, a simple procedure of encircling the orifice of the fistula with a fine purse-string suture. This is inserted as close to the orifice as possible and tightened, so as to close the opening. In a few days continued secretion distends the fistula, transforming it into a cyst, which thus facilitates dissection.

Orientation as to the extent of the involved tract may be accomplished by the injection of methylene blue or other color substances, in the manner outlined by Baumgartner.¹³ After determining with a probe the direction of the tract, avoiding too great pressure, methylene blue is injected, using a blunt needle. The methylene blue is then thoroughly washed out, thus preventing soiling of the adjacent tissues during surgery from an excessive amount of dye remaining in the tract.

Branchial cysts frequently have a pedicle which must be removed with the cyst, involving at times extensive dissection. Too much stress cannot be placed upon the importance of not rupturing the cysts, with or without fistulas, during removal, as dissection after their collapse is very difficult.

In the removal of thyroglossal duct cysts the tract is always in such close relationship to the hyoid bone that it is necessary to sever the hyoid or take a section out of it in order to effect a complete dissection. The duct is tied and resected at the foramen cecum. The method of Sistrunk¹⁵ is probably the best.

Cutler and Zollinger¹⁶ reported the use of a modification of Carnoy's solution in a few cases with good results; yet I hardly think it has been used in enough cases or over a long enough period of time to warrant the displacement of surgery.

SUMMARY. From the foregoing review of cases and literature it seems to me that branchial and thyroglossal duct cysts and fistulas may be considered, at least in part, laryngological subjects.

BIBLIOGRAPHY.

1. Keith, Sir Arthur: Human Embryology and Morphology, Baltimore, William Wood & Co., 1933.
2. Andrews, E. W.: Keen's Surgery, **3**, 278, 1908.
3. Bailey, H.: The Clinical Aspect of Branchial Cysts, Brit. Jour. Surg., **10**, 565, 1923.
4. Hyndman, O. R., and Light, G.: Branchial Apparatus, Arch. Surg., **19**, 410, 1929.
5. Carp. L.: Branchial Fistula, Its Clinical Relation to Irritation of the Vagus, Surg., Gynec. and Obst., **42**, 772, 1926.
6. Thomson, J. W.: A Case of Branchial Cyst, Lancet, **1**, 76, 1927.
7. Coplin, W. M. L.: Branchial Cysts and Fistulas, Proc. Path. Soc. Philadelphia, **4**, 109, 1900.
8. Virchow, R., and Hirsche, A.: Dissection of a Congenital Hydrocele of the Neck, Jahresb., **1**, 280, 1882; quoted by Pranesk.
9. Kleinert, M. N.: Branchial Fistula, Arch. Otolaryngol., **18**, 510, 1933.
10. Klingenstein, P., and Colp, R.: Congenital Cysts and Fistulas of the Neck, Ann. Surg., **82**, 854, 1925.
11. Wagensteen, O. H.: Differentiation of Branchial From Other Cervical Cysts by X-ray Examination, Ann. Surg., **93**, 790, 1931.
12. Hitz, J. B.: Sublingual Epithelial Cyst: Report of a Case, Arch. Otol., **21**, 338, 1935.
13. Baumgartner, C. J.: Branchial and Thyroglossal Duct Cysts and Fistulas in Children, Surg., Gynec. and Obst., **56**, 948, 1933.
14. Love, R. J. McN.: A Simple Method of Dealing With Congenital Fistulae, Lancet, **2**, 122, 1929.
15. Sistrunk, W. E.: Thyroglossal Duct, Ann. Surg., **71**, 121, 1920.
16. Cutler, E. C., and Zollinger, R.: The Use of Sclerosing Solutions in the Treatment of cysts and fistulae, Am. Jour. Surg., **19**, 411, 1933.

DISCUSSION

DR. THOMAS E. CARMODY, Denver, Colo.:

I think Dr. Brown is to be congratulated on bringing this subject before us and I, like Dr. Brown, believe this is a laryngological subject.

I have seen 4 cases of this kind in the last year, 2 of branchial, both on the right side, and 2 thyroglossal. The ages of these patients were: branchial, a girl of twenty-two, and a boy three; thyroglossal, a girl of sixteen, and a man of fifty-four.

Dr. Brown speaks of one thing here which leads me to say that the

man of fifty-four years complained a great deal of swallowing, and of pain in the larynx, of hoarseness, and even calling at night thinking he was going to choke to death.

The difficulty in removing that one was that we ruptured the cyst, and the cyst was found to be branched, and of course that made it a little bit more difficult.

The cyst in the thyroglossal—I do not know whether Dr. Brown mentioned that or not (I failed to get it if he did)—sometimes runs in front of the bone, sometimes through the bone, and sometimes posterior to the hyoid bone. Sometimes it is necessary to remove a section in certain cases. The operation is necessary in order to get all of the cyst, to remove the bone, and to core it out up to the foramen cæcum so as to close the tongue muscles and prevent recurrence.

Most of these are like Dr. Brown's third and sixth cases. Somebody has fooled with them and opened the cyst externally, and there is so much scar tissue that it is very difficult sometimes to find it. The idea of putting a purse-string around the end of the fistula is good in some cases, but in one case of mine even the little scab that would form over it would distend the cyst so much and cause so much pain that it would have to be taken off, so that the purse-string in that case would not do. A person should be prepared to operate within a few hours.

One of these cases of mine, the girl of twenty-two, had been opened a number of times because of infection, which ran down from the base of the tonsil. There was a piece of stub of tonsil present. In the other case, the boy of three, I removed the tonsils and found no opening at the inside, but there was one on the outside. After injection of methylene blue, passing a probe, and outlining the complete cyst, I dissected it out.

There will not be recurrence if the cyst is completely removed, but if it is not completely removed there will be.

In the case of the thyroglossal cyst, however, care must be taken that there is some other thyroid tissue, because sometimes in coring out one removes the whole thyroid gland, and then hypothyroidism may result.

Fistula through the hyoid sometimes requires a little care, sometimes the use of Carnoy's fluid (occasionally also called Cutler's fluid because it was popularized by Cutler). In some of these cases the fistula can be obliterated, but that is somewhat dangerous because only a portion of it may be obliterated, and if there is infection remaining in the rest there may be serious trouble.

DR. JOHN F. BARNHILL, Indianapolis, Ind.:

I wish to emphasize what Dr. Carmody has just said, that this is a laryngological problem very largely, and that therefore it is rather amazing that laryngologists have been so slow in taking up surgical problems that come very squarely in their fields.

In that part of our country where it has been my pleasure to practice, there has been no objection on the part of surgeons; indeed, the head surgeon of our University long ago turned over neck surgery to the laryngological department, and because of this I have had the good fortune to see a rather large number of these cases, in our State hospitals.

What Dr. Brown has said leaves little to add concerning the origin of these troubles. They occur exactly as he has stated. They are congenital, although in many instances their presence may not be known even to the patient for a long time; in other words, the tumor may not produce symptoms or become visible until the individual is fifteen, twenty, or even thirty years of age.

I remember one instance in a professor who never dreamed of having such a thing. He had throat trouble and choking, and, if he had been a woman, his affliction would have been called hysterical. One day as he played golf vigorously, "something popped out on his neck," he said, and when I saw him, he had something which simulated a very considerable goiter only it was slightly above the region.

What Dr. Carmody has said about the meddlesomeness of these tumors should, I think, interest us most. I have seen only two or three of them that had not been cut into, and the usual history is that the mother takes the child, or the young adult goes of his own accord to the doctor, the home physician, and, since the affection seems to be a simple sort of thing he lances it, and then, for all time, unless somebody who understands the nature of the disease operates, as has been described, by the Sistrunk method, that individual has a leaky neck, a nasty neck that compels him to wear a bandage about the neck. No one should ever be guilty of lancing a thyroglossal cyst.

Nearly every thyroglossal cyst I have ever seen has not been a cyst when it came to me, but a leaky neck; somebody two, three, four, or six years before had cut into it; there is only a scab on the neck, and often many scars over the neck.

It is true, as has been said here, that the hyoid bone must be resected partially. About a quarter of an inch usually is taken out, and sometimes surgeons are apprehensive as to whether it will do harm. Well, it does not do harm. The fascia here passes behind the hyoid as well

as the thyroid, and if one dissects it off posteriorly, one will have good support for the hyoid bone and healing without defect will follow. The rule to follow is, unless one intends to take these thyroglossal cysts out, or the branchial cysts out, from end to end, that it is better to let them alone entirely, because failure to cure will almost certainly follow any other procedure.

If you noticed Dr. Brown's pictures closely, especially the one which showed the branchial tract, you must have been impressed by its great length, beginning in the neck far down and ascending to the tonsillar region. It required a deep tedious dissection to take it out. But it can be done and should be done by laryngologists whose knowledge of the anatomy of the neck should be exceeded by none and whose surgical technique and surgical training should equal the best.

DR. CHARLES J. IMPERATORI, New York City:

Not many years ago I presented before the New York Academy of Medicine a case of branchial cysts of the larynx. This cyst intruded itself into the ventricle of the larynx. The patient was fifty-one years of age and the method of removal was by thyrotomy. This woman is entirely well and there has been no recurrence of any of the tissue from the branchial cleft.

My experience with thyroglossal cysts has been that if a laryngoscope is used to press the tissues outward as suggested by Dr. New—the dissection is greatly facilitated.

DR. EDWARD CECIL SEWALL, San Francisco, Calif.:

I had an experience in my early practice with one of these cysts that taught me a lesson. I was referred a patient by a physician for removal of tonsils and adenoids. I foolishly determined to operate upon the case without examination and, upon opening the mouth, I discovered one of these cysts at the base of the tongue.

DR. GORDON BERRY, Worcester, Mass.:

A word may fittingly be inserted concerning a modified Carnoy's solution: a ferric chloride and alcohol solution resembling Zenker's fluid described by Dr. Elliott Cutler about two years ago in the *American Journal of Surgery* (March, 1933).

It was at that time that I reported 2 recent cases of branchial cyst. In 1 case a distended cystic tract was dissected out, reaching from above the tonsil to below the level of the cricoid. The second case had a narrow long fistulous tract and loaned itself well to the use of this Carnoy's solution. This case and one on which we have since tried it were both cured, without operative interference.

The hazard in the use of this solution is that it is extremely caustic and will blister the skin or pharyngeal mucous membrane if allowed to reach it. The advantage is that it destroys epithelial tissue and that being in a fluid state it can be injected along the entire tract where this tissue needs to be destroyed. It seems to be of more value in long narrow fistulous tracts where much dissection would otherwise be necessary. I join with Dr. Carmody in recommending its trial in such cases, and then if this conservative effort fails, radical operative dissection can be employed.

DR. J. M. BROWN (in closing):

Thank you for the discussion.

Dr. Gordon Berry mentioned using Carnoy's solution* which was tried by one of my colleagues at the County Hospital on 1 case about six months ago and it has been successful to date. Another colleague tried it and caused such a severe reaction that he was cured from ever trying it again. This work is chiefly due to the kindly interest of Dr. John Barnhill who has been teaching head and neck surgery at the University of Southern California Medical School the past few years and I have had Dr. Lewis Morton, a general surgeon, associated with me in most of these cases.

* Carnoy's solution is

Absolute alcohol	6 cc.
Chloroform	3 cc.
Glacial acetic acid	1 cc.
Ferric chloride	1 gram

SOME OBSERVATIONS ON SURGERY OF THE NECK AS IT CONCERNS THE OTOLARYNGOLOGIST

BRANCHIAL CYSTS AND FISTULÆ

NORMAN PATTERSON, F.R.C.S.
LONDON, ENGLAND

CONGENITAL fistulæ in the neck were first described by Dzoudi in 1829 under the name of tracheal fistulæ. Shortly afterwards they were shown to be connected with the pharynx.

EMBRYOLOGY AND ANATOMY. The usual theory is that these conditions arise in connection with the development of the branchial clefts. In the pharyngeal region of the early embryo from four to six branchial arches have been described. Caudal to the arches are corresponding depressions or clefts. The external auditory meatus and Eustachian tube are formed from the first cleft. The tonsil develops in the region of the second cleft, Rosenmüller's fossa appearing as the upper extension of this cleft. The anterior pillar of the fauces is formed from the second, the posterior pillar from the third arch. During development of the embryo the first and second arches grow more rapidly than the rest, which they overlap producing the cervical sinus. This sinus tends to close, but it is connected with the exterior for some time by a duct which eventually disappears. Due to alterations in the normal course of development a fistula opening internally in the region of the tonsil or externally on the surface of the neck or continuous from the pharynx to the exterior may result. In other cases a cyst unconnected with the pharynx or skin surface develops in the course of the tract. There are, therefore, four possibilities: (1) an opening into the pharynx; (2) an opening on the neck; (3) a complete sinus opening in both regions; (4) a cyst opening in neither region. The internal opening is generally situated in the region of the tonsillar cleft close to the posterior faucial pillar. It is usually small, but may be so large as to allow food or even air to pass into its lumen. The outer opening

is found as a rule just above the sterno-clavicular joint and corresponds to the anterior border of the sterno-mastoid. Wenglowski, in 1912, after elaborate researches on a large number of embryos and cadavers, accounted for lateral cysts and sinuses as due to abnormalities in the development of the so-called thymico-pharyngeal duct which arises from the third pouch. He stated that thymic rests might sometimes be found in the region of the pharynx. It is said that the orifice of a branchial fistula may be situated in the region of the pyriform fossa which represents the third cleft. Since the usual opening is in the region of the tonsillar cleft, Wenglowski's hypothesis seems to be disproved.

In connection with the skin opening a nipple-shaped elevation has rarely been noticed. This has been found to consist of yellow fibrocartilage (Bland-Sutton described such a case). It represents an aberrant auricle. Hensinger stated that portions of skin like auricles occur in the necks of sheep, goats and pigs.

A complete fistula passes from its skin opening along the anterior border of the sterno-mastoid, and then lies on the sterno-hyoid and sterno-thyroid muscles. In the region of the posterior belly of the digastric it alters its course and turns acutely inwards, passing between the external and internal carotids to end in the tonsillar region. The tract may be closely connected with the vagus nerve.

A branchial cyst lies underneath the upper part of the sterno-mastoid muscle and generally projects from under its anterior border. The wall of a cyst or fistula consists of fibrous tissue of some thickness, often associated with much lymphoid tissue. The lining membrane may be composed of columnar, occasionally ciliated epithelium, sometimes the epithelium is of the stratified squamous variety. The cyst may contain mucoid fluid. Generally the contents are opaque. Sometimes they resemble those of a true dermoid, sebaceous material and hairs being present.

PATHOLOGY. Inflammation may alter the walls, the lining epithelium and the contents. Pyogenic organisms may be present in abundance and tubercle bacilli have been discovered. Chevassi, quoted by Ewing, has shown that branchial cysts may contain pharyngeal epithelium and salivary glands. This furnishes a satisfactory origin for some of the salivary tumors. Malignant

degeneration of a branchial cyst was first reported by Volkmann in 1882. Balk, in 1927, reported 10 cases. I have seen 1 case (Fig. 1).



FIG. 1.—Myxo-fibro-sarcoma. Probably mixed tumor of salivary gland type.

SYMPTOMS AND CLINICAL SIGNS. A watery or milky discharge from the neck, intermittent or continuous, generally scanty in amount may prove a source of annoyance to the patient. Occasionally the discharge is purulent. Cough has been ascribed to irritation of the vagus or superior laryngeal nerve caused by

sudden increase in the size of a cyst or inflammation around a cyst or sinus. Carp has referred to a boy with a cough of two years' duration which disappeared after excision of a tract adherent to the vagus. Various symptoms, such as hoarseness, cough, pulse changes, pallor have been noticed on probing a sinus. It is said that a discharge from the upper end of a fistula might produce a cough. The opening into the pharynx is generally small, but cases have been reported when it was so large that particles of food passed into it. Douglas mentions the case of a man who, when he closed his mouth and occluded his nostrils, could force air into a blind fistula and distend the neck. I have met with a similar case. W. R. Watson reports an aberrant branchial cyst encroaching on the glottis and causing death by suffocation. At autopsy the cyst was found to have suppurated and broken into the larynx. A somewhat similar case is reported by H. C. Rosenberger. Herman mentions a patient with cancer of the larynx which he considered was proved to be due to spread of the disease from a branchogenetic cyst which had become carcinomatous.

Fistulous tracts can be demonstrated by the injection of fluids opaque to roentgen-rays such as lipiodol. A colored fluid like methylene blue may be injected into the skin opening of a complete fistula and it will appear in the tonsillar region. In 1 case after tonsillectomy it could be made to appear in the tonsillar fossa. If a bitter solution is employed the patient may taste it. H. W. Meyer refers to a case of a swelling associated with an opening in the lower part of the neck from which issued a foul discharge. When the swelling was squeezed the patient noticed a bad taste and odor. The fistulous opening in the neck is generally present at birth, but may not be noticed till later. It may occupy an unusual position if it follows incision of a cyst.

DIAGNOSIS. Hamilton Bailey has written lucidly on this subject. He and others have referred to the great similarity in onset, site, course and clinical signs of branchial cysts to tumors due to tuberculous glands. In both inflammation, resulting in temporary increase in size, may occur especially following tonsillitis. If aspirated fluid is examined in either case the bacteriological findings will probably be negative. Bailey reports the case of a young

woman who had a cyst treated by aspiration, tuberculin and so forth for ten years. He states that almost every case of branchial cyst is at first wrongly diagnosed. It is most important to examine the fluid for cholesterol crystals: if present the diagnosis of a cyst can be made with certainty. After repeated inflammation aspiration may be of little value. If the fluid is drawn off, lipiodol injected and a roentgen-ray taken, a clear-cut outline indicates a cyst, an irregular outline points to a tuberculous abscess. As the result of inflammatory changes, or if the contents are semi-solid the condition may be diagnosed as a malignant new growth. In a case of mine, what appeared to be a simple cyst proved at operation to have undergone carcinomatous degeneration of its walls though the cavity was full of thin fluid. Other conditions which may be confounded with cervical cysts are dermoid, cystic hygroma, lymphangioma, cyst of the thyroid, parotid tumor, Hodgkin's disease, angioma, lipoma, carotid tumor, chronic retro-pharyngeal abscess.

TREATMENT. A solution containing absolute alcohol, chloroform, glacial acetic acid, and ferric chloride has been injected. Electrolysis, cautery and diathermy have been tried. All these methods appear to be haphazard and surgical treatment would seem to be the correct procedure.

In 1891 extirpation was suggested by Sachs. Von Haker in complete sinuses, after dissecting out the external end, pulled a ligature threaded through the eye of a probe into the mouth. The ligature was then fastened to the portion of the sinus lying free in the neck and the tract invaginated into the pharynx, ligatured and cut off. König, in adherent fistulæ, after dissecting as far as possible, brought the free end into the pharynx through a fresh opening so that both ends of the tract opened into the pharynx.

Treatment should not be instituted till inflammation, if present, has subsided. Bailey advises introduction of lipiodol mixed with liquid paraffin under local anesthesia three or four hours before operation with a blunt-ended syringe. The lipiodol is kept in position by a purse-string suture. He recommends a collar incision which encircles the fistula. The fistula is dissected up as far as possible. A second incision higher up may be necessary in order

to follow up the fistula, the tract is threaded through into the fresh opening and dissection is carried upwards and inwards beneath the posterior belly of the digastric till its termination, which may be in the tonsil, is reached. The tract generally runs between the external and internal carotids. It may be adherent to the vagus or internal jugular. Drainage is usually advisable.

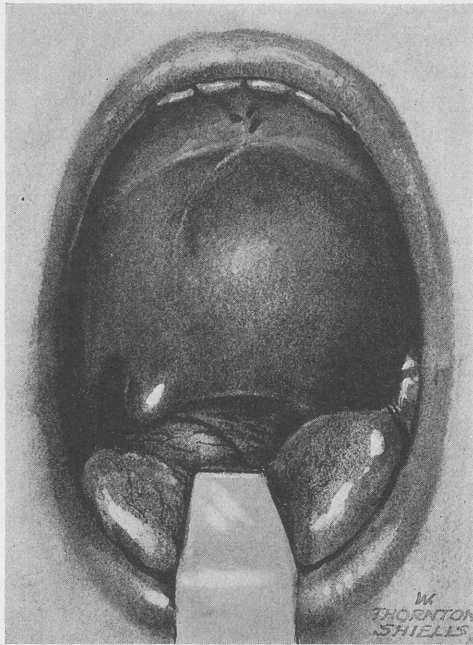


FIG. 2.—Myxo-fibro-sarcoma. Same patient as in Fig. 1.

Cysts are treated in the same way as fistulæ. Seed reports a case which was incised four times under the impression that it was tubercular. The whole of the cyst wall must be removed. In one of my patients the cyst was visible as a marked swelling of the larynx, and had caused partial displacement of this organ. It had been twice punctured. The cyst was adherent to the thyro-hyoid membrane and pharynx, and much difficulty was experienced in its removal not to perforate the pharynx (Fig. 2). This case

and others have impressed on me the advisability of laryngoscopic examination in all patients suffering from tumors of the upper part of the neck.

THYROGLOSSAL CYSTS AND TUMORS.

The key to successful treatment may lie in the relationship of the thyroglossal tract to the body of the hyoid bone. In early embryonic life a downgrowth occurs in the middle line between the mandibular or first arch and the hyoid or second arch; this represents the thyroglossal diverticulum which disappears about the same time that the hyoid begins to develop, therefore, the true relationship of these two structures is difficult to ascertain. According to His and Frazer the tract occupies a position anterior to the hyoid. Frazer states that at the lower border of this bone it may take a bend backwards and upwards so as to occupy for a short part of its course a posterior or dorsal position before it turns downwards in front of the thyrohyoid membrane. Parsons held that the body of the hyoid consists of a main portion developed from the third arch in front of which is a bar derived from the second arch and that sometimes a small canal, which represents the thyroglossal tract, exists in this region. If this were the case resection of the hyoid body would be necessary in dealing radically with a persistent tract. In the embryo the thyroid gland develops in relationship to the upper surface of the pericardium; the thyroglossal tract, should it persist, lengthening as growth takes place. This explains why sometimes aberrant thyroid tissue may be found below the level of the thyroid gland. When thyroid masses are met with in abnormal positions they should be regarded as compensatory structures associated with arrest in development of the normal thyroid. They are likely to become apparent about puberty.

Solid masses of thyroid tissue are generally found in the region of the upper part of the tract lying in the substance of the tongue. Sometimes they are very vascular and large veins may course over their surface. Before attempting to remove such a tumor the surgeon must ascertain if normal thyroid tissue is present in the usual situation. If it were absent a complete operation on the lingual tumor would result in cachexia strumipriva and the

patient would require to take thyroid gland extract for the remainder of his life. If a tumor in the tongue happens to be cystic, or partly cystic, incomplete removal may result in a fistula and periodic suppuration causing great inconvenience. Last year I operated on a patient who suffered from recurring attacks of great swelling of the tongue followed by discharge of pus from a sinus far back on the dorsum. The discharge resulted in relief. These attacks had been present for eighteen months following incomplete removal by another surgeon of a thyroglossal cyst. I operated a second time approaching the diseased area, which was really an indefinite indurated mass, by splitting the anterior portion of the tongue and removing the whole of the central part of the back of the tongue by diathermy excision dealing with the condition just as if it had been a malignant growth. There has been no return of the symptoms. Sir Arthur Keith refers to a specimen in the museum of the Royal College of Surgeons of a double aberrant thyroid: one tumor being in the tongue, the other below the hyoid. Dr. A. B. Bratton kindly worked out for me the pathology of 65 specimens obtained from material at the London Hospital. Of these, 2 were dermoid cysts, 2 epidermoid cysts. In 2 cases there were intracystic papillary growths. Of 30 cysts examined, the lining varied; all types from stratified squamous to columnar ciliated epithelium being found. In one the lining epithelium had almost disappeared. Lymphoid tissue was seldom found in the wall of the cyst. Thyroid tissue was frequently present. The ducts examined contained a variety of epithelial linings.

SYMPTOMS AND SIGNS. In the neck of a thin woman the cyst need be of no great size to prove unsightly, especially when viewed in profile. A large cyst may give rise to discomfort and interfere with the wearing of a collar. Inflammation may occur with eventual involvement of the skin which may rupture with the formation of a fistula. A cyst or tumor occupying the region of the base of the tongue may interfere with deglutition, speech, or respiration as the result of inflammatory edema in the region of the upper laryngeal aperture. Bertwhistle reports the case of a child suffering from dysphagia and attacks of dyspnea which ended fatally. A cyst was discovered in the region of the foramen

cecum. Similar cases have been recorded by others. Solid tumors may ulcerate, causing severe hemorrhage from the mouth. A cyst in the neck can be seen to move on deglutition. The skin can be moved freely over it unless adherent as the result of inflammation. It may be translucent and occasionally fluctuation can be detected. A band of tissue may be felt passing from the upper pole of the cyst towards the hyoid. A fistula is almost always situated in the middle line, but a cyst may lie on one side of the thyroid ala. Some years ago I operated on a patient where the cyst was so far from the middle line that a correct diagnosis was not made till the parts were exposed. In another case there were three independent cysts anterior, inferior and posterior to the hyoid. Tumors situated in the region of the foramen cecum are usually solid, while those in the neck are generally cystic, but this is not always the case. Solid tumors have been described lying in front of or even in the lumen of the trachea. An ectopic thyroid is softer than a cyst.

A fistula may result from suppuration and rupture of a cyst or it may follow incision. The excretion is watery, mucoid or purulent. Iodine may be present. A swelling may form after cessation of the discharge. A fistula may occupy any position in the neck along the course of the tract, sometimes it may be found just above the suprasternal notch. The opening usually lies in a depressed scar. It is doubtful whether a complete fistulous tract ever passes from the neck to the foramen cecum. The same means as are used in branchial fistulæ may sometimes be employed in demonstrating the tract.

A thyroglossal tumor or cyst may be mistaken for an enlarged suppurating or tubercular gland, an enlarged thyrohyoid bursa, a sebaceous cyst which, however, is situated in the skin and can be moved freely in all directions; a lipoma, angioma, or gumma may be placed centrally. A thyroglossal tumor at the base of the tongue may be confounded with ordinary hypertrophy of the lingual tonsils, a tumor or cyst of one of the mucous glands, malignant disease, gumma, abscess, blood cyst, angiona, cysticercus cellulosa, echinococcus cyst or amyloid tumor. When the swelling occupies a position in the floor of the mouth it may resemble a ranula which is bluish in color and does not bulge the neck, or

a sequestration dermoid which is yellowish, pits on pressure and causes a swelling in the neck. The diagnosis of a thyroglossal from a branchial fistula depends on the former opening being centrally situated and always preceded by a swelling. A sinus may develop in the middle line as the result of a suppurating gland, disease of one of the laryngeal cartilages or following an operation or injury in this region.

OPERATIVE TREATMENT. It is only of recent years that the surgery of the thyroglossal tract has been put on a satisfactory basis. Prior to the introduction of modern technique results were unsatisfactory. Repeated operations generally failed to cure the patient. Removal of the cyst and its stalk up to the hyoid resulted in a fistula; the operation must be carried right up to the region of the foramen cecum. I remember operating three times on a patient with no success because the uppermost portion of the tract was not dealt with. Apparently Eliot of New York first recommended removal of the central portion of the hyoid, and Spencer of London reported, in 1914, 2 cases where this procedure was adopted. Embryologists may differ as to the exact relationship of the hyoid to the tract, but certainly the routine removal of the central portion of this bone seems to be the correct procedure. Beer and Sistrunk indepedently developed an operation for the radical treatment of cysts and fistulæ. The first operation should be curative.

It is stated that the injection of a solution of methylene blue or gentian violet assists in differentiating the tissues which must be removed. Bismuth paste has also been recommended. If the sinus is to be injected it is freed for a distance of $\frac{1}{2}$ inch and the nozzle of a fine syringe inserted and tied in position. A fine probe, or silkworm gut may be used to demonstrate the course of the tract.

Sistrunk has described his operation in detail. It is carried out through a collar incision and leaves a very insignificant scar. I will only state that it consists in removing the whole tract, whether the case be one of a cyst or fistula right up to the region of the foramen cecum. This entails removal of the central portion of the hyoid and coring out the tract with its surrounding muscular tissue as it passes through the substance of the tongue.

I would suggest that the chance of opening into the mouth may be lessened by applying the cautery or diathermy to the region of the foramen cecum some weeks prior to the neck operation.

The treatment of tumors or cysts situated at the base of the tongue requires careful consideration. Puncture of a cyst, or removal of a portion of a tumor for microscopic investigation may cause severe hemorrhage. It is seldom necessary to operate on solid tumors whatever their situation. Complete removal is likely to be followed by myxedema as the tumor may be the only thyroid tissue the patient possesses. Spencer suggests removing a wedge from a lingual tumor when it interferes with function or the application of the cautery when hemorrhage has occurred. Diathermy might prove more efficient. Even small operations carried out through the mouth are liable to cause alarming hemorrhage and approach by way of the neck with the division or removal of a portion of the hyoid is a more surgical procedure. It may be found sufficient to remove only a part of the tumor. Preliminary tracheotomy may be necessary. If the pharynx has been opened it must be carefully sutured at the conclusion of the operation. These operations are dangerous and should not be lightly undertaken.

REFERENCES

Thyroglossal and Branchial Conditions.

- Bailey, H.: Thyroglossal Cysts and Fistulæ, *Brit. Jour. Surg.*, **12**, 579, 1924-1925; On Similarity of Certain Tuberculous Cervical Abscesses and Branchial Cysts, *Brit. Jour. Tuberc.*, **25**, 167, 1931; Clinical Aspects of Branchial Fistulæ, *Brit. Jour. Surg.*, **21**, 173, 1933.
- Beer, E.: *Ann. Surg.*, **71**, 218, 1920.
- Bertwhistle, A. P.: *Brit. Jour. Surg.*, January, 1925.
- Bland-Sutton, J.: *Jour. Anat.* (also Tumours), pp. 519 and 558, 1887.
- Boss, G. R.: Ueber eine Cyste des Ductus thyreoglossus, *Beitr. z. klin. Chir.*, **126**, 658, 1922; *Berl. klin. Wehnschr.*, **58**, 185, 1921.
- Bouzom, G.: Sur un kyste thyrohyoidien a prolongement avec la glande thyroide, *Jour. de méd. de Bordeaux*, **93**, 561, 1923.
- Butlin, H.: *Diseases of the Tongue*, 1900.
- Carp, L.: *Surg., Gynec. and Obst.*, **42**, 772, 1926.
- Christopher, F.: *Surg., Gynec. and Obst.*, **38**, 329, 1924.
- Cleminson, F. J.: Case of Thyroglossal Cyst, *Proc. Roy. Soc. Med.*, **23** (Sect. Laryngol.), 13, 1924-1925.
- Colp, R.: *Surg., Gynec. and Obst.*, **40**, 183, 1925.
- Douglas, J.: *Ann. Surg.*, **67**, 240, 1918.

Frazer, J. E., and Bertwhistle, A. P.: Thyroglossal Cysts, *Brit. Jour. Surg.*, **22**, 551, 1924-1925.

Freer, O. T.: Cyst of the Thyroglossal Duct: Report of Two Cases, *Trans. Am. Laryngol. Assn.*, **40**, 239, 1918; *Ann. Otol., Rhinol. and Laryngol.*, **27**, 1113, 1918.

Froelich: Macroglossie congenitale du á un enorme kyste du canal thyroglosse, *Rev. méd. de l'est.*, **53**, 644, 1925.

Johnson, J. A.: *Minnesota Med.*, **9**, 514, 1926.

Johnson, R.: *Lancet*, May 10, 1890.

Hammar, J. A.: *Beitr. z. path. Anat. u. z. allg. Path.*, **36**, 506, 1904.

Herman, A. L.: Double Branchial Cysts Complicated by Carcinoma of Larynx, *Minnesota Med.*, **14**, 555, 1931.

Hensinger, quoted by Bland-Sutton.

His, W.: *Arch. f. Anat. u. Physiol., Anat. Abth.*, 1886.

Hyndman, O. R., and Light, G.: *Arch. Surg.*, **19**, 410, 1929.

Keith, A.: Congenital Malformations of Palate, Face and Neck, *Brit. Med. Jour.*, 1909.

Kleinert, M. N.: Bronchial Fistula, *Arch. Otolaryngol.*, **18**, 510, 1933.

Klingenstein, P., and Colp, R.: Congenital Cysts and Fistulæ of the Neck: A Review of Forty-two Thyroglossal Cysts and Fistulæ, *Ann. Surg.*, **82**, 854, 1925.

Koch, F.: Zur Vorkommen branchiogener Zysten am Halse, *Monatsschr. f. Ohrenh.*, **66**, 1331, 1932.

Kostanecki and Mileki: *Arch. f. path. Anat.*, **121**, 55, 1890.

Kramer, R.: *Laryngoscope*, **36**, 517, 1926.

Kyle, J. T.: *Laryngoscope*, **15**, 880, 1905.

Meyer, H. W.: Congenital Cysts and Fistulæ of Neck, *Ann. Surg.*, **95**, 1, 226, 1932.

McKenty, F. E.: Tumors of the Neck, *Surg., Gynec. and Obst.*, **19**, 141, 1914.

Moatti, L.: Les fistules congenitales de la région latérale du cou: Etude anatomique, pathogénique et clinique, *Rev. de méd.*, **12**, 39, 1931; Sur quelques notions d'embryologie pouvant servir á l'étude pathogénique des fistules et des kystes lateraux du cou, *Ann. d'oto. larong.*, p. 11, 1931.

New, G. B.: *Surg. Clin. North America*, **4**, 521, 1924.

Neiden, H., and Asbeck, C.: Kongenitale Knorpelreste am Halse und ihr Beziehung zu den Seitlichen Halsfisteln, *Beitr. z. klin. Chir.*, **153**, 47, 1931.

Owens, M. J.: Lingual Thyroid, *Jour. Kansas Med. Soc.*, **26**, 160, 1926.

Parcelier, A., Venot, A., and Bonnin, H.: Les thyroïdes aberrantes laterale et leurs tumeurs, *Rev. de chir.*, **61**, 393, 1923.

Pashond, H.: Kystes cervicaux fistules cervicales, *Rev. méd. de la Suisse*, **54**, 300, 1934.

Patzelt, V.: Ueber Anomalien des Ductus thyreoglossus u. Schilddrüsenanlagen in der Zunge des Menschen, *Verhandl. d. anat. Gesellsch.*, **32**, 220, 1923.

Patterson, N.: Thyroglossal Cysts and Allied Conditions, *Jour. Laryngol. and Otolaryngol.*, May, 1928.

Pauchet, V.: Extirpation des kystes thyroglosses, *Paris chir.*, **16**, 391, 1924.

Paul, J. R.: Aberrant Thyroids, *Atlantic Med. Jour.*, **29**, 684, 1926.

Rosenberger, H. C.: *Laryngoscope*, **37**, 360, 1927.

- Ruttin, E.: *Zur Klinik und Pathologie der branchiogenen Zysten*, Monats-schr. f. Ohrenh., **66**, 1111, 1932.
- Seelig, M. G.: *Surg., Gynec. and Obst.*, **4**, 623, 1907.
- Semken, G. H.: *Nelson's Loose Leaf Surgery*, **2**, 783.
- Shedden, W. M.: *New England Jour. Med.*, **205**, 800, 1931.
- Sistrunk, W. E.: *Ann. Surg.*, **71**, 121, 1920.
- Sistrunk, W. E.: *Cysts of Thyroglossal Duct*, *Minnesota Med.*, **9**, 235, 1926.
- Spencer, W. G.: *Lancet*, **1**, 522, 1914.
- Vaughan, A. E.: *Brit. Med. Jour.*, **1**, 148, 1899.
- Villar, F., and Papin, F.: *Kyste du canal thyreoglosse*, *Jour. de méd. de Bordeaux*, **49**, 471, 1919.
- Wangenstein, O. H.: *Differentiation of Branchial From Other Cervical Cysts by X-ray Examination*, *Ann. Surg.*, **93**, 790, 1931.
- Wardill, W. E. M.: *Suppurating Thyroglossal Cyst*, *Brit. Jour. Surg.*, **13**, 567, 1926.
- Watson, W. R.: *Arch. Oto-laryngol.*, p. 7, 1928.
- Wenglowksi, R.: *Arch. f. klin. Chir.*, **98**, 151, 1912.
- Zöllner, F.: *Fehl Diagnosen verursacht durch angeborene Fisteln und Kysten Ohr. und Halse*, *Ztschr. f. Hals-, Nasen- u. Ohrenh.*, **32**, 54, 1932.

ABSCESSSES AND TUMORS OF THE RETROPHARYNGEAL REGION

The so-called retropharyngeal space contains areolar tissue which loosely binds the buccopharyngeal fascia to the prevertebral fascia; this allows of movement taking place between these two structures during deglutition. The potential space is definitely limited above by the attachment of the pharynx to the base of the skull, but below it passes downwards behind the esophagus into the posterior mediastinum; laterally it extends outwards to the carotid sheaths. This space is frequently occupied in part of its extent by fluid, forming a retropharyngeal abscess, or by an enlarged retropharyngeal gland. It is rarely the site of a tumor or cyst. I shall make but a few remarks about retropharyngeal abscess. It is a tragedy that in young children this condition frequently passes unobserved or even unsuspected, occasionally with fatal consequences. The pharynx of an infant may sometimes be difficult to see, but it is always easy to palpate.

So far as treatment is concerned I think that opening by the buccal route should be limited to abscesses due to pyogenic organisms, all tubercular collections being evacuated through a cervical incision. In either case if the abscess be of large dimensions aspiration may precede formal opening. When a tubercular abscess

extends far downwards repeated aspiration is probably the safest method to employ, as an open incision may cause mixed infection and extension to the mediastinum. I think that failure to effect a cure in tubercular abscesses would be a less frequent occurrence if in certain cases formal removal of the gland which is the origin of the mischief were undertaken. I carried out this procedure many years ago, but I have not seen it mentioned in the literature of the subject. In 1 patient I opened an abscess twice, but a sinus formed which continued to discharge; it healed completely after excision of the gland, which was found to be caseous and partly calcified. The route of approach is the usual one through an incision corresponding to the posterior border of the sternomastoid. If excision of the gland is decided on the incision must be of ample length, the dissection passes deep to the sternomastoid muscle and carotid sheath, these structures being strongly retracted forwards in order to bring the retropharyngeal region into the field of operation. The diseased gland can then be carefully freed from its surroundings and removed. If the gland is calcareous a roentgen-ray taken before operation might reveal this fact. In some cases tuberculosis of the retropharyngeal gland is associated with a similar condition affecting the deep cervical glands and an extensive dissection may be necessary. In all cases of retropharyngeal abscess the patient's head should be kept as immobile as possible for some time subsequent to operation; this applies more especially to tuberculous cases. When the abscess is secondary to Pott's disease the treatment naturally lies in the domain of the orthopedic surgeon.

Tumors of the retropharyngeal region are rare. They are generally innocent and occur as a rule in patients over thirty. Tumors occupying this region in the young are usually sarcomas. A case of lipoma I have published elsewhere was treated as a malignant growth, and a similar condition which I saw with a colleague was mistaken for an abscess. The most common tumors in this region appear to be of a neuro-fibromatous nature. Professor Natanson of Moscow has recently published an exhaustive paper on the subject founded on 55 cases collected from the literature. He states that tumors vary a good deal in consistency.

They may pass upwards into the nasopharynx and simulate

fibromas arising in this region, or they may extend downwards below the upper laryngeal orifice. They may appear to be situated in the soft palate, but will be found on close examination to lie behind this structure. Sometimes they extend laterally, causing a swelling on the side of the neck. If the tumor is thought from its softness and the sensation of fluctuation to be an abscess or cyst, aspiration will settle the point. Additional information might be obtained by aspiration followed by replacement of the fluid withdrawn by one opaque to roentgen-rays. When the tumors assume large proportions they may interfere with deglutition, speech and respiration; urgent symptoms requiring tracheotomy may develop. When they have their origin in the superior cervical ganglion of the sympathetic or its nerve filaments they may cause symptoms due to irritation or pressure, myosis, enophthalmos, alteration of the salivary or sweat function. Natanson mentions a large number of tumors which may occupy the region under discussion, but apart from neuro-fibromata and allied conditions, lipomas, aberrant goiters, fibromas, cysts and sarcomas, the others are surgical curiosities. It is remarkable that he should report such a comparatively large number of tumors originating from the sympathetic as such tumors appear to be rare in the neck. Among the cases he has collected there was one of cancer for which different explanations are given, the most likely seems to be a malignant branchial rest.

Removal of these tumors is sometimes possible by the buccal route, but on account of restricted access and fear of sepsis such a procedure is not to be recommended.

The usual mode of approach is *via* the anterior triangle of the neck, either through an incision corresponding to the anterior border of the sterno-mastoid, a collar, or a flap incision. If the tumor presents in the neck its exposure will be an easy matter, and if it is encapsuled its delivery may present no difficulties. Adhesions may, however, render the dissection difficult in the extreme. Removal may be facilitated by an assistant inserting his finger into the pharynx and pressing the tumor towards the neck. Intratracheal anesthesia will be a wise procedure, and if dyspnea is present a preliminary laryngotomy or tracheotomy may be necessary.

So-called parotid tumors may cause symptoms and signs not unlike retropharyngeal tumors: they are situated, however, mainly laterally and they may invade the palate or tongue. As a rule they are best dealt with by an open operation carried out through the neck.

ACUTE SEPTIC CONDITIONS OF THE NECK

These are often associated with some easily demonstrated change in the mouth, pharynx or larynx. As a rule, there should be no undue haste in carrying out surgical treatment unless some condition such as threatened edema of the larynx calls for prompt intervention. It is, I think, generally agreed that incisions into inflammatory swellings before pus has formed may be dangerous; moreover, such swellings frequently subside. If there is tolerable certainty that abscess formation has taken place, or if for some other reason active treatment is considered necessary, it is better, except when the abscess obviously points toward a mucous surface, to open through the neck. A typical instance of this is Ludwig's angina, when swelling of the floor of the mouth may displace the tongue upwards. This condition is best dealt with by a vertical incision between the chin and hyoid bone, or by a curved incision below the jaw, dividing, if necessary, the mylo-hyoid muscle, so as to reach the abscess and at the same time relieve tension. Abscesses occurring in other situations in the neck are dealt with on the same principles. It is always well to remember that an abscess may be due to actinomycosis. The gross characters of the pus should receive attention and a specimen should be sent in every case for pathological examination. In order to avoid subsequent disfigurement, incisions should, when possible, correspond to a crease in the neck, being of the collar type.

Operation on the neck in cases of lateral sinus infection where septic clotting has extended to the jugular vein may prove difficult on account of pathological changes. The vein which may be overlaid by enlarged and matted glands is sometimes indistinguishable as such. In cases of this nature it is advisable to look for the vein low down in the neck, where it is less likely to be altered, than nearer the seat of infection. Once found it can readily be traced

upwards. In any case the common carotid artery can always be identified and the relative position of the artery to the vein is almost constant.

METASTASES IN THE CERVICAL GLANDS SECONDARY TO MALIGNANT DISEASE OF THE UPPER RESPIRATORY AND FOOD PASSAGES

I think it is generally held that up to the present time treatment, whether by roentgen-rays or gamma rays, of malignant glands in the neck, at any rate those of a carcinomatous nature, has not been satisfactory. It is hoped that telerradiation by means of a bomb will give better results than the application of radium collars, the insertion of radium into the neck, or deep roentgen-ray therapy. The implantation of radium or radon is a haphazard and unscientific procedure. Needles or seeds may be thrust through normal as well as malignant tissues, producing tracks which may be sown with tumor cells. There is also the possibility of portions of the tumor being driven into lymphatics or bloodvessels, so causing further dissemination. It is impossible to estimate the correct dose and to apply the active agent in such a way that the gamma rays are evenly and adequately distributed throughout the diseased area. Irradiation of the whole glandular territory seems to be by this means impracticable, and it is quite possible that diseased glands just outside the range of a lethal dose may be stimulated into increased activity. I have seen clinical evidence that this may happen. In the case of a mass adherent to, or invading, such a structure as the internal jugular vein, it would not be possible to distribute the needles or seeds in such a manner that they acted efficiently without at the same time jeopardizing the vein.

In considering the purely surgical treatment of glandular metastases we are faced with many problems. At operation, secondary deposits may be discovered in the glands, although clinically none were demonstrable.

Sometimes a mass of apparently malignant glands is removed which on careful microscopic examination shows no evidence of malignancy. Such a mass might have been treated with irradiation, and in the event of a good result the case would be claimed as a cure. We are aware, however, that a negative pathological

finding does not necessarily mean that the neck is free from metastases. Innumerable serial sections of the mass removed from the gland-bearing area would be necessary to prove a negative, and each section would have to be scrutinized with the utmost care. The impossibility of making a definite statement to the effect that no malignant deposits are present is evident when we consider that 3,000,000 cancer cells may be packed into a space the size of a pin's head. Probably 1 or 2 cells are sufficient to constitute a potential metastasis. The locating of such a deposit would be more difficult than the proverbial finding of a needle in a haystack. We have probably all met with patients who have developed secondary malignant glands in the neck at a long interval after successful treatment of the primary growth. If in any such case the glands had been removed at the time of the operation, it is highly probable that a negative report would have been obtained from the pathologist. Apparently islets of malignant disease may remain dormant for years. Suddenly they burst into activity and the disease progresses sometimes with alarming rapidity. Glandular developments may be more marked on the side opposite to the tumor, or they may be discovered only on the contralateral side. This has been explained as due to obstruction to the lymph flow caused by the primary tumor; a theory which may account for some cases. I knew a patient who, twelve years after a successful operation for cancer on the left side of the mouth, developed carcinomatous glands on the opposite side of the neck.

Sometimes we meet with what may be termed apparent cross-infection. Just over two years ago an old gentleman was brought to me by my friend Dr. George Cathcart. There was a large tumor which proved to be an epithelioma situated on the left side of the soft palate. No glands could be palpated on either side of the neck. I removed the tumor by diathermy excision. About nine months later the patient came to see me and I found a mass of malignant glands on the right side of the neck. Inspection of the pharynx showed a healthy scar on the left side. There was a slight swelling about the center of the right anterior faucial pillar, but no ulceration, and the condition did not look like an epithelioma, but the nodule which was about the size of a pea was felt to be firm on palpation. I carried out a block dissection and

subsequently removed the nodular area by diathermy. Both this area and the glands proved to be carcinomatous.

The operation for removal of glands is confined within certain anatomical boundaries beyond which we cannot trespass. Unfortunately we have no means of ascertaining whether the disease has spread beyond these boundaries. For instance, there may be diseased glands within the interstices of the parotid salivary gland, or even further afield, perhaps in the mediastinum. More distant territories may have been invaded through the agency of the veins, or the disease may have spread directly from the lymphatic glands to a neighboring organ, such as the thyroid gland.

Where no primary focus can be discovered in the regions of the upper alimentary or respiratory tract, and a very thorough examination, which includes search of the nasopharynx, tonsils, pyriform fossa, subglottic region, must be made to be certain that no such focus is present; it should be borne in mind that metastases in the neck may in rare instances be secondary to primary tumors in the esophagus, lung, stomach and other abdominal organs. Branchiogenetic carcinoma, or primary endothelioma, is exceedingly rare. Bland-Sutton mentions a case where a diagnosis of the former was made which had to be altered when a small growth was discovered in the external auditory meatus. I have seen a large mass of cervical glands secondary to an almost invisible melanoma of the conjunctiva.

Under what circumstances should the glandular operation be performed and what should be its scope? For reasons such as these, namely, the character, size and site of the primary tumor, the fact that no enlarged glands can be palpated, although, as previously stated, this does not eliminate the possibility of metastases, the age, or state of health of the patient, or an expressed objection on his part to such a procedure, an operation may not be carried out. In all such cases ray treatment should be employed. It will be admitted that there is no use carrying out a gland operation unless there is a reasonable chance of curing the primary tumor. In cases where there are definite cervical metastases, an operation would be advised if the invaded glands are movable and not too widely disseminated and provided the patient is in a fit state for an operation of magnitude. Even when

no metastases can be discovered it is wiser, unless there is some special contraindication, to operate on the neck.

An operation on the glands is also called for when they develop after a successful attack has been made on the primary growth. When the glandular mass is of an indefinite type, appearing to merge into the surrounding tissues, or is fixed to the deep structures, operation is generally out of the question. The hard, well-defined mass is likely to give the best results. Sometimes after sepsis in the mouth has been attended to, a condition which appeared to be inoperable may become operable.

It must be admitted that sometimes a most unpromising case has with drastic treatment been followed by a long period of freedom. In some cases the surgeon has to abandon the operation for reasons which were not foreseen. Sometimes the gland operation has to be carried out on both sides, but extensive bilateral dissection should never be undertaken at one sitting. In inoperable cases the form of radiation thought to be most suitable if available should be employed. In probably every case radiation should follow operation. By such additional treatment better results may be looked for in the future. Some surgeons recommend radiation as a preliminary to operation.

The question of the extent of the operation may be difficult to settle. Personally I favor a block dissection, carried out on the principle laid down by Crile. For some specific reason, such as the condition of the patient, it may be contraindicated. Occasionally removal of the gland-bearing area in the upper part of the neck may be deemed sufficient. Sometimes it will be thought consistent with sound surgery to spare the whole or a portion of the sternomastoid. In some patients it is very important to avoid injury to the spinal accessory nerve. In one of my recent cases the patient was a keen sportsman and one of the first questions asked after the operation was would he be able to shoot. I took special care in this case, where there was a large gland situated high up on the right side of the neck to preserve the nerve intact.

When cervical metastases can be demonstrated the outlook is much less favorable. As an instance I may mention that of 51 cases of carcinoma of the tonsil or its neighborhood treated by me, 23 had proved glandular metastases and only 13 per cent of

these lived for over five years, whereas of the remaining 28, 32 per cent survived after that limit had been reached.

The following are my reasons for operating on the neck prior to excising the primary tumor:

1. After treatment of the primary growth the patient may think that his pain or discomfort having disappeared, there is no need for any further treatment.

2. Inflammatory changes in the neck may follow diathermy and interfere with the performance of a clean and adequate dissection.

3. At the completion of the operation the external carotid can be ligatured.

4. During the interval between the dissection and the operation on the primary growth septic teeth can be removed, thus saving valuable time.

In performing an operation for malignant glands a knife with the keenest possible edge should be selected; no tearing or bruising of the tissues with blunt instruments is permissible, as shock is thereby increased. The superficial surfaces of muscles should be stripped of their fascial coverings, and in some cases the fascia intervening between them should be removed. The triangles of the neck are not the extensive areas depicted in books on anatomy; they are largely an invention to facilitate description and distort facts. Most of the important structures of the neck lie beneath muscles, and the sternomastoid forms for a great many of them a covering, partial or complete. With the sternomastoid in position it is not possible to carry out a thorough removal of the gland-bearing area. A portion of the digastric may in some cases require to be removed. The dissection is carried downwards to the supraclavicular region, and on the left side great care must be exercised not to injure the thoracic duct. Here a little blunt dissection is permissible. In an upward direction the dissection reaches the structures in the regions of the base of the skull and floor of the mouth; the cervical portion of the parotid gland is freed and temporarily turned upwards. The dissection is carried forward to the middle line and backwards to and underneath the anterior border of the trapezius muscle. The jugular vein must, as a rule, be resected, especially as glands may lie in very intimate

relationship to this structure or even invade its walls. Enlarged glands may sometimes be situated posterior to the vein. The superior cervical ganglion of the sympathetic which is quite a substantial structure must not be mistaken for a gland. In the case of a large mass extending up to the base of the skull, I have exposed the lateral sinus by removing the overlying bone as in an operation for suspected lateral sinus thrombosis. This having been accomplished, it is an easy matter to occlude the vessel by packing ribbon gauze between it and the skull wall. After this is done the upper end of the jugular vein can be sought for with more confidence, with the knowledge that if it is injured, blood is only entering the vessel from the comparatively small inferior petrosal sinus. This procedure has much the same control over the venous flow from above that a clamp on the carotid has on the arterial blood coming from below.

Sometimes the surgeon may decide not to remove the jugular vein. If this should be the case, it must not be too completely dissociated from its surroundings for fear of the formation of a thrombus. One reason for leaving the vein intact may be that it has been removed on the opposite side of the neck.

A NEW METHOD OF LIGATURE OF THE EXTERNAL CAROTID ARTERY

In certain cases, on account of the presence of large veins over the carotid bifurcation, great difficulty may be experienced in ligating this vessel. My attention was especially directed to this difficulty in a case of hemorrhage following the opening of a quinsy. The operation had been carried out by a practitioner who sent the patient to hospital on account of alarming loss of blood. When the patient arrived there was persistent oozing from the wound and she was in an extremely grave condition. It was found impossible to control the bleeding by pressure or other means, and I decided to ligature the external carotid; it seems difficult to explain why in hemorrhage from a quinsy certain textbooks advise tying of the common carotid, as the internal carotid supplies no branches to the region of the tonsil. In this patient there was considerable swelling in the upper part of the neck, due

to inflamed glands, and on this account alone the exposure of the carotid proved a very difficult procedure.

The main difficulty, however, was the presence of a regular plexus of large veins crossing over the artery, and I managed to divide the veins between forceps, but found it practically impossible on account of the friability of the tissues to apply ligatures. In the end I had to leave several pairs of artery forceps in position. They

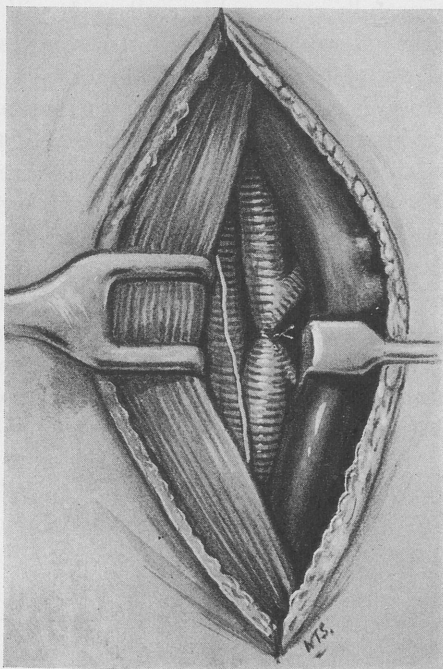


FIG. 3.—Author's method of ligating external carotid artery.

were removed without incident a few days later. A similar case led me to devise the modified operation now described (Fig. 3). The technique depends on the fact that, as a rule, there are no tributaries entering the postero-lateral aspect of the internal jugular vein, whereas entering its antero-medial aspect, generally in the neighborhood of the carotid bifurcation, there may be the superior thyroid, lingual and common facial veins, all of which may have

to be negotiated. The first stages of the operation differ in no respects from those of the classical procedure. When the internal jugular is reached it is displayed in the upper part of its course for a distance of from 2 to $2\frac{1}{2}$ inches. The fascia along its posterior aspect is then carefully divided for the same distance and the vein is retracted medially, at the same time being gently elevated from the underlying arteries. The carotid bifurcation is now exposed. If the view is not adequate, the uppermost portion of the common carotid may be carefully retracted laterally. It will now be found easy to display the external carotid with its branches, the superior thyroid, lingual and facial, which should always be identified. The external carotid is now freed from any further fascial covering at the seat of the intended ligature, and it is tied at the usual site. If thought advisable, the ascending pharyngeal artery may also be secured. Care must be taken not to interfere with the vagus or hypoglossal nerves. This operation has an additional advantage over the classical one in not causing any venous obstruction, as no large veins are ligatured and, therefore, there is no tendency to increase the bleeding should there be hemorrhage from the veins as well as the arteries. If the ligature is performed as a preliminary to operations on the mouth, pharynx or nose, the absence of venous congestion is distinctly advantageous.

PARALYSIS OF THE LARYNX

A SUGGESTED EXPLANATION OF THE SO-CALLED CONTINUED MEDIAN POSITION OF THE VOCAL CORDS IN BILATERAL PARALYSIS: A CONSIDERATION OF SEMON'S LAW

CHARLES J. IMPERATORI, M.D.

AN explanation of the so-called sustained or continued median position of the vocal cords in bilateral abductor paralysis is presented purely on an anatomical basis.

Paralysis of the vocal cords following injury to the recurrent laryngeal nerve results in one of two conditions. (1) Adduction with the vocal cords straight in the median line, or (2) the cord is found in the cadaveric position, that is, midway between adduction and complete abduction.

New¹ has shown the reverse of this, that is, following injury to the recurrent laryngeal, the cord assumes the cadaveric position, and after several months approaches the mid-line position.

Ziegelman² has confirmed by dissections the findings of other anatomists, that the internal branch of the superior laryngeal nerve sends branches, which communicate with the recurrent laryngeal and that, contrary to the usual teaching, in most instances the arytenoid muscle is supplied by the superior laryngeal.

Burger³ states that the nerve supply of the adductors is both the recurrent and the superior laryngeal.

It may be, therefore, assumed that in those persons who possess this innervation of the arytenoid muscle and in whom the recurrent nerve is injured, that there would occur a paralysis of the posterior cricoarytenoid muscle inducing adduction, that is, phonatory position of the cords.

In those persons who possess the usual innervation they would have a complete paralysis, that is, the cords would be abducted and be in the cadaveric position.

Based on this anatomical fact, it is easily conceived that adduction of the cords would remain constant in those cases in which this innervation of the arytenoid muscle was present.

Assuming that the recurrent nerve is injured, and the superior laryngeal nerve does not innervate the arytenoid, then the cord will assume the cadaveric position, but if the superior laryngeal does supply the arytenoid muscle, there will be sufficient adduction to keep the cords in partial contact, assisted by the cricothyroid, which is also innervated by the superior laryngeal. The tensing and adduction of the cricothyroid and arytenoid thus keep the cords in the straight mid-line position, assuming that the other adductors are paralyzed.

This position of continued adduction is not so uncommon.

New and Childrey⁴ conclude: 1. Usually paralyzed vocal cords in the cadaveric position change from this position to the median line within a few months, with return of voice. If the condition is bilateral, dyspnea develops as the voice improves.

2. Vocal cords in the median line may return to complete function, but most of them remain in the median line.

3. None of the vocal cords observed in the median line change to the cadaveric position.

They are of the opinion that the paralyzed cord moves from the cadaveric position to the mid-line position because of paralysis of the superior laryngeal.

Smith, Lambert and Wallace⁵ do not agree with New and Childrey, that a concurrent superior nerve paralysis is present. They have found in a series of cases that 33 were in median position and 83 in the cadaveric.

Lemere's⁶ experiments have shown that section of the recurrent laryngeal nerve produces little change in the glottic picture, excepting the mobility of abduction, and that the cricothyroid tends to stretch the cord anteroposteriorly and draws them toward the mid-line, also that the arytenoid muscle assists in this adduction. He denies that the superior laryngeal plays a part in this paralysis, but acknowledges that the fibers of the superior laryngeal runs through the arytenoid muscle.

He has demonstrated that blocking the superior laryngeal nerve with alcohol or novocaine in those patients with bilateral abductor paralysis gives considerable relief from the accompanying dyspnea. This relief he attributes to relaxation of the cricothyroid muscle.

When the superior laryngeal innervates the arytenoid muscle, undoubtedly the relief will be greater.

CONCLUSIONS. In many individuals the arytenoid muscle is innervated by superior laryngeal nerves.

In no way does this suggested mechanism of continued adduction interfere with Semon's law.⁷

This law of Semon's deals entirely with the abductor fibers of the recurrent laryngeal in that they become affected sooner than the adductor fibers.

Lemere⁸ has shown that the abductor muscles possess more lipoid granules in them than the adductors and that they are more susceptible to trauma.

A total paralysis, so-called, with the vocal cords in the cadaveric position would seem to consist of a paralysis of the posterior cricoarytenoid muscles and the innervation of the arytenoid muscle by the recurrent laryngeal nerve.

A sustained mid-line position of the cords would consist of a paralysis of the posterior cricoarytenoid and the innervation of the arytenoid muscle by the superior laryngeal nerve.

The arytenoid muscle assisted by the cricothyroid muscle, both innervated by the superior laryngeal nerve, thus sustain the cords in the position of adduction.

Clinically this appears to be so, for in abductor paralysis, with the cords in adduction, there is considerable relaxation and lessening of the dyspnea when the superior laryngeal nerve is blocked by the injection of novocaine or alcohol, thus interfering with this nerve's action.

BIBLIOGRAPHY

1. New, G. B.: Laryngeal Paralysis Associated With Jugular Foramen Syndrome and Other Syndromes, *Am. Jour. Med. Sci.*, **165**, 727, 1923.
2. Ziegelman, E. F.: Laryngeal Nerves, *Arch. Otolaryngol.*, **18**, 793, 1933.
3. Burger, H.: Associated Paralysis of the Vocal Cord (Semon Lecture, 1933), *Laryngol. and Otol.*, **49**, 1, 1934.
4. New, G. B., and Childrey, J. H.: Paralysis of the Vocal Cords, *Arch. Otolaryngol.*, **16**, 143, 1932.
5. Smith, A. B., Lambert, V. F., Wallace, H. L.: Paralysis of Recurrent Nerve, *Edinburgh Med. Jour.*, **40**, 344, 1933.
6. Lemere, F.: Innervation of the Larynx, *Arch. Otolaryngol.*, **18**, 413, 1933.
7. Semon, F.: Clinical Remarks on the Proclivity of the Abductor Fibers of the Recurrent Laryngeal Nerve to Become Affected Sooner than the

Adductor Fibers or Even Exclusively, in Cases of Undoubted Central or Peripheral Injury or Disease of the Roots or Trunks of the Pneumogastric Spinal Accessory or Recurrent Nerves, *Arch. Laryngol.*, **2**, 197, 1881.

S. Lemere, F.: Innervation of the Larynx: IV. An Analysis of Semon's Law, *Ann. Otol., Rhinol. and Laryngol.*, **43**, 537, 1934.

DISCUSSION

DR. GORDON B. NEW, Rochester, Minn.:

The suggestion that Dr. Imperatori has made regarding the etiology of laryngeal paralysis is a most interesting one. Years ago, in doing some work on animals, we came to about the same conclusion that he has, although it is impossible to be sure. There are many contradictory findings in paralysis of the larynx, so that one cannot say definitely the exact etiology of such conditions.

In studying a group of cases of goiter immediately after operation, and from time to time later, one sees some extremely interesting laryngeal pictures that are difficult to fit in with the usual textbook teaching regarding laryngeal paralysis. Immediately following an operation for goiter, one may see the vocal cord in the midline or in the cadaveric position. In most cases in which the recurrent nerve is injured, the vocal cord is in the midline position. Examination within twelve to twenty-four hours after an operation for goiter may show a paralyzed vocal cord, the result of edema about a nerve which had functioned perfectly immediately after operation. The patient with the cord in the cadaveric position after operation may return in two or three months with it in the midline position, and with a good voice. I feel that there is variability in the nerve supply of the larynx because of the plexus of nerves that enter the larynx, and this accounts for the fact that, in most cases, complete injury to the recurrent nerve produces a midline position, and in only a small percentage of cases the cadaveric position.

I should like to ask some of the older men who have been studying laryngeal paralysis for years whether they have seen cases in which the vocal cord was first in the midline position and then changed to the cadaveric position, following Semon's law.

DR. HENRY HALL FORBES, New York City:

I don't want to be classed among the older men.

These cases are certainly most interesting to the laryngologist, and I know Dr. Imperatori has been exceedingly interested in the study of

what we term Semon's law, and I know how interested you have all been. The point I should like to bring out is not so much how these cases follow, because I don't think any of us have had the opportunity to follow them as much as we will try to follow them from now on, where there have been so many thyroid clinics established in our hospitals and dispensaries.

I should like to say to you and I should like to tell the members that recently one of our general surgeons in New York, a man with a very large experience, had the fact brought to his attention in a thyroid clinic that it was a very wise measure to have every thyroidectomy case examined by either himself or a laryngologist to note the condition of the vocal cords, in other words a preoperative paralysis. I think that is a very important point that we should impress on the clinics that are being formed in the larger hospitals where thyroid operations are going on. Of course, it is not at all new to us that a preoperative paralysis may exist, and I should be very much surprised to find a surgeon with the broad experience of this gentleman, not having an examination made to protect himself from a question of operative injury to the recurrent laryngeal nerve.

DR. D. CROSBY GREENE, JR., Boston, Mass.:

I think there is still another possibility to account for the adductor position of the cords after section of the recurrent laryngeal nerve.

We find both in Piersol and Krause a description of a twig of the superior laryngeal nerve going to the lateral cricoarytenoid muscle which is the adductor muscle. That would explain the phenomenon.

DR. ISAAC D. KELLEY, JR., St. Louis, Mo.:

It is with some hesitation that I arise to discuss this subject. I do so only because I have been interested in an attempt to repair the recurrent laryngeal nerves by direct union or by autogenous grafts, and have made certain observations which might be of interest.

We have in the Oscar Johnson Institution cut the laryngeal nerves in a number of dogs and have observed some rather interesting phenomena. If the two recurrent nerves are severed practically simultaneously we find that the dog breathes quite well, at least for a time. It was with fear and trepidation that I severed these nerves simultaneously without a preliminary tracheotomy. In the beginning I tried to devise elaborate tracheotomies before cutting the recurrent nerves which didn't succeed on account of the anatomy of the dog's neck. To my surprise, however, we found when both nerves were cut, that the cords went in the cadaveric position and remained there for

a longer or shorter time, but inevitably the cords gradually approached the midline and the dog had increasing difficulty in breathing until eventually a disaster happened which caused the death of the dog. This I attributed probably to the anesthesia of the lower part of the larynx and the upper portion of the trachea as well as the difficulty in breathing, because, we know, the recurrent laryngeal nerve also supplies sensation to the lower half of the larynx and upper part of the trachea.

This paper of Dr. Imperatori's interests me greatly because I do not think we can doubt that partial motor innervation of the larynx also comes from the superior laryngeal nerve. This is interesting because this innervation produces a tension of the cords by its anterior supply to the cricothyroid muscle, and its posterior supply of half of the interarytenoideus. Although the recurrences are cut, we can still get partial adduction of the cords by the action of these two muscles.

There is another very interesting factor that takes place in this adduction. If we consider our extrinsic muscles of the larynx, we know that a pull on the sternothyroid and associated muscles will pull the thyroid forward and downward and this together with the hook-up of the cartilages of Santorini (their recurved ends), with the longitudinal fibers of the esophagus will also pull the larynx backward. This with the superior innervation already mentioned, plus the gradual education of the remaining muscular function of the cords will eventually produce sufficient tension for adduction.

If two recurrent nerves have been severed, and we watch the larynx with the cords primarily in the cadaveric position, which means complete severance of the nerves with interruption of all nerve impulse, we find that gradually the cords assume a midline or an adductor position.

This adduction of the cords brings in another very interesting question; the operation of Semon's law, and I think our observations studied in relation to Semon's law, clarifies what happens.

In Semon's law, if we have a bilateral paralysis of the postici muscles, we get complete abduction paralysis of the cords. Naturally, tracheotomy is necessary. Why do we get complete abductor paralysis? If we go back to study the evolution of the larynx, as Mr. Negus has done, we find that in the first larynx known to man (the first evolutionary larynx is found as you know in the lungfish), we find there a large constrictor muscle which surrounds and closes the larynx. In this larynx there was only a need for a constrictor muscle

because voluntarily, due to the elasticity of the air way it opened when the constriction was released, but when the cartilaginous larynx was built this cartilaginous framework split up the original laryngeal constrictor muscle bundle into dilators or abductors as well. Mr. Negus, of London, has proven this most conclusively, in his original study of the evolution of the larynx. In the study of embryology, it is interesting to find in the human larynx, in its development, that this same constrictor muscle bundle is present, as it was in the lungfish, and your guest Mr. Patterson, knows that Mr. Frasier, of the St. Mary's Hospital Medical School in London, has demonstrated the complete embryological development of the larynx in such a way that this fact cannot be questioned.

We find that as the innervation for these newer muscles is evolved, with the development of the larynx, that the old original paleokinetic innervation which was a constriction or flexor innervation, has superimposed upon it an abductor, dilator or elevator innervation; in other words, the neurological law that in neurospinal diseases, the first function lost is the newer extension or abduction nervous mechanism applies to the larynx as well. Semon was never able to explain this, because Semon had not studied the evolution of the larynx from its original form in the lungfish to the present. It was simply missed until Mr. Negus found this original constrictor muscle of the larynx. Mr. Negus explained abductor paralysis from an anatomical basis and said that Semon's Law, because of the evolution of the constrictor muscle was inevitable. In a neurospinal lesion abduction of the larynx is lost first, and anatomically you have, he states, only to go to the laryngeal musculature system to find the cause. Mr. Negus stopped at this point as he didn't seem to be interested in the innervation of the larynx as an explanation.

I say that Semon's law can be explained by the fact, and a neurological fact as well, that the neokinetic innervation of the larynx, in other words, the abductor function which is the newer innervation and more vulnerable to disease, has been superimposed upon the older or less vulnerable constrictor innervation and this is the reason for the older function remaining to the last.

Now, in recurrent paralysis, if we cut both nerves or rather put it this way; in a recurrent paralysis, if we study a one-sided paralysis, it is extremely interesting because we can divide the paralysis into three rather definite stages: first, a paresis of abduction, where the cord fails to go completely in inspiration to the outer wall; the next stage, we will say, is the stage of complete adduction, where the cord

stays in the midline; and the final stage of the paralysis is where the cord remains in the cadaveric position.

How does the cord arrive at the first stage of paralysis? If we injure peripherally the recurrent nerve, only slightly we see the action of Semon's Law, in the beginning. We have injured the vulnerable neokinetic fibers which control abduction; therefore abduction is incomplete. This means, however, only a very slight injury. If we now injure the nerve more, not completely however, but if we injure all the vulnerable, neokinetic fibers, we get the cord in the midline position, which is identical with the Semonian position found in double-sided abductor paralysis. Of course, in Semon's day there were no double-sided peripheral abductor paralyses, because to produce this, the neck must have been completely severed; therefore it was not observed in the living. Now, however, with thyroidectomies, and operations about the neck the double-sided peripheral abductor paralysis is often seen and easily studied.

DR. E. ROSS FAULKNER, New York City:

I wanted to say a word about the analogy between a spasm of one group of muscles and paralysis of the opposite group. The discrepancy in the appearance of these things I think often occurs from the fact that you can get an adductor spasm which practically gives you the same symptoms as abductor paralysis.

I believe that can happen, from one case I have seen. A laryngologist sent to me a patient from out of town. The history was that on three different occasions he had been called to see this woman in a severe attack of dyspnea, and he contemplated a tracheotomy, but she escaped in each case. He examined her larynx during the attack and the cords were tight together in the midline.

When I saw her, she had a definite abductor paralysis of the cord on the left side, with the right cord moving fairly freely. Unquestionably, at the time he saw her, both cords were quite close together, as he was a reliable observer, so she must have had an adductor spasm on the right side, as well as an abductor paralysis on the left. I have failed to follow her subsequent history, but that was the condition of that patient at that time and it shows you how confusing it can be between the spasm of one group of muscles producing the same symptoms as paralysis of the other group.

DR. MERVIN E. MYERSON, New York City:

Several years ago I was asked by the pathologist in one of our large hospitals to sever both recurrent laryngeal nerves in dogs. A few

days after the severance of the nerves, the dogs barked just as much as ever, a little more weakly, but they did bark and disturbed the patients, so we abandoned that procedure and simply did direct laryngoscopies and cleared out as much of the cord tissue as we could.

A year ago I had occasion to work with a large number of cows' and lambs' larynges, and I had the good fortune of having an anatomist advise me that the cow's larynx was a fine thing to dissect if one wanted to understand the human larynx. When one dissects it, he is impressed with the fact that the fibers of the superior laryngeal nerve go to every muscle of the larynx. If one uses a large, male, adult larynx, he can trace these same fibers to the muscles in the human larynx.

It seems to me that the possible explanation of the phenomenon that has been discussed this morning may lie in the fact that the motor fibers of the superior laryngeal nerves which innervate the muscles of adduction, might be more powerful than the fibers of the superior laryngeal nerve that influence abduction, and so we have the midline position. I think that would be more plausible if we could prove the superior potency of those superior laryngeal fibers in the adductor muscles.

DR. CHARLES J. IMPERATORI (in closing):

I want to thank Dr. Kelley for his demonstration and say that a great deal of this has been explained by Burger in the Semon lecture for 1933.

Lemere seems to attempt his explanation by etherization of young animals and he finds that these various flexor and extensor paralyses occur, depending on the age of the animal and the length of the anesthesia. I would be rather inclined to feel that it is a question of innervation that is unusual and that we get this midline position in these patients that have this different innervation.

OSSIFICATION OF THE CARTILAGES OF THE LARYNX AND ITS POSSIBLE RELATIONSHIP TO SOME TYPES OF LARYNGEAL DISEASE

H. MARSHALL TAYLOR, M.D.

NEARLY a century ago, in an address before the French Academy of Sciences, Segond¹ discussed the ossification of the cartilages of the larynx. He stated that Columbus, the pupil and successor of Vesalius, found these cartilages frequently ossified in persons advanced in years and considered age the chief cause of this change. Other early anatomists also made mention of the ossification of the laryngeal cartilages with increasing age. Segond,¹ Schottelius,² Chievitz³ and other writers of the nineteenth century recognized the wide variability of the age period at which ossification of these cartilages occurs, and distinguished between the pathological process and the process which is to a certain extent normal and in the development of which senile change has for centuries been regarded as the sole causative agent.

Segond¹ felt that individual "dispositions" and certain morbid conditions were undoubtedly factors in determining the course and the extent of the osseous change. In 1879, Schottelius² stated that normal calcification of the laryngeal cartilages results from the increasing vascularity of the larynx following puberty, that vascularity of these cartilages is pathologically increased in chronic inflammatory processes, and that calcification may, therefore, occur prematurely and extend more rapidly than normally. In the normal process, he observed, the calcified cartilage is a pale yellow in color and is dry; when abnormal calcification is present, it is reddened and unduly rigid. Retterer,⁴ forty years later, stated that this reddening represents a process of vascularization and calcification which precedes true ossification. In the dog he found the process essentially the same as in man. He regarded the formation of bone in the cartilaginous tissue of the larynx a normal development rather than a senile regression, and was of the opinion that the change takes place by a process quite different from that in growing bones.

Second,¹ Thost⁵ and others were of the opinion that singing is a causative factor in hastening the process of ossification, since, as a rule, the initial processes are found at the points of insertion of the ligaments or muscles in the laryngeal cartilages. In a recent article, Terracol⁶ stated that roentgen studies of the larynx in professional singers and in nonsingers show no difference in the extent and degree of calcification of the laryngeal cartilages. Nevertheless, on theoretical grounds, he, too, was of the opinion that the advancing calcification and ossification of these cartilages affects the voice, especially the singing voice.

The consensus as to the age factor is that, in general, the ossification of the laryngeal cartilages advances with age; so great, however, is the variability of the age period that it is impossible to determine the age of persons from the degree of ossification of these cartilages. Second¹ found that after the age of sixty years usually there is definite ossification and at seventy the process may be completed, but in some persons of eighty years of age, ossification is only slight and limited to certain areas. In 1866, Hunt⁷ observed a man, aged one hundred and three years, whose larynx postmortem showed not even beginning ossification. Two decades later, Meunier⁸ presented to the Anatomical Society of Paris a specimen of abnormal ossification of the hyoid bone from a man, aged sixty-four years, in which the thyroid and the cricoid cartilages were completely ossified and the arytenoid cartilage nearly so. Schottelius² concluded from his observations that the process begins soon after the age of twenty in normal healthy persons.

In 1882, Chievitz³ reported a study of the ossification of the laryngeal cartilages in 232 anatomical specimens, 127 from men and 105 from women. The earliest age period at which ossification was found in the individual cartilages was the twentieth year for the thyroid and cricoid cartilages in both sexes, the middle twenties for the arytenoids in men, and between twenty and thirty in women. Chamberlin and Young⁹ stated, in a recent (April, 1935) article, that all of the original work pertaining to the age factor has resulted in the conclusion that actual bone formation takes place before full maturity is reached, and they mentioned that Chievitz³ put it exceptionally well when he said that ossification begins normally when skeletal growth is otherwise complete.

In specimens from boys, aged fourteen and fifteen years, Dreyfuss,¹⁰ in 1916, observed crepitation on puncture with a needle and roughness of the cut surface in the cricoid cartilage. After the age of fifty years the process in men is well advanced and at the age of seventy the entire cartilage is usually completely ossified, he noted. In the thyroid cartilage the process begins in the male in puberty, he observed, and at about the same time as in the cricoid cartilage. He found partial ossification of the inferior cornu in a boy, aged fourteen years, and stated that after the age of forty the ossification of the alæ is almost complete in men. In the arytenoid cartilage, he also observed that the process begins at puberty in males, but about two years later than in the cricoid cartilage; it progresses much more slowly than in the cricoid cartilage, however, and is complete only at an advanced age. He concluded that in all three cartilages the process is more gradual and less extensive at all ages in women than in men.

Dissection of the larynx from several subjects, aged eighty to ninety years, reported by Segond,¹ showed complete ossification in these three cartilages, but in the epiglottis, the corniculate and the cuneiform cartilage there was no evidence of osseous change. Dreyfuss¹⁰ stated that he had never found bone formation in a normal epiglottis, and Gardner¹¹ recently observed that "the epiglottis, the cuneiform cartilage and the apexes of the arytenoid cartilages are composed of yellow elastic tissue and show little, if any, tendency to calcification."

Pathological processes of ossification, according to Dreyfuss,¹⁰ may be found in the larynx in three forms: (1) Ossification in cartilage tumors of the larynx; (2) excessive bone formation in the form of exostoses or bone plates formed in cartilage rests in the mucosa; and (3) premature and excessive bone formation in the laryngeal cartilages in chronic infectious processes.

The earlier anatomical writers were of the opinion that ossification begins first in the cricoid, next in the thyroid and last in the arytenoid cartilage, although some of them concluded, as did Chievitz,³ that in the cricoid and thyroid cartilages this change begins at approximately the same time. This author described in detail the advances of the process and stated that in no instance

did he find evidence of bone formation in the arytenoid cartilage if none was present in the thyroid and cricoid cartilages. In the thyroid cartilage, he noted, the process progresses differently in the two sexes, and in the cricoid cartilage, in women, the median portion of the ring rarely shows ossification.

Agreeing with Chievitz³ in most particulars, Bergeat¹² noted that the initial processes are found at the points of insertion of ligaments or muscles in the laryngeal cartilages. Segond,¹ fifty years earlier, reported that ossification begins in the cricoid cartilage at the point of insertion of the cricothyroid muscle, in the thyroid cartilage in the posterior border of the alæ and in the arytenoid cartilage at the base, extending outward to the points of insertion of the cricothyroid muscles. In both sexes, Dreyfuss¹⁰ found, the osseous change in the thyroid cartilage begins in the inferior cornu, and almost at the same time in the superior cornu, extending from these points along the posterior border of the alæ and then forward along their lower border. In the specimens which Kofler¹³ studied, calcification and ossification were most marked at the periphery of the cartilages; toward the center of the cartilage the bone tissue was less in extent, but there were large marrow spaces fairly well vascularized and filled with fatty marrow as in normal spongy bone elsewhere. Some specimens showed rarefaction of the bone and serous atrophy of the fatty marrow.

To a great extent the findings of the roentgenologists are in accord with the conclusions of the anatomists. Both groups are agreed that ossification of the laryngeal cartilages advances with age, although it is impossible to determine the age of persons from the degree of ossification of these cartilages. Roentgenologists have found, however, that in general the process occurs in the thyroid earlier than in the cricoid cartilage.

As early as 1896, Scheier¹⁴ pointed out the value of a roentgen examination of the larynx as a means of studying the process of ossification in the cartilages. He was evidently the first to use the roentgen-ray to determine the extent and variety of sites of bone formation. Two years later, he reported a roentgen study of the larynx in 70 cadavers of both sexes and stated that his findings were in accord with his study of anatomical specimens

from Virchow's collection. With the roentgen equipment and technique available at that time, he was unable to obtain roent-

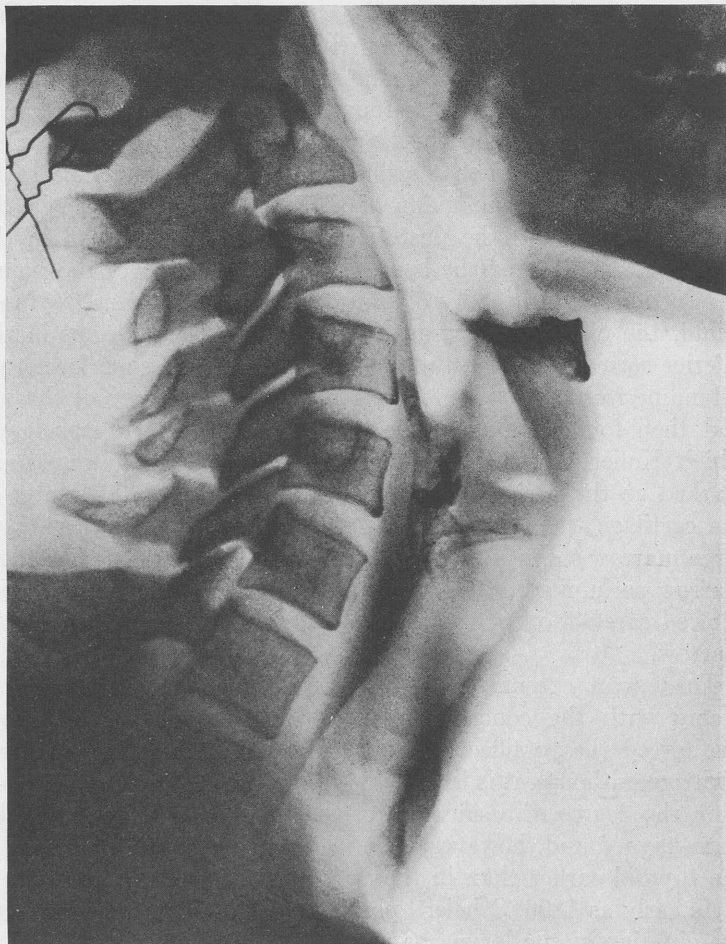


FIG. 1.—A roentgenogram of the larynx of a woman, aged thirty-three years, showing a dense ossification of the arytenoids and partial ossification of the superior and inferior cornua.

genograms of the larynx in the living that demonstrated the ossification of the cartilages clearly and definitely, but in an article

published in 1901 he noted that such roentgenograms may show ossification of the laryngeal cartilages and may offer a means of studying this process in the living. In this article he reported roentgen studies of anatomical specimens of the larynx from 65 men and 55 women, which confirmed the conclusions of his study of 1898, especially in regard to differences of sex. As did Chievitz,³ he noted that in the thyroid cartilage following ossification of the posterior border, the process advances differently in the two sexes, and he concluded that complete ossification of this cartilage is unusual in women. He also observed that the entire posterior portion of the cricoid cartilage may become ossified, but the anterior portion is rarely completely transformed into bone, especially in women. Although the first centers in the arytenoid cartilage are at the base, in one woman, aged thirty-seven years, he found that the process began at the upper point of the pyramid. He stated that this cartilage may undergo complete ossification after the age of forty-five years.

This author concluded that the thyroid cartilage first shows osseous change, the cricoid next and the arytenoid last. In his specimens he found that all of the laryngeal cartilages had undergone complete ossification in several men, but never in a woman. Two years after Fraenkel,¹⁵ in 1908, reported that he found no differences of sex in the development of ossification other than that the process begins somewhat earlier in women than in men, Sheier¹⁴ confirmed his original findings by a special study of specimens, chiefly from women. In one specimen from a woman, aged one hundred and two years, he found the degree of ossification not much further advanced than is usual in women thirty to forty years of age, and in another from a woman, aged one hundred and one years, the anterior half of the thyroid cartilage remained cartilaginous. Although in one man, aged fifty-eight years, the ossification of the laryngeal cartilages was no further advanced than in another man, aged twenty-five years, and in one woman, aged seventy-five years, it showed the same degree of ossification of the thyroid cartilage as in another woman, aged twenty-one years; in general, Sheier¹⁴ concluded, the process advances with age.

Because of the wide variability in the rapidity and degree of

change, Thost,⁵ in 1913, likened the process of ossification to the graying of the hair. In his roentgen study of the larynx in 261 persons in whom previous laryngoscopic examination had shown the larynx to be normal, he demonstrated the advantages

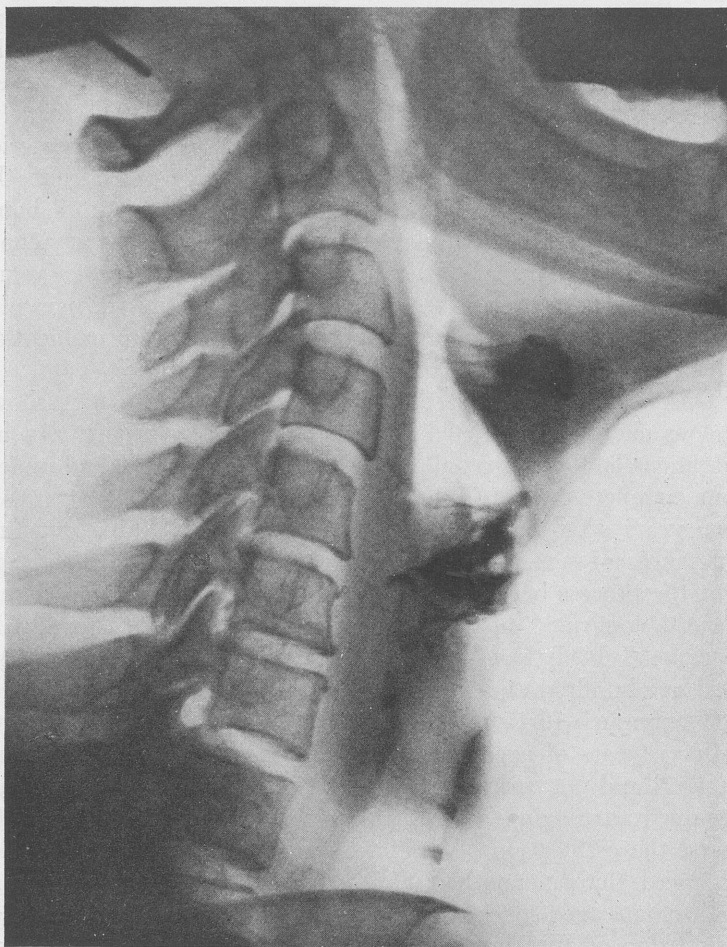

FIG. 2.—A roentgenogram of the larynx of a woman, aged fifty-five years. The thyroid cartilage shows marked ossification except at the round or oval windows which represent remaining cartilage. The superior and inferior cornua also show ossification.

of roentgenograms over the laryngoscope in studying the structure of the laryngeal cartilages and the process of ossification in these cartilages. The next year, Weingärtner¹⁶ showed roentgenologically in living subjects the progressive stages of bone formation typical of the normal larynx, and six years later, Ceresole¹⁷ stressed the importance of correct interpretation of areas of ossification, especially in the anterior portion of the thyroid cartilage where the process is best shown in lateral roentgenograms. This author studied the lateral roentgenograms of the larynx in 3708 patients, aged from twenty to fifty-two years, at the military hospital in Vienna, and in the majority of younger men who showed ossification in the anterior portion of this cartilage, he observed that some chronic disease was present, chiefly syphilis and tuberculosis, though not laryngeal tuberculosis. Several had chronic arthritis.

Wulfson and Ginsburg¹⁸ stated, in 1930, that the laryngeal cartilages are not visible in the roentgenogram until the beginning calcification and progressive ossification, which follow the attainment of sexual maturity, render them so. These authors described the difference in the development of the process in the thyroid cartilage in the two sexes, which Chievitz³ and Scheier¹⁴ noted. They found that, having advanced upward from the region of the inferior cornu along the posterior border in both sexes, it develops in men after about the age of thirty, from the cornua forward along the borders until the areas of bony tissue meet and thus form round or oval areas or windows of cartilage, which become progressively smaller until the whole cartilage may undergo complete ossification, while in women it advances through the entire width or may take place by degrees in various areas. They stated that at the age of fifty to sixty years both the shape and the structure of the bony tissue of this cartilage are usually shown in the roentgenogram, but they concluded that the extent of the process does not depend so much on age as has been supposed, for extensive ossification may occur in young persons and, on the other hand, only a limited degree in older persons. In the cricoid cartilage the process advances from the upper lateral border and the region of articulation with the thyroid cartilage, they observed, the border adjacent to the thyroid cartilage showing ossification before

that adjacent to the trachea, while in the arytenoid cartilage it proceeds from the base to the apex.

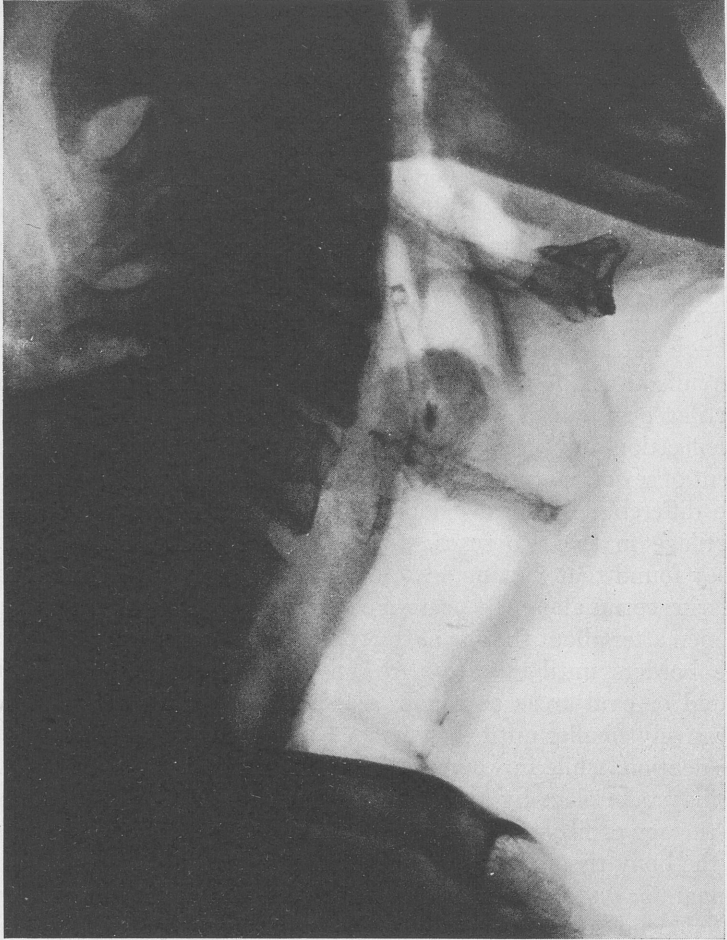


FIG. 3.—A roentgenogram of a man, aged sixty years, showing ossification of the superior cornua.

Also in 1930, Pancoast¹⁹ stated that ossification of the laryngeal cartilages is easily shown at the earliest stages in roentgenograms

of the larynx, and suggested that the anatomical knowledge as presented in the textbooks of today be checked by extensive roentgen examination in a large number of living subjects. The information in our present-day textbooks of anatomy and histology, such as those by Cunningham,²⁰ Jordan,²¹ Piersol,²² Bremer,²³ and Maximow,²⁴ corresponds to that reported by Chievitz³ half a century ago. The textbooks dealing with diseases of the larynx, however, give little, if any, space to abnormal aspects of the process or even to the possible relationship of the normal aspect to disease. For example, in the textbook by Thomson,²⁵ and in the recent one edited by Turner,²⁶ there are no references to the process of ossification of the laryngeal cartilages as such, either physiological or pathological.

The findings of Baldenweck and Gauillard,²⁷ reported in 1933, correspond closely with those of the early anatomical writers. They stated that the roentgen shadow is denser at the centers of ossification, as the process is more marked at these points, and that clear visualization of the laryngeal cartilages depends to a large extent upon the stage of pre-ossification and the "incrustation" of calcium. One year later, Terracol⁶ reported a study in which he found no differences in the calcification of the cartilages in patients with dysfunction of the sex glands and in women whose ovaries had been removed, as compared with others of the same ages.

Bergeat¹² found no evidence that chronic tuberculosis hastens the process of ossification. On the contrary, he found the ash content of the laryngeal cartilages less for the tuberculous persons than for the nontuberculous in the same age period, but in 3 cases of chronic gastric disease, 2 of carcinoma and 1 of ulcer, and in 1 case of Bright's disease in his series, the ash content of these cartilages was definitely increased. According to the observations of Fraenkel,¹⁵ tuberculosis tends to delay ossification. Also, disturbances of development in childhood may delay it, and chronic nasal infection, specific infection or constitutional disease, such as gout or diabetes, do not hasten the process in his opinion.

In cases of tuberculosis of the larynx, Thost⁵ found that true ossification of the cartilages does not progress normally; a more diffuse calcification is present and as a result, the tuberculous

larynx shows a fainter, less well-defined roentgen picture. Weingärtner¹⁶ reported that several cases of laryngeal tuberculosis in his series showed infiltration of calcium in the laryngeal cartilages, rather than actual ossification. Wulfson and Ginsburg¹⁸ found a tendency to "demineralization" of these cartilages in such cases, which they regarded as related to general decalcification in this disease. They stated that scattered denser areas of ossification may be observed, especially in the lower part of the thyroid cartilage.

Thost⁵ found that syphilis of the larynx tends to increase the intensity of ossification and to lead to the formation of hyperostoses and osteophytes. Wulfson and Ginsburg¹⁸ stated that in this disease the roentgenogram shows an abnormal degree of ossification in the lower posterior border of the thyroid cartilage, occurring in irregular bands, and extending in all directions.

In carcinoma of the larynx, Thost⁵ found that where the carcinoma is not of rapid growth, causing early destruction of the cartilages, it appears to hasten the process of ossification. The thyroid cartilage showed complete ossification in 2 cases of laryngeal carcinoma in the series of Weingärtner.¹⁶ Wulfson and Ginsburg¹⁸ reported that the cartilages are often destroyed in this disease, but from the perichondrium new cartilage and bone tissue may be formed, which appear in the roentgenogram as scattered areas of calcified and ossified cartilage. In 1 case of cancer of the larynx presented by Baldenweck and Gauillard,²⁷ the roentgenogram showed the arytenoid cartilage calcified and clearly demonstrable and the thyroid cartilage largely destroyed.

More than half a century ago, Eppinger²⁸ stated that foreign bodies occurring in the larynx may have been formed there through some pathological process. As early as 1901, Scheier¹⁴ warned that in roentgenograms there is danger that a normal area of ossification may be mistaken for a foreign body in the living subject. Ceresole¹⁷ reported a case in which the patient was a man, aged thirty-eight years, who, despite absence of symptoms, thought he had accidentally swallowed the metal key from a can of meat. A roentgenogram showed an opacity with the shape of a hook at the level of the median portion of the angulus of the thyroid cartilage. The shadow was found to represent ossification

of the anterior portion of the thyroid cartilage at this point. In their recent article, Chamberlin and Young⁹ stated: "Those cases in which isolated ossifications have occurred in parts of the cartilages which are superimposed upon the food passages, as seen in the lateral roentgenogram, are of particular interest on account of the possibility of confusion with foreign body. That these osseous shadows may be mistaken for foreign body has been proved by actual occurrence."

In a boy, aged twelve years, in whom a tracheotomy had been done, Weingärtner¹⁶ observed premature ossification of the cartilage in the region of the tube which had been inserted. Halsted,²⁹ in 1933, reported a case of a woman in which aphonia of about eight months' duration was the only symptom. Examination of the patient showed the right vocal cord fixed and the trachea pushed to the left side. Roentgenograms showed a fusion of the third and fourth vertebræ and "what appeared to be a foreign body, $\frac{1}{4}$ inch long by $\frac{1}{16}$ inch in width, lying horizontally at about the cricoid in the tracheo-esophageal wall." As there was a history of a minor injury in an automobile accident in which the patient was thrown forward and downward, Halsted²⁹ suggested that the foreign body might be a calcification of one of the laryngeal cartilages and that it was "thrown off" at the time of the accident and embedded in the larynx, interfering with the movement of the right cord. In 1867, Mackenzie³⁰ reported the case of a man, aged fifty-eight years, complaining of aphonia, who had fallen from "a great height" on his head and who, six months later, expelled the left arytenoid cartilage, completely ossified. In 1 of the 3 cases reported at different times by Gibb,³¹ the patient had been thrown from a horse and had fallen on his head.

In the 13 reports of cases of or associated with ossification of the laryngeal cartilages which occurred in the literature reviewed, six authors mentioned 7 instances in which bone was expelled. Five of these, reporting 6 of the cases, were the earlier anatomists whose reports were published between 1867 and 1882. Mackenzie³⁰ and Gibb³¹ reported trauma as a concomitant factor, Fyffe³² an abscess, Seiler,³³ cited by Wagner,³³ syphilitic laryngitis in 2 cases, and Wagner³³ papilloma. In Fyffe's case "a piece of bone" was expelled; in the others the arytenoids, one or both.

In the case reported by Weil,³⁴ in 1912, the patient expelled the ossified bodies of the arytenoids, extending as far forward as the *processi vocali*. A roentgenogram of the larynx showed "nothing striking;" although the laryngeal cartilages were "hazy" in appearance, there was no definite evidence of ossification of the remaining cartilages.

In a recent article Nelson and Hirsch³⁵ warned of the dangers of damage to the larynx from roentgen therapy. Hautant³⁶ and Jackson³⁷ called attention to the fact that the sensitiveness of the cartilages of the larynx to radiation is most marked at the site of greatest calcification. In all severe inflammatory reactions to endolaryngeal burns, whether they are due to the actual cautery, hot liquids, chemicals or radiation, the possibility of an ossified cartilage lying loose in the larynx should be considered, particularly when there is evidence of pus formation or a discharging fistula.

My interest in the rôle of ossification in some types of laryngeal disease was aroused by a case of carcinoma of the larynx in which the patient expelled one of the superior cornua of the thyroid cartilage, completely ossified. Dr. Chevalier Jackson³⁸ confirmed my identification of this specimen. When the patient, a man, aged forty-three years, first came under my observation, on February 21, 1933, he was suffering from an extrinsic inoperable carcinoma of the larynx with an advanced metastasis into the neck. Indirect laryngoscopy showed an ulceration of the epiglottis, a marked involvement of the aryepiglottic folds, ulceration and complete fixation of both cords, and a subglottic tumor mass. Roentgen therapy was advised and was carried out by Dr. L. W. Cunningham and Dr. W. McL. Shaw,³⁹ according to the method of Coutard, except that the dosage per day was slightly less than Coutard advocated, although the total dosage was the same. Treatment was begun on February 22 and continued to March 24. An improvement of the laryngeal picture was observed, and there was also improvement in phonation and deglutition. On June 5, fourteen weeks after this therapy was started, the patient expelled an ossified superior cornu of the thyroid cartilage and at the same time expectorated a rather large amount of pus. Following this occurrence the patient showed a definite temporary improvement

and was more comfortable for some time, but on August 11 a tracheotomy was required. Roentgen therapy was again instituted on September 21 and was given on alternate days until October 2. The patient died on March 26, 1934, as a result of a carcinomatosis, a laryngeal hemorrhage occurring three days before his death.

It is interesting to observe that in not 1 of the 7 cases reported in the literature in which expulsion of ossified cartilage occurred, was the presence of this foreign body diagnosed. Doubtless in all of these cases there was evidence of an inflammatory process, caused by the misplaced bone or sequestrum lying somewhere within the laryngeal tissues. In the case which came under my observation the condition was not diagnosed. Had a roentgen study been made, the foreign body might have been recognized. Occurrences such as featured these cases indicate the importance of more frequent roentgen studies of morbid conditions of the larynx, particularly where there is evidence of change caused by deep inflammatory processes. In these inflammatory processes in older persons, in whom the laryngeal cartilages may have undergone a complete ossification with the periosteum replacing the perichondrium, it would seem essential that a roentgen study be made. Thomson²⁵ mentioned perichondritis in the aged, but made no reference to the fact that the cartilages may be transformed into bone. The possibility of inflammatory change, such as an osteitis in the ossified cartilages, should always be considered, and an effort made to differentiate this condition from a perichondritis. In some of the recent textbooks, reference is made to perichondritis and chondral necrosis as etiological factors of abscess of the larynx, but no mention is made of misplaced ossified cartilage, which also may be an etiological factor of this condition. In a case reported by Fyffe,³² in 1878, in which the patient expelled ossified cartilage, there was an abscess located between the middle of the thyroid cartilage and the lower jaw.

The subject of the ossification of the laryngeal cartilages is of more than classical interest, for its relation to some types of laryngeal pathology is worthy of careful consideration. While laryngoscopy, both direct and indirect, is indispensable, the laryngologist is in large measure dependent upon the roentgenolo-

gist for his study of this relationship, and with the improvement in recent years of roentgen equipment and technique, the roentgenologist is now able to render invaluable aid in diagnosis, which could otherwise be gained only by autopsy.

Although it is generally conceded that age is the principal factor determining the advance of the process of ossification in the laryngeal cartilages, nevertheless the great variability of the age period at which it occurs points to the possibility of other etiological factors, particularly in relation to its abnormal aspects. Since the literature reveals that the process has been found in a youth,¹⁶ aged twelve years, and has not been found in a man,⁷ aged one hundred and three years, the wide discrepancy in age suggests that modern research may find a causative agent such as endocrine disturbance, vitamin or mineral imbalance, improper metabolism or disturbed electrolyte balance which, when understood, will make possible the control of abnormal aspects of this phenomenon. Advances in the science of nutrition indicate, as Dr. R. A. Hetler⁴⁰ has said, that interrelationship in the concentration of minerals, vitamins and protein of the diet must have an influence on metabolic normality. Recent developments in research pertaining to the parathyroid suggest its importance in the production of bone.

CONCLUSIONS. While age is the primary factor in ossification of the cartilages of the larynx, the wide variability of the age period suggests that there may be other etiological factors which have not as yet been definitely determined.

In general, ossification of the laryngeal cartilages begins later and advances more slowly in women than in men.

Roentgen study shows that normally the process begins in the thyroid cartilage, occurs next in the cricoid cartilage and last in the arytenoid cartilage.

Some diseases seem to retard ossification of the laryngeal cartilages, while others seem to hasten it.

An ossified portion of laryngeal cartilage may as a sequestrum become an etiological factor in abscess of the larynx.

The diagnosis of perichondritis is not infrequently made in the aged. A roentgen study might determine that the cartilages have been transformed into bone.

Roentgen studies of morbid conditions of the larynx, particularly

where deep inflammatory processes are present, are invaluable aids to diagnosis and should be made with greater frequency.

REFERENCES.

1. Segond, L. A.: Mémoires sur l'ossification des cartilages du larynx, Arch. gén. de méd., Ser. 4, **15**, 364, 1847.
2. Schottelius, M.: Untersuchungen über physiologische und pathologische Texturveränderungen der Kehlkopf-Knorpel, Marburg University Thesis, 1879.
3. Chievitz, J. H.: Untersuchungen über die Verknöckerung der menschlichen Kehlknorpel, Arch. f. Anat. u. physiol. Anat., p. 303, 1882.
4. Retterer, F.: Du mode d'ossification des cartilages du larynx, Compt. rend. Soc. de biol., **82**, 102, 1919.
5. Thost, A.: Der normale und kranke Kehlkopf des Lebenden im Röntgenbild, Fortschr. u. d. Geb. d. Röntgenstrahlen, No. 31, 1931.
6. Terracol, J.: La calcification du larynx et la voix, Rev. franç. de phoniatrice, **2**, 20, 1934.
7. Hunt: Fractures of the Larynx, Am. Jour. Med. Sci., **51**, 378, 1866.
8. Meunier, H.: Ossification de l'appareil hyoïdien, Bull. Soc. anat. de Paris, **62**, 876, 1887; **63**, 382, 1888.
9. Chamberlin, W. E., and Young, B. R.: Ossification (So-called "Calcification") of Normal Laryngeal Cartilages Mistaken for Foreign Body, Am. Jour. Roentgenol. and Rad. Therap., **33**, 441, 1935.
10. Dreyfuss, R.: Normale und krankhafte Verknöcherungen im Kehlkopf und Luftröhre, Beitr. z. klin. Chir., **102**, 426, 1916.
11. Gardner, H. O.: Fractures of the Larynx, Arch. Otolaryngol., **18**, 449, 1933.
12. Bergeat, H.: Gewichtsbestimmungen an der Kehlkopfknochen, Arch. f. Laryngol. u. Rhinol., **6**, 198, 1897.
13. Kofler, K.: Histopathologische Veränderungen am Alterskehkopf, Monatsschr. f. Ohrenheilk., **66**, 1468, 1932.
14. Scheier, M.: De l'ossification du larynx, Arch. internat. de laryngol., **11**, 531, 1898; also in German (with additions) in Arch. f. mikr. Anat., **59**, 220, 1901; Ueber die Architectur des ossificirten Kehlkopfs, Internat. Cong. Med. Trans., Sect. Laryngol., p. 325, 1900; Zur Verknöcherung des menschlichen Kehlkopfs, Beitr. z. Anat., Physiol., Path. u. Therap. d. Ohres., **3**, 279, 1910.
15. Fraenkel, E.: Ueber die Verknöcherung des menschlichen Kehlkopfs, Fortschr. a. d. Geb. d. Röntgenstrahlen, **12**, 151, 1908.
16. Weingärtner, M.: Demonstration von Röntgenbildern aus dem Gebiete der Laryngologie, Berl. klin. Wehnschr., **51**, 1477, 1914.
17. Ceresole, G.: Osservazioni radiologiche sull'ossificazione del margine anteriore della cartilagine tiroide e della porzione anteriore dell'anello cricoideo nei maschi, Arch. ital. di otol., **31**, 128, 1920.
18. Wulfson, S., and Ginsburg, W.: Die klinische Bedeutung der Röntgendiagnostik bei Kehlkopfkrankheiten, Röntgenpraxis, **2**, 158, 1930.
19. Pancoast, H. K.: Roentgenology of Upper Respiratory Tract, With Special Reference to the Larynx and Adjacent Structures, Jour. Am. Med. Assn., **95**, 1318, 1930; Trans. Sect. Laryngol., Otol. and Rhinol., Am. Med. Assn., p. 131, 1930.

20. Cunningham's Textbook of Anatomy, New York, William Wood & Co., p. 1069, 1931.
21. Jordan, H. E.: A Textbook of Histology, New York, D. Appleton & Co., p. 300, 1927.
22. Piersol's Normal Histology, Philadelphia, J. B. Lippincott Company, p. 234, 1929.
23. Bremer, J. L.: A Textbook of Histology, Philadelphia, P. Blakiston's Son & Co., p. 318, 1930.
24. Maximow, A. A.: A Textbook of Histology, Philadelphia, W. B. Saunders Company, p. 437, 1930.
25. Thomson, Sir St. Clair: Diseases of the Nose and Throat, New York, D. Appleton & Co., 1922.
26. Turner, A. L.: Diseases of the Nose, Throat and Ear, 3d ed., New York, 1932.
27. Baldenweck, L., and Gauillard, R.: Recherches sur la radiographie normale et pathologique du larynx, Jour. de radiol. et d'électrol., **17**, 353, 1933.
28. Eppinger, H.: Pathologische Anatomie des Larynx und der Trachea, in E. Klebs' Handbuch der pathologische Anatomie, Berlin, vol. **2**, Pt. 1, 1880.
29. Halsted, T. H.: Foreign Body Embedded in the Larynx, Ann. Otol., Rhinol. and Laryngol., **42**, 1229, 1933.
30. Mackenzie, M.: Ossified (Expectorated) Arytenoid Cartilage, Trans. Path. Soc. London, **18**, 31, 1866-1867.
31. Gibb, G. D.: Complete Ossification of the Thyroid and Cricoid Cartilages, Trans. Path. Soc. London, **10**, 68, 1858-1859; Lancet, **1**, 521, 1859; Calcification of the Cartilages of the Larynx, Including the Arytenoid, Trans. Path. Soc. London, **12**, 51, 1860-1861; Exfoliations From the Thyroid Cartilage, Chiefly Composed of Phosphate of Lime, Trans. Path. Soc. London, **19**, 88, 1867-1868.
32. Fyfe, W. J.: Observations on a Case of Ossification and Necrosis of the Laryngeal Cartilages, Trans. Bristol Med.-Chir. Soc., **1**, 4, 1878.
33. Wagner, C.: On Ossification of the Right Arytenoid Cartilage, Trans. Am. Laryngol. Assn., **4**, 114, 1882.
34. Weil, A. I.: Ossification and Subsequent Expulsion of Both Arytenoid Cartilages, Laryngoscope, **22**, 1124, 1912.
35. Nelson, P. A., and Hirsch, E. F.: Roentgen Radiation Necrosis of Larynx and Other Structures of the Neck, Jour. Am. Med. Assn., vol. **104**, No. 18, 1935.
36. Hautant, A.: Radionécrose des Cartilages du Larynx, Ann. d. mal. de l'oreille, du larynx, du Nez et du Pharynx, **46**, 1198, 1927.
37. Jackson, C., and Coates, G. M.: The Nose, Throat and Ear and Their Diseases, Philadelphia, W. B. Saunders Company, p. 845, 1929.
38. Personal communication to the writer.
39. Report supplied by Drs. Cunningham and Shaw from their records.
40. Personal communication to the writer.

ADDITIONAL REFERENCES.

- Behn: Kehlkopfverknöcherung nachgewiesen am Lebenden, Fortschr. a. d. Geb. d. Röntgenstrahlen, **4**, 43, 1900.

Bertoye, H.: Aperçu sur les échondroses et exostoses du larynx, *Ann. de mal. de l'oreille du larynx*, **12**, 125, 1886.

Henckel, K. O.: Sur la structure fonctionnelle des éléments cartilagineux du larynx, *Compt. rend. Soc. de biol.*, **108**, 648, 1931.

Sayama, M.: Ueber die Verknöcherung des Kehlkopfes bei Chinesen, *Jour. Oriental Med.*, **14**, 53, 1931.

Seiferth, L. B.: Histologische Untersuchungen über Chondritis und Perichondritis des Kehlkopfs, *Ztschr. f. Hals- Nasen- u. Ohrenheilk.*, **24**, 555, 1929.

Travers, F.: Case of Ossification and Bony Growth of the Cartilages of the Larynx, *Med.-Chir. Trans.*, **7**, 150, 1816.

DISCUSSION

DR. FRANK ROBERT SPENCER, Boulder, Colo.:

Some years ago I undertook the roentgen-ray study of the larynx of each patient, with the hope that something could be learned about laryngeal pathology. It was used first for patients suffering with laryngeal tuberculosis. A few other patients with syphilis and arthritis were also examined by the radiologist. The films failed to show the pathology of tuberculosis as I had hoped they would, but they did show in some of the patients ossification of the cartilages. One patient with extensive syphilis of the larynx and one with extensive chronic arthritis of many large and small joints of the entire body, including the cricoarytenoid joints, also showed ossification.

The few patients with laryngeal tuberculosis, who showed ossification, had areas of calcification much like those sometimes found in the lungs, but these were all found in patients who had suffered from laryngeal tuberculosis for a number of years in mild form. I have not seen this in recent cases nor did I see it in all of the patients roentgen-rayed.

The patient with syphilis showed a more or less uniform ossification and the one with arthritis showed ossification of the cricoid and arytenoid chiefly. The radiologist called my attention to the changes, but I gave the condition very little thought until I saw the title of Dr. Taylor's paper on the program.

The late Dr. William V. Mullin found slight ossification of the larynx in several patients at Asheville while he was stationed there in the army. All of these patients had suffered from pulmonary tuberculosis but not necessarily from the laryngeal disease. I discussed these findings with him several times before he left Colorado Springs for Cleveland in January, 1926.

He believed, as I did, that the ossification was not frequent enough to be very important, but I cannot agree with the statement made by

one of the authors, quoted by Dr. Taylor, that ossification does not take place in the larynx of the tuberculous.

My series is too small to justify any very sweeping conclusions, but it does give an idea of what may be expected in a larger series.

DR. JOSEPH C. BECK, Chicago, Ill.:

I had the pleasure of reading this paper with Dr. Taylor and was enabled to ask him questions directly. In view of the fact that he was reading the paper quite rapidly now I think some important points might not have been impressed upon some of the hearers, particularly that point regarding vascularization aiding ossification. This fact should be borne in mind in connection with the work of Witmaak on the capsule of the labyrinth in Otosclerosis.

While the structure of the capsule of the labyrinth and the cartilages of the larynx are not at all similar, the experiment, as you know, in artificially producing otosclerosis are very definitely related to the findings in Dr. Taylor's cases, namely, engorgement. There is considerable enthusiasm throughout the world on producing artificially otosclerosis and Witmaak's work stands out preëminently in this line. Of course, constitutional defects and errors in diet, vitamin deficiencies, etc., are to be borne in mind when discussing changes in calcification of cartilage.

When one considers the cases reported here as to their ages, one is struck with the great discrepancy between the age of thirteen and one of one hundred and three. Calcification in the aged is, of course, quite common, but surely in a young person it must be considered rather a disease than a natural sequence of age, probably some local manifestation producing premature ossification.

Then there was a new thought expressed in the paper, to me at least, and that was the question of muscle pull on the cartilages, especially in singers, being productive of early ossification. I was looking for some explanation for changes in tone in some of these cases but Dr. Taylor failed to mention anything regarding that point.

The question of radio-sensitivity is surely a very important one in connection with stimulation of calcareous formation in cartilage. In conditions about the neck like thyroid disease or glands in the neck where so much treatment is being carried out by roentgen-ray or radium one should expect changes, if it is proven that roentgen-ray is responsible for this in laryngeal cartilage. I do not know of any special work having been done along these lines.

The question of roentgenograms is really a discussion for the radiol-

ogist, and it certainly matters a great deal as to who makes the roentgen-ray and who interprets it, in order to prove whether we are dealing with actual bone formation or simply calcareous infiltration as one finds in chronic septic processes.

I do not believe that this can be proven roentgenologically. I feel that it can only be proven by histologic examination. I should like, if I may be permitted a moment longer, to quote a case which I had mentioned to Dr. Taylor, which fits into this subject very well.

Dr. Taylor failed to mention in his report, and I hope he will mention it in his closing remarks, regarding otosclerosis and this disease of the larynx, for he showed me two roentgenograms, namely of the father and son, or daughter, who had changes in their larynges similar in character. Both of these individuals were otosclerotic, and this brings me to the case I wish to mention, not at all otosclerotic, but a case of a foreign body that may remain for a longer period of time like a sequestrum and then be expelled.

A patient, a veteran at the Hines Hospital, was referred to me because of a suspected carcinoma, and required an immediate tracheotomy. Following this, we were able to study him more carefully and upon roentgenographical examination we found a definite outline, especially in the lateral view of the thyroid cartilage, an area of rarefaction with something like a sequestrum in the center.

The patient gave a subsequent history that seven years ago he had had a very severe case of typhoid fever. We all remember in those early days when typhoid fever was very prevalent, the laryngeal complications namely, chondroperichondritis, with sequestration. Frequently great portions of the laryngeal cartilages were expelled *en masse* and in many instances a cartilage became calcified subsequently to the infection. I would like to refer you back to an old paper of Chevalier Jackson and Ewing Day some twenty years ago in which all these matters were clearly brought out.

The biopsy in our patient proved to be nonmalignant granuloma and my conclusion was that he had a chronic chondroperichondritis with abscess formation and a sequestrum of the cartilage. This was subsequently verified in an expulsion of the sequestrum.

DR. JOHN F. BARNHILL, Indianapolis, Ind.:

I also had the pleasure of reading Dr. Taylor's paper on the way from Florida. Dr. Taylor was just a bit nervous about it, I thought. It was not a bread-and-butter paper, and he was afraid nobody would take any interest in it; but after I read it, it seemed to me a classic

and I fancy that in future those who wish to know something about the development of the larynx and what its behavior may be in later years, will wish to study Dr. Taylor's paper.

It is my good fortune to see a great many larynges in the dissecting room. Most of these are adults, and I should say that practically all are ossified in some part. So it is rather amazing to me that anybody should be found at one hundred and three years of age in whom the cartilage is not ossified.

The history which Dr. Taylor gives here, and which we know to some extent, brings up a question in anatomy as to whether our classification for this cartilage is correct. Should we ever state that these are cartilages? Should we not rather call them bones? And why not? Since in the individual who lives to be seventy or seventy-five years of age, the ossified period of the cartilage is very much greater than the cartilaginous period?

Such proof as Dr. Taylor offers would be a good basis for such a revision.

Dr. Taylor speaks of an interesting thing in regard to the failure to diagnose foreign body, or mistaking a foreign body for what he found—I mean mistaking ossification of the cartilage for a foreign body. I recall an instance which I had once upon a time, of an individual who claimed there was a foreign body in her throat. The woman was more or less demented, had her tonsils removed some years ago fancied something had been left in her throat, became a migratory, went from city to city determined some one should find a foreign body. One day she came to me all smiles, the happiest individual I had seen in a long time, and said, "I have a picture which shows a husk in my throat." It was proven to be an ossified cartilage.

I wish to congratulate Dr. Taylor. More papers like his ought to be brought forward.

DR. CHEVALIER L. JACKSON, Philadelphia, Pa.:

I have very little to add to this very complete presentation. There is just one point I should like to emphasize, in connection with the differential diagnosis of ossifications in the laryngeal cartilages and bones lodged as foreign bodies in the hypopharynx or upper esophagus. I have heard the differential point made, that bones lodging as foreign bodies are always seen at a lower level than these isolated spots of ossification which may be mistaken for bones, but this general rule, while true in 90 per cent of the cases, does not hold in all cases. Dr. W. Edward Chamberlain and I have been much interested in this

question, and we have seen several striking examples of bones occurring as foreign bodies exactly at the level of the cricoid cartilage. We fully recognize the fact that they generally lodge at a lower level, but they can lodge at exactly the same level as the spots of ossification in the cricoid cartilages.

DR. FREDERICK M. LAW, New York City:

Speaking of this from a roentgenological standpoint, there is very little to say, but in defense of the roentgenologist, I will say we have observed and reported shadows in the thyroid for many years as ossifications, merely as an observation. We have not attached a great deal of importance to them because we considered those shadows simply in a differential diagnosis from foreign bodies, although there have been papers which described various appearances.

Dr. Jackson has just taken the words out of my mouth as to the method of differential diagnosis; however, if the calcification is extensive, there is no difficulty, but if it is minute, as it often is, and forms a linear shadow, in the presence of the history of a foreign body, then the roentgenologist is up against a problem.

This paper of Dr. Taylor's is just adding another load on the roentgenologist, opening up a field of investigation which every roentgenologist in your hospitals is going to be put to, and perfectly rightly. There is something there which the roentgenologist, or rather which the roentgen-ray alone can determine, and it is a very fertile field in the films which you will see of the larynx, made under modern technique. The old reports were done at the time when the equipment was inadequate. Now we can make films, perfect films, of the larynx under instantaneous exposures, and with your close coöperation, I think possibly some information can be obtained as to the reason and the meaning of this ossification.

DR. SAMUEL IGLAUER, Cincinnati, Ohio:

There are just one or two points that Dr. Taylor did not mention, and one is ossification in the trachea. It can be shown in the roentgen-ray occasionally that the tracheal rings are ossified and that has some surgical and clinical importance, and I believe in the literature you will find occasional reference to ossification of the epiglottis, though I think that is exceedingly rare.

I recall, too, that in one roentgen-ray film, calcification (we will call it) was shown about the tracheotomy tube which the patient had worn for a long time, so that one can have ossification in the soft tissues in a tracheotomy.

I think Dr. Taylor has made an error in trying to have the exception prove the rule. He had a one-hundred-and-three-year-old man without ossification and a boy fourteen with considerable ossification, but those are the exceptions, and, as a rule, ossification, from what I have read and seen, follows a pretty general plan according to age.

Typhoid fever was also mentioned, and you will recall that in typhoid fever patients you occasionally get an ulceration of the mucosa on the back wall of the cricoid cartilage, and this is supposed to be due to the patient's lying in a stupor with the cricoid pressing against the vertebral column, and since the cricoid ossifies, particularly in the seal portion of the ring, the presence of ossification may promote ulceration in a patient lying in a stupor for a long, long time.

DR. LEE WALLACE DEAN, St. Louis, Mo.

I would like to mention the similarity of ossification of the cartilages of the external ear with that which occurs in the larynx. Sometimes the external ear becomes so brittle that it can be easily fractured. One such case was carefully studied and no metabolic or endocrine disturbance found. It seems to be a variation of the normal physiological osseous change in the external ear.

It would be interesting to study the changes in the ear and larynx of the same patient. Routine roentgen-ray examination of the external ears of adults shows that islands of calcification, often ossification, are commonly present.

DR. H. M. TAYLOR (in closing):

Dr. Spencer has referred to the relationship of tuberculosis to the ossification of the laryngeal cartilages. According to the literature which I reviewed, tuberculosis retards ossification.

Dr. Beck has spoken of otosclerosis and its possible relationship to the subject of this paper. I have seen two otosclerotics under forty-five years of age who showed very marked ossification of the laryngeal cartilages. A woman, aged thirty-three years, showed marked ossification of the arytenoids, which are the last cartilages supposed to be ossified. A man of forty who showed a marked ossification of the thyroid, cricoid and arytenoid cartilages. At this time I would hesitate to venture the opinion that any relationship exists between these two conditions.

Dr. Barnhill spoke of the case I have reported as a foreign body. It was of interest to me that in the literature reviewed that not one of the 8 cases in which cartilage was expelled was the diagnosis made

beforehand. Some of these cases, doubtless, had an abscess of the larynx. If a roentgen study had been made these foreign bodies might have been diagnosed and the patient saved much distress.

In reply to Dr. Iglauer, will state that Segond reported that after a dissection of a large number of larynges of subjects over eighty years of age, that he could not observe any ossification in the epiglottis, the corniculate and the cuneiform cartilages.

I think it would be interesting if Dr. Dean would have a roentgen study made of the larynx of his patient who had such a marked ossification of the cartilages of the ear.

I wish to thank the gentlemen for their discussions.

FURTHER STUDY OF THE EFFECTS OF DRUGS ON CILIARY ACTIVITY. A NEW METHOD OF OBSERVATION IN THE LIVING ANIMAL*

D. M. LIERLE, M.D.

AND

P. M. MOORE, M.D.

SEVERAL years ago the authors became interested in the immediate direct effects of certain drugs on the speed and continuation of ciliary activity. It seemed desirable to know whether any of the drugs used in the daily treatment of the nose had a deleterious influence on this mechanism. Accordingly, a series of the more commonly used drugs was selected and their effects noted upon: (1) The extirpated human mucosa mounted in a special chamber, and (2) the nasal mucosa, *in situ*, of freshly killed guinea-pigs.¹

It was realized that the conditions under which the observations were made differed considerably from those existing in the noses and sinuses of living animals. Care was taken to keep the tissue at the optimum temperature, to protect it from drying and to supply it with the proper nourishment. The mucous sheet was largely eliminated by continuous washing with Locke's solution, so that the effects noted were due to the simple direct action of the drug upon the cilia, uncomplicated by any variable modifying influences.

After noting the simple reactions of the cilia to the drugs employed, the next step was to see how results might be modified in the living animal. Accordingly, the present work was undertaken and an attempt made to approximate, as nearly as possible, the natural conditions existing in the maxillary sinus *in vivo*. Although some observations were made upon the live guinea-pig, this animal proved unsatisfactory for the study. The successful observations upon the living rabbit, reported by Proetz,^{2,3} suggested a suitable subject for the present experiment.

* From the Department of Otolaryngology and Oral Surgery, University Hospital, Iowa City, Iowa.

In 1924, J. C. Sandison,⁴ working under E. R. Clark, reported the use of transparent windows in the microscopic study of living cells and bloodvessels in the rabbit's ear. A number of subsequent publications have given the results of these studies and have recorded certain improvements.^{5,6}

It was quite obvious that conditions in the unopened sinus could not be duplicated. Nevertheless, it was felt that the use of the transparent window would come much closer to the normal conditions than any method previously used. This method leaves much to be desired, and it is hoped that some future work will eliminate the shortcomings of the present method. There was no escaping the trauma and shock of a surgical procedure and a certain amount of serous exudate from the cut tissue was unavoidable. It was necessary also to remove the membrane completely from the lateral wall of the sinus, reducing the number of mucous secreting elements and possibly interfering with some of the normal currents of mucous flow.

Two materials were tried for the windows: glass and pyralin. The glass was much clearer for microscopic observations, but because it offered so little resistance to the passage of light rays, it was difficult to keep it sufficiently warm to prevent fogging on its inner surface, without subjecting the membrane beneath it to too much heat.⁷ On the other hand, pyralin scratched easily, and at times revealed the image slightly distorted, but it absorbed heat from the light so readily that it was easily defogged without raising the temperature of the membrane above 97° F.

Because of the low magnification required, the poorer optical qualities of the pyralin did not interfere with the observations. The material used was .025 inch and was cut in an oval shape to fit over the opening made in the lateral surface of the maxillary bone. Two holes were bored in each window. When the window was in place, one hole was in an antero-inferior position for the drainage of serum and excess fluids, and the other was in a postero-superior position for the introduction of drugs. When not in use, both holes were closed with moistened plugs of cotton, to check drying and to prevent passage of air and consequent disturbance of air currents.

The rabbits were anesthetized by intravenous injection of 0.3 cc.

veterinarian nembutal per pound of body weight. This gave a deep satisfactory surgical anesthesia. It was necessary to repeat half of the original dose when the observations extended over more than a two-hour period.

This procedure was followed: The side of the nose was shaved. a longitudinal incision was made over the groove on the side of the nose just below the nasal bone and the frontal process of the premaxilla. This groove is produced by a large dehiscence in the maxillary bone and is filled with fibrous tissue. The angular vein lies in the middle of the groove. The dissection was carried down to the frontal process of the premaxilla, reflecting the angular vein downward. The fibrous tissue was dissected away from the edges of the bone and lifted off the mucous membrane of the lateral wall of the antrum. If great care is taken, this can be accomplished without tearing the mucous membrane. The membrane next was elevated from the inner surface of the maxilla and the bone removed with rongeurs to the floor of the sinus. All bleeding was controlled carefully before the sinus cavity was opened. When the wound was dry the mucous membrane was removed from the lateral wall of the antrum. No bleeding attended this procedure. The window, already prepared, was inserted beneath the skin and subcutaneous tissues, where it acted as a partial retractor, keeping the skin edges apart. Usually the skin overlapped the edges of the window sufficiently so that the tissue juices sealed it in place, making the cavity airtight again. When this did not take place, the skin was drawn together at one end of the incision with sutures.*

The first three windows inserted were provided with only one hole. This was threaded and could be closed with a brass screw. These windows were left in place. In one instance there was necrosis of the skin, and the window fell out at the end of three weeks. The skin healed firmly around the other two and held them in place. However, by the end of a month, granulation tissue had grown in beneath the windows from all sides, so that the opening into the sinus had been markedly reduced. One of these windows was removed and the opening carefully enlarged.

* In a very recent work, Lucas and Douglas⁸ have used a similar procedure in making observations on the trachea of the turtle, and have tried the transparent window in experiments on ducks.

There was some thick exudate in the sinus. When this was washed out with Locke's solution, active cilia could be seen.

An improved type of window is being developed at the present time which may prevent the encroachment of tissue from the sides, and so provide a permanent transparent inset through which the ciliary reactions can be observed over periods of days or weeks. In the meantime it was decided that observations would be made upon the freshly prepared rabbit to determine the immediate effects of the drugs used, and to record those recoveries which occurred within a relatively short time.

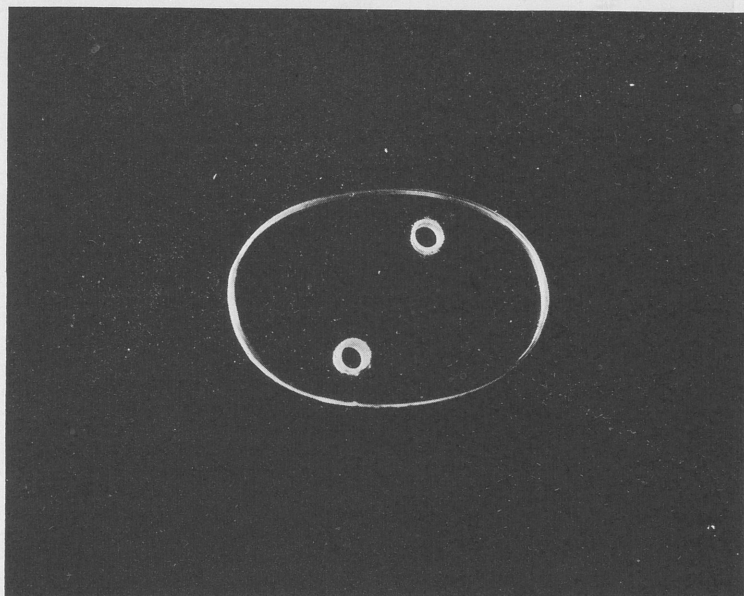


FIG. 1.—Transparent window.

The prepared rabbit was put in a holding box which was placed on a movable stage (Fig. 1, 2 and 3).

Because of the small size of the aperture through which the observations were made, a more compact lighting arrangement than that used on the guinea-pigs was required. A Leitz ultrapak illuminator was placed on the microscope and illumination similar

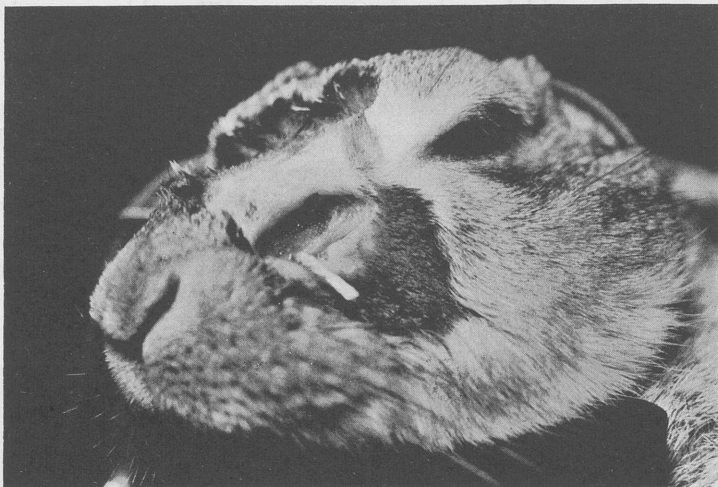

FIG. 2.—Window in place.

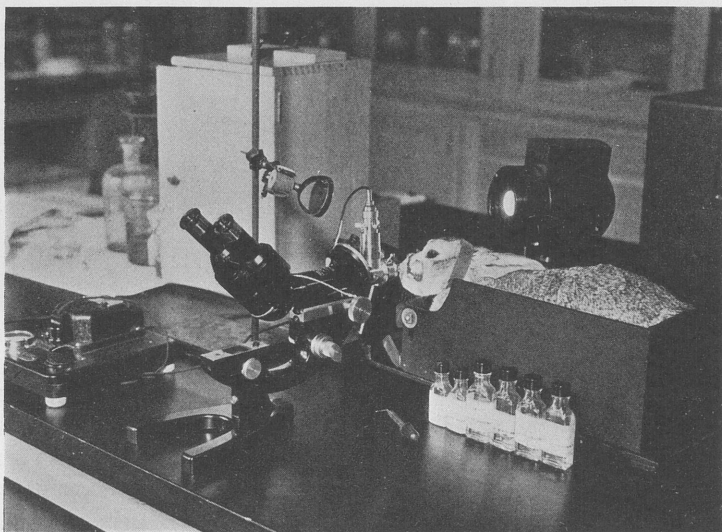


FIG. 3.—Complete apparatus.

to that used by Proetz^{2,9,10} was obtained. There were times, however, when the mirror reflection method,^{1,11} used previously, gave better results on a given subject. The ultrapak illuminator did not give off sufficient heat to keep the window free from fog, so that when observations were being made the mirror reflection was used from time to time to clear the window.

The drugs were applied with medicine-droppers drawn out to fine points. The plug in the postero-superior hole was removed. The tip of the dropper was inserted through the hole until it could be seen in the microscopic field, and 1 or 2 small drops of the drug were applied directly to the cilia which had been visualized. Only one application of the drug was made. The hole was plugged again and the immediate effect of the drug was noted. During observations requiring five minutes or less, the area was watched constantly. Those requiring longer periods were noted at regular intervals.

When a drug caused a slowing or cessation of the beat, timed observations were continued until there was a recovery, or until all hope of recovery without regeneration was gone. No washing of any kind was employed. All drugs which were compatible with Locke's solution were placed in it, as in previous experiments. This was done to eliminate any possible slowing, due to a water solvent. Those drugs which were incompatible with Locke's were used in aqueous solution.

The tables of results obtained in previous studies are repeated here so that the *in vivo* observations may be compared with them. The saturated thymol in Locke's solution and the 0.5 per cent silver nitrate were eliminated from the present list of drugs because of their marked toxicity. The 10 per cent solution of the mild silver protein was the only one repeated. Phenyl mercuric nitrate, 1 to 10,000, was added to the list.

There were some essential differences in the *modus operandi* of the observations made on the excised tissue, the freshly killed guinea-pig, and of those made on the living animal. In the former experiments, the tissues were bathed continuously in the drug until a reaction was observed. They were then washed in Locke's solution until recovery took place. In the living animal only 1 or 2 drops of a drug were applied and no washing of any kind

was done. This latter procedure was used to approximate the application of drugs in the nose, by drops or by spray from an atomizer. The actual use of the spray was not practical during these experiments, because droplets deposited upon the inner surface of the window would have interfered with observations.

TABLE 1.—RESULTS OF DETERMINATIONS MADE IN THE CHAMBER.*

Drug.	Effect.												
	1.	2.	3.	4.	5.	6.	7.	8.	9.	10.	11.	12.	13.
Ephedrine, 3 per cent .	0	0	0	0	0	0	0	0	0	I 2'	0	I	0
Cocaine, 5 per cent .	DR	DR	DR	0	0	0	0	0	0	0	DR	0	0
Menthol, 1 per cent .	DR	DR	DR	0	DR	DR	DR	DR	DR	DR	0	DR	DR
	2'		2'										3'
Thymol, 1 per cent .	SR	S	DR	DR	DR	DR	DR	S	S	S	S	S	S
	1'30"	1'30"	40"	30"	30"	40"	30"	3'15"	3'	3'	1'15"	1'	1'15"
Eucalyptol, 1 per cent .	SR	S	S	S	S	DR	S	S	S	S	S	S	S
	2'				2'		3'	3'				2'15"	2'30"
Atropine, 1 per cent .	DR	0	0	0	0	0	0	0	0	0	0	0	0

* Time five minutes unless otherwise specified. I indicates increase; D, decrease; 0, no change; S, stopped; R, recovery after washing with Locke's solution.

ANALYSIS OF DATA. In general, the reactions were the same. Those drugs which stopped or slowed the ciliary beat did so in all three series. The elapsed time from the application of a drug to the reaction did not differ materially in the three series. In many instances a more rapid and more marked effect was obtained in the living rabbit than in the tissues used in the previous series. This would seem to indicate that the normal mucous sheet does not prevent the penetration of a drug incorporated in an aqueous or a Locke's solution.

Five per cent cocaine hydrochloride in Locke's solution produced no effect in any of the three series. Ten and 20 per cent cocaine hydrochloride in Locke's solution produced a more rapid and more marked effect in the living rabbit than in the freshly killed guinea-pig.

Three per cent ephedrine sulphate in Locke's solution produced no slowing of the beat in any of the series. In the freshly killed guinea-pig it produced a mild increase in speed in those cases where the activity was below par from the previous application of a drug. This was the only drug used under such conditions, and it was so used deliberately in some of the determinations to establish this

TABLE 2.—RESULTS OBTAINED ON INTACT TURBINATE WITH DRUGS IN LOCKE'S SOLUTION*

Drug.	Effect.																			
	1.	2.	3.	4.	5.	6.	7.	8.	9.	10.	11.	12.	13.	14.	15.	16.	17.	18.	19.	20.
Cocaine, 5%	0	DR	0	0	0	0	0	0	DR	0										
Cocaine, 10%	DR	DR	DR _a	DR	0	DR	DR	DR	DR	DR										
	3'15"	2'15"	1'12"	4'35"		3'35"	2'	2'	1'30"	2'										
Cocaine, 20%	SR	SR	DR _a	DR	SR	SR	SR	DR	DR	DR										
	2'	1'30"	35"	1'30"	45"	30"	30"	2'	1'	1'										
Ephedrine, 3%	Ia	Ia	Ia	0	0	0	0	I	I	I	0	Ia	0	0	I	0	Ia	Ia	Ia	0
						3'	3'				3'				45"	1'45"	1'30"	1'30"	1'20"	4'
Menthol, 1%	DR	DR	DR	0	DR	DR	DR	DR	DR	DR	DR	DR	DR	DR	DR	DR	DR	DR	DR	DR
	2'30"	4'			3'	2'15"	3'	4'10"	1'15"	2'30"				3'30"	3'10"		4'		3'45"	
Menthol, 0.5%	0	0	DR	DR	DR	DR	DR	DR	DR	DR	DR	DR	DR	DR	DR	DR	DR	DR	DR	DR
				3'	4'		2'30"	3'	4'		3'	1'		2'		3'15"	3'15"	3'15"	2'30"	
Thymol, 0.5%	S	DR	S	S	DR	S	S	S	S	DR	DR	DR	DR	DR	S	S	S	DR	DR	DR
	1'	2'	2'	1'	1'15"	1'20"	1'10"	1'15"	2'	1'30"	30"	49"	1'30"	30"	45'	1'	1'20"	40"	1'15"	1'
Thymol, 1%	S	S	S	DR	S	DR	S	DR	DR	S	DR	DR	S	DR	DR	DR	DR	DR	DR	DR
	1'	2'	2'	30"	1'	50"	1'30"	30"	45"	45"	45"	1'	1'10"	1'30"	30"	30"	30"	1'	15"	30"
Eucalyptol, 0.5%	0	0	0	0	0	0	0	0	0	0	0	0	0	0	I	0	0	0	0	0
Eucalyptol, 1%	DR	DR	S	DR	DR	DR	DR	DR	DR	DR	DR	DR	DR	DR	S	DR	DR	DR	DR	DR
	4'20"	3'51"	2'	3'	3'		1'30"	1'45"	3'30"	1'15"	3'30"	3'	1'	2'	4'5"	4'	2'	1'	1'20"	2'5"

* Time five minutes, unless otherwise specified. I indicates increase; D, decrease; 0, no change; a, activity impaired before application of drug; S, stopped; R, recovery after washing with Locke's solution.

particular effect. It seems to restore normal activity in certain instances where the speed has been depressed.

The saturated solution of menthol in Locke's (approximately 1 per cent) gave the same results in all three series; a mild slowing of the beat with complete recovery.

The saturated solution of eucalyptol in Locke's (approximately 1 per cent) gave somewhat variable results. In the excised tissue and the live rabbit, it stopped the beat. In the former there was seldom any recovery. In the latter, recovery always took place. In the guinea-pig the beat was seldom stopped, but this may have been the result of very prompt washing. If washed before the beat ceased there was fairly good recovery. The effect appeared more quickly in the live rabbit than in the other two series.

Epinephrin hydrochloride, 1 to 1000, gave the same immediate cessation of activity in both series in which it was used. Recovery in the freshly killed guinea-pig depended on immediate washing with Locke's solution, and failed to occur in six of the twenty determinations. In the live rabbit, recovery occurred in all of the five tests without washing.

Two per cent mercurochrome gave the same slowing, with recovery in both series in which it was used.

Two per cent zinc sulphate produced a very rapid reaction in both series. If washed with Locke's solution before the beat was stopped or at the moment of cessation of movement, there was fair recovery in the guinea-pig. In the living rabbit there was no washing and no recovery.

Ten per cent mild silver protein resulted in the same slowing of the ciliary beat, with recovery in both series. The initial acceleration was not noted in the live rabbit and the depressing effect appeared sooner than in the freshly killed guinea-pig.

Phenylmercuric nitrate, 1 to 10,000, produced rather prompt cessation of the beat, but recovery ensued in from one and a half to five minutes.

DISCUSSION. The degree and prolongation of the effect in the living rabbit depended largely upon the location of the area under observation. When the drug merely touched the area and was carried away by gravity and the flow of mucus, the reaction was slight and the recovery prompt. In one instance there was no

TABLE 3.—RESULTS OBTAINED ON INTACT TURBINATE WITH DRUGS IN AQUEOUS SOLUTION*

Drug.	Effect.																			
	1.	2.	3.	4.	5.	6.	7.	8.	9.	10.	11.	12.	13.	14.	15.	16.	17.	18.	19.	20.
Cocaine, 5%	DR 3'30"	DR 4'	DR 1'	DR 2'	DR 1'15"	DR 4'15"	DR 2'40"	DR 1'50"	DR 1'5"	DR 2'3"										
Cocaine, 10%	DR	DR 3'	SR 3'	DR 3'	DR 1'15"	DR	DR 3'30"	DR 1'	DR	DR 2'40"										
Cocaine, 20%	DR 3'	DR	SR 0'	DR 1'	DR 3'	DR 1'40"	DR 1'50"	DR 1'	DR 3'	DR 4'	DR 1'	DR 2'								
Epinephrin, 1 to 1000 . .	S 45"	SR 0'	S 0'	S 1'	DR 20"	S 55"	DR 28"	SR 45"	SR 1'30"	S 30"	SR 0'	SR 0'	DR 5"	DR 0'	DR 0'	DR 5"	DR 0'	DR 10"	DR 1'	S 1'
Mercurochrome, 2% . .	DR 1'	DR 1'	S 1'	DR 1'	DR 1'	S 1'	S 1'	DR 2'	DR 30"	DR 20"	DR 20"	S 2'30"	DR 2'30"	S 2'	S 1'40"	DR 1'	DR 1'1'	DR 1'30"	DR 2'7"	DR
Silver nitrate, 0.5% . .	S 1'	S 0'	S 1'15"	S 1'	S 0'	S 15"	S 0'	S 1'	S 30"	S 1'30"	S 0'	S 0'	S 15"	S 0'	S 0'	S 0'	S 0'	S 0'	S 0'	S 0'
Zinc sulphate, 2% . .	SR 30"	S 2'	SR 3'	SR 2'	SR 15"	DR 55"	SR	DR	DR	DR 15"	DR 10"	DR 15"	DR 30"	DR 30"	DR 1'30"	DR 1'	DR 1'	S 1'	DR 38"	DR 30"
Mild silver protein, 5% .	†DR	†SR 4'	†DR 4'	DR 2'45"	†DR	†DR 4'	†DR 3'30"	†DR 2'	†DR 3'	†DR	†DR 3'20"	†DR	†DR	†SR 2'15"	†DR 2'	†DR 3'10"	†DR 3'10"	†DR 4'	†DR	†DR
Mild silver protein, 10% .	†DR	†DR 4'	†DR	†DR	†DR	†DR 3'30"	†DR 4'30"	†DR 2'	†DR 2'	†DR 3'30"	†DR 3'	†DR 2'	†DR 2'30"	†DR	†DR 2'	†DR 3'40"	†DR 3'	†DR 4'45"	I	†DR
Mild silver protein, 20% .	†S	†DR 2'30"	†DR 4'	†DR	†DR 3'	†DR 2'45"	†DR 1'15"	†DR 2'30"	†S	†DR 3'15"	†DR 4'	†DR 1'30"	†DR 4'	†DR 3'10"	I	†DR 3'30"	†DR 4'30"	†DR 4'	†DR	I

* Time five minutes, unless otherwise specified. I indicates increase; D, decrease; 0, no change; S, stopped; R, recovery.
† Initial speeding.

TABLE 4.—RESULTS OBTAINED ON MUCOUS MEMBRANE OF RABBIT'S ANTRUM IN VIVO*

Drug.	1.		2.		3.		4.		5.	
	Effect.	Recovery.	Effect.	Recovery.	Effect.	Recovery.	Effect.	Recovery.	Effect.	Recovery.
Cocaine 5 per cent in Locke's . .	None in 5'		None in 5'		None in 5'		None in 5'		None in 9'	
Cocaine 10 per cent in Locke's . .	D 1'	Norm. 2'20"	D 1'45" S 2'40"	Fair 15'40" Norm. 22'	S 15"	Fair 9' Norm. 13'	S 15"	Fair 2'30" Norm. 6'	S 45"	Fair 4' Norm. 12'
Cocaine 20 per cent in Locke's . .	S 0"	Fair 24'30" Norm. 61'	S 0"	Norm. 30'	None in 5'		S 15"	Norm. 27'	S 20"	Fair 7' Norm. 10'
Ephedrine 3 per cent in Locke's .	None in 5'		None in 5'		None in 7'		None in 8'		None in 12'	
Menthol sat. sol. in Locke's . .	D 3' D 6' Very	Norm. 24'	D 6'	Norm. 19'	D 40"	Norm. 2'	D 1'30"	Norm. 3'	Not seen until 3'	Norm. 3'
Eucalyptol sat. in Locke's . .	D 45"	Norm. 30'	S 0"	Norm. 5'	S 1'	Fair 7' Norm. 29'	S 0"	Norm. 13'	S 0"	None in 5'
Epinephrin 1 to 1000	S 2'	Norm. 80'	D 0" S 1'	Fair 78' Norm. 84'	S 0"	Norm. 13'	S 0"	Fair 14' Norm. 18'	S 0'	Fair 12' Norm. 55'
Merurochrome 2 per cent	D 1'	Norm. 2'30"	D 35" S 1'15"	Fair 2' Norm. 4'	D 8" S 35"	Fair 1'45" Norm. 2'15"	D 1'	Fair 2'30" Norm. 3'30"		
Zinc sulphate 2 per cent	S 5"	None in 3 hr.	S 10"	None	S 5"	None	S 10"	None	S 15"	None
Mild silver protein 10 per cent .	D 25"	Fair 1'30" Norm. 2'40"	D 40"	Norm. 2'	D 20"	Norm. 2'	D 30"	Norm. 4'	D 20"	Norm. 5'
Phenyl mercuric nitrate 1 to 10,000	S 1'	Norm. 3'45"	S 50"	Fair 2'15" Norm. 5'	S 30"	Norm. 2'30"	S 10"	Norm. 1'30"	S 25"	Fair 2'20" Norm. 4'30"

* D indicates decrease; S, stopped; Norm., normal.

reaction at all to 20 per cent cocaine in the area which was visualized. If the cilia were near the floor of the sinus where the drug remained in contact, or was carried back over the cilia by the normal flow of mucus, the reaction was more marked and more prolonged.

In one of the observations two areas were visualized, one above the other. Eucalyptol was applied to the lower one and the cilia stopped immediately. The flow of mucus was maintained, however, by the cilia above, and at the end of one and a half minutes had carried the drug up to the second area, and these cilia were also stopped. Twenty per cent cocaine, 2 per cent zinc sulphate and phenyl mercuric nitrate, 1 to 10,000, usually stopped the flow of mucus as well as the beat of the cilia.

Lucas and Douglas¹² have demonstrated by careful observation and numerous fixed and stained microscopic slides that the normal mucous sheet is composed of two layers. There is an overlying viscid sheet which is in contact with the tips of the cilia and a serous fluid layer in which the cilia vibrate. They make the following statements: "(1) Slight drying, which does not affect the underlying cilia, could increase the viscosity of the mucous layer so that ciliary action would fail to move it. (2) Overabundance of fluid in the lower layer could elevate the mucous sheet so that the cilia would fail to make contact with it and thus be unable to propel it along. (3) Diminution of the fluid layer to the extent that the mucus settled close to the cellular surface would slow and probably stop the action of the cilia."

In the course of these experiments the mucous sheet was observed to change character under certain conditions. Phenyl mercuric nitrate immediately produced a glazed, uneven appearance, as though the serous fluid layer had been drawn away, allowing the mucus to drop down on the cells themselves. Zinc sulphate and mercurochrome produced a similar effect, but in addition deposited a precipitate on the mucus itself. After the immediate reaction and recovery had taken place with mercurochrome and mild silver protein, there seemed to be a continued precipitation on and into the mucous sheet, interfering with its movement and with the visualization of the cilia beneath it. There were also times when the addition of some fluid to the surface of the mucous membrane seemed to lift up the mucous layer. The reflex highlight became

indistinct, the flow of the mucus decreased or stopped, and no evidence of the ciliary beat could be seen. All of these reactions had to be considered in interpreting the results of these experiments. When the mucous sheet was so altered that ciliary activity could not be seen, even if it were present, the observation was discarded.

Several times ephedrine and argyrol were applied to the mucous membrane on tampons which were left in place five minutes each. This was done to see what effect the pack itself might have. When the pack was soft and gently applied the drugs produced the same effects which were noted when they were dropped on the membrane. The pack did alter the surface of the mucus slightly, however. When the pack was wound tightly and wedged against the membrane no ciliary activity could be visualized after its removal.

In comparing these results with those of other workers in this field, one must make allowances for the difference in methods. One investigator reports more marked response to 5 and 10 per cent cocaine in both the extirpated membrane and the living rabbit. He found a prolonged action with the 5 per cent solution and only occasional recovery with the 10 per cent solution. He noted the same immediate response to epinephrin, 1 to 1000, but saw no recovery. He obtained the same response with 2 per cent mercurochrome, but interpreted the 10 per cent argyrol as interfering mechanically with streaming and not affecting the ciliary beat. The difference in response to cocaine may be due to the fact that the drug was placed in Locke's solution for the tests reported in this paper. In the work with the freshly killed guinea-pig the effects of cocaine in Locke's solution and in aqueous solution were compared. Five per cent cocaine in water uniformly depressed ciliary activity but showed no such effect when used in Locke's solution. The ability of the cilia to recover after cocaine and epinephrin in this series may have been due to the added protection afforded by the transparent window.

Injections of epinephrin, pilocarpine, atropine, morphine and alcohol into the blood stream of the turtle were made by Lucas and Douglas.⁸ They found these to have no effect on the activity of the tracheal cilia. Florey, Carleton and Wells¹³ had previously reported acceleration of the flow of mucus in the trachea of the cat

after injection of pilocarpine. They did not comment on the speed of the ciliary beat. The result they noted was probably due to a change in the viscosity and supply of mucus.

Lucas and Douglas⁸ reported the tracheal cilia to be normally continuously active, in contrast to those in the frog's mouth, which were inactive until aroused by definite stimuli.¹¹ In the course of the present experiments, the cilia of the upper respiratory tracts of man, dog, rabbit and guinea-pig were found to be normally continuously active. This coincides with the concept of the function of the cilia of the respiratory tract,¹⁴ where their constant activity is required to keep the membranes clean.

CONCLUSIONS. 1. The use of transparent windows in the lateral walls of the maxillary sinuses of living rabbits permits the study of the cilia of the mucous membrane under conditions more nearly normal than heretofore has been possible. However, the method does not duplicate the natural conditions present in the unopened sinuses.

2. There are no essential differences as far as could be determined in the reaction of drugs of this series in freshly killed and in living animals.

3. The mucous sheet in the living animal does not constitute a barrier to the penetration of drugs incorporated in an aqueous or a Locke's solution.

4. Although many drugs depress or stop the activity of the cilia, only those in this series which are actual cauterizing agents produce any permanent injury. The effects of the others are only temporary when applied as drops, sprays or on tampons left in place but a short time.

5. When possible, it would be advisable to use the least toxic drug, or the most dilute solutions of a drug, to produce the desired effect. Menthol and eucalyptol, if used, should not be stronger than 0.5 per cent, and either one is preferable to thymol. Epinephrine would be better than epinephrin.

6. It is best to avoid as much as possible those drugs which clog up the mucous sheet with precipitate and interfere with its efficiency. This is especially true of mercurochrome, and to less extent of the higher concentrations of mild silver protein.

7. When nasal tampons are used they should be soft and should be inserted very gently.

8. Distilled and tap water cause slowing of ciliary beat. Therefore, it is suggested that drugs which are compatible be used in an isotonic solution, such as Locke's solution, rather than in ordinary aqueous solutions.

BIBLIOGRAPHY

1. Lierle, D. M., and Moore, P. M.: Effects of Drugs on Ciliary Activity of Mucosa of Upper Respiratory Tract, Arch. Otolaryngol., **19**, 55, 1934.
2. Proetz, A. W.: Nasal Cilia in the Living Mammal, Ann. Otol., Rhinol. and Otolaryngol., **42**, 778, 1933.
3. Proetz, A. W.: Effects of Certain Drugs Upon Living Ciliated Epithelium, Ann. Otol., Rhinol. and Laryngol., **43**, 450, 1934.
4. Sandison, J. C.: A New Method for the Study of Living Growing Tissues by the Introduction of a Transparent Chamber in the Rabbit's Ear, Anat. Rec., **28**, 281, 1924.
5. Sandison, J. C.: Demonstration of Growing Tissues as Seen in a Transparent Chamber Introduced into a Rabbit's Ear, Anat. Rec., **35**, 54, 1927.
6. Sandison, J. C.: The Transparent Chamber of the Rabbit's Ear, Giving a Complete Description of Improved Technique of Construction and Introduction, and General Account of Growth and Behavior of Living Cells and Tissues as Seen With the Microscope, Am. Jour. Anat., **41**, 447, 1928.
7. Proetz, A. W.: Effect of Temperature on Nasal Cilia, Arch. Otolaryngol., **19**, 607, 1934.
8. Lucas, A. M., and Douglas, L. C.: Principles Underlying Ciliary Activity in the Respiratory Tract: III. Independence of Tracheal Cilia *in Vivo* of Drug and Neurogenous Stimuli, Arch. Otolaryngol., **21**, 285, 1935.
9. Proetz, A. W.: Apparatus for Observing Ciliary Motion, Trans. Sect. Laryngol., Otol. and Rhinol., Am. Med. Assn., p. 260, 1933.
10. Proetz, A. W.: Nasal Ciliated Epithelium, With Special Reference to Infection and Treatment, Jour. Laryngol. and Otolaryngol. vol. **49**, No. 9, 1934.
11. Lucas, A. M.: Principles Underlying Ciliary Activity in the Respiratory Tract: I. Method for Direct Observation of Cilia *in Situ* and Its Application, Arch. Otolaryngol., **18**, 516, 1933.
12. Lucas, A. M., and Douglas, L. C.: Principles Underlying Ciliary Activity in the Respiratory Tract: II. A Comparison of Nasal Clearance in Man, Monkey and Other Animals, Arch. Otolaryngol., **20**, 518, 1934.
13. Florey, H., Carleton, H. M., and Wells, A. Q.: Mucous Secretion in Trachea, Brit. Jour. Exp. Path., **13**, 269, 1932.
14. Yates, A. L.: Methods of Estimating Activity of Ciliary Epithelium Within the Sinuses, Jour. Laryngol. and Otol., **39**, 554, 1924. Hilding, A.: Ciliary Activity and Course of Secretion Currents of Nose, Proc. Staff Meet. Mayo Clin., **6**, 285, 1931; Influence of Ciliary Activity on Bacteriology of Nose: Direction of Ciliary Currents in Frontal Sinus of Dog, Ibid., **6**, 320, 1931; Physiology of Drainage of Nasal Mucus: Flow of Mucous Currents Through Drainage System of Nasal Mucosa and Its Relation to Ciliary Activity, Arch. Otolaryngol., **15**, 92, 1932; Physiology of Drainage of Nasal Mucus: Cilia and Mucin in Mechanical Defense of Nasal Mucosa, Ann. Otol., Rhinol. and Laryngol., **41**, 52, 1932. Lucas, A. M.: The Nasal Cavity and Direction of Fluid by Ciliary Movement in Macacus Rhesus, Am. Jour. Anat., **50**, 141, 1932.

THE RESPONSE OF ALLERGIC PHENOMENA TO IONIZATION*

ARTHUR M. ALDEN, A.M., M.D., F.A.C.S.

IONIZATION, or iontophoresis, has for many years been used in the treatment of various diseases of the skin and mucous membranes. One of the first references to its use in the nose was that by Baber,¹ published in 1898. He suggested its employment in the treatment of nasal hydrorrhea and in the light of our present information it is probable that many of his watery nose cases were really allergic in origin. At one time or another ionization has been employed in the treatment of almost all of the obstructive or infective diseases of the nose. Fox,² Hollender and Cottle,³ Harris,⁴ Feldman,⁵ Gale,⁶ Smith,⁷ Cahill,⁸ McCoy,⁹ Sputh,¹⁰ McCurdy¹¹ have each reported on the use of the galvanic current and solutions of zinc or other metals in the treatment of these various nasal conditions.

In 1927, Demetriades¹² reported that ionization of the nasal mucosa, using a weak galvanic current and a calcium electrolyte, gave relief in certain cases of seasonal and perennial nasal allergy. Franklin,¹³ in 1931, and again in 1932,¹⁴ announced definite successes in the treatment of these conditions by the use of zinc ionization.

Warwick,¹⁵ in 1934, reported a large series of cases which had obtained partial or complete relief from their allergic symptoms following ionization with a combination of both zinc and cadmium in the electrode and electrolyte.

Ionization depends upon this principle: When a galvanic current is passed between two electrodes which are immersed in a conducting solution, positively charged metallic ions pass from the cathode and are deposited upon the metallic anode. When certain areas of the body are substituted for the conducting solution, the same principle holds good, and the ion-carrying current passes

* From the Department of Otolaryngology, Washington University Medical School, St. Louis, Mo.

from the positive to the negative pole, the intervening tissues merely acting as a conductor. At first it was supposed that the action of the treatment upon the tissues contiguous to the cathode was due to metallic ions which were driven into the tissues. This has been definitely disproven. Lierle and Sage¹⁶ examined tissues removed from ionized ears of animals and, after careful chemical and spectroscopic study, found no evidence that metallic zinc

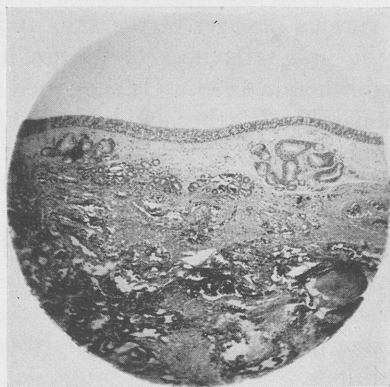


FIG. 1.—M. G., female, aged forty-five years. This patient was ionized because of urticaria and asthma which had existed for more than twenty years. Both conditions have been so severe as to greatly interfere with her secretarial work. She had had three ionizations: October 31, 1933, December 5, 1933 and February 6, 1934. She has now been entirely free of asthma since immediately following her first ionization and has had no recurrence of hives since the last ionization. This patient was so grateful for the result secured that she was more than willing to have us remove a portion of middle turbinate which was done under local anesthesia, June 5, 1934, more than four months following her last ionization. It will be seen that the ciliated layer of the mucosa is intact and normal in every respect. True, there is a slight fibrosis in the subepithelial layer, but no more than one would expect in a patient, aged forty-five years. The glandular structures are entirely normal.

had actually penetrated the tissues during the process of ionization. However, a surface change in the mucosa exposed to the charged electrolyte does take place.

At the expiration of a nasal ionization, using a zinc electrode and a salt of zinc in the electrolyte, the mucous membrane is covered with a gray deposit which is probably a mild surface coagulation. That this is not due to the chemical action of the electrolyte solution alone has been definitely proven. Hollender¹⁷

tested this in control patients where noses were packed in every way similar to the preparation for ionization, but no current was used. The results were entirely negative in each case. I ionized 5 patients, doing the left side of each case in the routine manner. On the right side of each of these patients, saline was substituted for the zinc sulphate electrolyte and the same electrode and same

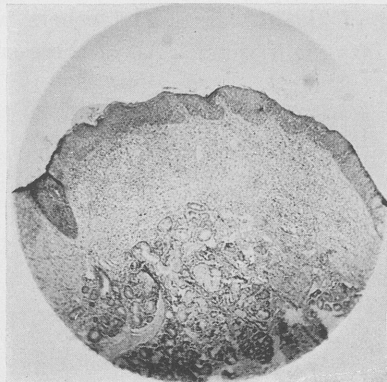


FIG. 2.—W. P. L., a male, aged forty years. This patient was ionized because of perennial nasal allergy for more than fifteen years. During all of this time the patient has been subject to recurrent attacks of sneezing, rhinorrhea and nasal obstruction. He had been subjected to all sorts of allergic investigation and therapy from which he had received, as he termed it, "no good whatsoever." Examination of smears from his nasal secretion showed a large proportion of the round cells present to be eosinophiles. All skin tests were negative. He was ionized, April 16, 1934, with complete symptomatic relief and has remained so up to the present time. A small portion of middle turbinate was removed under local anesthesia, June 30, 1934. This section shows a marked increase in the fibrous portion of the submucosa and some change in the epithelial layer. This change is in the direction of replacement of columnar epithelial cells with those of the squamous variety with some loss of the superficial glandular elements. The deep glandular structures are intact and normal. When one takes into consideration the fact that this patient has been subject to recurrent attacks of nasal intumescence for more than fifteen years, the residuum of submucosal thickening that is present in this case can be considered no more than normal.

time-ampere ratio was used. The results on the side where saline was used were entirely *nil*, and each was reionized in the standard manner a few days later. Thus, neither the electrolyte nor the galvanic current alone can produce the reaction, but the proper combination of the two is a prerequisite for success.

My experience with ionization in the treatment of hayfever

began the first week in September, 1933, when Dr. Warwick was kind enough to come to St. Louis and demonstrate this procedure to me. The results in the demonstration cases were so prompt and satisfactory that I decided to investigate this treatment more thoroughly on a group of my own cases.

During the 1933 season, I ionized 19 cases of typical autumnal hayfever. One of these patients was a child, aged ten years, in her third season of the disease. The others were all between twenty-two and fifty-eight years. All of these cases were ionized

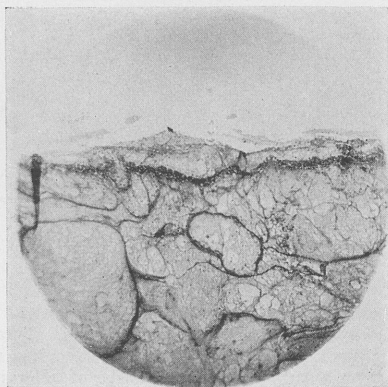


FIG. 3.—This section is from a portion of the membrane removed from the nose three days after ionization. This membrane was gently separated from both the septum and the lateral wall of the nose and removed with forceps. The diagnosis is, of course, that of a coagulated transudate. The deeper portion of this membrane is composed of fibrin enclosing many pockets which are filled with serum. The superficial border shows a moderate degree of infiltration with round cells, but there is no evidence of necrotic remains of nasal epithelium along the separating line.

during the period when the symptoms of the disease were definitely manifest, and 4 of the adults also had asthma at time of the ionization. Eleven of these patients had previously been treated by desensitization with unsatisfactory results. Five had received only local treatment, and 3, including the child, had received no treatment of any sort.

The result of the ionization in this group was immediate complete relief in each case of all allergic symptoms for the remainder of the season. The promptness with which the eye symptoms and the nasal itching abated following the treatment was little short

of spectacular. In all of these cases the nose was entirely blocked with a membrane the day following the ionization. This membrane remained in place for three to four days, then began to loosen and was, as a rule, entirely gone by the end of the sixth day. Immediately following the expulsion of the membrane, the nasal

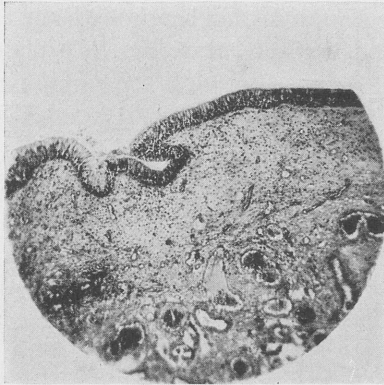


FIG. 4.—M. F., male, aged sixty-four years. This patient was referred by an eye specialist because of an allergic conjunctivitis which had been present for several years and had been completely resistant to all other methods of therapy. The patient said that he had had hayfever every year for more than half a century. Smears from the secretions of both the nose and conjunctiva were heavily loaded with eosinophiles. This was our first case of ionization done for relief of an allergic eye condition and was carried out purely upon an experimental basis. The marked diminution in the eye symptoms which followed the first ionization, done January 18, 1934, was so striking that a second treatment was requested, and this was done ten days later, January 28, 1934. While the relief from the eye symptoms was not complete, it was so marked as to make the remainder of his eye treatments much easier. Another interesting fact is that, although this patient was ionized more than seven months before the onset of the 1934 hayfever season, he went through the entire summer with no symptoms referable to this disease. The biopsy from his nasal mucosa was done five months after the first ionization. This is a magnification of $57\times$, showing mucosa, submucosa and normal glandular structures. The superficial ciliated layer of mucosa is normal and intact in every respect. There is a moderate amount of fibrosis in the submucosal layer. Considering the fact that this patient is sixty-four years of age and has had hayfever for more than half a century, this slight submucosal fibrosis can be considered as only normal in this case.

mucosa was found to be reddened and quite sensitive, but this condition subsided very rapidly, and by the end of the second week all noses appeared to be normal.

Since this first season we have used this method of treatment for all of our cases of both perennial and seasonal nasal allergy. Our

percentage of complete relief has varied from 60 to 70 per cent, depending upon the type of the disease and the seasonal timing of the treatment. Our total failures have been less than 20 per cent. During the year of 1934, we found that those cases of hayfever which were ionized prior to the beginning of the disease, presented a much larger number of recurrences than the group treated after the onset of their symptoms. There were some exceptions to this rule, however, and we were at a loss to explain several of our failures.

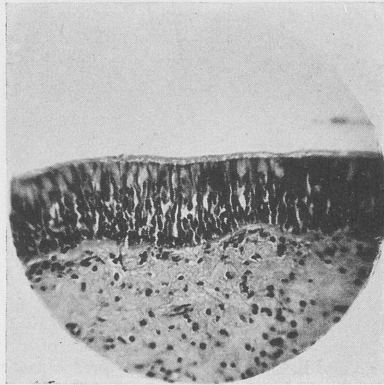


FIG. 5.—This is a higher power magnification, 256 \times , of the last section. This shows the normal functional layer of the mucosa with its intact cilia covered with a blanket of mucus, the goblet cells and other structures in this layer being entirely within normal limits. There is the slight fibrosis in the submucosal layer, but entirely without round-cell infiltration or other evidence of inflammatory reaction or previous trauma.

In an effort to learn more about the mechanism involved in the symptomatic relief that so frequently followed ionization and yet in other apparently similar cases failed, we had a group of patients studied from an immunologic standpoint before and after the treatment. These patients were treated in the Washington University Out-patient Department after a careful allergic history had been taken and rhinologic examination done by one of the members of the staff. This included a cytologic study of the nasal secretions in which the percentage of eosinophiles was estimated, intradermal skin tests done, positive reactions measured with a planimeter and recorded in square centimeters. The presence of specific reagins was determined by the usual passive transfer of

blood serum to the skin of a non-sensitive individual. The patient was then ionized and these same procedures repeated and recorded at the end of two weeks and again three months later. This work was done under the direction of Dr. H. L. Alexander,¹⁸ and reported in detail by him in the March, 1935, *Journal of Allergy*.

Although this was a relatively small number of cases, it was noteworthy that the group in which ionization gave the best results were those in which reagins in the blood serum were absent or present in small numbers. The converse was also true. Those cases in which ionization gave little or no relief were generally those in which the reagin content in the blood serum was relatively high.

In the period from sixty to thirty days before the beginning of the ragweed pollen season of 1934, 10 ragweed hayfever patients were tested and treated according to the following schedule:

Intradermal skin tests were done. The nasal mucosa was tested for sensitivity by the application of 1 drop of extract of whole ragweed pollen to the anterior tip of the right inferior turbinate. Starting with the dilution of 1 to 100,000, successively increasing concentrations were used until a definite reaction was secured. A sufficient time interval was allowed between tests to prevent cumulative action. After the degree of mucosal sensitivity had been determined, the patient was ionized and as soon as the nose appeared to be normal again, the skin and mucosal tests were repeated. The following is a tabulation of the results obtained in this experiment:

Case.	Before ionization.		After ionization.		Relief from symptoms. season of 1934.
	Skin test.	Mucosal test dilution.	Skin test.	Mucosal test.*	
1 . .	++	80,000	++	No reaction	90 per cent relief.
2 . .	+	50,000	++	No reaction	No symptoms.
3 . .	++	40,000	+	No reaction	No symptoms.
4 . .	++	70,000	++	1 to 1000	20 per cent relief; reionization done.
5 . .	++	80,000	++	No reaction	No symptoms.
6 . .	++	40,000	++	No reaction	80 per cent relief.
7 . .	+++	50,000	++	1 to 500	80 per cent relief.
8 . .	++	30,000	+	No reaction	No symptoms.
9 . .	++	40,000	++	No reaction	No symptoms.
10 . .	++	50,000	++	No reaction	50 per cent relief.

* Where no symptoms appeared after application of 1 drop of 1 to 100 extract, it is recorded as "no reaction."

An analysis of this group of cases is interesting and certain conclusions seem to be justified.

1. There was little or no change in the skin tests after ionization.
2. Tests of the sensitivity of the nasal mucosa to dilutions of pollen extract exhibited a marked change after ionization. Although the nose appeared to be normal in each case after the treatment, it was apparent that some change had taken place in 8 of the 10 cases, whereby the shock cells of the nasal mucous membrane were no longer reactive to the atopen, and in the 2 others a much greater concentration was required to produce a reaction.
3. These tests offered no criterion by which the symptomatic result from ionization might be predicted. The case which, after treatment, still reacted to a dilution of 1 to 1000 exhibited typical symptoms in the second week of the hayfever season and thirty-three days after ionization. A repetition of the treatment still failed to give adequate relief. Five cases had complete freedom from the disease and the other 4 were quite comfortable.

It would appear from this experiment that one is justified in the conclusion that the physiologic mechanism of relief is purely local, and yet there have been many notable exceptions to this that could not be explained upon the basis of a local change in the nasal mucosa. The relief in certain cases of urticaria, asthma and migraine without nasal symptoms which have followed ionization of the nose are at least difficult of explanation upon this basis and suggest some more far-reaching effect of the treatment. The complete disappearance of a 3+ skin test to orris root which followed ionization leaves the investigator even more in doubt.

Whether or not these immunologic studies before and after ionization will offer a criterion as to the result that may be expected from the treatment in any given patient, and will explain more fully just what happens during the process of ionization, can only be determined after a much larger series of patients have been studied. The preparation of such a series of carefully investigated cases is now well under way in the Department of Otolaryngology at Washington University, and a further report upon this investigation at some future time is anticipated.

The criticism of this work by McMahon¹⁹ and others, based upon the hypothetical damage that might possibly accrue to the nasal

mucous membrane as the direct result of the ionization, has little scientific basis. When we stop to think that we can entirely denude the maxillary sinus of its lining epithelium, and yet in a few weeks find it completely covered with a ciliated mucosa which is functionally normal in every respect, and in addition to this, considering the fact that the mucosa of the nasal chamber proper is much more resistant to trauma or environmental change than is that lining the sinus cavities, it is difficult to believe that, as the result of the slight irritative factor involved in ionization or other similar procedures, any permanent damage would occur to the nasal mucous membrane.

However, to be entirely certain about this point, sections of the nasal mucosa were removed from the noses of both animals and humans who had been previously ionized, and these sections have shown in every case a complete return to normal with no microscopic evidence of pathology that could logically be attributed to the ionization.

During the last one and a half years, ionization along the lines suggested by Warwick has been used, not only in our own clinic, but it has been employed with success in the treatment of several of the manifestations of allergy by well-recognized otolaryngologists all over America. A group of these men was asked to tabulate their results, and the following slides represent a summary of the relief obtained by them in over 700 bilateral ionizations, all done for seasonal or perennial allergic rhinitis and asthma.

HAYFEVER, UNCOMPLICATED. TOTAL CASES, 416		
Relief.	No.	Per cent.
Complete.	260	63.4
80 to 95 per cent	46	11.2
60 to 80 per cent	17	4.1
20 to 60 per cent	54	13.1
No relief	32	7.7

COMMENT. Although the complete relief was only 63 per cent, if one adds to this the 80 to 95 per cent group, it gives 75 per cent of the cases that received 80 to 100 per cent relief following ionization. It is noteworthy that the complete failures in this group were only about 8 per cent. It must be remembered that the majority of these patients was ionized just before or after the onset of their symptoms last year, and it is by no means expected

that the same ratio of freedom from symptoms will hold good in these patients during the coming season. Certainly, some of them will have resensitized their nasal mucosa and will need retreatment during this coming summer.

ASTHMA. TOTAL CASES, 27			
Relief.	No.	Per cent.	
Complete	10	37	
80 to 95 per cent	3		
60 to 80 per cent	1		
20 to 60 per cent	1		
No relief	12	44	

COMMENT. The percentage of relief obtained in this group of cases is only slightly more than one-half that in the preceding table, and the failures are more than five times as many as occurred in hayfever. One possible explanation is that there have been included in this relatively small group several cases of asthma that were not of allergic origin.

HAYFEVER AND ASTHMA. TOTAL CASES, 161				
Relief.	Hayfever.		Asthma.	
	No.	Per cent.	No.	Per cent.
Complete	106	66.2	85	53.1
80 to 95 per cent	14	8.7	13	8.2
60 to 80 per cent	15	8.9	18	11.2
20 to 60 per cent	14	8.7	23	14.3
No relief	12	7.4	21	13.1

COMMENT. It is interesting to note that in this group the 80 to 100 per cent figure of hayfever relief is exactly the same as that in the table for hayfever alone. The relief for the asthma in this group is much higher and the figure for failures much lower than in the preceding table, which was for asthma alone. This is probably accounted for by the fact that the asthma in all these cases was associated with hayfever and is thus definitely allergic in origin.

ALLERGIC RHINITIS. TOTAL CASES, 73		
Relief.	No.	Per cent.
Complete	34	46.5
80 to 95 per cent	11	15.0
60 to 80 per cent	5	0.8
20 to 60 per cent	14	19.1
No relief	9	12.3

COMMENT. The figure for complete relief in this series of collected cases is surprisingly low when compared with the results obtained in our own clinic. In our clinic the diagnosis of this condition is made only after having taken a careful allergic history and a cytologic study of the nasal secretions and intradermal tests. Our results obtained by ionization in cases of perennial rhinitis of definitely proven allergic origin are much better than these. My impression is that there have probably been included in this group cases of rhinitis that were not allergic and thus did not respond so well to ionization.

HAYFEVER AND ALLERGIC RHINITIS. TOTAL CASES, 28					
Relief.	Hayfever.		Allergic rhinitis.		
	No.	Per cent.	No.	Per cent.	
Complete	22	78.5	19	64.3	
80 to 95 per cent	3	17.1	
60 to 80 per cent	2	7.1	2	7.1	
20 to 60 per cent	1	3.5	1	3.5	
No relief	3	17.1	3	17.1	

COMMENT. The hayfever relief figure is again about the same as in the preceding tables. The figure for relief from allergic rhinitis which is here probably properly classified is more than 80 for the 80 to 100 per cent relief group. This is about the same that we have been able to obtain in similar cases.

CONCLUSIONS. 1. Nasal ionization following the technique elaborated by Warwick, when given after the hayfever symptoms have started, apparently stops the disease in the majority of patients for the remainder of the season.

2. About 75 per cent of cases of perennial allergic rhinitis are relieved of their symptoms following ionization.

3. The relief in cases of allergic asthma has been much less frequent, but there are still enough good results to warrant further investigation as to the causes of the failures.

4. Clinical observation and microscopic examination of nasal tissues removed from both animals and humans who have been ionized has *thus far* shown no evidence of permanent nasal damage which could logically be attributed to the treatment.

BIBLIOGRAPHY

1. Baber, C.: Proc. Laryngol. Soc., London, 5, 29, 1898.
2. Fox, M. C.: The Postoperative Treatment of the Maxillary Sinus by the Ionizing of Zinc, Northwest Med., 23, 82, 1924.

3. Hollender, A. R., and Cottle, M. H.: Recent Advances in the Treatment of Nasal Accessory Sinus Disease, Eye, Ear, Nose and Throat Month., **5**, 575, 1926; Physical Therapy in Diseases of the Eye, Ear, Nose and Throat, New York, The Macmillan Company, 1926.
4. Harris, M. L.: Zinc Ionization as a Treatment for Intermittent Nasal Obstruction, Arch. Otolaryngol., **10**, 75, 1926.
5. Feldman, L.: A Rational Treatment of Hypertrophic Rhinitis, New England Jour. Med., **198**, 682, 1928.
6. Gale, J.: Zinc Ionization in the Treatment of Intumescent Rhinitis Arch. Phys. Therap., X-ray and Rad., **10**, 486, 1929.
7. Smith, F.: Asthma: Its Etiology and Surgical Treatment, Ann. Otol., Rhinol. and Laryngol., **38**, 1095, 1929.
8. Cahill, A. J.: Electric Ionization in Oto-Rhinology, Eye, Ear, Nose and Throat Month., **12**, 59, 1929.
9. McCoy, J.: Zinc Ionization of the Ethmoids, The Laryngoscope, **40**, 640, 1930.
10. Sputh, C. B.: Zinc Ionization in the Treatment of Rhinitis and Nasal Accessory Sinusitis, Jour. Indiana Med. Assn., **24**, 461, 1931.
11. McCurdy, G. J.: Electric Ionization in Otorhinology, Rhode Island Med. Jour., **14**, 151, 1931.
12. Demetriades, T. D.: Zur Behandlung der vasomotorischen Störungen der Nase durch Iontophorese, Arch. f. Nasen-, Hals- und Ohrenh., Monatschr. f. Ohrenh., **61**, 524, 1927.
13. Franklin, P.: Treatment of Hayfever by Intranasal Zinc Ionization, Brit. Med. Jour., **367**, 1115, 1931.
14. Franklin, P.: Intranasal Treatment by Ionization in Hayfever, Vasomotor Rhinitis and Ozena, Brit. Med. Jour., **1**, 751, 1932.
15. Warwick, H. L.: Treatment of Hayfever and Its Allied Conditions by Ionization: Preliminary Report, The Laryngoscope, **44**, 173, 1934.
16. Lierle, D. M., and Sage, R. A.: The Underlying Factors in the Zinc Ionization Treatment of Middle Ear Infections, Ann. Otol., Rhinol. and Laryngol., June, 1932.
17. Hollender, A. R.: Intranasal Zinc Ionization: Its Fundamental Aspects and Clinical Value, Arch. Phys. Therap., X-Ray and Radium, October, 1934.
18. Alexander, H. L. and Alexander, J. H.: Ionization of the Nasal Mucosa: Relation Between Reagents in the Blood and Effect of Treatment, Jour. Allergy, March, 1935.
19. McMahon, B. J.: Effects of Ionization on the Mucosa of Frontal Sinuses of Dogs, Ann. Otol., Rhinol. and Laryngol., September, 1934.
20. Hazeltine, B.: The Place of Ionization in the Treatment of Hay Fever, The Laryngoscope, September, 1934.
21. Alden, A. M.: A Year's Work With Ionization in the Treatment of Hayfever, The Laryngoscope, September, 1934.
22. Hurlbut, J. A.: Treatment of Hayfever by Ionization Method, Wisconsin Med. Jour., February, 1935.
23. Hays, H.: Ionization of the Nasal Mucosa for Hayfever, Hyperesthetic Rhinitis and Certain Types of Asthma, Med. Rec., January, 1935.
24. Tobey, H. G.: Experiences in Ionization of the Nasal Mucous Membrane, Ann. Otol., Rhinol. and Laryngol., March, 1935.
25. Bryant, B. L.: The Warwick Ionization Treatment for Hayfever and Hyperesthetic Rhinitis, With Report of Cases, Ohio Jour. Med., February, 1935.

DISCUSSION

DR. WILLIAM B. CHAMBERLIN, Cleveland, Ohio:

I want to ask Dr. Alden if in those cases complicated by polypi, the polypi were first removed and then ionization attempted after that.

DR. BERNARD J. McMAHON, St. Louis, Mo.:

We have just heard a very interesting paper on the results obtained from the ionization of the nose in humans for the relief of allergic rhinitis and allied disorders. With the question in mind as to whether or not certain damage might be caused in such noses, I conducted some experiments on dogs over a period of two years. The frontal sinuses and noses of dogs were ionized with the zinc sulphate solution used in humans, the opposite sides of the noses being kept unionized and studied as controls. The dogs were anesthetized with amytal solution injected intraperitoneally. They were then killed at intervals of from immediately after ionization to twelve weeks. The tissue was studied for progressive changes.

The lantern slides of photomicrographs illustrate the progressive fibrosis which has taken place throughout the entire mucosa following the reparative changes after partial destruction of the mucosa by the ionization. One slide illustrates the coagulum removed from a human nose after forty-eight hours. This coagulum contains many polymorphonuclear leukocytes and a large block of sloughed epithelium, demonstrating immediate destructive changes in a human nose.

From the foregoing findings we cannot help but question the ultimate efficacy of ionization as a logical curative measure, inasmuch as a nasal mucosa in which there is extensive progressive fibrosis, compression of glands, depression of secretions, limitation of blood supply and possible pressure on nerve ends, may not be considered in an optimum condition for its proper functioning.

DR. HENRY M. GOODYEAR, Cincinnati, Ohio:

I have been following the literature on the ionization methods for several years and have examined the machine which has been recommended for this work, which is very elaborate, and I have tried to figure out in my mind why such an elaborate outfit should be necessary to do this work. If we are getting results simply from coagulation of the surface of the mucous membranes of the nose, why can't we produce the same results by some local applications? Along with this line, I have attempted to make some observation.

With the histories of the ionization method, apparently the sloughing is rather severe and lasts for three or four days. There are not many chemicals which one can apply to the nose which will produce the same severe reaction. One hundred per cent phenol will make the membranes swell, and the patient will be rather uncomfortable for twenty-four to forty-eight hours; a gray membrane may form and separate, and a few of my patients have apparently been relieved of hayfever symptoms by a single application.

I have a number of patients in whom I have used a 10 per cent silver nitrate solution who have gotten a result which I think compares rather favorably with the ionization method. Several applications may be necessary at a week or ten-day interval, with each successive application the nose seems to be less sensitive.

We also know that we may relieve a hayfever patient by the injection of 50 per cent alcohol solution, and many get relief by injecting even the inferior turbinate alone.

In this work it would be interesting if Dr. Alden would try to determine the sensitive areas for hayfever. Is there any particular part of the nose which will respond and produce the result we want, without doing the entire membrane of the nose?

If ionization is just a destructive process on the surface, we should be able to duplicate its effect with chemicals applied locally without any elaborate apparatus. If it is due to absorption, what is absorbed other than the zinc or cadmium that is used?

I think it would be interesting for the doctor to compare one side of the nose treated by ionization method and the other side treated by some chemical solution which will produce about the same surface reaction.

It seems to me that we would have to use practically 50 or 100 per cent silver nitrate to get a sloughing that would last three or four days.

DR. HAROLD G. TOBEY (Boston): As many of you know, I have for several years been interested in these allergic conditions of the nasal mucous membrane.

First, I may say, that my results from ionization in perennial vasomotor rhinitis have been parallel with those of Dr. Alden. My experiences with season hayfever patients have been fewer, but equally as satisfactory as with the perennial conditions. My first concern, on acquiring the instrument, was to treat the very persistent cases of perennial vasomotor rhinitis which had resisted all previous modes of treatment. The excellent results were surprising.

I would like to bring up for discussion the *modus operandi* of ionization. Dr. Alden states that the electric current is necessary for the ionization of the solution. I have noticed the appearance of the nasal membrane, after packing with the solution, to be the same, except in degree, in a patient in whom for various reasons the current was not passed. Therefore, I would like to ask if the passing of the current is absolutely essential or simply enhances the process of ionization—which normally takes place.

We are dealing with an acid solution and recognize that the action of an acid depends upon the hydrogen-ion concentration and that this action is not dependent upon the passage of an electric current. The action of our familiar cauterants is due to hydrogen-ion concentration. Therefore we may say that all chemical cauterization of the nasal membranes which has been in use for years is in the modern sense an ionization.

It seems to be true that there is a constant recrudescence of the older forms of cauterization in the treatment of these conditions. Lately the use of full strength phenol has been used with satisfactory results. The older custom was to cauterize a few hypersensitive areas with strong cauterizing agents and this often was sufficient to control the symptoms. The present treatment by ionization seems to be a milder form of chemical cauterization, the success of which depends upon the degree with which the entire nasal mucous membrane is treated.

The stronger cauterants undoubtedly cause marked coagulation and even necrosis of the surface of the mucous membrane wherever it is applied. Dr. Warwick's contribution has been that he has prepared a solution which will cause a sufficient coagulation of the surface epithelium without going on to the stage of necrosis, and upon this depends the success of the treatment.

In regard to the treatment of asthma I believe that this treatment would be of benefit to those patients in whom the asthma is due to a reflex from the nasal mucous membrane in exactly the same way as relief is had from the removal of polyps or the clearing up of some localized area of infection.

Dr. Alden has included some immunological studies which may bear fruit at some later time.

I think the things we should stress are:

1. The importance of a true diagnosis of an allergic condition in the nose, in the manner that Dr. Alden has brought out.

2. The postponing of surgery until a thorough search for the causative agent has been made.

3. Treatment by ionization should be resorted to in case of failure to find the causative agent, or for relief, if the search proves to be too prolonged.

Dr. Seydell, of Wichita, who has done a good deal of this work and is somewhat of an electrical engineer, is in the audience and perhaps could elucidate the point.

DR. ERNEST M. SEYDELL, Wichita, Kansas:

I am afraid that I cannot qualify as an electrical engineer, as Dr. Tobey suggests.

As far as I have been able to learn, there is no difference in the galvanic current produced by a dry cell battery, a motor generation apparatus, or a tube rectifying machine, except in the smoothness of the current. The average motor generator apparatus produces a current whose impulses are greater and consequently more painful than those produced by a tube rectifying machine.

I have found that it is not necessary to purchase an expensive galvanic apparatus to obtain good results. I have personally experimented with a number of machines and have found that one of the least expensive of the tube rectifying apparatus gives me excellent results. The cost of this machine is \$36.

I have had very good results in the treatment of seasonal hayfever with zinc ionization. With allergic rhinitis, however, they have not been so satisfactory. One reason for this may be that I do not resort to zinc ionization until I have failed in each case to control the symptoms with the use of skin testing and exclusion diets.

DR. ARTHUR W. PROETZ, St. Louis, Mo.:

In relation to Dr. Tobey's question, and the remarks of Dr. Good-year, I should like to inject this one clinical observation, to go into the record as a preliminary report, since it covers only one season:

Last year, in England, I heard that they were injecting turbinates with alcohol for hayfever. That was done a great many years ago, I think, by Dr. Stein of Chicago, with some effect, and other people have been using various escharotics, actual cautery, and so forth. We know that operations on the nose sometimes hold in abeyance attacks of hayfever or asthma; the same thing may occur when a patient breaks his arm. It occurs to me the one common factor here is trauma (whether local or general does not seem to matter). However, to test

it out, last year, during the hayfever season, I took a little right-angled ossiculectomy knife and made a series of 8 punctures on the turbinate and 8 more on the septum opposite—straight punctures going down to the bone but producing a minimum trauma.

Whether it was the effect on the vasomotor control, or the liberation of tissue juices, or something else, I don't know. It is simply a clinical observation, but the important thing is that the effect over a period of three weeks was identical with that produced by these other injuries, including ionization and I simply put in the observation for what it is worth.

DR. ARTHUR MAXWELL ALDEN (in closing):

First I should like to answer Dr. Chamberlin's question relative to removal of polypi before ionization. Anything that prevents complete contact between the nasal mucosa and the electrolyte solution would interfere with the success of the treatment. Accordingly, if polypi are present they should be removed. If there is an obstructive deviation of the septum which prevents proper packing of the nose on the side of the convexity, the patient should have a submucous operation before the ionization is done. We have ordinarily allowed about five weeks to elapse between the submucous operation and the ionization.

I want to make only one remark relative to Dr. Goodyear's discussion. He spoke about the slough that occurs following ionization. This word has no place whatsoever in the discussion of ionization. In the observation of more than a hundred bilateral ionizations, I have yet to see the slightest evidence that even suggested a mucosal slough. This is also the experience of other men who have had the opportunity to observe many cases of ionization.

Dr. Tobey spoke about the mechanism involved. Much remains to be done before we will have answered the question of the exact physiological mechanism involved in the relief that certain of these patients most certainly do get. We have taken on this job as part of our work at Washington University and I hope to be able to answer this question at least in part within the next year or two.

Relative to Dr. Proetz's success of two or three weeks with the treatment which he suggests for some of these conditions, the experience as related here today with ionization which consists of a cross-section of the results obtained by some of the best trained men in America does not represent merely a few weeks' observation, but extends over a duration of more than two years. It would seem that this is all that is necessary to say about his suggestion.

Dr. McMahon's work on dogs has been very interesting. I have watched it over a period of months and at the same time have had the opportunity to watch for more than eighteen months, the noses of more than a hundred patients who have been ionized. When they tell you that they are free of their symptoms they have no axe to grind and they know what they are talking about. When we look into their noses and find that their mucosa is normal in every respect, then we know what we are taking about. The conclusion that one invariably comes to with regard to this work of Dr. McMahon's is that he has raised a sort of hypothetical bogeyman relative to ionization. I hope that he will continue with his work because while I am sure that he is entirely wrong in his conclusions, if he can definitely demonstrate that as the result of ionization permanent detrimental changes occur in the nasal mucosa in humans, I should certainly like to be the first one to be told of it.

SINUSITIS ALLERGY AND THE "COMMON COLD"

A CONCEPTION OF THEIR RELATIONSHIP

EDWARD CECIL SEWALL

INFLAMMATORY disease of the nose and sinuses is noninfectious and infectious in origin.

Wittmaack has shown that noninfectious irritants change the character of the young aural mucosa and make it more susceptible to chronic infection. His outstanding contribution to pathology has failed to recognize allergy, which I believe is perhaps the most important irritative influence.

Edema is the chief characteristic of allergic inflammation. By its action the fibers of the submucosa are separated and floated apart. Immediate swelling of the tissue results, more marked in infantile mucosa, which still retains the embryonic reticular arrangement of its fibers. The immediate swelling of the tissues may be considerable. However, it has been exaggerated to explain the evanescent shadows on the roentgen-ray film. It is obviously impossible for normal mucosa, which is as thin as cigarette paper, to become 1 or 2 cm. thick without the time element essential for tissue hypertrophy. Some other explanation must be given for this type of roentgen-ray evidence. Either the tissue is diseased and abnormally thick before the acute swelling occurs, or thickened mucosa is simulated. Inspissated mucous pads will do this, as has been demonstrated by our Roentgen-ray Department. They have noted a reduction in the thickness of the shadow immediately after blowing the nose.

No permanent changes in the tissues have been ascribed to acute allergic phenomena. While this may be essentially correct for a single attack, recurrent involvement must, eventually cause permanent morbid alterations. Stimulation of submucosal fibrous tissue characterizes inflammation. Such attacks early in life exaggerate and perpetuate the reticular character of the submucosal fibrous tissue. Thus is built by noninfectious agencies a type of mucosa favorable to bacterial growth and prone to chronic

involvement. This *allergically altered* mucosa will be discussed in connection with acute and chronic sinusitis.

The discharge from an allergically altered mucosa is clear in the absence of infection. The few cells present may be eosinophiles. Purulent or mucopurulent discharge from the sinus is only the result of the chemotactic activity of bacteria, and is thus an evidence of infection and *infection is always more than allergy*.

Infectious inflammatory processes may be divided into acute and chronic.

Acute infectious rhinosinusitis, or the "common cold," is the most important challenge in medicine today. The ravages of its complications pale into insignificance all other scourges, including cancer. Most opinion is divided between the common pus-forming germs and a filterable virus as causative agents. It seems to me possible to combine these two apparently divergent opinions and find the true answer to the problem.

The "common cold," in my opinion, is always due to the *pus-forming bacteria*, and they are always activated by a *filterable virus*.

The objection to their etiological importance has been raised that (1) it is frequently impossible to communicate the disease experimentally by bacterial transference; and (2) it *is* possible to pass the disease by transference of nasal discharge from which all bacteria have been filtered.

The first objection is easily satisfied because it is impossible to determine for experimental purposes those who are not at the time immune to colds. Some rare individuals have practically a permanent immunity. Most persons are granted an immunity of from six months to a year by an acute "cold." During the immune period they will not "take cold." One or two "colds" a year, in spite of almost universal exposure, is the recognized average. While there may be some variation from this affirmation, the fact is that so-called "frequent" or "recurrent colds" are not reinfections but exacerbations of chronic sinusitis. Chronic sinusitis is so frequent that the confusion in the minds of many is understood.

The second objection may also be met by a consideration of bacterial characteristics. The pus-forming germs are almost universal in the upper air and food passages. They lead for the time a saprophytic existence. An outside agency is required to raise

their virulence to the point where they will attack the tissues and give rise to the clinical picture, known as a "common cold." Their low virulence has been determined and has been repeatedly increased by animal inoculation. Increase in virulence is understood by the immunologist and is associated with the products of bacterial activity in the tissues. These substances, variously described as aggressins, etc., have antiphagocytic actions and have power to reduce body resistance and increase bacterial virulence. This is the virus that not only increases the virulence of bacteria in the tissues of the host, but, I believe, is transmitted with the secretion to activate the temporarily saprophytic germs of similar type in the nose of the host and also in that of another to whom it may be communicated. Under its stimulation their virulence is increased to the point where they attack the tissues which have carried them as surface saprophytes.

There must, therefore, be a never-ending source of this virus or colds would vanish from the earth. Just as are malaria, typhoid, etc., so is the common cold dependent upon some ever-replenished reservoir. That focus must be a place where the pus-forming germs are *in the tissues*.

A satisfactory ideal for such a reservoir is furnished by chronic sinusitis which I believe is the chief source and endemic reservoir for the perpetuation of the "common cold."

I do not mean that one must have chronic sinusitis to contract a "cold," but that chronic sinusitis must exist in some one for the pus germs lying in the chronically diseased mucosa to produce the virus capable of activating the same bacteria in others.

To recapitulate, I believe that colds are perpetuated only in the following manner: The common pus-forming germs are the direct cause. They lie in the mucosa of the chronically diseased sinus. The lapse of immunity, associated with the complicated factors that reduce resistance, allows them to become active in the tissues. This activity is associated with the production of a virus that not only promotes the virulence of the sinus infection but, secreted from the sinus as discharge, activates the same type of bacteria lying in a saprophytic state on the mucous membrane of that same individual. The result is the common cold engrafted upon a chronic sinusitis.

The virus secreted from the nose will activate the same type of pus germs lying in a saprophytic state in another individual and cause an acute "cold." Thus the vicious circle of the common cold appears never ending until such time as the endemic reservoir in the chronic sinus may be rendered innocuous or removed.

This conception of the importance of chronic sinusitis as the reservoir for the activation of the common pus germs may even be carried to the probably theoretical absurdity that without it there would be few pus germs. It is recognized that operating in the farmhouse, as our pioneer western doctors did, reduced infection to a minimum.

The morbid changes that characterize a "common cold" depend upon the histological structure of the mucosa. One can distinguish three types of mucous membrane. Each is subject to infection and determines the character of the inflammatory process.

1. NORMAL ADULT MUCOSA. It is as thin as tissue paper, 0.1 mm. The fibrous layer is compact in arrangement. It contains few bloodvessels and glands. It acts as a periosteum and also supports the columnar, ciliated epithelium resting upon an ill-defined basement membrane. There are very few goblet cells.

The normal, active cilia, the layer of protective mucus and the inherent immunity ward off infection. When these resistant barriers are penetrated, there is little in the tissue itself to impede the entrance of disease. However, the inflammatory process that results is of short duration and mild in character because there is little food for activity in such bloodless, glandless tissues. The process quickly burns itself out for lack of fuel. The normal tissue reacts properly and intensely to the infection. Exudation is unimpaired. The products of infection and the infectious agents themselves are soon carried away. This explains their scarcity which has been assumed to dim their significance and deny their etiological importance.

Whatever may be the importance of virus in inciting bacteria or tissues, the bacteria themselves at first induce an activity comparable to the noninfective irritants described. A clear, watery discharge, the *ultimate* effect of the *noninfectious* irritants, is immediately secreted. The bacteria, however, soon assert their inherent chemotactic activity. This is characterized by cellular

infiltration, predominantly polymorphonuclear, and is reflected in the discharge by yellowish coloring and thickened consistency. There is comparatively little mucus because of scarcity of glands and goblet cells. As the defense forces gain mastery, the bacteria lose their chemotactic activity, act only as irritants and allow the discharge again to become clear. When recovery takes place it soon disappears, except for the normal layer of cohesive mucus *of which one is never conscious*.

Each inflammatory attack, however mild in character, stimulates an increase in the fibrous tissue. In normal mucosa it is left more dense by such an acute attack of short duration. This reduces the food value for subsequent infection. As a result, each succeeding attack of "common cold" that *entirely heals* promotes greater resistance to disease. Normal individuals have fewer and milder acute "colds" as age advances unless they develop a chronic sinusitis. Because of normal functioning defense, this type of mucosa rarely develops chronic sinusitis. It may do so on occasion. If so, a characteristic type of sinusitis results—*purulent sinusitis*. This statement will be expanded under Chronic Sinusitis.

2. ALTERED MUCOSA. It is thicker than normal mucosa, due to the reticular arrangement of the fibrous tissue. Such tissue is essentially edematous. It contains more media available for infection. There is clinical evidence to make us believe that it becomes diseased more readily. Abnormality of structure and lowered resistance are concomitant. The process at once becomes more vicious than with a normal mucosa. The bacterial action is at first comparable to that of the *noninfective* irritants. Like them, the bacteria at first cause an exudation of clear, watery serum. Soon, however, they exert their chemotactic activity and cause a more or less dense cellular infiltration. Polymorphonuclear leukocytes predominate in proportion to the severity of the process. Both serum and cells leave the tissues and accumulate in the sinus as discharge.

While the battle may be protracted, the body defenses usually modify the activity in a few days. The call for leukocytes lessens. They decrease in numbers. The discharge becomes more viscid. It consequently moves sluggishly and drains inadequately. Its retention acts to stimulate morbidity and impede recovery. It is

this thick viscid discharge adherent to the sinus wall that may simulate in the roentgen-ray mucous membrane thickening.

Eventually there may be complete recovery from the acute attack even in the face of an altered mucosa. The tendency toward chronicity in fact depends, to a large extent, upon the degree of morbid change. If recovery takes place all discharge ceases. Each acute attack adds to the reticular edematous fibrosis. The tissues then gain vulnerability, and are prone to eventually develop chronic sinusitis. *This is in contrast to the effect of acute healed inflammation in a normal mucosa which tends to increase the compact fibrosis and make it more resistant.*

When recovery does not take place, chronic hyperplastic sinusitis is established. This is the most common type of chronic sinusitis because of the prevalence of an underlying altered mucosa.

3. DISEASED MUCOSA. This is always present in chronic sinusitis. It is chronically infected. It is subject to frequent exacerbations which are not reinfectious. They are often confused with a "common cold." It also may become reinfected, however. A "common cold" is then engrafted upon a chronic sinusitis.

Chronic Infectious Rhinosinusitis. Two distinct types of this disease have been long recognized because of their clinical dissimilarity. No explanation for their variation has been given. Hajek* has said: "In cases of long-standing empyema, rhinoscopic examination reveals the objective findings of an atrophic rhinitis. *We have never clearly understood why atrophy has followed disease of the accessory sinuses.*" I believe that the atrophic character of chronic sinusitis depends upon whether it has been engrafted upon a *normal mucosa*. *It never occurs in allergically altered mucosa.*

1. CHRONIC PURULENT RHINOSINUSITIS. This disease is rare, as compared to chronic hyperplastic sinusitis. It is usually the result of a "common cold" or acute infection in an individual with a normal mucosa. Such mucous membrane is thin, poor in glands and blood supply. The fibrous layer is compact and ill-fitted to encourage chronic infection. Its density may even have been increased by previous healed, acute infection. Unusual factors embracing anatomy, immunity and virulence must conspire to accomplish its chronic infection.

* Hajek: Nasal Accessory Sinuses, St. Louis, C. V. Mosby Company, p. 561, 1926.

Due to lack of considerable edema, the mucosa remains comparatively thin. The irritated and engorged vessels shine through to give a characteristic redness to the nasal mucosa, which color often extends along the respiratory tract even into the bronchi. The same lack of protective tissue moisture, edema, allows the epithelium to feel the full brunt of the inflammation, and it is altered in atrophic fashion. Cilia are lost and the columnar cells may be changed by metaplasia into the protective squamous variety. The mucosa tends then to display a smooth, glazed surface. This is particularly true in the pharynx and nasopharynx and gives rise to distressing irritation manifested by persistent and spasmodic coughing.

As there are few glands and goblet cells, lack of mucus in the discharge is characteristic of this type of sinusitis. In the height of an acute exacerbation it is frank, disintegrated pus. The microscope then shows it to contain mostly polymorphonuclear leukocytes. It does not coagulate because this property of the serum is destroyed by bacteria. In latent periods of the disease the discharge may be almost absent, watery in consistency, clear in character. It can be seen bathing the mucosa as a transparent, or sometimes milky, film. It is apt to be of this character in the later stages of the disease when atrophy is manifest, and is one reason why its etiological importance in atrophic rhinitis has been rejected. Lacking mucus, which retains moisture, the water is soon lost from this type of discharge as it accumulates in the nose, nasopharynx, pharynx, larynx, trachea, etc. Consequently crusts form from the solid matter contained. These crusts through mechanical pressure and consequent irritation increase the surface atrophy. The nasal mucosa becomes more thin, glazed and, consequently, bleeds easily. The crusts may, in the exaggerated stage of the disease, accumulate and exhale a characteristic odor. They are particularly adherent in the nasopharynx where air currents rapidly dry and cause them to adhere. Their presence is so frequent and their source so ill-understood that they are still often described as a disease entity, "nasopharyngitis."

The underlying bone may show mild to extreme atrophic changes, depending upon the chronicity and severity of the process.

Thus only, in my opinion, can one reasonably explain atrophic

rhinitis. It can be prevented by curing the purulent sinusitis. I have satisfied myself as to this by stopping its obviously early stages. Purulent sinusitis is not influenced by chilling and unfavorable climatic conditions in the way or to the extent that is the hyperplastic type. In a dry climate crusting is an important characteristic and may be increased by desiccation to the discomfort of the patient.

2. CHRONIC HYPERPLASTIC RHINOSINUSITIS. This is the usual form of chronic sinusitis. It is very common. It differs from chronic purulent sinusitis in that it does not occur in those with a normal adult mucosa. It is the result usually of a "common cold" on an *altered* mucosa. It may present in infancy while the mucosa still retains embryonic characteristics and is delicate, reticular and well nourished or, at any period in life in mucosa that has been chronically altered by noninfective inflammation, particularly allergy.

This type of sinusitis is essentially edematous. Goblet cells, secreting abundant mucus replace the columnar ciliated cells. In extreme cases the cells are confused with the cap of viscid mucus covering them. The basement membrane is thickened and the yellow elastic layer distended and ruptured to allow the formation of polypoid masses. The submucosa is hyperplastic, edematous, more or less infiltrated and tremendously thickened. The edema protects the underlying bone so that it is rarely involved. This form of sinusitis, therefore, never causes atrophic rhinitis.

The etiological allergic influence, if present, may persist as a contributing factor that acts with infection to exaggerate and perpetuate the disease.

Allergy alone does not suffice to cause chronic sinusitis. It acts as a mechanical irritant without considerable chemotactic activity. The discharge that it produces, without the aid of infection, contains, therefore, few leukocytes. It is clear and watery in consequence.

Infection is always more than allergy. It exerts chemotactic properties during periods of activity. This is characterized in chronic sinusitis by a leukocytosis that thickens and colors the discharge. This distinction is affirmed by the microscope, an important diagnostic aid that may serve to lead the clinician

upward, even from the trachea itself, through pharynx, nasopharynx and nose, eventually to the source of the cells in the defective sinus, even as the prospector "pans" his "trace" of gold from the gravel of the creek bed successively upward to the "mother lode." This is made possible because pus cells are wanton to these parts and their source so frequently a diseased sinus. The infectious process is established mostly in the submucosa, where it lies fairly dormant except during vasomotor disturbances and acute bacterial exacerbations.

With the passing of the acute infection, whether initial or a subsequent reinfection, the morbid activity quiets down, controlled by the forces of bodily resistance. The bacteria, to a large extent, lose their chemotactic activity. They act again as irritants, keeping up a more or less constant discharge that is almost acellular. The polymorphonuclear leukocytes, evidence of virulent bacterial activity, are replaced by mononuclears, significant of chronic infection. Cells may be so scarce in the sinus that a cytological aspiration study of the sinus content is required to demonstrate them and show that the disease is not "cured," as is frequently presumed. The tissues now carry an immunity granted by the last acute infection. No reinfection with the typical picture of a fulminating "common cold" ordinarily again takes place for six months or a year. Later in life even a much longer period between acute attacks supervenes.

The mucosa in chronic hyperplastic sinusitis, while still immune to acute bacterial attack, is subject to morbid changes that lead to disturbances closely simulating a reinfection. These processes are usually erroneously referred to as "colds." One is said to have repeated or "frequent colds," or "one cold after another." This is not true, if we are to assume that a "cold" is "an acute self-limited disease." They are not reinfections and, therefore, not true "colds." They are almost invariably caused by chilling of the body and may be considered provocatively vasomotor. These exacerbations repeat themselves frequently even in warm weather, particularly where the humidity is low. The response occurs so quickly that it is a cause of wonderment. Chilling of the body, cold, wet feet or even hands causes a blanching of the surfaces including the upper respiratory tract in response to the

phenomenon of heat conservation. An immediate reduction in the defense factors allows the latent infection to again assert its irritative activity. A resultant increased watery discharge follows immediately. If now the body is warmed, the blood again with startling rapidity causes a cessation of activity and the discharge resumes its chronic status. If, however, chilling is extreme and prolonged, the chemotactic powers of the bacteria assert themselves and leukocytes appear in the secretion in great numbers. The discharge assumes a yellowish character, more than ever simulating a reinfection. However, a return of body warmth again limits the process, and what the patient thought was a beginning "cold" clears up inexplicably and the chronic picture again presents. These vasomotor attacks may repeat themselves frequently and have given rise to the opinion that the "common cold" may occur repeatedly.

When *immunity does expire* these chronic sinuses are subject to reinfection from within and without. The acute process is usually ushered in by body chilling. Such mucosa, however, grows more resistant to acute attack with the years, perhaps due to the greater thickness of the basement membrane that shows almost invariably histologically. *There are fewer true "colds" as age advances in this type of sinusitis.*

In this article I have had the temerity to state that *chronic sinusitis is the chief endemic focus from which develops the infection called the "common cold."*

There is much authoritative material to support this opinion. Very significant is experience in the polar regions. The natives are free from "colds," except when brought to them by persons from the "outside." They have developed epidemic "colds" on meeting a crew of explorers who up to that time had themselves for months been free from "colds." After the "cold" was well started among the natives, the crew of explorers in turn developed the same epidemic "colds."

The explanation of this phenomenon seems obvious—a portion of the crew had, according to statistical incidence, chronic sinusitis. In those affected the germs occupied the tissues. The product of their activity *in those tissues* passed *via* the nasal discharge freely

among them. The low temperature and their habituation to civilization's bacterial flora prevented their "taking cold" from one another. The esquimaux, however, were unused to the flora and fell an easy prey to the germs and virus from the outside. These were the products of the *action of bacteria in the tissues* of the crew, as distinguished from the bacteria lying in the nose and mouth in a saprophytic state. It is this action of germs *in the tissues* that gives them virulence, as shown by laboratory work and is the important factor in the transmission of "colds."

The activity of the germ *in the tissues* of the nonimmune esquimaux quickly engendered a virulence—so frequently demonstrated in clinical experimentation—that the crew themselves could not resist. They then fell victims to their own rejuvenated germs.

DISCUSSION

DR. LEE WALLACE DEAN, St. Louis, Mo.:

I have been delighted with Dr. Sewall's paper. I quite agree with everything that Dr. Sewall has said.

I want, however, to bring into the discussion the question as to whether or not metabolic disturbances will not produce the identical picture which Dr. Sewall has presented to us.

To begin with the end-result. We see in elderly children and adults noses that present the typical allergic picture except that there are no polyps. The nasal mucosa is thickened and edematous. There is a thickening of the sinus lining. Such cases are usually diagnosed as allergic rhinitis. The eosinophilia, the sensitivity of the nasal mucosa and skin to various substances is absent. Such patients on a proper diet will make a consistent progressive improvement. I think the nutritional disturbance plays just as important a part in producing changes in the nasal mucosa as allergy. In short, I consider malnutrition a more important factor.

With a pure nutritional treatment, I have seen every two weeks for two or three months these noses improve. There has been a progressive thinning of the nasal mucosa. One patient that was considered allergic had a bilateral Caldwell-Luc operation; later a bilateral ionization, without improvement. The use of a proper diet produced a satisfactory result.

DR. E. ROSS FAULKNER, New York City:

One thing I should like to emphasize, is what was said about the chronic sinus cases being probably the great source of endemic pus infection. I have regarded chronic sinusitis a menace to public health. Those cases probably infect every one in the immediate neighborhood where they live.

Unquestionably it is a family disease, and anyone in practice for many years, who has seen a good many of the cases, will observe this phenomenon: that a young man or young woman with chronic sinusitis gets married and infects the other partner. The baby at the age of four or five months will develop an acute illness and the pediatrician will not know anything about it. The temperature may be 105° and there will be a lot of guessing over the baby's illness. It is getting its initial sinusitis or initial tonsillitis. I have seen this thing go through families for three or four generations, and I have treated the left antrum in three generations in one family, and while I believe in Dr. Rosenau's theory of specific localization, Dr. Sewall's explanation of the local character of the membrane might be a more logical explanation. The cases I mentioned had identical anatomy, the grandmother, the mother, and the child.

I believe we will all know more about this when the specific quality of an infection is established. We all know different epidemics have pretty much the same manifestations. If we see a dozen cases of acute sinusitis in the morning, all probably will show pretty much the same thing. You can get a type of infection in the nose with very little discharge in the initial stages. In other cases where other organisms predominate, you get typical coryza, which is less likely to become chronic than the streptococcus cases with sore throat, headache, and red nose. These are the ones the ordinary general doctor always calls flu or grippe. If he doesn't see a coryza, he always calls it grippe. Those cases are far more prone to become chronic than those with a good, free-running nose, that washes away some of the infection.

DR. ROY NELSON, Oakland, Calif.:

A sense of honor compels me to admit that I am Dr. Sewall's "stooge," having been his student for eight or ten years, and in close enough contact to get stimulating and illuminating ideas from him at rather frequent intervals ever since, so this paper is to be a stimulating and also an illuminating thing.

There are a few points I should like to discuss in connection with it. I should like to feel that my efforts would rather strengthen his paper than detract from it, though the interpretations I should put on his points might be somewhat different.

In the first place, in regard to chronic sinusitis being the reservoir, the endemic reservoir, from which the common cold is spread; it is difficult for me to conceive how a minute droplet of secretion from the nose, an inanimate droplet which can therefore act only by purely physical or biochemical means, could so upset the balance of the defense mechanism of the body as to allow organisms previously there but saprophytic to penetrate the defense mechanism and set up a generalized, acute infection, especially in the light of what Dr. Lierle has shown—some drugs with rather powerfully active pharmacologic effects, easily demonstrable, do not do so, but even if they produce marked local changes, the effect wears off harmlessly in a few hours. However, I must admit that this is no more difficult to understand, and seems just as possible as that a viable, animate, filterable virus could cause this and still the patient lose his immunity within months or a year, whereas most filterable virus infections of which we know leave more permanent immunity than that, generally for life.

I think Dr. Sewall's extension of Wittmaack's theory, the middle ear and mastoid being only another of the pararespiratory sinuses, is particularly brilliant and will act as a guide toward further elucidation of pathology there.

There are a few points in which I would question his interpretation; for instance, he referred several times to the "fuel value" of the tissues, in which the normal tissue had less and the diseased tissue more. That to me was not an easily understood term scientifically. I would rather place the interpretation in this way, that the normal tissue has a better blood supply, a reticular tissue has less blood supply in proportion to its volume than a normal, a myxomatous has still less, and edematous has very small blood supply, which accounts for the grayness and pallor, etc., when seen in the nasal mucous membrane. The edema, etc., increasing tissue tension, further reduces the blood supply, thereby establishing a vicious circle, and difference in blood supply wherever it may occur, throughout the body, is a strong factor in resistance to infection. That might be a better explanation.

Dr. Sewall's selection of allergy as the cause for the alteration from the normal might prove a little unfortunate and throw us immediately into a field of discussion of allergies, and the allergists are sufficiently puzzled themselves as to what all that means. If you will pardon me for making a few personal references, it seems to me there are other differences in tissue reactions which must be based on some constitutional thing, not necessarily allergic. What I mean to say is; if I get a crack on my head, I do not develop a great, big doornob. I get

very little swelling, though it may hurt like the deuce. Another striking thing is in dermatitis from poison oak, or poison ivy, as you call it in the East and Middle West. I have had it frightfully all over my body and have had to stay in bed three or four days at a time, but I *never swell*. I have seen plenty of people with their eyes swollen shut from poison oak and ivy, and I have had it as bad as I can imagine anyone having it. I am not, however, edematous, whatever that may mean. Certainly the crack on the head would not be allergy, and although I *am* "allergic" if I want thus to say I am "susceptible" to poison ivy, nevertheless my tissue reaction to insults is not edema. Whether or not the state of my nutrition might have anything to do with my reaction to a crack on the head, I do not know! I should like to inquire of Dr. Dean! I should really like to know.

I think the conception of a normal mucous membrane responding with a purulent sinusitis, whereas one altered in some way, including perhaps allergy as one of the factors altering it, tends to hyperplastic reactions and chronicity, is particularly rational, and should be particularly useful in unraveling the problems of pathology; however, I feel that attention should be given and we must consider the possible effect of perivascular fibrosis; if it be periarterial, tending to produce atrophy; and perivenous tending to produce back pressure, stasis, and edema. I don't believe that can be ruled out as being a strong factor in distinguishing between "atrophic" and "hyperplastic" nasal tissue reactions.

DR. EDWARD CECIL SEWALL (in closing):

I agree completely with what Dr. Dean has said. There are many factors, some ill understood, that play a rôle in the preparation of the mucosa for chronic involvement. From the present viewpoint allergy seems to play an outstanding part.

I am delighted that Dr. Faulkner brought up the question of heredity. We have learned that tuberculosis is rarely hereditary though often transmitted by familial propinquity. The same factor he has said transmits sinus disease. Therefore, atrophic rhinitis occurs in families but it is not inherited. It is the result of purulent sinusitis engrafted upon a normal type of mucosa.

I am proud of my pupil, Dr. Nelson. I didn't know he had it in him. I have never heard him talk before.

As to whether the products of bacterial activity which I take to be the so-called "virus," are powerful enough to do what I propose, I think he has answered by saying that discharge from a man's nose has been filtered, and placed in a monkey's nose transmitting the cold.

Now about this term "allergically altered," I agree with him again. I think the term is poor. We know little about allergy. A more general term would be better. "Altered mucosa" would sufficiently describe the noninfectively changed mucosa and would include all the pertinent etiological factors. I must admit a confusion in my mind concerning this thing called allergy. I am not certain that infection is not the factor that makes the individual sensitive to certain things. Pollen sensitization seems clear and understandable. There are, however, many angles of the subject which are vague and where the rôle of infection is possibly an important one.

A patient of mine, well into middle life who always had sinus infection, gradually developed for the first time typical "hayfever" symptoms—paroxysmal attacks of sneezing, nasal obstruction and watery secretion. She was not benefited by the resourcefulness of the allergic clinic. Investigation showed the sphenoids to be chronically diseased. Cytologic study of the sphenoids repeatedly disclosed that the discharge contained a great preponderance of eosinophiles. Operation upon the sphenoid sinuses relieved pain, improved health and, strangely enough, "cured" the *allergic symptoms*. No "hayfever" since. This case is typical of many instances that lead us to wonder which is "the owl and which is the egg."

OBLITERATIVE FRONTAL SINUSITIS

SAMUEL R. SKILLERN, JR., M.D.

THE partial or complete obliteration of the frontal sinus cavity by osteogenesis is, what I believe to be, a hitherto undescribed complication of chronic frontal disease.

A chronic infection of the mucosa may spread into the bony walls of the sinus to terminate in osteomyelitis, or osteogenesis, if I may use this latter term as a disease rather than an entity. In osteomyelitis, which is a destructive osteitis, the tissues are overwhelmed and destroyed by the invading organisms, as so notably described by Wilensky,¹ Dan McKenzie,² Furstenberg,³ Mosher,⁴ and others,⁵ whereas in osteogenesis, which is a proliferative osteitis, the tissues become proliferous to wall off or encapsulate the infecting organisms.

Quoting from Jonathan Wright:⁶ "So far as the bone changes are concerned, the pathological condition is directly related to the normal processes of bone growth in the nose, in its origin, and throughout its whole course. This relationship is not difficult to recognize. I have become accustomed to look upon this sort of inflammation, as due to the substitution of the stimulus of irritation, whether from external surface agents, from bacterial agents of disease within the surface, or from systemic vasomotor disorders, for that mysterious physiological stimulus of growth which carries with it some agency which shapes the symmetry of form."

"In pathological processes, that agent which shapes the symmetry of form is absent or works badly and we get unsymmetrical development in the hyperplastic irregular forms." He states further "that the new bone growth starts as a sequence of an ordinary hyperplasia of the mucous membrane."

It is, therefore, the product of the infection, within the hyperplastic membrane lining the sinus cavity, that forms the stimulus of irritation to the granulations in the diploic spaces. These, according to Furstenberg, are converted into fibrous connective

tissue, which may be followed by the development of a dense layer of compact bone.

The periosteum beneath the infected lining membrane may be so traumatized by the disease that it becomes congested and thickened, to assume the appearance of granulation tissue. This latter serves as a young connective-tissue base of an embryonic character in which ossification may follow. There is a rapid multiplication of the connective-tissue elements, with a differentiation of some of the cells into osteoblasts. Thus there is formed an interlacing framework of trabeculæ, which is at first uncalcified and is spoken of as osteoid tissue. This later is infiltrated with the calcium salts to complete the process of ossification. Such changes constitute a most effective protective mechanism on the part of Nature to imprison the infection and prevent its invasion into the diploë and calvarium.

My conception of the different reactions of the frontal bone to a chronic infection of the mucous membrane within the sinus is based upon:

1. The histogenesis of the frontal plate.
2. The virulence of the invading organism.
3. The resistance of the individual to the infection.
4. Traumatism to the bone (external or operative).

The study of the frontal bone shows, in the great majority of instances, that the frontal sinuses have, in apposition to the lining mucosa, a dense layer of compact bone. Occasionally this layer of compact bone is so thin that the diploë is in close proximity to the mucous membrane. With this thought in mind, let us consider the structural difference of the compact bone, with its ability to wall off the infection, and the cancellous bone, with its aptitude for dissemination of the infection.

The dense or compact bone lining the sinus cavity, and also forming the outer shell of the frontal bone, consists of superimposed layers of calcified connective tissue, called lamellæ, surrounding a central channel, termed an Haversian canal.

Quoting from Virchow: "Between these lamellæ, and arranged concentrically around the central canal, are a number of minute spaces (lacunæ). These lacunæ are connected with each other, and with the central Haversian canal, by a number of fine chan-

nels (canaliculi) radiating like the spokes of a wheel. Between these units, and filling in the irregular intervals between them, are other lamellæ, with their lacunæ and canaliculi, running in various directions. These are termed the interstitial lamellæ. Still other lamellæ are found on the surface of the bone, which are called circumferential, or primary, lamellæ, to distinguish them from the special lamellæ around the axis of the Haversian canals."

"The Haversian canals, which average $\frac{1}{500}$ of an inch in diameter, contain two blood vessels, some nerve fibers, lymphatic vessels and spaces, and a minute amount of connective tissue."

"The lacunæ are occupied by a branching cell, termed a bone cell, the processes of which pass through the adjoining canaliculi. These bone cells are flattened, nucleated cells and are homologous with connective-tissue cells."

Between the very thin periosteum lining the sinus cavity and its surface cortical bone, there is found a layer of scattered cells, which are designated as osteoblasts, and are important for the growth and repair of bone.

Protected by the covering of compact bone, with its microscopic channels, is the cancellous bone, or diploë, so-called for its structure of thin plates surrounding large tortuous vascular canals. When this bony structure is divided, the vessels do not collapse in the canals, but remain patulous. If infection gains entrance to these wide-open venous channels, their construction tends to promote and facilitate the spreading of a progressive continuation of the infection by thrombotic process.

Histogenesis. It is my opinion that the likelihood of osteomyelitis occurring in chronic frontal sinus disease depends upon the thickness of the compact bone separating the infection from the diploë.

Infection and Resistance. If the compact bone is of adequate thickness to withhold the invading organism from the diploë, and the individual's resistance is capable of responding to the bacterial stimulus (by an excitation of the osteoblasts), we have additional protection by new bone growth. Once started, this new bone growth may continue until the sinus cavity is obliterated by the apposition of the sinus walls.

Traumatism. That osteomyelitis may follow such minor intranasal operations as the enlargement of the frontal ostium, or even the removal of a fronto-ethmoidal polyp, is a recognized fact, but I do not believe that osteogenesis has ever been described as a complication of frontal sinus disease following intranasal instrumentation.

I believe that if the cancellous bone is exposed to the infecting organism, osteomyelitis may develop, whereas if the compact bone is exposed and the traumatism is slight, nature responds by the stimulation of a new bone growth.

The statement is erroneous that the thickness of the anterior plate of the frontal sinus is dependent upon the quantity of cancellous bone separating the two layers of compact bone. I shall demonstrate a relatively thin frontal plate, with a preponderance of cancellous bone, and another slide of a relatively thick wall of pure compact bone. There are two specimens showing failure of development of the frontal sinus. One is chiefly cancellous bone, the other compact bone.

The diagnosis of osteogenesis depends chiefly upon the astuteness of the rhinologist. All of the cases that I have seen have had some prior intranasal instrumentation, ranging from removal of polyps to intranasal pansinus surgery.

The subjective symptoms are: sense of weight with dull pain over the entire frontal area, and occasionally facial neuralgia and orbital symptoms. Toxemia seems to be the most predominant and persistent subjective symptom, affecting chiefly the nervous and gastrointestinal tracts.

Intranasal examination usually shows, in the fronto-ethmoidal area, intermingled scar tissue with a hyperplastic membrane, occasionally polyps. The discharge is generally tenacious, mucous or mucopus, seldom frank pus. There is tenderness under the supraorbital ridge of the affected side, and the sinus is dark to transillumination.

The roentgenogram shows the outline of one frontal sinus ending abruptly in the mid-line of the frontal area. The roentgenologist's usual report reads: "A failure of development or absence of one frontal sinus." To the uninitiated, this erroneous information is

so misleading that they hesitate to advise such radical surgery as the removal of the external plate of the sinus in the face of such contradictory opinions and vague subjective symptoms.

If we will but recall in our anatomy that the frontal sinuses, in their upward development into the ascending ramus of the frontal bone, form a pyramidal-shaped cavity directly over the nasal fossa, and that they will occupy this allotted space even though their relative shape and size may be inconstant, we will not be misled by a roentgenogram.¹⁰

It is true that the total failure of development of the frontal sinuses is not uncommon. Onoda reported 5 per cent in 1200 specimens, Oppekofer 3.7 in 200 specimens, and, in the preparation of 54 skulls, we were fortunate enough to find 2 such abnormalities.

Inequality in the size and shape of the frontal sinuses is a rather common finding. The roentgenogram often shows one large sinus encroaching upon the space of its fellow. A single sinus occupying the entire frontal area has been reported, but R. H. Skillern⁷ states: "A complete absence of the intersinus septum never occurs."

The normal frontal sinus area is divided in half by the continuation upward of the perpendicular line of the nasal septum. I have never seen, at operation, or in a specimen, fully developed frontal sinuses confined exclusively to one side of this mid-line of the frontal area. Every roentgenogram showing one or more frontal cells ending against this perpendicular line, with opacity of the space that should reveal the outline of its fellow, was erroneously diagnosed as an absent sinus, not only by the roentgenologist, but by several rhinologists. This was proven at operation, and acknowledged as an error in diagnosis.

The roentgenologist reports only his interpretations of the plate; consequently, if the rays fail to penetrate the thickened, eburnated bone, the sinus area appears opaque, like the adjacent bone, with the demonstrable sinus shown occupying practically one-half of the frontal area.

It is necessary for us to differentiate osteogenesis, with its generalized distribution of new bone, from an osteoma, with its circumscribed encapsulation, and from mucocèles, malignant and benign tumors. These latter growths sooner or later manifest themselves

in the nasal or orbital cavity, occasionally above the superciliary ridge, whereas osteogenesis is not demonstrable except in the roentgenogram.

Starting, as it does, from the point of injury, this new bone growth spreads upward and outward, like a fan, over the anterior wall of the affected sinus. It is thickest at the original point of bone excitation, growing thinner as it extends outward, to be lost in the normal bone.

Points of interest are the central limitation of the growth at the intersinus septum, which is usually involved, and the thick eburnated bone forming the floor, which walls off the sinus from the nasal cavity. In several instances, the thickening of the anterior wall had progressed to a complete obliteration of the sinus. That the growth was in the anterior plate could be proven by demonstrating the smooth shining lining of the posterior wall of the sinus. That infection persisted was shown by cultures from the deeper recesses and pockets. All but one case gave a pure growth of *Staphylococcus albus*, that one being negative to culture.

The subjective symptoms, pain and sense of weight over the frontal area, are due to the exostosis, with its irritation of the anterior ethmoidal nerve, as described by Fenton.⁸ The post-orbital pains, otitic and facial neuralgias, are due to the irritation of the sphenopalatine ganglion⁹ by the discharge, with its encrustations. The toxemia, with its manifold symptoms, can only be from the lymphatic and vascular transmission through the Haversian system. I have found that the numerous pockets of infection are encapsulated within the new bone filling the sinus, and, as there is no other means of absorption, it must be through the vascular system of the compact bone itself.

It has been rather difficult for me to convince some of my colleagues that the orbital manifestations of foci of infection are from an osteogenetic frontal sinusitis, but after all, the proof of the pudding is in its eating, and the removal of this infection within the bone has relieved the condition. It is, therefore, my opinion that the reason complete relief is not obtained in many of our operated cases is because we have failed to remove these intraosseous foci of infection.

Complete relief of symptoms has been obtained in every case

by the resection of the entire anterior wall above the superciliary ridge, and the thorough removal of all tissues, until the posterior sinus wall was fully exposed.¹⁰

Dr. Frederick M. Law was kind enough to review the films, and *from* them made the slides. He feels that the films are so poor that they should not be used for demonstration purposes. His criticism was confined to the making of the films, and the diagnosis made from these roentgenograms.

We Philadelphia surgeons are rather proud of our colleagues in roentgenology, but we must acknowledge we have no otorhinologist that has gone over to specialize in otorhinoroentgenology; therefore, New York may claim originality in Dr. Law.

The slides are shown as misinterpretations of the true condition. They give the examining rhinologist the erroneous information that the focus of infection cannot be, where in reality it lies, in the apparently absent frontal sinus. When the average roentgenologist can satisfactorily demonstrate the osteogenetic proliferation obliterating the frontal sinus, then "he who runs may read," but until such time, the diagnosis of this rare condition must, of necessity, depend upon the astuteness of the examining rhinologist.

CASE REPORTS. Mrs. L. L., aged forty-five years. H. W. Referred, 1931.

Chief Complaint. Constant, dull, boring pains radiating from left mastoid to mid-line of the face. Paroxysmal, sharp shooting pains over area of the fifth nerve. With these paroxysms, there would be pain in the posterior nares and left orbit.

Past History. Was in normal health until 1917, when she had a severe attack of influenza. Sinusitis diagnosed, 1918. Tonsillectomy and submucous resection, 1920. Diagnosis of tic douloureux with alcoholic injection into Gasserian ganglion, 1929. Left radical maxillary operation, 1930. From the family physician's history, and her numerous complaints, as well as her general appearance, a diagnosis of neurasthenia could easily have been substantiated.

Present Illness. November 17, 1931: Intranasal examination revealed a hyperplastic ethmoidal area, with seropustular discharge from sphenoids. The return washings from each maxillary sinus revealed milky-white pus with foul odor. Roentgenogram diagnosis of a pansinusitis, the right frontal showing the least involvement.

Operations. January 15, 1932: Bilateral ethmoidectomy and sphenoidotomy.

March 18, 1932: Bilateral Caldwell-Luc. The previously operated left maxillary had completely regenerated its walls. Patient was comparatively free of pain and discharge until April, 1933.

Following a so-called severe head cold, pains and discharge recurred. Intranasal examination revealed left sphenoid closed by synechia, excepting for an opening in upper portion, approximately 2 mm. in diameter. This sinus was filled with pulsating white pus. For the first time, a seropustular discharge was noticed coming from the left frontal sinus area. Large encrustations covered the left posterior ethmoidal area. Enlargement of frontal ostium and removal of synechia gave relief for three months. This procedure was repeated (by different methods) on two other occasions, giving but temporary relief.

September 15, 1933: Left external ethmoidectomy. Large supra-orbital ethmoidal cell encountered when opening the floor of the left frontal sinus. As large an opening as possible was made through the frontal sinus septum to allow for aëration and drainage through a normal right frontal ostium. Deep in the curvature of the left orbital wall, two infected posterior ethmoidal cells were opened.

Following another intranasal infection, pains recurred in left mastoid area, and over the left frontal and maxillary areas. Intranasal examination showed crusting from the frontal sinus area to the face of the sphenoid. The sphenoid was partially walled off by synechia, but was apparently free of discharge. It was impossible to probe the frontal sinus. Five consecutive examinations, at weekly intervals, revealed the same crusting, which, when removed, gave relief of pains for variable periods of time.

February 26, 1935: Bilateral radical frontal operation (Skillern). Periosteum very adherent over left frontal area. Small trephine opening showed anterior wall of the right frontal to be 2 mm. in thickness. The left was penetrated for 7 mm. without entering the sinus cavity. Upon the removal of the bony plate of the right frontal wall, the loose lining mucous membrane was seen to fill and empty with each respiration, like a toy balloon, giving a beautiful demonstration of sinus respiration. Inspection failed to reveal the opening made through the intersinus septum during the radical ethmoid operation in 1933.

Being desirous of obtaining the full thickness of the anterior wall, with its new bony growth, for histological study, the left frontal sinus

was attacked by hammer and gouge through the septal wall. When the small half-round gouge had penetrated 1 cm. without entering the sinus cavity, this point of attack was abandoned for the usual superciliary bone incision. The sinus cavity was outlined with the Killian V chisel in accordance to the measurements taken from the roentgenogram, then, with a broad flat chisel, an attempt was made to remove the anterior wall *in toto*. This, as in the other cases, met with failure, as when the piece was removed, there remained a layer of eburnated cancellous bone covering the posterior wall. Numerous pockets were found from which a pure culture of *Staphylococcus aureus* was obtained.

Breaking through a very hard, dense layer of bone forming the floor of the sinus, the surgical ostium of the former operation was found completely closed by scar tissue.

Drainage into the nose established by rubber tubing. Wound closed by sutures. Tubing removed in twenty-four hours, sutures in forty-eight hours.

Uneventful recovery. Patient discharged on the fifth day.

On May 15, the patient was seen seated in the waiting-room. Her general appearance and mental state were so changed that my nurse and several patients spoke of her improvement.

When ushered into the office, her first remark was, "I have come to pay my bill, not to see you, as I have no further need for a doctor." In our conversation, she stated, "I have not felt so well for years. I feel as though some terrific load has been lifted from my mind. Before, if any one so much as pointed a finger at me, I felt like bursting into tears. Now, I can take my own part in any argument. All of the pains and aches have gone, and I can eat food that I would not have dared to touch a year ago, and as for work, I can do five times as much as before the operation."

The removal of the foci of infection from the osseous tissues, thus eliminating the source of her toxemia, is responsible for a so-called typical neurasthenic's return to become a normal individual.

Harry M., aged twenty-three years, printer. History obtained from Dr. Bobb, of Reading, Pa. Present condition of two years' duration. First seen by Dr. Bobb, August, 1934, with polyps filling both nares, making nasal breathing impossible. All sinuses dark. Pus in nose and pharynx. Dr. Bobb removed all visible polyps, and reported that the antral washings showed heavy, thick, ropy, white pus. He feels that the ethmoidal cells and antra are filled with diseased membrane, and states that the condition is growing progressively worse. No history of headaches or pains.

Examination. February 8, 1935: Nasal cavities completely occluded by pus, polyps and hyperplastic tissue. All sinuses dark. Right maxillary 4+ and left 3+ of white milky pus.

Diagnosis. Purulent hyperplastic pansinusitis of two years' duration. No history of sinus surgery.

Roentgenographic Report (Dr. Kornblum).

"Frontals: Rather small. There is a complete obliteration of the frontal sinus on the left side by new bone formation. Its outline is barely visible. There is a large ethmoidal cell projecting upward into the frontal region. The right frontal sinus is hazy.

"Ethmoids: Clouding on both sides.

"Maxillaries: Very marked thickening of the mucous membrane lining both sides.

"Sphenoids: The right is clouded and the left is hazy. There is an increased density of the bones about the paranasal sinuses, such as is commonly seen in long-standing infection.

"CONCLUSION. Pansinusitis with complete obliteration of the left frontal sinus by proliferative osteitis."

February 12, 1935: Bilateral ethmoidectomy. All of the cells were found to be filled with a thickened polypoid membrane and pus. Sphenoids opened—membrane found polypoid. Anterior walls of sphenoids removed. Uneventful convalescence.

February 19, 1935: Bilateral radical frontal above the superciliary ridge. Right frontal sinus opened through a thickened anterior wall to find the sinus cavity filled with gelatinous pus and a thickened loose membrane. A large supraorbital cell was opened through the floor of this right frontal. An attempt was made to perforate the intersinus septum. This was abandoned after the gouge had penetrated 1 cm. into the left frontal sinus area. Starting from within the outer confines of the sinus, the anterior wall was chipped away until smooth white bone of the posterior wall was fully exposed. When removing the floor, which was of dense eburnated bone, the gouge suddenly entered what my assistants thought to be the orbital cavity. Pressure on its yellowish-white glistening contents failed to disturb the orbit. Enlarging this opening, demonstrated a large supra-orbital cell completely filled by a single fibrous polyp. After the removal of this thickened false floor of the frontal, the normal frontal ostium could be demonstrated. Both frontals thrown into one large cavity, with rubber drainage tubes in each enlarged ostium. Convalescence complicated by stitch abscesses involving the upper eyelid. Recovery in three weeks, with marked improvement in asthmatic condition.

Six weeks later, this patient developed an acute mastoid, which required surgical intervention. Following this operation, patient gained 12 pounds and was greatly improved.

At the present writing, this patient is recovering from a bilateral radical maxillary operation, which showed both maxillaries to be filled with degenerated mucous membrane, polyps and pus. No asthmatic seizures have occurred to date since this last operation.

B. B., aged twenty-five years. Referred by ophthalmologist with diagnosis of neuroretinitis affecting chiefly the color fields.

Past History. Denied all of the usual subjective symptoms of sinus disease. Complained chiefly of nausea and vomiting following the use of her eyes (reading) for longer than ten to fifteen minutes.

Previous Operations. 1929 and 1930: Bilateral ethmoidectomy, sphenoidotomy and radical maxillary. Following each of these operations, her eye condition improved.

Present Complaint. Dull, heavy sensation over left side of forehead. If the eyes are used continually for an hour's close work, her former symptoms of headache with nausea and vomiting occur.

Intranasal Examination. The ethmoidal cells have apparently been removed; also the anterior wall of the sphenoids. There is a large window beneath the inferior turbinates. Right side free of all discharge or encrustations. Left ethmoidal area covered by crusts, sphenoid by synechia. A thin seropustular discharge noted in the fronto-ethmoidal area.

With transillumination, the right frontal showed an abrupt ending of the light at the mid-line of the forehead. No transmission of light could be seen on the left side.

Roentgenologist's report confirmed by films: "Failure of development, or absence of left frontal sinus. Remaining sinus area opaque, probably from scar tissue of previous operations."

Second and subsequent intranasal finding similar to first examination. The right nasofrontal duct was patulous and easily probed, whereas it was impossible to sound the left frontal sinus.

July 25, 1932: Bilateral radical frontal operation (Skillern). The right frontal sinus apparently normal. Left filled with eburnated cancellous bone containing pockets of degenerated membrane and seropus, which at culture proved to be a pure growth of *Staphylococcus aureus*. Uneventful recovery with relief from all former symptoms, and now in apparently excellent health.

Rev. G. B., aged forty-six years. First consulted in February, 1929, complaining of constant dull headache over left frontal and temporal areas, with feeling of fullness and pains in left ear.

Past History. Severe attack of sinusitis with radical bilateral maxillary operation, 1926. Left turbinectomy with removal of polyps, 1927. Ethmoidectomy, 1928.

Examination showed crusts covering left ethmoidal area. Sphenoid almost completely closed by synechia. Small opening in upper half filled with white pus. Seropustular discharge from frontal area.

Roentgen-ray Reports. Dr. Manges reports no frontal sinus to right of median line. Divided frontal on left side.

Quoting from Dr. Widmann's report: "March 13, 1929: Frontal sinuses: left frontal sinus of average normal size and contour and clear. Surrounding bone structure of average normal density and healthy. Right frontal sinus outline indeterminate. The density in this region is compatible with that of an osteitis of a chronic bone infection. I believe that this density of the right frontal sinus area, as compared with the transparent left frontal sinus, is more apparent than actual, due to increased bone thickness in this region. A. P. depth at base of left frontal sinus, about 8 mm. This admits of free and wide aëration on the left side."

Report of March 16, 1929: "Further roentgen-ray study of the frontal sinus region in the case of Rev. G. B. reveals:

(I first want to compliment you on this most extraordinary piece of work which demonstrates conclusively and beautifully the conditions that are represented as follows.)

"*Frontal Sinuses.* Right frontal sinus: Shows a probe *in situ*. This is clearly and definitely within a frontal sinus, the outline of which is obscured by disease, probably bone density of an osteitis plus extensive exudation. The upper limits of the sinus cavity blurred and diffuse with surrounding bone structure because of this extensive disease. The large cell of the left frontal sinus which probably should be called a median cell, but is definitely to the left of the median line, presents a haze of a sufficient degree and character to regard as also disease with exudate. Incidentally the bone detail and fine lines of the ethmoid, sphenoid and maxillary regions are shown very distinctly and clearly in various projections and substantiate the original report of March 13.

"SUMMARY. Opacity of right frontal sinus indicating definite disease with probably bone involvement and decisively proven with the roentgen-ray film showing a metal probe *in situ* in A. P. and lateral films."

April 2, 1929: Bilateral radical frontal (Skillern). Left frontal sinus anterior wall, 5 mm. in thickness. Mucopurulent discharge. Right

side, the anterior wall, 8 to 9 mm. in thickness. Entire sinus cavity filled by eburnated bone excepting for a small canal leading upward from the ostium to the termination of upper extremity of sinus. Uneventful recovery with complete relief of all pain and nasal discharge.

May 15, 1935: This patient, being now a personal friend, is seen once or twice weekly, and has been, and is to date in excellent mental and physical condition.

The following is such an unusual case that I feel that the past history must be taken into consideration in making our final summation as to the likelihood of our surgery giving permanent relief.

G. T., Jr., aged nineteen years. Referred, November 1, 1932.

Chief Complaint. Chronic purulent sinusitis, asthma and epileptiform seizures.

Past History. Influenza at the age of eight years, resulting the following winter in chronic purulent nasal discharge, with intermittent severe headaches.

The following year, asthma symptoms developed, which have persisted at irregular periods.

At the age of fourteen years, first epileptic attack. These muscular spasms are now periodic, occurring every eighteen to twenty days. The attack starts in the right hand, which becomes spastic, with course jerking tremors. These muscular spasms extend upward to involve the entire body. The attack is apparently a typical epileptic seizure, although the patient never loses consciousness, and he can repeat sentences heard throughout the entire attack. He never voids nor injures himself in any way during one of these seizures.

At the age of sixteen years, was studied by Drs. McCarthy, Temple Fay, Flick and Manges, with a diagnosis of epilepsy and pulmonary tuberculosis.

Manges: "The roentgenographic study reveals: (1) Pansinusitis. (2) There is an apparent absence of the bony wall (wings of the sphenoid), dividing the left anterior from the middle fossæ of the skull. (3) There are no signs of new growths or calcifications within the cranial cavity. (4) There are no unusual blood channels in any portion of the skull. (5) No changes in sella turcica nor any evidence of increased intracranial pressure."

At the age of seventeen years, Dr. Walter E. Dandy diagnosed, through a large frontoparietal osteoplastic flap, a congenital malformation of the brain, with a very large vein traversing the left motor area.

Intranasal ethmoidal and radical maxillary surgery done at the age of eighteen years.

Present history is simply a continuance of past history symptoms. The asthmatic attacks have become more frequent, are of longer duration and of greater severity. Nasal breathing is almost completely obstructed, with a continual heavy pustular discharge.

Intranasal Examination. Both nares were so filled with pus that nasal irrigation was necessary before further examination could be made. Both nares filled with large polyps, which, when removed, revealed a sloughing mass of polypoid and scar tissue covering the entire speno-ethmoidal areas. The former opening, beneath the inferior turbinate, was completely closed by thickened, eburnated bone. The surgical opening into the right sphenoid was almost completely closed by synechia. There was a large mass in the left posterior ethmoid completely hiding the sphenoid sinus. It was impossible to sound either frontal.

Dr. Piersol's report of his medical examination: "Healed tubercular lesion in both lungs, asthma and bronchiectasis. Normal cardiovascular and renal system."

Neurological examination by Dr. T. Weisenburg, who gave a diagnosis of epilepsy:

Over a period of three years, Dr. Manges has made numerous roentgenographic studies of the skull and sinuses, and he states that in all of his films, there is no evidence that there has ever been a right frontal sinus. He reports that his most recent films show a slightly greater amount of aëration in the left frontal, left ethmoid and sphenoids than in the former films.

Consensus of opinion—sinus surgery essential for the removal of foci of infection.

Operation. Intranasal removal of scar tissue and polyps from the ethmoidal areas, exposing small left sphenoid, which, when opened, was found filled with degenerated mucous membrane, polyps and pus.

One week later, radical bilateral frontal (Skillern). The left frontal of normal size and shape, but filled with a peculiar dark greenish, semisolid, jellylike mass, smears from which failed to show growth on culture.

The right frontal completely obliterated by a bony growth. This new bone was made up of spots of ivorylike density, with intervening areas of softened bone and degenerated membrane. Swabs from this area showed a pure growth of *Staphylococcus aureus* on the culture media.

Uneventful convalescence, excepting for a very severe asthmatic seizure on the third and fifth days. There were no further asthmatic attacks nor epileptic convulsions during the three weeks' stay in the hospital, following which the patient returned to his home in a distant city.

I have recently learned that his asthmatic symptoms have shown improvement in that they are less frequent and of a shorter and milder character. There was but a slight, if any, improvement in the epileptic seizures.

Notation. It was definitely understood by all concerned that the sinus surgery was to remove the foci of infection, and it was hoped that this might improve his general health, which, in turn, would favorably influence his asthmatic and epileptiform seizures.

It might be well to mention that all of the usual routine laboratory examinations, such as Wassermann's, blood counts, urinalysis, bacteriological and pathological studies were made for each patient, but only the findings thought to be of importance have been mentioned.

I was extremely anxious to get a slide of a microscopic section of the full thickness of the anterior wall, and sent such a specimen to the laboratory from each of the last eight cases, but our pathologist has been unable to obtain a satisfactory section. He states that the bone is so hard, and requires so long to decalcify, that all osteoblasts and new bone cells are destroyed by the decalcifying solution before a section can be cut for microscopic study. The chips from the softer bone do show new bone growth.

CONCLUSIONS: 1. Obliterative frontal sinusitis, being an osteogenetic thickening from pathological stimulus, may be classified as a benign bony tumefaction.

2. Osteogenesis is nature's protective mechanism to the dispersion of infection.
3. Osteogenesis depends upon the ability of the compact bone to respond to a bacterial or traumatic stimulus.
4. Unilateral osteogenetic thickening, affecting chiefly the anterior plate of one frontal sinus, is the usual finding.
5. Obliterative frontal sinusitis is often erroneously diagnosed from the roentgenogram as a failure in development, or an absence of the affected sinus.
6. The roentgenogram should be used *only* as "a helping hand" to the diagnosis.
7. No roentgenographic diagnosis of paranasal sinus disease, especially if negative, should ever be accepted without the confirmation of a rhinologist.
8. Failure to diagnose has occasioned multiple intranasal operations without complete relief of symptoms.
9. When the roentgenogram shows a large unilateral frontal cell ending abruptly at the mid-line of the forehead, its fellow should be suspected of osteogenesis.
10. Radical surgery above the superciliary line has proven to be the operation of choice.

BIBLIOGRAPHY.

1. Wilensky, A. O.: Osteomyelitis, New York, The Macmillan Company, 1934; Osteomyelitis of the Skull, Am. Jour. Roentgenol., **16**, 123, 1929; Discussions of Modes of Dissemination of Bacteria in Osteomyelitis, Arch. Surg., **13**, 228, 1926; Arch. Surg., **27**, 83, 1933.
2. McKenzie, D.: Osteomyelitis of Frontal Bone, Jour. Laryngol. and Otol., **28**, 6, 1913-1914; Further Observation on Spreading Osteomyelitis of the Skull, Jour. Laryngol. and Otol., **42**, 293, 1927.
3. Furstenberg, A. C.: Osteomyelitis of the Skull: Osteogenetic Processes in the Repair of Cranial Defects, Ann. Otol., Rhinol. and Laryngol., **40**, 996, 1931; The Pathology of the Spread of Osteomyelitis of the Skull, Trans. Laryngol., Rhinol. and Otol. Soc., p. 423, 1933.
4. Mosher, H. P., and Judd, D. K.: Acute Osteomyelitis of the Frontal Bone, The Laryngoscope, March, 1933.
5. Dixon, O. J.: Diffuse Cranial Osteomyelitis Complicating Frontal Sinusitis, Ann. Otol., Rhinol. and Laryngol., **43**, 16, 1934. Hastings, H.: Acute Fulminating Osteomyelitis of the Frontal Bone, Arch. Otolaryngol., **6**, 559, 1927. Myers, G.: Osteomyelitis of the Skull, Jour. Am. Med. Assn., **95**, 406, 1930. Bulson, A. E.: Osteomyelitis of the Frontal Bone Complicating Frontal Sinus Disease, Trans. Am. Acad. Ophthalmol. and Otolaryngol., p. 103, 1925. Dabney, V.: Osteomyelitis of the Frontal Bone, Arch. Otolaryngol., **8**, 177, 1928. Woodward, F. D.: Osteomyelitis of the Skull, Jour. Am. Med. Assn., **95**, 927, 1930.

6. Wright, J.: Introduction, Headaches and Eye Disorders of Nasal Origin, by Greenfield Sluder, St. Louis, C. V. Mosby Company, 1918.
7. Skillern, R. H.: Accessory Sinuses of the Nose, 4th ed., Philadelphia, J. B. Lippincott Company, p. 202.
8. Fenton, R. A.: Nasociliary Neuralgia Caused by Osteoma, Ann. Otol., Rhinol and Laryngol., **42**, 911, 1933.
9. Sluder, G.: Headaches and Eye Disorders of Nasal Origin, St. Louis, C. V. Mosby Company, Chap. II, p. 57, 1918.
10. Skillern, Jr., S. R.: Clinical *Versus* X-ray Diagnosis of Sinusitis, Ann. Otol., Rhinol and Laryngol., **41**, 1096, 1932; The Advantages of the Modified Lothrop Operation Over the Killian Procedure in the Treatment of Chronic Frontal Sinusitis, Trans. Am. Acad. Ophthalmol. and Otolaryngol., 1928.

DISCUSSION

DR. FREDERICK M. LAW, New York City:

Dr. Skillern's films illustrated the condition better than I expected. I had the privilege of seeing these films last winter and the subject brings up an interesting question, which confirms my long sought attempt at coöperation between the rhinologist and roentgenologist. Also the necessity for the rhinologist to become familiar with interpretation. This is a very interesting subject and years ago I observed in the posteroanterior views made at that time, in the so-called Caldwell angle, what we called an absence of a frontal sinus, but there was a variation in the appearance. Sometimes a film would show a very faint outline of what you might think to be a frontal sinus but turning to the lateral film you could see an outline of a sinus which seemed to be filled with very dense material. We know that no soft tissue will materially change the appearance on a lateral film but bone makes a distinct appearance.

There are two types. Stereolateral films would show a uniform density in the frontal sinus region and another type would produce an indefinite blur on one side which showed a cancellous appearance, but we thought nothing of that and called it an absence of a frontal sinus.

About a year ago Dr. Skillern spoke about the cases which he presented today and I recalled these previous impressions. Since then I have observed more carefully the appearance in the so-called absent frontal sinus cases and considered his phase of the diagnosis. In order to have a frontal sinus obliterated by bone there must have been a frontal present at some time. Now, the outline of that sinus is not entirely obliterated on a film by the consequent overgrowth. There

is an outline remaining similar to that remaining in the sclerotic mastoid, and properly made and properly interpreted sinus films will demonstrate a difference in those 2 types of cases, but not to the point where the roentgenologist is justified in saying there is an osteogenesis in that frontal sinus.

He can say there is an apparent absence of a frontal sinus cavity but the consistency of the cavity is less dense than upon the opposite side. This is as far as he dare go.

The films which Dr. Skillern showed illustrating the irregularity of the anterior wall are quite interesting. They frequently occur and there also can be seen a difference in the density of the anterior wall, but still I do not feel that it is within the province of the roentgenologist to state it is definite pathology. This irregularity of the anterior wall may produce an appearance of granulations within the sinus and must be considered in the interpretation. The rhinologist, with his knowledge of the clinical evidence, and the knowledge gained by his study of the films, a study in which the rhinologist is becoming much more proficient, will help to lead you to a correct interpretation, but do not blame the poor roentgenologist. He has nothing to go on but his films, and sometimes films are good and sometimes they are not, but there is nothing that I can see on the films which we saw today and which I have examined in the last year which would justify me in saying osteogenesis is present.

I think we must learn more about this proposition and when you receive films from a roentgenologist and you see the absence of a frontal sinus and find that he has submitted to you simply the postero-anterior and lateral views, do not be satisfied with that. Return the case to him and ask for films made in the nose-chin position, otherwise called the "Waters position," whereby you get an image up through the orbit to outline the possibility of an anterior and posterior wall. Also have a stereo pair made obliquely through the orbit. In other words, get the films made to distort the frontal sinus so that the walls will not be superimposed, and you may get a double outline if there is an anterior and posterior wall present.

I feel very grateful to Dr. Skillern for bringing this fascinating condition before us.

DR. THOMAS E. CARMODY, Denver, Colo.:

I think we are to be congratulated on this paper and on Dr. Law's discussion. I remember very distinctly an operative case in which I did an external frontal sinus, in fact, three of them on the same case. That is an admission that maybe most of you do not want

to make. I do not like to make it, but, at the third operation on this case, I found the sinus filled with osteogenetic material, such as Dr. Skillern has called our attention to, and I believe that that is the kind of case that we have here.

The roentgen-ray in this case did not show what it did in the first case before the first operation, but it did show the filling of this cavity. The reason, of course, was that the two operations were not complete, and we left infection behind which simply stimulated bone growth. Now, why infection should stimulate the formation of bone in one case and only the formation of pus and granulation tissue in another is difficult to understand. We have done a great deal of work, as some of you know, on the development of the frontal sinus and the effect of infection of the other sinuses on development of the frontal, and we have frequently found the absence of the frontal sinuses in children. That, of course, is a different proposition entirely from this, because there we have the two layers close together.

Now, whether this is a lack of osteoblasts in absorbing—we used to speak of them as osteoclasts (I have not heard that term lately)—whether they act to absorb bone in the one case and form a frontal sinus, and to build up bone in another case and formulate new bone in that frontal sinus, I am not prepared to say.

There are other elements that enter into this, that we probably cannot follow. There is a possibility that this overlapping mentioned in Dr. Sewall's paper is to a certain extent due to some endocrine element along with infection in all these cases.

Maybe, as Dr. Dean has said, there may be a food element. I should like to refer to Dr. Sewall's paper to make one observation, and that is, in our work we have followed these cases and we have always found that in a mother with infected sinuses, the child has infected sinuses also.

Dr. Sewall and Dr. Faulkner spoke about the husband and wife, and there is no question that we have infection passing there, but there is one point Dr. Carroll called attention to when I was sitting here, and that is, why do we have immunity in the doctor? We quite often do.

DR. WILLIAM B. CHAMBERLIN, Cleveland, Ohio:

I hate to prolong this discussion, but I understood Dr. Skillern to say that this was due entirely to the osteogenesis of the anterior wall, and in opening up the frontal sinuses he found the shiny posterior wall uninvolved. He did not state whether he found periosteum covering this posterior wall or not, and mucous membrane. I should like to have him answer this question.

DR. GEORGE M. COATES, Philadelphia, Pa.:

I should like to say a word on this paper because I have been very much interested in this work of Dr. Skillern's, and I have seen all the cases with him both before and after operation, and at operation, and the study has been interesting, and illuminating to me.

The first cases that I noticed were not, strictly speaking, the cases he describes. They were cases that followed operation on the frontal sinus itself, and particularly cases where the operation had been of the Lynch or Sewall type; removing the inferior rather than the anterior wall, I ran across two or three that needed operation, and found the sinus entirely obliterated. That may be common enough, but when Dr. Skillern began to find cases in which the frontal sinus had not been operated upon at all, the cases having had minor operative procedures in the nose only, it seemed that the thing might have more significance.

The degree of osteogenesis that takes place, of course, depends on when you see your case and investigate it. The cases Dr. Skillern showed were those with a very much thickened anterior wall. The last of these cases that I saw him operate upon, the sinus had been practically entirely obliterated and, by careful removal of this new bone growth, he came down to the original inner wall of the sinus and found that it was intact, so that it seems a definite thing that the growth does take place from the anterior wall. In some of the cases where the sinus was entirely obliterated, the nasofrontal duct was obliterated also, and there was no passageway into the nose at all.

DR. JOSEPH C. BECK, Chicago, Ill.:

I have just been fortunate enough in the last week or two to have seen a case that has proven to be the type of disease spoken of here, as osteogenesis, most probably of post-traumatic origin.

It occurred in a man about thirty years of age who since his injury five years ago continually complained of a headache over the frontal region definitely across both frontal sinuses. He consulted a rhinologist who referred him to a good roentgenologist, namely, Dr. Case. I mention the name of the roentgenologist advisedly. I think our member, Dr. Law, will agree that he is one of the very best men that we have in the West. Dr. Case took the pictures and decided that they showed normal condition of the frontal sinuses. Nevertheless this patient continued to suffer and therefore consulted a second rhinologist who, without looking at the roentgen-ray pictures had the frontal sinus probed on the right side. This occurred after the first roentgen-ray pictures were taken. You know, if that probe had been

passed before these pictures had been taken, one could have thought the problem was that the introduction of this probe caused stimulation trauma forming the osteogenesis. This case was seen by me three months later and at my instigation another roentgen-ray picture was taken by Dr. Case and at this time there was observed a definite obliteration on the right side of the sinus. Therefore, if I hadn't seen or if Dr. Case hadn't taken a previous picture three months ago when the frontal region sinus was normal, you would not have believed that there was a sinus on that side at all, both by the frontal and lateral view.

The patient was operated upon, because he complained very bitterly of pain in the frontal region. An external operation was performed. Part of the frontal sinus on the left or opposite side was entered to get to the obliterated point. We found an obstruction of the right frontal sinus blocking its outlet and you would say from the appearance that it was an osteoma. However, the differentiation was established in the histological examination which was so splendidly brought out by Dr. Skillern, according to the type of bone change that is found in osteogenesis.

Recklinghausen's disease must not be forgotten in mentioning the differential diagnosis, and Dr. Chamberlin's point is important in that respect. If Dr. Skillern said, and I understood him correctly, the posterior wall of the frontal sinus was white and not covered with mucous membrane, then I would expect bony changes there as well. Therefore, in such cases we have to consider the possibility of Recklinghausen's disease, which of course, is never confined to one sinus, nor even one part of the body. It is a disease of multiple areas.

I think this was a fine subject to bring to the attention of this Society.

DR. SAMUEL RUFF SKILLERN, JR. (in closing):

I wish to thank you gentlemen for your discussion.

I have been ten years collecting 12 cases of obliterative frontal sinusitis. Three were operated upon within the last six months.

We no longer accept a roentgenological diagnosis of the absence of one frontal sinus when its fellow is seen as occupying its normal position with its inner border at the midline of the forehead.

Dr. Law, I have been following your suggestion of consultation, coöperation, and coördination, consequently repeated roentgenographic study is often required in conjunction with repeated clinical examinations to eliminate some misplaced hidden cell as the focus of infection.

When examining the films in the box, it is sometimes possible, by stepping back 10 or 12 feet and observing the films from different angles, to find the apparently absent sinus suddenly appear on the film resembling its fellow in size and shape.

Occasionally by making a positive and negative film, and superimposing the negative on the positive, the opaque area will show the outlines of the frontal sinus, which appeared as solid bone in the single film.

Dr. Carmody's question as to the condition of the mucous membrane on the posterior wall, and Dr. Chamberlin's inquiry as to the appearance of the bone of the posterior wall can be answered together. Considering that we must remove a tremendously thickened anterior wall of ivory-like bone, which is often impinging upon the posterior wall, if not in entirety, at least in spots, we must use great care to shave off this anterior wall in very thin slices. It requires a mallet and sharp chisel or gouge to cut this bone. I have found it impossible to remove the bone without injury to the sinus mucosa. It has been my experience to find the posterior bony plate as a white shiny surface of bone denuded of mucous membrane. The mucous membrane that I have found has always been thickened and degenerated, apparently detached from the bone. Occasionally a small pocket will require curettement of a fibrous polypoid membrane, but on the whole, I should say the entire lining membrane is diseased and detached from the bone. As the posterior bony wall of the sinus has always appeared to be healthy, I have never cut into it so I cannot express an opinion.

Dr. Beck's histopathological mind speaks of following one of these cases from its alpha to omega. I have given the history and roentgenological findings of one over a period of six years, which will be found under case reports. The reading of the case reports has been omitted to save time, but the entire article will be found in the Annals.

I believe, as Dr. Fenton says, this has been an overlooked sinus complication, and I hope that you gentlemen will prove my statements by operating all cases of suspected obliterative frontal sinusitis.

RHINOSCLEROMA—IS IT AN INDIGENOUS DISEASE?

WM. B. CHAMBERLIN, M.D.

MANY of man's greatest inventions have been in the annihilation of distance or space, in making possible instant communication between individuals and places separated far from each other, thus enabling him to transport not only himself but his chattels and his products also over vast areas in comparatively short intervals of time. This victory over space has brought its sorrows as well as its blessings, its pains and likewise its pleasures, its advantages as well as its disadvantages. So a disease, whether of plants or animals, at present rarely remains for a long time confined to any one area or locality, but, due to our increased facilities of travel and transportation, soon finds its way over the entire civilized world, wherever climatic conditions may permit of its development. In plant life one recalls at once the San José scale, the chestnut blight, the white pine blister, the Tussock moth, and now the Dutch or elm tree beetle, threatening the total destruction of our elms as the blight has already destroyed our chestnuts. The epidemic of *Amoeba coli*, having its origin in Chicago, soon found its way into almost every corner of the United States and Canada.

Similarly rhinoscleroma, or scleroma, as it is more properly called, when first described by Hebra, in 1874, seemed to confine itself almost exclusively to the inhabitants of southwestern Russia and the Balkans. But especially in the last ten years it has been found practically throughout Europe, with some cases in South America, Japan, China and Sumatra, many more in Central America and a few sporadic cases in North America as well. Reyes has reported 300 cases in San Salvadore, mostly in workers in deep blue aniline dyes, and suggests that there may be some organism in the dye which may be a causative factor.

Frisch, in 1882, described a bacillus which is easily obtained in all cases, not only in cultures, but in the tissues as well; but the bacillus of Frisch, morphologically, closely resembles the bacillus

of Friedländer and of Abel and shows a variety of protean forms when grown on different culture media. It fails to satisfy the postulates of Koch, and so the etiology of the disease, as well as its mode of transmission, are still matters of conjecture and as yet incapable of proof. Characteristic microscopic lesions have been produced in animals, notably white mice and rabbits, but there have been no successful cases of the transmission of the disease itself. Rona inoculated the ear and cheek of a patient with cultures of the bacteria, and Simoni placed pledgets of cotton soaked in the secretions from the nose of a patient in the nose of a second patient, without result. Von Schroetter went still further and placed bits of scleromatous tissue beneath the skin of his own arm, but was unable to infect himself. By some the disease is thought to thrive only in unhygienic surroundings and so have advocated national or even international measures for its control. Lascagna reports 11 cases as occurring in the same family, country people of one village, and Figi calls it "the disease of the great unwashed."

Pathologically it is an especially chronic disease of the upper air passages, which localizes itself in the mucosa and submucosa and may attack first the nose, the nasopharynx or the larynx. It may even attack first the nose and then the larynx, or *vice versa*, leaving the intervening mucosa and submucosa entirely uninvolved. Likewise it may confine itself to any one of these three locations without involving the other two. Most authors speak of three stages:

1. A catarrhal stage, characterized by profuse secretion and crust formation in the nose, closely resembling atrophy.
2. A stage of tumefaction or proliferation, small tumor masses ultimately coalescing to form larger ones.
3. A stage of cicatrization or concentric stenosis, causing a marked narrowing of the airway.

The tumor masses are at first soft and red and do not tend to ulcerate, unless irritated through trauma or when involved by secondary infection. Death always results from intercurrent complications and never apparently from the disease itself, the victims not infrequently living to an advanced age. In the larynx the disease is always *bilateral* and *subglottic* and must be distinguished

from acute and chronic swelling, as well as from tuberculosis, syphilis and perichondritis. Involvement of the trachea and bronchi is always secondary and late in the course of the disease.

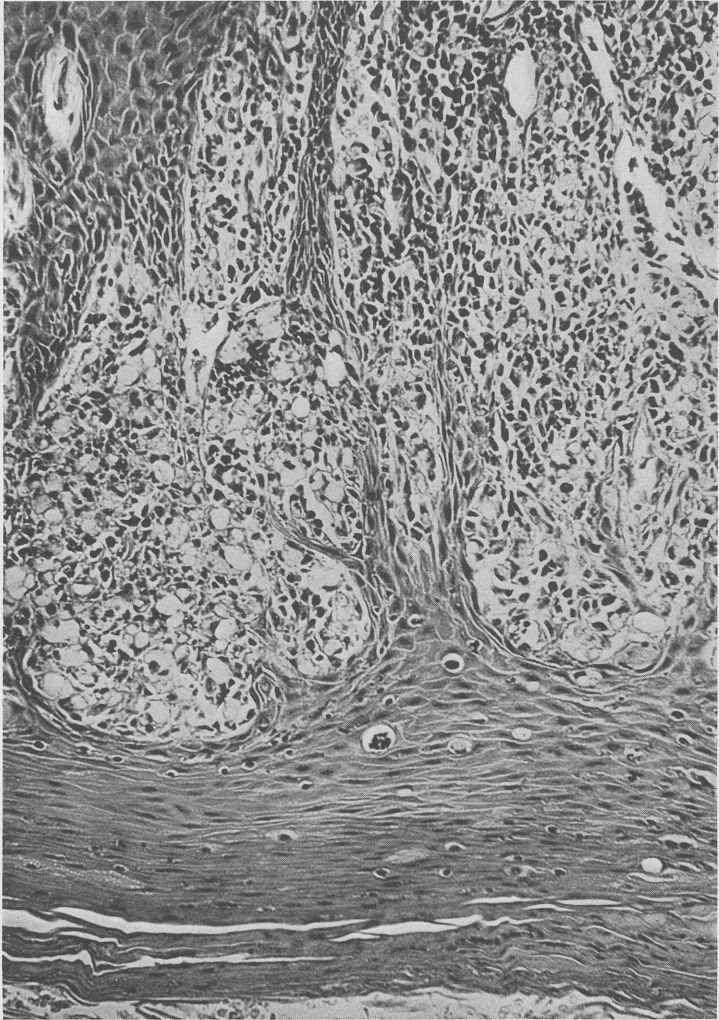


FIG. 1.—Low-power view—to show surface epithelium infiltrated with leukocytes and lymphocytes, immediately under which are clusters of Mikulicz cells and epithelioid cells.

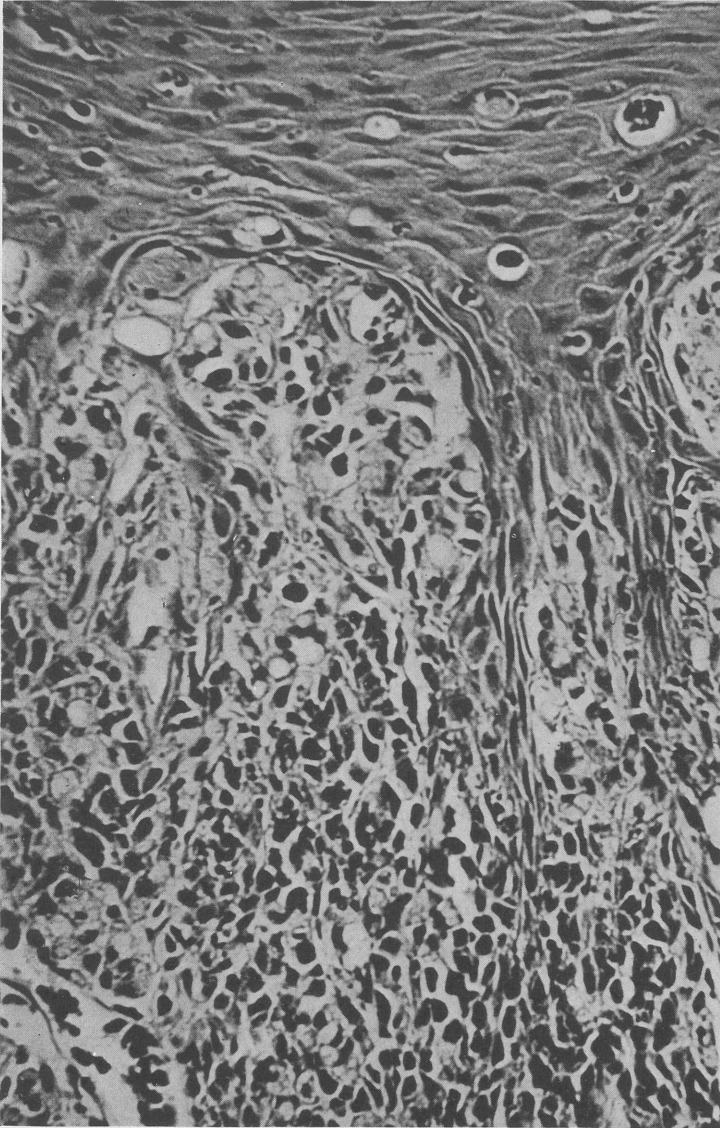


FIG. 2.—High-power view—showing part of surface epithelium and several Mikulicz cells, one of which, in the middle of the slide, shows the partitions produced by the small vacuoles.

Histologically the disease picture is characterized by the vacuolated cells, first described by Mikulicz. These are also described as foam or lace cells and contain the bacteria, often in large numbers. The sections also show frequent masses of hyaline tissue, or Unna bodies, as they are sometimes called. As the sclerosing process supervenes these characteristic cells are gradually lost, their presence or absence depending largely upon the stage of the sclerosing process.

The symptoms of scleroma are a gradual impairment of respiration, either nasal or laryngeal, depending upon the site of involvement, with no pain or dysphagia and no impairment of the voice. In my first patient the voice was fairly normal, although a tracheotomy had been performed to relieve the obstruction. Yet the finest probe could not be passed through the larynx under general anesthesia, either from above downward or from below upward, through the tracheotomy wound. In my second patient there was some pain and the nose was so extremely tender that no entirely satisfactory examination of the depths of the nasal fossæ could be made, even under attempted cocaine anesthesia. In resecting bits of tissue from the anterior nares, and especially the anterior part of the septum, cocaine had but little or no effect and infiltration of 0.5 per cent novocaine only partially relieved the discomfort of resection.

Before the introduction of roentgen-ray and radium, various therapeutic measures have been tried without result, notably excision, cauterization and diathermy, as well as autovaccination, agressins and neosalvarsan. Hassan Bey Shaheen reports favorable results from the injection of colloidal iodine, with a possible cure in one case. Radium and roentgen-ray at the present time seem to offer the greatest assurance of arrest or cure, although no therapeutic measures are of value after firm cicatrization has taken place. In the nose and nasopharynx, dilatation is of little use. In the larynx, however, the dilators introduced many years ago by von Schroetter are still of value in maintaining the patency of the larynx and postponing, if not avoiding, the day when tracheotomy must be resorted to. When the dyspnea becomes severe this, however, is unavoidable.

Two cases of rhinoscleroma have come to my attention during a

period of thirty years in clinical work. So far as I know, these have been the only cases in Lakeside Hospital or the other hospitals of Cleveland as well.

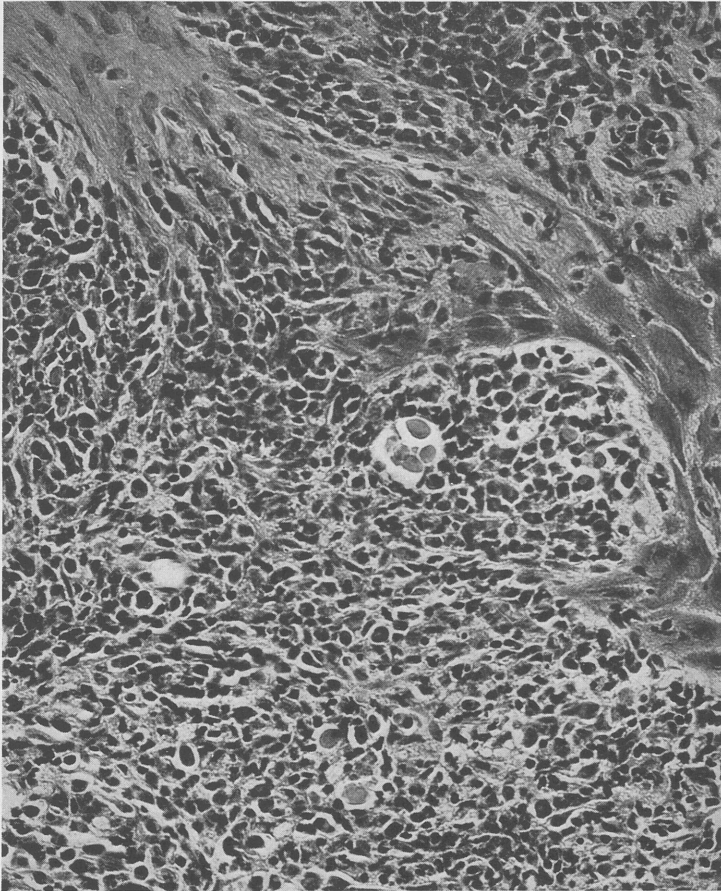


FIG. 3.—Medium-power view—to show hyaline bodies. There is a cluster of four of these bodies, probably situated in a lymphatic. Two other small bodies are in the opposite end of the section and one of them shows a nucleus about to be extruded.

The first was a patient seen in 1914, a male, aged twenty-four years, and born in Russia. He came to the United States eight years previously and one year later began to experience difficulty in

breathing. This patient was subsequently reported by Gleitsman, who excised bits of tissue from the larynx three times in four years and ultimately performed a tracheotomy. In 1914, I removed masses of tissue from both above and below the vocal cords. Although his

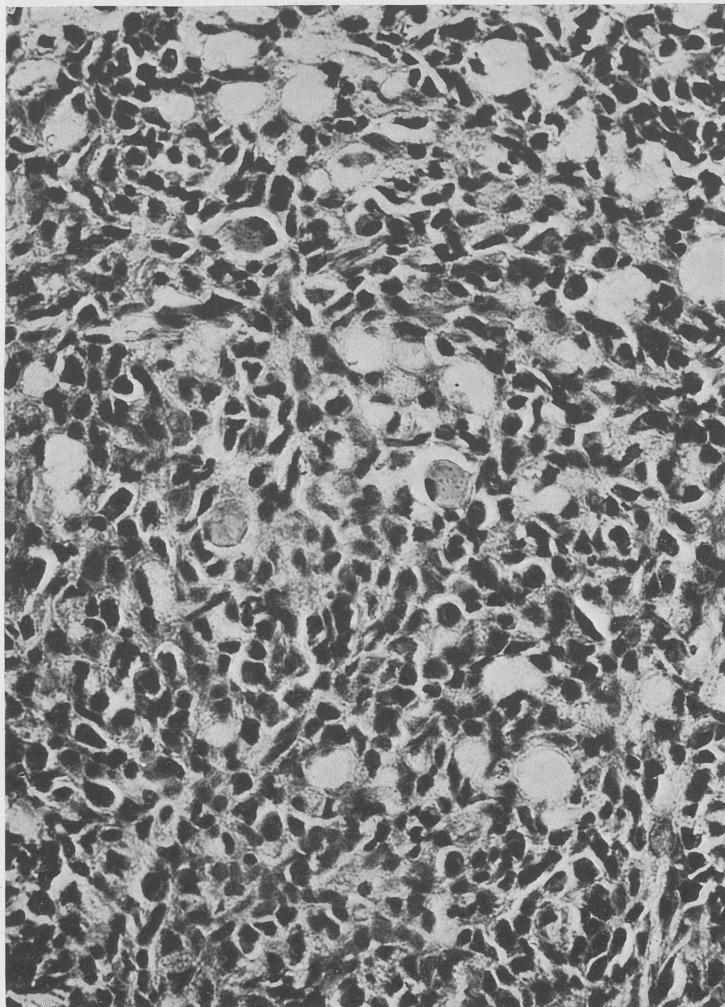


FIG. 4.—High-power view—to show hyaline bodies, two of which are found in the slide. One of these shows a nucleus about to be extruded.

voice was somewhat hoarse, it was of good volume, yet a probe could not be passed through the larynx even under general anesthesia. I have kept in touch with this patient ever since. When last seen he was still wearing a tracheotomy tube but otherwise his health was excellent, the disease apparently not having progressed to the trachea or bronchi. The nose and nasopharynx were uninvolved.

The second patient, a man, aged fifty-two years, born in Russia, came to this country twenty-six years ago. His family history was unimportant. He was wounded in the left chest in 1916 and had a serious infection of the dorsum of the right hand in 1928, requiring incision and drainage. Otherwise his health had been excellent. He worked as a laborer until two years ago, since which time he has been unemployed. About fifteen years ago he first complained of nasal obstruction with excessive crust or scab formation. Later he noticed a growth on the right side of the nose. The growth was painful but never bled unless it was disturbed. One year later a portion of this growth was excised, as were other masses on several occasions since. Recently the growth has become more painful and tender and has increased in size, thereby increasing the nasal obstruction.

Examination. I cannot improve upon the description of one of my assistants, Dr. H. W. Allen, which is as follows:

"The nose appears to be thickened at the tip and in the region of the alar cartilages. There is a marked widening of the columella which is due to a proliferative mass involving the skin and mucous membrane of both anterior nares, more markedly on the right. The granulomatous growth is pale, hard, extremely tender and painful and is covered with a thin, dry crust.

"The tumor extends along both sides of the septum and involves the lateral walls of both vestibules. The remainder of the nasal cavity appears dry, with a thickened mucous membrane. The full extent of the lesion cannot be determined because of the extreme tenderness and failure of the mucous membrane to respond to shrinking solutions as well as to cocaine.

"On direct examination the uvula is not apparent. The two anterior pillars appear to be under tension, meeting in the mid-line. The posterior pillars are practically fixed and retracted upward, especially the right, which brings the right tonsil into view. From the medial surface of this tonsil a leukokeratosis extends backward to the posterior pillar and up the lateral wall of the

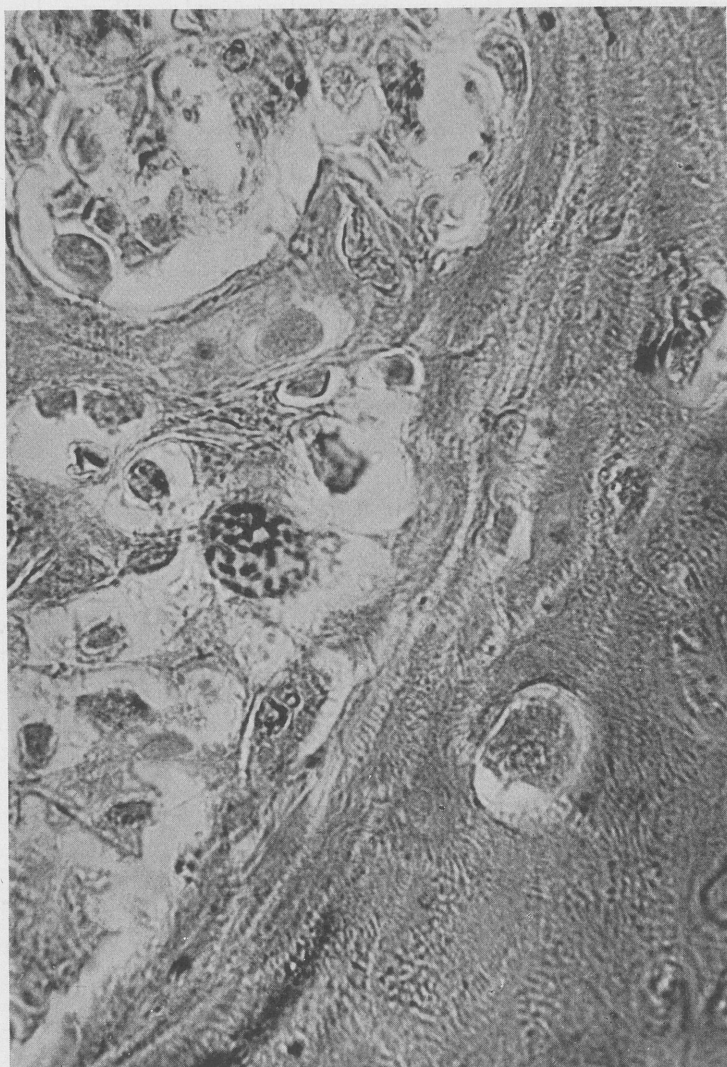


FIG. 5.—High-power view of Mikulicz cell, containing bacilli stained by methylene blue.

pharynx and nasopharynx. The use of the mirror shows a marked contraction of the nasopharynx, apparently due to encroachment of the lateral wall toward the midline as a result of infiltration and cicatricial contraction. The uvula is seen projecting upward and backward into the nasopharynx. As a result of this atresia the landmarks of posterior rhinoscopy are not visible."

On examination with the mirror the uvula is found to be present and intact, but is drawn upward and backward by strong bands of cicatricial tissue, so that on looking directly into the mouth it appears to be amputated at its base. The remainder of the nasopharynx is filled on either side with masses of dense, firm cicatricial tissue. The posterior border of the septum can be recognized, but the eminence of the Eustachian tubes cannot be seen, although there is little impairment of hearing.

The larynx and epiglottis were normal and the voice was unimpaired.

On my last examination, May 15, 1935, there had been a marked increase in the stenosis of the nasopharynx. The posterior border of the septum could still be seen through a round sclerosed opening, about 1.5 cm. in diameter, or the size of the average postnasal mirror. Three applications of radium had produced a decidedly beneficial effect upon the anterior nares and vestibule. There was a marked decrease in the size of the growth, the pain had practically disappeared and there was much less tenderness to pressure. The radium was applied as follows: one 50-mg. tube, screened with 5 mm. of silver, 1 mm. of brass and 1.5 mm. of aluminum, was so applied as to come in contact with the surface of the lesions for three hours, thus making a dosage of 150 mg. hr. There had been two surface applications and one implant of 2 gold seeds of 1 mc. each. Ranzi first reported the treatment of rhinoscleroma by roentgen-ray, in 1904, and Kahler was the first to use radium, in 1905. Wunderlich, of Guatemala, presented 3 cured cases before the Pan-American Medical Congress, in 1908, and later reported 14 additional cures.

Examination of the tissue, as well as that of the cultures and smears, was made by Dr. Harry Goldblatt and Dr. E. E. Ecker, of the Department of Pathology of the School of Medicine of Western Reserve University, and is as follows:

Dr. Goldblatt: "The surface epithelium is of the squamous type, of irregular outline and variable thickness. In some places, it is greatly thickened and there are projections of the epithelium deep into the corium. Parts of the surface epithelium are covered by a thick layer of keratinized cells. The basement membrane is everywhere intact. The surface epithelium is everywhere moderately, but diffusely infiltrated by polymorphonuclear leukocytes. The corium is trabeculated. Between the trabeculae, which consist of dense, partly hyalinized connective tissue, are masses of plasma cells and lymphocytes, between which are interspersed a large number of *very large cells* with pale staining foamy-looking cytoplasm. In a few areas there are nodules, which consist practically entirely of these large foamy cells. Some of these nodules are situated immediately beneath the surface epithelium. The infiltration of the plasma cells, lymphocytes and foamy cells (Mikulicz's cells) extends into the subcutaneous tissue and to the lowermost limit of the sections.

"NOTE. Special stains for the demonstration of bacteria within the foamy cells showed the presence of Gram-negative bacilli in moderate numbers.

"*Diagnosis.* Granulomatous inflammation of nasal mucous membrane. (Rhinoscleroma.)"

Dr. Ecker: "Swabs from the nose and throat show Friedländer-like bacilli, which are culturally and morphologically identical with *encapsulatus rhinoscleromatis*. These organisms have been isolated in pure culture several times.

"*Bacteriological Data.* Cultures were made from pieces of tissue of the nasal vestibule and also from material taken with a platinum loop directly from the pharynx. The materials were streaked on blood agar and plain agar plates, and within twenty-four hours, large numbers of colonies of organisms belonging to the mucoid-encapsulated group were observed. Smears of the colonies showed the organisms to be pleomorphic rods, with rounded ends and variable in size. They appeared to be nonmotile, showed a capsule and were Gram-negative. The intracellular mucoid was characteristic of the group. The organisms were aerobic.

"The growth on agar was white, translucent, moist, smooth and sticky. Litmus milk was acidified and clotted but the clot was

not broken. Glucose, lactose, sucrose, inositol and maltose were acidified, but with no gas formation. Mannite showed little or no change, while arabinose, dulcitol and xylose showed no change. Rhamnose gave a slightly acid reaction.

"Gelatin was not liquefied. Clotted blood serum was not changed. The organisms failed to produce indol and nitrates were reduced to nitrites.

"The organisms of the *Klebsiella* group vary greatly.

"The organism of rhinoscleroma (*Klebsiella rhinoscleromatis*) was described by Frisch, in 1882, and Wilde (1896) thought that by forming no gas in dextrose broth, and in producing no acid in lactose broth and in not coagulating milk, it could be distinguished from the Friedländer bacillus. But Small and Julianelle observed Friedländer strains possessing similar biochemical characteristics. Variability in the rhinoscleroma group has also recently been described by H. Weisels and E. Mikulaszek."

COMMENT. The two cases here reported are neither of them in native-born Americans, although in the second patient, due to his long sojourn in this country (twenty-six years), there might be more than a suspicion of its indigenous origin. The patient's home surroundings were not inspected, but personally he was always fairly well dressed and of unusually cleanly habits. He was of more than average intelligence and could remember no contacts with similar cases either at home or since his arrival in this country. Emil Mayer, writing, in 1908, after a careful review of the literature, stated that no authentic case had ever been reported in a native-born American. Since then cases in native-born Americans have been reported by Wende, Watkins, Wood, Figi and Canfield; while Helwig and Jaime reported the case of a Mexican youth, who died of acute suffocation at the age of twenty years, who had been born and reared in Kansas City.

Hajek, in an excellent article in his recent handbook on the larynx, wisely suggests that the recent recognition of scleroma throughout practically the entire civilized world may not necessarily be due to its wider distribution, but rather to an increased acquaintanceship with the disease, previous cases having escaped unnoticed. Our recent case had previously been in the hands of a rhinologist and had not been diagnosed.

CONCLUSIONS. 1. Scleroma or rhinoscleroma is no longer confined to a fairly definite locality in southeastern Europe, but is fairly well distributed over the entire world.

2. The bacillus of Frisch is easily found in all cases in practically pure cultures. This bacillus is very similar to the bacillus of Friedländer and of Abel. Although typical local lesions can be produced by its injection into animals, it fails to satisfy the postulates of Koch in that the disease itself cannot be reproduced in animals or in man.

3. The bacilli of Frisch are not necessary to the absolute diagnosis of the disease. Necessary, however, are the vacuolated, lace or foam cells of Mikulicz and the hyaline bodies of Unna.

4. The mode of transmission or contagion is still unknown, and until this is discovered no definite means of combating the disease is available.

5. At the present time roentgen-ray or radium in proper doses offer the best hope of control or cure.

DISCUSSION

DR. RALPH ALBERT FENTON, Portland, Ore.:

This is an interesting and scholarly contribution. May I remind the members that some two or three years ago, at a meeting in Los Angeles Dr. Eugene Lewis presented 3 cases of rhinoscleroma, 1, I think, laryngological; the other 2 in the nose; 1 with involvement of the pharynx. As I recall them, these were all in Mexicans. One, I think, was born in Los Angeles, and the other two were immigrants from neighboring states in Mexico. They were not, however, Americans in the proper sense, and apparently all of these people who have been picked up, with the exception of three or four, in the last four years, have been persons of different races from the predominant race in our country.

I should like to ask Dr. Chamberlin whether any experiments referable to the possibility of a filterable virus as an activating agent for this bacillus have ever been carried on.

MR. NORMAN PATTERSON, London, England:

I saw a case many years ago in London and the other day one in Montreal, but this has aroused fresh interest, and I shall certainly go through the literature and try to find something about it.

DR. ROBERT SONNENSCHN, Chicago, Ill.:

I have nothing special to add to Dr. Chamberlin's excellent report, but simply want to state that I had the privilege (as did my good friend, Dr. Grove, who succeeded me at Koenigsberg, in 1910, where I was assistant for a time), of seeing many of these cases because there came to Professor Gerber's clinic, patients from Silesia, Poland and Russia, where the disease was endemic. I saw a very large number of these cases, and my recollection is that the nasal cases were quite common as compared with the laryngeal cases.

DR. JOSEPH C. BECK, Chicago, Ill.:

I want to make a little personal remark regarding rhinoscleroma, which might not be amiss. It was while associated in service at the Cook County Hospital with the late Dr. Friedberg, that we had 3 cases of rhinoscleroma under our supervision. One of these, a young woman in question, was being examined for the first time by means of a bronchoscope. This was in a day when we were just learning how to use these direct instruments. Looking down into the trachea and upper bronchi, I was so astounded with the findings and so pleased that I failed to close my mouth just at the time when the patient gave a cough and I received a good load of these secretions directly into my mouth. Inasmuch as this patient was born in Bohemia, and as I am of that same extraction, I began to think a bit of the possibility of contact infection. Of course, today we know better and that such a thing is impossible in rhinoscleroma. Nevertheless, they were moments of considerable worry. I had an opportunity of studying this disease with Dr. Friedberg and in this particular case that I mentioned, both radium and roentgen-ray were used, as were large amounts of potassium iodide. These had practically no effect and the reason is easy to understand. Final changes in rhinoscleroma, namely, sclerosis and fibrosis will not be affected by any such remedy and only dilatation or excision may affect and improve it.

While in the city I had the pleasure of examining a case of rhinoscleroma and I trust that some of you gentlemen will visit the clinic and have Dr. Goldsmith, our president, or Dr. McGregor show you this same case. It is of particular interest to study the clinical side with the histopathological material which is also shown in connection with the case.

DR. JOHN DEVEREUX KERNAN, New York City:

I saw a case of rhinoscleroma in a middle-aged Russian Jewess last summer, one that had been in existence for twenty or thirty years, It had had very extensive treatment with roentgen-ray. The Radio-

therapy Department refused to use roentgen-ray any more on the case so I undertook to remove it with a diathermy knife. It extended toward the right cheek, and as I got down into it, it began to look queer for rhinoscleroma, so I stopped and sent the tissue to the laboratory. The report came back that it was a carcinoma. So that was a case in which a proved case of rhinoscleroma had grafted on it a carcinoma of the antrum.

I should like to ask Dr. Chamberlin if he has looked into the literature of the subject and has come across any similar case.

DR. WILLIAM B. CHAMBERLIN (in closing):

In regard to Dr. Fenton's question, I did not find any reference to a filterable virus.

Now, as to Dr. Beck's question in regard to the use of radium: Of course, your cicatrization is an end process, a healing process, we might say, and is subsequent to the stage of tumefaction and swelling. After cicatrization has occurred, I don't think that radium has any effect at all, or it might produce, if you used it in sufficient quantities, a sloughing effect. It is interesting, too, in the advanced lesions where cicatrization has taken place, that we find little or no evidence of the unibodies or the Mikulicz cells. Those are only in the stage of tumefaction.

I hate to disturb Dr. Beck's peace of mind, but, as you know, this is a very slow-growing process, and there is a possibility of his getting it yet!

DR. BECK: That was thirty years ago.

DR. CHAMBERLIN: Dr. Kernan spoke of the differential diagnosis. Hajek calls special attention to this in the larynx, where he says it must be distinguished from acute and chronic swelling, as well as from tuberculosis, syphilis, and also from malignancy; however, in the nasal pharynx it doesn't seem to me one should encounter great difficulty.

I want to call attention especially to Hajek's dictum that probably the recognition of the disease is due to our greater familiarity with it, and the fact that all of us are on the lookout.

Now, as to these cases which have been reported: Watkins' case was one of the first. This was in a colored man who lived in Baltimore and had never been out of the country except on two trips as a sailor to Central America. Another very interesting case was this one reported by Canfield. This was a girl, as I remember, sixteen, seventeen or eighteen years of age. She was born not far from Ann Arbor; however, her parents were from Southeastern Europe, so there are certainly a few reported cases in this country, but none, so far as I know, in real Americans. They are all of foreign extraction.

THE SPHENOID SINUS AND THE SPHENOPALATINE GANGLION AS FACTORS IN SO-CALLED ATYPICAL TRIGEMINAL NEURALGIA

H. W. LYMAN, M.D.

Tic douloureux, or trigeminal neuralgia, is a definite clinical entity, characterized by intermittent paroxysms of intense pain limited to the distribution of the fifth nerve. These paroxysms are usually induced by the slightest stimulation of a so-called trigger zone somewhere in the distribution of that nerve. For these cases, resection of the sensory portion of the posterior root of the Gasserian ganglion affords the only method of securing complete and permanent relief.

However, the term "trigeminal neuralgia" is often used in describing any severe pain in the face, and variations from the typical tic douloureux, either in the distribution of the pain, or character of the attacks, is accounted for by calling them "atypical trigeminal neuralgias."

In this group of so-called atypical trigeminal neuralgias there are probably a number of different pathological conditions, either in conjunction with true tic douloureux, or entirely independent of that clearly marked affliction.

When posterior root resections are done in these atypical cases, varying results are obtained. In some there is no relief; in others partial or temporary amelioration of symptoms follows; and in still others, the pain is more intense than before. Cervical sympathectomy (usually of the superior cervical ganglion) is frequently recommended in these atypical cases.

Frazier¹ reports 10 selected cases from a series of 13 such operations performed in his service at the University Hospital.

The operator excised the superior cervical sympathetic ganglion, and in some cases, also the middle ganglion and the intervening trunk, and stripped the periarterial plexus from the common carotid artery from a point 2.5 cm. below the bifurcation to 2 cm. above on the external carotid artery. He says:

"Of this series, the sensory root operation in 5 instances had been performed, and in all but 1 of these, no doubt there had been an error in diagnosis. The patients probably did not have true trigeminal neuralgia. The records of this series speak for themselves. In only 1 case did the patient obtain any relief, and in this case there remains the doubt as to whether the relief was permanent, as the patient cannot be traced.

"These observations, if accepted, demonstrate rather conclusively that if patients continue to have discomfort after the major operation for trigeminal neuralgia, an operation on the cervical sympathetic ganglion does not offer any hope of relief.

"Furthermore, the operation is equally ineffective in that group of painful syndromes which, for want of a better term, I have been in the habit of calling 'atypical neuralgias.'

"That one of the patients was entirely relieved by Christian Science suggests a functional rather than an organic basis for the pain, and one may have to be content to view the condition as of psychogenic origin, and discontinue any effort to modify or relieve it by physical procedures."

While it is quite possible that some of these cases grouped as atypical trigeminal neuralgias may be purely psychic, as suggested by Frazier and many others, my own opinion is that in many instances the so-called neurotic state of the patient has an underlying cause, whether we are able to discover it or not, and in the disease we are considering, the so-called neurosis may well be the effect of the prolonged and intense suffering, and the many unsuccessful surgical procedures attempted, rather than the cause of that condition.

Greenfield Sluder,² as early as 1908, called attention to a set of neuralgic phenomena that, in his opinion, were produced by lesions affecting the sphenopalatine ganglion.

In 1919,³ after an observation of several hundred cases, he described the neuralgic syndrome as follows:

"A short time after an upper respiratory infection, of slight or great intensity, the pain began at the root of the nose, in and about the eye, the upper jaw and teeth (sometimes the lower jaw and teeth) and extending backward to the temple and about the zygoma to the ear, making earache; emphasized at the mastoid

but always severest at a point 5 cm. back of that; thence reaching backward by way of the occiput and neck, it may extend to the shoulder blade and shoulder, and in severe cases to the arm, forearm, hand and even the fingertips."

In the same volume³ he reports several cases which he diagnosed as tic douloureux with sphenoiditis which were relieved by cocainization of the sphenopalatine ganglion. In some of them he later injected the ganglion with 5 per cent phenol in 95 per cent alcohol, and in others he exenterated the sphenoid and ethmoid cells. He mentions 1 case in which relief was obtained for four years and then pain recurred, and a resection of the Gasserian ganglion was done. He also mentions several cases in which the constant sinus pain was anterior to the ganglion and the tic seemed to involve the vidian nerve. Some of these were probably so-called atypical trigeminal neuralgias; but in 1916 he reported⁴ 2 cases which he believed to be true tic douloureux, and which he thought were due to an acute inflammation of the sphenoid sinus, and which were cured by the clearing up of that inflammatory process. The pain was of the sharp, stabbing, recurrent type of tic douloureux, rather than the aching type of longer duration, which usually characterizes sphenoiditis.

In one of these cases the pain ran through the upper jaw, around the eye, backward under the zygoma to the ear, and from there backward and downward into the shoulder. This distribution of pain is that which he describes as due to irritation of the sphenopalatine ganglion. The attacks were brought on by movements of the head. In the other case the pains were of the same type, characteristic of tic douloureux, but limited sharply to the distribution of the second and third divisions of the fifth nerve. This case complies with all the requirements of a typical tic douloureux.

He says: "There are some statements in our literature, more or less at random, attributing the sinuses of the nose as the etiological factor of tic douloureux, but a record of such perfectly well-defined cases as these that I describe is unknown to me."

In May, 1916, he presented before this Association drawings of anatomical specimens in which the Gasserian ganglion was in close contact with the sphenoid sinus, and offered this as an

explanation of why semilunar ganglion neuralgias and tic douloureux of sphenoidal origin sometimes recover if the sphenoidal lesion can be controlled.

Cushing⁵ gives the following classification of cases which may be mistaken for tic douloureux:

1. Neuralgias accredited to the sphenopalatine ganglion (Sluder's neuralgia).
2. Post-zoster neuralgias.
3. Neuralgias accredited to the geniculate ganglion.
4. Painful tic convulsif.
5. Neuralgias from tumor involvement.
6. The minor trigeminal neuralgias.

Concerning the last classification, he says: "They may follow injuries, particularly when nerves have been contused, or more seriously damaged. They are particularly common as the aftermath of dental procedures. . . . Again, extension of nasal infections to the accessory sinuses is a common precursor of neuralgia, due, unquestionably, to some inflammatory involvement of the adjacent nerve trunks.

". . . Oftentimes, it must be confessed, conditions which we have placed in the category of minor neuralgias are regarded by the patients themselves as most intolerable; but we have done so for the reason that only a single division has been involved and in due consideration, it has seemed unwise to perform a Gasserian operation even when intense pain is complained of. When some definite irritative lesion is found, one may look with more or less equanimity on these local neuralgias, but in cases in which the initial paroxysm, unrelated to any discoverable cause, strikes unannounced, and others tend to follow, one must realize that these attacks may be the precursors of the major type of neuralgia."

Concerning the neuralgias accredited to the sphenopalatine ganglion, he believes they should be capable of differentiation from true tic douloureux, by the history or presence of sinus infection, by their frequent bilateralism, by their situation and tendency to radiate to the neck and shoulder, and by their more or less continuous pain, which is not inaugurated by stimulation of a "trigger zone." He describes such a case in which section of

the posterior root of the fifth nerve gave no relief, but also cites a case of supposed sphenopalatine neuralgia in which the Gasserian operation resulted in a cure of the trouble.

He believes there is a type of neuralgia conforming to Sluder's description, which, however, he is inclined to attribute to irritation of the maxillary nerve rather than to the sphenopalatine ganglion. Because of the failure to obtain relief in this type of case by the Gasserian operation, he feels that a careful segregation of these cases should be made.

None of the cases I have seen comply with all the requirements for the diagnosis of true tic douloureux. However, I believe the cases here reported demonstrate that posterior sinus infections, with a consequent irritation of the sphenopalatine ganglion, either in connection with, or independent of, tic douloureux, explain some of these cases so loosely grouped together as atypical trigeminal neuralgia.

My attention was forcibly directed to this relationship, in 1923, by the case of a man, aged fifty years, who suffered from severe typical attacks of tic douloureux for four and a half years. In addition to these attacks, he had constant severe pain in the retro-mastoid and occipital regions on the same side. Before the posterior root of the Gasserian ganglion was resected, I opened his right sphenoid. This relieved the pain in the back of his head, but had no effect on the paroxysmal pain of the tic douloureux, which, however, was completely abolished by the posterior root resection. Evidently, in this case, the patient was suffering from two separate conditions, and both operations were necessary to relieve him.

In addition to the case mentioned, I wish to present the records of several other representative cases of so-called atypical trigeminal neuralgia in which relief was obtained by operation on pathological sphenoids and ethmoids, and by the injection of the sphenopalatine ganglion with 5 per cent phenol in 95 per cent alcohol. These cases were referred to me through the kindness of Dr. R. M. Klemme for the study of this problem.

S. R., white, female, aged fifty-four years. On August 27, 1931, this patient had a posterior root resection for trigeminal neuralgia. The fibers of the second and third division were severed, and the first division and the motor root preserved.

Her history was that of a typical tic douloureux of the second division.

She was free from pain after this operation.

In November, 1932, she complained of pain over the right eye, forehead and "in her nose." This had continued at intervals, and recently it had become almost constant. This pain was repeatedly relieved by cocainization of the right sphenopalatine ganglion, but the relief was only temporary.

On December 12, 1933, the right sphenopalatine ganglion was injected with 0.5 cc. 5 per cent phenol in 95 per cent alcohol, and the right sphenoid and ethmoids were opened freely. The tissue removed was sent to the laboratory and reported as showing chronic inflammation. The patient was promptly relieved of her pain, showing that the ganglion injection had been successful, and that the pain was not due to a tic douloureux of the unsevered first division of the fifth nerve.

M. B., white, female, aged forty years. This patient gave a history of pain of five years' duration. This pain was at first intermittent, later becoming constant. It involved the right maxillary and mandibular regions, and radiated to the lower temporal, aural and occipital regions. It also involved the back of the neck. The patient also described paroxysms of typical tic douloureux. In fact, she had such an attack in Dr. Klemme's office.

In May, 1932, she had a posterior root resection of the fifth nerve, including the fibers of the second and third division. This relieved a great deal of the pain, but she continued to have severe pain in the region of the right eye, the zygomatic, aural and mandibular regions. This pain, except that in the lower jaw, was relieved on several occasions by cocainization of the sphenopalatine ganglion.

In September, 1932, under twilight and local anesthesia, the sphenopalatine ganglion was injected with 0.5 cc. of 5 per cent phenol in 95 per cent alcohol. The middle turbinate was resected, the posterior ethmoid cells exenterated and the sphenoid opened. The sphenoid showed little gross pathology, but the ethmoids were filled with polypoid material.

The pathological report was chronic inflammation of the ethmoid cells.

The patient was relieved of all of her pain except that along the lower jaw.

On March 14, 1933, she had a resection of the right sympathetic trunk below the superior cervical ganglion for this condition, by which procedure the pain in her mandible was relieved.

The pain in this case extended beyond the limits of the fifth nerve and had the characteristics of a sphenopalatine ganglion irritation, due to inflammation of the posterior sinuses. This was in addition to the true tic douloureux. The relief was prompt, showing that the sphenopalatine ganglion injection was successful. However, injection of the ganglion had no effect on the pain in the lower jaw.

This patient later developed a glossopharyngeal neuralgia, for which the ninth nerve was severed in the posterior fossa, on April 2, 1935, with relief from pain.

L. M., white, female, aged sixty-one years. She gave a history of left facial tic, involving both eyelids, beginning in 1914, with gradual increase. She had no pain at that time.

In March, 1916, she had an attack of influenza. Severe headaches began the following summer. At this time the apices of both lungs were dull, and the patient gave a positive tuberculin skin reaction.

In 1921, the attacks of pain had become more frequent and more severe, and the pain was now constant over the left side of the face and down to the left shoulder. The left eyelids twitched constantly. The patient believed that the facial twitching induced the attacks of pain. This case was diagnosed as tic douloureux, but the diagnosis was not concurred in by the neuro-surgeon.

The tubercular process was quiescent at this time.

I first saw the patient in September, 1932, at which time she complained of severe pain above both eyes, and on both sides of the head and neck. Much worse, however, on the left side. Because the pain could be controlled by cocaineization of the sphenopalatine ganglion, and because the posterior sinuses on the left side showed evidence of infection, on September 27, 1932, the left sphenopalatine ganglion was injected with 0.5 cc. of 5 per cent phenol in 95 per cent alcohol, the left sphenoid was opened and a large amount of pus released. The mucous membrane was greatly thickened. The posterior ethmoid cells were opened and also showed greatly thickened mucous membrane. The pathological report was chronic inflammation of the sphenoid and ethmoid. Cultures from the sphenoidal pus showed a profuse growth of *Streptococcus viridans* and a scanty growth of hemolytic *Staphylococcus albus*.

The relief in this case was prompt, indicating a successful injection of the ganglion, and her chief complaint thereafter was the twitching, due to the seventh nerve tic. However, she has had several reinfections of her sinuses, and, with each attack of sinusitis, there has been a return of the pain, more, more or less severe, but never as bad as before the operation.

This case illustrates the fact that frequently the effects of alcoholic injection of the ganglion are only temporary, and pain can later be excited by irritation of the revived ganglion.

J. M., white, male, aged twenty-eight years. Since the age of twenty-one, the patient has complained of severe headaches, especially on the left side of the face. There was increased nasal discharge and the eye became red. The pain spread over the side of the head and back to the left occiput. Attacks sometimes lasted for two hours. Cocainization of the sphenopalatine ganglion relieved these attacks. The left sphenoid was irrigated and thick muco-pus washed out of the sinus.

On April 27, 1934, the left sphenopalatine ganglion was injected with 5 per cent phenol in 95 per cent alcohol, and the left sphenoid and ethmoids opened. Pus was found in the sphenoid, and the lining membrane of both the sphenoid and ethmoid cells was thickened and showed a chronic inflammatory process. The relief from pain in this case was prompt, indicating a successful injection of the ganglion.

On June 25 he had a severe attack of pain, and the left ethmoid cells were found to be acutely inflamed. Subsequent to this time his attacks of pain varied with the condition of his sphenoid sinus. These sphenoid infections usually responded to treatment, but in March, 1935, he had an attack of pain, and this time the sphenoid infection did not respond to treatment as readily as it had previously. On March 10, the sphenopalatine ganglion was again injected with 5 per cent phenol in 95 per cent alcohol, which promptly controlled the pain, in spite of the presence of the sphenoiditis. His sinuses at the present time appear to be in good condition and he is free from his pain.

In this case, while the attacks of pain came on in paroxysms, they lasted longer than a typical tic douloureux, and the pain extended beyond the distribution of the fifth nerve. While the alcoholic injection of the ganglion gave immediate relief, this effect wore off in two months, although the attacks of pain were not as disabling as they had been before the operation. The second injection of the ganglion again gave prompt relief. This patient was also markedly allergic, but there was never any difficulty in distinguishing between the effects of his allergy and the neuralgic condition.

J. B. C., white, male, aged about fifty-five years. In 1929, this patient complained of severe paroxysms of pain in the left side, centering in the left eye and spreading to the face, vertex and occiput. These

attacks usually came on in the night and lasted twenty-five to forty-five minutes. During these attacks the conjunctiva of the left eye became intensely injected. The attacks persisted for about six weeks and then were followed by an interval of freedom from pain for about the same length of time. The patient stated that the attacks were more severe if he was worried.

At this time, and again in 1931, a diagnosis of trigeminal neuralgia was made, and resection of the posterior root of the Gasserian ganglion was recommended, although neither the distribution of the pain nor the duration of the attacks were characteristic of tic douloureux.

In January, 1933, he was examined and the sinuses were said to be normal. Resection of the superior cervical sympathetic ganglion was advised.

I first saw this patient in April, 1933. Cocainization of the left sphenopalatine ganglion promptly stopped several of the attacks. On May 1, roentgen-ray plates of the sinuses were made, after the displacement instillation of lipiodol by Proetz's method. Ninety-six hours later, lipiodol was still present in the left sphenoid and left posterior ethmoid cells.

May 5, 0.5 cc. of 5 per cent phenol in 95 per cent alcohol was injected into the region of the left sphenopalatine ganglion, and the left sphenoid and ethmoid cells were opened. The frontal sinus, at this time, was open and a probe could be easily passed into that sinus.

The pathological report was chronic inflammation of the mucosa of the sphenoid and ethmoid.

The relief from pain was not prompt in this case, the reason probably being that the alcoholic injection did not reach the ganglion, the needle having been introduced too low.

May 11, he contracted a severe upper respiratory infection, and on May 20 had severe attacks of pain. At this time the left sphenoid could be seen filled with pus. As the sinusitis cleared, under treatment, the attacks of pain diminished and finally cleared up.

July 31, he complained of pain above the left eye, but no occipital pain. This appeared to be due to obstruction of the left frontal sinus.

September 11, he complained of pain in the left occipital region and left arm. At this time the left sphenoid was again full of pus. This cleared up promptly after washing out the sphenoid with weak ephedrin-saline solution.

During the winter his pain fluctuated with the condition of his sinuses.

In March, 1934, he had a series of attacks of very severe pain over

his left eye, accompanied by a mucopurulent discharge from his left frontal sinus. The severity of the pain was probably aggravated by a profound psychological disturbance, and, because of this condition, it was not deemed wise by his physician to enlarge the opening into the left frontal sinus at this time.

The failure to obtain prompt relief in this case was because injection of the ganglion was probably unsuccessful, but relief did follow the clearing-up of the sphenothmoiditis, with relapses occurring with each reinfection of those sinuses. The pain caused by inflammation of his frontal sinus was distinct in character and distribution from that due to the sphenoiditis.

This paper is simply a clinical study in which an attempt has been made to separate from the heterogeneous mass of atypical trigeminal neuralgias a group of cases having a definite pathology and a recognizable symptomatology.

The cases in which the ganglion injection was successful obtained almost immediate relief, but if the injection was unsuccessful, the relief came on more slowly, as the sinusitis, which was responsible for the irritation of the ganglion, cleared up. It was attempted in each case because, if successful, the relief was so prompt.

The described procedure has not been undertaken in any case in which cocainization of the sphenopalatine ganglion failed to relieve the pain.

Whether this syndrome is due to irritation of the sphenopalatine ganglion by the inflammatory process in the sphenoid and posterior ethmoids, as believed by Sluder, or is due to irritation of the vidian nerve, as suggested by Vail,⁶ must be left to the anatomists and physiologists to answer. When our knowledge of the structure and functions of the complicated nerve supply of the head and neck becomes sufficiently complete, this, as well as the many other puzzling phenomena of atypical neuralgias can be accurately and scientifically solved. Until such time, physiological hypotheses, based on clinical observation and our present incomplete knowledge of these structures in the human being, will often be proven inaccurate and even false. However, this should not deter us from using every facility at our command for the relief of our patients suffering from these afflictions.

CONCLUSIONS. 1. "Atypical trigeminal neuralgia" is a term loosely used to describe a number of different pathological conditions, which are not true *tic douloureux*.

2. These cases are not relieved by the Gasserian operation.
3. Cervical sympathectomy also usually proves inadequate.
4. Among these so-called "atypical trigeminal neuralgias" are some in which the character of the attacks and the distribution of the pain correspond to the sphenopalatine neuralgia, described by Sluder. This condition may exist in conjunction with true tic douloureux or independently of that condition.
5. If we can recognize this condition and remove the cause of the ganglion irritation, we can relieve these patients of their pain and spare them the ordeal of an unnecessary and unsuccessful Gasserian operation.
6. If the pain can be controlled by cocainization of the sphenopalatine ganglion, the free opening of the adjacent, infected sinuses, either with or without the injection of the sphenopalatine ganglion with 5 per cent phenol in 95 per cent alcohol, offers a rational and successful method of treatment.

BIBLIOGRAPHY

1. Frazier, C. H.: Atypical Neuralgia, *Arch. Neurol. and Psychiat.*, **19**, 650, 1928.
2. Sluder, G.: The Rôle of the Sphenopalatine Ganglion in Nasal Headaches, *New York Med. Jour.*, May 23, 1908.
3. Sluder, G.: Headaches and Eye Disorders of Nasal Origin, St. Louis, C. V. Mosby Company, 1919.
4. Sluder, G.: Two Cases of Tic Douloureux of Sphenoidal Inflammatory Origin, *Laryngoscope*, February, 1916.
5. Cushing, H.: The Major Trigeminal Neuralgias and Their Surgical Treatment, *Am. Jour. Med. Sci.*, August, 1920.
6. Vail, H. H.: Vidian Neuralgias From Diseases of the Sphenoid Sinus, *Arch. Surg.*, **18**, 1247.

DISCUSSION

DR. RALPH ALBERT FENTON, Portland, Ore.:

May I call the attention of the Fellows to the fact that the sphenopalatine ganglion is a sympathetic ganglion with a lot of sensory and pain fibers running through it in various directions; this is, I think, axiomatic. Injection of the sphenopalatine ganglion for pain interrupts the course of pain fibers in various directions, some back through the vidian nerve, and others through perhaps more direct connections

to the Gasserian ganglion; in fact, the Casselberry prize money awarded to Dr. Larsell, in 1928, was used by him and one of his pupils, Mr. Burns, in the attempt to carry these pain tracts down toward the region of the jugular bulb and the lacerated foramen by following the course of the carotid; and in the series of sections which we made at that time, we found that myelinated fibers passed down from the ganglion, clear down and into the glossopharyngeal, and it is possible that some of these may be pain routes.

As a matter of fact, atrophic impulses and sensations which come from the skin are not necessarily carried by the same myelinated fibers that carry pain; they may travel by entirely different routes; it is possible this may explain why the recent posterior sections of the Gasserian have been more successful so far as the comfort of the patient has been concerned, and have not resulted in danger of damage to the cornea, which the classical removal of that ganglion used to bring about.

We should also, I think, remember that many of these atypical neuralgias, discussed in this excellent contribution of Dr. Lyman's may be due merely to turgescence of the posterior end of the middle turbinate against a neighboring high thickening of the septum, and that the difficulty is somewhat a mechanical one which may be activated by disturbances in the sympathetic system at remote points: for example, in the sacral plexus or mesenteric plexus, due to diverticula in the bowel, a congested uterus, or whatnot.

Purely mechanical relief in the nose at that point, removal of the posterior end of the middle turbinate, and thinning down of the septum may do all that may be done by the somewhat dangerous procedure of injecting alcohol, which in itself is also often transitory in its effect; it seems to me we should consider these factors of vasomotor change in the evaluation of the various types of atypical neuralgias of this sort.

DR. HARRIS P. MOSHER, Boston, Mass.:

I am very pleased indeed to have this subject brought up by a paper as dispassionate and clear as that which we have just heard.

As you know, we were all under the spell, deeply under the spell of Sluder's gigantic physical physique. It was dangerous to disagree with him. We were also under the spell of his magnificent reasoning. He started a furor for the injection of Meckel's ganglion. It was dangerous, as you know, for anyone with a headache to get within 100 miles of St. Louis. It was the same in Chicago, Boston and all the other cities.

Most of us did not get as many successful results as Dr. Sluder did. The furor for the procedure subsided and nearly died out. This paper is very welcome because it is so dispassionate. It straightens a number of things out for me.

The first point I want to make is that if you are going to deal with these cases, you have got to be more of a neurologist than most of us are, or you should get in touch with a neurologist you can trust.

Dr. Lyman has described a definite type of case which can be relieved. Not all types of pain in the head can be relieved by this procedure.

The furor for the injection of the ganglion did not cross the Atlantic, and I have heard some adverse remarks about it there. I should like to have the President call on Mr. Patterson and have him tell us the present status of alcohol injection of the ganglion in England.

MR. NORMAN PATTERSON, London, England:

I am not prepared to discuss the problem without consideration, but in England we have always guarded against the enthusiasm which I think sometimes is very prevalent in this country for ascribing all these neuralgias to some condition of the sphenopalatine ganglion. We have approached that with a great deal of reticence, and as far as I am concerned, I find the treatment of these neuralgias extremely difficult.

You come across a case sometimes which is sent over to you by the neurologist or the neurosurgeon. He demands that you should put your finger on some particular trigger which is causing these distressing symptoms, but, as a rule, I find very often a negative condition in them. In examining the nose one occasionally discovers ethmoiditis, especially disease in the posterior ethmoidal cells or in the sphenoid, which may be responsible for the neuralgia, or again, congestion of the mucosa in the region of the posterior middle turbinate.

On the other hand, 9 cases out of 10 one reports negative and the case goes back to the neurologist or neurosurgeon.

Some of these cases are treated with great success by division of the root of the same ganglion, I gather from papers I have read recently—there was a very good paper written by Jefferson, of Manchester, on the subject, and I think his successes, in his cases of true trigeminal neuralgia, are almost 90 per cent. I think the successes treated by the rhinologist are something like possibly 10 per cent.

I think I really have nothing more to say in the matter but we never really approached the Sluder question with the same enthusiasm as has been displayed over here. I dare say we miss a great number of cases because we are not perhaps as enthusiastic as we ought to be.

DR. ARTHUR W. PROETZ, St. Louis, Mo.:

It seems to me in the present state of our knowledge, a great many of the pains arising about the face are "atypical" or the diagnosis, one might better say, is atypical. Until one knows more about the mechanism of pain, it is bound to be so.

It seems to me that those of us who deal with sinuses have a peculiarly urgent job on our hands to find out just what is the mechanism of pain. We think of it as being pressure or intoxication, or, as Dr. Lyman says, perhaps a mechanical defect from some remote cause, but the fact remains that a sinus membrane which, as we were told yesterday, is as thick as a cigarette paper, can suddenly stretch to half a centimeter or a centimeter in thickness without causing any pain at all. There must be terrific mechanical pulling in that instance, without any pain resulting.

On the other hand, we see membranes that do not thicken, and in the sphenoid, for instance, very painful. We open the sinuses. They look approximately normal, and the pain disappears. We see others with extreme hyperplasias. For half an hour the patient has terrific pain, and for the rest of the twenty-four he has none, with apparently no change in the appearance of the thing. We know that the pathology cannot change as quickly as that. Whether it is an intoxication in that case or not, we do not know, but until we find out whether these pains originate in the surface, in the end organ, whether they come along the trunk of the nerve or whether they do both, or how we are going to distinguish them, most of these pains are going to be atypical, and I hope that the next research will occupy itself with this problem.

DR. JOHN F. BARNHILL, Indianapolis, Ind.:

Dr. Lyman asked me to say a few words concerning his paper, which I had the pleasure of reading this morning. It occurred to me that from a practical standpoint there are several features that ought to be discussed and understood by our Society and our men.

In the first place, the diagnosis is absolutely important. In the past every surgeon who has seen a large number of cases of tic-douloureux has made the same complaint to the otolaryngologist, namely, that he has not always made a good diagnosis. He has operated on sinuses, on teeth, on tonsils, and on other tissues of the nose and nasopharynx, when very clearly there was a tic-douloureux present, so the classification which Dr. Lyman made this morning is one that is most excellent and it ought to be given very close attention.

Every one of you, of course, knows the characteristic symptoms of

tic-douloureux, and it would seem that an uncomplicated case ought never to be mistaken by anyone.

But there is another type of case that ought not be mistaken by anyone either—the one in which pathology is clearly present; and while Dr. Lyman did not mention it, there is a third type, the mixed type, and that is the one in which there are atypical symptoms and corresponding difficulties in making a diagnosis.

Now, in the very typical case, it would be very unwise, indeed it would be, as Cushing once said, rather criminal to open a sinus to operate on the sphenoid, to disturb the nose, to extract the teeth as is so often done, when there is clearly present a trigger neuralgia which is never caused by pathology in any one of the above structures.

As to the diagnosis, as to when one type of neuralgia is present and when the other: Dr. Lyman very properly went into the cocainization question, and it has seemed to me in a number of cases cocainization of a sphenopalatine ganglion by the ordinary methods is not sufficient. By merely applying the drug to the site of the ganglion, it is not possible, I believe, in all instances to get a good result in so far as cocainization of the ganglion is concerned. Why? Because examination as to the exact situation of a large number of sphenopalatine ganglions shows that some lie rather deeply and that there is intervention of bone in some instances, while others lie a number of millimeters beyond the sphenopalatine foramen. Hence the cocaine does not reach the ganglion, and in such instances, if there is strong suspicion of the presence of sinus disease as a cause one should inject the cocaine into the ganglion and note the result. It is easily done and far more certain in doubtful cases.

Dr. Lyman makes one statement on which I wish to comment. I think he would wish to correct it; namely, that the only means of permanently or satisfactorily curing a genuine tic-douloureux is by means of resection of the posterior root. Anyone who will inject a Gasserian ganglion and put the alcohol directly into the cavity—I mean inside the dural envelope which encloses the ganglion—will cure that neuralgia just as certainly as if he resected the root; and the amazing thing to me is that more surgeons have not used the injection method which when properly carried out is equally safe, certain and satisfactory.

DR. E. ROSS FAULKNER, New York City:

I just want to call attention to one thing which I don't think has been mentioned. After the publication of Sluder's work, we were all looking for cases of sphenopalatine ganglion neuralgia. I did not

find as many as I expected, though I see many cases referred to me on account of severe headache with trouble in the posterior part of the nose, largely due to mechanical pressure, and you can test your diagnosis in those cases so thoroughly that you can be 100 per cent sure of your diagnosis.

If you use cocaine in this region, you don't know whether you have cocainized the ganglion or merely shrunk up the tissue. You can use it first in a trial method and then use instead of cocaine, adrenalin or ephedrine-hydrochloride 3 per cent, which will shrink them up and relieve the pain as quickly as cocaine if it is a pure pressure effect; then give them ephedrine-hydrochloride to use at home, with the head in a prone position, drop in 10 drops on the side of the pain, and in a great many cases that will relieve the symptoms temporarily and they get along fairly comfortably for a while, but a permanent cure will require an operation.

The operation is a complete submucous with removal of the posterior end of the middle turbinate. I think either one or the other would be enough, but I always do both to make sure. I am never certain in some of the cases of their symptoms being purely from pressure because with that mechanical obstruction high up in the posterior part of the nose, you have poor drainage of the spheno-ethmoidal recess, and the operation facilitates drainage of posterior ethmoids and sphenoid.

I have injected over 50 cases with alcohol for tic-douloureux and I learned enough not to touch the atypical one. I have by mistake injected one or two atypical, II Division, and got complete anesthesia of the area distribution, and still they referred pain to that region. I had to give this up. My nerves would not stand that business. I would come into my office at 9 o'clock in the morning, and, as everyone knows, you have a large percentage of failures in the alcohol injections, and my failures would be sitting around the office to greet me in the morning. It was a most terrible picture of agony. I knew I could never get any other patients if I kept on having my waiting room filled with these poor people suffering with tic-douloureux.

In the latter stages of my alcohol injection experience, I ran across a doctor who had definitely sphenoid sinus disease. Every time he had an acute exacerbation, he had an attack of tic-douloureux, and treating his sphenoid would relieve the attack.

I think it must be a condition due to local irritation. Dana said he cured it in many case by giving castor oil. It seems to be almost purely local and there must be some bone irritation somewhere about the nerve trunks.

I think the sympathetic is a pretty big proposition. As a field for study I believe that the cyclical character of these things is so characteristic of the autonomic nerve phenomena, that perhaps the castor-oil cure by relieving intestinal stasis with toxemia, relieved the sympathetic irritation which may be a factor in the attack. It may be that the relief of certain allergic-like symptoms in the nasal mucous membranes, such as Dr. Dean was speaking of yesterday, is obtained by clearing out the intestinal tract and abolishing a toxic absorption which acts on the sympathetic nervous system.

I saw the most interesting atypical pain about two weeks ago. The patient had had sinus work done, and the sphenoid opened up to the floor of the sella turcica, and that is the extent of the opening in a great many sphenoids that come to me after having had sinus operations. There was a pocket beyond the floor of the sella and lateral roentgen-rays showed it very definitely. Putting an applicator inside gave a pain analogous to the *tic-douloureux* in the area of the superior cervical ganglion. This localization is hard to explain anatomically unless one assumes that irritation of the vidian nerve could give pain transmission through the deep petrosal nerve.

DR. HENRY M. GOODYEAR, Cincinnati, Ohio:

I should like to ask Dr. Lyman what Dr. Frazier's results were in the 10 cases in which he resected the sympathetic plexus above the carotid artery.

I have been much impressed with the size of the great superficial petrosal nerve which, together with the sympathetic plexus, goes to make up the vidian nerve proximal to the sphenopalatine ganglion.

In doing a transplant for facial paralysis I had to expose the geniculate ganglion, and the great superior petrosal nerve stood out so prominently it seemed that it should be the nerve to contact rather than the facial. It occurred to me that it might be as rational to sever the great superficial petrosal nerve as to resect the sympathetic plexus. It could be done by a radical mastoid operation, reaching this nerve through the middle ear without disturbing the facial nerve.

In 1 patient on whom I had done a radical mastoid operation there was a wide exposure of the carotid artery at the upper end of the Eustachian tube. I was able to demonstrate, by touching this vessel at the dressings, thereafter, severe pain in the corresponding temporal region, deep in the nose and along the deep vessels of the neck.

One case I should like to report is that of a patient with a trifacial neuralgia on whom a posterior root resection had been done. Pain continued about the eye and the pain to the ear was terrific. As a

last resort, after trying alcohol injections, I did a resection of the sphenopalatine ganglion. By going through the antrum, opening the posterior wall, and tying the sphenopalatine artery, it was easy to expose the ganglion, where it showed up very nicely. I carried the dissection through the floor of the sphenoid to get enough of the vidian nerve to destroy the branch to the otic ganglion.

Dr. Frazier, in a personal communication stated that of all the facial tics, only about 2 per cent of them have an involvement of the ophthalmic branch. I had a man I wanted to send to Dr. Frazier, with an ophthalmic involvement but he refused to go. He had been in the hospital four weeks with terrific pain, and we could not get him out of bed. He had a radical antrum operation, ethmoid and sphenoid, with no relief, so, by making the usual frontal curved incision I dissected back and cut the posterior ethmoid nerve. It was done under local anesthesia and after cutting this nerve, the patient said "that is the area, and that is the point that is giving me my trouble."

The pain was relieved and after the previous four weeks in bed and some months of considerable suffering this man made a good recovery.

I have done this operation twice since. It relieves the patient of pain in the temporal region and sometimes also about the eye.

I should like to ask Dr. Lyman how he injects his ganglions. Often in the case we most want to inject it is impossible to get through the sphenopalatine foramen.

I should like briefly to mention 3 cases. Sluder said that with a speno-palatine ganglion irritation you may have pain not only in the fingers and chest, but even in the leg, on the corresponding side. I have seen 2 such cases and have one now. This woman has pain, typically distributed down to the arm, fingers, side of chest, and even to the leg, and she gets relief by cocainizing the sphenopalatine ganglion on the corresponding side.

The overflow from the fifth nerve into the other nerves of the head is certainly rather extensive. We even see tics of the ninth or glossopharyngeal nerve. I had a typical case in whom the trigger point was in the lateral pharynx, with pain shooting along the lower jaw. I reported this case several years ago.

DR. H. W. LYMAN (in closing)

I want to thank the gentlemen for their discussion and for bringing up a number of points which I was unable to present, some from lack of time and some because they did not seem to fall within the scope of this paper.

I have simply tried to make the point that there are certain cases

of atypical trigeminal neuralgia, with definite pathology in the sphenoid or posterior ethmoids, which respond to cocainization of the sphenopalatine ganglion, and that these cases with posterior sinus pathology, if recognized, can be spared an unnecessary and unsuccessful Gasserian operation. In other words, it simply takes a specific group of cases out of the numerous atypical neuralgias.

I want to thank Dr. Fenton for mentioning some of the high spots in our present knowledge of the nervous system of this region. Dr. Sluder's one idea was to find someone who could tell him more about the anatomy of the nervous system as connected with the sphenopalatine ganglion, and I think that if he were alive today, he would find a great deal has been contributed to our knowledge along that line. However, there still remains much to be learned.

It seems to me our study of the nervous system, as based on animal experimentation and clinical observation, is very much like cutting out individual frames from a moving picture film, and, from these frames, trying to reconstruct the entire reel. As we get more and more of these definite "frames" of absolute knowledge, we will be able more nearly to approximate the story told in the film itself.

In regard to the injection of the ganglion, I have always believed that the attack in sphenopalatine neuralgias should be directed toward the etiological factor; that is, that an attempt to clear up the offending sinusitis was the logical method, rather than the mere injection of the ganglion, which, after all, only cuts the "wires" conveying the pain impulse, and that severance, as is shown clinically, is oftentimes only temporary.

I appreciate Dr. Mosher's comment on the character of my paper. I did try to point out a clinical fact which had come under my observation, as a result of collaboration with a neurosurgeon.

In the diagnosis of the sinus condition, in one of the cases I quoted, we were able to make a positive diagnosis only by the fact that lipiodol instilled into the sinuses by Proetz' method was not evacuated in ninety-six hours, showing a definite obstruction of the ostium. There was no pus at that time to be seen in the nose, and there was nothing else by which we could make a diagnosis of sinusitis except the distribution of the pain and the failure of the sinuses to empty.

Dr. Barnhill, in his comment on my statement that posterior root resection offered the only method of affording complete and permanent relief in typical tic-douloureux, seems to have overlooked the word, "permanent." It is well known that relief from injections of the divisions of the fifth nerve and of the ganglion itself are not always

permanent; that is, in some of these cases the pain does come back and the injection has to be repeated, or even a resection done later, so I was careful to include in that remark the words, "complete and permanent cure," but, at that, it was a quotation from a neurosurgeon.

Taking up the discussion of Dr. Faulkner, there are, of course, many sinus conditions which cause pain, in which there is no question of the differential diagnosis between sinus pain and trigeminal neuralgia, which this paper covered. We have a great many sinus cases, with the so-called Sluder's syndrome, in which there is no suspicion of a trigeminal neuralgia, either typical or atypical.

Whether the irritation is in the sphenopalatine ganglion itself, or in the vidian nerve, is something which will necessarily require further knowledge, both clinical and anatomical, before it can be answered positively.

Dr. H. H. Vail, who, as you know, is very much interested in this question, and who is unable to be here today, told me that his comment on the paper could be summed up in the statement that he does not believe the pain is due to irritation of the ganglion itself, because it is a sympathetic ganglion, but is due to an irritation of the vidian trunk. We do know, however, that the sensory fibers at least go through the ganglion, and if the ganglion is injected, as Dr. Fenton says, these pain sensations will be blocked off.

That cocainization of the ganglion does not always block painful sensation from the sphenoid is shown by a series of cases of supposed mastoiditis that I reported in 1924,* in which cocainization of the ganglion had no effect at all, but cocainization within the sphenoid, after it had been opened, controlled the pain. Also irritation inside the sphenoid in the region of the vidian nerve, after operation, incited supposed mastoid pain. So, in some of the cases, the point of irritation is in the vidian trunk, and in others it may be in the ganglion itself.

Referring to Dr. Goodyear's discussion, Dr. Frazier reported 10 cases of atypical neuralgia in which 5 had had the posterior root resection without result, and he stated that in these 10 cases where the cervical sympathetic had been resected and the carotid artery stripped, relief was obtained in only one. Consequently, he felt that method of attack afforded no hope of relief in these cases. However, in 1 case of Dr. Klemme's, resection of the superior ganglion did relieve the pain. "Always" and "never" are not good terms to use in medicine.

* Lyman, H. W.: Simulated Mastoidities Relieved by Sphenoidectomy, Laryngoscope, December, 1924.

The method of injection was with the straight needle, according to Sluder's directions. This injection, as I stated, was done because of the prompt relief afforded, and also for the additional knowledge it gave us in a diagnostic way. The cases in which the injection was unsuccessful eventually received relief from pain when the sphenoiditis subsided. Consequently, if the ganglion injection is considered unnecessarily dangerous, it may be omitted, because if the pathology in the posterior sinuses in this group of cases is cleared up, the relief from pain will follow.

CANCER OF THE EPIGLOTTIS; TOTAL EXTIRPATION OF THE EPIGLOTTIS BY THE LARYNGOFISSURE ROUTE

GABRIEL TUCKER, M.D.

CANCER invading the epiglottis is ordinarily classified in the extrinsic group of laryngeal malignancies. Extrinsic malignancy as a rule gives rise to early metastasis and extension of the growth. In cancer of the epiglottis this holds true when the cancer invades the upper or lingual surface of the epiglottis. Cancer of the under surface of the epiglottis, however, may be slow growing and very slow to metastasize and in this regard it resembles more closely the intrinsic cancers probably due to the barrier afforded by the cartilage of the epiglottis. In cancer of the under surface of the epiglottis conservative surgical treatment may effect a cure although the lesion has existed for a considerable length of time. If the disease has not penetrated the cartilage and there is no evidence of metastasis, removal of the epiglottis should be sufficient to effect a cure.

Methods of Removal of the Epiglottis. Three methods of treating cancer of the epiglottis are in common use. (1) Removal of the epiglottis by thermocautery or snare through the mouth by means of suspension laryngoscopy. (2) Excision of the epiglottis by the transhyoid approach. (3) Excision of the epiglottis by the lateral pharyngotomy approach. When the growth extends downward involving the ventricular bands the procedure most commonly employed is total laryngectomy.

A case presented itself in which the growth was limited to the under surface of the epiglottis at and below the point of attachment to the hyoid bone, rendering the case unsuitable for excision of the epiglottis through the mouth. After study of the case it seemed logical to approach the epiglottis by a laryngofissure incision. In this way the interior of the larynx could be carefully inspected in order to determine the exact limit of the extent of the growth downward and by incising the thyrohyoid membrane upward to the level of the hyoid bone adequate exposure of the

base of the epiglottis could be obtained to allow total removal. Total extirpation of the epiglottis was therefore carried out by the laryngofissure route.

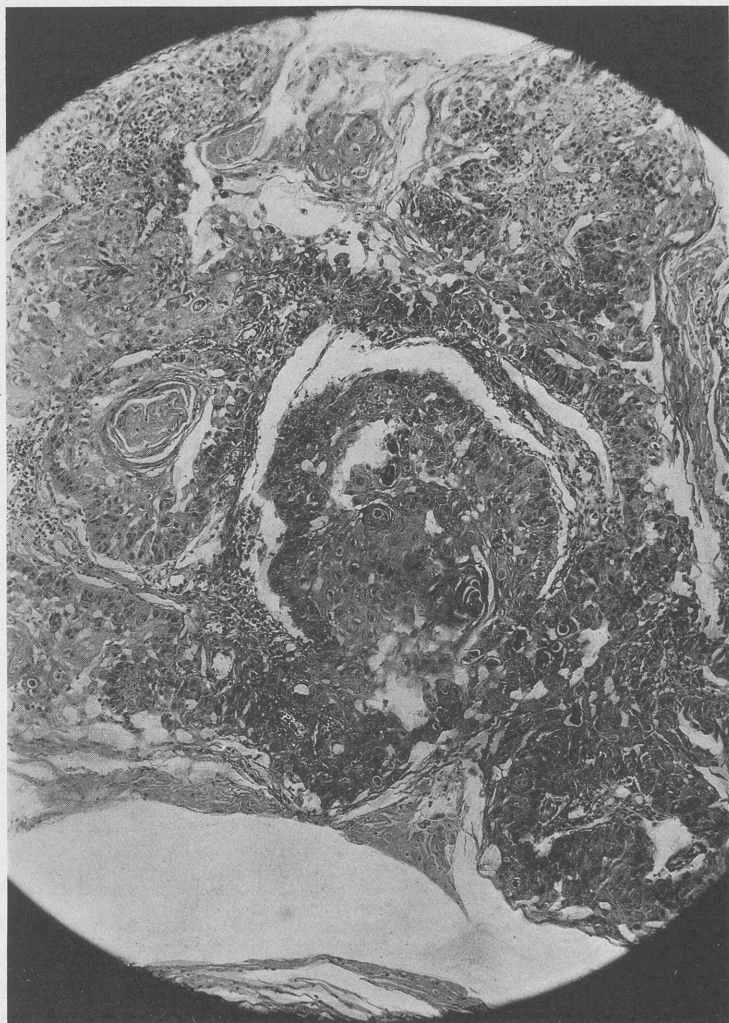


FIG. 1.—Microphotograph of tissue removed from the under surface of the epiglottis by direct laryngoscopy, showing "carcinoma grade No. 1." (Dr. E. A. Case.)

CASE REPORT. Case No. C.S.G. 180, male, aged sixty-seven years, by occupation, clerk. Had complained of local discomfort in his throat for the past year. This was accompanied by pain radiating to the left ear when he attempted to swallow. Never continuously hoarse. Family history was negative. Moderate user of tobacco, no

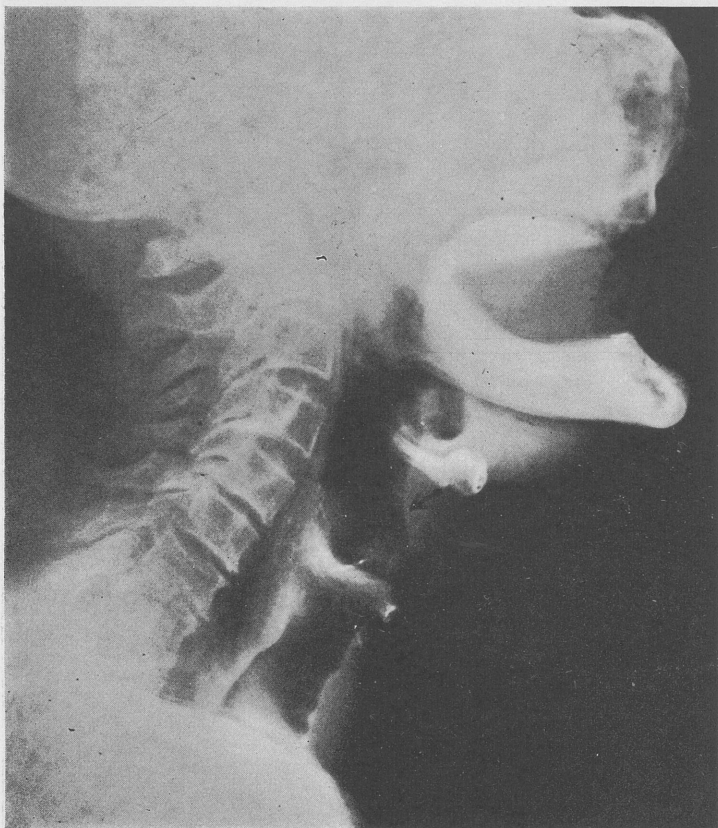

FIG. 2.—Lateral roentgenogram of the neck showing location of the lesion on the under surface of the epiglottis. (Roentgenogram by Dr. Pancoast.)

alcohol. General examination was negative. Patient had an osteochondroma of the maxilla which, on consultation with Dr. George Coates, we were assured had no bearing on his laryngeal condition

and was not a contraindication to the operation on the larynx. Mirror examination showed the under surface of the epiglottis presenting an ulcerating area extending from the midline toward the left fairly well down to the ventricular band on the left side. The surface was elevated and had the appearance of a cancerous infiltration. The lesion did not extend to the margin of the epiglottis and there was no involvement of the upper surface of the epiglottis. Careful examination of the neck showed no adenopathy. Direct laryngoscopy and biopsy confirmed the mirror findings and the tissue submitted to Dr. E. A. Case showed squamous-cell carcinoma, Type No. 1. (Fig. 1.) The decision to treat the patient by removal of the epiglottis only, was discussed with Dr. John L. Johnson, the referring physician, and the patient came in for operation. Lateral roentgen-ray examination of the neck demonstrated well the lesion on the under surface of the epiglottis. (Fig. 2.)

Realizing that several difficulties might be encountered during and after the removal of the epiglottis we did a preliminary tracheotomy as the first stage. We hoped that preliminary tracheotomy would aid in the control of hemorrhage should it occur and also help to prevent aspiration of food into the tracheobronchial tree during the time that the patient was acquiring the proper compensatory protective mechanism after the removal of the epiglottis.

Tracheotomy under local anesthesia was done December 31, 1932. The tube was placed low. A transverse incision was made just above the suprasternal notch, a small section of one tracheal ring was removed and a No. 5 tracheotomy tube was inserted. Ten days later the epiglottis was removed.

Thyrotomy for Removal of the Epiglottis. Anesthetic, avertin 70 mg. per rectum, novocain infiltration. Operation: Midline vertical incision from the hyoid bone to a point just above the tracheotomy fistula. The front of the larynx was exposed from the cricoid cartilage to the thyroid notch. Cricothyroid membrane was incised vertically, thyroid cartilage divided with a turbino-tome. The wings of the thyroid cartilage were retracted and an excellent view of the interior of the larynx showed the lesion to be limited to the under surface of the epiglottis and to extend downward to a point about 1 cm. above the ventricular band. The involvement was on the left half of the epiglottis on its under surface. In order to be well beyond the growth, a subperichondrial resection of the inner surface of the left wing of the thyroid for

about 1 cm. from the left side of the thyroid notch was done. This excision included the anterior end of the left ventricular band. The same procedure was carried out on the right side. Hemorrhage was controlled without difficulty. The thyrohyoid membrane was divided sufficiently to allow exposure of the base of the epiglottis. The base of the epiglottis was grasped and pulled downward and the mucous membrane on the upper surface of the epiglottis was removed by subperichondrial dissection. This freed the epiglottis except at its attachments on either side. The

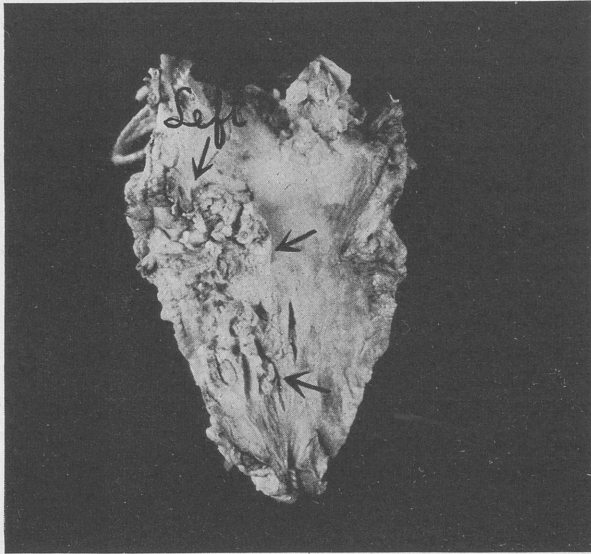


FIG. 3.—Photograph of the epiglottis after removal. The arrows indicate location of cancer on the left side of the under surface of the epiglottis.

incisions through the ventricular bands were extended upward, the tissues removed including the aryepiglottic fold on either side, and the epiglottis was removed. (Fig. 3.) The bleeding points were easily grasped as a good exposure was obtained, points were ligated with suture ligatures and the flap of mucous membrane which had previously covered the upper surface of the epiglottis was pulled downward covering the denuded area on the front of the hyoid bone where the base of the epiglottis had been previ-

ously attached. A small piece of cartilage was removed from the upper corner of the thyroid wings on either side, the external perichondrium being dissected off from the removed cartilage and left in position. This permitted the thyrohyoid membrane and the tissues on either side to be pulled together with a deep silk-worm gut suture which was carried around from the skin surface on one side encircling the tissues where the base of the epiglottis had been attached and coming from within outward through the skin on the opposite side. This deep suture closed completely the opening remaining after the removal of the epiglottis. The laryngofissure wound was closed after the usual technique, using interrupted silk-worm gut sutures.

No difficulty was encountered in removing the epiglottis by this method. The excision was entirely above the level of the true cords and mirror examination following the removal showed that the cords approximated perfectly and that their function had been disturbed very little.

Postoperative Course. The convalescence was uneventful. A feeding tube was placed through the nasopharynx immediately following the operation and all fluids were given by tube. The only difficulty encountered was after the fifth day when we attempted to remove the feeding tube. The patient complained of great difficulty and choking when he attempted to swallow although there was very little food passed beyond the level of the cords. He gradually overcame this difficulty, however, and at the end of the seventh day the feeding tube was removed. The patient left the hospital at the end of two weeks, the tracheotomy tube having been removed and the difficulty in swallowing having been practically overcome.

I have had frequent reports on the progress of this patient but have not had the opportunity of seeing him. In January last at the meeting of the Section of the Triological in Portland, Maine, Dr. Louis H. Clerf very kindly saw him for me and reports that there is no evidence of recurrence and that his general condition is excellent. The report six months later, now three and a half years following the removal of the epiglottis, from Dr. John L. Johnson, the laryngologist who originally referred him, states that his larynx is in excellent condition.

COMMENT. 1. A case of cancer of the under surface of the epiglottis is presented in which total extirpation of the epiglottis was done by the laryngofissure route and reported as cured three and a half years following the removal of the epiglottis. The larynx functions normally, including a normal voice. (2) Attention is called to a type of cancer of the epiglottis that is slow growing and late in extension beyond the epiglottis. A method of conservative surgical treatment is suggested by total extirpation of the epiglottis by the laryngofissure route.

DISCUSSION

DR. FRANK ROBERT SPENCER, Boulder, Colo.:

There is one point I am interested in. I have not had an extensive experience with malignancies, but I see quite a few infections of the epiglottis. Whether on the laryngeal or lingual surface, it seems to me they tend to travel down rather rapidly, and often beyond the point where you see them, by the direct or indirect method. It is not uncommon to remove an epiglottis and find that the tongue is badly infected, or the larynx is badly infected, and you are disappointed with the result.

I hope Dr. Tucker will tell us several years hence the outcome of these cases, if his results are good, and I believe they will be. It will be worth while to know about them.

DR. GORDON B. NEW, Rochester, Minn.:

I think Dr. Tucker should be congratulated on using conservative methods in the treatment of tumors of the supraglottic region, particularly those of a low grade of malignancy. His method of thyrotomy in removing an epithelioma of the epiglottis is entirely new.

I follow three methods of removing a carcinoma of the epiglottis. For low-grade lesions limited to the epiglottis alone, I usually do preliminary tracheotomy and then, with the Lynch suspension, destroy the growth by surgical diathermy. In the more advanced cases, when there is a question of involvement of the base of the tongue and aryepiglottic fold, I divide the hyoid bone through a midline incision retracted laterally, which gives excellent exposure. I then perform a pharyngotomy, thus obtaining an excellent view, and feel the extent of the lesion. Through this exposure the growth can be widely

removed. Owing to the fact that most of these growths are more extensive than they seem, cases in which the conservative method of treatment by means of the Lynch suspension apparatus is followed should be carefully selected.

In still more advanced cases, the method of Trotter, lateral pharyngotomy, is used. The histological character of the lesion and the extent of the growth should determine the method of treatment. In Dr. Tucker's case in which there was a very inactive growth, the plan he followed should give an excellent result.

DR. LOUIS H. CLERF, Philadelphia, Pa.:

It was my pleasure to see this patient at the meeting of the Eastern Section of the Triological during January. At that time there was no question that the result secured was excellent. There was no evidence of recurrence. The patient's voice was normal.

I agree with Dr. New in regard to one of the methods of removal, that I personally would be inclined to practice, namely the transhyoid method. I have been impressed with the excellent view one can secure by this method, and also the satisfactory approach so far as removal of tissue is concerned.

DR. GABRIEL TUCKER (in closing):

I wish to thank Dr. Clerf for his follow-up report on the case and him and the other gentlemen for their discussion. I have nothing further to add.

XANTHOMA OF THE PHARYNX AND LARYNX

GORDON B. NEW, M.D.

XANTHOMAS of the pharynx and larynx are of interest from a diagnostic standpoint on account of their rarity. During the last four years we have examined 4 patients with this condition at The Mayo Clinic. Two of these were reported by Finney, Montgomery, and New in 1932, and since that time I have seen 2 additional cases. Previous to 1930, this condition had not been recognized in the upper respiratory tract in the cases which were seen at the clinic. At the time of the previous report, 26 cases of xanthoma multiplex had been seen at the clinic, and I was able to find only 16 cases in the literature in which the mouth and pharynx were affected, and only 3 cases in which the larynx and trachea were involved.

REPORT OF CASES

CASE 1.—A married woman, aged forty-eight years, came to the clinic on May 25, 1933, because of difficulty in swallowing, which had been present for the past three months. A year ago, palpitation of the heart had developed after an attack of influenza. A physician who examined her at that time had found that the value for the hemoglobin was low, and he had made a diagnosis of pernicious anemia. She had responded well to liver therapy and, except for the low value for the hemoglobin, she had been getting along very well. There had not been any numbness, tingling or difficulty in the use of the extremities. In the last three months she had had attacks of vomiting once or twice a week. She had attributed these attacks to the use of certain kinds of food, especially fats. She never had been jaundiced. For the last three months she had complained of difficulty in swallowing and had found that it had been necessary to eat bland foods and to chew them very well in order to get them down. During the last month the condition had become much worse. She recently had noticed some hoarseness.

Examination of the pharynx revealed extensive yellowish deposits on the anterior pillars of the tonsils, on either side of the palate, in the hypopharynx, on the epiglottis and on the vallecula. There was one small nodule in the subglottic region, below the anterior commissure. There were multiple small nodules in the posterior wall of the hypopharynx. Both of the arytenoid cartilages appeared to be scarred and to be pulled forward. General examination revealed a very small nodule in the left mid-cervical region and another small nodule on the back of the right shoulder; otherwise there was not any involvement of the skin. There were 3,600,000 erythrocytes and 4400 leukocytes per c.mm. blood. The value for the hemoglobin was 12.4 grams per 100 c.mm. of blood. The differential blood count revealed the following percentages: Lymphocytes, 59; monocytes, 2; neutrophiles, 37; eosinophiles, 1; basophiles, 0.5; myelocytes, 0.5. There was slight poikilocytosis, marked anisocytosis and slight polychromatophilia. The percentage of reticulated erythrocytes was 1.3. The specific gravity of the urine was 1.016, the reaction was acid and there was not any albumin or sugar. Roentgenologic examination of the stomach and duodenum did not reveal anything abnormal. The flocculation test was negative. The bromsulphthalein test of hepatic function did not reveal any retention of the dye. Chemical analysis of the blood disclosed the following values: for cholesterol, 84 mg. per 100 cc. of plasma; for fatty acids, 237 mg. per 100 cc. of plasma; and for the total lipoids, 321 mg. per 100 cc. of plasma. A specimen of the deposit, which was situated in the pharynx, was obtained for biopsy, which showed that the condition was xanthoma.

The pernicious anemia was treated and the patient was sent home to continue this treatment, which was considered more important than the treatment of the xanthoma. She was advised to undergo a course of roentgenotherapy if the xanthoma progressed.

CASE 2.—A married woman, aged forty-six years, came to the clinic on August 13, 1934, because of hoarseness, which had been present for eight months. The hoarseness had gradually increased in severity. The patient had not had any pain, cough, bleeding or increased amount of mucus. She said that her throat felt tired after much talking. Her general health had been good and she had not lost any weight.

Examination revealed a tumor that involved the posterior three-quarters of the true and false vocal cords, on the left side. The tumor had produced slight limitation of movement of the vocal cords. The surface of the tumor was not ulcerated, but was yellowish and slightly nodular in appearance, which is similar to the appearance in

the other cases of xanthoma that I have seen. General examination revealed nothing of note. The specific gravity of the urine was 1.014, and the reaction was acid. There was not any albumin or sugar in the urine. There were 4,550,000 erythrocytes and 7500 leukocytes per c.mm. of blood. The value for the hemoglobin was 12.5 mg. per 100 cc. of blood and the flocculation test was negative. Roentgenologic examination of the chest did not reveal anything abnormal. Roentgenologic examination of the larynx did not reveal any involvement of the cartilage. A thyrotomy was advised for the laryngeal tumor, which was thought to be a xanthoma, or possibly a carcinoma of the mixed tumor type. A preliminary tracheotomy was done, and following this, the larynx was explored by means of a thyrotomy. The tumor bulged the true and false cords in their posterior three-quarters over an area of about $2\frac{1}{2}$ cm. in diameter. The mucous membrane was not ulcerated but it was yellowish and nodular. By means of a longitudinal incision just below the vocal cord, the tumor was removed, and the base was destroyed with surgical diathermy. The tumor was not completely encapsulated but had infiltrated into the muscle. Microscopic examination revealed that it was a xanthoma. The patient made an uneventful recovery and was examined again on February 19, 1935. At this time, there was not any evidence of return of the growth and the patient had a good speaking voice.

COMMENT. The etiology of xanthoma is not known, but it is thought that an abnormality of lipid metabolism, associated with some local condition, is responsible for the deposits of fat. In many cases, however, there is not any demonstrable metabolic disturbance. In some cases the condition is associated with diabetes mellitus, and hypercholesteremia has been thought to be an essential antecedent of xanthoma. In Case 1 the condition was associated with pernicious anemia, and in Case 2 the general examination did not disclose any etiologic factor. Case 1 seems to be of the type in which the condition is associated with a general metabolic condition. In 16 cases of xanthoma, in which the values for cholesterol and fat in the blood were determined at the clinic, the values were found to be higher than normal in 9 cases. In Case 2, however, the localized laryngeal tumor may be similar to the fatty degeneration that is present in fibromas, although microscopically the picture is the same as is found in those tumors which are associated with general metabolic disturbances. Multiple

nodules or plaques may be present in the mouth, pharynx, larynx and trachea. These present a smooth surface, which sometimes is nodular and has a yellow color. Finney, Montgomery and New have reported that, although the lesions may vary in number, size and distribution, the histopathologic picture is similar for all types of xanthoma. The pathologic changes may be divided rather arbitrarily into an early or inflammatory stage, a tumor stage and a stage of regression or fibrosis. The most prominent feature is the presence of the xanthoma or foam cells which, when stained for fats, are seen to be laden with various lipids and are apparently derived from the reticulo-endothelial system. Frequently, especially in the tumor stage, numbers of "Touton" giant cells are seen; these are characterized by a central circular arrangement of their nuclei with a peripheral zone of lipid-containing cytoplasm.

The scarring which was present in Case 1 of the first report, and in Case 1 of this paper, is worthy of note. In Case 1 of the first report, tracheotomy was necessary on account of scarring of the supraglottic region, and the mucous membrane on the disk of cartilage, which was removed at the time of the tracheotomy, showed the same microscopic picture as did xanthomatous nodules which were situated elsewhere in the pharynx.

Many types of treatment have been advocated for this condition. The nodules or plaques may be excised or removed with the cautery, or with diathermy. Various general measures have been advocated, but the results have been indifferent. Dietary régime, in some of the cases in which the lesion is associated with diabetes mellitus, with or without the administration of insulin, has produced little improvement and the results have not been uniform. Spontaneous disappearance may occur. In the first two cases that were seen at the clinic, in which medical treatment was used, no material change was produced by any form of treatment. A diet that was low in calories and fat, and roentgenotherapy were employed. In Case 1 no treatment for the xanthoma was given on account of the fact that the patient had pernicious anemia, and treatment for this was considered to be more important than the treatment of the xanthoma. In Case 2 the tumor was removed by means of a thyrotomy. There was no recurrence of the tumor and the functional result was good.

A NEW PROCEDURE IN THE TREATMENT OF WEBS IN THE LARYNX, WITH REPORT OF A CASE*

SAMUEL IGLAUER, M.D.

A WEB or diaphragm in the larynx may either occur congenitally or be acquired in the form of adhesions following injury to or ulceration of the laryngeal mucosa. A congenital web almost invariably occurs in the form of a membrane, uniting the vocal cords at the anterior commissure and extending backward for a variable distance. According to Himmelreicher,¹ Radasch,² and others, the congenital web represents an arrested development of the larynx. In the embryo the division between the air and food passages is present during the middle of the second month. In the larynx the two arytenoid mounds and the future vocal cords are in approximation, and begin to separate from behind forward during the third month. The failure or arrest of this process leads to the presence of a congenital web. The web is always thickest at the anterior commissure and tends to thin out toward the posterior free border. It is covered with epithelium on both its upper and under surfaces, and may contain connective tissue, muscle fibers, glands and cartilage.

A perusal of the literature shows that congenital webs are of very infrequent occurrence. The acquired diaphragms, resulting from the formation of scar tissue within the larynx, may occur in any portion of the lumen. Adhesions may unite the vocal cords, but the most common obstruction is usually found in the subglottic area.

The symptoms pointing to the presence of a laryngeal web vary with the site and extent of the obstruction. There is more or less interference with voice production, stridor may be present and dyspnea may become manifest on exertion. Indirect or direct laryngoscopy reveals the presence of the obstruction.

* From the Department of Otolaryngology, College of Medicine, University of Cincinnati.

TREATMENT. A review of the more recent literature shows that the treatment of webs uniting the vocal cords has not been very satisfactory and that mere division of the web in the mid-line has usually been followed by the reformation of the adhesion, especially at the anterior commissure, where the web is thickest and the motion limited.

McKenzie³ expressed the following opinion: "When discovered accidentally and causing no symptoms—the usual event—it is better left alone. If stridor, dyspnea or hoarseness necessitate treatment, the structure may be cautiously destroyed by diathermy cauterization. Simple incision affords only temporary relief as the web reforms, and removal through thyrofissure opening is no better. After its destruction the glottis should be kept patent by a vulcanite tube."

Hodge⁴ recorded a case of a web in a boy, aged nine years. He made an incision along one cord followed by repeated use of metal dilators. After two months there was a slight reformation of the web at the anterior commissure, which was again incised, followed by weekly dilatations, with no evidence of recurrence. The voice gradually improved, but the patient remained somewhat hoarse.

At the 1931 meeting of this Association, Clerf⁵ reported 3 cases of congenital stenosis. Two of the patients were infants and were successfully treated by division of the membrane, combined with tracheotomy and repeated dilatations to keep the incised edges apart.

Schröder⁶ employed laryngofissure with excision of the diaphragm. He then sutured the mucosa over the raw surfaces remaining after the removal of the web. The stitches pulled out on one side, adhesions reformed and the patient was discharged with the anterior third of the cords reunited.

Kriegsman⁷ reported a case in which at intervals he employed the knife and punch, the diathermy knife and coagulation, and, finally, repeated incisions and daily bouginage. He came to the conclusion that he would recommend surgery for a congenital web only as an operation of necessity, and would not expect an ideal result, but would be content with dividing the web in its thin posterior portion. With "thick membranes" he would advise laryngofissure with removal of the web and keeping the larynx open until healing had occurred.

Beck⁸ came to a similar conclusion. He stated that "various methods of treatment of laryngeal diaphragms have hitherto not been completely satisfactory." He reported an unusual case in a girl, aged sixteen years, who had been operated upon in 1921 and again in 1932, with a recurrence of all her symptoms by the following year. He, therefore, performed laryngofissure, and inserted a rubber tube for three weeks, followed by closure of the laryngostomy. Eleven months later the glottis was free, but there was firm cicatricial tissue at the anterior commissure.

A year ago Wilkinson⁹ reported a case treated by midline incision followed by bouginage. Subsequently a second incision became necessary. The final result showed the glottis about four-fifths patent.

In Tucker's¹⁰ recent case, repeated incisions were found to be necessary to prevent adhesions, and at the time of writing there was still some fusion of the cords at the anterior commissure for which further incisions were recommended.

In addition to the methods of treatment mentioned above, Haslinger¹¹ succeeded in preventing the reformation of adhesions by inserting a small silver plate between the severed tissues, but this method carried with it some danger of exciting a perichondritis.

Jackson¹² advocated an incision to release the web on one side only, followed by daily endoscopic dilatation to prevent union. Later, if necessary, the redundancy on the other side was removed.

Arbuckle¹³ recommended the use of surgical diathermy as a means of destroying scar tissue within the larynx.

A few months ago a patient with a cicatricial web between her vocal cords came under my care. Mindful of the uncertain results achieved by the usual methods of treating a laryngeal web, and considering the analogy between webbed fingers and a laryngeal diaphragm, I decided to apply the principle of the two-stage operation sometimes employed by the general surgeon for the treatment of syndactylism. This consists in passing a wire through the proximal portion of the web between the fingers and leaving the wire in place until the epithelium has grown through from both surfaces, forming a new commissure. At the second operation the web between the fingers is completely divided, the epithelial lined commissure preventing adhesions from reforming.

CASE REPORT. Mrs. A. F., aged twenty-six years, came for treatment on December 6, 1934. Her chief complaint was hoarseness. She stated that she had been treated for laryngeal papillomata, beginning at the age of four and a half years. The papillomata had been removed on fifty-two occasions over a period of from two to three years.

About eighteen months after treatment had been started, a tracheotomy tube was inserted and was worn for two years. After insertion of the tube no further laryngeal treatments were given, and she was pronounced free of papillomata at the age of seven and a half years. There had been no treatment thereafter. During her childhood she had had typhoid fever (twice) and anterior poliomyelitis without residua.

A tonsillectomy had been performed under ether anesthesia in June 1934, and she had been told that she took the anesthetic very poorly,

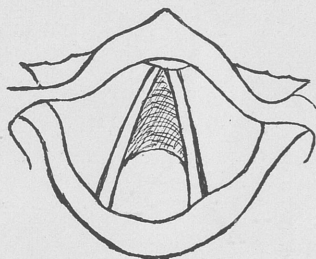


FIG. 1.—Sketch of cicatricial web between the vocal cords.

and had required CO₂ and O₂ inhalations and adrenalin injection as restoratives.

General physical examination revealed nothing bearing on her case. Wassermann, Hecht-Gradwohl and Kahn tests (taken later) were all negative.

Examination. The patient was well developed and well nourished. She was of a rather nervous temperament. A vertical keloid scar was present at the site of the former tracheotomy. Her voice was low pitched, coarse and hoarse. She spoke with some effort. There was no dyspnea or stridor unless she became excited. She cleared her throat frequently, but was free from cough. Mirror examination of the larynx showed normal false cords and arytenoids without impairment of arytenoid movements. There was a well-defined web between the vocal cords, extending from the anterior commissure to the middle of each cord (Fig. 1). The free border of the web was thin, crescentic

in outline, and whitish in color. The remainder of the web had the color of the laryngeal mucous membrane. The web apparently increased in thickness toward the anterior commissure. Laterally it fused with each cord. On phonation, it folded up between the cords. There were no papillomata in the larynx.

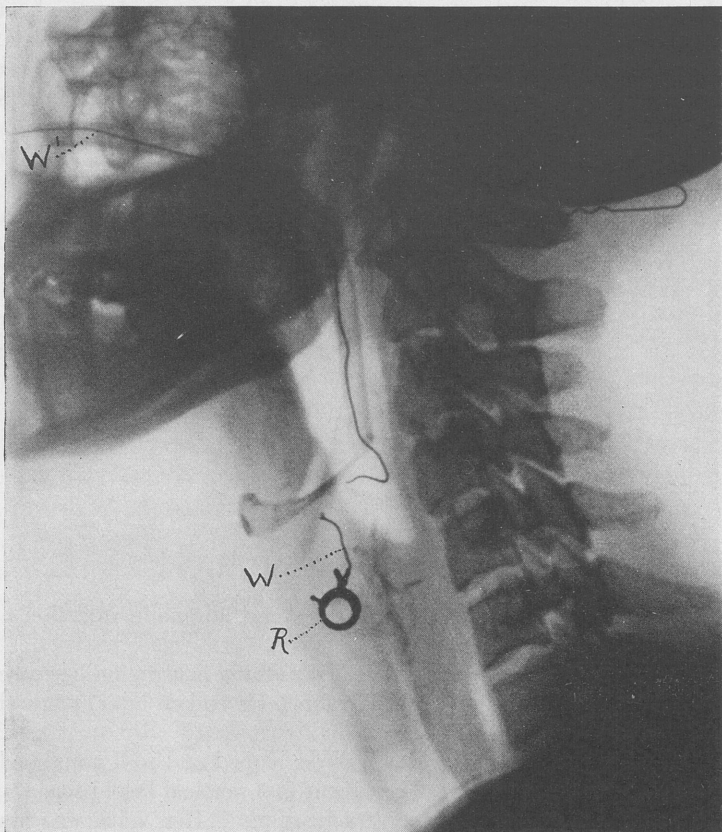


FIG. 2.—Lateral roentgenogram, showing spring ring anchored in the laryngeal web.
R, ring; W-W', wire.

Operation. December 7, 1934: Under cocaine anesthesia, a Haslinger directoscope was introduced and a knife puncture was made through the web near the commissure. (A specially modified Bard Parker knife and handle were used for this purpose.) A spring ring

(from a watch chain), to which a long piece of thin copper wire had been soldered, was held open by a laryngeal forceps and inserted through the puncture. The spring was then released, closing the ring. The attached wire was then brought out through the pharynx and nose. A piece of rubber tubing was slid over the wire, which was held in place with adhesive plaster attached to the cheek (Fig. 2—roentgen-ray).

During the following week the patient complained of some soreness in the throat, occasional gagging, a slight cough and some difficulty in swallowing. On the fifth postoperative day a roentgen-ray picture of the neck was taken. This showed the ring in good position within the larynx but that the wire had broken (Fig. 2). It, therefore, became necessary to remove the ring. This was done the following morning, at which time the second operation was performed.

Second Operation. December 13, 1934: The larynx was cocaineized by the drop method and a Haslinger directoscope was inserted. Upon applying cocaine through the directoscope, the ring became detached and was removed with forceps. The web was then excised by a V-shaped incision, beginning at the hole left by the ring, and small remaining fragments were removed with a punch forceps. The piece removed measured approximately 8 mm. in diameter and varied from 1 to 2 mm. in thickness. The microscopic report read: "Dense, highly vascular, subacute and chronically inflamed, fibrous tissue, covered in part by epithelium, some of which appears to be proliferative in character. There are several small areas showing epithelial erosion of an ulcerative character."

After-treatment. Following the second operation there was a slight tendency for the adhesions to reform near the anterior commissure. In order to counteract this, four days after the web had been excised, an O'Dwyer intubation tube was inserted and allowed to remain for two days. Thereafter the intubation tube was inserted for one to two hour periods at four to seven day intervals. The patient was advised to practice vocalization with her voice placed at a higher pitch. At the end of a month the patient was dismissed. At that time she spoke with less effort; her voice was improved, but was still hoarse and low pitched. A slight adhesion (about 1 mm.) was still present at the anterior commissure.

Through the kindness of Dr. John Myers, the patient was re-examined in Kansas City, where she resides. About two months after operation he reported that there was a web of from 2 to $2\frac{1}{2}$ mm. in the anterior commissure (Fig. 3) and that the cords

moved and coapted properly, but that her voice was "husky and heavy."

Four months after operation the patient wrote: "I have spoken aloud several times. This strange, new voice is at its best in the morning. In the evening it is almost entirely gone. This voice sounds as though I were recovering from laryngitis. . . . It seems funny to possess two voices."

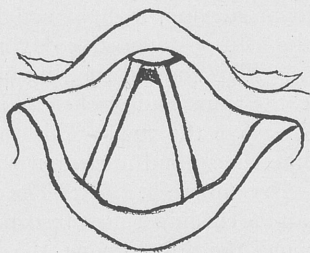


FIG. 3.—Appearance of larynx about two months after operation. (Sketch by Dr. John Myers.)

COMMENT. By the method of treatment employed in this case, a very fair but not entirely perfect anatomical and functional result was obtained. As stated above, the breaking of the wire attached to the ring rendered it necessary to remove the latter before the time originally planned for its removal. Within limits, the longer the ring can be retained the better the chances of obtaining an epithelial-lined commissure essential for the success of this procedure. Should I repeat this operation on another patient, I should allow the ring to remain in the larynx for about three weeks, and should use a piece of braided silk instead of wire to anchor the ring. This would be more comfortable for the patient.

It is questionable whether the ring technique could be carried out on an infant without resorting to tracheotomy as an adjuvant.

SUMMARY. A review is given of the various methods of treatment of laryngeal webs as reported in the more recent literature.

A new, two-stage procedure, based on an operation for syndactylism has been applied to the treatment of a laryngeal web.

The operation consists of inserting an indwelling spring ring through a puncture in the web at the anterior commissure.

After epithelization has occurred about the ring, the web is removed by a V-shaped excision with its apex at the newly formed commissure.

A case is reported in which this technique was carried out.

BIBLIOGRAPHY

1. Himmelreicher, G.: Kongenitale Stimmbänderverwachsung, Arch. f. Ohren-, Nasen- u. Kehlkopfh., **101**, 169, 1917.
2. Radasch, H. E., quoted by Clerf.
3. McKenzie, D.: Diseases of the Throat, Nose and Ear (Textbook), St. Louis, C. V. Mosby Company, **1**, 110, 1928.
4. Hodge, G. E.: Congenital Web of the Larynx, Canad. Med. Jour., **22**, 535, 1930.
5. Clerf, L.: Congenital Stenosis of Larynx, etc., TRANS. AM. LARYNGOL. ASSN., **53**, 204, 1931.
6. Schröder, K.: Ueber 3 Fälle von stenosierender Kehlkopfmissbildung, Ztschr. f. Hals-, Nasen- u. Ohrenh., **28**, 183, 1931.
7. Kriegsman, G.: Zur operativen Behandlung des Diaphragma Laryngis Congenitum, Ztschr. f. Hals-, Nasen- u. Ohrenh., **3**, 218, 1933.
8. Beck, K.: Ueber eine operative Behandlung des sog. Diaphragmas des Kehlkopfes, Ztschr. f. Hals-, Nasen- u. Ohrenh., **35**, 303, 1934.
9. Wilkinson, R. W.: Congenital Stenosis of Larynx, Jour. Am. Med. Assn., **102**, 1756, 1934.
10. Tucker, G.: Congenital Web of the Larynx, Arch. Otolaryngol., **21**, 172, 1935.
11. Haslinger: Synechie im vorderen Anteil d. Stimmbänder, Zentralbl. f. Hals-, Nasen- u. Ohrenh., **8**, 496, 1926.
12. Jackson, C.: Personal communication; Practice of Surgery, by Dean Lewis, Hagerstown, Md., Prior & Co., **4**, 5, 1930; Peroral Endoscopy, St. Louis, Laryngoscope Company, p. 430, 1915.
13. Arbuckle, M.: Treatment of Cicatricial Stenosis of the Larynx, etc., TRANS. AM. LARYNGOL. ASSN., p. 63, 1932.

DISCUSSION

DR. GABRIEL TUCKER, Philadelphia, Pa.:

Dr. Iglauer very kindly mentioned a case of mine in discussion. At the time that case was reported the result was not perfect as the patient was still under observation. At the present time there is a complete restoration of both cords, the patient is able to sing and all laryngeal functions are restored.

In the method of treatment which I presented in this case, repeated incision was made through the direct laryngoscope with a special knife and the tincture of benzoin was applied immediately to the cut surface. The local applications apparently prevented adhesion of the

raw surfaces and epithelization occurred until complete restoration of the cords was obtained. I wish to submit this as a further report on the case that Dr. Iglauer mentioned.

I should also like to compliment Dr. Iglauer on his method of treatment. If I ever get another case of web stenosis of the larynx I certainly shall keep his method in mind.

DR. GEORGE W. FLETCHER, Winnipeg, Manitoba:

I am not a member of the Society; I am here simply by courtesy.

I should like to mention the case of a woman, about thirty-two years of age, with a congenital web of the larynx, about like this (drawing on the board). There are several different ways of doing every procedure and obtaining the same result, and it seems to me the simpler way is the better.

I had read about that operation. I don't know where I saw it, but I heard of this procedure. I inserted a knife and split this cord as far as this, and cut it a little back there, and did not do anything else. I allowed this flap to hang down. The net result after about six months was a small web, which didn't interfere with the breathing, and she has a fairly good voice. If I had slit it off, I would have obtained the same condition as before, because I would have opposed, two open surfaces. I had one open surface here and one point in which the epithelium was intact, therefore, I had the net result shown. It is a simple procedure and easily carried out, and yields an excellent result.

DR. WILLIAM B. CHAMBERLIN, Cleveland, Ohio:

The case of which I wish to speak is not a web between the cords, but is subglottal. Dr. Clerf was in Cleveland some months ago and I had him see this patient with me. The history of the case was as follows:

This young girl, aged twelve years, who had a tracheotomy performed at three years of age; had worn a tracheotomy tube for nine years and had a complete stenosis of the trachea between the level of the cords and the tracheotomy wound. I ultimately got through this and, by using a soft rubber tube anchored by a string through the nose, and the lower end through the tracheotomy wound, obtained a fairly perfect trachea so that she has been able to speak ever since. On the other hand, I have never been able to allow the tracheotomy wound to close or to close it, although she no longer wears the tube.

For some time I practised dilatation two or three times a week and had the trachea so patent that I could insert a No. 36 French sound by direct laryngoscopy. Subsequently she developed a tonsillitis, I think, and did not appear for some weeks. When she reappeared, the stenosis had reformed, so that on looking in her larynx, one gets the following picture:

Now this, of course, is at a lower level, but I will have to draw it at the same level (drawing on the board), and here she has an opening through which she can breathe fairly readily with the opening in the trachea still patent.

I am reporting this case simply because I want suggestions and help. Nobody has offered very much so far.

I tried at one time to make an incision here, and then to follow this with subsequent dilatation, but it was unsuccessful. Dr. Clerf suggested doing a thyrotomy and dissecting out all of the tissue. Of course, this is a very thick, dense, fibrous band, much thicker than one gets in these congenital webs between the vocal cords.

I must confess I am at a loss to know what to do. Though this youngster did not talk for nine years, I think she has made up for it since so at the present time her total of conversation is about 100 per cent.

DR. JOSEPH C. BECK, Chicago, Ill.:

I don't know that I am going to be able to give a great deal of advice on the case of Dr. Chamberlin, except that it corresponds a great deal with a case that I recently showed before the Chicago Laryngological Society.

A girl, aged nineteen years, who had, at the age of five, diphtheria and an obstruction requiring tracheotomy. When extubation was attempted following the recovery from this acute process, it was found to be impossible. She was referred to me and I advised a laryngostomy, which I performed when she was eight years old. At the operation I found that the cords were practically united in their entirety and there was very little motion of the interarytenoid space. An up and down laryngostomy tube was worn until recently, when she came in to see if the slit in the thyroid cartilage could be closed. I removed the tube and hermetically sealed the laryngostomy wound with adhesive plaster for twenty-four hours to see if she could breathe without the use of the tube. She could. She also had a slight voice which is getting stronger all the time. The final closure of the laryngostomy was performed on April 27, 1935, by making use of a pedicle flap from the clavicular region, using part of the periosteum from the clavicle

as stiffening material. That much for the answer to the question asked by Dr. Chamberlin.

As to the technique of Dr. Iglaue, I would like to say that I have had a case very much like the one he describes in which I employed bronze wire instead of a metal ring, making use of Lynch's suspension apparatus, thus having both hands free to tie the wire in a mattress fashion. Removal of the wire occurred after a period of three weeks when practically all of the reaction had disappeared. The result in this case has been equally as good as Dr. Iglaue describes in his case and it is more than ten years since the operation was performed. I think Dr. Iglaue already suggested that instead of using a ring for anchorage, he would use some other material. I believe that bronze wire is the best substitute to use. I don't see why a bronchoscopist such as he is, need fear a little foreign body getting loose, but still, that cannot occur with the use of the bronze wire.

DR. JOHN H. FOSTER, Houston, Texas:

It seems to me that we have gotten clear away from what Dr. Iglaue is writing about in our discussion. The type of case Dr. Chamberlin reports, for instance, is probably inflammatory in character. In this connection I want to say that in subglottic obstructions with scar-tissue formation, decidedly the best results I have been able to obtain have followed dissection of the scar tissue and then using skin grafts.

DR. DUNCAN CAMPBELL SMYTH, Boston, Mass.:

I have had 2 cases similar to Dr. Chamberlin's, that is, subglottic closure of the trachea, and narrowing of the glottis. After various efforts to get a larger glottis, with the aid of Dr. Kazanjian, the cases were treated by splitting the thyroid cartilage and taking out all possible scar tissue, and grafting skin. At the same time a transplantation of cartilage was made into the soft tissues of the neck, the idea being to use this as a wedge to enlarge the box of the larynx.

After the skin graft had done all it could, the transplanted cartilage was swung with the flap of skin between the thyroid cartilages. One of the 2 cases has gotten along very nicely; the other is still under treatment. The first case has been released from her tracheotomy tube worn since she was an infant. She has not a good voice. Our problem in this case, besides building up a larynx with skin grafting, was to enlarge the thyroid box which was rather infantile in type. In the second case the thyroid cartilage was completely gone. This was an old intubation case.

If we can increase the size of the thyroid box and keep the cords apart by means of a late transplantation of cartilage between the halves of the thyroid, I think we can get results.

DR. S. IGLAUER (in closing):

It seems to be advantageous to be the last on the program because there is no hurry about discussion and I thank the gentlemen for their remarks.

In regard to Dr. Tucker's case: at the time he published his article, the case was not complete, and I am glad to hear that he finally got an excellent functional result.

The operation which Dr. Fletcher has demonstrated here was originally proposed by Dr. Jackson. Dr. Jackson finds it is necessary to make this incision and subsequently remove a redundancy on the other side. Theoretically it appears to me that you have the same problem here when you divide the web along the margin of the cord or divide it in midline, because you still have a raw angle at the commissure. It seems to me that adhesions will form in the angle just as they will form in the finger if the surgeon separates two web fingers.

Dr. Jackson reports some very excellent results with this technique, though he goes further than Dr. Fletcher, inasmuch as he dilates the larynx, daily or almost every other day, to prevent adhesion.

Dr. Chamberlin brought up the question of the subglottic stenosis, and I think he has been pretty well answered. The method which he described of putting in a rubber tube, I reported some years ago; that is, where you have a tracheotomy, you can put a rubber tube through the larynx and down upon your tracheal cannula and twist a string around the cannula bringing the two into place. A soft tube leads to some absorption of the scar tissue, but even then, continuing it for a long time, makes it very difficult to get rid of the scar tissue.

As has been suggested by some of the other gentlemen, splitting the larynx, removing the scar tissue, implanting skin, and, as Dr. Smyth has said, planting cartilage over the laryngostomy opening, may eventually give a very good result.

Dr. Beck inserts bronze wire instead of the ring. The reason for selecting a spring ring is its automatic mechanism. One does not have to tie any knots down in the larynx, which is not so easy to do. It occurred to me possibly, in a case of this kind, one might insert a safety-pin, and put the safety-pin up through the web and close the pin, leave it there and finally get a skin-lined hole, and then, if one divided the scar tissue, you would have the same principle that I have applied to the larynx.

I think that is all I have to say.

BILATERAL ABDUCTOR PARALYSIS OF THE LARYNX
CAUSED BY THE INJECTION OF ANTITETANUS
SERUM AND ITS SUBSEQUENT STENOSIS
DUE TO PERICHONDritis

(Case presentation)

CHARLES J. IMPERATORI, M.D.

THE patient, a young man, aged twenty-six years, was admitted to the New York Post-Graduate Hospital on March 31, 1932. At that time he had a compound fracture of the tibia and fibula, the accident having been sustained on March 30, 1932, while repairing an escalator in the subway. He was taken to the Lincoln Hospital and from there transferred to Fordham Hospital, and eventually was brought to the Post-Graduate.

While in the ambulance, he was injected with some serum, the exact type of serum not being known. He was operated upon by Dr. J. J. Moorhead, on April 4, and at that time was given antitetanus and antiwelchii serum. He was again operated upon, April 10, and received antigangrene serum. These injections were all preceded by proper desensitization observations.

On April 10 he began to develop a trismus and went through a period of almost complete paralysis of all the muscles of the body, with semiconsciousness, and eventually, by May 8, a diagnosis was arrived at definitely, bacteriologically, that he had a tetanus. The injection of antitetanic serum was continued, and in all he received 90,000 units, and by June 15 he was in sufficiently good condition and left the hospital.

However, within seven days he returned, stating that he had some difficulty in breathing for the past three days. On examination it was seen that there was some degree of edema of both arytenoids, but both the vocal cords and the arytenoids themselves did not move, the cords being in the median position. At this time his disability was marked and there were marked efforts on breathing and retraction of the supraclavicular and substernal spaces.

A tracheotomy was done that afternoon. He wore the tracheotomy tube until April, 1933, the tube being replaced with a smaller one, so that eventually he wore a plugged one-year-old tube.

During that time reestablishment of movement occurred in the right arytenoid and right cord. There was no movement on the left side and there was definite evidence of a perichondritis of the arytenoid.

He remained in good condition until November 15, 1934, when he was again seen, and it was found that there was considerable retraction in the conus elasticus, and there was a distortion of the larynx on the left side, mainly located in the left cord, ventricular band and arytenoid. The conus elasticus was contracted down so that a 5-mm. bronchoscope could not be passed. He was retracheotomized.

Since that time he has been dilated regularly, so that now we have been able to pass a 42-French Jackson direct dilator. He is still wearing the tracheotomy tube.

There are few cases that have been reported in which the larynx has been involved following the therapeutic injection of serum. Roger, Prevot, Whal and Bremond, in the review, *d'Oto-neurolophth.*, **12**, 419, 1934, report 2 cases of laryngeal paralysis following the injection of antitetanic serum.

There are 2 cases reported, 1 by Lavarand and another by Shanwecker.

Usually these nerve accidents following the therapeutic injection of serum, involve the brachial plexus and are of the polyneuritic type. It is exceptional that localization occurs in any of the cranial nerves.

A CASE OF A MALIGNANT LARYNGEAL GROWTH IM- PLANTED ON TISSUES, THE DEEPER LAYERS OF WHICH WERE INFECTED WITH TRICHINI

CHARLES J. IMPERATORI, M.D.

THIS is a report of a case of a patient, aged sixty years, who had a laryngeal growth, clinically that of a carcinoma, localized to one cord, and on whom a biopsy was done.

The report from the pathological laboratory was that of an epidermoid carcinoma, Grade 2. A week later a thyrotomy was done on this patient, under local anesthesia, and the cord and adjacent tissues, including most of the arytenoid, were removed. Examination of the remains of the cord and adjacent tissues showed carcinoma, and a trichinosis of the muscles of the larynx.

This is rather an uncommon combination of pathological findings.

TREATMENT OF A SERIES OF CASES OF SO-CALLED CARCINOID TUMORS OF THE BRONCHI BY DIATHERMY

A REPORT OF TEN CASES

JOHN DEVEREUX KERNAN, M.D.

INTRODUCTION. The so-called carcinoid tumors of the lung, a series of which I am reporting today, have only recently been differentiated from true carcinomas. In the *Archives of Surgery*, January, 1929, Dr. Arthur J. Cracovaner, of New York City, and the present author reported one of these cases as a carcinoma of the lung cured by diathermy. As more of these tumors have been encountered, it has been possible to check their history and course more carefully, and at the present time it is evident that they form a very distinct class by themselves. It is very important that they should be properly differentiated from true carcinomas, for even now competent pathologists report them as carcinomas, and, on the basis of that diagnosis, a pneumonectomy is proposed. As I hope to show, much less serious surgery is required for their cure.

PLACE OF ORIGIN OF TUMOR. As a rule, these tumors are found in the larger bronchi, most often in a primary bronchus. They take their origin beneath the surface of the epithelium, in all probability from some of the cells in the walls of the ducts of the glands. They grow freely in the lumen of the bronchus, and only after a somewhat prolonged existence have they any tendency to invade the lung tissue. It may be said with certainty that they never metastasize or infiltrate, but, as they increase in size, they compress the surrounding tissue and cause atrophy.

MICROSCOPIC PATHOLOGY. Their microscopic appearance is very characteristic. The sections show anastomosing columns of cells which in places have a tendency to form gland-like structures. It is on the basis of this appearance that some pathologists report them as benign adenoma. (*Slides.*) The slides which I show you

here illustrate the appearance very well: the first one the anastomosing strands of cells, and the second, the glandlike formation.

LIFE HISTORY. As I have said, they grow beneath the epithelium of the bronchi. In none of the microscopic sections has the surface epithelium been found broken through. The *slide* which I am presenting here will illustrate this point. As they continue to grow larger, they eventually break through the bronchial wall and invade the lung tissue, not by infiltration as has already been said, but by an increase in size which causes a pressure atrophy. If you will carry in your mind the picture now on the screen and then will note the one now shown, you will be able to form an idea of their continuous life history from a small tumor growing into the lumen of the bronchus to a large tumor almost completely replacing two lobes of the lung.

SYMPTOMS. The symptoms mainly are those caused by obstruction to the bronchus. This would mean that when small-sized, they are symptomless, unless, as it occasionally happens, there is bleeding. In several of the 10 cases I am reporting, this symptom of bleeding was found, and other operators have reported it even more frequently. Once the tumor is large enough to obstruct the bronchus, serious symptoms may begin. These may be mild—merely cough, and more or less sputum. As the area below the obstruction becomes infected, a bronchiectasis results. Then occur severe attacks of coughing; dyspnea, cyanosis and high fever, which are often considered to be bronchopneumonia or lobar pneumonia, according to the physical signs and the roentgen-ray appearance. Often the obstruction may be so severe as to cause a complete massive collapse of one lung with all of the signs accompanying that condition, namely, fixation of one side of chest, elevation of the diaphragm, pulling over of the heart and mediastinum, and severe dyspnea and cyanosis.

ROENTGEN-RAY APPEARANCES. The roentgen-ray appearances are most varied. If only a small bronchus is obstructed, a limited shadow of collapse will appear in the roentgen-ray films. If one of the main bronchi is obstructed, all lung markings on one side of the chest will disappear.

BRONCHOSCOPIC APPEARANCES. The bronchoscopic appearances are very characteristic. The tumors are rather soft, give

a suggestion of being pedunculated, and may even move with respiration. The wall of the bronchus is not fixed and indurated, as it is in true carcinoma, so that respiratory motion can be seen except when the tumor is very large. The tumor itself is quite vascular and bleeds easily when touched with the bronchoscopic tools or when a biopsy is taken.

TREATMENT. Once the diagnosis is made, the question of therapeutics urgently presents itself. The treatment proposed by various authors has varied from none at all to pneumonectomy.

As an example of no treatment I may quote the case of L. K., Case 6, a woman, aged fifty-eight years, admitted to Lenox Hill Hospital, October 12, 1930, complaining of dyspnea and cough for two weeks. For three days she had had pain over the left chest. That aggravated her breathing. Physical examination showed that there was a complete lack of breath sounds over the whole left chest with tympany on percussion. The right lung was hyperresonant. Bronchoscopy showed the left bronchus to be completely closed by a tumor, which was typical in its gross and microscopic appearance of these carcinoid tumors. The right bronchus was partly closed. In other words, here was a tumor involving both main bronchi of sufficient size to deprive the left lung of its function, and on its way to do the same to the right. The prognosis appeared to be exceedingly bad. Several pieces of tissue were taken for examination. The diagnosis at that time was "probably small-celled carcinoma." This woman was rather better two days later on discharge from the hospital, the left lung showing more aëration. Nevertheless, it was felt that she was being sent home to die. She came back to the hospital eight months later seemingly in good health. A roentgen-ray examination of chest showed clear lungs. No trace of the tumor could be found on bronchoscopic examination. The mere taking of a biopsy appeared to be sufficient to check the growth of this tumor and reverse its course.

Jackson, some years ago, reported a case in which a small tumor was found in one of the bronchi, probably of a similar nature to these which I am reporting. That tumor was removed by forceps and there was no recurrence.

In one of my cases, H. G., Case 2, a short series of roentgen-ray

treatments was sufficient to check the chief symptom, which was hemoptyses. (*Slide.*) That patient has been followed for eight years and has remained well, although there is still a shadow in the lung, at the site of the tumor.

Taking of biopsies certainly will not cure every case. The first of these tumors encountered by the Author, A. B., Case 1, was treated by the implantation of radon seeds and the application of diathermy. Several large portions of it were removed in the making of biopsies. In spite of all of this trauma, it persisted for two years and only thorough coagulation finally destroyed it.

One case of the author, A. J., Case 3, was beyond all help by bronchoscopic treatment, when first encountered. In spite of implantation of radon seeds and many attempts at coagulation, the tumor persisted and manifested its presence by extremely profuse hemoptyses. Finally, in a desperate attempt to save her life, a lobectomy was done, to which operative procedure she succumbed. (*Slide of lung removed.*)

It has been necessary in several cases to consider, in addition to the treatment of the tumor itself, treatment of the accompanying bronchiectasis. As a rule, bronchiectasis is always present, once the tumor has become large enough to seriously obstruct a large bronchus. Usually removal of the tumor will cure the bronchiectasis, or at least permit it to become dry, although the pathology may persist. Here is a *slide* of the lung of Case 8 after the tumor had been destroyed and all pulmonary symptoms were relieved. You will see that there are many cavities in the lung, but they are empty and sterile.

In another one of the author's cases, Case 4, A. D., in spite of the fact that the tumor was successfully destroyed, bronchiectasis (*slide*) persisted and finally became so severe in its symptoms that a (*slide*) lobectomy was called for. This was successfully performed and the woman is now well. It is of interest to note that none of the original growth was found in the lobe removed, which would demonstrate a successful destruction of the tumor. One cause of failure may be a persistence of the stricture of the bronchus after removal of the growth. In the author's Case 7, B. B., a boy, aged seventeen years, the growth was sufficiently removed, but the work was only too extensively done, as there occurred at

the site of the growth a fibrous stricture. Repeated infections recurring beyond this stricture, and insufficient drainage because of it, finally resulted in such severe invalidism that a lobectomy had to be performed. This was done without success, the patient succumbing to the shock of the operation. Here, also, as in the case of No. 4 examination of the specimen showed no trace of the original growth.

INSTRUMENTS. With increasing experience and greater perfection of instrument, it has been possible to secure quicker and better results in the destruction of these tumors by diathermy. The original applicator used by the author, of which I show an illustration, (*slide*) was one improvised from a suction tube through which was led a long piece of tonsil snare wire. It was insulated by drawing over it a piece of rubber tubing. This could be passed through the bronchoscope and the end plunged with more or less accuracy into the growth. Once in place, the wire was touched with an electrode leading from the diathermy machine, thus completing the circuit. You will realize at once that the bulk of this improvised instrument prevented any accurate placement of the wire, and, moreover, prevented observation of the effects of the current on the growth. It was necessary to guess as to when sufficient current had been applied, and often its removal and replacement several times during the course of one treatment was called for. Inaccurate placement was also a danger, and I think accounts for the stricture which occurred in Case 7, which I have already mentioned.

The perfected instrument which I show you now allows most accurate placement of the tip and observation during the whole course of application of the current. The degree of the destruction of the growth may be seen and the current stopped once the operator judges the procedure has been carried as far as is safe. You will note that the tip takes the form of a thick bead, such as is used for the front sight of a rifle. It was found that a thin blade could not be seen sufficiently well. Also, the tip should be long enough to reach well into the lumen of the bronchoscope, which permits it to be plunged deeply into the growth. This perfection of instrument has made possible much better results, more quickly obtained. For instance, the destruction of the

tumor in Case 1, A. B., called for applications during two years. Case 4, which was the next one successfully treated, had only three treatments. On the other hand, she had a continuing bronchiectasis which might have been caused by stricture, due to too extensive destruction of the bronchial wall. Case 7, as has been noted, had a stricture following treatment. Case 8 had only four applications of the diathermy current. Case 9 needed six treatments. This tumor, however, was growing from the wall of the left upper lobe bronchus, $\frac{3}{4}$ inch from the main bronchus, and was so difficult to visualize that the application of the current had to be proceeded with very cautiously. Case 10 had three applications of diathermy in the course of three weeks. At the end of that time the tumor completely disappeared. Two months later a bronchoscopy showed only a little dimpling of the mucous membrane at the site of the former growth. This is my most successful case up to the present time. It was possible with the instrument I now use to get a perfectly accurate application of the electrode and to observe the destruction of the growth as it proceeded.

As I have already mentioned, the fact that these tumors grow outside as well as inside the bronchus, the question may well be asked how can one be sure that the outside part is destroyed. It will be recalled that when diathermy is applied, the current concentrates about the small electrode and heats the tissue in its neighborhood. The picture which I now show you will give you a rough idea of the manner in which I conceive it works and tends to destroy the whole growth, not merely that portion within the bronchus.

Summary. The detailed histories will not be read as that would be too tedious, but I will give a brief summary of the 10 cases.

Here is the chart summarizing the whole series. (*Slide.*) You will notice on this chart that of the 10 patients 8 are female. This proportion of females has been noted in other series of cases.

The ages range from thirteen to fifty-eight years. In connection with the older patients, it may be said that we have no means of knowing how long the tumor had been in their lungs, and it may very well be that they started in childhood, for they would give no symptoms until they were large enough to obstruct a bronchus.

Hemoptysis has been a very prominent symptom, occurring in 5 cases. In 1 case there were no pulmonary symptoms at all. The roentgen-ray findings vary so greatly according to the position and size of tumors, that no rule can be given. The bronchoscopic appearances are rather characteristic and have already been described.

I have used diathermy in every case. In the early cases radon was also used, but I have come to the conclusion that it is unnecessary.

Eight of the cases are in good health at the present time. Of these, 1 still shows a tumor shadow in the lung. Another one has had a lobectomy. Of the 2 cases that have died, 1 had persistent hemoptyses and died following a lobectomy. The other had persistent attacks of acute infection in a bronchiectatic area below a stricture. This boy also died following a lobectomy. This gives a mortality of 20 per cent and 80 per cent seeming cures up to the present time.

CASE 1.—A. B., white, female, aged thirty-five years, was admitted to Lenox Hill Hospital, December 12, 1926.

Previous History. Negative except for yearly attacks of hayfever for last fourteen or fifteen years. In December, 1922, she complained of a heavy sensation on chest accompanied with dyspnea. In September, 1923, she had another attack with much more trouble in getting her breath, diagnosed as asthma. During 1924 she was apparently perfectly well. In 1925, she began to have again difficulty in breathing, and in September of that year she suffered severe pain in the left side of the chest with severe dyspnea, diagnosed as a collapsed lung; roentgen-ray confirmed this diagnosis. She was bronchoscoped, with negative findings, but a slight constriction was thought to be found; this condition lasted two weeks, when the lung expanded again, and breathing could be heard over the entire chest wall. Four weeks later, roentgen-ray pictures and fluoroscopic examination were negative. In February, 1926, she had another attack, diagnosed as a pleuropneumonia, and ran a fever. Roentgen-ray again taken, showed left lung to be collapsed. Eight weeks later, roentgen-ray was comparatively normal. From April to July, 1926, she gained 7 pounds, feeling almost normal. Another attack began in December, when she came into Lenox Hill Hospital.

At the time of her admission she was complaining of marked dyspnea and pain in the side of chest. She appeared acutely ill, with

temperature of 103.4° F., pulse rate of 114 and respiration 28. She was cyanotic and very uncomfortable from the distressing dyspnea.

Examination. The physical signs gave the impression of solidity of the left lung. She was observed for a few days. Her temperature remained high, going up to 104.4° F. She coughed considerably and expectorated a moderate amount of phlegm. Roentgen-ray examinations were unsatisfactory, and reports were doubtful at this time. A provisional diagnosis of atelectasis was made. On December 18, bronchoscopy was performed. The left main bronchus contained a tumor which almost filled the lumen. It was rough, vascular and friable. The appearance suggested malignancy.

The following microscopic report on the section was made: "The tissue fragments showed a malignant neoplasm composed of small hyperchromatic cells, containing scanty cytoplasm and relatively large round nuclei which were either solid or vesicular. The outlines of the cells were poorly delineated, though the predominating cells appeared round. The cells were disposed in small solid alveoli, in diffuse masses and in multiple rows about central cores of vascular fibrous tissue. The peripheral cells of the alveoli were often elongated, with their long axes directed at right angles to the stroma. The latter was generally sparse. In places it was vascular, while in other places it was dense and hyaline." A diagnosis of a malignant tumor, either carcinoma or endothelioma, was made.

Roentgen-ray Examination. The following is the report made three days after her first admission to Lenox Hill Hospital. "From the history in this case, and examination of the roentgenograms submitted, it would appear to be one of a bronchiectasis which apparently suddenly flares up, producing considerable pulmonary exudate in the left lung, and a good deal of pleural thickening. The most remarkable phase of the picture is its ability to quickly clear up. This has occurred more than once. I believe it would be well to hold this patient under observation, making frequent stereoroentgenographic examinations, to watch the progress of resolution. In this way we may be able to recognize the primary lesion more accurately."

Summary of Treatment. Beginning December 29, 1926, and ending March 20, 1928, this patient was bronchoscoped twelve times, the lesion being partly coagulated with diathermy. On March 23, 1927, 3 radon seeds were inserted into the base of the growth. One of these was removed, March 23. The other 2 could not be located. A total of 9 millicuries was used. At the last bronchoscopy, March 20, no sign of growth could be seen, the site being occupied by a small area of white scar tissue. It has been found possible in the treatment of

more recent cases to greatly diminish the number of bronchoscopies and to shorten the period of treatment. It must be remembered that in this first case the treatment was experimental.

This patient has remained well up to the present time, having been bronchoscoped, April, 1932, for observation, over four years after the first observation of the growth. A recent report from her stated that she was in perfect health now.

CASE 2.—H. G., white, female, aged seventeen years, was admitted to Lenox Hill Hospital, April 26, 1927, with a history of having had hemoptyses for six years. Except when troubled with bleeding, she had been in good health. Roentgen-ray films made in January, 1924, showed a shadow in the right lower lobe which suggested to the radiologists either an abscess or a tumor, perhaps benign in character.

A roentgen-ray examination made in April, 1927, showed the same shadow in the right lower lobe. The radiologists felt that it had not grown any in the interval of three years and that it must be non-malignant. A bronchoscopy, April 26, 1927, showed a large vascular tumor in the lower right main bronchus.

Biopsy was taken at that time, on which the following report was received: "Diagnosis: Malignant tumor, probably carcinoma. Tumor emboli in bloodvessels. Gross appearance: The specimen in formalin consists of several small irregular fragments, designated 'tumor of right bronchus.' Microscopic examination: Sections of the tissue fragments show a malignant growth, the bulk of which is composed of small alveoli filled with rather small cells with poorly defined outlines and round or oval nuclei. The alveolar walls are usually thin and cellular. In one part of the tumor the cells take a deeper basic stain and appear somewhat larger than the rest of the cells. These cells are disposed in compact masses or in imperfect columns supported by strands of vascular stroma. Tumor emboli are present in several of the smaller bloodvessels. The general structure of the tumor suggests a pulmonary origin."

This patient had four or five deep roentgen-ray treatments in the summer of 1927 and thereafter no treatment. From then until December, 1931, she had no more hemoptyses. At the present time she continues to be in good health.

Because it was deemed impossible that the original tumor could have been malignant and the patient at the same time had remained in good health, the slides taken at the biopsy were reexamined by Dr. Grethman, of Bellevue Hospital, and Dr. James Ewing. They both confirmed the diagnosis of carcinoma from the slides. It is

important to note that the diagnosis of carcinoma was made in this case. Such a diagnosis should not be responded to by the operation of pneumonectomy unless the other data concerning the tumor confirm such a diagnosis.

CASE 3.—A. J., white, female, aged fifty-four years. First admission to Presbyterian Hospital was on May 6, 1929; the last admission, August 15, 1934. On her thirteenth and last admission to the hospital, the following summary was made of her history:

Chief Complaint. Hemoptyses at intervals for forty years.

Family History. Irrelevant.

Past History. Exclusive of the present illness, the patient has always been well save for a fistula *in ano* and an esophageal diverticulum, both of which have been incidental findings and have never caused hospitalization.

Present Illness. The patient developed a cough at the age of six years. At thirteen she had her first hemoptyses of varying severity, necessitating frequent hospitalization. The patient was first seen here in 1929, and a diagnosis of carcinoma of the right main bronchus was made from a bronchoscopic biopsy. This impression persisted until a subsequent biopsy at Mt. Sinai Hospital, three years ago, showed the growth to be simply a benign polyp. Attempted treatments by electrocoagulation and radium implantation have been unsuccessful. Bronchoscopic cauterization has relieved symptoms for only short periods. Bronchiectasis of a rather marked degree occurred in the right upper lobe. Roentgen-ray findings have repeatedly shown atelectasis of right middle lobe and right lower lobe, a dense round shadow in the right lower lobe, bronchiectasis of the right upper lobe and a traction diverticulum of the esophagus to the right. In recent months, the hemoptyses have become more frequent and up to 200 cc. in amount, and the patient has been reduced to a state of chronic invalidism.

Physical Examination. Temperature, 98.8° F.; pulse, 84; respiration, 20; blood-pressure, 130/68. A chronically ill, thin woman, aged fifty-four years, in no distress, but coughing up a small amount of sputum made up mostly of dark blood. No dyspnea or cyanosis. Pupils small and react to light. Fundi not seen. Ears and nose negative. Many teeth out, others in fair condition. Tonsils out. Pharynx negative. No general glandular enlargement. Trachea is shifted to right. Chest, expansion greatly diminished on right. Tactile fremitus absent in lower half of right chest. Dulness to flatness in lower two-thirds of right chest anteriorly, with rather harsh

breath sounds above, absent sounds below. No râles heard with quiet respiration. (*Slide.*) Heart shifted markedly to right, with left border just to left of left external border. Sounds of good quality. Systolic murmur at base. Rhythm regular. Pulses equal. Abdomen soft, negative. Pelvic and rectal examination omitted. Reflexes normal. Extremities normal.

Laboratory Findings. Red blood cells, 3,800,000; hemoglobin, 74 per cent; white blood cells, 5700; polymorphonuclears, 84 per cent. Smear normal. Stool negative for blood and parasites. Urine negative on all examinations. S. P. Report (No. 40563), September 9, 1929: "Section shows connective tissue, a large portion of which is necrotic, appearing as homogeneous, acellular, pink strands at the edges of which there is calcium deposit. The rest of the tissue is a fairly dense stroma in which there are a moderate number of bloodvessels and which is everywhere infiltrated by collections of small cuboidal cells, which in places show a tendency toward alveolar arrangement. The nuclei of these cells are hyperchromatic. Mitotic figures are not seen. A few polymorphonuclear leukocytes and lymphocytes are scattered through the tissue. Diagnosis: Carcinoma of lung. Note: It is impossible to tell from this section whether this is a carcinoma or a mesothelioma of the pleura which has invaded a bronchus. The cells resemble mesothelial cells rather than epithelial cells, but in the absence of definite roentgen-ray evidence as to primary pleural involvement, this diagnosis does not seem justified." V. Kneeland Frantz. On October 29, 1930, the following note was made: "Drs. Pappenheimer and von Glahn agree that specimen is small round-cell carcinoma of bronchial origin, a slow-growing neoplasm in view of absence of mitotic figures."

Course. On the immediately previous admission, a thorough review of the case was made, and it was felt that pneumonectomy was the only course left to pursue. The patient favored this procedure, although being fully aware of the risk. For the first five days of the present admission, only a small amount of bleeding occurred, and the left lung, being absolutely clear, operation was performed by Dr. Moore on August 20, 1934. Since considerable difficulty was experienced in freeing up the right lung, which was adherent to the parietal wall, diaphragm and adjacent pericardium, it was decided during the course of the operation to merely separate the adhesions, put a loose tourniquet around the hilum, and leave the completion of the pneumonectomy for a later date. During the first twenty-four hours postoperatively, the patient's condition was remarkably good, blood-pressure remained up, color excellent, and breathing free and not labored.

On the morning of the second day, respiration became considerably more difficult with a pronounced expiratory grunt, moist râles at both bases and there was slight cyanosis. Her temperature gradually rose to 103° F.; the pulse rose to 130 and became thready and feeble. Throughout the day cyanosis increased, respirations became progressively more rapid and shallow. At 8 o'clock that evening, Cheyne-Stokes type of respiration set in and at 8.45 she died.

AUTOPSY. Clinical Diagnosis. Hemorrhage from tumor of bronchus; atelectasis of right lung; bronchiectasis of right lung; secondary anemia; postoperative bronchopneumonia.

Lungs. The right lung weighs about 560 gm. The pleural surface is covered with a profusion of old fibrous adhesions, and superimposed on them is a more recent grayish-white fibrinopurulent exudate. The entire organ is collapsed, very firm and rounded, measuring roughly 15 by 10 by 8 cm. The lobes are so adherent, the interlobar septa so obscured by fibrous adhesions, and the external appearance of the organ so distorted by collapse and fibrosis, that it is only with great difficulty that the differentiation of the lung into three lobes can be demonstrated. At the point of bifurcation of the right main bronchus on the anterior inferior aspect of the lumen, there is a moderately firm, raised, white, smooth nodule, about 2 cm. in diameter, and apparently covered with bronchial mucosa, save for a small red ulcerated area at the apex, measuring 2 mm. in diameter. This nodule projects into the lumen of both the secondary bronchi in such a way as to almost completely occlude the eparterial bronchus. The bronchi to the middle and lower lobes are completely obliterated by the tumor. On sectioning the lung downward and laterally through the apex of this nodule, a much distorted architecture is revealed. In the middle lobe, immediately beneath the nodule and apparently continuous with its base, is a rather symmetrical oval mass of soft, friable, brownish-red homogeneous tissue, measuring roughly 10 by 6 cm. This mass seems to be almost completely surrounded by a narrow capsule of fibrous tissue and is not invading the lung parenchyma. Portions of this fibrous capsule and adjacent lung are calcified. The remainder of the middle lobe is compressed, hard and fibrotic. The lower lobe is also compressed and fibrosed, and on section reveals numerous large and small cavities, at least some of which seem to be dilated bronchi, and which are filled with spheroid masses of brownish-red friable material continuous with the large mass immediately beneath the bronchial nodule. Along the base of the lower lobe is a series of four to five silk sutures, which when cut through reveal an abscess cavity large enough to admit the examining

forefinger for 1 cm. and filled with purulent material. Section of the upper lobe discloses many large and small bronchiectatic cavities partially filled with mucopurulent material. The surrounding lung parenchyma is firm, fibrous and non-air-containing.

MICROSCOPIC EXAMINATION. *Tumor Nodule at Bifurcation of Right Bronchus.* The surface of the nodule is everywhere covered by a fairly thick band of fibrous tissue. In this at one side of the section there is a mass of dark purple calcified material. Here the collagenous tissue is widest, is relatively anuclear and has a homogeneous hyaline appearance. Farther along the remnants of a columnar epithelial covering can be seen. Small vessels occur in this coat, and some parts of it are more cellular than others. At one point the connective tissue is extremely thin and the underlying tissue is on the point of breaking through. There are some small regions where the fibers are separated and the tissue seems edematous. At approximately the apex of the nodule there is a slight depression from the bottom of which a broad band of dense connective tissue extends downward into the tumor, growing narrower as it goes. Beside it, and reaching almost to the surface, there is a small, thin-walled artery distended with blood. Beneath this fibrous coat lie masses of tumor cells in a sparse, loose connecting tissue stroma. The arrangement of the neoplastic cells varies remarkably, sometimes even in the same field. In some places the tissue has an adenoid appearance, with the cells arranged circularly around a definite lumen. Elsewhere it consists of large, irregular masses or cords loosely surrounded by fine connective-tissue membranes. In still other places it appears as delicate branching and anastomosing strands. The greater portion of the tumor seems to be growing free in alveolar spaces. The intervening connective-tissue strands contain capillaries and seem to be separate structures rather than a tumor stroma. In addition there are many large areas of degeneration from which all nuclei have disappeared, and only a uniformly pink or violet staining area in which, although necrotic, the original architecture can still be seen. Other regions are composed of amorphous, closely packed masses of rounded tumor cells accompanied by little or no fibrous elements. In these places there are usually foci of nuclear loss and beginning necrosis. Occasional small hemorrhages can be seen. The individual cells of the tumor vary only slightly, although in the larger masses and cords they tend to be larger and their cytoplasm to be less acidophilic. Likewise, their nuclei are larger and lighter. Elsewhere they have small, round or oval, very dark nuclei. In those which are less dark and in which separate chromatin masses can be made out, the latter

tend to have a somewhat radial distribution suggestive of the plasma cell. The cytoplasm is homogeneous, pale pink and is not abundant. The cells are rounded or irregularly polygonal, depending on the pressure of neighboring cells. No mitotic figures are seen, and there is no keratinization. There are several moderately large thrombosed vessels in the neoplastic area.

Elastic Tissue Stain. There is no elastic tissue in the fibrous septa resembling alveolar walls seen in the hematoxylin and eosin stain between the smaller masses of tumor cells. Elastic fibers in the walls of the arteries are well stained.

Mallory Connective-tissue Stain. There is an extremely sparse, fibrous stroma. Relatively large areas are practically devoid of connective tissue. In some areas of more abundant fibrous tissue, the tumor seems to be invading the collagenous tissue rather than the latter acting as a support for it. At one point the tumor cells have broken through the fibrous coat separating them from the lumen of the bronchus.

TUMOR. A. The pleomorphism of the tumor is again evident here. There also are large regions of degeneration. In addition there is a small area of calcification in which true bone formation has occurred with beginning development of a narrow cavity. Near this is a broad band of fibrous tissue sparsely infiltrated with polymorphonuclears, lymphoid and mononuclear cells, and containing occasional deposits of greenish-black pigment. Small masses of tumor cells lie in spaces in the collagenous tissue.

Mucicarmine Stain. There is no mucin production by the tumor cells. The alveolar structure is well brought out.

Elastic Tissue Stain. The absence of elastic fibers in the connective tissue surrounding small masses of tumor cells is again evident, although elastic tissue in the arterial walls is well stained.

B. The tumor here is essentially similar to that in the previous slides. There is a large degenerated area in which lie several relatively large arteries containing thrombi.

Foot Bielschowsky Stain. Around the masses of tumor cells there is a coarse reticulum from which finer fibers run into the mass and between individual cells.

C. This is a section from the base of the middle lobe. The pleural side consists of loose fibrous tissue through which run large and small vessels engorged with blood. Extensive hemorrhage has occurred into the greater portion of this fibrous tissue, but there is little cellular infiltration. The outermost portion contains some fibrin and numerous bacteria, but even here there is no cellular reaction. Some of

the inner portions of this fibrous tissue are hyalinized, while others appear as a homogeneous, pale pink, anuclear material. There are occasional areas of elastic tissue scarring in the fibrous portions. There are a few small deposits of greenish-black pigment granules. The rest of the section, inside the fibrous region, consists of degenerated tumor tissue, all of which, including the nuclei, takes a bluish-pink stain. Along the outer margin of the tumor there are deposits of a dense dark purple material lying between or replacing the tumor cells.

BASE OF RIGHT LOWER LOBE. The inner portion of the section consists of tumor, largely degenerated, in which are several large thrombosed arteries, frequent foci of calcification and two moderately large spicules of true bone. The tumor cells are closely packed together or strung along branching strands of connective tissue. As in previous sections many seem to be growing in alveoli. In the fading nuclei, the previously mentioned radial distribution of chromatin masses, which gives them their resemblance to lymphoid cells, is clearly seen. Surrounding the tumor mass there is a smooth, regular capsule of dense connective tissue which over an appreciable portion of its outer surface is covered with a single layer of low cuboidal cells. A few small collections of tumor cells occur outside of this capsule, but there is no change in the character of these cells. Opposite the capsule and separated from it by an open space is a similar layer of uniform connective tissue. Immediately outside of this there are a few more masses of tumor cells, and then a broad region of loose, irregular, collagenous tissue, much of which appears hyaline and through which run many engorged vessels of varying size. There are occasional collections of lymphocytes, much hemorrhage, some calcification and frequent deposits of anthracotic pigment. Caught in the strands of the outermost portion there are numerous masses of bacteria.

Gram Stain. The organisms seen in the hematoxylin and eosin stain are chiefly Gram-positive cocci, but large Gram-positive bacilli are also numerous.

TUMOR CAPSULE. On the inner side there are a few bits of tumor. Nearby is a relatively large area of bone formation. The rest of the section consists of fairly dense, hyalinized, interwoven strands of collagenous tissue. Included are two large arteries, the walls of which are thickened, almost to the point of occlusion.

RIGHT UPPER LOBE. Along the pleural surface there is a small coating of finely granular material containing occasional fibrin strands. Beneath this the pleura is much thickened, edematous and contains many small engorged vessels. The parenchyma is greatly distorted.

The alveoli are compressed and their walls thickened by connective tissue. Most of the alveolar spaces are filled with extravasated red blood cells. Many of them also contain numerous large mononuclears, often filled with greenish-black pigment. In the neighborhood of the dilated bronchi there are large areas of fibrosis, many composed of loose and edematous tissue. In these areas only an occasional remnant of an alveolus can be seen. Everywhere throughout the section vessels are distended with blood. The bronchioles are immensely dilated and are for the most part empty, but some contain a deep blue-staining coagulum. They are lined by tall columnar epithelium. Metaplasia of the epithelium has occurred in several. The connective tissue around many of the bronchioles is densely infiltrated with lymphoid cells and polymorphonuclears. Partial calcification has occurred in the bronchial cartilage.

FINAL NOTE. An interesting case of a woman, aged fifty-four years, who had had large hemoptyses for five years. Four years ago a diagnosis of carcinoma of the lung was made from a piece of tissue which was removed at the time of bronchoscopic examination. In the lower and middle lobes of the right side is a tumor infiltrating the lung extensively, and occluding the bronchi of these two lobes, and extending into the bronchus of the upper lobe. The tumor is composed of small cells of uniform size, having infrequent mitoses and not tending to form glands nor to produce mucin. The morphology of the cells suggests that the tumor grew slowly. The origin of the tumor is probably not from the larger bronchi but from the more distal portion, as, for example, the ductus alveolarus. No metastases were found in the opposite lung or in the bronchial lymph glands.

ADDITIONAL NOTE. This case was presented at conference, November 22, 1934, as an example of the group of cases which Dr. Stout calls "tumors" of bronchus. It would seem to be a malignant tumor which arose from what is called "intra-bronchial polypoid adenoma" by Reisner (*Archives of Surgery*, **16**, 1201, 1928) and "adenoma" by Wessler and Rabin (*American Journal of the Medical Sciences*, **183**, 164, 1932). These tumors have also been called "basal-cell carcinoma," arising from mucous gland ducts, at Johns Hopkins Hospital, and also "carcinoids."

These tumors, of which some thirty have been reported, form a clinically recognized group which begin as smooth polypoid adenomata, partly occluding a main bronchus, and in most cases remain benign and noninfiltrating over a period of months or

years. They do not, even after becoming invasive, involve the regional lymph glands, nor do they metastasize.

The origin of the tumor is not entirely clear. There are three possibilities: bronchial epithelium, mucous glands and duct epithelium of these glands. The fact that in the early stages, at least, these tumors are covered by an intact bronchial mucous membrane, argues against this as the origin. Furthermore, they do not characteristically form mucus, as would be expected if they originated in the mucous glands of the bronchi. This leaves the epithelium of the ducts of these glands as the most probable origin. The occurrence of cilia with basal corpuscles in one of the sections in this case would seem to exclude an alveolar origin.

CASE 4.—A. D. Her first admission to Presbyterian Hospital was October 16, 1929, and her last admission was June 13, 1933.

The following is the summary of her history: This Russian-jewish housewife, aged thirty-three years, was admitted to Presbyterian Hospital about thirty-four times between December 14, 1929, and May 22, 1933, mostly for bronchoscopic examinations and roentgen-rays. The patient started having trouble about March, 1928, when she developed a productive cough. The sputum was sometimes of large amount and of bad odor. Several small hemoptyses also occurred. The cough was persistent. Bronchoscopic examination, on November 6, 1929, revealed a vascular tumor just beneath the left upper lobe bronchus. Pathological report, November 12, 1929, by Dr. A. P. Stout: "Carcinoma of unknown origin. No mitoses, poorly differentiated." The diagnosis at the later admissions was "bronchiectasis of left lower lobe due to carcinoma of the bronchus." The treatment consisted of diathermy, implantation of radium seeds and postural drainage, and bronchoscopic drainage. Clinically the patient got no worse, as would be expected in a poorly differentiated neoplasm of presumably five and a half years' duration. The patient was admitted the last time for a partial oestectomy preliminary to a cautery left lower lobectomy. Sputum had varied from 0 to 250 cc. in twenty-four hours. Her past history and family history were essentially negative. She had had a tonsillectomy nine years ago.

PHYSICAL EXAMINATION. Temperature, 98.6° F.; pulse, 70; respiration, 20; blood-pressure, 120/80. She is a moderately obese, alert and coöperative Russian woman, aged thirty-three years, not acutely ill, but coughing a great deal and raising up a considerable quantity of thick green sputum. Trachea in midline, no tug.

Thorax: Emphysematous type, symmetrical. Lungs: Right clear. Left diminished expansion. Numerous râles and rhonchi. Signs suggesting limited cavitation in left lower lobe. No friction rub heard. Heart: Not enlarged to percussion, rhythm regular, sounds good quality, no murmurs.

IMPRESSION. (1) Bronchiectasis in the left lower lobe. (2) Neoplasm ? type—left lower bronchus. (3) Obesity.

Roentgen-ray examination of the chest, June 13, 1933, was as follows: "Film of the chest following the instillation of lipiodol into the left lower lobe bronchus, presumably at a bronchoscopy, shows the lipiodol outlining a few saccular cavities here. This suggests a bronchiectasis. The lumen of the main bronchus is not completely filled nor is the entire left lower lobe bronchial tree. I should like to bronchoscope this case, since I understand it was formerly said to be a bronchial carcinoma. At present we have no evidence of an atelectasis of the L. L. L. to suggest that there has been a bronchial occlusion with possible secondary bronchiectasis. The two-year course of this case makes one wonder if it is a true bronchial carcinoma." Signed by Dr. Abbott.

The growth was destroyed by diathermy in the course of three treatments. Thereafter, her symptoms were those of an extensive bronchiectasis. Numerous bronchoscopic treatments were given for this condition, but without avail. On account of the persisting symptoms due to the bronchiectasis, a lobectomy was done, which was entirely successful in restoring her to robust health. A note made in May, 1935, shows that the patient was in good health.

Examination of the tissue found in the lobe removed at the operation showed no evidence of the original growth.

CASE 5.—A. Q. was admitted to the Lenox Hill Hospital on August 21, 1930, with a chief complaint of loss of weight, 20 pounds in six months, and loss of appetite for ten months. She had been treated for various stomach ailments for ten months but to no avail.

She came to the Clinic for examination and during fluoroscopic examination Dr. Illick noted a small shadow in the right lung. He suggested a bronchoscopy and the patient was admitted. Note that there had been no pulmonary symptoms. The lung condition was found in a routine examination.

Examination revealed a poorly nourished, small, white woman, aged about forty years. Her examination was negative except the chest, where the tactile fremitus was decreased slightly over the anterior chest on the right side. No râles were audible and breath sounds were normal vesicular.

On August 21, 1930, a bronchoscopy revealed the following: Below the level of the right upper lobe bronchus, there is a tumor mass, shiny, irregular and polypoid in appearance, which apparently obstructs the entire lumen of the bronchus. Biopsy taken. Profuse bleeding.

The pathological report was the following:

Microscopic Examination. Section of one of the fragments shows a carcinoma composed of acini, usually of small size, intermingled with small solid islands of cells. The cells lining the acini are usually low columnar in form and one to several rows thick. The solid structures are formed by small polyhedral cells with deeply staining nuclei and sparse cytoplasm. The stroma of the tumor is relatively scanty, though it varies in amount in different areas. It is, for the most part, poor in cells, though well vascularized and often shows considerable edema. In small localized areas it is myxomatous.

Section of the other fragment shows a carcinoma apparently composed exclusively of small glandular acini, the cells of which are larger and more chromatic than those of the first described fragment. These structures are crowded close together, being separated by strands of vascular fibrous tissue.

Diagnosis. Adenocarcinoma of the bronchus.

On August 28, 1930, 3 radon seeds were implanted in the tumor mass through a bronchoscope. Their position was checked by roentgen-ray. She was discharged on August 30.

On September 25, she was bronchoscoped again and the mass on the right bronchus seemed small and covered with a slough. It was treated by diathermy.

On October 2, patient was readmitted to the hospital because of temperature. She was bronchoscoped but no diathermy was done. Temperature subsided within a week and she was discharged.

October 22: Bronchoscopy. No change in mass. Diathermy.

November 6: Bronchoscopy. Tumor is diminished in size and one can now see down bronchus. Diathermy.

November 30, 1930: Bronchoscopy. The right main bronchus is patent. The tumor mass is still further diminished in size.

November 30, 1931: Patient was readmitted to the hospital saying that she was improved in her general condition following the last bronchoscopy until five months ago. She began then to have various complaints referred to her stomach and also nervousness. She raised a little mucus upon arising ever since her discharge from the hospital. No excessive coughing during the day and no pain in her chest. She gained about 6 pounds.

Roentgen-ray of the chest shows a large triangular area filling the region between the right heart border and the right side of the diaphragm. Three radon seeds are still visible from the apex of the triangle. The upper three-fourths of the right lung field and the entire left appear normally clear.

Roentgen-ray of the gastrointestinal tract was negative.

December 3, 1931: Bronchoscopy examination. Just opposite the first dorsal branch and surrounding the middle lobe branch on the right side, there is marked irregularity of the bronchial walls.

December 9: Bronchoscopy. The thickening about the middle lobe bronchus is noted. Biopsy taken. Injected first dorsal branch with lipiodol and then the lower lobe. A scanty amount of secretion is coming from the lower lobe.

December 17: Bronchoscopy. There is considerable swelling about the orifice of the internal branch of the lower lobe. There is some purulent material in this vicinity; 5-cc. injection of collene into the lower lobe branch.

Biopsy report was as follows:

Microscopic Examination. Section of the fragment shows somewhat degenerated cartilage, one surface of which is covered with mucous membrane, the stroma of which is dense and cicatricial and infiltrated in places with small round cells and polymorphonuclear leukocytes, the inflammatory cells being nowhere abundant. The mucous gland acini are usually atrophic, though several of them are converted into small cysts. Throughout the mucous membrane are small scattered hemorrhages. A large part of the surface is devoid of epithelial covering, the remaining portion being covered with small cuboidal or low cylindrical cells.

There is no evidence of malignancy. (See report No. 27758.)

Diagnosis. Chronic inflammatory tissue from the bronchus.

Patient discharged from the hospital.

December 24, 1931: Bronchoscopy. There is a narrowing of the bronchus seen near the mouth of the cardiac branch. Place of biopsy can be seen. No pus noted. Painted with silver nitrate, 10 per cent.

Admitted to the hospital, March 23, 1932, again complaining of nervousness and sleeplessness. The cough was only slight and non-productive. Stomach symptoms not definite. Was diagnosed as neurosis of the stomach.

March 24: Mucous membrane from the mouth of the upper lobe bronchus to below the middle lobe bronchus is thickened, red and vascular; shows signs of chronic irritation. It does not have the appearance of a local recurrence. Pus from below it is very scanty. Five cc. collene injected. Discharged from the hospital.

September 21, 1933: Bronchoscopy. Mucous membrane cardiac branch is rough and vascular, not ulcerated. Has appearance of chronic inflammation rather than recurrence. Painted with silver nitrate. Biopsy taken.

Pathological report is as follows:

Microscopic examination shows a carcinoma, the structure of which corresponds closely to that of the tumor previously removed. (See report No. 27758.) It differs from the original tumor in that the acini are usually imperfect. Mitotic figures are scanty.

Diagnosis. Recurrent adenocarcinoma of the bronchus, Grade 2.

October 18, 1934: Inflammatory tissue again noted near the cardiac branch with scanty amount of discharge. Does not appear like recurrence. Cauterized with silver nitrate, 10 per cent.

These symptoms are evidently due to the bronchiectasis.

CASE 6.—L. K., white, aged fifty-eight years, was admitted to Lenox Hill Hospital, October 12, 1930, complaining of dyspnea and cough for two weeks. For three days she had pain over the left chest which was not aggravated by breathing. Cough was unproductive. Slight loss in weight. Previous history was negative.

Examination. Left side of chest expands very little. There is dulness of the whole upper half. Flatness at base both anteriorly and posteriorly. There is absent fremitus and absent breath sounds at base. In upper half of chest anteriorly is a high-pitched distant tympanic percussion sound. Breath sounds have an amphoric quality. Same exists posteriorly, but breath sounds are distant. No râles anywhere. Gastric tympany exists unusually high on to the chest. Right lung overaërated, hyperresonant with exaggerated vesicular breath sounds. No râles or other abnormal sounds. Heart shifted well out to midaxillary line. Right border difficult to percuss, but there seem to be percussion changes along left sternal border. Sounds of good quality. Regular in rate and rhythm. No adventitious sounds.

Tentative Diagnosis. Massive collapse of left lung, due to occlusion of left bronchus by possibly a carcinoma.

Bronchoscopy. On October 16, 1930, the following report: The left bronchus is completely closed by a mass of tumor tissue which springs from the wall of the left bronchus and also involves the trachea for 1 inch above the bifurcation. The right bronchus is also closed by tumor masses. The tumor is vascular and friable and bleeds easily when touched by tube. It appears to be malignant and several sections were taken. On October 13, a roentgen-ray showed the atelectasis of the left lung. On October 18, two days after the bronchoscopy,

a roentgen-ray showed that the entire left lung field is much clearer and also normally aerated, as contrasted with the atelectasis of the previous examination four days ago.

Physiological Report. *Microscopic examination of biopsy taken at bronchoscopy* shows the specimen to have a stroma of very dense hyaline connective tissue in which there is a most intense round-cell infiltration. One small portion of the section has a new growth, composed of polyhedral cells arranged in small acini. The individual cells are intensely hyperchromatic; the nuclei are central.

A classification of the tumor type cannot be made on the material submitted, but the most likely diagnosis is that of a small-celled carcinoma.

Diagnosis. Malignant tumor, most probably small-celled carcinoma.

Wassermann. Negative.

A follow-up roentgen-ray was taken on June 30, 1931, and revealed no roentgen evidence of the lesion in the left bronchus.

On March 21, 1934, patient was readmitted for a bronchoscopic examination. She was feeling fine. Complained of no cough, loss of weight, fatigue or chest symptoms.

Bronchoscopic examination revealed the following: The bifurcation and right main bronchus showed nothing pathological. Near the mouth of the left main bronchus there is a fibrous band stretching across the lumen posteriorly, forming a sort of shelf with a little canal running under it. The fibrous adhesion was ruptured and a small spot of what appeared to be granulation tissue was seen on the posterior wall.

CASE 7.—B. B. was admitted to the Lenox Hill Hospital, February 5, 1931, as a patient of Dr. Carl Eggers and Dr. Geiger. Gave a history of having taken cold eleven days before admission, with pain in the legs and temperature of 101° F. Two days later temperature went up to 104° F; developed a cough with considerable expectoration, at times blood-streaked. No pain.

A few days before admission he vomited with a great deal of blood, and this has recurred several times since. Three days before admission, Dr. Geiger reported he had quite a hemorrhage. This occurred a day after patient was supposed to have had a crisis, following a left lobar pneumonia. Roentgen-ray at this time showed uniform density of the lower half of the left chest. Heart was drawn to the left. The upper left chest was also cloudy, though not to the same degree.

Diagnosis. Presence of pleural fluid in the lower left chest.

Patient was observed for a possible empyema. He began to improve and continued to do so. A possible foreign body in the bronchus was suspected. Though bronchoscopy was considered, it was not done.

On February 9, 1931, the lesion in the left chest showed considerable clearing up in the upper half, and lower half remained uniformly dense. The heart was displaced to the left side but not to as great a degree as previously.

On June 27, 1932, he was readmitted to the hospital with a recurrence of symptoms of cough, temperature and pain in the left chest for eight weeks. Roentgen-ray at this time revealed a recurrence of the processes which had been present before. Bronchoscopy on July 7: About 1 inch down the left main bronchus there is a tumor protruding from the left and posterior wall of the bronchus partially blocking the lumen. It is rough, firm and vascular. Biopsy was taken. Tumor is well situated for destruction by diathermy. Mucous membrane below and above it is normal.

Microscopic Examination. Shows a malignant epithelial growth, the bulk of which is situated in the deeper part of the tissue. In this region the structure consists of compact nests of rather small, rounded or polyhedral cells supported by a relatively small amount of dense fibrous tissue which is poor in cells and bloodvessels. The cell nuclei are round and usually vesicular and the cytoplasm is scanty and moderately acidophile. Here and there are noted larger cells containing a single nucleus. More superficially, the cells become smaller, more compressed and grow in narrow and often irregular and ramifying strands which show a tendency to retract from the supporting stroma. Some of these cell strands extend into the mucous membrane, but have no connection with the surface epithelium. The latter, however, in places is completely eroded away. In parts of the tumor are noted round or slitlike spaces bordered by one or several rows of tumor cells. Definite glandular structures, however, are not observed. Neither intercellular bridges nor epithelial pearls are demonstrable. The stroma shows rather slight round-cell infiltration and a few small scattered hemorrhages. Careful search fails to reveal the presence of mitotic figures.

Diagnosis. Small-celled carcinoma of the bronchus.

July 14, 1932: Bronchoscopy. Growth thoroughly treated with diathermy and quite a large piece was cut away and removed. The bronchoscope could be passed into the lower lobe, the lumen now being wide open.

July 17: Bronchoscopy. The growth about the mouth of the left upper lobe bronchus is very much smaller. Mouth of the upper lobe bronchus can be defined. Lumen of the upper lobe bronchus is wide and open. Quite a bit of pus comes from the lower lobe. Roentgen-ray.

Microscopic examination shows a malignant growth of a structure like that of the biopsy specimen. The tumor cells in places are compressed and often assume a fusiform or elongated shape, some appearing cylindrical. The stroma is scanty, dense, poor in cells and only moderately well supplied with bloodvessels. The tumor is evidently growing slowly, as dividing cells are not observed. A part of one surface is covered with a rather thick layer of fibrous tissue which in places is richly infiltrated with polymorphonuclear leukocytes.

Diagnosis. Carcinoma of the bronchus. (See report No. 30432.)

July 20, 1932: Left chest shows some increased aëration into the upper and outer half. Heart and trachea pulled over and into the left chest with elevation of the diaphragm. Distinct improvement.

July 28: Bronchoscopy. Growth in the lung very much reduced in size and no longer obstructs bronchus. Still extremely vascular. Diathermy applied.

Roentgen-ray, October 3, reveals a marked clearing up of the entire left lung. There is slight molting remaining, but aëration appeared to be greatly improved.

August 4: Lumen of the bronchus on the left side is quite wide open, and neoplasm is reduced to a roughening on the posterior wall of the bronchus about the mouth of the upper lobe bronchus and extending a short distance into the lower lobe.

August 11: Patient was discharged from the hospital.

September 7: Bronchoscopy. Growth which has been described as being just below the mouth of the upper lobe bronchus has disappeared.

Section below the bronchus has contracted seemingly by scar tissue. There is an area on the anterior wall opposite the mouth of the right dorsal branch of the lower lobe which is ulcerated. Roentgen-ray at this time reveals the left lung field contains moderately exaggerated pulmonary marking with no residual areas of consolidation. Heart is still to the left of the midline. Diaphragm elevated slightly.

September 15: Bronchoscopy. Cannot make out any growth. There is granulation tissue. Attempted to do biopsy unsuccessfully. Granulation tissue is considerable below former site of neoplasm. Bronchus has a tendency to stricture formation. May need stretching later.

September 29: Tube passed into left bronchus. Below the level of the upper lobe bronchus the lumen of the left bronchus is greatly constricted. There appears to be a mixture of scar and granulation tissue at this point. Impossible to say if constriction is due to a healing process or more neoplasm. There is a little mucopurulent secretion in the neighborhood of bifurcation.

October 13: Bronchoscopy. Under the fluoroscope, lipiodol injected into the left lower lobe. Obstruction described on previous examination was encountered. Lipiodol was injected into the left main lobe bronchus. Roentgen-rays taken. Roentgen-rays revealed left main bronchus outline, and there is considerable sacculated bronchiectatic involvement of the bronchi in the midleft chest. Left lower bronchus is very incompletely outlined, but seems the most dilated of any of the bronchi. We would suspect narrowing of the left lower bronchus near the junction with the left main bronchus.

October 20: On bronchoscopy it is found that the area seems to have healed. Small amount of mucus aspirated. Mucous membrane in the left bronchus is red and congested. Some pus in left lower lobe.

December 1: No evidence of return of growth. Left lower bronchus much constricted.

February 2, 1933: No evidence of return of growth. Bronchus not as contracted as previously.

April 20: Bronchoscopy. Bronchus is clear as far as growth is concerned. Upper lobe bronchus and first dorsal branches are wide open. Main bronchus below first dorsal branch congested.

July 20: There is no pus involvement or neoplasm to be seen. Main lower lobe bronchus constricted; will need stretching.

December 24: Readmitted to the hospital with chills, cough, dyspnea and pain in chest. A diagnosis of occlusion of the left main bronchus with atelectasis of the entire left lung was made. Roentgen-ray examination revealed mottled density at the left base, so that the left dome of the diaphragm is indistinguishable. The heart is pulled over into the left chest and the trachea deviates markedly over to the left side.

January 8, 1934: Further roentgen examination demonstrates considerable clearing up of the process of the left lobe, although quite a patchy area of density still persists. Bronchoscopy on January 1: We did not find any new growth above the stricture. Upper lobe bronchus all right. Lower lobe bronchus presents dense mass of scar tissue through which are two openings. It is the anterior one which discharges pus. Impression is that the posterior opening is the first dorsal branch fairly well open. Anterior opening represents

the constricted lumen of the main bronchus. In it can be seen granulation tissue. A flexible tip suction tube can be passed down, but nothing large. Attempt made to dilate with dilator, but not successful.

Roentgen-ray, January 13, lower half of the left chest is cloudy, and a bronchiectasis would be strongly suspected. The upper left and the entire right lung field are fairly clear. There is considerable pneumonitis present at the left base surrounding what appears to be multiple small cavities.

Subsequently the patient developed small abscesses below the level of the stricture in the left lower lobe and was operated upon. Rib resection with drainage of small multilocular abscesses and biopsy of lung was done. The pathological report was chronic suppurative inflammation of the lung with bronchiectasis and chronic interstitial pneumonitis. There was no evidence of neoplastic disease.

On October 15, he was again operated upon for a chronic fistula.

October 15: He was again operated upon for a lobectomy, but the patient died the following day.

The pathological report at the time of lobectomy was chronic pneumonitis with bronchiectasis. No evidence of malignant disease.

CASE 8.—R. F., white, female, aged thirteen years, was admitted to Lenox Hill Hospital on January 4, 1933, with a complaint of weakness, frequent colds, chronic cough, hemoptysis. About a year before admission she had caught a bad cold which developed into pneumonia. She was admitted to St. John's Hospital, Long Island City, where her condition was finally diagnosed as tuberculosis. Roentgen-rays were taken and a left pneumothorax was performed. She was discharged in February, 1932, with a very poor prognosis.

In March, she went to the Department of Health for reëxamination, where she was told she did not have tuberculosis, and was sent to Bellevue Hospital for diagnosis. There she had bronchoscopy four times. Two biopsy reports were carcinoma of bronchus and two were reported as polyp of bronchus. She also gave a history of catching cold very easily and complained of a persistent cough for the past two years with no expectoration. She had a slight hemoptysis about fourteen months before admission. She has never had any sputum, but she has had intermittent attacks of fever. No loss of weight. The rest of her history was negative except that her father had a carcinoma of the lip and her grandmother died of a carcinoma. Also one aunt died of a carcinoma of the stomach.

On examination, the patient appeared well developed and nourished,

with no apparent discomfort. Lungs showed a few râles in the upper part of the right chest posteriorly, with no evidence of previous pneumothorax. Remainder of chest clear, otherwise her examination was negative. A bronchoscopy was performed, and in the left main bronchus above the level of the upper lobe bronchus on the antero-lateral aspect there was a small nipple-like tumor. A biopsy was taken. A roentgen-ray taken at that time revealed that there was "an indefinite density in the left lower half of the chest with pulling over of the cardiac shadow, and elevation of the left side of the diaphragm. Lung tumor with bronchial obstruction would be suspected as a cause of the appearance presented."

Report of the biopsy revealed the following:

Microscopic Examination. Section of the fragment shows it to consist largely of rather dense and only moderately cellular fibrous tissue which is fairly well supplied with bloodvessels. In places this tissue is dense and hyaline, while in other places it is loose and edematous. In several areas it is rather cellular, the cells being for the most part of spindle shape and uniform size. Included in these cellular areas are small masses of yellowish-brown or blackish granular material, possibly hemosiderin. The fibrous tissue shows capillary hemorrhages and slight focal chronic inflammatory infiltration. The surface of the fragment is somewhat irregular and largely covered with stratified cylindrical epithelium.

Diagnosis. Fibrous nodule from the bronchus, probably inflammatory.

A week later another biopsy was taken and the following is the report:

Microscopic Examination. Section of the fragments show them to be composed of fibrous tissue, the surface of which is irregular or ragged and partly covered with stratified cylindrical epithelium. The epithelial cells in places are rounded in form and disorderly arranged, though appear to be confined within the basement membrane. Parts of the fibrous tissue are dense and poor in cells or hyaline. Other parts are loose, very fascicular and fairly cellular. Included in the fibrous tissue of two of the fragments are a number of small nests and slender strands of small round cells, the nuclei of which are round and for the most part chromatic and occasionally pycnotic. The cell masses show a tendency to retract from the supporting tissue and often appear as masses which occupy irregular spaces in the tissue. The cells show a general uniformity in size and mitotic figures are not demonstrable.

Diagnosis. Probably small-cell carcinoma of the bronchus.

January 12, 1933: Fulguration applied to tumor through bronchoscope.

January 19: Tumor mass much smaller than the last examination. Tumor fulgurated.

January 26: Tumor appeared as whitish mass. Edges fulgurated.

February 23: Tumor much shrunken in size.

March 23: Site of tumor is now replaced by scar and the bronchus is wide open. Patient gaining weight.

Bronchoscopies were performed at irregular intervals and when last examined, on August 9, 1934, there was no sign of recurrence. However, a lipiodol injection by the drip method, performed by Dr. McLeod Riggins, showed that the patient had an extensive bronchiectasis which concluded as being dry, since the patient had no symptoms of cough or expectoration.

CASE 9.—M. S. First admission to Presbyterian Hospital, September 18, 1934; the last admission was on April 11, 1935. On his admission the following note was made: Chief complaint, cough and fever for thirteen months. Thirteen months ago the patient had a mild cold which he disregarded. Following exposure, it became suddenly worse, with chest pain, cough with a little sputum of forgotten type, and fairly severe fever. The local doctor diagnosed pneumonia and sent him into St. Luke's Hospital, Utica, N. Y., for three weeks. The pneumonia was a lobar one of the left upper lobe with perhaps some involvement of the right lower lobe. Type IV pneumococcus was found. On discharge the patient still had considerable cough and spells of fever every few days. Two ounces of sputum. Twelve months ago the patient went home, but the spells of fever and cough continued, and the patient weighed 18 pounds less than usual. He suffered from severe night sweats. Sputum was scanty, with only occasional small greenish bits of mucus, not foul, never blood. Eleven months ago roentgen-ray pictures were taken at St. Luke's, in Utica, which were interpreted as tuberculosis. No sputum examination was made. Ten months ago, as symptoms continued, the patient went to Broadacres Sanatorium, in Utica, where he remained six months. Two more sputum examinations before admission were negative, and in hospital at least a dozen more were negative, and two guinea-pig inoculations were unproductive. Roentgen-rays of his chest were said to show a "honeycomb shadow" in the left upper lobe. Sanatorium doctors apparently disagreed as to diagnosis and never would call it tuberculosis. During the stay the patient regained his lost weight back to normal. Cough improved, but roentgen-ray

shadow changed little. Fever became less frequent, coming about every two weeks and lasting only a few days, still of "spiky" type. Patient had no more night sweats. For the last four months the patient has been in the Catskills, pretty much in bed. Same fever spells continued and became more frequent, coming every few days or lasting fairly steadily. No more night sweats and no weight loss. Sputum negative again two months ago. Sputum has increased slightly in the last month. A bout of fever comes more at night than in the morning. The patient finally came to the Presbyterian Hospital because of failure to improve. The patient says that doctors have always commented that no one had ever recorded hearing râles in his chest.

Examination of lungs: Anteriorly over an area about 6 cm. in diameter, extending from the clavicle to the fourth rib and from the sternum out 6 cm. laterally, there is dullness, diminished but normal B. S. and decreased T. F. and V. F. Above the clavicle and lateral to this area all is normal. Posteriorly over a corresponding area (interscapular and superscapular, but not to true apex) the V. F. and T. F. are decreased, but B. S. and resonance are normal. No râles heard. Rest of lungs clear. Both bases level and descend well. The impression gained was a possibility of lung abscess or interlobar empyema.

Stereoscopic chest films on September 19, 1934, showed an extra-density in the left middle lung field which steros anteriorly. There was a suggestion of a cavity in the center, but no definite fluid level was seen. The findings were thought to be pretty definitely those of a lung abscess. (Dr. Swenson.)

On October 1, 1934, the following note was made: "The history is consistent with lung abscess, and this diagnosis is pretty definitely proven by the roentgen-ray studies, which place it in the left upper lobe. The process now is in an advanced chronic stage, and I do not believe that there is any possibility of its healing spontaneously. Surgical drainage should not prove difficult and the sooner done the better. A partial pneumonectomy (or lobectomy) may have to be done eventually, but the immediate indication is drainage." (R. Moore.)

On October 2, the following note was made: The possibility of this being a lung abscess in association with bronchial neoplasm cannot be definitely ruled out without bronchoscopy. For this reason a bronchoscopy is to be done. (R. Moore.)

On October 3, the following bronchoscopic note was made:

Pathology. The right side was negative. There was a cluster of granulation tissue or soft neoplastic mass seen coming out of the mouth of the left upper lobe bronchus. No pus descends from this bronchus. No pathology or pus seen in the lower lobe bronchi. Procedure: Under local anesthesia an 8-mm. tube was passed into the right main bronchus and the larger bronchi on the right visualized. The tube was then passed down the left main bronchus and the tumor mass *on the anterior lip of the left upper lobe bronchus visualized.* The bronchi of the lower lobe were then examined and no pathology found. With biting forceps a small piece of tissue from the tumor was removed for biopsy. *N.B.* The tumor tissue is probably blocking drainage from the upper lobe. Treatment will be determined by the biopsy findings. (Dr. Fowler.)

Biopsy Report. October 3, 1934. Gross: The specimen consists of a very small mass of soft pink tissue partly covered by mucous membrane. It measures 7 by 5 by 4 mm. The mucus-covered surface is slightly nodular. The cut surface is soft. Specimen fixed in Bouin-embedded *in toto*. Microscopic: Sections of the pieces of tissue removed show that it is almost completely filled by a tumor. This is composed of slender, solid, anastomosing strands of cells which are rather small, cuboidal, have centrally placed nuclei and faintly acidophilic, finely granular cytoplasm. The cords of tumor cells are separated, one from the other, by rather delicate strands of collagen fibers, in which the bloodvessels are found. No mucin is seen in the cells, and there seems to be no tendency to form acini. A small amount of the bronchial musculature is present, and along one margin a little bronchial mucous membrane. The growth seems to lie deep to the small fragment of muscle which is present in the section. No mitoses are seen. This is the type of tumor of the bronchus which tends to grow slowly, project into the lumen, causing partial or complete obstruction with resulting bronchiectasis and infection. It tends slowly to penetrate the bronchial wall and to grow to a limited extent in the tissues outside of it, but so far as our experience extends, it does not metastasize. No satisfactory name has been generally accepted. Both the terms "adenoma" and "carcinoma" have been used, and at the present time we are using the noncommittal term "tumor." If the case is operable, a cure may be effected by lobectomy or pneumonectomy. Diagnosis: "Tumor" of the bronchus. (A.P. Stout.)

On October 17, 1934, the following bronchoscopic note was made:

Pathology. The tumor described at the previous bronchoscopy in the mouth of the left upper lobe bronchus was encountered as before. It barely showed in the mouth of the bronchus when first seen. After the patient coughed it protruded to a much greater degree into the

lumen of the main bronchus. Thus one gets the impression that it is soft and more or less pedunculated, since it moves rather freely. Several bits of the tumor were bitten away. This released a considerable amount of yellow pus which was evidently dammed up by the tumor. Procedure: A 7-millimeter bronchoscope was passed through the left main bronchus, and the tumor visualized. A biopsy was taken and considerable thick yellow pus sucked from the 1-foot upper lobe bronchus with a spiral suction tube. (Kernan.)

On October 31, 1934, the following bronchoscopic note was made:

Pathology and Procedure. A bronchoscope was passed into the left main bronchus and the tumor was found to be somewhat smaller than on previous examination. It also appeared somewhat more accessible. This time it did not flap up and down into the bronchus on respiration. The entire visible tumor mass was fulgurated with the diathermy current. No exudate was obtained from the left upper lobe. (Kernan.)

On November 17, 1934, the following bronchoscopic note was made:

Pathology and Procedure. A bronchoscope was passed and the tumor mass in the left bronchus was visualized. Apparently it had diminished in size since treatment last week. The tumor was fulgurated at this time. Condition is apparently improved. (Kernan.)

On November 21, 1934, the following bronchoscopic note was made:

Pathology and Procedure. An 8-millimeter bronchoscope was passed and the tumor visualized in the left upper lobe bronchus. It seemed to grow from the upper wall and was somewhat shrunk, as compared with previous examination. The left upper lobe bronchus was more patent and no exudate was seen to exude from it. The tumor mass was heavily coagulated. (Kernan.)

On December 4, 1934, the following bronchoscopic note was made:

Pathology and Procedure. The tumor in the left upper lobe bronchus seemed to be very much smaller. All that was apparently left of it was destroyed by diathermy. (Cracovaner.)

On December 19, 1934, the following bronchoscopic note was made:

Pathology and Procedure. A small growth remaining at the entrance to the right upper lobe bronchus, was treated with diathermy. Growth appears much diminished in size. (Kernan.)

On January 2, 1935, the following bronchoscopic note was made:

Pathology and Procedure. Bronchoscope was passed and the growth in the left main bronchus was scarcely perceptible at this time. There was one very small remnant which was treated with diathermy. (Kernan.)

On January 23, 1935, the following bronchoscopic note was made:

Pathology and Procedure. Except for slight roughening on the lower edge of the opening of the left upper lobe bronchus, there is no

indication of the spot where the neoplasm was. This roughened spot was touched with diathermy. Incidentally, the bronchoscope was introduced about $\frac{3}{4}$ inch into the left upper lobe bronchus, and the openings of the tertiary bronchi seen. There was no evidence of bronchiectasis in the lung. (Kernan.)

On February 20, 1935, the following bronchoscopic note was made:

Pathology and Procedure. No visible tumor is present in the left upper lobe bronchus. Bronchoscope was passed well up into the upper lobe bronchus, so that the secondary and tertiary branches could be seen. No exudate exuded from these. M. M., on the lower side at the lip of the bronchus, is slightly rough and vascular, not firm, hard scar tissue. The patient is to be seen again in six weeks. (Kernan.)

On April 10, 1935, the following bronchoscopic note was made:

Pathology and Procedure. The bronchoscope was passed to the mouth of the left upper bronchus. It is notable that the roughness of the mucous membrane at the last bronchoscopy has disappeared. No trace of neoplasm. (Kernan.)

The final note made, May 13, 1935, states: "He appears to be in very excellent condition. No cough, no sputum and no hemoptyses. The breath sounds over the left chest come through quite distinctly, indicating that the lung has reexpanded. This would seem to be an excellent result. He has promised to return in the fall for another bronchoscopy, and, of course, he should be followed."

CASE 10.—G. E., white, female, aged twenty-six years. This patient has had cough and shortness of breath for a year. Occasionally there were acute febrile attacks, due seemingly to complete plugging of the right bronchus and collapse of the lung. These attacks had been increasing in frequency and in severity.

On June 14, 1934, this patient was bronchoscoped. A soft tumor was found which appeared to have a tendency to be pedunculated. A biopsy was taken at this bronchoscopy. The pathologists who examined the sections differed greatly in their reports, some insisting that it was a carcinoma, on the basis of which report the thoracic surgeon urged a pneumonectomy. Consent was given to try the effect of diathermy.

On June 28, July 5, and on July 19, 1934, she was bronchoscoped and diathermy was used.

On September 25, 1934, she was bronchoscoped again, at which time no remains of the tumor could be seen.

DISCUSSION

DR. C. L. JACKSON, Philadelphia, Pa.:

I have seen a few more of these cases since the one mentioned by Dr. Kernan, but I should like to speak of another case, a case of a tumor histologically somewhat different from these, but in which I have for the first time followed the example of Dr. Kernan in using diathermy through the bronchoscope.

The case is that of a young girl who had had a large tumor removed by thoracotomy several years previous to the time I first saw her. This tumor was regarded as a neurofibroma. It was removed by the posterior approach by Dr. George Muller. The patient was perfectly well for a year or two after this operation; then she developed slight shortness of breath, and roentgen-ray examination showed an atelectasis of the entire right lung. I did a bronchoscopy and found a large tumor in the right main bronchus, just below the bifurcation. I thought this would be an excellent case in which to use diathermy. I had been a little apprehensive about possible damage to the bronchial wall, but this seemed to be an ideal case, since the tumor was large and located in a main bronchus. I prepared an 8-millimeter, full-lumen aspirating bronchoscope, with a channel for an electrode, similar to the instrument Dr. Kernan has been using, and with it I applied diathermy (in consultation with Dr. Frank Krusen) three or four times, with great satisfaction. I have been able to visualize the field perfectly and to avoid any damage to the bronchial wall. There is still some tumor remaining in the bronchus but the lung has become almost completely aerated and I think we shall be able to destroy the entire endobronchial tumor before long.

The histology has been just the same as that of the extrabronchial tumor removed by Dr. Muller. Whether or not there remains some extrabronchial tumor to be dealt with by thoracic surgery, it is impossible to say until aeration of the lung is complete. The results I have obtained in this case have encouraged me to go on and use diathermy in cases where the lesion is down in the smaller bronchi and the use of a smaller bronchoscope is required. I feel that this is extremely important work, and I have enjoyed very much hearing Dr. Kernan for the third or fourth time on the subject.

DR. LOUIS H. CLERF, Philadelphia, Pa.:

I have been impressed with the existing confusion particularly among pathologists concerning the character of this particular bronchial

tumor. It has been designated as carcinoid tumor, adenoma and benign glandular tumor. Certain of our clinically benign cases have been considered as adenocarcinoma, low grade, by Dr. Ewing. The opinion of the bronchoscopist is particularly important in diagnosis. He must determine if there is fixity and rigidity with infiltration of the bronchial wall.

In the earlier cases deep roentgen therapy was employed with remarkably little effect on the tumor. I then tried fulguration with apparently satisfactory results. Later I found that removal with the aid of forceps and the tip of the bronchoscope was effective particularly in the smaller tumors.

DR. WILLIAM B. CHAMBERLIN, Cleveland, Ohio:

I wanted to ask Dr. Kernan a question, just why it was necessary to introduce his electrode through a separate channel, why he couldn't have introduced it through the scope just as well and still have clear vision.

DR. DUNCAN CAMPBELL SMYTH, Boston, Mass.:

As Dr. Clerf said, there is a paper before the Bronchoscopic Society tomorrow on adenoma.

At the Massachusetts General we have had 9 cases of pure adenoma of the bronchus. As far back as four years ago one case was diagnosed as malignant and operated upon, having the middle and lower lobes removed by Dr. Churchill. The patient is well today. A check-up on her specimens showed she had a pure adenoma of the bronchus. The pathologists around Boston are agreed it is an adenoma. They have not seen any of these cases metastasize, therefore they call them benign.

Seven of our cases were preceded by hemoptysis as an early sign. It is too bad that we are getting these cases so late and in the stage of atelectasis.

I noticed that Dr. Kernan mentioned that some of his cases were also in the atelectatic stage. I think 4 of ours were sent in with pronounced secondary bronchiectasis as well as atelectasis.

What we should endeavor to do and what I have pleaded for, for years, is to recognize bronchial tumors early and teach the medical men how we can detect them. A roentgen-ray should be taken in all cases of hemoptysis. Any sign of destructive emphysema is just as useful in making a diagnosis of benign adenoma as it is in making a diagnosis of foreign body. If we teach the medical men what obstructive emphysema means, and the value of full inspiration and expira-

tion plates, we will be doing much toward the early recognition of new growths of the lung. I doubt if we can effect a cure in many of these cases.

DR. GABRIEL TUCKER, Philadelphia, Pa.:

I have nothing to add to Dr. Kernan's excellent presentation. I should like to ask one question, however.

We have all encountered the same difficulty in the histologic diagnosis of these tumors. The bronchoscopist, however, can make one important contribution in most cases. He can keep the air way open by the bronchoscopic removal of tissue and in my experience I have found the implantation of radon very efficient in this regard. The radon implantation is combined, of course, with deep roentgen-ray therapy.

In 1 patient whom we saw in consultation with Dr. Fletcher Woodward, a diagnosis of carcinoma was established from the bronchoscopic biopsy by Dr. Woodward and deep roentgen-ray therapy combined with radon implantation was used by Dr. Pendergrass at the hospital of the University of Pennsylvania, and after six years the man is still free of any evidence of disease. I have never seen any bad effects from radon implantation and I should like to ask Dr. Kernan if he has had any unfavorable results with radon.

DR. J. D. KERNAN (in closing):

I will try to be very brief. I am sure Dr. Jackson doesn't want to hear me at very great length the fifth time.

I think in the use of diathermy, the diathermy aspirating tube would be good because sometimes a little smoke will get in the way and interfere with observation.

In regard to the destruction of a tumor, I am not sure it is necessary to destroy it all. I think if it is well coagulated so that it shrinks down white, the probability is that it will continue to disappear.

With regard to the nomenclature, I am completely at sea. Dr. Stout, at Presbyterian Hospital, has embarked on the same boat for he refuses to call them anything now except tumors of the lung. As I have said, many call them carcinoid, many call them carcinomas, and many call them adenomas. The pathologists are by no means agreed as to what they are.

There is no doubt about it, you will encounter the diagnosis carcinoma very often. I have encountered it in the last year twice from competent pathologists and on the basis of that diagnosis the chest surgeons have wanted to remove a lung, and so it is certainly important to establish the correct diagnosis, if you can.

About removing them with forceps, I think that removing them with forceps is sufficient if the tumor is pedunculated and all inside the bronchus, but remember, I showed you a slide in which there was a considerable portion of the tumor outside the cartilages and I cannot quite see how forceps could reach that portion.

Now, as for passing the electrode in a separate channel, that is merely for the purpose of keeping it out of the way as much as possible and giving the best vision possible.

As for the atelectasis, bronchoscopy is very important and very effectual in removing the atelectasis itself. It disappears very promptly, as I showed you in one case that was very much obstructed. After bronchoscopy and taking of biopsy she was considerably relieved and, with no more treatment at all, went on to find a seemingly complete cure.

I have no objection to radon at all except that it does not seem to be necessary and it hasn't seemed to me advisable to use something that could be done without, but there is no objection to it. I have used it in 4 or 5 cases, and, if I thought it was necessary, I would use it again, without the slightest hesitation.

Memorials



WILLIAM SCOTT RENNER

WILLIAM SCOTT RENNER

1861-1934

DR. WILLIAM SCOTT RENNER, for over thirty years a loyal member of the American Laryngological Association, died October 10, 1934, at his home, 341 Linwood Avenue, Buffalo, New York, of bronchopneumonia. He was born March 31, 1861, in the township of Louth, Lincoln County, Ontario, Canada. His father, Thomas Morgan Renner, also born in Louth, was the son of William Renner, who came originally from what is now Frederick City, Maryland, about 1775. When about twenty-one years old he migrated to Canada and purchased land granted by the English Government to a United Empire Loyalist, about 1796. He was a farmer, and his second wife, the grandmother of the subject of this biography was, of the Dutch stock of Pennsylvania.

The mother of Dr. Renner, Nancy Ann Rogers, was a daughter of Alkanah Rogers, of English descent who, with his wife of North of Ireland origin, migrated to Canada from Massachusetts about the same time, 1796.

The early life of Dr. Renner was spent near his birthplace, where his preliminary education was gained at the country school. He then entered the Collegiate Institute near St. Catharines, where he gained about the equivalent of two years' College course of Toronto University. In 1884, he graduated in medicine from McGill University of Montreal and, having substituted for internes at the Montreal General Hospital during the summers of 1882 and 1883, went to Vienna where he began the study of Laryngology with the distinguished Professor Schroetter, in 1884 also taking courses with Schnitzler and Chiari (then Docent) and at the Ear Clinics of Professors Politzer, Gruber and others.

Returning to this country he settled in Buffalo and there began a long career of usefulness.

His hospital connections were many and of a high order. They included the Buffalo Eye and Ear Infirmary, the Children's, Sisters of Charity, Erie County, German Deaconess, Mercy,

and Municipal Hospitals, and the J. N. Adam Memorial Hospital at Perrysburg, New York.

Dr. Renner became Professor of Laryngology at Niagara University in 1891 and in 1898 Clinical Professor of Laryngology and later Associate Professor of Otolaryngology at the University of Buffalo, which latter position he resigned in 1920.

He was admitted to Active Fellowship in the American Laryngological Association in 1903 and was one of its Vice-Presidents in 1911.

He was also a member of the Erie County Medical Society, New York State Medical Society, the American Medical Association, the Central New York Medical Association, the American Otological Society, the American Academy of Ophthalmology and Otolaryngology, the American Rhinological, Otological and Laryngological Society and the Buffalo Academy of Medicine. In 1901 he was Chairman of the Eastern Section of the American Rhinological, Laryngological and Otological Society, and in 1912 President of the Buffalo Academy of Medicine. He became a Fellow of the American College of Surgeons in 1915 and was also a member of the Buffalo Medical Club and the Medical Union.

During the World War he was a member of the American Advisory Board No. 43 of New York.

He was President of the Buffalo Otolaryngological Society from 1922 to 1924 and also belonged to the Society of McGill University.

Dr. Renner was an Episcopalian, and in politics a Republican.

Aside from his profession, he enjoyed the game of golf and was especially interested in motor boating, while his love of nature found a beautiful outlet in his exceptionally fine garden. He was a member of the Saturn, the Buffalo and the Country Clubs.

On June 15, 1888, he married Miss Katherine Diehl, who did not long survive him.

He is now survived by his son, Alan D. Renner, of Jordan Station, Ontario, Canada.

BIBLIOGRAPHY OF WILLIAM SCOTT RENNER

1890-1930

Adenoid Vegetations of the Naso-pharynx, Buffalo Med. and Surg. Jour., 29, 523, 1890.

Affections of the Lingual Tonsils, Buffalo, 1896.

Chronic Follicular Tonsillitis, *Med. Rec.*, **52**, 303, 1897. Also: *Trans. Am. Laryngol., Rhinol. and Otol. Soc.* (1897), **3**, 26, 1898.

Paroxysmal Sneezing, *Buffalo Med. Jour.*, **35**, 31, 1895.

Infection Through Upper Air Passages, Buffalo, A. T. Brown, 1900.

The Indications for the Radical Mastoid Operation With a Description of Its Technique, *Buffalo Med. Jour.*, **41**, 785, 1902.


Tertiary Syphilis of the Nose and Pharynx, *Trans. Am. Laryn. Assn.*, **25**, 15, 1903. Also: *New York Med. Jour.*, **79**, 385, 450, 483, 546, 1904.

Treatment of Acute Otitis Media, *Buffalo Med. Jour.*, **44**, 720, 1904-1905.

Nasal Tuberculosis; a Case and Remarks, *Trans. Am. Laryn. Assn.*, **31**, 120, 1909. Also: *Ann. Otol., Rhinol. and Laryngol.*, **18**, 571, 1909.

The Middle Turbinate Body; Some Indications for Its Removal, *Trans. Am. Laryn. Assn.*, **34**, 198, 1912. Also: *Ann. Otol., Rhinol. and Laryngol.*, **21**, 443, 1912.

Diseases of the Nasopharynx, in: *Nose, Throat and Ear and Their Diseases* (Jackson and Coates), Philadelphia, W. B. Saunders Company, p. 344, 1930.



Cornelius F. Crakley

CORNELIUS GODFREY COAKLEY

1862-1934

THE death of Dr. Coakley, November 22, 1934, removed one who for many years had been a prominent specialist in New York City.

He was born in Brooklyn, New York, August 14, 1862. His father, George Washington Coakley, originally of St. Kitts, West Indies, of Irish origin, became professor of mathematics and astronomy at New York University. His mother, Isabella Hoe Godfrey, of English ancestry, came from Fishkill, New York.

Dr. Coakley's early life was spent in Brooklyn, Hempstead, L. I., and New York City. From 1875 to 1878 he attended Grammar School 35 and, later, in 1879 entered the College of the City of New York, where he graduated in 1884 and in 1887 received the title of A.M. Having graduated in medicine from the Medical School of New York University in 1887 he was for eighteen months interne in the Second Medical Department of Bellevue. He then entered upon general practice in New York City and later began the study of Laryngology at the University Medical School with Dr. William C. Jarvis. Meanwhile, he joined the Faculty of the University Medical College, first as Lecturer on Anatomy, and later as an Instructor in Histology. He resigned from the latter course in 1896, as he did from the Department of Histology at the Loomis Laboratory, of which he was Director. In 1894 he became clinical Professor of Laryngology at the University Medical School and in 1908 advanced to full professorship. In 1914 he was called to the College of Physicians and Surgeons (Columbia) as Professor of Laryngology and in 1916 was made Professor of Otolaryngology.

The clinical facilities of Dr. Coakley were unusually extensive. Beginning with the dispensary of the New York University Medical School, he subsequently belonged to the DeMilt, the New York Eye and Ear Infirmary and the Vanderbilt Clinic. He was consulting surgeon to the Bellevue, Presbyterian, Sloane, Neuro-

logical, Woman's and Sea View Hospitals and the Hospital of Southampton, Long Island; with all of these he was connected at the time of his death.

Dr. Coakley was admitted to the Fellowship in the American Laryngological Association 1902 and was one of its Vice-Presidents in 1909. He became its President in 1918. He was also a Fellow of the American Otological Society, of the American Medical Association, of the American College of Surgeons and of the New York Laryngological Society, and Corresponding Fellow, La Société de Laryngologie des Hôpitaux de Paris.

He was married September 10, 1890, to Annette J. Perry, of Rush, New York. Her father was American, her mother Scotch. She died August 18, 1922. Two years later he married her niece, Mary Louise Perry. He left no children. His favorite diversions were golf, hunting and fishing. He was a Presbyterian. His secular associations included the Lotus Club of New York City, the National Golf Links of America, Long Island Country Club and Mountains Lake Club, Florida. In politics he was independent.

The career of Dr. Coakley, including his published articles, suggests that he was a man of energetic nature and great industry. His councils and discussions were respected, while his viewpoint on many of the problems of laryngology which had demanded solution in past years was generally reliable. He was the successor of two of the foremost laryngologists of our time, Dr. Bosworth who instituted the Bellevue Clinic, and later, Dr. Lefferts, who at the College of Physicians and Surgeons, in 1873, organized the best and most comprehensive school of instruction of undergraduates in laryngology that has ever been known, either here or abroad. Dr. Coakley was particularly impressed by the work of foreign operators, especially that of Killian, and sought to introduce some of the methods of that radical operator; several of these did not prove popular.

He died, at the Presbyterian Hospital, New York, after several weeks' illness of coronary thrombosis, November 22, 1934.

The bibliography of his published articles herewith appended will demonstrate the versatility and the active interest of the man in subjects pertaining to the advancement of his profession. He

early compiled a small manual of the nose and throat, for undergraduates, the last revision of which was published in 1930.

BIBLIOGRAPHY OF CORNELIUS GODFREY COAKLEY
1892-1934

Books

A Manual of Diseases of the Nose and Throat, New York and Philadelphia, Lea, 1899, with subsequent editions to 1930.

Articles in Medical Journals

The Arrangement of the Muscular Fibres of the Œsophagus, Research, Loomis Lab., Univ. City of New York, **2**, 113, 1892.

A Case of Nasal Osteoma, Jour. Laryngol., **9**, 194, 1895.

Empyema of the Antrum of Highmore, New York Med. Jour., **61**, 377, 1895.

Statistics of Diphtheria, Med. Rec., **49**, 796, 1896. Also: Med. News, **68**, 697, 1896.

Observations Upon the Pathology of Chronic Suppurative Inflammation of the Antrum of Highmore, Trans. Am. Laryn. Assn., **24**, 39, 1902.

An Unusual Case of Frontal Sinusitis; Absence of the Septum, Trans. Am. Laryngol., Rhinol. and Otol. Soc., **9**, 179, 1903. Also: Ann. Otol., Rhinol. and Laryngol., **12**, 230, 1903.

The Treatment of Abscess of the Septum With Special Reference to the Prevention of Subsequent Deformities, Laryngoscope, **13**, 215, 1903. Also: Ann. Otol., Rhinol. and Laryngol., **12**, 64, 1903.

A Bony Cyst in (of) the Antrum of Highmore, Trans. Am. Laryn. Assn., **25**, 249, 1903. Also: Ann. Otol., Rhinol. and Laryngol., **12**, 435, 1903.

An Easy Method of Entering the Sphenoidal Sinus for Diagnostic Purposes, Laryngoscope, **14**, 271, 1904.

A Branchial Cleft Cyst Simulating a Chronic Retropharyngeal Abscess, Trans. Am. Laryn. Assn., **26**, 19, 1904.

Report on the Use of Stovaine, Med. News, **86**, 683, 1905. Transl. ("Ueber Stovain und dessen Anwendung"), Zahntech. Reform, **35**, 27, 1905.

The Frontal Sinus, Trans. Am. Laryn. Assn., **27**, 222, 1905.

Frontal Sinusitis; Diagnosis, Treatment and Results, Ann. Otol., Rhinol. and Laryngol., **14**, 431, 1905. Also: Trans. Am. Laryngol., Rhinol. and Otol. Soc. (1905), **11**, 101, 1906.

Skiagraphy as a Means of Determining the Size of the Frontal Sinus, With Exhibition of Plates, Trans. Am. Laryngol., Rhinol. and Otol. Soc. (1905), **11**, 490, 1906.

Skiagraphy as an Aid in the Diagnosis and Treatment of Diseases of the Accessory Sinuses of the Nose, With Exhibition of Plates, Ann. Otol., Rhinol. and Laryngol., **14**, 16, 1905. Also: Jour. Laryngol., **21**, 537, 1906. Also: Brit. Med. Jour., **2**, 1373, 1906. Also: Trans. Am. Laryn. Assn., **28**, 323, 1906. (Title varies slightly.)

The Diagnosis and Treatment of Antrum Suppuration, Dental Cosmos, **49**, 909, 1907.

Removal of Papillomata of the Larynx by Direct Instrumentation with the aid of Killian's Tubes, *Trans. Am. Laryn. Assn.*, **29**, 126, 1907.

The Value of Skiagraphs in the Diagnosis and Treatment of Diseases of the Accessory Sinuses of the Nose, *Homœop. Eye, Ear and Throat Jour.*, **13**, 402, 1907.

Primary Melano-sarcoma of the Nose; Report of a Case and Review of Literature, *Trans. Am. Laryngol., Rhinol. and Otol. Soc.*, **13**, 430, 1907.

Throat and Sinus Complications of Grip, *New York State Jour. Med.*, **8**, 192, 1908.

Intracranial Lesions Consecutive to Nasal and Accessory Sinus Infections, *Jour. Am. Med. Assn.*, **52**, 108, 1909.

Diseased Conditions Involving Accessory Sinuses in Which External Operation is Indicated, *Jour. Am. Med. Assn.*, **53**, 1023, 1909.

Experiences in the Use of Vaccines in Chronic Suppuration of the Nasal Accessory Sinuses, *Trans. Am. Laryn. Assn.*, **32**, 105, 1910 (with A. I. Kendall).

Report of Fatal Case of Asphyxia Due to Pressure on the Trachea and Bronchus by a Tuberculous Mediastinal Gland, *Trans. Am. Laryn. Assn.*, **32**, 196, 1910.

Observations on the Association of Suppurative Diseases of the Nasal Accessory Sinuses in Adults and Acute Otitis Media, *Trans. Am. Otol. Soc.*, **12**, Pt. 1, 42, 1910. Also: *Am. Jour. Med. Sci.*, **141**, 242, 1911.

Foreign Bodies in the Esophagus; Report of Two Cases, *Trans. Am. Laryn. Assn.*, **35**, 248, 1913.

Empyema of the Nasal Accessory Sinuses in Children Under Fourteen Years of Age; Surgical Consideration, *Trans. Am. Laryn. Assn.*, **36**, 126, 1914. Also: *Ann. Otol., Rhinol. and Laryngol.*, **23**, 661, 1914.

Lung Abscess Following Tonsillectomy, *Laryngoscope*, **26**, 1008, 1916.

Epithelioma of the Larynx Treated by Radium, *Laryngoscope*, **26**, 1250, 1916.

Observations on Pneumococcus Infection of the Nasal Accessory Sinuses, *Trans. Am. Laryn. Assn.*, **40**, 307, 1918. Also: *Ann. Otol., Rhinol. and Laryngol.*, **27**, 1127, 1918. Also: *Boston Med. and Surg. Jour.*, **179**, 647, 1918. Also: *Laryngoscope*, **28**, 915, 1918.

President's Address, *Trans. Am. Laryn. Assn.*, **41**, 4, 1919.

External Surgery of the Nasal Accessory Sinuses, *Surg., Gynec. and Obstet.*, **30**, 309, 1920.

Cellulitis of and Abscess in the Para-pharyngeal Tissues Causing Laryngeal Edema; the Symptoms, Diagnosis and Treatment, *Laryngoscope*, **30**, 65, 1920.

Chronic Frontal and Ethmoidal Sinusitis; External Operation, *Laryngoscope*, **30**, 325, 1920.

Hemorrhage During and After Tonsillectomy; Surgical Principles and Methods for Its Control, *Jour. Laryngol.*, **37**, 3, 1922.

Diagnosis and Treatment of Disease of the Nasal Accessory Sinuses in Children, *Trans. Am. Laryn. Assn.*, **44**, 48, 1922.

Analysis of the Systemic and Local Conditions Following Tonsillectomy and Adenoidectomy, *Laryngoscope*, **32**, 81, 1922 (with E. L. Pratt).

Tuberculosis of the Larynx; Diagnosis, Prognosis and Modern Treatment, *Bull. New York Tuberc. Assn.*, **4**, No. 4, 1, 7, 1923.

Paroxysmal Cough, a Frequent Symptom of Infection of the Para-nasal Sinuses in Children, *South. Med. Jour.*, **17**, 38, 1924.

Exophthalmos Due to Chronic Abscess of Orbit and Chronic Frontal Sinusitis, *Laryngoscope*, **39**, 654, 1929.

Tumors of Larynx, *Surg. Clin. North America*, **13**, 295, 1933.

Diagnosis of Early Cancer of Larynx, *Laryngoscope*, **43**, 106, 1933.

Common Cold, *Jour. Florida Med. Assn.*, **20**, 393, 1934.

Otitis Media, *Jour. Florida Med. Assn.*, **20**, 568, 1934.

Cancer of Larynx, *Jour. Florida Med. Assn.*, **21**, 23, 1934.

Para-nasal Sinusitis, *Jour. Florida Med. Assn.*, **21**, 60, 1934.



HARMON SMITH

HARMON SMITH

1872-1934

AMONG the many important happenings of the past year the American Laryngological Association has suffered supremely in the loss of its splendid friend, Dr. Harmon Smith. From the beginning of his long continued Fellowship we recognized in him a man of remarkable qualities, worthy of the fullest appreciation and esteem. Everything considered, he was one of the most broadly intelligent, bright minded and personally attractive men of his time. His was the quiet dignity inherited from an ancestry which, first of all, endowed him with the attributes of a gentleman, together with a repose of mind which rested upon the basis of real acquirement, relying more upon the attainment that resulted rather than upon the promise of it. The story of his life, both varied and to a certain extent romantic, is worthy of a permanent place in our history.

The record of his early ancestry abroad is pure, from ancient times. He himself was a specimen of the American of fine extraction. We cannot find that there was any admixture of race.

Dr. Harmon Smith was born at McDonough, Georgia, March 20, 1872. His father, Samuel Owen Smith, of Savannah, Georgia, was the son of William Henry Smith and Ann Harmon, of English extraction. His mother, Alice Cloud Stokes, also of McDonough, Georgia, was the daughter of Dr. Stokes and of Mary Cloud, his wife, whose ancestors had come from France, the family name originally having been St. Cloud.

That Dr. Smith was a member of the Sons of the Revolution is not strange, for his ancestry on both sides engaged in the conflict which liberated the Colonists from England. His maternal grandmother drew a pension from the Government for her husband's services in Mexico, during the Mexican War. His mother in her later years also drew a pension from the Government for his father's services in the Civil War; for, while a Southerner at heart, he ran away from school in Indiana at the age of fifteen and a half

years and, quite inadvertently, joined the Northern Army, under the command of General Sherman. This obliged him to march into his native state, where he fought against his own brother who was a Confederate. At the age of seventeen and a half years, after two years' service in the Federal Army he was dismissed in Washington, and when he returned to his native city, Savannah, was promptly ostracised. During his term of service when the mother and grandmother had fled from McDonough, Georgia, to escape Sherman's March to the Sea, his mother did not suspect that his father was not of the Southern Army, nor did she learn this for a number of years. Her decision to break the engagement was discouraged by his grandmother, and the marriage was finally consented to. Notwithstanding this, however, his father never overcame the antipathy of the Southerners in any locality in which he lived because of his having served in the Union Army. The great-grandfather, for whom the father of Dr. Smith was named, has left a picture of himself, as well as his midshipman's commission, signed by John Adams. Undoubtedly, he fought in the United States Navy during the War of 1812.

The early life of Harmon Smith was spent in Savannah, Carrollton, and Senoia, Georgia. Beginning at the Excelsior Academy, Senoie, his early school days were passed there, and later at the Georgia Military Academy, Savannah. He then entered the University of Georgia at Athens, and was graduated with the degree of A.B. in 1892. Subsequently he came to New York City to study medicine and graduated at Bellevue Medical College in 1897 under the preceptorship of that excellent surgeon, Dr. Jasper Garmany. Following this he was for sixteen months interne both in the medicine and surgery in the Kings County Hospital. Very soon he began work at the Manhattan Eye, Ear and Throat Hospital, in laryngology, under the direction of Dr. Walter S. Chappell.

The association of Dr. Smith with the Manhattan Eye, Ear and Throat Hospital was long continued and brilliant. He became connected with the Hospital at about the time that great Institution was inaugurated in East 64th Street, and he was one of its active surgeons during these last twenty-eight years. His

appointments there will show the high esteem in which he was held by the other members of the Manhattan's Board of Surgeons and by its Directorate. Thus, he became Clinical Assistant in the Throat Department in 1898 and a year later was promoted to the position of Assistant Surgeon. In March, 1907, he was made Full Surgeon, and under the amended charter of the Hospital in 1924 became Surgeon Director, in which position he remained until his death. In 1932 he became a member of the Executive Committee of the Hospital and so continued.

Manuel Garcia, then of London, who through his invention of the laryngoscope brought light to the darkness which confronted Horace Greene of New York, rightly called the father of laryngology, was the great teacher of vocal music of all time. He was about to be a Century old, a man of remarkable vigor and extraordinary personality; for besides his other accomplishments he was an active member of the London Conservatory of Music, Chairman of its Executive Committee and of its Committee on New Music. Famous throughout the world, great preparations were made for the celebration of his birthday which was to be honored by the presence of distinguished representatives of the various countries in which the science of laryngology had become established. Dr. Smith was chosen to represent the United States. He attended the celebration in person and presented to Garcia a formal tribute which well represented the wonderful growth of laryngology in this country and our debt to Garcia. The occasion, interesting in itself and bringing together as it did many prominent men, was one of the notable incidents of Dr. Smith's life.

In 1908 Dr. Smith became a Fellow of the American Laryngological Association and quickly established himself as one of its most valuable members. The position of Secretary of the Association, which had been ably held for a number of years by Dr. James E. Newcomb, was resigned by him in 1911, and Dr. Smith was elected to his place. His incumbency was highly successful in itself and gave abundant evidence of his own well marked intellectual superiority. His correspondence, both at home and abroad, was clear, dignified and courteous, and secured for him many friends in this country and in Europe. The Volumes of the

Transactions of the Association issued by him will amply attest his good judgment and scientific skill.

In 1918 Dr. Smith as well as all other active members of the Association who were available for the position of Secretary had undertaken War Duties and were in active service. A meeting of the Council held at this time developed the fact that it seemed impossible to find a satisfactory substitute for the then Secretary, actively to conduct the affairs of the Association. The only possible course seemed the temporary suspension of its affairs, including the Annual Meeting and the publication of its Volume of *Transactions*, and this for the first time in its long history of forty years. Strong objection was made by Dr. Delavan, whereupon Dr. Smith suggested that the place be temporarily taken over by him. Although already overwhelmed with important war work Dr. Delavan consented, and held the position for one year, then committing it to Dr. J. U. Ingersoll for the year 1919 who, in 1920, was succeeded by Dr. George M. Coates.

The contributions of Dr. Smith to the scientific proceedings of the Association and elsewhere were valuable. The titles of his many papers will be found in the record of his bibliography.

The friendly attitude of his fellow members is shown in his election to the Presidency of the Association in 1921, a position which he filled with distinguished ability, and in 1922 presided at its Forty-fourth Annual Meeting, held May 1, 2 and 3 in Washington, D. C.

A notable event in the professional career of Dr. Smith was his appointment to the professorship of Laryngology in the Cornell Medical College. This came to him in 1913, and was actively held until 1926. Diligent and faithful in the discharge of his duty, those who enjoyed his instruction as undergraduates deeply respected his personality and regarded him an excellent teacher. While he used few notes in the course of his lectures he was eminently clear and concise, and often humorous. The lectures were illustrated, generally by the projectoscope instead of the stereoscopic lantern. An outline for the course of his lectures, which covered the Diseases of the Nose and Throat very completely, was prepared by himself and was given to his students in order to

help them in their knowledge of the subject. The completeness and good judgment shown in this hand-book is highly creditable to his familiarity with the various subjects treated therein and with the needs of the students. I know of none more accurate and practical. Toward the younger men with whom he came in contact he was friendly and encouraging; thus he made many warm adherents.

In addition to the above the opinion of Dr. Smith in difficult cases was highly valued, both in general and in private practice. He was Consultant to the Memorial Hospital and to the Babies' Hospital, New York, to the Muhlenberg Hospital, Plainfield, New Jersey, and was Consulting Otologist to the Monmouth Memorial Hospital of Long Branch, New Jersey.

Among his private patients the years will recount that he had many of distinguished name and influence and that his professional opinions were held in deep respect. His general skill in operating upon new growths of the larynx by the indirect method was remarkable. Like Sir Morell Mackenzie he was able to remove small nodules or papillomata from the vocal cords by means of laryngeal forceps, or laryngeal snare, under indirect laryngoscopy, and this with great dexterity. He was especially interested in neoplastic diseases of the larynx; his handling of them could hardly be surpassed by more recent methods.

The literary record of Dr. Smith was by no means the least of his accomplishments. This includes his chapter on the Nose and Throat in Keen's System of Surgery, The Nose and Throat Section in the Text Book of Nursing, published in 1922, and most important of all, the admirable "Text Book Upon Diseases of the Nose and Throat," a comprehensive treatment of the whole subject written by himself and Dr. Jonathan Wright in 1914. This latter volume was the most important contribution to the subject made at that time, and today stands out as one of the best of its kind. Unfortunately, it appeared at a time when the general excitement caused by the Great War diverted all minds from scientific channels and prevented the successful circulation of new books. The minds of men were filled with other thoughts so serious that scientific progress was effectually stopped,

and contributions, however, good, were ignored. Today, the work stands as a tribute to its authors. The exceptional feature brought forward in it is the emphasis placed upon the Etiology and Pathology of the diseases of the upper air passages. The various morbid processes have been dealt with from this viewpoint, which also involves an extended consideration of the normal Histology and Physiology of the mucous membranes of the parts. Much of the work rests on original investigations pursued for many years by the authors themselves.

As a Fellow of the American Laryngological Association, Dr. Smith held successively the Offices of Secretary, Treasurer, Second Vice-President, First Vice-President and President of our Association. He was also a Fellow of the American College of Surgeons, of the American Medical Association, and of the Academy of Medicine of New York, and a member of the Cancer Research, and of the Rhinological, Laryngological and Otological Societies; of the latter he was Vice-President.

During the World War he held the military position of Captain of the Medical Corps, 9th Coast Artillery. The University of Georgia very properly presented him with the Honorary Degree of Doctor of Science—Sc.D.

Hunting and fishing and, to a certain extent, golf were his favorite diversions. An ardent admirer of Thoreau, his summers were spent at his camp in Maine, where quietude, change of scene and abundant opportunity for the diversions of the region gave him the most rational of all vacations. His Clubs were the New York Athletic and the Campfire Club of America. It is natural that in politics he should have been an independent. In social life he was conspicuous in his hospitality; generous and beautiful, it was a true inheritance from his Southern ancestors.

He was married June 30, 1915 to Miss Ruby Williams of San Diego, California, and their one child, Harmon Smith, Jr., is now at Boarding School at the Military Academy at Chester, Pa.—a brave lad of great promise and of lovely nature.

Dr. Smith's sudden death, December 11, 1934, in the midst of a life of great usefulness and charm, has brought unspeakable sadness to us all.

BIBLIOGRAPHY OF HARMON SMITH
1902-1934*Books*

The Nose and Its Accessory Sinuses—in Surgery (Keen). 8°. Philadelphia and London: Saunders, **3**, 399, 1908.

Ibid., **3**, 399, 1912.

Ibid., supplementary chapter, **6**, 354, 1913.

Nursing in Diseases of the Eye, Ear, Nose and Throat. By the Committee on Nurses of the Manhattan Eye, Ear and Throat Hospital (J. E. Giles, A. B. Duel, H. Smith, assisted by J. R. Shannon and J. R. Page, with chapters by H. B. Wilcox and E. D. Ayers). Philadelphia and London: Saunders, 281 pp., 8°, 1910.

Ibid., 2d ed., 291 pp., 8°, 1915.

Ibid., 3 ed., 333 pp., 8°, 1922.

Ibid., 4th ed., 335 pp., 8°, 1927.

Ibid., 5th ed., 338 pp., 8°, 1931.

Wright, J., and Smith, H.: A Text-book of the Diseases of the Nose and Throat, Philadelphia and New York: Lea & Febiger, 683 pp., 8°, 1914.

Periodical Articles

Subcutaneous Injection of Paraffin in the Correction of Nasal Deformities, New York Med. Jour., **75**, 837, 1902.

Paraffin Injected Subcutaneously for the Correction of Nasal and Other Deformities, Jour. Am. Med. Assn., **41**, 773, 1903; discussion, p. 776.

Alarming Hemorrhage Following Tonsillotomy: Its Cause and Care, Laryngoscope, **14**, 121, 1904.

A Consideration of Septal Spurs and Deflections, Internat. Jour. Surg., **17**, 355, 1904.

Naso-fibroma Treated by Injections of Monochloracetic Acid, Laryngoscope, **15**, 292, 1905.

Primary Epithelioma of the Uvula, With Report of a Case Where Recurrence Took Place After Two Operations for Removal, New York Med. Jour., **81**, 850, 1905.

Laryngeal Edema, Med. Rec., **69**, 624, 1906.

Report of a Case of Radical Operation for Chronic Otitis Media Suppurativa, New York Med. Jour., **83**, 542, 1906.

Abscess of Both Nostrils, With Saddleback Deformity Corrected by Paraffin Injection, Laryngoscope, **18**, 217, 1908.

The Accessory Sinuses of the Nose From an Operative Standpoint, New York Med. Jour., **87**, 575, 1908.

The Correction of Nasal Deformities by the Use of Paraffin, Trans. Am. Laryngol., Rhinol. and Otol. Soc., **14**, 47, 1908.

Multiple Papilloma of the Larynx in Children, Trans. Am. Laryngol. Assn., **30**, 64, 1908. Also: Laryngoscope, **19**, 81, 1909.

A Case of Laryngeal Carcinoma: Laryngectomy After Twelve Years' Observation, Laryngoscope, **19**, 52, 1909; discussion, p. 54.

A Case of Laryngeal Carcinoma Under Observation for Thirteen Years: Ultimate Laryngectomy, *Trans. Am. Laryngol. Assn.*, **31**, 79, 1909; discussion, p. 91. Also: *Laryngoscope*, **20**, 139, 1910.

Edema of the Tonsil and Pharynx, Condition Two Years After Dawbarn's Operation for What Was Considered at the Time to be Inoperable Epithelioma, *Laryngoscope*, **19**, 553, 1909.

A Case of Laryngeal Syphilis. With a Description of the Difficulties of Differential Diagnosis, *Trans. Am. Laryn. Assn.*, **32**, 16, 1910. Also: *New York Med. Jour.*, **92**, 258, 1910.

Multiple Papilloma of the Larynx, *Laryngoscope*, **20**, 571, 1910; discussion, p. 572.

Reports of Some Cases of Optic Neuritis, Benefited by Operation Upon the Sphenoidal Sinus and Posterior Ethmoidal Cells, *Trans. Am. Laryngol., Rhinol. and Otol. Soc.*, **17**, 65, 1911; discussion, p. 71.

Rhino-scleroma, *Laryngoscope*, **21**, 759, 1911; discussion, p. 761.

Report of a Case of Optic Neuritis Benefited by Operation on the Sphenoid and the Posterior Ethmoid, *Laryngoscope*, **23**, 67, 1913; discussion, p. 68.

Safety Pin Removed From Larynx of Child by Direct Laryngoscopy, *Laryngoscope*, **23**, 1097, 1913; discussion, 1098. Article with same title but slightly different text in: *New York Med. Jour.*, **98**, 313, 1913.

Carcinoma of the Larynx, Tracheotomy, Thyrotomy, Radium Treatment, *Laryngoscope*, **24**, 620, 1914.

Intra-venous Injections of Colloidal Copper and Mercury in the Treatment of Two Inoperable Cases of Carcinoma of the Larynx and Tongue, *Laryngoscope*, **24**, 624, 1914. (Written in collaboration with C. J. Imperatori.)

Laryngeal Cancer, *New York Med. Jour.*, **99**, 877, 1914.

Lymphosarcoma. Involving the Right Tonsil, Lateral Pharyngeal Wall, Soft Palate and Uvula, *New York Med. Jour.*, **99**, 779, 1914.

Lympho-sarcoma of the Tonsil, *Laryngoscope*, **24**, 621, 1914.

Papilloma of the Larynx, *Jour. Am. Med. Assn.*, **63**, 2207, 1914.

Plastic Operation for the Restoration of the Severed Vocal Cords on One Side Following Traumatic Self-inflicted Injury of the Throat, *Laryngoscope*, **24**, 552, 1914. Also, with title "Plastic Operation for the Restoration of Severed Vocal Cords; Permanent Thyroid Fistula Following Attempted Suicide with a Razor," in *New York Med. Jour.*, **99**, 731, 1914.

Blindness Incidental to External Ethmoidal Operation, *Laryngoscope*, **25**, 216, 1915; discussion, p. 302.

Cancer of the Larynx Complicated with Laryngocele, *Laryngoscope*, **25**, 560, 1915; discussion, p. 590.

Case of Naso-pharyngeal Sarcoma and Two Cases of Naso-pharyngeal Fibromata, *Laryngoscope*, **25**, 224, 1915; discussion, p. 186.

Empyema of the Nasal Accessory Sinuses. A New Instrument for Treatment, *New York Med. Jour.*, **101**, 1314, 1915.

Case of Nasal Fibroma, *Laryngoscope*, **26**, 132, 1916; discussion, p. 133.

Case of Frontal Sinusitis With Orbital Fistula, *Laryngoscope*, **27**, 55, 1917.

Empyema of the Nasal Accessory Sinuses and Its Nonsurgical Treatment, *New York Med. Jour.*, **105**, 721, 1917.

Endolaryngeal Removal of Malignant Growth; No Recurrence at End of Over Eighteen Months, *Laryngoscope*, **28**, 199, 1918; discussion, p. 201.

Two Cases of Syphilis of the Epiglottis and One of Tuberculosis Granuloma, Illustrating the Difficulty of Diagnosis in Throat Lesions, *Laryngoscope*, **28**, 175, 1918.

[Obituary of Walter Franklin Chappell.] *Trans. Am. Laryn. Assn.*, **41**, 285, 1919.

[Discussion During Symposium on Radium.] *Trans. Am. Laryn. Assn.*, **42**, 97, 1920.

An Unusual Case of Syphiloma of the Nose and Naso-pharynx, *Laryngoscope*, **30**, 749, 1920.

Address of the President, *Trans. Am. Laryn. Assn.*, **44**, 19, 1922.

Influenzal Sinusitis, *New York Med. Jour.*, **115**, 734, 1922.

Case of Pachydermia Laryngis, *Laryngoscope*, **33**, 110, 1923.

Mucocele of Left Frontal Sinus, *Laryngoscope*, **33**, 108, 1923.

Progressive Edema of the Larynx, Specific, *Laryngoscope*, **33**, 881, 1923.

Prolapsed Ventricle of the Larynx, *Laryngoscope*, **33**, 552, 1923.

The Common Cold, *Med. Jour. and Rec.*, **120**, 577, 1924.

Cyst of Mediastinum, Probably Dermoid, With Left Laryngeal Paralysis, *Laryngoscope*, **34**, 919, 1924; abstract, p. 662; discussion, p. 663.

Fulminating Septic Infection of the Pharynx and Larynx, *Trans. Am. Laryn. Assn.*, **46**, 138, 1924. Also: *Ann. Otol., Rhinol. and Laryngol.*, **33**, 1339, 1924.

Intrinsic Cancer of the Larynx, *Laryngoscope*, **34**, 214, 1924.

Local Versus General Anesthesia in Tonsillectomy, *Laryngoscope*, **39**, 751, 1929; discussion, *Ibid.*, **40**, 150, 1930.


[Memorial to Dr. Jonathan Wright.] *Med. Jour. and Rec.*, **130**, 50, 1929.

Myoma of the Larynx, *Laryngoscope*, **39**, 764, 1929.

Nonsurgical Consideration of Empyema of the Maxillary Antrum, *Laryngoscope*, **40**, 5, 1930.

[Discussion of I. S. Hirsch's Paper on the Roentgen Ray in Laryngeal Neoplasms.] *Laryngoscope*, **43**, 601, 1933.

[Discussion of Two Papers: One, by L. K. Guggenheim, on Otosclerosis; and the Other, by A. C. Furstenberg, on Osteomyelitis.] *Laryngoscope*, **44**, 344, 1934.



DAVID JAMES GIBB WISHART

DAVID JAMES GIBB WISHART

1859-1934

DR. D. J. GIBB WISHART for many years a leading Laryngologist in Canada, died at his residence, 76 Collier Street, Toronto, December 5, 1934, after a somewhat prolonged period of declining health.

He was born in Madoc, Ontario, September 11, 1859, the son of the late Rev. David and Maria Torrence Wishart, his father having been born at Blairburn, Perthshire, Scotland, and come from Edinburgh to Canada in the early days. Both were directly Scotch.

Dr. Wishart had a good preliminary education and graduated from the University of Toronto in 1882, three years later obtaining the medical degree from McGill University. He then became Licentiate at the Royal College of Physicians, London. On returning to Toronto he began the study of Laryngology with Dr. G. Sterling Ryerson and soon became Professor of Otolaryngology at the Ontario Medical College for Women, of which he was Secretary and Treasurer for thirty years. He was also Professor at Trinity Medical College, and Secretary. For many years Dr. Wishart was Chief Surgeon of the Throat Department of the Toronto General Hospital. He was also on the staff of the Toronto Hospital for Sick Children. He was admitted to Fellowship in the American Laryngological Association in 1922 and was a member of the American College of Surgeons and of the Royal Society of Medicine. He was Secretary of the Ontario Medical Association from 1887 to 1894 and in 1915 became its President. He had also been President of the Toronto Academy of Medicine.

All the years of his practice were spent in Toronto, as practitioner and teacher of Laryngology, and he held many other appointments and belonged to other societies besides those already mentioned. He was a member of the Senate of the University of Toronto.

During the World War he served with distinction at home as

consultant in Otolaryngology, with the rank of Lieutenant Colonel, Military District No. 2.

He was twice married and is survived by his second wife, two sons, one of them Dr. D. E. Staunton Wishart, of Toronto, and three daughters. Like his father before him, he was a Presbyterian.

He was a member of various social societies and of the York and Toronto Golf Clubs. He was fond of the outdoors. His summer residence at Bellevue, Go-Home Bay, Ontario, was a genial place to visit.

The record of his life, embracing as it does so many and such varied activities, is one suggestive of long-continued, diligent usefulness, not only in his own profession, but in every other relation throughout a wide circle of those to whom he had actually ministered and who, knowing his sterling worth, held him in highest esteem.

The bibliography of his published articles embracing a period of over thirty years and containing many interesting contributions follows.

BIBLIOGRAPHY OF DAVID JAMES GIBB WISHART*
1891-1923

Sympathetic Ophthalmitis; a Practical Study. *Canada Lancet*, **24**, 193, 1891-1892.

Ocular Paralysis from Basal Lesions; Report of Cases, *Canada Lancet*, **25**, 83, 1892-1893.

Peach Stone in Esophagus; Perforation; Death, *Canada Lancet*, **31**, 714, 1898-1899.

Post Typhoidal Ulceration and Abductor Paralysis of the Larynx: Tracheotomy; Recovery, *Phila. Med. Jour.*, **8**, 402, 1901.

Nose Building with Paraffin, *Dominion Med. Month.*, **19**, 329, 1902.

Report of a Case of Double Otitis Media with Mastoid Involvement; Operation and Termination in Fatal Purulent Leptomeningitis, *Canad. Pract. and Rev.*, **29**, 505, 1904.

The Lymphoid Tonsillar Circle; Observations on the Faucial and Lingual Tonsils, *Canada Lancet*, **39**, 19, 1905-1906.

Malignant Disease of the Nose, *Canad. Jour. Med. and Surg.*, **23**, 265, 1908. Also: *Canada Lancet*, **42**, 930, 1908-1909.

Bronchoscopy and Esophagoscopy, *Canada Lancet*, **42**, 411, 1908-1909.

Date Stone in Trachea; Report of Case, *Canad. Jour. Med. and Surg.*, **26**, 27, 1909.

* Dr. David James Gibb Wishart was a former member of the American Laryngological Association.

Laryngeal Paralysis; Report of Cases, *Canad. Jour. Med. and Surg.*, **26**, 27, 1909.

Papillomata of the Larynx, *Canad. Pract. and Rev.*, **34**, 553, 1909.

Esophagoscopy and Tracheobronchoscopy, *Dominion Med. Month.*, **33**, 98, 1909.

Foreign Body in the Esophagus, *Dominion Med. Month.*, **33**, 100, 1909.

Facial Paralysis Due to Aural Lesions, *Laryngoscope*, **19**, 832, 1909.

Hyperpyrexia and Death After Tonsillectomy, *Dominion Med. Month.*, **32**, 216, 1909. Also: *Canada Lancet*, **43**, 111, 1909-1910.

The Radical Mastoid Operation and Its Technique, *Canad. Jour. Med. and Surg.*, **27**, 69, 1910.

Obstinate Stenosis of the Larynx Following Diphtheria; Reports of Two Cases, *Ann. Otol., Rhinol. and Laryngol.*, **19**, 335, 1910.

Clinical Oto-laryngology: Syphilis of the Nose and Pharynx; Enucleation of Tonsil; Facial Paralysis Improved by Relief of Pressure on the Nerve Trunk in the Fallopian Canal; Atresia Auris; Bleeding Polyp of Septum; Double Frontal Sinus (Killian); Blood-clot Dressings in Mastoid Operations; Suppuration of the Labyrinth and Operation, *Canad. Jour. Med. and Surg.*, **29**, 196, 1911.

Frontal Lobe Abscess Associated with Acute Mastoiditis, *Laryngoscope*, **21**, 824, 1911.

Syphilis of the Larynx, *Laryngoscope*, **21**, 823, 1911.

The International Collective Investigation of Ozæna, *Canad. Jour. Med. and Surg.*, **32**, 427, 1912. Also: *Canada Lancet*, **45**, 824, 1911-1912.

The Relation of Accessory Sinus Disease to General Medicine, *Canad. Pract. and Rev.*, **37**, 133, 1912.

A Case of Mastoiditis with Perisinus Abscess and Paralysis of One Leg, *Canad. Med. Assn. Jour.*, **3**, 972, 1913.

Presidential Address (Ontario Medical Association): The Evolution of the Specialist in Otolaryngology, *Canad. Med. Assn. Jour.*, **5**, 469, 1915. Also: *Canad. Pract. and Rev.*, **40**, 271, 1915.

Animal Extracts in Rhinology and Laryngology, *Canad. Med. Assn. Jour.*, **5**, 676, 1915.

The Tonsil Operation, an Enquiry Into the Actual Results Observed in a Series of Cases, *Ann. Otol., Rhinol. and Laryngol.*, **24**, 641, 1915; **25**, 166, 1916.

The Combination of Local and General Anæsthetics and the Use of Adrenalin, *Canad. Pract. and Rev.*, **41**, 1, 1916.

The Origin of the Naso-antral Polyp, *Canad. Med. Assn. Jour.*, **6**, 7, 1916.

The Disease Ozæna, *Canad. Med. Assn. Jour.*, **8**, 606, 1918.

Tumor of the Hypopharynx in a Child of Eleven Weeks, *New York Med. Jour.*, **113**, 458, 1921.

Oto-laryngologic Education, *Laryngoscope*, **31**, 551, 1921.

Osler from the Standpoint of the Undergraduate, *Canad. Pract.*, **47**, 242, 1922.

Chronic Catarrh of the Naso-pharynx, *Laryngoscope*, **33**, 267, 1923.



John W. Larnach

JOHN WALTER CARMACK

1885-1934

At the Annual Congress of the American Laryngological Association, held in Cleveland in 1934, Dr. John Walter Carmack, of Indianapolis, Indiana, was recommended for Active Fellowship by the Council and duly elected. Shortly afterward, both he and Dr. Arthur Mendenhall, also of Indianapolis, were killed in an aeroplane accident, *en route* from Detroit where they had addressed the Wayne County Medical Society. The daughter of Dr. Mendenhall was killed at the same time. The death of these noted physicians, both at the summit of their usefulness, at once suggests the loss of our other eminent friends, Dr. Lynch, of New Orleans, and his companion, Dr. Stuckey.

Dr. Carmack was born March 24, 1885, in Dana, Indiana. Completing a good preliminary education he graduated from the Medical Department of Indiana University in 1907, and in 1909 settled in Indianapolis, after having served a regular internship in the City Hospital. He began as a general practitioner and became a specialist shortly before the World War, in which he served as First Lieutenant at Camp Taylor.

He limited his practice to Otolaryngology about 1918. At the time of his death he was Clinical Professor of Laryngology, Rhinology and Otology in the Indiana University School of Medicine.

He was an active member in the local and state societies, a Fellow of the American College of Surgeons, the American Board of Otolaryngology, the American Rhinological, Laryngological and Otological Society and a member of the Indiana Academy of Ophthalmology and Otolaryngology.

His hospitals were the Methodist, St. Vincent's, Indianapolis City and University and he was at the head of the Otolaryngological Department of the Indiana University School of Medicine.

Dr. Carmack was unusually active in interests other than medicine. This was especially true with regard to the Boy Scouts,

in which enterprise he was greatly interested and was a member of the Scout Official Board and the Executive Committee. He was also actively concerned in the affairs of the local Health Commission and the local Council.

He was a Methodist.

Dr. Carmack was nationally known in Otolaryngology. He was recognized as a teacher of unusual distinction, beloved by his students and thoroughly respected by the fellow members of the Faculty. A man of unusual activity and energy as well as marked ability, his achievements were many. The highly successful results of his work as General Chairman of Arrangements for the recent meeting of the Indiana State Medical Association were conspicuous. His professional skill and understanding of those about him made for him many friends and were combined with a quiet but forceful character.

BIBLIOGRAPHY OF JOHN WALTER CARMACK

1919-1934

Observations from Nine Months in Oto-laryngology, Base Hospital, Camp Taylor, Kentucky, *Indianapolis Med. Jour.*, **22**, 512, 1919.

Mastoiditis at Camp Taylor, *Jour. Indiana Med. Assn.*, **13**, 52, 1920.

Local Indications for Tonsillectomy and Adenoidectomy, *Jour. Indiana Med. Assn.*, **13**, 376, 1920.

Infections of Nose and Nasal Accessory Sinuses, *Jour. Indiana Med. Assn.*, **20**, 14, 1927.

Aberrant Internal Carotids and Their Relation to Surgery of the Pharynx, *Trans. Am. Laryngol., Rhinol. and Otol. Soc.*, **35**, 33, 1929. Also: *Laryngoscope*, **39**, 707, 1929.

Mastoiditis with Gastrointestinal Disturbance in Infants, *Trans. Am. Laryngol., Rhinol. and Otol. Soc.*, **36**, 426, 1930. Also: *Ann. Otol., Rhinol. and Laryngol.*, **39**, 75, 1930. Also: *Trans. Indiana Acad. Ophthalmol. and Otolaryngol.*, **13**, 66, 1929.

Sinusitis, Chronic Polypoid, Atrophic Type—Multiplicity of Co-existing Diseases; Case Report, *Jour. Indiana Med. Assn.*, **23**, 218, 1930.

Sinusitis in Children, *Ann. Otol., Rhinol. and Laryngol.*, **40**, 515, 1931.

Neothesis in Nose and Throat Practice, *Med. Arts and Indianapolis Med. Jour.*, **34**, 638, 1931.

Osteomyelitis of Skull, *Trans. Indiana Acad. Ophthalmol. and Otolaryngol.*, **15**, 9, 1931.

Sinus Disease with Bloodstream Infection, *Trans. Am. Laryngol., Rhinol., and Otol. Soc.*, **38**, 368, 1932. Also: *Ann. Otol., Rhinol. and Laryngol.*, **41**, 439, 1932.

After-care Following Radical Mastoid Operation, Trans. Sect. Laryngol., Otol. and Rhinol., Am. Med. Assn., p. 112, 1932.

Infection in Petrous Pyramid, Trans. Indiana Acad. Ophthalmol. and Otolaryngol., **16**, 82, 1932. Also: Jour. Indiana Med. Assn., **26**, 596, 1933.

Relation of Increased Intracranial Pressure to Disease in Pneumatic Spaces, Trans. Am. Laryngol., Rhinol. and Otol. Soc., **39**, 411, 1933. Also: Ann. Otol., Rhinol. and Laryngol., **42**, 364, 1933.

Therapeutics in Otolaryngology, Trans. Am. Acad. Ophthalmol., **38**, 345, 1933.

Comments on Treatment of Thrombo-phlebitis of Lateral Sinus, Trans. Am. Laryngol., Rhinol. and Otol. Soc., **40**, 333, 1934.



Joseph H. Bryan

JOSEPH HAMMOND BRYAN

1856-1935

IN the history of the American Laryngological Association which now covers more than half a century, few records mark more interesting careers than does that which pertains to this memorial. Dr. Joseph Hammond Bryan died at his home in Washington, D. C., February 3, 1935.

The coming of Dr. Bryan was prophetic of his whole career, for his birthday was July 4, 1856, in the city of Washington. Patriotism was one of his most conspicuous attributes.

He was the son of Joseph Brooke Bryan of Washington, D. C., of American birth and merchant. His mother, Louise Sterns Hammond, was from St. John, New Brunswick, and of English extraction.

In early life Dr. Bryan lived in his native city but soon was taken to his father's farm, in Prince George County, Maryland. He prepared for college in private schools in Washington, and in 1874 entered the Medical Department of Virginia University, receiving the degree of M.D. in 1877. He then graduated from the Medical Department of New York University in 1878 and for the following eighteen months was interne at Charity Hospital, Blackwell's Island.

In 1880 he entered the medical service of the United States Navy as Passed Assistant Surgeon, but in 1885 resigned and went abroad for special instruction in laryngology, first going to Heidelberg where he studied under Professor Jurasz and in the physiological laboratory of the university prepared and published a valuable article upon the Degeneration and Regeneration of the Nerves. He then went to Vienna and studied under Professors Schroetter, Storck and others. On returning here in 1887 he established himself in Washington and there began his long and useful career, with Ethelbert Carroll Morgan and Frank Hyatt as fellow specialists. All three had prepared themselves by extensive study abroad.

From the beginning Dr. Bryan displayed an earnest interest in the scientific aspects of his profession. He began early to publish articles of value and demonstrated originality of thought and of practical suggestion which did much to advance the progress of his specialty in its pioneer days, especially with regard to the rôle played by the Sinuses. He was one of the first to recognize their importance and to devise and advocate rational means of treatment. In 1889 he published a paper on Suppurative Diseases of the Antrum, in 1893 one on Suppurative Ethmoiditis and in 1897 made a noteworthy contribution to the surgery of Frontal Sinus Disease, advocating the necessity of providing nasal drainage in connection with the exterior opening of the anterior walls. He was also one of the first in the establishment of the relationship between Sinus Disease and the eyes, reporting from time to time cases substantiating the possibility of this idea.

In the study and recognition of these conditions he antedated those who afterwards became authorities upon the subject, both here and abroad, while his own prominence brought him into contact with many of the advanced investigators of the world. He was widely consulted by those who recognized in him at that time an authority, unique; for he was distinctly advanced in principle, keen in diagnosis and particularly successful in treatment. While not hesitating to operate when surgery was clearly indicated, he was nevertheless conservative in his management of cases, relying upon the skillful treatment of certain conditions rather than upon radical interference. In this he differed from some of the later European authorities who, like Killian, advocated extreme measures which have long since fully proved the wisdom of more conservative means.

His position in Washington commanded a large group of those distinguished in many important departments who gather there from the various other parts of the world as well as from our country, all of greater or less influence and intelligence. Of these, as well as with the public at large, he had a generous share, for he was held in the high distinction that was justly his and appreciated in the best leading circles, both scientific and otherwise.

Dr. Bryan became a Fellow of the American Laryngological Association in 1891. In 1902 he was elected President of the

Association, an office which he filled with conspicuous credit to himself and approval of his friends. On that occasion, as at the subsequent times when the Association held its Tri-Annual meeting at Washington, he never failed to give a reception of particularly delightful character to which all Fellows of the Laryngological Association, together with other distinguished guests were invited. These occasions invariably formed an attractive feature of the meeting.

In 1903 Dr. Bryan was elected Librarian of the Association, to succeed Dr. Thomas Rushmore French, who after ten years of devoted service had assembled an interesting collection of books, pamphlets, etc., but had found so little response from the Association at large that he resigned. It was arranged that the books and other material which he had accumulated during that time and which represented the nucleus of a valuable special collection should be handed over to the Library of the Surgeon General at Washington and that future contributions should be so disposed of. The Library of the Association therefore was sent to Washington, where the boxes were thrust aside and, until recently, remained unopened. The few books which meanwhile had been donated to our Library having been turned over to the Library of the Surgeon General, were swallowed up in that vast collection; other opportunities which otherwise might have been utilized with advantage were lost and the publications of the Association itself (*Transactions*) left to the care of others.

As Librarian, Dr. Bryan was automatically a member of the Council of the Association and held that position from 1902 until 1932, a period of thirty years, by far the longest incumbency in the history of any office in the Association. He attended the meetings of the Council with praiseworthy regularity, rarely missing any one of them. His intimacy with affairs in general at Washington, his wide acquaintance with distinguished men of many types, his experience in the Naval and Military Services of the United States, his eminence as a specialist and practitioner, united with the well balanced judgment in general which characterized him and his profound knowledge of the past history of the Association itself, made him an invaluable member of its Council.

Dr. Bryan was formerly Lecturer on Diseases of the Nose, Throat

and Ear in the Medical Department, Georgetown University, Washington, D. C.

He was a member of the American Medical Association, the American College of Surgeons, the American Otological Society.

Formerly Past Assistant Surgeon, United States Navy, he enlisted June 18, 1917, as Major in the Medical Corps in the United States Army, and after the war remained in the Service as Colonel in the Reserve Corps.

Dr. Bryan never married but lived happily in the home made for him by his two unmarried sisters at 1644 Connecticut Avenue, Washington.

His principal diversions were out-of-door sports. He was an accomplished collector of art. His church was the Episcopal and in politics he was a Republican. He was a member of the Cosmos Club, the Chevy Chase Club and other social organizations of Washington.

For several years Dr. Bryan had been distressed by advancing age and by the general results of the depression, but seemed in extraordinary health for one of his time of life. Becoming somewhat indisposed, at the end of about ten days he suffered a slow rupture of one of the cerebral vessels and died February 3, 1935.

The life of Dr. Bryan was one of tireless activity. This, with his vast experience and genial nature, readily accounted for the dignity and importance of his standing. The value of his career is eloquently demonstrated by the originality and extent of his bibliography.

To his old friends of the Association, Washington will never seem the same.

BIBLIOGRAPHY OF JOSEPH HAMMOND BRYAN
1883-1935

Compound Fracture of the Inferior Maxilla, Proc. Med. Soc. Kings County (Brooklyn), **8**, 124, 1883-1884.

Dissecting Bubo, Proc. Med. Soc. Kings County (Brooklyn), **8**, 126, 1883-1884.

Double Aneurism of the Arch of the Aorta, Proc. Naval Med. Soc., **1**, 151, 1882-1884.

Cerebellar Abscess Due to Disease of the Ear, Jour. Am. Med. Assn., **10**, 176, 1888.

Diagnosis and Treatment of Abscess of Antrum, Jour. Am. Med. Assn., **13**, 478, 1889.

Some Recent Advances in the Diagnosis and Treatment of Abscess of the Antrum of Highmore, *Virginia Med. Month.*, **17**, 18, 1890-1891.

Laryngismus Due to a Congenital Valvular Formation of the Upper Orifice of the Larynx, *Jour. Am. Med. Assn.*, **17**, 503, 1891.

Acute Edema of the Larynx, With Report of a Case Resulting From Pyema, *Med. News*, **60**, 141, 1892.

A Case of Suppurating Ethmoiditis, *Trans. Am. Laryn. Assn.* (1892), **14**, 104, 1893. Also: *New York Med. Jour.*, **57**, 97, 1893.

On Some of the Manifestations of Syphilis of the Upper Air Passages, *Trans. Am. Laryn. Assn.* (1893), **15**, 124, 1894.

Surgery of the Maxillary Sinus, *Trans. Cong. Am. Phys. and Surg.*, **3**, 217, 1894.

The Surgical Treatment of Chronic Suppurating Otitis Media, *Jour. Am. Med. Assn.*, **25**, 700, 1895.

A Further Contribution to the Study of Suppurative Disease of the Accessory Sinuses, With Report of Cases, *Trans. Am. Laryn. Assn.* (1895), **17**, 76, 1896. Also: *New York Med. Jour.*, **62**, 450, 1895.

A Contribution to the Study of the Anatomy of the Fronto-ethmoidal Region, *Brit. Med. Jour.*, **2**, 1393, 1897.

Catarrhal Inflammations of the Upper Air Passages as They Appear in Washington and Its Vicinity, *Nat. Med. Rev.*, **7**, 182, 1897-1898.

On the Treatment of Chronic Frontal Sinusitis by Means of an Opening Through the Anterior Wall of the Sinus and Drainage Through the Nose, *New York Med. Jour.*, **66**, 451, 1897. Also: *Trans. Am. Laryn. Assn.* (1897), **19**, 47, 1898.

Treatment of Empyema of the Frontal Sinus, *Jour. Am. Med. Assn.*, **30**, 483, 1898.

Report of Two Cases of Suppurating Mastoiditis, *Jour. Am. Med. Assn.*, **30**, 534, 1898.

Further Results of Operative Treatment of Chronic Frontal Sinusitis, *New York Med. Jour.*, **68**, 881, 1898. Also: *Trans. Am. Laryn. Assn.* (1898), **20**, 155, 1899.

Pemphigus Chronicus Vulgaris of the Larynx and Mouth, *Trans. Am. Laryn. Assn.* (1899), **21**, 119, 1900.

Chronic Abscess of the Frontal, Ethmoidal and Sphenoidal Sinuses Followed by Meningitis and Death, *Trans. Am. Laryn. Assn.* (1899), **21**, 193, 1900. Also, *New York Med. Jour.*, **71**, 77, 1900.

A New Aural Syringe, *Trans. Am. Laryn. Assn.* (1900), **22**, 247, 1901. Also: *New York Med. Jour.*, **73**, 263, 1901.

Suppurating Mastoiditis, With Report of Cases. Suppurating Otitis Media, Both Ears; Suppurating Mastoiditis on Right Side, Abscess Extending Into the Deeper Tissues of the Neck and Extradural Abscess, *Jour. Am. Med. Assn.*, **36**, 1311, 1901.

Chronic Empyema of the Frontal, Ethmoidal and Both Sphenoidal Sinuses With Extensive Necrosis, Complicated with Adenoma of the Posterior Ethmoidal and Sphenoidal Regions, *Trans. Am. Laryn. Assn.*, **23**, 65, 1901. Also: *Am. Jour. Med. Sci.*, **124**, 416, 1902.

President's Address, *Trans. Am. Laryn. Assn.*, **25**, 1, 1903.

Malignant Disease of the Tongue, With Report of Two Cases, *Trans. Am. Laryn. Assn.*, **28**, 19, 1906. Also: *Med. Rec.*, **70**, 553, 1906.

Report of a Case of Removal of a Foreign Body, a Grain of Corn, From the Trachea of a Child, *Trans. Am. Laryn. Assn.*, **30**, 99, 1908.

Operative Treatment of Suppurative Sinus Diseases Producing Orbital Complications, *Jour. Am. Med. Assn.*, **57**, 624, 1911.

A Further Contribution to the Study of Diseases of the Accessory Sinuses in Relation to Diseases of the Eye, and the Surgical Methods to be Adopted for their Relief, *Surg., Gynec. and Obst.*, **14**, 565, 1912.

On the Relation of Diseases of the Posterior Sinuses to Painful Conditions of the Ear, *Trans. Am. Otol. Soc.*, **12**, Pt. 3, 481, 1912. Also: *Laryngoscope*, **22**, 1362, 1912.

Report of a Case of Myxo-fibroma of the Nasopharynx, *Trans. Am. Laryn. Assn.*, **34**, 302, 1912. Also: *Ann. Otol., Rhinol. and Laryngol.*, **21**, 790, 1912.

Report of a Case of Ulceration of the Larynx; Perichondritis of the Arytenoid Cartilages, Abscess and Partial Exfoliation of Both Cartilages Resulting From Typhoid Fever, *Trans. Am. Laryn. Assn.*, **35**, 181, 1913. Also: *Ann. Otol., Rhinol. and Laryngol.*, **22**, 811, 1913.

Report of Two Cases of Mastoid Abscess, Infective Thrombosis of the Lateral Sinus and Jugular Vein; Resection of the Jugular; Recovery, *Trans. Am. Otol. Soc.*, **13**, Pt. 3, 424, 1915. Also: *Ann. Otol., Rhinol. and Laryngol.*, **24**, 543, 1915.

On the Relation of Diseases of the Accessory Sinuses to Diseases of the Eye, Especially in Children, With a Report of Two Cases, *Trans. Am. Laryn. Assn.*, **38**, 226, 1916. Also: *Jour. Laryngol.*, **32**, 68, 1917.

The Tonsils as a Foci of Infection in Streptococcus Hemolyticus Carriers *Jour. Am. Med. Assn.*, **71**, 1813, 1918 (with H. J. Nichols).

Report of a Case of Influenza, Followed by Pneumonia, Laryngitis, Otitis Media Suppurativa Acuta, Right Side, Tonsillitis Hypertrophic Chronic Bilateral Streptococcus Type, *Trans. Am. Laryn. Assn.*, **41**, 22, 1919. Also: *Ann. Otol., Rhinol. and Laryngol.*, **38**, 1009, 1919.

A Symposium on Streptococcus Hemolyticus Carriers; Chemical Aspect, *Trans. Am. Laryn. Assn.*, **41**, 62, 1919. Also: *Ann. Otol., Rhinol. and Laryngol.*, **38**, 337, 1919.

Report of Case of Otitis Media; Suppurative, Chronic Right, Mastoiditis, Operation Followed by Meningitis, and on Postmortem Examination Finding of Old Abscess in the Temporosphenoidal Lobe of Brain, *Trans. Am. Otol. Soc.*, **15**, 93, 1919. Also: *Ann. Otol., Rhinol. and Laryngol.*, **38**, 1083, 1919.

Report of a Case of Extradural and Subdural Abscess Following Suppurating Frontal Sinusitis and Osteomyelitis of the Frontal Bone, *Trans. Am. Laryn. Assn.*, **42**, 156, 1920. Also: *Am. Jour. Med. Sci.*, **160**, 687, 1920.

Osteomyelitis of the Skull. *Trans. Am. Laryn. Assn.*, **47**, 254, 1925.

Laryngologic Aspect of Suppuration of Lung, *Trans. Am. Laryn. Assn.*, **49**, 162, 1927. Also: *Arch. Otolaryngol.*, **7**, 119, 1928.

Abscess of Brain of Otic Origin. *Trans. Am. Otol. Soc.*, **18**, 276, 1928. Also: *Ann. Otol., Rhinol. and Laryngol.*, **37**, 819, 1928.

Report of a Case of Papillary Carcinoma of the Maxillary Sinus, *Trans. Am. Laryn. Assn.*, **54**, 74, 1932. Also: *Ann. Otol., Rhinol. and Laryngol.*, **41**, 983, 1932.

History of Laryngology and Rhinology and Influence of America in the Development of This Specialty, *Ann. Med. Hist.*, **5**, 151, 1933.



W. Mullin

WILLIAM VALENTINE MULLIN

1884-1935

OF those taken from us during the past year there was one who, in every way will long be an irreparable loss, to the Association and to ourselves. In the midst of a career of unusual distinction his life work promised ultimate success of the highest order; for, brilliant in intelligence and character, a splendid executive, he was, before all things else, one whom we all held in warm personal friendship. But for the loyal self-sacrifice of our former Secretary, Dr. Coates, the position of the Association this year might have been unfortunate.

Dr. William Valentine Mullin was born in Iowa City, Iowa, February 14, 1884. His father, William Mullin, a farmer of Queens County, Ireland, and his mother, Catherine Mullin, met one another in Ireland, were married and moved to this country, locating in Iowa City, Iowa. There Dr. Mullin spent his early days and gained his preliminary education, graduating in 1902. He then studied two years in the State University of Iowa and in 1908 received the degree of Doctor of Medicine from the Medical Department of the Denver and Gross University of Denver, Dr. J. P. Mullin having been his preceptor. The following year was spent as interne in St. Joseph's Hospital, Denver, with rotating service.

He entered upon general practice in southern Colorado, but in 1912 became interested in laryngology, studying with Dr. F. P. Gildea at Colorado Springs, and later at Berlin in 1914. Returning to the United States, he began to make himself known in various creditable ways and drew about him a large coterie of professional friends throughout the country, steadily advancing in reputation. Meanwhile, during his residence at Colorado Springs he had been connected with the Glocker, the Bethel, and the St. Francis Hospitals and the National Union Printers' Home. In 1926 he removed from Colorado Springs to Cleveland, Ohio, and there became asso-

ciated with the Cleveland Clinic, as Head of the Department of Oto-Laryngology.

He was admitted to Fellowship in the American Laryngological Association in 1925, was soon made a Vice-President and was elected Treasurer in 1932. He was also a member of the American College of Surgeons, the American Otological Society, the American Academy of Ophthalmology and Oto-Laryngology, the American Rhinological, Laryngological and Otological Society, the American Medical Editors' Association and the Association for the Study of Allergy.

In these various societies he was proverbially an interested and highly active member. For example, he was Secretary of the Section of Laryngology, Rhinology and Otology of the American Medical Association for two years, and the year following Chairman of the Section; Secretary for Instruction of the American Academy of Ophthalmology and Oto-Laryngology; Chairman of the Section of Otology of the Ohio State Medical Society, 1933, not to mention other similar duties in which he played a valuable part. During the World War he was Lieutenant in the United States Medical Corps in the years 1918 and 1919.

Dr. Mullin was married in 1913 to Miss Louise N. Nichols of Colorado Springs. She was of American parentage and with one daughter, Harriet C. Mullin, survives.

His favorite diversions, among others, were the study of nature and fishing, and he was fond of the theatre, but his greatest attribute was his keen enjoyment in making friends and in having them. In politics he was Republican. He was a member of the Town Club and of the Mayfield Country Club, both of Cleveland, and of the Phi Zeta Sigma Medical Fraternity.

He was the author of a continued series of published medical articles, many of them of unusual value. Indeed, through his untimely death American Oto-Laryngology loses one of its most active exponents. His deep interest in the progress of medical science, his passion for truth, will insure for his contributions a permanent place in the literature of the specialty. His investigation of the lymphatic drainages of the nasal sinuses is one of these.

Dr. Mullin will be especially mourned as one whose friendly enthusiasms contributed much to the various activities in which

he took such prominent and useful part. A well-trained and careful scientist, an indefatigable worker and a genial and loyal colleague, his handshake never failed to impart a real thrill of friendliness. These things rightly counted for his popularity and for the deep affection in which he will ever remain in our memory.

Dr. Mullin died of cavernous sinus thrombosis, of undetermined origin, on April 25, after an illness of but four days' duration.

The Annual Meeting of the American Laryngological Association was due in Toronto on May 29. Already Dr. Mullin, the efficient Secretary of the Association, had perfected arrangements for the Meeting which promised under his supervision to be a brilliant success. His sudden loss would have been followed by serious consequences had not our former Secretary, Dr. Coates, assumed responsibilities, and by the highest type of loyalty and self-sacrifice, caused the arrangements already undertaken to proceed without interruption and the Meeting itself to be a brilliant success.

BIBLIOGRAPHY OF DR. WILLIAM VALENTINE MULLIN
1918-1935

Abscess of the Left Frontal Lobe Following Suppuration of the Frontal Sinus; Report of a Case and Exhibition of Specimen, *Ann. Otol., Rhinol. and Laryngol.*, **27**, 667, 1918.

The Lymph Drainage of the Accessory Nasal Sinuses, *Trans. Am. Laryngol., Rhinol. and Otol. Soc.*, p. 73, 1919.

Indifference of the Laryngologist Toward Tuberculous Laryngitis and the Tuberculosis Problem, *Jour. Am. Med. Assn.*, **75**, 300, 1930.

Experimental Lesions of the Lungs Produced by the Inhalation of Fluids From the Nose and Throat, *Am. Rev. Tuberc.*, **4**, 683, 1930 (with C. T. Ryder).

Studies on Lymph Drainage of Accessory Nasal Sinuses, *Laryngoscope*, **31**, 158, 1921 (with C. T. Ryder).

Deformity of Nasal Bones Following Chronic Nasal Suppuration in Rabbit, *Laryngoscope*, **31**, 634, 1921.

Accessory Sinuses as Etiologic Factor in Bronchiectasis, *Ann. Otol., Rhinol. and Laryngol.*, **30**, 683, 1921.

Value of Direct Inspection in the Diagnosis of Chronic Maxillary Sinus Disease, *Laryngoscope*, **32**, 300, 1922 (with F. L. Dennis).

The Management of Tuberculous Laryngitis, *Southern Med. Jour.*, **15**, 501, 1922.

Pollen and Hay Fever—a Regional Problem, *Trans. Am. Acad. Ophthalmol. and Oto-laryngol.*, p. 467, 1922. Also: *Colorado Med.*, **20**, 96, 1923.

An Analysis of Some Cases of Tubercles in the Tonsil, Jour. Am. Med. Assn., **80**, 1211, 1923.

Diagnostic Limitations in Laryngology, Trans. Am. Laryn. Assn., **46**, 207, 1924. Also: Ann. Otol., Rhinol. and Laryngol., **34**, 197, 1925.

The Relation of Paranasal Sinus Infection to Disease of the Lower Respiratory Tract, Jour. Am. Med. Assn., **87**, 739, 1926.

Rhinological Aspect of Bronchial Asthma, Radiology, **8**, 482, 1927.

The Routine of the Specialist and His Relations to Other Branches of Medicine in the Diagnosis of Ear, Nose and Throat Disease, Memphis Med. Jour., July, 1927.

Studies of Pathologic Tissue Removed From Chronically Infected Nasal and Accessory Sinuses: A Preliminary Report, Ann. Otol., Rhinol. and Laryngol., **37**, 182, 1928 (with R. P. Ball).

The Physiology of the Larynx, Ann. Otol., Rhinol. and Laryngol., **37**, 627, 1928. Also: Trans. Am. Laryngol., Rhinol. and Otol. Soc., **33**, 505, 1927.

What is the Relation of the Thyroid to the Larynx? Trans. Am. Laryn. Assn., **50**, 30, 1928.

Accessory Sinus Disease as It Concerns the General Practitioner, Kansas City Southwest Clin. Bull., 1929.

The Anatomy, Physiology and Diseases of the Salivary Glands, Trans. Am. Acad. Ophthalmol. and Otolaryngol., **34**, 354, 1929.

The Work of the Section on Laryngology, Otology and Rhinology, Chairman's Address, Sect. Laryngol. Rhinol. and Otology of American Med. Assn., Jour. Am. Med. Assn., **94**, 312, 1930.

Malignant Tumor of the Breast With Metastasis to the Opposite Side of the Larynx and Contralateral Vocal Cord Paralysis, Ann. Otol. Rhinol. and Laryngol., **39**, 125, 1930.

The Management of Chronic Sinus Disease, New York State Jour. Med., **30**, 1280, 1930.

Symposium on the Relation of Sinus Disease to Pulmonary Infection From the Standpoint of the Rhinologist, Trans. Coll. Phys. of Philadelphia, **52**, 245, 1930.

The Salivary Glands, 1930 Proceedings of the Inter-State Post-Graduate Medical Assembly of North America, Minneapolis (1931), p. 91.

Experience with Chronic Deafness, Illinois Med. Jour., **60**, 70, 1931.

The Filament-nonfilament Count: Its Diagnostic and Prognostic Value, Jour. Am. Med. Assn., **97**, 1133, 1931.

Diagnosis and Treatment of Cancer of the Larynx, Proc. Inter-State Post-Graduate Medical Assembly of North America (1931), p. 198, 1932.

The Interrelation of Allergy and Otolaryngology, Arch. Otolaryngol., **15**, 413, 1932.

Allergy, Ann. Otol., Rhinol. and Laryngol., **41**, 387, 1932.

The Relation of the Thyroid Gland to Disturbances of the Larynx; The Nose, Throat and Ear and Their Diseases, Jackson-Coates, Philadelphia, W. B. Saunders Company, p. 801.

Tumors of the Mouth, Pharynx and Fauces; The Nose Throat and Ear and Their Diseases, Jackson Coates, Philadelphia, W. B. Saunders Company, p. 322.

Laryngeal Disturbances in Hyperthyroidism; Diagnosis and Treatment of Diseases of the Thyroid Gland, Dr. Crile and Associates, Philadelphia, W. B. Saunders Company, p. 176.

Review of Sinus-Chest Infections, *Ann. Otol., Rhinol. and Laryngol.*, **41**, 794, 1932. Also: *Trans. Am. Laryn. Assn.*, **54**, 48, 1932.

The Diagnosis and Treatment of Cancer of the Larynx, *Jour. Iowa State Med. Soc.*, **22**, 525, 1932.

Circumscribed Arachnoid Cyst Giving Symptoms of an Acoustic Neuroma, *Laryngoscope*, **43**, 213, 1933.

Principles of Modern Surgery in Otolaryngology, *Trans. Am. Acad. Ophthalmol. and Otol.*, 1933.

The Present Status of Infection of the Upper Respiratory Tract in Its Relation to Focal Infection, *The New England Jour. Med.*, p. 50, January 10, 1935.



John R. Lincoln-

WILLIAM REYNOLDS LINCOLN

1862-1935

DR. WILLIAM REYNOLDS LINCOLN died at his home in Cleveland, Ohio, May 24, 1935. He was born January 28, 1862, at Philadelphia, Pennsylvania. His father, Charles F. Lincoln, was a lawyer of that place; his mother was Anna Reynolds Lincoln.

The early life of Dr. Lincoln was spent in Philadelphia and that vicinity where he received his preliminary education and later attended the University of Pennsylvania, graduating in Medicine from it in 1888. He then became an interne in the Presbyterian Hospital of Philadelphia for the usual term of service and entered upon the practice of his profession, soon leaving Philadelphia and moving to Cleveland, which became his permanent home and where he was a member of the staffs of several of its important Medical Institutions.

His excellence as a Specialist in Laryngology attracted the attention of the American Laryngological Association, to which he was elected an Active Fellow in 1903. He was a fairly regular attendant at our Annual Meetings until about ten years ago, when he retired from practice because of angina pectoris, but still retained his active membership in the Association, until recently placed on the Emeritus list.

On August 20, 1890, he was married to Miss Virginia M. Gibb of Philadelphia. His favorite outdoor diversion was golf; his Church, the Unitarian. He was a member of various professional Societies, in addition to our own. His social connections included the Mayfield, Country, Union and Tavern Clubs, all of Cleveland.

He died May 24, 1935, of coronary thrombosis, at his home 2984 Hampshire Road, Cleveland, Ohio, and was buried in the family vault at Laurel Hill, Philadelphia, having outlived his wife but a short time. He leaves one son, Donald Lincoln, of Ithaca, Pennsylvania, and three daughters, Mrs. Ralph R. Buck and Mrs. Herbert W. Porter, of Cleveland, Ohio, and Mrs. Henry H. Rogers, Jr., of New York.

During the ten years of his greatest professional activity, Dr. Lincoln published various articles, a bibliography of which is appended.

BIBLIOGRAPHY OF WILLIAM R. LINCOLN
1895-1906

Abscess of the Nasal Septum With Report of Two Cases, *Cleveland Med. Gaz.*, **11**, 321, 1895-1896.

The Complications of Purulent Otitis Media, *Cleveland Jour. Med.*, **1**, 314, 1896.

Infectious Granulomata of the Nose, *Trans. Ohio Med. Soc.*, p. 338, 1897.

Fibroma of the Nose, With Report of a Case, *Am. Jour. Med. Sci.*, **122**, 643, 1901.

Tubercular and Syphilitic Granulomata of the Nose, *Laryngoscope*, **12**, 33, 1902.

Operations for the Relief of Malignant Growths of the Larynx, With Report of Seven Cases, *Trans. Am. Laryn. Assn.*, **25**, 54, 1903.

Mouthbreathing, *Trans. Am. Laryn. Assn.*, **28**, 139, 1906.

THOMAS MORRIS MURRAY

1851-1934

DR. THOMAS MORRIS MURRAY died at his home in Pomfret, Conn., on December 16, 1934,. He was of distinguished ancestry, for the forebear from whom he derived his name was one of the group of cavaliers who, in 1607, landed on the shores of Virginia and there founded Jamestown.

He was born at Rockburn, Howard County, Maryland, a place long in the family, on July 5, 1851. His father, Francis Key Murray, Captain in the United States Navy, was descended from Dr. James Murray of Annapolis and other ancestors of Maryland. His mother, Anna Morris, was a daughter of Thomas Willing Morris of Philadelphia and Caroline Calvert, daughter of George Calvert of Maryland and Rosalie, originally a Baroness of Antwerp, Belgium, his wife.

Dr. Murray was educated at St. John's College, Maryland. He graduated in Medicine from the University of Maryland and was interne in the Alms House Hospital, Baltimore. Later, he studied Laryngology in Vienna under Professor Stoerck and finally associated himself with Dr. Morell Mackenzie, in London.

Returning to this country he established himself in Washington, D. C., as a Laryngologist and became a member of the Medical Staffs of the Emergency and Garfield Hospitals, and Professor of Physical Diagnosis, Rhinology and Laryngology at the University of Georgetown.

He was elected an Active Fellow of the American Laryngological Association in 1892 and after several years of professional activity retired in 1906 making his residence in Pomfret, Connecticut.

Always a man of importance and of professional prominence, he continued to use his excellent training and his influence to the best advantage of the interests of medicine, as his means were ample and his social position of the best. He thus became a desirable acquisition for the executive boards of various medical and other institutions in his vicinity and served with credit to himself and advantage to the institutions themselves.

Dr. Murray was married July 11, 1900, to Eleanor Vinton Clark of Boston, Mass., daughter of Randolph M. Clark and Mary Vinton. Mrs. Murray with their four children, a son and three daughters, survive.

He was a member of the Protestant Episcopal Church. His favorite diversions were golf, shooting and fishing and in politics he was a Democrat. His secular associations were the Metropolitan, Grasslands and Chevy Chase Clubs of Washington and the Somerset of Boston.

Dr. Murray was ill for nine months, suffering from angina pectoris with complications, from which he died.

BIBLIOGRAPHY OF T. MORRIS MURRAY*

A Contribution to the Study of the Treatment of Laryngeal Phthisis. *Tr. Am. Laryng. Assn.*, (1897) **19**, 133, 1898. Also: *New York Med. Jour.*, **67**, 8, 1898.

Tracheal Injections in the Treatment of Pulmonary Tuberculosis. *Tr. Am. Laryng. Assn.*, (1900) **22**, 173-175, 1901. Also: *New York Med. Jour.*, **73**, 241, 1901.

* Dr. T. Morris Murray was a former member of the American Laryngological Association.

MAYO COLLIER

1857-1931

THE death of Mark Purcell Mayo Collier, on September 20, 1931, at his home at Kearnsey Abbey, in Kent, removed one of the most distinguished of the early laryngologists of England, for many years an honored Corresponding Fellow of the American Laryngological Association. He was a man of marked ability and dignity, the son of G. F. Collier, physician-in-ordinary to George IV and William IV and was educated at Godolphin Grammar School, Hammersmith, University College, London, and St. Thomas's Hospital, qualifying as L.S.A. In 1878 he went to the Turko-Russian War, in medical charge of the Dardanelles Expedition; returning to England he held a number of resident posts at St. Thomas's Hospital, graduated as M.B. with honors in 1881 and was appointed surgeon to the throat and ear department at the North-West London Hospital. At one time he was also assistant demonstrator of anatomy and physiology at the London Hospital Medical College and later, in 1889, Professor of Comparative Anatomy and Physiology at the Royal College of Surgeons. The variety of his interests was shown in a book on the "Physiology of the Vascular System" and in his researches on the mechanism of the heart beat (1887) as well as in numerous papers on general surgery. He soon joined the full surgical staff of the North-West Hospital, but remained in charge of the laryngological department, paying close attention to his specialty.

The American Laryngological Association, founded in 1878, was *the first National Society of laryngologists in the world*. Ten years later, in 1888, the British Laryngological Society, its pioneer follower abroad, was founded by Sir Morell Mackenzie, then at the height of his fame and a fair mark for certain of his jealous vituperators through whom the Society, excellently organized by him and representing the best talent in Great Britain, was forced out of existence. Mr. Collier was one of its earliest Presidents.

The outlook of Mr. Collier was unusually broad; it comprised

many branches of medicine besides Laryngology. As an author he collaborated with Morell Mackenzie in a book on the "Hygiene of the Vocal Organs" and with Lennox Browne in "Diseases of the Throat and Nose." His independent work included studies of mouth breathing, suggested by Catlin of the United States in 1851, progressive deafness, and intermittent nasal obstruction. In 1901 he married Florence, daughter of the late Dr. Spooner Hart of Calcutta.

For the main facts of the above we are indebted to The *Lancet*, London, October 3, 1931

List of Fellows
1935

LIST OF FELLOWS

1935

Attendance during last ten years shown by figures following each name.
Asterisk (*) indicates year paper was read.

Active Fellows

1923. BABBITT, JAMES A., 1912 Spruce Street, Philadelphia, Pennsylvania, 1923, '24*, '25, '26, '27, '28, '29*, '30, '31, '32, '33*, '34, '35.
1929. BARLOW, ROY ALEXANDER, 277 Alexander Street, Rochester, New York, 1923, '24*, '28, '29*, '30*.
1915. BARNES, HARRY ALDRICH, 520 Commonwealth Avenue, Boston, Massachusetts, 1920, '24, '27*, '28, '30.
1921. BERRY, GORDON, 36 Pleasant Street, Worcester, Massachusetts, 1921*, '22, '23, '24, '25, '26, '27, '28*, '29*, '30, '31, '32, '33, '34, '35.
1893. BIRKETT, HERBERT S., 1190 Mountain Street, Montreal, Canada, 1920, '21, '22*, '23, '25, '26, '27, '28*, '29, '30, '31, '32, '34, '35.
1925. BLAIR, VILRAY P., 400 Metropolitan Building, St. Louis, Missouri, 1922, '23*, '25*, '28*, '31*, '33.
1932. BROWN, JOHN MACKENZIE, 1136 W. 6th Street, Los Angeles, California, 1935*.
1913. BUTLER, RALPH, 1930 Chestnut Street, Philadelphia, Pennsylvania, 1920*, '21, '23, '24, '27, '29, '31, '32.
1933. CAMPBELL, EDWARD HASTINGS, 1904 Spruce Street, Philadelphia, Pennsylvania, 1930, '31*, '32*, '33, '35.
1927. CARMODY, THOMAS E., 806 Metropolitan Building, Denver, Colorado, 1924, '26*, '27, '28, '30, '32*, '34, '35.
1917. CHAMBERLIN, WILLIAM B., 10515 Carnegie Avenue, Cleveland, Ohio, 1920, '21*, '22, '26, '27*, '28, '29, '30*, '31, '32, '33*, '34, '35*.
1929. CLERF, LOUIS H., 1530 Locust Street, Philadelphia, Pennsylvania, 1925, '27*, '28, '29*, '30*, '32, '33, '34, '35.
1917. COATES, GEORGE MORRISON, 1721 Pine Street, Philadelphia, Pennsylvania, 1920, '21, '22, '23, '24, '25, '26, '27, '28, '29, '30*, '31, '32, '33, '34, '35.

1918. DEAN, LEE WALLACE, School of Medicine, Washington University, St. Louis, Missouri, 1920*, '21*, '22, '23, '24, '25*, '26, '27*, '28, '29*, '31, '32, '34, '35.
1881. DELAVAN, D. BRYSON, 30 East Sixtieth Street, New York City, 1920*, '21*, '22*, '23*, '25*, '26*, '27*, '28*, '29*, '31, '32*.
1935. EVES, CURTIS C., 1910 Spruce Street, Philadelphia, Pennsylvania, 1935.
1919. FAULKNER, E. ROSS, 101 East Fifty-eighth Street, New York City, 1920, '21, '22, '23*, '25, '27, '28, '30, '32, '33, '34, '35.
1926. FENTON, RALPH ALBERT, 806 Medical Arts Building, Tenth and Taylor Streets, Portland, Oregon, 1923, '25*, '26, '28, '30, '32*, '34, '35.
1934. FIGI, FREDERICK A., Mayo Clinic, Rochester, Minnesota, 1930, '32*, '34, '35.
1922. FORBES, HENRY HALL, 40 East Sixty-first Street, New York City, 1922, '25*, '27, '28, '29, '31, '32, '34, '35.
1933. FOSTER, JOHN H., 1304 Walker Avenue, Houston, Texas, 1934, '35.
1935. FURSTENBERG, ALBETT CARL, 201 South Main Street, Ann Arbor, Michigan, 1933*.
1933. GITTINS, THOMAS ROY, 408 Davidson Building, Sioux City, Iowa, 1928, '31, '32*, '34.
1922. GOLDSMITH, PERRY G., 513 Medical Arts Building, Toronto, Ontario, 1922*, '23*, '24, '26, '28, '35.
1913. GOLDSTEIN, MAX A., 4574 West Papin Street, St. Louis, Missouri, 1920, '21, '22, '25*, '26, '27, '28, '29, '30, '32*, '34.
1898. GOODALE, JOSEPH L., 258 Beacon Street, Boston, Massachusetts, 1920, '21, '22*, '23, '24, '26.
1932. GOODYEAR, HENRY M., 556 Doctors' Building, Cincinnati, Ohio, 1928, '29, '30*, '31, '32, '33, '34*, '35.
1932. GRAHAM, HARRINGTON B., 490 Post Street, San Francisco, California, 1932, '35.
1905. GRAYSON, CHARLES P., 262 South Fifteenth Street, Philadelphia, Pennsylvania, 1921.
1906. GREENE, D. CROSBY, JR., 23 Bay State Road, Boston, Massachusetts, 1920*, '21*, '22, '23, '24*, '25, '26, '27, '34, '35.
1917. GREENE, JOSEPH B., 331 Haywood Building, Asheville, North Carolina, 1921, '22, '23*, '24, '26, '27, '28, '29*, '31, '32, '33, '35.
1934. GROVE, WILLIAM E., 324 Wisconsin Avenue, Milwaukee, Wisconsin, 1934, '35.

1915. HASTINGS, HILL, 306 Medical Office Building, 1136 West Sixth Street, Los Angeles, California, 1921*, '24, '27*, '28, '30*, '35.
1931. HILL, FREDERICK THAYER, Professional Building, Waterville, Maine, 1928, '29*, '30*, '31, '32, '33, '34, '35.
1933. HOUSER, KARL MUSSER, 2010 Spruce Street, Philadelphia, Pennsylvania, 1930, '32*, '33, '34*.
1919. HURD, LEE MAIDMENT, 39 East Fiftieth Street, New York City, 1921, '23, '25, '26*, '28, '32*, '34.
1925. IGLAUER, SAMUEL, 707 Race Street, Cincinnati, Ohio, 1926, '27, '30, '32, '33*, '35*.
1920. IMPERATORI, CHARLES JOHNSTONE, 108 East Thirty-eighth Street, New York City, 1921*, '22, '24*, '25*, '26*, '27*, '28, '31, '32, '33*, '35*.
1907. JACKSON, CHEVALIER, 3432 North Broad Street, Philadelphia, Pennsylvania, 1921*, '22*, '23, '24*, '25*, '27*, '28, '29, '30, '31, '32, '33, '34, '35.
1933. JARVIS, DEFOREST CLINTON, Room 7, Quarry Bank Building, Barre, Vermont, 1928, '30, '32*, '33, '34*, '35.
1918. KENYON, ELMER L., 104 South Michigan Boulevard, Chicago, Illinois, 1922, '24*, '28.
1921. KERNAN, JOHN D., JR., 120 East Seventy-fifth Street, New York City, 1921*, '22, '25, '26, '27, '29, '31, '34*, '35*.
1929. KISTNER, FRANK B., 600 Mayer Building, Portland, Oregon, 1930, '35.
1927. LARGE, SECORD HERBERT, Hanna Building, Cleveland, Ohio, 1924*, '25, '26, '31, '34.
1918. LEWIS, FIELDING OTIS, 259 South Seventeenth Street, Philadelphia, Pennsylvania, 1921*, '22*, '23, '25*, '28, '29, '31, '32, '33, '34.
1925. LILLIE, HAROLD I., Mayo Clinic, Rochester, Minnesota, 1923*, '24*, '25, '26*, '28, '31*, '35.
1911. LOCKARD, LORENZO B., Metropolitan Building, Denver, Colorado.
1935. LOOPER, EDWARD A., 104 West Madison Avenue, Baltimore, Maryland, 1935.
1932. LUKENS, ROBERT M., 1923 Spruce Street, Philadelphia, Pennsylvania, 1927, '28, '31*, '32, '35.
1928. MACPHERSON, DUNCAN, 140 East Fifty-fourth Street, New York City, 1928, '29, '30, '31, '33, '34*.
1921. MCCULLAGH, SAMUEL, 2 East Fifty-fourth Street, New York City, 1921*, '22, '23*, '25, '26*, '27, '28, '31, '34, '35.

1929. MCKINNEY, RICHMOND, 899 Madison Avenue, Memphis, Tennessee, 1923, '24*, '26*, '27, '29, '31, '32, '33.
1904. MOSHER, HARRIS P., 828 Beacon Street, Boston, Massachusetts, 1920, '21*, '22, '23*, '24, '25, '26, '27, '28*, '29, '30, '31*, '32*, '33, '34.
1932. MYERSON, MERVIN C., 136 East Sixty-fourth Street, New York City, 1927, '28*, '29, '30, '31*, '32*, '33*, '34*, '35.
1922. NEW, GORDON B., Mayo Clinic, Rochester, Minnesota, 1922, '24, '25*, '26*, '28*, '31*, '33*, '35*.
1926. NEWHART, HORACE, 527 Medical Arts Building, Minneapolis, Minnesota, 1923, '25*, '26, '28, '30, '33, '34, '35.
1931. ORTON, HENRY BOYLAN, 24 Commerce Street, Newark, N. J., 1927, '28, '29, '30*, '31, '32, '33*, '35.
1903. PACKARD, FRANCIS R., 302 South Nineteenth Street, Philadelphia, Pennsylvania, 1920, '21, '22, '23, '24, '25, '26, '29, '30, '31*, '32, '33, '34, '35.
1906. PIERCE, NORVAL H., Del Mar, San Diego Co., California, 1920*, '21, '22, '23, '24, '25, '26*, '27*, '28, '30, '33.
1932. PORTER, CHARLES TERRELL, 520 Commonwealth Avenue, Boston, Massachusetts, 1927, '28, '30, '31*, '32, '35.
1931. POTTS, JOHN B., 1620 Medical Arts Building, Omaha, Nebraska 1931, '33*.
1927. PROETZ, ARTHUR WALTER, Beaumont Building, St. Louis, Missouri, 1924, '25*, '26*, '27, '28, '29, '30*, '31, '32*, '33*, '34, '35*.
1930. RIDPATH, ROBERT F., Central Medical Building, Eighteenth and Chestnut Streets, Philadelphia, Pennsylvania, 1930, '31, '33.
1913. ROY, DUNBAR, Grand Opera House Block, Atlanta, Georgia, 1921*, '22, '23, '26, '28, '31, '32, '33*, '34, '35.
1921. SAUER, WILLIAM E., 3720 Washington Boulevard, St. Louis, Missouri, 1921, '23, '25, '28, '31, '32, '35.
1935. SCHALL, LEROY ALLEN, 270 Commonwealth Avenue, Boston, Massachusetts, 1934*, '35.
1923. SEWALL, EDWARD CECIL, 430 El Escarpado, Stanford University, San Francisco, California, 1924, '26*, '28*, '35*.
1933. SEYDELL, ERNEST M., First National Bank Building, Wichita, Kansas, 1930, '31*, '33*, '34, '35.
1932. SHEA, JOHN JOSEPH, 1018 Madison Avenue, Memphis, Tennessee, 1928, '29, '30*, '31, '32*, '33, '34, '35.
1909. SHURLY, BURT R., 62 Adams Avenue W., Detroit, Michigan, 1920, '21*, '22, '24, '25*, '26, '27*, '28, '29*, '30, '31, '33, '34, '35*.

1932. SMYTH, DUNCAN CAMPBELL, 375 Commonwealth Avenue, Boston, Massachusetts, 1932, '33, '35.
1928. SONNENSCHNEN, ROBERT, 180 North Michigan Avenue, Chicago, Illinois, 1928, '29*, '30, '31, '32, '33, '34, '35.
1926. SPENCER, FRANK ROBERT, Physicians' Building, Boulder, Colorado, 1923, '24*, '26, '27*, '28, '30, '32*, '34, '35.
1889. SWAIN, HENRY L., Colonial Building, 195 Church Street, New Haven, Connecticut, 1920, '21*, '22, '23, '24, '25, '26, '27, '28, '29, '30*, '31, '32, '33, '34.
1928. TAYLOR, HERMON MARSHALL, 111 West Adams Street, Jacksonville, Florida, 1924, '25*, '26, '27, '28, '31, '34, '35*.
1931. TOBEY, HAROLD G., 270 Commonwealth Avenue, Boston, Massachusetts, 1927, '29*, '30*, '31, '32, '35.
1929. TUCKER, GABRIEL, 326 South Nineteenth Street, Philadelphia, Pennsylvania, 1925, '26*, '27*, '29, '30, '31, '32, '33, '34, '35*.
1892. WAGNER, HENRY L., 518 Sutter Street, San Francisco, California, 1926.
1933. WANAMAKER, ALLISON T., 817 Summit Avenue, Seattle, Washington, 1933.
1892. WATSON, ARTHUR W., 2013 Locust Street, Philadelphia, Pennsylvania, 1921, '23, '25, '27, '31, '32.
1928. WHERRY, WILLIAM P., 1500 Medical Arts Building, Omaha, Nebraska, 1924, '25*, '26, '27, '28, '29, '30, '31, '33, '34, '35.
1925. WHITE, FRANCIS W., 471 Park Avenue, New York City, 1922, '23*, '25, '26, '27, '28, '29, '31, '32.
1908. WILSON, J. GORDON, 5755 Kenwood Avenue, Chicago, Illinois, 1920, '21, '22, '24, '25, '26, '28, '29, '30, '31*, '32, '33, '35.
1905. WOOD, GEORGE B., Suite 504, Physicians' Building, Twentieth and Chestnut Streets, Philadelphia, Pennsylvania, 1921, '22*, '23*, '25*, '28, '29, '31*, '32, '33, '34.

Associate Fellows

1932. BAUM, HARRY LESTER, 510 Republic Building, Denver, Colorado, 1934*.
1933. BUCKLEY, ROBERT E., 50 East Sixty-third Street, New York City, 1935.
1933. HARKNESS, GORDON FOLLETTE, 2410 River Drive, Davenport, Iowa, 1934, '35.
1934. HASTY, FREDERICK E., Enquirer Avenue, Belle Meade Park, Nashville, Tennessee.

- 1934. HOURN, GEORGE E., 511-14 University Club Building, St. Louis, Missouri, 1934, '35.
- 1935. JACKSON, CHEVALIER L., 3432 North Broad Street, Philadelphia, Pennsylvania, 1935.
- 1933. LIERLE, DEAN M., University Hospital, Iowa City, Iowa, 1933, '34, '35*.
- 1929. LYMAN, HARRY WEBSTER, 906 Carleton Building, St. Louis, Missouri, 1929, '31, '34, '35*.
- 1933. McMAHON, BERNARD J., Missouri Theatre Building, St. Louis, Missouri, 1934*, '35.
- 1931. McNALLY, WILLIAM JAMES, 1509 Sherbrooke Street, West Montreal, Canada, 1931, '33, '34*.
- 1934. RICHARDS, LYMAN GILDER, 319 Longwood Avenue, Boston, Massachusetts, 1934, '35.
- 1934. SCHENCK, HARRY P., 1912 Spruce Street, Philadelphia, Pennsylvania, 1934, '35.
- 1934. SKILLERN, SAMUEL RUFF, JR., 1734 Pine Street, Philadelphia, Pennsylvania, 1934, '35*.
- 1934. STEVENSON, WALTER, 904 W. C. U. Building, Quincy, Illinois, 1934.
- 1933. STILES, PORTER, 501 Medical Arts Building, Birmingham, Alabama, 1934.
- 1935. WOODWARD, FLETCHER D., Box 1685, University, Virginia, Box 398, Charlottesville, Virginia, 1935.

Honorary Fellows

- 1910. MOURE, E. J., 25 bis Cours de Verdun, Bordeaux, France.
- 1914. THOMSON, SIR ST. CLAIR, 64 Wimpole Street, W., London, England.

Corresponding Fellows

- 1893. DESVERNINE, CARLOS M., 52 Cuba Street, Havana, Cuba.
- 1930. EMERSON, FRANCIS P., Franklin, Massachusetts.
- 1901. GRANT, SIR JAMES DUNDAS, K. B. E., 148 Harley Street, London, W. 1, England.
- 1919. KELLY, ADAM BROWN, 26 Blythwood Square, Glasgow, Scotland.
- 1931. LASAGNA, PROFESSOR FRANCESCO, Royal University, of Parma, Parma, Italy.
- 1926. LAW, FREDERICK M., 140 East Fifty-fourth Street, New York City, 1934, '35.

- 1921. LE MAITRE, FERNAND, Avenue Victor Hugo, 120 (XVI), Paris, France.
- 1903. MCBRIDE, P., 3 St. Peter's Grove, York, England.
- 1919. MCKERNON, JAMES F., 636 Fifth Avenue, New York City.
- 1896. MACDONALD, GREVILLE, Wildwood, Haslemere, England.
- 1920. MACKENZIE, DAN, 9 Weymouth Street, Portland Place, London, W 1, England.
- 1930. NEGUS, VICTOR E., 149 Harley Street, London, W 1, England.
- 1919. PATERSON, DONALD ROSE, 15 St. Andrew's Crescent, Cardiff, Wales.
- 1919. ROGERS, JOHN, JR., 177 East Seventy-first Street, New York City.
- 1924. SCHAEFFER, J. PARSONS, Jefferson Medical College, Philadelphia, Pennsylvania, 1934.
- 1896. SCHMIEGELOW, ERNST, 18 Norregade, Copenhagen, Denmark.
- 1903. TILLEY, HERBERT, 72 Harley Street, Cavendish Square, London, W., England.
- 1913. TURNER, LOGAN, 27 Walker Street, Edinburgh, Scotland.
- 1901. WINGRAVE, WYATT, Lyme Regis, Dorset, England.

Emeritus Fellows

- 1934. (1908) BARNHILL, JOHN F., 408 Pennway Building, Indianapolis, Indiana, 1935.
- 1935. (1928) BECK, JOSEPH C., 185 North Wabash Avenue, Chicago, Illinois.
- 1914. (1901) BROWN, J. PRICE, 15 Glebe Road, W., Toronto, Canada.
- 1934. (1897) CLARK, T. PAYSON, 71 Marlborough Street, Boston, Massachusetts.
- 1922. (1899) COBB, FREDERICK C., Riverview, Gloucester, Massachusetts.
- 1928. (1893) COOLIDGE, ALGERNON, 198 Beacon Street, Boston, Massachusetts.
- 1934. (1913) DABNEY, VIRGINIUS, 1633 Connecticut Avenue, Washington, D. C.
- 1918. (1892) FARLOW, JOHN W., 127 Bay State Road, Boston, Massachusetts.
- 1933. (1905) HALSTED, THOMAS H., 906 Chimes Building, Syracuse, New York.
- 1927. (1896) HARDIE, T. MELVILLE, 30 N. Michigan Boulevard, Chicago, Illinois.

1932. (1903) HARRIS, THOMAS J., 104 East Fortieth Street, New York City.
1918. (1888) HINKEL, F. WHITEHILL, 28 Norwood Avenue, Buffalo, New York.
1926. (1895) HOPKINS, FREDERICK E., 146 Chestnut Street, Springfield, Massachusetts.
1927. (1895) HUBBARD, THOMAS, 234 Michigan Street, Toledo, Ohio, 1934.
1933. (1904) INGERSOLL, JOHN M., 1700 S. Bayshore Lane, Miami, Florida.
1934. (1914) LEVY, ROBERT, Metropolitan Building, Denver, Colorado.
1931. (1901) MYLES, ROBERT C., 1075 Park Avenue, New York City.
1935. (1884) RICE, CLARENCE C., 52 Park Avenue, New York City.
1933. (1907) SHAMBAUGH, GEORGE E., 122 South Michigan Avenue, Chicago, Illinois.

Recipients of the De Roaldes Award

1928. DR. CHEVALIER JACKSON.
1931. DR. D. BRYSON DELAVAN.
1934. DR. HARRIS P. MOSHER.

Recipients of the Casselberry Award

1923. DR. GEORGE FETTEROLF and DR. HERBERT FOX.
1928. DR. RALPH A. FENTON and DR. O. LARSELL.
1929. DR. RICHARD A. KERN and DR. HARRY P. SCHENCK.
1929. DR. EDWARD H. CAMPBELL.
1931. DR. ARTHUR W. PROETZ.
1934. DR. ANDERSON HILDING.

Benefactors

DR. ARTHUR W. DE ROALDES.
 DR. WILLIAM E. CASSELBERRY.
 DR. SAMUEL JOHNSTON.

PAST OFFICERS

Presidents

(Year of Election)

1879. Louis Elsberg	1907. H. S. Birkett
1880. J. Solis Cohen	1908. A. Coolidge, Jr.
1881. F. I. Knight	1909. J. E. Logan
1882. G. M. Lefferts	1910. D. Braden Kyle
1883. F. H. Bosworth	1911. James E. Newcomb
1884. E. L. Shurly	1912. George A. Leland
1885. Harrison Allen	1913. Thomas Hubbard
1886. E. Fletcher Ingals	1914. Alexander W. MacCoy
1887. R. P. Lincoln	1915. G. Hudson Makuen
1888. E. C. Morgan	1916. Joseph L. Goodale
1889. J. N. Mackenzie	1917. Thomas H. Halsted
1890. W. C. Glasgow	1918. Cornelius G. Coakley
1891. S. W. Langmaid	1919. Norval H. Pierce
1892. M. J. Asch	1920. Harris P. Mosher
1893. D. Bryson Delavan	1921. Harmon Smith
1894. J. O. Roe	1922. Emil Mayer
1895. W. H. Daly	1923. J. Payson Clark
1896. C. H. Knight	1924. Lee Wallace Dean
1897. T. R. French	1925. Greenfield Sluder
1898. W. E. Casselberry	1926. Chevalier Jackson
1899. Samuel Johnston	1927. D. Bryson Delavan
1900. H. L. Swain	1928. Charles W. Richardson
1901. J. W. Farlow	1929. Lewis A. Coffin
1902. J. H. Bryan	1930. Francis R. Packard
1903. J. H. Hartman	1931. George E. Shambaugh
1904. C. C. Rice	1932. George Fetterolf
1905. J. W. Gleitsmann	1933. George M. Coates
1906. A. W. de Roaldes	1934. Dunbar Roy

Vice-Presidents

1879. F. H. Davis	J. O. Roe
1880. W. C. Glasgow	W. Porter
1881. E. L. Shurly	E. F. Ingals
1882. C. Seiler	S. Johnston
1883. S. W. Langmaid	W. H. Daly
1884. J. H. Hartman	G. W. Major
1885. H. A. Johnson	

1886.	E. C. Morgan	J. N. Mackenzie
1887.	J. N. Mackenzie	S. W. Langmaid
1888.	W. C. Glasgow	C. E. DeM. Sajous
1889.	E. Holden	C. E. Bean
1890.	J. O. Roe	J. H. Hartman
1891.	M. J. Asch	S. Johnston
1892.	S. Johnston	J. C. Mulhall
1893.	J. C. Mulhall	W. E. Casselberry
1894.	C. C. Rice	S. H. Chapman
1895.	J. Wright	A. W. de Roaldes
1896.	T. M. Murray	D. N. Rankin
1897.	A. W. MacCoy	H. S. Birkett
1898.	J. W. Farlow	F. W. Hinkel
1899.	T. A. De Blois	M. R. Brown
1900.	H. L. Wagner	A. A. Bliss
1901.	J. W. Gleitsmann	D. Braden Kyle
1902.	G. A. Leland	T. Melville Hardie
1903.	J. H. Lowman	W. Peyre Porcher
1904.	Thomas Hubbard	W. J. Freeman
1905.	J. L. Goodale	C. W. Richardson
1906.	G. H. Mackuen	A. B. Thrasher
1907.	J. P. Clark	J. E. Rhodes
1908.	E. Mayer	F. R. Packard
1909.	C. G. Coakley	H. P. Mosher
1910.	Robert C. Myles	J. M. Ingersoll
1911.	F. C. Cobb	B. R. Shurly
1912.	A. W. Watson	W. Scott Renner
1913.	F. E. Hopkins	Geo. E. Shambaugh
1914.	Clement F. Thiesen	Lewis A. Coffin
1915.	J. Gordon Wilson	Christian R. Holmes
1916.	Thomas H. Halsted	Greenfield Sluder
1917.	John Edwin Rhodes	D. Crosby Greene
1918.	G. E. Shambaugh	John R. Winslow
1919.	Francis R. Packard	Harmon Smith
1920.	Harmon Smith	W. B. Chamberlin
1921.	Dunbar Roy	Robert C. Lynch
1922.	George Fetterolf	Lorenzo B. Lockard
1923.	Hubert Arrowsmith	Joseph B. Greene
1924.	Ross H. Skillern	Gordon Berry
1925.	John E. Mackenty	Robert Levy
1926.	Lewis A. Coffin	William V. Mullin
1927.	Charles W. Richardson	Hill Hastings

1928.	Robert Clyde Lynch	Francis P. Emerson
1929.	William B. Chamberlin	Ralph Albert Fenton
1930.	Harris P. Mosher	James A. Babbitt
1931.	Joseph B. Greene	E. Ross Faulkner
1932.	Gordon Berry	Frank R. Spencer
1933.	E. Ross Faulkner	Thomas E. Carmody
1934.	Gordon B. New	Samuel McCullagh

Secretaries and Treasurers

1879.	G. M. Lefferts	1895.	H. L. Swain
1882.	D. Bryson Delavan	1900.	J. E. Newcomb
1889.	C. H. Knight	1911.	Harmon Smith

Secretaries

1912.	Harmon Smith	1919.	J. M. Ingersoll
1918.	D. Bryson Delavan	1920.	George M. Coates
1933.	William V. Mullin		

Treasurers

1912.	J. Payson Clark	1932.	William V. Mullin
1923.	George Fetterolf	1933.	James A. Babbitt

Librarians

1879.	F. H. Bosworth	1903.	J. H. Bryan
1883.	T. R. French	1930.	John F. Barnhill
1934.	Burt R. Shurly		

PAST MEMBERS

DeceasedHonorary Fellows*

- *1915. Bosworth, Francke H., New York City.
- *1914. Cohen, J. Solis-, Philadelphia, Pa.
- *1893. De Roaldes, Arthur W., New Orleans, La.
- *1914. De La Sota Y Lastra, Ramon, Seville, Spain.
- *1880. Garcia, Senor Manuel, London, England.
- *1928. French, Thomas R., Brooklyn, N. Y.
- *1924. Johnston, Samuel, Baltimore, Md.
- *1914. Lefferts, George Morewood, Katona, N. Y.
- *1922. MacKenzie, John N., Baltimore, Md.
- *1883. Mackenzie, Sir Morell, London, England.
- *1910. Massei, Ferdinand, Naples, Italy.
- *1879. Oliver, H. K., Boston, Mass.
- *1909. Semon, Sir Felix, Great Missenden, England.
- *1914. Wagner, Clinton, New York City.
- *1921. Wright, Jonathan, Pleasantville, N. Y.

Corresponding Fellows

- *1892. Browne, Lennox, London, England.
- *1901. Collier, Mayo, Kearsney Abbey, Kent, England.
- *1887. Gouguenheim, A., Paris, France.
- *1894. Holden, Edgar, Newark, N. J.
- *1881. Labus, Carlo, Milan, Italy.
- *1902. Lermoye, Marcel, Paris, France.
- *1897. Luc, H., Paris, France.
- *1894. MacIntyre, John, Glasgow, Scotland.
- *1880. Meyer, Wilhelm, Copenhagen, Denmark.
- *1896. Mygind, Holger, Copenhagen, Denmark.
- *1894. Sajous, C. E. DeM., Philadelphia, Pa.
- *1881. Thornton, Pugin, London, England.
- *1880. Whistler, W. McNeil, London, England.
- *1894. Wolfenden, R. Norris, Kent, England.

Emeritus Fellows

- *1934. Bryan, Joseph H., Washington, D. C.
- *1931. Coffin, Lewis A., New York City.
- *1914. De Blois, Thomas Amory, Boston, Mass.
- *1924. Freer, Otto T., Chicago, Ill.

- *1914. Gleitsmann, Joseph W., New York City.
- *1912. Knight, Charles H., New York City.
- *1923. Leland, George A., Boston, Mass.
- *1912. Lincoln, William R., Cleveland, Ohio.
- *1922. MacCoy, Alexander W., Philadelphia, Pa.
- *1931. Mayer, Emil, New York City.
- *1914. Porter, William, Ocean Springs, Miss.
- *1934. Renner, W. Scott, Buffalo, N. Y.
- *1924. Rhodes, John Edwin, Chicago, Ill.
- *1932. Richards, George L., South Yarmouth, Mass.
- *1914. Robinson, Beverley, New York City.
- *1934. Smith, Harmon, New York City.

Active Fellows

- *1880. Allen, Harrison, Philadelphia, Pa.
- *1917. Arrowsmith, Hubert, Brooklyn, N. Y.
- *1878. Asch, Morris J., New York City.
- *1880. Bean, C. E., St. Paul, Minn.
- *1904. Berens, T. Passmore, New York City.
- *1924. Bigelow, Nolton, Providence, R. I.
- *1893. Bliss, Arthur Ames, Philadelphia, Pa.
- *1895. Boylan, J. E., Cincinnati, Ohio.
- *1892. Brown, Moreau R., Chicago, Ill.
- *1915. Canfield, R. Bishop, Ann Arbor, Mich.
- *1934. Carmack, John Walter, Indianapolis, Ind.
- *1889. Casselberry, William E., Chicago, Ill.
- *1883. Chamberlain, C. W., Hartford, Conn.
- *1896. Chappell, W. F., New York City.
- *1882. Chapman, S. Hartwell, New Haven, Conn.
- *1902. Coakley, Cornelius G., New York City.
- *1913. Coffin, Rockwell C., Boston, Mass.
- 1918. Cox, Gerard H., New York City.
- *1880. Cushing, E. W., Boston, Mass.
- *1878. Cutter, Ephraim, West Falmouth, Mass.
- *1880. Daly, W. H., Pittsburgh, Pa.
- *1878. Davis, F. H., Chicago, Ill.
- 1926. Dennis, Frank Lowndes, Colorado Springs, Col.
- *1901. Dickerman, E. T., Chicago, Ill.
- *1878. Donaldson, Frank, Baltimore, Md.
- *1914. Fetterolf, George, Philadelphia, Pa.
- *1901. Freeman, Walter J., Philadelphia, Pa.

- *1917. Friedberg, Stanton A., Chicago, Ill.
- *1897. Frothingham, Richard, New York City.
- 1901. Getchell, Albert C., Worcester, Mass.
- *1907. Gibb, Joseph S., Philadelphia, Pa.
- *1878. Glasgow, William Carr, St. Louis, Mo.
- *1878. Hartman, Jacob H., Baltimore, Md.
- *1879. Holden, Edgar, Newark, N. J.
- *1907. Holmes, Christian R., Cincinnati, Ohio.
- *1882. Hooper, Franklin H., Boston, Mass.
- *1893. Hope, George B., New York City.
- *1901. Hyatt, Frank, Washington, D. C.
- *1882. Ives, Frank L., New York City.
- *1878. Ingals, E. Fletcher, Chicago, Ill.
- *1880. Jarvis, William C., New York City.
- *1878. Johnson, Hosmer A., Chicago, Ill.
- *1879. Johnson, Woolsey, New York City.
- *1879. Kealhofer, R. H., St. Louis, Mo.
- *1901. King, Gordon, New Orleans, La.
- *1885. Knight, Charles H., New York City.
- *1878. Knight, Frederick Irving, Boston, Mass.
- *1898. Kyle, D. Braden, Philadelphia, Pa.
- *1880. Langmaid, Samuel W., Boston, Mass.
- *1878. Lincoln, Rufus P., New York City.
- *1913. Loeb, Hanau W., St. Louis, Mo.
- *1897. Logan, James E., Kansas City, Mo.
- *1888. Lowman, John H., Cleveland, Ohio.
- *1919. Lynah, Henry L., New York City.
- *1915. Lynch, Robert Clyde, New Orleans, La.
- *1879. McBurney, Charles, New York City.
- *1927. McGinnis, Edwin, Chicago, Ill.
- *1885. McSherry, H. Clinton, Baltimore, Md.
- *1914. Mackenty, John E., New York City.
- *1898. Makuen, G. Hudson, Philadelphia, Pa.
- *1881. Major, G. W., Montreal, Canada.
- *1881. Morgan, E. C., Washington, D. C.
- *1886. Mulhall, J. C., St. Louis, Mo.
- *1925. Mullin, William V., Cleveland, Ohio.
- 1901. Munger, Carl E., Waterbury, Conn.
- *1892. Murray, T. Morris, Washington, D. C.
- *1881. Mynter, H., Buffalo, N. Y.
- *1893. Newcomb, James E., New York City.

- *1895. Nichols, J. E. H., New York City.
- 1894. Park, William H., New York City.
- *1892. Porcher, W. Peyre, Charleston, S. C.
- *1908. Randall, B. Alexander, Philadelphia, Pa.
- *1880. Rankin, D. N., Allegheny, Pa.
- *1902. Richardson, Charles W., Washington, D. C.
- *1879. Roe, John O., Rochester, N. Y.
- *1881. Robertson, J. M., Detroit, Mich.
- *1878. Rumbold, T. F., St. Louis, Mo.
- *1879. Seiler, Carl, Philadelphia, Pa.
- *1893. Shields, Charles M., Richmond, Va.
- *1878. Shurley, E. L., Detroit, Mich.
- *1919. Skillern, Ross H., Philadelphia, Pa.
- *1909. Sluder, Greenfield, St. Louis, Mo.
- *1879. Smith, Andrew H., Geneva, N. Y.
- *1892. Simpson, William Kelly, New York City.
- 1924. Stein, Otto J., Chicago, Ill.
- *1911. Stout, George C., Philadelphia, Pa.
- *1879. Tauber, Bernhard, Cincinnati, Ohio.
- *1903. Theisen, Clement F., Albany, N. Y.
- *1899. Thorner, Max, Cincinnati, Ohio.
- *1892. Thrasher, Allen B., Cincinnati, Ohio.
- *1888. Van der Poel, S. O., New York City.
- 1896. Ward, Marshall R., Pittsburgh, Pa.
- *1879. Ward, Whitfield, New York City.
- *1886. Westbrook, Benjamin F., Brooklyn, N. Y.
- *1924. White, Leon E., Boston, Mass.
- *1922. Wishart, David J. G., Toronto, Ontario.
- *1896. Woolen, Green V., Indianapolis, Ind.

Associate Fellows

- 1929. Alden, Arthur Maxwell, St. Louis, Mo.
- 1929. Arbuckle, Millard F., St. Louis, Mo.
- *1932. Atkins, Richard Travis, New York City.
- 1930. Hansel, French K., St. Louis, Mo.
- 1925. King, James Joseph, New York City.
- 1922. Monroe, Otho Lee, New York City.

