Transactions

American Laryngological Association

SIXTY-SEVENTH VOLUME

"DOCENDO DISCIMUS"

TRANSACTIONS

OF THE

SIXTY-SEVENTH ANNUAL MEETING

OF THE

American Laryngological Association

1946

HELD AT THE DRAKE HOTEL

CHICAGO, ILL.

MAY 29TH AND 30TH, 1946

PUBLISHED BY THE ASSOCIATION

1010 BEAUMONT BUILDING

SAINT LOUIS

1946

CONTENTS

List of Officers 6

President's Address. Harold I. Lillie, M.D. 9

Cleft Palate. Hugh G. Beatty, M.D. 29

The Danger of Unrecognized Anoxia in Laryngology. Thomas C. Galloway, M.D. 41

Some Causes of Hoarseness in Children. Francis W. White, M.D. 57

Aphonia. Carl H. McCaskey, M.D. 65

Associated Paralyses of the Larynx. Claude C. Cody, Jr., M.D. 76

Intralaryngeal Operation for Cancer of the Vocal Cord. Francis E. LeJeune, M.D. 92

Intranasal Medication—An Investigation into the Relative Merits of Certain Methods of Introducing Fluids into the Nose. Terence Cawthorne, F.R.C.S. (by invitation) 105

Sensitivity from Insufflation of the Powdered Sulfonamides in Acute Infections of the Nose and Throat. Howard C. Ballenger, M.D. 114

The Influence of the Sulfonamides and Antibiotics on the Future of Otolaryngology. Bernard J. McMahon, M.D. 121

Neurogenic Tumors of the Nose and Throat. Gordon B. New, M.D. and Kenneth Devine, M.D. (by invitation) 137

The Problem of Secondary Frontal Surgery. Francis L. Weille, M.D. 151

Congenital Cysts and Fistulae about the Head and Neck. Charles D. Blassingame, M.D. 189

Frontal Sinus Drainage. O. E. Van Alyea, M.D. 199

Adamantinoma of the Maxillary Sinus with a Report of Two Cases. Clyde A. Heatly, M.D. 215

Presentation of Patient. Samuel Salinger, M.D. 230

A New Anterior Commissure Laryngoscope. Paul H. Holinger, M.D. 232

Memorials

Allison Temple Wanamaker, M.D. 235

Samuel Iglauer, M.D. 237

Sir James Dundas-Grant 239

James A. Babbitt, M.D. 241

Greville Matheson MacDonald, M.D. 247

George E. Hourn, M.D. 249

Lee Maidment Hurd, M.D. 251

Elmer L. Kenyon, M.D. 254

Charles Terrell Porter, M.D. 257

Horace Newhart, M.D. 259

Robert Levy, M.D. 263

Executive Sessions and Reports of Officers and Committees, 1946 267

List of Fellows, 1946:

Active Fellows 286

Honorary Fellows 292

Corresponding Fellows 292

Emeritus Fellows 293

Benefactors 295

Recipients of the DeRoaldes Award 296

Recipients of the Casselberry Award 297

Recipients of the Newcomb Award 298

Past Officers 299

Past Members 303

OFFICERS FOR 1944-46

PRESIDENT

HAROLD I. LILLIE, M.D.

FIRST VICE-PRESIDENT

JOHN J. SHEA, M.D.

SECOND VICE-PRESIDENT

THOMAS C. GALLOWAY, M.D.

SECRETARY

ARTHUR W. PROETZ, M.D.

TREASURER

FREDERICK T. HILL, M.D.

LIBRARIAN AND HISTORIAN

LOUIS H. CLERF, M.D.

COUNCIL

The above Ex-officio and

HENRY B. ORTON, M.D.

GORDON BERRY, M.D.

THOMAS E. CARMODY, M.D.

CHARLES J. IMPERATORI, M.D.

TRANSACTIONS OF THE SIXTY-SEVENTH ANNUAL MEETING

OF THE

AMERICAN LARYNGOLOGICAL ASSOCIATION

HELD AT THE

DRAKE HOTEL, CHICAGO, ILL.

MAY 29TH AND 30TH, 1946

The Sixty-seventh Annual Meeting of the American Laryngological Association was called to order by the President, Dr. Harold I. Lillie at the Drake Hotel, Chicago, Illinois at 10 A. M. on May 29th, 1946.

He extended a cordial welcome to all the members and the guests present and declared the Scientific Session open.

REGISTRATION

The following Fellows were in attendance:

ASHLEY, REA E.
BALLENGER, HOWARD C.
BEATTY, HUGH G.
BERRY, GORDON
BLASSINGAME, CHARLES D.
BOIES, LAWRENCE R.
BROYLES, EDWIN N.
CAMPBELL, PAUL A.
CANFIELD, NORTON
CARMODY, THOMAS E.
CLERF, LOUIS H.
COATES, GEORGE M.
CODY, CLAUDE C.
CUNNING, DANIEL S.
DAVIS, WARREN B.
DIXON, FRED W.
FOSTER, JOHN H.
FURSTENBERG, ALBERT C.
GALLOWAY, THOMAS C.
GILL, WILLIAM D.
GOODALE, ROBERT L.
GOODYEAR, HENRY M.
GROVE, WILLIAM E.
HANSEL, FRENCH K.
HARKNESS, GORDON F.
HAVENS, FRED Z.
HEATLY, CLYDE A.
HICKEY, HAROLD L.
HILDING, ANDERSON C.
HILL, FREDERICK T.
HOLINGER, PAUL H.
HOOPLE, GORDON D.

Fenton, Ralph A.
Jackson, Chevalier L.
Jarvis, DeForest C.
Johnston, William H.
Jones, Marvin F.
King, Edward D.
LeJeune, Francis E.
Lierle, Dean M.
Lillie, Harold I.
Lukens, Robert M.
Lupton, Irving M.
Lyman, Harry W.
McCaskey, Carl H.
McLaurin, John G.
McMahon, Bernard J.
Mosher, Harris P.
Nash, C. Stewart
New, Gordon B.
Orton, Henry B.
Proetz, Arthur W.
Hunt, Westley M.
Robb, James M.
Salinger, Samuel
Schall, LeRoy A.
Schenck, Harry P.
Seydell, Ernest M.
Shea, John J.
Shurly, Burt R.
Simpson, W. Likely
Spencer, Frank R.
Taylor, H. Marshall
Tobey, Harold G.
Tucker, Gabriel
VanAlyea, Oliver E.
Viole, Pierre P.
Weille, Francis L.
White, Francis W.
Williams, Horace J.
Wishart, D. E. Staunton
Wood, V. V.

The fact that the attendance at these sessions equalled those of other years in spite of a general railroad strike a few days preceding the meeting is to be attributed to the unusual efforts of the Fellows, many of whom came by plane and by motor from great distances.

PRESIDENT'S ADDRESS

OSTEOMYELITIS OF THE MAXILLA SECONDARY TO SUPPURATIVE MAXILLARY SINUSITIS

H. I. LILLIE, M.D.

ROCHESTER, MINNESOTA

When a patient presenting signs of osteomyelitis of the facial bones secondary to suppurative sinusitis is encountered, most clinicians rightfully are much concerned about the prognosis. There had always been a high mortality rate in this disease before sulfonamides and antibiotics (penicillin) were used as adjuvants in treatment. It has been found difficult accurately to classify clinically the pathologic process in the early stages of the disease, although much has been learned about the pathologic characteristics of the disease. There are two general classes: (1) the localizing or self-limiting type, in which sequestration of bone takes place, and (2) the spreading or nonlocalizing type of infection. It is probable in the light of recent information that the localizing type may be due not only to certain reparative processes of the person afflicted but to a certain degree to the type of infecting organism and to the character of the blood supply of the particular bone that is involved.

In the spreading type of osteomyelitis it is, I think, the general consensus that the nature of the bone and its blood supply are important, but more important is the fact that the infecting organism is an anaerobe as Williams and Heilman[1] have suggested, and therefore is not susceptible to the usual therapeutic measures. It is fortunate that recently adjuvants in treatment have proved effective in combating this type of infection. Studies on the effect of sulfonamides and antibiotics (penicillin) have shown that when they are used in conjunction with well-directed proved clinical and surgical management, the disease may be controlled more satisfactorily than when they are not used. Reliance must not be placed

on sulfonamides and the antibiotics alone. It must be emphasized that they are adjuvants in treatment.

Literature

A considerable body of literature has accumulated on osteomyelitis of the cranial bone secondary to suppurative disease of the frontal sinus. There has been much less written on osteomyelitis of the maxilla secondary to suppurative disease of the maxillary or ethmoidal sinuses.

Disease of the bones of the head was described in the Smith Surgical Papyrus.[2] This report is thought to embrace the period between 5000 and 6000 B. C. According to Wilensky,[3] Hippocrates included a rather accurate description of exfoliation of bone in his "Injuries of the Head." There was apparently a higher incidence of osteomyelitis of the mandible and long bones than of the maxilla and frontal bones.

In 1926, I[4] reported four cases of what I called peridacryocystitis and periosteomyelitis of the maxilla following operation on the maxillary sinus. The symptoms and signs were characteristic. The initial symptom was severe pain in the face developing some days after operation. At this time there was no evidence of swelling or redness but they developed in a few days in the region of the lacrimal sac. Infection in the lacrimal sac could not be demonstrated at this stage. Suppuration took place in the region of the lacrimal sac and drainage was instituted. In one case the lacrimal sac was removed some months later. In two cases infection in the lacrimal sac was never demonstrated. In the fourth case the patient died of meningitis. It was suggested that the complication might have developed because of injury to the nasolacrimal duct when the window of the antrum was fashioned and that this resulted in the involvement by infection of the adjacent periosteum. It had occurred in cases in which intranasal operations had been performed and also in cases in which extranasal or alveolar operations had been performed. In all subsequent cases in which the disease has developed the same clinical syndrome has been observed.

In 1940, Porto[5] gave a report of this disease.

In 1941, Pastore and I[6] reported a case of osteomyelitis of the maxilla following sinusitis. At the time this patient was treated sulfonamides were being used as adjuvants.

In 1941, Tavares[7] reported a case from Brazil. This report was reviewed by Salinger.[8] Tavarres collected 11 other cases from the literature. In all cases the termination had been fatal.

In 1945, Hallberg[9] reported two such cases in which penicillin was used.

In 1945, Sadovsky[10] reported a case in which the localizing type of disease was treated successfully.

Pathologic Characteristics

The pathologic characteristics of osteomyelitis of the maxilla differ considerably from those of osteomyelitis of the frontal bone. In the first place, the blood supply of the maxilla is derived from terminal branches of the internal maxillary artery. The vessels anastomose freely so that when an infective process involves one of the lesser loops, there is a minimal loss of bone. However, if the main artery is involved, great loss of bone may follow. Havens[11] and Harlowe[12] have made such observations. Because the maxilla does not have porous bone, there is little or no opportunity for pus to be confined within the bone. In the frontal bone, extension of infection takes place by thrombophlebitis of the dural, diploic and pericranial veins, all of which communicate. The venous sinuses in the diploe play a very important role because infection can be confined in the spaces.

Extension of infection in osteitis or periosteomyelitis of the maxilla must be through the veins in the periosteum for the most part. In the region of the lacrimal sac the direction would be toward the cavernous sinus and the brain through the angular vein.

The anatomic characteristics of the lacrimal duct and the surrounding tissues have much to do with the sequence of events (Fig. 1) which lead to the clinical syndrome. Wolff[13] described the lacrimal sac as enclosed by a portion of the periorbita or lacrimal fascia. Areolar tissue between the sac and the fascia contains a fine plexus of veins continuous with the plexus around the duct

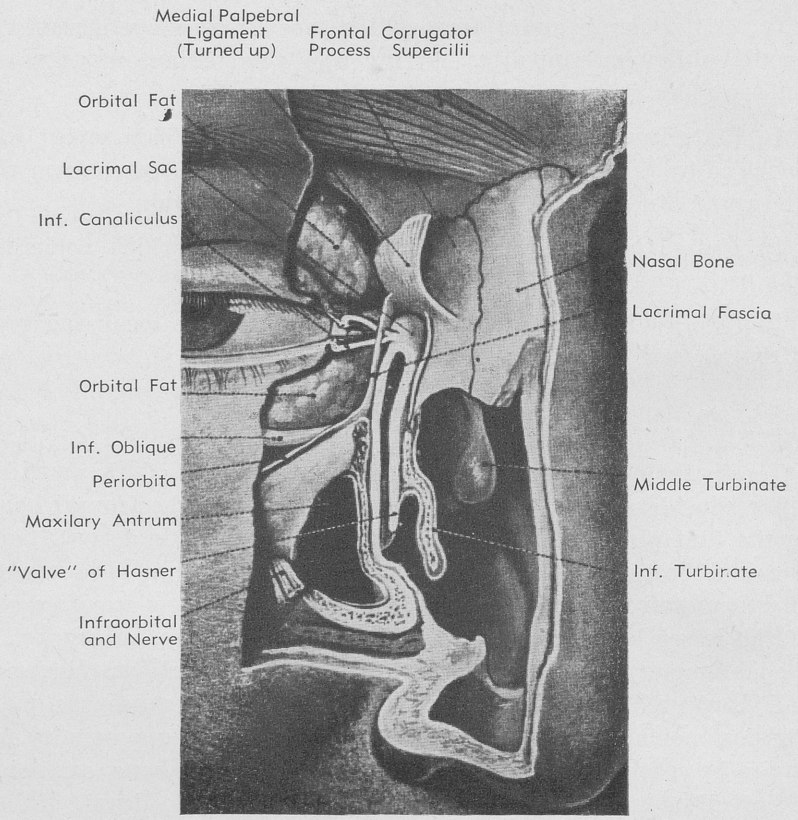

FIG. 1.—Dissection to show the relations of the lacrimal sac and the naso-lacrimal duct from in front. (Figure 114 from Wolff.[13] Used with permission of the publishers.)

except over the fundus of the sac where the sac is closely adherent to the fascia. The medial palpebral ligament is free but it is continued upward and laterally as a sheet blending with the fascia covering the fundus. The portion of the sac below the level of the ligament is covered only by a few muscle fibers. This protection offers little resistance to distention and swelling. It is in the region below the ligament that abscesses and fistulas develop.

The average length of the nasolacrimal duct is 5/8 inch (1.6 cm.). The position and shape of the inferior orifice vary greatly. This fact, it seems to me, is of the greatest importance when considering the syndrome under discussion. In some instances, the orifice is round and corresponds to the opening of the bony canal at the highest part of the inferior meatus. In others the orifice runs as a membranous tube for some distance under the mucous membrane, is found at different points down the lateral wall of the meatus and becomes a slitlike opening as it descends. It may be difficult to identify. The duct is said to have valves but actually the valves are folds of the membrane difficult to identify. The most constant of these is the plica lacrimalis, which is located in the orifice at the lower end. It is said to represent the remains of the fetal septum. The lacrimal duct is surrounded by a rich plexus of veins really forming an erectile tissue resembling the structure of the inferior turbinate. Engorgement of this plexus is enough to constrict the duct at its upper end where the duct can be separated easily from the bone. Below, however, it is closely adherent, forming a mucoperiosteum and thus infection may spread easily from duct to bone or vice versa.

The question immediately arises, should the surgeon in each case identify the lower orifice of the nasolacrimal duct before he fashions an opening in the naso-antral wall? Could such a refinement in technic be carried out successfully? Would avoidance of injury to the lower orifice prevent the occurrence of osteomyelitis? I am not prepared to answer these questions satisfactorily at this time.

If my idea, that it is injury to the nasolacrimal duct at the time of operation that causes the complication, is correct, then the answer to the questions would be in the affirmative. When one considers the low incidence of the complication and the actual difficulty in locating the lower orifice of the nasolacrimal duct, one hesitates to make positive statements concerning the advisability of locating the lower orifice of the duct.

With the anatomic characteristic of the nasolacrimal duct in mind, the sequence of events leading to the clinical syndrome could

be: (1) injury to the orifice of the nasolacrimal duct; (2) congestion of the plexus surrounding the duct, producing severe pain; (3) retrograde thrombosis extending to the lower end of the lacrimal sac, causing swelling of the region of the inner canthus; (4) suppuration, causing abscess in the region of the sac; (5) elevation of the periosteum by an abscess; (6) thrombosis of terminal vessels, resulting in sequestration; or (7) spreading of infection through the angular vessels to the orbit with extension to the meninges, the cavernous sinus or the superior longitudinal sinus, terminating in death.

Material

The cases of osteomyelitis of the maxilla secondary to operations on the maxillary sinus that I have encountered over a period of years always have been approached with misgivings because of the previous unfavorable experience with the disease. More recently the more favorable effect of treatment with sulfonamides and antibiotics (penicillin) in conjunction with other methods of treatment has been so striking that I decided to study the comparative effect of present methods of treatment with those in use before the era of sulfonamides and antibiotics.

Methods of Treatment

Before the use of sulfonamides and antibiotics became known, reliance had to be placed on the use of time-honored methods of treatment: hot compresses and sedatives for relief of pain, surgical drainage of abscesses or phlegmons, transfusions of blood as supportive treatment and subsequent removal of sequestra that prevented final healing. In the localizing type of infections due to staphylococci and hemolytic streptococci, these methods of treatment were reasonably successful. The use of a sulfonamide suitable for the infecting organism proved to be greatly advantageous as an adjuvant.

If the infecting organism proved to be an anaerobe, the effect of treatment with sulfonamides was very disappointing. The adequate use of penicillin under such circumstances has proved to be dramatically effective in certain cases. It must be emphasized,

however, that when pus is present sulfonamides and penicillin are not effective until adequate surgical drainage has been established. Further, it should be emphasized that surgical drainage should not be instituted before the formation of an abscess or phlegmon is manifest.

At the present time it would be considered best to start the use of sulfonamides and penicillin at the very onset of the complication. It is possible that in so doing the infection can be controlled before actual suppuration takes place. It is known that both agents are most effective at the time when the organisms are most actively reproductive. If abscesses or phlegmons develop, drainage must be established. Administration of the therapeutic agents should be continued for several days following apparent control of the disease. If sequestration develops, surgical measures designed to remove adequately the diseased bone are indicated. Unlike osteomyelitis of the frontal bone, it is not necessary originally to plan a surgical attack intending to remove bone well beyond the diseased bone.

Report of Cases

In this report I am including only the patients I have personally been responsible for. Six other such patients have been observed by other members of the staff. The four cases that I reported before this Society in 1926[4] are not included in this report. Cases in which osteomyelitis occurred following injury to the maxilla also are not included. Only those cases in which the disease developed following an operation on the maxillary sinus at the Mayo Clinic or which were referred to me after the development of the complication are reported.

Case 1.—In May 1928, a man 46 years old was seen who complained of severe pain and swelling over the left side of the face and the eyelids. He gave a long history of suppurative sinusitis and stated that he had submitted on May 17 to a Caldwell-Luc operation on the left maxillary sinus. Eight days following the operation severe pain had occurred in the region of the left inner canthus. This had been followed soon by swelling of the lacrimal sac and edema of the eyelids and face.

Examination revealed that drainage had been established in the lower rim of the orbit near the inner canthus. Bone could be felt with a probe. A culture of the pus obtained from the wound revealed Staphylococcus aureus. Nothing was disclosed in the roentgenologic examination other than diffuse cloudiness of the region.

During observation in the hospital there was no evidence of any untoward febrile reaction. The examinations of the blood were considered to give results within normal limits. Hot compresses were applied over the face and after several days an external operation was performed on the maxillary sinus. At this time definite sequestration was encountered and the sequestra were removed.

The condition apparently remained in abeyance for a considerable time. Some months later the patient again presented himself at the clinic and another sequestrum was encountered and was removed. Since that time he has remained in good health although there is considerable deformity of the left side of the face.

Case 2.—In 1939 a man 33 years old presented himself at the Clinic. He said that a Caldwell-Luc operation had been performed for a long-standing suppurative infection of the right maxillary sinus. Four days following operation severe pain had developed in the region of the inner canthus. Swelling of the region had followed rapidly and had involved the face and the eyelids. After 12 days an incision had been made in this region but no pus had been obtained.

On admittance to the hospital the patient appeared very ill. The temperature was 103° F. The history revealed that sulfonamide drugs had been used adequately. At least, he was getting 20 grains (1.3 gm.) every four hours. The right eye was closed and there was some swelling of the inner canthus on the left side. There was an incision near the region of the lacrimal sac. The buccal wound was open and draining. No fluctuation could be felt in the edematous soft tissues. Examination of the central nervous system and of the eye gave normal results. The culture of the blood showed no organisms to be present. The culture of the pus from the wound showed a micrococcus to be present. The roentgenologic examination revealed what was said to be osteomyelitis of the floor of the

orbit and the maxillary sinus. During the stay in the hopital the level for the sulfonamide drugs was kept at from 13 to 19 mg. per 100 cc. of blood. Two transfusions of blood were given as supportive treatment when it was found that secondary anemia was developing as a result, it was thought, of the use of sulfonamide drugs. Intravenous administration of solution of glucose was used to support the patient further.

On the eighteenth day sequestrectomy was performed with the patient under pentothal sodium anesthesia. Following this there was marked improvement in the condition and much of the pain that he had complained of during his stay in the hospital was relieved. He was permitted to leave the hospital. He returned on the sixty-ninth day with an acute swelling of the face. Examination revealed a sequestrum presenting in the buccal wound. With the patient under general anesthesia applied through an intratracheal tube this sequestrum was removed and it was found to consist of practically all of the maxilla.

Following this there was rapid healing. The patient has been observed at frequent intervals since. He was last seen in December 1945, and has remained in excellent condition. There is surprisingly little deformity of the face.

Case 3.—A man 43 years old was observed at the Clinic in 1942. He had had maxillary sinusitis for a year and a half following the extraction of a tooth. He stated that in the middle of March 1942 an intranasal antrum window operation had been performed. The immediate convalescence had been without incident but on April 2 very severe pain in the region below the eye and toward the inner canthus had been experienced. Swelling of the eyelids and face rapidly followed. He had been severely ill and the fever had been high. On April 11 drainage had been instituted and the sulfonamide drugs had been given as adjuvants in treatment.

When the patient presented himself at the Clinic he was seen to be very ill and was considered to be an emergency type of patient. The very distressing symptom was that pain was worse at night, occurring in the region of the forehead and the root of the nose. Marked tenderness was elicited over the bregma and in the region of the

FIG. 2. CASE 3.—Patient on entrance to hospital.

inner canthus. The eyelids were so swollen that the eye was closed and it was seen that the globe was partially fixed (Fig. 2). The leukocyte count was very high. Examination of the fundus revealed that the disk seemed full. Culture of the discharge from the incision that had been made was found to contain Streptococcus viridans. During observation in the hospital great difficulties were encountered with the use of the sulfonamide drugs. The patient did not tolerate adequate dosage.

On May 1 an exploratory type of operation was conducted through an alveolar incision and extensive sequestration involving the floor of the orbit was encountered. This operation did not check the progress of the disease. Swelling occurred over the root of the nose. The clinical course did not seem favorable. A week later a second operation was performed over the root of the nose and the nasal bones were found sequestrated and enveloped in a definite

capsule. There seemed to be no direct evidence of involvement of the frontal bone.

The patient's course was unsatisfactory and death occurred on May. 28. Necropsy revealed thrombosis of the cavernous and superior longitudinal sinuses and extensive meningitis.

Case 4.—In 1943 a man 21 years old presented himself at the Clinic with the history of long-standing bilateral suppurative sinusitis. An intranasal operation was performed in September 1943. The immediate convalescence was very satisfactory but on the ninth postoperative day the patient complained of severe pain in the left side of the face, especially localizing it to the region of the inner canthus. At this time there was no redness or swelling. Tenderness was present. Redness and more tenderness occurred after the third day of pain. The pain was not controlled by heat or cold compresses and it was necessary to use sedatives. Swelling developed rapidly and there was severe edema of the lower eyelid. Penicillin was administered intravenously in adequate doses over a period of 25 days. Suppuration developed and drainage was instituted in the region below the inner canthus. Examination of the pus on culture revealed an anaerobic bacterium. Rapid recovery took place after the drainage of the suppurative process.

The patient was dismissed from observation and returned in February 1944, because the incision at the lateral aspect of the nose had broken down. A small sequestrum could be felt with a probe. In the meantime the patient had gained 25 pounds (11.3 kg.) and considered himself to be in better health than at any time previously. The sequestrum was removed without its being necessary to employ anesthesia. Rapid healing took place and this has remained permanent (Fig. 3). The patient has been seen at intervals of four to six months and has remained in excellent health.

Case 5.—In 1943 a man 36 years old presented himself at the Clinic complaining of long-standing nasal obstruction on the left side. This was found to be due to a wide deflection of the nasal septum and a large naso-antral polyp which filled the nostril behind the deflected septum and presented in the choana.

FIG. 3. CASE 4.—Patient after recovery.

An intranasal operation for the removal of this obstruction was carried out with apparent good result and the immediate convalescence was without incident. The patient was dismissed eight days after operation.

On the sixteenth day after the operation, the patient complained of pain in the region over the inner canthus. No redness could be seen. Physical therapy in the form of diathermy was used but this was not effective. A rapid swelling of the lid and upper maxillary region ensued and evidence suggesting suppuration was present. Drainage was carried out. The sulfonamide drugs in adequate doses were given over a period of time following the apparent recovery. Penicillin was not used as none was available at that time. The patient was dismissed from the hospital apparently well.

Four weeks following his dismissal a recurrence took place. At this time he was hospitalized and penicillin was administered in-

travenously for 11 days. Rapid involution of the disease without suppuration took place and he has remained well since. He was last seen in December 1945. There was practically no scarring and no disfigurement of the face. In this particular case sequestration did not take place.

Comment

It is seen that the syndrome developed in a like manner in each case. All patients but one had sequestration. The sequestration involved a considerable portion of the maxilla in three cases. In Case 2 the sequestration was very considerable. In Case 5 sequestration did not develop. It is probable that the use of penicillin prevented thrombophlebitis sufficiently so that the terminal vessels supplying the bone were not involved.

The first case was encountered before sulfonamides were used in the treatment of infection. The infecting organism was identified as Staphylococcus aureus.

In Case 2, a sulfonamide was used in what was considered to be adequate dosage but did not change the course of the disease. It may have limited the disease. Examination of the blood and clinical signs suggested that the sulfonamide was not well tolerated. The infecting organism was identified as a micrococcus. Transfusion of blood as supportive treatment clinically had a beneficial effect.

In Case 3, the patient was more seriously ill than is usual. Adequate doses of sulfonamides were used before he came to the Clinic and during his stay in the hospital although some difficulty was encountered in their use. The patient continued to fail despite all supportive treatment. The infecting organism was identified as streptococcus viridans, known to be resistant to both sulfonamides and penicillin. Penicillin was not available at that time. Death occurred because of extension of the uncontrollable infection.

In Case 4, penicillin was used from the onset and although an abscess developed, the sequestra that formed were relatively insignificant although until removed they interfered with healing. The infecting organism was identified as an anaerobe.

In Case 5, penicillin was not available at the initial stage of the disease and reliance was placed on sulfonamide therapy and drainage of a small abscess. Sequestration did not take place. At the onset of recurrence of symptoms and signs, penicillin was administered intravenously for 11 days. The signs disappeared on the third day. Apparently, suppuration was prevented. The infecting organism during the original episode was identified as a microaerophilic bacterium.

Conclusions

1. The mechanism of the occurrence of osteomyelitis of the maxilla following operations on the maxillary sinus is suggested, as the sequence of symptoms and signs seems to be explained on anatomic and pathologic bases.

2. The pathologic characteristics of osteomyelitis of the maxilla that occurs secondarily to suppuration of the maxillary sinus differ greatly from the pathologic characteristics of osteomyelitis of the frontal bone that occurs secondarily to suppuration of the frontal sinus, largely because of the difference in the character of the bone involved and particularly because of the difference in the blood vessel arrangement.

3. The use of penicillin in conjunction with well-known general surgical principles of treatment of suppurative processes is very advantageous and gives promise of great improvement in the management of such a serious disease as osteomyelitis of the maxilla secondary to operation on the maxillary sinus.

4. It should be emphasized that accurate classification of the infecting organism is essential if penicillin as an adjuvant in treatment is to be employed effectively.

5. It should also be emphasized that in the presence of pus neither sulfonamides nor penicillin can be relied on as curative agents. The use of sulfonamides and penicillin should be continued for several days following apparent resolution of the infective process.

Mayo Clinic.

References

1. Williams, H. L., and Heilman, F. R.: Spreading Osteomyelitis of the Frontal Bone Secondary to Disease of the Frontal Sinus; With a Preliminary Report as to Bacteriology and Specific Treatment, Arch. Otolaryng. 25:196-207 (Feb.) 1937.

2. Breasted, J. H.: Quoted by Pickett, J. C.: A Short Historical Sketch of Osteomyelitis, Ann. M. Hist. n.s. 7:183-191 (Mar.) 1935.

3. Wilensky, A. O.: Osteomyelitis, Its Pathogenesis, Symptomatology and Treatment, New York, The Macmillan Company, 1934, pp. 7-8.

4. Lillie, H. I.: Peridacryocystitis and Periosteomyelitis of the Superior Maxilla Following Operations on the Maxillary Sinus; Report of Four Cases, Tr. Am. Laryng. Assn. 48:228-233, 1926.

5. Porto, G.: Osteo-omielite do crâino conseqüente à operaçao de Caldwell-Luc, Rev. brasil. de oto-rino-laring. 8:165-178 (May-June) 1940.

6. Pastore, P. N., and Lillie, H. I.: Osteomyelitis of Maxilla Following Sinusitis: Report of Case, Proc. Staff Meet., Mayo Clin. 16:761-766 (Nov. 26) 1941.

7. Tavares, A.: Osteomielite dos ossos do crâino post Caldwell-Luc, Rev. brasil. de oto-rino-laring. 9:161-168 (Mar.-Apr.) 1941.

8. Salinger, S.: Paranasal Sinuses; Summaries of Bibliographic Material Available in Field of Otolaryngology. Arch. Otolaryng. 36:243 (Aug.); 393 (Sept.) 1942.

9. Hallberg, O. E.: Spreading Osteomyelitis of the Maxilla, Minnesota Med. 28:126-127 (Feb.) 1945.

10. Sadovsky, N.: Osteomyelitis Postoperativa of Maxillary Bone with Sluder's Syndrome, Acta otolaryng. orient. 1:52-55, 1945.

11. Havens, F. Z.: Osteomyelitis of the Jaws, Proc. Staff Meet., Mayo Clin. 8:617-619 (Oct. 11) 1933.

12. Harlowe, H. D.: Acute Osteomyelitis of the Superior Maxilla in Children. Case Report, Laryngoscope 51:464-469 (May) 1941.

13. Wolff, Eugene: Anatomy of the Eye and Orbit Including the Central Connections, Development and Comparative Anatomy of the Visual Apparatus, 2nd ed., Philadelphia, The Blakiston Company, 1940, 374 pp.

RHINOSPORIDIOSIS

FRANK R. SPENCER, M.D.

BOULDER, COLORADO

When Dr. George M. Coates asked me to write the section of chronic granulomata for the new encyclopaedia of otolaryngology I found a few case reports of rhinosporidiosis. It is a tropical disease about which little is known in the United States.

Many of the fellows of the American Laryngological Association hold responsible positions in the Medical Schools of the Association of American Medical Colleges. They are often called in consultation in difficult or obscure cases. They should know the difference between ordinary nasal polypi and polypi in rhinosporidiosis.

The disease has been reported in East India, Argentina and the United States. The likelihood of more cases being brought back from East India since the close of the second World War gives added importance to a disease which has so far been rare in the United States. Three cases have been reported from Argentina and at least 25 from East India since the first case was reported in East India in 1903. Seeber reported this disease in Argentina in 1900 in Buenos Aires. There have been three cases in the United States according to Weller and Riker.[2] Ashworth[1] has given a complete history of the disease. Shrewsbury[3] has also shown excellent plates of the Rhinosporidium seeberi on artificial media.

Etiology.—The cause is the rhinosporidium seeberi. Very large, almost round spores are formed. These should be easy to recognize. The sporidium belongs to the lower fungi in the sub-order chytridinease.

Pathology.—The gross appearance is much like that of an ordinary nasal polyp. At least those from the nose are. The tumor is more vascular than a nasal polyp and the surface is often rough. The growths are friable and bleed easily. They are usually pedunculated. The rhinosporidium can be seen by the naked eye as white, pin-point spots. This is "a fungus infection of the mucous mem-

brane of the nose, with polypi, tumors of the cheek, conjunctivae, lacrymal sac, and uvula. It occurs in Argentina, India, Ceylon *and the U.S.A.* It is due to the Rhinosporidium seeberi, a yeast or phycomycete, spherical organism in polypoid growth; oval spheres (6 u) with chitinous envelope, vacuolated cytoplasm and vesicular nucleus. When fully grown, the sporangium measures 0.25 — 3 mm., it bursts and discharges spores which spread to connective tissue via the lymph channels. It can be cultivated with difficulty on Sabourands' medium."[4]

The polypi are edematous with a connective tissue stroma when examined with the lower powers of the microscope. There are many infiltrating cells, chiefly lymphocytes and plasma cells. There are a few polynuclear and polymorphonuclear leucocytes. Very few eosinophiles have been found.

Symptomatology.—There may be more or less complete nasal obstruction on one or both sides of the nose. Often there is a single polyp attached to the mucous membrane of the nose over the quadrangular cartilage. The attachment may be rather high or it may be at the anterior end of the inferior turbinate and to the turbinate. There is some nasal discharge, but no pain. All of the cases to date are in males of ages from 10 to 60. There are more than 40 cases reported to date. The polypi recur for a few years following removal, but not indefinitely. Upon removal these bleed freely.

Diagnosis.—The growths are likely to be mistaken for ordinary nasal polypi. The microscopic examination, with a culture of the fungus, will show the difference from an ordinary nasal polyp. All nasal polypi should be examined microscopically. Those caused by the rhinosporidium are more vascular and consequently bleed more when removed. Many of these have been reported as a single polyp attached to the septum or the anterior end of the inferior turbinate.

Treatment.—Surgical removal with a snare, under local anesthesia, is best. However, all of the pedicle should be removed and the base cauterized with the galvanocautery or desiccated by surgical diathermy. The polypi whether single or multiple tend to recur unless the base is cauterized. Recurrence may take place

from another part of the nasal mucosa. Care should be exercised to avoid rupture of the polypi and infection of the surrounding nasal mucosa from the infected fluid contained in the polyp. The intravenous administration of tartaremetic has been used with some advantage.

Ashworth[1] reported a case seen with Dr. Logan Turner in Edinburgh. The patient was Dr. M., a graduate in medicine, who was born in April 1891 at Ernakulam, the capital of the State of Cochin, on the southwest coast of India, and he lived there until he was about 20 years of age. In late 1910 or early 1911 he became aware of a growth in his nose extending into the nasopharynx. He was able to see the lower end of the growth, below the free edge of the soft palate, when he used a mirror to view the oral cavity. Before swallowing he had to force the polyp up into the nasopharynx. The growth was removed about a year later in Cochin. It returned and had to be removed a second time in eight or nine months. One year later the patient (Dr. M.) was in Madras. He felt a growth in the left side of the nose farther forward than the first. This bled occasionally. In 1913 the patient went to Edinburgh. He was annoyed by the bleeding and profuse viscid mucous discharge. In 1914 the growth was removed by Dr. Logan Turner and on two subsequent occasions the growth was removed by Turner. In May 1917 Dr. Turner again removed growths, which was the sixth time these had been excised. At this time Ashworth[1] examined the specimens for parasites and he found the rhinosporidium. Dr. Logan Turner removed polypi on seven subsequent occasions.

In June 1917 the tumor was 15 x 10 x 7 mm. in size. Another removed a few days later was 33 x 10 x 7 mm. The polypi had a mammillated appearance and contained many large parasites. The polypi were redder than ordinary nasal polypi.

On May 12, 1921, Dr. Logan Turner did a Rouge operation. He tried to remove the growth completely from its attachment to the nasal septum over an area 20 x 14 mm. in size. He also removed tissue from the ethmoidal region and from near the antrum.

Ashworth's[1] article is long and very complete. He has 38 references to the literature and 5 plates.

In conclusion the important points to be remembered about the disease are as follows:

1. The disease is rare even in tropical and semitropical countries.

2. The lesions are usually confined to the nasal cavities.

3. These resemble polypi, but are redder; are often attached to the septum or inferior turbinate; these bleed easily; and, the fungus can be seen with the naked eye as small, white or gray dots.

PHYSICIANS' BUILDING.

REFERENCES

1. ASHWORTH, J. H.: On Rhinosporidium Seeberi with Special Reference to its Sporulation and Affinitis, Trans. Roy. Soc. Edinburg, 53, part. 2:301-342, 1922-1924.

2. WELLER, C. V., and RIKER, A. D.: Rhinosporidium Seeberi: Pathological Histology and Report of the Third Case from the United States. Am. J. Path. 6:721-731, 1930.

3. SHREWSBURY, J. F. D.: Rhinosporidiosis, J. Path. & Bact. 36:431-434 1933.

4. MANSON and BAHR: Synopsis of Tropical Medicine, Baltimore, Williams and Wilkins Co., 1943.

DISCUSSION

DR. JOHN J. SHEA: It was my pleasure to have seen one case of rhinosporidiosis which Dr. E. C. Ellett of Memphis, reported some years ago, and recently I have seen another case which we are not entirely satisfied as being rhinosporidiosis.

This case is one with a very unusual type of tumor attached to the septum, which had the physical characteristics of this disease. The tumor was removed and sent to the Army Museum's Laboratory, and they reported it as plasmocytoma.

The tissue reaction to rhinosporidiosis is of a granulomatous type or inflammatory.

The culturing of this spore is nearly impossible; so much so that the mycologists don't believe one another when one reports that they have been able to culture it.

(Slide) The giant cell which is most commonly seen is the foreign body type. The granuloma for a great part is due to an irritation of a shell which is formed about the spore. The central body of the spore is a chromatin body which multiplies many thousand times and then ruptures. The pressure of the growth brings the cell to the surface and it ruptures and new chromatin bodies are then deposited in the tissue. The shell which is left behind produces round cell infiltration of the foreign body type. The center cell is a foreign body giant cell and makes up the majority of the tumor.

If our present patient develops rhinosporidiosis, I shall report it to this association.

Dr. H. Q. Penta, Albany, N. Y. (by invitation): I was very much interested in the slide showing the fungus in the section which Dr. Spencer showed.

You noticed that cell body completely filled with spores. There is only one type of fungus that does that and that is Coccidioides immitis. Endosporulation is only one type.

The only way to differentiate the blastomycotic lesions from the bacterial lesions is that the C. immitis, which is probably a little large, forms endospores instead of multiplying by division. It ruptures. It grows and fills and the tension is so great that the spores are liberated.

Dr. F. R. Spencer (closing): I would like to mention that I am indebted to our Department of Pathology, particularly the head of the department for suggestions regarding this and other diseases. We see them frequently and they often give us valuable information, as they did in this case.

CLEFT PALATE

HUGH G. BEATTY, M.D.

COLUMBUS, OHIO

The history of attempts to correct cleft palate goes back to 1766 when Le Mormir reported his results. Eustachi in 1779 reported results, and in 1783 he wrote what seems to Dorrance[1] to have been the first description of a technique for closure of cleft palate.

The fundamentals of corrective measures for cleft lip and palate have remained the same for these past 50 years. However, variations, improvements and undesirable methods have naturally been introduced by many during the last half century. In selecting the method for his adoption, the young surgeon has a variety from which to choose and should select a satisfactory one acceptable to the majority of competent men, which he in particular can do best. Later he can add his own variations.

This paper deals with clefts of the soft and hard palates only, since this discussion is focused on these parts, and not the clefts of the alveolar arch and the lip. Our present-day treatment of these clefts is indeed a great advance over the earlier surgical procedures. Improved operating-room equipment to facilitate the work, present-day excellence of anesthesia, well-trained assistants probably outweigh any great changes in surgical ideas in so far as the good of the patient is concerned.

In our practice, great attention is given the preoperative examination and preparation of the patient. Since the great majority of these patients are operated on while very young, we do not have more than a few leads as to the fitness of these young subjects for this rather radical and often extensive operation. Therefore, we feel that the following preoperative observation of each patient is important.

Preoperative Orders

(These orders should be read by the resident and the interne before seeing any patient.)

(The nurse in charge should be thoroughly familiar with all of these orders.)

1. A careful physical examination is to be done, including ears, nose and throat, teeth or gingiva, and a report is to be written and signed by the interne or the resident on admission.

2. The interne is to question the family carefully as to recent illnesses or exposure to communicable disease or infection and as to family tendencies to disease; later the family should be questioned by the nurse in charge because they may forget or refuse to tell the doctor of recent exposure to infectious diseases, family tendencies toward such diseases as hemophilia or others that would contraindicate operation.

3. If the child is fretful after admission, give a hypnotic, in dosage according to age.

4. No patient will be operated on with acute inflammation of the upper or lower respiratory tract or ears. The patient should be examined 12 hours before operation as the patient may show signs of infection after the examination has been done on admission.

5. A throat culture should be made on admission, to be repeated 24 hours before the operation. The following laboratory work is to be done on all patients:

Kahn test Complete blood count Hemoglobin determination Coagulation and bleeding time determination Urinalysis Vaginal swabs on all females, taken by the nurse in charge X-ray study of thymus on all children six years of age or under.	Reports of these tests are to be on the chart within 24 hours after admission.

6. Give soda bicarconate (or other alkali) in a sufficient amount 24 hours before operation to produce alkaline urine, together with 1 cc. of vitamin K.

7. Give adrenal cortex hypodermically, 1 cc. the night before and 1 cc. the morning of operation.

8. Give adequate fluids (water and orange juice) in amounts according to age—up to six hours before operation. GIVE NOTHING AFTER. Do not waken. Caution relatives not to feed or give fluids to the patient.

9. Take the patient's temperature one-half hour before operation. IMPORTANT.

10. Before sending the patient to the operating room, cleanse the operative area and the nostrils with boric acid swabs.

11. Medication preliminary to operation:

1. Codein is to be given *only on order of the surgeon.* (The use of atropine has been absolutely discontinued.)

2. An unusually restless or active patient two years of age or under should always have a hypnotic the night before and the morning of the operation.

3. Children two years of age or older should have a hypnotic the night before and the morning of the operation. No opium is to be given except on order of the surgeon.

12. Keep the family from going to the operating room.

13. Send the infant or the child to the operating room in a gown and a blanket—no diaper. Be sure the colon and the bladder are empty. Send the patient to the operating room only when the anesthetic is to be started.

14. No infant is to be operated on:

(a) Unless modified cow's milk, mother's milk or other satisfactory formula has been provided. (Ask the surgeon.)
(b) Unless the stools are normal.
(c) Unless he is gaining weight. (Weigh daily.)
(d) If there is regurgitation of feedings.
(e) Unless he "seems good" to the pediatric nurse.
(f) Unless instructions 1, 2, 4, 5 are satisfactory to the surgeon.

Preoperative Iodine or Thyroid Therapy

The surgeon is to be questioned regarding this by the nurse in charge on admission of the patient.

IMPORTANT: According to age, a suitable form of iodine in maximum dosage is given from the time of admission.

Adults: Lugol, 10 to 15 drops a day.

Children (from 4 to 6 years of age): Iodide of Iron or Syrup of Hydriodic Acid, one-half to one teaspoonful a day (If necessary, Oridine—chocolate-coated tablets).

Babies: Syrup of Hydriodic Acid, 10 to 15 drops a day.

All patients: Thyroid therapy—on order. Ask the surgeon. Thyroglobin. (Each drop contains 1/15 gr. thyroid extract.) Thyroid extract, for older patients.

In our experience, a statement by the pediatrician that the patient is in good condition for operation is not always sufficient. Too often pediatricians fail to realize that the child is to undergo a serious operation, when all body functions should be as nearly normal as possible. In the repair of a cleft of the hard palate in a young child where the blood supply to the flaps is not too extensive, a good quality of blood is most important if primary union is to be expected.

A carefully made, complete blood count and satisfactory information on the status of the thymus gland are our leading sources of information for these patients aside, of course, from a good report on the other vital organs. A nearly normal balance in the hemoglobin, red cell and lymphocyte count is of greatest importance in this operation since the flaps are stiff and rigid and the blood supply not nearly so adequate as in the soft palate and the lip. We have found by sufficient experience that any child with a high lymphocyte count is a dangerous risk and subject to severe physiological reactions.

One hour before operation the patient is given a hypnotic, usually nembutal; no atropine or narcotic.

Ether-oxygen vapor is the preferred anesthetic except in adults or large children, when the anesthetist may change this routine.

We prefer the Brophy mouth gag with ether tube attached as modified and made by Mueller. Instead of the bright nickel-plated ones, we have had them made of black nickel plate on the outside to reduce the glare. The inside is bright nickel for reflection within the mouth.

A No. 1 plain catgut suture is placed through the tip of the tongue for retraction.

The operation is begun by an incision along the extent of the cleft border where the oral and nasal mucous membranes join. This is done with the MacKenty half-circle knife. The elevation of the soft tissues and periosteum of the hard palate from the horizontal plates of the superior maxillary bone and the palatine bone is begun and continued with Brophy elevators. Some of these we have changed to suit our own personal likes. This must be carefully done. In many instances there are deep crevices in the soft tissues of the hard palate caused by deep attachment to the highly deflected horizontal plate. Tearing or mutilation of the apex of this crevice produces subsequent fibrosis in the newly formed palate. We make no attempt to fracture and include the horizontal bony plate in the palatal flaps as some operators do. We feel that the reattachment of the flaps to the plates and the subsequent contraction of the flaps bring these plates to a good position. The detachment of the flap extends toward the alveolar process, as far as necessary in each individual instance to secure good approximation.

Incisions along the lateral borders of the palate are never made unless necessary to secure adequate approximation of the medial borders of the cleft. Occasionally this step is necessary but only in a wide bilateral cleft of the hard palate and in some wide single ones. We feel that this, as a routine procedure, is not at all necessary and is to be condemned. The chief purpose of this paper is to establish this fact and encourage operators who begin the elevation of the flaps from the area of the alveolar arch instead of from the borders of the cleft to reconsider the Brophy technique.

The next step is the detachment of the hard and soft palate from the horizontal plates of the palate bones. This step again requires care not to rupture the oral surface and not, if possible, to break structures emerging from the posterior palatine canal. There is an excellent illustration by New on page 139 of Brophy's[2] book, "Cleft Lip and Palate".

A description of the muscle attachment and important muscles is given by Brophy: "The muscles concerned in this attachment and the subsequent contractions on the suture line of the closed velum or soft palate are: Commencing with the mesial line, one can dissect out the attachment of five muscles, each of which is, of course, duplicated on the opposite side and each of which has such relations to a mesial line that in case of cleft or split, it serves more or less to draw the parts posterolaterally. These muscles, mentioned in order of their significance to such lateral displacement, and consequently, in their relation to the operation of staphylorrhaphy, are the tensor palati, palato-glossus, levator palati, palato-pharyngeus and azygos uvulae. Of all of these structures the tensor palati plays the most important part and it is, therefore, entitled to the first consideration. The muscle arises from the scaphoid fossa, at the root of the internal pterygoid plate, from the anterior surface of the Eustachian tube and from the spinus process of the sphenoid bone. If the student carry his finger in his own mouth back to the wisdom tooth of the superior jaw and let it drop over and back of this organ, it will fall on the tuberosity of the maxillary bone; carry it about half an inch farther back and it will come to a second prominence; this is the hamular process of the pterygoid plate of the sphenoid bone. The tensor palati muscle descends from the origin of which we have just informed ourselves, and meeting this hamular process, it winds, as a tendon, around it and then by a fan-like expansion spreads itself into the substance of the soft palate. Its action is evident: it expands the palate laterally and dilates the pharyngeal orifice of the Eustachian tube."

Next the entire border of each cleft is pared sufficiently to secure good approximation without tension and an adequate surface for good blood supply.

Next, two pilot sutures of No. 1 moistened plain catgut are introduced through the body of the soft palate. These are to draw through each body of the cleft muscular soft palate No. 20 gauge silver wire and to be united over lead plates as stay sutures to overcome the contraction of muscles which will inevitably tear out the suture line. You will note that the *only* areas for fibrosis in the muscle body is a perforation for a 20-gauge silver wire. No lateral incisions and no section of the muscle have been done. Neither have any wide incisions around the periphery of the soft palate been done. The abstinence from these procedures reduces fibrosis and contraction, which can be very extensive.

The cleft borders are then approximated. Suture material is horsehair and steel or tantalum wire, usually both. The posterior or nasopharyngeal mucosa is closed with horsehair up to the attachment to the aponeurosis. Lastly, when the entire palate cleft has been closed, the silver stay wires are united over the plates, and no tension is put on these sutures with the intention of drawing the cleft borders together as this will result in necrosis.

This procedure, when it can be followed out, gives good speech and a nearly normal-looking palate. The functional success of any cleft palate technique should be evaluated when the patient has attained full growth and *not* six months after operation.

Postoperative care is given. It will be noticed that these orders, as well as the preoperative orders, apply to all cleft lip and palate patients.

Postoperative Orders

(For babies and children—special orders for adults.)
Upon the patient's return from the operating room:

1. See that the patient has dry clothing; wrap him in a dry warm sheet and a warm blanket and use hot water bottles. Have a warm bed. Do not chill the patient in changing his garments or wrappings. Put on wrist cuffs or restrain hands at once.

2. Watch respiration, i.e., see that the patient has easy free breathing especially if he had had a cleft palate operation. Call the interne if necessary.

3. Give saline glucose, by clysis or intravenously, with ascorbic acid (100 mg. for babies and from 500 to 1000 mg. for adults). Adrenal cortex is given and repeated if needed.

4. See that freshly prepared 6% solution of sterile glucose is ready *when the patient is returned from the operating room.* Have ready a sterile bottle (2-4 oz.), with sterile rubber covered medicine dropper tip, in hot water container for glucose solution. When the patient reacts and can swallow, give glucose solution (warm) carefully p.r.n., ad lib. by mouth to quiet and for 12 hours thereafter.

5. Feeding is to be ordered by the pediatrician. Have orders and formula established BEFORE the operation.

6. If the patient shows signs of shock or unnatural postoperative reactions, call the interne and surgeon. DO NOT WAIT.

7. If the patient is not quieted by glucose and is unusually restless and crying, give codein by hypodermic (by the interne's orders) for three doses. After that, the needed dose may be repeated every four hours if required. *Never give any narcotic until the effect of the anesthetic has passed off completely.* If it has been found by test dose of hypnotic that the patient reacts favorably to a hypnotic, use this in repeat doses in preference to codein or other narcotic. However, codein may be necessary if a hypnotic will not be retained.

8. After each feeding (formula) give sterile water to cleanse the mouth. The liquid formula should be started in part 24 hours after operation; sterile glucose solution should be given up to that time. Rapidly increase to full liquid formula.

9. Give an enema the night of operation day. After that give a daily enema unless or until bowel movement is normal. Much must be left here to the discretion of the carefully observant pediatric nurse in charge. Sufficient cleansing is to be done but not overdone.

10. Ask the surgeon about postoperative treatment of wounds.

11. Watch that relatives do not feed the patient.

12. *Never give solid food or semi-solid food until so ordered by the surgeon.*

13. Removal of sutures: The nurse in charge is to ask the surgeon about this soon after the operation.

Lip: Superficial skin sutures should be removed on the fourth day—by the interne or pediatric nurse in charge but never by a student nurse. Deep sutures are to be removed later. *All sutures should be out in ten days.*

Palate: Suture removal is to be directed by the surgeon. If plates are in, watch closely from three days after operation that they are not too tight (indicated by swelling of the tissue).

Any lip suture, loose or superficial, should be removed when not supporting tissue closure. Also, any suture which seems to be promoting infection should be removed and the surgeon notified.

Palate sutures showing white or necrotic areas should be reported to the surgeon.

14. Notification of relatives: Permission of relatives of patients, private and State Welfare Department, must be obtained in writing. An understanding between the nurse in charge and relatives must be in effect. A baby may not be in condition on the day set for operation but may be two days later. She must arrange the notification and have permission to *operate when the patient is in condition.*

15. The lip bridge in cleft lip operations remains in position for eight days; it must be tight and adjusted daily. The lip bridge is to be removed *only* on order of the surgeon.

16. Postoperative sedatives are to be given just as preoperative. Hypnotics are preferred, but if not feasible to administer, give codein or other narcotics *on order*. I do not want an infant or older child to have an unnecessary restless or excited postoperative period. Some are in pain, some nervous, some frightened and homesick—some are spoiled; be as sure as you can of the condition.

17. Thyroid medication, if prescribed before operation, is to be continued, but with the surgeon's attention called to it.

18. If at any time the condition of the patient does not "seem good" to the pediatric nurse experienced in the care of general surgical as well as cleft palate and lip patients, she is to call the surgeon in charge.

150 East Broad Street.

References

1. Dorrance, G. M.: The Operative Story of Cleft Palate, Philadelphia, W. B. Saunders Co., 1933, p. 441, quoted by Beatty, H. G.: The Care of Cleft Palate Patients, Trans. Amer. Laryng., Rhin. & Otol. Soc., 1935.

2. Brophy, T. W.: Cleft Lip and Palate, Philadelphia, The Blakiston Co., 1923.

DISCUSSION

Dr. W. B. Davis: All of us who have had considerable experience in cleft palate surgery have the same objects in view, namely, complete closure of the clefts, securing palates of good length, with best possible muscle action and good function in speech and deglutition. Yet the methods of operation preferred in different clinics often show wide variations. Doctor Beatty discussed in his paper only those clefts of the palate which extend no further anteriorly than to the premaxilla. His preoperative care and studies are important. In addition I would suggest being sure that the child is free from sinus infection. We believe the optimum time for palate repair is somewhere between the fifteenth and twenty-second months, always selecting a time when the patient is in good general condition. We prefer using osteoplastic flaps, rather than mucoperiosteal, and our operations are all done in two stages, at eight or ten day intervals between the two steps. The advantages are that a child stands two short operations better than one longer one, and that during the several days interval the collateral circulation in the flaps has increased to a degree which makes complete primary union more certain.

Dr. Thomas E. Carmody: Relative to Dr. Beatty's remarks concerning thymus pictures, we feel that it is safer to make them—at

least up to two years. We find very few enlarged thymus glands after the second year.

We formerly tried to sterilize all the food and dropped some antiseptics in the nose. We found that neither was worth while. Intravenous glucose for five or six days has given better results. We try to do these operations as early as is feasible.

We have found maxillary infection as well as the ethmoid infection mentioned by Dr. Davis.

This is the type of plastic surgery which the otolaryngologist should be able to do. I believe that it is coming into our field more and more.

Dr. Francis Lederer, Chicago, Ill. (by invitation) : While this may be a controversial matter with regard to the technique involved, because each time you hear a discussion of the subject the essayists and the discussers seem to differ a bit, there is one field of which we should be particularly cognizant in our cleft palate work and that is speech. I don't know how many laryngologists do oral surgery but from their standpoint it is of the utmost importance that they keep the matter of speech in mind.

Dr. Davis mentioned that the results in speech are good. Those are not spontaneous results. I have heard it said by men of the University of Wisconsin, who have an excellent state program—and one might also mention that Pennsylvania has an excellent program for cleft palate cases—that only 30 per cent of the success of the cleft palate case can be ascribed to surgery, that 70 per cent is due to the speech training of these youngsters. Therefore it is perhaps important that one recognize the psycho-social aspects, the importance of the prosthetic technician and the importance of the speech training. It is not so important therefore that one achieve the closure of the palate and have the patient incapacitated for speech, but it is very important that one follow up these cases with speech correction and training.

Dr. H. G. Beatty (Closing) : I agree with the Doctor regarding speech. That is why we select the age we mentioned for operation, 12 to 14 months, before the child begins to talk. If the child is

allowed to go five or six years and learns to talk with his cleft palate he builds up imperfect speech memories and ideas in his centers and he has to learn to talk all over again when his palate is closed.

Speech training is important but if the patient has a short, soft palate, attached higher on the one side than the other, he will have imperfect speech.

THE DANGER OF UNRECOGNIZED ANOXIA IN LARYNGOLOGY

THOMAS C. GALLOWAY, M. D.

EVANSTON, ILLINOIS

While in general the academic and theoretical aspects of oxygen want are well known, it does not seem equally true that the importance and serious implications of anoxia are always appreciated, especially under the stress of emergency. This discussion is intended to show that some degree of anoxia frequently is unsuspected and untreated in conditions which the laryngologist sees or ought to see; to indicate that even brief periods of hypoxia or anoxia may cause serious damage; to point out some conditions responsible for anoxia; to review the signs and symptoms which may indicate its development; and to present measures for its prevention and treatment. Usually, however, it will be sufficient to recognize the condition and diagnose its cause for the right course to be followed.

It has been difficult to establish the true histologic picture of damage from anoxia because the most notable injury is to brain tissue and such changes occur as well with other acute circulatory and degenerate disturbances. Also anoxia is usually associated in the human with other grave conditions such as anesthetic depression and septic, degenerative or circulatory diease. In addition it requires a survival time of from 24 to 48 hours for demonstrable changes to develop in brain tissue after injury. Agonal and postmortem changes in this tissue, too, are hard to prevent or estimate.

Windle[1] recently has given a clear-cut demonstration of the effects of oxygen want in guinea pig embryos at term. The uterine circulation was interrupted until asphyxia occurred, the animals resuscitated, allowed to survive and later killed with the tissue fixed in situ. Although it is accepted that brain tissue of young animals is less sensitive than that of adults, all animals in whom the circulation was interrupted for eight minutes or more showed neurologic symptoms and pathologic changes. The symptoms included

incoordination, ataxia, spasticity, tremors, convulsive seizures, diminished learning ability and even decerebrate states. Histologically, in 65 per cent of the animals there occurred edema, chromatolysis, necrosis, capillary hemorrhages, glial proliferation and loss of brain cells with changes varying from slight atrophy to marked sclerosis.

Morrison[2] has recently demonstrated similar profound changes in the brains of dogs and guinea pigs subjected to repeated short periods of anoxia. The critical level seemed to be a reduction from the normal 20, to 12 or 13 volumes per cent of oxygen in inspired air with repeated exposures of 25 minutes, although for greater degrees of anoxia the time of dangerous exposure seemed to be correspondingly lessened. He found in the monkey that a single exposure to a simulated altitude of 32,000 feet for 25 minutes was capable of producing extensive laminar necrosis of the cortex.

Frank necrosis occurred usually only after episodes of anoxia sufficiently severe to produce cessation of respiration. The frontal lobe was most often involved, the temporal lobe least often. The cerebellum was more frequently involved than the basal ganglia and the medulla least. These experiments and many others[3, 4] from the laboratory show definitely the grave and lasting effects of even short periods of anoxia of as little as three to five minutes.

Yet these do probably not represent the extreme picture since it is very difficult to exclude such reservoirs of oxygen supply as the placenta and the lungs, as in Windle's experiments, or to completely exclude cerebral circulation through collaterals even after ligation of the carotid and vertebral arteries.

In clinical conditions, it has been somewhat difficult to establish the picture of anoxia. The studies by Courville[5] of material obtained after death from nitrous oxide anesthesia are classical and his conclusions that these represent the effects of anoxia are quite generally accepted. He lists such changes as sclerosis of scattered pyramidal cells, patchy necrosis, degeneration of limited portions of the cortex and lesions in the lenticular nucleus. Degenerated areas tend to become confluent and to form necrosis of the various

laminae. It is to be remembered that only when the patient survived a sufficient time, usually 24 to 48 hours, are histological changes found, and in the more fulminating cases these were not demonstrable. He believes irreversible changes may occur after three to eight minutes.

Many authors have shown similar changes, as for instance Schreiber[6] in asphyxia neonatorum, Hartman[7] in surgical conditions. It is not beyond controversy that the effects of carbon monoxide poisoning are due solely to oxygen want so the many reports on this disease are not cited.

The data so far presented are related to gross laboratory and clinical demonstrations. But it is hardly to be doubted that in patients surviving, there are important changes besides those effecting immediate circulatory collapse and general depression. Courville[8] lists among sequelae of oxygen want, twitchings, convulsions, even decerebrate rigidity, residuals of Parkinsonism, emotional flattening or psychic aberrations. He believes that the condition of many patients in hospitals for the feeble-minded or the insane should be classed as postanesthetic states due to anoxia.

McClure[9] reports the case of a brilliant girl who had led her college class, but after nitrous oxide anesthesia for dental extraction, was forced to leave school because she could not keep up in her school work. I have seen rather marked emotional changes after bulbar poliomyelitis in patients who suffered serious periods of anoxia.

Thorner and Lewy[10] believed that even one single period of anoxia of 60 seconds duration leaves distinct evidence of morphologic changes and that no prolonged period of oxygen want will leave the brain totally unscathed.

Barach[11] concludes that anoxia in nitrous oxide anesthesia has produced death from anoxia, psychosis from permanent brain damage, personality changes, and impairment of circulatory and respiratory function which may contribute to atelectasis, edema or cardiac failure. (He does not, however, condemn this anesthetic if properly given.)

An editorial in the Journal of the American Medical Association states that asphyxia of even short duration must be regarded as "a grave hazard to the great majority of persons."[12]

It does not seem necessary to go further in the great mass of available evidence to prove that oxygen want even for short periods and perhaps of mild degree may be serious. I shall attempt, however, to point out some of the situations, frequently unsuspected, in which it may devolve upon the laryngologist to recognize the factor of anoxia and to aid in its correction before irreversible changes have taken place.

Anoxia is usually classified after Barcroft and Peters and Van Slyke,[13] as follows:

1. Anoxic anoxia—resulting from defective oxygenation of the blood in the lungs due to (a) low oxygen in the inspired air, as at high altitude, (b) pulmonary abnormality, as obstruction, pneumonia, edema, atelectasis.

2. Anemic anoxia—resulting from insufficient means of oxygen transport as in anemia or carbon monoxide poisoning.

3. Stagnant anoxia in which there is poor delivery although the hemoglobin may be saturated—due to heart failure, obstruction of venous return and shock.

4. Histotoxic anoxia—in which the cells are unable to utilize oxygen, as in cyanide poisoning.

We are concerned chiefly with the anoxic type especially as it is related to abnormalities of the respiratory tract.

The symptoms of anoxia are important to have in mind, especially in dealing with conditions associated with similar manifestations. Close analysis will disclose that in many of these it is the anoxia itself which causes the disturbances which may have been ascribed to sepsis, decompensation, shock, virus infection and the like.

Mental symptoms are early. As Barcroft points out, these may resemble those of acute alcoholism and may vary with the patient's temperament and surroundings. There may even be preliminary exhilaration and excessive confidence in faulty judgements, such as

aviators had at high altitude. More common, however, are depression, confusion, disorientation, irrationality, unresponsiveness, lethargy and finally coma. Antagonism and combativeness occur often. This was found in a considerable percentage of my bulbar poliomyelitis cases and has been important because it has made necessary more active measures, such as tracheotomy, which could have been avoided if the patient had cooperated in simple aspiration. It was interesting in reviewing the nurses' records of bulbar poliomyelitis cases to find that confusion and irritability had been frequently noted before respiratory difficulty was yet suspected.

Restlessness is an important early symptom both because the active patient increases his oxygen want and also because the unwary are too often tempted to attempt its relief by sedation which may be followed by complete surrender by an overburdened respiratory mechanism.

Dyspnea is usually an early symptom but may not be recognized easily in an exhausted patient or in one who has had sedatives.

Cyanosis may be a late symptom of oxygen need since it may not occur while there is compensation by increased rate or depth of respiration, and increased rate and stroke output of the heart. If obstruction develops slowly, cyanosis may be a late sign and I believe that if severe cyanosis develops in acute tracheobronchitis of less acute onset, we are liable to have overwaited the indication for trachotomy. Cyanosis may be absent in anemia since it depends on an absolute amount of reduced hemoglobin in the capillaries. Likewise, it may not appear in the presence of an uncompensated carbon dioxide deficit in which condition, surface capillaries are constricted. Such a condition may occur after shallow breathing in encephalitis, and possibly where there is much fluid in the tracheobronchial tree. This may occur in the type of tracheobronchitis described by Gittins[14] which may have only a gray cyanosis and few obstructive signs. This may be, however, simply part of a shock picture.

The effect of anoxia upon the heart is apparently not so great as that of the usually associated carbon dioxide excess.[15] There will be frequently an early increase in rate and stroke output with later

rise and finally serious disturbance of rhythm. It is to be remembered that a rapid pulse of poor quality is a sign of imminent heart failure which again may mean that we have waited too long to intervene.

Bulbar poliomyelitis was one of the conditions which rather rudely awakened me to the need of alertness in considering anoxia. Perfunctory contact had led me to believe that the effects were, as seems generally accepted, chiefly due to localization of the virus in specific nerve nuclei. A group of interns had been rather frantically trying to keep alive a patient with proven poliomyelitis who had gone from confusion and disorientation to complete coma. An alert supervisory nurse suggested that a laryngologist be called. On seeing this patient, my first impression was that his depression was due to virus infection or sepsis. As described in a previous report,[16] direct laryngoscopy disclosed that the pharynx, larynx and trachea were filled with secretion and aspiration produced improvement for a time. Eventually respiration ceased completely for an estimated three minutes while a tracheotomy was done. Secretions were aspirated, and artifical respiration was given until the patient could be placed in a respirator. He was conscious in 45 minutes and nearly normal mentally in two hours. It is hard to see how any other condition than anoxia could have produced a condition so quickly correctable.

In a study of quite a number of cases of bulbar poliomyelitis in which the primary disturbance has been in the swallowing mechanism with the flooding of the airway, it has seemed to me that anoxia has been the chief trouble. Even the disturbed rhythm, which was held to be part of the central picture and was considered to make these patients unsatisfactory candidates for the respirator, seemed due to anoxic depression of the center combined with instinctive or reflex resistance to drowning by aspirating secretion. On clearing the airway of these patients most of them developed a fairly good rhythm and did well in the respirator.

The reverse of the preceding experience occurred because I did not myself appreciate the seriousness of even limited periods of hypoxia. A young woman with bulbar poliomyelitis was doing well

as long as the secretions were aspirated. She was found, however, during a nursing shortage under the care of a relief student nurse, badly blocked with secretion, cyanotic and unconscious, this condition having occurred within a half hour. Aside from correcting the immediate condition nothing further was done, as I had been criticized for suggesting tracheotomy in such cases with the statement which is probably true, that careful nursing, postural drainage and aspiration should make it unnecessary. In this patient another half hour of serious interference with oxygen intake occurred due to fluid accumulation. The patient sank into a profound coma with dilated pupils and lost reflexes, apparently a true decerebrate state from which she did not recover, although in the respirator her heart continued to beat for two days longer.

This and several experiences brought me back to my original belief that when the patient with bulbar poliomyelitis is not doing well because of inability to get proper care, or uncooperativeness which may itself be a result of anoxia, tracheotomy may be a life-saving measure.

Any condition in itself depressing may make a patient unduly sensitive to slight degrees of oxygen want and such patients must be closely watched. Shock is likely to have associated with it a stagnant anoxia due to pooling of the blood in the splanchnic area.[17] Not only may oxygen administration then be of value but it is important that the airway be kept clear and the patient, especially if unconscious, be placed in the best position to breathe easily. Military surgeons report that unconscious, shocked casualties were frequently greatly helped by turning the patients to the prone position with the face to the side.

A case in point was a young woman who had been shot through the frontal lobes with explosive effect and had been unconscious for eight days. The nurse reported that she was dying. She was found with a thready pulse and gasping shallow respiration, lying on her back with sagging jaw and tongue. Although she was in an apparently terminal state, slight retraction suggested respiratory obstruction. A bronchoscope was hastily passed, considerable thick mucus aspirated, oxygen given, the patient placed in the half prone position and she lived to become a fairly normal individual.

I have written of anoxia in tracheobronchitis and respiratory obstruction considered chiefly in terms of terminal asphyxia. It should rather have been pictured like a wolf at the heels of a wounded animal, nagging, harrying and tiring until it closes in on its weary prey in one final cruel slashing attack. From the moment in respiratory obstruction that any degree of oxygen want develops, it begins to operate adversely and unless relieved it may be largely responsible for an unfavorable outcome. It produces restlessness with further activity and increased oxygen consumption. It and its accompanying carbon dioxide accumulation lead to increased respiratory effort, increased negative thoracic pressure, increased congestion, exudate and even capillary hemorrhage, increased lymph flow and increased capillary permeability, shown by Drinker[18] to follow anoxia. This exudate leads to still further blocking of the bronchioles and the lung bed, with perhaps atelectasis and emphysema and deepening oxygen want. There is evidence also that vasomotor tone is seriously impaired by depression of function of the suprarenal glands by anoxia.

By now the respiratory center is depressed, the heart and the respiratory muscle cease to function efficiently due to oxygen need and the fight nears its end. In this as in many other conditions associated with anoxia, the physio-pathology must be visualized almost from the outset if it is not to become irreversible or leave tragic sequelae. Oxygen administration and other measures will relieve most cases of tracheobronchitis and respiratory obstruction but no undue complacency should, in progressive cases, delay the certain and relatively safe relief by tracheotomy.

Anesthetic misadventures are perhaps the field where anoxia plays the greatest role and Courville[5] believes that accepted figures of mortality and morbidity for nitrous oxide are wrong and he has reported nine deaths and other serious accidents he believed due to anoxia from this agent. He[19] has reported also serious sequelae from ether which he considers the simplest and safest of anesthetics. Waters[20] recent statistics, although they do not separate anesthetic deaths from other operative and immediate postoperative causes, suggest a much higher figure for such accidents than those usually given.

The modern trained anesthesiologist is alive to the hazards of anoxia and has given much thought to the problem and its prophylaxis, so that it would be presumptious to discuss at any length this phase of the subject.

A question may be raised, however, whether there may not at times be undue confidence in procedures which, though having much greater potentialities, must yet be used with greater alertness and discrimination. The normal respiratory apparatus with its accurate nervous, chemical and reflex control is not likely to have a perfect mechanical substitute.

Some matters for serious consideration are: the heavy levels of premedication with morphine, scopolamine and barbiturates often advised before general anesthesia; the use of curare, unless quite essential as in some chest surgery, with its paralysis of the voluntary muscles and a loss of some of the excursion desirable for good circulation in the lung bed necessary to prevent congestion and even atelectasis; the more or less irregular introduction, in fairly large doses, of irremovable intravenous agents with laryngeal spasm not always perfectly counteracted; the dependence at times on intratracheal insufflation of oxygen without chest movement which Comroe and Dripps[21] believe seriously dangerous for longer than 15 minutes. I am not yet ready to forget the teachings of Chevalier Jackson and St. Clair Thomson, that one must not dull for long the cough and other protective mechanisms of involved air passages by opiates or other drugs, though some anesthesiologists consider us alarmists in this situation. The laryngologist in his own cases at least can not delegate entire responsibility and must be alive to the hazards of anoxia in anesthesia and know the counter measures. If he works in one of the smaller hospitals where he assumes some of the responsibility, he may even gain some satisfaction in cooperating with the efficient and pliable nurse anesthetist.

Especially since laryngological procedures usually involve the airway it is his responsibility to see that it is clear during deep anesthesia. In a patient on the dangerous edge of anoxia the additional block of the tongue clumsily pressed into the pharynx or the accumulation of blood or secretions may be very dangerous.

One very interesting problem is the relationship of anoxia to possible carbon dioxide deficit. In spite of the strong belief of Haldane and others that this may be frequent there is still much disagreement of physiologists on this subject. Grodins and Adler's[22] experiments indicate to them that there is no deficiency in chemical stimuli to the respiratory center "during the entire course of obstructive asphyxia." Men like Barach[23] with considerable experience in inhalation therapy believe that carbon dioxide should seldom be given in such cases.

Excessive elimination of carbon dioxide has been shown to occur after forced breathing. Best and Taylor state that in certain types of shallow breathing as in pneumonia, after breathing of irritant gases, occasionally in encephalitis and even in severe anoxia itself, by its depression of the respiratory center, there may be dangerous loss of carbon dioxide. Thereby, they state there may be induced "one of the gravest types of anoxemia since the cardiovascular system as well as suffering from oxygen want is seriously affected by the excessive loss of carbondioxide . . . The acapnia would also magnify the oxygen want of the tissues for the hemoglobin gives up its oxygen less readily at low oxygen tensions."

Negus[24] has reported a dramatic instance of carbon dioxide need in his discussion of sudden death after successful tracheotomy. His explanation was that after tracheotomy in a previously anoxic patient with increased respiration the free carbon dioxide is quickly blown off. "The acid base ratio is upset, the percentage of carbon dioxide present as carbonic acid is suddenly lowered, while that fixed as carbonate remains stationary. The arterial blood has become so alkaline that the respiratory center no longer receives the necessary stimulation," and respiration ceases. He advised, to prevent this, very slow opening of the trachea or administration of carbon dioxide. Some physiologists believe, however, that the respiratory failure occurs because the respiratory reflex had been previously maintained not by the action of carbon dioxide on the medullary center, now out of commission, but by the effect of anoxia on the chemoreceptors in the carotid area—and that this stimulation is gone with sudden access of oxygen. Seevers calls a similar condition developing after high carbon dioxide levels during

anesthesia an uncompensated respiratory alkalosis. He states that it takes as long for readjustment when the patient returns to breathing air as it did to adjust originally to the high carbon dioxide atmosphere.

A marked reduction of the carbon dioxide content of the venous blood might give some indication of this state. An improvement as judged by clinical signs and the patient's feeling of relief on cautious administration for a short time of 5% carbon dioxide in oxygen would be another sign. This could more accurately be determined by the finding of the pH and the carbon dioxide content of the arterial blood. According to Gamble,[25] knowing that the disturbance was respiratory rather than metabolic, the relative carbon dioxide excess or deficit could then be closely estimated.

It has been the intent of this discussion to make the reader visualize the narrow margin between oxygen want and disaster. It is hoped that it will help save some anesthetized patient on the edge of dangerous anoxia from being throttled with sponge or instrument; or a sufferer from bulbar poliomyelitis from drowning in his own secretions; or another from struggling for air with half a lung bed not functioning properly when that condition can be relieved. And may the picture be so clear that even in states of shock, exhaustion, cardiac failure or the like where stagnant anoxia has already crippled the brain and the heart, there will not be permitted the further shutting off of precious oxygen by poor position or obstructed airway.

636 Church Street.

References

1. Windle, W. F., and Becker, R. F.: Asphyxia Neonatorum, Am. J. Obs. & Gyn. 45:183 (Feb.) 1943.

2. Morrison, L.: Histopathologic Effects of Anoxia on the Central Nervous System, Arch. Neuropsych. 55:1-34 (Jan.) 1946.

3. Stewart, G. N., Guthrie, C. C., Burns, R. L., and Pike, F. H.: The Resuscitation of the Central Nervous System of Mammals, J. Exper. Med. 8:289.

4. Gildea, E. F., and Cobb, S.: Effects of Anemia on Cerebral Cortex, Arch. Neurol. and Psych. 23:876, 1930.

5. Courville, C.: Asphyxia Following Nitrous Oxide Anesthesia, Medicine 15:129, 1936.

6. Schreiber, F.: Apnea of the New Born and Associated Cerebral Injury, J. A. M. A. 111:1263, 1938.

7. Hartman, F. W.: Some Etiological Factors and Lesions in Cerebral Anoxia, Am. J. Clin. Path. 8:629, 1938.

8. Courville, C. G.: Pathology of the Central Nervous System, Mountain View, Calif., Pacific Press Pub. Co., 1945.

9. McClure, R. D.: Discussion in J. A. M. A. 115:1689 (Dec.) 1940.

10. Thorner, M. W., and Lewy, F. H.: Effects of Repeated Anoxia on Brain, J. A. M. A. 19:1595 (Nov. 6) 1940.

11. Barach, A. L., and Rosenstine, E. A.: Hazard of Anoxia during Nitrous Oxide Anesthesia, Anesthesiology 6:449, 461 (Sept.) 1945

12. Editorial, J. A. M. A. 130:213 (Jan. 26) 1946.

13. Best, C. H., and Taylor, N. B.: The Physiological Basis of Medical Practice, 4th ed., Baltimore, Williams and Wilkins Co, 1945.

14. Gittins, J. R.: Laryngeotracheobronchitis, Annals of Otology, Rhinology and Laryngology 45:1165 (June) 1932.

15. Seevers, M. H.: The Narcotic Properties of Carbon Dioxide, New York State J. Med. 44:597, 1944.

16. Galloway, T. C.: Tracheotomy in Bulbar Poliomyelitis, J. A. M. A. 123:1906 (Dec. 25) 1943.

17. Circulation in Traumatic Shock, Bulletin U. S. Army Med. Dept. No. 87, April, 1945.

18. Drinker, C. K.: Pulmonary Edema and Inflammation, Cambridge, Mass., Harvard Univ. Press, 1945.

19. Courville, C.: Ether Anesthesia and Cerebral Anoxia, Anesthesiology 2:44, 1941.

20. Waters, M.: Anesthesiology in the Hospital and in the Medical School, J. A. M. A. 130:909 (April 6) 1946.

21. Comroe, J. H., and Dripps, R. D.: Artificial Respiration, J. A. M. A. 130:381 (Feb. 16) 1946.

22. Grodins, F. S., and Adler, H. F.: Changes in Blood Acid-Base Balance during Asphyxia and Resuscitation (to be published).

23. Barach, A. L.: Inhalation Therapy, Philadelphia, J. B. Lippincott, 1944.

24. Negus, V. E.: Respiratory Failure After Successful Tracheotomy, Proc. Amer. Laryn. Assoc., 1938, p. 93.

25. Gamble, J. L.: Chemical Anatomy, etc. of Extracellular Fluid, Cambridge, Mass., Harvard University Press, 1942.

DISCUSSION

Dr. Henry M. Goodyear: As we know today, there seems to be a very definite relation between congenital cataract and measles (rubella) occurring in the mother in early pregnancy. There also seems to be a very definite relation between juvenile delinquency and whooping cough which occurs in infants under two years of age and, especially under one year of age.

We have in Cincinnati a very beautiful clinic, laboratory and hospital for the study of delinquent children. In discussing anoxia with the head of this department, he has told me on several occasions that there is a definite relation between delinquency in children and whooping cough. Definite irreversible degeneration changes have been demonstrated in infants dying of whooping cough. The role of anoxemia in the production of structural changes in the brain is paramount.

I am very much concerned about a child that stops breathing temporarily on the table during an operation for tonsils or adenoids. Prolonged anoxia during resuscitation may do irreparable damage to the brain cells.

Dr. Frederick T. Hill: I think when we consider that the important factor in surgical shock is really tissue anoxia, we must realize this merits a lot of consideration.

I would like to call your attention to some recent experimental work which has been done by Dr. Proger at the New England Medical Center, working with the respiratory enzyme Cytochrome C. This is based on the well known physiological fact that the venous blood returning to the heart contains a certain amount of oxygen which is not made use of. By using Cytochrome C it is possible to increase the tissue uptake of oxygen.

In working with rats, it was found that the survival time was markedly increased even in severe degrees of anoxia such as 3 per cent of oxygen. Working with humans it was found that the visual disturbances of anoxia, the electrocardiographic changes, and the electroencephalographic changes with anoxia can be prevented by preliminary intravenous injection of Cytochrome C, and that certain

of these states can be reversed by administering 60 or 70 mg. of Cytochrome C.

It is derived from beef hearts and it is stable and non-toxic. It has been used in cases of barbituric acid poisoning. I think it is worth while and may offer something to us in the control of anoxia.

Dr. W. L. Simpson: I would like to make one suggestion with regard to the anesthesiology department. At the John Gaston Hospital in Memphis it has been suggested that the advisory supervision of it be by a committee from the staff and that the chairman of this staff always be a laryngologist.

Dr. Gordon B. New: I would like to ask Dr. Galloway one question about the group of polio cases in which he does a tracheotomy. From my rather limited experience in this group, I am wondering just what per cent of the patients in whom it was necessary to do a tracheotomy, ultimately died of intercostal involvement rather than tracheal obstruction.

Dr. DeForest C. Jarvis: If one is interested in mild degrees of anoxia, another simple test which one may perform in order to estimate if anoxia is present at the time of the test is to ask the patient to hold the breath and to time this breath holding with a stop watch. The normal time for holding the breath is 30 to 40 seconds which presupposes a sufficient amount of oxygen in the body to carry on respiration in the tissues. You would be surprised how many patients can hold the breath for only 10 to 25 seconds. That, however, can be built up with iron, iodine, or some oxidizing agent up to 60 seconds. Another way in which mild anoxia is suggested is by a subnormal temperature which can be built up with oxidizing agents in one week's time.

The relief of anoxia is best demonstrated in the anginal pain. Dr. Weston Price has been all over the world studying primitive people, studying dental conditions, and at one time came to see me just after he had come from a trip to Peru where he studied individuals living high in the Andes Mountains. He told me he was unable to go to that height but only up to a height of 12,000 feet. However, he found the natives were living at an altitude of 16,000,

and so he arranged to have some of the natives from the 16,000 feet level come down in order that he could study their dental condition. He found that each one of them was carrying a little bag. In that bag he discovered was the seed of kelp. He asked where they got the seed and was told they got it from the ocean. It took two weeks to go to the ocean and two weeks to return. Centuries of trial and error had determined that they were able to control the anoxia of the heart by the use of kelp.

It is surprising how if one takes a five grain tablet of kelp, iron, manganese and copper, the four best oxidizing metal agents the anginal pain is relieved in one to four days when the anoxia of the heart is relieved.

DR. T. C. GALLOWAY (Closing): I assume that Dr. Goodyear meant to say, although I did not hear him say it, that the connection between whooping cough and deliquency is periodic anoxia. That is a very important connection.

I was quite interested in Dr. Hill's discussion about Cytochrome C, which I have seen mentioned. I have had no experience with it.

(Slide) The respiratory difficulty in bulbar polio is described as of three types: (1) the peripheral paralysis of the intercoastals and the diaphragm, (2) disturbances of the respiratory center in rate and rhythm, (3) the bulbar type in which the difficulty is in swallowing. These of course may be combined.

In the second type disturbances of rate and rhythm are supposedly due to involvement of the respiratory center. The disturbances are, I think, due often to fluid with reflex and voluntary interruption of respiration in an attempt to prevent aspiration.

The third type is the true bulbar paralysis which interferes with swallowing causing a collection of fluid. If such a patient is put in to the respirator without providing for removal of secretions, he will have that drawn into the lung bed with marked reflex and semi-volitional resistance or the patient may then even drown in his own secretions. Such patients can be well treated in a respirator but only if secretion is kept removed.

(Slide) What can trachetomy do in such cases? It can prevent immediate asphixiation. It short circuits the airway around secretion and permits aspiration and more certainly clears the lung bed than any other method and may be life saving.. It is true that if the patient is seen rather early and is cooperative, one can put him face downward especially if a child, and so get good postural drainage. If one has a nasal catheter in place with continuous water suction before much hypoxia develops it is very seldom necessary to do a tracheotomy. The important thing is that even short periods of anoxia must be prevented.

The stage of activity of bulbar polio is usually short and practically all of these cases unless they have had the extensive myeloencephalitic type recover their swallowing function in five to eight days, and when one has carried them by that stage they will usually do very well. Some of them are associated also with intercoastal and diaphragmatic paralysis which may cause trouble much longer.

SOME CAUSES OF HOARSENESS IN CHILDREN

FRANCIS W. WHITE, M.D.

NEW YORK, NEW YORK

One subject in laryngology that has not received sufficient attention is hoarseness, or other faulty voice conditions in pre-adolescents or young adolescents. We all seem to expect to hear the "cracked" voice in boys and have a tendency to laugh it off, and to assume that the lowering of the voice in girls is just part of the transition phase. It is not fair to these children to take this attitude and it is our duty to investigate these conditions, as many times there are associated remedial causes which should be eliminated. Hoarseness, nasality or denasality, inability to pronounce words, and slurring of words in children has not been of major interest to laryngologists. Appropriate treatment, plus intelligent instruction in voice improvement can frequently produce results which immeasurably improve the lot of these little sufferers. The general practitioner struggles along with such a case hoping the condition will be outgrown, and in this hope he is often aided and abetted by members of the child's family. Later, depending upon the sensitivity to ridicule, an inferiority complex of varying degree is developed, and the sufferer may thereby be handicapped both economically and socially. If pride in having a pleasant voice can be instilled in a child, instead of allowing fear and a sense of inferiority to dominate because of an unpleasant voice, then much can be done to aid our medical and surgical treatment. It is only with concerted action that the multitude of defective speech cases are discovered. This obtains in large centers where a Department of Speech Improvement is part of the public school system.

It is my privilege to be in close contact, in a voluntary capacity, with the Department of Speech Improvement in New York City. Over a period of many years, scores of school children were referred to my clinic at the Manhattan Eye, Ear, and Throat Hospital. It is interesting to note that about eight to ten per cent of the school children in the elementary schools, and about eight per cent in the

high schools suffer from speech defects. Of these defects, hoarse voice is the most common. In general, more boys than girls are affected, and among stutterers the proportion may be eight to one. One survey of 50 stutterers showed that all but five were of superior intelligence. Unfortunately, all cases of hoarseness are not laryngologically examined, probably due to family neglect or lack of interest. About 50 per cent of the cases are seen by Laryngologists.*

In examining the children at the Clinic a method was employed, similar to the screening process recently used in general by the Armed Forces. The object was to try and find some underlying causes for the speech disorders and eliminate such pupils while handicapped by remedial conditions, from taking part in group instruction. Not only was the time of the children and the instructor conserved, but the procedure also lessened the possibility of disrupting the morale of other class members who were not held back by similar handicaps. After some experience, the following syllabus was evolved to expedite the examinations by suggesting the ground to be covered.

Age: Instability of nervous system first manifesting itself at puberty.

Onset: Date and mode.

Corrective measures taken:

History of infectious diseases, trauma, psychic shock. A complete family history especially concerning neuroses.

Inciting causes: Congenital anomalies—malformations of larynx, cartilage, muscles, choanae, jaws, innervation, cleft palate, harelip, tongue-tie.

Environment:

Inflammations: Primary and secondary.

Mechanical obstructions:

Hearing difficulties: Unilateral or bilateral.

*Data in personal communication from Dr. Letitia Raubicheck, Director of Speech Improvement, Board of Education, New York City.

This was a comprehensive guide which could easily be expanded to individual needs to include laboratory tests, direct laryngoscopy, and bronchoscopy. At times, collaboration between the laryngologist, neurologist, ophthalmologist, and dentist was necessary to complete the diagnostic picture.

The ages ranged from 7 to 18 years, with an average of 14 years. This span of life is an important epoch, as development both physical and mental should be normally progressive and at times, rapid. It is the period of greatest sensitivity, and psychic shocks and unfavorable impressions are carried over into adult life, acting as a cause of introspection. It is during these years that the infectious diseases of childhood are prevalent and may act as added causes as paralysis following diphtheria, at times so mild it is not even considered. Chorea takes its toll.

Patients with congenital causes, such as cleft palate and harelip, were not referred to this Clinic. No case of an abnormally small larynx was seen, and extraordinarily, not one case of papilloma was seen. Only one case of tongue-tie was noted. Malocclusions required the attention of the dentist. Of the other congenital causes, the unusual case histories of four patients are of interest.

Report of Cases

A girl, 14 years of age, was referred to the Clinic with the following history. Three years before she had suffered a febrile attack that kept her in bed for one week. She was not ill enough to have medical attention. A year later, she complained of increasing hoarseness. An indirect laryngoscopy revealed a left abductor paralysis. She was referred to the Bronchoscopic Clinic where this diagnosis was confirmed, but no cause for the condition was discovered. All laboratory tests, including x-ray studies and fluoroscopy, were reported negative. She was referred to a neurological clinic in her own neighborhood (Queens General Hospital) and there, a diagnosis of possible postmyelitic paralysis was made. Later, she was admitted to the Neurological Institute for a complete study. The diagnosis was agenesis of the left vagus.

Two pitiful cases of congenital stenosis of the larynx were seen in siblings: a 16-year-old girl and a 14-year-old boy. They were referred to the Clinic for diagnosis and treatment. The girl's history was that at the age of seven weeks a tracheotomy was performed for a congenital web of the larynx. The boy had a similar condition and a similar operation was performed at the age of one week. In each case, it was impossible to examine them without the use of local anesthesia, and even then, only much deformed larynges without definite landmarks could be seen. The web in the girl's larynx occupied most of the anterior part. In the boy's larynx, only a small opening in the posterior part could be seen in the neighborhood of the arytenoids. The patients were referred to the Bronchoscopic Clinic, but not much more could be learned about their condition. Unfortunately, there was very little cooperation on the part of the patients even though a representative from their school tried very hard to induce them to allow us to proceed with treatments. The last time I saw the girl was in the spring of 1945 when she was 18 years old. She was very much depressed. She had girl friends but no boy friends because of her "terrible" voice. Both patients were referred to Dr. Louis Clerf[1] at this time, as he had operated upon them, as noted above, and reported their case histories.

The fourth case history is that of a 15-year-old girl who came to the Clinic complaining of voice trouble: inability to phonate properly and a very hoarse voice. There was no demonstrable thyroid gland in the neck, but one was present on the base of the tongue. Because of its size, it acted mechanically on the larynx impeding its normal action and entirely obstructing the view into the larynx, so that only a very small portion of each arytenoid could be seen upon forced phonation. It was deemed advisable to try to shrink the mass in the region of the epiglottis by means of radium. She was referred to the Radium Clinic for treatment but, unfortunately, this made matters worse. Then electrocoagulation was tried, and three or four small areas in proximity to the epiglottis were coagulated. This procedure was carried out every two weeks for twelve treatments and at the same time thyroid extract was given by mouth. The gland in the region of the epiglottis was gradually

reduced in size and the voice became clearer. The cords and the arytenoids became progressively easier to see, and the parts naturally involved in speech moved freely upon the slightest effort at phonation. The larynx became normal in color. The patient was under observation for two years, and during this time she grew taller with a proportionate increase in the size of the larynx. She was happy with the result when last seen, because her voice was clear and strong. Numerous other cases of goiter were observed but they were of the pretracheal type and also acted mechanically. In some cases, there seemed to be a sort of paresis of the epiglottis in which it quivered but had no definite motion. In a few instances, the epiglottis would flap back against the posterior wall of the pharynx en masse or, possibly, just the tip would do so during phonation. In all such cases medical treatment was supplemented by local laryngeal treatments as indicated.

One of the most important factors after obtaining a history—including age and evaluating the presence of an anomaly—is environment. Age and environment are naturally entwined as young children do not have much to say as to where they shall dwell. In other words, if the neighborhood is in proximity to an elevated railway and there is much trucking or other vehicular traffic in the streets, it is not only a noisy neighborhood but a dusty one as well. In any event, irrespective of the source of the noise and dust, a child able to play in the street is not only going to be seen but is going to be heard, and that by yelling and screaming. Thus, more insult is added to an already overworked larynx. Home environment is also of importance. A sensitive child exposed to unhappy surroundings is at a great disadvantage in trying to become adjusted during the pre- or mutational stage. Most of the children seen at the Clinic were of the nervous or emotional type and often one or both parents were similarly affected.

The inflammatory reactions in the average case had the appearance of the so-called "rheumatic larynx," but pain was not a symptom in any case. In all instances the true cords, but most characteristically the arytenoids, were involved. They were red and moved very sluggishly, due to the inflammation and the trauma incident to excessive efforts to speak louder. Interarytenoid thick-

ening was seen in only a few cases. Although most all of the cords approximated comparatively well, they could not hold their position except momentarily. "Head cold" was the most common complaint. Catarrhal and suppurative sinusitis were frequently associated conditions. The ever-present postnasal drip was in evidence and the intra- and extralaryngeal structures were bathed in the discharge. In the simple type of laryngitis, treatment was directed to the condition itself, but in laryngitis due to other causes, the larynx was treated concomitantly. The desire of the child to talk above the laryngitis handicapped our efforts markedly. Not infrequently, children with a mild type of laryngitis stated they could get along pretty well until suddenly called upon to recite or answer questions. Due to emotion, plus the physical handicap of laryngitis, they could not phonate and were "scared stiff" as they expressed it because they knew they could not speak out loud under such circumstances. In all instances, vocal rest was insisted upon as far as possible, including the limiting or the elimination of recitations in classrooms, gymnasium work, and the enlisting of the cooperation of the members of the family at home.

Of the obstructive causes, tonsils and adenoids, with the presence of a deviated septum, naturally predominated. There was often a history of one or more tonsil and adenoid removals without beneficial results. In fact, this history became so common that, when given, instead of our examining the throat, a nasal examination was immediately made to ascertain if the real cause was not a nasal obstruction, possibly a deviated or markedly irregular nasal septum. The thyroid gland was always investigated, especially in girls, and in many instances it was found enlarged, causing pressure upon the larynx. Naturally, proper treatment was instituted.

Hardness of hearing, either unilateral or bilateral, is a potent factor in causing faulty speech. It is impossible to repeat correctly what one does not hear distinctly. The requirement to have regular and comprehensive hearing tests made in public schools is of inestimable help. A great responsibility lies with those of the teaching profession who are in contact with children having speech defects.

Attention is being brought to the fact that all changes in the voices of children are not to be classified as a part of the physiological changes either before or during puberty. The lasting ill-effects not only to the larynx but to the psyche of the person may be caused by failure to thoroughly investigate laryngologically all young persons suffering disagreeable changes in their voices. Much can be done to improve the speaking voice by cooperation between the laryngologist and the speech teacher.

An interesting aspect of this work has been the fact that so many children of various ages and nationalities could be examined by the indirect method of inspection. In other words, it can be done but it does take quite a little patience and, I might say, a little dexterity.

471 Park Avenue.

Reference

1. Clerf, L. H.: Congenital Stenosis of the Larynx: Report of Three Cases, Annals of Otology, Rhinology and Laryngology 40:770, 1931.

DISCUSSION

Dr. L. H. Clerf: Hoarseness among school children is not uncommon, and Dr. White is fortunate to be on the staff of an organization which examines these children. It is important that they do have someone who knows laryngology and is sympathetic.

I have seen a number of these patients and the question concerning the cause of the hoarseness arises. There usually always is a cause although one may not see it at the first examination. One can with patience and a moderate degree of dexterity examine the larynx by mirror examination, as Dr. White has indicated. It may be necessary to see the patient several times before the larynx is visualized. If necessary direct examination may be required but the laryngologist should make the differential diagnosis.

In my experience the most common cause of voice disturbances in youngsters is what are called "screamer's nodes". There commonly is a history of much voice use or shouting and screaming while playing baseball, football, etc. They might be considered as

being equivalent to simple vocal nodules except they are larger and may be associated with hyperplastic changes.

Treatment always constitutes a problem. They may be removed but will recur unless the cause is removed.

I have been impressed that much can be done by discussing the problems with the families, the teacher, and the patient. Many of these children are very proud of their voices, even if they are a bit husky, and if you can get them to visualize the importance of a good voice and how absurd it is to be screaming and yelling they will cooperate amazingly well, and fortunately for them, it will not be necessary to remove the nodes.

I am greatly interested in this important field of preventive medicine, and a good time to start is during school days.

Dr. Francis W. White (closing): The most discouraging element in this work is the lack of cooperation on the part of the patient and members of the family.

The mother of the last patient I saw had but one question on her mind, namely was the condition dangerous! I explained in simple terms that the condition was not dangerous in so far as life was concerned but it would be a serious handicap in after life if he had opportunities for advancement but was retarded by a disagreeable voice.

If the laryngologist and the speech teacher will cooperate much can be done for these kind of cases.

APHONIA

CARL H. McCASKEY, M.D.

INDIANAPOLIS, INDIANA

Aphonia is defined as a loss of voice, but it is a loss of voice which is not due to a central lesion. This discussion will be limited to functional aphonia, or perhaps a better term would be psychosomatic aphonia. This type of aphonia has been, and is, more commonly referred to as hysterical aphonia. If the term hysterical aphonia is used as the name of the disease, it will be well to set up a basis whereby a better understanding of this syndrome can be made.

It is necessary to examine the etiological factors in hysterical aphonia. It is well to discuss the psychosomatic conception of hysteria, of which aphonia is one of the multitude of symptoms, hysteria being a mental disorder which is always due to emotional causes and not to organic causes.

The manifestations of hysteria are myriad, and almost any organ, or organ system, may be the site of these manifestations. When the basic mechanism in hysteria is analyzed, some type of conversion is most commonly found. By this it is meant that an emotional problem is converted into a physical manifestation. The individual is faced with a problem for which he is not able to find a satisfactory, efficient, and acceptable solution at the moment. It may be that the solution of the problem, if the individual acts in accordance with recognized principles of social behavior, is distasteful, unpleasant, or actually dangerous. For this reason he hesitates to do the difficult or unpleasant act demanded by the realities of the situation, but he finds every other pathway of escape blocked because of criticism by society or by his own conscience. A simple example of this is the soldier who is ordered to advance to a dangerous position which is defended by enemy machine guns. He is

From the Department of Otorhinolaryngology, Indiana University School of Medicine.

forced to advance by his own conscience, by his concept of bravery and soldierly behavior, by his own self-esteem and the conviction that his comrades will hold him in disdain if he does not comply with the order. On the other hand he is held back by the fear of pain, mutilation or death which almost certainly will occur if he follows the order to advance. He is thus caught between the ethical concepts of courage, obedience to orders, and service to society on one hand, and his own desires of self-preservation on the other hand. The psychological and emotional conflicts become severe, and it may be that he is unable to force himself either to advance or to refrain from advancing. In this instance the psychological dilemma is resolved by the conversion of the conflict into physical symptoms; that is, paralysis of the legs, hysterical blindness, or convulsions. Any one of these conversion manifestations is sufficient to enable him to escape from the distasteful situation without loss of prestige or personal esteem.

In ordinary life many individuals will be caught in a similar conflict, and they may not be able to cope with the situation at the moment. This emotional conflict will bring about a marked emotional tension and intolerable anxiety. When this conflict becomes intolerable, the process of conversion with the production of some physical symptom is both a symbolization of, and a solution to, the conflict which has been raging. The question then arises as to which persons will adopt this mode of solving the psychological dilemma.

Psychiatrists have found that individuals who have been badly spoiled in childhood, individuals who are emotionally immature and fundamentally childish in their attitude toward life, and similar types of self-indulgent individuals will often utilize this method of escape. It is frequently found among persons of a rather primitive and somewhat childish make-up, but on the other hand it has been noted among better integrated personality types under tremendous emotional stress, such as war, sudden catastrophe, train wrecks and other highly emotional experiences. More often, however, it is found in individuals who seem to have an insufficient ability to meet the ordinary vicissitudes of modern life.

I have mentioned before that the physical symptom is a symbolization of, and a solution to, the conflict. This means that the physical symptom is not chosen at random, but that an unconscious selection has occurred and the physical symptom is carefully chosen to fit the problem. A symptom is chosen which will evade the issue at hand, such as a paralysis of the limbs, or a severe limp, as in the case of the soldier who had been ordered to march in the front line. It is also necessary that the symptom chosen will solve the conflict in which the patient is placed. In the example of the soldier the paralysis of the leg symbolizes his conflict over "walking to his death" and at the same time removes the problem, because a paralyzed soldier obviously cannot march to the front. It must be emphasized, however, that this conversion and the production of physical symptomatology occurs unconsciously and that the patient is not aware of the nature of his symptom or of the cause. He finds himself possessing a physical symptom and does not realize why he has developed this symptom or what it represents, but instead he firmly believes he is suffering from some organic catastrophe. The unconscious and unwitting development of the symptom by this hysterical patient differentiates him from the malingerer who wilfully and purposefully simulates his symptom for the purpose of deception to gain his own ends.

Hysterical, or conversion, aphonia represents a specialized form of the previously mentioned mechanism. In this instance the individual is unable to talk in a normal voice, or, if able to say a few words, his voice soon dies away to a whisper. There are numerous tests which otolaryngologists use to detect whether or not the presenting symptomatology is organic or not, and they need not be enumerated here. If the total situation of the patient is investigated carefully, it will be found that the hysterical, or conversion, aphonia in some way symbolizes the problem and offers a solution to it. For example, a patient who consulted me with this type of aphonia was dissatisfied with his lot in life, his marriage, and his vocation. It was his obligation to go to the employer of a coal mine and ask for a job, but he whispered almost triumphantly to his family, "No one would hire a man to work in the mine who cannot talk out loud to ask for a job, let alone talk and yell to the other

miners." He found that his aphonia would not enable him to ask for work, and it would actually prevent him from working if he had a job.

A middle-aged woman whispered to me of her antagonism and hatred for her mother-in-law who lived with her and who, in spite of the fact that she was very hard of hearing, wanted to carry on a conversation all the time. Conversation with the mother-in-law required shouting into an ear trumpet, and this usually brought impatient, sarcastic or resentful rejoinders. The patient smiled happily as she whispered that she had lost her voice. She had tried to be a good daughter-in-law, and certainly no one could blame her if she did not converse with the old lady all day long.

Mrs. M. consulted me for loss of voice. She had been ill for several years having had many complaints. She had had a functional aphonia for three years. After a tedious and painstaking conference with her she finally admitted that by whispering she received a great deal of sympathy which she had never received before. She was induced to speak normally before leaving the consultation room. She was then referred to a psychiatrist for further handling of her case, and, as far as I know, she has never had a recurrence.

Mr. C. R., a farmer, consulted me for a loss of voice. In the history of his case it was discovered that he was worried because his son was about to leave home to take up residence in another state. After the patient's voice was gone, except for a whisper, his family sympathized with him and his son remained at home. On gaining his confidence he admitted to me that this was true, and by persuasion I convinced him that he could talk. Before leaving the consultation room his voice was normal, and as far as I know, it has remained so ever since.

Miss M., the daughter of the president of a normal school, consulted me for the loss of voice which she had had over a period of three months. It was found that her parents had forbidden her to see a certain boy friend of whom she was very fond. She arose one morning and could speak only in a whisper. This patient was treated by using an astringent to her larynx. She uttered a con-

siderable sound and was told that inasmuch as she had made a sound she could talk, which she did. After two weeks she had a recurrence, the same procedure was carried out and she recovered her voice, and four weeks later she had another recurrence with the same treatment and the same result. It was then decided by the family to allow the girl to see her boy friend at weekly intervals, and after that there was no recurrence of the whisper.

Mrs. D. could speak only in a whisper for three years, except for a few short intervals when she had some local treatments to her larynx. For a short time she would have a normal voice, but soon would relapse into the whisper. It was discovered that her stepson, whom she disliked, lived with the family. Upon further questioning it was found that when she did not talk, a great deal of sympathy was expressed toward her, even by the stepson, but when she had her normal voice she received no sympathy. It was decided to have the stepson reside with other relatives. She was persuaded that she could talk normally and she did so without any local treatment. She turned out to be a psychiatric problem and was referred to a psychiatrist for observation and study. To my knowledge this patient never has had a recurrence.

Mrs. V. H. had a loss of voice for a period of one month. In discussing the condition with her I thought she was holding something back and I asked her whether she had had a familial disturbance of any kind. She burst into tears and told me that she thought her husband was paying attention to another woman and since learning of it she had lost her voice. I asked her to have her husband come in to see me. During my interview with him I learned that he was not philandering, whereupon I asked them to come in to see me together. Mrs. H. admitted that since she had lost her voice her husband had, she thought, been more attentive to her; therefore, she had continued to talk in a whisper. After convincing her that she was wrong in her surmise as to her husband, and that I was sure she could speak in a normal tone, she did so, and continued doing so. I have seen this patient from time to time and she seems to be happy.

Mrs. J. A. had been unable to talk above a whisper for four months when she consulted me. She had had this condition three

times previously, each attack lasting from three to five days. She gave a history of having had an appendectomy, some type of ovarian operation, pyelitis which was worse during pregnancy, constipation, anosmia and many other minor illnesses. She was a poor sleeper and was very neurotic. I could not elicit a history of a familial disturbance of any kind. She did state that her family and friends were sympathetic with her in the loss of her voice. I told her I was sure they would be equally happy if she were able to talk and she agreed that they would. I worked patiently with her but could not get a sound by any suggestion that I could offer. I finally resorted to a local treatment of tincture of chloride of iron to her larynx. When this was applied, she made a very noticeable sound, and I proceeded to follow this up by asking her to utter words. Before she left the office, she was talking and has continued doing so to the present time. I feel, however, that if I had unearthed the real cause I could have induced her to speak by treating the case as an organic condition.

In each of these instances the aphonia was merely the presenting symptom of a major emotional disturbance and represented the only avenue of escape from a difficult dilemma. In this sense the larynx became the organ of conversion of the psychological problem and was not itself the site of a pathological process.

This discussion will serve to indicate the therapeutic necessities in the handling of such patients. The otolaryngologist would not treat a patient for the general symptom of "cough" without ascertaining the cause of the cough and the basic underlying pathological disturbance, and then attempting to eradicate it in its entirety. Treatment directed only toward the aphonia may be successful in restoring the voice by direct and often primitive attacks upon the larynx. The removal of the symptom, however, leaves the patient with unsolved conflicts, and these conflicts will soon be converted into symptoms elsewhere in the body. Thus the aphonia becomes converted into backache, anesthesia of an arm or any of the other hysterical phenomena.

The treatment of functional, or conversion, aphonia must be directed toward the basic emotional problem. A direct attack upon

the larynx with astringent drugs, galvanic current, or other suggested measures may bring temporary amelioration but may cause the symptom to return at a later date or in a different form. The patient is no longer open to an attack upon the emotional problem because the otolaryngologist has, by his therapeutic procedures, tacitly implied that a laryngeal disturbance which requires organic treatment does actually exist. There can be no second chance then for emotional therapy because the patient who is anxious to hold on to his symptom then attacks the doctor with, "But if there was no disease in my throat, why did you treat it?"

The treatment of these cases of aphonia can often be carried out by an experienced, sympathetic and understanding otolaryngologist who is willing to listen to the patient's story and to help him understand the underlying factors which brought about his illness. It is only by these means, and in difficult cases by calling in a competent psychiatrist, that the otolaryngologist is able to reach the ideal therapy, to treat the patient as a whole and in such a way to restore health, happiness and efficiency to the total organism rather than to remove the symptoms from a single organ.

Summary

1. Aphonia is defined as loss of voice, but it is loss of voice which is not due to a central lesion.

2. This type of aphonia may well be called conversion aphonia because an emotional problem is converted into a physical manifestation.

3. This type of aphonia is a symptom, and as such should not be treated locally.

4. An attempt should be made to find the emotional instability and see that it is corrected. This is a safe method of solving the problem.

5. A psychiatrist is a very able adjunct in a great many cases of aphonia.

608 Guaranty Building.

DISCUSSION

DR. RALPH A. FENTON: I am very glad that Dr. McCaskey has brought up this interesting and sometimes very puzzling subject. He did not discuss the physical changes which sometimes actually occur in a resting larynx, which has been given rest of this type too long. There are actual physical changes.

Of course he and all of us recognize that for such physical changes some type of stimulating treatment is sometimes a good thing. Too much emphasis to the patient on the psychological angle, particularly in young individuals, is sometimes not so desirable.

I am reminded of cases in past years, of novices in religious orders who were sent by their superior, or brought in the hospital. They had lost their voices because their "profession" was not sufficiently warm and complete. They were perhaps thoroughly secure in their religious beliefs, and they had sought a way out in silence. Those girls were taught to hum some hymn tune or something of that sort with their mouths closed and we found out they had voices, but they had other fixations which had to be taken care of by psychological means, and by the discipline which their order established.

The same holds with others who are not subjected to such rigid discipline as these young ladies had undertaken. It seems to me that we should, as otolaryngologists, carry on the psychological treatment which these young people deserve; and we need not necessarily send them to the psycho-analyst, who should be the person to whom they go as of last resort.

DR. E. M. SEYDELL: I have seen quite a number of these patients and thus far have had only one case in which it was impossible to bring about normal speech without referring the patient to a psychoanalyst. In my own practice recurrences have been quite rare after the treatment which I shall describe. The diagnosis of this condition is not difficult and has been amply covered by Dr. McCaskey. My method of treatment is quite simple. I first make a complete examination of the patient's nose, throat, and larynx, and then impress upon him that there are no pathological findings. I explain to him that for some reason there is a short circuit between the

higher centers of the brain, and the lower centers that have control of vocal muscles, which prevents the normal action of his vocal cords. Next I call his attention to the fact that his voice is pitched too high, and that before he can again speak normally he must place his voice in normal pitch. The next step is to ask him to cough, which he usually does in a normal manner. I then very pointedly call to his attention the fact that his cough was normal vocally.

Next I hum in such a manner that I produce a distinct vibration in my upper maxilla. He is then asked to place his fingers on my upper lip to feel this vibration. He is told to make the humming sound in such a manner as to develop this vibration. Then I tell him that I am going to hurt him slightly by pressing on his larynx to help him bring back his voice. This is done chiefly to divert his attention. Now I have him continue his humming. After a few moments I have him sound the letter "M", still in a humming manner, and then gradually I have him add other letters and sounds, e.g.: mo—do—so—go—etc. He is now asked to repeat simple words, making certain that he constantly maintains a low pitch. Soon he is told that his voice has returned. He is observed for several days. I stress constantly that he must maintain a low pitch. By this simple method a complete restoration of normal vocal processes is restored.

Dr. Fred Z. Havens: Dr. Seydell mentioned the high pitched type of voice. It has been my fortune to see a number of these patients. They are in the same category as those patients the reader of the paper discussed, and their difficulty is on the same basis, but the term "aphonia" does not seem quite appropriate since these patients do have a voice. For my own records I have used the expression "dysphonia (strained type of speech)".

Dr. Gordon F. Harkness: I only rise to say that I have had occasion to ask very many men as to the objective picture of functional aphonia. I have been surprised at the number who do not seem to know that picture.

Essentially as you look in the larynx there is always a bilateral abduction. When you ask them to phonate the cords move inward

bilaterally; just before they get into the position of phonation they relax.

It is to my mind absolutely a typical objective picture on which you can make a positive diagnosis, and it seems to me that a great many men do not seem to realize that we have a purely objective type of diagnosis.

Dr. R. F. Marks, San Francisco (by invitation): In the Air Force in combat we had some aphonias which occurred which I thought might be of interest to you.

Over Bougainville we had one combat mission scheduled at 35,000 feet. During that time we noticed over the "intercoms", who used the laryngeal type of "intercoms" for gunners and pilot that the gunners would not hear at all when the pilot observed and announced that the Zeroes, the Japs were coming in. That was due of course as you probably all know to changes in pressure. At 35,000 feet approximately we have one-fourth the air pressure and over the "intercom" your voice would sound something like "huh, huh", the sound of heavy breathing. You were not able to hear at all. We had to develop some other kind of communication. We used a tick on the microphone by tapping with metal. By that way we were able to communicate.

With the advent of the B-29 and our pressure chambers, we kept our pressure approximately 8,000 feet when flying 30,000, so that relieved that difficulty.

Dr. C. H. McCaskey (closing): I want to thank the doctors very much for the way they entered into the discussion of this paper.

In the case histories, which I omitted reading, the same presentments will be found which will cover this type of so-called conversion aphonia.

I, too, have tried various methods, as Dr. Seydell suggested, but I could not sing quite as well as he did, so I had to use other methods. Nevertheless, when cases are treated in that manner they are being treated as a disease of one organ and not as a whole. A great many of these patients do have a recurrence of aphonia; in fact, I was surprised when I looked through the records to find

such a large number of them. A great many of these people have had familial problems which disturbed the psychological entity of the family. If these patients can be made to understand that they do not have anything wrong with the larynx, and can be assured that they will continue speaking normally, they will not have a recurrence, but if they are treated locally, many of them will have a recurrence. As I pointed out in my paper, the problem as a whole has to be solved.

Dr. Fenton stated that many students in religious institutions have this type of aphonia. I saw two sisters who were taking teachers' training in a school. They were dissatisfied with their lot and they both took this avenue of escape to get away from the school. Both of them admitted this was true and I finally had them talking normally and returning to their school work.

ASSOCIATED PARALYSES OF THE LARYNX

CLAUDE C. CODY, JR., M.D.

HOUSTON, TEXAS

The paralyses of the larynx may be divided into three groups. The largest is that of paralysis of the recurrent nerve as the only neurological sign. The second is paralysis of the vocal cord as merely one of many symptoms occurring in some of the systemic nervous diseases. Multiple sclerosis, pseudobulbar paralysis, syringobulbia, locomotor ataxia, the bulbar form of progressive muscular atrophy, apoplexy and the bulbar type of acute poliomyelitis may present at some stage a paralysis of the vocal cord as one of many other findings. The smallest group in the associated paralyses of the larynx with neurological symptoms from various combinations of lesions in the last four cranial nerves. The associated paralyses of the larynx may be classified as the laryngeal syndrome of the medulla and the laryngeal syndrome of the jugular foramen. There are several syndromes of the medulla in which the motor nerves to the larynx are not involved. This classification includes the eponymic syndromes from lesions in the medulla oblongata as well as those at or near the jugular foramen.

Jackson[1] in 1864 reported a case showing homolateral paralyses of half of the soft palate, half of the tongue with atrophy, of the vocal cord and of the sternomastoid and trapezius muscles. The laryngoscopic examination was made by Morell Mackenzie who described a complete paralysis of the vocal cord. Mackenzie[2] in 1880 reported on a patient who had been seen with Jackson in 1868, with symptoms that now would be diagnosed as Tapia's syndrome. Mackenzie also differentiated between lesions in the medulla oblongata and those at or near the jugular foramen. In 1886, Jackson[3] reported a series of cases one of which would now be called the syndrome of the posterior inferior cerebellar artery. It seems clear that for some 30 years the English laryngologists

From the Otolaryngological Department of Baylor Univerity College of Medicine.

recognized the associated paralyses of the larynx, understood the etiology, located the lesion and regarded certain groups of symptoms not as separate entities but merely as variations of essentially the same condition. It is regrettable that this view did not persist. Then the Germans and later the French individualized these groups of symptoms almost into clinical entities as eponymic syndromes. Avellis[4] reported the syndrome which bears his name in 1891, Schmidt[5] in 1892, Tapia[6] in 1906, Vernet[7] in 1915, Collet[8] in 1915 and Villaret[9] in 1917. Since that time, the American Laryngologists have tacitly refused to add any more eponymic syndromes to this collection and so add further to the confusion already prevailing.

The incidence of the associated paralyses of the larynx is rare. The consolidated reports on paralyses of the larynx by New and Childrey,[10] Suehs[11] and Work[12] total 734 cases, of which 30 were the associated paralyses, or four per cent of the total. The laryngeal syndrome of the medulla occurred in 21 of these 30 cases, and the syndrome of the jugular foramen in 9. However, the relative incidence of the associated paralyses and the syndromes of the medulla and jugular foramen varies considerably in the respective reports. Thus it is apparent that if a clear picture is to be obtained of the subject as a whole, reference must be made not to personal experience but to the literature, unsatisfactory though this is.

The etiological factors in the laryngeal syndrome of the medulla are infections and vascular disease. The most frequent infection causing this syndrome is the bulbar type of acute poliomyelitis. Syphilis is next in frequency and is regularly manifested as endarteritis of the arteries supplying the medulla, though a gumma is sometimes present. Tuberculosis has occurred as a tuberculoma of the nucleus ambiguus. Thrombosis of the arteries supplying the medulla is statistically less frequent than lues, but such was not the case in my limited experience. Vasoconstriction of the radicular arteries to the motor nuclei must be added to thrombosis as a vascular condition. One of my patients had a sudden onset with paralysis of half of the soft palate, half of the tongue, an abductor paralysis of the vocal cord and complete loss of voice. When examined seven hours later, the palate, tongue, vocal cord and voice were normal. Vasoconstriction of the medullary arteries may be

more frequent than is indicated by reports in the literature. Hematobulbia occurs in extensive lesions and seems to be included usually under the diagnosis of thrombosis.

The etiology of the laryngeal syndrome of the jugular foramen is quite diverse. The chief cause is a neoplasm usually from the nasopharynx but occasionally from the tympanum. The next in order of frequency is thrombophlebitis of the jugular bulb. Other factors are abscess in the parapharyngeal space, tuberculosis of the cervical glands, fracture of the base of the skull, and gunshot and stab wounds.

The symptomatology of the associated paralyses of the larynx is dependent upon the location and extent of the lesion in the medulla oblongata, or at or near the jugular foramen. The medulla oblongata containing the nuclei of the last four cranial nerves, decussation of the motor and sensory tracts and the paths of other motor and sensory tracts is the switchboard and relay station of the nervous system. The extension of a lesion in this area may occasion many combinations of neurological and laryngeal symptoms. The nucleus ambiguus is, of course, invariably affected in the laryngeal syndrome of the medulla. For this nucleus contains, as it descends through the medulla, the origins of the motor fibers of the IXth, Xth and XIth cranial nerves in the order named. A lesion extending to successive levels of this nucleus causes a combination of lower motor neuron or flaccid paralysis of the glossopharyngeal, vagus and accessory nerves. To illustrate, a lesion in the lower part of the nucleus ambiguus produces a unilateral flaccid paralysis of the vocal cord; if it extends upward, half of the soft palate is paralyzed. But if it extends downward, torticollis or wry-neck is also present.

The upper motor neuron of the nucleus ambiguus is the corticobulbar tract which arises in the inferior precentral area of the cortex. As a part of the corticobulbar tract is another tract, designated the aberrant pyramidal by Dejerine in 1914, which descends through the medulla in or near the medial lemniscus. The latter tracts at successive levels usually have a bilateral or bridle decussation to each nucleus ambiguus as shown in Fig. 1. Thus the vocal cords usually have a bilateral cortical innervation as first demonstrated

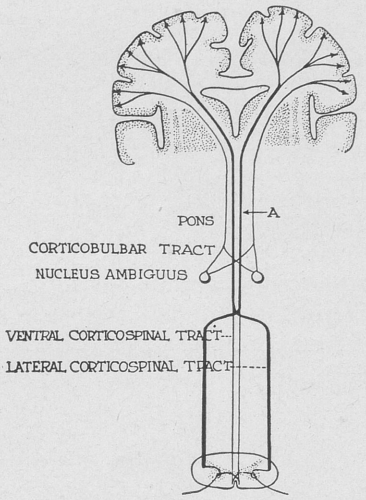

FIG. 1—Schema of bilateral cortical innervation of each nucleus embiguus.

by Krause in 1884 and since confirmed by many anatomists. A lesion of one corticobulbar tract, marked "A" in the schema, usually does not cause a unilateral paralysis of the vocal cord; but if sufficiently large to involve both corticobulbar tracts may cause a bilateral spastic paralysis of the vocal cords. This supranuclear innervation of the nucleus ambiguus is not unique, for all other pontinebulbar nuclei of cranial nerves to muscles which move bilaterally to perform their functions likewise have a bridle decussation. The corticobulbar and aberrant pyramidal tracts are subject to considerable individual variations. While the bridle decussation to the nuclei ambigui usually occurs, it is by no means invariable. Furstenberg[13] has pointed out that a unilateral supranuclear lesion may cause a unilateral spastic paralysis of the vocal cord. A unilateral lesion of the vocal cord is presumptive evidence but hardly positive proof that a supranuclear lesion does not exist. His clinical experience thus confirms the anatomical dissections.

The relation of the nucleus ambiguus to the tracts and other nuclei accounts for the wide diversity of symptoms encountered in

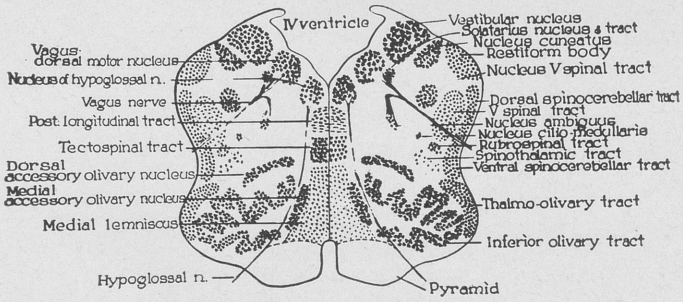

FIG. 2.—Schematic location of nuclei and tracts in the medulla oblongata. (Modified after Ransom)

the syndrome of the medulla. The schematic outline of the location of other nuclei and tracts usually involved in this syndrome is shown in Figure 2. The blood supply of the medulla is derived from the vetebral artery through its branches, the anterior spinal, the posterior spinal and the posterior inferior cerebellar arteries, and to a lesser extent from the basilar. The anterior spinal artery through its central branches supplies the pyramid, the medial lemniscus, and the inferior olive, and its radicular branches accompany the fibers of the cranial nerves to their nuclei. The posterior spinal artery supplies the choroidal plexus and sends branches to the nuclei near the floor of the fourth ventricle. The branches of the posterior inferior cerebellar artery pass through the lateral wall to supply the superficial and deeper tracts. The nucleus ambiguus through the long and slender radicular arteries is more exposed to vascular disorders and so is more frequently affected. The nuclei on the floor of the fourth ventricle have a larger arterial supply than any other area and so are less often involved. The anatomy of the arterial supply is important clinically in locating the site and extent of thrombosis and hematobulbia.

LARYNGEAL SYNDROME OF THE MEDULLA

The one constant symptom in the laryngeal syndrome of the medulla is hoarseness. The onset is sudden. Additional symptoms

appear as the lesion may extend from the nucleus ambiguus to other nuclei and tracts. The voice may have a nasal tone, articulation may be poor or aphonia may be present. The paralysis is flaccid. An abductor paralysis is present and the affected vocal cord may be fixed in the intermediate or even in the mediate position. The arytenoid may be tipped forward, lying slightly below its fellow. On the other hand, the affected cord in the intermediate position may on phonation approximate the midline slightly below its fellow. The innervation of the interarytenoid muscle by a branch of the recurrent nerve of the opposite side causes the adduction. The laryngoscopic appearance is a paralysis of the superior and inferior laryngeal nerve. Anesthesia of the affected vocal cord is variable.

The degree of dysphagia varies from slight inconvenience to regurgitation through the nose. Unilateral paralysis of the soft palate, tongue and pharyngeal constrictors accounts for the difficulty in swallowing, but not for the regurgitation in some and its absence in others. Imperatori[14] may have given the lead to the explanation, for he seems to have been the first to report a spasm of the cricopharyngeus muscle. This suggests a reflex action analogous to a hyperactive knee-jerk.

Eponymic Syndromes

The description of the eponymic syndromes[15] begins with the one in which the lesion affects only a part of the nucleus ambiguus. The extension of the lesion is traced step by step until a large part of the medulla is involved. To the extent of being repetitious, a practical demonstration is thus afforded of the difficulty in associating a syndrome with the correct proper name. A nomenclature that is easy to remember and is associated with the area of the lesion is desirable.

Schmidt's syndrome is hoarseness, torticollis and drooping shoulder. Homolateral paralyses of the vocal cord and the sternomastoid and trapezius muscles are present. The lesion is confined to a part of the nucleus ambiguus and involves the vagus and accessory nerves. A variation shows paralysis of half of the soft palate with involvement of all of the nucleus ambiguus.

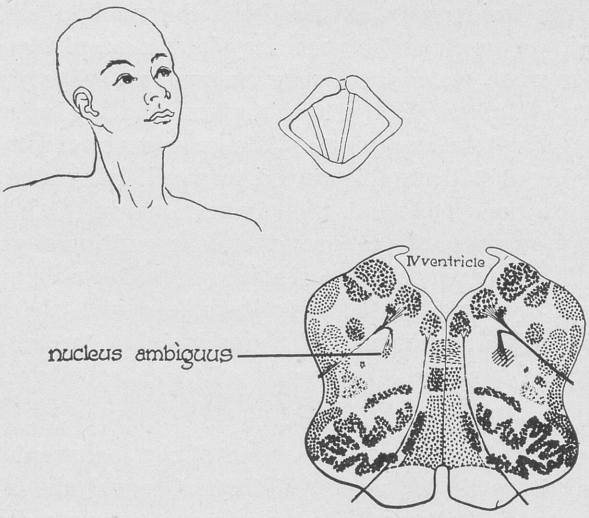

FIG. 3.—Schema of Schmidt's Syndrome.

Tapia's syndrome is hoarseness and dysphagia. On phonation, the unaffected half of the soft palate and uvula is elevated, while the paralyzed part is drawn over as a curtain. The tongue on protrusion deviates toward the affected side and later atrophies. Homolateral paralyses of the soft palate, tongue, pharyngeal constrictors and larynx are present. The lesion involves the nucleus ambiguus and the nucleus hypoglossus.

Jackson's syndrome is hoarseness, difficulty in swallowing, deviation of the tongue, torticollis and drooping shoulder. Homolateral paralyses of the soft palate, tongue (with atrophy later) pharyngeal constrictors, larynx and sternomastoid and trapezius muscles are present. The lesion affects the nucleus ambiguus and the nucleus hypoglossus and involves the vagus and the accessory nerves. Loss of taste on the posterior third of the affected side of the tongue indicates an involvement of the glossopharyngeal nerve, but testing for taste is uncertain. One of my patients, E. B. C., had the classical symptoms associated with this group.

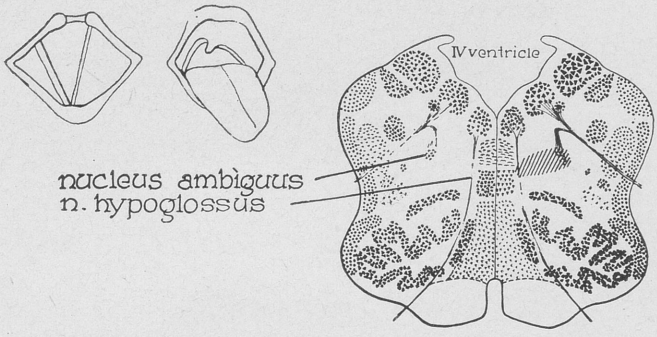

FIG. 4.—Schema of Tapia's Syndrome.

Avellis' syndrome is hoarseness or aphonia, dysphagia may or may not be present. The patient notices a loss of pain and temperature sensations on half of the body below the face. Homolateral paralyses of the soft palate and larynx are present with a contralateral loss of pain and temperature sensibility. The lesion affects the nucleus ambiguus and the spinothalamic tract. The syndrome has several variations, in one of which there is also homolateral enophthalmos, pseudo-ptosis and miosis—a pseudo-Horner's syndrome—from involvement of the nucleus ciliomedullaris. One of my patients, R. A. W., presented this variation of the syndrome. In another variation there is also vertigo and spontaneous nystagmus. Burger[9] emphasizes the importance of a laryngeal examination in all cases of vertigo and nystagmus in order to differentiate brain tumor from the laryngeal syndrome of the medulla.

Wallenberg's syndrome is now regularly referred to as the syndrome of the posterior inferior cerebellar artery. The symptoms are hoarseness or aphonia, dysphagia with regurgitation, and asynergia, lateral pulsion, ataxia, vertigo, nystagmus and conjugate deviation to the affected side. Homolateral paralyses of the soft palate and larynx are present from a lesion in the nucleus ambiguus. Homolateral vertigo falling, nystagmus or conjugate deviation occur from a lesion affecting the descending vestibulbar tract or

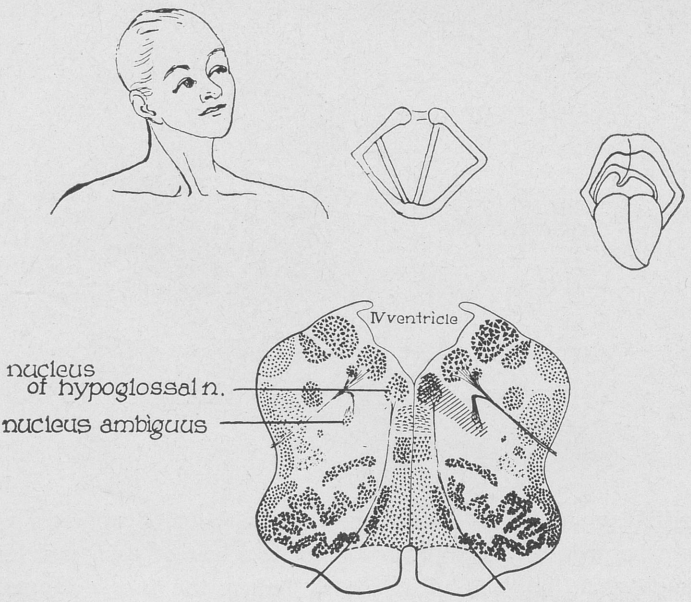

FIG. 5.—Schema of Jackson's Syndrome.

the nucleus. Homolateral asynergia and lateral pulsion are from a lesion in the dorsal and ventral spinocerebellar tract, and ataxia from the rubrospinal tract. Homolateral enophthalmos, miosis and pseudo-ptosis occur from a lesion in the nucleus ciliomedullaris. Homolateral anesthesia of the face occurs from a lesion in the descending tract of the trigeminal nerve. Contralateral loss of pain-temperature sensibility is from a lesion in the spinothalamic tract. The symptoms from a thrombosis of the anterior spinal artery added to this syndrome are the same as those from a thrombosis of the vertebral artery.

Cestan-Chenais's syndrome is the result of multiple lesions in the medulla from degenerative processes persisting after a thrombosis of the vertebral artery. Homolateral paralysis of the soft palate and larynx is caused by a lesion in the nucleus ambiguus. Homolateral enophthalmos, miosis and pseudo-ptosis are from a

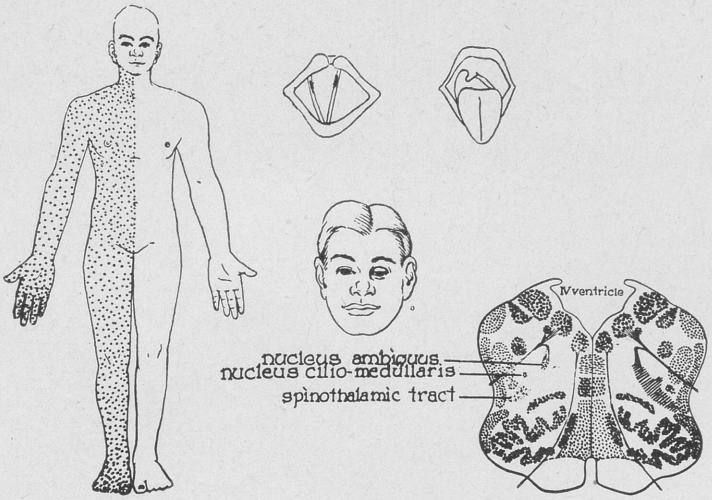

FIG. 6.—Schema of Avellis' Syndrome.

lesion in the nucleus ciliomedullaris. Homolateral asyneria and lateropulsion are from the dorsal and ventral spinocerebellar tract, and ataxia from the rubospinal tract. Contralateral loss of pain-temperature sense is from a lesion in the spinothalamic tract. Contralateral loss of discriminative, proprioceptive and tactile sensibility is from the involvement of the medial lemniscus. Contralateral hemiplegia is from a lesion in the pyramid.

LARYNGEAL SYNDROME OF THE JUGULAR FORAMEN

The laryngeal syndrome of the jugular foramen is the associated paralysis from a lesion at or near the jugular foramen. The eponymic syndromes tabulate only the last four cranial nerves; but the optic and the Vth to the XIth cranial nerves were involved in one of my cases, and other reports have implicated all of the cranial nerves except the olfactory. The onset may be sudden or slow. The sensory functions of the nerves are regularly impaired along with the motor. The sense of taste on the posterior third of the tongue on the affected side is lost, and in one of my patients the ageusia

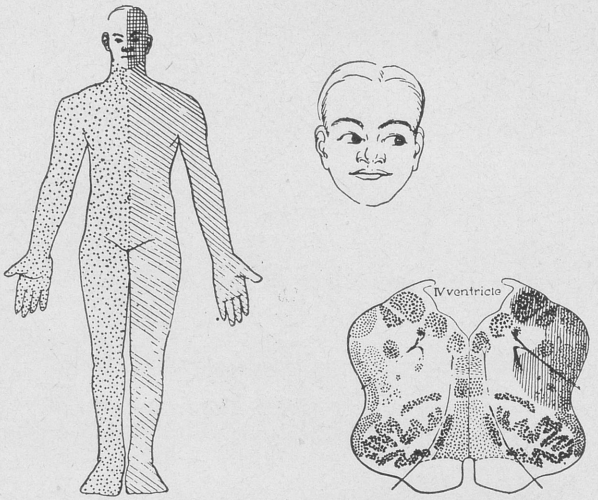

FIG. 7.—Schema of the syndrome of the posterior inferior cerebellar artery.

was complete. The pulse and respiratory rates are affected if the onset is sudden. I have had three patients with this syndrome: one, M. S. H., with thrombophlebitis of the internal jugular vein, who recovered; another, R. H. W., with carcinoma of the nasopharynx, who died; another C. H. with chordoma of the nasopharynx, who is living but unimproved. M. S. H. with thrombophlebitis had Vernet's syndrome but the other two cases do not conform to any of the eponymic syndromes.

The larynx was observed in each of these from the inception of the neurological symptoms. M. S. H. with thrombophlebitis had an abductor paralysis with the vocal cord in the intermediate position and on phonation it approximated the midline. The larynx became normal with recovery from the thrombophlebitis. R. H. W. with carcinoma had an abductor paralysis with the vocal cord fixed in the intermediate position. C. H. with chordoma has an abductor paralysis with the vocal cord in the mediate position.

The schema (Fig. 9) illustrates the relations of the last four cranial nerves with each other and the superior cervical sympa-

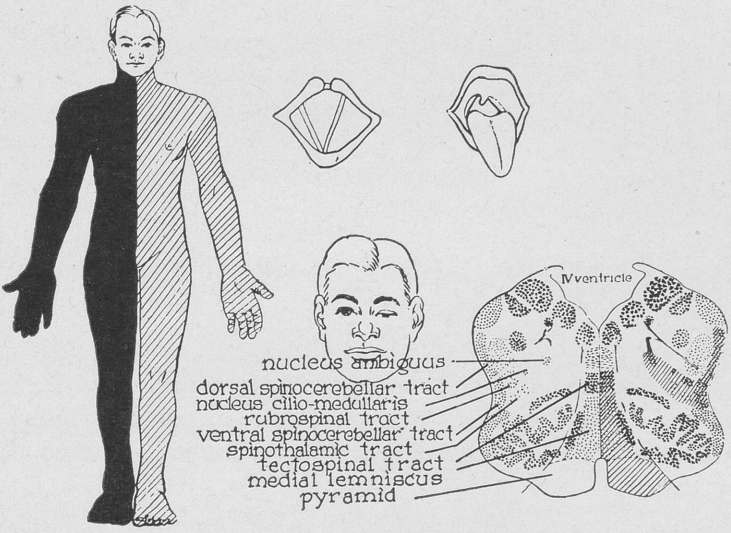

FIG. 8.—Schema of Cestan-Chenais' Syndrome.

thetic ganglion. The sympathetic ganglion is shown to be affected only in Villaret's syndrome, but it may be in the others. The graphic identification of a syndrome is to show the nerves involved and not the location of the lesion. The lesions may be at or near the jugular foramen or in the parapharyngeal space.

EPONYMIC SYNDROMES

Garel-Gignoux's syndrome is hoarseness, torticollis and drooping of the shoulder. The unilateral paralysis of the vocal cord is from damage to the recurrent nerve. The unilateral paralysis of the sternomastoid and trapezius muscles is from the accessory nerve. The syndrome is marked "a" on the schema.

Vernet's syndrome is hoarseness, dysphagia, torticollis and drooping shoulder. Paralysis of the glossopharyngeal nerve causes ageusia on the posterior third of the tongue and anesthesia about the base of the tonsil. Unilateral paralysis of the soft palate, the

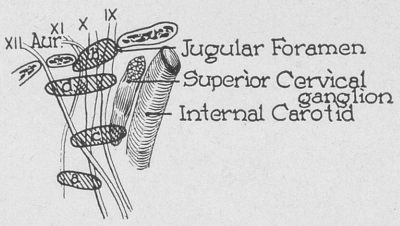

FIG. 9.—Schema of syndrome of the jugular foramen.

pharyngeal constrictors and the larynx follows paresis of the vagus. Paralysis of the sternomastoid and trapezius muscles follows involvement of the accessory nerve. The syndrome is marked "b" on the schema.

Villaret's syndrome is hoarseness, dysphagia, ageusia, deviation of the tongue on protrusion and later atrophy. Horner's syndrome is present following involvement of the sympathetic ganglion. The syndrome is marked "c" on the schema.

The syndrome of Collet-Sicard is a hemiplegia of the last four cranial nerves. It is marked "d" on the schema.

CONCLUSION

Who can remember the correct proper name to apply to a particular syndrome? The eponymic syndromes no longer facilitate the diagnosis of this condition, but act as an unnecessary handicap. As demonstrated here, their continued use is needlessly tedious and repetitious. The recognition of the laryngeal symptoms is unmistakable, but fitting them with the correct proper name is a puzzle not a diagnosis. The Babinski-Nageotte syndrome plus an involvement of the nucleus ambiguus is the same as that of Cestan-Chenais. The nomenclature should be revised, and instead of the eponyms there should be employed terms easy to remember with an application to the involved area.

The term increasing applied to this condition for the past 30 years has been associated paralyses of the larynx. This is awk-

ward, may be confused with the laryngeal symptoms of systemic nervous diseases and particularly does not conform to the usual form of medical terminology. It is suggested that the name to be applied to these paralyses in the future could well be synoplegia laryngis (*syn* a prefix indicating united or associated and *plegia* a stroke or paralysis). The laryngologist would have a term equally applicable to all syndromes whether the lesion was in the medulla or at or near the jugular foramen. The eponymic syndromes could then be enshrined in medical history in grateful appreciation to the skillful clinicians who first described them.

References

1. Jackson, Hughlings: Report of Neurological Cases, London Hospital Reports 1:361-368, 1864.

2. MacKenzie, Morell: Diseases of Throat and Nose, Philadelphia, Blakiston, 1880, Vol. 1, p. 414.

3. Jackson, Hughlings: Case Reports on Paralysis of Tongue, Palate and Vocal Cord, Lancet 1:689-690, 1886.

4. Avellis, Georg: A Clinical Report on Unilateral Paralysis of the Larynx, Berl. Klin. 40:1-26, 1891.

5. Schmidt, Moritz: Diseases of the Upper Air Passages, Berlin, Springer, 1897, p. 883.

6. Vernet, Maurice: Classification of the Syndromes of Associated Laryngeal Paralyses, J. Laryng., Rhin. & Otol. 33:354-365, 1918.

7. Vernet, Maurice: Syndrome of Posterior Lacerated Foramen, Paris Med. 23:78-81.

8. Collet, M.: A New Syndrome of Pharyngeal-Laryngeal Paralysis of Larynx from Battle Injuries, Lyon. Med. 124:121-129, 1915.

9. Burger, H.: Associated Paralysis of the Vocal Cord, J. Laryng. & Otol. 49:1-34, 1934.

10. New, G. B., and Childrey, J. H.: Paralysis of Vocal Cords, 217 Medical Cases, Arch. Otolaryng. 16:143-149, 1932.

11. Suehs, O. W.: Study of 272 Cases, Texas State J. Med. 38:665-671, 1943.

12. Work, W. P.: Paralysis and Paresis of Vocal Cord, Statistical Review, Arch. Otolaryng. 34:267-280, 1941.

13. Furstenburg, A. C.: Anatomic and Clinical Study of Central Lesions Producing Paralysis, Annals of Otology, Rhnology and Laryngology 46:39-54, 1937.

14. Imperatori, C. J.: Syndrome of Avellis, Arch. Otolaryng. 1:277-282,

15. Tilney, F., and Riley, H. A.: Form and Function of Central Nervous System, New York, Paul Hoeber, 1921.

DISCUSSION

Dr. F. L. Weille: For a long time it has been suggested that we forget the names of the nine syndromes of the last four nerves mentioned in the textbooks of neurology, and today Dr. Cody has given us a much easier nomenclature.

I was very much interested in what Dr. Cody had to say about the bulbar tracts.

About a week ago in talking with a neurologist, Dr. G. C. Caner of Harvard Medical School, I asked him if he thought decussation of the corticobulbar tract was analogous to that of the pyramidal tract.

As you know the fibers going to the forehead are supposed to have a bilateral supply centrally. There is a differential point in that you expect to have a bilateral supply from the corticobulbar mechanism whereas the pyramidal tract chiefly decussates first just above the spinal cord at the beginning of the medulla in its inferior portion and the remaining fibers always cross to the opposite side. This is not true of the corticobulbar tract.

I did not understand clearly from Dr. Cody whether or not he thought the cranial portion of the eleventh nerve supplied both cords through the tenth nerve. It is my understanding that this has been established as fact.

How does Dr. Cody distinguish between spastic and flaccid paralysis in the larynx? I presume the only way to do this is by associated paralyses of other muscles outside of the larynx.

Dr. Cody (closing): Dr. Weille asks whether the vagus or the cranial portion of the accessory is the motor nerve of the larynx. Opinions of the anatomists on this question have varied to the degree of almost occupying a cycle. In 1888, Beevor and Horsley concluded that the XI cranial nerve supplied the vocal cords. Today, the consensus is that the X cranial nerve supplies the larynx, the three pharyngeal constrictors and the palate. Also, the IX cranial nerve has only one motor branch and that to the stylo-pharyngeus. The explanation for this difference is that both the continuity of the

nucleus ambiguus and bulbar course of the filaments originating therein are subject to wide variations. There is usually a gap in the nucleus ambiguus between the origins of the vagus and the accessory; but in some individuals the origins of the X and XI cranial nerves are in close juxtaposition. A lesion involving the nucleus ambiguus in the latter group could produce, depending on its location and extent, a syndrome of either Jackson, Schmidt or Tapia.

In bilateral spastic paralysis of the vocal cords, the voice is hoarse, raucous and explosive. On inspiration, the vocal cords are abducted; and on phonation, an over movement of the muscles occurs similar to that in ataxia. In unilateral spastic paralysis, it is reported that the voice is disturbed but slightly; but a detailed description of the movements of the vocal cords has not been encountered in the literature.

INTRALARYNGEAL OPERATION FOR CANCER OF THE VOCAL CORD

FRANCIS E. LEJEUNE, M.D.

NEW ORLEANS, LOUISIANA

It is with much fear and trepidation that I discuss today the intralaryngeal operation for certain types of cancer of the larynx. Fear, because of the statement made years ago by one of our beloved confreres that "intralaryngeal surgery for malignancies should be mentioned only to be condemned." Trepidation, because of my boldness in championing a condemned procedure. Experience over a period of many years has, in my opinion, definitely established a place for the intralaryngeal operation, provided the surgeon rigidly adheres to certain requirements in selecting the cases.

Cancer of the larynx is still a major problem partly solved but not completely conquered. Eminent authorities have outlined the surgical methods generally accepted in the treatment of carcinoma of the larynx. The end results from these operations are truly astonishing, as emphasized by the late Dr. George Crile when he said that intrinsic carcinoma of the vocal cords offers a larger percentage of cures than carcinoma occurring in any other internal organ of the body provided an early diagnosis is made. Early diagnosis, then, is of paramount importance and universal acceptance of the dictum that "every case of persistent hoarseness should be considered potentially malignant until proved otherwise" would insure early diagnosis in most cases of cancer of the larynx.

The accepted surgical procedures for malignant growths of the larynx are *laryngofissure* and *laryngectomy.* The selection of either procedure depends upon the location, type and extent of the growth. Laryngofissure is an ingenious technical conception which yields excellent results when properly employed. I am thoroughly cognizant of its high merit and fully appreciative of its great value to

From the Department of Otolaryngology, School of Medicine, Tulane University of Louisiana and the Department of Otolaryngology, Ochsner Clinic, New Orleans.

laryngology. Laryngectomy is a heroic, life-saving operation which, unfortunately, must be performed all too frequently. While performing a laryngectomy, I am ever conscious of the fact that if the patient had received the proper attention at the proper time total removal of the larynx would not have been necessary.

My experience has proved that there are certain cases of carcinoma of the larynx in which a third type of operation can be performed with equally good, if not better, results than those obtained by laryngofissure, provided certain fundamental requirements are rigidly observed. This third type of operation is intralaryngeal dissection of early intrinsic carcinomas of the vocal cord. The technic is not original but was acquired during my association with the late Dr. R. C. Lynch[1] and it has now been used over a period of many years with such gratifying results that I believe it deserves serious consideration.

For the purpose of analyzing cases of intrinsic carcinoma of the larynx and in an effort to classify them into surgical groups more easily, it has been found convenient to divide them arbitrarily into three classes: (1) early cordal lesions, (2) cordal lesions and (3) cordal fixation or extension to the opposite vocal cord. Groups 2 and 3 represent those cases requiring laryngofissure and laryngectomy. There can be little or no disagreement in the selection of cases which fall into these two groups. This presentation is primarily concerned with the early cordal carcinomas which have been placed in Group 1.

Occasionally, one sees an early cordal carcinoma which appears so limited in extent that one wonders whether an operation as extensive as laryngofissure is necessary to eradicate so small a growth. Such a small growth, representing the earliest and most definitely limited malignant lesion encountered in the larynx, is confined to one vocal cord and may well be considered a surface lesion. These small surface lesions are slow to infiltrate the surrounding tissue because of the usually low type of malignancy and the paucity of the lymphatic supply in this area. The growth may be only the size of a grain of rice, a pea or a dimpled match head, and it is usually situated near the junction of the anterior and

middle thirds of the cord. However, it is not size alone which makes it amenable to intralaryngeal extirpation; in order to warrant such treatment it is absolutely necessary that healthy cordal tissue be visualized on all sides of the neoplasm. In a case of this kind, the histologic diagnosis may be made by rush biopsy and the amount of tissue to be removed will be governed by the principles on the extension of malignant tumors as set forth by New and Fletcher.[2] According to Clerf[3] in 40 per cent of all patients with carcinoma of the larynx reporting to the laryngologist for the first examination, the lesion is so far advanced that little or no surgical treatment can be offered. When this is taken into consideration, it should be no surprise that few cases will be found to satisfy the requirements for intralaryngeal dissection. Briefly, these requirements are that the lesion must be in the early stages of development, small in size, limited to one vocal cord and completely surrounded by normal cordal tissue. If there is any question about its being too extensive for intralaryngeal dissection, laryngofissure is advised. As one gains experience in intralaryngeal surgery, border line cases may be attempted, but they must be watched more carefully for the possibility of recurrence.

The prognosis of early cordal carcinoma is good because of 1) the location of the lesion, 2) the type of malignancy and 3) the lymphatic supply in this region. The lesion is located on a limited portion of the surface of one vocal cord and is surrounded on all sides by healthy tissue. Because of the histologic structure of the vocal cord, 95 per cent of the lesions are of the squamous cell variety; they are usually of low gradation and develop slowly. Since the lymphatic vessels of the true cords are small in size and number, there is no early metastasis.

The advantages of intralaryngeal extirpation are: (1) simplicity of operation, (2) no external incision, (3) preservation of continuity of the thyroid cartilage, (4) better postoperative phonation, (5) shorter hospitalization and (6) good prognosis.

Intralaryngeal extirpation for intrinsic cordal carcinoma is best accomplished by means of suspension laryngoscopy. This method affords excellent direct visualization of the vocal cords and per-

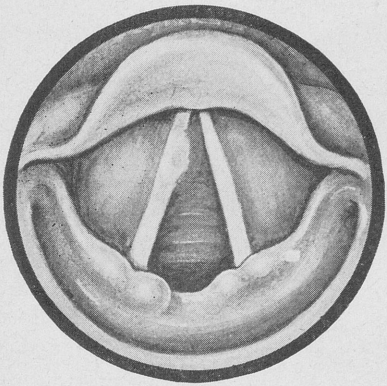

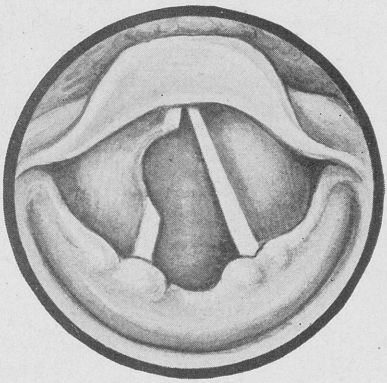

FIG. 1.—Early cordal carcinoma.

FIG. 2.—Appearance of larynx immediately following extirpation of cordal tumor.

mits the use of both hands for performing the operation. This approach and technic are largely responsible for simplifying intralaryngeal operations so that malignant lesions may be adequately treated. Once the larynx is exposed, the tumor is again carefully examined to check on its size and extent (Fig. 1). The vocal cord is retracted and the undersurface is examined. The tumor is then grasped with fixation forceps and traction is made toward the opposite side, thus placing the cord on medial tension while the tumor together with a wide margin on all sides of normal-appearing tissue is excised. Ambidexterity is a valuable asset in performing these operations. After the tumor has been removed, the edges of the wound are electrocoagulated and bleeding or oozing controlled (Fig. 2). Pentothal sodium is the anesthetic of choice in such cases because of the necessity of electrocoagulation. There is, as a rule, comparatively little postoperative reaction. Serious hemorrhage has never occurred and it has never been necessary to perform postoperative tracheotomy on any of the patients in my series. Vocal rest is observed and the patients are kept abed for several days.

During the healing process the filling defect in the anterior half of the vocal cord is gradually repaired. Occasionally, there de-

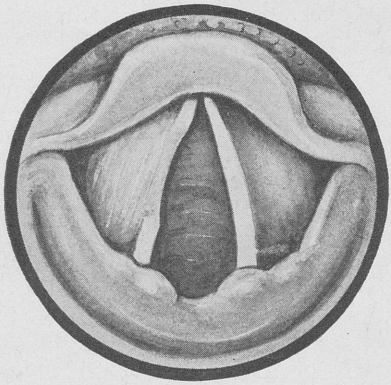

FIG. 3.—Appearance of cord when healed.

velops granulation tissue which, when persistent, may require removal and cauterization. Because of the small size of the tumor and the consequent limited portion of the cord removed, wound healing and repair rapidly occur (Fig. 3). In many cases a band of cicatricial tissue replaces the lost portion of the cord and occasionally the repair by nature closely resembles the original structure. With such satisfactory repair one can reasonably expect a voice far superior to that obtained in the average patient subjected to laryngofissure.

Patients who have had intralaryngeal extirpation are given the same scrutiny and careful postoperative observation accorded all patients with laryngeal neoplasms. They are not considered cured until five years have elapsed during which time it is imperative that the larynx be subjected to repeated examinations. Probably, the surgeon gets better cooperation from his patients and keeps his own thinking in the proper direction if, after treatment, patients with carcinoma of the larynx are considered "well without recurrence" rather than "cured." Only in this manner can an early recurrence be discovered. Early recognition of recurrence followed by cauterization or the performance of laryngofissure might still preserve a crippled but precious and partially functioning

organ. If the continuity of the larynx is destroyed by splitting the thyroid cartilage, recurrence of the neoplasm may be attended by serious developments.

I have operated on 39 patients with early intrinsic carcinoma of the vocal cords by the intralaryngeal route and electrocoagulated the base of the lesion following the operation. Nineteen of these patients have survived the five-year period after which they are considered "cured." Fifteen patients are living and well from one to five years after operation. Two patients have been operated on so recently that no result can be given now. Three patients have had recurrences; two required laryngofissure, and one later required laryngectomy. In this latter patient, 11 years after an intrinsic tumor of the left vocal cord had been successfully removed by intralaryngeal dissection, a tumor developed on the opposite vocal cord which, when first seen, showed fixation of the cricoarytenoid joint with involvement of the entire right side of the larynx.

With the extensive cancer program now being carried on throughout the nation it is reasonable to expect that more and more cases of early carcinoma of the larynx meeting the rigid requirements for intralaryngeal operation will be seen. Complete eradication of the malignant lesion with maximum preservation of organic function is the ideal and in early cordal cancers this can be achieved by intralaryngeal extirpation of the tumor.

Ochsner Clinic Building.

References

1. Lynch, R. C.: Cancer of the Larynx, Trans. Indiana Acad. Ophth. & Otolaryng. Jan., 1926.

2. New, G. B., and Fletcher, E.: Selection of Treatment for Cancer of the Larynx, J. A. M. A. 99:1754-1758 (Nov.) 1938.

3. Clerf, L. H.: Cancer of the Larynx, Arch. Otolaryng. 32:484-498 (Sept.) 1940.

DISCUSSION

Dr. George J. Taquino, New Orleans, La. (by invitation): Dr. LeJeune's paper was most instructive. His method of treatment is one which I have followed for quite a long time. It was my priv-

ilege to have been associated with the late Dr. Robert C. Lynch when he first began intralaryngeal dissections for early carcinoma of the larynx, also to have been with Dr. Lynch when he designed the instrument for suspension laryngoscopy. I helped him with the first case and many succeeding cases thereafter. I have performed a number of intralaryngeal cases for early carcinoma of the larynx. At a meeting of the New Orleans Graduate Medical Assembly I was given an opportunity to show a series of about ten cases with excellent voices, some of them of over seven years' duration. In this series the latest was of two years' duration. At the present time and as far as I know they are still living and well. The important point is to make an early diagnosis of carcinoma of the larynx, then select your cases for this particular type of surgery. I have used local anesthesia through-out this group of cases. I have not tried to preserve tissue, but have made large dissections followed by electrocoagulation. In no instance was a tracheotomy done nor was one indicated. I also supplement the treatment with deep X-ray therapy and to my knowledge there has not been a single recurrence in these selected cases.

Dr. Fred Z. Havens: I have employed the method Doctor LeJeune has described, not as many times as he has, but several times and with highly gratifying results. It is of course, as he has said, important that the method be used only in very carefully selected cases. I wish to commend him for his courage in following it up and using it, and I think it certainly has a place in the laryngeal surgeon's technic, but it is not a procedure for "Tom, Dick and Harry" to employ.

Dr. Samuel Salinger: Despite the fact that the paper was extremely interesting and very well presented, I don't believe that there will be a wild stampede to do intralaryngeal extirpations of carcinoma of the larynx.

In my own experience I have but very seldom seen the type of case which I thought would be amenable to this type of surgery, and can only recall two instances in which it was successfully done. In one of them it was done by design because the patient refused external operation and in the other it was purely accidental. The

lesion was very small, superficial. It occurred in a physician and we removed it for biopsy purposes. To our amazement we found it was malignant, but there was a perfectly healthy zone of tissue around it. Both of those cases got well.

It may be that with the increasing attention focused on the cancer problem we may get more cases that are suitable to this type of surgery. I don't see any reason why any well qualified laryngeal surgeon should not be able to perform it and I do think that the suspension method is the procedure which affords the maximum exposure with freedom to use both hands, as Dr. LeJeune has mentioned.

DR. C. C. CODY: Dr. LeJeune's paper is so important as to merit extensive discussion, though to speak twice embarrasses me. Intralaryngeal surgery has a distinct and limited place in treating cancer of the larynx. The flat type of papilloma of the larynx not infrequently recurs after removal with the punch. Recurrent papilloma of the larynx is cancer until proven otherwise. When a papilloma is removed with the punch, its base should be fulgurated as an attempt to prevent its recurrence.

It is a surgical axiom that the earlier cancer is definitively treated the larger the percentage of recoveries. A corollary to this is that cancer is seen earlier after the development of a definitive treatment which causes little or no impairment of function or of appearance. The experience of the dermatologists, as one example, demonstrates this. Dr. LeJeune's method is an important advance in the definitive treatment of laryngeal cancer. Further experience will be necessary to appraise accurately the value of fulguration after biopsy of an ulcer less than 5 mm.

DR. M. JACKSON, Johannesburg, South Africa (by invitation): Mr. Chairman and Gentlemen, first of all I wish to thank you very much for the kindness you have extended to me since my arrival here and for the privilege of allowing me to attend this meeting.

I would like to ask Dr. LeJeune about a case which I had two and one-half or three years ago, of a man of about 53, who had what I termed to be a papilloma situated practically in the anterior

commissure. I thought it was a papilloma but decided to do a biopsy and found it was a squamous cell carcinoma. I explained to him that I thought the only thing to do was a laryngectomy, but he was very much adverse to that, so I removed the upper third of both cords. This was three years ago and I have been seeing him subsequently every six months and just before I left to come over here he was still doing well.

Dr. J. W. McCall, Cleveland (by invitation): I feel that Dr. LeJeune is to be congratulated on seeing thirty-nine cases of carcinoma of the larynx that were recognized early enough to have this intralaryngeal procedure done. This, in itself, proves that Dr. LeJeune has done a good job in teaching the public of New Orleans, that hoarseness may be a symptom of a serious laryngeal condition.

Unfortunately, in Cleveland we do not see them this early. Practically all our cases are in the later stages, and we have to do a total laryngectomy.

I would like to ask Dr. LeJeune if limitation of motion of a cord plays any part in determining whether the intralaryngeal procedure can be carried out?

Dr. Gabriel Tucker: I wish to compliment Dr. LeJeune on the excellent results he has obtained in the treatment of very early cases of cancer of the vocal cord. I have seen very few cases in which endolaryngeal excision seemed justified.

However, in five cases in my series in which positive biopsy was performed in early cancer, careful histologic section of the tissue removed by subsequent laryngofissure showed no evidence of cancer and in another patient, a woman 63 years of age, with a lesion of the middle third of the right side of the larynx, a positive biopsy had been done at another hospital, and the patient brought the tissue slide with her when she was referred in consultation and our pathologist confirmed the finding of Grade 11 squamous cell carcinoma. The site of the previous biopsy on the right cord showed a smooth surface and we thought that it was possible that all the cancer had been removed, however, a second biopsy was done which showed no evidence of cancer. It was recommended that no further

surgery be done and the patient has been kept under close observation. After 3½ years the larynx is entirely clear, and there is no evidence of metastatic extension to the cervical lymph nodes. The direct laryngoscopic biopsy had removed the entire growth.

I believe that it would be possible to remove a great many of the early cancers of the cord by direct laryngoscopy. However, the internal perichondrium provides a very efficient barrier to cancer in the cord and with thyrotomy and excision of the growth with a wide margin of the normal tissue including the internal perichondrium we are more certain to remove any local extension of the growth into the laryngeal tissues. This technique can be carried out by laryngofissure and where the growth is limited to the cord the cord will reform and the function of the larynx will be restored to normal. It seems logical that this wide excision will give a greater margin of safety from recurrence in the individual case than intralaryngeal excision. After excision by thyrotomy the cut margins of the mucous membrane surrounding the excised area may be approximated by sutures. This technique reduces the deformity of the operated side of the larynx to the minimum.

From my experience in the removal of laryngeal tumors I believe that there would be a better chance of development of a clear voice where the anterior end of the cord has been removed than where the mid portion of the cord were punched out as sometimes occurs when benign tumors of the cord are not skillfully removed.

I want to thank Dr. LeJeune for his most excellent presentation. He always brings us something that stimulates us to bigger and better things.

DR. J. H. FOSTER: Having retired from active practice it had been my intention not to enter into the discussions at this meeting, but I cannot refrain from saying a few words about Dr. LeJeune's excellent paper.

I was a very close friend of Dr. Lynch whom Dr. LeJeune mentions as having begun this work and had the opportunity to observe some of his cases and admire the unusual skill of Dr. Lynch in intralaryngeal surgery. I have had several cases that have had permanent cures after intralaryngeal removal of malignant tumors.

I think that everyone will agree that the number of cases suitable for this type surgery is limited and depends upon our seeing them fairly early. However, I am impressed by the fact that we in Texas and Louisiana do now see a fairly large number of cases of early cancer of the larynx. A campaign of education of the general practicioners to suspect all cases of hoarseness and have them examined has been of great value and has resulted in our seeing many early cases of malignancy.

There are two points that I am constrained to stress. The first is that this work requires that some form of exposure of the larynx must be used that permits the use of both hands in operating. You cannot do it with punch forceps. The second point is that what was said today about the fenestration operation applies to this work, namely that it will be successful only in the hands of those who possess unusual skill in this type of surgery. It will not replace other types of surgery, but is valuable in properly selected cases.

Dr. Gordon B. New: I have visited Dr. LeJeune in New Orleans and know the excellent work he is doing. We have recently reviewed a group of cases of cancer of the larynx and find that 77.4 per cent were operated on and 22.6 per cent were treated with irradiation. Of the operated cases, 47.7 per cent had a laryngectomy, 41 per cent had a thyrotomy and 11 per cent were treated by laryngeal suspension, fresh frozen microscopic examination and then removal of the cancer with surgical diathermy. This shows that there is a definite group of cases where cancer can be removed by means of suspension laryngoscopy when the microscopic examination and the other clinical features are evaluated. Of the cases treated under suspension laryngoscopy, 33 per cent were grade I; 49 per cent were grade II and 14 per cent were grade III. This includes, of course, the carcinoma of the epiglottis and some of the aryepiglottic fold. The growths were removed with surgical diathermy and at times radium seeds were inserted. The end results in this series show that 92 per cent of the patients so treated were living and well over a five-year period. It is interesting to note in the end results that the larger percentage of patients who are living and well are the ones who had low grade tumors (grade I and grade II). A large percentage of the laryngeal lesions are grade I and

grade II. The patients who had grade III cancers and who are living and well are those who had lesions of the epiglottis and base of the tongue which were removed with surgical diathermy and had radium seeds inserted. The treatment of cancer of the larynx under suspension laryngoscopy has a definite place in this field and Doctor LeJeune is doing an excellent job in carrying on the work started by Doctor Lynch many years ago.

Dr. A. H. Andrews, Jr., Chicago, Ill. (by invitation): As we follow along with carcinoma of the larynx I believe we are going to be seeing more and more of the earlier cases.

There is one diagnostic procedure which has not been discussed this afternoon which deserves mention, namely the use of the laryngostroboscope.

In our experience with this instrument in tumors of the larynx it has been possible to make some rather interesting observations. The normal undulating movement of the vocal cords may be very plainly seen. Small tumors on one cord may be seen to move to and fro with a rather gross type of movement. Anterior and posterior to the tumor the normal undulating movements may be seen.

In some tumors which were malignant we have noticed that there was more or less of a rigidity to the vocal cords anterior and posterior to the bulk of the tumor. It may be that when undulating movements are visible anterior and posterior to a small malignancy that such a case may be suitable for operation by the intralaryngeal extirpation method.

I do not believe that I have had sufficient experience with the laryngostroboscope to make very definite statements, but I do believe it is a diagnostic procedure to be considered and to be studied in connection with this type of diagnostic work.

Dr. F. E. LeJeune (closing): I probably did not emphasize one point sufficiently. These cases are highly selected. The tumor or the lesion must be very small and must be surrounded by what apparently looks like normal tissue on all sides.

In answer to Dr. Cody's question I might say that I have never used the fulgurating current on the patients who have a papilloma.

In the case of a flat papilloma of the vocal cords if it were malignant and much of the cord were involved, I certainly would perform laryngofissure instead of intralaryngeal dissection.

In answer to Dr. Jackson's question about the papilloma which involved the anterior commissure of the vocal cords, I think he did exactly what I would have done under similar conditions. He carried out the Chevalier Jackson anterior commissure technique of laryngofissure; he took out the portions of both vocal cords which were involved and I think that is the proper thing, and apparently from what he reports he has gotten excellent results, as we would expect.

Dr. McCall asked about the limitation of the cord. In my estimation, if a cord is fixed or if there is limitation or interference with motion, the lesion is extensive and is not suitable for intralaryngeal extirpation, nor, in my opinion, for laryngofissure, because it means that the crico-arytenoid joint is involved and nothing short of laryngectomy will afford any permanent relief in such a case as that.

Dr. Tucker seems fearful that we are taking a chance with intralaryngeal surgery. If the lesion is large, by all means do a laryngofissure. Don't take a chance by doing the intralaryngeal operation. If the lesion meets the requirements that we have tried to enumerate, then try the intralaryngeal operation. If it is a surface lesion, an early lesion, usually it will be of Grade I or Grade II malignancy at the most, and it can be extirpated successfully by the intralaryngeal route, and only a small amount of the tissue is removed from the vocal cord, much less than is removed by means of laryngofissure. Naturally, under these circumstances we could expect better regeneration of the vocal cord in the postoperative procedure as well as a better voice quality.

I am glad that Dr. New brought out the fact that these early tumors are of low gradation and, therefore, we have more chance to expect a good prognosis in these cases.

I have never used the laryngostroboscope. Probably, it is an instrument to which I should give more attention.

INTRANASAL MEDICATION — AN INVESTIGATION INTO THE RELATIVE MERITS OF CERTAIN METHODS OF INTRODUCING FLUIDS INTO THE NOSE

TERENCE CAWTHORNE, F.R.C.S.

LONDON, ENGLAND

(By Invitation)

Mr. President, Members of the Association and Guests, I feel very privileged to be given such an opportunity as this of addressing the American Laryngological Association. I hope the subject of this very short communication is worthy of your consideration. I am very conscious of the threadbare nature of the material.

I would first of all like to give you a little outline of the background which led up to this investigation being carried out.

In 1943 there was published in the Lancet the discovery of a new antibiotic, one of the penicillins, penicillin patulum. In addition to this new antibiotic being reported, at the same time reports were given of the results of instilling this patulum into the nose in cases of service men suffering from acute upper respiratory infection. The claims made were that as the result of these instillations the colds were cut short or cured very quickly.

This raised a very great deal of interest and the general press got hold of it and even started the asking of questions in our Houses of Parliament about it. It was decided by the Medical Research Council to set up a committee to carry out a thorough investigation and so the Medical Research Council set up a Penicillin Trials Committee. They asked me to be one of the members and to advise them on the best way of instilling this penicillin solution into the nose, because they were proposing to carry out a large number of field experiments on the factory workers throughout the country. In point of fact that was done and many thousands of factory workers were treated but in the end, as you can well imagine, it turned out to be not quite so good as the original things described.

But I want to tell you this morning about the way we decided was best to instill this fluid into the nose because in the original reports it was quite clear that the fluids were being instilled in what was a rather happy-go-lucky fashion and probably in such a way that most of the fluid would merely come into contact with the floor of the nose. Therefore, when I was asked to carry this out, to advise them how it should be instilled, I had my ideas on the best ways of getting the medicament to all parts of the nose. I thought before giving them the advice I better carry out this small investigation and that is what I propose talking about this morning.

The introduction of fluid medicaments into the nose has always been a favourite form of local treatment for most nasal disorders.

In order that such medicaments may be allowed to act to the fullest advantage, it is clearly desirable that they should come into contact for an adequate period with as wide an area of the affected nasal mucous membrane as conditions will permit.

The upright position adopted by man, and the configuration of the outer wall of the nasal fossa, both hinder the even distribution of fluid instilled into the nose by the conventional methods of drops, sprays and sniffs. In order to overcome the disadvantage of having to diffuse the fluid against the force of gravity, Proetz (1927) advocated the head-low position, and later Parkinson (1933) described a head-lateral position. Recently mention has been made of a forward head-low position, which is said to be effective without being uncomfortable.

An inquiry (Lancet, 1944) into the claims made for the value of the nasal instillation of a solution of Penicillin Patulum (Lancet, 1933) in the treatment of the common cold made it necessary, for the purposes of the inquiry, to decide upon a standard method of introducing the solution into the nose. It was felt that in order to give the preparation, which was known as Patulin, a fair trial it was important to employ a method that brought the solution into adequate contact with the widest possible area of nasal mucous membrane.

Before advising on the method of intranasal medication to be employed, I carried out a series of tests with different methods in a small series of normal subjects. Later these tests were repeated in another small group of normal subjects with almost identical results.

In order to test the efficiency of the methods under review, it was decided to take advantage of the paralytic effect of cocaine upon sensory nerve endings. It was known that the application of a solution of cocaine to the area of the nose supplied by the trigeminal nerve rendered it insensitive to common sensation, and it was considered that in addition it probably abolished the chemical sensation stimulated by pungent fumes, such as ammonia, chlorine, menthol, etc. At the time of this investigation no information could be found concerning the effect of cocaine on the olfactory nerve endings, but it was hoped that its application in a suitable concentration to the olfactory mucous membrane would paralyse the sense of smell, in the same way as it is known to affect taste. Preliminary tests confirmed this hope, and it has since been found that the paralytic effect of cocaine on the olfactory nerve endings had already been noted by Zwaardemaker.

It was decided, therefore, to compare the effect upon olfaction and the chemical sense of introducing in different ways a solution of cocaine into the nasal passages of normal subjects.

The number of methods to be tested was limited to the following four, all of which are in general use for intranasal medication, though of course many different variations of each method are practised.

1. *Drops.* With the subject seated in an ordinary wooden chair of the "Windsor" type, the head was inclined as far backwards as was compatible with comfort and 1 dram of the cocaine solution was introduced by a medicine dropper, drop by drop, into each nostril, the subject being instructed to breathe through the mouth. In all cases a pause was necessary after the solution had been introduced into each side, because it rapidly dropped into the throat and had to be spat out to prevent its being swallowed.

2. *Spray.* With the subject sitting upright, a trained observer sprayed, under direct vision, each side of the nose in turn with an all-glass spray. At first the spray used was so fine that only half a dram could be conveniently used on each side, but later a coarser spray was used so that one dram of the solution could be used on each side. The results were the same with both quantities. With each spray the subject was instructed to inspire through the nose.

3. *Sniff.* With the head bent forward, one dram of the solution was sniffed up each nostril in turn.

4. *Head-Low Position.* With the subject lying supine with the head hanging backwards and downwards so that the crown of the head faced the floor, one dram of the solution was dropped by a medicine dropper into each nostril in turn, the subject breathing through the mouth. This position was maintained for 30 seconds after the solution had all been instilled.

After some preliminary trials with solutions of different strengths, it was decided to carry out the tests with a 10% solution of cocaine.

Because of the paralytic nature of the solution it was necessary, and on account of its potency it was felt desirable, to carry out only one test on any subject in any one day.

The following tests of function were started not more than two minutes after the end of each test instillation.

Olfaction. Solutions in light liquid paraffin of nitrobenzol (3.05 gm. per liter), Guaiacol (0.302 gm. per liter) and Xylol (1.75 gm. per liter) were prepared and employed according to the method described by Proetz, and it will be noted that the concentrations used were 100 times stronger than the minimal perceptible odour which he established for each substance. In addition a bottle of plain liquid paraffin was also used to check, from time to time, the accuracy of the responses.

Before testing, the subjects were allowed to make themselves familiar with each of the odours and at each test identification of the odour in question was requested. Three types of reply were noted.

(a) The odour could be identified. This was considered normal and recorded as "unaffected."

(b) The odour could not be identified, but an aroma could be appreciated. This was considered to be a diminished response and was recorded as "diminished."

(c) No odour could be detected. This was considered an abolition of olfactory function and recorded as "abolished."

Chemical Sense. The sensitivity to pungent vapours of that part of the nasal mucous membrane supplied by the trigeminal nerve was tested for its reaction to the inhalation of ammonia fumes. In the unanesthetised nose it was found that quite a gentle sniff from a two-ounce bottle of Liquor Ammoniae Fortis held within two inches of the nose was sufficient to cause a painful reaction with subsequent lachrymation.

The reactions to testing with ammonia after intranasal instillation of the cocaine solution were also grouped under three headings.

(a) *Normal.* No deviation from the normal response was either observed or experienced. This was recorded as "unaffected."

(b) *Diminished.* There was an increased toleration of the ammonia fumes with a noticeable diminution in the local sensation and the lachrymation. This was recorded as "diminished."

(c) *Abolished.* There was no sensation in the nose nor was there any lachrymation. This was recorded as "abolished."

SUMMARY OF RESULTS OF TESTS OF OLFACTION AND CHEMICAL SENSATION

METHOD OF INSTILLATION	SENSE	EFFECT		
		UNAFFECTED	DIMINISHED	ABOLISHED
Drops	Olfaction	7	0	0
	Chemical sense	5	2	0
Sprays	Olfaction	4	3	0
	Chemical sense	1	5	1
Sniffs	Olfaction	3	4	0
	Chemical sense	2	5	0
Head-low position	Olfaction	0	1	6
	Chemical sense	0	2	5

It was felt that the results were sufficiently uniform to justify drawing certain preliminary conclusions from this small series of cases, and these will be summarized under each method.

Drops. Drops do not appear to reach the higher part of the nasal fossae at all and only in two cases was there a slight effect upon the respiratory area. It would seem that by this method of instilling fluid into the nose only a very small area of the nasal mucous membrane is affected, and it does not appear to have enough time in which to act effectively upon the membrane with which it comes into contact.

Sprays. Sprayed solutions affected the olfactory area in three cases only, and then but slightly. The respiratory area was affected in five cases and in one of these it was paralysed. Vigorous spraying under good conditions of direct vision enabled the respiratory area to be reached in most cases, but here again the solution did not often remain in contact with the mucous membrane long enough to produce its maximum effect.

Sniffs. Sniffs or douches affected the olfactory area in four cases, but in no instance was olfaction abolished.

The respiratory area was affected in five cases but paralysed in none.

By this method it appeared that a wider area of the nasal mucosa could be reached than by drops or sprays, but once again the inhaled fluid did not have time to act effectively.

Head-Low. In the head-low position olfaction was affected in all cases, being abolished in six cases and diminished in one.

The respiratory area was affected in two cases and sensation was abolished in five cases.

The striking difference in the results between this method and the others can, it is suggested, be attributed to two main factors. In the first place the fluid, encouraged by gravity, filled the nose, thus coming into contact with the whole of the accessible nasal mucous membrane; and in the second place, it was kept in contact with the membrane sufficiently long to have an effective action.

This small investigation could, with advantage, have been extended both in scope and in the number of subjects tested, but the results seemed to be sufficiently conclusive to answer the purpose for which the investigation was started. Moreover, the subjects of the test, with one exception all young adults between the ages of 20 and 30, found the effect of applying solutions of cocaine to their noses on at least eight different occasions, definitely unpleasant. I can speak with personal experience of this investigation, because I was one of the subjects, and the discomfort experienced makes it difficult to appreciate why the application of cocaine to the nose in physically healthy subjects could ever lead to an addiction. It was noted that sensation gradually returned, until, within four hours at the most, it appeared to be normal.

I would not like to end this short paper without recording my thanks to the volunteers who, by allowing themselves to be sub-

jected to these tedious and often unpleasant tests, made this investigation possible.

149 Harley Street.

DISCUSSION

Dr. A. W. Proetz: This investigation of Mr. Cawthoone is naturally of great interest to me. The fact that his solutions reached all parts of the nose when he turned the head upside down is no surprise to me because in the early days we investigated this feature by means of lipiodol and took x-rays of the nose with the head in that position. What I am surprised to see is that the other methods were so relatively ineffectual and also that the sniff was more effective than anything else excepting the head-low position. The half minute's time, as Mr. Cawthorne said, is very important.

I should like to ask on the side, what may have been the effect of a 10 per cent cocaine solution in quantities of a dram on each side lying in contact with the entire nasal mucosa, for a period of half a minute. One would expect some toxic effects from that and I am curious to know what the reactions on the individuals were.

That is a relatively big dose and the absorption from such a surface must be quite considerable and quite abrupt. The danger of cocaine lies in the rapidity of absorption other than in the total dose and I wonder if Mr. Cawthorne would say a word about it.

Mr. Cawthorne (closing): With regard to the cocaine, we tried first of all to work with weaker solutions, one, two and five per cent, but we could not get the olfaction abolished with anything less than 10 per cent, and so reluctantly we did use the stronger solution.

In none of these cases were there any toxic effects of absorption. I was terrified, I don't mind telling you, all the time because most of these subjects were medical students, and it would not have looked very well if I had made a medical student ill.

With regard to the effect on them, I can only talk about myself. We usually did these late in the afternoon. My wife always knew

when I had been at the cocaine again. I used to get home and was a little bit restless. I could not settle down promptly. I could not taste and the throat felt a bit miserable, and it did take about two or three hours to wear off. I felt diffident about saying this about cocaine because I suspected somebody was going to get at me for using cocaine, and my senior colleague, needless to say, held up his hands in horror. "You know what you do when you put two per cent cocaine on the cilia? They just lie down and die". But it did not seem to do us any permanent harm at all.

SENSITIVITY FROM INSUFFLATION OF THE POWDERED SULFONAMIDES IN ACUTE INFECTIONS OF THE NOSE AND THROAT

HOWARD C. BALLENGER, M.D.

CHICAGO, ILLINOIS

The local use of the sulfonamides in treating acute infections of the nose and throat has received much attention in the last three or four years. The soluble sodium salt of the sulfonamides, especially sodium sulfathiazole, had the earliest[1] and formerly the most frequent use. The principal objection to the soluble sodium salts is their high alkalinity (pH of 10 to 11), whereas the range of normal mucous membrane in man in situ is from a pH of 5.5 to 6.5 (Fabricant[2]). The pH of the 2.5 per cent sodium sulfathiazole solution in a 0.125 per cent vasoconstrictor dl-desoxyephedrine hydrochloride has a pH of 8.6 to 9.2, still more alkaline than the normal nasal mucosa. Callomon[3] found this solution produced inflammation and partial caustic effects, and a two per cent diasone solution with acid properties (pH below 5) caused greater damage to the nasal mucous membrane of normal mice than a three per cent solution of the same compound with a (alkaline) pH of 8.8. A three per cent sulfathiazole solution in propylene glycol, with a pH value near the physiologic range of the nasal secretion in man, showed the least irritating effects. Yonkman and associates[4] also found the three per cent solution of sodium salts with propylene glycol as a menstrum well tolerated. Hunnicutt[5] reports a marked inflammation of the mucous membrane of mice during the first three days from a five per cent solution of sodium sulfathiazole. It may be concluded, therefore, from the work done up to the present that an excessive alkalinity or acidity in the sulfonamide solutions, compounds or preparations should be avoided.

A suspension of the microcrystalline form of the sulfonamides in normal saline would not have the objection of an excessive alkalin-

From the Department of Otolaryngology, Northwestern University Medical School, Chicago.

ity or acidity. If they are suspended in other menstrums, any irritation to the mucous membrane would depend upon the substance used. Kully[6] found, when vasoconstrictor drugs are added, particularly to sulfathiazole solutions, the irritating properties of the preparation are generally increased. Lierle and Evers[7] found, when chlorbutanol was used as a preservative in various solutions or suspensions, that ciliary activity was stopped. A freshly prepared isotonic solution of ephedrine sulfate was found more satisfactory as a menstrum.

Another valid objection to the use of the various solutions, suspensions or compounds would be the possible lack of concentration of the sulfonamides to be sufficiently bacteriostatic. When used as drops, gargles, lozenges or in chewing gum, the preparation may not reach a large enough area to be effective.

The insufflation of the powdered sulfonamides in the nose and throat would seem to be the best answer to these various objections, as it would be in sufficient concentration to the maximum area, is not irritating to the mucous membrane from excessive alkalinity or acidity and from the evidence we have does not stop or slow ciliary activity. Lierle and Evers[7] found that sulfanilamide, sulfathiazole and sulfadiazine powders, left in contact with the mucous membrane for varying lengths of time (5 to 65 minutes) neither stopped nor slowed the ciliary activity. From clinical observations the powder seems to remain on the nasal mucosa much longer than when the microcrystals in suspension are used.

The sulfonamides in whatever form used, have no inhibiting action on the initiating virus of the common cold or influenza. However, the activated secondary pathogens, most commonly found in acute infections of the upper air passages, such as the beta hemolytic and other streptococci, pneumococcus and the Staphylococcus aureus are inhibited if sufficient concentration of the drug is obtained over long enough time. The hemophilus influenza and the hemolytic Staphylococcus are also inhibited, but to a lesser degree. Novak[8] found the local application of the sulfonamide compounds bacteriostatic to all species of pathogenic bacteria if sufficiently high concentrations were made.

During a period of three years from July, 1, 1943, to July 1, 1946, approximately 6,000 insufflations of the powdered sulfonamides, singly or in various combinations, have been administered to approximately 1,500 individuals for various types of acute infections of the nose and throat. An average of about two and one half treatments were given for each acute attack. Many individuals have had two, three or more attacks during the three-year period.

The first eight months powdered sulfathiazole was used.[9] During the second eight months equal parts of sulfathiazole and sulfanilamide were the agents. Sulfanilamide is the most soluble of the sulfonamides, and it was thought this factor might have some value in treating acute infections of the upper respiratory tract. However, from a clinical viewpoint no increased therapeutic advantage was noted. The principal objection to sulfanilamide was the bitter taste to which most patients objected. For a short period (one month) equal parts of sulfathiazole, sulfanilamide and sulfadiazine were employed. During the remainder of the three-year period equal parts of sulfathiazole and sulfadiazine were used with more satisfactory results.

Method of Treatment

The nasal cavities were first sprayed with a one or two per cent isotonic solution of ephedrine hydrochloride. This was done to obtain sufficient shrinkage of the turbinates for a maximum distribution of the powdered sulfonamides. Standard De Vilbiss powder blowers, motivated by compressed air, were used to insufflate the powder into the nose, nasopharynx, pharynx, and to some extent into the larynx until the visible mucosa was covered by a thin, chalky white film. If tonsils were present, an effort was made to blow some of the powder into the crypts. Care was taken to avoid "piling up" the powder in the nose or larynx, as a foreign body-type of discomfort was occasionally noted for a short time if this occurred. Otherwise discomfort was absent except for a feeling of dryness in the nose for a short time. If the patient inhaled while the powder was being insufflated, a momentary tickling cough occurred as from breathing any dusty substance.

The amount of powder used at any one treatment was difficult to estimate but was probably much less than 0.3 gm. as one pound of the powder was sufficient for more than 1,500 treatments. Much of the substance did not adhere to the mucosa but was exhaled or was returned by the compressed air stream.

The patient was asked to refrain from blowing the nose for as long a period of time as possible. Many individuals retained some of the sulfonamide powder in the nasal cavity and nasopharynx until the following morning despite ciliary activity. Visible evidence of the powder on the pharyngeal or laryngeal mucosa was of short duration except what continued to enter the nasopharynx from the ciliary activity of the nasal mucous membrane.

Results

An exact valuation of the clinical results is difficult, but when compared with those in patients who did not receive the insufflation of the sulfonamides for one reason or another or with those in an equal number of patients with acute infections of the nose and throat treated by other means previous to this method, the conclusion is inescapable that the course of the infection was shortened and the number of complications lessened. The sore throat and inflammation especially of the palate, nasopharynx and pharynx were frequently stopped within 24 hours. However, the rhinitis and cough would continue to develop in many individuals, but not as frequently as formerly observed. The advent of sinusitis and the various forms of otitis were definitely lessened when compared with patients not receiving this method of treatment. The greatest value of insufflation of the powdered sulfonamides to the upper respiratory tract appeared to be in the first three or four days of the acute infection.

Golderman and Kiesewetter[10] report the average length of time spent in the hospital by military personnel with acute pharyngitis and tonsillitis lessened by approximately one fourth (controls 4.4 days, treated 3.3 days) after insufflations of sulfanilamide powder two times daily. No evidence of sensitivity was found in their series.

This method of treatment seems to be of questionable value in the latter stages of the acute infection. However, Williams[11] found chronic nasopharyngitis responded to insufflations of sulfapyridine powder, especially in carriers of hemolytic Streptococci.

Sensitivity

The objections to the local use of the various sulfonamides to the nasopharyngeal mucous membranes would be the same as for their oral or parenteral use, but evidently to a much less degree. These objections would be the possibility of general or local allergic reactions, dermatitis, blood dyscrasias, central nervous system reactions, kidney or liver complications, hyperpyrexia, weakness, pallor, nausea and vomiting. The possibility of establishing sulfonamide resistant organisms or sensitization should also be considered.

Seven individuals out of the 1,500 treated gave evidence of sensitivity as manifested by a dermatitis, hives or hay fever-like symptoms. This was less than 0.5 per ecent. One patient developed a moderate temperature with a local dermatitis on two occasions when sulfathiazole was used. The rash was localized around the nose or face in most cases, but generalized in a few instances. The rash and hives disappeared after from one to several days. No other complication was noted. No instance of asthma developed although most patients inhaled some of the powder. No patient with a known sensitivity to the sulfonamides was accepted for treatment by this method.

Sensitivity to the sulfonamides from the local application to the respiratory mucosa seems to be less than when taken by mouth and much less than when applied to the skin. Fink and Smith[12] report sensitization of less than 1.4 per cent in 5,000 infants and children receiving sulfonamides, chiefly sulfadiazine, by mouth. The reactions in the affected children were febrile with a rash in 60 per cent. Seven of these children were given test doses of different sulfonamides and two reacted, but both received a third sulfonamide without evidence of toxicity. Coburn[13] found an incidence of sensitivity of 0.5 per cent in 600,000 Navy personnel who received oral sulfadiazine prophylaxis for respiratory diseases.

Mild dermal reactions occurred in 0.5 per cent and severe reactions in 0.01 per cent. Darke[14] reports a sensitivity of 5.5 per cent from the topical application of sulfathiazole cream to 218 minor surgical patients, a high incidence when compared to 0.5 per cent sensitivity found in this and other series.

Sulfa-resistant strains have been reported as developing from prolonged oral administration. Young[15] et al (Epidemiology Unit No. 22) report sulfadiazine-resistant strains occurring after three months of successful sulfadiazine prophylaxis of respiratory infections at a large naval training center. The resistant strains of beta hemolytic streptococci were Group A, type 19 and later type 17. Other types did not become sulfa resistant. No known instance of sulfa-resistant organisms was developed in this series.

Conclusions

Insufflation of sulfathiazole, sulfanilamide and sulfadiazine powders, alone or in combinations, to the mucous membrane of the upper respiratory tract to 1,500 individuals (6,000 applications) suffering from various acute infections of the nose and throat, proved to be as safe or safer than their oral use. A sensitivity of less than 0.5 per cent was found.

The greatest usefulness is in the early stage of the infection.

References

1. Turnbull, F. M.: Intranasal Therapy with Sodium Salt of Sulfathiazole in Chronic Sinusitis, J. A. M. A. 116:1899 (April 25) 1941.

2. Fabricant, N. D.: Significance of the pH of Nasal Secretion in Situ, Arch. Otolaryng. 34:150 (July) 1941.

3. Callomon, F. T.: Tissue Changes Produced in the Nasal Mucous Membrane of Normal Mice by Prolonged Local Administration of Some Solutions Containing Sulfonamide Compounds, Arch. Otolaryng. 43:31 (Jan.) 1946.

4. Yonkman, F. F., Craver, N. N., Lehman, A. J., and Chase, H. F.: Propylene Glycol as a Menstrum for Sodium Sulfathiazole, J. A. M. A. 118: 1317 (April 11) 1942.

5. Hunnicutt, L. G.: Reaction of Mucous Membrane to Five Percent Solution of Sodium Sulfathiazole, Arch. Otolaryng. 36:837 (Dec.) 1942.

6. Kully, B. M.: The Use and Abuse of Nasal Vasoconstrictor Medications, J. A. M. A. 127:307 (Feb. 10) 1945.

7. LIERLE, D. M., and EVERS, L. B.: Effects of Certain Drugs upon Ciliary Activity of the Mucous Membranes of the Upper Respiratory Tract, Laryngoscope 54:176 (April) 1944.

8. NOVAK, M.: Specific in Vitro Action of Sulfonamide Compounds on Pathogenic Organisms, Annals of Otology, Rhinology and Laryngology 52:161 (March) 1943.

9. BALLENGER, H. C.: The Local Use of Powdered Sulfathiazole in Acute Nasopharyngitis, Quart. Bul. Northwestern Medical School 18:109 (Summer Quarter) 1944.

10. GOLDERMAN, J. R., and KIESEWETTER, W. B.: Treatment of Acute Pharyngeal Infections by Insufflation of Sulfonilamide Powder, Arch. Otolaryngol. 43:99 (Feb.) 1946.

11. WILLIAMS, H. L.: Chemotherapy in Otolaryngology, Wisconsin Medical J. 44:507 (May) 1945.

12. FINK, H. W., and SMITH, C. A.: Incidence of Reactions to Sulfonamide Drugs in Infants and Children, J. Ped. 28:40 (Jan.) 1946.

13. COBURN, A. F.: Mass Sulfadiazine Prophylaxis of Respiratory Diseases in the U. S. Navy, Bull. New York Acad. Med. 21:281 (June) 1945.

14. DARKE, R. A.: Sensitivity to Topical Applications of Sulfathiazole Ointment, J. A. M. A. 124:403 (Feb. 12) 1944.

15. YOUNG, D. C., et al (Epidemiology Unit No. 22): Sulfadiazine Resistant Strains of Beta Hemolytic Streptococci, J. A. M. A. 129:921 (Dec. 1) 1945.

DISCUSSION

DR. RALPH A. FENTON: I should like to ask a question as to the nature of the sensitivity responses which occurred and as to just about how severe they were.

I recall two instances—and we used this method of insufflation regularly for this type of acute case—in which persons who were probably more allergic than the average (being hay fever cases in the summer) suffered very violent reaction and dermatitis of the face around the nose. I make this inquiry to find out whether the responses varied from our observation in such sensitive cases.

DR. HOWARD C. BALLENGER (closing): I accepted allergic patients if there was no history of sensitivity to the sulfonamides. I noted no greater percentage of sensitivity to the sulfonamides in these patients than in those without a history of allergy. However the number of allergic individuals was not great.

THE INFLUENCE OF THE SULFONAMIDES AND ANTIBIOTICS ON THE FUTURE OF OTOLARYNGOLOGY

BERNARD J. McMAHON, M.D.

ST. LOUIS, MISSOURI

There are many factors which may influence otolaryngologic trends over the course of years. At times these factors may be clearly apparent, while again they may be more insidious and gradual and thus difficult to evaluate.

We have seen the treatment of sinusitis change either to the radical or the conservative in a locality as a result of the influence of one who holds the respect of his fellow otolaryngologists and has thus shaped the policy, however, unconsciously, of the conduct of his associates, probably by reason of his stronger medical or surgical inclinations respectively towards otolaryngologic problems. The pattern of infections, which may change from year to year or cyclically, is another important factor of which we are fully aware. These variable endemic episodes are as frequently the result of the occurrence of different strains as of entirely different bacteria or of viruses which show variations in resistance to therapeutic agents, especially since the advent of chemotherapy. The lack of recognition of these factors may often lead to false and unwarranted modifications of therapeutic methods.

One of the earlier flurries in chemotherapy occurred in 1919 when Young and his collaborators of Baltimore,[1] introduced Mercurochrome 220 as a urinary antiseptic for the gonococcus, B. coli and the staphylococcus, and later in 1924 when Young and Hill[2] advocated it as a germicide with great promise in the treatment of septicemia caused by B. coli and Staphylococcus when used intravenously. Within these years mercurochrome was used very extensively in the treatment of a variety of infections and many glowing reports of its efficacy were published. However, this enthusiasm

From the Department of Otolaryngology, St. Louis University School of Medicine, St. Louis, Missouri.

about its therapeutic value as a deep tissue germicide was short lived and its use was abandoned.

It is an accepted fact that the Sulfonamides and Penicillin exert a beneficial effect upon infections of the upper and lower respiratory tract. Reports of animal experimentation, and clinical results have proven conclusively that they deserve a place in our armamentarium in combatting and controlling the pathological changes induced in the body tissues by the invasion of certain micro-organisms. That other micro-organisms are invulnerable to these drugs by reason of their innate properties is apparent from the clinical fact that we are unable to influence or control the course of some diseases by the adequate administration of this group of drugs. We speak principally of penicillin because of its more general use. Tyrothricin and gramicidin also have a definite place in anti-biotic therapy, when used locally, but in a much more limited manner. Streptomycin therapy is still in an early experimental stage.

Experimental evidence has pointed to the conclusion that the sulfonamides are bacteriostatic in action[3] and clinical experience has substantiated this conclusion. On the other hand the action of Penicillin is said to be not only bacteriostatic but bactericidal as well, according to Chain and Duthie.[4]

The adverse results that have been reported have been due to the biological resistance of the micro-organism or the intolerance of the patient. The former is either a natural characteristic of certain bacteria or an acquired property as a result of small inadequate clinical doses or frequent short courses of treatment with either the sulfonamides or penicillin. Abraham, Chain and others[3] have rendered a culture of staphylococcus aureus, grown in vitro in increasing concentrations of penicillin, resistant to the drug, and Rammelkamp and Maxon[5] have similarly increased the resistance of two strains of staphylococci. This phenomenon was later corroborated by McKee and Houck with staphylococci, pneumococci and streptococci,[6] as also by Schmidt and Sealer with pneumococci.[7]

The intolerance of the patient to sulfonamides is much more frequently encountered than it is to penicillin. This intolerance is manifested by a variety of reactions from a localized wheal to a

generalized erythema, or from mucosal reaction of the nose to an alarming asthmatoid diathesis.[8] Such reactions following the administration of penicillin are less common than post-sulphonamide reactions, although they do occur, and should be recognized. Certain patients are inherently sensitive to the molds of Penicillium notatum. This was strikingly illustrated in a child which was referred by a pediatrician for the removal of a suspected non-opaque foreign body from the right main bronchus. This diagnosis was concurred in by the radiologist who reported a moderate atelectasis of the inferior half of the right lung. A bronchoscopy was performed which revealed an engorgement and edema of the right main bronchus, but no foreign body. On subsequent questioning we ascertained that the patient had been receiving penicillin for several days for an acute respiratory infection. This was withdrawn and within 48 hours all pulmonary signs and symptoms subsided.

It is obvious that chemotherapeutic agents, in order to be effective, must gain access to the foci which they are intended to reach. Therefore, an adequate local circulation is a sine qua non for the fulfillment of this purpose as well as for that of carrying the phagocytic cells to the area. The drug must be brought into contact with the vulnerable micro-organisms in sufficiently high concentration and this contact must be maintained for a sufficient length of time to enable the body defenses to elaborate the necessary phagocytes to destroy the invading organisms.

It has been repeatedly stated that the action of these drugs is bacteriostatic, but it has never been explained how organisms of attenuated virulence can possess sufficient stimulus to the hematopoietic and the reticulo-endothelial systems to adequately and successfully activate the formation of leucocytes, histiocytes and other phagocytic and reparative cells. The explanation may rest in the fact that these drugs do not completely interrupt cellular respiration, inasmuch as bacterial cells inhibited in their growth continue to metabolize even in the presence of an excess of sulfonamides.[9] Since the leucocytes are the chief phagocytic cells which are being elaborated during bacteriostasis, a special study of the effect of the sulfonamides, penicillin and other drugs on the viabil-

ity and activity of these cells was conducted by Abraham, Chain, Florey and others[3] in 1941. They reported that while leucocytic activity was retarded or completely abolished by sulfathiazole, it was not affected by penicillin solutions in similar dilutions. Dubos,[9] states that "The occurrence of secondary irreversible alterations during bacteriostasis may also explain the observation that the bacteriostatic effect of the sulfonamides can be converted into a bactericidal effect by raising the temperature at which the reaction is taking place from 37° C. to 40° C." A similar bactericidal effect of sulfanilamide was observed by Wolff and Julius[10] in 1939, and Hobby, Meyer and Chaffee[11] in 1942 showed that penicillin exerted a powerful bactericidal action on streptococci, pneumococci and staphylococci when acting under conditions favorable to their growth, 99% of the organisms being killed. This conclusion was confirmed by Chain and Duthie[4] in 1945.

From the foregoing statements we are therefore justified in assuming that both the sulfonamides and penicillin are bactericidal as well as bacteriostatic.

In evaluating the effectiveness of the sulfonamides and penicillin, their clinical limitations and comparative advantages should be realized fully. We are familiar with the specific bactericidal properties of these substances, the contraindications to the administration of the sulfonamides and to a lesser degree to the administration of penicillin. We know that the sulfonamides are rendered less active in the presence of necrotic tissue and exudates because of the para-aminobenzoic acid and the other substances which reverse the action of sulfonamides that are produced by many cells and released during tissue breakdown.[9] Penicillin on the other hand does not affect the viability of leucocytes except in high concentrations and is consequently more effective under such conditions.[3]

Significant observations were made by Abraham, Chain, et al,[3] by Rammelkamp and Maxon,[5] and by McKee and Houck,[6] relative to the resistance induced by penicillin in certain strains of staphylococcus aureus and pneumococci, types I, II and III. These investigators found that repeated serial passages of these micro-

organisms through cultures containing penicillin in increasing amounts resulted in a greatly increased resistance to the penicillin, while at the same time there occured a marked decrease in the virulence of the micro-organism for mice, though less so in the type I and II pneumococci. Furthermore, the resistance to penicillin was not decreased or the virulence increased by repeated passages of the cultures through mice. It is significant that penicillin-resistant strains are not resistant to sulfonamides and sulfonamide-resistant strains are not resistant to penicillin, unless such resistance is induced by the specific drug.[12, 13]

In discussing the use of the sulfonamides and penicillin it is timely to comment upon the manner in which they are used and applied. It is generally conceded, as we have mentioned, that these drugs must be in contact with the micro-organisms in sufficiently high concentration for sufficient length of time to retard the growth of the organisms in order to allow the leucocytes and other phagocytes to be carried to the area of infection, destroy the bacteria and bring the infection under control. The tissue sulfonamides and penicillin cannot penetrate or diffuse through well-established fibrosed cavity walls since the blood vessels are narrowed due to a thickening of their walls or completely obliterated as a result of compression by the fibrosed tissue which they traverse. In an acute infection the neighboring lymphatics and capillaries are so completely blocked by fibrin and histiocytic cells after 24 hours that the blood and lymph streams are reversed and diverted away from or around the focus of infection.[14-16] At present the sulfonamides are administered by mouth, locally, and by lozenges, gum. Penicillin is similarly administered and in addition parenterally, intra-thecally and by inhalation.

We feel that applications of either of these substances to the surface of a mucous membrane of the respiratory tract is entirely unavailing and futile. The pathogenic micro-organisms are in the subepithelial tissues, while the surface epithelial cells are either swollen, and relatively impermeable, or they have sloughed away. In either case the stream of transudation is to the surface of the mucosa, so that it is impossible for the fluid or substance to penetrate the subepithelial tissues in the face of the greater pressure. If the

cilia are functioning, any substance imposed upon their surface is carried back to the portal of entry of the cavity or, as in the nose, to the naso-pharynx, in a relatively short time. The germicidal activity of penicillin in a cavity, only serves to retard the growth of or kill such bacteria as are in the cavity and thus prevent the spread of viable bacteria to other localities.

We are thus forced to conclude that intra-nasal or intra-tracheal administration of solutions containing the sulfonamides or penicillin are totally inadequate in enhancing any results accomplished by the use of these drugs when carried through tissue channels to penetrable areas of infection. Mutch and Rewell[14] state however that calcium penicillin administered as a mist is very rapidly absorbed through the respiratory mucous membrane, and that the concentration in the blood subsequently approximates that found after the injection by intramuscular and intravenous routes.

The fact that such solutions frequently contain ephedrine or other synthetic tissue constrictors does not in any way enhance their value, because when these drugs are in the form of emulsions, the mechanically irritating effect of the crystals will more than offset the possible shrinking effects of the vehicle, assuming that this in itself has no irritating properties.

In recent years there has been an inclination on the part of some otolaryngologists to seek more highly specialized fields within their specialty as a result of the temporary restrictions of their activities supposedly from the use of the sulfonamides and the antibiotics.

It is true to some extent that there has been a reduced incidence of the more serious sequelae of otitis media, sinusitis, tonsillitis and deep tissue infections of the neck, but it is likewise true that there has been a much greater incident of relapses or recurrences following these infections. Our own observations are corroborated in a report by Spink, et al,[17] who conducted a survey of 210 young men suffering from acute infections of the upper respiratory tract. They concluded that "Sulfadiazine did not shorten the clinical course of patients with tonsillitis or eradicate hemolytic streptococci from the pharynx—although it did appear to diminish the severity of the disease in severely ill patients," and also "that clinical relapses

following the administration of penicillin were frequently encountered and appeared to be related to the reappearance of hemolytic streptococci in the throat."

This syndrome of diminution of symptoms and clinical relapses corroborates the experimental evidence that these drugs have principally a bacteriostatic action and that certain strains of micro-organisms must become sulfa-resistant or penicillin resistant, but continue their biological growth and resume their multiplying activities when the drugs are withdrawn. The practical and ominous clinical application of this phenomenon lies in its potentialities regarding the transmission of sulfa-resistant micro-organisms of unattenuated virulence through a community in epidemic proportions, since such bacteria do not lose their sulfa-resistant qualities, but do acquire increased virulence by animal passage.

Penicillin-resistant micro-organisms likewise lose their virulence while retaining their ability to multiply on transfers in vitro and on animal passage without regaining either their sensitiveness to penicillin or their virulence.[6] This does not necessarily mean that such micro-organisms are incapable of transmitting infection, since both of the above faculties are relative and will be modified by the reactions of the individual hosts. The recurrence of these micro-organisms is, as a rule, in symbiosis with other pathogens and of equal importance under such circumstances. We are, therefore, faced with the fact that the application of the sulfonamides and the anti-biotics in the control of respiratory infection is limited. It is of interest to conjecture whether in the future we shall not revert to the usual medical and surgical methods of treating respiratory infections and their complications because of the presence of simultaneously sulfa-resistant and penicillin-resistant micro-organisms, which require enormous doses of these drugs, beyond the tolerance of the patient.

Any consideration of a modification of otolaryngologic teaching and methods is untimely. We are agreed, I am sure, that there is no system of therapeutics which should not be accompanied by careful observation of the locus which the medication is intended to influence. In chemotherapy particularly there is an undeniable

masking of symptoms which at times requires the most careful and accurate diagnostic acumen possessed by a well trained oto-laryngologist, for proper evaluation.

The younger oto-laryngologist should be even more carefully instructed and better trained. More time should be devoted to the teaching of immunology, physiology, bio-chemistry, endocrinology and pathology in their relations to oto-laryngology. A fuller and more accurate knowledge of these subjects will make him more capable in the use of chemotherapy, as applied to the treatment of respiratory diseases and of certain types of deafness. This should not be at the expense of a thorough general surgical training especially in the head, neck and thorax during his internship, preliminary to his basic training in oto-laryngology.

The present military emergency which has interfered with proper and orderly medical studies and training, has been most keenly felt by the physician in the specialties. There has been a dehiscence which it is the duty of the educators engaged in graduate medical teaching to bridge over. There will of necessity be a period during which the ideal plan cannot be fully operative, but in time this compromise will be adequately met and the final desideratum fully achieved.

Summary

1. The sulfonamides and anti-biotics have a definite place in the treatment of oto-laryngologic conditions.

2. Their uses are limited by the sensitiveness of the patient to these drugs, by the acquired 'sulfa-resistance' or 'penicillin-resistance' of the micro-organisms, and by the potential dangers of masked symptoms.

634 North Grand Avenue.

References

1. Young, H. H., White, E. C., and Swartz, E. O.: A New Germicide for Use in the Genito-Urinary Tract, "Mercurochrome 220", J. A. M. A. 73:1483 (Nov. 19) 1919.

2. Young, H. H., and Hill, J. H.: The Treatment of Septicemia and Local Infections by Intravenous Injections of Mercurochrome 220 Soluble and of Gentian Violet, J. A. M. A. 82:669 (Mar. 1) 1924.

3. ABRAHAM, E. P., CHAIN, E., FLOREY, H. W., et al: Further Observations on Penicillin, Lancet 11:177 (Aug. 16) 1941.

4. CHAIN, E., and DUTHIE, E. S.: Bactericidal and Bacteriolytic Action of Penicillin on the Staphylococci, Lancet 1:652 (May 26) 1945.

5. RAMMELKAMP, C. H., and MAXON, T.: Resistance of Staphylococcus Aureus to the Action of Penicillin, Proc. Soc. Exp. Biol. & Med. 51:386, 1942.

6. MCKEE, C. M., and HOUCK, C. L.: Induced Resistance to Penicillin of Cultures of Staphylococci, and Pneumococci and Streptococci, Proc. Soc. Exp. Biol. & Med. 53:33 (May) 1943.

7. SCHMIDT, L. H., and SEALER, C. L.: Development of Resistance to Penicillin by Pneumococci, Proc. Soc. Exper. Biol. & Med. 52:353 (Apr. 1) 1943.

8. KOLONDY, M. H., and DENHOFF, E.: Reactions in Penicillin Therapy, J. A. M. A. 130:16 (Apr. 20) 1946.

9. DUBOS, R. J: The Mode of Action of Chemotherapeutic Agents, (Bull.) New York Acad. Med. 21:27 (Jan.) 1945: Woods 32.

10. WOLFF, L. K., and JULIUS, H. W.: Action du Sulfanilamide in Vitro et in vivo, Ann. Inst. Pasteur 62:616, 1939.

11. HOBBY, G. L., MEYER, K., CHAFFEE, E.: Activity of Penicillin in Vitro, Proc. Soc. Exp. Biol. 50:277, 1942.

12. MCKEE, C. M., and RAKE, G.: Activity of Penicillin Against Strains of Pneumococci Resistant to Sulfonamide Drugs, Proc. Soc. Exp. Biol. 51:275, 1942.

13. SPINK, W. W., FERRIS, V., and VIVINO, J. J.: Comparative in Vitro Resistance of Staphylococci to Penicillin and to Sulfathiazole, Proc. Soc. Exp. Biol. 55:207, 1944.

14. MENKIN, V.: The Mechanism of Fixation by the Inflammatory Reaction, J. Exp. Med. 53:171, 1931.

15. MENKIN, V.: Fixation of Bacteria and of Particulate Matter at the Site of Inflammation, J. Exp. Med. 51:.., 1930.

16. MENKIN, V.: Studies on Inflammation, J. Exp. Med. 51:.., 1930.

17. SPINK, W. W., RANTZ, L. A., BOISVERT, P. J., and COGGESHALL, H.: Sulfadiazine and Penicillin for Hemolytic Streptococcus Infections of the Upper Respiratory Tract, Arch. Int. Med. 77:260 (March) 1946.

DISCUSSION

DR. T. C. GALLOWAY: There is a point which seems to be worthy of further discussion, and that is what happens to the natural immunological responses of the body when chemotherapy and antibiotics are used.

In ordinary untreated infections nature frequently walls it off with cells, pours in enzymes; there is liquefaction of pus and drainage, or regression, with the cure of the process.

In those cases in which the sulfonamide therapy or antibiotics are not completely effective, it may be that we have really done harm by their use. A case in point is the type of ear which we have seen, I think not so frequently, in which after ineffectual therapy, we see the patient later with markedly impaired hearing, a retracted fixed brownish drum, and apparently a plastic process has organized within the middle ear so that we are unable by ordinary measures to get improvement.

DR. O. E. VAN ALYEA: Dr. McMahon has given us a very fine review of the situation as it appears at the present and an outlook into the future in relation to sulfonamide therapy and the use of antibiotics.

He touched upon one phase which I would wish him to elaborate on. It is a condition recognized by pathologists throughout the country and on which very little has appeared in the literature. I think it is important to mention the dangers associated with sulfonamide therapy.

Recently our local ear, nose and throat society had a meeting at which Davishon, the pathologist from one of the large hospitals in Chicago, enumerated the various conditions occurring with uncontrolled sulfonamide therapy, some of a very serious nature. Discussing his paper, another pathologist called attention to the fact of the preponderance of the loose administration of sulfonamides by the laity and by physicians in general. He cited as an example its use in the acute ears in children particularly. He has seen many of these cases at autopsy the fatal termination being attributed to improper use of the sulfonamides. A child with an acute otitis usually receives sulfadiazine or some other product early in the disease. The symptoms are relieved, the temperature goes down and the drug is stopped. A few days later as the organisms start growing the symptoms recur. Then the child may see another physician who again gives sulfadiazine. This goes on and on. The mastoid surgery is diminished but the effects are increased, the

serious effects. The germs during all this various treatment and cessation of treatment are quietly progressing toward the cranium and if the sulfonamide had been properly controlled under the careful supervision of an otologist during the entire episode no doubt the drum would have been opened or the mastoid drained at the proper time.

The pathologists, although recognizing the fact that mastoid surgery has diminished feel that otologists and physicians in general should realize that they are tampering with a dangerous condition with this type of therapy.

Dr. F. T. Hill: This is a most timely paper. There are so many things which we have got to know more about before we can intelligently use these drugs.

I think we will all accept the statement that with an acute inflammatory condition these drugs will not penetrate through the fibrotic wall whidh is set up. How then are we going to explain the fact that with normal meninges we will not recover penicillin from the spinal fluid unless given intrathecally, yet with an inflammation like meningitis a certain amount of penicillin given parentally, can be found to penetrate the subarachnoid space.

I understand that the eye men find that penicillin can be recovered from the anterior chamber in acute inflammatory conditions and not under normal conditions. Perhaps Dr. McMahon would explain that, in closing his discussion.

Dr. W. E. Grove: In the developement of a suppurative lesion of the ear in which complication takes place, and I am accustomed to fear the development of a mastoiditis, I place a great deal of confidence in repeated x-ray examinations.

The x-ray men tell me that where there has been indiscriminate use of the sulfonamides in these conditions they are not able to properly evaluate their x-rays.

In a recent case in which I was called into consultation in which penicillin had been used before the incision of an ear drum and had been continued after the incision of the ear drum, in which the

clinical symptoms gradually disappeared, I investigated the first x-ray which had been taken several days prior, and asked for another x-ray to be made. When I consulted with the radiologist in that particular case and viewed the films with him and asked him to give me his opinion as to whether there had been progress of the disease from the radiological standpoint, he said, "I don't want to go on record but I am quite unable to state to you positively, Doctor, whether there has been any progression of the disease from a radiological standpoint or not".

DR. JOHN G. MCLAURIN: This subject is especially interesting to me because I read a paper on a similar subject before the Southern Section of the American Triological Society several years ago, shortly after the advent of the sulfonamides. That was before sulfonamides were being used locally in otolaryngology.

In December, 1945, Dr. Fletcher Woodward of Charlottesville, Virginia read a paper before the Texas O. & O. Society Meeting in San Antonio, Texas, in which he reported a large series of acute upper respiratory infections where he had used penicillin locally. The strength of the solution was 500 units per cc. He concluded that the duration of these acute infections was diminished by about 50 per cent under that plan of therapy. He found that penicillin, used locally, had no value in the control of chronic infections. It appeared, however, that in exacerbations where chronic infection existed, penicillin did seem to control the acute flare-up.

I have used penicillin locally not only by instillation into the nasal chamber proper, but by direct instillation into sinuses from which I had previously found pus on irrigation. Up to this time, I have not realized any great value from use of penicillin instilled as I have described. Possibly it reduces the purulent discharge to some extent, but as a rule there is a definite tendency for it to recur. Unquestionably, where antibiotic agents are used to control infection, nature has not been given the best opportunity to develop its highest degree of immunity before the infection is controlled by such an agent; therefore, the tendency for such an infection to recur is definite.

If the sulfonamides are to be used, it is certainly best to give them in large doses for a comparatively short time and then abandon

the use of the drug. If there is a recurrence, the drug can be used again, and possibly then in smaller doses over a longer period of time to prevent further recurrences. We must remember, however, that during the time sulfonamides are being used, important symptoms can be masked, especially where the drug is used over a long period of time. Furthermore, the bacteria producing the trouble may become desensitized to the drug where large enough doses were not given originally, and these sulfonamide-fast bacteria then would become very difficult to handle by the same specific agent.

MR. CAWTHORNE (by invitation): I have been very interested indeed in this paper and in the subsequent discussion because we have had, on somewhat different levels, discussions in England, the feeling running pretty high between the pro-sulfonamide and anti-sulfonamide.

I must confess I myself am rather on the side of the pro-sulfonamides, and the antibiotics in a number of respiratory infections, but I feel there are two main principles which have to be very carefully thought of in all these cases. The first is the way in which the sulfonamides are administered. I think most people are in the habit of administering or giving sulfonamides to the patients in their own homes. I believe that is where the whole thing lies. We can never give proper sulfonamide therapy unless we have the patient under our care in the hospital because no matter how carefully one tries to insist that the mother or the relative wakes the child up in the middle of the night for the dose, they will not do it although they will promise to do it faithfully, and then the child does not get the proper therapy.

The other thing I feel is that we have clearly with all these conditions, perhaps more particularly with ear conditions than with others, to reeducate possibly ourselves, certainly our assistants and doctors to an entirely altered clinical picture in the various conditions for which the sulfonamides are used.

DR. LEROY A. SCHALL: The discussion on Dr. McMahon's very excellent and timely paper has emphasized the first part of his subject.

I would like to emphasize the second part: the future of otolaryngology. Those of us who have been charged with the education of the future laryngologists have been, I am sure, keenly aware of the change in otolaryngology. We see a change from a strictly surgical specialty to somewhat of a medical specialty, changed by the sulfonamides and antibiotics, so therefore we must recognize this fact in our training of otolaryngologists. We must see that they get more training in pathology and bacteriology and we must change our conceptions and the indications for certain procedures which in the old days were standardized. I have been consulted many times and the opinion has been expressed to me, that our specialty is so shrinking that there is no future to otolaryngology; and, would I have my son follow my footsteps or would I have him become an ophthalmologist or pediatrician.

I feel that we are on the verge of greater expansion than ever before if we as otolaryngologists would so perfect ourselves that we could take care of at least 80 per cent or even 50 per cent of those patients who consult us who have allergy or allergic conditions; if I could find a young man who would become interested in the malignancies and would perfect himself in the study of the tumor pathology and the care of the cancer patient; if I could find a young man who would go into surgical, bacteriology; or a young man who would, after his residency in otolaryngology take a residency in neurosurgery, so that he could handle and act as consultant in our brain abscesses, I am sure that there would be a good future for that man in otolaryngology.

Dr. F. W. Dixon: I should like briefly to report the history of two patients which puzzled me recently:

These were two girls ten years of age who, after four weeks' aural discharge, were admitted to the hospital in which the clinical signs were those which indicated operative procedure. The x-ray evidence likewise corroborated this, the report being that there was breaking down of the mastoid air cells. These patients were placed on penicillin. After two or three days the temperature became normal, the redness and pain over the mastoid disappeared. The whole picture seemed to clarify. After five days more penicillin

therapy, they were discharged from the hospital. Ten days after the discharge they were again re-admitted because of the redness and swelling over the mastoid. The temperature was elevated one or two degrees, there was no fluctuation, and again the x-ray picture indicated operative procedure. This was carried out and in both patients there was found a subperiosteal thickening, the mastoid was filled with healthy granulations, there was no pus. There was no exposure of sinus or dura. The patients made an uneventful recovery and were discharged from the hospital on the sixth post-operative day with a dry ear.

I did not feel it was safe in the second admission to the hospital not to operate, yet I believe, had we again instituted penicillin therapy, we might have avoided operation.

Dr. B. J. McMahon (closing): Dr. Galloway spoke of the immunological reactions of the body being interfered with by the early adminisration of chemotherapy. If we accept the statement of certain investigators that the biological activity of the microorganism persists, despite the fact that its multiplication is temporarily checked by chemotherapy, we can assume that it is this activity which stimulates the multiplication of the phagocytic cells, which eventually control the infection.

The use of heat or x-ray on certain superficial areas to help overcome infection with or without sulfonamides, may increase the circulation and thus enhance the effectiveness of chemotherapy. On the contrary, I have always felt that the use of cold, as used in mastoiditis, when we are giving these drugs mitigates their effectiveness by reducing the local circulation, not only of the drugs but of the phagocytes as well.

Dr. VanAlyea mentioned the recognition of the dangers to the patient in giving sulfonamides. This admonition cannot be too often repeated. Under the present conditions of overcrowded hospitals when patients must be attended at home we should always be alert to these dangers. The ideal measures of daily blood counts, hemaglobin determinations, and urinalyses for crystals are not practical, so that we do not feel free to use the Sulfonamides in such great concentrations, as are usually advocated. Such administra-

tion of adequate doses should not be continued longer than four to five days however, without the proper laboratory examinations. We have found liver and iron therapy to be a very useful adjunct to permit the continuation of sulfonamide therapy in patients suffering from a mild secondary anemia.

With regard to massive doses, one may conjecture on the possibility of death resulting from a foreign protein intoxication because of the spontaneous death of excessively large numbers of bacteria caused by these drugs, in certain fulminating infections.

Dr. Grove called our attention to the fact that the x-ray findings in mastoiditis may be masked, and therefore misleading in patients who have been receiving sulfonamide or antibiotic therapy. It is true that these findings may be modified and the otolaryngologist should be prepared to interpret these modifications.

Dr. Cawthorne further corroborated that attitude in stating that we have to know our clinical picture, and in the administration of sulfonamides we have to be guided by what we see and what we know, in order to correctly evaluate the x-ray evidence of the progress of the mastoid infection.

Dr. Dixon likewise stressed the point of misleading x-ray evidence of infection. Haziness of the mastoid in early acute conditions results not only from mucosal engorgement, but also from bony septa from which the calcium has been resorbed and which are present as fibrous strands within this mucosa.

Dr. Schall's substantiation of our statement on the future in otolaryngology was encouraging. We do have to develop a definite medical approach to our problems in otolaryngology. This aspect has been sacrificed in certain training centers where the surgical approach has been particularly stressed.

We should be able to appreciate the general condition of the patient, his metabolism, his allergic reactions and his mental attitude to his sinusitis or his deafness.

NEUROGENIC TUMORS OF THE NOSE AND THROAT

GORDON B. NEW, M.D.

AND

KENNETH D. DEVINE, M.D.

(By Invitation)

ROCHESTER, MINNESOTA

Neurogenic tumors, primarily in the nose and throat, are rare, and there are probably few other tumors about which there is so much confusion in the literature. When they are encountered, and this is usually unexpectedly, one may be at a loss to know what to do, even though most of them are amenable to successful surgical correction or removal.

Any tumor derived from nervous tissue, or its coverings may be considered a neurogenic tumor. Neurogenic tumors in the nose or throat may be divided into two large groups consisting of first, developmental errors and secondly, neoplasms.

Developmental errors may be meningoceles, encephaloceles or hydroencephaloceles. In the literature these have been called sincipital[1] or basal hernias,[2] encephalomas,[3] rhino-encephaloceles,[4] gliomas,[5] fibrogliomas[6] and neurocytomas.[7] They are most frequently referred to as meningoceles and encephaloceles or sincipital or basal hernias.

These three conditions have in common a protrusion of some part of the cranial contents through a defect of the bones. The only exceptions to this are the small encephaloceles, which frequently are not connected to the brain at all by any stalk nor is there any evidence of defect of the bones.

In a meningocele there is a protrusion of the membranes alone. They form a sac which communicates with the subarachnoid space and which is usually distended with fluid.

In an encephalocele there is a protrusion of a portion of the brain substance or tissue resembling brain substance. This is con-

nected with the rest of the brain by a constricted neck or pedicle except for those small encephaloceles noted previously. Their rarity is stressed by the fact that Browder and de Veer[4] have gathered from the literature data on only about fifty cases in which tissue more or less resembling brain tissue has been found subcutaneously at the base of the nose, in the nasal or nasopharyngeal cavity, or in both locations.

A hydro-encephalocele is a protrusion of a portion of the brain substance which contains within it part of the ventricles. A hydro-encephalocele may or may not be congenital. If it is acquired, it appears shortly after birth and is the result of hydrocephalus. The increasing intracranial pressure finds a weak spot in one of the suture lines, which yields. Herniation of cerebral contents results.

These congenital errors are most easily understood if one considers them in a general way as sincipital or basal hernias with the supposition that there is a defect of the bones or that there was a defect during embryologic development which permitted brain matter or its coverings to protrude or to be pinched off and left behind as a vestigial structure. Lampert stated that the frontal and occipital portions of the embryologic medullary tube close much later than the rest of the tube. Consequently, there are greater chances for abnormalities to take place in these regions. Following this line of thought, a sincipital hernia could produce tumors visible externally in the midline at the root of the nose, at the junction of the bony and cartilaginous portions of the nose or near the inner canthus, depending on whether the actual or hypothetical bony defect was located between nasal and frontal bones; between the frontal, nasal and ethmoid bones; or between the frontal, nasal and lacrimal bones.[1] A basal hernia would not produce tumors visible on the face. They would be present in the nasal or nasopharyngeal cavities or even in the mouth, the posterior portion of the orbit or the sphenomaxillary fossa, depending on whether the defect was located between the sphenoid and ethmoid bones, at the sphenoorbital fissure or at the infra-orbital fissure.[2]

Microscopically the neurogenic tumors of developmental origin vary from the ordinary meningocele, consisting of a sac lined with

epithelium and with a fibrous wall, to a solid tumor of the encephalocele variety, consisting of tangled masses of glial cells interspersed among strands of fibrous tissue. Occasionally atypical nerve cells may be seen.

The neoplasms of neurogenic origin encountered in the nose and throat are neurofibromas, ganglioneuromas and meningiomas. In the literature, neurofibromas have been called perineural fibroblastomas, neurinomas, perineural fibromas, schwannomas and neurogenic fibromas.[9] Ganglioneuromas have been called ganglion cell neuromas and gangliomas. Meningiomas have been called dural endotheliomas, psammomas, neuro-epitheliomas and meningeal fibroblastomas.

Neurofibromas arise from the specialized investment which separates and insulates nervous tissue from surrounding structures. They are usually recognized as fibroblastomas arising from the connective sheath (perineurium) of nerves. Some believe that they arise from the cells of the sheath of Schwann (schwannoma) and are therefore ectodermal in origin.[9] A neurofibroma forms a benign encapsulated tumor of the sheath of spinal nerve roots, cranial nerves and peripheral nerves and appears as a solitary tumor, much more often in a central location[10] than in a peripheral one. Occasionally there may be hundreds of these tumors growing from the fine cutaneous nerves, deeper and visceral nerves and cranial nerves; a condition known as Recklinghausen's disease. It is not uncommon to find a neurofibroma in the nose or throat of one of these patients.

Microscopically a neurofibroma is composed of long slender cells, the elongated nuclei of which are arranged in palisades grouped into eddies or streams. Sometimes there is a great deal of myxomatous, jelly-like material present and the typical palisading streams and eddies may not be so evident. There may be hemorrhages or other evidences of degeneration such as formation of cysts particularly in the larger tumors of the pharynx.

A ganglioneuroma is a nerve tumor containing adult ganglion cells, glial cells and nerve fibers. The most generally accepted hypothesis concerning the origin of ganglioneuromas is that they

arise by multiplication of embryonal neurocytes which continue to multiply and differentiate through the various stages up to adult ganglion cells.[11] They are exceedingly rare in the nose and throat. Geschickter[12] said that portions of the olfactory ectoderm in the upper ethmoidal region are neuro-epithelial in character and that gangliomas may rarely form from these cells.

Meningiomas are usually believed to be benign tumors rising from some component of the meinges. It is generally accepted now that they are derived from embryonal rests in the arachnoid. To explain the occurrence of primary extracranial meningiomas in the paranasal sinuses or subcutaneously at the root of the nose, one could assume that the embryonal arachnoid rests were pinched off and left behind in these locations during embryologic development and became neoplastic at a later date to form meningiomas. Others might account for the presence of meningiomas in these locations by assuming that some ancient trauma or cerebral hypertension displaced bits of arachnoid that potentially were neoplastic.

Microscopically the meningiomas showed elongated fibroblastic nuclei in a whorled arrangement. Here and there the whorls may have undergone hyaline change, forming the typical sandlike bodies called "psammomas," from which comes the term "psammoma."

We have not included chordomas in this group because, strictly speaking, they are not neurogenic tumors since they arise from remnants of the primitive notochord.

In the last twenty-seven years at the Mayo Clinic, thirty-three cases of neurogenic tumors in the nose or throat have been encountered. These include nine cases of developmental error (six cases of meningocele and three of encephalocele) and twenty-four cases of neoplasm (nineteen cases of neurofibroma, one case of ganglioneuroma and four cases of meningioma).

Meningoceles

There were six cases of meningocele. In five cases the tumor was external (at the root of the nose) and in one case it was intranasal. Four of the meningoceles were large, pulsating, compressible, congenital tumors at the root of the nose. In another case

there was a small, firm, rounded mass at the root of the nose, which was thought to be a dermoid cyst. At the time of the operation it was recognized as a meningocele and the pedicle, which entered the cranium at the midline, at the junction of the frontal and nasal bones, was ligated. The child had had epileptic attacks and the mother said that these ceased after operation. In one case the tumor presented as a cyst of the nasal cavity. Rhinorrhea developed following an intranasal operation elsewhere. These intranasal meningoceles appear to spring from the septum but are really protrusions of the arachnoid and dura through the oribriform plate of the ethmoid bone to one side or the other of the crista galli.

It is hard to confuse meningoceles with any other tumor. Intranasal meningoceles may be difficult to identify but any purplish cystic mass that dents with a probe and that is causing nasal obstruction in a child should be considered a meningocele, and particularly so, if there is any dripping of clear cerebrospinal fluid after aspiration or attempts at removal.

External meningoceles at the root of the nose are generally covered with skin but may be covered only with granulation tissue. Other deformities, such as spina bifida, clubfoot, harelip or mental deficiency, are frequently present. These external meningoceles may be confused with cavernous hemangiomas, which do occur in this region. A roentgenogram of the skull may, and usually does, show a defect of the bones. When this defect is present it will aid in a differential diagnosis.

Meningoceles are neurosurgical problems, and we shall not discuss them further except to say that it is hazardous to aspirate an intranasal cyst in a child because of the possibility of meningitis following such a procedure.

Encephaloceles

There were three cases of encephalocele. In each case the tumor was external (at the root of the nose). These three tumors seen by us were firm, rubbery, round congenital tumors at the root of the nose lying just to the right of the midline. There had been practically no change in size since birth, and the average diameter

was 1.3 cm. They were mistaken preoperatively for dermoid cysts. In one case reported in the literature an encephalocele was mistaken for a mixed tumor because of the firm, rubbery consistency.[13]

There was no intranasal extension of any encephalocele seen by us but such extensions have been described in the literature.[14] Some may extend all the way to the brain, as in Lampert's case. It is usually impossible to remove such a tumor without the death of the patient during the postoperative period. In a few cases, meningitis and death have followed the extirpation of small encephaloceles which apparently had no gross intracranial connection. In Eggston's opinion this result is due to the presence of a sheath similar to that surrounding the olfactory or other cranial nerves, along which infection was able to travel to the cranial tissue.

These small external encephaloceles with no intranasal or intracranial connections are best removed through a horizontal incision over the root of the nose so that any scarring that results will be minimal and easily covered by a pair of spectacles. These tumors are not encapsulated and must be removed by sharp dissection, care being taken to remove all of the tumor. There may be a small teatlike projection which fills a dehiscence between the two nasal bones or at the junction of the bony and cartilaginous portions of the nose. This was seen in two of our cases and has been described previously.[13]

An intranasal encephalocele may have intracranial connections. For this reason, any surgical procedure undertaken for its removal must furnish adequate exposure so that the distal pedicle or attachment of the tumor may be ligated or electrocoagulated if there is any evidence of intracranial connections. Fenger[15] turned down the maxillary bone through an external incision to remove such a tumor successfully. The transantral approach for intranasal or antral tumors as advocated by New and Erich[16] or the fronto-ethmoid approach would also furnish adequate exposure.

If a child has a firm, hard, external tumor at the root of the nose with evidence of an intranasal tumor as well, he is almost certain to have an encephalocele. Our three patients had no other

evidence of abnormalities or of mental deficiency. Most reports in the literature agree with this finding.

Hydro-encephaloceles

There were no hydro-encephaloceles in our group. A typical hydro-encephalocele is round and elastic, giving evidence of fluid. When the communication with the cranial cavity is sufficiently large, the tumor usually pulsates. Many of these patients exhibit signs of mental impairment or manifestations of organic brain disease. These cases should be handled by a neurosurgeon and treatment should be postponed, if possible, to determine if there is complicating hydrocephalus.

Neurofibromas

There were 19 neurofibromas in our group. Their location was as follows: nasopharynx, one; nasopharynx and hypopharynx, one; oropharynx and hypopharynx, three; tonsillar region, three; larynx, two; antrum, nasopharynx and sphenoid sinus, one; nasal cavity, two; vestibule of the nose, two; bridge of the nose, two; and ala of the nose, two.

In these 19 cases there were only four of Recklinghausen's disease. These included two cases with pharyngeal tumors, one case with involvement of the ala in a diffuse neurofibroma of the upper lip and cheek and one with involvement of the bridge of the nose and supraorbital region. These latter two neurofibromas were a special kind, commonly seen on the face, in the distribution of one or more of the branches of the fifth cranial nerve, in patients with Recklinghausen's disease, or those who have some stigmata of the disease. Clinically these tumors are frequently mistaken for angiomas because of their sponginess and diffuseness, especially if the patient has only a few of the typical pigmented spots on the trunk, or only a few small inconspicuous neurofibromas on unexposed parts. They are instantly recognized once the tumor is cut into at operation. It is composed of loosely assembled masses of small individual neurofibromas varying from 2.5 mm. in size, sometimes larger. Grossly it looks like a cluster of small white grapes or tiny white marbles.

Neurofibromas are slow growing, benign tumors. The average age at the onset of symptoms was 26.9 years. The average duration of symptoms was 7.8 years. Neurofibromas may appear cystic or solid with no overlying ulceration. If they are located in the pharynx, they are usually mistaken for mixed tumors, although, desmoids or lipomas should also be considered in the differential diagnosis. The diagnosis is made easy if there is any evidence of brownish pigmentation of the skin (café au lait) or multiple tumors of the extremities or trunk. Symptoms and chief complaint vary with the location. Pharyngeal neurofibromas may cause some difficulty in talking and swallowing but rarely do they reach a size large enough to produce respiratory obstruction. These patients usually have been aware of a slowly growing painless tumor in the throat for years. Only one patient had pain and that was due to a large neurofibroma that involved the vault of the nasopharynx. Only one patient complained of bleeding. The bleeding was caused by a neurofibroma of the nasal fossa, primarily on one of the turbinates. The first and usually the only symptom of a neurofibroma primarily in the nose or antrum is obstruction.

The only symptom in a case of neurofibroma of the free border of a vocal cord was persistent and slowly increasing hoarseness over a period of ten to twelve years. The other neurofibroma that involved the larynx was situated on a posterior surface of the arytenoid and caused noisy breathing for one year in a child five years old. Up to February 1944, only 15 neurofibromas of the larynx had been reported in the literatue. This total includes only one of our cases. According to Smith,[17] neurofibromas are most likely to occur in the early decades of life and the usual site is the ventricular band or aryepiglottic fold. They are usually smooth, round tumors without mucosal ulceration and it is difficult or impossible to obtain tissue for biopsy. In one of our cases the tumor was removed under suspension laryngoscopy and in another it was necessary to perform thyrotomy to expose the tumor adequately and remove it.

Neurofibromas of the oropharynx, hypopharynx and tonsillar region are best attacked surgically through the mouth after preliminary

ligation of the external carotid artery on the side involved in order to minimize bleeding at the time of removal. They shell out easily from the capsule and rarely recur. An occasional pharyngeal neurofibroma may be so large that it is necessary to do preliminary tracheotomy to facilitate an adequate airway at all times and to minimize postoperative obstruction or aspiration of fluids and secretions into the trachea. It is usually necessary to approach these large tumors through an external incision. Five of these neurofibromas of the pharynx and tonsillar region were removed intraorally after preliminary ligation of the external carotid artery on the involved side. As noted by others and seen in one of our cases, there may be temporary paralysis of the larynx, pharynx or palate or findings suggestive of Horner's syndrome after removal of one of these large tumors of the pharynx.

Sometimes, because of its location, it is impossible to shell such a tumor out. This may happen in the nasopharynx, antrum or nasal cavity and consequently it may become necessary to destroy the tumor with surgical diathermy. These tumors are not radiosensitive and irradiation would not be expected to produce any results.

Ganglioneuromas

We have encountered only one ganglioneuroma in the nose or throat. This was a firm tumor involving the left basal region of the tongue of a man, 26 years of age. It extended forward to a point opposite the bicuspid area and back almost to the tip of the epiglottis. The same tumor extended down through the floor of the mouth and presented in the left submaxillary region. The tumor had been slowly enlarging for seven years. The patient stated that two courses of roentgen therapy had been given with no effect on the tumor. He came to the Mayo Clinic because of severe hemorrhages in the previous four months and at the time of examination was found to have a hemoglobin level of 6 gm. per 100 cc. of blood. After preliminary ligation of the left external carotid artery, the tumor was removed through the mouth. It was a very friable vascular tumor surrounded by a thin capsule and had to be removed piecemeal. It measured 10 by 12 cm. and weighed 100 gm.

Only one other ganglioneuroma in the nose or throat has been reported in the literature. This was a ganglioneuroma of the pharynx, reported by Foster[18] in 1942. Ganglioneuromas are encapsulated, benign, firm, rubbery tumors usually associated with the sympathetic nervous system. Ganglioneuromas of the neck have been reported by McFarland and Sappington,[19] Bosse and his associates[11] and others. It is conceivable that such tumors might bulge into the throat and be classified as tumors primary in that location. Their surgical problems are no different from those of neurofibromas. Their exact diagnosis must await microscopic examination and this can be said for almost any tumor of the nose and throat.

Meningiomas

There were four cases of meningioma. In three cases the tumor was in the frontal sinus and in one case it was located subcutaneously at the root of the nose.

We have not considered any intracranial meningiomas, such as the meningiomas of the olfactory groove, sphenoidal ridge or orbit, that secondarily invaded the nose or throat.

In one of these cases, the tumor filled the frontal sinus, invaded the antrum and ethmoid sinus and had encroached on the medial wall of the orbit.

Another frontal meningioma occurred in a woman, 52 years of age, who complained chiefly of a slow-growing, painless, hard tumor at the root of the nose. Roentgenograms were interpreted as showing an osteoma involving the left frontal sinus. Surgical exploration revealed a friable vascular tumor lying in the frontal sinus with a few attachments to the inner wall.

The third meningioma encountered in the frontal sinus was associated with a very large osteoma of the left frontal bone which had caused a slowly enlarging external deformity for 15 years. At the time of the operation, the involved bone was removed and found to contain "nests" of meningioma with a meningioma in the frontal sinus. The inner plate of the frontal bone was intact and there

was no attachment to the dura or evidence of intracranial meningioma. This is a good illustration of the invasion of the bone by tumor cells and the hyperostosis which may develop.

The fourth meningioma was found to be located subcutaneously in the midline at the root of the nose in a woman, 40 years old, who had had a bony hard swelling, 2.5 by 3 cm., which had been enlarging slowly for 13 months. A roentgenogram showed an irregular periosteal proliferation involving the nasal bones and external surface of the frontal bones. Surgical exploration through an external incision over the tumor revealed a meningioma involving the base of the nasal bone and lower part of the frontal bone. The bone had been destroyed in this region. There was no evidence of tumor in the frontal sinus nor any intracranially or intra-orbitally. The tumor was destroyed with surgical diathermy and sequestrectomy was performed two months later. Seven months and sixteen months later, small recurrences were removed with surgical diathermy. Four years later, the patient wrote that she had minimal deformity with no evidence of recurrence.

Meningiomas are slowly growing expansile tumors that usually grow by pushing aside surrounding tissue. They do not metastasize but recur locally if not completely removed. A considerable percentage produce a marked effect on adjacent bone. There may be slight pressure absorption or marked hyperostosis.[20] This hyperostosis may be the reaction of the bone without its having been invaded, but in 20 per cent of the cases, these tumors tend to invade the haversian system of the overlying bone. Absorption of bone and formation of new bone occur simultaneously and may produce a large bony mass.[21] In time these tumor nests may replace the thickened bone by a core of solid tumor. The effect on adjacent bone is so characteristic that a preoperative diagnosis of meningioma by roentgenographic examination can be made with confidence in most of the cases that exhibit it. This picture may be confused with chronic osteomyelitis or osteoma.

Meningiomas in the nasal sinuses and subcutaneously at the root of the nose are best removed with surgical diathermy for two reasons: surgical diathermy controls the bleeding which invariably

occurs when one curets or dissects these tumors and it destroys the involved bone or periosteum, preventing recurrence.

MAYO CLINIC.

REFERENCES

1. VON MEYER, EDWARD: Quoted by Browder, Jefferson, and de Veer, J. A.[4]

2. HEINECKE, W.: Quoted by Fenger, Christian.[15]

3. BERGER, PAUL: Quoted by Browder, Jefferson, and de Veer, J. A.[4]

4. BROWDER, JEFFERSON, and DE VEER, J. A.: Rhino-Encephalocele, Arch. Path. 18:646-659 (Nov.) 1934.

5. JACKSON, CHEVALIER, and COATES, G. M.: The Nose, Throat, and Ear and Their Diseases; In Original Contributions by American and European Authors, Philadelphia, W. B Saunders Company, 1929, p. 166.

6. ROCHER, H. L., and ANGLADE: Quoted by Browder, Jefferson, and de Veer, J. A.[4]

7. EGGSTON, A. A.: Histopathology of the Nose and Throat. In: Nelson's New Loose-Leaf Surgery, 1942, chap. 8, pp. 654-655.

8. LAMPERT, F. M.: Pathogenesis and Treatment of So-Called Congenital Cerebral Herniae, Surg., Gynec. & Obst. 38:159-162 (Feb.) 1924.

9. BOYD, WILLIAM: A Textbook of Pathology: An Introduction to Medicine, Ed. 3, Philadelphia, Lea & Febiger, 1938, pp. 961-964.

10. PENFIELD, WILDER: Cytology and Cellular Pathology of the Nervous System, New York, Paul B. Hoeber, Inc., 1932, vol. 3, p. 968.

11. BOSSE, M. D., NETTROUR, W. S., SOFFEL, J. A., and ROHM, J. Z.: Ganglion Cell Tumors of the Neck; Two Case Reports, Am. J. Surg. 65:120-122 (July) 1944.

12. GESCHICKTER, C. F.: Tumors of the Nasal and Paranasal Cavities, Am. J. Cancer 24:637-660 (July) 1935.

13. FÈVRE, MARCEL, and HUGUENIN, RENÉ: Encéphalocèle atypique réalisant une tumeur solide à la racine du nez, Ann. d'anat. path. 13:333-336 (Mar.) 1936.

14. CLARK, J. P.: Glioma of the Nose, Am. J .M. Sc. 129:769-774 (May) 1905.

15. FENGER, CHRISTIAN: Basal Hernias of the Brain, Am. J. Med. Sc. 109:1-17 (Jan.) 1895.

16. NEW, G. B., and ERICH, J. B.: In Jackson, Chevalier, and Jackson, C. L.: Diseases of the Nose, Throat, and Ear, Philadelphia, W. B. Saunders Company, 1945, pp. 72-81.

17. SMITH, T. T.: Solitary Neurofibroma of Larynx, Arch. Otolaryng. 39: 144-151 (Feb.) 1944.

18. Foster, J. H.: Ganglion Cell Neuroma of the Pharynx, Arch. Otolaryng. 36:372-376 (Sept.) 1942.

19. McFarland, Joseph, and Sappington, S. W.: A Ganglioneuroma in the Neck of a Child, Am. J. Path. 11:429-448 (May) 1935.

20. Cushing, Harvey: The Meningiomas (Dural Endotheliomas): Their Source and Favored Seats of Origin, Brain 45:282-316 (Oct.) 1922.

21. Brain, W. R.: Diseases of the Nervous System, Ed. 2, London, Oxford University Press, 1940, 950 pp.

DISCUSSION

Dr. Pierre Viole: This excellent paper by Dr. New Should not be passed over without some discussion.

In June of 1944 in New York City I reported before this Society my experience in the removal of a carotid body tumor. This tumor was removed through the intra-oral approach under general anesthesia without preliminary exposure or ligation of the carotid. Considerable bleeding occurred during the operation but appeared to be under control. The patient was returned to bed but succumbed three hours later due to severe hemorrhage.

Recently I presented before the Western Section of the Triological Society a report on schwannoma of the pharynx. This tumor was removed under local anesthesia also through the intra-oral approach without preliminary exposure or ligation of the carotid. The operative course and post-operative recovery was uneventful.

The thought I wish to convey in this discussion is that a preliminary exposure of the carotid should be performed whenever extensive surgery of the pharynx or neck is contemplated. Ligatures then should be placed loosely around the carotid but not tied. Ligation can then be done with deliberation and ease, should it be justified by the operative developments.

It is obvious that in the first case to which I refer ligation may have changed the course of events. In the second case ligation would have proved to be unnecessary since the patient's recovery was wholly satisfactory.

Dr. Robert C. McNaught, San Francisco (by invitation): I had the unusual experience of seeing within a period of two weeks two

patients similar to the first picture which Dr. New showed, of an infant with a midline cystic tumor, which presented the probable diagnosis of meningioma. I had never seen one before but had been told it was a true meningioma and that the proper course was not to operate at the tender age of seven months. However, if it was a dermoid type of cyst the earlier the operation was done the less the deformity.

The deformity was already present in the nasal bones and there was a little pit in the midline. On the basis of that more than anything else I decided to operate on the first of these children and it turned out to be a cystic tumor, which was full of sebaceous material and there was an uneventful healing. A week later another child came in with exactly the same condition and this one had been diagnosed elsewhere at birth as a meningioma. We applied the test which Dr. Furstenberg described of compressing the jugulars to see if the tumor would expand, and it did. That proved to be confusing because this one had also a midline pit, and because of the very recent experience with the first case, which was proven to be a dermoid cyst, we proceeded to dissect out the second one, which also fortunately was a dermoid cyst. It did present an unusual picture in that the cyst was a sort of dumb bell shaped one. The one over the nasal bone was the smaller of the two compartments. There was a constrictive neck which dipped down between the nasal and frontal bones subperiosteally and then expanded over the frontal bones under the periosteum. That had created quite a bony defect but did not penetrate the inner table.

THE PROBLEM OF SECONDARY FRONTAL SINUS SURGERY

FRANCIS L. WEILLE, M.D.

BOSTON, MASSACHUSETTS

At the Massachusetts Eye and Ear Infirmary during 1944 a patient who had had eight external frontal sinus operations—four on each side without obliteration—came under the care of the writer. He was having sulfadiazine therapy for recurrent swelling, redness and tenderness of the right orbit. This occurred several days of each week in spite of a right Lynch frontal revision which had been meticulously carried out by one of our staff members a few weeks previously. Scar tissue closure of the nasofrontal opening had occurred and the ethmoid area was occupied by scar tissue which involved the septum. A further revision was done and the patient recovered without obliteration of the frontal. He has been followed for a year and a half and has had no further difficulty, apparently because he has a patent nasofrontal opening measuring about 3 by 8 millimeters. He has gained thirty lbs. or more in weight and has survived without incident several head colds and has had no further chemotherapy other than locally.

The presentation of this case at staff meetings aroused a good deal of argument about the desirability of proceeding at once with obliteration of the affected frontal sinus (or of both frontals, since a small sequestrum had been found by x-ray on the other side; this disappeared in later films). Lively discussion also arose regarding the use of the bell-end of a large, soft rubber French catheter which was left in the nasofrontal opening for seven and a half weeks, since many reasonable criticisms can be levelled at this method.

Four other "secondary" external frontal surgical cases who appeared for treatment at about this same time caused further debate

---

From the Department of Otolaryngology, Massachusetts Eye and Ear Infirmary.

as to methods. (For example, it was stated by one surgeon that obliteration never failed if there were no osteomyelitis). It seemed worthwhile, therefore, to look up just what had happened with other similar patients in the previous fifteen years' experience (1930 to 1944) at the Infirmary, since this would offer facts and figures instead of more or less isolated impressions regarding the problem of secondary frontal sinus surgery.

Incidentally this period divided itself almost equally into years when chemotherapy was unknown, and years when it developed to approximately its present state.

During these 15 years 294 patients underwent external frontal sinus surgery. By deleting carcinomas and lost or misfiled records 276 were included in the survey. These cases had had a total of 862* operations upon the nasal cavities, sinuses and cranium, including plastic and brain procedures. Of these, 447* were directly upon the frontal sinus or sinuses externally, including 47 which were bilateral and 8 cases having one frontal done at one time and the other later. 42 patients died; a mortality of 15%.

95 of the patients had more than one external operation on one or both frontal sinuses. The highest on one patient was nine, five on the right and four on the left, in the case described in the beginning of this paper. 181 of the group did not have either frontal operated on more than once during the time they were followed at the Infirmary. These patients included bilateral procedures done at one operation, and those having one side done at one time and the other later. This group does not take into account any other procedure other than direct attack on the frontal sinus. Thus it deletes incision and drainage of the orbit before or after frontal surgery, secondary resection of osteomyelitic bone of the cranium, exploration for or drainage of brain abscess, subdural abscess.

The average total operations per patient were 3.1, while the average frontal sinus operations per patient equalled 1.6. The average follow-up was 67.2 weeks, measured from the time of the last (or

*Many of these operations were done outside the Infirmary, the patient being referred there as a "last resort."

only) frontal operation until the patient was last seen. In some cases the follow-up period was very short, and in others many years.

Evaluation of Obliteration of the Frontal Sinus

Since obliteration of the frontal sinus is so relied upon by surgeons of wide experience in secondary frontal sinus surgery, it might be well to discuss plastic procedures in this study as a preliminary to considering obliteration. The rhinologist usually employs a skilled plastic surgeon postoperatively to restore the patient's appearance and alleviate his mental reaction to deformity. By a few facts and figures one can properly evaluate the disadvantages of the disfigurement which causes hesitance in the adoption of the method.

Plastic Repair

71 cases of the 276 required plastic repair. 111 plastic operations were done on these patients. The average time from the last frontal operation to the last plastic procedure was 48 weeks. This average was weighted by cases for whom simple closure of an open wound was done a few days after a frontal operation to those requiring months or years of plastic repair. In one instance, for example, 5 years 3½ months were required for three plastic operations. 3 other cases required over 4 years for such work, while 11 patients required one and a fraction to two and a fraction years. These figures do not take into consideration the adverse mental reactions which may have occurred in some of the cases.

Purpose of Obliterataon

The purpose of obliteration is to seal off the frontal sinus communication with the nasal cavity and to obliterate any air space in the sinus itself. Obliteration is supposed to be a solution for frontal sinuses which have failed to do well after repeated efforts to establish drainage into the nose. The operation is designed to collapse the soft tissues of the anterior wall of the sinus against the bare bone of the posterior wall or the dura. That is, the anterior

bony wall is always excised completely in any form of obliteration. Since the Lynch procedure removes the floor completely, this is often not a problem. Removal of the posterior bony wall offers theoretically a greater chance for successful obliteration since adhesions will form more readily, thereby, between the anterior and posterior walls. The interfrontal septum must remain in unilateral obliterations and provides a mechanical source for failure, especially as the region of the frontal ostium lies very near the interfrontal septum posteriorly and adhesions must seal off all communication between the frontal sinus and the nasal cavity. If left behind, any bony wall of the frontal sinus, including the interfrontal septum, is also a source of possible regeneration of mucous membrane. If the ostium seals off and mucous membrane regenerates, a mucocele is likely to develop.

The obliteration of both frontals simultaneously is supposed to offer advantages for success since the interfrontal septum is out of the way. Obliteration has the virtue of utilizing the tendency of some postoperative frontal sinuses to shut off entirely any drainage into the nose because of scar tissue formation.

A wide variety of obliterative operations have been tried including those mentioned above and initial obliterations have been done without any previous frontal sinus surgery where only a little of the floor is excised.

Results in 96 Cases of Osteomyelitis and 4 Cases of Osteoporosis

In the total group of 276 patients there were 96 who had osteomyelitis. In 44 the disease process extended beyond the limits of the frontal sinus into the cranium while in the remainder the disease was limited to the frontal sinus itself. 53 of the group had a single operation directly upon the frontal sinus or sinuses, while 43 had multiple operations. 4 of the 43 had multiple frontal sinus operations without obliteration; 14 had frontal sinus surgery followed by obliteration; 25 had obliteration followed by more surgery and 8 of the 25 had external frontal sinus surgery before obliteration.

A total of 77 cases had obliterative operations; 15 of the 77 had re-obliteration; 7 more had other frontal sinus surgery after obliteration, while 3 others had incision and drainage of the orbit (once in each case) after obliteration.

Of the 15 patients who had re-obliteration the original obliterative procedure in every case was removal of the anterior wall and the floor. All of the fifteen had the posterior wall removed at re-obliteration and in 13 of the 15 cases obliteration was the first procedure.

Of the 7 patients having further frontal sinus surgery after obliteration: 3 had initial removal of all walls bilaterally; one had bilateral removal of the anterior and posterior walls and floor of one side. All 4 of these cases were re-operated, 3 once each and the fourth twice more. The remaining 3 (of the 7 patients) had unilateral obliteration with the anterior wall and the floor removed. One of the 3 had 5 further frontal sinus operations on the same side plus incision and drainage of the orbit and drainage of a brain abscess. The remaining 2 patients had one further operation each.

Three patients had simple incision and drainage of the orbit (once each) after obliteration. In 2 of these, the anterior wall and the floor had been removed, bilaterally in one and unilaterally in the other. In the third the anterior and posterior walls had been removed on one side. In summary, 25 of 77 cases of osteomyelitis required direct frontal sinus surgical procedures or incision and drainage of the orbit after obliteration operations.

TABLE 1.—OSTEOMYELITIS

	CASES	MORTALITY CASES
Total patients	96	23
Single operations	53	12
Multiple operations	43	11
Total operations directly on frontal sinus in these cases — 124		
Average — 2.9		
Obliterative operations	77	20
Further surgery required after obliteration (Total number of operations — 31)	25	6

TABLE 2.—FURTHER SURGERY AFTER OBLITERATION IN OSTEOMYELITIS: 25 CASES

	CASES
Type of operation at original obliteration:	
Removal of anterior wall and floor (bilateral in 7)	20
Removal of all walls bilaterally	3
Removal of anterior and posterior walls on both sides and floor on one side	1
Removal of anterior and posterior walls	1
Surgery at further operations:	
Removal of posterior wall	15
Incision and drainage of orbit	3
Miscellaneous	7
Mortality ..... 6 cases.	

TABLE 3.—SINGLE OBLITERATIVE OPERATIONS IN OSTEOMYELITIS

Total patients 52

	ONE SIDE	BOTH SIDES	TOTAL
Type of Surgery Done:			
Anterior wall and floor removed	11	1	12
Anterior wall, posterior wall and floor removed	10	19	29
Anterior wall and posterior wall removed	4	5	9
Anterior wall, posterior wall and part of floor removed	0	2	2
Mortality ..... 5 cases.			

TABLE 4.—OSTEOMYELITIS

	CASES	MORTALITY CASES
Patients *not* having obliterative operations	19	3
Type of surgery:		
Modified Lynch	15	1
Miscellaneous	3	1
No surgery	1	1

TABLE 5.—OSTEOPOROSIS

	CASES	MORTALITY CASES
Total patients	4	0
Type of operation:		
Lynch	2	
Incision and drainage of floor of frontal	1	
Miscellaneous surgery (4 operations—cured by use of tantalum foil; reported by Goodale in this case)	1	

Tables 1, 2, 3, and 4 summarize the above facts, including the types of surgical procedure and the mortality, while Table 5 epitomizes the group of osteoporosis cases.

The purpose of reviewing carefully the experience with osteomyelitis is that the seriousness of the disease process and the high mortality may justify surgical decisions especially for obliteration, which might not be tenable otherwise. Since approximately one-third of the obliterative cases required further surgery in osteomyelitis, it becomes of interest to study the facts and figures obtained in the non-osteomyelitic group.

What Happened in 176 Non-Osteomyelitic Cases

Of the remaining 176 Cases, only 52 had multiple operations. Table 6 summarizes some of the more interesting findings, including the fact that of 23 who had obliteration, 8 required further surgery. Table 7 gives further details regarding these 23 patients, while Table 8 emphasizes the remarkable finding that only 29 cases of 276 had *no* osteomyelitis, *no* obliteration, *and* repeated operations on the frontal sinus itself. That is, of 176 who had no osteomyelitis, 52 had multiple operations, divided 23 with obliteration and 29 without.

The type of surgery and the mortality occurring in the 124 patients with one operation on one or both frontal sinuses is summarized in Table 9. It is of interest here that 17 of 23 cases having obliteration by removal of the anterior wall and floor had no further surgery during the Infirmary follow-up period, and that the 5 who had excision of the floor, anterior and posterior walls all died. (This was not related to simple removal of the posterior wall, but to the fact that these were complicated cases.)

While the Lynch operation was the commonest in the survey (191 Lynch operations or Lynch-type "revisions" were done), a total of 123 obliterative cases places the obliteration operation second in frequency.

Causes of death in the total group were meningitis, subdural abscess, brain abscess, thrombophlebitis and septicemia, pneumonia and in one case pinealoma.

TABLE 6.—NON-OSTEOMYELITIC CASES

		CASES	MORTALITY CASES
Total number of patients		176	19
No secondary surgery during follow-up		124	14
Patients having secondary frontal surgery		52	5
Total operations in these 52 cases:			
Nasal, sinus, cranial, etc.	224		
Directly on frontal sinus or sinuses	134		
Bilateral frontal at first operation	2		
One side, with other side later	8		
Obliterations		23	5
Further frontal surgery required	8		

TABLE 7.—OBLITERATION IN NON-OSTEOMYELITIC CASES

	CASES	FURTHER SURGERY CASES	MORTALITY CASES
Total patients	23		5
Type of surgery:			
Original surgical obliteration with removal of anterior wall and floor	6	6	
Lynch or other frontal surgery, then obliteration	17	2	

TABLE 8.—NON-OBLITERATION IN NON-OSTEOMYELITIC CASES WITH MULTIPLE OPERATIONS

	CASES	MORTALITY CASES
Total patients	29	0
Total operations in these 29 cases—77		
Type of surgery:		
2 to 9 Lynch type operations	11	0
Miscellaneous frontal surgery followed by Lynch, or vice versa	16	0
Miscellaneous frontal surgery	2	0

TABLE 9.—SINGLE OPERATION ON ONE OR BOTH FRONTALS (NON-OSTEOMYELITIC GROUP)

	CASES	MORTALITY CASES
Total patients	124	14
Type of surgery:		
Lynch	86	7
(31 were bilateral)		
Miscellaneous	15	2
(2 were bilateral)		
Obliteration	23	5
Technique:		
Removal of anterior wall and floor (one was bilateral)	17	0
Removal of all walls (two were bilateral)	5	5
All walls on one side; anterior wall and floor on other side	1	0

Comment

It seems obvious from the facts and figures stated that the acceptance of obliteration as a choice of surgical procedure is not an unmixed blessing even when plastic repair and the mental state of the patient as a reaction to deformity were completely discounted.

On the other hand, the alternative fact that 29 "secondary" frontal surgical cases *not* having obliteration underwent 77 operations is discouraging. Is the surgeon confronted with the dilemma of choosing between obliteration and its drawbacks, or the probability of having to "revise" a secondary frontal repeatedly? The causes for failure of an ordinary Lynch frontal have been listed by Goodale[1] as: (1) adhesions; (2) remnants of the floor of the frontal; (3) residual ethmoidal cells, particularly a fronto-ethmoidal cell or an ethmoid extension into the roof of the orbit.

To these may be added, closure by growth of bone. The writer recently found in a secondary frontal operation a mass of bone 2 cm. in diameter causing complete closure between the medial portion of the frontal sinus and the anterior ethmoid, with total obliteration of the former surgical opening.

The "remnants" of the frontal floor found at a secondary operation are not infrequently simple regeneration of bone, and it is

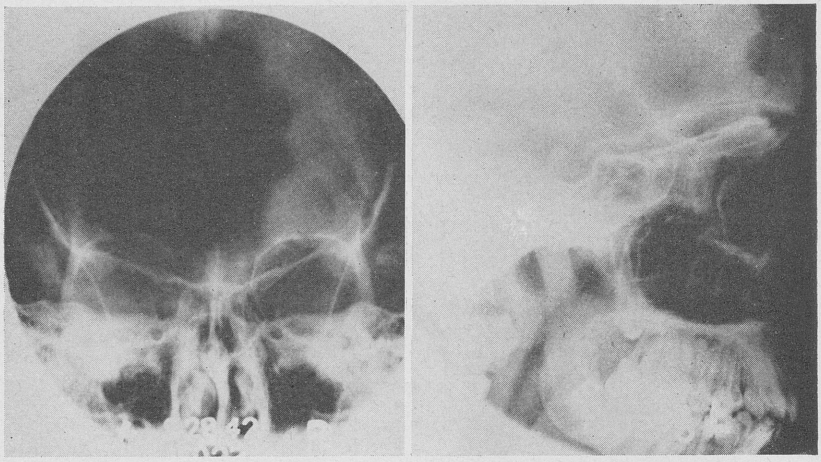

FIG. 1.—Roentgenograms showing excision of frontal sinuses and frontal bone for osteomyelitis.

pertinent to challenge the validity of the hallowed axiom among rhinologists that a completely excised frontal sinus floor never regenerates.

In Figure 1 is seen a postoperative x-ray film of a 14-year-old girl who had osteomyelitis of the frontal bone excised along with all walls of both frontal sinuses through a coronal incision with immediate closure of the wound. She had previously had a left Lynch frontal. The only drainage after the frontal bone excision was through this wound She was discharged on the thirty-second day with the wounds completely healed.

Figure 2 shows further x-rays two years later. Dr. A. S. Macmillan reported the lower third of the bony defect to have regenerated and the frontal sinuses to have reformed.

The most important reason for failure in non-obliterative external frontal sinus surgery—primary or secondary—is simple closure of the nasofrontal opening. Can this unhappy situation be improved? Several considerations are in order;

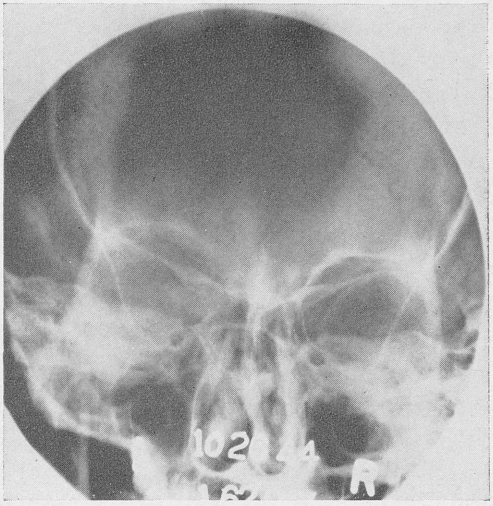

FIG. 2.—Roentgenograms showing postoperative bone regeneration.

A. Applied surgical anatomy.

B. The process of wound repair in this region.

C. Methods of keeping the nasofrontal opening patent.

D. Avoidance or simplification of surgical treatment when possible.

E. Chemotherapy.

These will be discussed in this order.

A. *Applied Surgical Anatomy.* Since the normal ostium lies posteriorly and medially near the crista galli, certain anatomical facts should be kept in mind in attempting to establish a surgical opening into the nose. The first of these is that the ethmoid is the normal surgical pathway into the nose from the frontal sinus; that it extends anteriorly only as far forward as the ascending process of the superior maxilla. That is, a large part of the nasal part of the frontal bone is in relation with the ascending process and the nasal

bone laterally and anteriorly. There is merely a 3 mm. wide groove in the roof of the nasal cavity at the floor of the frontal sinus. The floor of the frontal sinus anteriorly and medially consists of heavy thick bone which tapers posteriorly to thin bone in the region of the frontal sinus ostium. If an attempt is made to establish a pathway between the floor of the frontal sinus anteriorly and the nasal cavity, anatomically the space is narrow and thick bone must be tunneled permanently.

In terms of healing, the establishment of the nasofrontal opening in the ethmoid relationship has many added advantages: The ethmoid is, according to Mosher,[2] 5 mm. wide anteriorly and widens further to 15 mm. at the face of the sphenoid. The greater the depth of the frontal sinus and the greater its ethmoidal relationship, the greater is the possibility for utilizing ethmoidal space from before backward and from side to side for the nasal opening. The 3 mm. groove beside the septum at the roof of the nose on the floor of the frontal sinus adds just so much space to that gained by utilizing the ethmoidal anatomical relationship. Furthermore, a large fronto-ethmoidal cell in series with the posterior wall of the frontal sinus medially would seem to offer anatomically definite aid in making a Lynch operation successful by utilizing it as an anatomical pathway for drainage after its anterior wall had been excised completely. In the fundamental healing process, it should be remembered that the "large opening" which the surgeon makes from the frontal sinus into the nose in the Lynch operation becomes anatomically very much smaller when the wound is closed.

B. *The Process of Wound Repair in Secondary Frontal Sinus Surgery.* The tissues concerned in post-operative repair are:

(a) Bone denuded of mucoperiosteum. The denuded bony walls of the frontal sinus and ethmoid cells have, even with "complete" removal of the sinus lining, microscopic fragments of mucoperiosteum from which regeneration of the sinus lining takes place.[3, 4, 5]

(b). True bare bone. Most important is a wedge of freshly cut raw bone lying between the frontal septum superiorly and the nasal septum inferiorly. This is in relation, in a skillfully performed operation, inferiorly with the intact mucoperiosteum of the septum.

It has no diploe.

Adult bone cells here as elsewhere will not proliferate; bone repair therefore proceeds from osteoblasts of the haversian canals, as well as from "neighborhood" osteoblasts including those of the nasal mucoperiosteum and islands left on the frontal sinus septum and other walls of this sinus.

(c). Mucoperiosteum of the nasal cavity.

(d). The diploe, if the operative field involves the anterior wall of the frontal sinus and the uppermost portion of the posterior wall, or the "outer angle" of the frontal. (In an ordinary Lynch frontal operation, the diploe is avoided, or almost avoided).

(e). The orbital periosteum, and that of the lateral external nose.

(f). The skin, subcutaneous tissue, and orbicularis oculi muscle.

The most important "common denominators" for repair are, therefore:

1. Epithelium.

2. Connective tissue stroma and its contents.

3. Bone.

A few facts regarding these tissues can be briefly but profitably reviewed.

Kazanjian teaches that soft tissue contracture occurs near bone in a certain orderly manner as follows: If granulation tissue is completely encircled by bone, it tends to contract toward the bony circumference and away from the center of the circle. Granulation tissue which is surrounded solely by soft tissue tends to contract centrally, pulling in the surrounding parts toward the center of an imaginary circle. There are wide degrees of variation between these two extremes but the greater percentage of a circle of bone which can be maintained around an intended lumen, the less likely is the opening to close. The practical application of this

point is that the surgical communication between the large frontal sinus cavity and large naso-ethmoidal cavity has to be made at a relatively narrow point and that *the wide removal of bone in the region of the upper portion of the ascending process and the nasal bone or the contiguous portion of the nasal part of the frontal bone lessens the periphery of the partial residual circle.* This sacrifices a valuable adjunct in healing in direct proportion to the amount of bone lost. In other words, the junction of the posterior inferior margin of the frontal sinus with the orbital plate of the frontal bone constitutes part of the bony circle; the wedge of bone lying between the nasal septum and the frontal septum, another part of the circle; while the bone just described constitutes what is left of the circle anteriorly. Inasmuch as the technique of the Lynch frontal operation requires the destruction of the lateral portion of the circle, the area of such destruction should be as limited as possible so far as is compatible with adequate technique. Furthermore when bone is widely sacrificed, the disadvantage should be known to the operator before he does it, rather than afterward. This does not mean retention of any portion of the floor of the frontal, or failure to have a smooth surface of bare bone between the frontal septum superiorly and the nasal septum inferiorly.

The last is quite important, as bare smooth bone is ideal for the growth of epithelium from the well-preserved nasal septal mucoperiosteum upward onto the frontal septum. The growth tendency of *under*lying granulation tissue (whether osseous or connective tissue granulations) is restrained by a covering of epithelium. Furthermore, everyone recognizes that adhesions will not form between intact sheets of epithelium and *over*lying granulations.

The sources for epithelial regrowth are: (1) the undisturbed mucosa of the nasal cavity and, (2) microscopic islands left in the ethmoid and frontal when the bone is denuded. It is known that in the denuded antrum epithelization is unmistakably present only at four weeks.[5] It is therefore imperative for immediate postoperative repair that the undisturbed nasal mucous membrane not be traumatized beyond the field required for adequate surgery.

Arey[6] believes the restoration of epithelial defects "is brought about by the movement of epithelial tissue from the intact border

zone over connective tissue or other substrate. Advancing from all sides these modified reparative epithelial sheets meet and then return to their normal state of organization." Conditions which alter this process and its time relationships are "the size and shape of the wound; the preparation of a proper bed in secondary repair; the occurrence of mechanical obstacles; the presence of infection; the kind of epithelium involved (simple or stratified)".

The extension of epithelium is in progress even on the first day. In the first two weeks the epithelial tongues adhere more firmly to a wound scab than to underlying connective tissue, so that lifting up of the scab tends to carry the epithelium with it.

Hajek is said to have devised a surgical technique for observing directly the process of epithelial repair of the nasofrontal passageway following radical external frontal operations. Hajek taught his pupils that three to six months were required for complete healing.

Since epithelial repair in mucous membrane proceeds in approximately the same manner fundamentally as in skin,[6] it is interesting to know that skin epithelial growth is at the rate of 0.5 mm. per day[7] and begins after a latent period of three to six days. Frequent dressings prolong the latent period by tearing away epithelial cells as they advance. In early weeks the rate of repair is constant; that is, the growth of skin epithelium is not rapid for a few days followed by slowing down. Local conditions in the wound influence the amount of daily extension of epithelium; for example, *infection stops epithelization entirely.*

Connective tissue repair is described by Arey.[6] The cells involved are neutrophiles, polyblasts, fibroblasts, and endothelium. Polyblasts, which are said to arise from lymphocytes, monocytes and histiocytes may revert to histiocytes (reticulo-endothelial macrophages) or be transformed into fibroblasts. In relatively clean wounds, fibroblasts and endothelium are proliferating plentifully—the latter as vascular sprouts—on the second day. While the great source of fibroblasts is proliferation by fibroblasts, these cells may come, in later healing, partly from endothelium.

Infection, necroses, foreign bodies, and blood clots, are adverse factors in the growth of healthy granulation tissues. Blood stasis tends to produce thick weals of tissue.

A "granulation" has a vascular tree as a core with an enveloping mantle of young fibroblasts and wandering cells.

Pressure sufficient to blanch a fingernail, when applied to granulation tissue, tends to lessen its growth by diminishing vascularity. Such pressure still allows epithelial growth to take place.

The laying down of collagen fibrils is largely responsible for wound contracture in the late stages. It is this contracture which results in the closure of an apparently good nasofrontal opening several months after operation when success has seemed assured. The use of any form of obturator in a soft tissue stroma in which no epithelial covering occurs usually fails to prevent closure by contracture. Possibly elastic fibrils which appear from about three to nine months after the onset of soft tissue wound healing play a part in late contracture, but the collagen fibrils with which everyone is familiar are all-important. Aging collagen contracts[8] through losing water, presumably water that is closely related to the protein collagen as water of crystallization is to a crystal.

It is known[6] that contracture occurs early in wounds of skin and mucous membranes which are loosely attached to deeper structures. Carrell is cited[8] as finding that contraction enters after a quiescent period of two to five days in large and medium-sized wounds and proceeds fastest immediately thereafter, followed by gradual slowing to a standstill. Some mechanical factor such as shrinkage is presumably the cause. The more firmly anchored the soft tissue is to deeper rigid structures, the less important is this early contracture, and it does not occur in wounds less than 10 mm. in size.

Bone healing is less clearly understood than is soft tissue repair.

Normal bone metabolism has been briefly outlined by Reifenstein and Albright[9] as follows: Normal bone consists of an organic

matrix in which a calcium-phosphate-carbonate salt is deposited. On normal bone there are areas where nothing is happening, where bone is being formed, and where bone is being resorbed. In the last area osteoclasts are seen. Bone formation has two steps: The laying down of the matrix by osteoblasts; and the deposition of calcium salt. Bone formation and bone resorption occur simultaneously. This is probably made possible by the enzyme phosphatase, which is said to be produced by osteoblasts. This enzyme increases the local concentration of phosphate ions by splitting off such ions from organic phosphate compounds, and thereby permits the deposition of calcium, phosphate, carbonate salt. Calcium metabolism is regulated by the parathyroid glands and vitamin D.

No tissue in the body is capable of so much overgrowth on one hand or absorption on the other as bone.[10] Proliferation of osteoblasts may be so rapid and massive that no other non-malignant process is comparable with it.

The raw bone surfaces in a post-operative frontal sinus become bathed by blood and exudate. Osteoblasts from mucoperiosteum and from the haversian systems would in normal bone repair join with new capillaries in forming a kind of granulation tissue. In four or five days trabeculae would be formed around central spaces —later becoming haversian canals. This is osteoid tissue which with calcium deposition becomes bone.

But in the Lynch frontal operation, the purpose is to *defeat* such normal healing and it is postulated that normally, after complete removal of the floor of the frontal sinus, no such bone regeneration occurs. This postulate is of doubtful merit, as has been pointed out above.

In the Lynch frontal when the wound is closed, periosteum is sewed to periosteum. What is to prevent osteoblastic activity? It is true that bone regeneration is irregular, especially in membranous bone. To secure regeneration: (1) Get a great big blood clot. (2) Strip the cambium layer of bone with the periosteum, making the latter look pebbly, and using extremely sharp periosteal elevators. Then when (3) the periosteum is sutured to periosteum,

bone may regenerate, as osteoblasts cause secretion of osseomucin and phosphatase. Prevention of regeneration may possibly be avoided in proportion to the accomplishment of the opposite of these measures.

In summary, fundamental tissue healing in relation to epithelium, connective tissue and bone has been briefly reviewed with the particular purpose of seeing what aid could thus be obtained in establishing a permanent nasofrontal opening. While many factors may make for failures requiring secondary frontal surgery the most important one is simple closure of the stoma between the nasal cavity and the frontal sinus. If the frontal is regarded as one circle in a figure of eight and the nasal cavity as another circle, it is vital to have a patent opening between the two at the anatomical hour-glass constriction.

C. *Methods of Keeping the Nasofrontal Opening Patent.* (1). Anatomically there is reasonable likelihood that many Lynch frontals will succeed, particularly if the patient is fortunate enough to have a large medially placed fronto-ethmoidal cell which, when made a part of the frontal sinus by complete removal of its common wall, allows drainage near the region normally occupied by the frontal ostium. Such an opening may occur without the use of any foreign body as a drain or obturator. Some surgeons believe that the irritation resulting from the use of a foreign body such as a catheter induces a damaging granulation tissue response.

(2). However, it was Lynch,[11] himself, who left in a soft rubber drainage tube three-eighths of an inch in diameter with one end cut on a long bevel, taking the tube out at the end of five days. He then used a large dilator for ten days more and concluded that then "healing seems to be established and convalescence about complete." Schall modified this technique by using the bell end of a large soft rubber French catheter. He placed the bell end in the frontal sinus and the small end was allowed to protrude from the nasal vestibule where it was secured externally. Such a catheter has the advantage of acting as a drain and of permitting irrigation of the frontal sinus with penicillin solution or other chemotherapeutic agents. It produces a minimal granulation tissue response

if the bell end fits well into the nasofrontal opening. The fact that it is not a non-irritating foreign body can be minimized so far as healing responses are concerned by leaving it in for a very few days after Lynch's technique or permitting it to remain deliberately for many weeks so as to obtain its maximum value as an obturator. As has been stated above, failure of epithelial growth around the catheter will in the end permit enough contracture of connective tissue to cause failure.

The method worked well in the patient who had the highest number of Lynch revisions in this survey of 276 cases.

An attempt by the writer to use a paraffin-covered catheter was successful in establishing drainage into the nose in dealing with a postoperative mucocele in which 2 cm. of solid bone occluded what had once been a Lynch frontal opening into the nasal cavity. The tube was placed posteriorly into the ethmoid behind the occluding bone and it was hoped that the paraffin might mitigate some of the ill effects produced by soft rubber. Meltzer had suggested this technique as a result of experience with the fenestration operation and stated that Holmgren had successfully employed paraffin originally in preventing bone regeneration.

(3). Mucous membrane flaps have been frowned upon by the majority of surgeons dealing with frontal sinus surgery. Sewall[12] reported the successful use of such flap many years ago. The writer has occasionally employed a flap from the upper anterior lateral nasal wall by turning the flap like a hinge onto the frontal septum. A chief disadvantage is the maintainence of the flap in situ. The method was dramatically successful in the following case:

A 48-year-old white male had had a right external frontal operation in London in 1928 which had been repeated there in 1935. From then until the time he was seen in 1942 he had had recurrent orbital abscesses with closure of the right eye for about a week out of each month. The frontal sinus was explored and "revised"; complete closure of the opening between the frontal sinus and the nasal cavity was found to have occurred. A mucous membrane flap was turned from the lateral nasal wall against the frontal septum at

the operation. At the time of his discharge he had a widely patent opening from the nose into the frontal. The patient was last heard from in April 1945 when he reported that he was completely well and that he had had no trouble since the operation.

(4). *Probing.* Every experienced rhinologist has occasionally been chagrined to observe, over a course of months, what seemed like a perfectly successful secondary nasofrontal opening (or primary opening for that matter) slowly close in spite of every effort in local wound management. He is then compelled periodically to dilate the opening with probes in trying to keep at least an intermittently patent fistula present. The process is uncomfortable and troublesome for the patient and in the hands of the writer has been of only palliative value.

(5). Skin grafts have been found useful by some rhinologists. Smith has reported[13] their use in over 100 cases with only three closures of the nasofrontal opening.

(6). *Non-Irritating Foreign Bodies.* It should be pointed out that the distinction between irritating and non-irritating foreign bodies as used in the frontal region needs careful understanding. It is of prime importance that no dead space exist around a foreign body of either type; this insures the least tissue response in either case. If a French rubber catheter fits well in the nasofrontal opening, the slight pressure which it exerts upon surrounding granulation tissue lessens the blood supply of the granulations and thereby lessens their growth, while at the same time this pressure is insufficient to stop or prevent epithelization. If, for example, an acrylic resin tube were substituted for the catheter, it would excite a foreign body response if its fit were poor even though the tissues have great tolerance for methyl methacrylate.

Non-irritating foreign bodies which have proved useful in frontal sinus surgery include tantalum,[14] acrylic resin, and vitallium.[15] To this list may be added fibrin film as a promising substance for trial.

In using foreign bodies to aid in establishing a permanent nasofrontal opening, the material must be sterilizable; it must cause as little tissue reaction as possible; it must check the growth of gran-

ulation tissue (whether osteogenic or fibrogenic) throughout the period required for healing of the operative field. Furthermore, the material must be easily available. If absorption of the foreign body occurs, the period must be relatively prolonged. Some of the properties of fibrin film, vitallium, acrylic resin, and tantalum will be outlined.

(a). *Fibrin Film.* The material is prepared from human fibrinogen and thrombin and is dispensed as a thin firm translucent, rather brittle, dry, sterile sheet sealed in a glass ampule. After the film is soaked in cool, physiologic, sterile solution, it becomes flexible and elastic and should be used the same day the ampule is opened and should be kept immersed in cool, sterile, sodium chloride solution until it is required. It cannot be resterilized. If the surgeon believes there is danger of its slipping out of place it can be sutured as desired provided it is kept moist. It is completely absorbed within six months, but is still present in dural wounds at three months. Dr. John Edsall of the Department of Physical Chemistry at the Harvard Medical School has recently made available to the writer sufficient fibrin film for a trial in frontal sinus work. A report about its use will be published later. The ability of this substance to prevent meningocerebral adhesions[16] would seem to offer hope for good results from it as a surgical aid in establishing a permanent nasofrontal opening.

(b). *Vitallium.* Vitallium[17] is an alloy composed chiefly of cobalt and chromium, with a small percentage of molybdenum. Its specific gravity is 8.29. It is very strong and very light. It is boilable, and is said to be inert in body tissues.

Its use in strictures of the common bile duct[18] suggested that it might be of value in the surgical construction of a nasofrontal opening. Because the metal is not pliant or easily adaptable to molding in the operating room, an effort by the author to make use of a vitallium tube in frontal sinus surgery was abandoned.

(c). *Acrylic Resin.* Harmon[19] describes the methacrylate resins as plastic materials having the following properties: They are polymers of methyl methacrylate. When cast in rods, sheets, or blocks the material is crystal clear, light in weight, with a specific

gravity of 1.16. They are slightly flexible, and are durable and strong. Solid methacrylate is not affected by alkalies, oils, dilute acids, solutions of mineral salts, or dilute alcohol. Cast methacrylate softens between 190° and 240° F; moldings withstand 140° to 190° F., depending upon whether prepared from "soft" or "hard" powder.

Irritating solvents called "plasticizers" used in industry are present only in traces in the methacrylates employed in surgery.

The tissues show great tolerance to the acrylic plastics. The material can be made into tubes of any desired size or shape and by using "soft" powder it is possible to mold material as desired at the time of operation. It can also be made into a film upon a catheter as a coating in an effort to convert soft rubber into a non-irritating foreign body.

(d). *Tantalum.* Tantalum is an element having an atomic weight of 180.88, a valence of 5, a specific gravity of 16.6, and a melting point of 2996° C. It is biologically inert and has the advantage of being an element, not an aloy as is vitallium. Chemically it is similar to glass in its resistance to acids. It is resistant to weak but not strong alkalies. Its chemistry is such that theoretically it should be inert in a body-tissue environment. This hypothesis has been borne out experimentally.

The metal is both malleable and ductile, so that it may be rolled into sheets of any desired thickness or drawn into extremely fine wire. The high tensile strength of the latter permits twisting and tying in tight knots. Very thin rolled sheets are called tantalum foil, which measures 0.00025 of an inch in thickness. Tantalum sutures are two and a half times stronger than the U.S.P. requirements for catgut (knot pull).

Tantalum combines the advantage of resistance to corrosion and chemical change with the advantages of the strength, workability, and malleability of steel.

Tantalum has been employed by the writer as a tube permanently implanted with one end in the frontal sinus and the other in the

nasal cavity, using tantalum sutures and molding of the tube to fix it in place.

Brief details of this case are as follows:

When the patient, a 9-year-old white male was first seen by the writer, his history was as follows: He had had left-sided acute pansinusitis with orbital cellulitis. Decalcification of the outline of the left frontal sinus developed in spite of chemotherapy. A left external fronto-ethmoidectomy was done with complete removal of the anterior wall and floor of the left frontal sinus. The patient was well for six months, but then complained of severe pain in the left orbit, which was accompanied by swelling and tenderness of the forehead. The edema improved, but did not disappear with chemotherapy. X-ray films showed that the back wall of the frontal sinus up high was gone in two areas. Re-obliteration was carried out with excision of the posterior wall. Because of a small perforation in the interfrontal septum, this structure was removed entirely. His convalescence was uneventful, and he remained well for about eight months, except for recurrent swelling of the forehead with head colds.

Then, following swimming, he developed swelling, redness and tenderness over both frontal regions. An abscess of the left frontal area was incised and drained. About seven weeks later, a tantalum tube was placed by the writer in the right frontal sinus at its posterior wall just lateral to the margin formerly occupied by the interfrontal septum; the tube was brought into the left nasal cavity, and was fixed by tantalum sutures. Its position is shown in Fig. 3. Convalescence was uneventful. The patient has been well during a follow-up of one and a half years, despite several head colds.

Tantalum foil can be used to cover an ordinary soft rubber French catheter to make it relatively innocuous to tissues. Tantalum wire ties hold the foil in place. This was found useful in a case of tuberculous rhinitis complicated by right ethmoiditis and frontal sinusitis with orbital abscess, operated upon by the Lynch technique. It was possible for the patient to tolerate the tube, without difficulty, for four and a half months, when it was finally withdrawn. A tantalum retention suture through the upper end of the tube

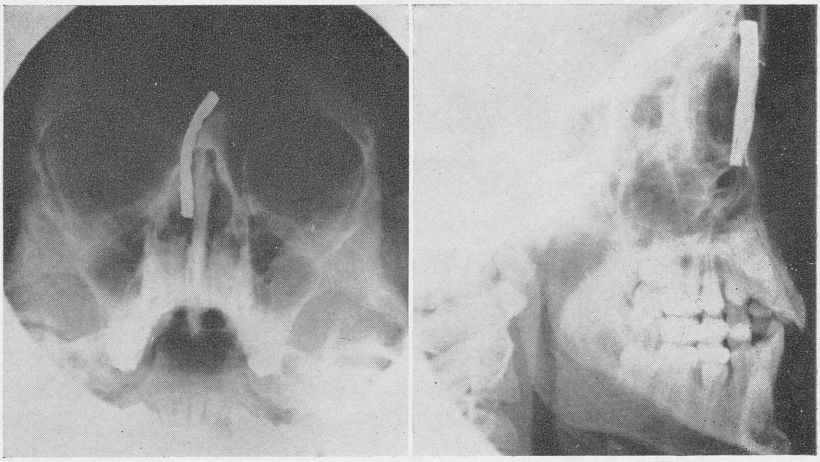

FIG. 3.—Roentgenograms showing tantalum tube in the frontal sinus.

anchored it during this time. The suture, emerging through the wound, was fixed to the forehead with Scotch tape and was completely innocuous also. The patient has required no further surgery to date, but while the tuberculous process has been slowly becoming dormant, meticulous care of the nasal cavity has been required. Fig. 4 shows x-ray films of the tube in situ.

The Goodale operation[14] in which tantalum foil is sutured to the orbital periosteum has, in difficult cases, much to recommend it. It has the great advantage of relative simplicity. He has found no disadvantage from leaving tantalum foil permanently in situ in the eight cases reported by him.

D. *Avoidance or Simplification of Surgical Treatment When Possible.* Experience with radical external frontal sinus surgery has developed among rhinologists a wholesome respect for the frontal sinus and its complications. They require convincing evidence of necessity before surgical interference is undertaken. If the first external frontal operation can be avoided entirely by rea-

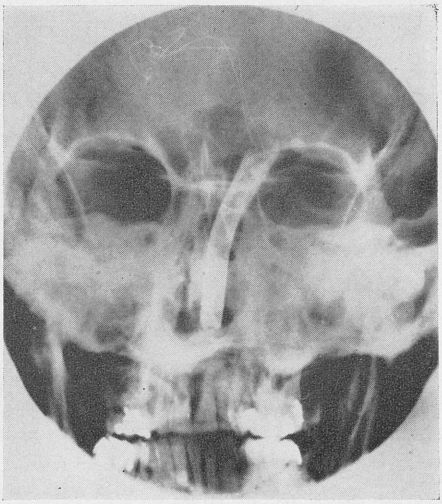

FIG. 4.—Roentgenogram showing foil covering a soft rubber catheter in the frontal sinus. A tantalum wire retention suture is seen also.

sonable conservatism, the judgment and skill of the rhinologist deserve praise.

Moreover, Brown,[20] Walsh,[21] and others have advocated greatly simplified initial surgical techniques for dealing with many of the problems encountered. Thus, Brown has described simple trephination of the frontal floor with the establishment of external drainage in many of the acute cases requiring surgical intervention. He routinely orders adequate penicillin therapy throughout the infection.

In certain chronic frontal sinus cases Brown has trephined the frontal floor and removed the partitions and the mucosa except in the region of the ostium. The wound is closed except for a drainage tube which is withdrawn when discharge from it ceases.

Simple trephination was undertaken initially in 7 of the 276 cases summarized in the first part of this report. In three of the patients

there was uneventful convalescence; one had no chemotherapy; while the other two were given penicillin. Four patients required one to several further operations. Two of these had sulfonamide therapy, while the other two had none. There was one death—chemotherapy was not in use at the time of this patient's illness.

The preservation of the frontal ostium and the mucous membrane near it in the MacKenzie Brown operation for chronic frontal sinusitis is predicated upon clearing the nose of anatomical and pathological obstructions, together with preliminary studies ruling out allergy and endocrine dysfunction, and the failure of simple conservative treatment.

Since the nasofrontal communication is ordinarily not a duct[2] but an ostium in the floor of the frontal sinus posteromedially leading into an air space between the agger nasi and the lacrimal anterior ethmoidal cells, it is occasionally possible in intranasal ethmoidectomy not only to identify the frontal ostium but to preserve the mucosa in the ethmoidal side. This procedure alone will sometimes permit chronic frontal sinusitis to clear up.

It is highly desirable in "sinus" cases — especially in those in which external frontal surgery has been done or is contemplated—to make the nasal cavities as mechanically and physiologically perfect as possible relatively early rather than late in the course of the disease process.

The pathological, accidental or deliberate surgical perforation of the interfrontal septum is not always so serious as is commonly supposed. There is a sort of axiom among some rhinologists that such a perforation almost invariably means that the normal side if perforated will come to surgery. In only 5 to 18 cases in the present series in which such perforations occurred was a further operation done.

E. *Chemotherapy.* Chemotherapy penicillin therapy, has raised the hope that a great deal of frontal surgery can be avoided entirely or markedly simplified. While its aid is invaluable in gram-positive infections at the present time, *it is not a substitute for fundamental surgical principles.*

Simpler surgical methods have proven satisfactory when combined with adequate chemotherapy. For example, G. B. Fred has given me permission to mention that at the clinical staff meeting of the Massachusetts Eye and Ear Infirmary on April 3, 1946, he reported a 25-year-old male patient who had acute left frontal sinusitis with superior sagittal sinus thrombophlebitis. The man was unconscious and having convulsions. The neck was stiff and there were 2200 cells in the sterile spinal fluid, chiefly lymphocytes. Sulfadiazine was given together with penicillin intravenously, and 32,000 units of penicillin were given intrathecally three times a day. No operation was done for six days during which time the patient first became worse and seemed moribund, then recovered completely symptomatically. Electro-encephlagrams, which showed widespread disturbances over the frontal cortex of both sides, had become normal at the end of six days. Fred then carried out incision and drainage of the floor of the left frontal sinus, disturbing the mucous membrane only at the point of the entry into the sinus. A staphylococcus aureus was found in the pus contained in the sinus. He placed a tube to but not through the opening in the frontal floor and irrigated the sinus systematically every few hours with penicillin. When he opened the sinus he was able to observe the point of probable entry of the infection into the meninges—posteromedially near the superior sagittal sinus. The tube was withdrawn after a few days, the wound closed with uneventful further recovery of the patient who had been followed about three months when the report was made.

Monto and Lyle[22] have reported a case of acute pansinusitis with orbital cellulitis, septicemia and meningeal irritation, with recovery by means of penicillin therapy, nasal shrinkage, and an orbital stab wound. The organism was a staphylococcus aureus.

Allman,[23] in a wide experience with scarlet fever, treated 52 cases of orbital cellulitis with penicillin given intramuscularly combined with the usual local therapy. None of these patients were operated on despite the fact that 12 had considerable exophthalmos, and 3 of these had complete loss of motion of the eye.

After the advent of chemotherapy, sulfonamide drugs and penicillin were used in the present series of 276 cases, in 82 of the pa-

tients. Prontylin, sulfanilamide, sulfapyridine, sulfathiazole and sulfadiazine were utilized in this sequence and then penicillin with or without the sulfonamides (sulfadiazine and sulfamerazine). It is of particular interest that only one patient died after sulfadiazine and penicillin were used.

Summary and Conclusions From a Review of 276 Frontal Sinus Surgical Cases

1. These patients had a total of 862 operations upon the nasal cavities, sinuses and cranium, including plastic and brain procedures. Many of these operations were done outside of the Massachusetts Eye and Ear Infirmary.

2. Of these, 447 were directly upon the frontal sinus or sinuses externally. Some of the cases were referred to the infirmary as a "last resort."

3. 95 of the patients had more than one external operation on one or both frontal sinuses. The highest on one patient equalled nine.

4. Aside from deformity the obliterative operation is not an unmixed blessing. Thirty-three of 123 patients treated by this method required further frontal surgery.

5. The repair of the deformity required an average of about one year in 71 patients. The longest time was five years, three and a half months for such repair.

6. Only 29 of the 276 patients had no osteomyelitis and multiple non-obliterative operations (totalling 77) on the frontal sinus or sinuses.

7. A basic knowledge of applied surgical anatomy, and a fundamental understanding of epithelial, connective tissue, and bone responses in wound healing in the frontal region are helpful in avoiding repeated frontal operations.

8. Simple closure of the nasofrontal surgical opening is a paramount cause for the necessity of secondary frontal sinus surgery. Some surgical methods for dealing with this problem are outlined.

9. The avoidance or simplification of surgical methods in the treatment of frontal sinus disease may be greatly aided by chemotherapy, especially penicillin. However, chemotherapy is not a substitute for surgical fundamentals.

10. Only one death occurred in the series after sulfadiazine and penicillin were used.

247 Commonwealth Avenue.

References

1. Goodale, R. L.: Some Causes for Failure in Frontal Sinus Surgery, Annals of Otology, Rhinology and Laryngology 51:648 (Sept.) 1942.

2. Mosher, H. P.: The Surgical Anatomy of the Ethmoidal Labyrinth, Annals of Otology, Rhinology and Laryngology 38:869 (Dec.) 1929.

3. Knowlton, C. D., and McGregor, G. W.: How and When the Mucous Membrane of the Maxillary Sinus Regenerates, Arch. Otolaryng. 8:647, 1928.

4. Coates, G. M., and Ersner, M. S.: Regeneration of the Mucous Membrane of the Frontal Sinus after Its Surgcal Removal (in a Dog), Arch. Otolaryng. 12:642, 1930.

5. Gorham, C. B., and Bacher, J. A.: Regeneration of Human Maxillary Antral Lining, Arch. Otolaryng. 11:763, 1930.

6. Arey, L. B.: Wound Healing, Physiol. Rev. 16:327 (July) 1936.

7. Howes, E. L.: The Rate and Nature of Epithelization in Wounds with Loss of Substance, Surg., Gynec. and Obst. 76:745, 1943.

8. Wolbach, S. Burt: Personal Communication, 1946.

9. Reifenstein, E. D., and Albright, F.: Paget's Disease; Its Pathologic Physiology and the Importance of This in Complications Arising from Fracture and Immobilization, New England J. Med. 231:343 (Sept.) 1944.

10. Boyd, W.: Pathology, Philadelphia, Lea and Febiger, 1941.

11. Lynch, R. C.: The Technique of Radical Frontal Sinus Operation Which Has Given Me the Best Results, Tr. Am. Laryng., Rhin. and Otol. Soc., 1920.

12. Sewall, E. C.: External Operation on the Ethmosphenoid-frontal Group of Sinuses Under Local Anesthesia, Arch. Otolaryng. 4:377 (Nov.) 1926.

13. Smith, Ferris: Management of Chronic Sinus Disease, Arch. Otolaryng. 19:157 (Feb.) 1934.

14. Goodale, R. L.: The Use of Tantalum in Radical Frontal Sinus Surgery, Annals of Otology, Rhinology and Laryngology 54:757 (Dec.) 1945.

15. Kazanjian, V. H., and Holmes, E. M.: Reconstruction after Radical Operation for Osteomyelitis of the Frontal Bone, Surg., Gynec. and Obst. 79:397 (Oct.) 1944.

16. Ingraham, F. D., Bailey, O. T., and Cobb, C. A.: The Use of Fibrin Film as a Dural Substitute, J. A. M. A. 128:1088 (Aug.) 1945.

17. Doherty, W. B.: Orbital Implants, Arch, Ophth. 25:637, 1941.

18. Carlusci, G. A.: Am. J. Surg. 60:209, 1943.

19. Harmon, P. H.: Arthroplasty of the Hip for Osteoarthritis Utilizing Foreign-body Cups of Plastic, Surg., Gynec. and Obst. 76:327, 1943.

20. Brown, J. M.: Frontal Sinusitis, Laryngoscope 56:116 (March) 1946.

21. Walsh, T. E.: Experimental Surgery of the Frontal Sinus. The Role of the Ostium and Nasofrontal Duct in Postoperative Healing, Laryngoscope 53:75 (Feb.) 1943.

22. Monto, R. W., and Lyle, P. L.: Treatment of Complicated Acute Sinusitis with Penicillin, Arch. Otolaryng. 43:298 (March) 1946.

23. Allman, C. H.: Personal Communication.

DISCUSSION

Dr. Harris P. Mosher: Dr. Weille asked me to discuss his paper, and as Dr. Weille is one of our own hospital men, I naturally am pleased to do so.

I shall confine my discussion to a few points because the paper is a rather complicated one and requires quiet reading to get all there is in it. I shall discuss mostly the obliterating operation, when this is attempted after the primary operation for chronic infection of the frontal sinus has failed.

I consider this one of the most informative papers on the frontal sinus surgery which has come to my knowledge for a long time.

Frontal sinus surgery in my hands has been bitterly disappointing. Temporary favorable results have been common. Favorable results could not be guaranteed. I do not consider that any type of operation can be called a permanent success until you get beyond three or four, perhaps five years. It will rank as a temporary result up to that time. Any type of operation for chronic suppuration of the frontal sinus I believe can fail.

I have held that failure of the operation for chronic infection of the frontal sinus is due to two chief causes; failure to recognize and open an infected sinus and to closure of the enlarged nasal frontal duct.

There are two classical operations for chronic infection of the frontal sinus, the Killian and the Ritter-Lynch. I was brought up on the first. The Lynch is the popular operation to-day.

Many of the cases analyzed by Dr. Weille occurred while I was in flower, so to speak, at the hospital and it bothers me that a discouraging report like this should follow my teaching, but I have a feeling that a frank report from some other hospitals would give an equally disappointing report.

Of the 276 cases reported by Dr. Weille, one-third had more than one external operation. One patient had nine. Many of the secondary operations, however, were done outside our hospital and the cases were referred to the Infirmary as the last resort, so the story is not quite as sad as it sounds when you take the statistics alone.

Among the secondary operations, the so-called obliterating operations figured largely. Most of these were obliterating only in name. They consisted in taking off the anterior wall or part of it, removing the floor and packing the sinus until it obliterated, which in many, if not most cases, did not happen. The obliterating operation, I feel, has a chance of success only if the removal of the anterior and posterior walls of the sinus is carried out, as well as the removal of the floor. This has to be done regardless of resulting deformity. We have learned that a tantalum implant will correct this, and with chemotheraphy to help out you do not have to wait a year before correcting the deformity. Dr. Weille cited one case where it took five years with multiple operations before the deformity was corrected. This should never be necessary again.

Unless the newer methods of keeping the enlarged nasofrontal duct open, as well as keeping a sufficient opening from the floor of the sinus into the nose, are successful—I refer to Goodale's method of suspending a strip of tantalum foil in the enlarged nasofrontal duct, or using a tantalum tube as employed by Weille, or an acrylic mould as advocated by Hoople and others, unless these procedures, one or all, prove to be successful the operation of choice for a secondary operation, is an obliterating operation worthy of the name, one which is something more than wishful thinking.

Walsh's experimental work on the frontal sinus is significant. He did not enlarge the nasofrontal duct and left the sinus opening of the duct alone. When the duct was not interfered with it stayed open. He quoted a wise crack of mine made many years ago but which has had a long life. It referred to enlarging the nasofrontal duct from the nose. He applied it to enlarging the nasofrontal duct within the sinus. The remark was "Respect the Virginity of the Nasofrontal Duct or Take the Consequences."

I should like to be allowed a few more words about the obliterating operation. Since I am no longer doing surgery the type of operation I am about to describe might be called arm chair surgery as I have not done it. It is based on the favorable results in obtaining obliteration of the frontal sinuses in the radical operation for osteomyelitis. Perhaps some adventurous spirit sitting in the audience before me might like to try it. The procedure which I have in mind for obliterating the frontal sinus is as follows:— Remove thoroughly both the anterior and posterior walls of the sinus. Leave a bridge at the inner angle of the sinus. Do not remove the floor. Curette the nasofrontal duct lightly as you want it to close. Do as much in the ethmoidal labyrinth as the patient's condition permits. Finish the ethmoidal labyrinth at a secondary operation if necessary. In dealing with a large sinus press the skin and soft tissues back against the dura with a small sinus pack and let the sinus obliterate from the bottom. Do not worry about deformity. This can be corrected easily and soon by a tantalum cast.

Time alone will tell whether our surgical dream of many years of keeping the nasofrontal duct continuously open can now be accomplished by the use of tantalum foil, a tantalum tube or an acrylic mould and make the majority of primary operations for chronic infection of the frontal sinus successful. When these procedures fail and a secondary operation becomes necessary I feel that an obliterating operation after the technique just described offers the best chance of success.

The success to date of the use of tantalum foil or the tantalum tube in the naso frontal duct is distinctly encouraging.

DR. W. L. SIMPSON: I think Dr. Mosher made a very fine statement when he said any case may fail. The cases should be rare but I can hardly visualize every case staying well.

I want to say in a good-sized number of cases, all the acute cases handled at the John Gaston University Hospital as well as at the Baptist Hospital, we drained all the acute cases. We never tried to do a complete operation on a frontal in an acute stage. If more people would learn that the complications would be far less. You cannot do complete surgery on an acute case and get by with it.

If you have an erupted frontal sinus or an acute frontal sinus and you want to do something about it externally, drain it but wait at least three months before you do any complete surgery. You cannot do it in a week or ten days and get by.

I have only seen one case of osteomyelitis of the skull following any operation in any of our cases. I know that does not agree with the literature but that is a matter of record.

It seems to me the procedure which has been most helpful in preventing any further symptoms after the external frontal sinus operation had been done was a complete ethmoid exenteration. I have opened enough of the frontal sinuses for the second time to know that it is not uncommon at all to find the ethmoids regenerating.

Some of the secondary operations I have done were where the ethmoidal cells were overlooked, especially the median line cells. I have seen mentioned that it was the posterior but the median line cells, the ones which extend clear over across the median line on the opposite side and all around the front, they are often overlooked.

The complete removal of all mucous membrane from the frontal sinus at the primary operation is the basic principle which cannot be overlooked. If you don't remember that, you are looking for complication. The entire floor of the frontal should be removed. It is practically impossible to remove all the mucous membrane without the use of mirrors. Unless an unnecessary amount of the anterior

wall of the sinus is removed you cannot see into the frontal sinus, unless you look in there with a mirror.

Of course, you could if you had a little button, but I am not talking about that. That is not the one which gives complications anyway, but the big sinuses; the removal of mucus with sharp narrowance and antero-posterior wall, that is time consuming. However, that is a very important procedure, and this can only be done with curettes and a mirror. There is not any other way to get it out.

If some of you have had those tall, narrow sinuses which run up to a hair line and have tried to get the mucous membrane out without mirrors and have succeeded then you have done more than I have ever seen anybody do. To me it is a physical impossibility.

No matter how far the frontal sinus extends laterally the outer angle is not a real problem. You can always get the other angle. Since instituting the two above steps I have had very few if any symptoms from frontal sinuses.

The removal of the middle turbinate in frontal sinus surgery is not indicated. There is no reason why you should remove the middle turbinate.

Skin or mucous grafts have not been helpful to me. I have used most all types, the mucous grafts according to Schall, Frank Kistner and all of them. I have used skin grafts according to Ferris Smith, and none of them have been perfectly satisfactory.

No attempt is made to keep the opening of the frontal sinus into the nose patent. I know you all think that is terrible to say, that I make no attempt whatever to keep the nasal frontal duct or that region patent, and unless attention is given to the nasal frontal region the better the final result. I used to put big tubes in the frontals — and I am not talking about three or four cases, I am talking about many cases that have had rupture, who have had osteomyelitis — but not any more. We have a fairly good-sized number every year at the University with ruptured frontal sinuses, osteomyelitis of the skull.

By the way, in all our osteomyelitics, after the osteomyelitis is perfectly quiet we remove all the mucous membrane from that frontal. In fact, I have seen a good many bad results if the frontal sinus is not degenerated after the osteomyelitis is cured. You are just looking for more trouble.

It has been several years since I have seen any symptoms suggesting some secondary opening of the frontal sinus which has been operated as outlined before. This does not cover a period of one year but it covers a period of fifteen or twenty years. I have been criticized for mentioning numbers but it covers quite a considerable group. These are borne out by the records of the hospital and you need not pay any attention to my statements.

DR. A. C. HILDING: I do so little frontal sinus surgery that I hesitate to discuss this paper, but I have done a few animal experiments which might bear on the subject.

The most significant ones were done at the Mayo Clinic twelve or fourteen years ago. The first consisted in removal of annular strips of mucoperiosteum from the interior of the frontal sinuses of dogs. When such denuded rings healed, there formed concentric scars which extended into the cavity of the sinus. The free margin of these ring-like scars came to a knife edge. The other margin, which lay in contact with the bone, was broad or narrow, depending upon whether the denuded strip had been broad or narrow. Also the broader the strip, the deeper the scar extended into the sinus cavity. If the denuded strip were sufficiently wide, in time there formed a complete diaphragm across the sinus cavity dividing it into two cavities, one of which had no outlet.

It was stated here that, if granulation forms within a bony cavity, that the contracture of the resulting scar would be toward the bone, peripherally. That was not the case in these experiments on the sinus of dogs. The contracture was centrally, toward the center of the sinus cavity.

Neither was the contracture peripheral in direction in the following experiments. The trachea of two turkeys were split under anesthesia and annular rings of varying widths denuded of muco-

perichondrium. Four such rings were denuded in one bird with a tracheotomy opening below all of them. An annular stenotic scar formed at each site thus treated. The severity of the stenosis was roughly proportional to the width of the denuded bands.

Another experiment involved the ostium of the frontal sinus of the dog. An annular ring of mucoperiosteum was removed from about the ostium in some and from within the lumen of the ostium in others. The ostium became occluded by contracting scar tissue in each case. It contracted centrally and not peripherally.

The results in all of these experiments seemed to depend essentially upon the tendency of newly formed white fibrous connective tissue (scar) to contract.

It has been said that, in operating upon the ostium of the frontal sinus for the purpose of enlarging it, bony walls should be left on all sides in order to prevent the soft parts from collapsing and thus closing the ostium. According to these experiments, closure (not collapse) will occur, if the bone is denuded of mucous membrane irrespective of how rigid the bone surrounding the lumen may be. This would seem to explain the clinical experience of all of us, that an operated frontal sinus ostium tends to close. We are all aware of the fact that annular ulceration in the urethra, intestinal tract, ear canal, and larynx are all followed by stenotic scars. Why should it be different in the case of the sinuses?

I am glad that it has been emphasized that the ostium is the vital point in the drainage mechanism of the sinus. This was illustrated in some other experiments performed upon the maxillary sinus of rabbits. There is only a very thin bony plate between the maxillary sinus and the nasal cavity in this animal, and artificial windows can readily be made in it surgically. They stay open without any difficulty, and the sinuses thus treated will remain clean, unless the window is made at or very close to the ostium. In such case, the sinus fills with secretion, which becomes infected.

It seems to me that Dr. Simpson is right in maintaining that, if you remove any considerable amount of mucous membrane from a sinus, then you must remove it all. Such complete removal in the

case of the dog's frontal results in more or less complete obliteration of the sinus with the exception of a small cavity which reforms at the ostium. I believe that Dr. Walsh is right when he leaves the ostium alone in order to drain such residual sinus cavity.

It seems to me that much of our failure in frontal sinus surgery can be explained upon the basis of stenotic scars which form upon denuded annular areas of bone left lying within the operated ostium.

Dr. H. G. Tobey: I wish to emphasize, that there is no assurance that a sinus once operated upon will not become reinfected. This is certainly true of the operated antrum.

Our attention is called more frequently to the reinfected frontal sinus because of its more serious nature. Even if we succeed in leaving the operated frontal sinus open for drainage into the nasal cavity, we are still faced with the possibility of reinfection.

Dr. Mosher stated that three to five years should elapse before we can say that the condition has been cured. Just this year I have reoperated two patients, one after twenty years, the other after fifteen years. Both had developed infected mucoceles. One frontal sinus had been blocked off by adhesions to the roof of the ethmoid. The floor had been completely removed and no ethmoid cells had been left. The extreme outer portion of the sinus, which extended to the outer orbital rim, had been blocked off by scar tissue which was adherent to the posterior wall and it was in this area that the infection was seated.

The second patient had a Killian's operation and the bridge was necrotic, probably due to pressure from the mucocele.

I agree with Dr. Mosher that the only sure cure of the infected frontal sinus which comes to operation is complete obliteration. I also agree with him that this can only be accomplished by the removal of the posterior wall.

Dr F. L. Weille (Closing): In regard to failure from not opening the fronto-ethmoidal cell, Dr. Mosher, all I can say is that that is a hopeful kind of failure, because there is the possibility of doing something fairly easy about it.

As to taking off the posterior and anterior walls and leaving the floor, I heard Dr. Mosher say something about this a few months ago and I looked up the cases which had been done. Actually there were only two in this particular series in which anterior and posterior walls and part of the floor were removed. Those patients did well.

I think Dr. Simpson is extremely fortunate if he has had no secondary frontal sinus surgery to deal with. These patients often come to us with an orbital abscess or some serious complication. The deaths in the 22 cases of brain abscesses were 77 per cent. In the 7 cases of subdural abscesses all died. There were numerous meningitis cases. There were three patients with superior sagittal sinus thrombosis, who died. We had no choice as to what to do with most of them. Dr. Simpson spoke of waiting three months before doing any surgery. I feel that chemotherapy combined with his idea of drainage may make a radical change in our future position about these cases.

In reply to Dr. Hilding, I read some of his experimental work at least a year ago on this subject and was very much interested in it. What he says for the dog is of course correct, and may be for humans. However I would refer him to Arey, whose review of wound healing summarizes 376 publications, and he does not agree with Hilding's idea. Perhaps Dr. Hilding can revise Dr. Arey's ideas on wound healing.

Dr. Tobey mentioned having mucoceles developing over ten or fifteen years. You might be interested to know that there were 48 mucoceles in this group of whom 16 were post-operative and the average time for developing was 9.2 years.

CONGENITAL CYSTS AND FISTULAE ABOUT THE HEAD AND NECK

CHARLES D. BLASSINGAME, M.D.

MEMPHIS, TENNESSEE

Because of the unorthodox origin of congenital cysts and fistulae of the head and neck, the information regarding their clinical aspects has not been thoroughly standardized. I feel, therefore, that the report of a case which presents a slight variation from those previously recorded may be of interest. It is universally conceded that all cysts and fistulae of the head and neck, having an epithelial lining, should be treated surgically by extirpation of the entire lining and allowing the cavity to close by first intention. Without a knowledge of their embryologic background, however, one cannot be prepared beforehand for many of the anatomic pitfalls encountered in their management.

Broadly speaking, these anomalies are classified into two main groups: (1) The midline group, or thyroglossal cysts and fistulae, and (2) lateral cysts and fistulae, or those arising on the side of the neck.

There is practically no disagreement regarding the view that thyroglossal cysts and fistulae are derived from the thyroglossal duct, and that this duct is formed by a bud of hypoblast in the midventral floor of the pharynx, growing downward between the mandibular and pharyngeal parts of the tongue, eventually forming the isthmus of the thyroid body and parts of the lateral lobes of the thyroid gland. It has been observed that cysts may form anywhere along the path of the thyroglossal duct from which they are derived, the most common location being immediately below the hyoid bone. Not infrequently, these cysts form in the body of the tongue in front of the hyoid bone. In a smaller number of cases they form between the foramen caecum and the hyoid. In some, they involve the hyoid bone itself. In any location, these cysts present peculiar anatomic and technical problems.

Lateral cysts and fistulae are even less understood than those of the first group. This is due to a wide divergence of opinion regarding the derivation of lateral cysts and fistulae of the neck. Two distinct and contradictory concepts prevail. One is, that these anomalies develop primarily from the branchial apparatus.[1-5] Adherents of this theory are further divided into two groups. One group believes the branchial apparatus in the human embryo is analagous to the gills in adult fish, except that in fish the arches are separated by clefts, whereas in human beings the depressions between the arches represent thin membranes. In rare instances, these membranes are perforated, leaving clefts which persist into adult life as branchial cysts or fistulae. This theory was held by the early investigators, being predicated upon the assumption that there was a fusion of the epipericardial ridges with the lower border of the second and midventral ends of the third and fourth branchial arches, thereby closing the precervical sinus. In refutation of this assumption, it is pointed out that epithelial rests from this source would of necessity be ectodermal in origin, whereas, the histological findings of removed specimens of lateral cervical cysts and fistulae strongly indicate that these structures are of entodermal origin. The significance of this will be brought out later.

For purposes of clarity, I wish to present some material furnished by Frazer, with which he demonstrated that the precervical sinus is formed and disappears without the possibility of its taking any part in the formation of lateral cervical cysts and fistulae.[6] Fig. 2 shows the head of an embryo less than 5 mm. in length. The arches and grooves are shown to be well formed. Their relationship to the position of the heart and their general direction horizontal to the general direction of the body are shown. The otocyst is noted. At this stage, one observes that what is to become the neck of the adult is at a right angle to the main body axis, since the cervical flexure takes place at the second branchial groove. If we now examine the semi-schematic pictures of the lower aspect of the pharyngeal region as given by Frazer, the pericardium having been removed save for its roof, we can understand the relationship of the ventral ends of the branchial arches to each other and to the epipericardial ridge beneath. It is noted that the ventral ends of the first and

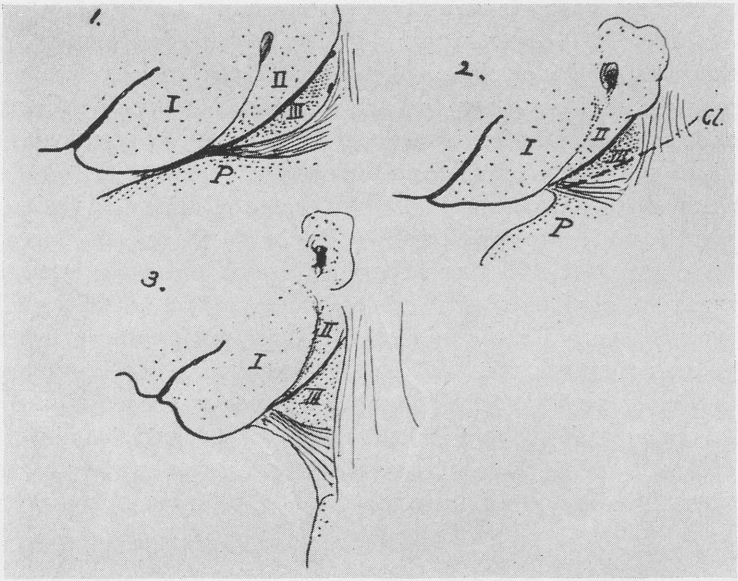

FIG. 1.—Three schemes to show the situation acquired by the third arch as the neck forms. *Cl.* gives the general position and line of the clavicle. Other references as before.

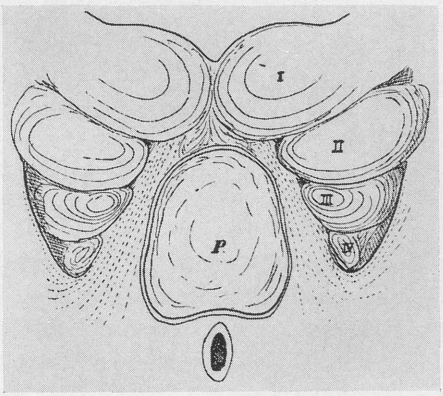

FIG. 2.—Semi-schematic view of the lower aspect of the pharyngeal region, the pericardium having been removed, save for its roof. *I, II, III, IV,* pharyngeal arches, external; *P,* roof of pericardium. The whole region is somewhat flattened out to show the relations.

second arches approach each other and are united, while the ventral ends of the third, fourth and fifth arches recede, leaving a triangular area which encircles the dome of the pericardium. This relationship of the arches to each other and to the pericardium makes it easy to visualize what later becomes the precervical sinus. The pericardium is below the sinus but does not form its lower boundary directly. There is an epipericardial ridge opposing the outer ends of the arches and forming with those structures the paraxial boundaries of the precervical sinus. A rapid growth of the paraxial boundaries results in a corresponding deepening of the precervical sinus. In the subsequent development, there is fusion of the ventral ends of the first and second arches, the lower border of the second arch thereby becoming the upper border of the paraxial boundary of the precervical sinus. The ventral ends of the third, fourth and fifth arches recede in succession and, as a result, the lateral borders of the paraxial boundaries become more caudal.

From the foregoing facts, the foundation of the neck, with certain fixed points, and its formation in the second and third months can be traced. The first scheme shows the general arrangement of the embryonic parts: the ventral ends of the first, second and third arches and the epipericardial ridge. The second scheme shows the same conditions when the clavicular rudiment (Cl) is first present and the sternomastoid is distinct. The third scheme represents the later stage, showing the lengthening of the neck. The infrahyoid muscles are drawn out on the ventral side and fixed to the clavicle and hyoid. From this concept of Frazer's, it can be readily understood that the floor of the precervical sinus ultimately becomes the anterior surface of the neck. Thus, no vestigial enclosures could be associated with the precervical sinus.

In contrast to the theory of the branchial origin of lateral cysts and fistulae of the neck is the later concept which was brought out by Wenglowski,[8] a Russian surgeon who published a monograph on this subject in 1913. Wenglowski spent five years investigating the origin of neck cysts and fistulae, studying serial sections of 65 embryos from 2.6 mm. to 40 mm., and dissecting 10 adult bodies. From this work, he made two important observations. The first was that in the human embryo the gill or bronchial apparatus com-

pletely disappears by the end of the second month. This suggested to him the impossibility of that structure's having any part in the later developmental phenomena in the neck. The second observation was that the thymus gland anlage, from its point of origin as a diverticulum at the bottom of the third pharyngeal pouch, is transferred to the post-sternal space, leaving a duct or corridor in its path between the point of origin and the terminal point, where the gland subsequently reaches its full development. This change in position occurs as a result of the caudal movement of the heart in its pericardium simultaneously with the formation of the neck. Wenglowski argues strongly against the possibility that lateral cysts of the neck have their origin from the branchial apparatus, first, because of the anatomic aspect and, second, because thus far in no higher vertebrate animal has any proof been given of the possibility of the growing of a ruptured gill fold into a fistula. He argues that the axis of the third gill arch is the external carotid artery, and in order for the second gill furrow to empty to the outside, it would be necessary for it to pass through the area between the internal and external carotid arteries. In reality, the fistulae do not reach this intermediate area, but lie in front close to the carotid sheath and extend from there toward the lateral pharyngeal wall. He argues, further, that since the branchial apparatus completely disappears by the end of the second month of embryonic life, it would be impossible for it to form the basis of fistulae below the hyoid bone except in the form of diverticula.

The course of the thymus corridor passes laterally from the pharyngeal wall and slightly downward to the area between the angle of the jaw and the lobe of the ear. Arching from here, it passes obliquely downward and forward medially, lying close to the lateral border of the thyroid gland. Its path is below the posterior belly of the digastric muscle, near its middle, and anterior to the carotid sheath, yet very close to that structure. It will be observed from this same picture that the lateral lobes of the thyroid gland have their origin in the floor of the fourth pharyngeal pouch and pass downward to join the median thyroid lobe. No cysts have been reported as having their origin from the lateral thyroid lobes. These observations on the embryo, however, must be regarded with

caution, since there are many changes in the arrangement of the blood vessels in adult life. The thymus corridor usually shrinks entirely or in part. In exceptional cases, it persists either wholly or in sections. More often, it is the lower sections which persist. If the entire corridor persists, a complete fistula is formed, such as is shown in the case herein reported; if only a part of the corridor persists, an incomplete fistula will result. In this group lie those fistulae which open into the tonsil fossae and, after tonsillectomy, give the impression that the operation was incomplete.

The external opening of a lateral fistula is determined by a rupture of the fistula on the external surface of the neck, usually as a result of infection in the fistula, and a chronic discharge of mucous, serous or purulent material. The location of these openings along the anterior border of the sternomastoid muscle conform to a strict pattern and follow the course of the thymus corridor. Those fistulae which have been described as having their openings in the larynx, trachea, esophagus and other unusual areas are no departures from the basic concept of their origin and development, but are examples of the variations in the clinical aspects resulting from infections of the original thymus duct.

In his studies of the 65 bodies of infants, Wenglowski found thymic anlage rests in serial sections 21 times, 12 times in the lower half of the neck, seven times in the upper half, and twice close to the pharynx. In the 10 adult bodies studied by dissection, he found these rests in two. Histologically, these rests are small canals or cysts, sometimes with squamous epithelium, sometimes ciliated epithelium, and at other times mixed epithelial lining. Hassel's bodies are sometimes found and the walls of the cysts are lymphoid in character, similar to the thymus. Further, he found in the fistulae walls several enclosures, such as tranversely striped muscle fibers, cartilage, glands and phenomena similar to those found in the thymus duct wall. Particularly characteristic of lateral fistulae is the existence of lymphoid tissue in large quantities. In the walls of cysts formed in the upper part of the thymus duct may be found vestiges from the lateral pharyngeal wall which have been drawn into the tissue at the time of the descent of the thymic anlage. These vestiges may be glands, lymphatic tissue, cartilage and other ele-

ments. The lower one goes along the course of the duct, the fewer the occurrences of these vestiges. Round cell infiltration will be observed in the walls of those cysts and fistulae wherein infection has developed.

It seems to me that this concept of Wenglowski, built upon a long period of painstaking investigation both in the embryo and in adults, as well as upon clinical observation in his surgical practice, lifts the subject of lateral cysts and fistulae of the neck from a haze of mysticism, at least to a degree. To me, the pattern is much simpler than the fishgill theory. It permits one to approach surgery on these structures with greater assurance of a satisfactory outcome.

Within the scope of this paper are those cysts and fistulae having their point of egress about the pinna of the ear. These are of ectodermal origin at the caudal end of the first branchial cleft and are of little consequence surgically. Unless complicated by infection, they do not open inside the pharynx.

Report of Case

B. A. C., white, female, seven years of age, gave a history of having since birth a discharging fistula, the outer opening of which was at the anterior border of the sternomastoid muscle near the sternal notch on the right side. The fistula would heal and then break out, depending largely upon the presence or absence of colds and sore throat. She also had a history of recurring attacks of tonsillitis.

She was operated upon under general anesthesia. An elliptical incision was made around the external opening of the fistula and, by removing adherent tissue from the sac with scissors, it was followed in its upward course after piercing the platysma and superficial fascia. The ribbon muscles were pushed medially and, by extending the skin incision along the route, the lateral border of the thyroid gland was passed, the posterior belly of the digastric muscle came into view from above, and the duct seemed to arch medially toward the lateral pharyngeal wall. At this point methylene blue was injected into the outer end of the duct with a medicine dropper; on opening the mouth, it was observed that the methylene



FIG. 3.—Tonsils and fistulae intact.

blue passed through and came out of the body of the tonsil on the same side at its upper pole. We had not intended to remove the tonsil at this operation, but now such a procedure seemed indicated. The tonsil was therefore dissected from above, according to our usual technique. It was observed that the fistula from the point of its emergence passed through the body of the tonsil and became connected with the tonsillar capsule, passing downward along the posterior surface of the tonsil to its lower pole. After reaching the lower pole of the tonsil, dissection was extended along the fistula until connection was made with our previous dissection from the outside. After completing the dissection, we were able to remove the tonsil and fistula intact through the mouth. The opening through the pharyngeal wall was closed below the tonsillar fossa by a purse-string suture and drainage was provided externally after the skin incision had been closed.

SUMMARY

General agreement upon the origin of the thyroglossal duct has resulted in standardized criteria of diagnosis and treatment of cysts and fistulae having their origin from this duct.

The embryologic background of lateral cysts and fistulae of the neck influence the clinical, or anatomic and technical problems associated with them. Wide divergence of views in regard to their

derivation has created much uncertainty and confusion as to their surgical management.

Early observers believed that lateral cysts and fistulae of the neck were derived from the branchial apparatus. In 1913, Wenglowski published a monograph disputing the possibility of the branchial origin of lateral cysts and fistulae, presenting evidence instead that these anomalies have their origin from persistence of parts or all of the thymus corridor.

A case is reported illustrating a complete lateral fistula of the neck having its internal opening in the right tonsil at the upper pole, and its external opening at the anterior border of the right sternomastoid muscle near the sternal notch. In this case, the tonsil was removed with the fistula notch. In this case, the tonsil was removed with the fistula intact. We were unable to find in the literature another case in which a similar procedure was used.

414 Physicians and Surgeons Building.

References

1. His: Quoted by Meyer, Ref. 7.

2. Robl: Quoted by Wenglowski, Ref. 8.

3. Ascherson, F. M.: Quoted by Wenglowski, Ref. 8.

4. Hyndman, O. R., and Light, George: The Branchial Apparatus, Arch. Surg. 19:410, 1929.

5. Thompson, J. E.: Surgery and Embryology, Surg., Gyn. & Obst. 31:18, 1920.

6. Frazer, J. E.: Disappearance of the Precervical Sinus, J. Anat. 61:132, 1926-27.

7. Meyer, H. W.: Congenital Cysts and Fistulae of the Neck, Ann. Surg. 95:1, 1930.

8. Wenglowski, R.: Ueber die Halsfisteln u. Cysten, Arch. f. Chir. 98:151, 1912.

9. Wenglowski, R.: Ueber die Halsfisteln u. Cysten, Arch. f. Chir. 100:789, 1913.

DISCUSSION

Dr. Gordon Berry: May I ask whether Carnoy's solution has been tried in any of these cases?

I had a case very parallel to this one which emptied up above the tonsil. We dissected it all out. We have had other cases which have been small fistulae, long in nature. These lend themselves particularly to an escharotic. This can be injected and the epithelial lining so destroyed that healing takes place without the more radical procedure with its scar formation.

Carnoy's solution is similar to Zenker's Fluid and is made up of absolute alcohol, 6 cc., chloroform, 3 cc., glacial acetic acid, 1 cc., and ferric chloride, 1 gram.

Dr. C. D. Blassingame (closing): The concensus of the literature is that any kind of escharotic in a cyst or fistula is somewhat begging the question, and inadequate. That is my feeling. If the cyst can be reached, and it should be reached, the lining should be entirely removed and that absolutely insures complete, permanent cure.

FRONTAL SINUS DRAINAGE

O. E. VAN ALYEA, M.D.

CHICAGO, ILLINOIS

The frontal sinus may become infected through extension of an infectious process from the nasal cavity or from another sinus of the anterior group, or as the result of direct introduction of virulent organisms into the sinus, such as occasionally occurs with swimming and diving.

During the onset and height of the infection, the lumen of the frontal ostium is narrowed or completely occluded by the engorged tissues which line the sinus and nasal cavities. As the swelling recedes, the ostium becomes patent and drainage is established.

Most cases of frontal sinusitis heal spontaneously within a week or ten days but on occasions, the infection persists until something is done to improve the drainage space. In some cases a prolongation of infection may be attributed to an organism of unusual virulence or some factor which causes a marked lowered resistance on the part of the individual. In most cases, however, the inflammation persists because of some structural defect which prevents free drainage from the sinus.

Structural Barriers To Sinus Drainage

In those cases which persist despite an open ostium, drainage is impaired by one or both of two structured defects, to-wit, a blocked middle meatus or encroachment on the drainage space by an ethmoid or frontal cell. It has been shown that cells either within the lumen of the sinus or encroaching on one of its walls are present at least unilaterally in 50 per cent of all individuals and that in one-third of these, the encroachment is in the neighborhood of the frontal ostium.[1] Such cells are undoubtedly potential factors in the prolongation of an inflammatory process of the frontal sinus

From the Department of Otology, Rhinology and Laryngology, University of Illinois, College of Medicine.

and may well be the sole reason for the progression of an infection to a chronic state.

The other anatomic factor, the blocked middle meatus, in most instances is caused by an impingement of the middle turbinate against the lateral nasal wall. This may be unilateral with pressure from a deviated septum as the apparent cause. In other cases there may be no septal defect worth mentioning, yet on one or both sides the middle turbinate is in close apposition with the lateral wall. The blocked middle meatus also may be due to a cellular turbinate, the presence of polyps or may be simply the condition often observed in thin-nosed individuals in which the upper straits of the nose are unusually narrow.

Restoration of Drainage

With the removal of structural barriers, acute attacks of frontal sinusitis tend to heal quickly because of the ample size of the ostium and because of its location in the most dependent portion of the sinus floor. Many cases clear up immediately following infraction of the middle turbinate, the crushing of a cellular turbinate or the removal of polyps. Others tend to improve with shrinkage of the tissues of the middle meatus and in still others, displacement therapy with mild suction brings about the desired results. In those cases which do not show improvement following these procedures, irrigation of the sinus through a cannula is indicated. This may be induced after the acute engorgement of the tissues has subsided, with comparative safety and a fair assurance of success. Often a single irrigation is sufficient, for in many cases a cannula which reaches the sinus penetrates or obliterates completely thin-walled cells which have been acting as barriers to normal drainage. Also, it is a recognized fact that removal of an accumulation of toxic exudate by lavage eliminates one of the causative agents of the closed ostium.

Many rhinologists hesitate to probe the frontal ostium, feeling that the trauma thus induced is harmful even though the manipulation is carried out with great care; yet it is felt that the harm caused is more than offset by the benefits attained through the

establishment of improved drainage channels and the removal of exudate. Clinically this has been shown to be the case and only in isolated cases do the harmful effects of the trauma overweigh the beneficial effects of the irrigation. It should be kept in mind that the ciliated mucosa possesses great recuperative power and even though denuded of epithelium rapidly returns to normal. Many also refrain from attempting the irrigation technic believing that in order to reach the sinus the cannula tip must engage and pass through a duct. Schaffer,[2] and other anatomic observers years ago upset the theory of the nasofrontal duct and called attention to the fact that the approach to the frontal ostium is through a comparatively wide space in most instances.

Other Therapeutic Measures

The cases which do not do well with irrigation are those of a severe toxic nature with fever and those in which local immunity has not been established. In these cases considerable swelling of the tissues is present and local manipulation accomplishes little, aside from adding to the congestion. With this type of condition, patients should be kept in bed under careful surveillance. Heat should be applied locally, anodynes given freely and proper vasoconstrictors instilled into the nose on the affected side.

As the patient becomes afebrile and shows evidence of improved resistance, local intranasal measures as outlined previously, may be considered to induce drainage. Should the symptoms, however, become more severe and show signs of intracranial or impending intracranial complications, it might be deemed advisable and imperative to establish drainage through an external opening. This may be done through a small opening in the floor of the sinus as described by Hajek,[3] Muck,[4] and Von Bajkay[5] abroad, and at various times by Crowe,[6] Lillie,[7] Boies,[8] and J. M. Brown[9] of this country. The accumulated secretions may be withdrawn by suction through the opening thus made, the sinus may be irrigated gently with warm physiologic sodium chloride solution, or merely left alone, but at no time is the ostium to be tampered with or the lining mucosa of the sinus disturbed. In conditions such as this, the sulfonamide drugs and penicillin administered internally, are of

extreme value and may be the means, along with the release of toxic secretions, of effecting a cure in that which might otherwise have been a fatal case.

Recurrent Cases

A prolonged case of acute frontal sinusitis implies faulty drainage facilities with a likelihood of recurrence or progression to a chronic state. It is highly important in these cases to correct structural defects and to establish as nearly as possible adequate drainage channels.

The measures necessary for correction may be introduced during or following an acute attack. All cases should be studied from an allergic standpoint with the idea in mind that the dominant pathologic characteristic of allergy is edema and that edema blocks drainage outlets. Atypical allergy or borderline cases are constantly overlooked by the rhinologist; yet in many of these recognition and proper management removes one of the major etiologic factors in frequent nasal and sinus infections.

Structural defects such as deviated septa, impinging turbinates and polyps should be handled by proper surgical procedures. The middle turbinate may be pushed toward the septum and if cellular it may be crushed or the cell may be obliterated by removal of the thin lateral wall of the turbinate, but rarely is it necessary to disturb the medial or anterior surfaces.

The remaining sinuses must be carefully scrutinized as possible foci and concentrated efforts made to clear up any co-existing infection. In the examination of the sinuses, special attention is directed toward the frontal area for cells which may constrict the lumen of the frontal ostium or any other portion of its drainage pathway. The search for encroaching cells properly carried out may require diagnostic irrigations and roentgen studies with the use of iodized oil.

Cells which tend to encroach on the frontal area are often broken down by the mere passage of a cannula, and a permanent improvement in the drainage channels is established forthwith. In certain

cases a cell or osseous tumor within the lumen of the frontal sinus encroaching on the ostium may be a factor in the recurring cases and responsible for the prolongation of an acute attack. These growths require removal through the external route but this should be done with the least possible disturbance of the sinus mucosa.

Chronic Inflammatory Conditions

Most patients with long-standing suppuration of the frontal sinus may be helped immeasurably and many may be completely relieved of symptoms by the adoption of the methods outlined above for the removal of barriers to drainage.

On the other hand, in many chronic inflammatory cases radical removal of the lining sinus membranes fails to effect a cure of the disease. The removed mucosa is usually replaced by one less resistant to disease and the case often requires coniderable treatment indefinitely with an occasional re-operation.

All rhinologists are familiar with the chronic nasal invalid, the multi-operated patient who haunts their offices in desperate search for relief from symptoms which are far worse than those which he had previous to his first operation.

Sewall,[10] in 1941, after observing the unfortunate results on innumerable sinus cases which had been subjected to radical procedures wrote, "Through the study of cases at revision one comes to appreciate the responsibility that is assumed by the surgeon when he removes the lining from the bony walls of any sinus."

In the radical operation, the lining membrane is completely removed on the basis of its gross appearance which is usually described as "thickened, irregular, hyperplastic mucosa." Microscopic examination, however, fails to bear out the contention of the surgeon that the membrane has undergone extensive pathologic changes and that its removal was justified. The changes which take place are those of a defensive nature with the epithelial layer relatively intact and a stroma richly endowed with powerful inflammatory cells capable of resisting invading organisms for an indefinite period of time. This membrane functions as a defense mechanism

and even though it may be thickened and irregular, it is functioning to the best of its ability in a poorly draining cavity and it should be protected rather than destroyed.

Snitman,[11] in 1943, voiced his disapproval of radical procedures on the sinuses, basing his conclusions on the microscopic study of tissues removed from the sinuses of a large series of chronically infected cases. He states, "These sinus membranes show no other changes than those of chronic inflammation. Microscopically they present every characteristic of being able to repair themselves in due course, when favorable conditions are provided, the most potent of which is the establishment of a functioning drainage pathway."

Certainly there will be no return of function with removal of sinus mucosa, which is resisting disease if functioning normally.

Summary and Conclusions

The health of a sinus is maintained only as long as it is lined with a functioning mucous membrane and equipped with adequate drainage facilities.

Persistence of an infection in the frontal sinus implies a complete or partial blockage of the nasofrontal passageways.

Infections, however, tend to clear up with removal of drainage barriers, and this fact clarifies the role of the rhinologist. He must direct his attention toward the restoration and maintenance of adequate drainage channels, this to be done with the least possible damage to functioning nasal and sinus structures.

During the early stages of acute frontal sinusitis, intranasal manipulations are of little value and may be harmful. With the establishment of local immunity, however, as the temperature recedes and the acute engorgement of the tissues subsides, local measures may be introduced which will aid materially in an early termination of the disease.

Some cases respond readily to certain fairly simple procedures such as turbinal infraction, removal of polyps and sinus irrigation,

but others persist and require more extensive treatment before sufficient dainage is established.

In many cases it may be necessary to correct a deviated septum in order that the middle meatus may be properly unblocked.

Co-existing infections in other sinuses should receive proper attention and every effort made to clear them up; in others cases allergy may be responsible for the maintenance of the infection and this must be properly investigated and controlled. In a final group, ethmoid and frontal cells which construct the lumen of the frontal ostium and the nasofrontal channels must be removed.

Failure to correct frontal sinus drainage defects leads to recurrence and chronicity. The above measures, however, may be induced between attacks or during the chronic state with the assurance of considerable help, if not a complete elimination of the disease.

The alternative, the radical procedure, offers little more and with it also go the last hopes of a cure of the disease by restoration of sinus function.

The external approach to the frontal sinus is reserved for:

1. The cases in which annoying symptoms are present which have resisted all available conservative measures.

2. The release of pus under pressure in severe cases with threatening complications.

3. The removal of cells and growths within the sinus which are encroaching on the ostium.

4. The treatment of malignant growths, osteomas and inflammatory conditions with bone involvement.

135 South LaSalle St.

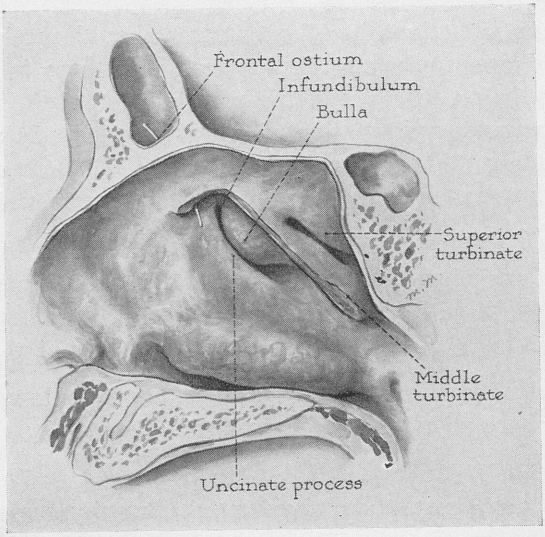

FIG. 1.—In the specimen illustrated the frontal sinus drains directly into the frontal recess. This type of drainage is found in approximately 55 per cent of cases and the ostium is usually easily reached with a cannula in cases of this type.

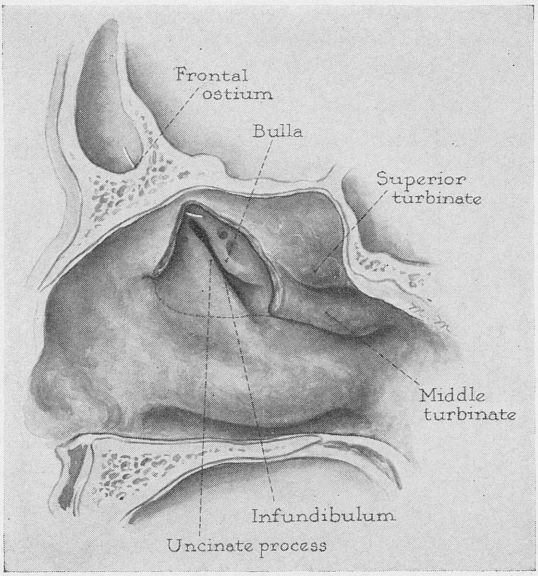

FIG. 2.—The frontal ostium in the specimen illustrated opens above the infundibulum but not into it. This type of drainage occurs in approximately 30 per cent of cases. The ostium is usually easily accessible in this type of case.

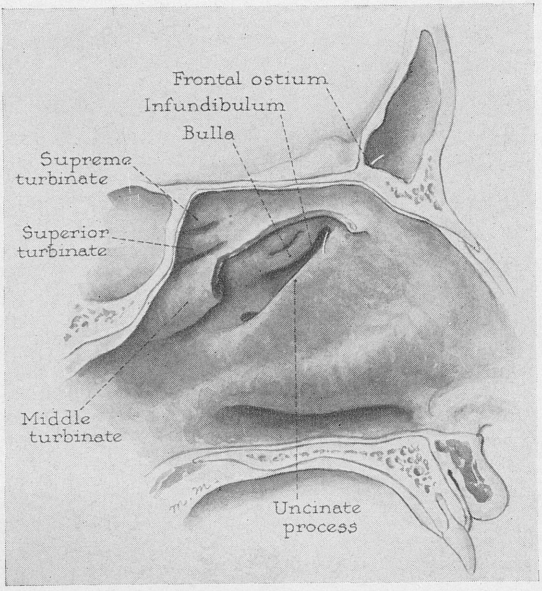

FIG. 3.—In the specimen illustrated the drainage is above the ethmoid bulla. Specimens of this type are rare occurring in approximately 1 per cent of cases .

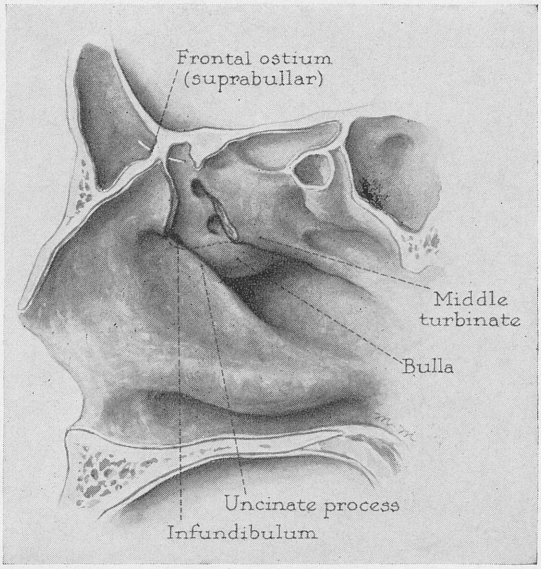

FIG. 4.—The frontal sinus is continuous with the ethmoid infundibulum. This type of drainage occurs in approximately 15 per cent of cases. To reach the sinus the cannula first must be passed into the infundibulum.

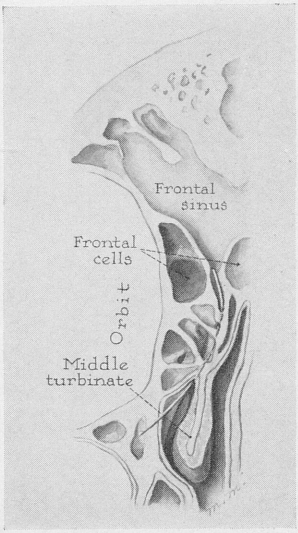

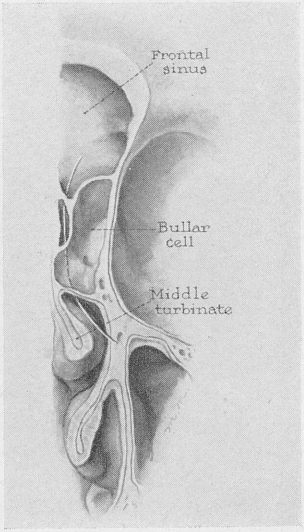

FIG. 5.—Frontal view showing unimpeded drainage from a frontal sinus.

FIG. 6.—Impaired drainage due to two frontal cells which constrict the frontal ostium.

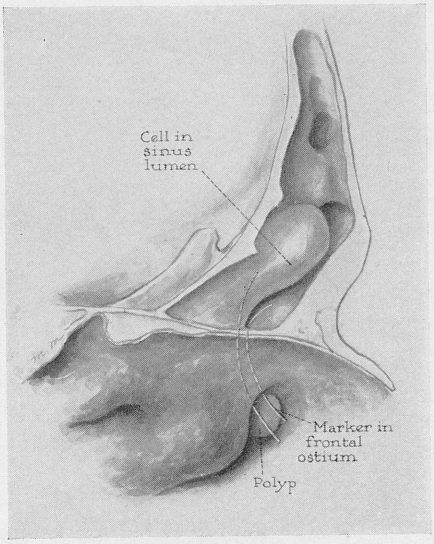

FIG. 7.—Cell in the floor of frontal sinus constricting the ostium. Frontal cells have their own separate drainage outlets in the middle meatus but in approximately 15 per cent there is an opening of communication between the cell and the frontal sinus.

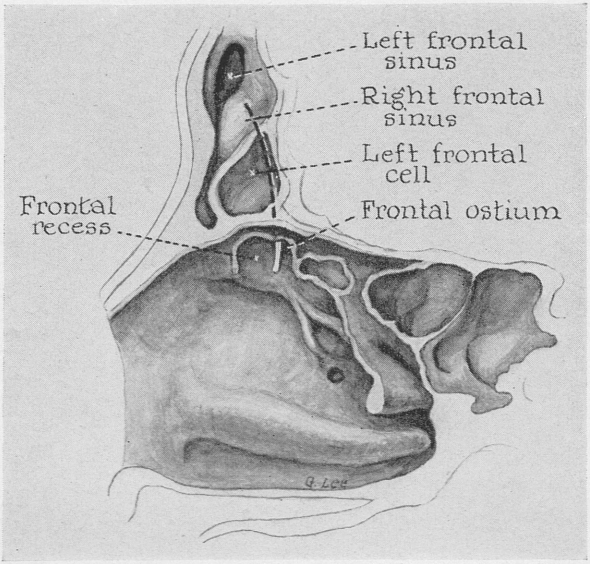

FIG. 8.—Large cell within the lumen of the frontal sinus overhanging the drainage space. A polyp in the middle meatus adds further to drainage impairment.

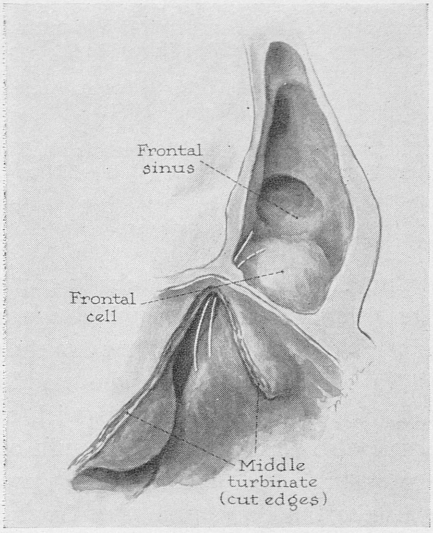

FIG. 9.—Encroachment on the terrain of the right frontal sinus by the left frontal sinus and a large cell between the two cavities.

REFERENCES

1. VAN ALYEA, O. E.: Frontal Cells, Arch. Otolaryng. 34:11-23 (July) 1941.

2. SCHAEFFER, J. PARSONS: The Nose, Paranasal Sinuses, Naso-Lacrimal Passageways and Olfactory Organ in Man, Philadelphia, P. Blakiston's Son & Co., 1920.

3. HAJEK, M.: Meine Erfahringen uber die radical Behandlung der Stirnhohleneiterungen, Monatschr. f. Ohrenh. 70:641 (June) 1936.

4. MUCK, O.: Heilung chronischer Stirnhohleneiterungen ohne Entstellung dursch ein chirurgisch-physikalisches Verfahren, Ztschr. f. Hals-, Nasen- u. Ohrenh. 39:477, 1936.

5. VON BAJKAY, T.: Beitrage Zur Chirurgie der Stirnhohle, Monatschr. f. Ohrenh. 68:1341 (Nov.) 1934.

6. MULLIGAN, E. J., and CROWE, S. J.: Treatment of Acute Infection of the Frontal Sinus, Annals of Otology, Rhinology and Laryngology 50:499 (June) 1941.

7. LILLIE, H. I.: Personal Communication.

8. Boies, Lawrence R.: Laryngoscope, vol. 52 (June) 1942.

9. Brown, J. M., and MacKenzie, J.: Frontal Sinusitis, Annals of Otology, Rhinology and Laryngology 50:435-499 (June) 1941.

10. Sewall, E. C.: Surgery of the Nasal Sinuses, Annals of Otology, Rhinology and Laryngology 50:463-468 (June) 1941.

11. Snitman, M. F.: Interpretation of Biopsies from Sinus Operation, Eye, Ear, Nose and Throat Monthly 22:377-379 (Oct.) 1943.

DISCUSSION

Dr. B. J. McMahon: There are certain important points which Dr. Van Alyea has brought out, upon which I would like to comment. One is the ease of irrigation of the frontal sinuses in some cases. Favorable topography between the middle turbinate and lateral wall, facilitating careful irrigation with normal saline solution only by means of a small flexible cannula after the purulent discharge has been established, is frequently productive of good results and helps to shorten the course of a frontal sinusitis.

Gross suction applied by inserting a tube into the external nares is definitely contra-indicated, though too frequently used. This will invariably increase the oedema and engorgement of the mucosa of the naso-frontal duct, and cause more pronounced blockage. However, by the introduction of tip suction into the middle meatus we can secure and remove small strands of tenacious mucus, to relieve the obstruction.

Another measure which we use, based upon the fact that a great many of these reactions, while they are not entirely allergic may be accompanied by a local allergic reaction, causing more edema of the mucosa than usual, is the use of Ephedrine with a barbiturate, taken internally, in the early stages.

ADAMANTINOMA OF THE MAXILLARY SINUS WITH A REPORT OF TWO CASES

CLYDE A. HEATLY, M.D.

ROCHESTER, NEW YORK

Adamantinoma occurs far more frequently in the mandible than in the maxilla. Involvement of the maxillary sinus by this tumor is uncommon in the experience of most rhinologists. When first encountered, therefore, the true nature of the neoplasm may not be recognized and inadequate surgical measures may be employed. The clinical picture furthermore may be mistaken for malignancy of the antrum and the microscopic examination in cases of the undifferentiated types of this tumor may be misleading. The purpose of this presentation is to review briefly the pathological and clinical characteristics of the adamantinoma and to discuss the problems concerned in its removal.

Definition: The adamantinoma may be defined according to Robinson[1] as "an epithelial tumor arising from the odontogenic apparatus or from cells with a potentiality for forming tissues of the enamel organ." The term adamantinoma, introduced by Borst in 1902, is obviously misleading inasmuch as this tumor never forms enamel (adamantine) tissue. The term adamantoblastoma has been suggested by Thoma[2] as being more accurate in this respect and Robinson and Churchill refer to the tumor as ameloblastoma, deriving the term from ameloblast, the enamel forming cell. The name adamantinoma will be retained in this paper because of its common usage and wide familiarity. This tumor is classified with the epithelial cystic odontomas which also include dentigerous and dentoperiosteal cysts.

Pathogenesis: The most widely accepted view at present is that the adamantinoma arises from paradental epithelial rests. Melassez first observed cordlike and glandlike groups of epithelial cells around

From the Department of Surgery, Division of Otorhinolaryngology, The University of Rochester School of Medicine and Dentistry, Rochester, New York.

the roots of the teeth and referred to them as "paradental epithelial debris." He further demonstrated that these cells may remain as scattered epithelial rests even late in life. Under certain irritative conditions these cells become proliferative and give rise to tumor formation. The site of predilection of the adamantinoma in the region of the lower third molar, the most difficult of the teeth to erupt, is pointed out by New[3] as evidence of the important influence of irritation. It is a clinical fact that many reported cases record preceding traumatic or irritative factors in the form of dental extraction, injury to the jaw, impaction or infection.

Clinical Pathology: The adamantinoma may be described as a central tumor, slow and intermittent in its growth, anatomically benign but clinically persistent. *Macroscopically* two types are recognized, the solid and the cystic. Most authorities agree with Kronfeld that the adamantinoma is originally a solid growth and that the cystic variety represents a later degenerative process occurring within the epithelial strands of the tumor. Although monocystic forms occasionally occur, most tumors are of the polycystic variety. In a series of 219 cases reviewed by Robinson 57.5 per cent were cystic, 24.2 per cent were both cystic and solid and 19.1 per cent were solid. It is important in this connection to point out that such tumors involving the maxilla are more often of the solid variety than those found in the mandible. The solid tumors are usually of a white, finely granular consistency, containing connective tissue trabeculae and small cavities and are definitely encapsulated. In the cystic types, compartments of varying size may be noted, some filled with solid tumor and others with a thin yellowish fluid. Fibrous or bony septa can be seen separating the various cysts. Teeth are frequently found in these tumors and may cause a mistaken diagnosis of dentigerous cyst. *Microscopically*, the solid areas consist of a normal connective tissue stroma and columns of epithelial cells which may be elongated, rounded or arranged in acini-like forms. These cells resemble in varying degree the epithelial structures seen in the embryonic stage of the normal tooth. The peripheral layer is composed of a continuous palisade of columnar cells (ameloblasts) arranged in a single row upon an outer basement membrane. The middle layer is made up of ves-

icular cells and the center of the cell nest is composed of stellate cells representing the central stellate cells of the enamel organ. The stellate cells undergo disintegration and gradually disappear, leaving cysts containing fluid and lined with the outer columnar cells. In the larger cysts the walls consist of fibrous tissue only. Authorities agree that no information can be gained from the microscopic picture concerning the malignant possibilities of the tumor although Ewing[4] considers the solid tumors to be more malignant than the cystic types.

Pathologists commonly classify the adamantinoma as a benign neoplasm. As Havens[5] and other authors however have emphasized, its relentless growth, its persistent recurrence if incompletely removed and finally the evidence of several proved instances of metastasis indicate that for clinical purposes at least it should be regarded as a malignant growth. Microscopic study of the bone surrounding this tumor frequently shows proliferation of the tumor cells in the spongiosa or the haversian system of the cortex. Both Thoma and Havens have stressed this important fact and presented illustrations of the microscopic finger-like extensions of the tumor into the surrounding bone (Fig. 1). Robinson, in his review of 379 cases from the literature found 17 cases of malignant adamantinomas, an incidence of 4.5 per cent. Both carcinomatous as well as sarcomatous changes have been reported. One rare case of melanotic adamantinoma was described in 1926 by Mummery and Pitts. For many years it was believed that this tumor does not metastasize. There are now on record however several accepted cases of metastasis to regional glands or internal organs. Schweitzer and Barnfield[6] in 1943 after a careful review of the literature were able to collect ten reports of metastasis from adamantinomas, although in their opinion four of these were not acceptable. They also presented a case occurring in the mandible of a young negress which recurred locally despite twenty-four operations and finally metastasized by the blood stream to the lungs. Vorzimer and Perla in 1932 described an adamantinoma in the maxilla of a 17-year-old boy which metastasized by the aerogenous route to the right lung and pleura. Phelps[7] in 1939 reported a case of malignant adamantinoma with metastases to the liver, lungs, ribs and clinically to the

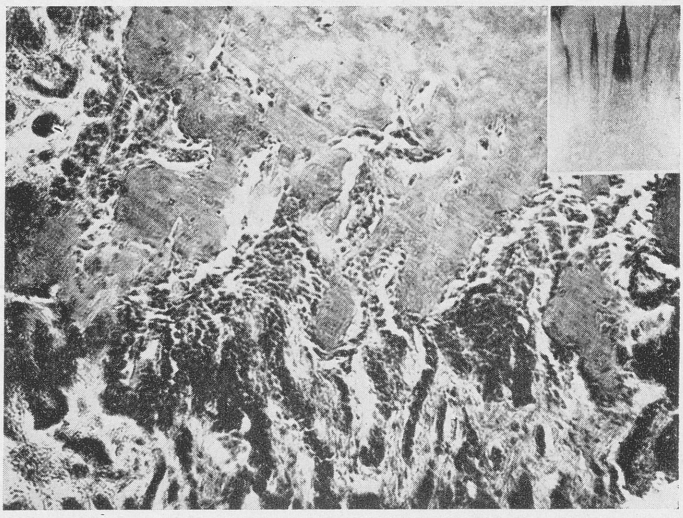

FIG. 1.—Section of alveolar bone surrounding an adamantinoma showing finger-like extensions of the tumor into the bone. (From Thoma[2] with permission of the author.)

left retina. Chont[8] in 1943 reported eight cases of adamantinoma in one of which metastases from a tumor in the mandible occurred in the cervical glands and lungs. Metastases to the submaxillary glands and cervical lymph nodes have been reported by New, Havens, Horsley, Simmons, Weissenfels and others. It must be concluded therefore that while the adamantinoma characteristically grows slowly by expansion rather than by infiltration and does not metastasize, malignantly infiltrative varieties as well as true metastasis may occur.

Clinical Considerations: Age: Adamantinoma may occur at any age. It has been reported in early childhood and, by Lewis, in a man of seventy-five. In Robinson's survey of 379 cases, the average age at the time of observation was 37.6 years. The average age incidence in 114 cases reviewed by McFarland and Patterson[9] was slightly less than forty years. The average duration of symp-

toms in Robinson's survey was 8.5 years and in McFarland and Patterson's, seven years. The average age at the onset of symptoms therefore may be considered to be the early thirties. Murphy[10] observed that the solid variety of this tumor is more common in younger patients and the cystic type more frequent in later life. This observation is in accord with the characteristic cystic degeneration already described in the evolution of these tumors.

Location: The majority of adamantinomas occur in the mandible. Eighty-three and seven-tenths per cent of 379 cases reviewed by Robinson involved the lower jaw. In a series of 58 cases reported by Havens from the Mayo Clinic only five were in the maxilla. In 114 cases reviewed by McFarland and Patterson, 17 involved the upper jaw. They considered the proportions to be roughly five to one. Interesting recent reports of this tumor involving the maxillary sinus have been made by Phelps[7] (1939), Golden[11] (1942), and Mosher[12] (1944). Ewing and Murphy both agree that solid adamantinomas are more frequent in the upper jaw and further that this location shows a greater incidence of the malignant forms.

Symptomatology: The adamantinoma is a slow growing, centrally expansive tumor. In the upper jaw the relatively large dimensions of the maxillary sinus permit great expansion of the growth before its presence is clinically apparent. Early diagnosis is uncommon and ill-defined pressure pains are usually mistaken for dental causes. Roentgenograms in this early stage are inconclusive. Slow expansion of the facial and nasal walls of the maxilla with resulting deformity of the face and obstruction of the nasal passage is commonly the chief presenting symptom. At this stage the thin, parchmentlike bony capsule, crepitating on pressure, is often noted. Pain is usually slight except in the more advanced tumors. Occasionally a cystic tumor may rupture into the mouth and the patient seek advice because of a persistent oral drainage. Extension into the orbit with exophthalmos and into the nasopharynx with dysphagia has also been reported[4] (Ewing). Broadening of the alveolar ridge with displacement of the adjacent portion of the hard palate may occur.

Diagnosis: The diagnosis of adamantinoma is suggested by the slow, frequently painless development of the tumor, by the absence

of evidence of soft tissue invasion, by the crackling sensation which can commonly be elicited on palpation over prominent portions of the tumor, by the usual absence of regional glandular involvement (exceptions to this have been pointed out), and finally by the roentgenogram in which the multilocular cystic arrangement of the bony shell and trabeculae is characteristic. The tumor is often clinically mistaken for malignancy of the antrum and the roentgenographic signs of destruction of portions of the bony walls without evidence of trabeculation may strongly suggest this diagnosis. Malignancy however differs in the rapidity of its growth, the more common association of glandular metastasis, the frequent evidence of soft tissue invasion as well as the absence of crepitation. Dull, persistent facial pain is more common in malignant tumors. Dentigerous cysts may also prove confusing especially in view of the fact that teeth are frequently found in adamantinomas. Oesterreich in 1936 emphasized this point and reported three cases which were roentgenographically diagnosed as cysts but which on histologic examination proved to be adamantinomas. Ewing also recorded two instances of monocystic adamantinomas clinically mistaken for periodontal cysts. Adamantinoma in his opinion must "always be kept in mind even if the roentgen film shows a monocystic defect or if the cyst contains a tooth."

Prognosis: The adamantinoma must be regarded as a slow-growing expansive tumor with a strong tendency to recurrence. In Robinson's review of 379 cases, recurrences were reported in 119 cases in which from one to twenty-two recurrences were noted. Incomplete removal tends to disrupt the expansive growth of the tumor and induces a more malignant and infiltrating variety which in the maxilla may eventually involve inaccessible and ultimately fatal locations. Recurrence is frequently caused by the spread of the tumor into the spongiosa or haversian system of the surrounding bony cortex as well as by small tumor rests not easily accessible to surgical removal. It is generally agreed that the prognosis in the solid type of tumor is not as favorable as in the cystic variety. Unilocular cystic tumors as well as multilocular tumors with few compartments are more easily completely eradicated than honeycomb tumors with numerous small scattered loculi. Ewing

states that "tumors of the upper jaw are much the more serious and that solid adamantinomas of all types recur locally and involve antrum, orbit and nasopharynx. In spite of their relatively benign structures, the prognosis in this group is unfavorable." All authorities agree that any adamantinoma in which the rate of growth is suddenly increased should be given a guarded prognosis because of the strong likelihood of malignant changes.

Treatment: Complete and radical removal of the tumor is necessary because of the clinical certainty that recurrences will occur if small areas remain. Although the adamantinoma is properly considered as a benign tumor by the pathologist, it is better for the rhinologist to treat it as a malignant growth from the outset and to employ radical measures for its complete removal. Perhaps the greatest difficulty in this respect is caused by the tendency of the tumor to proliferate in the spongiosa or the haversian system of the surrounding bony cortex. The literature is rich with examples of the failure of conservative measures. In the series of 166 cases collected from reported sources by McFarland and Patterson in 1931, there were 65 cases in which a variety of conservative methods had been employed and in this group recurrence was reported in 50.7 per cent. Simple curettement will seldom succeed in eradicating this tumor. Havens reporting in 1939 on the experiences at the Mayo Clinic urged radical resection with the meticulous use of surgical diathermy. Waldron[13] similarly stressed the value of surgical diathermy as the method of choice in accomplishing complete removal. The bony wall surrounding the tumor should be removed where possible or coagulated with the diathermy current. Tumor nests in the ethmoid cells should be sought out and carefully destroyed. Accessibility of the antrum for subsequent examinations should be made possible by the creation of a large window in the inferior meatus as well as by maintaining the opening in the canine fossa for a considerable period. This will also supply adequate drainage for the slough following electrocoagulation. Many writers, including Kotany, Quick and Chont advise the routine use of intensive postoperative irradiation. It is well recognized however that the adamantinoma is extremely resistant to radiation and it is doubtful in the opinion of the writer if the

dangers of radio-osteonecrosis justify the slight possibility of help from this source. It must be admitted however that in extremely extensive or recurrent invasive types of adamantinomas postoperative irradiation should not be withheld. Finally, periodic examination for possible recurrence must be continued for several years following operation in view of the fact, already emphasized, that the rate of recurrence may be exceedingly slow.

Case Reports

Case 1.—H. M., a white Greek woman of 65, was admitted to the Strong Memorial Hospital on September 13, 1943. Two years before she had noticed a fullness of the right side of the face and difficulty in breathing through the right side of the nose. She was advised by her physician that a sinus infection was present and had had frequent nasal treatments without relief. During the previous year the right side of the face had become increasingly prominent and the right nasal passage completely obstructed. There was no history of regional pain.

On examination there was definite prominence of the right cheek with swelling of the lower eyelid. There was no evidence of soft tissue infiltration nor could any definite bony defect be palpated. No enlargement of the cervical glands was present. The entire lateral nasal wall was pushed over tightly against the nasal septum but no intranasal evidence of infection nor actual tumor invasion was present. The right antrum was completely opaque on transillumination. Roentgenograms showed the right antrum to be greatly enlarged and obscured by a shadow of rather uniform density (Fig. 4). No evidence of trabeculation could be seen. Destruction of the medial and lateral walls was noted together with thinning of the inferior orbital margin. This evidence indicated a tumor of the right antrum with considerable bony destruction.

A Caldwell-Luc operation was performed under sodium pentothal anesthesia. The anterior wall of the maxilla at the point of entrance was markedly thinned and easily entered. The antrum was found to be filled with a whitish, encapsulated tumor of rather firm consistency. A mass about 3 cm. in diameter was removed without

FIG. 4, Case 1.—Adamantinoma involving the right maxillary sinus. The true nature of the tumor can not be diagnosed from the roentgenogram.

any troublesome bleeding. The remainder of the tumor was then destroyed by coagulation. It was noted that this tissue presented a distinctly granular consistency. No large cystic areas were evident. The marked enlargement of the antrum with erosion of the medial and lateral walls noted in the roentgenogram was confirmed. All of the bony walls were greatly thinned. The ethmoid cells were cleaned out as thoroughly as possible through the antrum approach. A large window was resected into the inferior meatus and the canine fossa incision packed open.

Pathological Report: *Gross specimen.* A mass of smooth firm whitish tissue measuring about 3½ cm. in diameter. It contains small cysts and masses of solid, and rather granular tissue. *Microscopic*: The tumor has a complex structure which consists of ramifying columns and masses composed of an outer single row of tall columnar epithelial cells arranged in palisade formation. The

central areas are occupied by irregularly arranged stellate cells which stain lighter than the columnar cells. Numerous large and small cysts are seen; these are lined by columnar epithelial cells and contain either a pink coagulum or a delicate stroma of connective tissue and blood vessels. There are areas of fresh hemorrhage and numerous foci of phagocytes containing blood pigment. Diagnosis—Adamantinoma (Fig. 2).

The patient's postoperative course was uneventful and she was discharged from the Hospital on September 17, 1943. She was followed at two month intervals. A small recurrence was observed on April 27, 1944, in the right middle meatus. This was thoroughly destroyed with the diathermy current. On September 5, 1945, another small mass in the inferior meatus was similarly coagulated. In both instances the recurrent tumor was about the size of a grape. No postoperative irradiation was given. This patient was last examined in April 1946 and showed no evidence of reccurence. The possibility of further recurrence, however, is considered likely in view of the solid nature of the tumor as well as its great size.

Case 2.—C. M., a white American man of 65, was admitted to Strong Memorial Hospital on December 26, 1945, because of a draining fistula from the left antrum into the mouth. Twelve years before the patient had a wisdom tooth removed from the left upper jaw. The extraction was extremely difficult and the dentist reported that a fragment of bone came away with the tooth. The socket, however, finally healed after about four weeks of treatment. During the past year the patient had noticed a thin, slightly blood-tinged drainage in the mouth. Three months before admission a large opening was observed along the posterior portion of the alveolar ridge and the drainage increased considerably in amount. At the time of entrance into the Hospital the drainage averaged about a tablespoonful a day. There had been no pain in the face at any time but some intermittent sense of fullness.

The important clinical findings were as follows: (1) Slight prominence of the left cheek. (2) A large draining sinus tract about 1 cm. in diameter in the approximate position of the left upper third molar. (3) Broadening of the alveolar ridge, slight but defi-

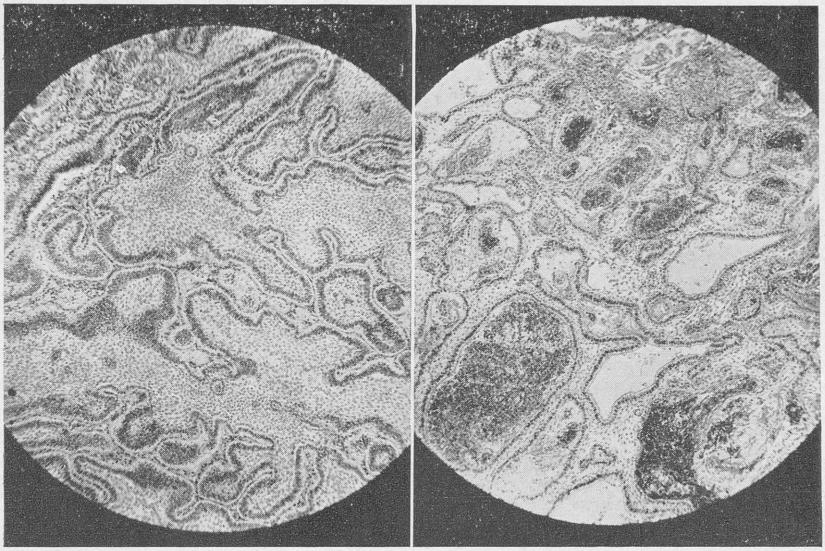

FIG. 2, Case 1.—Adamantinoma of the maxillary sinus (solid type).

FIG. 3, Case 2.—Adamantinoma of the maxillary sinus (polycystic type).

nite downward displacement of the adjacent hard palate and definite boggy crepitation on pressure over the palate as well as the anterior wall of the left maxilla. (4) No intranasal changes. (5) Completely opaque left antrum on transillumination testing. (6) No enlargement of the cervical glands. (7) Roentgenograms showed considerable expansion of the walls of the left antrum with evidence of destruction of the anterior wall and floor. It was considered likely that we were dealing with an expansive and probably cystic tumor of the left antrum, possibly an adamantinoma.

A Caldwell-Luc operation was performed on December 28, 1945, working with sodium pentothal anesthesia. Most of the anterior wall of the antrum as well as the greater portion of its floor was found to be reduced to eggshell thinness and at the point of entrance the bony wall had been completely destroyed. The antrum

was filled with a whitish, granular tumor containing many small cysts. In the center of the mass was a large cystic cavity which communicated directly with the alveolar opening. The floor of the orbit as well as the lateral nasal wall was intact. The tumor tissue was meticulously removed and the ethmoid cells cleaned out thoroughly. No gross tumor tissue was found in the ethmoid cells. The bone of the anterior wall as well as the floor of the antrum and the lateral nasal wall was removed. The diathermy electrode was carefully used throughout the cavity. The alveolar opening was dissected out and closed. A large window was resected into the inferior meatus and the canine fossa incision packed open. The postoperative course was uneventful and the patient was discharged from the Hospital ten days later.

Pathological Report: One gram of friable, granular, whitish colored tissue is received. On microscopic study the tumor has a varied structure. In most areas the tumor consists of complex, branching columnar structures lined by a layer of tall columnar epithelial cells in palisade arrangement. The central portion of many of the columns contains pale, irregular stellate cells in varying stages of preservation. In others there are cystic spaces, some of which contain pale eosinophilic coagulum, while others are filled by recent and organizing hemorrhage. A few islands of squamous epithelium are seen. There are large areas of degeneration and hyalinization involving tumor cells and stroma. Many chronic inflammatory cells are present in these areas. Diagnosis—Adamantinoma (Fig. 3).

Comment

These two cases are examples of the solid and polycystic types of adamantinoma. The true nature of the tumor was not recognized in the first iase at the time of operation, but was correctly diagnosed in the second instance. The experience gained in the first case as well as a better understanding of the recurrent nature of this tumor prompted a more radical plan of management in the second patient. The possibilities, however, for recurrence in both cases are fully appreciated.

Conclusions

1. Adamantinoma involving the maxillary sinus should be treated as a potentially malignant tumor in view of its established tendency to recurrence if incompletely removed.

2. The likelihood of recurrence will be lessened by the removal of the bony antral walls where possible, as well as by the meticulous use of the coagulating current.

3. The early detection of recurrence will be aided not only by the creation of a large antral window but also by maintaining the opening in the canine fossa for a long period.

4. The value of postoperative irradiation is distinctly limited in view of the radio-resistant nature of this tumor.

5. The necessity for frequent reexamination of these patients for many years must be emphasized. The rate of recurrence is characteristically slow and malignant changes occasionally occur.

Strong Memorial Hospital.

References

1. Robinson, H. B. G.: Ameloblastoma: A Survey of 379 Cases From the Literature, Arch. Path. 23:831 (June) 1937.

2. Thoma, K. H.: Oral Pathology, St. Louis, C. V. Mosby Company, 1941.

3. New, G. B.: Cystic Odontomas, J. A. M. A. 64:34-39 (Jan.) 1915.

4. Ewing, J.: Neoplastic Diseases, Philadelphia and London, W. B. Saunders Company, 1940.

5. Havens, F. Z.: Benign Cysts and Adamantinomas of the Jaws, Arch. Otolaryng. 30:762-774 (Nov.) 1939.

6. Schweitzer, F. C., and Barnfield, D. D. S.: Ameloblastoma of the Mandible with Metastases to the Lungs: Report of A Case, J. Oral Surg. 1:287-295 (Oct.) 1943.

7. Phelps, K. A.: A Case of Malignant Adamantinoma of the Right Maxillary Sinus, Trans. Am. Laryng., Rhino., and Otol. Soc., 1939, pp. 393-395.

8. Chont, L. K.: Adamantinoma: Report of Eight Cases, Am. J. Roentgenol. 50:480-490 (Oct.) 1943.

9. McFarland, J., and Patterson, H. M.: Adamantinomata: A Review of One Hundred and Ninety-Six Cases Reported in the Medical and Dental Literature, Dent. Cosmos 73:656-670 (July) 1931.

10. MURPHY, J. T.: Adamantine Epithelioma, Radiology 3:377-387 (Nov.) 1924.

11. GOLDEN, M. G.: Ameloblastoma of the Left Maxillary Sinus, Annals of Otology, Rhinology and Laryngology 51:378-388 (June) 1942.

12. MOSHER, W. F.: Adamantinoma of the Maxillary Sinus, Arch. Otolaryng. 40:61-62 (July) 1944.

13. WALDRON, C. W.: Tumors of the Upper Jaw, Surg., Gynec. and Obst. 72:503-511, 1941.

DISCUSSION

DR. JOHN J. SHEA: I wish to show three slides to illustrate a case.

Slide 1—This patient came in while pregnant with a history of having had a swelling in her face for three years which she accused a tooth of causing. Her tumor was five years old when she was admitted and this was her first pregnancy, being in her fifth month when we did a biopsy on her.

Slide 2—This is the type of biopsy which we obtained, which was diagnosed as an adamantinoma. We told her to come back after she had been delivered and the child has gotten old enough to be bottle fed, but we did not see any more of her again until two years later. We were asked to see the patient in the maternity ward and there was the lady back again with another pregnancy and this is her picture at that time.

Slide 3—You see there has been very little growth in two years. We asked her to be sure and return after this baby was delivered but it has now been a couple years and she has not returned either with a pregnancy or a tumor.

DR. T. C. GALLOWAY: It should be emphasized again that although these tumors look very harmless and seem to grow very slowly, they are very insidious, very treacherous tumors. I have seen three cases. My last case looked very simple and easy, but it kept eluding me. It grew along the periosteum till it invaded the orbit and became intracranial.

I think one must be very radical in these cases. I would not think it enough to make an antrum window, or go through the canine fossa, but make a external incision which Mosher has pointed out which gives such splendid access. It will stay open for observation with very little mutilation.

PRESENTATION OF PATIENTS AND INSTRUMENTS

SAMUEL SALINGER, M.D.

I will take only a few minutes to tell you something about this case.

I reported this case two years ago at the last meeting of this Association. It is a case of intractable nasal hemorrhage of undetermined origin, which was later published in the Annals. Speculation as to the cause of the nasal bleeding still continues. My original theory was that it was due to self-inflicted trauma. I have had this patient under observation for about four years beginning with a tiny ulcer on the septum which finally eroded to the point where the entire septum is gone. The turbinates are completely atrophied. We opened one antrum because it looked suspicious on x-ray examination and found some hyperplastic tissue. At various times we found many evidences of self-inflicted trauma, but the psychopathic examination of the patient was resisted to such a degree that it was abandoned for some time and it has never been taken up again. The patient has been under the care of a hematologist who says that her anemia is secondary. She has been running an average of about two million red cells, hemoglobin of about 39, white count around 6,000, a fairly normal differentiation, normal bleeding and clotting time over a period of several years. She is kept going by transfusions and various other medicaments.

Several years ago she developed a bluish swelling over the dorsum of the nose which I had difficulty in evaluating. I believed it was traumatic but in order to make sure I excised the whole mass, which accounts for the deformity which is now present. The mass was subjected to every possible form of pathologic and bacteriologic investigation and the net result was simple inflammatory process. The patient is here. I have a picture which I would like to show you which was taken at the time when the swelling was present.

(Slide) This was taken at the time when the swelling appeared at the bridge of her nose. It would appear and disappear at various times.

(Slide) This picture shows the scar following excision.

(Presentation of patient)

DR. SALINGER: She maintains her daily occupation. The external wound has healed very well, although for a period of several months it would open up periodically. There were times when we kept it completely covered with a plastic appliance which I believe is why it eventually healed. At some future time I expect to repair the deformity.

A NEW ANTERIOR COMMISSURE LARYNGOSCOPE

PAUL H. HOLINGER, M.D.

A laryngoscope is merely a retractor designed to elevate the tongue and epiglottis for exposure of the larynx. The design of the anterior commissure instrument herein described increases the field exposed both anteriorly and laterally by adapting the design of the Yankauer nasopharyngoscope to the C. L. Jackson laryngoscope. The distal end of the new laryngoscope is made to flare laterally and its anterior tip is elevated. The inferior surface of the proximal end is lowered slightly to permit greater anterior exposure and to allow forceps to advance anteriorly beyond true direction of the tube.

To avoid pressure on the lower teeth as the laryngoscope is inserted into the right side of the mouth, the light carrier and its canal have been placed on the left rather than the right side of the tube.

Memorials



ALLISON TEMPLE WANAMAKER, M.D.

1881-1944

Dr. Allison T. Wanamaker was born at St. Martin's, New Brunswick, March 13, 1881 and died in Seattle on June 21, 1944.

Dr. Wanamaker graduated from the School of Pharmacy, University of Washington in 1901. Two years later he enrolled in Northwestern University Medical School in Chicago and graduated with honors in 1907. After a year's internship at the Pittsburgh Hospital he served his residency at the Illinois Eye and Ear Infirmary and worked with Dr. Norval Pierce. He was assistant in the office of Drs. Frank Allport and Casey Wood of Chicago and later studied at the Vienna Clinics.

With Drs. Swift and Plummer he founded the Seattle Eye, Ear, Nose and Throat Hospital in 1916 and maintained this association until his death.

Dr. Wanamaker became a Fellow of the American Laryngological Association in 1933. He was a member of the American Laryngological, Rhinological and Otological Society, American College of Surgeons, the Pan-Pacific Surgical Association, an organizer and past-president of the Pacific Oto-ophthalmological Society and a member and past-president of the Puget Sound Academy of Ophthalmology and Otolaryngology. He was on the Staffs of the Children's Orthopedic Hospital and the Harborview Hospital. Dr. Wanamaker was very active in the Pacific Coast otolaryngologic societies and a majority of his many contributions appears in their publications. He was recognized as an authority on thrombotic lesions about the head and neck and deep infections of the pharynx.

On October 20, 1915 Dr. Wanamaker married Mary Helen Allmond. He is survived by Mrs. Wanamaker and a son and daughter, also a nephew Dr. Frank Wanamaker who has succeeded to his practice.

Dr. Wanamaker was not only an eminent physician but also played an important role as a community builder. He will be missed by his colleagues and his many friends.

SAMUEL IGLAUER, M.D.

1871-1944

Samuel Iglauer of Cincinnati, Ohio died on June 23, 1944. Dr. Iglauer was born in Cincinnati, Ohio December 28, 1871. He received his preliminary education in Cincinnati schools and was graduated from the Medical College of Ohio in 1898. He was appointed to the otolaryngologic staff of the College of Medicine, University of Cincinnati in 1901 and in 1930 was elected Professor of Otolaryngology which position he held until his death. His hospital connections were numerous and his unfailing willingness to lend aid and advice in complicated cases was a source of inspiration to associates, residents and internes. His medical interests were diversified and in addition to otorhinolaryngology Dr. Iglauer was active in plastic surgery of the face and bronchoesophagology.

He was elected a Fellow of this Association in 1925. In addition he enjoyed membership in the American Broncho-Esophagological Association of which he was a Founder-member and Past-President in 1923, the American Laryngological, Rhinological and Otological Society, American Academy of Ophthalmology and Otolaryngology, American College of Surgeons, American College of Chest Physicians, American Board of Plastic Surgeons, Academy of Medicine of Cincinnati and County and State Societies.

He devoted much time to civic organizations and was a member of the Cincinnati Anti-Tuberculosis League, Ohio Public Health Association, Better Housing League of Cincinnati and the City Charter Committee. Dr. Iglauer was married in 1906 to Helen Ransohoff, the daughter of Dr. J. L. Ransohoff a surgeon of Cincinnati. Of his three children, a daughter, Dr. Helen I. Glueck chose the field of medicine.

Dr. Iglauer thoroughly enjoyed teaching, writing or discussing medicine and its problems. He inaugurated the Annual Post-Graduate Ear, Nose and Throat Course at the University of Cincinnati Medical School. He gave generously of his time and energy

in the planning of this course and, attracting large groups of students, greatly enhanced the College's prestige.

Dr. Iglauer's contributions to medical literature were numerous and covered a wide field including deep infections of the neck, plastic surgery, bronchoesophagology and otolaryngology.

SIR JAMES DUNDAS-GRANT, K.B.E., M.D., F.R.C.S.

1854-1944

Sir James Dundas-Grant, one of the best known British otolaryngologists, died on November 13, 1944. In general practice for ten years when he specialized in 1886 he was a prominent figure in meetings of ear, nose and throat surgeons for more than 50 years. He died at the age of 90 years.

James Dundas-Grant was born in Edinburgh in 1854, the son of a Scottish lawyer. He received his education at Edinburgh Academy, Dunkirk College, France, University of Edinburgh and University of Wurzburg, Bavaria and completed his medical studies at St. Barthalomews', London. He became a Fellow of the Royal College of Surgeons of Edinburgh and the Royal College of Surgeons of England. In 1879 he was appointed Surgeon to the Central London Throat and Ear Hospital an appointment he held until 1913 when retiring under the age limit, he became consultant. He had many hospital appointments including the Brompton Hospital for Consumption. He held a teaching post in otolaryngology in connection with the University of London.

He was a prolific writer and contributed many articles to medical journals. In addition he devised many contrivances such as a cannula for aspirating the middle ear, a ligature applicator for tonsillar and other deep seated vessels and a modification of an aid for hearing.

He was elected a Corresponding Fellow of this Association in 1901. He also was associated with otolaryngological societies on the Continent.


James A. Baldwin

JAMES A. BABBITT, M.D.

1869-1944

Dr. James A. Babbitt, one of the most beloved Fellows of our Association, died on October 15, 1944, at the Lankenau Hospital in Philadelphia of cerebral hemorrhage. He had had a less severe attack in May of the same year from which he made sufficient recovery so that for a short time he resumed the practice of his specialty.

Dr. Babbitt was born in Waitesfield, Vermont, on October 22, 1869. His father was the Reverend James Howard Babbitt a Congregational minister, a New Englander born in Taunton, Massachusetts. His mother, Mary French Babbitt, also a New Englander, was born in Seabrook, New Hampshire.

He attended schools in various Vermont towns where his father held church appointments, finally graduating from Phillips Andover Academy in 1889. He received his A.B. degree from Yale in 1893. After graduating from Yale he went to Haverford College to become Professor of Hygiene and Physical Education and conducted classes in anatomy and bacteriology. He received his A.M. degree from Haverford in 1896. When later he resigned from the Haverford Faculty he was elected Emeritus Professor. While still carrying on his professorial work at Haverford he attended classes at the Medical School of the University of Pennsylvania, obtaining his Doctorate in Medicine in 1898. He was elected secretary of this Class, which position he held from the time of graduation until his death. He was a member of Phi Beta Kappa and Sigma Xi.

His early training in Otolaryngology was largely acquired in the clinics of the old Polyclinic Hospital under the tutelage of such men as Packard, Gibb, Van Sant, Freeman and Watson and at the University of Pennsylvania Medical School where he studied under that pioneer otologist, Dr. B. Alexander Randall.

Starting as an assistant under Dr. Randall, he was steadily advanced until he became Professor of Clinical Otolaryngology in the

University of Pennsylvania Medical School. He was later appointed Associate Professor of Otolaryngology in the Graduate School of the same institution. On reaching the age of retirement in the undergraduate school he was made Emeritus Professor of Clinical Otolaryngology, a high honor, as such awards were very seldom made. During his professional career he was also connected with many other Philadelphia hospitals such as the Childrens', the Misericordia, the Fitzgerald Mercy, the Mary Drexel and the Lankenau and was on the courtesy staff of the Bryn Mawr, the Chestnut Hill, the Presbyterian and the Episcopal Hospitals.

Probably Dr. Babbitt's most intimate hospital connection was with the Lankenau. He had retired from active service in this hospital just before the beginning of World War II but when Dr. Edward H. Campbell and Dr. Robert J. Hunter entered the Armed Forces he was recalled to take charge of the otolaryngological work and was later made chairman of the hospital staff and medical director.

In spite of his large practice and hospital connections Dr. Babbitt was a prolific writer. He contributed chapters to three text books and published over fifty original articles covering almost the whole field of otolaryngology, though the greater part of his writings concerned otologic subjects.

In his latter years he became deeply concerned with the problems of the hard of hearing, of the prevention of deafness and the relation of geriatrics to ear, nose and throat diseases. His investigations into causes of progressive deafness and otosclerosis were noteworthy but one of the most original of his contributions concerned a conservative operation for the drainage of the attic. By this procedure he obtained excellent results, many radical operations being avoided.

In World War I Dr. Babbitt served in France as a major in the American Red Cross with the Service Unit of the Society of Friends from 1917 to 1918. During that time he had to perform not only the operations of his specialty but also many appendectomies and other general surgical procedures.

It was his unusual organizing ability as well as his medical knowledge that made him such an invaluable member of the various

organizations to which he gave so much of his time and energy. Among the lay groups of societies he contributed much to the success of his two fraternities, the Phi Gamma Delta and the Alpha Nu Pi Omega (medical).

Probably his participation in the activities of his medical societies and the intimate association with their fellows was one of the greatest pleasures of his professional life. However, he was not in any sense a self-seeking politician and the honors that came to him were a just reward not only for his high ability as an otolaryngologist but also for the skill and energy which he showed in the planning of annual meetings, in the development of programs and in the social functions of these societies.

He was elected a Fellow of the Americal Laryngological Association in 1923 and began a career of activity and devotion that has seldom been equalled by any other Fellow. He had the almost unique distinction of having never missed an annual meeting from the time of his election until his death. He was elected treasurer in 1933, secretary in 1935 and president in 1939. To these official positions he brought an untiring enthusiasm that was so characteristic of his whole attitude toward life.

The national recognition of his standing as one of America's great in otolaryngology is shown by the fact of his election to official positions in most of the national ear, nose and throat societies.

In his earlier days he was a most efficient clerk of the Section of Otolaryngology of the College of Physicians of Philadelphia and was later elected chairman of the Section. A few years after his presidency of the American Laryngological Association he became president of the American Laryngological, Rhinological and Otological Society. For many years he was the necrologist of the American Academy of Ophthalmology and Otolaryngology and during his term of service wrote an unusually large number of memorials of its fellows. A few years before his death he was elected president of this body. He also served on two of its most important committees, one for the prevention of deafness and another for the establishment of a Pan-American Otolaryngological

Congress. He was a member of the Board of Governors of the American College of Surgeons and a Fellow of the American Otologic Society, a member of the Philadelphia Laryngological Association, a Fellow of the American Medical Association and a member of the affiliated Pennsylvania State and Philadelphia County Societies.

Dr. Babbitt had a very active interest in collegiate athletics which began while he was a student at Yale where he was a member of the football squad; and for many years he devoted much of his time to the study of problems that arose in inter-collegiate athletic relations. For six years he was president of the Middle Atlantic States Collegiate Athletic Association, and later a member of the National Football Rules Committee and chairman of the Central Board of Officials. He is also credited with the introduction of the game of soccer to this continent and was responsible for bringing basketball to the state of Pennsylvania, the first game of the latter being played by the Students at Haverford College. Although the pressure of his professional life finally made it necessary for him to give up his official positions he never lost his interest in inter-collegiate athletics. He could almost always be seen at the football games at Franklin Field in Philadelphia and frequently travelled to other stadiums just for the relaxation and joy which this great American game always brought to him.

He loved the out of doors and for years took his summer vacations in New Brunswick salmon fishing, and at one time was a member of the Swiftwater Preserve, a trout fishing club in the Pocono Mountains. Golf was another hobby and as a member of the Doctors' Golf Club he spent many happy hours on the greens with his medical associates.

Dr. Babbitt belonged to the University Club of Philadelphia, the Union League and the Merion Cricket Club. His outgoing personality, his ready conversation and kindly spirit made the social contacts in these clubs always a source of new friends, and friendship meant so much to him. He was a very warm human being. He was a member of the Masonic Order and of the Society of Mayflower Descendants.

Music to him was an enjoyable pastime and relaxation and he had considerable natural ability. We of the American Laryngological Association will long remember the song he composed and dedicated to his eminent fellow members, Dr. D. Bryson Delavan, Dr. Harris P. Mosher and Dr. Chevalier Jackson, and the singing of it at the annual dinners of our Association.

Dr. Babbitt married Mary A. Adams in 1895. She died in 1911 leaving him three daughters, Mary Evelyn, now Mrs. Alan W. Hastings, Helen Adams now Mrs. Edward F. Webster, and Mary Adams. In 1921 he married Marcella Stovall Hardwick Cordray of Augusta, Georgia, who survives him as do her two children by a former marriage, Mrs. Renwick McIver and Lieutenant David P. Cordray who is a very promising otolaryngologist.

Dr. Babbitt was brought up as a member of the Congregational Church but the intimate contacts that he made while at Haverford College, his association with the students, members of the faculty and trustees of this institution greatly influenced his spiritual thinking and he became an associate member of the Haverford Meeting. One of the most inspiring spontaneous prayers that I can remember was made by Dr. Babbitt at the opening of one of the war-time meetings of the Council of our Association. In fact, his whole life was characteristic of an individual who had a religious belief strong enough to influence his life actions. As a physician his contacts with patients and other doctors were of the highest ethical standard and his undoubted sincerity and kindliness made him beloved alike by patients and colleagues. He was seldom if ever heard saying a word of unkind criticism and loved to give aid and advice to younger men.

Dr. Babbitt's life was one of usefulness and earnest endeavor. In his profession he gained a deserved national recognition. He was beloved by his patients, friends and medical associates. He lived a life worth while. In his death American otolaryngology suffers a grievous loss. We, his Fellows of the American Laryngological Association, knew him as a comrade and the warmth of his friendship we can never forget. It is an abiding memory.

G. B. W.

GREVILLE MATHESON MacDONALD, M.D.

1856-1944

Dr. Greville M. MacDonald, a Corresponding Fellow of this Association since 1896, died at Haslemere, England on November 3, 1944, age 88 years.

Dr. MacDonald was born in Manchester on January 20, 1856, the eldest son of George MacDonald, L.L.D. poet and novelist. He was reared in a musical and literary environment and on a visit to this country in 1872 with his father met Whittier, Longfellow, Oliver Wendell Holmes and Emerson. He entered Kings College and was graduated in medicine in 1877. During his clinical course he became one of Lord Lister's clerks.

Dr. MacDonald's career in laryngology began in 1886 when he was appointed to the staff of the Hospital for Diseases of the Throat. He received an appointment as throat physician and lecturer on diseases of the throat and nose at King's College Hospital in 1893 and served until 1906 when elected consulting physician.

His appointment to the Golden Square Hospital was due to Sir Morell Mackenzie whose private work in London he looked after when Sir Morell was in attendance on Emperor Frederick at San Remo and Charlottenburg.

Dr. MacDonald ranked high as a lecturer in his specialty. He was Vice-President of the Section of Laryngology, British Medical Association in 1895 and President of the Section at the meeting in Montreal in 1897. In addition to writing many medical publications he wrote a number of philosophical essays, studies in human personality, biographies of his parents and in 1932 Reminiscences of a Specialist.

GEORGE E. HOURN, M.D.

1878-1944

On December 10, 1944 George Hourn, an Active Fellow of the Association died in St. Louis.

Even after long weeks of a lingering illness the news of his passing came as a shock to his friends. In their affections George Hourn occupied a unique position. Many of them had known him since his college days as a gentle, patient, understanding soul, full of interest in their problems, full of sympathy for their woes.

Into the offices of his colleagues came his patients one by one, sadly, and always with a quiet remark which meant, no matter what it may have said, "I was Dr. Hourn's patient, please try to be a little like him, if you can."

George Hourn was born June 2, 1878 at Peterson, Minnesota, the son of Norwegian parents. His school days were spent in Minnesota and the Dakotas and he graduated in Dentistry in 1903 from the University of Minnesota where he had had also some schooling in the Liberal Arts.

Seven years later, he yielded to the urge to wider fields and entered the Washington University School of Medicine as a freshman at the age of thirty-two. After his internship he began his training in otolaryngology under the preceptorship of Greenfield Sluder and John B. Shapleigh at that time heads of their separate departments of Laryngology and Otology.

Giving much of his time to charitable endeavors, he was associated at various periods of his career with many hospitals and clinics: Barnes, Children's, St. Luke's, Barnard Free Skin and Cancer, Jewish, DePaul, Mullanphy, Missouri Baptist and the St. Louis City Hospitals and their clinics.

He was, at the time of his death, Assistant Professor of Clinical Otolaryngology in Washington University School of Medicine, and a Fellow of the Academy and the St. Louis Nose and Throat Club.

He was a member of Alpha Omega Alpha, Nu Sigma Nu and Phi Delta Theta.

Of the Lutheran faith, he was an active Mason: Scottish Rite and Shrine, and for many years a member of a male choral society.

In the files of the Association he made the following notation, describing his diversions: "Orange and grapefruit orchard; tung tree orchard; hunting and fishing; amateur photography; music; basement tinkering."

It was the basement tinkering, no doubt, which burgeoned in the shape of a series of original and very practical instruments. One of these was a fool-proof tonsil suture needle for sewing the pillars together without damaging the large vessels. Others were designed for special purposes in antrum surgery.

One paper was read before the Association and appears under the title, "X-ray Visualization of the Naso-lachrymal Duct" in the Transactions for 1937.

In his memory, Mrs. Hourn, the former Josephine Holm of Slayton, Minnesota, has established an annual scholarship grant to be administered by the Memorial Fund Committee for the purpose of educating students in otolaryngology. Beside his widow, two daughters by a former marriage survive him.

A. W. P.

LEE MAIDMENT HURD, M.D.

1873-1945

Dr. Lee Maidment Hurd died on May 15, 1945 at the age of seventy-one. He was elected to active Fellowship of this Association in 1919 and placed on the Emeritus list in 1942.

Born in St. Charles, Minnesota in 1873, his early education was secured there and in upper New York State, and he received his medical degree at the College of Physicians and Surgeons, Columbia University in 1895. After a period of time spent on the European continent in various medical centers, he returned to New York and began practice as one of the pioneers of otolaryngology. He was one of the progressive group of young specialists who first worked out the technique of such operations as dissection of the pharyngeal tonsil in its capsule, the submucous resection of the nasal septum, and intranasal sinus surgery. He developed instruments suitable for these procedures some of which, along with the techniques still are used. Gifted with almost complete ambidexterity and endowed with a perpetual curiosity and desire for better knowledge, more perfect technique, and greater benefit to his patients, he became one of the great practicing otolaryngologists of his time. His skill in intranasal surgery and the almost forgotten art of indirect intralaryngeal surgery were outstanding.

He devoted much time to undergraduate and postgraduate teaching and for many years was professor of laryngology at New York University and Bellevue Medical College and the New York Polyclinic Postgraduate Medical School and Hospital. He was at the time of his death emeritus professor in the latter institution and attending laryngologist and consultant to the Fifth Avenue and Broad Street Hospitals.

His membership in medical societies was wide, and included the American Medical Association, the New York County and State Societies, the American College of Surgeons, The American Laryngological, Rhinological and Otological Society of which he was a



past president, the American Academy of Ophthalmology and Otolaryngology, The American Broncho-Esophagological Association, the New York Academy of Medicine, The Pan-American Medical Association and the New York Laryngological Society.

He was a member of the Seventh New York Regiment in earlier years and still was a member of the Society of Colonial Wars.

His medical writings comprised more than thirty monographs on a wide variety of subjects, and a chapter on otolaryngology in Binnie's Regional Surgery.

In 1903, he married Violet Reed who died a few months before his own passing. He is survived by one son J. Anson and a daughter Mrs. Edward Pinney, of New York.

He will never be forgotten by a host of friends nor by another host of those whom he inspired and taught to be true clinicians in the field of otolaryngology.

W. W. M.

ELMER L. KENYON, M.D.

1865-1945

Elmer L. Kenyon, elected a Fellow of the American Laryngological Association in 1918 and an Emeritus since 1938 was a pioneer in the field of speech defects. He established the second clinic for the treatment of these disorders in the United States at Rush Medical College in 1904. He was one of the founders of the American Speech Correction Association, serving as its President from 1928 to 1932. Although his contributions to medical literature were few they were characterized by depth of thought and a profound knowledge of the subject and always gave one the impression of scholarly and philosophic study. He was the first to call attention to the importance of the external masculature of the larynx in the production and control of speech and his contributions on this topic evoked the greatest praise. He was the author of the section on "Defects of Speech of Congenital and Developmental Origin" in Abt's Pediatrics, 1925.

Dr. Kenyon was born at Onondaga, New York in 1865, received his A.B. at Harvard in 1890 and his M.D. at Rush Medical College in 1896. He did Postgraduate work at the Philadelphia Polyclinic in 1904 and in Berlin in 1911-12. He was a member of the faculty at his Alma Mater from the time of his graduation until 1937 when he retired with the rank of Associate Clinical Professor Emeritus of Laryngological and Otology. In addition to his affiliation with the National Speech Correction Association he was a member of a number of Medical Societies including the Chicago Laryngological and Otological Society (President in 1919), the Jackson Park Branch of the Chicago Medical Society (President 1917-1918), the Alumni Association of Rush Medical College (President 1922-23) the House of Delegates of the American Medical Association in 1917, Fellow of the American College of Surgeons, the Chicago Physicians Club, the Alpha Kappa Kappa and Delta Kappa Epsilon Fraternities.

Dr. Kenyon was a very quiet and unobtrusive man of dignified and scholarly mien who spoke only when he had something im-

portant to say. He was a gentleman in every sense of the word and was highly respected by all who knew him and appreciated his work. In his later years he was seen but infrequently at society meetings but his interest in the subject of speech defects never faltered. He was devoting a great deal of his time on the preparation of a text book on "Speech Defects" but never lived to complete it. He died on February 2, 1945 of a cerebral hemorrhage at the age of seventy-nine.

With the passing of Elmer Kenyon the medical profession has lost a pioneer, a profound scholar and a gentleman whose talents were appreciated only by the few who had the opportunity of meeting him frequently and hearing him speak.

S. S.



CHARLES TERRELL PORTER, M.D.

1889-1945

Dr. Charles T. Porter died suddenly in Boston, April 19, 1945 of coronary thrombosis. He was 56 years old.

Dr. Porter was born in Hackneyville, Alabama, February 18, 1889. He received his preliminary education in the schools of Alabama, graduated as an engineer from the Alabama Polytechnic Institute and in Medicine in 1912 from the University of Virginia. He spent one year as house officer on the eye side of the Massachusetts Eye and Ear Infirmary and then received an appointment on the ear, nose and throat side. With this background he escaped falling into the petty things which can go with a specialty.

Because of this clinical training and experience he was much sought after and enjoyed appointments on the staffs of many hospitals including the Massachusetts Eye and Ear Infirmary, Massachusetts General Hospital, Peter Bent Brigham Hospital, Waltham General Hospital, Massachusetts Women's Hospital, New England Baptist Hospital, Brooks, Cambridge and Faulkner Hospitals. Due to his interest in teaching he was appointed Instructor in Otology at Harvard Medical School.

He did little research work but attained recognition by reason of his profound clinical knowledge which was backed by a rich experience, his surgical ability, solidity and dependability. In medical discussions he was forthright, terse and to the point. He was a formidable opponent in debate and it was a comfort to have him support one's views.

He was elected a Fellow of the American Laryngological Association in 1927. He was a member of the American Otological Society and one time Vice-President, a member of the American Laryngological, Rhinological and Otological Society and President-elect at the time of his death, the American Academy of Ophthalmology and Otolaryngology, American College of Surgeons, New England Otological and Laryngological Society and a member of local societies. He participated actively in their deliberations.

Dr. Porter married Barbara Worcester, the daughter of Dr. Alfred Worcester of Waltham, Mass., on April 4, 1916. He had one daughter who strangely was married several months previously in the same church from which her father was buried.

Dr. Porter was connected by marriage with the Canadian Minister of Transportation who made possible luxurious fishing trips. He was an accomplished sportsman being proficient in hunting, fishing and golf. He had the gallantry and high sense of honor characteristic of the Southerner. How he happened to lose his Southern drawl and accepted the New England accent will never be known.

Dr. Porter had a hobby of collecting guns and pistols, appreciated their workmanship and was familiar with their use. He was a judge of thoroughbred dogs. He was a fine host and a man's man.

In Dr. Porter's death the Massachusetts Eye and Ear Infirmary lost one of its outstanding men and we of this Association have been deprived of a colorful Fellow and a fine gentleman.

H. P. M.

HORACE NEWHART, M.D.

1872-1945

Horace Newhart, Emeritus Professor of Otolaryngology at the University of Minnesota, died in Minneapolis on July 9, 1945 at the age of 72 years. He is survived by Mrs. Horace Newhart, a son, Elwood, and a daughter-in-law and their two children, and a sister. All live in Minneapolis.

Dr. Newhart was born in New Ulm, Minnesota, on December 9, 1872. He attended Carleton College from 1891 to 1893, then transferred to Dartmouth College, where his scholarship won for him a Phi Beta Kappa Key and his A.B. degree in 1895. He then attended the University of Michigan Medical School and obtained his M.D. in 1898. Following his graduation from Michigan he went to Vienna for further study and remained there through 1899. In 1900 he returned to Minneapolis and began general practice although his special interest was ophthalmology and otolaryngology in which he had taken some courses while abroad. After a couple of years of private practice an opportunity came to broaden his background by a position on the staff of the Jackson Sanitorium in Danville, New York. While there he met Anne Hendrick of Albany to whom he was married September 4, 1904.

Another trip to Vienna followed in 1905, and then he returned to Minneapolis to resume general practice. After a third visit to Vienna in 1908, Dr. Newhart limited his practice to ophthalmology and otolaryngology.

The year 1912 again found him studying in Europe. It was in that year that he was appointed to the staff of the Department of Ophthalmology and Otolaryngology at the University of Minnesota. His major interest developed to which he gradually limited his work. Dr. Newhart became Professor of Otolaryngology and Director of the Division of Otolaryngology at Minnesota in 1930.

Dr. Newhart became a familiar figure in national otolaryngological circles where he was a tireless worker in the interest of



Horace Newhart

problems related to the hard of hearing. He was elected to Fellowship in the American Laryngological Association in 1923 and was a member of the American Academy of Ophthalmology and Otolaryngology, the American Laryngological, Rhinological and Otological Society, the American Otological Society, the American Acoustical Society and the American Society for the Hard of Hearing. In several of these societies he was honored with the presidency; the American Academy of Ophthalmology and Otolaryngology in 1924-25, the American Society for the Hard of Hearing in 1939, the American Otological Society in 1939.

Dr. Newhart was a pioneer in the promotion of periodic testing of the hearing of school children. He became consulting otologist for the Minneapolis Public Schools in 1925, a position which he held at the time of his death. He was closely identified with the activities of the Minneapolis Society for the Hard of Hearing in which he served as president from 1925-29. For a number of years he served as Chairman of a Committee on the Conservation of Hearing of the Minnesota Medical Association. As chairman of this group, he made repeated efforts to secure legislation to establish a state program for the detection and care of early hearing impairment, particularly in childrn. To date this work has not been rewarded but very likely a groundwork has been laid which will eventually be a monument to his efforts.

Dr. Newhart's hobby was his work. However, his social affiliations were numerous. He was a member of the Sigma Chi and Phi Rho Sigma fraternities, and of the Minneapolis, Minikahda, La-Fayette and Campus Clubs of Minneapolis. His religious affiliation was Congregational.

Dr. Newhart's fellow practitioners will remember him as a kindly, patient physician who was always considerate of others' interests. One competitor once said of him, "he is always a gentleman". His many friends subscribed to this.

L. R. B.



Robert Levy

ROBERT LEVY, M.D.

1864-1945.

Dr. Robert Levy died July 1, 1945 in Denver, Colorado, at the age of 81 years. He is susvived by two daughters, Mrs. Leona L. Eichberg and Mrs. Samuel Rose of Denver. His wife, the former Rebecca Goldsmith died in 1940.

Dr. Levy was born in Hamilton, Ontario, May 30, 1864. After attending the University of Denver, he received his M.D. degree from Bellevue Hospital Medical College, New York 1884, and later did postgraduate work in Berlin, Vienna and Freiberg.

He began the practice of medicine in Denver in 1884 with his uncle, Dr. John Elsner. After five years of general practice, he took up otolaryngology as a specialty and continued in this until his death.

Always active in his specialty Dr. Levy held many distinguished positions pertaining to it. From 1887 to 1895 he was Professor of Laryngology, Rhinology and Physiology at Gross Medical College, Denver, becoming Professor of Otolaryngology at the Denver and Gross College of Medicine when these two schools consolidated in 1895. In 1911 the Denver and Gross College merged with the University of Colorado School of Medicine and Dr. Levy was Professor of Otolaryngology at that institution until 1936 when he was made Professor Emeritus. He also served as Secretary of the Gross Medical College and from 1902-1909 of the Denver and Gross College; in 1896 he was elected president of the Colorado Medical School. He was otolaryngologist to the Colorado General, St. Joseph's, Denver General, St. Luke's Childrens and the National Jewish hospitals, at which latter institution he served as Chairman of the Medical Advisory Board for the past 35 years.

Dr. Levy was elected to active Fellowship in the American Laryngological Association in 1914, to Emeritus in 1934 and Honorary

Fellowship in 1944. He also was a member of the American Medical Association, serving as Chairman of the Section on Otolaryngology in 1916; the American Academy of Ophthalmology and Otolaryngology; American Laryngological, Rhinological and Otological Society, serving as President in 1915; American College of Surgeons; Colorado State and other local medical societies.

During the first World War he served in the United States Army Medical Corps and was discharged with the rank of major in 1919.

Dr. Levy was the author of numerous articles on otolaryngological subjects, especially on laryngeal and oral tuberculosis, and contributed chapters on laryngeal surgery to Loeb's "Operative Surgery of the Nose, Throat and Ear."

Among the many honors bestowed upon him in 1932 he was elected president for the third time of the Denver Clinical and Pathological Society and made President Emeritus. On April 4, 1934, the Denver Medical Society commemorated Dr. Levy's 50th anniversary in the practice of medicine, and a portrait of him by Waldo Love was presented to the Association.

In addition to his activities in medical circles, Dr. Levy was concerned with all philanthropic and community activities. He participated in the organization of the local community chest and several years ago a medal was presented to him for this outstanding service.

He was a Trustee of Temple Emanuel for forty years, later serving as President, and being elected Honorary President for life. In his youth he was organist in a Methodist Church.

In 1923 Dr. Levy toured Japan where he delivered a series of lectures, making the principal address at the dedication ceremonies of the Hospital and Medical School in Tokyo.

He was an extensive traveller and delivered many illustrated talks on foreign lands and people. He steadfastly refused to retire,

contending that a man was not old as long as he retained his sense of humor. He was able to perform operations in his later years with the same skill and steadiness of hand that he displayed in his younger days. He was Dean of otolaryngologists of the West and a national figure for many years.

T. E. C.

Executive Sessions

1 9 4 6

FIRST EXECUTIVE SESSION

MAY 29, 1946

The First Executive Session of the American Laryngological Association held in connection with the Sixty-Seventh Annual Meeting at the Drake Hotel in Chicago, Illinois, May 29, 1946, convened at 12:35 noon following the First Scientific Session, Dr. Harold I. Lillie, President, presiding.

On recommendation of the Council the following were elected:

To Emeritus Fellowship:

DR. JOHN H. FOSTER
DR. GEORGE B. WOOD

To Corresponding Fellowship:

DR. ELISEO V. SEGURA, Buenos Aires
DR. JUSTO M. ALONSO, Montevideo, Uruguay

There were no recommendations to Honorary or Active Fellowship.

The Association elected the following to serve as a Nominating Committee:

DR. SAMUEL SALINGER

DR. RALPH A. FENTON

DR. GEORGE M. COATES

DR. LEROY A. SCHALL

DR. DANIEL S. CUNNING

There being no further business the Session adjourned at 12:55.

ANNUAL BUSINESS MEETING

MAY 30, 1946

The Second Executive Session, the Annual Business Meeting of the Association was called to order at 12:25 noon following the close of the Scientific Session, by President Lillie.

REPORT OF THE SECRETARY

May 29, 1946

No Annual Meeting of the Association having been held in 1945, the business of the Association was conducted by the Council which met in New York City on January 13 and on June 9, 1945, and in Saint Louis on January 12, 1946.

The proceedings of these three meetings, together with the reports of officers and of standing and special committees, may be summarized as follows:

The Council, after careful deliberation and an informal discussion with the members of the Council of the American Otological Society, voted to omit the Annual Meeting for 1945. This was in conformity with the action of the other special societies and with a restricting directive of the War Department.

Dr. Henry B. Orton was elected councillor to fill the unexpired term of Dr. James A. Babbitt.

The Treasurer reported that a canvass of the membership indicated an overwhelming desire to continue charging the same general fee to all Fellows attending the Annual Meeting, regardless of their attendance at the Annual Dinner.

Dr. Arthur Proetz and Dr. Louis H. Clerf were appointed a committee to rewrite the Constitution, supplying certain minor

omissions and clarifying certain passages, and to submit the revised document to the Fellows at the next Annual Meeting.

The Memorial Fund Committee was authorized to resume the solicitation of gifts, suspended during the war.

Dr. Bernard McMahon was appointed in 1945 to succeed Dr. F. T. Hill and Dr. O. E. Van Alyea in 1946 to succeed Dr. George M. Coates, as members of the Memorial Fund Committee.

The Council voted to modify the regulations governing the De-Roaldes Medal to permit its award at intervals of three, four or five years at the discretion of the Committee.

On recommendation of a committee, consisting of Dr. Louis H. Clerf and Dr. Henry B. Orton, appointed to review the conditions of the Newcomb Award, these were amended to provide for its presentation "annually to a Fellow of the American Laryngological Association presenting the most outstanding contribution to the literature of laryngology during the previous calendar year, or as a mark of esteem and appreciation for services to the Association." The Committee further recommended that the Award be made at the first business session of the Association at its Annual Meeting.

The Newcomb Award Committee, Dr. Burt R. Shurly, Chairman, recommended that, owing to the omission of the Annual Meeting, no award be made in 1945.

The Council placed itself on record as recommending that the certificate of the Board of Otolaryngology be required only of candidates for Active Fellowship; also that the records of candidates for Corresponding and Honorary Fellowships be not included in the lists of candidates mailed to the membership. It recommended further that candidates for Corresponding and Honorary Fellowships be considered only upon the written proposal of two Active Fellows who will be required to furnish the necessary data.

Dr. Charles J. Imperatori was appointed to act as Curator of the Delavan Collection of Historic Laryngeal Instruments, with a request to catalog it.

Dr. Samuel Salinger was re-elected Abstract Editor to serve for one year.

The Candidates' Nominating Committee was discontinued and the Secretary was instructed to request the membership from time to time to submit names of potential candidates. This in no way alters the accepted method of proposal, comment and vote as laid down in the Constitution, but merely broadens the field formerly covered by the Candidates' Nominating Committee.

By mail ballot the Association elected since its last Annual Meeting:

To Emeritus Fellowship:

Dr. Horace Newhart

To Active Fellowship:

Dr. Paul A. Campbell, Chicago, Ill.

Dr. Harold L. Hickey, Denver, Colo.

Dr. Paul H. Holinger, Chicago, Ill.

Dr. John G. McLaurin, Dallas, Texas

Dr. James M. Robb, Detroit, Mich.

The Council recommends for election at this Meeting:

To Emeritus Fellowship:

Dr. John Foster

To Corresponding Fellowship:

Dr. Eliseo V. Segura, Buenos Aires, Argentina

Dr. Justo M. Alonso, Montevideo, Uruguay

Since the last Annual Meeting, the Association has lost through death five Active Fellows, three Emeritus Fellows, two Corresponding Fellows and one Honorary Fellow, whose memorials are recorded in the current report of the Historian.

The Membership of the Association at this time consists of:

Active Fellows	98
Emeritus Fellows	20
Corresponding Fellows	15
Honorary Fellows	4
Total	137

Respectfully submitted,

(Signed) ARTHUR W. PROETZ,
Secretary.

The report was accepted and filed.

REPORT OF THE TREASURER

Balance Sheet May 15, 1946

ASSETS

Cash in bank	$ 2,364.80	
Less due Trust Funds	124.48	$ 2,240.32

Trust Fund Investments: Bonds:	Book Value
$3,000 U. S. Treasury 3 1/8 1946-49	$3,307.20
1,000 U. S. Treasury 2 3/4 1948-51	1101.20
1,000 U. S. Treasury 2 3/4 1958-63	1101.20
3,000 U. S. Defense Bonds 2½ Series G. 1953	3,000.00
1,000 U. S. Defense Bonds 2½ Series G. 1954	1,000.00
3,000 U. S. Treasury 2½ 1964-69	3,000.00
1,000 U. S. Treasury 2¼ 1956-59	1,003.50
5,000 U. S. Defense Bonds 2½ Series G. 1956	5,000.00

1,000 U. S. Defense Bonds 2½ Series G. 1957	1,000.00		
2,000 U. S. Defense Bonds 2½ Series G. 1958	2,000.00		
1,000 U. S. Treasury 2½ 1967-72	1,000.00	$22,513.10	
Savings Deposits:			
Waterville Savings Bank	2,645.39		
Due from General Cash	124.48	2,769.87	25,282.97
Total Assets			$27,282.97

LIABILITIES AND CAPITAL

Trust Funds:			
Casselberry Fund	5,000.00		
Johnston Fund	5,000.00		
DeRoaldes Fund	2,000.00		
Dr. James Edward Newcomb Prize Fund	500.00		
Dr. James Edward Newcomb Trust Fund	2,000.00		
Memorial Funds	9,204.19	23,704.19	
Reserve for losses on Investments		74.88	
George E. Hourn Scholarship Grant		250.00	
Unused Income:			
Casselberry Fund	263.20		
Johnston Fund	241.40		
DeRoaldes Fund	(90.79)*		
Newcomb Prize Fund	(24.46)*		
Newcomb Trust Fund	351.74		
Memorial Funds	512.81	1,253.90	$25,282.97
General Capital and Surplus			2,240.32
Total Liabilities and Capital			$27,523.29

*Represents Overdraft

STATEMENT OF INCOME AND EXPENSE
FOR THE PERIOD MAY 15, 1945 TO MAY 15, 1946

Income:		
Dues	$ 2,225.00	
Sales of Transactions	124.25	
Income from Trust Funds	535.88	$ 2,885.13

Expenditures:		
Honorariums—Officers (clerical hire)	450.00	
Pre-Convention Expense	88.90	
Council Meeting	280.31	
Cost of Transactions	51.27	
Postage & Express	131.59	
Stationery & Printing	259.35	
Miscellaneous Expense	9.95	
All Other (Treasurer's Bond)	62.50	
Amortization	40.19	1,374.06
Excess of Income over Expenditures		$ 1,511.07

DISPOSITION OF TRUST FUND INCOME

Total Income on Trust Funds:		$ 535.88
Prorated as follows:		
Casselberry Fund	$ 119.77	
Johnston Fund	119.77	
DeRoaldes Fund	29.95	
Newcomb Prize Fund	11.74	
Newcomb Trust Fund	47.96	
Memorial Funds	206.69	$ 535.88

STATEMENT OF INCOME (TRUST FUNDS)

	Unused Income 5/15/45	Income 1945-46	Unused Income 5/15/46
Casselberry Fund	$143.43	$119.77	$ 263.20
Johnston Fund	121.63	119.77	241.40
DeRoaldes Fund	(120.74)*	29.95	(90.79)*
Newcomb Prize Fund	(36.20)*	11.74	(24.46)*
Newcomb Trust Fund	303.78	47.96	351.74
Memorial Fund	306.12	206.69	512.81
	$718.02	$535.88	$1,253.90

*Represents Overdraft

RECONCILIATION OF GENERAL CAPITAL AND SURPLUS

General Capital and Surplus—May 15, 1945		$2,765.13
Transferred to DeRoaldes Fund		1,500.00
		$1,265.13
Excess of Income over Expenditures	$1,511.07	
Income prorated to Unused Income of Trust Funds	535.88	975.19
General Capital and Surplus, May 15, 1946		$2,240.32

SECURITIES PURCHASED

$1,000	U. S. Defense Bond 2½% Series G. 1957	— Cost $1,000
2,000	U. S. Defense Bond 2½% Series G. 1958	— Cost 2,000
1,000	U. S. Treasury 2½% 1967-72	— Cost 1,000

The following contributions have been received and credited to the Memorial Funds during the year:—

Dr. Gordon Berry	$400.00
Dr. Frederick T. Hill	300.00
Dr. T. E. Carmody	100.00
Dr. Duncan Macpherson	100.00
Dr. A. W. Proetz	200.00
Dr. Louis H. Clerf	50.00

Respectfully submitted,

FREDERICK T. HILL,
Treasurer.

May 16, 1946.

This is to certify that I have examined the books of the American Laryngological Association for the fiscal year 1945-46. The financial reports, as presented, correctly reflect the financial condition and operations of the Association, and the accounts are kept in accordance with sound accounting practice.

A. G. EUSTIS,

Treasurer, Colby College, Waterville, Maine.

The report of the Treasurer was accepted and filed.

The Association then adopted a resolution of appreciation to be extended to Dr. A. G. Eustis, Treasurer of Colby College, Waterville, Maine, for his very generous assistance given to the Treasurer, Dr. Hill, on various occasions.

Report of the Nominating Committee

The Nominating Committee is pleased to recommend the following Fellows to serve as a Board of Directors of the Association for the year 1946-47:

Dr. Frank R. Spencer, Boulder, Colo.

Dr. H. Marshall Taylor, Jacksonville, Fla.

Dr. C. Stewart Nash, Rochester, N. Y.

Dr. Arthur W. Proetz, St. Louis, Mo.

Dr. Frederick T. Hill, Waterville, Maine

Dr. Louis H. Clerf, Philadelphia, Pa.

Dr. Gordon Berry, Worcester, Mass.

Dr. Thomas E. Carmody, Denver, Colo.

Dr. Charles J. Imperatori, New York, N. Y.

Dr. Harold I. Lillie, Rochester, Minn.

(Signed)

Dr. Samuel Salinger,
Chairman.

The report was accepted and filed.

The Report of the American Board of Otolaryngology

There were some sixty candidates for the June examination. The fall examination was cancelled.

A committee of the Board is working on a program for the teaching of the basic sciences. The Surgical Board feels that all candidates for certification in the surgical specialties should pass a special examination in the basic sciences, featuring those which especially apply to surgery. The American Board of Otolaryngology holds that each Board of a surgical specialty should give its own examination in the basic sciences because, to take but one example, the applied anatomy of the ear, nose and throat as taught by otolaryngologists goes further than the anatomy of these regions necessary for the general surgeon.

The hospitals which give full services in otolaryngology should be able to teach the basic sciences by their own staff with or without the help of an affiliated medical school.

The Board of Otolaryngology is stiffening its examinations. Thanks to Proetz questions on physiology are now available. Up to now the main function of the Board has been to determine whether a candidate was "safe to practice otolaryngology". Some three thousand have been so certificated. These men are safe within their limits and in their localities. Many, however are not what can be called fully rounded specialists. The ideal aim of the Board is that every candidate should have what might be called a complete training.

There are but few hospitals which have such training. Programs of courses in otolaryngology given in medical schools are often only window dressing, Dr. Wherry had this problem of obtaining full training for otolaryngologists at heart throughout his whole life. The committee of the Board of Otolaryngology just mentioned hopes by personal investigation to get a confidential appraisal, and a confidential file of the various Departments of Otolaryngology. To publish such a list at the present time would cause much hard feeling. When the list becomes large enough publication might be considered.

There are two types of specialists in otolaryngology, the limited and the full specialist. The surgical proficiency of the limited specialist hardly embraces more than tonsillectomy, correcting obstructing nasal septa, the simple mastoid operation, washing antra, and the palliative treatment of acute infection of the frontal sinus. Such men are useful and safe in many localities, and are safe when near a fully trained otolaryngologist whom they are willing to call in consultation, and many do this. Often the public considers the limited specialist as fully trained. The self styled specialist, of course, comes within the group of limited specialist. I feel that there are more self styled specialists in otolaryngology than in any other specialty. They breed fast during a war. The American Board of Otolaryngology has done a good job in weeding out such men whenever they have possessed enough medical conscience to come up for examination.

Of the otolaryngologists who served during the present war in the Army and the Navy those who had had full training, and they were usually the older men, generally received assignments to their specialty, often, however, not without a fight for it. The younger men did not fare so well. They had to be content in satisfying their patriotism by serving their country, and when all is over, time will steadily increase this feeling, of having done their duty regardless.

This brings up the subject as to how much credit the Board should grant a candidate for service in the Army or the Navy. The Credential Committee of the Board has a hard job ahead of them in deciding this question. For one, I do not consider the recommendation of any Commanding Officer as worth much.

The major problem before the American Board of Otolaryngology, and the problem should become a personal one for every member of the American Laryngological Association—is how to increase the facilities for obtaining full training in laryngology and otology. There is a temptation in the senior societies for members to ship their oars. Arm chairs are always alluring, but much can be accomplished between naps.

ADDENDUM:

PROPOSED REQUIREMENTS FOR ADMISSION TO EXAMINATION IN 1950

1. Class I
   a. One year's general internship in an approved hospital.
   b. Three years' residency including training in the basic sciences.
   c. One year restricted practice.

2. Class II
   a. One year's general internship in an approved hospital.
   b. Four years' combined EENT residency including basic sciences.
      (At least 50% of training to be in otolaryngology)
   c. One year restricted practice.

3. Class III
   a. One year's general internship in an approved hospital.
   b. One year's training in the basic sciences.
   c. Five years' restricted practice under the preceptorship of a certified otolaryngologist approved by the Board.

Respectfully submitted,

(Signed) HARRIS P. MOSHER.

REPORT OF THE HISTORIAN

The Historian, Dr. Louis H. Clerf, then reported the death of eleven Active and Corresponding Fellows since the last Meeting of the Association. Dr. Clerf read in brief the memorials to these Fellows, which appear in another part of this Volume.

The report was accepted and filed.

May 29, 1946

Report of the Committee on the Revision of the Constitution and By-Laws

At the direction of the Council your Committee has presented a revised draft of the Constitution and By-Laws. The revision consists chiefly in the rewording and amplification of certain paragraphs for the sake of clarity and completeness. No major changes are suggested. Radical departures from the last printed copies of the Constitution consist chiefly of amendments already adopted by the Association.

Copies of the new draft have been distributed to the Fellows 30 days in advance of the Annual Meeting.

Respectfully submitted,

(Signed) Louis Clerf
(Signed) Arthur Proetz,
Chairman.

The report was accepted and filed.

President Lillie called the attention of the Meeting to the fact that the rewriting of the Constitution is not a revision but only a clarification. It was his understanding that parliamentary law permitted consideration of the whole instrument or of each article by itself on call at the pleasure of the meeting. On motion by Dr. Carmody, seconded by Dr. Simpson the Association voted to deal with it as a whole.

By unanimous vote the new Constitution was adopted.

Casselberry Prize Committee

Through the Secretary the Casselberry Prize Committee reported that the Casselberry Prize for 1946 had been awarded to Dr. Paul

H. Holinger of Chicago for his photography of the larynx, the lower respiratory tract and the esophagus.

The report was accepted and filed.

Report of the Memorial Fund Committee

The Memorial Fund Committee reports progress. In these days of heavy taxes, some members are finding it easier and more satisfying to give now a moderate sum annually until a desired total is reached, rather than to make a larger bequest by will in the uncertain future. The Committee invites other members to join in this simple and constructive plan of instalment giving.

Gifts to date are as follows:

$250 from Mrs. George E. Hourn in a separate Grant, $1,000 from Dr. Barnhill, $5,000 from Dr. and Mrs. Dean, and cash receipts from the Fellows of $4,204.19, making a cash total of $9,454.19, together with an assured bequest from Mrs. Fetterolf Kennedy for $5,000 more.

The Committee reports the establishing of a George E. Hourn Scholarship Grant by Mrs. Hourn, the terms of which accompany this report. The Council has given its approval; and has directed our Treasurer to receive and set aside this annual sum for the purposes stated in the Grant. The Committee is now seeking as the first recipient a promising student in Laryngology at Washington University.

MOTION: It is moved:

(1) that this report be accepted;

(2) that the action by the Memorial Fund Committee and by the Council, in accepting and arranging for this George E. Hourn Scholarship Grant, be approved by the Association;

(3) that the part of the report dealing with the nature of this Grant and the conditions governing it, be spread upon our permanent records and printed in our Transactions;

(4) that the Secretary be instructed to express to Mrs. Hourn our appreciation and our pleasure in this Memorial to her husband and our honored Fellow.

The Memorial Fund Committee,

Dr. George M. Coates '46
Dr Duncan MacPherson '47
Dr. William E. Grove '48
Dr. Bernard J. McMahon '50
Dr. Gordon Berry, Ch. '49

The report was accepted and filed.

The George E. Hourn Scholarship Grant of the Memorial Fund for Research of the American Laryngological Association

A bequest to the Memorial Fund of the American Laryngological Association is given by Mrs. Josephine M. Hourn in memory of her husband, who, at the time of his death on December 10, 1944, was an Active Member of the Association. The Memorial Fund Committee accepts this gift in the name of the Association and under the following conditions:

1. The bequest is to be known as the George E. Hourn Scholarship Grant.

2. Beginning in 1945, it is Mrs. Hourn's intent to give $250 annually to the Treasurer of the American Laryngological Association during her lifetime, and at her death to establish in the St. Louis Union Trust Company a trust of $10,000, the income from which shall be paid by the Trustee annually, or at other mutually agreeable intervals, to the Treasurer of the American Laryngological Association.

3. The income so received is to be considered as Income for the Memorial Fund and it to be applied towards study and research in Laryngology and allied fields, in such manner as the Memorial

Fund Committee may decide. As Dr. Hourn was peculiarly interested in the Department of Otolaryngology at Washington University, St. Louis, Missouri, and was serving on its Medical Faculty at his untimely death, it is requested by the donor that preference in the selecting of recipients be given to students in that University, when satisfactory and promising applicants are found available.

FINAL EXECUTIVE SESSION

MAY 30, 1946

The Final Executive Session was called to order by President Lillie on Thursday afternoon, May 30, 1946 at 5:10 P. M.

On motion from the floor the Report of the Nominating Committee was accepted as presented and the Secretary was directed to cast a ballot for the incoming Board of Directors. The meeting recessed briefly while the new Board of Directors retired and elected the following officers for the ensuing year:

FRANK R. SPENCER, M.D., *President*
H. MARSHALL TAYLOR, M.D., *First Vice-President*
C. STEWART NASH, M.D., *Second Vice-President*
ARTHUR W. PROETZ, M.D., *Secretary*
FREDERICK T. HILL, M.D., *Treasurer*
LOUIS H. CLERF, M.D., *Librarian and Historian*
GORDON BERRY, M.D., *First Councilor*
THOMAS E. CARMODY, M.D., *Second Councilor*
CHARLES J. IMPERATORI, M.D., *Third Councilor*
HAROLD I. LILLIE, M.D., *Fourth Councilor*

The President-Elect was conducted to the rostrum and delivered a brief address in acceptance.

There being no further business, the Meeting adjourned sine die.

List of Fellows

1946

LIST OF FELLOWS

Date Indicates Year Admitted to Active Fellowship.

Attendance at meetings is shown by the figures following each name. Asterisk (*) indicates year paper was read.

Active Fellows

1942. Ashley, Rea E., 384 Post Street, San Francisco 8, California, 1946.

1936. Ballenger, Howard C., 723 Elm Street, Winnetka, Illinois, 1936, '37, '38*, '40, '41, '42, 46*.

1944. Beatty, Hugh G., 150 East Broad Street, Columbus 15, Ohio, 1944, '46*.

1921. Berry, Gordon, 36 Pleasant Street, Worcester, Massachusetts, 1921*, '22, '23, '24, '25, '26, '27, '28*, '29*, '30, '31, '32, '33, '34, '35, '37, '38, '39, '40, '41*, '42, '44, '46.

1938. Blassingame, Charles Decatur, 414 P. and S. Building, Memphis 3, Tennessee, 1938, '39, '41, '42, '44, '46*.

1944. Boies, Lawrence R., 1631 Medical Arts Building, Minneapolis 2, Minnesota, 1944, '46.

1941. Bowers, Wesley C., 17 East 61st Street, New York City 21, 1941, '42, '44.

1932. Brown, John Mackenzie, 1136 W. 6th Street, Los Angeles, 14, California, 1935*, '37, '40*, '41, '42, '44.

1940. Broyles, Edwin N., 1100 North Charles Street, Baltimore, Maryland, 1940, '41*, '42*, '46.

1930. Campbell, Edward Hastings, 2035 Delancey Street, Philadelphia 3, Pennsylvania, 1930, '31*, '32*, '33, '35, '38, '39*, '40, '41.

1945. Campbell, Paul A., 700 North Michigan Avenue, Suite 314, Chicago, Illinois.

1942. Canfield, Norton, 789 Howard Avenue, New Haven, Connecticut, 1942, '46.

1923. Carmody, Thomas E., 806 Metropolitan Building, Denver, Colorado, 1924, '26*, '27, '28, '30, '32*, '34, '35, '37*, '38, '39*, '40, '41, '42*, '44, '46.

1925. Clerf, Louis H., 1530 Locust Street, Philadelphia 2, Pennsylvania, 1925, '27*, '28, '29*, '30*, '32, '33, '34, '35, '36*, '37, '38, '39, '40, '41*, '42*, '44*, '46.

1917. Coates, George Morrison, 1721 Pine Street, Philadelphia, 3, Pennsylvania, 1920, '21, '22, '23, '24, '25, '26, '27, '28, '29, '30, '31, '32, '33, '34, '35, '36, '37*, '38, '39, '40, '41, '42, '44, '46.

1939. Cody, Claude Carr, 1304 Walker Avenue, Houston, Texas, 1939, '41, '42, '44, '46*.

1937. Crowe, Samuel James, 4332 North Charles Street, Baltimore, 18, Maryland, 1937, '38*, '40, '42, ('44*).

1941. Cunning, Daniel S., 121 East 60th Street, New York City 22, 1941, '42*, '44, '46.

1941. Davis, Warren B., 135 South Eighteenth Street, Philadelphia, Pennsylvania, 1941, '42*, 46.

1941. Dixon, Fred W., 1027 Rose Building, Cleveland, Ohio, 1941, '42*, '44, '46.

1923. Fenton, Ralph Albert, 806 Medical Arts Building, Tenth and Taylor Streets, Portland, Oregon, 1923, '25*, '26, '28, '30, '32, '34, '35, '37*, '39, '40*, '42, '44, '46.

1930. Figi, Frederick A., Mayo Clinic, Rochester, Minnesota, 1930, '32*, '34, '35, '38*, '42*.

1932. Furstenberg, Albert Carl, 201 South Main Street, Ann Arbor, Michigan, 1933*, '36*, '38*, '46.

1936. Galloway, Thomas Cyrus, 636 Church Street, Evanston, Illinois, 1936, '37, '38*, '39, '40, '41, '42*, '46*.

1940. Gatewood, E. Trible, Professional Building, Richmond, Virginia, 1940, '41, '42*, '44.

1940. Gill, William D., 705 East Houston Street, San Antonio, Texas, 1940, '41*, '46.

1928. Gittins, Thomas Roy, 408 Davidson Building, Sioux City, Iowa, 1928, '31, '32*, '34, '36, '39*, '40, '42*.

1940. Goodale, Robert L., 330 Dartmouth Street, Boston, Massachusetts, 1940, '41, '42*, '44*, '46.

1928. Goodyear, Henry M., 556 Doctors' Building, Cincinnati 2, Ohio, 1928, '29, '30*, '31, '32, '33, '34*, '35, '36, '37, '38, '39, '40, '42, '44*, '46.

1934. Grove, William E., 324 East Wisconsin Avenue, Milwaukee, 2, Wisconsin, 1934, '35, '36*, '37, '38, '39, '40, '41, '42*, '44, '46.

1940. Hansel, French K., 634 North Grand Avenue, St. Louis 3, Missouri, 1940, '42, '46.

1933. Harkness, Gordon Follette, 2410 River Drive, Davenport, Iowa, 1934, '35, '36*, '40, '41, '44, '46.

1944. Havens, Fred Z., 102 Second Avenue S-W., Rochester, Minnesota, 1944, '46.

1942. Heatly, Clyde A., 11 North Goodman Street, Rochester, N. Y., 1942, '46*.

1945. Hickey, Harold L., 1612 Tremont Street, Denver 2, Colorado, 1946.

1943. Hilding, Anderson C., 324 West Superior Street, Duluth, Minnesota, 1944*, '46.

1928. Hill, Frederick Thayer, Professional Building, Waterville, Maine, 1928, '29*, '30*, '31, '32, '33, '34, '35, '36, '37*, '38*, '39, '40, '41*, '42, '44*, '46.

1945. Holinger, Paul H., 700 North Michigan Ave., Chicago 11, Illinois, 1946.

1944. Hoople, Gordon D., Medical Arts Building, Syracuse, New York, 1946.

1930. Houser, Karl Musser, 2035 Delancey Street, Philadelphia 3, Pennsylvania, 1930, '32*, '33, '34*, '37, '38, '39, '40, '41, '44.

1939. Hunt, Westley Marshall, 907 Fifth Avenue, New York City 21, 1939, '40*, '41, '42, '44, '46.

1920. Imperatori, Charles Johnstone, 108 East Thirty-eighth Street, New York City 16, 1921*, '22, '24*, '25*, '26*, '27*, '28, '31*, '32, '33*, '35, '36, '37*, '38, '39*, '40*, '41*, '42*, '44*.

1938. Jackson, Chevalier Lawrence, 255 South Seventeenth Street, Philadelphia 3, Pennsylvania, 1938, '39, '40, '41*, '42, '44*, '46.

1928. Jarvis, DeForest Clinton, Quarry Bank Building, Barre, Vermont, 1928, '30, '32*, '33, '34*, '35, '37*, '38, '39, '40, '41, '44, '46.

1939. JOHNSTON, WILLIAM HOWARD, 1515 State Street, Santa Barbara 7, California, 1939, '40, '41, '42, '44, '46.

1944. JONES, MARVIN F., 121 E. 60th Street, New York City, 1944, '46.

1942. KELLY, JOSEPH D., 140 East Fifty-fourth Street, New York City 22, 1942, '44*.

1921. KERNAN, JOHN D., JR., 103 East Seventy-eighth Street, New York City 21, 1921*, '22, '25, '26, '27, '29, '31, '34*, '35*, '36, '37*, '39, '40*, '42*.

1942. KING, EDWARD D., 1002 Carew Tower, Cincinnati, 2, Ohio, 1942, '46.

1929. KISTNER, FRANK B., 600 Meyer Building, Portland 5, Oregon, 1930, 35, '37, '40.

1936. LEJEUNE, FRANCIS ERNEST, Ochsner Clinic Building, Prytania and Aline Streets, New Orleans, Louisiana, 1937, '46*.

1933. LIERLE, DEAN M., University Hospital, Iowa City, Iowa, 1933, '34, '35*, '37, '38, '39, '40*, '42*, '44*, '46.

1922. LILLIE, HAROLD I., Mayo Clinic, Rochester, Minnesota, 1923*, '24*, '25, '26*, '28, '31*, '33, '36*, '37, '38, '40, '44, '46*.

1935. LOOPER, EDWARD A., 104 West Madison Avenue, Baltimore 1, Maryland, 1935, '36, '37, '38*, '39, '41, '42, '44.

1927. LUKENS, ROBERT M., 1001 Medical Arts Building, Philadelphia 2, Pennsylvania, 1927, '28, '31*, '32, '35, '36, '38, '39, '40*, '42, '46.

1939. LUPTON, IRVING MARTIN, 806 Medical Arts Building, Portland, Oregon, 1946.

1929. LYMAN, HARRY WEBSTER, 906 Carleton Building, St. Louis 1, Missouri, 1929, '31, '34, '35*, '36, '38, '39, '42, '44, '46.

1928. MACPHERSON, DUNCAN, 920 Fifth Avenue, New York City 21, 1928, '29, '30, '31, '33, '34*, '39, '40, '41, '44.

1941. MARTIN, ROBERT C., 384 Post Street, San Francisco 8, California, 1941, '44.

1939. MCCASKEY, CARL HEBER, 608 Guaranty Building, Indianapolis 4, Indiana, 1939, '40, '41, '42*, '44, '46*.

1945. MCLAURIN, JOHN G., 1322 Medical Arts Building, Dallas 1, 1946.

1933. McMahon, Bernard J., Missouri Theatre Bldg., St. Louis 3, Missouri, 1934*, '35, '36, '38*, '41, '44, '46*.

1931. McNally, William James, 1509 Sherbrooke Street West, Montreal, Canada, 1931, '33, '34*, '39, '44.

1940. Morrison, William W., 140 E. 54th Street, New York City 22, 1940, '41*, '44.

1904. Mosher, Harris P., 127 Front Street, Marblehead, Massachusetts, 1920, '21*, '22, '23*, '24, '25, '26, '27, '28*, '29, '30, '31*, '32*, '33, '34, '36, '37, '38, '39, '40, '41, '42, '44, '46.

1939. Myers, John Llewellyn, 1115 Grand Avenue, Kansas City, Missouri, 1939, '40*, '44.

1927. Myerson, Mervin C., 416 North Bedford Drive, Beverly Hills, California, 1927, '28*, '29, '30, '31*, '32*, '33*, '34*, '35, '36, '37, '38, '39*, '40, '41*, '42, '44.

1937. Nash, Carlton Stewart, Medical Arts Building, Rochester 7, New York, 1937, '38*, '40, '42, '44, '46.

1922. New, Gordon B., Mayo Clinic, Rochester, Minnesota, 1922, '24, '25*, '26*, '28*, '31*, '33*, '35*, '37*, '39*, '41*, '46*.

1927. Orton, Henry Boylan, 224 Delavan Avenue, Newark 4, New Jersey, 1927, '28, '29, '30*, '31, '32, '33*, '35, '36, '37, '38*, '40, '41, '42, '44*, '46.

1924. Proetz, Arthur Walter, 1010 Beaumont Building, St. Louis 3, Missouri, 1924, '25*, '26*, '27, '28, '29, '30*, '31, '32*, '33*, '34, '35*, '36, '37, '38*, '39*, '40, '41, '42*, '44, '46.

1934. Richards, Lyman Gilder, 520 Commonwealth Avenue, Boston, Massachusetts, 1934, '35, '36*, '37, '38, '39.

1930. Ridpath, Robert F., 1737 Chestnut Street, Philadelphia 3, Pennsylvania, 1930, '31, '33, '37, '38*, '40, '41*, '44.

1945. Robb, James M., 641 David Whitney Building, Detroit, Michigan, 1946.

1938. Salinger, Samuel, 25 E. Washington Street, Chicago, Illinois, 1938, '39, '40*, '42, '44*, '46.

1921. Sauer, William E., 3720 Washington Boulevard, St. Louis 8, Missouri, 1921, '23, '25, '28, '31, '32, '35, '37, '39*, '41, 44.

1932. Schall, Leroy Allen, 243 Charles Street, Boston 14, Massachusetts, 1934*, '35, '38, '40*, '41, '42, '44*, '46.

1934. SCHENCK, HARRY P., 1235 Wyngate Road, Wynwood, Pennsylvania, 1934, '35, '36*, '37, '38, '39, '40, '41*, ('44*), '46.

1930. SEYDELL, ERNEST M., First National Bank Building, Wichita, Kansas, 1930, '31*, '33*, '34, '35, '37*, '38, '39, '40*, '41, '42, '46.

1928. SHEA, JOHN JOSEPH, 1018 Madison Avenue, Memphis, Tennessee, 1928, '29, '30*, '31, '32*, '33, '34, '35, '36, '37, '38, '40, '41*, '42, '46.

1909. SHURLY BURT R., 62 Adams Avenue W., Detroit, Michigan, 1920, '21*, '22, '24, '25*, '26, '27*, '28, '29*, '30, '31, '33, '34, '35, '36, '37, '38, '39, '40, '41, '42, '44, '46.

1939. SIMPSON, W. LIKELY, 512 Physicians' and Surgeons' Building, Memphis 3, Tennessee, 1939, '41, '44*, '46.

1923. SPENCER, FRANK ROBERT, Physicians' Building, Boulder, Colorado, 1923, '24*, '26, '27*, '28, '30, '32*, '34, '35, '37, '38, '40*, '41, '42, '46*.

1924. TAYLOR, HERMON MARSHALL, 111 West Adams Street, Jacksonville 5, Florida, 1924, '25*, '26, '27, '28, '31, '34, '35*, '36, '37, '38, '39*, '40, '41, '42, '44*, '46.

1937. TOBEY, GEORGE L., JR., 403 Commonwealth Avenue, Boston 15, Massachusetts, 1937, '38, '39.

1927. TOBEY, HAROLD G., 403 Commonwealth Avenue, Boston 15, Massachusetts, 1927, '29*, '30*, '31, '32, '35, '37, '39, '41, '46.

1925. TUCKER, GABRIEL, 250 South Eighteenth Street, Philadelphia, Pennsylvania, 1925, '26*, '27*, '29, '30, '31, '32, '33, '34, '35*, '36, '37, '38, '39, '40*, '41*, '42, '46.

1943. VAN ALYEA, OLIVER E., 135 South La Salle Street, Chicago, Illinois, 1944, '46*.

1941. VIOLE, PIERRE P., 1930 Wilshire Boulevard, Los Angeles 5, California, 1944*, '46.

1940. WEILLE, FRANCIS L., 247 Commonwealth Avenue, Boston 16, Massachusetts, 1940, '41, '42, '44, '46*.

1922. WHITE, FRANCIS W., 471 Park Avenue, New York City 22, 1922, '23, '25, '26, '27, '28, '29, '31, '32, '37, '39, '40, '41, '42, '44, '46.

1939. WILLIAMS, HORACE JAMES, 5908 Greene Street, Germantown, Philadelphia, 1939, '40, '41, '42, '46.

1942. Wishart, D. E. Staunton, 170 St. George Street, Toronto, Canada, 1942, '44, '46.

1940. Wood, V. Visscher, 3720 Washington Boulevard, St. Louis 8, Missouri, 1940, '41, '42*, '46.

1935. Woodward, Fletcher D., 104 East Market Street, Charlottesville, Virginia, 1935, '36*, '37, '38, '39*, '40, '42, '44.

Honorary Fellows

1939. (1907) Jackson, Chevalier, 255 South Seventeenth Street, Philadelphia 3, Pennsylvania, 1939*, '40*.

1943. (1918) Lewis, Fielding O., Providence Road, Media, Pennsylvania.

1937. Nager, F. B., Freiestrasse 30, Zurich, Switzerland.

1943. (1906) Pierce, Norval H., Del Mar, San Diego County, California.

Corresponding Fellows

1946. Alonso, Justo M., Mercedes 1233, Montevideo, Uruguay.

1942. Batson, Oscar V., 133 South Thirty-sixth Street, Philadelphia, 4, Pennsylvania, 1942*.

1938. Blair, Vilray P., 508 North Grand Avenue, St. Louis 3, Missouri.

1940. Colledge, Lionel, 2 Upper Wimpole Street, London, W. 1, England.

1943. Eggston, Andrew O., 653 Park Avenue, New York City, 1944.

1931. Lasagna, Francesco, Royal University of Parma, Parma, Italy.

1926. Law, Frederick M., 140 East Fifty-fourth Street, New York City 22, 1934, '35, '36, '37, '38, '39*, '40, '41, '42, '44*.

1921. Le Maitre, Fernand, Avenue Victor Hugo, 120 (XVI), Paris, France.

1919. McKernon, James F., New Canaan, Connecticut.

1930. Negus, Victor E., 149 Harley Street, London, W I, England, 1938*.

1941. Patterson, Norman, Nobs Creek, Ashbridge Park, Berkhamsted, Herts, England.

1937. Portmann, Georges, 25 bis Cours de Verdun, Bordeaux, France.

1924. Schaeffer, J. Parsons, Jefferson Medical College, Philadelphia, Pennsylvania, 1934.

1896. Schmiegelow, Ernst, 18 Norregade, Copenhagen, Denmark.

1946. Segura, Eliseo V., Carlos Pellegrini 1080, Buenos Aires, Argentina.

1936. Vialle, Jacques, 27 Rue de France, Nice (Alpes Maritimes), France.

Emeritus Fellows

1941. (1923) Barlow, Roy A., Medical Arts Building, Winchester, Virginia.

1937. (1915) Barnes, Harry Aldrich, Pembroke, Massachusetts.

1944. (1913) Butler, Ralph, 1930 Chestnut Street, Philadelphia, Pennsylvania.

1946. (1933) Foster, John H., 1304 Walker Avenue, Houston, Texas.

1941. (1922) Goldsmith, Perry G., 513 Medical Arts Building, Toronto, Canada.

1936. (1898) Goodale, Joseph L., Argilla Road, Ipswich, Massachusetts.

1943. (1932) Graham, Harrington B., Bohemian Club, San Francisco 2, California.

1940. (1917) Greene, Joseph B., 331 Haywood Building, Asheville, North Carolina.

1933. (1905) Halsted, Thomas H., 475 Fifth Avenue, New York City, 17.

1927. (1896) Hardie, T. Melville, 30 N. Michigan Boulevard, Chicago, Illinois.

1940. (1915) Hastings, Hill, 2090 South Harvard Boulevard, Los Angeles, California.

1918. (1888) Hinkel, F. Whitehill, 28 Norwood Avenue, Buffalo, New York.

1933. (1904) Ingersoll, John M., 1700 S. Bayshore Lane, Miami, Florida.

1939. (1923) LARGE, SECORD HERBERT, 170 Eddy Road, Cleveland, Ohio.

1943. (1921) MCCULLAGH, SAMUEL, 116 E. 63 St., New York, 21, N. Y.

1941 (1903) PACKARD, FRANCIS R., 302 South Nineteenth Street, Philadelphia, Pennsylvania.

1942. (1931) POTTS, JOHN B., 1620 Medical Arts Building, Omaha, Nebraska.

1940. (1923) SEWALL, EDWARD C., 430 El Escarpado, Stanford University, California.

1933. (1907) SHAMBAUGH, GEORGE E., 122 South Michigan Avenue, Chicago, Illinois.

1941. (1892) WATSON, ARTHUR W., 2013 Locust Street, Philadelphia, Pennsylvania.

1939. (1908) WILSON, J. GORDON, Old Bennington, Vermont.

1946. (1905) WOOD, GEORGE B., 504 Physicians' Building, Philadelphia 3, Pennsylvania.

BENEFACTORS

Dr. Arthur W. deRoaldes

Dr. William E. Casselberry

Dr. Samuel Johnston

Dr. Cornelius G. Coakley

Dr. James E. Newcomb

Dr. John F. Barnhill

Dr. Lee Wallace Dean

Dr. George E. Hourn

Obverse of the deRoaldes medal

RECIPIENTS OF THE deROALDES AWARD

1928. Dr. Chevalier Jackson.

1931. Dr. D. Bryson Delavan.

1934. Dr. Harris P. Mosher.

1937. Dr. Lee Wallace Dean.

1943. Dr. Ralph A. Fenton.

RECIPIENTS OF THE CASSELBERRY AWARD

1923. Dr. George Fetterolf and Dr. Herbert Fox.

1928. Dr. Ralph A. Fenton and Dr. O. Larsell.

1929. Dr. Richard A. Kern and Dr. Harry P. Schenck.

1929. Dr. Edward H. Campbell.

1931. Dr. Arthur W. Proetz.

1934. Dr. Anderson C. Hilding.

1936. Dr. Francis E. LeJeune: Dr. Joel J. Pressman.

1939. Dr. H. Marshall Taylor: Dr. Brien T. King.

1940. Dr. French K. Hansel.

1941. Dr. Noah D. Fabricant.

1946. Dr. Paul H. Holinger.

RECIPIENTS OF THE NEWCOMB AWARD

1941. Dr. Burt R. Shurly.

1942. Dr. Francis R. Packard.

1943. Dr. George M. Coates.

1944. Dr. Charles J. Imperatori

PAST OFFICERS

Presidents

(Year of Election)

1879. Louis Elsberg
1880. J. Solis Cohen
1881. F. I. Knight
1882. G. M. Lefferts
1883. F. H. Bosworth
1884. E. L. Shurly
1885. Harrison Allen
1886. E. Fletcher Ingals
1887. R. P. Lincoln
1888. E. C. Morgan
1889. J. N. Mackenzie
1890. W. C. Glasgow
1891. S. W. Langmaid
1892. M. J. Asch
1893. D. Bryson Delavan
1894. J. O. Roe
1895. W. H. Daly
1896. C. H. Knight
1897. T. R. French
1898. W. E. Casselberry
1899. Samuel Johnston
1900. H. L. Swain
1901. J. W. Farlow
1902. J. H. Bryan
1903. J. H. Hartman
1904. C. C. Rice
1905. J. W. Gleitsmann
1906. A. W. deRoaldes
1907. H. S. Birkett
1908. A. Coolidge, Jr.
1909. J. E. Logan
1910. D. Braden Kyle
1911. James E. Newcomb
1912. George A. Leland
1913. Thomas Hubbard
1914. Alexander W. MacCoy
1915. G. Hudson Makuen
1916. Joseph L. Goodale
1917. Thomas H. Halsted
1918. Cornelius G. Coakley
1919. Norval H. Pierce
1920. Harris P. Mosher
1921. Harmon Smith
1922. Emil Mayer
1923. J. Payson Clark
1924. Lee Wallace Dean
1925. Greenfield Sluder
1926. Chevalier Jackson
1927. D. Bryson Delavan
1928. Charles W. Richardson
1929. Lewis A. Coffin
1930. Francis R. Packard
1931. George E. Shambaugh
1932. George Fetterolf
1933. George M. Coates
1934. Dunbar Roy
1935. Burt R. Shurly
1936. William B. Chamberlin
1937. John F. Barnhill
1938. George B. Wood
1939. James A. Babbitt
1940. Gordon Berry
1941. Thomas E. Carmody
1942-3. Charles J. Imperatori
1944-5. Harold I. Lillie

Vice-Presidents

1879.	F. H. Davis	
1880.	W. C. Glasgow	J. O. Roe
1881.	E. L. Shurly	W. Porter
1882.	C. Seiler	E. F. Ingals
1883.	S. W. Langmaid	S. Johnston
1884.	J. H. Hartman	W. H. Daly
1885.	H. A. Johnson	G. W. Major
1886.	E. C. Morgan	J. N. Mackenzie
1887.	J. N. Mackenzie	S. W. Langmaid
1888.	W. C. Glasgow	C. E. DeM. Sajous
1889.	E. Holden	C. E. Bean
1890.	J. O. Roe	J. H. Hartman
1891.	M. J. Asch	S. Johnston
1892.	S. Johnston	J. C. Mulhall
1893.	J. C. Mulhall	W. E. Casselberry
1894.	C. C. Rice	S. H. Chapman
1895.	J. Wright	A. W. de Roaldes
1896.	T. M. Murray	D. N. Rankin
1897.	A. W. MacCoy	H. S. Birkett
1898.	J. W. Farlow	F. W. Hinkel
1899.	T. A. De Blois	M. R. Brown
1900.	H. L. Wagner	A. A. Bliss
1901.	J. W. Gleitsmann	D. Braden Kyle
1902.	G. A. Leland	T. Melville Hardie
1903.	J. H. Lowman	W. Peyre Porcher
1904.	Thomas Hubbard	W. J. Freeman
1905.	J. L. Goodale	C. W. Richardson
1906.	G. H. Makuen	A. B. Thrasher
1907.	J. P. Clark	J. E. Rhodes
1908.	E. Mayer	F. R. Packard
1909.	C. G. Coakley	H. P. Mosher
1910.	Robert C. Myles	J. M. Ingersoll
1911.	F. C. Cobb	B. R. Shurly
1912.	A. W. Watson	W. Scott Renner
1913.	F. E. Hopkins	Geo. F. Shambaugh
1914.	Clement F. Theisen	Lewis A. Coffin
1915.	J. Gordon Wilson	Christian R. Holmes

1916.	Thomas H. Halsted	Greenfield Sluder
1917.	John Edwin Rhodes	D. Crosby Greene
1918.	G. E. Shambaugh	John R. Winslow
1919.	Francis R. Packard	Harmon Smith
1920.	Harmon Smith	W. B. Chamberlin
1921.	Dunbar Roy	Robert C. Lynch
1922.	George Fetterolf	Lorenzo B. Lockard
1923.	Hubert Arrowsmith	Joseph B. Greene
1924.	Ross H. Skillern	Gordon Berry
1925.	John E. Mackenty	Robert Levy
1926.	Lewis A. Coffin	William V. Mullin
1927.	Charles W. Richardson	Hill Hastings
1928.	Robert Clyde Lynch	Francis P. Emerson
1929.	William B. Chamberlin	Ralph Albert Fenton
1930.	Harris P. Mosher	James A. Babbitt
1931.	Joseph B. Greene	E. Ross Faulkner
1932.	Gordon Berry	Frank R. Spencer
1933.	E. Ross Faulkner	Thomas E. Carmody
1934.	Gordon B. New	Samuel McCullagh
1935.	Edward C. Sewall	H. Marshall Taylor
1936.	William P. Wherry	Harold I. Lillie
1937.	Frank R. Spencer	Bernard J. McMahon
1938.	Ralph A. Fenton	Frederick T. Hill
1939.	John H. Foster	Thomas R. Gittins
1940.	Charles T. Porter	Gordon F. Harkness
1941.	Arthur W. Proetz	Henry B. Orton
1942-3.	Harold I. Lillie	Dean M. Lierle
1944-5.	John J. Shea	Thomas C. Galloway

Secretaries and Treasurers

1879.	G. M. Lefferts	1895.	H. L. Swain
1882.	D. Bryson Delavan	1900.	J. E. Newcomb
1889.	C. H. Knight	1911.	Harmon Smith

Secretaries

1912.	Harmon Smith	1933.	William V. Mullin
1918.	D. Bryson Delavan	1935.	James A. Babbitt
1919.	J. M. Ingersoll	1939.	Charles J. Imperatori
1920.	George M. Coates	1942.	Arthur W. Proetz

Treasurers

1912. J. Payson Clark
1923. George Fetterolf
1932. William V. Mullin
1933. James A. Babbitt
1935. Charles J. Imperatori
1939. Frederick T. Hill

Librarians

1879. F. H. Bosworth
1883. T. R. French
1903. J. H. Bryan
1930. John F. Barnhill
1934. Burt R. Shurly
1935. George M. Coates

Librarian and Historian

1936. George M. Coates
1944. Louis H. Clerf

PAST MEMBERS

Dates indicate original election to the Association

**Deceased*

Honorary Fellows

*1908. Barnhill, John F., Miami Beach, Florida.
*1893. Birkett, Herbert S., Montreal, Canada.
*1878. Bosworth, Francke H., New York City.
*1878. Cohen, J. Solis-, Philadelphia, Pa.
*1918. Dean, Lee Wallace, St. Louis, Mo.
*1881. Delavan, D. Bryson, New York City.
*1893. deRoaldes, Arthur W., New Orleans, La.
*1890. De La Sota Y Lastra, Ramon, Seville, Spain.
*1879. French, Thomas R., Brooklyn, N. Y.
*1880. Garcia, Senor Manuel, London, England.
*1903. Harris, Thos. J., New York City.
*1878. Johnston, Samuel, Baltimore, Md.
*1878. Lefferts, George Morewood, Katonah, N. Y.
*1914. Levy, Robert, Denver, Colo.
*1883. Mackenzie, John N., Baltimore, Md.
*1881. Mackenzie, Sir Morell, London, England.
*1910. Massei, Ferdinand, Naples, Italy.
*1910. Moure, J. J. E., Bordeaux, France.
*1918. Oliver, H. K., Boston, Mass.
*1909. Semon, Sir Felix, Great Missenden, England.
*1889. Swain, Henry L., New Haven, Conn.
*1914. Thomson, Sir St. Clair, London, Eng.
*1903. Tilley, Herbert, London, England.
*1914. Wagner, Clinton, New York City.
*1890. Wright, Jonathan, Pleasantville, N. Y.

Corresponding Fellows

*1892. Browne, Lennox, London, England.
*1901. Collier, Mayo, Kearsney Abbey, Kent, England.
*1893. Desvernine, Carlos M., Havana, Cuba.
*1930. Emerson, Francis P., Franklin, Mass.

*1936. Fraser, John S., Edinburgh, Scotland.
*1901. Grant, Sir James Dundas, London, England.
*1887. Gouguenheim, A., Paris, France.
*1894. Holden, Edgar, Newark, N. J.
*1919. Kelly, Adam Brown, Helensburgh, Scotland.
*1881. Labus, Carlo, Milan, Italy.
*1902. Lermoyez, Marcel, Paris, France.
*1897. Luc, H., Paris, France.
*1896. MacDonald, Greville, Haslemere, Surrey, England.
*1894. MacIntyre, John, Glasgow, Scotland.
*1903. McBride, P., York, England.
*1920. McKenzie, Dan, London, England.
*1880. Meyer, Wilhelm, Copenhagen, Denmark.
*1896. Mygind, Holger, Copenhagen, Denmark.
*1919. Paterson, Donald Rose, Cardiff, Wales.
*1919. Rogers, John, Jr., New York City.
*1894. Sajous, C. E. DeM., Philadelphia, Pa.
*1940. Soto, E. Fernandez, Havana, Cuba.
*1881. Thornton, Pugin, London, England.
*1913. Turner, A. Logan, Edinburgh, Scotland.
*1880. Whistler, W. McNeil, London, England.
*1901. Wingrave, Wyatt, Lyme Regis, Dorset, England.
*1894. Wolfenden, R. Norris, Kent, England.

Emeritus Fellows

*1928. Beck, Joseph C., Chicago, Illinois.
*1901. Brown, J. Price, Toronto, Canada.
*1891. Bryan, Joseph H., Washington, D. C.
*1897. Clark, J. Payson, Boston, Mass.
*1899. Cobb, Frederick C., Bradenton, Florida.
*1905. Coffin, Lewis A., New York City.
*1893. Coolidge, Algernon, Boston, Mass.
*1913. Dabney, Virginius, Washington, D. C.
*1882. De Blois, Thomas Amory, Boston, Mass.
*1892. Farlow, John W., Boston, Mass.
*1922. Forbes, Henry H., New York City.
*1905. Freer, Otto T., Chicago, Ill.
*1880. Gleitsmann, Joseph W., New York City.

*1906. Greene, D. Crosby, Jr., Boston, Mass.
*1895. Hopkins, Frederick E., Springfield, Mass.
*1927. Hubbard, Thomas, Toledo, Ohio.
*1919. Hurd, Lee Maidment, Rowayton, Conn.
*1918. Kenyon, Elmer L., Chicago, Ill.
*1885. Knight, Charles H., New York City.
*1894. Leland, George A., Boston, Mass.
*1943. Lincoln, William R., Cleveland, Ohio.
*1886. MacCoy, Alexander W., Philadelphia, Pa.
*1896. Mayer, Emil, New York City.
*1923. McKinney, Richmond, Memphis, Tenn.
*1901. Myles, Robert C., New York City.
*1923. Newhart, Horace, Minneapolis, Minn.
*1878. Porter, William, Ocean Springs, Miss.
*1903. Renner, W. Scott, Buffalo, N. Y.
*1897. Rhodes, John Edwin, Chicago, Ill.
*1884. Rice, Clarence C., New York City.
*1905. Richards, George L., South Yarmouth, Mass.
*1878. Robinson, Beverly, New York City.
*1908. Smith, Harmon, New York City.
*1892. Wagner, Henry L., San Francisco, Calif.

Active Fellows

*1880. Allen, Harrison, Philadelphia, Pa.
*1917. Arrowsmith, Hubert, Brooklyn, N. Y.
*1879. Asch, Morris J., New York City.
*1923. Babbitt, James A., Philadelphia, Pa.
*1906. Ballenger, William L., Chicago, Ill.
*1880. Bean, C. E., St. Paul, Minn.
*1904. Berens, T. Passmore, New York City.
*1924. Bigelow, Nolton, Providence, R. I.
*1893. Bliss, Arthur Ames, Philadelphia, Pa.
*1895. Boylan, J. E., Cincinnati, Ohio.
*1892. Brown, Moreau R., Chicago, Ill.
*1933. Buckley, Robert E., New York City.
*1915. Canfield, R. Bishop, Ann Arbor, Mich.
*1934. Carmack, John Walter, Indianapolis, Ind.

*1889. Casselberry, William E., Chicago, Ill.
*1883. Chamberlain, C. W., Hartford, Conn.
*1917. Chamberlin, William B., Cleveland, Ohio.
*1896. Chappell, W. F., New York City.
*1882. Chapman, S. Hartwell, New Haven, Conn.
*1902. Coakley, Cornelius G., New York City.
*1913. Coffin, Rockwell C., Boston, Mass.
1918. Cox, Gerard H., New York City.
*1880. Cushing, E. W., Boston, Mass.
*1878. Cutter, Ephraim, West Falmouth, Mass.
*1880. Daly, W. H., Pittsburgh, Pa.
*1878. Davis, F. H., Chicago, Ill.
1926. Dennis, Frank Lowndes, Colorado Springs, Col.
*1901. Dickerman, E. T., Chicago, Ill.
*1878. Donaldson, Frank, Baltimore, Md.
*1935. Eves, Curtis C., Philadelphia, Pa.
*1919. Faulkner, E. Ross, New York City.
*1914. Fetterolf, George, Philadelphia, Pa.
*1901. Freeman, Walter J., Philadelphia, Pa.
*1917. Friedberg, Stanton A., Chicago, Ill.
*1897. Frothingham, Richard, New York City.
1940. Fuchs, Valentine H., New Orleans, La.
1909. Getchell, Albert C., Worcester, Mass.
*1907. Gibb, Joseph S., Philadelphia, Pa.
*1878. Glasgow, William Carr, St. Louis, Mo.
*1913. Goldstein, Max A., St. Louis, Mo.
*1905. Grayson, Charles P., Philadelphia, Pa.
*1878. Hartman, Jacob H., Baltimore, Md.
*1879. Holden, Edgar, Newark, N. J.
*1907. Holmes, Christian R., Cincinnati, Ohio.
*1882. Hooper, Franklin H., Boston, Mass.
*1893. Hope, George B., New York City.
*1938. Hourn, George E., St. Louis, Mo.
*1901. Hyatt, Frank, Washington, D. C.
*1925. Iglauer, Samuel, Cincinnati, Ohio.
*1878. Ingals, E. Fletcher, Chicago, Ill.
*1882. Ives, Frank L., New York City.
*1880. Jarvis, William C., New York City.
*1878. Johnson, Hosmer A., Chicago, Ill.

*1879. Johnson, Woolsey, New York City.
*1879. Kealhofer, R. H., St. Louis, Mo.
*1901. King, Gordon, New Orleans, La.
*1885. Knight, Charles H., New York City.
*1878. Knight, Frederick Irving, Boston, Mass.
*1898. Kyle, D. Braden, Philadelphia, Pa.
*1880. Langmaid, Samuel W., Boston, Mass.
*1878. Lincoln, Rufus P., New York City.
*1911. Lockard, Lorenzo B., Denver, Colo.
*1913. Loeb, Hanau W., St. Louis, Mo.
*1897. Logan, James E., Kansas City, Mo.
*1888. Lowman, John H., Cleveland, Ohio.
*1919. Lynah, Henry L., New York City.
*1915. Lynch, Robert Clyde, New Orleans, La.
*1879. McBurney, Charles, New York City.
*1927. McGinnis, Edwin, Chicago, Ill.
1936. McGregor, Gregor, Toronto, Canada.
*1913. McKimmie, O. A., Washington, D. C.
*1885. McSherry, H. Clinton, Baltimore, Md.
*1914. Mackenty, John E., New York City.
*1898. Makuen, G. Hudson, Philadelphia, Pa.
*1881. Major, G. W., Montreal, Canada.
*1881. Morgan, E. C., Washington, D. C.
*1886. Mulhall, J. C., St. Louis, Mo.
*1925. Mullin, William V., Cleveland, Ohio.
*1914. Munger, Carl E., Waterbury, Conn.
*1892. Murray, T. Morris, Washington, D. C.
*1881. Mynter, H., Buffalo, N. Y.
*1893. Newcomb, James E., New York City.
*1895. Nichols, J. E. H., New York City.
*1894. Park, William H., New York City.
*1892. Porcher, W. Peyre, Charleston, S. C.
*1927. Porter, Charles T., Boston, Mass.
*1908. Randall, B. Alexander, Philadelphia, Pa.
*1882. Rankin, D. N., Allegheny, Pa.
*1902. Richardson, Charles W., Washington, D. C.
*1879. Roe, John O., Rochester, N. Y.
*1881. Robertson, J. M., Detroit, Mich.
*1913. Roy, Dunbar, Atlanta, Ga.

*1878. Rumbold, T. F., St. Louis, Mo.
*1879. Seiler, Carl, Philadelphia, Pa.
*1893. Shields, Charles M., Richmond, Va.
*1878. Shurly, E. L., Detroit, Mich.
*1892. Simpson, William Kelly, New York City.
*1919. Skillern, Ross H., Philadelphia, Pa.
*1909. Sluder, Greenfield, St. Louis, Mo.
*1879. Smith, Andrew H., Geneva, N. Y.
*1932. Smyth, Duncan Campbell, Boston, Mass.
*1928. Sonnenschein, Robert, Chicago, Ill.
1924. Stein, Otto J., Chicago, Ill.
1934. Stevenson, Walter, Quincy, Ill.
*1911. Stout, George C., Philadelphia, Pa.
*1879. Tauber, Bernhard, Cincinnati, Ohio.
*1903. Theisen, Clement F., Albany, N. Y.
*1899. Thorner, Max, Cincinnati, Ohio.
*1892. Thrasher, Allen B., Cincinnati, Ohio.
*1888. Van der Poel, S. O., New York City.
*1938. Vail, Harris H., Cincinnati, Ohio.
*1936. Voislawsky, Antonie P., New York City.
*1933. Wanamaker, Allison T., Seattle, Wash.
1896. Ward, Marshall R., Pittsburgh, Pa.
*1879. Ward, Whitfield, New York City.
*1886. Westbrook, Benjamin F., Brooklyn, N. Y.
*1924. Wherry, William P., Omaha, Neb.
*1924. White, Leon E., Boston, Mass.
*1922. Wishart, David J. G., Toronto, Ontario.
*1896. Woolen, Green V., Indianapolis, Ind.