DR. PAUL H. HOLINGER
700 N. MICHIGAN AVE.
CHICAGO 11, ILLINOIS

# Transactions

# American Laryngological Association

---

SIXTY-EIGHTH VOLUME

"DOCENDO DISCIMUS"

CLARK PRINTING HOUSE, INC.
PHILADELPHIA, PA., U.S.A.

# TRANSACTIONS

OF THE

SIXTY-EIGHTH ANNUAL MEETING

OF THE

# American Laryngological Association

1947

HELD AT THE STATLER HOTEL

ST. LOUIS, MO.

APRIL 23RD AND 24TH, 1947

PUBLISHED BY THE ASSOCIATION

PHILADELPHIA

1947

# CONTENTS

List of Officers ..... 8

Registration ..... 9

President's Address, Frank R. Spencer, M.D. ..... 11

The Pathology of Nasal Polyps. John J. Shea, M.D. ..... 17

Unusual Sinuses of Interest to the Rhinologist. Fred W. Dixon, M.D. ..... 27

Malignant Tumors of the Nasopharynx. Horace James Williams, M.D. ..... 30

The Surgical Treatment of Nasopharyngeal Fibroma. John Mackenzie Brown, M.D. ..... 36

A Study of the Eustachian Tubes and Their Orifices and Lumens on Patients with Large Operative Defects Giving Direct Visualization. W. Likely Simpson, M.D., and Jones E. Witcher, M.D. (By Invitation) ..... 43

Pathology and Surgery of Extrinsic Cancer of the Larynx. Henry Boylan Orton, M.D. ..... 55

Hemangiomas of the Mouth. Frederick A. Figi, M.D. ..... 67

The Thyroid and the Nose. Arthur W. Proetz, M.D. ..... 79

Present Status of Diphtheria. Edwin H. Place, M.D. ..... 84

Benadryl in the Treatment of Allergic Rhinitis. D. M. Lierle, M.D. and J. D. Dickinson, M.D. ..... 95

Tissue Changes in Sinus Membranes After Penicillin Treatment. Ralph A. Fenton, M.D., Sc.D., and Olof Larsell, Ph.D., Sc.D. (by invitation) ..... 101

Chordomas of the Cervical Region. Charles J. Imperatori, M.D. ..... 106

Scleroma in Two Native Born Brothers. Daniel S. Cunning, M.D. ..... 118

Pulsion Diverticulum of the Hypopharynx and Its Surgical Treatment. Chevalier L. Jackson and Charles M. Norris ..... 128

Bronchography in Bronchiectasis in Children. D. E. Staunton Wishart, B.A., M.D. ..... 133

Presentation of Instruments.

A Bronchoscopic Anti-Fogging Device, Edwin N. Broyles, M.D. ..... 149

An Improved Laryngeal Loupe, C. J. Imperatori, M.D. ..... 150

Memorials

Frank Whitehill Hinkel, M.D. ..... 153

Thomas Melville Hardie, M.D. ..... 155

Peter McBride, M.D. ..... 157

Thomas E. Carmody, M.D. ..... 159

Eliseo Segura, M.D. ..... 163

Norval Harvey Pierce, M.D. ..... 164

John Marvin Ingersoll, M.D. ..... 167

Frederick Manwaring Law, M.D. ..... 169

Executive Sessions and Reports of Officers and Committees ..... 171

List of Fellows, 1947:

Active Fellows ..... 185

Honorary Fellows ..... 191

Corresponding Fellows ..... 191

Emeritus Fellows ..... 192

Benefactors ..... 194

Benefactors of the Memorial Fund ..... 195

Recipients of the DeRoaldes Award ..... 196

Recipients of the Casselberry Award ..... 197

Recipients of the Newcomb Award ..... 198

Past Officers ..... 199

Past Members ..... 203



**Those in attendance at the**

**FRONT**

| | | |
|---|---|---|
| Hansel | Figi | Shurly |
| Morrison | Berry | Portmann |
| Gittins | Coates | Kernan |
| | | Imperatori |

**MIDDLE**

| | | |
|---|---|---|
| Broyles | Schall | Goodale |
| Simpson | Paul Campbell | Lyman |
| Hilding | Woodward | Tucker |
| | Grove | Seydell |

**BACK**

| | | |
|---|---|---|
| Engler | Viole | Fenton |
| Canfield | Holinger | Hunt |
| Dixon | Ashley | Cunning |
| | Wishart | McMahon |
| | | Hoople |



**Sixty-eighth Annual Meeting**

ROW

| | | |
|---|---|---|
| Taylor | Hill | Johnston |
| Mosher | Clerf | Gatewood |
| Lillie | Ridpath | Richards |
| Proetz | King | |

ROW

| | | |
|---|---|---|
| Goodyear | Brown | Salinger |
| Beatty | Goldsmith | Shea |
| Looper | Orton | McCaskey |
| Harkness | Foster | |

ROW

| | | |
|---|---|---|
| Weille | Blassingame | Theobald |
| Campbell, E. | Potts | Galloway |
| Schenck | LeJeune | Hickey |
| Van Alyea | Ballinger | |
| Cody | | |

## OFFICERS FOR 1946-47

PRESIDENT

FRANK R. SPENCER, M.D.

FIRST VICE-PRESIDENT

H. MARSHALL TAYLOR, M.D.

SECOND VICE-PRESIDENT

C. STEWART NASH, M.D.

SECRETARY

ARTHUR W. PROETZ, M.D.

TREASURER

FREDERICK T. HILL, M.D.

LIBRARIAN AND HISTORIAN

LOUIS H. CLERF, M.D.

COUNCIL

The above Ex-officio and

GORDON BERRY, M.D.

THOMAS E. CARMODY, M.D.

CHARLES J. IMPERATORI, M.D.

HAROLD I. LILLIE, M.D.

# TRANSACTIONS OF THE SIXTY-EIGHTH ANNUAL MEETING

OF THE

# AMERICAN LARYNGOLOGICAL ASSOCIATION

HELD AT THE

STATLER HOTEL, ST. LOUIS, MO.

APRIL 23RD AND 24TH, 1947

The Sixty-eighth Annual Meeting of the American Laryngological Association was called to order by First Vice-President Dr. H. Marshall Taylor at the Statler Hotel, St. Louis, Mo., at 10 A.M. on April 23, 1947. The President, Dr. Frank R. Spencer, was unable to attend owing to critical illness in his family.

Vice-President Taylor extended a cordial welcome to all the members and the guests present and declared the Scientific Session open.

## REGISTRATION

The following Fellows were in attendance:

ASHLEY, REA E.
BALLENGER, HOWARD C.
BEATTY, HUGH G.
BERRY, GORDON
BLASSINGAME, CHARLES D.
BOIES, LAWRENCE R.
BROWN, JOHN MACKENZIE
BROYLES, EDWIN N.
CAMPBELL, EDWARD H.
CAMPBELL, PAUL A.
CANFIELD, NORTON
CLERF, LOUIS H.
COATES, GEORGE M.
CODY, CLAUDE C.
CUNNING, DANIEL S.
DIXON, FRED W.
FENTON, RALPH A.
FIGI, FREDERICK A.
FOSTER, JOHN H.
FURSTENBERG, ALBERT C.
GALLOWAY, THOMAS C.
GATEWOOD, E. TRIBLE
GITTINS, THOMAS R.
GOLDSMITH, PERRY G.
GOODALE, ROBERT L.
GOODYEAR, HENRY M.
GROVE, WILLIAM E.
HANSEL, FRENCH K.
HARKNESS, GORDON F.
HICKEY, HAROLD L.
HILDING, ANDERSON C.
HILL, FREDERICK T.

Holinger, Paul H.
Hoople, Gordon D.
Hunt, Westley M.
Imperatori, Charles J.
Jackson, Chevalier L.
Jarvis, DeForest C.
Johnston, William H.
Jones, Marvin F.
Kelly, Joseph D.
Kernan, John D.
King, Edward D.
LeJeune, Francis E.
Lierle, Dean M.
Lillie, Harold I.
Looper, Edward A.
Lyman, Harry W.
Martin, Robert C.
McCaskey, Carl H.
McMahon, Bernard J.
McNally, William J.
Morrison, William W.
Mosher, Harris P.
Myers, John L.
Nash, C. Stewart
Orton, Henry B.
Portmann, Georges
Potts, John B.
Proetz, Arthur W.
Richards, Lyman G.
Ridpath, Robert F.
Salinger, Samuel
Sauer, William E.
Schall, LeRoy A.
Schenck, Harry P.
Seydell, Ernest M.
Shea, John J.
Shurly, Burt R.
Simpson, W. Likely
Taylor, H. Marshall
Tucker, Gabriel
VanAlyea, Oliver E.
Viole, Pierre P.
Weille, Francis L.
Williams, Horace J.
Wishart, D. E. Staunton
Wood, V. Visscher
Woodward, Fletcher D.

# PRESIDENT'S ADDRESS

FRANK R. SPENCER, M.D.

BOULDER, COLORADO

First I want to thank the American Laryngological Association for electing me its president. It is the greatest honor which can be accorded a laryngologist and I deeply appreciate it.

What future problems of laryngology should we direct? We should wholeheartedly support the American Board of Otolaryngology in the board's efforts to raise the standards of our specialty. Beginning in 1950 the board will require of each candidate a year's internship, three years of training as a resident in a recognized hospital with eight or nine months of the three years spent in the study of the basic sciences and one year in the practice of otolaryngology before taking the board examination. Nearly every member of this Association holds a responsible position in a large city hospital. Give the board your support in raising the standards of our specialty. It is your board, because it is sponsored by the five ear, nose and throat societies. Please let the board members have your suggestions.

During World War II otolaryngology was not given a proper place in the Army although it fared better in the Navy. Even in the latter, conditions left much to be desired. We, of this American Laryngological Association, must do everything we can to defend our specialty. Many general surgeons, but not all I am glad to say, try to belittle otolaryngology. They want to make our specialty subservient to general surgery. This was so well demonstrated in the Army in World War II that very few rose above the rank of Captain or Major as otolaryngologists.

The late Charles M. Schwab, while he was president of the United States Steel Corporation, wrote a book entitled "Succeeding with What You Have." There are only 63 pages of wisdom in the book, but it is excellent. In civilian life otolaryngologists have many opportunities to succeed with what they have. In the armed services everything is ordered. This must be so, but not to extremes. During World War I,

those of us who were in the Army had Col. Harris P. Mosher in the office of the Surgeon General and we were given recognition, as well as an opportunity to do the thing we were best qualified to do as otolaryngologists. You as members of this Association have succeeded with what you have. You are all leaders. However, unless this Association and the other otolaryngological societies act within the next few years to remedy the situation, the Army will do nothing about it. If we bring the proper pressure to bear upon Congress for legislation to require the proper recognition of our specialty by an otolaryngologist with the rank of not less than Colonel in the Office of the Surgeon General of the Army, we will safeguard our specialty. The same may be said of the Navy.

In some medical schools of the United States an effort has been made to make the department of otolaryngology a division of general surgery. Some of this propaganda has originated in the Association of American Medical Colleges, but not while our own member, Dr. A. C. Furstenberg, was president of the Association last year. As Dean of the University of Michigan Medical School he will very adequately represent our specialty, but we must not expect him to carry on without our help. Many of you hold responsible positions, with the Class A Medical Schools in the United States and Canada. Please watch with zeal your responsibility. If otolaryngology becomes a division of general surgery in the medical schools, it will surely be continued in the Army and Navy as a right arm of general surgery or should I say left arm or foot. What affects medical schools, the Army and the Navy is immediately reflected in private practice. I am for private industry and private practice. I have no use for "communists, pinks and fellow travelers." Private enterprise has made scientific medicine right here in the United States and Canada the greatest in the entire world. The two wars since 1900 have had much to do with this. We, as laryngologists, are not trying to claim all the credit. While we have this golden opportunity, let us make the most of it. If we do not, we will have no one to blame but ourselves.

As a teacher of nurses, medical students, interns, residents and graduate students for almost half a century I cannot refrain from commenting upon some observations. While an undergraduate student I took several courses in psychology. Today psychologists speak of intro-

verts and extroverts. The nomenclature has changed, but human nature hasn't changed very much. This never-ending parade of personalities, of successes and occasional failures offers many opportunities for fruitful observation. Some of these graduates return for a friendly call. Some are psychiatrists, others general surgeons or general practitioners, but most of those who call are otolaryngologists. Most of these are men who have done their best and have done everything to make them successful. A few are men who have done less than their best and have done very little. One otolaryngologist, from a distant city, with almost 25 years of experience in private practice informed me last year he had made enough to take life easier. In other words he wants to "rest on his oars." So far as I am personally concerned he hasn't any oars. He wanted something handed to him on a gold plate and I didn't need more than one guess to know what he wanted.

The real test of greatness is giving opportunity to others, as our highly esteemed Dr. Harris P. Mosher has done for so many years to undergraduate medical students, graduate students and assistants. However, he gives to those who are willing to work, and work hard, and not to those who want to "rest on their oars."

A very successful district manager of one of the big life insurance companies and I were very good friends for many years before his death. His work required him to visit many of his agents in several western states. An acutely infected middle ear forced him to consult an otolaryngologist in a neighboring state. The large check he was forced to write for the professional services rendered caused him to remark that he didn't mind paying, with one check, for the first six months of the otolaryngologist's medical education, but that he hated to have to pay for all four years of it.

Socialization of medicine may be just around the corner, but it is a long way to the corner. Be that as it may, large fees, unless earned justly, will rapidly shorten the distance to the corner. I am personally in favor of good fees, but we must all try to render professional service commensurate with the fee or face the inevitable socialization of all medicine and surgery. We must not leave the job of defending our position in the lap of the A.M.A. and the committees established for this pur-

pose. Individual physicians can do much to postpone the socialization of medicine.

"Life is a sheet of paper, white,
Whereon each man of us may write,
His word or two, and then comes night."

You have all made good or you would not be Fellows of the American Laryngological Association, but some of your best work may be just ahead.

"The fame that a man wins himself is best;
That, he may call his own."

At one of the English ports used extensively by our Army and Navy during World War II, there were two signs: The one on the left read, "Look before you leap lest you land in Eternity." The one on the right read, "Look before you jeep lest you land in maternity."

The late Dr. William J. Mayo once said, "The greatest surgeon isn't the one who makes no mistakes, but the one who makes the fewest." He is the one who looks before he leaps.

The Federal Government is entering into the practice of medicine in a "big way" and from many different angles about as follows:

1. Following World War I any ex-service man was entitled to free examinations, x-rays, laboratory tests and examinations, surgery, and treatment. This seemed fair for service-connected disabilities, but the service was rendered to any and all regardless of the time or place the disability was incurred and no questions were asked.

2. The U. S. Public Health Service has been and is now a very important branch of the Federal Government, but it is encroaching more and more upon private practice directly and indirectly. The U. S. Public Health Service would like to regiment all physicians, dentists and nurses. The Wagner-Murray-Dingell Bill appeals to them.

3. The newer G.I. Bill of World War II has been and is very generous or even lavish in its use of free medical, dental and hospital service to men and women regardless of whether or not they have any service-connected disability. I am in favor of any and all reasonable rewards for service rendered our country by serving with our armed forces, but some rewards are carried to extremes. These all tend to make

people more and more dependent upon the Federal Government and less reliant upon their own efforts. The thing which has made the United States the greatest country in the world is self-reliance, individual initiative and hard work. Leaning on the Federal Government does not and will not develop individual initiative.

4. Research is one of the things the Federal Government is anxious to control more and more. It is proper for atomic or nuclear energy to be so controlled, but not all scientific research to improve the diagnosis and treatment of disease and the prevention of disease.

Please don't misunderstand my good intentions. We need the U. S. Public Health Service, the Veterans Administration, the Army, Navy and Air Corps, but we don't need regimentation.

What should be the remedy to meet this challenge? More and better trained otolaryngologists is one of the first steps from our point of view. The average otolaryngologist may be good, but he isn't good enough. When one third of the candidates taking a board examination fail, the standard isn't too high; the candidates just are not well enough trained.

Second, more and better hospitals, so that medical, surgical and dental services can render more and better service to the public is a prerequisite.

Third, hospital insurance, sickness insurance, which will include medical and surgical care and laboratory fees, will go a long way to prevent the socialization of medicine. The public will not clamor for socialization of medicine if we help to meet the challenge.

You as leaders in laryngology are leaders in scientific medicine and as leaders you can do much to help keep laryngology on a high plane of achievement. All otolaryngologists should be trained to do neck surgery, oral and plastic surgery, laryngeal surgery, etc. Too many are doing tonsil and adenoid surgery with an occasional submucous resection, but this is not enough.

Should the American Laryngological Association sponsor more research directly and indirectly? I believe it should. This is not a new suggestion; it has been offered before.

The medical schools of the United States and Canada have the

scientific equipment, the libraries and the scientists to conduct research, but these schools often lack funds. We should set aside more each year for research and the council should be authorized to expend funds for worthwhile research. This may be done for contemplated research or completed research as the council may decide.

I doubt if the money should be given in one lump sum, but rather handed out as needed by that particular project. This need not be advertised, but it should be done. At first, a small beginning may be better and later a more extensive program. These are after all minor details to be decided by the council or a secret research committee appointed by the council.

I am familiar with the de Roaldes, the Casselberry and the Newcomb Awards just as you are. These all have a very useful place. What I want to emphasize is financial aid to research.

Dr. Norton Canfield is concerned about the encroachment by the federal government in the practice of medicine and justly so. He has given it serious consideration.

"We must not hope to be mowers
And to gather the ripe gold ears,
Unless we have first been sowers,
And watered the furrows with tears.
It is not just as we take it,
This mystical world of ours:
Life's field will yield as we make it
A harvest of thorns or of flowers."

GOETHE.

In closing let me remind you: "All the world's a stage, and all the men and women merely players." Let's all do our best.

I now declare this session of the American Laryngological Association open for the scientific program.

# THE PATHOLOGY OF NASAL POLYPS

JOHN J. SHEA, M.D.

MEMPHIS, TENNESSEE

The impression is prevalent that all nasal polyps are allergic. This is an exaggeration but uniformly shared by many of the younger surgeons. Kern and Schenck state "allergy is constantly a factor in the causation of nasal mucous polyps," but there are other types of nasal polyps that have a non-allergic background and whose management requires nasal surgery.

## Pathology of Nasal Polyps

*Mucous polyps of the allergic variety*—These are usually pedunculated and found most frequently in the middle nasal meatus, either originating from the ethmoid membrane or the middle turbinate. (Fig. 1)

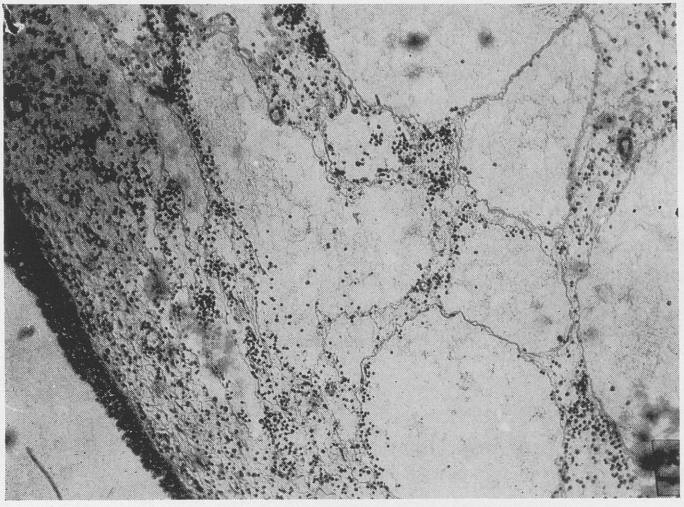

*Fig.* 1.—Photomicrograph of allergic polyp, high power.

The age of the polyps determines their color and consistence. The epithelial covering is stratified squamous or columnar. The stroma is very loose and liberally infiltrated with exudate containing a few mononuclear cells, both large and small, the latter chiefly plasma cells. The number of eosinophiles varies and polyps removed from the same nose

will during an allergic attack be rich in number, whereas, another polyp removed during a quiescent state will be free of them. All allergic patients do not develop nasal polyps, many of the hay fever sufferers go for years untreated and when the season ends their nasal membrane returns to normal, whereas, the vasomotor rhinitis patient, sensitive to dust and fungi, whose system is also disturbed by foods, constantly possesses them. The younger the individual, the more difficult it appears to prevent their recurrence and in the author's experience the incidence of fatal complications has been among young subjects.

*Inflammatory polyps*—These polyps differ from the mucous type in that they contain less exudate and their cells are predominating polymorphonuclear leucocytes. Their distribution is not limited to the middle meatus and may be found in the superior meatus. In this position they are dangerous, as their removal may open an atria into the cranial fossae. These polyps are the result of vascular changes induced by chronic sinusitis. The inflammation is about the blood vessels producing a periphlebitis or a perilymphangitis.

Case I—W.R.B., aged 26, was admitted to the hospital unconscious with the history of having been found at the foot of the stairs of the University Infirmary. The lad had a cerebrospinal rhinorrhea and signs of an active meningitis. Apparently he had become dizzy and while going to the bathroom had fallen down the stairs. At autopsy there was an inflammatory polyp in the superior meatus which had ruptured through into the anterior fossa of the cranium and was the cause of the headache for which he had entered the infirmary.

*Angiomatous polyps*—The predominating pathological type of tissue differentiates the hemangioma from the lymphangioma. The vessels anastomose freely. Simple angiomas are located on the hard palate, tongue or nasal septum. The polypoid types are pedunculated and lobulated. The lymphangiomas are frequently cystic. The endothelial hyperplasia being characteristic.

Case II—V.F., aged 12, presented himself with a tumor that had eroded through the palate. His history was that for the past year he had complained of increasing blockage of the right naris and one month before admission noticed the bulging of his palate, with finally an erosion of the tumor into his mouth. The tumor originated from the postethmoid cells.

The pathological report was "Section showed many large empty spaces lined by endothelial cells. In places there is marked hyperplasia of these cells merging into the stroma. The covering epithelium is hyperplastic. Diagnosis—lymphangioma."

Case III—B.M., aged 16. For one year complained of progressive nasal obstruction. Examination—The right naris was filled by a polyp with a cyanotic hue attached posteriorly to the middle turbinate. Microscopic Examination—"Many vascular spaces scattered throughout the section. The cells are large and small monocytes. Diagnosis—hemangioma."

*Mulberry Polyp*—Found on the posterior end of the inferior turbinate and consists of a hyperplasia of the turbinate tissue. Their glands are cystic and their blood vessels dilated.

*Pressure Polyps*—When the septum is deflected to impinge on the middle turbinate, sufficient pressure may be exerted upon the ethmoid capsule to cause a stasis of circulation and as Woakes stated, produce a necrotizing ethmoiditis with the formation of polyps. The majority of solid tumors of the antrum are accompanied by ethmoidal polyps.

Case IV—Mrs. J.H., aged 22, adamantinoma of the antrum. The middle meatus was filled with polyps. The pathology of these pressure polyps is similar to the mucous type, but their blood vessels are dilated and areas of necrosis appear throughout the polyp.

*Choanal Polyps*—They arise either within the maxillary sinus or from the nasopharyngeal wall. The polyps are unilateral and become apparent when their size is a nuisance. Their epithelial covering is stratified squamous and their consistence solid. The blood supply is rich and any glands present are dilated. If originating from the maxillary sinus the attachment is immediately within the sinus close to the ostium and best removed by a transantral approach. Those attached to the lateral wall should be removed by avulsion or destroyed by radium implants. (Fig. 2.)

Case V—S.J., aged 17, while vomiting strangled on a fleshy mass that hung down his throat. The tumor originated within the antrum Microscopic Report—"The polyp is covered by a hyperplastic stratified squamous epithelium. The stroma is of loose areolar connective tissue and the blood vessels are dilated at its attachment."

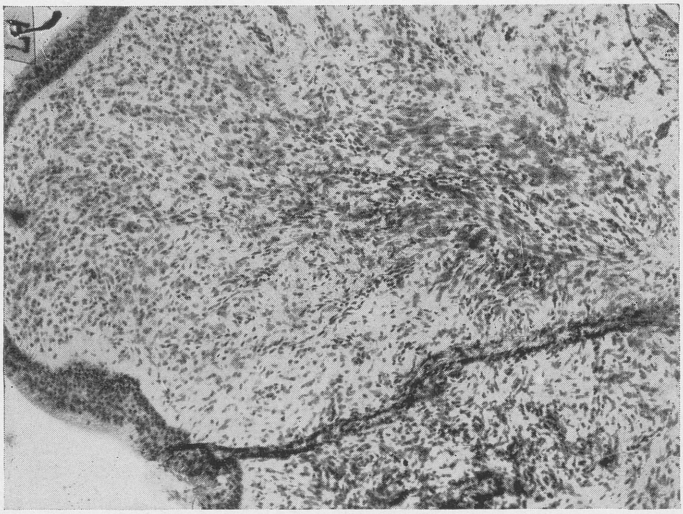

*Fig.* 2.—Photomicrograph of fibrous polyp. The overlying respiratory epithelium is well preserved. The cilia are distinct. The dense cellular stroma of the polyp is made up of fibroblastic cells with a few scattered round cells. The fibroblasts are arranged in definite whorls and bundles.

*Cholesteatoma*—The rarest nasal polyp is a cholesteatoma. The author has encountered one in his practice.

Some inflammations, particularly chronic ones, produce squamous metaplasia of more differentiated mucosal linings, such as, the pseudostratified ciliated columnar lining in the respiratory tract. Vitamin A deficiencies are capable of producing essentially the same type of metaplasia. This metaplastic process is usually focal but may be diffuse. With the addition of layer upon layer of squamous epithelium a keratin layer is formed similar to that of the skin. These sloughed cells by continuing to accumulate within a closed cavity produce by pressure a bony necrosis or at least a thinning of the bone. Ulceration of portions of the metaplastic lining may occur as well as invagination, in other words, the process may assume a polypoid appearance. When such foci with their sloughing keratinous elements takes place a great deal of tissue irritation is set up. Keratin cannot be digested by the tissue juices or by the leucocytes brought to the scene in the inflammatory process. Disintegration may occur around the deposits of sloughed keratin, or their disintegrated products which are chiefly cholesterol will set up a

foreign body giant cell reaction. This granulomatous response may be widespread and in turn produce polypoid excrescences. The evolution of the process is either a mass of sloughed keratin accumulating within a confined space or a polyp. Nature has no tissue enzyme capable of digesting keratin.

Case VI—M.P.S., aged 55. During the performance of a radical antrum operation, a polyp was removed from the outer margin of the floor over the site of a recent extraction.

The microscopic examination revealed a deposit of cholesterol needles seen as slit-like spaces.

*Plasmacytoma*—Plasmacytoma is one of the rare nasal polyps and of 127 reported by Hellwig only 63 arose in the upper respiratory tract. (Fig. 3.)

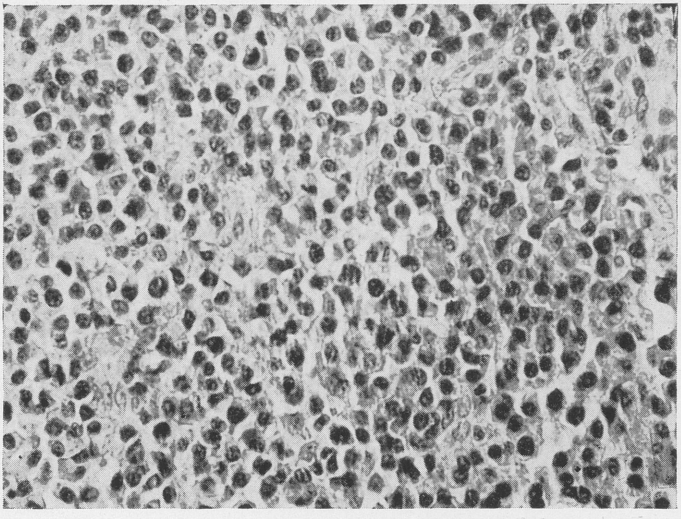

Fig. 3.—Photomicrograph of plasmocytoma—section showing center of tumor. Numerous large hyperchromatin cells and many mitotic figures are seen. The nuclei are eccentrically placed.

Case VII—W.W.C., aged 43, was conscious of a bleeding growth in the right side of the nose. The tumor was fleshy in type and filled the right naris. It arose from the mucous membrane covering the septum and was very vascular.

The original laboratory report was a lymphosarcoma. The Army Medical Museum changed the diagnosis to a plasmacytoma with the following report—"Microscopic examination reveals a section partially covered by squamous epithelium. The main bulk consists of closely packed cells which have, for the most part, eccentric nuclei and a basophilic cytoplasm. The nuclei occasionally have the appearance of a cartwheel with chromatin collected in the periphery. We believe these cells to be plasma cells. Practically no stroma is seen. The diagnosis is plasmacytoma."

The base of the tumor was thoroughly cauterized and received 100 mgm.-hours of radium radiation.

Plasmacytomas are composed of extramedullary plasma cells. These cells are oval to round with an abundance of cytoplasm. Their nucleus is eccentrically placed with small central nucleolus and the chromatin arranged like a cartwheel. In as much as plasma cells are members of the hematopoietic group, these tumors are true myelomas and repeated roentgenograms should be made of the osseous system.

*Malignant polyps*—All polyps removed should be studied, as their recurrence can become malignant.

CASE VIII—Mr. T. J. S., aged 58. In 1926 his first crop of polyps was removed. Yearly thereafter he presented himself for their removal and in 1942 the polyps removed were diagnosed as transitional cell carcinoma.

## CONCLUSION

The majority of nasal polyps are allergic and simple, but there are a sufficient number of serious growths to justify a thorough microscopic study of all polyps removed.

## REFERENCES

KERN, R. A., and SCHENCK, H. P.: J.A.M.A. 103:1293, 1934.
KERN, R. A., and SCHENCK, H. P.: J.Allergy, 55:485, 1933.
WOAKES, E.: Lancet, 2:108, 1885.
HELLWIG, C. A.: Arch.Path. 36:95, 1943.

## DISCUSSION

HARRY P. SCHENCK, M.D.: I think if there is any lesson to be derived from Dr. Shea's paper, it is in the plea he has made to section polyps when they are removed.

I have received a great deal of heckling in the last 14 years because on one occasion Dr. Kern and I wrote a paper on so-called mucous nasal polyps and the title was "Allergy, a constant factor in the etiology of so-called mucous nasal polyps." Ever since that time students on examination when asked what is the cause of polyps immediately reply "Allergy." Such an answer indicates they have not read the paper or succeeding papers, and they are not familiar with the subject.

The classification of nasal polyps is not new. Billroth, when he first got his hands on a microscope in 1855, made a classification of polyps which is not much improved upon today.

There are a few tumors which look like polyps, for example, neurilemmoma or schwannoma, which come from the sheath of Schwann. I cannot tell those grossly from mucous polyps, nor can I tell the carcinomatous polyps grossly from the mucous polyps. Zuckerkandl in 1882, and Hopmann in 1885 made a classification of nasal polyps which still holds today. Both of these investigators and even Billroth recognized mucous polyps. They put them in a distinct and separate class. Zuckerkandl made another observation that all polyps (and he was including carcinomatous polyps, fibrous polyps, adenomatous polyps) had a common origin from the nasal mucous membrane, and stated that they had one other thing in common in that they had all the components of the normal mucous membrane, but in abnormal relationship.

The main reason I came up here is that after reading Dr. Shea's paper, I was afraid everybody would forget about mucous polyps. After all, they are the most common type of polyp found in the nose. If someone pins one down as to how you can prove that they have an allergic origin you are hard put to it to answer the question. But there is a great deal of evidence which is almost incontrovertible.

One other point I would like to bring out is that there is often faulty observation in localizing the site of polyps. Zuckerkandl, and this was in 1882, pointed out very accurately the sites of origin, and he mentioned eight. I am going to read them. First, on the edge of the hiatus semilunaris; 2, in the infundibulum; 3, at the ethmoidal ostia; 4, at the ostium frontale; 5, at the ostium maxillare; 6, on the edge of the middle turbinate; 7, and this is very important, on the edges of the accessory furrows on the mesial side of the middle turbinate; 8, on the ethmoidal bulla, and 9, in the ethmoidal cells.

It is a curious thing that when you check up these sites as described by Zuckerkandl, they agree with a series of ridges which Van Alyea has described in his textbook on sinuses, and those ridges have been overlooked. They are extremely important in the formation of mucous nasal polyps. The reason for that is that in allergy the shock tissue is actually the turbinate and everything else which occurs is secondary to what occurs in the turbinal tissues. The sinuses first involved are the ethmoidal cells and the maxillary sinuses. The reason they are involved immediately after the involvement of the turbinates, provided the reaction lasts long enough, is that the whole mechanism is a vascular one which has been observed in living tissues. We can explain the involvement of these sinuses secondary to the turbinal allergy. Then the sinuses become the sites of

further polypoid degeneration, particularly the ethmoidal cells.

We get one lesson out of Dr. Shea's paper and that is emphasis on pathology. Every time you remove a polyp or a series of polyps, at least section one of them. If you are not doing this you are not practicing good otolaryngology.

J. M. Robison, M.D. (Houston, Texas) (by invitation): Dr. Shea has asked me to discuss his paper extemporaneously; so, without any preparation to do so, I would like to approach the mechanism of mucous polypus formation from the same angle from which I have explained it previously in the literature.

As I see it, mucous polypi formation is a part of, or is related to, nature's attempt to create and maintain a constantly changing pericellular environment for the cells of sinal mucosa. Mucous polypi form most frequently during the progressive pathologic changes which occur in the sinal mucosa during subacute and chronic allergic sinusitis. These pathologic changes are related to the "invasive characteristics" of the offending bacteria or antigen. By "invasive characteristics" I mean the reaction produced in the body by agents which penetrate its surface. For instance, the staphylococcus aureus produces coagulation and closing of the intercellular and interstitial spaces which results in this organism being walled off in an area of local inflammation while the streptococcus hemolyticus may enter the tissues through an invisible portal and within a few hours be found in a distant lymph node without leaving any evidence of the location of its entrance or route of travel. Virus disease has as its invasive characteristic preparation of the tissues for the growth of secondary bacterial infection which often terminates as the "common cold" or purulent sinusitis. Sensitizing antigens which diffuse into the nasal and sinal mucosa produce an excess of tissue fluid in the stroma of the mucosa which has a tendency to remain and become stagnant and usually is susceptible to recurrent infection. As this process progresses the sinal mucosa is characterized by the formation of alternating areas of fibrosis and dilated tissue spaces. Following repeated episodes of infection as the tissue pressure rises polypoid protrusions of the mucosa occur from the areas of dilated tissue spaces. Mucous polypi do not form from the areas of fibrosis but their pedicles may undergo fibrosis. Extravascular fluid is moved normally by active and passive motion of the body, muscle contraction, massage, gravity, tissue pressure and pulsations transmitted from the arteries to the interstitial tissue spaces and lymph vessels. The sinuses, being bony enclosed cavities, are deprived of active and passive motion, muscle contraction and massage to aid in removing excess extravascular fluid. During pathologic states they depend primarily upon gravity, increased tissue pressure, and pulsations transmitted from the arteries and dilated arteriovenous anastomoses to the lymph channels. An increase in tissue pressure is acquired by the edematous sinal mucosa swelling against the normal tissue elasticity and, as it approximates the capacity of the sinus, impinging against the rigid walls of the sinus. This results in obliteration of the air-containing cavity with secretion and edematous membrane and allows arterial pulsations to be more efficiently transmitted to the lymph vessels by hydrostatic pressure. During acute inflammation of the sinal mucosa, this process occurs uniformly through-

out the mucosa, but in subacute and chronic conditions when areas of fibrosis and dilated tissue spaces have formed in the mucosa, nature's attempt to increase the tissue pressure results in polypoid protrusions from a mucosa which has lost its inherent contractility.

This process may be simulated by the application of local pressure to the edematous mucosa of the maxillary sinus. This is accomplished by inserting into the maxillary sinus, through a small intranasal antrotomy, a balloon filled with iodized oil. As the balloon is inflated with oil and the tissue pressure is increased for a few weeks, newly formed polypi may appear in the middle meatus. These newly formed polypi differ histologically from polypi formed by pathologic processes operating over a protracted period in that their interstitial septa have been destroyed by the movement of the interstitial fluid occasioned by the hydrostatic pressure exerted against the edematous mucosa by the balloon.

BURT R. SHURLY, M.D.: Mr. Chairman, I have enjoyed this very fine paper of Dr. Shea.

Naturally, we of the older school have been brought up to believe in certain definite ways of procedure, and we recognize the importance of the pathology and the complete examination of the material we have at hand.

I happen to be one of those who feels that the study of the individual case is of the greatest importance.

I feel very keenly that the American way of medical life is toward exaggeration. Many times many of our ideas run away with us and when this problem is considered purely allergic I feel we are here prone to exaggerate in that direction and that phase of it is being overdone.

When patients need more air and need more drainage and they look for such relief, when there are polyps obstructing these passages, then in keeping with our teaching in physiology I believe the removal of these is indicated and should be carried out. Then we can study the pathology and whatever treatment may be necessary for the allergy we will gladly give them at that time. I feel the removal of the polypi for comfort and relief and for drainage is the first and most important thing in almost all of these cases and not to wait for the allergic medication to take the time which might be necessary to shrink those polypi.

ROBERT F. RIDPATH, M.D.: In the discussion of a paper I feel that any discussion should follow as closely as possible the title of the paper and its contents. However, Dr. Shea has gone over the pathology so very thoroughly that there is not much more to be said.

The question we are all interested in is the causative factors resulting in polyposis. There have been several suggestions in regard to this, the causative factor. I still feel we have not gone into this phase as thoroughly as we should.

Personally we all believe that so-called allergy has its place in the formation of polyps. We must also be cognizant that comparatively few people, so to speak, have polyposis. There are certain types of people who have a continuous rhinitis

or continuous upper respiratory tract infections. These are the people, as well as those who have a hereditary taint towards polyposis, that we must consider under this heading.

Some years ago I tried to do some experimentation along this line of a biochemical nature. During this experimentation upon various patients, we found that people who were prone to have a polyposis and a repeated polyposis after removal of the polyps were all deficient, first, in calcium and a certain increase in leucocytes. In other words, in spite of all our treatment the leucocytes would remain 8-, 9- or 10,000.

These two factors I am bringing to your attention because I feel in going into the pathology of nasal polyps we must go deeper than we have so far. We should try finding out their etiology. I bring my findings to your attention because I hope some of you may have time for going further into this perplexing question.

SAMUEL SALINGER, M.D.: I believe that much confusion has arisen from the fact that we have included under the term of nasal polyp a variety of growths that have different pathogenesis and different pathologic characteristics. I think the fault is rather in our nomenclature and in the loose application of the words "nasal polyp."

The average physician considers a nasal polyp to be an edematous pedunculated mass or series of masses which he thinks are due to an allergic background.

Dr. Shea has shown us a variety of other tumors, such as a mucous polyp, hyperplasia, hemangioma and fibrous polyp. All of these various types can be differentiated pathologically and I think that in the future if we will designate these as benign tumors of the nose until we find out exactly what their characteristics are, it will clarify the atmosphere considerably.

J. J. SHEA, M.D.: (Closing) I wish to thank the discussers and to merely make one statement.

We have tried for over a year to study the bacteriology of all polyps removed with the hopes of obtaining something that would be reportable and helpful, but the data is so mixed and so inconsistent that we could crystallize no conclusions. Somebody else may try and see what they can do with the bacteriology of polyps for there is a possible connection.

# UNUSUAL SINUSES OF INTEREST TO THE RHINOLOGIST

FRED W. DIXON, M.D.

CLEVELAND, OHIO

In the past 10 years it has been our custom to take the skulls as they pass through the dissecting room at Western Reserve University and saw them into various planes in order to show the development of the nasal sinuses. No two skulls show the same arrangement of their sinuses. The terminology used has been the location of the ostium or point of drainage, rather than the bones invaded. If the arrangement was unusual these skulls were dissected, prepared, painted and preserved. I am presenting some of them in the hope that they may be of interest to you.

The frontal sinuses may be absent. One frontal sinus may be developed, while on the opposite side the frontal may be fully developed or it may extend across the midline and invade the entire frontal bone.

The maxillary sinus is the most constant. It is always present but may be small.

The ethmoids are the most variable in their arrangement and size. They may occupy any position in their relationship to each other.

The sphenoids are rarely symmetrical. They may be extremely small in size and the walls largely membraneous, producing only a dimple on the surface of the bone, or they may be enormous in size.

(A film of the sinuses was shown.)

In the first two specimens in the film, neither of the frontal sinuses developed. In the next skull one side developed normally while the other frontal did not develop—only compact bone is seen. The next skull, however, shows one frontal invading both frontal areas, while the opposite frontal shows no development whatsoever.

The next skull shows a maxillary sinus with a capacity of only 1 cc. A difficult sinus to irrigate. The next maxillary sinus has many septa on its floor. The maxillary ostium may be very large as in the next specimen.

The next group shows the varied arrangement of the ethmoid

sinuses. The anterior and posterior ethmoids may be superior or inferior, anterior or posterior, internal or external to each other.

The sphenoids are rarely symmetrical. Their combined capacity may vary from one-half cc. to 28 cc. The vidian and the optic nerves are often prominently on its walls.

In presenting this group of specimens an effort has been made to show the varied arrangement of the sinuses.

## DISCUSSION

B. N. Colver, M.D. (Los Angeles, Calif.) (by invitation): Certainly nothing can be added to the beauty of this wonderful anatomical study.

I would like to mention two cases. Some years ago, Dr. M. A. Mortenson referred a lady to me who had had asthma for two months. Examination showed in the left side a single polyp. We advised its removal and found that its tail went over the lateral border of the middle turbinate and disappeared. The turbinate was large and cellular. We split the turbinate, infracted and molded it, and in the lateral half which was removed there were two or three baby polyps which had not yet developed. The patient's asthma was completely relieved, showing that this was a one cell involvement, infection or otherwise, and there were no more polypi.

The second case is that of a man who was hit by a traveling roll of paper in a printing shop and knocked unconscious. A few days later he blew his nose and developed an emphysema of the left upper lid. This became infected. He developed an abscess. The left upper lid was lanced, and the pus pressure relieved, and the pain ameliorated. I saw him two years later and the fistula remained. X-ray showed what seemed to be involvement of the left frontal sinus so a radical procedure was advised. When the left frontal sinus was opened there was no pathology, but traveling a little lateral-ward we found that the sinus which was involved was an ethmoid which had intruded out to the end of the eyebrow. The two sinuses, left ethmoid and left frontal were thrown together by removing the partition between them and the pathology thus relieved. The combined sinuses were handled just as a chronic frontal sinus would have been.

Oliver E. Van Alyea, M.D.: I wish to commend Dr. Dixon on this excellent presentation. He has shown us varieties of what should be termed "normal anatomy."

J. Parson Schaeffer, some years ago in his monograph, stated that the anatomy of the sinuses is so variable that what appears to be abnormality occurs often enough to justify the term "normal anatomy."

When two sinuses grow up together, as occurs in the frontal bone and sphenoid bone, you are more apt to have overriding of one sinus on the area usually assigned or allocated to the other sinus. Consequently invasion of a sphenoid or

frontal on the territory of its fellow sinus is common. It is to be expected. It should be looked for preceding any surgical procedure, or as far as that is concerned, any medical procedure.

Dr. Dixon mentioned the fact that osteomas appear in the neighborhood of the frontal ostium and interfere with drainage.

I was a little disappointed that he did not also include the factor of frontal cells which invade that area. The frontal sinuses, as you know, originate in the middle meatus, usually in the frontal recesses, as an embryologic bud, along with two or three others. One of them grows upward to become the frontal sinus. The others usually trail along, perhaps as a nuisance value.

In my experience in dealing with frontal sinusitis I have noticed that one or the other of two anatomic factors is usually present. One is the impinging middle turbinate which blocks the general drainage from the frontal area, and the other is one or more of these frontal cells which are located above and near the ostium in the sinus itself or below the ostium in the pathway of drainage. These are usually present in cases of lingering frontal sinusitis. If we keep that in mind I think we can account for the remarkable cures which we obtain in cases of frontal sinusitis by the passage of a cannula which breaks down these cells in the middle meatus near the opening of the frontal sinus, thereby establishing proper drainage channels.

W. Likely Simpson, M.D.: Mr. Chairman and Fellows of the American Larygological, in doing antrum operations, twice I have seen the infraorbital nerve entirely surrounded by bone and having no connection with the superior above.

In doing frontal sinus operations, twice I have seen bone surrounding the optic nerve entirely within the lumen of the frontal and having no connection with the periphery except anteriorly and posteriorly.

These beautiful illustrations emphasize, it seems to me, the fact that in suppurative sinusitis how very difficult conservative treatment is in a reasonable number of cases. It is almost impossible for some of these cases with partial or complete septa in some areas to get good drainage, and it would only be by some external operative procedure that a reasonable number of the cases could get entirely well.

F. W. Dixon, M.D. (Closing): Dr. Van Alyea's point of securing ventilation and drainage of the sinuses is most important. Much of the pathology will disappear if this is accomplished.

I wish to thank Dr. Simpson, Dr. Colver and Dr. Van Alyea for contributing to the discussion.

# MALIGNANT TUMORS OF THE NASOPHARYNX

HORACE JAMES WILLIAMS, M.D.

PHILADELPHIA, PENNSYLVANIA

The object of this paper is to bring to the attention of the otolaryngologists, ophthalmologists, neurologists, and the general practitioners the importance of early recognition of nasopharyngeal malignant tumors.

These tumors are comparatively rare although they are probably more frequent than is generally supposed. Their location tends to make them easy to be overlooked. Many patients have had a malignant lesion in the nasopharynx but the metastases so overshadowed it that the primary lesion was never suspected.

Otolaryngologists should be quite familiar with the appearance of the mucous membrane in the nasopharynx in the normal both when using a nasopharyngoscope and the pharyngeal mirror. Some parts of the nasopharynx cannot be readily visualized with the nasopharyngoscope so to complete the examination a pharyngeal mirror should be used. When the pharyngeal wall and soft palate are anesthetized practically all parts of the nasopharynx can be inspected with a pharyngeal mirror.

These new growths are more common in the male than the female. So it is with malignancy of the faucial tonsil. They may occur at any age but the most frequent age is between forty and sixty years.

There is a difference of opinion as to the most frequent location in the nasopharynx of the primary lesion. In general it is agreed that it is found most often either in the pharyngeal tonsil area just to either side of the midline or in the lateral wall.

New growths in the lateral wall invariably produce some degree of hearing loss. The hearing loss depends upon the amount of pressure on the orifice of the eustachian tube. The location of the primary lesion has much to do with the early symptoms.

Digby, Thomas and Tse[1] have found that the Chinese are very susceptible to nasopharyngeal malignancies. They report that it is not unusual to have four or five patients with malignant pharyngeal tumors at the same time in a service of forty-two surgical beds in a Hong Kong

hospital. This frequence occurs in Chinese born in China but who have lived the greater portion of their lives in the United States. This suggests the tendency is racial. These also occur frequently in Java, Singapore, Sumatra, and the Far East.

Erik Godtfredsen[2] found that nasopharyngeal cancer constitutes three per cent of all forms of cancer. The most frequent tumor forms are the squamous cell carcinomas and the reticular cell sarcomas.

No real causative factors appear in the literature to be responsible for the appearance of these tumors. Frequent nasal and sinus infections should be considered but there is nothing to substantiate this reasoning.

A positive Wassermann was no more frequent than in the average range of patients. Malignant tumors in the nasopharynx are approximately three times as frequent as benign tumors. The symptoms of the benign tumors are largely obstructive and at times a hemorrhage occurs. These symptoms appear as soon as the growth increases in size sufficient to interfere with breathing.

Martin and Blady report the pathology of the new growth when its origin is the pharyngeal tonsil as a highly anaplastic epidermoid carcinoma and lymphosarcoma. Minor salivary glands are present in the mucous membrane lining the lateral and posterior walls of the nasopharynx, consequently, adenocarcinoma is to be expected.

There is considerable disagreement as to the terminology used in describing these tumors. Epidermoid carcinomas constitute a fair percentage of these nasopharyngeal tumors.

New growths in the nasopharynx tend to be anaplastic and they metastasize readily. One of the earliest symptoms is involvement of the cervical glands before any lesion can be located in the nasopharynx. Headache and local pain occur fairly early.

These new growths of the nasopharynx are radiosensitive.

As the growth increases in size it interferes with breathing and on blowing of the nose some bloody discharge is seen. Some loss of hearing may result depending upon the location and extent of the obstruction to the orifice of the eustachian tube. An excessive amount of mucus in the nasopharynx is a common symptom.

There is a tendency for the growth to extend intracranially and to the orbit. The sixth and fifth nerves are usually the first to be involved. Involvement of the sixth nerve produces paralysis of the external rectus muscle and involvement of the fifth nerve produces pain over its three divisions. This symptom of nasal obstruction tends to lead to operation on the nasopharyngeal tumor to relieve the inability to breathe. Involvement of the fifth nerve is responsible for the removal of teeth, suspecting tic douloureux, etc.

Cervical lymphoadenopathy was the first and only complaint on admission in about 50 per cent of the group of Martin and Blady.[3] The lymph nodes most frequently involved are those of the upper deep cervical group. There may be metastases to the lower portion of the neck. Lymphoadenopathy covering a wide area is present in the last stage of the disease.

The retropharyngeal lymph nodes are seldom involved. If they become involved bulging in the posterior pharyngeal wall occurs. Systemic metastases are more frequent with cancer of the nasopharynx than with most other growths in the respiratory tract.

When the disease is uncontrollable there is widespread involvement of the cervical nodes. Horner's syndrome develops where there is a local extension along the internal carotid artery and its accompanying sympathetic plexus in the foramen lacerum.

The fossa of Rosenmeuller is frequently invaded by the growth. This fossa is under the mesial portion of the foramen lacerum. The growth may extend by direct continuity of the soft tissue from the nasopharynx through the foramen lacerum and into the cranium, a distance of about one cm., without erosion of the bone. The nasopharynx is not particularly sensitive to pain. Growths in the posterior wall will produce no symptoms until they increase in size sufficient to produce obstruction or until they metastasize to the cervical glands and they appear without any evidence of other pathology to produce the tumor.

Early paralysis of the sixth nerve is explained on an anatomical basis. The nerve passes forward between the posterior clinoid process and the tip of the petrous portion of the temporal bone and therefore in its course passes directly over the foramen lacerum nearer to it than any other cranial nerve. The third, fourth, and fifth nerves are

next in proximity and as the disease progresses forward into the orbit the second nerve is involved.

Recently the writer saw a male patient, sixty years of age, whose only symptoms were enlarged cervical glands and excessive amount of secretion in the nasopharynx. One gland had previously been removed for biopsy which proved to be malignant. When the nasopharynx was examined only a small swelling in the fossa of Rosenmeuller was found.

*Case I*—Mrs. J. McL. aged 64 years. Her chief complaints were intense pain over the right temporal region and in the right eye, dysphagia, and marked impairment of hearing in the right ear.

Twenty years ago she had a right mastoidectomy and when a child she had scarlet fever.

On examination both tympanic membranes were markedly thickened and retracted. There was a large amount of secretion on the floor of the nose otherwise the nose was negative. The pharynx revealed a large ulcerated area on the right lateral wall and on the level with the eustachian tube which bled freely when touched. There were no palpable glands. A piece of tissue was removed for examination. The report was squamous cell carcinoma very actively growing. She was referred to St. Mary's Hospital for therapy. In the meantime she developed a suppurative otitis media of right side. Under x-ray therapy the growth rapidly decreased in size and within less than a year there was no evidence of it to be found. I did not see her for about three years, from the 12th of July, 1944, to April, 1947, when she came to the office by request. Her symptoms had subsided, there was still no evidence of the tumor. She has lost considerable weight and her general appearance is that of an ill patient but she states that she feels well. The right ear is still discharging.

*Case II*—Mr. L. W., aged 46 years. This patient was seen in the latter part of November, 1944. He complained of nasal obstruction, pain over the temporal region and in the right eye, and some impairment of hearing of the conductive type. He gave a history of having had polypi removed several times for the relief of difficult breathing.

In preparing the patient for a nasopharyngoscopic examination an application containing an anesthetic was placed on the floor of the nose and immediately there was so much bleeding that examination was

impossible. On the following visit a piece of tissue was removed and the microscopic examination showed that the tissue consisted of sheets of cells which were uniform, poorly differentiated epithelial cells with numerous mitosis and occasional areas partially resembling squamous carcinoma but without pearls or intercellular bridges. There were a few scattered lymphocytes. The diagnosis was anaplastic carcinoma of the nasopharynx.

Under x-ray therapy the growth in the nasopharynx decreased in size so that it was difficult to see it although x-ray showed an erosion of the bone into the middle fossa. The pain in his eye and temporal region and the paralysis of the external rectus muscle persisted. As he became worse the cranial symptoms increased. He lived approximately one year.

*Case III*—Mr. C. D., aged 58 years. His chief complaint was deafness in the left ear associated with tinnitus aurium which developed December, 1946. There had been no pain just a sense of discomfort in the left ear and some difficulty in breathing through the left side of his nose. The patient was first seen by his family physician who referred him to a local specialist who in turn reported the presence of a tumor in the left side of the nasopharynx. He made a provisional diagnosis of malignancy. The diagnosis was based on the history of the patient who had had a tumor removed from the left side of his neck two years previously. This tumor had been present for thirty years and was non-malignant.

On examination the patient showed a hearing loss of 40 per cent in the right ear and 72 per cent in the left one. He had an old obstructive lesion on both sides.

Both tympanic membranes were thickened and retracted but to a greater extent on the left side; the cone of light was absent on both sides. Mirror examination of the nasopharynx showed the presence of a rounded lesion situated on the lateral wall impinging on the orifice of the left eustachian tube. The lesion was not ulcerated.

A striking feature of the tumor was that with the nasopharyngoscope it was covered with submucosal elevations of varying sizes. These nipple-like elevations were red at the base and pink at the apex. On examination three weeks later these elevations had disappeared and were replaced by depressions. The first small specimen suggested tuberculosis

but when the tumor was removed the pathologist did not make a definite diagnosis.

The x-ray studies were negative except for the sclerotic changes in the mastoid.

Following the removal of the tumor the patient has partially regained his hearing, has gained weight and feels normal.

Treatment of the malignant nasopharyngeal tumors is essentially irradiation. Patients should be referred to a radiologist who is interested in and is familiar with the reaction of these rather rare malignant tumors to therapy. Treatment is first of the primary lesion and second, the metastases to the cervical glands. These growths are the most radiosensitive of all tumors of the upper respiratory tract. This area when properly administrated tolerates heavy doses of radiation.

Martin and Blady[3] recommend external radiation through the cheek and intracavity radiation by radium and radon. Supplementary treatment perorally through the palate.

The most serious consequence in radiology is the constitutional effect due to such a large area requiring therapy. The patient may become weak, toxic, and have a loss of weight. Patients between the ages of 50 and 60 years respond to therapy better than any other age.

Metastases of these tumors is the most important determining factor in its progress.

1. Nasopharyngeal tumors are difficult to diagnose.
2. They are very malignant.
3. Metastases to the cervical lymph glands is often the first symptom.
4. They are highly radiosensitive.
5. Many patients under careful treatment live for years following irradiation.
6. The roentgenologist should be trained in the treatment of these radiosensitive malignant tumors.

REFERENCES

1. DIGBY, K. H.; THOMAS, G. H.; and TSE, H. S.: Notes on Carcinoma of the Nasopharynx. Caduceus, 9:2, 1930.

2. ERIK GODTFREDSEN: Acta Otolaryngologica Supplementum 56, 1944.

3. MARTIN, H. E. and BLADY, J. V.: Cancer of Nasopharynx, Arch. Otolaryng. 32:696, 1940.

# THE SURGICAL TREATMENT OF NASOPHARYNGEAL FIBROMA

JOHN MACKENZIE BROWN, M.D.

LOS ANGELES, CALIFORNIA

Fibroma of the nasopharynx is a relatively uncommon tumor which occurs predominately in adolescent males. It has a definite tendency to regress in adult life. It is not malignant histologically but may become malignant clinically because of pressure or location.

Nasopharyngeal fibromata appear to arise most commonly from the periosteum covering the base and anterior face of the sphenoid and the basilar process of the occipital bone. The tumors vary greatly in size and in extent. Grossly, the tumors represent fairly hard, firm masses of tissue which are most frequently firmly attached to the bony site of origin. They are very rarely pedunculated except in their late stage when they become very large. During the early stage of their development they are broadly attached to the bone of the occiput and sphenoid, and are not easy to separate. They may extend into the sphenoid sinus, the nasal fossae, the ethmoid, antrum, orbit or inferiorly into the pharynx, and may extend below the soft palate and uvula. Microscopically, these tumors consist of dense collections of fibroblasts with numerous blood vessels. The vascularity is so great in some tumors that they are termed angiofibromata. Numerous reports have appeared in the literature regarding the pathology and treatment of this condition—notable are the writings of Allan, Brunner, Coates, Delavan, Friedberg, Goldsmith, Hill, and New and Figi. When the treatment of this disease is considered, one is confronted at once by the wonderful results reported by New and Figi in the use of radium and diathermy. Sixty-five cases, all successfully treated by this method, were reported in 1940. The present paper deals with the author's experience in six cases treated surgically at the Los Angeles County General Hospital in private practice.

There are two main surgical approaches. The first is the transnasal approach, either by Moure's lateral rhinotomy, or via the Denker route through the upper lip encircling the ala nasi. The second is the transpalatine approach which will be discussed in this paper. Chevalier

Jackson in 1907 reported eight successful cases in which fibromata were removed through the oropharynx by forceps and snares without splitting the soft palate. He tied one or both external carotids in these cases. This transpalatine approach has been used for years but was abandoned chiefly because of postoperative infection in the suture line resulting in perforations. This objection can now be removed by the use of penicillin. The other objection to this route was hemorrhage. Such hemorrhage can be controlled by ligature around the external carotid.

The surgical technique is as follows: Intratracheal anesthesia is preferred. The external carotid artery is exposed on the side in which there appears to be greater involvement. The ligature is placed around the vessel, but is not tied. The soft palate is incised longitudinally in the midline up to the hard palate. The incision inferiorly goes to one side of the uvula. Each palatal half is retracted laterally. The tumor mass is then freed by the fingers to the base; then a strong, flat, semi-sharp elevator is used to pry the growth from its attachment at the base of the skull. This is the most difficult and most painstaking part of the procedure. Here is where hemorrhage is most severe and where extreme care is required in separating the mass. After the base is separated, the extensions are loosened and traction is applied by a heavy snare or Brandegee forceps. If hemorrhage is not controlled by pressure, the external carotid is tied. The cavity is then packed with gauze. The palate is now sutured in two layers; the dorsal layer is closed by interrupted catgut sutures; the ventral layer by silk. Two silk mattress tension sutures are used. If the external carotid is not tied, the ligature is left in place for twenty-four hours after the packing has been removed.

My first patient was a boy of 17 sent from a mountainous part of the state where there was no medical practitioner for many miles. His chief complaint was frequent nasal hemorrhage, two of them severe enough to require transfusions. Examination showed the tumor mass filling the entire postnasal space and extending into the left naris. For several reasons it was decided to approach this surgically through the palate as the most direct route to the mass. I was further influenced by observing on several occasions the satisfactory repair work in the palate by my colleague, Dr. E. F. Tholen.

The next patient, a man of 29 who gave a history of nasopharyngeal symptoms of more than ten years duration, was referred on account of

the presence of a mass in the pharynx, occasional nasal hemorrhage, and difficult deglutition. He had been living on a milk diet for two months, and it was approaching the point where even milk was difficult to swallow. He had lost 30 pounds in three months. Examination showed the tumor filling the entire nasopharynx down to the hypopharynx. At operation, the origin was on the left side of the base of the skull, and the growth extended into the left naris. The tumor measured 12 cm. by 4 cm. after removal.

A boy of 16 was admitted to the hospital for nasal hemorrhage which could not be controlled by packing. Examination revealed a large fibroma. As an emergency measure, the right external carotid was ligated, promptly stopping the hemorrhage. A transfusion was given. Later, the growth was removed in the usual manner and was found to originate from both sides of the base of the skull. On removal of the mass from the left side, the bleeding was so severe that it was necessary to tie the left external carotid in order to control the hemorrhage.

The other three cases were without incident.

## Summary

The tumors were large in all of the cases, and, in the majority, filled the postnasal space. All had nasal extensions. Five patients were referred because of severe hemorrhage. Preoperative transfusions were necessary in three cases. No postoperative transfusions were required. The ages ranged as follows: 13, 16, 16, 19, 28, and 29. All were males. One boy of 16 had a recurrence in seven months with severe bleeding, as he had had before the first operation. The same approach was used, and a very hard, small, fibrous mass was removed from the original site. It was apparent that a small base of this mass was missed at the first operation. There has been no recurrence in six years in this case.

All the patients recovered. There was one recurrence. The last patient was operated upon three years ago. All tumors were diagnosed microscopically before or afterward or both. The period of hospitalization averaged ten days.

## Conclusion

In the treatment of nasopharyngeal fibromata there are two main therapeutic measures—radium and diathermy, or surgery. If one chooses

surgery, it is believed that the transpalatine route offers the best opportunity for successful removal. The preliminary ligature around the external carotid adds considerable security to the procedure. The double line of sutures in the palate, plus chemotherapy, prevents perforation. We believe the transpalatine approach has a definite place in any consideration of the treatment of this type of tumor.


References

1. Allan, W.B.: Nasopharyngeal Fibroma. Arch. Otolaryng., 19:216, 1934.
2. Brunner, H.: Nasopharyngeal Fibroma. Ann. Otol., Rhin. & Laryng. 51:29, 1942.
3. Coates, George Morrison: Nasal and Naso-pharyngeal Fibroma, with a reference to multiplicity of growths. (Candidate's thesis) Trans. Am. Laryng. Assn. 1917.
4. Delavan, D. Bryson: Naso-pharyngeal Fibroma. Trans. Am. Laryng. Assn. 1911.
5. Friedberg, S. A.: Vascular Fibroma of Nasopharynx (Nasopharyngeal fibroma) Arch. Otolaryng. 31:313, 1940.
6. Goldsmith, P. G.: Naso-pharyngeal Fibroma. J. Laryng. & Otol. 38: 565—1923.
7. Hill, F. T.: Nasopharyngeal fibroma—with report of case with secondary pneumocephalus. Ann. Otol., Rhin. & Laryng. 51: 105, 1942.
8. New, G. B. and Figi, F. A.: Treatment of Fibromas of Nasopharynx. (C. P. Mayo '24). Am. J. Roentgenol. 12:340, 1924.
9. Figi, F. A.: Fibromas of Nasopharynx. J. A. M. A. 115: 665, 1940.


## DISCUSSION

Perry G. Goldsmith, M.D.: I arise not to add very much to the nice presentation which Dr. Brown has given you, but to make a confession.

I happen to be one of those who in his earlier years operated on a fair number of these cases, one of which I will tell you about.

It was done very similarly to the way the incisions were done in the palate, and it was done at the time when we first secured a suction apparatus. The hemorrhage was very free but we had seen them before. We thought we were unusually brilliant in stopping this. But this was the first time we worked with a suction apparatus and the patient bled to death because we did not see the blood. It went down under the table into a receptacle which we could not see. The patient got back into bed but he died of hemorrhage.

A South African Surgeon has devised a method by which he uses rasps and taking advantage of the formation of these tumors, that they are attached to periosteum, he attacks going down to the periosteum, lifting up, crushing and twisting them off.

Some call them sarcomata. That all depends upon the pathologist who gets hold of it. If you happen to have the type of tumor in which the cellular elements are unusually developed, then it becomes a sarcoma. If it is all practically fibrous

tissue then it becomes a fibroma. It really does not matter a great deal because a large fibroma is malignant in the sense of pressure and doing damage.

I hope this Association will encourage the recitation of mistakes rather than brilliant results.

In another case of a young man there was a very large fibrosarcoma. In this case hemorrhage was feared. He was operated on and the hemorrhage was terrific. One carotid was tied. They tied the wrong side. The other side was then tied. There was still hemorrhage but not a great deal. The tumor was not all removed. But here was a boy who had both carotids tied. What was his ultimate result? High voltage was used in the nasopharynx and the remainder of the growth rapidly disappeared. The end result was he was one of the finest airmen the Canadian Army had in the last war.

I am simply telling you these two things, that both of these mistakes were somebody's mistakes. The second was not mine if it will suit anybody, but the first one was my mistake, and I have also reached the conclusion that however brilliantly this surgery may be done, there still remains the use of radiation which produces I think unusual results and is very much safer for the patient.

F. T. Hill, M.D.: Dr. Brown has suggested that there are two approaches to this problem.

I think it is perhaps rather unfortunate that we use the term "fibroma of the nasopharynx" because it does suggest a surgical approach. While these tumors derive from the fibrous tissue of the periosteum of the base and body of the sphenoid, actually they are very vascular. Perhaps the term "vascular fibroma" or "angiofibroma" would be a more accurate description of it.

We also must keep in mind that they may invade various adjacent structures and may make operation not always the thing to do.

I have two slides I would like to show.

(Slide) Here was a case of spontaneous pneumocephalon from an angiofibroma which had invaded not only the nasopharynx but the ethmoid and orbit and had eroded the floor of the anterior fossa causing this spontaneous pneumocephalon.

(Slide) Under treatment with radon implantations plus electrocoagulation, as has been suggested by Figi, we got a very excellent result with complete regression and the young man was accepted in the Navy during the last war.

It is well to keep in mind that oftentimes the approach to these tumors may not be surgical, that they may have rather masked extension into adjacent tissues.

John H. Foster, M.D.: Dr. Brown has given a beautiful description of an operation, one that is evidently satisfactory in its results despite the fact that there have been some recurrences.

Those of us who have had occasion to deal with these tumors over many years have sought an operation that was effective and free from the really terrible hemorrhage seen if the external carotids are not tied. As a substitute we have

tried radiation in different forms. As a result I may say that I have become convinced that the necessity of surgery arises in few cases. Since we have used radon seed implantation, I have not seen a case that did not respond to radiation. True in the case of large tumors it is necessary to observe them for a considerable period and repeat the implantation from time to time, but with long needles it is possible to cover a large part of the tumor at one time and I have never had any severe hemorrhage after the first treatment. After two or three treatments I have in two cases removed a small tumor remaining without trouble from bleeding. The vascular mass seemed to have become a simple fibroma.

The point I wish to make is that radon implantations will cause absorption of these tumors and control the bleeding. Where the patient cannot be seen for a long time, of course we must resort to surgery and Dr. Brown has described an operation to fit such cases.

FREDERICK A. FIGI, M.D.: Mr. Chairman, Fellows and guests. I wish to congratulate Doctor Brown on the excellent results he has obtained in this group of cases. The surgical removal of juvenile basal fibromas of the nasopharynx is one of the most formidable procedures in rhinolaryngologic surgery.

In our experience such surgical removal is possible in only comparatively few instances, since most of these tumors are not limited to the nasopharynx. Many of them extend from this situation and fill a varying portion of the nasal fossae, the antrum, ethmoid cells, orbit and retromaxillary fossa. At times they protrude posterior and lateral to the tuberosity of the maxilla and bulge the cheek externally.

At present our choice of treatment in these cases is to electrocoagulate the accessible portion of the tumor and use interstitial radiation in the remainder. With this therapy even the most extensive of these neoplasms have been controlled. I agree with Dr. Foster's statement that these fibromas can be eradicated with radiation alone. In fact, for a period, we employed this therapy exclusively in this group. However, it requires a longer period of time, a greater number of treatments are necessary and later the patients experience more difficulty with atrophy of the mucous membrane, foul crusting and recurring hemorrhages.

A case which I have recently had under treatment may be of interest in this connection. The patient, a young man, 18 years of age, came to the clinic eight months ago with a very extensive fibroma of this type filling the nasopharynx, the right nasal fossa, the antrum, the ethmoid cells and the retromaxillary fossa, and bulging the right cheek markedly. Following preliminary ligation of the right external carotid artery, the tumor was exposed through a trans-antral approach and as much of it as possible destroyed with the diathermy electrode. Radon seeds were implanted in the portions that could not be safely electrocoagulated.

Recently a letter was received from this boy's local throat specialist stating that the patient had developed a cerebro-spinal rhinorrhea and he was advised to return for observation. Upon his return the patient was greatly depressed mentally over what he had been told about his condition. Inquiry revealed that

the nasal discharge was watery, was most profuse at meal time and was greatly increased by drinking fluids. Examination showed the opening of Stensen's duct to be situated directly opposite the postoperative defect through the alveolus into the antrum. There was complete absence of the naso-antral wall and it was evident that secretion from Stensen's duct drained directly into the antrum and out of the nostril.

Investigation of the nasal discharge showed that it was salivary secretion, not cerebrospinal fluid. Closure of the perforation between the mouth and the antrum cured the condition.

J. M. Brown, M.D. (Closing) : Mr. Chairman, I have no quarrel with those who wish to use radium. It does, however, take considerable time to get a satisfactory result. Also it has some definite deleterious after-effects in the atrophy of the mucosa of the nose and pharynx.

The younger patients with a greater tendency for recurrence may be better treated by radium and also the types of cases mentioned by Drs. Figi, Hill and Foster with intercranial and other complications, but for the types presented in my paper I believe surgery has a distinct advantage and should be preferred to radium and I would consider the transpalatine approach the best for this class of tumors.

# A STUDY OF THE EUSTACHIAN TUBES AND THEIR ORIFICES AND LUMENS ON PATIENTS WITH LARGE OPERATIVE DEFECTS GIVING DIRECT VISUALIZATION

## Further Studies of the Muscles of Phonation and Deglutition*

W. LIKELY SIMPSON, M.D.
JONES E. WITCHER, M.D.
(By invitation)
MEMPHIS, TENNESSEE

The usual textbook description of the eustachian tube is as follows: "The eustachian tube is composed of an osseous and cartilaginous portion, being narrowest near this junction. The osseous portion opens into the middle ear in the upper half of the anterior wall of the tympanum. The cartilaginous portion is pharyngeal and forms two-thirds of the entire length. While the osseous portion is always open, the trumpet-shaped pharyngeal end is closed except during the act of swallowing or yawning, when its lumen is temporarily widened by the contraction of the levator and tensor veli palati muscles, mainly the latter. The manner in which air pressure equalization is effected is through intermittent openings of the muscular portion of the tube which takes place simultaneously with the act of swallowing."

Schwarzbart[1] describes the osseous portion of the tube as being an anterior evagination of the tympanic cavity and always open as are the epitympanum or hypotympanum, and gives this bony space the name protympanum. He states that according to Fraser the cartilaginous tube originates from the first branchial cleft while the protympanum or osseous portion originates along with the tympanic cavity from the second branchial cleft.

Cartilage wherever found in the body is serving certain functions: strength, contour, bone formation and patency. Examples: larynx, external ear, trachea, nose, etc.

The tubal cartilage is in the form of an elongated triangular sheet with its base directed antero-medially and with its apex at the isthmus

* From the Department of Otolaryngology and Broncho-Esophagology, University of Tennessee, Memphis, Tennessee.

where it joins the osseous portion. The cartilage is thickest inferiorly, narrows gradually superiorly and finally becomes a hook of cartilage which bounds the eustachian canal superiorly and anteriorly, generally in the shape of a shepherd's crook. Two parts are distinguished in the cartilage of the tube, a medial lamina which is protruding posteriorly, and a lateral lamina which is situated superiorly and anteriorly. In a series of cross sections the cartilage near the pharyngeal ostium is in the shape of a right angle, while that of the tube farther away is crook shaped. A varying number of accessory cartilages are described.

Being of the structure and form to insure patency, why then should the tubal cartilages depart from the usual function and allow the tube to be closed as described by many writers.

Rich,[2] in his excellent paper on the physiology of the eustachian tube and its related muscles, reviewed the controversial history and after many experiments came to the following conclusions: 1. Normally, the eustachian tubes are closed. They are opened during the swallowing and sneezing reflexes. They exhibit no independent reflex dilations either periodic or irregular. Normally, they are not opened by respiratory movements, either quiet or forced, and are unaffected by mouth-breathing or by simple elevation of the soft palate (produced by contraction of the levatores palati alone).

2. Although a most important function of the eustachian tube is that of equalizing the atmospheric pressure on both sides of the tympanic membrane, the mere existence of a disturbed pressure equilibrium will bring about no regulatory reflex. Deglutition, as a means of restoring pressure equilibrium to the ear-drum, is performed, when necessary, consciously or through habit; but this reflex is never set in motion directly by the stimuli arising from tension of the tympanic membrane.

3. The levator palati, the palatopharyngeus, the internal pterygoid and the superior constrictor muscle of the pharynx (each of which has been variously described as a dilator or constrictor muscle of the eustachian tube), were found to exert, by their contractions, no influence whatever upon the patency of the orifice or lumen of the tube.

4. The tensor palati is the only muscle which is functionally related to the eustachian tube. Contraction of this muscle is always accompanied by a dilatation of the tubal orifice and lumen. There exists no con-

strictor muscle of the tube. Relaxation of the tensor palati is followed by a passive return of the tubal walls to the condition of approximation which they normally occupy when at rest.

Graves[3] and Edwards, in their paper, did an excellent piece of work on the anatomy and physiology of the eustachian tube, especially as regards the microscopic anatomy. They describe the tubal cartilages and sections of the tube at different levels. They describe the lumen of the tube from the pharyngeal opening to the isthmus without reference to its being collapsed or closed, saying, "At the isthmus the lumen is still somewhat slit-like, but the vertical height is reduced."

Perlman,[4] in his article on patency of the eustachian tube discussed the clinical entity of the abnormally patent eustachian tube and quotes a number of cases. He states that the eustachian tube is normally closed and its walls are held in apposition by the tonus of the tubal muscles.

Shambaugh,[5] in his articles on the continuously open eustachian tube, states, "The normal eustachian tube lies closed in its cartilaginous portion forming a vertical slit. This closure is maintained by a thick pad of fat which surrounds the lateral wall of the cartilaginous tube. During yawning or swallowing the tube opens momentarily, as a result of the action of two muscles, the levator palati and the tensor palati."

Joachim[6] was fortunate in having a patient in which there was a defect enabling him to directly visualize the eustachian tube and palate from above and externally. He describes the movements of the soft palate and labia of the eustachian tube during phonation, deglutition, coughing, retching, yawning, etc., and concludes, "From the observations made on this patient I came to the conclusion that the tube opens during the act of swallowing, as it was possible to look deeply into the gaping ostium, when the patient was examined for a length of time, during which the mucous membrane would become dry. In the position of rest the lips of the orifice of the tube are in contact in their whole extent, and the cleft is turned forward."

Toynbee[7] says the eustachian tube is closed except during muscular action and that the tympanum forms a cavity distinct and isolated from the outer air.

Cutter[8] says the eustachian tube is open normally but closed in deglutition.

Von Troltsch[9] says the tube is normally closed but must open during deglutition.

Semeleder[10] says the tube narrows in all movements.

Patel and Pellanda[11] said that through a neoplastic opening there were vague movements of opening and closing of the tube during respiration.

Caldera[12] says the tube is always open.

Cleland[13] states that the tube is always open and momentarily closes in swallowing. He had a patient in which an ulcerative defect was so situated that the orifice of the eustachian tube could be clearly visualized. He states that the patient's hearing was unimpaired and he heard as well in one ear as the other. He says that the walls of the tube were ascertained not to be in contact, at least for a considerable distance back from the orifice. He says that a stopper placed up into the tube for more than one-half an inch made no observable difference in hearing through the external auditory meatus.

"To disprove the theory that the eustachian tube is usually closed, and is opened in swallowing, we have yet to seek an explanation of the phenomena on which the theory is based, and particularly of the circumstance that when air is blown into the tympanum, displacement of the membrana tympani continues until the act of swallowing is performed. The explanation that a film of moisture occludes the tube, an explanation which must have forced itself on every uninitiated person suffering from coryza, is, I believe, the right one. The propulsion of air through the nares acts powerfully in setting the moisture of the mucous membrane in motion; and in the eustachian tube it sends it back in the contrary direction to that in which it is normally carried by the cilia of the epithelial lining. The transverse diameter of the tube is extremely small, and a very slight accumulation of moisture in any part of it will cause, by capillary attraction, an obstruction sufficiently strong to resist a considerable pressure of air, or possibly may even cause its sides to adhere with the action of a sucker. The sudden closure and alteration of the form of the tube in swallowing, and the equally sudden recovery of its natural form is precisely the operation most likely to burst such an obstruction, expel superabundant moisture, and allow the escape of pent-up air. The disagreeable sensation in the ears

in descending in a diving bell seems to depend on more than one cause, but engorgement of the mucous lining of the eustachian tube and atmospheric pressure at its pharyngeal extremity are things very likely to occasion obstructions of the lumen. Once such obstruction is formed and the freedom of communication of the tympanic cavity with the external air is checked, discomfort may be expected to begin immediately.

"A point in favor of this view, is to be found in the circumstance that when the sensation of pressure on the tympanum has been accidentally produced by blowing the nose or in some other way, if it be allowed to remain, or if swallowing is ineffectual to remove it, it will often, after a little, suddenly disappear with a slight noise when no act of swallowing is being performed."

Our observations have been made upon five patients in whom there were large operative defects, making possible direct visualization of the palate, nasopharynx and eustachian tube regions.

The first patient was a man in whom a tumor mass had been pres-

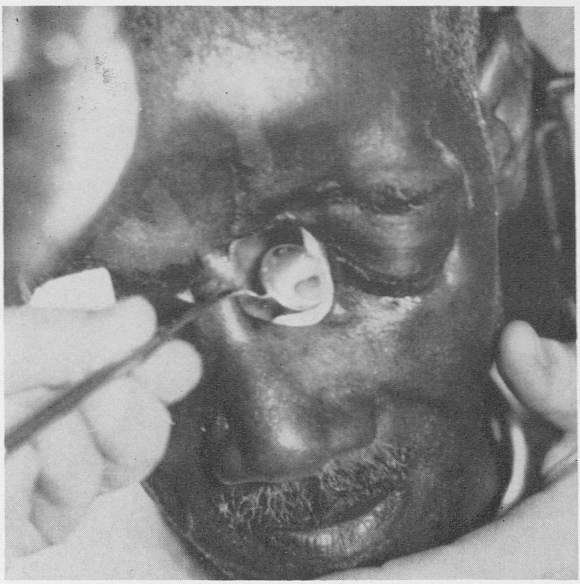

*Fig.* 1, *Case* 1.—The open eustachian tube as visualized in the mirror.

ent for five years with marked external deformity for two or three years and almost complete obstruction of the nose. The patient's face was greatly deformed by the presence of a bulging mass situated between the eyes, extending up to the forehead. The left eye was displaced very much laterally and downwards. The mass was firm and immobile and did not seem to be attached to the skin.

On January 30, 1943, the tumor mass was removed in toto. It was attached to the dura by a pedicle from its posterior superior aspect, in the region of the posterior ethmoids. The dura was removed with the tumor over an area of about two inches in diameter, overlying the left frontal lobe. There was a true retrobulbar abscess which was evacuated and drained. All of the sinuses on both sides of the nose were in a suppurative condition. Sulfanilamide was dusted into the wound after hemostasis was secured and the cavity was packed with iodoform gauze. Within a few weeks after the primary operation, all of the sinuses on both sides were exenterated, leaving a large external opening through the bridge of the nose and sinus region.

*Fig. 2, Case 2.*—A combined view of the open eustachian tube: one direct and the other in the mirror.

The second patient is a 55-year-old colored male who had an ulcerative, soft intranasal tumor which had been present for eight months, increasing rapidly in size. The biopsy was returned with the diagnosis of lymphosarcoma. Under general anesthesia, a modified Moure incision was made and the interior of the nose exposed. The tumor was firmly attached to the skin and involved the antrum and ethmoids on the right. The incision was then extended and the entire nose removed along with the involved antrum and ethmoids on the right side. The resulting defect gave an excellent opportunity for study of the nasopharyngeal region.

The third patient is a 63-year-old colored female, with a large ulcerative lesion of the left eye, orbit and bridge of the nose. The lesion had been present for two years, during which time she had received extensive radiation without beneficial results. A biopsy was taken reconfirming the diagnosis of basal cell carcinoma. The tumor mass was removed in block, with exenteration of the orbit and all of the involved sinuses on this side, leaving a large defect through which the nasopharynx can be directly visualized and studied.

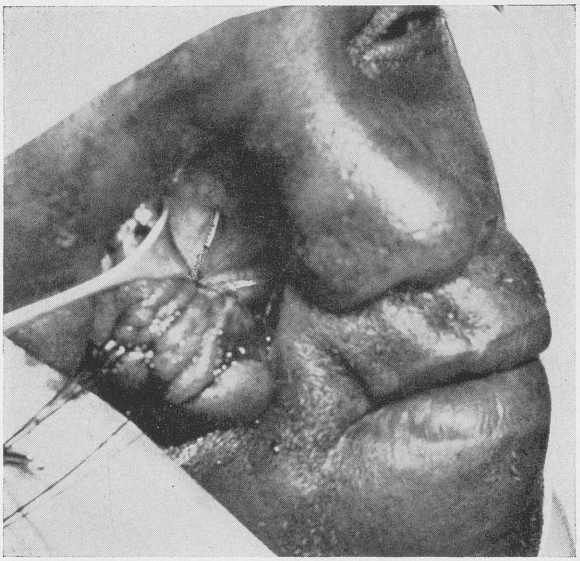

*Fig. 3, Case 4.*—Eustachian tube as seen directly with a calibrated probe 12 mm. within its lumen.

The fourth patient is a 67-year-old colored male who had a tumor of the right malar, alveolar and orbital regions for about one year with an obstructing, bleeding mass on the right lateral wall of the nose. A biopsy of the tumor from the lateral wall of the nose was reported as squamous cell carcinoma. Under intracheal anesthesia a modified Moure incision was made. Resection of the right maxilla and all soft tissues except the skin anterior to the prominent portion of the maxilla, the hard palate to the median line, as well as an exenteration of the right orbit and all sinuses on the right was done. The patient made a rather rapid recovery and through the defect in the mouth as well as the orbit an excellent study of the nasopharyngeal region and eustachian tube was made.

The fifth patient is a 65-year-old white female who had a large adeno-carcinoma of the upper jaw, filling the antrum, destroying the lateral wall of the nose and the floor of the orbit. Under local anesthesia the tumor mass was removed with exenteration of the orbit and lateral wall of the nose. The patient responded nicely and at the pres-

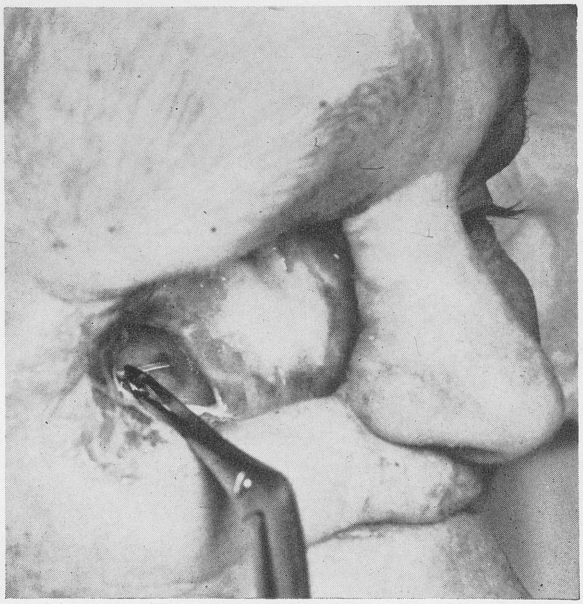

*Fig.* 4, *Case* 5.—Direct visualization of the open eustachian tube.

ent time has a large defect through which the nasopharynx and eustachian tubes can be visualized and studied directly.

Study of these cases demonstrates the following: The movements of the soft palate, uvula, eustachian tube and lateral walls of the pharynx in pronouncing the vowels and consonants are the same except for degree.

As the letters are pronounced, the soft palate and uvula are drawn superiorly. The lateral walls of the pharynx are drawn superiorly, posteriorly and medially. There is a slight displacement of the torus tubaris upward and posteriorly and the region of the mouth of the eustachian tube, especially inferiorly and posteriorly, due to the above described actions, but there is no tendency for the tubes to close. If there is any appreciable change it is for the lumens to become larger.

When the patients yawn, the movements of the soft palate and lateral walls of the pharynx and the lumen of the tubes are the same as in pronouncing the vowels, except the action is prolonged.

In swallowing, there is no change in the lumen of the eustachian tube in the first four cases; in the fifth there is a slight widening of the orifice and lumen.

In swallowing, the soft palate and uvula have two movements; the first, a very minor movement, consisting of slight elevation of the soft palate in the region of the uvula, with the lateral walls of the pharynx below the eustachian tube being drawn towards the median line. This primary movement is followed immediately by the second, the major movement, consisting of the posterior one-third of the soft palate and uvula being drawn about one-half inch higher than the resting plane. The remainder of the soft palate is drawn downward, the lowest portion being about one-half inch posterior to the attachment of the soft and hard palate. The depression is across the whole extent of the soft palate but is most marked at the middle portion. Following the initial depression of the soft palate and uvula in swallowing, they are drawn superiorly, posteriorly and medially along with the lateral walls of the pharynx.

The highest point of the soft palate in phonation, deglutition, etc., is 3—5 mm. below the level of the hard palate.

There is hermetic closure of the nasopharynx from the hypopharynx during deglutition.

A moving picture, "The Action of the Muscles of Phonation and Deglutition as Viewed Through Operative Wound of the Frontal and Ethmoid Sinuses," was shown at the annual meeting of the American Academy of Ophthalmology and Otolaryngology in 1944.

The anterior labia of the eustachian tube (salpingo-palatinus muscle) extends anteriorly and inferiorly in the superior part and then runs vertically inferiorly to the soft palate, disappearing as it joins the soft palate. The lengths of the anterior labia are from 12-14 mm.

The posterior labia are more prominent, the superior part being known as the torus tubaris. The inferior part of the labia becomes the salpingo-pharyngeal fold which encloses muscle of the same name. This fold runs inferiorly, disappearing from view, joining the soft palate. The length of the posterior labia are from 14—16 mm.

From the lower end of the anterior labia (in a horizontal direction posteriorly) to the torus tubaris is approximately 13 mm.

The anterior and posterior labia gradually converge as they extend superiorly and finally join at their upper extremities.

A calibrated probe enters the tubes from 10—20 mm. without difficulty and can be visualized clearly by use of a mirror.

The anterior labia of the eustachian tube orifice is 6½-7½ mm. posterior to the posterior end of the inferior turbinate.

It is 12—15 mm. from the posterior ends of the inferior turbinates to the posterior labia.

The lower borders of the inferior turbinates, if extended posteriorly, would cross the superior one-third of the eustachian orifices.

The first three and the fifth cases discussed have bilateral patent eustachian tubes. The fourth case has a patent tube on the left and scarred hypertrophic, occluded tube on the side of the lesion. The occluded tube does not change or open with any type of voluntary or involuntary movements and is readily seen to be a pathological eustachian tube.

## Summary

Five cases, with large anatomical defects, enabling direct visualization and direct mirror examination and study of the soft palate, nasopharynx and the lumina of the eustachian tubes, were presented and discussed. Special attention was given to the study of the movements of the palate and patency of the eustachian tube.


## Conclusions

1. The normal eustachian tube is open at all times.
2. No voluntary movement closes or occludes the eustachian tubes.

## References


1. Schwarzbart, A.: New Otological Views, J. Laryng. and Otol. 59:47, 1944.
2. Rich, A. R.: A Physiological Study of the Eustachian Tube and Its Related Muscles, Johns Hopkins Hosp. Bull. 31:206, 1920.
3. Graves, G. O., and Edwards, L. F.: Eustachian Tube, Arch. Otol. 39:359, 1944.
4. Perlman, H. B.: The Eustachian Tube, Abnormal Patency and Normal Physiologic State, Arch. Otol. 30:212, 1939.
5. Shambaugh, G. E., Jr.: Continuously Open Eustachian Tube, Arch. Otol., 29:420, 1938.
6. Joachim, O.: Contribution to the Physiology of the Soft Palate.
7. Toynbee, J.: On the Muscles Which Open the Eustachian Tube, Proc. Royal Soc. Lond. 6:286, 1935.
8. Cutter, E.: Normal Condition of the Eustachian Tube, Boston M. and S. J. 76:75, 1867.
9. vonTroltsch: Beitrage zur anatomischen und physiologischen wurdingung der Tubenund Gaumen- Muskulatur. Arch.f.Ohrenheilk, 1:15, 1864.
10. Semeleder: "Die Rhonoscopie u ihr. Werth f.die artzliche Praxis" Liepzig, 37, 1862.
11. Patel and Pellanda: Notes sur la physiologie du viole du palais. J. de phys. et de path. gen. 5:47, 1903.
12. Caldera: Arch. Ital. di Otol. 29:149, 1918.
13. Cleland: On the Question Whether the Eustachian Tube is Opened or Closed in Swallowing, J. Anat. & Physiol. 3:97, 1869.


## DISCUSSION

F. T. Lederer, M.D. (By invitation): Dr. Simpson has endeavored to make a physiological observation in the presence of a non-physiologic medium.

I have no brief with the thought that the eustachian tube is either closed or open. However, it is apparent from a remark that he made, that he considers it necessary for normal functioning to have, in addition to proper muscular structures, a hermetically sealed cavity. I wish only to draw attention to the fact, that inasmuch as we require for speech a resonating chamber, is it not true that it would be necessary to observe the eustachian tube, if we wished to appraise

its normal physiologic action, under other circumstances than these which have been used as evidence?

I think many of us have had the very rewarding experience of doing maxillary resections such as Dr. Simpson has shown and have observed this eustachian orifice very clearly. It has made excellent student presentation. But I would just like to ask Dr. Simpson whether he considers this a proper physiologic medium for making certain, as he does in his statement, that there is no change in the eustachian orifice under these conditions which he has told us about?

B. N. Colver, M.D. (By invitation): I was impressed, as was the last speaker, that with altered anatomy one might logically expect altered physiology. Besides this, I have always felt that whatever happened in the way of closure, or opening, or the remaining opening or remaining closure, happened not at the orifice which is visible but at the isthmus, which, as you know, is well up toward the middle ear.

Whether the opening or closing is strictly the result of muscular action, or whether it is due to the pneumatic plus or minus pressure is another question which should be considered.

W. Likely Simpson, M.D.: In closing the discussion, and answering the question of Dr. Lederer, I would say that these examinations were made soon after the operative procedure, and they did not change from the first time I examined them over a period of years.

The tube is closed at the pharyngeal end. With the normal ears and hearing, in the five cases we have examined, the tube is not closed at any time and any amount of swallowing, deglutition and what not, does not open or close the tube. It does not change. There is hardly any possibility from my viewpoint to see how you can have a tube almost completely surrounded by cartilage to be normally closed.

I think my discussion has also answered Dr. Colver's question.

# PATHOLOGY AND SURGERY OF EXTRINSIC CANCER OF THE LARYNX

HENRY BOYLAN ORTON, M.D.

NEWARK, NEW JERSEY

Extrinsic cancers of the larynx are causing a great deal of controversy as to their treatment. It is true, they are more malignant than the intrinsic type. Insidious in their onset, they spread rapidly to the glands at a very early stage. Some authorities say they are not arrested or cured by surgical operation, and should be turned over to the radiologist for deep x-ray therapy. In this I most emphatically disagree. For example, a patient on whom I did a lateral pharyngotomy for a lateral wall pharyngeal cancer lived 11 years after operation. It is true that the diagnosis must be made early, and proper operative procedure instituted.

Extrinsic cancers originate around the glottic opening or on its outer surfaces. They may be subdivided into those neoplasms arising from the epiglottis, the aryepiglottic folds, the arytenoids, the pyriform sinuses, the postcricoid area and the lateral and posterior walls of the pharynx. The last two may be considered pharyngeal. I believe that with the diagnosis made early, good results can be obtained by the proper surgical procedure. However, too often when the patients present themselves for examination they are beyond any hope of a five-year cure. All types of involvement should be diagnosed early, for they are readily seen by direct or indirect examination.

Extrinsic cancers are usually of squamous cell type, although they may be papillary or occasionally of basal cell type. Sarcoma is also found. The lymphatic glands are invaded early and consistently; the course is fairly rapid, and unless prompt treatment is instituted, a year and a half is the average span of life for the patient.

It is true that cancer cannot be cured in all cases, but certainly if this region is examined with painstaking thoroughness much can be accomplished by early diagnosis and radical operation, as cosmetic consideration has no place in the treatment of malignant growths. Let us take up the different locations of these tumors.

*The epiglottis.* Some authorities say that a cancer on the edge or on the laryngeal surface of the epiglottis, may be approached by a lateral pharyngotomy and the epiglottis excised, so as to leave the main structure of the larynx intact.[1] I shall qualify that statement by saying that the growth on the epiglottis must be above the level of the hyo-epiglottic ligament since early invasion of the pre-epiglottic space is certain to take place with any growth below this level. This pre-epiglottic space, or the space of Boyer, will be taken up later. Suffice it to say that I strongly recommend that with any growth of the epiglottis below the level of the hyo-epiglottic ligament, the epiglottis with the larynx and hyoid bone should be removed in toto. This seems radical, but radical we must be if success is our goal. Any growth above the hyo-epiglottic ligament may be removed by lateral pharyngotomy.

*The lateral walls of the pharynx.* This type of cancer can be removed by lateral pharyngotomy, preceded by gland dissection at the time of the operation preferably, followed by plastic reconstruction at a later date if necessary.

*The aryepiglottic folds.* If seen early, cancer in this region may be removed by lateral pharyngotomy, but usually by the time the patients present themselves to the surgeon for operation, the growth has already extended beyond the area for this type of operation, and we must resort to a wide excision of the larynx with the hyoid bone and pre-epiglottic space, and maybe some of the lateral wall of the pharynx.

*The pyriform sinus.* Here the tumor infiltrates both the outer as well as the inner walls of the sinus which is so closely connected with the larynx, that nothing short of a complete laryngectomy with the hyoid bone and pre-epiglottic space would be of any good. Even then a gland dissection may be necessary in conjunction with the procedure.

*Postcricoid.* If seen early, a lateral pharyngotomy with plastic reconstruction following at a later date, but if a cord is fixed and the cancer has advanced nothing but a pharyngo-laryngectomy, followed by plastic reconstruction, if necessary, is of any use.

The operation of lateral pharyngotomy is an ideal operation for inspection and removal of cancer of the lateral and posterior wall of the pharynx. It has, however, its limitations. It is like the laryngofissure operation in intrinsic cancer of the larynx. Lateral pharyngotomy

is only for early cases of extrinsic cancer of the lateral and posterior walls of the pharynx, and the epiglottis, if the growth is above the hyo-epiglottic ligament as mention above. Complete destruction of all cancer cells is at present the only known method of effecting a permanent cure, whether this be by surgery, radiation or by some biological change in our makeup.

Sarcoma of the larynx based on the number of cases reported in the literature during the past two decades would indicate that it is rare. It is a disease of adult life more common in males than in females, the ratio being about one in 71. The varieties are melanosarcoma, pre-epithelial sarcoma, lymphosarcoma, myxosarcoma, schwannoma and a fibrosarcoma. Another rare tumor but on the borderline is chondroma which arises either from the thyroid or cricoid cartilages.

We know the prognosis in the extrinsic type of cancer is not as good as in the intrinsic type, owing to the early invasion of the lymphatics in the former. However, among my patients with growths of Grade IV one who had an adenocarcinoma died two and a half years after operation of metastasis in the brain and lung. Another, who had intrinsic cell carcinoma died of apoplexy two and a half years following operation without recurrence. A third, who had a squamous cell epithelioma of the right pyriform sinus is still living and a fourth who had a squamous cell carcinoma died of pneumonia six days following operation.

In Gordon New's observation on the microscopic extension of the tumor taken at five, ten, and 15 millimeters from the apparent margin of the growth, he found that the maximal extension of highly malignant tumors from the apparent margin of the growth was 15 millimeters. This has been confirmed by Broyles[2] and Snitsman,[3] who have both shown that the cancer cells have extended beyond the apparent growth histologically, in the anterior commissural tumors of the cord—an additional reason why the pre-epiglottic space is invaded early, and should be removed with the larynx. I have also demonstrated this at time of operation in pre-epiglottic cancer below the hyo-epiglottic ligament. I make it a routine practice to examine every biopsy histologically before operation in all my cancer cases, in conjunction with the pathologist—to me, a most valuable procedure.

*The pre-epiglottic space or the space of Boyer.* Jean LaRoux

Robert[4] in a beautiful article in 1936, demonstrated the invasion of the pre-epiglottic space and Tambein demonstrated histologically that cancer of the vestibule and ventricle of Mogagni, invaded the pre-epiglottic space and stated that the classical laryngectomy is insufficient for the complete eradication of cancer in these cases. In 1939 at the American Academy of Ophthalmology and Otolaryngology I showed a movie of this procedure. Later Clerf[5] brought the subject up again in a paper "The Pre-Epiglottic Space—Its Relation to Cancer of the Epiglottis," and stated that the keynote is, that we should get away from the conservative treatment of carcinoma of the extrinsic type, as we gain nothing by appeasing carcinoma by subperichondrial resection, or narrow field operation. This space has been described very completely by Robert and time will not be taken up to discuss it further.

In extrinsic cancer again the operability of the growth may be determined only by the actual exploration with or without the pharynx being open. At present we must rely upon methods which have been employed for some time—chief among these are surgery and radium. If surgery is to secure the best results, the diagnosis must be made early. Therefore, once the diagnosis is made it is necessary to decide without prejudice which treatment is best for the patient, surgery or irradiation. If by irradiation, then the radiologist must be given full charge and left to pick the technique he believes best. If by surgery, then the surgeon's experience with this type of surgery must be taken into account. In a recent paper by the late Sir St. Clair Thompson,[6] he emphasizes strongly the need of trained surgeons for this type of work. Lionel Colledge also states that the cases of extrinsic cancer of the larynx suitable for excision must be selected with care and judgment and with some regard to the capacity of the operator. This type of work should be in the hands of the laryngologist. The surgical treatment for the extrinsic cancer of the larynx, is more difficult, in that the entire larynx with some pharyngeal tissue must of necessity, according to the site of tumor, be removed along with the larynx, with the possible exception of the cancer of the epiglottis on the laryngeal surface above the level of the hyo-epiglottic ligament as has been stated above. If such a case presents itself then the upper part of the epiglottis can be removed by a lateral trans-thyroid-pharyngotomy, with excellent prospects of a lasting cure. For the other types of extrinsic laryngeal cancer, we may have, due to free lymphatic drainage of the area involved, some glands

along the deep cervical chain. These must be taken care of if present, and the only way you can thoroughly explore the deep cervical chain is by a wide exposure of the operative field. By removing the larynx from above downward one has before him the entire field of operation macroscopically, and is able to judge the necessary amount of pharyngeal tissue to be included in the operation. This procedure is known as pharyngo-laryngectomy. In this operation so much of the pharynx may be removed that the closure must be a pharyngostomy and a secondary operation performed later to close this opening. The steps are similar to the lateral pharyngotomy and that operation. In view of the known results of surgery of the pharynx, is it fair to ask what are the results without surgery? There is no more dreadful form of malignant disease than the favorable easy types left untreated and which are spared nothing in the end. From an anatomical and surgical standpoint, the operation of lateral trans-thyroid-pharyngotomy gives a splendid exposure to the side of the neck. In the laryngo-pharyngectomy cases all of the larynx and the necessary part or all of the lower pharynx is removed. The raw surface is covered with skin, leaving an upper and a lower stome, which must be closed later on by one or two plastic operations for the reconstruction of the pharynx and upper esophagus.

This now brings us to irradiation therapy. Treatment by irradiation has been widely studied in the treatment of laryngeal cancer and is very interesting. Unfortunately, the results of the treatment do not lend themselves to satisfactory comparison and the subject is not sufficiently advanced to be reviewed historically. For instance, the type of case in which the radiologists promise most is that type of intrinsic cancer limited to one cord. It is in this type of case that the lasting benefits of treatment by surgery is well established, and the percentage of cures by surgery far surpasses those cured by irradiation. To me, in all cases where surgery can hold out good promises of lasting cure, it still must be given the preference. When the extent or nature of the disease, or the age or health of the patient are counter indications then irradiation should be given a trial. It is commonly supposed that the use of radium or some form of radiation has greatly simplified the treatment of epithelioma of the pharynx. This supposition is not true. Radium has given us a new and a very powerful addition to our means of attack, but far from simplifying the attack has made it more than ever dependent on experienced judgment and expert handling. It is

possible even that up to the present time the total results as to cure or notable periods of freedom from recurrence are actually worse for the introduction of radium, since it seems likely that many patients who might have had a good chance of cure by operation in competent hands have had their chances frittered away in ineffective irradiation treatment. This may only be a transit phase, for a proper appreciation of the technical requirements of sound irradiation treatment is already replacing the cruder view and must in time result in the full benefits of radiation being made manifest. And I am absolutely in accord with Colledge[1] when he states "as to results of irradiation, however, are so impossible to predict and the results at the end of three to five years so poor that I have abandoned it for every operable case, and only recommend it when the operation is refused or the case is inoperable. It is then a useful palliative measure and the growth often disappears for some months, but the lasting results are few." The claims of the radiologist now complicate the picture. These claims are often exaggerated. However, these claims may not be without good foundation. The surgeons use a five-year period as their basis for success whereas the radiologists do not. But they use a term that the growth has "regressed." Most of their claims are based on the fact that the cases best suited for radiology, are the very ones that are best suited for surgery, and in the inoperable cases when surgical treatment is more difficult, the radiologist has very little success. True palliative results may be obtained but patients are often made worse by perichondritis and radionecrosis. And so we might go on for and against surgery and irradiation. In order to try to simplify the matter, I include a table of the results according to the anatomical classification of extrinsic malignant growths by three radiologists and then a table of my own cases anatomically classified treated by surgery. The classification used by Lenz,[7] Martin[8] and Blady[9] is slightly different than the one that I use. They use the anatomical classification as follows: All tumors below the level of the ventricular band are called intrinsic cancer and all growths above this line are called extrinsic cancer. Whereas I have in the anatomical classification specified the site of cancer, also, I have included in my figures cancer of the lateral and posterior wall of the pharynx, which I do not believe they have.

## Conclusions

It is difficult to compare and appraise vital results; they are often incompletely recorded; some surgeons decline doubtful cases and will only accept those which promise definite results. I know of no operation that puts a greater strain on the surgeon than a complete laryngectomy, laryngo-pharyngectomy, or one which requires more meticulous care than a laryngo-fissure. In all of them, close, continuous, anxious and skilled after-care and attention is most necessary. Nurses and assistants should be specially trained. The surgeon must be prepared to make himself responsible not only for the operation but for all the necessary precautions and the important after-care. The difficulty and disagreements seems to be about the so-called extrinsic type of case. According to reports, there seems to be a controversy between operation and irradiation. With the incomplete reports of irradiation where the radiologist claims beneficial results, the erroneous belief has arisen that almost all, if not all cases of extrinsic cancer, should be irradiated in preference to surgery, and that the roentgenologist should be called in consultation as to the advisability of irradiation before surgery is attempted. Such fallacy I have attempted to show in my tables. I feel that surgery still holds a very important place in the battle against extrinsic cancer of the larynx and pharynx. This statement has been confirmed by others who are doing extensive neck surgery. It is a challenge to the younger men of laryngology to associate themselves with the men doing this type of surgery and by their efforts establish the same results as are obtained in the intrinsic cases.

EXTRINSIC CANCER OF THE LARYNX TREATED BY IRRADIATION AS COMPARED WITH SURGERY

| AUTHOR | NO. OF CASES | NO. FREE FROM DISEASE | PERCENTAGE OF CURES |
|---|---|---|---|
| Lenz | 32 | 5 | 15% (3 years) |
| Martin | 147 | 14 | 9% (5 years) |
| Blady | 12 | 3 | 25% (5 years) |
| Orton (surgery) | 51 | 14 | 27% (5 years) |

## CANCER OF THE LARYNX

### 140 CASES OF EXTRINSIC CANCER OF THE LARYNX OPERATED ON OR GIVEN SOME FORM OF RADIATION SHOWING RESULTS BY YEARS

| | | RADIATION: YEARS | | | | | | SURGERY: YEARS | | | | |
|---|---|---|---|---|---|---|---|---|---|---|---|---|
| SITE OF CANCER | NO. | 1 | 2 | 3 | 4 | 5 | NO. | 1 | 2 | 3 | 4 | 5 |
| Epiglottis | 9 | 7 | 1 | 0 | 1 | 0 | 12 | 3 | 1 | 1 | 2 | 5 |
| Epiglottic fold | 11 | 9 | 2 | 0 | 0 | 0 | 13 | 7 | 3 | 1 | 0 | 2 |
| Arytenoid | 7 | 5 | 2 | 0 | 0 | 0 | 6 | 2 | 1 | 1 | 0 | 2 |
| Pyriform sinus | 25 | 22 | 3 | 0 | 0 | 0 | 20 | 8 | 6 | 1 | 0 | 5 |
| | 52 | 43 | 8 | 0 | 1 | 0 | 51 | 20 | 11 | 4 | 2 | 14 |
| Radiation 3 years and over 1. Over 5 years 0. Surgery 3 years and over 39%. Over 5 years 27%. | | | | | | | | | | | | |
| Postcricoid | 8 | 8 | 0 | 0 | 0 | 0 | 16 | 10 | 4 | 0 | 0 | 2 |
| Lateral wall pharynx | | 0 | 0 | 0 | 0 | 0 | 13 | 6 | 2 | 2 | 1 | 2 |


REFERENCES

1. COLLEDGE, LIONEL: Trans. Med. Soc. of London. Vol. 53: 1943.

2. BROYLES, E. N.: Anterior Commissural Tendon, Trans. Am. Laryng. Assoc. 64:251, 1942.

3. SNITSMAN

4. ROBERT, JEAN LAROUX: Les Epitheliomes Endolarynges.

5. CLERF, L. H.: Preepiglottis Space: Its Relation to Cancer of the Epiglottis, Arch. Otolog. 40:177, 1944.

6. THOMSON, SIR ST. CLAIR: History of Cancer of the Larynx, J. Laryng. and Otolaryng. 54:70, 1939.

7. LENZ, MAURICE: Causes of Failure of Roentgen Therapy in Cancer of the Larynx, Am. J. Roentgenol. 46:21, 1941.

8. MARTIN, HAYS: Surgery of the Nose and Throat, Kernan, Thomas Nelson Sons, N. Y. Chapter V; pp. 431-507, 1942.

9. BLADY, J. V., W. E. CHAMBERLAIN: Treatment of Cancer of the Larynx by Roentgen Irradiation, Am. J. Roentgenol. 51:481, 1944.


## DISCUSSION

FRANCIS E. LEJEUNE, M.D.: Mr. Chairman, Dr. Orton's excellent presentation revises our thoughts on extrinsic cancers of the larynx. Anyone of course can obtain good results with textbook picture cases of intrinsic cancers.

I was just amazed to see the type of cases that Dr. Orton has obtained such excellent results in, in which the pathology involved the base of the tongue and the pyriform fossas. Truly remarkable work!

Of course, this means heroic surgery. It means that these patients have to have block dissections of the neck in extensive cases in order to get good results.

I think it was Jackson who told us or made a report that extrinsic cancers have a life expectancy of from 12 to 15 months without any surgery and, heretofore little surgery has been performed in the extrinsic cases. With the method which

Dr. Orton has just described, it is now possible in a certain percentage of cases to get excellent results, such as he has shown us.

I believe that we ought to make more attempts to do surgery on these extrinsic cases. I have had several such cases in which I have obtained excellent results, particularly in the cases in which we were able to make an early diagnosis in lesions involving the epiglottis, removing them by suspension laryngoscopy, followed by electrocoagulation.

I want to compliment Dr. Orton on his excellent presentation. I think this is going to revise our thoughts on laryngology a great deal.

HARRIS P. MOSHER, M.D.: Mr. Chairman, can I leave my place in this discussion to Dr. Schall? I would like to have Dr. Schall speak on the technique of the operation.

I would like to congratulate Dr. Orton, and agree with the last speaker that more men in this Society should tackle these very extreme cases.

LEROY A. SCHALL, M.D.: Mr. Chairman and Gentlemen: I have the highest respect for the wonderful work of Dr. Orton. It does me good to hear him plead for wide dissection of the neck.

We speak of intrinsic and extrinsic cancer of the larynx. Yet none of us know what the other one means by using these terms. To me an intrinsic cancer of the larynx is one within the funnel of the larynx; from the base of the epiglottis and from the aryepiglottic fold down.

We know from radical neck dissections that in those without demonstrable palpable glands, ten per cent show metastatic cancer in the glands. Therefore, I have followed Gluck, Sorenson and Thompson in removing the sternohyoid muscles with the hyoid bone or the body of the hyoid bone in a total laryngectomy, on the theory that because cricothyroid gland is so frequently involved by metastasis, that these muscles having a rich lymphatic bed, could be easily an area of metastatic extension.

I have now microscopic proof in a patient in whom there was no mascroscopic evidence of cancer in the pretracheal muscles, that there was extension in the muscle.

I like to hear Dr. Orton say that he exposed and explored the carotid sheaths. I like the radical surgery of Alonzo of Montevideo.

So every cancer of the larynx is a potential extrinsic cancer of the larynx. The hardest part, for me at least, in dealing with cancer is selecting the type of treatment for that cancer.

I recently surveyed the cancers of the larynx seen at the Massachusetts Eye and Ear Infirmary since 1930. Of 99 cases of extrinsic—and by that I mean cancer that involved glands, the epiglottis, the aryepiglottic fold, the pyriform sinus—treated by external radiation between 1930 and 1940, 24 per cent are living after five years. The cancers limited to one cord with a movable cord, cases that we considered ideal for laryngofissure but which on other reasons, irradiation was

used; of 11 cases, 46 per cent have been free of disease five years or longer. I make a plea too that we should follow these cases as long as they live.

I cannot get rid of my cancer patients. At the end of ten years I tell them to write if anything goes wrong but they insist upon coming in for a yearly examination.

Dr. Orton's paper is marvelous, but I like to emphasize that by working with our radiologist and tumor clinic experience is valuable. Follow your cancer patients and you will be greatly rewarded by grateful patients.

L. H. CLERF, M.D.: I wish to congratulate Dr. Orton on his presentation, and the excellent results he has secured in the surgical treatment of laryngeal carcinoma.

I too favor surgical treatment in preference to irradiation whenever possible. I believe it is universally admitted that he who institutes the first plan of therapy in a case of cancer of the larynx has the best chance to get that patient well. There are too many radiologists who think in terms of palliation. In the treatment of cancer I like to think in terms of non-recurrence after five years. Recurrences are not uncommon after two or three years. I have had opportunity to operate a number of cases after two-year radiologic cures. They are always difficult problems, and my results then are not as good as they would have been had I treated the patient originally.

The question of extrinsic and intrinsic is very confusing to me because what one considers as intrinsic, another would classify as extrinsic. I prefer to designate the anatomical location of a lesion and determine if there is impaired motility. When there is fixation of the vocal cord, the laryngologist must determine whether it is a suitable case for laryngofissure or laryngectomy. I believe that type of case ought to be treated by laryngectomy. Your non-recurrence rate will be much less if you do that and from the patient's standpoint that is the thing which counts.

With those lesions involving the epiglottis, aryepiglottic fold and arytenoid, many can be treated successfully by surgery provided one is radical enough. It is necessary to erase from one's mind a narrow field operation when treating cancer. One cannot temporize, one cannot compromise with malignancy. One must be radical or one is not fitted for the treatment of carcinoma and that applies to carcinoma generally.

With epiglottic lesions, surgery is the only plan of therapy. One should remove the hyoid bone as well as the pre-epiglottic space. Block dissection is necessary. It has been very gratifying to see five-year non-recurrences in patients treated originally for extensive cancers which appeared hopeless.

FREDERICK A. FIGI, M.D.: I too would like to congratulate Doctor Orton upon this excellent presentation and the splendid results which he has shown us. I admire his fortitude in taking on for surgical removal some of these extremely extensive throat lesions.

I scarcely need state that our group at the Mayo Clinic very strongly favors surgical treatment of operable cancer of the larynx. Like all of the rest of you we have repeatedly seen patients lose their chance to get well because inadequate

radiation was used in the early stages of the disease when surgical removal would have offered a good prognosis.

However, in the later stages of these lesions radiation often is more effective than surgical measures. This is especially true in cases of advanced highly malignant carcinoma of the hypopharynx and base of the tongue and of extrinsic cancer of the larynx with involvement of the cervical lymph nodes. Almost miraculous results have been observed in many of these cases following fractional roentgen therapy. A number of patients who came to us with what we considered wholly inoperable lesions which were likely to prove fatal within a few weeks, were treated in this manner and are now free from evidence of the disease after periods ranging up to six and seven years. However, to secure such results the treatment cannot be given haphazardly. It must be accurately applied and the dosage carefully determined and controlled.

EDWIN N. BROYLES, M.D.: I wish to congratulate Dr. Orton on his paper and the fine surgery in these big cases. I must admit we don't do it very much, and I believe in the future we will attempt it.

In discussing carcinomas of the larynx which have broken out, mainly through the cricothyroid membrane, heretofore we usually would back out and send them over to x-ray. I have not seen one of those cases cured with x-ray.

In discussing this with Dr. Blalock, he suggested that possibly it might be wise to go ahead and remove all possible carcinoma in these cases even though there has been a break-through from the larynx; this we propose to do in the future.

So far the results have been quite good.

With your consideration I would like to show one or two sections of carcinoma of the larynx which Dr. Guild cut for us. Dr. Guild cut these sections horizontally.

(Slide) You see the carcinoma is located on this one cord (indicating). It extends up into the ligament here, and with a high-power microscope carcinoma cells can be seen growing right up almost into the cartilage.

(Slide) This shows the carcinoma growing around the anterior commissure of the larynx. If you notice, in this section we don't have the same anterior commissure ligament attachment because the thyroid cartilage is ossified here and the change takes place. Instead of the ligament fading away into the cartilage as it does before the thyroid has ossified, with ossification of the thyroid cartilage there is a true ligamentous attachment to bone.

(Slide) I had an idea because the ligament did go into the cartilage that would be the place the carcinoma broke through anteriorly to get out of the larynx but this section, and one which I think is typical of most of these cases, demonstrates the carcinoma instead of going through the thyroid cartilage, grows down and perforates the cricothyroid membrane.

(Slide) You see the carcinoma has gone through the anterior portion of the cricothyroid membrane.

In carcinoma of the larynx it is very difficult for me to tell whether it is extended out through the cricothyroid membrane. As a rule if the patient requires a tracheotomy, it is about a 100 per cent bet that the carcinoma has already extended out through the cricothyroid membrane.

I wish again to congratulate you, Dr. Orton.

CHARLES J. IMPERATORI, M.D.: Mr. Chairman, I am in very hearty accord with what Dr. Orton has said, and what all the other gentlemen have said, with regard to the present-day methods, that we have to attempt to cure these cases.

I do not want to prophesy but I doubt very much if in the future, maybe in 25 years, maybe in 50 years from now these extensive surgical operations will be done. They will be things of the past, similar to our mastoid operations, to our operations on the membrane tympani, etc. because we have sulfa drugs and antibiotics which apparently are phenomenal in their reactions.

Dr. Orton, do not think in any way that I am not in accord with what you have done. I would do exactly the same thing that you have done if I were capable of doing these extensive operations.

I do think as laryngologists and as the outstanding Laryngological Society, that we should give very serious thought to these various other things which are now being discussed generally. We must consider these other things such as hormones and what are they doing; are they of any value; will they help these cases; the carbamates which have been exploited recently; the nitrogen mustards, whether or not these will help the extensive lesions of cancer which can only be helped by very extensive and mutilating operations; maybe there is an antibiotic which will be developed that will be curative. There are these radiosotopes such as strontium, iodine and phosphorus.

Very definitely the field of carcinoma which we are concerned with is simply one of about 15 per cent of all cancer cases and including the larynx, pharynx and respiratory tract. We definitely know that one in ten of our population of the United States today is dying from cancer some place in the body.

Personally at this particular time I would say very definitely that we should have surgery and radiation but let us give thought to what these others are doing and do not let us take the attitude that they are valueless.

HENRY B. ORTON, M.D. (Closing): The allotted time did not permit me to read my entire paper. To answer Dr. Imperatori's question, I state in my paper that complete destruction of the cancerous cells is the only known method for effecting a primary cure, whether this be done by surgery, irradiation or some biological change in our makeup.

With regard to Dr. Schall's classification of intrinsic and extrinsic carcinoma of the larynx, the classification I prefer is one according to site; namely, Intrinsic—involving the cord and any growth below this level as subglottic; the Epilaryngeal group—where the growth is on the epiglottis, aryepiglottic fold, the arytenoid and the pyriform sinus; the Hypopharyngeal group—where the growth is postcricoid, or on the post or lateral wall of the lower pharynx. The site of origin is important, as by the time a patient presents himself, an original intrinsic growth may have become one of the epilaryngeal group, or an epilaryngeal growth may have extended downwards into the glottic chink.

I showed about 48 slides of so-called extrinsic group 18 of which the patients were alive five years or over. That is a little better than 40%.

I wish to thank the gentlemen for their kind remarks.

# HEMANGIOMAS OF THE MOUTH

FREDERICK A. FIGI, M.D.

ROCHESTER, MINN.

Hemangiomas are often encountered about the face and neck and those presenting externally may also involve the oral cavity. However, lesions of this type limited to the interior of the mouth are only infrequently seen. Those affecting the buccal cavity alone or in conjunction with other structures at times attain considerable size, produce marked deformity and dysfunction, are subject to frequent trauma and to recurring acute inflammatory processes and may give rise to serious and even fatal hemorrhage. Treatment is advisable for many of these tumors but the type of treatment and the optimal time for administering it varies in different cases.

## Classification

These benign blood vessel tumors are congenital or appear shortly after birth and are of several distinct types. Much confusion regarding the nomenclature of the various forms of hemangiomas exists in the literature and many authors have presented their own classifications. In general there are two principal types, the capillary and the cavernous. However, noteworthy differences in the clinical and histologic features render subdivision of both of these groups essential.

## Capillary Hemangiomas

The capillary hemangiomas include the port wine stain or nevus flammeus and the strawberry birthmark or hemangioma simplex. The latter are circumscribed, finely lobulated, slightly elevated lesions composed of a new growth of dilated capillaries, veins and arterioles. They are bright red to purple in color and may occur on any part of the surface of the body but are most common on the face and arms. The lips, especially the upper lip, frequently are involved. I have not observed this type of hemangioma inside the mouth.

Capillary hemangiomas of the port wine stain type are usually flat, nonelevated lesions varying in color from faint pink to bright red or magenta. Microscopically these present in the skin a narrow zone of dilated vessels lined with adult endothelium. They often are present on the lips and extend over a considerable portion of the oral mucous membrane. When situated on the gums, they often give rise to recurring

bleeding. Not infrequently the involved regions are enlarged to a varying extent due to the presence of an associated cavernous hemangioma.

### Cavernous Hemangiomas

Cavernous hemangiomas are soft, compressible tumors consisting of large thin-walled sinuses with a limited quantity of intervening stroma. They often occur in adults as small varix-like enlargements on the vermillion border of the lips or in the oral mucous membrane (fig. 1). These may be due to trauma. Those of congenital origin may form a huge vascular mass which produces diffuse enlargement and distortion

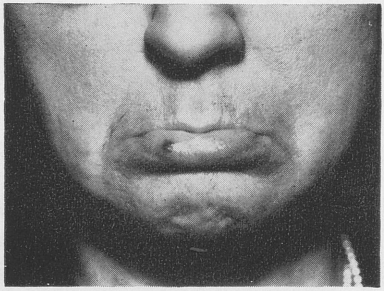

Fig. 1.—Small vascular lesion of lower lip probably traumatic in origin. The blue-black color of this lesion suggested the possibility of a melanoma.

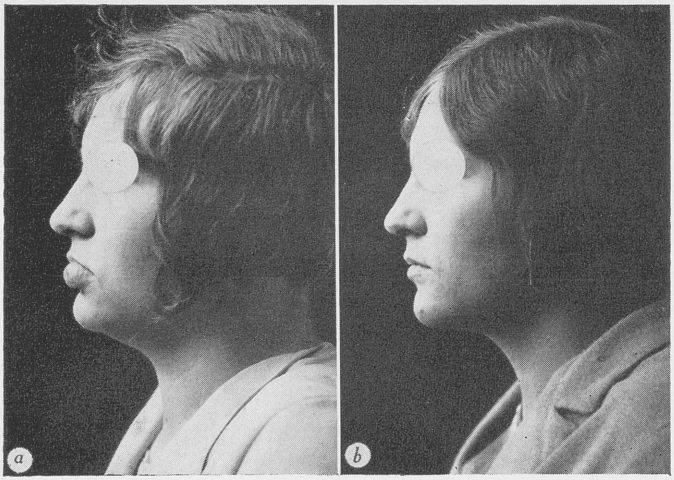


Fig. 2*a*.—Cavernous hemangioma of the lower lip; b, result following electrocoagulation and plastic procedure.

FIG. 3*a*.— Actinodermatitis with extensive malignant change resulting from excessive radiation of a capillary hemangioma (port wine stain); *b*, result seven years following excision and repair with pedicle flap.

of the involved parts. Those of smaller size usually are asymptomatic but the larger growths may loosen the teeth and interfere with mastication. They also may give rise to severe hemorrhage. Trauma from the teeth at times induces active bleeding and also recurring infection. Reder[1] reported alarming hemorrhage from an angioma of the cheek because the patient bit the growth. Fatal hemorrhage following dental extraction in cases of hemangioma of the mouth has been recorded by Broderick[2] and by Kroh.[3] In the latter's case the hemangioma involved the mandible and its presence apparently had not been recognized prior to the extraction. When tumors of this type about the mouth extend up over the frontal and temporal region, severe persistent pain may be complained of in these regions. This complaint is more likely to be made when phleboliths are present in the tumor than under other circumstances.

Macrocheilia and macroglossia at times result from these vascular tumors (fig. 2*a* and *b*). The tongue of a man fifty years of age seen a few years ago was so greatly enlarged and elongated that it readily protruded below the point of the chin and rendered it difficult for the patient to close his mouth. During the periods of acute inflammatory reaction in the tongue which recurred at frequent intervals complete

closure of the mouth was impossible. Not only were the functions of speech and deglutition interfered with but the patient's rest was disturbed seriously. This disturbance of rest resulted from the fact that whenever he dropped off to sleep the tongue became excessively engorged and protruded from the mouth much like a penile erection.

*Plexiform hemangiomas.*—Plexiform or racemose hemangiomas, also known as cirsoid aneurysms, are closely allied to the cavernous hemangiomas but are encountered much less frequently. Actually they probably are essentially cavernous hemangiomas with single or multiple arteriovenous fistulas. They are expansile pulsating tumors which may be diffuse and of considerable extent. They can be only partially obliterated by compression and they become more tense than simple cavernous angiomas when the patient strains or the involved part is dependent. A bruit usually is audible on auscultation over the surface and a distinct thrill frequently is palpable. Because of the arterial pressure they are firmer than the simple cavernous hemangiomas and they tend to progress.

## Phleboliths

Phleboliths are commonly encountered in cavernous hemangiomas in adults. They vary from rather soft, friable, almost putty-like consistency to calcareous hardness and range in diameter from 2 or 3 mm. to more than a centimeter. In a given case they are likely to be of approximately the same size but wide variation in diameter may exist. Usually they are few in number; generally from two to six are palpable but a score or more may be present. They often produce no symptoms and universally are considered of little clinical significance. However, frequently they cause considerable discomfort especially when present in a hemangioma overlying a bony surface which is subjected to pressure. Patients with hemangiomas of the cheek often complain of pain when they lie with the side of the face on a pillow due to pressure of a phlebolith against the jaws or the malar prominence. In these situations phleboliths tend to traumatize the soft tissue sufficiently to create a chronic inflammatory process which in turn produces persistent tenderness with some induration and more or less continuous discomfort.

## Treatment

*Capillary hemangiomas.*—Since the blood vessels composing the strawberry type of capillary hemangioma are lined with an infantile form of endothelium, these growths respond well to radiation and usually are best dealt with by means of a screened radium plaque. Cautious



FIG. 4*a*.—Capillary hemangioma (port wine stain) of lower lip; *b*, result following plastic procedure inside the lip.

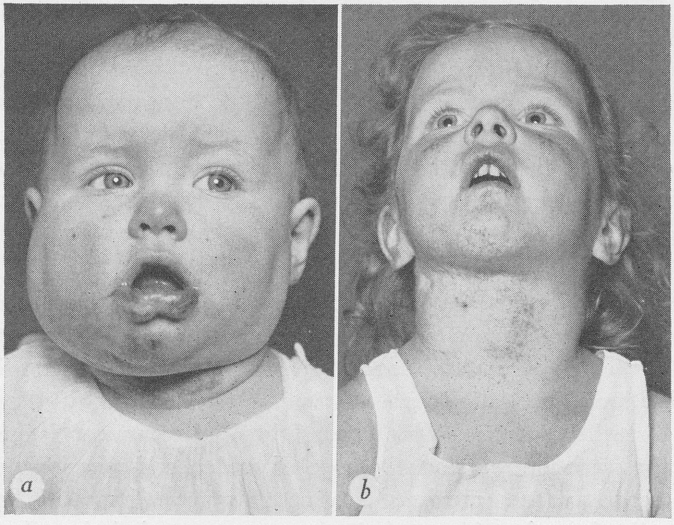

FIG. 5*a*.—Extensive cavernous and capillary hemangioma; *b*, result following interstitial radon and radium packs.

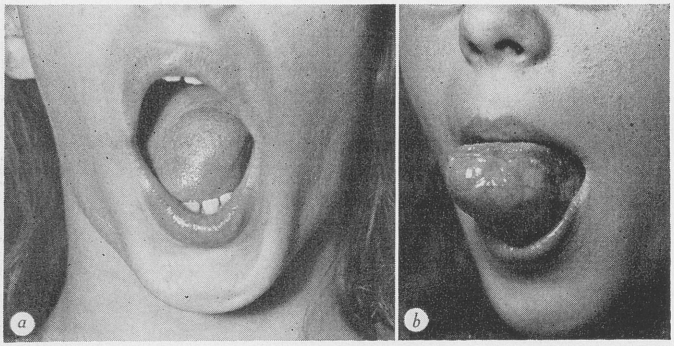

FIG. 6*a*.—Cavernous hemangioma of the tongue and floor of the mouth with the tongue flaccid; *b*, appearance of lesion with the tongue protruded.

application of radium with the plaque kept moving continuously as a rule will result in complete disappearance of the hemangioma and leave little visible scarring. Some physicians prefer to treat these vascular growths by excision or by applications of carbon dioxide snow, but in our hands, radiation has yielded most satisfactory results and produced a minimum of scarring.

Since port wine stains are formed largely of blood vessels lined with a flattened adult type of endothelium, one would naturally expect little or no response to radiation and this is definitely the case. Yet in spite of this usual observation and its frequent publication in the literature these lesions continue to be subjected to repeated applications of radium and roentgen therapy. As a result actinodermatitis with subsequent malignant degeneration is often observed in these cases (fig. 3*a* and *b*). Less serious sequelae are unsightly depressed scars and mottling. These also may result from applications of carbon dioxide snow.

Port wine capillary hemangiomas of the lips without associated cavernous involvement in females are best taken care of by means of cosmetics which serve to conceal them effectively when skillfully applied. Such applications are distasteful to men and if the patient is not disturbed mentally by the condition, no treatment is indicated. When the situation warrants because of undue self-consciousness, unsightly scarring from previous treatment or actinodermatitis, excision with application of a skin graft is the treatment of choice. Inside the mouth these lesions obviously are of no consequence and treatment

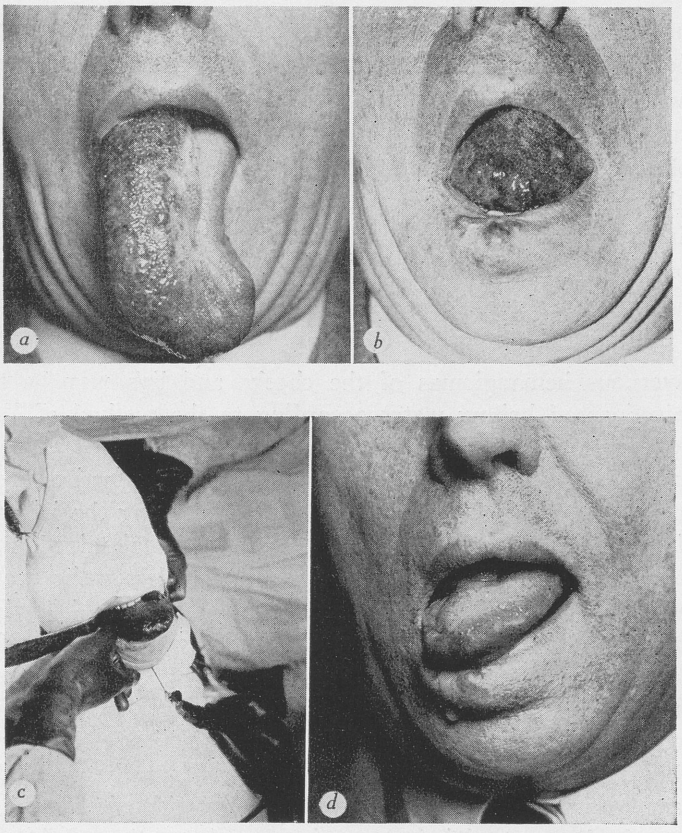

FIG. 7*a*.—Large cavernous hemangioma of the tongue and lower lip; *b*, the tumor rendered it impossible for the patient to close the mouth; *c*, electrocoagulation of the tumor with an insulated electrode inserted through a stab wound in the submental region; *d*, result one month following electrocoagulation.

is not necessary. When a nevus flammeus of the lip is associated with a cavernous hemangioma which is producing deforming enlargement, the latter lesion should be controlled by electrocoagulation or by injection of sclerosing solution before excision and plastic replacement of the involved surface is undertaken (fig. 4*a* and *b*).

*Cavernous hemangiomas.*—Cavernous hemangiomas of the lips and mouth in infants and children are best treated with radiation. Radon seeds of from 0.25 to 0.3 mc. each implanted into the tumor and spaced approximately 1 cm. apart usually produce satisfactory reduction with a

minimum of deleterious effects. Such treatment can be repeated in from four to six months if indicated. While roentgen therapy or radium packs will sclerose these cavernous lesions if applied repeatedly, their use is indicated in only the diffuse lesions of this type and in those they are applied to supplement interstitial radiation (fig. 5*a* and *b*). Repeated external therapy is likely to produce pigmentation, telangiectasis and sclerosis in the overlying skin which may interfere with subsequent development of the soft tissues and bony structures. Such unfortunate results are now being observed in some of the patients treated years ago by this method.

Cavernous hemangiomas of the cheeks and lips may be treated with injections of boiling water according to the method of Wyeth.[7] However, some of the other sclerosing agents, notably five per cent solution of sodium morrhuate, appear to be equally effective, are more easily handled and involve less risk of slough. During the injection of sclerosing solution peripheral pressure should be maintained in order to prevent too rapid diffusion of the agent and to lessen the possibility of embolism. Maintaining the pressure for some hours following the injection has appeared also to increase the efficacy of this type of treatment. About the mouth and face injection of a sclerosing solution frequently is ineffective because of the impossibility of localizing the solution for a sufficient period of time. The injection of boiling water and other sclerosing agents into the tongue bears the possibility of sepsis and of producing excessive local reaction with edema which may spread to the larynx and induce respiratory obstruction. I feared that trachectomy would be necessary after injection of boiling water in one of my cases and it was required within a few hours after such an injection in one of Reder's cases.

Because of its better localization and greater effectiveness cavernous hemangiomas of the lips, cheeks, tongue and other intra-oral structures in adults are more satisfactorily treated by means of electrocoagulation than with sclerosing agents (fig. 6*a* and *b*). For this purpose a sharp pointed, insulated electrode is employed and this is inserted either directly through the overlying mucous membrane into the tumor or is carried into it through a minute stab wound in the skin. When the latter approach is made, it is essential that the insulation on the shaft of the electrode be intact; otherwise leakage of the current may damage

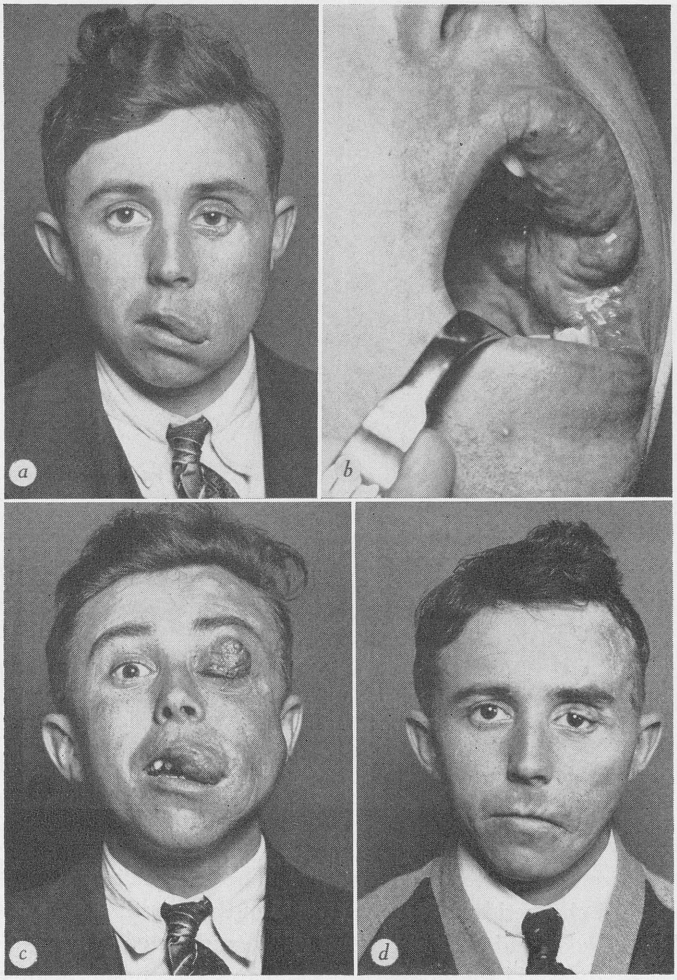


FIG. 8*a*.—Extensive, diffuse plexiform hemangioma of the mouth, face and scalp with the patient in repose; *b*, portion of the hemangioma involving the mouth; *c*, same patient straining; *d*, result following use of intensive electrocoagulation several times. Note that facial nerve is intact. At the time this photograph was taken straining or holding the head down produced little change in the patient's appearance.

important structures and at the same time prevent sufficient coagulation of the neoplasm. More intensive coagulation of the vascular tumor is necessary than might be anticipated by the uninitiated since the heat is diffused rapidly by the blood and carbon forming on the electrode

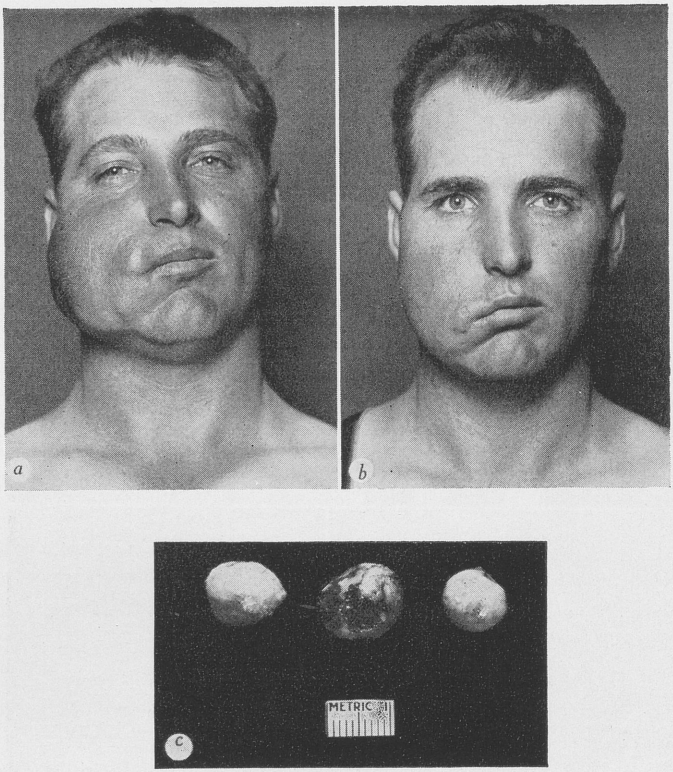


FIG. 9*a*.—Extensive plexiform hemangioma of the mouth, lips and cheeks; *b*, phleboliths removed from this lesion; *c*, result two months after a single treatment with electrocoagulation.

tends to produce an effective insulator. The intensity of the coagulation should be checked by keeping a finger in the mouth directly over the tip of the electrode and also by observing the surface of the tumor during electrocoagulation. If the color of the mucous membrane changes even slightly from red to gray, coagulation should be stopped immediately. The margin of safety between effective electrocoagulation and that which will result in a slough is very narrow and can be determined only by experience.

As might be anticipated coagulation proceeds more rapidly when the blood is kept expressed from the tissues immediately about the electrode. Unless sloughing occurs, secondary hemorrhage is unusual in these cases. Primary bleeding from the stab wound in the skin is

readily controlled by superficial coagulation as the electrode is withdrawn.

During the coagulation the electrode should be kept as far as possible from Stensen's duct, the muscles of mastication, the motor nerves and other important structures. It is especially important that ample clearance be given the branches of the facial nerve. Spasm of the facial muscles often will occur during intensive electrocoagulation even when the tip of the electrode is almost a centimeter from a branch of the facial nerve. This may result from direct stimulation of the muscle or from transmission of the current to the nerve by the intervening tissues. Accordingly active contraction of the facial muscles is not necessarily an indication of impending injury to the seventh nerve.

On a number of occasions I have inserted an insulated electrode through a small stab wound in the submental or anterior part of the submaxillary region for treating large cavernous hemangiomas of the tongue and floor of the mouth (fig. 7*a, b, c* and *d*). This procedure obviates direct contamination of the coagulated region and if care is taken to avoid burning through the oral mucosa the operative wound remains clean, there is little likelihood of secondary bleeding and convalescence is materially shortened. This method has proved most effective in shrinking down some of these lesions that had not responded to radiation or to injection of sclerosing agents.

*Plexiform hemangiomas.*—Plexiform or racemose hemangiomas are more difficult to obliterate than simple cavernous angiomas because of the increased pressure within the component blood vessels resulting from the arteriovenous communications (fig. 8*a, b, c* and *d*). The force of the impulse presented by these tumors is directly dependent on the size of the fistulous openings and is a factor in determining the type of treatment indicated. These lesions are encountered most often in adults but they may occur in infants. When seen early in life interstitial radiation may control them but ligation of the afferent vessels frequently is also necessary. In adults lesions of this type with only a slight impulse often can be shrunk by means of electrocoagulation, while radiation or injection of sclerosing agents alone are not likely to be of benefit. If the lesion is not too extensive, excision may be feasible and at times is the most effective means of control. This frequently is the case also when the expansile force is pronounced. Because of the

free collateral circulation, ligation of the external carotid artery usually is less effective than tying off the afferent vessels directly about the periphery of the tumor. In an occasional case the mass will become flaccid immediately after ligation of a single large vessel at its border and electrocoagulation or the injection of boiling water or of a chemical sclerosing agent then will readily bring it under control.

*Phleboliths.*—In cases in which phleboliths in hemangiomas about the jaws cause discomfort removal of the offending phleboliths is indicated (fig. 9*a, b* and *c*). Usually these vein stones are readily palpable and they may be removed with surprisingly little bleeding. Removal is accomplished by holding the stone firmly against the bone or against a finger placed inside the mouth with the soft tissues drawn tightly over it. The skin is then incised and the soft tissues spread with sharp pointed scissors until the phlebolith is exposed. In this manner the offending concretion can be expressed through a small opening.

## Summary

The various forms of hemangiomas occurring about the lips and mouth are reviewed, and the treatment of these different lesions and of the phleboliths at times encountered in cavernous angiomas is discussed. In general, radiation is the treatment of choice for strawberry birthmarks and the cavernous hemangiomas in infants and small children. In adults cavernous lesions are more effectively treated with electrocoagulation and injections of boiling water or chemical sclerosing agents. Well-circumscribed hemangiomas often are best excised. Plexiform or racemose hemangiomas usually require ligation of the afferent vessels in addition to the measures employed in treatment of cavernous hemangiomas.

## References

1. Reder, Francis: Remarks on the Treatment of Cavernous and Plexiform Angioma, Illinois M. J. 32:387, 1917.

2. Broderick, R. A., and Round, H.: Cavernous Angioma of the Maxilla; Fatal Hemorrhage after Teeth Extraction, Lancet, 2:13, 1933.

3. Kroh, F.: Fatal Hemorrhage After Extraction of Tooth. (Abstr.). J.A.M.A. 86:236, 1926.

4. Wyeth, J. A.: Quoted by Reder, Francis: Hemangioma and Lymphangioma, Their Response to the Injection of Boiling Water. M. Rec. 98:519, 1920.

# THE THYROID AND THE NOSE

ARTHUR W. PROETZ, M.D.

ST. LOUIS, MO.

For a long time it has been my impression, more or less casual, that certain indolent and intractable nasal conditions were peculiar to the type of individual regarded as hypothyroid. These conditions, usually of such a low order of acuity that they should have responded to simple measures, existed in pale asthenic individuals as a rule but not invariably; none were obviously myxedematous; only occasionally was there a spontaneous complaint of chilliness or of dry skin and hair.

When a closer study of the records revealed that almost 90 per cent of the suspects sent for a determination of the basal metabolic rate turned up with sizable deficiencies, it seemed worth while to coordinate the data and to present them to this meeting.

The survey comprises 84 cases personally seen in private practice. Of this number 34 patients were known previously to be hypothyroid; 50 were sent first by the laryngologist for basal metabolism tests.

The appearance of the nasal mucosa in these cases was not uniform either in color or texture but there was one dominant characteristic which is difficult to define. It may best be characterized as "indolent and unresponsive" both as to its physiological state and its reaction to treatment. In 75 per cent the membrane was slightly red, inclined to stickiness and even dryness, sometimes a little bloody and of a poor texture. It might be said to be "chapped." In the remaining 25 per cent the membrane was pale and sometimes boggy. Less than half of the latter type was found in demonstrably allergic subjects, although the series is not large enough to make this proportion significant. The change gave the impression of being nutritional rather than vasotonic or essentially infectious.

In the "chapped" type the average basal metabolic rate was minus 17 per cent; in the pale, boggy type minus 20.8 per cent. It was not surprising to find headache of some description present in 40 of the 84 patients. Asthenia was the (unprompted) complaint in 15, and chilliness in only four.

Twenty-four of the series were males, 60 were females. In both sexes the fourth age decade predominated overwhelmingly.

Among the chief complaints nasal obstruction appeared 29 times, headache 40 times, frequently recurring or continuous cold 30 times, rhinorrhea (as in hay fever) five times.

Thyroid extract was administered in all cases, sometimes combined with thiamine chloride, in doses to meet requirements and ranging from 0.5 grains to five grains daily. The average was a little over one grain. The results of this treatment were as follows:

| | |
|---|---|
| Pronounced improvement | 37 |
| No improvement | 12 |
| Doubtful, incomplete, or possibly improved by some associated measures | 35 |

In the group of 50 cases suspected for the first time as a result of nasal examination alone the metabolic rate was:

| | |
|---|---|
| 0 to —10 per cent | 9 cases |
| —11 per cent to —20 per cent | 18 cases |
| —21 per cent to —30 per cent | 8 cases |
| —31 per cent to —40 per cent | 4 cases |

In five cases the rate was increased (plus three per cent to plus 15 per cent).

In the six remaining cases exact figures were not available.

The series is as yet too small to make statistical details of much value but the facts: (1) that thyroid deficiency could be suspected by the rhinologist from the appearance of the membrane and its failure to respond to treatment; (2) that the deficiency could be demonstrated in 39 of 44 suspected cases, and (3) that pronounced improvement followed administration of thyroid in 29 (compared to eight not improved, 13 doubtful or incomplete) establishes the local symptomatology at least to our own satisfaction.

The foundations upon which the preceding findings rest are generally accepted. To quote from Byrom,[2] the cells in their normal environment are surrounded by a "freely circulating, relatively protein-free ultrafiltrate of the blood plasma, the secretion of which is regulated by the hydrodynamic pressure within the capillaries opposed by the colloidal osmotic pressure of the plasma protein." What protein there is, is of

two kinds: first, the dispersed protein (about one per cent), second, the so-called ground substance, a fixed colloidal gel which acts as a scaffolding or cement to maintain the structural form of the tissue.

Byrom is of the opinion that myxedema consists of an expansion of the ground substance into the circulating substances.

Knowing the highly vascular nature of the nasal tissues and considering the looseness of their integration, it is entirely possible that something resembling a myxedematous process may appear here under conditions too minor to cause general myxedema in more rugged tissues. Certainly the symptoms arising in the nose which respond to the administration of thyroid substance: namely, extravasation, changes in the nature of the surface fluids, permeability, malnutrition, swelling and edema, could reasonably result from the process suggested by Byrom. All of them would render the tissues more susceptible to bacteria and just possibly to antigens.

In this connection may be mentioned an observation by Hirschberg and Bronstein[4] regarding the effect of thyroid deficiency upon agglutination following typhoid inoculation. They found briefly that in a 22-year-old cretin the agglutination test remained persistently negative following typhoid vaccine. Only after the administration of thyroid in one grain doses could partial agglutination be observed which became strongly positive after the administration of two grains daily for six months.

To quote their conclusion, "It appears that the patient showed no response to typhoid inoculation in the absence of thyroid activity. Following the administration of thyroid extract antibody response was noted. This would seem to indicate a relation between thyroid function and immune response." The basal metabolic rate was impossible to obtain in this case due to lack of cooperation.

This is the only report one was able to find relating to human subjects. The literature on animals is confused. Some investigators report an increased, others a decreased immune reaction in thyroidectomized animals.[5] It is significant, however, that all of them report some alteration.

Relations between nephrosis and hypothyroidism have been suspected[1] and other processes which may well be analogous to those noted

in the nose have been described in the vestibular apparatus,[7] in the cornea,[6] and in the endometrium.[3]

"Broadly speaking," writes Means, "[the thyroid hormone] has to do with the rate of growth and differentiation of tissues, with the rate of energy exchange, with the metabolism of proteins, carbohydrates, fats and lipoids, salts and water, with the irritability of various tissues and with the activity of other endocrines."

Commenting upon a suggestion of Moehlig[8] that the thyroid hormone has a selective action upon ectodermal tissues, Means (page 48) states as his belief, "that the thyroid hormone acts on all cells, not only on those of ectodermal origin. The effects on ectodermal structures simply happen to be very conspicuous."

In any case there is reason to believe that the nasal tissues are so affected. Sweat glands are known to be influenced by the hormone and I have on more than one occasion called attention to the related activity of these and the glands of the respiratory mucosa.

At the risk of being prematurely didactic I should like to offer the following observations:

1. That deficiency of the thyroid hormone may result in changes in the nasal mucosa which can be recognized as such.
2. That these changes are of two types: (a) red, dry, irritated, "chapped" or desquamative; (b) pale and boggy.
3. That patients deficient in the thyroid hormone may have an increased tendency to nasal infection and nasal allergy which can be corrected by the administration of thyroid extract alone.
4. That headache and nasal obstruction are prominent symptoms.
5. That the basal metabolic rate is helpful but not infallible in distinguishing cases suitable for treatment with thyroid extract. Five patients of the 37 who showed improvement had rates between minus 10 and minus three, and one had a rate of plus three.
6. That the basal metabolic rate is not a reliable prognostic index. Four patients showing the greatest improvement had basal rates of —4, —9, —11, and —34 (later —12), respectively. In all cases the response of the patient was considered more useful than the basal metabolic rate in determining the most effective dosage of thyroid extract.

1010 Beaumont Building.

References

1. Barker, M. H., and Kirk, E. J.: Experimental Edema (Nephrosis) in Dogs in Relation to Edema of Renal Origin in Patients, Arch. Int. Med. 45:319, 1930.

2. Byrom, F. B.: The Nature of Myxedema, Clin. Sc. 1:273, 1934.

3. Haines, S. F., and Mussey, R. D.: Certain Menstrual Disturbances Associated with Low Basal Metabolic Rates without Myxedema, J.A.M.A. 105:557, 1935.

4. Hirschberg, N., and Bronstein, I. P.: Note on a Cretin's Response to Typhoid Inoculation, Am. J. M. Sc. 202:333, 1941.

5. Launoy, L., and Levy-Bruhl, M.: (cit. 4) Ann. Inst. Pasteur 29:213, 1915.

6. Means, J. H.: The Thyroid and Its Diseases, Philadelphia, J. B. Lippincott Co., 1937.

7. Moehlig, R. C.: Vertigo and Deafness Associated with Hypothyroidism, Endocrinol. 11:229, 1927.

8. Moehlig, R. C.: The Embryohormonic Relations of the Thyroid Gland to Ectodermal Tissues, Ann. Int. Med. 1:400, 1927.

# PRESENT STATUS OF DIPHTHERIA

EDWIN H. PLACE, M.D.

BOSTON, MASS.

The mortality of diphtheria has dropped for a considerable time but especially since the increasing immunization with toxin-antitoxin and toxoid from 1920.

Chart I gives the curve of the Boston mortality. Similar curves can be demonstrated in most cities. The severe diphtheria which had affected Boston since 1861 allows for a more marked decrease since the use of antitoxin in 1895.

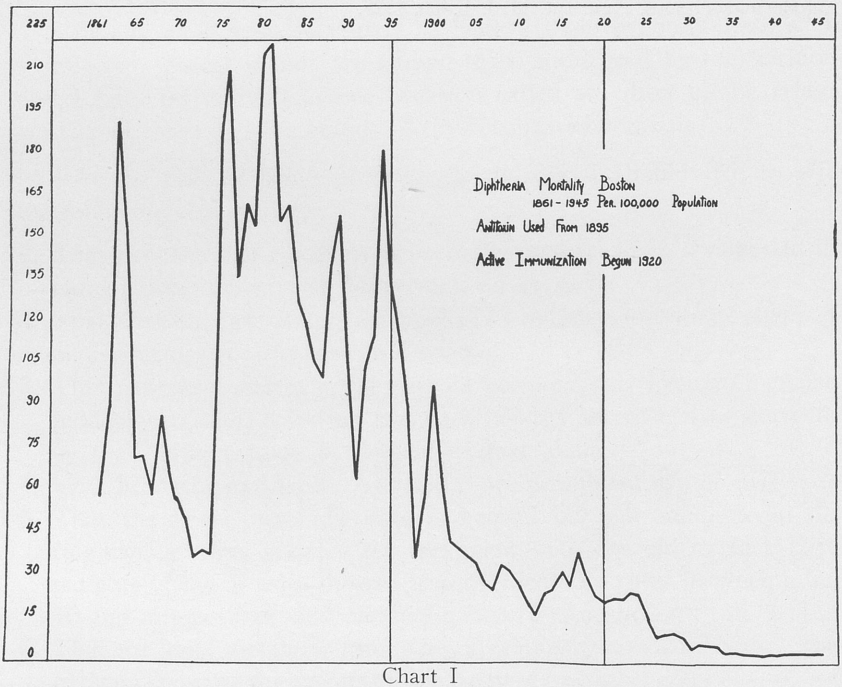


Chart I

With antitoxin treatment great variation in mortality occurs with promptness of treatment and age of patients but it is evident that there is variation in the severity of disease from unknown factors.

In chart II comparison of the fatality rate per cent in the South

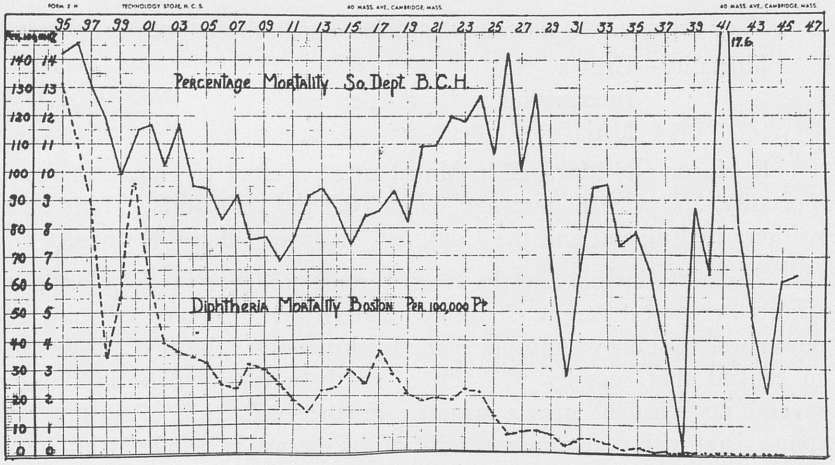


Chart II

Department, Boston City Hospital with the mortality per 100,000 population in Boston shows what is clearly evident to the clinicians, viz., the present low mortality is due to the reduction in the number of cases rather than in the severity of the disease.

The marked yearly fluctuation of percentage fatality of the past 20 years may be ascribed to too small a number of cases for statistical significance. No change, except in frequency, has been noted in recent years; the same clinical pictures, frequency of paralysis and cardiac involvement, appear.

In 1931 an explanation of the greatly increased virulence which had appeared in Europe and Britain was apparently found by the discovery at Leeds, by Anderson *et al.*, of a strain of diphtheria bacillus associated with this severe type and named by the authors—gravis. This type distinguished from a type found in mild diphtheria, mitis, by colony appearance on chocolate agar tellurite media and differences in physiology.

Table 1

| | *Starch* | *Glycogen* | *Hemolysis* | *Colony form in Tellurite Media* |
|---|---|---|---|---|
| Gravis | + | + | 0 | Grey-black "daisy head" |
| Mitis | 0 | 0 | + | Shiny black |
| Intermedius | 0 | 0 | 0 | Grey-black, crenated |

They reported the mortality associated with these types as follows—

| | | |
|---|---|---|
| Mortality—Gravis | 13.1 per cent |
| Intermedius | 8.7 per cent |
| Mitis | 0 |

Robinson and Marshall in Manchester reported 15.1 per cent gravis mortality, 7.7 per cent intermedius and 0.5 per cent mitis. Many other workers in England and the Continent confirmed these findings.

Toxin production and the type of toxin produced by these different strains were not different. It seemed that virulence rather than toxigenic power was in some way responsible. In this country, however, it was not so evident that severity was related to these types. Frobisher found several non-virulent gravis strains. Further collection of strains and comparison with type and mortality of the disease is being carried on.

In a type of severe diphtheria in Baltimore in 1941, reported by Eller and Frobisher, no gravis strains were found although bull neck was striking and the mortality was 15.1 per cent. A strain with minute colonies on tellurite agar and a markedly lower splitting of dextrose was responsible and named "minimus."

In the gravis epidemic in Halifax, studied by Wheeler and Morton, the mortality was 3.69 per cent, although this low rate may have been due to the trend to older age groups. However, twice this mortality would be within that commonly encountered.

It is probable that variations in virulence are not related to the differences in these types. There is no reason why antitoxin should be useless in therapy or active immunization ineffectual.

Pappenheimer, in 1936, had noted great susceptibility of diphtheria toxin production to slight increases in the iron content of media. Mueller found some gravis strains that produced toxin freely in the presence of sufficient iron to markedly reduce the toxin production of other strains.

While Europe had a mild diphtheria, in this country for many years we had had a severe form. It was clinically frequently noted that large doses of antitoxin, given early, were needed to control many severe cases. Fatal intoxication leading ultimately to death can occur in a little over 24 hours after the onset, and even large doses of antitoxin would not stop the progress of the disease within 36-48 hours, although ultimately the signs began to rapidly decrease. The practice of giving

antitoxin at once in all cases in which diphtheria could not be certainly excluded rather than proved present, was taught to each generation of medical students.

That these cases are not hopeless in trained hands was evident from the fact that from 1895 to 1915 in 800 cases developing under observation no deaths occurred. No doctor, nurse nor ward worker has died in the South Department.

The blood level of antitoxin required to protect against the disease varies; about 1/100 (0.01) unit per cc. is sufficient to give a negative Schick test. Ipsen of Copenhagen has recently reported the blood antitoxin level of diphtheria cases on admission to hospital. He found high levels in two fatal cases and in about 30 per cent levels sufficient to give a negative Schick. In his cases, however, all patients who had had any immunization recovered, although the death rate was over eight per cent. In a few cases here we have found more than one unit per cc. occasionally. Certainly the cases entering the South Department during the past 20 years have not been previously immunized except in a small per cent (10 per cent). In the epidemic at Baltimore in 1941, 63 per cent of the cases had had prior toxoid.

Immunization with alum precipitate or aluminum hydroxide toxoid in two doses or soluble toxoid in three doses, at intervals of three weeks to three months, has been highly successful. The need of a booster or "call" dose of 0.5 cc. at intervals of three to five years is now generally recommended. There is no sound reason to feel that our immunizing program will fail but it should be carried out in all infants at from six to 12 months.

The use of despecificated antitoxin serum (by pepsin HCl digestion or other digestant) has reduced the protein reactions to negligible levels in striking contrast to the 80 per cent serum disease which followed the crude antitoxic sera of a generation ago.

Of the new antibiotics, varied results have been reported. The sulfonamides are useless in diphtheria. While penicillin is effective against the diphtheria bacillus, I can see no reason for its use in treating the disease. Antitoxin is essential and penicillin adds nothing for the safety.

For carriers, no more efficient treatment has been devised than penicillin, however. Weinstein reported favorable effects on carriers.

We have not been able to get persistent effects with local applications but intramuscular injection with large doses up to 200,000 units daily is highly effective in three to five days.

I cannot strongly urge carrier treatment of any kind as it is inconsistent. There is little evidence that clearing carriers has any value in control of the disease.

Since the marked decrease in the number of cases during the past 25 years little opportunity to become proficient in intubation has offered. The practitioners graduating during this time are turning more and more to tracheotomy.

In our clinic we still have a marked preference for intubation and the laryngoscopic method suggested by Mosher has largely displaced the O'Dwyer method.

Special facilities for the supervision of the cases are needed and special instruments and techniques. The chief cause of death in these cases has been pneumonia and with our present antibiotics this danger has been largely removed as would be true also of tracheotomy. We have no suitable comparison of tracheotomy and intubation and statistics are difficult to secure.


References

Anderson, J. S., Happold, F. C., McLeod, J. W. and Thomson, J. G.: J. Path. and Bact. 34:667, 1931.

Christie, A. B. and Preston, J. C.: Brit. M. J. 1:433, 1946.

Eller, C. H. and Frobisher, M. Jr.: Am. J. Hyg. 42: 179, 1945.

Frobisher, M., Jr.: Am. J. Pub. H. 33:1244, 1943.

Frobisher, M., Jr., Adams, M. L. and Kuhns, W. J.: Proc. Soc. Exper. Biol. and Med. 58:330, 1945.

Gibbons, R. J.: Canad. J. Pub. H. 36:34, 1945.

Ipsen, J.: J. Immunol. 54:325, 1946.

Mueller, J. H.: J. Immunol. 42: 353, 1941.

Pappenheimer, A.M.: Brit. J. Exp. Path. 17:335, 1936.

Robinson, D. T. and Marshall, F. N.: J. Path. and Bact. 38:73, 1934.

Weinstein, L.: Am. J. Med. Sc. 213:308, 1947.

Wheeler, S. M. and Morton, A. R.: Am. J. Pub. H. 32:947, 1942.


## DISCUSSION

Harris P. Mosher, M.D.: Mr. Chairman and Fellows of the Association, today you heard one of Boston's best! Yesterday you heard two examples of the near best perhaps.

I have been under many obligations to Dr. Place and one of my greatest obligations to him is his coming here today to give us his very ripe experience.

All of you in your hospital life have had experiences with consultants. You have never had an experience with Dr. Place. To me he is the ideal consultant. His consulting work is not easy. It comes at inopportune times. It comes at midnight. It comes on Sundays. It comes on the day he is going to take his vacation, if he ever does take a vacation. But he always comes. He always comes with a smile and as I said, I am now putting in print and in large type my thanks to him as the ideal consultant.

Another thing, he used the direct intubation, and he uses my instruments, or he did.

BURT R. SHURLY, M.D.: I have enjoyed this important talk on diphtheria.

I happen to be the survivor of three children, the other two having succumbed to the disease when I was a mere child. For that particular reason, if none other, I took the greatest interest in this disease.

In Detroit we used the first Viering antitoxin, the few that were sent over from Germany, and immediately the results were so striking and so wonderful that Parke Davis manufactured the antitoxin. That is now 50 years ago. It was my privilege to use it in 25 cases before it was put upon the market, and we had only two deaths. That was a most tremendous change because in the five years preceding the diphtheria work done at Harper Hospital, all tracheotomies died. The work was done by various surgeons and the mortality was always 50 to 75 per cent in the laryngeal cases. Thus the coming of antitoxin was a great achievement, one of the greatest in medicine.

We had in the short period of three years tremendous epidemics in Detroit. During the winter months, there were always at least 250 cases of diphtheria and during that period of three years, I did over 500 intubations, and that meant in the horse and buggy days, night after night, replacing intubation tubes which were coughed out. Where the mortality had been 80 per cent for laryngeal cases, it was very quickly reduced to 20 per cent. The great difficulty was in making the profession realize the value of antitoxin.

I have had some practitioners say they would not allow me to intubate if we used antitoxin because it was a terrific poison and the danger was from its use. I mention that to show how our great profession will sometimes get off on the wrong foot and will follow through ideas which are absolutely erroneous.

Of course, the early treatment and diagnosis are of the greatest importance. We were afraid to give over 1000 units in the first days of treatment, and we soon found out that that dosage, which the doctor did not mention in his talk, could be run up to 10,000 units with greater and greater effect, so that the mortality in our city was reduced to 25 per cent, and finally to five per cent.

The advent of toxin-antitoxin was another great achievement and today in Detroit we have but one or two cases of diphtheria reported.

Tonsillectomy for the case that is carrying diphtheria is a well-known and very splendid method of cutting down the carriers. I think this was brought out in the last war by Dr. Fernberg of Chicago in a very excellent paper at that time.

I believe that intubation by a properly skilled man is a wonderful way of dealing with laryngeal diphtheria. Tracheotomy can always be done later, if necessary, but with penicillin protecting secondary infections and antitoxin protecting the child from the disease, we have today made great achievement in modern medicine.

GORDON F. HARKNESS, M.D.: Mr. Chairman, I too would like to express my appreciation for this splendid paper.

I wish, in closing, Dr. Place would talk a little bit about those membranous inflammations of a non-virulent nature and their diagnosis, those inflammations of the nose and throat in which the organism as identified in the laboratory is in that genus of Coryne diphtheria, in that group, such as bacillus Hofmann, B. xerosis. It is my understanding as non-virulent organisms they are not variants of the virulent organism at any time. It is as if in each disease East is East and West is West and the twain shall never meet. They do not produce toxins and are not affected by antitoxin, and yet they are very puzzling at times.

According to my knowledge, the only positive identification is by guinea pig inoculation. I would like to have Dr. Place tell us something about that. That is of some practical importance.

I know of one case in which there was the possibility of legal entanglement because of quarantine in which the family and the wage earner were quarantined on account of a non-virulent membranous inflammation which was present in the family. It does not happen often.

I observed a school teacher with a subglottic membranous inflammation in which morphologically the organism came within this genus; she went back to school and took charge of her class and everything went along all right.

I have also seen it in nasal conditions. I think that Dr. Place can give us some valuable information concerning this.

PAUL H. HOLINGER, M.D.: Mr. Chairman, Members: Dr. Place, we certainly appreciate your bringing this presentation to us as a laryngological group. Diphtheria is one of the things we are prone to overlook in its importance to our particular specialty, principally because of the tremendous number of children now who have been immunized and in whom the incidence of diphtheria is low. In our own Children's Hospital the incidence of diphtheria on admission is so low that we sometimes overlook it as a possibility in youngsters admitted with laryngeal obstruction. I hope that Dr. Place will discuss the incidence of diphtheria in infants prior to the usual age of immunization. In our own experience we have seen one infant, 22 days of age, with overwhelming diphtheria who died practically on admission to the hospital, and another infant, two months of age, who died shortly after admission with an overwhelming diphtheria.

H. B. ORTON, M.D.: I certainly have enjoyed Dr. Place's paper and would like to ask the doctor a few questions concerning chronic laryngeal stenosis following intubation.

Following Dr. Henry Lynah's death, I fell heir to about 20 cases of chronic laryngeal stenosis following intubation. At the Essex County Hospital for Con-

tagious Diseases, since we established the rule that in all intubated cases where it is found necessary to re-intubate, or where the tube has been coughed up, a tracheotomy is performed immediately, we have not had any more chronic laryngeal stenosis.

The questions I would like Dr. Place to answer are, first, how often does he intubate a given patient at the Boston Hospital? Secondly, if the intubation tube is coughed up will he re-intubate or perform a tracheotomy?

F. T. HILL, M.D.: I would like to ask Dr. Place whether or not the program of mass immunization, perhaps inadequately carried out, might tend to decrease the natural immunity of the individual?

H. MARSHALL TAYLOR, M.D.: Mr. Chairman, the fact that we do not see diphtheria now as we did previously is all the more reason why we should keep our eyes and minds open relative to it.

Just recently I was called to see a case, a child which had been suffering with an epistaxis. Several men had seen the case. I was called in consultation. I went to see the child and the child met me at the door on a velocipede. The child had a paralysis of the lower extremities.

I would like to ask Dr. Place whether he has seen more post-diphtheritic paralysis from the nasal type or from the pharyngeal type of diphtheria, and also has he any suggestions as to the treatment of only the post-diphtheritic paralysis.

I have observed through the years three cases of paralysis of the lower extremities, and after having had that experience with this child meeting me at the door on the velocipede, I find that these children who have a paralysis of the lower extremities if you put them on a velocipede that they get along very well. While they are not ambulatory, they can get around in the home.

Diphtheria has a predilection for the extensors or for the flexors. It has been an interesting experience to me to note that if you put these children with paralysis on a velocipede or on a bicycle they get along perfectly well whereas they are not ambulatory.

E. H. PLACE, M.D. (Closing): It is very flattering to have Dr. Mosher say such nice things about me. I think any of us would appreciate that. I always before this put a great value in his judgment. Now I am afraid I have lost it.

Regarding the coughing of tubes, that is one of the problems of intubation cases. We have found by using the short French tube, the Bayeux tube, there is much less tendency to cough tubes. This was used many years ago. Whenever an O'Dwyer tube was coughed we would replace it by the Bayeux tube. We rarely have the repeated problem of coughing tubes. However, the Bayeux tube is now almost exclusively used.

If you cannot keep a tube in, it means increased intubation to the patient, and not only the danger of it coming out and asphyxiation but the danger of trauma in inserting the tube. The chief danger, of course, to the larynx of intubation is the pressure of the tube if it is not the right size. It must fit in an inexpansible box of cartilage. It must not be too large and small enough to fit in readily be-

tween the swollen membrane and the cartilage, otherwise you get pressure necrosis. It should be put in with a great deal of care and no force. It is a question of manipulation and not force.

As it was said here, skill is extremely important. If they keep coughing the tube, do a tracheotomy of course, but it is a rare occurrence in our clinic.

Toxoid is more generally used than toxin-antitoxin because it is a more efficient stimulus for antibodies in the host. Of the treated toxin you can use a dose which would kill a person easily many, many times over, without any harm at all because the toxin is all removed in the process of making the toxoid; in removing the toxin, however, the antigenic substance is left.

In all children toxoid is probably preferable to toxin-antitoxin. The toxin-antitoxin is remaining chiefly for the adults. The large amount of toxin, modified by formalin, in one cc. as compared to the very small amount of toxin in the toxin-antitoxin mixture is more likely to produce a reaction in the adult. The Moloney's test, which tests sensitivity to toxoid by skin test is used in adults before they are immunized.

Dr. Harkness speaks of membranous infections of the nose and throat and larynx and trachea not associated with diphtheria bacilli. Of course there is no basis for maintaining there is a non-virulent diphtheroid infection. There is not such a thing as a diphtheroid disease as we know it. The diphtheroids produce no disease. They may be found in a great variety of conditions. They are widely distributed in nature and found everywhere and many bacteriologists, no matter what the disease is report the presence of diphtheroids. Diphtheroids have, as far as we know, no pathological significance whatever, but the problem of recognizing the non-diphtheritic inflammations is a problem you are all familiar with and it is extremely difficult. You must depend upon all the evidence you can secure bacteriologically, epidemiologically, although that is not of great value, and the clinical course in response to treatment. Diphtheria bacilli are identified most significantly by the virulence test.

As I said, and as has been emphasized by speakers here, antitoxin should be given as soon as you have a suspicion of one of those infections. It is far better to treat a large number of non-diphtheritic infections with antitoxin than letting one case of actual diphtheria go without treatment. That is the principle because it is relatively harmless to patients who have no diphtheria unless they have serum sickness.

My experience with the membranous diseases of the throat leads me to acknowledge the frequency of great difficulty in diagnosis. Streptococcal infections and more rarely pneumococcal and staphylococcal infections, neutropenia, acute mononucleosis, leukemias and pernicious anemia, Vincent's angina, syphilis, and traumatic lesions such as poisoning with the heavy metals require differential diagnosis.

Then, as shown, you must keep in mind the possibility of diphtheria combined with other diseases. It is not an everyday affair but it can occur, and it may be your problem to deal with it. It is not easy to prove but we have had cases

where we proved they had diphtheria bacilli which were virulent but the patient did not have diphtheria. Then we have proved in a culture taken from cases which were supposed to be diphtheria and they were non-diphtheritic, as for instance with syphilis in the old days. You can prove they are carcinomatous and a few other things but very often if the diphtheria bacilli are present we can entirely prove it. We used to accept immunity to a large amount of toxin because they never developed damage or death. We have been compelled to give that up.

It has been shown you can have diphtheria if it is virulent enough and there is inadequate antitoxin in the blood stream but that is a question which time will have to settle.

Dr. Holinger spoke of the age incidence. That is shifting toward the older age period. It has been striking during the last 15 years. It has not shifted to a degree or never was of a degree characteristic enough so that you could depend upon the age for diagnosis. There is no sense in attempting to take the age as a diagnostic measure. The shifting of the age toward the adult is believed to be due to the general immunization, chiefly in childhood which has removed the higher incidence of childhood and leaves the adults more susceptible. That occurred in smallpox. Smallpox was a disease of infants and children, previous to 1800. It shifted to the older age group only after immunization which was done in children.

Dr. Orton's remarks on chronic stenosis are very pertinent. Chronic stenosis is a great fear of the intubationers. It is not very common. We believe that the factors which lead to it are chiefly those I mentioned, too large a tube or unskillful manipulation, using force.

In the cases of streptococcal infection of the larynx, however, intubation may be an important factor, even with all these conditions being controlled because the streptococcus is an invasive organism and tends to involve the perichondrum and chondritis is not infrequent. We have had cases which were markedly stenotic and had ceased breathing; rapid tracheotomy was done and as soon as one got to the trachea, he reached the abscess which squirted pus out and immediately the patient was relieved. These pre-tracheal and perichondritic and chondritic cases are better treated by tracheotomy. There is tenderness over the larynx and upper trachea with loss of landmarks to palpation. In any case of streptococcal laryngitis, which are quite numerous, it is probably wise to do a tracheotomy fairly early. We always make a practice if we use intubation, which we customarily do, of resorting to secondary tracheotomy as soon as we have evidence that the larynx is not doing well; if there is a tendency to ulceration seen with the laryngoscope or if there is a tendency to bleed, or if the laryngeal swelling does not begin to subside quickly, in the course of a few days. Patients do better after that period with primary tracheotomy. They have had a chance to develop some immunity. We have not had a chronic tube now for over ten years. The number of cases has been enormously reduced. I don't recall the exact numbers. The percentage now is about the same as it used to be but the total number of cases is very small. As I said, in the period from 1928 to 1946 inclusive, we had

only something over 5000 cases while in the period from 1895 to 1920 we had over 33,000 cases of diphtheria, and of course intubations were very numerous in those days.

Chronic stenosis in the group they had in New York City many years ago was extraordinarily large in number because of being cumulative and over-emphasized the danger of intubation. I feel and felt at the time that the method of dealing with the problem was not the best one. Unfortunately Dr. Lynah's sudden death interrupted any real study of the problem, but I believe that Dr. Lynah had the wrong idea in attempting to dilate and keep open an inflamed tissue. Nowadays, we feel it is far better to do tracheotomy below, and leave the larynx entirely alone and resort to manipulation only after the lesion is completely healed.

Regarding Dr. Taylor's remark about paralysis, we have no treatment for paralysis as far as I can see which is worth anything. They all get well. We have never had residual diphtheric paralysis. We must remember there are cases of cerebral damage following diphtheria which lead to cerebral paralysis, quite different from diphtheritic paralysis. They may be transient, permanent or fatal. There may be thrombosis of vessels of the brain. Diphtheritic paralysis gets well.

On mass immunization, it is the chief procedure for diphtheria. It must be universal. We cannot pick out cases with safety. We have got to immunize everybody.

# BENADRYL IN THE TREATMENT OF ALLERGIC RHINITIS

D. M. LIERLE, M.D.

J. T. DICKINSON, M.D.

IOWA CITY, IOWA

This paper is a preliminary report of seventy-six cases of allergic conditions in otolaryngology over a period of two years. This group includes 13 cases of asthma associated with allergic rhinitis.

Benadryl or beta dimethyl aminoethyl benzhydryl ether is a synthetic antihistamine preparation with the property of preventing at least some of the pharmacaloric effects of histamine. It is soluble in alcohol and water and is stable under ordinary conditions.

Locer, Korse and Moore first demonstrated its antihistamine activity. It has been shown pharmacologically to alleviate vasodepressor effects of histamine and the histamine-induced spasm of smooth muscle.

Studies indicate it has an antihistamine effect 650 times as effective as papaverine. Its antispasmodic action is 1.3 times as effective as papaverine in antagonizing the contractile effects of barium chloride. It is 15 to 30 times as effective as aminophylin in alleviating the bronchial constriction caused by histamine or aminophylin as shown in pharmacologic studies in animals. Histopathologic studies failed to show evidence of acute or chronic degenerative changes after its use.

McGavach, Elias and Boyd observed no abnormal changes in basal metabolism, circulation time, renal function, red and white cell counts, hemoglobin, differential white counts, blood urea, nitrogen, creatinine, glucose, protein, cholesterol, etc.

According to early investigators, 30 per cent of the patients treated with Benadryl did not have so-called side actions. The remaining cases developed certain side actions such as drowsiness, dizziness, nervousness, numbness of extremities, nausea and dry mouth. It is claimed that true side actions may occur at any time and that there is no direct relationship to the size of the dose of Benadryl.

Clinical physiologic observations showed that Benadryl is capable of decreasing the cutaneous vasodilating effect of histamine, even during

the intravenous administration of the histamine. It can also alleviate nasal congestion due to the action of histamine. This response varies with the degree of the patient's sensitivity to histamine, and the amount of the drug used. It has shown a tendency to depress the gastric response to histamine administration, and in a case of physical allergy, it was capable of lowering the blood histamine levels and gave prompt symptomatic relief.

Treatment with Benadryl is based on the theory that histamine, or a histamine-like substance is responsible for the manifest symptoms of allergic diseases and of other diseases not now recorded as being allergic. Benadryl has an affinity for the cell protoplasm and crowds out the histamine. The chief physiologic properties of histamine to be counteracted are capillary dilatation and increased permeability, manifested in skin and mucous membranes; contraction of smooth muscle—bronchial, vascular, intestinal, uterine, and a secretagogue for glands of external secretion.

Benadryl is used to give prompt relief from symptoms due to these tabulated reactions, and does not compete with substances such as hapamine which are used for active desensitization to histamine. Benadryl is used to give prompt decrease in the body histamine. Further care must be given in continuing the drug, eliminating the causative factor or desensitizing to specific allergens or to histamine itself.

In general, the diseases to be treated with Benadryl are those whose sole etiologic factor is hypersensitivity to histamine or the histamine-like substance; cases in which an antispasmodic effect is desired, or when a combination of an antihistamine and antispasmodic effect is desired, or cases of obscure etiology which have not been amenable to other forms of therapy and are being treated purely on an investigative or empirical basis.

Some of the specific diseases which respond to the treatment are hay fever, vasomotor rhinitis, Meniere's disease, acute urticaria and angioneurotic edema, chronic urticaria, with or without angioneurotic edema, asthma, tension headache with vasodilatory features, histamine cephalalgia, and cases with indefinite diagnosis and questionable etiology, which might well respond to therapeutic trials.

A total of 76 cases of allergic rhinitis—some with asthma—were observed over a period of two years. There were 23 cases of seasonal

allergy, 30 non-seasonal or perennial cases, and thirteen patients with both asthma and allergic rhinitis.

1. Pre- and post-treatment blood studies including WBC, RBC, Hb and differential counts revealed no marked variations. The minor variations that were seen occurred within normal variations and did not tend to be in any single direction.

2. Pre- and post-treatment urine examination including the routine color, specific gravity, P.H., sugar, albumin and microscopic data failed to produce any pathologic changes in these findings.

3. The blood pressures of nine hospitalized patients were checked closely under controlled conditions. Five cases showed reduction of the systolic pressure of 5-10 mm. of Hg. and a 5 mm. drop in the diastolic pressure. Four cases showed no change.

4. Histamine sensitivity was present in but nine cases. The administration of the drug reduced, temporarily, the local reaction in seven cases. No permanent desensitization was noted.

General directions for dosage:

ORAL ADMINISTRATIONS Use 50 mg. capsules

*Adults*

1st Day—1 capsule B.I.D.

2nd Day—Insufficient therapeutic response and no toxicity—1 capsule T.I.D.

3rd Day—Insufficient therapeutic response and no toxicity—1 capsule Q.I.D.

4th-5th Day—Insufficient therapeutic response and no toxicity—2 capsule B.I.D.

6th Day—Insufficient therapeutic response and no toxicity—1 capsule 5X d

7th-8th Day—Insufficient therapeutic response and no toxicity—2 capsule T.I.D.

9th and 10th Day—Insufficient therapeutic response and no toxicity—2 capsule Q.I.D.

*Children*—Use a daily dose of 2 mg. per pound of body weight and divide this dose into two to four doses. If an insufficient therapeutic response does not occur and no contraindicative toxicity arises, follow

the following chart. If the 50 mg. capsules are not satisfactory use approximate proportions from the capsule and administer in syrup, jelly, or make up a known solution and calculate the dosage. A 50 mg. capsule dissolved in 50 cc. of water (1 mg. per cc.) is convenient. Elixir Benadryl—each 4 cc. (one tablespoon) contains 10 mg. of Benadryl.

1st-2nd Day—1 mg. per lb. body weight—2-4 doses
3rd-4th Day—1.5 mg. per lb. body weight—2-4 doses
5th-6th Day—2 mg. per lb. body weight—2-4 doses
7th-8th Day—2.5 mg. per lb. body weight—2-4 doses

The administration of the drug was limited to the oral route and given according to the above table. In cases in which immediate relief was not imperative the patients were instructed to start with one 50 mg. capsule per day; preferably 30 minutes prior to the most uncomfortable period for the individual case. They then added a 50 mg. capsule per day until (1) complete alleviation of symptoms occurred, (2) no further increase in improvement was noted with an increase in dosage.

When the side effects offset the clinical response the dosage was reduced to a minimum that would maintain maximal symptomatic relief. The individual dose was limited to 100 mg. and the daily dosage to 500 mg. In the absence of unfavorable side effects the patients that did not receive symptomatic improvement were kept on an average daily dosage of 300 mg. for five days before the drug was discontinued. No common dosage could be ascertained for individuals. The yardstick used for children's dosage was 2 mg. per pound of body weight and was varied in the same manner as the adult scale.

## Side Effects

The most common side effect noted was drowsiness. This recurred in varying degrees in 85 per cent of the 76 cases treated. Generally speaking, the drowsiness was not marked. A few of the cases which received relief said they preferred the symptoms of hay fever to the drowsiness produced by the drug. However, the majority of the cases noted that the rather constant mild sedative effect was more beneficial than detrimental.

The drug appeared more effective and agreeable when given in smaller doses in combination with other types of treatment such as desensitization, eliminative regimes, etc.

Dryness of the mouth was present in 17 or about 28 per cent of the cases. This was apparently an accompaniment of the desired reduction of the allergic secretions of the respiratory system. Most of these patients were being treated for a condition which was not accompanied by excessive nasal discharge. No one discontinued the use of the drug because of this effect.

Eleven or about 14 per cent of the patients complained of mild nervousness and an accompanying fatigue but all but one case overcame this difficulty by regulation of the dosage and the time of day that the drug was taken. Although the nervousness was not severe in the one case that discontinued the drug, it was sufficient to more than offset the fair therapeutic response that she was receiving.

Seven or approximately nine per cent of the cases had complaints referable to the eyes. This was described as dimmed or blurred vision. This appears to have been due to an atropine-like effect on the accommodation mechanism but further study along this line is being carried out by our department of ophthalmology.

There were no voluntary complaints referable to gastrointestinal, respiratory, cardiovascular, or genitourinary systems. Upon routine questioning six or about seven per cent of the cases admitted a mild urinary frequency but this seemed to be in direct relationship to an increased fluid intake.

Five or approximately six per cent complained of moderately severe headaches. None of the more serious side effects being reported in the literature were encountered. However, the indiscriminate use of any drug will lead to such reactions and should be watched for:

| Side Effect | Mild | Moderate | Severe |
|---|---|---|---|
| Drowsiness | 30 | 11 | 4 |
| Dry Mouth | 17 | | |
| Nervousness | 10 | 1 | |
| Dimmed Vision | 7 | | |
| Urinary frequency | 6 | | |
| Headaches | | 5 | |

## Results

The results tabulated on the accompanying chart are based on symptomatic relief only: Excellent 75-100 per cent; Good 50-75 per

cent; Fair 25-50 per cent; Poor 0-25 per cent. Generally the best results were obtained during the acute manifestations of seasonal and perennial allergic rhinitis. In a few of these cases that were of short duration, the nasal mucous membrane, on examination after several treatments, was nearly normal in appearance. In two cases in which nasal polyps were forming for the first time, there was a definite reversal of the process, in accompaniment with the usual alleviation of edema and watery discharge. Minor complaints referable to rather mild perennial rhinitis responded with only fair consistency. Several cases of mild bronchial asthma namely associated with allergic rhinitis received excellent improvement but the few cases with the typical severe asthma did not obtain relief.

### Results

| Diagnosis | Cases | Exc. | Good | Fair | Poor |
|---|---|---|---|---|---|
| Seasonal allergic rhinitis | 33 | 12 | 11 | 5 | 5 |
| Perennial allergic rhinitis | 30 | 11 | 8 | 7 | 4 |
| Asthma | 13 | 5 | 4 | 1 | 3 |

### Comment

We still do not know the answer to our allergic problems. However, the armamentarium for its control has been on the increase and until more specific elements are developed, the so-called antihistaminic drugs should have their role. At present they are far from being the cure-all of allergy. A limited series of cases reveals that Benadryl has not given rise to any alarming toxicologic factors. Its use does not produce any lasting effect. It is merely a symptomatic drug and like all such drugs its indiscriminate use should be controlled. It has proven to be of great value in the symptomatic control of the allergic patient whose etiologic factors can eventually be removed or whose allergic season is of short duration. It should continue to be used for the more prolonged allergies in conjunction with desensitization and other types of treatment whenever possible in selected cases.

# TISSUE CHANGES IN SINUS MEMBRANES AFTER PENICILLIN TREATMENT

RALPH A. FENTON, M.D., Sc.D.

OLOF LARSELL, PH.D., Sc.D. (by invitation)

PORTLAND, OREGON

After six years of work on the histopathology of experimentally produced sinusitis, we were convinced by 1935 that "owing to the defensive factors inherent in sinus epithelium and the connective tissue elements of its tunica propria, almost every sort of surface application to such membranes becomes an irritant unless its strength be isotonic."[1] This point was amplified in our discussion of the defense mechanisms of the upper respiratory tract before this Association in 1937.[2]

Among the various chemotherapeutic agents (zephiran, parachlorophenol, and tyrothricin) recently tested for use in wound healing, Howes found that dilutions strong enough to inhibit bacterial growth were toxic to epithelial cells and fibroblasts. Streptomycin and sulfamylon were mildly inhibitory of cell growth. However, penicillin calcium proved inert as to cellular damage.[3]

Numerous reports of excellent results from local use of penicillin, as nose drops, by the Proetz postural method, by instillation through cannulas, and by atomization, have been current for the past few years. It has become fairly evident, through many clinical trials, that local use of this valuable antibiotic is only justified in the very early stages of sinus involvement; that certain bacterial types are penicillin-resistant, while others may become so; that some individuals are allergic to penicillin; and that chronic infections are unlikely to be helped by such local applications.[4,5,6] Our own experience for the past three years has convinced us that penicillin locally used in the sinuses is of value only in acute and subacute cases.

No reports of microscopic examination of acutely inflamed sinus membranes have come to our attention. It was therefore decided to

---

From the Departments of Otolaryngology and Anatomy, University of Oregon Medical School.

infect a number of cat frontal sinuses with a virulent hemolytic streptococcus culture of human upper respiratory origin, using the techniques described in our reports of 1931 and 1932.[7,8]

Six cats were inoculated with beta-streptococcus pyogenes, grown in a Hartley broth culture, introduced by puncture into each right frontal sinus on November 6, 1946. On November 8, the left frontal sinuses were similarly inoculated. On November 11, all of the sinuses of four of the animals were perfused with sodium penicillin at a concentration of 2,000 units per cc. of normal saline solution, about 0.5 cc. of the solution being injected into each sinus. The animals were sacrificed (or died) on the dates indicated in the individual protocols. The frontal and nasal bones were dissected out, the bone above the sinuses was chipped away, and the sinus membranes were fixed, in situ, in formol-Zenker solution. After the usual subsequent preparation for histologic study, paraffine sections were stained with hematoxylin-eosin-azur, or with Goodpasture's stain for bacteria in tissues.

The sections show the following features:

CAT 1. Weight five pounds. Tissues secured November 15, four days after use of penicillin.

*Left sinus.* Membrane greatly thickened, showing acute stage of reaction to infection (as shown in earlier experiments),[1,2] modified by a large number of macrophages and plasma cells, in addition to the predominant polymorphonuclears characteristic of acute reaction. Epithelium broken in many places, but elsewhere showed ciliated columnar cells and goblet cells. No granules in epithelium or elsewhere.

*Right sinus.* Membrane thickened and filled with polymorphonuclears, plasma cells and histiocytes, with a larger proportion of plasma cells than in the left sinus membrane; no granules.

CAT. 2. Weight four and one-half pounds. Tissues secured Nov. 14.

*Left sinus.* Membrane edematous and thickened, with many polymorphonuclears, plasma cells and histiocytes. Epithelium shows numerous purple-blue granules (streptococci), especially in the goblet cells, but also between the columnar cells; many are dumbbell shaped.

*Right sinus.* Membrane thickened, with polymorphonuclears, etc. numerous. A deep pocket of streptococci (Goodpasture stain), surrounded by a dense mass of cells, occurs below a broken part of the epithelial surface. No granules appear on the epithelial surface.

CAT 3. Weight four and one-half pounds. Tissues secured Nov. 13.

*Left sinus.* Marked acute inflammation. Polymorphonuclears and macrophages predominant.

*Right sinus.* Subacute inflammation. Membrane thinner than left side, and with fewer polymorphonuclears. Goblet cells contain numerous purple-blue granules resembling streptococci.

CAT 4. Weight four and one-half pounds. Animal died November 8, six hours after second inoculation with streptococcus culture. No penicillin treatment. Sinus membranes fixed immediately.

*Left sinus.* Early stage of inflammation. Some polymorphonuclears present, membrane beginning to thicken. Goblet cells laden with streptococcus-like granules, also some in columnar cells of epithelium.

*Right sinus.* Early stage of inflammation. Streptococcus-like granules on epithelial surface and in epithelium. Rounded masses of granules in epithelium and in goblet cells. Some plasma cells in the fibrous layer of the membrane.

CAT 5. Weight four and one-half pounds. Tissues secured Nov. 12.

*Left sinus.* Membrane too broken for good sections, but apparently normal.

*Right sinus.* Early stage of inflammation, with fairly numerous polymorphonuclears and many macrophages with granules; also engorgement of blood vessels.

CAT 6. Weight four and one-half pounds. Animal died during night of November 8, following second (left) inoculation with streptococcus culture. No penicillin treatment.

*Left sinus.* Membrane thin; no indication as yet of inflammation.

*Right sinus.* Acute inflammation, with many polymorphonuclears, histiocytes, etc., and thickening of membrane. Polymorphonuclears also in epithelium. Goodpasture stain shows cocci in many cells.

## Comment

The acute inflammatory reaction appears to continue longer after local treatment with penicillin than in the earlier experiments in which no such treatment was employed. This suggests that the active stage of phagocytosis by polymorphonuclears is of longer duration and is therefore, in all probability, more effective. Some allege that penicillin in solution is a local cellular irritant exciting polymorphonuclear activity, but it may possibly exercise a true bacteriostatic stimulus to phagocytosis, at least in living ciliated membranes.

In the two animals that received no penicillin, and in a deep mucosal pocket of one so treated, streptococcic granules were present. Similar

granules were found in the goblet cells of some of the other animals, but none on the surface. Thus it would seem that in the cat streptococci are rapidly destroyed on the surface and in the epithelium of acutely inflamed sinus membranes, through the bacteriostatic properties of sodium penicillin, 2,000 units per cc. of normal saline solution.

For perfusion of acutely inflamed sinuses in human subjects, and for intratracheal injection, we have found during the past three years that a solution containing 1,000 units per cc. gives rise to no complaint of local burning or irritation. This adds strength to the hypothesis that phagocytosis is greatly accelerated by the local use of penicillin.


References

1. Fenton, H. A., and Larsell, O.: Research Report on Experimental and Clinical Sinusitis, Arch. Otolarlyng. 23:18, 1936.

2. Fenton, R. A., and Larsell, O.: The Defense Mechanisms of the Upper Respiratory Tract, Ann. Otol. Rhinol. and Laryng. 46:303, 1937.

3. Howes, E. L.: Local Chemotherapy of Wounds, Surg. Gyne. and Obst. 83:1, 1946.

4. Crowe, S. J., Fisher, A. M., Ward, A. T. and Foley, M. K.: Penicillin and Thyrothricin in Otolaryngology, Ann. Otol. Rhinol. and Laryng. 52:541, 1943.

5. Proetz, A. W.: Cilia and Penicillin, Ann. Otol. Rhinol. and Laryng. 52:94, 1945.

6. Krauss, F. H.: Penicillin Therapy in Otorhinolaryngologic Practice, Arch. Otolaryng. 44:647, 1946.

7. Fenton, R. A. and Larsell, O.: Reticulo-endothelial Components of Accessory Sinus Mucosa, Arch. Otolaryng. 14:586, 1931.

8. Fenton, R. A., and Larsell, O.: Histiocytes in Acute and Chronic Inflammation of the Accessory Sinuses, Laryngoscope. 42:233, 1933.


## DISCUSSION

Dr. A. W. Proetz: Mr. Chairman, Dr. Fenton can always be depended upon for a good sound, accurate, concise scientific report.

I think in this case, it is especially important because it deals with a subject which has had so much unscientific and superficial observation.

Our findings have been the same as Dr. Fenton's so far as the clinical use of penicillin is concerned. In chronic cases we feel that it is practically useless. In the acute cases it probably has considerable use. We are not too sure whether it is more effective than some of the older treatments but certainly if it has a place in the treatment of sinusitis it is in the acute stages.

We must always remember that there is a distinction between treatment in the nose and treatment in the sinus, and there is a time element which we must not overlook. Fluid remaining in the sinus over a period of time can do damage; the same fluid in the nose may not, since it does not stay in contact with the mucosa long enough.

Our own observations on the action of penicillin on the ciliated epithelium were that in concentrations of 250 units per cc. no effect could be seen. The controls and the tissues under study remained active for about the same length of time, which was about 17 hours. As we increased the concentration we found some shortening of the time of ciliary activity, not important but reducing that time from 17 hours to perhaps 7 or 8 hours. Clinically, this is unimportant but I believe it is a good indication of the effect of penicillin on cells, because ciliary activity indicates almost exactly the viability and the physiological reactions of the cell itself. We almost never see ciliary cessation in an intact epithelium. As the cilia stop beating the cells usually begin to peel away from the surface and disintegrate.

I am very grateful to Dr. Fenton for this contribution because I think it will eliminate unnecessary and useless treatment in chronic cases.

DR. C. J. IMPERATORI: May I ask Dr. Fenton, has he had any experience with the use of aero-penicillin?

DR. FENTON: No, sir.

# CHORDOMAS OF THE CERVICAL REGION

CHARLES J. IMPERATORI, M.D.

NEW YORK

These rare tumors that are vestigial remnants of the notochord[1] (an axial structure characteristic of all vertebrates), are usually located at those areas representing its extremities, viz., the spheno-occipital synchondrosis and the sacro-coccygeal region. Rarely are they found in the cervical areas.

Normally,[2] portions of the notochord persist in the intervertebral discs as the central mucoid cores or pulpy nuclei (nuclei pulposi).

Virchow[3] in 1857 described small jelly-like tumors occurring in the region of the dorsum sellae and named them "ecchondrosis physaliphora." These were attributed to islets of degenerated cartilage from the spheno-occipital synchondrosis.

Fabricius reported[4] a case history of a patient with a chordomatous growth of the nasopharynx and pharynx, who was operated upon twice, the second operation being four and one-half years later, and who remained well without further recurrence. Complete details are not given.

Syme and Cappell[5] described in some detail such a tumorous growth. It was located on the posterior pharyngeal wall and grew upward toward the nasopharynx and downward toward the larynx, being attached to the 2nd, 3rd and 4th cervical vertebrae. The chief symptoms were pain in the head and neck, stiffness in the neck and difficulty in swallowing. The patient was operated upon in July, 1926, and by January, 1927, a second operation became necessary, but was unsuccessful. The approach was externally. There was no lymph node involvement and no invasion of the adjacent structures observed at the operation done in January. However, one lymph node was found to be involved at the second operation.

Andre-Thomas and Villandre[6] reported a case, and Cappell[7] reported two such tumors attached to the cervical vertebra.

Chiari[8] reported a cervical chordoma which was attached to the surfaces of the borders of the 4th and 6th cervical vertebrae.

Definitely, chordomas of the pharyngeal and mid-cervical areas are of such uncommon occurrence that they warrant recording, and such a report will be included in this communication.

Ridpath[9] states these tumors "have been reported as occurring in various locations in the following order of frequency: In the sacro-coccygeal in ninety-one cases; in the spheno-occipital region in fifty-two cases; in the cervical portion of the spine in twelve cases, and in other locations, rarely."

Gavin Livingstone[10] groups these tumors into three classifications.

"TYPE 1. The small tumors called by Virchow 'ecchondrosis physaliphora.' They occur in two per cent of post-mortem examinations and are composed of the same type of cells as the nucleus pulposus of the intervertebral discs.

"TYPE 2. The malignant tumor in which active mucin-producing cells predominate and in which recurrences and metastases occur.

"TYPE 3. The main feature of this type is the production of cells which resemble cartilage and the tumors are usually encapsulated, and do not recur."

A great many of the cases reported as occurring in the cervical area have been high, usually arising from the 1st and 2nd cervicals, and they were usually associated with growths in the spheno-occipital synchondrosis. Very complete and detailed articles by Owen, Hershey and Gurdjian;[11] by C. M. Haas[12] and by Adson, Kernchan and Waltman[13] have dealt mostly with cranial and high cervical located tumors.

Many authors have expressed varying opinions as to the cause and origin of these tumors.

It would seem that there is a unanimity of opinion that they originate from displaced notochordal remnants. The cause of their growths has not been satisfactorily explained for Stout[14] reports a maxillary chordoma in a day-old infant, and the patient on whom this report is being made is 63 years old.

## Diagnosis

The exact diagnosis cannot be made without biopsy. However, a slowly growing tumorous mass appearing in the oro or laryngopharynx, producing pressure symptoms on the adjacent nerves of the cervical

plexus, disturbance in breathing and deglutition, running an afebrile course, and on palpation having a tense jelly-like feel, should be suspected as possibly being a chordoma of this region.

X-ray will show a bulging shadow into the pharynx of varying density. With barium, the shadow is very clearly outlined. Also, any involvement of the bodies of the vertebra and the intervertebral discs may be determined. The amount of obstruction to the food and air passages may also be evaluated.

Aspiration biopsy will, very likely, give negative results, excepting that if the tumor mass contained contents that were more fluid than semisolid, a diagnosis might be arrived at.

Cysts, retropharyngeal abscess, etc., etc., must be differentiated.

Stout[15] epitomized the microscopic findings by stating that chordomas are characterized by the so-called physaliferous cells which are polyhedral with a small nucleus and cytoplasm much distended with glycogen and vacuoles containing a mucin-like material. This gives to the tumor its characteristic jelly-like gross appearance.

The desiderata necessary to diagnose a chordoma has been postulated by Linck[16]:

1. Syncytial giant cells.
2. Curious concentric nests of cells.
3. Nuclear vacuolation possibly filled with glycogen.
4. Physaliferous cells (nucleus is located peripherally and the cytoplasm is filled with mucinous globules).
5. Irregular trabeculae of tumor cells separated by abundant intercellular mucinous matrix.

It has been refuted by many who have studied these tumors that the substance within the much distended cell is glycogen, the chemical test having been confused by the fixative.

## Treatment

This tumor is invasive and very resistant to roentgenotherapy. Its anatomical situation is such that the external surgical approach is difficult.

Suspension laryngoscopy gives an excellent exposure of the pharynx and laryngopharynx, and should be the method of choice in

the excision of such a tumor, located between the 3rd and 6th cervicals.

The mucous membrane, submucosa and pharyngeal aponeurosis may be dissected from the tumor, and excepting where it is attached to the bodies of the vertebra, may be removed intact. These tumors are usually well encapsulated.

The following case report is briefly detailed:

W. C., male, aged 62, American, referred by Dr. W. R. Brandon of New York City.

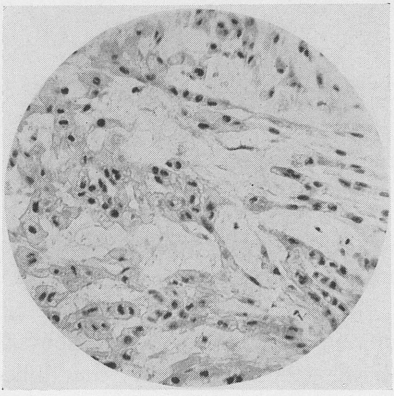

FIG. 1. Chordoma. 4 mm. obj: 6 x occ.
Cells arranged in strands.
Many physaliferous cells—large cells with distended cytoplasm and small nuclei.

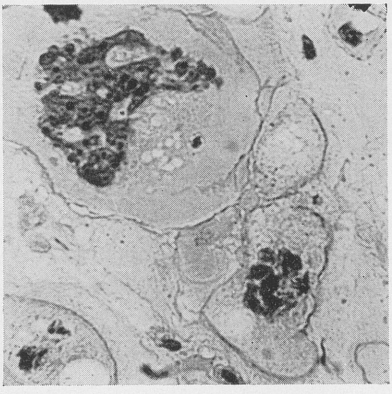

FIG. 2. Chordoma. 4 mm. obj: 6 x occ.
Physaliferous cells showing distention of the cytoplasm, vacuolation and pyknosis.

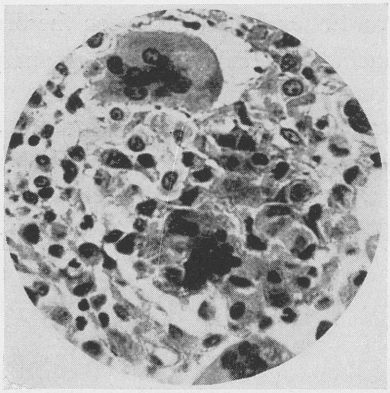

FIG. 3. Chordoma. 4 mm. obj: 6 x occ.
Giant cells.

The patient states his father died when 76 years old from a tumorous growth of the rectum, that necessitated a colostomy. Up to June, 1945, he had no serious illness. About that time, he noticed that he was having slight difficulty in swallowing, but attributed this to the trouble he was having with his teeth. Recently, the difficulty in swallowing increased so that he experienced a sensation of complete obstruction, and particularly so when the larynx is drawn up by the hyoid muscles during the act of swallowing. He states that it feels as though a "ball valve" closed.

During the past few months, he has lost considerable weight (40 lbs.) and his strength and vigor have diminished accordingly. There have been no pain or pressure symptoms on any of the adjacent nerves.

## PHYSICAL FINDINGS

The general appearance of the patient is that of an emaciated elderly male, very apprehensive, and somewhat non-cooperative. All of his teeth are in a state of partial or total decay, gums swollen and inflammed, and many areas of superficial ulceration of the mucous membrane of the mouth. The epipharynx and nostrils were negative.

By indirect laryngoscopy, there is seen an obstructing mass slightly to the right of the mid-line. It is smooth in outline, covered by the normal mucous membrane of the pharynx and without irregularities or ulcera-

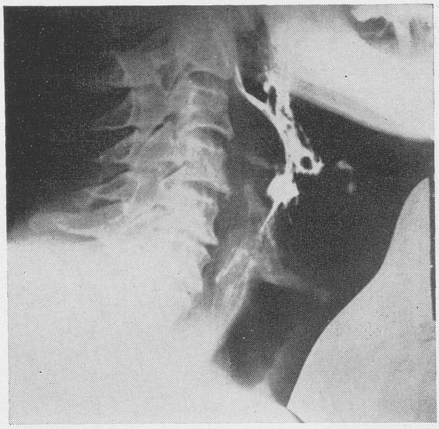

FIG. 4. Chordoma.
"Lateral roentgenogram taken November 7, 1945, shows a shadow extending forward from the vertebral region. The upper margin of the bulge is at the top of the 3rd cervical body. The apex of it is level with the middle of the 4th. The normal thickness of the tissues resumes at the level of the 6th. Barium mixture outlines the tumor mass."

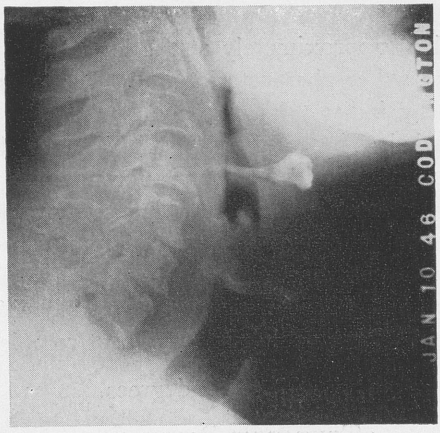


FIG. 5. Chordoma.
"On November 7, 1945, the roentgenogram showed a very prominent bulging forward of the posterior pharyngeal wall centering over the 4th cervical body. There is no bulge as of January 10, 1946."

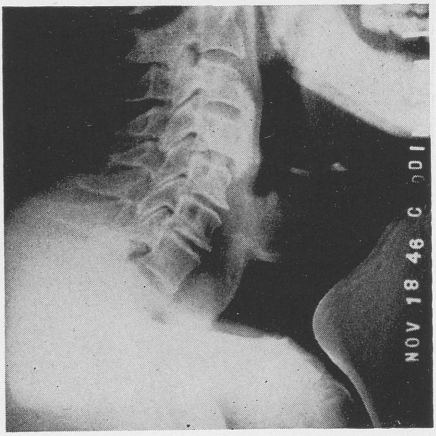


FIG. 6. Chordoma.
"On November 7, 1945, there was a soft mass of which the apex was level with the middle of the 4th cervical body and the upper margin at the level of the top of the 3rd. There is nothing now (November 18, 1946) that suggests any recurrence of the tumor which was removed.
"There is a shadow of bony density and texture that is apparently calcification originating in the 3rd and 4th cervical bodies, and which seems to bridge the ventral surfaces of these two. At the first examination I noted a rarefaction of the ventral surface of the 4th body, and it seems reasonable that this calcification may be the end stage of some process that was going on in it at that time. The retro-pharyngeal wall measures on the film only 3 mm. thick over this calcification.

tions. The growth is approximately at the lower level of the epiglottis and extends downward on the posterior wall. The larynx, including the epiglottis, is seen by indirect laryngoscopy, when the chin is elevated and the neck extended. The vocal cords were visualized in their entirety to the anterior commissure. The ventricular openings appeared to be normal. External palpation showed the larynx movable but not freely, and no crepitations were felt on the spinal column. The mass within the hypopharynx cannot be palpated externally with any degree of certainty as to its outline. There were no enlarged lymph nodes. Digital palpation reveals that the hypopharynx is almost completely obstructed.

Temperature range was 98 to 99 degrees.

### TENTATIVE DIAGNOSIS

Soft tumor of the hypopharynx, possibly a cyst. Advised Roentgenogram, aspiration biopsy and biopsy.

The x-rays made by Dr. Ramsay Spillman of New York showed the extent of the tumor—from the 3rd to the 6th cervical and protruding forward. The meager report was helpful in that it showed the extent of the obstructing mass but nothing else, excepting in a negative way—to state that there was no osteomyelitis of the spine, or tuberculous.

Aspiration of the tumor was productive of no data.

Under local anesthesia, a biopsy was done into the center of the tumor. The opening into the pharyngeal tissue was less than 5 mm. There was no reaction following this procedure. The patient was given sulfadiazine, and after two days was permitted to leave the hospital in order to adjust his affairs, have his decayed teeth removed and return to the hospital within two weeks.

The pathological report of the biopsy was somewhat confused but after consultation with several pathologists, it was decided that it was a chordoma and that this would be confirmed by the gross and microscopical examination of tumor, when it was removed.

### Operation

On November 19, 1945, at the Manhattan Eye, Ear & Throat Hospital, the tumor was removed with the patient in the suspension laryngoscope. Ether anesthesia. The procedure consisted of making a transverse incision of the mucous membrane and subadjacent tissues over the greatest prominence of the tumor, and separating a rather thin-walled capsule of the tumor from the adjacent structures. The tumor was attached to the 4th cervical region and it was necessary to use sharp dissection in order to free it. The tumor mass was delivered from its bed almost intact. The posterior attachment was somewhat ragged. There was comparatively little bleeding and this was controlled by pressure. There were no distinct bleeding points, the bleeding being of the capillary type.

A nasal feeding tube was inserted and the patient returned in very good condition. Within 18 hours, the patient was out of bed for a short period (five minutes) and within five days, the feeding tube was removed. He was able to leave the hospital November 25, 1945.

For the four days after operation, he received 25,000 units of penicillin every three hours.

### Pathological Report

GROSS: Gelatinous mass enclosed in a fibrous capsule approximately 5 cm. x 4 cm. x 2 cm. with fibrous bands running through it and attaching themselves to the capsule. It has a slightly reddish color and a peculiar odor.

### Microscopic

Sections show that there is a tumor made up of peculiarly large, polygonal cells which are arranged, sometimes in cords, and are surrounded by mucoid material. The individual cells sometimes attain a gigantic size and some are vacuolated, producing a physaliferous effect. The tumor grows diffusely and tends to infiltrate. This seems to be a characteristic chordoma in one of the less common situations.

### Diagnosis

CHORDOMA OF THE HYPOPHARYNX.

A. A. Eggston, M.D.
Pathologist, Manhattan Eye, Ear & Throat Hospital.
Arthur P. Stout, M.D.
Consultant.

### Conclusions

Herewith is a report of a chordoma situated in the cervical region (3rd to 6th vertebrae) with diagnostic procedure and method of treatment.

There has been no recurrence to date, and the patient is in good physical condition.

### References

1. Cunningham, Daniel J.: Textbook of Anatomy. Oxford Univ. Press. P. 39, 1943.
2. Pancoast, H. K., Pendergrass, E. P., and Shaffer, J. P.: The Head and Neck in Roentgen Diagnosis. C. C. Thomas, Springfield, Ill. P. 617, 1940.
3. Stout, Arthur P.: Human Cancer. Lee and Febriger. P. 957, 1932.
4. Fabricius, Moller J.: Hosp. Tid. Kobenhavn. Vol. LXII, P. 849, 1919.
5. Syme, W. S. and Cappell, D. F.: J. Laryn, and Otol. 61:200, 1919.
6. Andre-Thomas and Villandre: Presse Med. 36:344.
7. Cappell, D. F.: J. Path. & Bact. 31:787.
8. Chiari, H.: Centralbl. f. Allg. Path. 42:481.

9. RIDPATH, ROBT. J.: Chordoma. Ann. Otol. Rhin. & Laryn. 47:649, 1938.

10. LIVINGSTON, GAVIN: Chordoma. J. Laryn. & Otol. 50:852, 1935.

11. OWNE, C. I., HERSHEY, L. N. and GURDJIAN, E. S.: Chordoma Dorsalis of the Cervical Spine. Am. J. Cancer, 16:830, 1932.

12. HAAS, C. M.: Chordomas of the Cranium and Cervical Portion of the Spine. Arch. Neur, and Psych. 32:300, 1934.

13. ADSON, KERNCHAN, WALTMAN.: Cranial and Cervical Chordomas. Arch. Neur. and Psych. 33:246, 1935.

14. STOUT, ARTHUR P.: Human Cancer. Lee and Febriger, p. 959, 1932.

15. Ibid. p. 955.

16. LINCK, A.: Chordoma Malignum. Ein Beitrag Zur Kenntnis der Geschwulste an der Schadelbasis. Ziegler's Beitrag, Jena, Vol. 46, p. 573, 1909.

## DISCUSSION

DR. J. J. SHEA: Dr. Imperatori has given us a classical paper. These tumors are very rare and the diagnosis is a complicated laboratory procedure, because the pathologists see so few of them.

The pathological specimen of the case I wish to report was studied for nearly three months before we could come to a satisfactory conclusion. The majority are teratomas.

(Slide) This is the other type, not like the lower cervical, but the more common variety occupying the sphenoidal occipital region. This woman's chief complaint was vertigo, and during the study of her case it was found that she had a tumor in the region of the sphenoidal cavity.

The internal maxillary artery was injured while doing a biopsy through the post-antral route, necessitating a ligation of the external carotid to control the hemorrhage.

The patient has remained under my observation for nineteen (19) years, with a yearly study of her tumor, and a roentgenological study every two years. The tumor has not increased in size and there were no eye changes during that time, though the tumor completely filled the sphenoidal cavity and the posterior ethmoidal region. Her only symptom has been that she continues to have an occasional attack of vertigo.

The characteristic cell of a chordoma is unusual, the cytoplasm being foamy and the intracellular material not true cartilage. It is really a carrying on of a fetal type of tissue.

DR. ROBERT F. RIDPATH: These are very interesting cases. When I presented my paper before this Association at the Atlantic City meeting, I reported two cases of this condition. At that time I only found three cases reported in the literature.

My first case was of a man, a doctor from Cuba. The history of these two cases as well as the one which I have not reported so far, is that they are always

associated with a decided trauma. I am sorry Dr. Imperatori did not go into the history of his case as I feel that is very important.

In my first case reported, a doctor, a large beam fell from a house and hit him on the occipital portion of his neck. This was followed by an unconscious condition lasting for some time. He did not notice any particular effect at the time of the accident, outside of the ordinary effect one would experience from a blow of that kind, until after six months. He then found that he was having considerable trouble with his breathing, and he went to a laryngologist who diagnosed the case as adenoids and operated. This however, resulted in one of the symptoms which I found in my cases, that of bleeding. It is a peculiar thing with the character of this tumor that we do have bleeding and this man had persistent and continuous bleeding from the time of his original operation until the time I saw him and until his death.

The other factor which I emphasized was the involvement of the sphenoid and the tissues in that particular region.

The vertigo, as Dr. Shea indicated in the discussion of his case, was of a decided nature. He also mentioned one other thing, that is that in his case he had no eye symptoms. In all of my three cases the eye symptoms have been rather pronounced. As a matter of fact, they have all gone blind, a gradual diminution of vision, with complete blindness before death.

In tumors of this character the history is something we should go into thoroughly. I make particular reference to tumors in the epipharyngeal space. We should endeavor to diagnose these particular involvements in counter-distinction to the ordinary tumorification which we have in that area.

Dr. Imperatori is to be complimented on his case. The position in which it occurred is a very unusual one, although we can have this tumor occurring anywhere when we have a small portion of the notochord remaining.

Dr. Shea is also to be complimented because he has a living case. All of my three cases died. To be sure I did not have much of a chance to treat them. They all died before I could do anything for them.

This is the kind of case of which Dr. Parvin said we must be careful or we will find what we are looking for.

DR. EDWIN N. BROYLES: Mr. Chairman, I would like to add just one additional case with Dr. Imperatori's permission, of cervical chordoma.

This is a 21-year-old girl, a Porto Rican with no history of trauma. As a matter of fact, she had hardly any symptoms. One day she happened to look in the mirror and saw the swelling in her pharynx. The swelling was about half way up behind the soft palate.

On examination I thought at first that this was some kind of a cyst, but I did hedge a little by giving her strong local radiation to try to cut down what bleeding I might meet at the time of operation. Then with using what we call the Crowe-Davis mouth gag with which we remove tonsils, this is almost a suspension

apparatus, we made an incision in the mid-line and found this tumor behind the anterior vertebral ligament. As far as I could tell it was not encapsulated. It came out easily. It felt, I thought, like fat. The section showed it to be mucus and not fat.

(Slide—X-ray) If you look very carefully you can see this smooth, round swelling in the upper portion of the pharynx and the beginning of the naso-pharynx.

(Slide—X-ray) This picture was taken about six months after operation. There is no swelling whatever. As far as I can tell she has been well and I hope she will remain well.

(Slide) This is a microscopical section of the evacuated mucin, non-structural with the highly pigmented nuclei in the cells.

(Slide) The next one shows a higher magnification of the same condition. As far as I know they are non-malignant, although they can be confused with a mucoid carcinoma.

Dr. C. J. Imperatori: (Closing) Regarding chordomas, a majority which have been reported are either at the upper or lower end of the notochord and the reason that there were practically no symptoms either in the case which I have reported or in the case which Dr. Broyles reported, and his case would seem almost a facsimile of mine excepting it was much higher up, is that they are not in a location to produce any pressure symptoms.

The slides which Dr. Broyles showed, particularly the last one showed typical physaliferous cells, that is, a large vacuolated cell with a nucleus at the periphery of the cell itself.

The patient which I presented had the mouth much lower than Dr. Broyles' patient extending from the 4th to the 6th cervical vertebra.

The thing which I wanted to direct your attention to more than anything else is that the diagnosis is always confusing. In this, as well as in any other type of pathological lesion where there is any question, it would seem to me, just as we have consultants for our clinical observations, we should have consultants for our pathological observations. In my case the first diagnosis was that of a mixed tumor, a second one as a leiomyoma and eventually in conjunction with the last consultant it was decided that this definitely was a chordoma.

The method of treatment which I have suggested and which Dr. Broyles has used are practically the same. I do not recall what the Crowe-Davis mouth gag is like, but I assume it is something of the nature of a self-retaining mouth gag, with an adjustable tongue depressor.

# SCLEROMA IN TWO NATIVE BORN BROTHERS

DANIEL S. CUNNING, M.D.

NEW YORK, N. Y.

A study of the literature reveals that scleroma in the past, too strictly referred to as rhinoscleroma, is not limited geographically but may occur in many countries throughout the world. In June, 1942, the writer presented before the section on Laryngology, Otology and Rhinology of the American Medical Association, a series of six cases of scleroma, two of which occurred in native-born Americans.

At that time a brief review was presented of the literature on scleroma dealing with etiology, history, world-wide incidence, therapy and pathology. It is unnecessary, therefore, to repeat in detail, the material already presented, but refer to specific features of the disease intrinsic to this paper.

The purpose of the present report is to record the terminal course of one of the patients reported in 1942 and to describe an additional case of scleroma occurring in a native-born American. The additional case is a brother of the patient reported in 1942 whose terminal report now follows—complete case history appears in 1942 report (Case III).

Case I—M. I., a 21-year-old unmarried white male, born in Perth Amboy, New Jersey, of immigrant parents. His mother died of pulmonary tuberculosis; his father died after a rib resection. Both were born in Russia.

Patient had a history of three years duration of progressive dyspnea and hoarseness, preceded by crusting of nose, foul discharge and nasal blockage. In December, 1939, dyspnea was so pronounced as to necessitate emergency tracheotomy. Three months later he was decannulated. A diagnosis of scleroma was made following biopsy and histopathologic examination of the suspected tissue. Profuse growths of typical von Frisch bacilli were also obtained from cultures of the affected areas—nose, pharynx and larynx.

Six months after decannulation, dyspnea again became severe and patient was re-admitted to the Manhattan Eye, Ear and Throat Hospital, where original tracheotomy and diagnosis had been made. A second

tracheotomy was performed through the old scar and sulfanilamide therapy instituted.

There was subjective improvement in the patient during the time of drug administration. Nasal crusting disappeared, pharyngeal lesions were less pronounced and the vocal cords appeared less thickened. Biopsy from affected regions showed "improvements," and cultures revealed considerable lessening of growth of von Frisch bacilli. However, decannulation was not believed advisable and therefore not attempted. Since that time the patient was seen at infrequent intervals in the clinic. Dyspnea was still present at times and some crusting was evident. Patient frequently had paroxysms of coughing.

He remained quite well until March 10, 1944, when he had a severe coughing spell, coughing up large crusts through the tracheotomy tube. To prevent the tube from coming out he knotted the cord behind his neck. A short time later he went up the stairs to retire. On reaching the second floor he had another violent coughing spell and could not breathe. He tried to take the tube out but owing to the knot he had put in the string he was unable to do so and fell to the floor, unconscious. His wife, hearing the noise, rushed upstairs and found him cynotic and unable to breathe. She broke the cord, removed the tube and attempted artificial respiration, to no avail. On examining the tube later it was found to be plugged with large crusts which completely occluded its lumen. No autopsy was obtained.

## Report of New Case

S. I., a 21-year-old white male, born in Perth Amboy, New Jersey, of immigrant parents. Brother of M. I., reported above.

S. I. was first seen in the Bronchoesophagologic clinic of the Manhattan Eye, Ear and Throat Hospital, on March 22, 1944. He gave a history of progressively increasing dyspnea for two years, first symptoms having been noticed following pubertal voice change.

On March 22, 1944, a direct laryngoscopy was done under local anesthesia. The epiglottis was small and infantile and the larynx was exposed with difficulty. The cords were covered with a papillomatous-like tissue which extended subglottically on the left side. A biopsy of this tissue showed granuloma not unlike rhinoscleroma. He was not seen from April, 1944, until June 4, 1945.

On June 4, 1945, he was re-admitted to the hospital because of increasing dyspnea. He had been back at work off and on, (approximately half the time) as a carpenter's helper, being forced to take frequent rests because of shortness of breath on exertion. Laryngoscopy on June 6, 1945, showed a rather firm infiltration of both tonsils and soft palate giving a granular appearance. A similar infiltration was noted in the larynx, obliterating the landmarks. The glottis was very constricted. The epiglottis was shrunken and rounded into a small mass. Biopsies from the glottis and tonsillar region were taken. The tonsil section showed rhinoscleroma, the glottic section showed hypertrophic inflammatory tissue. Except for the nose and throat findings the physical examination was negative. Section from biopsy showed marked infiltration with lymph and plasma cells, numerous foam cells and many Russell bodies and von Frisch bacilli.

On June 22, 1945, a low tracheotomy was done. He remained in the hospital for two months receiving penicillin, 15,000 units every three hours, which cleared up the secondary infection considerably.

On September 18, 1945, he was referred to the radiotherapy department where he received 8400 Roentgen units through six portals from September 19, 1945, until January 24, 1946.

He has been followed to the present time in the clinic. He has continued to wear the tracheotomy tube and has just started to work as a landscaper on a golf course.

Patient has been greatly improved since x-ray therapy but it is still impossible to expose his larynx.

Eggston recently gave an excellent clinical and pathological description of scleroma which will be of interest to many students of this disease. According to Eggston:

The lesion of scleroma begins as a small nodule but soon attains considerable size, protruding from the nostril or into the choanae and causing partial or complete nasal obstruction. It may be unilateral or bilateral. The mucous membrane over the lesion is tense and tenacious and of a rubberoid consistency.

Upon microscopic examination, there is a papillary hyperplasia and hypertrophy of the surface epithelium, pseudo-epitheliomatous in nature. It may resemble a similar hyperplasia which exists in syphilis

or tuberculosis or other chronic inflammatory processes. The lamina propria beneath the epithelium is trabeculated and intensely infiltrated with a type of cell so distinctly characteristic as to leave little doubt as to the nature of the condition. These cells are chiefly of a plasma-cell nature, with some histiocytes and lymphocytes present and a moderate number of eosinophils. While the lesion usually begins in the nose and remains in this region, it may often extend into the nasopharynx, larynx, and trachea. Occasionally, the structures of the mouth are involved.

The pathology of the disease usually develops in the following order:

1. A diffuse stage presenting a picture similar to atrophic rhinitis, characterized by reddening and infiltration of the mucosa, formation of crusts, and exudation of a watery, foul-smelling discharge.

2. A circumscribed state marked by the emergence of reddish-blue nodules from the edematous surface, these nodules soon coalescing into granular masses which are so firm that they give a sensation similar to that of touching cartilage.

3. The cicatrical stage wherein the involved nasal tissues become hard and tense, owing to the formation of scar tissue, adhesions, and deformity due to shrinkage.

The condition often causes progressive concentric stenosis which completely closes the air passages.

Under the microscope, accumulations of plasma cells will be quite generally diffused through the affected area. This differs from gumma or tubercle formations, which are usually accumulated in localized areas. There are many plasma cells and some large mononuclears, but characteristic of the lesion are the large foam or Mikulicz cells. These cells have centrally placed nuclei, around which are many vacuoles which divide the cytoplasm into compartments. Within these vacuoles can be seen the Frisch bacilli. This organism somewhat resembles the Bacillus capsulatus of Friedlander. The Frisch bacillus has been accepted by some as the etiologic factor in rhinoscleroma, but this has not been proven. There is also to be found another cell, the Russell bodies or Una cells, so characteristic of diseases due to filterable viruses. This is a plasma cell with an eccentrically placed nucleus and abundant cytoplasm which stains intensely with eosin.

Animal inoculation with the Frisch bacillus alone does not reproduce rhinoscleroma. If it is the etiologic factor, it probably functions in symbiosis with some other agent. It is interesting that the causal agent was formerly considered indigenous to certain geographical locations.

Streit, in 1935, stated that Mikulicz cells found in scleroma may be developed from various cells as fibroblasts, plasma cells, histiocytes, leucocytes and epithelial cells. Every cell which is invaded by the Frisch bacillus undergoes a specific degeneration and becomes a Mikulicz cell. The formation of these cells is regarded as a defensive mechanism against the bacteria, particularly where the toxicity of the organism is relatively low.

Schwedkowa-Rosche states that under the influence of the invading Frisch bacillus in the epithelium, the Mikulicz cells are formed, which are identical with the Mikulicz cells of mesenchymal origin. The ones of epithelial origin participate immediately in the formation of the typical scleromatous granulation tissue. The Frisch bacilli involve the nuclei of the cells and cause hydropic degenerations. Ptuschowsky describes the pathology of scleroma in four stages:

1. Atrophic stage, which is a clinical picture of trophic rhinitis in which the secretion contains the Frisch bacilli.

2. The stage of indefinite granulation tissue. The specific elements consist of the Mikulicz cells and Russell bodies, which appear later, but plasma cells, polymorphonuclear cells, lymphoctyes and new-formed vessels are numerous.

3. The stage consisting of foam cells and hyaline bodies, infiltrations which are hard like cartilage, with deformity of the nose, pharynx, and larynx. This is the typical histological picture of scleroma.

4. These stages are followed by the formation of fibrous connective tissue and a diminution in the number of specific cells and bacilli present.

That same author states that in the earlier stages a complement fixation test will be positive; while in the latter stage, it becomes negative. In all seven cases that came under the writer's observation the Wassermanns and Kahns were negative.

In a previous article this author reported some observations made on seven hundred clinical cases and made the statement that quite a few of his patients with scleroma had tuberculosis of other organs, par-

ticularly of the cervical glands. In the older patients the tuberculous lesions were usually of the fibrotic type. If the tuberculous lesions were associated with tuberculosis of the larynx, particularly in a young person, the prognosis was usually bad. Scleroma of the trachea without involvement of the larynx was observed in five of that author's cases.

The diagnosis of scleroma is not difficult if the disease is kept in mind and a biopsy taken. The typical pathological picture is that of a chronic inflammatory process in which considerable lymphocytic and plasma cells have occurred and in which large vacuolated foam cells and the hyaline cells of Russell are present, the former harboring within their walls the von Frisch bacillus.

## Summary

1. Terminal report of a native-born scleroma patient previously reported in 1942.

2. Report of another case of scleroma occurring in a native-born American.

3. Review of the gross and histopathology of scleroma (according to Eggston).

4. The diagnosis is not difficult.

## References

Alderson, H. E.: J. Cutan. Dis. 32:308, 1914.
Scleroma: Report of Case, Arch. Dermat. & Syph. 26:639, 1932.
Rhinoscleroma: Report of Case, ibid. 36:1018, 1937.
Bailey, C. H.: J. Cutan. Dis. 37:447, 1919.
Ballin, M. J.: New York M. J. 35:490, 1907.
Bellinoff, S.: Rapp. Cong. internat. d'oto-rhinolaryng., Madrid, 1932, p. 362.
Zentralbl, f. Hals-, Nasen-, u. Ohrenh. 26:193, 1936.
Berge, C.: Study of Frisch's Bacillus Isolated from First Case of Rhinoscleroma Published in Tunisia. Arch. of Inst. of Pasteur, Tunis, 31:197-202, 1942.
Bierkowski, cited by Symurlo.
Bingham, E. M., and Cutler, O. I.: California & West Med. 42:463, 1935.
Braun, A.: Laryngoscope 20:124, 1910.
Canfield, N.: Ann. Otol. Rhin. & Laryng. 42:903, 1933.
Chamberlin, W. B.: Rhinoscleroma—Is It an Indigenous Disease? Arch. Otolaryngology. 33:285, 1936.
Crowe, S. M.: Rhinoscleroma of the Larynx and Pharynx in Two Immigrants, Arch. Path. 5:1125, 1928.
Cunning, D. S. and Gerry, D.: Scleroma—Arch. Otolaryng. 36:662, 1942.
Danziger, E.: Laryngoscope 15:935, 1905.
Day, D. W.: Tr. Chicago Path. Soc. 6:414, 1903.
Dittrich and Mibelli, cited by Guntzer.
Dixon, F. M.: Tr. Am. Laryng. Assoc. 64:138, 1942.
Durkee, J. W.: Laryngoscope 20:1132, 1910.

FARGES, BARRETT and BERGE: Cae. Rev. de Laryng. 63:80, 1942.
FALCAO, P. C.: Cases. Rhinoscleroma in Brazil. Brazil Med. 59:136, 1945.
FALCAO, P. C.: Case. Rhinoscleroma in Brazil. Rev. de Otorhinolaring. 13:139, 1945.
FIGI, F. A. and THOMPSON, L.: Rhinoscleroma, J.A.M.A. 91:637, 1928.
FREEMAN, W. J.: Ann. Otol., Rhin. & Laryng. 9:141, 1900.
FREUDENTHAL, W.: New York M. J. 13:132, 1896.
VON FRISCH, A.: Wien. med. Wchnschr. 32:969, 1882.

GADOMSKI, C. F.: Rhinoscleroma: Report of Case, Arch. Otolaryng. 29:681, 1939.
GEBER, E. Arch. f. Dermat. u. Syph. 4:491, 1872.
GERHARDT, cited by Mikulicz.
GHOSH, L. M. and PANJA, D.: Case. Indian Med. Gazette 80:511, 1945.
GOTTHEIL, W. S.: J. Cutan Dis. 24:37, 1906; Internat. Clin. 2:244, 1908; j. Cutan Dis. 35:269, 1917.
GUNTZER, J. H.: M. Rec. 76:129, 1909.
GUTTMAN, J.: New York M. J. 102:711, 1915.

HAUB: Growing Significance of Scleroma Due to Immigration from the East. Munchen Med. Wochenschrift. 91:197, 1944.
VONHEBRA, F.: Wien. med. Wchnschr. 20:1, 1870.
and KAPOSI, M: Lehrbuch der Hautkrankherten, ed. 2, Stuttgart, Ferdinand Enke, 1874, Vol. 1.
HELWIG, F. C. and JAIME, N.: Laryngeal Scleroma in Native Missourian: Report of Case, Arch. Otolaryng. 18:310, 1933.
HILL, J. L.: Case. Annals of O., R. & L. 52:496, 1943.
HOLINGER, J.: Illinois M. J. 27:402, 1915.

IGLAUER, S.: Tr. Am. Laryng., Rhin. & Otol. Soc. 18:443, 1912.
IRELAND, E. P.: Canad. M.A.J. 34:149, 1936.

JACKSON, J. T.: J. Cutan. & Genito-Urin. Dis. 11:381, 1893.
JARECKY, H.: M. News 78:420, 1901.
JERVEY, J. W.: Rapp. Cong. internat. d'oto-rhinolaryng., Madrid, 1932, p. 352.

KAEMPFER, L. G.: New York M. J. 99:636, 1914.
KELLERT, E.: Case. New England J. Med. 229:647, 1943.
KENYON, E. L.: Laryngoscope 19:225, 1909.
KONSTANTINOWITSCH, W. N.: cited by Guntzer.
KOUWENAAR, W., MASSLAND, J. H. and WOLFF, J. W.: Geneesk. tijdschr. v. Nederl-Indie 74:1447, 1934.

LEWIS, E. R.: Tr. Am. Laryng., Rhin. & Otol. Soc. 38:459, 1932.
LIEBERTHAL, D.: J. Cutan. Dis. 29:638, 1911.
LUSTGARTEN, D.: J. Cutan. Dis. 25:303, 1907.

MAYER, E.: Am. J. M. Sc. 133:751, 1907; Laryngoscope 17:957, 1907; 18:964, 1908.
MCGEE, G. M. and WISE, F.: J. Cutan. Dis. 35:190, 1917.
MIKULICZ, J.: Arch. f. klin. Chir. 20:485, 1877.
MOHANTY, J. K.: Rhinoscleroma in Karaput District of Southern Crissa. Indian Medical Gazette 80:458, 1945.
MORRISON, L. F.: Scleroma (Rhinoscleroma): Report of Three Cases, Arch. Otolaryng. 28:531, 1938.

PERKINS, R. G.: J. Infect. Dis. 4:51, 1907.
PICENA, J.: Study Apropos of Autochthonous Case. A. M. Ameriso, J. Picena and J. Ameriso. Rev. of Otorhinolaryng. de Litoral. 1:273, 1942.
POLLITZER, S., and MORROW, P. A.: System of Genito-Urinary Diseases, New

York. D. Appleton & Co., 1894, Vol. 3, p. 516; Laryngoscope 16:963, 1906; J. Cutan. Dis. 28:388, 1910.

Quast, G.: Centralbl. f. Bakt. (Abt.1) 97:174, 1926.

Roe, J. O.: Tr. Am. Laryng. Assoc. 20:206, 1898.

Schwartz, A. A.: Rhinoscleroma: Report of Two Cases, Arch. Otolaryng. 21:199, 1935.

Simpson, C. D., and Ellis, F. A.: Rhinoscleroma: Report of Two Cases, Arch. Dermat. & Syph. 39: 503, 1939.

Smith, H.: J. Cutan. Dis. 30:100, 1912.

Stelwagon, M.: Ann. Otol., Rhin. & Laryng. 9:141, 1900.

Stout, P. S.: Laryngoscope 44:142, 1934.

Stubbs, F. S.: Laryngoscope 17:399, 1907.

Szmurlo, J.: Rapp. Cong. internat. d'oto-rhinolaryng., Madrid, 1932, p. 34.

Thro, W. C.: Proc. New York Path. Soc. 10:96, 1910-1911.

Toeplitz, M.: and Kreuder, H.: Am. J. M. Sc. 130:81, 1905.

Tomasek, V.: Centralbl. f. Bakt. (Abt. 2) 79:564, 1925.

Topley, W. W. C., and Wilson, G. S.: Principles of Bacteriology and Immunity, ed. 2, Baltimore, William Wood and Co., 1937, pt. 4, p. 1417.

Watkins, S. S.: Surg. Gynec. & Obst. 33:47, 1921.

Weiss, J. A.: Scleroma (Rhinoscleroma) Histologic Changes Following Teleradium Therapy; Review of Scleroma in United States, Arch. Otolaryng. 30:38, 1939.

Wende, G. W.: Buffalo M. J. 35:642, 1895.

Wood, G. B.: Tr. Am. Laryng. A. 47:87, 1925.

Wurm, K. and Hsia, Y. D.: Therapy: Sulfonamide in Infections with Capsular Bacteria. Zeitschr. f. Immunitatsforsch u. Exp. Therap. 101:81, 1942.

## DISCUSSION

Dr. I. H. Blaisdell (Syracuse, N. Y.) (by invitation): I would like to present a case of rhinoscleroma that has been under my care and in which streptomycin was used therapeutically. Mrs. A. K., aged 35, a white female of Polish descent was first examined on July 18, 1946. She gave a history of nasal obstruction for about five or six years. During the past year, she had had symptoms of itching and burning, and irritation of the nose in addition to her nasal obstruction. She also complained of deformity of the nose and the presence of a tumor mass which presented in the nasal vestibule in both nares. She was born in this country and had never been out of the United States. There was no family history of any similar disease.

In May, 1932, a submucous resection of the septum had been done in Nanticoke, Pennsylvania. In 1937, she was examined in Philadelphia because of an obstruction, due apparently to a deviation of the septum and at that time showed a marked thickening resembling an osteomatous growth in the lateral wall of the left nostril. X-ray studies of the sinuses and skull were negative. A biopsy of the tumor mass was done in 1937, and the report was that the tumor was inflammatory tissue composed of connective tissue with extensive leucocytic infiltration and the conclusion was that the lesion was evidently chronic inflammatory with no evidence of tumor. Smears of the lesion were negative for fungus.

Subsequently, she received a series of irradiation treatments in Philadelphia, over a period of six weeks and was discharged.

Examination in 1946 showed a large tumor mass involving the septum and columella, extending outward onto the skin of the external nose. The mass completely obstructed both nares, was irregular in outline, somewhat ulcerated superficially, and yet was quite soft and somewhat cystic to the touch.

On September 28, 1946, a biopsy of the lesion was done. The pathological report was rhinoscleroma and the pathological picture was quite typical of this disease. Bacteriological studies revealed the presence of Klebsiella type C which has also been classified as Friedlander's bacillus type c, or bacillus rhinoscleromatis. In vitro the organism showed a very marked sensitivity to streptomycin and was killed by .4 of a microgram of this drug.

The patient was admitted to the hospital on October 24, 1946. The nose was re-cultured before the medication was started. During the next ten days the patient was given 11.5 grams of streptomycin in addition to the usual dose of 1 gram of sulfadiazine every four hours. The patient was ambulatory and had no untoward symptoms during the treatment. All laboratory work was within normal limits. The patient's nose was re-cultured following the termination of the drug and at that time no Klebsiella were isolated after 72 hours of incubation.

An audiogram was done on October 27, 1946, before starting streptomycin and showed normal hearing. The patient was re-examined at intervals during November, December and January. There was definite improvement in the appearance of the lesion and there was significant improvement in that the itching and burning, and irritation had ceased. A repeat audiogram was done on January 31, 1947, and showed normal hearing again. A repeat culture of the nose, however, was positive for Klebsiella type C.

On February 10, 1947, the patient was again started on a second course of streptomycin of 1.5 grams per day. This was continued for ten days for a total of 15 grams. There was apparent regression of the nasal lesion with continued improvement although the bacteriology still remained positive.

It is possible that streptomycin will offer a form of therapy in the treatment of rhinoscleroma. In this case, there was significant improvement as well as regression of the lesion although the bacteriology was not apparently affected, in spite of the high degree of susceptibility of the organism to the drug in vitro.

DR. FRED W. DIXON: Mr. Chairman and Fellows of the Association, and Guests, some five years ago before this Society at Atlantic City I reported a case of rhinoscleroma which had been under my care for eight years. This involved the nose and the trachea.

Someone made a remark at that time that it would be a nice thing if we would report these cases a little later, as to whether or not they remained cured.

I would like to report on this patient. He has now been under my care for thirteen years. During this time I have had to remove the granulation tissues from the trachea on four occasions, or every three years, and follow it by x-ray therapy.

The granulation tissue has been removed from the nose on three occasions, or every four years, and followed by radiotherapy.

He was in my office last week. He is feeling well. He is very comfortable. The nose is open and he is breathing freely, and says he has no complaint. He is now 70 years of age.

I do not believe we can cure these patients by radiotherapy, but I want to report on this man who is alive and comfortable after thirteen years.

Dr. LeRoy A. Schall: Mr. Chairman and Gentlemen, Dr. Cunning's paper, like Dr. Place's paper this morning, gives us something to think about.

For fifteen years I have followed a patient with rhinoscleroma of the nares. She has had radiation and plastic surgery but the disease still progresses.

We have had two patients with schleroma of the larynx.

In these days of rapid transportation and particularly with the travel to the South, we must realize that this disease is prevalent in the Latin American countries. It is common in Mexico.

In the Municipal Hospital of Guatemala City, last summer, I had the privilege through the courtesy of Dr. Quevedo of personally examining 15 cases of nasal rhinoscleroma.

In Puerto Rico at the Spanish Hospital, through the courtesy of Dr. McCormack, I saw six cases and I saw several cases in the Municipal Hospital at Mayaquez. We can no longer think of it as a disease of the southern part of Europe. It has spread to these countries and with our intermingling and with our traveling we must think of rhinoscleroma.

I am very happy to hear the report of Dr. Blaisdell on the effects of streptomycin. Up until now treatment has been of no avail. Surgery was useless. Radiation was thought to be of some value but in everybody's hands it has proven very disappointing. Streptomycin may be the hope.

Dr. D. S. Cunning (closing): It was interesting to see Dr. Blaisdell's pictures and to hear of the encouraging results he has obtained with his streptomycin therapy.

If you recall that first series I reported five years ago, you will then remember that the only antibiotics we had at the time were the sulfa drugs. Those six cases mentioned in the first series were hospitalized and given large doses of sulfa, maintaining the blood concentration at 15 mg. for an entire month. Immediate improvement was shown. We then knew that the secondary infection was lessened but discovered that as far as the real pathology of the disease was concerned, there was no progress noted.

This last case, which was just reported, was treated with penicillin approximately two years ago.

I am certainly glad that Dr. Blaisdell, with the use of streptomycin has had such excellent results. We will follow his example with our next case and hope we will be as successful as he.

# PULSION DIVERTICULUM OF THE HYPOPHARYNX AND ITS SURGICAL TREATMENT

CHEVALIER L. JACKSON
AND
CHARLES M. NORRIS

This is not a new subject, but one that appears to be of perennial interest. Several excellent papers have appeared this year in the general surgical journals (Sweet,[1] MacNeely and Stassman.[2]) Furstenberg[3] presented a paper on the subject at the Southern Section of the American Laryngological, Rhinological and Otological Society just a few months ago.

## Definition and Terminology

The diverticula of which we are speaking are hypopharyngeal—*not* esophageal and *not* pharyngo-esophageal. Such a diverticulum is a hernia of the mucosa and submucosa of the hypopharynx through a weak point in musculature—*generally* through the triangle between the circular fibers of the inferior constrictor (which constitute the cricopharyngeus) and the oblique fibers of the inferior constrictor proper.

The diverticula are "pulsion" rather than "traction," to use the terms first suggested by Rokitansky[4] in 1840. Chevalier Jackson[5] pointed out that diverticula of the esophagus proper *may* also be of the "pulsion" type, in cases where they occur above stenosis, but generally they are of "traction" type. A common error in terminology worth mentioning is the use of the plural form diverticula for the singular diverticulum.

## Etiology

There has been much discussion of the etiology of pulsion diverticula based on clinical observation, as well as upon anatomical and physiological study. Time does not permit us to go into this phase of the subject at length, but we may say that it is our personal opinion that the typical diverticula of the variety with which we are concerned are the result of the giving way of the wall of the hypopharynx just above the cricopharyngeus. As pointed out by Chevalier Jackson and others, this may be due in part to incoordination of the cricopharyngeal pinchcock, with failure to open at the proper time, immediately sequential to the

contraction of the oblique fibers of the inferior constrictor; but it is our opinion that even without incoordination, the posterior wall may be subjected to enough strain in the early phases of the swallowing act to cause herniation, especially with the weakened musculature of the patient past fifty. The anatomy of the pharyngo-esophageal segment has been very well studied, both in the laboratory and in the literature, by Nora Brandenburg[6] and her paper is most helpful—though she gives more consideration to the esophageal triangle of Laimer, just below the cricopharyngeus, than to the one above it, in the posterior hypopharyngeal wall, where diverticula of the hypopharynx occur. The triangle of Laimer is also a weak place and diverticula of the esophagus do occur as herniations through it, though they are very rare. This is as might be expected, because though there is a weak point here, there is not the obstruction below as in the case of the upper (hypopharyngeal) triangle. Negus[7] has made some interesting observations on etiology, basing his opinions partially on studies of comparative anatomy. He believes that pulsion diverticula occur because of the following factors: a. *descent of the larynx* in the neck and "fanning out" of the inferior constrictor muscle fibers with absence of longitudinal fibers at the lower end of the pharynx and upper end of the esophagus. b. *Lack of relaxation of the cricopharyngeus muscle,* especially when swallowing large boluses of ill-masticated food. Chevalier Jackson[5] has also called attention to this factor. Zenker[8] suggested that diverticula might be due to a tearing of the hypopharyngeal wall. He reported twenty-seven cases, including five of his own.

## Symptomatology and Diagnosis

The principal symptoms of pulsion diverticulum of the hypopharynx are dysphagia, regurgitation, gurgling sound on swallowing. Cough has been considered an important symptom by some writers (Jacksons[9a]) and foul odor or taste also occurs. The duration of symptoms in patients we have seen varies from a few months to a number of years. The sac gradually increases in size and hence symptoms gradually increase in severity. When the sac gets so large that when filled with food it causes compression stenosis of the esophagus, dysphagia becomes severe; until this occurs there may be little actual difficulty in swallowing, though a great deal of annoyance from the regurgitation.

The diagnosis may be made from the symptoms and objective examination, but the x-ray is the only certain means. It is necessary to demonstrate fluoroscopically at least, and preferably also by films, that the neck of the sac, through which it empties, communicates with its upper end, not the bottom. In this way the differential diagnosis is made from a dilatation of the esophagus above a stenosis. Mirror examination of the hypopharynx shows frothy secretion in the pyriform sinuses, and squeezing of the neck will produce an air bubble, both audible and visible. Hypopharyngoscopy and esophagoscopy may be done to supplement the other studies and to clean out the sac but they are not absolutely essential to establish the diagnosis. Introduction of the esophagoscope into the esophagus proper is generally difficult in these cases without the guidance of a previously swallowed string.

## Treatment

Many different methods of treatment have been advised for pulsion diverticulum of the hypopharynx. "Surgical drainage" was advised by Sir Charles Bell, who is credited with diagnosing the first case clinically, in 1816! Dilatation of the esophageal orifice has been advised. Inversion of the sac has been done by certain operators. Surgical excision, however, in one or in two stages, has been the only effective method of treatment. A one-stage operation with esophagoscopic aid was described by Gaub and Jackson[10] in 1915 and this operation, with various modifications, has remained the favorite procedure in the Philadelphia clinics for thirty years. (Jackson and Shallow,[11] Babcock and Jackson,[12,13,14] Shallow.[15]) Lahey[16] has always preferred the two-stage operation. Since the Temple University Clinic was established in 1930, over two hundred of these operations have been performed there, with a mortality of less than one per cent, and we are strongly of the opinion that the one-stage operation, with or without esophagoscopic aid, is the treatment of choice.

## Technic

For anesthesia, avertin and local supplemented by intravenous sodium pentothal has been very satisfactory, but some operators prefer cervical block. The incision we prefer is one along the anterior border of the left sterno-mastoid muscle, though a transverse incision may be used if preferred. The sac is sought by blunt dissection, retracting the

thyroid gland medially and the sterno-mastoid muscle laterally. The omo-hyoid muscle is retracted or divided. Incidentally, the thyroid gland is the structure most likely to be mistaken for the diverticulum, which lies just a little deeper.

The esophagoscope may be used to transilluminate the sac, and this facilitates its identification, affording at the same time a means of aspirating its contents. After the sac is grasped with visceral forceps and dissected free, guide sutures of black silk are placed at the upper and lower margins of the neck. These sutures may be placed more accurately if the esophagoscope is inserted into the esophagus but if this is done the scope should be withdrawn before the sac is amputated and closure of the neck completed, because the esophagoscope holds the esophagus and the neck of the sac deeply in the wound and thus makes completion of the operation unnecessarily difficult. As before mentioned, introduction of the esophagoscope into the esophagus is greatly facilitated, in these cases, by the aid of a previously swallowed string. Just before amputation of the sac the neck is transfixed with a suture or clamped. After amputation with a knife or scissors the cut edges are touched with iodine and closed with one or two continuous sutures of No. 00 chromic catgut on an atraumatic needle, and this closure is reinforced with interrupted sutures of the same material. One small rubber tube is left at the lower end of the incision for drainage, and the skin closed with Michel clamps. The patient is fed for seven to nine days through a tube which may be inserted after closure of the wound or through the esophagoscope, just before it is withdrawn.

We are now at work on an analysis of the entire series of patients operated upon since 1930, but the follow-up is not complete enough to tabulate the data pertaining to them. To summarize the patients operated upon during the year 1946 might be of interest, however. Fourteen patients were operated upon, eleven of them males and three females. The average of these patients was fifty-eight, the youngest thirty-six and the oldest sixty-nine. The duration of symptoms in four of the cases was only five or six months; in three it was over ten years. All of these fourteen patients had uneventful convalescence, and the period of hospitalization was from ten to fourteen days.

## References

1. Sweet, Richard H.: Pulsion Diverticulum of the Pharyngo-Esophageal Junction. Technic of One-stage Operation. Ann. of Surg. 125:41 (Jan.) 1947.

2. McNealy, Raymond W. and Stassman, Jacob: One-stage Pharyngo-esophageal Diverticulectomy, Surgery, 21:470 (April) 1947.

3. Furstenberg, A. C.: Diverticulum of the Esophagus, Ann. Otol. Rhinol. and Laryngol. 56:305 (June) 1947.

4. Rokitansky, Karl: Spindelforminge Erweiterung der Speiserohre. Med. Jahrb. d.k.k. osterr. Staates, 21:219-222, 1840.

5. Jackson, Chevalier: (a) Peroral Endoscopy and Laryngeal Surgery, St. Louis, Laryngoscope, 1915. (b)

6. Brandenburg, Nora: Musculature Variations of the Pharyngeal Segment, Laryngoscope, (March) 1944.

7. Negus, Victor: Evolutionary Factors in the Production of Pharyngeal Diverticula, J. Laryngol. and Otol. (November) 1925.

8. Zenker, F. A.: Krankheiten des Oesophagus, in H. von Ziemssen's Handbuch der speciellen Pathologie und Therapie, Leipzig. F. C. Vogel, 7:50-87, 1877.

9. Jackson, Chevalier and Jackson, Chevalier L.: (a) Pulmonary Complications of Esophageal Disease, Arch. Otolaryng. 18:554 (Oct.) 1933. (b) Pulsion Diverticulum of the Esophagus and Hypopharynx, Southern Surg. 11:255 (December) 1933.

10. Gaub, Otto and Jackson, Chevalier: Pulsion Diverticulum of the Esophagus, Surg. Gyn., and Obstet., 21:52 (July) 1915.

11. Jackson, Chevalier and Shallow, Thomas A.: Diverticula of the Esophagus, Pulsion, Traction, Malignant and Congenital, Ann. Surg. 81:1-19 (January) 1925.

12. Jackson, Chevalier and Babcock, W. Wayne: Diverticulosis of the Esophagus. One-Stage Operation With Esophagoscopic Assistance, Surg. Cl. North America, 10:1249 (Dec.) 1930.

13. Babcock, W. Wayne and Jackson, Chevalier: The Single-Stage Operation for Pulsion Diverticulum of the Esophagus, Surg. Gyn. and Obstet. 53:667 (November) 1931.

14. Babcock, W. Wayne and Jackson, Chevalier L.: The Treatment of Pharyngeal and Esophageal Diverticulosis, Trans. Amer. Therapeutic Soc., 1936.

15. Shallow, Thomas A.: Combined One-Stage Closed Method for the Treatment of Pharyngeal Diverticula, Surg. Gyn. and Obstet., 62:624 (March) 1936.

16. Lahey, Frank: (*a*) The Management of Pulsion Esophageal Diverticulum, J. A. M. A., 109:1414 (Oct. 30) 1937. (*b*) Pharyngoesophageal Diverticulum, New England J. Med. 216591 (April 8) 1937. (*c*) Arch. of Surg. 41:1118 (Nov.) 1940.

# BRONCHOGRAPHY IN BRONCHIECTASIS IN CHILDREN

D. E. STAUNTON WISHART, B.A., M.D.

TORONTO, ONTARIO

The conquest of bronchiectasis by the surgeon has made bronchography of major importance. Bronchography in the adult patient is being achieved in many hospitals in a fairly satisfactory manner but in the bronchiectatic child it presents such great difficulties that the procedure is avoided as much as possible. Where it is being attempted the results are not wholly satisfactory.

Bronchiectasis can be cured by modern chest surgery. To effect a cure the thoracic surgeon has learned that he must excise every diseased portion of the bronchiectatic lung.[1]

Kergin[2] reports that follow-up examinations of the adult cases of bronchiectasis operated upon at the Toronto General Hospital over the past nineteen years have abundantly demonstrated that the disease is not progressive, that once cured the patient remains cured and that the failures and imperfect results have been consequent upon incomplete excision of the diseased areas of the lung because of inadequate bronchography.

At the Hospital for Sick Children, Toronto, since 1944, Janes of the Toronto General Hospital and Wilkinson[3] of our Surgical Service have performed twenty-eight consecutive lobectomies and five pneumonectomies in children under 14 without a death and without an empyema and with no pleuro-bronchial fistulae.

Enough experience has been obtained in the great surgical thoracic services to know that certain sequences of operative procedure greatly lessen the operative risk. For example, if the surgeon has removed successfully a severely bronchiectatic left lower lobe in the belief that the bronchiectasis was confined to that lobe, the slow development of unfavorable signs and symptoms may lead to the discovery of bronchiectasis in the lingula—the anlage of the middle lobe of the right side. The surgical removal of this lingula at a second operation on the left thorax

---

From the Department of Otolaryngology of the Faculty of Medicine, University of Toronto, and the Hospital for Sick Children, Toronto.

is now greatly more difficult and much more hazardous than it would have been at the first surgical intervention.

Few thoracic surgeons believe that disease in such a lingula can be ascertained at operation by inspection or palpation. The presence or absence of bronchiectatic lesions in the bronchi of that lingula must be determined before operation by adequate lung mapping. Bronchograms, which four years ago would have been considered complete, are no longer considered adequate. The chest surgeon is now vitally aware of all branches of the bronchial tree which are of importance. He is aware that these cannot be seen adequately in any one picture. Exposures in certain positions enable special bronchial branches to be seen and in those same positions other branches cannot be seen.

Therefore today before he will operate upon a bronchiectatic patient the chest surgeon requires for study many bronchograms in many positions of all lobes of each lung. If he is not satisfied with the delineation of some part of the bronchial tree he will demand more bronchograms of that particular portion. For he must plan his surgical attack and he cannot do that until the bronchography is complete to the last segmental bronchus.

In many articles published within the last twenty years and in some of the latest texts the demonstration of bronchiectatic lesions is dealt with as if it were almost contemptuously easy. For adults the catheter technique described Jackson and Bonnier[4] is followed more or less in perhaps the majority of clinics. In many the procedure has long since passed from the laryngologist or bronchoscopist to the medical chest specialist and in many it is now passing from the latter to the radiologist. The factors determining this need not be discussed here. Suffice it to say that bronchography is of vital importance for the surgeon about to deal with a bronchiectatic lung. That complete bronchography in the adult can be anything but easy is known only too well by those who endeavor to satisfy the thoracic surgeon of today.

Were bronchiectasis only a disease of adult life and did it not, in a high percentage of cases, have its beginnings in childhood, it would be necessary to add nothing more.

Unfortunately, however, bronchiectasis has been found present and of sufficient degree to require major chest surgery in very early years[5]

and this fact is getting wider and wider recognition so that bronchography in children is becoming of great importance. In our series of lobectomies four have been in children under three years of age. If the work is always arduous and frequently exasperatingly difficult in the adult patient, the difficulties of doing adequate bronchography in every bronchiectatic child are obviously greater.

Comparatively little has been written on bronchography in children. The article by Jackson and Bonnier is followed by an excellent bibliography and recommends that the method used for adults be used with certain slight modifications, for children. In spite of this recommendation bronchography in children has been used and is still being used far too little. Many hospitals rarely bronchograph a child and in very few has an attempt been made to meet adequately the needs of the children's medical chest service. For that requires work on a wholesale scale.

The reason is not far to seek. The catheter technique demands the cooperation of the patient—and while this can be obtained in selected unusual children, often of the pay classes, it is so almost unobtainable in the very great percentage of miserable, coughing, apprehensive, unconditioned little clinic patients as to make the catheter technique on the whole impractical for little children.

The authors advised against the use of the bronchoscope for bronchography in children for various reasons. They mentioned that too much of the lipiodol was coughed out and that often there was delay in the transportation of the patient to the x-ray department or in taking the pictures. We believe we have overcome those objections by performing the entire procedure of the fluoroscopic table in the x-ray department under general anesthetic.

Illustrations 3, 4 and 5 of the above article[4] portray excellently heavy lower lobe bronchiectasis in the child, but there is no statement in that paper that the method can be used in all children, no matter how small, how sick, and how unconditioned, to map completely every portion of the bronchial tree to the satisfaction of the modern chest surgeon. And that is our present problem.

Amenable cooperative children of 13 and 14 can eventually be completely mapped by the adult catheter technique. Such children may

submit to several repeat bronchographies. A healthy normal child of much younger age may submit to one bronchography but is likely to receive such an unfavorable impression that its cooperation for subsequent attempts is gone forever. Apprehension is ruinous. One cough at the wrong moment and almost instantaneously before the radiologist can make his exposure, the iodized oil has disseminated from the bronchial tree to the alveoli and the procedure has become a failure. Sedation does not safely correct this factor.

Therefore, at the Hospital for Sick Children, the practice described in 1942[6] has been continued. The bronchography is not preceded by sedation. It is performed under general anesthesia. The cough reflex starts working almost immediately after the operation is over and is a great factor in the invariable rapid postoperative recovery. No ill effects have resulted and the children invariably sit up to enjoy their evening meal. In 1942 we reported that general anesthesia in bronchoscopic work had been performed 1268 times. Since then we have used general anesthesia in hundreds of cases for this purpose with excellent results.

During the past twelve months nearly all our bronchography has been completed at two delineations. Four members of the bronchoscopy staff take the work in turn.

The table top portrayed in that article has been abandoned. The present table has a space under it which permits the film to be easily taken in and out. The table is shock-proof, completely grounded and the air in the room is continually replenished so that there is no anesthetic risk.

The pictures obtained by the method there described long since have been considered inadequate because of the already mentioned increasing exactitude of delineation required by the surgical chest service. At that time mapping of the upper lobes and the right middle lobe and the lingula was rarely demanded. Since then there have been two instances of bronchiectasis confined to an upper lobe and many of bronchiectasis of the right middle lobe and of the lingula.

Consequently every child, no matter how young, suspected to have bronchiectasis, now requires complete mapping regardless of how many attempts may be necessary. Only one lung should be bronchographed at

a time. For complete mapping of one lung the patient's body must be moved into various positions and roentgenograms must be taken in each of these. The time involved is of less importance than the efficiency and thoroughness with which the mapping is done.

But this extra time gives rise to two new difficulties in the performance of bronchography per bronchoscope under anesthesia.

The first of these is the care that must taken to do no harm with the rigid bronchoscope. This objection has proven more apparent than real. With the bronchoscope in the right or left bronchial tree the patient's body can be turned to any desired position, even face down, without any trauma occurring. It is fair to state that this has been done many times without damage. But it cannot be denied that these manipulations with the bronchoscope in situ necessitate great care and meticulous cooperation on the part of all members of the operating team and that acts against the popularity of the method.

The second difficulty is that of maintaining a long, quiet, even anesthesia. The anesthetic state is maintained by delivering ether vaporized by an oxygen current conveyed through a rubber tube attached to the anesthetic arm of the bronchoscope.

Anesthesia is not easily maintained through the bronchoscopes used; for the procedure while similar to is not identical with normal intratracheal anesthesia. In the latter a large soft intra-tracheal catheter which tightly fills the larynx is used. But in bronchography it has been our practice to use as small a bronchoscope as possible. In consequence a greater ventilation of the bronchial tree occurs through the larynx outside the bronchoscope than occurs through the bronchoscope. There is also the additional handicap that the already small lumen of the bronchoscope is encroached on for quite a portion of the time by the suction tube or the tube for the iodized oil.

It is on the maintenance of a proper degree of anesthesia that the bronchography depends to a greater extent than on any other single factor.

To make the anesthesia more satisfactory we are now using thin-walled metal intubation tubes. The advantages and technique are

described later. We believe that this alteration in method has greatly diminished the difficulties of bronchography in bronchiectatic children.

It is no longer considered sufficient to demonstrate the presence or absence of bronchiectasis in each of the five pulmonary lobes.

Clinical experience is demonstrating repeatedly that lobes infrequently are completely diseased, but that the bronchiectasis rather involves certain segments of lobes leaving other segments healthy. The result is that an entire lobe is no longer considered the surgical unit. The bronchopulmonary segment has become the surgical unit and in the adult is now lending itself to satisfactory removal.

While it is possible that the excision of segments may become a recognized procedure for children no patients have yet been operated upon in this fashion (except the excision of the lingular process) at our hospital. It has been considered in several cases but in each instance the final decision has been for lobectomy and subsequent examination of the excised lobe has proven the decision wise.

Jackson and Huber in 1943[7] proposed a nomenclature of the segments of the bronchial tree which has met wide approval and use. It has been adopted at our hospital until such time as thoracic surgeons adopt a standardized nomenclature. Their scheme was accompanied by an excellent colored chart which, however, had the disadvantage of being difficult to reproduce so we have been quick to adopt the numbering of the bronchial segments proposed by Overholtz and Langer.[8]

Radiological Report on Bronchogram No.....

Patient Ward Date
Surgeon Anesthetist

| Lung | Lobe | Segmental Bronchi | | Abnormal | | Shown in Film No. |
|---|---|---|---|---|---|---|
| | | | | Sac. | Cyl. | |
| Left | Upper Lingula | Upper Apical posterior | 1 & 2 | | | |
| | | Anterior | 3 | | | |
| | | Superior | 4 | | | |
| | | Inferior | 5 | | | |
| | Lower | Superior | 6 | | | |
| | | Anterior medial | 7 & 8 | | | |
| | | Lateral | 9 | | | |
| | | Posterior | 10 | | | |
| Right | Upper | Apical | 1 | | | |
| | | Posterior | 2 | | | |
| | | Anterior | 3 | | | |
| | Middle | Lateral | 4 | | | |
| | | Medial | 5 | | | |
| | Lower | Superior | 6 | | | |
| | | Medial | 7 | | | |
| | | Anterior | 8 | | | |
| | | Lateral | 9 | | | |
| | | Posterior | 10 | | | |

Notes :

Signed.....
Radiologist

Their modification has been followed in the printed form used, by our radiologist, to report on the films of each bronchography. It can be seen that this form makes it easy for the surgeon and the medical chief to readily agree on precisely what bronchopulmonary segments require delineation at the next bronchography. Their request comes to the bronchoscopist on this form and greatly facilitates his work.

Request for Bronchography Date.....

*Patient* Age ..... Ward.....

Segmental bronchi to be outlined:.....

.....

.....

.....

.....

.....

Signed .....

### Brief Outline of Our Technique

1. Induction of anesthesia.
2. Suction aspiration of bronchial tree per bronchoscope.
3. Insertion of special intubation tubes.
4. Insertion of small catheter into bronchial tree.
5. Injection of iodized oil.
6. Spot films (Bucky not used).
7. Large sized regular films (Bucky used).

### Commencement Technique

The whole procedure takes place in the x-ray department.

The patient comes to bronchography without sedation. The success of the procedure depends, in part, on the rapid return of the cough reflex once the anesthetic has been stopped. No local anesthetic is used.

The excitement of coming for operation excites coughing and this coughing is encouraged in order to free the bronchial tree of as much of the purulent material as possible.

We are in agreement with Smith & Schall[9] that thorough cleansing of pus from the bronchial tree is essential to good mapping because iodized oil cannot fill bronchi plugged with heavy bronchiectatic secretion.

The conscious patient lies on the fluoroscope table-top on his side with the more diseased lung dependent and with his shoulders perpen-

dicular to the plane of the table. This position is of assistance to the anesthetist during the induction of anesthesia. Induction is carried out as rapidly as possible in order that the cough reflex may not be stimulated and result in the expression of material from the lung periphery into the main bronchial tree which would interfere with aeration. The induction is continued until an anesthesia is reached deep enough to allow the introduction of the bronchoscope without any damage to the patient or embarrassment to the bronchoscopist and without arousing any reflex from the introduction. Then the patient is turned on his back and a 5 mm., or a 4 mm., bronchoscope inserted.

Suction is used through the bronchoscope to clear the trachea and main bronchi. The anesthesia is diminished during this procedure, so that deeper respiration and cough may favor the expulsion of exudate from the inaccessible parts of the bronchial tree.

When no more material is being produced for suction the anesthetist increases the depth of anesthesia to the degree he considers advisable for bronchography. The bronchoscope is withdrawn and as large a special intubation tube as possible is inserted into the larynx through the long slit on the side of an anesthetist's laryngoscope or using a Jackson laryngoscope from which the slide has been removed. Special metal introducers devised by Dr. C. H. Robson, our chief anesthetist, make the insertion easy. These tubes are very thin-walled and are really very short intratracheal tubes of large lumen. Care should be taken to select a tube of suitable diameter in order to avoid trauma to the larynx. Through this anesthesia is easily maintained by an ether hook in the corner of the patient's mouth.

Using a Jackson laryngoscope an ordinary soft rubber catheter, which has been slightly shortened by cutting off the olive tip and the side apertures, is passed by the bronchoscopist through this intubation tube and by fluoroscopic guidance is inserted into whatever part of the bronchial tree the radiologist desires. The bronchoscopist anchors the tube with his fingers.

Maintenance of anesthesia now becomes relatively simple. The patient's body can be turned into any position desired without any danger of trauma. The two difficulties previously mentioned have been surmounted.

Burrell's syringe, partly filled with cold iodized oil, is fitted into the end of the catheter by the bronchoscopist's assistant. The oil is injected very slowly as the radiologist desires.

### Method of Bronchography for the Right Lung

Assistants turn the patient's body to the left anterior oblique chest position and use sand bags to maintain the position. A nurse at the foot of the table holds the patient's ankles, or they can be secured by orthopedic anklets and ties.

The oblique positions are desirable because the bronchial tree divides in a direction oblique to the horizontal (when the patient is in the horizontal position). In consequence the oblique positions permit clear separation and identification of the secondary bronchial divisions.[10]

With the patient in this oblique position the table is tilted down to approximately 20 degrees from the horizontal. The injection of iodized oil is begun and the upper bronchi are filled until well delineated. A "spot" film is taken at the desired moment (before alveolar flooding has taken place). The table and patient are then maneuvered into the second position. The table is tilted head up to approximately 10 degrees above the horizontal. This facilitates filling the lower bronchi and the middle lobe of the right lung. A second "spot" film is taken after optimum filling has taken place.

Following this the patient is quickly returned to the horizontal and three films are taken on the bucky in the oblique, A.P. and lateral positions.

The settings are:

| | M.A. | K.V. | T.S.D. Time 48 | |
|---|---|---|---|---|
| 3-year-old child | | | | |
| Oblique | 150 | 74 | 1/20 | |
| A.P. | 150 | 70 | 1/20 | |
| Lateral | 150 | 50 | 1/20 | |
| 10-year-old child | | | | 48" |
| Oblique | 150 | 76 | 1/10 | |
| A.P. | 150 | 72 | 1/10 | |
| Lateral | 150 | 80 | 1/10 | |
| | | | Bucky 1/10 | |

If the middle lobe bronchi have not filled properly the patient is turned face downward and the bronchial filling watched in the fluoroscope until the desired picture can be taken.

The oil is drawn into the bronchi by inspiration; it is never forced in by the syringe.

The keynote to good results lies in the absolute cooperation of bronchoscopist, anesthetist and radiologist. The pictures all must be taken as rapidly as possible.

At the conclusion of the procedure the intubation tube is pulled out. The patient comes rapidly out of the anesthetic and it is rare that there is any embarrassment to those watching the post-anesthetic recovery. The work is performed in the morning between 10 and 12:30 and the child is usually sitting up at 4:30 p.m., enjoying supper and almost invariably is discharged next morning. *Bronchography for the left lung* is done at a subsequent occasion after an interval of several weeks. The main consideration is that most of the iodized oil injected at the first bronchography should have vanished so that the delineation of the left bronchial segments be not impaired by overlying iodized oil in parts of the right lung. The patient's body is first placed in the right anterior oblique position. The face-down position is sometimes necessary for proper mapping of the bronchus leading to the lingula.

In the past the main problem has been the proper delineation of the bronchi to the right middle lobe, the lingula and the right and left upper lobes. The delineation of all these is very satisfactorily accomplished by our present technique. The filling of the posterior segment of the lower lobe is sometimes difficult.

### Modifications of Technique That Have Been Discarded

1. The Thomson catheter[11] was given an adequate trial. (It was inserted without the use of the rustless wire carrier.) It has only one opening—at the distal end—and this must serve to convey oxygenated ether and later iodized oil. This small end aperture will only maintain anesthesia by the use of pressure and then only for a short time and during that time the ventilation of the patient is precarious to say the least. Then iodized oil quickly is substituted for the oxygenated ether and during the period of injection there is no ventilation. As soon as

the oil has been delivered the catheter must quickly be pulled back into the trachea so that the anesthetist may blow in oxygen. Then the concern of anesthetist and bronchoscopist is with the patient and not with the bronchography and the radiologist is lucky if his pictures are good.

Cutting holes in the sides of the catheter helps the anesthetist's problem but the consequent escape of the iodized oil ruins the radiologist's efforts.

2. The passage of a large intratracheal catheter and the insertion through this of a fine soft catheter has also been tried.[12]

The method is to insert as large an intratracheal catheter as possible into the trachea proximal to the carina and to insert a glass Y tube into its proximal end. Through one arm of the Y the anesthetic is delivered and through the other arm is inserted a long, fine, soft catheter, the end of which is directed by gravity and fluoroscope to any position in the bronchial tree desired. The iodized oil is delivered through it by the syringe already mentioned.

This method is not as easy as it sounds. The main difficulty is the maintenance of the anesthesia—for a catheter inside the intratracheal catheter makes for great resistance to ventilation. The method described in this paper is very much easier.

3. Dr. Basil Bradley, one of my colleagues, is developing a modification of a two-way irrigating urethral catheter, but in its present form the friction inside the rubber air-way prevents adequate ventilation.

## Conclusion

Many years ago Kernan[13] stated—"For the purpose of lung mapping the right amount of lipiodol should be injected into the lung and it should be put in the right place to fulfill the requirements. It is necessary to introduce it under the guidance of the eye. The use of the fluoroscope offers further guidance." The problem could hardly have been presented in fewer words. The intervening years have shown that the procedure is not as easy as it sounds but we believe we have made a further contribution to the solution of a difficult problem.

## References

1. Churchill, Edward D.: Bronchiectasis, Physical and Psychologic Manifestations, New Eng. Jour. Med. 97, 1938.

2. KERGIN, FREDERICK G.: personal communication.

3. WILKINSON, F. R.. personal communication.

4. JACKSON, C. L. and BONNIER, M.: Technique of Bronchography. Ann. Otol., Rhinol., and Laryngol. 771, 1937.

5. DIAMOND, S., and VAN LOON, E. L.: Bronchiectasis in Childhood. Jour. A.M.A. 771, 1942.

6. WISHART, D. E. S.: Bronchoscopy in the Diagnosis and Treatment of Bronchiectasis in Children, Jour. A.M.A. 1181, 1942.

7. JACKSON, C. L., and HUBER, J. F.: Correlated Applied Anatomy of the Bronchial Tree and Lungs with a System of Nomenclature. Diseases of the Chest. 1943.

8. OVERHOLT, R. H., and LANGER, L.: A New Technique for Pulmonary Segmental Resection. Surg., Gynecol., and Obstet. 257, 1947.

9. SMYTH, D. C., and SCHALL, L. A.: Pneumonography by Lipiodol, Its Present Uses and Limitations. Trans. Am. Bronchos. Soc. 104, 1927.

10. MYERS, D. W., and BLADES, D.: The Values of Proper Interpretation of Lipiodol Bronchograms in Thoracic Surgery. Am. Jour. of Roentgenol. 530, 1940.

11. THOMSON, S. A.: Bronchial Catheterization. Am. Jour. Surg. 260, 1936.

12. BAKER, A. H. L.: Endobronchial Lipiodol under General Anaesthesia in Children. Brit. Jour. Anaesth. 112, 1941.

13. KERNAN, JOHN: The Use of Lipiodol for Lung Mapping under the Guidance of the Fluoroscope. Trans. Am., Bronchos. Soc. 96, 1927.

## DISCUSSION

DR. L. H. CLERF: Mr. Chairman, I wish to congratulate Dr. Wishart on his presentation, and on the excellent work which he has done in this field.

At the meeting of the American Medical Association held in Atlantic City, he presented a paper covering this subject before the Section of Otolaryngology. After the meeting we discussed this matter at length, because up to that time I had not been fully convinced general anesthesia was a safe thing in these cases. We were dealing with a bronchopulmonary infection and one did not want to add to the hazards.

The thoracic surgeon must have positive information regarding the extent of bronchiectasis if he is to remove all the diseased pulmonary tissue and this information often was not available by bronchography as we had performed it. As a result I have been converted to the need for general anesthesia.

Secondly, I appreciate the need for meticulous attention to the many details which he refers to, both on the part of the bronchologist as well as the roentgenologist. I am not familiar with his intubation tube but the technique we employ now is essentially identical with his except that after ridding the patient of all the secretion possible we insert a small catheter pernasally, guide it into the broncheal tree with a laryngoscope and then carry out the bronchography as he has indicated. It is absolutely imperative that adequate bronchograms are secured for the thoracic surgeon for information gained by palpating the lining often is misleading.

I want to compliment Dr. Wishart on his excellent contribution to this very difficult problem.

Dr. Robert L. Goodale: I was particularly glad to hear Dr. Wishart's paper today because as a member of the team at Massachusetts General Hospital and the laryngologist who examines the noses and the sinuses, I felt that the children were not being taken care of early enough.

As you know, a third of all the bronchiectatic cases arise in the first decade of life, but frequently the team, the thoracic surgeon, the pulmonary specialist, the bronchoscopist, etc., do not get the patient until the case has gone on for a long time so that I think early diagnosis, early recognition of the child's disease is one of the most essential things that we can insist on.

I was very glad to hear him bring that point out and also the fact that he uses general anesthesia. I am afraid that at some clinics general anesthesia is not advocated because they are afraid of precipitating a pulmonary accident, either inducing a fresh attack of pneumonia or causing further damage to the bronchiectasis. I don't believe that that is true.

The chest surgeons certainly operate on bronchiectasis under general anesthesia and I don't see why bronchograms cannot be done the same way.

I would like to ask Dr. Wishart, though, if he has used other forms of anesthesia. We run into this objection by the pediatricians. I would like to know if he has ever used rectal or intravenous anesthesia?

Dr. Lyman G. Richards: Genius is said to be the capacity for taking infinite pains.

As a junior house officer under Dr. Wishart at the Eye and Ear Infirmary, I shall never forget my feeling of amazement at the meticulous orders, such as for a dose of morphine, which Dr. Wishart used to write out. He almost prescribed the length of needle which was to be put in the skin. We see today what that sort of attitude and determination to stick to detail has produced. I blush when I think of the bronchograms I have made by merely introducing a bronchoscope and secondarily, a metal suction tube and attaching thereto a syringe full of warm lipiodol and calling that a bronchogram. I am really humble in Dr. Wishart's presence when I think of the detail to which he has carried this work.

The two previous speakers have stressed the value and lack of risk of general anesthesia. I would like also to subscribe to that. I think we greatly overestimate the risk and that goes also for the subject of foreign bodies. Also I think much is accomplished by the use of a combination of x-ray and bronchoscopic manipulations in one place. The transfer of the patient from one spot to another, often necessitated by the operative setup in many hospitals, certainly works against the success of this procedure.

Dr. Wishart has many times before and again today brought home the value of taking pains and paying attention to the minor details. I am very gratified for the lessons which he taught me as far back as 1924 and he never ceases to impress me every time I see him or read whatever he writes.

DR. C. L. JACKSON: Mr. Chairman, I appreciated very much the opportunity to study over Dr. Wishart's paper. He was kind enough to send me a copy of it some time ago. I must say that I am in complete agreement with him as to the vital importance of bronchography in connection with modern thoracic surgery, and it is just as important in children as in adults.

I am also in complete agreement with him that the time is past when we just map the large bronchi and that we have to map the bronchi of all the pulmonary segments completely. Furthermore, I agree that we get a much more satisfactory lobar and segmental presentation when the two sides are mapped separately.

I wish to compliment Dr. Wishart on his mastery and ingenuity. I have no doubt that his team accomplishes wonderful success with his technic. I must confess, I am one who still has doubts, however, about giving general anesthesia, particularly for endoscopic procedures in the fluoroscopic room. It also seems to me that it is complicating matters to add a third member to the team. It is difficult enough, sometimes, to secure good teamwork between the bronchologist and the radiologist and to add the anesthetist, who must also have had some experience in the particular job, seems to me adds another complication. I say this not because I disapprove of all use of general anesthesia in endoscopic work. I do use it myself some. But we still prefer to do bronchography in children with no anesthesia or with the use of larocaine through the tube and some preliminary medication. We use a soft rubber catheter through the nose introducing the catheter under fluroscopic guidance. We find if we tilt the head just a little that we can find the right angle for the curve of the nasopharynx to guide the tip of the catheter into the larynx, in the case of a cooperative child. If the child is not cooperative and cannot be persuaded by reasonable tact and patience, then we resort to the use of the direct laryngoscope, changing from the flexible catheter to a rigid one. This type of catheter, once placed under direct laryngoscopic guidance, won't be coughed out.

By this technic, we are able to obtain satisfactory bronchograms, though not always at the first sitting. I don't like to disagree with Dr. Wishart and Dr. Clerf and others on the use of general anesthesia, but in all frankness I want to state what is still our current practice at the Temple Clinic.

Once again, let me thank Dr. Wishart for the privilege of reading his paper and discussing it.

DR. PAUL H. HOLINGER: Mr. Chairman, just one note aside from thanking Dr. Wishart for this presentation, and that is that there is the problem of building codes in our particular part of the country. We are not permitted to use general anesthesias in any x-ray room or even where there is x-ray apparatus which is not only shock-proof but actually explosion-proof. The entire set-up for explosion-proof x-ray equipment in which ether can be used is exceedingly difficult to obtain and must comply with proper building codes. I simply mention this from the standpoint of those who might wish to use the technique and possibly do not have the apparatus which Dr. Wishart is using.

DR. D. E. S. WISHART (closing): Mr. Chairman, Gentlemen, Dr. Goodale asked if I had any experience with other types of anesthesia. We have no experience with the other methods. In trying to work out this problem we have followed the advice of our anesthetist, and so far he has not encouraged us to use anything except ether.

Dr. Holinger mentioned a very practical point, which I felt sure would be brought up today, namely, that in certain cities the laws prohibit ether anesthesia in certain types of operating room.

In my paper you will find that I have described the table which we use and the measures which have been taken to make the work done under anesthesia safe. As far as our legal requirements are concerned, we meet them.

I expected several to ask me regarding the intratracheal catheter. I had prepared pictures of those catheters and the introducer, but for some perfectly unexplained reason, which I cannot understand, the pictures show the instruments bent, which they are not. The lantern slides I had prepared consequently convey the same wrong impression. These little intubation tubes are metal cylinders open at each end, about two inches in length, and there is a blunt introducer—a long straight steel tube—which goes through this intratracheal metal tube. The introducer and intubation tube, as one piece, are inserted in the larynx and then this little intratracheal intubation tube is pushed off the introducer. The introducer is pulled out and the intratracheal intubation tube is left in the larynx. When the lipiodol procedure is finished the intratracheal intubation tube is pulled out by a string attached to it.

Dr. Jackson, as I fully expected, mentioned his preference for the work being done without anesthesia. The work that we do at the Hospital for Sick Children at Toronto is done under disadvantageous conditions, because our building is very old and antiquated.

DR. JACKSON: So is ours.

DR. WISHART: I don't think anything could be equal to ours, and we have not got the necessary facilities for handling little children nicely in a skilled way and doing the things I am sure Dr. Jackson does in his clinic. Were we to get the facilities Dr. Jackson has, I can assure you that I would come down to Philadelphia to learn his method and give it a trial. I and my staff have tried to follow his printed technique but under our conditions it does not give us the results we obtain with our technique.

I am glad to note that Dr. Richards and Dr. Goodale and Dr. Clerf spoke approvingly of anesthesia.

Each one of my discussers has been most kind. I want to thank you all for your good attention.

# PRESENTATION OF INSTRUMENTS

## A BRONCHOSCOPIC ANTI-FOGGING DEVICE

EDWIN N. BROYLES, M.D.

BALTIMORE, MD.

Dr. Edwin N. Broyles: Mr. Chairman, in doing endoscopic work or any work around the mouth where the warm air is breathed out, you are apt to have fogging of either the operator's glasses, shield or mirror. We have all noticed that in looking at the larynx indirectly with the laryngeal mirror that when the mirror becomes too cold as the patient breathes out the mirror is fogged, whereas if he breathes in you get a clear image. It occurred to me that perhaps this idea of a cold stream of air, not warm and not moist, passing over the edges of the orifice of the tube would keep this fogging from occurring and so accordingly to some bronchoscopes and laryngoscopes we attached a small tube through which is passed compressed air. This blows the patient's exhaled breath away from the operator and keeps his glasses or the windshield clear from mucus, blood, or warm moist air.

(Demonstration of a bronchoscope and laryngoscope with the anti-fogging device manufactured by Pilling.)

# AN IMPROVED LARYNGEAL LOUPE

C. J. IMPERATORI, M.D.

NEW YORK, N. Y.

DR. C. J. IMPERATORI: Mr. Chairman, I have an improved laryngeal loupe which I would like to submit for your consideration.

It is intended to provide better depth of perception, magnification (approximately 1¾ times) and binocular vision of the laryngeal structures.

It consists of a loupe, the lenses of which are spheroprisms of 3.50 dipters and an adjustable head mirror attached in such a way that either eye may be used behind the reflecting mirror.

In the use of this device it is important that the hole of the reflecting mirror is so adjusted that the vision is unobstructed.

Reflected light is focused on the posterior pharyngeal wall before the warmed laryngeal mirror is introduced. Focus of the image in the laryngeal mirror is sharpened by moving a trifle closer to the patient.

Magnification is easily obtained and binocular vision can be attained only by unobstructed vision of both eyes.

# Memorials

# FRANK WHITEHILL HINKEL, M.D.

1858-1946

Dr. Frank Whitehill Hinkel of Buffalo, New York, died on April 2, 1946, aged 88 of myocardial failure. Born in Lexington, Ill., on March 5, 1858, he spent his earlier life in southern Pennsylvania, securing his education at Gettysburg and Lafayette College. He was graduated in Medicine at the School of Medicine, University of Pennsylvania in 1882.

Dr. Hinkel began his study in laryngology at the University Hospital, Philadelphia. In 1886 he was appointed Clinical Professor of Laryngology of the Medical Department of the University of Buffalo. He was laryngologist and aural surgeon to the Buffalo General Hospital.

In addition to membership in local societies he was a member of the Buffalo Academy of Medicine, the American Laryngological, Rhinological and Otological Society and the Medical Club of Buffalo. He was elected to active Fellowship in the American Laryngological Association in 1888 and to Emeritus Fellowship in 1918. He retired from the practice of medicine in 1922.

Practically all of his contributions to medical literature were published in the local medical journals and the New York Medical Journal.



# THOMAS MELVILLE HARDIE, M.D.

1862-1946

Dr. Thomas Melville Hardie of Chicago, Ill., a graduate of the University of Toronto, Faculty of Medicine, Toronto, Ontario, Canada, in 1888, died on June 2, 1946, at the age of 84 years of arteriosclerosis.

He was born in Newcastle, New Brunswick, on April 14, 1862. His early life was spent in Ottawa, Canada, where he received his preliminary education. In 1884 he was graduated from the University College in Toronto and entered the Faculty of Medicine.

Dr. Hardie began the study of Laryngology in London under Sir Morrell MacKenzie and continued his work in the Clinics of Berlin, Vienna, Prague and Paris. He became associated with the Medical School of Chicago in 1891 and was Professor of Histology at the College of Physicians and Surgeons of the Medical Department of the University of Illinois from 1894 to 1897. In 1897 he was appointed Professor of Otology which position he held until 1900.

He was associated with the Postgraduate School Hospital and Dispensary, St. Luke's Hospital and St. Elizabeth's Hospital of Chicago. He was associate editor of the Annals of Ophthalmology and Otolaryngology from 1892 to 1896 and editor of the Annals of Otology, Rhinology and Laryngology from 1896 to 1899.

Dr. Hardie was a member and past president of the Chicago Laryngological Society. He was elected to Active Fellowship of the American Laryngological Association in 1896 and to Emeritus Fellowship in 1927.

# PETER McBRIDE, M.D.

## 1854-1946

Dr. Peter McBride, F.R.C.P. Ed. the veteran Scottish laryngologist, who for many years was head of the Ear and Throat Department of the Edinburgh Royal Infirmary, died on June 16, 1946, at St. Peter's Grove, York, England.

Born on August 16, 1854, he took his medical course at Edinburgh University, graduating in 1876. He was elected F.R.C.P. Ed. in 1880 and the following year attended clinics in Vienna to study diseases of the ear and throat. On his return he was appointed to the Staff of the Eye, Ear and Throat Dispensary and began to lecture on diseases of the throat. In 1883 he took charge of a new department for ear and throat diseases at the Royal Infirmary and held that position for 20 years. He was made consulting surgeon in 1904.

Dr. McBride was President of the Laryngological Society of London, twice President of the Section of Otology and Laryngology of the British Association and President of Otologic Section of the Royal Society of Medicine for two years. He had also been Vice-President of the Otological Society of the United Kingdom.

He was an Honorary Member of many societies including the Scottish Otological and Laryngological Society, Corresponding Member of the Berlin and Vienna Laryngological Societies and of the French Oto-Rhinol-Laryngological Society. In 1903 he was elected a Corresponding Fellow of the American Laryngological Association. In 1913, three years after retirement he gave the Semon Lecture in Laryngology at the University of London.

He contributed much to medical literature. His first textbook was published in 1884 and his Diseases of the Throat, Nose and Ear reached a third edition in 1900; he also contributed many papers on diseases of the ear, nose and throat, as well as miscellaneous writings not related to otolaryngology. Dr. McBride was a member of the British Medical Association continuously for 66 years.

# THOMAS E. CARMODY, M.D.

## 1875-1946

Dr. Thomas E. Carmody died while asleep on a Branif plane flying from Denver to Pueblo, on Friday afternoon, August 30, to attend a dinner in honor of Dr. Wm. H. Baker, a very prominent Pueblo general surgeon. When the stewardess attempted to awaken Dr. Carmody, she found him dead.

Dr. Thomas Edward Carmody was born in Shiawassee County, Mich., May 22, 1875. He was a son of Thomas and Mary Ann Carmody of Irish parentage. His early life was spent in Owasso, Mich., where he graduated from high school. He attended the University of Michigan Dental School, where he received a D.D.S. degree in 1897. In 1908, he received a D.S.Sc. degree from the same school.

He located in Denver in 1897 for the practice of dentistry and attended the Denver and Gross College of Medicine, where he received an M.D. degree in 1903. He was professor of bacteriology and histology at the University Dental College from 1898 to 1905, and professor of oral surgery and rhinology at the same dental college from 1905 to 1932. He was assistant in laryngology and otology at the Denver and Gross College of Medicine from 1905 to 1911. On Jan. 1, 1911, the University of Colorado absorbed the Denver and Gross College of Medicine and the latter passed out of existence. He continued with the Department of Otolaryngology until 1912 at the University of Colorado School of Medicine in Denver. He was connected with the Research Department of the Child Research Council, as an otolaryngologist, at the University of Colorado School of Medicine from 1928 to 1936. The Child Research Council is in the Department of Pediatrics.

Dr. T. E. Carmody became a Fellow of the American College of Surgeons in 1913, of the American College of Dentists in 1929, and of the International College of Surgeons in 1941. He became a member of the Denver Dental Society in 1897 and was its president in 1907. He became a member of the Denver City and County Medical Society in 1903; was its secretary in 1904 and president in 1923. He joined the

Denver Clinical and Pathological Society in 1912 and was its president in 1931. He became a member of the Colorado State Dental Association in 1897, and of the Colorado State Medical Society in 1903. He was the first president of the Colorado Society for Crippled Children. The Colorado Otolaryngological Society was founded about 1910 and held meetings for about five years. It was reorganized in 1918 and 1919, at which time he became the first president of the reorganized society.

During World War 1, Dr. T. E. Carmody was commissioned a major, M.C., U.S.A., and was stationed at Fitzsimmons Army Hospital. He had held the rank of first lieutenant in the Medical Corps from 1914 to 1918.

He was a charter member of the American Board of Otolaryngology and joined the American Academy of Ophthalmology and Otolaryngology in 1903. He was president of the Academy in 1923. He belonged to the American Bronchoesophagological Society and was its president in 1930. He joined the American Laryngological, Rhinological and Otological Society in 1912 and was its president in 1936. He joined the American Laryngological Association in 1924 and was its president in 1941. He became a member of the American Otological Society in 1925. He became a member of the A.M.A. early and was chairman of the Ear, Nose and Throat Section in 1931. He was a member of the American Society of Oral and Plastic Surgeons.

He held honorary memberships in the Pacific Coast Oto-Ophthalmological Society, The Texas Ophthalmological and Otological Society, the Kansas City Ear, Nose and Throat Society and the Illinois State Medical Society. He was a member of the first International Otolaryngological Congress in Copenhagen, Denmark, 1929. He was a member of the Board of Directors of the National Society for Crippled Children. He took postgraduate work, as an assistant to Dr. T. W. Brophy and in American clinics.

He held staff appointments as oral and plastic surgeon at Children's Hospital, Denver; Consulting otolaryngologist and bronchoesophagologist, St. Luke's and Mercy Hospitals, Denver; Evangelical Lutheran Sanitorium, Wheatridge; Swedish National Sanitorium, Englewood; and Jewish Consumptive Relief Sanitorium, Spivak.

He was a contributor on plastic surgery to the Jackson, Coates and Jackson textbook on ear, nose and throat diseases in 1929, and on diseases of the mouth and tongue for the Jackson and Jackson book in 1945. He wrote numerous articles covering diseases of the mouth, nose, throat and ears. He was a member of the editorial board of the Annals of Otology, Rhinology and Laryngology.

On Nov. 7, 1899, he was married to Mary Jane McBride in Denver. Mrs. Ruth Carmody Sumners, Denver; Mrs. Mary Alice Carmody Cobb, Minneapolis; and District Attorney David W. Carmody, Santa Fe, N. M., are the surviving children.

His hobbies were golf and photography. He belonged to the Denver and University Social Clubs and the Denver Country Club. He was an Episcopalian.

Dr. T. E. Carmody was very devoted to his wife and children. His wife accompanied him to all board and medical meetings and took an active interest in his professional work. Denver and Colorado lost a distinguished otolaryngologist, a great citizen of the Rocky Mountain region, and a loyal member of the medical and dental professions.

F. R. S.



# ELISEO SEGURA, M.D.

## 1870-1946

Dr. Eliseo Segura of Buenos Aires, Argentina, elected to Corresponding Fellowship of the American Laryngological Association in June, 1946, died suddenly on September 16, 1946. His death occurred on the eve of his departure for Chicago to attend the Pan-American Congress of Oto-rhino-laryngology and Broncho-esophagology.

Dr. Segura was born in Cordoba in 1870. He pursued his early medical studies in Cordoba where he was graduated and specialized in oto-rhino-laryngology. He later went to Buenos Aires and then took extensive postgraduate courses in the Clinics of Paris, Berlin and Vienna. Shortly after his return to Buenos Aires he was elected assistant professor of oto-rhino-laryngology and in 1918 was made Professor at Muniz.

His contributions to his specialty were numerous, he traveled extensively, and gave many lectures and demonstrations of operative procedures that he had devised particularly in the field of disturbed nasal respiration and the treatment of sinusitis.

He was President of the first South American Congress of Otolaryngology which was held in Buenos Aires in 1940. He also was active in organizing the Pan-American Congress and was elected Honorary President. He was a member of all of the local medical societies as well as many foreign associations including the Academy of Medicine in Paris, the Association of the Society of Laryngology of Berlin and of the same societies in France, Italy, Brazil and Uruguay. He was a member of the Legion of Honor.

He was one of the outstanding otolaryngologists in South America and was always interested in the advancement of national medicine to which he himself was a notable contributor.

# NORVAL HARVEY PIERCE, M.D.

## 1863-1946

Dr. Norval H. Pierce, born in Washington, D. C., May 13, 1863, was the son of Harvey Linsley (Surgeon U. S. Volunteers) and Katherine Elizabeth Purington Pierce. His father, who had served in the Civil War, died in Libby prison when Dr. Pierce was an infant. He was reared by his grandparents on his mother's side, and educated in the public schools of Philadelphia. He received his medical education at the College of Physicians and Surgeons, Chicago, graduating in 1885.

He obtained his postgraduate training at Wurzburg, Bavaria and Vienna.

Dr. Pierce was married in Milwaukee to Drucilla Wahl of Chicago in 1895. He enjoyed an outstanding practice in Chicago until 1928, when he retired and moved to Del Mar, California, where he lived to enjoy his home and gardens, until the time of his death on October 26, 1946, at the age of 83.

His relationship of doctor to patient is noteworthy—"be honest with your patient and be honest with yourself." This was the basis of his professional philosophy. He was endowed with a charming personality. He was a student, a teacher and a contributor to significant medical literature. Successful in his chosen profession, he had unusual and keen talents and he achieved distinction in diagnosis and was a gifted surgeon. He was the first in this country to introduce the technic of antral lavage by way of the natural, or accessory opening. The Pierce cannula which is still in use bears his name.

Besides these gifts, Norval Pierce possessed an artistic sense. Being a lover of music he rarely missed a symphony concert. As a singer he gained distinction among his friends and colleagues. Those who knew him, will always remember his ringing tenor in "On the Road to Mandalay" at our National Society meetings.

Dr. Pierce was not without a military career. He served in the U.S.N. during the Spanish-American War. He was a Major in World

War I as a consultant in Otolaryngology at Camp Grant, and acted in the same capacity at Vichy, France.

He was head of the Department of Otolaryngology, College of Medicine, University of Illinois, Attending Surgeon to the Illinois Eye and Ear Infirmary and Senior Attending Otolaryngologist at St. Luke's Hospital. He was fifth president of the Chicago Laryngological and Otological Society in 1903. His activities included membership in the American College of Surgeons, Institute of Medicine, A.M.A., and Illinois State and Chicago Medical Societies.

He was president of the American Laryngological, Rhinological and Otological Society in 1903-4, president of the American Laryngological Association in 1919 and president of the American Otological Society in 1918.

He is survived by his wife, Dr. Mary Howell Pierce of Del Mar and a daughter Mary.

W. H. T.

# JOHN MARVIN INGERSOLL, M.D.

## 1869-1947

Dr. John Marvin Ingersoll passed away at Miami, Florida, on January 16, 1947, of uremia at the age of 77 years. Born on March 11, 1869, at Youngstown, Ohio, he spent his early life in Washington, D. C., and Cleveland, Ohio. Following his graduation from the Medical Department of Western Reserve University in 1893, he began the study of otolaryngology at the Cleveland City Hospital and later went to Vienna where he continued his graduate work under Professors Chiari, Politzer and Hajek.

On his return to America he became a member of the Department of Otolaryngology of the Medical Department, Western Reserve University and ultimately became the Professor and Head of the Department. He served on the Staffs of the Lakeside and the Cleveland City Hospitals and on his retirement joined the Staff of St. Francis Hospital, Miami Beach, Fla.

Dr. Ingersoll was elected to Fellowship of the American Laryngological Association in 1904 and held the offices of Vice-President and Secretary. He maintained an active interest in its affairs until his election to Emeritus Fellowship in 1933. He was a member of the American Otological Society, member and Past President (1926) of the American Laryngological, Rhinological and Otological Society and a member and Past President (1919) of the American Academy of Ophthalmology and Otolaryngology. He also was a Fellow of the American College of Surgeons. During World War I he was a Colonel in the Medical Reserve Corps but was not on active duty.

He was a prolific writer and contributed many papers before this Association as well as other specialty groups. Although manifesting a very active interest in the entire field of otolaryngology he was particularly interested in the nasal accessory sinuses.



# FREDERICK MANWARING LAW, M.D.

1875-1947

Frederick Manwaring Law was born in Willoughby, Ohio, on August 29, 1875. He was educated in private and public schools until 1894 when he entered the Drexel Institute of Technology in Philadelphia, receiving the degree of Bachelor of Science in Electrical Engineering in 1897. The same year he entered the University of Pennsylvania and in 1901 received the degree of Doctor of Medicine.

In 1902 he came to New York City to take up the study of Ear, Nose and Throat in the Harmon Smith Clinic at the Manhattan Eye, Ear and Throat Hospital as Clinical Assistant under the supervision of Dr. Duncan Macpherson. Later he also became an instructor at the New York Postgraduate Medical School and Hospital. In 1906 he was advanced to Assistant Surgeon at the Manhattan; in 1909 became Assistant Radiographer to Dr. Edward Zabriskie; in 1910 Radiographer, which title was changed later to Roentgenologist to conform to the times. In 1912 he resigned from the Clinic to devote his entire time to Roentgenology. The combination of clinical experience and roentgenology might well be expressed in the term Surgeon-Roentgenologist!

Ill health caused his resignation in 1945 and after a lingering but bravely and uncomplainingly fought attack of Amyotrophic Lateral Sclerosis, he died on Lincoln's Birthday, February 12, 1947.

Dr. Law's professional life was an active but unobtrusive one. He was genuinely interested in his specialty and developed the X-ray laboratory from the old plate glass stage to the modern up-to-date films of today. He kept abreast of the times and as the art of Endoscopy progressed he became second to none in the use of the bi-plane fluoroscope. His services were in great demand both clinically and in writing of papers and the discussion of others' papers. He wrote, besides many papers on Roentgenology, the first volume of Paul Hober's "Annals of Roentgenology" entitled Mastoids and three years later the volume entitled Nasal Accessory Sinuses.

In the World War I he entered the Medical Corps as a Captain, shortly was promoted to Major. He was in charge of Roentgenology at Base Hospital No. 115 in Vichy, France.

Other hospital affiliations were the Manhattan Eye, Ear and

Throat Hospital, Flushing Hospital and Dispensary, and at one time the Woman's Hospital, New York City, in all as Roentgenologist.

Dr. Law was a member of:

New York State and County Medical Societies
American Medical Association
Diplomate American Board of Otolaryngology
Diplomate American Board of Radiology
Fellow of American College of Radiology
Fellow of American College of Surgeons
American Laryngological, Rhinological and Otological Society
American Academy of Ophthalmology and Otolaryngology
American Laryngological Association (Corresponding Fellow)
American Broncho-Esophagological Society
American Roentgen Ray Society (Past Vice-President)
New York Laryngological Society (Past Vice-President)
New York Bronchoscopic Club
New York Roentgen Ray Society (Past President)
New York Electrical Society
Fellow New York Academy of Medicine

In 1913 Dr. Law married Miss Bessie Tackett Glen. They were a happy and devoted couple, inseparable whether on pleasure trips as automobiling, motorboating, vacationing at their camp in the Maine woods or attending medical meetings in other cities. Their home life was ideal.

It was my good fortune to have been assigned to the same clinic treatment table with him at the Manhattan Eye, Ear and Throat Hospital, and from that incident developed one of the finest friendships of my experience. Fred was a man's man and to know him was to admire and trust him. He could waft away with a gesture and an inimitable smile the ordinary tragedies of everyday life, but always had time to listen to and help solve the supposed tragedies of his friends and colleagues. His sense of humor was boundless and he was not too proud once in awhile to "put over" some grotesque X-ray finding which only could be done by one versed in electrical, mechanical and X-ray legerdemain! Naturally these wonders were fully explained as to how and why he perpetrated them!

In the passing of Fred Law hundreds of us have lost a dear, dear friend—we miss him greatly. F. W. W.

# Executive Sessions

# 1947

## FIRST EXECUTIVE SESSION

April 23rd, 1947

The First Executive Session of the Association for 1947 was called to order by Vice-President Taylor at the Statler Hotel in St. Louis at 11:50 A.M. Immediately following the first Scientific Session:

Dr. Harris P. Mosher was elected Honorary Fellow.

Dr. Frank B. Kistner was elected Emeritus Fellow.

Dr. Watt Weems Eagle of Durham, North Carolina, Dr. Clarence William Engler of Cleveland, Ohio, and Dr. Walter H. Theobald of Chicago were elected to Active Fellowship.

The Newcomb Award for 1947 was given to Dr. Harris P. Mosher.

The following Fellows were elected to serve as a nominating committee:

Dr. Charles J. Imperatori

Dr. Gordon Berry

Dr. Ralph A. Fenton

Dr. Harris P. Mosher

Dr. Robert Ridpath

The meeting adjourned for the Annual Photograph at 12:25 P.M.

Respectfully submitted,

Arthur W. Proetz, *Secretary*

# ANNUAL BUSINESS MEETING

## April 24th, 1947

The meeting was opened at 12:25 P.M. by Vice-President Taylor.

The newly elected Active Fellows, Dr. Engler and Dr. Theobald were introduced to the Association. Dr. Eagle was not present.

The report of the Secretary was accepted as printed, and the membership received the recommendations of the Council relative to the suggested changes in the publication of the Transactions:

1) That the duty of editing the Transactions and preparing for publication be taken from the Secretary and transferred to the Librarian and Historian.

2) That the present practice of delaying publication awaiting receipt of engravings from various journals in order to save the expense be discontinued, and that a deadline be set at September 1, after which cuts not available be made by the association for the Transactions at the expense of the essayist. (The Constitution provides that manuscript and illustrations be submitted to the Secretary before the paper is read, which would make this procedure practical.)

3) That the selling price of the Volume to non-members be regulated yearly by the Council to meet the expense of publication.

4) That announcements be printed bearing subscription blanks; that payment for volumes be strictly in advance; and that sales through agencies be discontinued as the majority of these operate in such a manner as to add immeasurably to the correspondence and record files of the Editor. (Discounts to agencies were discontinued several years ago).

The combined report of the Auditor and the Treasurer was received and accepted with thanks and appreciation.

The nominating Committee then recommended for election as Councilors:

Dr. Arthur W. Proetz
Dr. John J. Shea
Dr. Frederick A. Figi
Dr. Louis H. Clerf
Dr. Frederick T. Hill
Dr. Harry P. Schenck
Dr. John D. Kernan
Dr. Charles J. Imperatori
Dr. Frank R. Spencer

There were no nominations from the floor.

The Biographer and Historian read the names of the eight fellows whose deaths had occurred in the past year:

Dr. F. Whitehill Hinkel
Dr. T. Melville Hardie
P. McBride, Esq.
Dr. Thomas E. Carmody
Dr. Eliseo V. Segura
Dr. Norval H. Pierce
Dr. John M. Ingersoll
Dr. Frederick M. Law

The Membership rose and stood in silence in honor of the departed Fellows.

The Association by unanimous vote ratified the Council's recommendation of Dr. Fletcher B. Woodward to serve on the Memorial Fund Committee; of Dr. Arthur Proetz and Dr. F. T. Hill to serve as representatives on the American Board of Otolaryngology; and of Dr. Harold I. Lillie to serve as representative of the Association on the Board of Governors of the American College of Surgeons.

Dr. Ralph Fenton and Dr. Gordon Berry were appointed to draft a formal resolution expressing the sympathy and good wishes of the Association to President Spencer.

There being no further business the meeting adjourned at 1:15 P.M.

Respectfully submitted,

Arthur W. Proetz, *Secretary*

## REPORT OF THE SECRETARY

April 24, 1947

The Sixty-Seventh Annual Meeting of the Association was held on May 29 and 30, 1946, at the Hotel Drake in Chicago under the presidency of Dr. Harold I. Lillie. Seventy-two Fellows and one hundred twenty guests attended.

Fifteen scientific papers were presented which were well received and liberally discussed. Mr. Terence Cawthorne, F.R.C.S., of London was the guest of the Association and participated in the program.

Dr. John H. Foster and Dr. George B. Wood were elected to Emeritus Fellowship, and Dr. Eliseo V. Segura, Buenos Aires, Argentina and Dr. Justo M. Alonso, Montevideo, Uruguay, to Corresponding Fellowship. No Active Fellows were elected.

By unanimous vote the Constitution was revised to conform with recommendations of a committee appointed for the purpose, and copies were ordered printed.

The Casselberry Prize was awarded to Dr. Paul H. Holinger for photographs of the larynx, esophagus and lower respiratory tract.

The following officers were elected:

Frank R. Spencer, M.D., *President*

H. Marshall Taylor, M.D., *First Vice-President*

C. Stewart Nash, M.D., *Second Vice-President*

Arthur W. Proetz, M.D., *Secretary*

Frederick T. Hill, M.D., *Treasurer*

Louis H. Clerf, M.D., *Librarian*

Gordon Berry, M.D., *First Councilor*

Thomas E. Carmody, M.D., *Second Councilor*

Charles J. Imperatori, M.D., *Third Councilor*

Harold I. Lillie, M.D., *Fourth Councilor*

The Association has lost through death in the past year one Honorary Fellow, three Emeritus Fellows, three Corresponding Fellows and one Active Fellow.

The membership at the present writing is

| | |
|---|---|
| Active Fellows | 94 |
| Emeritus Fellows | 19 |
| Corresponding Fellows | 14 |
| Honorary Fellows | 3 |
| Total | 130 |

The Council at its Annual Meeting elected Dr. John D. Kernan Councilor to fill the vacancy created by the death of Dr. Thomas E. Carmody. It also voted to present to the Annual Meeting the following candidates for election to Active Fellowship:

Dr. Watt Weems Eagle, Durham, N. C.

Dr. Clarence William Engler, Cleveland, Ohio

Dr. Walter H. Theobald, Chicago, Ill.

Dr. Harris P. Mosher is recommended for Honorary Fellowship.

Dr. Samuel Salinger was reappointed Abstract Editor.

In order to foster a closer relationship between the three national societies and to expedite arrangements for the Annual Meetings, a liaison has been established between the secretaries of the American Otological Society, the American Laryngological, Rhinological and Otological Society and the American Laryngological Association. Through the courtesy of their councils the three secretaries have attended all council meetings of the three societies.

Changing conditions in the printing industry and the publication of medical journals are rendering increasingly difficult the publication of the Transactions of the Association under the present plan, which has been operative for a number of years.

With these conditions in mind the Secretary (and editor) respectfully submits the following recommendations to the Fellows for their consideration:

1) That the duty of editing the Transactions and preparing for publication be taken from the Secretary and transferred to the Librarian and Historian.
2) That the present practice of delaying publication awaiting receipt of engravings from various journals in order to save the essayist expense be discontinued, and that a deadline be set at September 1, after which cuts not available be made by the Association for the Transactions at the expense of the essayist. (The Constitution provides that manuscript and illustrations be submitted to the Secretary before the paper is read, which would make this procedure practical.)
3) That the selling price of the volume to non-members be regulated yearly by the Council to meet the expense of publication.
4) That announcements be printed bearing subscription blanks; that payment for volumes be strictly in advance; and that sales through agencies be discontinued as the majority of these operate in such a manner as to add immeasurably to the correspondence and record files of the Editor. (Discounts to agencies were discontinued several years ago.)

Respectfully submitted,

(SIGNED) ARTHUR W. PROETZ,

*Secretary*

## AMERICAN LARYNGOLOGICAL ASSOCIATION

### REPORT OF THE TREASURER

Balance Sheet April 10, 1946

### ASSETS

| | | |
|---|---|---|
| Cash in Bank | | $ 3,098.18 |
| Less due Trust Funds | | 1,145.73 |
| | | $ 1,952.45 |
| Trust Fund Investments: | Book Value | |
| Bonds: | | |
| $1000 U. S. Treasury 2¾ 1948-51 | $1,101.20 | |
| 1000 U. S. Treasury 2¾ 1958-63 | 1,101.20 | |
| 3000 U. S. Treasury Defense Bonds 2½ Series G. 1953 | 3,000.00 | |
| 1000 U. S. Defense Bonds 2½ Series G. 1954 | 1,000.00 | |

| | | | |
|---|---|---|---|
| 3000 U. S. Treasury 2½ 1964-69 | 3,000.00 | | |
| 1000 U. S. Treasury 2½ 1956-59 | 1,003.50 | | |
| 5000 U. S. Defense Bonds 2½ Series G. 1956 | 5,000.00 | | |
| 1000 U. S. Defense Bonds 2½ Series G. 1957 | 1,000.00 | | |
| 2000 U. S. Defense Bonds 2½ Series G. 1958 | 2,000.00 | | |
| 1000 U. S. Treasury 2½ 1967-72 | 1,000.00 | | |
| 4000 U. S. Treasury Savings Bonds 2½ Series G. 1959 | 4,000.00 | | |
| | | 23,205.90 | |
| Savings Deposits: | | | |
| Waterville Savings Bank | 2,671.84 | | |
| Due from General Cash | 1,145.73 | 3,817.57 | 27.023.47 |
| Total Assets | | | $28,975.92 |

LIABILITIES AND CAPITAL

| | | | |
|---|---|---|---|
| Trust Funds: | | | |
| Casselberry Fund | $5,000.00 | | |
| Johnston Fund | 5,000.00 | | |
| DeRoaldes Fund | 3,000.00 | | |
| Dr. James Edward Newcomb Prize Fund | 500.00 | | |
| Dr. James Edward Newcomb Prize Fund | 2,000.00 | | |
| Memorial Funds | 9,404.19 | | |
| | | $24,904.19 | |
| George E. Hourn Scholarship Grant | | 500.00 | |
| Unused Income: | | | |
| Casselberry Fund | 256.28 | | |
| Johnston Fund | 334.48 | | |
| DeRoaldes Fund | (34.94)* | | |
| Newcomb Prize Fund | (15.16)* | | |
| Newcomb Trust Fund | 388.94 | | |
| Memorial Funds | 689.65 | | |
| | | 1,619.28 | 27,023.47 |
| General Capital and Surplus | | | 1,952.45 |
| Total Liabilities and Capital | | | $28,975.92 |

* Represents Overdraft

## STATEMENT OF INCOME AND EXPENSE

## FOR THE PERIOD MAY 15, 1946, TO APRIL 10, 1947

| | | |
|---|---|---|
| Income: | | |
| Dues | $2,350.00 | |
| Registration Fees | 504.00 | |
| Income from Trust Funds | 465.38 | $3,319.38 |
| Expenditures: | | |
| Annual Meeting | 752.06 | |
| Honorariums—Officers (clerical hire) | 450.00 | |
| Council Meeting | 341.13 | |
| Cost of Transactions | 59.22 | |
| Postage and Express | 48.00 | |
| Stationery and Printing | 152.82 | |
| Miscellaneous Expense | 21.32 | |
| All Other (Treasurer's Bond) | 85.00 | |
| Amortization | 34.90 | 1,944.45 |
| Excess of Income over Expenditures | | $1,374.93 |

## DISPOSITION OF TRUST FUND INCOME

| | | |
|---|---|---|
| Total Income on Trust Funds: | | $465.38 |
| Casselberry Fund | 93.08 | |
| Johnston Fund | 93.08 | |
| DeRoaldes Fund | 55.85 | |
| Newcomb Prize Fund | 9.30 | |
| Newcomb Trust Fund | 37.23 | |
| Memorial Funds | 176.84 | 465.38 |

## STATEMENT OF INCOME (TRUST FUNDS)

| | Unused Income 5/15/46 | Expended | Income 1946-47 | Unused Income 4/10/47 |
|---|---|---|---|---|
| Casselberry Fund | 263.00 | 100.00 | 93.08 | 256.28 |
| Johnston Fund | 241.40 | | 93.08 | 334.48 |
| DeRoaldes Fund | (90.79)* | | 55.85 | (34.94)* |
| Newcomb Prize Fund | (24.46)* | | 9.30 | (15.16)* |
| Newcomb Trust Fund | 351.74 | | 37.23 | 388.97 |
| Memorial Fund | 512.81 | | 176.84 | 689.65 |
| | 1,253.90 | 100.00 | 465.38 | 1,619.28 |

* Represents Overdraft

## RECONCILIATION OF GENERAL CAPITAL AND SURPLUS

| | | |
|---|---|---|
| General Capital and Surplus—May 15, 1946 | | $2,240.32 |
| Transferred to DeRoaldes Fund | $1,000.00 | |
| Loss on Investments (in excess of reserve) | 197.42 | 1,197.42 |
| | | $1,042.90 |
| Excess of Income over Expenditures | 1,374.93 | |
| Income prorated to Unused Income of Trust Funds | 465.38 | 909.55 |
| General Capital and Surplus, April 10, 1947 | | $1,942.45 |

## SECURITY TRANSACTIONS

*Called* — *Book Value*

3,000 U. S. Treasury 3 1/8 '46-'49 @ 3000 ..... 3,307.02

*Purchased*

4,000 U. S. Savings 2½ Series G. 1959 ..... 4,000.00

The following contributions have been received and credited to the Memorial Funds during the year:—

| | |
|---|---|
| Dr. Gordon Berry | $100.00 |
| Dr. Duncan Macpherson | 50.00 |
| Dr. W. E. Grove | 50.00 |
| | $200.00 |

Respectfully submitted,
FREDERICK T. HILL,
*Treasurer.*
April 10, 1947

This is to certify that I have examined the books of the American Laryngological Association for the fiscal year 1946-47. The financial reports, as presented, correctly reflect the financial condition and operations of the Association, and the accounts are kept in accordance wth sound accounting practice.

A. G. EUSTIS,
Treasurer, Colby College, Waterville, Maine.

## REPORT OF THE MEMORIAL FUND COMMITTEE

APRIL 1947

On pages 488-489 of the 1940 Transactions the Rules governing the Memorial Fund instruct this rotating committee of five to "determine what bequests and memorial gifts shall be applied to this Fund; arrange

to fittingly honor the Benefactors on our records; make periodic reports —to the Association." In compliance with these directions, the Memorial Fund Committee reports the following:

Promised bequests:

| | |
|---|---|
| $ 5,000.00 | Mrs. Lila Fetterolf Kennedy (1936 Transactions—Page 313) |
| $10,000.00 | An Anonymous Donor (1941 Transactions—Page 280) |
| $ 1,000.00 | An Anonymous Donor (1943 Transactions—Page 160) |
| $10,000.00 | In Trust, Mrs. George E. Hourn (1946 Transactions) |

Cash gifts:

| | |
|---|---|
| $ 5,000.00 | Dr. and Mrs. Lee Wallace Dean (By Bequest) |
| $ 1,000.00 | Dr. John F. Barnhill |
| $ 900.00 | Dr. Gordon Berry |
| $ 500.00 | Dr. Frederick T. Hill |
| $ 200.00 | Dr. Thomas A. Carmody |
| $ 200.00 | Dr. Duncan Macpherson |
| $ 200.00 | Dr. Arthur W. Proetz |
| $ 150.00 | Dr. W. E. Grove |
| $ 100.00 | Dr. J. M. Brown |
| $ 50.00 | Dr. Louis H. Clerf |
| $ 50.00 | Dr. F. W. Dixon |
| $ 50.00 | Dr. T. C. Galloway |
| $ 25.00 | Dr. Horace Newhart |
| 979.19 | Memorial Assessment Fund |
| $ 8,425.00 | |
| $ 9,404.19 | |

250.00 Annually by Mrs. Hourn—to be spent as income.

This makes a total of $26,000 promised and $9,354 paid, together with $250 annually until Mrs. Hourn's death makes her bequest become operative.

The Committee has voted that all those giving a total of $500 or over be recorded in our Transactions as Benefactors of this Fund. In the order of the receipt of these gifts, the following members and friends have

given the designated amount and their listing as Benefactors of this Fund is recommended:

Dr. John F. Barnhill

Dr. and Mrs. Lee Wallace Dean

Dr. Gordon Berry

Dr. Frederick T. Hill

Dr. and Mrs. George E. Hourn

We now have an annual income of about $450 and are seeking some earnest student or research worker in Laryngology whose ability and promise would make him a worthy recipient of this financial help. The membership is requested to help in the discovering of such an able worker. In the meantime, the Committee urges the making of a bequest or of a moderate voluntary annual gift which will both lessen each member's income tax and ultimately find him listed as a Benefactor in this Fund.

In keeping with the recommendations of the Committee it is moved:

1. That a Donor of $500 or over be listed as a Benefactor of the Memorial Fund.
2. That the names of Benefactors as they are presented by the Committee be so listed in our Transactions.
3. That the Association ratify the following appointments by the Council: Dr. Fletcher D. Woodward to succeed Dr. Macpherson as a committee member for five years; and Dr. Berry to serve as chairman for the ensuing year; both to commence their term of service at this meeting.

Respectfully submitted,

GORDON BERRY '47
WILLIAM E. GROVE '48
GORDON BERRY Ch. '49
BERNARD J. MCMAHON '50
OLIVER E. VAN ALYEA '51
FLETCHER D. WOODWARD '52

## FINAL EXECUTIVE SESSION

April 24, 1947

The final Executive Session was called to order by Vice-President Taylor at 4:20 P.M. on April 24, 1947, immediately following the Scientific Session.

The resolution to Dr. Frank R. Spencer prepared by Dr. Fenton and Dr. Berry was read.

The Association directed the Vice-President to cast the ballot electing as Councilors the Fellows recommended in their report by the Nominating Committee.

A short recess was declared while the new Councilors retired and elected the following officers:

Arthur W. Proetz, M.D., *President*

John J. Shea, M.D., *First Vice-President*

Frederick A. Figi, M.D., *Second Vice-President*

Louis H. Clerf, M.D., *Secretary*

Frederick T. Hill, M.D., *Treasurer*

Harry P. Schenck, M.D., *Biographer and Historian*

John D. Kernan, M.D., *First Councilor*

Charles J. Imperatori, M.D., *Second Councilor*

Harold I. Lillie, M.D., *Third Councilor*

Frank R. Spencer, M.D., *Fourth Councilor*

The new President having been conducted to the rostrum briefly expressed his profound appreciation and adjourned the meeting.

Respectfully submitted,
Arthur W. Proetz,
*Secretary*

# List of Fellows

# 1947

# LIST OF FELLOWS

*Date Indicates Year Admitted to Active Fellowship*

Attendance at meetings is shown by the figures following each name.
Asterisk (*) indicates year paper was read.

## *Active Fellows*

1942. Ashley, Rea E., 384 Post Street, San Francisco 8, California, 1946, '47.

1936. Ballenger, Howard C., 723 Elm Street, Winnetka, Illinois, 1936, '37, '38*, '40, '41, '42, '46*, '47.

1944. Beatty, Hugh G., 150 East Broad Street, Columbus 15, Ohio, 1944, '46*, '47.

1921. Berry, Gordon, 36 Pleasant Street, Worcester, Massachusetts, 1921*, '22, '23, '24, '25, '26, '27, '28*, '29*, '30, '31, '32, '33, '34, '35, '37, '38, '39, '40, '41*, '42, '44, '46, '47.

1938. Blassingame, Charles Decatur, 414 P. and S. Building, Memphis 3, Tennessee, 1938, '39, '41, '42, '44, '46*, '47.

1944. Boies, Lawrence R., 1631 Medical Arts Building, Minneapolis 2, Minnesota, 1944, '46, '47.

1941. Bowers, Wesley C., 17 East 61st Street, New York City 21, 1941, '42, '44.

1932. Brown, John Mackenzie, 1136 W. 6th Street, Los Angeles, 14, California, 1935*, '37, '40*, '41, '42, '44, '47*.

1940. Broyles, Edwin N., 1100 North Charles Street, Baltimore, Maryland, 1940, '41*, '42*, '46, '47.

1930. Campbell, Edward Hastings, 2035 Delancey Street, Philadelphia 3, Pennsylvania, 1930, '31*, '32*, '33, '35, '38, '39*, '40, '41, '47.

1945. Campbell, Paul A., 700 North Michigan Avenue, Suite 314, Chicago, Illinois, 1947.

1942. Canfield, Norton, 789 Howard Avenue, New Haven, Connecticut, 1942, '46, '47.

1925. Clerf, Louis H., 1530 Locust Street, Philadelphia 2, Pennsylvania, 1925, '27*, '28, '29*, '30*, '32, '33, '34, '35, '36*, '37, '38, '39, '40, '41*, '42*, '44*, '46, '47.

1917. Coates, George Morrison, 1721 Pine Street, Philadelphia 3, Pennsylvania, 1920, '21, '22, '23, '24, '25, '26, '27, '28, '29, '30, '31, '32, '33, '34, '35, '36, '37*, '38, '39, '40, '41, '42, '44, '46, '47.

1939. Cody, Claude Carr, 1304 Walker Avenue, Houston, Texas, 1939, '41, '42, '44, '46*, '47.

1937. Crowe, Samuel James, 4332 North Charles Street, Baltimore, 18, Maryland, 1937, '38*, '40, '42, ('44*).

1941. Cunning, Daniel S., 121 East 60th Street, New York City 22, 1941, '42*, '44, '46, '47*.

1941. Davis, Warren B., 135 South Eighteenth Street, Philadelphia, Pennsylvania, 1941, '42*, '46.

1941. Dixon, Fred W., 1027 Rose Building, Cleveland, Ohio, 1941, '42*, '44, '46, '47*.

1947. Eagle, Watt Weems, Duke Hospital, Durham, N. C.

1947. Engler, Clarence W., 2323 Prospect Avenue, Cleveland, Ohio, 1947.

1923. Fenton, Ralph Albert, 806 Medical Arts Building, Tenth and Taylor Streets, Portland, Oregon, 1923, '25*, '26, '28, '30, '32, '34, '35, '37*, '39, '40*, '42, '44, '46, '47*.

1930. Figi, Frederick A., Mayo Clinic, Rochester, Minnesota, 1930, '32*, '34, '35, '38*, '42*, '47*.

1932. Furstenberg, Albert Carl, 201 South Main Street, Ann Arbor, Michigan, 1933*, '36*, '38*, '46, '47.

1936. Galloway, Thomas Cyrus, 636 Church Street, Evanston, Illinois, 1936, '37, '38*, '39, '40, '41, '42*, '46*, '47.

1940. Gatewood, E. Trible, Professional Building, Richmond, Virginia, 1940, '41, '42*, '44, '47.

1940. Gill, William D., 705 East Houston Street, San Antonio, Texas, 1940, '41*, '46.

1928. Gittins, Thomas Roy, 408 Davidson Building, Sioux City, Iowa, 1928, '31, '32*, '34, '36, '39*, '40, '42*, '47.

1940. Goodale, Robert L., 330 Dartmouth Street, Boston, Massachusetts, 1940, '41, '42*, '44*, '46, '47.

1928. Goodyear, Henry M., 556 Doctors' Building, Cincinnati 2, Ohio, 1928, '29, '30*, '31, '32, '33, '34*, '35, '36, '37, '38, '39, '40, '42, '44*, '46, '47.

1934. Grove, William E., 324 East Wisconsin Avenue, Milwaukee, 2, Wisconsin, 1934, '35, '36*, '37, '38, '39, '40, '41, '42*, '44, '46, '47.

1940. Hansel, French K., 634 North Grand Avenue, St. Louis 3, Missouri, 1940, '42, '46, '47.

1933. Harkness, Gordon Follette, 2410 River Drive, Davenport, Iowa, 1934, '35, '36*, '40, '41, '44, '46, '47.

1944. Havens, Fred Z., 102 Second Avenue S-W., Rochester, Minnesota, 1944, '46.

1942. Heatley, Clyde A., 11 North Goodman Street, Rochester, N. Y., 1942, '46*.

1945. Hickey, Harold L., 1612 Tremont Street, Denver 2, Colorado, 1946, '47.

1943. Hilding, Anderson C., 324 West Superior Street, Duluth, Minnesota, 1944*, '46, '47.

1928. Hill, Frederick Thayer, Professional Building, Waterville, Maine, 1928, '29*, '30*, '31, '32, '33, '34, '35, '36, '37*, '38*, '39, '40, '41*, '42, '44*, '46, '47.

1945. Holinger, Paul H., 700 North Michigan Ave., Chicago 11, Illinois, 1946, '47.

1944. Hoople, Gordon D., Medical Building, Syracuse, New York, 1946, '47.

1930. Houser, Karl Musser, 2035 Delancey Street, Philadelphia 3, Pennsylvania, 1930, '32*, '33, '34*, '37, '38, '39, '40, '41, '44.

1939. Hunt, Westley Marshall, 907 Fifth Avenue, New York City 21, 1939, '40*, '41, '42, '44, '46, '47.

1920. Imperatori, Charles Johnstone, 108 East Thirty-eighth Street, New York City 16, 1921*, '22, '24*, '25*, '26*, '27*, '28, '31*, '32, '33*, '35, '36, '37*, '38, '39*, '40*, '41*, '42*, '44*, '47*.

1938. JACKSON, CHEVALIER LAWRENCE, 255 South Seventeenth Street, Philadelphia 3, Pennsylvania, 1938, '39, '40, '41*, '42, '44*, '46, '47*.

1928. JARVIS, DEFOREST CLINTON, Quarry Bank Building, Barre, Vermont, 1928, '30, '32*, '33, '34*, '35, '37*, '38, '39, '40, '41, '44, '46, '47.

1939. JOHNSTON, WILLIAM HOWARD, 1515 State Street, Santa Barbara 7, California, 1939, '40, '41, '42, '44, '46, '47.

1944. JONES, MARVIN F., 121 E. 60th Street, New York City, 1944, '46, '47.

1942. KELLY, JOSEPH D., 140 East Fifty-fourth Street, New York City 22, 1942, '44*, '47.

1921. KERNAN, JOHN D., JR., 103 East Seventy-eighth Street, New York City 21, 1921*, '22, '25, '26, '27, '29, '31, '34*, '35*, '36, '37*, '39, '40*, '42*, '47.

1942. KING, EDWARD D., 1002 Carew Tower, Cincinnati 2, Ohio, 1942, '46, '47.

1936. LEJEUNE, FRANCIS ERNEST, Ochsner Clinic Building, Prytania and Aline Streets, New Orleans, Louisiana, 1937, '46*, '47.

1933. LIERLE, DEAN M., University Hospital, Iowa City, Iowa, 1933, '34, '35*, '37, '38, '39, '40*, '42*, '44*, '46, '47*.

1922. LILLIE, HAROLD I., Mayo Clinic, Rochester, Minnesota, 1923*, '24*, '25, '26*, '28, '31*, '33, '36*, '37, '38, '40, '44, '46*, '47.

1935. LOOPER, EDWARD A., 104 West Madison Avenue, Baltimore 1, Maryland, 1935, '36, '37, '38*, '39, '41, '42, '44, '47.

1927. LUKENS, ROBERT M., 1001 Medical Arts Building, Philadelphia 2, Pennsylvania, 1927, '28, '31*, '32, '35, '36, '38, '39, '40*, '42, '46.

1939. LUPTON, IRVING MARTIN, 806 Medical Arts Building, Portland, Oregon, 1946.

1929. LYMAN, HARRY WEBSTER, 906 Carleton Building, St. Louis 1, Missouri, 1929, '31, '34, '35*, '36, '38, '39, '42, '44, '46, '47.

1928. MACPHERSON, DUNCAN, 920 Fifth Avenue, New York City 21, 1928, '29, '30, '31, '33, '34*, '39, '40, '41, '44.

1941. MARTIN, ROBERT C., 384 Post Street, San Francisco 8, California, 1941, '44, '47.

1939. MCCASKEY, CARL HEBER, 608 Guaranty Building, Indianapolis 4, Indiana, 1939, '40, '41, '42*, '44, '46*, '47.

1945. MCLAURIN, JOHN G., 1322 Medical Arts Building, Dallas 1, 1946.

1933. MCMAHON, BERNARD J., Missouri Theatre Bldg., St. Louis 3, Missouri, 1934*, '35, '36, '38*, '41, '44, '46*, '47.

1931. MCNALLY, WILLIAM JAMES, 1509 Sherbrooke Street West, Montreal, Canada, 1931, '33, '34*, '39, '44, '47.

1940. MORRISON, WILLIAM W., 140 E. 54th Street, New York City 22, 1940, '41*, '44, '47.

1939. MYERS, JOHN LLEWELLYN, 1115 Grand Avenue, Kansas City, Missouri, 1939, '40*, '44, '47.

1927. MYERSON, MERVIN C., 416 North Bedford Drive, Beverly Hills, California, 1927, '28*, '29, '30, '31*, '32*, '33*, '34*, '35, '36, '37, '38, '39*, '40, '41*, '42, '44.

1937. NASH, CARLTON STEWART, Medical Arts Building, Rochester 7, New York, 1937, '38*, '40, '42, '44, '46, '47.

1922. NEW, GORDON B., Mayo Clinic, Rochester, Minnesota, 1922, '24, '25*, '26*, '28*, '31*, '33*, '35*, '37*, '39*, '41*, '46*.

1927. ORTON, HENRY BOYLAN, 224 Delavan Avenue, Newark 4, New Jersey, 1927, '28, '29, '30*, '31, '32, '33*, '35, '36, '37, '38*, '40, '41, '42, '44*, '46, '47*.

1924. PROETZ, ARTHUR WALTER, 1010 Beaumont Building, St. Louis 3, Missouri, 1924, '25*, '26*, '27, '28, '29, '30, '31, '32*, '33*, '34, '35*, '36, '37, '38*, '39*, '40, '41, '42*, '44, '46, '47*.

1934. RICHARDS, LYMAN GILDER, 520 Commonwealth Avenue, Boston, Massachusetts, 1934, '35, '36*, '37, '38, '39, '47.

1930. RIDPATH, ROBERT F., 1737 Chestnut Street, Philadelphia 3, Pennsylvania, 1930, '31, '33, '37, '38*, '40, '41*, '44, '47.

1945. ROBB, JAMES M., 641 David Whitney Building, Detroit, Michigan, 1946.

1938. SALINGER, SAMUEL, 25 E. Washington Street, Chicago, Illinois, 1938, '39, '40*, '42, '44*, '46, '47.

1921. Sauer, William E., 3720 Washington Boulevard, St. Louis 8, Missouri, 1921, '23, '25, '28, '31, '32, '35, '37, '39*, '41, '44, '47.

1932. Schall, Leroy Allen, 243 Charles Street, Boston 14, Massachusetts, 1934*, '35, '38, '40*, '41, '42, '44*, '46, '47.

1934. Schenk, Harry P., 1235 Wyngate Road, Wynwood, Pennsylvania, 1934, '35, '36*, '37, '38, '39, '40, '41*, ('44*), '46, '47.

1930. Seydell, Ernest M., First National Bank Building, Wichita, Kansas, 1930, '31*, '33*, '34, '35, '37*, '38, '39, '40*, '41, '42, '46, '47.

1928. Shea, John Joseph, 1018 Madison Avenue, Memphis, Tennessee, 1928, '29, '30*, '31, '32*, '33, '34, '35, '36, '37, '38, '40, '41*, '42, '46, '47*.

1909. Shurly, Burt R., 62 Adams Avenue W., Detroit, Michigan, 1920, '21*, '22, '24, '25*, '26, '27*, '28, '29*, '30, '31, '33, '34, '35, '36, '37, '38, '39, '40, '41, '42, '44, '46, '47.

1939. Simpson, W. Likely, 512 Physicians' and Surgeons' Building, Memphis 3, Tennessee, 1939, '41, '44*, '46, '47*.

1923. Spencer, Frank Robert, Physicians' Building, Boulder, Colorado, 1923, '24*, '26, '27*, '28, '30, '32*, '34, '35, '37, '38, '40*, '41, '42, '46*.

1924. Taylor, Hermon Marshall, 111 West Adams Street, Jacksonville 5, Florida, 1924, '25*, '26, '27, '28, '31, '34, '35*, '36, '37, '38, '39*, '40, '41, '42, '44*, '46, '47.

1947. Theobald, Walter H., 207 N. Michigan Avenue, Chicago, Illinois, 1947.

1937. Tobey, George L., Jr., 403 Commonwealth Avenue, Boston 15, Massachusetts, 1937, '38, '39.

1927. Tobey, Harold G., 403 Commonwealth Avenue, Boston 15, Massachusetts, 1927, '29*, '30*, '31, '32, '35, '37, '39, '41, '46.

1925. Tucker, Gabriel, 250 South Eighteenth Street, Philadelphia, Pennsylvania, 1925, '26*, '27*, '29, '30, '31, '32, '33, '34, '35*, '36, '37,'38, '39, '40*, '41*, '42, '46, '47.

1943. Van Alyea, Oliver E., 135 South La Salle Street, Chicago, Illinois, 1944, '46*, '47.

1941. Viole, Pierre P., 1930 Wilshire Boulevard, Los Angeles 5, California, 1944*, '46, '47.

1940. Weille, Francis L., 247 Commonwealth Avenue, Boston 16, Massachusetts, 1940, '41, '42, '44, '46*, '47.

1922. White, Francis W., 471 Park Avenue, New York City 22, 1922, '23, '25, '26, '27, '28, '29, '31, '32, '37, '39, '40, '41, '42, '44, '46.

1939. Williams, Horace James, 5908 Greene Street, Germantown, Philadelphia, 1939, '40, '41, '42, '46, '47*.

1942. Wishart, D. E. Staunton, 170 St. George Street, Toronto, Canada, 1942, '44, '46, '47*.

1940. Wood, V. Visscher, 3720 Washington Boulevard, St. Louis 8, Missouri, 1940, '41, '42*, '46, '47.

1935. Woodward, Fletcher D., 104 East Market Street, Charlottesville, Virginia, 1935, '36*, '37, '38, '39*, '40, '42, '44, '47.

*Honorary Fellows*

1939. (1907) Jackson, Chevalier, 255 South Seventeenth Street, Philadelphia 3, Pennsylvania, 1939*, '40*.

1943. (1918) Lewis, Fielding O., Providence Road, Media, Pennsylvania.

1947. (1904) Mosher, Harris P., 127 Front Street, Marblehead, Mass., 1947.

1937. Nager, F. B., Freiestrasse 3, Zurich, Switzerland.

*Corresponding Fellows*

1946. Alonso, Justo M., Mercedes 1233, Montevideo, Uruguay.

1942. Batson, Oscar V., 133 South Thirty-sixth Street, Philadelphia 4, Pennsylvania, 1942*.

1938. Blair, Vilray P., 508 North Grand Avenue, St. Louis 3, Missouri.

1940. Colledge, Lionel, 2 Upper Wimpole Street, London, W. 1, England.

1943. Eggston, Andrew O., 653 Park Avenue, New York City, 1944.

1931. Lasagna, Francesco, Royal University of Parma, Parma, Italy.

1921. Le Maitre, Fernand, Avenue Victor Hugo, 120 (XVI), Paris, France.

1919. McKernon, James F., New Canaan, Connecticut.

1930. Negus, Victor E., 149 Harley Street, London, W I, England, 1938*.

1941. Patterson, Norman, Nobs Creek, Ashbridge Park, Berkhamsted, Herts, England.

1937. Portmann, Georges, 25 bis Cours de Verdun, Bordeaux, France, 1947.

1924. Schaefer, J. Parsons, Jefferson Medical College, Philadelphia, Pennsylvania, 1934.

1896. Schmiegelow, Ernst, 18 Norregade, Copenhagen, Denmark.

1936. Vialle, Jacques, 27 Rue de France, Nice (Alpes Maritimes), France.

*Emeritus Fellows*

1941. (1923) Barlow, Roy A., Medical Arts Building, Winchester, Virginia.

1937. (1915) Barnes, Harry Aldrich, Pembroke, Massachusetts.

1944. (1913) Butler, Ralph, 1930 Chestnut Street, Philadelphia, Pennsylvania.

1946. (1933) Foster, John H., 1304 Walker Avenue, Houston, Texas.

1941. (1922) Goldsmith, Perry G., 513 Medical Arts Building, Toronto, Canada.

1936. (1898) Goodale, Joseph L., Argilla Road, Ipswich, Massachusetts.

1943. (1932) Graham, Harrington B., Bohemian Club, San Francisco 2, California.

1940. (1917) Greene, Joseph B., 331 Haywood Building, Asheville, North Carolina.

1933. (1905) Halsted, Thomas H., 475 Fifth Avenue, New York City, 17.

1940. (1915) Hastings, Hill, 2090 South Harvard Boulevard, Los Angeles, California.

1947. (1929) KISTNER, FRANK B., 600 Meyer Building, Portland 5, Oregon.

1939. (1923) LARGE, SECORD HERBERT, 170 Eddy Road, Cleveland, Ohio.

1943. (1921) MCCULLAGH, SAMUEL, 116 E. 63 St., New York 21, N. Y.

1941. (1903) PACKARD, FRANCIS R., 302 South Nineteenth Street, Philadelphia, Pennsylvania.

1942. (1931) POTTS, JOHN B., 1620 Medical Arts Building, Omaha, Nebraska.

1940. (1923) SEWALL, EDWARD C., 430 El Escarpado, Stanford University, California.

1933. (1907) SHAMBAUGH, GEORGE E., 122 South Michigan Avenue, Chicago, Illinois.

1941. (1892) WATSON, ARTHUR W., 2013 Locust Street, Philadelphia, Pennsylvania.

1939. (1908) WILSON, J. GORDON, Old Bennington, Vermont.

1946. (1905) WOOD, GEORGE B., 504 Physicians' Building, Philadelphia 3, Pennsylvania.

## BENEFACTORS

Dr. Arthur W. deRoaldes

Dr. William E. Casselberry

Dr. Samuel Johnston

Dr. Cornelius G. Coakley

Dr. James E. Newcomb

Dr. John F. Barnhill

Dr. Lee Wallace Dean

Dr. George E. Hourn

## BENEFACTORS OF THE MEMORIAL FUND

Dr. John F. Barnhill

Dr. and Mrs. Lee Wallace Dean

Dr. Gordon Berry

Dr. Frederick T. Hill

Dr. and Mrs. George E. Hourn

*Obverse of the deRoaldes medal*

## RECIPIENTS OF THE DEROALDES AWARD

1928. DR. CHEVALIER JACKSON

1931. DR. D. BRYSON DELAVAN

1934. DR. HARRIS P. MOSHER

1937. DR. LEE WALLACE DEAN

1943. DR. RALPH A. FENTON

## RECIPIENTS OF THE CASSELBERRY AWARD

1923. Dr. George Fetterolf and Dr. Herbert Fox

1928. Dr. Ralph A. Fenton and Dr. O. Larsell

1929. Dr. Richard A. Kern and Dr. Harry P. Schenck

1929. Dr. Edward H. Campbell

1931. Dr. Arthur W. Proetz

1934. Dr. Anderson C. Hilding

1936. Dr. Francis E. LeJeune: Dr. Joel J. Pressman

1939. Dr. H. Marshall Taylor: Dr. Brien T. King

1940. Dr. French K. Hansel

1941. Dr. Noah D. Fabricant

1946. Dr. Paul H. Holinger

## RECIPIENTS OF THE NEWCOMB AWARD

1941. Dr. Burt R. Shurly

1942. Dr. Francis R. Packard

1943. Dr. George M. Coates

1944. Dr. Charles J. Imperatori

1947. Dr. Harris P. Mosher

## PAST OFFICERS

*Presidents*

(Year of Election)

1879. Louis Elsberg
1880. J. Solis-Cohen
1880. J. Solis Cohen
1881. F. I. Knight
1882. G. M. Lefferts
1883. F. H. Bosworth
1884. E. L. Shurly
1885. Harrison Allen
1886. E. Fletcher Ingals
1887. R. P. Lincoln
1888. E. C. Morgan
1889. J. N. Mackenzie
1890. W. C. Glasgow
1891. S. W. Langmaid
1892. M. J. Asch
1893. D. Bryson Delavan
1894. J. O. Roe
1895. W. H. Daly
1896. C. H. Knight
1897. T. R. French
1898. W. E. Casselberry
1899. Samuel Johnston
1900. H. L. Swain
1901. J. W. Farlow
1902. J. H. Bryan
1903. J. H. Hartman
1904. C. C. Rice
1905. J. W. Gleitsmann
1906. A. W. deRoaldes
1907. H. S. Birkett
1908. A. Coolidge, Jr.
1909. J. E. Logan
1910. D. Braden Kyle
1911. James E. Newcomb
1912. George A. Leland
1913. Thomas Hubbard
1914. Alexander W. MacCoy
1915. G. Hudson Makuen
1916. Joseph L. Goodale
1917. Thomas H. Halsted
1918. Cornelius G. Coakley
1919. Norval H. Pierce
1920. Harris P. Mosher
1921. Harmon Smith
1922. Emil Mayer
1923. J. Payson Clark
1924. Lee Wallace Dean
1925. Greenfield Sluder
1926. Chevalier Jackson
1927. D. Bryson Delavan
1928. Charles W. Richardson
1929. Lewis A. Coffin
1930. Francis R. Packard
1931. George E. Shambaugh
1932. George Fetterolf
1933. George M. Coates
1934. Dunbar Roy
1935. Burt R. Shurly
1936. William B. Chamberlin
1937. John F. Barnhill

1938. George B. Wood
1939. James A. Babbitt
1940. Gordon Berry
1941. Thomas E. Carmody
1942-3. Charles J. Imperatori
1944-5. Harold I. Lillie
1946. Frank R. Spencer

*Vice-Presidents*

1879. F. H. Davis
1880. W. C. Glasgow
1881. E. L. Shurly
1882. C. Seiler
1883. S. W. Langmaid
1884. J. H. Hartman
1885. H. A. Johnson
1886. E. C. Morgan
1887. J. N. Mackenzie
1888. W. C. Glasgow
1889. E. Holden
1890. J. O. Roe
1891. M. J. Asch
1892. S. Johnston
1893. J. C. Mulhall
1894. C. C. Rice
1895. J. Wright
1896. T. M. Murray
1897. A. W. MacCoy
1898. J. W. Farlow
1899. T. A. De Blois
1900. H. L. Wagner
1901. J. W. Gleitsmann
1902. G. A. Leland
1903. J. H. Lowman
1904. Thomas Hubbard
1905. J. L. Goodale
1906. G. H. Makuen
1907. J. P. Clark
J. O. Roe
W. Porter
E. F. Ingals
S. Johnston
W. H. Daly
G. W. Major
J. N. Mackenzie
S. W. Langmaid
C. E. DeM. Sajous
C. E. Bean
J. H. Hartman
S. Johnston
J. C. Mulhall
W. E. Casselberry
S. H. Chapman
A. W. de Roaldes
D. N. Rankin
H. S. Birkett
F. W. Hinkel
M. R. Brown
A. A. Bliss
D. Braden Kyle
T. Melville Hardie
W. Peyre Porcher
W. J. Freeman
C. W. Richardson
A. B. Thrasher
J. E. Rhodes

| | | |
|---|---|---|
| 1908. | E. Mayer | F. R. Packard |
| 1909. | C. G. Coakley | H. P. Mosher |
| 1910. | Robert C. Myles | J. M. Ingersoll |
| 1911. | F. C. Cobb | B. R. Shurly |
| 1912. | A. W. Watson | W. Scott Renner |
| 1913. | F. E. Hopkins | Geo. F. Shambaugh |
| 1914. | Clement F. Theisen | Lewis A. Coffin |
| 1915. | J. Gordon Wilson | Christian R. Holmes |
| 1916. | Thomas H. Halsted | Greenfield Sluder |
| 1917. | John Edwin Rhodes | D. Crosby Greene |
| 1918. | G. E. Shambaugh | John R. Winslow |
| 1919. | Francis R. Packard | Harmon Smith |
| 1920. | Harmon Smith | W. B. Chamberlin |
| 1921. | Dunbar Roy | Robert C. Lynch |
| 1922. | George Fetterolf | Lorenzo B. Lockard |
| 1923. | Hubert Arrowsmith | Joseph B. Greene |
| 1924. | Ross H. Skillern | Gordon Berry |
| 1925. | John E. Mackenty | Robert Levy |
| 1926. | Lewis A. Coffin | William V. Mullin |
| 1927. | Charles W. Richardson | Hill Hastings |
| 1928. | Robert Clyde Lynch | Francis P. Emerson |
| 1929. | William B. Chamberlin | Ralph Albert Fenton |
| 1930. | Harris P. Mosher | James A. Babbitt |
| 1931. | Joseph B. Greene | E. Ross Faulkner |
| 1932. | Gordon Berry | Frank R. Spencer |
| 1933. | E. Ross Faulkner | Thomas E. Carmody |
| 1934. | Gordon B. New | Samuel McCullagh |
| 1935. | Edward C. Sewall | H. Marshall Taylor |
| 1936. | William P. Wherry | Harold I. Lillie |
| 1937. | Frank R. Spencer | Bernard J. McMahon |
| 1938. | Ralph A. Fenton | Frederick T. Hill |
| 1939. | John H. Foster | Thomas R. Gittins |
| 1940. | Charles T. Porter | Gordon F. Harkness |
| 1941. | Arthur W. Proetz | Henry B. Orton |
| 1942-3. | Harold I. Lillie | Dean M. Lierle |
| 1944-5. | John J. Shea | Thomas C. Galloway |
| 1946. | H. Marshall Taylor | C. Stewart Nash |

*Secretaries and Treasurers*

1879. G. M. Lefferts
1882. D. Bryson Delavan
1889. C. H. Knight
1895. H. L. Swain
1900. J. E. Newcomb
1911. Harmon Smith

*Secretaries*

1912. Harmon Smith
1918. D. Bryson Delavan
1919. J. M. Ingersoll
1920. George M. Coates
1933. William V. Mullin
1935. James A. Babbitt
1939. Charles J. Imperatori
1942. Arthur W. Proetz

*Treasurers*

1912. J. Payson Clark
1923. George Fetterolf
1932. William V. Mullin
1933. James A. Babbitt
1935. Charles J. Imperatori
1939. Frederick T. Hill

*Librarians*

1879. F. H. Bosworth
1883. T. R. French
1903. J. H. Bryan
1930. John F. Barnhill
1934. Burt R. Shurly
1935. George M. Coates

*Librarian and Historian*

1936. George M. Coates
1944. Louis H. Clerf

## PAST MEMBERS

Dates indicate original election to the Association

**Deceased*

### *Honorary Fellows*

*1908. Barnhill, John F., Miami Beach, Florida.
*1893. Birkett, Herbert S., Montreal, Canada.
*1878. Bosworth, Francke H., New York City.
*1878. Cohen, J. Solis-, Philadelphia, Pa.
*1918. Dean, Lee Wallace, St. Louis, Mo.
*1881. Delavan, D. Bryson, New York City.
*1893. deRoaldes, Arthur W., New Orleans, La.
*1890. De La Sota Y Lastra, Ramon, Seville, Spain.
*1879. French, Thomas R., Brooklyn, N. Y.
*1880. Garcia, Senor Manuel, London, England.
*1903. Harris, Thos. J., New York City.
*1878. Johnston, Samuel, Baltimore, Md.
*1878. Lefferts, George Morewood, Katonah, N. Y.
*1914. Levy, Robert, Denver, Colo.
*1883. Mackenzie, John N., Baltimore, Md.
*1881. Mackenzie, Sir Morell, London, England.
*1910. Massei, Ferdinand, Naples, Italy.
*1910. Moure, J. J. E., Bordeaux, France.
*1918. Oliver, H. K., Boston, Mass.
*1906. Pierce, Norval Harvey, San Diego, Calif.
*1909. Semon, Sir Felix, Great Missenden, England.
*1889. Swain, Henry L., New Haven, Conn.
*1914. Thomson, Sir St. Clair, London, Eng.
*1903. Tilley, Herbert, London, England.
*1914. Wagner, Clinton, New York City.
*1890. Wright, Jonathan, Pleasantville, N. Y.

### *Corresponding Fellows*

*1892. Browne, Lennox, London, England.
*1901. Collier, Mayo, Kearsney Abbey, Kent, England.
*1893. Desvernine, Carlos M., Havana, Cuba.

*1930. Emerson, Francis P., Franklin, Mass.
*1936. Fraser, John S., Edinburgh, Scotland.
*1901. Grant, Sir James Dundas, London, England.
*1887. Gouguenheim, A., Paris, France.
*1894. Holden, Edgar, Newark, N. J.
*1919. Kelly, Adam Brown, Helensburgh, Scotland.
*1881. Labus, Carlo, Milan, Italy.
*1926. Law, Frederick M., New York, N. Y.
*1902. Lermoyez, Marcel, Paris, France.
*1897. Luc, H., Paris, France.
*1896. MacDonald, Greville, Haslemere, Surrey, England.
*1894. MacIntyre, John, Glasgow, Scotland.
*1903. McBride, P., York, England.
*1920. McKenzie, Dan, London, England.
*1880. Meyer, Wilhelm, Copenhagen, Denmark.
*1896. Mygind, Holger, Copenhagen, Denmark.
*1919. Paterson, Donald Rose, Cardiff, Wales.
*1919. Rogers, John, Jr., New York City.
*1894. Sajous, C. E. DeM., Philadelphia, Pa.
*1946. Segura, Eliseo, Buenos Aires, Argentina.
*1940. Soto, E. Fernandez, Havana, Cuba.
*1881. Thornton, Pugin, London, England.
*1913. Turner, A. Logan, Edinburgh, Scotland.
*1880. Whistler, W. McNeil, London, England.
*1901. Wingrave, Wyatt, Lyme Regis, Dorset, England.
*1894. Wolfenden, R. Norris, Kent, England.

*Emeritus Fellows*

*1928. Beck, Joseph C., Chicago, Illinois.
*1901. Brown, J. Price, Toronto, Canada.
*1891. Bryan, Joseph H., Washington, D. C.
*1897. Clark, J. Payson, Boston, Mass.
*1899. Cobb, Frederick C., Bradenton, Florida.
*1905. Coffin, Lewis A., New York City.
*1893. Coolidge, Algernon, Boston, Mass.
*1913. Dabney, Virginius, Washington, D. C.
*1882. De Blois, Thomas Amory, Boston, Mass.
*1892. Farlow, John W., Boston, Mass.

*1922. Forbes, Henry H., New York City.
*1905. Freer, Otto T., Chicago, Ill.
*1880. Gleitsmann, Joseph W., New York City.
*1906. Greene, D. Crosby, Jr., Boston, Mass.
*1896. Hardie, Thomas Melville, Chicago, Ill.
*1888. Hinkel, Frank Whitehill, Buffalo, New York.
*1895. Hopkins, Frederick E., Springfield, Mass.
*1927. Hubbard, Thomas, Toledo, Ohio.
*1919. Hurd, Lee Maidment, Rowayton, Conn.
*1904. Ingersoll, John Marvin, Miami, Fla.
*1918. Kenyon, Elmer L., Chicago, Ill.
*1885. Knight, Charles H., New York City.
*1894. Leland, George A., Boston, Mass.
*1943. Lincoln, William R., Cleveland, Ohio.
*1886. MacCoy, Alexander W., Philadelphia, Pa.
*1896. Mayer, Emil, New York City.
*1923. McKinney, Richmond, Memphis, Tenn.
*1901. Myles, Robert C., New York City.
*1923. Newhart, Horace, Minneapolis, Minn.
*1878. Porter, William, Ocean Springs, Miss.
*1903. Renner, W. Scott, Buffalo, N. Y.
*1897. Rhodes, John Edwin, Chicago, Ill.
*1884. Rice, Clarence C., New York City.
*1905. Richards, George L., South Yarmouth, Mass.
*1878. Robinson, Beverly, New York City.
*1908. Smith, Harmon, New York City.
*1892. Wagner, Henry L., San Francisco, Calif.

*Active Fellows*

*1880. Allen, Harrison, Philadelphia, Pa.
*1917. Arrowsmith, Hubert, Brooklyn, N. Y.
*1879. Asch, Morris J., New York City.
*1923. Babbitt, James A., Philadelphia, Pa.
*1906. Ballenger, William L., Chicago, Ill.
*1880. Bean, C. E., St. Paul, Minn.
*1904. Berens, T. Passmore, New York City.
*1924. Bigelow, Nolton, Providence, R. I.
*1893. Bliss, Arthur Ames, Philadelphia, Pa.

*1895. Boylan, J. E., Cincinnati, Ohio.
*1892. Brown, Moreau R., Chicago, Ill.
*1933. Buckley, Robert E., New York City.
*1915. Canfield, R. Bishop, Ann Arbor, Mich.
*1934. Carmack, John Walter, Indianapolis, Ind.
*1924. Carmody, Thomas E., Denver, Colo.
*1889. Casselberry, William E., Chicago, Ill.
*1883. Chamberlain, C. W., Hartford, Conn.
*1917. Chamberlin, William B., Cleveland, Ohio.
*1896. Chappell, W. F., New York City.
*1882. Chapman, S. Hartwell, New Haven, Conn.
*1902. Coakley, Cornelius G., New York City.
*1913. Coffin, Rockwell C., Boston, Mass.
1918. Cox, Gerard H., New York City.
*1880. Cushing, E. W., Boston, Mass.
*1878. Cutter, Ephraim, West Falmouth, Mass.
*1880. Daly, W. H., Pittsburgh, Pa.
*1878. Davis, F. H., Chicago, Ill.
1926. Dennis, Frank Lowndes, Colorado Springs, Col.
*1901. Dickerman, E. T., Chicago, Ill.
*1878. Donaldson, Frank, Baltimore, Md.
*1935. Eves, Curtis C., Philadelphia, Pa.
*1919. Faulkner, E. Ross, New York City.
*1914. Fetterolf, George, Philadelphia, Pa.
*1901. Freeman, Walter J., Philadelphia, Pa.
*1917. Friedberg, Stanton A., Chicago, Ill.
*1897. Frothingham, Richard, New York City.
1940. Fuchs, Valentine H., New Orleans, La.
1909. Getchell, Albert C., Worcester, Mass.
*1907. Gibb, Joseph S., Philadelphia, Pa.
*1878. Glasgow, William Carr, St. Louis, Mo.
*1913. Goldstein, Max A., St. Louis, Mo.
*1905. Grayson, Charles P., Philadelphia, Pa.
*1878. Hartman, Jacob H., Baltimore, Md.
*1879. Holden, Edgar, Newark, N. J.
*1907. Holmes, Christian R., Cincinnati, Ohio.
*1882. Hooper, Franklin H., Boston, Mass.
*1893. Hope, George B., New York City.

*1938. Hourn, George E., St. Louis, Mo.
*1901. Hyatt, Frank, Washington, D. C.
*1925. Iglauer, Samuel, Cincinnati, Ohio.
*1878. Ingals, E. Fletcher, Chicago, Ill.
*1882. Ives, Frank L., New York City.
*1880. Jarvis, William C., New York City.
*1878. Johnson, Hosmer A., Chicago, Ill.
*1879. Johnson, Woolsey, New York City.
*1879. Kealhofer, R. H., St. Louis, Mo.
*1901. King, Gordon, New Orleans, La.
*1885. Knight, Charles H., New York City.
*1878. Knight, Frederick Irving, Boston, Mass.
*1898. Kyle, D. Braden, Philadelphia, Pa.
*1880. Langmaid, Samuel W., Boston, Mass.
*1878. Lincoln, Rufus P., New York City.
*1911. Lockard, Lorenzo B., Denver, Colo.
*1913. Loeb, Hanau W., St. Louis, Mo.
*1897. Logan, James E., Kansas City, Mo.
*1888. Lowman, John H., Cleveland, Ohio.
*1919. Lynah, Henry L., New York City.
*1915. Lynch, Robert Clyde, New Orleans, La.
*1879. McBurney, Charles, New York City.
*1927. McGinnis, Edwin, Chicago, Ill.
1936. McGregor, Gregor, Toronto, Canada.
*1913. McKimmie, O. A., Washington, D. C.
*1885. McSherry, H. Clinton, Baltimore, Md.
*1914. Mackenty, John E., New York City.
*1898. Makuen, G. Hudson, Philadelphia, Pa.
*1881. Major, G. W., Montreal, Canada.
*1881. Morgan, E. C., Washington, D. C.
*1886. Mulhall, J. C., St. Louis, Mo.
*1925. Mullin, William V., Cleveland, Ohio.
*1914. Munger, Carl E., Waterbury, Conn.
*1892. Murray, T. Morris, Washington, D. C.
*1881. Mynter, H., Buffalo, N. Y.
*1893. Newcomb, James E., New York City.
*1895. Nichols, J. E. H., New York City.
*1894. Park, William H., New York City.

*1892. Porcher, W. Peyre, Charleston, S. C.
*1927. Porter, Charles T., Boston, Mass.
*1908. Randall, B. Alexander, Philadelphia, Pa.
*1882. Rankin, D. N., Allegheny, Pa.
*1902. Richardson, Charles W., Washington, D. C.
*1879. Roe, John O., Rochester, N. Y.
*1881. Robertson, J. M., Detroit, Mich.
*1913. Roy, Dunbar, Atlanta, Ga.
*1878. Rumbold, T. F., St. Louis, Mo.
*1879. Seiler, Carl, Philadelphia, Pa.
*1893. Shields, Charles M., Richmond, Va.
*1878. Shurly, E. L., Detroit, Mich.
*1892. Simpson, William Kelly, New York City.
*1919. Skillern, Ross H., Philadelphia, Pa.
*1909. Sluder, Greenfield, St. Louis, Mo.
*1879. Smith, Andrew H., Geneva, N. Y.
*1932. Smyth, Duncan Campbell, Boston, Mass.
*1928. Sonnenschein, Robert, Chicago, Ill.
1924. Stein, Otto J., Chicago, Ill.
1934. Stevenson, Walter, Quincy, Ill.
*1911. Stout, George C., Philadelphia, Pa.
*1879. Tauber, Bernhard, Cincinnati, Ohio.
*1903. Theisen, Clement F., Albany, N. Y.
*1899. Thorner, Max, Cincinnati, Ohio.
*1892. Thrasher, Allen B., Cincinnati, Ohio.
*1888. Van der Poel, S. O., New York City.
*1938. Vail, Harris H., Cincinnati, Ohio.
*1936. Voislawsky, Antonie P., New York City.
*1933. Wanamaker, Allison T., Seattle, Wash.
1896. Ward, Marshall R., Pittsburgh, Pa.
*1879. Ward, Whitfield, New York City.
*1886. Westbrook, Benjamin F., Brooklyn, N. Y.
*1924. Wherry, William P., Omaha, Neb.
*1924. White, Leon E., Boston, Mass.
*1922. Wishart, David J. G., Toronto, Ontario.
*1896. Woolen, Green V., Indianapolis, Ind.