G.F.TUCKER

# Transactions

# American Laryngological Association

---

SEVENTY-FOURTH VOLUME

"DOCENDO DISCIMUS"

# TRANSACTIONS

OF THE

SEVENTY-FOURTH ANNUAL MEETING

OF THE

# American Laryngological Association

1953

HELD AT THE ROOSEVELT HOTEL

NEW ORLEANS, LA.

APRIL 26TH AND 27TH, 1953

---

PUBLISHED BY THE ASSOCIATION

ST. LOUIS, MO.

1953

# CONTENTS

List of Officers ..... 7

Index of Titles (Volumes 66-74) ..... 11

Index of Authors (Volumes 66-74) ..... 32

Registration ..... 41

President's Address ..... 49

Primary Plasma Cell Tumors of the Upper Air Passages. Clyde A. Heatly, M.D., Rochester, N. Y. ..... 52

The Mesenchyme of the Nose and Sinuses. Aubrey G. Rawlins, M.D., San Francisco, Calif. ..... 71

Primary Amyloid Diseases of the Larynx. Julius W. McCall, M.D., and William R. Fisher, M.D., Cleveland, Ohio ..... 82

The Laminagraph as an Aid in the Diagnosis of Diseases of the Larynx. LeRoy A. Schall, M.D., Alexander S. Macmillan, M.D., and Paul M. G. St. Aubin, M.D., Boston, Mass. ..... 96

The Clinical Significance of Keratosis of the Larynx as a Premalignant Lesion. F. Johnson Putney, M.D., and John J. O'Keefe, M.D., Philadelphia, Pa. ..... 117

Carcinoma-in-situ of the Larynx. Alden H. Miller, M.D., and H. Russell Fisher, M.D., Los Angeles, Calif. ..... 129

Chordoma—Final Report and Re-Evaluation of Treatment. Henry B. Orton, M.D., Newark, N. J. ..... 145

Neurilemmoma (Schwannoma) of the Larynx. L. Chester McHenry, M.D., Oklahoma City, Okla. ..... 167

Remarks by Frederick T. Hill re Newcomb Award ..... 175

Hemilaryngectomy with Immediate Skin Graft for the Removal of Carcinoma of the Larynx. Frederick A. Figi, M.D., Rochester, Minn. ..... 176

Treatment of Hyperplastic Sinusitis. Francis W. Davison, M.D., Danville, Pa. ..... 191

Some Recent Items of Interest to Laryngologists Concerning Anesthesia. John Adriani, M.D., New Orleans, La. ..... 208

## Contents


Presentation of Instruments ..... 216

Pharyngeal and Laryngeal Phenomena of Vascular Origin. French K. Hansel, M.D., St. Louis, Mo. ..... 218

Precision Bronchology: A "Must" for the Thoracic Surgeon. Robert E. Priest, M.D., Minneapolis, Minn. ..... 227

The Surgical Complications of Diverticulum of the Pharynx. Kenneth A. Phelps, M.D., Minneapolis, Minn. ..... 240

Realism in the Surgery of the Tonsils and Adenoids. Chas. D. Blassingame, M.D., Memphis, Tenn. ..... 247

Memorials

- Gordon Berry ..... 257
- Edward Anderson Looper ..... 259
- John J. Shea ..... 263
- William D. Gill ..... 267
- Harrington B. Graham ..... 269
- Marvin Fisher Jones ..... 271

Executive Sessions and Reports of Officers and Committees ..... 273

List of Fellows, 1953:

- Active Fellows ..... 288
- Honorary Fellows ..... 295
- Corresponding Fellows ..... 295
- Emeritus Fellows ..... 296

Benefactors ..... 298

Benefactors of the Laryngological Research Fund ..... 299

Recipients of the de Roaldes Award ..... 300

Recipients of the Casselberry Award ..... 301

Recipients of the Newcomb Award ..... 302

Past Officers ..... 303

Past Fellows ..... 307



THOSE IN ATTENDANCE AT THE SEVENTY-FOURTH ANNUAL MEETING

*Top Row*: Nash, Cody, Davison, Work, Lederer, Ireland, McNally, Williams, Eagle, L. F. Morrison, Holinger, Murtagh, Putney, Lyman, Blassingame, Havens, Erich, Miller.

*Third Row*: Roberts, Weille, McCall, Hoople, Lindsay, Boyden, Maxwell, Kline, Smith, Van Alyea, Simpson, Goodale, Cunning, Foster, Orton, Dixon, McHenry, Rawlins, Lynch.

*Second Row*: W. W. Morrison, Figi, Tapia Acuna, C. L. Jackson, Phelps, Heatley, Beatty, Theobald, Salinger, Galloway, Woodman, Hilding, Wishart, Boies, Priest, Ballenger.

*Front Row*: Kelly, Tucker, Schall Seydell, Taylor, Proetz, Fenton, Brown, Clerf, Harkness, Schenck, McMahon, Broyles, LeJeune, Hansel, Wilkerson, Ashley.

## OFFICERS FOR 1952-53

---

PRESIDENT

LOUIS H. CLERF, M.D.

VICE-PRESIDENT

J. MACKENZIE BROWN, M.D.

SECOND VICE-PRESIDENT

EDWIN N. BROYLES, M.D.

SECRETARY

HARRY P. SCHENCK, M.D.

TREASURER

GORDON F. HARKNESS, M.D.

LIBRARIAN, HISTORIAN AND EDITOR

BERNARD J. McMAHON, M.D.

COUNCIL

The above Ex-officio and

FREDERICK T. HILL, M.D.

RALPH A. FENTON, M.D.

GORDON B. NEW, M.D.

H. MARSHALL TAYLOR, M.D.

# Index

# of

# Titles and Authors

# Volumes 66-74

# 1944-1953

# TRANSACTIONS

OF THE

# AMERICAN LARYNGOLOGICAL ASSOCIATION

## VOLS. 66 to 74 (1944-1953) INCLUSIVE

---

# INDEX OF SUBJECTS

---

A


Abductor
paralysis, bilateral of larynx, some problems in surgical treatment of (Kelly), 1944, 149.
paralysis of larynx, bilateral, extra-laryngeal surgical approach for arytenoidectomy in (Orton), 1944, 160

Absorption of air from frontal sinus, vacuum frontal sinusitis. Experimental study on dogs (Ballenger, H. C., and Ballenger, J. J.), 1952, 104

Accessory Sinus, stereoscopic vs plain films in examinations of (Law), 1944, 109

ACTH and cortisone, use of in the field of otolaryngology (Williams), 1952, 49

Acute
suppurative frontal sinusitis, discussion of, intracranial complications (Maxwell) 1950, 56
suppurative frontal sinusitis, discussion of, pathology (McMahon), 1950, 44
suppurative frontal sinusitis, discussion of, treatment (Goodale) 1950, 51
suppurative frontal sinusitis, discussion of, summary (Mosher) 1950, 66

Aerosinusitis resume (Campbell), 1944, 65

Adamantinoma of maxillary sinus, report two cases (Heatly), 1945-46, 215

Adenoids
and tonsils, realism in surgery of (Blassingame, C. D.), 1953, 247
and tonsils, surgery of, realism in (Blassingame, C. D.), 1953, 247

Advances, recent, in our knowledge of cancer (Aub), 1949, 187

A former secretary's appraisal of earlier programs of the association (Coates), 1949, 174

Aid, the laminagraph, in diagnosis of diseases of larynx (Schall, L. A.), 1953, 96

Air
absorption of, from frontal sinus, vacuum frontal sinusitis. Experimental study on dogs (Ballenger, H. C., and Ballenger, J. J.), 1952, 104

Air
currents, respiratory: Their clinical significance (Proetz), 1951, 73
passages, upper, plasma cell tumors of, primary (Heatly, C. A.), 1953, 52
passages, upper, primary plasma cell tumors of (Heatly, C. A.), 1953, 52
Allergic rhinitis, Benadryl in treatment of (Lierle and Dickinson), 1947, 95
Aliphatic versus aromatic amines as vasoconstrictors (Chen), 1948, 122
Allergy, special emphasis on, in otolaryngology, modern trends in (Ashley), 1951, 177
Amines, aliphatic versus aromatic, as vasoconstrictors (Chen), 1948, 122
Amyloid disease of larynx, primary (McCall, J. W.), 1953, 82
An allergic disease, Lermoyez's syndrome (Eagle), 1948, 33
Analysis:
renown arises from personal effort (Lillie), 1949, 169
what lessons may we derive from these: accent on youth (Proetz), 1949, 166
Anesthesia, recent items of interest on, to laryngologists (Adriani, John), 1953, 208.
An internist looks at specialism (Doane), 1949, 103
Anoxia, unrecognized, danger of in laryngology (Galloway), 1945-46, 41
Antibiotics
and chemotherapeutic drugs, influence of, on incidence and course of deep neck infections (Beck), 1952, 73
influence of, on future of otolaryngology (McMahon), 1945-46, 121
Aphonia (McCaskey), 1945-46, 65
Apparatus to record the appearance of the subglottic larynx by photography (Tucker), 1949, 212
Apparently cured with streptomycin, rhinosclerosis (New, Weed, Nichols and Devine), 1948, 157
Applicator, New, Universal. Radium and the lymphoid tissue of the nasopharynx and pharynx (Morrison), 1949, 30
Approach, suprahyoid, to surgical lesions at base of tongue (Blassingame), 1952, 32
Arytenoidectomy, extra-laryngeal approach for, in bilateral abductor paralysis of larynx (Orton), 1944, 160
Associated
paralyses of the larynx (Cody, Jr.), 1945-46, 76
symptomatology of diseases of the epipharynx (Theobald), 1948, 89
Atresia of pharynx (Imperatori), 1944, 187
Aureomycin therapy, preliminary report of: Review of 109 cases papilloma of the larynx (Holinger, Johnston and Anison), 1950, 171
Azygos lobe of the lung (Neil), 1950, 14

B

Base of tongue, surgical lesions at, suprahyoid approach to (Blassingame), 1952, 32
Benadryl in treatment of allergic rhinitis (Lierle and Dickinson), 1947, 95
Benign tumors of the larynx (Holinger and Johnston), 1951, 140
Bilateral
abductor paralysis of larynx, extra-laryngeal surgical approach for arytenoidectomy in (Orton), 1944, 160

Bilateral
abductor paralysis of larynx, some problems in surgical treatment of (Kelly), 1944, 149
Body carotid, tumor of (Viole), 1944, 209
Bony stenosis of the larynx (Canfield), 1949, 129
Botulism and residual polio cases, tracheotomy in (Orton), 1952, 124
Branchiogenetic carcinoma (Hill and Goodof), 1952, 21
Bronchial tree, volume of, at various levels and its possible physiological significance (Hilding, A. C., and Hilding, D.), 1948, 47
Bronchiectasis in children, bronchograph in (Wishart), 1947, 133
Bronchography
in bronchiectasis in children (Wishart), 1947, 133
in children (Wishart), 1952, 61
Bronchology, precision. A must in thoracic surgery (Priest, R. E.), 1953, 227
Brothers, scleroma in two natice born (Cunning), 1947, 118
Bulbar poliomyelitis, present status of tracheotomy in (Priest and Boies), 1951, 106

C

Cadavers
dissection of one hundred, revised conception of recurrent laryngeal nerve paralysis, based on (Morrison), 1952, 132
revised conception based on dissection of one hundred; recurrent laryngeal nerve paralysis (Morrison), 1952, 132
Cancer
extrinsic, of larynx, pathology and surgery of (Orton), 1947, 55
of larynx, a statistical study (Schall and Ayash), 1948, 164
of larynx, choice of treatment (Cunning), 1950, 72
of the vocal cord, intralaryngeal operation for (Le Jeune), 1945-46, 92
recent advances in our knowledge of (Aub), 1949, 187
Carcinoma
branchiogenetic (Hill and Goodof), 1952, 21
in-situ of larynx (Miller, A. H., and Fisher, R. R.), 1953, 129
larynx, laryngofissure, window for (Broyles), 1951, 173
larynx, window laryngofissure for (Broyles), 1951, 173
of larynx, removal of, with immediate skin graft for repair (Figi), 1950, 82
of trachea (Engler), 1948, 178
Carotid-body, tumor of (Viole), 1944, 209
Cartilage hemografts in rhinoplasty: a critical evaluation (Salinger), 1952, 94
Case reports, rhinolith (Van Alyea and Makart), 1952, 41
Cases
botulism and residual poliomyelitis (Orton), 1951, 124
one hundred nine, review of, with preliminary report of aureomycin therapy, papilloma of larynx (Holinger and Johnston), 1950, 171
report of two, moniliasis of larynx (Cody), 1948, 151
Causes of hoarseness in children (White), 1945-46, 57
Cell, plasma, tumors, primary, of upper air passages (Heatly, C. A.), 1953, 52
Cervical region, chordomas of (Imperatori), 1947, 106
Changes tissue, in sinus membranes after penicillin treatment (Fenton and Larsell), 1947, 101
Chemotherapeutic drugs and antibiotics, influence of, on incidence and course of deep neck infections (Beck), 1952, 73

Children
bronchiectasis, bronchography in (Wishart), 1947, 133
bronchography in (Wishart), 1947, 61
bronchography in, bronchiectasis in (Wishart), 1947, 133
some causes of hoarseness in (White) 1945-46, 57
Choice of treatment in cancer of larynx (Cunning), 1950, 72
Chordoma, final report and re-evaluation of treatment (Orton, H. B.), 1953, 145
Chordomas of the cervical region (Imperatori), 1947, 106
Chronic
cicatricial stenosis, plastic reconstruction of the larynx for (Woodward), 1950, 97
frontal sinusitis, surgical treatment of (Boyden, G. L.), 1952, 121
sinus infection, etiology, treatment and prevention of (Crowe and Lett), 1948, 82
Cicatricial stenosis, chronic, larynx, plastic reconstruction of the (Woodward), 1950, 97
Clinical
entity, disappearing: tuberculosis laryngitis (Fenton), 1952, 16
entity: hypertrophy of masseter muscle (Maxwell and Waggoner), 1951, 193
entity, masseter muscle, hypertrophy of (Maxwell and Waggoner), 1951, 193
entity, muscle, masseter, hypertrophy of (Maxwell and Waggoner), 1951, 193
pathological entity, smoker's larynx (Myerson), 1950, 162
significance of laryngeal keratosis as a pre-malignant lesion (Putney, F. J., and O'Keefe, J. O.), 1953, 117
significance of nerve distributions in laryngology (Furstenberg and Crosby), 1948, 65
significance, respiratory air currents (Proetz), 1951, 73
Cold, common, summary of some known facts concerning (Hilding), 1944, 87
Common cold, summary of some known facts concerning (Hilding), 1944, 87
Complications
ear, nose and throat, in sarcoidosis (Lindsay and Perlman), 1951, 205
following irradiation of the thyroid gland (Lukens) 1948, 99
intracranial, frontal sinusitis, acute suppurative, discussion of (Maxwell), 1950, 56
surgical, of diverticulum of pharynx (Phelps, K. A.), 1953, 240
Conception revised, based on dissection of one hundred cadavers, recurrent laryngeal nerve paralysis (Morrison), 1952, 132
Congenital
cysts and fistulae about the head and neck (Blassingame), 1945-46, 189
dermoid of nasopharynx (Foster), 1944, 179
lymphangiomatous macroglossia with cystic hygroma of the neck (Lierle), 1944, 194
Contact ulcer granuloma (New and Devine), 1949, 42
Contribution of older fellows, 1949, 150
Cord, vocal, intralaryngeal operation for cancer of (Le Jeune), 1945-46, 92
Cortical venous thrombosis—Its location and its sources (Stuart, O'Brien and McNally), 1951, 39
Cortisone
and ATCH, use of in the field of otolaryngology (Williams), 1952, 49
effect of on nonspecific granuloma of the midline tissues of the face Williams and Hochfilzer), 1950, 134

Course
and incidence of deep neck nfections, influence of chemotherapeutic drugs antibiotics on (Beck), **1952,** 73
post-operative, superichondral total laryngectomies, report of (Welzl and Broyles), **1948,** 197

Cranial injuries, place of tracheotomy in (McCart), **1952,** 160

Crtical evaluation: cartilage hemografts in rhinoplasty (Salinger), **1952,** 94

Cured, apparently, with streptomycin, rhinosclerosis (New, Weed, Nichols and Devine), **1948,** 157

Currents, air, respiratory: their clinical significance (Proetz), **1951,** 73

Cystic
degenerative lesions of the frontal and ethmoidal sinuses (Lillie and Lake), **1948,** 110
hygroma of neck, with congenital lymphangiomatous macroglossia (Lierle), **1944,** 194

Cysts, congenital, about the head and neck (Blassingame), **1945-46,** 189

D

Danger of unrecognized anoxia in laryngology (Galloway), **1945-46,** 41

Deep neck infections, influence of chemotherapeutic drugs and antibiotics on, in the course of (Beck), **1952,** 73

Deformities, traumatic of the nasal septum (Salinger), **1944,** 46

Degenerative cystic lesions of the frontal and ethmoidal sinuses (Lillie and Lake), **1948,** 110

Dermoid, congenital of nasopharynx (Foster), **1944,** 179

Diagnosis
and therapy, etiology of head pain, modern role of rhinologist in (Boies), **1950,** 119
diseases of larynx, laminagraph, as an aid in (Schall, L. A.), **1953,** 96
laminagraph, as an aid in, diseases of the larynx (Schall, L. A.), **1953,** 96

Diphtheria, present status of (Place), **1947,** 84

Direct visualization of eustachian tubes, orifices and lumens, study of, on patients with large operative defects (Simpson and Witcher), **1947,** 43

Disappearing clinical entity: tuberculous laryngitis (Fenton), **1952,** 16

Discussion
of acute suppurative frontal sinusitis:
pathology (McMahon), **1950,** 44
treatment (Goodale), **1950,** 51
intracranial complicatons (Maxwell), **1950,** 56
summary (Mosher), **1950,** 66

Disease
amyloid, primary, of the larynx (McCall, J. W.), **1953,** 821
an allergic, Lermoyez's syndrome (Eagle), **1948,** 33
primary amyloid of larynx (McCall, J. W.), **1953,** 821

Diseases
of the epipharynx, associated symptomatology of (Theobald), **1948,** 89
larynx, diagnosis of, laminagraph as an aid in (Schall, L. A.), **1953,** 96

Dissection, one hundred cadavers, revised conception on; recurrent laryngeal nerve paralysis (Morrison), **1952,** 132

Distributions, nerve, of clinical significance, in laryngology (Furstenberg and Crosby), **1948,** 65

Diverticulum
pharynx, surgical complications of (Phelps, K. A.), 1953, 240
pulsion, of hypopharynx and its surgical treatment (Jackson, C. L., and Norris), 1947, 128
Dogs, experimental study on. Agsorption of air from fontal sinus, vacuum frontal sinusitis (Ballenger, H. C., and Ballenger, J. J.), 1952 104,
Drainage, frontal, sinus (Van Alyea) 1945-46, 199

E

Ear, nose and throat complications in sarcoidosis (Lindsay and Perlman), 1951, 205
Effect of cortisone on nonspecific granuloma of the midline tissues of the face (Williams and Hochfilzer), 1950, 134
Emphasis on allergy in otolaryngology, modern trends in (Ashley), 1951, 177
End results of treatment of parotid tumors, pathology (Kirklin, Harrngton, McDonald and New), 1951, 104
Entity
clinical, hypertrophy of masseter muscle (Maxwell and Waggoner), 1951, 193
clinical, masseter muscle, hypertrophy of (Maxwell and Waggoner), 1951, 193
clinical, muscle, masseter, hypertrophy of (Maxwell and Waggoner), 1951, 193
clinical, pathological, smoker's larynx (Myerson), 1950, 162
disappearing clinical: tuberculous laryngitis (Fenton), 1952, 16
Epiptharynx
associated symptomatology of diseases of (Theobald), 1948, 89
diseases of, associated symptomatology of (Theobald), 1948, 89
Ethmoid region, fibroma of (Simpson), 1944, 203
Ethmoidal
and frontal sinusitis, treatment of osteomyelitis of the skull resulting from (Simpson), 1951, 30
sinuses, mucoceles, pyoceles and cystic degenerative lesions of (Lillie and Lake), 1948, 110
sinuses, mucocele, simplified surgical treatment of (Goodyear), 1944, 19
Etiology
head pain, diagnosis and therapy of, the modern role of rhinologist in (Boies), 1950, 119
treatment and prevention of chronic sinus infection (Crowe and Lett), 1948, 82
undetermined, in malignant recurring nasal hemorrhage (Salinger), 1944, 197
Eustachian tubes, their orifices and lumens, study of, on patients with large operative defects, giving direct visualization (Simpson and Witcher), 1947, 43
Evaluation, critical: cartilage homografts in rhinoplasty (Salinger), 1952, 94
Examinations, accessory sinus, stereoscopic vs plain films, in (Law), 1944, 109
Experimental study on dogs. Absorption of air from frontal sinus, vacuum frontal sinusitis (Ballenger, H. C., and Ballenger, J. J.), 1952, 104
Extrinsic cancer of the larynx, pathology and surgery of (Orton), 1947, 55

F

Face nonspecific granuloma of, midline tissues of, effect of cortisone on (Williams and Hochfilzer), 1950, 134

Facial midline tissues, lethal granulomatous ulceration involving the (Williams), 1949, 54

Factors influencing the growth of lymphoid tissue (White), 1949, 17

Facts, summary of some known, concerning the common cold (Hilding), 1944, 87

Fibroma

-neuro, pharynx, with paralysis of larynx following operation (Hill), 1944, 182

ethmoid and frontal region (Simpson), 1944, 203

nasopharyngeal, surgical treatment of (Brown), 1947, 36

Fibro-sarcoma of larynx (Foster), 1944, 171

Field of otolaryngology, use of Cortisone and ACTH in (Williams), 1952, 49

Films, stereoscopic vs plain, in accessory sinus examinations (Law), 1944, 109

Final report and re-evaluation of treatment of chordoma (Orton, H. B.), 1953, 145

Fistulae, congenital, about the head and neck (Blassingame), 1945-46, 189

Frontal

and ethmoidal sinusitis, treatment of osteomyelitis of the skull resulting from (Simpson), 1951, 30

fibroma of region (Simpson), 1944, 203

sinus, absorption of air from, vacuum frontal sinusitis. Experimental study on dogs (Ballenger, H. B., and Ballenger, J. J.), 1952 104

sinus drainage (Van Alyea) 1945-46, 109

sinuses, mucoceles, pyoceles and cystic degenerative lesions of (Lillie and Lake), 1948, 110

sinusitis, acute suppurative, discussion of, intracranial complications (Maxwell), 1950, 56

sinusitis, acute suppurative, discussion of, pathology (McMahon), 1950, 44

sinusitis, acute suppurative, discussion of, summary (Mosher), 1950, 66

sinusitis, acute suppurative, discussion of, treatment (Goodale), 1950, 51

sinusitis, chronic surgical treatment of (Boyden G. L.) 1952, 121

sinusitis, vacuum: absorption of air from frontal sinus. Experimental study on dogs (Ballenger, H. C., and Ballenger, J. J.), 1952, 104

surgery secondary, problem of (Weille) 1945-46 151

sinuses, mucocele, simplified surgical treatment of (Goodyear), 1944, 19

Future

otolaryngology, and present status of (Lierle), 1950, 105

of otolaryngology, influence of sulfonamides and antibiotics on (McMahon), 1945-46, 121

G

Graft

hemilaryngectomy and subtotal laryngectomy, immediate skin in (Figi, F. A.), 1953, 176

immediate skin, in hemilaryngectomy and subtotal laryngectomy (Figi, F. A.), 1953, 176

skin, for repair, larynx, after removal of carcinoma of (Figi), 1950, 82

subtotal laryngectomy and hemilaryngectomy, inmmediate skin in (Figi, F. A.), 1953, 176

Gland, thyroid, complications following irradiation of (Lukens), 1948, 99

Granuloma

contact ulcer (New and Devine), 1949, 42

nonspecific of midline tissues of face, effect of cortisone on (Williams and Hochfilzer), 1950, 134

Granulomatous lethal ulceration involving the midline facial tissues (Williams), 1949, 54

Growth of lymphoid tissue, factors influencing (White), 1949, 17

H

Head
congenital cysts and fistulae, about the (Blassingame), 1945-46, 189
pain, diagnosis and therapy of etiology of, the modern role of the rhinologist in (Boies), 1950, 119

Hemangioma of the mouth (Figi), 1947, 67

Hemografts, cartilage, in rhinoplasty: a critical evaluation (Salinger), 1952,
method of maintaining a satisfactory airway and voice (Goodyear), 1949, 205

Hemilaryngectomy and subtotal laryngectomy with immediate skin graft (Figi, F. A.), 1953, 176
94

Hemorrhage, recurring nasal, malignant, of undetermined etiology (Salinger), 1944, 197

Hoarseness, some causes of in children (White), 1945-46, 57

Hygroma, cystic of neck, with congenital lymphangiomatous macroglossia (Lierle), 1944, 194

Hyperplastic sinusitis, treatment of (Davison, F. W.), 1953, 191

Hypopharynx pulsion, diverticulum of, its surgical treatment (Jackson, C. L., and Norris), 1947, 128

I

Immediate
hemilaryngectomy and subtotal laryngectomy skin graft in (Figi, F. A.), 1953, 176
skin graft in hemilaryngectomy in subtotal laryngectomy (Figi, F. A.), 1950, 82
skin graft in hemilaryngectomy an dsubtotal laryngectomy (Figi, F. A.), 1953, 176
subtotal laryngectomy and hemilaryngectomy, skin graft in (Figi, F. A.), 1953, 176

Incidence and course of deep neck infections, influence of chemotherapeutic drugs and antibiotics on (Beck), 1952, 73

Infections
acute, of nose and throat, sensivitity from insufflation of powdered sulfonamides in (Ballenger), 1945-46, 114
chronic sinus, etiology, treatment and prevention of (Crowe and Lett), 1948, 82
1948, 82
neck, deep, influence of chemotherapeutic drugs and antbiotics on (Beck), 1952, 73.
of the nose and throat, viral (Shea), 1951, 20
sinus, chronic, etiology, treatment and prevention of (Crowe and Lett),
viral, of the nose and throat (Shea), 1951, 20

Infestation, screwworm, cochliomyia Americana in man (Taylor), 1950, 150

Influence
of chemotherapeutic drugs and antibiotics on incidence and course of deep neck infections (Beck), 1952, 73
of sulfonamides and antibiotics on future of otolaryngology (McMahon), 1945-46, 114
on future of otolaryngology, of sulfonamides and antibiotics (McMahon), 1945-46, 114

Injuries, cranial, place of tracheotomy in (McCart), **1952,** 160

In-situ carcinoma of larynx (Miller, A. H., and Fisher, H. R.), **1953,** 82

Instruments

bronchoscopic anti-fogging devices (Broyles), **1947,** 149
bronchoscopic tubes with optical telescopes, set of (Broyles), **1948,** 204
forceps, suction (Broyles), **1953,** 216
laryngeal Loupe, improved (Imperatori), **1947,** 150
laryngoscope, an improved (Broyles), **1949,** 212
laryngoscope anterior commissure (Tucker), **1950,** 192
laryngoscope, new anterior commissure (Hollinger), **1945-46,** 232

Insufflation of powdered sulfonamides in acute infections of nose and throat. sensitivity from (Ballenger), **1945-46,** 114

Internist looks at specialism (Doane), **1949,** 103

Intracranial complications, frontal sinusitis, acute suppurative, discussion of (Maxwell), **1950,** 56

Intralaryngeal operaton for cancer of the vocal cord (LeJeune), **1945-46,** 92

Intranasal medication, investigation into relative merits, certain methods of introducing fluids into the nose (Cawthorne), **1945-46,** 105

Irradiation of the thyroid gland, complications following (Lukens), **1948,** 99

Items, recent, on anesthesia, of interest to laryngologists (Adriana, John), **1953,** 208

K

Keratosis

laryngeal as a pre-malignant lesion, clinical significance of (Putney, F. J., and O'Keefe, J. O.), **1953,** 117
laryngeal, clinical significance of, as pre-malignant lesion (Putney, F. J., and O'Keefe, J. O.), **1953,** 117

Knowledge of cancer, recent advances in our (Aub), **1949,** 187

L

Laryngeal

and pharyngeal phenomena of vascular origin (Hansel, F. K.), **1953,** 218
keratosis as a pre-malignant lesion, clincal significance of (Putney, F. J., and O'Keefe, J. O.), **1953,** 117
nerve paralysis, recurrent; a revised conception based on dissection of one hundred cadavers (Morrison, L. F.), **1952,** 132
stenosis (Robb), **1949,** 136
tuberculosis, observations based on twenty-eight years experience with (Looper and Lyon), **1948,** 134

Laryngectomies, superichondral, total, report of post-operative course of **1948,** 197

Laryngectomized

patient, rehabilitation of (Schall), **1950,** 96
patients, the nasal mucosa in the (Dixon, Herr and McCall), **1949,** 113

Laryngectomy

hemilaryngectomy and sub-total, with immediate skin graft (Figi, F. A.), **1953,** 176
sub-total, and hemilaryngectomy with immediate skin graft (Figi, F. A.), **1953,** 176

Laryngitis, tuberculous: a disappearing clinical entity (Fenton), **1952,** 16

Laryngocele (Richards), **1951,** 157

Laryngocele, ventricular (Taylor), **1944,** 114

Laryngologists
anesthesia, recent items of interest to (Adriani, John), 1953, 208
recent items on anesthesia of interest to (Adriani, John), 1953, 208
Laryngology
danger of unrecognized anoxia in (Galloway), 1945-46, 41
nerve distributions of clinical significance in (Furstenberg and Crosby), 1948, 65
Laryngoscope, improved, for infants, equipped with an oxygen insufflation apparatus (Tucker), 1949, 212
Larynx
amyloid disease of, primary (McCall, J. W.), 1953, 82
associated paralysis of (Cody Jr.), 1945-46, 76
aureomycin therapy, for papilloma of: review of 109 cases with a preliminary report of (Holinger, Johnston and Anison), 1950, 171
benign tumors of (Holinger and Johnston), 1951, 140
bilateral abductor paralysis of, extra-laryngeal surgical approach for arytenoidectomy in (Orton), 1944, 160
bilateral abductor paralysis of, some problems in surgical treatment of (Kelly), 1944, 149
bony stenosis of (Canfield), 1949, 129
cancer of (Clerf), 1944, 167
cancer of, choice of treatment (Cunning), 1950, 72
cancer of, a statistical study (Schall and Ayash), 1948, 164
carcinoma in-situ of (Miller, A. H., and Fisher, H. R.), 1953, 129
carcinoma, laryngofissure, window for (Broyles), 1951, 173
carcinoma, removal of, with immediate skin graft for repair (Figi), 1950, 82
carcinoma, window laryngofissure for (Broyles), 1951, 173
diagnosis of diseases of, laminagraph as an aid in (Schall, L. A.), 1953, 96
diseases of, laminagraph as an aid in the diagnosis of (Schall, L. A.), 1953, 96
disease of, primary amyloid (McCall, J. W.), 1953, 82
extra-laryngeal surgical approach for arytenoidectomy in bilateral abductor paralysis of (Orton), 1944, 160
fibro-sarcoma of (Foster), 1944, 171
in-situ carcinoma of (Miller, A. H., Fisher, H. R.), 1953, 129
lamnagraph as an aid in diagnosis of, diseases of (Schall, L. A.), 1953, 96
moniliasis of, report of two cases (Cody), 1948, 151
neurilemmoma (Schwannoma) of (McHenry, L. C.), 1953, 167
papilloma of: review of 109 cases with a preliminary report of aureomycin therapy (Holinger, Johnston and Anison), 1950, 171
paralysis of, following operation for neurofibroma of pharynx (Hill), 1944, 182
plastic reconstruction of, for chronic cicatricial stenosis (Woodward), 1950, 97
smoker's. A clinical pathological entity (Myerson), 1950, 162
tumors of, benign (Holinger and Johnston), 1951, 140
Laminagraph as an aid in diagnosis of diseases of larynx (Schall, L. A.), 1953, 96
Lermoyez's syndrome, an allergic disease (Eagle), 1948, 33
Lesions
cystic degenerative of the frontal and ethmoidal sinuses (Lillie and Lake), 1948, 110
keratosis, pre-malignant laryngeal, clinical significance of (Putney, F. J., O'Keefe, J. O.), 1953, 117
pre-malignant, laryngeal keratosis, clinical significance of (Putney, F. J., O'Keefe, J. O.), 1953, 117
surgical at base of tongue, suprahyoid approach to (Blassingame), 1952, 32

Lethal granulomatous ulceration involving the midline facial tissues (Williams), 1949, 54

Lobe, azygos, of the lung (Neil), 1950, 14

Location
- and sources, cortical venous thrombosis (Stuart, O'Brien and McNally), 1951, 39
- and sources, thrombosis, cortical venous (Stuart, O'Brien and McNally), 1951, 39
- cortical venous thrombosis, and sources (Stuart, O'Brien and McNally), 1951, 39

Lung, azygos, lobe of (Neil), 1950, 14

Lymphangiomatous macroglossia, congenital, with cystic hygroma of the neck (Lierle), 1944, 194

Lymphoid
- tissue, factors influencing the growth of (White), 1949, 17
- tissue of the nasopharynx and pharynx, radium and the. A New Universal Applicator (Morrison), 1949, 30

M

Macroglossia
- congenital lymphangiomatous, with cystic hygroma of the neck (Lierle), 1944, 194
- lymphangiomatous, congenital, with cystic hygroma of the neck (Lierle), 1944, 194

Maintaining method of, a satisfactory airway and voice: hemilaryngectomy (Goodyear), 1949, 205

Malignant
- recurring nasal hemorrhage of undetermined etiology (Salinger), 1944, 197
- tumors of the nasopharynx (Williams), 1947, 30

Man, screwworm infestation in (Taylor), 1950, 150

Masseter muscle, hypertrophy of, a clinical entity (Maxwell and Waggoner), 1951, 193

Maxillary sinus, adamatinoma of, report two cases (Heatly), 1945-46, 215

Medication, intranasal (see intranasal) (Cawthorne), 1945-46, 105

Membrane, nasal mucous, pathology of, suggestions as to treatment of (Schall), 1944, 127

Membranes, sinus, tissue changes in, after penicillin treatment (Fenton and Larsell), 1947, 101

Mesenchyme of nose and sinuses (Rawlins, A. G.), 1953, 71

Method of maintaining a satisfactory airway and voice: hemilaryngectomy (Goodyear), 1949, 205

Midline
- facial tissues, lethal granulomatous ulceration involving the (Williams), 1949, 54
- tissues of face, nonspecific granuloma of, effect of cortisone on (Williams and Hochfilzer), 1950, 134

Modern
- role of the rhinologist in diagnosis and therapy of etiology of head pain (Boies), 1950, 119
- trends in otolaryngology with special emphasis on allergy (Ashley), 1951, 177

Moniliasis of the larynx, report of two cases (Cody), 1948, 151

Mouth, hemangioma of (Figi), 1947, 67

Mucocele
ethmoidal sinuses, surgical treatment of (Goodyear), 1944, 19
frontal sinuses, surgical treatment of (Goodyear), 1944, 19
pyoceles and cystic degenerative lesions of the frontal and ethmoidal sinuses (Lillie and Lake), 1948, 110
Mucosa, nasal, in the laryngectomized patients (Dixon, Herr and McCall), 1949, 113
Muscle, masseter, hypertrophy of, a clinical entity (Maxwell and Waggoner) 1951, 193

N

Nasal
hemorrhage, malignant, of undertemined etiology (Salinger), 1944, 197
mucosa in the laryngectomized patients (Dixon, Herr and McCall), 1949, 113
mucous membrane, pathology of, suggestions as to treatment of (Schall), 1944, 127
polyps, pathology of (Shea), 1947, 17
septum, traumatic deformities of (Salinger), 1944, 46
Nasopharyngeal fibroma surgical treatment of (Brown), 1947, 36
Nasopharynx
congenital dermoid of (Foster), 1944, 179
malignant tumors of (Williams), 1947, 30
radium and the lymphoid tissue of. A New Universal Applicator (Morrison), 1949, 30
Native born brothers, two, scleroma in (Cunning), 1947, 118
Neck
congenital cysts and fistulae about the (Blassingame), 1945-46, 189
cystic hygroma of, with congenital lymphangiomatous macroglossia (Lierle), 1944, 194
infections, deep, influence of chemotherapeutic drugs and antibiotics on (Beck), 1952, 73
lymphangiomatous macroglossia, congenital, with cystic hygroma of (Lierle), 1944, 194
macroglossia, lymphangiomatous, congenital, with cystic hygroma of (Lierle), 1944, 194
Nerve
distributions of clinical significance, in laryngology (Furstenberg and Crosby), 1948, 65
paralysis, recurrent laryngeal; a revised conception based on dissection of one hundred cadavers (Morrison, L. F.), 1952, 132
Nervus terminalis (Larsell), 1950, 19
Neurilemmoma (Schwannoma) of larynx (McHenry, L. G.), 1953, 167
Neurofibroma, pharynx, with paralysis of larynx following operation (Hill), 1944, 182
Neurogenic tumors of the nose and throat (New and Devine), 1945-46, 137
New Universal Applicator—Radium, and the lymphoid tissue of the nasopharynx and pharynx (Morrison), 1949, 30
Nonspecific granuloma of the midline tissues of the face, effect of cortisone on (Williams and Hochfilzer), 1950, 134
Nose
and sinuses, mesenchyme of (Rawlins, A. G.), 1953, 71
and throat, viral infections of (Shea), 1951, 20
ear and throat complications in sarcoidosis (Lindsay and Perlman), 1951, 205

Nose
neurogenic tumors of (New and Devine), **1945-46,** 137
relative merits, certain methods of introducing fluids into (Cawthorne), **1945-46,** 105
saddle, plastic repair of (King, Boyden and Ashley), **1949,** 199
sensitivity from insufflation of powdered sulfonamides, in acute infections of (Ballenger), **1945-46,** 114
the thyroid and (Proetz), **1947,** 79

O

Obituaries, Hubbard, Thos., **1944,** 217; Emerson, F. P., **1944,** 221; Dean, L. W., Sr., **1944,** 225; Kenyon, E. L., **1945-46,** 254; Porter, C. T., **1945-46,** 257; Newhart, H., **1945-46,** 259; Levy, R., **1945-46,** 263; Wanamaker, A. T., 235; Iglauer, S., **1945-46,** 239; Dundas-Grant, Sir James, **1945-46,** 239; Babbitt, J. A., **1945-46,** 241; MacDonald, G. M., **1945-46,** 247; Hourn, G. E., **1945-46,** 249; Hurd, L. M., **1945-46,** 251; Law, F. M., **1947,** 169; Hinkel, F. W., **1947,** 153; Hardie, T. M., **1947,** 155; McBride, Peter, **1947,** 157; Carmody, T. E., **1947,** 159; Sigura, E., **1947,** 163; Pierce, N. H., **1947,** 164; Ingersoll, J. M., **1947,** 167; Lasagna, Francesco, **1948,** 207; Kistner, Frank B., **1948;** 211; Davis, Warren B., **1948,** 213; Shambaugh, G. E., **1948,** 215; 215; Watson, Arthur W., **1948,** 219; Tobey, George L., **1948,** 221; Hastings, Hill, **1948,** 223; Colledge, Lionel, **1949,** 214; Large, S. H., **1949,** 217; McCullagh, S., **1949,** 219; McKernon, J. F., **1949,** 223; Potts, J. B., **1949,** 225; Schmiegelow, E. C., **1949,** 229; Wilson, J. G., **1949,** 231; Wood, V. V., **1949,** 235; Greene, J. B., **1950,** 197; Imperatori, C. J., **1950,** 199; Packard, F. R., **1950,** 203; Patterson, N., **1950,** 207; Goldsmith, P. G., **1951,** 229; Grove, W. E., **1951,** 231; Hunt W. M., **1951,** 233; Ridpath, R. F., **1951,** 237; Shurly, B. R., **1951,** 239; Williams, H. J., **1951,** 243; Gill, W. D., **1953,** 266; Jones, M. F., **1953,** 270; Graham, H. B., **1953,** 269; Shea, J. J., **1953,** 263; Looper, E. A., **1953,** 259; Berry, Gordon, **1953,** 257.

Observations based on an experience of twenty-eight years with laryngeal tuberculosis (Looper and Lyon), **1948,** 134

Operation
intralaryngeal, for cancer of the vocal cord (LeJeune), **1945-46,** 92
paralysis of larynx following, for neurofibroma of pharynx (Hill), **1944,** 182

Origin vascular, pharyngeal and laryngeal, phenomena of (Hansel, F. K.), **1953,** 218

Osteomyelitis of skull, resulting from ethmoidal and frontal sinusitis, treatment of (Simpson), **1951,** 30

Otolaryngology
Cortisone and ACTH, use of in field of (Williams), **1952,** 49
field of, use of Cortison and ACTH in (Williams), **1952,** 49
influence of sulfonamides and antibiotics on future of (McMahon), **1945-46,** 121
inter-American relations in (Jackson), **1944,** 137
local use of sulfadiazine solution, radon, tyrothrycin and penicillin, in (Crowe), **1944,** 25
status, present and future of (Lierle), **1950,** 105
teaching of in war time (Schenck), **1944,** 59
with special emphasis on allergy, modern trends in (Ashley), **1951,** 177

Our knowledge of cancer, recent advances in (Aub), **1949,** 187

P

Pain, head, etiology of, diagnosis and therapy of, the modern role of the rhinologist in (Boies), **1950,** 119

Papilloma of the larynx: a review of 109 cases with a preliminary report of aureomycin therapy (Holinger Johnston and Anison), **1950,** 171

Paralysis
associated, of the larynx (Cody, Jr.), 1945-46, 76
bilateral abductor of larynx, extra-laryngeal surgical approach for arytenoidectomy in (Orton), 1944, 160
bilateral abductor of larynx, some problems in surgical treatment of (Kelly), 1944, 149
laryngeal, recurrent nerve: a revised conception based on dissection of one hundred cadavers (Morrison), 1952, 132
larynx, following operation for neurofibroma of pharynx (Hill), 1944, 182
Passages
air, upper, plasma cell tumors of, primary (Heatly, C. A.), 1953, 52
upper air primary plasma cell tumors of (Heatly, C. A.), 1953, 52
Pathological entity clinical, smoker's larynx (Myerson), 1950, 162
Pathology
and surgery of extrinsic cancer of the larynx (Orton), 1947, 55
frontal sinusitis, acute suppurative, discussion of (McMahon), 1950, 44
nasal mucous membrane, suggestions as to treatment of (Schall), 1944, 127
of nasal polyps (Shea), 1947, 17
treatment and end results of parotid tumors (Kirklin, McDonald, Harrison and New), 1951, 104
Patient
laryngectomized, rehabilitation of (Schall), 1950, 96
rehabilitation, of the laryngectomized (Schall), 1950, 96
Patients laryngectomized, the nasal mucosa in (Dixon, Herr and McCall), 1949, 113
Penicillin
local use of, in otolaryngology (Crowe), 1944, 25
tissue changes in sinus membranes, after treatment with (Fenton and Larsfell), 1947, 101
Pharyngeal and laryngeal phenomena of vascular orgin (Hansel, F. K.), 1953, 218
Pharynx
atresia of ((Imperatori), 1944, 187
diverticulum of, surgical complications of (Phelps, K. A.), 1953, 240
neurofibroma of, with paralysis of larynx following operation (Hill), 1944, 182
radium and the lymphoid tissue of. A New Universal Applicator (Morrison), 1949, 30
surgical complication of, diverticulum of (Phelps, K. A.), 1953, 240
Phenomena of vascular origin, laryngeal and pharyngeal (Hansel, F. K.), 1953, 218
Physiological significance, possible, of the volume of the bronchial tree at various levels (Hilding, A. C., and Hilding, D.), 1948, 47
Place of tracheotomy in cranial injuries (McCart), 1952, 160
Plasma cell tumors, primary, of upper air passages (Heatly, C. A.), 1953, 52
Plastic
reconstruction of the larynx for chronic cicatricial stenosis (Woodward), 1950, 97
repair of saddle nose (King, Boyden and Ashley), 1949, 199
Poliomyelitis
bulbar, present status of tracheotomy in (Priest and Boies), 1951, 106
residual cases, in botulism, tracheotomy in (Orton), 1951, 124
Polyps, nasal, pathology of (Shea), 1947, 17
Possible physiological significance of the volume of the bronchial tree at various levels (Hilding, A. C., and Hilding, D.), 1948, 47
Post-operative course of superichondral total laryngectomies, report of (Walzl and Broyles), 1948, 197

Precision bronchology. A must in thoracic surgery (Heatly, C. A.), **1953,** 227

Preliminary report of aureomycin therapy, review of 109 cases, papilloma of larynx (Holinger, Johnston and Aniston), **1950,** 171

Pre-malignant lesion, laryngeal keratosis, clinical significance of (Putney, F. J., and O'Keefe, J. O.), **1953,** 117

Present
- status and future of otolaryngology (Lierle), **1950,** 105
- status of diphtheria (Place), **1947,** 84
- status of tracheotomy in bulbar poliomyelitis (Priest and Boies), **1951** 106

President's Addresses, Imperatori, C. J.,**1944,** 11; Lillie, H. J., **1945-46,** 9; Spencer, F. R., **1947,** 11; Proetz, A. W., **1948,** 11; Hill, F. T., **1949,** 11; Fenton, R. A., **1950.** 11; New, G. B., **1951,** 11; Taylor, H. M., **1952,** 11; Clerf, L. H., **1953,** 49

Prevention and treatment of chonic sinus infection (Crowe and Lett), **1948,** 82

Primary
- amyloid disease of larynx (McCall, J. W.), **1953,** 82
- plasma cell tumors of upper air passages (Heatly, C. A.), **1953,** 52

Problem of secondary frontal surgery (Weille), **1945-46,** 151

Problems, some, in surgical treatment of bilateral abductor paralysis of larynx (Kelly), **1944,** 149

Pulsion diverticulum of the hypopharynx and its surgical treatment (Jackson, C. L., and Norris), **1947,** 128

Pyoceles and cystic degenerative lesions of the frontal and ethmoidal sinuses (Lillie and Lake), **1948,** 110

R

Radium and the lymphoid tissue of the nasopharynx and pharynx. A New Universal Applicator (Morrison), **1949,** 30

Radon, local use of, in otolaryngology (Crowe), **1944,** 25

Realism in surgery of tonsils and adenoids (Blassingame, C. D.), **1953,** 247

Recent
- advances in our knowledge of cancer (Aub), **1949,** 187
- items on anesthesia of interest to laryngologists (Adriani, John), **1953,** 208

Reconstruction, plastic, larynx, for chronic cicatricial stenosis (Woodward), **1950,** 97

Recurrent laryngeal nerve paralysis; a revised conception based on dissection of one hundred cadavers (Morrison, L. F.), **1952,** 132

Recurring nasal hemorrhage, malignant, of undetermined etiology (Salinger), **1944,** 197

Re-evaluation and final report of treatment of chordoma (Orton, H. B.), **1953,** 145

Region, cervical, chordomas of (Imperatori), **1947,** 106

Rehabilitation of the laryngectomized patient (Schall), **1950,** 96

Relations, inter-American, in otolaryngology (Jackson), **1944,** 137

Remarks re Newcomb Award (Hill, F. T.), **1953,** 175

Removal of carcinoma of larynx with immediate skin graft for repair (Figi), **1950,** 82

Repair
- larynx, with immediate skin graft, after removal of carcinoma of (Figi), **1950,** 82
- plastic, of saddle nose (King, Boyden and Ashley), **1949,** 199

Report
final, and re-evaluation of treatment of chordoma (Orton, H. B.), 1953, 145
of two cases, moniliasis of larynx (Cody), 1948, 151
of post-operative course of superichondral total laryngectomies (Walzl and Broyles), 1948, 197
prelimary, of aureomycin therapy, review of 109 cases papilloma of larynx (Holinger, Johnston and Anison), 1950, 171
Reported, two cases, adamantinoma of the maxillary sinus (Heatly), 1945-46, 215
Reports, case rhinolith (Van Alyea and Makart), 1952, 41
Residual polio cases, botulism, tracheotomy in (Orton), 1951, 124
Respiratory air currents: their clinical significance (Proetz), 1951, 73
Results, end , treatment of parotid tumors, pathology (Kirklin, Harrington, McDonald and New), 1951, 104
Resume, aerosinusitis (Campbell), 1944, 65
Review, one hundred nine cases with a preliminary report of aureomycin therapy, papilloma of larynx (Holinger, Johnston and Anison), 1950, 171
Revised conception based on dissection of one hundred cadavers; recurrent laryngeal nerve paralysis (Morrison), 1952, 132
Rhinitis, allergic, benadryl in treatment of (Lierle and Dickinson), 1947, 95
Rhinologist
modern role of, in diagnosis and therapy of etiology of head pain (Boies), 1950, 119
unusual sinuses, of interest to (Dixon), 1947, 27
sinuses, unusual, of interest to (Dixon), 1947, 27
Rhinolith: case reports (Van Alyea and Makart), 1952, 41
Rhinoplasty, cartilage hemografts in: a critical evaluation (Salinger), 1952, 94
Rhinoscleroma
apparently cured with streptomycin (New, Weed, Nichols and Devine), 1948, 157
streptomycin, apparently cured with (New, Weed, Nichols and Devine), 1948, 157
Role, modern, of rhinologist in diagnosis and therapy of etiology of head pain (Boies), 1950, 119

S

Saddle nose, plastic repair of (King, Boyden and Ashley), 1949, 199
Sarcoidosis
ear, nose and throat complications (Lindsay and Perlman), 1951, 205
complications, ear, nose and throat (Lindsay and Perlman), 1951, 205
Sarcoma-fibro of larynx (Foster), 1944, 171
Satisfactory airway and voice, method of maintaing a: hemilaryngectomy (Goodyear), 1949, 205
Screwworm (Cochliomyia Americana) infestation in man (Taylor), 1950, 150
Schwannoma, neurilemmoma of larynx (McHenry, L. C.), 1953, 167
Scleroma in two native born brothers (Cunning), 1947, 118
Secondary frontal surgery, problem of (Weille), 1945-46, 151
Septum, nasal, traumatic deformities of (Salinger), 1944, 46
Sensitivity from insufflation, powdered sulfonamides in acute infections of nose and throat (Ballenger), 1945-46, 114

Significance
clinical, in laryngology, of nerve distributions (Furstenberg and Crosby), 1948, 65
clinical, of laryngeal keratosis as a pre-malignant lesion (Putney, F. J., O'Keefe, J. O.), 1953, 117
clinical, respiratory air currents (Proetz), 1951, 73
possible physiological, of the volume of the bronchial tree at various levels (Hilding, A. C., and Hilding, D.), 1948, 47

Sinus
accessory, stereoscopic vs plain films in examinations of (Law), 1944, 109
chronic infection, etiology, treatment and prevention of (Crowe and Lett), 1948, 82
drainage, frontal (Van Alyea), 1945-46, 199
frontal, absorption of air from, vacuum frontal sinusitis. Experimental study on dogs (Ballenger, H. C., and Ballenger, J. J.), 1952, 104
maxillary, adamantinoma of, report two cases (Heatly), 1945-46, 215
tissue changes in membranes of, after penicillin treatment (Fenton and Larsell), 1947, 101

Sinuses
and nose, mesenchyme of (Rawlins, A. G.), 1953, 71
cystic degenerative lesions of (Lillie and Lake), 1948, 110
frontal and ethmoidal, mucocele, simplified surgical treatment of (Goodyear), 1944, 1
mucoceles, pyoceles and cystic degenerative lesions of, frontal and ethmoidal (Lillie and Lake), 1948, 110
pyoceles, mucoceles and cystic degenerative lesions of, frontal and ethmoidal (Lillie and Lake), 1948, 110
unusual, of interest to rhinologist (Dixon), 1947, 27

Sinusitis
ethmoidal, treatment of osteomyelitis of the skull resulting from (Simpson), 1951, 30
frontal, acute suppurative, discussion of, intracranial complications (Maxwell), 1950, 56
frontal, acute suppurative, discussion of, pathology (McMahon), 1950, 44
frontal, acute suppurative, discussion of, summary (Mosher), 1950, 66
frontal, acute suppurative, discussion of, treatment (Goodale), 1950, 51
frontal, chronic, surgical treatment of (Boyden, G. L.), 1952, 121
frontal, treatment of osteomyelitis of the skull resulting from (Simpson), 1951, 30
frontal vacuum: absorption of air from frontal sinus. Experimental study on dogs (Balenger, H. C., and Ballenger, J. J.), 1952, 104
hyperplastic, treatment of (Davison, F. W.), 1953, 191
treatment of, hyperplastic (Davison, F. W.), 1953, 191

Skin
graft for repair, larynx, after removal of carcinoma of (Figi), 1950, 82
graft, immediate, in hemilaryngectomy and subtotal laryngectomy (Figi, F. A.), 1953, 176
hemilaryngectomy and subtotal laryngectomy, immediate graft in (Figi, F. A.), 1953, 176

Skull, osteomyelitis of, resulting from ethmoidal and frontal sinusitis, treatment of (Simpson), 1951, 30

Smoker's larynx. A clinical pathological entity (Myerson), 1950, 162

Sources
and location, cortical venous thrombosis (Stuart, O'Brien and McNally), 1951, 39
and location, thrombosis, cortical venous (Stuart, O'Brien and McNally), 1951, 39

Specialism, an internist looks at (Doane), 1949, 103
Statistical study, cancer of larynx (Schall and Ayash), 1948, 164
Status
of diphtheria, present (Place), 1947, 84
present and future, of otolaryngology (Lierle), 1950, 105
present, of tracheotomy in bulbar poliomyelitis (Priest and oBies), 1951, 106
Stenosis
bony, of the larynx (Canfield), 1949, 129
cicatricial, chronic, plastic reconstruction of the larynx for (Woodward), 1950, 97
laryngeal (Robb), 1949, 136
Stereoscopic vs plain films in accessory sinus examinations (Law), 1944, 109
Streptomycin, rhinosclerosis, apparently cured with (New, Weed, Nichols and Devine), 1948, 157
Study
of the eustachian tubes and their orifices and lumens, on patients with large operative defects, giving direct visualization (Simpson and Witcher), 1947, 43
on dogs, experimental. Absorption of air from frontal sinus, vacuum frontal sinusitis (Ballenger, H. C., and Ballenger, J. J.), 1952, 104
statistical, cancer of larynx (Schall and Ayash), 1948, 164
Sub-total laryngectomy and hemilaryngectomy with immediate skin graft (Figi, F. A.), 1953, 176
Sulfadiazine solution, local use of, in otolaryngology (Crowe), 1944, 25
Sulfonamides
influence of, on future of otolaryngology (McMahon), 1945-46, 121
powdered, sensitivity from insufflation of, in acute infections of nose and throat (Ballenger), 1945-46, 114
Summary, some known facts concerning the common cold (Hilding), 1944, 87
Superichondral, total laryngectomies, report of post-operative course of Walzl and Broyles), 1948, 197
Suppurative
acute frontal sinusitis, discussion of, intracranial complications (Maxwell), 1950, 56
acute frontal sinusitis, discussion of, pathology (McMahon), 1950, 44
acute frontal sinusitis, discussion of, summary (Mosher), 1950, 66
acute frontal sinusitis, discusion of, treatment (Goodale), 1950, 51
Suprahyoid aproach to surgical lesions at base of tongue (Blassingame), 1952, 32
Surgery
and pathology of extrinsic cancer of the larynx (Orton), 1947, 55
secondary frontal, problem of (Weille), 1945-46, 151
thoracic, bronchology, precision (Priest, R. E.), 1953, 227
thoracic, precision bronchology (Priest, R. E.), 1953, 227
tonsils and adenoids, realism in (Blassingame, C. D.), 1953, 247
Surgical
approach, extra-laryngeal for arytenoidectomy in bilateral abductor paralysis of larynx (Orton), 1944, 160
complications of diverticulum of pharynx (Phelps, K. A.), 1953, 240
lesions at base of tongue, suprahyoid approach to (Blassingame), 1952, 32
treatment of chronic frontal sinusitis (Boyden, G. L.), 1952, 121
treatment of nasopharyngeal fibroma (Brown), 1947, 36

Surgical
treatment of pulsion diverticulum of hypopharynx (Jackson, C. L., and Norris), 1947, 128

Symptomatology, associated, diseases of the epipharynx (Theobald), 1948, 89

Syndrome, Lermoyez's, an allergic disease (Eagle), 1948, 33

T

Teaching otolaryngology in war time (Schenck), 1944, 59

Terminalis nervus (Larsell), 1950, 19

The
influence of chemotherapeutic drugs and antibiotics on incidence and course of deep neck infections (Beck), 1952, 73
laminagraph as an aid in diagnosis of diseases of larynx (Schall, L. A.), 1953, 96
mesenchyme of nose and sinuses (Rawlins, A. G.)
modern role of the rhinologist in the diagnosis and therapy of the etiology of head pain (Boies), 1950, 119
nasal mucosa in the laryngectomized patients (Dixon, Herr and McCall), 1949, 113
place of tracheotomy in cranial injuries (McCart), 1952, 160
present status and future of otolaryngology (Lierle), 1950, 105
present status of tracheotomy in bulbar poliomyelitis (Priest and Boies), 1951, 106
suprahyoid approach to surgical lesions at base of tongue (Blassingame), 1952, 32
thyroid and the nose (Proetz), 1947, 79
use of Cortisone and ACTH in field of otolaryngology (Williams), 1952, 49
volume of the bronchial tree at various levels and its possible physiological significance (Hilding, A. C., and Hilding, D.), 1948, 47

Therapy
and diagnosis, etiology of head pain, modern role of rhinologist in (Boies), 1950, 119
aureomycin, preliminary report of: review of 109 cases papilloma of the larynx (Holinger, Johnston and Anison), 1950, 171

Thoracic
surgery, bronchology, precision (Priest, R. E.), 1953, 227
surgery, precision bronchology (Priest, R. E.), 1953, 227

Throat
and nose, viral infections of (Shea), 1951, 20
ear and nose complications in sarcoidosis (Lindsay and Perlman), 1951, 205
neurogenic tumors of (New and Devine), 1945-46, 137
sensitivity from insufflation of powdered sulfonamides, in acute infections of (Ballenger), 1945-46, 114
venous, cortical, location and sources (Stuart, O'Brien and McNally), 1951, 39

Thyroid
and the nose (Proetz), 1947, 79
gland, complications following irradiation of (Lukens), 1948, 99

Tissue
changes in sinus membranes after penicillin treatment (Fenton and Larsell), 1947, 101
lymphoid, factors influencing the growth of (White), 1949, 17
lymphoid of the nasopharynx and pharynx, radium and the. A New Universal Applicator (Morrison), 1949, 30

Tissues
midline facial, lethal granulomatous ulceration involving the (Williams), 1949, 54
midline of face, nonspecific granuloma of, effect of cortisone on (Williams and Hochfilzer), 1950, 134
Tongue, base of, suprahyoid approach to surgical lesions at (Blassingame), 1952, 32
Tonsillectomy in the United States (Boies), 1948, 17
Tonsils and adenoids, realism in surgery of (Blassingame, C. D.), 1953, 247
Trachea, carcinoma of (Engler), 1948, 178
Tracheotomy
in botulism and residual polio cases (Orton), 1951, 124
in bulbar poliomyelitis, present status of (Priest and Boies), 1951, 106
place of, in cranial injuries (McCart), 1952, 160
Traumatic deformities of the nasal septum (Salinger), 1944, 46
Treatment
and end results of parotid tumors, pathology (Kirklin, Harrington, McDonald and New), 1951, 104
and prevention of chronic sinus infection (Crowe and Lett), 1948, 82
choice of, in cancer of larynx (Cunning), 1950, 72
chordoma, final report and re-evaluation of (Orton, H. B.), 1953, 145
frontal sinusitis, acute suppurative, discussion of (Goodale), 1950, 51
of allergic rhinitis, benadryl in (Lierle and Dickinson), 1947, 95
of hyperplastic sinusitis (Davison, F. W.), 1953, 191
of osteomyelitis of skull resulting from ethmoidal and frontal sinusitis (Simpson), 1951, 30
pathology of nasal mucous membrane (Schall), 1944, 127
penicillin, tissue changes in sinus membranes, after (Fenton and Larsell), 1947, 101
simplified surgical, mucocele in frontal and ethmoidal sinuses (Goodyear), 1944, 19
surgical of bilateral abductor paralysis of larynx, some problems in (Kelly), 1944, 149
surgical, of chronic frontal sinusitis (Boyden, G. L.), 1952, 121
surgical, of nasopharyngeal fibroma (Brown), 1947, 36
surgical, pulsion diverticulum of hypopharynx (Jackson, C. L., and Norris), 1947, 128
tissue changes in sinus membranes, after penicillin (Fenton and Larsell), 1947, 101
Tree, bronchial, volume of, at various levels and its possible physiological significance (Hilding, A. C., and Hilding, D.), 1948, 47
Trends, modern, in otolaryngology with special emphasis on allergy (Ashley), 1951, 177
Tuberculosis, laryngeal, observations based on twenty-eight years experience with (Looper and Lyon), 1948, 134
Tuberculous laryngitis: a disappearing clinical entity (Fenton), 1948, 16
Tubes, eustachian, orifices and lumens, study of, on patients with large operative defects, giving direct visualization (Simpson and Witcher), 1947, 43
Tumor of carotid-body (Viole), 1944, 209
Tumors
larynx, benign (Holinger and Johnston), 1951, 140
malignant, of the nasopharynx (Williams), 1947, 30
neurogenic, of nose and throat (New and Devine), 1945-46, 137
parotid, pathology, treatment and end results of (Kirklin, Harrington, McDonald and New), 1951, 104
plasma cell, primary, of upper air passages (Heatly, C. A.), 1953, 52

Twenty-eight years with laryngeal tuberculosis, observations based on experience of (Looper and Lyon), **1948,** 134

Two native born brothers, scleroma in (Cunning), **1947,** 118

Tyrothrycin, local use of, in otolaryngology (Crowe), **1944,** 25

U

Ulcer, contact, granuloma (New and Devine), **1949,** 42

Ulceration, lethal granulomatous, involving the midline facial tissues (Wil liams), **1949,** 54

United States, tonsillectomy in (Boies), **1948,** 17

Universal Applicator, New. Radium and the lymphoid tissue of the nasopharynx and pharynx (Morrison), **1949,** 30

Unusual sinuses of interest to rhinologist (Dixon), **1947,** 27

Upper
air passages, plasma cell tumors of, primary (Heatly, C. A.), **1953,** 52
air passages, primary plasma cell tumors of (Heatly, C. A.), **1953,** 52

Use of Cortisone and ACTH in field of otolaryngology (Williams), **1952,** 49

V

Vacuum, frontal sinusitis: absorption of air from frontal sinus. Experimentl study on dogs (Ballenger, H. C., and Ballenger, J. J.), **1952,** 104

Vascular origin, pharyngeal and laryngeal, phenomena of (Hansel, F. K.), **1953,** 218

Vasoconstrictors, aliphatic versus aromatic amines, as (Chen), **1948,** 22

Venous thrombosis, cortical, location and sources (Stuart, O'Brien and McNally), **1951,** 39

Ventricular laryngocele (Taylor), **1944,** 114

Viral infections of the nose and throat (Shea), **1951,** 20

Visualization, direct, on patients with large operative defects, study of eustachian tubes, their orifices and lumens (Simpson and Witcher), **1947,** 43

Vocal cord, intralaryngeal operation for cancer of (LeJeune), **1945-46,** 92

Voice, satisfactory airway and, method of maintaining a: hemilaryngectomy (Goodyear), **1949,** 205

Volume of the bronchial tree at various levels and its possible physiological significance (Hilding, A. C., and Hilding, D.), **1948,** 59

W

War time, teaching of otolaryngology in (Schenck), **1944,** 59

Window laryngofissure for carcinoma of larynx (Broyles), **1951,** 173

# TRANSACTIONS

OF THE

# AMERICAN LARYNGOLOGICAL ASSOCIATION

## VOLS. 66 to 74 (1944-1953) INCLUSIVE

---

# INDEX OF AUTHORS

---


A

ADRIANI, J.
recent items on anesthesia of interest to laryngologists, 1953, 208

ANISON, G. C.
papilloma of the larynx, a review of 109 cases with a preliminary report of aureomycin therapy (with P. H. Holinger and K. E. Johnston), 1950, 171

ASHLEY, F. L.
plastic repair of saddle nose (with E. D. King and R. C. Boyden), 1949, 199

ASHLEY, R. E.
modern trends in otolaryngology with special emphasis on allergy, 1951, 177

AUB, J. C.
recent advances in our knowledge of cancer, 1949, 187

AYASH, J. J.
cancer of the larynx. A statistical study (with L. A. Schall), 1948, 164

B

BALLENGER, H. C.
sensitivity from insufflation of the powdered sulfonamides in acute infections of the nose and throat, 1945-46, 114
vacuum frontal sinusitis: absorption of air from the frontal sinus. Experimental study on dogs (with J. J. Ballenger), 1952, 104

BALLENGER, H. C. (*continued*)
tion of air from the frontal sinus. Experimental study on dogs (with J. J. Ballenger), 1952, 104

BALLENGER, J. J.
vacuum frontal sinusitis: absorption of air from the frontal sinus. Experimental study on dogs (with H. C. Ballenger), 1952, 104

BARNES, H. A.
contribution of older fellows, 1949, 150

BEATTY, H. G.
cleft palate, 1945-46, 29

BECK, A. L.
the influence of chemotherapeutic drugs and antibiotics on the incidence and course of deep neck infections, 1952, 73

BLASSINGAME, C. D.
congenital cysts and fistulae about the head and neck, 1945-46, 189
the suprahyoid approach to surgical lesions at the base of the tongue, 1952, 32
realism in the surgery of the tonsils and adenoids, 1953, 247

BOIES, L. R.
tonsillectomy in the United States, 1948, 17
the modern role of the rhinologist in the diagnosis and therapy of

Boies, L. R. (*continued*)
the etiology of head pain, 1950, 119
the present status of tracheotomy in bulbar poliomyelitis (with R. E. Priest), 1951, 106

Boyden, G. L.
surgical treatment of chronic frontal sinusitis, 1952, 121

Boyden, R. C.
plastic repair of saddle nose (with F. L. Ashley and E. A. King), 1949, 199

Brown, J. M.
the surgical treatment of nasopharyngeal fibroma, 1947, 36

Broyles, E. N.
presentation of instruments: a bronchoscopic antifogging device, 1947, 149
report of post-operative course of superichondral total laryngectomies (with E. M. Walzl), 1948, 197
presentation of instruments: set of bronchoscopic tubes with optical telescopes, 1948, 204
presentation of instruments: an improved laryngoscope, 1949, 212
window laryngofissure for carcinoma of larynx, 1951, 173
forceps, suction, 1953, 216

Butler, R.
contribution of older fellows, 1949, 151

C

Campbell, P. A.
aerosinusitis—a resume, 1944, 65

Canfield, N.
bony stenosis of the larynx. Report of a case, 1949, 129

Cawthorne, T.
intranasal medication — an investigation into the relative merits of certain methods of introducing fluids into the nose, 1945-46, 105

Chen, K. K.
aliphatic versus aromatic amines as vasoconstrictors, 1948, 122

Clerf, L. H.
cancer of the larynx, 1944, 167
president's address, 1953, 49

Coates, G. M.
a former secretary's appraisal of earlier programs of the association, 1949, 174

Cody, C. C. Jr.
associated paralyses of the larynx, 1945-46, 76
moniliasis of the larynx: report of two cases, 1948, 151

Crosby, E.
nerve distributions of clinical significance in laryngology (with A. C. Furstenberg), 1948, 65

Crowe, S. J.
local use of sulfadiazine solution, radon, tyrothricin and penicillin in otolaryngology, 1944, 25
the etiology, treatment and prevention of chronic sinus infection (with J. E. Lett), 1948, 82

Cunning, D. S.
scleroma in two native born brothers, 1947, 118
choice of treatment in cancer of the larynx, 1950, 72

D

Davison, F. W.
treatment of hyperplastic sinusitis, 1953, 191

Devine, K. D.
rhinoscleroma apparently cured with streptomycin (with G. B. New, L. A. Weed and D. R. Nichols), 1948, 157
contact ulcer granuloma (with G. B. New), 1949, 42

Dickinson, J. D.
benadryl in the treatment of allargic rhinitis (with D. M. Lierle), 1947, 95

Dixon, F. W.
unusual sinuses of interest to the rhinologist, 1947, 27
the nasal mucosa in the laryngectomized patients (with N. L. Hoerr and J. W. McCall), 1949, 113

Doane, J. C.
an internist looks at specialism, 1949, 103

E

EAGLE, W. W.
Lermoye's syndrome — an allergic disease, 1948, 33

ENGLER, C. W.
carcinoma of the trachea, 1948, 178

F

FENTON, R. A.
tissue changes in sinus membranes after penicillin treatment (with O. Larsell), 1947, 101
president's address, 1950, 11
tuberculous laryngitis: a disappearing clinical entity, 1952, 16

FIGI, F. A.
hemangiomas of the mouth, 1947, 67
removal of carcinoma of the larynx with immediate skin graft for repair, 1950, 82
hemilaryngectomy and subtotal laryngectomy with immediate skin graft, 1953, 176

FISHER, H. R.
carcinoma in-situ of the larynx (with A. H. Miller), 1953, 129

FISHER, W. R.
primary amyloid diseases of the larynx (with J. W. McCall), 1953, 82

FOSTER, J. H.
fibro-sarcoma of larynx, 1944, 171
congenital dermoid of nasopharynx, 1944, 179

FURSTENBERG, A. C.
nerve distributions of clinical significance in laryngology (with E. Crosby), 1948, 65

G

GALLOWAY, T. C.
the danger of unrecognized anoxia in laryngology, 1945-46, 41

GOODALE, J. L.
contribution of older fellows, 1949, 53

GOODALE, R. L.
discussion of acute suppurative frontal sinusitis: treatment, 1950, 51

GOODOF, I. I.
branchiogenetic carcinoma (with F. T. Hill), 1952, 21

GOODYEAR, H. M.
mucocele in frontal and ethmoidal sinuses: simplified surgical treatment, 1944, 19
hemilaryngectomy: method of maintaining a satisfactory airway and voice, 1949, 205

GREENE, J. B.
contribution of older fellows, 1949, 154

H

HALSTED, T. H.
contribution of older fellows, 1949, 154

HANSEL, F. K.
pharyngeal and laryngeal phenomena of vascular origin, 1953, 218

HARRINGTON, S. W.
pathology, treatment and end results of parotid tumors (with J. W. Kirklin, J. R. McDonald and G. New), 1951, 104

HEATLY, C. A.
adamantinoma of the maxillary sinus with a report of two cases, 1945-46, 215
primary plasma cell tumors of the upper air passages, 1953, 52

HILDING, A. C.
summary of some known facts concerning the common cold, 1944, 87
the volume of the bronchial tree at various levels and its possible physiological significance (with D. Hilding), 1948, 47

HILDING, DAVID
the volume of the bronchial tree at various levels and its possible physiological significance (with A. C. Hilding), 1948, 47

HILL, F. T.
neurofibroma of the pharynx with paralysis of the larynx following operation, 1944, 182
president's address, 1949, 11
branchiogenetic carcinoma (with I. I. Goodof), 1952, 21
remarks, re Newcomb award, 1953, 175

HOCHFILZER, J. J.
effect of cortisone on nonspecific granuloma of the midline tissues of the face (with H. L. Williams), 1950, 134

HOERR, N. L.
the nasal mucosa in the laryngectomized patients (with F. W. Dixon and J. W. McCall), 1949, 113

HOLINGER, P. H.
a new anterior commissure laryngoscope, 1945-46, 232
papilloma of the larynx: a review of 109 cases with a preliminary report of aureomycin therapy (with K. C. Johnston and G. C. Anison), 1950, 171
benign tumors of the larynx (with K. C. Johnston), 1951, 140

IMPERATORI, C. J.
president's address, 1944, 11
atresia of the pharynx, 1944, 187
chordomas of the cervical region, 1947, 106
presentation of instruments: an improved laryngeal loupe, 1947, 150

J

JACKSON, C. L.
inter-American relations in otolaryngology, 1944, 137
pulsion diverticulum of the hypopharynx and its surgical treatment (with C. M. Norris), 1947, 128

JACKSON, CHEVALIER
contribution of older fellows, 1949, 156

JOHNSTON, K. C.
papilloma of the larynx: a review of 109 cases with a preliminary report of aureomycin therapy (with P. H. Holinger and G. C. Anison), 1950, 171
benign tumors of the larynx (with P. H. Holinger), 1951, 140

K

KELLY, J. D.
some problems in the surgical treatment of bilateral abductor paralysis of the larynx, 1944, 149

KING, E. D.
plastic repair of saddle nose (with R. C. Boyden and F. L. Ashley), 1949, 199

KIRKLIN, J. W.
pathology, treatment and end results of parotid tumors (with S. W. Harrington, J. R. McDonald and G. New), 1951, 104

L

LAKE, C. F.
mucoceles, pyoceles and cystic degenerative lesions of the frontal and ethmoidal sinuses (with H. I. Lillie), 1948, 110

LARSELL, O.
tissue changes in sinus membranes after penicillin treatment (with R. A. Fenton), 1947, 101
nervus terminalis, 1950, 19

LAW, F. M.
stereoscopic versus plain films in accessory sinus examinations, 1944, 109

LEJEUNE, F. E.
intralaryngeal operation for cancer of the vocal cord, 1945-46, 92

LETT, J. E.
the etiology, treatment and prevention of chronc sinus infection (with S. J. Crowe), 1948, 82

LIERLE, D. M.
congenital lymphangiomatous macroglossia with cystic hygroma of the neck, 1944, 194
benadryl in the treatment of allergic rhinitis (with J. D. Dickinson), 1947, 95
the present status and the future of otolaryngology, 1950, 105

LILLIE, H. I.
president's address, 1945-46, 9
mucoceles, pyoceles and cystic degenerative lesions of the frontal and ethmoidal sinuses (with C. F. Lake), 1948, 110
analyses: what lessons may we derive from these: renown arises from personal effort, 1949, 169

LINDSAY, J. R.
sarcoidosis: ear, nose and throat complications (with H. B. Perlman), 1951, 205

LOOPER, E. A.
observations based on an experience of twenty-eight years with laryngeal tuberculosis (with I. B. Lyon), 1948, 134

LUKENS, R. M.
complications following irradiation of the thyroid gland, 1948, 99

LYON, I. B.
observations based on an experience of twenty-eight years with laryngeal tuberculosis (with E. A. Looper), 1948, 134

M

MACMILLAN, A. S.
the laminagraph as an aid in the diagnosis of the larynx (with L. A. Schall and P. M. St. Aubin), 1953, 96

MAKART, C. D.
rhinolith: case reports (with O. E. Van Alyea), 1952, 41

MAXWELL, J. H.
discussion of acute suppurative frontal sinusitis: intracranial complications, 1950, 56
hypertrophy of the masseter muscle: a clinical entity (with R. W. Waggoner), 1951, 193

MCCALL, J. W.
the nasal mucosa in the laryngectomized patients (with F. W. Dixon and N. L. Hoerr), 1949, 113
primary amyloid disease of the larynx, 1953, 82

MCCART, H. W. D.
the place of tracheotomy in cranial injuries, 1952, 160

MCCASKEY, C. H.
aphonia, 1945-46, 65

MCDONALD, J. R.
pathology, treatment and end results of parotid tumors (with J. W. Kirklin, S. W. Harrington and G. New), 1951, 104

MCHENRY, L. C.
neurilemmoma (Schwannoma) of the larynx, 1953, 167

MCMAHON, B. J.
the influence of the sulfonamides and antibiotics on the future of otolaryngology, 1945-46, 121
discussion of acute suppurative frontal sinusitis: pathology, 1950, 44

MCNAILY, W. J.
cortical venous thrombosis — its location and its sources (with E. A. Stuart and F. H. O'Brien), 1951, 39

MILLER, A. H.
carcinoma in-situ of the larynx (with H. R. Fisher), 1953, 129

MORRISON, L. F.
recurrent laryngeal nerve paralysis; a revised conception based on the dissection of one hundred cadavers, 1952, 132

MORRISON, W.
radium and the lymphoid tissue of the nasopharynx and pharynx, 1949, 30

MOSHER, H. P.
contribution of older fellows, 1949, 158
discussion of acute suppurative frontal sinusitis; summary, 1950, 66

MYERSON, M. C.
smoker's larynx. A clinical pathological entity, 1950, 162

N

NEIL, J. H.
azygos lobe of the lung, 1950, 14

NEW, G. B.
neurogenic tumors of the nose and throat (with K. Devine), 1945-46, 137
rhinoscleroma apparently cured with streptomycin (with L. A. Weed, D. R. Nichols and K. D. Devine), 1948, 157
contact ulcer granuloma (with K. D. Devine), 1949, 42
pathology, treatment and end results of parotid tumors (with J. W. Kirklin, S. W. Harrington and J. R. McDonald), 1951, 104
president's address, 1951, 11

NICHOLS, D. R.
rhinoscleroma apparently cured with streptomycin (with G. B. New, L. A. Weed and K. D. Devine), 1948, 157

NORRIS, C. M.
pulsion diverticulum of the hypopharynx and its surgical treatment (with C. L. Jackson), 1947, 128

O

O'BRIEN, F. H.
cortical venous, thrombosis—its location and its sources (with E. A. Stuart and W. J. McNally), 1951, 39

O'KEEFE, J. J.
clinical significance of laryngeal keratosis as a pre-malignant lesion (with F. J. Putney), 1953, 117

ORTON, H. B.
extra-laryngeal surgical approach for arytenoidectomy. Bilateral abductor paralysis of the larynx, 1944, 160
pathology and surgery of extrinsic cancer of the larynx, 1947, 55
tracheotomy in botulism and residual polio cases, 1951, 124
chordoma, final report and re-evaluation of treatment, 1953, 145

P

PACKARD, F. R.
contribution of older fellows, 1949, 159

PERLMAN, H. B.
sarcoidosis: ear, nose and throat complications (with J. R. Lindsay), 1951, 205

PHELPS, K. A.
surgical complications of diverticulum of the pharynx, 1953, 240

PLACE, E. H.
present status of diphtheria, 1947, 84

PRIEST, R. E.
the present status of tracheotomy in bulbar poliomyelitis (with L. R. Boies), 1951, 106
precision bronchology. A must in thoracic surgery, 1953, 227

PROETZ, A. W.
the thyroid and the nose, 1947, 79
president's address, 1948, 11
analyses: what lessons may we derive from these: accent on youth, 1949, 166
respiratory air currents: their clinical significance, 1951, 73

PUTNEY, F. J.
clinical significance of laryngeal keratosis as a pre-malignant lesion ,with J. J. O'Keefe), 1953, 117

R

RAWLINS, A. G.
the mesenchyme of the nose and sinuses, 1953, 71

RICHARDS, L. G.
laryngocele, 1951, 157

ROBB, J. M.
laryngeal stenosis, 1949, 136

S

ST. AUBIN, P. M. G.
the laminagraph as an aid in the diagnosis of the diseases of the larynx (with L. A. Schall and A. S. Macmillan), 1953, 96

SALINGER, S.
traumatic deformities of the nasal septum, 1944, 46
case of malignant recurring nasal hemorrhage of undetermined etiology, 1944, 197
cartilage hemografts in rhinoplasty: a critical evaluation, 1952, 94

SCHALL, L. A.
pathology of nasal mucous membrane and suggestions as to treatment, 1944, 127
cancer of the larynx. A statistical study (with J. J. Ayash), 1948, 164
rehabilitation of the laryngectomized patient, 1950, 96

SCHALL, L. A. (*Continued*)
the laminagraph as an aid in the diagnosis of diseases of the larynx (with A. S. Macmillan and P. M. St. Aubin), 1953, 96

SCHENCK, H. P.
teaching otolaryngology in wartime, 1944, 59

SHEA, J. J.
the pathology of nasal polyps, 1947, 17
viral infections of the nose and throat, 1951, 20

SHURLY, B. R.
contribution of older fellows, 1949, 161

SIMPSON, W. L.
fibroma of the ethmoid and frontal region, 1944, 203
a study of the eustachian tubes and their orifices and lumens on patients with large operative defects giving direct visualization (with J. E. Witcher), 1947, 43
treatment of osteomyelitis of the skull resulting from ethmoidal and frontal sinusitis, 1951, 30

SPENCER, F. R.
president's address, 1947, 11

STUART, E. A.
cortical venous thrombosis — its location and its sources (with F. H. O'Brien and W. J. McNally), 1951, 39

T

TAYLOR, H. M.
ventricular laryngocele, 1944, 114
screwworm (Cochliomyia Americana) infestation in man, 1950, 150
president's address, 1952, 11

THEOBALD, W. H.
associated symptomatology of diseases of the epipharynx, 1948, 89

TUCKER, G.
presentation of instruments: improved laryngoscope for infants, equipped with an oxygen insufflation apparatus, 1949, 212

TUCKER, G. (*Continued*)
apparatus to record the appearance of the subglottic larynx by photography, 1949, 212
presentation of instruments: the anterior commissure laryngoscope family, 1950, 192

V

VAN ALYEA, O. E.
frontal sinus drainage, 1945-46, 199
rhinolith: case reports (with C. D. Makart), 1952, 41

VIOLÉ, PIERRE
carotid body tumor—case report, 1944, 209

W

WAGGONER, R. W.
hypertrophy of the masseter muscle: a clinical entity (with J. H. Maxwell), 1951, 193

WALZL, E. M.
report of post-operative course of superichondral total laryngectomies (with E. N. Broyles), 1948, 197

WEED, L. A.
rhinoscleroma apparently cured with streptomycin (with G. B. New, D. R. Nichols and K. D. Devine), 1948, 157

WEILLE, F. L.
the problem of secondary frontal surgery, 1945-46, 151

WHITE, A.
factors influencing the growth of lymphoid tissue, 1949, 17

WHITE, F. W.
some causes of hoarseness in children, 1945-46, 57

WILLIAMS, H. J.
malignant tumors of the nasopharynx, 1947, 30

WILLIAMS, H. L.
lethal granulomatous ulceration involving the midline facial tissues, 1949, 54

WILLIAMS, H. L. (*Continued*)
effect of cortisone on nonspecific granuloma of the midline tissues of the face (with J. J. Hochfilzer), **1950,** 134
the use of cortisone and ACTH in the field of otolaryngology, **1952,** 49

WISHART, D. E. S.
bronchography in bronchiectasis in children, **1947,** 133
bronchography in children, **1952,** 61

WITCHER, J. E.
a study of the eustachian tubes and their orifices and lumens on patients with large operative defects giving direct visualization (with W. L. Simpson), **1947,** 43

WOOD, G. B.
contribution of older fellows, **1949,** 162

WOODWARD, F. D.
plastic reconstruction of the larynx for chronic cicatricial stenosis, **1950,** 97

TRANSACTIONS OF THE SEVENTY-FOURTH ANNUAL MEETING

OF THE

# American Laryngological Association

HELD AT

THE HOTEL ROOSEVELT, NEW ORLEANS, LA.

APRIL 26 AND 27, 1953

---

The Seventy-Fourth Annual Meeting of the American Laryngological Association was called to order by the President, Dr. Louis H. Clerf, at the Hotel Roosevelt, New Orleans, La.

## REGISTRATION

The following Fellows were in attendance:

ASHLEY, REA E.
BALLENGER, HOWARD C.
BEATTY, HUGH G.
BLASSINGAME, CHARLES D.
BOIES, LAWRENCE D.
BOYDEN, GUY LEE
BROWN, JOHN MACKENZIE
BROYLES, EDWIN N.
CLERF, LOUIS H.
CODY, CLAUDE C.
CUNNING, DANIEL S.
DAVISON, FRANCIS W.
DIXON, FRED W.
EAGLE, WATT W.
ERICH, JOHN B.
FENTON, RALPH A.
FIGI, FREDERICK A.
FOSTER, JOHN H.
FURSTENBURG, ALBERT C.
GALLOWAY, THOMAS C.
GOODALE, ROBERT L.
GOODYEAR, HENRY M.

Hansel, French K.
Harkness, Gordon F.
Havens, Fred Z.
Heatly, Clyde A.
Hilding, Anderson C.
Hill, Frederick T.
Holinger, Paul H.
Hoople, Gordon D.
Ireland, P. E.
Jackson, Chevalier L.
Kelly, Joseph D.
Kline, Oram R.
Lederer, Francis L.
LeJeune, Francis E.
Lierle, Dean M.
Lindsay, John R.
Lyman, Harry W.
Lynch, Mercer G.
Martin, Robert C.
Maxwell, James H.
McCall, Julius W.
McCaskey, Carl H.
McHenry, Lawrence C.
McMahon, Bernard J.
McNally, William J.
Miller, Alden H.
Morrison, Lewis F.
Morrison, William W.
Mosher, Harris P.
Murtagh, John A.
Nash, C. Stewart
Orton, Henry B.
Phelps, Kenneth A.
Priest, Robert E.
Proetz Arthur W.
Putney, F. Johnson
Rawlins, Aubrey G.
Roberts, Sam E.
Salinger, Samuel
Schall, LeRoy A.
Schenck, Harry P.
Seydell, Ernest M.
Simpson, W. Likely
Smith, Austin T.
Tapia Acuna, Ricardo
Taylor, H. Marshall
Theobald, Walter H.
Tremble, G. Edward
Tucker, Gabriel
Van Alyea, Oliver E.
Viole, Pierre P.
Weille, Francis L.
Wilkerson, William W., Jr.
Williams, Henry L.
Wishart, D. E. Staunton
Woodman, De Graff
Work, Walter P.

## GUESTS

John Adriani, Charity Hospital, New Orleans, La.
Lucian W. Alexander, New Orleans, La.
E. R. V. Anderson, Los Angeles, Calif.
William F. Andrew, Pottstown, Pa.
Albert H. Andrews, Jr., Chicago, Ill.
Richard P. Ariagno, Chicago, Ill.
Joseph P. Atkins, Philadelphia, Pa.
L. J. Barnes, Los Angeles, Calif.
Shirley H. Baron, San Francisco, Calif.
William T. Barr, Dallas, Tex.
John H. Barrett, Houston, Tex.
Philip J. Bayon, Natchez, Miss.
F. T. Beatrous, New Orleans, La.
Joseph W. Begley, Evansville, Ind.
Irl H. Blaisdell, Syracuse, N. Y.
John E. Bordley, Baltimore, Md.
Lemann H. Bounds, Meridian, Miss.
Harold Boyd, Los Angeles, Calif.
Wesley H. Bradley, Ann Arbor, Mich.
Durwin H. Brownell, San Diego, Calif.
Wm. T. K. Bryan, St. Louis, Mo.
James Y. Bryson, Chattanooga, Tenn.
Paul G. Bunker, Aberdeen, S. D.
Robert G. Busboom, Greeley, Colo.
Frank F. Bryant, Shreveport, La.
Charles C. Campbell, Chicago, Ill.
Alfred J. Canton, San Diego, Calif.
James A. Cleary, Salt Lake City, Utah
Clause C. Cody, III, Houston, Tex.
Seymour R. Cohen, Los Angeles, Calif.
Arthur J. Coombs, Chicago, Ill.
Arthur J. Cracovaner, New York, N. Y.
W. H. Craddock, Cincinnati, Ohio
James E. Croushore, Detroit, Mich.
T. L. Curran, Hartford, Conn.
S. Eugene Dalton, Atlantic City, N. J.
John F. Daly, New York, N. Y.
M. O. Dart, Denver, Colo.

J. Calvin Davis, Omaha, Neb.
Kenneth M. Day, Pittsburgh, Pa.
Bert DeBord, Temple, Texas
Russell M. Decker, Pasadena, Calif.
Myers B. Deems, Evansville, Ind.
David D. DeWeese, Portland, Ore.
J. Charles Dickson, Houston, Tex.
J. Lewis Dill, Detroit, Mich.
Daniel J. Dolan, New York, N. Y.
J. E. Dougherty, Canton, Ohio
James A. Downing, Des Moines, Iowa
J. C. Drooker, Boston, Mass.
B. R. Dysart, Pasadena, Calif.
Lee G. Eby, Milwaukee, Wis.
B. E. Ellis, Indianapolis, Ind.
H. D. Emsweiler, Columbus, Ohio
J. D. Evans, Memphis, Tenn.
S. S. Evans, Memphis, Tenn.
Reginald Everett, New York, N. Y.
J. V. Ewin, Laurel, Miss.
S. Z. Faier, Fort Smith, Ark.
W. D. Farmer, Greensboro, N. C.
David Farrell, Jackson, Miss.
Charles F. Ferguson, Boston, Mass.
G. B. Ferguson, Durham, N. C.
H. Russell Fisher, Los Angeles, Calif.
James A. Fisher, Asbury Park, N. J.
G. S. Fitz-Hugh, Charlottesville, Va.
Juan H. Font, San Juan, Puerto Rico
Edmund P. Fowler, New York, N. Y.
Stanton A. Friedberg, Chicago, Ill.
James F. Gavin, Shreveport, La.
John P. Gibson, New York, N. Y.
E. King Gill, Corpus Christi, Tex.
R. O. Gillies, Jr. Omaha, Nebr.
Irwin A. Goldman, New Orleans, La.
Glenn Greenwood, Los Angeles, Calif.
Charles C. Grace, St. Augustine, Fla.
Cesar Guajordo, New Orleans, La.
H. James Hara, Los Angeles, Calif.

Frederick L. Harcourt, Washington, D. C.
J. A. Harrill, Winston-Salem, N. C.
E. W. Harris, Columbus, Ohio
Harold G. Harris, Cleveland, Ohio
V. K. Hart, Charlotte, N. C.
Paul P. Hearn, Greenville, S. C.
C. J. Heinberg, Pensacola, Fla.
John W. Henrickson, San Diego, Calif.
G. A. Henry, New Orleans, La.
Seerl B. Hert, Rochester, N. Y.
Jerome A. Hilger, St. Paul, Minn.
George A. Hilleman, Rochester, N. Y.
Raymond L. Hilsinger, Cincinnati, Ohio
Kenneth H. Hinderer, Pittsburgh, Pa.
John J. Hochfilzer, St. Paul, Minn.
Edgar M. Holmes, Boston, Mass.
W. B. Hoover, Boston, Mass.
Leland P. House, Los Angeles, Calf.
Russell H. Huff, Seattle, Wash.
Charles R. Hume, Vicksburg, Miss.
Frank E. Hussey, Wilmette, Ill.
Frank J. Hynes, New York, N. Y.
F. M. Irwin, Jacksonville, Fla.
C. C. Roe Jackson, Cleveland, Ohio
Charles I. Johnson, Boston, Mass.
Leighton F. Johnson, Boston, Mass.
A. Curtis Jones, Boise, Idaho
Horace S. Jones, Anderson, Ind.
K. M. Kahn, Staten Island, N. Y.
C. M. Kos, Iowa City, Iowa
Hugh A. Kuhn, Hammond, Ind.
H. I. Laff, Denver, Colo.
F. A. Lamberson, Detroit, Mich.
V. Latraverse, Montreal, Canada
W. N. Laun, St. Louis, Mo.
Miles L. Lewis, New Orleans, La.
Charles E. Long, Memphis, Tenn.
Manuel Lopez y Lopez, Mexico City, Mexico
Serson Lowenthal, Cincinnati, Ohio
Donald K. Lewis, Boston, Mass.

C. S. Munoz MacCormick, Santurce, Puerto Rico
Frank Macneil, Winnipeg, Canada
Marlow W. Manion, Indianapolis, Ind.
Paul L. Mahoney, Little Rock, Ark.
Carl D. Makart, Chicago, Ill.
Walter H. Maloney, Philadelphia, Pa.
Guy M. Maness, Nashville, Tenn.
R. H. Marcotte, Nashua, N. H.
Roland F. Marks, Walnut Creek, Calif.
Victor McCuaig, New York, N. Y.
Eugene F. McElmeel, Seattle, Wash.
F. Lambert McGannon, Lakewood, Ohio
Oliver B. McGillicuddy, Lansing, Mich.
T. H. McGlade, Camden, N. J.
W. Raymond McKenzie, Baltimore, Md.
J. W. McLaurin, Baton Rouge, La.
R. C. McNaught, San Francisco, Calif.
W. A. McNichols, Dixon, Ill.
George S. McReynolds, Galveston, Tex.
F. W. Merica, Lakewood, Ohio
Paul Mertins, Montgomery, Ala.
O. H. Miller, Ada, Okla.
S. C. Missal, Cleveland, Ohio
James A. Moore,New York, N. Y.
Benoit Morin, Quebec City, Canada
Werner Mueller, Boston, Mass.
C. S. Mumma, Santa Monica, Calif.
J. B. Naftzger, Beverly Hills, Calif.
W. A. Newlands, Tarrytown, N. Y.
Frank S. Normann, New Orleans, La.
E. W. O'Brien, Rochester, N. Y.
John J. O'Keefe, Philadelphia, Pa.
Joseph H. Ogura, St. Louis, Mo.
Harold Owens, Los Angeles, Calif.
Tauno Palva, Turku, Finland
L. Q. Pang, Honolulu, T. H.
George L. Pattee, Denver, Colo.
Emery A. Pick, Los Angeles, Calif.
Joel J. Pressman, Los Angeles, Calif.
York N. Pitkin, Shaker Heights, Ohio

Charles H. Rank, Suffolk, Va.
John R. Richardson, Wellesley Hills, Mass.
R. H. Riggs, Shreveport, La.
Otto C. Risch, New York, N. Y.
Albert F. Roberts, Washington, D. C.
Robert B. Robertson, Red Bank, N. J.
J. M. Robison, Houston, Tex.
Thomas A. Rodenberg, Buffalo, N. Y.
Russel Sage, Indianapolis, Ind.
Meyer Schindler, San Francisco, Calif.
C. B. Schoemperlen, Winnipeg, Canada
Harold F. Schuknecht, Chicago, Ill.
Frank P. Schuster, El Paso, Tex.
Leo Schwartz, New York, N. Y.
Ben H. Senturia, St. Louis, Mo.
James B. Shannon, Montclair, N. J.
Lardner M. Shannon, Montclair, N. J.
Allan R. Shuster, Philadelphia, Pa.
Benjamin H. Shuster, Philadelphia, Pa.
Urpo Siirrala, Turku, Finland
J. T. Simmons, Jasper, Ala.
Leon Slipakoff, New Iberia, La.
J. K. Brydon Smith, Toronto, Canada
T. T. Smith, Omaha, Neb.
Sanford Snyderman, Fort Wayne, Ind.
B. Sotoodeh, New Orleans, La.
David B. Stark, Syracuse, N. Y.
V. A. Staton, West Palm Beach, Fla.
M. J. Stearns, Ogdensburg, N. Y.
Hawthorne Steele, Toronto, Canada
William C. Stephens, New Orleans, La.
J. B. Stevens, Greensboro, N. C.
George L. Stimson, Washington, D. C.
E. A. Stewart, Montreal, Canada
Oliver W. Suehs, Austin, Tex.
J. M. Sutherland, Detroit, Mich.
Harold G. Tabb, New Orleans, La.
Marvin Tamari, Chicago, Ill.
George J. Taquino, New Orleans, La.
L. R. Teasdale, Palm Beach, Fla.

Pierce W. Theobald, Chicago, Ill.
Cecil Thomas, Tampa, Fla.
Wm. C. Thomas, Cincinnati, Ohio
H. K. Tippins, New Orleans, La.
John Tolan, Seattle, Wash.
Frank Turchik, Bridgeport, Conn.
Hans V. Von Leden, Chicago, Ill.
Robert E. Votaw, St. Louis, Mo.
George I. Uhde, Louisville, Ky.
Linden J. Wallner, Chicago, Ill.
Theodore E. Walsh, St. Louis, Mo.
Joe Walthall, New Orleans, La.
William A. Wagner, New Orleans, La.
J. S. Wendel, Detroit, Mich.
George Whelan, Philadelphia, Pa.
Russell I. Williams, Cheyenne, Wyo.
William H. Wilson, Denver, Colo.
Walter L. Winkenwerder, Baltimore, Md.
W. C. Wolfe, Louisville, Ky.
Charles C. Wolcott, Bronxville, N. Y.
J. William Wright, Indianapolis, Ind.
Harry Zoller, New Orleans, La.
Samuel Zurik, New Orleans, La.

# REMARKS BY THE PRESIDENT

LOUIS H. CLERF, M.D.

PHILADELPHIA, PA.

We are assembled this morning in the romantic city of New Orleans in response to the call of our Council for the Seventy-Fourth Annual Meeting of the American Laryngological Association.

I am not unmindful of the high honor done me by my election to the Presidency of this Association. I wish to take this opportunity to thank you, the Fellows, for the vote of confidence and regard which places me in this enviable position.

This is our first meeting in New Orleans and our second in the Southland. It is indeed fortunate that New Orleans was selected for our annual meeting place in 1953, since this year will be celebrated the sesquicentennial of the Louisiana Purchase. While it was the desire of the United States Government in 1803 to purchase only New Orleans to insure control of the mouth of the Mississippi, Napoleon was insistent on giving us a bargain and selling the whole colony without reservation and this he did. The advantages that have accrued from this acquisition are very evident in every respect. This becomes even more apparent if we consult the roster of Fellows of this Association.

Dr. Arthur W. deRoaldes, who was an eminent laryngologist in this city, became a Fellow of our Association in 1893. In 1907, the year of his Presidency, he contributed a sum of money to establish an award for outstanding accomplishments and contributions in the field of rhinology and laryngology. Now known as the "deRoaldes Award" it represents the highest honor that this association can confer.

Dr. deRoaldes was an outstanding teacher, a man of fine character and of great ability. By these attributes and high professional attainments he exerted a profound influence on laryngology, particularly in this area, and aided many of the younger men. One of these, Dr. Robert Clyde Lynch, heeded the old adage, namely, to hitch his wagon to a star, and became associated with Dr. deRoaldes in 1904.

He attained Fellowship in the American Laryngological Association in 1915.

Although Dr. Lynch's life came to an untimely end in 1931, he accomplished much in his chosen profession. Those who met him at medical meetings, in his clinics, and in the classroom will remember him as a clear, well grounded, forceful, and inspiring teacher. His successors are carrying on in the old traditions under his inspiration.

The contributions to laryngology of these Fellows and of their contemporaries and successors represent in essence the history and traditions of our Association. We cannot hope to carry on today because of their accomplishments of yesterday; however, they afford a source of inspiration. We must build today with the materials that are available now if we wish to retain the prestige and the distinction that has been, and should continue to be that of our Association.

I should like, at this time, to address my remarks particularly to the younger group of Fellows for we must look to them to carry on the tradition of this Association and to supply leadership. I find that about 84 per cent of our Fellowships either have been or are presently on a faculty of an undergraduate or a graduate school of medicine. This does not imply that a place on a faculty of a medical school is necessarily a requisite for Fellowship. It does indicate, however, that by and large, the teacher or investigator more often gains recognition. I would recommend, therefore, that the younger Fellows take advantage of every opportunity to teach.

Teaching of medicine is more than an art. The true aim of every one who aspires to be a teacher should be not to impart his own opinions but to enkindle the minds of his students. While certain qualities that go to make a good teacher may be inherited much more can be gained by association, observation, and hard work. A teacher need not be a prolific writer nor a scientific investigator. The latter possesses an advantage, however, for, in addition to imparting knowledge, he arouses in young men certain qualities that he himself possesses, namely a desire for exploration and for discovery in pursuit of nature's hidden secrets. Whoever attempts to teach without inspiring the student to learn is hammering on cold iron.

I believe the successful teacher is one who is familiar with his subject, is able to present it in an interesting and constructive manner and conveys the impression that his every effort and purpose is

to impart knowledge to his students. Above all, he must not create the impression that he possesses superior knowledge or ability in a particular subject that the student need not, in fact, could not expect to attain.

An important activity in the development of the laryngologist and the teacher is attendance at medical meetings with participation in the deliberations. Here one will find an opportunity to weigh the character and often the abilities of others. It also affords others an opportunity to make an estimate of him.

I vividly recall one of my early presentations at a meeting of a national medical society. In response to an inquiry by my teacher, Dr. Chevalier Jackson, concerning the paper, I replied that I was not pleased with my presentation. His statement that he never had been satisfied with any of his presentations was most impressive and thought provoking. It emphasized certain fundamental rules in the preparation of lectures and papers, namely, that one should carefully prepare material to be presented and reflect on the method of presentation and, secondly, one should view the presentation in retrospect and provide remedies for one's shortcomings.

I have found it useful to attend meetings in other fields of medicine merely to observe the approach and method of handling the subject by the speaker. One should not imitate others even though it is said to be flattering. It is far better to develop one's own approach. Training, practice, and observation of others may not lead to perfection but they surely will compensate for early inadequacies.

One does not so often respect men in medicine for the abundant possessions they may have accumulated but for their contributions to clinical medicine, research and medical education. The desire to amass a fortune in the practice of medicine often deprives one of certain joys and may blunt one's moral sensibilities. It often seriously impairs one's usefulness in our profession.

May I therefore recommend that, in the interests of our profession, we, the Fellows of this Association, maintain a lively and active interest in the clinical practice of our specialty. In addition, we should be in the forefront in teaching and disseminating medical knowledge.

1530 Locust St.

G.F.TUCKER

# PRIMARY PLASMA CELL TUMORS OF THE UPPER AIR PASSAGES WITH PARTICULAR REFERENCE TO INVOLVEMENT OF THE MAXILLARY SINUS

CLYDE A. HEATLY, M.D.

ROCHESTER, N. Y.

Primary plasma cell tumors involving the upper air passages are of interest not only because of their rarity but also because of the puzzling and unpredictable behavior which sets them apart from other neoplasms encountered in this area. Although reports of approximately 175 cases have gradually accumulated since the original description by Schridde in 1905, many of these are lacking in critical value because of incomplete clinical and follow-up information. Stout and Kenney[1] for such reasons were compelled to discard 50 of the series of 104 cases which they assembled for analysis from published reports. The evolution of these tumors is characteristically slow and widely varied. Periodic observations over a period of many years are necessary for an accurate appraisal of their true nature and behavior.

## THE PLASMA CELL

The plasma cell which forms the basis for these tumors is commonly associated with many inflammatory conditions and shows a predilection for the conjunctiva, alimentary and respiratory systems. Granulomas and polyps of the mouth and upper air passages frequently contain considerable numbers of these cells. Their function is unknown. Most present day opinion agrees that plasma cells are primarily of lymphatic origin, developing as Maximow demonstrated, from lymphocytes. Both plasma cells and lymphocytes are known to be normal although perhaps rare constitutents of bone marrow so that the possible sites of development for plasma cell tumors are

From the Department of Surgery, Division of Otolaryngology, the University of Rochester School of Medicine, Rochester, New York.

widespread. The plasma cell presents distinctive characteristics including abundant cytoplasm and a small eccentrically placed nucleus with from five to eight distinct, deeply stained blocks of chromatin arranged in cartwheel fashion.

## RELATIONSHIP TO MULTIPLE MYELOMA

The exact relationship of primary plasma cell tumors to multiple myelomatosis has never been fully established. Certainly they have much in common. The age and sex incidence of the two tumors are strikingly similar. The metastatic bone lesions are also alike in distribution and identical roentgenologically as well as pathologically. The life expectancy however, differs markedly in the two groups. Few patients with multiple myeloma survive longer than an average period of two to three years. There are on the contrary many recorded cases of patients with primary plasma tumors of the upper air passages surviving longer than eight years and Oppikofer[2] reported a patient alive and well 31 years after the removal of the original tumors. There are also important laboratory tests which aid in differentiating in nearly two-thirds. Bence-Jones proteinuria can be demonstrated in nearly two-thirds of the cases of multiple myeloma but has never been observed in extramedullary tumors except in the presence of skeletal metastases. A pronounced hyperproteinemia is commonly present in multiple myeloma with a high total serum protein and a reversal of the normal albumin-globulin ratio. Small numbers of myeloma or atyptical plasma cells may also be identified in the blood in over half of these cases according to Sturgis.[3] Furthermore, sternal puncture in cases of multiple myelomatosis will usually demonstrate the presence of typical myeloma cells and roentgenographic examination will show characteristic punched out areas without evidence of bone regeneration especially in the spine, thoracic cage, skull, shoulder and pelvic girdles. It is of interest to note, however, that many authors, including Jackson and Parker[4] feel that there is no sharp line of demarcation between the two conditions, and Ringertz[5] observes that the two groups are undoubtedly closely related although not genetically identical. The cranial lesions of multiple myeloma occasionally involve the jaws and the bony boundary walls of the upper air passages forming tumors within these structures which may be mistaken for primary growths. Nine of the twenty-seven cases reported by Ewing and Foote[6] were of this variety presenting tumors in the nose and throat as the first clinical mani-

festation of what was already a widely disseminated although hitherto silent disease. It is of great importance therefore, when confronted with plasma cell tumors in these areas to rule out the presence of an underlying multiple myelomatosis by appropriate laboratory and roentgenological examinations.

## INCIDENCE

All writers on the subject are impressed by the rarity of plasma cell tumors in the upper air passages. New and Childrey[7] observed two such cases among 230 malignant neoplasms of the oropharynx and tonsil. Figi, Broders and Havens[8] found only six cases among nearly 625 malignancies of the nose and sinuses during a 14 year period and only one case among 1,600 cancers of the larynx. Mattick[9] reported two cases among 62,000 admissions to a large clinic for malignant diseases. The number of cases reported in recent years however, has markedly increased indicating a growing awareness of the frequency and significance of the disease in this area.

All writers are similarly agreed on the predilection of these tumors to males after the age of 40 years. In Ringertz's analysis of 47 cases, 80.8 per cent occurred in men between 40 and 70. Geschickter and Copeland[10] reported similar findings. Hellwig[11] observed that the frankly malignant varieties of plasmocytomas tend to occur in a somewhat older group than the so called noncancerous type. Rawson, Eyler and Horn[12] found the average age in the malignant group to be 66 and noted this similarity to multiple myeloma. They found benign lesions occurring in a considerably younger group ranging from 33 to 45. One of the youngest cases observed was reported by Vogt in a 20 year old male with a tumor of the pharynx associated with lymph node metastases.

## PATHOLOGIC ANATOMY

Plasmocytomas present a soft, red, lobulated appearance and seldom ulcerate. They occur in three forms as stalked or sessile tumors or as limited areas of submucosal thickening. They vary in size from bean to egg-size dimensions. They usually appear as solitary tumors but are occasionally multiple. Hellwig collected only nine instances of these multiple tumors in his series of 64 cases and Stout and Kenney found 10 such instances in a survey of 104 cases. Blacklock and Macartney[13] reported the presence of five tumors in the nasopharynx and 2 in the larynx in a man of 64. Recent interesting

reports of single cases of multiple tumors have been contributed by Mattick (loc. cit.) and more recently by Priest[14] whose patient, a man of 50, presented multiple recurrent polyp-like tumors involving the nose, nasopharynx, pharynx, and larynx and continued well without evidence of metastases after a period of at least 15 years from the onset of the original lesion. The stalked variety of neoplasm is most commonly observed in the pharynx and larynx but the other types may also occur in any portion of the upper air passages. In the nose, the tumor characteristically fills the passage with a bulky mass which tends to extend into the adjacent sinuses. The tumors originating in the maxillary sinus have for the most part been of soft, friable, easily bleeding character with a tendency to destroy the bony antral walls and to invade the adjacent ethmoids and nasal cavity. As such they are indistinguishable from any malignant neoplasm. In both of my own cases I was impressed by the tremendous vascularity of the plasma cell antral tumor. Lumb and Prossor[15] apparently had a similar experience for they note that the vascularity of the plasmocytoma group in this area tends to be greater than in the case of other tumors. The depth to which these tumors invade is problematical but a survey of reported cases suggests that there must be considerable variations in view of the fact that in many instances superficial removal has resulted in apparent cure while in others radical measures have not prevented local recurrence. As Stout and Kenney have pointed out however, superficial spread in the mucous membranes is common and deep invasion of bone uncommon in marked contradistinction to other malignant neoplasms in this area. The gross appearance of these tumors offers no reliable index of their degree of malignancy since many seemingly innocent polyp-like varieties have subsequently developed fatal lesions in glands and bones.

## HISTOLOGIC ASPECTS

The plasma cell tumor consists of a solid growth of plasma cells in massive clusters in a delicate stroma of capillaries and separated by thin septa of connective tissue. Wide variations in actual cell structure occur and, as has been repeatedly emphasized, the microscopic examination provides neither a reliable guide to malignancy nor a dependable clue to the future course of the tumor. Recently, Rawson, Eyler and Horn, while emphasizing that malignant plasma cell tumors may not show the usual cytologic characteristics of malignancy, point out that such criteria, if present in considerable

degree, may be regarded as reliable diagnostic evidence. They believe that *the replacement of tissue* by broad sheets of plasma cells arranged in a delicate capillary stroma is definitely indicative of a malignant tumor and that the absence of this pattern makes malignancy unlikely. The general opinion however, is that in most instances neither the gross nor the histologic appearance of these tumors can be relied upon for help in prognosis or treatment as in the case of other neoplasms.

## SITES OF INVOLVEMENT

Plasmocytomas may originate in any portion of the upper respiratory tract as well as on the tongue, alveolar process, palate and floor of the mouth. The tumor has also been observed in the mastoid cells. The conjunctiva is a frequent site of a benign form of this tumor and 47 of Hellwig's series of 128 cases were in this area. It appears from the literature that the nose and sinuses are the section of the upper air passages most commonly involved and further that the most malignant varieties of the plasmocytoma occur in this group. The distribution and frequency of these tumors is indicated in Table 1 compiled from five representative series of case reports.

## METASTASES

It is well recognized that in a definite but as yet undetermined percentage of primary plasma cell tumors so-called metastatic lesions appear after varying intervals either in the adjacent lymph glands or bony skeleton. In the latter group the distribution and character of the lesions are entirely similar to those seen in multiple myelomatosis and the roentgenograms as well as histological studies are also identical. These so-called metastatic lesions may be found by careful roentgenographic examination at the time or shortly after the discovery of the original tumor but long periods may elapse before evidence of their presence appears. Jackson and Parker report a case followed for eight and one-half years before local recurrence as well as multiple bone lesions were observed. In a case described by Piney and Riach a 12-year interval elapsed before skeletal metastases appeared. On the other hand, Oppikofer's patient survived 31 years and Priest's 15 years without evidence of metastases. In the series of 104 cases reviewed by Stout and Kenney, 54 showed no metastases, 24 showed metastases to cervical nodes and 15 to single or multiple bones. The fact that *pulmonary* metastases have not been reported,

in the opinion of Stout and Kenney, strongly suggests that these skeletal lesions are not true metastases but rather "new lesions of the same type as the primary tumor, the development of which has been incited by a common, undetermined etiological factor." This of course links this group of tumors with multiple myelomata and Jackson and Parker believe that there is no sharp line of demarcation between the two groups. Lumb and Prossor also favor the conception of multifocal origin rather than spread by metastases. Many reported cases have little value in clarifying this situation because of failure to examine periodically for skeletal lesions, to obtain autopsies whenever possible, and above all to include a followup period over many years.

## CLINICAL ASPECTS

The symptoms and signs of plasma cell tumors in the upper air passages are entirely similar to those of other tumors more commonly encountered in this area and the true diagnosis is seldom suspected. In the nose and maxillary sinus in particular the clinical picture corresponds to that of any malignant tumor in this region. In the pharynx and larynx the symptoms are mainly those of obstruction, although in a few instances hemorrhage has been the first presenting complaint. The tumors may appear as pedunculated, sessile or diffuse submucosal elevations. True involvement of the cervical lymph glands is decidedly less frequent than might be expected.

Attempts at classification of these tumors have been unsatisfactory because of the difficulty in separating the benign and malignant varieties on the basis of microscopic and gross characteristics as well as the unpredictable tendency of many apparently innocent lesions later to develop locally invasive or metastatic tendencies. For clinical purposes however, they may be divided into three groups: (1) Apparently benign tumors, solitary or multiple, which are confined to soft tissues. Recurrence may be observed in this group, particularly in the multiple tumors, but invasion of underlying bone does not occur. (2) Solitary or multiple tumors which exhibit local malignancy in the form of invasion and destruction of adjacent soft and bony structures as well as a strong tendency to local recurrence. (3) Tumors associated with invasion of the regional lymph nodes or skeletal osteolytic lesions or combinations of both. In the latter group with bony lesions the clinical picture becomes indistinguishable

TABLE 1.

SITES OF INVOLVEMENT IN THE UPPER AIR PASSAGES.

| AUTHORS & DATES OF SURVEY | NASAL CAVITY | SINUSES | NASO-PHARYNX | TONSIL & PHARYNX | LARYNX | MULTIPLE |
|---|---|---|---|---|---|---|
| Ringertz (1938) | 5 | 4 | 0 | 2 | 3 | 0 |
| Hellwig (1943) | 27 | 8 | 8 | 9 | 10 | 9 |
| Figi, Broders and Havens (1945) | 0 | 0 | 2 | 2 | 1 | 1 |
| Stout & Kenney (1949) | 17 | 11 | 20 | 25 | 0 | 6 |
| Ewing & Foote (1952) | 6 | 6 | 1 | 3 | 1 | 0 |
| Totals | 55 | 35 | 31 | 39 | 15 | 16 |

from that of multiple myelomatosis with characteristic pathological and laboratory findings.

## PROGNOSIS

A careful survey of the literature strengthens the opinion that the plasmocytoma represents a frankly or potentially malignant tumor. There are, however, many interesting variations in its behavior. Local recurrence for example may not take place for as long as nine years after the primary removal (Jaeger's case recurred nine and one-half years later) or may be noted within a few months or years. In other instances, after years of apparent cure, without local recurrence, secondary foci may suddenly become evident in lymph nodes, internal organs or bones and progress rapidly to a fatal outcome. It is also possible for patients with local recurrences or lymph node metastases to survive in good health for many years without development of bone marrow involvement. Wachter, Oppikofer, Figi,

TABLE 2.—REPORTED PRIMARY PLASMA CELL TUMORS OF THE MAXILLARY SINUS.

| AUTHORS & DATE | AGE & SEX | LYMPH NODES | METASTASES | THERAPY | CLINICAL COURSE |
|---|---|---|---|---|---|
| Baldenweck and Periot[17] (1933) | ? | 0 | 0 | Surgery | Recurrence after 5 yrs.; controlled by radium; well 19 months later. |
| Cooper[18] (1934) | Male 89 | 0 | 0 | Surgery & Radium | Unknown. |
| Blumenfeld[19] (1936) | Male 37 | 0 | 0 | Surgery, Resection Maxilla | Unknown. |
| Ringertz (1938) | Male 54 | + | + Left femur | Surgery & X-ray | Died 2 weeks later. |
| Ringertz (1938) | Male 52 | + | 0 | Surgery | Well—5 months later. |
| Ringertz (1938) | Male 20 | + | 0 | Surgery & Radium | Recurrence in cervical glands 7 months later, died 13 months later. No local recurrence. |
| Ringertz (1938) | Male 59 | 0 | 0 | Surgery | Died of hemorrhage—3 months later. |
| Figi, Broders & Havens (1945) | Female 54 | 0 | + (skull) | Surgery & Radium | Metastases to skull, ribs, spine and pelvis after 21 months with death 26 months later. |
| Figi, Broders & Havens (1945) | Female 37 | 0 | 0 | Surgery & Radium | Died—meningitis 5 months later. |
| Figi, Broders & Havens (1945) | Female 70 | 0 | 0 | Surgery & Radium | Died—9 months later. |

TABLE 2.—(Continued)

| AUTHORS & DATE | AGE & SEX | LYMPH NODES | METASTASES | THERAPY | CLINICAL COURSE |
|---|---|---|---|---|---|
| Figi, Broders & Havens (1945) | Male 55 | 0 | 0 | Surgery & Radium | No recurrence—4 months later. |
| Figi, Broders & Havens (1945) | Male 55 | 0 | 0 | Surgery & Radium | Well, without recurrence — 2 years later. |
| Lumb & Prossor (1948) | Female 24 | 0 | 0 | Surgery & Radium | Recurrence after 5 years; controlled by further surgery and radium; *well 2 years later.* |
| Lumb & Prossor (1948) | Male 44 | 0 | 0 | Surgery & Radium | Recurrence in 3 months; further radium; metastases to glands, ribs and spine 1 year later. Died 3½ years later. |
| Wille[20] (1948) | Male 55 | 0 | 0 | Radiation | Dramatic improvement; alive and well 6 years later. |
| Parkes and Burtoff[21] (1949) | Male 60 | 0 | 0 | Surgery & X-ray | Well—7 months later. |
| Fuerste and Zuckerman[22] (1950) | Male 56 | + | 0 | Radiation | No improvement of note. Died 2 years later. |
| Ewing & Foote (1952) | Male 45 | | | Details not given | Alive—8 months later. |
| Ewing & Foote (1952) | Male 73 | 0 | 0 | Details not given | Died—2 years later. |

TABLE 2.—(Continued)

| AUTHORS & DATE | AGE & SEX | LYMPH NODES | METASTASES | THERAPY | CLINICAL COURSE |
|---|---|---|---|---|---|
| Ewing & Foote (1952) | Male 70 | | | Details not given | Alive 2 years later; no recurrence. |
| Ewing & Foote (1952) | Female 54 | | | Details not given | Alive 9 months later; no recurrence. |
| Ewing & Foote (1952) | Male 76 | | | Details not given | *Died*, pneumonia, 16 months later. |
| Rawson, Eyler & Horn (1950) | Male 33 | 0 | 0 | Surgery only | Well and no recurrence—3 years later. |

Table 2.—Summary of available data on all reported cases of primary plasma cell tumors of the maxillary sinus. Cases with secondary invasion from adjacent structures are *not* included. Of the total of 23 patients, 10 died from two weeks to three and one-half years after treatment. Eleven reported living from four months to seven years later. Fate of 2 cases unknown. In most instances treatment consisted of combined surgery and irradiation.

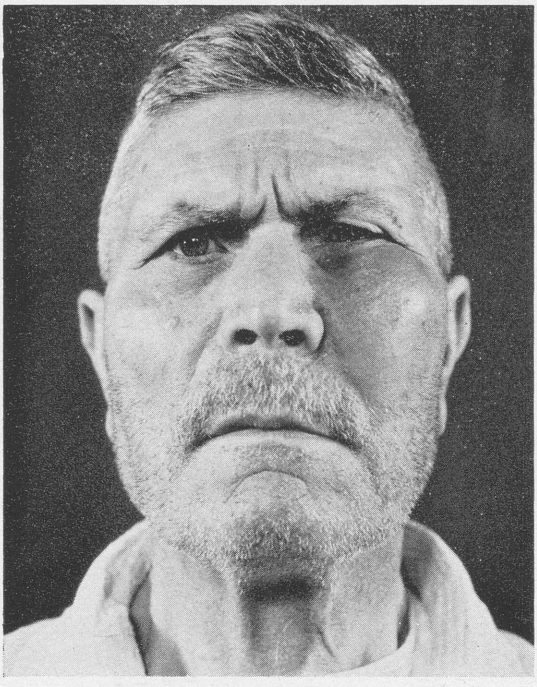

Fig. 1, Case 1.—Plasmocytoma of the left maxillary sinus in a man of seventy.

Stout and Kenney have all reported such patients surviving seven and one-half to thirteen years without difficulty. It may be accepted that the best although necessarily guarded prognosis can be rendered in cases confined and localized to soft tissues and the most unfavorable to those showing local invasion of bone or distant skeletal structures. Tumors of the maxillary sinus in particular appear to exhibit a high degree of malignancy. Stout and Kenney however, report one patient with a primary tumor in th nasopharynx alive and well seven years after multiple osseous metastases were demonstrable and collected three similar cases from the literature surviving from 4 to 10 years. It is evident therefore that the prognosis is decidedly uncertain in these tumors. It should be stressed again that neither the gross nor the microscopic appearance of these neoplasms affords reliable prognostic information and that the histologic features of the

benign granulomatous lesions of the conjunctiva may closely resemble those of the rapidly growing malignant varieties in the air passages. Figi, Broders and Havens conclude their study with the opinion that these tumors should be classified and treated as malignant tumors and the accumulated evidence certainly supports this view.

## TREATMENT

The treatment employed in reported cases consists of surgical removal, radiotherapy, or a combination of both methods. The plasma cell as would be anticipated from its close relationship to the lymphocyte is usually radiosensitive although some cases with indifferent response to irradiation have been reported. Stout and Kenney after analyzing the methods of therapy employed in 16 patients surviving more than five years conclude that "since irradiation is less mutilating than surgery and has at least as good, if not better, chance of success as surgery, it would seem to be the treatment of choice in most cases." Cade[16] also considers these tumors to be radiosensitive and advises irradiation. Ewing and Foote report encouraging and occasionally dramatic early responses to irridation in several of their cases including the difficult nose and sinus group accompanied by bone involvement. Rawson, Eyler and Horn also stress the radiosensitivity of these tumors and feel that radiotherapy is the treatment of choice except in the frankly benign group which can be adequately treated by surgical excision. Pedunculated tumors in most reported cases have been removed surgically, their base cauterized or coagulated and subsequent irradiation frequently employed. The combination of surgery with intracavitary radium and deep roentgen therapy seems to be the accepted method of dealing with plasma cell tumors involving the maxillary sinus (Table 2). The tremendous variation in the known response of plasma cell tumors to any type of therapy as well as the strong possibility of subsequent involvement of lymph glands or bone marrow in spite of any known form of local treatment increase the difficulties of thoughtful management. Indeed if such so-called extensions actually represent multiple primary involvements rather than true metastases, the advisability of extreme radical surgical measures in eradicating the original tumor seems questionable. Until more reports are available which include careful follow-up studies over a period of several years, it would seem more in keeping with our present knowledge of this tumor to employ both surgery and irradiation but to avoid needlessly radical procedures.

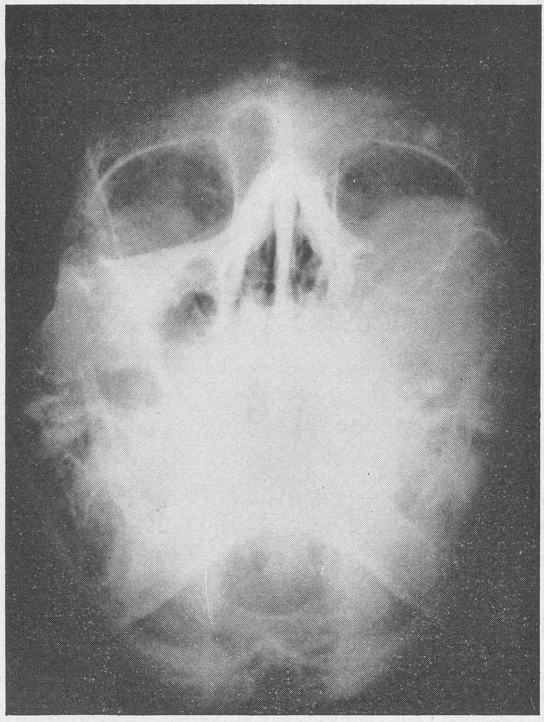

Fig. 2, Case 1.—Roentgenogram showing a large tumor with extensive destruction of the walls of the left maxilla.

## REPORT OF CASES

CASE 1.—A 70-year old Italian was first seen at the Strong Memorial Hospital on October 16, 1946 complaining of progressive swelling of the left side of the face of nine months' duration accompanied by recent intermittent pain (Fig. 1). A firm mass could be palpated over the left maxilla and at one point distinct pulsation could be felt. The roof of the mouth was intact and there was no intranasal evidence of extension. There were no palpable cervical glands. The roentgenograms showed a tumor mass which had destroyed the anterior and the upper walls of the left maxillary sinus and had involved the adjacent malar bone (Fig. 2). The chest films showed evidence of an old apical tuberculosis. A diagnosis of malig-

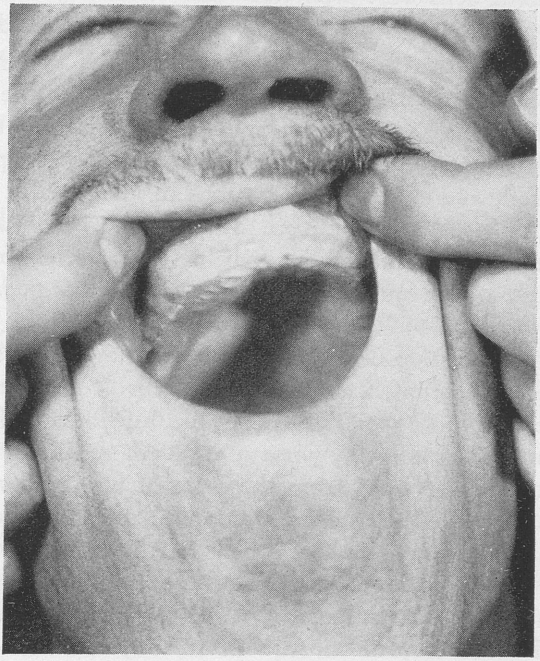

Fig. 3, Case 2.—Palatal swelling, the chief presenting complaint in a man of forty-five.

nant tumor of the left antrum was made and exploration was advised. This was carried out on October 20, 1946, entering the antrum by way of the canine fossa. The sinus cavity was found to be filled with friable tissue which adhered to the bony walls and was tremendously vascular. Attempts to control the bleeding by coagulation and hot packs were unsuccessful and ligation of the external carotid artery was carried out with surprisingly little immediate effect. Finally, however, the bleeding was controlled by firm packing. The patient was supported by transfusion and made a rapid postoperative recovery. The histologic examination of the tissues removed at operation showed a characteristic plasmocytoma. A complete metastatic survey of the bony skeleton showed no roentgenological evidence of metastases. The electrophoretic studies were not suggestive of multiple myeloma. The urine was negative for Bence-Jones protein.

The Wasserman was negative. A sternal puncture was carried out and no myeloma cells were reported. The lesion therefore, was considered to represent a primary plasma cell tumor limited to the left maxillary sinus. Roentgen therapy was instituted delivering 5800R to the tumor through three portals. Following this the soft tissues over the inferior orbital and malar aspects gradually broke down and several sequestra were removed through this large opening. The patient was followed closely and remained in good health until April, 1949 when he began to complain of pain over the lumbar spine. Roentgenograms now showed an early destructive lesion in the first lumbar vertebra. A metastatic survey was again negative except for a small punched out area in the left frontal region. There was now a definitely positive Bence-Jones proteinuria present and a sternal puncture showed an increase in plasma cells. The electrophoretic studies were still not typical of multiple myeloma. The patient's course became progressively worse and death occurred on October 20, 1949, nearly four years from the onset of his facial swelling. An autopsy was carried out and showed bilateral apical pulmonary tuberculosis with miliary tuberculous lesions in the liver, spleen, adrenals and kidneys. Bronchopneumonia was present. The destructive lesion in the first lumbar vertebra was considered to be entirely tuberculous until more careful subsequent restudy showed early plasma cell involvement as well. The internal organs were free of plasma cell metastases and there was no involvement of the cervical glands.

CASE 2.—A white male, age 45, was first seen on February 18, 1936 complaining of chronic right-sided nasal discharge and recent swelling of the roof of the mouth on the right side. Examination showed slight fullness of the right side of the face and moderate swelling of the palate beneath the right antrum (Fig. 3). There were no palpably enlarged regional glands. The right antrum was opaque on transillumination and an attempt to irrigate this sinus met with resistance suggestive of tumor. Roentgenograms reported the right antrum to be completely obliterated by a dense shadow with evidence of thinning and irregularity of the bony floor suggestive of a malignant neoplasm. Blood studies were normal. On March 10, 1936 the right antrum was explored through the canine fossa. The antrum was found to be filled with a friable, adherent, *extremely vascular* tumor which had apparently originated along the floor of the sinus. It was removed by curettage. Microscopic examination revealed a typical plasmocytoma. A complete metastatic

survey was then carried out and found to be negative. There was no Bence-Jones proteinuria. The blood studies and blood chemistry were not altered. Sternal puncture studies were not made. The patient was given intensive Roentgen therapy over the right antrum, receiving 5,600r through multiple portals. The result was clinically satisfactory and he was entirely free of local symptoms except for a small draining tract into the mouth. He was followed at frequent intervals in the Out-Patient Department and remained well until his admission to the hospital on March 18, 1939 after drinking 100 cc of Carbona. A confirmed alcoholic, he had accidentally taken this solution during a bout of drinking. Death occurred on March 27, 1939 due to acute carbon tetrachloride poisoning. Autopsy showed no local recurrence nor evidence of metastatic plasma cell tumor. This patient therefore remained free of clinical or post-mortem evidence of plasmocytoma three years after the diagnosis had been first established.

## CONCLUSIONS

1. The controversial and unpredictable behavior of primary plasma cell tumors can be clarified only by careful clinical, laboratory and postmortem studies as well as by continued observation of these cases over long periods. A large number of reported cases possess little critical value because of incomplete follow-up data.

2. The discovery of a plasma cell tumor in the upper air passages requires first of all careful roentgenological as well as laboratory studies to rule out the possibility of multiple myelomatosis. Sternal puncture should be included in this study. The course of this disease is notoriously silent for long periods.

3. The relationship of these tumors to multiple myeloma appears to be a close one although there are characteristic and important differences including a slower progression and the possibility of long survival in certain cases.

4. The increasingly prevalent opinion among pathologists and clinicians is that primary plasma tumors in the upper air passages, whether limited to the soft tissues or also involving bone, are in the vast majority of cases, variants of multiple myelomatosis. In any event, there can be no question about their malignant or potentially malignant character.

5. The methods of management as well as the prognosis must necessarily vary with the individual case. The radiosensitivity of these tumors favors radiotherapy. Experience does not appear to justify the radical surgical procedures commonly employed in the treatment of the more familiar malignant neoplasms encountered in this region.

11 North Goodman St.

## REFERENCES

1. Stout, A. P., and Kenney, F. R.: Primary Plasma-Cell Tumors of the Upper Air Passages and Oral Cavity, Cancer 2:261, 1949.

2. Oppikofer, E.: Das Plasmocytom, Beitr. Anat. Physiol. u Therap. Ohres. 23:574, 1926.

3. Cecil, R. L., and Loeb, R. F.: A Textbook of Medicine, Philadelphia and London, W. B. Saunders Co., 1951, p. 1048.

4. Jackson, H. Jr., Parker, F. Jr., and Bethea, J. M.: Studies of Diseases of the Lymphoid and Myeloid Tissues. II. Plasmatocytomata and Their Relation to Multiple Myelomata, Am. J. M. Sc. 181:169, 1931.

5. Ringertz, N.: Pathology of Malignant Tumors Arising in the Nasal and Paranasal Cavities and Maxilla, Acta Otolaryng. Suppl. 27:234, 1938.

6. Ewing, M. R., and Foote, F. W. Jr.: Plasma-Cell Tumors of the Mouth and Upper Air Passages, Cancer 5:499 (May) 1952.

7. New, G. B., and Childrey, J. H.: Tumors of the Tonsil and Pharynx (Three Hundred and Fifty-Seven Cases), Arch. Otolaryng. 14:713 (Dec.) 1930.

8. Figi, F. A., Broders, A. C., and Havens, F. Z.: Plasma Cell Tumors of the Upper Part of the Respiratory Tract, Annals of Otology, Rhinology and Laryngology 54:283, 1945.

9. Mattick, W. L.: Plasmocytoma: An Unusual Case With Progressive Involvement of Waldeyer's Ring and the Larynx, Bronchus and Pleura, Arch. Otolaryng. 51:263, 1950.

10. Geschickter, C. F., and Copeland, M. M.: Tumors of Bone, 3rd ed., Philadelphia, J. B. Lippincott Co., 1949.

11. Hellwig, C. A.: Extra Medullary Plasma Cell Tumors as Observed in Various Locations, Arch. Path. 36:95, 1943.

12. Rawson, A. J., Eyler, P. W., and Horn, R. C. Jr.: Plasma Cell Tumors of the Upper Respiratory Tract: A Clinico Pathologic Study with Emphasis on Criteria for Histologic Diagnosis, Am. J. Path. 26:445, 1950.

13. Blacklock, J. W. S., and Macartney: Plasmocytoma of the Nasopharynx, J. Path. and Bact. 35:69, 1932.

14. Priest, R. E.: Exratmedullary Plasma Cell Tumors of the Nose, Pharynx and Larynx, Trans. Amer. Laryng., Rhin. and Otol. Soc., Inc., pp. 278-287, 1952.

15. Lumb, G., and Prossor, T. M.: Plasma Cell Tumors, J. Bone and Joint Surg. 30-B:124, 1948.

16. Cade, Sir S.: Malignant Disease and Its Treatment by Radium, Bristol, John Wright and Son, Ltd., 1945, Vol. 2, p. 202.

17. Baldenweck, L., and Perrot, N.: Cancer Sinuso-nasal, Rev. de laryng. 54: 1267, 1933.

18. Cooper, K. C.: Plasmocytoma and Rhabdomyoma of the Paranasal Sinuses. Arch. Otolaryng. 20:329, 1934.

19. Blumenfeld, L.: Plasma Cell Tumors of the Nose and Nasopharynx, ANNALS OF OTOLOGY, RHINOLOGY AND LARYNGOLOGY 45:436, 1936.

20. Willie, C.: Malign Tumours of the Nose and Accessory Sinuses, Acta Otolaryng., Supp. 65-69, 5, 1947-48.

21. Parkes, M., and Burtoff, S.: Plasma Cell Tumor Simulating Bilateral Maxillary Sinusitis, Arch. Otolaryng. 50:666, 1949.

22. Fuerste, F. Jr., and Zuckerman, S. S.: Extramedullary Plasma Cell Tumor, Arch. Otolaryng. 51:608, 1950.

## DISCUSSION

DR. JULIUS W. MCCALL: I have enjoyed Dr. Heatly's paper very much and to me it is most timely because we have just had diagnosed probably the 16th case of plasmocytoma of the larynx. This was a white male, age 41, referred by a nose and throat man of Akron, Ohio who sent him in with the tentative diagnosis of a polyp in the anterior commissure and the patient's complaint was progressive hoarseness for the past six months.

Examination on April 16th, of his sinuses, ears, nose and nasopharynx revealed no visible pathology or tumor masses. There was a cherry red polypoid mass in the anterior commissure about a centimeter in diameter. A direct laryngoscopy was done, the polypoid mass removed, and the diagnosis of plasmocytoma of the larynx was made by our pathologist, Dr. Domingus. There have been 15 cases of plasmocytoma of the larynx reported.

I would like to show 2 slides. May we have the slides please?

(Slide) This shows the normal laryngeal mucosa, tunica propria and the plasma cells were rather large, much protoplasm. This tumor was only moderately vascular, as you can see.

(Slide) This is a highpower and you will notice the reason for showing this. In this particular patient there is no mitosis of the nuclei, so Dr. Domingus, our pathologist, did not feel that this was very malignant, but, as Dr. Heatly brought out, it is very hard to determine what the outcome of these cases will be from a histological study. As you can see, there is no mitosis at all in the cell nuclei and they all have a rather large cytoplasm. I would like to ask Dr. Heatly, what in his opinion should be the method of treating this man? Should we treat him expectantly and watch for possible recurrence? Should we treat him with x-ray or should we do a thyrotomy because this springs apparently from the very anterior end of the right vocal cord?

DR. FREDERICK A. FIGI: Dr. Heatly has given us a most instructive and interesting presentation. I was especially pleased to see that he sharply distinguishes

between inflammatory plasma cell lesions and those that are true neoplasm. Some of the articles that have appeared in the literature have not made that distinction. Certainly the neoplasms that he has reported are definitely neoplastic and any tumor that is not a true neoplasm should not be considered in this category. The pathologist at times has difficulty in distinguishing certain inflammatory lesions from true plasma cell myelomas. However, careful study by a competent pathologist will definitely place these neoplasms in a category entirely distinct from the inflammatory group.

Dr. Heatly's reference to the unpredictable nature of these lesions certainly is well founded. It is extremely difficult to anticipate the response of these neoplasms to therapy.

Recently I had correspondence with two patients who are of interest in this connection. One of them, a dentist who had an extensive plasmocytoma of the antrum and ethmoid labyrinth was treated eleven years ago by the method to which Dr. Heatly referred, i.e. electrocoagulation, intracavity radiation and external radiation. He reported that he had experienced no further difficulty, in fact, was in robust health and practicing right along.

The other patient had a plasmocytoma on the posterior aspect of the epiglottis. This lesion was electrocoagulated transorally and was treated with interstitial and external radiation fifteen years ago. The present status of this patient's health is not known.

Another patient, dismissed from our service a few days ago, had a plasmocytoma of the nasopharynx.

In our experience lymph node metastasis occurs infrequently in patients with plasmocytoma while osseous deposits are quite common. It is my feeling that such extension occurs by way of the blood stream.

DR. CLYDE A. HEATLY: I wish to thank the discussers of my paper. In Dr. McCall's case, I feel that local removal of the polyp plus full external irradiation would be my method of handling it. I do not feel that there would be any advantage in thyrotomy in such a case.

I particularly appreciate Dr. Figi's remarks on these tumors because his is an experience which I think is equalled by none of us in the management and recognition of this type of neoplasm. Thank you very much!

# THE MESENCHYME OF THE NOSE AND SINUSES

AUBREY G. RAWLINS, M.D.

SAN FRANCISCO, CALIF.

Rarely in the history of medical science has a large structure of the body been neglected for so long a time as has the ground substance of connective tissue. On the other hand, almost never has a large structure gained such sudden and tremendous scientific importance as has recently been given to this supposedly dull and uninteresting amorphous gel.

Why has this structure suddenly developed this great personality, which has drawn so much interest from the medical profession all over the world?

I believe the main reasons to be as follows: (1) In the past, stained preparations of ground substance have shown little, if anything, of interest. Newer techniques now give visible evidence of this structure. (2) The development of electron microscopy has brought detail into connective tissue which previously could only have been hypothesized or imagined. (3) The use of tissue cultures has added much to the knowledge of connective tissue physiology and growth. (4) The advent of ACTH and Cortisone has stimulated great interest in this tissue.

Connective tissue and its elements have a wide and large distribution in the body. Some of the common areas are found submucosally, subcutaneously, surrounding vessels, nerves, and muscle fibers, and in the parenchymatous organs.[1] If the ground substance under the epithelium of the nose and sinuses alone were flattened out into one plate it would make quite a display of gel.

Mesenchyme is embryonic connective tissue and is the precursor of adult connective tissue. Mesenchyme is a loose gel, consisting mostly of ground substance with some small cells and a few fine

From the Department of Otolaryngology, Stanford University School of Medicine.

branching fibrils.[1] Wharton's jelly of the umbilical cord is a good example of this structure. The tissue from a nasal polyp or from an allergic nose resembles mesenchyme. The ground substance of any loose, adult connective tissue is practically the same as mesenchyme and is often so designated.

Adult connective tissue consists of this homogeneous matrix in which are incorporated certain fibers and cells.[2] The tissue may be loose or firm, depending upon the relative amounts of these constituents.[1] Loose connective tissue contains more ground substance, dense connective tissue contains more fibers. The connective tissue in the nose is of the loose type.

Cellular elements in connective tissue consist mostly of fibroblasts. Other cells of importance are macrophages, mast cells, eosinophils, and plasma cells.[1]

The fibrillar elements consist mostly of collagen fibrils and fibers. The fine fibrils develop from fibroblasts and are characterized by having crossed striations placed at regular intervals. These fibrils become matted together as in a cable, to form adult collagen fibers (Fig. 1). Collagen makes up about forty percent of the mass of the body.

The ground substance is often referred to as amorphous substance, gel, mucopolysaccharides, or mesenchyme. As stated previously, this structure is a gel-like homogeneous mass and is made up chemically of a combination of carbohydrate and protein.[1, 3] The carbohydrate part is composed of polysaccharides. The main polysaccharide involved is hyaluronic acid. The mucopolysaccharide combination is polymerized.[4] By polymerized, we mean that the structure is made up of small aggregates. The more highly polymerized it is, the firmer it is. However, this gel may be broken down, depolymerized, or made less firm by enzyme activity. The main enzyme involved is hyaluronidase. Collagenase may also be of importance in this regard. The gel is maintained and built up by enzymatic activity of the fibroblasts. Hence, the consistency of the ground substance may vary from a firm gel to a more liquid or soluble state depending upon the activity of the enzymes. Existence of hyaluronidase and other enzymes in some of the mesenchymal cells has to be postulated if maintenance of the amorphous substance is to be explained.[14] Like all structures in the body this gel is constantly being built up and broken down. Therefore the enzymes must be present in the substitute in large

Fig. 1.—Connective tissue fibrils seemingly developing from the surface of a fibroblast. Reprinted by permission from Ralph W. G. Wyckoff: The Fine Structure of Connective Tissues. Trasactions of the Third Conference on Connective Tissues. Josiah Macy, Jr. Foundation, Publishers. (Feb. 14-15) 1952.

amounts. Hence they must be present in inactive or bound form ready to be activated as needed. Mayer[17] has shown that in allergic and non-allergic skin inflammations there is a forty fold increase in local hyaluronidase. Since these inflammations can be reduced by neutralizing the hyaluronidase Mayer concludes that this enzyme participates actively in inflammatory reactions.

The extracellular tissue fluid is incorporated in the ground substance and comes from the blood plasma, containing water soluble proteins, metabolites, crystalloids, gases, et cetera. In normal connective tissue, this tissue fluid is in bound form and is not free.[1] In other words, if one should stick a knife into the amorphous sub-

stance of a normal turbinate, no fluid would run out. However, in any inflammatory edema, free fluid is present.

In the past, about the only function given to the ground substance was to hold the body together and give it a certain amount of mobility. Let us see whether or not this structure has other duties.

After an infectious organism passes the surface epithelium, the ground substance is the first structure it encounters. Hence, the importance of this gel as a barrier against the spread of infection must not be overlooked. In general, a normal firm gel acts as a good barrier against the spread of an ordinary infection. On the other hand, a more liquid gel aids in the spread of most infectious organisms. However, a condition known as the colonial effort must be taken into consideration.[5] It takes a certain number of infectious organisms to infect an animal or to grow in a given amount of medium. If only a few weak or nonvirulent bacteria are placed in a large amount of medium, they will die out. A larger number of the same organisms in the same amount of medium will survive. If the organisms are stronger or more virulent, just a few will survive in this same large amount of medium. This is also true in the animal body. This shows that there is a definite relationship between the quantity of infectious agent and the amount of material in which it is grown. This ratio is definite for each organism. This is known as the colonial effect and it applies to the ground substance. In other words, hyaluronidase, which liquifies and increases the amorphous substance, will enhance the activity of organisms of high virulence while the dilution effect of the same enzyme will suppress the growth of nonvirulent organisms. Hence, in some cases the host and the condition of the ground substance may be of more importance than the invading organism. This may help to explain why nothing serious happens to patient A when he catches a cold or goes swimming, but under the same conditions, patient B develops an acute and fulminating pansinusitis.

Another phenomenon of importance in this regard is the fact that many streptococci and pneumococci, as well as some staphylococci, secrete hyaluronidase.[5] This produces even further invasiveness and more damage from these virulent organisms. For example, in cases of pneumococcus pneumonia which develop bacteremia, the pneumococcus produces excessive amounts of the spreading factor.

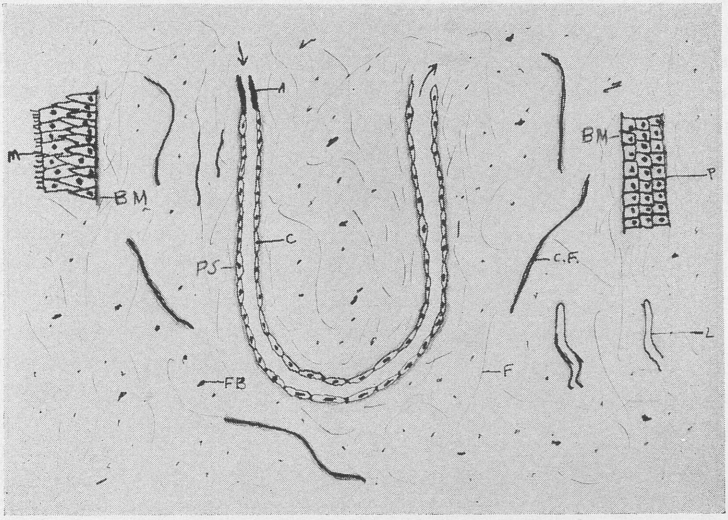


Fig. 2.—A: Arteriole; C: Capillary; F: Fibril; L: Lymphatic; M: Nasal mucosa; P: Parenchyme; BM: Basement membrane; CF: Collagen Fiber; FB: Fibroblast; PS: Peri-capillary sheath.

In uncomplicated cases of pneumococcus pneumonia, there is less production of this enzyme by the organism.[6] This shows that both the host and the invader participate in producing the difference in the hypothetical cases of patients A and B.

As usual in such situations, nature has not let us down. The body also develops anti-spreading factors, or anti-hyaluronidases.[7, 2] These inhibitors may be demonstrated in the blood-stream. There is a specific antihyaluronidase and a non-specific inhibitor. For example, in many streptococcus infections, a specific antibody is built up to overcome the spreading factor produced by the streptococcus. In cases of acute rheumatic fever this antibody is very high. The non-specific inhibitor is not an antibody and its exact nature is not known. Recent work indicates that it may be heparin or a derivative thereof.[2, 8] My personal feeling is that it is in some way connected with the stress hormones of the adrenal cortex. This non-specific anti-hyaluronidase is high in the acute stages of all connective tissue disease and in fact, in most acute infections and in other

conditions of stress and strain.[2] Hence, the common denominator which is necessary for the production of this substance is a stimulation of adrenal cortex by some stress.[9] This statement can be proven by the experiments in which normal animals under stress produce a high blood level of the non-specific inhibitor, while stressed adrenalectomized animals do not.[9]

The ground substance also has certain growth functions. It has been shown that around the edges of rapidly growing tumors, the gel is liquefied (probably by hyaluronidase activity) thus enabling the tumor to spread and grow more readily.[10] This can be determined by the use of intravital staining. For example, Evans Blue has a selective staining action on depolymerized ground substance. If this dye is injected intravenously into animals with rapidly growing tumors, it shows up in the ground substance near the edges of these tumors.[10]

A similar process may take place in regard to metastases. Gersh and Catchpole[10] believe that metastatic tumors live and survive where the ground substance is favorable. They believe that the metastatic cells may stimulate the secretion of depolymerizing enzymes which produce a favorable site in the ground substance.

How does material get from the blood-stream to the cell? It must go through the capillary wall, the pericapillary membrane, the ground substance, and the cell membrane.[1] Substances from the cell get back into the circulation in the reverse manner. Again the consistency of the ground substance will help to determine this process. Undoubtedly, this is a function of this structure (Fig. 2).

While regular enzymatic activity maintains the connective tissue elements, certain vitamins and hormones participate in speeding up or inhibiting these reactions. Ascorbic acid is the most important vitamin in this regard.[2] Vitamin C is very high in the adrenal cortex, and when the body is under stress the cortex is quickly depleted of this vitamin. In some way, ascorbic acid is a factor in the production of the stress hormone.[11, 12] In vitamin C deficiency, there is a failure to produce the polysaccharides and therefore, a poor ground substance results.[2] Also, in this deficiency, new collagen fibers are not formed, although the old fibers will be fully maintained without ascorbic acid.[2] Thus, scurvy is associated with poor healing.

Various of the hormones are important in this picture.[2] Thyrotropic hormone stimulates the production of ground substance and

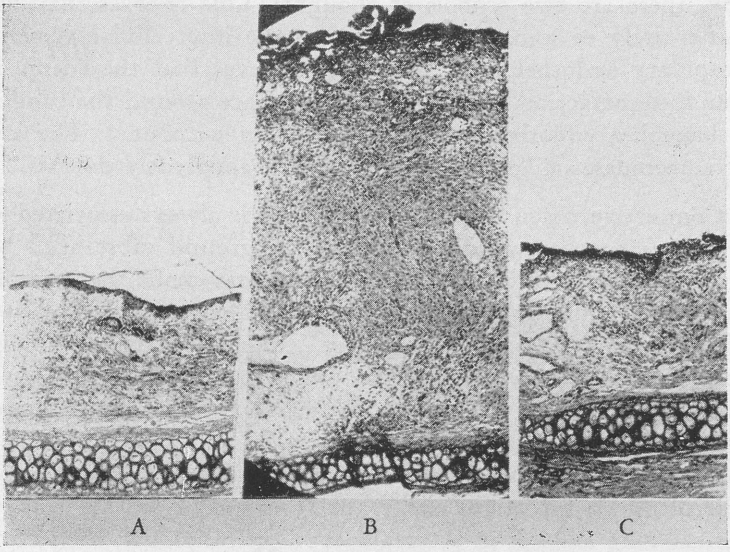


Fig. 3.—A—Cross section of normal rabbit's ear—left. B—8 day granulating wound control—center. C—8 day granulating wound, animal treated with cortisone—right. Note difference in thickness in granulation tissue in control and animal treated with cortisone. Reprinted by permission, from Bull. N. Y. Acad. Med. 25:252.

collagen. For example, if a thyroidectomized guinea pig is given thyrotropic hormone exophthalmos is produced from an excessive production of retrobulbar gel.[2] Estrogens decrease the permeability of amorphous substance while gonadotropins increase it.[13] Cortisone decreases the permeability of the ground substance while desoxycortisterone increases it. Cortisone depresses the production of all of the elements of connective tissue, namely, the ground substance, collagen, fibroblasts, and capillaries.[14] Therefore, this hormone may inhibit wound healing[18] (Fig. 3).

Edema is the accumulation of excessive fluid in the intercellular spaces, i.e. in the ground substance. For example, Reinhart's special staining technique has shown that allergic reactions involving the respiratory tract produce edema in the mucopolysaccharides of the nose and the bronchial tree.[15] The mechanism of the production of edema is somewhat in question. Time does not permit a complete

discussion of the pros and cons of this subject. However, to put it briefly, there are two schools of thought: One believes that edema is due entirely to some direct action on the intercellular cement of the capillary endothelium. The other believes that the edema may be due to liquefaction of the ground substance around the capillaries thus loosening endothelial connections from without.[16] The action of hyaluronidase on ground substance will apparently do this.

Connective tissue damage of any kind is always associated with an increase as well as a liquefaction of the ground substance.[1, 2] In fact this liquefaction, or depolymerization, may make the amorphous substance so soluble that it passes into the blood-stream where it can be found and measured.[2] Therefore, connective tissue damage is associated with, or results in, the following: (1) edema in the ground substance, (2) increase in the ground substance, (3) seepage of the ground substance into the circulation, and (4) increase in the non-specific antihyaluronidase in the blood. The damage may be of an allergic or an infectious nature, or from any stress. If this stress continues long enough in a certain type of individual, then further degenerative processes may take place. Precipitates may be deposited in the ground substance producing amyloid degeneration, hyaline degeneration, and so forth. The ultimate end result will be more collagen and less ground substance with eventual sclerosis.[2] This process is probably one of the reasons why some individuals grow old prematurely.

There are many other interesting points that can be made in reference to the ground substance of the nose and sinuses, but lack of time and lack of knowledge eliminate further observations.

## SUMMARY AND CONCLUSIONS

The development and the morphology of the mesenchymatous ground substance has been pointed out. The possibility of new and interesting functions of this structure has been presented. The enzymatic and hormonal control of the mesenchyme has been reviewed. The importance of the ground substance in allergic and non-allergic inflammations of the respiratory tract has been stressed. A brief resume of connective tissue pathology from edema to sclerosis has been given.

The intent has been to place the ground substance of the respiratory tract in the position of a structure of some importance, and

not merely as an inert tissue whose single duty is to hold the anatomical structures together.

384 Post St.

## REFERENCES

1. Angevine, D. Murray: Structure and Function of Normal Connective Tissue, Transactions of the First Conference on Connective Tissues, 13-43 (April 24-25) 1950.

2. Ehrich, W. E.: Nature of Collagen Diseases, Am. Heart J. 43:121-56 (Jan.) 1952.

3. Meyer, Karl: Chemistry of Connective Tissue, Mucopolysaccharides, Transactions of the First Conference on Connective Tissues, 88-100 (April 24-25) 1950.

4. Gersch, Isidore: Some Functional Considerations of Ground Substance of Connective Tissues, Transactions of the Second Conference on Connective Tissues, 11-44 (May 24-25) 1951.

5. Sprunt, Douglas H.: The Ground Substance in Infection, Ann. New York Acad. Sc. 52:1052-1060 (May 31) 1950.

6. Thompson, Robert T.: Anti-hyaluronidase Antagonistic to Pneumococcus Hyaluronidase in the Serum of Normal Human Beings and Patients with Pneumococcic Pneumonia: Rise of Titer in Bacteremic Pneumococcic Pneumonia, J. Lab. & Clin. Med. 33:919-932 (Aug.) 1948.

7. Friou, George J.: Further Observations of an Inhibitor in Human Serums of the Hyaluronidase Produced by a Stain of Hemolytic Streptococcus, Ann. New Yord Acad. Sc. 52:1112-1117 (May 31) 1950.

8. Glick, David, and Sylven, Bengt: Evidence for the Heparin Nature of the Nonspecific Hyaluronidase Inhibitor in Tissue Extracts and Blood Serum, Science 113:388-389 (April 6) 1951.

9. Good, T. A., Good, R. A., Kelley, V. C., and Glick, D.: Mucolytic Enzyme Systems. XVI. Factors Influencing Hyaluronidase Inhibitor Levels in Serum; Role of Adrenal Cortex, Am. J. Physiol. 166:555-565 (Sept.) 1951.

10. Gersh, Isidore, and Catchpole, Hubert R.: The Organization of Ground Substance and Basement Membrane and Its Significance in Tissue Injury, Disease and Growth, Am. J. Anat. 84:457-522 (Jan., Mar., May) 1949.

11. Teilum, Gunnar: Cortisone-Ascorbic Acid Interaction and the Pathogenesis of Amyloidosis. Mechanism of Action of Cortisone on Mesenchymal Tissue, Ann. Rheumat. Dis. 11:119-136 (June) 1952.

12. Penny, J. R., and Balfour, B. M.: J. Path. Bact. 61:171, 1949.

13. Lurie, Max B.: Mechanisms Affecting Spread in Tuberculosis, Ann. New York Acad. Sc. 52:1074-1090 (May 31) 1950.

14. Duran-Reynals, F.: Introduction: The Ground Substance of the Mesenchyme and Hyaluronidase, Ann. New York Acad. Sc. 52:946-957 (May 31) 1950.

15. Reinhart, J. F.: The Role of the Connective Tissue Ground Substances (Mucopolysaccharides) in Allergic Injury, California Med. 75:335-340, 1951.

16. Zweifach, B. W., and Chambers, Robert: The Action of Hyaluronidase Extracts on the Capillary Wall, Ann. New York Acad. Sc. 52:1047-1051 (May 31) 1950.

17. Mayer, R. L.: Hyaluronidase and Inflammation of the Skin, Ann. New York Acad. Sc. 52:1041 (May) 1950.

18. Ragan, Charles: Effect of ACTH and Cortisone on Connective Tissue, Transactions of the First Conference on Connective Tissues, 137-164 (April 24-25) 1950.

## DISCUSSION

DR. ARTHUR W. PROETZ: This exciting and important paper stimulates a number of questions in a person's mind. Dr. Rawlins mentions the fact that patient A goes in swimming and takes a cold and patient B goes in swimming and does not take a cold. It seems to me the same thing applies also to patient A's going swimming this week and patient A's going swimming next week, and I believe that is one of the most important corollaries of this paper.

In the study of allergy and of infection it becomes more and more obvious to me that one can treat a patient as a constant in point of space, but not in point of time. We have been told we must treat a patient and not merely a disease. Now we go a step farther and have to treat the patient as of *now* and as of *then* Why is it that a glass of orange juice will block up a man's nose at one time and not at another? Why is it that a patient is in complete distress from allergic reactions or from constantly recurrent colds at one time and not at another, without change of environment, of occupation, of almost anything that the practitioner can discover? This paper is a warning signal to people who practice routine medicine.

The electron microscope, of course, is one of the most stimulating influences of recent years. Only recently the cilia at which we have been looking critically for a hundred years without being able to discover any structural characteristics, have suddenly been shown to possess a bundle of central fibers. Today we get a beautiful picture of connective tissue cells, such as we have never seen before, which opens up great avenues for invesigation.

It seems to me that if a young investigator today is hunting for a research problem here is the spot to look. Since our patient is a functioning organism, which is not the same two days or two seasons running, a better understanding of the mesenchyme may prove a valuable diagnostic instrument.

DR. BERNARD J. MCMAHON: Mr. Chairman and Gentlemen, I want to congratulate Dr. Rawlins on this excellent presentation especially from the biochemical standpoint. I would like to say a few words to complete the picture of the spread of infections.

Several years ago we injected particulate matter, India Ink in suspension, subepithelially in the anterior end of the inferior turbinates of rabbits in order to determine the pattern of the spread of infection and the nature of phagocytosis. We found that there was a definite streaming of carbon particles posteriorly within the subepithelial tissue, which eventually lead to the perivascular lymphatics, indicating that the perivascular lymphatics are protective barriers around the vessels themselves. In other words, the infection does not always go directly into the vessels, it is carried to the termination of the perivascular lymphatics in the lymph nodes adjacent to the area into which it is injected.

The phagocytes which we have to consider, are not only the polymorphonuclear leukocytes but principally the histiocytes. Our experiments demonstrated that connective tissue cells are definitely phagocytic, not only the free cells but those fixed in the blood vessel walls and in the periosteum. The carbon particles were incorporated within these connective tissue cells. These particles appeared to become adherent to the cell, especially the histiocyte, and were eventually enveloped by it.

The thought that occured to us at that time was that the entire process of attraction of foreign particle to cell might be explainable on an electrical basis.

In other words, since particulate matter as well as bacteria carry a negative electrical charge these would be attracted to a phagocytic cell which has a positive charge. Therefore could resistance to infection be hypothecated on the basis of the relative electrical potentials of the invading organisms and the body cells? This relationship could well be modified by the biochemistry of the individual.

DR. FRANCIS L. WEILLE: Mr. Chairman, Fellows and Guests, I would like to ask Dr. Rawlins one question. We have had eight research workers at the Massachusetts General Hospital study collagen fibers in the past two or three years. This phenomenon has been discovered: that it is possible to take these things that look like cables with cross-striations at a magnification of 10-50,000 and changing the saline concentration to make them simply seem to disintegrate and dissolve so that a clear solution can be shown. Then by adding a little saline one can bring all the structures back, so that complete destruction as shown under the electron microscope is changed to complete rehabilitation. I would like to ask the Doctor if he has any evidence as to why this occurs.

DR. AUBREY G. RAWLINS: Thank you, gentlement, very much for your discussion. I certainly agree with Dr. Proetz about the difference in the individual from time to time. The difference in the condition of their ground substance, is probably what determines the variation. I believe, Dr. McMahon, that the fibroblasts certainly are active. The fibroblasts seem to be one of the main factors in this whole picture. They not only build up the ground substance, but they also break it down and they help in forming collagen fibers. There is a circulation of substances in the ground substance and hence, we have the interstitial circulation as well as the regular circulation.

I do not know very much about collagen. Collagen fibrils are probably formed by protein precipitation. The protein molecules precipitate in a certain way so the crossed striations are regularly spaced. Investigators have taken certain proteins, in vitro, and produced fibrils with crossed striations quite similar to regular collagen.

# PRIMARY AMYLOIDOSIS OF THE LARYNX

## WITH A REPORT OF EXPERIMENTAL TREATMENT WITH CORTISONE

JULIUS W. MCCALL, M.D.

AND

WILLIAM R. FISHER, M.D.

CLEVELAND, OHIO

During the past three years we have observed four cases of so-called primary or idiopathic amyloidosis of the larynx. This condition is of sufficient interest, despite its rarity, that it seems worth while to present a brief review of current opinion about this type of lesion and to note the direction of research studies now being carried out in relation to amyloid deposits in various tissues of the body, along with a report of a clinical trial with cortisone in two of our own cases and with ACTH in a case observed by Dr. Irl Blaisdell, of Syracuse, New York.

### INCIDENCE

The reported incidence of primary amyloidosis either of generalized type or in solitary sites such as the larynx, is very low. For example, Dillon and Evans[1] reported that only three cases of primary amyloid disease were observed at Peter Bent Brigham Hospital in Boston during a twenty-eight year period from 1913 to 1941, which included 120,785 admissions and 41,551 autopsies; and in none of the three cases was the lesion situated in the larynx. A very recent communication from DeGraf Woodman[2] informed me that he had just observed a patient with primary amyloid tumor of the larynx which was the second such case ever recorded at Presbyterian Hospital in New York.

In our Cleveland hospitals, it would appear that the incidence of amyloidosis of the larynx is considerably higher. Besides the four cases we have seen since 1950, thirteen cases of amyloid disease of the

larynx have been recorded at another hospital during the last fifteen years. This experience is similar to that reported, in 1949, by Kreissl, Muirhead and Darrough,[3] of Dallas, Texas. They reported five cases of primary amyloidosis of the larynx seen in a period of twenty-four months in a surgical pathology service associated with two laryngology services; during this period, specimens from thirty-one laryngeal lesions were examined. Beavis,[4] in 1934, reported five cases he had observed and commented that amyloidosis of the larynx is probably not so rare as the paucity of reports in the literature would seem to indicate.

Whether the apparently higher incidence of primary amyloidosis of the larynx in some places, such as Cleveland and Dallas, is due to greater interest on the part of the pathologists in carrying out special staining techniques for the recognition of amyloid, or whether there is some geographical, nutritional or environmental factor which causes an actually increased incidence in certain places cannot be answered now. However, it seems likely that if amyloid disease of the larynx were looked for more systematically by both clinicians and pathologists, there might be an increase in the reported incidence.

## CLASSIFICATION

The association of amyloid deposits in various tissues of the body in the presence of chronic wasting diseases, such as tuberculosis and syphilis, has long been recognized as a secondary degenerative process, in which the organs most usually affected are the spleen, liver, kidneys and adrenal glands. There is also a type of so-called primary systemic amyloidosis, in which there is no demonstrable pre-existing infection, and the amyloid deposits are found in the heart and organs other than those usually involved in secondary amyloidosis. Besides this generalized type of primary amyloidosis, there are the solitary amyloid tumors situated in various sites, but particularly in the larynx and upper respiratory tract, which are also regarded as primary lesions, since they occur without any demonstrable pre-existing chronic infection.

The foregoing is an oversimplified statement of the principal categories of amyloid disease. Actually, the cases show many deviations from any such categories, and the elaborate classifications that have been proposed by some writers have served only to confuse the picture. Since there are still so many questions to be answered re-

garding amyloid deposits in the body and their localization, the trend at present is to simplify the basis of classification.

King,[5] in 1948, registered an objection to the terms, primary and secondary amyloid disease, suggesting that when the basic mechanism is known, all cases will be found to be of secondary type. King proposed a classification in which the main differentiation is based on the so-called typical or atypical distribution. Whittlesey,[6] in 1950, suggested reversing these headings, that is, basing the principal differentiation on whether or not the amyloidosis is associated with some other disease, rather than on its distribution in the body. His scheme is as follows:

1. Primary amyloidosis (not associated with a disease)
    a. Typical distribution
    b. Atypical distribution
2. Secondary amyloidosis (associated with a disease)
    a. Typical distribution
    b. Atypical distribution

The classification proposed by Dahlin,[7] is the following:

1. Primary amyloidosis
    a. Systemic
    b. Focal or tumefactive
2. Amyloidosis complicating myeloma
    a. Systemic
    b. Focal or tumefactive
3. Secondary amyloidosis

According to the classification of Dahlin, the cases of laryngeal amyloidosis that we have observed are of the primary type, with focal distribution, since no evidence of amyloidosis elsewhere in the body could be adduced. It must be stressed, however, that this classification is a clinical one and, as such, is valid only for the time during which the patients have been under observation. Future findings might indicate the presence of amyloid deposits in other organs of the body, as in the case cited by DeWolf and Clarke,[8] in a man aged 59, with clinical symptoms simulating carcinoma of the larynx, carcinoma or ulcer of the stomach, rheumatic endocarditis and adhesive

pericarditis. This patient's first symptom had been hoarseness present for four or five years before he sought medical help for the relief of gastric symptoms. Throughout the two-year observation period, the laryngeal symptoms became more severe, and biopsy confirmed the diagnosis of amyloidosis. Necropsy showed excessive deposits of amyloid in the tongue, larynx, myocardium and cardiac valves, submucosa and muscularis of the gastro-intestinal tract, lymph nodes, urinary bladder, mesentery and beneath the serous surfaces. On reading the literature, it is impossible to determine whether laryngeal involvement was present in the cases which have been reported as primary systemic amyloidosis, since most of the authors failed to mention the larynx which is not routinely examined *post mortem* in most institutions.

Although the supposedly primary solitary amyloid tumor of the larynx no doubt is accompanied by disseminated amyloidosis in some cases in which the generalized condition is not recognized, there is good evidence that many of these cases are indeed solitary, localized lesions. The separation of the local nodular deposits from the systemic or disseminated deposition is not necessarily clear-cut, but so far, according to Kreissl and his associates,[3] the reports of the focal form have exceeded the cases of the systemic form by at least a factor of 2. Stark and New[9] and others have called attention to the fact that amyloidosis of the larynx tends to be self-limiting, another factor which would seem to indicate that it is a localized and not a generalized progressing condition.

## SYMPTOMS

The symptoms due to amyloidosis of the larynx are caused by mechanical factors and hence are conditioned by its size and location. If there is no infringement of the vocal cords or obstruction of the airway, the lesion is asymptomatic and may be discovered only on routine examination. Hoarseness of several months' duration is the principal symtom, but dyspnea may also be present in the case of larger lesions. According to Stark and New,[9] men are more frequently affected than women in a ratio of two or three to one, and the disease occurs most commonly in the fifth, sixth and seventh decades of life. Two of our patients were young women in their early thirties, and it is our impression from this experience and from reading the literature that primary amyloidosis of the larynx tends to occur at an earlier age in women than in men.

Fig. 1.—Low-power view of the laryngeal mucosa stained with hematoxylin-eosin. Note that in the center of the field there is a hyaline-like tissue arranged in sparsely nucleated broad, irregularly anastomosing bands. Some of this tissue change is particularly apparent around a small blood vessel in the center of the section. The degenerative changes are more obviously demonstrated at a higher magnification with this type of stain; they are brought out by selective staining in Fig. 2.

## CLINICAL FINDINGS

Amyloidosis of the larynx may appear as a local tumor, but often, the lesion is not well localized and may be described as "diffuse submucosal thickening." The surface may be smooth or nodular, but characteristically the superficial mucosa is healthy. Clinically, the absence of ulceration of the mucous membrane is the most significant observation leading to the suspicion of amyloid tumor. In some instances, the lesion has a definite yellowish color, as has been noted by numerous authors. In other instances, the laryngeal swelling has a reddish, hyperemic appearance. The diagnosis is made by microscopic examination of stained sections of tissue removed for biopsy.

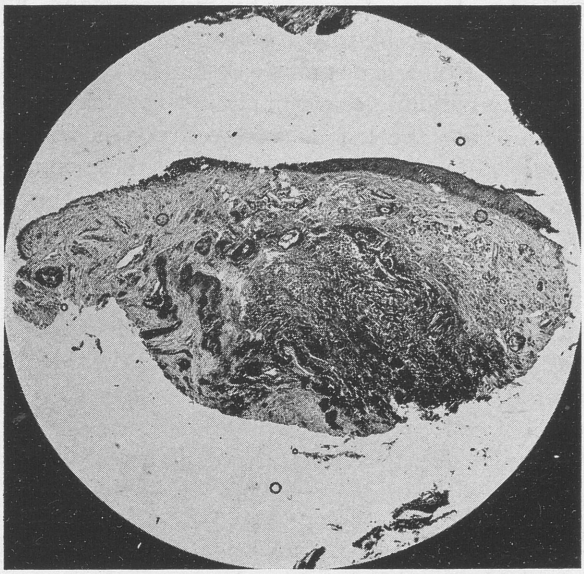

Fig. 2.—Low-power view of layngeal mucosa in a field comparable to that of Fig. 1. Crystal violet stain shows the metachromasia of the tissue which is the seat of amyloid degeneration. The distinctive staining of the amyloid is well demonstrated in the broad bands of purple-staining tissue in the walls of the blood vessels and in the collagen which occupies most of the center of the section.

## PATHOLOGIC FINDINGS

In microscopic sections of tissue removed from the larynx, amyloid deposits are seen as a homogeneous material which is revealed by staining with eosin, crystal violet and methyl green. Figure 1 shows the appearance of amyloid deposits in a section of laryngeal mucosa stained with hematoxylin-eosin and Figure 2 a comparable field stained with crystal violet.

Stark and McDonald[10] reported a histologic study of fifteen cases of amyloid tumor of the larynx, trachea and bronchi, in 1948. Although their study was limited to the "tumor"-forming amyloid lesions, they found no significant difference microscopically in these and in the diffuse lesions. These authors excluded seven cases which had previously been diagnosed as amyloid tumor. In these cases the

lesions were considered to be caused by hyalinized fibrin or tissue exudate identical to lesions described by Huebschmann, who regarded them as an early stage of formation of amyloid. Although Stark and McDonald could not determine whether the pathologic findings in these seven cases did represent incipient amyloidosis, they commented that clinically the lesions were easily removed and did not recur, and hence differed prognostically from those considered to be definitely amyloid. The pathologic features that they considered characteristic of true amyloid lesions were: (1) amorphous amyloid material occurred mainly in the form of "flakes" or "concentric layered masses" and (2) this amyloid material reacted characteristically with one or more of the so-called amyloid stains. They found crystal violet stain the most satisfactory for the identification of amyloid material.

In their pathologic study of five cases, Kreissl, Muirhead and Darrough[3] emphasized that in all these larynges, fibrinoid changes, as noted by Huebschmann, were prominent. At times, the smudgy, eosinophilic appearance of the connective tissue suggested the early phases of amyloid deposition; hence it appeared that collagen degeneration constituted an integral part of the local process. Microscopic hemorrhages seemed partially related to similar disintegration of the walls of the small blood vessels of the area. These authors commented that "apparently primary amyloid deposition may follow a pattern not unlike that of other mesenchymal disease. A local form and a systemic or disseminated form are observed, the former being more prevalent. The true relationship betwen these forms is not established. Fibrinoid degeneration of the adjoining tissue at times constitutes a part of the local process. This may not be significant but should be further studied."

## TREATMENT

In the treatment of primary amyloidosis of the larynx, a conservative and expectant course is usually advised. Unless surgical removal promises to relieve the hoarseness which is usually the only complaint, operation, as a rule, is not recommended. If dyspnea supervenes, or the tumor shows a tendency to progression and recurrence, as in the case reported by Clerf,[11] then thyrotomy or some other procedure may be necessary. Patients in whom an amyloid tumor of the larynx is diagnosed are advised to return for follow-up examinations at frequent intervals, so that any progression of the

lesion may be dealt with. Generally, the lesion develops slowly and in many cases is self-limiting.[9]

Numerous medical treatments have been tried in the past, more particularly in the cases of secondary amyloidosis, and of these, liver extract has appeared to be the most promising.[12]

## REPORT OF CASES

Before presenting a brief resumé of our own cases, the following record, furnished by Dr. Irl Blaisdell, of Syracuse, of a case of laryngeal amyloidosis treated by ACTH, is reported.

A man, aged 63, was first examined on June 2, 1952. He was complaining of hoarseness which had been present for the past year and had become progressively worse during the last two months. Examination of the nose, sinuses, ears and nasopharynx revealed no significant abnormalities. A mirror examination of the larynx showed an irregularity and fulness of the left cord, particularly in the posterior half. There appeared to be a small mass on the inferior surface of the posterior portion of the cord. On June 11, a direct laryngoscopy was performed under local anesthesia, and this revealed an indurated lesion, extending from the anterior commissure back to the arytenoid and beneath the surface of the left cord. Movement of the vocal cord was definitely limited. The lesion was round and smooth. Tissue was removed from the anterior and posterior portions of the lesion; histologic examination of these showed masses of homogeneous material with a foreign-body giant-cell reaction. Special stains confirmed the presumptive diagnosis of amyloidosis.

The patient was sent back to the referring physician who was advised to administer ACTH for two weeks. This treatment was carried out in the hospital in the patient's home town. He received a dosage of 100 milligrams of ACTH per day, and had no adverse reaction until the fourteenth day, at which time he became somewhat disoriented, and the medication was stopped. During this two-week period, his voice improved and his physician reported that the mass in the larynx seemed to disappear.

Re-examination by Dr. Blaisdell two months later, on August 15, showed that there was no limitation of motion of the left vocal cord, and the mass had definitely decreased in size. Another follow-up examination, on September 2, gave evidence of continued im-

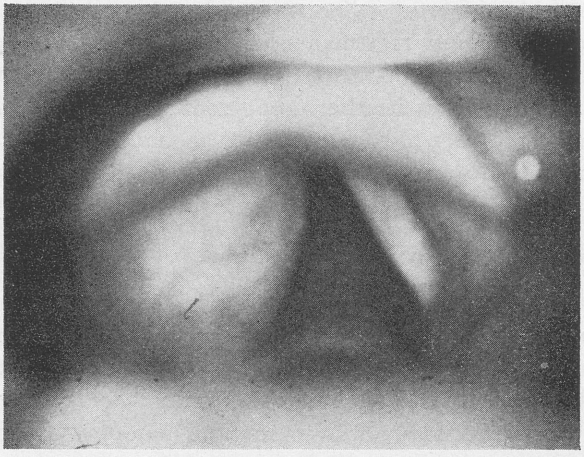

Fig. 3—Photograph of the larynx (Case 1) taken from a colored motion picture.

provement. The patient's voice was quite clear and he himself said that he could speak better than for some time past. A small quantity of abnormal tissue was still present beneath the left cord posteriorly, but the anterior portion of the mass had completely disappeared. It was Dr. Blaisdell's opinion that ACTH had caused definite improvement, and a second course of treatment for this patient was being planned.

CASE 1.—A married woman, aged 33, had a mild huskiness of the voice for six months before she was first examined, in April, 1951. A laryngoscopy was performed on April 6, 1951, and the biopsy was positive for amyloid. The mass filled the right ventricle, overhanging the glottis and extending over the right false cord (Fig. 3). The mucous membrane over the amyloid mass was not ulcerated. This lack of ulceration is of diagnostic significance. By direct laryngoscopy, when the amyloid mass was displaced laterally, a normal true cord with normal movements was revealed. For this reason, voice impairment in this patient was slight. Physical examination showed no evidence of infection or amyloidosis elsewhere in the body.

In July, she was readmitted to the hospital for a series of cortisone injections directly into the tumor mass. The injections, each

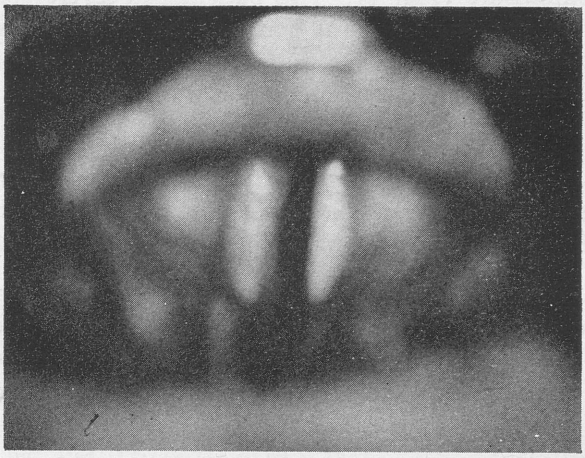

Fig. 4.—Photograph of the larynx (Case 2) taken from a colored motion picture.

containing 25 milligrams of cortisone in 1 milliliter of saline solution, were made through a laryngoscope, using a long laryngeal needle and a tuberculin syringe. A series of eight injections daily were administered; during the period of treatment, there was no appreciable change in the size of the mass, nor was there any improvement in her voice. The cortisone used in this manner caused no toxic signs nor evidence of systemic effect.

Another course of four local injections of cortisone was given six weeks later, and again this treatment had no noticeable effect on the size of the tumor. Later, cortisone was administered by mouth, 200 milligrams daily for eight days and then 100 milligrams for six days. On the next day, the patient exhibited a severe reaction, with swelling of the face and of the ankles and pronounced vertigo, so the medication was discontinued.

Follow-up examinations were made in June, 1952, and again in February, 1953. The mass had not decreased in size, and probably eventually will require thyrotomy for its removal.

CASE 2.—A woman, aged 32, consulted us early in 1951, with a complaint of severe hoarseness, which had existed for two years. A mirror examination revealed several small red masses on the edge

of both vocal cords anteriorly and a larger reddish mass under the anterior commissure (Fig. 4). This patient had severe voice impairment. Direct laryngoscopy was done, and microscopic examination of multiple specimens of tissue showed the presence of amyloid deposits. A thorough physical examination was made to rule out amyloidosis in other organs and systemic disease.

This patient received eight injections of 25 milligrams of cortisone directly into the amyloid masses in July, 1951, and four injections of cortisone in September, 1951.

Examination in December, 1951, showed that the masses were smaller, particularly the one under the anterior commissure, and that the voice had improved. She did not return for observation for a year, and came in then only at our request. She stated that her voice had improved so much that she felt there was no need for further treatment.

The last examination of this patient, in February, 1953, showed that the improvement in laryngeal appearance and in the voice had been maintained.

## COMMENT

The administration of cortisone in these cases was undertaken on an empirical basis, but a review of some of the recent literature on experimental amyloidosis has revealed a most interesting study by Gunnar Teilum,[13] of Copenhagen, reported in 1952, which suggests a rationale for the use of cortisone in primary amyloidosis and a possible explanation for the improvement noted in Dr. Blaisdell's case and in our second case in which the amyloid deposit was of the diffuse type.

After reviewing a considerable number of recent experimental studies,[14-26] it seemed obvious that Teilum's work has correlated the various experimental, pathological and clinical findings, with appraisal of their significance in such a way as to answer certain questions about amyloidosis more satisfactorily than has been possible heretofore. His observations and conclusions offer much elucidation of the subject, of interest to clinicians.

Teilum stresses that the mechanism whereby the hormone of the adrenal cortex maintains the structure and function of mesenchymal tissue in general is an indirect one, mediated by ascorbic acid. Well-

defined structural and functional phases in the natural diseases and in experimental disorders of the mesenchyma, which may in some way be associated with a disturbance of some enzyme system, such as ribonuclease, hyaluronidase, seem to be controlled by an interaction of a hormone of the adrenal cortex of cortisone type with ascorbic acid. These findings offer an approach to the elucidation of the following: (1) the pathogenesis of amyloidosis, (2) certain apparently antagonistic effects of cortisone and ascorbic acid on the mesenchymal tissue, and (3) the mechanism of action of cortisone and ascorbic acid on mesenchymal tissue in general.

610 Rose Bldg.

REFERENCES

1. Dillon, J. A., and Evans, L. R.: Primary Amyloidosis: Report of Three Cases, Ann. Int. Med. 17:727-731 (Oct.) 1942.

2. Woodman, DeGraf: Personal communication.

3. Kreissl, L. J., Muirhead, E. E., and Darrough, L. E.: Primary Amyloid Deposits in the Larynx, Arch. Otolaryng. 50:309-318 (Sept.) 1949.

4. Beavis, J. O.: Local Amyloid Disease of the Upper Passages; Report of Five Cases, Arch. Otolaryng. 19:439-445, 1934.

5. King, L. S.: Atypical Amyloid Disease, with Observations on a New Silver Stain for Amyloid, Am. J. Path. 24:1095-1115 (Sept.) 1948.

6. Whittlesey, W. N.: Primary Atypical Amyloidosis, Arch. Int. Med. 86: 245-252 (Aug.) 1950.

7. Dahlin, D. C.: Classification and General Aspects of Amyloidosis, M. Clin. N. America 34:1107-1111 (July) 1950.

8. DeWolf, H., and Clarke, B. E.: Primary Amyloidosis, Am. J. Clin. Path. 20:165-170 (Feb.) 1950.

9. Stark, D. B., and New, G. B.: Amyloid Tumors of the Larynx and Trachea, M. Clin. N. America 34:11145-11150 (July) 1950.

10. Stark, D. B., and McDonald, J. R.: Amyloid of Larynx, Trachea and Bronchi; Histologic Study of Fifteen Cases, Am. J. Clin. Path. 18:778-788, (Oct.) 1948.

11. Clerf, L. H.: Amyloid Tumor of the Larynx, Tr. Am. Laryng. A. 64:146-149, 1942.

12. Trasoff, A., Schneeberg, N., and Scarf, M.: Recovery from Multiple Rheumatoid Arthritis Complicated by Amyloidosis in a Child, Arch. Int. Med. 74:4-10 (July) 1944.

13. Teilum, Gunnar: Cortisone-Ascorbic Acid Interaction and the Pathogenesis of Amyloidosis, Ann. Rheumat. Dis. 11:119-136 (June) 1952.

14. Ott, H., and Schneider, G.: Plasma Proteins in Experimental Amyloidosis of the White Mouse, Ztschr. ges. exper. Med. 116:545-566, 1951.

15. Bohle, A., Hartmann, F., and Pola, W.: Electrophoretic Serum Protein Studies in Experimental Amyloidosis of the Mouse, Arch. Path. Anat. 319:231-246, 1950.

16. Lautsch, E., and Gagne, F.: Experimental Amyloidosis in Vitamin C Deficient Guinea Pigs, Rev. Canad. Biol. 10:119-122 (May) 1951.

17. Letterer, E.: New Aspects of Experimental Amyloidosis, J. Path. & Bact. 61:496-498 (July) 1949.

18. Ahronheim, J. H.: The Nature of Hyaline Material in Pancreatic Islands in Diabetes; Relation to Amyloidosis, Am. J. Path. 19:873-882 (Sept.) 1943.

19. Atlas, D. H., Gaberman, P., and Stern, K.: Primary Amyloidosis Associated with Hyperlipemia and Hypercholesterinemia, Am. J. Clin. Path. 20:371-376 (Apr.) 1950.

20. Hoffman, I., Friedfeld, L., Fishberg, E. H., and Fishberg, A. M.: Amyloidosis and Hypertension in Cholesterol-fed Rabbits, Proc. Soc. Exp. Biol. 78:37-40 (Oct.) 1951.

21. Parsons, L. D., and Turnbull, H. M.: Tissue Changes in Experimental Mice Treated with Pentose Nucleotides; Similarity to Changes Induced by Reticulosarcoma, J. Path. & Bact. 57:9-20 (Jan.) 1945.

22. Peters, J. T.: Epicellular and Pericellular Depositions of Amyloid as the Starting Point of Amyloidosis, Arch. Path. 35:832-835 (June) 1943.

23. Schneider, G.: Blood Proteins in Experimental Amyloidosis, Arch. Path. Anat. 317:26-33, 1949.

24. Weidlich, N.: Development of Amyloidosis in Animals Used for Production of Erysipelas Antiserum, Ztschr. f. Infektionskr. 58:278-305, 1942.

25. Heston, W. E., Larsen, C. D., and Deringer, M. K.: Variations in the Occurrence of Pathologic Calcification, Nephritis and Amyloidosis in Mice Fed Control and Modified Diets, J. Nat. Cancer Inst. 6:41-47 (Aug.) 1945.

26. Pirani, C. L., Bly, C. G., Sutherland, K., and Chereso, F.: Amyloidosis in the Guinea Pig, Science 110:145-146 (Aug. 5) 1949.

## DISCUSSION

DR. IRL H. BLAISDELL: I wish to thank Dr. McCall for including our case in his series.

I would like also at this time to give you a brief follow-up in the last two or three months on the same problem. The patient lives about 125 miles from Syracuse, so I do not see him as regularly and frequently as I might like. In late January of this year he returned to the office for examination, and his voice seemed to have deteriorated since we had seen him in September, so we decided that a second course of ACTH should be given. This treatment was carried out by his family physician in Ogdensburg, under our recommendations. His voice has again improved and when I last saw him in March, about five or six weeks ago, the lesion had again disappeared to a great degree. His voice was clear and yet there was still a demonstrable difference between the characteristics of the two sides of the larynx. There is still a fullness submucosally. The appearance of his larynx is very much like the first view that Dr. McCall showed you, except that it is not as extensive and large as that one.

DR. HUGH G. BEATTY: Mr. President and Members: I rise to report an interesting case which has several complications with it. The 21 year old married lady presented herself in June 1946 with a history of having had a laryngeal biopsy one year before by Dr. Schall, who, I think, later performed surgery. Complete examination was difficult because of lack of control. The left side of the larynx was involved, and a large mass extended down the right side of the pharynx, just behind and below the palatopharyngeus muscle. A direct laryngoscopy with the directoscope showed the larynx free from the growth; the larynx was moderately fixed by instrumentation (directoscope). A large tongue-like piece of tissue appeared just above the larynx, apparently springing from the posterior pharyngeal wall. This was grasped, detached and removed. It was approximately 3 cm long and 1 cm thick and 1½ cm broad and was diagnosed amyloidosis by the hospital laboratory. She did not report regularly for observation. We saw her again in 1949 (three years later) when we removed a good sized tumor from the posterior surface of the epiglottis and anterior part of the pharynx and a large amount of tissue from the left vocal cord. The laboratory report was "tissue is composed of hemogenous pink, wax-like material arranged in irregular, poorly indefinite nodule." The vascular elements are thin-walled, and the more important point is it was diagnosed as amyloid disease. We saw her again ten days later at which time she showed infection of the nasopharynx and some infected tissue in the left side of the pharynx. Examination of the larynx was impossible under local anesthesia because of a gag reflex. She returned four months later at our request, and there was a medium sized round mass still left in the left side of the larynx and possibly some in the nasopharynx. She has been instructed to return for observation but has not done so. We report this because of the long extensive disease and the extra-laryngeal involvement.

DR. PAUL H. HOLINGER: Mr. Chairman and Members of the Association and Guests, I assume that time did not permit Dr. McCall to include all of the details of his case report, but it was not clear as to whether or not a biopsy was obtained in the second and third cases. The picture that Dr. Clerf obtained looks so much like a cyst similar to one of the cases Dr. Laff described in the last Laryngoscope that the point of biopsy is important. I would like to question, too, whether these were cases of true amyloid disease or merely amyloid deposits in a more or less degenerative type of tissue in the polyp itself and whether confirmation of true amyloid disease was obtained by Congo Red tests, or other systemic studies.

DR. JULIUS W. MCCALL: I would like to thank the discussants of this paper. The Congo Red test was not done, Dr. Holinger, but there were three biopsies, three separate ones made. This looks like a cystic but this was a very solid mass. It was a large tumor and three biopsies were made and all of them were definite according to the pathologist on a methyl violet stain.

# THE LAMINAGRAM AS AN AID IN THE DIAGNOSIS OF DISEASES OF THE LARYNX

LeRoy A. Schall, M.D.*

Alexander S. Macmillan, M.D.†

and

Paul M. G. St. Aubin, M.D.‡

Boston, Mass.

In the evaluation of laryngeal disease, the laryngologist should employ all appropriate methods of investigation to aid in the correct diagnosis. Not only should there be a thorough history, a careful clinical study by indirect and direct laryngoscopy, and laboratory examination of biopsy material, but there should also be a competent radiographic study of the diseased larynx.

The larynx has for many years been visualized by means of a lateral, soft-tissue radiograph of the neck. Credit for the initial use of this projection goes to Coutard.[1] Only by means of the lateral, soft-tissue view can the epiglottis, tumors of the anterior and of the posterior commissure, the post-cricoid area, and of the arytenoid area be best seen. The use of barium to outline the related pharyngeal structures need be resorted to only occasionally.

More recently laminagraphy has been included as a method of investigating laryngeal disease. By means of this radiological procedure, a roentgenogram is produced having only one section or plane of the body in sharp focus. This plane is approximately 0.5 to 1 cm in thickness while planes lying above and below are blurred and obliterated. This blurring is the result of motion in opposite directions of the focal point above the patient and the film below the patient during exposure. A line drawn from the focal point to a fixed point

*Department of Otolaryngology, Massachusetts Eye and Ear Infirmary.

†Department of Radiology, Massachusetts Eye and Ear Infirmary.

‡Department of Radiology, Massachusetts General Hospital.

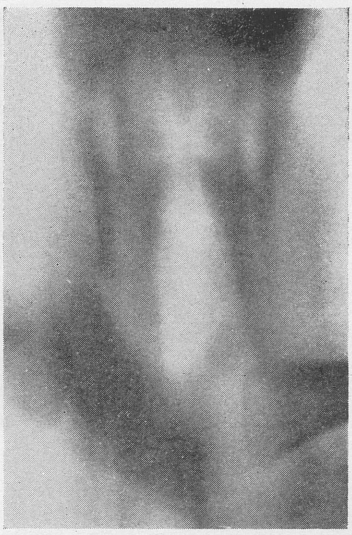

Fig. 1.—The first laminagram to appear in the literature; published by Dr. Felix E. Leborgne in the "Revista de Tuberculosis del Uruguay" Tomo V No. 4, 1936. Reproduced by permission.

on the film would rotate, during their motion, through an axis lying in the plane of focus. As a result, the shadow cast on the film by a point at the level of the axis of rotation will be in the same position throughout the excursion of the tube and the film, whereas the shadow cast by a point either above or below the axis will strike the film at a different position throughout the excursion resulting in a linear blur. This blurring will obviously be greater the farther the point is from the axis. Sections at various levels in the body can readily be obtained merely by changing the level of the axis of rotation. This procedure was first suggested by Bocage[2] in 1921; and was first applied by Vallebona[3] in 1930 to a study of the skull. Actually, Vallebona's method involved rotation of the patient on an axis related to a stationary film and a focal point, while Bocage's systems are the basis of present-day laminagraphy. The mathematical explanations of his methods have been worked out by Ziedses des Plantes[4] and by Grossmann[5] in 1935. An excellent historical review and mathematical analysis is given by Andrews[6] and by Andrews and Stava.[7]

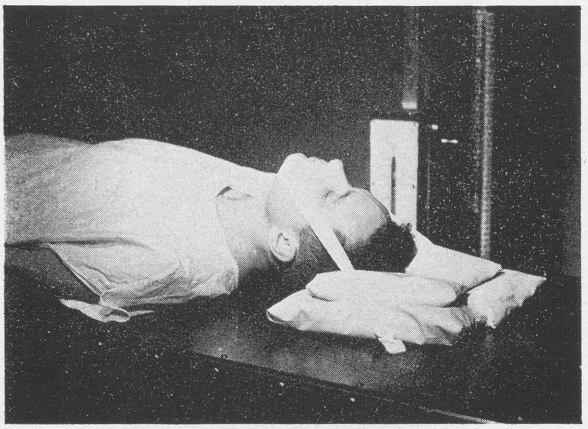

Fig. 2.—Position of the patient.

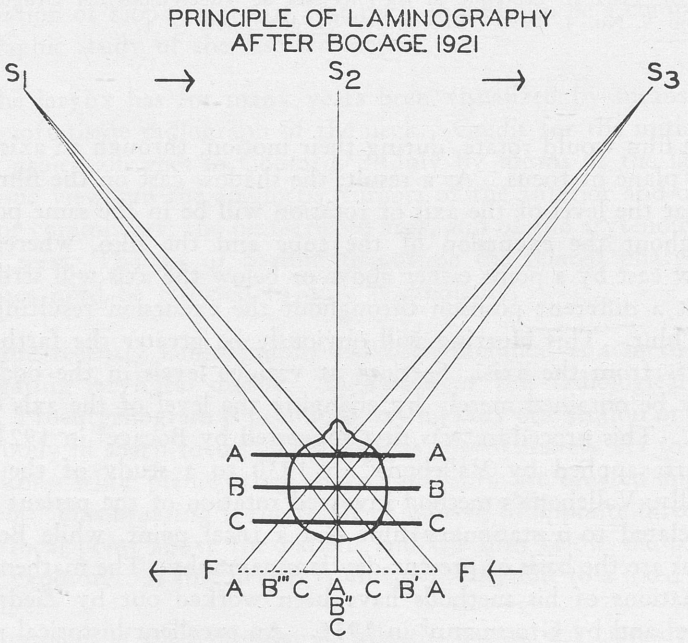


Fig. 3.—S1 to S3, excursion of the focal point; F to F, excursion of the film; Plane B, Plane of the laminagram; Plane A and C, Blurred.

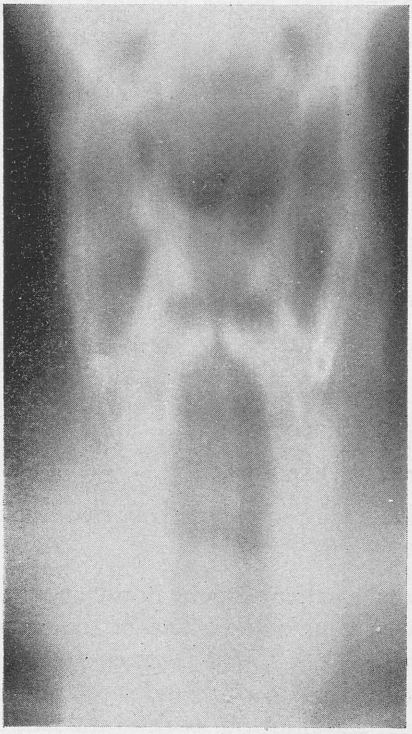

Fig. 4.—Laminagram of the normal larynx.

Laminagraphy as applied to the study of the larynx should be credited to Felix E. Leborgne[8, 9] of Montevideo. In 1947 it was the senior author's privilege to visit Leborgne in Montevideo and to become familiar with his technique and to observe the value of the laminagram in diseases of the larynx.

In practice the larynx presents an almost ideal structure for laminagraphy. The air outlining the soft tissue of the respiratory passages forms an excellent contrast medium permitting easy visualization of the true and false cords, the ventricles, the trachea and immediate subglottic area, the pyriform sinus, and the vestibule. In addition, calcification of the laryngeal cartilages, which interferes with good visualization in the intrapharyngeal method actually improves the details in the laminagraph by clearly outlining the cartilages

in section. The permanent record provided by the laminagram for future comparison and the ability to compare the two sides on the film are of obvious value.

The apparatus employed by us consists of a conventional Bucky table converted with a motor-driven, detachable laminagraph apparatus which is available for almost any machine. The technique used is as follows:

| | |
|---|---|
| Target to film | 41.5 in. |
| Target excursion | 14 in. |
| 50 Milliamperes | |
| 48-58 Kilovolts | |
| 3 second exposure | |
| Intensifying screen with Potter-Bucky grid | |

Positioning of the patient is done in such a way as to obtain comparable films in succeeding sections and in later studies. The patient lies supine with his neck halfway between full flexion and full extension. The head is fixed with sandbags and an adhesive plaster strap is placed under the chin and stuck to the sandbags for additional stability. The beam is then centered halfway between the laryngeal prominence and the tip of the chin. If the ventricles are seen in the previously taken soft-tissue lateral view of the neck, a second lateral view is taken with the patient positioned on the laminagraph table using a portable machine in order to get the ventricles in a vertical position and produce undistorted sections through the ventricle.

Laminagraphy has been used as a routine procedure at the Massachusetts Eye and Ear Infirmary only during the past year. In spite of the short time in which this additional method of examination has been used, our volume of cases has been such that, in our opinion, laminagraphy is of value:

(1) In confirming the findings of both indirect and direct laryngoscopy.

(2) In furnishing a permanent visual record of the lesion.

(3) In determining the exact limits of a subglottic extension.

(4) In visualization of the regression (or extension) of the disease during treatment by external irradiation.

(5) As an aid in those patients with short, thick necks and a backward tilt of the epiglottis who are difficult to examine under local or general anesthesia.

## CONCLUSIONS

A thorough history, a careful indirect and direct laryngoscopy and a microscopic examination of biopsy material removed from the lesion are procedures essential in the investigation of laryngeal disease.

Laminagraphy is an additional method of examination that will aid the laryngologist in the care of the patient with lesions involving the larynx.

243 CHARLES ST.

## REFERENCES

1. Coutard, H.: Preliminaire sur la Radiographie du Larynx normal et du Larynx Cancereux, J. Belge de Radiologie 3:287.

2. Bocage, A. E. M.: French Patent No. 536464 (June 3) 1922.

3. Vallebona, Alessandro: A Modified Technique of Radiographic Dissociation of Shadows Applied to the Study of the Skull, Radiol. Medica 17:1090-1097 (Sept.) 1930.

4. Ziedses des Plantes, B. G.: Planigraphy, A Differentiation Method. (Thesis for doctorate degree) Kemink and Son N. V., Utrecht, Netherlands, 1934.

5. Grossmann, G.: Tomography I and II, Fortschr. a.d. Geb. der Röntgengtrahlen, pp. 51, 61-80, 191-209, 1935.

6. Andrews, J. Robert, and Stava, Robert J.: Planigraphy II, Mathematical Analysis of the Method, Description of Apparatus, and Experimental Proof, Am. J. Roent. and Radium Therapy 38:145-151, 1937.

8. Leborgne, Felix E.: Nueva Tecnica Radiologica per cortes o Secciones, Anales del Ateneo des Clinica Quirurgica 13-15 (July) 1936.

9. Leborgne, Felix E.: Cancer Laryngeo y Tomografia Casa A. Barbeiro y Ramos, 1943.

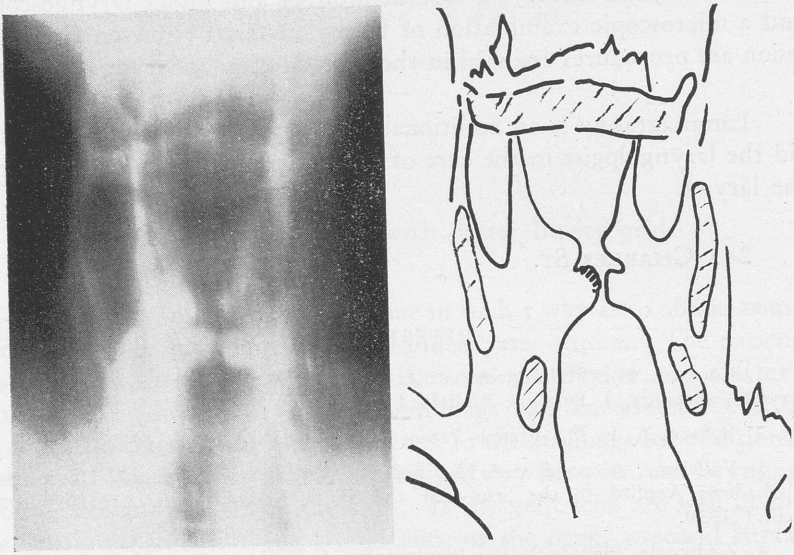

Case No. 700073. Male. Aged 71. Hoarse for two months. Laryngoscopy—The right cord thickened and red. No limitation of motion. Biopsy—Chronic inflammation. Laminagram—Normal left true cord. Ventricle well visualized. Right cord swollen with narrowing of the vestibule.

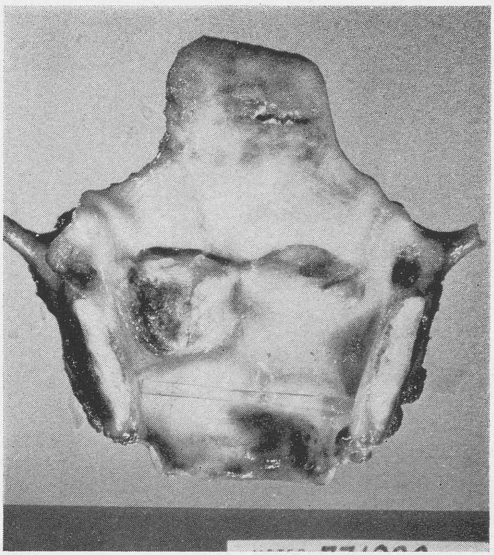

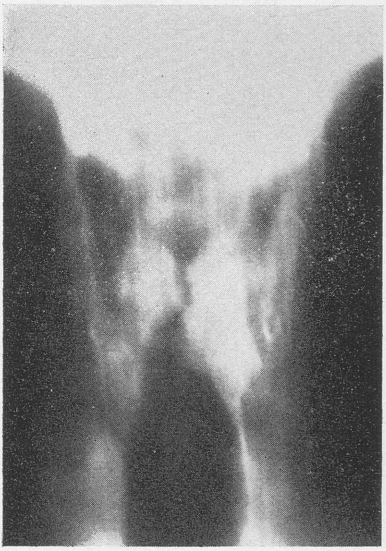

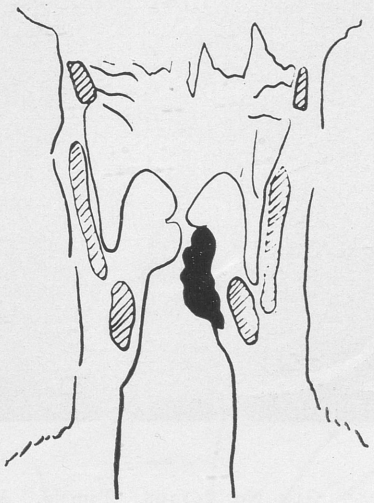

Case No. 771090. Male. Aged 39. Hoarse for one year. Laryngoscopy—new growth involving entire left true cord extending subglottically. Biopsy—Epidermoid Carcinoma Grade 2. Laminagram—Excessive new growth of left vocal cord with subglottic extension. The ventricle is obliterated. Treatment—Total laryngectomy.

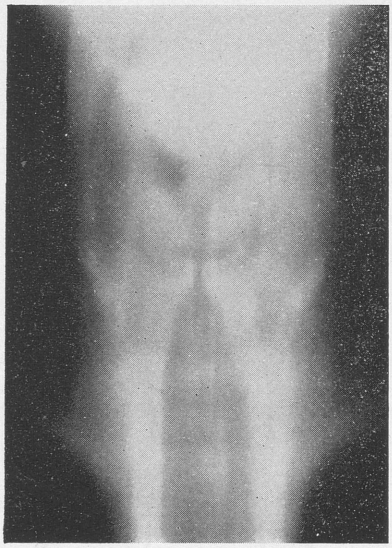

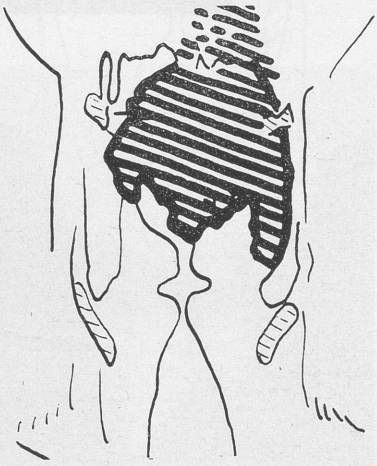

Case No. 765508. Female. Aged 29. Sensation of "lump" in the throat. Laryngoscopy—Large, smooth mass filling the hypopharynx and obliterating a view of the vocal cords. Lateral radiogram shows the mass to be supra-glottic extending above the tip of the epiglottis. Biopsy—Lymphosarcoma. Laminagram—revealed mass coming from the right pyriform sinus and entirely supraglottic.

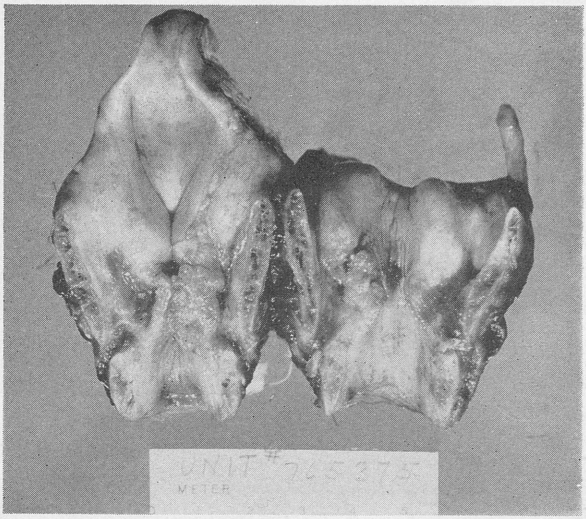

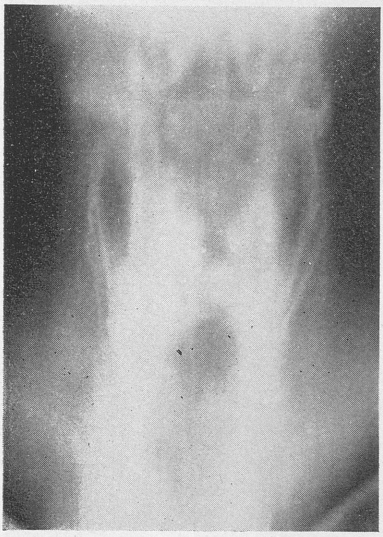

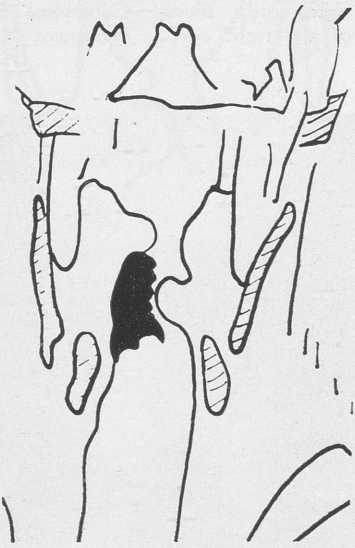

Case No. 765375. Male. Aged 72. Hoarse for five months. Laryngoscopy—Large mass involving entire right vocal cord with fixation. Biopsy—Epidermoid Carcinoma grade 3. Laminagram—The true cord was replaced by shaggy mass filling ventricle and pushing the false cord upward, with subglottic extension. Treatment—Total laryngectomy.

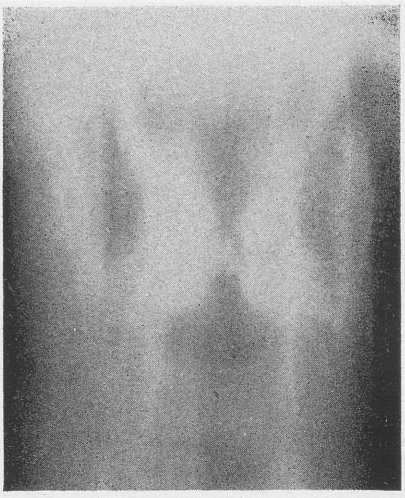

Case No. 806320. Male. Aged 60. Trouble with voice since 1947. Two biopsies in 1947 showed chronic inflammation. In 1953 was hoarse for two months. Laryngoscopy—localized lesion of the midportion of the right cord. Biopsy—Carcinoma grade 2. Laminagram—shows the lesion of the right cord. Treatment—Laryngofissure.

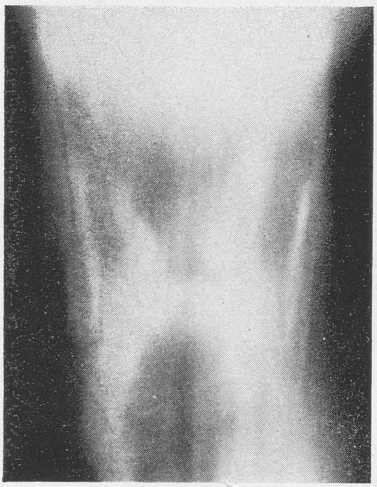

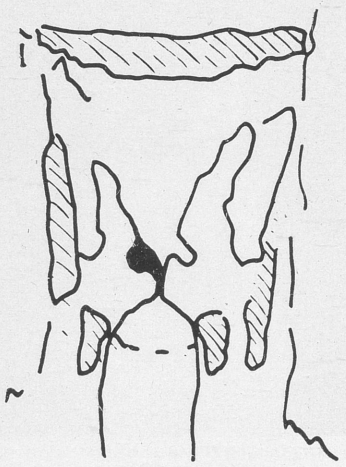

Case No. 801705. Male. Aged 60. Hoarse over one year. Laryngoscopy—new growth on midportion of right vocal cord. No limitation of motion. Biopsy—Epidermoid carcinoma grade 1. Laminagram—demonstrates lesion. Treatment—Laryngofissure.

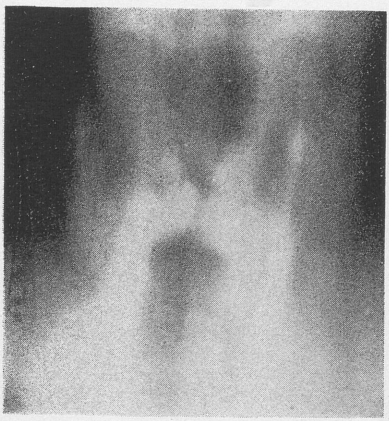

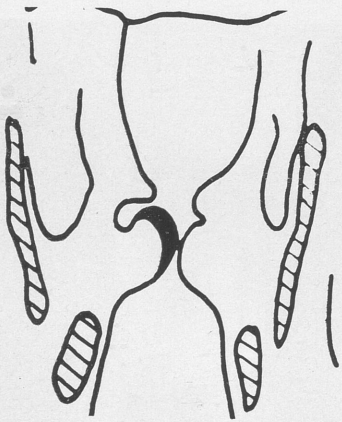

Case No. 756284. Male. Aged 45. Hoarse for three months. Laryngoscopy—thickened left vocal cord. Biopsy—Carcinoma grade 2.

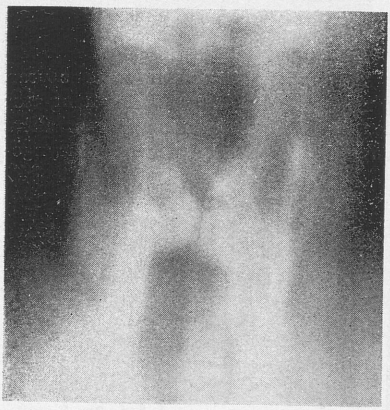

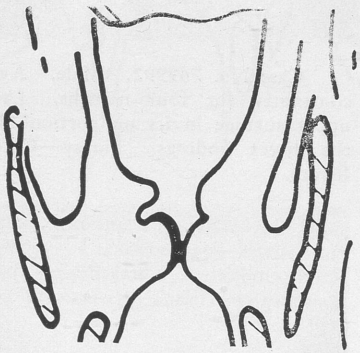

Fours weeks after external irradiation.

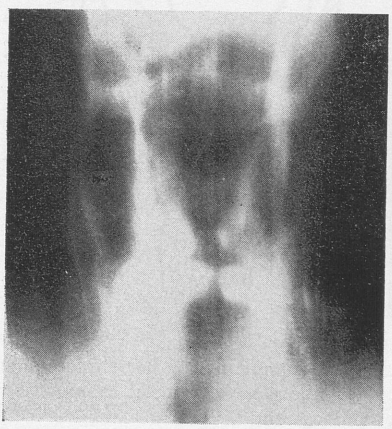

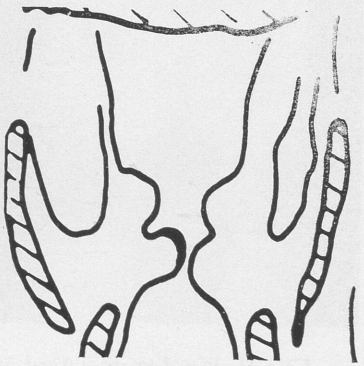

Six weeks after external irradiation.

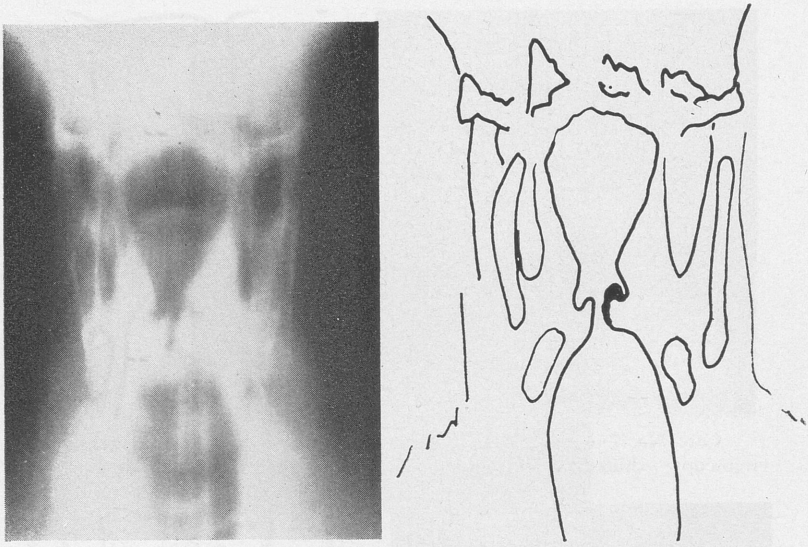

Case No. 769992. Male. Aged 42. Hoarse off and on for one year, constantly for four months. Laryngoscopy—new growth involving the upper surface in its midportion of the right cord. Laminagram confirms the direct findings. Biopsy—Carcinoma grade 2. Treatment—Laryngofissure.

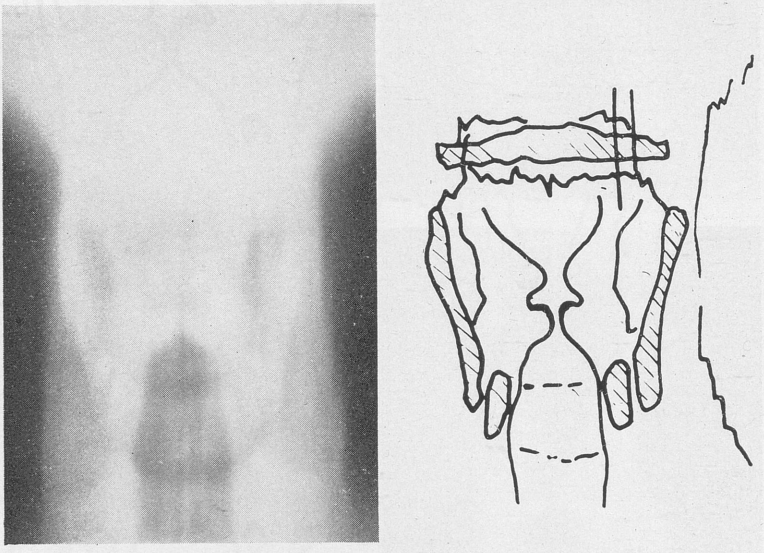

Case M. W. Female. Aged 36. Many complaints of her throat some of which suggested the possibility of a laryngocele. Laryngeal examination negative which was confirmed by the laminagram.

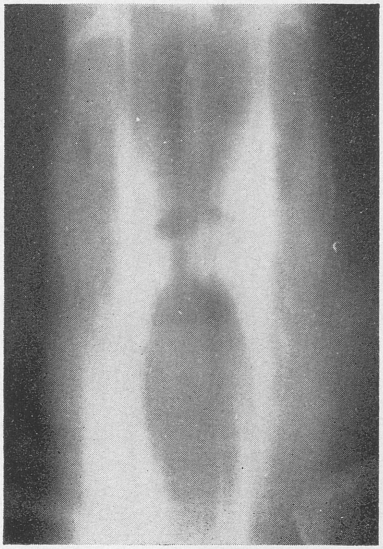

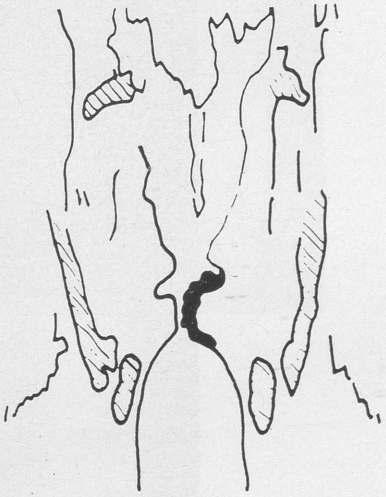

Case No. 799630. Male. Aged 71. Intermittent hoarseness three years. Constant hoarseness for six months. Laryngoscopy—Entire left vocal cord involved with fixation. Biopsy—Epidermoid carcinoma grade 3. Laminagram—demonstrates the lesion. Treatment—Total laryngectomy.

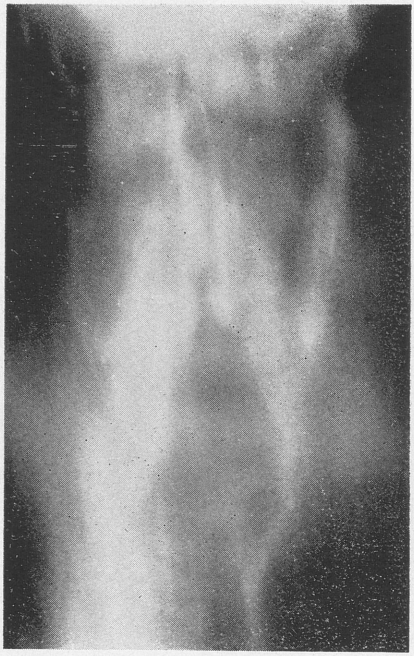

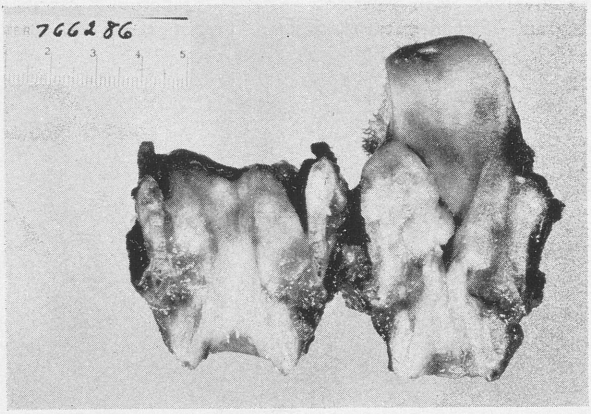


Case No. 766286. Male. Aged 74. Alteration in voice one year. Hoarse-constant three months. Large fungating lesion left false cord and right true cord. Biopsy—Epidermoid Carcinoma grade 3. The laminagram shows enlargement of the left false cord with obliteration of the left ventricle and extension to the ary-epiglottic fold.

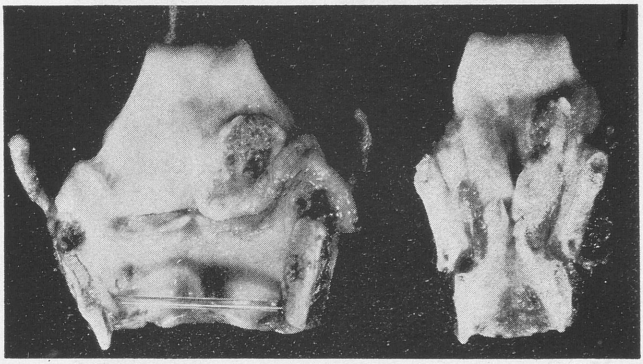

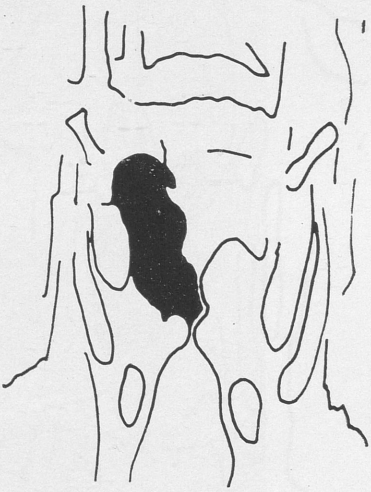

Case No. 771594. Male. Aged 56. Hoarse for three weeks with pain upon swallowing. Laryngoscopy—proliferating new growth at base of epiglottis extending to ary-epiglottic fold and right supraglottic area of larynx. Biopsy—Epidermoid Carcinoma Grade 2. Laminagram shows the extent of the lesion. Treatment— Total laryngectomy.

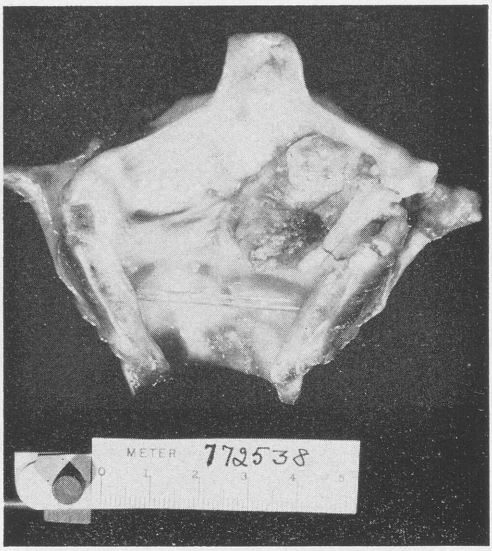


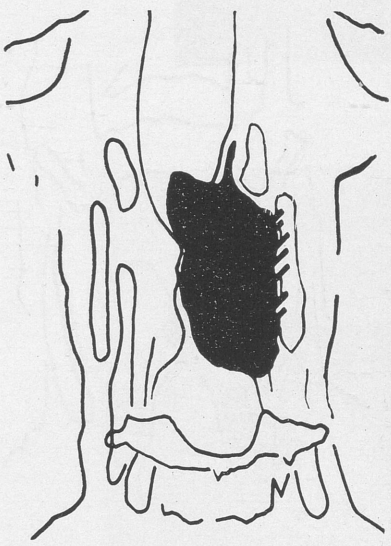

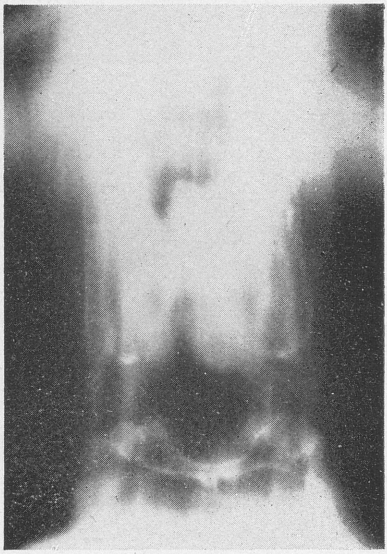

Case No. 722538. Male. Aged 70. Hoarse for three years. Pain referred to right ear. Laryngoscopy—Lesion of the right vocal cord involving ventricle, false cord, and extending almost to the ary-epiglottic fold. Biopsy—Epidermoid Carcinoma Grade 3. Laminagram—Extension of lesion of the right side of the larynx, obliteration of the ventricle, and extension upward toward the ary-epiglottic fold. Treatment—Total laryngectomy.

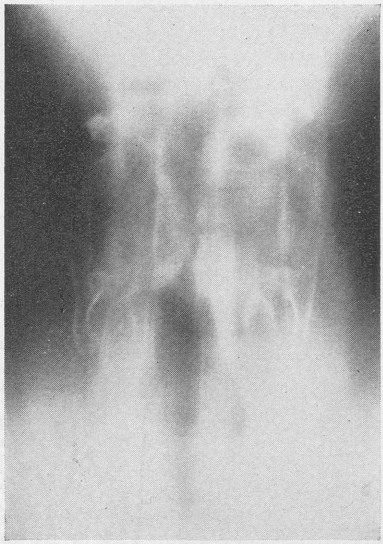

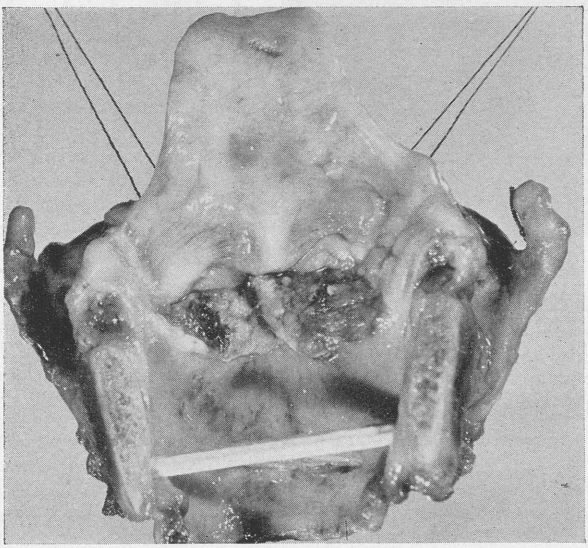

Case No. 766161. Male. Aged 45. Intermittently hoarse for two or three years—continuous for three months. Laryngoscopy—fungating lesion of both vocal cords with subglottic extension and fixation of the right cord. Laminagram—marked enlargement of both true cords with obliteration of the ventricles and subglottic extension on the right side. Biopsy report—Epidermoid carcinoma grade 1. Treatment—Total laryngectomy.

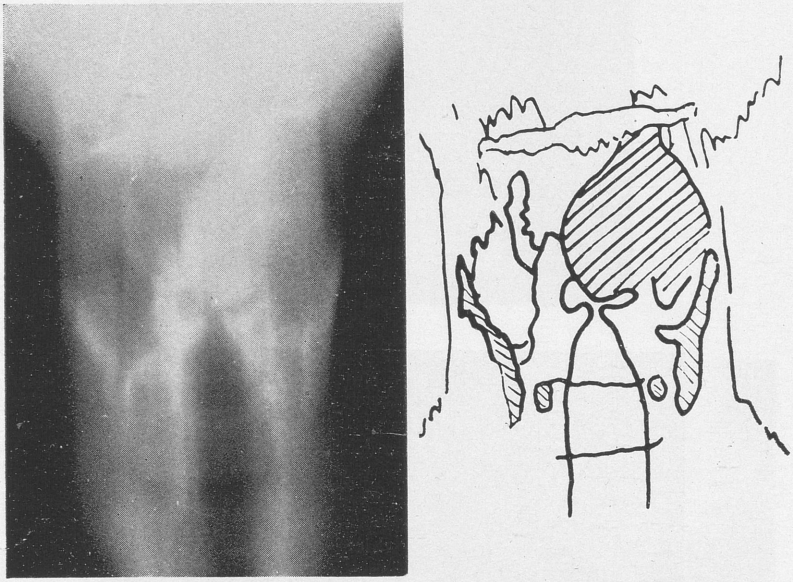

Case No. 212878. Female. Aged 36. This patient has been under observation since 1936 for an angioma involving the left false cord. The laminagram shows the lesion occupying the space of the left false cord and extending upward to the ary-epiglottic fold and piriform sinus. The ventricle is closed due to pressure from above. The true cords are not involved.

## DISCUSSION

DR. HENRY B. ORTON: Mr. Chairman, Members of the Association and Guests, this has been a very interesting presentation by Dr. Schall, and I think his procedure probably should be used more often than it is. I have used laminagrams since 1938 in obscure cases; they are of help in visualizing the lesions in the upper laryngeal type of growth, especially in the lateral and depth of the extension. Thank you.

DR. CHEVALIER L. JACKSON: Mr. Chairman, Members and Guests, I want to say that I am very glad Dr. Schall has seen fit to bring this very important method of studying the larynx to our attention.

Some years ago I wrote a little paper on the value of roentgenography of the neck. At that time we had chiefly the ordinary lateral films but our Department of Roentgenology was trying very hard to get, by the ordinary techniques, an antero-posterior view to go with the lateral. They managed to get a few pictures where the soft tissues could be fairly well seen in spite of the shadows of the cervical vertebrae, but we did not yet have laminography. This method has now become almost a routine with us in laryngeal cases. We find it most useful, as Dr. Schall has, in determining the subglottic extent of carcinomas. That is one of the method's most useful accomplishmens, but I recall one or two cases where it has been particularly useful as a method of graphically demonstrating a tumor of the ventricular band. I had intended to bring with me slides from one of these cases. Unfortunately I did not do so, but I should like to cite the case briefly. The patient was a male school teacher, who had a dampened sort of voice, not exactly hoarse but dampened, and laminagraphy showed beautifully a rounded tumor mass involving the ventricular band but not the cord. We kept this man under observation for several months, and after the interval comparative laminagraphy showed an increase in size of the tumor. We did an exploratory laryngofissure and removed this tumor, after frozen section biopsy showed it to be a benign cylidroma. In addition to the preoperative laminagrams we have also very satisfactory postoperative laminagrams which give an excellent graphic record of the postoperative condition showing absence of the tumor and preservation of a normal vocal cord.

Again let me say that I am very glad Dr. Schall has brought laminagraphy again to our attention. I know we are criticized by laryngologists from South America and Europe for not using this method more, and think we *should* use it more!

DR. SAMUEL SALINGER: I should like to add a word with reference to apparatus. You know, originally the first machines that were used for this purpose were very expensive; they were built especially for taking laminagrams and they ran into thousands of dollars. Since the advent of this detachable apparatus the expense has been considerably reduced. I think it only amounts to a few hundred dollars and any good x-ray man will know how to attach it and how to use it. It is therefore not beyond the means of the average laboratory.

DR. PAUL H. HOLINGER: Mr. Chairman, in addition to the antero-posterior laminagram, I believe mention should be made of the lateral laminagrams. It adds greatly to the study of the neck in the lateral projection, particularly in those cases in which the shoulders are unusually high and the larynx unusually low, where the lesion is lost in the shoulder shadow in the regular lateral view; also in those lesions that are not easily outlined when the patient has an extensive

ossification of the thyroid cartilages and consequently the ordinary lateral view of the neck does not give the differentiation that the lateral laminagram will give. These are to be used in addition to the antero-posterior laminagram, and while Dr. Schall may have included this technic in his paper, it was not mentioned in the presentation.

DR. LEROY A. SCHALL: Mr. Chairman, I wish to thank my discussers. I should have emphasized that for me lesions on the upper surface of the true vocal cord, and lesions that arise in the laryngeal ventricle, are the most difficult lesions to diagnose by direct or indirect laryngoscopy. The laminagram does show these lesions by the obliteration of the ventricle and I should have added this type of lesion as an indication.

Dr. Salinger mentions expense. Dr. Leborgue says he can make an apparatus with a piece of pipe and a couple of boards and bolts for $9.00. We paid $950 for our apparatus.

Dr. Holinger, we have used the lateral laminagram but due to the shortness of my presentation, of the multiplicity of slides, I did not mention the lateral, but we do use it. It is useful, as you have said. I omitted it so I could condense my paper for this presentation.

Thank you very much!

# THE CLINICAL SIGNIFICANCE OF KERATOSIS OF THE LARYNX AS A PREMALIGNANT LESION

F. JOHNSON PUTNEY, M.D.

AND

JOHN J. O'KEEFE, M.D.

PHILADELPHIA, PA.

The detection of a premalignant lesion before the development of clinical evidence of invasion presents a challenge to physicians. Frequently the challenge is not accepted, thus allowing for the development of an attitude of complacency, both on the part of the physician and of the patient, lulling them both into a feeling of false security based entirely on the negative character of a single histologic study. In keratosis of the larynx that is histologically benign one cannot speak of absolute benignity for the factors responsible for malignant degeneration may be activated to exert an uninhibited stimulus. When these changes may occur cannot be predicted, so that benign keratosis must always be considered as fertile soil for malignant development, making subsequent, frequent and prolonged periods of observation and histologic study essential.

The relationship between keratosis and carcinoma is controversial. In the presence of laryngeal keratosis carcinoma can easily be missed because of its limited extent at its inception. Are laryngeal keratosis, then, which are not malignant when first seen to be regarded as precarcinomatous? If so, is it in the sense that such degeneration is usual, occasional, or rare? It is our feeling that keratosis of the larynx is a premalignant lesion in a certain definite percentage of cases, and when the disease persists carcinoma is the usual outcome.

In a series of 125 patients with keratosis of the larynx studied at Jefferson Hospital (Table 1) the youngest was 32 years and the oldest 82 years with an average age of 54. The duration of symp-

From the Department of Laryngology and Bronchoesophagology, Jefferson Medical College, Philadelphia, Pa.

TABLE 1.

KERATOSIS OF LARYNX IN 125 PATIENTS

| | | |
|---|---|---|
| Age | 32 to 82 years | |
| Sex | Male | 117 |
| | Female | 8 |
| Duration of symptoms | 2 weeks to 10 years | |
| Location of lesion | Unilateral | 89 |
| | Bilateral | 36 |

toms ranged from two weeks to 10 years, the average being one year. There were 117 males and eight females. The keratosis was unilateral in 89 cases and bilateral in 36 cases.

The clinical term keratosis does not describe a definite and specific disease. While keratosis may be simply a surface manifestation of an underlying disease process it may also represent the sole pathological lesion. Keratosis implies a whitish patch, either flat or raised, smooth or nodular, localized or diffuse, surrounded by normal tissue or by an area of inflammation. The clinical picture is so variable that it necessitates confirmation by an exact histologic study to be of value. Histologically the findings consist of incomplete desquamation and abnormal cornification of the epithelial layer of mucosa with the formation of excessive keratin on its surface. In places the epithelium may dip deeply into the connective tissue, but the basement membrane remains intact. Subepithelial inflammatory cells are present and when these are numerous some observers have felt that they indicate a predilection for carcinoma. In keratoses of long standing, fibrous tissue develops in the subepithelial layers.

The cause of laryngeal keratosis has generally been attributed to chronic irritation of long duration. Metaplasias of the mucous membranes of other parts of the body have been frequently observed, and in about 50% of the cases studied by Niskanen[6] metaplasias were found in the bronchi in association with various inflammatory diseases of the lung. It would appear that keratosis of the larynx is equally common

following chronic irritation. The exact mechanism of these chronic, irritating factors producing epithelial metaplasia has not yet been fully uncovered. The irritation from smoking has long been considered a salient factor. In this series only 11.2% were non-smokers. This figure may be significant when compared with the smoking habits in the cross-section of the normal population as determined in Columbus, Ohio, in which 34% were non-smokers.[4] The majority of the smokers admitted to excessive use of tobacco. Yet in certain individuals who have submitted their larynges to this form of irritation over many years no such lesion has developed. Factors other than chronic irritation are probably necessary to produce this change. In some individuals this heaping up of epithelium may represent a regenerative process in an attempt to overcome the damage from the chronic inflammation. When the damage is repaired and the causative factor removed, epithelization becomes complete and proliferation ceases. The danger lies in the fact that the reaction to the stimulation may at some stage overstep its normal bounds and initiate a premalignant phase, eventually to be followed by malignant invasiveness.

In some instances keratosis has completely disappeared without any form of treatment. The keratosis experimentally produced by avitaminosis and deficiency in estrogenic hormonal substances is reversible. This reversability may extend to those cases in which chronic irritation is a factor. Clerf[1] pointed out that it is difficult if not impossible to predict the outcome in any one case.

In carcinoma of the larynx of low-grade malignancy, before there is fixation and invasion, keratosis may be the first sign because of the well-differentiated epithelium and formation of keratin. Infiltrating carcinoma may begin from a simple keratotic change, or the keratosis may appear as a stage in the malignancy, or develop on the surface of the carcinoma after it has formed.

The cases forming the basis of this report were classified clinically into three groups: (1) those which were carcinoma when first seen (57 cases), (2) those which were first benign and later developed into carcinoma (27 cases), and (3) those which never showed evidence of malignant degeneration, some after years of observation (41 cases).

It is the second and most interesting group of 27 patients first diagnosed as keratosis and progressing to carcinoma with which this discussion is particularly concerned. There were six cases in which the malignancy occurred less than six months after the first biopsy.

TABLE 2.

GROUP OF 27 CASES OF KERATOSIS OF THE LARYNX WHICH SUBSEQUENTLY BECAME MALIGNANT INDICATING TIME INTERVAL BETWEEN THE BENIGN AND MALIGNANT PHASES.

| TIME | NUMBER |
|---|---|
| under 6 months | 6 |
| ½ to 1 year | 4 |
| 1 to 2 years | 6 |
| 2 to 3 years | 3 |
| 3 to 4 years | 2 |
| 4 to 5 years | 2 |
| over 5 years | 4 |

These cases were undoubtedly malignant when first examined, but the carcinomatous change was not present in the biopsy specimen at that time. Subsequent histologic study revealed the malignancy which must have been present earlier but was not represented in the initial tissue. Of particular significance is the occurrence of carcinoma in four patients beyond a five-year period. In three of these there were intervals of from eight to ten years between the keratosis and the carcinoma (Table 2).

In observing keratosis of the larynx clinically we have felt that those lesions which exhibited a definite inflammatory zone around the periphery of the keratosis were more apt to be malignant or undergo malignant degeneration than those in which there was no inflammatory zone. In addition, those lesions which were irregular in their projection above the surface with a papillary appearance more often were found to contain carcinoma than those in which the lesion was flat with no sharp line of demarcation between the keratosis and the normal mucosa.

In those cases which undergo malignant degeneration the first change commonly observed is an alteration in the intraepithelial

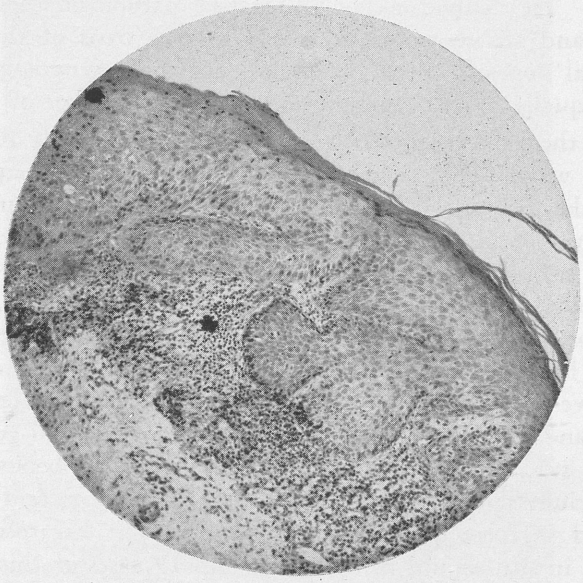

Fig. 1 (A).—Histologic section of keratosis of vocal cord. Area of mucosal change was regarded as premalignant and not definite enough to be diagnosed as intraepithelial carcinoma.

cellular structure which is now designated as carcinoma in situ. This stage of malignant cellular change limited to the epithelium, and without invasion of the basement membrane, may last for many years, and its exact potentialities are in doubt. On the other hand this change may be the first indication of invasive carcinoma. At times one may find carcinoma in situ adjacent to invasive carcinoma or invasion may be present in other parts of the lesion. The distinction between intraepithelial carcinoma and simple keratinization, while difficult, is of prime importance.

Formerly the pathologic diagnosis, as benign or malignant, was used to determine treatment to the exclusion of all other factors. The uncertainties of the now existent borderline conditions of premalignant and preinvasive carcinoma has rendered our selection of treatment debatable.

Repeated histologic examination of different portions of the keratotic lesion may be needed to make an accurate diagnosis. The

management of the case depends upon the clinician's evaluation of the lesion. He cannot accept a negative pathologic report as unequivocal and advise treatment solely on the basis of this finding. The clinical appearance of the lesion and the laryngologist's judgment are equally potent factors in determining the type of treatment.

With the modern emphasis on prevention and early diagnosis of carcinoma we may be carried away with the desire to prevent or eradicate the disease without properly verifying the diagnosis. This is especially true in dealing with carcinoma in situ, and care must be taken not to make an erroneous diagnosis on a few suspicious cells. Vast pathologic experience is needed to make this diagnosis, and there is room for error even by the most experienced pathologist. When this latter lesion of carcinoma in situ is present it is our feeling that conservative management can be followed. When the lesion is not extensive and is limited to a small portion of the vocal cord, it can be excised surgically. In its removal, however, we believe that the perichondrium should not be included so that a better functioning vocal cord is formed. Simple excision of the keratosis with its carcinoma in situ should be sufficient. In 19 cases of this group the entire lesion was removed in the biopsy specimen, and when thyrofissure was performed no residual carcinoma was found histologically in the excised tissue. This type of early carcinoma can also be treated with irradiation therapy, which has been reported as curative in a high percentage of cases. Such a lesion would also appear ideal for electrosurgical removal with suspension laryngoscopy as advocated by New and his associates[5] and Le Jeune.[3]

In addition to the 41 cases of initial benign keratosis there were nine patients who developed it following laryngofissure for keratotic carcinoma. Two of these occurred at the operative site, five developed in other portions of the larynx unconnected with the original lesion, and two spread throughout the larynx. Whereas this subsequent formation of keratosis might be independent of the former lesion it suggests that there is a predilection for keratosis in certain individuals, and when removed in one location it may occur in other areas of the larynx. The following case illustrates the tendency to recurrence:

CASE 1.—In 1948 a 37 year old white male was examined for hoarseness of three months' duration. He smoked at least three packs of cigarettes daily. On indirect laryngoscopy a raised, whitish area was seen on the left vocal cord which proved on histologic examination to be squamous cell carcinoma. The lesion was treated by laryngofissure with removal of the left vocal At this time there

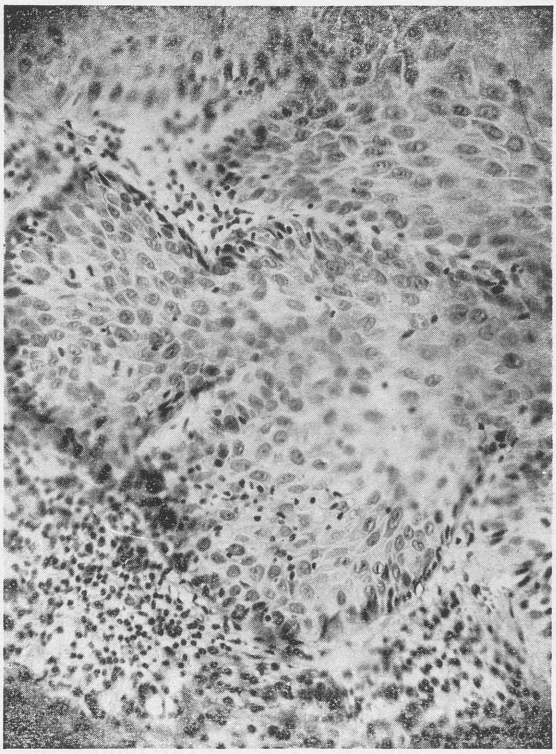

Fig. 1 (B).—Higher magnification of suspicious area of mucosal malignant change.

was no abnormality of the right vocal cord. One year later benign keratosis developed on the left vocal band at the operative site. In 1950 the right vocal cord which had previously been normal became the site of benign keratosis, and in 1951 squamous cell carcinoma developed in the right vocal cord. Since the entire lesion on the right was removed by biopsy no further surgical treatment was carried out at that time. The patient resumed smoking, and two years later, in 1953, carcinomatous changes limited to the mucosa of both vocal bands returned. Irradiation therapy was administered with disappearance of the lesion, and close watch is being maintained on the condition of the larynx.

In 1942 Graham[2] stated that most cases of keratosis can be handled with ease by removal of the lesion. While it is true that some cases are managed by this method, it has been our experience that in the majority of cases successful treatment has proved more difficult. A benign keratotic lesion with no histologic evidence of malignancy can be removed, and the elimination of all forms of irritation may

help prevent its return. When the lesion recurs after this treatment the problem becomes more complicated. The following case is an example of keratosis which remained benign but recurred over a six year period:

CASE 2.—Hoarseness was present for one month in a 52-year-old white male, who had smoked a pack of cigarettes daily for many years. The entire right vocal cord was involved by a raised, whitish nodular lesion on the edge and upper surface.

Forceps removal of the material at direct laryngoscopy was done, and the histologic diagnosis was keratosis. The lesion returned the following year, and the pathologic report was still keratosis but with some irregularity suspicious of carcinoma. For the next five years the lesion would disappear and recur, and histologic study at yearly intervals consistently revealed benign keratosis. Shortly before his death from coronary thrombosis keratotic material was removed from the right vocal cord, and no evidence of malignancy could be demonstrated.

When the keratosis is benign but is more extensive and involves an entire vocal cord or extends over a considerable portion of both vocal cords the problem of management becomes even more involved. If the keratosis persists after the elimination of all forms of irritation, is there anything else that can be done to eliminate the keratosis and prevent the carcinoma which will subsequently develop in many cases? Irradiation therapy was given to some of these patients, even though these well-differentiated lesions do not lend themselves well to this type of therapy. Radiologists have reported cases of keratosis with malignant degeneration, particularly in the buccal mucosa, in which irradiation therapy eradicated the carcinoma, but the keratosis persisted. The need for absolute safety against extension of the lesion is essential, yet the necessity for avoiding needless interference with the voice is extremely important. Surgical removal in this type of case would entail either a complete laryngectomy or else extensive intralaryngeal surgery, so that the voice would be markedly impaired. It is our feeling that irradiation therapy is beneficial in the treatment of extensive, persistent keratosis. This is illustrated in the two following case reports:

CASE 3.—In 1941 a 48-year-old white male complained of hoarseness of six months' duration. He admitted to smoking two packs of cigarettes daily. Mirror laryngoscopy revealed a raised whitish lesion on the anterior halves of both vocal cords. On the left side the involved cord appeared irregular surrounded by an inflammatory zone. All of the material was removed with forceps at direct laryngoscopy and the histologic report was keratosis, suspicious of malignancy. The lesion recurred persistently and tissue examinations were repeated each year with pathologic reports varying from simple keratinization to keratosis, suspicious of malignancy (Fig. 1). In 1949, eight years after the original keratosis, the pathologist diagnosed squamous cell carcinoma of the left vocal cord (Fig. 2). Because of the generalized extent of the keratosis on both vocal cords the patient

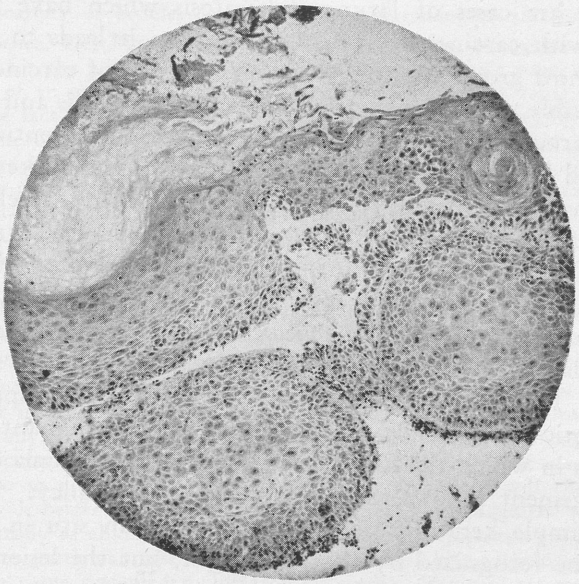

Fig. 2.—Eight years after the beginning of keratosis with premalignant characteristics invasive carcinoma was present on histologic section.

was treated with irradiation. He received a tissue dose of 6080 r delivered in a 5.5 cm field to the midline of the larynx over a period of five weeks. When last examined three years later generalized redness with edema and thickening of the mucosa was apparent, but there was no recurrence of either the keratosis or the carcinoma.

CASE 4.—A 38-year-old white male complained of hoarseness of three months' duration. On examination of the larynx an irregular, whitish lesion involving the anterior two thirds of both vocal cords extending to the anterior commissure was seen. The tissue was heaped up in the middle third of the right vocal cord. On histologic study of the tissue benign keratosis was found. Since the keratosis recurred after removal frequent tissue examinations were made, the report always being keratosis. Approximately one year after the original biopsy squamous-cell carcinoma developed in the right vocal cord. Laryngofissure was performed, and the anterior portions of both vocal cords including the anterior commissure were removed. The specimen revealed squamous-cell carcinoma in the right vocal cord and benign keratosis in the left vocal cord. Six months following operation keratosis began to reappear on the left vocal cord. It increased during the next four years until it again involved both vocal cords and extended onto both ventricular bands, involving almost the entire intralaryngeal mucosa. Irradiation therapy was given in the dosage of 4560 r delivered in a 25 sq cm field to the midline of the larynx over a five-week period. Following irradiation the keratosis completely disappeared, and when last seen the larynx remained free from it but exhibited post-irradiation changes.

SUMMARY

There are cases of laryngeal keratosis which have nothing in common with carcinoma. In another group it leads to carcinoma, and in a third group keratosis develops as a sign of carcinoma. Since it is impossible to tell which area will remain keratosis and which will undergo carcinomatous change, the elimination of the entire keratotic area should be practiced if at all possible. In simple keratinization marked improvement will follow within two or three weeks after the removal of all forms of irritation and abuse of the larynx. If the lesion has not exhibited definite clinical evidence of healing within this length of time, it must be regarded with suspicion. Persistent or recurrent keratosis requires repeated histologic study including the subepithelial layer to detect the malignant change which is the usual outcome. Treatment with irradiation may produce disappearance of the keratotic lesion while it is still in the premalignant stage. In those cases in which the first manifestation of carcinoma is keratosis, the management follows that of laryngeal malignancy. Distinction between simple keratinization and carcinoma in situ in the larynx can now be recognized by the pathologist, but the lesion should be evaluated by the laryngologist and the method of treatment dictated by his clinical experience.

255 South 17th Street.

REFERENCES

1. Clerf, L. H.: Keratosis of the Larynx, J. A. M. A. 132:823 (Dec. 7) 1946.

2. Graham, H. B.: Keratosis of the Larynx, Arch. Otolaryng. 36:735 (Nov.) 1942.

3. Le Jeune, F. E.: Intralaryngeal Operation for Cancer of Vocal Cord, Annals of Otology, Rhinology and Laryngology 55:531 (Sept.) 1946.

4. Mills, C. A., and Porter, M. M.: Tobacco Smoking Habits and Cancer of the Mouth and Respiratory System, Cancer Research 10:539 (Sept.) 1950.

5. New, G. B., Figi, F. A., Havens, F. Z., and Erich, J. B.: Carcinoma of Larynx, Surg. Gyn. & Obst. 85:623 (Nov.) 1947.

6. Niskanen, K. O.: On Keratosis of the Larynx and its Significance as a Precancerous Stage, Acta Otolaryng. 39:503 (Dec.) 1951.

DISCUSSION

Dr. John J. O'Keefe: Mr. President, Members and Guests, I believe Dr. Putney has presented the subject of keratosis of the larynx as a pre-malignant lesion in a very able and concrete way. Certainly from the context of the paper this is shown to be a very complex matter, one that certainly cannot be considered in a superficial or light way. There are few more baffling conditions that are encountered by the laryngologist than the subject of keratosis of the larynx, and there are fewer that present a more interesting academic controversy.

It is obvious, I am sure, to all of us, that keratosis of the larynx is far from being an absolutely known and appreciated subject, if for no other reason than from the scarcity of articles in the literature pertaining to this subject.

In essence, Dr. Putney's paper reflects just a few thoughts that are worth reiterating for the sake of emphasis. One is that the whole paper is devoted to a promotion of an interest on the part of the laryngologist to recognize and to appreciate the fact that keratosis of the larynx is a potentially serious matter. Even though some of them persistently maintain a benignity, the few that do change their nature warrant sufficient interest on our part to consider them all as important, or all as pre-malignant, until after a final and complete examination, the ultimate malignant nature of the lesion is obtained. If we develop an attitude of seriousness concerning the condition of keratosis of the larynx, I am sure few instances will be neglected and few patients will be overlooked as far as the carcinomatous element is concerned. In order that such a situation be attained, of course, and as Dr. Putney has stated, it means that the patient must be carefully examined, must be controlled by repeated clinical examinations, and that repeated histologic studies must be made on tissues secured from the larynx.

The one other thought contained in this presentation is the fact that keratosis in many or in several instances is a benign lesion and maintains itself so. Apparently it is only in the few instances that do degenerate into carcinoma that we have to be particularly careful, and it is only through this type of control that those few will be so diagnosed, and in whom proper treatment will then be affected. It probably is better that we rely more on our clinical judgment than to use the histologic study as absolute proof of malignancy or benignity: one's clinical judgment in this particular case is probably better than the pathologist's report concerning the tissue presented to him for his study. If we so use our judgment on patients who present this type of lesion, it is better that we consider them as having a malignant rather than a benign lesion, and treat them accordingly.

DR. FRANCIS E. LEJEUNE: Mr. Chairman, Members of the Laryngological Association, I enjoyed Dr. Putney's paper. I have become deeply interested in the subject of keratosis of the vocal cords because in the last few years we have been seeing an increasing number of such cases. Practically all these patients gave a history of excessive smoking. Recently, we have had occasion to see several truck drivers who had extensive keratosis of the vocal cords. These men, driving huge trucks at night, smoked incessantly to keep awake; one of them smoked as much as four packs of cigarettes each night. This means that their vocal cords are subjected to much abuse during this period of time. It is my opinion that some individuals are more sensitive to the products of combustion of vegetative material than are other people. Consequently, in these sensitive individuals there will be more irritation of the vocal cords as a result of smoking and eventually keratosis will develop.

When the keratotic lesion on the vocal cord shows a heavy deposit of keratin, manifested by a thick whitish granular lesion, I am always suspicious of a malignant growth. If this same thick whitish lesion of keratosis shows a dimpling of the structure in its center, deep biopsy will usually indicate presence of a malignancy. In all biopsies of keratotic lesions a sufficiently deep biopsy must be obtained in order to obtain a true picture of the existing pathologic alterations.

We have noted in recent years an increase of keratosis in women. This is probably due to excessive and concentrated periods of smoking while playing card games. Patients with keratosis are always warned of the dangers of the lesion degenerating into a malignancy. I plead with them to curtail their smoking habits drastically or preferably to stop smoking. If little cooperation is manifested on their part, I then use the word cancer instead of malignancy. This dreaded word

seems to awaken them to the realization of the potential seriousness of the existing lesion.

In patients with mild superficial keratosis, stripping is the procedure of choice. I am in accord with Dr. Putney that surgical removal usually gives excellent results. Dr. Putney mentioned x-ray treatment. I would be interested in hearing more about this as our results with x-ray have not been successful.

I thoroughly enjoyed this most interesting presentation of Dr. Putney.

PRESIDENT CLERF: This, incidentally, is a subject which I have been interested in for quite some time because it is a baffling subject. We know so little about it, and secondly, it is unpredictable. We have been seeing an increasing number of cases of keratosis in women and I have been impressed with the fact that the inveterate cigarette smoker is particularly the victim of keratosis and I am not so certain that it is entirely the matter of the combustion of the vegetable material alone. I am concerned that it may be the combustion of vegetable material and the paper that has been treated by some material to insure even burning and also treated with some cohesive that will permit it to remain moist. I have observed that pipe smokers and cigar smokers do not get keratosis to the same degree as do the cigarette smokers. Of course they don't inhale either and that is a factor that we cannot ignore.

The facts are that smoking and keratosis to me are almost synonymous since I rarely see it in a non-smoker.

There are several diagnostic points that the clinician can in time learn to not only observe but to attach some importance to and Dr. Putney referred to this inflammatory zone. I think that is a bad sign if you are thinking in terms of malignancy because keratosis around inflammation maintains bad tidings for the patient unless he mends his habits.

The second point, keratosis is something more than just a film. It begins to project from the surface either on the superior surface or beyond the edge of the cord, exhibits a nodular appearance. That may not be carcinoma now but it will ultimately become carcinoma unless there is some change in that patient's habits and that usually means to stop smoking.

There is one thing I should like to emphasize and that is this, not infrequently we see a patient who has a bilateral keratosis and we plan to do a biopsy and inadvertently the nurse places the specimen of the right vocal cord and the specimen from the left vocal cord in the same container and then you receive a diagnosis of carcinoma and I will defy you to decide what to do in that particular case. That is very important because it has happened in the experience of a number of us and it is just a little tip.

DR. F. J. PUTNEY: I wish to thank the discussers.

Dr. LeJeune brought up the question of stripping the vocal cords. We have practiced this a great deal and have attempted to remove all the keratotic material. In some cases the keratosis which is superficial can be stripped off the vocal cord, but the subepithelial tissue which may show malignancy is not obtained in a specimen of this kind. It is necessary to obtain sufficient and representative tissue including the subepithelial layer before malignancy can be eliminated.

The irradiation therapy of these patients was carried out by Dr. Eberhard, and on an average they were given between 5000 and 6000 r as a tissue dose. They received approximately this amount to the interior of the larynx. This dosage was given when the diagnosis of malignancy had been substantiated and was usually administered in a 25 cm field over a period of from four to five weeks. These larynges received a large amount of irradiation, and afterward they showed considerable irradiation reaction. The longest patient has now been treated over three years and his larynx still shows the effect of the irradiation with marked post-irradiation changes.

# CARCINOMA-IN-SITU OF THE LARYNX

ALDEN H. MILLER, M.D.

AND

H. RUSSELL FISHER, M.D.

LOS ANGELES, CALIF.

Carcinoma-in-situ of the larynx is being recognized with increasing frequency in biopsy material from cases in which the clinical diagnosis of carcinoma was not apparent. Undoubtedly this is due in large measure to a growing appreciation and awareness of the concept of an intra-epithelial, non-invasive stage of carcinoma by both laryngologists and pathologists coupled with an increased use of the biopsy in superficial lesions of the larynx. The disclosure of the presence of carcinoma-in-situ raises in each case a series of questions as to the pathogenesis of this legion, the criteria for its identification, the invasive potential that might be anticipated, and the most appropriate treatment for it. With these problems in mind, a review of our experiences with thirteen cases is presented.

The term carcinoma-in-situ was used by Broders[1] in 1932 to describe an early pre-invasive stage of intra-epithelial carcinoma that is recognized by the profound cellular alteration in intact surface epithelium. The realization of the true, potentially malignant nature of this lesion was expressed by the earlier term of intra-epidermal carcinoma, and dates back at least to the observations of Bowen (1912). In the last two decades a voluminous literature has recorded the increasing recognition of this pathological state. Although much of the work has concerned the uterine cervix, the possibility of this condition appearing in any epithelium was recognized early, as the report by Mallory[2] in 1940 indicates. Votaw[3] reviewed the evolution of the acceptance of this entity and described five cases of carcinoma-in-situ of the larynx. Additional mention appears to be confined to the case reports of Brighton and Altman,[4] Clerf,[5] Snitman,[6] Brun-

From the Department of Otolaryngology and Pathology, School of Medicine, University of Southern California.

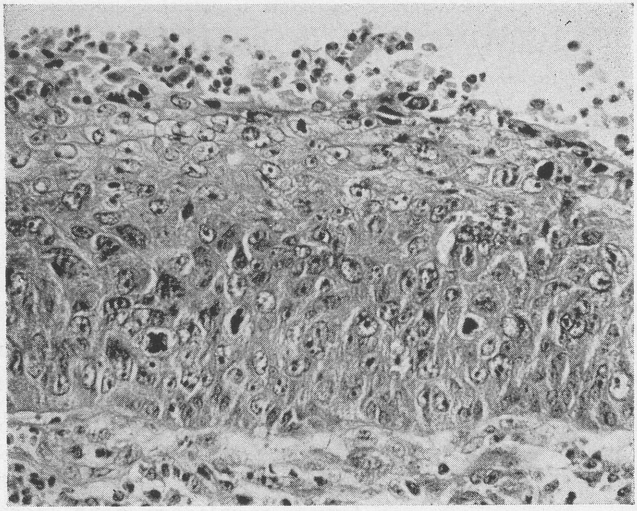

Fig. 1.—Carcinoma-in-situ, larynx. x 350. Mitotic figures prominent.

ner,[7] Gordon,[8] and the group of cases reported from the Presbyterian Hospital by Altman, Ginsberg and Stout.[9]

## HISTOLOGICAL CRITERIA

The histologic features of carcinoma-in-situ are reasonably obvious, particularly in stratified squamous epithelium which is the site usually affected by the process. At first glance, the epithelium appears hyperchromatic and basophilic and the normal stratiform differentiation of the epithelium is lost (Fig. 1). The normal layers are indistinct or missing and the regular progression from basal cell layer to surface is no longer present. The basal cells vary in size and shape and their type is abnormally extended up through the more superficial layers, so that the normal single cell layer of basal units is no longer distinct. In the prickle-cell layer the intercellular bridges have usually disappeared. In this region the cells tend to be rounded or irregularly polyhedral; the nuclei vary in size and shape and large "bird's eye" nuclei with large nucleoli are present. The absence of a distinct and uniform basal cell layer and the occurrence of anisonucleosis throughout the thickness of the epithelium are the most arresting and convincing features to the observer. Mitotic

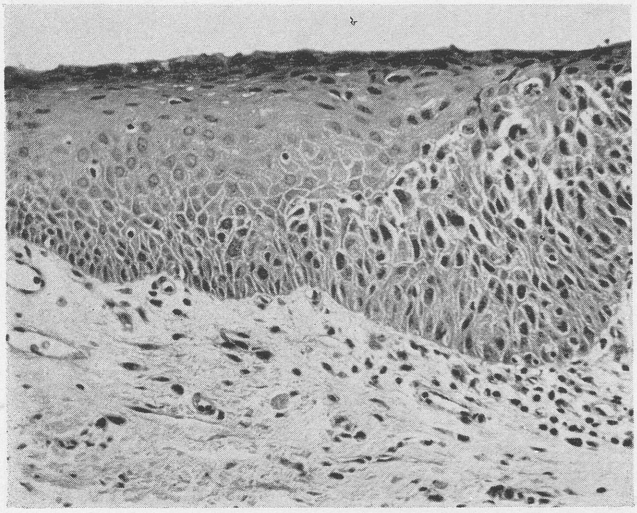

Fig. 2.—Margin of carcinoma-in-situ, larynx. x 350. The junction is diagonal.

figures are usually numerous and they can always be found in the area involved. These figures may be normal or atypic and muli-polar in appearance.

Irregular foci or keratinization can be found in any portion of the epithelial layer. In some cases this occurs near the surface, and occasionally the entire surface is covered by a keratotic or parakeratotic layer of considerable thickness. The appearance of the process of carcinoma-in-situ either without or with accompanying well-defined hyperkeratosis, suggests that this profound change can occur in previously normal epithelium or in epithelium which is the seat of keratosis.

Usually the layer of epithelium involved by carcinoma-in-situ is increased in thickness but this is not invariably so, as the same changes can be seen in extremely thin epithelial surface layers. The epithelium can extend in a flat unvarying layer or its epithelial pegs can be markedly deepened and widened. The supporting tissue varies from practically a normal state to one which is greatly changed by edema, congestion and inflammatory alteration. The presence of a

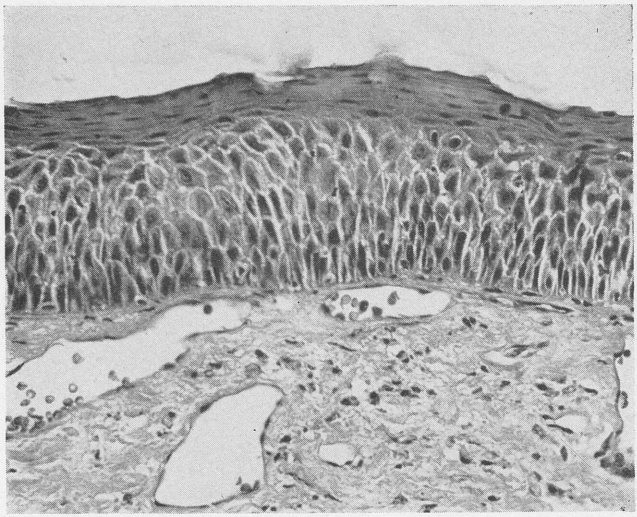

Fig. 3.—"Basal zone hyperplasia," larynx. x 350.

lymphocytic infiltration of considerable intensity just beneath the involved epithelium appears to suggest that invasion is imminent; it is seen most often when the large epithelial pegs intrude deeply into the supporting tissue.

The presence of in-situ carcinomatous change in epithelium is most obvious at the junction of unaltered and carcinomatous epithelium (Fig. 2). The junction line is usually sharp and distinct, except in those cases of carcinoma-in-situ developing in previous keratosis.

In approaching the microscopic diagnosis of carcinoma-in-situ, the difference between it and normal stratified squamous epithelium or simple keratosis is usually obvious, but it can be confused with a condition we refer to as "basal zone hyperplasia" (Fig. 3). In this latter lesion, the basal type of cell continues up through a portion of the prickle-cell layer developing a zone in which the cells are uniformly hyperchromatic and have a vertical polarity. Commonly this process terminates abruptly at the upper prickle-cell layer with a sharp zone of transition to horizontally oriented cells. Although the cells in this basal zone are hyperplastic and mitotic figures are

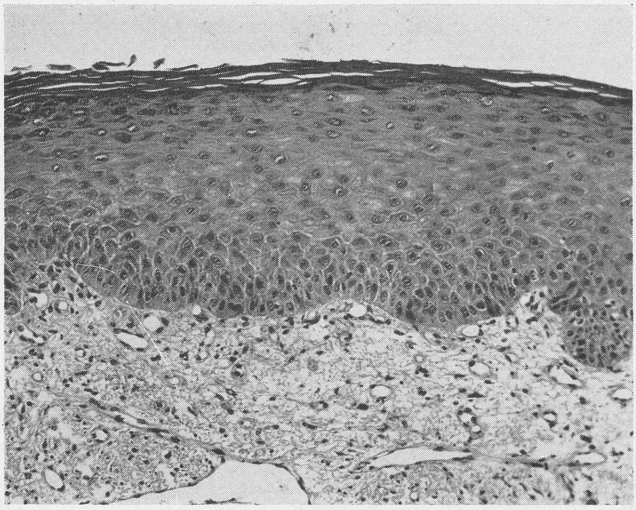

Fig. 4.—Keratosis, larynx. x 175.

encountered, the absence of anisonucleosis and the perfectly regular pattern presented by this change argue for the exclusion of this lesion from those identified as carcinoma-in-situ. We believe that this process or basal zone hyperplasia represents a transitional phase prior to carcinoma-in-situ in which the biological intent for malignant proliferation has not yet been declared. This process occurs as an isolated phenomena and also has been found to be associated with carcinoma-in-situ and invasive carcinoma.

The recognition of carcinoma-in-situ has developed more precise criteria for the non-malignant hyperplastic phenomena of the laryngeal mucosa. Keratosis is manifested by regular hyperplasia with a normal sequence of differentiation from the basal layer to surface, usually with an accentuation of the zone of keratinization (Fig. 4). Anisonucleosis is absent. Although mitotic figures can be anticipated, peculiar atypic mitoses and isolated bizarre giant cells are not encountered in simple keratosis. As in carcinoma-in-situ, the keratotic epithelium can vary markedly from a thin to a thick epithelial layer; usually it is greatly thickened, exceeding in width the average case of carcinoma-in-situ.

TABLE I.

| NO. | CASE | AGE | SEX | DURATION OF HOARSENESS (MONTHS) | SMOKING | VOCAL ABUSE |
|---|---|---|---|---|---|---|
| 1. | D. W. | 37 | M | 3 | Heavy | + |
| 2. | P. B. | 57 | M | 12 | Heavy | 0 |
| 3. | S. K. | 44 | F | 9 | No | + |
| 4. | F. F | 29 | M | 1½ | Moderate | 0 |
| 5. | D. A. | 34 | F | 1¼ | Moderate | 0 |
| 6. | T. T. | 46 | F | 12 | Moderate | 0 |
| 7. | G. J. | 68 | M | Years | Heavy | 0 |
| 8. | C. C. | 78 | M | 5 | Moderate | 0 |
| 9. | F. B. | 56 | M | Years | No | + |
| 10. | L. S. | 50 | M | 15 | Heavy | 0 |
| 11. | A. S. | 55 | M | 6 | Heavy | 0 |
| 12. | H. A. | 40 | M | 12 | Heavy | 0 |
| 13. | H. B. | 63 | M | 1½ | Heavy | 0 |

By definition, carcinoma-in-situ is confined to the surface epithelium and has not extended by invasion into the supporting connective tissue (Fig. 5). The process can continue down into the ducts of glands without violating this concept. There is always a clear-cut, regular and continuous demarcation between epithelium and connective tissue.

## CLINICAL FEATURES OF CARCINOMA-IN-SITU

Since September of 1948 we have encountered 13 patients with superficial lesions of the larynx which on histopathologic examination revealed intra-epithelial carcinoma without invasive tumor (Table I). (The many cases of carcinoma-in-situ associated with invasive carcinoma are not being considered in this report.) The youngest patient was 29 years of age and the oldest 78. The average age was 46 and the median age was 48. Only three of the thirteen were women.

TABLE II.

CLINICAL APPEARANCE.

| | | |
|---|---|---|
| *Leukoplakia* | 8 | |
| Thick | | 5 |
| Thin and punctate | | 3 |
| *Thickening* | 2 | |
| *Redness* | 8 | |
| All larynx | | 1 |
| Entire cord | | 4 |
| Focal | | 3 |
| *Distribution* | | |
| One cord | 11 | |
| Entire | | 6 |
| Partial | | 5 |
| Both cords | 2 | |

Hoarseness, the only symptom, was present in all patients and was continuous from one and one-half to fifteen months before diagnosis. Four patients had been intermittently hoarse for years. Of the entire thirteen, seven were heavy smokers; four smoked moderately, and two were non-smokers. One of the non-smokers, a woman, is one of the two patients who have had a recurrence. There probably had been vocal abuse in three patients. Two of these were salesmen and one was a lecturer.

Upon indirect or direct laryngoscopic examination there was no characteristic or distinctive picture. In fact, a clinical diagnosis of carcinoma-in-situ was not made in any patient prior to biopsy and the appearance in only two lesions suggested that they might be malignant.

(Table II) Leukoplakia was prominent in eight cases. In five of these the white coating was very thick and somewhat shaggy, and was the only visible lesion other than slight thickening of the area involved (Fig. 5). In three there was thin, punctate leukoplakia over slight thickening. The remaining five patients (Fig. 6) exhibited only redness and thickening. One entire cord was diffusely involved by a smooth, red swelling in three of these five cases, (Fig. 7) while the other two (Fig. 8) had localized irregular red thickening of only a part of a true cord. In all of the cases in this series the lesion was intrinsic in location. Both cords were involved in only two cases (Fig. 9). In seven cases all of one cord from anterior to posterior commissure was involved so that a laryngo-fissure operation could not be expected to safely remove all disease.

One larynx was especially interesting. The original lesion was a small, sesile, dark-red mass on the mesial border of the middle third of the right true cord. This lesion was stripped away and histopathological examination revealed carcinoma-in-situ with a small amount of infiltrating epidermoid carcinoma, grade II. Two days later all of this cord was removed by laryngo-fissure. At operation a tiny, 3 mm area of thin leukoplakia was noted on the center of the opposite cord. Anteriorly and posteriorly this cord was normal in appearance and the anterior commissure was clear. Biopsy of this small area of leukoplakia exhibited carcinoma-in-situ as a lesion separate from the invasive carcinoma of the right cord which was well surrounded by normal tissue in all directions.

## TREATMENT

When we encountered our first case in 1948 it was necessary to draw upon the experiences of those working in other fields to determine our management of this lesion. Most of these experiences have been with carcinoma-in-situ of the cervix and the majority of the writers were convinced that invading carcinoma would ultimately develop. The length of time necessary for invasion to occur in cases of carcinoma-in-situ was thought to be quite variable; Pund, et al[10] concluded that carcinoma-in-situ averaged five to six years before becoming invasive. Therefore, we concluded that this lesion must be treated practically the same as an invasive one. Because this patient's visible lesion was a coating of leukoplakia involving all of one cord from anterior to posterior commissure, and because multiple areas of carcinoma-in-situ were found in the tissue stripped

TABLE III.

TREATMENT AND RESULTS.

| | NUMBER | CONTROLLED | RESIDUAL CA-IN-SITU | RESIDUAL KERATOSIS |
|---|---|---|---|---|
| Stripping | 1 | 1 | | |
| Laryngo-fissure only | 2 | 2 | | |
| Radiation only | 3 | 3 | | |
| Radiation and stripping | 7 | 5 | 2 | 2 |

from the surface, it was decided that just this stripping could not be considered as having removed all possible areas of carcinoma-in-situ. Similarly it did not seem that a laryngofissure could insure removal of all potentially invasive tumor. It was decided to give this larynx a cancericidal course of deep x-ray irradiation. We were supported in this decision by the satisfactory experiences of most radio therapists in treating carcinoma-in-situ of the cervix.

This patient (Case 1) received a tumor dose of 3936 roentgens in 30 treatments. In 33 days his larynx was clear of leukoplakia or other lesion. One year and nine months later, in July of 1950, after having started smoking again for a few months, leukoplakia reappeared in the middle of the opposite vocal cord. This disappeared in one month on again discontinuing smoking. This cycle of events was repeated in March of 1951 and again in May of 1952. On May 16, 1952 the left cord, the site of the original leukoplakia with carcinoma-in-situ, was normal, but thick leukoplakia was stripped from the anterior and posterior thirds of the right cord. This was reported as keratosis with no carcinoma-in-situ. After four and a half years following x-ray treatment there is no evidence of invasive carcinoma or carcinoma-in-situ.

Since the first case, nine additional patients in our series have been treated by fractional deep x-ray irradiation receiving a tumor dose of 3690 to 4305 roentgens (Table III). In seven of the total of ten patients so treated the superficial lesion was first stripped away. Seven of the ten patients treated with x-ray now appear to be clinically controlled; the longest elapsed time following treatment being

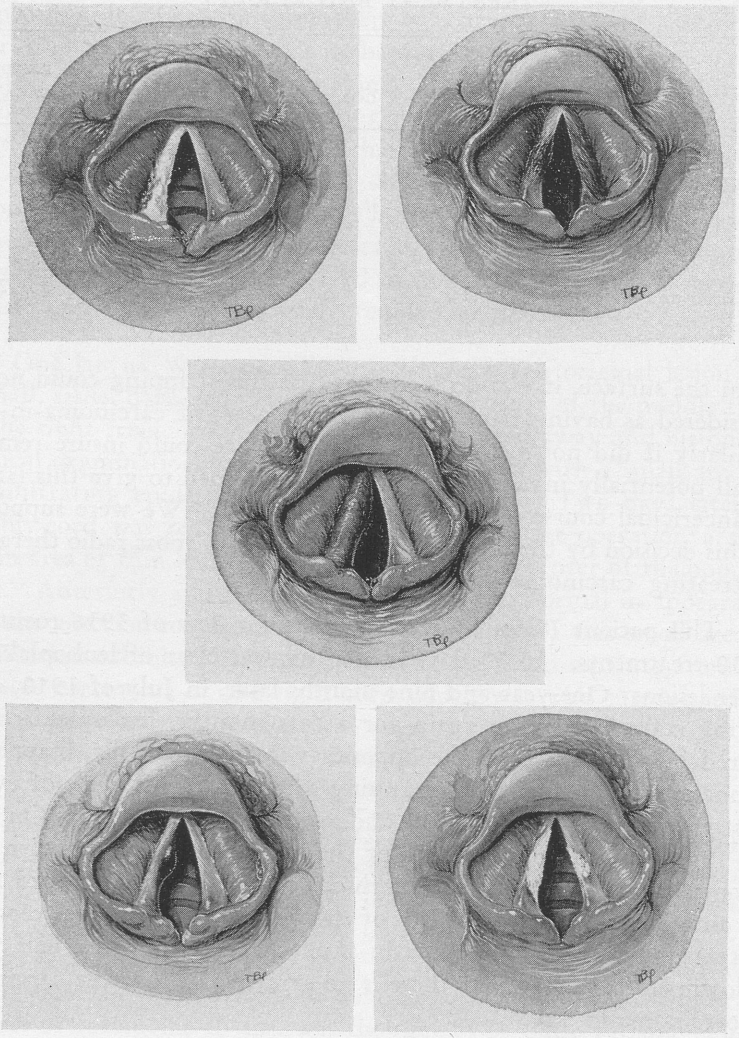

Fig. 5.—Thick leukoplakia with carcinoma-in-situ.

Fig. 6.—Thin and punctate leukoplakia over thickening with carcinoma-in-situ.

Fig. 7.—Diffuse red swelling with carcinoma-in-situ.

Fig. 8.—Localized red swelling with carcinoma-in-situ.

Fig. 9.—Both cords involved by leukoplakia with carcinoma-in-situ.

53 months and the shortest, five and one-half months. Two patients had a recurrence of carcinoma-in-situ appearing 6 months and 16 months respectively; in two tiny, 2 mm nodules in each case. Following endolaryngeal removal of these nodules the larynx has remained normal in appearance to the present time, for ten months in one case and for six months in the other. The tenth patient completed his course of x-ray treatment only four weeks ago. The first patient treated with irradiation has residual keratosis but no carcinoma-in-situ.

Two patients were treated by laryngo-fissure only. After 31 and 16 months respectively both are apparently controlled. Stripping only, was done in one patient and this larynx has remained normal for the past eighteen months.

## COMMENT

We have leaned toward radiation therapy because of the general radiological experience with carcinoma-in-situ, and the ability of this modality to reach all possible sites of involvement by this early and superficial malignancy. Our experience suggests that carcinoma-in-situ of the larynx can usually be controlled by irradiation, but that recurrence after this type of treatment does develop in some cases.

Conservative surgical treatment by stripping, or even laryngo-fissure, presumably has limitations to the completeness with which all possible foci of carcinoma-in-situ can be removed. Nevertheless, our three cases having only this type of therapy remained controlled.

Combination of stripping with radiation has been elected most frequently with the underlying concept that the advantage of both forms of treatment would be secured. The stripping was usually done in the extensive lesions before the exact nature of the lesion was known. This obtained complete removal of the superficial lesion and decreased the chance of overlooking any small foci of carcinoma-in-situ. Obviously it is imperative to individually judge each case as distribution of the lesion will influence the degree and type of surgical treatment possible. In all cases we advise complete discontinuance of smoking and vocal abuse. Recently we have prescribed a high vitamin intake.

So far, no firm conclusions can be drawn concerning the ideal treatment that should be utilized and many questions remain unanswered. The case that returned to normal after only biopsy is

provocative. We believe it will require large groups of cases treated with the several possible combinations of radiation or surgery or both of these and observed over long periods of time, before any final conclusions can be drawn. To this end we suggest that a separate tumor registry for this lesion be established.

500 S. Lucas Ave.

## REFERENCES

1. Broders, A. C.: Carcinoma-in-situ Contrasted with Benign Penetrating Epithelium, J. A. M. A. 99:1670-1674, 1932.

2. Mallory, T. B.: Carcinoma-in-situ of the Stomach and Its Bearing on the Histogenesis of Malignant Ulcers, Arch. Path. 30:348-362, 1940.

3. Votaw, R.: Carcinoma in Otolaryngology, Laryngoscope 62:973-997, 1952.

4. Brighton, G. R., and Altmann, F.: Bowen's Disease and Superficial Mucosal Epithelioma of Upper Respiratory and Alimentary Tracts, Arch. Otolaryng. 36:354-371, 1942.

5. Clerf, L. H.: Cancer of the Larynx, Report of Unusual Case, Annals of Otology, Rhinology and Laryngology 53:335-338, 1944.

6. Snitman, M. F.: Carcinoma of the Larynx: Significance of Histopathologic Study of Serial Sections; Preliminary Report, Arch. Otolaryng. 42:178-185, 1945.

7. Brunner, H.: Superficial Epidermoid Carcinoma of the Larynx, Arch. Otolaryng. 51:49-64, 1950.

8. Gordon, R. G.: Keratosis of the Larynx. Report of a Case with Underlying Carcinoma-in-Situ, Laryngoscope 60:1201-1209, 1950.

9. Altman, F., Ginsberg, I., and Stout, A. P.: Intraepithelial Carcinoma (Cancer-in-situ) of the Larynx, Arch. Otolaryng. 56:121-133, 1952.

10. Pund, E. R., Nettles, J. B., Caldwell, J. D., and Nieburgs, H. E.: Preinvasive and Invasive Carcinoma of Cervix Uteri: Pathogenesis, Detection, Differential Diagnosis and Pathologic Basis for Management, Amer. J. Obst. and Gynec. 55:831-837, 1948.

## DISCUSSION

Dr. LeRoy A. Schall: Mr. President, it is an honor to discuss Dr. Miller's paper. It was so wonderfully and, so excellently done that it deserves discussion. Being associated with the late Dr. Tracy Mallory, who used the term "carcinomata-in-situ," I have been familiar with the problem. My experience parallels that of Dr. Miller.

I wish to thank Dr. Miller for the fine presentation and the extraordinary slides he showed.

Dr. Gabriel Tucker: I enjoyed Dr. Miller's paper very much. I think all the men who are doing this work have encountered this type of patient. As to the use of radiation in such cases, knowing what radiation does to the larynx, the

question arises, just what are you going to be able to determine by observation of this larynx? We have had five cases of local carcinoma removed by direct laryngoscopy. These cases go from eight years to the last three years. The question of giving these people radiation may add to your confusion. If it is a very superficial lesion, you can wait a certain length of time before you can start the radiation. If there is recurrence after removal, then you may do something more in this regard. We have had five cases which we have had localized carcinomata which have not recurred over varying periods of time and we have been content to follow these cases and observe them without using irradiation, until specifically indicated.

DR. PAUL H. HOLINGER: Mr. Chairman and Members, certainly this paper as well as the previous one is extremely interesting and timely, and in spite of the remarks of our eminent President, I can hardly see how they can be separated. They should be discussed together and presented as a single subject because of the progression from one to the other.

One characteristic that has not been mentioned is the texture of the lesion and this is one of the reasons that the person who is to carry out the therapy should have the opportunity of doing the original biopsy. I think the texture of the lesion and the manner in which it strips from the cord may influence the decision as to subsequent therapy. The removal of a single superficial plaque, as was so beautifully shown in one of the pictures may give a normal appearing base to the cord subsequently and allows one to consider the lesion much more conservatively than a lesion which shows no differentiation on the surface from which it has been removed. In keratotic lesions that extend up to the false cord and yet show some evidence of carcinoma in situ, irradiation therapy might be preferred because the surgical alternative would be a total laryngectomy under these circumstances.

I appreciate the opportunity to hear both of these extremely important papers.

DR. CLERF: The term "carcinoma-in-situ" may be confusing to the clinician if he is not aware of its significance. I always am concerned about this diagnosis if there is no submucosal tissue in the specimen. The pathologist should have an adequate specimen so that he can give an opinion not only of the epithelium itself but also its relation to the submucosal layer. If the specimen is adequate and if the carcinoma is truly in situ, if the patient is competent to appreciate the importance of being observed at frequent intervals and to follow advice concerning his habits I do not believe that one is jeopardizing his life, health or future by keeping him under observation for a time rather than proceeding with either a course of irradiation therapy or further surgical treatment. I have several cases now that have been under observation for more than five years without evidence of recurrence. This is of course poor advice to give the patient who probably will not return again until he exhibits evidences of an extensive carcinoma.

It is important for the laryngologist to take into account many factors in addition to the pathological diagnosis in evaluating such a case.

DR. WALTER P. WORK: Mr. Chairman, Members, and guests. I would like to say one thing about this problem. All have discussed observing the lesion clinically, however, if one is not satisfied with the stained pathological section, the tissue block can be turned over or sectioned tangentially, and sometimes the diagnosis will be made. Thus further biopsy may be avoided.

DR. H. RUSSELL FISHER: Mr. Chairman, and Members of the Association, we certainly would agree with Doctor Putney that any pathologist can be in error

in making a judgment on borderline cases of carcinoma-in-situ and keratosis. We believe that the error can be minimized by cooperation between the laryngologist and the pathologist so that the submitted tissue is better understood, and by care in handling of the tissue material during preparation for microscopic study.

Every piece or fragment of tissue submitted, particularly as a biopsy, should be studied. The fragments can be arranged in clusters so that they are all in one plane, and the larger pieces arranged in rows. A number of sections of each block are cut in semi-serial fashion and placed on each slide, (as illustrated). It is of the greatest help if each fragment is oriented so that the section passes perpendicularly to the mucosal surface. To accomplish this, each piece of tissue should be placed on its side with the aid of a hand lens, if necessary, as it is embedded in the paraffin block. Improper orientation of tissue fragments results in oblique or tangential sections in which differentiation and invasion cannot be properly and accurately studied.

The smallest amount of invading epithelium (as in the projected slide) in a case which is otherwise typical carcinoma-in-situ, modifies its classification. Small islands of invading epithelium can be recognized by their lack of a basement membrane and by the peripheral position of squamous-type cells. The presence of the smallest amount of invasion indicates that the tumor has declared its biological potency for active malignant growth.

At the benign end of the spectrum there are cases (projected slide) in which the differentiation between keratosis and carcinoma-in-situ resolves itself into a matter of personal judgment on the part of the pathologist. A slight degree of anisonucleosis of itself does not necessarily indicate that the process is carcinoma-in-situ. When the epithelium retains its normal tendency to stratiform differentiation, we usually classify it with the keratosis. The perfect progression of differentiation is interrupted and anisonucleosis also usually is present in early cases of carcinoma-in-situ. The presence of numerous mitotic figures, and particularly abnormal mitoses, adds to the persuasion for this diagnosis. No matter how carefully the features of each process are defined, there will always be borderline cases in which the classification is subject to personal judgment. We believe that the most critical feature is the presence or loss of the normal ability to differentiate.

In carcinoma-in-situ the disturbance usually extends through all layers of the epithelium. Occasionally we will make this diagnosis in instances of basal zone hyperplasia with deep bizarre formations even though the superficial layers of the epithelium are normally squamous.

In those rare instances in which the biopsy includes the junction between normal epithelium and carcinoma-in-situ, (projected slide) the sharp contrast offers a happy reinforcement of one's judgment on basophilia, differentiation and anisonucleosis.

One can hardly overemphasize the importance of subjecting every tiniest fragment of biopsy tissue to microscopic study. Not infrequently carcinoma-in-situ will occur in only one fragment of relatively abundant material, the remainder of which indicates only the presence of keratosis. (The present slide indicates such a minute area of carcinoma-in-situ arising in tissue which is otherwise only keratotic.) Carcinoma-in-situ apparently can arise in normal epithelium, in a keratosis or in the type of hyperplastic process, possibly intermediate in nature, which we have designated as basal zone hyperplasia.

Thank you!

DR. ALDEN H. MILLER: First I should like to thank the discussants. They have added very much to the paper. I am happy that Dr. Schall feels about the same as we do about many aspects of the subject.

Dr. Tucker: We consider x-ray the safest because of our inability to be sure that we have proven that every bit of that larynx does or does not have carcinoma-in-situ and we feel safe that in using low dosages, which seem to have been effective, we are going to get no ill effects from the irradiation.

Dr. Holinger: As you noticed, keratosis was present in more than half of our cases but then in the others there was no clinical suggestion of keratosis. You might be interested in one of the cases that I ran across in the literature in which the laryngologist completely and characteristically described two little vocal cord nodules and yet when he nipped the two off, they both had carcinoma-in-situ.

Dr. Clerf: The reason why we don't like to wait too long I think is colored because of my associations on the Tumor Board with the men who are dealing with carcinoma-in-situ in the cervix. There they have been surprised to find it in clinical specimens that looked completely normal.

I am very happy that Dr. Putney touched on a few of these points and I am very happy that most of his thoughts were the same as mine.

In conclusion, I think you can understand why all of us in Los Angeles are so happy that we have someone like Dr. Fisher to help us with our patients.

# CHORDOMA—FINAL REPORT AND RE-EVALUATION OF TREATMENT

HENRY B. ORTON, M.D.
NEWARK, N. J.

In 1947 Imperatori reported a case of chordoma of the cervical vertebrae before this Society, with a very promising result. The purpose of this paper is to follow-through the subsequent progress of this same patient. To read the paper in its entirety would take up too much time.

There is no need for my going into the histopathology of chordoma, as this has been very clearly defined by Imperatori in the first part of this paper.

The paper is divided into three parts:

Part I is a report in detail by Dr. Imperatori as published in the Transactions of the American Laryngological Society in 1947; with comments in several instances as noted in brackets.

Part II concerns the subsequent progress of the case from Imperatori's record to the time the patient came under my observation, also with comments.

Part III is the subsequent progress of the case while under my observation until his demise. The rapid development of the final symptoms are facts of interest.

## PART I

Imperatori reported before this Society in Volume 68, in 1947, a very interesting paper on "Chordomas of the Cervical Region." I shall include his paper with my own so as to bring the history of this case to its conclusion.

To quote Imperatori's paper: "These rare tumors that are vestigial remnants of the notochord[1] (an axial structure characteristic of all vertebrates), are usually located at those areas representing its

extremities, viz., the spheno-occipital synchondrosis and the sacro-coccygeal region. Rarely are they found in the cervical areas.

"Normally,[2] portions of the notochord persist in the intervertebral discs as the central mucoid cores or pulpy nuclei (nuclei pulposi).

"Virchow,[3] in 1857 described small jelly-like tumors occurring in the region of the dorsum sellae and named them "ecchondrosis physaliphora." These were attributed to islets of degenerated cartilage from the spheno-occipital synchondrosis.

"Fabricius reported,[4] a case history of a patient with a chordomatous growth of the nasopharynx and pharynx, who was operated upon twice, the second operation being four and one-half years later, and who remained well without further recurrence. Complete details are not given.

"Syme and Cappell,[5] described in some detail such a tumorous growth. It was located on the posterior pharyngeal wall and grew upward toward the nasopharynx and downward toward the larynx, being attached to the 2nd, 3rd and 4th cervical vertebrae. The chief symptoms were pain in the head and neck, stiffness in the neck and difficulty in swallowing. The patient was operated upon in July, 1926, and by January, 1927, a second operation became necessary, but was unsuccessful. The approach was externally. There was no lymph node involvement and no invasion of the adjacent structures observed at the operation in January. However, one lymph node was found to be involved at the second operation.

"Andre-Thomas and Villandre,[6] reported a case, and Cappell,[7] reported two such tumors attached to the cervical vertebra.

"Chiari[8] reported a cervical chordoma which was attached to the surfaces of the borders of the 4th and 6th cervical vertebrae.

"Definitely, chordomas of the pharyngeal and mid-cervical areas are of such uncommon occurrence that they warrant recording, and such a report will be included in this communication. [The ultimate result of this case will be reported by the present author.]

"Ridpath[9] states these tumors 'have been reported as occurring in various locations in the following order of frequency: In the sacro-coccygeal in ninety-one cases; in the spheno-occipital region in fifty-two cases; in the cervical portion of the spine in twelve cases, and in other locations, rarely.'

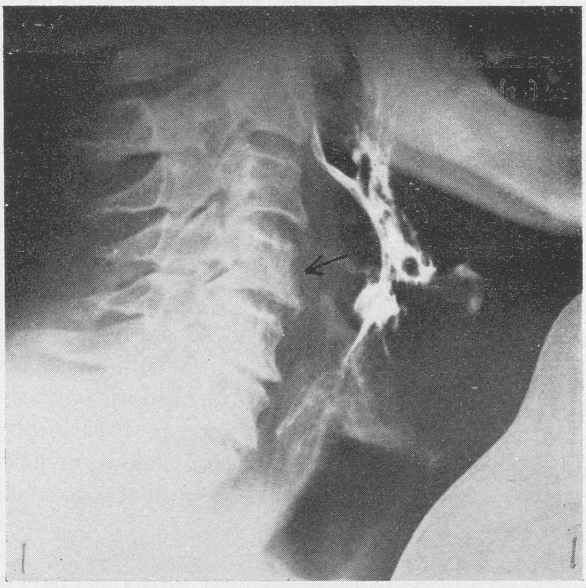

Fig. 1.—Lateral roentgenogram, November 7, 1945. Shows a shadow extending forward from the cervical vertebral region. (From Imperatori's paper)

"Gavin Livingstone[10] groups these tumors into three classifications: 'Type 1. The small tumors called by Virchow " ecchondrosis physaliphora." They occur in two per cent of postmortem examinations and are composed of the same type of cells as the nucleus-pulposus of the intervertebral discs.

" 'Type 2. The malignant tumor in which active mucin-producing cells predominate and in which recurrences and metastases occur.

" 'Type 3. The main feature of this type is the production of cells which resemble cartilage and the tumors are usually encapsulated, and do not recur.'

"A great many of the cases reported as occurring in the cervical area have been high, usually arising from the 1st and 2nd cervicals, and they were usually associated with growths in the spheno-occipital synchondrosis. Very complete and detailed articles by Owen, Hershey

and Gurdjian;[11] by C. M. Haas[12] and by Adson, Kernchan and Waltman[13] have dealt mostly with cranial and high cervical located tumors.

"Many authors have expressed varying opinions as to the cause and origin of these tumors.

"It would seem that there is a unanimity of opinion that they originate from displaced notochordal remnants. The cause of their growths has not been satisfactorily explained for Stout[14] reports a maxillary chordoma in a day-old infant, and the patient on whom this report is being made is 63 years old.

*Diagnosis.* The exact diagnosis cannot be made without biopsy. However, a slowly growing tumorous mass appearing in the oro or laryngopharynx, producing pressure symptoms on the adjacent nerves of the cervical plexus, disturbance in breathing and deglutition, running an afebrile course, and on palpation having a tense jelly-like feel, should be suspected as possibly being a chordoma of this region.

"X-ray will show a bulging shadow into the pharynx of varying density. With barium the shadow is very clearly outlined. Also, any involvement of the bodies of the vertebra and the intervertebral discs may be determined. The amount of obstruction to the food and air passages may also be evaluated.

"Aspiration biopsy will, very likely, give negative results, excepting that if the tumor mass contained contents that were more fluid than semisolid, a diagnosis might be arrived at. Cysts, retropharyngeal abscess, etc., etc., must be differentiated.

"Stout[15] epitomized the microscopic findings by stating that chordomas are characterized by the so-called physaliferous cells which are polyhedral with a small nucleus and cytoplasm much distended with glycogen and vacuoles containing a mucin-like material. This gives to the tumor its characteristic jelly-like gross appearance.

"The desiderata necessary to diagnose a chordoma has been postulated by Linck:[16] 1. Syncytial giant cells. 2. Curious concentric nest of cells. 3. Nuclear vaculation possibly filled with glycogen. 4. Physaliferous cells (nucleus is located peripherally and the cytoplasm is filled with mucinous globules.) 5. Irregular traveculae of tumor cells separated by abundant intercellular mucinous matrix.

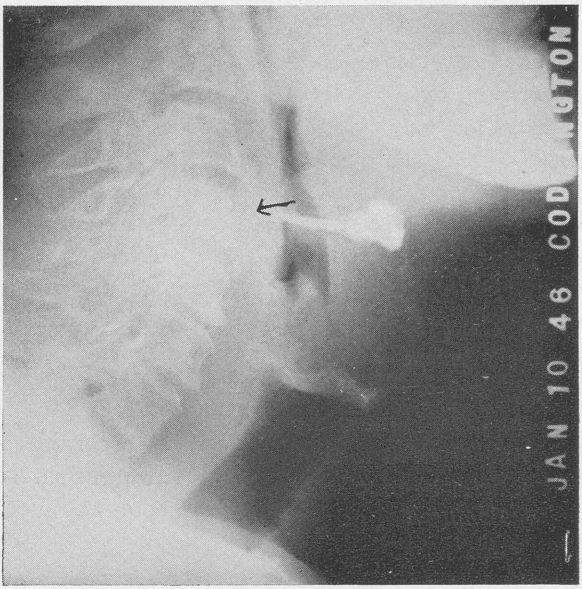


Fig. 2.—January 10, 1946. There is no bulge in this roentgenogram of the posterior pharyngeal wall, but you do see a beginning bridging of the 3rd and 4th cervical bodies and a rarification of the 4th cervical. (From Imperatori)

"It has been refuted by many who have studied these tumors that the substance within the much distended cell is glycogen, the chemical test having been confused by the fixative.

"*Treatment.* This tumor is invasive and very resistant to roentgenotherapy. Its anatomical situation is such that the external surgical approach is difficult. [This is not so, as I will show later in Part III of this paper. H.B.O.]

"Suspension laryngoscopy gives an excellent exposure of the pharynx and laryngopharynx, and should be the method of choice in the excision of such a tumor, located between the 3rd and 6th cervicals.

"The mucous membrane, submocosa and pharyngeal aponeurosis may be dissected from the tumor, and excepting where it is

attached to the bodies of the vertebra, may be removed intact. These tumors are usually well encapsulated.

"The following case report is briefly detailed. W. C., male, aged 62, American, referred by Dr. Brandon of New York City. The patient states his father died when 76 years old from a tumorous growth of the rectum, that necessitated a colostomy. Up to June 1945, he had no serious illness. About that time, he noticed that he was having slight difficulty in swallowing, but attributed this to the trouble he was having with his teeth. Recently, the difficulty in swallowing increased so that he experienced a sensation of complete obstruction, and particularly so when the larynx is drawn up by the hyoid muscles during the act of swallowing. He states that it feels as though a "ball valve" closed.

"During the past few months, he has lost considerable weight (40 lbs.) and his strength and vigor have diminished accordingly. There have been no pain or pressure symptoms on any of the adjacent nerves.

"*Physical Findings*: The general appearance of the patient is that of an emaciated elderly male, very apprehensive, and somewhat non co-operative. All of his teeth are in a state of partial or total decay, gums swollen and inflamed, and many areas of superficial ulceration of the mucous membrane of the mouth. The epipharynx and nostrils were negative.

"By indirect laryngoscopy, there is seen an obstructing mass slightly to the right of the mid-line. It is smooth in outline, covered by the normal mucous membrane of the pharynx and without irregularities or ulcerations. The growth is approximately at the lower level of the epiglottis and extends downward on the posterior wall. The larynx, including the epiglottis, is seen by indirect laryngoscopy, when the chin is elevated and the neck extended. The vocal cords were visualized in their entirety to the anterior commissure. The ventricular openings appeared to be normal. External palpation showed the larynx movable but not freely, and no creptitations were felt on the spinal column. The mass within the hypopharynx cannot be palpated externally with any degree of certainty as to its outline. There were no enlarged lymph nodes. Digital palpation reveals that the hypopharynx is almost completely obstructed. Temperature range was 98 to 99 degrees.

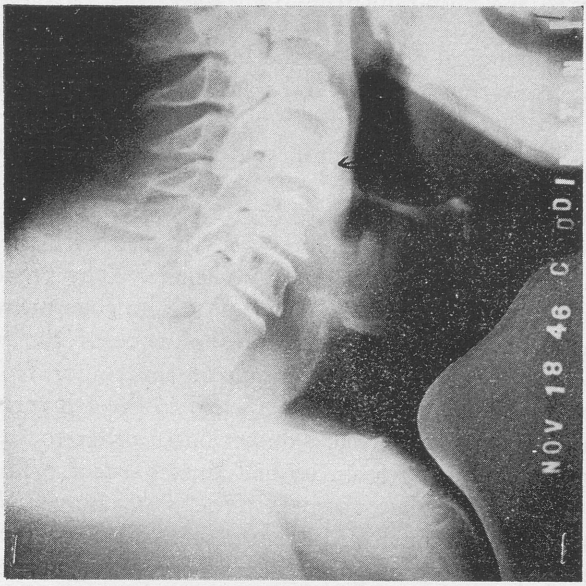


Fig. 3.—Roentgenogram taken November 18, 1946. There is nothing to show any recurrence of the tumor which was removed, but there is increase of the calcification in the 3rd and 4th cervical bodies bridging these two bodies. (From Imperatori)

"*Tentative Diagnosis*: Soft tumor of the hypopharynx, possibly a cyst. Advised Roentgenogram, aspiration biopsy and biopsy.

"The x-rays made by Dr. Ramsay Spillman of New York showed the extent of the tumor—from the 3rd to the 6th cervical and protruding forward. The meager report was helpful in that it showed the extent of the obstructing mass but nothing else, excepting in a negative way—to state that there was no osteomyelitis of the spine, or tuberculous.

"Aspiration of the tumor was productive of no data.

"Under local anesthesia, a biopsy was done into the center of the tumor. The opening into the pharyngeal tissue was less than 5 mm. There was no reaction following this procedure. The patient was given sulfadiazine, and after two days was permitted to leave the

hospital in order to adjust his affairs, have his decayed teeth removed and return to the hospital within two weeks.

"The pathological report of the biopsy was somewhat confused but after consultation with several pathologists, it was decided that it was a chordoma and that this would be confirmed by the gross and microscopical examination of tumor, when it was removed.

"*Operation*: On November 19, 1945, at the Manhattan Eye, Ear and Throat Hospital, the tumor was removed with the patient in the suspension laryngoscope. Ether anesthesia. The procedure consisted of making a transverse incision of the mucous membrane and subadjacent tissues over the greatest prominence of the tumor, and separating a rather thin-walled capsule of the tumor from the adjacent structures. The tumor was attached to the 4th cervical region and it was necessary to use sharp dissection in order to free it. The tumor mass was delivered from its bed almost intact. The posterior attachment was somewhat ragged. The was comparatively little bleeding and this was controlled by pressure. There were no distinct bleeding points, the bleeding being of the capillary type.

"A nasal feeding tube was inserted and the patient returned in very good condition. Within 18 hours, the patient was out of bed for a short period (five minutes) and within five days, the feeding tube was removed. He was able to leave the hospital November 25, 1945.

"For the four days after operation, he received 25,000 units of penicillin every three hours.

"*Pathological Report*: Gross: Gelatinous mass enclosed in a fibrous capsule approximately 5 cm x 4 cm x 2 cm with fibrous bands running through it and attaching themselves to the capsule. It has a slightly reddish color and a peculiar odor.

"Microscopic: Sections show that there is a tumor made up of a peculiarly large, polygonal cells which are arranged, sometimes in cords, and are surrounded by mucoid material. The individual cells sometimes attain a gigantic size and some are vacuolated, producing a physaliferous effort. The tumor grows diffusely and tends to infiltrate. This seems to be a characteristic chordoma in one of the less common situations.

"Diagnosis: Chordoma of the Hypopharynx. A. A. Eggston, M.D. Pathologist, Manhattan Eye, Ear and Throat Hospital; Arthur P. Stout, M.D. Consultant.

"*Conclusions*: Herewith is a report of a chordoma situated in the cervical region (3rd to 6th vertebrae) with diagnostic procedure and method of treatment. There has been no recurrence to date, and the patient is in good physical condition."

REFERENCES

(From Imperatori's paper)

1. Cunningham, Daniel J.: Textbook of Anatomy, Oxford Univ. Press, p. 39, 1943.

2. Pancoast, H. K., Pendergrass, E. P., and Shaffer, J. P.: The Head and Neck in Roentgen Diagnosis, C. C. Thomas, Springfield, Ill., p. 617, 1940.

3. Stout, Arthur P.: Human Cancer, Lee and Febriger, p. 957, 1932.

4. Fabricius, Moller J.: Hosp. Tid. Kobenhavn, 62:849, 1919.

5. Syme, W. S., and Cappell, D. F.: J. Laryng. and Otol. 61:200, 1919.

6. Andre-Thomas and Villandre: Presse Med. 36:344.

7. Cappell, D. F.: J. Path. and Bact. 31:787.

8. Chiari, H.: Centralbl. f. Allg. Path. 42:481.

9. Ridpath, Robert J.: Chordoma, ANNALS OF OTOLOGY, RHINOLOGY AND LARYNGOLOGY 47:649, 1938.

10. Livingston, Gavin: Chordoma, J. Laryng. and Otol. 50:852, 1935.

11. Owne, C. I., Hershey, L. N., and Gurdjian, E. S.: Chordoma Dorsalis of the Cervical Spine, Am. J. Cancer 16:830, 1932.

12. Haas, C. M.: Chordomas of the Cranium and Cervical Portion of the Spine, Arch. Neur. and Psych. 32:300, 1934.

13. Adson, Kernchan, Waltman: Cranial and Cervical Chordomas, Arch. Neur. and Psych. 33:246, 1935.

14. Stout, Arthur P.: Human Cancer, Lee and Febiger, p. 959, 1932.

15. Ibid. p. 953.

16. Linck, A.: Chordoma Malignum. Ein Beitrag Zur Kenntnis der Gerschwülste an der Schadelbasis, Ziegler's Beitrag. Jena. 46:573, 1909.

## PART II

The second part of this paper pertains to the follow-up, studies and operations from Dr. Imperatori's own record which the patient gave me, having received the same from Dr. Imperatori at the time of his retirement from practice. The following, therefore, are his progress notes from 1945 until the patient's first visit to me on January 21, 1950.

"February 23, 1946—there is no evidence of any recurrence; the larynx and piriform sinuses are clear. X-rays taken January

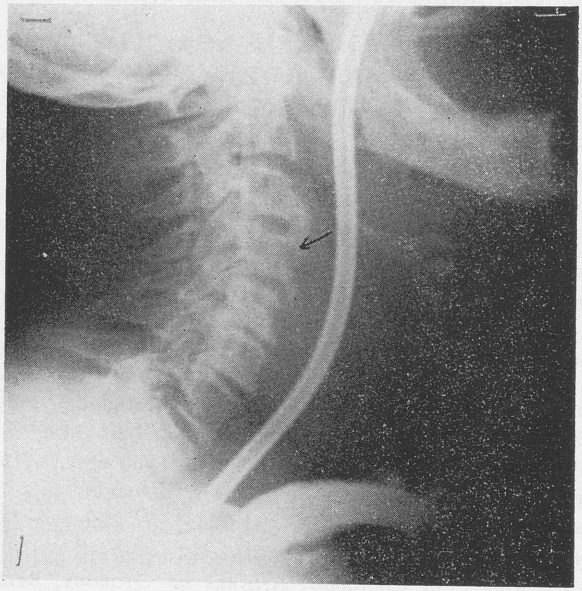

Fig. 4.—Roentgenogram taken December 15, 1947, shows rarification of the 3rd and 4th cervical vertebrae, with feeding tube in position following laryngectomy.

10, 1946 revealed absence of any growth. The patient continued in good condition until January 21, 1947 when he complained that he was having some difficulty in swallowing, especially on eating meat. The examination at this time revealed there was a mounting up of tissue in the pharynx, just above the right arytenoid, about the size of a small olive. The following September 1947, patient had the sensation of obstruction; the growth beginning to fill up the pharynx, and also in front of the larynx.

" 'X-rays taken show evidently a local recurrence of the tumor in the same location as before. There is a rounded mass encroaching on the entrance to the larynx, not only behind, but in front, displacing the epiglottis backward, and there is only a filiform channel as visualized in profile that gives any air-way. In the A.P. projection, the tumor lies on the right side. There is no evidence of involvement in the chest." (R. Spillman, M.D.)'

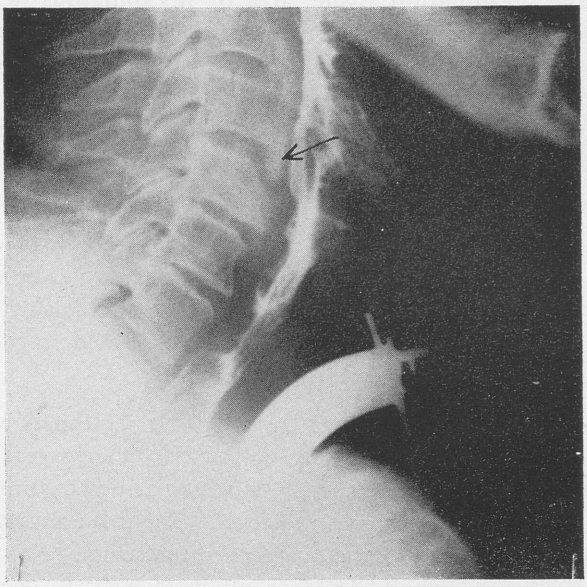

Fig. 5.—Shows the pharynx outlined with barium following laryngectomy.

"December 11, 1947, the patient's weight was 145 pounds and he was admitted to the Manhattan Eye, Ear and Throat Hospital, and under general ether anesthesia attempted a suspension laryngoscopy, which gave a fair exposure but not sufficient to operate properly; the patient had considerable difficulty in breathing during the anesthesia. It was decided that any further attempt would be futile, that the growth should be removed by subhyoid or lateral pharyngotomy. A preliminary tracheotomy in the lower trachea was done. There were no post-operative complications.

"December 15, 1947, an attempt was made to remove the growth through a subhyoid pharyngotomy, but found this could not be done without removing the larynx, which was done. The growth was large and attached to the bodies of the 4th, 5th and 6th cervical vertebrae. These were eroded. The lesion was soft and mushy, most of the mucous membrane on and over the tumor was saved. The trachea was sutured to the skin. There were no post-operative complications.

" 'The pathological report on section shows striated muscle, dense fibrous tissue, granulation tissue, area of myxomatous degeneration, areas of necrosis. Some large infiltrating syncitial like masses of cells, some stratified squamous epithelium apparently esophageal; some sero-mucinous glands. Very little tumor tissue present, some cells show mitosis, and some contain globules, and are physaliferous; an area shows acute inflammatory reaction. Diagnosis: Recurrent chordoma.' (Dr. Eggston.)

"The nasal feeding tube was removed December 24, 1947, and on the 29th of December, the patient was discharged from the hospital. He was seen a number of times in the office during the month of January 1948; by February 14th he had gained in weight, now 155 pounds, and was swallowing normally.

"April 1, 1948, x-rays were taken by Dr. Spillman who reports as follows: 'There is no thickening of the retropharyngeal and retroesophageal tissues in the neck as shown by barium examination, nor do I find anything abnormal in the chest. The changes involving the 4th and 5th cervical vertebrae are very interesting. At the original examination, November 7, 1945, I reported a little decalcification of the ventral surface of the 4th cervical body, and had no conception of its presumable significance. On November 18, 1946, I noted a bony density apparently originating in the 3rd and 4th cervical bodies, and bridging the ventral surfaces. Since then the process has extended both up and down, and a tongue of bone casting a shadow about 5 x 7 mm extends down into a notch at the upper ventral angle of the 5th body, and a similar small bony mass is seen just ventral to the lower half of this body. If this process is related to the chordoma, it shows a spontaneous calcification.'

"January 10, 1949, the patient is swallowing very well, the laryngectomy stoma looking very good and apparently no recurrence." [This Dr. Imperatori's last note concerning the patient.]

## Part III

I shall now take up from here when the patient was referred to me by Dr. Sandella of New Brunswick, New Jersey, on January 21, 1950.

My examination showed a well-developed white male, aged 67 years, with a laryngectomy stoma, having difficulty in swallowing, and choking at times, which had been gradually becoming worse.

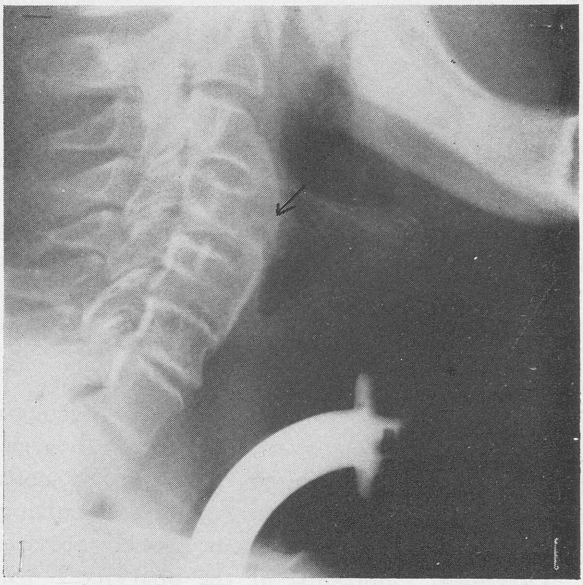

Fig. 6.—Roentgenogram taken January, 1950, shows definitely an increase of this rarification of the 3rd cervical vertebrae.

On further examination I found on the right side of his pharynx, a swelling, extending downwards for a distance of 3 cm. Palpating this swelling revealed that it was hard and extending from the third cervical vertebrae downward to the fourth and fifth. No palpable lymph node enlargment was noted.

X-rays taken at this time accorded with the above; a diagnosis was made of a recurring chordoma of the pharynx, and a lateral pharyngotomy was indicated.

February 24, 1950, the patient was admitted to the Presbyterian Hospital in Newark, and on March 2nd a lateral pharyngotomy was performed under avertin-ether anesthesia. Incision was made along the anterior border of the right sterno-mastoid muscle, at the lower part of which it was extended mesially to make a skin flap to be used in the closure. All vessels coming off anteriorly from the large vessels in the neck were ligated and severed. The thyroid gland was isolated. Fortunately we found a piece of the right horn

of the thyroid cartilage which had not been removed at the time of the laryngectomy; this served as a guide. The attachment of the inferior constrictor to this was severed, thereby exposing the pharyngeal aponeurosis. This was incised and the growth visualized. The growth extended over the bodies of the third and fourth cervical vertebrae, and was removed without difficulty. At the same time some material contained in the growth was noticed in the fourth cervical foramen. This predisposes to further recurrence. The pharynx and overlying structures were closed, and the patient returned to his room. The only difficulty encountered in the operation was that all the normal landmarks for this type of operation had been eradicated.

The pathological report of the growth is as follows "The growth is 3 x 2 x 1 cm. It appears to project from a mucous membrane, forming crypts. Microscopically it shows atypical large cells with large irregular hyperchromatic nuclei separated by collagen fibers and vacuolated in areas. It is generally quite a vascular growth. In places it contains hematogenous pigment. There are areas of bone formation. Diagnosis: Chordoma of the pharynx." (S. A. Goldberg, M.D.)

The post-operative period was uneventful and the patient was discharged from the hospital on March 15, 1950. He progressed nicely until December 21, 1951, when he came to the office complaining of a stiff neck. In looking into the possible cause of this condition, and upon questioning him, he disclosed the fact that during the past month he had been doing some painting in his home, and thought he had strained some muscles in his neck, and this might be the result. He also stated that he had some pain in his shoulders before he finished painting but did not think much of it until after painting the ceiling which caused him to have severe pain in his neck. The pain had increased with muscle spasm for the past two weeks. This was followed with difficulty in elevating his arms, especially when he attempted to lift some coal or ashes. At the present time he has noticed some unsteadiness while walking and is afraid to go out, also that his shoulders are getting numb.

X-rays taken on the same day, December 21st, are as follows: "Examination was made of the cervical spine in the antero-posterior, lateral and oblique projections. Examination of the cervical spine shows the normal lordotic configuration of this portion of the spine.

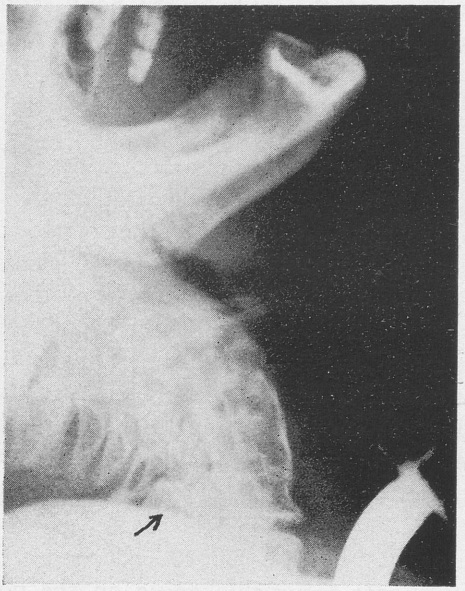

Fig. 7.—December 21, 1951. Roentgenogram shows marked rarification of the 3rd cervical vertebrae with some involvement of the 4th; also the lower arrow shows a slight amount of pantopague in the canal.

The vertebrae are all in good alignment. There are changes seen in the mid-cervical region. The body of the fourth cervical segment shows irregular areas of decalcification and sclerosis obliterating and distorting the normal cancellous bony structure throughout the entire body of this vertebra. Similar but less marked changes are seen in the body of the sixth cervical segment. There is a rather extensive intervertebral bridging extending along the anterior border of the vertebrae from the third to the sixth segment inclusive. This is rather thick in the mid-cervical region and has immobilized this portion of the spine. There are also arthritic changes noted in the lower cervical region and partial collapse of the intervertebral spaces between the fifth and sixth as well as the sixth and seventh. There is no collapse of any of the vertebral bodies. The antericular facets posteriorly show very little evidence of pathology.

"The changes in the fourth cervical body could be the result of direct extension of neoplasm into the bone substance. However,

I am inclined to believe that there would be greater changes noted probably with collapse of the body if the bony structure were involved. The bridging anteriorly obscures much of the bony detail and could give the appearance seen here because of the superimposed density.

"While there is considerable osteo-arthritis with lipping of the faces of the bodies of the vertebrae throughout the entire circumference of the superior and inferior faces, the arthritis does not appear to be advanced enough to cause the symptoms in this case. Some of the lipping is seen posteriorly extending beyond the limits of the bodies of the vertebrae but this would not cause any marked compression of the cord. There are some changes in the vertical diameter of the intervertebral foramen as the result of the collapse of the two interspaces which may be contributing to the symptoms. Radiating pain over the shoulders and down the arms is frequently seen with this amount of spondylitis, and I believe it could very well explain the symptoms.

"There is some soft tissue thickening on the posterior wall of the lower pharynx just anterior to the fourth cervical vertebra but no soft tissue mass can be seen. The question, therefore, of extension of a neoplasm into the fourth cervical segment in this case cannot definitely be determined on the basis of this one examination. There are changes seen in the bony structure which could be the result of neoplasm, but I believe that after the length of time since the original lesion this may be the result of the changes around the cervical spine. One would expect a certain degree of collapse of the body if this were all neoplastic tissue." (F. P. Carrigan, M.D.)

On December 22, 1951, the patient was admitted to the Presbyterian Hospital. The report of the examination by the neurosurgeon, Dr. Richard Swain, is as follows: "Diminution of sensation in both arms up to the top of the shoulder. Marked motor weakness in some areas. Biceps reflexes weak. K.I. hyperactive. Ankle clonus present bilaterally. Babinski plus bilaterally R to L. C-1, C-2, C-3, C-4, seem to be clear. There is probably some cord compression as well as root involvement of C-3 to C-7 or T-1. The question arises of a laminectomy for exploration and possible decompression of roots and cord in the involved area. This would depend somewhat on his life expectancy as to prognosis."

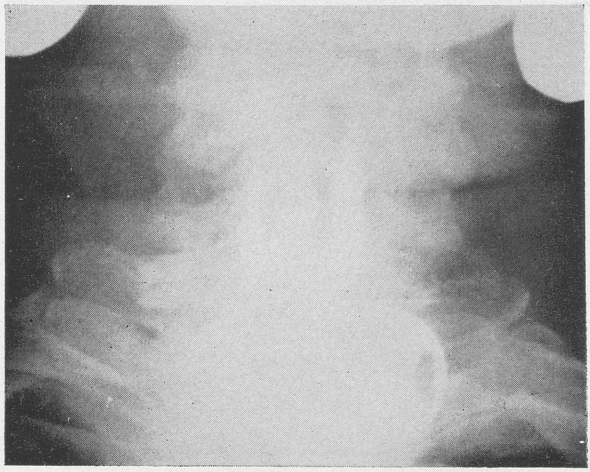

Fig. 8.—December 21, 1951. Shows x-ray of the myelogram with pantopaque material.

On December 24 a cervical myelogram was done and the examination of the roentgenogram made with the patient in the Trendelenburg position shows the opaque medium to be at about the level of the upper border of the C-6. The upper border is somewhat irregular in outline. This confirms by fluoroscopic observation that there is a block in the spinal canal at about the level of upper border of the C-6.

On December 25 the patient became much worse with difficulty in breathing, both legs were paralyzed, and laminectomy was immediately performed.

The preoperative diagnosis was cervical chordoma compressing the spinal cord at the level of the third and fourth cervical vertebrae.

A midline incision was made in the cervical region; the muscles were separated from the spine and laminae of the second, third and fourth cervical vertebrae. These laminae were removed with rongeurs exposing the dura. The tumor mass removed as far as possible, but the bones of the bodies of the vertebrae were evidently infiltrated by the tumor, preventing removal. The dura was opened in the midline. The wound was closed with interrupted sutures, muscles

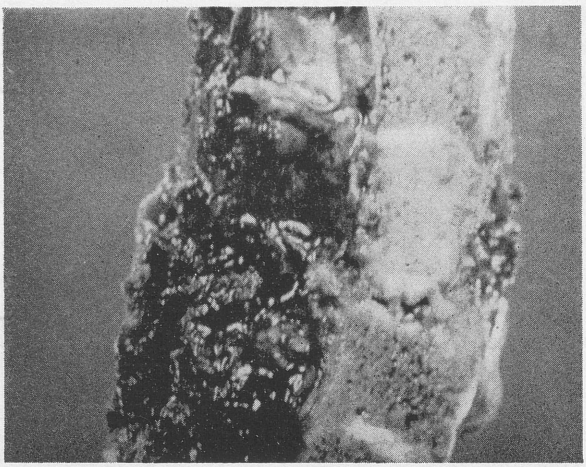

Fig. 9.—Photograph of post-mortem specimen showing fracture of the 3rd cervical and involvement of the 4th cervical vertebrae.

and skin with black silk. The patient was returned to bed. (Dr. Swain.)

Findings: A tumor mass was present in the vertebral canal anterior to the cord. The spinal cord had been greatly compressed by the extradural tumor.

December 26, at 2:45 a.m. the patient ceased breathing.

Post-mortem findings: Chest—Lateral adhesions on both sides, and on the left side there is an adhesion to the diaphragm; Lungs—Pericardial sac clear; Heart—mitral valve contains small atheromata; Abdomen—free and clear. Liver not enlarged. Spleen negative. Kidneys, adrenals, bladder and prostate negative.

On opening the cervical canal the cord at the level of the third cervical vertebra was markedly thinned, soft and mushy. The lining of the canal in the area was roughened. On section the anterior horns were discolored.

The anatomical diagnosis was: Respiratory collapse, contributary cause compression of the cervical cord at the level of the third cervical vertebra.

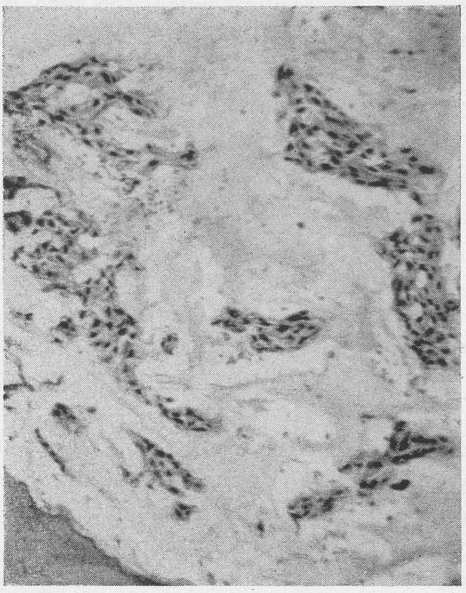

Fig. 10.—Photomicrograph of the tumor from post-mortem specimen shows atypical large cells with large irregular hyperchromatic nuclei separated by collagen fibres and vacuolated in spaces.

The lining of the canal in the region of the third cervical vertebra ventral to cord, was composed of atypical large cells with large hyperchromatic nuclei separated by hyaline substance. The cells were pleomorphic, and a very occasional one contains a vacuole. The bony substance in the body of the third cervical is infiltrated and eroded out by these cells. These fill the marrow spaces and replace the marrow elements. There are areas of necrosis with neutrophilic infiltration. The intervertebral cartilage in the area is markedly degenerated. In the cord below the compressed area practically all of the motor cells are degenerated, very few remaining which contain nuclei.

The ependymal canal is compressed and practically obliterated. There are scattered areas of hemorrhage and hematogenous pigment. The Nissl's granules are gone from practically all of the motor cells. Rarely there is one which still contains a few Nissl's granules. The

vessels of the cord are congested so that the Virchow Robin spaces are nearly obliterated. Higher up, where the cord is partially compressed, the general outline of the cord is altered. There are large areas of hemorrhage. At the compressed area the cord is completely disorganized and contains irregular vacuolated areas and small areas of hemorrhage. The vessels are congested. Motor cells are not seen.

The histological diagnosis is chordoma of the body of the third cervical vertebra producing a pathological fracture and pressure upon the cord, causing atrophy of the cord in that area and paralysis of the upper and lower extremities; acute suppurative osteomyelitis of the third cervical vertebra. Atrophy and hemorrhage of the cord from the third cervical down. Early adenocarcinoma of the prostate.

### TREATMENT

Chordomata are resistant to irradiation. Under treatment (Part I) it is mentioned that, "its anatomical situation is such that the external surgical approach is difficult; and it is further stated that suspension laryngoscopy gives excellent exposure and should be the operation of choice in the excision of such a tumor located between the 3rd and 6th cervicals."

With a recurrence December 11, 1947, the author states (in Part II) "that a suspension laryngoscopy did not give sufficient room to operate properly." [At this time I had suggested that a lateral pharyngotomy be performed. H.B.O.] On December 15, 1947, a subhyoid pharyngotomy was performed, but it having been found that this could not be done without removing the larynx, laryngectomy was done.

The patient came under my observation in January 1950, (Part III) with a recurrence in the same region, and the only operation that could be done was a lateral pharyngotomy which gave ample space to operate, notwithstanding that many of the landmarks for this type of operation were gone due to previous operations.

My re-evaluation indicates that the best procedure for this type of chordoma is a lateral pharyngotomy, thereby saving the patient's larynx.

Irrespective of what type of operation was done, the body of the vertebra was involved even from the time of the first operation; painting and stretching his neck caused the patient to sustain a path-

ologic fracture of the third cervical vertebra causing compression of the cord, and death.

## SUMMARY

A complete report is given, of a patient with a cervical chordoma, including the various operations and findings, from the inception of the tumor to the patient's demise.

Part I concerns the first report by Dr. Imperatori with his comments on treatment and references; Part II, his follow-up of the patient with subsequent operations for recurrence; Part III, the record of the patient since he came under my observation, with operations, follow-up and post-mortem findings.

## CONCLUSION

Chordoma of the pharynx is rare and usually fatal. It is usually of slow growth and rarely metastasizes: but apparently it invades the surrounding bones with destruction of the adjacent bony structures.

Involvement of the vertebrae was demonstrable in the roentgenograms, but apparently the roentgenologists did not associate the lesion in the pharynx with the changes in the bone, although they did mention the fact that arthritic changes had taken place.

The diagnosis is not difficult when the lesion projects into the pharynx. In the early stages the mass must be differentiated from sarcoma, and fibroma. They are all smooth, round, firm growths which erode bone. Absolute diagnosis is by biopsy.

224 Delavan Ave.

## DISCUSSION

Dr. DeGraaf Woodman: In my brief history I know of three cases at Presbyterian Hospital, two of which I operated. All terminated fatally. One which we reoperated was a middle aged woman. The growth was high in the pharynx. We approached it with the regular tonsillectomy mouth gag. That part of the tumor which was not attached to the bone appeared to be encapsulated and shelled out smoothly. It was about five cm long and we were quite hopeful that we had gotten it all out but at the point of attachment it appeared to be attached deeply, at the division point between the vertebra. I think this one was between the 2nd and 3rd vertebrae. There was no assurance whatsoever of having

gotten the whole tumor pedicle. Her course was followed. Two years later she began to experience difficulty and pain on moving her neck. She was transferred to the orthopedic service, and then to the neuro-surgical service. They were hopeful of doing something to relieve her, but decided that it was inadvisable. We finally re-operated her and found that the tumor showed greater invasiveness. She had no relief from the last exploration and six months later she died.

Thank you.

DR. SAMUEL SALINGER: These tumors are growths that originate from the vestige of the fetal notochord and the difficulty in eradicating the tumor can be easily visualized from the fact that there always must be a stalk somewhere in the canal between the vertebra which cannot be reached. I don't recall any time in all the literature that I have read of ever seeing a case that recovered. I think the reason is that it is similar to trying to eradicate a thyroglossal cyst without following the stalk to its other end. In the case of the spinal cord it is evident that this is impossible.

DR. HENRY B. ORTON: I wish to thank the two discussants. There is nothing further I can add. The purpose in presenting this paper was to bring the case to its conclusion.

# NEURILEMMOMA (SCHWANNOMA) OF THE LARYNX

L. Chester McHenry, M.D.

Oklahoma City, Okla.

There has been a great deal of confusion regarding neurilemmomas, neurofibromas and other tumors arising from nerves and nerve sheaths. Stout[1] and Ewing[2] seem to be in very close agreement, in classifying and in differentiating neurilemmomas and neurofibromas. We take our description from Stout. He classifies neurilemmoma under "Neuroectodermal Neoplasms—Supportive Tissue Type—Benign," and gives twenty names which the tumor has been called. Among these are: neurilemmoma (Stout), neurinoma (Ewing), acoustic neuroma, schwannoma and perineural fibroblastoma.

We quote from Stout: "This is the characteristic solitary, benign, encapsulated tumor occurring in the peripheral, cranial and sympathetic nerves; and arising from the sheath of Schwann. . . . While usually solitary and spontaneous, neurilemmomas may be multiple, and can be found in Von Recklinghausen's Disease. They may arise at any age, in either sex, and probably in all races from any nerve or nerve root that has a schwannian sheath. . . . These tumors are benign and always encapsulated. They rarely recur after removal even if the capsule is left behind. It is questionable whether or not a malignant tumor ever develops from them.

"Histologically the picture is characteristic. Inside the sheath the tumor tissue is composed of two parts intermingled but quite sharply defined one from the other. The nuclei often show a tendency to be aligned in rows with intervening spaces without nuclei. This is often called palisading of nuclei. In the neurilemmoma this arrangement of cells, nuclei and fibers often assumes an organoid appearance suggesting an exaggerated tactile corpuscle sometimes called a Verocay body. . . . "

In the literature regarding laryngeal conditions these tumors are called neurofibromas in most instances. From the gross and

microscopic descriptions given we feel that some are neurilemmomas and some are neurofibromas. We quote again from Stout in order to justify this opinion.

"The neurofibroma is characterized by a diffuse proliferation of the peripheral nerve elements in contradistinction to the neurilemmoma which is the encapsulated tumor. It may occur as a solitary localized phenomenon but is much more commonly observed as part of the condition known as multiple neurofibromatosis or Von Recklinghausen's disease. . . . The neurofibroma grows in a number of different ways. A common one is at the end of a nerve. This can produce isolated small nonencapsulated nodules. . . .

In a search of the American literature we have been able to find reports of 21 tumors of the larynx diagnosed as neurofibromas, Schwannomas or neurilemmomas. We have not included those reported as being associated with Von Recklinghausen's disease, nor eight cases reported from foreign literature by Fisher and Odess,[3] nor 22 laryngeal neurinomas reported in abstract in the 1950 Yearbook by Helg[14] of Lausanne, Switzerland. These latter groups have been omitted because sufficient descriptive information was not available to attempt differential classification.

Study of the gross and microscopic descriptions of the tumors reported in the American literature reveals that ten of the 21 are described as polyps or tumors of the vocal cord margin. These do not mention encapsulation and in some instances mention suspicion of malignancy because of recurrence after removal. We believe that these are neurofibromas rather than neurilemmomas according to the classifications of Stout and Ewing.

These ten cases are reported as follows:

1. New and Erich[4] in a study of 722 benign tumors of the larynx list one neurofibroma from the middle third of a vocal cord.

2. Jackson and Jackson[5] list four neurofibromas of the vocal cords without detailed description.

3. New and Devine[7] found one marginal cord tumor and one from the posterior surface of the arytenoid among 19 neurofibromas of the nose and throat. Four of the 19 tumors were associated with Von Recklinghausen's disease, not including either of the laryngeal tumors. We are listing one of these as a neurofibroma and one as a neurilemmoma, perhaps incorrectly.

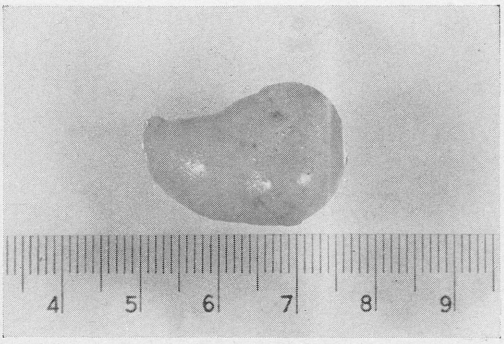


Fig. 1.—Photograph of Tumor.

4. Perlman, Friedman and Appel[8] restudied the microscopic sections of a series of fifty tumors originally diagnosed as fibromas of the larynx and found four vocal cord polypi which in their opinion were neurofibromas. They reported that these tumors were not encapsulated, had invasive characteristics and a tendency to recur after removal.

The tumors which we believe to be neurilemmomas are reported as follows:

1. Jackson and Coates[6] report as a neurofibroma a tumor of the larynx in a patient who had carcinoma of the thyroid but make the statement that the microscopic picture looks like a neurilemmoma.

2. One of the two tumors reported by New and Devine as listed above.

3. Vail[9] in 1933 described a large Schwannoma removed from the aryepiglottic fold. Incidentally, this is the location of five of the eleven neurilemmomas found.

4. Thomas Smith[10] reported three large tumors of the aryepiglottic fold, two of which it was necessary to remove by laryngofissure and the third by external hypopharyngotomy. He described them as solitary, benign, encapsulated, slow growing and having no tendency to recurrence. He also mentioned that it was difficult or

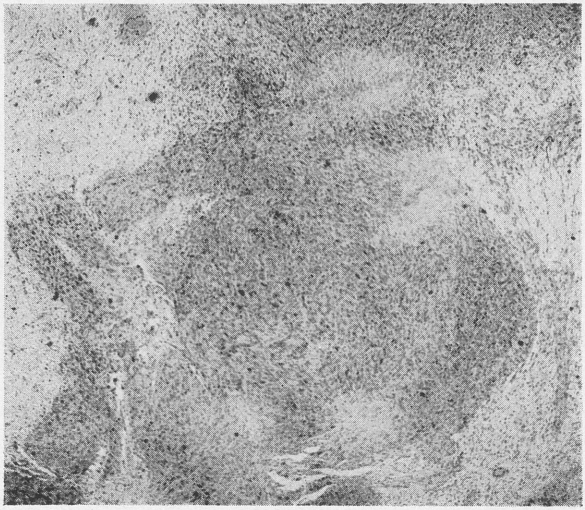

Fig. 2.—Low power photomicrograph of neurilemmoma of the larynx. Note Verocay bodies and division into Antoni type A and Antoni type B tissue.

impossible to obtain biopsies by direct laryngoscopy because of the consistency of the tumors.

5. VanLoon and Diamond[11] reported a large encapsulated tumor causing gross swelling of one side of the larynx with obliteration of the ventricle. Repeated biopsies yielded only mucosa overlying the tumor. It was removed by laryngofissure and diagnosed as neurofibroma. We believe that this was a neurilemmoma according to the classification of Stout and Ewing.

6. Hoover[12] in 1940 reported a series of benign tumors of the larynx and described one large solitary neurofibroma of the aryepiglottic fold removed through an external approach. Detailed microscopic study was not reported but it is classed as a neurilemmoma because of its clinical similarity to others.

7. Oliver, Diab and Abu-Jadeb[13] reported an encapsulated large neurofibroma of the aryepiglottic fold removed perorally and mentioned that it was too hard to punch with laryngeal biopsy forceps.

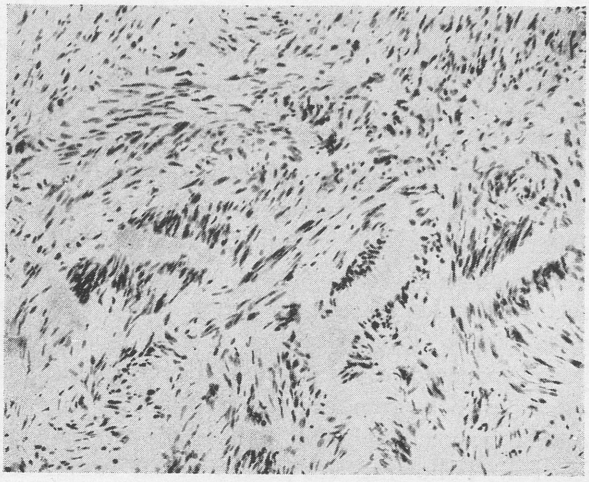

Fig. 3.—High power photomicrograph of neurilemmoma of the larynx. Verocay bodies.

8. Fisher and Odess[3] in 1949 reviewed the literature and listed nineteen tumors as solitary neurofibromas of the larynx. Eight of these were from foreign literature and not available to us. The other eleven are included in the above review. They reported one small yellowish nodular tumor from the base of a vocal cord and another nodule from the aryepiglottic fold. Their discussion would indicate these tumors to be neurilemmomas.

Neurilemmomas are, at least, very unusual tumors to find in the larynx. Neurofibromas also are unusual. If we include those mentioned above from foreign literature approximately only forty of both types of these tumors have been reported. From the articles read, tumors of the larynx associated with Von Recklinghausen's disease seem to be even less frequent. Holinger and Cohen[15] reported such a case and several others have mentioned them. Neurilemmomas sometimes grow to very large size in the pharynx and in the neck. Those interested in the clinical problems of their treatment are referred to the articles by Viole,[16] Turchik,[17] Koop, et al,[18] and Slaughter and DePeyster.[19]

REPORT OF A CASE

Mrs. E. B., aged 48, was first seen in April, 1948, with symptoms suggesting vocal fatigue and strain. She was not objectively hoarse but her voice was weak. Upon examiation there was no visible tumor in the larynx but the left ventricular band looked full and partially hid the vocal cord. There was an apparent bulging medially of the subglottic area on this same side. The arytenoid appeared to move normally. On repeated examinations this medial bulging of the ventricular band and the subglottic area became more definte. On direct laryngoscopy the mucous membrane of the floor of the ventricle seemed thickened and bulging. Two small pieces were removed with biopsy forceps and a smooth, fairly firm, grayish, domelike lesion appeared in the mucosal defect. This was obviously a tumor too large to be removed through the laryngoscope and an attempt to take a specimen with double-cupped laryngeal forceps was unsuccessful. Following this procedure the tumor could be seen bulging from the ventricle on mirror examination. At laryngofissure the tumor was found between the inner thyroid perichondrium and the lateral mucosal wall of the larynx. It was smooth, encapsulated, roughly ovoid and was readily dissected intact from its bed. It measured approximately 2.75 x 1.5 x 1.5 cm (Fig. 1). The larynx healed readily but with scarring of the anterior commissure and left the patient with a husky voice. There has been no evidence of recurrence during more than three years of operative observation.

The gross specimen consisted of an encapsulated, ovoid, relatively mass 2.5 x 1.7 x 1.2 cm. The external surface had a pinkish pale yellow appearance. Cross section showed semi-translucent tissue varying from pinkish gray in its outer portion to orange at its center.

Microscopic examination of a full thickness section of the tumor shows an extremely thin fibrous outer capsule. The tumor proper has a somewhat lobulated appearance due to wide variation in the density of the tumor. In the denser areas there was seen a tangled and frequently whorled arrangement of moderately cellular fibrous tissue. The cells had spindle shaped nuclei in which there was slight variation in the sign of the nuclei, but not to the extent to be indicative of sarcomatous change. Neither were mitotic figures observed. In several of these lobules there were seen very characteristic "Verocay bodies" as evidenced by parallel lines of palisaded nuclei and bands of

collagenous fibrils that stretched between them, forming meandering ribbon-like zones. It is the presence of these Verocay bodies especially that indicate this tumor to be of neurogenic origin. Between these lobules was extremely loose, almost myxomatous type stroma and here small capillaries were observed (Figs. 2 and 3).

This was a benign type tumor which apparently originated from the sheath of Schwann. This type of growth has a predilection for the acoustic nerve. There was no evidence of malignancy. Diagnosis: Benign Neurilemmoma, "Schwannoma." (W. F. Keller, M.D.)

On a second opportunity to remove a tumor in such a location we would approach the tumor laterally through the thyroid wing rather than through the anterior commissure and hope to leave the patient a better voice.

117 N. Broadway.

REFERENCES

1. Stout, Arthur Purdy: Tumors of the Peripheral Nervous System, Atlas of Tumor Pathology, Armed Forces Institute of Pathology, 1949.

2. Ewing, John: Neoplastic Diseases, W. B. Saunders Co., Philadelphia, 1940, p. 163.

3. Fisher, Gilbert E., and Odess, John S.: Solitary Neurofibroma of the Larynx (Report of Two Cases), Laryngoscope 59:1345-1349 (Dec.) 1949.

Suchanek: Neurinoma des Kehlkopfeinganges, Monatsschr. f. Ohrenh., 50:613, 1925.

Holmgren, G., and Bertstrand, H.: Neurinoma: Case Report, Acta Oto-Laryngol. 12:514, 1928.

Claus: Demonstration d'une Preparation d'un Neurinoma du Larynx, Soc. O., R., L. du Berlin, 5 Cance du 17-1-30.

Gignoux, A.: Presentation d'une Malade Atteinte de Schwannome du Larynx, Soc. O., R., L., Lyon, Sceance du 6 Fullet, 1936.

Malan, A.: Neurinoma; Case, Valsalva 13:417, 1937.

Seidel, O.: Very Rare Tumor (Neurinoma) of Unusual Size in Boy 12 Years Old, Arch. f. Ohren., Nasen. u. Kohlkapfh. 148:210, 1940.

Baldenwech, J., and Leroux, H.: Neurinoma; Case, Ann. d'Otolaryngoi. 91 (Apr.-June) 1942.

4. New, G. B., and Erich, J. B.: Benign Tumors of the Larynx: Study of 722 Cases, Arch. Otolaryng. 28:841, 1938.

5. Jackson, Chevalier and Jackson, Chevalier L.: Textbook—Diseases and Injuries of the Larynx, MacMillan Co. 1942, p. 401.

6. Jackson, Chevalier, and Coates, George M.: Textbook—The Nose, Throat and Ear and Their Diseases, W. B. Saunders Co., 1930, p. 902.

7. New, G. B., and Devine, K. D.: Neurogenic Tumors of the Nose and Throat, Arch. Otolaryng. 46:163-179 (Aug.) 1947.

8. Pearlman, S. J., Friedman, E. A., and Appel, Max: Neurofibroma of the Larynx, Arch. Otolaryng. 52:8-14 (July) 1950.

9. Vail, H. H.: Schwannoma of the Larynx, Trans. Amer. Laryng., Rhino. and Otol. Soc. 1933, p. 418.

10. Smith, Thomas T.: Solitary Neurofibroma of the Larynx, Arch. Otolaryng. 39:144-151 (Feb.) 1944.

11. Van Loon, Emily L., and Diamond, Sidney: Neurofibroma of the Larynx, ANNALS OF OTOLOGY, RHINOLOGY AND LARYNGOLOGY 51:122-126 (May) 1942.

12. Hoover, Walter B.: Benign Tumors of the Larynx: Diagnosis and Treatment, Surg. Clin. N. America 20:697, 1940.

13. Oliver, K. S., Diab, E. E., and Abu-Jadeb, C. N.: Solitary Neurofibroma of the Larynx, Arch. Otolaryng. 47:177-179 (Feb.) 1948.

14. Helg, J. R., Lausanne, Switzerland: Laryngeal Neurinoma and Recklinghausen's Diseases, Pract. Oto-Rhino-Laryng. 12:165-184, 1950. Abstracted in Yearbook of Eye, Ear, Nose and Throat. Year Book Publishers, Chicago, 1950, p. 378.

15. Holinger, Paul H., and Cohen, L. L.: Neurofibromatosis (Von Recklinghausen's Disease) with Involvement of the Larynx. Report of a Case, Laryngoscope 60:193-196 (Feb.) 1950.

16. Viloé, Pierre: Schwannoma of the Pharynx, Trans. Amer. Laryng., Rhin. and Otol. Soc. 318-325, 1946.

17. Turchik, Frank: Schwannoma of Pharynx with Paralysis of Vocal Cord, Arch. Otolaryng. 44:568-573 (Nov.) 1946.

18. Koop, C. E., Jordan, E., and Horn, R. C.: Neurilemomma of Pharynx, Surg. Gynec. and Obstet. 85:641-645 (Nov.) 1947.

19. Slaughter, D. P., and dePeyster, F. A.: Pharyngeal Neurilemmomas of Cranial Nerve Origin, Arch. Surg. 59:386-397 (Sept.) 1949.

## DISCUSSION

DR. GABRIEL TUCKER: Mr. Chairman, Members and Guests of the Society, I found one of these tumors some ten years ago. It appeared as a swelling in the side of the larynx. The history of duration was some 16 years. It was thought that it was possibly a cyst.

The tumor was removed, it was encapsulated, and did not infiltrate the surrounding tissues. There is a little dyspnea here because the airway is increased on removal of the tumor.

The second case is quite different because it was below the ventricle of the larynx and we had to do a tracheotomy on the patient. This is about the same size as Dr. McHenry's case and when we cut through the center it looked like the surface of an onion. This patient has been followed for 15 years and there has been no difficulty in breathing. The voice has been restored because it was above the true cord, above the ventricle. The specimens were referred to the neuropathologist who pronounced them Schwannoma.

DR. FREDERICK A. FIGI: Mr. President, Members and Guests, I would like to congratulate Dr. McHenry on his excellent presentation and his management of this case. It is confusing and I feel unfortunate that pathologists generally are not in agreement regarding the nomenclature of these neurogenic tumors of the larynx.

Actually these tumors, Schwannoma, neurilemmona, neurofibromas or whatever you may designate them, tend to follow much the same clinical course. They are all slowly progressive, obviously benign clinically, and their histologic structure is so similar that it is a rather fine distinction to place them in the various categories mentioned. Some pathologists designate all of these neurogenic tumors of the larynx as neurofibromas. Our pathologists at the Mayo Clinic take this stand.

Dr. Stark and I are presenting a group of five of these tumors before the Triological meeting. One of these was included being that presented by New and Devine a few years ago and the others are cases that have been seen more recently.

I might mention that in one of these, a tumor approximately the size of that shown by Dr. McHenry and Dr. Tucker was removed by means of suspension laryngoscopy, that is, transorally, and during the course of the removal of this a rather amusing incident occurred. The dissection progressed without any difficulty and the tumor was nicely encapsulated, started to bulge through the incision and all of a sudden while we were trying to get some movies of it, it completely disappeared, vanished from sight entirely. We located it in the nasopharynx.

As to the statement made by Dr. McHenry, quoting one of the pathologists, that these tumors probably never become malignant, we have observed malignant change in one in a patient from whom we had on two previous occasions removed neurofibromas about the face. On the patient's return several years later she had a rounded mass in the temporal region about four centimeters in diameter and this was excised and proved to be a grade IV sarcoma, apparently neurogenic in origin.

DR. L. CHESTER MCHENRY: I have nothing to add. I feel like a person who was host at a party and was congratulated on the fine party. It is always the guests who make the party. The discussers make the paper and I appreciate it.

PRESIDENT CLERF: Before proceeding with the next paper, I should like to ask Dr. Frederick T. Hill of Waterville, Maine, to come to the rostrum. We were deprived yesterday of the pleasure of seeing Dr. Hill in person because of his illness when he was given the Newcomb Award and he is here now and I am going to ask him to say a word.

DR. FREDERICK T. HILL: President Clerf, Members and Guests, all I can say is thank you very much. I have been wondering by what stretch of the imagination the Committee could have considered me worthy of this honor, but nevertheless I appreciate it more than I can tell you.

# HEMILARYNGECTOMY WITH IMMEDIATE SKIN GRAFT FOR THE REMOVAL OF CARCINOMA OF THE LARYNX

FREDERICK A. FIGI, M.D.

ROCHESTER, MINN.

In recent years greater consideration has been given to preservation of function in the surgical treatment of carcinoma of the larynx. Unnecessarily radical operative procedures are now performed less frequently since experience has shown that adequate removal of moderately advanced lesions often can be effected by technics which do not disturb normal physiologic function. The field of usefulness of laryngofissure has expanded considerably during the past few decades. The operation has been made increasingly radical by supplementing sharp excision with electrocoagulation and by sacrificing more of the cartilaginous structures. However, there are definite limits to the extent of tissue that can be removed by means of a thyrotomy or a classic hemilaryngectomy without directly destroying function or causing danger of collapse of the airway. Relining the larynx with a skin graft has at times been carried out secondarily in order to correct the stenosis induced by exceeding these limits. Hemilaryngectomy with immediate skin graft renders it possible to effect more extensive local removal without destroying the voice or disrupting the airway. A preliminary report on this procedure was made before this Association at its meeting in San Francisco three years ago. The procedure has now been performed in a sufficient number of cases to permit adequate evaluation and the results warrant its inclusion in the armamentarium of the laryngeal surgeon.

Hemilaryngectomy with immediate skin graft for the removal of carcinoma of the larynx evolved from the application of certain basic principles of plastic surgery. Among these is the precept that

---

From the Section of Plastic Surgery and Laryngology, Mayo, Clinic.

appreciable loss of surface covering or of the lining of a viscus must be restored in order to secure prompt healing with minimal scarring and to obviate contracture. Further, a skin graft should not be used to cover a defect unless there is reasonable assurance that the pathologic process responsible for the loss has been completely eradicated. Experience with the surgical removal of cutaneous epitheliomas and with the immediate repair of the resulting wounds by means of skin grafting suggested the application of the same method in the management of carcinoma of the larynx. Observations in using free skin grafts to correct severe cicatrical laryngeal stenosis indicated the feasibility of the procedure. The method was first applied in 2 carefully selected cases a little more than five years ago and the patients were closely observed for more than a year before further application of the plan was made. It has now been used on our service in 20 cases. During the same period thyrotomy has been performed in 293 cases and total laryngectomy in 276 cases for the removal of carcinoma of the larynx. Thus it is obvious that the procedure has only limited application. However, it must be borne in mind that the time under consideration included the period of the development of this operation and of observation of results in the initial cases; also that except for performance of the procedure all 20 of the patients mentioned above would have required a total laryngectomy. It seems certain to be carried out in a greater proportion of cases of carcinoma of the larynx in the future. In the author's experience it has been applicable in a greater number of cases than has transoral removal during the same period.

In all cases of moderately advanced malignant lesions of the larynx it has for some years been the practice of my colleagues and myself to withhold a definite decision regarding the type of operative procedure to be performed for removal pending surgical exploration. The patient is told in advance that the most conservative method consistent with safety will be followed but that total laryngectomy may be required. In most instances, exploration is made through a laryngofissure, but involvement of the anterior commissure at times renders this approach inadvisable. In this event, evaluation of the situation usually is obtained by means of transverse incisions through either or both the thyrohyoid and cricothyroid membrane. When this is not feasible because of the situation and extent of the lesion, a laryngofissure is performed and if the tumor is opened into, the margins of the laryngeal wound are thoroughly cauterized before

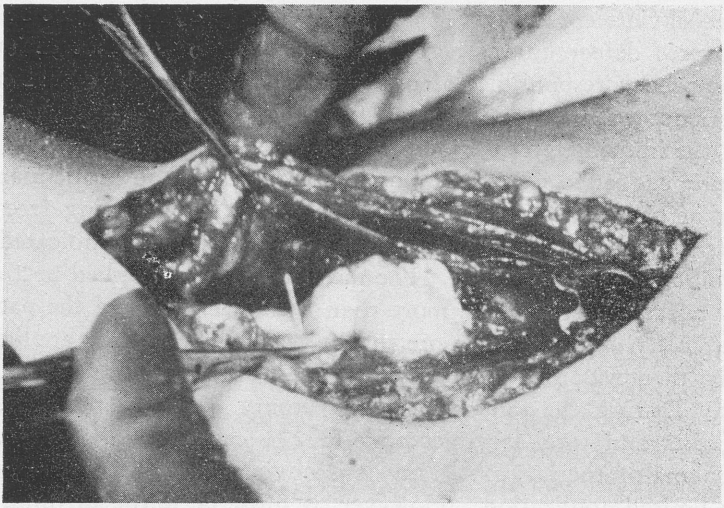

Fig. 1.—Sponge rubber stent wrapped with skin graft being anchored in larynx by means of transfixing wires.

proceeding further. As this is accomplished with regional anesthesia and the patient is conscious, he is now informed of the surgeon's recommendation and the operation is proceeded with forthright. In the past, if the neoplasm was too extensive for removal by thyrotomy or a classic hemilaryngectomy, laryngeal forceps were applied to the margins of the divided thyroid cartilage and a total laryngectomy was performed. Now, by means of hemilaryngectomy and immediate skin graft, a certain proportion of these more advanced lesions can be adequately removed without sacrificing the entire larynx, for the support furnished by the skin graft permits more extensive excision of cartilage without risk of collapse of the laryngeal lumen. Moderately advanced lesions involving the entire length of one cord, the anterior commissure and up to approximately half of the opposite cord may be removed in this manner even though fixation is present. In some of the cases in which this method was used there was in addition to the cordal growth, involvement of an entire ventricle and ventricular band. Extension onto one arytenoid was present in several instances.

Lesions of a low grade of malignancy or of moderate activity are better suited for this method of removal, as is also true of cutaneous neoplasms in which immediate plastic repair is planned since the actual extent of these slower-growing malignant tumors corresponds more nearly to their gross limits. Localized high-grade malignant tumors have at times been dealt with in this manner but because of their indefinite extent greater risk of inadequate removal is involved.

The operation consists essentially of performing a radical hemilaryngectomy, removing as much of the ala of the thyroid cartilage on the side of the principal involvement as is indicated and up to approximately one half of the ala on the opposite side, if required. Generally, a narrow strip of the superior or inferior border of the thyroid cartilage can safely be left in place and when possible this is done to lend support. One half or slightly more of the anterior or anterolateral part of the cricoid cartilage is taken away if necessary. Removal of these portions of the cricoid ring has produced no disturbances of function as would almost certainly result were the posterior portion sacrificed. The arytenoid on the involved side was removed in several of the cases but experience has shown that when this is done it is advisable to limit removal of the adjacent soft tissues as much as possible; otherwise difficulty with aspiration during swallowing may occur postoperatively. The involved soft tissues together with the overlying cartilaginous structures are excised en bloc. The trachea is opened prior to doing the hemilaryngectomy so that the respiratory tract below this level can be packed off to prevent gravitation of blood. The specimen is immediately carefully checked microscopically, using fresh frozen sections in order to make certain that there has been adequate clearance of the malignant process. Should any of the margins be too narrow, further removal is carried out. Painstaking hemostasis is essential. To secure this, the larger vessels are ligated while the smaller bleeding points are electrocoagulated.

Now, using a clean surgical setup, a dermatome graft of moderate thickness is taken from a hair-free area of the chest or abdomen, using procaine hydrochloride infiltration anesthesia. A stent of sponge rubber is prepared of sufficient size that it will exert moderate pressure upon the entire laryngeal wound when the soft tissues of the neck are closed over it. The skin graft is fastened to the stent with mastisol or rubber cement, placed in the laryngeal defect and immobilized by transfixing it with two or three stainless steel wires which pass

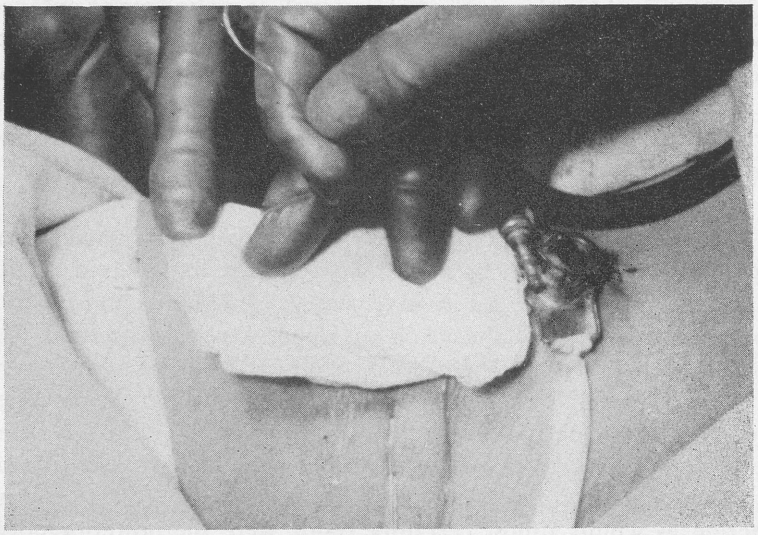

Fig. 2.—The neck wound has been closed and the transfixing wires are being tied over the gauze dressing covering it.

entirely through the soft tissues of the anterior portion of the neck and through the larynx or upper part of the trachea (Fig. 1). Additional anchorage usually is secured by passing a heavy silk suture vertically through the rubber mold and tying it to the tracheal cannula. The larynx and soft tissues of the neck are closed as in the usual thyrotomy or hemilaryngectomy. No drainage is used other than a small iodoform gauze pack below the tracheotomy tube. The ends of the transfixing wires, which have been left long, are tied firmly over a fluffed gauze pad applied to the wound on the front of the neck (Fig. 2). This is supplemented with a firm pressure bandage and the patient is urged to refrain from coughing during the first few hours.

The postoperative course generally is quite mild. Antibiotics are given routinely as a prophylactic measure and sedatives are administered as necessary for cough or discomfort. After approximately ten days, the patient is anesthetized intravenously with pentothal sodium and the larynx is exposed with the suspension apparatus. The transfixing wires and the ligature attached to the trache-

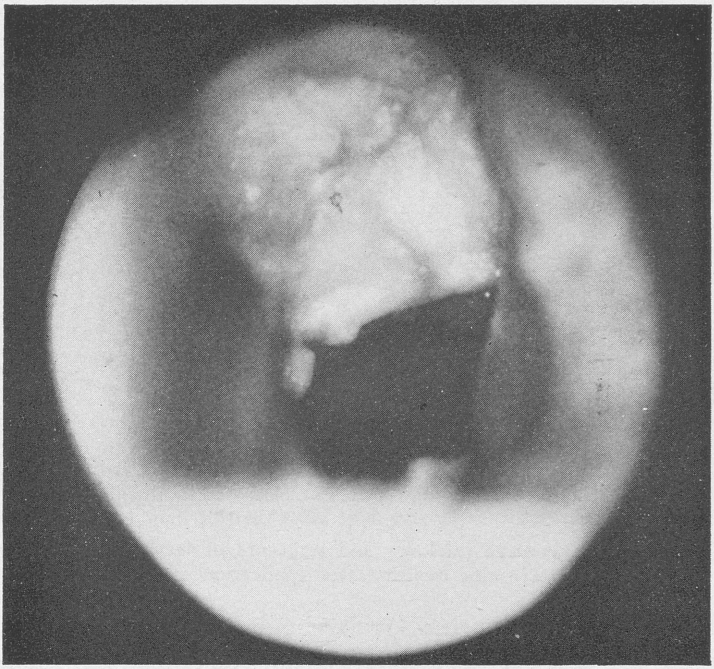

Fig. 3.—Skin graft in larynx two and a half months after hemilaryngectomy. Patients now well for approximately four years.

otomy tube are freed and the sponge rubber stent is removed through the mouth. Almost invariably the skin graft will be found to have taken perfectly where it has covered denuded areas. Elsewhere the graft will have sloughed off or is necrotic and sharply demarcated so that these portions can be pared away. An elastic dilator is now made of sponge rubber covered with a condom, inserted into the larynx and anchored in position by tying it to the tracheal cannula. This is worn for ten days to two or three weeks and is then removed through the mouth. A day or two later the tracheotomy tube is lifted out and the tracheal fistula is permitted to close. Subsequently observation of the larynx is made at intervals of two to three months for a year, thence at intervals of six months to a year.

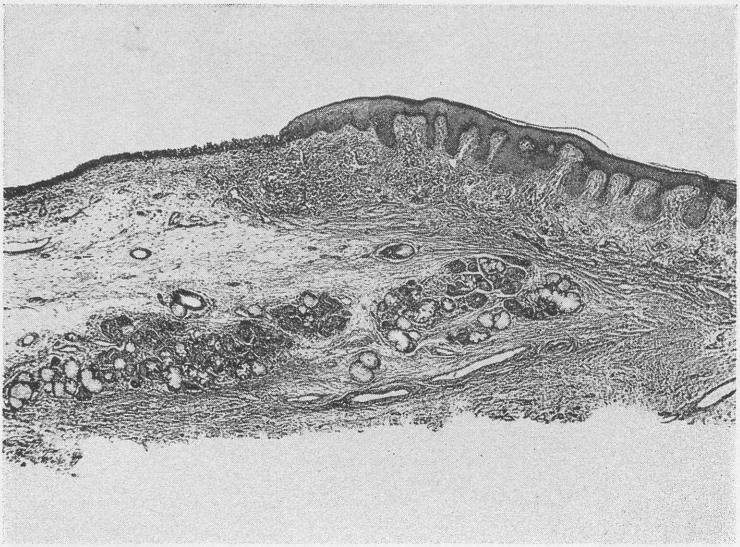

Fig. 4.—Comparative thickness and structure of laryngeal mucosa and of adjacent skin graft nine months after application of graft (x 30).

The skin graft in the larynx remains thick, dry and rigid for a variable period following the operation and in some patients ozena results from the accumulation of mucus and crusting (Fig. 3). In the course of time these features tend to undergo spontaneous correction to a great extent, the graft becoming moist, softer and more pliable. Because of its thickness and whitish color, the graft remains permanently sharply demarcated from the adjacent mucosa; however, from a functional standpoint, it serves very satisfactorily. Microscopic sections made of the laryngeal lining nine months after operation in one of these patients strikingly show the difference in thickness of the skin and the mucous membrane (Fig. 4).

The 20 patients who underwent this procedure included 19 men and one woman, ranging in age from 34 to 65 years. They had been hoarse for periods of two months to five years. In all of those with hoarseness of more than a year's duration, there had been marked accentuation during recent months. The lesions varied in situation and extent. In all of the cases there was involvement of the glottis, ranging from the entire length of one cord to the full

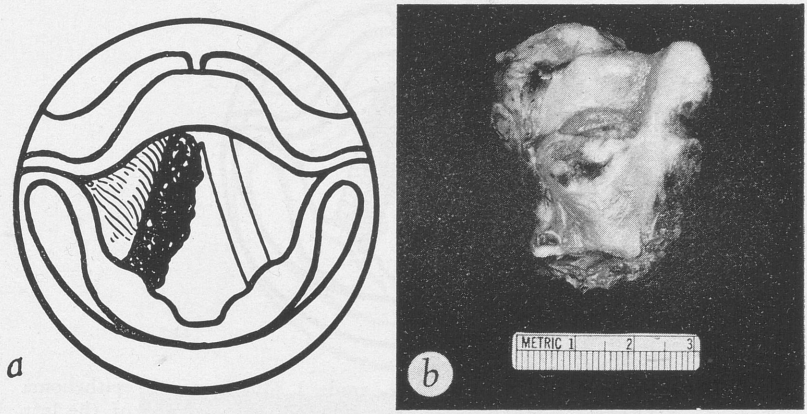


Fig. 5.—*a*. Approximate situation and extent of fixed grade 2 squamous cell epithelioma of larynx in a man 40 years of age. *b*. Specimen removed by means of hemilaryngectomy. The patient is free from symptoms and has a good, although hoarse, voice two years after operation.

extent of both cords together with the anterior commissure and one arytenoid. In addition to the cordal infiltration there was extension into the ventricle and ventricular band in most instances, also varying degrees of limitation of movement, up to complete fixation (Figs. 5 and 6). In one patient, the tumor extended form the posterior commissure over the right arytenoid and involved the entire length of the right cord and ventricle, the anterior commissure and the anterior two thirds of the left ventricule. In another there was involvement of the full length of both vocal cords, the anterior commissure and the left arytenoid without fixation (Fig. 7).

In still another patient the lesion was situated on the ventral aspect of the anterior two thirds of the right cord and the anterior half of the left cord and extended to the upper border of the second tracheal ring. This patient, as well as several others in the group, had previously been advised to undergo total laryngectomy but had refused. As a matter of fact, at the time surgical exploration of this patient's lesion was carried out, removal of the entire larynx appeared to be the only procedure that would permit adequate removal of the lesion. As he still was unwilling to accept loss of the larynx, a sub-

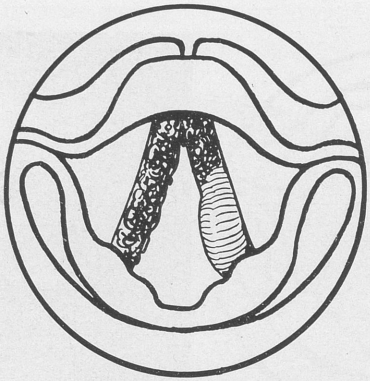

Fig. 6.—Situation and extent of a grade 1 squamous cell epithelioma of the larynx in a man 52 years of age. The posterior portion of the left cord was covered by a myxomatous lesion.

total laryngectomy was performed after the trachea had been opened, through the fifth ring. The operation required sacrifice of a portion of the right arytenoid, the entire length of the lower part of the right cord, the anterior part of the inferior aspect of the left cord, most of the cricothyroid membrane, a little more than the anterior one half of the cricoid and the anterior one half of the first two tracheal rings. A vertical bridge of subglottic mucosa, only 1 cm in width, remained below the posterior commissure. It was feared that this radical removal of laryngeal and tracheal structures probably would result in collapse of these parts and in serious disturbance of function. However, the skin graft immediately applied to line the wound has afforded ample support and at present, eighteen months after operation, there is no functional impairment and the voice is essentially normal.

The great majority of the laryngeal carcinomas in this group of patients were of moderate activity, 17 of the 20 being graded 2 on a basis of 1 to 4. Only one of the tumors was graded 1 and 2 were graded 3. One of the grade 3 lesions was considered by the pathologist to be of grade 4 at the time it was studied in fresh frozen sections made at operation. Because of the tendency for lesions of this degree of activity to infiltrate well beyond the apparent gross

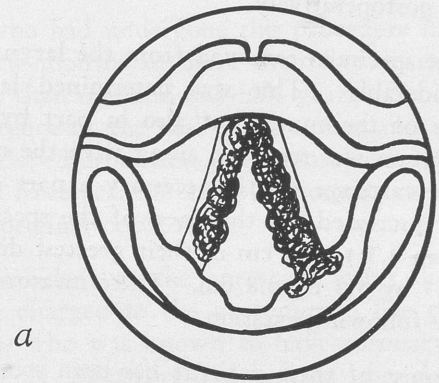


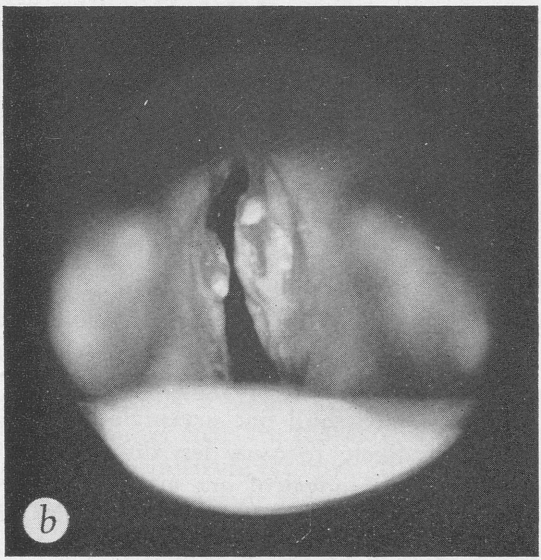


Fig. 7.—Drawing and actual photograph of grade 2 squamous cell epithelioma of the larynx in a man 55 years of age. The lesion involved the entire length of both vocal cords, the anterior commissure and the left arytenoid. Patient is now free of complaints other than hoarseness two years after removal and skin graft.

limits of the disease, correspondingly wider removal was carried out and in one of the patients, a man 36 years of age, fractional roentgen therapy was given postoperatively.

The size of the specimen removed from the larynx in these patients varied considerably. This was determined largely by the extent and activity of the tumor but also in part by its situation. The fact that the lesion was removed along with the overlying portion of the thyroid cartilage and if necessary a part of the cricoid as well appreciably increased the thickness of the specimen. Several of these ranged from 4.5 to 5.5 cm in their greatest dimension. The largest measured 5.5 by 5.5 by 0.8 cm. These measurements do not allow for shrinkage following excision.

The voice in most of these patients has been somewhat hoarser than that after the usual thyrotomy. This is as one might well anticipate in view of the greater sacrifice of tissue and the resulting more limited mobility of the laryngeal structures. As following thyrotomy, the voice tends to become stronger and clearer in the course of time but only infrequently is a fair degree of resonance regained after this procedure. Generally the patients are in excellent spirits and deeply appreciative since they realize that they retain an essentially normal voice and have been spared the necessity of a permanent tracheotomy.

Experience has shown that much wider removal of tissue can be carried out safely in the anterior portion of the larynx than in the posterior part and less disturbance of function will result. Sacrifice of the entire epiglottis and one aryepiglottic fold, ventricular band and ventricle is likely to cause less difficulty with aspiration during deglutition than removal of one arytenoid. However, there is a decided variance in the difficulty experienced by different individuals following excision of corresponding tissues of the posterior part of the larynx. After limited parts of both arytenoids were taken away, no trouble with aspiration of fluids was experienced and most patients had only slight difficulty after sacrifice of an entire arytenoid. On the other hand, in one patient in whom one arytenoid was removed serious disability developed. His convalescence was protracted because of the necessity of continuing tube feeling for a number of weeks. Aspiration pneumonia ensued after the tube feeding was discontinued and eventually it became necessary to sacrifice the remainder of the larynx even though there was no recurrence of

the carcinoma. Convalescence following the laryngectomy was uneventful.

Patients who had undergone this procedure have now been followed for a few months to more than five years, three fourths of them for more than one and one-half years. To date none has presented a recurrence of the malignant tumor and except for the patient who developed aspiration pneumonia and required total laryngectomy, there have been no complications or complaints. All have resumed their original occupation.

The risk incident to the operation seems slight, although one death must be charged to the procedure. The patient was a man 62 years of age who was known to have coronary sclerosis. Death occurred suddenly following removal of the elastic dilator using suspension laryngoscopy and light intravenous pentothal sodium anesthesia and after the surgeon had left the operating room. The airway was unobstructed and although a necropsy was not obtained, death appeared to be of cardiac origin. It would seem that this termination might equally well have occurred while the patient was sitting quietly in his home or while walking along the street.

SUMMARY

A report is presented of 20 cases in which hemilaryngectomy with immediate skin graft was carried out for the removal of moderately advanced carcinoma of the larynx.

The procedure affords a highly satisfactory means of dealing with laryngeal carcinomas that are too extensive for removal by a thyrotomy or a classic hemilaryngectomy. It offers a good prognosis and does not destroy the voice or interrupt the airway.

DISCUSSION

DR. FRANCIS E. LEJEUNE: Mr. Chairman, I certainly want to compliment Dr. Figi on this beautiful presentation. I think to be able to have a larynx in such cases as he has just shown us is simply marvelous and wonderful. A vast majority of us would have done, as he mentioned, a laryngectomy in most of the cases presented and these poor patients would have been laryngectomized patients the rest of their lives. Here he is showing us a procedure by which it is possible to preserve a larynx, and regardless of how poor a voice is, or regardless of how poor a larynx is, it is still better than no larynx at all. His presentation is certainly an incentive to me and I shall now go back and try to emulate the example that he has set and carry out this great work that he has started.

Thank you very much Dr. Figi for the privilege and pleasure of seeing such beautiful work.

DR. HENRY B. ORTON: Mr. President, I also wish to congratulate Dr. Figi on his excellent presentation. I wonder if we will have to reclassify our indications for laryngectomy. I should like to hear from Dr. Figi at the end of five years how these cases have progressed. We have all been informed and instructed that a growth involving both cords, or one cord involving the anterior commissure and ventricle should have a total laryngectomy. We have seen here that possibly it is not necessary. However, I think we should wait until a five year period has transpired before we definitely eliminte total laryngetcomy. Also in these cases I should like to ask Dr. Figi whether or no there was any palpable cervical node present, and if so, would the procedure be the same, or would he do a prophylactic block dissection? Thank you very much, Dr. Figi.

DR. C. L. JACKSON: Mr. Chairman and Gentlemen, I agree that this is an extremely important contribution by Dr. Figi. I think that for several years we went along feeling rather satisfied that we had solved the problem of selection of treatment for cancer of the larynx. I know that I have smugly said, in several communications, that we recognized laryngofissure, either of the clipping type or of one of the anterior commissure types, and laryngectomy as the procedures of choice in the treatment of cancer of the larynx. We condemned hemilaryngectomy and said that while it had been well thought of in Europe, in this country it was not customarily considered. Dr. Figi has been one of the pioneers here who has not been satisfied to continue using the conventional techniques alone, but has kept devising new techniques, and we have been very much interested in his contributions, as we have also been in the contributions of Dr. Alonso in South America. We are at the present time doing everything from the simple clipping laryngofissures and the "extended" laryngofissures (including anterior commissure techniques) to partial laryngectomies of various kinds, hemilaryngectomies, total laryngectomies of the narrow field type, which I still say are permissible in some cases, and wide field laryngectomies with neck dissection in continuity.

In 1951 we had done only two partial laryngectomies with a graft and mold but in 1952 we did nine with a graft or mold or both. In seven of the nine cases a mold was used; in only four a graft, but the results functionally have been excellent in all of those except one. We had one case just like Dr. Figi's where there was some difficulty in swallowing. The spillover, even after several months of trial, was such that we decided to go ahead and take out the rest of the larynx. As Dr. Orton said, it is of course too soon to draw conclusions as to cure rate in these cases, but we are inclined to think from our personal experience that this is a well worth while type of procedure.

Among the nine cases above mentioned, two were done by the Alonso technique, one in two stages and one in one stage. The rest were all partial laryngectomies for cordal lesions just a little too extensive for ordinary laryngofissure.

Thank you!

DR. GABRIEL TUCKER: I certainly want to thank Dr. Figi for this presentation. It was my privilege several years ago, when he presented this subject of resection with skin graft, to discuss the paper.

In the wide excision we have done we have tried to bring the mucous membranes together, to cut away widely from the growth. We have been quite successful. We take out the cartilage of the epiglottis and bring it down and use it to line the inside of the larynx. If you take half of it you still have enough to support the side of the laynx. I certainly am going to try this procedure of

using the mucous membrane of the epiglottis to line the inside of the larynx. It seems that it can be done. There is sufficient blood supply to support this.

In the earlier days, of course, the lack of antibiotics made these procedures quite different from what they are today. The difficulty, of course, was the skin graft. If you can either pull the mucous membrane down and line the larynx, or use the mucous membrane of the epiglottis and accomplish the same thing I believe the result would be very much worth while.

DR. SURALA (Finland): Mr. President, I just want to show the shape of the plastic flap used by Professor Murman and me in Filand to cover the defect of tissue after the removal of a tumor of the vocal cord through laryngofissure (drawing on board). Here is the incision in midline for the laryngofissure. Here is the tumor on the left side. You have to cover the defect of the tissue after the removal of this tumor. That can be made through a skin flap, taken below the border of the bed and you just turn it in in the larynx. You have the defect here. You just turn the flap in and sew it to the mucous membrane. We have had very good results and the patients have made early recovery. I think the voice has been rather good after this operation.

Thank you!

DR. CLERF: Dr. Figi has made a very fine contribution to the surgical treatment of carcinoma of the larynx. While many of us have been fairly radical in our partial laryngectomies we have gotten into difficulty because of our failure to provide a immediate skin graft to prevent the occurrence of marked cicatrization and granulation tissue. His method provides an adequate airway which in a majority of his patients has remained permanently large enough so that tracheotomy was not necessary.

DR. HENRY M. GOODYEAR: Mr. President, Members and Guests, I am very much pleased to hear this paper and I feel that Dr. Figi has made a great contribution. My early training in laryngeal work was with Dr. John E. McKenty and any carcinoma, even in situ, was an indication for a total laryngectomy; thyrotomies were not considered good surgery. Some years later, in my own experience I felt that we were removing much normal tissue, which might be saved, and I become interested in partial laryngectomies, and in one of my early cases, following total laryngectomy an obturator was used and a small airway was developed, no sufficient for breathing, but sufficient for a voice understandable over the telephone.

Our greatest point of obstruction in these cases is not more than one or two centimeters in length and this obstruction is at the level of the cricoid. If we can save a part of the cricoid, our problem of developing an airway is greatly simplified. I have used an acrylium obturator which I presented before this Society in 1948. I also made an attempt to line the denuded field with mucous membrane. I was under the impression that skin grafts were eventually replaced by mucous membrane. After seeing Dr. Figi's pictures today, apparently the skin graft must remain for many years. Apparently, the acrylium obturators I am using should be larger if judged by the obturators Dr. Figi is using, which are quite tremendous. The space he creates is very great, in fact, perhaps too great for the best voice, yet his patients apparently have a useful voice. In his cases there seems to be some motion on the side from which the lesion was removed. I have not noticed any motion in my cases. I have removed half of the larynx, the arytenoid and most of two rings of the trachea in an extensive lesion. This patient, a lawyer, is able to use his voice but the airway is not sufficiently large for good breathing and I still have an opening in his trachea. I have a surgeon on whom I removed

more than half the larynx. This man now is carrying on his work as usual but he wears a rubber stopper in a small tracheotomy tube, such as the laboratory uses in vaccine bottles. He says he must have it there as a safety valve because he gets frightened when without it.

Thank you very much!

DR. FREDERICK A. FIGI: Mr. Chairman, the discussers have been very kind. My sincere thanks!

Replying to Dr. Orton's inquiry regarding the presence of involved nodes—there were no involved nodes in any of these cases. Had there been, I would not have considered this method of removal but would have carried out gland dissection and laryngectomy in continuity. I think his suggestion that we have a five year follow-up should be observed and an attempt will be made to do this.

Dr. Tucker's suggestion regarding the use of mucosa from the epiglottis for relining the laryngeal defect I think is commendable and there are instances in which this might well be utilized. As we all know, the entire epiglottis can be removed without the patient experiencing difficulty during deglutition. In fact, more of the larynx than the epiglottis can be sacrificed without appreciable disturbance of function. On a number of occasions, we have removed not only the entire epiglottis but a considerable portion of both aryepiglottic folds so that on mirror examination after healing was complete the hypopharynx presented the appearance of a funnel extending down to the glottis. Yet these patients carry on without particular functional difficulty.

Dr. Alonzo's use of a skin flap might well be applied in some of these cases. However, one must bear in mind that it takes a fairly thick pedicle and a greater thickness of skin to insure the viability of such a flap, and this increased thickness produces more desirability than would be produced by a free skin graft.

In Dr. Goodyear's patient who has a good voice following hemilaryngectomy but who is having some respiratory difficulty, I think he could correct this stenosis by performing a thyrotomy dissecting out the stenosing scar and lining the larynx with a free skin graft.

I prefer to use soft compressible laryngeal dilators made of sponge rubber since these obviate the possibility of pressure necrosis.

# TREATMENT OF HYPERPLASTIC SINUSITIS

F. W. Davison, M.D.

Danville, Pa.

Hyperplastic sinusitis may be defined as a type of chronic sinus disease manifest by polypoid thickening of the nasal and sinus mucosa. In addition, one can usually see mucopus in the nose and nasopharynx and usually pus can be washed out of an antrum. I agree with Kern and Schenck[6] and use the presence of nasal polyps as one reliable index of the allergic constitution. In my opinion this disease is due to local sensitization of the submucosal tissues to bacterial proteins, most often those of the Gram positive cocci. I do not think that polyps are due to food or inhalant sensitivity.

Quoting Rich,[13] "It is important to recall that there are two main types of sensitization, which differ from each other in a number of ways. One of these is the tuberculin type of hypersensitivity, so called because the reaction of the tuberculous body to the proteins of the tubercle bacillus is its prototype, though the same form of hypersensitivity develops as a result of infection with other bacteria, fungi and filterable viruses. The other is the anaphylactic type which, too, may result from infection with microorganisms, but also from contact with a wide variety of substances derived from other sources. Each type arises from a bodily alteration resulting from parenteral contact with a foreign antigen, or with a non-antigenic substance that is capable of uniting readily with body protein to form an antigen foreign to the host. When this bodily alteration has occurred, tissues will be injured, and even killed, by local contact with amounts of the foreign substance that would be harmless to the normal body; and constitutional symptoms, and even death will occur when amounts that are entirely harmless to the normal body enter the blood stream of the hypersensitive one.

" . . . We found that while in both types of hypersensitivity extravascular tissue cells can be damaged and killed at the site of

From the Department of Otolaryngology and Broncho-Esophagology, Geisinger Memorial Hospital, Danville, Pa.

injection of the specific antigen, the death of the cells in anaphylactic local reactions is the result of vascular damage that interferes with the nutrition of the cells, whereas in the tuberculin type of hypersensitivity the cells of even an avascular tissue such as the cornea, or, indeed, cells from the sensitized body, washed and isolated in tissue culture, are killed by contact with the specific antigen.

"The *tuberculin type* of hypersensitivity can play an important role in the pathogenesis of infection. As a result of the development of this type of sensitization, even microorganisms which possess little toxicity for the normal body become able to damage seriously the tissues of the sensitized one."

## METHOD OF DIAGNOSIS

History, of course, is important in eliciting etiology. Many patients stated that their symptoms began with an acute severe febrile respiratory infection. The usual symptoms are nasal obstruction, nasal and postnasal discharge, which is frequently yellow in color, and anosmia. It is interesting that patients with long-standing and severe hyperplastic sinusitis seldom have headache.

The usual ear, nose and throat examination is carried out and smears and cultures are made from the exudate in the middle turbinate region. I use smears stained with the Gram and Hansel methods. It is important to examine the smears under an oil immersion lens; otherwise the heavy bacterial flora usually present will not be seen. Cultures are made on blood-agar plates, including sensitivity cultures using penicillin, streptomycin, erythromycin and terramycin. Radiological examination is always necessary. In my experience the use of contrast media is seldom necessary. Puncture and lavage of all cloudy antra is, for me, an essential diagnosis method. I prefer needle puncture under the inferior turbinate and I use an 18 gauge 3½-inch straight needle because this method permits lavage of antra of patients of any age, no matter how abnormal the intranasal anatomy.

We make our own allergy studies, fully realizing that the history is more important than the skin tests. However, we do make 70 skin tests by the skin puncture method described by Walker.[11] In addition I make three intradermal tests with Endo's house dust extract, using 1:10,000, 1:100,000 and 1:1,000,000 dilutions.

Some of these patients with hyperplastic sinusitis had positive reactions to Endo's house dust extract with no clinical evidence of sensitivity to dust. My deduction was that the positive skin tests were due to bacterial proteins in the house dust extract.

The frequent association of hyperplastic sinusitis with infectious asthma proves not that one disease causes the other, but that both have a common etiology, namely sensitivity to bacterial proteins.

It should be realized that the same individual may have food or inhalant sensitivity, bacterial allergy, physical allergy and vasomotor rhinitis due to emotional turmoil. Therefore, all four factors should be looked for and treated if found.

I do examine smears for eosinophils. It is my considered opinion that the dictum that the presence of eosinophils means "allergy" has done more harm than good because it has led many people to place great stress on foods and inhalants as the probable cause of nasal symptoms so that infection as a cause of symptoms was ignored or undertreated. The fact that there are large numbers of eosinophils in the exudate as well as in the tissues of patients having bacterial allergy has been amply demonstrated by Cooke,[1] Grove[5] and Silcox.[8, 9] My experience is in complete accord with these observers.

There are, of course, other causes for eosinophilia. Stewart Wolf[12] states that nasal hyperfunction in association with stress is accompanied by a marked eosinophilia locally and in the peripheral blood as well.

## SELECTION OF CASES AND DATA DERIVED

In an effort to collect reliable data for this paper, I studied the charts of 50 patients who had chronic hyperplastic sinusitis. The criteria for selecting these cases and throwing them into one group for analysis were the presence of polyps in the nose, plus density in the sinuses demonstrated by roentgenograms.

There were 23 females and 27 males, too small a sex difference to be statistically significant. Twelve patients had unilateral disease. In my opinion, the strongest evidence that hyperplestic sinusitis is due solely to bacterial allergy is presented by the *unilateral* cases, meaning those individuals who have pus and polyps only in one side of the nose. The raidological examination of these patients showed clouding of the antrum and ethmoid on the side of the polyps and

TABLE I.

AGES OF PATIENTS BY DECADES.

| | |
|---|---|
| 1 - 10 years | 0 cases |
| 11 - 20 years | 1 case |
| 21 - 30 years | 7 cases |
| 31 - 40 years | 10 cases |
| 41 - 50 years | 8 cases |
| 51 - 60 years | 16 cases |
| 61 - 70 years | 8 cases |

pus was washed from the antrum. Some of these individuals did, in addition, have a history of food or inhalant sensitivity and had positive skin tests, but the opposite side of the nose appeared normal and roentgenograms showed clear sinuses on the normal side.

Ten of the 50 patients in this series had asthma, usually due to an obvious chronic suppurative bronchitis, and three of the fifty had bronchiectasis. The other 37 patients had no chest symptoms, which I think is strong evidence that lymphatic drainage from the sinuses to the chest is not the reason for development of chest symptoms when it does occur. They all had lymphatics.

The duration of nasal symptoms is shown in the following table.

TABLE II.

DURATION OF SYMPTOMS.

| | |
|---|---|
| 6 - 12 months | 8 cases |
| 1 - 5 years | 18 cases |
| 6 - 10 years | 7 cases |
| 11 - 20 years | 10 cases |
| 21 - 30 years | 7 cases |

The symptoms most frequently listed were nasal obstruction, nasal and postnasal discharge and anosmia. Headache was seldom a symptom. Following removal of polyps and ethmoidectomy it was not unusual to find the sense of smell returning even when it had been

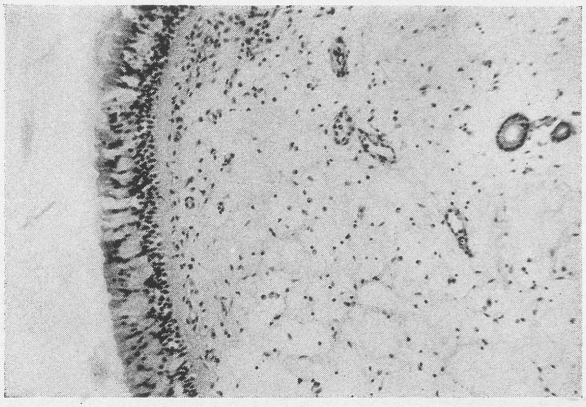

Fig. 1

absent five or ten years. One patient who had had no sense of smell for twenty-two years reported a normal sense of smell after a bilateral Caldwell-Luc operation and a bilateral transantral ethmoidectomy.

Microscopic examination of the tissue removed in cases of hyperplastic sinusitis shows a type of inflammation differing from ordinary inflammation in (1) excessive edema; (2) increased numbers of eosinophils; (3) relatively fewer neutrophils.

Eggston and Wolff[3] state: "The hypertrophic type of sinusitis may be explained histopathologically on the basis of an inflammatory reaction around the veins and lymphatics, a periphlebitis or perilymphangitis. These inflammatory processes result in obstruction of these respective vessels, causing a loss of fluid into the tissues, which distends the stroma of the tunica propria. This, in turn, is followed by various degenerative changes in the surface epithelium, glands, and bones, with distention of the tissues and polyp formation."

In my opinion the cause of the pathologic changes seen in hyperplastic sinusitis is suggested by the work of Schenck and Abell,[7] who observed the anaphylactic reaction in the living tissues of a rabbit's ear: "We concluded that the injection of horse serum into the rabbit, sensitized to this antigen, causes:

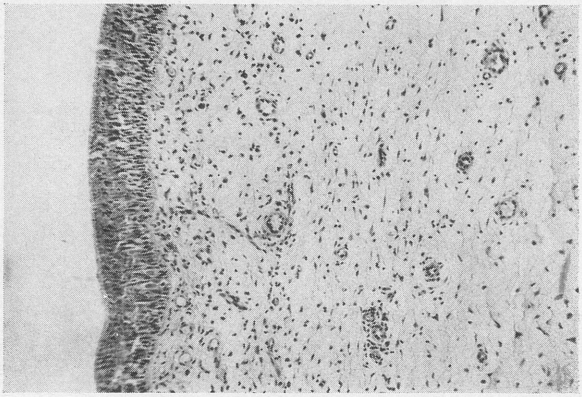

Fig. 2

1. Arteriolar contraction, which blocks the circulation;

2. A change in consistency of the endothelium, such that leukocytes adhere to the walls of the capillaries and venules in large numbers, and emigrate into the surrounding tissue;

3. A change in the leukocytes so that they become *sticky toward each other,* frequently occluding the capillaries and small venules, and sometimes forming leukocytic emboli;

4. No contraction of blood capillaries or of small venules occurs."

Thus, in my opinion, the perivascular leukocytic infiltration observed by Eggston and Wolff and seen in our own tissue specimens is explained by the *in vivo* observations of Schenck and Abell.

The histologic examination conveys the impression that in most cases these tissue changes are reversible unless there are discrete abscesses or necrosis. It was this observation that led me to try using cortisone to shrink the edematous infiltrated tissue. An additional thought was that germs are the stimulus for regrowth of such tissue. Therefore, if the germs could be eradicated by *bactericidal* doses of penicillin the tissue hypertrophies would not recur at least until an-

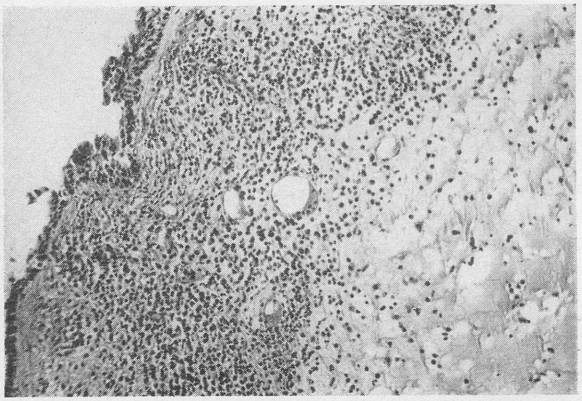

Fig. 3

other infection developed. The tissues examined were usually well vascularized, which led me to think that penicillin could diffuse effectively into the infected tissue. (See Figs. 1 and 2.)

Some type of staphylococcus was recovered in 38 cases. Twenty-seven of them were hemolytic strains and only eight were coagulase positive. Ten were not sensitive to five units of penicillin. This explains why even five million units a day may be inadequate. Eagle and associates[2] say that a serum concentration ten times the sensitivity level will usually provide the maximally effective concentration at the site of infection.

## TREATMENT

In my experience there are several useful methods of treatment of hyperplastic sinusitis and usually the best results can be achieved by combining treatment methods. The methods I find useful are:

1. Antibiotics in bactericidal doses;
2. Vaccines to increase immunity;
3. Surgery to remove tissues which have suffered irreversible damage, and also to provide ventilation and drainage;
4. Management of co-existing food or inhalant sensitivity.

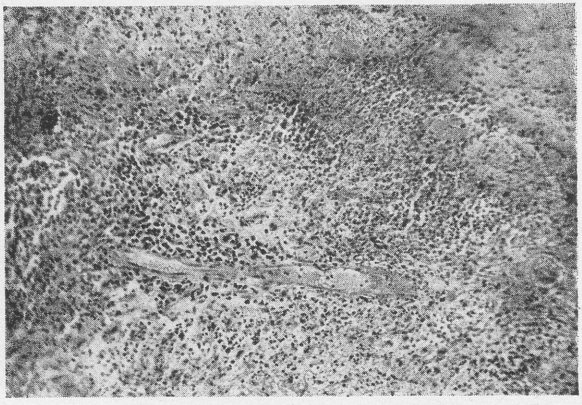

Fig. 4

In the treatment of these patients it has been my purpose to utilize the smallest amount of surgery which will produce permanent relief from symptoms. The review of these cases leaves me with the conclusion that by using 4 or 5 million units of penicillin intramuscularly daily for periods of seven to ten days, I have been able to clear up infections with intranasal surgery that otherwise would have required the external operative approach for the purpose of complete removal of the sinus linings.

The question should properly be raised: What is reversible and what is irreversible disease? Most of our tissue specimens show reversible changes; namely, marked edema of the submucosa and varying degrees of cellular infiltration, chiefly with plasma cells and eosinophils. (See Figs. 3 and 4.) The ciliated columnar epithelium is surprisingly normal in most cases. It is this histologic evidence that led me to try minor surgery such as intranasal antrostomy and removal of the pedunculated polyps, combined with bactericidal doses of penicillin, plus cortisone, to shrink the remaining hyperplastic tissue and thus afford better drainage from the ethmoids.

In my experience the antibiotic of choice is fortified duracillin, a million or more units intramuscularly every four hours for a period of at least a week, and I think my results have been better since I

TABLE III.

FIFTY CASES OF HYPERPLASTIC SINUSITIS.

Treated by removal of polyps, penicillin 4 or 5 million units I. M. daily, plus the surgery indicated. Twelve patients also had submucous resection of the septum.

| | CASES | RESULT | | | |
|---|---|---|---|---|---|
| | | EXCELLENT | GOOD | FAIR | POOR |
| Unilateral antrostomy | 7 | 7 | | | |
| Unilateral intranasal ethmoidectomy | 1 | 1 | | | |
| Unilateral antrostomy plus unilateral intranasal ethmoidectomy | 4 | 4 | | | |
| Bilateral antrostomy | 16 | 11 | 3 | 1 | 1 |
| Bilateral intranasal ethmoidectomy | 4 | 4 | | | |
| Bilateral antrostomy plus bilateral intranasal ethmoidectomy | 14 | 9 | 3 | 1 | 1 |
| Bilateral Caldwell-Luc plus bilateral transantral ethmoidectomy | 4 | 4 | | | |
| Total | 50 | 40 | 6 | 2 | 2 |

There were no deaths and no post-operative complications.

have been using two million units intramuscularly every four hours. In addition, I frequently give a half gram of streptomycin intramuscularly every eight hours for 7 days. In my experience topical application of antibiotics is without value. I also think vasoconstrictors have very minor therapeutic value.

Recently I have found cortisone to be of considerable value in treatment of these patients because it suppresses the inflammatory reaction, shrinks the hyperplastic tissue and thus improves drainage.

Cortisone has great value in suppressing asthmatic symptoms, so that the necessary sinus surgery can be done. The initial daily

dose of 200 mg. by mouth was gradually reduced over a two-week period, so that the average total dose per patient was 900 mg. No toxic effects were seen in the ten patients treated with Cortone.

Cortisone is of distinct value also during the week following operation because it decreases postoperative edema. It suppresses formation of granulation tissue, but does not interfere with regeneration of epithelium. Its action is transient. It does not kill germs. Hyperplastic tissue recurs unless the germs are killed.

## COMMENT

Table III shows the results of treatment. The four patients listed as having only fair or poor results should have had more complete surgery. I now think that vaccines should have been used more frequently. Only seven of these fifty patients had vaccine therapy. Its value has been demonstrated by Silcox[9] and Solis-Cohen.[10]

Fenton[4] pointed out the value of vaccine therapy in a paper given at the meeting of this Association in 1925. The fact that some of our cultures show staphylococci resistant to 20 units by the tube dilution method indicates that vaccines or radical surgery must be used in some cases.

GEISINGER MEMORIAL HOSPITAL.

## REFERENCES

1. Cooke, R. A.: Infective Asthma, The American Journal of the Medical Sciences 183:309 (Mar.) 1932.

2. Eagle, H.: Fleischman, R., and Levy, M.: Continuous vs. Discontinuous Therapy with Penicillin, The New England Journal of Medicine 248:481 (Mar. 19) 1953.

3. Eggston, A. A., and Wolff, D.: Histopathology of the Ear, Nose and Throat, Baltimore, The Williams and Wilkins Co., p. 639, 1947.

4. Fenton, R. A.: Vaccines from Hemolytic Cocci in Spheno-Ethmoidal Disease, Tr. A. L. A., 1925, p. 189.

5. Grove, R. C., and Cooke, R. A.: Etiology and Nature of Chronic Hyperplastic Sinusitis, Arch. of Otolaryng. 18:622 (Nov.) 1933.

6. Kern, R. A., and Schenck, H. P.: Allergy a Constant Factor in the Etiology of So-Called Mucous Polyps, J. Allergy 4:485, 1933.

7. Schenck, H. P., and Abell, R. G.: The Anaphylaxis Reaction: Tissue Changes as Observed in Living Tissues in the Rabbit, Transactions of the American Laryngological Association, p. 210, 1938.

8. Silcox, L. E.: The Role of Bacterial Infection in Respiratory Allergy, The Laryngoscope 60:225 (Mar.) 1950.

9. Silcox, L. E.: Treatment of Hyperplastic Sinusitis, Tr. Am. L. R. & O. Soc., p. 60, 1952.

10. Solis-Cohen, M.: Effective Vaccine Therapy in Chronic Bacterial Infections of Upper Respiratory Tract, Arch. of Otolaryng. 56:485 (Nov.) 1952.

11. Walker, D. H.: A Method and Apparatus for Rapid Performance of Skin Tests, ANNALS OF OTOLOGY, RHINOLOGY AND LARYNGOLOGY 57:1041, 1948.

12. Wolf, S. G.: Causes and Mechanisms in Rhinitis, The Laryngoscope, 62:601 (June) 1952.

13. Rich, A. R.: Hypersensitivity in Disease, The Harvey Lectures, The Science Press Printing Co., 1946-47.

## DISCUSSION

DR. WATT W. EAGLE: Mr. Chairman, Ladies and Gentlemen, this very interesting and excellent paper of Dr. Davison's has covered a large field quite adequately.

For many years we too have been quite interested in bacterial allergy. Our cases have been managed somewhat differently, however, since we have not used penicillin prior to surgery routinely. We do attempt to reduce edema and promote ischemia by the use of propradrine hydrochloride or calcium, preferably intravenous calcium gluconate either prior to, during or after the surgery. Usually 10 cc of 10% calcium gluconate is used on the average-sized adult. This provides a post-operative course of less edema, and the patient is much more comfortable. We have not used cortisone to any extent.

Personally, I was very interested in the cortisone therapy as discussed by Dr. Davison because it reflected so well on the paper by Dr. Hawkins yesterday in which he described the mechanism of the fluids shifting from the vessels to the tissues. Undoubtedly the future has much in store for the therapy of allergic states with cortisone therapy.

In our section of the country we find, of course, that bacterial allergy is most predominant in the winter months, and we attribute this fact to the repeated infections of the lymphoid tissues of the pharynx and nasopharynx. I was indeed glad to hear Dr. Davison discuss dust sensitivity. A good example is that of a school child. He is in a room with many other children, and in the winter months the heat of the schoolroom is invariably extremely dry with dust particles floating in the air. These dust particles carry the infection from a coughing child to the other students. Those having lymphoid tissue hypertrophy have a tendency to pick up these infections and there is a repetition throughout the winter months of such an infection. Antibiotic therapy provides only temporary benefit usually. Some attention should be given by our School Boards to the provision of humidity in the heat of the schoolrooms, not only for the comfort to be derived but also from the standpoint of reducing the respiratory infections of the children. Furthermore, the expense of heating school plants would be markedly diminished because one is comfortable at 70° temperature if the air is moderately humid. Hotels, hospitals and dormitories all have notoriously dry heat in the winter months, and individuals who live in such places are indeed more prone to have their lymphoid tissues irritated, due to nasal obstruction and poor ventilation, and they are therefore subject to infections. In our hospital we have provision of humidity by a basin of water boiling on an electric hot plate, or a steam humidifier, for the allergic patient, or even a humidifier on the radiator to allow steam to escape. It is very essential to have steam in a room to properly settle the dust to the floor; and in doing so, it is amazing to observe patients having bacterial allergy—as

evidenced by asthmatic bronchitis—to show immediate improvement by the provision of steam in the hospital room or in the bedroom at home.

Some of us are fortunate enough in our location of work to be associated with an allergist. Through his cooperative work—including vaccine therapy—we feel that we accomplish satisfactory to excellent results in the management of the bacterial allergy patient. Cultures from the upper respiratory tract are made prior to any surgery, with subsequent vaccine preparation; and if pathological tissues are removed at the time of surgery, another vaccine is prepared from cultures made from these tissues.

Irradiation of lymphoid tissues to destroy these tissues is indicated in many cases, and we prefer x-ray therapy to radium therapy because the field includes the pharynx, base of tongue and nasopharynx.

Thank you very much.

DR. HENRY L. WILLIAMS: This paper of Dr. Davison is the typical stimulating and thought provoking paper with which he always provides us and to me it has been a very interesting experience to listen to this paper this morning.

There are one or two points, however, that have surprised me somewhat. In the first place, the 26 per cent incidence of unilateral hyperplastic sinusitis is rather contrary to my own experience. I have been hunting over a good many years to find instances of unilateral allergy, which I think that Dr. Davison would admit that these cases are, and I certainly have not been able to find an incidence of this degree. As matter of fact a unilateral allergy in my experience is extremely unusual as a finding, unless one wishes to include those cases of naso-antral polyps in this group, which I think probably are not on an allergic basis.

The hypothesis of bacterial allergy I also have occasion to be at least somewhat doubtful about. I found that these cases of "bacterial allergy," have rather as one might say, a hyperplastic sinusitis as the result of indolent allergy. Quite frequently if one can eliminate the indolent allergy the infection tends to disappear. I believe instead of being sensitive to bacterial proteins these patients are allergic individuals in whom the allergic condition reduces their normal resistance to infection. In my experience, although we also work in very close association with our Department of Allergy, our results with skin testing, elimination diets and particularly in the use of vaccines and cortisone, have been very disappointing. Cortisone will give temporary relief to the symptoms of allergy and somewhat to the symptoms of infection, but in a week or ten days after the cortisone is discontinued, the symptoms and the pathologic changes are back in full force. So I believe that cortisone is an illogical drug to use in these conditions and the dangers of cortisone are so great and so many complications are being produced by the indiscriminate use of cortisone, particularly the dangers of using cortisone in patients in whom surgery is contemplated, that I would urge individuals to avoid rather than to adopt its use.

I have been interested in Solis-Cohen's method of securing vaccines, yet in talking it over with our bacteriologists they are in very violent disagreement with this method of pathogen selective culture technique and they have not been able to secure the results that Dr. Solis-Cohen reported.

I believe the type of surgery that is done in these cases is of the utmost importance. I advise intranasal surgery with careful preservation of functioning nasal tissues which I believe is the type indicated in these individuals. One finds particularly in the ethmoids very definte collagen disease. Removing this collagenous hyperplasia and then following operation with the application of radium

has seemed to give good results. Radium seemes to have a tendency to alter the local sensitivity as does x-ray. In many instances the use of x-ray to the chest in an asthmatic individual has produced good results. I believe that surgical drainage in getting rid of the infection is helpful, but that getting rid of the allergic factor which reduces the resistance of the individual to the infection that produces the most benefit.

I have been very much stimulated by Dr. Davison's work in the bactericidal use of penicillin and have tried it and I have had favorable response but at the same time I have not got the complete relief to the allergic symptoms, the polyps, the collagen disease which probably by the misreading of Dr. Davison's paper I was led to expect. I believe that the allergy is the fundamental condition here, the infection being secondary. While one cannot get rid of the allergy by operating on the sinuses, if one can get rid of the allergy I believe that in many instances the sinus infection will take care of itself. Yet many of these cases I believe to be physical types of allergy and therefore not amendable to the usual allergic therapy, so that we are caught in a sort of cleft stick and must do the best we can by surgical methods, and by non-specific therapy for allergy.

DR. BERNARD J. MCMAHON: Mr. Chairman and Gentlemen, I would like to congratulate Dr. Davison on an excellent paper and the manner in which he has worked it out.

I might call your attention to the difference between hyperplastic tissue changes and hypertrophic tissue changes. Dr. Davison has mentioned permanent hypertrophic tissue changes. Hypertrophy as we have seen it is caused by an increase in the size of the tissue due to the increase of fluid in the tissue, to the thickening and increase in size of the original structural cells, and some infiltrating cells such as plasma cells, histiocytes and young connective tissue cells. While they are structural cells, they are resorbed when the condition reverses itself. Hyperplastic tissue changes follow the increase in structural tissue cells within the stroma, around the blood vessels, in their walls, and in the periosteum. The invading connective tissue cells remain and mature in the tissue, thus establishing an irreversible change.

This results in the compression of the glands, the limiting of the circulation by the extrinsic pressure and by the narrowing of the lumen of the blood and lymphatic vessels. When that takes place in the afferent and efferent vessels posteriorly we are likely to have an edema anteriorly which will result in certain types of polypoid degeneration or polypoid changes, either superficial or deep, or projectile, as polys, so that when we speak of the hyperplastic sinusitis it is in terms of that type of tissue change. The circulation is the important thing. In other words in a hyperplastic sinusitis there are not only the changes in the functioning elements of the subepithelial tissues but also certain changes in the bone. We know that the maintenance of the life of a bone depends upon the circulation. Consequently when the circulation is reduced there is a resorption of calcium and the bone becomes fibrous also. We feel that infection is a big element in these conditions, that is, in the hyperplastic type of sinusitis.

Dr. Davison mentioned the sensitivity tests. We routinely use the 24-hours plate method instead of the 72-hour reculturing techniqne. Our method consists of immersing and agitating the 'swab' in 8 cc of a nutrient broth. That is then flooded over a blood-agar plate and the discs of graduated concentrations of the antibiotics are placed on the plates. After 24-hours incubation the plates are read. The reason I think this method more important and more accurate is that you are determining the sensitivity of the entire flora of the infection instead

of selecting those organisms which you think are the most virulent. In other words, symbiosis is important in the infection, and we are guided in our therapy by our 24-hour findings. In certain instances we also work them out individually according to organisms, which takes four or five days, as you know.

I have had very good results with autogenous vaccines on patients, with allergic rhinitis and recurrent infectious sinusitis. Some allergists fail to realize that every change that takes place in the nose is not due to an allergy and seem to ignore the fact that a nose can become periodically infected.

Our procedure is to reculture the nose after a rest period following the termination of the first course of injections, and have a new autgenous vaccine made for continued use if indicated.

Thank you.

DR. SAM E. ROBERTS: I want to thank Dr. Davison for a very provocative thoughtful discussion. There are a number of things I do not understand. For instance, if Dr. Davison is dealing with a chronic allergic situation, where there are but a few secondary bacterial invaders I do not understand why he uses such heavy doses of antibiotics, especially if these patients are afebrile. The same thing is true for the sulfa preparations. Woolley of the Rockerfeller Institute has shown definitely that sulfas are antimetabolic and I am quite sure we will find the same thing is true of the antibiotics. I agree with Dr. McMahon that hypertrophic tissue changes are frequently reversible. I have often prayed for a recurrence of some polypoid tissue when I have been too energetic in removing too widely and cauterizing too deeply, which resulted in an atrophic condition with crust formation. The patient was much more comfortable when he had some hyperplastic tissue remaining even though there were some polypoid areas.

Several years ago, Fabrikant of Chicago wrote a classical monograph on the pH of nasal secretion. I believe the reason we have not followed through with his suggestion was that his technique of determining pH of nasal secretion was quite complicated. We have simplified this technique by using Squibb's nitrazine paper in the nose from which we can get an immediate reading on a colorimetric chart. If the pH is high, which it nearly always is in the allergic patient, we advise acidulation locally in the nose and usually dilute hydrochloric acid by mouth.

We must not neglect endocrine investigation. For generations women have told us that during pregnancy particularly the 7th and 8th months when the estrogenic levels were running the highest, that their allergies frequently disappeared, their migraines improved and general health better in every way. Minimum doses of estrogenic preparations have been helpful in our experience. We are still doing some extensive clinical investigation of the subject at the present time. Thank you very much!

DR. ARTHUR W. PROETZ: I wonder whether Dr. Dixon or Dr. McCall would care to tell us whether, in that remarkable series of cases which they reported, of noses which returned to normal after laryngectomy. There were such membranes as the ones we have had described here this morning. Their cases were to my mind the finest example of reversibility of tissue that I have ever seen, and I believe they are important in this connection.

HARRY P. SCHENCK, M.D.: Over 20 years ago, Dr. Richard A. Kern and I published a paper in which we suggested that the majority of nasal mucous polyps were caused by an underlying allergy, and further indicated that of all the allergies, bacterial allergy was the most important factor. When poor results are obtained

with bacterial vaccines, the fault often lies in careless culture methods or improper laboratory technic in the preparation of the vaccine itself. It is generally conceded that in asthmatics, vaccine therapy has proven most effective when the vaccine has been prepared from bronchoscopic cultures. This certainly emphasizes the importance of uncontaminated cultures as the basis for vaccines.

Bacterial allergy has not been sufficiently emphasized because skin tests with bacterial antigen are notoriously worthless. I feel that these unreliable results are due to faulty preparation of the antigen and not to absence of a mechanism which will react in a sensitized individual. Heat or chemicals so alter the antigenic properties of the bacteria that satisfactory reactions are not to be anticipated. When bacteria are broken up in a ball mill and then subjected to enzymic action, a fairly definite response can be obtained in the sensitized individual.

It is probable that globulins, including gamma globulin, are largely manufactured by the plasma cells. Mere contact of the bacteria with plasma cells will not set in motion the mechanism for the manufacture of globulins and other immune substances. Plasma cells must be stimulated to action by contact with certain fractional products of bacteria, and these can only be provided by reticuloendothelial cells and polymorphonuclear leucocytes after they ingest and digest bacteria. Plasma cells also require building stones for the production of globulins and these building stones are provided by the materials resulting from the breakdown of lymphocytes. It is reasonably certain that a somewhat similar mechanism is involved in a typical allergic reaction.

Perhaps too much attention has been given to the significance of histamine and the triple response in allergy. Not only is histamine liberated but also heparin and a choline. Moreover, our occupation with the chemical phases of the allergic reaction has blinded us to the concomitant cytologic changes.

Dr. Fred W. Dixon: Mr. Chairman, in reply to Dr. Proetz's question regarding the frequency of sinusitis and upper respiratory infections in the laryngectomized patients which Dr. McCall and I reported, these patients stated that post-operatively, since the nose was no longer a functioning organ, they were free from sinusitis and colds. No polyps were seen.

The surprising findings in addition were the pale purple color of the turbinates, the return of the ciliated columnar epithelium to the inactive areas in the anterior third of the nose, and the sub-epithelial changes.

If I might comment on Dr. Davison's excellent presentation, it is my belief that if you can eliminate allergy, provide ventillation and drainage, and judiciously use penicillin, you can promise relief to these patients. Some may require surgery, but whether the treatment is medical or surgical, most patients can be made comfortable.

Dr. Oliver E. Van Alyea: Thank you very much, Dr. Broyles! I was afraid I would not make it. I know these laryngologists are twitching in their seats because temporarily the rhinologists have stolen the show and they are anxious to get back to their subject again, so I won't continue this very long.

Most of the things that I had in mind have been said much more ably than I could possibly say them, by Dr. Williams, Dr. McMahon and the other discussers. There are just a couple of items which I would like to stress. One of them, it seems that although Dr. Davison has a leaning toward simpler methods than we have employed in the past, he has omitted some of the really simple things that we do in our office, which often get these patients into a much better condition

and sometimes return them to a condition of no symptoms and a return of the membranes to a normal state. The procedures referred to are those which improve drainage from the sinuses because you know that is after all the goal of the rhinologist, to establish adequate drainage to the sinuses. Infraction of the middle turbinate, which is a procedure often overlooked in the management of these cases, may prove effective. Also a few irrigations of the sinuses or Proetz' displacement when the ethmoids are involved, combined with proper allergy management will eliminate even the need of any surgical procedures in the vast majority of the cases. One other thing, I would like to ask Dr. Davison. We have had a lot of conversation about reversible, irreversible changes. I am still looking for the irreversible changes in this type of case. When you have irreversible changes with the collection of abscesses under the mucous membrane or in the stroma, or breakdown of the epithelial layer, it is in those cases which have had previous surgical procedures, and in that slide which he showed us, I would like to ask him if that is not the case. Was this a revised operation that he performed?

Thank you!

DR. THEODORE E. WALSH: I enjoyed Dr. Davison's paper too, Mr. Chairman. I want to make one comment about vaccines. Dr. Davison talked about the use of vaccine and I presume it was given by parental injection. I would like to interject one thought about the subject of immunity.

When a patient acquires an acute infection, living organisms enter the tissues and the immediate defense reaction of the host is a polymorphonuclear one. One wonders why, when the polymorphonuclear cells have ingested the invading organisms, there is very little immunity established as in the cases with which Dr. Davison is dealing.

Some time ago we did some experiments in an attempt to elucidate this question. We took organisms ingested them in polymorphs and in macrophages in vitro and in vivo, and using the digest as an antigen followed the serum antibody content of the host. It was interesting that the polymorphonuclear digest produced almost no antibody. On the other hand, a macrophage digest produced very much more antibody but most antibody was produced by the injection of killed undigested organisms. It is important how organisms are killed as Dr. Schenck mentioned just now. Heat killing is apt to alter the antigenicity and in my experience vaccines made from organisms ground up in a ball mill have no antigenicity whatever. Apparently it is necessary to have killed bacterial bodies which can be ingested by macrophages. Whether macrophages produce antibody or whether it is produced by other tissue cells I don't know. There is considerable argument as to whether lymphocytes, plasma cells or macrophages produce antibody. Nevertheless when dead organisms are ingested and digested in tissues by macrophages, antibodies are produced. I don't agree with Dr. Williams about the cases of unilateral so-called allergy. I doubt that the term is properly used. These are cases of chronic infections with hyperplasia which can be explained perfectly well on the inability of the host to produce enough antibody to combat the infection. If in those cases you will take a vaccine and put it into the sinus so that the organisms can be ingested by the living macrophages in the tissues you will produce antibodies and I think you will get rid of such infections.

DR. FRANCIS W. DAVISON: First I would like to thank all the discussers for their comments. Obviously I cannot answer all the questions raised.

Just one or two additional comments: I was glad to hear Dr. Eagle say that he finds the use of vaccines helpful. If large doses are used the patient's symptoms will be increased. The doses must be small enough to avoid focal or constitutional

symptoms. Often the original 1% suspension must be diluted 1:10 or 1:100 and then the first dose should be 0.05 cc given *intradermally*.

I have high regard for Dr. Williams' opinions but I knew that he would not agree with me about bacterial allergy. These were not selected cases; 12 out of 50, which means 24 per cent, had unilateral disease. I would like to repeat my reasons for my belief in bacterial allergy: (1) the unilateral cases; (2) the history of onset of symptoms with acute infection; (3) good therapeutic response when the infecting organisms are sensitive to penicillin in adequate dose; (4) the recreation or re-exacerbation of symptoms by administration of too large a dose of vaccine. The latter fact is well known by people who deal with asthma. I just don't see how anyone with an open mind can fail to admit the existence of bacterial allergy.

I would like to thank Dr. McMahon, who put me straight regarding terminology. His experience goes way back and he knows much more about the subject than I do. I was glad to hear him say he gets good results with properly prepared autogenous vaccines.

I was also glad to hear Dr. Schenck say there is bacterial allergy. Much of my interest in the subject has been stimulated by his papers.

I agree with Dr. Van Alyea that some useful things can be done by office treatment. Improvement of drainage is very helpful. The patient whose antral lining contained discrete chronic abscesses had not had any previous surgical treatment. Of course in a 20-minute paper I could not mention all the things that are useful.

I also agree with Dr. Walsh about the use of properly prepared chemically killed vaccines. I have not used vaccines topically so cannot give a first-hand opinion about the value of this method.

One may go beyond the nerve endings and administer a drug which depresses the smooth muscle of the blood vessels directly. The nitrates and nitrites are used for this purpose. They are not practical for hypotensive anesthesia because they lack controllability. The pressure may also be lowered by decreasing the blood volume by employing the procedure known as arteriotomy. A cannula is placed in the radial artery and blood is withdrawn temporarily into a container with an anticoagulant. It is reintroduced when the need for the hypotension is over. The chief disadvantage of this method is that generalized vasodilatation is not present and vasomotor control remains active. In due time irreversible shock may occur. Also it is tedious, cumbersome and involves sacrifice of an artery.

The chief use of controlled hypotension is for situations in which considerable bleeding is anticipated. The hypotension is induced during surgery just prior to the moment that bleeding is anticipated. A relatively bloodless field results for a brief period and the surgery can be accomplished with greater ease. Controlled hypotension facilitates neurosurgery when highly vascular tumors or aneurysm are to be excised. It facilitates surgery about the head and face since the blood vessels are abundant in these areas. The technique may be applicable to radical dissections of the neck, resections of the mandible, laryngectomies and other operations in which excessive blood loss is anticipated.

Obviously there are bound to be objections and hazards in the use of this method and it cannot be employed routinely in every case. The relaxation of the vascular bed, of course, reduces the blood flow through the vital organs. If the cardiovascular system is diseased the incidence of complications, untoward reactions and undesirable sequela mounts. The circulation time is prolonged, sometimes twice the normal value. When the coronary arteries are diseased, the myocardium may not receive an adequate blood supply and coronary insufficiency follows. Coronary thrombosis is a likely occurrence. The brain likewise may suffer damage to lack of nourishment or oxygen deficiency. The slowing of the circulatory system in sclerotic vessels predisposes to thrombosis and later emboli in any organ. Cerebral thrombosis and coronary thrombosis have been the most frequent complications of the technique. At least 60 mm of mercury pressure is necessary to maintain adequate filtration by the kidney. If the blood pressure remains below this level for any length

of time, damage to the tubules may result. Anuria follows in the post-operative period.

In executing the technique the patient is anesthetized in the usual manner. Ten or fifteen minutes before the anticipated time of excessive bleeding the vasodilator drug is administered intravenously. Usually the blood pressure is reduced to 60 to 80 mm of mercury. If maintained above 80 mm of mercury, the results are not satisfactory. The blood in the vascular space is influenced by gravity and may be shifted about at will. The pressure may be reduced further by inclining the patient with the head up and the feet down. If the pressure falls below the desired depth, the head may be tilted downward and the feet up. The effects of gravity cause an increase in the amount of blood returned to the heart and brain and the pressure rises. After the denervation is instituted the blood pressure is controlled by varying the position of the patient until the effects of the drug wear off. Blood must be replaced as it is lost. These patients do not tolerate blood loss. Little anesthetic is required during the period of hypotension. The depth of anesthesia necessary is nowhere as much as it is without hypotension. The period of hypotension should be as brief as possible, not to exceed one hour at the most. At the conclusion of the portion of the operation requiring the hypotension the blood pressure may be raised by tilting the patient or by injecting a vasoconstrictor drug such as Neosynephrin, Arterenol or Desoxyephedrine.

The most frequent complication in the post-operative period is slow recovery. Patients require a long time to recover from the post-anesthetic depression. The second frequent complication is reactionary hemorrhage. Bleeding points which have not been detected and tied off before closure resume bleeding as the pressure rises. Anuria, cerebral thrombosis, apoplexy, coronary thrombosis, pulmonary embolus, encephalopathy are occasional complications encountered.

The technique is not to be used routinely. In the light of our present knowledge its use in benign conditions is not justified except in circumstances in which the possibility of serious sequela is the lesser of two evil choices. One cannot deny that it does facilitate the more formidable types of surgery and if used with discretion in malignant conditions, is a worthwhile procedure notwithstanding the possible complications. The procedure is not an anesthetic one. The anesthetist merely executes the technique because he ordinarily

watches the blood pressure for the surgeon and is in the best position to direct its management. The procedure is merely one of disturbing the physiology during surgery in order to accomplish vasodilatation.

The second item of interest to surgeons is the use of muscle relaxants as adjuncts to anesthesia. In laryngology the muscle relaxants play an important role, particularly for endoscopy. Originally, the sole muscle relaxant available was curare. Before 1936 specimens of curare were of doubtful purity. The drug was nothing more than a pharmacological curiosity. Richard Gill, an American explorer was instrumental in locating and bringing to the United States from South America the authenticated botanical specimen of curare. The active principle in curare is the alkaloid tubocurarine. Since the reintroduction of curare and isolation of its active principle many other synthetic muscle relaxing agents have been prepared. Each of these has certain merits and demerits. The majority of these have many features in common and it is best to classify and study them in groups rather than as individual compounds. From a pharmacologic standpoint these compounds fall into major groups. The first group, which includes curare, its alkaloid, tubocurarine and synthetic substances derived from the alkaloid, such as methyl tubocurarine, interfere with the action of acetylcholine on the somatic nerve endings. It is now recognized that as the impulse in a somatic nerve fiber supplying skeletal muscle, reaches the nerve ending, acetylcholine passes through the subneural space to the neuro-junctional membrane. This membrane is polarized in its resting state. As the acetylcholine reaches the membrane depolarization occurs and contraction of the muscle fiber is initiated. As soon as the stimulus resulting from the depolarization recedes the muscle relaxes to its resting state and remains relaxed unless the membrane becomes repolarized so that it will be influenced by the next impulse. In the meantime, cholinesterase splits the acetylcholine into acetic acid and choline which are physiologically inactive. Removal of the acetylcholine causes the membrane to regain its polarity and is then ready to receive the next impulse. The next impulse once again liberates more acetylcholine and the cycle is repeated. When tubocurarine and substances which act similarly are administered, it fixes itself in some manner at the membrane and prevents the acetylcholine from causing depolarization. The membrane then remains polarized and the muscle fiber is unable to contract even though acetylcholine is liberated with each impulse coming down the nerve fiber.

Curare, tubocurarine, metubine, flaxedil and mytolon all act in this manner. The blockade caused by these drugs may be reversed in one of two ways. Substances which inhibit cholinesterase cause acetylcholine to accumulate at the membrane in sufficient concentration so that it then is able to act on the membrane. Eserine and prostigmine both inhibit cholinesterase from destroying acetylcholine. Theoretically they reverse the action of curare and curare like drugs. In actual practice, however, the results are disappointing. A recently introduced substance related to prostigmine known as tensilon is an effective antagonist. Presumably it acts by combining with the relaxant or removing it from the site of action at the myoneural junction. Acetylcholine then is free to initiate the contraction in a normal fashion.

The second group of muscle relaxants act in a somewhat different manner but all in the group are pharmacologically similar. They cause relaxation by causing persistant depolarization. If acetylcholine is present in excessive amounts and remains at the junctional membrane, the membrane remains depolarized. The muscle fiber then remains relaxed. Any drug which has an acetlycholine action and causes sustained depolarization of the junctional membrane will produce relaxation. A contraction preceeds the relaxation. When administered to a patient such a drug induces fasciculations for 20 to 30 seconds, then relaxation follows. Syncurine is the better known drug of this type. A newer drug which offers promise of being clinically useful is succinyl choline (Anectine). It appears to be safer than the muscle relaxants heretofore studied. This is largely due to the method by which it is detoxified. Most muscle relaxing agents are either eliminated unchanged by the kidney or are destroyed by the liver or by a combination of both methods. Their duration of action varies depending on the rate of elimination. Some act longer than others. Succinyl choline, however, is different in this respect. Succinyl choline is an ester. Like acetylcholine it is attacked by the naturally occurring enzyme, cholinesterase, which converts it into succinic acid and choline. Both of these products of detoxification are naturally occurring body constituents. It is advantageous to have the detoxification products of a drug not be biologically foreign to the body. The destruction occurs rapidly. Usually its effects have disappeared within two to three minutes.

There are several other reasons why succinyl choline is more desirable than other muscle relaxants. In many instances when

muscle relaxing agents are used as adjuncts to anesthesia, the respiratory pattern is disturbed and does not return to normal for quite sometime. Succinyl choline, however, does not appear to act in this manner. As soon as the paresis has disappeared the respiratory pattern is restored to normal. Then, too, when succinyl choline is used one may interrupt the blockade at any time desired. This cannot be done with the other muscle relaxants. If a sustained blockade is desired for many minutes, the drug may be administered by a continuous intravenous drip. It must be remembered that neither prostigmine or tensilon are effective for reversal of the action of syncurine and succinyl choline. As a matter of fact, the prostigmine may enhance and prolong the effect. No suitable antagonist has been discovered for these two agents. The doses ordinarily used for muscle relaxation do not appear to affect the central nervous system. There is neither stimulation nor depression.

It must be remembered that muscle relaxants are not anesthetic substances. An operation may be performed upon a subject using a muscle relaxant alone, if one chooses to do so. However, the operation is performed without any resistance because the subject is incapable of voluntary movement. The central nervous system is still active. The subject feels the pain and remembers the experience but is unable to protest. It is customary to combine the muscle relaxants with a basal narcotic, such as thiopental (Pentothal) or other barbiturate. The narcotic produces the desired hypnotic effect but still does not cause a blockade of the painful impulses. A third substance must be added for satisfactory results. The third subtsance must be analgesic or anesthetic. For this reason it is common in present day practice to use a combination of nitrous oxide which supplies the analgesia, thiopental which supplies the depression of the central nervous system which is only obtained with difficulty with nitrous oxide, and the muscle relaxant which supplies the relaxation which neither the nitrous oxide or thiopental is capable of producing. For endoscopic work the combination of a muscle relaxation and ultrashort-acting barbiturate is widely used. It must be emphasized that satisfactory topical blockade is most desirable in this type of instrumentation, otherwise excessive amounts of these drugs will be required. The difficulties which arise from these combinations in endoscopic work are largely the result of overdosage.

One must remember, too, that the muscle relaxants have other effects besides those of interrupting the impulses at the nerve endings

of skeletal muscle. They also have autonomic effects, that is, they either stimulate or depress the ganglia. Large doses of curare, for example, block the autonomic ganglia. The doses that are ordinarily used during anesthesia, however, have little effect on the autonomic nervous system. Some of the newer synthetic substances have vagal stimulating effects or vagal depressing effects. The curare preparations as a whole have a histamine-like action. Occasionally bronchial constriction is encountered. This must be borne in mind during bronchoscopy and laryngoscopy. Such bronchial constriction is best relieved by the use of a bronchial muscle relaxant such as aminophylline.

CHARITY HOSPITAL AND DEPT. OF SURGERY
TULANE UNIVERSITY.

## PRESENTATION OF INSTRUMENTS

---



## SUCTION FORCEPS

EDWIN N. BROYLES, M.D.

BALTIMORE, MD.

Mr. President and Gentlemen: Occasionally a waving polyp far back in the posterior nares or one arising from the anterior commissure of the larynx can be pulled into view easily with a suction tip, but it is very difficult to apply forceps to a polyp so exposed. It seemed that it might be helpful in these cases to combine the suction tip and a cup of the forceps to be used. This has been done and these suction forceps have been used with success on several occasions. Longer forceps for endoscopic use have not yet been completed.

(Slide) This is the nasal forceps with the suction tip a part of the lower cup.

(Slide) The angle forceps work in the same manner. The suction holds the polyp tightly in place. Solid tissue cannot be pulled into the cups of the forceps.

(Slide) This is the laryngeal straight forceps with the suction tip in the lower jaw. It has been helpful in the removal of small polypi and papillomas from the vocal cords. I wish to present these instruments and hope that they may be of some help.

They are manufactured by A. C. M. I. of New York City.

Thank you very much.

# PHARYNGEAL AND LARYNGEAL PHENOMENA OF VASCULAR ORIGIN

FRENCH K. HANSEL, M.D.

ST. LOUIS, MO.

In the practice of otolaryngology a significant number of patients are encountered, complaining of vague pains, and various types of discomfort in different parts of the head and neck which cannot be definitely classified and for which no pathology is demonstrable to account for the cause of symptoms.

In the reported observations of Greenfield Sluder,[1] a great variety of these cases was described in which the cause was not infrequently attributed to hyperplastic sinusitis, or to involvement of the nasal ganglion and the Vidian nerve. In many instances, symptoms were referred to the pharynx or the larynx.

During the course of observation of a large number of headache patients during the past 12 years, we[2, 3] noted that not infrequently cramping pains were also described in the leg on one side or the other and that upon relief of the headache symptoms, the leg pains also disappeared. This observation suggested therefore that the arteries of practically any part of the body may become involved with the production of vasoconstrictor and vasodilator phenomena. The so-called "abdominal migraine" described by Osler certainly is of vascular origin. It is not unreasonable to assume also that in certain cases of precordial, back or pelvic pain the same type of mechanism may be concerned. We have noted that aside from the true headache, pains and discomforts may also be referred to the ear, the parotid, the maxillary and dental regions and that they may be explained on a vascular basis. Later, it was further observed that patients with painful and annoying symptoms referred to the nasopharynx, tonsillar, pharyngeal, laryngeal and deep cervical regions could also be classified as of vascular origin.

It was also observed that in some cases of headache, certain symptoms may be caused by the involvement of those vessels which

affect specific functional structures. For example, a patient with histaminic cephalgia had transitory attacks of blindness lasting 20 to 30 minutes on the side affected by the headache. The blindness, however, never occurred with the headache. Both conditions disappeared completely with histamine therapy. In another patient, swelling of the common carotid artery with marked tenderness on palpation occurred with attacks of headache involving the temporal area on one side or the other, mostly on the right. During a period of eight years of headaches, she had three attacks of Bell's palsy, one on the left, two on the right. Under these circumstances, it is reasonable to assume that the attacks of facial paralysis were of vascular origin.

In the case of another patient who is now 65 years of age, attacks of transitory aphasia occurred off and on from childhood. A sister had similar attacks. The aphasia, characterized by an inability to express himself, would last usually 1 to 3 hours, sometimes longer. Attacks would come in cycles or there would be long periods of several years with no symptoms, following the pattern of histaminic cephalgia rather than migraine. These attacks of aphasia could be controlled with the use of histamine or with the administration of ergot compounds.

We have also encountered many instances of vestibular and cochlear phenomena, which appeared to fit into these patterns of vascular involvement.

The diagnosis of these various phenomena as of vascular origin was based upon the fact that the complaints were referred to the area of distribution of certain arteries such as the lingual, the tonsillar, the ascending or descending pharyngeal, the vertebral, the thyroid, the superior or inferior laryngeal. The symptoms were comparable to these noted in cases of headache of the migraine, tension or histaminic cephalgia types, as manifested by vasoconstrictor, vasodilator and secretory phenomena. The onset of symptoms may be slow as in migraine and especially tension headache in which vasoconstriction precedes vasodilatation, or suddenly as in histaminic cephalgia. Secretory phenomena occur typically in the latter group of cases and are manifested by sweating of the skin, lacrimation, nasal discharge and stuffiness on the involved side.

In the pharynx and larynx, symptoms may be comparable to those of migraine and tension headache. With the latter, the onset

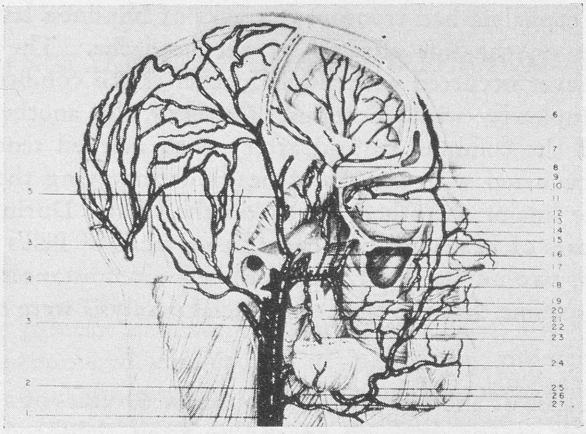

Fig. 1.—1, External carotid A. 2, Internal carotid A. 3, Occipital A. 4, Posterior auricular A. 5, Superficial temporal A. 6, Cerebral A. (Asc. Br.). 7, Frontal A. 8, Middle meningeal A. (Ant. Br.). 9, Supraorbital A. 10, Dorsalis nasi A. 11, Ophthalmic A. 12, Zygomaticoorbital A. 13, Optic nerve. 14, Angular A. 15, Infraorbital A. 16, Deep temporal A. 17, Middle meningeal A. 18, Masseter A. 19, Buccinator A. 20, Lingual nerve. 21, Inferior alveolar nerve. 22, Superior labial A. 23, Inferior alveolar A. 24, Inferior labial A. 25, External maxillary A. 26, Lingual A. 27, Facial nerve.

is characterized by premonitory visual symptoms, nausea, vomiting and a sense of tension. In the pharynx, vasoconstrictor symptoms may be manifested by a sense of constriction or choking and dryness. Upon the appearance of vasodilation, pain of a dull, throbbing or boring character may ensue. The involved vessels may be tender to palpation. As in the case of migraine, symptoms may last for 24 to 72 hours.

In the vasodilator types, following the pattern of histaminic cephalgia, the onset is sudden with symptoms of deep-seated boring pain or aching which ends rather suddenly after a few hours. Attacks are not uncommon at night, awakening the patient from sleep. These patients differ from the ther types in that there are no nervous or tension factors. The vasodilator type is a calm, relaxed individual.

## DIAGNOSIS

A tentative diagnosis of these vascular phenomena is based upon the nature of the symptoms and the distribution of the pain or dis-

comfort. Final proof, however, is corroborated by the response and relief of symptoms with vasodilator agents such as histamine or nicotinic acid. Symptomatic relief of symptoms may be obtained by the use of various vasoconstrictors, especially those containing ergot compounds.

### DIFFERENTIAL DIAGNOSIS

These disturbances of the vascular mechanism are not associated with any gross pathologic changes. When some pathologic condition is present, however, it must be determined whether it is or is not the cause of the symptoms. Certainly, there is a great variety of conditions which may involve the head and neck which may produce symptoms similar to those caused by vascular phenomena. There are some conditions which are readily recognized so there should be no difficulty in establishing a definite diagnosis. The most important to be considered in differential diagnoses may be enumerated as follows:

1. Edema of the uvula, palate, epiglottic, pharynx and larynx.
2. Tumors and ulcerations.
3. Tonsillar diseases.
4. Elongated styloid process.
5. Cysts, glands and tumors in the neck.
6. Thyroiditis, substernal goitre.
7. Neuritis or neuralgia of the glossopharyngeal or laryngeal nerves.
8. Ear diseases—referred.
9. Jugular-foramen syndrome.
10. Bulbar syndrome.
11. Esophageal disease.
12. Referred-cardiac.
13. Effect of drugs.
14. Effect of nose drops.

### TREATMENT

Acute, more or less severe attacks may be relieved with Cafergot, D.H.E. 45 (dihydro-ergotamine), Valoctin, or hydergine. For the

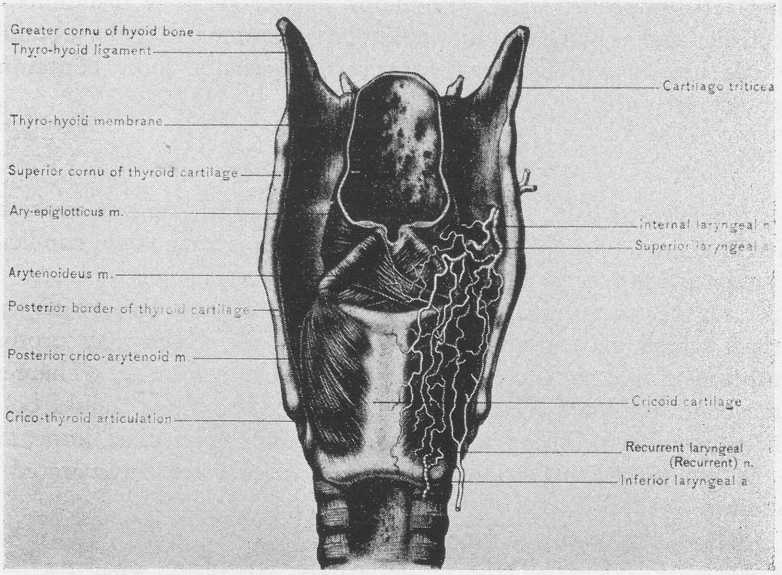


Fig. 2.—The nerves and arteries of the larynx (from Deaver).

more prolonged attacks, Bellergal may be administered 3 to 4 times daily.

The active treatment of these patients by the administration of histamine and sometimes nicotinic acid is usually followed by prompt relief of symptoms. As in the case of headache, the cycle of attacks may be broken with only a few injections. In some instances, however, prolonged treatment may be necessary. Periods of freedom from symptoms vary from months to several years.

Any procedure which increases the local blood supply, such as tonsillectomy for example, may result in a dramatic relief of symptoms, but after a period of a few weeks, the symptoms usually return. In some instances, however, the interruption of the cycle of attacks may last for six months or longer.

The following case reports present convincing evidence that these phenomena are vascular in nature:

CASE 1.—(No. 6868) J. J., a male, aged 56 years was observed for the first time on February 12, 1946. He complained of a sense of tightness and discomfort in the left laryngeal region of three months' duration. At times, there was also a sense of soreness in the tongue. The attacks would come on at night after going to sleep. Activity gave relief. Treatment with histamine (No. 6) 1-1,000,000, gave complete relief for nine months when he returned with soreness referred to the tongue. Again, treatment was effective for five months, then 4 months. For five years since then, there has been no return of symptoms.

The vascular involvement in this case appeared to be in the superior laryngeal artery and in the lingual artery (Fig. 1).

CASE 2.—(No. 11,535) Mrs. G. K., aged 58 years, reported for observation on September 5, 1951, complaining of a tender or sore area in the left side of the upper laryngeal region of many years' duration. The symptoms would recur without cause and were better when she was active. She also had attacks of pain referred to the left cheek area. Treatment with histamine (1-10,000,000) produced almost immediate relief, and after four weeks there were no more symptoms for a period of five months.

In this case, the symptoms were referred to the left superior laryngeal artery as in the preceding case. Mild involvement also occurred in the left superior maxillary artery.

CASE 3.—(No. 11,581) Mrs. M. B., aged 70 years, reported for observation on September 28, 1951. She stated that for about 25 years, she had suffered with attacks of "biting pains" first on one, then the other side of the neck, but mostly on the left, referred to the upper laryngeal region. Attacks would sometimes occur at night and awaken her from sleep. She was better when out of bed. She had never been free of attacks for longer than 1 month in 25 years. Within two weeks the symptoms were entirely relieved with histamine therapy (1-10,000,000) and there was no return after three months.

Although this case is similar to the two preceding, this patient had almost continuous discomfort for 25 years. She had many examinations and treatments with no relief.

CASE 4.—(No. 12,089) Mrs. L. P., aged 31, was seen on August 4, 1952, complaining of an intermittent burning pain in the left

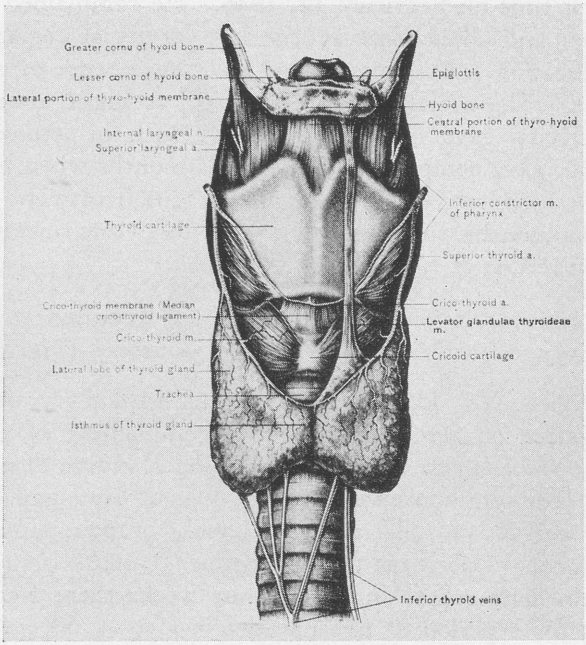


Fig. 3.—The superior thyroid artery and its branches (from Deaver).

side of the neck of three years' duration. Eight months previously, he had had a tosillectomy as well as removal of part of the lingual tonsil. For three weeks following this, there was complete relief of pain, but subsequently, the symptoms became more pronounced. All examinations were negative including a G.I. series of x-rays. With histamine therapy, supplemented with the administration of Bellergal for symptomatic relief as indicated, the symptoms were entirely relieved except for occasional attacks. Initial therapy was given for three weeks, then discontinued for three months and resumed again for three weeks. After four months, there were no significant complaints.

In this case, the pain was referred to the region of the superior thyroid artery (Fig. 2). As in most cases of this type, complete relief was obtained for about three weeks following tonsillectomy.

CASE 5.—(No. 12,310) C. W., aged 47 was observed for the first time on December 29, 1952, complaining of a sensation of some-

thing sticking in the throat and a constant desire to clear the throat, of ten years' duration. While talking to the patient, it was noted that he cleared the throat every few seconds. This was very embarrassing to him in conducting a retail business. He had no pain, but there was a sensation of a lump in the upper laryngeal region. He also complained of a stuffy nose for which he used nose drops off and on for ten years. Abstinence from smoking of cigarettes made no change in the symptoms. The examination was negative except for slight redness and some overdevelopment of the veins on the posterior wall of the pharynx.

Treatment consisted of the avoidance of nose drops and the administration of histamine and Bellergal. After ten days, there was marked relief, and after six weeks, the symptoms were completely relieved with no further treatment.

In this case, the excessive use of vasoconstrictor nose drops probably played a part. The constant clearing of the throat may have been habitual but a part of the vascular disturbance.

## SUMMARY

On the basis of these observations, it is reasonable to assume that certain symptoms, at times somewhat vague, referred to the arterial regions of the pharynx and larynx may be of a vascular nature. Most of these patients, because of the absence of any visible pathological changes have been classified as of the so-called, "globus" type.

In general, the symptomatic patterns resemble those of migraine, tension and histaminic headaches. Response to the administration of histamine and symptomatic relief with compounds of ergot indicate that in certain patients pharyngeal and laryngeal symptoms may be of vascular origin.

634 N. Grand Blvd.

## REFERENCES

1. Sluder, G.: Nasal Neurology, Headaches and Eye Disorders, St. Louis, The C. V. Mosby Company, 1927.

2. Hansel, F. K.: Clinical Allergy, St. Louis, The C. V. Mosby Company, 1953.

3. Hansel, F. K.: Vascular Headaches and Related Phenomena, Trans. Am. Acad. Ophth. and Otolaryng., 1953.

## DISCUSSION

DR. ERNEST M. SEYDELL: I am very much interested in Dr. Hansel's paper. I wish to discuss headaches of vascular origin which, in my experience, constitute the majority of the cases that some to me complaining of this symptom.

I am not in accord with that school of thought that holds that these so-called tension headaches are almost always the result of psychic tension. In fact, I think the reverse is true; however, my real reason for arising is to discuss their treatment.

Before October 1951 I prescribed heat to the neck muscles followed by the use of an ointment containing histamine and massage. The results obtained by this therapy were disappointing.

On a number of occasions I had noticed that when the nose was thoroughly cocainized the tension in the neck muscles, as well as the headache of which the patient complained, was relieved. At present I cocainize the sphenopalatine ganglion, using a fine metal applicator tipped with cotton and dipped in flaked cocaine. This is allowed to remain in the vicinity of the ganglion for ten minutes. As a rule the patient's neck muscle spasm is greatly relieved. The treatment is repeated the next day and again on the fourth day. In addition I prescribe an ounce of 1:10,000 histamine diphosphate solution with the following directions:

The first day the patient places one drop under the tongue ten minutes before eating. The number of drops are increased one drop before each meal until seven drops are taken before meals. The drops are continued for from one to three months. In case the patient develops a headache within thirty minutes after taking the drops, he is instructed to reduce the number to a point where no symptoms are produced.

The results from using this treatment have been far beyond my expectations.

DR. AUBREY G. RAWLINS: Mr. President and Gentlemen, there is one thing that I would like to mention in reference to vascular headaches. The cycle, as Dr. Hansel calls it, can be broken with small doses of ACTH. I have recently had two patients with very severe histaminic cephalgia who absolutely could not be controlled with vasodilators or any other form of treatment. Fifteen units of ACTH, intravenously, broke the cycle and by carrying on with vasodilators, the headaches were kept under control. By just making the patient hyperadrenal, one can stop this cycle.

DR. FRENCH K. HANSEL: Before the advent of the use of histamine in the treatment of headache, cocainization of the nasal ganglion, as mentioned by Dr. Seydell, offered a means of relieving an individual attack. In addition to, or in place of injection, histamine may also be administered by the sublingual route, employing a dosage about ten times stronger.

Doctor Rawlins' observations on the use of ACTH are certainly worthy of further consideration. In certain cases of headache, the use of estrogens, thyroid or other hormones which may play a part in maintaining normal vascular balance may be indicated in therapy.

# PRECISION BRONCHOLOGY: A "MUST" FOR THE THORACIC SURGEON

ROBERT E. PRIEST, M.D.

MINNEAPOLIS, MINN.

Precision is the sum total of many small details each as nearly perfect as possible, none very important by itself, but all necessary to make up a really precise whole.

For many years the author has been privileged to work closely with thoracic surgeons having a wide experience in the management of all types of pulmonary disease, serving as bronchologist and carrying out pulmonary studies prior to lung surgery. These thoracic surgeons have said many times that the bronchologist could serve them best when he learned to "think like a thoracic surgeon." As time has gone on, the precision of these bronchologic efforts has increased.

What factors distinguish a precise bronchologic study from a mediocre one? As a beginning, consider what is meant by precision. The dictionary defines it as "sharply or exactly limited as to meaning; exact, definite, not loose, vague or equivocal." This definition standardizes the word "precision" but not with respect to any particular usage. In actual practice "precision" may mean almost anything. Its meaning varies with the development of the field to which it is applied. The higher the development, the more minute the detail connoted by the term "precise." The following examples from Collier[1] illustrate this idea.

Early in the nineteenth century a machinist advertised possession of a boring mill "capable of turning the cylinders of steam engines accurate to plus or minus the thickness of a shilling." A shilling is three thirty-seconds of an inch thick. In 1953 steam engine cylinders made to an accuracy of only three thirty-seconds

From the Division of Otolaryngology of the University of Minnesota and the Thoracic Surgery Service of St. Mary's Hospital, Minneapolis.

of an inch would be extremely crude. Today's tolerances would be within a few thousandths of an inch.

As a second illustration consider the problems of the highway construction engineer. A highway construction engineer could maintain the straightness of a road to plus or minus one foot per mile but this would probably be unnecessary. Plus or minus one yard per mile would probably be accurate enough. But in an international boundary survey one foot per mile would be relatively poor accuracy. What constitutes precision in one field is not precision in another; and what is precision at one stage of the development of an art or craft is not precision at a later stage of the development of that art or craft.

What can the thoracic surgeon expect from the bronchologist? The thoracic surgeon can expect that the bronchologist will be intensely interested in his work; that he will study diligently to perfect his knowledge of pulmonary anatomy, physiology and pathology; that he will fully merit being called a bronchologist or student of the bronchi rather than a bronchoscopist who sees the bronchi but may not understand what he sees. The papers of Jackson and Huber,[9] of Boyden et al,[10] and of Kane[11] will be essential to this study.

The thoracic surgeon can expect the bronchologist's description of the entire respiratory system to be of a quality to enable the thoracic surgeon to picture the respiratory system in his mind's eye just as if he himself had made the examination. The thoracic surgeon should reasonably expect the bronchologist to study the patient's problem before the bronchoscopy. The surgeon and bronchologist should discuss the entire problem, examine the x-rays and the bronchologist should talk to the patient about the bronchoscopic procedure. A few minutes of explanation prepare the patient for bronscopy. By reducing nervous tension one greatly increases the quality of the studies.

The thoracic surgeon can expect to learn the condition of the patient's pharynx and larynx, including motility and structural state of the vocal cords. He can expect to know the position, size and shape of the trachea with a description of any abnormality produced by extrinsic pressure or by intrinsic tumors or ulcers. He can expect to know the state of the mucous membrane as concerns

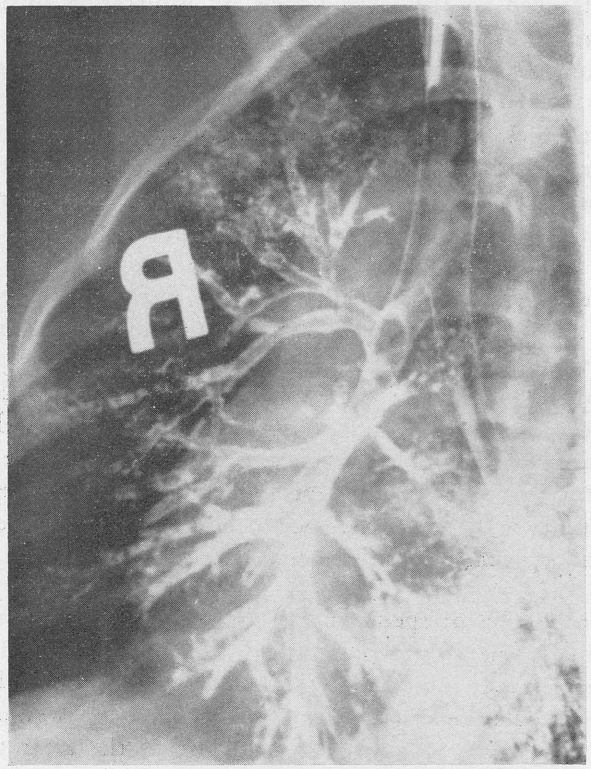


Fig. 1.—Shows normal right bronchial tree in a five year old girl who had bronchiectasis in the left lung. Note that all ten major bronchi are clearly visible plus a duplication of the apical division of the lower lobe. This is a so-called "B*" bronchus of Boyden. This bronchogram and the other children's bronchograms were obtained by the method reported by Priest.[7]

inflammatory reactions within it and evidence of suppuration as shown by pus coating the mucosa of the trachea.

The thoracic surgeon can expect a bronchologist to indicate to him what the tracheal carina looks like. It may be straight and slim covered with normal mucosa; it may be broadened due to the patient's habitus or to tumor masses lying in the angle between the right and left main bronchi. It may be kinked during the expiratory phase of respiration, and straight during the inspiratory phase

suggesting the presence of tumor masses adjacent to the carina. It may be attached to the large vessels by infiltration of tumor and therefore make excursions with the vessels in a transverse direction. These excursions will be out of phase with the respiratory excursions.

The thoracic surgeon can reasonably expect the bronchologist to be thoroughly familiar with bronchial anatomy and to examine the orifices of the ten major branch bronchi present within the right and left bronchial trees. Such examination should include routine telescopic observations of the upper lobe bronchi with the right angled telescope and occasionally with the retrograde telescope. Examination of the middle and lower lobe bronchi should include observation with the foroblique telescope except for the apical division of the lower lobes; this bronchus should be examined with the right angled telescope. Right angle and foroblique telescopes should be a normal part of the setup for each case and should not be used only in cases presenting special problems. The same observation described in connection with the trachea should be made routinely of the mucosa of the bronchi of both bronchial trees.

The collection of specimens by aspiration as described by Clerf should be routine. Material should be collected from whatever branch bronchus is indicated by previous study of the chest x-rays and by study of the patient before bronchoscopy, as well as by bronchoscopic findings. Specimens removed with the aspirating device should be subjected to certain routine tests. These should include cytologic study of the secretions for tumor cells by a clinical pathologist familiar with such study. The use of the Papanicolaou technique has been found to be extremely valuable but it is subject to limitations based on the experience of the pathologist. Early in the author's experience false positives were obtained and some patients had portions of lungs removed when it is now believed that carcinoma was not actually present. Inflammatory metaplasia of cells in lesions such as bronchiectasis is the most frequent cause of this difficulty. A second routine test which should be applied to all specimens removed by aspiration is culture for tubercle bacilli. All specimens should be labeled immediately as to their exact source within the bronchial tree. If possible the exact bronchus from which they were aspirated should be listed. It is preferable to say that one has aspirated the medial basal bronchus of the right lower lobe rather than that one has aspirated the right lower lobe bronchus. Sometimes such accuracy is not

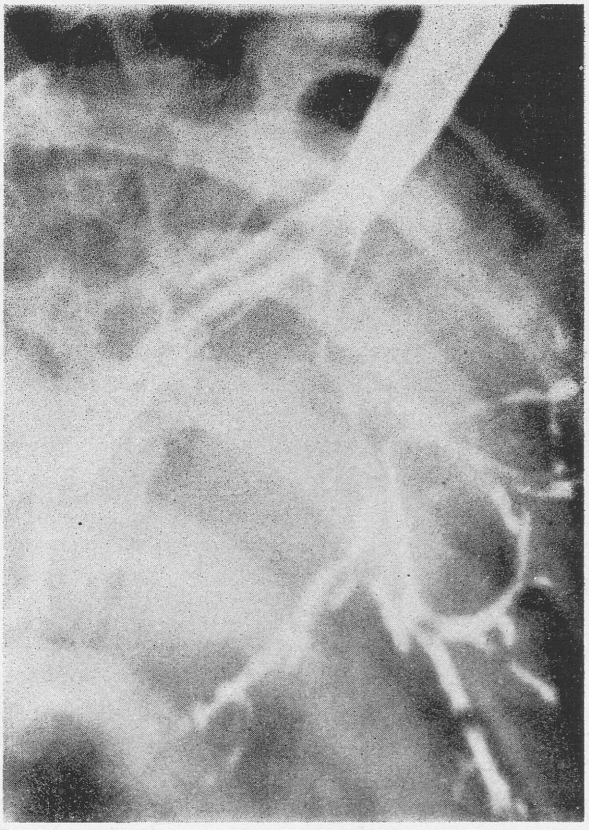

Fig. 2.—Patient was a ten month old baby who had marked whistling sound to his breathing. Bronchoscopy showed compression of left main bronchus and bronchogram shows compression below the takeoff of the left main bronchus from the trachea. The left lower lobe bronchus and the left upper lobe bronchus together with several divisions may be seen. The compression of the left main bronchus as it skirts the mass is visible. A partial bronchogram of the right bronchial tree is shown, but no effort was made to make a good bronchogram on this side.

necessary or possible but if one strives for a high level of routine accuracy he is more apt to get information of value to the thoracic surgeon than if he strives for a medium level of accuracy.

When it is possible to make a biopsy of a tumor using bronchoscopic forceps, what does the thoracic surgeon want to know about the bronchi? He wants to know how much clearance he has between the end of the tumor and the point where he will have to resect in order to achieve a cure. If the tumor is so situated that it would seem that he has ample clearance he wants to know if the bronchus proximal to the tumor is rigid suggesting tumor infiltration within or adjacent to its wall. He also wants to know if the bronchus is narrowed as though compressed by masses lying outside of it. On several occasions it has been necessary to subject patients to a second bronchoscopy because the first bronchoscopist was not sufficiently accurate in his localization of the tumor although he had obtained a positive biopsy for carcinoma. In these cases the thoracic surgeon could not tell whether there was room to attempt a resection or not. It is useful to make aspiration studies on all cases in which forceps biopsies are obtained. This gives the pathologist known positive material on which to practice his cytology. When excessive bleeding follows biopsy this is not possible.

The question of measurements within the bronchi has been raised by several authors. A bronchial yardstick and an intrabronchial caliper have been devised by Emerson.[2, 3] An experimental recording bronchial caliper has been used by Andrews.[4] The presence of such instruments on a bronchoscopic table is of unquestionable value. On the other hand, one must not forget that he can make use of simple instruments always present and can achieve reasonable accuracy of measurement sufficient for most purposes. This is especially true of longitudinal measurements of the bronchi and is not so true of measurement of bronchial diameters. One can use an ordinary suction tip and ruler. The suction tip can be placed against the tumor and the measurement made. The suction tip can then be placed against the nearest anatomic landmark, for example the tracheal carina, and a second measurement can be made. This simple method gives excellent results and removes from the thoracic surgeon's mind any doubt as to the accuracy of the bronchologist's observation. Such statements as "a long way down the left main bronchus," "half way down the left main bronchus," "it was a pretty

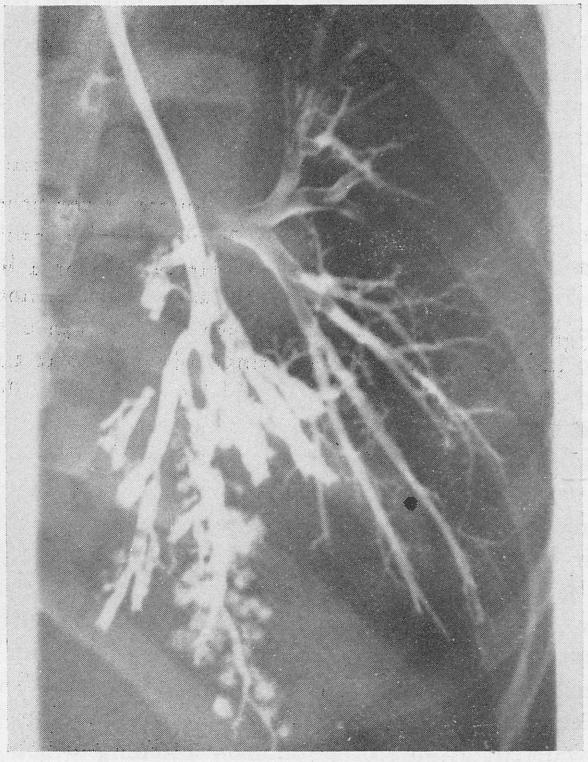

Fig. 3.—Shows bronchogram of a seven year old girl. There is marked cylindrical bronchiectasis of all branches of the left lower lobe while the upper and lower divisions of the left upper lobe are shown to be entirely free from bronchiectasis.

big one," and so forth have no place in the accurate bronchology of today. They may have been adequate in that phase of bronchology corresponding to the three shilling tolerance of the steam engine but they are not sufficiently accurate for today.

The preparation of proper bronchographic studies using contrast medium injected into the tracheobronchial tree has been discussed by many authors and will be touched upon briefly here. As in other phases of precise bronchology the making of bronchograms must be carried out with a detailed plan and technique. The patient must be psychologically prepared ahead of time. Adequate anesthesia

must be obtained. This is not the same for every patient and may require the use of various anesthetic agents in different patients. In some patients the application of topical anesthesia within the tracheobronchial tree is adequate. In some patients, particularly bronchiectatics, it is necessary to empty the bronchi by bronchoscopy and suction and to apply more anesthetic agent to the areas laid bare by the removal of secretion. In some patients it is necessary to give drugs such as codeine by vein during the course of the bronchoscopy to decrease the desire to cough. In an occasional nervous patient the anesthesiologist may administer a sedative dose of a barbiturate intravenously during bronchoscopy. In an adult it is not desirable to use enough of this drug to induce sleep but one can use a smaller quantity to induce sedation with distinct advantages at times. The injection of the contrast medium should be done under fluoroscopic control and preferably with cooperation between the radiologist and the bronchologist. In some hospitals the radiologist is too busy to do this work or lacks sufficient interest in it. In such cases the bronchologist may be forced to do the entire procedure. We have been fortunate in having a great deal of interest on the part of our radiologists and as a result the quality of the bronchographic studies has continually risen until we now are completely dissatisfied with anything except a very adequate demonstration of all major and most minor bronchi. This effort has enabled us to demonstrate small areas of bronchiectasis as described by Overholt and Walker, forming a basis for recurrent asthma or pulmonary bleeding which we would have missed completely in years past, and which we have reason to believe are missed now in less exact studies of the bronchial tree. Recently several techniques for the making of bronchographic studies in children have been described.[6,7] These require careful planning but they permit entirely satisfactory bronchographic studies at almost any age (Figs. 1 through 4).

Not long ago Overholt[8] published a comment on the diagnosis of early pulmonary cancer and the relationship of the various branches of medicine concerned with this diagnosis. His statements are well worth examining and every person doing bronchology should consider the ideas he puts forth. His primary tenet is that the positions of some lesions in the lung make their histologic diagnosis impossible except through biopsies obtained on thoracic exploration. He believes that sometimes lesions which are clearly visible by x-ray are passed over by the family doctor, the internist or the bronchologist

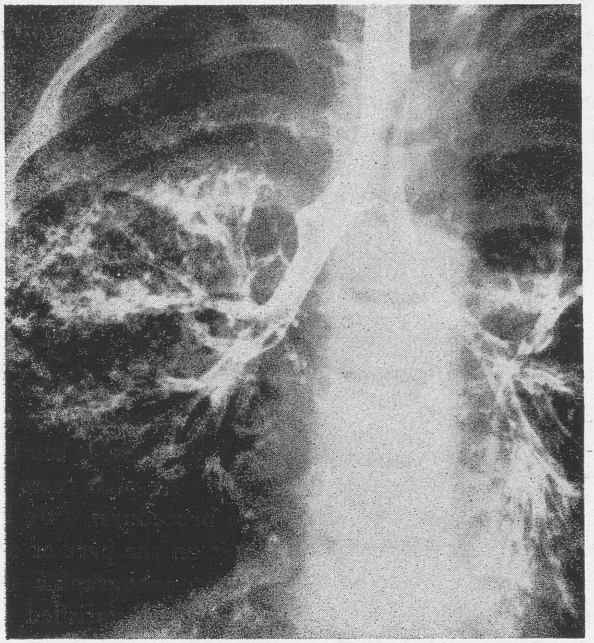

Fig. 4.—Bronchogram of a three year old boy showing a completely normal right lung except for total stenosis of the right upper lobe bronchus. All major branch bronchi can be fairly well visualized in this film. In the films of the series of bronchograms all these bronchi could be seen. The left major bronchi are also visible in this film although special views are necessary to separate one from the other.

as being unimportant when the bronchoscopic findings seem normal. He feels that repeated bronchoscopy is sometimes carried out in such cases in a fruitless effort to determine the type of lesion and that valuable time is lost to the patient before surgery is finally done. With this point of view the author is entirely in accord. Our procedure in Minneapolis has been to have all cases studied by the bronchoscopist and the thoracic surgeon. When an internist or family doctor refers a patient for bronchoscopy the thoracic surgeon is always consulted before or after the bronchoscopic studies have been carried out. We do not subscribe to Overholt's idea that in most instances bronchoscopy can be most advantageously carried out on the day of thoracic exploration. We feel that it is advisable

to study the case ahead of time and to get all information possible. It is an advantage to the thoracic surgeon if cell studies have been made and if a biopsy has been made and paraffin sections rather than frozen sections studied. On the other hand, we certainly agree that loss of time due to such studies should be minimal. We frequently see patients, bronchoscope them, find that we cannot make a diagnosis by the bronchologic study, and immediately recommend thoracic exploration. If the patient accepts this recommendation his exploration can be carried out within two or three days of the time he starts his study and there is no significant loss of time.

SUMMARY

Precisely performed bronchology will forearm the thoracic surgeon with information about his patient which cannot be obtained otherwise. This "precision bronchology" will include many small individual parts each of which must be well done to make the final product as good as it can possibly be.

The parts will include preliminary study of the patient by internist, family doctor, bronchologist and thoracic surgeon; psychological preparation of the patient; careful bronchoscopy including telescopic observation of bronchi, aspiration of specimens, bronchial measurement; the careful preparation of bronchograms by the bronchologist working with the radiologist and a group of x-ray technicians prepared to work quickly and efficiently; and finally a summing up of the problem with final disposition of the patient made after consultation between bronchologist, radiologist and thoracic surgeon; such disposition not causing undue delays which may prejudice the patient's chances for recovery because thoracic exploration is not promptly performed.

REFERENCES

1. Collier, George X. M.: What Price Precision? Part I, QST, A Radio Amateurs Journal 36:42-44 (Sept.) 1952, published by American Radio Relay League, West Hartford, Conn.

2. Emerson, E. B., Jr.: A Bronchial Yardstick, J. Thoracic Surgery 21:516-518 (May) 1951.

3. Emerson, E. B., Jr.: Intrabronchial Caliper, Arch. Otolaryng. 55:724-725 (June) 1952.

4. Andrews, A. H.: Observations On Bronchial Movements and Elasticity by Means of a Recording Bronchial Caliper, ANNALS OF OTOLOGY, RHINOLOGY AND LARYNGOLOGY 61:1181-1197 (Dec.) 1952.

5. Overholt, R. H., and Walker, James H.: Hidden or Unsuspected Bronchiectasis in the Asthmatic, ANNALS OF OTOLOGY, RHINOLOGY AND LARYNGOLOGY 61:1198-1205 (Dec.) 1952.

6. Wishart, D. E. S.: Bronchography in Bronchiectasis in Children, ANNALS OF OTOLOGY, RHINOLOGY AND LARYNGOLOGY 56:404-415 (June) 1947.

7. Priest, Robert E.: Bronchography in Infants and Children, ANNALS OF OTOLOGY, RHINOLOGY AND LARYNGOLOGY 61:651-655 (Sept.) 1952.

8. Overholt, Richard H.: Virus Pneumonia, Tuberculosis, Cancer: That Is The Problem, Supplement to the Fourth in a series of monographs on "Cancer of the Lung," Am. Cancer Soc., Inc., 47 Beaver Street, New York 4, N. Y.

9. Jackson, C. L., and Huber, J. F.: Correlated Applied Anatomy of the Bronchial Tree and Lungs with a System of Nomenclature, Dis. Chest 9 (July-Aug.) 1943.

10. Boyden, E. A., et al: Minnesota Studies on the Anatomy and Variations of the Bronchopulmonary Segments.

a.) *The whole lung*
Boyden, E. A.: Surgery 18:706-731, 1945.
Boyden, E. A.: Dis. Chest 15:657-668, 1949.

b.) *Right upper lobe*
Boyden and Scannell: Am. J. Anat. 82:27-74, 1948.
Scannell and Boyden: Jour. Thor. Surg. 17:232-237, 1948.
Boyden: Azygos Lobe and Pre-eparterial Bronchi, Radiology (June) 1952.

c.) *Middle lobe*
Boyden and Hamre: Jour. Thor. Surg.21:172-188, 1951.

d.) *Right lower lobe*
Smith and Boyden: Jour. Thor. Surg. 18:195-215, 1949.
Ferry and Boyden: Jour. Thor. Surg. 22:188-201, 1951.

e.) *Left upper lobe*
Boyden and Hartmann: Am. J. Anat. 79:321-360, 1946.
Boyden: Surg. 20:828-829, 1946.
Scannell: Jour. Thor. Surg. 16:530-537, 1947
Boyden: Surg. 26:167-180, 1949.

f.) *Left lower lobe*
Berg, Boyden and Smith: Jour. Thor. Surg. 18:216-236, 1949.

g.) *Agenesis of right lung*
Thomas and Boyden: Surgery (Mar.) 1952.

h.) Lateral views of Lungs, Radiology (in press) 1953.

i.) "International" Nomenclature of Segments, Dis. Chest (in press) 1953.

11. Kane, Irving J.: Segmental Localization of Pulmonary Disease on the Postero-Anterior Chest Roentgenogram, Radiology 59:229-237 (Aug.) 1952.

## DISCUSSION

DR. EDWIN N. BROYLES: Mr. Chairman, I am sure we all enjoyed Dr. Priest's presentation. I know I certainly did. If we are working in large thoracic clinic, like many of us do, the thoracic surgeon wants a description, to give him a picture of what he is going to find when he opens up the chest. Of course many times

we are not able to give him a positive diagnosis but I think when we say it is a negative bronchoscopic examination we must go ahead and describe all the different bronchi that we have examined. This also is a very important thing for the surgeon to know. The tumor may be out in the distal portion of the lung where we cannot see any growth or any change in the bronchoscopic view. But an accurate description of the tracheo-bronchial tree is most important.

I think the pictures of the children with bronchiectasis and different abnormalities in the tracheo-bronchial tree are very interesting. It is a different procedure in our hands to get satisfactory bronchograms on some of these children and I am delighted to see Dr. Priest's method of making bronchograms on the small children.

Thank you very much!

DR. D. E. STAUNTON WISHART: Mr. Chairman and Gentlemen, it is a pleasure to have listened to Dr. Priest describe his elaborate method of bronchography. It is excellent. I am very pleased that at our hospital we are able to continue doing the method that I described last year, but I can assure you that if something happens and we are not able to carry out our technique that I shall certainly try his. I have seldom seen anything prettier than some of the demonstrations that he showed us today.

DR. PAUL H. HOLINGER: Mr. Chairman and Members of the Association, Dr. Priest has stressed a number of points, but in reading his title, I wonder whether one might consider changing it to "Precision Bronchoscopy, A Must in Bronchology;" and yet, with the work he has shown in bronchography, we follow the logic of his title.

He mentioned the character of the operative report and I think this is one of the constant mutual problems in thoracic surgery and in bronchoscopy. We must speak the same language that the thoracic surgeon and the internist speak in writing the report that is submitted following a bronchoscopic procedure, and we must so train our residents. For us to use one terminology and for them to use another makes for confusion. As Dr. Priest mentioned, if we say the lesion was "half way down" or use some such vague phrase as one sees occasionally, or if we use terms which are unfamiliar to the thoracic surgeon, we fail in the cooperative, teamwork effort that is so necessary. For these reasons, I should like again, if I may, to stress the fact that the American Bronchoesophagological Association at regular intervals should meet with the chest groups, either medical chest or surgical chest groups so that we correlate our thinking and our terminology in so many of the problems that Dr. Priest mentioned.

DR. CLERF: Precision should be applied to all diagnostic procedures and it should apply not only with regard to the method of carrying out these procedures but also our interpretation of what has been observed.

Too often the bronchologist has not been of much help to the thoracic surgeon or internist for he merely reports "Bronchoscopy negative." He must be more specific than that particularly when others are to read our reports for they may not understand our language and that often is an incentive for one to do one's own bronchoscopy.

In our work in cytology it is very important to practice precision bronchology, for unless one is aware of the lobar bronchus that needs to be investigated and does it properly the pathologist may be critized because he does not properly or adequately study the specimens that have been submitted. Too often a negative cytologic report means that the bronchologist did his part of the examinations im-

properly for he failed to properly interpret the roentgen report and very probably secured secretions from an improper source or did it in an improper manner.

I am a firm believer in precision in the art of bronchology and also in the interpretation of our findings.

DR. FRANK TURCHIK (Bridgeport, Conn.): Doctor Priest has stressed the need for close co-operation between the thoracic surgeon and the bronchoscopist, emphasizing the need for detailed pre-operative findings in localizing lesions of the bronchial tree. I would like to point out the need for co-operation during the post-operative course as well.

Two recent cases demonstrated this quite well. Bronchograms two weeks prior to surgery showed bronchiectasis limited to the left lower lobe in both cases. Following surgery, both patients complained of chest pain, dyspnoea and continued cough with elevated temperature for several days. Chest x-rays showed a diffuse opacity on the left side. A diagnosis of bronchial obstruction with atelectasis of the upper lobe due to retained iodochloral was made by the bronchoscopist. Bronchoscopic drainage with lavage of the bronchi to the left upper lobe with ¼% neosynephrine solution completely cleared the x-ray picture and relieved the symptoms, immediately.

I may add, following bronchography, thoracic surgery might better be delayed for at least a six weeks period or until one is reasonably sure the residual radio-opaque material has been eliminated.

# THE SURGICAL COMPLICATIONS OF DIVERTICULUM OF THE PHARYNX

KENNETH A. PHELPS, M.D.

MINNEAPOLIS, MINN.

The complications of any operation often determine its success or failure. Surgeons, being influenced by the frequency and severity of complications, develop the best operation by learning to avoid complications. This applies to the development of the surgical treatment of diverticula of the pharynx, which is related to the progress of radiology, esophagology, anesthesiology, and the antibiotics. In spite of great progress, complications are still of considerable importance in present day surgery for pharyngeal diverticulum, even though little mention of this is made in most recent articles.

Diverticulum of the pharynx has interested many medical authors since the first reference to it by Ludlow of England in 1764. His original specimen is still in the Hunterial Museum of Glasgow. In 1840, Rokitansky studied this condition and considered diverticulum of the pharynx as due to internal pressure or pulsion in contradistinction to diverticulum of the esophagus proper, which is produced by external pull or traction. In 1877, Zenker found twenty-two cases reported in the literature and added five of his own. He correlated the patient's symptoms to the pathological findings and established diverticulum of the pharynx as an organic entity. Since this time the term Zenker's Diverticulum has been used by many to designate this condition. Negus[6] clarified the etiology of pharyngeal diverticulum by his study of comparative anatomy.

The first operation, excision of the sac, was performed by Kunge in 1864, the second by Hamburger in 1871. Both patients died operative deaths.[1] The third operation, performed by Niehaus in 1884, resulted in death from hemorrhage on the twenty-fourth postoperative day. Not until 1885, twenty years after the first attempt, was this operation successfully performed by Wheeler of Dublin, resulting in a cure.

During the next twenty-five years considerable progress was made. Stetton,[2] in 1910, collected from the literature all the cases in which operations had been performed, amounting to sixty. The death rate was "only 16.6%." In the group of forty-eight cases having direct excision of the sac, the mortality was 18.7%. The most common complications were infection, mediastinitis, pneumonia, and cervical cellulitis. Stetton believed a preliminary gastrostomy was advisable, as it solved the post-operative feeding problem. He was not impressed with the two-stage operation, invagination of the sac, or destruction of the mucosa of the sac. His paper taught the surgeons to fear the complication of infection in the one-stage operation, so other procedures were developed.

Two-stage operations were reported by Goldmann, Mayo, Murphy, Lahey, and others. Invagination of the sac was reported by Halstad, McClure, Girard, and others. Imperatori, in 1927, inverted and excised the sac by endoscopic means, and diverticulopexy was reported by Hill and Konig. Mosher reported endoscopic division of the common wall between the sac and the esophagus, but gave it up because of the danger of mediastinitis. Gaub and Jackson, in 1915, devised a combined esophagoscopic and surgical method, and in 1926, Jackson and Shallow[3] reported a series of fifteen operations performed by this method. One patient died of postoperative massive collapse of both lungs. These authors state that the two-stage operation has been complicated by insufflation pneumonia, mediastinitis, secondary hemorrhage, fistula, and recurrence of the sac. They successfully avoided the complication of infection in a one-stage operation.

The esophagologist can aid the surgeon by locating the sac and deciding on which side of the neck the incision should be made, and by emptying the sac before it is excised. He can place the end of the esophagoscope into the sac, thus positively identifying the structure. This maneuver has been of particular value to the surgeon when the tip of the sac extends below the clavicle.

After the sac is pulled up, the esophagoscope can be inserted into the esophagus below, thus helping the surgeon to amputate the sac in the place least likely to be followed by postoperative stenosis.

Jackson and Coates'[5] book "Diseases of the Nose, Throat, and Ear," published in 1929, contains an article by Mosher stating that the writer considered the one-stage operation unjustifiable as it had

a mortality of 20%. Jackson and Jackson's, "Diseases of the Nose, Throat, and Ear," published in 1945, states that there should be no mediastinitis, no persistant fistula or sinus, and no stricture with the one-stage operation. With the two-stage operation laryngeal paralysis occurs in 9%, permanent fistula in 9%, incomplete removal of the sac in 36%, and stenosis in 9% of the cases. Shallow and Clerf,[7] in 1948, reported 186 cases operated upon by the combined one-stage method. Mediastinitis was prevented. In the last 100 cases, nine patients developed unilateral vocal cord paralysis, seven had minor wound infections, four had parotitis, one fistula, one atelectasis, one pneumonia, and two heart complications.

In 1928, Kennedy[1] and I reported the first successful operation done by the combined method in our community. Following this, I have seen 23 additional cases, which make up this report. All are private cases. The surgery was done by 13 different surgeons. General anesthesia was used in all. Infection did not occur in any case, so this once frequent and often fatal complication has now been successfully eliminated. Better surgical technique, including pre- and post-operative care, better anesthesia, more effective antibacterial agents, and earlier diagnosis are all responsible for this improvement. However, other complications did occur.

Fistula, of a temporary nature, occurred in three patients. All closed spontaneously. This is worthy of mention, as the surgical method of closing the stump, varied from careful suturing, layer by layer, to no suturing of any kind, but merely applying a clamp and allowing it to slough off in a few days, according to the method of Maxeiner.[4]

Stricture at the site of removal of the diverticulum occurred once. A few dilations relieved this patient promptly.

Recurrence of the sac was noted twice. It seems that this might well happen, as the original causative factors have not been altered by the operation.

Chest complications occurred in three patients; (1) unilateral pneumothorax, (2) post-operative atelectases and (3) post-operative aspiration of vomitus, requiring immediate suction of the bronchi. All recovered.

Unilateral vocal cord paralysis occurred in two cases. One was that of a large sac extending into the chest and had a pack of oxy-

cell left in place to control hemorrhage. The other occurred in a two-stage operation. Both recovered spontaneously.

Failure to find the sac, in one case, by both the surgeon and the esophagologist. The sac was still present post-operatively in x-ray.

Pre-existing complications in four cases contraindicated operation:

(1) Bulbar paralysis, as well as diverticulum. A gastrostomy was done and successful feeding was carried out for several months.

(2) A fish bone lodged in the sac which required removal, but no surgery for the diverticulum was desired by the patient.

(3) A serious cardiac condition.

(4) A nasal suction tube was needed after a major surgical Procedure. About forty-five minutes was spent searching unsuccessfully with the esophagoscope for the subdiverticular orifice. Any time a patient with a diverticulum has major surgery, he should swallow a thread previous to the operation. The thread would serve as a guide in passing the suction tube should the need occur.

Excision of the diverticulum should be advised even though it is small and the symptoms seem insignificant. The sac will surely enlarge, increasing the patient's discomfort until operation is a necessity. As a general rule, the smaller the sac, the easier the operation is on both the patient and the surgeon.

The earlier patients were all fed postoperatively through a transnasal tube left in place in the esophagus. After observing some patients who pulled the tube out, it was found that they did as well as those who kept the tube in place. The use of the feeding tube is now eliminated and the patient is fed intravenously for the first few days.

Infection has been practically eliminated by the antibiotics. Fistula, stricture, vocal cord paralysis, and recurrence should be preventable by earlier diagnosis and operation while the sac is small; by better preoperative care; by better surgical technique, including gentle manipulations of the strictures; by putting less pull on the laryngeal nerves; and by accurately suturing the mucosa and muscle layers. Chest complications will be minimized when the anesthesia is carefully given and extra attention is paid to the air way to keep it completely clear. Elimination of the feeding tube is recommended.

Undoubtedly, the development of better teamwork for this operation would help avoid complications. The latest articles on the surgery of pharyngeal diverticulum make no mention of the combined operation. Some surgeons may find that they do better without any internal manipulations, though none has so stated. None has stated that he feels the use of the esophagoscope is a cause of complications.

## CONCLUSIONS

Twenty-four cases of diverticulum of the pharynx are presented of which twenty were operated upon.

No death occurred, but twelve patients had some serious complication develop and eight had smooth, uncomplicated recoveries.

No infection such as mediastinitis or cervical cellulitis occurred.

Surgery should be advised as soon as the diagnosis is made.

Postoperative feeding tubes can be eliminated.

1137 Medical Arts Bldg.

## REFERENCES

Kennedy: Claude C.: Surgical Treatment of Pharyngeal and Esophageal Diverticula, Minn. Med. (Oct.) 1928.

2. Stetton, M. D.: The Radical Extirpation of Pharynx-Esophageal Pressure Diverticula, Ann. of Surg. 51:200, 1910.

3. Jackson, C., and Shallow, T. A.: Diverticulum of the Esophagus, Pulsion, Traction Malignant, and Congenital, Ann. of Surg. 83:1-19 (Jan.) 1926.

4. Maxeiner: S.: Present Surgical Management of Esophageal Diverticulum with Presentation of a New Method, Minn. Med. 24:91 (Feb.) 1941.

5. Jackson, C., and Coates, G. M.: The Nose, Throat and Ear and Their Diseases, W. B. Saunders, 1929.

6. Negus, V. E.: Evolutionary Factors in the Production of Pharyngeal Diverticula, Jour. Laryng. 11:702, 1925.

7. Shallow, T. A., and Clerf, L.: One Stage Diverticulectomy, Jour. of Surg., Gyn. and Obst. 86:317, 1948.

## DISCUSSION

Dr. Chevalier L. Jackson: Mr. Chairman and Gentlemen, I just want to comment on the reference to combined operation. I think that those of us who have done a good many diverticulectomies have come to feel that we can generally locate the sac without much trouble and don't really need to put the

scope in and transilluminate it in order to be sure that we have the right structure; and yet I found that in our own experience we got a little bit too confident. The only case in which we have had even the slightest stenosis in our whole series was a case in which we thought we were smart enough not to use the esophagoscope at all. We had not used it in several other patients who got along all right. Personally, I have gone back to having the eosphagoscope always at hand. Even if it is not felt necessary to use it to locate the sac or confirm the identity of the sac, you can slip it on down the esophagus proper to check on the position of the neck. Moreover, we still find the esophagoscope useful for aspiration of the sac and the esophagus before amputating the sac. But we don't leave the scope in place in the esophagus after we have checked the position of the neck and put in two marker sutures at the upper and lower poles, because if you leave the scope in place, the neck of the sac is held too deeply in the wound and the amputation and closure are much more difficult. After the marker sutures are inserted we withdraw the scope and proceed with the amputation of the sac. Generally a feeding tube is inserted through the scope before it is withdrawn.

Dr. Jos. P. Atkin: (Philadelphia): One of the unusual things that can occur in esophageal diverticulum is to encounter a patient who is unable to swallow at all. We have seen a great many patients, of course, who had dysphagia but to see a patient who is completely unable to swallow was a unique experience that we had several months ago in a thin, shriveled-up, little man in his late sixties. He looked as though a good gust of wind would blow him completely out of sight. We attempted to find the opening to his esophagus on a number of occasions and each time we were completely unable to do so. He was gastrostomized and fed until his nutritional balance was restored. At the time of operation it was found that the segment of the esophagus immediately below the diverticulum was extremely narrow. Dr. Julian Johnson, who did the operation, was quite concerned about the matter of not having any lumen in the esophagus. Nevertheless after the operation, by dilatation of the upper segment of the esophagus perorally, we were able to get a lumen through which we could pass a 30 French bougie without any difficulty. The patient continued to have difficulty in swallowing. Several weeks after his wound was healed and we expected him to be perfectly free of symptoms we began to notice superficial ulcerations on the mucous membrane of the pharynx. For a long period of time these rather baffled us. We could not understand why we were having these difficulties. We thought of over-medication. We thought of sensitivities. We thought of fungus infections. All of these things eventually gave negative results. Finally he developed a lesion on his cornea which his ophthalmologist saw and diagnosed as pemphigus. Then we awakened to the fact that we were seeing the mucosal lesion of pemphigus. Whether that has any relation to the difficulties which he had prior to his operation I cannot say. The end of this story is not yet but at least I think we know now where we stand.

Dr. Walter B. Hoover: Members and Guests of the American Laryngological Society, it is a privilege to appear before you to discuss this paper. I wished to compliment the author because it takes considerable fortitude to report one's complications when the complications have been rather numerous.

I have had considerable experience with the postoperative treatment and complications of this condition. I spent some ten years in convincing the surgeons at our clinic that the routine use of a feeding tube after operation was worth while. I would not give it up, as he has suggested. I would continue to use it. Certainly if a fistula is present it will heal much more rapidly if there are no food elements or foreign substance in the tissues where the fistula has formed. I have seen several fistulas. On two occasions fistulas with food material went on to inflammatory processes which led to a rheumatic condition. Because of this com-

plication I was able to put over the point that each patient should have a feeding tube as long as nine days or until there is definite evidence that a fistula is not present.

I agree that may patients got along and will get along all right without a tube, but it is an added precaution that we should take, just the same as having a transfusion ready when a patient is likely to need blood. Continue to use your tubes; don't throw them away. It took me a long time to put over that point and I like to emphasize it.

I would like to point out another fact about the diagnosis. X-ray of diverticula may show filling defects in the diverticular sac. This filling defect may be a foreign body or a bolus of food, but I have seen the filling defect in two cases due to carcinoma. Unless you have a pliable sac that can be emptied and cleaned you should use an esophageal speculum to find out why that filling defect is present and also for a biopsy.

We have seen a number of people who have been, as Dr. Phelps pointed out, unable to swallow. Several patients had the sac for many years and got along in spite of the sac. However, when they are unable to eat, the patients consent to treatment. A few patients have been in such poor condition that they died of their complications before operation. Nearly always, with the antibiotics and parenteral, tube or gastrostomy feedings, you can get the patient in condition for operation. I wanted to emphasize one point—don't throw away your postoperative feeding tubes.

DR. HEATLEY S. EATON: Mr. Chairman and Gentlemen, Dr. Hoover mentioned what I ought to mention. I had nothing to do with the management of these cases but occasionally my colleagues who do deal with them send them up to us to have a look in the hypopharynx by indirect laryngoscopy to see whether we can visualize the opening, which we very seldom can.

This patient came up and I was impressed by the diagnosis already established by x-ray and so on. I was impressed that the mass felt very firm. I ventured the suggestion that there was carcinoma. They took out the diverticulum without any particular problem. When laid open there was carcinoma completely contained within the diverticulum. I don't know how frequently that sort of thing is encountered. I would just like to mention it.

DR. KENNETH A. PHELPS: I want to thank the men who so kindly discussed this small report. As Dr. Jackson points out, I made reference to passing the esophagoscope below the diverticulum to aid the surgeon in amputating the neck of the sac. Actually, I place an esophageal bougie through the esophagoscope, and after removing the esophagoscope the bougie serves as a flexible guide to the surgeon.

I am glad to know that in other localities the use of the feeding tube is considered to be a necessity. I wondered if some of the complications, which are the subject of this paper, might not be less frequent if the tube were left out. Difficulty in swallowing while the tube is in place possibly might lead to more chest complications, such as post-operative atelectasis and so forth. After reading a report by Dr. Harrington of Rochester, Minnesota, in which he recommended discontinuing the use of the feeding tube, I followed his recommendation. Up to date, my patients seem to do better without the tube.

My only purpose in discussing this small matter was to review and remind you that while we have done pretty well controlling infection we still have considerable progress to make to eliminate some of the other types of complications that still persist.

# REALISM IN THE SURGERY OF THE TONSILS AND ADENOIDS

CHAS. D. BLASSINGAME, M.D.

MEMPHIS, TENN.

The concept governing tonsil and adenoid surgery has undergone important and radical changes in recent years. Historically, the management of the tonsil and its allied problems has always reflected the evolutionary developments characterizing the various epochs in medicine. The first record of tonsil surgery occurred as far back as the year 1000 B.C. The operative procedure was extremely primitive and consisted of the removal of one-third of the tonsil with a curved knife, the tonsil being held by means of forceps. Fear of fatal hemorrhage prevented a more extensive operation. Thus, even in this early era of the development of medicine, it is apparent that the tonsil presented a serious medical problem recognized as such by the pioneers and treated surgically by the best available weapons at their disposal. A few centuries later, we find that the need for the complete removal of the tonsil was recognized, the procedure being to tear the tonsils out with the fingers. Only in the presence of marked adhesions, was cutting resorted to. The first instrument designed for the enucleation of the tonsil was the ordinary spoon with a hole in the center. According to historical legend, it was devised by a Norwegian peasant.

The guillotine is a comparatively recent innovation. It has had a tremendous impact on tonsil surgery. It has facilitated the successful removal of the tonsil by well-trained operators. In the hands of untrained operators, it has yielded poor results. The simplicity of its use has encouraged many untrained individuals to employ it on a large scale. At the present time, at least fifty per cent of the cases are operated upon by individuals unqualified by training to perform this operation. Furthermore, it has focused the spot-light on the operative procedure at the expense of the broader concept underlying the pathogenesis of infections of the pharyngeal lymphoid tissue.

The pharyngeal lymphoid tissue plays an important role in acute infections of this area. In chronic infections, it assumes even greater importance as a possible source of focal infection. Then it must always be recognized as a factor leading to middle ear diseases, either by direct extension or secondarily by obstruction of the eustachian tube with subsequent ascending infection. It is obvious that the successful surgical treatment of infected pharyngeal lymphoid tissue requires the complete extirpation of all such infected tissue. Partial removal limited to the tonsils or even the tonsils and adenoids fails to recognize the anatomical and pathological entity of the lymphoid structures in this area. Complete extirpation should include the faucial tonsil, the lingual tonsil, the pharyngeal tonsil and all secondary lymph nodes.

The faucial or palatine tonsil offers the surgeon the least difficulty, since it can readily be visualized and offers a ready approach for its removal. Unfortunately, the importance of the preservation of the posterior pillars during operative manipulations is not fully recognized or emphasized. Eliminating them destroys the symmetry of the pharynx, causing the palate to be distorted and effecting the modulation of the voice. Destruction of the anterior pillars usually or often results in extensive scar tissue accompanied by a feeling of tension and discomfort.

The lingual tonsil has come to the front only during recent years, as a surgical problem. Many factors explain this delayed evaluation of its importance in infections and focal infections. It is not readily accessible for routine examination so that it ordinarily is not considered in its true role. It also presents many problems for its operative removal. Treatment by radiation was usually resorted to in the past for obvious reasons. At the present, with the development of suitable instruments, the successful removal of the infected lingual tonsil can be accomplished in all cases, and should be done routinely at the time of the removal of the faucial tonsil, when found to be necessary or desired.

In our experience, at least 85% of tonsillectomized patients require the removal of concomitantly infected lingual tonsil nodules. Anatomically, the lingual tonsil presents the same picture of infected cypts and pockets as characterizes the palatine and the pharyngeal tonsils. During operations, exudative products of inflammation can be readily extruded from such pockets by the application of pressure.

On gross examination, the experienced surgeon can readily discern the presence of inflammation. The lingual tonsil tissue extends across the base of the tongue and inferiorly to the floor of the valecula. Upon its complete removal, a comparatively smooth, fresh surface reaching down to the epiglottis is formed. With tonsil scissors, that portion of the lingual tonsil adjacent to the lower pole of the faucial tonsil is dissected free from the underlying tongue muscle. The lingual tonsillotome and the snare are then employed to extirpate the lymphoid aggregates lying posteriorly and medially. When removed, the lymphoid nodules, varying in size up to several millimeters in diameter, are held together in a loosely arranged clump by the adjacent mucous membrane and its matted fibrous stroma. The use of a suitable tongue depressor determines the ease and success of the operation. Many of the instruments marketed for this purpose are entirely unsatisfactory. Extreme flexibility is a prime requisite. Provided the underlying muscular layer of the tongue is avoided, there is very little blood loss.

In the case of the pharyngeal tonsil, the surgical problems are even more extensive. Until recent years, the end results were poor. This could be attributed to the use of inadequate instruments, the lack of proper visualization of the surgical field and of a good approach. The value of removal of adenoids could, therefore, not be estimated with any degree of certainty or accuracy. As previously stated, this aggregation of lymphoid tissue plays the same role in acute and focal infections as the faucial and lingual tonsils. Crypts and pus pockets may be present throughout the entire structure. Furthermore, due to its location, it plays an additional role in middle ear infections. The concept governing the removal of the pharyngeal tonsil as outlined above is an evolution of an experience dating back for the past 15 years. It was soon recognized that the lymphoid tissue occupying this anatomical area was much more extensive than is generally understood. The need for instruments for better visualization of the operative field, with particular reference to the pharyngeal recesses, soon became apparent. The type of instrument employed for the removal of the diseased tissue also underwent a gradual development. At first, following the usual operation with the La-Force adenotome, we employed the punch forceps to remove the adenoid tissue in the lateral pharyngeal recesses. The Yankauer nasopharyngeal speculum afforded a very satisfactory approach. A series of punch forceps were evaluated for this purpose. The first punch

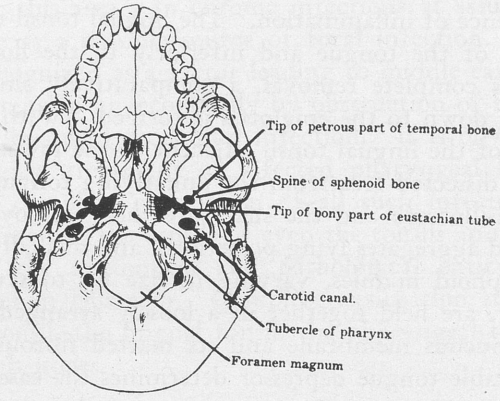


Fig. 1.

forceps was the Hartman round ring forceps on the universal handle. It was succeeded by a triangular type of forceps which in turn was superseded by the use of three types of basket forceps, a large and a medium sized triangular forceps and a small elliptical forceps. With the basket type forceps, by the use of two or three sizes, it was soon discovered that the tissue could be more readily and accurately removed. We found that by placing the tip of the Yankauer speculum behind the mouth of the eustachian tube, it could then be more readily displaced forward, thus affording a much wider view and more adequate approach to the pharyngeal recesses. The following technique was finally adopted and is now used for the removal of the adenoid tissue. The lymphoid tissue is grasped with the basket forceps of choice and, by rapid biting, not attempting to take too large a bite, in any case, more frequently not making a complete bite but instead taking hold of small bits of tissue and stripping them off the base, the tissue is separated and removed with frequent application of the suction tube. With alternate use of the forceps, a suction tube and stick sponges, all the tissue is removed down to a clean base which can be verified by direct inspection after the hemorrhage is controlled. By this method, all the lymphoid tissue extending to the lateral pharyngeal walls can be removed. The lymphoid tissue on the lateral walls will be found to cover the base diffusely and does not occur in nodular aggregates as one would ordinarily expect. Bleeding is readily controlled by pressure with sponge sticks.

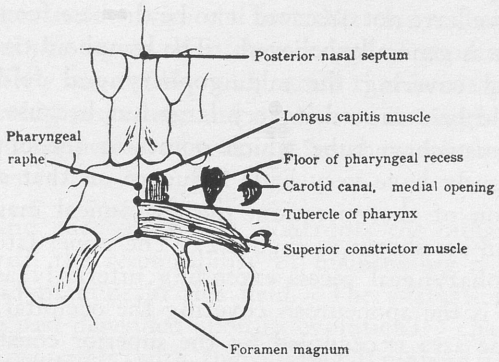


Fig. 2.

The wide limit to the lateral extension of the pharyngeal recesses, which we have found to exist while operating on these cases, is substantiated by reference to texts on the anatomy of this area. Cunningham's text on anatomy establishes the extent of these spaces by designating three points of attachment which are demonstrated in Figure 1. They are the tip of the petrous part of the temporal bone, the spine of the sphenoid bone and the tip of the bony part of the eustachian tube. The anatomists tell us that, because of changes that occur in cadaveric material, a correct impression of the size of the pharyngeal recesses cannot be obtained from such material. We have found, at operation, that by extending the removal of tissue to the anatomical points given above, a relatively large space is encountered. We have confined the removal of tissue to the posterior wall of the space and avoided traumatizing the mucosa around the opening of the eustachian tube as much as possible, for the obvious purpose of keeping down adhesions. This situation is more readily appreciated when we consider that the opening of the eustachian tube is related to the anterior wall of the pharyngeal recess, being in the neighborhood of an inch nearer the midline of the pharynx than the lateral points of attachment of that structure as we have shown on the anatomical illustration. The so-called tubal tonsil is not in the mouth of the eustachian tube, as it is generally believed to be, but it is, according to Cunningham's Anatomy, a lateral prolongation from the pharyngeal tonsil onto the posterior wall of the pharyngeal recess. Our observation is in accord with the view as just stated.

The posterior lip of the eustachian tube is frequently hypertrophied, but we have not observed it to be the base for the growth of lymphoid tissue as generally believed. The lymphoid tissue, which is frequently found covering the salpingopharyngeal fold, is objectionable and should be removed if very large but because of its remoteness from the eustachian tube which points in the opposite direction, would obviously have very little influence on that structure. At the conclusion of the operation, the anatomical markings that can be observed are shown in Figure 2. The upper lateral part of the floor of the pharyngeal recess extending inferiorly as far as the eustachian tube is the aponeurosis covering the occipital bone. The lower part of the area is occupied by the superior constrictor muscle. Lateral to the pharyngeal raphe and above the superior constrictor is the longus capitus muscle. The raphe, in the midline, as stated above, shows a considerable depression at the lower part, marking the area between the anterior arch of the atlas and the base of the occipital bone. This depression marks the position of an increased depth of the adenoid body and an increased likelihood for formation of focal infection points and sometimes frank abscesses. The lateral walls of the pharyngeal recesses are loosely attached to the under surface of the petrous part of the temporal bone. The fibrous wall on either side bridges over the space between the lateral margin of the base of the occipital bone and the points of attachments of the lateral pharyngeal wall, as previously stated, viz., the tip of the petrous part of the temporal bone, the spine of the sphenoid bone and the tip of the bony part of the eustachian tube. The pulsations of the carotid artery can frequently be observed following the removal of the lymphoid tissue in this space.

The technical difficulties in this operation are greatly enhanced by the tendency to profuse bleeding which, however, can be soon controlled, since it is usually due to capillary oozing and not to vessels of any large proportions. The Yankauer speculum has given us the best approach, due to its flexibility and the small diameter of its lumen. By traversing the oral cavity at an angle of 45 degrees, with this instrument, the posterior lip of the eustachian tube can be easily retracted foreward away from the posterior pharyngeal wall with the lip of the instrument, as previously stated and the entire field made accessible to operation under direct vision. Instruments for retracting the palate, having larger diameters than the Yankauer speculum, are obviously less effective in reaching the higher areas.

My experience lecturing to senior medical students at the University of Tennessee impresses me with the fact that this is the year that is most favorable to present to them the concept of good tonsil and adenoid surgery. They can readily understand that it is a painstaking and time consuming procedure and because of its magnitude will require a relatively long period of training for those who are to enter this field of surgery.

Realism in tonsil and adenoid surgery confronts the otolaryngologists inescapably, with the responsibility of maintaining a high standard of training and practice in this field. The evaluation of this procedure has in the past depended upon its evolutionary changes in attempting to deal adequately with the diseased lymphoid tissue of the pharynx. The same evaluation must continue to be the criterion of the operation, if it is to be accorded its relative value in the treatment of diseases of the pharynx.

414 PHYSICIANS AND SURGEONS BLDG.

## DISCUSSION

DR. WALTER B. HOOVER: I wish to compliment Dr. Blassingame on his paper upon this subject. It is a subject of interest to more people, lay and medical, than any other. Although it is a well known subject, it is not emphasized enough because adenoidectomy is more poorly done than any other operation in any field today. Many are doing adenoidectomies who do not see the adenoid before the operation, during the operation, and who never see the adenoid region after the operation has been done. Consequently they do not know what they have done.

The suggestion that adenoidectomy particularly, and the surgical treatment of the lymphoid tissues of the pharynx, should be brought to the attention of each senior medical student of every medical school is an excellent one. Since almost every medical school has representatives here, you should do something about this technique in your school.

To complete the record, I would like to ask Dr. Blassingame a question: What do you do about the lateral pharyngeal bands and scattered lymph follicles in the pharynx?

The Discussion has been very complete.

Thank you.

DR. CHARLES D. BLASSINGAME: Mr. Chairman, In answer to Dr. Hoover's question in regard to the lateral red bands in the posterior pharyngeal wall: There are two distinct types of lymphatic tissue observed in this area. One type represents a lymphatic system of drainage for infection and other noxous substances from the accessory sinuses and an engorgement of the lymph vessels in this type is pathognomonic of infection of the accessory sinuses and do not require separate

treatment aside from that which should be directed to the sinuses. The other type of lymphoid tissue in this area occurs in the form of lymphoid nodules and is a part of the Waldeyer's Ring of lymphoid tissue, becoming the seat of focal infection. These nodules manifesting foci of infection are removed as completely as possible with the punch forceps or with any other suitable cutting instrument.

# Memorials

# GORDON BERRY, M.D.

1880-1953

Gordon Berry, an honored Member of the American Laryngological Association for thirty-two years and an Emeritus Member since 1950, died on March 17, 1953 of a cerebral hemorrhage at the Massachusetts Memorial Hospital, Worcester, Mass.

He was born in Okayama, Japan on March 7, 1880, where he Mlived until he was thirteen years of age. He was the son of a Medical Missionary, Dr. John C. Berry, who was stationed in Japan from 1872 to 1893. Dr. Berry's father was born in Phippsburg, Maine, and his mother, Maria Elizabeth Gove, in Bath, Maine.

He returned to the United States with his family in 1893 and continued his education at the Newton High School, Phillips-Andover and Worcester Academy from 1894 to 1898. He entered Amherst College in 1898 and received his A.B. degree in 1902, having spent an interval year at Colorado College. He then entered the Medical School of the University of Michigan from which he graduated in June, 1906.

He served a general internship of eighteen months at the Worcester City Hospital after which he spent eighteen months as an Aural Intern at the Massachusetts Charitable Eye and Ear Infirmary.

He was consulting Otologist to the Fairlawn Hospital, Worcester City Hospital and Memorial Hospital.

He served in the United States Army in 1918-1919, holding the rank of Major, and then in the Reserve Corps for the following ten years. He was the author of many papers which were read before this Society from the time of his election.

He was elected to Membership in the American Laryngological Association in 1921. The esteem of his fellow members was manifested by his selection as Second Vive-President in 1924, as First Vice-President in 1932, and as President in 1940, as the culminating honor.

His many years of faithful service to the Association, and his contributions to otolaryngology, were rightfully recognized by his selection for the Newcomb Award in 1948.

He held membership in all of the National Societies of his specialty, having been Vice-President of the American Otological Society in 1943-44, and President in 1945-46. He was also Vice-President of the American Laryngological, Rhinological and Otological Society in 1925, and an Honorary Member since 1948. To add to his many honors he was awarded the Degree of Doctor of Science by Amherst College in June of 1952. In addition he was a member of the American Broncho-Esophagological Association and President in 1937, the New England Oto-laryngological Society and the Massachusetts Medical Society.

His outside diversions were many, including golf, tennis, boating and tramping, though it is difficult to conceive how he allowed himself time to enjoy them.

In Gordon Berry one could see the reflection of the tenets of his early training as the son of an ardent Medical Missionary. He was a member of the Congregational Church.

His own hearing deficiency, which he so nobly surmounted, served to stimulate him in his mission to help the hard of hearing; the success of his efforts being crowned by the encomiums heaped upon him by his fellow workers in this worthy project. He was president of the American Hearing Society from 1927 to 1927.

His friendliness and kindliness, his sterling honesty and zealous interest in his associates will long be remembered. Their loss is only exceeded by that of his wife, who survives him.

# EDWARD ANDERSON LOOPER, M.D.

1888-1953

Edward Anderson Looper, a member of the American Laryngological Association since 1935, died suddenly in his home, 504 Overhill Road, Baltimore, Md., about 3:30 P. M., Wednesday, January 14, 1953.

Born December 16, 1888 in Silver City, Ga., he was the son of John Anderson and Jennie Stewart Looper. His early education was obtained in Silver City and at Emory University in Atlanta, where he took his first two years in Medicine, 1908-1910. He then entered the Medical School of the University of Maryland where he received his M.D. degree in 1912. He then went to the University of Colorado where he received a degree of Doctor of Ophthalmology in 1913. Returning to Baltimore he began the practice of his specialty and his career in teaching at the University of Maryland.

During the first world war he was commissioned a First Lieutenant in the Medical Corps, but soon gained a promotion to Captain. He served overseas for two years as head of the Department of Oto-laryngology, University of Maryland unit, Base Hospital No. 42. During his tour of overseas duty, he took two courses in Plastic Surgery of the Head and Face, one in London and one in Paris. After his discharge from the service, he again returned to his Alma Mater to resume his teaching career. In 1921, he was apointed Professor of Diseases of the Nose and Throat and head of the Department of Oto-laryngology in the University Hospital. Both of these positions he still held at the time of his death. He was also a staff member of the Maryland General and the Baltimore Eye and Ear hospitals in Baltimore, and consultant to others in the city and throughout the State of Maryland.

Early interest in his chosen Specialty seemed to be directed towards diseases of the Larynx, especially Tuberculosis and Carcinoma. He was a pioneer in the use of the actual cautery in the treatment of Laryngeal Tuberculosis, for many years, working at the Maryland State Sanitarium for Tuberculosis. He was also a pioneer in the treatment of Carcinoma of the Larynx by Laryngectomy and described an original operation which is still described in most modern

textbooks. He was one of the first men in Maryland in the field of Broncho-esophagology. In 1930, he established the Looper Clinic in the University Hospital as a memorial to his daughter, Lola Elsie, who at the age of two died of Broncho-pneumonia following the aspiration of a piece of celery. Dr. Looper was a member and an indefatigable worker in many Medical Societies. He was a member of the American Laryngological Association, The American Broncho-Esophagological Society, The American Laryngological, Rhinological and Otological Society, The American Academy of Ophthalmology and Oto-laryngology. He was a past State regent of the International College of Surgeons, a member of the State advisory council of the American College of Surgeons, Past Councillor of the Southern Medical Association, the American Medical Association, the Medical and Chirurgical Faculty of Maryland and the Baltimore City Medical Society.

Dr. Looper contributed much to Medical Literature. He published numerous articles in various Medical Journals, and is the author of a textbook, "The Diagnosis and Treatment of Laryngeal Tuberculosis."

His hobbies were making Natural Color Movies and Boating. His collection of these movies is really outstanding, having travelled extensively all over North and South America, and to many foreign lands to obtain these films.

A very good amateur architect, he designed his beautiful summer home, "Linstid," on Eagle Hill overlooking the Magothy River and Gibson Island. Here he enjoyed his boating on the beautiful Chesapeake Bay and it's tributaries.

On January 15, 1920, he married Lola Patenall, by whom he is survived with their two children, Edward A., Jr., and Sybil Ann. The day following his death was to have been their 33rd Wedding Anniversary.

J. R. M.



# JOHN J. SHEA, M.D.

1889-1952

John J. Shea, an active Fellow of the American Laryngological Association since his admission in 1928, died in New Orleans, Louisiana, on November 28, 1952, following an operation for malignancy of the pancreas. He was actively engaged in his practice until but a few weeks before his death, having also participated in the examination of the American Board of Otolaryngology, of which he was Vive-President, early in October—a typical example of his unselfish devotion to his duty as a physician and an educator dedicated to the advancement of the Science of Otolaryngology.

John was born in Memphis, Tennessee on January 17, 1889, where he received his early education, later attending high school and college at the Christian Brothers College from which he received his Bachelor of Arts Degree in 1906. He received his M.D. degree from New York University and Bellevue Medical College in 1911.

He served his internship at St. John's Seaside Hospital, Staten Island, N. Y., Manhattan Maternity Hospital, New York, and Bellevue Hospital, New York from 1911 to 1913. His Post-Graduate training was obtained at the New York Post Graduate School and Hospital in 1914 and 1915, and the University of Paris, in 1918 and 1919.

He was Commissioned as a First Lieutenant in the United States Army Medical Corps in 1917 in which he saw service at Camp Meade, Md., Red Cross Hospital No. 7 Juilly Seine et Marne and U.S.A. Base Hospital No. 57, A.E.F. Paris, France. He was honorably discharged in 1919 with the Rank of Major. He later held the position of examiner for the Department of Aeronautics from 1925 to 1932.

After his discharge from the Military Service he returned to Memphis where he engaged in the practice of Otorhinolaryngology and Maxillo-facial Surgery in the offices of Drs. Ellett and Farrington. In 1926 he established the Dr. John J. Shea Clinic, where he practiced until the time of his last illness.

He was a prominent member of the Staffs of the Baptist Memorial Hospital, St. Joseph Hospital and the Memphis Eye, Ear, Nose

and Throat Hospital. He was also a consultant for the Campbell Clinic and the Kennedy Hospital.

His intense interest in Otolaryngology and his indomitable energy were manifested by his regular participation in the activities of the numerous National Medical Societies of which he was not only a Member but by which he had been honored by election to many high offices. He was a Fellow of the American Medical Association (Secretary, Section of Otolaryngology 1931-32-33; Chairman 1934-35) Southern Medical Association (Secretary of Section O. & O. 1920-21-22; Vice-chairman 1923 and Chairman 1924). American College of Surgeons 1922. American Academy of Ophthalmology and Otolaryngology (Vice-President 1924; Member of Council 1929-30-31-32; President-Elect 1953). American Larlyngological, Rhinological and Otological Society (Council 1937-38-39; President 1948-49). American Otological Society (Council 1943-44-45). American Laryngological Association (1st. Vice-President 1944-45 & 47).

He was a prolific writer, having published ninety-four papers on all phases of Otorhinolaryngology, maxillo-facial surgery, allergy and several on diseases of the hematopoetic system. He was likewise credited with devising the 'Shea Tube' for use in the postoperative treatment of naso-antral surgery in children.

On July 5, 1917 he married Catherine Flanagan, his constant and delightful companion at the Meetings of the American Board of Otolaryngology and the Meetings of the National Otolaryngological Societies, with an attendance record second only to his own. There are six children, Jeanne (Mrs. Wm. A. Leatherman), Catherine (Mrs. W. L. Roberts), Ellen (Mrs. L. K. Thompson, Jr.), Mary (Mrs. David F. Dixon), Martin and John, Jr. The last having selected the practice of Medicine for his career and the specialty of Otolaryngology also, in emulation of his father. They enriched his life by giving him fifteen grandchildren.

If he could be said to have had a hobby it was above all his family, of which he was inordinately proud, and which brought him the greatest happiness. He was never more radiant than when he was showing the many photographs of his wife, his children and his grandchildren, and relating interesting anecdotes of their every day lives, and the great family dinners which were a part of the Sunday ritual at his home.

John was an ardent Catholic whose religion meant everything that it should mean to a man and to a Physician. He was a man of the highest principles, of great charity to his fellow men, a man of tolerance and understanding of the shortcomings of others, as well as his own ineptitudes. Those of us who had the privilege of being associated with him on the American Board of Otolaryngology appreciated his honesty, his sagacity, his straightforwardness and his unswerving sense of duty towards his fellow members and the Candidates alike. His disposition was always cordial and ebullient, his sense of humor unfailing at all times. He was the exemplary 'Southern Gentleman.' It was most regrettable that he did not attain the honor of serving as President of "the Board," being President-elect at the time of his death, as he was also the President-elect of the American Academy of Ophthalmology and Otolaryngology.

The greatest tribute to his memory was the last which was paid to him by the hundreds of grieving patients and friends of all walks of life and the large number of fellow Physicians who were in attendance at his funeral Mass in Memphis.

We shall miss John Shea, but he shall always be remembered as the epitome of kindliness and loyalty and as a man of great professional achievements and highest integrity.



# WILLIAM D. GILL, M.D.

1896-1952

Dr. William D. Gill, a member of the American Laryngological Association since 1940, died on May 24, 1952, at San Antonio, Texas, of chronic myocarditis.

Dr. Gill was the son of a pioneer family of Dallas, Texas, Mr. and Mrs. J. P. Gill, Sr. He was born November 24, 1896, in Dallas, attended Dallas schools, the University of Cincinnati and Baylor University, and was graduated in 1917 from the Vanderbilt School of Medicine, Nashville, where he served as instructor in chemistry while receiving his medical education. Dr. Gill was Clinical Assistant at New York Skin and Cancer Hospital and served an internship at the New York Hospital in 1917 and 1918.

From 1919 to 1928 while Dr. Gill was serving in the Army Medical Corps he studied at the Army Medical School, Washington, D. C., the Medical Field Service School, Carlisle Barracks, Pa., and the University of Vienna, Austria. He later served as head of the Department of Ophthalmology, Station Hospital (now Brooke General Hospital) at Fort Sam Houston, Chief of the Department of Ophthalmology and instructor in diseases of the eye at Army Medical School, Washington, D. C., and head of the Eye Clinic at Walter Reed General Hospital, Washington, D. C.

Dr. Gill who spoke four languages, spent two years in France and Germany during World War I and was awarded a silver medal for "conspicuous military service" by the State of New York in appreciation of his service at Boppard, Germany, in checking a serious epidemic. He also received the French Medaille d'Honneur for services rendered during World War I.

In 1926 he resigned from the Army and moved to San Antonio, where he practiced until his death. Dr. Gill served as consultant to the Air Force School of Aviation Medicine, Randolph Field in 1948 and 1949 and was past Chairman of the San Antonio Board of Health.

A member of the American Medical Association and the Texas Medical Association through Bexar County Medical Society, Dr. Gill

held membership in the Southern Medical Association, Texas Society of Ophthalmology and Otolaryngology and the American Laryngological, Rhinological and Otological Society. He was a Diplomate of the American Board of Ophthalmology and the American Board of Otolaryngology. A Fellow of the American College of Surgeons, Dr. Gill also was a member of the Association for Research in Ophthalmology, and the American Society of Ophthalmologic and Otolaryngologic Allergy. He was an Associate in the American Editors and Authors Association. Dr. Gill was a Presbyterian and a member of the Masonic Lodge, Scottish Rite Bodies and Alzafar Shrine.

He was on the attending Staffs of the Medical Arts, the Nix, The Santa Rosa and the Baptist Memorial Hospitals, at the time of his death.

Dr. Gill contributed many articles on subjects relating to Ophthalmology as well as to Otolaryngology.

# HARRINGTON B. GRAHAM, M.D.

1874-1952

Dr. Harrington B. Graham, an active Member of the American Laryngological Association since 1932 and an Emeritus Fellow since 1943, died on July 20, 1953, in San Francisco. He was born in Santa Barbara, California in 1874.

Dr. Graham received his M.D. Degree from the University of California Medical School in 1899, at which time he entered into the practice of Medicine.

He was an intern at St. Luke's Hospital in 1899 and took his Post Graduate work in Ear, Nose and Throat at the Vienna University, Austria, Greifswald and Berlin, Germany in 1908 and 1909.

He soon took up the specialty of Otolaryngology which he practiced in San Francisco until 1945, when he was forced to retire by crippling arthritis. He was associated with the Stanford Medical School from 1910 until 1941 when he became Emeritus, having been Associate Clinical Professor of Surgery, division of Otolaryngology. Dr. Graham served as a medical officer during World War I. His office for many years was at 516 Sutter Street. He never married and passed the later part of his life in residence at the Bohemian Club.

He served as Chief of the Ear, Nose and Throat Department of the Southern Pacific Hospital in San Francisco, until May 1, 1944. His confreres saw little of him after his retirement from active practice.

He was also a Member of the American Laryngological, Rhinological and Otological Society, the American College of Surgeons, The American Medical Association and the Pacific Coast Oto-Ophthalmological Society.

# MARVIN FISHER JONES, M.D.

1889-1952

Marvin Fisher Jones, an active Fellow of the American Laryngological Association since 1944, died on May 26, 1952, at the Manhattan Eye and Ear Infirmary in New York, after a short illness.

Born in 1889, at Spencer, New York, he was the son of George Edward Jones, a merchant, and Sadie Fisher Jones. His early life was spent in Spencer. He received his A.B. Degree from the University of Buffalo in 1909, and graduated from the Medical School of this University in 1913. After serving his internship at the Moses Taylor Hospital in Buffalo, New York he began the study of Otolaryngology at the New York Post-Graduate Hospital in 1915.

At the termination of his Residency in 1917 he joined the Medical Corps of the United States Army, being commissioned as a First Lieutenant. He saw service in France and Italy, and after the cessation of active hostilities was a Consultant in Otology in the Army of Occupation in Germany. After his discharge from the Army he received his appointment as a member of the staff of the Manhattan Eye, Ear, and Throat Hospital in New York. His great interest in Resident teaching and his organizational ability soon became apparent by his establishing the excellent program which is now in operation. Later, he inaugurated the conservation of Hearing Clinic which dealt with all phases of the 'hard-of-hearing,' including the fitting of hearing aids and the educational instruction of the young.

Through the American Otological Society he established a Research Center for the investigation of the cochlear function and the physiology of the inner ear. This produced the technique known as aural barometry for the detection of stapedial fixation. When the fenestration operation became part of the otologist's armamentarium, he investigated the possibilities of this technique and pioneered in its introduction to his hospital.

For the past several years until the time of his death he served with distinction as Surgeon Director of Otology in this Institution.

He was also former Professor of Clinical Oto-laryngology of the New York Post-Graduate Medical School and Hospital of Columbia University and on the staffs of many other hospitals in the environs of New York City.

His intense interest in pure research relating to Otological problems stimulated him to participate in the activation of the Otological Research Council, which was fostered by the American Otological Society. In just recognition of his idealistic efforts he was elected to the Presidency of the Research Council within the past year. As a further evidence of his interest in Otology he was largely instrumental in establishing the Award of Merit Medal of the American Otological Society, which is bestowed by this Society from the funds of the Research Council for pre-eminent work in the advancement of the Science of Otology.

He was an active member of and held offices in many local Oto-laryngologic Societies, and a member of the National Societies, including the American Laryngological Association, the American Otological Society, by which he was honored by the Presidency in 1949, the American Laryngological, Rhinological, and Otological Society, and the American Academy of Ophthalmology and Otolaryngology. In addition, he was a member of the American Therapeutic Society and the American College of Surgeons.

Dr. Jones was a prolific and valuable contributor to the literaature on Otolaryngologic subjects, particularly those pertaining to Otology. He was an idealist, a zealous advocate of the truth, a ruthless antagonist of sham and deception, a man of strong convictions.

His chief outside interest was painting, operating in the media of both oil and water color. As a member of the Salmagundi Club since 1935, he contributed much to this Institution of Art. He served as Editor of the house organ for 1950 and 1951. Most significant were the outstanding honors afforded him as an 'exhibiting' member during the season of 1951. Dr. Jones was likewise an ardent fisherman.

In June of 1922 he married Jessie Hill, by whom he is survived with their three children James McKernon, Beatrice Clair, and Robert Marvin.

# Executive Sessions

## 1953

## FIRST EXECUTIVE SESSION

APRIL 26, 1953

The First Executive Session of the Seventy-Fourth Annual Meeting of the American Laryngological Association held at the Hotel Roosevelt, New Orleans, Louisiana, convened on April 26, 1953, at 12:15 P. M., following the First Scientific Session. Dr. Louis H. Clerf, President, presided.

The following were elected to *Active Fellowship* in the Association:

DR. FRANCIS L. LEDERER
DR. JOHN A. MURTAGH
DR. SAM E. ROBERTS
DR. WILLIAM W. WILKERSON, JR.
DR. WALTER P. WORK

To *Emeritus Fellowship:*

DR. HAROLD I. LILLIE
DR. WILLIAM E. SAUER
DR. HAROLD G. TOBEY

The Newcomb Award was presented to Dr. Frederick T. Hill for his distinguished services to this Association and to American Medicine.

The following Fellows were elected to serve as a Nominating Committee:

DR. GABRIEL TUCKER
DR. GUY L. BOYDEN
DR. FRANCIS E. LEJEUNE
DR. SAMUEL SALINGER
DR. PAUL H. HOLINGER

## REPORT OF THE NEWCOMB AWARD COMMITTEE

For the Newcomb Award of the American Laryngological Association, 1953, your Committee recommends Frederick Thayer Hill, M.D., Sc.D., Waterville, Maine, in consideration of his scientific contributions to this Association, of his great service to this Association in revising the structure of its finances during his tenure of the office of Treasurer, and of his distinguished services to American Laryngology through his life-long activities in the liaison between the specialty and the various agencies of general medicine and surgery, of medical education and of hospital management.

Signed,

Newcomb Award Committee.

## ANNUAL BUSINESS MEETING

April 27, 1953

The meeting convened at 11:30 A. M. on April 27, 1953. The President, Dr. Louis H. Clerf presided.

The report of the Secretary was accepted as circularized.

The combined reports of the Treasurer, Auditor were received with thanks.

The Nominating Committee recommended for election as Councillors the following:

Gordon F. Harkness
Claude C. Cody
Daniel S. Cunning
Harry P. Schenck
Fred W. Dixon
Bernard J. McMahon
Ralph A. Fenton
John Mackenzie Brown
H. Marshall Taylor
Louis H. Clerf

There were no nominations from the floor and the Committee's recommendations were approved unanimously and the Secretary was instructed to cast the ballot.

The report of the Librarian, Historian and Editor was presented and accepted unanimously.

Dr. Arthur W. Proetz reported for the Representatives to the American Board of Otolaryngology. The Board examined 96 candidates at the Chicago examination in October 1952, and of these 77 candidates were granted certificates. At the examination in New Orleans, April 20 to 24, 1953, 93 candidates were examined by the Board and of these, 73 were granted certificates. The report was accepted.

Dr. Arthur Proetz reported for the Laryngological Research Committee. He reported that the Committee had made an effective survey of the country in regard to possible candidates for funds. Several activities have been uncovered but these are too comprehensive and extensive to fit the budget. The research situation is peculiar, at the moment, in that grants by large institutions and by the government are for large sums and the demand for small sums is almost non-existent. The younger men, released from military service, are too busy in their adjustments that are not doing research. The Committee feels that their province is the help of individuals without contact or access to the enormous funds distributed by large foundations, and that these can be supplied with apparatus providing actual experiments are in progress and not merely in a visionary stage. The report was accepted.

Dr. Gordon F. Harkness pointed out the Association was organized 74 years ago with a limitation of 100 Active Fellows. It seemed likely that this constitutional limitation on numbers prevented excellent men, active in research and clinical work, from the benefits of Fellowship. Not only the population of the country but also the number of qualified otolaryngologists has greatly increased in the past 74 years. He suggested that the Association consider increasing the number of Active Fellows to 150.

Dr. Arthur Proetz, in the discussion, stated that he felt the smaller number was adequate since the quota for newly elected Fellows had rarely been filled during the past decade. He also felt that a small society enabled the members to become better acquainted with each other. There are other larger societies for activities suitable to a large membership.

President Clerf pointed out that the idea was brought up at this time merely as a matter of information and that the Fellows could consider the merits of the case at their leisure. No action was necessary at this time.

There being no further business the meeting adjourned at 1:10 P.M.

Respectfully submitted,
HARRY P. SCHENCK,
*Secretary.*

# REPORT OF THE SECRETARY
# AMERICAN LARYNGOLOGICAL ASSOCIATION

APRIL 27, 1953

The Seventy-third Annual Meeting of the American Laryngological Association was held on May 23rd and 24th, 1952, at the Royal York Hotel, Toronto, Canada, under the Presidency of Dr. H. Marshall Taylor.

There were 59 Fellows and 76 Guests in attendance.

Twelve scientific papers were presented.

The following were elected:

*Corresponding Fellowship:*

DR. RICARDO TAPIA ACUNA, Mexico City, Mexico

*Active Fellowship:*

DR. JOHN BERNHARDT ERICH, Rochester, Minn.
DR. PERCY EGERTON IRELAND, Toronto, Canada
DR. MERCER G. LYNCH, New Orleans, La.
DR. JULIUS WATKINS MCCALL, Cleveland, Ohio
DR. ALDEN H. MILLER, Los Angeles, Calif.

The Newcomb Award was presented to Dr. William J. McNally for his outstanding scientific contributions.

The following Officers were elected:

| | |
|---|---|
| President | Dr. Louis H. Clerf |
| First Vice-President | Dr. John Mackenzie Brown |
| Second Vice-President | Dr. Edwin N. Broyles |
| Secretary | Dr. Harry P. Schenck |
| Treasurer | Dr. Gordon F. Harkness |
| Librarian and Historian | Dr. Bernard J. McMahon |
| First Councillor | Dr. Frederick T. Hill |
| Second Councillor | Dr. Ralph A. Fenton |
| Third Councillor | Dr. Gordon B. New |
| Fourth Councillor | Dr. H. Marshall Taylor |

The Association has lost by death during the past year:

*Emeritus Fellows:*

Dr. Harrington B. Graham
Dr. Gordon Berry

*Active Fellows:*

Dr. William D. Gill
Dr. Marvin F. Jones
Dr. Edward A. Looper
Dr. John J. Shea

The Council at its Annual Meeting held in Syracuse, N. Y., on January 6, 1953, recommended for:

*Active Fellowship:*

Dr. Francis L. Lederer, Chicago, Ill.
Dr. John A. Murtagh, Hanover, N. H.
Dr. Sam E. Roberts, Kansas City, Mo.
Dr. William W. Wilkerson, Jr., Nashville, Tenn.
Dr. Walter P. Work, San Francisco, Calif.

*Emeritus Fellowship:*

Dr. Harold G. Tobey

Dr. Samuel Salinger was reappointed Abstract Editor.

The present membership of the Association is:

| | |
|---|---|
| Active | 95 |
| Honorary | 5 |
| Corresponding | 12 |
| Emeritus | 18 |
| | 130 |

Respectfully submitted,
Harry P. Schenck,
*Secretary*

EXHIBIT "A"

## REPORT OF THE TREASURER AND AUDITORS
## AMERICAN LARYNGOLOGICAL ASSOCIATION

### Balance Sheet

April 1, 1953

| | | |
|---|---|---|
| **General Fund:** | | |
| Assets: | | |
| Checking Account | | $ 2,327.91 |
| Liabilities and Equity: | | |
| Liabilities: | | |
| Due Trust Fund | | $ 1,656.73 |
| Equity: | | |
| Deficit Balance—April 1, 1952 | $ (140.83) | |
| Add: Excess of Income Over Expense—Year Ended April 1, 1953 (Exhibit "B") | 812.01 | |
| Surplus Balance—April 1, 1953 | | 671.18 |
| Total Liabilities and Equity | | $ 2,327.91 |

| | | | |
|---|---|---|---|
| **Trust Fund:** | | | |
| Assets: | | | |
| Savings Account | | | $ 2,376.40 |
| Due from General Fund | | | 1,656.73 |
| Bonds: | Par | Cost | |
| U. S. Defense 2½—G—1953 | $ 3,000.00 | $ 3,000.00 | |
| U. S. Defense 2½—G—1954 | 1,000.00 | 1,000.00 | |
| U. S. Treasury 2¼—1956/59 | 1,000.00 | 1,003.50 | |
| U. S. Defense 2½—G—1956 | 5,000.00 | 5,000.00 | |
| U. S. Defense 2½—G—1957 | 1,000.00 | 1,000.00 | |
| U. S. Defense 2½—G—1958 | 2,000.00 | 2,000.00 | |
| U. S. Treasury 2¾—1958/63 | 1,000.00 | 1,101.20 | |
| U. S. Treasury 2½—1964/69 | 3,000.00 | 3,000.00 | |
| U. S. Treasury 2½—1967/72 | 1,000.00 | 1,000.00 | |
| U. S. Savings 2½—G—1959 | 5,000.00 | 5,000.00 | |
| U. S. Savings 2½—G—1960 | 1,000.00 | 1,000.00 | |
| U. S. Savings 2½—G—1961 | 1,000.00 | 1,000.00 | |
| U. S. Savings 2.76%—K—1965 | 5,000.00 | 5,000.00 | |
| U. S. Savings 2.76%—K—1965 | 1,000.00 | 1,000.00 | |
| U. S. Savings 2.76%—K—1965 | 1,000.00 | 1,000.00 | |
| Total Bonds | $32,000.00 | | 32,104.70 |
| Total Trust Fund Assets | | | $36,137.83 |

Equity:

| Fund | Principal | Unused Income April 1, 1952 | Expended 1952-53 | Income 1952-53 | Unused Income April 1, 1953 | Principal and Unused April 1, 1953 |
|---|---|---|---|---|---|---|
| Casselberry | $ 5,000.00 | $ 7.33.84 | $ | $106.69 | $ 840.53 | $5,840.53 |
| Johnson | 5,000.00 | 252.36 | | 97.71 | 350.07 | 5,350.07 |
| de Roaldes | 3,000.00 | 382.86 | | 161.70 | 544.56 | 3,544.56 |
| Newcomb Trust | 2,000.00 | 349.06 | | 43.71 | 392.77 | 2,392.77 |
| Newcomb Prize | 500.00 | 18.60 | 4.00 | .92 | 15.52 | 515.52 |
| Hourne Scholarship | 20.23 | 1.30 | | .40 | 1.70 | 21.93 |
| Research | 16,014.19 | 2,112.16 | | 346.10 | 2,458.26 | 18,472.45 |
| Total | $31,534.42 | $3,850.18 | $ 4.00 | $757.23 | $4,603.41 | |
| Total Equity | | | | | | $36,137.83 |

EXHIBIT "B"

## AMERICAN LARYNGOLOGICAL ASSOCIATION

## STATEMENT OF INCOME AND EXPENSE—CASH BASIS

## YEAR ENDED APRIL 1, 1953

General Fund:

Income:

| | | |
|---|---|---|
| Dues: | | |
| 1951—1 Member @ $35.00 | $ 35.00 | |
| 1952—91 Members @ $40.00 | 3,640.00 | |
| 1952—5 New Members @ $100.00 | 500.00 | |
| | | $4,175.00 |
| Registration Fees | | 995.49 |
| Sale of "Transactions" | | 241.00 |
| Total Income | | $5,411.49 |

Expense:

| | | |
|---|---|---|
| Annual Meeting: | | |
| Banquet | $ 497.05 | |
| Ladies Dinner | 131.10 | |
| Programs | 395.90 | |
| Projection Equipment Rental and Operation | 54.50 | |
| Reporting Service | 128.31 | |
| | | $1,206.86 |

| | | |
|---|---|---|
| Council Meeting: | | |
| Council Dinner | $ 53.60 | |
| Travel Expense | 619.53 | |
| | 673.13 | |
| Clerical Hire | 500.00 | |
| Cost of "Transactions" | 1,695.74 | |
| Stationery and Printing | 241.55 | |
| Auditing | 100.00 | |
| Mimeograph Service | 10.20 | |
| Treasurer's Bond | 75.00 | |
| Transfer to de Roaldes Fund | 97.00 | |
| Total Expense | | 4,599.48 |
| Excess of General Fund Income Over Expense (Exhibit "A") | | $ 812.01 |
| Trust Fund: | | |
| Income: | | |
| Interest—U. S. Bonds | $ 625.00 | |
| Interest—Savings Account | 35.23 | |
| Transfer from General Account | 97.00 | |
| Total Income (Exhibit "A") | | $ 757.23 |
| Expense: | | |
| Newcomb Prize Fund—Engrossing Award (Exhibit "A") | | 4.00 |
| Excess of Trust Fund Income Over Expense | | $ 753.23 |

EXHIBIT "C"

AMERICAN LARYNGOLOGICAL ASSOCIATION

STATEMENT OF CASH RECEIPTS AND DISBURSEMENTS

YEAR ENDED APRIL 1, 1953

| | | |
|---|---|---|
| Cash Balance—April 1, 1952: | | |
| Checking Account | $6,197.90 | |
| Savings Account | 2,341.17 | |
| | | $8,539.07 |
| Cash Receipts: | | |
| Dues | $4,175.00 | |
| Registration Fees | 995.49 | |
| Donations to Research Fund | 1,600.00 | |
| Sale of "Transactions" | 241.00 | |
| Trust Fund Interest Received | 660.23 | |
| Total Cash Receipts | | $7,671.72 |

| | | |
|---|---|---|
| Cash Disbursements: | | |
| Annual Meeting | $1,206.86 | |
| Council Meeting | 673.13 | |
| Clerical Hire | 500.00 | |
| Cost of Transactions | 1,695.74 | |
| Stationery and Printing | 241.55 | |
| Treasurer's Bond | 75.00 | |
| Auditing | 100.00 | |
| Mimeograph Service | 10.20 | |
| Embossing Newcomb Award | 4.00 | |
| Purchase of U. S. Savings Bonds——Series "K" | 7,000.00 | |
| Total Cash Disbursements | | 11,506.48 |
| Excess of Disbursements Over Receipts | | (3,834.76) |
| Cash Balance—April 1, 1953 | | $4,704.31 |
| Consisting of: | | |
| Checking Account (Exhibit "A") | $2,327.91 | |
| Savings Account (Exhibit "A") | 2,376.40 | |
| Total Cash (As Above) | | $4,704.31 |

EXHIBIT "D"

## AMERICAN LARYNGOLOGICAL ASSOCIATION
## SECURITY AND FUND TRANSACTIONS
## YEAR ENDED APRIL 1, 1952

| | | |
|---|---|---|
| Security Transactions: | | |
| Bonds—April 1, 1952 | | $25,104.70 |
| Additions: | | |
| U. S. Savings Bond 2.76%—K—1965 | $5,000.00 | |
| U. S. Savings Bond 2.76%—K—1965 | 1,000.00 | |
| U. S. Savings Bond 2.76%—K—1965 | 1,000.00 | |
| | | 7,000.00 |
| Total Bonds—April 1, 1953 (Exhibit "A") | | $32,104.70 |
| Fund Transactions: | | |
| Principal of Trust and Scholarship Funds, April 1, 1952 | | $29,934.42 |

Additions:

Research Fund Contributions:

| | |
|---|---|
| Estate of William E. Grove | $ 500.00 |
| Estate of Dr. Burt R. Shurley | 1,000.00 |
| W. H. Johnston, M.D. | 100.00 |
| | 1,600.00 |

Principal of Trust and Scholarship April 1, 1953 (Exhibit "A") ..... $31,534.42

Your Treasurer would respectfully offer the following comments.

1. With our increase of dues to $40.00 it was felt that we could dispense with a registration fee from the members attending the meeting; that the increased dues would justify this change and that the entire membership would thereby be contributing to the annual meeting expense. This action has seemed justified and from "Exhibit "B" you will note an excess of General Fund Income over expenses of $812.01.

The annual dinner will be assessed only against those attending.

2. We have a total obligation to the Trust Funds of $36,137.83. We keep a small part of this in liquid assets (Commercial and Savings Accounts) in order to meet unexpected expenses. Our Society operating funds do not have a balance to meet such emergencies. While this may not seem just as it should be, your Treasurer feels that it is justified.

3. Donations to the Research Fund (1951-52) totaled $1,950.00. For the 1952-53 period they totaled $1,600.00. Developing this fund to an amount that will produce an income capable of real accomplishments is a difficult task. Without aid from philanthropy outside our group, it at times seems a Utopian dream. Lay philanthropy, your Treasurer believes, would be more receptive could we have a more specific research objective. To specify this at this time is equally difficult.

4. The cost of the transactions for the following years is as follows:

1950 —$1,922.52
1951 — 1,759.10
1952 — 2,019.13
1953 — 1,695.74

Not a bad record when one considers the fifty cent dollar.

5. Transactions receipts are as follows:

1951 —$451.00
1952 — 532.80
1953 — 241.00

Respectfully submitted,

GORDON F. HARKNESS, M.D., *Treasurer*

## ACCOUNTANT'S REPORT

We have examined the balance sheet of American Laryngological Association as of April 1, 1953, and the related statements of income and expense, and cash receipts and disbursements for the year then ended. Our examination was made in accordance with generally accepted auditing standards, and accordingly included such tests of the accounting records and such other auditing procedures as we considered necessary in the circumstances with the exception that the allocation of equities to the various funds was accepted as shown by the books without varification by us. This report is on a cash basis and does not include income receivable or expenses payable at April 1, 1953, which appear to be of minor consequence.

## ACCOUNTANT'S OPINION

In our opinion, except that as noted above allocation of fund equities was accepted by us without verification, the accompanying balance sheet and related statements of income and expense and cash receipts and disbursements present fairly the financial position of American Laryngological Association at April 1, 1953, and the results of its operations for the year then ended, in conformity with generally accepted accounting principles applied on a basis consistent with that of the preceding year.

McGladrey, Hansen, Dunn & Co.

Certified Public Accountants.

## FINAL EXECUTIVE SESSION

The Final Executive Session was called to order by President Clerf at 5:00 P. M. on April 27, 1953 immediately following the Scientific Session.

The Association Unanimously elected as Councillors the Fellows recommended by the Nominating Committee in their report. A short recess was held while the new Councillors retired and elected the following Officers:

| | |
|---|---|
| President | Gordon F. Harkness |
| First Vice-President | Claude C. Cody |
| Second Vice-President | Daniel S. Cunning |
| Secretary | Harry P. Schenck |
| Treasurer | Fred W. Dixon |
| Librarian, Historian and Editor | Bernard J. McMahon |
| First Councillor | Ralph A. Fenton |
| Second Councillor | J. Mackenzie Brown |
| Third Councillor | H. Marshall Taylor |
| Fourth Councillor | Louis H. Clerf |

President-elect Harkness accepted the gavel from the Presiding Officer, expressed his thanks to the Fellowship for their aid during his years as Treasurer and his gratitude for this great honor that has been conferred upon him.

The meeting adjojurned at 5:45 P. M.

Respectfully submitted,

HARRY P. SCHENCK,

*Secretary.*

# List of Fellows

# 1953

## LIST OF FELLOWS

*Date Indicates Year Admitted to Active Fellowship*

Attendance at meetings is shown by figures following each name. Asterisk (*) indicates year paper was read.

### *Active Fellows*

1942. ASHLEY, REA E., 384 Post Street, San Francisco 8, California, 1946, '47, '48, '49, '50, '51*, '53.

1936. BALLENGER, HOWARD C., 723 Elm Street, Winnetka, Illinois, 1936, '37, '38*, '40, '41, '46*, '47, '48, '51, '52*, '53.

1949. BECK, AUGUST LEO, 42 Hugenot Street, New Rochelle, N. Y., 1949, '50, '51, '52*.

1938. BLASSINGAME, CHARLES DECATUR, 414 Physicians and Surgeons Bldg., Memphis 3, Tennessee, 1938, '39, '41, '42, '44, '46*, '47, '50, '51, '52*, '53*.

1944. BOIES, LAWRENCE R., 1631 Medical Arts Building, Minneapolis 2, Minnesota, 1944, '46, '47, '48*, '49, '50*, '51*, '53.

1941. BOWERS, WESLEY C., 17 East 61st Street, New York 21, N. Y., 1941, '42, '44, '49.

1951. BOYDEN, GUY LEE, 1735 N. Wheeler St., Portland 12, Ore., 1952*, '53.

1932. BROWN, JOHN MACKENZIE, 1136 W. 6th Street, Los Angeles, 14, California, 1935*, '37, '40, '41, '42, '44, '47*, '49, '50, '51, '52, '53.

1940. BROYLES, EDWIN N., 1100 North Charles Street, Baltimore, Maryland, 1940, '41*, '42, '46, '48*, '49, '50, '51*, '52, '53.

1930. CAMPBELL, EDWARD HASTINGS, 133 S. 36th St., Philadelphia 4, Pennsylvania, 1930, '31*, '32*, '33, '35, '38, '39*, '40, '41, '47, '48, '49, '51, '52.

1945. CAMPBELL, PAUL A., School of Aviation Medicine, Randolph Field, Texas, 1946, '47, '49, '51.

1942. CANFIELD, NORTON, 175, St. Ronan St., New Haven 11, Connecticut, 1942, '46, '47, '48, '49*, '50, '51.

1925. CLERF, LOUIS H., 1530 Locust Street, Philadelphia 2, Pennsylvania, 1925, '27*, '28, '29, '30*, '32, '33, '34, '35, '36*, '37, '38, '39, '40, '41*, '42*, '44*, '46, '47, '48, '49, '50, '51, '52, '53*.

1939. CODY, CLAUDE CARR, 1304 Walker Avenue, Houston, Texas 1939, '41, '42, '44, '46*, '47, '48*, '49, '50, '51, '52, '53.

1941. CUNNING, DANIEL S., 118 East 53rd Street, New York 22, N. Y., 1941, '42*, '44, '46, '47*, '48, '49, '50*, '51, '52, '53.

1951. DAVISON, FRANCIS W., Geisinger Memorial Hospital, Danville, Pa., 1951, '52, '53*.

1941. DIXON, FRED W., 1027 Rose Building, Cleveland, Ohio, 1941, '42*, '44, '46, '47*, '49*, '50, '51, '52, '53.

1947. EAGLE, WATT WEEMS, Duke Hospital, Durham, N. C., 1948*, '49, '51, '53.

1947. ENGLER, CLARENCE W., 2323 Prospect Avenue, Cleveland, Ohio, 1947, '48*, '49, '50, '51.

1952. ERICH, JOHN B., Mayo Clinic, 102 Second Avenue, Rochester, Minn., 1953.

1923. FENTON, RALPH ALBERT, 1020 S.W. Taylor Street, Portland 5, Oregon, 1923, '25*, '26, '28, '30, '34, '35, '37*, '39, '40*, '42, '44, '46, '47*, '49, '50*, '52, '53.

1930. FIGI, FREDERICK A., Mayo Clinic, Rochester, Minnesota, 1930, '32*, '34, '35, '38*, '42*, '47*, '48, '50*, '53*.

1932. FURSTENBERG, ALBERT CARL, 201 South Main Street, Ann Arbor, Michigan, 1933*, '36*, '38*, '46, '48*, '50, '51, '53.

1936. GALLOWAY, THOMAS CYRUS, 636 Church Street, Evanston, Illinois, 1936, '37, '38*, '39, '40, '41, '42*, '46*, '47, '48, '50, '51, '52, '53.

1940. GATEWOOD, E. TRIBLE, Professional Building, Richmond, Virginia, 1940, '41, '42*, '44, '47.

1940. GOODALE, ROBERT L., 330 Dartmouth Street, Boston, Massachusetts, 1940, '41, '42*, '44*, '46, '47, '49, '50*, '53.

1928. GOODYEAR, HENRY M., 556 Doctors' Building, Cincinnati 2, Ohio, 1928, '29, '30*, '31, '32, '33, '34*, '35, '36, '37, '38, '39, '40, '44*, '46, '47, '48, '49*, '51, '53.

1950. HALL, COLBY, 1136 West Sixth Street, Los Angeles, Calif., 1950.

1940. HANSEL, FRENCH K., 634 North Grand Avenue, St. Louis 3, Missouri, 1940, '42, '46, '47, '51, '53*.

1933. HARKNESS, GORDON FOLLETTE, 215 Main Street, Davenport, Iowa, 1934, '35, '36*, '40, '41, '44, '46, '47, '48, '49, '50, '51, '52, '53.

1944. HAVENS, FRED Z., 102 Second Avenue S-W., Rochester, Minnesota, 1944, '46, '49, '51, '53.

1942. HEATLY, CLYDE A., 11 North Goodman Street, Rochester, N. Y., 1942, '46*, '49, '50, '51, '52, '53*.

1945. HICKEY, HAROLD L., 1612 Tremont Street, Denver 2, Colorado, 1946, '47, '48, '49, '50, '52.

1943. HILDING, ANDERSON C., 324 West Superior Street, Duluth, Minnesota, 1944*, '46, '47, '48*, '49, '50, '51, '53.

1928. HILL, FREDERICK THAYER, Professional Building, Waterville, Maine, 1928, '29*, '30*, '31, '32, '33, '34, '35, '36, '37*, '38*, '39, '40, '41*, '42, '44*, '46, '47, '48, '49*, '50, '51, 52*, '53.

1945. HOLINGER, PAUL H., 700 North Michigan Ave., Chicago 11, Illinois, 1946, '47, '49, '50*, '51*, '52, '53.

1944. HOOPLE, GORDON D., 1100 East Genesee St., Syracuse, New York, 1946, '47, '48, '49, '50, '51, '52, '53.

1930. HOUSER, KARL MUSSER, 2035 Delancey Street, Philadelphia 3, Pennsylvania, 1930, '32*, '33, '34*, '37, '38, '39, '40, '41, '44, '48.

1952. IRELAND, P. E., Room 82, Banting Institute, University of Toronto, Toronto, Ontario, 1952, '53.

1938. JACKSON, CHEVALIER LAWRENCE, 1901 Walnut, Philadelphia 3, Pa., 1938, '39, '40, '41*, '42, '44*, '46, '47*, '48, '49, '51, '53.

1939. JOHNSTON, WILLIAM HOWARD, 1515 State Street, Santa Barbara 7, California, 1939, '40, '41, '42, '44, '46, '47, '49, '50, '52.

1942. KELLY, JOSEPH D., 140 East Fifty-fourth Street, New York 22, N. Y., 1942, '44*, '47, '48, '49, '51, '53.

1921. KERNAN, JOHN, D., JR., 103 East Seventy-eighth Street, New York 21, N. Y., 1921*, '22, '25, '26, '27, '29, '31, '34*, '35, '36, '37*, '39, '40*, '42*, '47, '48, '51.

1942. KING, EDWARD D., 10220 Riverside Drive, North Hollywood, California, 1942, '46, '47, '49*, '50.

1950. KLINE, ORAM R., 514 Cooper Street, Camden, N. J., 1950, '51, '52, '53.

1953. LEDERER, FRANCIS LOEFFLER, 1853 W. Polk Street, Chicago 12, Illinois, 1953.

1936. LEJEUNE, FRANCIS ERNEST, Ochsner Clinic Building, Prytania and Aline Streets, New Orleans 15, Louisiana, 1937, '46*, '47, '50, '51, '52, '53.

1933. LIERLE, DEAN M., University Hospital, Iowa City, Iowa, 1933, '34, '35*, '37, '38, '39, '40*, '42*, '44*, '46, '47*, '48, '49, '50*, '51, '52, '53.

1949. LINDSAY, JOHN R., 950 E. 59th Street, Chicago 37, Illinois, 1949, '50, '51*, '53.

1927. LUKENS, ROBERT M., 1308 Hunting Park Avenue, Philadelphia 40, Pennsylvania, 1927, '28, '31*, '32, '35, '36, '38, '39, '40*, '42, '46, '48*, '49, '51.

1939. LUPTON, IRVING MARTIN, 806 Medical Arts Building, Portland, Oregon, 1946, '50.

1952. LYNCH, MERCER G., Ochsner Clinic, Prytania and Aline Sts., New Orleans 15, La., 1953.

1928. MACPHERSON, DUNCAN, 920 Fifth Avenue, New York City 21, N. Y., 1928, '29, '30, '31, '33, '34*, '39, '40, '41, '44, '49, '51.

1941. MARTIN, ROBERT C., 384 Post Street, San Francisco 8, California, 1941, '44, '47, '48, '50, '51, '53.

1948. MAXWELL, JAMES H., 201 S. Main Street, Ann Arbor, Michigan, 1948, '49, '50*, '51*, '52, '53.

1952. MCCALL, JULIUS W., 610 Rose Building, Cleveland 15, Ohio, 1952, '53*.

1951. MCCART, HOWARD W. D., Medical Arts Bldg., Toronto, Canada, 1951, '52*.

1939. MCCASKEY, CARL HEBER, 608 Guaranty Building, Indianapolis 4, Indiana, 1939, '40, '41, '42*, '44, '46*, '47, '48, '49, '50, '51, '52, '53.

1951. MCHENRY, LAWRENCE C., 117 North Broadway, Oklahoma City 2, Okla., 1953*.

1945. MCLAURIN, JOHN G., 1322 Medical Arts Building, Dallas 1, Texas, 1946, 49.

1933. MCMAHON, BERNARD J., 8230 Forsythe Blvd., Clayton 24, Missouri, 1934*, '35, '36, '38*, '41, '44, '46*, '47, '48, '49, '50*, '51, '52, '53.

1931. MCNALLY, WILLIAM JAMES, 1509 Sherbrooke Street West, Montreal, Canada, 1931, '33, '34*, '39, '44, '47, '49, '49, '52, '53.

1952. MILLER, ALDEN H., 500 South Lucas Ave., Los Angeles 17, Calif., 1952, '53*.

1950. MORRISON, LEWIS F., 3536 Jackson Street, San Francisco 18, California, 1950, '51, '52*, '53.

1940. MORRISON, WILLIAM W., 140 E. 54th Street, New York 22, N. Y., 1940, '41*, '44, '47, '49*, '50, '52, '53.

1953. MURTAGH, JOHN A., 2 Maynard Street, Hanover, New Hampshire, 1953.

1927. MYERSON, MERVIN C., 416 North Bedford Drive, Beverly Hills, California, 1927 '28*, '29, '30, '31*, '32*, '33*, '34*, '35, '36, '37, '38, '39*, '40, '41*, '42, '44, '50*.

1937. NASH, C. STEWART, Medical Arts Building, Rochester 7, New York, 1937, '38*, '40, '42, '44, '46, '49, '50, '51, '52, '53.

1922. NEW, GORDON B., 1516 Torrey Pines, La Jolla, California, 1922, '24, '25*, '26*, '28*, '31*, '33*, '35*, '37*, '39*, '41*, '46*, '48, '49*, '51*.

1927. ORTON, HENRY BOYLAN, 224 Delavan Avenue, Newark 4, New Jersey, 1927, '28, '29, '30*, '31, '32, '33*, '35, '36, '37, '38*, '40, '41, '42, '44*, '47*, '49, '51*, '52, '53*.

1948. PHELPS, KENNETH A., 1137 Medical Arts Building, Minneapolis 2, Minnisota, 1948, '50, '53*.

1951. PRIEST, ROBERT E., 79, S. Ninth St., Minneapolis 2, Minn., 1951, '53*.

1924. PROETZ, ARTHUR WALTER, 1010 Beaumont Building, St. Louis 8, Missouri, 1924, '25*, '26*, '27, '28, '29, '30, '31, '32*, '33*, '34, '35*, '36, '37, '38*, '39*, '40, '41, '42*, 44, '46, '47*, '48*, '49*, '50, '51*, '52, '53.

1951. PUTNEY, F. JOHNSON, 255 South 17th Street, Philadelphia 3, Pa., 1951, '52, '53*.

1951. RAWLINS, AUBREY G., 384 Post Street, San Francisco, Calif., 1951, '53*.

1934. RICHARDS, LYMAN GILDER, 1101 Beacon Street, Brookline 46, Massachusetts, 1934, '35, '36*, '37, '38, '39, '47, '49, '51*.

1945. ROBB, JAMES M., 641 David Whitney Building, Detroit, Michigan, 1946, '48, '49*, '51, '52.

1953. ROBERTS, SAM E., 5964 Overhill Road, Kansas City, Missouri, 1953.

1938. SALINGER, SAMUEL, 25 E. Washington Street, Chicago, Illinois, 1938, '39, '40*, '42, '44*, '47, '48, '49, '50, '51, '52*, '53.

1932. SCHALL, LEROY ALLEN, 243 Charles Street, Boston 14, Massachusetts, 1934*, '35, '38, '40*, '41, '42, '44*, '46, '47, '48*, '49, '50*, '51, '53*.

1934. SCHENCK, HARRY P., 326 South 19th Street, Philadelphia 3, Pennsylvania, 1934, '35, '36*, '37, '38, '39, '40, '41*, '44*, '46, '47, '49, '50, '51, '52, '53.

1930. SEYDELL, ERNEST M., First National Bank Building, Wichita, Kansas, 1930, '31*, '33*, '34, '35, '37*, '38, '39, '40*, '41, '42, '46, '47, '48, '51, '53.

1939. SIMPSON, W. LIKELY, 512 Physicians' and Surgeons' Building, Memphis 3, Tennessee, 1939, '41, '44*, '46, '47*, '48, '50, '51*, '52, '53.

1950. SMITH, AUSTIN T., 1830 Spruce St., Philadelphia 3, Pa., 1950, '51, '52, '53.

1924. TAYLOR, HERMON MARSHALL, 111 West Adams Street, Jacksonville 5, Florida, 1924, '25*, '26, '27, '28, '31, '34, '35*, '36, '37, '38, '39*, '40, '41, '42, '44*, '46, '47, '48, '49, '50*, '51, '52*, '53.

1947. THEOBALD, WALTER H., 307 N. Michigan Avenue, Chicago, Illinois, 1947, '48*, '49, '50, '51, '52, '53.

1950. TREMBLE, G. EDWARD, 1390 Sherbrooke St. W., Montreal, Quebec, Canada, 1950, '51, '52, '53.

1925. TUCKER, GABRIEL, 250 South Eighteenth Street, Philadelphia 3, Pennsylvania, 1925, '26*, '27*, '29, '30, '31, '32, '33, '34, '35*, '36, '37, '38, '39, '40*, '41*, '42, '46, '47, '48, '49, '50, '51, '53.

1943. VAN ALYEA, OLIVER E., 135 South LaSalle Street, Chicago, Illinois, 1944, '46*, '47, '48, '49, '50, '51, '52*, '53.

1941. VIOLÉ, PIERRE P., 1930 Wilshire Boulevard, Los Angeles 5, California, 1944*, '46, '47, '50, '52, '53.

1940. WEILLE, FRANCIS L., 247 Commonwealth Avenue, Boston 16, Massachusetts, 1940, '41, '42, '44, '46*, '47, '48, '49, '50, '51, '52, '53.

1948. WHALEN, EDWARD J., 750 Main Street, Hartford, Connecticut, 1948, '50, '51, 52.

1953. WILKERSON, WILLIAM WESLEY, JR., 1028 Bennie Dillon Building, Nashville, Tennessee, 1953.

1948. WILLIAMS, HENRY L., 2nd, Mayo Clinic, Rochester, Minnesota, 1948, '49, '50*, '51, '52*, '53.

1942. WISHART, D. E. STAUNTON, 170 St. George Street, Toronto, Canada, 1942, '44, '46, '47*, '49, '51, '52*, '53.

1951. WOODMAN, DEGRAAF, 156 E. 37th Street, New York 16, N. Y., 1951, '53.

1953. WORK, WALTER P., 384 Post Street, San Francisco 8, California, 1953.

*Honorary Fellows*

1949. (1917) COATES, GEORGE M., 1721 Pine Street, Philadelphia 3, Pa., 1949*, '51, '52.

1939. (1907) JACKSON, CHEVALIER, Schwenksville, Pennsylvania, 1939*, '40*.

1943. (1918) LEWIS, FIELDING O., Providence Road, Media, Pennsylvania.

1947. (1904) MOSHER, HARRIS P., 127 Front Street, Marblehead, Mass., 1947, '48, '49, '50*, '51, '52, '53.

1937. NAGER, F. B., Freiestrasse 3, Zurich, Switzerland.

*Corresponding Fellows*

1946. ALONSO, JUSTO M., Mercedes 1233, Montevideo, Uruguay.

1942. BATSON, OSCAR V., 133 South Thirty-sixth Street, Philadelphia 4, Pennsylvania, 1942*.

1938. BLAIR, VILRAY P., 508, North Grand Avenue, St. Louis 3, Missouri.

1943. EGGSTON, ANDREW O., 653 Park Avenue, New York, N. Y., 1944, '49.

1950. LARSELL, OLOF, University of Oregon Medical School, Portland, Oregon, 1950*.

1921. LE MAITRE, FERNAND, Avenue Victor Hugo, 120 (XVI), Paris, France.

1930. NEGUS, VICTOR E., 149 Harley Street, London, W 1, England, 1938*.

1950. NEIL, JAMES HARDIE, 64 Symonds Street, Auckland, New Zealand.

1937. PORTMANN, GEORGES, 25 bis Cours de Verdun, Bordeaux, France, 1947.

1924. SCHAEFER, J. PARSONS, 4634 Spruce Street, Philadelphia 3, Pennsylvania, 1934.

1952. TAPIA ACUNA, RICARDO, Napoles 9, Mexico 6, D. F., Mex.

1936. VIALLE, JACQUES, 27 Rue de France, Nice (Alpes Maritimes), France.

*Emeritus Fellows*

1941. (1923) BARLOW, ROY A., Berryville, Va.

1937. (1915) BARNES, HARRY ALDRICH, Kingston, Mass., R.F.D. No. 2.

1951. (1944) BEATTY, HUGH G., 150 E. Broad St., Columbus 15, Ohio, 1951, '52, '53.

1944. (1913) BUTLER, RALPH, 1930 Chestnut Street, Philadelphia, Pennsylvania.

1950. (1937) CROWE, SAMUEL J., Tuscany Apartments, Baltimore 10, Maryland.

1946. (1933) FOSTER, JOHN H., Eagle Lake, Texas, 1948, '49, '50, '51, '52.

1951. (1928) GITTINS, THOMAS R., 408 Davidson Bldg., Sioux City, Iowa.

1936. (1898) GOODALE, JOSEPH L., Argilla Road, Ipswich, Massachusetts.

1933. (1905) HALSTED, THOMAS H., 40 Trinity Place, Boston 16, Mass., 1949.

1951. (1928) JARVIS, DEFOREST C., Quarry Bank Bldg., Barre, Vt., 1952.

1953. (1922) LILLIE, HAROLD I., Mayo Clinic, Rochester, Minnesota.

1950. (1928) LYMAN, HARRY WEBSTER, 906 Carleton Bldg., St. Louis 1, Mo., 1950, '51, '52.

1948. (1939) MYERS, JOHN LLEWELLYN, 1115 Grand Avenue, Kansas City, Missouri.

1953. (1921) SAUER, WILLIAM E., 3720 Washington Boulevard, St. Louis 8, Missouri.

1940. (1923) SEWALL, EDWARD C., 430 El Escarpado, Stanford University, California.

1948. (1923) SPENCER, FRANK R., 429 Pine St., Boulder, Colorado.

1953. (1927) TOBEY, HAROLD G., 274 Commonwealth Avenue, Boston 16, Massachusetts.

1950. (1922) WHITE, FRANCIS W., 471 Park Avenue, New York 22, N. Y.

1946. (1905) WOOD, GEORGE B., 329 Hathaway Lane, Wynnewood, Pennsylvania.

1951. (1935) WOODWARD, FLETCHER D., 104 E. Market St., Charlottesville, Va.

## BENEFACTORS

Dr. Arthur W. deRoaldes

Dr. William E. Casselberry

Dr. Samuel Johnston

Dr. Cornelius G. Coakley

Dr. John F. Barnhill

Dr. James E. Newcomb

Dr. Lee Wallace Dean

Dr. George E. Hourn

## BENEFACTORS OF THE LARYNGOLOGICAL RESEARCH FUND

Dr. John F. Barnhill

Dr. and Mrs. Lee Wallace Dean

Dr. Gordon Berry

Dr. Frederick T. Hill

Dr. and Mrs. George E. Hourn

Dr. Samuel Salinger

Dr. H. Marshall Taylor

Dr. Louis H. Clerf

Mr. Lester T. Sunderland

Dr. William E. Grove

Dr. Burt R. Shurly

*Obverse of the deRoaldes medal*

## RECIPIENTS OF THE DEROALDES AWARD

1928. Dr. Chevalier Jackson

1931. Dr. D. Bryson Delavan

1934. Dr. Harris P. Mosher

1937. Dr. Lee Wallace Dean

1943. Dr. Ralph A. Fenton

1949. Dr. George M. Coates

1951. Dr. Arthur W. Proetz

## RECIPIENTS OF THE CASSELBERRY AWARD

1923. Dr. George Fetterolf and Dr. Herbert Fox

1928. Dr. Ralph A. Fenton and Dr. O. Larsell

1929. Dr. Richard A. Kern and Dr. Harry P. Schenck

1929. Dr. Edward H. Campbell

1931. Dr. Arthur W. Proetz

1934. Dr. Anderson C. Hilding

1936. Dr. Francis E. LeJeune: Dr. Joel J. Pressman

1939. Dr. H. Marshall Taylor: Dr. Brien T. King

1940. Dr. French K. Hansel

1941. Dr. Noah D. Fabricant

1946. Dr. Paul H. Holinger

1949. Dr. Henry B. Orton

## RECIPIENTS OF THE NEWCOMB AWARD

1941. Dr. Burt R. Shurly

1942. Dr. Francis R. Packard

1943. Dr. George M. Coates

1944. Dr. Charles J. Imperatori

1947. Dr. Harris P. Mosher

1948. Dr. Gordon Berry

1949. Dr. Gordon B. New

1950. Dr. H. Marshall Taylor

1951. Dr. John D. Kernan

1952. Dr. William J. McNally

1953. Dr. Frederick T. Hill

## PAST OFFICERS

### *Presidents*

(Year of Election)

1879. Louis Elsberg
1880. J. Solis-Cohen
1881. F. I. Knight
1882. G. M. Lefferts
1883. F. H. Bosworth
1884. E. L. Shurly
1885. Harrison Allen
1886. E. Fletcher Ingals
1887. R. P. Lincoln
1888. E. C. Morgan
1889. J. N. Mackenzie
1890. W. C. Glasgow
1891. S. W. Langmaid
1892. M. J. Asch
1893. D. Bryson Delavan
1894. J. O. Roe
1895. W. H. Daly
1896. C. H. Knight
1897. T. R. French
1898. W. E. Casselberry
1899. Samuel Johnston
1900. H. L. Swain
1901. J. W. Farlow
1902. J. H. Bryan
1903. J. H. Hartman
1904. C. C. Rice
1905. J. W. Gleitsman
1906. A. W. deRoaldes
1907. H. S. Birkett
1908. A. Coolidge, Jr.
1909. J. E. Logan
1910. D. Braden Kyle
1911. James E. Newcomb
1912. George A. Leland
1913. Thomas Hubbard
1914. Alexander W. MacCoy
1915. G. Hudson Makuen
1916. Joseph L. Goodale
1917. Thomas H. Halstead
1918. Cornelius G. Coakley
1919. Norval H. Pierce
1920. Harris P. Mosher
1921. Harmon Smith
1922. Emil Mayer
1923. J. Payson Clark
1924. Lee Wallace Dean
1925. Greenfield Sluder
1926. Chevalier Jackson
1927. D. Bryson Delavan
1928. Charles W. Richardson
1929. Lewis A. Coffin
1930. Francis R. Packard
1931. George E. Shambaugh
1932. George Fetterolf
1933. George M. Coates
1934. Dunbar Roy
1935. Burt R. Shurly
1936. William B. Chamberlain
1937. John F. Barnhill
1938. George B. Wood

1939. James A. Babbitt
1940. Gordon Berry
1941. Thomas E. Carmody
1942-3. Charles J. Imperatori
1949. Ralph A. Fenton
1951. H. Marshall Taylor
1944-5. Harold I. Lillie
1946. Frank R. Spencer
1947. Arthur W. Proetz
1948. Frederick T. Hill
1950. Gordon B. New
1952. Louis H. Clerf

*Vice-Presidents*

| | | |
|---|---|---|
| 1879. | F. H. Davis | |
| 1880. | W. C. Glasgow | J. O. Roe |
| 1881. | E. L. Shurly | W. Porter |
| 1882. | C. Seiler | E. F. Ingals |
| 1883. | S. W. Langmaid | S. Johnston |
| 1884. | J. H. Hartman | W. H. Daly |
| 1885. | H. A. Johnson | G. W. Major |
| 1886. | E. C. Morgan | J. N. Mackenzie |
| 1887. | J. N. Mackenzie | S. W. Langmaid |
| 1888. | W. C. Glasgow | C. E. DeM. Sajous |
| 1889. | E. Holden | C. E. Bean |
| 1890. | J. O. Roe | J. H. Hartman |
| 1891. | M. J. Asch | S. Johnston |
| 1892. | S. Johnston | J. C. Mulhall |
| 1893. | J. C. Mulhall | W. E. Casselberry |
| 1894. | C. C. Rice | S. H. Chapman |
| 1895. | J. Wright | A. W. deRoaldes |
| 1896. | T. M. Murray | D. N. Rankin |
| 1897. | A. W. MacCoy | H. S. Birkett |
| 1898. | J. W. Farlow | F. W. Hinkel |
| 1899. | T. A. DeBlois | M. R. Brown |
| 1900. | H. L. Wagner | A. A. Bliss |
| 1901. | J. W. Gleitsmann | D. Braden Kyle |
| 1902. | G. A. Leland | T. Melville Hardie |
| 1903. | J. H. Lowman | W. Peyre Porcher |
| 1904. | Thomas Hubbard | W. J. Freeman |
| 1905. | J. L. Goodale | C. W. Richardson |

| | | |
|---|---|---|
| 1906. | G. H. Makuen | A. B. Thrasher |
| 1907. | J. P. Clark | J. E. Rhodes |
| 1908. | E. Mayer | F. R. Packard |
| 1909. | C. G. Coakley | H. P. Mosher |
| 1910. | Robert C. Myles | J. M. Ingersoll |
| 1911. | F. C. Cobb | B. R. Shurly |
| 1912. | A. W. Watson | W. Scott Renner |
| 1913. | F. E. Hopkins | Geo. F. Shambaugh |
| 1914. | Clement T. Theisen | Lewis A. Coffin |
| 1915. | J. Gordon Wilson | Christian R. Holmes |
| 1916. | Thomas H. Halsted | Greenfield Sluder |
| 1917. | John Edwin Rhodes | D. Crosby Greene |
| 1918. | G. E. Shambaugh | John R. Winslow |
| 1919. | Francis R. Packard | Harmon Smith |
| 1920. | Harmon Smith | W. B. Chamberlin |
| 1921. | Dunbar Roy | Robert C. Lynch |
| 1922. | George Fetterolf | Lorenzo B. Lockard |
| 1923. | Hubert Arrowsmith | Joseph B. Greene |
| 1924. | Ross H. Skillern | Gordon Berry |
| 1925. | John E. Mackenty | Robert Levy |
| 1926. | Lewis A. Coffin | William V. Mullin |
| 1927. | Charles W. Richardson | Hill Hastings |
| 1928. | Robert Clyde Lynch | Francis P. Emerson |
| 1929. | William B. Chamberlin | Ralph Albert Fenton |
| 1930. | Harris P. Mosher | James A. Babbitt |
| 1931. | Joseph B. Greene | E. Ross Faulkner |
| 1932. | Gordon Berry | Frank A. Spencer |
| 1933. | E. Ross Faulkner | Thomas S. Carmody |
| 1934. | Gordon B. New | Samuel McCullagh |
| 1935. | Edward C. Sewall | H. Marshall Taylor |
| 1936. | William P. Wherry | Harold I. Lillie |
| 1937. | Frank R. Spencer | Bernard J. McMahon |
| 1938. | Ralph A. Fenton | Frederick T. Hill |
| 1939. | John H. Foster | Thomas R. Gittins |
| 1940. | Charles H. Porter | Gordon F. Harkness |

| | |
|---|---|
| 1941. Arthur W. Proetz | Henry B. Orton |
| 1942-3. Harold I. Lillie | Dean M. Lierle |
| 1944-5. John J. Shea | Thomas C. Galloway |
| 1946. H. Marshall Taylor | C. Stewart Nash |
| 1947. John J. Shea | Frederick A. Figi |
| 1948. Henry B. Orton | Anderson C. Hilding |
| 1949. LeRoy A. Schall | Fletcher D. Woodward |
| 1950. W. Likely Simpson | Lyman G. Richards |
| 1951. Wm. J. McNally | Thomas C. Galloway |
| 1952. J. Mackenzie Brown | Edwin N. Broyles |

*Secretaries and Treasurers*

| | |
|---|---|
| 1879. G. M. Lefferts | 1895. H. L. Swain |
| 1882 D. Bryson Delavan | 1900. P. E. Newcomb |
| 1889. C. H. Knight | 1911. Harmon Smith |

*Secretaries*

| | |
|---|---|
| 1912. Harmon Smith | 1935. James A. Babbitt |
| 1918. D. Bryson Delavan | 1939. Charles J. Imperatori |
| 1919. J. M. Ingersoll | 1942. Arthur W. Proetz |
| 1920. George M. Coates | 1947. Louis H. Clerf |
| 1933. William V. Mullin | 1952. Harry P. Schenck |

*Treasurers*

| | |
|---|---|
| 1912. J. Payson Clark | 1933. James A. Babbitt |
| 1923. George Fetterolf | 1935. Charles J. Imperatori |
| 1932. William V. Mullin | 1939. Frederick T. Hill |
| 1948. Gordon F. Harkness | 1953. Fred W. Dixon |

*Librarians*

| | |
|---|---|
| 1789. F. H. Bosworth | 1930. John F. Barnhill |
| 1883. T. R. French | 1934. Burt R. Shurly |
| 1903. J. H. Bryan | 1935. George M. Coates |

*Librarian and Historian*

| | |
|---|---|
| 1936. George M. Coates | 1947. Harry P. Schenck |
| 1944. Louis H. Clerf | 1952. Bernard J. McMahon |

## PAST FELLOWS

Dates indicate original election to the Association

**Deceased*

### *Honorary Fellows*

*1908. Barnhill, John F., Miami Beach, Florida.
*1893. Birkett, Herbert S., Montreal, Canada.
*1878. Bosworth, Francke H., New York City.
*1918. Dean, Lee Wallace, St. Louis, Mo.
*1881. Delavan, D. Bryson, New York City.
*1893. deRoaldes, Arthur W., New Orleans, La.
*1890. De La Sota Y. Lastra, Ramon, Seville, Spain.
*1879. French, Thomas R., Brooklyn, N. Y.
*1880. Garcia, Senior Manuel, London, England.
*1903. Harris, Thos. J., New York City.
*1878. Johnston, Samuel, Baltimore, Md.
*1878. Lefferts, George Morewood, Katonah, N. Y.
*1914. Levy, Robert, Denver, Colo.
*1883. Mackenzie, John N., Baltimore, Md.
*1881. Mackenzie, Sir Morel, London, England.
*1910. Masser, Ferdinand, Naples, Italy.
\$1910. Moure, J. J. E., Bordeaux, France.
*1918. Oliver, H. K., Boston, Mass.
*1906. Pierce, Norval Harvey, San Diego, Calif.
*1909. Semon, Sir Felix, Great Missenden, England.
*1878. Solis-Cohen, J., Philadelphia, Pa.
*1889. Swain, Henry L., New Haven, Conn.
*1914. Thomson, Sir St. Clair, London, Eng.
*1903. Tilley, Herbert, London, England.
*1914. Wagner, Clinton, New York City.
*1890. Wright, Jonathan, Pleasantville, N. Y.

### *Corresponding Fellows*

*1892. Browne, Lennox, London, England.
*1940. Colledge, Lionel, London, England.
*1901. Collier, Mayo, Kearsney Abbey, Kent, England.
*1893. Desvernine, Carlos M., Havana, Cuba.
*1930. Emerson, Francis P., Franklin, Mass.

*1936. Fraser, John S., Edinburgh, Scotland.
*1901. Grant, Sir James Dundas, London, England.
*1887. Cougenheim, A., Paris, France.
*1894. Holden, Edgar, Newark, N. J.
*1919. Kelly, Adam Brown, Helensburgh, Scotland.
*1881. Labus, Carlo, Milan, Italy.
*1931. LasSagna, Francesco, Parma, Italy.
*1926. Law, Frederick M., New York, N. Y.
*1902. Lermoyez, Marcel, Paris, France.
*1897. Luc, H., Paris, France.
*1896. MacDonald, Greville, Haslemere, Surrey, England.
*1894. MacIntyre, John, Glasgow, Scotland.
*1903. McBride, P., York, England.
*1920. McKenzie, Dan, London, England.
*1919. McKernon, James F., New Canaan, Conn.
*1880. Meyer, Wilhelm, Copenhagen, Denmark.
*1896. Mygind, Holger, Copenhagen, Denmark.
*1919. Paterson, Donald Rose, Cardiff, Wales.
*1941. Patterson, Norman, Herts, England.
*1919. Rogers, John, Jr., New York City.
*1894. Sajous, C. E. DeM., Philadelphia, Pa.
*1896. Schmiegelow, Ernst, Copenhagen, Denmark.
*1946. Segura, Eliseo, Buenos Aires, Argentina.
*1940. Soto, E. Fernandez, Havana, Cuba.
*1881. Thornton, Pugin, London, England.
*1913. Turner, A. Logan, Edinburgh, Scotland.
*1880. Whistler, W. McNeil, London, England.
*1901. Wingrave, Wyatt, Lyme Regis, Dorset, England.
*1894. Wolfenden, R. Norris, Kent, England.

*Emeritus Fellows*

*1928. Beck, Joseph C., Chicago, Illinois.
*1921. Berry, Gordon, Worcester, Mass.
*1901. Brown, J. Price, Toronton, Canada.
*1891. Bryan, Joseph H., Washington, D. C.
*1897. Clark, J. Payson, Boston, Mass.
*1899. Cobb, Frederick C., Bradenton, Florida.
*1905. Coffin, Lewis A., New York City.
*1893. Coolidge, Algernon, Boston, Mass.
*1913. Dabney, Virginius, Washington, D. C.

*1882. De Blois, Thomas Amory, Boston, Mass.
*1892. Farlow, John W., Boston, Mass.
*1922. Forbes, Henry H., New York City.
*1905. Freer, Otto T., Chicago, Ill.
*1880. Gleitsmann, Joseph W., New York City.
*1922. Goldsmith, Perry G., Toronto, Canada.
*1932. Graham, Harrington B., San Francisco, California.
*1906. Greene, D. Crosby, Jr., Boston, Mass.
*1917. Greene, Joseph B., Asheville, N. C.
*1896. Hardie, Thomas Melville, Chicago, Ill.
*1915. Hastings, Hill, Los Angeles, Calif.
*1888. Hinkel, Frank Whitehill, Buffalo, New York.
*1895. Hopkins, Frederick E., Springfield, Mas.
*1927. Hubbard, Thomas, Toledo, Ohio.
*1919. Hurd, Lee Maidment, Rowayton, Conn.
*1920. Imperatori, Charles J., Essex, N. Y.
*1904. Ingersoll, John Marvin, Miami, Fla.
*1918. Kenyon, Elmer L., Chicago, Ill.
*1929. Kistner, Frank B., Portland, Oregon.
*1885. Knight, Charles H., New York City.
*1939. Large, Secord H., Cleveland, Ohio.
*1894. Leland, George A., Boston, Mass.
*1943. Lincoln, William R., Cleveland, Ohio.
*1886. MacCoy, Alexander W., Philadelphia, Pa.
*1896. Mayer, Emil, New York City.
*1943. McCullagh, Samuel, New York, N. Y.
*1923. McKinney, Richmond, Memphis, Tenn.
*1878. Porter, William, Ocean Springs, Miss.
*1901. Myles, Robert C., New York City.
*1923. Newhart, Horace, Minneapolis, Minn.
*1903. Packard, Francis R., Philadelphia, Pa.
*1942. Potts, John B., Omaha, Nebr.
*1903. Renner, W. Scott, Buffalo, N. Y.
*1897. Rhodes, John Edwin, Chicago, Ill.
*1884. Rice, Clarence C., New York City.
*1905. Richards, George L., South Yarmouth, Mass.
*1878. Robinson, Beverly, New York City.
*1907. Shambaugh, George E., Chicago, Ill.
*1908. Smith, Harmon, New York City.
*1892. Wagner, Henry L., San Francisco, Calif.

*1892. Watson, Arthur W., Philadelphia, Pa.
*1939. Wilson, J. Gordon, Old Bennington, Vt.

*Active Fellows*

*1880. Allen, Harrison, Philadelphia, Pa.
*1917. Arrowsmith, Hubert, Brooklyn, N. Y.
*1879. Asch, Morris J., New York City.
*1923. Babbitt, James A., Philadelphia, Pa.
*1906. Ballenger, William L., Chicago, Ill.
*1880. Bean, C. E., St. Paul, Minn.
*1904. Berens, T. Passmore, New York City.
*1924. Bigelow, Nolton, Providence, R. I.
*1893. Bliss, Arthur Ames, Philadelphia, Pa.
*1895. Boylan, J. E., Cincinnati, Ohio.
*1892. Brown, Moreau R., Chicago, Ill.
*1933. Buckley, Robert E., New York City.
*1915. Canfield, R. Bishop, Ann Arbor, Mich.
*1934. Carmack, John Walter, Indianapolis, Ind.
*1924. Carmody, Thomas E., Denver, Colo.
*1889. Casselberry, William E., Chicago, Ill.
*1883. Chamberlain, C. W., Hartford, Conn.
*1917. Chamberlin, William B., Cleveland, Ohio.
*1896. Chappell, W. F., New York City.
*1882. Chapman, S. Hartwell, New Haven, Conn.
*1902. Coakley, Cornelius G., New York City.
*1913. Coffin, Rockwell C., Boston, Mass.
1918. Cox, Gerald H., New York City.
*1880. Cushing, E. W., Boston, Mass.
*1878. Cutter, Ephraim, West Falmouth, Mass.
*1880. Daly, W. H., Pittsburgh, Pa.
*1878. Davis, F. H., Chicago, Ill.
*1941. Davis, Warren B., Philadelphia, Pa.
1926. Dennis, Frank Lownes, Colorado Springs, Col.
*1901. Dickerman, E. T., Chicago, Ill.
*1878. Donaldson, Frank, Baltimore, Md.
*1935. Eves, Curtis C., Philadelphia, Pa.
*1919. Faulkner, E. Ross, New York City.
*1914. Fetterolf, George, Philadelphia, Pa.
*1901. Freeman, Walter J., Philadelphia, Pa.
*1917. Friedberg, Stanton A., Chicago, Ill.

1940. Fuchs, Valentine H., New Orleans, La.
1909. Getchell, Albert C., Worcester, Mass.
*1897. Frothingham, Richard, New York City.
*1907. Gibb, Joseph S., Philadelphia, Pa.
*1940. Gill, William D., San Antonio, Texas.
*1878. Glasgow, William Carr, St. Louis, Mo.
*1913. Goldstein, Max A., St. Louis, Mo.
*1905. Grayson, Charles P., Philadelphia, Pa.
*1934. Grove, William E., Milwaukee, Wisconsin.
*1879. Holden, Edgar, Newark, N. J.
*1907. Holmes, Christian R., Cincinnati, Ohio.
*1882. Hooper, Franklin H., Boston, Mass.
*1893. Hope, George B., New York City.
*1938. Hourn, George E., St. Louis, Mo.
*1939. Hunt, Westley Marshall, New York, N. Y.
*1901. Hyatt, Frank, Washington, D. C.
*1925. Iglauer, Samuel, Cincinnati, Ohio.
*1878. Ingals, E. Fletcher, Chicago, Ill.
*1882. Ives, Frank L., New York City.
*1880. Jarvis, William C., New York City.
*1878. Johnson, Hosmer A., Chicago, Ill.
*1879. Johnson, Woolsey, New York City.
*1944. Jones, Marvin F., New York City.
*1879. Kealhofer, R. H., St. Louis, Mo.
*1901. King, Gordon, New Orleans, La.
*1885. Knight, Charles H., New York City.
*1878. Knight, Frederick Irving, Boston, Mass.
*1898. Kyle, D. Braden, Philadelphia, Pa.
*1880. Langmaid, Samuel W., Boston, Mass.
61878. Lincoln, Rufus P., New York City.
*1911. Lockard, Lorenzo B., Denver, Colo.
*1913. Loeb, Hanau W., St. Louis, Mo.
*1897. Logan, James E., Kansas City, Mo.
*1935. Looper, Edward A., Baltimore, Maryland.
*1888. Lowman, John H., Cleveland, Ohio.
*1919. Lynah, Henry L., New York City.
*1915. Lynch, Robert Clyde, New Orleans, La.
*1879. McBurney, Charles, New York City.
*1927. McGinnis, Edwin, Chicago, Ill.
1936. McGregor, Gregor, Toronto, Canada.

*1913. McKimmie, O. A., Washington, D. C.
*1885. McSherry, H. Clinton, Baltimore, Md.
*1914. Mackenty, John E., New York City.
*1898. Makuen, G. Hudson, Philadelphia, Pa.
*1881. Major, G. W., Montreal, Canada.
*1881. Morgan, E. C., Washington, D. C.
*1886. Mulhall, J. C., St. Louis, Mo.
*1925. Mullin, William V., Cleveland, Ohio.
*1914. Munger, Carl E., Waterbury, Conn.
*1892. Murray, T. Morris, Washington, D. C.
*1881. Mynter, H., Buffalo, N. Y.
*1893. Newcomb, James E., New York City.
*1895. Nichols, J. E. H., New York City.
*1894. Park, William H., New York City.
*1892. Porcher, W. Peyre, Charleston, S. C.
*1927. Porter, Charles T., Boston, Mass.
*1908. Randall, B. Alexander, Philadelphia, Pa.
*1882. Rankin, D. N., Allegheny, Pa.
*1902. Richardson, Charles W., Washington, D. C.
*1930. Ridpath, Robert E., Philadelphia, Pa.
*1879. Roe, John O., Rochester, N. Y.
*1881. Robertson, J. M., Detroit, Mich.
*1913. Roy, Dunbar, Atlanta, Ga.
*1878. Rumbold, T. F., St. Louis, Mo.
*1879. Seiler, Carl, Philadelphia, Pa.
*1928. Shea, John Joseph, Memphis, Tennessee.
*1893. Shields, Charles M., Richmond, Pa.
*1909. Shurly, Burt R., Detroit 1, Mich.
*1878. Shurly, E. L., Detroit, Mich.
*1892. Simpson, William Kelly, New York City.
*1919. Skillern, Ross H., Philadelphia, Pa.
*1909. Sluder, Greenfield, St. Louis, Mo.
*1879. Smith, Andrew H., Geneva, N. Y.
*1932. Smyth, Duncan Campbell, Boston, Mass.
*1928. Sonnenschein, Robert, Chicago, Ill.
1924. Stein, Otto J., Chicago, Ill.
1934. Stevenson, Walter, Quincy, Ill.
*1911. Staut, George C., Philadelphia, Pa.
*1879. Tauber, Bernhard, Cincinnati, Ohio.
*1903. Theisen, Clement F., Albany, N. Y.

*1899. Thorner, Max, Cincinnati, Ohio.
*1892. Thrasher, Allen B., Cincinnati, Ohio.
*1937. Tobey, George L., Jr., Boston, Mass.
*1888. Van der Poel, S. O., New York City.
*1938. Vail, Harris H., Cincinnati, Ohio.
*1936. Voislawsky, Antonie P., New York City.
*1933. Wanamaker, Allison T., Seattle, Wash.
1896. Ward, Marshall R., Pittsburgh, Pa.
*1879. Ward, Whitfield, New York City.
*1886. Westbrook, Benjamin F., Brooklyn, N. Y.
*1924. Wherry, William P., Omaha, Neb.
*1924. White, Leon E., Boston, Mass.
*1939. Williams, Horace J., Philadelphia, Pa.
*1922. Wishart, David J. G., Toronto, Ontario.
*1940. Wood, V. Visscher, St. Louis, Mo.
*1896. Wollen, Green V., Indianapolis, Ind.

G.F.TUCKER