

G.F. TUCKER

Transactions

American Laryngological Association

SEVENTY-SIXTH VOLUME

"DOCENDO DISCIMUS"

TRANSACTIONS
OF THE
SEVENTY-SIXTH ANNUAL MEETING
OF THE
American
Laryngological Association

1955

HELD AT THE HOLLYWOOD BEACH HOTEL

HOLLYWOOD BEACH, FLORIDA

MARCH 13TH AND 14TH, 1955

PUBLISHED BY THE ASSOCIATION

St. Louis, Mo.


1955

CONTENTS

List of Officers.....	7
Registration	9
President's Address	17
The Indications and Technique of Lymph Node Dissection of the Neck. Alton Ochsner, M.D.	22
Evaluation of Neck Dissection in Carcinoma of the Larynx. Louis H. Clerf, M.D.	41
Mixed Tumors of the Posterior Pharyngeal Wall. Fred Z. Havens, M.D. and L. C. Butler, Jr., M.D.....	50
Vasomotor Rhinitis. Theodore E. Walsh, M.D.....	61
A Few Highlights Concerning Respiratory Cilia. G. Edwin Tremble, M.D.	67
The Radical Obliterative Frontal Sinus Operation: A Consideration of Technical Factors in Difficult Cases. Robert L. Goodale, M.D.....	78
Rehabilitation of Patients with Clefts of the Lip and Palate (Motion Pic- ture Presentation). Dean M. Lierle, M.D.....	96
Unilateral Cord Paralysis. Daniel S. Cuning, M.D.....	97
Ten Year Progress of Laryngofissure Operation. Mercer G. Lynch, M.D.	107
General Tonsillectomy: Suggestions for Management and Peritonsillar Injection. Paul M. Moore, M.D.....	116
Carcinoma of Maxillary Sinus in Youth. Bernard J. McMahon, M.D.....	131
Presentation of Instruments. Edwin N. Broyles, M.D.....	146
Functional Disturbances of the Upper Swallowing Mechanism. John R. Lindsay, M.D.	148

CONTENTS

The Cervical Spine and the Globus Syndrome. Lewis F. Morrison, M.D...	161
A Motor Pattern in the Nucleus Ambiguus. Its Clinical Significance. A. C. Furstenberg, M.D.	177
Blastomycosis of the Larynx. William C. Thornell, M.D.....	184
Laryngeal Papillomata: Surgical Technique for Removal of Recurring and Obstructive Growths. DeGraaf Woodman, M.D.....	194
Memorials:	
Harris Peyton Mosher.....	205
Harold Lowry Hickey.....	209
George Bacon Wood.....	212
Gordon Balgarnie New.....	215
Executive Sessions and Reports of Officers and Committees.....	220
List of Fellows, 1955:	
Active Fellows.....	234
Honorary Fellows.....	241
Corresponding Fellows.....	241
Emeritus Fellows.....	242
Benefactors	244
Benefactors of the Laryngological Research Fund.....	245
Recipients of the de Roaldes Award.....	246
Recipients of the Casselberry Award.....	247
Recipients of the Newcomb Award.....	248
Past Officers	249
Past Fellows	254



THOSE IN ATTENDANCE AT THE SEVENTH-SIXTH ANNUAL MEETING

Top Row: L. A. Brown, McMahon, Phelps, Cuning, E. H. Campbell, Broyles, Beatty, Furstenberg, Putney, Williams, Cody, Lederer, Maxwell, Hilger, Engler, Beck, Hoople, Davison, Harkness, Schenck, Eggston, McCall, Smith, Miller, Woodman, McCart, L. F. Morrison, Boies, J. M. Brown, Nash, Ireland.

Second Row: Lynch, Simpson, Schall, Taylor, Van Alyea, Heatly, Dixon, Hill, Orton, Goodyear, Proertz, Tucker, Whalen, Johnston, Theobald, McCaskey, Goodale, Equen.

Front Row: Murtagh, Havens, Walsh, C. L. Jackson, Wishart, Moore, Robb, Clerf, Tremble, Viole, Ballenger, Kline.

OFFICERS FOR 1954-55

PRESIDENT

HENRY B. ORTON, M.D.

VICE-PRESIDENT

CLAUDE C. CODY, M.D.

SECOND VICE-PRESIDENT

DANIEL S. CUNNING, M.D.

SECRETARY

HARRY P. SCHENCK, M.D.

TREASURER

FRED W. DIXON, M.D.

LIBRARIAN, HISTORIAN AND EDITOR

BERNARD J. McMAHON, M.D.

COUNCIL

The above Ex-officio and

RALPH A. FENTON, M.D.

J. MACKENZIE BROWN, M.D.

H. MARSHALL TAYLOR, M.D.

LOUIS H. CLERF, M.D.

TRANSACTIONS OF THE SEVENTY-SIXTH ANNUAL
MEETING

OF THE

American Laryngological Association

HELD AT

THE HOLLYWOOD BEACH HOTEL

HOLLYWOOD BEACH, FLORIDA

MARCH 13 AND 14, 1955

The Seventy-Sixth Annual Meeting of the American Laryngological Association was called to order by the President, Dr. Henry B. Orton, at the Hollywood Beach Hotel, Hollywood, Florida.

REGISTRATION

The following Fellows were in attendance:

BALLENGER, HOWARD C.

BEATTY, HUGH G.

BECK, AUGUST LEO

BOIES, LAWRENCE R.

BORDLEY, JOHN E.

BROWN, J. MACKENZIE

BROWN, LESTER A.

BRYLES, EDWIN N.

CAMPBELL, EDWARD H.

CLERF, LOUIS H.

CODY, CLAUDE C.

CUNNING, DANIEL S.

DAVISON, FRANCIS W.

DIXON, FRED W.

EGGSTON, ANDREW A.

ENGLER, C. W.

EQUEN, MURDOCK S.

FITZ-HUGH, G. SLAUGHTER

FURSTENBERG, ALBERT C.	MILLER, ALDEN H.
GALLOWAY, THOMAS C.	MOORE, PAUL M.
GOODALE, ROBERT L.	MORRISON, LEWIS F.
GOODYEAR, HENRY M.	MURTAGH, JOHN A.
HARKNESS, GORDON F.	NASH, C. STEWART
HAVENS, FRED Z.	ORTON, HENRY B.
HEATLY, CLYDE A.	PHELPS, KENNETH A.
HILDING, ANDERSON C.	PROETZ, ARTHUR W.
HILGER, JEROME A.	PUTNEY, F. JOHNSON
HILL, FREDERICK T.	ROBB, JAMES M.
HOLINGER, PAUL H.	ROBERTS, SAM E.
HOOPLE, GORDON D.	SCHALL, LEROY A.
IRELAND, P. E.	SCHENCK, HARRY P.
JACKSON, CHEVALIER L.	SIMPSON, W. LIKELY
JOHNSTON, WILLIAM H.	SMITH, AUSTIN T.
KELLY, JOSEPH D.	TAYLOR, H. MARSHALL
KLINE, ORAM R.	THEOBALD, WALTER H.
LEDERER, FRANCIS L.	THORNELL, WILLIAM C.
LEJEUNE, FRANCIS E.	TREMBLE, G. EDWARD
LIERLE, DEAN M.	TUCKER, GABRIEL
LINDSAY, JOHN R.	VAN ALYEA, OLIVER E.
LYNCH, MERCER G.	VIOLE, PIERRE P.
MARTIN, ROBERT C.	WALSH, THEODORE E.
MAXWELL, JAMES H.	WEILLE, FRANCIS L.
MCCALL, JULIUS W.	WHALEN, EDWARD J.
MCCART, HOWARD W. D.	WILKERSON, W. W., JR.
MCCASKEY, CARL H.	WILLIAMS, HENRY L.
McMAHON, BERNARD J.	WISHART, D. E. STAUNTON
McNALLY, WILLIAM J.	WOODMAN, DeGRAFF

GUESTS

Milton Abramson, Minneapolis, Minn.
Lucian W. Alexander, New Orleans, La.
Victor R. Alfaro, Washington, D.C.
Ralph Arnold, Durham, N. C.
Fred. S. Arragg, Lawrence, Mass.
Joseph P. Atkins, Philadelphia, Pa.
Daniel C. Baker, Jr., New York, N. Y.
David H. Ballon, Montreal, Canada
L. J. Barnes, Inglewood, Cal.
Shirley H. Baron, San Francisco, Cal.
John H. Barrett, Houston, Tex.
H. J. Barys, Chicago, Ill.
William P. Beatrous, New Orleans, La.
Richard Bellucci, New York, N. Y.
Leon L. Bernstein, Youngstown, Ohio
Harry I. Berland, St. Louis, Mo.
Anthony T. Bianco, Duluth, Minn.
Charles S. Blase, Cincinnati, Ohio
W. W. Bowers, Granite City, Ill.
B. M. Bowman, Youngstown, Ohio
J. Gordon Brachett, Atlanta, Ga.
David W. Brewer, Syracuse, N. Y.
Peter B. Brown, Seattle, Wash.
Albert I. Buchwald, San Jose, Cal.
J. J. Cantor, Los Angeles, Cal.
Neil Callahan, Norfolk, Va.
Edgar P. Cardwel, New York, N. Y.
E. J. Chapman, Asheville, N. C.
Claude C. Cody, III, Houston, Tex.
J. A. Costrino, St. Louis, Mo.
Wm. H. Craddock, Cincinnati, Ohio
James E. Croushore, Detroit, Mich
J. M. Daly, Washington, D. C.

J. Calvin Davis, Omaha, Neb.
Russel M. Decker, Pasadena, Calif.
J. R. Delahay, Ottawa, Canada
J. K. M. Dickie, Ottawa, Canada
D. J. Doelker, Freeport, Ill.
John Dougherty, Canton, Ohio
Alfred A. Doust, Syracuse, N. Y.
B. R. Dysart, Pasadena, Cal.
W. W. Eakin, Montreal, Canada
H. D. Emswiler, Columbus, Ohio
W. H. Evans, Youngstown, Ohio
J. Brown Farrior, Tampa, Fla.
Blair W. Fearon, Toronto, Canada
Charles F. Ferguson, Boston, Mass.
G. B. Ferguson, Durham, N. C.
Sidney S. Feuerstein, New York, N. Y.
J. Allan Fields, Fort Lauderdale, Fla.
Arthur J. Fischer, Pittsburgh, Pa.
S. G. Flanagan, Austin, Minn.
Meyn S. Fox, Milwaukee, Wis.
Harold Freedman, St. Louis, Mo.
Ruth Freedman, St. Louis, Mo.
Alex S. Friedlaender, Detroit, Mich.
E. G. Gill, Roanake, Va.
M. G. Gillespie, Duluth, Minn.
John S. Goldcamp, Youngstown, Ohio
Michael Goldenburg, Chicago, Ill.
Joseph L. Goldman, New York, N. Y.
Harvey A. Gollin, Chicago, Ill.
Pearl R. Gollin, Chicago, Ill.
Victor Goodhill, Los Angeles, Cal.
Vernon L. Goodwin, Youngstown, Ohio
Wm. James Gould, New York, N. Y.
Chas. C. Grace, St. Augustine, Fla.
Glenn J. Greenwood, Los Angeles, Cal.

Emile Gruppe, Gloucester, Mass.
John R. Gulash, Bridgeport, Conn.
Arthur E. Hammond, Detroit, Mich.
Irving Hanowerger, Chicago, Ill.
Fred Harbert, Philadelphia, Pa.
H. P. Harkins, Philadelphia, Pa.
H. D. Harlowe, Miles City, Mont.
Jas. Harrill, Winston-Salem, N. C.
Herbert H. Harris, Houston, Tex.
V. K. Hart, Charlotte, N. C.
C. J. Heinberg, Pensacola, Fla.
G. Arnold Henry, Toronto, Canada
M. R. Himalstein, St. Petersburg, Fla.
Martin Hirsch, Cleveland, Ohio
Eugene Hopp, San Francisco, Calif.
Walter T. Hotchkiss, Miami Beach, Fla.
W. B. Hoover, Boston, Mass.
Glenn Y. Hough, Akron, Ohio
D. P. Hoxie, Jacksonville, Fla.
Harold S. Hurst, Winnipeg, Canada
Quentin Jacks, Rochester, Minn.
E. M. James, St. Paul, Minn.
W. H. James, Lake Crystal, Minn.
Harry C. Jensen, Minneapolis, Minn.
Morris E. Katz, Norwich, Conn.
H. G. Kobrak, Clarkston, Mich.
James T. King, Atlanta, Ga.
C. E. Kinney, Cleveland, Ohio
E. F. Kortemeier, Freeport, Ill.
W. J. Kucera, Minneapolis, Minn.
William Kucera, Jr., Minneapolis, Minn.
Stephen C. Kyler, Pittsburgh, Pa.
James F. Land, Madison, Wis.
Stewart Lawwill, Chattanooga, Tenn.
Nathaniel Levin, Miami, Fla.

Byron N. Lingeman, Crawfordsville, Ind.
Gerson Lowenthal, Cincinnati, Ohio
C. E. Munoz MacCormick, Santurce, Puerto Rico
Joseph J. Mahoney, Norwich, Conn.
Walter H. Maloney, Philadelphia, Pa.
M. W. Manion, Indianapolis, Ind.
Abraham Marck, Milwaukee, Wis.
R. H. Marcotte, Nashua, N. H.
Daniel E. Martinez, Temple, Tex.
K. McAskile, Toronto, Canada
Geo. McGlinn, Oakland, Calif.
F. H. McGovern, Danville, Va.
J. W. McLaurin, Baton Rouge, La.
Carl S. McLemore, Orlando, Fla.
Charles H. McMullen, Loudonville, Ohio
Robert C. McNaught, San Francisco, Calif.
Lawrence McStravog, Upper Darby, Pa.
James H. Mendel, Miami, Fla.
F. W. Merica, Lakewood, Ohio
Eugene A. Meyer, Camden, N. J.
S. C. Missal, Cleveland, Ohio
W. J. Miller, Columbus, Ohio
W. F. Mosher, Ventura, Calif.
S. J. Havosymoener, Cleveland, Ohio
C. S. Mumnia, Santa Monica, Calif.
Julio T. Noguera, Santurce, Puerto Rico
E. W. O'Brien, Rochester, N. Y.
John J. O'Keefe, Philadelphia, Pa.
Earl P. Oliver, Scottsville, Ky.
James J. O'Neil, Omaha, Nebr.
B. B. Paul, Winston-Salem, N. C.
J. W. Phillips, Newport News, Va.
David L. Poushter, Syracuse, N. Y.
Procter Bruce, Detroit, Mich.
Julio Quevedo, Guatemala City, Guatemala

James E. Reeder, Sioux City, Iowa
Michael I. Reiffel, Chicago, Ill.
Frank J. Riccio, Bridgeport, Conn.
John R. Richardson, Boston, Mass.
Ralph W. Ridge, Wyandotte, Mich.
Ralph C. Rigby, Salt Lake City, Utah
E. L. Rigley, South Bend, Ind.
Otto C. Risch, New York, N. Y.
Stanley W. Roberts, Minneapolis, Minn.
J. M. Robison, Houston, Tex.
Bernard J. Ronis, Philadelphia, Pa.
Harry Rosenwasser, New York, N. Y.
Robert D. Russo, Bridgeport, Conn.
W. Y. Sayad, West Palm Beach, Fla.
Henry M. Scheer, New York, N. Y.
C. B. Schoemperlen, Winnipeg, Canada
M. A. Schofman, Miami Shores, Fla.
H. S. Schumacher, Milwaukee, Wis.
A. A. Seletz, Charleston, W. Va.
John G. Sellers, Norfolk, Va.
Chas. A. Seelig, New York, N. Y.
Ben H. Sebturia, St. Louis, Mo.
Albert H. Shafer, Camden, N. J.
Jas. B. Shannon, Montclair, N. J.
W. F. Sharkey, Charleston, W. Va.
Benj. H. Shuster, Philadelphia, Pa.
Bernard L. Silverblatt, Pittsburgh, Pa.
E. M. Skolnik, Chicago, Ill.
Graham G. Smith, Minneapolis, Minn.
S. Joseph Smith, Vincennes, Ind.
Thos. L. Smith, Lorain, Ohio
T. T. Smith, Omaha, Nebr.
R. W. Spenner, South Bend, Ind.
Y. A. Staton, West Palm Beach, Fla.
Cecil Stell, Dallas, Tex.

A. P. Stephan, Jefferson City, Mo.
Hugh L. Stevens, Nashville, Tenn.
H. B. Stone, Roanoke, Va.
John M. Strait, Ashland, Ohio
Gerhard D. Straus, Milwaukee, Wis.
Oliver W. Suehs, Austin, Tex.
M. F. Snitman, Chicago, Ill.
J. A. Sullivan, Toronto, Canada
J. M. Sutherland, Detroit, Mich.
C. C. Swann, Asheville, N. C.
Pierce W. Theobald, Chicago, Ill.
John F. Tolan, Seattle, Wash.
Frank G. Treskow, Milwaukee, Wis.
Ira J. Tresley, Chicago, Ill.
Frank Turchek, Bridgeport, Conn.
Hans von Leden, Chicago, Ill.
William A. Wagner, New Orleans, La.
R. C. Waisman, Milwaukee, Wis.
James S. Walker, Urbana, Ill.
J. S. Wendel, Detroit, Mich.
William H. Wilson, Denver, Colo.
C. C. Wolcott, Bronxville, N. Y.
W. C. Wolfe, Louisville, Ky.
William L. Wood, Red Bank, N. J.
Wm. K. Wright, Houston, Tex.
Y. A. Zanka, Butler, Pa.
G. E. Zerneck, West Chester, Pa.
Samuel Zurik, New Orleans, La.

PRESIDENT'S ADDRESS

OUR HERITAGE

HENRY B. ORTON, M.D.

NEWARK, N. J.

Fellows of the American Laryngological Association. It is indeed a very pleasant occasion for me to welcome you to the Seventy-Sixth Annual Meeting, and I trust that you will enjoy the meeting as well as the sunshine of the Peninsula State.

To be President of this Association is the highest honor that can come to a laryngologist; and when I was elected last May, I accepted with great humility, and was fully cognizant of the responsibility placed upon me to even attempt to measure up to the achievements of my predecessors. I wish at this moment to thank you for the privilege of serving as your President; it is a very great honor, and one which I deeply appreciate.

It is a time honored custom of this Association for the President to open the meeting with an address. I assure you mine will not be scientific, nor lengthy, and trust I may have your attention for a few moments.

I have taken for my subject (Psalm 16:7) which I quote: "The lot is fallen unto me in a fair ground; yea I have a goodly heritage."

What constitutes a heritage? "That which has been or may be inherited, anything given or received to be a permanent possession." It is therefore a great privilege to enjoy the heritage of this Association.

Is it not too often probable that the path the pioneer has blazed becomes in time converted into the crowded highway, while the pioneer is forgotten. Let us not lose sight of those pioneers, and give credit where credit is due.

We come to this meeting today with a heritage, and it is a goodly one. You are asked to direct your attention to the historic roots of our association. Roots are meant to provide nourishment

for life. In our association we have two main roots; one, the strongest and deepest, goes back to the early formation of this society; the other, our more intimate family roots, that grow out of the particular life of this group.

Let us look at this goodly heritage, and in particular these two historic roots. The first one, the formation of this association which took place seventy-six years ago.

The particular object for which this association was formed in 1879 was for the "promotion of knowledge in all that relates to diseases of the upper air passages of the human body." This was revised eight years later by such men as Birkett, Bryan, Coakley, Delavan, French, Halsted, Holmes, Johnston, D. Braden Kyle, and Harmon Smith; all names that some of us here remember, and whose company we have cherished. Their revision was:

First: To advance and promote the study of the science of medicine and surgery, devoting special attention to the upper respiratory tract, and to engage in, and encourage research with respect thereto.

Second: To encourage and to raise the standards of the fundamental study and teaching of rhinology and laryngology in the undergraduate, graduate and postgraduate medical schools of America.

Third: To honor those, who, by their contributions in the field of rhinology and laryngology, have aided in its advancement.

This revision was based upon the simple direct act of our founders. Here, then, is the elemental, essential backbone of the association which we have today. It was a simple direct action, performed together with the few who organized this society. There was no evidence shown of the subjective, or personal action; this was an act, a direct act, performed by all who were members (49) at that time; everyone doing his distinctive part. The development and refinement and changes in our association over these past years represent the unfolding of the laryngological thought and practice.

The pharyngeal voice following laryngectomy was demonstrated before this society in 1893. Malignancies of the oral cavity and thyroids in 1894. Sinus surgery and foreign body removal were all being done by the turn of the century.

The work of this society through its individual members has proved the foresight of its founders, and verified the predictions expressed by our officers of earlier days.

Now let us look at the Association of today. All we have to do is to look back over the Transactions and notice the surgical procedures performed by our members in their specialty. Can we not with propriety look forward to the time when every fellow will be identified with papers based upon results gained by experiments upon lower animals, or upon morphological data, as well as those secured from the operating table. We will be raised in our own esteem to the degree that we add a little more science to our art.

When we consider what rhinolaryngology includes in its scope, we have a wide area from which to select themes for study. All surgery of the head and neck, including thyroids, broncho-esophagology, and faciomaxillary surgery.

The time has come when others are making the assertion that rhinolaryngologists are not surgeons. This should be accepted as a reproach. This field should be occupied by our own men, as it has been in the past. It is for us to encourage the younger men to accept this challenge, to retain the heritage that is ours in research, facial maxillary, and head and neck surgery and, to our pride, it can be said to a great degree this is already the case.

We now come to the distinctive personal side of this Association, our more intimate family roots, and there are many of these.

In looking over the list of fellows, past and present, to have had the privilege of these friendships and comradeships is indeed a great heritage which I for one shall always keep.

I wonder how many of us realize, as we look back over the years what membership in this Association means to us. To look back twenty-eight years as a member: In those days we were on probation so to speak, for five years, so our peers could evaluate us as proper material for full membership. This five-year period no longer exists. I can remember, and I am sure there are others here present who will also recall, in that period we sat at the feet of and listened to the papers and the discussions of our peers. Finally, when at long last we were voted to full membership in this Association, we received a goodly heritage.

As I have mentioned, roots give nourishment. There are many, many, I could mention that have grown up in this body, but one in particular I should like to mention who has given real nourishment to this Association for fifty years—Harris P. Mosher, who was the Dean of this society. He, like many of the older members here, had surgical training and did general practice before taking up otolaryngology. His training as assistant in anatomy at the Harvard Medical School was exemplified in his post-graduate teaching at the Eye and Ear Infirmary. My acquaintance with Doctor Mosher began with the First War, when he was Chief of Otolaryngology in the Surgeon General's Office. His awards and honors were many. His seemingly mordacious exterior was softened by kindness, generosity and loyalty. During the past twelve years while spending our vacations on the North Shore of Massachusetts, Mrs. Orton and I had many pleasant times together with him and Mrs. Mosher. His untiring and capable energies, his dexterity and accomplishments, his ambitions and affections, I will deeply miss. His sudden departure was like a flower touched by an untimely frost. Whether these same untiring and capable energies found instant employment in another amphitheater; whether his dexterity was exalted to a higher degree in a more complicated sphere; whether all his powers and accomplishments were dissipated with his parting breath; whether his pleasures, ambitions and affections still remain intact; whether he still remembers us as we remember him, we do not know. But we do know, and will always remember, that he was one of the historic roots of our Association; the more intimate family root, that grows out of the particular life of this Association. As Fred Hill has stated: "His passing marks the end of an era in otolaryngology."

The conclusion of the matter is this—we have two great historical roots, given to nourish, undergird and strengthen our life in this Association. This is our goodly heritage, and there is also the more personal and intimate heritage of our own which has come to us from those members who have been in this Association.

Let us now recapture the vitality that comes from these historic roots through the years behind, and through the future that looms ahead. This will be determined by our response as members of this Association, each member making his specific contribution in his own way. We are thankful for this goodly heritage which has been given us, as we look backwards with thankfulness, and we look to the future with hope.

Let us hold dear the traditions of this honored Association and encourage the younger men who would welcome an invitation to this heritage.

In closing I wish to thank Dr. Harry Schenck, our Secretary, who has arranged this program; Dr. Fred Dixon who has guarded our Treasury so well; Dr. Bernard McMahon, Editor of the Transactions, and the Members of the Council for their helpful guidance while President of this Association.

I thank you for your attention in listening to this short address, and I now declare the 76th meeting open for the transaction of our business, scientific and otherwise, and finally, may I introduce to you the essayists of the day, and wish for you a pleasant and profitable session.

THE INDICATIONS AND TECHNIQUE FOR CERVICAL LYMPH NODE RESECTION

ALTON OCHSNER, M.D.

NEW ORLEANS, LA.

Intra-oral cancer is of extreme importance because of its frequency, the ease of early detection, and the fact that it is generally amenable to therapy. According to Hayes Martin,¹¹ cancer of the mouth represents 70 per cent of all cancers in the upper alimentary and respiratory tracts and five per cent of all cancers. It is primarily a disease of men. Eighty to 90 per cent of patients with carcinoma of the tongue, gums, tonsils, palate, and cheeks, and 98 per cent of patients with carcinoma of the lip and floor of the mouth are males.¹¹

Because of the rich lymphatic drainage from the oral cavity, lymph node involvement from lesions in the buccal cavity is extremely likely. Involvement of the lymph nodes is undoubtedly favored by the extremely rich lymphatic drainage and also the mobility of the area in which the primary lesion is located, both of which tend to favor extension through the lymph stream. Braund and Martin⁴ found cervical node metastasis at autopsy in 23 per cent of a group of patients with carcinoma of the mouth, pharynx, larynx, and esophagus. Although lesions of the oral cavity metastasize frequently, and usually quite early, to the cervical lymph nodes, it is of importance that the cervical lymphatic system is a relatively closed system and that distant metastases are not likely to occur (Figs. 1 and 2). Although most tumors of the buccal cavity, when they metastasize to the cervical nodes, usually remain localized in the cervical nodes indefinitely, there are two types of tumors in which widespread metastases are likely to occur. These are the transitional carcinomas and the lympho-epitheliomas which are found at the base of the tongue and in the region of the tonsils. In Duffy's⁶ series of cases, 20 per cent of lesions at the base of the tongue were

From the Department of Surgery, School of Medicine, Tulane University and the Ochsner Clinic, New Orleans, Louisiana.

either transitional carcinoma of lympho-epithelioma. According to Boyd⁸ lympho-epitheliomas or transitional cell carcinomas represent 10 per cent of malignant tumors of the mouth and pharynx. According to Martin and Blady,¹² 34 per cent of their patients with nasopharyngeal carcinoma had distant metastases on admission. These were primarily to the liver, lungs, mediastinal and abdominal nodes, and the lumbosacral area.

The indications for cervical lymph node dissection are dependent upon a number of factors. Obviously a lymph node dissection is not indicated unless the primary lesion has been cured or there is chance of its being cured, because the only reason for doing a lymph node dissection is in an attempt to cure. If the primary lesion has been eradicated or if there is a likely chance that it can be eradicated and there is obvious involvement of the cervical nodes, lymph node dissection is indicated. There is considerable controversy concerning the advisability of performing prophylactic lymph node dissection, that is, removal of cervical lymph nodes when there is no clinical evidence of their involvement. It must be emphasized, however, that the finding of enlarged lymph nodes does not necessarily mean involvement with carcinoma, because most malignant lesions of the oral cavity are infected and microorganisms as well as malignant cells can be carried through the lymph channels. Lymphadenopathy may be the result of an inflammatory enlargement. Blair et al² found that in their cases with clinically enlarged nodes no tumor was found microscopically following lymph node dissection in 35 per cent. Similarly, Phillips¹⁸ found that of 59 cases with lymph node enlargement which appeared clinically to be malignant no carcinoma was found in 22 (37 per cent). On the other hand, it is a well-known fact that the absence of palpable lymph nodes is no proof that the lymph nodes are not involved. Kennedy,⁹ in a series of patients with carcinoma of the lip with no clinical evidence of lymph node involvement, found microscopic evidence of involvement in 14 per cent. Martin¹⁰ found in 40 patients with carcinoma of the tongue with no palpable nodes that 12 per cent subsequently developed cervical metastases and that of 12 patients with carcinoma of the cheek with no palpable nodes, 17 per cent subsequently developed cervical metastases. Morrow¹⁷ found in a series of cases of carcinoma of the tongue that there was involvement of the cervical nodes in one-third of the cases in which there was no clinical evidence of lymph node involvement. Phillips,¹⁸ in a series of 31 cases of buccal carcinoma in which

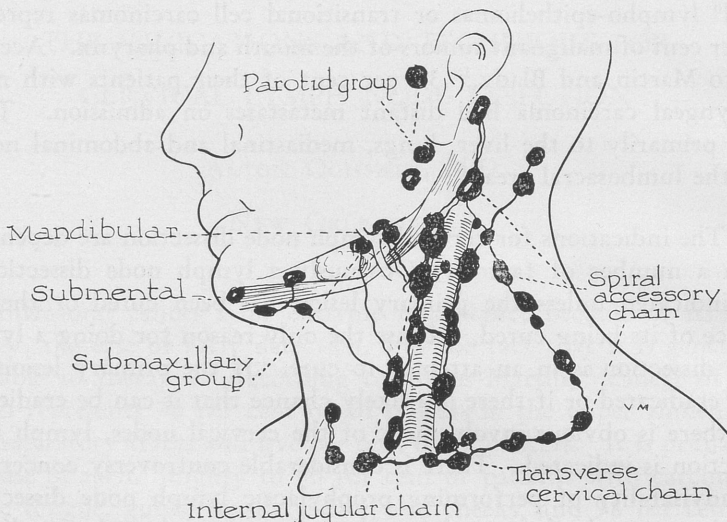


Fig. 1.—Diagram of lymph nodes of the cervical region, which may be involved in lesions of the mouth and pharynx. Radical neck dissection consists of removal of all the nodes shown in this drawing.

there was no clinical evidence of metastases, found that 16 (51 per cent) had microscopic involvement. Roux-Berger and Tailhefer,²⁰ in a series of 494 cases of carcinoma of the mobile portion of the tongue in which bilateral neck dissections were done, had 18 cases with no palpable nodes but in all of these the nodes were involved microscopically. Simmons²¹ found cervical node involvement on microscopic examination in 34 per cent of his patients, although there was no clinical evidence of involvement.

As mentioned previously, there is no uniformity of opinion concerning the advisability of performing prophylactic lymph node dissection. Brown et al,⁵ Ward and Hendrick,²⁵ and Willy Meyer¹⁶ are advocates of prophylactic dissection. Martin et al¹³ are opposed to prophylactic dissection. In a series of 237 consecutive cases with cancer of the lip treated at the Memorial Hospital, Martin et al found that if prophylactic dissection had been done, it would have been of value in only 6.25 per cent and that "fifteen useless operations would have been necessary in order to have been of benefit in one case." Similarly, in 120 cases of cancer of the tongue, prophylactic

dissection would have been of benefit in 20 per cent or "four useless operations would have been necessary in order to be of possible benefit in one case." In a questionnaire dealing with carcinomas about the mouth which they sent to 75 persons, 46 per cent replied that they would not perform prophylactic neck dissections either for cancer of the tongue or the lip, 75 per cent were opposed to prophylactic neck dissection for cancer of the lip, 17 per cent thought it was indicated in all cases of lingual cancer, and 10 per cent thought it should be done in all cases of lip cancer. There are many who believe that in lip cancer, careful observation of the patient can be done in order to determine whether lymph node involvement occurs or not because lip cancer is relatively slow-growing and because metastases, when present, are usually limited to the submaxillary and submental group of nodes. Such a plan of therapy is possible only if frequent examinations of the patient are possible, at least every three months for the first 18 months and then every six months for several years. Figi⁸ believes that the risk of prophylactic lymph node dissection is greater than the benefit of the procedure. On the other hand, Willy Meyer¹⁶ advocates prophylactic suprahyoid dissection in all lip carcinomas and states that in 14 per cent of their patients with no palpable nodes there was microscopic involvement of the nodes. He also found 39 per cent microscopic lymph node involvement in lesions of the tongue although there was no clinical evidence of the involvement. He is of the opinion that since there is a decussation of the lymphatics along the median raphe of the tongue that "in every tongue carcinoma the cancer field includes the entire lymphatic field on both sides of the neck. If you want to try to arrest the disease, you have to do a bilateral lymph node dissection and that dissection has to go from the mandible down to the clavicle on both sides, because the lymphatics of the tongue decussating go through the hypoglossal muscles and can go right along the omohyoid muscle into the supraclavicular fossa, skipping the nodes that lie over the jugular vein area."

It is our opinion that prophylactic lymph node dissection is necessary in many cases, but is not necessary in cancer of the lip unless the lesion is large, that is, greater than 3 cm or is highly malignant. There is considerable variation in the rate of metastases according to the location of the malignant lesion, the degree of malignancy, and its size. In Taylor and Nathanson's²⁴ series of lip carcinoma, metastases occurred as follows: in lesions less than 1 cm,

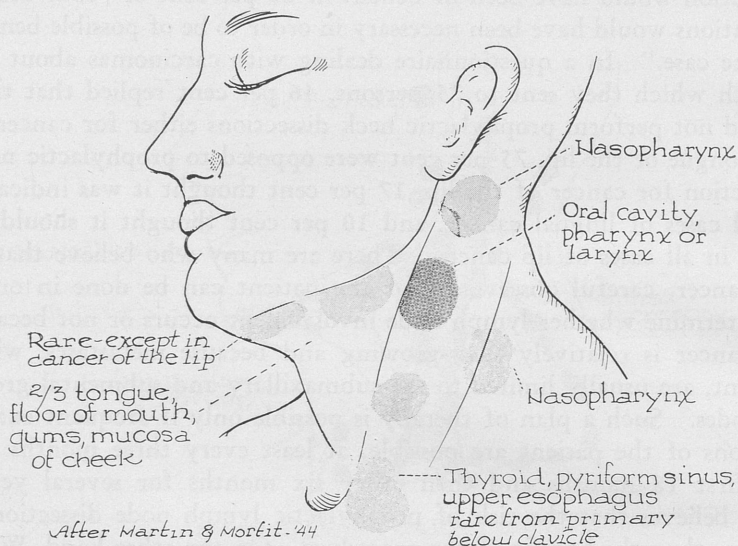


Fig. 2.—Diagram illustrating the usual sites of metastasis with the primary lesions designated. (Redrawn after Martin and Morfit)

7 per cent, from 1-2 cm, 13 per cent, 2-3 cm, 37 per cent, and over 3 cm, 24 per cent. They also found that lymph node metastases were dependent upon the degree of malignancy: Grade I, 6 per cent metastases, Grade II, 30 per cent metastases, Grade III, 52 per cent metastases. Similar results were found in carcinoma of the buccal mucosa. Lesions less than 1 cm had 15 per cent metastases, from 1-2½ cm, 34 per cent metastases, from 2½-4 cm, 37 per cent metastases, over 4 cm, 44 per cent metastases. Lesions of Grade I had 24 per cent metastases and Grades II and III, 45 per cent metastases.

Although cancer of the lip is the most frequent cancer involving the buccal cavity (25 to 30 per cent)¹ and in fact is the most frequent cancer of the upper respiratory and alimentary tracts, lymph node dissections are necessary and are done more frequently for cancer of the tongue. In a series of 500 consecutive cases of cervical metastatic cancer reported by Martin et al,¹⁴ the lip was the site of the original lesion in only seven per cent, the tongue was the site of the original lesion in 25 per cent, the floor of the mouth in 9 per cent, the nasopharynx in 8 per cent, the mucosa of the cheek in 6 per cent, the

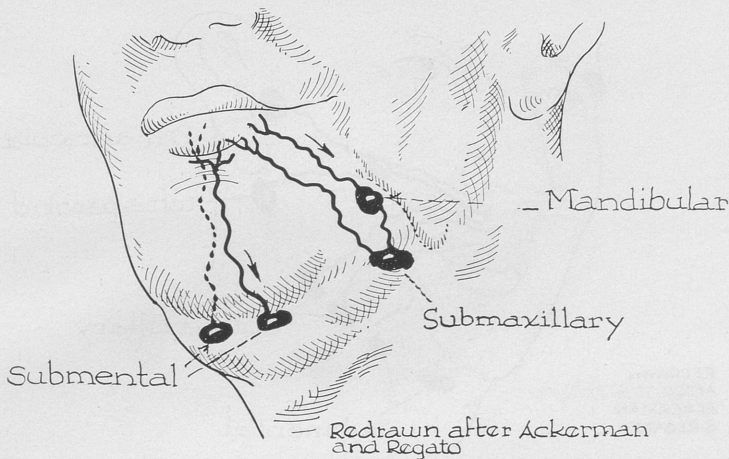


Fig. 3.—Diagram illustrating lymphatic involvement from lesions of the lower lip. The submaxillary nodes are most frequently involved. Occasionally a mandibular node is involved and rarely the submental if the lesion is in the midportion of the lip. (Redrawn after Ackerman and Regato)

jaws in 5 per cent, the pharyngeal wall in 5 per cent, and the palate in 4 per cent. It is thus seen that although cancer of the lip occurs more frequently than cancer of the tongue, metastases to the lymph nodes in the latter occur much more frequently. As mentioned previously, we are of the opinion that lymph node dissection in cancer of the lip is not necessary, provided there are no palpable nodes and provided the lesion is smaller than 3 cm and not anaplastic. In recurrent lesions of the lip which have been treated previously, it is desirable that at least a suprahyoid resection should be done. It is of importance, however, that the patient in whom a prophylactic node resection is not done, should be followed regularly at least every three months for one-and-one-half years, then every six months for five years, and then once a year for the rest of his life. Even though microscopic involvement of the lymph nodes can occur in carcinoma of the lip without clinical evidence, we believe since these lesions remain localized for a relatively long period of time that by careful follow-up examination a metastatic lesion can be detected at a time when it is still curable. The lymph nodes which are likely to be involved in cancer of the lip vary according to the location of the tumor. The lymph nodes involved in the drainage from the lower

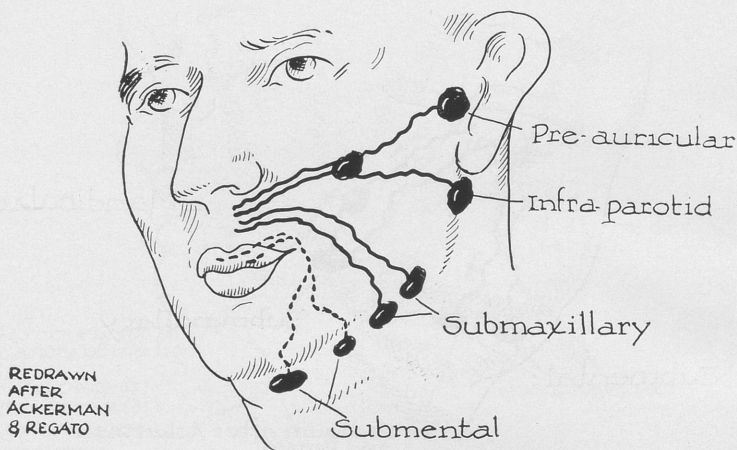


Fig. 4.—Diagram showing lymphatic drainage from lesions of the upper lip. Although lymph node metastases from lesions of the upper lip are much less frequent than those of the lower lip, they are likely to be widespread as illustrated in the diagram. (Redrawn after Ackerman and Regato)

lip are principally the submaxillary, mental, and submental nodes. (Fig. 3) When the lesion is near the midline there is involvement of the nodes at the mental mandibular foramen and occasionally the superior deep cervical nodes. Careful examination of all these areas should be made in any patient who has or has had a carcinoma of the lip. In carcinoma of the upper lip, involvement may be the pre-auricular nodes, the infraparotid, the submaxillary, the submental, and the deep cervical chain. (Fig. 4) In contradistinction to carcinoma of the lower lip, a malignant lesion of the upper lip is frequently associated with widespread lymph node involvement. Martin et al found 48 per cent of lymph node metastases in 21 cases of upper lip carcinoma.

The type of lymph node dissection for carcinoma of the lip varies somewhat according to the location of the lesion, the presence or absence of metastases, and the grade of malignancy. In large lesions or anaplastic lesions without evidence of lymph node involvement, a unilateral suprahyoid resection is indicated if the lesion is located on the lateral part of the lip. A bilateral suprahyoid resection is done for lesions in the midline. In the presence of suprahyoid involvement, a unilateral radical neck dissection on the involved side

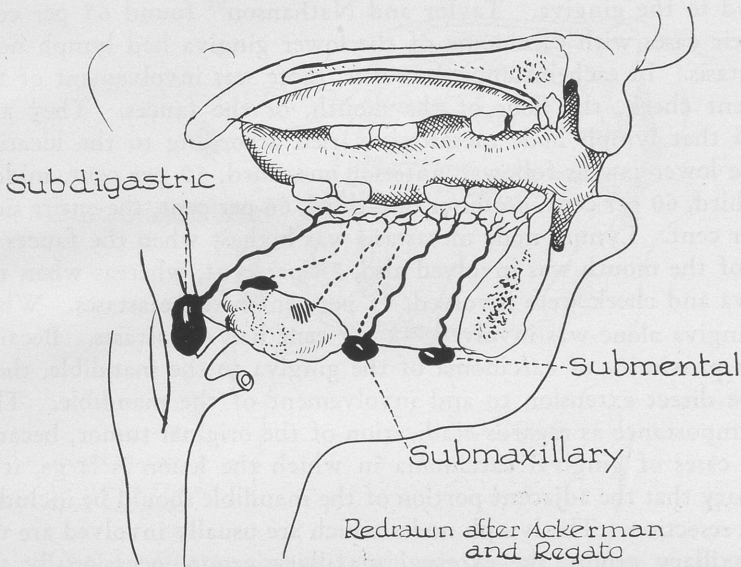


Fig. 5.—Diagram illustrating lymph node metastases from lesions of the lower gingiva. There is common involvement of the lymph nodes. Most frequently involved are the submaxillary group, the external maxillary group, occasionally the submental, and not infrequently the superior cervical nodes are secondarily involved. (Ackerman and Regato)

is done or a bilateral dissection at different stages if the lesion is near the midline. A suprahyoid resection carries much less risk than a radical neck dissection and can be done with a considerable degree of safety.

Carcinoma of the gingiva is usually a relatively benign lesion, but lymph node involvement varies according to location of the carcinoma. Those cancers involving the lower gingiva are likely to be associated with lymph node metastasis much more frequently than upper gingival lesions due to proximity of the lesion to the lymphatics on the outer surface of the mandible and the frequency of involvement of the floor of the mouth. (Fig. 5) When the lymphatic channels on the external surface of the mandible are involved, one can frequently feel thickened cords on the external surface of the lower jaw. Also the lesion is relatively close to the floor of the mouth and can, if neglected, extend to this area from which there

is a greater likelihood of metastatic extension than if it had remained limited to the gingiva. Taylor and Nathanson²⁴ found 65 per cent of their cases with carcinoma of the lower gingiva had lymph node metastasis. In each instance, however, there was involvement of the adjacent cheek, the floor of the mouth, or the fauces. They also found that lymph node metastasis varied according to the location on the lower jaw as follows: anterior one-third, 50 per cent, middle one-third, 60 per cent, posterior one-third, 66 per cent, the entire side, 70 per cent. Lymph node metastasis was highest when the fauces or floor of the mouth was involved also, 77 per cent, whereas when the gingiva and cheek were involved, 55 per cent had metastases. When the gingiva alone was involved, 48 per cent had metastases. Because of the proximity of carcinoma of the gingiva to the mandible, there can be direct extension to and involvement of the mandible. This is of importance as regards eradication of the original tumor, because in all cases of gingival carcinoma in which the lesion is large, it is necessary that the adjacent portion of the mandible should be included in the resection. The lymph nodes which are usually involved are the submaxillary group, the external maxillary group, occasionally the submental, and the superior deep cervical nodes.

The treatment of carcinoma of the lower gingiva, unless the lesion is small and superficial in which a wide location excision can be done, should consist of en bloc excision of the lesion, the adjacent mandible, and radical neck dissection on the homolateral side.

In contradistinction to carcinoma of the lower gingiva, carcinoma of the upper gingiva is associated with lymph node involvement infrequently and when present usually occurs late. The lymph nodes which are involved are the submaxillary nodes, seldom the superior cervical nodes, and relatively late, the jugular nodes. (Fig. 6) Although the lesion is a relatively rare tumor, it can metastasize and should be treated adequately with wide excision of the local lesion with radical neck dissection on the homolateral side, if palpable nodes are present and if the tumor is a large one. Carcinoma of the hard palate is very similar to carcinoma of the upper gingiva and can be treated in approximately the same way.

Carcinoma of the tongue is somewhat more frequent in women than other carcinomas of the mouth. Approximately one-fifth of the carcinomas of the tongue are found in the female sex. Although carcinoma of the tongue occurs much less frequently than carcinoma

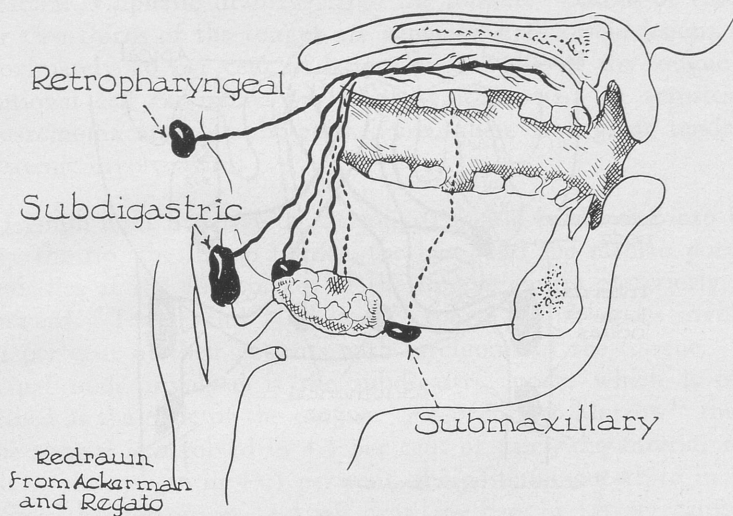


Fig. 6.—Diagram showing lymph node drainage in lesions of the upper gingiva. Although lymph node involvement of lesions of the upper gingiva are rare, when they do occur they are to be the submaxillary nodes and may extend to the superior cervical nodes. Rarely they extend to the retropharyngeal area. (Redrawn after Ackerman and Regato)

of the cheeks, lips, and lower gingiva, lymph node metastases occur much more frequently. In the cases reported by Sommervell²² the tongue was involved in only 13 per cent, whereas the cheeks and lips were involved in 52 per cent, the lower jaw in 28 per cent, and the upper jaw in 7 per cent. Martin, Munster, and Sugarbaker¹⁵ found that 35 per cent of their patients had lymph node metastases when admitted and 25 per cent subsequently developed them, giving a total of 60 per cent that had lymph node metastases and only 40 per cent who did not. They found that in 30 per cent of their cases with cancer of the posterior part of the tongue, the first manifestation was cervical lymphadenopathy. Thirty-nine per cent of their cases had, on admission, gross evidence of lymph node involvement and subsequently 24 per cent developed it, making a total of 63 per cent who had lymph node metastases. Of 500 consecutive cases with lymph node metastases reported by Martin et al,¹³ the originating lesion was the tongue in 25 per cent. Morrow¹⁸ found that in one-third of his cases with cancer of the tongue in which there were no

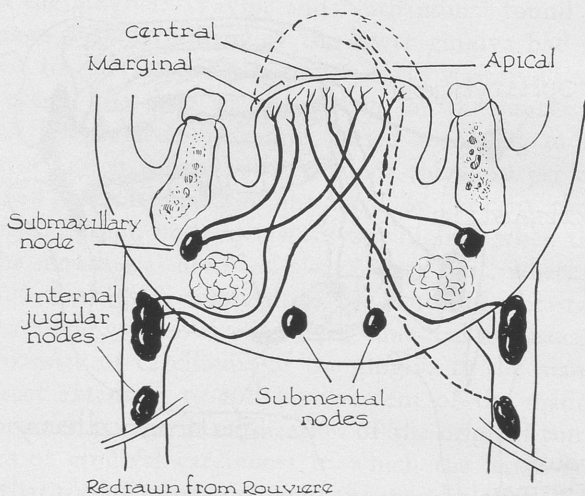


Fig. 7.—Diagrammatic drawing showing lymphatic drainage from the tongue. The lymphatic drainage from the tongue depends to a certain extent upon the lesion, whether it is at the tip, the base, the lateral border or the median portion. The superior cervical node or the subdiaphragmatic node is very frequently involved and is frequently described as "node of the tongue." As shown in the diagram, lesions of the tongue because of decussation of the lymphatic drainage, can metastasize to the opposite side. Lesions of the tip of the tongue can extend to the submental nodes. (Redrawn after Rouviere)

palpable lymph nodes tumor was found in the nodes microscopically. In 494 cases of carcinoma of the mobile portions of the tongue reported by Roux-Berger and Tailhefer,²¹ bilateral neck dissections were done in 18, none of which had palpable nodes, but cancer was found microscopically in all 18. In 306 cases of cancer of the anterior two-thirds of the tongue in which the lesion was strictly unilateral, 6 per cent had bilateral metastases. In 188 cases in which the lesion extended beyond the midline, 32 per cent had bilateral metastases. Sugarbaker²³ found metastases to the cervical lymph nodes in 63 per cent of his patients with carcinoma of the tongue and floor of the mouth. As evidenced by these statistics, malignant lesions of the tongue, particularly the mobile portions, are particularly likely to metastasize to the regional lymph nodes. (Fig. 7) This is undoubtedly due to several factors: 1) the extreme mobility of the tongue which tends to massage the tumor emboli through the lymphatics, 2) the

rich lymphatic drainage of the tongue, and 3) the fact that there is bilateral lymphatic drainage from the tongue. Lesions of the anterior two-thirds of the tongue are generally epidermoid lesions, but approximately 20 per cent of lesions of the base of the tongue are transitional cell carcinoma or lympho-epithelioma. In transitional cell carcinoma and lympho-epithelioma, there is a great tendency to systemic involvement.

Lymph node drainage of the tongue should be divided into four areas: the tip, the lateral border, the base, and the median portion. Lymphatics at the apex or tip of the tongue course posteriorly and downward. Taylor and Nathanson²⁴ found lymph nodes involved in 71 per cent of their patients with carcinoma of the tongue. The principal node involved is the subdigastric node, which is often described as the node of the tongue. According to Morrow¹⁷ the tip of the tongue is involved in 4.3 per cent of cases, the anterior two-thirds of the margin in 43.5 per cent, the posterior one-third in 16.3 per cent, the dorsum in 14.1 per cent, the base in 5.4 per cent, the undersurface in 10.8 per cent, and the whole tongue in 5.4 per cent. From the tip, the anterior jugular chain is involved. As emphasized by Figi,⁸ the more anterior the lesion, the lower in the jugular chain is the involvement likely to be. As mentioned previously, because of the bilateral lymph drainage of the tongue, contralateral metastases are likely to occur. (Fig. 7) In Martin et al series,¹³ in lesions of the anterior two-thirds, metastases crossed the midline in 21 per cent. In lesions which were distinctly unilateral and subsequently developed cervical metastases, 10 per cent appeared contralaterally at first and lymph node metastases occurred bilaterally in 24 per cent of the cases. There was a possible bilateral involvement in 32 per cent. Metastases from the lateral border of the tongue are to the submaxillary lymph nodes, the superior deep cervical nodes, and the deep cervical chain. As mentioned previously, the more anterior the location of the original lesion, the deeper the involvement of the cervical chain. (Fig. 8) Lymph node involvements from the base of the tongue are primarily to the superior cervical nodes; cervical node involvement is frequently the first evidence of disease. This is followed in frequency by involvement of the deep cervical chain. Bilateral involvement is likely to occur in such an instance. Lymph node involvement from the median portion of the tongue is almost invariably followed by bilateral lymph node involvement to the submaxillaries, superior deep cervical, and the cervical chain.

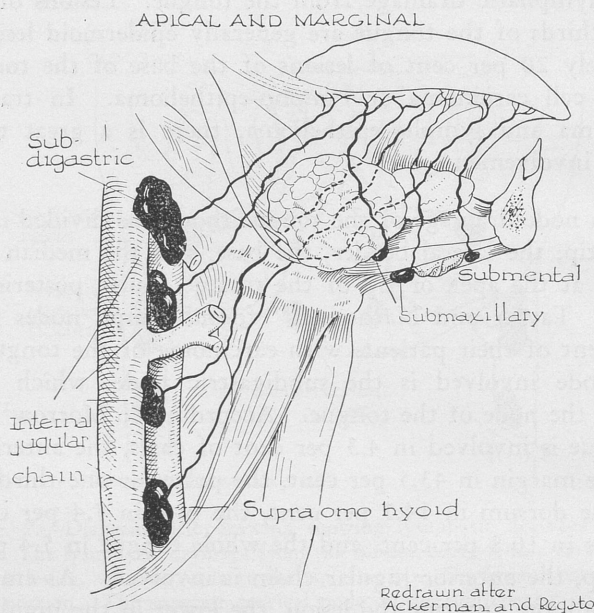


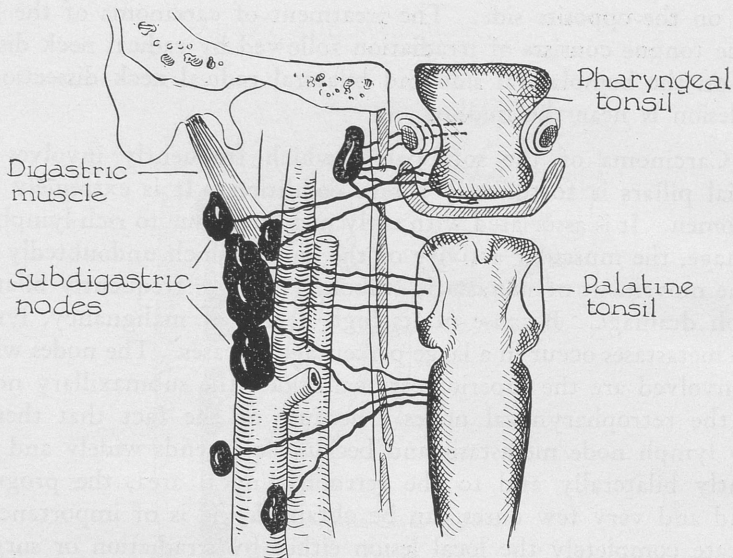
Fig. 8.—Diagrammatic drawing showing lymphatic drainage of the marginal and apical portions of the tongue. Drainage is primarily to the subdigastric or superior cervical nodes, but drainage can extend down to the deeper portions of the jugular lymph node group and generally the more anterior the lesion the more inferior in the internal jugular group is the nodal involvement. (Redrawn after Ackerman and Regato)

Because of the immediate attachment of the tongue to the floor of the mouth, lesions of the tongue can be considered together with those of the floor of the mouth. A lesion of the tip of the tongue can be treated by wide excision followed by bilateral suprahyoid dissection with unilateral neck dissection if more on one side. The treatment of cancer of the lateral border of the tongue and involvement of the floor of the mouth consists of irradiation followed by en bloc excision and radical neck dissection on that side or a radical en bloc hemiglossectomy and cervical block dissection. The treatment of cancer of the inferior surface of the tongue with involvement of the floor of the mouth consists of radical en bloc excision of the tongue lesion, the floor of the mouth, the adjacent mandible, and all the cervical nodes. If the lesion is near the midline, the same

procedure must be done, but later radical neck dissection should be done on the opposite side. The treatment of carcinoma of the base of the tongue consists of irradiation followed by radical neck dissection on the homolateral side and bilateral radical neck dissection if the lesion is near the midline.

Carcinoma of the soft palate which frequently involves the faucial pillars is fortunately a rare condition. It is extremely rare in women. It is associated with early metastasis due to rich lymphatic drainage, the muscular activity of the palate which undoubtedly aids in the movement of metastatic emboli. There is frequently bilateral lymph drainage. Because of its high degree of malignancy, lymph node metastases occur in a large percentage of cases. The nodes which are involved are the superior cervical nodes, the submaxillary nodes, and the retropharyngeal nodes. Because of the fact that there is early lymph node metastasis and because it extends widely and frequently bilaterally and to the retropharyngeal area, the prognosis is bad and very few cures can be obtained. It is of importance to radicate completely the local lesion either by irradiation or surgical extirpation. If this has been accomplished satisfactorily, a bilateral radical neck resection should be done.

Cancer of the buccal mucosa of the cheek is a relatively benign lesion except when it is located posteriorly near the angle of the jaw in which case it is usually much more malignant. In 98 cases reported by Duffy,⁶ there were lymph node metastases in 60 per cent. Martin¹¹ found that in 12 patients with carcinoma of the cheek with no palpable nodes, 17 per cent subsequently developed lymph node metastases. Richards¹⁹ has emphasized the relative benignancy of carcinomas of the buccal mucosa and states that they remain localized in from 50 to 60 per cent and that when they do extend they extend to the submaxillary gland and remain there. They do not extend beyond the submaxillary gland as rapidly and as far as do carcinomas of the tongue and the floor of the mouth. The lymph nodes which are involved in carcinoma of the cheek are usually the submaxillary and the superior deep cervical nodes. Although the involvement varies according to the location of the lesion, lesions located in the anterior portion of the cheek extend to the submaxillary nodes and the submental nodes. Those lesions which are located in the posterior portion of the cheek extend to the parotid nodes and the superior deep cervical nodes. It is imperative that the local lesion should be recognized early and treated adequately. This can usually be



Redrawn From
Rouviere

Fig. 9.—Diagrammatic representation of the lymph drainage from the pharynx. The drainage is to the internal jugular nodes, particularly the subdigastric nodes, the superior cervical nodes, and the retropharyngeal nodes. (Redrawn after Rouviere)

done satisfactorily by irradiation, but it should be followed by a unilateral radical lymph node dissection, because the lesion frequently extends to the deep cervical nodes. It is necessary in doing a lymph node dissection to do a much more radical excision than a suprahyoid dissection. It is for this reason that a radical lymph node dissection is indicated.

Cancer of the tonsil is a frequent lesion and according to Ewing⁷ represents 10 per cent of all buccal cancers. Malignant lesions of the tonsil are usually lympho-epithelioma, transitional cell carcinoma, or lympho-sarcoma. One-third of the lympho-epitheliomas and lymphosarcomas occur in women.¹ Squamous cell carcinomas are extremely rare. Lymph node involvement is frequent and early and may be the first clinical manifestation. This is due to the rich lymphatic drainage of the tonsil, the fact that there is bilateral lymph

drainage, and that the lesions are highly malignant. The nodes which are usually involved are the superior deep cervical nodes, the deep cervical chains, and the subparotid nodes. The treatment consists first of irradiation which should be done intensively and, if the lesion is a lymphosarcoma, usually good palliative results will be obtained. However, at the present time, there is an increasing tendency to do combined operations which consist of an en bloc excision of the original lesion and the unilateral radical neck dissection after irradiation of the primary lesion has been done. In this way, the primary lesion is shrunk and the operation can be done much more satisfactorily. If the lesion is close to the mandible, it is necessary to resect that portion of the mandible. On the other hand, the mandible may be divided and subsequently sutured in order to complete the operation.

Cancer of the pharynx is usually a highly malignant tumor and may be either epithelial or mesothelial in origin. According to Martin and Blady,¹² 34 per cent of their patients with nasopharyngeal carcinoma had distant metastases at the time of admission. These metastases were to the liver, lungs, mediastinal and abdominal nodes, and the lumbrosacral area. Sugarbaker²³ found positive lymph node metastasis in 80 per cent of his cases of carcinoma of the nasopharynx. The lymph node involvement is early due to the rich lymphatic drainage in the region of the pharynx and the highly anaplastic lesion. The lymph nodes which are involved are the superior deep cervical, the subparotid, and the deep cervical chain. The treatment consists of intensive irradiation, lymph node dissection seldom being indicated.

Radical lymph node dissection of the neck, which usually should be done when lymph node resection is indicated, is an operation which must be done carefully and meticulously. It consists of the removal of all the areolar, lymphatic, and fatty tissues together with the inferior pole of the parotid, and the external and internal jugular veins, the sternocleidomastoid muscle from the clavicle up to the mandible. It is a tedious procedure, but must be done carefully if good results are to be obtained. It is done as an en bloc dissection and the block of tissue contains the submental nodes, the submaxillary nodes, the submaxillary salivary gland, the inferior pole of the parotid, the deep cervical nodes, the digastric nodes high in the neck, in addition to the entire sternocleidomastoid, internal jugular vein, the omohyoid muscle, and the posterior belly of the digastric muscle and the sterno-

hyoid muscle. The vagus, the phrenic, the hypoglossal and lingual nerves, and the carotid artery are left intact. If there is any apparent involvement of the spinal accessory nerve, this should be sacrificed, although many times it can be spared.

In many instances, particularly in lesions of the gingiva and the floor of the mouth and tongue, it is desirable to do a combined operation which consists of an en bloc excision of the horizontal ramus of the mandible, the intra-oral lesion, and the cervical lymph nodes. The removal of the mandible is essential because it has been shown that in a high incidence of approximately 50 per cent of instances, lymphatics pass through the periosteum of the mandible.

Suprahyoid dissection consists of the removal of the subdigastric nodes, the submaxillary nodes, including the submaxillary gland, the submental nodes on both sides, the removal of all the fat, areolar tissue and lymphatic tissue in the submaxillary triangle. This may be done unilaterally or bilaterally.

OCHSNER CLINIC.

REFERENCES

1. Ackerman, L. and de Regato, J.: Cancer, Diagnosis, Treatment and Prognosis. St. Louis, C. V. Mosby Co., 1947.
2. Blair, V. B., Brown, J. B. and Womack, N. A.: Cancer in and About the Mouth. *Ann. Surg.* 88:705, 1928.
3. Boyd, W.: Surgical Pathology. 5th Ed., Philadelphia, W. B. Saunders Co., 1942, pp. 88 and 210.
4. Braund, R. R. and Martin, H. E.: Distant Metastasis in Cancer of the Upper Respiratory and Alimentary Tracts. *Surg., Gynec. & Obst.* 73:63 (July) 1941.
5. Brown, J. B. and McDowell, F.: Treatment of Metastatic Carcinoma of the Neck. *Ann. Surg.* 119:543, 1944.
6. Duffy, J. J.: Treatment of Cervical Nodes in Intra-oral Cancer. *Surg., Gynec. & Obst.* 71:664 (Nov.) 1940.
7. Ewing, J.: Neoplastic Diseases. 3rd Ed., Philadelphia, W. B. Saunders Co., 1928, p. 891.
8. Figi, F. A.: Epithelioma of the Lower Lip. *Surg., Gynec. & Obst.* 59:810 (Nov.) 1934.
9. Kennedy, R. H.: The Management of Lymph Nodes in the Neck, Metastatic for Carcinoma of the Mouth. *Ann. Surg.* 114:813, 1941.
10. Martin, H. E.: The Treatment of Cervical Metastatic Cancer. *Ann. Surg.* 114:972, 1941.
11. Martin, H. E.: Cancer of the Head and Neck. American Cancer Society Monograph, 1954.

12. Martin, H. E. and Blady, J. V.: Cancer of the Nasopharynx. *Arch. Otol.*, 32:692, 1940.
13. Martin, H. E., Del Valle, B., Ehrlich, H. and Caban, W. G.: Neck Dissection. *Cancer* 4:441, 1951.
14. Martin, H. E., MacComb, W. S. and Blady, J. V.: Cancer of the Lip. *Ann. Surg.* 114:226, 1941.
15. Martin, H. E., Munster, H. and Sugarbaker, E.: Cancer of the Tongue. *Arch. Surg.* 41:888, 1940.
16. Meyer, H. W.: Cancer of the Head and Neck Including Cervical Lymph Node Dissections. *J. Kans. Med. Soc.* 51:39A, 1950.
17. Morrow, A. S.: Cancer of the Tongue. *Ann. Surg.* 105:418, 1937.
18. Phillips, R.: Histology of Buccal Carcinoma in Relation to Prognosis and Radio-sensitivity. *Lancet* 1:118, 1931.
19. Richards, G. E.: Radiation Therapy of Carcinoma of the Buccal Mucosa (Cheek), in Pack, G. T. and Livingston, E. M.: *Treatment of Cancer and Allied Diseases*. New York, Paul B. Hoeber, 1940, 1:16.
20. Roux-Berger, J. L. and Tailhefer, A.: Cancer de la Partie Mobile de la Langue: Traitement des Adenopathies. *Mem. Acad. de Chir.* 65:835, 1939.
21. Simmons, C. C.: Cancer of the Mouth: The Results of Treatment by Operation and Radiation. *Surg., Gynec. & Obst.* 43:377 (Sept.) 1926.
22. Sommervell, T. H.: Recent Advances in the Treatment of Carcinoma of the Mouth and Jaws. *Brit. J. Surg.* 32:35, 1944.
23. Sugarbaker, E. D.: Surgical Problem of Lymph Nodes in Cancer. *Surgery* 18:608, 1945.
24. Taylor, G. W. and Nathanson, I. T.: *Lymph Node Metastases*. New York, Oxford Univ. Press, 1942.
25. Ward, G. E. and Hendrick, J. W.: *Tumors of the Head and Neck*. Baltimore, Williams and Wilkins, 1950, p. 267.

DISCUSSION

DR. LEROY A. SCHALL: Mr. President, I merely wanted to ask Dr. Ochsner a question. What has been your experience with the complications resulting from the resection of the carotid artery and the vagus nerve when it must be done as part of the radical neck resection?

PRESIDENT ORTON: Is there any further discussion? If not, I would like to ask Dr. Ochsner—probably this is not in our field—with regard to the papillary cyst adenocarcinomas of the thyroid. There seems to be some difference of opinion as to the type of operative procedure here.

DR. ALTON OCHSNER: Dr. Schall certainly brought up a difficult problem, when it does become necessary to resect the carotid and vagus and occasionally such is the case. Previously we had a great deal of difficulty with these patients and there is always a risk I think in interrupting the carotid because of the danger of cerebral damage. We now have a blood vessel bank and we don't fear the resection of the carotid any more because when it becomes necessary to resect the carotid we will do it and we can put in a graft immediately and since we have been using that we have no cerebral damage. Obviously, recurrent laryngeal nerve paralysis is inevitable if one has to resect the vagus but this is a rather cheap price to pay for the possibility

of cure, so that I think that one can now resect the carotid almost with impunity if one will put in a graft.

Dr. Orton's question about the papillary cyst adenocarcinomas of the thyroid is a good question. There is a tremendous difference of opinion about how these patients should be treated, from doing nothing, completely disregarding them to radical neck dissection, combined with a hemithyroidectomy. We understand why George Crile, Jr. is of the opinion that these patients can be treated conservatively for a long period of time, because they are slow growing tumors. One must recall what the natural history of this lesion is. They frequently go long periods of time, remain localized in the neck. The metastases from these tumors were previously spoken of as the aberrant thyroids. We thought they were aberrant thyroids. We now know they are not aberrant thyroids. They are lymph node metastases from a carcinoma of the thyroid. They are malignant tumors. They do metastasize; although they do run a relatively benign course, I see no reason why they should be treated as benign tumors. They are malignant tumors. It is our belief that these patients should have a radical lymph node dissection on that side, and occasionally bilaterally. Generally, however, the lesion is limited to the one side—and as you know, many times the originating tumor in the thyroid is not palpable, even at the time of operation—we do a hemithyroidectomy and take out the isthmus. If we find the tumor in the thyroid which we remove that is all we do, as far as the gland itself is concerned, watching the opposite side carefully for a long period of time. If the tumor is not found, then we remove the other side of the thyroid as well, the other lateral lobe, and almost without exception we have found the lesion in that opposite lobe. In that instance we do a bilateral lymph node dissection. Many of those who believe that a more conservative measure might be taken are of this opinion because they maintain that a radical lymph node dissection is a big operation and it is. On the other hand, we are dealing with a malignant tumor, even though its natural course is one of relative benignancy. I am sure that the ultimate results will be better if one will do a radical excision in these patients. I feel the same way about this as most surgeons do about malignant tumors generally. It is a good surgical adage that in the treatment of malignant tumors the earlier the lesion the more radical the resection, and if one will adhere to that concept one will cure more patients. It is true that we do extremely extensive procedures in these extensive lesions. We cure some of them but we don't cure enough of them because of the extent of the disease. By performing a good cancer operation which consists of a bloc excision of the original lesions plus the regional lymph nodes we will cure the largest number of cancer patients and in tumors about the oral pharynx we are particularly fortunate because they are a group of cases in which metastases occur relatively late generally. When they do occur they stay limited to the cervical area so by doing a radical lymph node dissection of the neck one can cure a larger percentage.

EVALUATION OF DISSECTION OF THE NECK IN CARCINOMA OF THE LARYNX

LOUIS H. CLERF, M.D.

ST. PETERSBURG, FLA.

Recurrence following the surgical treatment of carcinoma of the larynx by total laryngectomy commonly is due to an inadequate operation or to undetected preoperative metastasis to regional lymph nodes or to more distant areas. This discussion deals with the problem of block dissection of regional lymph nodes of the neck for clinical metastasis at the time of total laryngectomy, for postoperative metastasis and as an elective procedure.

While the incidence of metastasis in laryngectomized patients varies in different clinics it is generally believed to occur in from 25 to 30 per cent of all cases. This high recurrence rate exerts a profound influence on mortality.

When one recalls that in a majority of cases of carcinoma of the larynx the lesion begins on a vocal cord where lymphatic drainage is scant it would appear that metastasis in this group should be observed infrequently. Too often, however, definitive surgical treatment for the primary carcinoma is not performed until there is subglottic extension or involvement of either the thyroid or arytenoid cartilage. It is generally accepted that in primary carcinoma of the supraglottic and infraglottic regions of the larynx metastasis occurs comparatively early. But these do not constitute a majority of the cases.

The presence of palpable cervical lymph nodes associated with a carcinoma of the larynx should be considered as *prima facie* evidence of metastasis and treated accordingly. In my experience a combined total laryngectomy and complete block dissection have yielded the best results. Laryngectomy followed by block dissection, or vice versa, after an interval of about ten days is not good cancer surgery. If nodes are observed bilaterally one either can do a bilateral block dissection at the time of the laryngectomy or perform a uni-

lateral resection on the side of greater involvement at the primary operation and treat the opposite side in ten to fourteen days. While these constitute problems in treatment the indications are definite, since metastasis already has occurred.

Of greater importance are the 25 to 30 per cent of patients, who, treated by total laryngectomy, develop regional metastasis postoperatively. It would be a comparatively simple matter if one could institute appropriate treatment as soon as a node is palpated postoperatively. Too often, however, these patients do nothing until the nodes become very large and fixed, or the physician treats them as a simple adenitis for many weeks and then suddenly realizes that they are neoplastic. In the late stages this group usually cannot be treated satisfactorily by any method.

In a series of 285 total laryngectomies previously reported there occurred 67 cases of metastasis to the regional lymph nodes, a percentage rate of 23.¹ Of this group 34 were considered operable and a block dissection was carried out. Nine remained alive and free from carcinoma for five or more years, a survival rate of 26.4 per cent of the operated cases. Of the 33 not treated surgically a number were irradiated but only one survived more than five years without recurrence. That means of the 67 laryngectomized patients who developed metastasis to cervical nodes ten were saved, a total salvage rate of only 15 per cent. It would seem unnecessary to indicate that there was no demonstrable evidence of metastasis at the time of the laryngectomy in these cases, yet in each there was present carcinoma in the regional lymph nodes. If an elective block dissection could have been performed in every case the salvage rate would unquestionably have been much higher.

We are dependent very largely on digital palpation of the neck in our search for nodes. Impalpable nodes cannot be discovered by roentgen studies. A surgical exploration certainly is not warranted. It is imperative, therefore, that a very careful examination of the neck be made before a laryngeal biopsy is done for one often can detect a minute node on the cricothyroid membrane or in the deep cervical chain several days after a biopsy. I agree with Bocca, Ogura and Bello, Orton and others that additional factors must be considered in a determination of the best plan of surgical treatment of carcinoma of the larynx particularly when the lesion is of long duration or is not limited to a vocal cord and there is an absence of metastasis.²⁻⁴

A generally accepted principle in cancer surgery holds that one should remove by dissection certain lymph node bearing areas when treating a primary carcinoma on the assumption that these areas are potential sites of metastasis. In practically every field of surgery this principle is accepted. Laryngologists, however, have not generally practiced this and one still observes reports of laryngectomy being performed followed by irradiation therapy to the neck with the hope and expectation that this will destroy a residual carcinoma if present. My experience with irradiation has been disappointing.

An attempt will be made to analyze a series of cases of carcinoma of the larynx treated surgically from 1929 to January 1954 at the Bronchoscopic Clinic, Jefferson Hospital. For comparative purposes the cases will be considered in groups, the first, including all cases treated prior to 1940, then those from 1940 to 1944, from 1945 to 1949 and for a four-year period from 1950 to January 1954.

It will be observed that prior to 1940 there were few patients treated surgically for metastasis to cervical lymph nodes. Total laryngectomy was performed in 90 patients. There were 21 cases of postoperative metastasis to regional lymph nodes. Eight block dissections were performed and three patients were free from recurrence for more than five years, a salvage rate of 14 per cent. During this period one patient with cervical metastasis was treated by laryngectomy followed by block dissection in one week and lived 12 years without demonstrable carcinoma.

In the period 1940 to 1944 combined block dissection and laryngectomy were performed more frequently and elective block dissection with total laryngectomy was started. The first elective dissection was done during February 1942, in the case of a man with subglottic carcinoma of long duration but in whom no lymph nodes could be palpated. He has remained well to date in spite of finding carcinoma in two small lymph nodes along the internal jugular vein.

The number of total laryngectomies during this five year period was 121. Among these, metastasis to regional lymph nodes occurred in 43. Twenty-eight unilateral and one bilateral block dissection were performed with 14 free from recurrences five or more years. This includes the bilateral case now alive for more than 11 years. Among the irradiated patients one remained free from carcinoma for 10 years. This therefore gives a five-year salvage rate of 35 per cent following surgery and irradiation.

Combined total laryngectomy and unilateral block dissection for demonstrable metastasis were done in three cases with two patients still free from carcinoma.

Laryngectomy and elective block dissection were done in five cases. In all, enlarged lymph nodes were found at operation, but carcinoma was demonstrated in but two instances. All remain free from carcinoma.

In the five year period from 1945 to 1949 total laryngectomy was performed in 140 patients. Metastasis to cervical lymph nodes occurred in 49. Secondary block dissection was performed in 32 patients with 19 free from carcinoma after five years. These included five in which bilateral dissection was performed with two alive after five years. Irradiation gave no prolonged benefit.

Total laryngectomy combined with unilateral block dissection for clinical metastasis to the neck was carried out in 15 patients. Six remained free from carcinoma after five years.

Total laryngectomy with elective block dissection were performed in 12 cases. Carcinoma was found in the lymph nodes in four. All are free from any evidence of recurrence after five years.

From 1950 to January 1, 1954, a four-year period, total laryngectomy cases numbered 82. There have been 21 cases of metastasis to regional lymph nodes with 17 treated by unilateral block dissection. Ten of these remain free from carcinoma.

Total laryngectomy combined with block dissection for clinical metastasis was done in 41 cases. In five of these a block dissection was done on the opposite side for metastasis occurring after the first operation. Thirty-five of this group are alive and free from carcinoma. This includes four of the bilateral cases.

Total laryngectomy with elective block dissection was performed in 34. Although enlarged nodes could be demonstrated in all patients at operation, carcinoma in the lymph nodes was found in seven cases. There was one death from pulmonary metastasis. Curiously, there was no carcinoma found in the resected cervical lymph nodes in this case.

Statistics bearing on recurrences and mortality from carcinoma for the latter period (1950-1954) obviously cannot be accepted as final since too little time has elapsed. It is of interest to observe,

however, that the number of combined procedures either for clinical metastasis or as an elective operation have increased. They actually constituted 26 and 21.6 per cent respectively or slightly less than one-half of the total number of laryngectomies performed during this four-year period.

All are agreed that in the patient with carcinoma of the larynx and clinical metastasis to cervical lymph nodes, surgical treatment offers more than irradiation in selected cases. The number that can be salvaged is not great, however, irrespective of our surgical approach.

To return to the problem of secondary metastasis to cervical lymph nodes occurring after total laryngectomy, of 351 cases operated upon before January 1950 regional metastasis occurred in 113 (32 per cent). Block dissection was performed in 69 cases (61 per cent). This included six cases of bilateral dissection. There were 36 living and free from carcinoma for five or more years after surgical treatment. In addition one remained free from carcinoma for 10 years following irradiation. It is in this group that our surgical approach must be altered if we wish to improve the five year non-recurrence rate.

On the basis of these statistical data one may assume that in a patient with carcinoma of the larynx with no demonstrable metastasis treated by total laryngectomy only, there is a 25 to 30 per cent chance that there will be metastasis to the cervical lymph nodes. The likelihood that these can be removed surgically is slightly better than 50 per cent and there is a one to two chance that the patient will be free from carcinoma after five years. In this series of 351 cases, 76 (21.6 per cent) of the 113 patients with metastasis to the neck died irrespective of therapy and 37 (10.5 per cent) lived for five or more years without recurrence (36 by surgery, one by irradiation).

During the ten-year period from 1940 to 1950 there were performed 17 laryngectomies with elective block dissection. In six patients carcinoma was found in the cervical lymph nodes, although enlarged nodes were found in all cases. There was no operative mortality. There have been no recurrences to date. During that same period there were 92 patients with metastasis to the cervical lymph nodes after total laryngectomy and 58 of these have died.

While the data for 1950-54 cannot be accepted as final they can serve as straws in the wind. There were 21 instances of secondary metastasis to cervical lymph nodes following 82 cases of total laryngectomy, with 11 deaths. One death occurred among the 34 cases of combined laryngectomy and elective block dissection. This proved to be due to pulmonary metastasis. There was no operative mortality and there were no cases of metastasis to the neck.

On the basis of these data it would appear that total laryngectomy and elective block dissection of the neck should be practiced as the surgical procedure of choice in a greater number of cases than heretofore. These should include all cases of supra-and infraglottic lesions unless they are of recent origin and small. While early cordal lesions usually do not metastasize every patient with fixation of an arytenoid or with suggestive subglottic extension should be considered as a candidate for total laryngectomy and elective block dissection.

5575 8TH AVENUE, NORTH.

REFERENCES

1. Clerf, L. H., Putney, F. J. and O'Keefe, J. J.: Carcinoma of the Larynx, *Laryngoscope* 58:632 (July) 1948.
2. Ogura, J. and Bello, J. A.: Laryngectomy and Radical Neck Dissection for Carcinoma of the Larynx, *Laryngoscope* 62:1 (Jan.) 1952.
3. Bocca, E.: Functional Problems Connected with Bilateral Radical Neck Dissection, *J. Laryng. and Otol.* 67:567 (Sept.) 1953.
4. Orton, H. B.: Evaluation of Radical Neck Dissection, *Trans. Am. Acad. Ophthalmol. and Otolaryng.* p. 30 (Jan.-Feb.) 1954.

DISCUSSION

DR. CHEVALIER L. JACKSON: Mr. President and Members, the only reason I didn't offer to say anything was because of the very complete and convincing finality with which Dr. Clerf presented the results of his experience. All I can say is that I was most interested in hearing this report, that I agree with every one of his conclusions on the subject. I have nothing to add, except to say that I think we need more reports like this!

DR. JULIUS W. MCCALL: I certainly am in complete agreement with my good friend, Dr. Clerf's beautiful presentation of this subject. I would like to ask one question. How much intracranial complication has he had following bilateral ligation of the internal jugular vein? We have had three that wound up with a very disastrous brain damage.

DR. EDWIN N. BROYLES: Mr. President and Gentlemen, I regret bringing up a question on Dr. Clerf's paper because Dr. Clerf in my experience has been always right in most of the things he has talked about, but in our experience in early cord lesions with a simple laryngectomy we find that they are well for a long time. I have had recurrences in two patients 14 years following laryngectomy, but at least you give a patient 14 years of comparative comfort. These patients following a block dissection of the neck are not very comfortable and not very happy in my experience. We have done several of these block dissections following a questionable laryngeal tumor. In the last two that we did we could not demonstrate any carcinoma in the glands around the carotid sheath. On the other hand, a carcinoma of the larynx not only metastasizes to the cervical lymph nodes but it also does so to the peritracheal gland and especially with those cases that have had palpable nodes before operation you usually have metastases to the thyroid gland. It seems to me there is some question about the limit of surgery in these cases that have broken out of the larynx and go on to the cervical lymph nodes to the thyroid and to the peritracheal nodes. I may be wrong but to me a carcinoma of the larynx represents in early cases a bottle of mercury. If you can, take that whole bottle out. If it is broken it is difficult and almost impossible to remove it all.

DR. HARRIS (Houston, Texas): I would like to ask Dr. Clerf a question but first of all I want to thank him for such an interesting presentation. I don't think that I could disagree with him on any of the things that he has brought out. I would like to ask him one question. What do you do with the thyroid gland? Do you remove it on one or both sides if there is subglottic extension or a large pyriform sinus lesion when doing a combined radical neck dissection and laryngectomy?

DR. ANDREW EGGSTON: I would like to discuss briefly this paper from a pathologist's point of view. I have been associated with pathology of the nose and throat for 35 years. I certainly have seen the seriousness of the problem of laryngeal cancer and realize that you cannot cut it all out. Therefore the elective surgery that Dr. Clerf discusses is often indicated.

His reference about examining the neck nodes is well taken. When the pathologist gets a block of neck tissue he is often at a loss because of proper orientation. If the surgeon would mark the areas or the possible nodes that should be examined it would be of great help to the pathologist. This applies more to a general laboratory where the pathologists don't see as many cases as is seen in a special hospital. Often the nodes are very difficult to find and examine. Grossly we cannot tell more about them than the surgeon. Often the pathologist is more handicapped than the surgeon because he sees the living tissue in its natural place and state. The surgeon sees it personally and often we see it impersonally. One could spend days examining these nodes, to do it completely. In some places they clear the tissues and that makes the nodes more prominent. I am terribly frustrated when a surgeon comes to me and says, "Should this patient receive radiation; do you think this is intrinsic or extrinsic?" All I can do is be objective and say, "I find this and I find that." Even if one sectioned all the nodes he would still see that individual nodes would have recurrences, because one cannot in many instances identify the individual cancer cells. In these cells is where there occurs metastasis.

There is one other thing that strikes me so very forcibly in examining these cases: many of these nodes are congested and hemorrhagic and are probably really involved in a noditis and not in a metastasis. I just want to stress the point from the pathologist side of the picture as they are presented with a difficult problem in prognosticating metastasis.

I have been associated with otorhinolaryngologists for many years and I appreciate the very excellent presentation of the subject of cancer by Dr. Ochsner and I always love to hear Dr. Louis Clerf.

DR. JEROME A. HILGER: One of the most striking features of the report of Dr. Clerf is an unsung item—the minimal mortality in a series of very difficult surgical cases. I for one believe it will be a long time before a series of major surgical cases like these will be reported with such a mortality rate. This I think, above all else, indicates two things; excellent surgical technique and wonderful post-operative care. These are difficult patients to see through their immediate post-operative period. I certainly commend Dr. Clerf on reducing the mortality rate to such a small figure.

I should like to make another point too. The mass of evidence in the last five years, which has culminated very fittingly with this paper, points to a problem that is going to cry for leadership from this group.

I think it is fair to say that a significant number of men in this room, who have led laryngology through a very great period of growth, do not do neck resection surgery personally. On the other hand it is probably true that virtually the entire membership does do adequate total laryngectomy surgery. A great deal of this work is not going to be longer done properly by total laryngectomy alone. These figures indicate this. We must urge the younger men in our field to give the time, study, and energy to master this surgical phase. The great humility shown by the senior men at this time will be reflected in the continued growth and excellence of our specialty.

DR. LOUIS H. CLERF: Mr. President: This subject certainly cannot be considered as a "cut and dried" one, for comparatively few laryngologists who treat laryngeal carcinoma do elective block dissection. I am pleased that there has been discussion.

It is true that when one adds an additional surgical procedure there should be increased mortality and certainly increased morbidity. I shall comment on Dr. Hilger's statement first. We did have mortality but not in the elective group. Mortality occurred in those with clinical metastasis which necessitated a combined block dissection and laryngectomy. That was the only surgical procedure indicated and there was no choice. Such a patient must submit to laryngectomy with a unilateral or bilateral block dissection. There is a definite risk that one cannot ignore. I wanted to emphasize that there were no deaths in the group of elective block dissection combined with laryngectomy. This of course does not mean that there is no hazard with this procedure.

I have observed no intracranial complications following a unilateral block dissection. When it comes to a bilateral block dissection combined with laryngectomy or as a secondary procedure, that is an entirely different problem. I have done two cases, one a combined laryngectomy and bilateral block dissection and the other a bilateral block dissection as a secondary procedure. The first patient got along nicely. He was a young man in good physical condition and I believed it was necessary to do both sides at one sitting with the laryngectomy. The other patient survived the procedure but he was always a bit dizzy, had a florid complexion and marked scleral injection. He ultimately died from metastasis below the clavicles. I personally am not too enthusiastic about doing a bilateral block at the same time as the laryngectomy but there are situations as Dr. Ochsner pointed out when it may not be too great a price to pay if by so doing you hope to save the patient's life. That is always important and that is the thing you are shooting at.

I quite agree with Dr. Broyles, but the patient who had a laryngectomy is not happy nor comfortable. If there is present a fairly large lesion and an absence of metastasis I believe, on the basis of my experience, that patient will live longer and probably get by without secondary recurrence if an elective block dissection is done. It is largely a matter of experience in these cases. Having seen so many cases of secondary metastasis to the neck returning, many of them inoperable, I believe that laryngectomy and elective block dissection offers the golden opportunity to cure carcinoma.

With regard to metastasis to the thyroid gland, and this may often be the result of direct extension, the situation is not hopeful. I would recommend removal of a lobe or that portion of the gland involved. It increases the operative time and morbidity. In my experience when the thyroid gland is the seat of disease the likelihood is that one is a bit late.

Dr. Eggston, I do not wish to give the impression that I am critical of the pathologist. He has a difficult task. Apart from the fact that the laryngologist often does not help him much in localization, he has a difficult problem to find carcinoma in lymph nodes and often is confronted with economic problems that many hospitals encounter today, namely inadequate personnel and too much work. That has been our problem. The pathologists have done a fine job and I am not critical. I still believe that when there is an extensive lesion, in spite of the fact that there are no palpable nodes, one ought to consider seriously an elective block dissection in conjunction with the laryngectomy. The presence or absence of histologic evidence of metastasis in the extirpated nodes is not as important as having a cancer free patient at the end of five years.

MIXED TUMORS OF THE POSTERIOR PHARYNGEAL WALL

FRED Z. HAVENS, M.D.

AND

LEWELL C. BUTLER, M.D.

ROCHESTER, MINNESOTA

Mixed tumors have long been recognized and it has been noted that they occur predominately in the orofacial region. In 1948 McDonald and I wrote:¹

"According to Davis, mixed tumors may be defined as 'neoplasms of the orofacial region comprised of stroma of mucoid connective tissue often undergoing cartilaginous transformation with groups of epithelial cells which may be either glandular or squamous.' Bohme stated that mixed tumors occur ten times more frequently in the parotid than in the submaxillary gland and that the sublingual gland is the site of formation of the mixed tumor in one per cent of the whole number. While mixed tumors are common in the parotid gland, they cannot be considered uncommon in the mouth and throat and in the lips. It is exceedingly difficult to trace the genesis of these tumors. In an endeavor to explain the presence of the mesothelial and epithelial elements in mixed tumors, authors have contended that these tumors originate in various ways. There is, however, no unanimity of opinion as to their origin. Volkmann contended that these tumors are of endothelial origin. Krompecher maintained that they are of epithelial origin and that even the cartilage can be derived from the epithelium by metaplasia; however, this has not been considered satisfactory by most authors. The more commonly accepted view is that the cartilage is derived from branchial cleft elements, a hypothesis which was propounded by Cohnheim. McFarland expressed the belief that these tumors originate in sequestered embryonal material and that some of them originate in branchial cleft elements. . . .

From the Mayo Foundation of the Graduate School of the University of Minnesota, Rochester, Minn.

"Possibly we have been unwilling to classify certain lesions as mixed tumor when others might be willing to do so. We have insisted on the presence of two elements; namely, epithelial elements, usually glandular, and myxomatous connective tissue. . . . Squamous epithelium and cartilage are less common components of a mixed tumor, but we have not considered these as essential to the diagnosis."

In the consideration of any neoplasm, careful discrimination on the part of the pathologist is of extreme importance to the surgeon in helping him to decide upon the proper plan of treatment. The mixed tumor belongs to the adenocarcinoma family and in recent years pathologists have learned to discriminate more closely between certain branches of this family. The most notable example of this is the fact that they now separate from the mixed tumors and from the adenocarcinomas the lesion which formerly was placed in the adenocarcinoma group or possibly sometimes in the mixed tumor group but which is now known as cylindroma or, as some prefer to call it, adenocystic carcinoma. (I am inclined to believe that the latter term is the better.) It is noted for its marked tendency to recur in spite of energetic efforts to control it. The adenocarcinomas which those pathologists who employ the grading system will classify as Grades 2, 3, or 4 likewise are difficult to control. They give rise to metastasis and recur more actively and more rapidly than does the mixed tumor if not completely removed.

Pathologists consistently have declined to classify the mixed tumor as malignant, and refer to it as a benign tumor in spite of the fact that it grows relentlessly and recurs persistently if not completely removed. Instances are seen from time to time in which a very active type of adenocarcinoma has arisen from a long-standing mixed tumor. Two cases which illustrate this point come to mind.

CASE 1.—The first is that of a woman who had a tumor of the left submaxillary salivary gland which was known to have been present for 50 years, during which time it had attained a diameter of approximately 4 cm. She sought medical aid because in the previous five months she had noted a small additional nodule developing alongside the 50-year-old mass. Both masses were excised and microscopic examination revealed that the original lesion was a mixed tumor. The new accessory tumor was a Grade 4 adenocarcinoma.

CASE 2.—The other case was that of a man who came under observation in 1922. He had had incomplete removal of a tumor

of the parotid gland a short time previously. On microscopic study of biopsy material obtained from the operating surgeon the lesion was classified as a mixed tumor. This was more than 30 years ago when surgeons were not as bold about undertaking operations on the parotid gland as they are today, and further operative procedures were considered inadvisable. Instead, treatment was given by interstitial irradiation. The patient passed from observation and we know nothing of what transpired in the intervening years, but 30 years later, in 1952, a pathologist wrote that recently he had performed necropsy on this patient and requested information as to the original diagnosis. In return he kindly sent us a slide prepared from an intracranial metastatic lesion and stated that the same type of material had been found in and around the site of the original tumor. Microscopic examination of the slide he had sent revealed a Grade 4 adenocarcinoma.

Observations such as these serve to re-emphasize the necessity for careful and complete removal of all mixed tumors.

CLINICAL DATA

Mixed tumors occur more frequently in the parotid region than elsewhere, in the submaxillary salivary gland next most frequently, and probably third place is taken by the hard palate where the lesion originates in the general area of the greater palatine foramen. Otherwise such lesions may be found almost anywhere in the orofacial region down to and including the larynx. Among the cases in which the tumor occurs in the latter regions it has been our privilege to see a group of cases in which the tumor seems to follow a very definite pattern as to origin and clinical course. In this group of cases the tumor has had its origin under the mucous membrane of the posterior pharyngeal wall near its lateral limit, apparently at the level of the middle of the tonsil.

As the tumor of the posterior pharyngeal wall enlarges it causes bulging of the adjacent mucous membrane which rarely extends beyond the midpharynx medially but which often extends laterally under the mucous membrane of the lateral wall of the hypopharynx to dislocate the tonsil and sometimes push it over to or beyond the middle of the mouth. Similarly it may extend upward or downward or both. From the clinical description in 39 of our cases we were able to determine that in 18 the tumor had not extended either up into the nasopharynx or down into the hypopharynx; in 9 it had

extended both up and down, in 9 upward only, and in 3 downward only. In some instances the tumor tended to push outward between the mastoid and the ascending ramus of the mandible, and in 7 cases it was palpable externally. This external protrusion may appear as a mass close up under the auricle which may closely resemble a parotid tumor. We have not seen any instance in which there were two separate tumors, therefore, we believe that if the patient has a pharyngeal tumor and also has what might be thought to be a parotid tumor it is best to proceed on the assumption that the mass in the parotid is an extension from the pharyngeal tumor. We have seen primary parotid tumors extend in between the mastoid and ascending ramus but never have seen this extension to be sufficient to produce a pharyngeal mass.

It is the nature of the mixed tumor to grow very, very slowly; consequently, owing to the very slow enlargement the surrounding structures adapt themselves to it, so that rather frequently the patient may be totally unaware of any trouble in his throat until some day he accidentally discovers the tumor and then reports to his physician stating that this swelling has just appeared. (In several of our patients, particularly in the preantibiotic days, the physician who saw the patient under such circumstances had lanced the swelling in the belief it was a peritonsillar abscess.)

We have encountered only two types of lesions that may be mistaken for mixed tumor: lipoma and neurofibroma. Both are slowly growing lesions and either one may remain without symptoms and may become quite large before being discovered. The methods of surgical management recommended for mixed tumors can be and have been employed in the management of either of these lesions.

In our group of cases there were 27 male and 14 female patients. The age distribution is shown in Table 1. As shown in Table 2 these patients presented surprisingly few symptoms.

In 32 instances the clinician recorded his impression as to the consistency of the tumor, as follows: soft 3 cases, rubbery 2, firm 17 and hard 10. The mucous membrane over the tumors was always normal in appearance except when biopsy or "lancing" had recently been carried out.

In 36 of the cases in our series the distribution of the tumors according to the largest dimension was as follows: less than 4 cm,

TABLE 1
AGE DISTRIBUTION OF PATIENTS

AGE, YEARS	CASES
20 or less (youngest 16)	3
21 to 40	11
41 to 60	22
61 or more (oldest 69)	5

9 cases; 4 to 9 cm, 21 cases; and 10 cm or more (largest 17 cm), 6 cases.

TREATMENT

Because the mixed tumor cannot be expected to respond satisfactorily to irradiation, the treatment necessarily must be surgical. There are two methods by which surgical removal can be accomplished. One is by an external approach in which a suitable incision is made in the neck so that the external carotid artery first can be ligated after which the tumor is exposed between the angle of the mandible and the adjacent mastoid. These tumors are well encapsulated and the surgeon then can make a blunt dissection of the tumor with his finger. In four of our cases in which this method has been employed the procedure has proved to be very satisfactory.

The other method of removal is to approach the tumor transorally. An incision is made over the most prominent portion of the tumor after which the underlying tissues are separated carefully until the capsule of the tumor has been identified. The finger is then introduced and the tumor is freed by finger dissection. Usually the surgeon's finger is not long enough to reach around the tumor and to get it dissected free completely but usually 80 to 90 per cent of the tumor can be freed in this way. After this has been accomplished an incision is made in the capsule and the margins of it are held by suitable instruments. Through the opening thus made the greater portion of the contents of the capsule can be scooped out. After this has been done the instruments holding the margin of the capsule are rotated to twist the capsule into a cord and with the bulk of the tumor out of the way it usually is not difficult to remove the remainder of the capsule. The cavity remaining after the removal of the

TABLE 2
SYMPTOMS (41 CASES)

SYMPTOM	CASES
"Swelling," "mass" or "tumor"	28
Throat	22
Parotid region	5
Submaxillary region	1
Pain	5
Throat	4
Ear	1
None (tumor discovered on routine examination)	8

tumor is packed loosely with iodoform gauze which is removed in stages beginning after three or four days.

Transoral approach always should be preceded by ligation of the external carotid artery on the side on which the tumor lies. Such ligation may not be necessary but one is taking an unnecessary risk to carry out the operation without it. We know of an instance in which one of these tumors was discovered at the completion of tonsillectomy. The surgeon identified the capsule and thought it would be quite easy to shell out the tumor. He undertook to do so but encountered hemorrhage uncontrollable with the facilities at hand and the patient was lost.

The transoral approach was used in 37 and the external approach in 4 of the 41 cases in our series. The operative results in all 41 cases are shown in Table 3.

In the patient listed as well 11 years after treatment of recurrence the tumor had been removed by the transoral approach. A very small nodule of recurrence had been noted one year after the primary operation and this had been excised.

In the patient listed as well six years after treatment of recurrence the tumor had been removed by the external approach. One year after the primary operation a nodule was found just under the skin at the site of the incision. It was removed and is believed to have been an implantation tumor.

TABLE 3
RESULTS OF TREATMENT

RESULTS	CASES
Postoperative period less than 5 years	11
No recurrence	10
Recurrence (treated, now well 1 year)	1
Postoperative period more than 5 years	30
No recurrence (8 had less than 5-year follow-up) *	24
No follow-up	1
Recurrence	5
Treated (well 1, 6 and 11 years respectively)	3
Died of disease (tumor not removed)	2

*Of the eight patients, one died of other disease and without recurrence after 4½ years. The other seven returned for observation at least once, and since they all lived near enough to return easily it is reasonable to assume that none had further trouble.

Four other patients are known to have had recurrence and these will now be reported on in detail, with comments by the senior author.

CASE 3.—A woman, aged 66 years, had a tumor described as as being 10 cm in its greatest dimension. The tumor was explored transorally and found to be partially broken down in its center. Such softening would likely make it much more difficult to carry out a finger dissection of the tumor. We can only speculate as to what probably went through the surgeon's mind; since this was in 1927, before we had such aids as antibiotics and blood banks which now make us unafraid to operate upon the elderly person, presumably the surgeon decided that removal of such a tumor would be unjustifiably hazardous for a woman of 66. At any rate, he made no attempt to remove it but put in radium tubes and followed this with external roentgen-ray treatment. The patient died eight years later, reportedly of "carcinoma of the throat with extension to the cervical nodes." The slides in this case have been reviewed recently and the diagnosis of mixed tumor made 27 years ago has been confirmed.

Metastasis from a mixed tumor is not expected; hence, if the report of "extension to the cervical nodes" is correct, it seems that this mixed tumor probably underwent malignant change in the eight years after operation. Today, under the same circumstances but with all the aids that are now available for the care of the aged, we undoubtedly would go ahead and remove the tumor.

CASE 4.—In this case the surgeon explored the tumor transorally after having made a clinical diagnosis of mixed tumor. On examination of a fresh frozen section the pathologist classified the lesion as a lymphoma. The surgeon, therefore, did not attempt removal but treated the lesion with radium tubes and later radon seeds. It was not until the pathologist had studied the fixed sections that he revised his diagnosis to mixed tumor. This patient, like the previous one, was operated upon some 28 years ago.

Today that same surgeon, because the tumor could be removed readily, would go ahead and remove it in spite of the frozen section diagnosis of lymphoma. In view of the ultimate diagnosis it is obvious that this is what should have been done. The patient lived 13 years. The report of his death clearly indicates that he died of the effects of his tumor.

CASE 5.—In this case the tumor was removed in 1939 by a transoral approach. The patient returned 14 years later with a recurrent tumor that was almost as large as the original. The recurrent tumor was not encapsulated as the original tumor had been, but was made up of multiple nodules. The fact that the recurrence was in the form of multiple nodules made it extremely difficult to be sure of removing all of them. When the patient was re-examined a little more than a year after the second operation there was no evidence of any recurrence.

It is extremely doubtful in this case whether the patient will remain free of disease. There is a definite possibility that the recurrence might have been on the basis of implantation rather than on the basis of failure to remove all of the capsule.

CASE 6.—In the fourth case it seems from the record that when the surgeon made the incision (transoral approach) he must have carried it deeply enough to open the capsule, thus making it impossible for him subsequently to identify the capsule and to dissect it properly and remove it. This patient returned nearly three years

later with a very small nodule of recurrence and this was treated by interstitial irradiation.

It is doubtful whether this patient's tumor will be controlled. It is extremely important that the capsule be identified in order that the dissection can be made with a blunt instrument or with the finger.

SUMMARY

Mixed tumor is rarely found in the posterior pharyngeal wall. Our survey covered a period of 37 years, during which there were 1,500,000 clinic registrations.

In the literature there are scattered reports of similar cases but it is difficult to formulate a firm policy regarding the management of any particular type of lesion from a study of isolated case reports. We hope that this survey and its analysis will help in formulating definite principles in connection with the management of these lesions.

Although we believe that treatment should be surgical, it may be immaterial whether the surgeon chooses to remove the tumor by the external or by the transoral approach. There is, however, one thought that might be taken into consideration in deciding which approach to use. Since these tumors usually are large and since often it is necessary to open the capsule and remove part of its contents before the remainder of the capsule can be removed, there is of course the danger that recurrence might be brought about by "seeding" (implantation of fragments of tumors). Our records indicate that "seeding" was believed to have occurred in one of four cases in which the tumor was removed by the external approach, whereas it was believed to have occurred in only one of 35 cases in which the tumor was removed by the transoral approach. An explanation for this difference might be that a clean surgical wound that is closed as a neck wound is closed would provide much better soil for possible "seeding" than would a wound which is packed wide open with iodoform gauze and which is left in place for four to seven days.

MAYO CLINIC.

REFERENCE

1. McDonald, J. R. and Havens, F. Z.: A Study of Malignant Tumors of Glandular Nature Found in the Nose, Throat and Mouth. *S. Clin. North America* 1087-1106 (Aug.) 1948.

DISCUSSION

PRESIDENT ORTON: I would like to start the discussion by stating just about a month ago I was called in consultation to see one of these mixed tumors of the pharyngeal wall and in that case it was necessary to remove a portion of the ascending ramus of the mandible to completely get around the growth. The growth had extended from below the mandible up to the base of the skull. It was a mixed tumor, the carotid was not ligated; by removing the ascending ramus of the jaw it certainly gives you much more room.

DR. HARRY P. SCHENCK: I enjoyed Dr. Havens' presentation a great deal because these tumors always worry me. Several years ago I found a very large tumor in this region in a young man who had had the mass incised a number of times over a period of six months on the assumption that he had a peritonsillar abscess. It was removed by the transoral approach and those I have encountered have all been removed by this route.

Dr. Havens pointed out a number of important points based on his wide experience. The tissue over mixed tumors appears essentially normal when compared with that over malignant tumors such as adenocarcinoma or sarcoma and is readily separated from the mixed tumor capsule. In spite of the large size of several of the tumors we have removed, no ligation of the vessels in the neck was necessary. In order to remove such tumors the capsule must be incised and sufficient contents evacuated to decompress the mass. At this point seeding is prone to occur and recurrence follows. As Dr. Havens has emphasized, the recurrent masses are apt to be unencapsulated. Decompression facilitates further finger dissection, however, and the control of hemorrhage has not been a serious problem. The removal of mixed tumors in this region can best be accomplished by the otolaryngologist rather than the oral surgeon.

The large excavation remaining after I removed the first of these tumors worried me a great deal until I found that suturing, beginning at the bottom of the wound, closed the field with resulting symmetry. Perfection of technique so as to prevent seeding permits intraoral removal of the majority.

DR. ALBERT C. FURSTENBERG: I think it can be said that these lesions are teratological in origin. They represent some disturbance or irregularity in the mechanics of embryonic development; an aberrant collection of cells, misplacement of cells, or supernumerary cells present at birth which later in life become active and grow.

There is one point that I should like to emphasize, namely, that the fate of the patient rests in the hands of the first surgeon. When these lesions recur they tend to depart further and further from their original benign state and become more malignant. When you operate upon them the second time you will often find that you are dealing with a lesion much more malignant than the original one. For this reason it is necessary I believe to eradicate all of the neoplasm at the time of your first operation if you entertain the hope of preventing a troublesome recurrence. It has been mentioned that seeds may be found outside of the capsule. We have a number of microphotographs indicating that the seeds can be found in tissue beyond the capsule when the latter seems to be intact. When you are dealing with this lesion, in the parotid or submaxillary glands, I believe it is a good plan to remove a zone of surrounding tissue which appears to be free from neoplasm. We have been surprised in a few instances to find a number of seeds beyond what appeared to be an intact capsule.

DR. DEGRAFF WOODMAN: In view of the seeding problem I would like to ask what Dr. Havens' recommendations are as to the method of biopsy in these cases.

DR. FRED Z. HAVENS: Dr. Orton: I have considered using the method you mentioned of "opening the door a little wider" but so far no case has come to my attention where I felt I could not handle it in the manner I described. Certainly it is a good thing to bear in mind.

Dr. Schenck: Regarding the question as to whether or not to ligate the external carotid, I think that depends upon how badly one has been scared. The instance related in the paper came to my attention early in my career and made me want always to be sure about control of hemorrhage. I admit that very likely this operation could be done many times without ligation of the carotid, but I feel much safer if it is ligated before the tumor is removed.

Regarding closure of the wound, I let mother nature do that. I am speaking now of the transoral approach because that is the only approach that I personally have used. I don't suture anything, I simply pack the wound wide open with an iodoform pack which is probably two-thirds as large as the tumor. I start taking this pack out on the fourth day and take four more days to complete its removal. A year later there is remarkably little scarring to be seen. I think that this method of treating the pharyngeal wound is a very important factor in the rarity of seeding in the cases in which we employed the transoral approach.

I agree with Dr. Furstenberg wholeheartedly that the first man to attempt treatment is the man who has the best chance for success. That applies not only to this problem but to the management of any other type of malignant disease. I believe also that the mixed tumors that have undergone malignant change are more likely to be seen in patients who have had inadequate treatment than in patients whose tumor has had no treatment at all.

Dr. Woodman: With reference to the matter of biopsy in these cases, I will say that when your hair gets gray you sometimes do things that you would not have done when your hair was black. I do not take a biopsy until I have the capsule identified, and even then I may not remove a specimen. For all practical purposes when you have gone that far it does not make much difference, because you have determined that the tumor is encapsulated and you will remove it regardless of its histologic classification.

VASOMOTOR RHINITIS

THEO. E. WALSH, M.D.

ST. LOUIS, MO.

Although the literature of the past century abounds with articles on vasomotor rhinitis, the sufferers from this complaint remain some of the rhinologist's most distressing problems. It is the purpose of this paper to discuss the etiology and those contributory factors so important in the disease, and to invite discussion regarding the principles of therapy which may be expected to give some measure of relief to our patients.

The condition under discussion is that which is characterized by constant nasal stuffiness and increased postnasal discharge, accompanied by dull headache and a feeling of fatigue and nervousness. The common findings are a swelling of the turbinal mucosa with glairy mucus in the meatuses, a peculiar red or purplish color of the turbinates and excessive lymphoid nodules on the posterior pharyngeal wall and in the nasopharynx. In some instances there may not be found an excessive secretion in the nose and when smears of nasal secretions are obtained they show few cells, and eosinophilia is not usual except during exacerbations of the disease.

ETIOLOGY

If one accepts the definition of allergy as "the acquired specific altered capacity to react" then vasomotor rhinitis and allergic rhinitis are synonymous. By common usage, however, the term allergic is applied to those cases, exemplified by hay fever, in which there is an acute reaction characterized by vasodilatation, edema, excessive secretion of mucus and the presence of eosinophilic granulocytes in the secretions and tissues. This allergic state is the result of an antigen-antibody reaction in which there is a release of histamine with a resulting capillary dilatation, an increased capillary permeability and consequent tissue edema.

The problem of the acute allergic nose can be solved when the antigen is recognized and can be removed from the patient's environ-

ment or when he can be treated with a series of hyposensitizing injections. The problem of the vasomotor nose is much more difficult because it is rare to be able to find a causative allergen either from a careful history or from skin tests. There is one type of case, however, that is probably truly allergic. It is exemplified by the child with vasomotor rhinitis usually bright, intelligent and spoiled whose mother informs the physician that the child eats "hardly anything" and only "picks at his meals." Yet it is obvious that the child is not undernourished. If one is able to speak to such a child by himself, one can usually find out that although he eats little at meal times he is constantly eating candy bars and drinking Coca Cola between meals. It is not only in children that one sees such dietary indiscretions but also in adults. The resultant vasomotor rhinitis can be corrected if a properly balanced diet is followed. Dohlman¹ emphasized dietary indiscretions as a cause for vasomotor rhinitis and noted that in his patients it was usually a diet predominately carbohydrate which caused the trouble. He, too, found that when the diet was regulated and properly balanced the vasomotor symptoms in the nose disappeared.

There can be little doubt that endocrine dysfunction may cause nasal congestion. Swelling of the nasal tissues is not an uncommon accompaniment of the menses and all of us are familiar with the nasal congestion which occurs in some women during the last weeks of pregnancy. Proetz² in 1947 discussed the influence of the thyroid in nasal disease. Most of his cases were of the hypothyroid type having basal metabolic rates of less than —11 per cent. A few cases that he reported had increased basal metabolic rates. Laub³ in 1945 and Walsh⁴ in 1950 pointed out the influence of the endocrines on the nose, not only of the thyroid but of ovarian and testicular hormones. Both quote cases in which the nasal symptoms were relieved by the use of estrogens or androgens.

It is generally realized that emotional states may lead to peripheral vascular change. For example, the blanching that occurs with fear; the blushing with shame or embarrassment. Wolff⁵ and his co-workers have pointed out the influence of emotional disturbances on the function of the nose. They have even shown that emotional disturbances may lead to chronic organic changes in the nasal mucosa and that acute emotional disturbances may cause eosinophilia in tissues and in the peripheral blood.

The question arises: Are the psychosomatic and endocrine factors operative only in those individuals who are truly allergic or are these aberrations themselves the cause of the altered nasal state? Perhaps, the question is purely academic. In Proetz' series less than 15 per cent were demonstrably allergic. I have been unable to demonstrate an allergy in most of my patients who have responded to endocrine therapy. I believe, however, that in most instances it is probably the addition of psychic or endocrine insult to the injury, however mild, of allergy that causes trouble.

MANAGEMENT

The objectives of management are surely, 1) to determine and treat the cause of the vasomotor state and, 2) to provide the patient with some measure of relief during such investigation. In regard to the provision of relief for the patient, I believe the use of vasoconstrictors as nasal drops or sprays cannot be too highly condemned. It is probable that clinical investigation of a patient with vasomotor rhinitis will take time. The effect of a local vasoconstrictor in the nose is very temporary and continued use leads to turgescence. This is especially true of Privine® but I believe all local applications can become a habit and can themselves lead to a congested state indistinguishable from the condition for which they were prescribed. Relief of nasal congestion can be afforded by the use of vasoconstrictors by mouth and I have found Propadrine® $\frac{3}{8}$ gr useful for this. Occasionally its effect is enhanced when it is combined with an antihistaminic. The importance of a careful clinical history need hardly be emphasized here. Knowledge of the patient as a whole person is essential in evaluating his case. The greatest criticism of the specialist is that he is apt to concentrate on his particular field and forget that he is primarily a physician. A suggestive allergic history should be investigated by appropriate skin tests and by the regulation of the diet. In those instances in which the thyroid is suspected, I have found that the patients exhibiting a low basal metabolic rate with a high blood cholesterol have responded best to thyroid medication. In regard to the dosage, I think it is important that sufficient thyroid extract be given to be of use. It has been our routine to start the patient with one grain a day for perhaps two weeks, and then increase the dose to two grains a day for two weeks, then three grains a day for the next two weeks and so on until changes in the nasal mucosa can be observed. We have found in some instances

that as high a dose as four or five grains a day is necessary. We have seldom observed changes in the basal metabolic rate even with high doses. After mucosal changes have occurred we diminish the dose until an adequate maintenance dose is found. We have also found that the use of vitamins with the thyroid has been helpful and we have suggested that 50 mgs of thiamine chloride and 0.5 gm of ascorbic acid a day is of benefit.

For those patients whose emotional problems seem to be of paramount importance, I believe that a sympathetic ear and human understanding is as useful in an otolaryngologist as in a psychiatrist. The patient should be allowed sufficient time to avail himself of both. I have found it very difficult to persuade patients to see a psychiatrist and equally difficult to interest the psychiatrists in these patients. Consultation with an internist, allergist and endocrinologist is in the best interest of the patient. That the very small doses of histamine that Hansel⁶ advocates will cause amelioration of symptoms in some cases cannot be denied. I confess, however, that I cannot understand why this should be so.

SUMMARY

1. Endocrine, dietary and psychosomatic disturbances play an important part in the etiology of vasomotor rhinitis.
2. Allergic factors are not identifiable in a large percentage of cases.
3. The use of local vasoconstrictors or drops or sprays is inadvisable in the symptomatic treatment.

640 S. KINGSHIGHWAY.

REFERENCES

1. Dohlman, G.: Personal Communication.
2. Proetz, A. W.: The Thyroid and the Nose, *ANNALS OF OTOTOLOGY, RHINOLOGY AND LARYNGOLOGY* 56:328, 1948.
3. Laub, G. R.: Rhinitis Vasomotoria Due to Imbalance of the Endocrine Glands, *Laryngoscope* 55:479.
4. Walsh, T. E.: Vasomotor Rhinitis, *Laryngoscope* 60:360.
5. Holmes, T. H., Goodall, H., Wolf, S. and Wolff, H. G.: *The Nose*, C. Thomas Co., 1950.
6. Hansel, F. K.: The Treatment of Certain Specific Types of Headache with Histamine, *Trans. Am. Laryng. Rhin. & Otol. Soc.*, 228, 1947.

DISCUSSION

DR. OLIVER E. VAN ALYEA: Mr. Chairman and Members, I want to express my appreciation of this paper. It seems that what Dr. Walsh is describing has also been termed border line allergy or atypical allergy. The fact that he has shown an entity which we might distinguish from border line allergy is important.

Aside from the management which Dr. Walsh has suggested, endocrine and what not, and the lack of nose drops, which he deplures, and with which I thoroughly agree, how does he feel about cauterization of the turbinates in these stubborn cases? That is another phase of rhinology which has been carried over and of which I do not approve.

DR. HENRY L. WILLIAMS: I am sure this paper of Dr. Walsh's is of great interest to all of us who are engaged in the general practice of rhinology because the number of patients that come in to us with this complaint is very large. As Dr. Walsh pointed out, such patients are rather difficult to relieve adequately in many instances. In listening to Dr. Walsh's discussion of vasomotor rhinitis, it occurred to me that it might be possible to differentiate amongst these cases that he presents a little more adequately than he has done.

In my experience patients with violaceous mucous, swollen mucous membrane are those whom we designate as low BMR without myxedema. We have also had success in treating these cases with thyra. On the other hand, the group of cases who have a watery nasal discharge, with a red or relatively normal colored mucous membrane, in my experience are not helped by the use of endocrines and it is my feeling that these could be better classified as so-called physical allergy.

Certainly the insistence of Dr. Walsh on antigen-antibody reaction in all allergy seems to me to be out of line with the general thinking, even of the immunologists at this time. Certainly the concept of physical allergy, as all allergists are willing to admit, cannot be disproven and they are also willing to admit that vast numbers of these cases of vasomotor rhinitis, which are clinically indistinguishable from so-called allergic rhinitis, do not give clinically significant skin tests.

Dr. Walsh's remarks about the dietary treatment of these cases recalls to my mind the work of Dr. Sam Roberts, who has written extensively on dietary treatment, very much along the same lines that Dr. Walsh has mentioned, and I believe that his type of therapy has considerable success in treating patients of this sort.

I cannot agree with Dr. Van Alyea's remark about the effect of cauterization of the nose as being uncalled for. In my own experience these patients, certain of them, do very well with cauterization of the sphenopalatine ganglion. In my experience there has been no contraindication to this treatment. It does not produce any permanent change in the functioning nasal mucosa. There is no damage to the cilia if done properly and it gives relief for very long periods of time in certain of these patients. I think it is the type of treatment that is valuable, effective and doesn't produce any harm to any of our patients.

DR. LOWENTHAL: I am particularly interested in Dr. Walsh's emphasis of the emotional or psychosomatic factors. I wonder if in taking the history of these patients he has not noted that many of them sometimes have a history of spastic colitis, ulcerative colitis, or even peptic ulcer, and if we are really not treating some sort of a derangement of the sympathetic nervous system. It seems to me that these patients are improved by merely taking the time to discuss emotional or psychosomatic factors with them.

DR. THEODORE E. WALSH: I want to thank the discussers for their kind remarks.

Apropos of what Dr. Van Alyea said, I cannot agree with cauterization of the turbinates. I believe cauterization does alter the nasal physiology. I think that Dr. Williams probably misunderstood what Dr. Van Alyea was talking about. He said cauterization of the ganglion does no harm and I agree. I think one can give many of these patients relief by injection of alcohol in the sphenopalatine ganglion. I reported a number of cases years ago and the relief, if one is accurate with the injection, is pretty permanent. The nose changes from a vasomotor to a reasonably normal state. The injection is done through the posterior palatine foramen which is the easiest and most accurate way of getting at the ganglion. I believe that appropriate surgery will help. I didn't mention it in the paper because there seemed to be no point to it. A grossly deviated septum, for example, may give some of these patients a great deal of relief when corrected. But I don't mean destructive surgery, but constructive surgery.

Dr. Williams, about the question of physical allergy, I feel particularly incompetent to discuss it. I know there is such a thing. At least it is believed there is and I know that many of these patients have their chief trouble when they get up in the morning and their feet hit the cold floor or when they move from a hot to a cold room, etc., but the majority of the patients are not like that. Those that I was trying to describe have their trouble almost all the time and I do think the psychosomatic approach is extremely important. I don't mean that we have to be psychiatrists but we have to be physicians. I believe that many of these conditions did not occur in the old days when we had the good old "family doc" who knew everything about the patient from the time he was born till the time he died. He knew all the problems that went on in the home because he knew the home and many times I am sure just by talking to his patients he could give them relief. Most of these people that we see have more than one factor operative. Many of them may have a basic allergy. They may have on top of that some endocrine dysfunction and an emotional factor besides. It is a very difficult problem and I think one has to investigate it from all angles. That is why I tried to emphasize the fact that one should know the patient as a whole and should try to find out as much as possible about him as a person. It is no use, in my opinion, sending these people to psychiatrists. In the first place, they won't go. In the second place the psychiatrist is not interested. I think if we will spend the time—it is difficult I admit—to get the patient's complete confidence and can find out something about his background, then I think we can help him a great deal.

A FEW HIGHLIGHTS CONCERNING RESPIRATORY CILIA

G. EDWARD TREMBLE, M.D.

MONTREAL, CANADA

According to the American Medical Dictionary (Dorland), physiology is described as the science which treats of the functions of the living organism and its parts.

Although many observations have been made concerning nasal physiology during recent years, some important facts remain to be clarified. For instance, we know that after removal, nasal mucosa often regenerates complete with cilia, and functions normally within a few weeks. On the other hand, we do not know whether the newly-formed cilia originate on the cellular surface or develop within the substance of the cell. We also are at a loss to explain the exciting cause of ciliary activity and where it begins. Perhaps this is not surprising "when we remember that really nothing is known of the machinery whereby a muscle develops a tension when it is stimulated."¹

Another intriguing problem concerns the rhythm of the beat. The co-ordinating mechanism which produces a wave-like motion without the cilia interfering with one another is quite unknown at the present time.

Until a few years ago our knowledge of ciliated cells has been very limited. It is true that by means of a standard type light microscope we have been able to study cilia and their attachments to the columnar cells. The basal bodies from which the cilia seem to arise are seen as bulbous swellings at or just below the surface of the cell. The cuticular border or plate on the surface refracts the light and suggests a supporting structure through which the cilia pass. The basal body (which stains deeply) has been considered by many to be the source of stimulation or the "spark plug" of the cell. In many animals fine rootlets are seen to extend from the basal bodies down

into the cytoplasm toward the nucleus. Their function at present is unknown. A single cilium appears as a homogeneous extension of the cell even when magnified 1,000 times and viewed under the phase contrast microscope. Although this instrument gives greater detail than an ordinary light microscope, until very recently this has been the extent of our knowledge. From this one would judge a cilium to be a fine thread-like filament of undifferentiated protoplasm enclosed in a sheath. Instead, a cilium is a highly complicated structure with a very regular and constant pattern. In view of some newer findings it was thought an appropriate time to touch on some of the highlights as they developed.

Histology has been described as the science which deals with minute structures and the composition of tissues. This relatively new subject was a closed book until about 300 years ago. At that time a native of Delft, Holland, Antony van Leeuwenhoek, began grinding lenses and later developed the first compound microscope. Imagine the wonder and excitement that Leeuwenhoek must have experienced when he first peered through his single glass lens at the minute inhabitants of a drop of canal water, at the strange things in cheese and anything else that took his fancy! What a teeming incredible underworld to come across and what a thrill to be its first explorer. With the advent of histology observers were able to see microscopic fibres and cells for the first time. Another Dutchman, Anton de Heide,² noted and described cilia in 1683 and then 12 years later in 1695 Leeuwenhoek³ observed and drew attention to ciliary movement. After 300 years we are still exploring this field and those interested in electron microscopy are particularly fortunate in being the first to penetrate into the molecules themselves. As a result a whole new chapter has opened up and observers can now look down with the human eye and study details that were undreamed of even five years ago.

For want of a better explanation, until recently it was thought that a cilium was a curved tubular extension of a cell filled with hyaloplasm. In order to explain the to and fro motion it was thought that protoplasm was forced in and out of the cilium. Others seeking an explanation suggested that a contractile core on one side of the cilium made it bend over during the effective stroke and straighten up when the core relaxed. These theories, of course, have become obsolete when cilia are viewed under the tremendous magnifying power of the electron microscope.

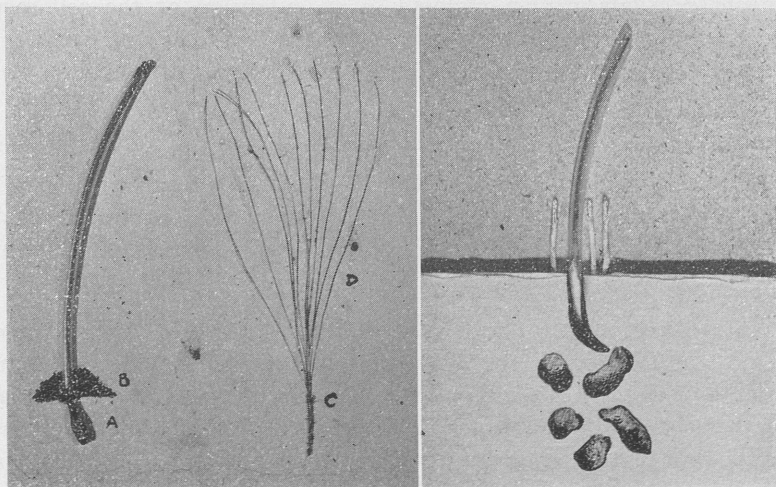


Fig. 1.—Diagrams of a cilium. A—Basal body, B—Cuticular plate. After freezing the outer peripheral sheath is destroyed and the fibrils often spread out like a fan. C—Shaft, D—Longitudinal fibrils.

Fig. 2.—A human cilium shown diagrammatically. On the cell surface are three vertical striations which refract the light under the microscope. They form the cuticular plate or supporting structure.

For many years some investigators have suspected that in certain lower animals the cilia consist of a dense axial core and a thin peripheral sheath. As long ago as 1889 Butschli⁴ mentioned axial fibres in certain flagellata. Under polarized light and dark field illumination the central core was thought to consist of many individual fibrils running the length of the cilium.^{5,6} This was not confirmed until greater magnification was possible. In 1945 Brown⁷ described flagellated protozoa in which the flagella contained an axial fibrillar core and a peripheral sheath and a year later Jakus and Hall⁸ examined the cilia of paramecium and found longitudinal fibrils, usually eleven in each cilium.

This arrangement seems to be a universal finding throughout the animal kingdom. In a recent publication Fawcett and Porter⁹ reported their findings in lamellibranches, amphibians and mammals with the electron microscope. Quoting from their article, "throughout this range of animal forms cilia exhibit the same internal struc-

ture consisting of eleven longitudinal fibrils embedded in homogeneous protoplasm and enclosed in an extension of the cell membrane. In cross section the cut ends of two fibrils are situated in the center and the other nine are evenly spaced in a circle around them."

Previous to this Engström¹⁰ had given a detailed description of the vibratile cilia of tracheal cells in some higher mammals and in man. It is surprising how constant they appear. By means of various agents cilia were studied both singly and in groups under the electron microscope.

As has been mentioned, each cilium consists of a basal body which is embedded in the cell. Just above the basal body a small cuticular ring can often be seen. When a number of cilia are seen together these rings are attached to each other at the same height and form a thin plate. The cilium itself consists of an axial fibrillar bundle and a semitransparent, thin peripheral sheath. When treated with osmic acid or formalin, the outer sheath remains "fixed" around the axial core. The axial core or bundle is composed of 10 or 11 fibrils which extend from the cuticular plate to the tip of the cilium.

Although the basal body is considered by many to be the center of ciliary activity, the fibrils are thought to produce the contractions of the cilium. Under certain conditions the peripheral sheath can be dissolved or ruptured allowing the fibrils to separate. Although they can be loosened from one another, there is a strong tendency for the fibrils to adhere near the base and again at the tip of the cilium.

After strenuous treatment such as freezing Engstrom noted a tiny shaft above the cuticular plate. From this shaft the fibrils when separated often assume a fan-like appearance. This is apparently due to the fact that they are more firmly attached at the shaft than at the tip. Between the shaft and the tip, the fibrils run parallel to one another and are loosely attached. Extending downward into the cell from each basal body are one or two minute rootlets. These rootlets are more commonly seen in lower forms of animal life.

In a later article Engström and Wersall¹¹ attempted to estimate the number of cilia on the surface of a cell in the respiratory tract. The length of a cilium in the human trachea is 6 to 7 microns, about the size of a red blood corpuscle. According to their findings there

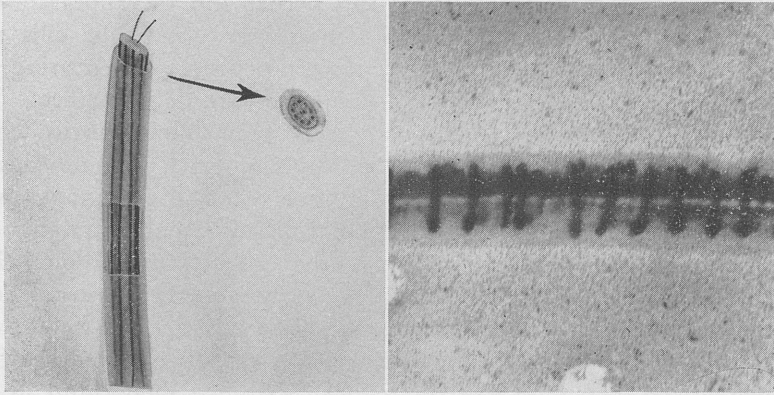


Fig. 3.—Diagram showing section of human cilium with longitudinal fibrils embedded in homogeneous protoplasm. Arrow points to cut surface of cilium.

Fig. 4.—A longitudinal section of the principal part of the tail of a rat spermatozoon showing the spiral winding. It resembles a tightly-coiled corkscrew. Magnified 45,000 X.

were 25 to 35 cilia per square micron on a tracheal cell. Thus a single cell with a surface area of 50 square microns would contain over a thousand cilia. This estimate is so high that it is difficult to believe, however they admit that these figures are somewhat uncertain.

When electron studies were first carried out on ciliated epithelium, the fragments of tissue were simply placed on the specimen grid. The heat from the instrument dried the tissue and as a result the internal structure was distorted. Within the last few years newer methods have been found of fixing tissue in plastic material and cutting much thinner sections.^{12,13} As a result sections of less than a twentieth of a micron can now be obtained with little or no distortion.

A year ago Fawcett¹⁴ reported his findings after a comparative study of ciliated epithelium in certain mollusks, amphibia and three different mammals including man. Quoting from his article: "When these cells are examined with the electron microscope, several new details of fine structure are observed even at relatively low magnifications. The cuticular border is comprised of a very great number of slender, vertically oriented cell processes (80 μ wide and 1.5 μ

long) in closely-packed parallel array. These processes are doubtless responsible for the refractility of this border and the appearance of vertical striations noted with the light microscope. The cilia pass through this thick pile or nap of shorter processes constituting the cuticular border and project several microns above its surface. The shaft of the cilium contains a bundle of longitudinal fibrils which are embedded in a homogeneous protoplasmic matrix, and this in turn is surrounded by a ciliary membrane which is continuous with the cell membrane. The longitudinal filaments are straight and parallel and have no detectable periodic cross-striation along their length. In submammalian forms they do not pierce the basal body and continue into the cytoplasm as has been suggested heretofore, but they end abruptly in a dense transverse plate fixed to the flattened upper surface of the basal body." In the mouse and in the human there is no transverse plate as in the lower forms of animal life and the longitudinal fibrils continue into the substance of the basal body. "The basal body is asymmetrical and has a dense cortex and a core of relatively low density which gives it the appearance of being hollow. A fiber connecting successive basal bodies in the same row has not been observed, but a blunt process does project from each basal body in a horizontal direction. The alignment of these processes is probably responsible for the appearance with the light microscope of a continuous line joining the basal bodies."

Ciliary rootlets are well developed in lower forms of animal life such as mollusks and amphibia but are only faintly seen or are absent in mammals including man. They have been observed to approach the nucleus of cells so were thought by many to be connected with ciliary movement. However their poor development or absence in humans rules out this theory.

On cross section the longitudinal fibrils show a definite pattern which is constant. Even in various species, sections of ciliated mucous membrane show a remarkable similarity in the distribution of the longitudinal fibrils. From a rhinologist's point of view this is interesting, because sections of human respiratory cilia show a pair of large fibrils in the center of the cut surface of each cilium with nine smaller pairs evenly spread near the periphery. At first it was thought that these fibrils were single but under greater magnification and clearer resolution they have recently been found to be paired. In man the fibrils run the length of the cilium from the basal body to the tip, like the wires in a cable.

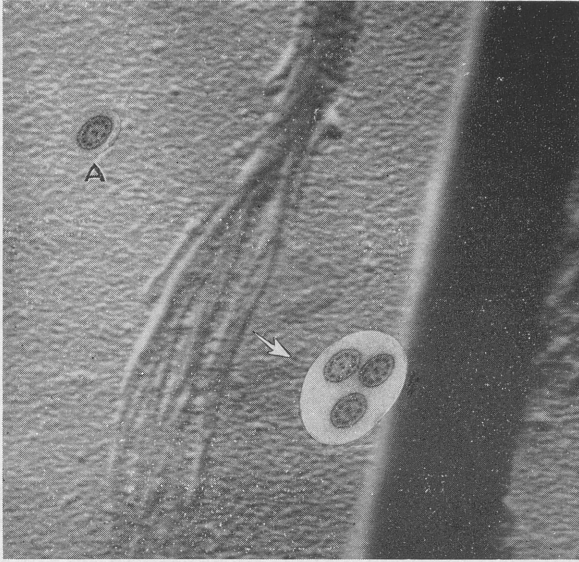

Fig. 5.—Photograph of fringed tip of rat spermatozoon magnified 22,500 X. Diagram of a cross section of three components of the tail under higher magnification. They exhibit the same internal structure as human cilia. A, a human respiratory cilium magnified over 40,000 X.

Since the electron microscope has come into use many animate and inanimate objects have been eagerly studied by histologists and anatomists. As one would expect, the finer structures of spermatozoa of mammals including man have been carefully noted. Surprisingly enough Retzius in 1906 described a spiral winding which extends from the head almost to the flagellated end of the tail of spermatozoa. The illustrations in his article show this spiral wrapping which resembles a tightly coiled spring. This observation is indeed remarkable when we realize that the only instrument available at the time was the light microscope.

During the past two years Leblond and his associates at McGill University have been studying the spermatozoa of rats. In their last paper which will appear in print shortly, they reviewed a few known facts about the principal part of the tail of rat spermatozoa and the flagellated tip. They also added some newer findings of their own concerning the nucleus and the head. Although the main

portion of the tail is not of particular interest to nose and throat specialists, the spiral coil is beautifully depicted in the accompanying photograph. It circles the longitudinal fibrils as shown and is well within the enveloping membrane and not at the surface as first noted by Retzius. The principal piece of the tail is perhaps ten times the length of the head and it ends in a flagellum or fringed tip. If any excuse is necessary for citing these few points in comparative anatomy it might be mentioned that most of the investigative work on cilia was done primarily on lower forms of animal life. However, it has been stressed many times that it is dangerous to assume that cilia in experimental animals are similar or function in the same way as those in humans.

In view of this it is interesting from our point of view to learn that the terminal ends of the flagellum of rat spermatozoa (or for that matter human spermatozoa as well) on cross section are exactly the same in structure as human cilia from the nose or trachea. In other words the extreme tip is made up of cilium-like projections having two longitudinal fibrils in the center and nine pairs evenly spaced nearer the periphery. They all appear to be embedded in a homogeneous mass bounded by the enveloping membrane.

Considering the fine caliber of the longitudinal fibrils in comparison to the width of human respiratory cilia it is little wonder that they were invisible with the standard type or phase contrast microscope. In retrospect it is remarkable that axial fibres were even suspected in certain flagellata nearly 70 years ago, as mentioned previously. Now that we are able to examine these minute structures when magnified 20 to 60,000 times with newer staining methods the pattern of the cut fibrils is easily seen.

Whether the activating agent which produces the ciliary beat originates in the longitudinal fibres or in the basal bodies remains a question. At the present time it would appear that the stimulus arises in the basal bodies and is transmitted through the longitudinal fibrils to the tips of the cilia. This of course is purely a supposition. Although a number of points concerning their function need to be clarified as cited at the beginning of this paper, a thorough understanding concerning the structure of cilia is of primary importance.

In summing up, it might be mentioned that our knowledge has increased greatly regarding the structure of respiratory cilia during the last few years. From this one would expect still more informa-

tion in the future. At the present time we do not know where cilia originate, whether they grow from the surface of the cell or develop below in the basal bodies. Perhaps their origin will be discovered when specimens of regenerating mucous membrane are examined. Although the finer structure of cilia has been demonstrated we are at a loss to know the exciting influence of the beat.

At the beginning of this paper mention was made of the fact that we know nothing of the mechanism whereby a muscle develops a tension when it is stimulated, as noted by Gray in his book on "Ciliary Movement."

In view of this it may be a long time before we understand the site of origin of the ciliary beat.

1390 SHERBROOKE ST. WEST.

REFERENCES

1. Gray, J.: Ciliary Movement. Cambridge University Press Fetter Lane, London, p. 7.
2. De Heide, A.: *Anatome Militi*, 1683.
3. Van Leeuwenhoek, A.: *Arcana Naturae*, 1695, p. 48 et seq.
4. Butschli, O.: *Braun's Klassen und Ordnungen, Protozoa*, 3 Leipzig, 1889.
5. Dillinger, O. P.: The Cilium as a Key to the Structure of Contractile Proto-plasm. *Jour. Morph.* 20:171-210, 1909.
6. Grave, C., and Schmitt, F. O.: Mechanism for the Co-ordination and Regulation of Ciliary Movement as Revealed by Microdissection and Cytological Studies of Ciliated Cells of Mollusks. *Jour. Morph.* 40:479-512, 1925.
7. Brown, H. P.: On the Structure and Mechanics of the Protozoan Flagellum. *Ohio Jour. Sci.* 45:247-301, 1945.
8. Jakus, M. A., and Hall, C. E.: Electron Microscope Observations of Trichocysts and Cilia of *Paramecium*. *Biol. Bull.* 91, N:02, 141-144 (Oct.) 1946.
9. Fawcett, D. W., and Porter, K. R.: A Comparative Study of Ciliated Epithelium with the Electron Microscope. *Anat. Rec.* 115:2:425, 1953.
10. Engström, H.: The Structure of Tracheal Cilia. *Acta Otolaryngol.* 39:360, 1951.
11. Engström, H., and Wersall, J.: Some Principles in the Structure of Vibratile Cilia, *ANNALS OF OTOTOLOGY, RHINOLOGY AND LARYNGOLOGY* 61:1027 (Dec.) 1952.
12. Newman, S. B., Borysko, E., and Swerlow, M.: New Sectioning Technique for Light and Electron Microscopy. *Science* 110, 66-68, 1949.
13. Porter, K. R., and Blum, J.: A Study in Microscopy for Electron Microscopy. *Anat. Rec.* 117:685-713, 1953.
14. Fawcett, D. W.: The Study of Epithelial Cilia and Sperm Flagella with the Electron Microscope. *Trans. Amer. Laryngol., Rhinol. and Otol. Soc.* pp. 318-330, 1954.

DISCUSSION

DR. AUGUST L. BECK: I don't know much about the research problems related to ciliated epithelium. Some of you may remember a motion picture film which Dr. H. P. Mosher showed at a meeting of the American Academy of Ophthalmology and Otolaryngology back in the decade of 1930. It was somewhat crude as compared with the photography of the present day, but it showed an interesting phenomenon of the action of one cell (upper drawing) which had become accidentally detached and which exhibited a very active swirling motion. That was positive evidence that the energy which caused this was inherent in the cell and its tuft of cilia. The row of epithelial cells in this lower drawing illustrates the ordinary picture of normal ciliated epithelium. I have compared the behavior of the single detached cell to the role of a soloist, and the lower drawing of the row of epithelial cells to a symphony orchestra led by a conductor, with the result that the ciliary waves are going constantly toward the ostium. I have pondered on what it is that initiates and maintains this coordinated ciliary beat.

DR. ARTHUR W. PROETZ: I thought it might be a novelty for you to listen to a paper on cilia in which I did not participate, so I kept quiet. Since your chairman called on me I have a few ideas.

At this stage it is almost futile for a man who has no electronmicroscope to discuss cilia. There has been a new epoch in regard to cilia since the advent of the electronmicroscope, just as there was when the light microscope first revealed them.

We have seen a number of papers in the last five or six years about the structure of these cells. This review by Dr. Tremble has demonstrated that the time is now for some genius to tell us how cilia move. He is going to have to have, first, an electronmicroscope, second, a vivid imagination, and third, some practical knowledge of physiology and physics to determine which of the things he imagines are possible and which are not, in order not to waste the time of the medical profession for a couple of hundred years.

I keep thinking always—I have mentioned it before—of our looking at the circulation for hundreds of years without seeing it. Finally when somebody discovered that there was movement of blood in the vessels it was thought of as pulsation, and years elapsed before the conception of circulation was arrived at.

We have within the last decade found out about the nine pairs of fibrils surrounding two other central pairs. Whether the spiral is part of the vibrating mechanism or not, no one knows, and it is high time that someone were putting these facts together. I hope that when he does he won't express himself until he has some confirmatory evidence.

I keep thinking that functions have been attributed to the sinuses which are so ridiculous that anybody could have disproved them in an afternoon but for a couple of hundred years nobody bothered. Now I hope somebody with an electronmicroscope will be more interested in cilia than in electronmicroscopes and will shortly devote himself to the problem of ciliary movement.

DR. G. EDWARD TREMBLE: I always feel embarrassed in talking about cilia in the presence of Dr. Proetz or Dr. Hilding as both these men have added greatly to our knowledge of ciliary movement. However, I was pleased to hear Dr. Proetz open the discussion.

In reference to the remarks of Dr. Beck. It is a well known fact that cilia continue to beat for hours as long as they are attached to some protoplasm. This is seen very frequently.

For example, if we get a patient with a head cold to blow his nose into a piece of wax paper, we often find under the microscope cast off mucosal cells complete with cilia.

These cilia continue to beat as long as they are immersed in Ringer's, Locke's or even normal saline solution in a hanging drop slide. The nucleus in the cell is not necessary.

All that cilia require is warmth and moisture such as normal saline and the attachment to a fragment of protoplasm. When these conditions are present they can often go on beating for days. Dr. Beck suggested that perhaps on the surface of a cell one cilium is the leaders of the band and the others follow suit. This would not appear to be the case, although there must be some co-ordinating mechanism to keep up the rhythmical beat without the cilia interfering with one another.

My reason for speaking on this subject was to emphasize a few points from the beginning of microscopy and to show how constant the cilia are throughout the animal kingdom and for that matter the vegetable kingdom as well. The short bit of movie film showed human nasal cilia magnified 1200 times under normal conditions and then speeded up in the presence of an acute infection.

Under electron microscopy the same type of cilia are demonstrated and their similarity to the structure of the fringe-like tail of the rat spermatozoa described.

It is indeed remarkable how constant they appear.

THE RADICAL OBLITERATIVE FRONTAL SINUS OPERATION

A CONSIDERATION OF TECHNICAL FACTORS IN DIFFICULT CASES

ROBERT L. GOODALE, M.D.

BOSTON, MASS.

The purpose of this paper is to call attention to some of the problems which the author has encountered in dealing with severe cases of frontal sinusitis. These cases are those in which complications exist so that surgical procedures such as the Jansen-Lynch-Smith operation are not adequate. They fall into three general groups: First, traumatic; second, chronic osteomyelitic; and third, cases which have had repeated operative failure.

The procedure which I am considering today is not by any means a new one. It actually antedates most of the present day operative techniques. At the Massachusetts Eye and Ear Infirmary, it is called the "Obliterative Frontal Sinus Operation." As a matter of fact obliteration was first attempted by Kuhnt¹ prior to 1895. At this operation, the anterior wall was removed but the floor of the frontal sinus was allowed to remain, the ethmoid cells were undisturbed and an attempt was made to maintain drainage and to administer medication by means of a temporary rubber drainage tube placed in the external incision. Riedel³ later removed not only the anterior but the inferior wall. Ropke² modified the operation further by including exenteration of the anterior ethmoidal cells thus establishing drainage into the nose. The need for external drainage was thus eliminated. While all of these operations attempted to obliterate the sinus so that there would no longer be any air space and no longer any mucous membrane which could later become reinfected, special attention was not paid to the role of the ethmoid cells. In my opinion, to perform this operation properly, not only the anterior wall and the floor of the frontal sinus should be removed completely so that there is no longer a vestige of cavity in the frontal area, but the

ethmoid labyrinth should also be completely exenterated, as it is by way of the ethmoid that reinfection will take place. All the partial septa of the frontal sinus and all of the mucous membrane should be meticulously removed. Leaving small areas of mucous membrane and small unobliterated spaces in the frontal area lead inevitably to formation of mucocoeles. As you can see, this operation allows the soft tissues of the forehead including the periosteum which originally covered the anterior wall of the frontal bone to come in contact with the denuded posterior wall of the frontal sinus. This union obliterates the air space of the frontal sinus.

In a previous paper, the author analyzed the cause for failure in frontal sinus surgery as found at re-operation of cases done at the Massachusettes Eye and Ear Infirmary. Most of these cases, to be sure, were of the Lynch type. The failures were due to the fact that 1) the entire floor of the frontal sinus was not removed, 2) partial septa were allowed to remain, 3) the operations had failed to remove all the ethmoid cells and, 4) obstructing adhesions sprang up in the nasofrontal duct area.

In a case requiring obliteration of the frontal sinus, it is no longer desirable or possible to maintain a nasofrontal duct but it is just as important to remove the entire floor of the frontal sinus and to complete the ethmoidectomy. In addition, it is absolutely necessary to curette away every vestige of mucous membrane from the posterior wall and to base-level every partial septum with painstaking thoroughness. I mention these points again because in several of the cases I am going to cite, partway measures were attempted at previous operation with the result that the obliterated sinus developed mucocoeles or pyocoeles and thus became severely reinfected.

When do we remove the posterior wall? Dr. Mosher advocated the routine removal of the posterior wall. In cases where the bone is grossly diseased I would agree with this, but in practice I believe that where the posterior wall is solid and healthy and there is no suspicion of intracranial disease, all that is required is the most careful removal of the mucous membrane.

In essence, this operation calls for no greater technical skill than that which we are accustomed to use in other radical operations on the sinuses. An important point, I believe, is to be psychologically

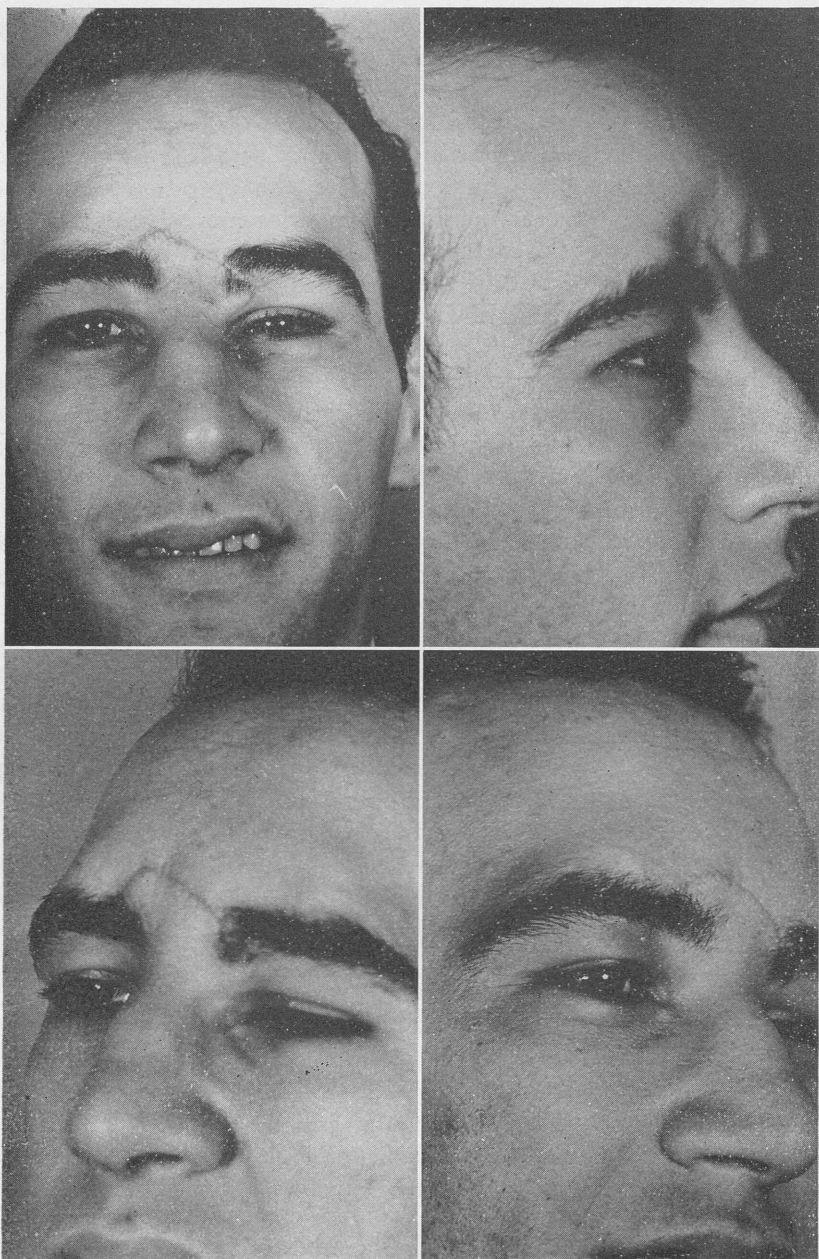


Fig. 1.—Case 1.—Above: Appearance before repair. Below: Appearance after repair by Dr. Bradford Cannon.

prepared to be thorough once we have committed ourselves to the obliterative operation.

When the obliterative operations were first performed, the ugly deformity which resulted deterred nearly all operators and patients, likewise, from these procedures. I think this point was over emphasized. Certainly there are many patients who have so suffered from the disease and from unsuccessful operations previously undertaken that the obliteration of the sinus, even with the deformity seems to have given such relief that they are satisfied with the result. To the surgeon it is not so agreeable to see a deformity that he has produced. But it is also a relief to know that the chances of the sinus becoming reinfectd are reduced to a minimum.

Fortunately for those of us who do this operation today we have an excellent chance to overcome the deformity through the improvement in plastic repair of the defect by living autogenous bone grafts. I would like to give a few case histories which will illustrate the problems which I have encountered.

REPORT OF CASES

CASE 1. (Figs. 1 and 2) A. S., a male, aged 20 years. The patient was seen on June 3, 1948, in consultation with Drs. Bradford Cannon, plastic surgeon, and Jost Mickelson, neurosurgeon, and Garrett Sullivan, ophthalmologist, at the Massachusetts General Hospital. The history related that on that day the patient was inflating a rubber tire on a wheel barrow when suddenly the tire blew up and struck him in the face and left hand. He was brought to the Baker Memorial of the Massachusetts General Hospital where an x-ray revealed a skull fracture involving the midfrontal region just above the frontal sinus, the posterior wall of the frontal, the right maxilla, the nasal bones, the ascending process of the maxillae and the lower orbital rim on the right, so that the alveolar process on this side was freely movable. There was a deep laceration of the upper lip. There was a cerebrospinal leak through a deep laceration in his forehead. The patient was conscious. On examination his right eye showed a severe laceration of the globe which eventually required removal of the eye. At this time the immediate problem was to debride the frontal sinus and examine the dura for a tear. Under intratracheal anesthesia a debridement of the frontal sinus was carried out by Dr. Mickelsen and myself. The laceration was so extensive that no further incision

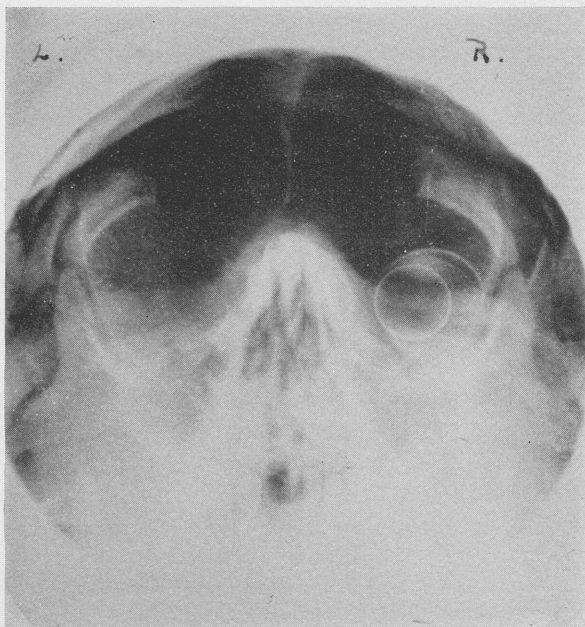


Fig. 2.—Case 1.—X-ray showing large defect resulting from debridement of frontal bone fracture before bone graft repair.

was needed to uncover the entire front wall of the frontal bone. The anterior walls were fractured into many small fragments. On removing these the posterior wall appeared to be fractured also on the right side. This fracture line extended through the roof of the orbit on both sides, the roof of the right ethmoid and the cribriform plate including the crista galli. The cribriform and the crista gallie were freely movable although still attached to the frontal lobe dura. The glabella and nasal bones, likewise, were freely movable but attached to the overlying skin and periosteum. At this operation all the loose fragments were removed from the anterior and posterior walls from the roof of the orbit and the ethmoid on the right side including the adjacent cribriform plate. The crista galli and the remaining portion of the cribriform on the left side were left in place. A tear in the dura about one-half cm in diameter was found in the anterior cribriform area on the right side. This was closed with a silk suture which included a small piece of gelfoam thus stopping the cerebrospinal leak.

Following this the wound was closed and pressure was applied externally, thus obliterating the entire frontal sinus area. The fracture of the maxilla and the laceration of the lip were repaired and the patient was returned to bed in fair condition. Later the eye was removed at another operation. By September 24 the patient had sufficiently recovered from these procedures so that a plastic repair was done by Dr. Cannon using living bone from the iliac crest to fill in the defect of the frontal sinus. Since then the patient has done extremely well and has not had any infection resulting from the injury.

CASE 2. (Figs. 3 and 4) G. A., a male, aged 18 years. This case illustrates frontal sinusitis following a fracture of the skull with osteomyelitic complications. On March 8, 1951, I first saw the patient with the following history. During the previous October he had been struck on the head while at work. An x-ray at that time confirmed the presence of fracture of the left frontal sinus. The sinus then became infected and he was then treated with antibiotics. The infection appeared to subside. However, three days before I saw him he contracted a head cold. The sinus again became infected and on the night before admission to the Massachusetts Eye and Ear Infirmary he noted some swelling of the forehead and upper eyelids on the left side. He had a dull headache and a purulent discharge. The following day the swelling of the forehead had begun to subside but his eyelids were still edematous and inflamed. There was marked tenderness over this area. A preliminary incision and drainage of an orbital abscess was undertaken. On exposing the front face of the frontal sinus a large defect was discovered apparently in line with the fracture as shown by x-ray. There was pus within the sinus. Two days later under intratracheal ether a radical obliterative frontal sinusectomy and ethmoidectomy was performed. A supraorbital incision was made to the outer limit of the frontal sinus and medially downward along the nasal bone to expose the lacrimal sac. The incision was carried upward medially and the periosteum was elevated to expose the entire front face of the left frontal sinus. The defect as before noted was found. There were two fracture lines on the front face of the frontal bone. Between them there was an area approximately 2 cm by 4 cm of soft osteomyelitic bone. Over the roof of the orbit there was another defect which represented a third fracture line. In the supraorbital rim there was a sharp spur which probably was due to a displaced fragment from the original trauma.

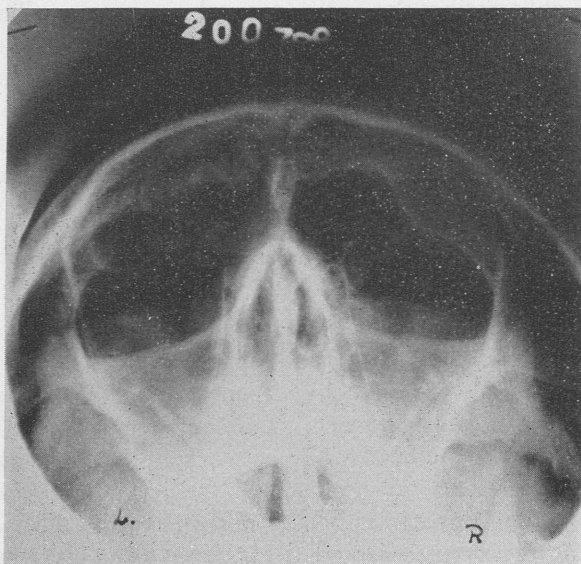


Fig. 3.—Case 2.—X-ray showing fracture of left frontal sinus.



Fig. 4.—Case 2.—On left: Appearance before repair. On right: Excellent appearance after repair by Dr. Edgar M. Holmes.

In view of the osteomyelitis, a radical obliterative frontal operation was done. There was a large lobular extension of the left frontal sinus beyond the midline partly overlapping the right frontal sinus, due to an oblique deviation of the interfrontal septum. All the partial septa were removed and the entire mucosa covering the posterior wall was curetted away. Ethmoid extensions were found overlying the posterior portion of the orbit. A complete ethmoidectomy was done including exenteration of all the orbital extensions. A small area of soft bone in the lateral portion of the frontal sinus was removed exposing an area of normal dura. The sphenoid ostium was identified and a probe passed easily into the sinus which was normal. A few months later a plastic repair was done by Dr. Edgar M. Holmes with the excellent result as shown in the accompanying illustration. Again living bone from the iliac crest was used.

CASE 3. T. K., a male, aged 18. This patient was first seen by me, May 6, 1947, with the following story. He previously had had severe infection of his frontal sinus and under local treatment had failed to respond satisfactorily in spite of the usual bed rest, sulfadiazine, heat and frequent nasal shrinkage. Then he had part of his middle turbinate and many polyps removed. An exenteration of the anterior ethmoid cells was also done. He was then given penicillin intramuscularly and locally. He improved under this regime but about three weeks before I saw him his frontal sinus had again become reinfected. He had headache and no treatment locally at that time seemed to have very much effect on his condition. When I saw him he had x-ray evidence of pus in his right frontal sinus. There were polyps in his nose, and there was no drainage visible intranasally. Under local anesthesia an external right frontal-ethmoid and sphenoid operation was undertaken. At this operation the entire ethmoid appeared to have degenerated. There were no partitions visible, the entire labyrinth being composed of thick infected mucous membrane with an occasional polyp. There was pus in the frontal sinus and here the membrane was markedly thickened and slightly polypoid. He recovered from these procedures very well but there was a tendency for his nasal frontal duct to block off. For this reason tantalum foil was inserted to provide permanent drainage. This was done on July 3, 1947, and following this he got along quite well until September, when he caught another head cold and developed some edema and inflammation around his right eye. At this time he was at home and the doctor in charge removed the tantalum. Following

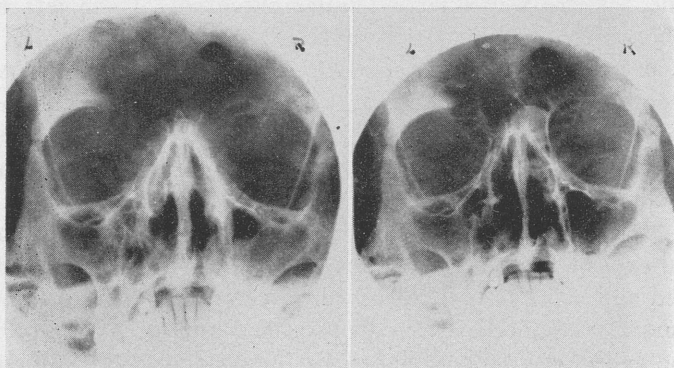

Fig. 5.—Case 6.—Right: X-ray of sinuses before latest operation. Many ethmoid cells can be seen over the roof of the frontal sinus. Large defect in posterior wall on the right is trephine for epidural abscess at a previous operation. Left: X-ray shows appearance after latest operation. The oval area in the roof of the orbit on the right represents the site of an ethmoid cell with unusually heavy bony outlines probably due to sclerosis.

this the nasofrontal passage closed off completely, and he returned to see me in October of the same year. Reoperation was done and pus was found just above the nasofrontal duct area. At this time as there appeared to be a low grade osteomyelitis of the front face of the frontal bone, an obliteration was undertaken. From this he recovered well. The large defect in the frontal area was repaired by Dr. Edgar M. Holmes, chief of the plastic service at the Massachusetts Eye and Ear Infirmary, the following autumn with very good results. From then till now, a period of eight years, he is symptom free.

CASE 4. L. D., a male. I first saw this patient on December 17, 1945, for chronic right frontal sinusitis. Several years before that he had had a severe left frontal sinusitis with osteomyelitis. This was operated on by another rhinologist who did a partial obliteration of the left frontal sinus. When I saw him there was marked supra-orbital tenderness on the right side. He had severe headache. X-ray showed mucocèles forming on the left and a very large mucocèle on the right. There was marked thickening of the mucosa of the left antrum but without retained secretion. The ethmoids were clear. This time his right frontal sinus was the one chiefly involved. There-

fore, a right radical Lynch frontal operation was undertaken. This included his ethmoids and exposure of the sphenoid sinus as well. At this operation it was found that the interfrontal septum was gone, and there was a large opening from the upper part of the left frontal sinus across the midline into the right frontal sinus. Hoping that drainage could be established in this way into the right nostril, no other procedure was contemplated at this time. However, he did not do well. His nasofrontal duct blocked off and as his occupation required him to be exposed to very severe wintry weather, it seemed wiser to obliterate his sinus than to go on hoping that his sinuses could be kept open and that he could develop enough immunity to ward off further infection. Consequently, a reoperation was performed on February 4, 1949, and at this time, because the two sinuses were virtually connected, a bilateral radical oblitative procedure was undertaken. The entire floor of the right sinus was removed and on the left side what appeared to be a Killian bridge was discovered, which hid several mucocoeles; therefore, this side was revised completely. The entire ethmoid region was revisualized and on this occasion every vestige of ethmoid extension was removed. The patient has had no further complications and no further inflammation or reinfection of his frontal area since then. In spite of the good results offered by plastic surgery, the patient has been content to let things stand as they are.

CASE 5. E. B., a female. This patient I saw first on February 14, 1950, with the following history. One year before she had had an acute fulminating left pansinusitis and was operated upon at another hospital. At that time she had had an oblitative frontal, ethmoid and a radical antrum. Unfortunately, during that operation her optic nerve was affected so that she had lost the vision on this side. When I saw her there was an exacerbation of infection on the left side with extension across the midline involving the right side. A revision of the left frontal sinus and an operation upon the right frontal sinus were undertaken. At this operation the left frontal sinus showed partial regeneration of the floor and remnants of the anterior wall. Pus was encountered in the midline near the interfrontal septum. There was more pathology than had appeared by x-ray. As part of the left frontal floor was still remaining, this was removed. This concealed some grossly infected mucous membrane. Following this a few posterior ethmoid cells were uncovered. A good portion of the middle turbinate appeared to be still present. All of

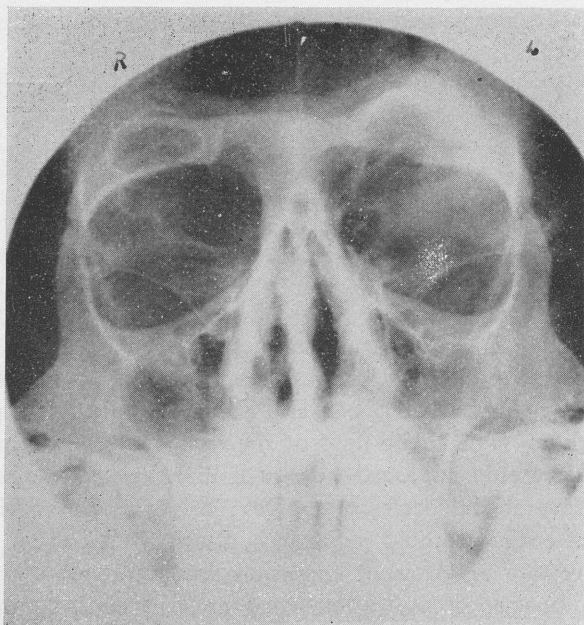


Fig. 6.—Case 7.—X-ray shows the Killian bridge with three areas of erosion by mucocoeles. There are also many ethmoidal extensions over the roof of both frontal sinuses.

this was removed. The sphenoid sinus was visualized. It contained a little thick membrane. The antrum appeared to be grossly infected and on removing the ethmoid overhang, pus flowed from the left antrum into the nose in spite of the fact that there was a good intranasal lower meatus opening. The right frontal sinus was then exposed and the frontal wall and floor were removed. The mucous membrane appeared to be grossly infected in the region of the naso-frontal duct. The ethmoid was exenterated and the sphenoid sinus opening was visualized. Again the ethmoid overhang concealed gross infection in the antrum and, on removing it, pus came out freely from this side. Following this procedure the patient made a good recovery and has not had any recurrent infection in her frontal sinuses. Her antra have cleared up following intranasal window operations, adequate drainage having apparently taken care of them. This patient is quite content to let things stay as they are without a repair of the defect.

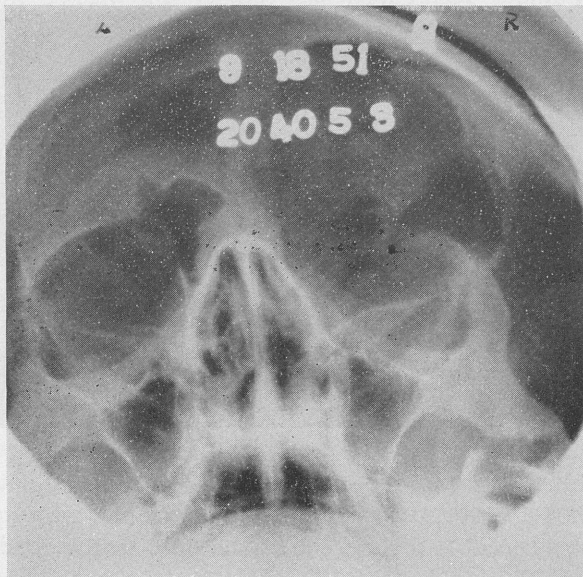


Fig. 7.—Case 8.—X-ray showing obliteration of right frontal sinus but with a large mucocoele forming. This became infected and required reoperation.

CASE 6. (Fig. 5) A. G. The patient was first operated upon in 1936 and since then has had multiple operations to correct a chronic bilateral frontal sinusitis. The infection, however, had progressed so that when I first saw him, May 19, 1954, there had been multiple attempts at obliteration of both frontal sinuses. He had had a trephine of the posterior wall on the right side because of an epidural abscess. In spite of all this the patient had become reinfected from time to time and when I saw him there was another exacerbation. There was pus on both sides of his nose and marked tenderness and headache over the entire frontal area. At his request I operated on him on the Nose and Throat Service of the Massachusetts Eye and Ear Infirmary. A complete revision of the frontal area was done. Many mucocoeles were discovered on both sides and cleaned out completely by curetting. Partial partitions were base-leveled still further. Then it appeared that ethmoidectomy had not been completed at previous operations. This was now undertaken. An aberrant cell



Fig. 8.—Case of Dr. Edgar M. Holmes.—Left: Appearance of deformity before repair. Right: Appearance after repair showing excellent result from use of autogenous bone graft.

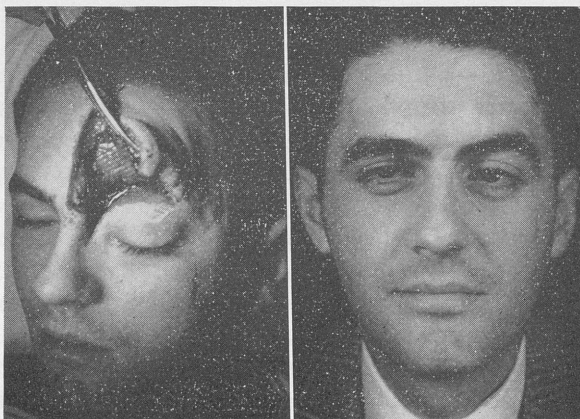


Fig. 9.—Case of Dr. Edgar M. Holmes.—Left: Appearance at time of operation showing extent of defect. Right: Appearance after repair with autogenous bone graft. An excellent result.

was found in the nasal septum. This required removal of the portion of the nasal septum just behind the nasal bones. This presented a little problem as it was somewhat difficult to close the incisions in the midline at this point. However, this was successful and since then the patient has had no nasal discharge or crusting, no inflammation and the entire area seems to be in good condition. He has had very little upper respiratory infection and on each occasion no involvement of the frontal sinus region. Likewise, his general health and well-being have improved so that he now says that he feels better than he has for many years. To date he refuses plastic repair.

CASE 7. (Fig. 6) L. H., a male, aged 59 years. This patient was referred to me by Dr. Schall on April 30, 1954, having been sent to the Massachusetts Eye and Ear Infirmary by his own doctor in New Brunswick. This patient had had a severe frontal sinus infection twenty-five years before and had been operated upon in another city. At that time a bilateral Killian operation was performed, and many nasal polypi were removed then and on subsequent occasions. He was mildly diabetic which complicated the control of his infection. When I saw him he was not anxious to have another operation and had been specifically told by another nose and throat man that he should never be operated on again. With this prejudice to overcome, my first attempt was to explain to him the situation and to get his acute inflammation under control, the patient at that time having had another flare-up. This was done and two weeks later he reported back to me stating that if I desired to operate, he was willing to go through with it. This was done on May 18. The revision of the frontal sinuses on both sides was performed under general anesthesia. An incision was made from right to left across the supraorbital ridge. The periosteum was elevated from the bone both above and below the Killian bridge which was then removed with mallet and chisel and rongeurs. Large pyoceles were encountered over the roof of the orbit on both sides. All of these were removed. The entire mucous membrane was dissected away from these cells. The ethmoidectomy was then revised through the orbit. The wound was closed and a pressure dressing applied. The patient has done extremely well since then. His diabetes was kept under control and had improved as one would expect because of the elimination of focal infection. This patient also is quite content to let things stay as they are and not undertake plastic surgery, although undoubtedly it would make him look more presentable.



Fig. 10.—Case of Dr. Edgar M. Holmes.—Photograph showing excellent cosmetic result of autogenous bone graft repair.

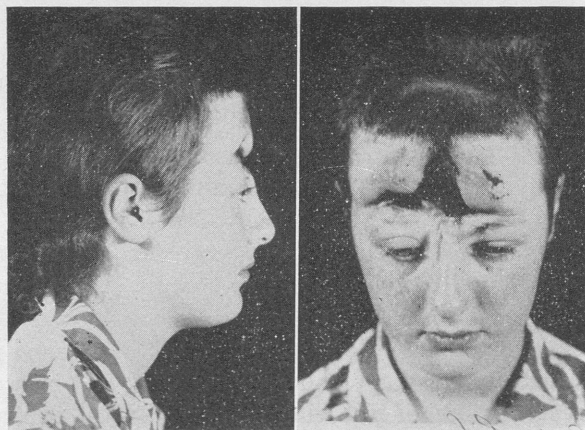

Fig. 11.—Case of Dr. Edgar M. Holmes.—Photograph showing condition just prior to plastic repair. This was a case of osteotomy for osteomyelitis of the frontal bone.

CASE 8. (Fig. 7) J. B., a male, aged 67 years. I present this case merely to show what can happen even after a good obliterative operation of a frontal sinus in which, however, a little mucous membrane is missed and which then forms a large and bothersome mucocele. This shows in the accompanying x-ray. In short, the only difficulty in this case was the recurrence of the mucocele; the obliteration, otherwise, having been quite successful. Reoperation to remove the mucocele was all that was needed.

I am much obliged to Dr. Edgar M. Holmes and Dr. Bradford Cannon for permission to use photographs of some of their patients illustrating the postoperative results of plastic repair of the frontal sinus defect. In these cases autogenous bone grafts from the iliac crest were used, the bone being cut, shaved, and fitted to the defect at the time of the implant. Banked bone was not used and for this reason probably better results were obtained. The following photographs illustrate the preoperative and postoperative appearance of the patient.

SUMMARY

A group of cases has been presented in whom simple operative procedures and the usual Lynch frontal operation do not seem to be indicated because of: 1) severe traumatic injury to the frontal sinus; 2) the presence of chronic osteomyelitic disease; 3) the history of repeated attempts at conservative operative measures which have resulted in the end in such complications that a revision of the frontal area by other than the most radical procedure would seem to give very little hope of success.

The operation under consideration entails removal of the anterior and inferior walls of the frontal sinus, the complete removal of the entire frontal sinus mucosa, the base leveling of all partial septa in sinus, a complete ethmoidectomy.

Previous failures at attempted obliteration have usually been the result of the presence of ethmoid cells, remnants of frontal mucosa and incomplete removal of the floor of the frontal sinus.

Once the operator has decided upon obliteration, he should not stop short of a complete and radical removal of these structures. The fear of disfigurement need no longer deter us as the defect can be successfully corrected by a living bone graft.

Eight case histories are given to illustrate the above points.

330 DARTMOUTH ST.

REFERENCES

1. Kuhnt, Hermann: Über Die Entzündlichen Erkrankungen Der Stirnhöhlen Und Ihre Folgezustände. Wiesbaden, 1895.
2. Röpke: Die Radicaloperation bei chronischen Verschleimungen und Eiterungen der oberen Nasennebenhöhlen. Berlin, 1898.
3. Riedel-Schenke, Heinrich: Ueber die Stirnhöhlen und ihre Erkrankungen. Inaugural Dissertation, Jena, 1898.
4. Goodale, R. L.: Some Causes for Failure in Frontal Sinus Operations. ANNALS OF OTOLGY, RHINOLOGY AND LARYNGOLOGY 51:3:648 (Sept.) 1942.

DISCUSSION

DR. JAMES M. ROBB: Dr. Maxwell and Members and Guests, there is a concept in the profession that, since the sulfa drugs and antibiotics have come in, all of the operative procedures on the frontal sinus have gone out. This is not true and I think it is a good thing to have Dr. Goodale present this subject for, though less frequent now, we do have this type of case come to us and we must have the courage to do what it demands.

DR. FRANCIS W. DAVISON: Dr. Goodale has demonstrated beautifully his ability to produce good results by following the principles he has outlined. I would also like to call to your attention the technique advocated by Dr. Jesberg in the 1945 Transactions of the American Laryngological, Rhinological and Otological Society. I have used Dr. Jesberg's technique for several patients who had very large frontal sinuses. The end results were satisfactory and there was only slight cosmetic defect.

FIRST VICE-PRESIDENT MAXWELL: There is one suggestion that I would like to bring up personally. In operating on large frontal sinuses, particularly in years past when we had many cases of osteomyelitis, and more recently in dealing with occasional large mucocoeles, I have found that the coronal incision is very satisfactory. We have not packed the wounds wide open even when treating osteomyelitis. The coronal incision permits excellent exposure of the entire frontal bone and if the supra-orbital ridges are removed it gives access to the ethmoids and sphenoids. The cosmetic result is good.

I noticed that Dr. Goodale's cases had brow incisions with vertical extensions. I wonder if those were packed open?

DR. ROBERT L. GOODALE: I want to thank all the discussers for their suggestions and comments.

I agree entirely with Dr. Robb on the question of the failure of antibiotics in the case of chronic infections such as we have had in the cases that I have presented, with the exclusion of the first case, which was a traumatic situation. We certainly are going to have to consider antibiotics in a somewhat different light in the future because of the emergence of resistant strains of staphylococcus and other bacteria such as *B. pyocyaneus*.

I am interested in Dr. Simpson's use of the burr. I think that this is a very good suggestion. I was trained with the curette and rongeur and I feel happy with them. I think it is like any other tool or instrument which you are trained to use. You have confidence in it and you probably can do better with it than with some other one. But I like the idea of that burr and the approach from above. Of course, in taking out the anterior wall of the frontal sinus I think you can do that in either way just as well but the point that I think Dr. Simpson made was a very good one. You have to be very thorough in reaching the outermost limits of the frontal sinus. You cannot just stop part way. You have got to really take it down to the very outer limit both above and laterally.

As to the Jesberg type that Dr. Davison mentioned, I had one patient, an 8-year-old girl who had a chronic frontal sinus inferior with a localized osteomyelitic process. This was a very shallow sinus laterally, so shallow that I did obliterate it in its lateral position. I didn't want to obliterate the whole sinus at that time, so I preserved the medial portion of the frontal sinus. She came back to see me a year ago and as she is now grown up and married she is thinking of having some bone repair done on the obliterated part of the sinus.

In the large frontal sinus that Dr. Maxwell spoke about, the coronal incision would certainly be a good one. In my case I went through the brow partly because that was the approach that had been used by previous operators and it seemed to me instead of making another incision it would be easier to go through the same one.

In the case I presented in which I had to make a medial vertical incision I didn't realize when I started what I was going to find. The osteomyelitis didn't show up in the x-ray. It was merely a fracture line in the film and I thought that when I started I could do a typical Lynch and therefore went in from a brow incision and then I found what I was up against and extended my exposure by means of a vertical incision up the midline.

REHABILITATION OF PATIENTS WITH CLEFTS
OF THE LIP AND PALATE

DEAN M. LIERLE, M.D.

IOWA CITY, IOWA

(A Motion Picture Presentation)

UNILATERAL VOCAL CORD PARALYSIS

DANIEL S. CUNNING, M.D.

NEW YORK, N. Y.

Two years ago, I read with great interest an article¹ on unilateral vocal cord paralysis written by one of our distinguished colleagues, Doctor Louis H. Clerf. I thought at the time and am of the same opinion still that it was a great contribution to our laryngological literature. This is a subject that has annoyed me for many years.

I was so impressed with this article that I was determined to study our cases at the Manhattan Eye, Ear and Throat Hospital, adhering as closely as possible to Doctor Clerf's clear-cut and orderly presentation of the subject. Unfortunately, I have nothing new to offer but I felt it would be worthwhile to record our cases and compare them with Doctor Clerf's series.

One of the most unsatisfactory conditions we are called upon to treat is hoarseness due to unilateral vocal cord paralysis. The diagnosis is relatively easy to make but to give an accurate prognosis is most difficult unless we are able to determine the cause of the paralysis. These paresis are rarely caused by disease within the larynx itself and as Clerf says "it is not a distinct clinical entity but rather a symptom of some local manifestation." The most common cause is usually some involvement of the vagus or its recurrent laryngeal branch, somewhere between the jugular foramen and its entrance into the larynx proper.

Approximately 10 per cent are caused by some intracranial disease before the nerve leaves the skull such as tumor, abscess, bulbar paralysis or vascular accidents. When caused by a central lesion there is usually some paralysis of the muscles supplied by the glossopharyngeal and spinal accessory nerves, as their nuclei are so closely related in the brain. So the first thing we should do as soon as we note paralysis of a cord is to examine the pharynx, palate and tongue

From the Manhattan Eye, Ear and Throat Hospital.

to see if there is any paralysis of these organs and if so, we can feel quite sure that we are dealing with an intracranial lesion.

One interesting case develops this point: A 65 year old man, seen by Doctor Morley T. Smith at the New Rochelle Hospital, was perfectly well until four days prior to admission when he awakened early in the morning and began to cough up a thick mucus. He developed nausea and vomiting. This continued each day and the patient was unable to take solid food. His voice became hoarse and on the day of admission he spoke in a whisper. He became extremely fatigued and progressively lethargic. No similar episode had occurred in the past. Physical examination revealed paralysis of the left vocal cord, edema of the pyriform fossa with pooling of mucus in this area. There was also sluggishness of the pharyngeal reflexes and difficulty in swallowing. The patient was noted to have pulmonary edema and expired on the day of admission.

The clinical findings of nausea, vomiting, hoarseness, lethargy, paralysis of the left vocal cord and stupor followed by death were indicative of a lesion involving the pons. This lesion, usually an infarction, knocks out the olive as well as the fibers of the tenth nerve, the filaradicularia.

At autopsy, the brain was examined after formalin fixation for 48 hours. With multiple sections there was noted a gray nodule measuring 8 mm in diameter and 16 mm in length within the left side of the pons. This nodule had distorted the olive on the left side so much that its normal convoluted pattern was no longer recognizable. The lesion extended from the olive to within 8 mm of the floor of the fourth ventricle.

Sections through the brain failed to reveal any microscopic changes but for the lesion of the left side of the pons. This lesion was composed of an area of almost complete necrosis of the nerve fibers and nuclei. The lesion histologically consisted of a defect containing irregular strands of degenerated fibrils. The edge of the lesion was fairly well demarcated. Sections through the cervical cord failed to reveal any pathological changes. Sections through the intrinsic arteries of the brain failed to reveal a thrombus. Other portions of the pons were normal.

This lesion was an infarct which was well defined histologically and was undoubtedly on the basis of thrombosis of a left pontine branch of the basilar artery. The artery at this point was of micro-

scopic size and the thrombus could be easily missed histologically and grossly.

This interesting case shows the importance of a histologic study of the brain in these intracranial lesions.

The vast majority of unilateral cord paralysis (about 90 per cent) are caused by peripheral lesions along the course of the vagus or recurrent laryngeal nerve. The left is more frequently involved than the right in the ratio of about ten to one and the reason is probably due to its longer and more tortuous course before reaching the larynx, although in this series the ratio was about two-and-one-half to one.

The position of the paralyzed cord and its tonicity should be noted in all cases whether it is in adduction, abduction or in the cadaveric position. King and Gregg² in 1948, showed by their meticulous and accurate anatomical dissections that 30 per cent of their recurrent laryngeal nerves divided extralaryngeally into two branches, the anterior branch supplying the adductor muscles and the posterior branch the abductor, and this is the reason why some of these paralyzed cords lie in adduction and some in abduction. If the recurrent nerve is injured before this division or if there is injury to the vagus itself, the cord will lie in the cadaveric position, that is, midway between abduction and adduction, completely paralyzed. Hinton and Weeks in their dissections found 76 per cent divided extralaryngeally. Morrison³ found 43 per cent in his dissections of 200 recurrent nerves.

Rustard and Morrison who have done a marvelous piece of work on the anatomy of the recurrent laryngeal nerve, have shown that the nerve may be divided extralaryngeally in from one to six branches on one side with a single branch on the opposite. They are in full accord with Fowler and Hansen as to the location in which the nerve may be injured in thyroidectomy, that is, not at the lower pole as is usually assumed, but at the posterior lateral junction of the middle and lower thirds, just above the point where the chief branches of the inferior thyroid artery enter the gland and the nerve is often in intimate relation with the posterior surface of the gland.

PARALYSIS OF THE VOCAL CORD OF PERIPHERAL ORIGIN

For the 15 years period from 1938 to 1953 inclusive 262 cases were studied in the Bronchosopic Clinic of the Manhattan Eye, Ear

and Throat Hospital. 163 were males and 99 females. Eighty-two had involvement of the right cord, 180 had involvement of the left. The average age was 46. They were divided as follows:

Traumatic	21	
Mechanical	29	
Neoplastic	72	27.5 %
Toxic or Inflammatory	58	
Idiopathic	82	31.3 %

TOXIC AND INFLAMMATORY

Many infections and toxic agents seem to have an affinity for attacking the vagus or recurrent laryngeal nerve. There was but one case of cord paralysis following lead poisoning. This young man, 36 years of age, a chemical engineer, became hoarse quite suddenly overnight. He was seen two days later. Examination revealed an abductor paralysis of the left vocal cord. In the routine physical examination it was discovered that he had free lead in his blood and urine. Although he changed his position to one in the office of the company away from the laboratory where he was inhaling the fumes of molten lead, and his blood and urine became free of lead, his paralysis still persists after three years.

Many of the cases following acute infections such as acute upper respiratory infections, colds, virus infections, etc., regained mobility of the cord in two or three months. Three cases were apparently due to diabetes. In the routine medical check-up it was discovered that they were suffering from diabetes, with high blood sugars. They were all put on diet restrictions, insulin, etc. Two of the cases recovered mobility of the cord in two or three months. The third, although his diabetes was kept under control, did not recover (probably due to degeneration of the nerve). There were two cases of paralysis, with the cord in the cadaveric position, that were due to neuromas of the vagus nerve.

MECHANICAL CAUSES

Under this heading are the cases of cord paralysis that are caused by pressure on the recurrent nerve itself, such as enlargement of the heart, apical tuberculosis, aortic aneurysm, in fact enlargement of any organ or gland that comes directly in contact with the nerve.

This can be readily explained when we remember the course of the nerve from the vagus, how it is in close proximity to the mediastinum, pleura, lungs, trachea and esophagus. In Clerf's series there were 15 cases of cord paralysis due to pulmonary tuberculosis and in all the 15 the left recurrent nerve was affected. In our series there were 11 due to tuberculosis with involvement of the left recurrent nerve, in six cases, and the right in five. In tuberculosis there are supposedly more patients with paralysis of the right recurrent than of the left. Why this should be is unknown as there are just as many patients with involvement of the left apex as there are the right.

NEOPLASTIC CAUSES

As in Clerf's series, the most common cause for unilateral cord paralysis was neoplastic growths. There were 26 cases from carcinoma of the lung either by direct invasion of the nerve or metastasis, 17 from carcinoma of the esophagus, 11 from mediastinal metastasis, 12 from malignant nodes in the neck and 6 from cancer of the thyroid.

Out of the 262 cases studied, 72 were caused by malignancies. One of those followed lymphosarcoma of the neck with an abductor paralysis. This case was treated by x-ray therapy and the cord returned to normal. It is now nine years since therapy. Mobility of the cord was regained three months after cessation of therapy.

In malignancies of the lung, mediastinum, esophagus and breast, paralysis of a cord is a bad omen and usually means that the disease is well advanced and as a rule is beyond hope and that surgery cannot eradicate the disease.

TRAUMA

There were 21 cases following trauma; 17 followed surgery on the thyroid gland; three followed injuries to the neck from automobile accidents; one followed manipulation of the esophagus in the mediastinum in an attempt to resect it for carcinoma. Paralysis of one or both cords following thyroid surgery is not uncommon and as a rule it is not due to cutting the nerve itself but to forgetting that in a large per cent of cases the nerve divides extralaryngeally into two or more branches and one or more of these branches are injured. Another common cause is injury to the branches of the inferior thyroid arteries. In clamping the vessels to control bleeding some of the branches of the nerve are included in the clamp pro-

ducing cord paralysis. It is therefore very important not to injure these vessels and cause bleeding.

It has been reported that paralysis of a cord can develop following child-birth either by pulling on the infant's neck or by improper application of the forceps.

It cannot be stressed too strongly that the larynx should be examined in every case before surgery is done on the thyroid so as to make sure that the cords are functioning normally.

In our attempt to arrive at the cause of these peripheral lesions a complete and thorough physical examination must be done by a competent internist, including the heart, lungs, abdomen, nervous system, blood chemistry, Wasserman, x-rays of the lungs, sinuses and neck. The blood and urine should also be examined for lead and arsenic. Bronchoscopy and esophagoscopy must also be done before the examination can be called complete. In spite of this thorough work-up, there were 82 cases or 31 per cent in which the cause of the paralysis could not be determined. Therefore it was impossible to give an accurate prognosis as to how long the hoarseness might persist.

Some of the patients have had their paralysis for years with no other signs or symptoms. Others recovered spontaneously with a normal functioning cord and a good voice, in all probability the cause being toxic or inflammatory in nature even though we were unable to find it.

TREATMENT

When there is an abductor paralysis, the voice is usually good and no treatment is necessary except in cases where the voice is used more or less constantly as in school teachers, public speakers, singers, etc. Such patients often complain of marked fatigue when using their voices in their accustomed manner.

When there is an adductor paralysis, the unaffected cord is unable to cross the midline to meet its fellow on the opposite side and the voice is very poor. Morrison⁴ has devised an operation for fixing the paralyzed cord in the midline. Such an operation has many technical difficulties and I have not dared to attempt it.

Most cases of cord paralysis should be placed in the hands of a competent voice instructor, as many times it is amazing how much they can be helped.

CONCLUSIONS

1. Paralysis of the cord is not an uncommon cause of hoarseness.
2. In our series, an etiological factor was found in 68.7 per cent. In the remaining cases, 31.3 per cent, no cause could be found.
3. Every patient with an unilateral cord paralysis must be thoroughly studied—complete physical, neurological examination, x-ray and serologic studies.
4. The toxic and idiopathic groups made up more than half of the cases (53 per cent) in our series.

115 EAST 65TH STREET.

REFERENCES

1. Clerf, L. H.: Unilateral Vocal Cord Paralysis, J. A. M. A. (Mar. 14) 1953.
2. King, B., and Gregg, R. L.: Anatomic Reasons for the Various Behaviors of Paralyzed Vocal Cords, ANNALS OF OTOTOLOGY, RHINOLOGY AND LARYNGOLOGY (Dec.) 1948.
3. Morrison, Lewis F.: Recurrent Laryngeal Nerve Paralysis, ANNALS OF OTOTOLOGY, RHINOLOGY AND LARYNGOLOGY, 1952.
4. Morrison, Lewis F.: The Reverse King Operation, ANNALS OF OTOTOLOGY, RHINOLOGY AND LARYNGOLOGY, 1948.

DISCUSSION

DR. LOUIS H. CLERF: Mr. President: The subject of paralysis of the larynx has always been interesting one to me and I am interested in Dr. Cuning's large series of cases and his findings. As he well stated, paralysis of the larynx in itself is not a disease but should be interpreted as a symptom.

His series has borne out the findings in previous studies, namely that neoplasm is the more common cause although I will admit the idiopathic group constituted about one-third. Unhappily there is little to be done for the neoplastic group but we as laryngologists can make our contribution by helping the thoracic surgeon or chest physician. I believe thoracic surgeons now have practically accepted as a fact that the occurrence of paralysis notably of the left cord in a patient with pulmonary carcinoma indicates that the case is inoperable. It is important therefore that the laryngologist and the thoracic surgeon work together in this field because the laryngologist can be of great help.

Another interesting group, one that we discovered a number of years ago, is paralysis usually of the left vocal cord occurring in a patient who had a mastectomy for carcinoma a number of years previously. That commonly is the first manifestation of mediastinal recurrence and is very significant and of prognostic importance.

Much useless and needless procedures probably would be carried out if one does not think of metastasis as a possible cause.

The cases due to traumatic causes, notably thyroid surgery indicate that our surgeons still need to learn a lot about the recurrent nerve and also that the larynx should be examined before as well as after operation, irrespective of the fact that the patient's voice may appear to be normal. A unilateral paralysis occurring following thyroidectomy commonly leaves a normal speaking voice and listening to the voice is a very poor means of examining the patient. It is far better to look at the larynx.

The toxic group also is an interesting one for I believe that many of our idiopathic cases can be put into this. The history is very important. A slight infection, malaise or slight headache, often not incapacitating but occurring at the time that the voice changes appeared is very suggestive that this patient had an infection. We do not know too much about viral infection but as a name it probably takes in the whole category of cases. In my series I found that the best results prognostically were secured in the toxic group because more of those recovered the use of their larynx than in the other groups.

Treatment poses a difficult problem as also does giving a prognosis. I heartily agree with Dr. Cuning that a speech therapist can help enormously, not only in the patient who has an abductor paralysis, with the paralyzed cord in the midline with reasonably good tension but whose voice will falter after prolonged use. Such a patient can be benefitted by speech therapy.

The operative procedure that Dr. Morrison devised I have tried and was successful in one case, but not in another. There is something that can be done for these people from a surgical standpoint if they have considerable voice disturbance due to one cord being abducted and with poor tension. I agree with Dr. Cuning that it ought to be done by someone who is well versed in this field. At times I am not so certain that I am.

DR. EDWIN N. BROYLES: Mr. President, Members of the Society, Dr. Cuning's encyclopedic paper has been very interesting and I merely want to bring up two recent cases that we have had and mention some ideas concerning these cases of idiopathic left unilateral cord paralysis in older adults with no indication of illness, or any toxic condition.

One of the prominent judges in Baltimore suddenly developed a left cord paralysis, complete physical examination failed to disclose any pathological condition. He was kept under close observation and about eight months later developed a mass in his thyroid region. This was removed and found to be a malignant growth. His paralysis was the first sign that demonstrated this pathological change.

Then in another case of carcinoma of the mediastinum a left cord paralysis was present for about a year before any other condition could be demonstrated.

It seems to me, and I have talked it over with some of the surgeons in Baltimore, that perhaps in these cases it would be wise to explore the left recurrent nerve, to follow it down around the aorta and back up and try to find the lesion.

I might say too that we have not done this as yet but we are seriously thinking about the possibility of exploration of the nerve, follow it down and follow it back up in the hope that in some of these cases we can locate early the pathological change that is causing the paralysis.

Certainly surgeons, in cases with an enlarged thyroid and a paralyzed vocal cord, feel that in most cases the thyroid is malignant. We have never seen a benign

thyroid cause a paralyzed vocal cord and if the vocal cord is paralyzed, the chances are we are dealing with a malignant thyroid.

Also in the case of this judge—I might bring this point up—with this tumor we never could decide whether it was thyroid or thymus or what. All the pathologist could say was, it was a carcinoma. At operation his left recurrent nerve had to be removed. He wanted to go back to the bench and keep doing work. Now he uses a small microphone and a loudspeaker and gets along very well with this aid to his speaking voice.

Certainly in a paralyzed vocal cord many people regain their speech but one thing they cannot regain is the singing voice, especially for the high notes, and if I am in doubt about the question of paralysis I ask the patient to try to sing a high note.

DR. CHEVALIER L. JACKSON: Mr. Chairman and Gentlemen, I have been looking forward to Dr. Cuning's paper with particular interest because just a few weeks ago I met two of these idiopathic cases on two successive days, on one day a right recurrent laryngeal paralysis and the next day a left recurrent laryngeal paralysis. Both of these cases remained mysteries after very careful study by x-ray and physical examination. We did not do endoscopies on either one because the x-ray studies were entirely negative. Perhaps they should have been done. I had hoped that Dr. Cuning would give us some further light on the etiologic explanation of this 60 per cent of cases but I don't mean to criticise his analysis because I think the larger the series of cases that are so analyzed the nearer we shall come to correct diagnosis.

I would like to ask Dr. Cuning one question: whether he has had any results at all from medical treatment in these cases of toxic or inflammatory types; whether he thinks it is worth while to give these patients any medication? Then one other thing, I have been dismayed by a few cases of left recurrent paralysis following diverticulectomy, even when the operation seemed very satisfactory in every other way, and should like to urge that great care be taken to avoid trauma to the left recurrent laryngeal nerve in diverticulectomy as in thyroidectomy.

DR. JULIUS W. MCCALL: I have enjoyed Dr. Cuning's very timely paper very much. I get the impression that unilateral vocal cord paralysis instead of causing hoarseness causes a voice weakness. These patients will say in the morning when they get up their voice is quite normal and as the day progresses and the use of the voice it becomes more and more weak and more difficult to speak. I think that instead of referring to this as a voice hoarseness that it might be better to speak of it as a voice weakness.

DR. BENJAMIN H. SHUSTER: Mr. Chairman and Gentlemen, thank you for the courtesy.

I want to make a comment on one phase of Dr. Cuning's talk and that is his first remark emphasizing the necessity of thinking in terms distant from the lesion. He was quite emphatic about it and then Dr. Clerf's remark, that just to look at the larynx does not necessarily give the picture of the entire situation, adds to the emphasis. That recalls to mind a case that I saw last week which is apropos.

The Department of Internal Medicine in the hospital sent a patient down for evaluation, a patient who suddenly became hoarse, at the same time he became weak, could not stand up and veered to the left. What they wanted was evaluation of his hoarseness and because he was a little ataxic they thought we might as well do a Barany test. I looked at the vocal cords and there was a paralysis of the left vocal

cord. I did a caloric test on both sides. The left side gave a normal reaction in type but rather poor compared to the one on the right side. Apparently a brain tumor was suspected.

Because of some interest I have in neurologic phases, I began to think—left cord paralysis, ataxia, veering to the left side and sudden onset of some amount of dizziness, maybe there is something else wrong neurologically, and then it struck me—the syndrome, inferior-posterior cerebellar artery thrombosis. I immediately set about to check it. I took a hot laryngeal mirror and put it on the right arm and he did not think it was so hot. I kept it there for half a minute or so. Then I put it on the left arm and he jumped. In other words, he had a spinal thalamic involvement on the opposite side of the vocal cord lesion, together with some numbness of the face on the left side which is also the side of involvement of the vocal cord. The only thing he did not have to suit the picture was the Horner's syndrome, but the fact of thinking in terms distant from the local lesion was here important. I believe the Department of Internal Medicine should have thought about it themselves. We were just messenger boys who were asked to take a look and tell them what we see instead of trying to give an interpretation. It certainly is important that we think in terms of distant things in relation to the lesions in our specialty.

DR. FRANCIS L. WEILLE: Mr. Chairman, Fellows and Guests, I would like to ask Dr. Cuning one question. I was very much interested in his reasons for the position of the vocal cord after injury and I would like to ask him if he attaches any significance to the anastomotic branch that runs from the superior to the inferior laryngeal nerve, which has been so beautifully demonstrated by Bassett at Stanford University.

DR. DANIEL S. CUNNING: I want to thank all the discussers who were so kind and generous.

Dr. McCall spoke about calling it not a real hoarseness. I think there are all phases of hoarseness. The one occurring in cord paralysis is not like the one due to carcinoma of the cord. I think after a while when you hear those patients talk you can almost make a diagnosis by their voice; in fact, my nurse does it today; I don't mean she is 100 per cent right but nine times out of ten she is. I don't know whether you call it a hoarseness or weakness but as far as I am concerned I will still call it hoarseness.

Dr. Shuster spoke about the 10 per cent of cases that are caused by spinal cord or brain lesions. I think we should always remember even though this is a small percentage, nevertheless it is one out of ten. It does not take long to see whether the pharyngeal reflexes are present or not. In fact, it is always well to think of the possibility of an intracranial lesion before we start working on the 90 per cent that occur peripherally.

Dr. Jackson asked if we gave medication for these pareses. Yes, Dr. Luther MacKenzie, our very capable internist, treated many of these cases with vitamins, potassium iodide, cortisone, etc. None seemed to help.

He also asked if any paresis followed surgery for diverticulum of the esophagus. There were none in our series.

As I said in the paper, there is one thing I dread more than any laryngeal lesion coming in the office—that is a patient with paralyzed cords. I figure 50 per cent of the cases are made up of the idiopathic and toxic causes. If you cannot find out the cause of these pareses you cannot do much about them. Many of these cases have gone on for years and years. There is simply the hoarseness and no other signs, symptoms, sickness or anything else.

PROGRESS IN LARYNGOFISSURE

MERCER G. LYNCH, M.D.

NEW ORLEANS, LA.

Thyrotomy or laryngofissure is one of the oldest surgical procedures in the repertoire of the present day laryngologist. Strangely enough, this operation, which has come to be associated with carcinoma of the larynx, was first employed for removal of a foreign body. It was not until 1851 that it was used as an approach to the surgical treatment of laryngeal carcinoma. The procedure received increasing attention in the early twentieth century but so few reports appeared in the literature that for a time its value was questioned. During this period the literature was absorbed with discussions of the surgical treatment of virulent infections, which were so prevalent. However, antibiotics have now controlled this problem and during the past ten years attention has been focused upon preventive medicine, control and cure of chronic infections and cancer. During this time the laryngofissure operation has become increasingly popular. It has proved to be an accepted operative procedure of unquestionable value not only in the arrest of cancerous growths of the larynx but also in the conservation of speech in these unfortunate patients.

As our technique has improved with experience, we have broadened our indications for the procedure. The original indication for laryngofissure was a lesion limited to the cordal level with good motion of the cord (Fig. 1). This is still considered the ideal type of case, and we have obtained the highest incidence of cure (86 per cent) in this group. Eighty per cent of these had Grade I or Grade II carcinoma, the remainder having the higher grades. Of the 1.4 per cent recurrences in this group, 85 per cent were Grade III or IV carcinomas.

It has been shown that the higher the degree of malignancy the further the spread of the lesion beyond the gross evidence of invasion. Therefore, in the past eight years we have performed much wider

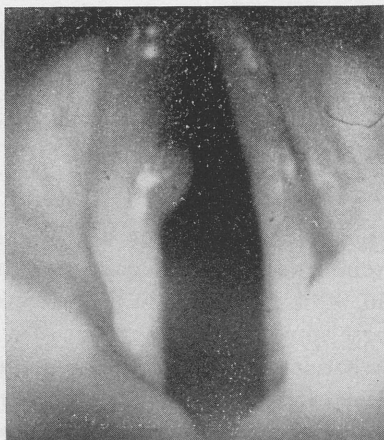


Fig. 1.—Ideal case for laryngofissure, and in low-grade carcinomas, for intralaryngeal extirpation.

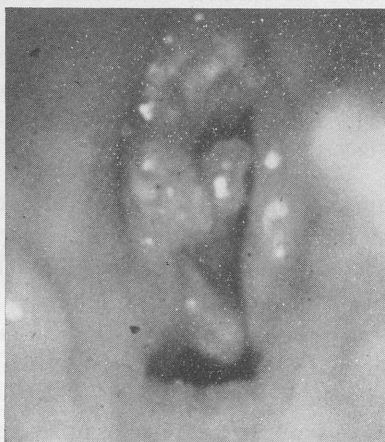

Fig. 2.—Malignant neoplasm of left vocal cord crossing the midline at the anterior commissure and extending to the vocal process. The cord alone is involved and motion is good. Although laryngofissure is usually considered contraindicated in this type of lesion, good results have been obtained in Grade I and Grade II carcinomas following extensive laryngofissure and cauterization.

excision of tissue and much more extensive cauterization than formerly. As a result of this the percentage of cures to date has been even higher (90.5 per cent). The 10 per cent recurrences in this group still are predominantly in the Grade III and Grade IV types. However, in the entire series the incidence of recurrences is not nearly this high, the reason being that in the majority of instances in which the lesion has crossed the commissure anteriorly but in which there is still good movement of the cords (Fig. 2) laryngofissure may still be done successfully. Broyles¹ has shown that if the lesion approaches the anterior commissure, often it extends beyond the insertion of the conus to invade the cartilage in small islands. Therefore, in lesions involving the commissure a section of the thyroid cartilage anteriorly surrounding the insertion of the conus must be removed. This has enabled us to do more extensive laryngofissures than formerly. Our results have warranted widening the field of indications by being radical and yet at the same time we have been able to conserve a functioning larynx.

If the anterior commissure is disturbed, and this is especially true in crossing the midline to remove a portion or all of the opposite cord, a web will result. Previous attempts at correction of this web have met with varying degrees of success. However, we have now adopted the technique of McNaught² in which a tantalum splint (Fig. 3) is inserted between the scarred tissues, which is nature's attempt to regenerate a cord. This requires two surgeons. One operator sitting at the head and using the suspension laryngoscope first removes the excess scar tissue up to the anterior commissure. The second surgeon then reopens the larynx but through a much smaller incision than the original laryngofissure incision. The opening is made first long enough to insert the tantalum splint. The first operator then guides this splint into the correct place, being sure it separates the tissues in the midline and that it is not too long so that there is no contact with the posterior wall of the larynx. This is usually removed in six to eight weeks under local anesthesia as an ambulatory case. We have found it unwise to insert this splint at the time of the original laryngofissure procedure because of the tendency to excessive granulation tissue as a result of this foreign body. However, six to eight months after operation when a firm web has formed, the extent of scar to be removed, and most importantly, the amount to be left for a good substitute cord, can then be accurately determined.

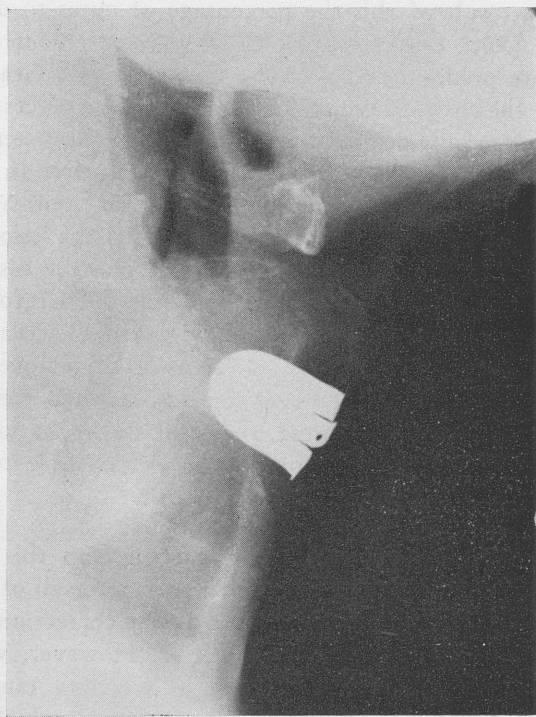


Fig. 3.—Roentgenogram showing laryngeal splint in place.

Our indications have been extended still further to include cases with early partial limitation of motion (Fig. 4) due to extension of the growth beyond the caudal line laterally or posteriorly to the attachment of the cord at the vocal process. However, once the arytenoid itself is involved or the growth is completely or almost completely fixed, laryngofissure is contraindicated. With limited motion by extension laterally subperichondral dissection is done, which incidently is done in all cases. The false cord ventricle and subglottic tissue to the lower border of the thyroid cartilage may be removed in this manner. Following removal by sharp dissection, the raw surfaces superiorly, inferiorly and posteriorly are subjected to extensive cauterization with the Bovie unit. If, however, the growth extends to the vocal process (Fig. 5), not only is the entire cord removed but also a portion of the arytenoid cartilage, followed

again by extensive cauterization. Cauterization in this area causes considerable reaction, and usually for the first two or three days patients are fed intravenously or by means of a Levine tube, as they have extreme difficulty in swallowing due to the reaction as well as pain. The laryngofissure operation may be carried even further with the recent procedure presented by Figi³ in which the ala of the thyroid cartilage may also be removed followed by skin grafting.

In none of these procedures has tracheotomy been necessary, either preliminary to or in conjunction with laryngofissure. The laryngofissure operation is performed under local anesthesia. Elimination of the tracheotomy has resulted in considerable reduction in the duration of postoperative hospitalization, the average time in the hospital being from five to seven days.

Complications of laryngofissure have been minimal. Emphysema is, of course, the commonest, because no tracheotomy is performed. It develops in only about 10 per cent of cases. The secret of preventing development of this complication is tight closure of the cricothyroid membrane. However, as our scope of indications has widened to include cases in which a portion of the anterior border of the thyroid cartilage has been removed, slight dehiscence remains. Tight closure of the perichondrium plus use of an elastic bandage prevents development of emphysema in many cases. In these cases a small twisted dermal drain is inserted and a direct pathway for the escape of air is established if this should occur. Emphysema develops superficial to the superficial fascia, may extend to the chest or even up to the eyes but does not embarrass respiration, and even when extensive, disappears by the third or fourth day. Secondary hemorrhage is exceedingly rare, having occurred in only two of our cases. Both times tracheotomy was necessary. In one the larynx could be packed following tracheotomy and general anesthesia but in the second the wound had to be reopened and the bleeding vessel ligated. Both of these occurred from one to two weeks postoperatively when the slough of the cauterized tissue was separating. In only one case was tracheotomy indicated postoperatively and this resulted from radical removal and more extensive cauterization producing secondary edema of the arytenoids.

In the treatment of carcinoma of the larynx we employ either laryngofissure or laryngectomy. With experience the indications for the former have gradually been broadened. Figi³ and Pressman⁴

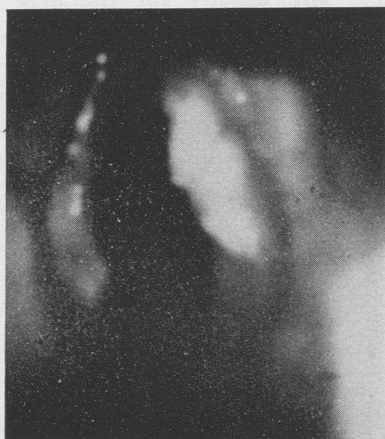

Fig. 4.—Borderline lesion with involvement beyond the cord and limited movement of the cord. Wide laryngofissure and cauterization even in Grade III carcinomas give good results.

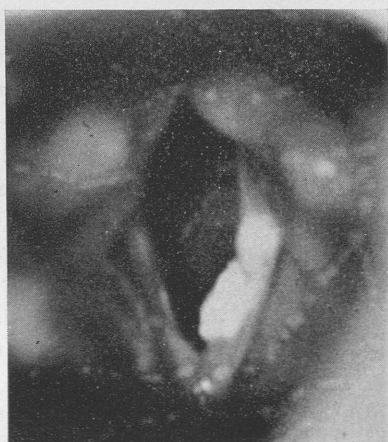

Fig. 5.—More advanced case with involvement of the vocal process necessitating partial removal of the arytenoid. Following laryngofissure an adequate airway is provided but a poor voice results.

have devised procedures to widen the scope even more in attempting to maintain an adequate airway and a functioning larynx. The wider the scope of laryngofissure, the more closely one approaches the line of demarcation between this procedure and total removal of the larynx. Therefore, these patients have to be watched more closely and for a longer period of time than those who have had less radical operations. Naturally, the incidence of recurrence is greater. However, in view of the fact that 73 per cent of our patients have not had a recurrence, this means that many more patients have been spared loss of their voice and laryngeal airway. In the remaining 27 per cent of recurrences, a further laryngofissure procedure is not attempted; laryngectomy is then the operation of choice. When these patients have returned for frequent periodic examinations, arrest of the disease has been obtained in 85 per cent of the recurrences.

Since the original laryngofissure operation, progress has been phenomenal. We are gradually approaching the possibility that in the majority of patients with cancer of the larynx adequate removal of the tumor can be accomplished without destroying the function of the larynx. This possibility, however, can be achieved only by more widespread education and preaching of the doctrine of the danger of persistent hoarseness so that patients may be seen early, as herein lies the secret of successful arrest of laryngeal carcinoma and at the same time preservation of a functioning larynx.

3503 PRYTANIA ST.

REFERENCES

1. Broyles, E. N.: New Operative Procedure for Laryngofissure. *South. M. J.* 42:825-827 (Oct.) 1949.
2. McNaught, R. C.: Surgical Correction of the Anterior Web of the Larynx. *Laryngoscope* 60:264-272 (Mar.) 1950.
3. Figi, F. A.: Hemilaryngectomy With Immediate Skin Graft for Removal of Carcinoma of the Larynx. *ANNALS OF OTOTOLOGY, RHINOLOGY AND LARYNGOLOGY* 62:400-411 (June) 1953.
4. Pressman, J. J.: Cancer of the Larynx; Laryngoplasty to Avoid Laryngectomy. *A. M. A. Arch. Otol.* 59:395-412 (Apr.) 1954.

DISCUSSION

DR. CHEVALIER L. JACKSON: Mr. Chairman and Gentlemen, I am glad that someone has raised his voice to speak in favor of laryngofissure in these days when the pendulum seems to be swinging away from it in many places. I say this in spite of having agreed with and still agreeing with Dr. Clerf's presentation and his recommendations of yesterday. I think that what Dr. Lynch said about the indications for laryngofissure has been well put. He has said the indications have broadened. They have broadened, but also in a way they have narrowed, because certainly the indications for the old classic simple laryngofissure have narrowed. The only thing that has permitted broadening of indications has been a broadening of techniques.

Anterior commissure involvement has never seemed to us a contraindication to laryngofissure provided the lesion was limited to the cordal level, and even before the days of Dr. Broyles' "anterior commissure tendon" we got away with a very high percentage of cure in cases where we used the technique suggested by Chevalier Jackson in 1922, of dividing the cartilage from the outside, separating off the inner perichondrium and then excising the lesion after careful inspection by raising a flap on the less involved side and looking at the lesion. The excision was generally carried out without removal of cartilage. However, I think that a great advance has been made since Dr. Broyles' study of the anterior commissure tendon and it is our current practice in anterior commissure cases to remove all of the underlying cartilage. Instead of dividing the cartilage in the midline by shears or saw, we divide the cartilage to the less involved side and remove part of the cartilage on one side and most of the thyroid ala on the other side, and furthermore, if there is the slightest impairment of motion, it is our practice to remove this *en bloc* with no perichondrial resection.

With regard to the web formation that develops in some of these cases, we have found that the use of the suspension suture suggested by Gabriel Tucker some years ago, anchoring the epiglottis forward in all cases in which its attachments have been divided even on one side. If you cut the anterior end of the ventricular band on one side and certainly if you have divided it on both sides, then the epiglottis must be anchored forward to prevent shortening of the anterior-posterior diameter of the larynx.

Dr. McNaught's technique seems very interesting. Frankly I have not tried it myself. I plan to and I intend to!

Finally, I would like to say, with regard to the term, that these operations really aren't just "laryngofissures." We are dealing with a partial laryngectomy here. Hayes Martin always favored the term "partial laryngectomy" and I think we have to use that term for all of these procedures. It is only the simplest clipping of the thyroid cartilage or division with a saw that can be called laryngofissure.

Lastly, a word of warning! I would say that those of us who are interested in preserving laryngofissure and other forms of partial laryngectomy, for the good of our patients and for the good of a tried and trusted procedure, should see to it that the indications are not widened too much, in order not to bring disrepute on partial laryngectomy; we should take care to use it in appropriate cases only!

We are at this time making a 25 year follow-up study that will be presented at the A. M. A. meeting in Atlantic City as a scientific exhibit. I am not going to give any figures at this time because the tabulations are not yet complete.

DR. HENRY M. SCHEER (N. Y. C.): Mr. Chairman, I thank you for the courtesy, allowing me to speak here before your very fine group of Fellows of the Association.

The title of this presentation, "Ten Year Progress of Laryngofissure Operation," interested me very much, and Dr. Lynch certainly covered a great portion, the greatest portion of what this laryngofissure procedure should be used for and what cases, dealing particularly with carcinoma of the larynx.

I wonder, since I am speaking to an audience of laryngologists of the nation, how many of you have applied the laryngofissure operation for the correction of bilateral abductor paralysis of the vocal cords. We all know of Orton's, Kelly's and other procedures, extralaryngeally, and we know of Thornell's intralaryngeal approach.

I am interested in bringing this before you for this reason: my son wrote a paper about three years ago which appeared in the Archives of Otolaryngology which probably most of you have read. That is why I put the question. I wonder how the results have been with the application of this rather simple approach to correction of bilateral paralysis.

In the very first case that he did, at which I assisted him, the patient was wearing a tracheotomy tube for nearly 2 years following very extensive removal of malignant thyroid gland, during which bilateral abductor paralysis occurred. The patient became a little concerned about his wearing the tube but was feeling well otherwise. Dr. Alan Austin Scheer studied this out in the cadaver room and approached the arytenoidectomy via a laryngofissure. It is an extremely simple exposure and is performed under local anesthesia. The paralyzed vocal cord is tied back to the thyroid cartilage with a stainless steel suture. That patient now for three years is breathing through his larynx. The tracheotomy tube was removed shortly after the surgery. I am curious to hear whether anyone has done it. I know several reports have been made to him by men throughout the country but speaking to the laryngologists of the nation I was interested to hear from you on it.

DR. MERCER G. LYNCH: I should like to thank Dr. Jackson and Dr. Scheer for their discussions.

As you recall, I mentioned that in our procedure we did laryngofissure, laryngectomy or intralaryngeal removal. There is a borderline between the laryngofissure and laryngectomy and in these cases instead of doing a hemilaryngectomy and removal of only half the larynx, personally I am much more satisfied when the case is this extensive and the indications are for a hemilaryngectomy, to do a complete laryngectomy on the patient.

In regard to the web formation, we have tried all sorts of things. I have not used Dr. Tucker's method of suturing the epiglottis forward but we have used the removal of the scar and the insertion of a splint. Formerly the procedure used was puncturing the webb anteriorly and inserting a rubber band for a period of six weeks until epithelization had taken place within this small opening and then removing the scar. We found by far the best results with the use of the tantalum splint. You would be surprised how well the patients tolerate it. It does not necessitate a tracheotomy and they are fairly comfortable for six weeks so far as swallowing is concerned, and so far as activity is concerned while carrying this splint.

Dr. Scheer, I think Dr. Walter Hoover of Boston reported years ago the use of submucosal dissection for bilateral vocal cord paralysis and he has reported some very nice results in this regard.

GENERAL TONSILLECTOMY

SUGGESTIONS FOR MANAGEMENT AND PERITONSILLAR INJECTION

PAUL M. MOORE, M.D.

CLEVELAND, OHIO

In glancing through the literature it would seem that the subject of tonsillectomy has been milked dry. It is hoped that it will be possible to express a few more drops with sufficient flavor to hold your interest. A good share of this presentation will be devoted to a condensation of many things that have been well established. A portion will deal with a procedure which has proved very satisfactory in the hands of the author. Lastly a few ideas will be offered as to how ACTH and cortisone may affect the operation for better or for worse.

There has been a considerable amount of comment concerning the emotional and psychological preparation of the child for surgery.¹⁻³ This phase of the problem is very important. Fortunately the majority of today's parents do an excellent job of telling the child why the operation is necessary and what he may expect. One mother called attention to a very clever record by Mercury Childcraft entitled "Peter Ponsil Lost His Tonsil." In this recording a little boy tells of his experiences in song and rhyme against a background of catchy music. This makes an interesting adventure of the whole experience and helps prepare the child for his operation. When one of the parents is nervous and fearful and transmits the fear to the child, there may be a real problem.

In our hospital the parents bring the child to the hospital the morning of the operation and stay with him until he is taken to surgery. They are with him through the rest of the day after he returns from the recovery room. He is thus shielded from the feeling of being abandoned among strangers. The operated cases are kept separated from those awaiting surgery. The ideal arrangement is the recovery room where the patients who have been operated upon remain until they have recovered from the effects of the anesthetic.

This not only keeps them from being seen by those awaiting operation, but insures careful supervision during the immediate post-operative period. Oxygen and suction are readily available. If there should be any bleeding or respiratory difficulty they are where they can receive immediate and expert attention.

There has been tremendous progress in considering the child's emotional reaction to surgery since the 1920's. At that time I observed the way tonsillectomies were done in a world-famous clinic in Europe. The nurse would sit down with the child in her lap, with its legs between hers. She then clamped a scissors hold on the child's legs and held the upper part of the child's body with one arm. A mask was then half filled with ether and the patient's face forced down over it. When the crying and struggling ceased, the patient was held upright while the surgeon inserted a mouth gag and operated as rapidly as possible without looking for bleeders. Even so, the child was beginning to struggle and cry by the time the adenoids were reached. Compare this with the consideration the little patient now receives. It is hard to imagine psychic trauma occurring when the child goes to sleep under the anesthetic while visiting with the anesthetist about pets, games or school.

The question of preanesthetic sedation of children has been raised by Eckenhoff.⁴ He studied the effects of various combinations of atropine or scopolomine with pentobarbital and morphine on 1500 children. He stated that crying increased such hazards of anesthesia as cyanosis and respiratory depression. Scopolomine, pentobarbital and morphine reduced the incidence of crying but also produced more frequent respiratory depression and cyanosis. He felt that pentobarbital should be used but that morphine was contraindicated in children. We have used nothing but atropine in children under the age of 14. This is given in graded doses according to the age and size of the patient, as worked out by the department of anesthesia. One-half hour before operation the following doses are given:

0 - 2 years	no atropine
2 - 3 years	1/400 gr atropine
3 - 4 years	1/300 gr atropine
5 - 12 years	1/200 gr atropine
13 - 20 years	1/150 gr atropine

At ages over 14 years they are given sodium pentobarbital $1\frac{1}{2}$ to 3 gr and morphine $\frac{1}{6}$ to $\frac{1}{4}$ gr. We prefer not to take chances with narcotic respiratory depression in children.

Some years ago I would approach an adult tonsillectomy under general anesthesia with a deep feeling of no enthusiasm. Added to the length of time required to anesthetize the patient was the excessive amount of bleeding usually encountered during the operation. The bleeding makes it difficult to keep the operation under adequate visual control. This in turn makes it almost impossible to hug the surgical capsule during the dissection and results in injury to the blood vessels lying in the muscle fibres just outside the capsule. More bleeding results and there are more vessels that require ligation. This is a marked contrast to the small amount of bleeding in the average local tonsillectomy in which the gag reflex has been controlled by the topical application of cocaine. Here the surgical anesthesia is produced by the injection of procaine with six minims of epinephrine to the ounce. The injected fluid distends the mucous membrane and enables the surgeon to stay close to the surgical capsule and so avoid the blood vessels just beyond. The epinephrine produces contraction of the blood vessels so that there is very little bleeding unless a vessel of some size is encountered. Very often no ligatures are required.

It was decided to apply the principle of peritonsillar injection to the tonsillectomies under general anesthesia to see if, 1) it would reduce the bleeding during the operation, and 2) if it would facilitate the dissection. The results have been most gratifying and this method has been used routinely on children as well as adults for several years. The first trial, however, almost caused the idea to be abandoned. The surgical nurse misunderstood the directions. One tonsil was prepared by injecting around it and promptly turned dead white. When asked what solution she had provided, she said 1-1000 adrenalin. Needless to say, that tonsil was removed in record time. No harm resulted but several weeks passed before the procedure was tried again.

No originality is claimed for this method. Many of you may use it—at least in your adult cases. A careful search of the literature reveals only two papers mentioning peritonsillar injection in preparing adult general tonsillectomies. In both of these instances the injection was used for purposes of anesthesia. Blaisdell,⁵ report-

ed the use of sodium pentothal and curare in 1949. He used local injection of procaine. He apparently did not use epinephrine, since he spoke of the excessive bleeding in his cases. Johnson,⁶ in 1952, reported 189 cases of 14 years and older in whom he used pentothal sodium, curare, pontocaine and 1 per cent novocaine with six minims of 1-1000 adrenalin to the ounce. Usually less than 10 cc of the novocaine mixture were used for both sides. He used no intratracheal tube and encountered no postoperative laryngospasm. In 1944 Grant,⁷ recorded a case of postoperative adenoid bleeding controlled by the injection of 20 cc of normal saline solution in the adenoid bed. Ball,⁸ in 1948, advised the use of 1 per cent procaine with 30 minims of 1-1000 adrenalin chloride to the ounce as an injection to control postoperative tonsil and adenoid bleeding. If there have been any other reports of this procedure in the literature they have probably been buried in obscurity by the ambiguous nature of the titles selected for the articles. None have been found where it has been used routinely in children as well as adults.

METHOD

The patient is placed with the head low and well crowned so that the blood will pool in the nasopharynx and will not run down toward the larynx. The Davis mouthgag with tongue blade attached is used. The adults are given sodium pentothal induction and intratracheal anesthesia with the intubation tube through the nose. The children receive vinyl ether induction and no intubation is used. Our anesthesiologists are all medical doctors and are experts at intratracheal anesthesia. They feel, as we do, that it is not necessary in the children and carries with it the added possibility of producing postoperative edema of the larynx in them. Seated at the head of the patient and using the Davis mouth gag the operator can easily inspect the larynx at any time by lifting up the epiglottis with the blunt dissector end of the pillar retractor.

Normal saline solution with six minims of 1-1000 epinephrine to the ounce has been selected for the injection. One per cent procaine with a similar amount of epinephrine was used for a time. This was abandoned for the normal saline because it was felt that the added anesthesia was unnecessary. The injection is carried out in the same manner as that which is used for the injection of procaine in the local tonsil operation. The injection is started at the upper pole just beneath the mucosa at its junction with the tonsil. This is made very superficially so that the membrane is ballooned out. The

needle is then pushed in deeply and the solution is injected around the upper pole of the tonsil. Injection is then made just beneath the mucous membrane of the posterior and anterior pillars. These injections are aided by pulling up the free margin of the soft palate with the pillar retractor, thus tensing these structures. An injection is then made just beneath the lower pole, and then thrusting the needle more deeply a second injection is made in the same place. From two to three cc of the solution is usually used on each side. Each tonsil is then grasped, pulled forward and up and 1.5 cc is injected through the anterior pillar lateral to the tonsil mass. In all the deeper injections the plunger should be pulled out to be sure that no blood vessel has been entered. After a moment's wait, to give the solution a chance to exert its action, the dissection is begun.

A variety of injections have been tried in the adenoid area. None of them has succeeded in reducing the amount of bleeding during their removal. Injection is now used only after their removal to help control any excessive bleeding from this area. The solution is injected and then pressure is brought to bear with a sponge. If this does not control the bleeding, a sponge, moistened with adrenalin and dusted with tannic acid powder, is applied and any visible blood vessels are ligated. In applying ligatures in either the adenoid or tonsil areas a slip knot is preferred to a needle ligature. Although a needle ligature will not slip off, the needle itself may penetrate a deeper vessel.

There has usually been very little bleeding during the removal of the tonsils, even in the adult cases. This has been sufficiently obvious for the anesthesiologists, who handle the suction as well as the anesthesia, to remark about it on many occasions. We had thought of measuring the blood lost during this part of the operation and comparing it with that lost in cases done without the peritonsillar injection. We were deterred by the report of King,⁹ who measured the blood loss in 176 adenotonsillectomies in children of 2 to 11 years of age. He was investigating the effect of Vitamin K on the blood lost at operation. In the Vitamin K group the blood lost ranged from a maximum of 150 cc to a minimum of 20 cc. In the control group it ranged from 165 cc to 14 cc.

CONTRAINDICATIONS

The solution used for the peritonsillar injection consists of normal saline to which has been added six minims of 1-1000 epinephrine

to the ounce. Usually 10 cc or less is used in the preparation of the tonsils for dissection. Thus only two minims of 1-1000 epinephrine is used. Another minim may be used in helping control the adenoid bleeding. In spite of this small amount of epinephrine, it is felt that it should not be used in certain situations. In these cases normal saline alone is injected.

1. Epinephrine is not used in children under the age of two years. Neither do they receive any atropine. It is felt that it is unwise to use any drugs other than antibiotics at this age.

2. Epinephrine increases the blood sugar. It will therefore increase the need for insulin in diabetic children. It should not be used in these cases.

3. Hosler¹⁰ sounds a word of caution, especially regarding the use of epinephrine in coronary sclerosis. To quote—"An irritable heart or one under the influence of an anesthetic may be the seat of sudden precipitation of ventricular fibrillation by epinephrine." He states that this is due to the drug causing the general rate of oxidation of all tissues to increase and therefore creating a greater need for oxygen.

4. Hamilton¹¹ advises against the use of epinephrine with cyclopropane. He states that cyclopropane not uncommonly produces cardiac arrhythmias and that epinephrine further enhances this tendency. The epinephrine-normal saline mixture has been used on one adult patient under cyclopropane anesthesia without any untoward results.

DISCUSSION OF CASES

Although this method was instituted in 1943 only the last 312 cases have been surveyed for this study. In this group there were 183 patients, aged three years through six years. The patients under the age of three years numbered seventeen and those over fourteen numbered twenty-eight. More adults are asking for general anesthesia. With the improvement in the technique of anesthesia and the use of the peritonsillar injection these patients are being granted their wish.

No figures concerning the incidence of primary bleeding were found in the literature. The question whether injection of normal saline with epinephrine will increase the number of primary hemorrhages may be raised. There is no reason to suppose that this would

occur more frequently in the general tonsillectomies than it would in the local operation where the same injection is used with procaine and epinephrine. There were six cases of primary hemorrhage, or 1.923 per cent, although no patient was allowed to leave the operating table until both tonsillar fossae and the adenoid bed were dry. Three of these cases were bleeding from the adenoid bed and three from a tonsillar fossa. The tonsillar bleeding was felt to be the result of ligatures slipping off during the recovery from the anesthetic.

The last ten years have produced many careful and excellent investigations into the causes of secondary or late bleeding in adeno-tonsillectomies.¹²⁻²³ The great majority of these have incriminated acetylsalicylic acid. In 1934 Ersner, Myers and Ersner²⁴ conducted extensive experiments on the effect of saliva on the clotting of blood. They found that saliva reduced the clotting time from 10 to 15 minutes down to 2 to 3 minutes. Acidification of the saliva prevented it from exerting this clotting action. Acetylsalicylic acid used locally in the mouth in post-tonsillectomy cases is changed by the saliva into free salicylic acid. This acid tends to digest and loosen the coagulum in the fossae prematurely.¹⁴ Bleeding results and the normal coagulating effect of the saliva is prevented by its acidification. In 1945 Singer²³ called attention to the lack of late bleeding in tonsillectomies in Central Europe where they did not use acetylsalicylic acid as compared with the United States where it was used freely. Neivert,¹⁹ in 1945, stated that acetylsalicylic acid lowered the blood prothrombin and thus tended to produce bleeding from the wound. Livingstone and Neary¹⁸ disagreed with this.

The present series has been divided into two groups. In the earlier group, comprising 89 cases, the local use of acetylsalicylic acid was not only allowed but advised. In this group there were six instances of secondary bleeding. Two of these were from the adenoid area. This represents a percentage of 6.741. In the second group of 223 cases the local use of acetylsalicylic acid was discouraged and more recently prohibited. In this group there were only three instances of secondary bleeding, or 1.345 per cent.

Penicillin is used in selected cases. Vitamin K is given both pre- and postoperatively as a routine measure.

EFOCAINE

Recently the literature has contained a number of reports on the use of a longacting local anesthetic, efocaine, to control post-

operative pain in various parts of the body. Penn²⁵ and Allen²⁶ reported good results in relieving post-tonsillectomy pain. They both warn against injecting the drug superficially. The fossae must be completely dry before the injection is made. Allen states that injection in the region of the upper pole produces edema of the uvula and soft palate. Davidson, Boles and Snyderman²⁷ injected only one side in each patient. The differential in pain between the two sides was so variable that they concluded that the drug was of questionable value.

Marks²⁸ encountered such a marked edema of the uvula and soft palate in one patient that he considered the possibility of having to do a tracheotomy. He reported good relief of pain but encountered large pale sloughs at the sites of the injections by the seventh postoperative day. Half of his cases had marked secondary hemorrhages.

An ominous note of warning is given by Angerer, Su and Head.²⁹ Their patient was suffering from a bilateral pulmonary tuberculosis. A thorocoplasty had been done on the left side. There was encapsulated fluid in the pleural cavity on the right side. The pain on the right side was severe and efocaine was injected in the right eighth intercostal space in the posterior axillary line. This injection was made without preliminary aspiration. The injection was made slowly. After 1.5 cc had been injected the patient suddenly complained of severe, electric, knife-like pains in the back and radiating down both legs. Both legs were soon paralyzed and the patient collapsed. Death occurred 44 hours later. A transverse myelitis of the spinal cord, thrombophlebitis of the intercostal vein and thrombosis of the intercostal artery were found at autopsy.

It is to be noted that this case was published after the reports of Penn, Allen, Davidson et al and Marks. The tonsillar fossae are as near the spinal cord as the posterior axillary line. Is post-tonsillectomy pain of sufficient magnitude to justify such tremendous risks in seeking its alleviation?

ACTH AND CORTISONE

The systemic use of ACTH and cortisone has far reaching effects on all of the metabolic processes of the body. Some of these effects may have an influence on the operation of tonsillectomy.

Kinney³⁰ encountered excessive bleeding during local tonsillectomy operations on two patients who had been on cortisone for ocular infections. He had extensive blood studies made on the second patient preoperatively, because of his experience with the first. The blood counts, coagulation and bleeding times, platelet counts and prothrombin values all were within normal limits.

The general consensus of opinion is that cortisone does not produce a decrease in the clotting mechanism.

On the other hand, Margulis³¹ found an increase in the circulating heparin levels of 0.04 or more and in the coagulation time of three minutes or more in patients subjected to surgical stress, systemic cortisone or ACTH therapy. These increased values appeared within the first twenty-four hours and then returned to normal or even below normal. Following this there was another slight but steady rise with a peak between the third and fifth days. The elevated levels persisted for three to four days after withdrawal of the drug.

Brust, Ransohoff and Reiser³² reported an increase in the blood pressure and the pulse pressure in patients receiving ACTH. After three weeks two of their patients developed swollen pink fingertips which persisted until the drug was stopped. They stated "A mere prick for blood counts produced an unusual gush of blood."

In planning a tonsillectomy on a patient receiving ACTH or cortisone it might be well to withdraw the drug four or five days before the operation is done.

Fortunately the question of severe surgical shock seldom enters the problem of tonsillectomy, yet deaths do occur on the operating table during the course of this operation. When they occur, they come with devastating swiftness. Many of these are due to anoxia. These can be avoided by an alert anesthetist and surgeon working as a team and constantly watching the airway and providing adequate oxygenation. Although the thymicolymphatic diathesis has been greatly discredited during the last few years, autopsy frequently shows these patients to have enlarged thymus, enlarged spleen and generalized hyperplasia of the lymphoid tissues of the body. These individuals seem to be peculiarly sensitive and may develop severe shock from relatively minor trauma. Stephen³³ says "... the pale, fat, listless, 'thymic' child can be anesthetized safely, if careful attention is given to the depth of narcosis and degree of oxygenation.

It is believed the patient suspected of having 'status lymphaticus' has less resistance than the normal child, and requires a smaller concentration of the anesthetic agent in his blood stream to provide satisfactory operating conditions."

When this condition has been recognized preoperatively, it has been the custom to give the patient roentgen irradiation over the thymus gland. This was done to reduce the size of the gland and to provide some protection against any untoward reactions. Selye and Jacot³⁴ state that cortisone has a thymolytic effect which is greatly enhanced by the simultaneous treatment with ACTH. Conn³⁵ suggests the use of 100-200 mgs of cortisone or hydrocortisone for two days preoperatively if the condition is recognized before surgery. It would seem that this might offer better protection than the roentgen therapy against the reaction to stress in these individuals.

Recently ACTH, cortisone and hydrocortisone have been reported to have a very beneficial effect on hypotension due to surgical shock. Hume and Moore³⁶ cite a patient with carcinoma of the anus who required extensive surgery. She developed shock during the first operation. There was hypotension, oliguria and peripheral circulatory collapse. She rallied from this under treatment with blood transfusions, vasopressors and other routine measures. Fifteen minutes after the start of the second operation the blood pressure fell to zero, although there was no undue blood loss. Stimulants and blood transfusions were given. The blood pressure rose to 50/40. She continued hypotensive all day. She was placed on ACTH, 30 mgm every six hours and the blood pressure rose further to 120/80. She was continued on ACTH and later cortisone. Ten days later the third operation was done without any hypotension developing, although the blood loss was much greater than in either of the other two operations.

Hydrocortisone has a much greater potency than cortisone. It can now be given intravenously. In 1954 Rukes, Orr and Forsham³⁷ reported its use in four cases of surgical shock. They added to this series in a report to the New York Academy of Sciences this year. Two of the four previously reported cases developed shock with hypotension during the course of extensive operative procedures. The first patient had been on a course of cortisone for 28 days followed by ACTH for five days. The operation was done six days later. Hypotension developed in spite of two transfusions and Vasoxyl®

intravenously. When the pressure reached 60/45, a slow intravenous drip of 100 mgm of hydrocortisone in 1000 cc of 5 per cent dextrose was started. Five minutes later the blood pressure rose to 100/70 and 25 minutes later it reached 130/80. The other three patients showed similar prompt response to the intravenous use of hydrocortisone in 5 per cent dextrose. They stated that 93 per cent of the hydrocortisone given intravenously is excreted within the next 24 hours. Blood loss should be replaced by transfusions and vasopressors should be used. The hydrocortisone potentiates the action of the vasopressors.

Conn³⁵ also suggests the intravenous use of hydrocortisone in patients who develop severe hypotension during or following operations. He recommends the drip method, using 100 mgm of hydrocortisone in 5 per cent glucose solution. If the shock is so extreme and precipitous as to produce a cardiac stand-still, immediate cardiac resuscitation seems to offer the only hope.

CONCLUSIONS

1. The general management of tonsillectomies done under general anesthesia has been reviewed.
2. A method of peritonsillar injection has been described which reduces the amount of bleeding during the operation and aids in the dissection.
3. There is a considerable amount of hazard in the use of focaine to relieve post-tonsillectomy pain.
4. Treatment with cortisone over a period of time may lead to excessive bleeding during a tonsil operation.
5. A short period of preoperative treatment with cortisone or hydrocortisone in the "thymicolymphatic" child might help protect him from the hazards of surgical trauma.
6. The intravenous use of hydrocortisone has been found to be useful in combating the hypotension of surgical shock.

10515 CARNEGIE AVE.

REFERENCES

1. Levy, David M.: *Psychic Trauma of Operations in Children*, Amer. J. Dis. of Children 69:7-26 (Jan.) 1945.
2. Coleman, Lester L.: *The Psychologic Implications of Tonsillectomy* New York State J. of Med. 50:1225-1228 (May 15) 1950.

3. Coleman, Lester L.: The Emotional Preparation of Children for Surgery, Transactions Amer. Laryng. Rhinolog. and Otolog. Soc., 1954. Television Kinescope shown at meeting in May, 1954.
4. Eckenhoff, James E.: Preanesthetic Sedation of Children, Arch. Otolaryngol. 57:411-416 (Apr.) 1953.
5. Blaisdell, Irl H.: The Use of Sodium Pentothal Anesthesia in Adult Tonsillectomies, Laryngoscope 59:721-725 (July) 1949.
6. Johnson, Fordyce: Adult Tonsillectomies Using Pentothal Sodium, Curare, Pontocaine and Novocaine as the Anesthetic, Laryngoscope 62:704-708 (July) 1952.
7. Grant, Heman: Hydrostatic Pressure in Adenoid Hemorrhage, ANNALS OF OTOTOLOGY, RHINOLOGY AND LARYNGOLOGY 53:576-577 (Sept.) 1944.
8. Ball, Chas. E.: Nasal and Postoperative Tonsil and Adenoid Hemorrhage, Tex. State J. of Med. 44:437-440 (Oct.) 1948.
9. King, James T.: Effect of Vitamin K Compound (Synkavite) on Computed Blood Loss During Adenotonsillectomy, ANNALS OF OTOTOLOGY, RHINOLOGY AND LARYNGOLOGY 63:1029-1030 (Dec.) 1954.
10. Hosler, Robert M.: Cardiac Arrest from the Otolaryngologist's Viewpoint, Arch. Otolaryngol. 57:371-377 (Apr.) 1953.
11. Hamilton, Norval E.: General Anesthesia in Otolaryngology, Trans. Amer. Laryngol. Rhinolog. and Otolog. Soc., pp. 263-268, 1954.
12. Coombes, Arthur J.: A Study of Delayed Bleeding Following Removal of Tonsils and Adenoids, Laryngoscope 60:296-307 (Mar.) 1950.
13. Fox, Samuel L. and West, A. Brooks, Jr.: Vitamin K and Late Tonsillar Bleeding, Bull. School of Med. Univ. of Maryland 32:215-220 (Apr.) 1948.
14. Fox, Samuel L.: Bleeding Following Tonsillectomy, Laryngoscope 62:414-425 (Apr.) 1952.
15. James, A. G.: Hemorrhage Following Tonsillectomy, Related to Weather During a Twelve Year Period, Ann. West. Med. and Surg. 2:558-561 (Dec.) 1948.
16. Jones, E. H.: The Prevention of Secondary Hemorrhage Following Tonsillectomy, South. M. J. 42:124-127 (Feb.) 1949.
17. Jones, E. H.: Better Tonsillectomies and Adenoidectomies; Fewer Post-operative Hemorrhages, South M. J. 16:15-20 (Jan.) 1953.
18. Livingstone, G. S. and Neary, E. R.: The Question of Prothrombinopenic Hemorrhage From Post-tonsillectomy Use of Chewing Gum Containing Acetylsalicylic Acid, Arch. Otolaryngol. 47:1-6 (Jan.) 1948.
19. Neivert, H.: Late Secondary Tonsillar Hemorrhage. I. Studies of Prothrombin and Vitamin K, Arch. Otolaryngol. 42:12-18 (July) 1945.
20. Neivert, H., Pirk, Leo A. and Engleberg, Richard: Late Secondary Tonsillar Hemorrhage. II Studies of Ascorbic Acid. Arch. Otolaryng. 43:568-577 (June) 1946.
21. Neivert, H.: Acetylsalicylic Acid and Bleeding from the Tonsillar Wound, Arch. Otolaryngol. 47:524-526 (Apr.) 1948.
22. Pearlman, S. J. and Loewy, A.: Secondary Tonsillar and Adenoid Hemorrhage in Relation to Barometric Pressure Changes, Arch. Otolaryngol. 53:527-529 (May) 1951.
23. Singer, Rudolf: Acetylsalicylic Acid. A Probable Cause for Secondary Post-tonsillectomy Hemorrhage, Arch. Otolaryngol. 42:19-20 (July) 1945.

24. Ersner, Mathew S., Myers, David and Ersner, Wm.: A Clinical and Experimental Study of the Action of Saliva on Blood Coagulation and Wound Healing in Surgery of the Oral Cavity and Throat, *ANNALS OF OTOTOLOGY, RHINOLOGY AND LARYNGOLOGY* 43:114-146 (Mar.) 1934.
25. Penn, S. E.: Control of Post-tonsillectomy Pain, *Arch. Otolaryng.* 56:59-60 (July) 1952.
26. Allen, Ridsen T.: New Method for Relieving Postoperative Pain Following Tonsillectomy, *Arch. Otolaryngol.* 57:86 (Jan.) 1953.
27. Davidson, Morris, Boles, Robert G. and Synderman, Sanford C.: A Prolonged Anesthetic in Control of Post-tonsillectomy Pain, *ANNALS OF OTOTOLOGY, RHINOLOGY AND LARYNGOLOGY* 61:1046-1047 (Dec.) 1952.
28. Marks, Roland F.: The Effect of Efocaine in the Control of Postoperative Pain, *Laryngoscope* 63:861-862 (Sept.) 1953.
29. Angerer, Alden L., Su, Hung H. and Head, Jerome R.: Death Following Use of Efocaine, *J. A. M. A.* 153:550-552 (Oct. 10) 1953.
30. Kinney, Charles E.: Discussion of Present Concepts of the Activities of the Pituitary-Adrenal Mechanism and of the Adrenal Steroids, by J. W. Conn Middle Sect, Meet. Amer. Otol. Rhinol. and Laryngol. Soc. (Jan.) 1955.
31. Margulis, R. R.: Blood Coagulation as Affected by ACTH and Surgical Stress, *Surg. Forum Amer. Col. Surg.* 507-515 (Oct.) 1950.
32. Brust, Albert A., Ransohoff, Wm. and Reiser, Morton F.: Vascular Responses to ACTH and Alterations in Sodium Intake, *Proc. Second Clin. ACTH Conf.*, Blakiston Co., 1951, 1:177-195.
33. Stephen, C. R.: Operating Room Fatalities in Pediatric Surgery, *Anes. and Analg.* 31:36-44 (Jan.-Feb.) 1952.
34. Selye, Hans and Jacot, Bernard: On the Effect of Various Steroids upon the Extra-adrenal Thymolytic Action of ACTH *Acta Endocrinol.* 9:333-336 (Apr.) 1952.
35. Conn, J. W.: Personal Communication.
36. Hume, D. M. and Moore, F. D.: The Use of ACTH, Cortisone and Adrenal Cortical Extracts in Surgical Patients, *Proc. Sec. Clin. ACTH Conf.*, Blakiston Co., 1951, 2:289-303.
37. Rukes, J. Max, Orr, Richard H. and Forsham, Peter H.: Clinical Uses of Intravenous Hydrocortisone, *Metabolism* 3:481-488 (Nov.) 1954.

DISCUSSION

DR. THOMAS C. GALLOWAY: I think unless you have read the recent pediatric literature some of you might get a shock at the attitude of men outside of our specialty toward tonsillectomy. At the Evanston Hospital in 1945 we did a little over 1,000 tonsil operations. In 1953 there were 400. We have one pediatrician who has a large practice who sends no patients for surgical tonsillectomy.

I have recently written a very difficult paper for the Quarterly Bulletin of Northwestern University reviewing the subject of Tonsillectomy, Irradiation and Poliomyelitis. There are some very striking reports that are very hard to refute. They purport to show that not only does tonsillectomy increase the danger of bulbar poliomyelitis, if a patient gets poliomyelitis within a month of operation as we agreed in a symposium at the A.M.A. three years ago, but there are other papers especially by Anderson, with a careful statistical review which indicates there is marked

increase in incidence of poliomyelitis any time after tonsillectomy. I think his paper proves only—if it proves anything—that a patient who has had a tonsillectomy has his tonsillectomy because he was susceptible to infection and he probably got his poliomyelitis because he was susceptible to poliomyelitis. The theory that it removes a barrier to infection is not compatible with the present theories of the pathogenesis of bulbar poliomyelitis.

From the point of view of the pediatrician I must admit that there is a good deal of evidence in favor of the efficacy of irradiation.

I read a paper before this Association in 1937 on the value of x-ray in such acute infection as adenitis and parotitis. Dr. Schenck has shown that germinal follicles in the tonsil may be destroyed and not recur within six months. There is a profound effect of irradiation and very careful and objective study on the human by Uhlmann, Rosenblum and Perlman* indicated that 30-50 per cent of patients were relieved of the trouble for which the tonsillectomy was advised. There is a swing again toward irradiation when that is well given with well controlled technique.

As to the technique of tonsillectomy, I think myself that it should be done most simply. I use the Beck instrument because I get less bleeding, require less anesthesia and the operation is much more rapidly done.

I was interested in reviewing a report by Rhoads from Wesley Hospital on patients with rheumatic fever. 27 per cent of those patients had bacteremia after operation when the operation was done by dissection. About five per cent only had bacteremia when the operation was done with the Sluder or Beck and the bacteremia was directly proportional to the time consumed in the operation.

Dr. Moore's paper is timely. It does show that we must take advantage of any opportunity to improve the operation but we still have to combat a pretty good wave of sentiment against the operation.

DR. HARKINS: Dr. Heatly and Dr. Schenck, Dr. Moore's paper certainly is a very timely one on a subject that is with us at all times. It seems to me we often treat it too lightly.

Recently, I completed a study of 200 tonsillectomies, including a control group, in which I used vitamin K and vitamin C, before, during and following operation. In the 100 cases in which vitamin K and vitamin C were used extensively I was able to reduce the incidence of all post-operative oozing or bleeding from 12 per cent to a little less than 3 per cent. I wanted to ask Dr. Moore whether he had used vitamin K or vitamin C orally in children and adults, before and after tonsillectomy and adenoidectomy.

Also, during the last five months we have used adrenochem (adrenachrome) which is manufactured by Messengill, 5 mgm given intramuscularly immediately following operation. Although I have no scientific data, I feel that this has further reduced our incidence of immediate postoperative bleeding. I should like to ask him whether he has used this preparation.

DR. PAUL M. MOORE: I would like to thank the discussers for their comments. I feel that all of you let me off rather easily. I am sure that many of you have thoughts that you would like to put on record.

Dr. Galloway's comment is very timely. An editorial appeared in the A.M.A. Journal not too long ago that thoroughly shocked me. They wrote an editorial

* Arch. Ped. 65:532, Oct. 1948.

claiming that tonsillectomies produced a tendency to poliomyelitis, no matter when the individual acquired it after the tonsillectomy had been performed. I could not help but feel that was skipping over the principles of normal healing of surgical wounds. Why would that particular place in the body leave an open pathway forever? I do know that a lot of the general men tend to resist any surgical procedures on the tonsils now, even when they are badly indicated.

Dr. Harkins asked about the vitamin K and C. I have comments about them in the paper. I do use vitamin K. I have been using it routinely. First I disdained it. I felt that it was only indicated where there was a lack of prothrombin. Then we had one youngster, I think it was during June or May, who kept coming back to the hospital with a little bit of oozing. For the first two or three times the resident took care of him and sent him home. After I heard that he had been back a couple of times, I said that I wanted to see him the next time he came in. I saw him. He was oozing. We put him in the hospital. He had a very low prothrombin time. I talked it over with the pediatrician who referred him to me and we agreed to use vitamin K as a safety measure. Today many children are getting aspirin and may have a low prothrombin time. I have not used vitamin C, but have been intending to.

As to the adrenoform, I have tried it on a few cases of nasal hemorrhage that continued to ooze in spite of packing. I have not been impressed. I have not tried it on tonsil bleeding.

CARCINOMA OF THE MAXILLARY SINUS IN A YOUTH OF TWENTY

BERNARD J. McMAHON, M.D.

ST. LOUIS, MO.

Squamous cell carcinoma of the paranasal sinuses is said to occur infrequently in the first three decades of life. Having encountered such a malignancy in the maxillary sinus of a youth of twenty years of age, we considered it worth bringing to your attention.

REPORT OF A CASE

G. J., aged 20, white, was referred to Dr. Franklin, of Ramsey, Illinois on December 1, 1950.

The patient stated that about four weeks previously he had noticed a numbness over the left side of his face and cheek from midline to the zygoma which gradually spread about his left eye. This was followed one week later by a moderate amount of painless swelling of his left cheek which slowly extended upward, until one week ago when his lower and upper lids became markedly puffy, lacrimation and purulent discharge from between the closed lids and the left side of his nose became marked, and his left eye seemed to be more prominent than the right, though not painful. The purulent discharge from the left side of his nose, though copious recently, had never been sanguinous, nor had epistaxis occurred. There had been no trismus. The hard palate did not show evidence of involvement. The sight was good in the right eye though blurred in the left. During this time his physician treated him with injections of penicillin, despite which his condition became progressively worse. He had had a fluctuating low-grade fever but no chills. He was not subject to nasal infections and had always been in good health.

From the Department of Otolaryngology, St. Louis University School of Medicine, St. Louis, Missouri.

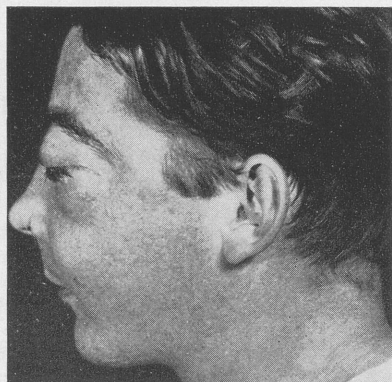
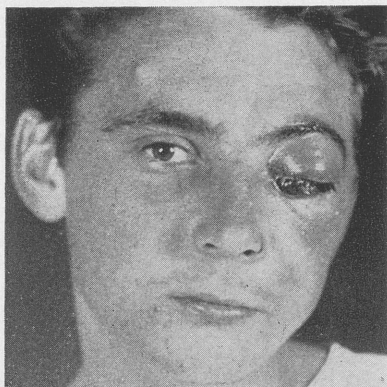

Fig. 1.—December 7th. Note proptosis of the left eye, edema of lids and chemosis of conjunctiva.

Fig. 2.—December 7th. Lateral view further accentuates features in Figure 1, and demonstrates absence of enlargement of cervical glands.

Examination. This revealed a well-nourished white male, mentally responsive and co-operative. His general physical, functional and neurological condition evidenced no abnormalities.

The lids of his left eye were extremely edematous, slightly purpuric and there was marked chemosis of both. The globe was moderately proptosed downward and outward and partially fixed. It was not painful to palpation. There was numbness over the left cheek and no tenderness on deep pressure over the antrum or frontal sinus. He was able to distinguish individual fingers at a few inches. The right eye was apparently normal but somewhat injected. The mucosa of the left side of his nose was intensely red, the turbinates were engorged, there was a moderate amount of pus on the floor and in the left middle meatus in which the mucosa was edematous, slightly polypoid and bled easily when touched. No growth was seen. The mucosa of the right side of his nose was generally reddened and there was some pus on the floor but none seen in the meatuses. His throat and ears did not show any significant pathological changes. There were no enlarged or tender glands about the head or neck (Figs. 1 and 2).

He was hospitalized immediately at Firmin Desloge Hospital in St. Louis. On admission to the hospital on December 1, 1950,

his temperature was normal, white blood count was 10,000, the differential normal, and the red blood count 5,500,000.

The x-ray of the paranasal sinuses on December 1, 1950, showed a moderate density of the left ethmoids, anterior and posterior, and a marked density of the left maxillary sinus. Both frontal and sphenoid sinuses as well as the right ethmoids and maxillary were clear.

Our tentative diagnosis was: 1) Acute purulent hyperplastic maxillary and ethmoidal sinusitis, left. 2) Retrobulbar edema, cellulitis, or abscess, left.

On December 2, 1950, under intratracheal ether anesthesia, the conventional Caldwell-Luc approach to the left antrum was made. The anterior bony wall was not bulging, but was thin and somewhat soft. The sinus was entered through the canine fossa and found to be filled with reddish, edematous mucosa, which bled freely when curetted and contained a small amount of pus. The mucosa was friable to the extent of not being cohesive and not adherent to the sinus walls. After the sinus had been curetted cleanly, there was seen to be a linear dehiscence about 1 x 2 cm in the medial wall into the inferior meatus. The bone of the superior portion of the medial wall was intact. Another dehiscence of about the same extent was also observed in the medial third of the orbital plate, and tissue similar in appearance to that found in the sinus was seen within the orbital fossa, except that it was not friable and did not bleed as actively. The fistula through the orbital plate was enlarged to obtain better drainage; no pus was obtained. The operation was completed by removing more of the nasoantral wall of the inferior meatus and a vaseline gauze drain placed in the opening.

The pathologist's report was: *Gross*: "Several pieces of reddish-tan tissue, the surfaces covered with a thick smooth, whitish membrane. There were also several fragments of bone." *Microscopic*: "Reveals large anaplastic basophilic pyramidal epithelial cells arranged in irregular tracts and clusters and surrounded by dense connective tissue: mitotic figures numerous. A few bony trabeculae between which clusters of anaplastic cells are seen." *Diagnosis*: Squamous cell carcinoma, poorly differentiated. (Figs. 3 and 4)

The pathologist expressed the opinion that this type of tumor should be radio-sensitive, which was concurred in by the radiologist, who advised irradiation with deep x-ray. Accordingly the patient

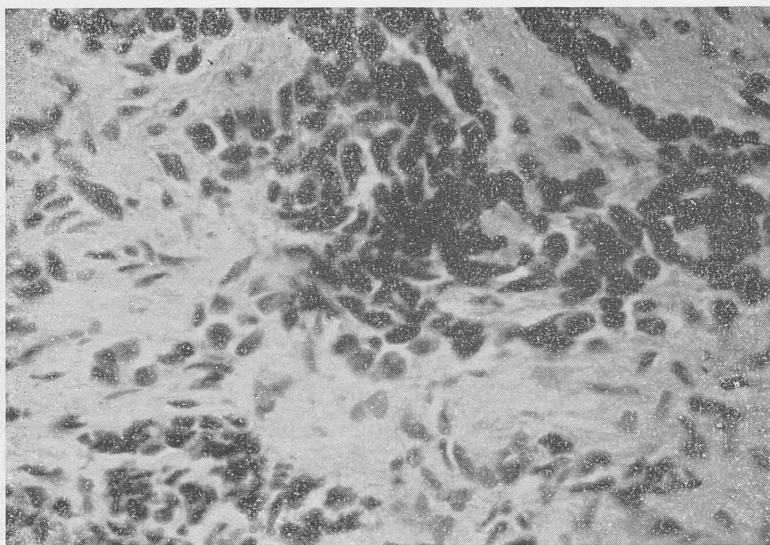


Fig. 3.—*Before irradiation*: High power photomicrograph showing highly anaplastic epithelial cells infiltrating connective tissue spaces. Note marked nuclear hyperchromatism and relative absence of cytoplasm.

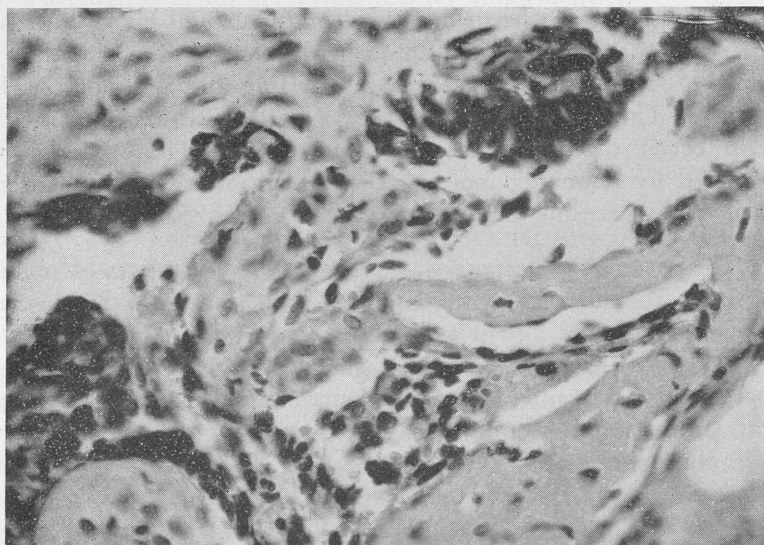


Fig. 4.—In this field tumor cells are seen invading bone of naso-antral wall. Small size and ragged edges of spicules indicate secondary osteolysis.

received daily treatments of 200 R. over a 5 x 7 area of the left side of his face, from December 9, 1950, to January 26, 1951, thirty-nine exposures: a total of 7800 R.

Within a few days the swelling about the left side of the face and eyelids began to subside, and in two weeks the proptosis had almost completely disappeared. About six weeks after x-ray treatments had been started, there was some improvement in the ocular movements and perception, though the eye was still injected, and there was some increase in sensation over the left cheek. In the meantime the intranasal condition had improved and the airway was clearer, but a small fragment of polypoid tissue removed from the left middle meatus with suction revealed a few malignant cells deep in the tissue (Fig. 5). However, at about this time there was noticed a large firm fixed mass in the left side of the neck just inferior to the angle of the mandible (Fig. 6). This mass was not tender or fluctuating. There was no trismus. Because of the status of the entire malignant picture it was decided that surgery of the neck glands was inadvisable. Deep x-ray therapy to the neck glands was inaugurated, and the patient received 1800 R. over a period of nine days without perceptible beneficial effect upon the glands, in fact, all anterior cervical glands and a few in the posterior chain were then enlarged and the original glands were markedly increased in size. Shortly thereafter he developed severe intractable pain in the left shoulder and chest, and pain and tenderness over the right sacroiliac area. X-ray of these areas did not show tumor formation. Realizing that metastases were becoming generalized, x-ray therapy of the neck was discontinued.

Since the eventual outcome was inevitable the patient was discharged on March 5, 1951, and returned to his home where he died within two months with symptoms of intracranial involvement and paralysis of the lower half of his body. The autopsy was not done.

REVIEW OF LITERATURE

While no attempt has been made to review the entire literature on malignancies of the paranasal sinuses, since our presentation is not that extensive, it is pertinent to mention that about 0.2 per cent of cancers in humans, or as high as 2 per cent in cancer hospitals, occur in the paranasal sinuses, according to Wilkins.¹

In reviewing 295 cases of malignancies of the upper jaws and antrum, New² reported an incidence of squamous cell carcinoma of

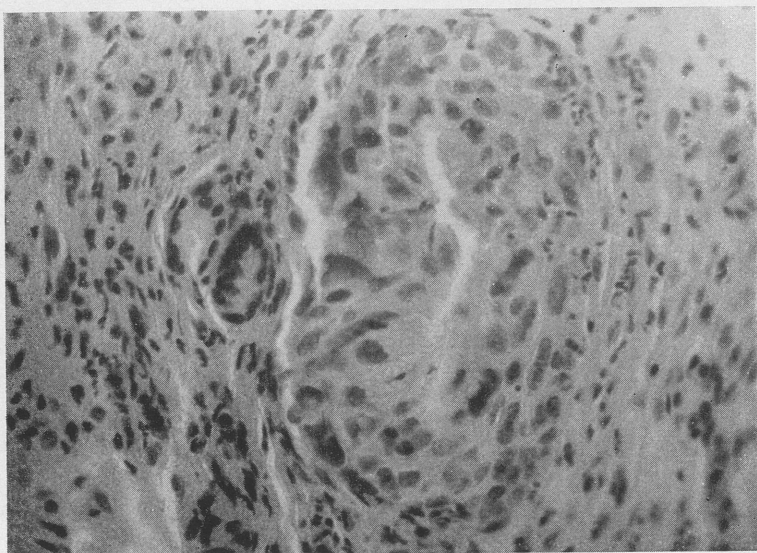


Fig. 5.—*After irradiation:* Small polyp from left middle meatus. A nest of atypical epithelium is seen surrounded by connective tissue with many inflammatory cells. Although the pleomorphism and lack of polarity point to the true nature of these cells, they are obviously less anaplastic than those seen in the previous photomicrographs.

66 per cent in the maxillary sinuses. Öhngren³ reported 187 cases with an incidence of 56.6 per cent in the maxillary sinuses. Ringertz⁴ reported 218 cases, with an incidence of 86.7 per cent carcinomas in the maxillary sinuses.

In reporting 168 cases of malignancies of the paranasal sinuses, New⁵ has stated the numerical occurrence of the carcinomas, the sarcomas and the mixed malignancies in decades, but not by the sinuses or by each type of malignancy. Robinson⁶ in reporting 60 cases has done likewise, and Houser⁷ 21 cases of the antrum alone, 19 being carcinoma. Öhngren³ has reported 149 cases of all types in decades, but he has been more specific in his case reports. He³ and Ringertz⁴ gave a detailed history of the youngest patient on whom such an accurate case history could be found. This was a woman aged 25 whose condition was diagnosed as squamous cell carcinoma, with hornification, of the maxillary and ethmoid sinuses and the orbit, in 1930.

The description of the physical appearance of this patient was similar to that of my patient, except that the right nasal cavity was filled with soft readily bleeding tumors, the ethmoidal area was necrotic and bulged into the right nasal cavity, and the mandibular angle glands were enlarged. The onset of the intranasal symptoms occurred five months before the patient reported at the clinic. The patient was treated with electrosurgery, radium and irradiation. She died with pulmonary metastases one year and four months after commencing treatment.

TABLE 1.
REPORTED AGE INCIDENCE.

Age	New ⁵	Robinson ⁶	Houser ⁷	Ringertz ⁴	Öhngren ³	Totals
1-10 Yrs.	3	2	0	0	0	5
10-20 Yrs.	7	3	1	0	1	12
20-30 Yrs.	4	6	0	2	5	17
Total	168	60	21	218	149	616
Types	Ca. Sarc. Mixed	Ca. Sarc. Mixed	Ca. Sarc. Antrum	Carci- noma	Ca. Sarc. Mixed	

While Heatly⁸ states that tumors in children under 15 are "not uncommon," the foregoing figures do not bear out this statement. However, since these reports include malignant tumors of all types, with the exception of Ringertz' and Öhngren's cases, we have no way of knowing how many and at which ages squamous cell carcinomas occurred.

SUMMARY

This report is submitted for your consideration with two purposes in mind, first, to bring out the fact that squamous cell carcinoma may occur in the paranasal sinuses of a younger person, and second, to bring forth comments relating to the treatment of such a condition.

Our original presumptive opinion was that the patient was suffering from an acute suppurative hyperplastic left maxillary and ethmoidal sinusitis, and a left retro-orbital cellulitis or abscess. This conclusion was arrived at because of the age of the patient and the rapidity of the onset and development of his symptoms. Because

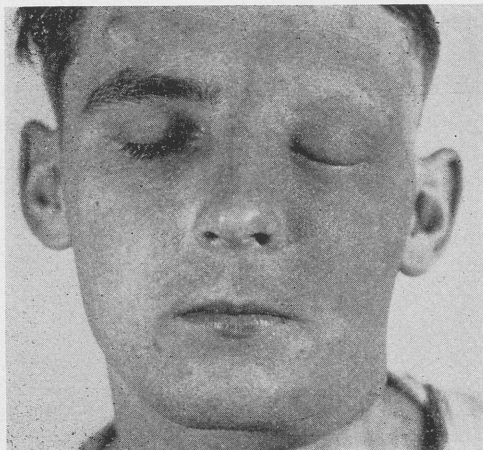

Fig. 6. February 21st. Seven weeks after start and three weeks after cessation of x-ray therapy. Note absence of proptosis left eye and very little edema of upper lid. Prominence of left side of neck caused by enlargement of anterior cervical glands.

the first symptom was a numbness over the left side of the face, indicating pressure on the infraorbital nerve, we presumed that the left maxillary sinus was the site of the original infection, and that it had extended into the orbit and thence to the ethmoidal sinuses. This extent of involvement was corroborated by the report of the x-ray examination of the sinuses. Immediate surgical measures were taken to relieve the pressure within the maxillary sinus. The findings at operation suggested a subacute purulent papillary sinusitis. However, the pathologist's report of squamous cell carcinoma in the tissue removed caused great concern.

Irradiation was decided upon as the optimum method of treatment because the lesion was so extensive, involving the entire left ethmoidal labyrinth and the retrobulbar orbital contents, that it did not seem possible to encompass it satisfactorily by surgery, especially since the microscopic section showed involvement of the bony walls of the maxillary sinus, implying a similar involvement of the walls of the ethmoidal sinuses, and the possibility of deeper extension into the cranial cavity. Likewise, the pathologist and radiologist agreed that the tumor should be radio sensitive, judging from its type of

architecture. Although Ringertz⁴ has stated that "it is difficult to determine the radio sensitivity of the various architectural types, in carcinoma of the nasal and paranasal sinuses, since the deep position of the tumors and the preponderance of operative treatment greatly limits the possibilities of grading the sensitivities."

The ophthalmologist and the radiologist were consulted regarding the enucleation of the left eye and they agreed that no advantage would be gained by so doing since no gross inequality between the optic foramina could be seen by x-ray, and there was some hope of saving the eye. The radiologist felt that the eye would not materially interfere with the penetration of the therapeutic x-rays to the retro-orbital and ethmoidal areas.

The progress towards recovery seemed to be favorable for the first six weeks after x-ray treatments were started, until the enlarged cervical glands were noted at the left mandibular angle, indicating the onset of metastasis. It was then but a few weeks before generalized metastases became established and death ensued.

The impression is prevalent that carcinoma of the maxillary sinus metastasizes late. Öhngren expresses the opinion that this impression is false, since the patient rarely comes to be examined early in the disease and also, that the first palpable gland is usually located in the deep jugular chain, secondary to the lateral retropharyngeal lymph glands which must have been involved at an earlier date. He very clearly traces the lymphatics from their "rich network in the mucosa of the antrum of Highmore with their numerous anastomoses." He goes on to say, "submucously we find larger stems running in a direction towards the opening of the maxillary antrum, diminishing in number but increasing in calibre. They leave the antrum here and before long join the lymph-vessels of the middle meatus, these vessels subsequently passing backward towards the choanae running together into a plexus in the lateral part of this wall, immediately anterior and superior to the eustachian orifice. From this plexus a few large lymph channels are given off backwards above as well as below the eustachian cushion towards the posterior pharyngeal wall. Here they pick up finer branches from the nasopharynx before entering the retropharyngeal space. The lateral retropharyngeal lymph nodes receive most of these lymph vessels, only small branches pass directly upwards emptying into the medial jugular glands located just below the base of the skull. From the lateral

retropharyngeal lymph glands the lymph is conducted in stems of larger calibre which empty into a node belonging to the deep jugular chain and usually located at the level of the carotid bifurcation."

Ringertz⁴ states that it is frequently impossible to determine whether a carcinoma is primary in the maxillary sinus or in the ethmoid when both are involved, because the majority of such patients are not seen early enough. Our patient was seen within one month of the onset of his symptoms. The first symptom, numbness of the left cheek, antedated by three weeks the orbital symptoms indicative of extension into the retro-orbital space from the antrum and probably the ethmoids, causing the proptosis and fixation of the eye. The microscopic picture of the invasion and destruction of the bone by the cancer cells illustrates the 'modus operandi' of these cells in their process of direct extension.

CONCLUSIONS

- 1) The report of a squamous cell carcinoma of the maxillary sinus and probably of the ethmoids, in a youth of twenty years of age is presented.
- 2) Treatment consisted of a radical exentration of the contents of the antrum followed by deep x-ray therapy of 7800 'R' within a period of seven weeks, and later 1800 'R' to the glands of the neck.
- 3) The patient died of generalized metastases six months after the symptoms were first noted and five months after treatment was started.
- 4) The sequence of symptoms suggest that this tumor occurred primarily in the maxillary sinus.

8230 FORSYTHE BLVD.

I wish to express my appreciation to the following for their valuable assistance: Photograph, Mr. P. A. Conrath; photomicrographs and kodachromes, Dr. Thomas Tombridge, Department of Pathology. Pathological diagnosis, Dr. Henry Pinkerton, Director of the Department of Pathology.

REFERENCES

1. Wilkins, S. A.: Surgery in the Treatment of Cancer of the Maxillary Antrum. *J. M. A.* 41:9 (Jan.) 1952.
2. New, G. B.: The Curability of Malignant Tumors of the Upper Jaw and Antrum. *Trans. Amer. L., R. and O. Soc.* 595-590, 1935.

3. Öhngren, L. G.: Malignant Tumors of the Maxillo-Ethmoidal Region. *Acta Otolaryngol. Supp.* 18-20: 1933-34.
4. Ringertz, Nils: Pathology of Malignant Tumors Arising in the Nasal and Paranasal Cavities and Maxilla. *Acta Otolaryngol. Supp.* 27: 1938.
5. New, G. B.: Malignant Tumors of the Antrum of Highmore. *Arch. of Otolaryngol.* 4:201-214 (Sept.) 1926.
6. Robinson, G. A.: The Diagnosis and Treatment of Malignant Tumors of the Nasal Sinuses. *Amer. Jour. Roent.* 34:641 (Nov.) 1935.
7. Houser, K. M.: The Diagnosis and Treatment of Primary Malignant Neoplasm of the Maxillary Sinus. *Arch. Otolaryngol.* 18:643-650 (Nov.) 1933.
8. Heatly, C. A.: Tumors of the Maxillary Sinus. *Oral Surg.* 5:1253 (Dec.) 1952.

DISCUSSION

DR. ANDREW EGGSTON: I felt that I would like to make a few remarks about this paper. It is certainly a most interesting one and as I come in contact with tissue diagnosis so many, many times at our hospital, all of these cases are of extreme interest to me.

Since World War II, just as in any other phase of medicine there has been a reclassification of tumors. New pathologists have come up, wonderfully trained men, and they have been able by the study of the histogenesis of the rare tumors to reclassify many of them.

I remember in older days we had clearcut but restricted diagnoses of many of these tumors. We heard just yesterday about mixed tumors of the nose and throat and the salivary glands, and certain new phases were presented. That is not only true of the clinical course of these cases but also in the pathological diagnosis. It makes our problem more interesting. Yet at the same time it makes it more complicated.

These slides presented are of the squamous cell type. They are certainly, as Dr. McMahon said, highly anaplastic. We get to a point in pathology where we are told to pigeonhole this tumor or that tumor and we make an attempt to do so. Sometimes we are in error and lots of times other pathologists won't agree on the type of tumor. I know all of you have had the experience of sending slides around from one pathologist to another and you probably got just about as many differences of opinion from the pathologies as you would on the clinical findings of the case. That is unavoidable. These anaplastic cells take on very peculiar morphology and behavior. Sometimes they undergo metaplasia while they are growing and metastasizing. I don't recall the number of tumors in the youth at Manhattan but we see many more cases of malignancy yearly and particularly of the paranasal sinuses.

I know Dr. Mackenty some years ago took out a squamous cell carcinoma in the larynx of a girl 18 years of age.

It has come to my attention just recently we have had several young people with malignancies of the nasopharynx and of the sinuses. I recall one Porto Rican child about five and one-half years of age that had a tumor presending in the posterior choanae and attached to the sphenoid or ethmoid region. It was highly anaplastic. I called it a fibrosarcoma at first. We had other pathologists, Dr. Stewart and others, and we all went back and reviewed the case and decided it was a neuro-

blastoma. Now we are finding several of these. This child had radiation, had a gland in the neck after a couple of months and that looked at that time like a squamous cell carcinoma. One would think it would be a lymphoid epithelioma in the early stage. That was not the case here because we see a number of those and feel that we can differentiate the various types. This child had metastases and died in spite of surgery and radiation in six months.

We had another case of a 12 year old boy with a tumor in the nose. A highly malignant tumor that was finally diagnosed a neuroblastoma. You don't get the nice rosettes in neuroblastomas here as you get in the neuroblastomas in the eye but there is a tendency to rosette formation in these cases.

We had another case, a woman, 45 years of age, who had a neuroblastoma. I am bringing up these cases, not so much apropos of this case, but just to bring out the fact that we are getting different types of tumor. It may be the same old tumor but we have different classifications. These are highly anaplastic tumors and hard to classify at times. In spite of the surgery and radiation, all the cases died in a short time. So there you are as far as malignancies go—we are getting into a great deal more difficulty of diagnosis and treatment. Pathologists are sending slides around much more often to have different opinions, not because of essential inadequacy, as great as that may be, but it is in the name of accuracy and at the same time quite educational.

We also had a young man with a leiomyoma sarcoma of the antrum. He was in his early twenties. This started from the smooth muscles of the blood vessels. This boy, after three or four surgical procedures and x-ray, all of which did nothing, died of metastases.

There is another problem which I think the general pathologists don't take into consideration seriously, and of which we see more, and it is the so-called papillomatosis of the sinus, often called papillary sinusitis. I thought first many years ago it was a virus infection but the more I see of papillomatosis the more I am reminded of the papillomatosis one gets in children in the larynx. They grow and fill the antrum or the nasal cavity. They keep on coming back even after rather thorough removal, or exenteration of the area. But in the course of eight, ten or fifteen years these cases often become malignant. I had one, a doctor with sinus trouble for 15 years, and now he has invasion of the bone by an epidermoid type of carcinoma.

I am sorry to have to digress so much from Dr. McMahon's case but I thought these points were worth mentioning.

DR. FREDERICK T. HILL: Mr. President, Fellows and Guests, as usual Dr. McMahon has given us a very valuable contribution. I think it would be valuable if in no other way than reminding us that youth is no barrier to malignancy. So often we have the same experience that he has had, where some patient has been treated with penicillin for some time before an actual diagnosis has been made.

We had a case of lymphosarcoma in a young woman of the early twenties treated the same way.

There is one thing that has impressed me in these cases and that is that numbness of the face, or any other symptom which suggests pressure in the antrum, should make one think of malignancy.

I would like to ask Dr. McMahon if the x-rays of the sinuses showed any change in the normal convexity of the canine fossa or a change in the normal contour of the orbital plate. Sometimes stereoscopic views of good films will be very helpful in showing the loss of that convexity which is often suggestive of malignancy.

DR. LE ROY, A. SCHALL: Mr. Chairman, Members of the Society, I cannot let this opportunity go by without congratulating Dr. McMahon on this excellent presentation, if for no other reason than to bring out the symptom of numbness, or paresthesia of the cheek, as suggestive of malignancy of the maxillary sinus.

At a meeting of the section of the American College of Surgeons not so long ago one of our recognized cancer specialists from one of our best known hospitals in a symposium stated that the only symptom that he encountered was unilateral swelling of the face. I like to think of the symptoms of unilateral nasal obstructions when there have been no previous nasal obstructions; of hemorrhage, of unilateral exophthalmos, when there is no symptom of thyroid disease or idiopathic exophthalmos; of unilateral swelling of the face without pain; of pain referred to the teeth without dental pathology; any sudden loss of vision, as the symptoms that suggest malignancy of the sinuses. If our medical profession would think of these seven symptoms, they would make the diagnosis more readily, and more easily.

In an analysis of some 212 cases some years ago we found the majority of our cases were the carcinoma. We too have seen other tumors in children.

My first meeting with the late Dr. Mosher was in 1920 when I called him as a consultant to see an ex-soldier, age 20, with a squamous cell carcinoma that involved the ethmoid and maxillary sinus. He assisted me and directed me at the operation. That young boy died of a lung abscess.

Then I can think in this age group of a high school graduate who took up secretarial work, and was a secretary at one of our neighboring hospitals, whose first symptom in 1940 was watering of the eye. Her ophthalmologist found a four millimeter exophthalmos of the right eye and referred her with the question of malignant disease. The right middle turbinate looked a little large. There was a palpable gland in the neck. Dr. McMillan's x-ray showed destruction of the floor of the frontal sinus, and destruction of the paper plate. Biopsy from the turbinate and gland was anaplastic new growth. Treated by external radiation, by 7200 r supervoltage radiation, there was prompt subsidence of the exophthalmos and disappearance of all symptoms. Six years later x-rays showed regeneration of the floor of the frontal sinus and regeneration of the inner wall of the orbit. Betty died in 1954 from generalized carcinomatosis.

Then there was a nice lady of 68 who complained of numbness of her face. "Doctor, my cheek feels queer. I have been to six otolaryngologists. They tell me they cannot find anything and I have asked six otolaryngologists would x-rays help me and I have been assured they would not." Her examination was negative. The x-rays showed thickening of the roof of the maxillary sinus and destruction of the zygoma. A biopsy from the roof of the antrum through the canine fossa was Grade III carcinoma. She died a very miserable death some 18 months later. So I merely pass on my experience of a few cases that have helped to make me "cancer-conscious."

DR. C. E. MUNOZ-MAC CORMICK (Puerto Rico): Thank you, Mr. Chairman, for allowing me to discuss this interesting presentation of Dr. McMahon. Puerto Rico was mentioned by one of my preceding discussers and I thought that I should stand up to bring to your consideration one more case.

This little girl, three and a half years old, was seen by us at the Auxilio Mutuo Hospital late in August of last year suffering from progressive painless swelling of the left cheek; no other symptoms. Anterior rhinoscopy revealed nothing more than medial displacement of the left antronal wall. X-rays taken prior to our

examination showed marked thinning and ballooning out of the walls of the antrum which was filled by a tumor mass taken to be benign from the roentgenologists' point of view.

Operation was finally consented upon and performed using the Caldwell-Luc approach. Much to our distress, we found that the tumor had already broken through the anterior wall of the antrum with invasion of the overlying soft tissues. A frozen section was taken with a report of a highly anaplastic undifferentiated malignant growth. We proceeded to eradicate the tumor with most of the anterior and medial walls of the antrum and the ethmoids. Irradiation was started at once.

The child did very well for about one month post-operatively, the cavity looking clean and apparently free from tumor tissue. At the end of this time, however, she began to complain of persistent pain in the left knee and thereafter rapidly deteriorated with evidences of generalized metastases to the lungs, liver and long bones, terminating in death towards the latter part of December.

The pathologists are still uncertain as to the exact nature of this tumor, having given consideration, from their point of view, to malignant lymphoma, reticulum cell sarcoma and lymphoepithelioma. I will be only too glad to send some slides to Dr. McMahon for further study.

DR. PIERCE THEOBALD: Mr. Chairman, Members and Guests, Dr. McMahon's paper is a very timely one for me because just ten days ago I operated on a young patient with carcinoma of the antrum. I would like to report to you briefly concerning this case. He was an 18 year old Army enlisted man. As I am now serving in the Armed Forces I eventually saw him. His symptoms began about the 1st of November, 1954, with nasal obstruction of the left side. He delayed going to his dispensary until after his Christmas leave. When he did go to the dispensary, the corpsman gave him nose drops which did no good. A couple of weeks later he went back again and was given some stronger nose drops which of course still did not help him, and a week or so later he again returned to the dispensary when finally he saw his medical officer. The medical officer made a tentative diagnosis of left sinusitis and referred him to the nearest naval hospital on the West Coast. He was then seen by an otolaryngologist. A large tumor growth was discovered in the left side of the nose which was biopsied and turned out to be a highly undifferentiated carcinoma. X-ray showed the tumor to involve the maxillary sinus, the ethmoids and in all probability the sphenoid. He was then referred to Great Lakes Naval Hospital, where I am stationed, because it was closer to his home and because at the original naval hospital x-ray therapy was not available. He presented the classic picture of left nasal obstruction, swelling of the cheek and hard palate, and left exophthalmos. His x-rays, repeated at that time, showed carcinoma of the antrum which had involved the ethmoids and the sphenoid. The optic foramina, however, were normal. A repeat biopsy of the tumor in the nose was positive for carcinoma. We felt that this was not a case for radical surgery, removing the entire orbit, skin of the face and so forth, because the chances were surgery would not cure him, since there was destruction of the floor of the orbit, of the anterior wall of the antrum, and the tumor had broken through the lateral wall of the nose. Ten days ago we operated on this boy. After ligation of the left external carotid artery, through a Caldwell-Luc approach we exenterated the tumor. The maxillary sinus was filled with carcinoma as were the ethmoids and the sphenoid. The hard palate was partially destroyed. The floor of the orbit was destroyed and the tumor extended into and involved the sphenoid bone. Immediately after surgery the swelling of his face and the exophthalmos receded. Now we are faced with a rather difficult problem since we felt that surgery and x-ray combined were the only possibility of giving this boy a chance. Perhaps this part better be off the record.

DR. BERNARD J. McMAHON: Mr. Chairman and Gentlemen, I want to thank Dr. Eggston, Dr. Hill, Dr. Schall, Dr. MacCormick and Dr. Theobald for their discussions.

Dr. Eggston mentions the type of tumor. Dr. Pinkerton, our pathologist at St. Louis University School of Medicine, expressed the opinion that this tumor should be radio-sensitive, consequently irradiation was used instead of extensive mutilating surgery.

The fact that this was unsuccessful in arresting his condition was probably because metastasis had already taken place when treatment was started, even though none was evident in the cervical glands, or in the lungs, by x-ray. A similar situation probably was present in the case of Dr. MacCormick's little patient. We are increasingly aware of our inability to see the patient sufficiently early in his disease. Dr. Schall has mentioned the numbness of the cheek as one of the first signs of malignant involvement of the maxillary sinus, and when it is present its significance should be realized. However, this numbness often does not occur until erosion or invasion of the anterior wall of the maxillary sinus occurs. We felt that the early age in which this type of tumor had been found was of sufficient significance to warrant this report.

PRESENTATION OF INSTRUMENTS

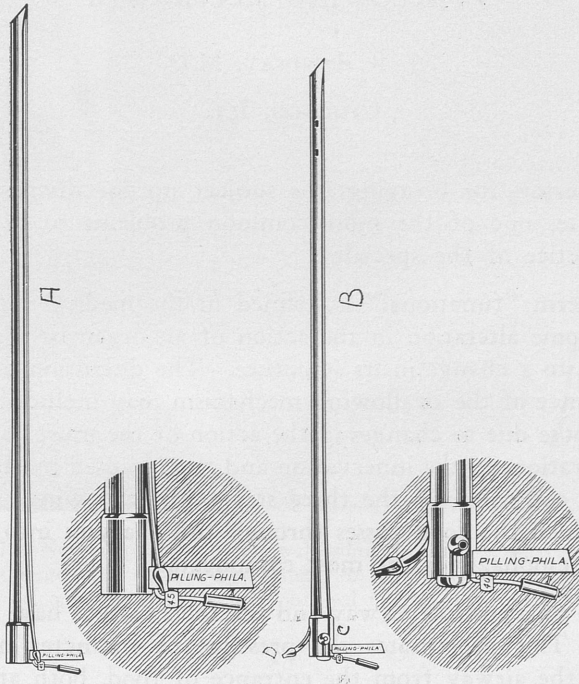
EDWIN N. BROYLES, M.D.

BALTIMORE, MARYLAND

I would like to demonstrate a set of endoscopes which have combined distal and proximal lighting. These scopes are shaped somewhat like Mr. Negus' scopes. They have a blower on the bronchoscope that prevents foggings of the operator's glasses or shield; also a small oxygen tube that supplies oxygen in cases with difficulty in breathing. And for examination, the brightest light that I know is the Brunings handle light. We have adopted this Brunings handle to fit on the proximal end of the scopes.

The distal lighting can be used without the proximal lighting and if more illumination is needed than the distal light will give, the Brunings handle is attached easily and quickly and when lighted gives a powerful concentrated light down through the tube, so that the operator can see on beyond, not just in the close proximity of the distal end of the scope. Certainly in some types of cases for observation the proximal lighting is a great aid. For operative procedures the distal lighting is the only thing to use and so with these types of instruments with both proximal and distal lighting we can see and learn things that we have not been able to in the past.

These scopes are made in all sizes, beginning with 3 1/2 millimeter bronchoscope and also different sizes in esophagoscopes. They are manufactured by Pilling and are to be called "The Universal Endoscopes."



THE UNIVERSAL ENDOSCOPES
(Pilling)

A—Esophagoscope, B—Bronchoscope, C—Anti-fogging air tube, D—Oxygen tube.

FUNCTIONAL DISTURBANCES OF THE UPPER SWALLOWING MECHANISM

J. R. LINDSAY, M.D.

CHICAGO, ILL.

The reason for bringing this subject up for discussion is that it constitutes one of the most common problems to be met with in the practice of the specialty.

The term "functional" is defined in the medical dictionary as implying some alteration in the action of an organ or a mechanism in contrast to a change in its structure. The discussion of this type of disturbance of the swallowing mechanism may include three main groups: Those due to changes in the action of the musculature, those due to alterations in the innervation and those caused by disturbances of psychic control. Of the three stages of swallowing¹ the second stage in which the food passes through the pharynx into the upper end of the esophagus is the most complicated.

In the pharynx the airway and the food passage have a common pathway. This necessitates the presence of sphincter mechanisms to protect the airway from the entrance of food, both at the nasopharyngeal and laryngeal openings as well as a sphincter at the junction of the pharynx and esophagus to isolate or protect the airway from contents of the esophagus and prevent entrance of air¹ into the esophagus during inspiratory effort.

The most important muscles which take part in the propulsion of food through the pharynx are the muscles of the soft palate, the constrictors and elevators of the pharynx, and the muscles which close the upper aperture of the larynx.

The action of part of this system of muscles can be observed on direct examination, for example the tongue, palate, and the constrictors of the laryngeal aperture. Also some of the symptoms caused

From the Division of Otolaryngology of the University of Chicago.

The x-ray pictures have been made by the Department of Roentgenology at the University of Chicago. Some of the illustrations have been used in *X-ray Examination of the Stomach* by Frederic E. Templeton, University of Chicago Press, 1944.

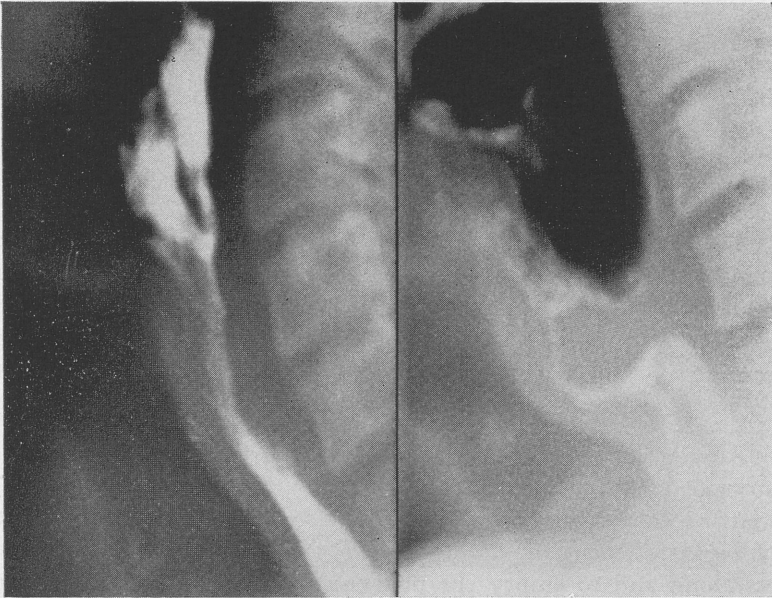


Fig. 1.—Normal pharynx after swallowing barium. a. Pharynx during the resting stage after swallowing barium. b. Pharynx during the Valsalva test. The cricopharyngeus muscle is outlined by this maneuver.

by weakness or failure of these muscles to function are readily recognized. The tongue may be unable to propel the bolus into the pharynx. Defective action of the palate may cause an escape of fluid or food into the nasopharynx and nose, interference with articulation of speech and rhinolalia operta. When the upper aperture of the larynx fails to close tightly there may be an escape of fluids into the airway with resulting cough and the possibility of complications from aspiration. Also if the glottis does not close adequately there may be air loss during speech and interference with such acts as the hiccough and laughing.

The action of the constrictor muscles of the pharynx and of the cricopharyngeal sphincter can be demonstrated best by fluoroscopic examination and x-ray pictures during and after swallowing a thick barium mixture. Spot films are used to record certain phases of the action. Special positions and manipulations may be used to get

increased information. The Valsalva maneuver^{2,3} just after swallowing with the patient in the straight lateral position as well as in the anterior-posterior position is particularly helpful in demonstrating any weakness or asymmetry of the pharyngeal constrictors and any failure of the sphincteric action of the cricopharyngeus muscle. (Fig. 1)

DISTURBANCES OF MUSCULAR ACTIVITY

Those diseases which may cause changes in the action of the musculature without obvious localized or gross changes in structure include the following: Myasthenia gravis, diffuse generalized scleroderma, dermatomyositis and myasthenia associated with some systemic diseases; i.e., tuberculosis, thyrotoxicosis and myasthenia associated with advanced senility.

Advanced myasthenia gravis may so impair muscular action as to prevent adequate closure of the glottis and the upper aperture of the larynx causing a tendency for fluids to enter the airway. There may be impairment of the ability of the constrictors to move the bolus along and to empty the pharynx (Fig. 2). On x-ray examination the barium tends to remain in the valleculae⁴ in this as in most disturbances which decrease the muscular activity of the constrictors.

In some cases of diffuse scleroderma and dermatomyositis the diffuse changes in the connective tissue and muscle may cause a similar functional disturbance. The laryngeal symptoms may be more prominent. Not only may liquids tend to enter the airway but the patient may have loss of air during speech and be unable to laugh or hiccough.

In advanced senility there may be asthenia, impairment of the gag reflex and defective closure of the upper aperture of the larynx (Fig. 3). Food or barium may stick in the valleculae and pyriform sinuses and liquids tend to escape into the larynx. Solid foods may be swallowed with less difficulty.

A similar type of generalized asthenic state has been observed in thyrotoxicosis and in tuberculosis without evidence of a local lesion in the pharynx.

The inability of the pharyngeal musculature to cleanse itself of the barium despite repeated swallowing may be evident on fluoro-

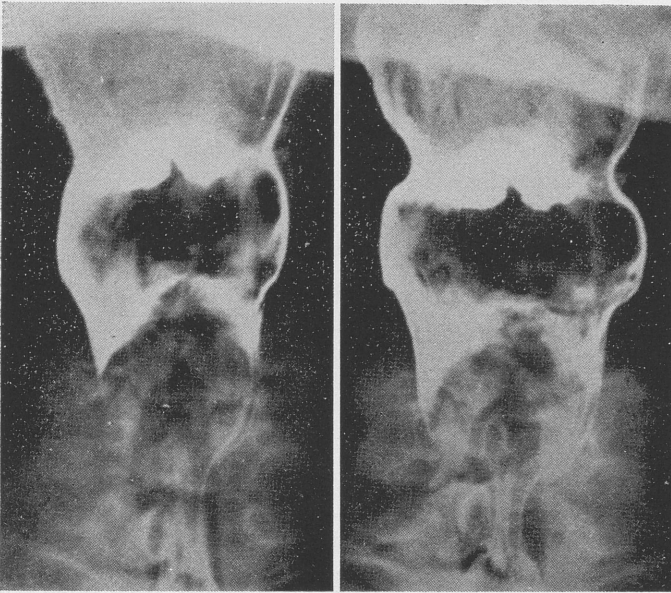


Fig. 2.—Generalized scleroderma. a. Resting stage after swallowing barium. Considerable barium remains in the valleculae and pyriform fossae because of impaired muscular contraction. b. During the Valsalva test.

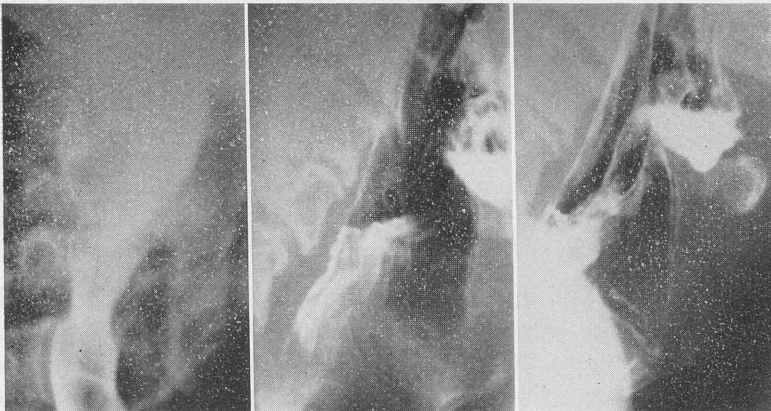

Fig. 3.—Disturbance of swallowing in the aged. a. Solid food and thick barium passes with no difficulty. b. Barium and food are retained in the vallecula due to generalized asthenia. Exostoses are seen on the vertebra. c. Some barium is seen in the larynx. Fluids tend to enter the airway on swallowing.

scopy. The cricopharyngeus muscle tends to retain its effectiveness as a sphincter and to prevent the escape of barium from esophagus to pharynx during the Valsalva maneuver. The interpretation has been made⁵ that the failure of the pharynx to empty represents achalasia or a failure of the cricopharyngeus sphincter to open, however, it would seem that the primary disturbance is of the pharyngeal musculature as a whole.

DISTURBANCES OF INNERVATION

These include both motor and sensory disturbances.

The motor nerve supply to the pharyngeal constrictors and the muscles of the glottis is the vagus. The tensors of the palate are supplied by the V nerve while the levators are said to be innervated by the vagus through the pharyngeal plexus.¹ The sensory supply to the pharynx is from the IX and X nerves.

Motor disturbances usually cause paresis but in some instances may cause spasm. The most common causes of paresis are:

1. Peripheral neuritis: This has commonly been observed after diphtheria and may follow other acute infections.
2. Jugular foramen syndrome: This includes a number of syndromes in which there are varied combinations of paralyses of palate, pharynx, larynx, tongue, neck and shoulder (Tapia, Avellis, Schmidt, Vernet, Jackson, Collet-Sicard) due to lesions in the region of the jugular foramen.
3. Lesions affecting the nerves as they leave the bulb and enter the jugular foramen, i.e. meningo-encephalitis, tumors, fractures, etc.
4. Intracranial lesions: Hemorrhage and embolism affecting the bulb, tumors pressing on the bulb, tabes dorsalis, poliomyelitis, disseminated sclerosis, syringomyelia and amyotrophic lateral sclerosis.

The diagnosis of disturbances affecting the innervation of the pharyngeal muscles is made partly upon the history, the symptoms and signs referable to the pharynx and the associated indications of neurological disease. The fluoroscopic examination and x-ray photographs are useful diagnostic aids in demonstrating the disturbances of muscular action of the pharynx.

In the presence of a severe paresis as in a bulbar palsy the examination with barium should be made with caution because of danger

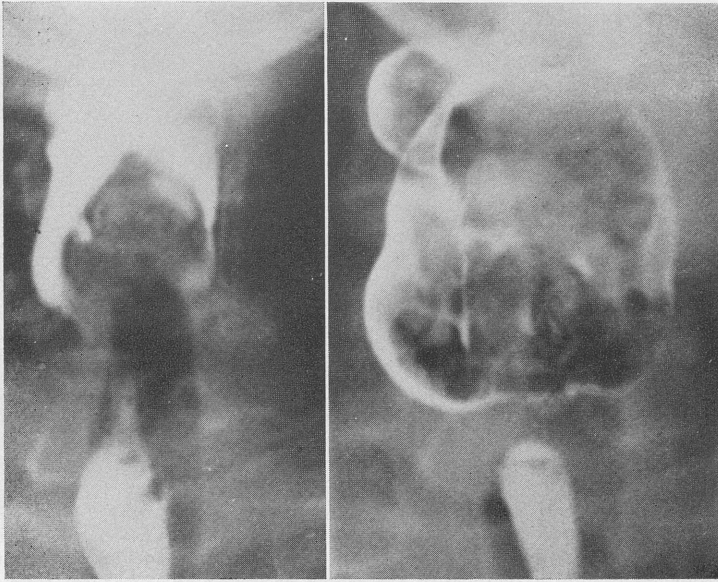


Fig. 4.—Unilateral paresis of pharyngeal muscles due to intracranial lesion. a. Barium remains in the right pyriform sinus after the bolus has passed. b. During the Valsalva test the right side of the pharynx balloons out more than the left.

of aspiration. Thick barium is less likely to be aspirated than a thin mixture. A bilateral weakness of the neuromuscular mechanism may cause a symmetrical delay in the emptying of barium from the valleculae and from the pyriform sinuses. A unilateral weakness may show a tendency for barium to remain in the pyriform fossa of the affected side and for that side to bulge outward to a greater extent on the Valsalva test (Fig. 4).

The cricopharyngeal sphincter tends to retain its function in unilateral pharyngeal paralysis (Fig. 5). In bilateral paralysis such as may occur in poliomyelitis or tabes (Fig. 6) the sphincter may lose some of its efficiency. Esophageal contents may tend to leak back into the pharynx on performing the Valsalva maneuver in the recumbent position.

The examination of the pharynx during the Valsalva maneuver therefore becomes a useful method to demonstrate a failure of the sphincteric action of the cricopharyngeus muscle.

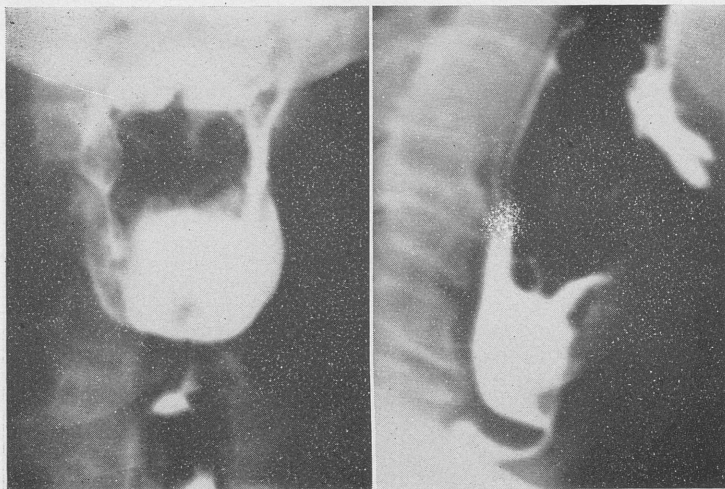


Fig. 5.—Unilateral pharyngeal palsy due to vascular accident. a. After swallowing barium is retained in the valleculae and in the pyriform fossa on the paralyzed side. b. During the Valsalva test the cricopharyngeus muscle is demonstrated and appears to retain its function as a sphincter.

Spasm. A tonic spasm of the pharyngeal musculature may occur in disorders of the central nervous system such as tetanus or brain injuries as well as in acute local infections. A tonic spasm probably also occurs in some psychogenic disorders (cricopharyngeal spasm, globus hystericus). The demonstration of such a spasm by means of x-rays has not yet been a practical possibility.

A disturbance which may have some relation to cricopharyngeal spasm is the development of a pulsion diverticulum. In the early stage the diverticulum may be observed to project backward with part of the sphincter muscle above but most of it below (Fig. 7). The pouch develops at the weakest point, where oblique and transverse fibres separate probably as a result of disturbed co-ordination of the sphincter.

The occurrence of unexplained pain in the region of the cricoid cartilage which is relieved by swallowing may suggest spasm of the cricopharyngeus.

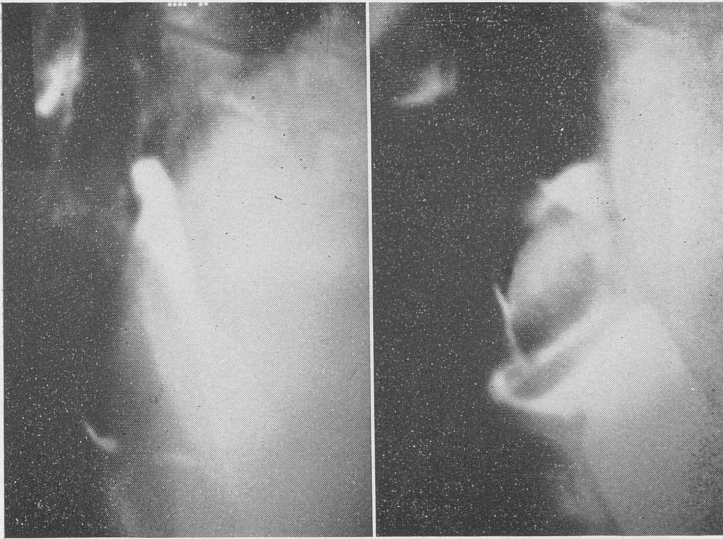


Fig. 6.—Impaired action of the cricopharyngeal sphincter in tabes dorsalis. a. Barium passes freely from the pharynx into the esophagus. Some has escaped into the larynx indicating either sensory loss or impaired muscular action at the upper aperture of the larynx. b. During the Valsalva test barium in the esophagus was forced upward against the cricopharyngeal sphincter. Impaired action of the sphincter allowed barium to escape into the pharynx and some to enter the larynx.

A chronic rhythmic contraction affecting the pharyngeal muscles along with the palate (palatal nystagmus) may occur. Visible rhythmic movements of the upper part of the neck may sometimes be detected. A clicking sound coming from the eustachian tube is likely to be the major complaint. The cause may be obscure but central nervous system disease is to be suspected.

DISTURBANCES OF PSYCHIC ORIGIN

In contrast to muscular and neural lesions the frequency of a psychic disturbance of the swallowing mechanism is high. Some of the complaints referable to the pharynx which may occur on this basis are pain, irritation, burning, dryness, choking or the sensation of a lump in the throat.

These disturbances are psychosomatic in the strict sense in that alterations in secretory activity as well as muscular contraction are

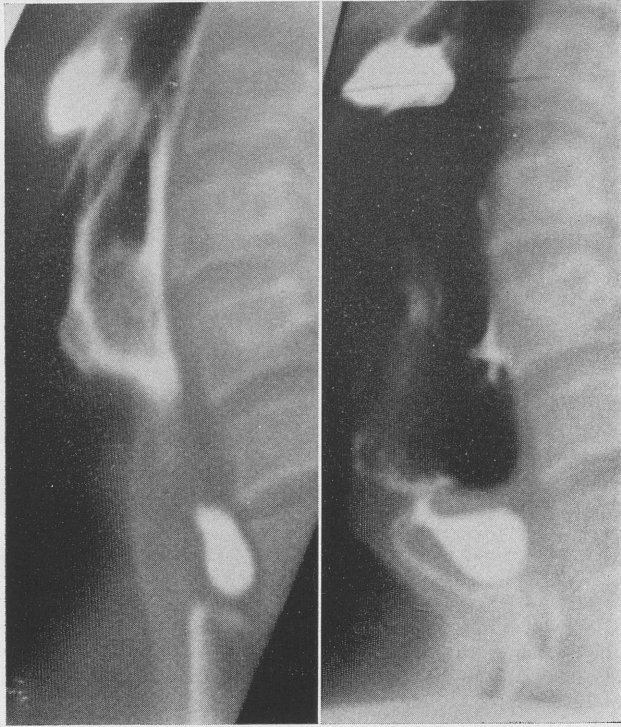

Fig. 7.—Early pharyngoesophageal diverticulum. a. The small diverticulum remains filled with barium after swallowing. b. During the Valsalva test the relation of the diverticulum to the contracting cricopharyngeal muscle is demonstrated.

probably a part of the process and produce the sensory stimuli. In occasional instances it has been found that a psychic disturbance occurred secondarily to an organic disease. Severe anxiety or depression has sometimes been the most prominent manifestation in early malignancy.⁶

Dysphagia of psychogenic origin varies widely in severity. In milder forms there may be the complaint of a lump in the throat which does not interfere with swallowing food. Fluids do not enter the airway. In these less severe types the common cause is the fear of cancer or other serious disease. A careful examination of the

swallowing mechanism is an essential part of the procedure to help rule out organic disease (i.e., early tumor, stricture, Paterson-Kelly or Plummer Vinson's syndrome, etc.).

In cases of psychogenic origin the x-ray examination is usually reported as showing no abnormality in the swallowing mechanism. While spasm or increased tonic contraction of the cricopharyngeus probably occurs it cannot be distinguished from the normal by the technique now in use.

The endoscopic examination may also be essential inasmuch as early malignant disease may be present without clear x-ray evidence.⁷

In practice it may be preferable to delay further examination procedures in some cases until the effect of the initial investigation and reassurance has been observed, but if relief is not produced promptly the endoscopic examination should be made.

In the more severe psychogenic types there may be inability or failure to swallow solid food. The bolus may not be passed into the pharynx from the mouth or it may be rejected. The action of the esophageal musculature as shown by x-ray may not be altered. These severe disturbances of swallowing are seldom due to a simple fear of malignancy or serious disease. They are commonly found in the more severe types of mental illness such as neurosis, hysteria or sometimes a psychosis. The complete examination is necessary in order to exclude a primary organic disease but reassurance may be of no help. The treatment in such cases requires the services of a psychiatrist.

In all cases in which the presence of a psychogenic dysphagia is suspected or indicated it is advisable to avoid all forms of local therapy. Treatment must be directed to the basic psychic disturbance if lasting results are to be obtained.

SUMMARY

Functional disturbances of the upper swallowing mechanism refer to alterations in the action of the mechanism as contrasted to any change in structure.

Functional disturbances may be divided into three groups—those affecting musculature, innervation and psychic control.

Direct observation of the action of the swallowing mechanism is not feasible but useful objective evidence can be obtained by fluoroscopy and x-ray films.

Weakness or asymmetry of action of the constrictor muscles and of the cricopharyngeus commonly seen in disturbances of musculature and innervation can be confirmed by x-ray examination. Evidence of increased tone or spasm of these muscles has not been afforded by present techniques.

950 EAST 59TH ST.

REFERENCES

1. Negus, V. E.: Affections of the Cricopharyngeal Fold. *Laryngoscope* 48:847 (Dec.) 1938.
2. Jönsson, G.: Roentgenological Findings in Malignant Tumors of the Nasopharynx, *Acta Radiol.* 15:1-7, 1934.
3. Templeton, Frederic E.: X-ray Examination of the Stomach. U. of Chi. Press, 1944, p. 85.
4. Kelly, A.: Spasm at the Entrance of the Esophagus. *J. Laryngol.* 34:285, 1919.
5. Asherson, N.: Achalasia of the Cricopharyngeal Sphincter. *J. Internatl. Coll. Surg.* 20:531, 1953.
6. Grinker, R. R. and Robbins, Fred P.: *Psychosomatic Case Book*. Blakiston Co., Inc., New York, 1954.
7. Clerf, Louis H. and Putney, F. J.: Cricopharyngeal Spasm. *Laryngoscope* 52:944, 1942.

DISCUSSION

DR. CLAUDE C. CODY: It seems to me this is too valuable a paper just to be passed without any expression of appreciation or any questions asked and I would like to ask this question. I notice that he mentioned the question of age. Age is not a disease. It is a condition it is granted but the question I would like to ask there is instead of the age, did this aged person whom we can consider to be edentulous have vitamin B₂ deficiency? Vitamin B₂ is a very frequent lack in the aged. Also it affects the swallowing and particularly affects the nerve supply to the motility of the esophagus. The same is true with tuberculosis, and there you see the vitamin B₂ is particularly a factor, the latent B₂ deficiency is quite frequent in tuberculosis. I would like to ask Dr. Lindsay if he had any other evidence in these patients of vitamin B₂ deficiency.

DR. WALTER B. HOOVER: Members of the Society and Guests: It is a great privilege to listen to Dr. Lindsay's paper. I considered the illustrations and slides excellent and they do give one an insight into the working of the hypopharynx.

I am quite interested in this subject and I would like to ask him some questions for my own information and hope that you also would be interested.

First, I have seen many cases of bilateral paralysis of the recurrent laryngeal nerve in which the recurrent nerves were paralyzed but I have not seen paralysis of the cricopharyngeus muscle from this condition, since the cricopharyngeus is

not supplied by the recurrent laryngeal nerve. I have also seen cases of tenth nerve paralysis in which the pharynx and vocal cord on one or both sides are paralyzed and in which the cricopharyngeus muscle was markedly weakened or relaxed. I see in his slides conditions which perhaps would indicate that the cricopharyngeus muscle was not relaxed with weakness of the pharyngeal constrictor muscles, possibly paresis or paralysis of the tenth nerve.

I would like to hear Dr. Lindsay's ideas concerning the innervation of the cricopharyngeus from the pharyngeal plexus and whether he thinks that with paralysis of the upper portion of the tenth nerve, near the jugular foramen or intracranially, there is relaxation of the cricopharyngeus. I think any person in whom the relaxation or wide opening of the cricopharyngeus cannot be demonstrated by x-rays should have an endoscopic examination, because in such cases there could well be fibrosis, web formation or some cause other than functional to account for the difficulty in swallowing.

DR. EDWIN N. BROYLES: Mr. Chairman and Members of the Association, this very interesting paper of Dr. Lindsay brings to my mind three cases that were more or less mechanical difficulties in swallowing situated at the region of the cricopharyngeus muscle. One was a lady with a web formation at that spot. She was diagnosed as hysterical because of her difficulty with swallowing until someone looked down and saw the web there. The two other cases evidently had fibrosis or narrowing of their cricopharyngeus opening and even under general anesthesia there was great difficulty in passing the esophagoscope through the cricopharyngeus. After being dilated they got along very well. I wish you would discuss that, please, Dr. Lindsay.

DR. MISSAL: Dr. Lindsay, at Cleveland City Hospital we have seen poliomyelitis cases with cranial nerve involvement who showed rather characteristic voice changes. Upon physical examination the laryngeal function was normal, the palatine muscles showed little if any impairment but the pharyngeal sphincter action showed moderate involvement. The voice in these cases had a nasal quality. In your cases did you observe any voice changes and if you did, what explanations, if any, did you have for this change in the quality of the voice? Could it be lack of control of the column of air due to impaired pharyngeal sphincter action?

DR. JOHN R. LINDSAY: In answer to Dr. Cody, in the case of senile asthenia of which I showed the x-ray, a vitamin B deficiency could be ruled out. When this patient came under observation he was in acute, severe distress and at that time he may have had a vitamin B deficiency. He had to be tube fed because of pain, associated with ulcerations in his mouth and pharynx. He was treated for some weeks and I am sure that his vitamin lack, if there was any, was made up. He has continued to have this mild difficulty, especially on swallowing liquids. If you look into his pharynx you can see thick mucus in valleculae and pyriform sinuses. As to the cases of thyrotoxicosis and tuberculosis, the reason for the asthenia is not completely clear.

It is worth mentioning that a case that has ulceration and pain on swallowing may have delayed or inefficient action of the musculature.

In this discussion I was trying to keep away from the organic causes of dysphagia and limit myself to what would come under the heading of functional.

In answer to Dr. Hoover's question, I do not think that the nerve supply of the cricopharyngeus is definitely known. I believe Negus has stated that he did not know the nerve supply. It is true that in some cases of a unilateral palsy, where

perhaps the larynx is involved along with the pharynx, there has been a question as to whether the cricopharyngeal mechanism was deficient. In the case where the x-ray showed that some of the barium went into the top of the larynx, it was quite difficult to show whether there was leakage past the cricopharyngeus. There may have been either a sensory deficiency or failure of the musculature at the upper aperture of the larynx to close efficiently. In the cases of unilateral bulbar palsy that we have seen, the sphincter mechanism has not seemed to be deficient, probably because one side only was at fault.

I have only mentioned some of the organic conditions in the paper that one must rule out before one can take a diagnosis of functional disturbance and this includes such conditions as fibrosis or the Patterson-Kelly, or Plummer-Vincent's syndrome. Webs incidentally will sometimes show up on the lateral x-ray views.

I would like to mention that these x-rays are all made by our X-ray Department at the University of Chicago and at the time we first became interested in this, Dr. Frederick Templeton was the main person interested in the x-ray demonstration of these structures. Some of these pictures have been used in his book. They were from cases which have been examined on our service.

Regarding associated voice changes, I mentioned that the scleroderma case had a bilateral weakness of the musculature of the larynx so that she was unable to close the glottis efficiently and there was air loss in talking and also the patient was unable to hiccough or to laugh because of the fact that the cords could not be brought together. It has only been in this scleroderma case that we noticed that problem.

I want to thank the discussers very much for bringing out these additional points.

THE CERVICAL SPINE AND THE GLOBUS SYNDROME

LEWIS F. MORRISON, M.D.

SAN FRANCISCO, CALIF.

The complaint of "a lump in the throat" is a common one. The otolaryngologist confronted with this problem remembers that the differential diagnosis insists that he consider postcricoid carcinoma, carcinoma of the pyriform fossa, stricture, Plummer-Vinson syndrome, enlarged styloid process, pharyngeal pouch, pharyngeal paralysis and other conditions. In routine order these various clinical entities are eliminated or verified. There is a group of patients who have had the advantage of such an examination and do not have any of these conditions to explain their complaint. This undiagnosed group is too frequently told that they are neurotic, and for want of a better term, are given the diagnosis of "globus hystericus."

The literature of the last few years has shown a revived interest in the globus syndrome. Some of the contributors have made a sincere effort to present tangible etiology and definitive therapy. Others, apparently mesmerized by the potentialities of the word "hysteria" (defined as a psychoneurotic disorder characterized by violent emotional outbreaks, perversions of sensory and motor functions, and various morbid effect due to autosuggestion) blithely skip over the drab mundane causes and expend their efforts in unravelling a psychogenic background for the complaint. If one is found, and seemingly one can always be found, psychiatric treatment can be expected to produce a cure. The psychiatric approach to this subject is an important one if for no other reason than it is too frequently overused and abused.

This presentation will deal with only one of the tangible causes of the globus syndrome. The complex neuro-anatomy in the cervical spine area can produce symptoms from the diaphragm to the top

From the Sub-Department of Otorhinolaryngology of the University of California School of Medicine, San Francisco, California.

of the head. Osteoarthritis of the cervical spine is one of the causes of the globus syndrome.

The underlying pathology responsible for the peripheral nerve manifestations is a gradual degeneration of the intervertebral disc elements which eliminates the normal cushioning effect and the weight of the head is then imposed on the neurocentral joints. Accompanying inflammation and the production of spurs adds to the insult. These factors produce compression of the cervical nerves. These changes are more common in the lower cervical area at C-5, C-6 and C-7. Naturally the clinical manifestations depend on the exact site and extent of the pathology.

Few patients respond favorably to being told that they are neurotic or hysterical and are resentful of the globus hystericus diagnosis. The patient who has received this diagnosis assumes, often too correctly, that he is being dismissed on the basis that his complaint is a figment of the imagination, that the whole thing is due to a neurosis, and since no specific instructions for either treatment or care were offered, that it is not at all important. Most patients accept this for a time, but the persistence of the symptoms sooner or later drives them to seek further help and advice. In some instances the above routine is repeated several times. Eventually the patient loses confidence in Doctors of Medicine, may truly become neurotic on the basis of frustration, and is in such a state of disorganization as to accept even the most fantastic measures suggested by any charlatan—naturally, for a fee. At least this is a change. Heretofore good money had been spent for no return and in this instance the patient does get something for his money. Whether it is something good or bad, helpful or detrimental, is quite beside the point. It is something.

The average general practitioner and otolaryngologist are adequately trained and equipped to do something more definite, constructive, and beneficial for the patient than to merely suggest that, "it is nothing, just go along your way and forget about it."

History taking is important. The patient should be afforded the opportunity to tell his own story in his own words. The recitation of symptoms, coupled with deviations as to cause and treatment, may be somewhat prolonged but is important to the trained listening ear. It affords an opportunity to determine the mental equipment and attitude of the patient. This supplies a concrete basis

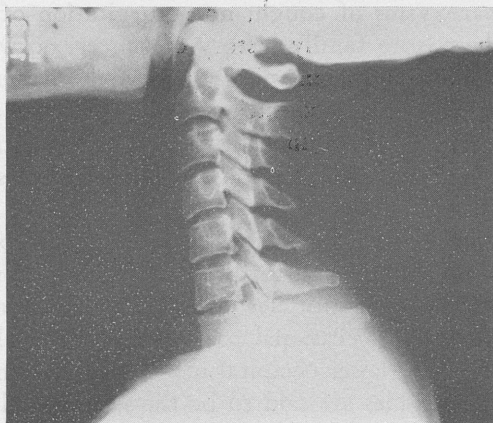


Fig. 1.—The so termed "Poker Spine" showing absence of the normal lordotic curve due to muscle spasm.

for the evaluation of the facts presented, the methods to be employed in determining the cause, the formulation of a plan for treatment, and for anticipating the amount of co-operation that may be expected. As previously stated, the causes of the complaint are many. Only one of the many causes will be considered at this time; namely, the globus complaint due to osteoarthritis of the cervical spine.

It is pathology in this area that produces peripheral nerve symptoms. In order to focus attention on this phase, it is assumed that the hypothetical patient, male or female, approximate age 40 to 50, has had the advantages of a recent general physical check-up and routine examination of the upper respiratory tract including the hypopharynx and larynx. The chief complaint is a sensation of a lump in the throat of eight months' duration. The patient is of a tense type, has seen other doctors, one an otolaryngologist, and seems a bit embarrassed about such a minor complaint; says that maybe it is foolish to even think about the trouble, especially since the family doctor who did an examination just two months ago said everything was fine. Such deviations from normal as were found were stated to be noncontributory and unimportant. A recent radio program and a current lay publication have stressed the importance of paying attention to all minor, chronic conditions. The patient ultimately states that there is a fear of cancer.

The history definitely establishes the absence of dysphagia. There have been no paroxysms of cough, no regurgitation of food and no hemoptosis. There is no family history of cancer, no weight loss nor insomnia, and no history of anemia. In fact, the patient is reported to be in very good physical condition, looks the part, and says that all is well except for the lump in the throat. Questioning brings out these additional facts: The condition is less troublesome at times, is not always present, and days go by when there are no symptoms. There is a grating sound in the neck on full rotation of the head to either side, and there is some indication of limitation of motion. There are periods when the muscles of the back of the neck are tight and painful. There are occasional pains, stab-like in character, that involve the greater and lesser occipital nerve distributions. The tight and painful neck muscles are said to be the result of drafts blowing on the neck and are more prevalent during the evening hours. The patient has noted that the lump in the throat is greatly relieved or completely absent for about one hour after eating. Several repetitions of the question relative to pain on swallowing, regurgitation of food, or evidences of a direct blocking when swallowing cannot be accomplished, are interspersed during the review of the history and the examination. In all instances the replies are definitely in the negative.

Examination of the upper respiratory tract reveals no visible evidence of pathology, either local or general, which would have any bearing on the complaint. The examination must be meticulous. While the actual examination of the upper respiratory tract is going on, there is ample opportunity to ask numerous leading questions relative to traumatic injuries to the neck, and to again repeat questions on subjects which may not have been answered too clearly during the history taking period. If the answers to the repeated questions are consistent, there is no reason to pursue this phase any further. Frequently during this period the patient unbends a bit and by the questions asked or the information presented offers the first opportunity the examiner has to evaluate the individual as a real person.

In order to simplify matters we will assume that this hypothetical patient has produced no visible evidences of pathology. The additional history obtained during the period of examination has brought out the fact that there are times when there has been some tingling in the fingers and forearms of one or the other of the upper extremities and there have been periods of occasional pains in the joints of the lower extremities. The patient is usually apologetic about these

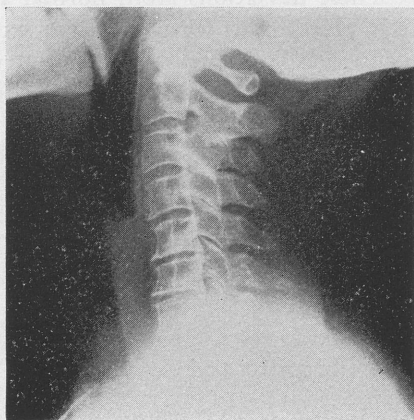


Fig. 2.—Slight reversal of the normal lordotic curve. Early arthritic changes showing spurs on the opposing surfaces of the lower cervical bodies.

minor infirmities and invariably has a logical explanation for them. One is often presented interesting therapeutic measures completely devoid of any basic background, pharmacologic, physiologic, anatomic, or even plain common sense, that were the direct cause of the ultimate improvement or temporary disappearance of the associated complaints.

You are now in exactly the same position the previous medical advisers were when they dismissed the patient. One should not feel justified in concluding on the basis that since nothing was found, no tangible etiology was discovered and a comprehensive examination was completed that the patient be told "there is nothing wrong—go along your way and forget about it!"

Experience has shown that the next step may be an important one. The patient is requested to submit to the expenditure of more time and money to obtain x-ray films of the cervical spine and examination of the esophagus (fluoroscopy and films, with and without contrast medium). The radiologist's report frequently states that the examination of the cervical spine shows no evidence of recent or old bony injury; moderate hypertrophic changes are present and involve both the anterior and posterior borders of the fourth, fifth, sixth and seventh cervical vertebrae; there is moderate narrowing of the discs between the fifth and sixth and sixth and seventh and

there are no cervical ribs. Too often the report does not mention the bony changes. These deviations from normal are of utmost importance. Also, it is pleasing to learn that the examination of the esophagus shows no cardiospasm, no defects along the lumen of the esophagus, no diverticula nor any evidence of delay or malfunction in the passage of the bolus of contrast medium.

The ability to read x-ray films with a moderate degree of facility and proficiency is a necessary acquisition. The knowledge obtained from the patient puts you in a most advantageous position to evaluate the roentgenological findings. The radiologist is of invaluable help in pointing out and explaining the minor, yet too often important, key points. Collaboration is essential if the best interests of the patient are to be served efficiently and economically.

The important finding is that there are degenerative arthritic changes in the cervical spine and that there is some diminution in the size of the intervertebral space. The otolaryngologist's realization of the significance of this pathology will make the difference between a relieved and grateful patient and one who is sent away to continue to suffer from the original complaint.

Having obtained this information, disposing of it in a satisfactory manner is another problem. All too frequently the medical co-workers are of little help. The radiologist more or less rapidly tries to efface himself by stating that it is not an uncommon finding, and the degree of change in this particular instance is not great. The internist states that cervical arthritis is a very common condition, may mumble a few words about aspirin, and, although amazed to think that you would suggest arthritis as a causative factor for globus complaint, is wholly unimpressed by your erudite dissertation on the subject. The neurologists and neurosurgeons are of considerable help in explaining some of the complexities of the nerve trunks which arise in this area, the opportunities for referred sensations to and from rather distant areas and for simplifying reflex pathways. The absence of any radiologic or clinical evidence that permits surgical exploration of the area eliminates the necessity for further attention. The average orthopedist, likewise, is of little help. The one or two suggestions relative to fusion of some of the bodies of the vertebrae or a full plaster collar seem a bit too drastic at the moment.

While the diagnostic procedures are in progress, there is no reason why some of the more simple, wholly innocuous but many times

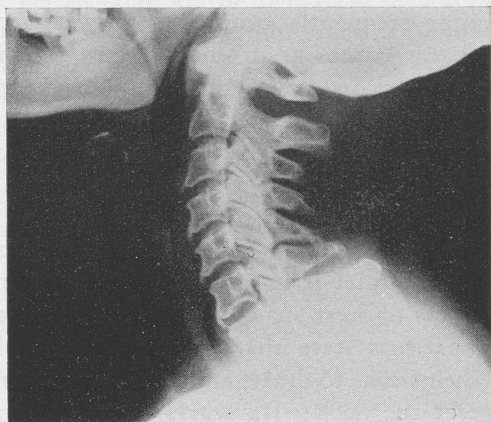


Fig. 3.—Moderately advanced changes showing lipping along the longitudinal ligaments which is more marked in the lower cervical area.

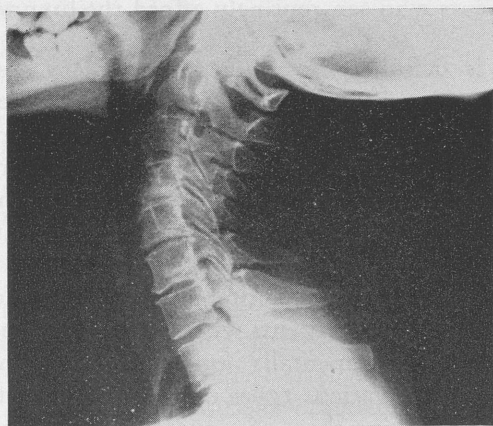


Fig. 4.—Degenerative changes with lipping. There is narrowing of the disc spaces and decrease in size of the intervertebral foramina.

helpful methods, should not be given a trial. Heat in any form, applied to the back of the neck and upper shoulder girdle is usually acceptable and frequently affords great, if not complete, temporary relief. Questioning frequently brings out answers from the patient that substantiate this statement. Whether they sit with their backs to the fire, use an infra-red ray lamp, enjoy an electric pad, obtain relief from soaking in a hot tub, or spend prolonged periods of time with a hot shower directed to the back of their necks, use a hot water bottle, flax seed poultice, or a hot brick or stove lid as a source of heat is wholly incidental. The result is gratifying—at least while the heat is applied. Others obtain similar benefit by the application of strong liniments or other counter-irritants. Further facts to substantiate the beneficial effects of heat may be obtained from a negative approach. Many patients state that they are extremely cautious to avoid exposing their necks to drafts and cold. It is a firmly ingrained practice to protect the neck with scarfs, shawls, or practically any acceptable wearing apparel which will afford protection from the cold. Some of the patients will almost gleefully describe the pleasures of the steam room and a good rub-down. They always omit the cold shower. By and large the response to moist heat is much more effective than the various forms of dry heat. However, there are few of the patients who can routinely afford the luxury of hot packs.

When it is definitely established that there are grounds for pursuing therapeutic measures directed to relieve the peripheral nerve manifestations which have their origin in or about the cervical spine area, intelligent and directed physiotherapy is the first choice. If possible, this should be outlined and supervised by the orthopedist. Haphazard and undirected physiotherapy is seldom satisfactory and when carried to its more complicated phases can be dangerous. I never feel wholly happy while listening to the recounting of the experiences of some of the patients who, either as a result of direction or being somewhat experimentally minded and wishing to conserve on expenses, construct various types of gallows for self-administered neck stretching. Nothing short of a guardian angel could have saved them from hanging themselves with the contraptions they used. In the average community there is at least one doctor who either specializes in treating arthritis or, at least, is willing to suggest and supervise the therapeutic measures. Obviously such a person will care for the patient more efficiently and with less total expense to the patient than one less familiar with this problem.

Radiation therapy has long been used as a therapeutic agent for certain forms of arthritis. When properly administered in small doses over a somewhat protracted period, the results are not only gratifying but persist from shorter periods of several months to longer periods of several years. Doses of 200r once or twice weekly for three or four treatments should not be considered as being small doses. It has been quite surprising to see what very small doses (20r - 30r), twice or even three times weekly for a period of four or five weeks, have accomplished. The total amount of radiation obtained in this way when judged on a basis of time consumed and total dosage permits further similar therapy at some later date. The exact mode of action of this form of therapy is open to considerable discussion. The results obtained in the properly selected cases leave no question in the patient's mind as to the advantages of this type of therapy.

Drugs run the gamut from the popular and generally used salicylates to the later day wonder drugs. Therapy with the vitamins, gold chloride, cortisone, or ACTH has produced spectacular results in some instances.

Therapeutic measures which have proved to be of value are listed in sequence of choice as follows:

1. Physiotherapy (heat, massage, manipulation, traction).
2. Drugs.
3. Radiation therapy.
4. Surgery.
 - a. Esophagoscopy. The trauma associated with the procedure frequently results in regression or elimination of symptoms.
 - b. Fixation—fusion—removal of spurs.

The various names by which the cervical vertebra have been known indicates that as a result of appearance, position or function, certain of them have been set apart from the rest of the members of the vertebral column and even from others of the cervical group for special attention. C-1 and C-2 have long been known respectively as the atlas and axis or epistropheus. These two have been grouped under the heading of rotation vertebrae. The remaining members of the column have been described as flexion vertebrae. C-7 is also known as the vertebra prominens because its spinous process projects beyond all others.

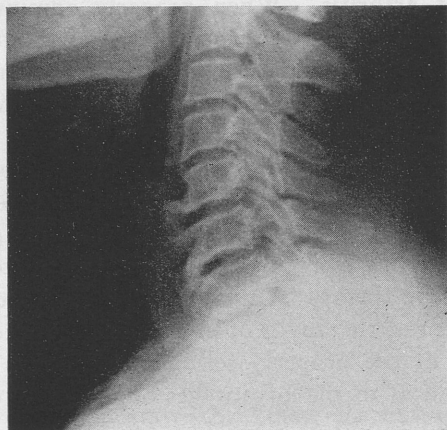


Fig. 5.—Advanced changes showing lipping, bridging and some narrowing of the disc spaces.

C-1 and C-2 differ from the others in this group. The outstanding features are that C-1 has no body and C-2 has a large odontoid process which rises perpendicularly from the body. These anatomical differences offer increased opportunities for nerve injury by trauma as well as insult resulting from inflammation and encroaching calcium deposits. The nerve roots of NC-1 and NC-2 emerge behind the lateral articular masses and are not protected posteriorly by the pedicles and facets which complete the root canal elsewhere in the vertebral column.

A consideration of the mechanics of the cervical spine shows that with the exception of C-1, there are five joints between the vertebrae: The articular facets, the intervertebral disc and the two small synovial joints on the posterior lateral margins. These last two are frequently referred to as the lateral intervertebral joints and some authors consider these to be the only true joints. The ligaments and the deep fascia divide the spaces into many compartments.

There is limited motion between the atlas and the occipital bone. This fact plus the knowledge that the first cervical nerve is usually devoid of a sensory component readily explains why this nerve root is seldom accused of playing a part in the production of unpleasant symptoms.

There is marked mobility of the joint between C-1 and C-2. Of the eight cervical nerves, C-2 is the most liable to suffer from trauma. The posterior ramus of NC-2 which makes up the bulk of the greater occipital nerve emerges between bony surfaces. The anterior ramus is liable to unusual stress under normal conditions. There are tremendous excursions of the articular facets of C-1 and C-2 in ordinary rotary motions of the head. NC-1 and NC-2 send branches to the tenth and eleventh cranial nerves by way of the cervical plexus.

Roentgenologic evidence of cervical spondylosis is most commonly seen in the areas subjected to maximum stress and strain resulting from flexion and extension. C-4, C-5 and C-6 are the areas which usually show the degenerative changes. Changes in the lateral intervertebral joints or shortening or encroachment on the neuroforamina by bone fringes, osteophytes or web-like calcifications satisfy the criteria for diagnosis. It should be accepted that the visible changes seldom represent more than fifty per cent of the actual change. The roentgenograms do not show the accompanying soft tissue changes.

The gradual degeneration of the intervertebral disc elements eliminates the normal cushioning effect. The neuro-central joints must then support the weight of the head and this produces opportunities for compression of the cervical nerves. The known opportunities for intercommunication and referral of afferent and efferent impulses between the cervical nerves and the cranial nerves V, IX, X and XI are almost legion. The literature on this subject is extensive but far from complete.

Further complex neuro-anatomy of the area has been deliberately omitted. Any simplified abstracted form could not be instructive or interesting. A point of progress has been made if this presentation stimulates a sincere desire to review the neuromuscular anatomy of this area. Cunningham, Grey, Pierosol, Toldt and other standard texts contain a surprising amount of information which is both informative and really pleasant reading. If a mind is sufficiently plastic, is still inquisitive and is willing to accept a challenge, it is offered in the form of a suggestion to review the neuro-anatomy of this area and consider the practical applications. The results of such a review will afford many advantages in handling most of these problems.

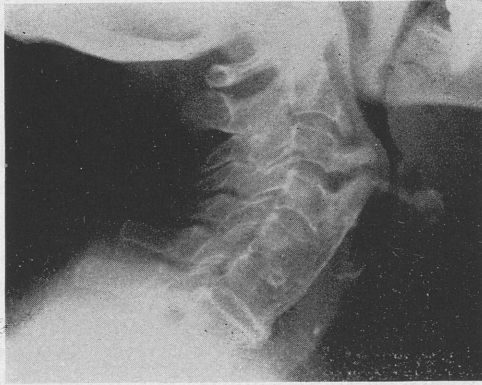


Fig. 6.—Marked osteoarthritic changes. In addition to some difficulty with swallowing there was occasional difficulty with respiration and a muffled somewhat slurring speech.

It is only in the last few years that osteoarthritis of the cervical spine, less well known as cervical spondylosis, has been given any consideration as being the cause of serious neurological disorders. It is seldom mentioned as a cause of dysphagia. The fact that cervical arthritis is never listed as the immediate cause of death explains why the routine postmortem examinations do not pay attention to this area. The available histological examination of tissues from this area is very scanty.

It is realized that cervical spondylosis is only one of the many causes of the globus syndrome. The management and treatment of the cervical spine pathology is not fundamentally within the field of otolaryngology. It is fitting that the patient should consult the otolaryngologist in regard to discomfort in and about the throat. It should be satisfying to both the examiner and the patient to have eliminated the immediate fear of cancer, establish a diagnosis and offer concrete suggestions for treatment. The responsibility of the otolaryngologist does not cease with the establishment of a diagnosis. The patient should be directed to the proper sources for intelligent treatment and should be requested to report for follow-up examinations. These subsequent visits should be based on the patient's progress.

The figures demonstrate varying degrees and types of pathology. All of the subjects had the one common complaint of "a lump in the throat."

CONCLUSIONS

1. Pathology of the cervical spine is presented as one of the tangible causes of the globus syndrome.
2. The complex neuroanatomy of the cervical spine area readily explains peripheral nerve manifestations in regions from the diaphragm to the top of the head.
3. A tentative diagnosis of osteoarthritis of the cervical spine may be made from the clinical history. Roentgenograms will confirm or negate the tentative diagnosis.
4. The relief of symptoms following simple therapeutic measures will substantiate the diagnosis.
5. Cervical arthritis should be ruled out as a tangible cause for the complaint of "a lump in the throat" before the patient is advised to forget about the discomfort or is sent for psychiatric evaluation and treatment.

490 POST ST.

DISCUSSION

DR. CHEVALIER L. JACKSON: Mr. Chairman and Gentlemen, I think this is a most worth-while presentation. We have all been reading these reports of x-ray studies of the neck in which no mention is made of the cervical spine, or the osteoarthritic changes are brushed aside as of no clinical significance. I had, just recently, a patient who had complaints referable to the upper esophagus or hypopharynx which had an x-ray appearance very much like the next to the last slide that Dr. Morrison showed, and I am going to go back over a number of these cases and look up the x-rays. We make it routine to take the films, but I am afraid we have been too ready to accept the radiologist's dismissal of the findings as of no clinical significance.

I am sure that Dr. Morrison has called our attention to something that is of real importance.

DR. LOUIS H. CLERF: Mr. President, I am greatly interested in this presentation which is a timely one. The problem of a lump in the neck and the great tendency for physicians generally and otolaryngologists particularly to ascribe it to a functional disorder is often very unfair to the patient. On the other hand, one can have a lot of changes in the cervical spine and yet not have a lump in the neck. In spite of that I feel as Dr. Morrison has indicated that a study of the cervical spine by

a competent roentgenologist who also is in a position to interpret these changes is most important. It is amazing how often patients who have been complaining for months or years of a lump in the neck or throat have failed to have a roentgen study made. That is disconcerting because in this day and age the average patient is anxious to have a roentgen study and may even suggest it if the physician does not. It commonly is not an economic problem for many either have or will consult osteopaths and chiropractors if their problem cannot be solved by us.

I am going to show a slide of a patient who had slight dysphagia but no subjective sensation of a lump (Slide). You will note 2 large exostoses. It would be foolhardy to consider giving an opinion in such a case without a roentgen study. On finding these changes the situation was explained to her. I had an opportunity to check her about three years later and singularly she has had no increase in her difficulty. She knows she has some changes in the spine that account for the difficulties and she is very happy to carry on with them.

DR. P. E. IRELAND: I would like to say that I think this is a very timely discussion. I have felt for years that many of these people have been neglected and I am sure that I have been able to help some of them.

I have a couple of questions that I would like to ask, the answers to which I suppose Dr. Morrison probably has in his written paper. One is, how important does he think posture is in this syndrome? I believe posture is very important, especially in women wearing high heeled, open-toed shoes. The rheumatologist and orthopaedist will tell you that these shoes throw the whole cervical spine out of line and have a great deal to do with changes in vertebral alignment. I think more important is the posture of the business executive who sits hunched over a desk all day long.

Another important thing to ask the patients is if they read in bed. People read themselves to sleep with the head forward. I think you should tell the business executive to get an executive's chair, because most of the time he is not writing. This chair should have a high back, against which he can lean to look at his work, with proper posture. This relaxes his tension and helps a great deal.

You spoke about not making a collar for these patients and not sending them to anyone to have a collar made. I myself have made a collar of heavy felt which they wear at home and especially when watching TV. The TV habit frequently gives hours of bad posture.

It is very difficult to convince the neurosurgeons and the neurologists that nerve distribution alone will explain why these patients have difficulty in swallowing. I would like to ask Dr. Morrison if he does not think that instead of just the nerve distribution cause, the myositis and fibrositis that accompany the bony changes might be more important than any distribution of the spinal nerve coming from that particular area.

I have enjoyed this paper very much. I felt it was just what I have been thinking on this subject for several years.

DR. THOMAS C. GALLOWAY: I was very much intrigued by a paper in the French literature some years ago in which the authors developed a thesis that these cases were associated with a peri-arthritis, a process that also involves the mucosa, that produced nerve effects, especially by disturbing the distribution in the upper end of Auerbach's plexus. I would like Dr. Morrison to tell us about the pathology of this. Is peri-arthritis sharply limited to the articular facets or is it also a process that is in soft tissues and may involve the sympathetic and the vagus plexuses? The author ascribed to it the production of diverticuli and the production of achalasia,

the thing that Dr. Lindsay was talking about. He considered it not functional but actually dependent upon the involving an inflammatory process in the soft tissues and involving the ramifying nerve distribution.

DR. ARTHUR W. PROETZ: I don't want to drag out the discussion but I wonder if Dr. Morrison has any idea what the lump is. Is it paresthesia? Is it edema? Is it myasthenia? Is it a myositis or is it any and all of these things? If it is a muscle spasm what muscle, because usually we cannot see it. If it is edema where is it? So often people with these conditions are symptom free or at least don't have lumps in the throat. Sometimes the lumps are gone for a week so that there must be a functional element in a great many cases.

DR. FREDERICK T. HILL: I certainly hesitate to add to the list of 70 odd causes for this condition but there is one condition of bony origin that I would ask if Dr. Morrison had encountered it. I am very certain that I have had two cases with symptoms of so-called "lump in the throat" due to ossification of the stylohyoid ligament. In these cases I think the postural element was a factor.

DR. LEWIS F. MORRISON: I take this opportunity to thank those who asked questions.

Doctor Clerf outdid me. The slide he projected shows two large calcified beaks on the cervical vertebrae. However, this does not minimize the importance of the one shown on the slide previously projected.

Answering the questions in order:

Doctor Ireland, posture is very definitely an important factor and I did not want to decry either the use of a collar or the use of traction. A major objective is to interest some of the orthopedic people and the neurosurgeons to the point where they will do something about treatment. It takes the responsibility for that phase off my chest. As far as desks, chairs and tables are concerned, posture is very important. Certain occupations foster poor posture. The copy typist who has her head down all of the time, the manufacturing jeweler who is hunched over a bench, the watch repair people and others who are exerting concerted effort as well as keeping their heads in a very definite position, are quite subject to stress and cervical spine change.

I am going to digress for a moment as to why this condition of pain or discomfort does not last forever. The symptomatology usually abates or disappears with increasing degrees of limited motion or fixation.

In regard to terminology for these people who have to have a name for this condition. The term "cricopharyngeous muscle syndrome complex" is adequate. I do not use the term "globus hystericus."

Doctor Arthur Proetz, as far as I can find out the feeling of a lump in the throat is due to a spasm of the cricopharyngeous muscle. It is not in spasm all of the time. The spasm is frequently relieved when this individual is given something to swallow. That is one reason why you are not going to see evidence of spasm on spot films taken during fluoroscopy. It is one of the reasons why these people feel happier after they have eaten. These patients are troubled mostly during the period between meals. They will go along symptom free and all of a sudden they will swallow. This will initiate the spasm and then there is a persisting feeling of a lump in the throat. Then they start swallowing more and more often. Many patients find that they get relief by just chewing gum. The majority will receive relief from swallowing something warm. Cold fluids seldom afford relief and frequently exaggerate the symptom.

Doctor Galloway, as far as pathology goes, I have seen that article and it is simply fascinating. I think they have gone a little bit off the deep end in regard to the interpretation of the pathology. I was much more interested in an article by an English author—I don't have the exact reference in mind at this moment—who started out his paper by saying that they have very little in the way of actual pathology in the cervical spine area to demonstrate on slides. Fundamentally, this is because it is not a direct cause of death. The necropsy surgeon does not explore the area and most of the pathology that we ascribe to the area is by reference and inference from pathology elsewhere along the vertebral column. He made a plea that the necropsy surgeon should at least look at the cervical area. However, as much as I have tried to encourage them, the response is very poor. Apparently, they do not like to go into the cervical spine area and carry out the more detailed dissections necessary for the removal of the desired tissues.

Whether the pathology is confined to the bone itself, which has produced the calcium on which the spur rests, or whether it is due to the laying down of calcium in the ligaments, or whether it is due to the laying down of calcium in the numerous spaces where calcium can be laid down is a question I don't think any of us can answer. First of all we do not have the necessary representative histological material and we are having a great deal of trouble in trying to get specimens showing the early phases. I have requested several of my neurosurgical friends to cooperate in this study.

A MOTOR PATTERN IN THE NUCLEUS AMBIGUUS. ITS CLINICAL SIGNIFICANCE

A. C. FURSTENBERG, M.D.

JOHN E. MAGIELSKI, M.D.

ANN ARBOR, MICH.

With the beginning of knowledge of laryngeal physiology the imaginations of laryngologists were captured by the almost unlimited possibilities of motor function. The complex and intricate mechanisms of the larynx both as regards the action of the sphincters and the innumerable relationships the cords may assume in harmonious action with each other have long suggested the logical practicality of a pattern for the cells of origin for the superior laryngeal and recurrent laryngeal nerves. We now hold the conviction established by evidence that such a pattern does exist in the nucleus ambiguus of the monkey.

The nucleus ambiguus is a motor nucleus extending from the upper border of the medulla and the region of the striae medullaris caudalward to the level of the motor decussation. It is generally recognized to be the origin of motor fibers to the striated muscles of the pharynx, larynx and the esophagus. These muscles are derived phylogenetically from the gill arch musculature. They are supplied by the glossopharyngeal, vagus and bulbar accessory nerves (branchiomeric special visceral efferent nerves). The pattern of cells of origin in the nucleus ambiguus for the larynx is particularly difficult to determine because the nucleus is long and composed of cells arranged in a complex manner. It has been described for carnivores (cat) by Szentagothi.¹ He placed small electrolytic lesions in the nucleus which he later studied. After a suitable interval he also observed the degeneration of the motor end plates in various laryngeal muscles. Thus he was able to establish a definite pattern with the following arrangement: 1) the cricothyroideus muscle in the rostral part of the nucleus and 4 mm rostral to the obex level. The remaining muscles were innervated in the following order behind the crico-

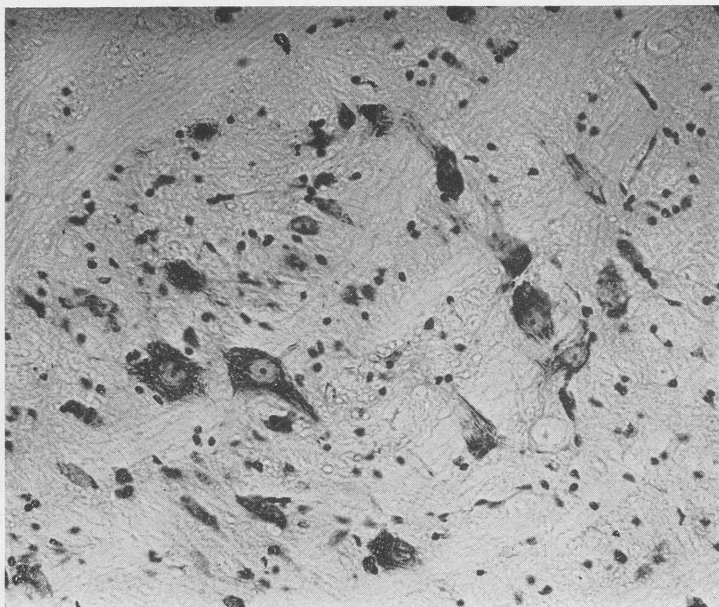


Fig. 1.—Normal motor neurones in the nucleus ambiguus of the monkey. Magnification approximately 90 x.

thyroideus and all rostral to the obex; 2) cricoarytenoideus dorsalis 2 - 4 mm in front of the level of the obex; 3) thyroarytenoid 2 - 3 mm rostral to the obex; 4) lateral cricoarytenoid 1 - 2 mm and 5) arytenoideus 1 mm in front of the obex.

In a series of experiments upon monkeys, a comparable pattern was obtained except that the innervation of the cricothyroideus was found to be slightly caudal to the plane indicated for this muscle in the cat, although still near the rostral end of the nucleus. Cells of origin for the adductor muscles were obtained about the obex level being both slightly in front and behind it. The abductor cells of origin were found between the levels in the nucleus for the cricothyroideus muscle and the adductor muscles.

EVIDENCE

These results in the monkey were obtained by the use of two different techniques. The first consisted in observing the chromo-

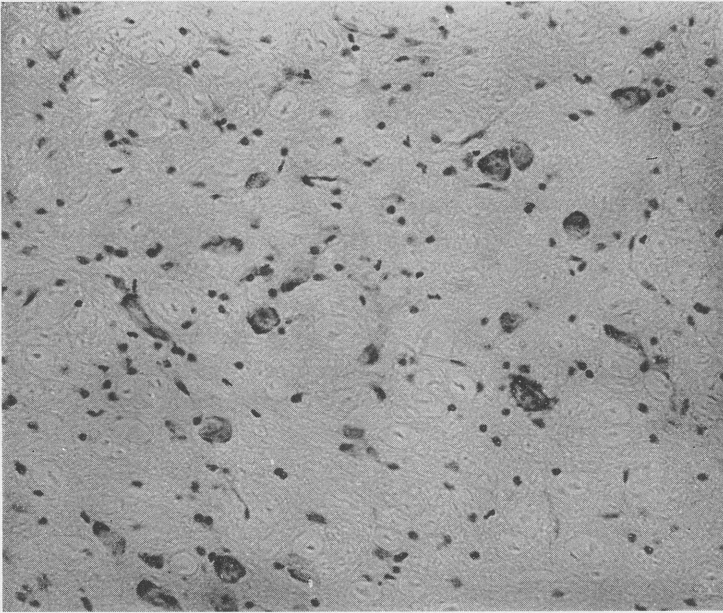


Fig. 2.—Motor neurones in the nucleus ambiguus of the monkey showing chromatolysis. Magnification approximately 90 x.

tolysis in the cells of the nucleus ambiguus after section of the posterior branch of the left recurrent laryngeal nerve. The monkey's larynx was examined by direct laryngoscopy before and after section of the nerve while the animal was under light ether inhalation anesthesia. The animal was allowed to live for two weeks. He was then sacrificed and the brain perfused with formalin and stained with thionin. (Thionin is a differential stain for Nissl granules.) After section of a nerve fiber such Nissl granules disappear producing the condition called chromatolysis. The portion of the nucleus which gave rise to the sectioned fibers of the recurrent laryngeal nerve had cells which were either void of Nissl granules or contained ones poorly stained.

The second technique which must be regarded as more conclusive was directed to the location of the cells of origin in the nucleus ambiguus by direct faradic stimulation. Ether anesthetized monkeys were placed in the McCulloch modification of the stereotaxic instru-

ment after preliminary direct laryngoscopy. A monopolar electrode was then inserted into the nucleus ambiguus according to the tables of D. Altas and W. R. Ingram.²

Before placing the monkey in the stereotaxic instrument, the larynx was exposed in the neck in order to obtain a direct view of this organ and especially the cricothyroideus muscle. This was accomplished without interfering with the peripheral nerve supply of the larynx. It was necessary to modify the readings for the monkeys used but ultimately stimulation with favorable readings produced a contraction of the cricothyroid muscle. The trachea was then opened in the midline ventrally to obtain a view of the vocal cords from below. Upon repeating the same stimulation, there was contraction of the cricothyroid muscle but no lateral or medial displacement of the vocal cords. The needle was then moved 1 mm caudoventralward from the first reading (which produced cricothyroid contraction) and the stimulus repeated. It was now evident that adduction of the vocal cord on the side of the stimulus could be obtained but that no movement of the cricothyroid muscle occurred at this level. A lesion was then placed at this last site. The lesion was obviously larger than the area stimulated but it was definitely in the nucleus ambiguus. These results were verified in three monkeys observing both cricothyroid contraction and adduction using approximately the same stereotaxic readings. It is obvious that the difference in position of the needle will vary with the size of the individual monkey.

The level in the nucleus which demonstrated chromatolysis after section of the posterior branch of the recurrent laryngeal nerve was then studied. It was found to be between the sites at which direct stimulation produced cricothyroid muscle contraction and adduction of the vocal cords.

The combined results of these two methods is evidence of a rostralcaudal pattern of innervation in the nucleus ambiguus for the larynx. The cricothyroid is the most rostral of the cells while the adductor muscle group is most caudal.

CLINICAL SIGNIFICANCE

Obviously the presence of such a pattern makes it possible for central lesions to cause impaired function of one or more muscles of the larynx without necessarily an involvement of all of them. Think of the many times we have seen unusual physiologic behavior

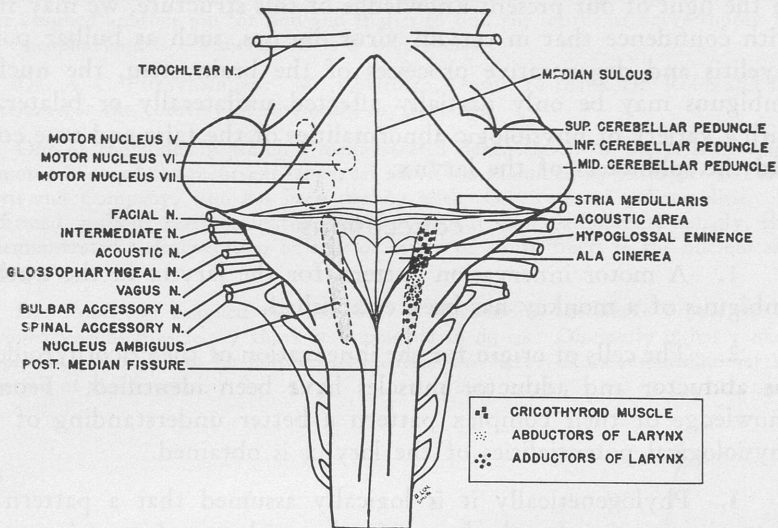


Fig. 3.—Diagram of the pons and medulla of the monkey. Note the shaded area illustrating the nucleus ambiguus. See key demonstrating the approximate location of the motor neurones in the nucleus ambiguus supplying the larynx.

of the larynx with no logical explanation for its occurrence and with despair in our attempts to classify it in accordance with any of our known entities of laryngeal dysfunction. These unusual clinical observations can be definitely attributed to the many cells of origin of motor stimuli which possess specific functions and which for many reasons may be disturbed or handicapped in their action. It is obviously unlikely that a peripheral lesion could be so small and selective as to produce a dysfunction of the isolated laryngeal muscles.

Pressman³ presented a study of the sphincters of the larynx which established sound reasons for signs and symptoms occasionally observed in central nervous system disease. It created an epoch in our knowledge of the function of the larynx. He reported his observation of a patient with a bilateral recurrent laryngeal nerve paralysis from a central lesion in whom the false vocal cords closed completely with no associated action of the true cords. It is an established fact that this can occur and the anatomical explanation is readily found in the pattern of the motor cells of origin of the superior laryngeal

and recurrent laryngeal nerves in the nucleus ambiguus of the medulla. In the light of our present knowledge of this structure, we may state with confidence that in certain virus diseases, such as bulbar poliomyelitis and degenerative processes of the brain stem, the nucleus ambiguus may be only partially affected unilaterally or bilaterally with a variety of physiologic abnormalities of the false and true cords and the sphincters of the larynx.

CONCLUSIONS

1. A motor innervation pattern for the larynx in the nucleus ambiguus of a monkey has been established.
2. The cells of origin for the innervation of the cricothyroideus, the abductor and adductor muscles have been identified. From a knowledge of their complex pattern a better understanding of the physiological potentialities of the larynx is obtained.
3. Phylogenetically it is logically assumed that a pattern of motor innervation for the larynx in the nucleus ambiguus is present and much more highly developed in man.

UNIVERSITY HOSPITAL.

REFERENCES

1. Szentágothai, J.: Die Lokalisation der Kehlkopfmuskulatur in den Vagus-kernen. *Zeitschr. f. Anat.* 112:704-710, 1943.
2. Atlas, D., and Ingram, W. R.: Topography of the Brain Stem of the Rhesus Monkey with Special Reference to the Diencephalon. *J. Comp. Neurol.* 66:263-289, 1937.
3. Pressman, J.: The Sphincters of the Larynx. *Trans. Am. Acad. of Ophthal and Otolaryng.* 57:724-737, 1953.

DISCUSSION

DR. LEWIS F. MORRISON: It is a pleasure to hear a paper like this. It is a subject that is of prime interest to me. It is pleasing to know that controlled experiments substantiate the clinical and anatomical distribution of the recurrent nerve.

I would like to take exception to the statement that the function of a single muscle or even a portion of a muscle cannot be impaired as a result of insult or injury to the extra laryngeal portions of the recurrent laryngeal nerve. It is now established that the recurrent laryngeal nerve frequently divides in the extra laryngeal space. It has been shown to divide into as many as six branches in the extra laryngeal space. One of the small branches can be injured and the other five left intact. This offers the probability of impaired function of a single muscle or even a portion of a muscle.

DR. JAMES M. ROBB: Mr. President and Gentlemen, I always enjoy Dr. Furstenberg's presentations because they are very accurate and not too long. However, I have assigned another job for him and that is to find the source of nerve supply for the cricopharyngeus. The rest of it is pretty clear.

DR. A. C. FURSTENBERG: Mr. Chairman, I want to thank Dr. Robb and Dr. Morrison for the courtesy of discussing my remarks.

One of the slides in which I demonstrated degeneration of the cells of origin of motor fibers of the recurrent laryngeal nerve was examined by an expert at Parke, Davis and Company, who has been dealing with the viruses of poliomyelitis. He confirmed without reservation the diagnosis of our own pathologist, namely, that it demonstrated a degeneration of cells of origin of motor fibers in the nucleus ambiguus.

Dr. Robb has assigned me the task of discovering the nerve supply to the cricopharyngeus muscle. I think it is possible to do so. Obviously it has a nerve supply and it ought to be possible to identify the nerve fibers responsible for the function of this muscle.

BLASTOMYCOSIS OF THE LARYNX

WILLIAM C. THORNELL, M.D.

CINCINNATI, OHIO

Blastomycosis is a chronic disease caused by the blastomyces fungus and may involve the skin, internal organs or any portion of the respiratory tract. Clinically, it may resemble tuberculosis and less frequently cancer. The disease under discussion will be limited to the North American variety of blastomycosis. The yeast-like fungus of blastomycosis is a spherical body with a double contoured wall measuring 6 to 15 microns in diameter and multiplies by budding, as contrasted to the organism of coccidial granuloma which multiplies by endosporulation. Microscopically, this may be viewed as a slight protrusion from a parent cell to a budding new cell ready to undergo division. Mycelium and hyphae are seen only on culturing the fungus, whereas the blastomyces organism and budding form may be found in the tissues and in the sputum.¹

In 1896 Gilchrist and Stokes² first described a verrucous type of skin lesion resembling tuberculosis, but caused by a yeast-like fungus. That same year Busse³ presented a case report on a patient who had a generalized fungus infection which ended fatally. Since then there have been numerous case reports on patients suffering from this parasitic fungus infection called blastomycosis.

Primary involvement of the larynx with the North American variety of blastomycosis is a rather uncommon involvement as manifested by the report of only 14 cases in the English literature.⁴⁻¹²

Ranier¹¹ and Ferguson¹² have presented excellent reviews of the literature and discussions on blastomycosis involving the larynx. Portions of this presentation will be but a repetition so as to refresh our memory on this unusually rare but so important disease.

In 1896 Gilchrist and Stokes² first described a verrucous type primary blastomycosis involving the larynx. From 1894 to 1918, 47

From the Department of Otolaryngology, University of Cincinnati, College of Medicine, Cincinnati, Ohio.

cases were reported with possible but not proven associated involvement of the larynx in three cases. Early reports revealed a large concentration of such cases around Chicago and the midwestern part of the United States. The greatest number of cases occur between the ages of 20 to 40 years. Blastomycosis is nine times more frequent in the male than in the female. It is reported that poor living conditions, damp, dusty and moldy living quarters may be predisposing factors. There is no racial predisposition. It is not regarded as contagious.

In reviewing the literature on blastomycosis of the larynx it was interesting to note that almost all reported cases apparently followed an acute upper respiratory infection with resulting persistent hoarseness as a primary complaint. In addition to this, anorexia, weakness, weight loss, dyspnea, cough, hemoptysis, chest pain, dysphagia and low grade fever were listed as associated symptoms.

In skin lesions, the infection begins as a papule which soon develops into a pustule. The surrounding areas become inflamed followed by the formation of many small abscesses which may contain opaque gelatinous material. These soon ulcerate, forming an ulcer with characteristic verrucous projections about the edge resembling tuberculous verrucosa cutis. It is this stage that is usually observed by the physician.¹³ The laryngeal lesions may exhibit any one of several stages. The early inflammatory stage reveals a marked reddened and granular appearance to the vocal cords and possibly the surrounding structures. Multiple small pin head abscesses then form and are noted as minute greyish papules with an occasional yellowish nodule. Ulcerations then develop and are covered with a thin grey membrane with an underlying fierce red color on removal of the membrane. New⁸ states that the greyish nodular infiltrating lesions present the appearance of mucous membrane touched with silver nitrate. With progression of the disease, fibrosis occurs, producing fixation of the vocal cords with resulting laryngeal obstruction, and still later, a stenosis of the glottis. Following this, fistulae may develop in the neck associated with multiple communicating abscesses and systemic manifestations of the disease.

Microscopically, the picture resembles that of tuberculosis with which it is frequently confused. This similarity of course necessitates the finding of multinucleated giant cells exhibiting phagocytosis of the solitary and also the budding yeast-like double contoured spher-

ical organisms. The final diagnosis rests with the microscopic examination. The most frequent picture is that of multiple small abscess formation with frequent giant cells and the presence of the blastomycetes organism within the giant cells. Caseous necrosis, tubercle formation and later fibrosis may be a prominent finding.

Epithelial hypertrophy is a prominent feature representing a pseudo-epitheliomatous hyperplasia. Ferguson,¹² Friedman and Signorelli¹⁴ emphasized the possibility of confusing the atypical pseudo-epitheliomatous hyperplasia of blastomycosis with squamous cell carcinoma. New⁸ and Clerf and Buscher¹⁰ have emphasized the importance in considering fungus infection involving the larynx when confronted with a clinical picture of an extensive chronic inflammatory lesion of the larynx suggestive of tuberculosis.

Blastomycosis has been found in the sputum of most cases showing positive biopsies from the larynx. The yeast-like organisms changing to the mycelial forms are noted on transferral from blood or beef infusion agar at 37 degrees centigrade to Sabouraud's agar at room temperature.

The complications of blastomycosis of the larynx have been listed by Ranier as: 1) pulmonary involvement, 2) perilaryngeal extension including the skin, 3) laryngeal stenosis resulting from fibrosis, 4) hematogenous dissemination, 5) esophageal stricture, 6) carcinoma.

TREATMENT

Large doses of iodides have been advocated in the treatment of this mycotic infection since it was used in the first laryngeal case reported by Dennis and Downing in 1918. Ethyl iodide has also been suggested as another means of introducing iodide into the body by the inhalation of this volatile preparation. The application of copper sulphate and iodine directly to the involved areas has also been used with reported success. X-ray therapy has been advocated by many observers. Surgical excision of all resectable lesions in localized involvement has again been advocated by Ferguson in individual cases after careful study and thorough trial, where other measures fail to produce improvement or cure.

Smith¹⁵ and Ferguson feel that skin testing and specific complement fixation tests to blastomycosis organism are necessary in determining the patient's immunologic state and serve as a valuable guide

regarding treatment and prognosis. They feel that skin testing and complement fixation tests should be carried out on all cases before any treatment is started. If there is evidence of a hypersensitivity, the patient should first be desensitized with vaccine and then given potassium iodide. If evidence of iodide sensitivity appears, Ferguson states it should then be withheld for a reasonable period of time before readministration in smaller doses. Arsphenamin, sulfonamides, penicillin and streptomycin have been advocated singly or in various combinations, but Altemeier¹⁶ has noted that the North American variety of blastomycosis is resistant to all antibiotics and sulfonamide agents.

More recently, there are reports of the successful use of the aromatic diamidines (stilbamidine and propamidine) in the treatment of blastomycosis.¹⁷⁻¹⁹ It was first reported by Elson²⁰ that the diamidines were fungistatic. Previously the drug had been used in the treatment of leishmaniasis and trypanosomiasis. Stilbamidine was first reported in the treatment of two cases of generalized blastomycosis in 1951.¹⁷ The immediate response was favorable. Heilman²¹ has shown that stilbamidine can exert a definite suppressive effect on blastomycosis, both in vitro and in vivo. The various evidences of toxicity to the aromatic diamidines have been listed as early or late. The early toxic effect may be a circulatory collapse. Late effects may be manifested by hepatic or renal damage, but this may result from old solutions. Thus, it is urged that only freshly prepared solutions be used. A curious but interesting late manifestation of diamidine toxicity is the development of a fifth cranial nerve neuropathy.²² This is manifested by paresthesia, hypalgesia and anesthesia over the area supplied by the fifth cranial nerve. As a result of this sensory change, Smith and Miller²³ have employed this drug in the treatment of tic douloureux.

REPORT OF A CASE

A 44 year old white man, a butcher, was first seen in my office on June 1, 1949. He presented a history of hoarseness following an acute head cold in December, 1948. He had been treated elsewhere for a chronic laryngitis. Examination of the larynx revealed a reddened, elevated, granular firm-appearing and infiltrating lesion involving the anterior two-thirds of the right vocal cord. The lesion did not extend into the anterior commissure. There was no limitation of motion of the vocal cord. Clinically, the lesion appeared to repre-

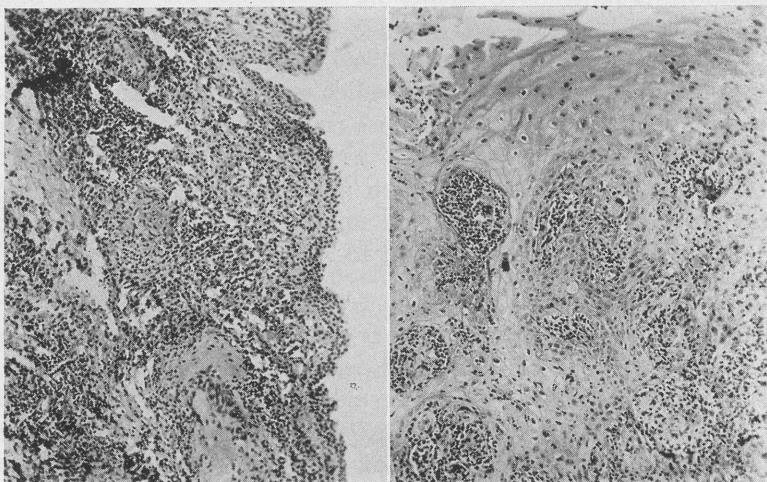


Fig. 1.—Severe chronic inflammatory reaction with a large multinucleated giant cell.

Fig. 2.—Pseudo-epitheliomatous hyperplasia with intraepithelial abscesses.

sent an early vascular malignancy. A biopsy was taken by indirect laryngoscopy under local anesthesia in the office. The microscopic section (Fig. 1) showed a severe chronic inflammatory reaction containing a few poorly defined granulomatous foci and an occasional very large multinucleated giant cell. The diagnosis was chronic inflammation consistent with tuberculosis.

The results of a general physical examination were essentially negative. X-rays of the chest revealed a mild fibroid lesion in the right apex and was reported as questionable in activity, probably the result of tuberculosis in view of the biopsy report. The blood counts were normal. Sputum studies were carried out and found to be negative for the tubercle bacilli and fungi. The patient was placed on complete voice rest and bed rest. On July 1, 1949, bronchoscopic examination was carried out and revealed essentially negative findings. Sputum studies carried out at this time were again negative. On July 8, 1949, x-ray pictures of the chest were repeated and compared with the original pictures. No change was noted. It was felt, in view of this, that the chest lesion was not involved with an active infection. Bed rest and complete voice rest was continued and

dihydrostreptomycin therapy was begun. In a period of several weeks, the patient showed a gradual weight gain. On August 1, 1949, no definite improvement was noted in the larynx and streptomycin was discontinued. On November 30, 1949, increased hoarseness developed and the right vocal cord was noted to be more thickened. Dihydrostreptomycin therapy was started by intramuscular injection and also by aerosol inhalation for a period of six weeks. On December 9, 1949, although slight improvement was noted in the voice, clinically there was no change noted in the larynx on laryngeal examination. Since no improvement was noted in the lesion involving the vocal cord, direct laryngoscopy and further biopsy studies were advised. On February 13, 1950, under general anesthesia, a repeat biopsy was carried out under direct laryngoscopy, and the base of the lesion extensively destroyed with the electrocoagulating unit. Histologically (Fig. 2) the lesion was characterized by a pronounced pseudo-epitheliomatous hyperplasia of the squamous mucosa within which were numerous minute suppurative foci containing multinucleated giant cells. Within a few of these giant cells (Fig. 3) were spheroidal bodies which had doubly refractile walls and were considered characteristic of blastomycosis.

The patient was started on gradually increasing doses of potassium iodide by mouth. By April 1950, marked improvement was noted in the appearance of the larynx. The patient was instructed to continue with the potassium iodide and to report to the office at frequent intervals for observation of the lesion. The patient did not return for examination until January 10, 1951. He stated that shortly after starting the medication, gradual improvement was noted and within a period of several months his voice had returned to normal. Following this, he discontinued the medication. Recurrence of hoarseness had developed six weeks before this last visit and had apparently followed an acute upper respiratory infection. Examination of the larynx at this time revealed both vocal cords to be moderately reddened and thickened. In view of the good response to potassium iodide on the previous occasion, he was instructed to take gradually increasing doses of potassium iodide again by mouth.

The patient did not return for re-examination until October 29, 1952, at which time he stated that shortness of breath on exertion had been noted for the past five months. Examination of the larynx revealed a bilateral fixation of both vocal cords with only a $1\frac{1}{2}$ mm opening, with a resulting inadequate airway. General physical exam-

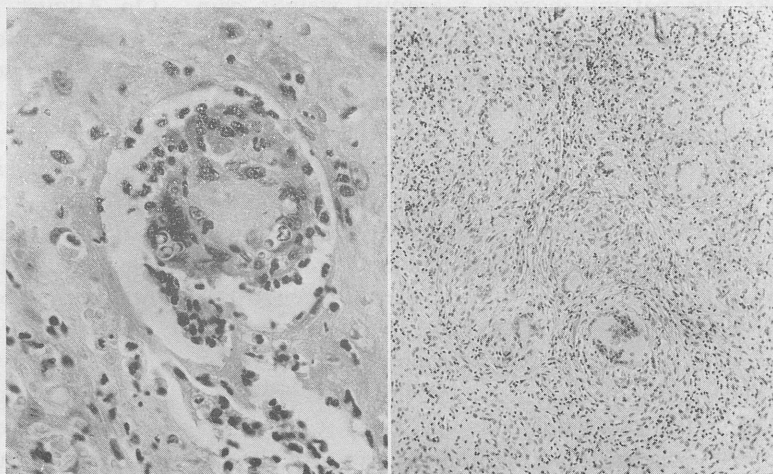


Fig. 3.—A giant cell containing several organisms.

Fig. 4.—Massive granulomatous inflammation with non-caseating tubercles and huge multinucleated giant cells.

ination was essentially negative, and x-ray pictures of the chest revealed no change in the lung fields. The vocal cords appeared somewhat thickened and greyish in color. There was no evidence of an acute inflammatory reaction nor of abscess formation. Since the patient again had stopped potassium iodide, he was advised to start the medication. In view of the bilateral fixation of both vocal cords with a resulting inadequate airway, an intralaryngeal arytenoidectomy was advised and this was carried out on the left side on November 13, 1952. Following a tracheotomy, the operation was performed through a transoral approach, using a Lynch laryngeal suspension apparatus under combined local and general anesthesia. During the procedure, it was noted that marked scarring surrounded the cartilage and extended into the muscle. The cartilage and adjacent tissue were sent to the pathologist for further studies. Histological examination (Fig. 4) revealed a massive granulomatous process characterized by non-caseating tubercles which were composed of histiocytes and huge multinucleated giant cells. These were scattered in a cellular fibrous stroma. The granuloma did not invade the cartilage.

Following the arytenoidectomy, the patient was noted to have only a 2 mm glottic space which still presented an inadequate airway

for normal activities. When no further improvement was noted by March, 1953, arytenoidectomy was then advised on the opposite side. This was carried out in a similar manner on March 19, 1953. The arytenoid cartilage was removed from the right side without complication.

Following the second arytenoidectomy, the patient has been observed at frequent intervals in the office. He has been advised to continue with the potassium iodide by mouth. Examination of the larynx at frequent intervals reveals an adequate airway. The voice has been hoarse, but adequate. There has been no evidence of further inflammatory reaction. He was last seen in my office on January 21, 1955.

COMMENTS

Primary blastomycosis of the larynx is a very uncommon disease. It is frequently confused with tuberculosis because of the similarity between the gross and microscopic appearance. The pseudo-epitheliomatous hyperplasia may lead to the possibility of confusion with squamous cell carcinoma. Because of these similarities it is possible that the incidence of blastomycosis of the larynx is greater than one would suspect.

A review of the literature and recent advances in treatment is presented. One case is reported in which a final complication of bilateral vocal cord fixation was treated by transoral intralaryngeal arytenoidectomy. This case demonstrates the importance of suspecting a fungus involvement in a chronic granulomatous lesion of the larynx when laboratory studies fail to reveal a tuberculous organism. This case also demonstrates the importance of frequent observations and the necessity for continued treatment with iodides when effective over a period of several years. With the introduction of the aromatic diamidines in the treatment of blastomycosis, these drugs should now be the ones of choice and thus the long continued administration of potassium iodide may be avoided.

2508 AUBURN AVENUE.

REFERENCES

1. de Rivas, D.: Blastomycosis. *Cycloped. of Med.* 2:506-509, 1937.
2. Gilchrist, T. C., and Stokes, W. R.: The Presence of an *Oidium* in the Tissues of a Case of Pseudo-lupus Vulgaris. *Bull. Johns Hopkins Hosp.* 7:129, 1896.

3. Busse: Quoted by de Rivas, D.¹
4. Dennis, F. L.: Blastomycosis of the Upper Respiratory Tract with Report of Case Primary in the Larynx. *ANNALS OF OTOTOLOGY, RHINOLOGY AND LARYNGOLOGY* 27:571-580, 1918.
5. Downing, E. D.: A Case of Blastomycosis with Laryngeal Involvement. *J. A. M. A.* 70:85, 1918.
6. Sartory, Petges, and Claoue: Quoted by Ranier.¹¹
7. Jackson, C.: Quoted by Ranier.¹¹
8. New, G. B.: Blastomycosis of the Larynx. *ANNALS OF OTOTOLOGY, RHINOLOGY AND LARYNGOLOGY* 37:240-250, 1928.
9. Fuller: Quoted by Ranier.¹¹
10. Clerf, L. H., and Bucher, C. J.: Blastomycosis of the Larynx. *ANNALS OF OTOTOLOGY, RHINOLOGY AND LARYNGOLOGY* 45:923-939, 1936.
11. Ranier, A.: Primary Laryngeal Blastomycosis. A Review of the Literature and Report of a Case. *Am. J. Clin. Path.* 21:444-450 (May) 1955.
12. Ferguson, G. B.: North American Blastomycosis: Review of Literature and Report of Two Cases Primary in the Larynx. *Laryngoscope* 61:851-873 (Sept.) 1951.
13. Kile, Roy: Personal communication to author.
14. Friedman and Signorelli: Quoted by Ranier, A.¹¹
15. Smith, D. T.: Quoted by Ferguson.¹²
16. Altemeier, W.: Personal communication to author.
17. Schoenback, E. B., Miller, J. M., Ginsberg, M., and Long, P. H.: Systemic Blastomycosis Treated with Stilbamidine. *J. A. M. A.* 146:1317-1318, 1951.
18. Curtis, A. C., and Harrel, E. R.: Use of Two Stilbene Derivatives in Treatment of Blastomycosis. *Arch. Dermat. and Syph.* 66:676, 1952.
19. Colbert, N. W., Strauss, M. J., and Green, R. H.: The Treatment of Cutaneous Blastomycosis with Propamidine. *J. Invest. Dermat.* 14:71, 1950.
20. Elson, W. O.: The Antibacterial and Fungastatic Properties of Propamidine. *J. Inf. Dis.* 76:193, 1945.
21. Heilman, F.: Effect of Stilbamidine on Blastomycosis in Mice. *Proc. Staff Mayo Clinic* 27:455-458 (Nov. 5) 1952.
22. Collard, P. J., and Hargreaves, W. H.: Neuropathy after Stilbamidine Treatment of Kala-azar. *Lancet* 2:686-688, 1947.
23. Smith, G. W., and Miller, J. M.: The Relief of Tic Douloureux with Stilbamidine. *Ann. Int. Med.* 38:335-338, 1953.

DISCUSSION

DR. HOWARD W. D. MCCART: Dr. Orton and Members of the Laryngological Society, I enjoyed Dr. Thornell's presentation very much. He mentioned that blastomycosis could simulate cancer.

(Slide) This is an example of a man who nearly lost his larynx because our junior pathologist told us this man had carcinoma of the larynx. He was a farmer, 60 years of age, who had been hoarse for six months and the interesting thing in his history was that he had a pneumothorax develop spontaneously on six occasions in five years. The medical service was unable to help us in this problem. Examination of the larynx showed a granulomatous lesion involving the posterior third of the

right cord with some fixation. It was really Dr. Ireland's case and he referred him to me, as to what should be done for the larynx? We thought the lesion was a little bit in the wrong area as far as carcinoma was concerned. There was considerable redness to the cord. However, the biopsy reports we got said it was carcinoma of the larynx. The junior pathologist happened to see this slide and because of the marked hyperplasia under the low power, down growing of the rete pegs in which the individual prickly cells retain their cytoplasmic processes he felt this was a carcinoma but then if we looked at a higher power—

(Slide) We will see that there is a marked hyperplasia of the prickly cell layer with many giant cells, some of which are vacuolated, these being cells of blastomycosis. The senior pathologist happened to see this case about a half hour before it was operated and recognized we were dealing with a blastomycosis. After we learned this, the man was put on stilbamidine 150 mg for a period of two weeks on three different occasions. His larynx cleared up without any evidence of blastomycosis.

DR. JAMES M. ROBB: Mr. Chairman and Gentlemen, it has been my experience lately to have seen a patient, a white woman, over forty years of age, who had had a sore throat and hoarseness with cough for some months. She developed a lump in her neck beneath the sterno mastoid muscle, which had become painful. I opened it and drained out a pultaceous material which was sent to the laboratory for study. The pathologist, Dr. Plinn F. Morse of Harper Hospital, Detroit, informed me: "This is not tuberculosis; it is not histoplasmosis; it is not blastomycosis; look up 'cat scratch fever'." This was a surprise to me, so I hurried to investigate. His supposition was correct. It is well to remember that sore throat and hoarseness may not be cancer, subacute infection, or the pharyngitis and laryngitis sicca of endocrine dysfunction. It can be blastomycosis or even cat scratch fever.

DR. LEWIS F. MORRISON: As always, Dr. Thornell has done a nice job. I want to ask one question. He showed us the high power of the initial or original biopsy showing the organisms in the joint cells. Were those organisms still present at the time of the arytenoidectomy when the last section was obtained?

DR. WILLIAM C. THORNELL: I wish to thank the discussers, Dr. McCart, Dr. Robb and Dr. Morrison.

In regards to the question on the tissue obtained at the time of the arytenoidectomy, blastomycosis organisms were found present on microscopic examination. This was noted after several interrupted courses of iodide therapy. As mentioned above, this patient was difficult to keep on the medication until he had these various complications develop, but now he has been faithful in continuing with the medication and reporting back for frequent observations.

LARYNGEAL PAPILLOMATA

A SURGICAL TECHNIQUE FOR THE REMOVAL OF MULTIPLE,
RECURRENT OBSTRUCTIVE PAPILLOMATA OF THE LARYNX

DEGRAAF WOODMAN, M.D.

NEW YORK, N.Y.

Laryngeal papillomata may occasionally be characterized by being multiple and persistent in their recurrences following their repeated removal. At times they recur to the point of complete obstruction of the glottis necessitating tracheotomy. At other times the repeated removal of the growths perorally has resulted in webbing, scarring, and stenosis of the glottis.

The treatment of this type of papillomata which persists and shows no let-up in momentum may result in glottic scarring and stenosis which requires frequent treatments via bouginages—which is economically hard on the patient and often ends up without permanent cure.

The case being presented is typical of those that have persistent multiple papillomata. This finally resulted in stenosis and obstruction of the glottis to the point of needing tracheotomy.

REPORT OF A CASE

Mrs. A. P., aged 35, had a history of fourteen hospital admissions for the removal of laryngeal papillomata via laryngoscopy since 1942.

The pathological reports of tissues removed were always laryngeal papillomata with no evidence of malignant changes. (Altmann and Basek in a recent survey about to be published, studied 51 cases of laryngeal papillomata from the Columbia-Presbyterian Medical Center and classified the histological characteristics of those cases which turned malignant.) A photomicrograph of a typical specimen obtained from this case is shown in Figure 1.

When first seen by me the patient was dyspneic and the glottis was filled with growths hiding any view of the true or false cords.

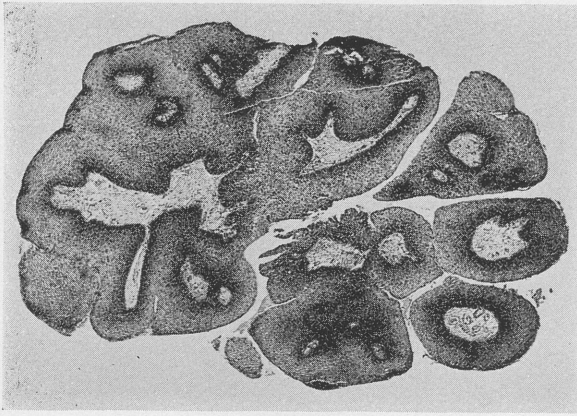


Fig. 1.

With the laryngoscope it was difficult to determine where the exact origin of the growths were located. A drawing made from a photograph of an indirect view of the obstructed glottis as seen at that time is shown in Figure 1.

A tracheotomy was done February 17, 1954. Three weeks later the following procedure was carried out: A horizontal collar incision was made about 1 cm above the tracheotomy stoma. The latter had been placed between the first and second rings of the trachea. The midline of the larynx was exposed. A typical fissure incision was made starting at the thyroid notch down through the periosteum continuing as far down as the cricothyroid membrane. The periosteum was elevated and lateralized about one-quarter inch over each ala. The cricothyroid membrane was incised horizontally in its mid-part. With a circular electric saw, the midline of the cartilage was cut through (Fig. 3). The alae were then retracted and a large polypoid mass exposed (Fig. 4). This mass measured 1 x 2 cm in diameter. It appeared to be attached mainly to the right side of the larynx. The growth on the right was removed by submucosal resection of the mucosa over the anterior two-thirds of the right true cord, retaining intact submucosal tissues (Fig. 5). With this mass removed, the left side of the larynx was seen to have polypoid tissue

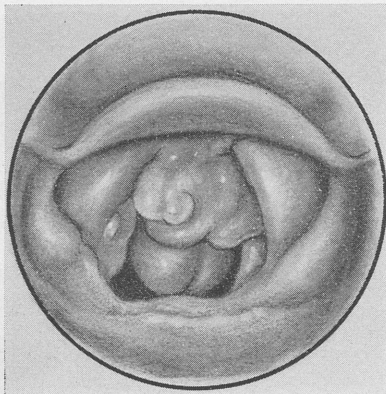


Fig. 2.

involving an even wider area than on the right, though not mounded up as high as that on the right side. The whole involved area on the left side was removed in block, by elevating the periosteum on the inner side of the left thyroid ala, removing both the true and false cords from the anterior commissure back to the vocal process as shown in Figure 6. Bleeding was controlled with cautery.

An acrylic mold (Fig. 7) was then placed with the ring fitted over the tracheotomy tube to hold it in place. The mold used is a modification of molds developed by Goodyear, Robb, Woodward, and Som,¹⁻⁴ with modifications by the author. The fit was snug. Molds should vary in length according to the rings involved in the tracheal stoma. It is recommended that they be colored to contrast against body tissues. They should have an airway completely through their axis as suggested by Woodward, be impregnated with radio opaque material as recommended by Robb. Som has more recently reinforced the ring end of his molds with a wire ring. The hole at the grasping end should be in the midline and large enough to be readily grasped with forceps so that it can be rotated when removed perorally.

The alae cartilages were brought together with atraumatic chromic sutures, muscle layers were brought together with interrupted gut sutures. The cricothyroid membrane was sutured with fine

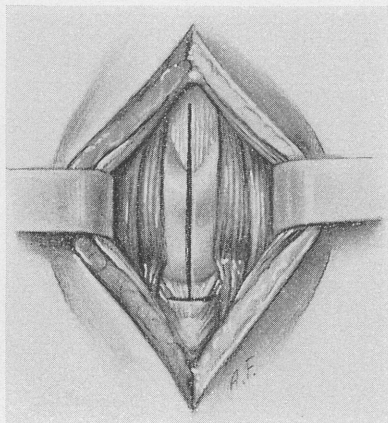


Fig. 3.

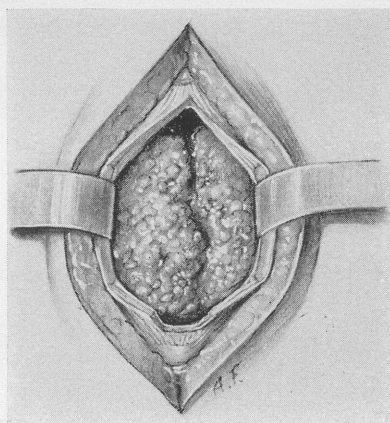


Fig. 4.

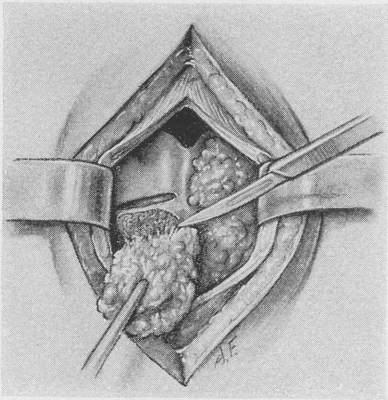


Fig. 5

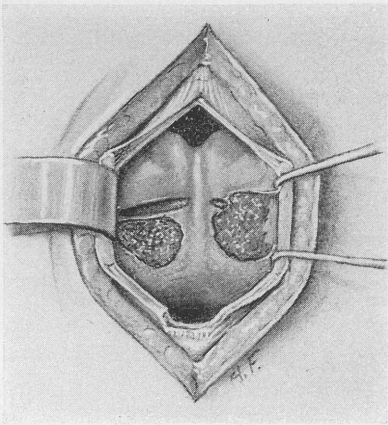


Fig. 6.

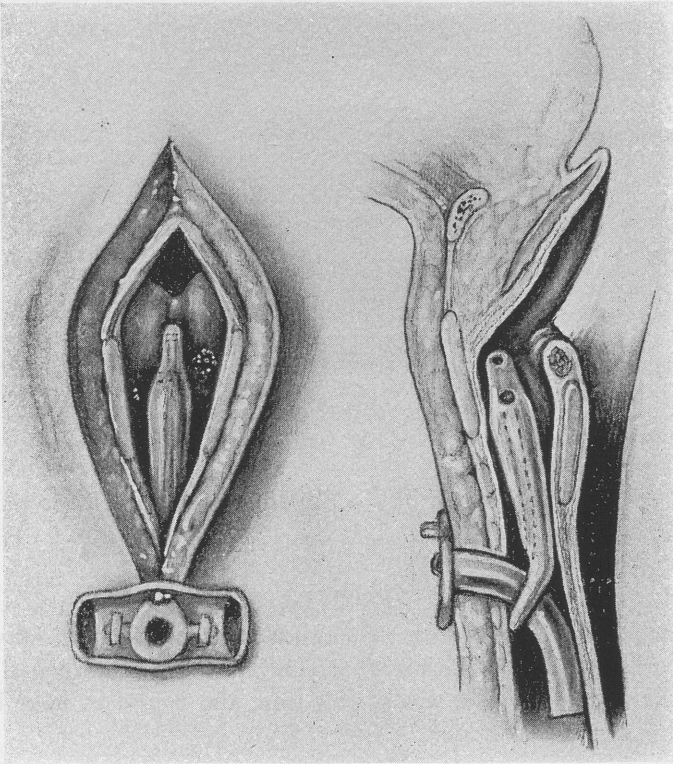


Fig. 7.

catgut. The skin was closed with interrupted atraumatic dermalon without a drain.

Eight weeks later the acrylic mold was removed perorally. The glottis was found smooth and covered with normal appearing mucosal lining. A drawing made from a photograph taken of an indirect view of the glottis four months after removal of the acrylic mold is shown in Figure 8.

The left cord area had no motion but the right side had adductor function. The voice was whispered in character and was adequate for communication over the telephone. The airway was larger than

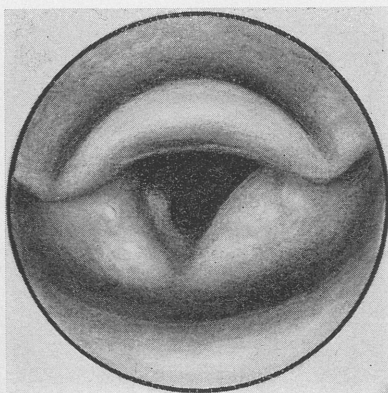


Fig. 8.

normal. Sphincteric action of the upper part of the glottis remained active.

COMMENT

This patient has a diathesis for mucosal pathology. In May 1953 she was admitted to the hospital for treatment of intramucosal carcinoma of the cervix. She was at this time also found to have benign papillomata in the bladder.

Since her operation she has had two growths removed from the trachea. One on August 3, 1954 and the other on November 12, 1954. Both were reported as papillomata. At no time since her operation has there been any evidence of recurrence where new epithelium replaced that which was removed from her larynx over a year ago. It is too early to declare or hope for a cure in this case. This procedure is presented as a means of treating those cases which build up such momentum that obstruction and laryngeal stenosis become imminent.

SUMMARY

A surgical technique via laryngofissure with the use of an acrylic mold has been demonstrated for the treatment of those cases of multiple recurrent papillomatosis which develop glottic obstruction.

156 EAST 37TH STREET.

REFERENCES

1. Goodyear, H. M.: Hemilaryngectomy: Method of Maintaining a Satisfactory Airway and Voice. *ANNALS OF OTOTOLOGY, RHINOLOGY AND LARYNGOLOGY* 58:581 (June) 1949.
2. Robb, J. M.: Laryngeal Stenosis, *ANNALS OF OTOTOLOGY, RHINOLOGY AND LARYNGOLOGY* 58:566 (June) 1949.
3. Woodward, F.: The Surgical Correction of Cicatricial Stenosis of the Larynx. *ANNALS OF OTOTOLOGY, RHINOLOGY AND LARYNGOLOGY* 59:488 (June) 1950.
4. Som, Max: Personal Communication.

DISCUSSION

DR. EDWIN N. BROYLES: This paper of Dr. Woodman demonstrates a useful method of the use of thyrotomy, or laryngofissure operations. I believe one of the first laryngofissure operations was done on a girl for a tumor of the larynx and some years later when she died with typhoid fever the larynx was examined with great interest and there was no recurrence. However, that was not a papilloma but a polyp. I think it has been the experience, especially in children, that even with the thyrotomy and opening the larynx the papilloma tend to recur and that is the reason why many have not used it in children. With the adult type of papilloma the tendency to implant is less and perhaps this is a satisfactory method. But in Dr. Woodman's case where she had papilloma of the trachea, it would seem questionable whether or not he is going to get away with it. I certainly hope he does. At least he is certainly giving her a good airway for a while. I hope that it does not recur. However, as a general rule most of these papillomas tend to recur and of course through the laryngoscope you cannot do a submucosal resection and that may be the secret of the complete removal of the papilloma. I believe you certainly have a wonderful idea.

DR. LEWIS F. MORRISON: I wish to ask Doctor Woodman whether he had considered the use of terramycin or achromycin either preoperatively or postoperatively? In certain instances these antibiotics have kept the papillomata in check, and in many instances have proved valuable in stopping them from recurring.

DR. MURDOCK S. EQUEN: I don't think we should take these cases of laryngeal papillomata in children lightly. Some I believe eventually become malignant. For example, a cheerleader at Georgia Tech had had several operations for papillomata as a child, apparently successful. Shortly after graduation, recurrent papillomata were removed in various clinics in other parts of the country as his engineering job took him from place to place. Eventually he returned to Atlanta and consulted us. A biopsy from each side of the larynx showed cancer and total laryngectomy was done.

This case brings up more questions than it answers. If he had not developed papillomata as a child would the abuse of his voice as a cheerleader have caused the subsequently malignancy? With the early onset of papillomata, if he had not abused his voice in college, would he have developed cancer? I don't know, but since operating on him I have had more respect for laryngeal papillomata in children.

DR. FRED Z. HAVENS: In the older person, management of "laryngeal papillomata," as Dr. Woodman has described, often gives very gratifying results. I think such a method would not be advisable in the case of a child, and I am sure Dr. Woodman would agree with this.

In the case of an adult patient with a papillomatous mass, I think removal by way of a thyrotomy is advisable, unless one can be absolutely sure that the entire lesion can be seen on direct laryngoscopic examination. Recently I made a direct laryngoscopic examination of an adult, and had intended to remove the lesion trans-orally. On visualization of the lesion I could not be sure that I was able to see all of it and, therefore, I did a thyrotomy for more adequate visualization and for removal of the tumor. I was very happy that I had made this decision, because I found that the mass extended far up into the ventricle so that, if I had attempted transoral removal, I would have missed almost two-thirds of the lesion and, of course, she very promptly would have had a recurrence. Following the treatment given, I believe there is no great likelihood that she will have any further trouble.

With reference to the question of malignant change in laryngeal papillomata, I have had one very interesting experience. The patient came to us at the age of about three. The papillomata were removed repeatedly and recurred persistently. Eventually papillomata were evident far down into the trachea, as well as within the larynx. When the patient was 12 or 13 years of age, the pathologist reported to us that the papillomata removed from the trachea were malignant. I was reluctant to accept this opinion, and chose to rely on clinical judgment rather than upon the microscopic picture. The subsequent progress of this patient has not supported the pathologist's opinion. She now is 23 years of age, and her general health is excellent. There progressively has been less tendency for recurrence of the papillomata, so that now on re-examination we only occasionally see a small inactive appearing lesion. Recently I asked the pathologist to review the slides made from specimens removed from the trachea ten years previously when on examination the opinion "malignant change" was given, and he has stated that on review of these slides now he cannot change this opinion.

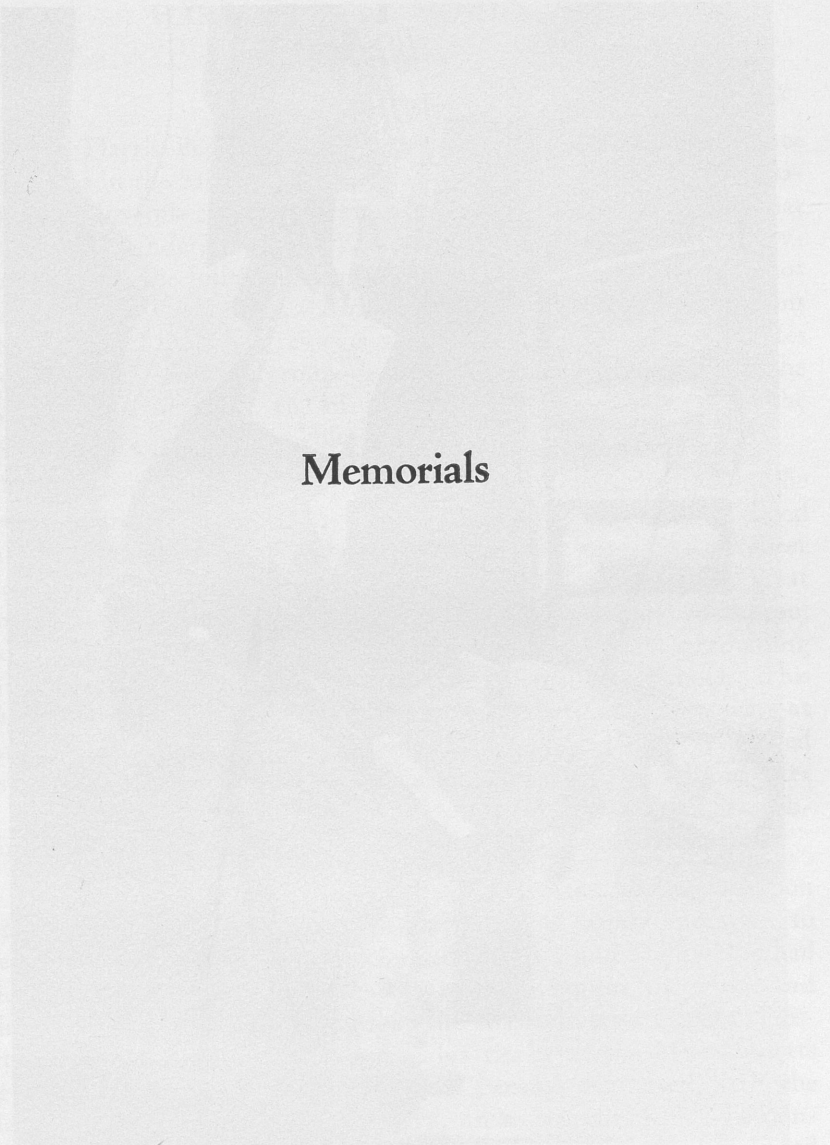
DR. DeGRAAF WOODMAN: I very much appreciate Dr. Broyles', Dr. Morrison's, Dr. Equen's and Dr. Havens' discussion. I am frank to say I hesitated to do this procedure especially after hearing the experience of others. One case came to mind, was reported to me by Dr. Babcock of a case of Dr. Coakley. This case after repeated removals of papillomata via the indirect method without relief went to Philadelphia where in that day direct laryngoscopy was being popularized. A month later Dr. Coakley examined the larynx and noted a row of small recurrent papillomata which followed the outline of the lip of the laryngoscope where it had elevated the epiglottis.

I certainly would not attempt this procedure in a child.

The patient reported had had 14 different attempts at removal via laryngoscopy and was getting nowhere and in the hopes of giving her a better airway and relieving her of the need of wearing a tracheotomy tube, this procedure was done. I am not too hopeful that she is going to remain cured. It is now going on 14 months and she is fine.

The question of the use of drugs. This patient did have occasions to use antibiotics of various kinds, because she had many upper respiratory difficulties with this obstructed larynx.

A recent discussion with Dr. Cardwell brought forth the fact that he and Dr. Orton had used Podophyllum, by coating the denuded site of the removed papillomata and these particular cases seemed to remain free from recurrences.



Memorials

In 1912 he became Chief of the Bureau of the Census, and in 1915 he became Chief of the Bureau of the Census, and in 1915 he became Chief of the Bureau of the Census.



HARRIS PEYTON MOSHER, M.D.

1867-1954

Dr. Harris Peyton Mosher, a Fellow of this Association since 1904, died in the Salem Hospital, near his Marblehead home in Massachusetts, November 4, 1954. He had been in failing health and that morning had undergone surgery, from which he failed to rally. Services were held the following Sunday afternoon in the Harvard Memorial Chapel in Cambridge. Among the large number of physicians present to pay their last respects were many of his former associates and students. As this group gathered for a few moments on the chapel steps afterwards, the oft-heard remark was "This marks the end of an era in Otolaryngology."

Dr. Mosher was born October 21, 1867 in Woodfords, Maine, the son of Andrew and Julia Harris (Woodford) Mosher. His boyhood was spent in Woodfords. When his father, who was a civil engineer and an inventor, responsible for much of the development of the great United Shoe Machinery Corporation, moved his family to Boston, the young man entered the Boston Latin School. After graduating he then spent a year in the Massachusetts Normal Arts School. This was followed by four years in Harvard University and four years at Harvard Medical School. He received his M. D. in 1896. He served a surgical internship at the Massachusetts General Hospital and later as Interne at the Boston Lying-In Hospital. During the Spanish-American War he served as contract surgeon at Montauk Point.

After four years in general practice in Boston he decided upon Oto-laryngology as the field most suited to his talents and went to Germany, taking post-graduate courses in Berlin and Halle. He had become interested in the specialty from serving in the Nose and Throat Out-Patient Department at the Massachusetts General Hospital. Returning home he renewed his ties with the Massachusetts General Hospital as Laryngologist and became associated with the Massachusetts Eye and Ear Infirmary, an association which he continued, in spirit, even after retirement from active practice, until the day of his death.

In 1922 he became Chief of Oto-laryngology at the Infirmary and Professor of Oto-laryngology at Harvard. From his first year

of practice, when he became assistant in Anatomy in the Harvard Medical School, he was continuously associated with the school until he retired in 1939.

The combined position of Professor at the school and Chief of Oto-laryngology at the Infirmary gave full play to Dr. Mosher's talents and raised both the hospital and the department at the school to heights never before attained. His residency program became the goal of every budding specialist, especially the sons of men prominent in Oto-laryngology. His post-graduate course at the school, which he conducted for 35 years consecutively, except for the period of the First World War, was famous throughout the Medical World.

In 1915 Dr. Mosher joined the first Harvard Unit and served in the British Army in France at General Hospital No. 22. With this Country's entry into the War he was commissioned as Major and assigned to the Surgeon General's office, where later he became Chief of Oto-laryngology with the rank of Colonel. As such he was responsible for the organization and conduct of departments of Oto-laryngology in the Army hospitals. This was a revealing experience for him and one which had tremendous effects upon the specialty. Certain inadequacies in training and qualifications, in many cases, were all too apparent. The resulting development of modern otolaryngology, with high standards of teaching, largely may be attributed to his dynamic leadership. One outstanding example is the American Board of Oto-laryngology, of which Dr. Mosher was the first, and for 22 years, its only President.

He was President of this Association and the American Laryngological, Rhinological and Otological Society in 1920; of the American Broncho-Esophagological Society in 1921; of the American Academy of Ophthalmology and Otolaryngology in 1929, and of the American Otological Society in 1938. In addition he served as Chairman of the Section of Oto-laryngology of the American Medical Association. In 1947 he was made an Honorary Fellow of this Association. He was a Fellow of the American College of Surgeons, and a Corresponding Fellow of the Royal Medical Society of London, the British Laryngological Society and the Medical Societies of Paris and of Vienna. He was Guest of Honor of each of our four National societies and was the first American to deliver the Semon lecture before the Laryngological Section of the Royal British Medical Society, receiving on that occasion the Semon Medal from the University of London. In 1934 he received the deRoaldes gold medal award and

in 1947, the Newcomb Award of this Association. In 1937 he was presented with the gold Medal of the American Academy of Ophthalmology and Oto-laryngology.

He was the recipient of honorary degrees of D. Sc. from the University of Pennsylvania, Colby College, and Jefferson Medical School, and of LL. D. from Wayne University.

Dr. Mosher was endowed with the inquiring mind of the true scientist and was indefatigable in his pursuit of knowledge. He was constantly engaged in research throughout his entire medical career. His work on the esophagus is especially outstanding. He published 89 scientific papers, many of them being presented before this Association. Perusal of these papers, dating from 1902 to 1951, furnishes a study of the scientific mind through the years, the changing focus, and the broadening scope of vision. Early papers dealt largely with anatomical subjects and with new instruments. Later we find attention devoted more to surgical procedures and techniques. This is followed by papers concerned with the pathology of the specialty. And in later years we find a definite philosophical trend in his writings, undoubtedly a reflection of the writer's habit of reading "regularly something worth while in non-medical literature."

No one who ever had the privilege of knowing Dr. Mosher could ever forget him. While he sometimes presented a bluff exterior, underneath he was the soul of kindness, generosity and loyalty. With it all he was frank and outspoken, and always a seeker for the Truth. He could not abide dishonesty or hypocrisy and was never hesitant in demonstrating this. He was unique in his objectivity and his ability to get at the solution of a problem. While he had understandable pride in those things he accomplished and demanded recognition of his priority, he never sought to keep them to himself. Unselfish to the core, he insisted that each of his associates be able to do everything he did. And with it all he was a humorous person, who loved a good joke. But Heaven help one who told an off-color story in his presence. While well-known for his wisecracks, as he called them, it may be surprising to the younger generation to learn that in his early days he was the outstanding producer of gags and comedy skits at the banquets of the various societies.

Dr. Mosher was married March 22, 1913 to Mrs. Helen Augusta Rothwell who survives him. Never were two people more devoted to each other and their married life can only be described as idyllic.

His clubs were the Boston Art Club and the Harvard Club of Boston. While not a member of any denomination he attended both the Congregational and Episcopal Churches.

His early training in Art enabled him to incorporate in his teaching certain unique features of inestimable value to his students, whereby they made drawings and models from original anatomical and surgical specimens. It also provided him with hobbies with which he occupied his spare moments. He worked in all media.

He once stated that his greatest professional satisfaction was his vicarious fatherhood of some five hundred men in his post-graduate course in the hospital. It is doubtful if any of us can begin to measure the extent of his influence in Oto-laryngology. More than any other he has been the leader, the teacher, the crusader.

F. T. HILL.

HAROLD LOWRY HICKEY

1892-1954

Harold Lowry Hickey was born in Denver, Colorado, on November 15, 1892. He received his A.B. and A.M. degrees from the University of Denver and decided to follow in the footsteps of his father, Clinton G. Hickey, M.D. He attended the Northwestern University Medical School, receiving his M.D. degree in 1917. While an interne at Wesley Memorial Hospital in Chicago he met Allena Clark of Godrich, Ontario, Canada, whom he married on March 16, 1918. Following his internship he served as a Lieutenant in the Medical Corps of the United States Navy for the duration of World War I.

After his discharge from the Navy he returned to Denver and was in charge of the regional Eye, Ear, Nose and Throat Clinic of the Veterans Administration. He decided to limit his practice to Otolaryngology, and following a postgraduate course at Harvard Medical School and the Massachusetts Eye and Ear Infirmary in 1928, he began the private practice of Otolaryngology in Denver.

He was always interested and active in the affairs of the Denver Medical Society, the Denver Clinical and Pathological Society and the Colorado Otolaryngological Society. He joined the Otolaryngological faculty at the University of Colorado Medical School in 1929 and was appointed Clinical Professor and head of the Department in 1947. He was a Diplomate of the National Board of Medical Examiners and served as the chief examiner for its Denver Subsidiary Board for many years. Following World War II he was appointed Senior consultant in Otolaryngology to Fitzsimons Army Hospital in Denver.

In addition to his activities in local and regional medical organizations and hospitals, he was a member of the American Academy of Ophthalmology and Otolaryngology, the American Laryngological, Rhinological and Otological Society and the American Laryngological Association. He was notably interested in young doctors, urging them to make the effort to attain membership in the senior societies.



Besides his medical activities he was active in numerous civic affairs. He was a member of the First Plymouth Congregational Church and a 32nd degree Mason.

He died suddenly and unexpectedly from coronary thrombosis about three hours after a successful prostatectomy on December 31, 1954. He is survived by his wife, Allena, and two daughters, Beatrice (Mrs. Robert G. Bonham) and Margery (Mrs. Graham T. Vaughn) and five grandchildren, all of whom live in Denver.

G. L. P.

GEORGE BACON WOOD

1871-1954


Dr. George B. Wood, known to many of his younger colleagues as Uncle George, was one of nature's noblemen. His father, Dr. Horatio C. Wood, was Professor of Materia Medica, and Clinical Professor of Nervous Diseases at the University of Pennsylvania. A number of other physicians of prominence were more distantly related. His mother, Eliza Huldah Longacre, was the daughter of James Boston Longacre and Eliza Stiles of Philadelphia. James Longacre was the Chief Engraver of the United States Mint and engraved the portrait of Benjamin Franklin for the first five cent stamp ever issued by our Government.

As a boy, Dr. Wood attended The William Penn Charter School and The George F. Martin School for Boys. In 1890 he was graduated from the Biological Department of the University of Pennsylvania and from the Medical School of the same Institution in 1894. Later he attended the University of Goettingen (1896) and the University of Berne (1897).

Before going abroad he interned for one and one-half years in the University Hospital in Philadelphia and on his return began the study of otolaryngology under the direction of Dr. Walter J. Freeman. During his professional life he was actively connected with the University, Graduate, Children's, Polyclinic, Howard, Orthopedic, St. Christopher's and St. Joseph's Hospitals and the Phipp's Institute.

In addition to this he was consultant to a number of other local schools and dispensaries. Later he was made Professor of Laryngology in the Graduate School of Medicine of the University of Pennsylvania. He was always a zealous teacher and loved dispensary work as a most valuable method of passing knowledge to the student. Even as Emeritus Professor in his late seventies and early eighties, once or twice a week he would put in an hour of two of dispensary teaching. The indigent to him were just as important as the wealthy.

He became a fellow of the American Laryngological Association in 1905 and served as President in 1938-39. He also belonged to The College of Physicians of Philadelphia, The American Medical



GEORGE BACON WOOD

Association, the Triological and the Philadelphia Pathological Societies. During World War I he served as major having charge of otolaryngology at Camp Mead for the duration.

Dr. Wood was a delightful companion. His outside interests were many. He served as Trustee and President of the Arch Street Methodist Episcopal Church for many years. He was an outdoor man and loved nature in all its aspects. He was an expert fisherman, both salt and fresh water. He tied all his own trout and salmon flies with a perfection seldom obtained by a professional. He had a droll sense of humor and never hesitated to attempt to set one right if he felt you to be wrong, in a gentle manner however, that never could offend.

During his life he made more than eighty contributions to medical literature.

In 1906 he married Helen Foss of Philadelphia who survives him along with two sons, one daughter and six grandchildren.

K. M. H.

GORDON BALGARNIE NEW, M.D., D.D.S.

1885-1954

Dr. Gordon Balgarnie New died at the Methodist Hospital, Rochester, Minnesota, on October 28, 1954, after an illness of only a few days.

Dr. New was born in Hamilton, Ontario, Canada, on November 6, 1885. He attended the University of Toronto and received the degree of doctor of dental surgery in 1906, that of bachelor of medicine in 1909 and that of doctor of medicine in 1915. In 1909 and 1910 he was an intern in the City Hospital in Hamilton, Ontario.

He became affiliated with the Mayo Clinic in May, 1910, at which time he was appointed head of the section of postoperative treatment and an assistant in laryngology and rhinology. In February, 1911, he was appointed head of the Section of Laryngology, Oral and Plastic Surgery. When the Mayo Foundation was established as a part of the Graduate School of the University of Minnesota in 1915, he was appointed assistant professor of rhinology, laryngology and stomatology, and later professor of laryngology. In 1950 he became Professor Emeritus.

Dr. New was married to Miss Ethel Bailey on June 28, 1914. Mrs. New and two sons, Gordon, of Solvang, California, and Robert, of Lakewood, Ohio, survive.

He was considered an international authority on tumors of the nose and throat and was a pioneer in the fields of laryngology and plastic surgery in this country and abroad. He was extensively honored for his contributions to these branches of surgery. In 1949 he was given the Newcomb Award of the American Laryngological Association for his scientific contributions to otolaryngology. In 1952 he was awarded a silver plaque by the American Society of Plastic and Reconstructive Surgery for his contributions to plastic surgery; this award was the highest that could be given to a surgeon by that Society.

He was elected president of the American Association of Oral and Plastic Surgeons in 1939, president of the American Academy



GORDON BALGARNIE NEW

of Ophthalmology and Otolaryngology in 1945, president of the Pan-American Congress of Ophthalmology and Otolaryngology in 1946 and president of the American Laryngological Association in 1950. In 1947 he served as second vice-president of the American College of Surgeons.

Dr. New was certified as a specialist in otolaryngology in 1925 by the American Board of Otolaryngology and as a specialist in plastic surgery in 1939 by the American Board of Plastic Surgery. In addition to fellowship in the American Laryngological Association, he was an active member of the American College of Surgeons, the American Medical Association, the American Laryngological, Rhinological and Otological Society, the American Academy of Ophthalmology and Otolaryngology, the American Society of Plastic and Reconstructive Surgery, the American Association of Plastic Surgeons, the Minnesota Academy of Ophthalmology and Otolaryngology, the Alumni Association of the Mayo Foundation and the Society of the Sigma Xi.

Those who were intimately acquainted with Gordon New will remember him professionally not only for his skill and dexterity as a surgeon, but also for his keen discernment in problems of clinical diagnosis. As an organizer and administrator, he was unexcelled. He was tremendously interested in all types of athletics and was an avid golf enthusiast.

In Dr. New's passing, surgeons in the fields of otolaryngology and plastic surgery alike have lost a sincere and earnest colleague who did much to advance the status of these specialties.

J. B. E.

Executive Sessions

1955

FIRST EXECUTIVE SESSION

MARCH 13, 1955

The First Executive Session of the Seventy-Sixth Annual Meeting of the American Laryngological Association held at the Hollywood Beach Hotel, Hollywood Beach, Florida, convened on March 13, 1955, at 12:00 noon, following the First Scientific Session. Dr. Henry B. Orton, President, presided.

The following were elected to *Active Fellowship* in the Association:

DR. JOHN E. BORDLEY

DR. LESTER A. BROWN

DR. G. SLAUGHTER FITZ-HUGH

DR. JEROME A. HILGER

To *Emeritus Fellowship*:

DR. E. TRIBLE GATEWOOD

DR. KARL M. HOUSER

The Newcomb Award was presented to Dr. Thomas Cyrus Galloway for his many contributions to laryngology and rhinology as related to the treatment of poliomyelitis.

In accepting the Award, Dr. Galloway said, "Dr. Orton and Fellows of the Association, one cannot help but feel abashed to receive such an honor in the noble companionship of this Association and the men who have previously received this honor.

"In considering the manner in which medical progress is made, I have concluded that no one individual deserves all the credit for any single advance. The field of medical progress is a battle line in which one or many may hold a flag at one salient which is more advanced and in doing so enunciate principles that many others have been thinking.

"I wrote a paper on anoxia in 1947 which I considered a pot boiler but it was very well received and succeeded in crystallizing the thinking that many were doing. Such things are not entirely

haphazard because many men are thinking along the same lines at the same time. We had conditioned ourselves to appreciate an entity referred to as respiratory obstruction especially as it applied to tracheo-bronchitis because it had been emphasized by many men from Baum, Orton, Davison and Holinger to Jackson. Our minds had accepted the concept of respiratory obstruction and anoxia as being important in disease.

"In the case of poliomyelitis, those entrusted with its treatment thought they had a pat explanation in the involvement of certain vital centers and even went so far as to present pathological slides showing definite lesions in these centers. Actually, they were going up a blind alley and were not making any progress.

"When we were accidentally confronted with this problem in 1943, we found that only three tracheotomies had been reported in the literature up to that time for the respiratory obstruction in poliomyelitis. Because we were conditioned to the process of respiratory obstruction and secretional obstruction as well as anoxia, our very ignorance of poliomyelitis led us to venture on a new approach. This resulted in the advances which have come largely through our Association and the men in our specialty, not only in the management of poliomyelitis but also in a wide range of diseases with respiratory obstruction including cranial cerebral injuries, chest trauma, botulism, tetanus and other diseases. No one individual can feel that he is an isolated thinker; he is a representative of a considerable body of thought and whatever he accomplishes results from contacts and discussions and thinking in this Association and other societies. I appreciate this honor deeply. Thank you."

The following Fellows were elected to serve as a Nominating Committee:

DR. ARTHUR W. PROETZ

DR. LEWIS F. MORRISON

DR. FREDERICK T. HILL

DR. LAWRENCE R. BOIES

DR. THEODORE E. WALSH

There being no further business the session adjourned at 12:20 P. M.

Respectfully submitted,
HARRY P. SCHENCK,
Secretary

ANNUAL BUSINESS MEETING

MARCH 14, 1955

The Annual Business Meeting held in connection with the Seventy-Sixth Annual Meeting of the American Laryngological Association at the Hollywood Beach Hotel, Hollywood Beach, Florida, on Monday, March 14, 1955, convened at 9:35 A. M., President Henry B. Orton presiding.

The report of the Secretary was accepted as circularized.

The combined reports of the Treasurer and Auditors were received with thanks.

The Librarian, Historian and Editor, Dr. Bernard J. McMahon, presented his annual report stating that the 1954 volume of the Transactions had been mailed to the Active, Honorary, Corresponding and Emeritus Fellows on January 1, 1955. The response of the Honorary, Corresponding and Emeritus Fellows to the payment of five dollars for their copy of the Transactions was very favorable. Several complete sets of the Transactions are on file and may be obtained for five dollars per volume for the years prior to 1950, and eight dollars per volume for subsequent years. The names of the following Fellows whose deaths occurred since the last Annual Meeting of the Association were reported:

Dr. Harry Aldrich Barnes, Kingston, Mass., an Emeritus Fellow since 1937 and an Active Fellow 1915-1937. Died on July 18, 1954.

Dr. Gordon B. New, Rochester, Minn., an Emeritus Fellow since 1954 and an Active Fellow 1922-1954. Died on October 29, 1954.

Dr. George B. Wood, Wynnewood, Pa., an Emeritus Fellow since 1946 and an Active Fellow 1905-1946. Died on November 2, 1954.

Dr. Harris P. Mosher, Marblehead, Mass., an Honorary Fellow since 1947 and an Active Fellow 1904-1947. Died on November 4, 1954.

Dr. Harold L. Hickey, Denver, Colorado, an Active Fellow since 1945. Died on December 31, 1954.

The Membership rose and stood in silence in honor of the departed Fellows.

The report of the Librarian, Historian and Editor was accepted unanimously.

Dr. Frederick T. Hill reported for the Representatives to the American Board of Otolaryngology. The Board conducted an examination at the Waldorf-Astoria Hotel, New York City, on September 13, 14, 15, 16 and 17, 1954. The clinical examinations were held at the Manhattan Eye and Ear Hospital. Sixty-seven candidates were examined and of this group 46 were passed, 15 conditioned and 6 failed. Owing to the rather small number of candidates applying for the examinations which were planned for Richmond, Virginia, in March 1955, it was deemed advisable to cancel this projected examination and utilize the candidates at the Board meeting in Chicago in October 1955. There were less than 40 applicants.

Dr. Arthur W. Proetz reported for the Laryngological Research Fund Committee. He stated that there had been no change in the situation and that the fund was available for the support of suitable projects even though there was no demand at the present time.

There being no further business the meeting adjourned at 10:00 A. M.

Respectfully submitted,

HARRY P. SCHENCK,

Secretary

REPORT OF THE SECRETARY
AMERICAN LARYNGOLOGICAL ASSOCIATION

MARCH 13, 1955

The Seventy-Fifth Annual Meeting of the American Laryngological Association was held on May 27th and 28th, 1954, at the Hotel Statler, Boston, Massachusetts, under the Presidency of Dr. Gordon F. Harkness.

There were 75 Fellows and 95 Guests in attendance.

Twelve scientific papers were presented.

The following were elected:

To *Emeritus Fellowship*:

DR. R. M. LUKENS, Philadelphia, Pa.

DR. DUNCAN MACPHERSON, New York, N. Y.

DR. GORDON B. NEW, Rochester, Minn.

DR. ERNEST M. SEYDELL, Wichita, Kan.

DR. JOHN D. KERNAN, New York, N. Y.

To *Active Fellowship*:

DR. MURDOCK S. EQUEN, Atlanta, Ga.

DR. PHILIP E. MELTZER, Boston, Mass.

DR. PAUL M. MOORE, Cleveland, Ohio

DR. JOEL J. PRESSMAN, Los Angeles, Calif.

DR. FRANCIS A. SOOY, San Francisco, Calif.

DR. WILLIAM C. THORNELL, Cincinnati, Ohio

DR. THEODORE E. WALSH, St. Louis, Mo.

The deRoaldes Award was presented to Dr. Louis H. Clerf, of Philadelphia, as that individual in the Americas who, by his outstanding accomplishments and contributions in the field of Rhinology and Laryngology, is recognized as worthy of this special honor.

The Newcomb Award was presented to Dr. Henry B. Orton in consideration of his scientific contributions to this Association and his outstanding work in Laryngology, particularly the surgery of malignant disease of the larynx, hypopharynx and neck.

The following Officers were elected:

President.....	Dr. Henry B. Orton
First Vice-President.....	Dr. James H. Maxwell
Second Vice-President.....	Dr. Clyde A. Heatly
Secretary.....	Dr. Harry P. Schenck
Treasurer.....	Dr. Fred W. Dixon
Librarian, Historian and Editor.....	Dr. Bernard J. McMahon
First Councillor.....	Dr. J. Mackenzie Brown
Second Councillor.....	Dr. H. Marshall Taylor
Third Councillor.....	Dr. Louis H. Clerf
Fourth Councillor.....	Dr. Gordon F. Harkness

The Association has lost by death during the past year:

Honorary Fellow:

DR. HARRIS P. MOSHER

Emeritus Fellows:

DR. GORDON B. NEW

DR. GEORGE B. WOOD

Active Fellow:

DR. HAROLD H. HICKEY

The Council at its Annual Meeting in New York City on January 8, 1955, recommended for:

Emeritus Fellowship:

DR. E. TRIBLE GATEWOOD

DR. KARL M. HOUSER

Active Fellowship:

DR. JOHN E. BORDLEY, Baltimore, Md.

DR. LESTER A. BROWN, Atlanta, Ga.

DR. G. SLAUGHTER FITZ-HUGH, Charlottesville, Va.

DR. JEROME A. HILGER, St. Paul, Minn.

Dr. Samuel Salinger was reappointed Abstract Editor.

The Council has voted to hold an Annual Session in Washington, D. C., on May 3, 1957. This will consist of a one day meeting and will be followed by the meeting of the American Otological Society on May 4, 1957, and Registration for the Sixth International Congress of Otorhinolaryngology on May 5, 1957. Papers presented by Fellows of the American Laryngological Association at the Sessions of the International Congress will be published in the Transactions of the Association for 1957.

The Association has been assured by the American Medical Association that the Directory of the American Medical Association will continue to include Fellowship in the A. L. A. in its biographic data.

The present membership of the Association is:

Active	98
Honorary	4
Corresponding	12
Emeritus	20
	<hr/>
	134

Respectfully submitted,

HARRY P. SCHENCK,
Secretary

EXHIBIT "A"

AMERICAN LARYNGOLOGICAL ASSOCIATION
GENERAL FUND - OPERATING STATEMENT

For Eleven Months Ending March 1, 1955

Income:

Dues—92 members @ \$40.00	\$3,680.00	
Dues—7 new members @ \$100.00	700.00	\$4,380.00
Registration Fees—Boston		1,160.00
Sale of "Transactions"		373.00
Interest Received—Savings Account		131.30
Canadian Exchange on Check60
Total Operating Income		\$6,044.90

Expenses:

Annual Meeting:

Projection Equipment	\$115.00
Reporting Service	130.69
Banquet	799.12
Programs	255.53
Entertainment	102.50
Flood Lights	6.00
	\$1,408.84
Less Overcharge Refund	5.00
Net Annual Meeting Expense	\$1,403.84

Council Expenses:

Dinner and Travel Expense	\$ 714.68
Annual Dinner	88.00
Total Council Expense	\$ 802.68

General Expenses:

Clerical Hire	\$ 500.00
"Transactions" (1954)	2,084.59
Stationery, Printing, Postage	460.20
Auditing	100.00
Treasurer's Bond	62.50
Sixth International Congress	500.00
Transfer to de Roaldes Fund	99.00
Total General Expense	\$3,806.29
Total Expenses	\$6,012.81
Net Profit to General Fund Balance Sheet	\$ 32.09
General Fund Balance April 1, 1954	730.96
Total General Fund Balance March 1, 1955	\$ 763.05

EXHIBIT "B"

AMERICAN LARYNGOLOGICAL ASSOCIATION
TRUST FUND—OPERATION AND VALUE

For Eleven Months Ending March 1, 1955

Trust Fund Income:

Interest—Government Bonds	\$ 842.00
Transfer from General Fund to de Roaldes Fund	99.00
Total Income	\$941.00

Trust Fund Expense:

Engraving de Roaldes Medal	\$ 116.06
Printing de Roaldes Award (1954)	4.00
Printing Newcomb Award (1954)	4.00
Printing Newcomb Award (1955)	4.00
Excess of Bond cost over face value—prior years	104.70
Total Expense	\$232.76
Net Trust Fund Addition	\$708.24
Trust Fund Balance 4-1-54	\$37,053.27
1954-1955 Additions (per above)	708.24
Trust Fund Balance 3-1-55	\$37,761.51

Trust Fund Balance Represented by:

U. S. Government Bonds, Par	\$32,000.00
Cash—Savings Account	5,671.30
Cash—Commercial Account	90.21
	\$37,761.51

EXHIBIT "C"

AMERICAN LARYNGOLOGICAL ASSOCIATION
REPORT OF TRUST FUNDS

March 1, 1955

Fund	Principal	Unused Income 4-1-54	Income 4-1-54 to 3-1-55	Expenses 4-1-54 to 3-1-55	Unused Income 3-1-55	Principal & Unused Income 3-1-55
Casselberry	\$ 5,000.00	\$ 973.45	\$135.74	\$	\$1,109.19	\$ 6,109.19
Johnson	5,000.00	471.86	124.36	596.22	5,596.22
de Roaldes	3,000.00	722.22	183.58	120.06	785.74	3,785.74
Newcomb Trust ..	2,000.00	447.22	55.61	502.83	2,502.83
Newcomb Prize ..	500.00	23.25	11.88	8.00	27.13	527.13
Hourne Scholarship	20.23	2.19	.50	2.69	22.92
Research	16,014.19	2,878.66	429.33	104.70	3,203.29	19,217.48
Totals	\$31,534.42	\$5,518.85	\$941.00	\$232.76	\$6,227.09	\$37,761.51

EXHIBIT "D"

AMERICAN LARYNGOLOGICAL ASSOCIATION
TRUST FUND INVESTMENTS

March 1, 1955

Government Bonds:

	Description	Par Value	Income 1954-1955
U. S. Savings (Purchased 7-1-54)	2.76—K—1965	\$10,000.00	\$100.00
U. S. Defense	2½ —G—1956	\$ 5,000.00	\$125.00
	2½ —G—1957	1,000.00	25.00
	2½ —G—1958	2,000.00	50.00
U. S. Savings	2½ —G—1959	5,000.00	125.00
	2½ —G—1960	1,000.00	25.00
	2½ —G—1961	1,000.00	25.00
	2.76—K—1965	7,000.00	193.20
U. S. Treasury	2¼ —1956/59	1,000.00	22.50
	2¾ —1958/63	1,000.00	27.50
	2½ —1964/69	3,000.00	75.00
	2½ —1967/72	1,000.00	25.00
	3¼ —1978/83	3,000.00	97.50
U. S. Savings (Purchased 7-1-54)	2.76—K—1966	1,000.00	13.80
U. S. Defense (Sold 7-1-54)	2½		12.50
Totals		\$32,000.00	\$842.00

February 22, 1955

ACCOUNTANT'S REPORT

American Laryngological Association

Gentlemen:

We have examined the records of the American Laryngological Association for the period from April 2, 1954, to date. Because all income and all expected expenses for the year are accounted for, and because the Association is having its convention early this year, it was decided to end the current fiscal year as of March 1, 1955, instead of the usual April 1 date.

All of the receipts and disbursements since April 2, 1954, were verified by us, and the U. S. Government Bonds counted and examined.

In the past some of the Bonds were purchased at a premium of \$104.70 over par value. This cost was absorbed and written off this year.

In our opinion the following statements present fairly the financial position of the American Laryngological Association as of the above date, and because there will be no income or expense for the next week, as of March 1, 1955.

CHARLES C. BARNES & Co.,

Certified Public Accountants.

COMMENT

The foregoing report includes income and expenses of the Association from April 1, 1954, to March 1, 1955. It was believed by the Council that the report should include only eleven months in order to avoid the confusion of reporting the expenses of two annual meetings in one year. The usual expenses of the Association for the current twelve month period have been paid.

The income over expenses for the year is small. This is largely due to the action taken by the Association last year when it was voted to advance the sum of \$500.00 to help defray the preliminary expenses of the Sixth International Congress of Otolaryngology which is to be held in Washington, D.C. in 1957.

Respectfully submitted,

FRED W. DIXON, M.D., *Treasurer*

FINAL EXECUTIVE SESSION

MARCH 14, 1955

The Final Executive Session was called to order by President Henry B. Orton at 4:50 P. M. immediately following the Scientific Session.

On motion from the floor the report of the Nominating Committee was presented and unanimously accepted. The meeting recessed while the new Board of Directors retired and elected the following Officers for the ensuing year:

President.....	Bernard J. McMahon
First Vice-President.....	Robert L. Goodale
Second Vice-President.....	Paul H. Holinger
Secretary.....	Harry P. Schenck
Treasurer.....	Fred W. Dixon
Librarian, Historian and Editor.....	Edwin N. Broyles
First Councillor.....	H. Marshall Taylor
Second Councillor.....	Louis H. Clerf
Third Councillor.....	Gordon F. Harkness
Fourth Councillor.....	Henry B. Orton

The President-Elect, Dr. Bernard J. McMahon, was conducted to the Rostrum and given custody of the historic gavel by President Henry B. Orton.

In accepting the gavel, Dr. McMahon pointed out that it had passed through some of the most illustrious hands in American Laryngology and then delivered a brief address of acceptance.

There being no further business the Seventy-Sixth Annual Meeting of the Association was adjourned at 5:00 P. M.

Respectfully submitted,

HARRY P. SCHENCK,
Secretary

List of Fellows

1955

LIST OF FELLOWS

Date Indicates Year Admitted to Active Fellowship

Attendance at meetings is shown by figures following each name.

Asterisk (*) indicates year paper was read.

Active Fellows

1942. ASHLEY, REA E., 384 Post Street, San Francisco 8, California, 1946, '47, '48, '49, '50, '51*, '53, '54.
1936. BALLENGER, HOWARD C., 723 Elm Street, Winnetka, Illinois, 1936, '37, '38*, '40, '41, '46*, '47, '48, '51, '52*, '53, '54, '55.
1949. BECK, AUGUST LEO, 55 Pell Place, New Rochelle, N. Y., 1949, '50, '51, '52*, '54, '55.
1938. BLASSINGAME, CHARLES DECATUR, 414 Physicians and Surgeons Bldg., Memphis 3, Tennessee, 1938, '39, '41, '42, '44, '46*, '47, '50, '51, '52*, '53*.
1944. BOIES, LAWRENCE R., University Hospital, Minneapolis 14, Minnesota, 1944, '46, '47, '48*, '49, '50*, '51*, '53, '54, '55.
1955. BORDLEY, JOHN E., Johns Hopkins Hospital, Baltimore 5, Maryland, 1955.
1941. BOWERS, WESLEY C., 2 East 54th Street, New York 22, N. Y., 1941, '42, '44, '49.
1951. BOYDEN, GUY LEE, 1735 N. Wheeler St., Portland 12, Ore., 1952*, '53, '54.
1932. BROWN, JOHN MACKENZIE, 1136 W. 6th Street, Los Angeles, 14, California, 1935*, '37, '40, '41, '42, '44, '47*, '49, '50, '51, '52, '53, '54, '55.
1955. BROWN, LESTER ALEXANDER, 490 Peachtree Street, N.E., Atlanta 3, Georgia, 1955.
1940. BROYLES, EDWIN N., 1100 North Charles Street, Baltimore, Maryland, 1940, '41*, '42, '46, '48*, '49, '50, '51*, '52, '53, '54, '55.

1930. CAMPBELL, EDWARD HASTINGS, 133 S. 36th St., Philadelphia 4, Pennsylvania, 1930, '31*, '32*, '33, '35, '38, '39*, '40, '41, '47, '48, '49, '51, '52, '55.
1945. CAMPBELL, COLONEL PAUL A., USAF (MC), Office of Air Attache Box 36, F.P.O. 100, New York, N. Y., 1946, '47, '49, '51.
1942. CANFIELD, NORTON, 175 St. Ronan St., New Haven 11, Connecticut, 1942, '46, '47, '48, '49*, '50, '51.
1925. CLERF, LOUIS H., 5575 Eighth Avenue, North, St. Petersburg 2, Florida, 1925, '27*, '28, '29, '30*, '32, '33, '34, '34, '36*, '37, '38, '39, '40, '41*, '42*, '44*, '46, '47, '48, '49, '50, '51, '52, '53*, '54, '55*.
1939. CODY, CLAUDE CARR, 1304 Walker Avenue, Houston 2, Texas, 1939, '41, '42, '44, '46*, '47, '48*, '49, '50, '51, '52, '53, '54, '55.
1941. CUNNING, DANIEL S., 115 East 65th Street, New York 22, N. Y., 1941, '42*, '44, '46, '47*, '48, '49, '50*, '51, '52, '53, '54, '55*.
1951. DAVISON, FRANCIS W., Geisinger Memorial Hospital, Danville, Pa., 1951, '52, '53*, '54, '55.
1941. DIXON, FRED W., 1027 Rose Building, Cleveland, Ohio, 1941, '42*, '44, '46, '47*, '49*, '50, '51, '52, '53, '54, '55.
1947. EAGLE, WATT WEEMS, Duke Hospital, Durham, N. C., 1948*, '49, '51, '53, '54.
1947. ENGLER, CLARENCE W., 2323 Prospect Avenue, Cleveland, Ohio, 1947, '48*, '49, '50, '51, '54, '55.
1954. EQUEN, MURDOCK S., 2505 Habersham Road N. W., Atlanta, Ga., 1954, '55.
1952. ERICH, JOHN B., Mayo Clinic, 102 Second Avenue, Rochester, Minn., 1953.
1923. FENTON, RALPH ALBERT, 1020 S.W. Taylor Street, Portland 5, Oregon, 1923, '25*, '26, '28, '30, '34, '35, '37*, '39, '40*, '42, '44, '46, '47*, '49, '50*, '52, '53, '54.
1930. FIGI, FREDERICK A., Mayo Clinic, Rochester, Minnesota, 1930, '32*, '34, '35, '38*, '42*, '47*, '48, '50*, '53*.

1955. FITZ-HUGH, GLASSSELL SLAUGHTER, 2003 Spottswood Road, Charlottesville, Virginia, 1955.
1932. FURSTENBERG, ALBERT CARL, Out-Patient Bldg., University Hospital, Ann Arbor, Michigan, 1933*, '36*, '38*, '46, '48*, '50, '51, '53, '54, '55*.
1936. GALLOWAY, THOMAS CYRUS, 636 Church Street, Evanston, Illinois, 1936, '37, '38*, '39, '40, '41, '42*, '46*, '47, '48, '50, '51, '52, '53, '54, '55.
1940. GOODALE, ROBERT L., 330 Dartmouth Street, Boston, Massachusetts, 1940, '41, '42*, '44*, '46, '47, '49, '50*, '53, '54, '55*.
1928. GOODYEAR, HENRY M., 556 Doctors' Building, Cincinnati 2, Ohio, 1928, '29, '30*, '31, '32, '33, '34*, '35, '36, '37, '38, '39, '40, '44*, '46, '47, '48, '49*, '51, '53, '55.
1950. HALL, COLBY, 1136 West Sixth Street, Los Angeles, Calif., 1950.
1940. HANSEL, FRENCH K., 634 North Grand Boulevard, St. Louis 3, Missouri, 1940, '42, '46, '47, '51, '53*, '54*.
1933. HARKNESS, GORDON FOLLETTE, Blackhawk Hotel, Davenport, Iowa, 1934, '35, '36*, '40, '41, '44, '46, '47, '48, '49, '50, '51, '52, '53, '54*, '55.
1944. HAVENS, FRED Z., 102 Second Avenue S-W., Rochester, Minnesota, 1944, '46, '49, '51, '53, '54, '55*.
1942. HEATLY, CLYDE A., 11 North Goodman Street, Rochester 7, N. Y., 1942, '46*, '49, '50, '52, '53*, '54, '55.
1943. HILDING, ANDERSON C., Research Laboratory, St. Luke's Hospital, Duluth 11, Minnesota, 1944*, '46, '47, '48*, '49, '50, '51, '53, '55.
1955. HILGER, JEROME A., 350 St. Peter Street, St. Paul 2, Minnesota, 1955.
1928. HILL, FREDERICK THAYER, Professional Building, Waterville, Maine, 1928, '29*, '30*, '31, '32, '33, '34, '35, '36, '37*, '38*, '39, '40, '41*, '42, '44*, '46, '47, '48, '49*, '50, '51, '52*, '53, '54, '55.

1945. HOLINGER, PAUL H., 700 North Michigan Ave., Chicago 11, Illinois, 1946, '47, '49, '50*, '51*, '52, '53, '54*, '55.
1944. HOOPLE, GORDON D., 1100 East Genesee St., Syracuse 10, New York, 1946, '47, '48, '49, '50, '51, '52, '53, '54*, '55.
1952. IRELAND, P. E., Room 82, Banting Institute, University of Toronto, Toronto, Ontario, 1952, '53, '54, '55.
1938. JACKSON, CHEVALIER LAWRENCE, 3401 North Broad Street, Philadelphia 40, Pa., 1938, '39, '40, '41*, '42, '44*, '46, '47*, '48, '49, '51, '53, '54, '55.
1939. JOHNSTON, WILLIAM HOWARD, 1515 State Street, Santa Barbara 7, California, 1939, '40, '41, '42, '44, '46, '47, '49, '50, '52, '55.
1942. KELLY, JOSEPH D., 140 East Fifty-fourth Street, New York 22, N. Y., 1942, '44*, '47, '48, '49, '51, '53, '54, '55.
1942. KING, EDWARD D., 10220 Riverside Drive, North Hollywood, California, 1942, '46, '47, '49*, '50.
1950. KLINE, ORAM R., 514 Cooper Street, Camden, N. J., 1950, '51, '52, '53, '54, '55.
1953. LEDERER, FRANCIS LOEFFLER, 1853 W. Polk Street, Chicago 12, Illinois, 1953, '54, '55.
1936. LEJEUNE, FRANCIS ERNEST, Ochsner Clinic Building, Prytania and Aline Streets, New Orleans 15, Louisiana, 1937, '46*, '47, '50, '51, '52, '53, '54*, '55.
1933. LIERLE, DEAN M., University Hospital, Iowa City, Iowa, 1933, '34, '35*, '37, '38, '39, '40*, '42*, '44*, '46, '47*, '48, '49, '50*, '51, '52, '53, '54, '55*.
1949. LINDSAY, JOHN R., 950 E. 59th Street, Chicago 37, Illinois, 1949, '50, '51*, '53, '55*.
1939. LUPTON, IRVING MARTIN, 806 Medical Arts Building, Portland, Oregon, 1946, '50.
1952. LYNCH, MERCER G., Ochsner Clinic, Prytania and Aline Sts., New Orleans 15, La., 1953, '54, '55*.
1941. MARTIN, ROBERT C., 384 Post Street, San Francisco 8, California, 1941, '44, '47, '48, '50, '51, '53, '54, '55.

1948. MAXWELL, JAMES H., Out-Patient Bldg., University Hospital, Ann Arbor, Michigan, 1948, '49, '50*, '51*, '52, '53, '54, '55.
1952. MCCALL, JULIUS W., 610 Rose Building, Cleveland 15, Ohio, 1952, '53*, '54, '55.
1951. McCART, HOWARD W. D., Medical Arts Bldg., Toronto, Canada, 1951, '52*, '54, '55.
1939. McCASKEY, CARL HEBER, 608 Guaranty Building, Indianapolis 4, Indiana, 1939, '40, '41, '42*, '44, '46*, '47, '48, '49, '50, '51, '52, '53, '55.
1951. MCHENRY, LAWRENCE C., 604 Medical Arts Bldg., Oklahoma City, Okla., 1953*.
1945. McLAURIN, JOHN G., 1322 Medical Arts Building, Dallas 1, Texas, 1946, 49.
1933. McMAHON, BERNARD J., 8230 Forsythe Blvd., Clayton 24, Missouri, 1934*, '35, '36, '38*, '41, '44, '46*, '47, '48, '49, '50*, '51, '52, '53, '54, '55*.
1931. McNALLY, WILLIAM JAMES, 1509 Sherbrooke Street West, Montreal, Canada, 1931, '33, '34*, '39, '44, '47, '49, '49, '52, '53, '54*, '55.
1954. MELTZER, PHILIP E., 285 Commonwealth Ave., Boston, Mass., 1954*.
1952. MILLER, ALDEN H., 500 South Lucas Ave., Los Angeles 17, Calif., 1952, '53*, '55.
1954. MOORE, PAUL M., 10,515 Carnegie Avenue, Cleveland, Ohio, 1954, '55*.
1950. MORRISON, LEWIS F., 3536 Jackson Street, San Francisco 18, California, 1950, '51, '52*, '53, '54, '55*.
1940. MORRISON, WILLIAM W., 140 E. 54th Street, New York 22, N. Y., 1940, '41*, '44, '47, '49*, '50, '52, '53.
1953. MURTAGH, JOHN A., 2 Maynard Street, Hanover, New Hampshire, 1953, '54, '55.

1927. MYERSON, MERVIN C., 416 North Bedford Drive, Beverly Hills, California, 1927 '28*, '29, '30, '31*, '32*, '33*, '34*, '35, '36, '37, '38, '39*, '40, '41*, '42, '44, '50*.
1937. NASH, C. STEWART, Medical Arts Building, Rochester 7, New York, 1937, '38*, '40, '42, '44, '46, '49, '50, '51, '52, '53, '54, '55.
1927. ORTON, HENRY BOYLAN, 224 Delavan Avenue, Newark 4, New Jersey, 1927, '28, '29, '30*, '31, '32, '33*, '35, '36, '37, '38*, '40, '41, '42, '44*, '47*, '49, '51*, '52, '53*, '54, '55*.
1948. PHELPS, KENNETH A., 1137 Medical Arts Building, Minneapolis 2, Minnesota, 1948, '50, '53*, '55.
1954. PRESSMAN, JOEL J., 10,911 Weyborn Avenue, Los Angeles 24, Calif., 1954.
1951. PRIEST, ROBERT E., 79, S. Ninth St., Minneapolis 2, Minn., 1951, '53*, '54*.
1924. PROETZ, ARTHUR WALTER, 1010 Beaumont Building, St. Louis 8, Missouri, 1924, '25*, '26*, '27, '28, '29, '30, '31, '32*, '33*, '34, '35*, '36, '37, '38*, '39*, '40, '41, '42*, '44, '46, '47*, '48*, '49*, '50, '51*, '52, '53, '54, '55.
1951. PUTNEY, F. JOHNSON, 1719 Rittenhouse Square, Philadelphia 3, Pa., 1951, '52, '53*, '54, '55.
1951. RAWLINS, AUBREY G., 384 Post Street, San Francisco, Calif., 1951, '53*.
1934. RICHARDS, LYMAN GILDER, Massachusetts Institute of Technology, Cambridge 39, Mass., 1934, '35, '36*, '37, '38, '39, '47, '49, '51*, '54.
1945. ROBB, JAMES M., 633 David Whitney Building, Detroit 26, Michigan, 1946, '48, '49*, '51, '52, '55.
1953. ROBERTS, SAM E., 5964 Overhill Road, Kansas City, Missouri, 1953, '54*, '55.
1938. SALINGER, SAMUEL, 1260 Alejo Road, Palm Springs, California, 1938, '39, '40*, '42, '44*, '47, '48, '49, '50, '51, '52*, '53, '54.

1932. SCHALL, LEROY ALLEN, 243 Charles Street, Boston 14, Massachusetts, 1934*, '35, '38, '40*, '41, '42, '44*, '46, '47, '48*, '49, '50*, '51, '53*, '54, '55.
1934. SCHENCK, HARRY P., 326 South 19th Street, Philadelphia 3, Pennsylvania, 1934, '35, '36*, '37, '38, '39, '40, '41*, '44*, '46, '47, '49, '50, '51, '52, '53, '54, '55.
1939. SIMPSON, W. LIKELY, 512 Physicians' and Surgeons' Building, Memphis 3, Tennessee, 1939, '41, '44*, '46, '47*, '48, '50, '51*, '52, '53, '54, '55.
1950. SMITH, AUSTIN T., 1830 Spruce St., Philadelphia 3, Pa., 1950, '51, '52, '53, '55.
1954. SOOY, FRANCIS A., 490 Post Street, San Francisco 2, Calif., 1954.
1924. TAYLOR, HERMON MARSHALL, 111 West Adams Street, Jacksonville 2, Florida, 1924, '25*, '26, '27, '28, '31, '34, '35*, '36, '37, '38, '39*, '40, '41, '42, '44*, '46, '47, '48, '49, '50*, '51, '52*, '53, '54, '55.
1947. THEOBALD, WALTER H., 307 N. Michigan Avenue, Chicago, Illinois, 1947, '48*, '49, '50, '51, '52, '53, '54, '55.
1954. THORNELL, WILLIAM C., 2508 Auburn Avenue, Cincinnati 19, Ohio, 1955*.
1950. TREMBLE, G. EDWARD, 1390 Sherbrooke St. W., Montreal, Quebec, Canada, 1950, '51, '52, '53, '54, '55*.
1925. TUCKER, GABRIEL, 250 South Eighteenth Street, Philadelphia 3, Pennsylvania, 1925, '26*, '27*, '29, '30, '31, '32, '33, '34, '35*, '36, '37, '38, '39, '40*, '41*, '42, '46, '47, '48, '49, '50, '51, '53, '54, '55.
1943. VAN ALYEA, OLIVER E., 135 South LaSalle Street, Chicago 3, Illinois, 1944, '46*, '47, '48, '50, '51, '52*, '53, '54, '55.
1941. VIOLÉ, PIERRE P., 1930 Wilshire Boulevard, Los Angeles 5, California, 1944*, '46, '47, '50, '52, '53, '55.
1954. WALSH, THEODORE E., 640 S. Kingshighway Blvd., St. Louis 10, Missouri, 1954, '55*.

1940. WEILLE, FRANCIS L., 247 Commonwealth Avenue, Boston 16, Massachusetts, 1940, '41, '42, '44, '46*, '47, '48, '49, '50, '51, '52, '53, '54, '55.
1948. WHALEN, EDWARD J., 750 Main Street, Hartford, Connecticut, 1948, '50, '51, '52, '54, '55.
1953. WILKERSON, WILLIAM WESLEY, JR., 1028 Bennie Dillon Building, Nashville, Tennessee, 1953, '54, '55.
1948. WILLIAMS, HENRY L., 2nd, Mayo Clinic, Rochester, Minnesota, 1948, '49, '50*, '51, '52*, '53, '54, '55.
1942. WISHART, D. E. STAUNTON, 170 St. George Street, Toronto, Canada, 1942, '44, '46, '47*, '49, '51, '52*, '53, '55.
1951. WOODMAN, DEGRAAF, 156 E. 37th Street, New York 16, N. Y., 1951, '53, '54, '55*.
1953. WORK, WALTER P., 384 Post Street, San Francisco 8, California, 1953, '54.

Honorary Fellows

1949. (1917) COATES, GEORGE M., 1721 Pine Street, Philadelphia 3, Pa., 1949*, '51, '52, '54.
1939. (1907) JACKSON, CHEVALIER, Schwenksville, Pennsylvania, 1939*, '40*.
1943. (1918) LEWIS, FIELDING O., Providence Road, Media, Pennsylvania.
1937. NAGER, F. B., Freiestrasse 3, Zurich, Switzerland.

Corresponding Fellows

1946. ALONSO, JUSTO M., Mercedes 1233, Montevideo, Uruguay.
1942. BATSON, OSCAR V., 133 South Thirty-sixth Street, Philadelphia 4, Pennsylvania, 1942*, '54*.
1938. BLAIR, VILRAY P., 508 North Grand Avenue, St. Louis 3, Missouri.
1943. EGGSTON, ANDREW O., 653 Park Avenue, New York, N. Y., 1944, '49, '55.

1950. LARSELL, OLOF, University of Oregon Medical School, Portland, Oregon, 1950*.
1921. LE MAITRE, FERNAND, Avenue Victor Hugo, 120 (XVI), Paris, France.
1930. NEGUS, VICTOR E., 149 Harley Street, London, W 1, England, 1938*.
1950. NEIL, JAMES HARDIE, 64 Symonds Street, Auckland, New Zealand.
1937. PORTMANN, GEORGES, 25 bis Cours de Verdun, Bordeaux, France, 1947.
1924. SCHAEFER, J. PARSONS, 4634 Spruce Street, Philadelphia 3, Pennsylvania, 1934.
1952. TAPIA ACUNA, RICARDO, Napoles 9, Mexico 6, D. F., Mex.
1936. VIALLE, JACQUES, 27 Rue de France, Nice (Alpes Maritimes), France.

Emeritus Fellows

1941. (1923) BARLOW, ROY A., Berryville, Va.
1951. (1944) BEATTY, HUGH G., 150 E. Broad St., Columbus 15, Ohio, 1951, '52, '53.
1950. (1937) CROWE, SAMUEL J., Tuscany Apartments, Baltimore 10, Maryland.
1946. (1933) FOSTER, JOHN H., Eagle Lake, Texas, 1948, '49, '50, '51, '52.
1955. (1940) GATEWOOD, E. TRIBLE, Professional Building, Richmond, Virginia.
1951. (1928) GITTINS, THOMAS R., 408 Davidson Bldg., Sioux City, Iowa.
1936. (1898) GOODALE, JOSEPH L., Argilla Road, Ipswich, Massachusetts.
1933. (1905) HALSTED, THOMAS H., 3500 West Adams Boulevard, Los Angeles 25, California.

1955. (1930) HOUSER, KARL M., 2035 Delancey Street, Philadelphia 3, Pennsylvania.
1951. (1928) JARVIS, DEFOREST C., Quarry Bank Bldg., Barre, Vt., 1952.
1954. (1921) KERNAN, JOHN D., JR., 103 East Seventy-eighth Street, New York 21, N. Y.
1953. (1922) LILLIE, HAROLD I., Mayo Clinic, Rochester, Minnesota.
1954. (1927) LUKENS, ROBERT M., 1308 W. Hunting Park Avenue, Philadelphia 40, Pa.
1954. (1928) MACPHERSON, DUNCAN, 2350 Broadway, New York 24, N. Y.
1948. (1939) MYERS, JOHN LLEWELLYN, 1115 Grand Avenue, Kansas City, Missouri.
1953. (1921) SAUER, WILLIAM E., 3720 Washington Boulevard, St. Louis 8, Missouri.
1940. (1923) SEWALL, EDWARD C., 430 El Escarpado, Stanford University, California.
1954. (1930) SEYDELL, ERNEST M., First National Bank Building, Wichita, Kansas.
1948. (1923) SPENCER, FRANK R., 429 Pine St., Boulder, Colorado.
1953. (1927) TOBEY, HAROLD G., 274 Commonwealth Avenue, Boston 16, Massachusetts.
1950. (1922) WHITE, FRANCIS W., 471 Park Avenue, New York 22, N. Y.
1951. (1935) WOODWARD, FLETCHER D., 104 E. Market St., Charlottesville, Va.

BENEFACTORS

DR. ARTHUR W. DEROALDES

DR. WILLIAM E. CASSELBERRY

DR. SAMUEL JOHNSTON

DR. CORNELIUS G. COAKLEY

DR. JOHN F. BARNHILL

DR. JAMES E. NEWCOMB

DR. LEE WALLACE DEAN

DR. GEORGE E. HOURN

BENEFACTORS OF THE LARYNGOLOGICAL
RESEARCH FUND

DR. JOHN F. BARNHILL
DR. AND MRS. LEE WALLACE DEAN
DR. GORDON BERRY
DR. FREDERICK T. HILL
DR. AND MRS. GEORGE E. HOURN
DR. SAMUEL SALINGER
DR. H. MARSHALL TAYLOR
DR. LOUIS H. CLERF
MR. LESTER T. SUNDERLAND
DR. WILLIAM E. GROVE
DR. BURT R. SHURLY
DR. HENRY B. ORTON



Obverse of the deRoaldes medal

RECIPIENTS OF THE deROALDES AWARD

- 1928. DR. CHEVALIER JACKSON
- 1931. DR. D. BRYSON DELAVAN
- 1934. DR. HARRIS P. MOSHER
- 1937. DR. LEE WALLACE DEAN
- 1943. DR. RALPH A. FENTON
- 1949. DR. GEORGE M. COATES
- 1951. DR. ARTHUR W. PROETZ
- 1954. DR. LOUIS H. CLERF

RECIPIENTS OF THE CASSELBERRY AWARD

1923. DR. GEORGE FETTEROLF AND DR. HERBERT FOX
1928. DR. RALPH A. FENTON AND DR. O. LARSELL
1929. DR. RICHARD A. KERN AND DR. HARRY P. SCHENCK
1929. DR. EDWARD H. CAMPBELL
1931. DR. ARTHUR W. PROETZ
1934. DR. ANDERSON C. HILDING
1936. DR. FRANCIS E. LEJEUNE: DR. JOEL J. PRESSMAN
1939. DR. H. MARSHALL TAYLOR: DR. BRIEN T. KING
1940. DR. FRENCH K. HANSEL
1941. DR. NOAH D. FABRICANT
1946. DR. PAUL H. HOLINGER
1949. DR. HENRY B. ORTON

RECIPIENTS OF THE NEWCOMB AWARD

- 1941. DR. BURT R. SHURLY
- 1942. DR. FRANCIS R. PACKARD
- 1943. DR. GEORGE M. COATES
- 1944. DR. CHARLES J. IMPERATORI
- 1947. DR. HARRIS P. MOSHER
- 1948. DR. GORDON BERRY
- 1949. DR. GORDON B. NEW
- 1950. DR. H. MARSHALL TAYLOR
- 1951. DR. JOHN D. KERNAN
- 1952. DR. WILLIAM J. McNALLY
- 1953. DR. FREDERICK T. HILL
- 1954. DR. HENRY B. ORTON
- 1955. DR. THOMAS C. GALLOWAY

PAST OFFICERS

Presidents

(Year of Election)

1879. Louis Elsberg	1909. J. E. Logan
1880. J. Solis-Cohen	1910. D. Braden Kyle
1881. F. I. Knight	1911. James E. Newcomb
1882. G. M. Lefferts	1912. George A. Leland
1883. F. H. Bosworth	1913. Thomas Hubbard
1884. E. L. Shurly	1914. Alexander W. MacCoy
1885. Harrison Allen	1915. G. Hudson Makuen
1886. E. Fletcher Ingals	1916. Joseph L. Goodale
1887. R. P. Lincoln	1917. Thomas H. Halstead
1888. E. C. Morgan	1918. Cornelius G. Coakley
1889. J. N. Mackenzie	1919. Norval H. Pierce
1890. W. C. Glasgow	1920. Harris P. Mosher
1891. S. W. Langmaid	1921. Harmon Smith
1892. M. J. Asch	1922. Emil Mayer
1893. D. Bryson Delavan	1923. J. Payson Clark
1894. J. O. Roe	1924. Lee Wallace Dean
1895. W. H. Daly	1925. Greenfield Sluder
1896. C. H. Knight	1926. Chevalier Jackson
1897. T. R. French	1927. D. Bryson Delavan
1898. W. E. Casselberry	1928. Charles W. Richardson
1899. Samuel Johnston	1929. Lewis A. Coffin
1900. H. L. Swain	1930. Francis R. Packard
1901. J. W. Farlow	1931. George E. Shambaugh
1902. J. H. Bryan	1932. George Fetterolf
1903. J. H. Hartman	1933. George M. Coates
1904. C. C. Rice	1934. Dunbar Roy
1905. J. W. Gleitsman	1935. Burt R. Shurly
1906. A. W. deRoaldes	1936. William B. Chamberlain
1907. H. S. Birkett	1937. John F. Barnhill
1908. A. Coolidge, Jr.	1938. George B. Wood

- | | |
|-------------------------------|--------------------------|
| 1939. James A. Babbitt | 1949. Ralph A. Fenton |
| 1940. Gordon Berry | 1950. Gordon B. New |
| 1941. Thomas E. Carmody | 1951. H. Marshall Taylor |
| 1942-3. Charles J. Imperatori | 1952. Louis H. Clerf |
| 1944-5. Harold I. Lillie | 1953. Gordon F. Harkness |
| 1946. Frank R. Spencer | 1954. Henry B. Orton |
| 1947. Arthur W. Proetz | 1955. Bernard J. McMahon |
| 1948. Frederick T. Hill | |

Vice-Presidents

- | | |
|------------------------|--------------------|
| 1879. F. H. Davis | J. O. Roe |
| 1880. W. C. Glasgow | W. Porter |
| 1881. E. L. Shurly | E. F. Ingals |
| 1882. C. Seiler | S. Johnston |
| 1883. S. W. Langmaid | W. H. Daly |
| 1884. J. H. Hartman | G. W. Major |
| 1885. H. A. Johnson | J. N. Mackenzie |
| 1886. E. C. Morgan | S. W. Langmaid |
| 1887. J. N. Mackenzie | C. E. DeM. Sajous |
| 1888. W. C. Glasgow | C. E. Bean |
| 1889. E. Holden | J. H. Hartman |
| 1890. J. O. Roe | S. Johnston |
| 1891. M. J. Asch | J. C. Mulhall |
| 1892. S. Johnston | W. E. Casselberry |
| 1893. J. C. Mulhall | S. H. Chapman |
| 1894. C. C. Rice | A. W. deRoaldes |
| 1895. J. Wright | D. N. Rankin |
| 1896. T. M. Murray | H. S. Birkett |
| 1897. A. W. MacCoy | F. W. Hinkel |
| 1898. J. W. Farlow | M. R. Brown |
| 1899. T. A. DeBlois | A. A. Bliss |
| 1900. H. L. Wagner | D. Braden Kyle |
| 1901. J. W. Gleitsmann | T. Melville Hardie |
| 1902. G. A. Leland | W. Peyre Porcher |
| 1903. J. H. Lowman | |

1904.	Thomas Hubbard	W. J. Freeman
1905.	J. L. Goodale	C. W. Richardson
1906.	G. H. Makuen	A. B. Thrasher
1907.	J. P. Clark	J. E. Rhodes
1908.	E. Mayer	F. R. Packard
1909.	C. G. Coakley	H. P. Mosher
1910.	Robert C. Myles	J. M. Ingersoll
1911.	F. C. Cobb	B. R. Shurly
1912.	A. W. Watson	W. Scott Renner
1913.	F. E. Hopkins	Geo. F. Shambaugh
1914.	Clement T. Theisen	Lewis A. Coffin
1915.	J. Gordon Wilson	Christian R. Holmes
1916.	Thomas H. Halsted	Greenfield Sluder
1917.	John Edwin Rhodes	D. Crosby Greene
1918.	G. E. Shambaugh	John R. Winslow
1919.	Francis R. Packard	Harmon Smith
1920.	Harmon Smith	W. B. Chamberlin
1921.	Dunbar Roy	Robert C. Lynch
1922.	George Fetterolf	Lorenzo B. Lockard
1923.	Hubert Arrowsmith	Joseph B. Greene
1924.	Ross H. Skillern	Gordon Berry
1925.	John E. Mackenty	Robert Levy
1926.	Lewis A. Coffin	William V. Mullin
1927.	Charles W. Richardson	Hill Hastings
1928.	Robert Clyde Lynch	Francis P. Emerson
1929.	William B. Chamberlin	Ralph Albert Fenton
1930.	Harris P. Mosher	James A. Babbitt
1931.	Joseph B. Greene	E. Ross Faulkner
1932.	Gordon Berry	Frank A. Spencer
1933.	E. Ross Faulkner	Thomas S. Carmody
1934.	Gordon B. New	Samuel McCullagh
1935.	Edward C. Sewall	H. Marshall Taylor
1936.	William P. Wherry	Harold I. Lillie
1937.	Frank R. Spencer	Bernard J. McMahon
1938.	Ralph A. Fenton	Frederick T. Hill

1939. John H. Foster	Thomas R. Gittins
1940. Charles H. Porter	Gordon F. Harkness
1941. Arthur W. Proetz	Henry B. Orton
1942-3. Harold I. Lillie	Dean M. Lierle
1944-5. John J. Shea	Thomas C. Galloway
1946. H. Marshall Taylor	C. Stewart Nash
1947. John J. Shea	Frederick A. Figi
1948. Henry B. Orton	Anderson C. Hilding
1949. LeRoy A. Schall	Fletcher D. Woodward
1950. W. Likely Simpson	Lyman G. Richards
1951. Wm. J. McNally	Thomas C. Galloway
1952. J. Mackenzie Brown	Edwin N. Broyles
1953. Claude C. Cody	Daniel S. Cunning
1954. James H. Maxwell	Clyde A. Heatly

Secretaries and Treasurers

1879. G. M. Lefferts	1895. H. L. Swain
1882. D. Bryson Delavan	1900. P. E. Newcomb
1889. C. H. Knight	1911. Harmon Smith

Secretaries

1912. Harmon Smith	1935. James A. Babbitt
1918. D. Bryson Delavan	1939. Charles J. Imperatori
1919. J. M. Ingersoll	1942. Arthur W. Proetz
1920. George M. Coates	1947. Louis H. Clerf
1933. William V. Mullin	1952. Harry P. Schenck

Treasurers

1912. J. Payson Clark	1935. Charles J. Imperatori
1923. George Fetterolf	1939. Frederick T. Hill
1932. William V. Mullin	1948. Gordon F. Harkness
1933. James A. Babbitt	1953. Fred W. Dixon

Librarians

- | | |
|----------------------|------------------------|
| 1789. F. H. Bosworth | 1930. John F. Barnhill |
| 1883. T. R. French | 1934. Burt R. Shurly |
| 1903. J. H. Bryan | 1935. George M. Coates |

Librarian and Historian

- | | |
|------------------------|--------------------------|
| 1936. George M. Coates | 1952. Bernard J. McMahon |
| 1944. Louis H. Clerf | 1955. Edwin N. Broyles |
| 1947. Harry P. Schenck | |

PAST FELLOWS

Dates indicate original election to the Association

**Deceased*

Honorary Fellows

- *1908. Barnhill, John F., Miami Beach, Florida.
- *1893. Birkett, Herbert S., Montreal, Canada.
- *1878. Bosworth, Francke H., New York City.
- *1918. Dean, Lee Wallace, St. Louis, Mo.
- *1881. Delavan, D. Bryson, New York City.
- *1893. deRoaldes, Arthur W., New Orleans, La.
- *1890. De La Sota Y. Lastra, Ramon, Seville, Spain.
- *1879. French, Thomas R., Brooklyn, N. Y.
- *1880. Garcia, Senior Manuel, London, England.
- *1903. Harris, Thos. J., New York City.
- *1878. Johnston, Samuel, Baltimore, Md.
- *1878. Lefferts, George Morewood, Katonah, N. Y.
- *1914. Levy, Robert, Denver, Colo.
- *1883. Mackenzie, John N., Baltimore, Md.
- *1881. Mackenzie, Sir Morel, London, England.
- *1910. Masser, Ferdinand, Naples, Italy.
- *1904. Mosher, Harris P., Marblehead, Mass.
- *1910. Moure, J. J. E., Bordeaux, France.
- *1918. Oliver, H. K., Boston, Mass.
- *1906. Pierce, Norval Harvey, San Diego, Calif.
- *1909. Semon, Sir Felix, Great Missenden, England.
- *1878. Solis-Cohen, J., Philadelphia, Pa.
- *1889. Swain, Henry L., New Haven, Conn.
- *1914. Thomson, Sir St. Clair, London, Eng.
- *1903. Tilley, Herbert, London, England.
- *1914. Wagner, Clinton, New York City.
- *1890. Wright, Jonathan, Pleasantville, N. Y.

Corresponding Fellows

- *1892. Browne, Lennox, London, England.
- *1940. Colledge, Lionel, London, England.
- *1901. Collier, Mayo, Kearsney Abbey, Kent, England.
- *1893. Desvernine, Carlos M., Havana, Cuba.

- *1930. Emerson, Francis P., Franklin, Mass.
- *1936. Fraser, John S., Edinburgh, Scotland.
- *1901. Grant, Sir James Dundas, London, England.
- *1887. Cougenheim, A., Paris, France.
- *1894. Holden, Edgar, Newark, N. J.
- *1919. Kelly, Adam Brown, Helensburgh, Scotland.
- *1881. Labus, Carlo, Milan, Italy.
- *1931. LasSagna, Francesco, Parma, Italy.
- *1926. Law, Frederick M., New York, N. Y.
- *1902. Lermoyez, Marcel, Paris, France.
- *1897. Luc, H., Paris, France.
- *1896. MacDonald, Greville, Haslemere, Surrey, England.
- *1894. MacIntyre, John, Glasgow, Scotland.
- *1903. McBride, P., York, England.
- *1920. McKenzie, Dan, London, England.
- *1919. McKernon, James F., New Canaan, Conn.
- *1880. Meyer, Wilhelm, Copenhagen, Denmark.
- *1910. Moure, J. J. E., Bordeaux, France.
- *1896. Mygind, Holger, Copenhagen, Denmark.
- *1919. Paterson, Donald Rose, Cardiff, Wales.
- *1941. Patterson, Norman, Herts, England.
- *1919. Rogers, John, Jr., New York City.
- *1894. Sajous, C. E. DeM., Philadelphia, Pa.
- *1896. Schmiegelow, Ernst, Copenhagen, Denmark.
- *1946. Segura, Eliseo, Buenos Aires, Argentina.
- *1940. Soto, E. Fernandez, Havana, Cuba.
- *1881. Thornton, Pugin, London, England.
- *1913. Turner, A. Logan, Edinburgh, Scotland.
- *1880. Whistler, W. McNeil, London, England.
- *1901. Wingrave, Wyatt, Lyme Regis, Dorset, England.
- *1894. Wolfenden, R. Norris, Kent, England.

Emeritus Fellows

- *1915. Barnes, Harry Aldrich, Kingston, Mass.
- *1928. Beck, Joseph C., Chicago, Illinois.
- *1921. Berry, Gordon, Worcester, Mass.
- *1901. Brown, J. Price, Toronto, Canada.
- *1891. Bryan, Joseph H., Washington, D. C.
- *1913. Butler, Ralph, Philadelphia, Pa.
- *1897. Clark, J. Payson, Boston, Mass.

- *1899. Cobb, Frederick C., Bradenton, Florida.
- *1905. Coffin, Lewis A., New York City.
- *1893. Coolidge, Algernon, Boston, Mass.
- *1913. Dabney, Virginius, Washington, D. C.
- *1882. De Blois, Thomas Amory, Boston, Mass.
- *1892. Farlow, John W., Boston, Mass.
- *1922. Forbes, Henry H., New York City.
- *1905. Freer, Otto T., Chicago, Ill.
- *1880. Gleitsmann, Joseph W., New York City.
- *1922. Goldsmith, Perry G., Toronto, Canada.
- *1932. Graham, Harrington B., San Francisco, California.
- *1906. Greene, D. Crosby, Jr., Boston, Mass.
- *1917. Greene, Joseph B., Asheville, N. C.
- *1896. Hardie, Thomas Melville, Chicago, Ill.
- *1915. Hastings, Hill, Los Angeles, Calif.
- *1888. Hinkel, Frank Whitehill, Buffalo, New York.
- *1895. Hopkins, Frederick E., Springfield, Mas.
- *1927. Hubbard, Thomas, Toledo, Ohio.
- *1919. Hurd, Lee Maidment, Rowayton, Conn.
- *1920. Imperatori, Charles J., Essex, N. Y.
- *1904. Ingersoll, John Marvin, Miami, Fla.
- *1918. Kenyon, Elmer L., Chicago, Ill.
- *1929. Kistner, Frank B., Portland, Oregon.
- *1885. Knight, Charles H., New York City.
- *1939. Large, Secord H., Cleveland, Ohio.
- *1894. Leland, George A., Boston, Mass.
- *1943. Lincoln, William R., Cleveland, Ohio.
- *1928. Lyman, Harry Webster, St. Louis, Mo.
- *1886. MacCoy, Alexander W., Philadelphia, Pa.
- *1896. Mayer, Emil, New York City.
- *1943. McCullagh, Samuel, New York, N. Y.
- *1923. McKinney, Richmond, Memphis, Tenn.
- *1922. New, Gordon B., Rochester, Minn.
- *1878. Porter, William, Ocean Springs, Miss.
- *1901. Myles, Robert C., New York City.
- *1923. Newhart, Horace, Minneapolis, Minn.
- *1903. Packard, Francis R., Philadelphia, Pa.
- *1942. Potts, John B., Omaha, Nebr.
- *1903. Renner, W. Scott, Buffalo, N. Y.
- *1897. Rhodes, John Edwin, Chicago, Ill.
- *1884. Rice, Clarence C., New York City.

- *1905. Richards, George L., South Yarmouth, Mass.
- *1878. Robinson, Beverly, New York City.
- *1907. Shambaugh, George E., Chicago, Ill.
- *1908. Smith, Harmon, New York City.
- *1892. Wagner, Henry L., San Francisco, Calif.
- *1892. Watson, Arthur W., Philadelphia, Pa.
- *1939. Wilson, J. Gordon, Old Bennington, Vt.
- *1905. Wood, George B., Wynnewood, Pa.

Active Fellows

- *1880. Allen, Harrison, Philadelphia, Pa.
- *1917. Arrowsmith, Hubert, Brooklyn, N. Y.
- *1879. Asch, Morris J., New York City.
- *1923. Babbitt, James A., Philadelphia, Pa.
- *1906. Ballenger, William L., Chicago, Ill.
- *1880. Bean, C. E., St. Paul, Minn.
- *1904. Berens, T. Passmore, New York City.
- *1924. Bigelow, Nolton, Providence, R. I.
- *1893. Bliss, Arthur Ames, Philadelphia, Pa.
- *1895. Boylan, J. E., Cincinnati, Ohio.
- *1892. Brown, Moreau R., Chicago, Ill.
- *1933. Buckley, Robert E., New York City.
- *1915. Canfield, R. Bishop, Ann Arbor, Mich.
- *1934. Carmack, John Walter, Indianapolis, Ind.
- *1924. Carmody, Thomas E., Denver, Colo.
- *1889. Casselberry, William E., Chicago, Ill.
- *1883. Chamberlain, C. W., Hartford, Conn.
- *1917. Chamberlin, William B., Cleveland, Ohio.
- *1896. Chappell, W. F., New York City.
- *1882. Chapman, S. Hartwell, New Haven, Conn.
- *1902. Coakley, Cornelius G., New York City.
- *1913. Coffin, Rockwell C., Boston, Mass.
- 1918. Cox, Gerald H., New York City.
- *1880. Cushing, E. W., Boston, Mass.
- *1878. Cutter, Ephraim, West Falmouth, Mass.
- *1880. Daly, W. H., Pittsburgh, Pa.
- *1878. Davis, F. H., Chicago, Ill.
- *1941. Davis, Warren B., Philadelphia, Pa.
- 1926. Dennis, Frank Lownes, Colorado Springs, Col.
- *1901. Dickerman, E. T., Chicago, Ill.

- *1878. Donaldson, Frank, Baltimore, Md.
- *1935. Eves, Curtis C., Philadelphia, Pa.
- *1919. Faulkner, E. Ross, New York City.
- *1914. Fetterolf, George, Philadelphia, Pa.
- *1901. Freeman, Walter J., Philadelphia, Pa.
- *1917. Friedberg, Stanton A., Chicago, Ill.
- 1940. Fuchs, Valentine H., New Orleans, La.
- 1909. Getchell, Albert C., Worcester, Mass.
- *1897. Frothingham, Richard, New York City.
- *1907. Gibb, Joseph S., Philadelphia, Pa.
- *1940. Gill, William D., San Antonio, Texas.
- *1878. Glasgow, William Carr, St. Louis, Mo.
- *1913. Goldstein, Max A., St. Louis, Mo.
- *1905. Grayson, Charles P., Philadelphia, Pa.
- *1934. Grove, William E., Milwaukee, Wisconsin
- *1945. Hickey, Harold L., Denver, Colo.
- *1879. Holden, Edgar, Newark, N. J.
- *1907. Holmes, Christian R., Cincinnati, Ohio.
- *1882. Hooper, Franklin H., Boston, Mass.
- *1893. Hope, George B., New York City.
- *1938. Hourn, George E., St. Louis, Mo.
- *1939. Hunt, Westley Marshall, New York, N. Y.
- *1901. Hyatt, Frank, Washington, D. C.
- *1925. Iglauer, Samuel, Cincinnati, Ohio.
- *1878. Ingals, E. Fletcher, Chicago, Ill.
- *1882. Ives, Frank L., New York City.
- *1880. Jarvis, William C., New York City.
- *1878. Johnson, Hosmer A., Chicago, Ill.
- *1879. Johnson, Woolsey, New York City.
- *1944. Jones, Marvin F., New York City.
- *1879. Kealhofer, R. H., St. Louis, Mo.
- *1901. King, Gordon, New Orleans, La.
- *1885. Knight, Charles H., New York City.
- *1878. Knight, Frederick Irving, Boston, Mass.
- *1898. Kyle, D. Braden, Philadelphia, Pa.
- *1880. Langmaid, Samuel W., Boston, Mass.
- *1878. Lincoln, Rufus P., New York City.
- *1911. Lockard, Lorenzo B., Denver, Colo.
- *1913. Loeb, Hanau W., St. Louis, Mo.
- *1897. Logan, James E., Kansas City, Mo.

- *1935. Looper, Edward A., Baltimore, Maryland.
- *1888. Lowman, John H., Cleveland, Ohio.
- *1919. Lynah, Henry L., New York City.
- *1915. Lynch, Robert Clyde, New Orleans, La.
- *1879. McBurney, Charles, New York City.
- *1927. McGinnis, Edwin, Chicago, Ill.
- 1936. McGregor, Gregor, Toronto, Canada.
- *1913. McKimmie, O. A., Washington, D. C.
- *1885. McSherry, H. Clinton, Baltimore, Md.
- *1914. Mackenty, John E., New York City.
- *1898. Makuen, G. Hudson, Philadelphia, Pa.
- *1881. Major, G. W., Montreal, Canada.
- *1881. Morgan, E. C., Washington, D. C.
- *1886. Mulhall, J. C., St. Louis, Mo.
- *1925. Mullin, William V., Cleveland, Ohio.
- *1914. Munger, Carl E., Waterbury, Conn.
- *1892. Murray, T. Morris, Washington, D. C.
- *1881. Mynter, H., Buffalo, N. Y.
- *1893. Newcomb, James E., New York City.
- *1895. Nichols, J. E. H., New York City.
- *1894. Park, William H., New York City.
- *1892. Porcher, W. Peyre, Charleston, S. C.
- *1927. Porter, Charles T., Boston, Mass.
- *1908. Randall, B. Alexander, Philadelphia, Pa.
- *1882. Rankin, D. N., Allegheny, Pa.
- *1902. Richardson, Charles W., Washington, D. C.
- *1930. Ridpath, Robert E., Philadelphia, Pa.
- *1879. Roe, John O., Rochester, N. Y.
- *1881. Robertson, J. M., Detroit, Mich.
- *1913. Roy, Dunbar, Atlanta, Ga.
- *1878. Rumbold, T. F., St. Louis, Mo.
- *1879. Seiler, Carl, Philadelphia, Pa.
- *1928. Shea, John Joseph, Memphis, Tennessee.
- *1893. Shields, Charles M., Richmond, Pa.
- *1909. Shurly, Burt R., Detroit 1, Mich.
- *1878. Shurly, E. L., Detroit, Mich.
- *1892. Simpson, William Kelly, New York City.
- *1919. Skillern, Ross H., Philadelphia, Pa.
- *1909. Sluder, Greenfield, St. Louis, Mo.
- *1879. Smith, Andrew H., Geneva, N. Y.

- *1932. Smyth, Duncan Campbell, Boston, Mass.
- *1928. Sonnenschein, Robert, Chicago, Ill.
- 1924. Stein, Otto J., Chicago, Ill.
- 1934. Stevenson, Walter, Quincy, Ill.
- *1911. Staut, George C., Philadelphia, Pa.
- *1879. Tauber, Bernhard, Cincinnati, Ohio.
- *1903. Theisen, Clement F., Albany, N. Y.
- *1899. Thorner, Max, Cincinnati, Ohio.
- *1892. Thrasher, Allen B., Cincinnati, Ohio.
- *1937. Tobey, George L., Jr., Boston, Mass.
- *1888. Van der Poel, S. O., New York City.
- *1938. Vail, Harris H., Cincinnati, Ohio.
- *1936. Voislowsky, Antonie P., New York City.
- *1933. Wanamaker, Allison T., Seattle, Wash.
- 1896. Ward, Marshall R., Pittsburgh, Pa.
- *1879. Ward, Whitfield, New York City.
- *1886. Westbrook, Benjamin F., Brooklyn, N. Y.
- *1924. Wherry, William P., Omaha, Neb.
- *1924. White, Leon E., Boston, Mass.
- *1939. Williams, Horace J., Philadelphia, Pa.
- *1922. Wishart, David J. G., Toronto, Ontario.
- *1940. Wood, V. Visscher, St. Louis, Mo.
- *1896. Wollen, Green V., Indianapolis, Ind.

G.F. TUCKER

