Transactions

American Laryngological Association

EIGHTY-FIRST VOLUME

"DOCENDO DISCIMUS"

TRANSACTIONS

OF THE

EIGHTY-FIRST ANNUAL MEETING

OF THE

American Laryngological Association

1960

HELD AT

THE DEAUVILLE HOTEL

MIAMI BEACH, FLORIDA

MARCH 18 AND 19, 1960

PUBLISHED BY THE ASSOCIATION

ST. LOUIS, MO.

1960

CONTENTS

PAGE

List of Officers 7

Registration 9

Address of President McNally 16

The Physiology of Olfaction and Gustation. L. M. Beidler, Ph.D. 27

The Electron-Microscopy of the Olfactory and Taste Pathways. A. J. de Lorenzo, Ph.D. 39

Cine-Fluorography in the Evaluation of Cancer of the Larynx. John Kirchner, M.D. 50

Laryngeal Manifestations of Systemic Disease. W. H. Maloney, M.D. 64

Phonation: Clinical Testing Versus Electromyography. David W. Brewer, M.D., F. B. Briess and K. Faaborg Andersen, M.D. 71

The Use of Regional Flaps in Surgery of the Neck. John J. Conley, M.D. 95

Choanal Atresia. D. C. Baker, M.D., J. Wallner, M.D., and William Novick, M.D. 108

Upper Respiratory Findings in Wegener's Granulomatosis. Henry A. Brown, M.D., Lewis B. Woolner, M.D. 115

The Cerebral Cortex and Hearing. Lamar Roberts, M.D. 135

Some Clinical Aspects of Aphasia. Joe R. Brown, M.D. 154

The Parotid Gland in Mikulicz Disease and Sjogren's Syndrome. W. G. Hemenway, M.D. 162

The Sphenoidal Sinus in its Relation to the Sella Turcica. Gunnar Hammar, M.D. 182

Trans-Antro Sphenoidal Hypophysectomy. Carl-Axel Hamberger, M.D. 185

Arytenoidectomy in Children. Robert E. Priest, M.D., H. S. Ulvestad, M.D., F. Van Dewater, M.D., and Robert J. Richardson, M.D. 192

Early Invasion of the Thyroid Gland in Carcinoma of the Glottis. Ricardo Tapia Acuna, M.D. 207

CONTENTS

PAGE

The Role of Radiation Therapy in Carcinoma of the Larynx. J. L. Goldman, M.D. and Sidney M. Silverstone, M.D. 215

Extramedullary Plasmacytoma of the Upper Air Passages. Julius McCall, M.D. and Carl H. Bailey, M.D. 235

Memorials:

- George M. Coates 250
- Claude C. Cody 255
- Daniel S. Cunning 258
- Felix Robert Nager 261
- Mercer G. Lynch 265
- E. Trible Gatewood 268
- William Wallace Morrison 270
- James H. Maxwell 273

Executive Sessions and Reports of Officers and Committees 279

List of Fellows, 1960:

- Active Fellows 314
- Honorary Fellows 321
- Corresponding Fellows 321
- Emeritus Fellows 322

Benefactors 324

Benefactors of the Laryngological Research Fund 325

Recipients of the de Roaldes Award 326

Recipients of the Casselberry Award 327

Recipients of the Newcomb Award 328

Past Officers 329

Past Fellows 334

THOSE IN ATTENDANCE AT THE EIGHTY-FIRST ANNUAL MEETING

Left to right as one faces the group: *front row,* Schall, Furstenberg, Atkins, McNally, Richards, Boies, Theobald, Proetz, Lederer; *second row,* Bateman, Schenck, Woodman, Equen, Alfaro, Tapia Acuna, Smith, Hilger, Dixon, LeJeune, Van Alyea; *third row,* Moore, Walsh, Barretto, Sanders, Woodward, O'Keefe, Silcox, Converse, Holinger, Weille; *fourth row,* Martin, Fitzhugh, J. Goldman, Daly, Tremble, Hill, Lindsay, Henry, McMahon, Baker, Broyles, Williams, Heatly, Norris, Robb, Roberts; *fifth row,* Hart, McCall, Harris, Clerf, Priest, Cardwell, Cracovaner, Richardson, Friedberg, Conley, Montreuil, Kline, Galloway, Putney, Hoople, Brewer, Harkness, Munoz-MacCormick, Goodale, Bordley, Davison, Meltzer, Johnston.

OFFICERS FOR 1959-60

PRESIDENT

WILLIAM J. McNALLY, M.D.

FIRST VICE-PRESIDENT

JAMES H. MAXWELL, M.D.

SECOND VICE-PRESIDENT

O. E. VAN ALYEA, M.D.

SECRETARY

LYMAN G. RICHARDS, M.D.

TREASURER

FRANCIS E. LeJEUNE, M.D.

LIBRARIAN, HISTORIAN AND EDITOR

EDWIN N. BROYLES, M.D.

COUNCIL

The above Ex-officio and

BERNARD J. McMAHON, M.D.

LeROY A. SCHALL, M.D.

HARRY P. SCHENCK, M.D.

FRED W. DIXON, M.D.

TRANSACTIONS OF THE
EIGHTY-FIRST ANNUAL MEETING

OF THE

American Laryngological Association

HELD AT

THE DEAUVILLE HOTEL

MIAMI BEACH, FLORIDA

MARCH 18 AND 19, 1960

The Eighty-first Annual Meeting of the American Laryngological Association was called to order by the President, Dr. William J. McNally, at the Deauville Hotel, Miami Beach, Florida, on March 18, 1960, at 9:00 A.M.

REGISTRATION

The following Fellows were in attendance:

ALFARO, VICTOR R.
ATKINS, JOSEPH P.
BAKER, DANIEL C.
BATEMAN, GEOFFREY H.
BARRETTO, PLINIO DE MATTOS
BOIES, LAWRENCE R.
BORDLEY, JOHN E.
BREWER, DAVID W.
BROYLES, EDWIN N.
CARDWELL, EDGAR P.
CLERF, LOUIS H.
CONLEY, JOHN J.
CONVERSE, JOHN M.
CRACOVANER, ARTHUR J.
DALY, JOHN F.
DAVISON, FRANCIS W.

Dixon, Fred W.
Eggston, Andrew O.
Equen, Murdock S.
Fitz-Hugh, Glassell S.
Friedberg, Stanton A.
Furstenberg, Albert C.
Galloway, Thomas C.
Goldman, Joseph L.
Goodale, Robert L.
Harkness, Gordon F.
Harris, Herbert H.
Hart, Verling K.
Heatly, Clyde A.
Henry, George A.
Hilding, Anderson C.
Hilger, Jerome A.
Hill, Frederick T.
Holinger, Paul H.
Hoople, Gordon D.
Johnston, Kenneth C.
Kline, Oram R.
Lederer, Francis L.
LeJeune, Francis E.
Lierle, Dean M.
Lindsay, John R.
Martin, Robert C.
McCall, Julius W.
McMahon, Bernard J.
McNally, William J.
Meltzer, Philip E.
Montreuil, Fernand
Moore, Paul M.
Munoz-MacCormick, Carlos E.
Nash, C. Stewart
Norris, Charles M.
O'Keefe, John J.
Pressman, Joel J.
Priest, Robert E.
Proetz, Arthur W.
Putney, F. Johnson
Richards, Lyman G.
Richardson, John
Robb, James M.
Roberts, Sam E.
Sanders, Sam H.
Schall, LeRoy A.
Schenck, Harry P.
Silcox, Louis E.
Simpson, W. Likely
Smith, Austin T.
Sooy, Francis A.
Theobald, Walter H.
Thornell, William C.
Tremble, G. Edward

VAN ALYEA, OLIVER E.
WALSH, THEODORE E.
WEILLE, FRANCIS L.
WILLIAMS, HENRY L.
WOODMAN, DEGRAAF
WOODWARD, FLETCHER D.

GUESTS

L. W. Alexander, New Orleans, La.
B. R. Alford, Houston, Texas
Ralph Arnold, Durham, N.C.
Carl H. Barley, Jr., Cleveland, Ohio
Carl H. Barley, Sharon, Pa.
John P. Baker, Brooklyn, N.Y.
John J. Ballenger, Glencoe, Ill.
Herbert J. Barak, Kalamazoo, Mich.
L. J. Barnes, Los Angeles, Calif.
Shirley H. Baron, San Francisco, Calif.
William B. Barry, Kansas City, Mo.
Oscar J. Becker, Chicago, Ill.
Lloyd M. Beidler, Talahassee, Fla.
Joseph H. Bergin, Alma, Michigan
Samuel M. Bloom, New York, N.Y.
Harold M. Boyd, Los Angeles, Calif.
F. Bertram Briess, Syracuse, N.Y.
H. A. Brown, Rochester, Minn.
Joe R. Brown, Rochester, Minn.
M. T. K. Bryan, St. Louis, Mo.
E. J. Chapman, Ashville, N.C.
Ned I. Oldat, Detroit, Mich.
Julian B. Cohn, St. Louis, Mo.
J. M. Cole, Danville, Pa.
D. A. Corgill, Dallas, Texas
C. A. Couch, Mogadore, Ohio
Kenneth L. Craft, Indianapolis, Ind.
Irving J. Cramer, Shaker Heights, Ohio

L. R. Cramer, Toledo, Ohio
James E. Croushore, Detroit, Mich.
A. Aquero, San Jose, Costa Rica
Adrian J. Delaney, Alexandria, Va.
J. L. Dill, Detroit, Mich.
Byron Dumm, Denver, Colo.
David A. Dolowitz, Salt Lake City, Utah
John Douglas, Austin, Texas
Larry O. Doyle, Minneapolis, Minn.
Lewis W. Dunn, New York, N.Y.
J. D. Evans, Memphis, Tenn.
Maurice Evans, Boston, Mass.
Wm. H. Evans, Youngstown, Ohio
K. Faaborg-Andersen, Nykobing, Denmark
Richard Farrior, Tampa, Fla.
Blair Fearon, Toronto, Canada
C. F. Ferguson, Boston, Mass.
J. Allan Fields, Ft. Lauderdale, Fla.
Ugo P. Fisch, Baltimore, Md.
Meyer S. Fox, Milwaukee, Wisconsin
Joseph Freeman, Miami, Fla.
Conrad K. Gale, New York, N. Y.
John Gersten, Columbus, Ohio
Raphael Giorgana, Mexico City, Mexico
N. H. Gladstone, Fort Wayne, Ind.
M. D. Glenn, Coral Gables, Fla.
Herbert Goldman, Rockville Centre, N.Y.
M. H. Goldrath, Detroit, Mich.
Arthur T. Gorney, Boston, Mass.
Chas. C. Grace, St. Augustine, Fla.
E. L. Grandon, Iowa City, Iowa
Oscar Green, Indianapolis, Ind.
John R. Goulash, Bridgeport, Conn.
C. A. Hamberger, Goteborg, Sweden
K. Hara, Milwaukee, Wis.

E. W. Harris, Columbus, Ohio
E. K. Haugseth, South Bend, Ind.
C. Heine, Monticello, N.Y.
Wm. G. Heminway, Chicago, Ill.
Cecil B. Hert, Rochester, N.Y.
M. R. Himalstein, St. Petersburg, Fla.
Albert Hohmann, Detroit, Mich.
Eugene Hopp, San Francisco, Calif.
Nazmi Hosal, Washington, D.C.
W. R. Hudson, Winston-Salem, N.C.
Quentin Jacks, Vancouver, B.C.
Thomas Johnson, Indianapolis, Ind.
Herbert Kean, Philadelphia, Pa.
W. F. Keim, East Orange, N.J.
John Kirchner, New Haven, Conn.
John S. Knight, Kansas City, Mo.
C. M. Kos, Iowa City, Iowa
H. I. Laff, Denver, Colo.
I. Michael Levin, Chicago, Ill.
Wm. H. Lippy, Columbus, Ohio
Wm. J. Loeb, Cleveland, Ohio
Manuel Lopez, Mexico 6, D.F.
Gerson Lowenthal, Cincinnati, Ohio
R. A. Luongo, Philadelphia, Pa.
F. H. McGovern, Danville, Va.
M. W. McInerney, Minneapolis, Minn.
Ralph J. McQuiston, Indianapolis, Ind.
F. O. Mahoney, Springfield, Mass.
P. H. Malone, Big Spring, Texas
Walter H. Maloney, Cleveland, Ohio
Mario Mansueto, Hammond, Ind.
Elliot C. Margles, Shaker Heights, Ohio
D. W. Muzique, Chicago, Ill.
T. J. Molony, Toronto, Canada
James A. Moore, New York, N.Y.

K. M. Morgenstein, New York, N.Y.
Alex E. Morse, Hollywood, Florida
Harold K. Moss, Cincinnati, Ohio
C. S. Mumma, Santa Monica, Calif.
David Myers, Philadelphia, Pa.
George Nager, Baltimore, Md.
James J. O'Neil, Omaha, Neb.
Ed. A. Newell, Dallas, Texas
Alvin Novick, New Haven, Conn.
Page Northington, Miami, Fla.
Jos. H. Ogura, St. Louis, Mo.
H. Oppenheim, Louisville, Ky.
L. Q. Pang, Honolulu, Hawaii
George L. Pattee, Denver, Colo.
Alfred A. Pedro, Havana, Cuba
Arthur Q. Penta, Schenectady, N.Y.
D. L. Poushter, Syracuse, N.Y.
Richard Rabkin, Dayton, Ohio
Daniel J. Reagan, Worcester, Mass.
J. B. Reddy, Philadelphia, Pa.
Frank J. Riccio, Bridgeport, Conn.
B. Riseman, Boston, Mass.
J. M. Robison, Houston, Texas
Lamar Roberts, Gainsville, Fla.
J. T. Robison III, Houston, Texas
Marta Rojas, Havana, Cuba
H. Rosenwasser, New York, N.Y.
D. L. Ruggles, Cleveland, Ohio
Antonio Rullan, San Juan, Puerto Rico
Wm. H. Saunders, Columbus, Ohio
Meyer Schindler, San Francisco, Calif.
C. B. Schoemperlen, Winnipeg, Canada
P. A. Sciarra, Sheboygan, Wis.
Eliahu Shanon, Tel Aviv, Israel
M. J. Shapiro, Newark, N. J.

Henry Small, Detroit, Mich.
Graham G. Smith, Minneapolis, Minn.
Burton T. Soboroff, Chicago, Ill.
Laurence McStravog, Upper Darby, Pa.
Oliver W. Suehs, Austin, Texas
J. J. Swann, Ashville, N.C.
Tato Juan, Buenos Aires, Argentina
Robert N. Tindall, St. Louis, Mo.
B. M. Volk, Albany, N.Y.
Carl Wagner, Cincinnati, Ohio
William A. Wagner, New Orleans, La.
Paul H. Ward, Chicago, Ill.
Sidi B. Wasser, East Meadow, Long Island, N.Y.
Joseph W. West, St. Louis, Mo.
Russel I. Williams, Cheyenne, Wyoming
C. D. Winborn, Dallas, Texas
H. C. Wise, Shaker Heights, Ohio

THE DOCTOR'S RESPONSIBILITY TO HIS PATIENT

PRESIDENTIAL ADDRESS

WILLIAM J. MCNALLY, M.D.

MONTREAL, CANADA

I find it most difficult to express to you, the Fellows of the American Laryngological Association, my sincere appreciation of the signal honor which you have bestowed upon me and my fellow countrymen when you chose me as your President for the 81st Annual Meeting of the Society. I trust that the scientific program which has been prepared for your enjoyment will best demonstrate the high regard in which I hold this illustrious Association.

If you permit me a glance into the past I will remind you that at the Thirtieth Annual Meeting held in 1908 in Montreal this same high office was held by my late chief and predecessor at McGill University, General Herbert S. Birkett, who will be remembered by some of the members present.

It is of passing interest that he succeeded de Roaldes as President; that his Secretary-Treasurer was Newcombe; and that at the Montreal meeting Casselberry read a paper—these were the originators of the three Laryngological Association awards.

I have the honor of succeeding as President our former Treasurer, Dr. Fred Dixon, who has contributed generously to, and who is interested in, promoting the development of a large all-purpose fund which could be used among other things for the betterment of the scientific programs of the Annual Meetings. I am sure that every Fellow of the Association will join me in expressing our thanks to Dr. Dixon and that each of us will do everything possible for the development of this worthy ideal.

SCIENCE AND EDUCATION

In this age in which we are living we hear on all sides the need for education and especially for scientific education and research. The space program race is on and our educational system has been considered lacking. It has been shown that there is a shortage of scientifically trained personnel. This has resulted in a panic reaction in a large section of the country. The achievements of the Soviets were first minimized and then exaggerated—there has been a certain loss of sense of proportion. After more sober thought it has been realized that though we are short of technically trained people, it is even more essential that we have people who are trained to think and that they must be able to think clearly. The prime purpose of a university is to teach us how to assess the ideas with which we are confronted—to develop prudence and wisdom.

The following is taken from the Book of Wisdom, chapter 7, verses 7 to 14.

> I prayed and Prudence was given me; I pleaded, and the spirit of Wisdom came to me. I preferred her to sceptre and throne and deemed riches nothing in comparison to her. Nor did I liken any precious gems to her; because all gold, in view of her, is a little sand, and before her, silver is to be accounted as mire.

A leading article in the British Medical Journal of September 3rd, 1949, page 520, includes the following.

> "The training in scientific method, whilst providing the student with capacity for logical, impersonal, objective thought, should add point to the skill with which he applies his treatment and to the understanding and fellow feeling that soften his conversation with his patient."

Some progress has been made especially in radio, television, radar, etc. The moon can now be used for the reflection of messages to communicate with faraway places. By reflecting radar off the planet Venus more accurate information can be determined about interplanetary distances, etc.

As a by-product of all these studies, medicine benefits from improvements in technique and equipment (radioactive isotopes, for example) as well as from increased knowledge about bodily functions and resistances under novel and "unearthly" conditions.

RESEARCH

It is now generally recognized that research is an essential part of medical practice and progress. In most of the special fields of medicine research is a fundamental part of the training. This is especially true of some of the newer specialties such as neurosurgery and psychiatry and the cardiorespiratory divisions. The major specialties of medicine and surgery have insisted upon research training in their programs.

Most of us in this Association are otorhinolaryngologists and I fear we must admit that research has, with a few outstanding exceptions, made its greatest strides in otology.

There is experimentation in progress which is concerned with respiration, with speech, with taste and smell, etc., but it has largely been carried out by physiologists, anatomists and neurophysiologists, and there are all too few rhinolaryngologists involved.

EXPERIMENTAL PROCEDURES ON PATIENTS

In the basic sciences allied to our specialty research is carried out in large part through animal experimentaion. In some cases, however, patients or normal human subjects are the experimental animals. In clinical research, on the other hand, the patient is very frequently directly involved in the experiment though many problems can be solved at least in part by animal experimentation or by study on the cadaver.

Clinical research can take many forms and may be very involved. As Walshe said, it is Nature that sets up the experiment. We must determine what is the stimulus and where it is acting.

There are some special problems which can be solved only by an experiment carried out on the patient with his full knowledge and consent. This is especially true when the patient's conscious co-operation is a necessary part of the experiment.

Medicine is an experimental science—every differential diagnosis implies some degree of experimentation, as do many of our everyday routine treatments. The matter of morality is not a problem for the

doctor whose guiding principle is his patient's well-being. However, we must guard against the temptations and dangers of too big a practice. It can happen almost imperceptibly

a) that we find ourselves not giving each patient the careful and complete examination he requires,

b) that we are having patients back for an extra visit in order to meet the rising overhead,

e) that we are falsifying insurance and other documents for the an assistant (sometimes non-medical) not carefully supervised,

d) that we are thinking of the patient as one of a series, and lose sight of his rights as an individual,

e) that we are falsifying insurance and other documents for the patient's or for our own benefit,

f) that we are recommending operations when the indication is not solely for the good of the patient.

These are some of the immoral practices which are all too widespread and which are contributing to a loss of the physician's former exalted place in the community, and are ammunition for those advocating State Medicine.

We are not considering here the morality of any do or die procedures adopted by the doctor when confronted with terminal illness. We are much concerned with the morality of those experimental procedures carried out on patients for the amelioration or cure of a disease which is not completely incapacitating or lethal though it may be a handicap.

Before considering the many problems which arise in connection with experimentation on patients we might recall a passage from the prayer of Maimonides.

"Inspire in me a love for my art and for Thy creatures. Let no thirst for profit or seeking for renown or admiration take away from my calling. Keep within me strength of body and soul, ever ready, with cheerfulness, to help and succor rich and poor."

And we might add, let us remember that Christ said, "As long as you do it unto one of the least of these My brethren, you do it for Me."

RESULTS OF EXPERIMENTATION ON THE PATIENT

When medical research is carried out on its immediate object, living man, it is to be hoped that the interests of science, of the patient, and those of the community will be served. Under such circumstances one cannot insist that all danger and risk be excluded. The weighing of the dangers and the advantages must be left to the experienced, competent and conscientious doctor.

A doctor must resist the temptation to do an experimental operation on a patient before he has subjected his idea to sufficient animal experimentation, especially if it is partly with a view to speeding up results or in order to get prior credit for a certain technique. This is particularly true when experimentation on animals closely allied to man would give many of the answers, as for instance where impaired parts of the body are replaced or reinforced by plastic implants. The long term behavior of such an implant and its possible effects on adjacent important parts of the body can be determined before a patient is exposed.

ETHICAL RULES OF THE AMERICAN MEDICAL ASSOCIATION

To conform to the requirements of the Americal Medical Association with regard to the carrying out of experimental procedures on a patient, three conditions must be satisfied. These are as follows:

1) The voluntary consent of the patient on whom the experiment is to be performed, must be obtained.

2) The danger of each experiment must be previously investigated by animal experimentation.

3) The experiment must be performed under proper medical protection and management.

THE PATIENT'S CONSENT

The patient's consent is the responsibility of the doctor. First of all it presumes that the doctor has given the patient all the infor-

mation possible to decide whether or not he will consent to the procedure. This means that the doctor must acquaint the patient with both the immediate and long term possible complications and risks and it implies that no pertinent information will be withheld. It also presumes that the patient will be told of other possible procedures and treatments with their relative chances of success and their risks.

The patient is often impatient of infirmity and in his anxiety to be better is over-optimistic. The surgeon must not take undue advantage of this.

The patient or his guardian must be able, by virtue of his circumstances, of his nationality and of education, etc., to comprehend the various possibilities so that he may give an enlightened consent. If he is not, then an added moral responsibility is placed upon the doctor.

The only rights which the doctor has over the patient are those conferred upon him by the patient.

THE DOCTOR-PATIENT RELATIONSHIP

Through the years the profession has won the confidence of the patient. He has been led to assume that his doctor would not propose a treatment which had not been fully tried or one which was not likely to have a reasonable chance of success. As doctors we must be fully conscious of our responsibilities. The golden rule applies—if you would not submit to the operation yourself or have it performed on your child then you are not at liberty to offer it to the least consequential patient.

Guttentag has said, "The physician-patient relationship is the justification of our profession—one human being is in distress, in need crying for help; and another fellow human being is concerned and wants to assist him."

To recommend or perform an experimental operation or treatment on a patient without adequate prior animal experimentation when possible or without full explanation of the risks involved are crimes which jeopardize the proper doctor-patient relationships of the whole profession.

Instead of speeding up results such practices are more likely to impede progress since most advances are based upon many preceding contributions. Great care must be exercised not to be responsible for a half-truth, for a misconception, or for poorly supported statements getting into the literature.

It is a crime for a doctor to betray the implicit trust placed in him by his patient. It is a greater crime than the dishonesty of payola or of the quiz programs with their associated perjury or of the ghost writing of academic theses. It is more akin to armed robbery because even if there is not the intent to kill, there is at least the readiness to maim; and it is even worse because the doctor is exposing to unnecessary risk or damage or destruction the well-being of a friend—a fellow man who has placed his implicit and childlike trust in him.

This responsibility can be shrugged off by saying the patient consented—but did he really know to what he had consented? This is particularly true when the treatment is elective and not a matter of imminent life or death. If the physician forsakes the golden rule his actions are in line with the present day deterioration in public morality. Guttentag warns us that "we must be alert with ourselves lest in our zeal for truth, we create healthy bodies at the cost of 'our own' morally dull minds."

SCIENTIFIC KNOWLEDGE

Christianity is well aware that the acquisition of new truths or the confirmation of accepted truths is a good which must be encouraged. However, we must be on our guard that the methods used are not likely to infringe on the rights of others. The mere fact that a certain method may yield results of scientific value does not establish it as necessarily licit. The personal right of the patient to the life of his body and soul is a value superior to that of scientific knowledge.

At a symposium of the medical staff of the University of California School of Medicine in San Francisco, discussing the problem of experimentation on human beings, Michael B. Shimkin has this to say:

"The complex problems of the use of human subjects in medical research involves many supra-scientific considerations. The application of the guiding principles to specific experimental situations, however, will always be open to individual interpretations and differences. Science per se is neither moral or immoral; it

becomes moral or immoral only as moral or immoral human beings use its powerful techniques."

PATIENTS' RIGHTS

Christian ethics points out that man is not absolute master of his body or of his soul. He has the right of use limited by the natural finality of his human nature. Since he is a user and not a proprietor his right to destroy or to permit the doctor to destroy any part of his body is limited.

According to the principle of totality and by virtue of his right to use the services of his body as a whole, the patient can allow a certain part to be removed if it is interfering with the health of the body generally. On the other hand, a patient cannot consent to an operation when it is reasonably sure that such an operation will deprive him of his higher faculties. The part exists for the good of the whole and may be disposed of under certain circumstances. Before applying the principle of totality it must be established that the object is in the relation of a whole to its parts. For example, is it on the level of essence or merely on that of action? Does it apply to the part in all its relations? Does it absorb the part completely or does the part have a limited independence? For example, a hand removed has by its own nature no finality or independence.

O'Donnell discusses the difference between absolute ownership over himself, which the individual does not possess, rather than wise administration which is licit. He points out that wise administration does not permit an individual to submit to a dangerous experiment. The objective probability of incurring some evil—if it would be judged to be a considerable risk by a group of ordinary individuals, if they have been placed in possession of the facts, would take the experimental act out of the realm of wise administration and place it in the category of ownership.

The State recognizes these limitations of an individual's rights over himself and considers it a crime for him to take his own life.

THE COMMON GOOD

We must beware of the fact that the community only exists for man. It is not a physical unity existing in itself and its members are

merely collaborating for the common good. Man, on the other hand, has a unity subsisting in himself—any one part of his body cannot subsist by itself.

Government can make demands upon a citizen but it may not interfere with his physical being. Pius XII explains that

> "When there is a question of the execution of a condemned man, the State does not dispose of the individual's right to life. In this case it is reserved to the public power to deprive the condemned person of the enjoyment of life in expiation of his crime when by his crime he has already disposed himself of his right to live."

The Nuremberg trials brought out many instances where the State transgressed on the above principles and shocked the civilized world by handing over its citizens as research subjects in the name of the common good and the advancement of science.

At the symposium of the California School of Medicine, San Francisco, already referred to, the broad problem of experimentation on human beings was discussed in some of its various aspects and was reported in *Science*. Great stress was laid upon the dignity of the individual and on the fact that he has inalienable rights that supersede any consideration of science or general public welfare. Before any experiment could be carried out on a patient they also endorsed the three provisos of the American Medical Association already listed plus the two following:

a) the sound hope of fruitful results but with due proportion between this and the risks involved,

b) avoidance of any experiment when there is *a priori* reason to believe that death or a disabling injury will occur.

SUMMARY AND CONCLUSIONS

I am sure that we are all agreed that the promotion of research is a fundamental function of our Association—the Association has funds set up for the encouragement of research.

Our annual scientific program should be designed to encourage research in its membership in addition to maintaining a high level of clinical performance.

Research training and productivity should be factors in the selection of new Fellows.

Our educational approach to research and experiment should tend to develop conceptual thinking in the student doctor and must also develop and expand his sense of moral responsibility in order that he may respect the rights of each individual patient.

As physicians we might ask ourselves:

1) Has the treatment which is proposed actually been subjected to sufficient and prolonged animal tests to know, not only its immediate effects but its probable long term results.

2) Is the condition from which the patient is suffering serious enough to justify the risk of total or partial destruction of the part under consideration.

3) Is there no other possible and less dangerous procedure with a prognosis nearly as good.

4) Has the patient been given a true picture of the possible dangers to which his consent exposes him.

5) Has the patient really understood the dangers involved.

6) Am I, the doctor, before God, prepared to assume the responsibility for the result as though I were the guardian of a minor patient and as though that patient were my own child?

The doctor must take great care to do nothing which will undermine the traditional role of the physician as the helper and friend of each individual sick man. He must retain the utmost concern for the welfare of the individual patient and must avoid the danger of thinking of the patient as only one in a long series in which he is getting a certain percentage of good results.

The doctor has only those rights which are conferred upon him through the enlightened consent of the patient or his guardian.

The patient may not confer unlimited rights which he does not possess—he does not have the absolute ownership of his body but only the right of use.

I should like to conclude with the following quotation from Pius XII:

"The great moral demands force the impetuous flow of human thought and will to flow, like water from the mountains, into certain channels. They contain the flow to increase its efficiency and usefulness. They dam it so that it does not overflow and cause ravages that can never be compensated for by the special good it seeks. In appearance moral demands are a brake. In fact they contribute to the best and most beautiful of what man has produced, for science, the individual, and the community.

May God Almighty in His benevolent providence give us His Blessing and grace to this end."

1509 Sherbrooke St. W.

REFERENCES

1. Guttentag, Otto E.: The Problem of Experimentation on Human Beings—the Physician's Point of View. Science 117:207-210 (Feb. 1953.

2. Ivy, A. C.: A Report of U.S. Government Representatives to a Review of War Crimes of a Medical Nature Committed by Germany. The American Medical Association Supplementary Report of the Judicial Committee, House of Delegates. J.A.M.A. 132:1090 (Dec. 28) 1946.

3. McNally, W. J.: Some Thoughts about Research in the Training of the Doctor—Address Guest of Honor. Trans. Amer. Acad. of Ophthal. and Otolaryn. pp. 803-808 (Nov.-Dec.) 1954.

4. O'Donnell, T. J.: Morals in Medicine. Newman Press, Westminster, Md. pp. 116-117, 1959.

5. Pope Pius XII: The Moral Limits of Medical Research and Treatment. Catholic Mind 51:1085:305-315 (May) 1953.

6. Shimkin, Michael B.: The Problem of Experimentation on Human Beings—the Research Worker's Point of View. Science 117:205-207 (Feb.) 1953.

7. Walsh, Sir Francis: On the Contribution of Clinical Study on the Physiology of the Cerebral Motor Cortex—the Victor Horsley Memorial Lecture. Edinburgh, E. & S. Livingstone, Ltd., 1947.

PHYSIOLOGY OF OLFACTION AND GUSTATION

LLOYD M. BEIDLER

TALLAHASSEE, FLA.

The chemoreceptors are among the first of the major sensory receptors to develop in the evolutionary sequence. In lower animal forms, they are intimately related to the major tasks of the animal such as mating, food searching, food selection and self preservation. It was shown by Richter[6] many years ago that lower mammals such as rats can select foods to maintain a balanced diet. Furthermore, if a salt or vitamin deficiency is present in the animal, the preference threshold to the needed substance will decrease and the animal will increase its uptake of the necessary food to overcome the deficiency. For example, an adrenalectomized rat shows preference for salt at very low concentrations and governs his diet accordingly.

Modern man lives in a world with a large variety of foods, so that self selection of food for bodily protection is seldom necessary. The ability to use chemoreceptors for this purpose when necessary, however, is shown by the fact that diet selection is sometimes made during certain diseases. Men living under primitive conditions also have highly developed senses of taste and odor.

GUSTATION

The function of the taste and olfactory receptors is to monitor the food intake and the air breathed. Receptors for the olfactory, visual and auditory senses are well protected, but those of the gustatory must be readily accessible to test food taken into the mouth. For this reason, other protective mechanisms have been developed for the sense of taste. For example, if the taste nerve is injured, the

This research was supported in part by grants from the National Institute of Health and the Office of Naval Research.

taste buds degenerate but reappear once again when the regenerated nerve arrives at the surface of the tongue. There is no similar receptor regeneration known for other major sense organs. Taste cell precursers continually undergo mitotic division so that each cell within the taste bud may be replaced. Another protective mechanism is afforded by the fact that several different nerves carry gustatory information. The chorda tympani nerves innervate the taste buds of anterior two-thirds of the tongue, whereas the glossopharyngeals innervate those of the posterior third of the tongue. Dual innervation protects taste function after injury to any one nerve bundle.

The anatomy of the taste receptors will not be considered here. There are three ways to study the function of taste receptors. First, taste sensations of humans may be analyzed by psychophysical methods. Second, the behavior of animals may be studied in the presence of various chemical stimuli. Third, electrical activity of the nervous system of experimental animals may be studied in response to chemical stimuli presented to the tongue of anesthetized animals. It may be mentioned that the latter method might also be applied to humans by recording from the chorda tympani nerve in the middle ear while various solutions are flowed over the surface of the tongue. The results of electrophysiological investigations of taste will be stressed in this paper.

METHOD

The animal is anesthetized with urethane or nembutal and the chorda tympani dissected free from surrounding tissue. The peripheral end of the nerve bundle is lifted on to a metal electrode. Another indifferent electrode is placed near the nerve. A flow chamber is placed over the tongue so that solutions can be continually flowed over the same area (Fig. 1).

RESULTS

Little neural activity is recorded from a rat when water is used as a stimulus. If sodium chloride, for example, is flowed over the surface of the tongue, a response is observed within 100 msec. Diffusion contributes little to this latency; accordingly most of the delay in response is due to processes in the taste cell itself. The response to sodium chloride approaches a steady state value within a few

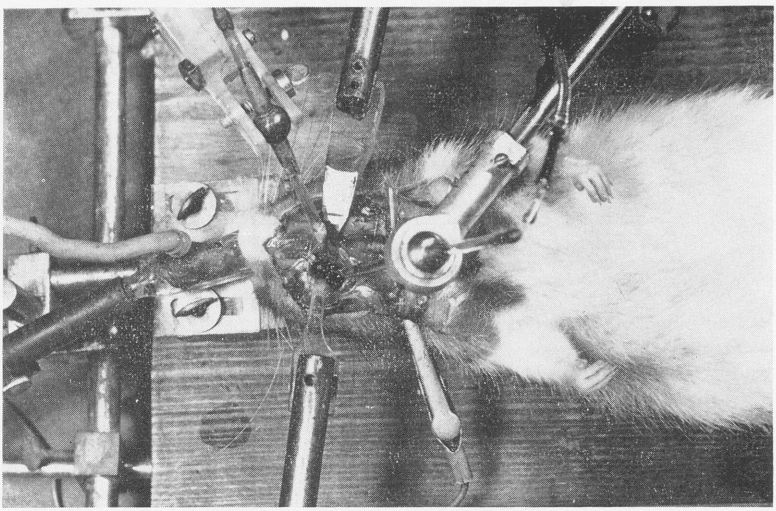

Fig. 1.—Ventral view of rat taste preparation. Notice the flow chamber with the tongue inserted. Two movable electrodes record the neural activity from the dissected taste nerve. This type of preparation may function for 30 hours with taste solutions applied to the tongue once a minute. (Photo by I. Y. Fishman)

seconds and maintains this magnitude for the duration of the stimulus. Thus, little adaptation occurs at the level of the taste receptors after the first few seconds. Since it is well known that the behavioral response of man to a similar stimulus rapidly adapts, this adaptation may be attributed to central and not peripheral neural processes. The stimulating efficiencies of a group of substances may be compared by using equimolar solutions, that is, solutions having the same number of molecules per unit volume of solvent. In such an experiment, the rat responds very well to sodium chloride and rather poorly to potassium chloride. However, other species of animals, such as carnivores, may respond well to potassium chloride and poorly to sodium chloride (Table I). The response of different animals also varies considerably with sweet substances. For example, the guinea pig and hamster respond very well to sucrose whereas the cat responds very poorly and the rat produces a moderate response.[5] This is a positive proof that there is considerable variation in the response to taste stimuli from one species of animal to another.

TABLE I

	RELATIVE TASTE RESPONSE $\frac{NA}{K}$
Carnivores	
Raccoon	0.75
Cat	0.67
Dog	0.43
Average	0.62
Rodents	
Rat	2.0
Hamster	2.8
Guinea Pig	2.6
Average	2.5

In order to study the mechanism of taste stimulation, it is useful to know the magnitude of response to a series of solutions of different concentrations of the same chemical. This may easily be found by recording the neural activity to a given concentration of stimulus, summating electronically and displaying the result on a Sanborn recorder. With this procedure, the height of the response is directly proportional to the magnitude of neural activity. The magnitude of response increases with concentration until a level of saturation is reached as shown in Figure 2.

What is the mechanism by which the chemical stimulates a taste receptor? One may assume that the atom or molecule simply is adsorbed to the surface of the taste cell, probably to the taste 'hairs'.[2] This reaction can be written as $A + B = AB$. One may assign the value N to the total number of sites to which the particular chemical can be adsorbed on the surface of the taste cells. The number of these sites filled at any concentration, C, of stimulus can be assigned the value Z. From elementary chemistry, the equilibrium constant K of this reaction is the concentration on the right hand side divided by

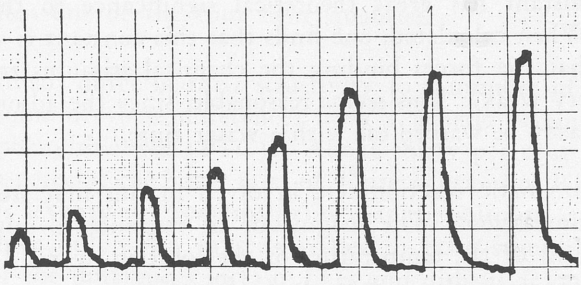

Fig. 2.—Summated electrical response of chorda tympani nerve of rat to NaCl solutions flowed over the surface of the tongue. Concentrations are 0.005M, 0.01M, 0.025M, 0.05M, 0.10M, 0.25M, 0.50M, 1.0M. Test solutions of 7 to 10 seconds duration of applications are interspaced with water rinses. One large division equals 20 seconds.

the product of the concentrations on the left hand side of the equation, or

$$K = \frac{Z}{C(N\text{-}Z)}$$

where C is the concentration of the stimulus, A, and (N-Z) the number of unfilled sites. It is impossible for us to know the numerical value for the number of sites available or the number of sites filled. However, if the magnitude of response is directly proportional to the number of sites filled ($R = aZ$), and if the maximum response obtained at high concentration of stimulus occurs when all sites are filled ($Rs = aN$), then the above equation becomes

$$\frac{C}{R} = \frac{C}{Rs} + \frac{1}{KRs}$$

where R is the magnitude of response to taste stimulus of concentration C and Rs is the maximum response available at high stimulus concentrations. This has been called the fundamental taste equation which relates the magnitude of response to the concentration of the stimulus. The only unknown in this equation is the equilibrium constant, K, which can easily be found if the magnitude of response to

two different concentrations of the stimulus is measured. The equilibrium constant has great theoretical significance to the physical chemist. When calculated, one finds that this constant is very small, meaning that the forces binding the chemical stimulus to the taste cells are very weak. This seems reasonable, since the adsorbed molecules can easily be washed off with a water rinse.

No enzymatic reactions are involved in this first step of taste receptor stimulation. The magnitude of response to salt solutions is independent of the temperature of the solution over a 15°C range and the response is also independent of hydrogen ion concentration from pH3 to pH11. After the molecules are adsorbed to the surface, the taste cell depolarizes. That is, most cells at rest have a difference of electrical charge between their interiors and exteriors. This difference in charge changes when a sensory cell is stimulated. Such is also the case for the taste cell as measured with microelectrodes inserted into single taste cells. These changes are the order of magnitude of 5-30 millivolts and initiate the nerve action potentials.

It is commonly believed that there are four fundamental taste qualities; salty, sour, bitter and sweet, from which all other tastes can be derived.[1] This certainly is an oversimplification of the sense of taste, but the generalization can be considered accurate when studying some of the simpler functions of taste. The evidence for four taste qualities comes from several sources. First, not all areas of the tongue respond to a given substance in the same manner. For example, the sweet tastes are better perceived near the tip of the tongue, whereas the bitter are better perceived near the posterior of the tongue. Second, many complex tastes may be duplicated by the proper mixing of various quantities of substances representing the four taste qualities. Third, certain drugs, such as the juice from Gymnema leaves, applied to the surface of the tongue, decrease the intensity of one taste quality without affecting the other three. Fourth, the neural activity from single taste nerve fibers may be recorded in response to various chemical stimuli. These fibers have been grouped according to their ability to respond to one or more of the four taste qualities.[5] Thus some fibers respond only to acids, others only to acids and salts, others to acids, salts, and sugars, etc. Does a single taste cell respond to but one of the four taste qualities or more than one? In order to answer this, microelectrodes were placed in the single taste cells and the electrical response measured to

various stimuli. It is concluded that most taste cells may respond to more than one of the four taste qualities.

Individuals differ in their sensitivity to a number of taste substances. Some of these differences have a genetic origin, as is the case with phenylthiourea (PTC). About thirty per cent of Americans do not perceive the bitter taste of dilute solutions of PTC, whereas the other seventy per cent maintain that the solution is extremely bitter. These differences in sensitivities to taste stimuli may well account for the differences in taste likes and dislikes among individuals of a population. There is also evidence that these likes and dislikes may change with certain diseases or changes in the internal environment of the body. Changes with pregnancy are well known, as are changes in sweet sensitivity in diabetics, certain bitter sensitivities in hyperthyroids, and increased salt sensitivity in people with adrenal deficiency.

Taste is quite dependent upon the chemical structure of the stimulating substance. For example, orthotolylurea is tasteless, whereas metatolylurea is bitter, and paratolylurea is sweet. Stereoisomers may also have different tastes. These observations suggest that the reaction of the taste substance to the cell surface is dependent upon the configuration and orientation of all the molecules involved.

OLFACTION

The olfactory sense differs greatly from that of the gustatory. Man can differentiate thousands of different odors at concentrations as much as a million times more dilute than those normally used in gustation. The olfactory receptors also differ greatly from the taste receptors. The former are bipolar neurons and not differentiated epithelia cells. The dendritic processes of these neurons may be stimulated by odors carried to the receptive area in a gaseous stream. There are about 100,000,000 of these receptors in the rabbit in contrast to less than about 5000 taste receptors in the same animal. The functional significance of this large number of receptors is not known, but it may be related to odor quality discrimination. The details of the receptor morphology will be discussed by Dr. DeLorenzo in the following paper, and will not be further considered at the present time.



Fig. 3.—Rabbit olfactory preparation. Nerve recording equipment and breathing chamber are shown.

METHOD

The small size of the olfactory nerve fibers (0.2 micron diameter) makes electrical recording from them very difficult. However, it is possible to dissect out a small twig of an olfactory nerve bundle as it passes through the cribriform plate and record from it in the anesthetized rabbit. A small branch of the ethmoidal nerve containing trigeminal sensory fibers can also be placed upon recording electrodes. The nose of the rabbit is placed into a flow chamber (Fig. 3) and an odor of a given concentration is flowed by the nares. The electrical activity is displayed on an oscilloscope or summated and displayed on a Sanborn recorder.

RESULTS

When purified air is presented to the animal, a small amount of spontaneous activity is recorded from the olfactory nerve fibers. During the inspiration of an odor, a large amount of neural activity appears but declines during each expiration (Fig. 4). The magnitude

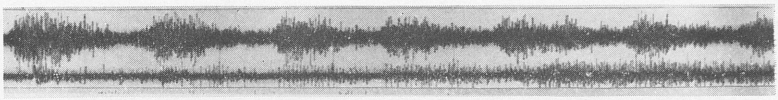

Fig. 4.—Olfactory (upper trace) and trigeminal (lower trace) nerve activity in response to 31 μM amyl acetate inspired once per second by rabbit.

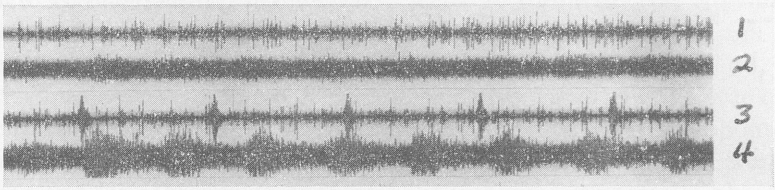

Fig. 5.—Response of rabbit olfactory nerve to orange odor before (Trace 2) and after (Trace 4) 30/min electrical stimulation of cervical sympathetic nerve. Traces 1 and 3 show ethmoidal nerve activity before and after electrical stimulation.

of this electrical neural activity during each inspiration increases with the concentration of the stimulus until a level of saturation is obtained (Beidler, 1958). The threshold of a rabbit to an odor such as amyl acetate is of the same order of magnitude as that observed psychophysically in man. Different odors of equal concentration initiate different magnitudes of neural response. At the present time it is not possible to record from a single olfactory nerve fiber and therefore we have little information concerning the ability of a single receptor to respond to different types of odors.

The magnitudes of the neural responses to successive inspirations of a low concentration of odor remain constant. At high concentrations of odor the neural magnitude declines with successive inspirations. Adaptation to some odors is complete such that no neural activity is recorded after several seconds of stimulation. Other adaptive processes occur in the olfactory bulb even at low odor concentrations so that the olfactory response quickly adapts after it is presented to an observer.

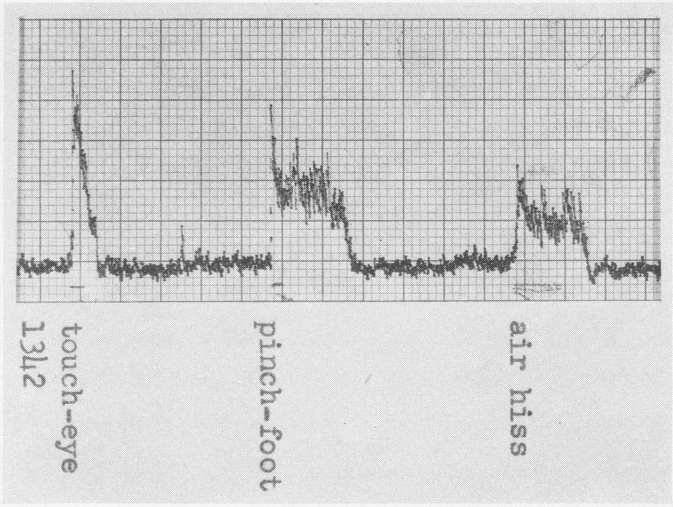

Fig. 6.—Summated electrical activity of ethmoidal nerve in response to stimulation of eye, foot and ear with appropriate stimuli. One large unit on the time scale equals 20 seconds.

Well controlled experiments with animals under normal breathing conditions are difficult to obtain, since the odor stimulus initiates reflexes which result in a change of rate and depth of inspiration. These in turn change the intensity of response. To overcome this obstacle, the trachea of the animal may be cannulated and the odor drawn through the nares by a syringe attached to the trachea. In such experiments adaptation occurs rapidly and may go to completion at high concentrations. If the magnitude of odor stimulus is abruptly increased, the neural activity will also immediately increase, but will decline within two seconds to a new steady state level. Conversely, if the odor concentration is suddenly decreased, the neural response immediately decreases and then rises slightly to a new steady level lower than the initial level.

The response of the olfactory receptors is also dependent upon the rate of flow of the odor through the nares. If the trachea is cannulated, the response to a low odor concentration passed through the nares will increase with the flow rate until it attains a value of 1-4

liters/minute. If a small polyethylene cannula is inserted into the nares and pushed up to the olfactory area so that the odor flows immediately over the epithelium, a maximum response to an odor is obtained when the flow rate is about 2 cc/second.

The trigeminal nerve innervates the olfactory region as well as many other areas of the nose. It is commonly thought that these bare nerve endings are excited only by very noxious stimuli such as ammonia. In order to determine whether this is true, electrical activities of the trigeminal nerve and the olfactory nerve are recorded simultaneously in response to various types of odor stimuli. Mild odors such as phenylethyl alcohol may actually stimulate the trigeminal nerves at lower concentration than the olfactory, even though the smell of the odor to man is not obnoxious. On the other hand, the odor of amyl acetate may excite the olfactory receptors at lower concentration than that of the trigeminal. The trigeminal response is more sluggish, so that the response slowly builds up to a maximum level and tends to remain at this level from one inspiration to the next without an appreciable decrease during such expiration (Fig. 4). One might conclude that the trigeminal nerve serves as an yet unknown function at low as well as high odor concentrations.

Since the magnitude of odor response is proportional to flow rate, it is not surprising that the response changes with nasal vasoconstriction. Upon electrical stimulation of the sympathetic nerve in the neck of the animal, the air passages of the rabbit increase in diameter. This results in an increase in the flow rate of the odor to the olfactory area and thus an increase in the magnitude of response of the olfactory receptors (Fig. 5). It is not known whether all this increase in sensitivity is due to the increased flow rate alone, or whether the sympathetic activity has a more direct effect on the response of the receptors, similar to that observed in other sensory systems. Sympathetic activity is supplied to the olfactory area by way of the ethmoidal nerve. The electrical activity recorded from this nerve greatly increases when the anesthetized animal's toe is pinched, a light is shown on the eye, or a noise made (Fig. 6). Concurrent with this is an increase in olfactory sensitivity to odors. In fact, a moderate concentration of odor may initiate an increase in sympathetic activity to the olfactory region, which in turn results in greater sensitivity of the olfactory receptors. Such reflexes are of great use to an animal since the olfactory sensitivity would be enhanced during times of stress,

such as when a strange sound is heard or an enemy observed. Little is known concerning the basic mechanisms involved in olfactory receptor stimulation. As better methods are developed to record from the olfactory receptors, a greater understanding of the olfactory processes will be obtained.

FLORIDA STATE UNIVERSITY

Much of the olfactory data was supplied by my co-worker, Don Tucker.

REFERENCES

1. Beidler, L. M.: Our Taste Receptors. Scientific Monthly 75:6:343-349 (Dec.) 1952.

2. Beidler, L. M.: A Theory of Taste Stimulation. Journal of General Physiology 38:2:133-139 (Nov. 20) 1954.

3. Beidler, L. M., Fishman, I. Y., and Hardiman, C. W.: Species Differences in Taste Receptors. Amer. Jour. of Physiol. 181:2:235-239 (May) 1955.

4. Beidler, L. M.: The Physiological Basis of Flavor. Flavor Research and Food Acceptance. Arthur D. Little, Inc., Reinhold Pub. Corp., N. Y., pp. 3-28, 1958.

5. Pfaffmann, C.: The Sense of Taste. Handbook of Physiology. John Field, ed. Amer. Physiol. Soc., Washington, D.C., pp. 507-533.

6. Richter, C. P.: Self-Regulatory Functions. Harvey Lecture, Ser. 38, 63-103, 1942.

DISCUSSION

DR. ARTHUR W. PROETZ: I should like to ask Dr. Beidler if he would say a word about the nature of what he terms "adaptation" and what I used to call "fractional fatigue," namely loss of sensitivity to a specific odor after protracted exposure to it without impairment to other, even related, odors; take for example the perception of tobacco odor in a smoke-filled room which soon diminishes while perception of some new odor remains keen.

Is this due to an obtunding of individual receptors among the multimillions or is it a rejection by the higher centers? Of course, giving the phenomenon a name as we both have done, doesn't quite dispose of it and perhaps a more intimate knowledge of it would throw some light on the nature of the olfactory process.

DR. L. M. BEIDLER (closing): I would like to say that adaptation is usually defined as the declining response under constant stimulation. In the case of the eye of course most of it is in the sense organ. In olfaction under constant stimulation, if you record directly from the receptor, you see no adaptation at low concentration of any odor. When studied at high concentration, you can get adaptation that is complete. If you take the same odor, in the same concentration and study the olfactory bulb, you find that adaptation does occur and at low concentrations. So we have adaptation in two places, one at the receptor at high concentrations and one at all concentrations in the olfacory bulb. I would say that adaptation is a property of all neural systems except possibly the peripheral nerve fiber itself.

ELECTRON MICROSCOPY OF THE OLFACTORY AND GUSTATORY PATHWAYS

A. J. DE LORENZO, M.D.

BALTIMORE, MD.

The olfactory epithelium and taste buds of mammals are quite simple in appearance when they are fixed and stained with the conventional methods and examined in the light microscope. These tissues consist, essentially, of a specialized receptor cell (the olfactory or the gustatory cell) supported by a second kind of cell, the sustentacular cell. In spite of the fact that the literature is filled with early descriptions of the chemo-receptors of smell and taste, dating from the middle of the 19th century, the present day cytologist has not paid a great deal of attention to these most interesting receptor cells. Some of the general points of interest concerning these tissues require enumeration. First, the olfactory receptors in spite of their rather simple organization and single type of receptor element are capable of rather remarkable fine sensory discriminations. Electrophysiological investigations have led several investigators to suggest that discrimination depends upon the existence of different types of olfactory receptors and that these different types of receptors have selected sensitivities to specific basic odors. Moreover, Ottoson[12] recently suggested that fine differentiation seems to depend upon specific sensitivity of individual receptors to particular molecular configurations. These observations pose the question whether olfactory receptors exhibit morphological differences that correspond to these functional responses. Likewise, the gustatory receptors are most interesting. The taste buds were described by Schwalbe[13] and Heidenhain[11] in the 19th century but despite these early descriptions a great deal of controversy still exists concerning the cytology of the taste buds, the number of cell types

---

From the Department of Otolaryngology and the Department of Anatomy, Johns Hopkins University, School of Medicine, Baltimore 5, Maryland.

Supported in part by Grants B-2173 and B-2182 from the United States Public Health Service, National Institutes of Health and the Alfred P. Sloan Foundation.

and the structure of the taste pore.[5] In addition, the functional studies of Pfaffman[10] and Beidler[1] suggest a high order of discrimination in the gustatory receptors as well. Of particular interest to the morphologist is the fact that the taste buds undergo degeneration following interruption of their nerve supplies, and suturing the sectioned gustatory nerves results in taste bud regeneration.[5] Thus, this pathway offers a unique area in which to study both the mechanism of the taste bud excitation or chemo-reception and basic problems of nerve degeneration and regeneration.

ELECTRON MICROSCOPY

The Olfactory System. Figure 1 is an electron-micrograph of the apical tip of the olfactory epithelium obtained from young rabbits 2 months of age. Adult rabbits have chronic rhinitis so young rabbits were employed in this study. The pale process labeled (OR) is the olfactory receptor extending beyond the limiting apical boundary of the olfactory epithelium. Seen extending from its apical portions are numerous cilia arranged in a sepal-like fashion. These cilia are identical in fine structure to cilia seen in other tissues. The olfactory receptor is bounded on all sides by darker, denser cells, the sustentacular cells. Only the very tip of the receptor is thus unsheathed and constitutes a bare receptor. In contrast to the light olfactory receptor, the sustentacular cells are characterized by very dense cytoplasm, containing numerous constituents of the endoplasmic reticulum and ribonucleic acid granules. The apical tip of the sustentacular cell is characterized by extensive arrangement of microvilli which project apically and interspersed between the numerous microvilli are cilia deriving from other adjacent olfactory receptors. Careful examination of serial sections of the olfactory receptors demonstrate that the cilia are approximately 0.3 to 3.0 microns in length. Since the sections that were examined routinely were on the order of 300 Angstroms in thickness, the probability of sectioning any particular cilium longitudinally, along its entire course, was highly improbable. Therefore, this information was only available from serial sections. Likewise, measurements of the length of the micro-villi, utilizing the same technique, show the micro-villi to be approximately 0.6 to 1.0 microns in length.

The central processes of the olfactory receptor cells are the unmyelinated axons which comprise the fila olfactoria. These axons

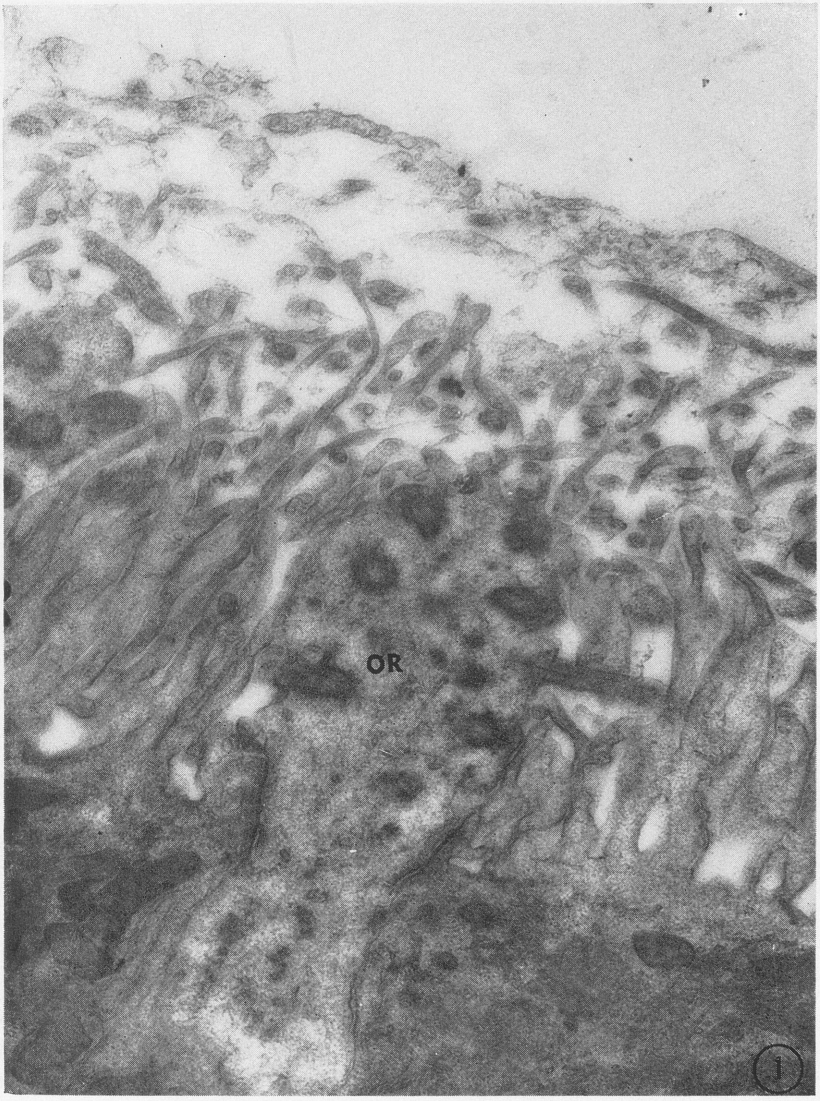

Figure 1

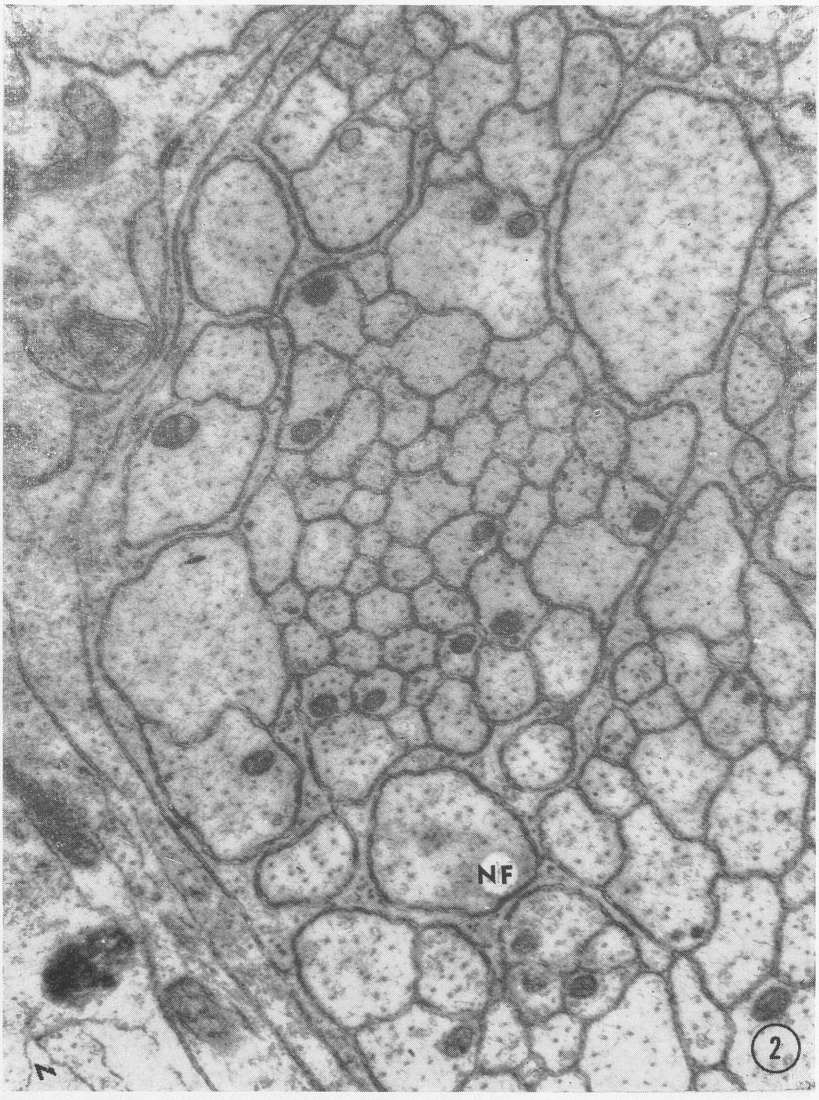

Figure 2

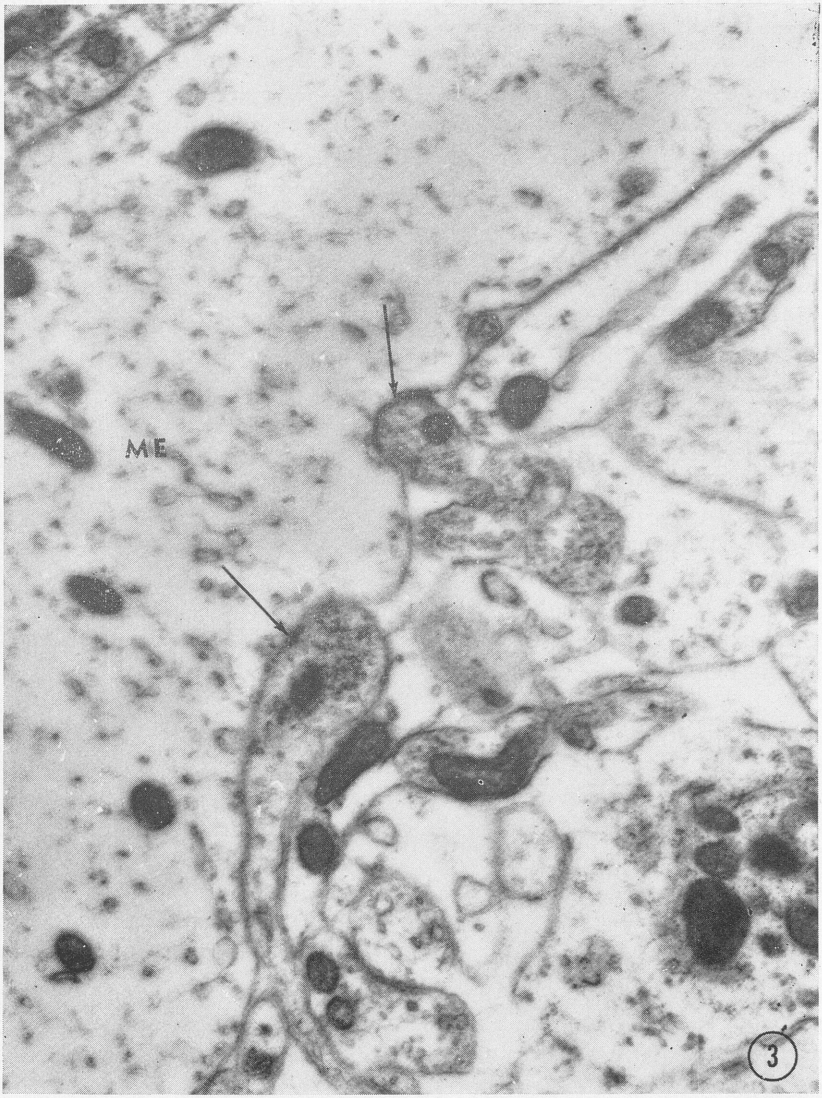

Figure 3

penetrate the basement membrane of the epithelium, pass through the cribrifrom plate of the ethmoid bone. They then group with others, enter the olfactory bulb and synapse in the olfactory glomerulus. As can be seen from Figure 2, the olfactory nerve fibers (NF) are extremely small in diameter. The mean diameter of these fibers is about 0.2 micron. Many of these fibers have diameters less than 0.1 micron; thus, in the light microscope these fibers would not be detected. The fine structural organization of the fila olfactoria has been more fully described elsewhere.[3,4] Figure 3 demonstrates the termination of these unmyelinated nerve fibers upon reaching the olfactory bulb. In Figure 3, to the left can be seen a large mitral cell dendrite labeled (ME). At the regions designated by the arrows, small terminal processes of the fila olfactoria are seen pushing into the dendrite in a fashion typical of synapses seen elsewhere in the nervous system.[6-9] These pre-synaptic fibers contain mitochondria and numerous synaptic vesicles. Examination of the olfactory mucus membrane throughout its extent in the rabbit has demonstrated a consistent fine structure pattern in all the olfactory receptors. Thus, in spite of their physiological heterogeniety, olfactory receptors are all identical in fine structure. Their central processes on the other hand are rather unique in that the majority of fibers are submicroscopic. The terminations of these axons in the olfactory bulb are much like synapses seen elsewhere in the nervous system.[8]

The Taste Buds. As mentioned above, since the early descriptions of the cytology of the taste buds, little attention has been paid to these most interesting structures. Much controversy still exists concerning the number of cell types and the structure of the taste pore. These problems lend themselves particularly well to an examination with the electron microscope. Figure 4 is an electron micrograph taken through the center of a taste bud of the papilla foliata of the rabbit. This figure typifies the numerous cytological differences in gustatory cells seen in any such section. Indeed, the cytological evidence suggests that many types of cells are present. Some cells, such as those labeled (A) demonstrate definite cytological characteristics of degeneration, while other cells labeled (B) are normal appearing cells containing the normal complement of cytoplasmic organelles. In view of Beider's recent observations with colchicine[2] suggesting a very rapid turnover rate in the gustatory cells, these observations are not inconsistent with physiological data. In Figure 4 one can see small pale processes containing mitochondria designated (N). These

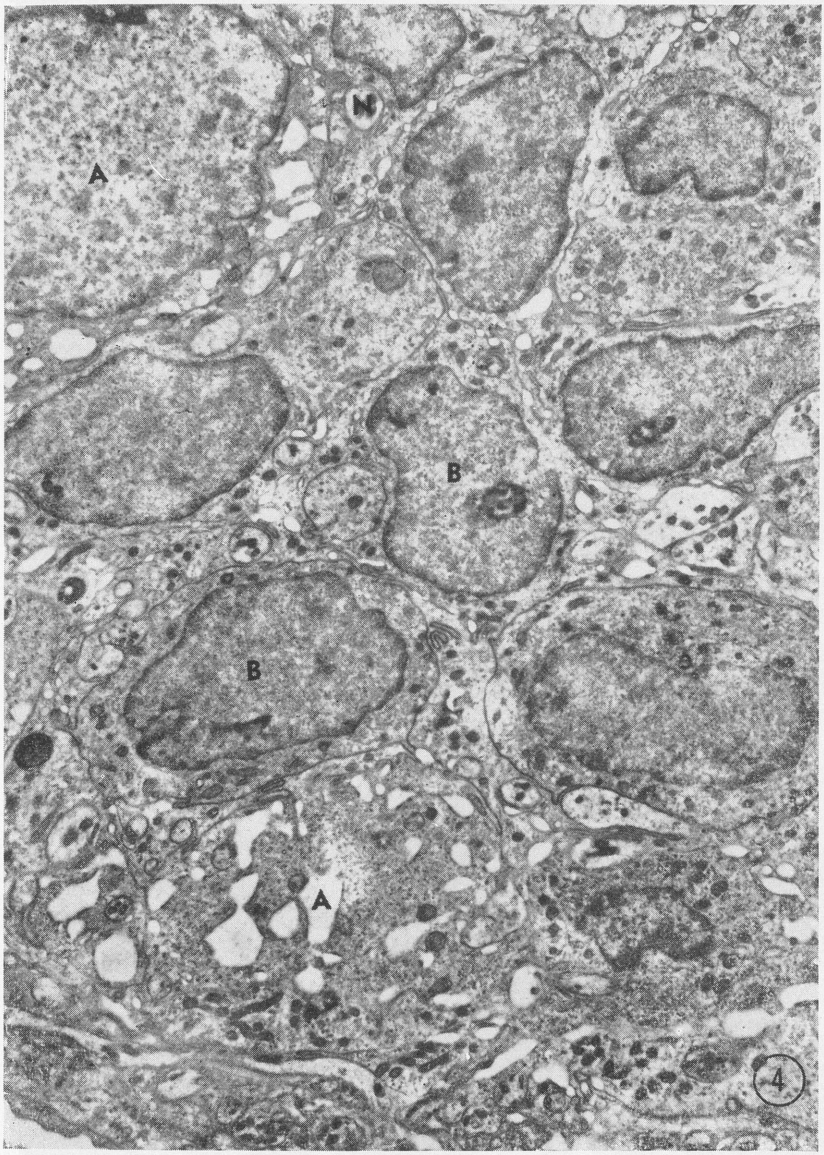

Figure 4

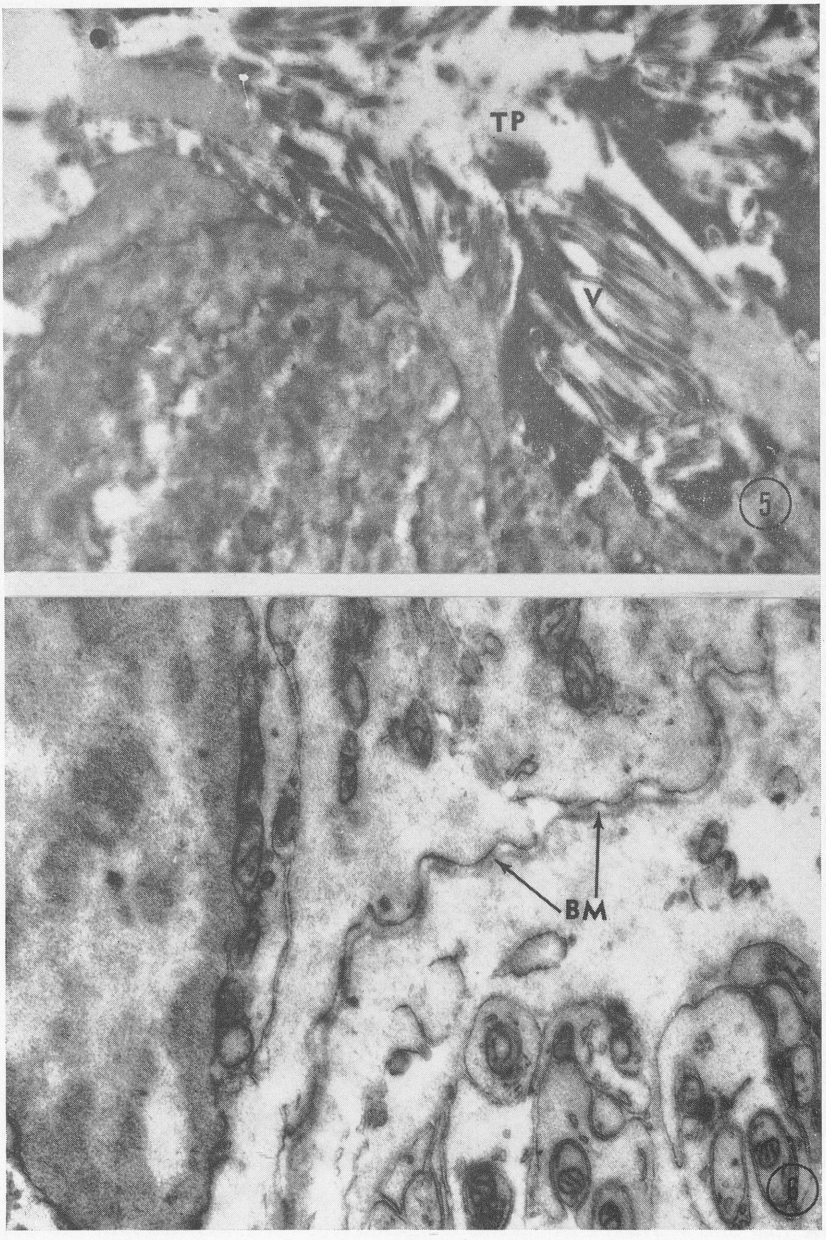

Figure 5

are the nerve fibers constituting the first order nerve cells which terminate upon the sensory receptor cell.

Of special interest is Figure 5, which is a section through the taste pore of a taste bud. To the left can be seen the non-gustatory epithelium and to the right the area of a taste pore labeled (TP). From the lower right to the upper left are located several gustatory cells. Extending from the apical tips of these cells are micro-villi (V) reminiscent of those seen in the sustentacular cell in the olfactory mucosa. Note that these processes are not hairs in any form, although gustatory hairs are traditionally described in the text books. Instead, the micro-villi are minute apical extensions of the plasma membrane of the gustatory receptor cells. Interspersed between the micro-villi is a dense osmiophilic material of unknown origin and may correspond to the "mucoid substance" of Ranvier. It is usually located between the cells as well as in the cells. Whether or not it plays a role in chemo-reception is not known. Likewise, note that there are no cilia protruding from the taste cells in contrast to the olfactory receptor cell. Finally Figure 6 demonstrates the basal portions of a taste bud. A basement membrane, (BM), designated by the arrow, separates the taste bud upper left from a nerve plexes at the lower right. The individual unmyelinated nerve fibers in the plexes constitute fibers of the glossopharyngeal nerve which will ultimately pierce the basement membrane and synapse upon the gustatory cells in the taste bud.

COMMENT

Examination of the olfactory mucosa and the papillae foliate of the rabbit with the electron microscope has made possible several interesting observations. First, in spite of the vast amount of physiological data suggesting a unique discrimination down to the molecular level in the olfactory receptor, no fine structural differences were seen in the olfactory mucus membrane of the rabbit. Secondly, examination of the taste bud of the rabbit has demonstrated a variety of cell types within the taste bud. Many of the cells appear to be undergoing degeneration and adjacent neighboring cells appear to be normal.

The gustatory cell shows, at its apical tip, an interesting structural modification, the terminal micro-villi. Cells of this type participate actively in the mechanism of pinocytosis.[5] It can be inferred,

therefore, that these cells have extremely active cell surfaces which may participate in providing extra cellular constituents with access to the intracellular environment of the cell.

Finally, it is interesting to speculate about the interactions between nerve fibers innervating the taste buds and the gustatory cell turnover rate. Since the life of an individual receptor cell seems rather brief (see Beidler, this journal), a nerve fiber must therefore reinnervate a new receptor cell upon the death of its former companion. This suggests that the nerves are at a constant state of migration and that the role of designating specificity of function is to a large extent determined by the axon to cell contiguity established at any particular time. This is a new and interesting concept; however, more evidence must be forthcoming before it can be accepted or rejected.

JOHNS HOPKINS HOSPITAL

REFERENCES

1. Beidler, L. M.: Species Differences in Taste Responses. Amer. J. Physiol. 181:235, 1955.

2. Beidler, L. M.: (this journal) 1960.

3. de Lorenzo, A. J.: Electron Microscope Observations of Degeneration in the Olfactory Epithelium of the Rabbit. Anat. Rec. 127:289, 1957.

4. de Lorenzo, A. J.: Electron Microscope Observations of the Olfactory Mucosa and Olfactory Nerve. J. Biophysic. and Biochem. Cytol. 3:839-850, 1957.

5. de Lorenzo, A. J.: Electron Microscope Observations on the Taste Buds of the Rabbit. J. Biophysic. and Biochem. Cytol. 4:143, 1958.

6. de Lorenzo, A. J.: The Fine Structure of Synapses in the Ciliary Ganglion and Nucleus Tangentialis of the Chick. Anat. Rec. 133:268, 1959.

7. de Lorenzo, A. J.: The Fine Structure of Synapses. Biol. Bulletin 117:390, 1959.

8. de Lorenzo, A. J.: Neural Mechanisms of the Auditory and Vestibular Systems, Chap. 4, Charles Thomas, Publisher, 1960.

9. de Lorenzo, A. J.: The Fine Structure of Synapses in the Ciliary Ganglion of the Chick. J. Biophysic. and Biochem. Cytol. 7:38, 1960.

10. Pfaffman, C.: Gustatory Afferent Impulses. J. Cell. Comp. Physiol. 17:243, 1941.

11. Heidenhain, M.: Über die Sinnesfelder und die Geschmacksknopsen der Papilla foliata des Kaninchens. Arch. mikr. Anat. 85:365, 1914.

12. Ottoson, E.: Analysis of the Electrical Activity of the Olfactory Epithelium. Acta Physiol. Scond. 35:Suppl.:122, 1956.

13. Stöhr, H.: Lehrbuch der Histologie und der mikroskopischen Anatomie des Menchen. Achte Auflage, 1898.

CINEFLUOROGRAPHY IN THE PRE- AND POST-OPERATIVE MANAGEMENT OF LARYNGEAL CANCER

JOHN A. KIRSCHNER, M.D.
JAMES H. SCATLIFF, M.D.
DONALD P. SHEDD, M.D.
NEW HAVEN, CONN.

Partial laryngectomy or well planned irradiation may control or cure cancer in locations where laryngectomy would involve unnecessary sacrifice of function. The possibility of carrying out function-sparing surgery or irradiation in any particular case depends upon the meticulous study of the tumor's size, inferior extent and invasion of neighboring tissues. This information frequently cannot be drawn from endoscopic examination alone, because of the distortion, fixation, bleeding, pain and anesthesia problems often produced by introduction of the laryngoscope. Much of this information, however, can be obtained from roentgenograms or laminograms of the larynx and hypopharynx,[1-5] particularly after coating them with a radiopaque material as described briefly by Farinas in 1942[6] and as illustrated and documented by Powers in 1957.[7]

Motion, however, is a particularly important feature of a neoplasm and its bed, since it reflects the degree of spread into neighboring tissues. This can be studied by fluoroscopy,[8] and recorded by instruments like the Fairchild rapid changer.[9] This instrument produces 9x9-inch roentgenograms of good detail, but since its maximum output is two pictures per second, it seems too slow to compare with cinefluorography in demonstrating the rapid movements of the larynx and pharynx.

From the Divisions of Otolaryngology, Radiology and General Surgery, Yale-New Haven Medical Center.

Supported by USPHS grant C-4435 (C1).

Cinefluorography dates almost from the time of the discovery of x-rays, but it was not until the availability of x-ray image intensifiers in 1953 that the techniques assumed a useful place in roentgen diagnosis. The history of its development and the various methods of carrying out the procedure are clearly described in a well-illustrated article by Tristan.[10]

Its application to the pharynx and larynx has consisted chiefly of recording normal deglutition, using barium mixtures.[11]

About three years ago, we began to use cinefluorography in our clinic to study dysphagia in patients recovering from laryngectomy (see report of cases). Next, we began using it to study motion and fixation in tumors under consideration for radiation therapy, and have found it so useful that it now forms a routine part of the investigation of every laryngeal or hypopharyngeal malignancy. The motion picture helps indicate the tumor's size, extent and degree of invasion, particularly in areas difficult to visualize endoscopically.

An even more interesting application of this technique is the postoperative investigation of such complications as cough, regurgitation, dysphagia, or recurrent neoplasm (see report of cases). From an investigative standpoint it affords a means of correlating esophageal voice with various modifications of laryngectomy or laryngopharyngectomy.

The examination consists of motion-picture fluoroscopy recording of a barium mixture as it passes through the pharynx on swallow. A Philip's five inch amplifier, 16 mm Auricon camera and linograph ortho film are used. The larynx is then locally anesthetized, oily Dionosil is instilled and a fluoroscopic motion-picture recorded during phonation, inspiration and Valsalva maneuver.

After development, the film is shown by a 16 mm projector equipped with a device which allows slow motion, complete stop or reversal of direction. In this way the laryngologist can study the tumor as often as necessary, and at his leisure.

REPORT OF CASES

CASE 1. V.R., a 73 year old white male admitted with irregular fungating mass over the anterior two-thirds of the right vocal

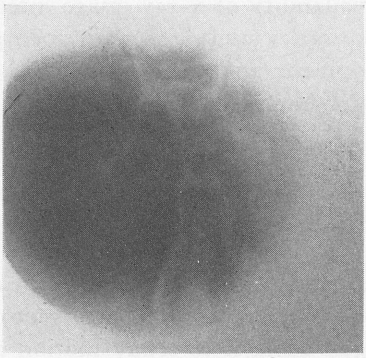

Fig. 1.—16 mm frame showing indentation of right tracheal wall by tumor mass, with fixation (lower arrow). Pyriform sinuses (P.S.) fill normally, left ventricle fills normally, but the right is occluded by tumor and does not fill with Dionosil.

cord. It appeared to originate from the ventricle, extend forward into the anterior commissure and downward into the subglottic area, although its extent could not be definitely determined. Left cord partially fixed. The false cord normal. Biopsy—epidermoid carcinoma.

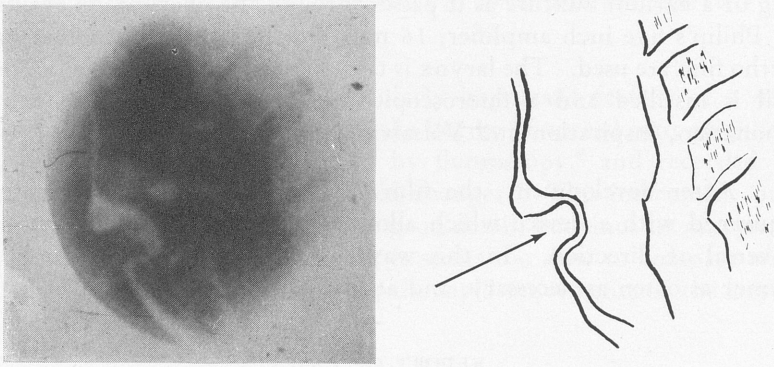

Fig. 2.—16 mm frame showing tumor involvement of anterior commissure with fixation (arrow) and with normal subglottic area.

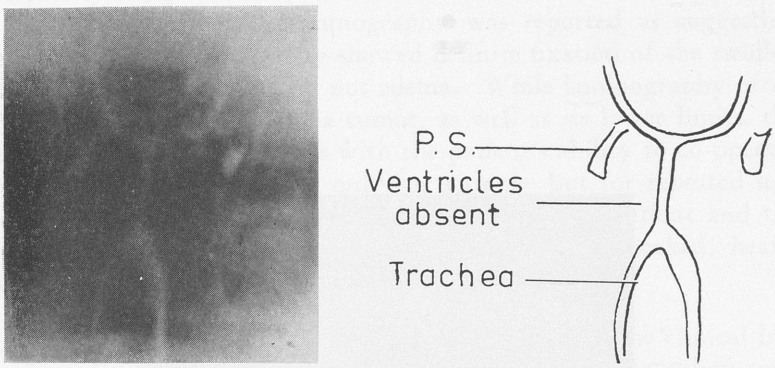

Fig. 3.—16 mm frame showing complete absence of ventricular filling in bilateral ventricular cancer with movable vocal cords and subglottic tissues.

Laminograms were reported as of poor quality but suggestive of subglottic edema.

Cinefluorograms showed fixation of the right true cord, absence of the right ventricle and a prominence and fixation of the wall of the subglottic area (Fig. 1).

Total laryngectomy carried out with uneventful recovery.

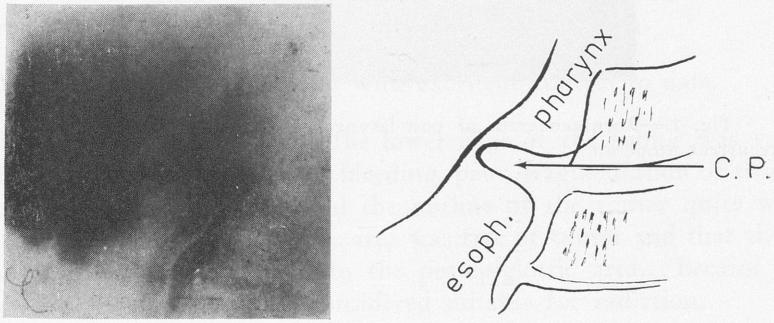

Fig. 4.—16 mm frame showing flattening and change in shape of the mass seen in Figure 4. When viewed in the motion picture, the mass resembles muscle, with good motion.

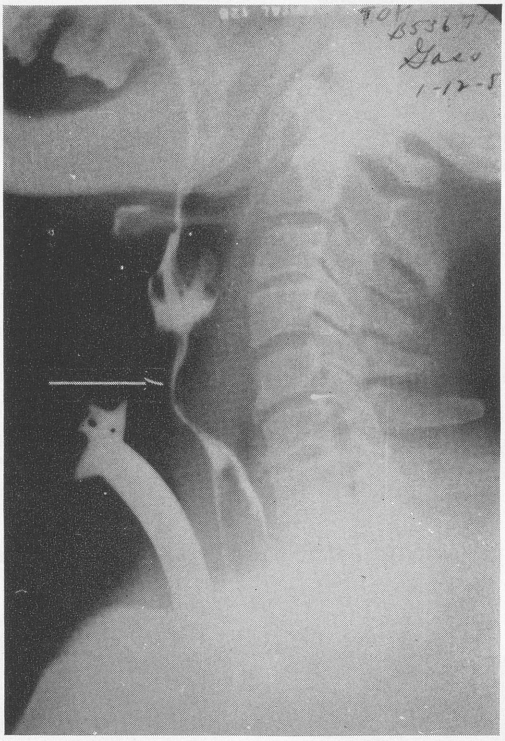

Fig. 5.—Roentgenogram of post-laryngectomy muscle mass suggesting recurrent neoplasm.

Comment. This lesion was difficult to visualize endoscopically, particularly the portion in the ventricle and the submucosal portion in the subglottic area. Laminography was reported as suggesting edema, while cinefluorography showed definite fixation of the swollen area, indicating neoplasm and not edema. While laminography often shows the size and extent of a tumor, as well as its lower limits, the success of the technique varies with the patient's ability to co-operate and to sustain phonation, not only for a single, but for repeated sections. The procedure is often difficult for both the patient and the examiner. Lateral laminograms often fail in short necked, heavy patients who cannot be positioned satisfactorily.

Cinefluorography in this case helped corroborate the clinical impression of fixation of the cord and demonstrated the submucosal extension of the tumor in its entirety.

By contrast, in the case of V.F., a small subglottic carcinoma showed excellent motion on cinefluorography. Radiation was carried out with excellent results and no evidence of tumor at present, 18 months after radiation.

CASE 2. G.V., a 64 year old white man. Laryngoscopy was complicated by bleeding from a large neoplasm involving the anterior two-thirds of the right vocal cord, with fixation. The anterior commissure could not be well seen. Tracheotomy performed. Biopsy of right vocal cord—epidermoid carcinoma. Lower edge of tumor could not be identified.

Cinefluorography showed involvement of the anterior commissure, movable cords, and a clear subglottic area (Fig .2).

Radiation was carried out with excellent control to date.

Comment. In this case the lower edge of the tumor was very difficult to identify because of bleeding, pain, fragmentation of tissue, etc. Cinefluorography showed the outline of the tumor quite well and showed that the subglottic area was free of tumor and that there was no anterior extension into the pre-epiglottic area. Because of these findings the case was considered suitable for radiation.

Involvement of the pre-epiglottic space and destruction of the thyroid cartilage by tumor can sometimes be demonstrated by cine-

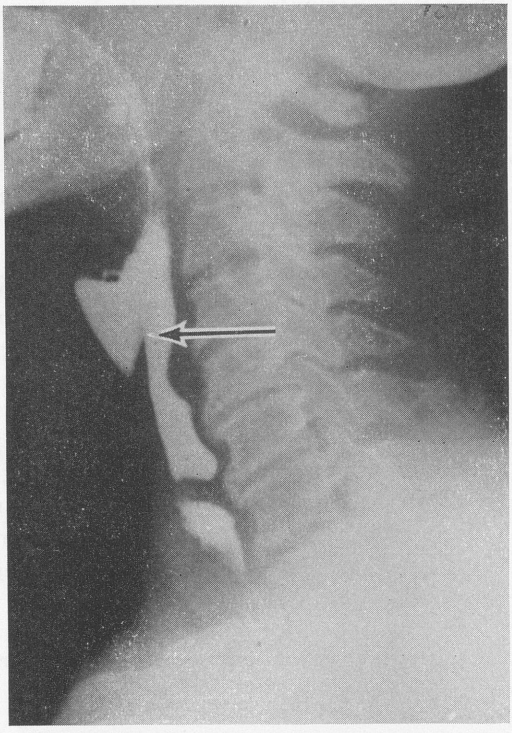

Fig. 6.—Postoperative out-pouching of pharynx which frequently develops where the upper end of pharyngeal suture line meets the base of the tongue.

fluorography, although they can be better demonstrated by enlarged lateral soft tissue films of the larynx.[1-5]

CASE 3. G.C., a 56 year old white male, hoarseness one year. Laryngoscopy showed a large fungating mass, easily bleeding, over the anterior two-thirds of the left true cord extending forward into the anterior commissure and down into the subglottic area. Anterior half of right cord involved.

Cinefluorography showed absence of ventricular recesses. There was good motion in the subglottic area (Fig. 3).

Course. Total laryngectomy, uneventful convalescence and discharge 12 days postoperative.

Comment. Cinefluorography revealed the extent of involvement of the ventricles in this case better than did laryngoscopy. One frame which was suggestive of a ventricle proved to be a transverse process of the cervical vertebrae, identified on motion in subsequent films. This would have been misleading in routine roentgenograms.

CASE 4. E.O'M., a 70 year old white female, admitted with progressive dysphagia for one year, with intermittent hoarseness.

Laryngoscopy showed a round, smooth, bleeding tumor about 3 cm below the arytenoids.

Biopsy—epidermoid carcinoma.

Further endoscopic examination showed a clear anterior wall, but did not demonstrate the lower edge of the tumor.

A Wookey type resection of the cervical esophagus was carried out, leaving the larynx in place. Reconstruction of the cervical esophageal segment was carried out six weeks after the original operation. Patient recovered well and is still alive, eight and one-half years after surgery.

Comment. At the time this patient was seen, cinefluorography was not available. It was extremely difficult, because of the large size of the tumor, to see even the lateral extent and to determine the degree

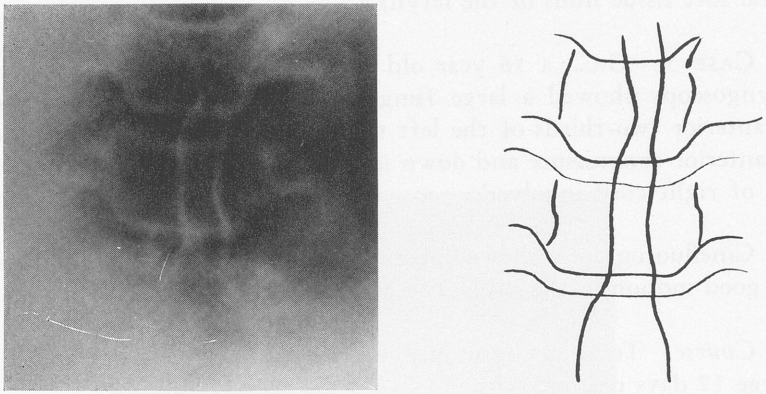

Fig. 7.—16 mm frame of esophageal speech showing open position of cervical esophagus on inspiration.

of fixation of surrounding tissues. Roentgenograms with barium swallow gave us a fairly good idea of the tumor's extent, but this was not definitely determined until the time of surgery.

The anterior wall of the laryngopharynx may be particularly difficult to evaluate by endoscopy, yet its freedom from neoplasm

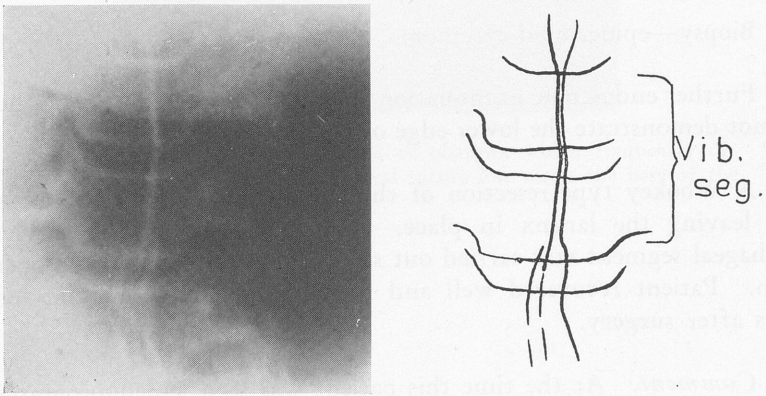

Fig. 8.—16 mm frame of esophageal speech showing the vibrating segment of cervical esophagus during phonation.

allows pharyngectomy without removal of the larynx in postcricoid cancer and this absence of involvement can often be demonstrated by cinefluorography.

Moderate dysphagia for solids, present since operation, was studied by cinefluorography, which showed a functioning cervical esophageal tube with good motion and no evidence of tumor.

Postoperative Applications. After laryngectomy, some patients develop dysphagia of different forms: 1) nasal regurgitation; 2) obstruction to the passage of food through the cervical esophagus; 3) regurgitation of partly digested food; 4) difficulty starting the bolus from the mouth into the pharynx. It is in the evaluation of these postoperative problems that cinefluorography has been particularly helpful.

CASE 5. A.G., a 53 year old white man referred for irradiation of residual tumor following laryngectomy.

6123 R delivered to pharynx.

Five years postoperatively patient developed CVA with hemiparesis.

Eight years postoperatively potient developed sudden dysphagia for solids, progressing in three weeks to dysphagia for liquids. Admitted to New Haven Hospital where the dysphagia gradually cleared over a period of one week.

Roentgenograms (Fig. 5) showed what could be considered a residual neoplasm. Cinefluorography, however, showed the rounded indentation on the posterior wall of the esophagus opening and flattening out so as to allow free passage of barium through the cervical esophageal lumen. This is strongly suggestive of a muscle bundle and not residual tumor (Fig. 4).

Comment. Cinefluorography showed the cervical mass contracting, changing shape and disappearing when a bolus passes the area. The mass represents the bunched up cricopharyngeus and inferior constrictor muscles which had been detached from their original cartilaginous attachments at laryngectomy.

In another patient (T.M.) with postlaryngectomy dysphagia, a larger mass appeared in the same area and that immediately above. After a 40 F. mercury dilator passed easily into the esophagus, motion picture studies showed a series of ineffective contractions of this mass. It is our impression that this represents both the inferior and middle constrictor, the latter having been separated from its attachment to the hyoid when this bone was removed during our routine technique.

CASE 6. J.D., a 64 year old white male, postlaryngectomy, uneventful convalescence. There was no fistula during his convalescence, but a tiny one appeared in a superior portion of the tracheal stoma, seven weeks postoperatively. This closed spontaneously within two weeks.

Nine months postoperatively a round "ulcer" was seen at the base of the tongue, at the site of the internal opening of the above-mentioned fistula. The patient reported the sensation of a foreign body in the throat and he brought up debris from this area into the mouth.

Cinefluorography showed a deep pocket or false diverticulum extending anteriorly at the base of the tongue at the upper limit of the surgical closure of the pharynx (Fig. 6). The recess could be seen to empty itself from time to time, although partially, and was freely mobile with the movements of the tongue and pharynx. The latter finding discredited any consideration of recurrent neoplasm.

Comment. The "exudate" found at the base of the tongue three months after laryngectomy was considered at first to be evidence of recurrent neoplasm. The cinefluorograms, however, revealed that this deep recess was partially filled with decomposed food and other debris from the mouth. This pocket has been found in other postlaryngectomy patients and represents an anterior outpouching the pharynx, probably the result of separation of the tissues along the line of closure where the pharynx joins the base of the tongue. It is probably an intermediate stage between a salivary fistula and primary healing

By comparison, the case of J.Y., with postoperative fistula, was well documented by cinefluorography, which showed the origin, course, and internal size of the fistula while being distended by the barium mixture. Such information may be of value in persistent fistulas, where the question of surgical closure is being considered.

CASE 7. W.M., a 38 year old white male referred for laryngectomy because of radiation failure in a cord lesion. Laryngectomy convalescence was complicated by salivary fistula which healed spontaneously within two weeks.

The patient has since developed an excellent esophageal voice which has been studied by cinefluorography and sound track. An interesting finding in this case is that the vibrating segment of the cervical esophagus is rather long, probably two inches in length, and does not consist of a vibrating, sphincter-like ring of muscle as is sometimes described in the production of esophageal voice (Figs. 7 and 8).

Cinefluorography offers a satisfactory means of studying voice production in patients who have been operated by various modifications of laryngectomy or laryngopharyngectomy.

CONCLUSIONS

By adding the important element of motion to the roentgenographic study of the larynx and pharynx, cinefluorography offers the laryngologist an important technique in the pre-operative diagnosis of laryngeal cancer and in the postoperative evaluation of surgical complications.

333 CEDAR ST.

REFERENCES

1. Coutard, H., and Baclesse, F.: Roentgen Diagnosis during the Course of Roentgen Therapy of Epitheliomas of the Larynx and Hypopharynx. Amer. Jour. of Roentgenology 28:293 (Sept.) 1932.

2. Worning, B.: Roentgen Examination of Laryngeal and Hypopharyngeal Tumors. Acta Radiologica 15:8-23, 1934.

3. Pendergrass, E. P., and Young, B. R.: The Roentgen Diagnosis of Neoplasms of the Air and Food Passages, with Particular Reference to the Larynx. Radiology 36:197, 1941.

4. Fletcher, G. G., Old, J. W., and Loquvam, G. S.: A Topographic Approach to the Roentgenologic and Pathologic Examination of the Laryngopharyngeal Tumors. Radiology 63:361-380, 1954.

5. Baclesse, F.: Carcinoma of the Larynx. Brit. Jour. of Radiology, Suppl. 3. 1949.

6. Farinas, P. L.: Mucosography of the Respiratory Tract. Radiology 39:84-87, 1942.

7. Powers, W. E., McGee, H. H., Jr., and Seaman, W. B.: Contrast Examination of the Larynx and Pharynx. Radiology 68:169-178, 1957.

8. Gay, B. B., Jr.: A Roentgenologic Method for Evaluation of the Larynx and Pharynx. Amer. Jour. of Roentgenology 79:301, 1958.

9. Bachman, A. L.: The Radiologic Study of Some Normal and Abnormal Swallowing Mechanisms; Aspiration Phenomena and Cricopharyngeus Spasm. Laryngoscope 69:7:947-969 (July) 1959.

10. Tristan, T. A.: Methods of Cinefluorography. Med. Radiol. and Photog. 35: 38-44 (Nov. 2) 1959.

11. Ramsey, G. H., Watson, J. S., Gramiak, R., and Weinberg, S. A.: Cinefluorographic Analysis of the Mechanism of Swallowing Radiology 64:498-518 (Apr.) 1955.

DISCUSSION

DR. JOSEPH OGURA: I wish to congratulate Dr. Kirchner for this very important piece of work.

Two days ago when I gave a similar paper I attempted to point out the importance of this method as an intermediary step between the indirect and direct examination. It helps determine what you can do surgically. I think this method of determining and classifying lesions, particularly with motion pictures and spot film technique, is of great value. One can accurately determine function by both of these methods. The disadvantage of course of one over the other is that it is a lengthy and costly procedure.

We have in many instances used radio cinography, along with it in the postoperative period. The site of the tumor can be accurately determined by this method.

I use oily dionosil. Oily dionosil is better since it is not complicated by granuloma formation. Aqueous dionosil has the theoretical consideration of increasing the incidence of granuloma. There are no serious reactions however with either of them.

DR. DONALD CORGILL: I think this is an important piece of work. I thought I had the answer to a recent case, but after seeing this work I would like to ask Dr. Kirchner a question: One of my patients who had a radical operation required removal of the left vagus nerve. This man has done well except on occasion he regurgitates soft foods and fluids through his nose. He would go for several days without doing so and would then have a recurrence of regurgitation. We were able to pass dilators and prove there was no stricture. I have removed many rightsided vagus nerves but leftsided vagus nerves I had not. Perhaps this represents malfunction of the cricopharyngeus similar to that which occurs in polio children who have to wear a feeding tube. Cutting the cricopharyngeus muscle enables them to swallow normally.

I believe that resection of the nerve supply, which I think is parasympathetic, is of value but the real benefit is the result of resecting the cricopharyngeus. If

this man continues to have these episodes, I plan to go back in his neck and resect the cricopharyngeus. These episodes occur when he has had a bad day and is tense.

DR. JOHN KIRCHNER (closing): I thank the discussers. I don't believe section of the cricopharyngeus would help, Dr. Corgill. In the pictures we have studied where we see the so-called spastic cricopharyngeus described by many authors, the entire muscle mass is behind the lumen of the hypopharynx. You see the barium go down byond it and very easily be regurgitated up and down past this muscle. I don't see how it could possibly be spasm, so I don't think sectioning the muscle would help a bit.

To make it more confusing, I have seen this type of regurgitation in patients who have not had any nerve resection at surgery and even in those who had no stricture of the cervical esophagus in whom you can pass a large dilator without difficulty. I am sorry I cannot give you a definite answer.

LARYNGEAL MANIFESTATIONS OF SYSTEMIC DISEASE

WALTER H. MALONEY, M.D.

CLEVELAND, OHIO

Many systemic diseases manifest themselves in the larynx. This fact should be constantly before us so we may avoid considering laryngeal disease solely as a regional problem when carrying out diagnostic and therapeutic measures.[1]

It is not intended to review all of the systemic diseases which might affect the larynx.[2-6] Discussion will center around those for which more effective diagnostic and therapeutic means are becoming available.

HYPOMETABOLIC AND HYPOTHYROID STATE

The first problem to be considered is that of the hypometabolic or hypothyroid state. In the larynx this is most often characterized by a diffuse edema, without inflammation and when biopsied, is gelatinous in character.[7] The patient may complain of hoarseness, may smoke too much, talk too much, and may have nasal infection, but a careful history will discover many systemic manifestations of a hypothyroid state and put the problem of hoarseness in its proper perspective, i.e., that of merely part of a systemic problem.

Because of the confusion and relative inaccuracy of the diagnostic tests available to determine this disease, many hypometabolic patients are denied proper replacement therapy. I feel there is a place for thyroid replacement in these borderline cases. If clear cut laboratory tests are not forthcoming I would urge therapy on clinical evidence alone, despite equivocal serum protein bound iodine levels, sedated basal metabolic rates and radioactive iodine uptake records.

From the Division of Otolaryngology, Western Reserve University School of Medicine and University Hospitals of Cleveland.

Hollender[8] has pointed out that allergic states, complicated by endocrine disturbances will be benefited by endocrine replacement. In addition, other factors such as tension, intercurrent infection and nutritional deficiencies will affect the hypometabolic state. When corrected this may allow replacement therapy or allergic therapy to be reduced or discontinued.

Hilger has stated that the hypometabolic state affects tissue healing and this in turn should be corrected before surgery is carried out.

GRANULOMATOUS LESIONS

The second problem is that of the granulomatous lesions. While we accept laryngeal tuberculosis as being secondary to pulmonary disease, we forget that the less common mycotic infections act the same way.[9] Histoplasmosis, blastomycosis and actinomycosis are rarely primary in the larynx. Search for systemic manifestations should be carried out. Specific etiological confirmation may not be available on one test such as tissue biopsy. A careful history of living, travel and working environments must be correlated with specific antigen reactions of the skin, biopsy and compliment fixation tests to arrive at a correct working diagnosis.

The granulomatous lesions of the larynx associated with chronic and recurrent diffuse infection may be part of the picture of agammaglobulinemia. Wallenborn,[10] in a recent review has emphasized the need to consider this entity and reminds us that paper electrophoresis of the serum proteins to determine the actual gamma globulin level will usually establish the diagnosis. The normal range is from 12 to 16 per cent of the total serum proteins. To measure low levels of gamma globulin, the precipitin method of measurement will detect levels not shown by electrophoresis.

Careful systemic study in the case of the noninfectious laryngeal granuloma will enable you to evaluate it so that therapy can be instituted on a more rational systemic basis.

Boeck's sarcoid is an example. This lesion may be encountered in the larynx, but is seldom primary there. Systemic search will show pulmonary lesions, as well as other diffuse systemic lesions. Cortisone therapy directed toward the systemic disease will improve and palliate both the laryngeal disease and systemic disease.

The finding of a necrotizing granuloma of the larynx, often called Wegener's granuloma is but part of a generalized systemic process of necrotizing angeitis and glomerulonephritis.[11,12] While prognosis is bad the realization that this is part of a systemic disease will stimulate more accurate observation and examination enabling further clarification and differentiation between this process and polyarteritis nodosum.

COLLAGEN DISEASE

Other systemic diseases which may be manifested in the larynx are those classified under collagen diseases.

Broadly classified they refer to rheumatoid arthritis,[13] dermatomyositis, lupus erythematosus, polyarteritis nodosum and scleroderma.

Biopsy of the larynx may reveal histologic evidence of this connective tissue disorder. When coupled with a careful history and systemic review, the systemic disease becomes apparent.

Many of these systemic diseases, with the associated laryngeal disease, are benefited by cortisone therapy. Because of this, certain aspects of such therapy should be discussed. I am indebted to Dr. William Jefferies[14] and Dr. Robert Post[15] for allowing me to draw freely from their notes and discussions relative to this aspect of the problem. The basic action of the adrenocorticosteroid is that of conversion of protein to carbohydrates, called gluconeogenesis, and control of sodium and potassium metabolism, the electrolyte regulating mechanism. A close relationship is necessary between these two actions in order to enable the body to adapt itself to changes in its environment, i.e., changes in temperature, food intake, exercise, trauma and infections. In broad clinical usage the corticosteroids are used where its anti-inflammatory effect is valuable, in auto-immune imbalance and to prevent over-response of the normal body defense reactions. The corticosteroids have been proven to be effective in the collagen diseases and many of the granulomatous diseases. Its exact mode of action is really not clearly understood. However, nearly every phase of physiologic reaction to disease or injury may be distorted. Since the inflammatory reaction may be inhibited and the antigen-antibody reaction may be prevented or reversed, these substances are of considerable benefit in diseases such as polyarteritis nodosum, rheumatoid

arthritis, sarcoidosis, lupus erythematosus, and other non-specific inflammatory or granulomatous lesions of the body. The ability to produce changes in the components of connective tissue formation, i.e., fibroblasts, collagen and ground substance, make its use especially valuable in those diseases where the pathologic physiology is primarily due to an abnormal response of the body to injury or infection. Yet, the attendant undesirable side effects of corticosteroid therapy make it necessary to use them with caution.

Retention of fluid and perforation of peptic ulcers is well known. In addition to sodium retention and potassium loss, there may be a negative calcium and nitrogen balance which in turn may have important effects on growth in children and actual skeletal demineralization in adults. This may be rapid and uncontrollable. It may result in actual muscular atrophy secondary to loss of muscle proteins from the catabolizing of the body proteins instead of building protein structures as occurs with a positive nitrogen balance.

Steroids in doses which suppress adrenocortical activities, and this may be as low as 20 mgm of Prednisone a day, may produce these and other serious changes.

A few of the more important ones other than the false sense of security provided by the anti-inflammatory action and euphoria are as follows:

A psychosis may be precipitated particularly in patients with history of emotional illness.

There may be increased blood clotting with phlebothrombosis and thrombophlebitis.

Many patients today are referred to specialists who are not aware of previous cortisone therapy being administered to their patient. Abrupt withdrawal on admission to the hospital may leave an adrenal insufficiency which may produce a shock-like state. It is interesting to note that the anesthesiologists have become quite aware of this complication and in their pre-operative rounds are checking this history carefully and ordering replacement therapy when indicated before the emergency arises in the operating room. Even slow withdrawal, after months or years of therapy, may result in a vascular

inflammatory reaction, or a polyarteritic and serositis reaction not seen before therapy.

Awareness of these complications has given us some guide to follow in our therapy.

First, we should use suppressive cortisone therapy only in cases where conventional therapy has been proven to be ineffectual.

Second, when used, it should be given in doses no larger than necessary to produce the specific action desired in the pathologic state under treatment. Small doses, i.e., 10 to 15 mgm of cortisone, may produce these effects without the undesirable side reactions of suppressive therapy.

Third, careful observation of our patients, with an awareness of the basic action of cortisone, should enable us to prevent or quickly correct any disturbance of protein or electrolyte imbalance as it arises.

Fourth, in infection problems, realizing that it takes large doses of steroids to lower resistance to infection and that the anti-inflammatory action will aid the antibiotic to reach the organism more quickly, there is every reason to consider its use here.

Lastly, we should continue to familiarize ourselves with the basic action of steroids and re-evaluate our difficult therapeutic problems in the light of this knowledge.

SUMMARY

Some of the systemic diseases which may manifest themselves in the larynx have been discussed.

An awareness of systemic disease as a factor in laryngeal disease will put proper emphasis on the need for a careful medical history and general physical examination.

Cortisone therapy is one of the more effective agents in the control of previously fatal systemic disease with laryngeal components. The basic rationale of use and the complication of steroid therapy have been discussed.

2065 Adelbert Road

REFERENCES

1. Maloney, W. H.: Beyond the Laryngeal Mirror. Pennsylvania Med. Jr. 61: 49-51 (Jan.) 1958.

2. Figi, F., and Stark, D.: Neurofibroma of the Larynx. Laryngoscope 63:652-659 (July) 1953.

3. Judge, A.: Bilateral Midline Paralysis of the Larynx of Central Origin. Laryngoscope 62:1069-1080 (Oct.) 1952.

4. Myerson, M.: Lymphogranuloma Venereum of the Hypopharynx and Larynx. J.A.M.A. 117:1877-1879 (Nov. 29) 1941.

5. Pietra, R.: Amyloidosis of the Larynx. Ann. Oto-Rhin-Laryngol, Uruguay, 26:71-85, 1956.

6. Quinn, F., and McCabe, B.: Laryngeal Metastasis from Malignant Tumors in Distant Organs. ANNALS OF OTOLOGY, RHINOLOGY AND LARYNGOLOGY 66:139-143 (Mar.) 1957.

7. Hilger, J.: Otolaryngologic Aspects of Hypometabolism. Ann. of Otolaryngology 65:395-413 (June) 1956.

8. Hollender, A. R.: Hypometabolism in Relation to Ear, Nose and Throat Disorders. Arch. Otolaryngology 63:135-141 (Feb.) 1956.

9. Gill, E.: Mycotic Infections in Otolaryngology. Laryngoscope 63:389-394 (May) 1953.

10. Wallenborn, P.: Agammaglobulinemia. Laryngoscope 70:1-36 (Jan.) 1960.

11. Atkins, J., and Eisman, S.: Wegener's Granulomatosis. ANNALS OF OTOLOGY, RHINOLOGY AND LARYNGOLOGY 68:524-547 (June) 1959.

12. Hoch, C.: Wegener's Granulomatosis. A.M.A. Arch. of Otolaryngology 63:120-123 (Feb.) 1956.

13. Polisar, I. A.: Cricoarytenoid Joint: Diarthrodial Articulation Subject to Rheumatoid Arthritic Involvement. Laryngoscope 69:1129-1164 (Sept.) 1959.

14. Jefferies, W.: The Present Status of Acth, Cortisone and Related Steroids in Clinical Medicine. New England Jr. of Med. 253-441-446 (Sept. 15) 1955.

15. Post, R.: Personal Communication, Department of Medicine, Western Reserve University School of Medicine.

DISCUSSION

DR. FRANCIS W. DAVISON: I thank Dr. Maloney for bringing this subject to our attention. I should like to think that some of his ideas developed while he was one of our associates about two years ago. It is important for us to recognize systemic causes of laryngeal dysfunction. Given a patient with laryngeal symptoms, after one has ruled out tumor, one must go on and find the systemic reason for the mucosal misbehavior.

I also agree with his thesis that it is legitimate to use thyroid when there are clinical signs of hypothyroidism, even though laboratory tests indicate normal thy-

roid function. A therapeutic test of four weeks duration will settle the question. I think it is legitimate for us as laryngologists to use endocrine products when they are indicated.

DR. W. H. MALONEY (closing): As I looked back over the audience and saw Dr. Davison, I anticipated and hoped that he would comment on this because there is no question that the awareness of this problem arose when I had the opportunity of working with him and his stimulation continued to make me observe and be aware of these problems.

I think we as laryngologists should know how to use endocrine products properly and should not have to run to the internist every time we wish to write a prescription for cortisone.

PHONATION

CLINICAL TESTING VERSUS ELECTROMYOGRAPHY

DAVID W. BREWER, M.D.

F. BERTRAM BRIESS

SYRACUSE, N. Y.

AND

K. FAABORG-ANDERSEN, M.D.

NYKOBING, DENMARK

By virtue of our training as laryngologists all of us have been primarily students of diseases of the larynx and their disturbing effect on its respiratory physiology. As a specialty group, we have devoted little time to the study of the physiology of phonation. This topic, however, has been the subject of considerable speculation by students of the voice (usually voice teachers but occasionally physicians). Much of what has been written necessarily has been based on empirical methods of voice training. This has caused the majority of us to categorize individual patients with voice problems as: a) surgical prospects because of visible lesions; b) candidates for long periods of voice rest; or c) psychosomatic problems. We have generally had little interest in the solution of voice problems seemingly unrelated to visible laryngeal pathology.

Attempting to bridge the gap between such voice terminology as divergence and falsetto and medical terminology such as thyro-arytenoid and hyperfunction is a time consuming and Herculean task.

The first clue came from Johannes Müller[4] who in 1837 indicated that the difference between natural voice and falsetto voice was pri-

---

From the Departments of Otolaryngology, S.U.N.Y. Upstate Medical Center at Syracuse, and Centralsygehuset, Nykobing, Falster, Denmark.

Supported in part by funds from the S.U.N.Y. Upstate Medical Center and by the services and facilities of the Centralsygehuset ,Nykobing, Falster, Denmark.

marily due to a difference in function of the thyroarytenoid and the cricothyroid muscles. Gutzman[5] in 1905, using cadaver larynges, further explained Müller's work, demonstrating for students that the "fundamental" or natural voice was due primarily to thyroarytenoid muscle function with thickening of the vocal cord and vibration of the whole mass of the cord while falsetto was due to only "free-edge" vibration since the cord was greatly stretched by the action of the cricothyroid muscle.

Many reports of additional anatomical studies stressing various theories of the individual functions of the intrinsic laryngeal muscles have been published during the intervening years. Stroboscopic as well as normal and high speed motion picture studies of vocal cord movements have been misleading in certain instances since necessary protrusion of the tongue brings intrinsic muscles into play which further distort the intrinsic muscle activity. Yet, even newer methods of sound analysis have failed to show the specific amounts of individual muscle participation in the production of the many tones and effects of the full range of the human voice.

Even though normal laryngeal physiology has not been well understood, singers', screamers' or speakers' nodes have long been identified with voice strain or vocal abuse as their cause. It has been accepted by most that voice rest or reduction of vocal activity will produce at least temporary disappearance of these lesions. Permanent elimination and prophylaxis must come from a better understanding of the physiology and physio-pathology of the larynx.

In 1954, two new entirely independent investigations were begun which dealt specifically with the "gear-box of the voice," i.e., the intrinsic laryngeal muscles. Briess, in Syracuse, using clinical voice tests, measured the activity of these muscles, while Faaborg-Andersen, then in Copenhagen, Denmark, measured their activity electromyographically.

Based primarily on his previous thirty years of experience in the field of voice, Briess clinically determined the patient's ability to produce carefully chosen test sounds and phrases.[1] Successful completion of this clinical voice testing indicated a healthy voice and normal balance relationships of all of the five sets of intrinsic muscles. Failure during the tests indicated specific muscle imbalances. These imbal-

ances were identified and reported in terms of hyperfunction or hypofunction. Such imbalance was found to be associated with 25 specific symptoms such as lump feeling, dryness in the throat, tickle, cough, pain referred to the ear, tenderness over the arytenoid, etc. Persistence of these imbalances and symptoms was found to eventuate in abuse lesions such as edema, nodes, contact ulcers, polyps, etc. From a knowledge of symptoms and laryngoscopic findings alone, the laryngologist was able to predict the major muscle imbalance responsible for the patient's laryngeal difficulties. Based on the information gained from clinical voice testing, Briess designed for each patient a special therapeutic voice regimen[2] which, with laryngoscopic guidance, restored the muscles to normal balance. As a result of this, both lesions and symptoms disappeared without requiring surgical interference or voice rest. This was documented by over 1,000,000 feet of tape recordings and detailed interval laryngoscopic examinations during the treatment of over 300 patients.

Visible proof of altered and subsequently restored muscle balances, however, was lacking. It therefore was unacceptable to most laryngologists.

Faaborg-Andersen, completing his advanced specialty training in otolaryngology in Copenhagen, and hearing that electromyographic studies of the intrinsic laryngeal muscles were technically impossible, accepted the challenge and devised a technique for their study.[3] He was able to measure accurately the electrical activity in microvolts in each of two pre-selected single muscles and established for the first time the average range of activity for all intrinsic muscles with the exception of the lateral cricoarytenoid. His investigations demonstrated that "considerable increase in electrical activity occurred even before phonation was audible; that whispered voice and 'silent speech' evoked a similar but lesser degree of electrical activity than did ordinary phonation; that with increase in intensity or loudness there was no corresponding increase in electrical activity in the adductor muscles; nor was there increase in the action potential pattern with change of vowel. During increase in pitch within the same voice register electrical activity increased considerably, but with simultaneous shift in register only slight increase in electrical activity was evident.

"In patients with a paralyzed vocal cord in the electrical pattern changes during respiration, cough, swallow and variations in phona-

tion were qualitatively the same as in subjects with normally movable vocal cords.

"On the paretic side evidence of neurogenic paresis was found in all muscles except the cricothyroid in patients with an immovable vocal cord in the paramedian position.

"The results of his investigations did not support the Husson theory which assumes that at a given pitch the number of nerve impulses per second must equal the number of vibrations per second of the vocal cords. He found that the maximum discharge frequency in single motor units was only 30 per second, i.e., far below the vibrational frequency of the vocal cords."

In his published monograph of these investigations, his "findings were in agreement with the assumption that it is mainly the modified mucous membrane of the vocal cords which participates in the vibrations and that the vibrational frequency is determined by the active and passive tension exerted by the different intrinsic laryngeal muscles as a result of differences in degree of their contraction."

At the First International Voice Congress in Chicago in 1957, his initial report of this major contribution prompted us to discuss with him at once the possibility of simultaneously studying patients using both his and our techniques. Here at last might be a way of establishing by visual means the validity of our approach and of opening up a combined medium for study of additional unsolved laryngeal problems.

Thus, it was that we visited Faaborg-Andersen in his new department in the Central Hospital, Nykobing, Falster, Denmark, in April of 1959 to study clinically and electromyographically twelve of his patients, ten with laryngeal pathology presumably produced by vocal abuse, and two normal controls.

This initial investigation was designed to study similarities and differences in our methods of evaluation of intrinsic laryngeal muscle function and relationships with voice production. By combining our efforts and examining the same patients on the self same day, it was possible to obtain data useful for direct comparison. Three means of mensuration were used: 1) indications of major muscle imbalance

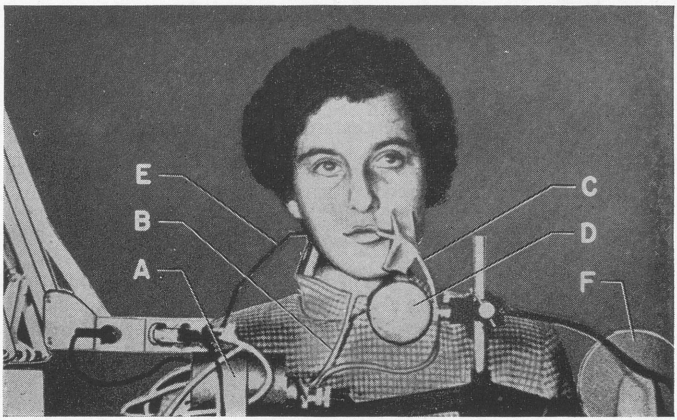

Fig. 1.—Experimental apparatus and arrangement. Left, the three channel electromyograph; right, the subject and the tape recorder with microphone (F). In front of the subject is seen the high-pass filter (A) inserted between the electromyograph and the electrodes. One needle electrode (B) is placed in the left cricothyroid muscle by insertion through the skin of the neck. Another needle electrode (C) is inserted through the mouth and placed in the vocal muscle. The third channel of the electromyograph is connected with a microphone (D) placed in front of the subject at a constant distance from the subject's mouth. A ground plate electrode (E) is attached to the back of the subject's neck.

by correlation of history and detailed description of even minor deviations from normal appearance of the larynx on indirect laryngoscopy (D.W.B.), the latter being performed independently by K.F.A. and D.W.B.; 2) clinical voice testing as expanded and reported by F.F.B.; 3) electromyographic study by the technique previously devised and reported by K.F.A. (Fig. 1).

METHOD OF PROCEDURE

A total of 12 patients comprised the group for examination. On each of seven patients the following procedure was carried out. For specific reasons indicated under the section entitled "Patients' Histories" it was impossible to perform the complete examination on five of the twelve. On two of these five EMG was performed but no sound tapes could be obtained.

1. History and otolaryngological examination.

2. Clinical voice testing recorded on tape.

3. Administration of intralaryngeal topical anesthesia.

4. Repeated clinical voice testing recorded on tape to detect any changes occasioned by use of the topical anesthesia (½ of 1% Tetracaine). This was discontinued by mutual agreement after no changes could be detected in three patients.

5. Insertion of electrodes into muscles in each case as indicated in Table I.

TABLE I

CASE NO.	ELECTRODES IN MUSCLES	EMG EILM OBTAINED	INTONATIONS TAPED DURING EMG	REMARKS
1	#1,2	No	No	
2	—	—	—	
3	1,2	Monitored only	No	
4	1,2;2,4;2,5	Yes	Yes	EMG microphone tracing poor
4	1,2;2,4;2,5	Yes	Yes	
5	—	—	—	
6	1,2	Yes	No	
7	4,5	Yes	Yes	
8	2,5	Yes	Yes	
9	1,2	Yes	Yes	
10	—	—	—	
11	2,4;3	Yes	Yes	
12	2	Yes	Yes	

6. Repeat clinical voice testing to ascertain any changes occasioned by placement of electrodes.

7. Simultaneous clinical voice testing and electromyographic tracings. In several instances, this was tape recorded after microphone interference problems were solved.

8. Repeat voice testing after removal of electrodes.

9. Comparison of results in the same patients as well as comparison of findings with all other studies.

For greater ease in identification of the intrinsic laryngeal muscles, and description of hypo- and hyperfunction, all three authors agreed to use the following, as routinely employed by D.W.B. and F.B.B.

Muscle No. 1—Thyroarytenoid.

Muscle No. 2—Cricothyroid.

Muscle No. 3—Lateral cricoarytenoid.

Muscle No. 4—Posterior cricoarytenoid.

Muscle No. 5—Interarytenoid.

Hyperfunction was identified as: 1+, 2+, 3+, 4+, 5+.

Hypofunction was identified as: 1—, 2—, 3—, 4—, 5—.

For example, No. 4: 4+ or No. 1: 2—.

In carrying out the investigation, all patients were those of K.F.A. Examinations were performed in the Research Laboratory of his Department of Otolaryngology at Centralsygehuset, Nykobing, Falster, Denmark. Voice history was taken by F.B.B. and D.W.B. Otolaryngological history was taken by K.F.A. Indirect laryngoscopy was performed by K.F.A. first and then D.W.B. The findings were not transmitted to F.B.B. until his voice testing was completed and he had given a prognosis as to the type of difficulty which the detected muscle imbalance should or would produce.

Muscles No. 1 and No. 2 were initially tested by requesting the patient to produce a phrase rich in "o" vowels consisting of eight to twelve syllables. By varying pitch from low to high and increasing and decreasing the musical intervals between the syllables an audible gap in sound production was provoked. The time-honored term for this gap is a "divergence." This gap represented a sudden collapse of muscle No. 1 and increased function of muscle No. 2. Normally, muscle No. 1 relaxes proportionately as muscle No. 2 contracts when pitch is raised. The frequency, in cycles per second, where the gap or divergency of muscle function was heard, indicated the voice type. There is a specific pitch for each of the ten major voice types. However, if muscles No. 4 and 4 showed imbalance, only a pseudo-divergence, unrelated to voice type, was heard. The relative propor-



Fig. 2.—Case No. 11 Retest

Band A: Phonation Scoop "O" Frequency 146-130-329 c.p.s.

Band B: Muscle No. 1. Clin. Voice Testing: With rise in pitch normally muscle No. 1 relaxes proportionately while muscle No. 2 contracts. Here, however, muscle No. 1 starts to relax, than suddenly contracts to plus 5 producing a divergence or gap in sound production.

EMG: Resting: 250 microvolts. Phonation: 200-550 microvolts.

Band C: Muscle No. 2. Clin. Voice Testing: Increasing to plus 3 and plus 4. EMG: Resting: 100 microvolts. Phonation: 500 microvolts.

tion of muscle No. 1 and No. 2 activity present in a particular voice determined whether it was of robust character with more participation of muscle No. 1 at a given pitch or of delicate character with more participation of muscle No. 2 at the same pitch.

Further testing of muscles No. 1 and No. 2 was done by designing specific phrases for each patient according to his voice type and character. These phrases were repeated from ten to fifty times. The degree of fatigue evidenced during this endurance test indicated the functioning condition of muscle No. 1. Hyper- or hypofunction of muscle No. 2 was determined by predominance or absence, as well as degree of inflexibility of free-edge vibration, called falsetto in male voices.

Muscles No. 3 and No. 4 were tested by noting the degree of breathiness evident on specific vowels and pitches in the same voice.

Activity of muscle No. 5 became evident either when staccato sounds produced fatigue or there was distortion of requested vowels.

By familiarity with such findings in thousands of voices previously tested, deviations from expected normal performance were indicated on a basis of hyperfunction of 1+ to 5+ and hypofunction of 1— to 5—.

The testing procedure could not be completed in cases with hypofunctioning voices—more than two pairs of muscles hypofunctioning —because of an accompanying subglottic undercompression. The amount of air pressure built up against the under surface of the vocal cords during the fraction of a second when the cords are closed during the phonation cycle is termed the subglottic compression. When this is too little the voice is weak.

The remainder of the routine was then carried out as indicated above. Following the completion of the initial examinations, the electromyograph recordings were studied by K.F.A. and the voice tests were restudied by F.B.B. Triplicate charts of the initial findings were prepared on completion of the patient's testing. Comparison of results, discussion, conclusion and summary were prepared some months after the patient investigation was completed. This gave still further objectivity to the results.

Following completion of the testing of patients, wide geographical separation of the authors necessitated preparation of duplicate sound tapes and duplicate EMG films for study. Following return of one of the early drafts of the findings K.F.A. reported that the range of mean amplitude of electrical activity measured in microvolts in adductor and abductor muscles, according to his previously established routine of measurement, did not correlate with the pre-EMG clinical voice testing as predicted by K.F.A. (These measurements are reported in each case history.) Of necessity, his findings were recorded in terms of "perhaps more than expected" or "perhaps less than expected" electrical activity since comparison was based on the range of activity encountered in his previous investigation.[3] He further explained this as follows: "In the intrinsic laryngeal muscles there is electrical activity of low amplitude and the single motor unit potentials cannot be distinguished from each other. In the adductor muscles the mean amplitude of the electrical activity is up to 200 microvolts in the absence of phonation during maximal relaxation and mostly 300-600 microvolts during phonation in high pitch. In

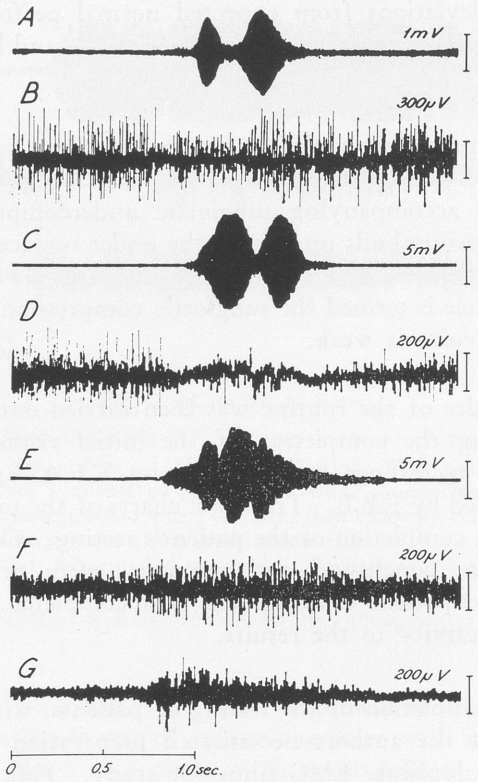

Fig. 3.—Case No. 4

Band A: Phonation: "Oh! Oh!" Frequency 207 and 196 c.p.s.

Band B: Muscle No. 4 *before* therapy. Clin. Voice Testing: Muscle No. 4 should relax as muscle No. 5 takes over to produce the staccato "Oh! Oh!" intonation. Before therapy the patient could not produce these sounds without breathiness due to extreme hyperfunction of the antagonistic muscle No. 3. No activity of muscle No. 4 was evident.

EMG: Resting: 390 microvolts. Phonation: 240 microvolts.

Band C: Phonation: "Oh! Oh!" Frequency 277 and 247 c.p.s.

Band D: Muscle No. 4 *after* therapy. Clin. Voice Testing: Here the same kind of staccato intonation again showed no activity of muscle No. 4. Absence of breathiness resulted from elimination of hyperfunction of muscle No. 3.

EMG: Resting: 400 microvolts. Phonation: 140 microvolts.

Band E: Phonation: Scoop "o" Frequency 220 to 440 c.p.s.

Band F: Muscle No. 4 *after* therapy. Clinical Voice Testing: The fact that the patient was able to produce a sustained tone without breathiness—even when pitch was raised—indicated that muscle No. 4 had returned to normal function.

EMG: Resting: 300 microvolts. Phonation: 400 microvolts.

Band G: Muscle No. 2 *after* therapy. Clinical Voice Testing: Increasing to 5+. This was possible before therapy and is normally expected with such a falsetto intonation.

EMG: Resting: 100 micdovolts. Phonation: 350 microvolts.

the posterior cricoarytenoid muscle the mean amplitude of the electrical activity is 200-500 microvolts in the absence of phonation during maximal relaxation, and considerably reduces during phonation in high pitch." This finding was also reported previously by K.F.A.[3] "After all direct comparisons cannot be made between electromyograms obtained from different persons, or from the same person on different occasions, since even electromyograms taken from different places in the same muscle (although the point for picking up the impulses may be located only a few millimeters apart) can be completely different from each other, depending on where the electrodes are inserted into the muscle. During this investigation we have picked up impulses from several points in the single muscles. A mean amplitude of the electrical activity from several points up to 300 microvolts is called 'perhaps less than expected,' 300-600 microvolts normal activity, and more than 600 microvolts 'perhaps more than expected'." (Table III) (K.F.A.)

The electrical activity in the lateral cricoarytenoid muscle has not previously been described. "In this muscle there was found electrical activity up to 200 mv during quiet respiration in spite of every effort to achieve relaxation, just as in the other intrinsic laryngeal muscles. Even when the subjects held their breath this activity was observed. During phonation the electrical activity in the lateral cricoarytenoid muscle increased markedly. This increase began ca. 0.3 sec. before an audible tone was recorded by the microphone. At the end of phonation, when audible tone had ceased as indicated by the microphone recording, the increase in electrical activity had also disappeared (cf. Fig. 5)." (K.F.A.)

It was obvious after this report that the process of EMG either changed the existing muscle activity or that the muscle balance—proportional activity of antagonistic muscles—should have been studied for each single intonation produced during EMG testing. In retrospect this had been proposed as part of the original testing procedure as step No. 7, but was conceived as actually performing the clinical voice tests with the electrodes in place. This, however, was set aside by our deep interest in observing for the first time K.F.A.'s routine testing procedure of electromyography.

Review of sound tapes showed that intonations during clinical voice testing were quite different in pitch and muscle balance than

those produced during EMG. Therefore, single intonation clinical muscle activity assay was proposed by D.W.B. and F.B.B. and carried out. This required: 1) no reference to EMG films while performing this portion of the study; 2) review of tape recordings alone to determine points of onset and turn-off of the EMG motor; 3) duplication on sound tape of all sounds by each patient during EMG; 4) pitch identification of each single intonation; 5) accurate identification of No. 1, 2, 3, 4, and 5 muscle participation by aural analysis of each single intonation. With this information in booklet form the EMG duplicate films were viewed and correlation appeared feasible. Since this was a different view of EMG interpretation than that routinely used by K.F.A. and in order to fully discuss these new findings with him, a second meeting in Denmark was deemed essential.

After two days of conferences and demonstrations at the suggestion of D.W.B., a measurement of resting activity compared with single intonation phonation activity of each muscle studied yielded an approach agreeable to all three investigators.

The term "clinical muscle activity assay" was introduced to indicate on a plus or minus basis the function of an individual muscle *during a single intonation.*

Clinical muscle activity assay of a single intonation is impossible without the detailed familiarity with a patient's voice obtained from clinical voice testing.

Ratios of "resting" activity and phonation activity had not previously been measured electromyographically; instead the range of average activity for a series of intonations had been used as the criteria for function of a specific muscle.

Charting of predominating muscle imbalances indicated by patient's symptoms and physical findings on mirror laryngoscopy was also done. Familiarity with this technique had been gained from several hundred patients previously examined by D.W.B. and F.B.B. (in preparation for publication) (Table II).

At the suggestion of D.W.B. and F.B.B. time was allowed for testing of any patient of K.F.A.'s choice. Patient No. 11 was chosen

TABLE II

SYMPTOMS AND INDIRECT LARYNGOSCOPY - PREDOMINATING IMBALANCE

CASE NO.	SYMPTOM	INDIRECT LARYNGOSCOPY	INDICATED IMBALANCE
1	Weak voice Tires easily Left neck pain		More than 2 pairs Hypo Fatigue No. 1 Hyper No. 3
		Tip rt. vocal process sl. pink Moderate thickening	Hyper No. 3
	Throat clearing	Mucous strand junct. post ⅓	Imbalance No. 3 & No. 4 Hyper No. 3
2	Hoarseness	Pink cords & lt. false cord Lt. false cord overhangs true cord by 50%	Acute abuse Hyper No. 1 with fatigue to Hypo No. 1
3	Hoarseness	Mild bowing on phonation Moderate thickening No lesion	Hypo No. 2 & Hyper No. 5
4		Pink cords and false cords Posterior nodes at tips of vocal processes	Acute abuse Hyper No. 3 Hypo No. 4
5	Weak voice Tires easily	Slightly pink cords Mucous strand junction anterior ⅓ Under surface of cord Visible rt. more than lt.	Acute abuse Imbalance No. 3 & No. 4 Early node diathesis Hypo No. 1 or subglottic Undercompression Hypofunctioning voice
6	Rt. neck pain Tender rt. arytenoid	Short cords Moderate sup. surf. Edema Moderate thickening	Hyper No. 3 Hyper No. 3 Congenital
7		Mucous accumulation at tips of vocal processes Cords slightly thickened	Hypo No. 1 Hyper No. 3 Hypo No. 1 - Fatigue
8	Neck pain rt. & lt. Excessive mucus	Slight bowing on high tone Slightly pink cords Left arytenoid sits slightly anterior to rt. arytenoid	Hyper No. 1 Hypo No. 2 or Hyper No. 5 Acute abuse Hypo No. 4 or Post-traumatic
9	Hoarseness 2 yrs.	Transverse vibration Superior surface edema Lt. cord post. ⅓ mounded on phonation	Hyper No. 1 with Hypo No. 2 Hyper No. 1 Hypo No. 4 or Alternating Hyper No. 3 and No. 5
10	Neck pain rt. & lt. Rt. more intermittent Lump feeling		((Hyper No. 3 Hyper No. 1
11	None	Normal larynx	None
12	None	Normal larynx	None

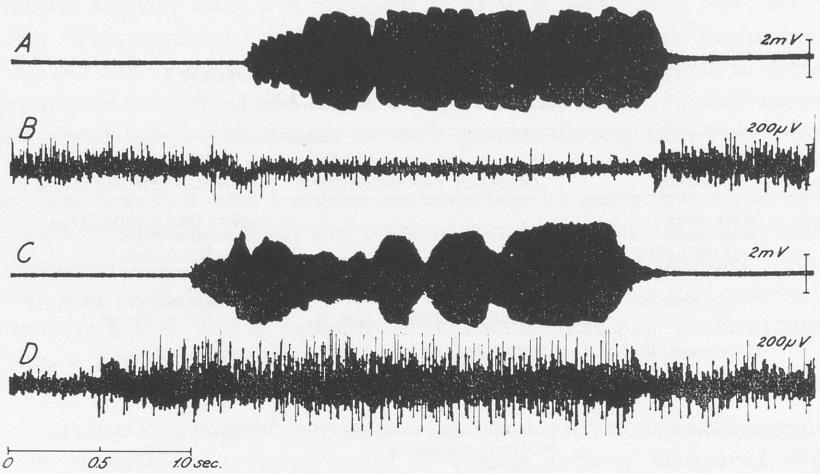

Fig. 4.—Case No. 12

Band A: Phonation "Oh" Frequency 87 c.p.s.

Band B: Muscle No. 2. Clin. Voice Testing: Very little activity is expected at such low pitch. It was estimated as minus 3.
EMG: Resting: 350 microvolts. Phonation: 80 microvolts.

Band C: Phonation "Oh" Frequency 349 c.p.s.

Band D: Muscle No. 2. Clin. Voice Testing: Essentially No. 1 participation and consequently No. 2 activity was estimated as plus 4.
EMG: Resting: 100 microvolts (120). Phonation: 500 microvolts.

since he was very co-operative and had been tested electromyographically on repeated occasions by K.F.A. in other investigations and demonstrations. This re-examination gave an additional opportunity to check F.B.B.'s clinical muscle activity assay. The sound tapes recorded during this EMG testing were immediately analyzed by F.B.B., and K.F.A. was able to observe this procedure and participate. Results were immediately written down. When the EMG films had been processed results were compared, and we were all utterly amazed at the close correlation between the clinical muscle activity assay reported by F.B.B. and the electrical activity reported by K.F.A. (cf. single tone comparisons Cases 4, 7, 9, 11, 12 and retesting Case 11) (Figs. 2, 3, 4 and 5).

RESULTS OF VOICE THERAPY

Although time was at a premium, it was possible for F.B.B. to treat two patients for approximately one hour each on four successive days. These patients are identified as Cases No. 2 and No. 4 in Table I. Unfortunately, it was impossible, because of excessive gagginess, to do EMG studies on Case No. 2. However, the patient's symptoms cleared and the overlying left false cord came back into normal position with definite tape recorded voice improvement during this short period. He returned at once to his night club singing. On repeated follow-up examinations, the patient's condition has regressed as predicted by F.B.B. since it was impossible to produce long-lasting results in such an extremely short therapy period. Yet, as might be expected, a summer vacation with decrease in vocal abuse has allowed the patient to remain partially improved.

Case No. 4 showed rapid regression followed by complete disappearance of bilateral nodes at the tips of the vocal processes in the short four-day period. This same patient had been treated previously over a period of months by two phoniatrists and had undergone two full weeks of total voice rest in the hospital, without noticeable improvement. However, phoniatrist No. 2 relieved the excessive hyperfunction of muscle No. 5 but had not reactivated muscle No. 4. As predicted by F.B.B., the nodes have reappeared since therapy while the patient has continued his regular vocal activities in the teaching profession. It is of special interest to note that the hypofunctioning muscle No. 4 was able to show normal function after therapy (Fig. 3).

COMPARISON OF RESULTS

The authors believe this to be the first investigation comparing symptoms and physical findings, clinical voice testing, and electromyographic testing simultaneously on patients.

By reference to Table III, it is demonstrated that there is accurate correlation between identification of predominating muscle imbalance determined by history and indirect laryngoscopy (D.W.B.) and clinical voice testing as routinely used by F.B.B.

Correlation between pre-EMG clinical voice testing and EMG mean amplitude of electrical activity for each muscle tested was im-

TABLE III
COMPARISON OF RESULTS

CASE NO.	HISTORY AND PHYS. FINDINGS	CLINICAL VOICE TESTING		INITIAL EMG INTERPRETATIONS	
1	#1 Hypo	#1 3—		#1 sl. but *not* l.t.e.*	
	#2 —	#2 2—		#2 Normal 200-300 m.sec.	
	#3 Hyper	#3 3+			
	#4 —	#4 3—			
	#5 —	#5 1+			
2	#1 Hypo	#1 3—		No EMG	
	#2 —	#2 2—			
	#3 —	#3 2—			
	#4 —	#4 2—			
	#5 —	#5 4+			
3	#1 —	#1 3—		#1 slight. p.l.t.e.**	
	#2 Hypo	#2 3—		#2 slight. p.l.t.e.**	
	#3 —	#3 2—			
	#4 —	#4 2—			
	#5 Hyper	#5 5+			
				Before Rx	After Rx
4	#1 —	Conversation	Teaching Voice		
		#1 3—	#1 3+	#1 p.m.t.e.	#1 normal
	#2 —	#2 Normal flexibility	#2 Normal flexibility	#2 normal	#2 normal
	#3 Hyper	#3 3+	#3 Normal flexibility	#3 —	#3 —
	#4 Hypo	#4 3—	#4 3+	#4 normal	#4
	#5 —	#5 3+	#5 3+	#5 normal	#5
5	#1 Hypo	Conversation	Loud Forced		
		#1 2—	#1 4+	No EMG	
	#2 —	#2 1—	#2 out		
	#3 (imbalance	#3 2+	#3 3—		
	#4 (imbalance	#4 2—	#4 3+		
	#5	#5 2—	#5 3+		
6	#1 —	Conversation	Yelling		
		#1 3—	#1 4+	#1 pronounced	
	#2 —	#2 2+	#2 out	#2 sl. p.l.t.e.	
	#3 —	#3 2+	#3 2—	#3 —	
	#4 —	#4 2—	#4 3+	#4 —	
	#5 —		#5	#5 —	
7	#1 Hypo	Conversation	Teaching Voice		
		#1 1—	#1 3+	#1 —	
	#2 —	#2 Normal flexibility	#2 3—	#2 —	
	#3 Hyper	#3 3+	#3 3—	#3 —	
	#4 —	#4 2—	#4 4+	#4 Normal	
	#5 —	#5 Normal flexibility	#5 4+	#5 —	
8	#1 Hyper	#1 4+		#1 —	
	#2 Hypo	#2 4—		#2 Normal	
	#3 —	#3 2—		#3 sl. p.l.t.e.	
	#4 —	#4 1+		#4 —	
	#5 Hyper	#5 1+		#5 —	
9	#1 Hyper	#1 4+		#1 sl. p.l.t.e.	
	#2 Hypo	#2 4— to out		#2 Normal	
	#3 —	#3 —		#3 —	
	#4 —	#4 —		#4 —	
	#5 —	#5 —		#5 —	
10	#1 Hyper	Conversation	#2 1+		
			#3 1+		
		#1 1+	#4 1—	No EMG	
	#2 —	#2 1—	#5 1—		
	#3 Hyper	#3 1+	#1 1+		
	#4 Hypo	#4 1—	Dr.'s Exam.		
	#5 —	#5 ?	Tongue Out		
11	#1 —	#1 (		#1 —	
	#2 —	#2 (		#2 Normal	
	#3 —	#3 (Healthy Voice		#3 Normal	
	#4 —	#4 (		#4 Normal	
	#5 —	#5 (		#5 —	
12	#1 —	#1 (		#1 —	
	#2 —	#2 (		#2 Normal	
	#3 —	#3 (Healthy Voice		#3 —	
	#4 —	#4 (		#4 —	
	#5 —	#5 (		#5 —	

* Less than expected
** Perhaps less than expected

possible (Table III). Review of all sound tapes showed that patients routinely produced entirely different sounds with respect to pitch, volume and muscle balance during these two procedures.

Full positive statistical correlation was found between clinical assay of muscle activity by F.B.B. and recorded electrical activity of these same muscles by EMG as determined by K.F.A. when compared in each separate intonation.

The effects of voice therapy have been shown to produce a specific, predicted change in intrinsic laryngeal muscle electrical activity with concomitant relief of symptoms and disappearance of lesions.

COMMENT

Completion of the full examination schedule was not possible in all cases because of such technical difficulties as patient's unsuitability for EMG testing (too gaggy, too apprehensive); unshielded cable from tape recorder to microphone which interfered with the EMG machine and had to be replaced; and difficulties in one case in identification of intonations on EMG microphone tracing.

It was particularly valuable to deal with patients unable to speak English and to find that their voices responded as accurately to the routine clinical testing. It was necessary to prepare patients for EMG in that they were asked to attempt certain sounds that they routinely had not been accustomed to produce. For example, many persons do not use falsetto in their daily conversation, but for testing such an attempt was necessary. Several patients, unable to do this on their own, were capable of producing a falsetto with the electrodes in place. This may have been due to increased familiarity with the desires of F.B.B. during EMG testing.

Case No. 4 showed a distinct change after four therapy sessions. First, the lesions originally visualized had disappeared and, secondly, the hypofunction of muscle No. 4 had been temporarily eliminated so that both clinically and electromyographically it showed its improvement to normal function. Thirdly, symptoms disappeared (Fig. 3).

Such function of muscle No. 4, known as normal to F.B.B. was distinctly abnormal to K.F.A. The composite American voice is able

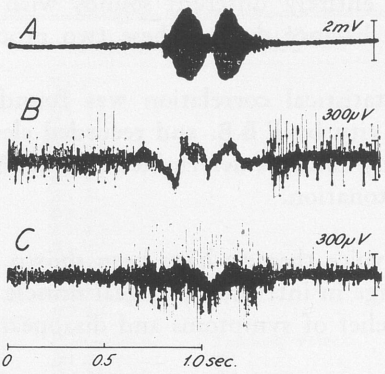

Fig. 5.—Case No. 11

Band A: Phonation: "Oh! Oh!" 247 and 196 c.p.c. This intonation designed to investigate balance of muscles No. 3 and 4 which are responsible for posterior closure.

Band B: Muscle No. 4. Clinical Voice Testing: No activity. Here muscle No. 5 has taken over, replacing muscle No. 4 to produce an attempted balance with muscle No. 3.

EMG: Resting: 600 microvolts. Phonation: 100 microvolts.

Band C: Muscle No. 3. Clin. Voice Testing: For each "Oh!" there was increase to plus 4 followed by sudden drop to no activity when the tone was the loudest, then again an increase to plus 4.

EMG: Resting: 200 microvolts. Phonation: 800 microvolts.

to show flexible interplay of muscles No. 3 and No. 4, whereas, except in the trained Danish voice, muscle No. 5 substitutes for No. 4, leaving No. 4 hypofunctioning.

Several voices, Cases No. 1, 2, and 3, were classified as hypofunctioning voices. This is a well known condition in clinical voice testing and is present when more than two pairs of the five pairs of intrinsic muscles are excessively hypofunctioning. The audible evidence of this is a voice of little volume. There is always subglottic undercompression present in such patients.

As previously reported,[1] in a healthy voice mechanism No. 1 muscle relaxes proportionately when No. 2 contracts and vice versa. In Danish voices, a predominating No. 1 (thyroarytenoid) function exists. In the presence of subglottic overcompression when pitch is

raised in such voices, No. 1 cannot relax but will hyperfunction (Fig. 2). Case No. 11 (retest) displayed a simultaneous increase in function of No. 1 and No. 2 muscles which, because of subglottic overcompression, showed an acute divergence. This is the first visual proof of the existence of this long recognized but easily misinterpreted audible phenomenon (cf. Fig. 2).

Since there are no two voices identical in every respect, the ratios of activity of No. 1 and No. 2 with No. 3, No. 4 and No. 5 differ with voice type and voice character. Clinical voice testing determines the existing ratios only by comparison with expected ratios. This is necessarily based on attempted performance during four essential tests. The expected ratios must be judged from experience. This is gained from testing and working with thousands of voices in this manner. Ratios change in a single voice when pitch is changed. However, at the same identical pitch different ratios are expected in voices differing in voice type and degree of voice character. Any deviation from the expected ratio in a particular voice is identified as plus or minus.

Having once become familiar with a voice clinical muscle activity assay involving a single tone irrespective of pitch can be made similarly by plus or minus deviation from the expected ratio of activity (Fig. 4).

From the personal interview, the voice diagnostician becomes familiar with the patient's daily voice habits and symptoms. During clinical voice testing, identification of kinds of abuse and the muscle imbalances associated with each kind of abuse is also accomplished.

Selecting the predominating abuse and having already determined its associated muscle imbalance and projecting the consequences in the light of knowing both voice type and degree of voice character makes possible prognosis of lesion present or incipient.

Laryngoscopy identifies presence and extent of lesions and often type of lesion. Corroborative laboratory studies must not be neglected. Although F.B.B. was not given any information regarding laryngeal findings in all 12 patients comparison of his prognosis and findings of indirect laryngoscopy showed positive statistical correlation (Table IV).

TABLE IV

CASE NO.	CLINICAL VOICE TESTING		VOICE TYPE	VOICE CHARACTER	PROGNOSIS
1	#1 3— #2 2— #3 3+ #4 3— #5 1+		High	Delicate	Contact Ulcer
2	#1 3— #2 2— #3 2— #4 2— #5 4+		Medium	Robust	Thickening after Edema
3	#1 3— #2 3— #3 2— #4 2— #5 5+		—	—	Dysphonia Plica
4	Conversation #1 3— #2 Normal flexibility #3 3+ #4 3— #5 3+	Teaching Voice #1 3+ #2 Normal flexibility #3 Normal flexibility #4 3+ #5 3+	High	Delicate	Contact Ulcer + Nodes Redness - Air Waste
5	Conversation #1 2— #2 1— #3 2+ #4 2— #5 2—	Loud Forced #1 4+ #2 out #3 3— #4 3+ #5 3+	Low	—	Voice trouble whole life
6	Conversation #1 3— #2 2+ #3 2+ #4 2—	Yelling #1 4+ #2 out #3 2— #4 3+ #5	—	—	Conversation - Node - Edema Yelling - Polyp - Thickening
7	Conversation #1 1— #2 Normal flexibility #3 3+ #4 2— #5 Normal flexibility	Teaching Voice #1 3+ #2 3— #3 3— #4 4+ #5 4+	High	Delicate	Contact Ulcer if #1 Voice Therapy continues
8	#1 4+ #2 4— #3 2— #4 1+ #5 1+		Medium High	Robust —	No prognosis Voice trouble whole life
9	#1 4+ #2 4— to out #3 — #4 — #5 —				
10	Conversation #1 1+ #2 1— #3 1+ #4 1— #5 ?	Dr.'s Exam. Tongue Out #1 1+ #2 1+ #3 1+ #4 1— #5 1—	Medium	Robust	No prognosis
11	Healthy Voice		High	Robust	No prognosis
12	Healthy Voice		High	Robust	No prognosis

Chart 1

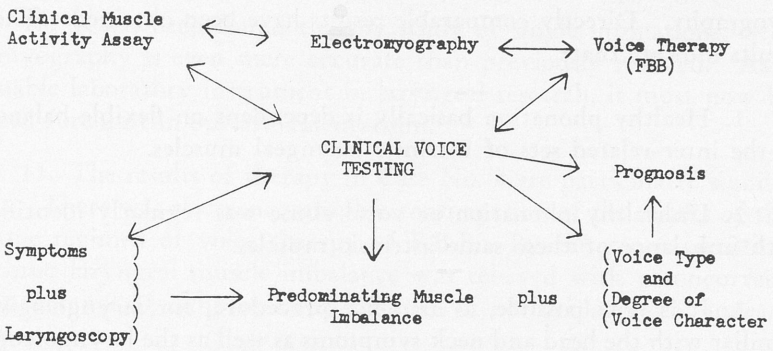

D.W.B. and F.B.B. have routinely, in their study of patients with voice problems prior to this investigation, correlated symptoms, laryngeal findings, and predominating muscle imbalance as determined by clinical voice testing. In this present investigation it was possible for them to predict accurately the predominating muscle imbalance to be found on clinical voice testing from knowing only symptoms and laryngeal findings. This was done without reference to any other information eight months after the initial examination without voice tape recordings or electromyographic findings available.

This procedure has a two-fold value. It enables the laryngologist, familiar with the head and neck symptoms and laryngeal findings of vocal abuse, to suspect the predominating muscle imbalance to be found later by the competent voice diagnostician and voice therapist. In addition, it indicates the patient's tissue reaction to the predominating abuse. This aids the laryngologist in prognosis and his evaluation of the necessary measures to be taken for relief of symptoms and lesion of each particular patient.

The relationships of the above major findings of this investigation may be indicated in chart form (Chart 1).

SUMMARY AND CONCLUSIONS

Activities of the intrinsic laryngeal muscles have been studied on the same patients on the same day by three separate techniques:

1) identification of major muscle imbalance by correlation of history and laryngoscopic findings; 2) clinical voice testing; and 3) electromyography. Directly comparable results have been obtained. These results indicate that:

1. Healthy phonation basically is dependent on flexible balances of the inter-related sets of intrinsic laryngeal muscles.

2. Unhealthy phonation or vocal abuse was regularly identified with imbalance of these same intrinsic muscles.

3. It is now possible, as an office procedure, for laryngologists, familiar with the head and neck symptoms as well as the laryngoscopic findings of vocal abuse, to suspect the responsible predominating muscle imbalance of the intrinsic laryngeal muscles.

4. Ratios of normal balances as well as imbalances in voice production were identifiable by clinical voice testing of F.B.B.

5. Based on clinical voice testing, it has been demonstrated that the amount of activity of these muscles required to produce voice sounds can be measured clinically both qualitatively and quantitatively even in a single intonation. This new technique has been termed clinical muscle activity assay.

6. In single intonations the electromyographically demonstrated ratio between "resting" and phonation amplitudes measured in microvalts is directly comparable with clinical muscle activity assay. Of 75 intonations so studied, full positive statistical correlation was found.

7. Clinical muscle activity assay can now be used as an additional clinical research tool to measure accurately the amount of vocal abuse occurring in each instance of imbalanced muscle activity in any individual voice.

8. F.B.B. and K.F.A. jointly present for the first time visual demonstration of divergence of function of thyroarytenoid and cricothyroid muscles.

9. K.F.A. for the first time presents in this paper a demonstration of the activity of muscle No. 3 or the lateral cricoarytenoid muscle.

Although he had examined this muscle in previous instances the report of its activity has not been previously published.

10. It has been found that by study of single intonations, electromyography is even more accurate than previously realized. As a valuable laboratory instrument in laryngeal research, it must now be placed foremost in our armamentarium.

11. The results of therapy in Case No. 4 are particularly significant. There was electromyographic confirmation of the results of the unique regimen of voice therapy of F.B.B. By this means, existing intrinsic laryngeal muscle imbalance was relieved with a concurrent disappearance of symptoms and a return of normal laryngeal appearance.

On the basis of these findings, it appears evident that a new school of voice diagnosis and therapy must be initiated. Here, well qualified individuals may be thoroughly trained in the techniques outlined above. With scientific training of this caliber, the great need for competent voice therapists can be met. By association with such therapists, the laryngologist who becomes familiar with clinical evidence of intrinsic laryngeal muscle imbalance can be fully effective in his management of patients with the many head and neck symptoms related to vocal abuse. We hope that this report will provide the stimulus for many additional research investigations in our chosen field of laryngology.

Last spring, we chose as the title of this paper "Phonation: Clinical Testing versus Electromyography." As a result of this investigation, we think it should now read "Phonation: Clinical Voice Testing and Electromyography."

1100 E. Genesee St.

(Detailed data, too voluminous for inclusion here, may be obtained from the authors.)

REFERENCES

1. Briess, F. Bertram: Voice Therapy, Part I. Identification of Specific Laryngeal Muscle Dysfunction by Voice Testing. A.M.A. Arch. of Otolaryng. 66:375-382 (Oct.) 1957.

2. Briess, F. Bertram: Voice Therapy, Part II. Essential Treatment Phases of Specific Laryngeal Muscle Dysfunction. A.M.A. Arch. of Otolaryng. 69:61-69 (Jan.) 1959.

3. Faaborg-Andersen, K.: Electromyographic Investigation of Intrinsic Laryngeal Muscles in Humans. Acta Physiologica Scandinavica, Vol. 41, Supplementum 140, Feb. 8, 1957.

4. Müller, Johannes: Handbuch der Physiologie des Menschen. Band 2, 1ste Teil, Koblenz 1837, pp. 133-245.

5. Gutzmann, H.: Physiologie der Stimme und Sprache. 1909, p. 10, Friedrich Vieweg und Sohn, Braunschweig.

DISCUSSION

DR. JOSEPH P. ATKINS: I think this is a very exciting paper and I want to compliment the authors on their fine work. It seems to me that this is a method for the evaluation of many problems in the larynx, not only related to voice production, but also to laryngeal paralysis. It suggests the possibility of evaluating laryngeal paralysis and its prognosis by means of electromyographic techniques. It seems to me a step which should not be long in coming. This is pioneering work and I congratulate the authors.

DR. DAVID W. BREWER (closing): I wish to thank Dr. Atkins very much for his kind remarks.

Dr. Faaborg Andersen in his first publication studied the effects of paralysis of the larynx in many patients with a paralyzed cord on one side and in several patients with a paralyzed cord on both sides. I am sure all of you will find that a most interesting research paper to read. I direct your attention to it.

THE USE OF REGIONAL FLAPS IN HEAD AND NECK SURGERY

JOHN J. CONLEY, M.D.
NEW YORK, N. Y.

The concept of neck replacement by regional flap transposition in instances where the risk of healing has been seriously handicapped by a devitalized tissue bed has much to recommend it. This concept should be an integral part of the pre-operative plan, including adequate flap replacement as a part of the composite resection in radical extirpative operations of the head and neck. This should be so regionally situated that it can be immediately transposed into the deficient neck wound as a continuance of the primary operation. This has improved the rehabilitation of these precarious wounds and added increased security to the operative technique. The technique has been developed over the past 15 years to include various types of tissue flap replacements to different deficiencies in unique positions in the neck in both the male and the female. These deficiencies relate to severe post-irradiation status, fungating metastatic cancers and pharyngostomes and esophagostomes.

In the past many seriously damaged wounds would undergo primary mucous membrane and skin repair with very little chance of healing. The postoperative course was frequently complicated by tissue slough, secondary infection, fistulization and often fatal carotid artery hemorrhage.

A pre-operative analysis of tissue-bed quality in the operative field is essential for proper planning. The most frequent and most serious type of tissue devitalization in the neck is the result of irradiation. The majority of the individuals in this status have undergone

From the Head and Neck Department of the Pack Medical Group and Surgical Service, St. Vincent's Hospital, New York City.

some type of intensive irradiation for a primary cancer in the oral cavity, hypopharynx, larynx, cervical esophagus or thyroid. Some of these individuals may have had intensive irradiation for metastasis to the cervical lymph nodes. Other individuals present with a history of having had radiation treatment for benign lesions of the thyroid, tuberculous glands of the neck, tonsillitis, papillomata, and for such conditions as acne, hypertrichiasis and various dermatological conditions. One of the prime considerations under these circumstances is an evaluation of the warranty for an extensive operation in this type of tissue bed. The intrinsic condition of the surface of the neck may range from mild atrophy, telangiectasia and fibrosis to a "frozen neck," where fibrosis, atrophy and diminished vascularity have reached critical proportions.

The general value of tissue resurfacing in the neck is to add an adequate healthy epithelial flap covering and supply protection to the common and internal carotid arteries. The acquisition of this tissue in the neck also facilitates tubular reconstruction of the gullet and/or may be used as a pedicled tissue flap over a newly formed gullet.

INDICATIONS

There are multiple situations requiring the use of regional flap transposition to the neck:

1. Radical neck dissection alone when the tissues of the neck have been irreparably damaged by irradiation and the primary cancer is controlled; these necks are firm, fibrous, atrophic and semi-fixed and do not have a reasonable chance of healing per primam when the neck flaps are repositioned. It is unreasonable to expect this quality of tissue to heal following radical surgical intervention when its biological capacity has been so seriously devitalized. The pre-operative planning of the resection of this devitalized tissue, and its replacement by an immediate rotated chest flap, is imperative.

2. Radical neck dissection where metastatic cancer has fungated through the skin and the primary cancer has been controlled by surgery or irradiation (irradiated or non-irradiated tissue bed): a wide epithelial surface resection is necessary and there is no choice but to plan pre-operatively appropriate regional tissue flaps to resurface the wound.

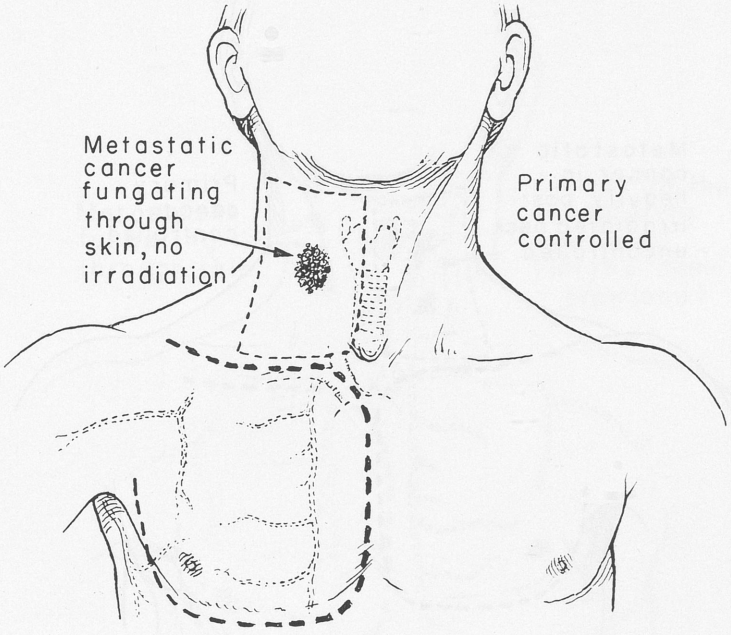

Fig. 1.—Radical neck dissection only, where metastatic cancer has fungated through skin. Primary cancer controlled. One-stage resurfacing procedure.

3. Composite extirpative operations in non-irradiated cases where the primary cancer in the oral cavity, pharynx, larynx, or cervical esophagus has not been treated and where the metastasis has compromised the skin of the neck: in a non-irradiated tissue bed one is justified in attempting a primary repair of the gullet if adequate mucous membrane remains, with immediate resurfacing by a regional tissue flap as a one-stage procedure.

4. Composite extirpative operations in heavily irradiated cases where skin may or may not be compromised: the increased risk of failure of primary healing of the post-irradiated mucous membrane tissues makes primary repair hazardous, frequently complicated by a breakdown of the mucous membrane suture line, fistula formation, secondary infection, protracted morbidity and possible carotid artery hemorrhage. Preferably, an elective pharyngostome, utilizing neck

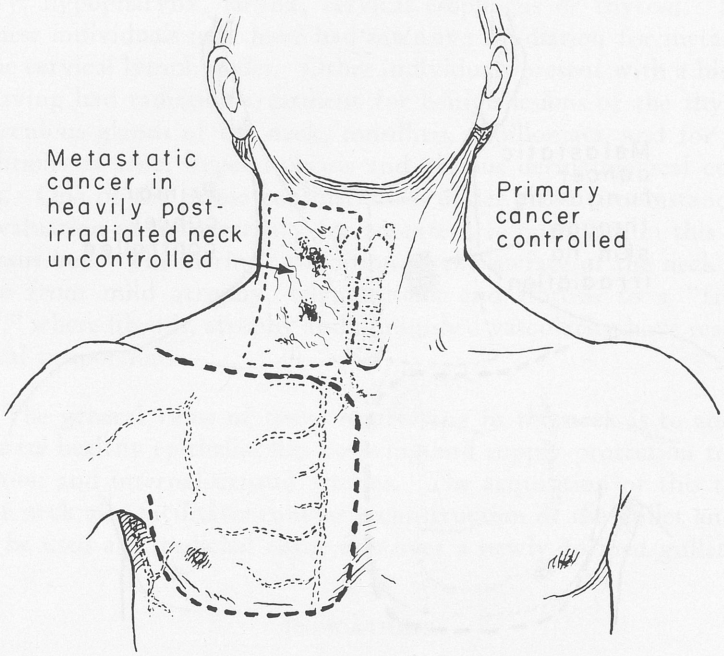

Fig. 2.—Radical neck dissection only, in compromised post-irradiated neck. Primary cancer controlled. One-stage resurfacing procedure.

flaps or chest flaps for covering the carotid artery is employed. The pharyngostome is then closed in an interval of one to two months as a secondary procedure by inverting the residual pharyngeal mucosa or neck skin, and then utilizing an immediate chest flap for resurfacing the new gullet.

5. Closure of pharyngostome problems when neck skin is used to create a new gullet but is inadequate for resurfacing: these situations include composite resections with unilateral neck dissection where the post-irradiation status prevails. Under these circumstances enough tissue remains in the neck to create a gullet, but the epithelial resurfacing of this new gullet is best accomplished by regional flap transposition. Composite operations with bilateral radical neck dissection in the normal, or post-irradiated wound status, create a problem where it is impossible to completely rehabilitate the gullet by neck flaps alone. A new gullet is formed by the inversion of the adjacent tissues

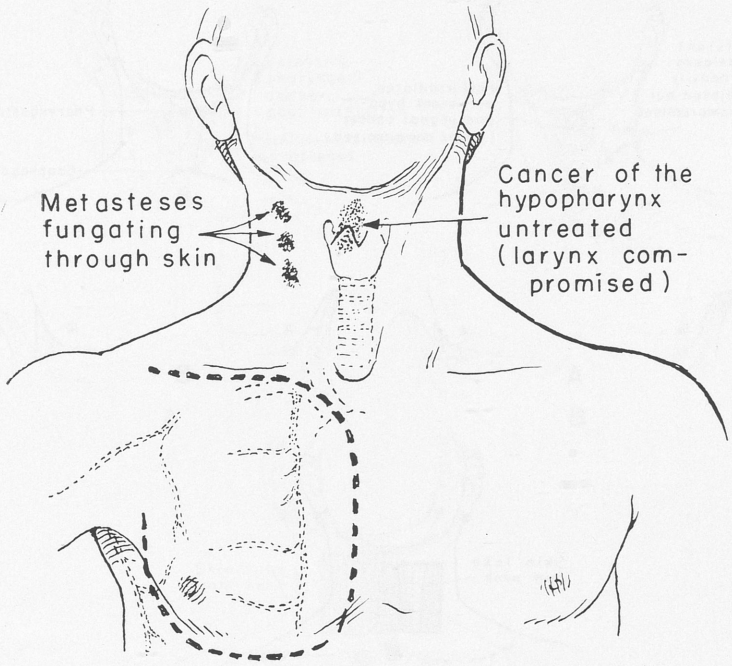

Fig. 3.—Composite resection, untreated, skin compromised. One-stage resurfacing procedure.

of the neck, but there is never adequate residual tissue in the neck to resurface this new gullet. Resurfacing is accomplished by regional flap transposition.

TYPES OF FLAPS

It should be emphasized that these flaps are not delayed in their transference, but are transplanted immediately in a one-stage technique. This single fact gives the regional flap its importance and distinction from distant and delayed flaps. The employment of distant pedicles from the abdomen, arm, chest, back, etc., formed into tubes and then over a period of months migrated into the wound and then remodelled after implantation, presented the patient with such a protracted morbidity and multiphase surgical experience that this in itself was often considered a deterrent to the advisability of an

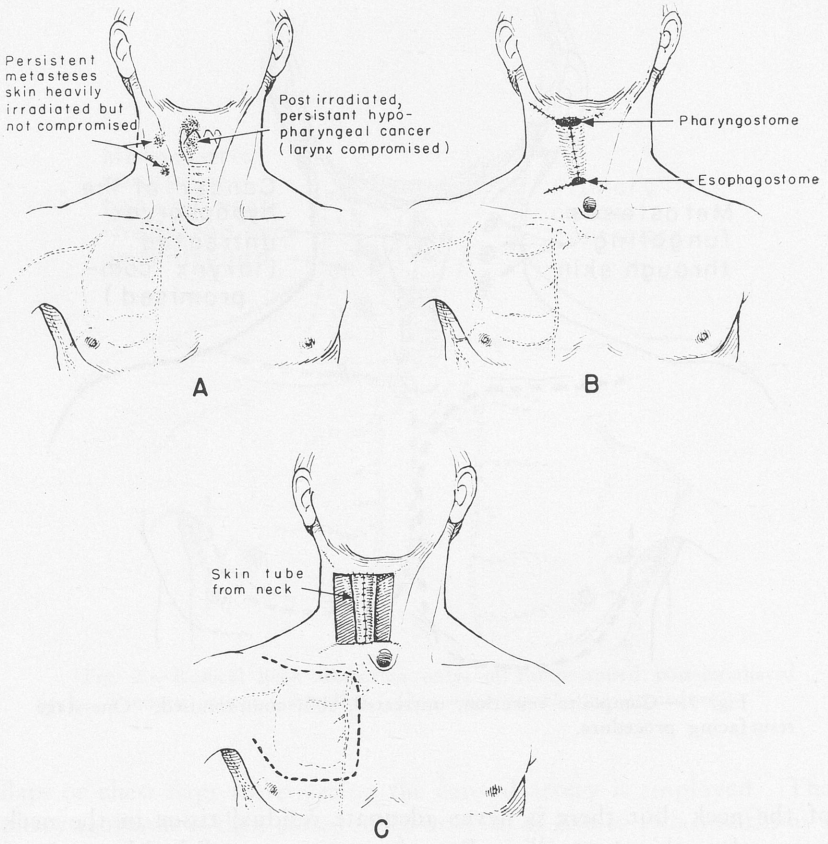

Fig. 4.—Composite resection, post-irradiated status, unilateral neck dissection. Two-stage rehabilitation procedure.

extensive primary resection. These protracted procedures have very little place in head and neck surgery today.

There are basically five types of regional flaps which are applicable for resurfacing maneuvers in the neck. These various flaps have particular and specific advantages relating to their regional blood supply, their local position in relation to the wound, the size of the wound, the presence or absence of local irradiation, the phenomenon of hair bearing coverings, and the variations in chest physiognomy in the male and female.

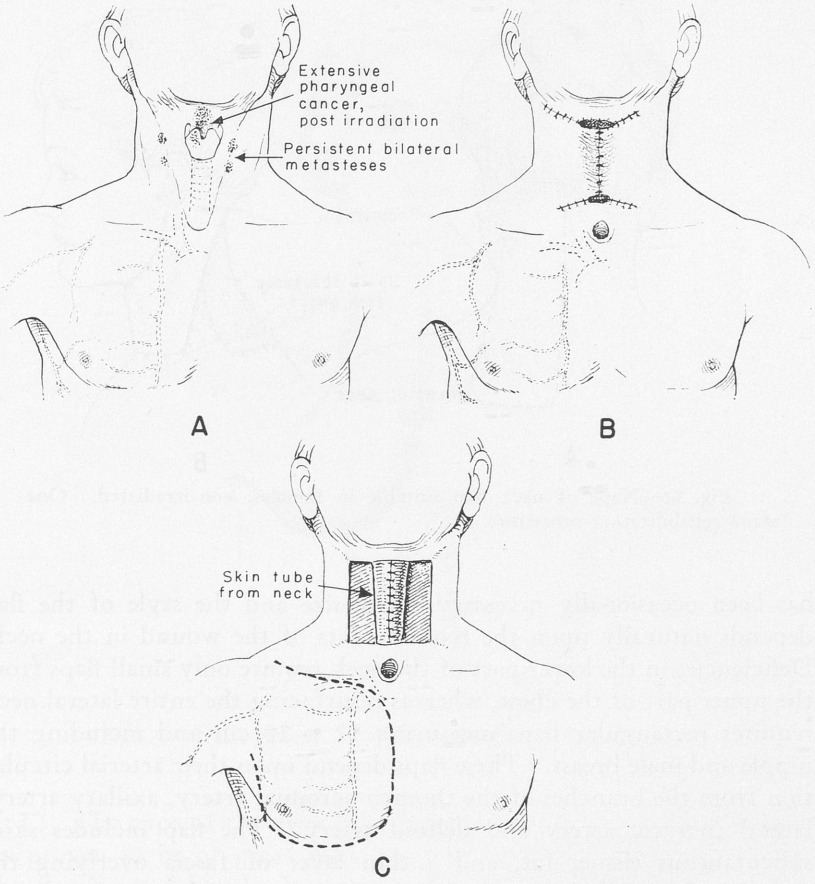

Fig. 5.—Composite resection, irradiated or non-irradiated, bilateral neck dissection. Two-stage rehabilitation procedure.

1. The most utilitarian flap used in resurfacing the neck is the anterior chest flap with the lateral pedicle. The vast majority of the primary cancers in this category requiring this special management occur in males. This flap has limitations in the female because of the size and position of the female breast and the factor of breast mutilation. The anterior chest wall is rarely included in the field of irradiation and contains little hair. Usually only unilateral pre-operative planning is required; however, the use of bilateral anterior chest flaps

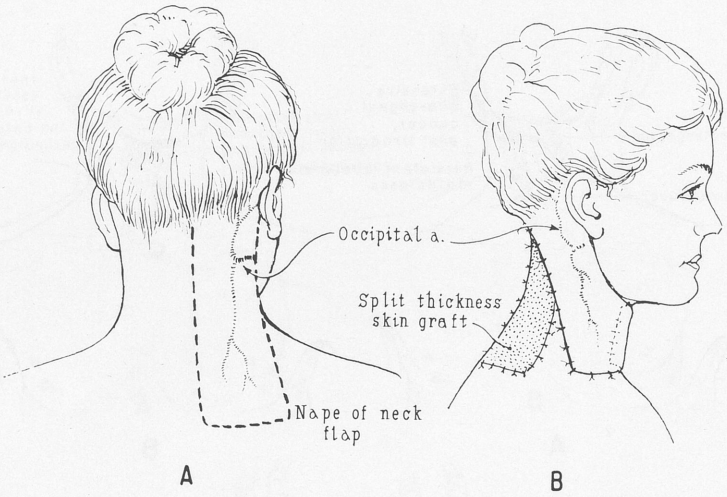

Fig. 6.—Nape of neck flap suitable in females, non-irradiated. One-stage rehabilitation procedure.

has been occasionally necessary. The size and the style of the flap depends naturally upon the requirements of the wound in the neck. Deficiencies in the lower part of the neck require only small flaps from the upper part of the chest, whereas resurfacing the entire lateral neck requires rectangular flaps measuring 12 x 20 cm and including the nipple and male breast. These flaps depend upon their arterial circulation from the branches of the thoraco-acromial artery, axillary artery, lateral thoracic artery and deltoid artery. The flap includes skin, subcutaneous tissue, fat, and a thin layer of fascia overlying the pectoralis muscles.

2. The anterior chest flap with the medial pedicle is particularly adapted to deficiencies in the lower part of the lateral or central neck. This flap ordinarily cannot be tailored as large as the laterally pedicled chest flap and will consequently not reach to the upper limits of the neck. Again, the absence of hair and the unlikelihood of this having been previously irradiated and its proximity to supraclavicular and suprasternal deficiencies gives it significant value. It also may be planned on unilateral or bilateral basis. Its essential blood supply is derived from the perforating branches of the internal mammary artery.

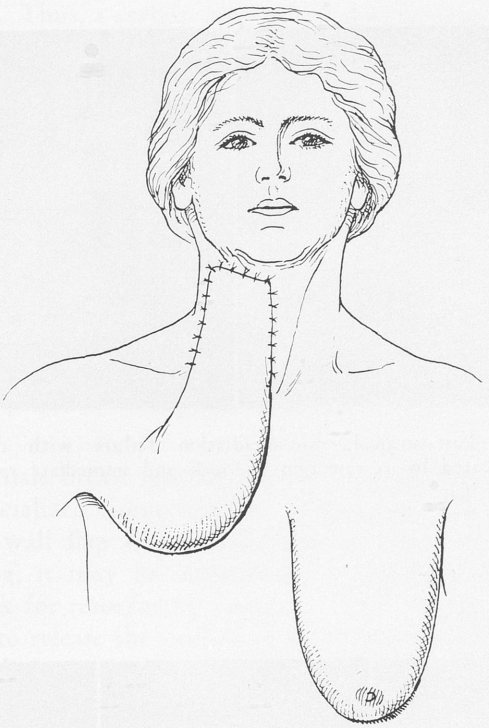

Fig. 7.—Breast pedicle. Two-stage rehabilitation procedure.

3. The nape of the neck flap with the superior subnuchal pedicle has proven to be of great value in resurfacing the neck in females. This flap is not delayed. It contains skin, subcutaneous tissue and fat, and the fascia over the trapezius muscle. It is wrapped around the neck like a muffler, leaving an inconspicuous donor site posteriorly and matching the naturalness of the neck well in color and consistency. Some have extended beyond the midline of the neck anteriorly and have measured 21 cm in length. This flap depends upon its essential nourishment from the postauricular artery and the occipital artery. If these arteries are inadequate, the flap is compromised. These flaps ordinarily contain little hair in the male or female. The principal disadvantages are that they are positioned posteriorly in the region of the nape of the neck and are awkward to mobilize and transpose. A biological deterrent is that these flaps are frequently included in or

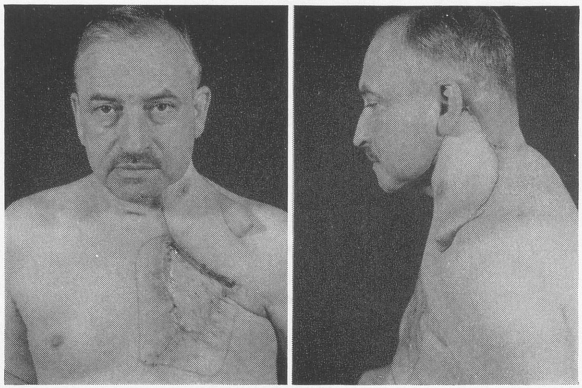

Fig. 8.—Post-surgical, post-irradiation failure with recurrent neck metastasis treated by re-resection of neck and immediate resurfacing with rotated chest flap.

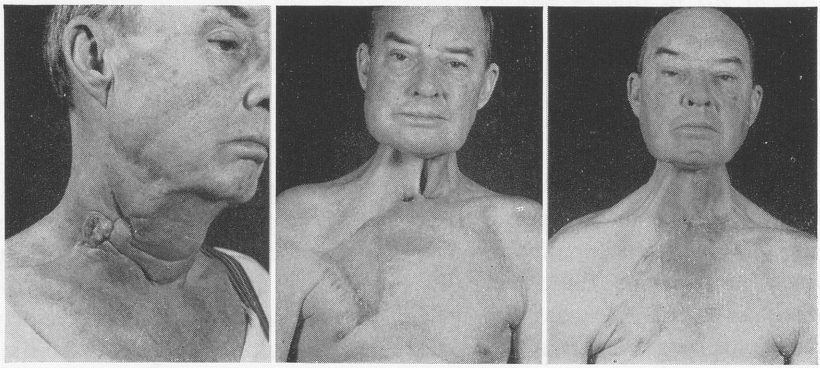

A B C

Fig. 9.—*A*, recurrent post-irradiated, post-operated cancer of thyroid with metastasis; *B*, post-thyroidectomy, -laryngectomy, -bilateral neck dissection; neck resurfaced with chest flap at same operation; *C*, rehabilitation of gullet.

approximate the field of irradiation for the primary cancer in the head and neck. Thus, a certain amount of post-irradiation effect may have altered the viability of the flap. This is considered a contra-indication to the use of the flap. There are modifications in the design and styling of the flap with its positions over the lower part of the neck and scapula that are suitable for special problems.

4. Scalp flaps have particular applicability to deficiencies in the upper part of the neck, about the ear, parotid gland and subdigastric areas. Scalp flaps are hair bearing flaps, except in alopecia, and are consequently best adapted to the male. The flaps are usually patterned in the occipital or parietal areas and utilize th perforating branches of the occipital artery, postauricular artery and superficial temporal artery.

5. The female breast may be used as a pedicle flap for the lower neck under specialized circumstances. If the nape of the neck flap or anterior chest wall flap is precluded and if the breast is thin and sufficiently long, it may be immediately transposed onto the lower part of the neck for resurfacing purposes. In this particular instance, it is necessary to release the pedicle after an interval of three or four weeks and tailor the breast tissue on the neck and return the residuum of the breast to the chest. This technique is rather curious but has a limited practical value.

TECHNIQUE

The dominant feature of the technique is that the flap is immediately raised and transposed. At this stage, it is soft, supple and flexible. It is sutured into the wound in layers without tension or distortion. Particular care should be taken to eliminate hematoma and saliva from the wound. Only slight pressure is applied to the pedicle flap with the dressing. If there are any signs of insufficient arterial supply or venous return, reposition of the flap into its original bed is mandatory. The flap may then be transposed two weeks later. There are many circumstances where this is not practical, namely when one is committed to cover the essential vascular structures of the neck with a regional flap at the primary operation. Under these circumstances, some type of modification of the flap, or the use of two flaps in conjunction with a free skin graft must be considered. If

the nipple is in a conspicuous position on the neck, it may be excised as a minor office procedure at a later date.

Slough of the nipple has never been observed. The flaps heal per primam in almost all instances. Very occasionally a 1 cm eschar may form superficially at the extreme periphery. There are "dogears" at the posterior inferior portion of the flap that may require minor modifications. The donor area on the chest or at the nape of the neck or scalp is dressed with a thick-split free skin graft held in position over a bolus.

SUMMARY AND CONCLUSIONS

1. Regional pedicle flaps offer the most efficient source of covering for deficiencies in the neck following radical neck surgery associated with fungating metastasis or severe post-irradiation status with compromise of the skin.

2. These flaps should be planned as an integral part of the primary excisional operation.

3. Their positions are on the anterior chest, the nape of the neck and the scalp.

4. Their great advantage over other techniques is that they can be moved without delay in a single stage procedure as a continuance of the primary operation.

5. They shorten morbidity and add surgical security to the operation.

6. They accomplish resurfacing, protect the carotid artery system, and add tissue for rehabilitation of the gullet.

139 East 36th Street

DISCUSSION

Dr. John M. Converse: Mr. Chairman, it gives me great pleasure to congratulate Dr. Conley on the marvelous presentation that he has just made. I think he has shown us the solution to this particular problem where obviously one needs full thickness skin and subcutaneous tissue maintained on a pedicle in order to protect the vital structures of the neck in an area where free skin grafts cannot be used. He has taken the skin from the most obvious areas and has transferred this skin without any preliminary delay in one stage. This is a great advantage because in this way you don't have to do a great deal of preliminary planning and preparation of flaps.

What he has perhaps not sufficiently emphasized are things which are obvious to anyone who has had a great deal of experience in reconstructive surgery. These are the skill with which he has done the transfers, the gentleness with which he has handled the flaps and the careful planning and design of te flaps. As you know, a pedicle flap will survive on its pedicle for a certain length of time, but you cannot count on the permanent survival of a flap on its pedicle. The flap must receive a blood supply from the recipient site. Particularly the flaps he has shown us must be revascularized from the neck after they have been transferred. This revascularization is very rapid and takes place within a few days. This means careful planning, careful handling of the flaps and careful coaptation of the flaps in the recipient site. Dr. Conley has given an excellent demonstration of his ability to do this exacting work.

Dr. Julius W. McCall: It is always interesting and enjoyable to listen to Dr. Conley. When you see him work you realize that he is an artist par excellence.

We became very much interested in this problem at St. Luke's Hospital in Cleveland several years ago when in one year we had four spontaneous ruptures of the carotid artery in patients who had had neck surgery following irradiation. We are now following Dr. Conley's method of using a chest flap for any patient who requires neck surgery following x-ray therapy.

Dr. John J. Conley (closing): I am indebted to the two discussers for their very kind remarks. At the Laryngological meeting last year, that snowy day in the mountains of West Virginia at the Homestead, Dr. Julius McCall showed us a picture of the transposition of a large chest flap on one of his problem cases. I am delighted to see that we have a more or less similar concept of the management of this problem, a concept that has evolved from the anguish of seeing carotid artery hemorrhages, sloughs and other complications.

POSTERIOR CHOANAL ATRESIA

DANIEL C. BAKER, JR., M.D.

JULES G. WALTNER, M.D.
(by invitation)

AND

WILLIAM NOVICK, M.D.
(by invitation)

NEW YORK, N. Y.

Atresia of the posterior nares is probably a common congenital anomaly. In recent years, there has been a marked increase in the number of papers dealing with this subject. This is due to two factors, one, the relation of bilateral choanal atresia to respiratory and feeding difficulties in the newborn, and the other, the increased interest in the surgical correction of the condition.

It is important for the otolaryngologist to think of choanal atresia whenever respiratory obstruction is present in the newborn. In addition, the possibility of this defect being the cause of unilateral nasal obstruction in children as well as adults has to be considered.

This presentation will show our experience with 15 cases of atresia of the posterior nares.

The excellent contribution of others to the subject has been most helpful. Boyd[1] made a very thorough study of congenital atresia of the posterior nares. Hanckel[2] reviewed the literature and noted that Otto described the anomaly in 1831. Hanckel discussed the theories as to the development of the disorder. It may be the result of a persistence of the nasobuccal membrane; or a medial overgrowth of the vertical and horizontal palatal processes; or a persistence of the

---

From the Department of Otolaryngology, Presbyterian Hospital and the College of Physicians and Surgeons, Columbia University, New York, New York.

nasopharyngeal membrane. Hanckel reported a case in an infant who had severe respiratory difficulties at birth. A tracheotomy was necessary. This was followed later by a transpalatal approach for removal of the bony atresia.

Beinfield[3-7] has described the symptoms of the newborn with bilateral choanal atresia. He has stressed its relation to asphyxia and the emergency nature of the problem. He has described the methods of correcting the condition by an intranasal approach.

Morrow[8] reported three cases of bilateral atresia of the posterior nares in the newborn. All were operated on successfully.

Hough[9] has described the mechanisms of asphyxia in bilateral choanal atresia. A newborn infant will not automatically open its mouth to breathe, if it cannot breathe through its nose. This is the important factor in the respiratory difficulties.

Wilson[10] and Rawdon and Baade[11] have described the surgical treatment of the condition by the transpalatal approach.

All of the authors mentioned have covered the subject of posterior choanal atresia very adequately. No attempt will be made to discuss the phases of the subject that are already well known. The experience gained by our study of 15 patients with this congenital disorder might be of value to others. It is presented with this object in mind.

ANALYSIS OF CASES

None of the cases presented were classified in the emergency group as mentioned by Beinfield and Morrow. There was no instance in our hospital where a diagnosis of bilateral atresia of the posterior nares was made at birth or shortly thereafter. All newborn infants with emergency respiratory disturbances are usually seen by a member of the otolaryngological service. In addition, infants with respiratory difficulties are referred to Babies Hospital from other institutions. There are a large number of patients. It is difficult to give a reason why we have not had infants requiring emergency nasal surgery at birth. It is possible that the patients are adequately treated elsewhere, and that there is no reason for referral. It is also possible that such

infants die from asphyxia due to lack of proper diagnosis and recognition of choanal atresia.

In our group there were 3 children with bilateral bony atresia of the posterior nares. All were operated on by a transpalatal approach. The youngest was 22 months. Two children of the group had bilateral membranous atresia and were operated on by the intranasal route. All 5 of these children were less than 5 years of age at the time of surgery. How they were able to survive the bilateral atresia of the posterior nares at birth is best explained by the fact that they developed the ability to breathe through their mouth shortly after birth. All of these infants had respiratory difficulty and disturbances in feeding at birth. They were not seen by our service until after they had adjusted to their disability.

After surgery was performed on these children, it was necessary to leave a catheter in place until healing had occurred and a lumen had been established. It was important to carry out dilatations after the catheters were removed. Treatment sometimes required six months or longer.

There were ten patients with unilateral posterior choanal atresia. The youngest case recognized in this group was one month of age. The oldest was 57 years of age. The unilateral cases had no respiratory or feeding problems. A persistent anterior nasal discharge from the obstructed side of the nose was the only constant symptom. Two patients had an infection of the sinuses on the involved side. It should be mentioned that Beinfield considers unilateral atresia of the posterior nares in the infant as potentially dangerous. If the infant's open nasal chamber becomes obstructed, as a result of infection or even position in a crib, asphyxia may result.

All of the patients had either an intranasal or transpalatal operation for the atresia. In a group of eight adults, seven had a previous submucous resection. The submucous resection was not successful in 5 cases, and a transpalatal operation was performed.

Care has to be taken during the operation so that mucosal flaps are preserved both from the nasal side as well as the pharyngeal side of the atresia. The flaps are used to cover the denuded bone. This was easier to accomplish when the transpalatal approach was used.

Some authors have recommended the use of a skin graft after the atresia was removed. This was not necessary in any of these patients.

Not all of the patients were successfully taken care of. There was no good follow-up in five of the patients. It can be presumed that they sought help elsewhere.

The patients on whom the transpalatal approach was performed had the best result. From a surgical standpoint, it is the logical approach to the area involved. There were no surgical complications. Healing of the palatal incision was by first intention. There was not as much discomfort as would be present from a tonsillectomy.

After the atresia was removed, a polyethylene tube was inserted. The tube extended from the anterior nares to the nasopharynx. The tube was removed once or twice a week and the nose was washed out. The tube was then reinserted. This adds to the comfort of the patient, as well as keeping down secondary infection.

The tube was completely removed on an average of 6 weeks after surgery. It became apparent to us that the operated area would then become smaller from above downward, leaving a small round opening along the floor of the posterior nares. The narrowing was due to fibrous tissue formation. In order to get a satisfactory opening, it was necessary to reopen the fibrous tissue with a knife and to carry out dilatations. The latter was not too successful. In order to solve this probelm, after the fibrous tissue was incised, a piece of cleared x-ray film was inserted through the stenosed area. The plastic film was cut so that it could be introduced into the nasal chamber. It was of such length that it extended from the nasal tip to the nasopharynx. The nasal tip kept the strip in proper position. The posterior edge of the plastic material was readily visible by posterior rhinoscopy. No reaction was seen even when left in the nose for three months. The use of the cleared plastic x-ray film was most helpful in obtaining a final good result.

SUMMARY

Fifteen patients were observed with atresia of the posterior choanae. There were ten unilateral and five bilateral cases. Ten of the patients had a bony atresia and five were of the membranous type.

Adequate surgery can be performed by either the intranasal or transpalatal route. The latter was found to be more satisfactory in our experience.

The use of cleared x-ray film, introduced in a vertical plane through the posterior choana, allows for better epithelialization and helps to prevent stenosis of the upper part of the posterior nares. The lumen thus obtained is more nearly normal, than if a polyethylene tube is used alone.

903 Park Ave.

REFERENCES

1. Boyd, H. M. E.: Congenital Atresia of the Posterior Nares. Arch. Otolaryng. 41:261, 1945.

2. Hanckel, R. W.: Bilateral Choanal Atresia. Annals of Otology, Rhinology and Laryngology 58:852, 1949.

3. Beinfield, H.: Treatment of Complete Unilateral Bony Atresia of the Posterior Nares. Arch. Otolaryng. 53:530, 1951.

4. Beinfield, H.: Bilateral Bony Atresia of the Posterior Nares in a One-month Premature Infant Who Survived. J. Pediat. 45:679, 1954.

5. Beinfield, H.: Surgical Management of Complete and Incomplete Bony Atresia of the Posterior Nares. Trans. Am. Acad. Ophth. and Otolaryng. 60:778, 1958.

6. Beinfield, H.: A Forgotten Cause of Infant Suffocation. The Possible Relation Between Atresia of the Posterior Nares to Asphyxia Neonatorum and Sudden Infant Death. J. Int. Col. Surg. 22:447, 1954.

7. Beinfield, H.: Surgery for Bilateral Bony Atresia of the Posterior Nares in the Newborn. Arch. Otolaryng. 70:1, 1959.

8. Morrow, R.: Bilateral Congenital Choanal Atresia: A Report of Three Cases Corrected Surgically in the Newborn. Annals of Otology, Rhinology and Laryngology 66:135, 1957.

9. Hough, J. V. D.: The Mechanism of Asphyxia in Bilateral Choanal Atresia. The Technique of Its Surgical Correction in the Newborn. Southern Med. J. 48: 588, 1955.

10. Wilson, C. P.: Treatment of Choanal Atresia. J. Laryng. and Otol. 71:616, 1957.

11. Rawdon, R. E., and Baade, E. A.: The Transpalatal Approach to Choanal Atresia. Trans. American Otorhin. Soc. Plas. Surg. 3:27, 1960.

DISCUSSION

DR. LYMAN G. RICHARDS: Occasionally one finds an adult patient with unilateral atresia whose chief complaint is chronic nasal discharge. He may have been treated for sinus infection for years. One way to avoid the more complicated procedure Dr. Baker has described is to do a generous removal of the nasal septum. This may seem unphysiological, but the results are excellent. The patient is rid of his nasal discharge. He can breathe in a sort of "Y" shaped fashion through both sides of the nose in front and one side down the back. As far as the comfort of these patients is concerned, they are completely cured.

DR. ARTHUR J. CRACOVANER: I want to compliment Dr. Baker on a very fine summary of this subject. I would like to make a few remarks based on my experience.

First of all, it is important to preserve the flaps so you can cover denuded surfaces. In addition, it is very important to make a large enough opening in the septum. In other words, remove as much of the vomer as possible because you do have a posterior choanal opening that is relatively small compared with the other side. You have to make the opening in the septum large enough to compensate for the small posterior choanal opening.

Concerning the incision I compromise a bit. I don't make the incision close to the teeth, because when I have done so there is a large flap to push backward. If the patient is a small child the large flap becomes cumbersome and is in the way. On the other hand, if you make a flap posteriorly I feel you should have some bone to support the line of incision.

Concerning the postoperative polyethylene tubing, I have used it not so much with the idea of keeping the opening patent, but with the idea of keeping the flaps in place.

DR. HERBERT H. HARRIS: I think Dr. Baker has covered this subject exceedingly well. He has a relatively large number of cases because they are not very common.

Recently we are doing tracheotomies for all of these children and are not operating on them until they are about two years of age. We are convinced that for children the best approach is the trans-palatine approach. We are using the dental burr to thin down the lateral wall, take off the posterior end of the septum and produce a much larger posterior choanal area. It is quite true that you will lose the flaps if you do not preserve the blood supply from the palatines. Our experience in adults is fairly good. I have operated on a number of adults by the intranasal route and I must agree that removing about a third of the septum, as Dr. Richards has mentioned, has given very good results. Sometimes it is necessary later to punch out obstructing scar tissue. I do think tracheotomy is the answer for newborns. I did have the misfortune to lose a four pound child who had pneumonia when he was admitted—despite the fact that a tracheotomy was done promptly.

DR. SHIRLEY BARON: I was interested to see that Dr. Baker's youngest patient was 22 months of age. We have operated on children as young as four months of age. I am not so sure that it is necessary to do a tracheotomy on these cases and then postpone operation until they are two years of age. I think it is important to have a large flap. Incidentally, this four months old patient was operated on by the transpalatal approach, which I think is the best approach. I had a palatal fistula

develop in one case. I think if a larger flap had been developed this would have been avoided.

I would like to call your attention to one diagnostic sign which I think is practically pathognomonic of bilateral choanal atresia in infants. It is what I call ballooning of the palate. When the tongue is depressed anteriorly the child cannot exhale with the tongue back against the palate and the pharynx, and the palate will balloon out.

DR. HENRY L. WILLIAMS: I did not intend to come up here until I heard Dr. Herbert Harris' remarks about the need of doing tracheotomies in these children. I would like to call your attention to a paper written by Dr. Gordon New about forty years ago, in which he suggested the solution to the immediate problem of the breathing difficulty of the newborn by putting a plastic tube into the mouth and fixing it in place. This allows the child to breathe so one doesn't have to do the operation as an emergency procedure. Operative treatment can be delayed until the child's condition is better. They do get along quite well and do not expire if the tube is maintained in place. It is a very simple solution even though it is forty years old. I suppose it is not well to advocate these old, sort of outmoded methods of therapy, even though they work.

DR. DANIEL C. BAKER (closing): I wish to thank the discussers. Dr. Richards mentioned removal of the posterior part of the septum. Actually this operation is simple enough. It does not require much more surgery than removal of the posterior part of the septum. It is much easier and is a more direct approach. I would be inclined to do it because of the assurance of the good result to be expected.

It is an interesting fact that the newborn infant does not learn to breathe through its mouth until five months of age. Prior to this time if the nose is pinched off the youngster does not have the reflex to open the mouth and breathe. Instead the mouth closes up, the lips are sucked in and the child has all the appearances of strangulation.

As far as tracheotomy is concerned, many of the cases that are reviewed in the literature have had a tracheotomy but not all of them. Several of the cases reviewed had a membranous type of atresia. It was possible to perforate the atresia and to introduce a rubber tube. This was maintained for five months, at which time definitive surgery was possible.

I was interested in Dr. Baron's remark about the ballooning of the palate. I shall look for this in the next case I see.

I was interested in the remarks of Dr. Williams. I was not familiar with the technique of Dr. New.

FINDINGS REFERABLE TO THE UPPER PART OF THE RESPIRATORY TRACT IN WEGENER'S GRANULOMATOSIS

HENRY A. BROWN, M.D.

LEWIS B. WOOLNER, M.D.

ROCHESTER, MINN.

In this paper we shall present reports upon six patients who had the presenting symptoms of infection of the upper part of the respiratory tract who later gave evidence of a generalized disease process in which the symptoms and signs of glomerulonephritis were prominent. Necropsy was done in four cases, and in these the pathologic diagnosis was periarteritis nodosa. In one patient who died with the diagnosis of acute nephritis, the diagnosis of periarteritis nodosa was assumed from the course of the disease and the multiple systemic involvement. In the patient who was still living two years after the onset, at the time of this report, the diagnosis of periarteritis nodosa was made on the same basis.

Of special interest is the speculation as to whether the periarteritis nodosa developed secondary to the infection in the upper part of the respiratory tract or whether the condition merely represents a local manifestation of periarteritis nodosa appearing initially in the tissues of the upper part of the respiratory tract.

REVIEW OF THE LITERATURE

In 1936 and 1939 Wegener[1,2] presented three cases in which destructive granulomatous rhinitis was associated with prominent pulmonary symptoms, glomerulonephritis and generalized angiitis. He realized that this unusual clinicopathologic symptom complex did

---

The Mayo Foundation, Rochester, Minnesota, is a part of the Graduate School of the University of Minnesota.

not apply to any known specific granulomatous disease, and he recognized that except for the granulomatous lesions found in the respiratory tract, the disease was very similar to periarteritis nodosa. Wegener[1,2] and others[3,4] have considered the disease a variant of periarteritis nodosa.

There is some debate as to whether Wegener's granulomatosis and the so-called lethal midline granuloma are somewhat similar but actually different disease processes or merely synonyms for the same disorder.[5-8] In describing his cases Wegener obviously was describing instances of midline granulomas, and he was the first to demonstrate the presence of generalized periarteritis nodosa in this condition at necropsy. On the basis of later reports in the literature it seems doubtful that any real distinction between the two conditions can be made, although Atkins and Eisman[9,10] have suggested that the difference lies in the location of the lesions. If the nose, sinuses and pharynx are involved, the lesion is lethal granuloma; but if the larynx, trachea and lungs are involved, the process should be termed "Wegener's granulomatosis." There seems to be little merit in such an artificial division, however, in view of the fact that Wegener was reporting on midline granulomas, and since granulomatous lesions often are found in the nasal chambers, sinuses, pharynx, larynx, trachea and lungs of the same patient. The modern tendency seems to be to include as many lesions as possible under a single heading rather than to produce artificial divisions in essentially similar conditions. The underlying periarteritis nodosa seems to be the important pathologic condition in these lesions, and therefore "Wegener's granulomatosis" and "midline granuloma" should be considered synonyms.

The exact causation of Wegener's granulomatosis is unknown, but most recent authors agree that it is a disease of hypersensitivity. Wilson and Alexander[11] wrote that in man the lesions of periarteritis nodosa have been found at necropsy in the bodies of persons who in life had had the presenting symptoms of various forms of allergy.[12] Granulomas, the other finding in Wegener's granulomatosis, have been produced experimentally by injection of egg white into the subcutaneous tissue of a sensitized animal.[13]

Blatt and associates[7] suggested that some noxious substance, such as a chemical, physical agent or more likely an infectious organism, might bring about local tissue destruction in the respiratory tract

which, acting as an auto-antigen, might react with auto-antibodies and produce a state of hypersensitivity. Stratton and associates[8] wrote that bacterial or chemical agents associated with infections of the upper part of the respiratory tract may produce a localized hypersensitivity reaction in the respiratory tract, sensitize the body generally and produce the arterial lesions associated with periarteritis nodosa. Some authors have felt that the sulfonamide compounds or antibiotic agents[12,14] used in the treatment of infections of the upper part of the respiratory tract may have been responsible for the development of granulomatous lesions of the respiratory tract and subsequent generalized periarteritis nodosa; however, instances of Wegener's granulomatosis have developed when sulfonamides or antibiotic agents have not been administered.[1,8]

Godman and Churg[6] said that Wegener's granulomatosis has clinically recognizable manifestations, a particular natural history and anatomically diagnostic features which distinguish the disease from the ordinary form of periarteritis nodosa, but they allowed that the two are close relatives. They wrote that the vascular lesions associated with Wegener's granulomatosis closely resemble those of the microscopic form of periarteritis nodosa.

Godman and Churg[6] have listed the pathologic characteristics of Wegener's granulomatosis as follows:

1. A necrotizing granulomatous process involving the upper or lower part of the respiratory tract, or both.

2. Generalized focal necrosing vasculitis involving both arteries and veins, almost always in the lungs and more or less widely disseminated in other sites.

3. Glomerulitis characterized by necrosis of loops or lobes of the capillary tuft, adhesions and development as a granulomatous lesion.

CLINICAL PICTURE OF WEGENER'S GRANULOMATOSIS

The following description of the manifestations of Wegener's granulomatosis was evolved by review of cases reported in the literature,[8,10,14-26] especially the excellent summation of clinical observations by Fahey and associates.[21] The disease affects men and women of all ages, most frequently in the fourth and fifth decades.

The patient initially complains of an acute infection of the upper part of the respiratory tract; or occasionally a cough or thoracic discomfort may be the first symptom. Bloody nasal discharge, symptoms of acute sinusitis or hoarseness or the symptoms and signs of infection of the ear may develop. The process continues to advance in spite of vigorous treatment, including use of the sulfonamide compounds and antibodies. Staphylococcus aureus and less frequently a hemolytic streptococcus, a pneumococcus, species of Proteus or other organisms may be cultured from swabbings of the nose or throat, but the patient does not improve after the organisms have been eradicated. Edema over the maxilla, ocular proptosis, antro-alveolar fistula or even saddleback nasal deformity may develop, but, conversely, there may be no external manifestations of the disease, in spite of varying degrees of intranasal disease.

An infection of the ear may persist in a subacute degree, producing some loss of hearing or possibly a collection of fluid behind the tympanic membrane. Occasionally, however, the infection of the ear may become the most active part of the disease process, producing severe neurosensory deafness or facial paralysis, and may require surgical treatment for mastoid disease. Intranasal examination carried out early in the disease may seem to indicate that ordinary acute rhinosinusitis is at hand. A little later the nasal septum or turbinates may take on a granular appearance and bleed somewhat easily when touched or when adherent scales are removed. Still later definite granulomas may appear in the nose, most frequently on the nasal septum. Late in the disease both nasal chambers may be filled with bloody crusts, and there may be extensive destruction of the intranasal structures, including the septum, or the nasal chambers may be filled with granulomatous tissue.

Ulcers may appear about the pharynx, mouth or tongue, and results of biopsy, culturing and inoculation of guinea pigs with swabbings will fail to establish the cause of the disease. Early in the disease acute laryngitis may appear to be present, and later granulomatous ulcers, covered by adherent crusts, may arise in the larynx. Occasionally the larynx may be extensively involved, with or without significant symptoms referable to the nose or ears, and subglottic granulomatous masses may produce sufficient respiratory obstruction to necessitate tracheotomy.

Patients who have Wegener's granulomatosis usually present constitutional symptoms out of proportion to the clinical findings. The patients are almost always febrile, lose weight, become anemic, and have leukocytosis and an elevated sedimentation rate.

The duration of the disease is short. Six months is the average length of time from the initial symptoms until death, although the patient occasionally may live for two or more years.

At some time during the course of the disease, usually from a few weeks to a few months after the onset, observations are made which indicate that the definite systemic disease is present. Arthritis, peripheral neuritis, evidence of involvement of the central nervous system, edema of an extremity, fibromyositis or even parotitis or orchitis may become apparent. Albumin and erythrocyturia may signify the onset of glomerulonephritis. Roentgenologic evidence of a thoracic lesion may be seen early in the course of the disease, or it may appear later and indicate that something is at hand other than a lesion localized in the upper part of the respiratory system.

Death is almost always caused by uremia, and may take place as rapidly as 10 days from the time of appearance of albuminuria and erythrocyturia.

OBSERVATIONS AT BIOPSY IN WEGENER'S GRANULOMATOSIS

Diagnosis of Wegener's granulomatosis is always difficult, particularly before the signs and symptoms of systemic disease have appeared. It would be very helpful if biopsy of a specimen of a suspicious lesion of the upper part of the respiratory tract would demonstrate vasculitis and indicate the true nature of the disease, but we have been unable to find a report in which biopsy did show definite vascular involvement. The table shows the results of biopsy in Wegener's granulomatosis as reported in the literature. Even when the specimen of tissue was from an extensively ulcerated nose or a mastoid process filled with abnormal tissue, microscopic examination demonstrated only inflammatory tissue or granulomas without signs of specificity.

Several authors[3,15,21] have found vasculitis in postmortem material taken from the upper part of the respiratory tract in instances of Wegener's granulomatosis (midline lethal granuloma), indicating that

TABLE I

BIOPSY OBSERVATIONS IN THE UPPER PART OF THE RESPIRATORY TRACT IN REPORTED CASES OF WEGENER'S GRANULOMATOSIS

CASES, NO., REFERENCE NO.	GROSS LESION	MICROSCOPIC APPEARANCE
1[8]	Widely ulcerated nasal mucosa	Granulation tissue, eosinophils, few giant cells
2[8]	Granular area of septum Nasal mucosa ulcerated with crusts	Chronic inflammatory reaction Inflammatory reaction with lymphocytes
1[14]	Ulcer of nasal septum	Granulation tissue
1[15]	Granuloma of nasal septum	Granuloma with giant cells
2[15]	Granuloma of nasal septum	Nonspecific inflammation, some giant cells
1[16]	Granular nasal mucosa with much crusting	Granulation tissue with giant cells and eosinophils
1[17]	Acute mastoiditis	Chronic nonspecific inflammatory tissue
	Ulcerated, crusted nasal membrane	Granulation tissue with giant cells
1[18]	Granulation tissue	Granulation tissue with eosinophils
1[19]	Granular mass of septum	Simple granuloma
1[20]	Acute mastoiditis	Inflammatory tissue with eosinophils and giant cells
5[21]	Laryngeal stenosis	Chronic inflammatory tissue

perhaps more adequate biopsy at times might help in arrival at the proper diagnosis.

DIFFERENTIAL DIAGNOSIS

The most important differential distinction is between Wegener's granulomatosis (lethal midline granuloma) and reticulum-cell sarcoma. De Faria and associates[27] went so far as to say that all midline granulomas of the type under discussion are in fact instances of reticulum-cell sarcoma. The important differential point, however, is the development of periarteritis nodosa generally. In none of the cases

presented by de Faria and associates[27] was there pathologic evidence of periarteritis, and in none of the four patients in our series in whom postmortem examination was done was evidence of any type of malignant process found.

It is important to distinguish these lesions also from the indolent ulcerations produced by anaerobic streptococci and also from the specific granulomas, especially histoplasmosis, blastomycosis, tuberculosis, syphilis, yaws and the like.

NATURE OF PRESENT STUDY

The histories and pathologic findings in six cases of Wegener's granulomatosis (lethal midline granuloma) are presented. The first patient was alive and seemed well after 2 years with no treatment except the use of salicylates, at the time of this report. The other five patients died; postmortem examination was done in all but one.

REPORT OF CASES

CASE 1. A previously healthy 14-year-old girl began to experience attacks of an influenza-like syndrome in September, 1955. Muscle pains, headache, cough, hoarseness and fever accompanied each of the 15 or 20 attacks, which usually resolved after a few days' penicillin therapy. In February, 1958, persistent hoarseness led to biopsy of specimens of abnormal tissue in the subglottic area.

The hoarseness became increasingly severe and the patient was admitted to the Mayo Clinic in August, 1958. Indirect laryngoscopy demonstrated injected, edematous vocal cords and an obstructing mass, covered by a red crust, in the subglottic area. The intranasal structures appeared to be atrophic, and were covered with dry adherent crusts. Tracheotomy was carried out and specimens of tissue for biopsy were taken from the larynx, subglottic area and nose. Staphylococcus aureus was isolated, and the patient accordingly received erythromycin.

Results of an extensive general examination were negative except for slight elevation of the sedimentation rate, and albuminuria of grade 1 and erythrocyturia of grade 2. A definite diagnosis was not reached, and the patient was allowed to return home.

In January, 1959, pain and swelling in multiple joints, numbness of the right heel and lack of energy developed. The patient was examined again. The sedimentation rate was now 65 mm in one hour (Westergren) and albuminuria of grade 2 and erythrocyturia of grade 3 were recorded. At this time the larynx was essentially normal. An ulcer had developed on the tongue. Wegener's granulomatosis was suspected, and needle biopsy of a kidney was carried out. Since the general condition of the patient was relatively good, steroid therapy was withheld and she was allowed to go home with a prescription of salicylate therapy. At the time of this writing she was still living and attending school, more than 2 years after the first biopsy of laryngeal tissue. Symptoms referable to the joints were much abated. Varying grades of albuminuria and erythrocyturia persisted, however.

Histopathologic findings (Fig. 1) in various biopsies were:

1. Nose: nonspecific inflammatory reaction.

2. Larynx: ulceration with granulomatous inflammation of the base; poorly defined tubercles with giant cells.

3. Tongue: nonspecific inflammation.

4. Kidney: focal glomerulitis with possible arteritis.

Comment on Case 1. This is an instance of relatively mild Wegener's granulomatosis in which the laryngeal findings dominated the early and very confusing clinical picture. The laryngeal lesions abated considerably as the systemic disease appeared. Repeated infections of the upper part of the respiratory tract seem to have led to the genesis of inflammatory lesions in the nose and ulcerated granulomas in the larynx, and appear to have been important in the eventual development of very probable generalized periarteritis nodosa.

CASE 2. A 21-year-old man had severe nasal congestion in October, 1945. Two weeks later severe pain arose over the right maxilla and right upper teeth, and a copious bloody nasal discharge became prominent. Acute otitis media on the right became apparent. The nasal symptoms and facial pain continued in increasing severity, as did general malaise, and the patient was admitted to the Mayo Clinic in April, 1946.

Examination revealed a seriously ill patient with both nasal chambers filled with abnormal tissue which bled easily on manipulation

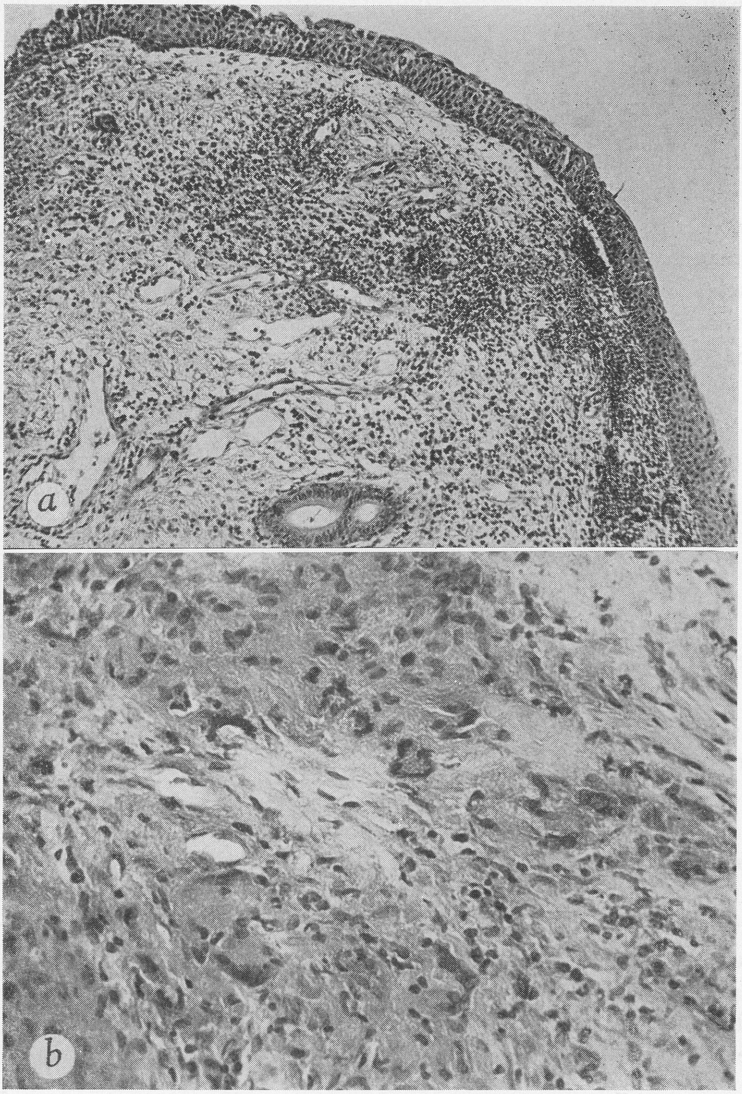

Fig. 1.—*a*. Nasal mucosa, showing nonspecific inflammatory reaction (hematoxylin and eosin; x100). *b*. Laryngeal biopsy. Note granulomatous inflammation with scattered giant cells (hematoxylin and eosin; x300).

and appeared to be malignant. A serosanguineous discharge was evident in the right external auditory canal. Roentgenograms showed the mastoid processes to be normal, but pansinusitis was present bilaterally. An extensive general examination demonstrated very little except anemia, leukocytosis, sedimentation rate of 110 mm in one hour (Westergren), erythrocyturia of grade 2 and albuminuria of grade 1 and axillary adenopathy. Intranasal surgical treatment was carried out and much abnormal tissue was removed from the nasal chambers and nasal septum. Pains in the joints, arms, legs and epigastrium developed. Periarteritis nodosa was suspected. Results of muscle biopsy were negative. In mid-May of 1946 ulcers developed on the patient's tongue, uvula and buccal mucous membrane, and roentgenograms disclosed congestion in the lower lobes of both lungs.

The patient died on May 26, 1946, about seven months from the onset of the respiratory symptoms. At the time of death the nose was filled with bloody scales and there was extensive destruction of the nasal septum.

Microscopic examination (Fig. 2*a* and *b*) of tissues taken from the nose showed granulomatous inflammation with poorly formed tubercles and scattered giant cells. Vasculitis was not evident.

Necropsy demonstrated periarteritis nodosa involving the lungs, liver, spleen and kidneys, with multiple infarcts.

Comment on Case 2. This case is an instance of Wegener's granulomatosis in which extensive granulomatous involvement of the nasal cavities dominated the picture in the upper part of the respiratory tract. The disease started as an apparently severe acute sinusitis, but soon systemic symptoms developed out of proportion to the nasal symptoms and signs and it became apparent that the disease process in the nose and ears was only one part of a widespread systemic disorder.

CASE 3. A 55-year-old man contracted an infection of the upper part of the respiratory tract in March, 1959. The infection did not abate and nasal polypi were removed a month later. Shortly after the operation bloody crusts began to form in the nose, and hearing became markedly impaired. Dyspnea developed at about the

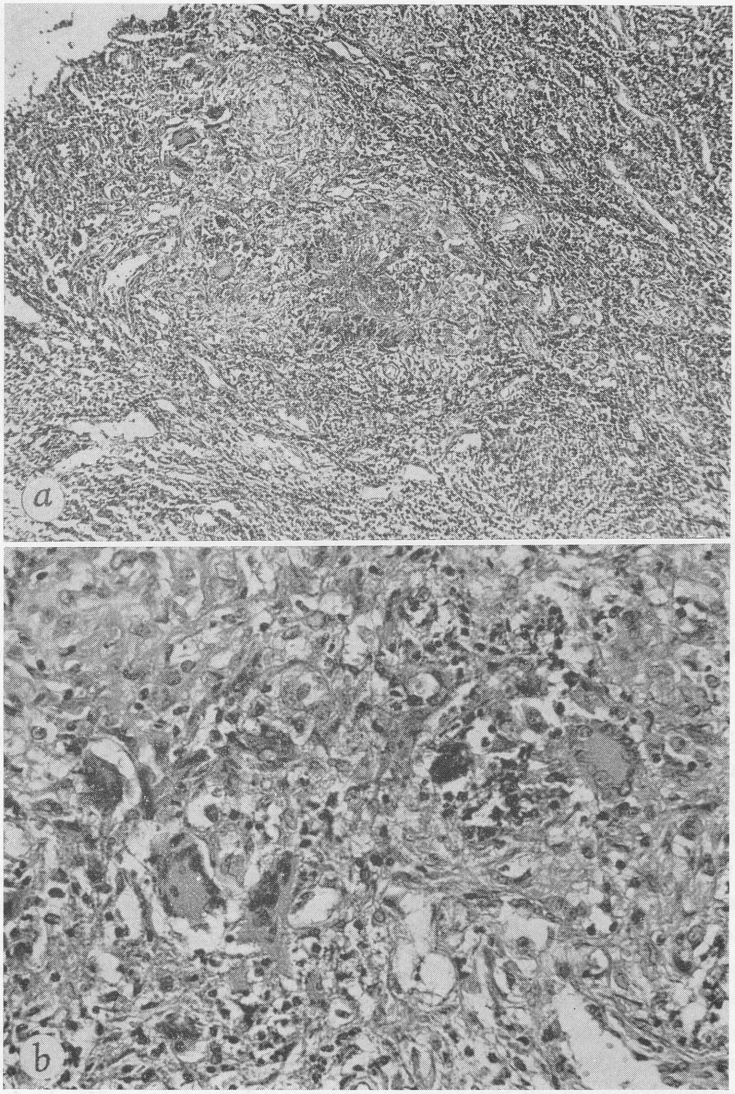

Fig. 2.—Wegener's granulomatosis. *a*. Low-power magnification of intranasal granuloma: note poorly formed tubercles with slight caseation and numerous giant cells (hematoxylin and eosin; x100). *b*. High-power magnification, showing prominent giant-cell reaction (hematoxylin and eosin; x300).

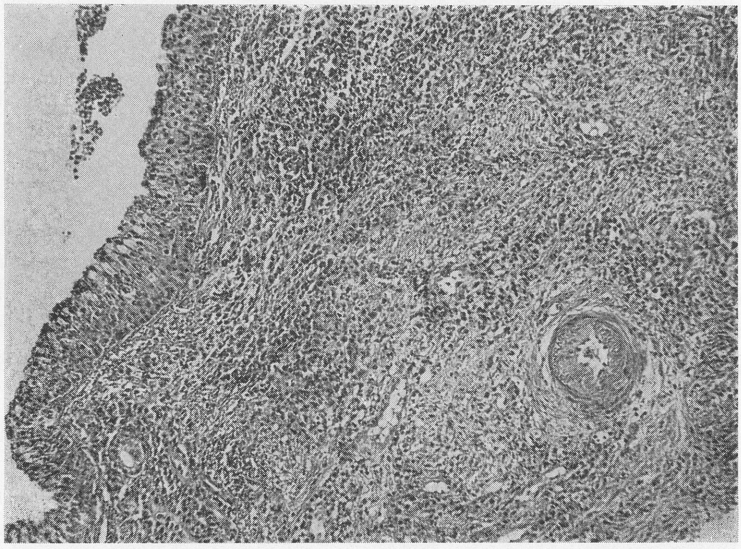

Fig. 3.—Nasal mucosa, showing marked nonspecific inflammatory reaction and obliterative change in one small artery (hematoxylin and eosin; x100).

same time, became progressively worse and was soon accompanied by hemoptysis.

At the time of admission of this patient to the Mayo Clinic on August 7, 1959, both nasal chambers were filled with large, odorous bloody crusts, removal of which left a granular, bleeding nasal membrane. Mild polypoid change of the vocal cords and some crusting in the subglottic area were noted. The tympanic membranes were thickened and there was fluid in the left middle ear. An audiogram showed a combined hearing loss of 85 decibels on the left and nerve deafness of 35 decibels on the right. Roentgenograms revealed thickened membranes in all the sinuses, sclerosis of the left mastoid process and indeterminate bilateral lesions in the thorax. Staphylococcus aureus and Streptococcus pyogenes were isolated from the nose. Albuminuria of grade 1 and erythrocyturia of grade 2 to 3 were consistently present, and the sedimentation rate was 113 mm in one hour (Westergren). Multiple biopsies of material from the nose showed

marked nonspecific inflammatory reactions with formation of granulation tissue (Fig. 3). Vasculitis was not seen.

Wegener's granulomatosis was suspected and steroid therapy was administered. The respiratory difficulty became progressively worse and the patient died on October 12, 1959, about 8 months after the onset of the initial upper respiratory infections. Postmortem examination demonstrated necrotizing granulomatous lesions of the lungs and spleen, associated with generalized periarteritis nodosa.

Comment on Case 3. The upper respiratory and thoracic lesions in this case appear to have developed at about the same time. Some degree of deafness on the right had been present before the onset of the patient's illness. The loss of hearing on the left was out of proportion to the inflammatory disease in the middle ear, and was of a neurosensory type, leading us to suspect that the loss of hearing may have been the result of vasculitis of the blood supply to the neural elements.

CASE 4. A 59-year-old man experienced marked nasal congestion, recurrent epistaxis, serosanguineous nasal discharge, severe facial pain, chills and fever in April, 1958. Unknown types of antibiotic agents were given. The symptoms did not abate and pain and swelling of the right lower leg developed.

The patient was admitted to the Mayo Clinic on April 28, 1958. The intranasal structures were found to be congested and the turbinates and septum were covered with small dry scales, removal of which left a raw bleeding surface. Roentgenograms of the sinuses showed nothing of significance. Multiple biopsies of material from the nose showed a marked nonspecific inflammatory reaction with formation of granulation tissue, some eosinophils (Fig. 4), but no vasculitis. Results of a general examination were negative except for indeterminate edema of the right leg and a sedimentation rate of 91 mm in one hour (Westergren). Staphylococcus aureus and Streptococcus pyogenes were isolated from the nose, and erythromycin was given. After some temporary regression of the nasal symptoms the formation of scales became more pronounced and a foul and bloody nasal discharge began. Hospitalization was necessary on July 8, 1958. Edema of the leg had increased and there were numbness, pain and tingling in both legs. Chills, fever, nausea and vomiting were prominent. Albuminuria of grade 2 and erythrocyturia of grade 3 were

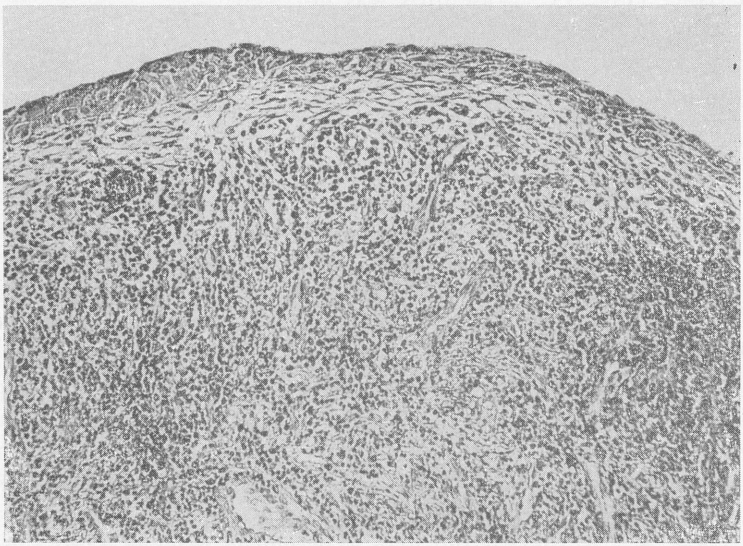

Fig. 4.—Nasal mucosa: marked nonspecific inflammation with formation of granulation tissue. The inflammatory infiltrate consists of lymphocytes, plasma cells and numerous eosinophilic leukocytes (hematoxylin and eosin; x125).

recorded and the value for urea was 182 mg per 100 cc of blood. The sedimentation rate was 134 mm in one hour (Westergren) and roentgenograms revealed patchy pneumonitis of the right midlung. At this time the patient's nose was filled with bloody crusts, without definite ulceration of the underlying membrane. The patient died of uremia about four months from the onset of nasal symptoms.

Postmortem examination was not done. Although we were unable to demonstrate granulomatous lesions in the respiratory tract, the roentgenograms of the thorax disclosed a condition which was abnormal. The rapid course of the disease, the development of multiple systemic symptoms and the terminal uremia make a diagnosis of Wegener's granulomatosis very probable.

Comment on Case 4. This was an instance of Wegener's granulomatosis in which the intranasal lesions were relatively mild. Late in the disease the nose was filled with bloody crusts, but there was no

definite destruction of intranasal structures. For 3 months it appeared that we were treating a somewhat unusual and severe intranasal infection accompanied by an increased sedimentation rate and indeterminate swelling of the right leg.

CASE 5. A 52-year-old man had acute sinusitis and acute otitis media in May, 1953. The use of many antibiotic agents did not eradicate the infection, and in August, 1953, submucous resection and bilateral antral operations were necessary. After these procedures bloody crusts began to form in the nose, recurrent epistaxis arose and the hearing became progressively worse. In September, 1953, general malaise and weakness of the lower extremities developed. The sedimentation rate was 90 mm in one hour, and albumin and erythrocytes appeared in the urine.

The patient was admitted to the Mayo Clinic on October 21, 1953. The nasal chambers were seen to be filled with bloody crusts and there was a large septal perforation. The tympanic membranes were intact but were thickened, and had been invaded by blood vessels. There was marked loss of hearing bilaterally. Roentgenograms of the thorax were not significant. The value for urea was 320 mg per 100 cc of blood.

Periarteritis nodosa was suspected and cortisone was given. The patient died of uremia on November 2, 1953, about 6 months from the time of onset of the symptoms of infection of the upper part of the respiratory tract. Necropsy was reported as showing periarteritis nodosa with multiple infarcts of the kidney and spleen, and involvement of the hepatic capsule and intestinal arteries.

Intranasal biopsy was not carried out and granulomas of the lung were not demonstrated. The destructive process in the nose, the course of the disease and subsequent development of generalized periarteritis nodosa strongly favor a diagnosis of Wegener's granulomatosis.

CASE 6. Tinnitus and fullness developed in the ears of a 37-year-old housewife in January, 1952. Four weeks later her otologist was unable to find appreciable infection in the ears and inflated the eustachian tubes. Severe pains in the left cheek and left upper teeth soon developed, but again examinations of the ears, nose, throat and teeth did not explain the symptoms. In March, 1952, general malaise

and severe headache led to confinement of the patient in bed, and penicillin and chloramphenicol (chloromycetin) therapy was administered for 5 days. Swelling and pain in multiple joints developed on April 1, 1952. Two weeks later bilateral myringotomy relieved most of the patient's pain in the head.

The patient was admitted to the Mayo Clinic on May 12, 1952, because of general malaise, bilateral aural discharge and migratory pains in the joints. Examination demonstrated a small quantity of thin discharge in each external auditory canal and some loss of hearing in each ear. Roentgenograms revealed questionable chronic infection in both mastoid processes and diffuse infiltrations in both lungs. There were no symptoms in the thorax. Albuminuria and erythrocyturia were present. The sedimentation rate was 105 mm in one hour (Westergren). Rapid loss of hearing took place on May 17, 1952. Within 24 hours the patient was unable to hear a loud shout in the right ear, but she could repeat what she heard spoken in a loud voice in the left ear. The deafness was accompanied by vertigo, vomiting and spontaneous nystagmus to the left. There was very little drainage from the ears and roentgenograms of the mastoid processes showed considerable improvement. The cerebrospinal fluid was normal. The value for blood urea was elevated. It was felt that all the observations pertained to a generalized systemic disease. Results of muscle biopsy were negative. The patient died of uremia on June 3, 1952.

Postmortem examination demonstrated generalized periarteritis nodosa. There were granulomatous as well as vascular lesions in the lungs.

Comment on Case 6. Symptoms referable to the ears were prominent throughout this patient's illness, and for 3 months she complained only of tinnitus, fullness in the ears, malaise and facial and head pains. Late in the illness rapid increase in deafness and marked vertigo occurred, probably caused by vasculitis, since there did not seem to be sufficient involvement of the mastoid processes to explain the symptoms, particularly in view of the fact that the increase in deafness was bilateral.

COMMENT

On the basis of consideration of our own cases as well as a review of the literature, it seems evident that manifestations in the upper part

of the respiratory tract are an important part of Wegener's granulomatosis (midline lethal granuloma), and may be the only findings for weeks or months before the development of a thoracic lesion or other signs and symptoms suggesting more or less general systemic disease. In Case 1 laryngeal symptoms were presented for 6 months before the appearance of albuminuria and erythrocyturia suggested the possibility of something other than localized disease of the upper part of the respiratory tract, and it was 11 months before involvement of joints and numbness in one heel provided further evidence of systemic disease. In Cases 4 and 6 signs of systemic disease did not develop until 3 months from the onset of significant symptoms in the upper part of the respiratory tract. All patients had an elevated sedimentation rate, and the appearance of albuminuria and erythrocyturia was an early indication of systemic involvement.

Biopsy of tissue from a lesion in the upper part of the respiratory tract was done in four of six cases and vascular involvement was not detected. In Case 1 laryngeal biopsy demonstrated granulomatous inflammation, while microscopic examination of intranasal tissue demonstrated only a nonspecific inflammatory reaction. In Case 2 granulomas were seen deep in a very adequate specimen of tissue with only nonspecific inflammatory tissue on the surface, which suggests that biopsy should be more extensive when Wegener's granulomatosis is suspected.

Wegener's granulomatosis should be suspected when apparent and prolonged infection of the upper part of the respiratory tract does not respond to extensive treatment, and when lesions varying from granulation and congestion of the turbinates, which become covered with crusts, to extensive destructive granulomas appear in the respiratory tract.

Definite diagnosis cannot be made on the basis of observations in the respiratory tract alone, but depends on recognition of the development of more or less generalized periarteritis nodosa.

From the fact that evidence of generalized systemic involvement did not appear until weeks or months after the initial infection in the upper part of the respiratory tract in the majority of cases reported in the literature and in our own group of cases, it may be suspected that these patients became generally hypersensitive to an auto-antigen produced by the infection, as suggested by Kahn.[28]

SUMMARY

1. Six instances of Wegener's granulomatosis with prominent features referable to the upper part of the respiratory tract have been presented.

2. The nose, larynx or ears or all three structures may be involved in a given instance of the disease.

3. Results of biopsy of specimens of tissue from lesions in the upper part of the respiratory tract usually are inconclusive, and even when specimens are taken from extensively involved structures histopathologic examination does not lead to a definite diagnosis of Wegener's granulomatosis.

4. Wegener's granulomatosis is to be suspected when necrotizing granulomas or crust-covered granular lesions appear in the nose or larynx of a patient whose prolonged and severe apparent infection of the upper part of the respiratory tract has not responded to vigorous treatment.

5. Lesions of the upper part of the respiratory tract can be suggestive of Wegener's granulomatosis, but accompanying periarteritis nodosa must be recognized before a definite diagnosis can be made.

MAYO CLINIC

REFERENCES

1. Wegener: Über generalisierte, septiche Gefässerkrankungen. Verhandl. deutsch. Path. Gesellsch. 29:202-208, 1936.

2. Wegener, F.: Über eine eigenartige rhinogene Granulomatose mit besonderer Beteiligung des Arteriensystems und des Nieren. Beitr. path. Anat. allg. Path. 102: 36-68 (Jan. 5) 1939.

3. Plummer, N. S., Angel, J. H., Shaw, D. B., and Hinson, K. F.: Respiratory Granulomatosis with Polyarteritis Nodosa (Wegener's Syndrome). Thorax 12:57-64 (Mar.) 1957.

4. Milner, P. F.: Nasal Granuloma and Periarteritis Nodosa: Report of a Case. Brit. M. J. 2:1597-1599 (Dec. 31) 1955.

5. Weinberg, Tobias: Periarteritis Nodosa in Granuloma of Unknown Etiology: Report of Two Cases. Am. J. Clin. Path. 16:784-791 (Dec.) 1946.

6. Godman, G. C., and Churg, Jacob: Wegener's Granulomatosis: Pathology and Review of the Literature. A.M.A. Arch. Path. 58:533-553 (Dec.) 1954.

7. Blatt, I. M., Seltzer, H. S., Rubin, Philip, Furstenburg, A. C., Maxwell, J. H., and Schull, W. J.: Fatal Granulomatosis of the Respiratory Tract (Lethal Midline Granuloma-Wegener's Granulomatosis). A.M.A. Arch. Otolaryng. 70:707-749 (Dec.) 1959.

8. Stratton, H. J. M., Price, T. M. L., and Skelton, M. O.: Granuloma of the Nose and Periarteritis Nodosa. Brit. M. J. 1:127-130 (Jan. 17) 1953.

9. Atkins, J. P., and Eisman, S. H.: Wegener's Granulomatosis. Tr. Am. Laryng. A. 80:253-276, 1959.

10. Atkins, J. P., and Eisman, S. H.: Wegener's Granulomatosis. ANNALS OF OTOLOGY, RHINOLOGY AND LARYNGOLOGY 68:524-547 (June) 1959.

11. Wilson, K. S., and Alexander, H. L.: The Relationship of Periarteritis Nodosa to Bronchial Asthma and Other Forms of Human Hypersensitiveness. J. Lab. and Clin. Med. 30:195-203 (Mar.) 1945.

12. Goddard, J. W.: Granuloma, A Characteristic "Qualitative" Change in Focal Anaphylactic Inflammation. Am. J. Path. 23:943-965 (Nov.) 1947.

13. Rich, A. R., and Gregory, J. E.: The Experimental Demonstration That Periarteritis Nodosa Is a Manifestation of Hypersensitivity. Bull. Johns Hopkins Hosp. 72:65-88 (Feb.) 1943.

14. Walton, E. W., and Leggat, P. O.: Wegener's Granulomatosis. J. Clin. Path. 9:31-37 (Feb.) 1956.

15. Seidelin, R., and Willcox, A.: Giant-Cell Granulomata of the Mucous Membranes and Polyarteritis Nodosa. Arch. Middlesex Hosp. 4:171-181, 1954.

16. Howells, G. H., and Friedman, I.: Giant Cell Granuloma Associated with Lesions Resembling Polyarteritis Nodosa. J. Clin. Path. 3:220-229 (Aug.) 1950.

17. Herberts, G., Hillerdal, O., and Ranström, S.: Rhinitis, Sinusitis and Otitis as Initial Symptoms in Periarteritis Nodosa: (Wegener's Granulomatosis). Acta Otolaryng. 48:205-218, 1957.

18. Kelly, H. D. B.: Granuloma of the Nose and Necrotizing Arteriolitis. J. Laryng. and Otol. 70:313-316 (May) 1956.

19. McCallum, A. G.: Sinusitis, Granuloma of Nose and Periarteritis Nodosa. J. Laryng. and Otol. 68:560-567 (Aug.) 1954.

20. Rose, G. A., and Spencer, H.: Polyarteritis Nodosa. Quart. J. Med. n.s. 26: 43:81 (Jan.) 1957.

21. Fahey, J. L., Leonard, Edward, Churg, Jacob, and Godman, Gabriel: Wegener's Granulomatosis. Am. J. Med. 17:168-179 (Aug.) 1954.

22. Chomet, Bernhard, Pilz, C. G., Vosti, Kenneth, and Levine, Victor: Case of Wegener's Granulomatosis. A.M.A. Arch. Path. 66:100-107 (July) 1958.

23. Felson, Benjamin, and Braunstein, Herbert: Noninfectious Necrotizing Granulomatosis: Wegener's Syndrome, Lethal Granuloma, and Allergic Angiitis and Granulomatosis. Radiology 70:326-334 (Mar.) 1958.

24. Tuhy, J. E., Maurice, G. L., and Nelson, R. N.: Wegener's Granulomatosis. Am. J. Med. 25:638-646 (Oct.) 1958.

25. Hoch, C. W.: Wegener's Granulomatosis. A.M.A. Arch. Otolaryng. 63:120-123 (Feb.) 1956.

26. Levine, Howard, and Madden, T. J.: Wegener's Granulomatosis: Report of a Case. Am. Heart J. 53:632-637 (Apr.) 1957.

27. de Faria, J. L., Cutin, Moyses, and Morgante, Paulo: Malignant Granuloma of the Face: Contributions to Its Nosology. A.M.A. Arch. Otolaryng. 65:255-262 (Mar.) 1957.

28. Kahn, R. L.: Tissue Immunity—Its Possible Relationship to Midline Facial Granulomatous Ulceration. Univ. Michigan M. Bull. 20:208-218 (Aug.) 1954.

DISCUSSION

DR. HENRY L. WILLIAMS: I was very pleased to hear Dr. Brown's paper. As you know, I have had some interest in this problem of midline lethal granuloma or granulomatosis. There have been a number of papers recently suggesting that there is considerable difference between midline granulomatosis and Wegener's granulomatosis, a position which I cannot bring myself to recognize. I believe that Dr. Brown's studies have shown that these two terms should be synonyms. Actually the condition we see is periarteritis nodosa and the nasal lesions are a secondary finding. Possibly the nasal lesions are primary and the development of the periarteritis is the result of the infection as has been suggested by Dr. Brown. This was also mentioned by Ruben Kahn in his book titled "Tissue Immunity." I want to congratulate Dr. Brown on a very fine, well-prepared presentation. I am very proud of him indeed.

DR. JOSEPH P. ATKINS: I must congratulate Dr. Brown on a brilliantly lucid paper which covers the subject extremely well. It has been our experience that Wegener's granulomatosis does not always present itself with the original lesion in the respiratory tract. We have seen cases which we felt would eventually meet the criteria for this diagnosis in which the lesion was primarily evident in the skin.

One of the things we have been concerned about is the fact that the histologic picture in the respiratory tract is often modified by secondary infection, because the lesion is in a potentially infected area. Perhaps one does not see the fundamental character of the disease in biopsy specimens from the area in contact with nasal mucosa. For this reason, if lesions are available elsewhere not in contact with the respiratory tract, they may serve as a more dependable source of tissue for histologic examination.

Since we don't know what periarteritis nodosa is and don't know why people develop it, we should try to keep the various clinical types separated at least in our mind. At this stage of the game I think we should keep our eyes open for possible clues to all of the various manifestations of what we call periarteritis nodosa.

DR. VAN ALYEA: I would like to ask Dr. Brown a question. In his series of cases he mentions the history of infection of the upper respiratory tract in many of them. Of course there must be something else because so many thousands of people have upper respiratory infections and do not develop this disease.

Some years ago, when sulfonamide drugs were first used, Dr. Safier, pathologist in Chicago, read a paper tying up many cases of periarteritis nodosa with the use of sulfanilamide. I am wondering if Dr. Brown has by any chance noted in the history of any of these cases the use of one of the sulfonamide drugs.

DR. HENRY A. BROWN (closing): I wish to thank the gentlemen who discussed my paper. Of course there are many thousands of upper respiratory infections that don't go on to develop into something serious like Wegener's granulomatosis. Why, I don't know. Apparently some of them produce a local sensitivity in the upper respiratory tract which develops into a form of periarteritis nodosa. There are many case reports in the literature suggesting that sulfonamide drugs or antibiotics may be important in producing this type of hypersensitivity in the nose, larynx or respiratory tract. I hope further knowledge will come from more complete study of biopsy and postmortem specimens.

THE CEREBRAL CORTEX AND HEARING

LAMAR ROBERTS, M.D.
(by invitation)

GAINESVILLE, FLA.

An attempt will be made to evaluate the present status of knowledge about the role of the cerebral cortex in hearing. Peripheral mechanisms as well as subcortical nuclei and pathways will not be reviewed and will be considered only when necessary to clarify cortical representation. The data obtained from stimulation and ablation experiments in animals, particularly cat and monkey, will be summarized briefly. The anatomical and physiological studies in man will be given and discussion and summary will follow.

A. ANIMAL EXPERIMENTS

1. *Evoked Potentials.* A considerable amount of work has been done using pure tone and click stimulations as well as stimulation of auditory nerve fibers and recording of evoked potentials from the cortex. The majority of this work has been done in the cat. The terminology used here is taken from Rose and Woolsey.[1] In Figure 1 is seen the cortical region activated by sound stimuli in the deeply anesthetized cat. AI is the primary auditory area and corresponds quite closely to the cyto-architectonic typical primary sensory area (koniocortex). In AI the pattern of projection from the periphery seems to be an orderly one in that stimulation of the base of the cochlea evoked responses anteriorly while stimulation of the apex produced it posteriorly.

The reverse is true of the projection to the second auditory area. Stimulation of the apex of the cochlea produced responses anteriorly (the crossed hatched area in Figure 1); whereas, stimulation of the

---

From the Division of Neurosurgery of the University of Florida.

base evoked responses posteriorly (in the cross hatched and dotted part of Figure 1). The upper part of the posterior ectosylvian area (EP) is cytologically different from the primary auditory area and smaller potentials are seen here from cochlea stimulation. There has been some difference of opinion as to whether the inferior part of EP (the dotted and crossed hatch area in Figure 1) is a part of the auditory area, but from the evoked potential studies this seems to be clearly the posterior part of the second auditory area.

Kiang[2] has recorded from isolated patches of cortex and has found that responses occurred from a patch in AI, AII or EP when all other auditory cortex of the same side and all auditory cortex of the opposite hemisphere had been removed. This would seem to indicate that these responses are mediated through subcortical rather than cortical connections, i.e. there are subcortical connections with AII and EP as with AI. Kiang also confirmed earlier work that an evoked response may be recorded from ventral EP after application of strychnine to a small area of AI or anterior AII.

In January of this year Thompson and Sindberg[3] from Woolsey's laboratory extended considerably the cortical area from which responses may be obtained to click stimuli. Responses occurred from the sensori-motor area as well as from the anterior lateral and suprasylvian gyri. These responses occurred even after bilateral ablation of the auditory cortex considered above.

Lilly[4] has used a recording technique which gives simultaneous samples of electrical activity from 25 electrodes on the cerebral cortex. He has recorded the spontaneous activity as well as that following click stimuli. In both instances the "forms and figures" follow a definite repeatable pattern. The "forms and figures" described by Lilly show the electrical activity in the numerous electrodes at a given time and how this activity spreads in time. There was a clear difference between deep, light, and no anesthesia. A figure which starts in AI or AII may progress posteriorly with a leading edge velocity of 1 to 2 meters a second; at the junction with EP this edge slows to about 0.1 meter a second. The retreating edge velocity over the entire area is about 0.1 meter per second. The spontaneous figures usually arise in EP and they have an advancing and retreating edge of about 0.1 meter per second. There are also responses in the sensori-motor cortex to click stimulation.

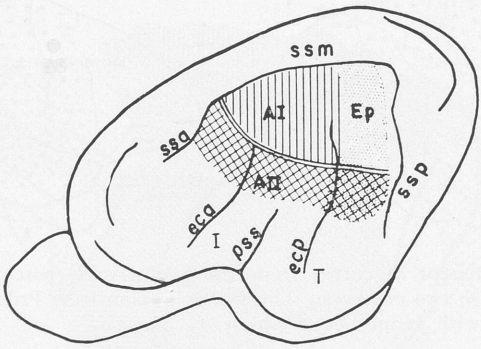

Fig. 1.—Cortical region activated by sound stimuli in deeply anesthetized cat. This figure is taken from Rose and Woolsey[1] and reproduced with permission of the University of Wisconsin Press.

In the monkey, Pribram et al[5] have shown the most extensive cortical responsive area to acoustic clicks. In contradistinction to the cat the primary auditory area in the monkey usually has been considered to be mostly in the supratemporal plane, i.e. within the sylvian fissure. The usual method of exposing this area has been to remove the parietal operculum. Pribram succeeded in teasing open the sylvian fissure and recording from the supratemporal plane, insula, and frontal and parietal opercula without cortical damage. Following click stimuli evoked potentials were recorded on the lateral surface as shown in Figure 2 and on the lateral surface as well as within the sylvian fissure as shown in Figure 3. Thus, it can be seen that the cortical response area to click stimuli in the monkey is quite similar to that in the cat.

2. *Cortical Stimulations.* Animals, of course, cannot communicate verbally to us what they hear; so that there are no reports comparable to those given below in man. The only cortical stimulation studies concerning movements of the ear are the ingenious experiments of John Lilly.[6] Lilly has implanted up to 610 electrodes covering approximately 19 square centimeters of cortex at about 1.5 to 2 millimeter intervals over one hemisphere. For stimulation he used symmetrical bi-directional pulse pairs instead of rectangular unidirectional pulses which were found injurious. In Figure 4 points of stimulation

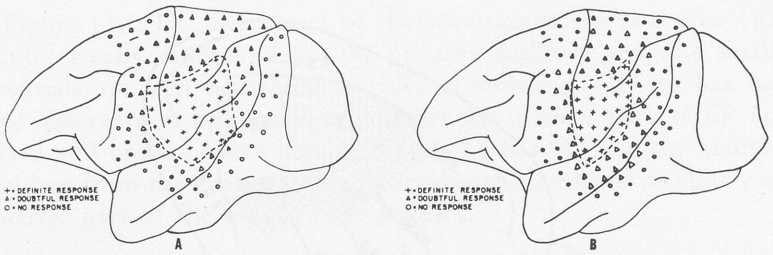

Fig. 2.—Extent of cortex from which observable potential deflections were recorded in two monkeys. This figure is taken from Pribram et al[5] and is reproduced with permission of Charles C. Thomas.

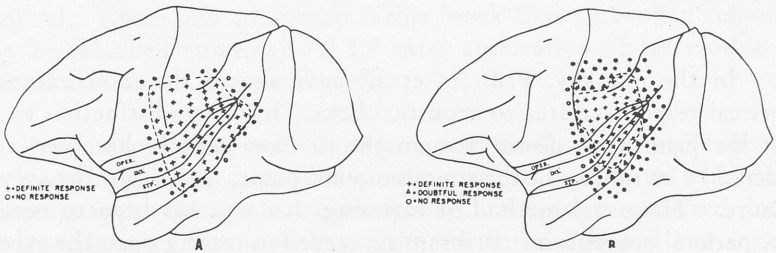

Fig. 3.—The extent of cortex activated by stimulation of contralateral (3a) and ipselateral (3b) ears. This figure is taken from Pribram et al[5] and reproduced with permission of Charles C. Thomas.

in the precentral gyrus and anteriorly (co-existent with what is usually considered the frontal eye field) and in the superior temporal region are seen which yielded movements of the ear. Sugar et al[7] have shown by the method of strychnine neuronography connections between the supratemporal plane of one hemisphere with that of the other as well as with the homolateral frontal "eye field" area and the anterior occipital region.

3. *Ablations.* It has been shown that the completely decorticate dog can acquire a conditioned response to sound although not as well as an intact animal. Most of the early work in this area was concerned with determining the intensity threshold of hearing for pure tones after various cortical ablations. It has been shown that absolute

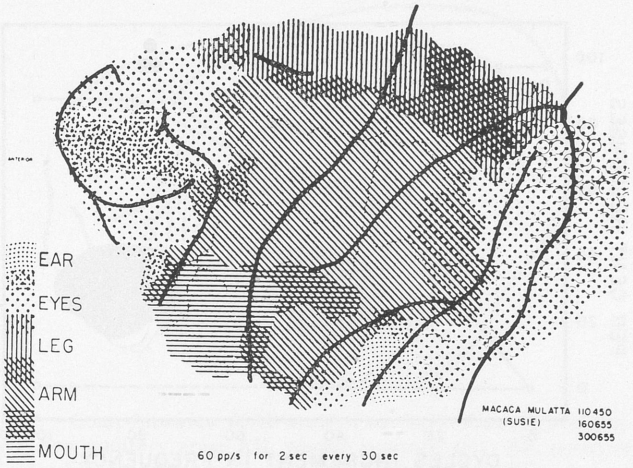

Fig. 4.—Map movements elicited at 60 pp/sec at threshold from the cortex of unanesthetized Macaca mulatta (610 electrodes). This figure is taken from Lilly[6] and reproduced with permission of the University of Wisconsin Press.

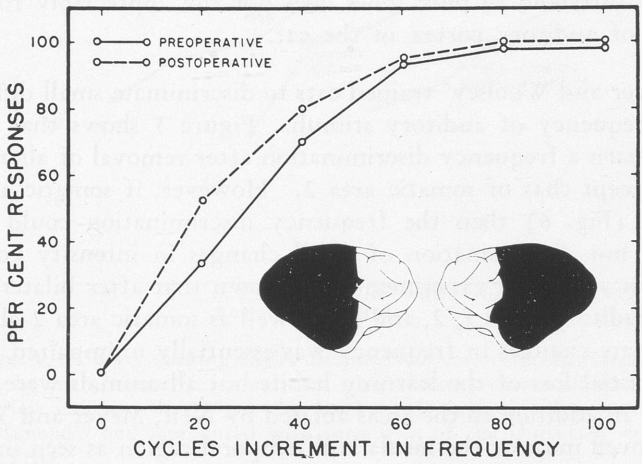

Fig. 5.—Massive extirpation of posterior cerebral cortex sparing somatic area 2. Capacity for frequency discrimination is retained, but extensive retraining is required. This figure is taken from Meyer and Woolsey[8] and reproduced with permission of Charles C. Thomas.

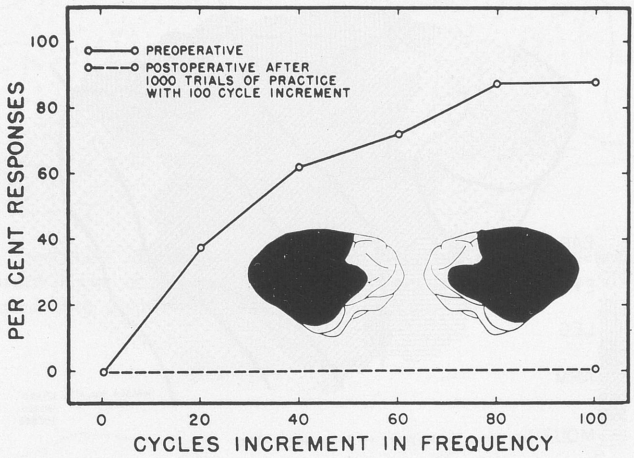

Fig. 6.—Massive extirpation of posterior cerebral cortex including entire auditory region. Postoperative there is no evidence for frequency discrimination within 50 sessions or 1,000 trials, nor for simple conditioning of a pure tone within 40 sessions or 800 trials. This figure is taken from Meyer and Woolsey[8] and reproduced with permission of Charles C. Thomas.

intensity threshold to pure tones does not rise appreciably following ablation of auditory cortex in the cat.

Meyer and Woolsey[8] trained cats to discrinimate small differences in the frequency of auditory stimuli. Figure 5 shows that the cat could relearn a frequency discrimination after removal of all auditory cortex except that of somatic area 2. However, if somatic area 2 is included (Fig. 6) then the frequency discrimination could not be acquired but discrimination of small changes in intensity could be. Neff[9-13] in a series of experiments has shown that after bilateral ablation of auditory areas 1, 2, and EP as well as somatic area 2 ability to discriminate changes in frequency was essentially unimpaired. There was an initial loss of the learning habits but all animals were able to relearn. In addition to the areas ablated by Neff, Meyer and Woolsey had removed most of the insula and temporal region as seen in Figure 7, taken from Harlow Ades' excellent article.[14]

Neff has trained cats to make a response requiring localization of sound in space. Figure 8 shows that cats with bilateral ablation

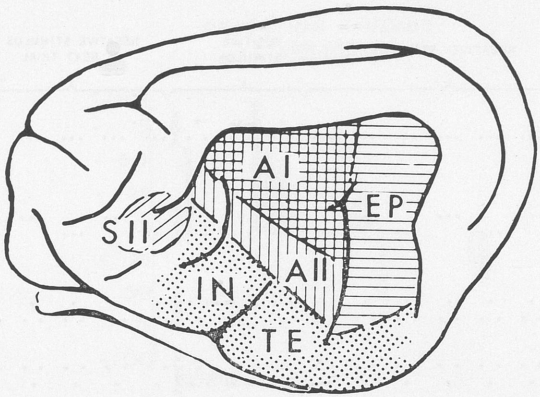

Fig. 7.—Composite view of all areas of cat brain showing auditory function. AI, first auditory area; AII, second auditory area; EP, posterior ectosylvian area; SII, second somatic area; IN, insula region, TE, temporal area. This figure is taken from Ades[14] and reproduced with permission of the American Physiological Society.

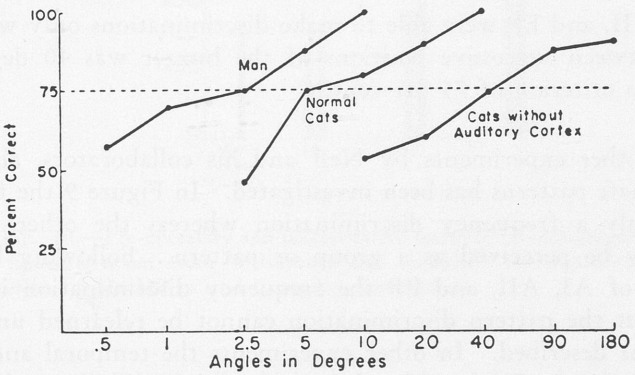

Fig. 8.—Curves showing angles discriminated correctly and sound localization by man, normal cats, and cats with auditory cortex ablated. The dotted line indicates the 75 per cent level. This figure is taken from Neff and Diamond[13] and reproduced with permission of the University of Wisconsin Press.

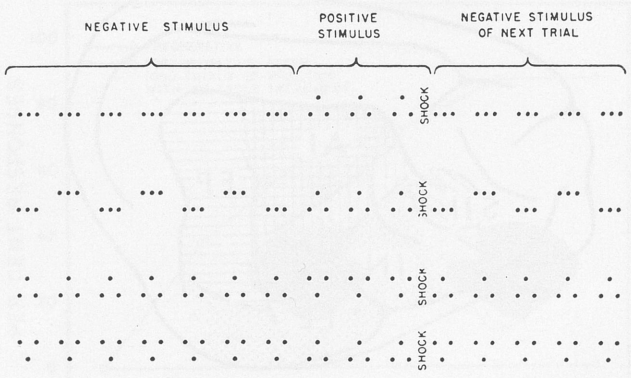

Fig. 9.—Diagram to show sequence of tones in testing discrimination of tonal patterns. This figure is taken from Neff and Diamond[13] and reproduced with permission of the University of Wisconsin Press.

of AI, AII, and EP were able to make discriminations only when the angle between successive positions of the buzzer was 40 degrees or more at a criterion of 75 per cent.

In other experiments by Neff and his collaborators, ability to discriminate patterns has been investigated. In Figure 9 the first line shows only a frequency discrimination whereas the others require that they be perceived as a group or pattern. Following bilateral ablation of AI, AII, and EP the frequency discrimination is maintained but the pattern discrimination cannot be relearned under the conditions described. In other experiments the temporal and insula region as seen in Figure 7 has been removed bilaterally with a profound loss in the ability to discriminate between groups of tones which differ only in temporal patterning (high-low-high vs. low-high-low).

Most of the preceding experiments have been accompanied by studies of degeneration of the thalamic nuclei. It seems from these studies that fibers from the medial geniculate go to the insula and temporal region as well as to AI, AII, EP, and SII.

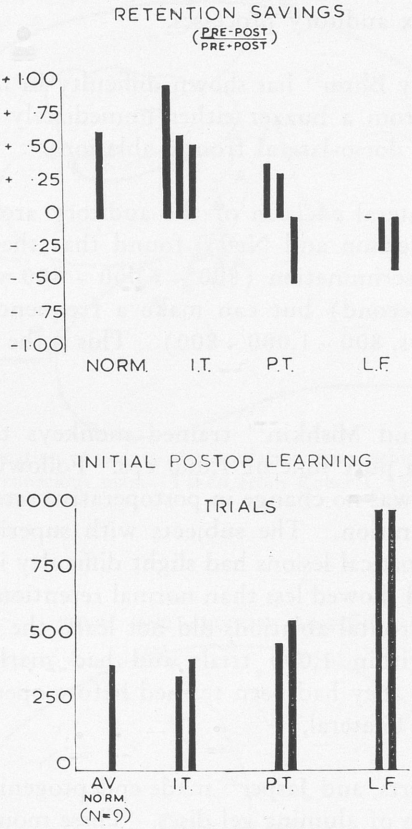

Fig. 10.—Pre-operative and postoperative learning of performance scores. This figure is taken from Weiskrantz and Mishkin[19] and reproduced with permission of MacMillan and Company, Limited.

Moore and Diamond[15] showed that after bilateral ablation of the hippocampus the cat lost the ability to avoid shock when preceded by the conditioned stimulus of a buzzer. Relearning occurred with 50 per cent saving. On the other hand after the same ablation a naive cat was able to learn the avoidance without difficulty. In another experiment Moore[16] found that when the conditioned stimulus was a flashing light this habit was not lost following bilateral hippocampal ablation. These experiments would seem to indicate that the hippo-

campus is involved in auditory learning but not in visual learning. This is one of the very few studies showing involvement of the hippocampus in complex auditory processes.

In the monkey Blum[17] has shown difficulty in the ability to discriminate a bell from a buzzer either immediately or after a delay following bilateral dorso-lateral frontal ablations.

Following biateral excision of the auditory area (as defined by Pribram et al[5]), Jerison and Neff[18] found that the monkey cannot make a pattern discrimination (800 - 1,000 - 800 vs. 1,000 - 800 - 1,000 cycles per second) but can make a frequency discrimination (800 - 800 - 800 vs. 800 - 1,000 - 800). This is the same type of loss as seen in the cat.

Weiskrantz and Mishkin[19] trained monkeys to discriminate a white noise from a pure tone of 1,000 cps. Following inferior temporal lesions there was no change in postoperative retention, or in new learning after operation. The subjects with superior temporal and adjacent parietal cortical lesions had slight difficulty in initial learning after operation and showed less than normal retention. Those animals with dorsolateral frontal ablations did not learn the problem initially after operation within 1,000 trials and had marked difficulty in relearning it when they had been trained before operation (Fig. 10). All removals were bilateral.

Morrell, Roberts, and Jasper[20] made epileptogenic lesions in monkeys by application of alumina gel discs. These monkeys had clinical seizures. When the alumina gel was applied to the superior temporal cortex or to the region of the amygdala the alpha rhythm could not be conditioned to auditory stimuli. Following excision of the cortex underlying the alumina gel as well as neighboring cortex the alpha rhythm could again be conditioned. It should be pointed out that the excision did not include the entire auditory cortex as outlined by Pribriam et al.

B. ANATOMICAL AND PHYSIOLOGICAL STUDIES IN MAN

1. *Stimulations.* During the course of operation for treatment of focal cerebral seizures, the exposed cerebral cortex has been stimulated while the patient is under local anesthesia (see Penfield and Ras-

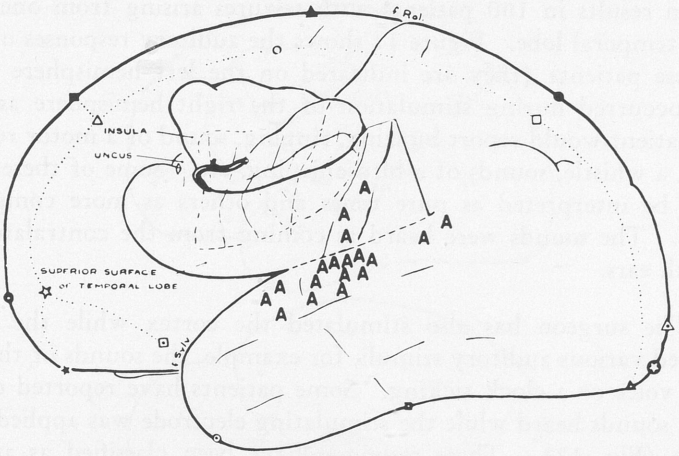

Fig. 11.—Location of points of stimulation from which auditory effects were obtained in conscious man. Taken from Roberts, 1960.

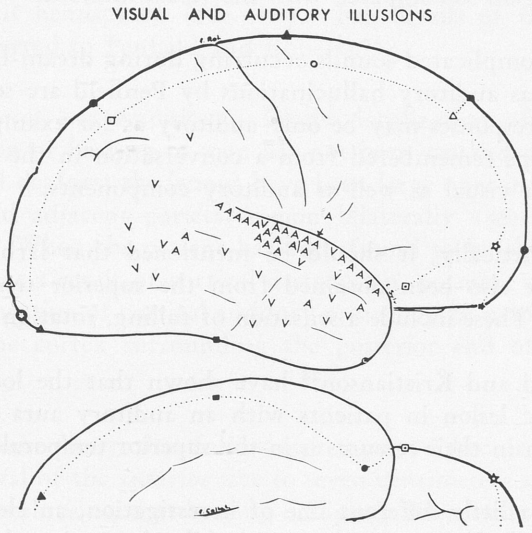

Fig. 12.—Location of points of stimulation producing visual and auditory illusions. Taken from Roberts, 1960.

mussen[21]). While working with Doctor Penfield I reviewed the stimulation results in 100 patients with seizures arising from one or the other temporal lobe. Figure 11 shows the auditory responses obtained in these patients (they are indicated on the left hemisphere though they occurred during stimulation of the right hemisphere as well). The patient would report buzzing, ringing, sound of a motor running, a bell, a whistle, sounds of a bird chirping, etc. Some of these sounds could be interpreted as pure tones and others as more complicated forms. The sounds were heard as coming from the contralateral ear or both ears.

The surgeon has also stimulated the cortex while the patient received various auditory stimuli, for example, the sounds of the operator's voice or a clock ticking. Some patients have reported changes in the sounds heard while the stimulating electrode was applied to the cortex (Fig. 12). These responses have been classified as auditory illusions. The sound may grow louder or softer; it may seem closer or farther away; it may build up in a crescendo with changes in quality or decrease; it may appear distorted or unusual. It is seen that the stimulations producing auditory illusions lie more superiorly in the temporal region as compared with the visual illusions.

More complicated sounds occurring during dream-like states and referred to as auditory hallucinations by Penfield are seen in Figure 13. These responses may be only auditory as for example a person's voice, perhaps remembered from a conversation in the past, or they may contain visual as well as auditory components.

Parenthetically, it should be mentioned that larbyrinthine responses have also been obtained from the superior temporal region (Fig. 14). These include a sensation of falling, rotation, or dizziness.

Penfield and Kristianson[23] have shown that the location of the epileptogenic lesion in patients with an auditory aura as the initial phenomenon in their seizures is in the superior temporal region.

Along a little different line of investigation, an electric current has been applied to cortical points while the patient has attempted to name a series of pictures of objects. The dysphasic or aphasic types of responses have been seen in the posterior temporal and parietal region as well as in Broca's area and the supplementary motor area of

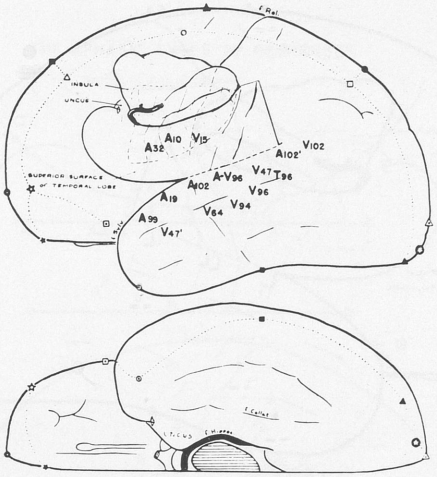

Fig. 13.—Location of points of stimulation producing auditory and visual hallucinations. Taken from Roberts, 1960.

the dominant hemisphere (Fig. 15). For details of this work the reader is referred to Penfield and Roberts.[24]

2. *Diseases and Excisions.* Precise localization of the cortical representation of hearing in man has not been worked out. In cases with cortical deafness the lesions have been large ones in the posterior temporal and adjacent parietal region bilaterally (see Penfield and Roberts[24]). When the patient has been found to be almost or completely deaf as a result of cortical destruction, no more accurate anatomical delineation of cortical auditory areas may be made than to say that it is the cortex surrounding the posterior end of the sylvian fissure.

It has been shown that following temporal lobectomy, consisting of the removal of the anterior five to seven centimeters and including Heschl's convolutions, that hearing is slightly decreased, more in high tone frequencies and more in the opposite ear. Sanchez-Long and Forster[25,26] have shown that localization of sound in space may be affected more in the contralateral ear with tumors of the temporal lobe and occasionally with frontal lobe tumors. Walsh[27] found that

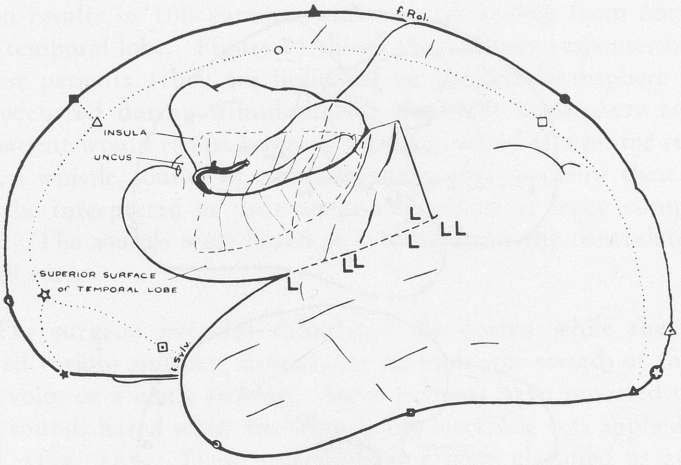

Fig. 14.—Location of points of stimulation where labyrinthine or vestibular responses occurred. Taken from Roberts, 1960.

the ability to localize sound in a vertical plane may be lost whilst localization in a horizontal plane remains possible.

It should be pointed out that numerous cases reported by Henschen[28] with lesions involving the dominant frontal lobe showed difficulty in the comprehension of auditory components of language as well as other dysphasic disturbances. Details are not available in these cases, however, as regards primary hearing as opposed to the more complicated aspects of understanding the spoken word.

C. COMMENT

No attempt has been made to give a complete review of all the work done in animals and man as regards the cerebral cortex and hearing. Much of the work given has been confirmed by other investigators. The selection of references was made according to the author's own interest and bias.

Most of the experimental studies have been carried out in the cat first and then extended to the monkey. It has been known for a long time that the auditory radiations extended to the ectosylvian gyrus

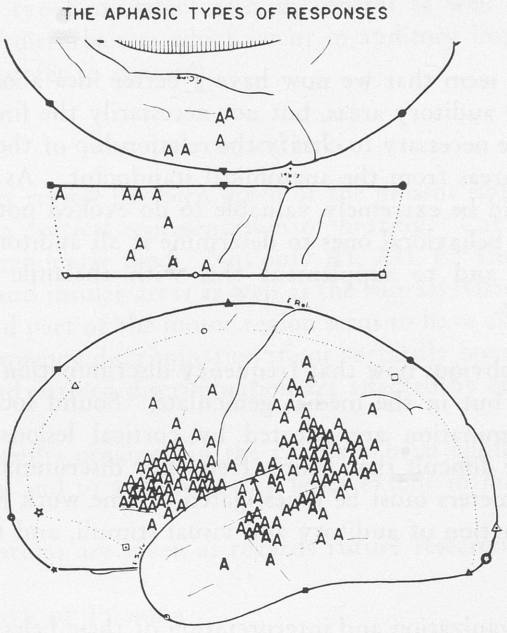

Fig. 15.—Location of points of stimulation where electrical interference produced dysphasia or aphasia. Taken from Penfield and Roberts, 1959.

in the cat and to the supratemporal plane in the monkey. These radiations are dissectible, and it was reasonable for attention to be focused on these cortical areas. For this reason it has taken longer to learn of the various cortical auditory areas other than the primary one. The experiments have been designed in such a way that territory at a distance from the superior temporal region has not been investigated —the exception to this is the recent studies involving the dorsolateral frontal area.

Pribram et al[5] have contended that areas other than the primary auditory area from which evoked potentials were obtained receive collaterals from the auditory radiation. If time were allowed for retrograde degeneration to occur in the thalamus, the evoked potentials could not be obtained. It has been found that thalamic degeneration following several cortical lesions may be less than that after one larger

lesion which includes no more than the combined smaller ones. This would indicate that the several areas receive thalamic fibers but few in number.

It would seem that we now have a better idea about the extent of the cortical auditory areas, but not necessarily the final one. Further studies are necessary to clarify the relationship of the frontal with the posterior areas from the anatomical standpoint. As suggested by Ades,[4] it would be extremely valuable to do evoked potential studies following the behavioral ones to determine if all auditory cortex had been excised, and to supplement this with thalamic degeneration determinations.

It seems obvious now that frequency discrimination is not bound in the cortex but in the medial geniculate. Sound localization and pattern discrimination are affected by cortical lesions. These are certainly more difficult than simple frequency discriminations. Other auditory parameters must be investigated. Some work has been done on the combination of auditory and visual stimuli, and this has to be extended.

In the organization and interpretation of these behavioral experiments, one should remember that the anatomical variables are not the only ones. False conclusions may be drawn from the anatomical standpoint, when in reality no conclusions were warranted (see the excellent critique by Meyer[29]).

Most of the time the human studies have lagged far behind animal experimentation. This is certainly true today as regards the cerebral cortex and hearing. Some of the techniques used in the laboratory can be carried over and used in man. We are now working on various auditory stimuli to be used during cortical stimulation of the locally anesthetized patient.

No mention has been made of the various theories of audition as none seems satisfactory, particularly when one reaches cortical levels of integration. Theories of auditory agnosia, especially when subdivided into verbal, literal, etc., are unsatisfactory. Proof of this last statement is given by Schuknecht and Woellner.[30] They demonstrated that two patients with acoustic neurinomas had abnormally poor speech discrimination as compared with pure tone thresholds in

the involved ears. This would be impossible if auditory verbal agnosia were only of cortical origin. Theories of hearing must take into consideration the types of defect seen in central as well as peripheral lesions, i.e. the disturbances which occur in auditory imperception (a term which I prefer to agnosia).

D. SUMMARY

1. A brief review has been given of the present status of knowledge about the cortical representation of hearing. Cat has been the animal most frequently used. Not only AI, AII, EP and SII but also the temporal and insular areas as well as the suprasylvian and anterior lateral gyri and part of the motor region seem to have auditory representation. Frequency discrimination is not cortically bound, but sound localization and pattern discrimination are affected by cortical lesions.

2. The results obtained in the cat have been confirmed in part in the monkey and to a considerably lesser extent in man.

3. Suggestions are given as regards future research.

UNIVERSITY OF FLORIDA

REFERENCES

1. Rose, J. E., and Woolsey, C. N.: Cortical Connections and Functional Organization of the Thalamic Auditory System of the Cat. Pp. 127-150 in: Harlow, H. F., and Woolsey, C. N., Eds. Biological and Biochemical Bases of Behavior. Madison, Wisconsin, University of Wisconsin Press, 1958.

2. Kiang, N.: Organization of Auditory Cortex in the Cat. Amer. J. Physiol. 183:635, 1956.

3. Thompson, R. F., and Sindberg, R. M.: Auditory Response Fields in Association and Motor Cortex of Cat. J. Neurophysiol. 23:87-105, 1960.

4. Lilly, J. C., and Cherry, R. B.: Surface Movements of Click Responses from Acoustic Cerebral Cortex of Cat: Leading and Trailing Edges of a Response Figure. J. Neurophysiol. 17:521-32, 1954.

5. Pribram, K. H., Rosner, B. S., and Rosenblith, W. A.: Electrical Responses to Acoustic Clicks in Monkey: Extent of Neocortex Activated. J. Neurophysiol. 17:336-44, 1954.

6. Lilly, J. C.: Correlations between Neurophysiological Activity in the Cortex and Short-term Behavior in the Monkey, pp. 83-100 in Harlow, H. F., and Woolsey, C. N., Eds., Biological and Biochemical Bases of Behavior. Madison, Wisconsin, University of Wisconsin Press, 1958.

7. Sugar, O., French, J. D., and Chusid, J. G.: Cortico-cortical Connections of the Superior Surface of the Temporal Operculum in the Monkey (Macaca mulatta). J. Neurophysiol. 1:175-84, 1948.

8. Meyer, D. R., and Woolsey, C. N.: Effects of Vocalized Cortical Destruction on Auditory Discriminative Conditioning in the Cat. J. Neurophysiol. 15:149-162, 1952.

9. Neff, W. D., Fisher, J. F., Diamond, I. T., and Yela, M.: Role of Auditory Cortex in Discrimination Requiring Localization of Sound and Space. J. Neurophysiol. 19:500-12, 1956.

10. Butler, R. A., Diamond, I. T., and Neff, W. D.: Role of Auditory Cortex in Discrimination of Changes in Frequency. J. Neurophysiol. 20:108-20, 1957.

11. Neff, W. D.: Behavioral Studies of Auditory Discrimination. ANNALS OF OTOLOGY, RHINOLOGY AND LARYNGOLOGY 66:106-14, 1957.

12. Goldberg, J. M., Diamond, I. T., and Neff, W. D.: Auditory Discrimination After Ablation of Temporal and Insula Cortex in Cat. Fed. Proc. 16:204, 1957.

13. Neff, W. D., and Diamond, I. T.: The Neural Basis of Auditory Discrimination, pp. 101-126 in: Harlow, H. F., and Woolsey, C. N., Eds. Biological and Biochemical Bases of Behavior. Madison, Wisconsin, University of Wisconsin Press, 1958.

14. Ades, H. W.: Central Auditory Mechanisms, pp. 585-613 in Field, J., Ed. Handbook of Physiology, Sec. 1, Neurophysiology, Vol. 1, American Physiological Society, Washington, D.C., 1959.

15. More, R. Y., and Diamond, I. T.: The Effect of Hippocampal Ablation on Conditioned Avoidance Behavior in the Cat. Paper read at Midwestern Psychological Association Meeting, 1957.

16. Moore, R. Y., Harvey, J. A., and Diamond, I. T.: Further Effects of Hippocampbale Ablation on Conditioned Avoidance Behavior in the Cat. Paper read at Midwestern Psychological Association Meeting, 1957.

17. Blum, R. A.: Effects of Subtotal Lesions of Frontal Granular Cortex on Delayed Reaction in Monkeys. A.M.A. Arch. Neurol. Psychiat. 67:375-86, 1952.

18. Jerison, H. J., and Neff, W. D.: Effect of Cortical Ablation in the Monkey on Discrimination of Auditory Patterns. Fed. Proc. 12:73-74, 1953.

19. Weiskrantz, L., and Mishkin, M.: Effects of Temporal and Frontal Cortical Lesions on Auditory Discrimination in Monkeys. Brain 81:406-14, 1958.

20. Morrell, F., Roberts, L., and Jaspeh, H. H.: Effect of Focal Epileptogenic Lesions and Their Ablation upon Conditioned Electrical Responses of the Brain in the Monkey. EEG Clin. Neurophysiol. 8:217-236, 1956.

21. Penfield, W., and Rasmussen, T.: The Cerebral Cortex of Man. New York, MacMillan Company, p. 235, 1950.

22. Roberts, L.: Activation and Interferences Produced by Electrical Stimulation of the Brain in Conscious Man. Symposium on Brain Stimulation. Univ. of Texas Press, Austin, Texas. Sheer, D., Ed. 1960, in press.

23. Penfield, W., and Kristianson, K.: Epilepsy Seizure Patterns. Springfield, Ill., Charles C. Thomas, p. 104, 1951.

24. Penfield, W., and Roberts, L.: Speech and Brain Mechanisms. Princeton University Press, Princeton, N. J., p. 286, 1959.

25. Sanchez-Longo, L. P., Forster, F. M., and Auth, T. L.: A Clinical Test for Sound Localization and Its Applications. Neurology 7:655-663, 1957.

26. Sanchez-Longo, L. P., and Forster, F. M.: Clinical Significance of Impairment of Sound Localization. Neurology 8:119-125, 1958.

27. Walsh, E. G.: An Investigation of Sound Localization in Patients with Neurological Abnormalities. Brain 80:222-250, 1957.

28. Henschen, S. E.: Klinische und Anatomische Beitrage zur Pathologie des Gehirns. Stockholm, Nordiska Bokhandeln, Vol. 5, Vol. 6, Henschen, Vol. 7, 1920-1922.

29. Meyer, D. R.: Some Psychological Determinants of Sparing and Loss Following Damage to the Brain, pp. 173-192 in: Harlow, H. F., and Woolsey, C. N., Eds. Biological and Biochemical Bases of Behavior. Madison, Wisconsin, University of Wisconsin Press, 1958.

30. Schuknecht, H. F., and Woellner, R. C.: An Experimental and Clinical Study of Deafness from Lesions of the Cochlear Nerve. J. Laryngol. and Otol. 69:75-97, 1955.

SOME CLINICAL ASPECTS OF APHASIA

Joe R. Brown, M.D.

Rochester, Minn.

It must be admitted at the outset that aphasia is a complex disorder. However, on many occasions the true complexity is compounded by the use of long and complicated terminology and by failure to define terms. Further complications occur when dogmatically rigid viewpoints are upheld too vigorously. I hope to be able to present a simple, flexible, and accurate evaluation of some of the clinical aspects of aphasia.

Aphasia may be defined as a primary disorder of the reception, manipulation, and expression of language. The word "primary" is used to exclude language disturbances which are secondary to special perceptual defects such as deafness, special motor loss of the speech musculature, general intellectual deficits as exemplified by dementias, and emotional disorders such as neuroses and psychoses. The phrase "reception, manipulation, and expression" is used specifically to imply that in almost all aphasic patients there is involvement of more than one aspect of language. The terms "reception" and "expression" are generally well recognized. The term "manipulation" of language is used to designate the conceptual language processes going on between reception and expression. These conceptual language processes have been variously designated as inner speech, inner language, symbolic formulation and so forth.

Language may be defined as a system of communication of ideas and feelings by the use of empiric symbols known as words. Some of the special forms of language are sign language, braille, mathematics and chemical formulas. In most aphasic patients concern is concentrated on the usual forms of language.

The Mayo Foundation, Rochester, Minnesota, is a part of the Graduate School of the University of Minnesota.

Language may be considered to consist of four major modalities: listening, speaking, reading, and writing. In most aphasic patients more than one language modality is involved.

LATERALITY OF LESION AND HANDEDNESS

It was recognized early that aphasia resulted from lesions limited to one hemisphere, usually the left. Subsequently possible interrelationship between handedness and the laterality of the lesion producing aphasia has been studied. There has been a remarkable divergence of views on this apparently simple point.

Nielsen,[1] an exponent of the viewpoint of detailed localization of various cerebral functions, stated, "In general, right-handed persons are left-brained and left-handed persons are right-brained; the proportion of instances in which brainedness and handedness are ipsilateral is small, perhaps 5%."

Wepman[2] expressed a contrary view. "Language deficits following damage to the right hemisphere either are of the nature of dysarthrias or, if aphasic-like last only a short time and are overcome spontaneously. Permanent aphasia . . . occurs only after injury to the left cerebral hemisphere, regardless of cortical dominance."

These two statements are illustrative of the wide diversity of opinion concerning the laterality of lesions producing aphasia. There are, of course, various opinions lying between these two extremes. In a reported study of 100 aphasic patients,[3] adequate evidence of a unilateral lesion which could be accurately lateralized was found in 93 patients. In 93.5 per cent of the group the lesion was in the left hemisphere; among the right-handed patients the lesion was in the left hemisphere in 96 per cent and in the right hemisphere in 4 per cent, while among the left-handed and ambidextrous patients the lesion was in the left hemisphere in only 73 per cent and in the right hemisphere in 27 per cent.

In six patients, aphasia was due to a lesion of the right hemisphere and the aphasic phenomena seen in these patients were no different from those seen in patients suffering from aphasia due to lesions of the left hemisphere. In one patient with a lesion in the right hemis-

phere which produced moderately severe aphasia, the onset had occurred eight months before his examination.

Penfield and Roberts,[4] on the basis of tests with sodium amytal and evidence from cortical excisions for epilepsy, estimated that less than 1 per cent of the right-handed population have speech represented in the right hemisphere while less than 10 per cent of the left-handed persons have some, and probably all, speech represented in the right hemisphere.

Further work with larger series of patients will be required to establish the percentages more exactly, but it seems safe to assume that among the right-handed population, aphasia in most patients in whom it develops is the result of a lesion of the left hemisphere. Among left-handed and ambidextrous patients, aphasia usually will be the result of a lesion in the left hemisphere and in contrast to right-handed patients, only a small although a definite percentage of left-handed and ambidextrous patients will have aphasia as a consequence of a lesion of the right hemisphere.

LOCALIZATION OF LESION

The localization within the hemisphere of lesions producing aphasia has similarly been the subject of controversy.

Nielsen[1] defined a cerebral center as "an anatomically delimited zone which is essential to a certain function." With such a definition in mind he cited evidence for the existence of centers for specific language skills including visual language receptive skills, auditory language receptive skills, language formulation, spoken language expression, written language expression, and visual object recognition.

In some contrast to this, Wepman[2] accepted the view that "aphasic language disorders are considered as affecting all the language modalities and cannot be limited to specific language skills."

An intermediate view has been proposed more recently by Penfield and Roberts.[4] Their evidence is based on obtaining aphasic responses while stimulating the cerebral cortex electrically and on studying the language of patients treated by cortical excision for focal epilepsy. They concluded that three cortical areas are of particular importance in language functions. Of greatest importance is a posterior area comprising the posterior temporal and adjacent parietal

lobe. The area of Broca is the second region in importance. Of still lesser importance is the supplementary motor area on the medial aspect of the hemisphere. They further observed that lesions near the junction of the parieto-occipital lobes (the posterior portion of their posterior area) may produce dysphasia with most pronounced difficulty in the visual sphere.

A study of 94 patients with aphasia in whom an accurate localization could be made on clinical evidence was reported in 1957.[3] In only three patients did the lesion producing the aphasia seem limited to the frontal lobe or adjacent temporal tip. In the remainder of the patients, lesions occurred more posteriorly and involved the midportion and posterior portion of the temporal lobe and the adjacent parietal or occipital regions. In 13 patients an aphasic defect of reading was considerably greater than other defects. In 10 of the 13 the lesion responsible for the aphasia was localized posteriorly and involved the posterior temporal anterior occipital region. Patients with predominant defects of reading were most frequently associated with homonymous hemianopsia suggesting a relatively posterior location of the lesion. Patients with severe defects of all language modalities (global aphasia) had the greatest frequency of hemiplegia and hemianesthesia suggesting a generally more massive lesion.

Although there are many details of localization which have not been touched on in this discussion, these are a few general principles which stand out. Aphasia may occur as the result of a lesion strictly limited to the frontal lobe, but such a location is statistically uncommon. By far the commonest location for a lesion producing aphasia is in the midportion and the posterior portion of the temporal lobe and adjacent to the parietal lobe. A lesion limited to the more posterior part of this general region tends to be associated with aphasia in which defects of reading are more prominent than the other aphasic defects.

DESCRIPTION OF APHASIC DEFECTS

Over the years a wide variety of systems of classification of aphasia have developed, often as a result of different points of view and with varying usefulness. Some classifications were designed for purposes of anatomical localization, others for purposes of therapy. For most physicians with not too deep an interest in aphasia it is per-

haps satisfactory to bypass systems of classification. It is important, however, to examine the patient for the presence of specific aphasic defects. In so doing, tests should include all four major language modalities: listening, speaking, reading, and writing.

Because it is most obvious, speaking is generally tested first. Abilities of speaking occur in a continuum of increasing difficulty, but for purposes of demonstrating severity of aphasic defects it is convenient to divide the continuum into separate groupings.

The lowest level of speaking might be categorized as *automatic speech.* It includes phonatory noises, exclamations, swearing, and stereotyped speech remnants. One patient with such a stereotyped remnant responded to everything with the words "baby shoes." Automatic speech of this character may convey emotional feeling but does little in conveying a variety of specific conceptual thoughts.

The next level of speaking can be characterized as *socially reactive speech.* It includes the ability to use "yes" and "no" meaningfully and to comment by parenthetical asides. One patient, after repeated failures during a therapy session, murmured parenthetically, "I hope I talk soon." The ability to react verbally to a situation of considerable personal meaning occurs at this level, as exemplified by a hospitalized patient, unable to speak volitionally, who, when presented with a dish of pudding, exclaimed, "No, I don't want that—I don't like it!" Conversing in generalities (often vaguely) about familiar daily events is also included at this level. When such socially reactive speech remains, a patient may not be recognized as aphasic by the casual observer.

The ability to utter the desired specific word is the third level of speaking. This might be designated as the level of *specific speech.* Included in this level is the ability to name objects accurately, to use the proper verb to describe an action, and to use the correct modifying adjectives or adverbs. Defects at this level are illustrated by the patient who was asked the name of an object (razor) and responded with "Well, to shave with." When asked what you do with a razor he said, "Well, on your face." Defects at this level are readily tested and are readily recognized as aphasic.

The next level of speaking, that of *concrete speech,* is characterized by the ability to convey ideas accurately and specifically and to

discuss events of a relatively concrete nature. Included in the term "concrete" are things which are familiar, personal, visible, palpable, or repeated. At this level a discourse by the patient would include relating specific details of the day's events, an accurate description of physical symptoms, or a detailed account of important factors in his job. Most aphasic patients make frequent errors of speaking when required to perform at this level. Other patients, unable to perform at a more abstract level, are able to respond when the concepts are converted to a more concrete level. Illustrative of this is the patient who was unable to answer the question, "What does one do with money?" However, this was converted to the concrete, personal, and familiar experience by changing the question to "What does your wife do with money?" His response came promptly with bell-like clarity, "She spends it."

The highest level of speaking is the ability to communicate high-level concepts clearly by abstract speech. Discussion of international events, the duties of a good citizen, and the meaning of proverbs are examples of this level of speaking. An example of an aphasic response at this level occurred in answer to a request to explain the meaning of "Don't change your horses in midstream." The response demonstrated aphasic circumlocution and followed in this manner: "You should go along and cover your condition before you try to change in the last minute what you are doing." At this level of performance it may be difficult to distinguish between aphasia and general impairment of intellectual functions in some patients.

In general terms, the severer the aphasia, the lower the level of speaking in the described continuum. The actual phenomenon observed in an aphasic patient will depend on the basic defect and on the way the patient compensates for the defect. There appear to be two basic defects in aphasic patients, namely, blocks and distortions.

Blocks are more or less transient absences of speech. They seem to represent an elevation of the threshold for the speaking of the specific word desired. In undisguised form, blocks appear as slowness, pauses, hesitations, and, rarely, as stuttering. A patient may compensate for blocks by the use of starters ("itsa," "well," "a-ah"), parenthetical asides ("oh, I should know that," "we have one of those at home") or the use of associations ("it's to write with, a pen, a pencil"). Another method of compensation is the substitution of another

word for the desired word. The substitution may be accurate enough to convey the correct meaning or it may be inaccurate and fail.

Distortions of the events of speaking furnish the second basic defect of speaking in aphasic patients. Distortions of speech sounds affect most the sounds that require fine co-ordination of tongue and lip movements; this gives a defect which may closely resemble the usual forms of dysarthria. Words rather than individual sounds may be distorted. One patient expressed his exasperation at being examined with the following distorted but recognizable words, "Pull a cenpil out, drive me prazy." Distortions may involve phrases, as with the patient who defined courage as "gotta person be brave." Many times the distortions are mild enough to permit understandable speech and they may be corrected by the patient. One patient was asked, "What do you use to eat soup?" The progressively correct reply was "soup—snoup—spoup—spoon." When distortions are severe and uncorrected, and when they result in unrecognizable words or phrases, the condition is known as "jargon."

The speaking defects observed in aphasic patients increase when the level of abstractness, the amount of retention, or the specificity of response required is increased. Patients attempt to compensate for these problems by converting the response to a more concrete and personal level, by shortening the response, and by giving an approximate reply.

Previous words or concepts often intrude and interfere with speaking, giving rise to the phenomenon known as "perseveration."

The defects of speaking also will be modified by the social situation of the moment. The patient often talks better and easier with close members of the family than with strangers. One aphasic patient commented, "I can talk better one person with." A calm unhurried reassuring approach by the examiner encourages better performance by the patient. Conversely, placing the patient "on the spot" will increase his aphasic difficulty.

Defects of other language modalities will be seen in almost all aphasic patients. Defects of writing generally parallel those of speaking. A description of defects of listening is beyond the scope of this article. However a few comments seem worth including. There seems to be a basic defect in the recognition of individual words with

severe listening defects and difficulty in comprehending the meaning of phrases and statements in milder defects. Some patients have commented that the sounds of words seem distorted. These basic defects of listening may produce some resemblance between the aphasic and the hard-of-hearing patient. In addition to the defects described there is also impairment of retention of things which have been heard. Many aphasic patients are able to interpret a general social situation and mask their receptive defect. Unless listening is tested specifically, the physician may fall into the belief that the defect is entirely expressive. Defects of reading appear to follow patterns similar to defects of listening.

A few words concerning prognosis in aphasia seem appropriate. Before attempting to estimate prognosis, the underlying neurologic lesion must be reasonably stable. Although spontaneous improvement may continue for much longer, sufficient stability will have occurred within 3 months after a nonprogressive lesion has been diagnosed to permit a reasonable estimate of prognosis. The occurrence of severe neurologic deficits other than aphasia is commonest among patients with severe aphasic defects. Only the rare aphasic patient has minimal neurologic defects or no neurologic defect other than aphasia. A persistent, severe defect of listening is indicative of a poor prognosis. Lack of motivation or evidence of general intellectual impairment imposes limitations on recovery. Detailed testing is necessary to establish an accurate prognosis. Such testing and therapy for aphasia are properly the function of speech pathologists with special training in aphasia.

MAYO CLINIC

REFERENCES

1. Nielsen, J. M.: Agnosias, Apraxias, Speech, and Aphasia. In Baker, A. B.: Clinical Neurology. Paul B. Hoeber, Inc., New York, pp. 352-378, 1955.

2. Wepman, J. M.: Recovery from Aphasia. Ronald Press Co., New York, 1951.

3. Brown, J. R., and Simonson, Josephine: A Clinical Study of 100 Aphasic Patients. 1. Observations on Lateralization and Localization of Lesions. Neurology 7:777-783, 1957.

4. Penfield, Wilder, and Roberts, Lamar: Speech and Brain-Mechanisms. Princeton University Press, Princeton, New Jersey, 1959.

THE PAROTID GLAND IN MIKULICZ DISEASE AND SJOGREN'S SYNDROME

WILLIAM GARTH HEMENWAY, M.D.

CHICAGO, ILL.

Mikulicz's name has been associated with parotid disease for many years. Most physicians are aware of this but few have a clear understanding of the actual disease processes involved. In 1888 Mikulicz presented a unique case before a medical meeting in Koeningsberg. A 42 year old man had developed bilateral lacrimal, parotid and submaxillary swellings. He published the case in 1892 and considered the disease to be a low grade infective process hitherto undescribed. Histologic examination of surgical specimens from the lacrimal and submaxillary glands disclosed atrophy of the parenchyma and diffuse replacement by lymphoid tissue. Unfortunately, the exact diagnosis in this case will always remain a mystery as insufficient information is available to assess the findings in the light of present day pathological knowledge.

A great deal of confusion about salivary and lacrimal gland swellings followed Mikulicz' report. Schaffer and Jacobson[1] in 1927 clarified the situation by classifying cases into Mikulicz disease and Mikulicz syndrome. Mikulicz disease was thought to be a low grade infection of unknown type running a slow course but eventually subsiding. Mikulicz syndrome included known diseases such as lymphomas, tuberculosis, syphilis, Boeck's sarcoid and toxic reactions to lead and iodides. This classification is widely followed today.

Only Mikulicz disease as it occurs in the parotid gland will be discussed in this report.

Godwin[2] in 1952 published a paper entitled "Benign Lymphoepithelial Lesion of the Parotid Gland." Pathological findings were

---

From the Section of Otolaryngology of the University of Chicago.

presented in 11 cases. Although the exact nature of the lesion was unknown he considered it to be an inflammation. The process occurred in scattered foci, diffusely involving the entire gland or localized as a single mass with or without a capsule. Lesions consisted of a mass of lymphoid tissue containing scattered foci of epithelial cells that were traceable to duct origin. There was a variable degree of acinar destruction. Although lymphoid tissue was abundant it was evident that the lesion was not a malignant lymphoma. The epithelium varied from well differentiated tubular epithelium to solid foci of closely packed cells. Occasionally cysts lined with metapastic epithelium were seen. Grossly, the disease appeared as a well circumscribed mass or as a diffuse process involving part or all of the gland. Symptoms were minimal, and enlarged gland was usually the only presenting complaint. Middle aged females were commonly affected. No case showed lacrimal involvement or subsequently developed malignant disease. The lesion was usually unilateral but the other side occasionally become involved later. Godwin proposed the name "Benign Lymphoepithelial Lesion" for the condition. He stated that the lesion was identical with that which had been called Mikulicz disease and recommended that the eponym be dropped. He classified it along with Warthin's tumor under the term adenolymphoma.

Morgan and Castleman[3] in 1953 presented a clinicopathological study of Mikulicz disease. The gross appearance that was of a diffusely enlarged gland with preservation of the architecture. Microscopically there was replacement of the acinar parenchyma by lymphoid tissue and an intraductal proliferation of two cell elements; epithelial and myo-epithelial. This resulted in the formation of epi-myoepithelial islands when the lumen of the duct was obliterated. They believed that the primary lesion was in the duct system and stated that the epi-myoepithelial islands were specific for the disease. The etiology was obscure.

Morgan[4] states that Mikulicz disease is commonly confined to the salivary glands, usually the parotid. It is rare in the lacrimal glands. He found the parotids showed identical pathological changes in Mikulick disease and Sjogren's syndrome and concluded that Mikulicz disease was a localized form of Sjogren's syndrome.

Patey and Thakray[5] in 1955 reported on studies based on surgical specimens. They described an uncommon and not too well recognized

inflammatory lesion of the parotid which was usually unilateral. A swelling developed in one parotid which gradually increased in size. This type was clinically and even pathologically difficult to distinguish from a tumor. Clinically they divided the cases into a diffuse form (inflammatory - obstructive) and a localized (tumor simulating) form. Their paper dealt with nine patients on whom total or partial parotidectomy was carried out. Careful study of the specimens showed that they were dealing with different degrees and manifestations of the same pathological lesion which they considered to be a chronic inflammatory process. Of the nine cases two were male and seven were female. Three cases were inflammatory obstructive, four were tumor simulating and two were intermediate forms. Sialographic findings were described in detail. The most characteristic x-ray finding was sialectasis. The main ducts were not usually involved and the typical picture was a glandular sialectasis. From serial sections of their material they concluded that the sialectatic picture was not due to filling of dilated ducts but to interstitial extravasation of lipiodal. This would explain why the lipiodal remains in the gland for weeks to even years after the injection. They concluded that these radiological findings are common to all types of chronic parotitis irrespective of the clinical picture and they may be occasionally found without clinical evidence of infection. Pathological findings are thoroughly described. They may be summarized as a progressive accumulation of lymphoid tissue around the intralobular ducts with associated hyperplasia and metaplasia of the ductal epithelium. The glandular elements atrophy and were replaced by lymphoid tissue. The larger intralobular ducts were mainly affected. The interlobular ducts showed only minor changes. The intralobular ducts became occluded with hyperplastic cells and the distal acini atrophy and were replaced by lymphoid tissue. The epithelial islands described were cross sections of solid intralobular ducts. These may undergo hyaline degeneration. They described clear spaces caused by extravasated lipiodal near the ducts if a recent sialogram had been performed. If a sialogram had been done sometime previously the pools of oily material would be surrounded by macrophages and foreign body giant cells. Eventually a dense fibrosis occurred. They summarized by stating that in this type of parotid disease there were two modes of presentation which may be described as inflammatory obstructive and tumor simulating. In both the pathological picture was one of chronic inflammation differing in degree and distribution. In both the radiological picture was that of glandular sialectasis. They recommended

conservative parotidectomy for the tumor simulating type and for the inflammatory obstructive type when severe clinical symptoms could not be controlled by conservative treatment.

Freund and Jonassen[6] described this disease under the name of benign lymphoepithelial disease. They postulated that the lesion arises from the parotid lymph nodes which normally contain ductal structures. Treatment proposed was excision of localized forms of radiation therapy for diffuse involvement.

Kay[7] described four lesions limited to the salivary glands in which the pathology was the same as that described by Godwin.[2] He concluded that the process was not systemic but confined to the salivary glands.

Orloff[8] grouped Warthin's tumor and Mikulicz disease under the heading of benign epitheliolymphoid lesions of the parotid gland. Mikulicz disease was often confined to one or both parotids and it was important for the surgeon to understand the nature of this benign self limited disease. Seventy-six per cent of 35 cases were female. Symptoms were minimal. The common complaint was a disfiguring mass which might fluctuate in size. The physical findings were of little help in distinguishing this lesion from other parotid diseases. Most commonly a diffuse swelling of the entire gland was noted but a circumscribed mass, either fixed or movable, may be present. In three cases x-rays revealed multiple small calcifications. Sialograms showed sialectasis in three of the four patients who had this examination. The gross appearance of the lesion usually showed preservation of the lobular pattern. The cut surface is smooth, resembling lymphoid tissue. There may be cystic spaces and small calcareous bodies. Microscopically the description conforms to that already described.[2-5] He concluded that this is an obscure type of chronic inflammatory disease which may continue for years without affecting the general health. He recommended surgical removal of localized lesions and x-ray therapy to diffuse lesions.

DuPlessis[9] found only three cases of Mikulicz disease in over 200 patients with parotid swellings. All three were in females. The average age was 35. The history was one of slowly progressive enlargement in one or both parotids. The process may be diffuse or localized. Stensen's duct orifice and the saliva were always normal. In the

advanced stages very little saliva was secreted but the patient should not complain of a dry mouth as the remaining major and minor salivary glands will keep it moist. Du Plessis stated that the earliest findings were an inflammation and fibrosis of the trabeculae between the lobules. Later the process spread to the gland parenchyma. Lymphoid infiltration commenced around the infralobular ducts. The epithelial and myoepithelial cells in these ducts proliferated and eventually filled the lumen of the duct thus forming solid cords. These appeared like islands on the microscopic section and sometimes underwent hyaline degeneration. The acini atrophied behind the obstructed cuts and were replaced by a diffuse lymphocytic infiltration. Sialographic findings were reviewed. The classical appearance was sialectasis which was usually assumed to be due to pooling of contrast material in dilated ducts but was actually the result of extravasation of the dye into the interstitial tissue through the weakened cut wall. Although the pathology in the parotid and sialographic pictures are similar in both Mikulicz and Sjogren's he did not feel they are otherwise related diseases. He felt that the parotid gland in Sjogren's underwent a primary atrophy with resultant diminution of salivary flow and increased likelihood of an ascending infection. He concluded that this pathological picture of proliferation of duct epithelium, lymphocytic infiltration, acinar atrophy and fibrosis was not pathognomonic of any disease but was a non-specific reaction of the parotid to chronic irritation. Mikulicz disease and Sjogren's syndrome must be differentiated on clinical grounds. He recommended that the name Mikulicz disease should be dropped and replaced by the term idiopathic chronic parotitis.

Bernier and Bhaskar[10] presented an extensive review of lympho-epithelial lesions of the parotid glands in 1958. They included cystic lymph nodes (benign lympho-epithelial cysts), Warthin's tumor (papillary cystadenoma lymphomatosum) mixed tumor in lymph nodes and benign lympho-epithelial lesion. There were 30 cases of benign lymphoepithelial lesions. They concluded that Mikulicz disease was primarily a lesion of the parotid lymph nodes which involved the parotid gland incidentally and represented a reactive hyperplasia of lymphatic tissue. A nodular type limited to the node and a diffuse type which infiltrates the parenchyma were described. The two types had a different microscopic picture. In the nodular type there was a diffuse lymphoid infiltration. Epithelial elements which were absent altogether or recognizable as widely isolated islands resembling glandu-

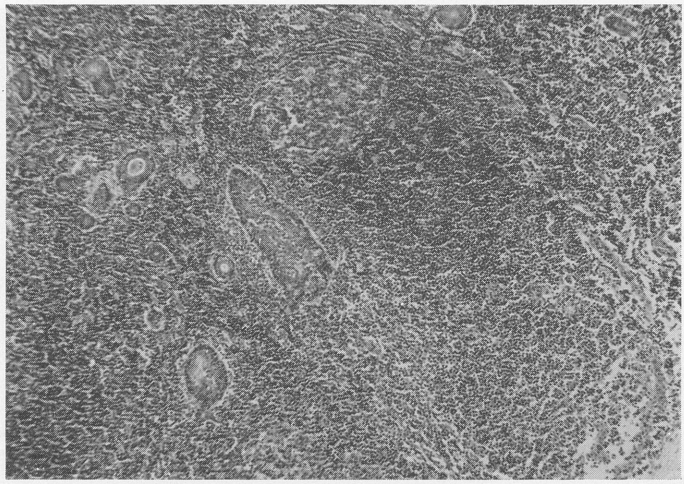

Fig. 1.—Case one. Histopathology of a localized mass in the parotid showing typical island formation, gross lymphoid infiltration and absence of acini.

lar tissue. Apparently they found no typical islands in this type. The diffuse type showed proliferating lymphoid tissue while the ducts had undergone squamous metaplasia and cyst formation.

Maxwell[11] recently presented an excellent description of this lesion.

Four cases of Mikulicz disease of the parotid gland are reviewed.

CASE 1. D.S. No. 587689. This 40 year old white man had a small mass 1 cm in diameter posterior to the angle of the mandible. He was otherwise in good health. At surgery the mass was found to be in the parotid gland and was excised. Histological study (Fig. 1) shows typical epithelial islands, chronic lymphatic infiltration and marked disappearance of the acini. A pathological diagnosis of solid adenolymphoma was made. This lesion could be called Mikulicz disease or the localized or tumor simulating type of chronic parotitis as described by Patey and Thakray.[5]

CASE 2. G.B. No. 650792. A lump in the left parotid area had been noticed for three weeks by this 59 year old white man. The

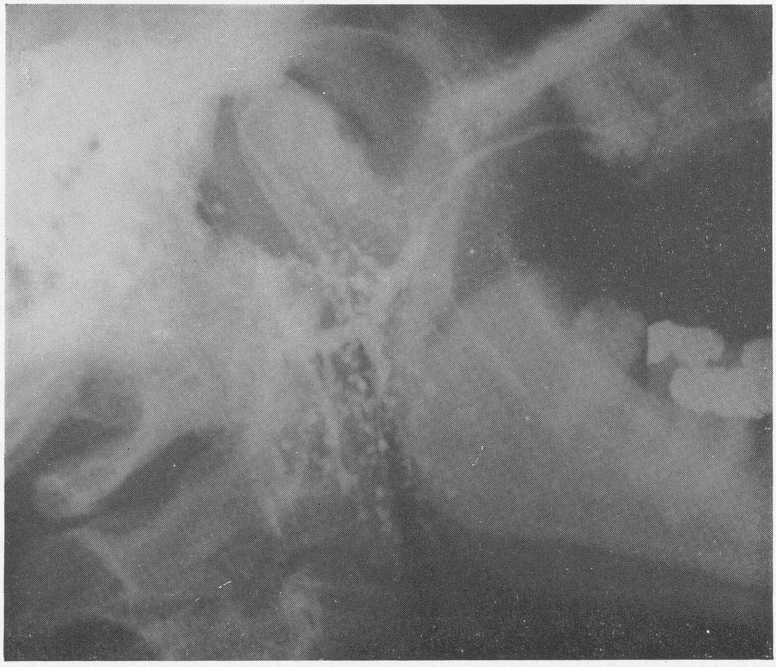

Fig. 2.—Case three. Sialogram showing sialectasis in a bilateral case of Mikulicz disease.

mass was about 1 cm in diameter, freely movable and situated just posterior to the angle of the mandible. The lump was excised under local anesthesia. A pathological diagnosis of solid adenolymphoma was made. The findings are typical of Mikulicz disease.

CASE 3. D.G. No. 295220. This 35 year old white woman was in the hospital in 1950 for treatment of obstructive jaundice. She had bilateral diffuse swellings of both parotids, more marked on the right. There were no symptoms or signs pointing to Sjogren's disease. X-rays showed multiple small calculi bilaterally. A sialogram was made on the right side (Fig. 2) and revealed moderate advanced sialectasis. No biopsy was done. Clinically this would seem to be a case of bilateral Mikulicz disease of the diffuse type.

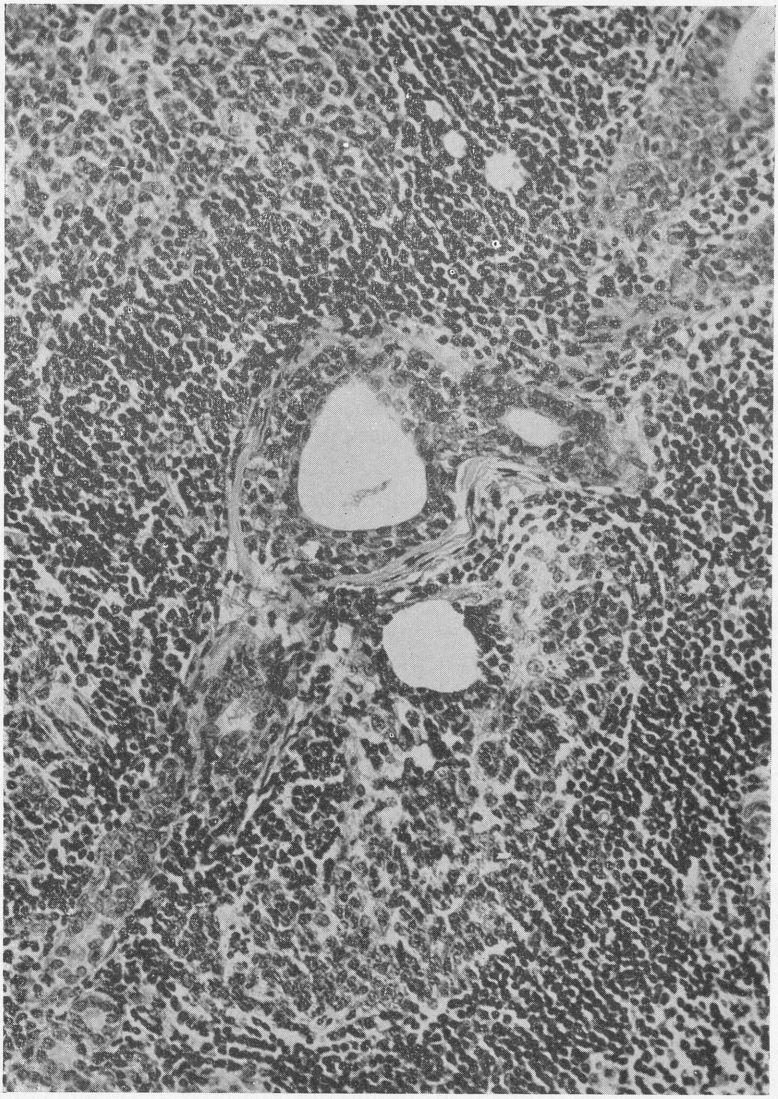

Fig. 3.—Case four. An early case of Mikulicz disease showing disappearance of the acini, lymphoid infiltration and metaplasia and dilatation of the intralobular ducts.

CASE 4. J.P. No. 668878. Mrs. J. P. was a 55 year old white woman who had a diffuse painless swelling of the left parotid gland of three weeks' duration. A sialogram showed early terminal sialectasis. A biopsy (Fig. 3) showed acinar destruction and lymphoid infiltration. The epithelium of the intralobular ducts was hyperplastic and the ducts were somewhat dilated. This was considered to be an early case of Mikulicz disease.

SJOGREN'S SYNDROME

Sjogren's Syndrome is generally considered to be a clinical entity of unknown etiology. Gougerot[12] in 1926 and Houwer[13] in 1927 reported frequent association of kerato-conjunctivitis sicca and rheumatoid arthritis but Sjogren[14] in 1933 published a full description of the condition. The disease occurs in women 86 to 95% of the time. The fully developed syndrome consists of:

1. Kerato conjunctivitis sicca,

2. Xerosotomia,

3. Pharyngitis, laryngitis, and rhinitis sicca,

4. Swelling of the parotid glands (a review of 19 autopsied cases showed parotid enlargement in eight),[17]

5. About two-thirds of cases have a polyarthritis closely resembling, if not identical with, rheumatoid arthritis.

By no means all cases develop the full clinical picture. Keratoconjunctivitis sicca, xerostoma, rheumatoid arthritis and parotid involvement are the common components. Any two of these occurring in a patient is usually sufficient for a diagnosis.

Morgan and Raven in 1952[15] called attention to the non-ocular findings in Sjogren's Syndrome. They summarized pathological findings in the parotid as consisting of epithelial atrophy with replacement by a large number of round cells and ultimately fibrosis. They stated that the earliest stage is a true lymphocytic infiltration of the parenchyma. As this becomes more marked while the secreting cells undergo atrophy with shrinking of the cytoplasm and condensation into

irregularly shaped masses showing squamous metaplasia. In the end stages only lymphoid tissue and condensed darkly staining epithelial clumps were left (Fig. 6). The ducts were surrounded by a zone of lymphoid tissue or by dense fibrosis. Similar changes were seen in the other major salivary glands and in the lacrimal gland which was never clinically enlarged.

Gurling[16] reported two female patients combining the features of Sjogren's disease with Felty's syndrome (rheumatoid arthritis, splenomegaly, leucopenia, anemia, skin pigmentation and lymphadenopathy).

In 1954 Cardell and Gurling[17] reported three cases with autopsy findings. They described two main pathological components, an atrophy of the salivary and lacrimal glands with associated mucosal dryness and rheumatoid arthritis. In the parotid earlier lesions showed two main features: a lymphoid infiltration which produced glandular enlargement and a parenchymal atrophy which resulted in impaired function. Both aspects showed slow progression and eventually both parenchyma and cellular infiltrate disappear and are replaced by adipose tissue. The histological picture was not one of an infective process although a secondary suppurative process may occur. For the present they placed Sjogren's syndrome into the ill-defined group of Collagen diseases.

MacLean and Robinson[18] reported LE cells in the peripheral blood of a patient with Sjogren's syndrome.

Coverdale[19] from a clinical analysis of over 200 cases of Sjogren's syndrome concluded that the clinical picture develops much earlier than is generally believed and that the disease is a manifestation of a constitutional defect.

McLenachan[20] reviewed 45 cases of Sjogren's syndrome. He found evidence of liver dysfunction in the majority of cases and postulates that the pathology is due to an inability of diseased liver to utilize vitamin A.

Heaton[21] states that Sjogren's syndrome and Systemic Lupus Erythematosis are manifestations of the same disease.

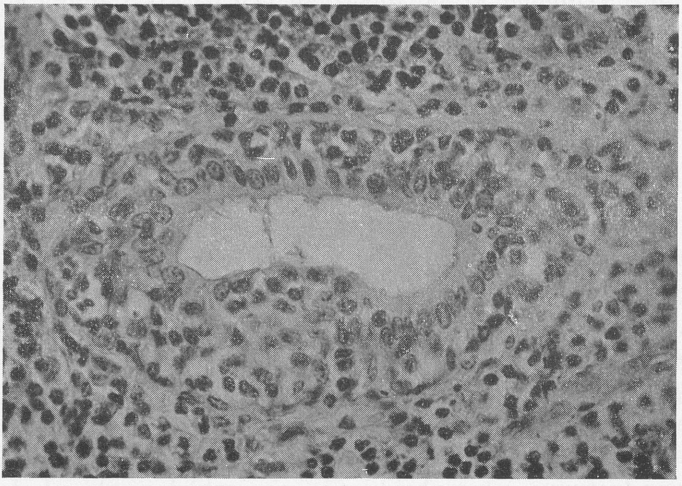

Fig. 4.—Case five. High power of the intralobular duct showing localized hyperplasia of the epithelial and myoepithelial cells.

Seven cases will be presented in which a clinical diagnosis of Sjogren's syndrome had been made and tissue from the parotid gland is available.

CASE 5. L.H. No. 260198. This 40 year old white female was seen on April 2, 1958. She presented with bilateral parotid swelling of about four months' duration. After the onset of the swelling she ran a fever of about one hundred and one degrees for four or five days. The amount of swelling had varied every two or three days. She had many complaints suspicious of a collagen disease. A diagnosis of lupus erythematosis had been entertained but ruled out by the medical department. A diagnosis of keratoconjunctivitis sicca had been made in 1956 and the patient had been using artificial tears daily. The mouth appeared moist and there was no evidence of arthritis. Sialograms showed bilateral terminal sialectasis. A biopsy of the right parotid gland was done and showed foci of lymphoid infiltration with destruction of the acini and early localized hyperplasia of the epithelium of the intralobular duct. The surrounding gland appeared healthy except that the cells contain few zymogen granules and superficially resemble a mucous gland. Figure 4 is a high power photomicrograph

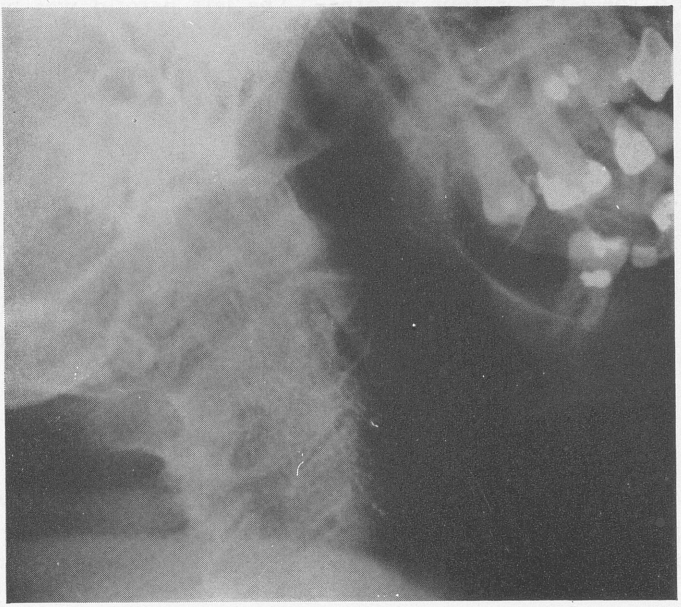

Fig. 5.—Case six. Sialogram showing minimal terminal sialectasis.

showing early hyperplastic changes in the duct. We consider this to represent a very early lesion of the intralobular duct in Sjogren's disease. It would seem reasonable that this hyperplasia would eventually result in obliteration of the lumen and the formation of an epithelial island on sectioning.

CASE 6. A.W. No. 692498. Rheumatoid arthritis and keratoconjunctivitis sicca had been present in this 58 year old white female for several years. Bilateral painless parotid enlargement had been noted for five months. A sialogram showed early sialectasis (Fig. 5). Parotid biopsy showed a focus of lymphoid infiltration with hyperplasia of the epithelial cells of an intralobular duct. The lumen of the duct was about half obliterated and early hyaline degeneration was present.

CASE 7. B.P. No. 652496. This white woman was 34 years of age when first seen. She complained of dry mouth for four years and

dry eyes for two years. The right parotid had been swollen for one year and the left for four months. The left parotid was biopsied under local anesthesia. The acini were almost completely replaced by lymphoid cells. The ductal epithelium was hyperpastic forming many myoepithelial islands.

CASE 8. A.K. No. 542588. This 30 year old white woman was seen on February 13, 1952. A history of intermittent bilateral swelling of the parotids for four years was obtained. Usually only one side at a time would be enlarged. When examined, both glands were diffusely enlarged, firm and non-tender. The left parotid was biopsied under local anesthesia. A diagnosis of "lymphoma of the parotid gland falling into the group of Mikulicz disease" was made with some reservations by the pathologist. X-ray therapy was given (1800 r to left gland and 1139 r to right gland). The parotid swellings receded and have not recurred. During the intervening years she has developed xerostomia and keratoconjunctivitis sicca as well as a pancytopenia. On re-evaluation the biopsy revealed the typical pathological picture of the parotid in Sjogren's disease.

CASE 9. H.S. No. 679363. This 47 year old white female complained of episodes of bilateral parotid swelling for several years. Swelling was often accompanied by pain. One month prior to being seen she had developed bilateral parotid swelling accompanied by pain and fever up to 104° F. The swelling subsided considerably under antibiotic therapy only to have the left side recur one week after therapy was stopped. The left parotid was diffusely enlarged and tender while the right gland was slightly enlarged. Pus could be expressed from Stensen's duct on the left. Culture was reported as showing Escherichia Coli, Micrococcus species and Alpha Streptococci. The mouth and pharynx were dry. An ophthalmologist diagnosed keratoconjunctivitis sicca. A left subtotal parotidectomy was performed under general anesthesia on May 9, 1957. The facial nerve was not injured. Histology was typical for Sjogren's Syndrome. This was a case of Sjogren's Syndrome with a secondary bacterial parotitis of such severity that a subtotal resection was indicated to control symptoms. Since operation two years ago she has had one mild episode of swelling on the other side which was easily controlled medically. As one would expect, there was no increase in xerostomia after the operation as parotid function had been completely destroyed by the disease.

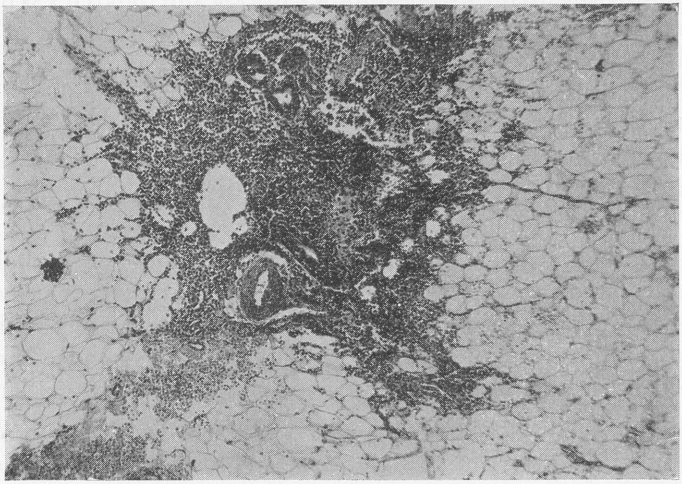

Fig. 6.—Case ten. Far advanced Sjogren's syndrome. The acini have disappeared and are replaced by fat cells. Small foci of lymphoid infiltrations are seen.

CASE 10. S.R. No. 681690. This 39 year old white female complained of recurrent episodes of unilateral and bilateral parotid swelling for over 15 years. Swelling would last about one week. She had had no enlargement for two years when seen on July 1, 1957. No saliva or pus could be expressed from Stensen's ducts. No parotid swelling was noted. She had severe xerostomia and had arthritis of the rheumatoid type. An ophthalmologist reported classical keratoconjunctivitis sicca. Left parotid biopsy was done under local anesthesia (Fig. 6). The acini were completely absent and replaced by fat cells. There were small areas of dense lymphoid infiltration surrounding small ducts and blood vessels. No epithelial islands were seen. Clinically this is a typical case of far advanced Sjogren's syndrome. The pathological findings are similar to those described in autopsy material. The acini have disappeared and are replaced by fat. The typical inflammatory changes seen in the other cases are absent. This may be the end stage of the inflammatory lesion or a case of Sjogren's syndrome showing only primary atrophy uncomplicated by secondary inflammation.

COMMENT

Some of the literature on Mikulicz disease and Sjogren's syndrome has been reviewed. A brief clinical summary of ten cases has been presented. Four cases were considered to have Mikulicz disease (three on pathological grounds and one on clinical features only) and six cases of Sjogren's syndrome were described. Five of the Sjogren's cases showed the same pathology in the parotid as did the three cases of Mikulicz disease in which tissue are available.

Morgan[4] has given us an excellent description of pathological findings common to the two conditions. Others have described the findings in the parotid in Sjogren's syndrome to be somewhat different than in Mikulicz disease. We have 8 cases which show the pathology described by Morgan and Morgan and Casteman.[3] In one late case of Sjogren's syndrome findings were similar to those described mainly in postmortem examinations.[17]

The definitive lesion consists of a progressive hyperplasia of the epithelial and myoepithelial cells of the intralobular ducts. At the same time the ducts are surrounded by a diffuse infiltration of lymphoid cells and the surrounding acini disappear. The ducts become solid cords which on section look like islands (epimyo-epithelial island or epithelial islands). Hyaline degeneration of the islands may take place. The lesion begins in foci which enlarge and coalesce. The lobular pattern of the gland is retained. The essential pathological phenomenon of this condition is the formation of the epithelial islands which do not occur in any other parotid disease except Mikulicz disease and Sjogren's syndrome. The fibrosis described by Morgan and Raven[14] has not been a prominent finding in our material. Epithelial islands were prominent in our two cases of localized Mikulicz disease which does not agree with Bernier and Bhaskar[10] who report that they are absent or only rarely seen in the localized form. Most other authors reviewed also find similar pathology in both groups. There is no evidence from our material that this is primarily a lymph node disease as concluded by Freund and Jonassen[6] and also by Bernier and Bhaskar.[10] Early lesions (Cases 4, 5, and 6) seem to indicate the lesion is primarily one of the intralobular ducts and surrounding acini. In Sjogren's disease the lesion is always bilateral and diffuse whereas in Mikulicz disease it is usually unilateral and may be either diffuse or localized.

Although Foote and Frazell[22] feel this lesion may be benign neoplasm the clinical behavior and pathological findings indicate to most workers that it is a chronic inflammation. The etiology remains obscure. It does not appear to be a bacterial infection although a secondary bacterial infection can occur (Case 9). Virus studies have not yet been fruitful but further search for a virus would seem to be indicated.

In our opinion there has been no satisfactory name for this type of parotid inflammation. Du Plessis' suggestion of idiopathic chronic parotitis has merit but there are other types of parotid infection of equally obscure etiology in which pathological findings are quite different. Chronic parotitis as suggested by Patey and Thakray does not exclude these other types of inflammation. Benign lymphoepithelial lesion was advanced by Godwin as a name for this condition. However, subsequent workers have included many unrelated diseases including neoplasms under this heading and the term as now applied leads to much confusion and probably should not be used. Mikulicz disease has historical significance but otherwise is not satisfactory. Maxwell[11] recently suggested the term chronic lymphoepithelial sialadenitis which appears to be most appropriate.

It is evident that we are dealing with a pathological process in the parotid gland which can occur in two different clinical situations. One is a local disease of the gland which may occur in both males and females and the other is associated with systemic disease which almost always is seen in females. There does not seem to be any real evidence that Mikulicz disease is a less highly developed form of Sjogren's disease as suggested by Morgan.[4] A more acceptable theory has been put forth by Du Plessis. He feels that the primary atrophy of the parotid acini in Sjogren's disease results in diminished flow of saliva which makes the gland peculiarly susceptible to a form of parotitis which occurs only rarely without the primary atrophy.

Sialography has been utilized in the diagnosis of salivary gland disease since 1925.[23] Many authors have described the finding of sialectasis or sialangiectasis as Swinburne[24] prefers to call it. Peripheral pooling of contrast media is variously called small duct, terminal or glandular sialectasis whereas a generalized dilatation of the large ducts due to an obstructive lesion may be called large duct sialectasis. Terminal sialectasis has been described as a congenital condition[25] but is

commonly reported as being found in chronic inflammatory lesions. Although it has been reported in chronic bacterial parotitis some authors believe it to be specific for the parotitis seen in Mikulicz disease and Sjogren's syndrome. The peripheral pooling of the contrast medium is generally considered to be due to dilation of the terminal parotid ducts.[26] Thakray[27] in an excellent study of parotid glands which had been surgically resected from patients showing sialectasis report that the sialectatic picture is mainly due to a rupture of ducts weakened by disease with subsequent extravasation of the contrast material into the periductal tissues. Our small amount of material does not shed any further light on the mechanism responsible for the sialectatic roentgenograms. Only occasionally a dilated duct is seen (Fig. 4) and we have not observed any spaces in the interstitial tissue which could be interpreted as recently or remotely extravasated contrast material. Further studies similar to those of Patey and Thakray[4] and Thakray[28] are necessary. In any case a finding of sialectasis on a sialogram is an important adjunct to diagnosis but should be supplemented by histopathological examination if possible.

As localized parotid lesions cannot be diagnosed accurately by clinical methods they should all be removed by a subtota parotidectomy. Occasionally a case of Mikulicz disease will be discovered. Recurrence may be treated by further surgery or x-ray therapy. While a presumptive diagnosis can be made on the diffuse form of Mikulicz disease by a sialogram which shows sialectasis a parotid biopsy should be done to make a definite diagnosis. A biopsy of the parotid gland is a simple innocuous procedure.[28] Symptoms are often mild and no treatment may be necessary once the diagnosis is established. Often the swelling subsides spontaneously. Surgery or x-ray therapy may be indicated if symptoms warrant.

The management of Sjogren's disease is usually supervised by the specialist in internal medicine with advice from consultants in ophthalmology and otolaryngology. Treatment is mainly symptomatic. The disease is slowly progressive. All suspected cases should have a sialogram and a parotid biopsy, whether or not the gland is enlarged, both for diagnostic purposes and to obtain more pathological information. Occasionally (Case 9) secondary bacterial inflammation became so severe as to require conservative parotidectomy. X-ray therapy is contra-indicated as it would tend to destroy any remaining functional salivary tissue in the oral cavity and pharynx.

Diamant[29] recommends ligation of the parotid duct for recurrent parotitis. However, no pathological information is given as to the type of lesion treated. If this minor procedure is applicable for the type of pathology described in this report it would seem to be the treatment of choice.

SUMMARY

1. Some of the literature on Mikulicz disease and Sjogren's syndrome as they involve the parotid gland has been reviewed.

2. Four cases of Mikulicz disease and six cases of Sjogren's syndrome have been presented.

3. The lesion appears to be a hyperplasia of the epithelial and myo-epithelial cells of the intralobular ducts which become solid cords and appear as islands on section. Concomitantly there is a periductal lymphoid infiltration and disappearance of acini.

When this lesion occurs in the salivary glands (usually in the parotid) without evidence of system disease it is called Mikulicz disease, benign lymphoepithelial lesion and many other names. The term chronic lymphoepithelial sialadenitis would seem preferable. The same pathological picture is usually seen accompanying a systemic disease called Sjogren's syndrome.

4. Most workers agree this is a chronic inflammatory lesion of unknown etiology which runs a benign course. Secondary bacterial infection may supervene causing more severe clinical symptoms.

5. A picture of sialectasis on a sialogram is suggestive of this pathological lesion. Whether the sialectasis is due mainly to dilated terminal ducts or to extravasated contrast medium is not yet clear.

6. Diagnosis and management are briefly outlined.

950 East 59th St.

REFERENCES

1. Schaffer, A. J., and Jacobsen, A. W.: Mikulicz Syndrome; Report of 10 Cases. Am. J. Dis. Child. 34:327-346 (Sept.) 1927.

2. Godwin, John T.: Benign Lymphoepithelial Lesion of the Parotid Gland. Cancer 5:1089 (Nov.) 1952.

3. Morgan, W. S., and Castleman, B.: Mikulicz Disease—A Clinico-Pathologic Study. Am. J. Path. 29:471 (May-June) 1953.

4. Morgan, W. S.: Mikulicz Disease—Probable Systemic Nature—Relation to Sjogren's Syndrome. New England J. Med. 251:5 (July 1) 1954.

5. Patey, D. H., and Thakray, A. C.: Chronic "Sialectatic" Parotitis in Light of Pathological Studies on Parotidectomy Material. Brit. J. Surg. 43:43-50 (July) 1955.

6. Freund, H. R., and Jonassen, O.: Benign Lymphoepithelial Disease of the Parotid Gland. Ann. Surg. 142:895 (Nov.) 1955.

7. Kay, S.: Mikulica Disease of the Salivary Glands. Am. J. Clin. Path. 26:291 (March) 1956.

8. Orloff, M. J.: Benign Epitheliolymphoid Lesions of the Parotid Gland. Papillary Cystadenoma Lymphomatosum and Mikulicz Disease. Internat. Abstr. Surg. 103:521 (Dec.) 1956.

9. DuPlessis, D. I.: The Problem of Mikulicz Disease. South African M. J. 32:264 (Mar.) 1958.

10. Bernier, J. L., and Bhaskar, S. N.: Lymphoepithelial Lesions of the Salivary Glands. Cancer 11:1156 (Nov.-Dec.) 1958.

11. Maxwell, James H.: Chronic Lympho-epithelial Sialadenopathy. Wherry Memorial Lecture. Tr. Am. Acad. Ophth. (Oct. 14) 1959.

12. Gougerot, H.: Bull. Med. 40:360, 1926.

13. Houwer, A. W. M.: Diseases of Cornea. Keratitis Filimentos and Chronic Arthritis. Tr. Ophth. Soc. U. Kingdom 47:88, 1927.

14. Sjögren, H.: Zür Kentnis der Keratoto-conjunctivitis sicca. Acta Ophth. Supp. No. 2 1-151, 1933.

15. Morgan, A. D., and Raven, R. W.: Sjogren's Syndrome: A General Disease. Brit. J. Surg. 40:154 (Sept.) 1952.

16. Gurling, K. J.: Association of Sjogren's and Felty's Syndromes. Ann. Rheumat. Dis. 12 (Sept.) 1953.

17. Cordell, B. S., and Gurling, K. J.: Observations on the Pathology of Sjogren's Syndrome. J. Path. and Bact. 68:137 (July) 1954.

18. MacLean, K., and Robinson, H. S.: Sjogren's Syndrome. Canad. M. A. J. 71:597 (Dec.) 1954.

19. Coverdale, H.: Sjogren's Syndrome as a Constitutional Defect. New Zealand M. J. 54:641 (Dec.) 1955.

20. McLenachan, J.: New Aspects of the Etiology of Sjogren's Syndrome. Tr. Ophth. Soc. U. Kingdom 76:413, 1956.

21. Heaton, J. M.: Sjögren's Syndrome and Systemic Lupus Erythematosus. Brit. M. J. 1:466 (Feb. 21) 1959.

22. Foote, F. W., and Frazell, E. G.: Tumors of the Salivary Glands. Cancer 6:1065 (Nov.) 1953.

23. Rose, S. S.: A Clinical and Radiological Survey of 192 Cases of Recurrent Swellings of the Salivary Glands. Ann. Roy. Coll. Surgeons England 15:374 (Dec.) 1954.

24. Swinburne, G.: Sialoangiectasis. Brit. J. Surg. 27:713-716 (Apr.) 1940.

25. Pearson, R. S. B.: Recurrent Swelling of Parotid Glands. Arch. Dis. Childhood 10:363-376, 1935.

26. Rubin, P., and Besse, B. E.: The Sialographic Differentiation of Mikulicz Disease and Mikulicz Syndrome. Radiology 68:477 (Apr.) 1957.

27. Thakray, A. C.: Sialectatis. Arch. Middlesex Hosp. 5:151, 1955.

28. Hemenway, W. G., and Allen, G. W.: Chronic Enlargement of the Parotid Gland: Hypertrophy and Fatty Infiltration. Laryngoscope 69:1508 (Dec.) 1959.

29. Diamant, H.: Ligation of the Parotid Duct in Chronic Recurrent Parotitis. Acta Oto-laryng. 49:375 (Sept.-Oct.) 1958.

THE SPHENOIDAL SINUS IN ITS RELATION TO THE SELLA TURCICA

GUNNAR HAMMAR, M.D.
(by invitation)
GOTEBORG, SWEDEN

I would first express my deep gratitude for being able to come to this lovely place and to this famous Association.

Soon after starting to do trans-sphenoidal hypophysectomies at the Department of Otolaryngology in Goteberg, Sweden, we found that success was highly dependent on the accuracy of the surgeon's knowledge of the anatomical relation of the sphenoid sinuses to the sella turcica.

Our experience so far is based on 105 hypophysectomies and 120 consecutive post mortem examinations.

Today I shall discuss the results of an analysis of x-ray appearances, including serial tomograms correlated with operative findings.

It is convenient to classify the sphenoid sinuses into three main groups, namely, concha, sella and pre-sella, depending upon the extent to which the sphenoid sinus bone is pneumatized.

The conchal type of sphenoid sinus does not reach into the body of the sphenoid bone. It is small and is separated from the sella turcica by cancellous bone about 10 mm thick.

The pre-sella type of sphenoid does not penetrate beyond the plane perpendicular to the sphenoidal plane through the tuberculum sella, a line easily located on the radiogram. The anterior wall of the sella turcica does not bulge in the sphenoid sinus in the way which is characteristic of the next group.

The sella type of sphenoid sinus is that in which the anterior wall of the sella turcica is only half a mm thick. This wall invariably and the sella floor sometimes bulge markedly into the sphenoid sinus. The sella type of sphenoid sinus is most common and occurred bilaterally in 59 per cent of our series. The pre-sella as well as the sella types may occur in the same patient owing to the fact that the pneumatization process on one side has outflanked that of the other by a wide margin.

Such mixed types, that is a sella type on one side and a pre-sella type on opposite sides, were observed in 27 per cent of our series.

Accordingly the sphenoid sinus was of the sella type at least on one side in 86 per cent. Thus the chances are extremely good that the anatomical relationships in a particular case will be favorable for transsphenoidal hypophysectomy. Both sphenoid sinuses were of the pre-sella type in 11 per cent and of the conchal type in 3 per cent of our series. The thickness of the anterior wall of the sella turcica is a factor. The thinner the wall, the easier the initial breakthrough to the pituitary. Operatively significant variations in thickness of the anterior sella wall may be encountered in patients whose sphenoid sinuses are both pre-sella or pre-sella on one side and sella on the other. The thickness of the wall can generally be estimated from serial tomograms in the lateral projection.

The intersphenoidal septum is always present between both sinuses, but lies partly outside the medial line in three cases out of four. Actually about 20 per cent of the intersphenoidal septums have the dorsal attachment on the carotid bulge, the bony canal giving passage to the internal carotid artery. This may be confusing and when the carotid bulge and anterior wall of sella turcica protrude equally through a sella sphenoid sinus, it may be very difficult to know which is which. Evidently therefore it is inadvisable to accept the dorsal attachment of the intersphenoidal septum as a reliable guide for direct identification of the anterior sella wall's midline.

The transverse septum is a structure which may be present in either or both sphenoid sinuses. The transverse septum at first has an oblique, ventral, caudal course, but after a short distance it takes a more direct caudal route to its termination near or at the floor of the sphenoid sinus.

The transverse septum shown in this slide appears on both lateral and axial x-rays and may confuse orientation, particularly with respect to the anterior wall of the sella turcica. Occasionally only the upper more horizontal portion of this structure is present. It is then called the transverse crest.

There are also other septums as the frontal lateral septum, the medial septum and the sagittal septum.

The lateral frontal septum is disposed in the frontal plane and attaches to the lateral wall and floor of the sphenoid sinus. In x-ray views this septum and a co-existing transverse crest may together simulate a transverse septum. Lateral septums of either or both varieties are encountered in about 50 per cent of our cases, but the frontal type is less common. The lateral sagittal septum, the commoner variety, lies very nearly in the sagittal plane and its margin points ventrally.

Although most lateral septums are small, they may be large, and if so, reach almost to the anterior wall of the sphenoid sinus from the attachment situated wholly or partly on the carotid bulge. Both at x-ray examination and during trans-sphenoidal interventions such a sagittal septum can easily be mistaken for the intersphenoidal septum. However, ordinarily the region of lower density is visualized on the conventional films near the ventral end of a lateral sagittal septym and such a region is sufficient for identification.

In case of doubt, certainty can be obtained by frontal and/or axial tomography. The sphenoid sinuses show the greatest anatomical variation of all bilateral cavities of the human body, so their relation to the sella turcica also varies. A systematic x-ray examination will provide adequate information on all details of significance for the surgeon prior to trans-sphenoidal hypophysectomy. Such information is an essential prerequisite for the establishment of a satisfactory approach to the sella turcica and to the pituitary.

TRANS-ANTRO SPHENOIDAL HYPOPHYSECTOMY

CARL-AXEL HAMBERGER, M.D.
(by invitation)

GOTEBORG, SWEDEN

May I start by expressing my sincere gratitude for the generous invitation to attend the annual meeting of the American Laryngological Association. I assure you that I am highly aware of the great honor thus accorded me.

The paper I am about to present deals with our experience with trans-antral sphenoidal hypophysectomy. At the Department of Otolaryngology, University of Goteborg in Sweden, the trans-sphenoidal approach has been the subject of much discussion.

In 1910, Oskelberg devised his trans-septal technique, which has been used in a large number of cases for operation of tumors in this region. The two chief objections raised to this procedure have been the risk of infection and the poor exposure considered to be provided by the operative field.

Denta, for example, stated that the intranasal approach affords an exposure of the sella turcica no wider than a lead pencil. As the result of the advances in neurosurgery the transcranial approach subsequently became the method of choice in the treatment of pituitary tumors.

It is however of interest to mention that Cushing considered the trans-sphenoidal route to be preferable under certain conditions.

When Olivecrona and Chowgren in Stockholm introduced hypophysectomy in the treatment of advanced mammary cancer, Olivecrona chose the transcranial approach, which has later been adopted by most neurosurgeons.

The main reasons for which we adopted the trans-sphenoidal route are the following:

1. The risk of infection was regarded to have decreased greatly as the result of new therapeutic resources.

2. An approach through the maxillary sinus does give excellent exposure. This is perhaps a most important consideration since in most cases complete extirpation is an essential for bringing about the desired effect.

3. All manipulations of the optic chiasma and optic nerves can be avoided and thus rule out visual damage.

4. Certain complications which are apt to follow all intracranial operations of this magnitude can be eliminated. Among them are postoperative intradural hematoma, brain damage, postoperative cerebral edema and development of epilepsy.

Before entering into the details of the method, I will show you the case material on which my experience is based.

We have had 150 patients, including 68 cases of mammary cancer.

The operative procedure can be divided into two phases. The first is a sinus operation and the second involves exposure of the sella turcica and extirpation of the hypophysis.

The schematic drawing shows the route through the maxillary sinus, the ethmoid and sphenoid to the sella turcica. The distance from the anterior wall of the maxillary sinus to the hypophysis is about 9 cm. After incising the buccal mucosa below the anterior wall of the maxillary sinus, the bony wall is removed.

The medial bony wall of the maxilary sinus is resected. This greatly increases the space in the operative field. The nose is largely left intact. Next we do an ethmoidectomy. After the ethmoidectomy, the anterior wall of the sphenoid sinus is visible.

As a rule the two openings of the sinus are easily visible. The anteroir wall of the sphenoid sinus is removed with punch forceps. Then you can see the sella turcica.

The thickness of the wall varies greatly. In some cases it is only as thick as parchment while in others it is a few millimeters thick. This is especially true at the midline. When the sphenoid sinuses have been opened by removal of the intersinous septum, the sella turcica is usually visible as shown by the next slide.

In many cases it is necessary after removing the dividing wall or transverse septa of the sphenoid sinus to resect the posterior-superior part of the nasal septum in order to give optimal exposure. At every operation in which the anatomic variations are not wholly clear beforehand, an absolute necessity is to determine them during operation. This is done by means of roentgenologic examination after insertion of roentgen opaque needles.

In our early cases we generally made this examination routinely.

This slide shows the structures encountered in the immediate neighborhood of the sphenoid sinus and the hypophysis. The bulge of the internal carotid artery is often seen. The vessel can be discerned in most cases through the usually thin bone. Its distance from the sinus must always be carefully noted. When the anterior wall of the sella has been definitely ocalized, removal of the bone is stopped. First a little piece about the size of a pea is lifted off with a small hook. Then the capsule of the hypophysis becomes visible.

The whole anterior wall can then be removed without any difficulty with a punch.

After exposure of the capsule, veins can be seen to run on both sides between the sinuses. There is generally one such venous communication in the upper margin, and one in the lower. Exact localization of these veins is of importance. You can also see the cavernous sinus. To understand how the capsule must be opened it is important to be acquainted with the layers of its wall.

This histologic picture distinctly shows underneath the bone, the periosteal layer, the vascular layer and near the gland, a fibrous layer. Vertical and horizontal incisions are made through the capsule with a fine knife, or diathermy knife. It is important to start the incision in an area devoid of veins. A small curved knife is used. After the first incision the capsule is freed from the actual tissue by elevation

with a small dural hook. The cruciate incision thus formed is seen in this slide. The hypophysis bulges forward, the flaps of the capsule are turned outward so that the anterior wall of the gland is visible. Then you can see the gland and the flaps of the capsule. At this point there may be moderate bleeding from the internal aspect of the capsule, but it can be arrested by very slight pressure. The operation is then continued with a dissector between the capsule and the gland. As a rule there is no dfficulty in shelling out the gland.

In some cases it seems to be adherent to the capsule, particularly at the sides. The gland is pressed downard so that the stalk becomes visible and stretched. This may be associated with slight leakage of cerebrospinal fluid. The pituitary stalk usually ruptures when the pressure on the dissector above the hypophysis is increased. When the stalk has ruptured the hypophysis is removed.

In view of the blood supply to the hypophysis, more copious bleeding from the stalk might be expected, but this is not the case. Moreover, when there is a leakage of cerebrospinal fluid, it usually ceases when the stalk has ruptured.

The stem of the stalk seems in fact to plug the hole in the diaphragm of the sella. It is very important in tumor cases to be able to see the whole diaphragma sella. We can see the diaphragma best by using this approach through the maxillary sinus. The empty cavity is filled with a small piece of muscle taken from the anterior aspect of the thigh. The cavity is then plugged with gauze which is gradually removed between six and nine days after operation. After removal of the endotracheal tube, the patient usually awakens rapidly. Even though only slight bleeding can be anticipated in most cases, the patient is given blood during the operation. This is because in some cases there may be unexpected moderate hemorrhage from the wide veins of the pituitary capsule.

As I pointed out in the beginning of this paper, use of chemotherapeutics and antibiotics make it possible to carry out this type of intervention on the hypophysis. Our rule is to give large doses of penicillin, streptomycin and a sulfa preparation starting the evening before operation.

Hormonal substitution starts preoperatively by intramuscular administration of 100 mg of cortisone acetate the evening before oper-

ation. This dose is repeated the next morning before operation as well as directly after. Cortisone is subsequently injected twice a day and is replaced by an oral preparation as soon as the patient can take nourishment by mouth. After a few days 150 mg are given daily and the dose is then decreased rapidly to 50 mg a day. The final dose is 12.5 mg of cortisone acetate by mouth, two or three times a day. It is important to increase the cortisone supply if there is stress or a new operation. When the patient has recovered from operation we have in most cases temporarily discontinued cortisone administration to verify the existence of adrenal insufficiency. In most cases polyuria occurs after hypophysectomy. It is usually moderate. Occasionally however, diabetes insipidus persists for a long time and must be treated with an antidiuretic hormone. We give pitressin acetate in oil which is seldom given more than every other day. No disturbance in electrolyte balance occurs during or after operation. Thus in cases of mammary cancer the postoperative course presents no medical problems. Diabetes patients obviously require special measures.

The complications of particular concern are hemorrhage, leakage of cerebrospinal fluid and infection. I have touched on the risk of hemorrhage several times, but I need only add that it is usually very slight. It must, however, be recorded that patients with widespread skeletal metastases are apt to have severe thrombocytopenia which greatly increases the bleeding tendency. It must also be borne in mind that diabetic patients, whose vessels are extremely fragile, bleed more easily than cancer patients. Leakage of cerebrospinal fluid has occasionally been observed at the time of removing the pack, but it has always ceased spontaneously after there to five days. The most severe complication is meningitis. Meningitis occurred in a few of our early cases during the first year. We had three fatal cases of postoperative meningitis, but all three patients were severely ill and debilitated before operation. In the past two years we have had no case of postoperative meningitis which leads us to believe that this complication can practically be ruled out. Naturally it must always be remembered that the patient should not be placed in a ward with infectious cases, at any rate during the early postoperative period.

We have done about 150 operations on the hypophysis. I do not want to make any definite statements about results. This is because so much depends upon the selection of cases.

As far as mammary cancer is concerned, the situation can be summed up as follows:

1. In young women for whom oophorectomy has been effective, good results from hypophysectomy can be expected in about 80 per cent.

2. In old women where primary hypophysectomy is done, an objective remission can be expected in only about 30 per cent.

We have done hypophysectomy in about 30 cases of diabetes with severe retinal changes. In such cases the following results can be expected.

1. All become insulin sensitive and the tendency to acidosis disappears.

2. Progression of the retinopathy ceases. Operation must, however, be performed before any severe proliferation of the vitreous has appeared. In two cases we have actually seen regression of the proliferative changes.

DISCUSSION

DR. GEOFFREY BATEMAN: Mr. President, thank you very much for giving me an opportunity to speak. I know time is short.

I have had the opportunity of watching Professor Hamberger and his colleagues work and I think no one in our part of the world knows more about this type of surgery than he and his team.

I have been interested in attempting to do hypophysectomies for some five years or more. I was unable to get a satisfactory technique until my colleagues from Scandinavia showed me early last summer this satisfactory technique of dissection of the pituitary which has been developed by Hamberger and his colleagues. I am not in the position to tell you anything about our results with carcinoma of the breast, because they are rather long term and you cannot tell immediately after operation what the ultimate success of the operation will be.

With diabetes it is different. The results are predictable. If total hypophysectomy is done, certain results inevitably follow. Our physicians who specialize in diabetes are very interested and are sending us cases for treatment. We are pleased with the immediate results of treatment.

As far as the technique is concerned, I think it is important that the best possible exposure of the pituitary should be obtained. Which surgical approach you use is a matter of personal preference. I have experimented with various approaches and have come to the conclusion that a combined technique through the

nasal septum and via the ethmoid with an orbital incision gives me the most satisfactory exposure for using the microscope. If I may show two or three slides I can demonstrate this.

This is not a particularly slow method of getting exposure. I do the nasal and septum operation and remove the bones of the septum and of the anterior wall of both sphenoid sinuses. The intersphenoid septum is largely removed through the nasal septum and the sphenoid is then packed.

We then make an orbital incision, go through the ethmoid trying to keep out of the nose and open the sphenoid through the ethmoid. We have a marker there already in the form of a pack, which makes it easy to check your direction. When the sphenoid is widely exposed through this orbital incision, the nasal mucosa back of the nose can be pushed out of the way because it has been detached medially from the septum and laterally from the bony wall of the ethmoid and posteriorly from the anterior wall of the sphenoid. The microscope is then set up.

Using the microscope through the ethmoid incision and using suction through the ethmoid with the left hand, one is able to insert instruments through the nasal septum incision and approach the pituitary fossa through the midline. Thus one observes the working end of the instrument without having the handle of the instrument or your hand get in the way of the microscope.

DR. W. LIKELY SIMPSON: I certainly enjoyed both of these papers. I want to speak to one point and that is the approach to the pituitary region. At the Ear, Nose and Throat Hospital, we who are accustomed to working through the antrum in doing the ethmoid and sphenoid operations are right at home in that area. As Dr. Bateman has said, an equally good approach is the external approach going through the orbit. One can remove the posterior ethmoids, the anterior wall of both sphenoids and the entire septum. If there is not enough space, take a sharp curette and fracture the posterior end of the septum inferiorly and superiorly, pressing it to the opposite side and one has a wonderful approach to the anterior wall of the pituitary region.

ARYTENOIDECTOMY IN CHILDREN

ROBERT E. PRIEST, M.D.

HAROLD S. ULVESTAD, M.D.

FRANK VAN DE WATER, M.D.

ROBERT J. RICHARDSON, M.D.
(by invitation)

MINNEAPOLIS, MINN.

This paper presents three cases of bilateral abductor paralysis of the vocal cords treated first by tracheotomy and later by arytenoidectomy. Such cases are commonplace and normally would not justify a special report; but our three patients were children, and arytenoidectomy is usually not done in children. We hope that this report may prove to be worthwhile as a means of directing attention to the occasional pediatric situation in which arytenoidectomy will be useful. The fact that in our own community we found three cases of arytenoidectomy in children suggests that the condition may not be rare, and that many unreported cases exist. It is true that references to arytenoidectomy in children are hard to find in the literature. Two of our cases had their paralyses as a result of poliomyelitis and in one the cause was never determined. In all three cases arytenoidectomy resulted in relief of stridor and permitted comfortable breathing without the use of a tracheotomy cannula. A brief summary of the literature with reference to vocal cord paralyses in children and arytenoidectomy follows.

The volume of written material describing vocal cord palsies in children is not great. In an excellent paper published by Florence Cavanaugh[1] of Manchester, England, in 1955, a comprehensive discussion is given. Cavanaugh reviews the literature from 1882 to 1955, and quotes some authors carrying the review back as far as 1872.

From the Division of Otolaryngology, University of Minnesota Medical School, Minneapolis, Minnesota.

Most authors report one or two cases of unilateral or bilateral vocal cord paralysis in children of various ages. In literature reviewed by Cavanaugh, and pertaining only to children, causes of the paralyses are legion. Causes include typhoid, diphtheria, syphilis, tuberculosis; adherence of the thymus to the pericardium and all structures of the neck including the recurrent nerve; epidural and subdural hematomata; 32 cases from the Philippines in children suffering from beri-beri; meningocele and hydrocephalus; toxic reaction from antimalarial drugs, and tumor of the fourth ventricle with extension into the pons. Numerous cases in which the cause of the bilateral paralysis was undetermined also appear.

Cavanaugh reports her own experience with 107 children having laryngeal lesions of various types, of which 37 were vocal cord palsies. She gives detailed information as to the duration of the paralyses and many other points. This material will not be recapitulated here, but is well presented in her paper for anyone who has a particular interest in this problem.

Inasmuch as we are dealing with bilateral abductor vocal cord paralysis here, it is of interest that of the four children seen by Cavanaugh with complete bilateral abductor paralysis, three showed no change, one after 4½ years, one after 6 years, and the third died after 3 months. The fourth child could not be persuaded to attend the clinic and be evaluated.

Quoting further from the same author's paper: "In most of the published series of vocal paralysis in adults, a large number of cases have been of unknown etiology and this investigation has been similarly disappointing." In her own cases, Cavanaugh was able to establish the following causes for paralyses, some permanent and some temporary: Measles at age 2½ years; pneumonia at age 3 months; tuberculosis of the right pulmonary apex; cystic hydroma with possible damage to the vagi at operation to remove the tumor; Arnold-Chiari malformation with associated meningocele.

Turning to other authors we find that Heatley[2] and Work[3] each described children with laryngeal paralysis and meningocele. In the Arnold-Chiari malformation, a tongue of cerebellar tissue in the midline herniates through the foramen magnum and descends over the posterior aspect of the cord, sometimes as low as the sixth cervical

segment. Associated with this, one finds elongation of the medulla. The foramen magnum may be occupied by the medulla as well as the tongue of cerebellum. Pressure is exerted on the medulla or the nerves emerging from it.

The only mention of an operation to restore the laryngeal airway by fixing one of the vocal cords in abduction found in our review of the literature pertaining to children is that of Cavanaugh. She said: "I had expected that this boy would need an operation to fix one of his cords in abduction—but he has learned the knack of breathing at just the right depth. He even plays games, but if his controlled breathing gets out of hand, he just moves to the side of the field and sits down until he is under control again!" The author then describes one occasion in which the boy enjoyed a game so much that he produced laryngeal syncope by overtaxing himself. This is the only occasion on which he overtaxed himself, she says. Therefore she did not feel justified in persuading the parents to consent to an operation.

A few other instances of laryngeal paralysis in children were located in the literature. Clerf[4] reported a boy of 14 years with bilateral recurrent laryngeal nerve paralysis following measles. Ross and Chambers[5] describe a unilateral paralysis in a child 11 months old in which the diagnosis of a lesion of the pons with pressure on the vagus nerve was suggested clinically and corroborated by autopsy.

The paper of Ross and Chambers presents an excellent differential diagnosis of recurrent nerve paralysis, together with good illustrations of the nerves and their relationship as they branch from the vagi and course upward to the larynx.

The main disability caused by bilateral abductor paralysis of the larynx is reduction of the size of the airway on inspiration. The vocal cords are always adducted, and are sucked together further on inspiration. This causes dyspnea and marked stridor. Surgical procedures are directed at restoring the airway. Tracheotomy bypasses the obstruction. Valved tracheotomy tubes permit expiration through the larynx with normal speech. Various plastic procedures on the larynx restore the laryngeal airway but usually compromise the voice somewhat. The usual cause for bilateral abductor paralysis is injury to the recurrent laryngeal nerves during thyroidectomy. The motivation for the development of the plastic corrective measures referred

to above has been the desire to rehabilitate postthyroidectomy cases, for the most part. In this paper the application of one of these techniques to patients having paralysis not due to surgical trauma is discussed.

The original laryngeal plastic surgical treatment of bilateral recurrent laryngeal nerve paralysis with fixation of the cords in a midline position, with resultant stridor was reported by King.[6] King transposed the omohyoid muscle and attempted to have it produce abduction of the arytenoid cartilage. This proved to be unsatisfactory.

In 1941, Kelly[7] resected the arytenoid through a window made in the ala of the thyroid cartilage. Orton[8] advised removal of the posterior portion of the wing of the thyroid cartilage to facilitate approach to the arytenoid cartilage. Woodman[9] recommended partial arytenoidectomy with retention of the vocal process and fixation of the vocal cord to the inferior cornu of the thyroid cartilage. Thornell[10] later reported transpharyngeal removal of the arytenoid cartilage for bilateral abductor paralysis together with his results in three cases. Since then other reports such as the one by Havens[11] have indicated that this procedure is satisfactory.

The standard procedures carried out now for the relief of bilateral recurrent laryngeal nerve paralysis with midline fixation of the cords involve arytenoidectomy, either intralaryngeal by the method of Thornell, or extralaryngeal by techniques advocated by Kelly, Woodman, King, and others. One or both arytenoids may be removed. The end result is abduction of the posterior end of the operated cord while the anterior end of the cord stays in adduction and permits production of an audible voice. If the airway created by the arytenoidectomy is adequate, the patient can be relieved of his tracheotomy cannula and the opening into the trachea can be closed. Of course, the alternative to these procedures is either continuing dyspnea and stridor or the wearing of a valved tracheotomy cannula permitting inspiration through the tracheotomy and expiration through the larynx when the valve closes.*

Reports of three cases treated by the authors or their associates follow. All patients were children having bilateral abductor paralysis

* Note supplementary references at the end of the paper.

of the larynx relieved by arytenoidectomy. Two of the children had paralysis due to polio, and in one the cause was never determined despite extremely vigorous and extensive study. In all cases relief of stridor and dyspnea occurred and decannulation was carried out. Social rehabilitation was successful and the children all are attending school without wearing tracheotomy tubes. A colored talking motion picture of the three children was presented at the conclusion of the paper so that breathing, general attitudes, and clinical results could be assessed by the listening audience.

REPORT OF CASES

CASE 1. J.S., University of Minnesota Hospital No. 806000, male, born June 29, 1945. (Operated upon by Dr. L. R. Boies, University Hospital, Minneapolis, Minnesota.) This boy suffered acute bulbar poliomyelitis in June and July of 1949 with paralysis of the abducens, facial and hypoglossal nerves; he had an inspiratory and expiratory stridor. Tracheotomy was done on June 22, 1949, and when decannulation was decided upon, the tube could not be removed because of dyspnea. Direct laryngoscopy on July 20, 1949 revealed bilateral vocal cord paralysis; the cords were fixed in the midline; they could not be abducted.

The boy was readmitted to the hospital in October of 1949 for re-evaluation of his laryngeal innervation and vocal cord paralysis. The midline paralysis was still present, and decannulation was not carried out. The left abducens and hypoglossal nerves remained paralyzed. Re-evaluation in July of 1950 showed some movement of the right cord and none in the left, and decannulation was carried out successfully. The patient was readmitted to the University Hospital with a diagnosis of bronchopneumonia in 1951. The patient continued to have persistent laryngeal stridor, although tracheotomy was not needed after decannulation. Because there was so much stridor and so much difficulty with respiration, and because the boy's glottis was narrowed, he was admitted to the hospital in August 1951, and arytenoidectomy was carried out. The right arytenoid was approached through an external incision and removed by a modification of Woodman's operation. The patient was relieved of his stridor and was able to breathe without his tracheotomy tube after the operation. The tube was left in for 10 days after the surgery. The patient still has

some inspiratory stridor but has a good voice and has been normally active to the present time without complications.

CASE 2. J.S., age 16, male (operated upon by Dr. Harold S. Ulvestad at Methodist Hospital, Minneapolis, Minnesota). This boy suffered bulbar poliomyelitis in 1952 at the age of nine years. Treatment at the Sister Kenny Institute in Minneapolis included a tracheotomy. Decannulation was accomplished by the time the boy was discharged from the hospital, although the airway was definitely and persistently diminished. For the next four years, he was able to go to school, but his physical activity was restricted and his weight remained constantly at 60 pounds.

In June of 1956, he developed an acute upper respiratory infection and laryngitis requiring an emergency tracheotomy by his family doctor. Three weeks later, he was first examined by Dr. Ulvestad. There was almost complete paralysis of both vocal cords in the paramedian position. The larynx appeared to be much smaller than normal for a boy his age. No treatment was prescribed other than the continued wearing of the tracheal tube. After two months had passed, the boy's weight had increased by 9 pounds, and he was generally stronger and more active. General improvement continued, although the boy did not tolerate the closing off of the tracheostomy.

In August 1957, 14 months after his first examination by Dr. Ulvestad, he was admitted to the hospital, and a Woodman type arytenoidectomy was performed on the right vocal cord. The arytenoid was removed and the posterior end of the right cord was sutured into a position of abduction. The tracheal cannula was removed one month later. Breathing was improved, although the voice was not as good as before surgery. The boy was able to return to school and ordinary activity with only moderate restriction. Two years later, he was again admitted to the hospital for closure of the persistent 1 mm sized tracheostomy stoma. His postoperative course following this surgery was uneventful. On the day of discharge from the hospital, he was able to climb 4 flights of stairs rapidly and without difficulty. Closure of his tracheal stoma apparently had no significant effect on his respiration. His general condition has remained good.

CASE 3. K.T., female, born May 23, 1952. (Operated upon by Dr. Robert E. Priest, at St. Mary's Hospital, Minneapolis, Minnesota,

referred by Dr. John P. Kelly, Minneapolis). At about the age of 8 months, on February 18, 1953, direct laryngoscopy was carried out at St. Mary's Hospital, Minneapolis, because of stridor which may have appeared first at the age of 3 months. The stridor was worse on inspiration, and there was some indrawing of the pretracheal tissues during inspiration. The larynx was examined with a Tucker twin lighted laryngoscope, and the vocal cords were not seen to abduct during inspiration. The opening which did form between them was fusiform in shape. The opening formed a long narrow ellipse and there was no more opening at the posterior end than at the anterior end. The anterior two-thirds of the cords were sucked down into the laryngeal aperture and this mechanism produced the noise. A 4 mm bronchoscope was passed into the trachea and the trachea and main bronchi were found to be normal. As the bronchoscope was withdrawn, it was seen that the arytenoids were pushed wide apart. This showed that there was no anomaly or ankylosis of the cricoarytenoid joint. On the other hand, there was no positive abduction of the cords. The attempt to discover the cause for this child's bilateral abductor paralysis included an esophagogram which showed no evidence of vascular ring; a chest film was normal except for bilateral basilar bronchitis and questionable pneumonitis. General examination was extensive and did not explain the cord paralysis.

On June 11, 1953, when the child was a little bit older than one year, the larynx was again visualized and conditions were identical to those seen on the first laryngoscopy. An airway was established by passing an endotracheal tube through the larynx, and a tracheotomy was carried out through the third or fourth tracheal ring. The child got along nicely with the increased airway, and definitely could not tolerate occlusion of the airway.

On January 19, 1954, the patient was referred to Dr. Paul Adams at the University of Minnesota Heart Hospital for cardiac evaluation. In his summary of the case, Dr. Adams noted that the patient had apparently been normal until approximately 3 months of age, at which time she developed laryngeal stridor which became progressively more severe. After her tracheotomy, her disposition, appetite and weight gain had been satisfactory. He noted that a heart murmur had been heard at St. Mary's Hospital prior to the reference of the patient to him at the University Hospital, and that configuration of the heart on x-ray at St. Mary's Hospital was slightly abnormal. This

abnormality had consisted of a slight and somewhat questionable right heart border.

On physical examination by Dr. Adams, the blood pressure was 88/50 mm mercury. The child was not cyanotic, was alert and healthy. No retraction or stridor were seen. The chest was normal, the heart tone and rate were normal, but there was a hollow-sounding soft systolic murmur in the pulmonic area. The femoral arteries were palpable.

The electrocardiogram showed a tendency to left axis deviation. There was a W configuration of the QRS complex in lead 3, and rr' in V1 suggesting a left ventricular hypertrophy.

The six foot heart films and cardiac fluoroscopy revealed a slightly enlarged heart. There was a slight congestion of the bronchial and vascular markings suggesting a left to right shunt. The pulmonary artery segment and the left atrium were increased, but these abnormalities seems to be less noticeable on the films made at the University Hospital than on the films made previously at St. Mary's Hospital. There was a shadow in the right upper mediastinum compatible with thymic enlargement, or perhaps right azygos lobe atelectasis.

It was Dr. Adams' impression that there probably existed an underlying congenital defect of undetermined origin. This could be an atypical patent ductus arteriosus. However, Dr. Adams did not feel that there were any primary cardiac symptoms unless the laryngeal paralysis was related to the patent ductus.

In his opinion, this could account for a left recurrent laryngeal nerve paralysis, but could have nothing to do with the right laryngeal nerve paralysis. It was Dr. Adams' opinion that further investigation of the cardiac status could be deferred until a later age, at which time the underlying pathology in the chest would be more evident, and cardiac studies would involve less risk and perhaps be more satisfactory. For this reason, the child was carried with tracheotomy from that point on, and no further attempt was made to elucidate the cause of the vocal cord paralysis for the time being.

In June 1955, at St. Mary's Hospital, the larynx was again exposed with an infant laryngostat, and the cords were seen to be fixed

in the midline. They were pushed out of the way using a 4 mm bronchoscope, and were found to be freely movable. This was exactly the same condition previously found on laryngoscopy. The child was equipped with a No. 3 tracheotomy tube instead of the previously worn No. 2 tube.

In February 1956, in order to permit the child to talk without closing her laryngeal tube, a No. 3 Tucker valved tracheotomy tube was prepared by the Pilling Company in Philadelphia. The child would not accept this tube, and her use of it was completely unsatisfactory, and we could never give her the benefit of speech without the necessity of closing her tracheotomy stoma.

In the spring of 1957, this little girl was facing the prospect of entering school at the age of 5 years. It was extremely desirable that she be relieved of her tracheotomy cannula. After much consideration and repetition of most of her studies, it was determined that the possibility of finding a cause for her laryngeal nerve paralysis through further cardiac studies was not great. Therefore, arytenoidectomy was decided upon as the best means for supplying her with a laryngeal airway large enough to permit her to discard her tracheal tube, and close her tracheal stoma. On June 24, 1957, the right arytenoid was removed by the operation of Woodman. Our intention was to leave the vocal process of the arytenoid in place, but it was so short in this young child that it was completely dissected out before the operator realized that he had reached the anterior end of it. An attempt to put a bridle suture through the mucous membrane of the cord and pull the cord laterally resulted in opening through the mucosa into the larynx, exposing the endotracheal anesthesia tube. Therefore, it was decided that suturing the cord laterally could not be done, and closure of the tissues over the arytenoid area was made in layers. Because the vocal process of the arytenoid was not left in place, and the cord was not sutured laterally, this was not truly a Woodman operation, but probably was as close an approximation of it as could be carried out in so young a child.

In June 1957, the patient was discharged from the hospital with the neck wound healed. She could close her tracheotomy tube quite nicely and breathe without difficulty. She had a small amount of leakage of liquid into the trachea when she swallowed. By July 17, 1957, the size of the tracheotomy cannula was reduced from No. 3

to No. 1, and the little girl could not detect the difference between the various tubes. In late August, the tube was removed entirely, and by August 26, the fistula had closed to about half of its original size. The child was doing well but was very apprehensive at the lack of a tracheotomy tube. Of course, she had worn a tube since her earliest memory, and her fright at having it out of her neck was quite marked. For this reason, the tracheal stoma was not closed surgically until January 1958. Then the skin around the stoma was dissected out, and the stoma was closed in layers.

The patient got along quite well but with some dyspnea and with some stridor. She entered school on schedule in September 1957, without a tracheotomy tube in place. She has been admitted to the hospital with respiratory infections on several occasions since decannulation. She always has marked stridor with these infections. She is a source of considerable worry to the house staff of the hospital when she comes in when they do not know her previous history. Her stridor always seems extremely marked. On one occasion, she was narrowly saved from the introduction of an endotracheal tube by an overzealous resident who came upon her in the middle of the night when she was making considerable noise during a respiratory infection. Without troubling himself to find out about her previous history, he obtained a laryngoscope and an endotracheal tube, and set out to intubate her. Fortunately someone familiar with her history appeared on the scene in time or we might have had to reinsert our tracheotomy cannula, after such a painful and long effort to remove it.

In December 1957, the parents and physician became concerned over the child's lack of growth. She was studied carefully by Dr. Rolf Andreassen who is a cardiologist in Minneapolis. It was his conclusion that "we have no evidence of heart disease or any vascular ring around the trachea and esophagus to account for her bilateral paralysis of the recurrent laryngeal nerves. There is definite retardation of maturation and growth in the skeleton, cause of which is not clear." Dr. Andreassen went on to say that he believed that thorough study of the child's endocrine system should be made in an attempt to discover the reason for retardation of bone growth.

For the purpose of this study, the child was referred to Dr. John Anderson, Professor of Pediatrics at the University of Minnesota Medical School. It was his conclusion that the child was not a dwarf,

as had been feared, but that she fitted into the lower end of the normal growth curve for children of her age. He felt that her retarded epiphyseal development also fitted properly into this level.

Since 1957, the little girl has done well except for the difficulty with acute respiratory infections detailed above. She is blessed with a higher than average intelligence and the personality of an extrovert despite her many trials. These attributes stand her in good stead in school. She loves to appear before the class and talk and is an excellent student. Her condition tends upward as she grows older. We feel that she probably has some anomaly within her chest, because she has developed some large veins on the right side of her neck, and to some degree upon her lower thorax. However, we feel that cardiac surgery certainly is not indicated since she is getting along this well, and it is likely that she will have a normal life despite her medical problems.

SUMMARY

This paper has presented three cases of bilateral abductor paralysis of the vocal cords treated first by tracheotomy and then by arytenoidectomy. These cases justify a special report only because they all occurred in children. Two were in patients suffering from bulbar poliomyelitis, and one was in a child having bilateral recurrent nerve paralysis of unknown cause. In all cases, the arytenoidectomy permitted the children to remove and to discard the tracheotomy tubes with closure of the tracheostomy. The authors feel that because they were able to find three cases of arytenoidectomy in children in their own community, the condition may not be rare. However, references to arytenoidectomy in children are difficult to find in the literature. A review of the literature for the last ten years is presented, and detailed case histories are given.

322 Medical Arts Bldg.

REFERENCES

1. Cavanagh, Florence: Vocal Cord Palsies in Children. J. Laryngol. and Otol. 69:399-418 (June) 1955.

2. Heatley, C. A.: Arch. Otolaryng. 29:90-103, 1939.

3. Work, W. P.: Arch. Otolaryng. 34:267-280, 1941.

4. Clerf, Louis H.: The Surgical Treatment of Bilateral Posticus Paralysis of the Larynx. Laryngoscope 60:142-151 (Feb.) 1950.

Clerf, L. H.: Bilateral Abductor Paralysis of the Larynx; Results of Treatment by Modified King Operation. ANNALS OF OTOLOGY, RHINOLOGY AND LARYNGOLOGY 64:38-46 (Mar.) 1955.

5. Ross, D. E., Chambers, D. C.: Recurrent Laryngeal Nerve Paralysis Occurring in an Infant. Amer. J. Surg. 94:513-516 (Sept.) 1957.

6. King, B. T.: Progress in Dealing with Vocal Cord Paralysis. J. Internat. Coll. Surgeons 12:288-296 (May-June) 1949.

7. Kelly, J. D.: Surgical Treatment of Bilateral Paralysis of the Abductor Muscles. Arch. Otolaryngol. 33:293, 1941.

8. Orton, H. B.: Extralaryngeal Surgical Approach for Arytenoidectomy. Bilateral Abductor Paralysis of the Larynx. ANNALS OF OTOLOGY, RHINOLOGY AND LARYNGOLOGY 53:303-307 (June) 1944.

9. Woodman, De G.: Bilateral Abductor Paralysis; Survey of 521 Cases of Arytenoidectomy via Open Approach as Reported by 90 Surgeons. A.M.A. Arch. Otolaryng. 58:150-153 (Aug.) 1953.

Woodman, De Graaf, and Pollack, Doreen: Bilateral Abductor Paralysis. Postoperative Care and Speech Therapy Following Arytenoidectomy. Laryngoscope 60:832-9 (Aug.) 1950.

Woodman, De G.: Rehabilitation of Larynx in Cases of Bilateral Abductor Paralysis; Open Approach to Arytenoidectomy with Report of Past Four Years' Experience. A.M.A. Arch. Otolaryng. 50:91-96 (July) 1949.

Woodman, De G.: Bilateral Abductor Paralysis; Arytenoidectomy for Bilateral Abductor Paralysis—Extralaryngeal Approach. Proc. Roy. Soc. Med. 45:821-826 (Dec.) 1952.

10. Thornell, W. C.: Intralaryngeal Arytenoidectomy in Bilateral Abductor Vocal Cord Paralysis. Surg. Gynec. and Obst. 95:63-66 (July) 1952.

Thornell, W. C.: Transoral Intralaryngeal Approach for Arytenoidectomy in Bilateral Vocal Cord Paralysis with Inadequate Airway. ANNALS OF OTOLOGY, RHINOLOGY AND LARYNGOLOGY 66:364-368 (June) 1957.

Thornell, W. C.: Intralaryngeal Approach for Arytenoidectomy in Bilateral Abductor Vocal Cord Paralysis. Tr. Am. Acad. Ophth. 53:631-636 (July-Aug.) 1949.

Thornell, W. C.: Intralaryngeal Approach for Arytenoidectomy in Bilateral Abductor Vocal Cord Paralysis. Tr. Am. Acad. Ophth. 53:631-636 (July-Aug.) 1949.

11. Havens, F. Z.: Bilateral Paralysis of Vocal Cords; Treatment by Transoral Arytenoidectomy. Laryngoscope 63:475-484 (June) 1953.

SUPPLEMENTARY REFERENCES

Lawson, H. P.: Treatment of Bilateral Abductor Vocal Cord Paralysis. J. Laryng. and Otol. 69:374-389 (June) 1955.

Carlens, E.: Bilateral Abductor Paralysis of Larynx. Acta Otolaryng. Supp. 116:57-62, 1954.

Morrison, L. F.: Evaluation of King Operation for Bilateral Abductor Paralysis of Laryngeal Muscles. Tr. Am. Goiter Ass'n. 247-261, 1954 (1953).

Grossman, A. A.: Modified Approach for Surgical Correction of Bilateral Abductor Vocal Cord Paralysis. Canad. M. A. J. 70:521-525 (May) 1954.

DeBord, B. A.: Paralytic Stenosis of Larynx: Modification of Intralaryngeal Approach to Arytenoidectomy. Laryngoscope 63:757-777 (Sept.) 1953.

DeBord, B.: Bilateral Abductor Paralysis of Larynx: Surgical Treatment. Texas J. Med. 48:635-636 (Sept.) 1952.

Hoover, W. B.: Surgical Procedures for Relief of Symptoms of Paralysis of Recurrent Laryngeal Nerves. Surg. Clin. N. America 33:879-885 (June) 1953.

Curkovic, M., and Horvatsky, M.: Extra-laryngeal Approach to Arytenoidectomy in Bilateral Paralysis of Abductors of Larynx. A.M.A. Arch. Otolaryng. 57:328-333 (Mar.) 1953.

Scheer, A. A.: Laryngofissure Approach in Surgical Treatment of Bilateral Abductor Paralysis. A.M.A. Arch. Otolaryng. 57:173-181 (Feb.) 1953.

Pearlman, S. J., and Killian, E. W.: Thyrotomy Approach for Arytenoidectomy in Bilateral Abductor Paralysis of Vocal Cords. ANNALS OF OTOLOGY, RHINOLOGY AND LARYNGOLOGY 62:207-212 (Mar.) 1953.

Edwards, T. M.: Progress in Surgical Treatment of Bilateral Laryngeal Paralysis. ANNALS OF OTOLOGY, RHINOLOGY AND LARYNGOLOGY 61:159-178 (Mar.) 1952.

Brown, L. A.: Intra-laryngeal Arytenoidectomy with Observations in Three Cases. Laryngoscope 61:332-340 (Apr.) 1951.

Von Leden, H.: Intralaryngeal Correction of Bilateral Abductor Paralysis; A Modification of Thornell Operation. Laryngoscope 60:1190-1200 (Dec.) 1950.

Faaborg-Anderson, K.: Recurrent Laryngeal Paralysis of Unknown Aetiology. Acta Oto-laryng. Supp. 118:68-75, 1954.

Ardran, G. M., Kemp, F. H., and Marland, P. M.: Laryngeal Palsy. Brit. J. Radiol. 27:201-209 (Apr.) 1954.

Capps, F. C. W.: "Abductor Paralysis" in Theory and Practice Since Semon. J. Laryng. and Otol. 72:1-31 (Jan.) 1958.

Barrett, J. H.: Surgical Treatment of Bilateral Abductor Paralysis. ANNALS OF OTOLOGY, RHINOLOGY AND LARYNGOLOGY 59:112-123 (Mar.) 1950.

Rethi, A.: Operation for Relief of Bilateral Vocal Cord Paralysis. J. Laryng. and Otol. 64:632-639 (Oct.) 1950.

Bosma, J. R., Goates, W. A., and Nielson, M. A.: Mechanisms of Disability of Speech Resulting from Poliomyelitis. ANNALS OF OTOLOGY, RHINOLOGY AND LARYNGOLOGY 66:67-85 (Mar.) 1957.

DISCUSSION

DR. KENNETH C. JOHNSTON: This has been a very interesting presentation.

One of the problems in children is knowing when to do the procedure. Most of the patients we have seen were infants or small children. We have observed

about 50 children with paralysis of the larynx. About a dozen of these which were bilateral and complete were in the newborn and in very small infants. The only possible procedure was tracheotomy. Another dozen we classified as bilateral incomplete in which one cord was completely paralyzed and the other cord partially paralyzed. In most cases there was 25 to 30 per cent motility, sufficient in most instances to allow the child to get by without a tracheotomy. In two of those instances tracheotomy was necessary. In 8 we found a unilateral right and about the same number had a unilateral left cord paralysis. The unilateral left cord paralyses were practically all due to some heart anomaly, usually an AV septal defect. In only one case of unilateral paralysis was a tracheotomy necessary. This was an infant who had had a bronchoscopy before being referred to us.

In one of our cases the paralysis was the result of poliomyelitis. We found bilateral paralysis in children who had meningoceles or hydrocephalus. In these cases tracheotomy was necessary because the paralysis progressed. We have not done any arytenoidectomies because most of our patients were infants or newborns. We thought that any operative procedure would probably result in scarring and failure to grow.

The problem then is at what age to do the arytenoidectomy. I think Dr. Priest has shown us that a good result can be obtained if the arytenoidectomy is done when the child is 5 or 6 years of age. We discussed this question with Dr. Thornell and arrived at the conclusion that it was best to wait until the child is ten or twelve years of age.

In the newborn or infant with bilateral paralysis there is always the possibility that function will return. We have had some of them who had a complete bilateral paralysis at birth, had tracheotomy before the age of two, followed by complete return of motility and decannulation.

I enjoyed the paper very much.

DR. EDGAR P. CARDWELL: I want to ask Dr. Priest a question. First I want to compliment him on the fine picture and the manner in which he synchronized the picture with the speech recording.

The young man I had an opportunity to see was a poliomyelitis patient who was in an iron lung. I did a tracheotomy and observed him for about a month. He was in the respirator about four and one-half weeks. At that time both cords were paralyzed and in the cadaveric position. He left the hospital after several months and went to a rehabilitation center. There, because of the lack of voice, voice exercises were given by a lady speech pathologist without looking at the larynx. The youngster attended classes twice a week for about a year and a half. He became increasingly dyspneic, was treated for pulmonary insufficiency and eventually had another tracheotomy when he had a cold. The next time I saw him his cords were entirely closed and there didn't seem to be any motion. I told the mother I thought we should watch him for another six months to see if there would be any return of abductor function. I thought possibly this was an example of adductor recovery without abductor recovery. I would like to ask Dr. Priest if he thinks these cases might ever improve without arytenoidectomy.

DR. EDWIN F. BROYLES: I would like to ask Dr. Priest a question. In these polio patients does the paralysis involve the entire vagus nerve or only the recurrent branch?

Dr. Joel J. Pressman: I would like to comment, one of the reasons for the extremely good results in children is the fact that their arytenoids are proportionately much larger than those of the adult. The usual displacement of arytenoids in the paralyzed cord contributes to the obstruction and an arytenoidectomy would therefore be expected to give them good results.

Dr. Robert E. Priest (closing): Mr. Chairman, I want to thank the discussers for their interest. I did mention in the presentation of the case report that in the little girl shown last on the film prior to her arytenoidectomy we verified by direct laryngoscopy the fact that she still had bilateral abductor paralysis. So, in her case at least, there wasn't any regeneration of the nerves.

To answer Dr. Cardwell's question, would these cases improve without arytenoidectomy; I think it is entirely possible that many of them would. Therefore one should allow quite a long time to go by before deciding to do arytenoidectomy.

I cannot answer Dr. Broyles. Neither of them were my cases.

Dr. Pressman's comment about the relative size of the arytenoid in children is particularly interesting and I think may well explain why we had such excellent results, particularly in the five year old child.

EARLY INVASION OF THE THYROID GLAND IN CARCINOMA OF THE GLOTTIS

RICARDO TAPIA ACUNA, M.D.

MÉXICO, D. F. MÉXICO

In my experience, it is evident that a discrete lesion of one vocal cord, if there is no fixation at all, can be treated either by x-rays or by cordectomy. In cases not enough advanced to justify total laryngectomy, I follow the contralateral aperture of the larynx and always remove an anterior portion of cartilage. In just a few cases I included the removal of the corresponding alae of the thyroid cartilage. I have nothing to add to what has been said about ineffectiveness of x-ray therapy when there are lymph node metastases at the neck. I have nothing to add either to the indications for total laryngectomy as accepted today.

After Billroth's laryngectomy (1870), Gluck described a more or less perfect technique for treatment of carcinoma of the larynx. After him, many authors made some improvements with the definite purpose of giving a better exposure, avoiding the salivary fistula, making a better support of the neck and permitting a complete excision of the tumor.

In spite of all known improvements, a good diagnosis, as stated by C. L. Jackson, is the basis of the treatment. Nevertheless, according to the reports from everywhere, the failure of laryngectomy is frequent and it all depends on the invaded tissues left or on the presence of metastatic lymph nodes in the neck.

There is one thing that strongly attracted my attention and it is the appearance of growing of the thyroid cartilage in the presence of carcinoma, involving only the vocal cords and the anterior commissure. I have seen this without evidence of neck metastasis or invasion of the surroundings in four cases. In two of these cases I performed total laryngectomy in a simple way and there was a recur-

rence in both, within the first year; one locally and the other as a metastatic neck gland.

Apparently, only a few have given real importance to the possibility of invasion of the thyroid gland or its capsule, unless there are definite symptoms. I think we should give more importance to this fact. An example of it is the case I have the honor to present today in a motion picture. In this particular case, there was a microscopic invasion of the capsule of the right lobe of the thyroid gland in spite of absence of any other macroscopic sign. To me, the danger signal was the increase of size of the thyroid cartilage. From the embryological point of view, it is admissible that in some cases small portion of the thyroid gland remains inside the larynx, without giving symptoms for the rest of life. A few years ago, I saw a child 2½ years old who had suffered hoarseness since birth. At the date of examination, he was dyspneic and presented papillomas of the glottis. When resecting those tumors, one of them, at least, was found to be thyroid gland tissue. This child recovered after a few laryngoscopic removals of the tumors and they happened to be only papillomas, according to the pathologist. Never again was thyroid tissue seen in the specimens. Two years ago, I saw a female patient, 55 years old, with an obstruction of the glottic and subglottic spaces, on the left side. She had been quite well until three months before. I removed the tumor by open approach and found out that the cartilages were absolutely normal and the airway was independent from the thyroid gland. The report of the pathologist was: "thyroid gland tissue without evidence of tumoral development." So far, this patient is quite well and has not shown a recurrence. There is no doubt that in both cases it was nothing but endolaryngeal aberrant thyroid gland.

These two cases demonstrate once more the close relations between the intralaryngeal and extralaryngeal organs. The thyroid gland invasion is easily diagnosed in advanced cases, but it is rather difficult to do if the lesions are apparently limited to the glottis. The gland may be free of neoplasic cells, even if its capsule is microscopically invaded. Therefore, the removal of the larynx will not be enough to keep the patient free of the disease.

Recently, Louis and associates spoke about a paramedian incision as an important factor in total laryngectomy. I have found that it is

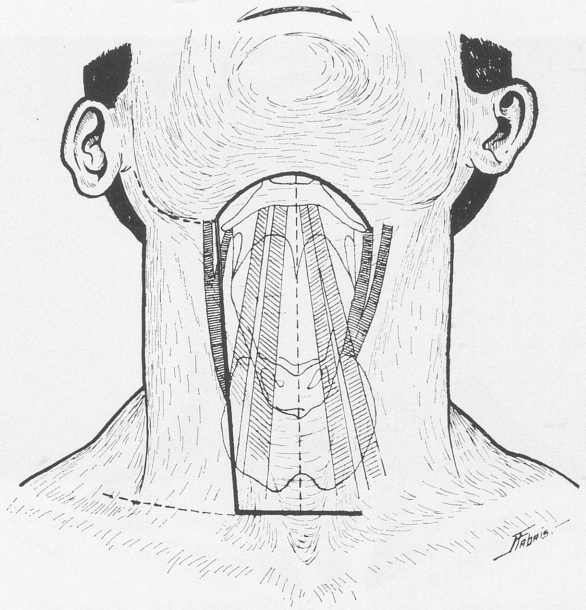

Fig. 1.—Incision of the skin for total laryngectomy.

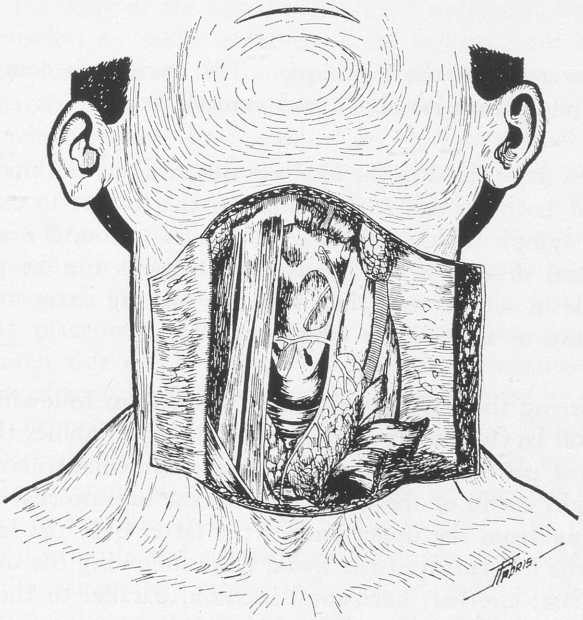

Fig. 2.—Wide field. Aponeurosis is cut at the middle line.

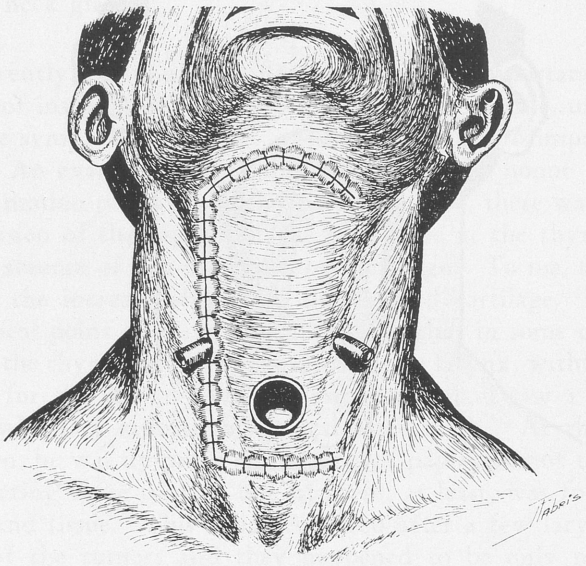

Fig. 3.—Total laryngectomy. Final aspect. Sub-aponeurotic drainage.

a real improvement in the technique. This incision is completed by two more: one transverse above and another below.

The skin flap is held to the opposite side and one can make a good inspection of both carotid regions and use the fingers to explore the presence of lymph nodes. Besides, in case it is found necessary to make a lateral dissection, the transverse incisions can be prolonged to either side in such a way that, without making extra cuts in the skin, it is easy to remove the whole contents.

Considering the different points of view, I am following a technique of total laryngectomy that in my opinion combines the advantages of those previously described: 1) a paramedian incision going from the right cornu of the hyoid bone to the suprasternal notch; an incision going from the upper end of the latter over the left side to the end of the left cornu of the hyoid bone following the upper margin of the last; another, horizontal incision, parallel to the last one, at the bottom; 2) dissection of the skin to bring a flap over the oppo-

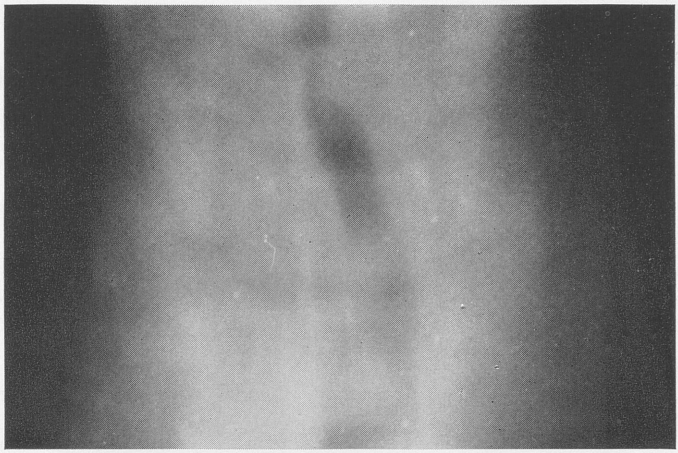

Fig. 4.—Tomogram. Showing subglottic aberrant thyroid. Case No. 2.

site side of the neck; 3) opening of the aponeurosis in the middle line and prolongation of the incision up and down in both cases; 4) removal of the body of the hyoid bone; 5) if necessary, removal of the ribbon muscles; 6) skeletonization of the larynx from above downward, including ligature of the superior thyroid artery at the desired side; 7) partial or total dissection of the corresponding lobe to include it in the whole mass to be excised, if an enlargement of the thyroid cartilage is found; 8) opening of the trachea with a curved flap at the posterior wall; 9) removal of the larynx from below upwards including a large portion of the thyrohyoid membranes; 10) suture of the pharynx in two steps: the first one continuous and the second one interrupted (Cushing's), following a double line with upper angle; 11) placement of drainage with rubber tubes going from the skin, at each side of the middle line, to the subaponeurotic space; 12) suture of muscles and aponeurosis by interrupted cross lines with a No. 0 chromic catgut; just in case the ribbon muscles are preserved, there should be a double suture so that they are kept superposed; 13) fixation of the stoma through an opening in the skin; 14) suture of the skin at the level of the incision; 15) placement of the tracheal cannula and covering of the entire field with dry gauze. To have a better support of the neck, it is advisable to place an elastic bandage around it, but not too tight. The feeding tube is placed

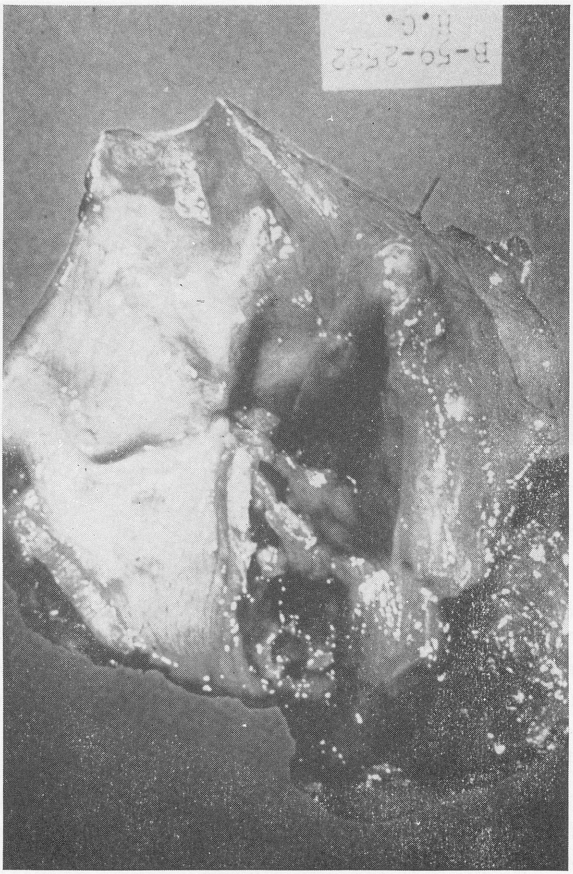

Fig. 5.—Larynx specimen, right thyroid gland lobe included. Continuity of the tumor at the right side.

through the nose, before closing the pharynx. I prefer the Levine rubber tube, to avoid acid regurgitations from the stomach.

The postoperative care is more or less the same as usual. I usually remove the feeding tube after two weeks, not before.

Speaking with some qualified laryngologists I found that there is not a definite method of examination, on which we can depend, to learn if the thyroid gland or its capsule is free of malignant invasion,

unless the case is well advanced. If we pay more attention to the enlargement of the thyroid cartilage in spite of the presence of limited lesions at the glottis, and remove the corresponding thyroid lobe, we may think that we have done something more for the cure of the patient.

On the other hand, it is disappointing that some laryngologists advise neck dissection even without macroscopic lymph nodes and others think it is unnecessary. The mentioned incision makes it possible to perform laryngectomy after an open search and to complete the operation with a neck dissection, if indicated.

SUMMARY

A brief comment is made on the different procedures for treating carcinoma of the larynx.

A complete clinical, endoscopic and radiological examination guides the surgeon to make the right choice of treatment.

It is very difficult to diagnose invasion of the envelopment of the thyroid gland or the gland itself, unless the case is well advanced.

In spite of absence of other symptoms or signs, in the presence of enlargement of the thyroid cartilage it is advisable to remove partially such a gland, at the same time that a total laryngectomy is performed.

A paramedian skin incision, prolonged to the opposite side above and below, is adequate also for neck dissection, completed with another lateral flap, with only an elongation of both horizontal incisions on the desired side.

INSURGENTES S. 300

REFERENCES

1. Grossman, Arnold: The Treatment of Carcinoma of the Larynx. ANNALS OF OTOLOGY, RHINOLOGY AND LARYNGOLOGY 64:1067 (Dec.) 1955.

2. Leroux-Robert, Jean: Indications for Radical Surgery, Partial Surgery, Radio-Therapy and Combined Surgery and Radio-Therapy for Cancer of the Larynx and Hypopharynx. ANNALS OF OTOLOGY, RHINOLOGY AND LARYNGOLOGY 65:137 (Mar.) 1956.

3. Lewis, G. Kenneth: Reconstruction Methods Following Laryngolpharyngectomy. ANNALS OF OTOLOGY, RHINOLOGY AND LARYNGOLOGY 66:86 (Mar.) 1957.

4. Norris, Charles M.: Technique of Extended Fronto-Lateral Partial Laryngectomy. Laryngoscope 65:1240 (July) 1958.

5. O'Keefe, John J.: The Surgery of Cancer of the Larynx. ANNALS OF OTOLOGY, RHINOLOGY AND LARYNGOLOGY 65:131 (Mar.) 1956.

6. Putney, F. Johnson: Preventive Dissection of the Neck in Cancer of the Larynx. ANNALS OF OTOLOGY, RHINOLOGY AND LARYNGOLOGY 67:136 (Mar.) 1958.

7. Sheline, Glenn E.: Carcinoma of the Larynx. ANNALS OF OTOLOGY, RHINOLOGY AND LARYNGOLOGY 67:1066 (Dec.) 1958.

8. Tapia Acuña, Ricardo: Glándula Tiroides Aberrante en Laringe. Gaceta Médica de México 88:899 (Dec.) 1958.

DISCUSSION

DR. LEROY A. SCHALL: Mr. President, since I have retired and am not doing surgery, I merely want to congratulate Dr. Tapia Acuna. I am very happy to see that he does a wide field operation. I fought for a wide field operation for many years and now everybody has discovered I believe that the wide field operation should be done. I enjoyed his paper very much.

DR. HERBERT H. HARRIS: I certainly enjoyed this discussion on the removal of the thyroid gland in glottic tumors. It was, I believe, when we met in Hollywood five years ago, in discussing Dr. Clerf's paper I mentioned that I felt it was important to remove the thyroid gland, at least one lobe, particularly in these low lesions. I have been doing this for approximately eight years, not every case, but certainly when I felt there was likely to be extension beyond the confines of the cartilaginous larynx. I had never seen an early lesion metastasize to the thyroid gland until last year. I had one man with a small superficial, you might say middle of the cord lesion. It did not extend to the anterior commissure. I advised radiation therapy for him. At the end of his radiation therapy, the lesion on the cord had regressed and he was told to return in three weeks. When he returned in three weeks he had a very large right lobe of the thyroid on the same side as the cordal lesion. I did not suspect at that time that this was a metastatic carcinoma. I felt it was some type of fast growing thyroid nodule, possibly benign. Some of those do grow rather rapidly, but he also admitted that his voice was growing worse. After I examined his larynx I discovered the recurrent laryngeal nerve on that side was paralyzed. This man was operated on by another surgeon who found a large squamous cell tumor which involved the entire lobe of the thyroid gland. According to this man it had grown to the size of a large egg in the period of about two days. It is hardly possible to believe that I could have missed a metastatic lesion in the thyroid gland, though I am sure it was present at the time that I biopsied this cord. This man expired in due course after radiation therapy and finally had a hemorrhage. I think he lived six months.

I believe it does no harm, and certainly it can do some good to remove these thyroid lobes, particularly for patients having subglottic or low pyriform sinus lesions. What we are gaining I do not know, but at least I feel better about it. I strip the pretracheal fascia and clean off everything when I do a neck dissection along with the laryngectomy.

Again I thank Dr. Acuna for bringing this to our attention.

THE ROLE OF RADIATION THERAPY IN CARCINOMA OF THE LARYNX

JOSEPH L. GOLDMAN, M.D.

AND

SIDNEY M. SILVERSTONE, M.D.

NEW YORK, N. Y.

For the past three and one-half decades patients suffering from cancer of the larynx have been cured by radiation therapy in many clinics throughout the world.[1] While there have been swings of enthusiasm and pessimism for this form of therapy as it has developed, considerable experience and various impressions have been gained in this modality of treatment during this period of time. It seems that the recent interest in head and neck surgery has tended to push radiation therapy into the background. Unfortunately, many surgeons do not give radiation therapy the consideration it deserves in the treatment of laryngeal cancer. They are quick to point out the failures and complications of radiation therapy and to overlook the successes. It must be admitted that surgery, too, has its quota of risks, complications and failures.

It is our purpose to show that radiation therapy, as we know it today, has the potential to play an important, active role in the treatment of laryngeal cancer and should be regarded as an effective modality in its own right. Surgery and radiation therapy should not be considered as competitive therapeutic methods. While some lesions can be treated equally well by either modality, the results are not the same functionally. This does not deny that there are instances where one might succeed where the other would fail. We believe that the time has come when radiation therapy should be the preferential primary form of treatment for the small cordal carcinoma suitable for

---

From the Departments of Otolaryngology and Radiotherapy, Mount Sinai Hospital.

partial laryngectomy. On the other hand, we recognize the fact that surgery is more effective as a primary method of treatment for laryngo-pharyngeal lesions, although results are poor with either modality. It is our opinion that the future successful handling of these cancers will depend more on a combination of radiation and surgery than on either form of therapy alone. Laryngeal cancer is in the unique position of having available two methods of treatment which have proved successful in a large percentage of cases, large, that is, for cancer. Cures might be increased if one modality is used to supplement the other.

We wish to state emphatically that success with radiation therapy requires expert management by those who are well trained and highly experienced in this field and who have the proper radiation facilities. Inexpert radiation therapy has no place in the treatment of laryngeal cancer and certainly is no substitute for surgery.

The authors have been involved actively in radiation therapy for laryngeal cancer for almost three decades—one (J.L.G.) since 1932 and the other (S.M.S.) since 1936. Together we have been studying this problem for 24 years, first as part of the group at The Mount Sinai Hospital originally started and headed by Dr. Rudolph Kramer and Dr. William Harris and then continued by ourselves and our staffs. Since 1931 patients treated by radiation for carcinoma of the larynx have been followed in a combined laryngeal-radiation therapy clinic which is held once every month.

Over this period of time, this group has studied 312 cases in which radiation was the primary form of treatment. While a number of radiation failures were cured subsequently by surgery, these cases were considered only as failures in our statistical analysis. Similarly, surgical failures which were cured by radiation also are not included in this study.

This series of cases is comprised of patients from the Otolaryngological Service and from the private practices of members of the staff of The Mount Sinai Hospital.

CLASSIFICATION

The literature on carcinoma of the larynx and laryngopharynx contains numerous and varied classifications. The lack of general

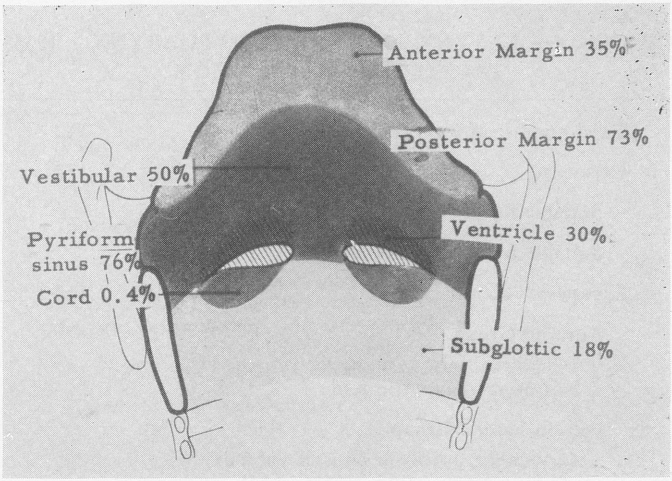

Fig. 1.—Percentage lymph node metastasis in 465 consecutive cases of carcinoma of larynx from Pietrantoni, L.: The Surgical Problem of Lymph Node Metastasis in Cancer of the Larynx.

agreement presents a serious and difficult problem in the comparison and evaluation of statistics and results. We are adhering to the classification presented by our original authors for the reason that it is based upon the practical aspect of prognosis.[2,3]

Our cases are divided into two major groups: the larynx proper or intrinsic larynx and the laryngopharynx or extrinsic larynx. The intrinsic larynx includes the vocal cords with the adjacent ventricular area above and subglottic area below and the anterior and posterior commissures. The laryngopharynx includes the false cords, epiglottis, aryepiglottic folds, arytenoids, pyriform sinuses and postcricoid region.

We have further subdivided our intrinsic laryngeal cases into those which could have been treated properly by partial laryngectomy and those which would have required laryngectomy. We are aware that there are some laryngologists who would perform hemi-laryngectomy in certain cases where others would prefer total laryngectomy.

TABLE I

CARCINOMA OF LARYNX AND LARYNGO-PHARYNX: 1931-1959
TREATED BY IRRADIATION

Total number of cases treated		312
INTRINSIC		179
Suitable for partial laryngectomy	68	
Suitable for laryngectomy	111	
EXTRINSIC		133
Anterior Group (epiglottis, false cord, upper half of ary-epiglottic fold)	59	
Postero-Lateral Group (arytenoid, pyriform sinus, lower half of ary-epiglottic fold, post-cricoid)	40	
Extensive Group (both anterior and postero-lateral locations involved)	34	

In the laryngopharynx, we have found a marked difference in prognosis between the anterior lesions which include the epiglottis, false cords and upper half of the aryepiglottic folds, and the postero-lateral lesions which include the lower half of the aryepiglottic folds, arytenoids, pyriform sinuses and postcricoid region. Wherever possible the laryngopharyngeal lesions were classified into these two groups. However, there were extensive lesions which involved both anterior and posterolateral areas and such cases were classified separately as the extensive group.

PROGNOSIS

Briefly, the most important single factor in prognosis is involvement of the cervical lymph nodes which is dependent chiefly on the site of the primary tumor. Besides others, Pietrantoni has demonstrated this fact in his analysis of 465 consecutive cases of carcinoma of the larynx (Fig. 1).[4] He showed that only 0.4 per cent of cordal lesions had metastasis in lymph nodes, while in the extrinsic carcinomas metastasis could be demonstrated in the lymph nodes in 35 to 76 per

TABLE II

CARCINOMA OF INTRINSIC LARYNX TREATED BY IRRADIATION SUITABLE FOR PARTIAL LARYNGECTOMY

Total number of cases treated, 1931-1959		68
Cases for 5 year study, 1931-1954		43
Indeterminate (N.E.D. on last exam.)		9
Lost to follow-up	3	
Died from other causes	6	
Determinate cases		34
5 year survivals		30 or 88%
Absolute 5 year survival rate:		30/43 or 70%

cent of the cases depending on whether the site of the primary lesion is anterior or posterolateral. The presence of positive lymph nodes in radical neck dissection specimens has reduced greatly the chances of survival in all series reported. Thus, the need for radical neck dissection when nodes are present and even when they are not palpable in cases which offer a bad prognosis has become clear.[5-9]

CLINICAL MATERIAL AND RESULTS OF RADIATION THERAPY

From 1931 to 1959, 312 cases of carcinoma of the larynx and laryngopharynx were treated by irradiation. Of these, 179 were intrinsic and 133 extrinsic. Of the 179 intrinsic lesions, 68 were suitable for partial laryngectomy while 111 would have required total laryngectomy. Of the 133 extrinsic lesions, there were 59 in the anterior group, 40 in the posterolateral group and 34 in the extensive group (Table I).

Of the 68 cases of carcinoma limited to the vocal cord and suitable for partial laryngectomy, there were 43 treated from 1931 to 1954 and, therefore, available for five year study. Of these 43 cases, nine were indeterminate, three having been lost to follow-up and six having died from other causes, but all showed no evidence of disease when last seen. Of the 34 determinate cases, there were 30 five year survivals, a determinate survival rate of 88 per cent. If the indetermi-

TABLE III

CARCINOMA OF INTRINSIC LARYNX TREATED BY IRRADIATION SUITABLE FOR LARYNGECTOMY

Total number of cases treated, 1931-1959		111
Cases for 5 year study, 1931-1954		94
Indeterminate (N.E.D. on last exam.)		21
Lost to follow-up	10	
Died from other causes	11	
Determinate cases		73
5 year survivals		46 or 63%
Absolute 5 year survival rate:		46/94 or 49%

nate cases are regarded as failures, the absolute five year survival rate was 70 per cent (Table II).

Of the 111 cases of carcinoma of the intrinsic larynx that were suitable for laryngectomy, 94 were treated from 1931 to 1954 and, therefore, available for five year study. Of these 94 cases, 21 were indeterminate, 10 having been lost to follow-up and 11 having died from other causes. All indeterminate cases had no evidence of disease on the last examination. Of the 73 determinate cases, there were 46 five year survivals, a determinate survival rate of 63 per cent. If the indeterminate cases are regarded as failures, the absolute five year survival rate was 49 per cent (Table III).

Of the 59 cases of carcinoma of the extrinsic larynx in the anterior group, 53 were treated from 1931 to 1954 and, therefore, available for five year study. Of these 53 cases, eight were indeterminate, four having been lost to follow-up and four having died from other causes, all having shown no evidence of disease on the last examination. Of the 45 determinate cases, there were 25 five year survivals, a determinate survival rate of 56 per cent. If the indeterminate cases are regarded as failures, the absolute five year survival rate was 47 per cent (Table IV).

Of the 40 cases of carcinoma of the extrinsic larynx in the posterolateral group, 36 were treated from 1931 to 1954 and, therefore,

TABLE IV

CARCINOMA OF EXTRINSIC LARYNX TREATED BY IRRADIATION
ANTERIOR GROUP: Epiglottis, False Cord, Upper Half of Ary-Epiglottic Fold

Total number of cases treated, 1931-1959		59
Cases for 5 year study, 1931-1954		53
Indeterminate (N.E.D. on last exam.)		8
Lost to follow-up	4	
Died from other causes	4	
Determinate cases		45
5 year survivals		25 or 56%
Absolute 5 year survival rate:		25/53 or 47%

TABLE V

CARCINOMA OF EXTRINSIC LARYNX TREATED BY IRRADIATION
POSTERO-LATERAL GROUP: Arytenoid, Pyriform Sinus, Post-Cricoid, Lower Half of Ary-Epiglottic Fold

Total number of cases treated, 1931-1959		40
Cases for 5 year study, 1931-1954		36
Indeterminate (N.E.D. on last exam.)		8
Lost to follow-up	3	
Died from other causes	5	
Determinate cases		28
5 year survivals		9 or 32%
Absolute 5 year survival rate:		9/36 or 25%

available for five year study. Of these 36 cases, eight were indeterminate, three having been lost to follow-up, five having died from other causes, but all showed no evidence of disease on the last examination. Of the 28 determinate cases, there were only nine survivals, a determinate survival rate of 32 per cent. Again, if the indeterminate cases are regarded as failures, the absolute five year survival rate became 25 per cent (Table V).

TABLE VI

CARCINOMA OF EXTRINSIC LARYNX TREATED BY IRRADIATION
EXTENSIVE GROUP: Both Anterior and Postero-Lateral Locations Involved

Total number of cases treated, 1931-1959		34
Cases for 5 year study, 1931-1954		26
Indeterminate (N.E.D. on last exam.)		5
Lost to follow-up	1	
Died from other causes	4	
Determinate cases		21
5 year survivals		3 or 14%
Absolute 5 year survival rate:		3/26 or 11%

Finally, of the 34 cases of extrinsic laryngeal cancer in the extensive group, 26 were treated from 1931 to 1954 and, therefore, available for five year study. Of these 26 cases, five were indeterminate, one having been lost to follow-up and four having died from other causes, but all showed no evidence of disease on the last examination. Of the 21 determinate cases, there were only three five year survivals, a determinate survival rate of 14 per cent. With the indeterminate cases regarded as failures, the absolute five year survival rate was 11 per cent (Table VI).

RADIATION DOSAGE AND REACTIONS

Radiation therapy, naturally, has its share of risks and complications. With the older yet effective method of irradiation as administered with the 200-400 Kv x-ray machines, mucous membrane reactions and radiodermatitis of moderate intensity occurred regularly but usually healed completely. The most troublesome complication among our patients has been persistent laryngeal edema, particularly of the arytenoids. At present with the use of Cobalt-60 teletherapy, the skin manifestations are minimal, the mucous membrane reactions are slight to moderate in intensity, but postradiation edema of the arytenoids still occurs not infrequently. This edema very seldom jeopardizes the patient's airway but it may produce hoarseness.

TABLE VII

CARCINOMA OF THE INTRINSIC LARYNX
5 YEAR SURVIVAL RATES FOR PARTIAL LARYNGECTOMY

Frazell, 1960	171/190	90%
McGovran, Spjut, and Ogura, 1959	45/79	57%*
Pietrantoni and Fior, 1958	37/46	80%
Jackson, Blady, Norris, and Robbins, 1957	183/210	87%
O'Keefe, 1956	298/371	80%
Putney and Vicens, 1956	26/42	62%*
LeJeune and Lynch, 1955	172/203	85%
Schall, 1951	32/54	59%
TOTAL	964/1195	80%
M.S.H. radiation therapy	30/34	88%

* Absolute survival rate

It has been our experience that postradiation edema, when it occurs, usually disappears or is reduced to an insignificant minimum after a year or two. Corticosteroids and antibiotics are helpful in lessening the edema when there is a superimposed infection.

Persistent postradiation edema is related to the total dose, the overall time of its administration and the volume of tissue irradiated. It is greatly increased by infection. When deep ulceration affects the cartilage, the edema will be aggravated by chondritis. The extreme complication is sloughing of the cartilage, but this complication can be anticipated if exposed cartilage is noted or if chondritis is already present before radiation therapy is instituted. If cartilage is involved at the onset, laryngectomy is preferable to radiation therapy, except for the case in which only the tip of the epiglottis is affected.

Tumor doses in the range of 5000 to 7000 r have been administered over a period of five to eight weeks. The higher doses require the longer period of time and are applicable to the more advanced cases with the larger treatment field size. To reduce postradiation edema it is preferable not to exceed a dose range of 5500 to 6000 r in

TABLE VIII

CARCINOMA OF THE INTRINSIC LARYNX

5 YEAR SURVIVAL RATES FOR LARYNGECTOMY

O'Keefe, 1959	85/108	79%
Pietrantoni and Fior, 1958	31/62	50%
*Jackson, Blady, Norris, and Robbins, 1957	128/201	64%
Putney and Vicens, 1956	56/102	55%†
TOTAL	300/473	64%
M.S.H. radiation therapy	46/73	63%

*Includes epiglottis and false cords

† Absolute survival rate

five to six weeks and to keep the treatment field size to the minimum necessary for the known extent of the growth. This dose range is cancerocidal for almost all of the radiocurable cases of laryngeal cancer and it would not complicate any surgical procedure should one become necessary. Large doses of radiotherapy rarely succeed, but usually create conditions unfavorable to further surgery.

COMMENT

The objectives in the treatment of carcinoma of the larynx and laryngopharynx are first to save life, secondly to save the larynx and thirdly to save the voice.

In the most favorable group of cases which are the true cord lesions suitable for cure either by partial laryngectomy or by radiation therapy, the determinate survival rates for either modality have been between 80 and 90 per cent. A number of the recent surgical reports indicates an average five year survival rate of 80 per cent (Table VII).[10-17] The results in this group are excellent for saving life and there is no problem in saving the larynx. The choice of modality, therefore, is concerned with the factor of voice. In our opinion there is no question that radiation therapy yields by far the better voice.

In the more advanced intrinsic cancers which are treated either by laryngectomy or radiation therapy, the survival rates are over 60 per cent for either modality. A review of some of the recent results from

TABLE IX

CARCINOMA OF THE EXTRINSIC LARYNX
5 YEAR SURVIVAL RATES FOR LARYNGECTOMY
LESIONS OF EPIGLOTTIS AND FALSE CORD

Norris, 1959	28/49	57%
Pietrantoni and Fior, 1958	94/166	57%
Orton, 1956	73/122	60%
Clerf, 1952	19/34	56%
TOTAL	214/371	58%
M.S.H. radiation therapy	25/45	56%

laryngectomy shows an average five year survival rate of 64 per cent (Table VIII).[12,13,15,18] The radiation successes have the great advantage of preservation of the larynx and voice. We can expect improvement in these figures with the judicious employment of radical neck dissection as an elective procedure when indicated either as part of the surgical procedure or after radiation therapy. We wish to emphasize at this point that radiation failure may still be amenable to successful laryngectomy. We believe, however, that laryngectomy with radical neck dissection should be performed as a primary procedure when a small intrinsic lesion and palpable cervical lymph nodes exist.

In the special instance of true subglottic cancer, as distinguished from subglottic spread of a cord lesion, the results with either surgery or radiation therapy are poor. In these cases as well as in the advanced intrinsic carcinoma with palpable cervical lymph nodes it is our plan to employ the combined technique of radiation and surgery as will be described later.

There is an intermediate group of cases in which the growth is too extensive for partial laryngectomy but can be excised by hemi-laryngectomy. It is our opinion that such lesions are also suitable for radiation therapy.

In the laryngopharynx the growths which are located anteriorly and which involve the false cords, epiglottis or upper half of the ary-

TABLE X

CARCINOMA OF THE EXTRINSIC LARYNX
5 YEAR SURVIVAL RATES FOR SURGERY
LESIONS OF THE HYPOPHARYNX

Norris, 1959	9/30	30%
Pietrantoni and Fior, 1958	7/44	16%
Orton, 1954	11/66	17%
Clerf, 1952	6/12	50%
TOTAL	33/152	22%
M.S.H. radiation therapy	12/49	24%

epiglottic folds can be treated either by surgery or radiation with a survival rate of about 57 per cent. Recent reports of laryngectomy in this group of cases indicate an average five year survival rate of 58 per cent (Table IX).[12,19-21] About half of these cases also had simultaneous radical neck dissections. This group is similar to the advanced intrinsic group in management and prognosis. Here again improved results can be expected with the addition of elective radical neck dissections and successful surgical procedures for radiation failures.

The posterolateral group of laryngopharyngeal growths, namely cancer of the lower half of the aryepiglottic folds, arytenoids, pyriform sinuses and postcricoid lesions, present the most serious challenge to laryngeal surgeons and radio-therapists. These are the neoplasms which are frequently complicated by deep infiltration, fixation of the larynx and involvement of regional cervical nodes when seen for the first time. The general impression is that the results of surgery including radical neck dissections are better than with radiation therapy, but the fact is that the results are poor with either modality. These observations apply equally as well to the extensive group of laryngopharyngeal lesions in which both anterior and posterolateral anatomic sites are involved. Evidently it is the involvement of the posterolateral area which determines the poor prognosis of this group.

A survey of the literature shows that a relatively small number of cases were reported in this group. The average five year survival

rate for surgery was 22 per cent (Table X).[12,19,21,22] It is noteworthy, however, that Clerf reported a 50 per cent survival rate for 12 cases in nine of which a radical neck dissection was performed. Of six patients who survived, an elective procedure was done in four.

It is in this posterolateral group of laryngopharyngeal cancer that we believe that combined radiation therapy and radical surgery is indicated with the view to improve the survival rate of these desperate lesions. This kind of combined therapy has been initiated in clinics in Italy,[23] France[24-26] and lately in this country.[27] There are three different plans in which this combination is used: 1) surgery followed by radiation, 2) radiation given before and after surgery which accordingly has been called the sandwich method and 3) radiation followed by surgery.

We at The Mount Sinai Hospital have instituted an integrated program for this type of lesion in which radiation therapy is followed by radical surgery. With Cobalt-60 teletherapy it is possible to administer a tumor dose high enough to be in the cancerocidal range but not enough to interfere seriously with the surgical procedure. A tumor dose of 5500 r in five weeks is cancerocidal for the most actively growing cells which are usually located in the periphery of the lesion, in the lymphatics and in tissue planes. Three weeks after the completion of radiation therapy the reaction is practically healed. Surgery then should be performed between the third and sixth week after radiation. We have not observed any undue interference with wound healing. It is unfair to attribute all surgical complications to radiation therapy.

Although our experience with this form of combined therapy is limited thus far, we have been impressed by its efficacy. We have observed instances where the tumor seemed to have disappeared, where neoplasms which originally appeared formidable and possibly inoperable became amenable to surgery and where cervical lymph nodes, originally large and fixed, became smaller and more easily resectable. At times radiation therapy permitted a more thorough surgical extirpation.

When Kramer and Harris instituted radiation therapy for cancer of the larynx in 1931 in this country, it was regarded as a radical departure from the accepted methods of treating cancer of the larynx

of that period. It is probable that these ideas of combined therapy will evoke similar reactions in the minds of some laryngologists. However, we sincerely believe that the combined method of therapy is part of the evolutionary process of the treatment of this disease and will save many additional lives.

SUMMARY

Almost three and one-half decades of experience with radiation therapy at The Mount Sinai Hospital for carcinoma of the larynx has demonstrated that this is an effective method of treatment for this disease. The classification used was based on the prognosis predicated by the various anatomic sites of the larynx and laryngopharynx.

An 88 per cent determinate five year survival rate was obtained in carcinomas limited to the vocal cord and suitable for partial laryngectomy; a 63 per cent determinate survival rate in lesions of the intrinsic larynx suitable for laryngectomy; a 56 per cent determinate survival rate in carcinomas of the anterior group of the extrinsic larynx; a 32 per cent determinate survival rate in the posterior-lateral group of the extrinsic larynx; and a 14 per cent determinate survival rate in the extensive group of the extrinsic larynx.

The reported results with radiation therapy are compared with recent surgical statistics for laryngeal cancer. A program of combined radiation therapy and surgery for lesions which have a poor prognosis is suggested.

1050 Park Ave.

REFERENCES

1. Cantril, S. T.: Radiation Therapy in Cancer of the Larynx; A Review. Am. J. Roentgenol. 81:456-474, 1959.

2. Harris, W., Kramer, R., and Silverstone, S. M.: Roentgen Therapy for Carcinoma of the Larynx. Radiology 51:708-718, 1948.

3. Harris, W., Silverstone, S. M., and Kramer, R.: Roentgen Therapy for Cancer of the Larynx and Laryngopharynx. Am. J. Roentgenol. 71:813-825, 1954.

4. Pietrantoni, L.: Il problema chirugico delle metastasi lingoghiandolari de cancro della laringe. Arch. Ital. Otol. Suppl. 14, 64:1-37, 1953.

5. Ogura, J. H., and Bello, J. A.: Laryngectomy and Radical Neck Dissection for Carcinoma of the Larynx. Laryngoscope 62:1-52, 1952.

6. Clerf, L. H.: Evaluation of Dissection of the Neck in Carcinoma of the Larynx. ANNALS OF OTOLOGY, RHINOLOGY AND LARYNGOLOGY 64:451-456, 1955.

7. O'Keefe, J. J.: Secondary Radical Neck Dissection. Laryngoscope 65:136-141, 1955.

8. Putney, F. J.: Preventive Dissection of the Neck in Cancer of the Larynx. ANNALS OF OTOLOGY, RHINOLOGY AND LARYNGOLOGY 67:136-147, 1958.

9. Reed, G. F., Mueller, W., and Snow, J. B., Jr.: Radical Neck Dissection; A Clinico-Pathological Study of 200 Cases. Laryngoscope 69:702-743, 1959.

10. Frazell, E. L.: Personal Communication.

11. McGavran, M. H., Spjut, H. J., and Ogura, J.: Laryngofissure in the Treatment of Laryngeal Carcinoma. Laryngoscope 69:44-53, 1959.

12. Pietrantoni, L., and Fior, R.: Clinical and Surgical Problems of Cancer of the Larynx and Hypopharynx. Acta Otolaryng., Stockholm, Suppl. 142, pp. 1-61, 1958.

13. Jackson, C. L., Blady, J. V., Norris, C. M., and Robbins, R.: Carcinoma of the Larynx. J.A.M.A. 163:1567-1570, 1957.

14. O'Keefe, J. J.: The Surgery of Cancer of the Larynx. ANNALS OF OTOLOGY, RHINOLOGY AND LARYNGOLOGY 65:131-136, 1956.

15. Putney, F. J., and Vicens, E. A.: Surgical Treatment of Carcinoma of the Anterior Commissure of the Larynx. Laryngoscope 66:1041-1058, 1956.

16. LeJeune, F. E., and Lynch, M. G.: The Value of the Laryngofissure Operation. ANNALS OF OTOLOGY, RHINOLOGY AND LARYNGOLOGY 64:256-262, 1955.

17. Schall, L. A.: Symposium: Carcinoma of the Larynx. Five Year Results. Laryngoscope 61:517-522, 1951.

18. O'Keefe, J. J.: Concerning the Criteria of Operability in Laryngeal Cancer. ANNALS OF OTOLOGY, RHINOLOGY AND LARYNGOLOGY 68:453-460, 1959.

19. Norris, C. M.: Causes of Failure in Surgical Treatment of Malignant Tumors of the Larynx. ANNALS OF OTOLOGY, RHINOLOGY AND LARYNGOLOGY 68:487-508, 1959.

20. Orton, H. B.: Surgery of Carcinoma of the Larynx. A.M.A. Arch. Otolaryng. 64:205-206, 1956.

21. Clerf, L. H.: Proceedings of the Second National Cancer Conference, New York City, American Cancer Society, Vol. 1, p. 462, 1952.

22. Orton, H. B.: Symposium: Carcinoma of the Larynx. Tr. Am. Acad. Ophth. 58:30-34, 1954.

23. Pietrantoni, L.: Personal Communication.

24. Leroux-Robert, J., et Ennuyer, A.: Cancer du Sinus Piriforme. Extrait du Rapport au Le Congres Francois d'Oto-Rhino-Laryngologie, Paris, 1952.

25. Leroux-Robert, J.: Indications for Radical Surgery, Partial Surgery, Radiotherapy, and Combined Surgery and Radiotherapy for Cancer of the Larynx and

Hypopharynx. ANNALS OF OTOLOGY, RHINOLOGY AND LARYNGOLOGY 65:137-153, 1956.

26. Romieu, C., Pourquier, H., Leenhardt, P., Gary-Bobo, J., Pages, A., and Pujol, H.: Telecobalt Therapy of Cervical Lymph Node Metastases. J. de radiol. et d'électrol. 39:369-377, 1958.

27. MacComb, W. S., and Fletcher, G. H.: Planned Combination of Surgery and Radiation in Treatment of Advanced Head and Neck Cancers. Am. J. Roentgenol. 77:397-414, 1957.

DISCUSSION

DR. JOHN J. CONLEY: Mr. Chairman, Members and Guests, this is an extremely interesting and I think important piece of work. I cannot help but be impressed with the statistics that Dr. Goldman exhibited. I think the curious part about them that I will pose in the form of a question is how does he account for the difference between his statistics and results obtained by almost all of the other radiotherapists of the world, whose statistics he did not present. I am thinking of Lederman of London; McLess, Curie Institute; Delragato, United States; Martin, Memorial; and Charlie Martin of Texas. All of these individuals have reported salvage rates in the hypopharynx by irradiation of anywhere from 6 per cent to about 12 per cent. What is the reason for this rather striking discrepancy? I think we all agree that when irradiation works, nothing matches it in excellence in this area.

I agree that if the individuals are operated on within three to six weeks after irradiation, the wounds usually heal per primam. I would like to interject a word of caution that pertains to the physiological capacity of people to tolerate massive irradiation followed by massive surgery. It is very easy to theorize about this particular aspect of the management of cancer of the head and neck. We know that the radiotherapist does not like to administer massive irradiation after radical surgery because the tissues will not, No. 1, tolerate adequate irradiation, and No. 2, the response will not be as satisfactory. I think the same thing applies to us. We are not anxious to operate after massive irradiation because although the operation may not technically be more difficult, wound healing is embarrassed if you operate after two or three months have elapsed.

This is a pilot project. We have to constantly search with an open mind for new techniques and new methods and new ideas regarding the best way to control this problem.

This project has been done in a small way by other people. It is possible to improve the salvage rate by a combined attack. Miller and Pack reported on this subject about ten years ago and found that they could take a series of cases that were declared incurable or inoperable, treat them with irradiation, operate on them and obtain almost a 10 per cent five year control rate for this particular group of people.

In the last analysis we are functioning in an extremely crude way in our attempt to control cancer. The surgeons are removing the large pieces of cancer and the therapists are burning out the large pieces of cancer, but all large cancers are essentially systemic diseases. Blood analyses show that in patients who have a large cancer of the tongue, 50 per cent have canceremia or free cancer cells in the internal jugular vein and almost 25 per cent of them have free cancer cells in

the peripheral veins. To get 25 per cent here the cells have to pass two filters, the pulmonary filter and the capillary filter. So I think that although I approve of this wholeheartedly as a pilot project, our basic concept of the biology of cancer should be altered and that perhaps more effort should be given toward a systemic attack rather than to increasing the intensity of local attack.

Regarding primary cancers in the oral cavity, or hypopharyngeal area, about 10 per cent are multicentric and almost 20 per cent recur locally. About the same statistics apply to the metastatic bed. This is obviously not the group that is controlled by one single regional operation. I believe the essential factor is a biological factor and not a factor of contamination, not a factor of the size of the growth. It is a host-tumor relationship functioning primarily as an immunological phenomenon. I don't think we can be too optimistic about changing this basic factor.

I would like to state one other thing about the use of irradiation in these cases. I would like to admit frankly that we cannot get along without irradiation. This is not a speech against irradiation, but it is important to give this concept its correct value, if in the last analysis host resistance is a factor.

I am sure we will all be interested in having a final report on this project.

It has been a pleasure to hear this paper, Dr. Goldman.

DR. F. JOHNSON PUTNEY: Mr. Chairman, I too have enjoyed the paper by Dr. Goldman, but must confess that his ideas are somewhat different from ours. Our radiologist has not been able to obtain the result that he has obtained. Our surgical results have been far superior to our radiologic results in large lesions of the larynx. Admittedly in small lesions limited to the cord, irradiation may have equal value.

I think it would be best in reviewing statistics if we would take the absolute figure rather than the determinant figure. When we say that patients are dead of other causes, we are not certain whether that patient had cancer or not when he died, unless he was autopsied and in some it might be missed. If a patient is dead and he had a cancer operation, he is dead as far as the statistics are concerned. Only the survivors should be considered in these statistics.

I am in complete agreement regarding the use of irradiation therapy in large lesions which are not primarily attacked surgically, because of their extent. We have seen large lesions become resectable after extensive irradiation therapy. Accurate determination of the presence of residual cancer may be very difficult. The edema may be so great that one does not see an actual ulceration. A biopsy of the swollen edematous mucosa may not reveal cancer, yet that patient may have cancer in the pyriform fossa or in the larynx. It is very difficult to evaluate residual cancer after extensive irradiation therapy in those locations. However, I think in all cases in which the indication for surgery is questionable, that irradiation therapy should be given first. It may make that case operable and result in a cure.

I have enjoyed Dr. Goldman's paper.

DR. JEROME A. HILGER: I concur with Dr. Conley in the importance of this paper. It strikes me that one thing we can glean from this paper is the value of co-operative work in these cases. One suspects from the reports across the land and in other countries that too few centers have an effective, co-operative program between the radiation therapists and laryngologists. I think it is common practice that cases delivered to the radiation therapist have none of the co-operative follow-up at the regular short intervals during therapy that are evidenced in these cases.

Dr. Conley's words for the future certainly betoken optimism in the treatment of cancer. It may well be that ten years hence we will be adding chemotherapy to the combined attack. One certainly hopes so. It is apparent in these circles that over the past ten years the trend is toward the inclusion of radiation therapy in the approach to more and more types of laryngeal cases. I am encouraged to hear Dr. Goldman speak of this project for treatment of the miserable and tragic posterior and lateral cases. These tumors seed themselves in the neck postoperatively and in the opposite lymphatics. For these cases Dr. Goldman advises a thorough irradiation program and then—the significant point—goes directly and with courageous decision to deliberate surgical resection of as thorough a type as though the patient had not received irradiation therapy. We have not done this. We certainly have gone toward the direction of including radiation therapy in the program as an initial procedure, but we have batted ourselves with the annoying question: is cancer still present? I am sure that everyone in the room has had that distressing situation evolve in which it became necessary to almost take the structure apart piecemeal with biopsy forceps to prove or disprove the presence of cancer. I do admire his forthright decision to go ahead with surgery and use this as a truly combined technique. I do hope that other men will carry on this program which Dr. Conley calls a pilot project; the hope being that the survival rate of this miserable group having such a poor outlook, 15 per cent, 20 per cent at the very most, can perhaps be improved.

Dr. Thomas C. Galloway: I wish to speak to two points. I have been very impressed by this study. Despite a great prejudice against irradiation therapy, I have come to the conclusion that it is a very important modality when it is used in consultation as a team between the roentgenotherapist and the surgeon. There is one point I wish to mention. In the treatment of carcinoma by irradiation, carcinoma itself may be induced.

The other point is the question of using irradiation when the expectancy of life of the patient to be treated is greater than the expectancy of the latent period of the carcinogenic action of irradiation.

There have now been over 121 cases of carcinoma of the thyroid reported which appear definitely to have been caused by irradiation. There have been at least 36 cases of postcricoid carcinoma so induced. I remember reporting either the seventh or eighth case of intralaryngeal carcinoma secondary to irradiation for papillomatosis of the larynx. This particular patient was reported in the Archives 29 years after the treatment of papilloma of the larynx. He developed a carcinoma of the larynx in the anterior commissure. He was not suitable for operation because of bullous emphysema and a recent attack of pneumonia. We elected with the radiotherapist to use irradiation. The roentgenotherapist believed irradiation cancer is as susceptible to treatment as any other cancer, but there is this to be borne in mind—good irradiation effect depends upon a healthy tissue bed and this does not exist in such a case. This patient had a recurrence after 16 months and was then able to have a successful operation. The biggest objection to using irradiation for this man was the fact that he was 37 years old. Since the latent period of carcinogenic action of X-ray may be from six to thirty odd years, if he had had no surgery he might have developed another cancer before he reached his full life expectancy. That is one reason I think the age of the patient should be considered and that the use of surgery should be emphasized for the younger patients.

Dr. Joel J. Pressman: I suppose everybody in the room would care to make a few remarks. We seldom lack for discussion. In this particular subject thoughts come to everyone's mind of course and they have come to mine too. I have not

dealt with large numbers of these cases that have been analyzed statistically as Dr. Goldman has and therefore cannot pose as an authority. On the other hand, in thinking about the subject in a broader sense one develops a distrust of statistics. I remember that about ten years ago Victor Negus circularized the people in the British Isles and Canada and some of the other British possessions. He had replies from approximately 100, some being laryngologists and some being radiotherapists and some being a combination of the two, as to their preference for the treatment of these lesions under a variety of conditions. I remember one had to do with the classification of carcinomas based on their activity, using Broder's classification.

We used these statistics in a very important way because we allowed them to influence our choice of therapy. Now we don't even mention Broder's classification when discussing the therapy of these tumors. Yet ten years ago, or whatever it was, we were guided not solely but to a large extent by the data which Negus had published. Now they are completely discarded. So that I wonder what the statistical figures really mean in a science like this.

The other question I would like to raise was mentioned by Dr. Conley.

How often do cells become detached and pass through the blood stream? You wonder how really important this is. We have heard a great deal about it lately from several institutions. You wonder whether or not we ought to become panicky because we do find cancer cells in the circulating fluids. If they are as important as some men suggest why don't they lodge, for instance, in the liver? Why don't we have early carcinoma rests in the liver in cases of carcinoma of the larynx? Why don't we see them more frequently in other distant foci? We don't. It is a local lesion, except in the late stages.

DR. J. L. GOLDMAN (closing): I am grateful to Dr. Conley, Dr. Putney, Dr. Hilger, Dr. Galloway and Dr. Pressman for their kind remarks, their comments and their contributions to this subject.

As you see, it is a very large subject. I am afraid it will be difficult for me to answer all the question or cope with the entire problem in a discussion. Dr. Conley has posed one of the most important questions: why cannot these results be duplicated elsewhere? Well, first of all I think they have been duplicated elsewhere. I think in certain clinics this work was started, but not continued far enough. I call to your attention Dr. Schall's report of 12 cures in 13 cases of cordal carcinoma. I don't know the percentage, but Dr. Lindsay reported a very high percentage of cures in cases of cordal carcinoma. Dr. Cunning did the same. I am certain that if these particular departments continued to extend their work to more advanced carcinomas, they would have the same results we did. There is no question that this work requires a very special kind of setup. This requires the most co-operative kind of teamwork. These cases must be under the supervision of the laryngologist, not the radiotherapist alone.

Dr. Conley mentioned the results of Dr. Lederman, Kless and others. These radiotherapists see these cases originally. They indicate the anatomic involvement. They treat the patients and follow their progress. I think this is a serious mistake. A laryngologist should evaluate these patients before and after treatment. At least that is the way it is done in our institution. Further, this sort of therapy must be administered meticulously. It must not be done by a technician. Every one of our patients was treated by the M.D. radiotherapist at every sitting. The patient was put in the exact position each time. The roentgen dose was measured and results observed and recorded every step of the way by the radiotherapist. We confer with

each other during the treatment. What is the mucous membrane reaction? Is the lesion responding? Do we think possibly the beam is too high, too low or just right? It is exacting work and there is no question in my mind that given the proper co-operation, facilities and manpower, that this work can be duplicated elsewhere.

Dr. Putney, I believe I am correct in making the statement that men at Temple University some years ago reported that for intrinsic lesions their results with surgery and radiotherapy were almost identical. Certainly as we go from the anterior lesions to the posterior and lateral lesions, our results become poorer, but that also applies to the results of surgical treatment.

Dr. Conley and Dr. Pressman touched on the question of canceremia. This is a very complicated problem. It isn't only the local cancer. Certainly we must think of the reaction of the host to the cancer. There are biological factors. There has been much work done in this field. One excellent piece of work in Hungary shows that cancer cells are affected by lymph nodes the same way as bacteria circulating in the blood stream. Cancer cells can be destroyed. They are destroyed in lymph nodes, but not in the liver. I think however that some of this spread can be controlled by preliminary irradiation in these serious and advanced lesions.

Since we have been doing this work we have investigated the spread of cancer in relation to the original lesion, and to our great amazement have found that there are cancer cells not only in lymph nodes, but in tissue planes. I am sure that these cells which are potentially lethal can be destroyed by preliminary radiation before surgery.

The problem of evaluating statistics is not new. Actually the true result is somewhere between determinate survival rate and the absolute survival. In our figures the patients whom we call indeterminate, whom we discarded, had as much as three or four year cures, but we disregarded these patients. However, I agree with Dr. Putney that if we are going to be able to compare statistics we must have some common base line.

We have followed these cases for many years. Dr. Galloway, may I say that we have never seen carcinoma which we thought was induced by radiation.

We are in the next ten years going to treat all these advanced lesions by the combined therapy just as Dr. Kramer did for many years treat all carcinoma of the larynx by irradiation therapy. There are certain patients who are too infirm or too old to be submitted to surgery, so we treat them with radiation therapy. In the last five years our results with these people too infirm for surgical therapy have been remarkably good. The results show the possibility of radiation therapy.

Dr. Pressman, concerning Broder's classification, may I say that in this study years ago the results were analyzed in relation to Broder's classification. This was done by Dr. Harris and Dr. Klemperer, who is now our Emeritus Pathologist. It was definitely found that the results bore no relationship to Broder's classification.

EXTRAMEDULLARY PLASMACYTOMA OF THE UPPER AIR PASSAGES

JULIUS W. MCCALL, M.D.
CARL H. BAILEY, JR., M.D.
CLEVELAND, OHIO

Plasmacytomas are rare tumors found usually in the upper respiratory passages, although their occurrence has been recorded in other parts of the body. There have been approximately 200 cases of plasmacytoma reported in the literature.

The cellular make-up of these tumors is identical with that of multiple myeloma. This tumor was first described by Schridde[1] in 1905.

Microscopically the plasma cells which compose a majority of the tumor have abundant cytoplasm and are of variable size, elliptical in shape, with eccentric nuclei having a spoke-like configuration of the chromatin material. The cytopalsm may stain in either a basophilic or neutrophilic fashion.

There were no mitotic figures seen in the microscopic examinations of our series, but this is not considered to be a criterion of malignancy in the disease. Rawson, Eyler and Horn[2] emphasize that malignant cell tumors may not show the usual cytologic characteristics of malignancy, and they point out that such criteria, if found in considerable degree, may be regarded as reliable diagnostic evidence. They believe that the replacement of tissue by broad sheets of plasma cells arranged in a delicate capillary stroma is definitely indicative of a malignant tumor and that the absence of this problem makes malignancy unlikely.

We did not encounter excessive bleeding in the surgical management of these individuals. Clyde Heatly,[3] who reported 2 cases of

plasmacytoma of the maxillary sinus, before this Association in 1953, was impressed by the tremendous vascularity of the antral tumor. The bleeding in one of his cases necessitated ligation of the external carotid artery. Lumb and Prosser[4] had a similar experience and concluded that the vascularity of the plasmacytoma in the maxillary sinus tends to be greater than those occurring elsewhere.

INCIDENCE AND AGE

This disease is less common in females than in males. In our five cases, all were males. All writers agree that most of these tumors occur in males after the age of 40; the age range in our group was 41 to 70 years.

Plasmacytomas usually appear as solitary tumors, but occasionally they may be multiple. Hellwig, Stout and Kinney, Blacklock and McCartney, and Mattick and Priest[1,5-8] have all reported cases of multiple tumor.

SIGNS AND SYMPTOMS

Plasmacytoma is such a rare tumor it is seldom considered in a differential diagnosis; the diagnosis is usually established by the microscopic examination of the tissues removed. In two of our cases obstruction was the predominant symptom; in two it was a mass; and in one it was diplopia and headache.

The tumor appears grossly as a soft, friable, pale gray mass with varying amounts of red, depending upon the amount of hemorrhage and necrosis present.

DIFFERENTIAL DIAGNOSIS, PLASMACYTOMA, MULTIPLE MYELOMA

Many pathologists feel that there is no line of differentiation between plasmacytoma and multiple myeloma. Multiple myeloma is a systemic disease of the bone marrow and is more common in people past 40 years of age. The symptoms are usually vague and are characterized by muscular pain and weakness. Often the osteolytic lesions lead to pathologic fractures. Laboratory findings usually include Bence-Jones proteinuria, normochromic anemia, elevated globulins

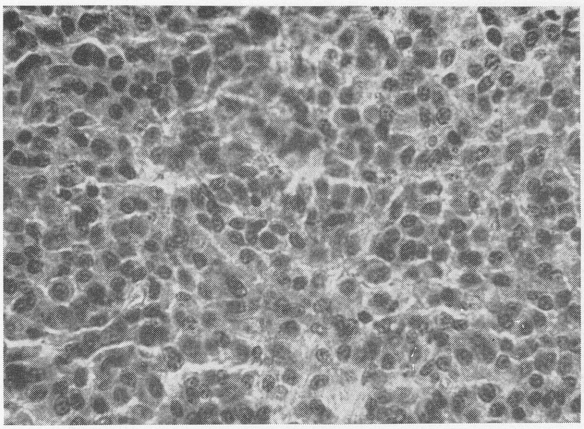

Fig. 1.—The plasma cells are elliptical in shape and variable in size. The nuclei, eccentrically located, have a spoke-like configuration of chromatin material. No mitotic figures were seen in this series.

in the plasma proteins and normal serum phosphates. The diagnosis is established by bone marrow aspiration showing an excessive number of myeloma cells.

Punched-out lesions, especially in the spine, skull, shoulder, and pelvis are characteristically seen on skeletal x-ray.

The histology of plasmacytoma is identical with that of multiple myeloma. Plasmacytomata seldom metastasizes to distant organs. If lesions appear in other parts of the body, these are probably multicentric primary foci rather than metastases. However, local extension to adjacent structures does occur.

TREATMENT

These tumors being lymphogenous in nature should be radio sensitive. The tumors in two of our group responded to irradiation.

In the patient with subglottic plasmacytoma the possibility of causing chondritis of the laryngeal cartilages, or severe respiratory distress prompted us to remove this tumor surgically. Heatley[3] sug-

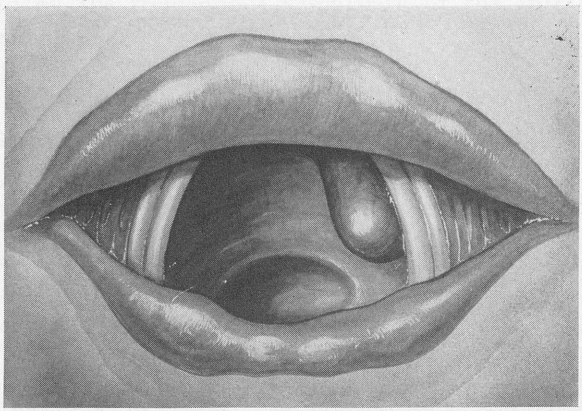

Fig. 2.—This illustration shows the location of the tumor by indirect laryngoscopy.

gests that pedunculated tumors are best treated by removal and cautery of the base. If massive surgery is required to remove the tumor irradiation should be the treatment.

REPORT OF CASES

CASE 1. B.M. This 58-year-old white male was admitted on February 24, 1957, because of a lump in the lower jaw of one month's duration.

Physical examination was not remarkable except for a 3 cm mass of the right lower alveolar ridge. Excisional biopsy was made with a histologic diagnosis of plasmacytoma.

The urine was negative for Bence-Jones proteins, total protein of 6.6, albumin-globulin ratio 1.5. The skeletal survey and gastrointestinal x-rays were reported as normal as was the bone marrow aspiration.

On March 4, 1957, the patient was returned for surgery. The adjacent margin of the mandible and soft tissue was excised leaving the inferior rim of the mandible intact.

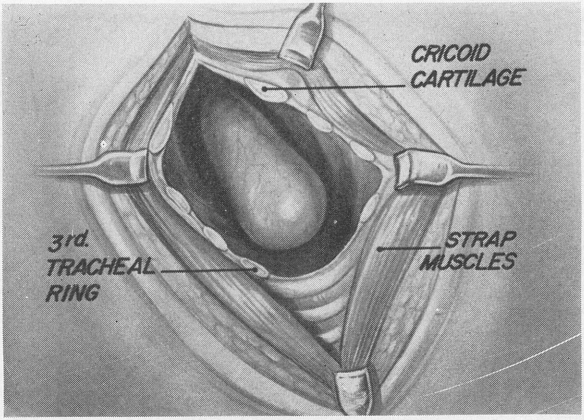

Fig. 3.—The tumor as it appears in the lumen of the trachea with anatomic relationships noted.

The patient did well until September, 1957, when a mass again became evident in the same area. The right ramus of the mandible was excised and an ipsilateral supraomohyoid dissection was performed. A tantalum plate was inserted in the surgical defect.

The patient has had no exidence of recurrence or metastasis and was last seen November, 1959.

CASE 2. G.V. This 70 year old white male was first seen on May 20, 1955, complaining of nasal obstruction and postnasal drip. Physical examination revealed a red granular mass obstructing the left naris. X-ray examination revealed a soft tissue density of the left ethmoid and maxillary sinuses. Nasal polypectomy and intranasal ethmoidectomy were done. An excision of the left middle and inferior turbinates was carried out at the same time. Histologic examination revealed plasmacytoma.

Laboratory studies which followed revealed the urine to be negative for Bence-Jones protein. Serum protein was 6.6. Albumin-globulin ratio was 0.6. The skeletal survey was negative.

The patient was seen only erratically following this procedure and in May of 1957, the patient returned complaining of blocking of the

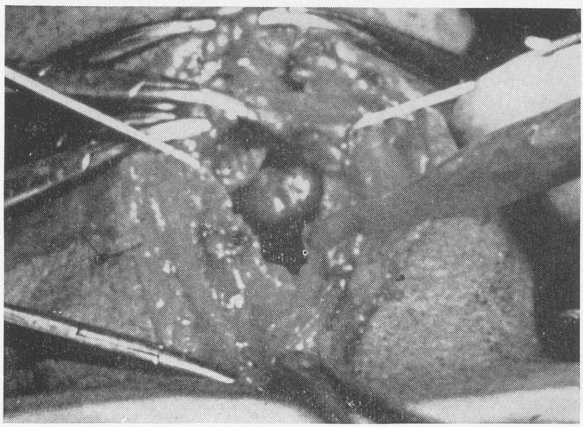

Fig. 4.—The surgical appearance of the pedunculated tumor after the cricoid cartilage has been severed.

right naris. Further therapy was advised but the patient was not again seen at our hospital.

Follow-up of the patient reveals that he presented himself at another institution complaining of nasal obstruction. Physical examination revealed obstruction of both nares by tumor masses.

X-ray therapy was begun September 18, 1957. Examination on September 26, 1957, showed the tumors to be reduced in size. X-ray therapy was completed October 4, 1957. He received a total dosage of 1500 R.

Examination on November 12, 1957, showed no further reduction in size of the tumors. On December 27, 1957, cobalt therapy was instituted and directed to the nasopharynx. An estimated tumor dose of 4000 R was given. The patient was next seen on February 3, 1958, at which time there was no change in the size of the masses. No further treatment was given. In October, 1958, the patient developed painless jaundice.

A diagnosis of carcinoma of the pancreas was made. He died of this disease in August, 1959. There was no autopsy performed but there was tumor present in his nose at this time.

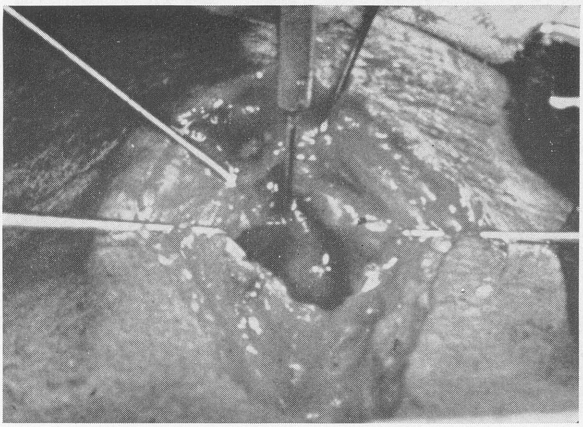

Fig. 5.—The nasal snare being applied to the base of the growth.

CASE 3. P.M. This 60 year old white male was admitted on January 27, 1954, for investigation of bony abnormalities discovered by dental x-ray. Physical examination revealed a slight prominence of the left maxillary and zygomatic areas with minimal tenderness on palpation. Examination of the alveolar ridge on this side revealed a fistulous tract to the maxillary sinus. X-ray showed the destruction of the medial, lateral, and superior margins of the left maxillary sinus, and soft tissue densities in the ethmoid labyrinth on the left side. Using a Caldwell-Luc approach a trans-antral ethmoidectomy and sphenotomy were done on January 30, 1954. A diagnosis of plasmacytoma was made.

Laboratory data following this showed the urine to be negative for Bence-Jones protein, serum protein to be 8.2, albumin 3.7, AG ratio 0.8. The bone marrow aspiration was normal.

Between April 6, 1954 and April 29, 1954, the patient received a total of 9200 R (air dose) to the left antral and orbital areas. In October, 1954, the patient developed a pathologic fracture to the left tibia. He received 3600 R to this area. In March, 1955, he developed a bony lesion of the left elbow for which he was given 3600 R. The following year the patient developed lesions of the lower lip and nose for which he received a total 9900 R. He died September 9,

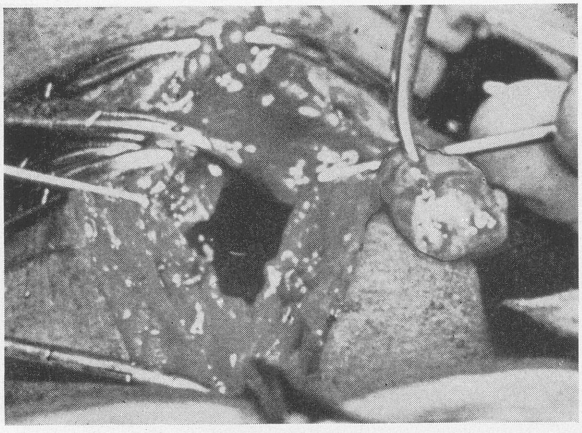

Fig. 6.—The specimen is seen to the right, the tracheal lumen is clear with minimal bleeding.

1956, apparently of this disease. No autopsy was performed. In retrospect this was probably plasmacytoma in its inception; however, the late clinical course of this disease was that of multiple myeloma.

Case 4. F.K. This 60 year old white male was admitted on August 22, 1955, with the chief complaint of increasing frontal headache of five months' duration and intermittent displopia of six weeks' duration.

Physical examination revealed only paresis of the right lateral rectus muscle. X-ray revealed a bony destruction of the floor of the sella turcica and a soft tissue mass filling the posterior two-thirds of the right sphenoid sinus.

On September 5, 1955, the right sphenoid was explored transnasally and a biopsy was taken. The Pathology Department described the specimen as an unclassified soft-tissue tumor. On September 19, 1955, another transnasal exploration and biopsy were done. At this time the diagnosis of plasmacytoma was made. Laboratory studies revealed the urine to be negative for Bence-Jones protein. The bone marrow aspiration was normal.

The patient received x-ray therapy from September 27 to October 12, 1955, of 4500 roentgens from four external portals.

The patient was last seen in November, 1959, at which time there was no clinical evidence of recurrence.

CASE 5. C.T. In April, 1953, this 41 year old white male was seen because of the voice change of six months' duration. He denied weight loss, dyspnea or memory of a preceding respiratory infection.

Physical examination revealed no significant abnormalities except a small red mass in the anterior commissure. Direct laryngoscopy and excision of the mass were performed and the diagnosis of plasmacytoma was established histologically.

The patient moved to another section of the country and was not seen again until January 3, 1959, when he returned complaining of moderate dyspnea and some recent voice change. A similar lesion just below the left true vocal cord was seen and biopsied. Microscopic sections were identical with those examined in 1953.

No further therapy was permitted until September 16, 1959, when he returned with marked dyspnea.

Laryngoscopy revealed no apparent involvement of the true cords, but a pedunculated tumor, apparently arising from the subglottic wall posteriorly which occluded more than half the diameter of the trachea. It was then decided to approach the tumor externally.

The first three tracheal rings were divided as well as the cricoid cartilage to adequately visualize the mass. It was attached by a short stalk to the posterolateral wall at the level of the cricoid cartilage. A wire snare was used to remove the mass and the base was cauterized. Bleeding was minimal. The postoperative course was uneventful.

Throughout the entire period laboratory studies, including Bence-Jones proteins, serum proteins, bone marrow aspiration, albumin-globulin ratio, skeletal surveys, and electrophoretic studies were normal. When last seen on January 10, 1960, there was no evidence of recurrence.

THERAPY AND OUTCOME

Of this group two were treated surgically without irradiation. One was treated by irradiation only. Two received both surgery and irradiation.

The two receiving surgical therapy are alive. The patient with plasmacytoma of the mandible has survived three years without evidence of recurrence.

The individual with plasmacytoma of the larynx has survived seven years since the recognition of the original tumor, but its recent reappearance in the larynx precludes evaluation of this therapy.

The patient with sphenoid plasmacytoma who received only irradiation has survived four and a half years without evidence of recurrence.

The other patient with primary maxillary sinus involvement developed multiple bony and soft tissue lesions. He succumbed to the disease within two and a half years after diagnosis.

It appears that the clinical course of plasmacytomas cannot be predicted from histopathological examination.

CONCLUSIONS

There is a close relationship between plasmacytoma and multiple myeloma. Indeed, multiple myeloma may be a progression of plasmacytoma. These tumors being of lymphatic origin should be and usually are radiosensitive. Irradiation should be the treatment of choice unless the tumor is pedunculated.

No individual or institution sees enough patients with this disease to qualify as an authority in its management.

610 Rose Bldg.

We are indebted to Mr. William M. Holmes for the illustrations.

REFERENCES

1. Hellwig, C. A.: Extra Medullary Plasma Tumors as Observed in Various Locations. Arch. Path. 36:95, 1943.

2. Rawson, A. J., Ailer, P. W., and Horn, R. C., Jr.: Plasma Cell Tumors of the Upper Respiratory Tract: a Clinico-Pathologic Study with Emphasis on Criteria for Histologic Diagnosis. Am. J. Path. 26:445, 1950.

3. Heatly, C. A.: Primary Plasma Cell Tumors of the Upper Air Passages with Particular Reference to Involvement of the Maxillary Sinuses. Trans. Am. Laryn. Assn. 74:52, 1953.

4. Lumb, G., and Prosser, T. M.: Plasma Cell Tumors. J. Bone and Joint Surg. 30-B:124, 1948.

5. Stout, A. P., and Kenney, F. R.: Primary Plasma Cell Tumors of the Upper Air Passages and Oral Cavity. Cancer 2:261, 1949.

6. Blacklock, J. W. S., and MacArtney: Plasmacytoma of the Nasopharynx. J. Path. and Bact. 35:69, 1932.

7. Mattick, W. L.: Plasmacytoma, an Unusual Case with Progressive Involvement of Waldeyer's Ring and the Larynx, Bronchus and Pleura. Arch. of Otolaryngology 51:263, 1950.

8. Priest, R. E.: Extra Medullary Plasma Cell Tumors of the Nose, Pharynx and Larynx. Trans. Am. Laryn., Rhin. and Otol. Soc., Inc. 278, 1952.

ADDITIONAL BIBLIOGRAPHY

Parks, M., and Burtoff, S.: Plasma Cell Tumor Simulating Bilateral Maxillary Sinusitis. Arch. Otolaryngology 50:666, 1949.

Fuerste, F., Jr., and Zuckerman, S. S.: Extra Medullary Plasma Cell Tumor. Arch. Otolaryngology 51:608, 1950.

Eggston, A. A., and Wolff, D.: Histopathology of the Ear, Nose and Throat. Baltimore, Williams and Wilkins Co., p. 778, 1947.

Connor, C. E.: Solitary Extra Medullary Plasmacytoma: Case Report. ANNALS OF OTOLOGY, RHINOLOGY AND LARYNGOLOGY 55:342, 1946.

Ash, J. E., and Raum, M.: An Atlas of Otolaryngic Pathology. Amer. A.M. Registry of Pathology, p. 237, 1949.

Chase, W. D.: Solitary Myeloma Mistaken for Frontal Sinusitis. Arch. Otolaryngology 48:244, 1948.

Moguda, R. A., and Maiden, S. D.: Plasmacytoma of Nasal Cavity. Arch. of Otolaryngology 51:258, 1950.

Shea, J. S.: Pathology of Nasal Polyps and Related Growths. ANNALS OF OTOLOGY, RHINOLOGY AND LARYNGOLOGY 56:1029, 1947.

Switzer, P. K., and Moseley, V., and Cannon, W. M.: Extra Medullary Cytoma Involving Pharynx, Skin and Lymph Nodes. Arch. Int. Med. 86:402, 1950.

Waltner, J. G.: Plasma Cell Tumors of Nasopharynx. ANNALS OF OTOLOGY, RHINOLOGY AND LARYNGOLOGY 56:911, 1947.

Cecil, R. L., and Loeb, R. F.: A Textbook of Medicine. Philadelphia, W. B. Saunders Co. 2:1113.

Ewing, M. R., and Foote, F. W., Jr.: Plasma Cell Tumors of the Mouth and Upper Air Passages. Cancer 5:499, 1952.

Figi, F. A., and Broders, A. C., and Havens, F. Z.: Plasma Cell Tumors of the Upper Part of the Respiratory Tract. ANNALS OF OTOLOGY, RHINOLOGY AND LARYNGOLOGY 54:283, 1945.

Greenfield, M. M.: Malignant Plasmacytoma of the Nasopharynx. A Case of Multiple Myeloma Primary in the Nasopharynx. Radiology 501:661, 1948.

DISCUSSION

DR. CLYDE A. HEATLY: Dr. McCall's paper has been comprehensive and is of great interest. These tumors are rare; so the experience that most of us have is extremely limited. Presentations of this type acquaint us with the behavior of these tumors and are extremely important. These tumors, as Dr. McCall has emphasized, are related to multiple myelomas and that of course makes the treatment and the choice of treatment extremely difficult. He has emphasized that the first step in the management of these problems is to rule out an underlying myeloma by appropriate laboratory and x-ray studies.

The type of tumor seems to differ considerably in relation to its location. In the pharynx and larynx many of the reported cases are of the pedunculated variety and this type of lesion seems to be particularly suitable to local resection, with cauterization of the base. There are many recorded cases of plasmacytomas of this type which have gone 14 to 20 years without recurrence.

The plasmacytoma found in the nose and particularly in the antra represents a much more malignant variety. It is destructive, invasive. It has great tendency to recurrence and I think universal experience with this type of lesion indicates that it is the most unsatisfactory tumor of this type for any form of treatment. We have felt that the extensive resection which would be used for malignancy should not be employed for this type of tumor because in many instances we see systemic recurrence. Even though the results of irradiation of this type of tumor in the nose and sinus have not been uniformly good, it seems like a better treatment than radical resection, knowing the possibility of later development of full blown multiple myelomatosis.

I congratulate Dr. McCall on this most interesting paper.

DR. ROBERT E. PRIEST: It was with some hesitation that I appear here again but Dr. McCall and I had a meeting downstairs in the bar the other evening and we were commiserating with one another on the fact that we were last on the program. We really thought the only people who would be here would be the other speakers. You gentlemen have done us the honor of staying to hear the presentations on Saturday afternoon and it is much appreciated.

This is a most interesting subject and I suppose almost everyone in the room has had a few of these cases.

I have one that I have followed since 1946. He had what was supposed to be a tonsillectomy some ten years prior to that. This man has plasma cell tumors in his nose, in his nasopharynx, in his oral pharynx, in his hypopharynx, and in his larynx. So far I have not seen any in his trachea but I have removed them on numerous occasions from all of these other situations. Just before I came to this meeting he came in to see me with his wife, his wife being a patient. I have a new associate and I wanted him to see this unusual patient. So I let him see him and this reminded the patient that recently he had uncovered in his possessions the pair of tonsils that had been removed many years before. The day before I came to the office with a bottle and presented me with what looked like plasma cell tumors. I have not had a chance to have them sectioned but I feel quite sure that this will carry this case back to at least the 25 year mark. He is still perfectly well except that when his larynx gets filled up so that he has trouble breathing he comes in and asks me if I will take out enough tissue to let him breathe comfortably.

Dr. Edwin N. Broyles: Some ten years ago we had a case in Baltimore very similar to the one shown in the movie. The patient came in expectorating blood. On examination of the larynx you could see what I thought at first was a big blood clot in the trachea. Direct laryngoscopy showed it to be a tumor. It was attached to about the fourth tracheal ring. The pathological diagnosis was angiosarcoma. The patient has remained perfectly well, so I believe he may have had a plasmacytoma.

Memorials

GEORGE M. COATES

GEORGE MORRISON COATES, M.D., F.A.C.S.

1874 - 1960

Dr. George M. Coates, a member of the American Otological Society since 1921, died at his home in West Whiteland, Pa., on February 7, 1960, at the age of 86. He was active to the time of his death, commuting thirty miles to his office in Philadelphia, three days each week, and was planning to attend the meetings of our special medical societies this year as had been his annual custom of many years.

Born of Quaker ancestry on March 24, 1874, except for the time he spent in the Military Service of his Country, he had always lived in Philadelphia or its environs. Two of his ancestors were among the founders of the Pennsylvania Hospital, the first hospital to be founded within the Continental United States. After graduating from the Haverford School, and the University of Pennsylvania, he received his M.D. from its Medical School in 1897. He served interneships at St. Christopher's Hospital for Children, 1897 to 1898, and at the Pennsylvania Hospital, 1899 to 1901. He began the study of laryngology with Dr. Francis R. Packard at Pennsylvania Hospital and with Walter Robertson at the Philadelphia Polyclinic and College for Graduates in Medicine between 1901 and 1905. He was certified by the American Board of Otolaryngology in 1925, the first year of the Board, becoming an Examining Director in 1930.

Serving on the staff of the Pennsylvania Hospital and the Polyclinic Hospital from 1901 to 1919, he became Professor and Chief of Service in the Graduate School of Medicine and Graduate Hospital of the University of Pennsylvania, retiring as Emeritus Professor in 1954. He was also Professor of Otolaryngology and Chief of Service in the Medical School, University of Pennsylvania and the University Hospital from 1933 to 1939, at which time he became Emeritus Professor. He was also Chief of Service in the Presbyterian Hospital and the Abington Memorial Hospital, later Consulting Otolaryngologist, and served as Otolaryngologist or Consulting Otolaryngologist to at least twelve other hospitals or institutions in the city or elsewhere.

He was a Past President or Chairman of the Philadelphia Laryngological Society; Section of Otology and Laryngology, College of

Physicians of Philadelphia; Section of Otolaryngology, Pennsylvania State Medical Society; Section of Laryngology, Otology and Rhinology, American Medical Association; Amercian Academy of Ophthalmology and Otolaryngology; American Laryngological, Rhinological and Otological Society; American Otological Society; American Laryngological Society; Section of Otolaryngology ard Ophthalmology, Clinical Congress of Surgeons of North America.

He was also a member or former member of the Pathologic Society of Philadelphia, Philadelphia Pediatric Society, Philadelphia County Medical Society, Association of Military Surgeons of the United States, American Society of Immunologists, American Broncho-Esophagological Association, American College of Surgeons (Fellow and member of Board of Governors), Kansas City Eye, Ear, Nose, and Throat Society (Honorary Member), Pacific Coast Oto-Ophthalmological Society (Honorary Member), Societe de laryngologic des Hopitaux de Paris (Corresponding Fellow).

He received the following honors:

Newcomb Award, 1943 American Laryngological Association

DeRoaldes Gold Medal Award, 1949, American Laryngological Association

Guest of Honor, 1956, American Laryngological Association

Guest of Honor and Award of Merit, 1946 American Academy of Ophthalmology and Otolaryngology

Award of Merit, 1949 American Otological Society

Guest of Honor, 1954, American Otological Society

Guest of Honor, 1959, Section of L. O. and R. of the A. M. A.

Award of Merit, General Alumni Society, University of Pennsylvania, 1959

He was Chief Editor of the A. M. A. Archives of Otolaryngology from 1937 until his death. He was also co-editor with Chevalier Jackson of "The Nose, Throat and Ear and Their Diseases"; with I. S. Ravdin of the American Edition of "Kirschner's Operative Surgery," Volume III; and with Harry P. Schenck and W. Valentine Miller of "Otolaryngology," five volumes. In addition, he contributed chapters to two of the above, as well as to other textbooks, and wrote over a hundred scientific papers for presentation before medical societies and publication in various journals.

Dr. Coates served as Assistant Surgeon in the U.S. Navy during the Spanish-American War and received two campaign medals; as First Lieutenant to Lieutenant-Colonel, Medical Corps, National Guard of Pennsylvania from 1900 to 1916; and as Major to Lieutenant-Colonel, Medical Corps, U.S. Army, 1917-1919. During the First World War he was Chief of the Section of Head Surgery in Base Hospitals at Camp Sevier in South Carolina and Camp Hancock in Georgia; Commanding Officer of Base Hospital No. 56 in Allerey, France; Otolaryngologist to Embarkation Camp, Bordeaux, France, U.S.S. Sierra. He was a Colonel in the Medical Corps, U.S. Army Reserve (retired), and Consultant to the Draft Board in World War II.

Dr. Coates married Mildred Aspinwall Hodge in 1910, and they had two children, Elizabeth Gardner Coates and George Woolsey Coates. Mrs. Coates died in 1954 and their son in 1955, leaving a widow and two young sons. Dr. and Mrs. Coates' son and daughter both served in the U.S. Army in the European Theatre in World War II.

Recipient of every honor within the gift of American Otolaryngology he was held in the highest esteem by his colleagues in the specialty and, indeed, throughout the medical profession. A skillful physician, he was beloved by his patients. A wonderful teacher, he was the idol of his many students in whom he always maintained the keenest interest. Kindly by nature he always saw the best in others and seemingly brought out that quality in those around him. Never did we hear him speak disparagingly of others. No one will ever know the innumerable young men he has helped by his encouragement, guidance and friendship. One of his greatest sources of satisfaction was to watch their careers in Otolaryngology. They were always "his boys."

A good citizen, a true patriot in the oldest tradition, a teacher in the truest sense of the word, and dedicated physician, his entire life can best be summarized in the proper designation of his ancestral religious creed, for above all he was a Friend. He will be sorely missed but his memory will endure among us for years to come.

F.T.H.

CLAUDE CARR CODY, JR., M.D.

1884 - 1959

Dr. Claude Carr Cody, Jr., an Emeritus Fellow, died December 30, 1959. Dr. Cody was born September 9, 1884, in Georgetown, Texas. His father was Professor of mathematics and Dean of Southwestern University, from which school Dr. Cody was graduated, receiving the degree of Bachelor of Arts in 1904 and Master of Arts in 1905. He studied medicine at Johns Hopkins University, where he received his M.D. in 1910. He served as intern and House Surgeon in Bellevue Hospital, N.Y., from 1910 to 1912.

He began the practice of general medicine in 1912 and was selected in 1917 to organize a Red Cross Hospital Unit. During World War I he served as Chief Surgeon of Base Hospital 116 in France, at other hospitals at home and abroad and received his honorable discharge August 20, 1919, as a major, Medical Corps, A.E.F., U.S.A.

Dr. Cody attended the Graduate Medical School, University of Pennsylvania, during 1920-21, studying Otolaryngology, with further training in Vienna in 1931.

He was one of the founders of the Houston Eye, Ear and Throat Hospital and was consultant at the Methodist Hospital from 1926. He was Professor and head of the Department of Otolaryngology at Baylor University College of Medicine from the location of the school in Houston until his retirement in 1954. He served as President of the Harris County Medical Society in 1923 and was a member of the Board of Trustees of the Houston Academy of Medicine for many years. The splendid library of the Academy is largely due to the untiring devotion of Dr. Cody.

He served as a member of the Council on Medical Economics of the Texas State Medical Association from 1936 to 1944. In 1946-1947 he was President of this Association. He also served as President of the Texas Ophthalmological and Otolaryngological Society in 1934.



CLAUDE CARR CODY, JR.

Dr. Cody was a member of the American Laryngological, Rhinological and Otological Society, the American Laryngological Association, the American Otological Society and fellow of the American College of Surgeons.

He was Chairman of the Board of Trustees of Southwestern University and was awarded the honorary degree of D.Sc. in recognition of his achievements in medicine and his service to his Alma Mater.

Dr. Cody is survived by his widow, the former Flora Root, a brother, M. D. Cody, and two nephews, both of whom entered the medical profession: Drs. Claude C. Cody, III, and Melville Cody.

DANIEL S. CUNNING

DANIEL S. CUNNING, M.D.

1893 - 1960

Dr. Daniel S. Cunning, an Emeritus Fellow of the American Laryngological Association, was born in Troy, New York, on March 14, 1893. He died on March 26, 1960, of carcinoma of the bronchus.

Dr. Cunning was one of nine children. He is survived by two sisters and four brothers. He graduated from Albany Medical College in 1914. He served his internships a the Troy Hospital, Troy, New York, and at the Carney Hospital, Boston, Massachusetts. He served in the U. S. Navy in 1918 and 1919. He started his graduate in otolaryngology under Dr. Harris P. Mosher at the Harvard Medical School. A lifelong friendship was established between these distinguished members of our Association. Dr. Cunning served a residency in otolaryngology at the Manhattan Eye, Ear and Throat Hospital, New York, N. Y., from 1923 to 1925. He was appointed to the Staff at the completion of his residency, and was actively associated with the Manhattan Eye, Ear and Throat Hospital up until the time of his death. He was Surgeon Director from 1940 to 1957 and was the Attending Bronchoscopist from 1939 to 1957. He was appointed a consultant and a member of the Board of Directors at the time of his retirement from the active Clinical Staff.

Dr. Cunning was Clinical Professor of Otolaryngology at the New York University College of Medicine. In addition to his appointment as Surgeon Director at the Manhattan Eye, Ear and Throat Hospital, he also served as a consultant to the Mary Immaculate Hospital of White Plains, New York; United Port Chester Hospital, Port Chester, New York; New Rochelle Hospital, New Rochelle, New York; Englewood Hospital, Englewood, New Jersey; St. Francis Hospital, Poughkeepsie, New York; Phelps Memorial Hospital, North Tarrytown, New York; Grasslands Hospital and the Norwalk Hospital, Norwalk, Connecticut.

He served as Trustee of the Albany Medical College from 1952 to 1956. He was also a member of the Alpha Omega Alpha Honorary Medical Society.

Dr. Cunning served as a member of the American Board of Otolaryngology. He was a member of the following organizations: the American Academy of Ophthalmology and Otolaryngology; the American Broncho-Esophagological Association (President in 1955 and Vice-President in 1954); the American Laryngological Association; the American Laryngological, Rhinological and Otological Society; the American Otological Society; the American College of Surgeons; the American College of Chest Physicians and the American Medical Association.

Dr. Cunning made an extensive survey of "The Relationship of Poliomyelitis to Tonsillectomy." His study, which extended over the 4-year period from 1946 to 1950, failed to establish a definite relationship between tonsillectomy and poliomyelitis. He contributed many important medical papers. He was a firm advocate of x-ray therapy for early carcinoma of the larynx.

In later years, his major interests were in the field of laryngeal cancer and bronchoesophagology. Earlier, he was very actively engaged in otology and was one of the early students of Dr. Julius Lempert.

Dr. Cunning was not married. He had many intimate friends and always made it a point to be gracious and pleasant to the wives of his friends. The latter will miss him as much as his colleagues do. He had a keen mind and an excellent sense of humor. His parents were of Irish extraction. This was evident in Dr. Cunning's approach to life. He was friendly and pleasant, but at the same time could be very firm.

Dr. Cunning played an important role in the training of otolaryngologists at the Manhattan Eye, Ear and Throat Hospital. He is known to several generations of specialists and will be long remembered by those who were closely associated with him.

FELIX ROBERT NAGER, M.D.

1877 - 1959

Dr. Felix Robert Nager, an honorary fellow, was born on December 9, 1877, in Lucerne, Switzerland. His father, Dr. Gustav Nager, was a well-known Otolaryngologist devoted to the welfare and rehabilitation of the hard of hearing. Felix R. Nager attended the public schools in that city and later went to the Universities of Basle, Geneva, Heidelberg and Zurich, where he was given his Medical Doctor degree in 1904.

He began his postgraduate training in Pathology, as an assistant to Professor P. Ernst in Zurich. Subsequently, he worked with Hofrat Professor Frederick Bezold in Munich and from 1904 to 1906 with Professor Frederick Siebenmann in Basle, the "founder" of Otolaryngology in Switzerland.

He began a private practice in Zurich and in 1908, for indigent patients, started a personally conducted clinic in the evenings. In 1915 he became Professor of Otolaryngology and in 1919 was appointed Director and Chairman of the newly-created independent Ear, Nose and Throat Clinic and Ear, Nose and Throat Out-Patient Department of the Zurich University School of Medicine. Ear, Nose and Throat Departments in Switzerland existed until then only in Basle, Berne and Lausanne. From 1940 to 1942 he was Dean of the Medical School and in 1948 he was retired as Emeritus Professor.

Professor Nager made great and extensive contributions to the literature of Otolaryngology. Almost two hundred scientific papers, in several languages, bear evidence of his profound interest in every aspect of Otolaryngology and in every problem that arose during his clinical activity. Many articles are concerned with clinical and anatomical pathology of the nose, paranasal sinuses, nasopharynx, throat, larynx, trachea, bronchial tree and the esophagus. His surgical interests were manifold. Thus he became a pioneer and expert in the paranasal approach to intrasellar tumors of the hypophysis. Bronchoesophagology and laryngeal surgery were greatly developed. His prin-

FELIX ROBERT NAGER

cipal interest, however, was the morbid anatomy of the temporal bone. Numerous are the monographic publications on bone diseases involving the otic capsule, on inflammatory disease, specific and non-specific, as they affect the ear, on developmental anomalies of the ear with or without association with facial-cranial and skeletal malformations, and on etiologies of forms of deafness. Many of these studies have enduring significance.

Professor Nager founded a histopathological laboratory which now houses a unique collection of temporal bone pathology. Visiting students from the entire world were welcomed here, and in this laboratory many scientists were introduced in the morbid anatomy of the ear. A large number of them made important contributions during their stay in Zurich or later as Directors of Departments in the United States and elsewhere. This international exchange of ideas and close team work on scientific problems of mutual interest started many wonderful friendships, created close bonds between Zurich and many centers of the Anglo-Saxon world and in its own way contributed much to the resumption of friendly co-operation after the disruptive effects of two world wars.

Following the tradition of his masters, Bezold and Siebenmann, Felix R. Nager created his own well-known school of Otolaryngology which produced excellent chairmen of departments, teachers, scientists and numerous outstanding speciaists throughout his country, and elsewhere.

At the time of the 25th anniversary of his clinic and also at his 70th birthday, pupils, colleagues, and friends throughout the Otolaryngic world honored Professor Nager with a Festschrift of Scientific papers.

His early recognition of the important scientific activity in the New World promoted his journey to America in the mid-twenties and his return visit in 1937. He often said that these trips added much to the knowledge of the visitor. They gave him some of his dearest friends and brought him a sincere admiration for American Otolaryngology.

He was elected to numerous honorary memberships. In the United States he was an Honorary Member of the American Academy

of Ophthalmology and Otolaryngology (1925), of the American Otological Society, Inc. (1937), of the American Laryngological Society (1937) and of the Harvey Society of New York (1925). In 1939 he delivered the Sir Felix Semon Lecture at the University of London. He became an Honorary member of the Otological and Laryngological sections of the Royal Society and of the Royal Society of Medicine. In 1949 he was elected an Honorary Fellow of the Royal College of Surgeons of England. He was one of the founders of the Collegium Oto-Rhino-Laryngologicum.

On April 15, 1948, Professor Nager retired as chairman of the department. After retirement, he continued a limited private practice, and devoted much time to the social and personal welfare of the hard of hearing and to his research. A progressive illness finally wrested his beloved activities from his hands.

Professor Nager died at his home in Zurich on September 7, 1959, in his eighty-second year. He is survived by his widow, the former Emily Reinhart, by three daughters and three sons.

MERCER G. LYNCH, M.D.

1908 - 1960

Mercer Genin Lynch became an active Fellow of the American Laryngological Association in 1951 and died February 9, 1960. He was born in New Orleans November 27, 1908, and received his early education in the public schools of that city. He attended Tulane University and was a member of Beta Theta Pi and Nu Sigma Nu. He received his medical degree in 1931 from Tulane University and served his internship at Touro Infirmary and his otolaryngological residency at the Massachusetts Eye and Ear Infirmary. World War II found him in the service of his country with the rank of Lt. Colonel. He was appointed Chief of the Division of Otolaryngology at Walter Reed Hospital, a position which he held for the duration of the war.

A coronary occlusion on February 9, 1960, caused his death at the age of 51 and at the height of his career. He had served as Secretary of the Section on Otolaryngology of the Southern Medical Association and was Chairman-Elect of the Section at the time of his death. He had also been designated as Chief of the Department of Otolaryngology of the Ochsner Clinic. He was a member of the local Medical Societies and of the Louisiana and Mississippi Ophthalmological and Otolaryngological Society, the American Academy of Ophthalmology and Otolaryngology, the American Laryngological, Rhinological and Otological Society, and the American Laryngological Association.

In 1955 he was Vice-President and Chairman of the Southern Section of the American Laryngological, Rhinological and Otological Society, and in 1957 he was taken into the Honor Society by the American Academy of Ophthalmology and Otolaryngology.

Son of a famous laryngologist, he earned fame in his own right and was recognized as an eminent teacher, an astute diagnostician and skilled surgeon. In spite of his busy professional life, he found time for hobbies, for he was an ardent fisherman, an expert marksman and hunter and a good golfer. Dr. Lynch was best known for his work on the larynx and neck and was in demand as a lecturer on these sub-

MERCER G. LYNCH

jects. He enjoyed the position of Associate Professor of Otolaryngology at the Tulane Medical School.

He is survived by his wife, the former Winifred Rainold, whom he married in 1933, a daughter, Joan Lois, and a son, Dr. Robert Clyde Lynch, III.



E. TRIBLE GATEWOOD

E. TRIBLE GATEWOOD, M.D.

1886 - 1960

Dr. E. Trible Gatewood, 73, an Emeritus Fellow and a founder of the Richmond Eye and Ear Hospital, died February 2, 1960.

Dr. Gatewood, Professor Emeritus at the Medical College of Virginia, was credited with being the first specialist in Virginia to perform a successful laryngectomy for cancer.

He is survived by his wife, the former Belle Winfree Moss, two sons, Emmette T. Gatewood, Jr., and William Gatewood; a brother, Dr. William L. Gatewood, and five grandchildren.

Dr. Gatewood, a native of James City county, was born December 6, 1886. He graduated in 1910 from the Medical College of Virginia, interned at Norfolk and New York and entered general practice in James City County. He returned to New York for specialized work and also studied at the University of Pennsylvania and the Haslinger Clinic in Vienna.

Dr .Gatewood served as President of the Richmond Academy of Medicine, of the Richmond Nose and Throat Society and the Virginia Society of Ophthalmology and Otolaryngology. He was a former vice-president of the American Laryngological, Rhinological and Otological Society.

He was appointed instructor of otolaryngology at Medical College of Virginia in 1920, named Clinical Professor in 1944, and Professor Emeritus in 1958. He was a director of Johnston-Willis Hospital and Chairman of its Department of Otolaryngology and Bronchoscopy.

Dr. Gatewood was a member of the Tri-State Medical Society, the Medical Society of Virginia, the American Academy of Ophthalmology and Otolaryngology, the Southern Medical Society and the American College of Surgeons. He became an Active Fellow of the American Laryngological Association in 1940 and an Emeritus Fellow in 1955.

WILLIAM WALLACE MORRISON

WILLIAM WALLACE MORRISON, M.D.

1894 - 1960

Dr. William Wallace Morrison, an Active Fellow of the American Laryngological Association, was born in Oxford County, Ontario, Canada, July 20, 1894. He died on April 17, 1960, of a coronary occlusion.

Dr. Morrison graduated from the University of Western Ontario, in Canada, in 1919. He interned at Bellevue Hospital, New York City, from 1919 to 1921. He served a residency in otolaryngology at the New York Eye and Ear Infirmary from 1921 through 1922.

He was Professor of Otolaryngology at the New York Polyclinic Graduate Medical School and Director of the Department of Otolaryngology at the New York Polyclinic Hospital. He also served as Associate Professor of Clinical Otolaryngology at the Graduate School of the New York University College of Medicine. He was Director of Otolaryngology of the New York Hotel Trades Medical Center and an Attending Otolaryngologist at the Sidney Hillman Health Center.

He was engaged in the practice of otolaryngology with Dr. Lee M. Hurd until his call to active duty in the U. S. Naval Reserve in 1941. While in the Navy, he attained the rank of Captain in the Medical Corps.

Dr. Morrison was best known for his textbook on Diseases of the Ear, Nose and Throat, which had two editions. The textbook is popular and contains many illustrations made by the author. The following is a quotation from Arthur Proetz' Foreword to the 1948 edition of Dr. Morrison's book.

"Fortunately every decade has produced a few authors who have towered above the crowd. Their books were simple, complete and scholarly. Their descriptions were authentic and they shared their references with the grateful reader. No Politzer, no Logan Turner, no Thomson or Kerrison or Skillern was ever pitched into the corner

in dismay. For my part, Morrison is a worthy successor to these. I do not always agree with him, but I always approve. His simplicity appeals to me and I find what I am looking for. Students can understand him and there is meat for more experienced minds. Wisely he is keeping his book up to date, and is handling his new material with discrimination. In this age of transition Morrison's book will render conspicuous service in stimulating and stabilizing American Otolaryngology in the years ahead."

Dr. Morrison also wrote many scientific articles on otolaryngological subjects.

His hobbies included photography, ceramics and work with silver. He was an amateur silversmith and his creations were interesting as well as objects of beauty.

He is survived by his wife.

Dr. Morrison belonged to the American Academy of Ophthalmology and Otolaryngology, the American Laryngological Association, the American Laryngological, Rhinological and Otological Society and the American Medical Association. He was also an active member of the New York Laryngological Society.

JAMES HOYT MAXWELL, M.D.

James Hoyt Maxwell was born in Paw Paw, Michigan, on December 15, 1901, the son of John Charles Maxwell and Cleo Lyle Stevens Maxwell. His father was a hard working practitioner of medicine who believed in honest toil and dedicated his long and arduous life of 85 years to study, civic interests and humanitarian service. Dr. Maxwell's boyhood home was a place of culture and refinement where the influence of medicine was constantly a motivating inspiration to follow in the footsteps of his father. In 1949 his father was awarded the distinction of being the outstanding physician of the year in Michigan, an honor which he richly deserved.

Dr. Maxwell attended the town high school in Paw Paw where he demonstrated a steady industrious attitude towards his studies and a brilliant mind. From high school he entered the University of Michigan College of Literature, Science and the Arts and received an A.B. degree in 1924. He graduated from the Medical School of the University of Michigan in 1927 with a notable record throughout his undergraduate and graduate studies which earned membership for him in the honorary societies of Alpha Omega Alpha, Phi Beta Kappa and Phi Kappa Phi.

From the beginning of his medical studies he wanted a chance to train in the field of Otolaryngology and to have a career in academic medicine. His industry, motivation and fine spirit of cooperation impressed his professors and led promptly to his appointment to a rotation internship in the University of Michigan Hospital from 1927 to 1928 and residencies in Otolaryngology from 1928 to 1932. He began his career in Academic Medicine in the University of Michigan Medical School as an Assistant Professor of Otolaryngology in 1933. Seven years later, in 1940, he was given indeterminate tenure with the rank of Associate Professor. In 1945 he was elevated to the rank of Professor of Otolaryngology and on July 1, 1958, he was appointed Chairman of the Department of Otolaryngology, a position he held until his death in June 2, 1960.

JAMES HOYT MAXWELL

Thus we note that Dr. Maxwell played a major role in the growth and development of the Medical Center and the Department of Otolaryngology at the University of Michigan for more than thirty years. During this period he never missed an opportunity for service and his own development. He possessed innate optimism, a constant eagerness to study and learn, and on all occasions in his teaching and clinical activities he would settle for nothing less than perfect accomplishment. It was these great attributes and many more that made him one of the world's outstanding members of the profession of Otolaryngology.

On February 15, 1936, Dr. Maxwell married Marjory Arnold, a resident of Milwaukee, Wisconsin, who had received her Baccalaureate degree at the University of Michigan. His marriage played an important role in his growth and progress in academic life. The two of them joined in team work of understanding and tolerance, aiding and encouraging each other in making their home a place of refinement for their two sons, Robert, aged 22, a recent graduate from the College of Engineering of the University of Michigan, and John, aged 19, a student in the College of Literature, Science and the Arts. Dr. Maxwell's work, no matter how exacting and long the hours was always something to be respected and encouraged by the indulgent members of his family.

Dr. Maxwell provided a large measure of leadership in programs of Undergraduate and Graduate Medical Education. He was ready at all times to take the latest information available to the otolaryngologists and present it rationally to his undergraduate students and the members of his staff. He had the ability to make his residents strong by precept and example and by pointing the way to a realistic and practical application of present day knowledge to the clinical problems at hand. He demanded that his staff members be ready to challenge authority, acquire resourcefulness and pursue independent thinking in the diagnosis and treatment of their patients. His kindly manner, uncommon diagnostic skill and rare solicitousness for the welfare of his patients commanded the respect and admiration of his friends and colleagues everywhere.

Dr. Maxwell's enlightened interest in organized medicine and devotion to the ideals for which it stands motivated him to serve with remarkable competence and tireless energies a wide range of important

offices. With continued vigor he guided the Otosclerosis Study Group as its President, labored diligently as Chairman of the Teacher's Section of the American Academy of Ophthalmology and Otolaryngology, the Committee on Undergraduate Education and the Committee for Scientific Exhibits. The President's Special Medical Advisory Group to the Administration of Veteran's Affairs of the Veteran's Administration benefited immeasurably by his vision and energy. To the Office of Secretary of the American Laryngological Association he gave strong support and added growth. Because of his competence in the Office of Secretary he was offered the Presidency of the American Laryngological Association but refused the nomination. He had resigned as Secretary because of ill health and his self-exacting discipline and conscientious integrity would not permit him to accept the leadership of an organization in which he felt incapable of discharging the duties of its Secretary.

A recognition of his contributions to the progress of medicine brought him membership in the Advisory Board of International Abstracts of Surgery, Gynecology and Obstetrics and on the Editorial Board of the Annals of Otology, Rhinology and Laryngology. His competence in Medical Education led to his appointment as a member of the Board of Directors of the American Board of Otolaryngology and to membership on the Special Training Grant Committee of National Institute of Neurological Diseases and Blindness of the National Institute of Health and the American Board of Otolaryngology Residency Review Committee of the American Medical Association and American College of Surgeons. He also served as Secretary for Otolaryngology of the American Academy of Ophthalmology and Otolaryngology and as Chairman of the Committee on Undergraduate Education for the American Academy of Ophthalmology and Otolaryngology.

Under Dr. Maxwell's leadership, significant studies were initiated and pursued in the anatomy and physiology of the facial nerve. As an investigator in this field, his name becomes a legend. He discovered important anomalies of the facial nerve, interesting processes of repair and recommended technical considerations of a most practical value. Some of his surgical accomplishments in this field were phenomenal and his enthusiasm for this subject was a constant inspiration to the members of his staff and his professional colleagues to strive for perfection comparable to his in restoring the function of the muscles

of expression of the face. He encouraged original research and joined with his residents many nights in the anatomical laboratory where they labored together for long hours on the anatomy of the head and neck to acquire that knowledge essential to the practice of Otolaryngology.

Dr. Maxwell was intensely interested in diseases of the salivary glands. He sedulously studied the histo-pathology of these structures and with the help of Dr. A. James French from the Department of Pathology, Dr. John Holt from the Department of Radiology and Dr. Robert Buxton from the Department of Surgery painstakingly prepared a classification of salivary gland tumors which is an epoch in the progress of medicine. He meticulously recorded his daily observations in the clinic and accumulated an important series of histories and photographs of patients with bizaare lesions of the salivary glands. His Wherry Lecture presented at the 1959 Meeting of the American Academy of Ophthalmology and Otolaryngology was a vivid account of his personal experiences with Sjogren's disease, a so-called entity about which there are many ethical differences of opinion. Dr. Maxwell had the courage of his convictions. He had accepted the challenge of preparing this paper and adhered strictly to his personal observations in preparing the narrative of this bizarre syndrome. His lecture on this difficult subject was widely acclaimed by his colleagues. Dr. Maxwell gave credit where credit was due and never failed to take full responsibility for his own utterances. When he finished his Wherry Lecture, he said to some of his friends that he hoped he had distinguished between theory and facts but that both might stimulate others to search further for the right answers. He was frank, unimpeachably honest and on all occasions a modest gentleman.

Approximately ten years ago Dr. Maxwell knew that he was afflicted with an emphysema that was beginning to show evidences of progression. In the years that followed he never let illness interfere with his professional duties and only a few of his friends were aware of his difficulty until recent years. His most enthusiastic hobby was fishing but he seldom indulged in this sport during the past several years because of the strenuous nature of wading a stream casting a fly. Here again his conscience would not permit him to engage in any less sportsmanlike method of fishing for trout.

The night before Dr. Maxwell's death he had requested a meeting with Dr. Furstenberg, his close friend and partner for twenty-eight

years, to announce that he would have to give up his surgical work and save his strength for teaching, research and the administrative responsibilities of the Department. This meeting was postponed and therefore never held.

Dr. Maxwell was a loyal and faithful member of the Medical Faculty and one of the great teachers of Otolaryngology with international stature. We can justly praise him for his uncommon diagnostic acumen and meticulous surgical skill. We have lost a valiant member of the medical profession, a man of honor, character and courage.

A.C.F.

Executive Sessions

BUSINESS SESSION

FRIDAY MORNING, MARCH 18, 1960

The First Business Session held in connection with the Eighty-first Annual Meeting of the American Laryngological Association, at the Deauville Hotel, Miami Beach, Florida, March 18, 1960, was called to order at 11:55 A.M., Dr. William J. McNally, President, presiding.

PRESIDENT MCNALLY: I would like to have Dr. Heatly, Dr. Woodman and Dr. Lederer to act as tellers. Will you please pass these ballots to each member of the Society?

. . . The ballots contained the following names:

Active Fellowship

DR. JOHN F. DALY

DR. HERBERT H. HARRIS

DR. KENNETH C. JOHNSTON

Emeritus Fellowship

DR. CARL H. MCCASKEY

DR. DANIEL S. CUNNING

DR. FRENCH K. HANSEL

DR. JOSEPH D. KELLY

Honorary Fellowship

DR. FREDERICK T. HILL

PRESIDENT MCNALLY: The tellers report that the vote is unanimous. We have elected to Active membership: Dr. John F. Daly, Dr. Herbert H. Harris and Dr. Kenneth C. Johnston; to Emeritus Fellowship, Dr. Carl H. McCaskey, Dr. Daniel S. Cunning, Dr. French K. Hansel, Dr. Joseph D. Kelly; and to Honorary Fellowship, Dr. Frederick T. Hill.

I shall ask Dr. LeJeune to introduce Dr. Harris, and will Dr. Holinger be prepared to introduce Dr. Johnston and Dr. Baker be prepared to introduce Dr. Daly?

DR. LEJEUNE: Mr. Chairman, Members of the Laryngological Association, I would like to present to you a man who hails from the second largest state in the Union. Herbert Harris was born in Manor, Texas, in 1906. He received his medical degree from Baylor University School of Medicine in 1929. Today Herbert Harris is Professor and Chairman of the Department of Otolaryngolgy at Baylor University, his Alma Mater. He is also Chairman of the Affiliated Residency Program at Baylor University. He has contributed generously to the otolaryngological literature and has been a very active member of the various medical societies in Texas, which is attested by the fact that he was President of the Houston Laryngological Society in 1948, President of the Graduate Medical Assembly of South Texas in 1959 and President of the Texas Otolaryngological Society in 1960.

I hope, Herbert, that you will manifest the same keen interest, energy and drive that have brought you so much honor in the societies of Texas, in the American Laryngological Association.

DR. PAUL H. HOLINGER: Mr. President and Members of the American Laryngological Association, it gives me great pleasure and pride to introduce my colleague and friend, Dr. Kenneth C. Johnston, to this organization. Dr. Johnston has been an active contributor to the literature and active in investigative work in our specialty. He has been outstanding in his attendance and participation in meetings. It is a great pleasure and distinct honor to introduce Dr. Johnston to you.

He is Professor of Otolaryngology at the University of Illinois College of Medicine and does bronchoscopic work in the Department of Bronchoesophagology at the Children's Memorial Hospital, in the

Department of Otolaryngology at the Presbyterian and at St. Luke's Hospitals in Chicago.

DR. DANIEL C. BAKER: Mr. President and Members, it gives me great pleasure to present Dr. John F. Daly of New York City as an Active member of this organization. Dr. Daly is Professor and Chairman of the Department of Otolaryngology at New York University College of Medicine and also at the New York Postgraduate School. In these positions he has been instrumental in not only teaching a large group of undergraduate students, but also has presented a large graduate program over a period of many years. He is an active participant in many of our national organizations. He has contributed heavily to the literature. I am sure he will make a good addition to this organization.

PRESIDENT MCNALLY: I would like to say welcome to the three new members and to assure them that the American Laryngological is not the President nor the Council. It will only be as good as the individual Fellows, particularly as the new Fellows, make this Society. The next matter of business is the presentation of awards. I shall ask Dr. Schall to read the citation for the Newcomb Award.

DR. SCHALL: Mr. President, members of the Association, in 1939 the American Laryngological Association was the recipient of a gift from the estate of the late James E. Newcomb of New York, the income of which was to be used for the establishment of an award. Dr. James E. Newcomb was a distinguished member of this Association. He served as its Secretary from 1900 to 1911, when he was elevated to the office of President. The Constitution of this Association stipulates that "The Newcomb Award is to be given annually to a Fellow of the American Laryngological Association presenting the most outstanding contribution to the literature of Laryngology during the previous year or as a mark of esteem and appreciation for services to the Association."

The Newcomb award has been given annually since 1941. The recipients have all been laryngologists of distinction. The Newcomb Award Committee recommended and the Council approved that, in recognition of research in the anatomy of the larynx that explains the spread of cancer, of research that deals with reconstruction of the trachea, and in recognition of models and exhibits presented before

national medical meetings, the Newcomb Award be made this year to Joel Jay Pressman, M.D., Sc.M., Sc.D., Professor of Surgery and Chief of Head and Neck Surgery, Assistant Dean of the Medical School of the University of California at Los Angeles.

PRESIDENT MCNALLY: I shall ask Dr. Proetz to give the citation for the De Roaldes Award.

DR. PROETZ: Dean McAllister Lierle, M.D., M.S., Sc.D., physician, surgeon, educator, humanitarian—your unflagging devotion to the elevation of standards in the teaching of otolaryngology and its related sciences, your contributions to the literature and the practice of your chosen specialty—your leadership in so many organizations by which American medicine is nurtured and guided, constitute an everlasting service to Otolaryngology in recognition of which the American Laryngological Association is honored to present you with the DeRoaldes Medal, the highest award within its power to bestow.

PRESIDENT MCNALLY: Gentlemen, the next matter of business is to elect the Nominating Committee for the officers for the coming year.

DR. W. LIKELY SIMPSON: Mr. Chairman, I would like to nominate Robert Martin of San Francisco.

DR. BAKER: I would like to nominate Dr. Putney of Philadelphia.

DR. VICTOR R. ALFARO: I would like to nominate Dr. Julius McCall of Cleveland.

DR. HOLINGER: I would like to nominate Dr. Edward Tremble of Montreal.

DR. ROBERT L. GOODALE: I would like to nominate Dr. John Lindsay of Chicago.

DR. FRANCIS L. WEILLE: I move that the nominations be closed.

DR. BAKER: I second it.

PRESIDENT MCNALLY: Will you read off the Nominating Committee?

DR. RICHARDS: The Nominating Committee consists of Drs. Martin, Putney, McCall, Tremble and Lindsay.

PRESIDENT MCNALLY: The Chairman of the Nominating Committee is Dr. Martin. We will appreciate it if the Nominating Committee will have their report ready for tomorrow morning. If there is nothing further, the business session is adjourned.

ANNUAL BUSINESS MEETING

MARCH 19, 1960

The Annual Business Meeting of the American Laryngological Association, held in connection with the Eighty-first Annual Meeting of the Association, at the Deauville Hotel, Miami Beach, Florida, March 19, 1960, convened at 9:12 A.M., Dr. William J. McNally, President, presiding.

PRESIDENT MCNALLY: Gentlemen, I declare the annual business meeting in session. May we have the report of the Secretary?

SECRETARY RICHARDS: I would like to preface this report by a short personal note. When I was asked to take on this job, I looked over the constitution with respect to the Secretary's duties, and found there listed in six short paragraphs what I was supposed to do. I thought, well, that does not seem like an insurmountable task, but by the time I had been out to visit Jim Maxwell and had returned with two suitcases loaded with material, I began to realize what a tremendous job my predecessors have done, particularly Jim Maxwell and Harry Schenck. I saw the voluminous correspondence they have carried on, the letters they have written and the attention they have given to detail. I want you to know we should be extremely grateful to those two men in particular and to their predecessors for the hard work they have done.

I hope I can come somewhere near doing as good a job as they have done.

. . . Dr. Richards then presented his report as follows:

REPORT OF THE SECRETARY
AMERICAN LARYNGOLOGICAL ASSOCIATION

The Eightieth Annual Meeting of the American Laryngological Association was held on March 8 and 9, 1959, at the Homestead, Hot Springs, Va. The President, Dr. Fred W. Dixon, presided. Fifteen scientific papers were presented. Seventy-nine Fellows and one hundred and fifteen guests were in attendance.

The Librarian, Historian and Editor, Dr. Edwin M. Broyles, reported the deaths of

Honorary Fellows:

DR. CHEVALIER JACKSON

DR. RALPH A. FENTON

Active Fellows:

DR. AUGUST L. BECK

DR. GUY L. BOYDEN

The de Roaldes Award was presented to Dr. Albert C. Furstenberg "as an able physician, a skillful otolaryngologist, a great teacher and a capable administrator."

The Newcomb Award was presented to Dr. Harry P. Schenck "for his contributions by word and by example to Otolaryngology and for his meritorious service to this Association."

The following officers were elected:

President	Dr. William J. McNally
First Vice-President	Dr. James H. Maxwell
Second Vice-President	Dr. Oliver E. Van Alyea
Secretary	Dr. Lyman G. Richards
Treasurer	Dr. Francis E. LeJeune

Librarian, Historian & Editor	Dr. Edwin M. Broyles
First Councilor	Dr. Bernard J. McMahon
Second Councilor	Dr. LeRoy A. Schall
Third Councilor	Dr. Harry P. Schenck
Fourth Councilor	Dr. Fred W. Dixon

The Association has lost by death during the past year:

Honorary Fellows:

Dr. F. R. Nager

Dr. George M. Coates

Emeritus Fellow:

Dr. E. T. Gatewood

Active Fellows:

Dr. Claude C. Cody

Dr. Mercer G. Lynch

The Council at its Annual meeting in New York on January 9, 1960, recommended for:

Active Fellowship:

Dr. John F. Daly, New York, N. Y.

Dr. Herbert H. Harris, Houston, Texas

Dr. Kenneth C. Johnston, Chicago, Illinois

Emeritus Fellowship:

Dr. Carl H. McCaskey, Indianapolis, Indiana

Dr. Daniel S. Cunning, New York, N. Y.

Dr. French K. Hansel, St. Louis, Mo.

Dr. Joseph D. Kelly, New York, N. Y.

Honorary Fellowship:

DR. FREDERICK T. HILL, Waterville, Maine

Dr. Samuel Salinger was reappointed Abstract Editor.

The Council voted to hold the Annual Session at the Lake Placid Club, Essex County, New York, on May 21 and 22, 1961.

The present membership of the Association is:

Active	98
Honorary	4
Corresponding	14
Emeritus	19
	135

Respectfully submitted,

LYMAN G. RICHARDS, M.D.

Secretary

PRESIDENT MCNALLY: Thank you, Mr. Secretary.

Gentlemen, would you stand a moment out of respect for those members who have died.

. . . The Fellows rose in a moment of silence in memory of their departed Fellows. . . .

PRESIDENT MCNALLY: Thank you.

SECRETARY RICHARDS: May I have one more word to say, a word about the list of candidates for Fellowship? This list is sent to each Fellow in October each year. You may be surprised to know that 20 per cent of the lists or ballots sent out are never returned. Fourteen per cent of them have no vote on them at all, and seven per cent of them don't rank the candidates in any way. The ballot is the

only way that the Council has of evaluating the new candidates and their qualifications.

I don't need to tell you that the vitality of this Association depends to a great extent on new members, the very best men we can get. I am sure you wonder why certain men who you thought deserved admission to the Association were not taken in. Partly it is because of lack of information that the ballot ought to contain. A comment which appeared repeatedly in the ballots was, "I don't know him." There is a lot of information about what each man has done, what he has written, what positions he holds, so you can select the best candidates. It is very necessary for each member to take this ballot seriously and to express his opinions about the candidates, so that when the information is all put together the Council will have available every possible chance to sift out this group and come up with the men that you are all going to want to have in the Association, who are going to do the best work for it.

It is interesting that the comments made, were made by a very small group of men. Each one of that small group would make comments on almost everybody and then there would be the long series of blanks in which there was nothing but "yes" checks. That is not much help. The more personal comment you make about these men, the easier it is for the Council and the better men you are going to get and the happier you are going to be with the selections that are made.

PRESIDENT MCNALLY: Thank you, Mr. Secretary.

Next is the report of the Treasurer. Dr. Putney and Dr. Bordley, will you pass this report out also?

TREASURER LEJEUNE: Mr. President, Members of the Association, I would like to remind you that the income for the Association comes solely from the dues from members and the sale of *Transactions.*

The copies that you are receiving at the present time do not bear the signature of the auditor because of the type of report that is made. I mean the typing of the report. We got the entire seventy-five copies that I had made for only $3.00 and it was impossible to get the signa-

ture of the auditor on the copies. The original has been turned in to the Secretary if any of you would like to see it.

I would like to go over this because I think the Treasurer's report is a very integral part of our meeting and a report in which everybody should be vitally interested.

We have 91 members, whose $60.00 dues amounted to $5,460. The initiation fees of the eight new members amounted to $800.00. The registrations fees, which actually are what we charged for the banquet, were $301.25.

This year we had an unprecedented sale of *Transactions*. We sold $1,361 worth of *Transactions*, $500 more than at any previous year. Volume 80 of the *Transactions* is a volume of which we should be justly proud. It has been in great demand.

The interest received from our savings account amounted to $254.49, so our total income for the year was $8,176.74.

I will not go through the routine expenses. You can see these as they are noted down there. The reporting service is about the same. The banquet is about the same. However, with the increases in prices that we are experiencing throughout the entire country the price of the banquet increases every year and we have found that that certainly is so in this particular location.

Midwinter travel expenses are just about the same.

The cost of the transactions was increased this year. There were two reasons for that. The *Transactions* is a much larger volume than we have had previously and it also includes our new by-laws which added 27 or 28 pages. We will not have that next year so we hope that the cost will not be as much.

Stationery, printing, postage and miscellaneous items are about what they have been in the past years. Unfortunately the auditors see every year that the past auditors have charged $100 for auditing the books which does not comprise very much work but still they soak us with the $100 fee. There is no way to get away from that. Also the Treasurer has to be bonded or else he might skip the country.

Last year, if you will recall, we showed a deficit of $641. This year I am glad to report that up to February 29th we had a profit of $1,441.91. That profit is going to be wiped out this afternoon when I settle accounts with the hotel. So the general fund balance as of March 1, 1959, was $3,257.75 and our General Fund Balance as of February 29, 1960, is $4,699.66.

Turning to the second page, we have a report on the trust funds. You will remember that these trust funds are all dedicated trusts and the interest we receive from these government bonds was $1,035.61. We were fortunate this year in that we received two generous donations that amounted to $1,500.

The trust fund expenses were a little bit more this year than usual because of the printing of the constitution and by-laws, that pamphlets that were sent to each of you. The expenses of that were taken out of the Johnson Fund, for which part of the Johnson Fund is dedicated. The cost of engraving the medal for the deRoaldes Award amounts to about the same each year. So the expenses of the trust funds were $382.18. The addition to the trust funds was $2,135.43, and the Trust Fund balance as of March 1, 1959, was $41,607.34, and the balance on February 29, 1960, was $43,760.77. The Trust Fund balance represented by government bonds was $39,500. The remaining balance in cash is $4,260.77.

In recapitulation, the cash in the trust fund is $4,260.77. Cash in the general fund is $4,699.66, making a grand total of $8,960.43. Cash in all the savings accounts for which we receive an interest of about 3 per cent is $6,767.60 and cash in our commercial account or checking account is $2,192.83, again making a total of $8,960.43.

Now turning to the next page, Exhibit C, you will see the principal of each of the funds that are in our trust. You will also see the unused income of these funds and the amount of principal, that is what was added to the fund this year and in the last column we have the principal and the unused income.

You will note that our Research Fund is by far the largest of the funds. So far we have had no call for the use of what little money we have for research. I say "little" because compared to other grants from other places we have only a small amount of money that we can grant for research. However, all our funds show a steady growth.

On the last page, Exhibit D, is a description of the government bonds in which our trust funds are invested. You will note that the last bonds purchased show a blank in the income. In the government bonds in the first column the last two have only 4 per cent but in reality those are 4¾ per cent bonds. The last bonds we bought pay a much larger interest rate and the last in the Treasury bonds also pay 4¾ per cent, which will help our income a little. Again we show par value and the income that we have now .

Now I would like to call your attention to the fact that:

1) The last bond, the $500 notation in the second column of the government bonds was donated by the late Dr. Marshall Taylor. While I have a notation here that it was not as yet allocated, in talking to Dr. Dekle Taylor, Dr. Marshall Taylor's son, and also I was informed by the Secretary, that we can allocate this donation to the Memorial Fund that we are trying to increase as much as possible.

2) This includes a $1,000 U.S. Treasury Bond donated by Dr. Fred Dixon and allocated to the Memorial Fund.

3) This represents a purchase on November 30, 1959, of $1,000 bond out of our savings account funds.

On the last page of the report I would just like to read the report of the Certified Public Accountant, who says:

> "I have examined the accounts and financial records of the American Laryngological Association for the twelve months ended February 29, 1960.
>
> "Cash receipts and disbursements were verified and United States Government Bonds were physically counted and examined.
>
> "In my opinion, the accompanying statement presents fairly the financial position of the American Laryngological Association as of February 29, 1960, and the results of its operations for the twelve months then ended."

As I previously said, the original of this is in the Secretary's hands.

. . . Dr. LeJeune then presented his report, the full report, including this being as follows:

Exhibit A

AMERICAN LARYNGOLOGICAL ASSOCIATION

GENERAL FUND OPERATING STATEMENT

For the Twelve Months Ended February 29, 1960

Income			
Dues—91 members @ $60.00	$5,460.00		
8 new members @ $100.00	800.00	$6,260.00	
Registration fees—Annual Meeting		301.25	
Sale of *Transactions*		1,361.00	
Interest Received—Savings Account		254.49	
Total Operating Income			$8,176.74
Expenses			
Annual Meeting—1959			
Reporting Service	214.30		
Banquet	944.30	1,158.60	
Annual Meeting—1960			
Entertainment advance	200.00	200.00	
Council Expenses			
Mid-Winter Meeting & Travel Expenses	996.70	996.70	
General Expenses			
Clerical Hire	500.00		
Transactions 1959	3,204.50		
Stationery, printing, postage and misc.	482.53		
Auditing	100.00		
Treasurer's Bond	62.50		
File Cabinet for Secretary	30.00	4,379.53	
Total Expense			6,734.83
Addition to General Fund			1,441.91
General Fund Balance March 1, 1959			3,257.75
General Fund Balance February 29, 1960			$4,699.66

Exhibit B

AMERICAN LARYNGOLOGICAL ASSOCIATION
TRUST FUND OPERATING STATEMENT
For the Twelve Months Ended February 29, 1960

Trust Fund Income		
Interest—Government Bonds	$1,035.61	
Donations—Government Bonds	1,500.00	
		$ 2,535.61
Trust Fund Expenses		
Medal for deRoaldes Award	123.00	
Engraving deRoaldes Award	3.00	
Engraving Newcomb Award	3.00	
Transfer and Storage of Archives	52.23	
Printing of Constitution and By-Laws	200.95	
Total Expense		382.18
Addition to Trust Fund		2,153.43
Trust Fund Balance March 1, 1959		41,607.34
Trust Fund Balance February 29, 1960		43,760.77
Trust Fund Balance Represented by Government Bonds, par		39,500.00
Remaining Balance Represented by Cash		$ 4,260.77
Cash Recapitulation		
Cash in Trust Fund	$4,260.77	
Cash in General Fund	4,699.66	
	$8,960.43	
Cash in Savings Account	$6,767.60	
Cash in Commercial Account	2,192.83	
Total Actual Cash	$8,960.43	

Exhibit C

AMERICAN LARYNGOLOGICAL ASSOCIATION

REPORT OF TRUST FUNDS

February 29, 1960

Fund	Principal	Unused Income 3/1/59	Income 3/1/59 to 2/29/60	Expense 3/1/59 to 2/29/60	Unused Income 2/29/60	Principal & Unused Income 2/29/60
Casselberry	$ 5,000.00	$ 1,762.40	$ 165.70	$ ------	$ 1,928.10	$ 6,928.10
Johnston	5,000.00	1,194.20	155.34	200.95	1,148.59	6,148.59
deRoaldes	3,000.00	1,495.06	113.92	126.00	1,482.98	4,482.98
Newcomb Trust	2,000.00	396.15	62.14	52.23	406.06	2,406.06
Newcomb Prize	500.00	71.01	10.35	3.00	78.36	578.36
Research	16,034.42	5,154.10	528.16	------	5,682.26	21,716.68
Memorial	1,000.00	------	------	------	------	1,000.00
Taylor (temporary)	500.00	------	------	------	------	500.00
Totals	$33,034.42	$10,072.92	$1,035.61	$382.18	$10,726.35	$43,760.77

Exhibit D

AMERICAN LARYNGOLOGICAL ASSOCIATION

TRUST FUND INVESTMENTS

February 29, 1960

Government Bonds	Description	Par Value	Income 3-1-59 to 2-29-60
U. S. Savings	2½ G 1961	$ 1,000.00	$ 25.00
	2.76 K 1965	7,000.00	193.20
	2.76 K 1966	1,000.00	27.60
	4 H 1970	1,000.00	------
	4 H 1970	500.00[1]	------
U. S. Treasury	2½ 1964-69	3,000.00	75.00
	2½ 1967-72	1,000.00	25.00
	3¼ 1968	3,000.00	86.80
	3¼ 1969	5,000.00	100.00
	3¼ 1978-83	3,000.00	97.50
	3 1995	5,000.00	150.00
	2¾ 1961	7,000.00[2]	178.75
	3⅝ 1962	1,000.00	36.26
	4¾ 1969	1,000.00[3]	------
Matured Bonds Exchanged		------	40.50
		$39,500.00	$1,035.61

[1] Donated by the late Dr. Marshall Taylor, not yet allocated.

[2] Includes $1000 U. S. Treasury Bond donated by Dr. Fred Dixon and allocated to the Memorial Fund.

[3] Purchased November 30, 1959, out of Savings Fund Account.

ACCOUNTANT'S REPORT

To the Members of the American Laryngological Association
Gentlemen:

I have examined the accounts and financial records of the American Laryngological Association for the twelve months ended February 29, 1960.

Cash receipts and disbursements were verified and United States Government Bonds were physically counted and examined.

In my opinion, the accompanying statement presents fairly the financial position of the American Laryngological Association as of February 29, 1960, and the results of its operations for the twelve months then ended.

Respectfully submitted,

CARROLL A. CHAUVIN

Certified Public Accountant

COMMENT

To the Members of the American Laryngological Association
Gentlemen:

The foregoing report includes income and expenses of the American Laryngological Association from March 1, 1959, to March 1, 1960. In spite of increased expenses we are able to show a comfortable margin in our General Fund.

The unprecedented demand for Volume 80 of our *Transactions* was most gratifying and helpful to the Treasurer. Cash bank deposit in the Trust Fund had increased to $5,260.77, and on authorization of the Council a $1,000.00 U.S. 4¾% Government Bond was purchased.

Our Trust Fund has increased by the receipt of a donation of a $1,000.00 U.S. Government bond from Dr. Fred Dixon and allocated to the Memorial Fund. A donation of a $500.00 check from the estate of the late Dr. Marshall Taylor was received from his son, Dr. Dekle Taylor. Donations and bequests such as these are urgently needed to place our Association on a firm financial basis. It is sincerely hoped that more contributions such as these will be received in the future.

Respectfully submitted,

FRANCIS E. LEJEUNE, M.D.

Treasurer

PRESIDENT MCNALLY: Thank you very much, Dr. LeJeune.

. . . The Treasurer's report was accepted. . . .

PRESIDENT MCNALLY: We will now have the report of the Nominating Committee by Dr. Martin.

DR. MARTIN: The Nominating Committee submits the following nominees for election to the Council:

Broyles, Edwin N.

Theobald, Walter

Hilding, Anderson

Richards, Lyman G.

LeJeune, Francis

Davison, Francis W.

Schall, LeRoy A.

Schenck, Harry P.

Dixon, Fred W.

McNally, William J.

PRESIDENT MCNALLY: Thank you very much, Dr. Martin.

DR. BAKER: I move the nominations be closed.

DR. ALFARO: I second that.

. . . There being no discussion, the motion was put to a vote and carried. . . .

PRESIDENT MCNALLY: The Council will meet and elect their own officers. Thank you very much, Dr. Martin, and your Committee.

Next we will have the report of the Historian and Editor, Dr. Broyles.

DR. EDWIN N. BROYLES: Mr. President, Members of the Society, since the March, 1959, meeting at Hot Springs, $843.00 has been col-

lected for Volume 79 and back issues, along with $548.00 so far for Volume 80, making a total of $1,391.00. There are approximately 1,089 volumes still on hand.

The corrected and prepared discussions of the papers along with the annual photographs and list of members were mailed to the printer on June 2, 1959. The corrected proofs were mailed to the printer on September 14, 1959, and the completed Volume 80 was received by the Editor on November 17, 1959.

As it is important to have a complete file for each member of the Association, it has been requested on several occasions that each member who has not done so please complete his biographical form and mail us a photograph.

Since the last meeting of the Association, I regret to report the deaths of:

Professor F. R. Nager, Honorary Fellow, September 7, 1959

Dr. Claude C. Cody, Emeritus Fellow, December 13, 1959

Dr. E. Trible Gatewood, Emeritus Fellow, January 5, 1960

Dr. George M. Coates, Honorary Fellow, February 7, 1960

Dr. Mercer G. Lynch, Active Fellow, February 9, 1960

. . . The Fellows rose in a moment of silence to the memory of their departed Fellows. . . .

. . . Dr. Broyles' report was accepted. . . .

PRESIDENT MCNALLY: The report of the American Board of Otolaryngology, Dr. Hill.

DR. HILL: Mr. President and Fellows, the American Board of Otolaryngology held examinations in Chicago the first week in October last and examined 100 candidates. Of these 62 were passed, 34 were conditioned and 14 were failed. I think the general impression of this examination is that there were fewer borderline candidates than in some previous years.

At the Executive Meeting of the Board new officers were elected and Dr. Bernard McMahon is the new President of the Board.

PRESIDENT MCNALLY: Thank you, Dr. Hill. The report of the Laryngological Research Fund Committee, Dr. Arthur W. Proetz.

DR. ARTHUR W. PROETZ: Mr. President and Gentlemen, the situation in this country, which governs the dispersal of such small funds as we have now in the Research Fund has not changed in the last few years, during which we have covered the ground rather thoroughly in some of our previous reports. No particular effort has been made to increase this fund and no applications have been received for disbursal.

I would like to say while I am here that the Memorial Fund of this Association is a much more fluid fund. It is elastic in its purposes and we have felt from year to year that it would be much more advantageous if money given to this Association were given to the Memorial Fund rather than to the Research Fund because it can be used better at our discretion than this other fund.

I have been told that there are legal reasons why the fund cannot be discontinued which I would think would probably be an advantageous thing to do. We have to keep it up. Possibly some of the people who donated money to it could legally transfer the funds to another. I don't know but the fund is at present, you might say, latent.

. . . Dr. Proetz' report was accepted. . . .

PRESIDENT MCNALLY: Is there any discussion of the Research Fund? If not, I would like to say a word. The amount is between $21,000 and $22,000, and the annual income is between $500.00 and $600.00. The Council is very badly off for money. Poor Dr. LeJeune has torn out all of his hair trying to find money to pay the costs of the meeting. We have kept them down to a minimum, but if the quality of the program is to be kept at a high level, it should be possible to offer him at least part of his expenses or part of his hotel bill. At the present time Council has no such fund. If there were $500 or $600 at the disposal of the Council we could offer to pay the travel expenses of one or more men who are doing outstanding research.

It was my hope that we could do this. Some members think we should have a legal opinion before using the Research Fund income in this manner. This is something I think the members should be considering. I would be pleased to hear if there is anyone who would like to express an opinion.

DR. HILL: We have been kicking this around I don't know how many years. Isn't it time we really found out if we cannot make some proper use of these funds? I would like to move you that the Council be instructed to get a final authoritative legal opinion as to the possibility of allocating these funds along the line you have suggested.

DR. PROETZ: I second that.

PRESIDENT MCNALLY: It has been moved and seconded. You heard the motion. Dr. Richards reminds me that this idea did come up at the Council Meeting. Immediately we were confronted with the thought that it is going to cost money for legal advice. If the membership would favor Dr. Hill's motion, which Dr. Proetz seconded, I am sure Council would proceed with more confidence.

DR. HILL: May I speak again?

PRESIDENT MCNALLY: Yes.

DR. HILL: I will be glad to undertake this if you wish. One of my own hospital trustees is Judge of the Supreme Court of the State and I can say that he will give an opinion without asking a fee.

DR. LEJEUNE: I move Dr. Hill be appointed a committee of one to carry this to a decision.

PRESIDENT MCNALLY: That will have to be an amendment to the original motion. Would the mover and seconder accept the amendment?

DR. PROETZ: Yes.

PRESIDENT MCNALLY: Gentlemen, is there any other discussion or are you ready for the motion? Do you have some comment, Dr. Proetz?

DR. PROETZ: Not on this motion. I want to say something later.

PRESIDENT MCNALLY: All in favor of the motion as amended please say "aye"; contrary minded "no." It is carried.

DR. PROETZ: I would like to add that while the Research Fund has been soft pedaled in the last few years, not enough stress has been laid on the Memorial Fund. It is not implied because one fund is not active that the other fund isn't badly in need of contributions. I would like to suggest that it become accepted custom for each member of this small and distinguished Association to specify in his will that a thousand dollars be given to the Memorial Fund of this Association. I don't think there is anybody here whose family would miss a thousand dollars and I am sure the family sitting here could use it very well. The income from the Memorial Fund can be used for any activity of the Association at the direction of the Council.

PRESIDENT MCNALLY: Thank you, Dr. Proetz.

Under the heading of miscellaneous business, could we call on Dr. Holinger in place of Dr. Salinger, with reference to the American College of Surgeons?

DR. HOLINGER: Mr. Chairman and Members of the American Laryngological Association, I had assumed that Dr. Salinger would make this report, but the Secretary asked me yesterday to do this in his stead. I have attempted to recall from memory the points of interest from the standpoint of reporting as your representative to the American College of Surgeons. The members of the Advisory Council for Otolaryngology of the American College are Dr. Schenck, Chairman, Dr. Baker, Dr. LeJeune, Dr. Baron and myself. Dr. Lierle has been elected a Vice-President of the American College of Surgeons. He is a member of the Board of Regents, re-elected as a member of the Board of Regents, and I think this is a very important point as far as otolaryngology is concerned. Dr. Lierle has represented the specialty enthusiastically and with a great deal of vigor and I think it is evident in the actions in the College itself.

Dr. Schenck was elected one of the six members of the Executive Committee of the Board of Governors of the College.

Two fields of direct interest to otolaryngology were further explored at the meeting of the Board of Governors and progress can be reported. One is the problem of the decreasing number of free patients necessary for teaching purposes as the result of insurance programs. This problem affects every specialty as well as general surgery. This has been discussed and further progress is being made.

The plan for the Surgical Year, as it affects our specialty, has also been discussed, as have the surgical residencies themselves in integrating the points of interest between the specialties and the general surgeons. Otolaryngology is represented on these committees. It accepts the responsibility and our representatives attend the meetings.

The direct conflict of dates between the Academy and the College this year has resulted in the need to drop the meeting of the Section of Otolaryngology from the program of the American College of Surgeons. This void on the program has not gone unnoticed I can assure you by other specialties nor by the general surgeons stressing surgery of the head and neck. However, there has been strong interest in otolaryngology in the sectional and regional meetings of the College. These programs have included general surgeons in the panel discussions in the sections on otolaryngology.

This is the report of your representative to the American College of Surgeons from the American Laryngological Association.

This report was accepted.

DR. HOLINGER: While I am here may I continue with the report of the Committee for the change in Academy meeting dates?

PRESIDENT MCNALLY: Yes.

DR. HOLINGER: You remember the other specialty societies participated with this society in nominating a committee to work towards a change in the Academy meeting dates to avoid conflicting with the meeting of the American College of Surgeons.

This committee consists of Drs. Hill, Putney, Friedberg, Schenck, Maxwell, Nash, Boies, Baron, LeJeune, Hoople, Lierle, Hilger, Day, C. L. Jackson and myself. We have had correspondence with the

Council of the Academy. One letter was received from the Council, from Dr. Benedict as follows:

"November 10, 1959

"At the Council meeting of the Academy last month, the President, Dr. John H. Dunnington, made the following appointments to the Committee to meet the Board of Regents of the American College of Surgeans regarding the time and place of the annual meeting of the Academy. This committee consists of Dr. Benedict, Dr. Dunphy, Dr. Higbee and Dr. Goodhill."

It should be noted that the Academy failed to propose three Academy members from whom the College would select a representative for the Board of Governors of the American College of Surgeons from 1959 to '62. Consequently, whereas three governors usually represent the Academy there are now only two: Dr. Harry Schenck was the retiring representative having served three years. He is also Chairman of the Advisory Committee for Otolaryngology, and was on the Executive Committee of the Board of Governors, a distinction which he earned through his serious efforts in representing otolaryngology in the College of Surgeons. Fortunately Dr. Schenck remained as a governor, having been elected by the general membership of the College in Pennsylvania. It is hoped that the members of this committee and the members of the American Laryngological Association will discuss with the members of the Council of the Academy the disadvantage to otolaryngologists that arises because of the failure to submit names for governors.

The growing disadvantages of combined ophthalmology and otolaryngology meetings are beginning to outweigh the advantages. The eventual separation of the two would allow adjustment of the meeting days to avoid the conflict with the surgical group. This would be advantageous for the scientific as well as organizational aspects of otolaryngology.

This is the summarized report. While some are not interested in furthering a definite total separation of ophthalmology and otolaryngology, they have voiced it slightly differently. I think it was Dr. Hill who said last year that there should not necessarily be a divorce but at least twin beds.

Thank you very much!

PRESIDENT MCNALLY: Will somebody move the acceptance of Dr. Holinger's report?

DR. TREMBLE: I so move.

DR. HILL: I second it.

PRESIDENT MCNALLY: All in favor say "aye"; contrary "no." It is carried.

DR. HOLINGER: Would there be any possibility of discussion?

PRESIDENT MCNALLY: Would anybody like to discuss this report?

DR. HILGER: Is this a continuing committee or appointed for the interim that has just been concluded? It is obvious that the pursuit of this objective has to be continuous.

PRESIDENT MCNALLY: Dr. Holinger.

DR. HOLINGER: I would hope it is a continuing committee and if so, if you would permit us, ask that the members of this committee whose names were read meet at the end of the scientific session at noon today and further discuss the problems.

PRESIDENT MCNALLY: Would Dr. Holinger read the names again?

DR. HOLINGER: Drs. Hill, Putney, Friedberg, Schenck, Maxwell, Nash, Boies, LeJeune, Baron, Lierle, Hilger, Day, C. L. Jackson and myself.

PRESIDENT MCNALLY: The time and place?

DR. HOLINGER: After the scientific session here today.

PRESIDENT MCNALLY: At the end of the scientific session at noon today. Is it your wish that this should be a continuing com-

mittee? All in favor of this being a continuing committee please say "aye"; contrary "no." Dr. Meltzer!

DR. MELTZER: Is this a committee from this association?

PRESIDENT MCNALLY: I would take it a multi-society committee, isn't it? We are just authorizing the member that we have appointed to continue in action. I would take it that is it.

DR. HILL: Multi-disciplinary committee.

PRESIDENT MCNALLY: Multi-disciplinary committee.

DR. MELTZER: The names read represent this association?

PRESIDENT MCNALLY: I would take it not. Dr. Holinger, will you answer that?

DR. HOLINGER: There was no official action at any of the other business sessions, but I believe that we can continue if there is authorization from this group for the part that the Laryngological plays in it. The original action started here since I am a representative of the Laryngological Association to the Board of Governors of the College. For that reason, in order to avoid duplication this report was given to this group. I think unnecessary duplication would have resulted if we had given this same report to each of the Specialty Societies.

PRESIDENT MCNALLY: Would it be better than that we should ask for a motion whether this should be continued or not?

DR. HILL: I so move.

PRESIDENT MCNALLY: Will anybody second that?

DR. BROYLES: I second it.

PRESIDENT MCNALLY: It has been moved and seconded this committee be continued. Is there any further discussion?

DR. HILGER: Does the original mandate to this committee still hold or is it modified? Are we clear as to the mandate to the committee; in continuing the committee are we clear as to the instructions

of the committee that the section change of date be sought, and so on? Is that clear?

DR. HOLINGER: That was implied in the original directive.

DR. LEDERER: May I ask, Dr. Benedict sent out some post cards? Is this report available to us as to what this resulted in so that we can be guided accordingly?

PRESIDENT MCNALLY: Dr. Holinger!

DR. HOLINGER: We have no evidence as to what the report held and no correspondence with Dr. Benedict in regard to that. He has not given us any information. We have asked for it.

DR. GALLOWAY: I think one point should be cleared up, whether this committee represents merely this society or the body of otolaryngologists. I have always had the feeling, I don't know whether it was justified, that the officials of the American College were in a sense trying to capture otolaryngology and have its scientific sessions come under the general meetings of the American College of Surgeons. I have always felt that it was much better for us to maintain our definite entity and independence and the separate meeting date. I think that is a point of some consideration. We must remember that we may represent otolaryngology but we do not represent the great mass of men who are trying to do good honest work and maintain their independence. There are certainly great advantages in the contact with the American College of Surgeons also, where we can defend our points of view which are in some conflict with them.

PRESIDENT MCNALLY: Would you like to reply to that?

DR. HOLINGER: As to Dr. Galloway's last statement, the position of the committee is definitely directed toward furthering Otolaryngology in general surgical and medical fields as a whole rather than attempting to substitute our meetings with otolaryngological sessions of the college. We need both and we are trying to provide the opportunity to participate in the college meetings. Without such opportunity (because of the conflict of meeting dates) others have taken over and will continue to take over the place of otolaryngology in the College meetings; unless we can meet with them and present

the scientific as well as organizational aspects of otolaryngology ourselves, we are lost in the overall policy-making positions and sessions of the College of Surgeons.

The College of Surgeons has a very basic position in forming surgical policy. If we are to participate in forming policies, we feel it is necessary to change the dates of the Academy meeting, so that we do not have a conflict of meeting dates with the College. The conflict next Fall is direct. Both organizations meet at the same time in different parts of the country. We cannot have a section of otolaryngology because there won't be any otolaryngologists in attendance. It would be worse to have a sectional meeting and a program with only those on the program present than to have no program at all. But this creates a void into which the surgeons will move and present those subjects from the standpoint of head and neck panels. For example, they will take over and present those subjects which we think we should be talking about on the panels.

For this reason we feel the change must be made, and not in any sense that the College is trying to direct otolaryngology! It is we who are trying to direct the otolaryngological aspects of the College, and the College is just as anxious that we do so.

PRESIDENT MCNALLY: Gentlemen, I take it in the past we have elected these gentlemen to co-operate with the other societies, the Otological and the Triological and the Broncho-Esophagological in their actions to solve this problem with the Academy and the American College of Surgeons. Am I right in presuming it is your wish this committee should continue in action and in co-operation with the representatives of the other societies in attempting to resolve this rather important problem? Is that the wish of the mover and seconder of this motion? If so, if there is no other discussion I will ask for a vote. All in favor say "aye"; opposed "no." *It is carried.*

Is there any new business?

DR. HILGER: This question arose at the Otological Society. There it was admitted if you had a thousand dollars "just to play with" for program it would be of great advantage to the strengthening of the program. We had 100 and some guests at the Homestead, which was not a crowded meeting and we have probably more guests

registered on this occasion. The question arose in the other group whether a registration fee of modest dimensions of $10.00, for example, would have brought the $1,000 to beef up the program and since the strength of the program is of great advantage to the guests, I am sure that its modest sum would be more than welcome to them in their contribution in making the President's hands more free in inviting speakers. I wonder whether the membership would care to instruct the Council to give thought to a registration fee at subsequent meetings. For this reason I move this, if it be germane.

DR. LEDERER: I second that.

PRESIDENT MCNALLY: It has been moved and seconded that the Council give consideration to the idea of charging guests a registration fee which would be used by the Council for the improvement of future meetings.

DR. ALFARO: On the first page or second page of the Treasurer's report there is "Registration fees - Annual Meeting, $301." May I ask what that is?

PRESIDENT MCNALLY: Dr. LeJeune.

DR. LEJEUNE: That is put down as a registration fee. In reality that was what was charged for the banquet. We have no registration fee. That is really a misnomer.

PRESIDENT MCNALLY: Is there any other discussion on this motion?

DR. ALFARO: I am in favor of Dr. Hilger's proposal, sir.

PRESIDENT MCNALLY: If not, all in favor say "aye"; contrary-minded "no." It is carried.

DR. HILL: I move to accept the Secretary's report upon which we had not voted.

DR. BAKER: I second it.

PRESIDENT MCNALLY: It has been moved and seconded that the Secretary's report be accepted. All in favor say "aye"; contrary-minded "no." It is carried.

If there is nothing further, we are going to declare the business meeting closed and would someone ask the guests to come in.

. . . Whereupon at 10:10 A.M. the business meeting was adjourned. . . .

* * *

BUSINESS SESSION

Saturday Afternoon, March 19, 1960

The session convened at 4:40 P.M., following the close of the Scientific Session, Dr. William J. McNally, President, presiding.

President McNally: The Council will now meet and have an election and in a few minutes the results of the election will be announced.

Secretary Richards: We have had the meeting and you can announce the results.

President McNally: This is the list of officers:

Dr. Broyles	President
Dr. Theobald	First Vice-President
Dr. Hilding	Second Vice-President
Dr. Richards	Secretary
Dr. LeJeune	Treasurer
Dr. Davison	Editor and Librarian
Dr. Schall	Councillor
Dr. Schenck	Councillor
Dr. Dixon	Councillor
Dr. McNally	Councillor

Just before asking the new President to take the throne, I would like to say a few words. I would like to tell the new President that if he wants to be a smart President, not necessarily a good one, he should spend half his time telling other people what to do and the other half thanking them for doing it. Then everything goes smoothly.

I think as retiring President I should say a word of thanks to the hotel people because certainly my own experience with them and I am sure the experience of others has been they have been extremely kind. Mr. Conlon, for instance, has very kind people with whom we have dealt very nicely. I would like to say a word of thanks to the musicians we had last night. I thought they were marvelous. They went all around and yet were relatively inconspicuous and I think they contributed a great deal to the dinner .

I would like to thank the Vice-President, Dr. Van Alyea, who was so helpful in conducting the meeting. I would like to thank the members who took part in the discussion. I would like particularly to thank the members who took part in the program. I thank the non-members on the program because I was so indebted to them for coming here at their own expense and helping us out. I would also like to thank the members, whoever has taken part in the program. I would like to thank the other members of the Council. They have been a tremendous help to Dr. Richards and to me.

On behalf of you and the Council I should say a word to Dr. McMahon who is the retiring member of the Council. He has been on for a number of years and has made a great contribution. We are all very much indebted to Dr. McMahon.

Again a word of thanks to Drs. Richards and LeJeune because for me personally they have been most helpful and anything that I have contributed to this meeting would have been impossible without their help and counsel.

Lastly a word of course takes me to my wife. All of you who are married know that in conducting a meeting like this you do have worries and trials and you take these all home to your wife and usually she gives you very good advice and keeps you from being more stupid than you would naturally be and I would like to thank her very much for being tolerant, and helpful.

Now I would like to call two members to conduct the new President to the podium. Will Dr. Galloway and Dr. Hilding conduct the new President?

Dr. Broyles, it is my great privilege to hand over this very office to you and to tell you how much I have enjoyed it and hope that you will enjoy it equally. It isn't entirely an unmixed blessing. There are some pains that go with it. When they are all over they in retrospect add to the total pleasure.

It gives me very great pleasure to introduce to the members the very distinguished and world-famous Dr. Broyles from Baltimore, and this is the gavel.

PRESIDENT BROYLES: Thank you, Mr. President.

It is difficult for me to really express in words my feelings now.

Several years ago just before the International Meeting in Washington something happened to me. As I lay in the hospital I thought, well here it goes and I determined then if I ever got out of the hospital that if I had to go I would like to go down swinging.

That brings up the point, that I certainly hope that Chevalier Jackson will be as lucky in his recovery as was I. The good Lord was good to me. I made a gradual recovery and here I am.

I might say that for years this Society and its members have been an inspiration to me. When I look at the line of my predecessors in office, it makes one feel awfully humble but it also makes one determine to do his very best to have a successful meeting. So I can only thank you very much for this great honor. I hope and look forward to a successful meeting next year, with your help, at Lake Placid in New York State.

My first duty as President is a very pleasant one. Dr. McNally, would you come to the rostrum please, sir? On behalf of the Council and the members of the Society and because of their appreciation of your interest and untiring work, plus their esteem and affection for you, they have requested that you be presented with this token, this golden key. I know that you will always treasure it.

PAST PRESIDENT MCNALLY: Well, Mr. President, this is indeed a delightful surprise. They certainly kept this under cover. I can assure you that this will be treasured. Not that one needs a memento to remind him of such an extraordinarily happy experience as this but at the same time it is very helpful and I appreciate it, particularly coming from such kind friends as have been on the Council. To me and to my heirs this will always be one of our treasured legacies. Mr. President, thank you very, very much.

PRESIDENT BROYLES: Is there any other business to come before the Society?

DR. LEJEUNE: I move we adjourn.

SECRETARY RICHARDS: I second it.

PRESIDENT BROYLES: All in favor say "aye"; opposed "no." We are adjourned.

. . . Whereupon at 4:50 P.M. the meeting was adjourned. . . .

List of Fellows

LIST OF FELLOWS

Date Indicates Year Admitted to Active Fellowship

Attendance at meetings is shown by figures following each name. Asterisk (*) indicates year paper was read.

Active Fellows

1958. ALFARO, VICTOR R., 917 - 20th St. N. W., Washington 6, D. C., 1958, '59, '60.

1942. ASHLEY, REA E., 384 Post Street, San Francisco 8, California, 1946, '47, '48, '49, '50, '51*, '53, '54, '56.

1958. ATKINS, JOSEPH P., 3400 Spruce St., Philadelphia 4, Pa., 1958, '59*, '60.

1956. BAKER, DANIEL CLIFTON, JR., 903 Park Avenue, New York 21, N. Y., 1956, '57, '58, '59*, '60.

1936. BALLENGER, HOWARD C., 723 Elm Street, Winnetka, Illinois, 1936, '37, '38*, '40, '41, '46*, '47, '48, '51, '52*, '53, '54, '55, '56, '59.

1938. BLASSINGAME, CHARLES DECATUR, 414 Physicians and Surgeons Bldg., Memphis 3, Tennessee, 1938, '39, '41, '42, '44, '46*, '47, '50, '51, '52*, '53*, '57, '58, '59.

1944. BOIES, LAWRENCE R., University Hospital, Minneapolis 14, Minnesota, 1944, '46, '47, '48*, '49, '50*, '51*, '53, '54, '55, '56, '57, '58, '59, '60.

1955. BORDLEY, JOHN E., Johns Hopkins Hospital, Baltimore 5, Maryland, 1955, '56, '57, '59, '60.

1941. BOWERS, WESLEY C., 115 E. 61st Street, New York 21, N. Y., 1941, '42, '44, '49.

1959. BREWER, DAVID W., 100 Genesee St., Syracuse 10, N. Y., 1959, '60*.

1955. BROWN, LESTER ALEXANDER, 490 Peachtree Street, N.E., Atlanta 8, Georgia, 1955, '56, '57, '58, '59.

1940. BROYLES, EDWIN N., 1100 North Charles Street, Baltimore 1, Maryland, 1940, '41*, '42, '46, '48*, '49, '50, '51*, '52, '53, '54, '55, '56, '58, '59*, '60.

1930. CAMPBELL, EDWARD HASTINGS, 133 S. 36th St., Philadelphia 4, Pennsylvania, 1930, '31*, '32*, '33, '35, '38, '39*, '40, '41, '47, '48, '49, '51, '52, '55, '56, '58, '59.

1945. CAMPBELL, COLONEL PAUL A., USAF (MC), School of Aviation Medicine, Brooks Air Force Base, Texas, 1946, '47, '49, '51, '57*.

1942. CANFIELD, NORTON, 175 St. Ronan St., New Haven 11, Connecticut, 1942, '46, '47, '48, '49*, '50, '51, '56, '57.

1959. CARDWELL, EDGAR P., 965 Broad St., Newark 2, N. J., 1959, '60.

1957. CONLEY, JOHN J., 139 East 36th Street, New York 16, N.Y. 1958*, '60*.

1957. CONVERSE, JOHN MARQUIS, 722 Park Avenue, New York 21, N.Y., '60.

1959. CRACOVANER, ARTHUR J., 103 E. 78th St., New York 21, N. Y., 1959, '60.

1951. DAVISON, FRANCIS W., Geisinger Memorial Hospital, Danville, Pa., 1951, '52, '53*, '54, '55, '56, '57, '58, '59, '60.

1941. DIXON, FRED W., 1027 Rose Building, Cleveland, Ohio, 1941, '42*, '44, '46, '47*, '49*, '50, '51, '52, '53, '54, '55, '56, '57, '58*, '59, '60.

1947. EAGLE, WATT WEEMS, Duke Hospital, Durham, N. C., 1948*, '49, '51, '53, '54, '56, '57, '59.

1954. EQUEN, MURDOCK S., Ponce de Leon Infirmary, Atlanta 8, Ga., 1954, '55, '57, '58, '60.

1952. ERICH, JOHN B., Mayo Ciinic, 102 Second Avenue, Rochester, Minn., 1953, '56*, '57.

1955. FITZ-HUGH, GLASSELL SLAUGHTER, 2003 Spottswood Road, Charlottesville, Virginia, 1955, '57, '59, '60.

1956. FRIEDBERG, STANTON A., 5730 South Kenwood Avenue, Chicago, Illinois, 1956, '57*, '58, '59, '60.

1932. FURSTENBERG, ALBERT CARL, Out-Patient Bldg., University Hospital, Ann Arbor, Michigan, 1933*, '36*, '38*, '46, '48*, '50, '51, '53, '54, '55*, '56, '57, '58*, '59, '60.

1936. GALLOWAY, THOMAS CYRUS, 636 Church Street, Evanston, Illinois, 1936, '37, '38*, '39, '40, '41, '42*, '46*, '47, '48, '50, '51, '52, '53, '54, '55, '56, '57, '58, '60.

1959. GOLDMAN, JOSEPH L., 1050 Park Ave., New York, N. Y., 1959, '60*.

1940. GOODALE, ROBERT L., 330 Dartmouth Street, Boston, Massachusetts, 1940, '41, '42*, '44*, '46, '47, '49, '50*, '53, '54, '55*, '56, '57*, '60.

1928. GOODYEAR, HENRY M., 556 Doctors' Building, Cincinnati 2, Ohio, 1928, '29, '30*, '31, '32, '33, '34*, '35, '36, '37, '38, '39, '40, '44*, '46, '47, '48, '49*, '51, '53, '55, '57, '59.

1950. HALL, COLBY, 1136 West Sixth Street, Los Angeles 14, Calif., 1950.

1933. HARKNESS, GORDON FOLLETTE, Blackhawk Hotel, Davenport, Iowa, 1934, '35, '36*, '40, '41, '44, '46, '47, '48, '49, '50, '51, '52, '53, '54*, '55, '56, '57, '58, '59, '60.

1957. HARRILL, JAMES A., Bowman Gray School of Medicine, Winston-Salem, N. C., 1957, '58, '59.

1960. HARRIS, HERBERT, 907 Hermann Professional Building, Houston 25, Texas, 1960.

1959. HART, VERLING K., 106 W. 7th St., Charlotte, N. C., 1959, '60.

1942. HEATLY, CLYDE A., 11 North Goodman Street, Rochester 7, N.Y., 1942, '46*, '49, '50, '52, '53*, '54, '55, '57, '58, '60.

1959. HENRY, G. ARNOLD, 170 St. George St., Toronto, Canada, 1959.

1943. HILDING, ANDERSON C., Research Laboratory, St. Luke's Hospital, Duluth 11, Minnesota, 1944*, '46, '47, '48*, '49, '50, '51, '53, '55, '56*, '57, '60.

1955. HILGER, JEROME A., 350 St. Peter Street, St. Paul 2, Minnesota, 1955, '56*, '57, '58, '59, '60.

1945. HOLINGER, PAUL H., 700 North Michigan Ave., Chicago 11, Illinois, 1946, '47, '49, '50*, '51*, '52, '53, '54*, '55, '56, '57, '58*, '59, '60.

1944. HOOPLE, GORDON D., 1100 East Genesee St., Syracuse 10, New York, 1946, '47, '48, '49, '50, '51, '52, '53, '54*, '55, '56, '58, '59, '60.

1957. HOLMES, EDGAR M., 330 Dartmouth Street, Boston 16, Mass., 1957, '59.

1952. IRELAND, P. E., Room 82, Banting Institute, University of Toronto, Toronto, Ontario, 1952, '53, '54, '55, '56*, '57, '59.

1938. JACKSON, CHEVALIER LAWRENCE, 3401 North Broad Street, Philadelphia 40, Pa., 1938, '39, '40, '41*, '42, '44*, '46, '47*, '48, '49, '51, '53, '54, '55, '56, '57, '58, '59.

1960. JOHNSTON, KENNETH C., 700 North Michigan Ave., Chicago 11, Ill., 1960.

1950. KLINE, ORAM R., 514 Cooper Street, Camden, N. J., 1950, '51, '52, '53, '54, '55, '56, '57, '59, '60.

1953. LEDERER, FRANCIS LOEFFLER, 1853 W. Polk Street, Chicago 12, Illinois, 1953, '54, '55, '56, '57*, '58, '60.

1936. LEJEUNE, FRANCIS ERNEST, Ochsner Clinic Building, Prytania and Aline Streets, New Orleans 15, Louisiana, 1937, '46*, '47, '50, '51, '52, '53, '54*, '55, '56, '57, '58, '59, '60.

1933. LIERLE, DEAN M., University Hospital, Iowa City, Iowa, 1933, '34, '35*, '37, '38, '39, '40*, '42*, '44*, '46, '47*, '48, '49, '50*, '51, '52, '53, '54, '55*, '56, '57, '58, '59, '60.

1949. LINDSAY, JOHN R., 950 E. 59th Street, Chicago 37, Illinois, 1949, '50, '51*, '53, '55*, '56, '57, '58, '59, '60.

1941. MARTIN, ROBERT C., 384 Post Street, San Francisco 8, California, 1941, '44, '47, '48, '50, '51, '53, '54, '55, '56, '58, '59, '60.

1952. MCCALL, JULIUS W., 610 Rose Building, Cleveland 15, Ohio, 1952, '53*, '54, '55, '56, '57, '58, '59, '60*.

1951. MCHENRY, LAWRENCE C., 604 Medical Arts Bldg., Oklahoma City, Okla., 1953*.

1933. MCMAHON, BERNARD J., 150 No. Meramec Ave., Clayton 5, Missouri, 1934*, '35, '36, '38*, '41, '44, '46*, '47, '48, '49, '50*, '51, '52, '53, '54, '55*, '56*, '57, '58, '59, '60.

1931. MCNALLY, WILLIAM JAMES, 1509 Sherbrooke Street West, Montreal, Canada, 1931, '33, '34*, '39, '44, '47, '49, '49, '52, '53, '54*, '55, '56, '57, '58, '59, '60.

1954. MELTZER, PHILIP E., 285 Commonwealth Ave., Boston, Mass., 1954*, '56, '57, '58, '59, '60.

1952. MILLER, ALDEN H., 500 South Lucas Ave., Los Angeles 17, Calif., 1952, '53*, '55, '57, '58*.

1958. MONTREUIL, FERNAND, 902 Sherbrooke St. E., Montreal, Canada, 1958, '60.

1954. MOORE, PAUL M., 10,515 Carnegie Avenue, Cleveland, Ohio, 1954, '55*, '56, '57, '59, '60.

1957. MUNEZ-MACCORMICK, CARLOS EDUARDO, 71 Park Terrace, Santurce, Puerto Rico, 1957, '58, '59, '60.

1953. MURTAGH, JOHN A., 2 Maynard Street, Hanover, New Hampshire, 1953, '54, '55, '56*, '57, '58, '59.

1937. NASH, C. STEWART, Medical Arts Building, Rochester 7, New York, 1937, '38*, '40, '42, '44, '46, '49, '50, '51, '52, '53, '54, '55, '56*, '58, '59, '60.

1956. NORRIS, CHARLES MORGAN, 3401 North Broad Street, Philadelphia 40, Pennsylvania, 1956, '57, '58*, '59, '60.

1958. O'KEEFE, JOHN J., 255 S. 17th St., Philadelphia 3, Pa., 1958, '59*, '60.

1954. PRESSMAN, JOEL J., Department of Surgery, UCLA Medical Center, Los Angeles 24, Calif., 1954, '56*, '59*, '60.

1951. PRIEST, ROBERT E., 79, S. Ninth St., Minneapolis 2, Minn., 1951, '53*, '54*, '56, '59, '60*.

1951. PUTNEY, F. JOHNSON, 1712 Locust St., Philadelphai 3, Pa., 1951, '52, '53*, '54, '55, '56, '58*, '59, '60.

1951. RAWLINS, AUBREY G., 384 Post Street, San Francisco 8, Calif., 1951, '53*, '56, '58.

1934. RICHARDS, LYMAN GILDER, 12 Clovelly Road, Wellesley Hills 81, Mass., 1934, '35, '36*, '37, '38, '39, '47, '49, '51*, '54, '56, '57*, '59, '60.

1956. RICHARDSON, JOHN ROBERT, 403 Commonwealth Avenue, Boston 15, Massachusetts, 1957, '58, '59, '60.

1945. ROBB, JAMES M., 633 David Whitney Building, Detroit 26, Michigan, 1946, '48, '49*, '51, '52, '55, '56, '57, '59, '60.

1953. ROBERTS, SAM E., 5964, Overhill Road, Kansas City, Missouri, 1953, '54*, '55, '56, '57, '58, '59, '60.

1959. SANDERS, SAM H., 1089 Madison Ave., Memphis 3, Tenn., 1959, '60.

1932. SCHALL, LEROY ALLEN, Scudder Lane, Barnstable, Massachusetts, 1934*, '35, '38, '40*, '41, '42, '44*, '46, '47, '48*, '49, '50*, '51, '53*, '54, '55, '57*, '59*, '60.

1934. SCHENCK, HARRY P., 326 South 19th Street, Philadelphia 3, Pennsylvania, 1934, '35, '36*, '37, '38, '39, '40, '41*, '44*, '46, '47, '49, '50, '51, '52, '53, '54, '55, '56, '57, '58*, '59*, '60.

1959. SILCOX, LOUIS E., 102 Lankenau Med. Bldg., Philadelphia 31, Pa., 1959, '60.

1958. SIMONTON, KINSEY M., 200 First St., S. W., Rochester, Minn., 1958, '59*.

1939. SIMPSON, W. LIKELY, 512 Physicians' and Surgeons' Building, Memphis 3, Tennessee, 1939, '41, '44*, '46, '47*, '48, '50, '51*, '52, '53, '54, '55, '57, '58, '59, '60.

1950. SMITH, AUSTIN T., 1830 Spruce St., Philadelphia 3, Pa., 1950, '51, '52, '53, '55, '56, '57, '58*, '59, '60.

1954. SOOY, FRANCIS A., 490 Post Street, San Francisco 2, Calif., 1954, '56*, '58, '60.

1947. THEOBALD, WALTER H., 307 N. Michigan Avenue, Chicago, Illinois, 1947, '48*, '49, '50, '51, '52, '53, '54, '55, '56, '57, '58, '60.

1954. THORNELL, WILLIAM C., 2508 Auburn Avenue, Cincinnati 19, Ohio, 1955*, '57, '59, '60.

1950. TREMBLE, G. EDWARD, 1390 Sherbrooke St. W., Montreal, Quebec, Canada, 1950, '51, '52, '53, '54, '55*, '56, '57, '58, '60.

1943. VAN ALYEA, OLIVER E., 135 South LaSalle Street, Chicago 3, Illinois, 1944, '46*, '47, '48, '50, '51, '52*, '53, '54, '55, '56*, '57, '58, '59, '60.

1941. VIOLÉ, PIERRE P., 1930 Wilshire Boulevard, Los Angeles 5, California, 1944*, '46, '47, '50, '52, '53, '55, '58.

1954. WALSH, THEODORE E., 640 S. Kingshighway Blvd., St. Louis 10, Missouri, 1954, '55*, '56, '57, '58, '59, '60.

1940. WEILLE, FRANCIS L., 247 Commonwealth Avenue, Boston 16, Massachusetts, 1940, '41, '42, '44, '46*, '47, '48, '49. '50, '51, '52, '53, '54, '55, '56*, '57, '58, '59, '60.

1948. WHALEN, EDWARD J., 750 Main Street, Hartford, Connecticut, 1948, '50, 51, '52, '54, '55, '57, '59.

1953. WILKERSON, WILLIAM WESLEY, JR., 1028 Bennie Dillon Building, Nashville, Tennessee, 1953, '54, '55, '57*, '59.

1948. WILLIAMS, HENRY L., 2nd, Mayo Clinic, Rochester, Minnesota, 1948, '49, '50*, '51, '52*, '53, '54, '55, '56, '57, '58*, '59, '60.

1951. WOODMAN, DEGRAAF, 156 E. 37th Street, New York 16, N. Y., 1951, '53, '54, '55*, '56, '58, '59, '60.

1953. WORK, WALTER P., 384 Post Street, San Francisco 8, California, 1953, '54, '56, '58, '59*.

Honorary Fellows

1957. (1925) CLERF, LOUIS H., 5575 Eighth Avenue, North, St. Petersburg 2, Florida, 1957, '58, '59, '60.

1960. (1928) HILL, FREDRICK THAYER, Professional Building, Waterville, Maine.

1943. (1918) LEWIS, FIELDING O., Providence Road, Media, Pennsylvania.

1957. (1930) NEGUS, SIR VICTOR E., 149 Harley Street, London, W 1, England, 1957*.

1957. (1924) PROETZ, ARTHUR W., 12 Westmoreland Place, St. Louis 8, Missouri, 1957, '58, '59, '60.

Corresponding Fellows

1946. ALONSO, REGALES JUSTO E., Mercedes 1233, Montevideo, Uruguay.

1959. BARRETTO, PLINIO DE MATTOS, Ru Cons Torres, Homer 371, Sao Paulo, Brazil, 1960.

1959. BATEMAN, GEOFFREY H., 55 Harley Street, London W.1., England.

1942. BATSON, OSCAR V., 203 South DeKalb St., Philadelphia 4, Pennsylvania, 1942*, '54*.

1943. EGGSTON, ANDREW O., 653 Park Avenue, New York, N. Y., 1944, '49, '55, '60.

1957. HUIZINGA, EELCO, Noorderhaven 7, Groningen, The Netherlands, 1957.

1950. LARSELL, OLOF, University of Oregon Medical School, Portland, Oregon, 1950*.

1921. Le Maitre, Fernand, Avenue Victor Hugo, 120 (XVI), Paris, France.

1957. Ono, Jo, 75 Zaimoku-cho, Azabu, Minato-ku, Tokyo, Japan, 1957.

1937. Portmann, Georges, 25 bis Cours de Verdun, Bordeaux, France, 1947.

1957. Ruedi, Luzius, Ramistrasse 100, Zurich, Switzerland, 1957.

1924. Schaefer, J. Parsons, 4634 Spruce Street, Philadelphia 39, Pennsylvania, 1934.

1952. Tapia Acuna, Ricardo, Insurgentes Sur 300, Mexico 7 D.F. 1953, '57, '60*.

1936. Vialle, Jacques, 27 Rue de France, Nice (Alpes Maritimes), France.

Emeritus Fellows

1941. (1923) Barlow, Roy A., Musquodoboit Harbor, Nova Scotia, Canada.

1951. (1944) Beatty, Hugh G., 150 E. Broad St., Columbus 15, Ohio, 1951, '52, '53.

1958. (1930) Figi, Frederick A., Mayo Clinic, Rochester, Minn.

1946. (1933) Foster, John H., Plaza Hotel, Houston, Texas, 1948, '49, '50, '51, '52.

1951. (1928) Gittins, Thomas R., 408 Davidson Bldg., Sioux City, Iowa.

1960. (1940) Hansel, French, 634 N. Grand Blvd., St. Louis, Missouri.

1957. (1944) Havens, Fred Z., 102 Second Avenue S.W., Rochester, Minnesota.

1955. (1930) Houser, Karl M., 2035 Delancey Street, Philadelphia 3, Pennsylvania.

1951. (1928) JARVIS, DEFOREST C., Quarry Bank Bldg., Barre, Vt., 1952.

1956. (1939) JOHNSTON, WILLIAM HOWARD, 1515 State Street, Santa Barbara 7, California, 1957, '58.

1960. (1942) KELLY, JOSEPH D., 140 East Fifty-fourth Street, New York 22, N. Y.

1954. (1921) KERNAN, JOHN D., JR., 103 East Seventy-eighth Street, New York 21, N. Y.

1954. (1927) LUKENS, ROBERT M., 1308 W. Hunting Park Ave. nue, Philadelphia 40, Pa.

1960. (1939) MCCASKEY, CARL H., 608 Guaranty Building, Indianapolis, Ind.

1954. (1928) MACPHERSON, DUNCAN, 2350 Broadway, New York 24, N. Y.

1948. (1939) MYERS, JOHN LLEWELLYN, 1115 Grand Avenue, Kansas City, Missouri.

1959. (1927) MYERSON, MERVIN C., The Beverley Hills Medical Clinic, 133 So. Lasky Dr., Beverley Hills, Calif.

1957. (1948) PHELPS, KENNETH A., 140 Bear Gulch Drive, Alpine Hills, Menlo Park, Calif., 1958.

1958. (1938) SALINGER, SAMUEL, 1105 No. Palm Canyon Drive, Palm Springs, Cal., 1958, '59.

1954. (1930) SEYDELL, ERNEST M., First National Bank Building, Wichita, Kansas, 1957.

1950. (1922) WHITE, FRANCIS W., 180 Central Park So., New York 19, N. Y.

1951. (1935) WOODWARD, FLETCHER D., 1326 Rugby Road, Charlottesville, Va., 1959, '60.

BENEFACTORS

Dr. Arthur W. deRoaldes

Dr. William E. Casselberry

Dr. Samuel Johnston

Dr. Cornelius G. Coakley

Dr. John F. Barnhill

Dr. James E. Newcomb

Dr. Lee Wallace Dean

Dr. George E. Hourn

Dr. Burt R. Shurly

Dr. Fred Dixon

BENEFACTORS OF THE LARYNGOLOGICAL RESEARCH FUND

Dr. John F. Barnhill

Dr. and Mrs. Lee Wallace Dean

Dr. Gordon Berry

Dr. Frederick T. Hill

Dr. and Mrs. George E. Hourn

Dr. Samuel Salinger

Dr. H. Marshall Taylor

Dr. Louis H. Clerf

Mr. Lester T. Sunderland

Dr. William E. Grove

Dr. Burt R. Shurly

Dr. Henry B. Orton

Obverse of the deRoaldes medal

RECIPIENTS OF THE deROALDES AWARD

1928. Dr. Chevalier Jackson

1931. Dr. D. Bryson Delavan

1934. Dr. Harris P. Mosher

1937. Dr. Lee Wallace Dean

1943. Dr. Ralph A. Fenton

1949. Dr. George M. Coates

1951. Dr. Arthur W. Proetz

1954. Dr. Louis H. Clerf

1959. Dr. Albert C. Furstenberg

1960. Dr. Dean M. Lierle

RECIPIENTS OF THE CASSELBERRY AWARD

1923. Dr. George Fetterolf and Dr. Herbert Fox

1928. Dr. Ralph A. Fenton and Dr. O. Larsell

1929. Dr. Richard A. Kern and Dr. Harry P. Schenck

1929. Dr. Edward H. Campbell

1931. Dr. Arthur W. Proetz

1934. Dr. Anderson C. Hilding

1936. Dr. Francis E. LeJeune: Dr. Joel J. Pressman

1939. Dr. H. Marshall Taylor: Dr. Brien T. King

1940. Dr. French K. Hansel

1941. Dr. Noah D. Fabricant

1946. Dr. Paul H. Holinger

1949. Dr. Henry B. Orton

RECIPIENTS OF THE NEWCOMB AWARD

1941. Dr. Burt R. Shurly
1942. Dr. Francis R. Packard
1943. Dr. George M. Coates
1944. Dr. Charles J. Imperatori
1947. Dr. Harris P. Mosher
1948. Dr. Gordon Berry
1949. Dr. Gordon B. New
1950. Dr. H. Marshall Taylor
1951. Dr. John D. Kernan
1952. Dr. William J. McNally
1953. Dr. Frederick T. Hill
1954. Dr. Henry B. Orton
1955. Dr. Thomas C. Galloway
1956. Dr. Dean M. Lierle
1957. Dr. Gordon F. Harkness
1958. Dr. Albert C. Furstenberg
1959. Dr. Harry P. Schenck
1960. Dr. Joel J. Pressman

PAST OFFICERS

Presidents

(Year of Election)

1879. Louis Elsberg
1880. J. Solis-Cohen
1881. F. I. Knight
1882. G. M. Lefferts
1883. F. H. Bosworth
1884. E. L. Shurly
1885. Harrison Allen
1886. E. Fletcher Ingals
1887. R. P. Lincoln
1888. E. C. Morgan
1889. J. N. Mackenzie
1890. W. C. Glasgow
1891. S. W. Langmaid
1892. M. J. Asch
1893. D. Bryson Delavan
1894. J. O. Roe
1895. W. H. Daly
1896. C. H. Knight
1897. T. R. French
1898. W. E. Casselberry
1899. Samuel Johnston
1900. H. L. Swain
1901. J. W. Farlow
1902. J. H. Bryan
1903. J. H. Hartman
1904. C. C. Rice
1905. J. W. Gleitsman
1906. A. W. deRoaldes
1907. H. S. Birkett
1908. A. Coolidge, Jr.
1909. J. E. Logan
1910. D. Braden Kyle
1911. James E. Newcomb
1912. George A. Leland
1913. Thomas Hubbard
1914. Alexander W. MacCoy
1915. G. Hudson Makuen
1916. Joseph L. Goodale
1917. Thomas H. Halstead
1918. Cornelius G. Coakley
1919. Norval H. Pierce
1920. Harris P. Mosher
1921. Harmon Smith
1922. Emil Mayer
1923. J. Payson Clark
1924. Lee Wallace Dean
1925. Greenfield Sluder
1926. Chevalier Jackson
1927. D. Bryson Delavan
1928. Charles W. Richardson
1929. Lewis A. Coffin
1930. Francis R. Packard
1931. George E. Shambaugh
1932. George Fetterolf
1933. George M. Coates
1934. Dunbar Roy
1935. Burt R. Shurly
1936. William B. Chamberlain
1937. John F. Barnhill
1938. George B. Wood

1939. James A. Babbitt
1940. Gordon Berry
1941. Thomas E. Carmody
1942-3. Charles J. Imperatori
1944-5. Harold I. Lillie
1946. Frank R. Spencer
1947. Arthur W. Proetz
1948. Frederick T. Hill
1949. Ralph A. Fenton
1950. Gordon B. New
1951. H. Marshall Taylor
1952. Louis H. Clerf
1953. Gordon F. Harkness
1954. Henry B. Orton
1955. Bernard J. McMahon
1956. LeRoy A. Schall
1957. Harry P. Schenck
1958. Fred W. Dixon
1959. William J. McNally
1960. Edwin N. Broyles

Vice-Presidents

1879.	F. H. Davis	
1880.	W. C. Glasgow	J. O. Roe
1881.	E. L. Shurly	W. Porter
1882.	C. Seiler	E. F. Ingals
1883.	S. W. Langmaid	S. Johnston
1884.	J. H. Hartman	W. H. Daly
1885.	H. A. Johnson	G. W. Major
1886.	E. C. Morgan	J. N. Mackenzie
1887.	J. N. Mackenzie	S. W. Langmaid
1888.	W. C. Glasgow	C. E. DeM. Sajous
1889.	E. Holden	C. E. Bean
1890.	J. O. Roe	J. H. Hartman
1891.	M. J. Asch	S. Johnston
1892.	S. Johnston	J. C. Mulhall
1893.	J. C. Mulhall	W. E. Casselberry
1894.	C. C. Rice	S. H. Chapman
1895.	J. Wright	A. W. deRoaldes
1896.	T. M. Murray	D. N. Rankin
1897.	A. W. MacCoy	H. S. Birkett
1898.	J. W. Farlow	F. W. Hinkel
1899.	T. A. DeBlois	M. R. Brown
1900.	H. L. Wagner	A. A. Bliss
1901.	J. W. Gleitsmann	D. Braden Kyle

1902.	G. A. Leland	T. Melville Hardie
1903.	J. H. Lowman	W. Peyre Porcher
1904.	Thomas Hubbard	W. J. Freeman
1905.	J. L. Goodale	C. W. Richardson
1906.	G. H. Makuen	A. B. Thrasher
1907.	J. P. Clark	J. E. Rhodes
1908.	E. Mayer	F. R. Packard
1909.	C. G. Coakley	H. P. Mosher
1910.	Robert C. Myles	J. M. Ingersoll
1911.	F. C. Cobb	B. R. Shurly
1912.	A. W. Watson	W. Scott Renner
1913.	F. E. Hopkins	Geo. F. Shambaugh
1914.	Clement T. Theisen	Lewis A. Coffin
1915.	J. Gordon Wilson	Christian R. Holmes
1916.	Thomas H. Halsted	Greenfield Sluder
1917.	John Edwin Rhodes	D. Crosby Greene
1918.	G. E. Shambaugh	John R. Winslow
1919.	Francis R. Packard	Harmon Smith
1920.	Harmon Smith	W. B. Chamberlin
1921.	Dunbar Roy	Robert C. Lynch
1922.	George Fetterolf	Lorenzo B. Lockard
1923.	Hubert Arrowsmith	Joseph B. Greene
1924.	Ross H. Skillern	Gordon Berry
1925.	John E. Mackenty	Robert Levy
1926.	Lewis A. Coffin	William V. Mullin
1927.	Charles W. Richardson	Hill Hastings
1928.	Robert Clyde Lynch	Francis P. Emerson
1929.	William B. Chamberlin	Ralph Albert Fenton
1930.	Harris P. Mosher	James A. Babbitt
1931.	Joseph B. Greene	E. Ross Faulkner
1932.	Gordon Berry	Frank A. Spencer
1933.	E. Ross Faulkner	Thomas S. Carmody
1934.	Gordon B. New	Samuel McCullagh
1935.	Edward C. Sewall	H. Marshall Taylor
1936.	William P. Wherry	Harold I. Lillie

1937.	Frank R. Spencer	Bernard J. McMahon
1938.	Ralph A. Fenton	Frederick T. Hill
1939.	John H. Foster	Thomas R. Gittins
1940.	Charles H. Porter	Gordon F. Harkness
1941.	Arthur W. Proetz	Henry B. Orton
1942-3.	Harold I. Lillie	Dean M. Lierle
1944-5.	John J. Shea	Thomas C. Galloway
1946.	H. Marshall Taylor	C. Stewart Nash
1947.	John J. Shea	Frederick A. Figi
1948.	Henry B. Orton	Anderson C. Hilding
1949.	LeRoy A. Schall	Fletcher D. Woodward
1950.	W. Likely Simpson	Lyman G. Richards
1951.	Wm. J. McNally	Thomas C. Galloway
1952.	J. Mackenzie Brown	Edwin N. Broyles
1953.	Claude C. Cody	Daniel S. Cunning
1954.	James H. Maxwell	Clyde A. Heatly
1955.	Robert L. Goodale	Paul H. Holinger
1956.	Henry M. Goodyear	Robert E. Priest
1957.	Francis E. LeJeune	Pierre P. Viole
1958.	Charles Blassingame	Chevalier L. Jackson
1959.	James Maxwell	Oliver Van Alyea
1960.	Walter Theobald	Anderson Hilding

Secretaries and Treasurers

1879.	G. M. Lefferts	1895.	H. L. Swain
1882.	D. Bryson Delavan	1900.	P. E. Newcomb
1889.	C. H. Knight	1911.	Harmon Smith

Secretaries

1912.	Harmon Smith	1942.	Arthur W. Proetz
1918.	D. Bryson Delavan	1947.	Louis H. Clerf
1919.	J. M. Ingersoll	1952.	Harry P. Schenck
1920.	George M. Coates	1957.	James H. Maxwell

1933. William V. Mullin
1935. James A. Babbitt
1939. Charles J. Imperatori
1959. Lyman G. Richards
1960. Lyman G. Richards

Treasurers

1912. J. Payson Clark
1923. George Fetterolf
1932. William V. Mullin
1933. James A. Babbitt
1935. Charles J. Imperatori
1939. Frederick T. Hill
1948. Gordon F. Harkness
1953. Fred W. Dixon
1958. Francis E. LeJeune

Librarians

1879. F. H. Bosworth
1883. T. R. French
1903. J. H. Bryan
1930. John F. Barnhill
1934. Burt R. Shurly
1935. George M. Coates

Librarian and Historian

1936. George M. Coates
1944. Louis H. Clerf

Librarian, Historian and Editor

1947. Harry P. Schenck
1955. Edwin N. Broyles
1952. Bernard J. McMahon
1960. Francis W. Davison

PAST FELLOWS

Dates indicate original election to the Association

**Deceased*

Honorary Fellows

*1908. Barnhill, John F., Miami Beach, Florida.
*1893. Birkett, Herbert S., Montreal, Canada.
*1878. Bosworth, Francke H., New York City.
*1917. Coates, George M., Philadelphia, Pa.
*1918. Dean, Lee Wallace, St. Louis, Mo.
*1881. Delavan, D. Bryson, New York City.
*1893. deRoaldes, Arthur W., New Orleans, La.
*1890. De La Sota Y. Lastra, Ramon, Seville, Spain.
*1923. Fenton, Ralph A., Portland, Oregon
*1879. French, Thomas R., Brooklyn, N. Y.
*1880. Garcia, Senior Manuel, London, England.
*1903. Harris, Thos. J., New York City.
*1907. Jackson, Chevalier, Schwenksville, Pa.
*1878. Johnston, Samuel, Baltimore, Md.
*1878. Lefferts, George Morewood, Katonah, N. Y.
*1914. Levy, Robert, Denver, Colo.
*1883. Mackenzie, John N., Baltimore, Md.
*1881. Mackenzie, Sir Morel, London, England.
*1910. Masser, Ferdinand, Naples, Italy.
*1904. Mosher, Harris P., Marblehead, Mass.
*1910. Moure, J. J. E., Bordeaux, France.
*1937. Nager, F. R., Zurich, Switzerland.
*1918. Oliver, H. K., Boston, Mass.
*1906. Pierce, Norval Harvey, San Diego, Calif.
*1909. Semon, Sir Felix, Great Missenden, England.
*1878. Solis-Cohen, J., Philadelphia, Pa.
*1889. Swain, Henry L., New Haven, Conn.
*1914. Thomson, Sir St. Clair, London, Eng.
*1903. Tilley, Herbert, London, England.
*1914. Wagner, Clinton, New York City.
*1890. Wright, Jonathan, Pleasantville, N. Y.

Corresponding Fellows

*1892. Browne, Lennox, London, England.
*1938. Blair, Vilray P., St. Louis, Missouri.
*1940. Colledge, Lionel, London, England.
*1901. Collier, Mayo, Kearsney Abbey, Kent, England.
*1893. Desvernine, Carlos M., Havana, Cuba.
*1930. Emerson, Francis P., Franklin, Mass.
*1936. Fraser, John S., Edinburgh, Scotland.
*1901. Grant, Sir James Dundas, London, England.
*1887. Cougenheim, A., Paris, France.
*1894. Holden, Edgar, Newark, N. J.
*1919. Kelly, Adam Brown, Helensburgh, Scotland.
*1881. Labus, Carlo, Milan, Italy.
*1931. LasSagna, Francesco, Parma, Italy.
*1926. Law, Frederick M., New York, N. Y.
*1902. Lermoyez, Marcel, Paris, France.
*1897. Luc, H., Paris, France.
*1896. MacDonald, Greville, Haslemere, Surrey, England.
*1894. MacIntyre, John, Glasgow, Scotland.
*1903. McBride, P., York, England.
*1920. McKenzie, Dan, London, England.
*1919. McKernon, James F., New Canaan, Conn.
*1880. Meyer, Wilhelm, Copenhagen, Denmark.
*1910. Moure, J. J. E., Bordeaux, France.
*1896. Mygind, Holger, Copenhagen, Denmark.
*1950. Neil, James Hardie, Auckland, New Zealand.
*1919. Paterson, Donald Rose, Cardiff, Wales.
*1941. Patterson, Norman, Herts, England.
*1919. Rogers, John, Jr., New York City.
*1894. Sajous, C. E. DeM., Philadelphia, Pa.
*1896. Schmiegelow, Ernst, Copenhagen, Denmark.
*1946. Segura, Eliseo, Buenos Aires, Argentina.
*1940. Soto, E. Fernandez, Havana, Cuba.
*1881. Thornton, Pugin, London, England.
*1913. Turner, A. Logan, Edinburgh, Scotland.
*1880. Whistler, W. McNeil, London, England.
*1901. Wingrave, Wyatt, Lyme Regis, Dorset, England.
*1894. Wolfenden, R. Norris, Kent, England.

Emeritus Fellows

*1915. Barnes, Harry Aldrich, Kingston, Mass.
*1928. Beck, Joseph C., Chicago, Illinois.
*1921. Berry, Gordon, Worcester, Mass.
*1901. Brown, J. Price, Toronton, Canada.
*1891. Bryan, Joseph H., Washington, D. C.
*1913. Butler, Ralph, Philadelphia, Pa.
*1897. Clark, J. Payson, Boston, Mass.
*1899. Cobb, Frederick C., Bradenton, Florida.
*1939. Cody, Claude C., Jr., Houston, Texas.
*1905. Coffin, Lewis A., New York City.
*1893. Coolidge, Algernon, Boston, Mass.
*1937. Crowe, Samuel J., Baltimore, Maryland.
*1941. Cunning, Daniel S., New York City.
*1913. Dabney, Virginius, Washington, D. C.
*1882. De Blois, Thomas Amory, Boston, Mass.
*1892. Farlow, John W., Boston, Mass.
*1922. Forbes, Henry H., New York City.
*1905. Freer, Otto T., Chicago, Ill.
*1940. Gatewood, E. Trible, Richmond, Va.
*1880. Gleitsmann, Joseph W., New York City.
*1922. Goldsmith, Perry G., Toronto, Canada.
*1898. Goodale, Joseph L., Ipswich, Mass.
*1932. Graham, Harrington B., San Francisco, California.
*1906. Greene, D. Crosby, Jr., Boston, Mass.
*1917. Greene, Joseph B., Asheville, N. C.
*1905. Halsted, Thomas H., Los Angeles, Calif.
*1896. Hardie, Thomas Melville, Chicago, Ill.
*1915. Hastings, Hill, Los Angeles, Calif.
*1888. Hinkel, Frank Whitehill, Buffalo, New York.
*1895. Hopkins, Frederick E., Springfield, Mas.
*1927. Hubbard, Thomas, Toledo, Ohio.
*1919. Hurd, Lee Maidment, Rowayton, Conn.
*1920. Imperatori, Charles J., Essex, N. Y.
*1904. Ingersoll, John Marvin, Miami, Fla.
*1918. Kenyon, Elmer L., Chicago, Ill.
*1929. Kistner, Frank B., Portland, Oregon.
*1885. Knight, Charles H., New York City.
*1939. Large, Secord H., Cleveland, Ohio.
*1894. Leland, George A., Boston, Mass.

*1922. Lillie, Harold I., Rochester, Minn.
*1943. Lincoln, William R., Cleveland, Ohio.
*1928. Lyman, Harry Webster, St. Louis, Mo.
*1886. MacCoy, Alexander W., Philadelphia, Pa.
*1896. Mayer, Emil, New York City.
*1951. McCart, Howard W. D., Toronto, Canada.
*1943. McCullagh, Samuel, New York, N. Y.
*1923. McKinney, Richmond, Memphis, Tenn.
*1922. New, Gordon B., Rochester, Minn.
*1878. Porter, William, Ocean Springs, Miss.
*1901. Myles, Robert C., New York City.
*1923. Newhart, Horace, Minneapolis, Minn.
*1903. Packard, Francis R., Philadelphia, Pa.
*1942. Potts, John B., Omaha, Nebr.
*1903. Renner, W. Scott, Buffalo, N. Y.
*1897. Rhodes, John Edwin, Chicago, Ill.
*1884. Rice, Clarence C., New York City.
*1905. Richards, George L., South Yarmouth, Mass.
*1878. Robinson, Beverly, New York City.
*1921. Sauer, William E., St. Louis, Mo.
*1923. Sewall, Edward C., Palo Alto, Cal.
*1907. Shambaugh, George E., Chicago, Ill.
*1908. Smith, Harmon, New York City.
*1923. Spencer, Frank R., Boulder, Colo.
*1927. Tobey, Harold G., Boston, Mass.
*1925. Tucker, Gabriel, Haverford, Pa.
*1892. Wagner, Henry L., San Francisco, Calif.
*1892. Watson, Arthur W., Philadelphia, Pa.
*1939. Wilson, J. Gordon, Old Bennington, Vt.
*1905. Wood, George B., Wynnewood, Pa.

Active Fellows

*1880. Allen, Harrison, Philadelphia, Pa.
*1917. Arrowsmith, Hubert, Brooklyn, N. Y.
*1879. Asch, Morris J., New York City.
*1923. Babbitt, James A., Philadelphia, Pa.
*1906. Ballenger, William L., Chicago, Ill.
*1880. Bean, C. E., St. Paul, Minn.
*1949. Beck, August L., New Rochelle, N. Y.

*1904. Berens, T. Passmore, New York City.
*1924. Bigelow, Nolton, Providence, R. I.
*1893. Bliss, Arthur Ames, Philadelphia, Pa.
*1951. Boyden, Guy L., Portland, Oregon
*1895. Boylan, J. E., Cincinnati, Ohio.
*1932. Brown, John Mackenzie, Los Angeles, Calif.
*1892. Brown, Moreau R., Chicago, Ill.
*1933. Buckley, Robert E., New York City.
*1915. Canfield, R. Bishop, Ann Arbor, Mich.
*1934. Carmack, John Walter, Indianapolis, Ind
*1924. Carmody, Thomas E., Denver, Colo.
*1889. Casselberry, William E., Chicago, Ill.
*1883. Chamberlain, C. W., Hartford, Conn.
*1917. Chamberlin, William B., Cleveland, Ohio.
*1896. Chappell, W. F., New York City.
*1882. Chapman, S. Hartwell, New Haven, Conn.
*1902. Coakley, Cornelius G., New York City.
*1913. Coffin, Rockwell C., Boston, Mass.
1918. Cox, Gerald H., New York City.
*1880. Cushing, E. W., Boston, Mass.
*1878. Cutter, Ephraim, West Falmouth, Mass.
*1880. Daly, W. H., Pittsburgh, Pa.
*1878. Davis, F. H., Chicago, Ill.
*1941. Davis, Warren B., Philadelphia, Pa.
1926. Dennis, Frank Lownes, Colorado Springs, Col.
*1901. Dickerman, E. T., Chicago, Ill.
*1878. Donaldson, Frank, Baltimore, Md.
*1947. Engler, Clarence W., Cleveland, Ohio.
*1935. Eves, Curtis C., Philadelphia, Pa.
*1919. Faulkner, E. Ross, New York City.
*1914. Fetterolf, George, Philadelphia, Pa.
*1901. Freeman, Walter J., Philadelphia, Pa.
*1917. Friedberg, Stanton A., Chicago, Ill.
1940. Fuchs, Valentine H., New Orleans, La.
1909. Getchell, Albert C., Worcester, Mass.
*1897. Frothingham, Richard, New York City.
*1907. Gibb, Joseph S., Philadelphia, Pa.
*1940. Gill, William D., San Antonio, Texas.
*1878. Glasgow, William Carr, St. Louis, Mo.
*1913. Goldstein, Max A., St. Louis, Mo.

*1905. Grayson, Charles P., Philadelphia, Pa.
*1934. Grove, William E., Milwaukee, Wisconsin
*1945. Hickey, Harold L., Denver, Colo.
*1879. Holden, Edgar, Newark, N. J.
*1907. Holmes, Christian R., Cincinnati, Ohio.
*1882. Hooper, Franklin H., Boston, Mass.
*1893. Hope, George B., New York City.
*1938. Hourn, George E., St. Louis, Mo.
*1939. Hunt, Westley Marshall, New York, N. Y.
*1901. Hyatt, Frank, Washington, D. C.
*1925. Iglauer, Samuel, Cincinnati, Ohio.
*1878. Ingals, E. Fletcher, Chicago, Ill.
*1882. Ives, Frank L., New York City.
*1880. Jarvis, William C., New York City.
*1878. Johnson, Hosmer A., Chicago, Ill.
*1879. Johnson, Woolsey, New York City.
*1944. Jones, Marvin F., New York City.
*1879. Kealhofer, R. H., St. Louis, Mo.
*1942. King, Edward D., North Hollywood, Calif.
*1901. King, Gordon, New Orleans, La.
*1885. Knight, Charles H., New York City.
*1878. Knight, Frederick Irving, Boston, Mass.
*1898. Kyle, D. Braden, Philadelphia, Pa.
*1880. Langmaid, Samuel W., Boston, Mass.
*1878. Lincoln, Rufus P., New York City.
*1911. Lockard, Lorenzo B., Denver, Colo.
*1913. Loeb, Hanau W., St. Louis, Mo.
*1897. Logan, James E., Kansas City, Mo.
*1935. Looper, Edward A., Baltimore, Maryland.
*1888. Lowman, John H., Cleveland, Ohio.
*1919. Lynah, Henry L., New York City.
*1952. Lynch, Mercer G., New Orleans, La.
*1915. Lynch, Robert Clyde, New Orleans, La.
*1879. McBurney, Charles, New York City.
*1927. McGinnis, Edwin, Chicago, Ill.
1936. McGregor, Gregor, Toronto, Canada.
*1913. McKimmie, O. A., Washington, D. C.
*1945. McLaurin, John G., Dallas, Texas.
*1885. McSherry, H. Clinton, Baltimore, Md.
*1914. Mackenty, John E., New York City.

*1898. Makuen, G. Hudson, Philadelphia, Pa.
*1881. Major, G. W., Montreal, Canada.
*1948. Maxwell, James H., Ann Arbor, Mich.
*1881. Morgan, E. C., Washington, D. C.
*1950. Morrison, Lewis F., San Francisco, Calif.
*1940. Morrison, William W., New York City.
*1886. Mulhall, J. C., St. Louis, Mo.
*1925. Mullin, William V., Cleveland, Ohio.
*1914. Munger, Carl E., Waterbury, Conn.
*1892. Murray, T. Morris, Washington, D. C.
*1881. Mynter, H., Buffalo, N. Y.
*1893. Newcomb, James E., New York City.
*1895. Nichols, J. E. H., New York City.
*1927. Orton, Henry B., Newark, N. J.
*1894. Park, William H., New York City.
*1892. Porcher, W. Peyre, Charleston, S. C.
*1927. Porter, Charles T., Boston, Mass.
*1908. Randall, B. Alexander, Philadelphia, Pa.
*1882. Rankin, D. N., Allegheny, Pa.
*1902. Richardson, Charles W., Washington, D. C.
*1930. Ridpath, Robert E., Philadelphia, Pa.
*1879. Roe, John O., Rochester, N. Y.
*1881. Robertson, J. M., Detroit, Mich.
*1913. Roy, Dunbar, Atlanta, Ga.
*1878. Rumbold, T. F., St. Louis, Mo.
*1879. Seiler, Carl, Philadelphia, Pa.
*1928. Shea, John Joseph, Memphis, Tennessee.
*1893. Shields, Charles M., Richmond, Pa.
*1909. Shurly, Burt R., Detroit 1, Mich.
*1878. Shurly, E. L., Detroit, Mich.
*1892. Simpson, William Kelly, New York City.
*1919. Skillern, Ross H., Philadelphia, Pa.
*1909. Sluder, Greenfield, St. Louis, Mo.
*1879. Smith, Andrew H., Geneva, N. Y.
*1932. Smyth, Duncan Campbell, Boston, Mass.
*1928. Sonnenschein, Robert, Chicago, Ill.
1924. Stein, Otto J., Chicago, Ill.
1934. Stevenson, Walter, Quincy, Ill.
*1911. Staut, George C., Philadelphia, Pa.
*1879. Tauber, Bernhard, Cincinnati, Ohio.

*1924. Taylor, Hermon Marshall, Jacksonville, Fla.
*1903. Theisen, Clement F., Albany, N. Y.
*1899. Thorner, Max, Cincinnati, Ohio.
*1892. Thrasher, Allen B., Cincinnati, Ohio.
*1937. Tobey, George L., Jr., Boston, Mass.
*1888. Van der Poel, S. O., New York City.
*1938. Vail, Harris H., Cincinnati, Ohio.
*1936. Voislawsky, Antonie P., New York City.
*1933. Wanamaker, Allison T., Seattle, Wash.
1896. Ward, Marshall R., Pittsburgh, Pa.
*1879. Ward, Whitfield, New York City.
*1886. Westbrook, Benjamin F., Brooklyn, N. Y.
*1924. Wherry, William P., Omaha, Neb.
*1924. White, Leon E., Boston, Mass.
*1939. Williams, Horace J., Philadelphia, Pa.
*1942. Wishart, D. E. Staunton, Toronto, Canada.
*1922. Wishart, David J. G., Toronto, Ontario.
*1940. Wood, V. Visscher, St. Louis, Mo.
*1896. Wollen, Green V., Indianapolis, Ind.