

Transactions

American Laryngological Association

EIGHTY-SECOND VOLUME

"DOCENDO DISCIMUS"

TRANSACTIONS
OF THE
EIGHTY-SECOND ANNUAL MEETING
OF THE
American
Laryngological Association

1961

HELD AT
THE LAKE PLACID CLUB
LAKE PLACID, ESSEX COUNTY, NEW YORK
MAY 21 AND 22, 1961

PUBLISHED BY THE ASSOCIATION

ST. LOUIS, MO.


1961

CONTENTS

	PAGE
List of Officers	7
Registration	9
Remarks by the President, Dr. Edwin N. Broyles	12
Remarks by the Guest of Honor, Dr. Louis H. Clerf	17
Remarks by Dr. Alfredo Celis-Perez	20
Man Made Air Problems and Limitations. Capt. Gerald J. Duffner, MC, USN	22
Man, Drugs and Space Flight. Lt. Col. Charles A. Berry, MC, USAF	30
A Histological Method for the Study of the Spread of Carcinoma of the Larynx. Gabriel Tucker, Jr., M.D.	40
Chemotherapy in Head and Neck Cancer by Continuous Arterial Infusion. John F. Daly, M.D., and Robert D. Sullivan, M.D.	54
The Problem of Stoma Construction in Laryngectomy. Arthur J. Cracovaner, M.D.	73
Surgical Decompression of the Recurrent Laryngeal Nerve for Idiopathic Uni- lateral Cord Paralysis. Joseph H. Ogura, M.D.	85
A Discussion of Forty-two Years' Experience with Otolaryngological Pathol- ogy. Andrew A. Eggston, M.D.	100
Trends in the Management of Parotid Lesions. George Shimo, M.D., and H. S. Dolan, M.D.	119
Laryngeal and Bronchial Cancer; a Study of Double Primary Malignancy. Paul H. Holinger, M.D., Kenneth C. Johnston, M.D., Robert J. Jensik, M.D., and Dietrich Hurzler, M.D.	142
Deficits in Irradiation Therapy for Carcinoma of the Larynx Followed by Surgery. Herbert H. Harris, M.D.	160
Five Years' Experience with the Anterior Osteoplastic Approach to Frontal Sinus Surgery. Robert L. Goodale, M.D., and William Montgomery, M.D.	175
The Electronic Synchron-Stroboscope; Its Value for the Practicing Laryngol- ogist. Hans von Leden, M.D.	200

CONTENTS

	PAGE
Sarcoma of the Larynx. Charles M. Norris, M.D.	215
Memorials:	
Sarcoma of the Larynx. Charles M. Norris, M.D., and Augustin R. Peale, M.D.	215
Chevalier L. Jackson	237
John D. Kernan	242
Carl H. McCaskey	244
William W. Wilkerson, Jr.	246
Executive Sessions and Reports of Officers and Committees	249
List of Fellows, 1961	271
Active Fellows	272
Honorary Fellows	279
Corresponding Fellows	279
Emeritus Fellows	280
Benefactors	282
Benefactors of the Laryngological Research Fund	283
Recipients of the de Roaldes Award	284
Recipients of the Casselberry Award	285
Recipients of the Newcomb Award	286
Past Officers	287
Past Fellows	292



THOSE IN ATTENDANCE AT THE EIGHTY-SECOND ANNUAL MEETING

Left to right as one faces the group: *front row*, Salinger, Woodward, McNally, Dixon, Lejeune, Schall, Harkness, Clerf, Broyles, Richards, Theobald, Schenck, O'Neil, Davison, Ireland, Brown; *second row*, Blassingame, Lederer, Weille, Harris, Simpson, Goodyear, Lindsay, Galloway, Smith, Kline, Daly, Cracovaner, Goldman, Atkins; *third row*, Pressman, Friedberg, Tremble, Priest, Hilding, Woodman, Munoz-MacCormick, Hill, McMahon, Goodale, Hoople, Alfaro, Fitzhugh, Meltzer, Boies, Sanders, Miller, Henry, Moore; *fourth row*, Heatly, Harrill, Murtagh, Walsh, Holmes, McCall, Pang, Jones, Ogura, Suehs, Holinger, Baker, Andersen, Brewer.

OFFICERS FOR 1960-61

PRESIDENT

EDWIN N. BROYLES, M.D.

FIRST VICE-PRESIDENT

WALTER H. THEOBALD, M.D.

SECOND VICE-PRESIDENT

ANDERSON C. HILDING

SECRETARY

LYMAN G. RICHARDS, M.D.

TREASURER

FRANCIS E. LeJEUNE, M.D.

LIBRARIAN, HISTORIAN AND EDITOR

FRANCIS W. DAVISON, M.D.

COUNCIL

The above Ex-officio and

LeROY A. SCHALL, M.D.

HARRY P. SCHENCK, M.D.

FRED DIXON, M.D.

WILLIAM J. McNALLY, M.D.

TRANSACTIONS OF THE
EIGHTY-SECOND ANNUAL MEETING
OF THE

American Laryngological Association

HELD AT
THE LAKE PLACID CLUB
LAKE PLACID, ESSEX COUNTY, NEW YORK
MAY 21 AND 22, 1961

The Eighty-second Annual Meeting of the American Laryngological Association was called to order by the President, Dr. Edwin N. Broyles, at the Lake Placid Club, Lake Placid, New York, on May 21, 1961, at 10:00 A.M.

REGISTRATION

The following Fellows were in attendance:

ALFARO, VICTOR R.	CAMPBELL, PAUL A.
ATKINS, JOSEPH P.	CARDWELL, EDGAR P.
BAKER, DANIEL C.	CLERF, LOUIS H.
BLASSINGAME, CHARLES D.	CONLEY, JOHN J.
BOIES, LAWRENCE R.	CONVERSE, JOHN M.
BREWER, DAVID W.	CRACOVANER, ARTHUR J.
BROWN, LESTER A.	DALY, JOHN F.
BROYLES, EDWIN N.	DAVISON, FRANCIS W.

DIXON, FRED W.	MARTIN, ROBERT C.
EGGSTON, ANDREW A.	McCALL, JULIUS W.
FITZ-HUGH, GLASSELL S.	McMAHON, BERNARD J.
FRIEDBERG, STANTON A.	McNALLY, WILLIAM J.
FURSTENBERG, ALBERT C.	MELTZER, PHILIP E.
GALLOWAY, THOMAS C.	MILLER, ALDEN H.
GOLDMAN, JOSEPH L.	MOORE, PAUL M.
GOODALE, ROBERT L.	MUNOZ-MACCORMICK, CARLOS E.
GOODYEAR, HENRY M.	MURTAGH, JOHN A.
HARKNESS, GORDON F.	NASH, C. STEWART
HARRILL, JAMES A.	NORRIS, CHARLES M.
HARRIS, HERBERT H.	OGURA, JOSEPH H.
HEATLY, CLYDE A.	O'NEIL, JAMES J.
HENRY, ARNOLD	PANG, LUP Q.
HILDING, ANDERSON C.	PASTORE, PETER N.
HILL, FREDERICK T.	PRESSMAN, JOEL J.
HOLINGER, PAUL H.	PRIEST, ROBERT E.
HOLMES, EDGAR M.	PUTNEY, F. JOHNSON
HOOPLE, GORDON D.	RICHARDS, LYMAN G.
IRELAND, P. E.	ROBB, JAMES M.
JONES, EDLEY H.	SALINGER, SAMUEL
JOHNSTON, KENNETH C.	SANDERS, SAM H.
KLINE, ORAM R.	SCHALL, LeROY A.
LEDERER, FRANCIS L.	SCHENCK, HARRY P.
LeJEUNE, FRANCIS E.	SILCOX, LOUIS E.
LEWY, ROBERT B.	SIMPSON, W. LIKELY
LINDSAY, JOHN R.	SMITH, AUSTIN T.

SUEHS, OLIVER W.

THEOBALD, WALTER H.

TREMBLE, G. EDWARD

WALSH, THEODORE E.

WEILLE, FRANCIS L.

WILLIAMS, HENRY L.

WOODMAN, DEGRAAF

WOODWARD, FLETCHER D.

SUNDAY MORNING SESSION

MAY 21, 1961

The first session of the Eighty-Second Annual Meeting of the American Laryngological Association, held at the Lake Placid Club, Essex County, New York, convened at 10:10 A.M., Dr. Edwin N. Broyles, President of the Association, presiding.

PRESIDENT BROYLES: I will ask the Secretary to call the roll.

(The Secretary, Dr. Lyman G. Richards, called the roll. As the roll was called, a Past President's pin was presented to Drs. Louis H. Clerk, Frederick T. Hill, Gordon Harkness, Bernard J. McMahon, LeRoy Allen Schall and Harry P. Schenck.)

PRESIDENTIAL ADDRESS

EDWIN N. BROYLES, M.D.

BALTIMORE, MD.

This, the 82nd meeting of the Association, has been called by your Council in this historic region, the land of the Algonquins and Iroquois. Later this region was fought over by the French and British, whose names and deeds are prominent in our history; Samuel de Champlain, Count Frontenac, Marquis de Montcalm, General James Wolfe and Lord Jeffry Amherst. This country was also the camping ground of that fabulous scout, Hawkeye, of J. Fenimore Cooper's "Leather Stocking Tales."

I am humbly and deeply grateful for the great honor you have given me and express to you my appreciation. It is a great honor to be a member of this Association and to be its President is far beyond my due. I thank you for this my greatest honor.

A meeting of this Association was held in Baltimore in May, 1890. Dr. John H. Mackenzie, a Baltimorean, was then President and

later an Honorary Fellow of this Association. This was 71 years ago. Dr. Mackenzie was a distinguished member of the Baltimore medical profession. He demonstrated that an attack of rose fever could be brought about when a patient suffering from this allergy was suddenly and unknowingly exposed to an artificial rose. Another one of his papers was entitled, "The Slaughter of the Tonsils." His lecture on certain phases of Rhinology is still talked about. The story is that when the subject of the lecture was announced by him to the class, the female medical students at Hopkins rose in a group, blushed and rapidly left the class room. Of course that was some 71 years ago. His obituary and bibliography are to be found in Volume 48 of our Transactions published in 1926.

This is a picture of our gavel which was presented to this Association in 1911, a half century ago by Dr. Samuel Johnston, also a Baltimorian. He insisted that the names of his three close friends along with his be engraved on it. This picture also is to be found in Volume 48. The names are J. N. Mackenzie, elected President 1889; D. Bryson Delevan, President 1893; Samuel Johnston, President 1899, and Jacob Hartman, President 1903.

We are now in the midst of a great revolution which involves the whole world and affects every aspect of our lives, including the practice of medicine and surgery. This practice is being taken over more and more by large groups or institutions, so much so that it is a great temptation for the young doctor to join one of these groups when he begins practice. These groups have some advantages, just as the shopping center has advantages over a single store. There are also some disadvantages. The family doctor who knew his patients and their families for three or four generations is rapidly becoming extinct and this may be one of the reasons that the medical profession is losing its close association with the public. Dr. Mosher felt this when he said, "When I gave up the practice of general medicine something very definite went out of my life, namely the personal touch with the patient. I am more and more an operating machine and as the change has gradually come about I have come to understand what is meant by the phrase, 'The laboratory eye is glassy and the operating hand is cold'." But when the laboratory eye is kind and the operating hand gentle, perhaps we can regain some of that personal touch with the patient.

We are teachers, our motto "Docendo Discimus" and our problems may be said to be twofold. We must bend our efforts to turning out a man of skill, experience, and judgement in order that he may be a good practitioner and at the same time endeavor to instil into him an eager desire for knowledge, a devotion to truth which will lead him to search in fields still unexplored or to follow clues already given to goals which have not yet been attained.

Both research and practice are necessary for advancement. The research physician may be compared to a composer of music and the practicing physician to the performing artist. The music of an opera is the product of the composer's mind, while the performance of a gifted artist in the composer's opera glorifies the composer's work. The same is true in the advancement of medicine. Rarely in medicine, as in music, is the good research man a good practitioner and the reverse statement is equally true. If the research worker and the practitioner cannot be united in the same individual they must work hand in hand. Each can help the other.

Emerson, in his essay on Circles, pictures intellectual progress as rhythmic. "At a given moment knowledge is surrounded by a barrier which marks its limit. It gradually gathers clearness and strength until some thinker of exceptional power burst the barrier and wins a wider circle within which though once more intrenches itself. But the internal force again accumulates, the new barrier is in turn broken and a wider horizon is presented."

In closing his Treasurer's Report last year, Dr. LeJeune stated that our trust fund was increased by the receipt of a donation of a \$1000 U. S. Government bond from Dr. Fred Dixon which was allocated to the Memorial Fund. Also a donation of a \$500 check from the estate of the late Dr. Marshall Taylor, one of our Past Presidents, was received from his son, Dr. Dekle Taylor. Donations and bequests such as these are urgently needed to place our Association on a firm financial basis. It is sincerely hoped that more contributions such as these will be received in the future.

This is a small Association. The membership is limited. Costs continue to mount. In reviewing the donations to the Association given in dollars or bonds, \$5000 given to this association in 1906 is now valued at \$7000, or \$3500 as far as dollar purchases are con-

cerned. If this gift had been given in stocks and the stocks held in the treasury, perhaps the dollar value would be much greater.

There is one profitable way to give. My plea is that we donate not only bonds or dollars, which by necessity are put in bonds, but also give some shares of stock in which you have a profit. These stocks may, after study, be kept in the treasury and not sold for the purchase of bonds. With a wide variety of stocks in our portfolio, some will advance. The more diversification, the greater the chance that some may increase greatly in value. The gifts or donations are tax-deductible. By donating or willing a small fraction of an estate, a diversified mixture of stocks and bonds will come to the Association, which in years to come may be the greatest help to our Association in combating rising costs and will place this Association in a position to contribute freely to research and investigation.

I have had word from the Treasury Department that all gifts to the Association are tax deductible. The shares of stock in which you realize a profit are counted as values at the market price, not the purchase price. For instance if you had bought shares of stock costing \$30.00 a share and the stock had risen in value to \$90.00 a share, the stock would be valued as a gift not at \$30.00, the purchase price, but at \$90.00, the market value, as a deductible gift with no capital gains tax.

All the holdings of this Association are in U.S. Government Bonds. On the other hand, large institutions with large investments always have stocks as well as bonds.

I cannot conclude without paying tribute to our Secretary, Dr. Lyman Richards, whose untiring devotion has made the tasks of the officers of this Association pleasant. I also pay tribute to our splendid Treasurer, Dr. Francis LeJeune, and to our Librarian, Editor and Historian, Dr. Francis Davison. I also express my appreciation to the Council for their cooperation and advice and lastly to the Fellows of the Association for their kindness and help. Thank you for your trust in me and for the honor and privilege of serving you.

PRESIDENT BROYLES: There is one privilege of this office that I have greatly enjoyed and that is the privilege of inviting a Guest of Honor. Today we have one of our Honorary Members as Guest of

Honor. He was President of this Association in 1952. He is also a benefactor of the Association. He served as Secretary. He was the Librarian and Historian.

He is a prodigious worker, an inspiring teacher and skillful operator, and one who stands high in the estimation and appreciation of all of the members of the Laryngological Association. It is with pleasure that I introduce to you our Guest of Honor, Dr. Louis Clerf.

REMARKS BY THE GUEST OF HONOR

DR. LOUIS H. CLERF: Mr. President and Fellows of the Association: This is indeed a great honor and I am very grateful to you and to the Fellows of the Association. I take it that this is an honor that I can share with all who have contributed to anything that I may have done that merits distinction. I should be happy to do so, for it has been my experience, as I have viewed the progress of men in medicine that few have attained distinction, shall we say, under their own steam. It has been the combined activity and interest of a large group, and I should like to share this with all of them.

I agree with Mark Twain, who said that Adam was fortunate, for whatever he said, he could say, "Well, this has never been said before." Much that I shall say has been said before.

Being the guest and not the ghost of honor gives me an opportunity to again appear on the rostrum of this Association and address a few words to you. I thought before I came here that Dr. Broyles had decided against having a Guest of Honor and I considered that a fine idea. When I arrived he told me that it was still in force, so I began to reminisce, and I recalled when I became a Fellow of this Association in 1925, which is only thirty-six years ago, and, singularly, I was just 36 years old then. Like Jack Benny, I am still in my thirties.

Dr. Greenfield Sluder was the President and he read a paper on "The Involuntary Nervous System in the Sphenopalatine and Nasal Ganglion," and at the same meeting Arthur Proetz presented his paper on "Displacement Irrigation of the Nasal Sinuses."

When the Secretary called the roll this morning, I found that none of more than ninety who were Fellows of the Association in 1925 responded to the roll call. There are still a few in the land of the living. I had hoped that Arthur Proetz would be here. Drs. Barlow, Fielding O. Lewis, Francis White and John Kernan were unable to attend, I assume for physical reasons.

GUEST OF HONOR



LOUIS HENRY CLERF, M.D.

PROFESSOR EMERITUS OF LARYNGOLOGY AND BRONCHO-ESOPHAGOLOGY
JEFFERSON MEDICAL COLLEGE OF PHILADELPHIA

Those were the grand old days. The most one could expect from the United States Government at that time was a free package of seed. The dollar does not go as far today as it did then, but what it lacks in distance it now makes up in speed. The people seemed calm and collected. These days when you see anybody who is calm, he probably isn't well.

During the past few years I personally have noticed that the future gets here quicker than it used to. I also have noted that whereas one's dreams don't always come true, neither do one's nightmares, and that is helpful.

But there is an additional gain that I have enjoyed, and probably some of you will conclude, "The old man is getting senile," but I do not attribute it to that. All one has to do is look about the world and see the possibility of the terrible holocaust that might envelop us all any day. I am very much like grandma who was 84 years old and devoting a lot of time to reading the Bible. She spent almost her entire day in the rocking chair reading and her grand-daughter was asked by a friend, "What is Grandma doing?" She answered, "I think Grandma is getting ready for her final examination."

I do a great deal of reading and I have noted in the past few years that, while I don't use a rocking chair, nonetheless I do use that grand old Book of Wisdom that Grandma was reading, and also a lot of scriptural writings which are, I am beginning to find, more interesting now than they used to be when I was very busy in my professional life and deeply engrossed in the problems of the world.

Now I have more time to speculate and soliloquize, and I must confess that that Book which mirrors the history of our civilization and can well serve as the mirror for the future of mankind is one that we ought to resort to now and again, particularly now more than ever before.

Mr. President, when I wrote to you I failed to tell you to beware of inviting old men as guests of honor. There is one thing about them, they can no longer be President of the United States since we now select younger men, but I warn the younger men of our Association that one of you may become President of the United States, but that is a chance you will have to take.

Old men become garrulous and so I shall end by quoting Alexander Pope, who said—

*"Words are like leaves and where they most abound
Much fruit of worth beneath is rarely found."*

PRESIDENT BROYLES: We would like to have a word from our distinguished guest, Dr. Alfred Celis Perez, who wants to talk to you about the Eighth Pan-American Congress of Otolaryngology. This is to be held in Caracas in February, 1962, and is to be dedicated to the memory of Dr. C. L. Jackson. Dr. Perez, do you have a few words to say to us?

DR. ALFREDO CELIS PEREZ: Mr. President, Members: I want first to ask you to excuse my English, because I find it somewhat difficult to express myself in your language.

I wish to take the opportunity given to me by the executives of this meeting to tell you that the Eighth Pan-American Congress of Otorhinolaryngology and Broncho-Esophagology will convene in Venezuela on February 25 through March 2, 1962.

This Congress was started in Chicago in 1947 and has helped to maintain a contact between specialists of the Americas, enabling them to get to know each other better, not only from the scientific, but from the human point of view. As a consequence, the Spanish, English and Portuguese speaking American Otolaryngologists, putting aside language barriers, have reached a better understanding and are contributing toward making of this continent a uniform bloc where all men of good will contribute to the harmony and progress of the great American family.

The founder and soul of these Congresses was Dr. Chevalier L. Jackson, who was devoted to Pan-Americanism, traveling from one end of the Americas to the other, serving as a bond of union between the Anglo-Saxon and Latin people who live in this beautiful American land.

The Organizing Committee wants the Congress to be a just homage to the friend of everyone, Chevalier Jackson, and during the celebration of the Congress an act in honor of his memory will take place. This is the reason we have come to this great country to invite everyone to attend the Congress, so that the homage to Jackson may turn out to be a great success.

We are working on the Congress organization and its scientific success is assured because we will have the contribution of great men in the specialty from North and South America.

The Congress will take place in Puerto Azul, located on the Caribbean Sea, a beautiful place full of tropical palm trees and exotic vegetation, only twenty minutes away from Caracas. We hope to make this Congress a great scientific and social event, but in order that our wishes may become a reality, we need your cooperation and that is the reason I have come personally to invite you. Out at your registration desk you will find a table where you may obtain full information.

I thank you for the opportunity you have given me to address these few words to you. Please remember that you are invited to go to Venezuela in February, 1962.

MAN-MADE AIR PROBLEMS AND LIMITATIONS

CAPTAIN GERALD J. DUFFNER, MC, USN

WASHINGTON, D. C.

Seventy per cent of the earth's surface is water. Ninety-nine per cent of this nation's overseas traffic is moved on the 70,000 miles of sea lanes of the world. Included in this traffic are the sixty-six vital imports this country needs—for we require seventy-seven strategic raw materials and are self-sufficient in only eleven. Without these vital imports, we could have not jet aircraft, ballistic missiles, telephones or television sets. These few facts should suffice to demonstrate the importance of controlling the seas to a maritime nation.

The submarine is particularly well suited as an instrument for the control of the seas. Its principal tactical advantage is that it cannot be seen nor detected by electromagnetic devices while submerged. It is, therefore, in a position to exploit the two major maneuvers of warfare, stealth and surprise. When the submarine is surfaced, however, it loses these advantages. The more it can stay submerged the better it can perform its mission.

Prior to 1955 we did not have submarines in the true sense of the word. Those earlier submarines were really submersible torpedo boats. They spent the majority of their time on the surface and submerged only when necessary to launch an attack or escape from a pursuer. When running on the surface, the propulsive power was furnished by diesel engines. When submerged, this power was furnished by batteries. The submerged endurance was thus limited by the capacity of the storage batteries. Even at slow speeds, they would be exhausted in 36 to 48 hours. Therefore, it was necessary for the submarine to surface at frequent intervals to charge its batteries. The advent of the snorkel or breathing tube for submarines after World War II did

Director, Submarine Medicine Division, Bureau of Medicine and Surgery, Department of the Navy.

The opinions or assertions contained herein are those of the author and are not to be construed as official or reflecting the views of the Navy Department or of the Naval Service at large.

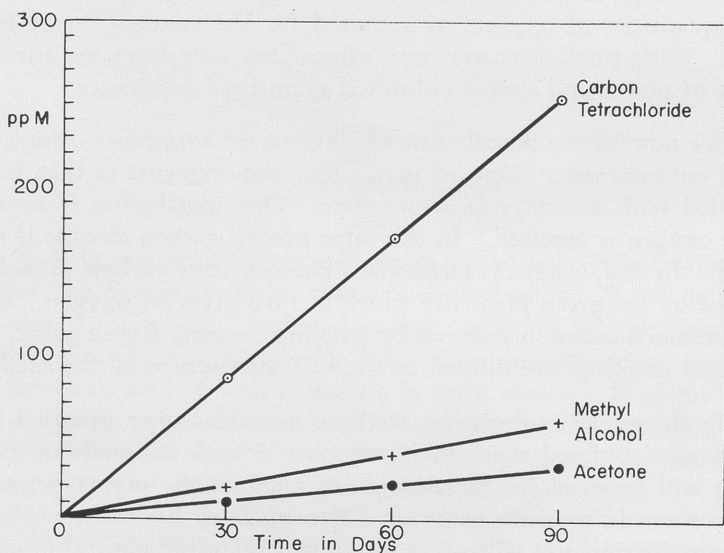
not materially change this situation. The submarine was still attached to the surface, inhaling large volumes of fresh air, a necessity, since large quantities of oxygen are required for the combustion of fossil fuels. With nuclear power, our submarines now have an anerobic source of power and almost unlimited submerged endurance.

We now have a situation in which men are living in a completely sealed environment. One of man's first requirements is that he be provided with a respirable atmosphere. Our metabolism is aerobic, hence oxygen is required. In this same process carbon dioxide is produced. In our ordinary terrestrial existence, this carbon dioxide is utilized by the green plant life which in turn gives off oxygen. Such contaminants as are introduced by gasoline engines, drying paint, and cigarette smoking, are diluted in the vast atmosphere of the earth.

In the nuclear submarine, we have no such happy situation. In this closely confined atmosphere we must provide a breathing media which will preserve the health and efficiency of the submarine crew. In other words, we must *make* air. Man-made air has many problems in its production and will never be equivalent to the natural product.

Through the years we have learned that submarine crews consume about one cubic foot of oxygen per man per hour. In our submarines, we maintain the oxygen content of the atmosphere at approximately 21 per cent. This is done by adding oxygen to the submarine air as it is consumed. This can be accomplished in a number of ways; either by using oxygen stored in high pressure flasks; by chemical production of oxygen; or by the electrolysis of water. The carbon dioxide produced by the respiration of the crew must also be removed.

One of the more serious problems involved in life in sealed environments is the continual contamination of the atmosphere by introducing small quantities of toxic materials. Figure 1 demonstrates this problem graphically. A hypothetical situation has been chosen in which one quart of a toxic substance is vaporized in 100,000 cubic feet every 30 days. One hundred thousand cubic feet is a very large space, e.g., a room 100 by 50 by 20 feet. Yet, if just a quart of carbontetrachloride is vaporized in the space over a 30-day period, the maximum allowable concentration of 90 parts per million has almost been reached. At the end of 60 days, the concentration would be in the neighborhood of 170 parts per million—and all of the occu-



Accumulation of toxic substances in a closed environment. Vaporizing one quart in 100,000 cubic feet every 30 days.

Figure 1

pants would be deceased. We solved this problem in submarines very easily, simply by not permitting carbontetrachloride to be taken on board. The accumulation of two other common solvents is also plotted. At the end of 90 days, the air would contain 60 parts per million of methyl alcohol, a level which would undoubtedly be damaging for continuous exposure. If a quart of acetone were vaporized every 30 days, the concentration would reach 33 parts per million within 90 days.*

In substance then the principal problems in sealed environments are: a) providing oxygen, b) removing carbon dioxide, and c) pre-

* The concentration of any solvent in the atmosphere in parts per million can be computed using the following formula:

$$\frac{\text{ml. of solvent vaporized} \times \text{Specific gravity}}{\text{Liters of air in space}} \times \frac{24.5}{\text{Mol. Wt.}^\dagger} \times 10^6$$

† Molecular weight of solvent

venting contamination of the air by other toxic substances. The temperature and humidity of the air must also be maintained within tolerable limits.

One may logically ask, "Where do these contaminants come from?" In general, they arise from three sources: first, those introduced in the construction and maintenance of the ship; second, those introduced by the crew and their activities; and third, those introduced in efforts to remove the first two. This last is not a facetious statement. The contaminants found in submarine atmospheres will now be listed and discussed. Following this my earlier statement will have more meaning.

CARBON DIOXIDE

This contaminant is produced by the respiration of the crew. Experience has shown that a respiratory quotient of one generally prevails. Therefore, about one cubic foot of carbon dioxide is produced by each occupant every hour. An intolerable situation would soon develop if this carbon dioxide were not removed from the air. Experiments conducted at the U. S. Naval Medical Research Laboratory during the period 1949 to 1954 disclosed that 1.5% was the upper limit of tolerance for carbon dioxide during prolonged exposures.¹ These findings were utilized in the design of equipment for continuous carbon dioxide removal. The device utilized for removing carbon dioxide on nuclear submarines is based on the principle that an amine solution sprayed in a scrubber tower will remove carbon dioxide from the flow of air passing up through to the tower. The amine combines with the carbon dioxide in a weak chemical bond and is collected as a solution at the bottom of the tower. It is then pumped to a heater where under increased temperature the carbon dioxide is released from the amine, isolated, and then discharged overboard. The heated amine now cleared of its carbon dioxide is available after cooling for passage to the scrubber tower.² This chemical scrubber is not an unmixed blessing. The amine solution is volatile. Within limits, the greater the volatility of an amine the greater is its efficiency as a scrubbing agent. These amines as a class were known to be toxic, but there was no specific knowledge of the degree of toxicity for long-term exposure. It was necessary to determine the MAC for monoethylene amine and by scrupulous attention to the operation of the scrubber, to maintain its content within this limit in the submarine air.

CARBON MONOXIDE

During the early experiments on carbon dioxide, it was learned that carbon monoxide would be a problem in sealed environments if tobacco smoking was permitted. During "Operation Hideout" where 23 men were sealed in a submarine for six weeks, carbon monoxide concentrations in excess of 100 parts per million were encountered in the atmosphere.³ There is also considerable evidence that carbon monoxide is produced by the oxidation of paint.⁴ Since carbon monoxide is a rather insoluble and unreactive compound, there is only one way to remove it from the atmosphere, namely, to burn it. Therefore, burners have been installed on nuclear submarines through which the submarine air is passed over a heated catalyst. Here, the carbon monoxide is oxidized to carbon dioxide.

AEROSOLS

The tobacco smoking also introduces aerosols into the submarine atmosphere. Measurements indicate that with all air revitalization equipment operating, the aerosol content of submarine air will reach levels of 0.5 micrograms of particulates per liter or higher after a few days' submergence.² In order to maintain the aerosol content of the submarine air within acceptable limits, it was necessary to install electrostatic precipitators with high capacity. In general, an aerosol level of about .2 microgram per liter is considered desirable.

HEAT AND WATER VAPOR

It is convenient to consider these two contaminants together. They are produced by the metabolic processes of the crew, and the steam power plant. The modern submarine also contains a large amount of electronic equipment which operates at a high temperature. This equipment adds a considerable heat burden to the submarine air. In order to maintain the temperature and humidity within acceptable levels, cooling coils are located at many points in the ship's ventilation system. These coils are cooled by expanding within them a common refrigerant, dichloro-difluoro methane or freon. Since the freon is compressed at a central location and delivered via piping at high pressure throughout the ship, leaks occur frequently. For all practical purposes, it is impossible to have a completely leak-proof system on any ship. A ship must be constructed in such a way that it will respond to a certain extent to the motions of the sea. A completely

rigid ship would soon break up; therefore, every ship does what is known in maritime circles as "works." The working of the ship causes motions in the piping with accompanying minute leaks. Therefore, the submarine air is never without a certain amount of freon contamination.⁴ Freon in itself is not a particularly toxic substance. Industrial workers have tolerated concentrations as high as one thousand per million for 40-hour week exposures. The problem with freon is that it is readily decomposed by heat. Therefore, the freon is oxidized to form hydrogen chloride and hydrogen fluoride in the carbon monoxide burner. In order to overcome this problem, it is necessary to install an absorbent cylinder on the outlet side of the carbon monoxide burner.

HYDROCARBONS

A study of submarine air during the first prolonged submergence of the Nautilus revealed a significant content of aliphatic hydrocarbons with traces of aromatics. The principal source of these hydrocarbons is found to be a liquid solvent called "mineral spirits." This liquid solvent is used for cleaning and brightening of painted and metallic surfaces. Between 100 and 200 gallons of this material might be on board at any time. Several gallons of this material might be used daily in judicious cleaning of the ship. Under prolonged submergence, all this is volatilized to the submarine's atmosphere. Further investigation disclosed that most of the aromatic hydrocarbon was entering the submarine atmosphere by the volatilization of paint solvents. It was found that volatile hydrocarbons may continue to be released for as long as two or three weeks after it is applied. A third source of hydrocarbons indicated was the use of liquid deck wax in submerged submarines. Ebersole² has presented data showing a two-fold increase in the hydrocarbon content of the air within one hour after deck wax was applied.

The foregoing discussion should provide a general view of the problems involved in providing a satisfactory atmosphere in sealed environments. It should be apparent that the contamination of a sealed environment atmosphere can only be avoided by one of two methods: either the introduction of the contaminant must be prevented or a system must be designed to remove it. If the introduction of a contaminant cannot be prevented, the following steps must be taken: 1) maximum allowable concentration for prolonged exposure must be established; 2) a system must be designed to remove

sufficient amounts of the contaminant to keep it at this level; 3) an analytical method must be designed by which the level can be detected in the atmosphere.

At this point one might ask, "Why settle for a maximum allowable concentration; why not remove all of the contamination?" Atmospheric contaminants can only be removed by utilizing a chemical reaction—either oxidation or the formation of a compound. The efficiency of any chemical reaction is directly proportional to the concentration of the reacting substances. Therefore, the lower we desire to keep the concentration of any contaminant the larger by many times must be the reacting surface or absorption column and the more times per unit time the air must be passed over the reacting surface. This latter requires a great increase in the ventilation system required to move the air. It would be possible to design a submarine with an ideal atmospheric control system but there would be no room to carry weapons.

SUMMARY AND CONCLUSIONS

1. The successful operation of nuclear submarines creates a situation in which men must live for prolonged periods in a sealed environment.
2. The most immediate and pressing problem in a sealed environment is the necessity for providing a respirable atmosphere.
3. The three principal problems are: a) providing a replacement for oxygen utilized by the crew members; b) removing carbon dioxide and other metabolics and c) a prevention or control of the introduction of other contaminants.
4. The principal limitation of man-made air is that all of the atmospheric contaminants can never be removed.

NAVY DEPT. BUREAU OF MEDICINE AND SURGERY

REFERENCES

1. Faucett, R. E., and Newman, P. P.: Operation Hideout: Preliminary Report, Confidential. Naval Medical Research Laboratory (Report No. 228, NM 002 015.10), July 3, 1953.
2. Ebersole, John H.: The New Dimensions of Submarine Medicine: Special Article New England Journal of Medicine 262:599-610 (Mar. 24) 1960.

3. Kinsey, J. L., and Nichols, G., Jr.: Carbon Monoxide as Habitability Factor in Prolonged Submarine Submergence. Naval Medical Research Laboratory (Report No. 223, NM 002 015.10.01), April 1, 1953.

4. Schulte, J. H.: The Medical Aspects of Closed Cabin Atmosphere Control Military Medicine 126:1:40-48 (Jan.) 1961.

MAN, DRUGS, AND SPACE FLIGHT

LT. COLONEL CHARLES A. BERRY, USAF, MC

WASHINGTON, D. C.

There is probably no one adventure that has so captured the interest of the public mind in recent times as has the preparation for man's journey into space. As in any venture into an unknown or new frontier, there is great concern expressed over the various hazards which are known and even more about those which are unknown. Columbus must have had these same concerns and also had many well-meaning groups and individuals supplying ideas about how he could protect himself against these hazards. The rocketing of man into space has exposed him to more serious degrees of the same hazards which he has previously encountered in high performance aircraft flight. There will undoubtedly also be some new hazards to face. We are well aware of the fact that this environment will stress man beyond his physiological tolerances unless we do something to "make up the difference." Traditionally we have used either protective devices or equipment, or tried to alter man himself. In most such endeavors time is a factor and thus we cannot wait for evolution to change man. The use of drugs for this purpose is the next logical suggestion, and has been tried on many occasions. Today I would like to describe the problems engendered by the space environment, outline the profile of a space mission, and then discuss some suggestions that have been made for extending man's abilities on such missions.

We have mentioned the fact that most of the medical problems of space flight are extensions of those encountered in current jet aircraft flight. This is well-illustrated by the demarcation of certain physiologically space equivalent altitudes which are well within our atmosphere. Man suffers from physiological insufficiency even from 10 to 50,000 feet. The area extending from 50,000 feet to 120 miles is partially space equivalent for man, and above this the environment is totally space equivalent even though he may be some 480 miles from the border of true space as defined by the physicists.

As we ascend into the atmosphere, we find that the decrease in barometric pressure brings about a corresponding decrease in the partial pressure of oxygen, and the early symptoms of hypoxia may be manifested at altitudes as low as 5,000 feet in the form of diminished night visual acuity. This is augmented by headache and more rapid respiratory rate shortly after the 10,000 feet level is reached, and more serious difficulty above this altitude. Hypoxia is usually avoided by either pressurizing the aircraft cabin or providing oxygen equipment. Continued ascent to 50,000 feet would lower the atmospheric pressure to 87 mm Hg and would bring about anoxia, for all the pressure space in the lung alveoli would be occupied by carbon dioxide and water vapor. Time of useful consciousness for the unprotected man at this altitude is limited to the lung to brain circulation time (8-15 seconds). The use of partial and full pressure suits provides adequate protection against hypoxia and ultimate loss of consciousness.

The decreasing barometric pressure alone produces a symptom complex termed *dysbarism*.¹ These symptoms, which may occur in severe form at altitude as low as 25,000 feet, include the well-known group resulting from gas expansion in body cavities, and the less well-known group resulting from or initiated by evolved nitrogen. Many of you have probably experienced pain in the ears, sinuses, teeth, or intestinal tract either on ascent to altitude or more commonly, for the ears and sinuses, on return to sea level after flight to altitude. Nitrogen bubbles evolving from body tissues and fluids produce pain about the joints (bends), cough and substernal burning (chokes), various neurological phenomena such as visual field defects, paralysis, etc., a mottled skin rash, and even neurocirculatory collapse resulting in death. Numerous in-flight cases have recently been reported.² Denitrogenation prior to flight or adequate cabin pressure will afford protection.

At approximately 63,000 feet the barometric pressure has dropped to 47 mm Hg. If man's blood and tissue fluids were exposed to this altitude they would "boil," a condition called ebullism.

In the 70-120,000 foot area there is a concentration of ozone which is toxic for man. This substance may be concentrated by the compressors and levels of 6 ppm for one hour may produce pulmonary edema.³

The most modern compressors are incapable of producing a pressure habitable atmosphere above an altitude of approximately 80,000 feet. Thus the sealed cabin rather than the pressurized cabin must be utilized above this altitude. The many environmental control problems of pressure, oxygen, carbon dioxide, water vapor, odors and wastes, temperature, etc., are thus introduced in addition to the problem of confinement.

Primary cosmic radiation becomes a hazard to consider at about 120,000 feet. These high energy particles (80% protons, 19% alpha particles, and 1% heavy nuclei) produce dense ionization tracts in tissue characterized by collision and thin down phenomena. Current information leads us to believe that astronauts in low orbits (less than 500 miles) should have no excessive radiation exposure problems. A great deal more information is needed about the Van Allen belts and radiation fields in space, however. The Van Allen belts form bands at the equator (1400-3400 miles, and 8,000-12,000 miles from the earth) capable of rendering dosage levels of 10-100 rads/hr.⁴

Ultraviolet rays also reach their unshielded potential at the 120,000 foot level and protection of the eyes is necessary.

The meteor hazard must be considered at 400,000 feet. It now appears that the chance of a large hit is unlikely, but erosion of optical and other surfaces is most likely.

The achievement of space flight requires exposure of the astronaut to accelerative force. Approximately 828 g seconds of exposure are required to attain orbital velocity and 1152 g seconds to reach escape velocity. Through the use of proper equipment and positioning, man is capable of withstanding the required exit and re-entry g loads.⁵

The loss of even the normal one g load of gravity resulting in weightlessness is an interesting phenomenon produced by the speeds of space flight. While the recent Russian and U. S. space flights should provide some needed information, unfortunately the majority of our studies have been for very brief periods in parabolic flight of fighter or transport type aircraft. Several of man's vital functions plus his performance of psychomotor tasks have been studied in these brief periods.^{6,7} We await an orbital laboratory for conclusive answers on

man's response to prolonged weightlessness and are particularly concerned about his ability to withstand accelerative forces after exposure to long periods of zero g.

Having outlined the various hazards lurking in the space environment, we will omit the details of selection of a bold adventurer to challenge this domain and now discuss a probable mission profile. A good example for our use is the proposed orbital mission for the Project Mercury astronauts. As you all know there is an extensive period of training, including the ballistic shot so successfully completed by Astronaut Shepard. Following this the man selected to fly the first mission will begin the Pre-Launch Phase lasting several days. This will include the ingestion of a low residue diet and numerous system checks as in the Redstone shot. A few hours prior to launch he will be dressed in his full pressure suit and after inevitable delays he will be strapped tightly to his form fitting couch in the capsule approximately two hours prior to launch. The entrance hatch will then be secured with 140 nuts, bolts, and screws. The capsule checkout procedure takes only about 30 minutes, so for approximately one hour he will have to sit secure in his capsule waiting for T minus zero or a sudden emergency abort signal which will send him 2500 feet into the air with an accelerative force lasting slightly over one second and peaking at about 20 g. If no emergency occurs and all goes well, the Atlas will accelerate to a peak of 8 g in a little over two minutes. Staging then occurs and the acceleration drops abruptly to one g but builds up to 9 g by sustainer burnout. The capsule and contents are then abruptly weightless. Approximately 5 seconds after sustainer separation the autopilot will stabilize the capsule, rotate it 180° in the yaw axis and also 35° base up in the pitch axis so that it is in the retrofire position. This is to assure that retrofiring can occur at the earliest possible moment to avoid landing on the continent of Africa if full orbital velocity or programmed orbit parameters have not been obtained. We have recorded no active role for the astronaut to this point, but he is playing a crucial passive role. He must monitor those instruments and indicator lights which indicate proper function of the rocket or which may indicate malfunction. His left hand will always be on the abort handle and he can fire the escape rockets at any time after the Atlas has ascended two inches off the launching platform. The pilot must be alert to note any errors of automatic function. If these occur he must activate the cabin oxygen purge bottles, escape tower jettison 15 seconds after staging,

capsule separation from the sustainer, and manually orient the capsule for retrofiring. After stabilization in orbit he must maneuver the capsule if he is to make purposeful observations of the earth and sky. The control device for doing this differs significantly from the usual aircraft control stick. Pitch is controlled by radial and ulnar deviation of the wrist; yaw by flexion and extension of the wrist; and roll by supination and pronation. Control is complicated by the lack of aerodynamic damping in space, and any movement initiated will continue until an equal and opposite force is applied. The recent flight demonstrated effective control in these axes.

Once in orbit, the pilot will be expected to make periodic and frequent reports to ground tracking stations. This vital information must be accurate. He will monitor cabin pressure, oxygen and carbon dioxide, and oxygen tank pressure. He will be called upon to make a variety of scientific observations. He will also navigate with the use of the earth viewing periscope. The faceplate to his suit must be manually closed in the event of a decompression, and the pilot must then be astute enough to analyze his situation and act. If at all possible he should not initiate re-entry at a point which would result in his landing anywhere but in the primary or secondary recovery areas. He must be prepared to survive any place between about 40 north and 40 south latitude.

Shortly prior to the completion of the third orbit, the capsule will be prepared for re-entry. It must be oriented with its broad base forward and elevated at an angle of 35° . If this is not done automatically, the astronaut must do it. This position must be attained prior to reaching the predetermined point where the retro-rockets are to be fired. If the capsule is out of alignment beyond specified limits, a locking device prohibits firing of the retrorockets. The exact center of gravity cannot be predicted and thus the vehicle attitude may be altered by thrust misalignment. The astronaut must correct this. After retrofiring, the capsule is oriented into the re-entry attitude which is a base down angle of 1.5° . As the aerodynamic forces build up on re-entry, oscillations occur in the attitude of the capsule. Though the reaction jets will not be able to stop these, proper application will keep them within acceptable limits. At 10,000 feet a ribbon parachute deploys and lowers the capsule to the surface with an impact of 30 feet/sec. The pilot may have to activate the chute. He

may then remain in the capsule and await pickup or get into a raft and do the same.⁸

Now that we have outlined the job of the early astronaut and the hazards he will face in the space environment, there is little wonder that there has been speculation on extending man's ability by various means, particularly when we consider prolonged missions. It should be emphasized that in using the Mercury mission for an example we do not mean to imply the use of drugs in this specific project; our discussion involves space flight in general. The demands of the space conquest are pushing at the tolerance limits in all the scientific fields, and the human and medical one is no exception. Though our margins of error are almost infinitesimal in the current high speed, high altitude aircraft, they have virtually disappeared in the space environment.

If we were to use drugs as a means of extending man's performance, where and how might this be done? The conceivable uses fall into three broad categories:

1. Treatment of some present loss or deficit.
i.e. anti-fever, meal pills, appetite reducers, norepinephrine.
2. Prophylaxis of some anticipated deficit.
i.e. antibiotics, antihistamines, radiation drugs, metabolism reducers (hibernation).
3. Enhance natural capability.
i.e. stimulants, hypnotics, tranquilizers, and mescaline.

Oberth as early as 1929 recommended the use of scopolamine for the treatment of space sickness. In more recent times there have been many suggestions which are less well-founded. One of the most recent of these suggested that "since space pilots would certainly develop hallucinations within days if not hours after take-off, they should be given hallucination drugs to block the incapacitating visions." This should "ignite a controlled mental fire to fight an uncontrolled mental fire." It was suggested that lysergic acid and mescaline might be tested in this regard. My previous comments on the job of the astronaut leave little doubt of the necessity of peak

performance and alertness. The use of any such drugs to produce dream states has no place in this performance. Numerous research studies have shown the possibility of development of hallucinations with rigidly channelized attention and severe reduction in sensory input. These may be prevented however by providing adequate sensory input, or simply keeping the pilot busy. This should be no problem on short missions, but the situation may be altered in interplanetary flights. The words of the proposer are judgment enough against this proposal, "We don't know the drug effects on the human psyche in space conditions," and we might add or even enough in earth conditions.

The use of the tranquilizers has also been suggested to allay anxiety prior to or during space flights. These drugs too produce a less than normal individual with unpredictable mental attitudes. They alter judgment and change orientation to reality. In addition it has been shown that the tranquilizers reduce the pilot's tolerance to stress of several types such as altitude, acceleration, etc.⁹ This would be a side effect which could not be accepted.

In prolonged space flight or even at the critical points of shorter flights, the use of stimulants has been suggested. The need for increased vigilance in a fatigued pilot at such critical times as re-entry or landing can hardly be questioned. Research has shown that the amphetamines are capable of mitigating fatigue and improving performance at psychomotor tasks. They appear to be useful in increasing and maintaining alertness. Missions and equipment should always be planned within the capabilities of the crew, then, if it is absolutely necessary to further extend performance, drugs such as the amphetamines may be used at crucial points if they are carefully controlled. Repetitive use should be avoided for it is not possible to make a superman with these drugs and it is possible to overextend man. In the future it may even be feasible to effect some control over diurnal or work rest cycles by the use of improved sedatives and stimulants. This must be investigated.

Some planners have looked into the future and the problems of interplanetary flight. The use of hypothermia to reduce metabolism and thus diminish the supplies of oxygen, food, etc., necessary on journeys of years has been suggested. Some basic studies are being done in this area, stemming from the use of hypothermia in surgery. The

development of a metabolism lowering drug to aid or supplant the hypothermia has been considered. At present small doses of meperidine, chlorpromazine, or promethazine are used to stop the shivering of patients undergoing hypothermia. It would seem that hypothermia for space pilots is still in the Buck Rogers status, for certainly no human in this state would do any performing of value.

Some fanciful writers have reported increases in the sexual drives of those going to space. Others have suggested that on prolonged missions or in missions with mixed crews some anti-sex drugs should be used. You may draw your own conclusions regarding these statements. It is quite possible, however, that the early women astronauts should be given hormonal therapy to stop menstrual flow until the mission is complete.

Considerable research effort will be necessary to determine which drugs will be useful in space flight. What should be investigated and what are the needs of the crewman for assistance by drugs? There are two basic principles which must pervade any decision to use drugs. First, any drug which is considered must have a thorough investigation into its specific modes of action not only in our normal environment, but at least in a space simulated one. Second, any drug selected for use must have a pre-test on each individual who is to use it. The testing of reactions to various drugs has even been suggested as a selection tool, predicated on the theory that drugs would be used in space flight and that such reactions would help to select among equally qualified candidates.

In the pre-flight or pre-launch period several drugs might be considered. There is little doubt that the astronaut will be quite excited and no doubt will have difficulty getting adequate rest prior to the flight. Hypnotics have been used prior to long missions to secure adequate rest, but performance decrement has been reported as long as 15 hours post ingestion. If necessary to obtain rest, some short acting hypnotic might be considered. In order to assure a calm astronaut the tranquilizers might be considered. These have been discussed previously, and their use is *not* recommended in our present state of knowledge. Consideration might be given to using antibiotics for prophylactic reasons. The value of such a procedure would have to be weighed against the risk of reaction. In such a costly enterprise as the first few flights, this might be good insurance in the carefully

pretested pilot. The hypotensive response to an intramuscular injection of mecholyl has been used as a selection test. It has been felt by some that this response is related to psychological status and thus to epinephrine-norepinephrine release and stress tolerance. Release of norepinephrine has been correlated with aggressive behavior, or the "tiger type." Perhaps in the future it may be possible to give an individual injections of a norepinephrine substance and make him a tiger. This may also be dangerous for it may place the drug-created tiger in a situation with which he cannot cope either psychologically or physiologically.

During the orbital phase of the mission the following might be considered. The weightless state may well create a form of motion sickness and thus anti-motion sickness drugs should be available. This may be particularly applicable if artificial gravity is supplied by rotating the space craft. In this event these drugs will alleviate labyrinthine effects of the Coriolis phenomenon produced by head movements during the rotation. On prolonged missions a drug to reduce the appetite, pills containing a meal, vitamins, and perhaps the analeptic drugs for critical periods would be useful. The possibility that the goals of hypothermia will be accomplished by pharmacologic means, as suggested in the work on artificial hibernation, should not entirely be disregarded. Chlorpromazine has been employed in a "lytic cocktail" to produce a state of general depression termed "artificial hibernation." Again, it is questionable whether such a hibernating pilot would be of value.

The radiation bands mentioned previously make it obvious that a drug protecting the pilot from an excessive dose of radiation would be valuable. The work in this area to date has not produced an acceptable drug. The energy sinks such as the sulfhydryl drugs (AET, glutathione) are toxic in helpful doses and give a variable response. They may provide 50% protection by reducing the effect of 1000 r to that of 500 r, but are no good for 700 r. The replacement bridges for the depleted hematopoietic system, such as autologous bone marrow, are palliative, and would be impractical in the space situation. The supportive drugs such as antibiotics, sedatives and tranquilizers would be for after the fact use. As of now no one drug will protect man.

In the re-entry and recovery phase the anti-motion sickness drugs and the analeptics might again be useful—the former particularly in

the rather severe oscillations of re-entry and the floating at sea awaiting recovery.

In conclusion then it would seem that a carefully selected and trained astronaut would better accomplish his mission without being under the influence of drugs. On prolonged missions he might be aided by the careful choice of drugs. We would prefer that he actually view Venus rather than hallucinate her through drug therapy. Prior to any drug use we must secure exact information on the specific mechanism of action, the toxicity, and the effect on performance of man in the space situation for each drug. The results of the clinical trial on ill patients and the determination of the LD/50 on rats is not enough information in this new environment where the margin of error is nonexistent.

OFFICE OF THE SURGEON GENERAL

REFERENCES

1. Berry, C. A.: Severe Dysbarism in Air Force Operations and Training. U. S. Armed Forces Med. J. 9:937, 1958.
2. Berry, C. A.: Dysbarism—An Inflight Case and a Discussion of the Current Status. Aerospace Med. 32:107 (Feb.) 1961.
3. Clamann, H. G.: Physical and Medical Aspects of Ozone. Chapt 9 in Benson and Strughold: Physics and Medicine of the Atmosphere and Space. John Wiley and Sons, Inc., 1960.
4. Langham, W. H.: Some Radiation Problems of Space Conquest. Report on USAF Contract 18(600)-1792, ARDC, Los Alamos Scientific Lab. of Univ. of Calif., Los Alamos, N. Mex. (Aug.) 1960.
5. Bondurant, S., Clarke, N. P., Blanchard, W. G., Miller, H., Hessberg, R. R. Jr., and Hiatt, E. P.: Human Tolerance to Some of the Accelerations Anticipated in Space Flight. U. S. Armed Forces Med. J. 9:1093, 1958.
6. Hawkins, R.: Space Flight Dynamics—Zero Gravity. Lectures in Aerospace Medicine, School of Aerospace Med., Brooks AFB, Tex. (Jan.) 1960.
7. Hawkins, W. R.: Physiological Measurements in the Weightless State. (To be published)
8. Douglas, W. K.: Selection and Training of Astronauts. Lectures in Aerospace Med., School of Aerospace Med., Brooks AFB, Tex. (Jan.) 1960.
9. McGuire, T., and Leary, F. J.: Tranquilizing Drugs and Stress Tolerance. WADC Tech. Rept. 58-64, Wright-Patterson AFB (Oct) 1958.

A HISTOLOGICAL METHOD FOR THE STUDY
OF THE SPREAD OF CARCINOMA
WITHIN THE LARYNX

GABRIEL F. TUCKER, JR., M.D.

BALTIMORE, MD.

(by invitation)

Since the late 19th century a considerable number of classifications of laryngeal carcinoma have been proposed. They range from simple ones, such as intrinsic versus extrinsic⁴ or vocal versus silent,⁸ to classifications such as that of Barretto¹ in which the laryngeal surface is divided into many small areas. The fact that many different classifications^{1,5} have been used, sometimes with conflicting definitions for a specific term, sometimes with a definition so insufficient that one cannot be certain what an author means, makes it difficult to assign categories to one's own material in a comparable fashion. Furthermore, even some of the more elaborate classifications do not take into account the submucosal anatomical structures. This situation is undergoing study by an international committee, but at present still presents a very real problem for one who wishes to classify material in a form that can then be compared with published statistics from other institutions.

The crux of this problem may be that the clinical classification of a lesion is usually based on laryngoscopic visualization and roentgenographic interpretation, whereas the pathological study of the same lesion is capable of a more precise determination of the relationship of the cancer to the structures beneath the mucosa.

From the Anatomical and Pathological Research Laboratory, Department of Otolaryngology, School of Medicine, Johns Hopkins University, Baltimore, Md. Supported in part by USPHS grant No. NINDB-B-2182 and American Cancer Society Grant No. IN-11.

PATHOLOGICAL REPORTS

To classify surgically obtained material from pathological reports presents further problems. In the first place, there is often confusion as to the precise anatomical location of the lesion within the larynx. Specific reference to landmarks is sometimes sufficiently vague that one cannot obtain a clear picture of exactly where the lesion was at the time the specimen was dissected by the pathologist. Secondly, the very nature of most pathological routines is such that the material is dissected before histologic preparation, and therefore cannot be re-examined in its original state. Thirdly, photographs of a lesion, when available, are usually of the split larynx and show only the relationship of the lesion to the laryngeal mucosa and, therefore, the deeper ramifications of the tumor are not discernible.

The key to the problem of classification probably rests with the determination of the precise anatomical relations of the lesion. The clinical relationships between the actual localization of a given lesion and many other pertinent factors are well established. Table I lists

TABLE I

Clinical appearance of lesion*	Age
Histological grade of lesion	Sex*
Classification*	Social habits
Staging*	Nature of symptoms*
Plan of treatment*	Duration of symptoms*
Prognosis*	General medical picture

a number of the facets of the problem usually recorded; those marked with an asterisk would seem to be related to actual localization of the lesion.

Upon localization depends not only the classification as to the primary site but the staging of a lesion, i.e., extension from the primary site. Clinically, the criterion for staging of extension within the larynx is usually whether or not cord mobility is lost or whether the cord is fixed in a given position. In relation to extension within

the larynx, Orton's⁶ emphasis on the pre-epiglottic space, the work by Broyles² on the anterior commissure, and more recently Pressman's work on laryngeal compartments⁷ have all pointed up the need to consider the submucosal spread of every lesion.

The above considerations demonstrate the need for a method whereby the relationship of the tumor to the laryngeal structures is preserved, thus making possible not only the study of the relationship of the lesion to normal deep structures without, in the process, dissecting the larynx, but also making possible a later review of the specimen with respect to classification of the lesion in whatever system is under study or seems pertinent at the time. To achieve these ends, it was decided the larynx should not be split or dissected but kept intact and studied by the method of serial histologic sections. According to Kernan,⁹ Leroux-Robert of Paris (1936) was the first to study serial sections of laryngeal cancer; Kernan combined the use of horizontal serial sections with wax reconstruction to delineate spread above and below the glottis.

CORONAL PLANE OF SECTION

The coronal plane (or frontal plane) is best for this purpose because it is perpendicular to a majority of the laryngeal mucosa and is parallel to the respiratory axis, and because the placement along the respiratory axis is the basis of most systems of classification. In coronal sections the diseased half of the larynx may be compared with its normal mirror image in the same section.

Actual sections were projected, like lantern slides, at the meeting. The illustrations in publication are very low magnification photographs. The sections, of course, can be studied with all powers of the microscope.

PRESENTATION OF SECTIONS

Since the sections are numbered serially from the anterior to the posterior margins of the specimen, the section number gives an exact measure of the A-P depth of the specimen at which a given section was cut.

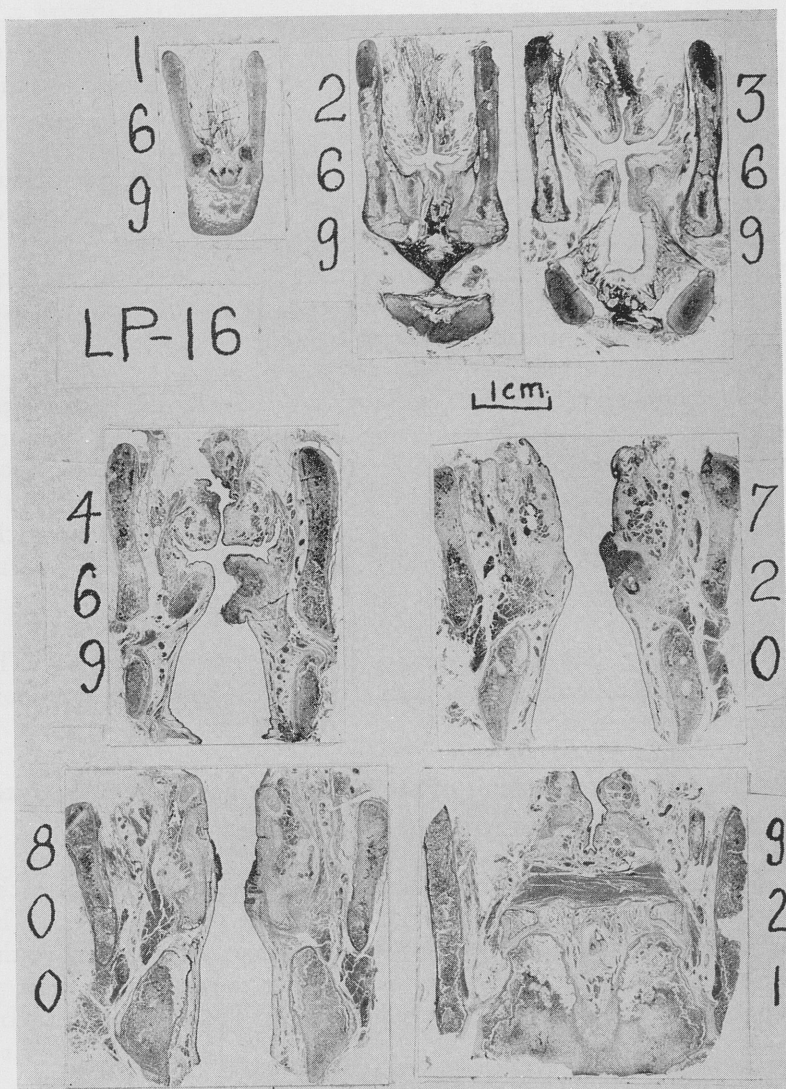


Figure 1

CASE 1. LP-16 (Fig. 1). Total number of sections, 1034.

Section No. 469—Midportion of the true vocal cords. Landmarks to be noted are the thyroid and cricoid cartilages, the true and false cords, and the ventricles extending toward the posterior limits of their respective appendices.

The lesion, squamous carcinoma, is seen to involve the undersurface of the free edge of the left true cord. It extends into the region of the vocalis muscle. Reinke's space is spared above the lesion. The irregularity of the subglottic profile stands out clearly when compared with the normal cord. Much of the space between the conus elasticus and the subglottic mucosa has been spared.

The conus elasticus stands out even more clearly in the next section shown (No. 369). This section is stained for elastic tissue and thus the conus elasticus picks up the stain. The lesion lies just below Reinke's space and just above the conus. As we move more anteriorly it may be noted that the thyroid and cricoid cartilages are approaching one another and that the mucosa is intact inside the cricoid cartilage. The saccules are better developed.

Section No. 269, similarly stained, is even further forward. The cricothyroid membrane may be seen attached to the anterior midportion of the cricoid ring.

This is the anterior limit of the lesion, just posterior to the anterior commissure.

Section No. 169, at the anterior commissure demonstrates the fusion and ossification of the inferior part of the thyroid wings. The anterior ends of the vocal ligament stand out nicely here. Above the anterior commissure the foremost part of the pre-epiglottic space is demonstrated just inside the thyroid notch.

The same lesion may be traced posteriorly:

Section No. 720, at the level of the tip of the vocal processes, shows the thyroid alae to be farther apart, the cricoid ring is enlarging, and the ventricles are no longer seen. The lesion persists just above the vocal process of the left arytenoid.

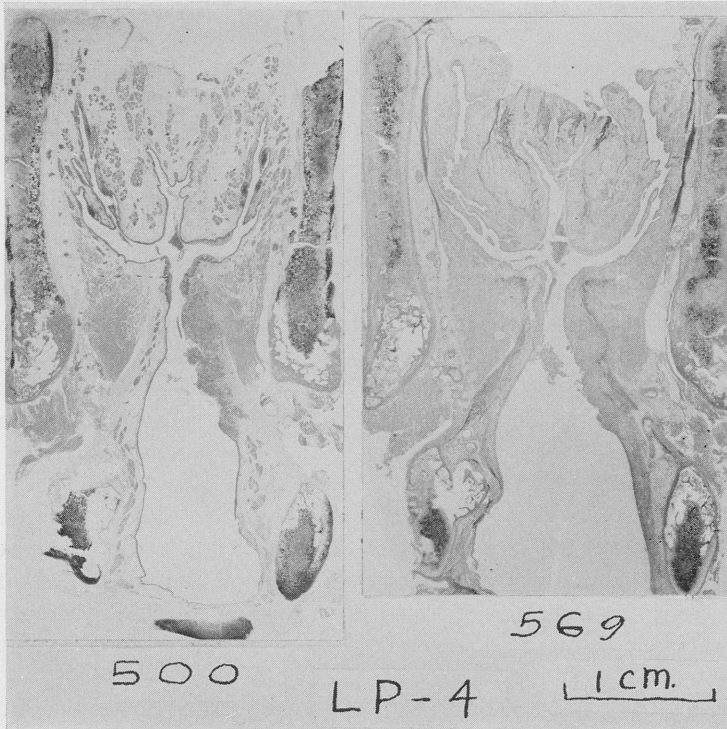


Figure 2

Section 800 shows the arytenoid cartilages better developed and the cut ends of the cricoid about to come together posteriorly. The last remnant of the lesion is on the medial face of the left arytenoid.

The last section shown from this case (No. 921) is at a plane posterior to the lesion. Here is demonstrated the lamina of the cricoid, the interarytenoideus muscle, the crico-thyroid joints, and the crico-arytenoid joints.

CASE 2. LP-4 (Fig. 2). (1300 sections). Two sections Nos. 500 and 569 are both near the midportion of the true cord; No. 500, routine H & E stain; No. 569, Orcein stain for elastic tissue. Landmarks seen here: thyroid and cricoid cartilages, true and false cords, ventricles.

Especially to be noted is the elaborate development of the laryngeal appendices. The lesion, squamous carcinoma, spreads along the subglottic surface of the left true cord. The special elastic stain shows that the conus elasticus is still intact, as is the areolar area inside the cricoid termed "the cricoid area" by Pressman.⁷

CASE 3. LP-17 (Fig. 3) (1290 sections). Section No. 572, (mid-cord), stained with Verhoeff-Van Giessen—for elastic tissue shows a much more extensive tumor. The supraglottic laryngeal structures are replaced by a squamous carcinoma which seems to stop at the level of the left ventricle. On the right side the cancer extends downward lateral to the true cord and is margined by the right conus elasticus.

This lesion when traced forward past the anterior commissure, section No. 369, to sections No. 269 and 169 is seen to fill the pre-epiglottic space.

Section No. 960 shows the posterior extension of the lesion lateral to the right arytenoid; here it encroaches on the anterior wall of the right pyriform sinus. Also, to be noted in this section is the entrance of the vessels through foramina in the alae of the thyroid cartilage.

CASE 4. (Fig. 4) LP-9 (900 sections) is of particular interest since the carcinoma shown here occupies the region normally occupied by the laryngeal appendix,³ or saccule.

Section No. 450 shows the endolaryngeal mucosa of the true and false cords to be intact. It was only on the third biopsy deep in the left ventricle, because of persistent fullness of the left false cord, that a diagnosis of carcinoma was made. The biopsy site is seen in section No. 410.

Sections No. 290, 250, and 210 show the anterior distribution of the lesion in planes through the anterior commissure and forward in the pre-epiglottic space just inside the thyroid notch.

PREPARATION OF THE LARYNGEAL SECTIONS

The method is essentially a modification of the technique for preparing temporal bones as used by Guild and Crowe in the otological

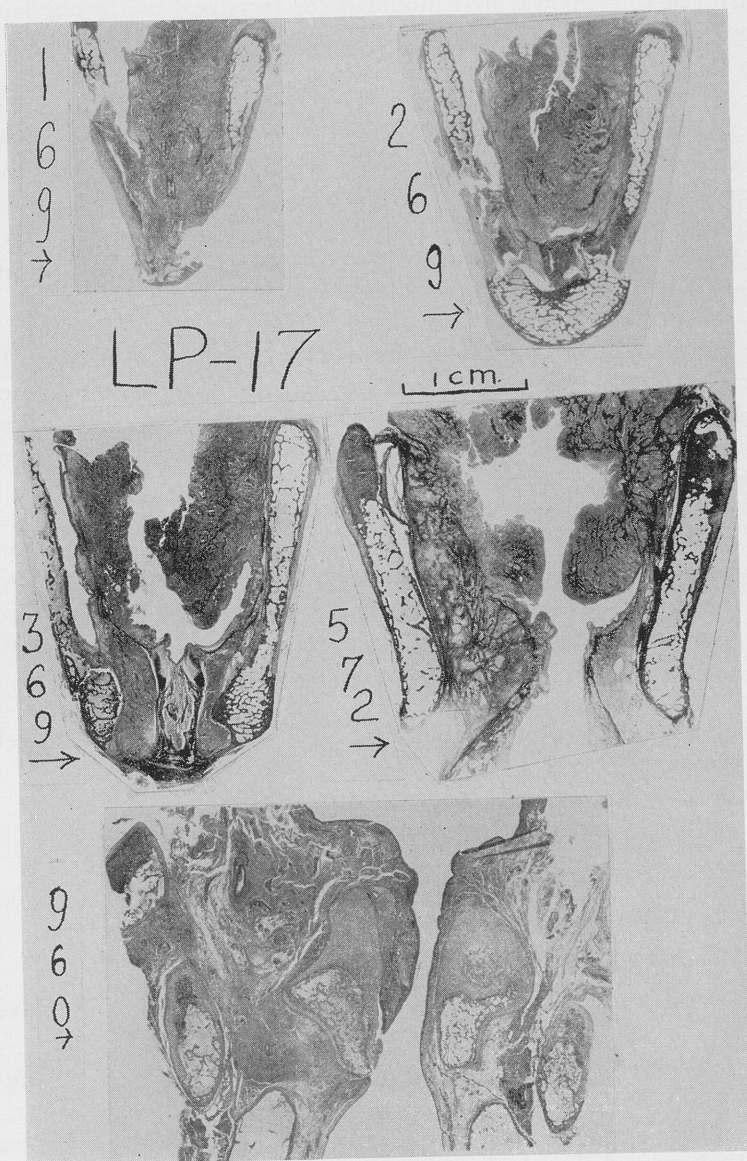


Figure 3

laboratory of the Johns Hopkins University School of Medicine for many years. This was first modified for laryngeal use in our laboratory by Broyles² in his classical work on the anterior commissure tendon and anterior commissure tumors.

Preservation. Material obtained from the operating room, in the case of simple laryngectomy, or from the pathological laboratory, after removal of the neck dissection part of the specimen in the case of composite laryngectomy, is placed in a large volume of 20% formalin for forty-eight hours. It is then carried through three daily changes of 10% formalin.

Decalcification. This is done with 1% nitric acid in 10% formalin. This solution is changed daily until the calcium precipitation test is negative, then carried through a 5% aqueous solution of sodium sulphate (two daily changes) and thoroughly washed in running water before dehydration.

Dehydration. This is accomplished by consecutive daily changes of alcohol of the following percentage concentrations: 35, 50, 80 (two days), 90, 95 (two days), absolute (two days) into equal parts absolute alcohol and ether, preparatory to imbedding in nitro cellulose.

Infiltration and Imbedding. This lengthy but important part of the technique is done by using increasing strengths of nitro-cellulose dissolved in ether alcohol.

6% nitro-cellulose . . . approximately seven weeks

12% nitro-cellulose . . . two weeks

20% nitro-cellulose . . . two weeks

30% nitro-cellulose . . . five weeks

35% nitro-cellulose . . . with very slow evaporation of the solvent

until sufficient hardening has occurred; this may require as long as 14 to 18 weeks. The specimen is then flooded with chloroform to complete the hardening and finally transferred to 80% alcohol. Blocks may be kept indefinitely in 80% alcohol.

Sectioning. Blocks are cut using a Spencer No. 860 microtome specially modified for large specimens. Spencer No. 865 microtome,

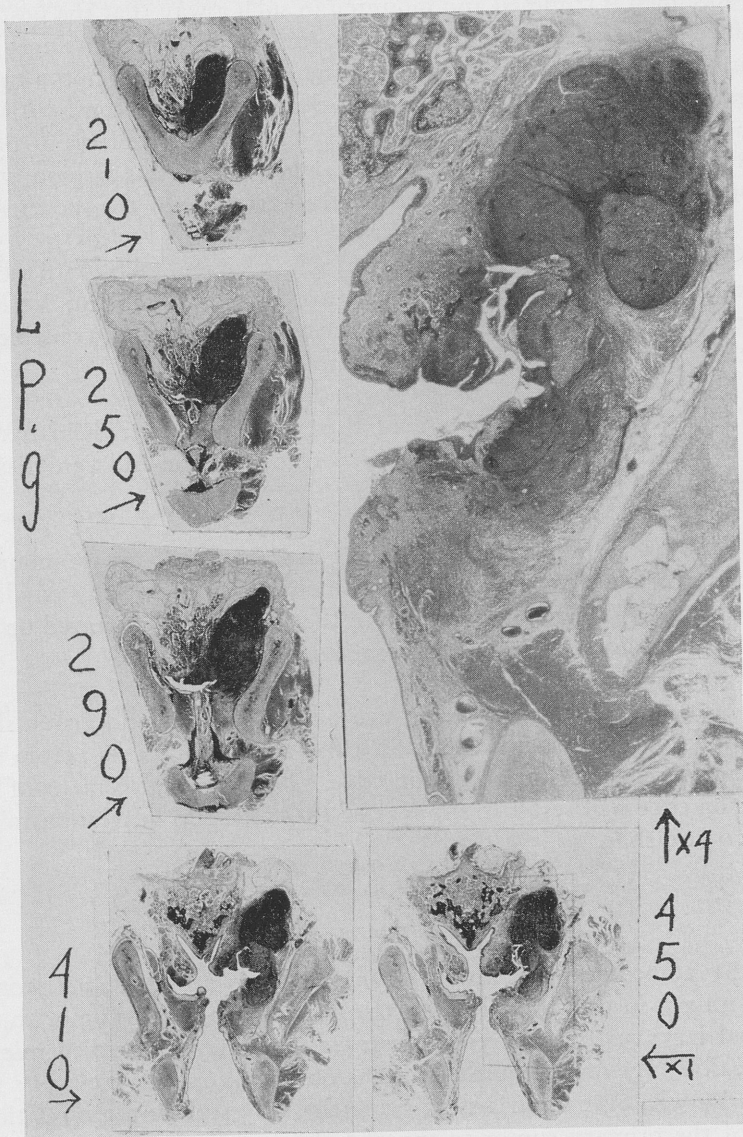


Figure 4

if available, is even more useful. The block of celloidin containing the specimen is trimmed and mounted in such a way that the posterior surface of the cricoid is parallel to the surface of the mounting block, thus placing the body of the hyoid bone and the thyroid notch uppermost. Serial sections are cut at a thickness of 24 microns. All sections are saved, and kept in serial order on numbered pieces of paper, in 80% alcohol. The average larynx, when cut in this fashion, yields 1100 to 1700 sections, depending on the exact size of the specimen.

Staining. For the first study of each specimen, each tenth section is stained, alternating between hematoxylin and eosin and Verhoeff elastic and eosin. This leaves nine-tenths of the sections available for special stains or further studies as desired.

The staining techniques used thus far have been: hematoxylin and eosin, Verhoeff elastic and eosin, Verhoeff elastic and van Giessen, Masson, PAS and Verhoeff-PAS.

Mounting. With large specimens all stained sections are mounted on lantern slide cover glass ($3\frac{1}{4} \times 4$ inches) using specially cut large cover slips. With smaller specimens, the sections are mounted on the 2 x 3 glass slides used for temporal bone sections.

Storage. Due to the large size of the sections and cover slips, the mounted sections must be stored flat for many weeks before any attempt is made to store them on edge. Premature placement of the slides on edge will result in slippage of the cover slip in relation to the section and slide.

SUMMARY

By embedding the intact larynx in nitro-cellulose and serially sectioning it in the coronal plane, the relationship of the tumor to the normal laryngeal structures is preserved, and may be studied microscopically. By review of the sections obtained, one may classify the lesion by whatever criteria seem pertinent. By studying the relationship of the primary tumor to the underlying connective tissue structures, especially the conus elasticus and the laryngeal compartments, inferences may be drawn as the initial mode of spread of a given lesion. The lesion is thus placed in perspective not only with relation to the mucosal surface of the larynx, but also to the underlying anatomical

structures. It is hoped that this method will shed some light on the method of extension of carcinoma within the larynx.

I am indebted to Dr. Stacy Guild not only for his basic method of preparation of material but for his interest and advice. The senior technician, Mr. James Clarke, who spent many years with Dr. Guild, did all the technical work on the early specimens. With the financial support of the American Cancer Society, Mr. Rhine Luha has continued Mr. Clarke's work.

Words cannot express the debt which I owe to Dr. Broyles for his initial work in the preparation of sections of the whole larynx; also the debt all of us at the Hopkins owe to Dr. Broyles who, as head of the Bronchoscopic Clinic, for many years, has kept an active interest in laryngology going in our institution.

REFERENCES

1. Barretto, P. deM.: Nomenclature and Staging of Malignant Tumors of the Larynx and of the Hypopharynx. *A.M.A. Arch. Otolaryngol.* 68:160-164 (Aug.) 1958.
2. Broyles, E. N.: The Anterior Commissure Tendon. *ANNALS OF OTOTOLOGY, RHINOLOGY AND LARYNGOLOGY* 52:342 (June) 1943.
3. Broyles, E. N.: Anatomical Observations Concerning the Laryngeal Appendix. *Trans. Amer. Laryngol. Assn.* 80:180 (Mar.) 1959.
4. Kirshaber, 1879: From Orton (see ref. 6 below).
5. Low-Beer, B. V. A., and Morrison, L. F.: Radiation Treatment of Carcinoma of the Larynx: in *Otolaryngology* (ed. by Coates, G. M., Schenck, H. P., and Miller, M. N.) 5:8:20-21, W. F. Prior Co., 1955.
6. Orton, H. B.: Laryngectomy and Pharyngectomy: in *Otolaryngology* (ed. Coates, Schenck, and Miller) 5:7:1-8.
7. Pressman, J. J.: Submucosal Compartmentation of the Larynx. *Trans. Amer. Laryngol. Assn.* 77:165-172 (Sept.) 1956.
Pressman, J. J.: Anatomical Studies Related to the Dissemination of Cancer of the Larynx. *Trans. Amer. Acad. Ophthal. and Otolaryngol.* 64:628-638 (Sept.) 1960.
8. Tucker, G.: Diagnosis and Treatment of Cancer of the Larynx. *J.A.M.A.* 149:119-121 (May) 1952.
9. Kernan, J. D.: The Pathology of Carcinoma of the Larynx Studied in Serial Sections. *Trans. Am. Acad. Ophthal. and Otolaryng.* 55:10-21 (Sept.-Oct.) 1950.

DISCUSSION

DR. JOSEPH P. ATKINS (Philadelphia): Dr. Tucker is to be complimented on this excellent presentation. He has presented us with a technique of study of laryngeal lesions which has a number of unique features, several aspects of which are, so far as I know, completely original. The idea of studying the anatomy by means of serial section is a widely accepted and useful technique and certainly many of

the advances in otology have been accomplished by the use of this technique. As Dr. Tucker has mentioned, the work at Johns Hopkins has been particularly outstanding in this field.

With regard to utilizing this technique in the larynx, he has already mentioned the work which Dr. Broyles has done in his classic work on the anterior commissure, but Dr. Tucker has taken two steps which I think we could call original. The first of these is that he orients us to the coronal plane of the larynx and this makes his study correspond well with clinical descriptions of the larynx. We can observe the larynx in the same plane both by mirror laryngoscopy and direct laryngoscopy.

A further original aspect of the technique of this study is its application to the investigation of the spread of carcinoma within the larynx. By so doing, he calls attention to the compartmentation which the larynx possesses and which Dr. Pressman has investigated by a different technique. It is obvious that a considerable amount of clinical material will have to be observed before Dr. Tucker is ready to draw any conclusions from these observations.

From what we have seen today, it becomes obvious that any system of classification of laryngeal carcinoma will have to consider the unique information which can be compiled from studies of material prepared in this manner. After looking at this material, one is concerned as to whether or not the characteristic of tumor growths in the larynx will permit us to plan operations which remove the supraglottic larynx and conserve laryngeal function or perhaps define more accurately which supraglottic lesions are amenable to such management and which are not.

I would like to ask Dr. Tucker if his observations thus far warrant the suspicion that the conus elasticus may be a barrier to tumor spread, as has been suggested by some of the material which he has shown us today.

I would also like to ask him if there are other aspects of laryngology which he feels might be amenable to the application of this method.

DR. EDWIN N. BROYLES (Baltimore): I would like to thank Dr. Tucker for the last slide he showed. I have been talking for a long time about the laryngeal appendix or the laryngeal saccule and have been looking for a tumor that started off in this region. It would be very difficult to diagnose. You see a swelling and take biopsy material. If you don't bite deep enough the biopsy comes out negative.

Dr. Tucker found a case with tumor growing in the saccule. He brought out the fact that it took three biopsies to finally diagnose it. I want to thank him for showing that repeat biopsies may be necessary.

DR. ANDERSON C. HILDING (Duluth): I wanted to ask Dr. Tucker, or anyone else who can answer the question, where squamous cell carcinoma of the cord is most apt to start, anterior third, middle third or posterior third.

DR. JAMES McNALLY (Montreal): I don't think we should let this moment go by without saying what a nice paper this was and how delighted Dr. Gabriel Tucker would be if he could have been here today to see his son carry on the tradition that he has firmly established in the Laryngological Association.

I would like to compliment young Dr. Gabriel very much on this excellent presentation

DR. GABRIEL TUCKER, JR. (Baltimore) (closing): I want first of all to thank the discussors for their kind remarks.

In reference to Dr. Atkins' question about the conus, I can say very little more than I have already said. These sections are suggestive but I don't think we can go further at this time

In relation to his other question about other aspects of otolaryngology, we haven't gone beyond the larynx. I do have one more specimen of a benign lesion.

(Slide) This is a photograph of a large lesion causing laryngeal obstruction. The patient came to us with his tracheotomy already performed. This was biopsied and thought to be hemangioma. Clinically, it was thought that it extended subglottically, and therefore a total laryngectomy was done because it was a massive lesion.

(Slide) The next section is so large that you can't place it on a lantern slide directly, but the epiglottis is here on the left. The trachea turns under a little; therefore, the rings seem to come together. This is the left true cord; this the right true cord. This is the angiomatous mass all through here, and what was clinically thought to be a subglottic extension is actually a pedunculation from the right false cord down through the glottis. You can see with the limited airway why this man had a tracheotomy before he got to us.

Another thing that shows is the cricoid area with a start of angiomatous dilatation. I think this may be significant in terms of the children with laryngeal hemangiomas which are subglottic.

With regard to Dr. Hildings' question, I think I have the same opinion that most people do, that the origin is somewhere in the anterior half, possibly the junction of the middle and anterior thirds. If you include the anterior commissure lesion, I believe you would bring all of these into the forward end of the anterior third.

THE TREATMENT OF
HEAD AND NECK CANCER
WITH THE CONTINUOUS ARTERIAL INFUSION OF
METHOTREXATE AND THE INTERMITTENT INTRAMUSCULAR
ADMINISTRATION OF CITROVORUM FACTOR

ROBERT D. SULLIVAN, M.D.

BOSTON, MASS.

AND

JOHN F. DALY, M.D.

NEW YORK, N. Y.

An increasing number of cancer chemotherapeutic agents have been developed and are currently in use in the management of incurable cancer in man. Definitive clinical studies have demonstrated that the usefulness of these compounds in the management of human cancer is largely limited to the leukemias and lymphomas.¹⁻⁴ Carcinomas of the head and neck region have shown only a slight and variable response to these compounds.^{1,4-6}

The different classes of chemotherapeutic compounds that have received some clinical trials in head and neck cancer include the alkylating agents (e.g., Nitrogen Mustard, Myleran, Cytosan, etc.),^{3,7-11} antimetabolites^{5,6,12} (purine analogues, pyrimidine analogues, antifolic acid compounds), antibiotics^{13,14} (e.g., Actinomycin D, Strepto-

From the Medical and Surgical Services, New York Veterans Administration Hospital and the Department of Otolaryngology, New York University, Schools of Medicine, Bellevue Medical Center and the Sloan-Kettering Institute, New York, N. Y.

This study was supported, in part, by research grant CY-3215 from the National Cancer Institute, Public Health Service, U. S. Department of Health, Education and Welfare.

nigrin, etc.) and miscellaneous compounds^{15,16} (e.g., Mitomycin C). Clinical reports have indicated that the systemic administration of these chemotherapeutic agents has resulted in little practical value in the management of most head and neck neoplasms.

Greater interest in the cancer chemotherapy of these neoplasms has centered around the regional administration of chemotherapeutic compounds in an attempt to enhance the anti-tumor effects in a given area. It has been shown that the arterial administration of Nitrogen Mustard (HN2) will produce profound local effects on normal structures as well as regressive effects on a variety of tumors that have not been observed after the intravenous use of this drug. Thus, the intra-arterial administration of HN2 into the external carotid artery has resulted in objective tumor regression of a variety of neoplasms as well as severe radiomimetic effects on normal structures in the distribution of the artery injected.^{17,18} However, the practical usefulness of this form of therapy is sharply limited by the lack of specificity of HN2.^{19,20}

It seemed feasible to extend the clinical studies of the arterial route of administration of chemotherapeutic agents in head and neck cancer to compounds having a more specific antitumor and antimetabolic effect^{4,12,21-24} than have the alkylating agents. Over the past several years, a number of antimetabolites have been studied by this route of administration, including the glutamine antagonists O-diazoacetyl-L-Serine (A z a s e r i n e), and 6-diazo-5-oxo-L-Norleucine (DON); the pyrimidine antagonists, 5-Fluorouracil, and 5-Fluoro-2'-deoxyuridine, and the anti-folic compound 4-amino-N¹⁰-methyl pteroylglutamic acid (Methotrexate).²⁵ Antimetabolites, however, require a more prolonged period of action before clinical antitumor effects are produced.^{26,27} It seemed reasonable, therefore, to prolong the duration of administration of an antimetabolite in order that those cells which at any given moment are in a metabolically inactive phase, might be affected by the antimetabolite as they sequentially enter a metabolically active phase.

The biologic effect of many antimetabolites can be effectively prevented by the concomitant administration of the specific metabolite (antidote).^{4,28,29} It was postulated that the continuous arterial (regional) administration of supralethal doses of an antimetabolite, together with the intermittent use of the metabolite (antidote) sys-

temically (i.e., intramuscular) might result in an enhanced differential anti-metabolic effect in the regional area, while the vulnerable systemic areas of the body (i.e., bone marrow) were protected by the antidote.

A method of therapy has been developed embodying these hypotheses as follows: The continuous 24-hour administration of an antimetabolite through a catheter inserted into a known site in the arterial blood supply of localized forms of head and neck cancer, together with the intermittent, intramuscular administration of the specific antidote. Clinical studies using Methotrexate as the antimetabolite and Citrovorum Factor (Leucovorin, C.F.) as the metabolite (antidote) have been described in patients with incurable head and neck cancer and other relatively localized neoplasms.³⁰⁻³⁴ This method of therapy is to be distinguished from extra-corporeal isolated perfusion³⁵ which embodies the temporary exclusion of the tumor bearing area from the general circulation for periods of 30 to 60 minutes during which time high concentrations of a drug are perfused in the isolated part.

The purpose of this communication is to describe further experiences with this method of therapy in incurable head and neck cancer.

METHODS

Selection of Patients. Patients with incurable, localized forms of head and neck cancer were selected for study. Patients with various types of incurable head and neck cancer without known metastases are the most suitable candidates for study. In some instances, a patient with an inoperable primary form of head and neck cancer, but with unilateral or bilateral resectable nodes may be a candidate for combination surgery and arterial infusion chemotherapy. In this situation, the neck metastases may be controlled with radical neck dissection while the inoperable primary lesion may be treated by arterial chemotherapy. Patients with various forms of primary head and neck cancer with diffuse bilateral neck metastases outside the distribution of the arteries catheterized (e.g., external carotids) and whose disease in these latter areas cannot be controlled, are not suitable candidates for this form of regional chemotherapy. Patients who have had prior radiotherapy whose recurrent or unresponsive disease is within the distribution of one or more of the external carotid

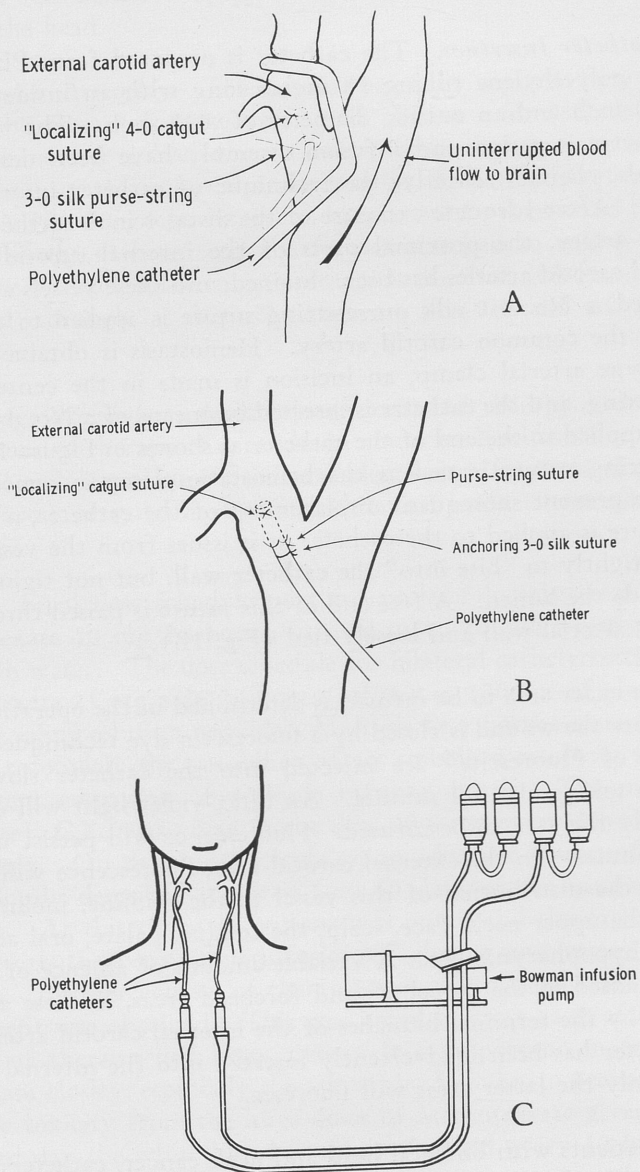


Fig. 1.—Catheter insertion and infusion assembly.

arteries are suitable candidates for a trial of the method of therapy herein reported.

Catheter Insertion. The catheter is prepared from PE-60 Clay Adams polyethylene tubing 18 inches long with an inside diameter of .030 inch and an outside diameter of .048 inch. The techniques of catheter insertion and infusion assembly have been described in detail elsewhere.³⁶ Briefly, the technique of catheter insertion is as follows: After adequate exposure of the distal 1 inch of the common carotid artery, the proximal parts of the internal carotid and the external carotid arteries has been obtained, and these vessels accurately identified, a No. 4-0 silk purse-string suture is applied to the distal part of the common carotid artery. Hemostasis is obtained with a Beck-Type arterial clamp, an incision is made in the center of the purse-string, and the catheter is inserted by means of a No. 4-0 catgut suture applied to the end of the catheter as shown in Figure 1A. The purse-string suture is tied as the hemostatic clamp is removed. In order to prevent subsequent displacement of the catheter, a No. 3-0 silk suture is applied to the catheter as it issues from the vessel, sufficiently tightly to "bite into" the catheter wall, but not tight enough to occlude the lumen. A free end of this suture is passed through the adjacent arterial wall and loosely tied (Fig. 1B).

The exact area to be infused is determined in the operating room and before the wound is closed by a fluorescein dye technique. Three to 6 cc of Fluorescite® are injected into the catheter slowly, the injection taking about 1 minute. An ultra-violet light will delineate accurately the area to be infused. Fluorescence will persist up to 30 to 60 minutes. In the external carotid area, fluorescence will be seen through the distribution of this vessel to the midline, including the skin of the upper neck, face, scalp, the tongue, palate, oral and nasal mucosa, hypopharynx, etc. A variable amount of absence of fluorescence is noted in the palpebrae and forehead areas, as these areas are supplied by the terminal branches of the internal carotid arteries. If the catheter has been inadvertently inserted into the internal carotid artery, only the latter areas will fluoresce.

In patients with bilateral head and neck cancer, catheters are inserted into both external carotid arteries through bilateral neck incisions. The catheter is brought out through the inferior margin of the skin incision, without fixation to the skin, flushed with saline and

the proximal end is clamped. The clamp is affixed to the anterior chest wall with adhesive tape, leaving sufficient slack to permit movement of the head.

Catheter Assembly. The infusion assembly is put in operation as soon as the patient has recovered and glucose and water or saline solution is infused to keep the catheter patent; therapy may be instituted at any suitable interval depending on the patient's general condition. A No. 20-gauge intravenous type needle is inserted into the free end of the catheter and the former attached to rubber tubing which passes through the fingers of a Bowman Infusion Pump and is connected through a drip chamber to liter bottles of infusate (Fig. 1C).

Dosage Schedules. An adequate course of therapy is defined as that amount of therapy that results in moderate local toxicity (diffuse unilateral or bilateral superficial oral ulcerations if unilateral or bilateral therapy) or systemic toxicity (mucosal lesions, hematologic depression).

The usual dose schedule used for unilateral catheterization was Methotrexate 50 mg/24 hours, infused in 1000-2000 cc of saline or glucose in water. The dose schedule for bilateral catheterizations was, Methotrexate 25 mg/side/24 hours, infused in 1000 cc of glucose and water or saline solution per side. Multiple liter bottles were set up in tandem to obviate the possibility of air embolism resulting from the inadvertent emptying of a single infusion bottle. The metabolite (antidote), C.F., was given in the dose of 6 mg every 6 hours intramuscularly. On these dose schedules, an adequate course of therapy as previously described required 5 to 10 days of continuous arterial infusion. At this time, the patient was rested and the catheter kept patent with the continuous infusion of glucose and water or saline solution. Further courses of therapy were given until maximal clinical benefit was obtained. This was noted in most cases after 1 to 3 courses of therapy had been given. It is important to follow the hemogram closely, especially the white blood count, to prevent serious systemic toxicity from the huge doses of Methotrexate given. After the third day the white blood count is obtained every 12 hours, and when definite leukopenia is evident, therapy is stopped or the amount of antidote (C.F.) increased. Patients with renal insufficiency do not excrete Methotrexate in a normal manner and severe toxicity may

TABLE I

RESULTS OF CONTINUOUS ARTERIAL INFUSION OF METHOTREXATE
AND INTERMITTENT INTRAMUSCULAR ADMINISTRATION OF
CITROVORUM FACTOR IN HEAD AND NECK CANCER

	NO. OF PATIENTS	NO. OF ADEQUATE COURSES*	NO. EVALUATED FOR THERAPEUTIC EFFECT	TUMOR RESPONSE	
				PARTIAL	COMPLETE
Epidermoid					
Carcinoma	40	31	27	21	6
Lymphosarcoma	6	6	6	4	2
Miscellaneous forms of cancer	2	2	2	1	0
	—	—	—	—	—
Total	48	39	35	26	8

* See text for definition of "adequate course of therapy."

rapidly develop; considerably larger doses of the antidote are necessary in these instances.

RESULTS

Forty-eight patients with various types of inoperable head and neck cancer have had unilateral or bilateral external carotid catheterizations as follows: Epidermoid carcinoma, 40 patients; lymphosarcoma, 6 patients; miscellaneous forms of cancer, 2 patients (Table I).

There were 39 patients in whom at least one adequate course of therapy was given. An adequate course of therapy has been defined above and was considered to have been given when moderate local or systemic toxicity was noted. Four patients who received one adequate course of therapy were not evaluated for therapeutic effect because of the difficulty in determining the clinical extent of the disease. Thirty-five patients were evaluated for therapeutic effect. In 26 patients there was some partial objective tumor regression, often associated with clinical benefit. In the majority of these patients, cancer was present in contiguous areas outside the actual area of

infusion therapy. In 8 patients whose disease was confined to the area of therapy, there was total objective tumor regression.

In those patients in whom measurable disease was present in the areas of therapeutic infusion, response was noted as early as the 4th day and was characterized by a progressive decrease in visible tumor. The tumors appeared cleaner as they regressed and were apparently absorbed as the neoplastic cells were sequentially killed. Mucosa covered the sites of absorbed tumor, but in many cases, large defects remained, especially in patients with sinus tumors with extensive involvement of the hard palate; in these patients there were residual oro-nasal defects.

REPORT OF CASES

CASE 1. Epidermoid carcinoma of the maxillary sinus. The patient is a 72 year old white male whose diagnosis was established by biopsy in January 1959. There was diffuse involvement of the right maxillary sinus with extension to the naris and hard palate bilaterally. Bilateral catheters were inserted into the external carotid arteries in February 1959, and the patient received continuous arterial infusion of Methotrexate with intermittent intramuscular C.F. therapy over a period of six days. Total gross tumor regression occurred and the patient was free of apparent disease for eight months. Recurrence in the right maxillary sinus and soft tissues of the face occurred in September 1959 (Fig. 2A). Bilateral external carotid catheters were again inserted and the patient received a 15-day course of therapy in the following dosage: Methotrexate 25 mg/side/day; C.F. 6 mg intramuscularly every 6 hours. Progressive tumor regression occurred and by the 15th day there was no gross evidence of cancer (Fig. 2B). There were no manifestations of systemic toxicity due to Methotrexate. The patient was in remission for the next 15 months when a small lesion was noted in the right naris. On biopsy, this proved to be epidermoid carcinoma. This has responded to a third course of therapy and the patient is at present free of apparent disease.

Comment. Total gross tumor regression was noted in each instance following three courses of therapy given over a 22-month period. There was no apparent development of "drug resistance."

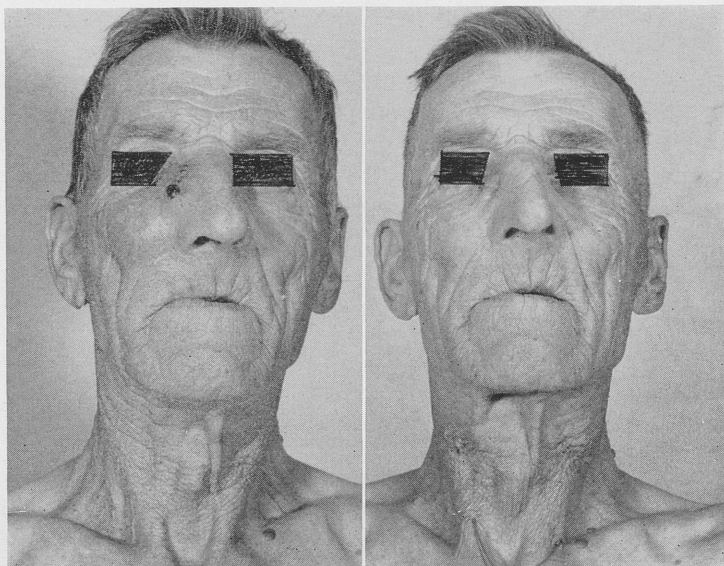


Fig. 2.—Case 1. Epidermoid carcinoma of the maxillary sinus. *Left.* before therapy. Note tumor extending into the soft tissues of the face. *Right,* after therapy. Note the total gross tumor regression that has occurred.

The patient is at present free of gross disease 28 months after the first course of therapy.

CASE 2. Epidermoid carcinoma of the hypopharynx. The patient is a 53 year old white male in whom the diagnosis of epidermoid carcinoma of the hypopharynx was established by biopsy in December 1960. He had had symptoms of increasing dysphagia, dysarthria and dyspnea over a 3 month period. There was a bulky, fungating tumor of the hypopharynx occupying the entire area of the hypopharyngeal wall posteriorly and extending to the lateral walls (Fig. 3). The mass was in contact with the epiglottis and limited the airway. There were no palpable neck nodes. On December 9, 1960, bilateral external carotid catheters were inserted and the patient received a 6-day course of infusion therapy as follows: Methotrexate 25 mg/side/24 hours; C.F. 6 mg every six hours intramuscularly. Progressive decrease in visible tumor occurred and the patient

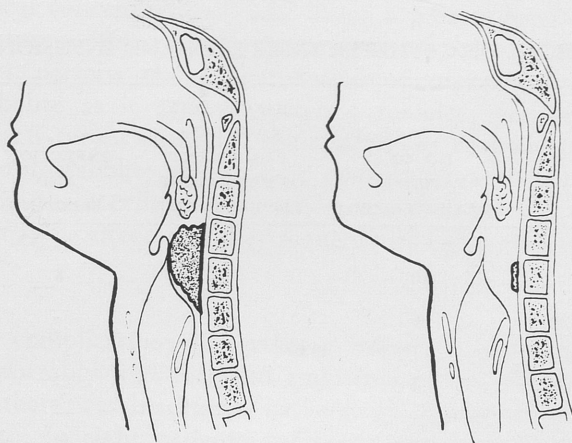


Fig. 3.—Case 2. Epidermoid carcinoma of the hypopharynx. *Left*, before therapy. Note the large, fungating tumor involving the posterior wall of the hypopharynx. *Right*, after therapy. Note the tumor regression that has occurred. There was a residual lesion on the posterior hypopharyngeal wall measuring approximately one cm in diameter.

became asymptomatic. A second five-day course of therapy was administered through the left external carotid catheter as follows: Methotrexate 50 mg/24 hours; C.F. 6 mg every six hours intramuscularly. On January 24, 1961, laryngoscopy demonstrated a slightly elevated lesion 1 cm in diameter on the posterior wall (Fig. 3B). Biopsy revealed epidermoid carcinoma. On February 10, 1961, excision of this area through a lateral pharyngotomy was performed. A skin graft was used to repair the posterior pharyngeal wall. The patient has remained free of gross disease to date, six months after onset of therapy.

Comment. This patient demonstrates the combined use of surgery and chemotherapy. An extensive fungating lesion of the hypopharynx was reduced in size by 90 to 95% by arterial infusion chemotherapy and was rendered easily resectable.

In those patients in whom partial tumor regression occurred, response has lasted for 1 to 3 months. In those patients in whom total

TABLE II
COMPLICATIONS OF CATHETER INSERTION AND INFUSION ASSEMBLY

	NO. OF PATIENTS CATHETERIZED	INACCURATE CATHETER PLACEMENT OR PREMATURE DISPLACEMENT	INFECTION AND BLEEDING	LEAKAGE
Epidermoid Carcinoma	40	6	8	3
Lymphosarcoma	6	-	-	2
Miscellaneous forms of cancer	2	-	-	1
	—	—	—	—
Total	48	6	8	6

tumor regression occurred, response has persisted for periods of follow-up of up to 15 months, before relapse was noted.

Complications relating to catheter insertion, and maintenance of infusion assembly are tabulated in Table II. Varying degrees of local or systemic Methotrexate toxicity were noted in most patients. The former was characterized by a mucositis and slight erythema of the skin within the areas of therapy. Systemic toxicity was characterized by varying degrees of hematologic depression and non-specific, diffuse oral ulceration. In most cases, systemic toxicity was moderate and could often be controlled by adjusting the dose of the antidote.

COMMENT

The results of this study demonstrate that the anti-tumor activity of an antimetabolite (Methotrexate) can be increased in patients with head and neck cancer by regional administration (arterial infusion) in supralethal doses, when the specific antidote (C.F.) is given in appropriate dosage by the systemic route to protect vulnerable areas of the body (i.e., bone marrow, gastrointestinal tract).

The increased anti-tumor activity of Methotrexate noted in this study is considered to be related to the following factors: a) route of

administration - The arterial route of administration results in a higher local concentration,³⁷ and hence a greater local antimetabolic and anti-tumor effect; b) the systemic use of the antidote (i.e., intramuscular) permits the administration of supralethal doses of the antimetabolite as it reduces systemic toxicity, yet preserves some regional anti-tumor effect; c) the *continuous* 24-hour administration of the antimetabolite results in a *continuous* anti-metabolic effect, and hence, those cells that at any given moment are metabolically inactive may be affected as they sequentially enter an active metabolic phase.^{38,39}

The complications of catheter insertion and maintenance of infusion assembly were frequent and often serious (Table II). In six patients, there was inaccurate catheter placement or premature displacement. In eight patients, infection associated with varying degrees of bleeding occurred. In several patients, the hemorrhage was of such severity that ligation of one or more of the great vessels of the neck was necessitated. Leakage of infusate of varying degree was noted in six patients. In most of these patients, the leakage prevented the completion of therapy.

Inaccurate placement of the catheter may be prevented by careful attention to techniques of catheter insertion and the use of the fluorescein dye technique to accurately demonstrate the area of infusion therapy. Premature displacement of the catheter results from the inadequate application of the "holding sutures" as the catheter issues from the artery. Infection around the catheter, in most cases the cause of hemorrhage, is usually due to failure to observe rigid sterile precautions. It must be emphasized that the most meticulous sterile techniques must be used whenever the catheter or the infusion assembly is manipulated in order to obviate the serious complication of infection and hemorrhage.

Other methods of catheter insertion, including retrograde catheter introduction and the ligation of various arteries to develop a collateral circulation into inaccessible areas are being explored to extend the usefulness of this method of therapy and to reduce the complications of techniques currently in use. Other dose schedules of Methotrexate and C.F. as well as other cancer chemotherapeutic agents are being investigated by this method of administration.

This method of therapy is in the area of clinical investigation and its possible place in the conventional therapy of head and neck cancer is not as yet clearly defined.

The casual use of this technique of drug administration is strongly discouraged; a team consisting of surgeons and cancer chemotherapists, cognizant of the problems of techniques and drug toxicity, together with a carefully planned program of clinical investigation is mandatory before initiating a program of regional infusion.

SUMMARY

The systemic administration of cancer chemotherapeutic compounds in patients with incurable head and neck cancer has resulted in little benefit in the practical management of these diseases.

A method of therapy is described which embodies the *regional* (arterial) 24-hour administration of supralethal doses of an anti-metabolite (Methotrexate), together with the intermittent use of the specific meabolite (antidote - Citrovorum Factor) to prevent serious systemic toxicity.

Techniques of catheter insertion and fixation, maintenance of infusion assembly and dose schedules are reported.

Forty-eight patients with various types of incurable head and neck cancer had unilateral or bilateral external carotid catheterization. There were 39 patients in whom at least one adequate course of therapy was given. Thirty-five patients were evaluated for therapeutic effect. Of these, 26 patients had partial tumor regression. In these patients, tumor was also present in contiguous areas outside the area of infusion therapy. In eight patients in whom tumor was present only in the area of therapy, there was complete apparent tumor regression. Response persisted from 1 to 3 months in the former category and up to 15 months in the latter category.

Complications were frequent and consisted of inaccurate placement of catheter or premature displacement of catheter - six patients; infection and/or bleeding around catheter - eight patients; leakage of infusion around catheter - six patients.

Techniques are being explored to extend this method of therapy to other areas of the body, and other chemotherapeutic compounds are being investigated for possible enhanced anti-tumor effects resulting from regional administration.

This method of administration is in the area of investigation and its place in clinical medicine is not yet defined. The casual use of this technique is strongly discouraged; a team consisting of surgeons and cancer chemotherapists, cognizant of the problems relating to techniques and drug toxicity, is mandatory before initiating a program of regional infusion.

605 COMMONWEALTH AVE., BOSTON

140 EAST 54TH ST., N. Y. C.

REFERENCES

1. Burchenal, J. H., Murphy, M. L., Ellison, R. R., Sykes, M. P., Tan, T. C., Leone, L. A., Karnofsky, D. A., Craver, L. F., Dargeon H. W. and Rhoads, C. P.: Clinical Evaluation of New Antimetabolite, 6-Mercaptopurine, in Treatment of Leukemia and Allied Diseases. *Blood* 8:965-999, 1953.
2. Curreri, A. R., Ansfield, F. J., McIver, F. A., Waisman, H. A., and Heidelberger, C.: Clinical Studies with 5-Fluorouracil. *Cancer Res.* 18:478-484, figs. 1-9, 1958.
3. Karnofsky, D. A., Burchenal, J. H., Armistead, G. C., Jr., Southam, C. M., Bernstein, J. L., Craver, L. F., and Rhoads, C. P.: Triethylene Melamine in Treatment of Neoplastic Disease; Compound with Nitrogen-Mustard-Like Activity Suitable for Oral and Intravenous Use. *A.M.A. Arch. Int. Med.* 87:477-516, 1951.
4. Magill, G. B., Myers, W. P. L., Reilly, H. C., Putnam, R. C., Magill, J. W., Sykes, M. P., Escher, G. C., Karnofsky, D. A., and Burchenal J. H.: Pharmacological and Initial Therapeutic Observations on 6-Diazo-5-oxo-L-norleucine (DON) in Human Neoplastic Disease. *Cancer* 10:1138-1150, 1957.
5. Taylor, S. G., III, Hass, G. M., Crumrine, J. L., and Slaughter, D. P.: Toxic Reactions of 4-Amino-pteroylglutamic Acid (Aminopterin) in Patients with Far-Advanced Neoplastic Disease. *Cancer* 3:493-503, 1950.
6. Sullivan, R. D., Miller, E., Murphy, V. B., and Mechanic, R.: The Value of 5-Fluorouracil in Human Cancer. *Proc. of the Amer. Assn. for Cancer Research* 3:1:68 (Mar.) 1959. (Abstr.)
7. Karnofsky, D. A.: Nitrogen Mustards in Treatment of Neoplastic Disease. *Advances Int. Med.* 4:1-75, 1950.
8. Karnofsky, D. A.: Summary of Results Obtained with Nitrogen Mustard in Treatment of Neoplastic Disease. *Ann. New York Acad. Sc.* 68:899-914, 1958.
9. Sullivan, R. D.: Myleran Therapy in Bronchogenic Carcinoma. *Ann. New York Acad. Sc.* 68:1038-1045, 1958.

10. Miller, E.: Clinical Trials of Nonane in Malignant Disease. *Ann. New York Acad. Sc.* 68:1205-1210, 1958.
11. Rhoads, C. P.: Nitrogen Mustards in Treatment of Neoplastic Disease; Official Statement. *J.A.M.A.* 131:656-658, 1946.
12. Ellison, R. R., Karnofsky, D. A., Sternberg, S. S., Murphy, M. L., and Burchenal, J. H.: Clinical Trials of O-diazoactyl-L-serine (Azaserine) in Neoplastic Disease. *Cancer* 7:801-814, 1954.
13. Tan, C. T. C., Dargeon, H. W., and Burchenal, J. H.: Effects of Actinomycin D on Cancer in Childhood. *Pediatrics* 24:544, 1959.
14. Hackenthal, C. A., Golbey, R. B., Tan, C. T. C., Karnofsky, D. A., and Burchenal, J. H.: Clinical Observations on the Effects of Streptonigrin in Patients with Neoplastic Disease. *Antib. and Chemotherapy* (in press).
15. Colsky, J., Escher, G. C., Evans, A., Mitus, A., Li, M. C., Roath, S., Sullivan, R. D., Sykes, M. P. and Tan, C. T. C.: Preliminary Clinical Pharmacology of Mitomycin C. *Proc. Amer. Assoc. Cancer Research* 3:13, 1959.
16. Submitted by the Cooperating Investigators: Mitomycin C - A Preliminary Report of Studies of Human Pharmacology and Initial Therapeutic Trial. *Cancer Chemotherapy Reports* 2:3-7, 1959.
17. Klopp, C. T., Alford, T. C., Bateman, J., Berry, G. N., and Winship, T.: Fractionated Intra-Arterial Cancer; Chemotherapy with Methyl Bis Amine Hydrochloride; Preliminary Report. *Ann. Surg.* 132:811-832, 1950.
18. Krakoff, I. H., and Sullivan, R. D.: Intra-Arterial Nitrogen Mustard in Treatment of Pelvic Cancer. *Ann. Int. Med.* 48:839-850, 1958.
19. Sullivan, R. D., Jones, R., Jr., Schnabel, T. G., Jr., and Shorey, J. M.: Treatment of Human Cancer with Intra-Arterial Nitrogen Mustard (Methylbis(2-chlorethyl)amine hydrochloride) Utilizing Simplified Catheter Technique. *Cancer* 6:121-134, 1953.
20. Sullivan, R. D., Mescon, H., and Jones, R., Jr.: Effect of Intra-Arterial Nitrogen-Mustard (Methylbis(2-chlorethyl)amine hydrochloride) Therapy on Human Skin. *Cancer* 6:288-293, 1953.
21. Karnofsky, D. A., Burchenal, J. H., Ormsbee, R. A., Corman, I., and Rhoads, C. P.: Experimental Observations on Use of Nitrogen Mustards in Treatment of Neoplastic Disease; in Moulton, F. R., Ed.: *Approaches to Tumor Chemotherapy*. Washington, D. C., Amer. Assoc. for the Advancement of Sci., pp. 293-305, 1947.
22. Hartman, S. C., Levenberg, B., and Buchanan, J. M.: Involvement of ATP, 5-Phosphoribosylpyrophosamide and L-Azaserine in Enzymatic Formation of Glycinamide Ribotide Intermediates in Inosinic Acid Biosynthesis. *J. Am. Chem. Soc.* 77:501-503, 1955.
23. Heidelberger, C., Chaudhuri, N. K., Danneberg, P., Mooren, D., Griesbach, L., Duschinsky, R., Schnitzer, R. J., Plevin, E. and Scheiner, J.: Fluorinated Pyrimidines, New Class of Tumour-Inhibitory Compounds. *Nature, London* 179:663-666, 1957.
24. Skipper, H. E., Bennett, L. L., Jr., and Schabel, F. M., Jr.: Mechanism of Action of Azaserine. *Fed. Proc.* 13:298-299, 1954.
25. Sullivan, R. D.: (Personal Communication).

26. Farber, S., Diamond, L. K., Mercer, R. D., Sylvester, R. F., Jr., and Wolff, J. A.: Temporary Remissions in Acute Leukemia in Children Produced by Folic Acid Antagonist, 4-Aminopteroyl-Glutamic Acid (Aminopterin). *New England J. Med.* 238:787-793, 1948.
27. Miner, R. W., Ed.: 6-Mercaptopurine. *Ann. New York Acad. Sc.* 60:183-508, 1954.
28. Burchenal, J. H., and Kingslye-Pillers, E. M.: Studies on Amethopterin, Citrovorum Factor, and Crude X-methyl Folic Acid in Leukemia (Abstr.). *J. Clin. Invest.* 30:631-632, 1951.
29. Murphy, M. L., Ellison, R. R., Karnofsky, D. A., and Burchenal, J. H.: Clinical Effects of Dicloro and Monochloro-phenyl Analogues of Diamino Pyrimidine; Antagonists of Folic Acid. *J. Clin. Invest.* 33:1388-1396, 1954.
30. Sullivan, R. D., Miller, E., and Sykes, M. P.: Antimetabolite-Metabolite Combination Cancer Chemotherapy. Effects of Intra-Arterial Methotrexate-Intramuscular Citrovorum Factor Therapy in Human Cancer. *Cancer* 12:6:1248-1262, 1959.
31. Sullivan, R. D., Miller, E., Wood, A. M., Clifford, P., Duff, J. K., Trussell, R., and Burchenal, J. H.: Continuous Infusion Cancer Chemotherapy in Humans—Effects of Therapy with Intra-Arterial Methotrexate Plus Intermittent Intramuscular Citrovorum Factor. *Cancer Chemotherapy Reports* 10:39-42, 1960.
32. Sullivan, R. D.: Continuous Arterial Infusion of Methotrexate with Intermittent, Intramuscular Citrovorum Factor Therapy in Head and Neck. *Transactions of the Pacific Coast Oto-Ophthalmological Society* (in press).
33. Sullivan, R. D., Wood, A. M., Clifford, P., Duff, J. K., Trussell, R., Nary, D. J., and Burchenal, J. H.: Continuous Intra-Arterial Methotrexate with Simultaneous, Intermittent Intramuscular Citrovorum Factor Therapy in Carcinoma of the Cervix. *Cancer Chemotherapy Reports* 8:1-6, 1960.
34. Sullivan, R. D., Miller, E., and Duff, J. K.: Effects of Continuous Intra-Arterial Methotrexate with Intermittent Intramuscular Citrovorum Factor Therapy in Human Cancer. *Proc. of Amer. Assoc. for Cancer Research* 3:3:271 (Abstr. No. 273) 1961.
35. Creech, O., Ryan, R. F., and Winblad, J. N.: Regional Perfusion Utilizing an Extra-Corporeal Circuit. *Ann. Surg.* 148:616, 1958.
36. Duff, J. K., Sullivan, R. D., Miller, E., Ulm, A. H., Clarkson, B. D., and Clifford, P.: Antimetabolite-Metabolite Cancer Chemotherapy Using Continuous Intra-Arterial Methotrexate with Intermittent Intramuscular Citrovorum Factor. *Method of Therapy.* (In press - will appear in July-August issue of *Cancer*, 1961.)
37. Liguori, V. R., Giglio, J. J., Miller, E., and Sullivan, R. D.: The Effects of Different Dosage Schedules of Methotrexate on Sera and Tissue Levels and Urinary Excretion Patterns. (In press)
38. Sullivan, R. D., Young, C. W., Miller, C., Glatstein, N., Clarkson, B., and Burchenal, J. H.: The Clinical Effects of the Continuous Administration of Fluorinated Pyrimidines (5-Fluorouracil and 5-Fluoro-2'-deoxyuridine). *Cancer Chemotherapy Reports* 8:77-83, 1960.
39. Miller, E., Sullivan, R., Young, C., and Burchenal, J. H.: Clinical Effects of the Continuous Infusion of Antimetabolites—Prevention of Toxicity of 5-Fluoro-2'-deoxyuridine by Thymidine. *Proc. of Amer. Assoc. for Cancer Research* 3:3:251 (Abstr. No. 192) 1961.

DISCUSSION

DR. JOHN CONLEY (New York): This is a most timely paper, exhibiting the imagination and daring that has gone into the hope of improving the specific treatment and management of cancer in the head and neck by regional perfusion. Doctor Daly and Doctor Sullivan, in their review, have selected a group of 48 patients with so-called incurable cancers in this region for continuous interarterial infusion with an antimetabolite agent, methotrexate. The inevitable toxicity factor was partially controlled by the citrovorum factor.

Cancer chemotherapy is nothing new but the organization of its methods and economic endorsement in the past six years has been startling. The Cancer Chemotherapy National Service Center alone spent \$30,000,000.00 on this program in 1959. Numerous institutions in various countries have concentrated in this work and accelerated the production of knowledge regarding agents, chemicals, techniques, and results.

A word concerning infusion and perfusion in respect to regional cancer chemotherapy may be in order. Infusion consists of supplying a calculated and regulated supply of drug into a selected artery for a given period of time. There is no attempt made to prevent this drug from entering the systemic circulation with its attendant toxicity. This toxicity is combated intermittently by antidote therapy. This technique has the advantages of a protracted primary attack with reasonable control. It is limited primarily to drugs that can be neutralized with specific antidotes. Methotrexate has had almost a monopoly in this category to date. However, antidotes are being sought and approximated for alkalating agents and other chemical compounds. Perfusion on the other hand uses the physiological principle of regional isolation and the administration of superlethal doses to the tumor only. This is accomplished by recovering the perfusate in the regional vein preventing it from entering the systemic circulation and perfusing it again and again through the tumor by means of the regional artery. In the area of the head and neck, complete systemic isolation has been impossible and seepage limits the extent and applicability of the technique. Alkalating agents have dominated in this field.

A review of Doctor Daly's experience highlights the fact that 74% of those patients treated had some clinical regression; 23% had total objective regression of the tumor. The longest control without evidence of tumor lasted 15 months. There is no doubt that the biological destiny of these tumors can be temporarily altered, that techniques are being perfected and that we are awaiting the advent of a more propitious group of chemicals.

Caution is highlighted by the fact that there were 42% complications with catheter insertion alone, not to mention systemic and bone marrow depressions. This certainly demands a specialized program of management rather than haphazard trial as these patients demand very careful observation.

At the present time these experiments and studies are essentially of a pilot nature. They do not supplant surgery or radiation therapy. There is no evidence that they enhance the effect of irradiation. It remains to be seen whether they can reduce local recurrences in resectable lesions and whether there is any significant effect on regional metastasis. They can palliate by reducing pain and to date this has been a significant aspect of their clinical application. They can diminish the size of the tumor, even rendering it operable in selected cases. The over-all pattern that appears to be developing in chemotherapy, however, is that regional perfusion will probably only be a phase in the eventual march toward systemic biological control.

In conclusion, I would like to ask Doctor Daly which artery he employs for infusion of the hypopharynx and superlaryngeal areas.

DR. FRANCIS LEDERER (Chicago): It was Shakespeare who said, "For desperate diseases desperate measures need to be applied." It has been conclusively shown this afternoon by the presentation and by Dr. Conley's remarks that this method of therapy is reserved for those cases that are utterly, if we can use that term, inoperable.

However, I think it is significant, when you review the literature, that thirty or more years ago, before one of our societies, Dr. Joseph C. Beck reviewed the many non-surgical methods that were being used and had been used over the past century—his century—in the treatment of malignancy. Many of these are even represented in this day and age of what one would choose to call, dislike it as you may, Dr. Conley, protoplasmic poisons. It is significant that these drugs or these elements—many of them were elements—had an effect in that they controlled pain, and many of them did reduce the size of tumor. So, it is quite possible that Dr. Sullivan and Dr. Daly will bring us some other means that may be more specific. But Dr. Conley calls attention to a very important anatomical fact and that is that all of these areas that we are concerned with do not permit perfusion of the particular site and that this is going to pose many difficulties.

I would direct your attention to the fact that Dr. Sullivan, I believe, works for the Veterans Administration (I don't know if he comes in under that No. 30 million outlay or not, or whether there is another fund available) and that many of these cases have had complications such as Dr. Conley called attention to. This should make it significant that not everyone should immediately jump into using these techniques. I think that for the present we are going to have to rely on certain centers and skilled experts working in the groups that have already been referred to. We hope for significant progress because neither the scalpel nor irradiation has solved many of the difficulties that confront us in head and neck tumors.

DR. HARRY P. SCHENCK (Philadelphia): I would like to ask Dr. Daly whether they ran into any complications as far as the tongue was concerned. I have seen considerable difficulty with speech after such a technique has been used, and I have also seen at least one instance where there has been considerable effect on the retina. I have been curious to know whether they have run into any of those complications.

DR. JOHN F. DALY (New York) (closing): I would like to thank my discussors for the very excellent treatment of this topic. One thing that may be a little confusing is the length of time that we have been able to maintain these patients alive and free of gross disease. The longest survival time has been twenty-eight months. This was the first patient we presented; the longest period of time any individual patient went without disease between course of therapy was fifteen months.

This form of therapy has some built-in limitations and one of them is posed by the arterial system, itself. More than three course of therapy are rarely given. In the treatment of the hypopharyngeal lesions, we have tried two things. First, we have tried to preserve the superior carotid artery and that is the reason we put the catheter into the bulb and then fixed it to the arterial wall so that the infusate would circulate through the superior thyroid artery.

We have used the superior thyroid artery, itself, on many occasions, but this eliminates that area from the circulation.

Secondly, we have put a catheter into the external carotid, a second into the subclavian, bringing it in contact with the thyrocervical trunk so that we could pick up the circulation through the ascending cervical and the inferior thyroid arteries.

Dr. Lederer has pointed out that man has been questing for a chemical to control cancer for a long time, and Dr. Conley has emphasized how the government has intensified this search by its support. We all agree that this is a very worthwhile cause.

Dr. Sullivan works not only at the Veterans, but also at the Sloan-Kettering Institute in New York City.

The complications are listed in the paper and they are many and they are serious, as Dr. Conley has pointed out. This is the reason why we emphasize that if you go into chemotherapy, do so very seriously because your first attempts will have all of the complications we have had. You will have infection, you will have blow-out of the carotid system, and you will also have depression of bone marrow that will be a progressive thing that you will not be able to reverse.

In relation to Dr. Schenck's question, we haven't seen any complications of this type with Methotrexate therapy. It has occurred, though, with the alkylating agents which are very damaging to the brain and to the retina. We haven't seen any limitation of motion to the tongue. As a matter of fact, in that one case that we showed, a tongue lesion was greatly benefited by this release when the tumor disappeared, the tongue became mobile.

THE PROBLEM OF STOMA CONSTRUCTION IN LARYNGECTOMY CASES

ARTHUR J. CRACOVANER, M.D.
NEW YORK, N. Y.

The construction and management of an adequate stoma in laryngectomy cases has been a problem to us. The subject is presented here, not because we have very unusual ideas about it, but rather to stimulate discussion and ascertain how others deal with this situation. This is very little on the question to be found in the literature and relatively few textbooks give only meager space to a problem that, in our experience, is an important one. The tracheostomata in laryngectomy patients have an unbelievable tendency to close. The opening becomes inadequate and the patient is unhappy, uncomfortable and panicky. A secondary plastic operation is necessary in order to improve the airway, or a laryngectomy tube must be worn constantly.

There was some difficulty in the pre-antibiotic days when fistulae, accompanied by, or produced by infection, seemed to be factors that caused stomata to become small. When antibiotics became available fistulae and infections were much more infrequent and the problem of an adequate stoma was reduced to a minimum. But then it became known that practically all carcinomas of the larynx, except those situated on the vocal cords, readily metastasized to the nodes of the neck. We, therefore, began doing radical neck dissections in continuity with laryngectomies, whether nodes were palpable or not. This added more trauma to the operated field with increased scarring, causing narrowing and distortion of the stoma. Then, to augment this dilemma, virulent staphylococcus infections appeared in the best and most meticulous of our hospitals. Pharyngeal fistulae were again obtained in great numbers and the tracheostomata became small again. This was our experience and I have reason to believe, after

From the Otolaryngological Services of Lenox Hill Hospital and New York Eye and Ear Infirmary.

verbally canvassing a few of our colleagues, that we were not alone in this distressing circumstance.

Let us review some of the reasons why a stoma has a tendency to close. The trachea may be small and its circumference is initially not adequate enough to allow for the scarring and shrinking that occurs with healing. The cartilages of the trachea may be rather thin and soft and unable to withstand the pressure of the surrounding scar contracture. Fistula formation with accompanying infection, or infection alone, will increase the cicatrization around the stoma. Infection of the edges of the opening, as well as perichondritis and chondritis of the tracheal cartilages, will reduce the size of the stoma. In some cases this may be due to the fact that the trachea has been freed too generously from the surrounding tissue, leaving an inadequate blood supply. The skin may not have been meticulously sutured to the mucosa of the trachea, permitting added scar formation. The stoma may retract into the suprasternal notch and prominent clavicular insertions of the sterno-cleido-mastoid muscles may approach the midline, making the retraction even more evident. Displaced, enlarged lobes of the thyroid gland may press upon the upper portion of the trachea, helping to narrow this area.

The addition of almost routine neck dissection to a laryngectomy has further influenced the situation with contracture of the tissue on the operated side of the neck. This is markedly increased when a fistula or an infection occurs. The stoma not only contracts but it is situated on a slant in the suprasternal area. This helps to narrow the opening and also may angulate the trachea just below the stoma.

To counteract this tendency for the tracheostoma to become reduced to a size that is inadequate, several procedures have been advocated. A "tongue" of mucous membrane is separated from the posterior portion of the cricoid cartilage and remains attached to the upper end of the stoma. The added mucosa can be carefully sutured to the skin and is more likely to heal by primary union. Of course, this cannot be done in a case of subglottic involvement. Also, the anterior surfaces of the upper two rings of the trachea are removed, leaving an oval opening which is larger than the circumference of the trachea. These maneuvers certainly help to obtain a larger opening, but are not always eventually successful because of the factors already mentioned that influence their narrowing.

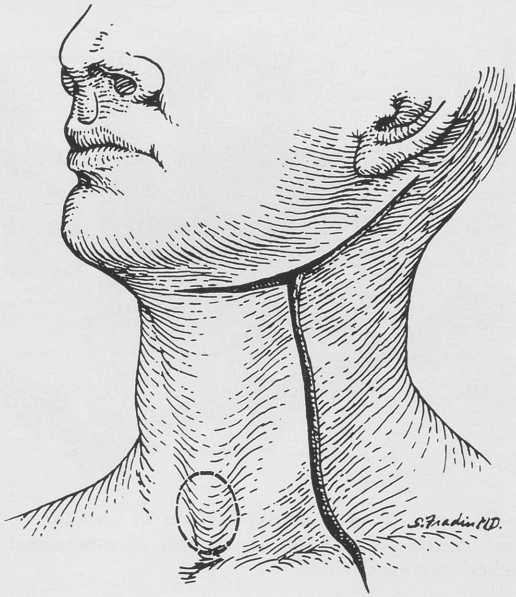


Fig. 1.—Area of excision of skin and subcutaneous tissue.

Another procedure which is sometimes helpful, is to preserve the lower portion of the cricoid cartilage. This leaves a firm cartilaginous ring at the mouth of the opening which would discourage contracture. However, at times this cartilage in its exposed position becomes infected and the stoma again becomes inadequate. On many occasions we have had to excise portions of the cricoid cartilage because of infection. Then, too, in using the cricoid cartilage, an involved pre-laryngeal node may be left behind.

Meticulous attention to the apposition of the skin of the neck to the mucous membrane of the trachea has always been advocated. Frequently this is not possible since the mucous membrane is within the trachea and it is difficult to draw the skin close to it and place sutures that will hold. It becomes necessary to use deep sutures that penetrate or surround the tracheal cartilages in order to obtain adequate apposition of skin to mucous membrane. These deep sutures may cause pressure necrosis and infection of the cartilages with subsequent narrowing of the opening.

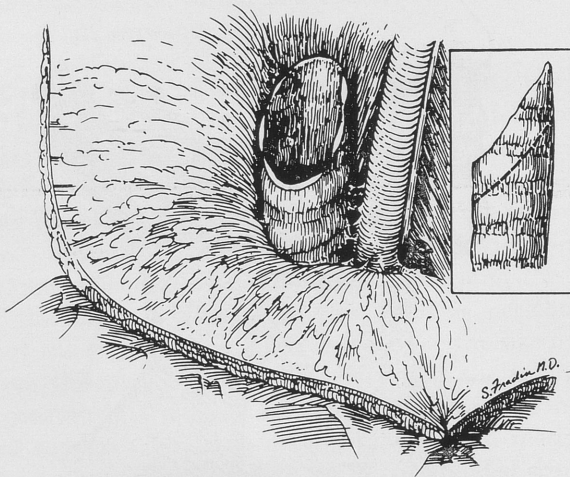


Fig. 2.—“Tongue” of mucosa and excision of anterior portion of tracheal cartilages. Insert—dotted line shows area of submucosal resection of additional tracheal cartilage.

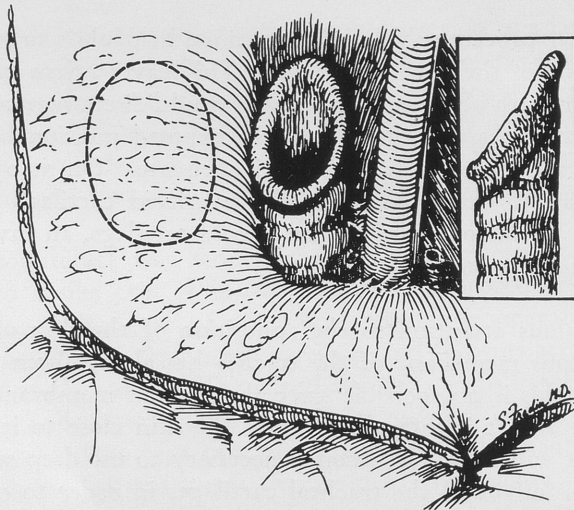


Fig. 3.—Submucosal resection of tracheal cartilage has been performed and mucosa is free and ready for suturing. Dotted line shows area of excision of skin and subcutaneous tissue.

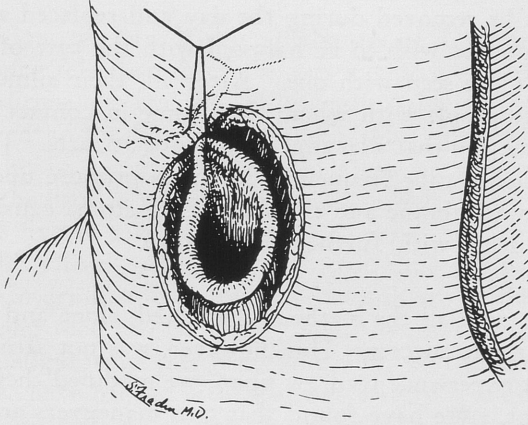


Fig. 4.—Beginning of suturing of mucosa to skin.

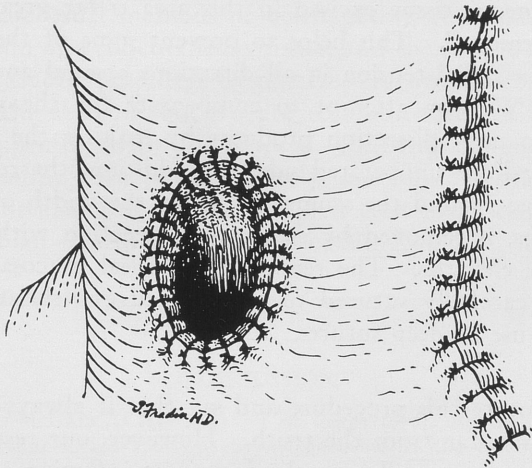


Fig. 5.—Final appearance of tracheostoma.

Of course, when the stoma becomes too narrow a laryngectomy tube can be worn permanently. At times we are able to recommend that the tube be removed during the day and replaced at night, but our patients do not wish to be harassed with the care of a tube, nor do they like to be seen with one. After all, their ailment is all too obvious to the people with whom they come in contact without the additional attention that a laryngectomy tube attracts. Then, too, the presence of such a tube frequently produces pressure upon the cartilage, mucous membrane and the skin of the stoma causing infection and perichondritis with further contracture.

We have used all the methods advocated, alone and in combination, with variable success. This, however, was not satisfactory, and with our past experience to draw upon, we modified these procedures to some extent. We have found that two maneuvers are important: A wide excision of the skin and submucosal excision of the tracheal cartilages around the stoma. The mucosal "tongue" from the posterior wall of the cricoid cartilage is used whenever possible. The anterior portion of the first and second rings of the trachea are excised so as to give an oval shape to the stoma. However, the amount of skin and subcutaneous tissue excised in this area is far greater than was previously removed. This helps to prevent some of the contracture by exerting a radial tension in all directions around and away from the stoma. We also attempt to compensate for the pull that the scarring of a neck dissection produces by making the skin excision a little toward the unoperated side. In addition, the remaining tracheal cartilage around the stoma for about the width of one or two tracheal rings, is removed by submucous resection with a scalpel or with a Freer elevator. The remaining tracheal mucosa can now be readily and carefully sutured to the skin edge without tension and without the use of deep sutures.

To advocate this procedure and say that it always produces the desired result is far from the truth. However, our results have improved, although we still have the factors of infection and fistulae to deal with. This, too, we have overcome to some extent. Previously, in closing the pharyngeal opening we used continuous chromic catgut sutures. This layer was reinforced with a secondary line of interrupted chromic catgut sutures, utilizing any available muscle and areolar tissue. We now use interrupted silk sutures in closing the

primary and the secondary layers. We feel that in this way a better, stronger and more meticulous closure of the pharynx is obtained.

In addition, we have given up the use of a feeding tube. We have long since felt that this tube was a source of irritation to the pharyngeal suture line and was so uncomfortable to the patient that he was forced to swallow frequently. This foreign body in the pharynx, rubbing against the sutured area, we feel, was the cause of many of the fistulae we obtained. We now feed the patient intravenously for five to seven days and encourage him to refrain from swallowing his saliva. At the end of that time the patient is given sterile water to drink, and his fluids by mouth are gradually increased until more solid food can be safely given. We have been very fortunate since inaugurating this procedure and, at the time of writing this paper, we have had no fistulae and relatively few infections. We feel that this manner of closing the pharynx and the elimination of the feeding tube have helped in avoiding factors that lead to a small tracheostoma.

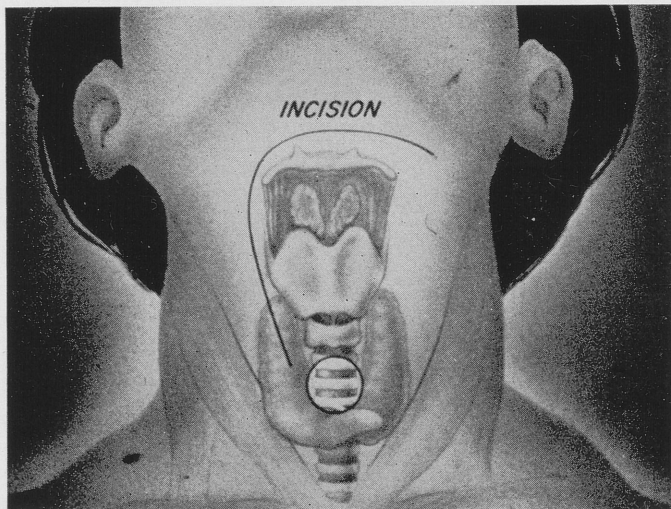
In conclusion, the reasons for the difficulty in maintaining an adequate tracheostoma in laryngectomy cases have been given. In addition to the usual methods of constructing the stoma, the wider excision of skin and subcutaneous tissue, and the submucous resection of additional tracheal cartilage to give free tracheal mucosa for careful suturing of the skin to mucosa, are recommended. Closure of the pharyngeal opening with interrupted silk, and elimination of the use of the feeding tube postoperatively, are considered added factors in avoiding fistulae and infection which contribute to the eventual formation of an inadequate tracheal opening.

103 E. 78TH ST.

DISCUSSION

DR. JULIUS MCCALL (Cleveland): I am happy to discuss this timely presentation of Dr. Arthur Cracovaner on the management of the tracheal stoma after laryngectomy.

The care and management of these people is not all champagne and caviar. Postoperative crusting and scabbing in the stoma and trachea is an annoying and often dangerous complication. Some of this crusting and scabbing is caused by traumatizing the mucous membranes of the trachea. The rough introduction of the intratracheal and tracheotomy tube and the over-enthusiastic use of suction in removing tracheal secretions can damage the mucosa.



A circular area of skin is excised below the cricoid cartilage. The thyroid isthmus is retracted downward. The skin flap formed by this lateral incision is added protection to the pharynx.

The contraction of the tracheal stoma after laryngectomy is universal. Some of this constriction can be prevented, if at the time of surgery the sterno-hyoid and sterno-thyroid muscles are completely removed.

I agree with him that these patients should be advised to replace the tracheotomy tube at intervals. We have our patients introduce the tube at night, once or twice a week.

We have all had the obstinate person who refuses to wear the tube until a frantic call from a wife that her husband can't breathe and can't get his tube in. A mad rush to the emergency room and the resident is only able to insert a 2, 3 or 4 mm tube. Then comes the task of enlarging the stoma again to adequate size. The development of pharyngeal leakage and fistula formation is a factor contributing to stoma contraction.

Personally, I would be reluctant to give up the use of the feeding tube. The lack of proteins in the diet could cause a nitrogen imbalance. With the combined neck dissection and laryngectomy, pharyngeal fistulae occur more frequently. To depend on intravenous feeding over a long period of time is not wise. If a fistula does develop, and it becomes necessary to introduce a feeding tube, this may damage the pharynx and enlarge the fistula.

(Movie)

I have prepared a short movie to show our method of making the trachea stoma and the skin incision used in simple laryngectomy. An area of skin and subcutaneous

fat the diameter of a penny is excised at the lower border of the cricoid cartilage. The thyroid isthmus is retracted downward or transected.

We believe that the lateral skin incision is superior to the mid line one, in that the skin flap that is formed gives added protection to the pharynx beneath it, and helps to prevent pharyngeal leakage and fistula formation. This incision has another advantage. If a fistula does develop, it usually drains through this lateral incision and thus avoids the spilling of secretions into the tracheo-bronchial tree.

The skin incision on this patient was made on the left side of the neck, as there was a possibility of doing a combined laryngectomy and elective left neck dissection, after closer inspection of the larynx. We close the pharynx with autraumatic triple 0, cat gut, using interrupted sutures in two layers. The trachea is sutured to the edge of the excised skin. A No. 12 tracheotomy tube is introduced at the conclusion of the operation.

This physician had a laryngectomy in 1957. He has an excellent esophageal voice and enjoys a large practice.

This individual had a bilateral neck dissection and laryngectomy in 1959. This picture was made in April, this year, and at that time there was no evidence of extension of the primary lesion. He, too, has a good esophageal voice.

DR. HERBERT HARRIS (Houston): I have enjoyed Dr. Cracovaner's report to us on the problem of tracheal stoma contraction. I might say that it has been somewhat of a problem in our service cases, though in my private practice, I have not encountered it very often. In one of our service hospitals, we found it to be quite troublesome, and I attribute this to the fact I was not there at the time of suturing of the tracheal stoma. I think most of our strictures are due to the lack of meticulous approximation of the skin and mucous membrane.

I must say that I agree with him on every point that he brought out: No. 1 is the cutting back of the cartilage so that the cartilage does not lie at the junction of the skin and mucous membrane. No. 2 is the cutting of the trachea at an angle, including about four rings, if at all possible.

No. 3 is the cutting of the skin much larger than you think necessary. In some instances I get a mucosal flap from the surface of the cricoid. I have about abandoned this because we have gotten recurrences in this area, especially in subglottic lesions.

One other thing I have used that I think is helpful is a long tracheotomy tube. I never use a laryngectomy tube. I build up a cone-shaped dressing about the tube to which I apply some type of antibiotic so that it fits firmly and holds the skin down. As these patients cough, I believe that it holds the skin in place better. Not only is this advantageous, but a large dressing can be applied without the tube being in a deep well.

I have enjoyed this presentation and may I again impress on you that the meticulous approximation of the skin and mucous membrane is absolutely necessary. Everywhere else in the body is it necessary to prevent contracture.

DR. LYMAN G. RICHARDS (Wellesley Hills, Mass.): I would like to ask Dr. Cracovaner what kind of initial incision he uses and whether he makes the circular opening in the skin first, the way it was shown in Dr. McCall's movie.

I am sure that he can do this but I have a feeling that if I were to deprive myself of what I have always felt was the support for the suture that goes through

the trachea by having first removed the tracheal rings, I would end up with an awfully delicate, tender, friable mucosal collar, so the least bit of pressure on sutures that were going to attach it to the skin would tear out through the mucous membrane.

It always seemed to me that one of the nice things about closing was the fact that you could put a suture below a tracheal ring and you could then make some reasonable degree of tension without the feeling that it was going to pull out. I have a feeling that the first time I tried this, I would end up with a "buttonholed" tracheal mucous membrane collar and the further down I went to try to get a fresh hold on this, the more trouble I would have. I want to know how you can remove the tracheal ring, leaving the mucosal collar with enough tissue in it so that you can put sutures through without having them tear out.

DANIEL C. MONTGOMERY, JR. (Boston): At the Eye and Ear Infirmary in Boston we have used various techniques to obtain an adequate stoma (i.e. Dr. LeRoy Schall's "U" flap, dissecting away the subcutaneous fat, suturing the thyroid lobes laterally under the sternocleidomastoid muscle and oblique transection of the trachea). Still we have been plagued with stenosis.

Recently we have modified our postoperative care. The nasogastric feeding tube has been omitted. Intravenous fluids are used during the first three postoperative days. Sterile liquids, by mouth, are started on the fourth day. In addition to this, we are using a new device, borrowed from the orthopedic surgeons, which is called a Hemovac. It is, in essence, a portable suction apparatus to which are attached two polyethylene multiperforated catheters. The catheters are placed under the skin flap to evacuate the sero-sanguineous fluid. The evacuation of this fluid seems to prevent fistula formation and secondary infection.

I feel that stenosis of the tracheostomy is most frequently caused by irritation from the tracheostomy tube and by infection in the region of the tracheal orifice. Using the Hemovac, we have eliminated the tight neck dressing into which is incorporated the tracheostomy tube. Little or no dressing is required. A Hayes-Martin tracheostomy tube is kept in place for only five days. The Hemovac is removed after the third postoperative day.

Thus by eliminating the source of irritation to the trachea and by using a device which is effective in preventing fistulae and infection, we seem to be reducing the incidence of tracheostom stenosis.

DR. DANIEL BAKER (New York): Mr. President and Members: One thing seems to be certain. There is a great deal of variation in the way you might handle a tracheal stoma and still get a satisfactory result.

I haven't been as fortunate as some of you who have spoken this afternoon with regard to the amount of trachea that I have left in order to create a stoma. In many instances there may be just one ring, or sometimes not even that, and one is faced with the problem of giving this patient an adequate stoma without being able to transect two or three rings.

One thing that has not been mentioned is the thyroid gland. I make it a point most of the time when I do a radical neck dissection in combination with a laryngectomy to remove the isthmus and also the lateral lobe of the thyroid gland on that side. It has been my experience that if a person has an enlarged lobe of the thyroid gland, it is one of the causes for narrowing of the tracheal stoma. Today, we are doing a great deal more of laryngeal surgery on women, who have a smaller

trachea to begin with than men do, and of course it is also important for them to have a good stoma.

It has been mentioned that one shouldn't wear the laryngectomy tube too long, that this might cause trauma. I take the reverse point of view. I like my patients to build firmly around the largest laryngectomy tube that the trachea will take, so that my patients may wear this tube for several weeks.

There is one thing that I have found most useful in order to enlarge the stoma at the time of the operation. This is also useful with women, and I can illustrate this best by a simple drawing. (*At blackboard*) Where there are two rings of the trachea you transect the uppermost one and allow that first ring to fold outward and then put a suture below the lowermost ring and attach that to the front of the neck, so that the opening you get, the stoma you get, is an enlarged oval one with an approximation of skin and trachea. In other words, you transect and pull one ring outward and then pull the next ring upward and attach it to the suprasternal notch.

DR. ARTHUR J. CRACOVANER (New York) (closing): I guess I was right—there is trouble, as you can see by the number of men who discussed the paper and by the lack of conformity in the discussion.

I want first to thank the speakers for making this an interesting discussion, and I especially want to thank Dr. McCall for taking the trouble to go over the paper in such detail and to show a very beautiful movie.

Concerning the use of the feeding tube, I first got the idea from an article I read that emanated from the Mayo Clinic, in which it was stated that they no longer use a feeding tube in cases of esophageal diverticulum. So, I tried it in several esophageal cases and it worked. I left the feeding tube out and these patients did beautifully.

Then I thought about leaving the tube out in the laryngectomy patients. After all, the tube must be irritating there as well as in the diverticulum cases. I was reluctant to do it because I was brought up in the days of John Kernan who taught me to use a feeding tube, but I had some nudging from my younger associates and residents, so we tried it and it worked beautifully. I am glad to hear that they do the same thing in Boston—I didn't know about it—because it really is a revelation not to be afraid of a fistula any longer. The postoperative care is now a pleasure; it used to be a chore. So I recommend it.

Concerning the nutrition of the patient, we do give them protein intravenously and we do keep the nutrition adequate. We have no difficulty whatsoever. I don't give them fluids in three days. I wait for five days, perhaps because I am a little timid but I think that I play it a little safer.

Dr. Harris agrees with me except for the placing of a tracheotomy tube in the trachea. He feels that with a vaseline gauze cuff around the tracheotomy tube he may prevent some injury to the mucosa of the trachea in coughing. I do the same thing around a laryngectomy tube. It works pretty well but, in addition, in these patients in order to prevent the expansion of the neck and the wound in coughing, I use an ace bandage around the neck. I don't know if it does any good but it makes me feel better to give the neck some support.

Dr. Richards wanted to know the type of incision I use. I use the incision that you saw on the diagram along the level of the hyoid and along the side of

the neck going over the midportion of the clavicle. I excise the ring of skin when I am ready to sew the trachea to the skin. In my experience, the mucosa and submucosa around the trachea is not as delicate as you indicated. If you do this dissection either sharply with a scalpel or if you do it with a Freer elevator, you get a thick layer of mucosa that is very readily attached to the skin. We haven't had trouble along those lines if we haven't "buttonholed" the mucosa to start with.

With reference to Dr. Baker's suggestions: first of all, concerning the thyroid gland, we also remove the thyroid gland on the involved side now, and we also make an attempt to move the other thyroid lobe away from the trachea so that it will be quite lateral and not press upon the trachea. In my experience with the ring that Dr. Baker suggested, sometime ago when patients came to us with laryngeal obstruction due to a carcinoma—they come a little earlier now so that we do not see it as frequently—but in the earlier days when we did see it, we used to do a tracheotomy first and then do our laryngectomy later, when convenient. When we did the tracheotomy we put it through the second and third rings and when we did our laryngectomy we split the cartilage in the midline from the tracheal opening to the tracheotomy opening below the larynx. Then we sutured the two or three rings to the skin, giving an oval opening. I found that these tracheal rings had a tendency to move to the midline again, they had a spring, and the patient would again have a narrowed opening. So that while this idea occurred to me, I had to abandon it because of my previous experience.

Again, I am very grateful to those who discussed this paper.

SURGICAL DECOMPRESSION OF THE RECURRENT LARYNGEAL NERVE IN IDIOPATHIC UNILATERAL VOCAL CORD PARESIS

PRELIMINARY REPORT

JOSEPH H. OGURA, M.D.
ST. LOUIS, Mo.

Unilateral vocal cord paresis is termed idiopathic when none of the circumstances which are understood to be associated with trauma to the recurrent laryngeal nerve may be demonstrated. However, the condition seems to possess characteristics of a peripheral nerve lesion. Spontaneous recovery by the majority of patients from a lesion of a nerve peculiarly prone to degeneration after injury, suggested that many instances of paresis might be attributed to physiological block of transmission of nerve impulses. Accordingly, the anatomic relationships of the recurrent nerve were re-examined in order to discover whether or not, in the course of its distribution, it was particularly susceptible to compression, the most common mechanism of physiologic block. The cricothyroid articulation appears to provide a zone in which the anterior division of the recurrent nerve might course between rigid structures. Subperichondrial resection of thyroid cartilage could amount to decompression in this area.

This report, which is of a preliminary nature, is concerned with our experience with treatment of idiopathic unilateral vocal cord paresis by means of decompression of the anterior division of the recurrent nerve.

PRESENT CONCEPT OF VOCAL CORD POSITION WITH RECURRENT NERVE PARALYSIS

Clerf and Suehs¹ have estimated that 90 per cent of recurrent nerve paralyses are of peripheral origin and 10 per cent have been

From the Department of Otolaryngology, Washington University School of Medicine.

ascribed to central lesions.² In most instances of unilateral paralysis, the specific local factors that have been stated to cause paresis are: diseases of the thyroid gland or injury to the nerve during thyroid gland surgery, severe trauma to the neck, cervical adenopathy, anterior mediastinal disease, aortic aneurysm, cancer of the esophagus, cardiac enlargement or lesions at the base of the skull. The remaining instances, for which no cause may be found, are called idiopathic. Various toxic and infectious agents have been stated to cause unilateral recurrent laryngeal nerve paralysis. Such instances of vocal cord palsy must be extremely rare. Lermoyez and Ramadier³ have stated that the hypothesis of peripheral neuritis is untenable. Frequently, cricothyroid arthritis is mistaken for idiopathic paresis and should be excluded by the passive mobility test at direct laryngoscopy.

There is considerable confusion in understanding the variations in position and tension of the vocal cord following injury to the recurrent laryngeal nerve. The midline, median or phonatory position all carry the same implication. This position according to Semon's Law,⁴ results with cases of paralysis of the abductor fibers of the recurrent laryngeal nerve.

The paramedian position leaves a space of 3 to 5 mm between the cords, and occurs with complete paralysis of the recurrent laryngeal nerve, when both the abductors and the internal adductor muscles are paralyzed. This position is influenced by the cricothyroid muscles which act as external adductors and rotators of the arytenoid cartilages.

Observations made by Clerf and Suehs on the position of the vocal cord during laryngectomy have shown that although the observations are brief, the cord assumes a midline position when the nerve is cut. It is incorrect to state that in cases of complete recurrent nerve paralysis the cadaveric position is taken up.

In the cadaveric or intermediate position, the glottic triangle measures about 7 mm. There is complete muscular relaxation and the position of the cord is assumed by virtue of the elasticity of the capsule of the cricoarytenoid joint. All of the muscles controlling the glottic margins are paralyzed, that is, the internal and external adductors and abductors. It is a position for recurrent nerve and

superior laryngeal nerve paralysis. In this state, the arytenoid is tilted forward, the cord occupies a lower position and the free edge is bowed.

In postthyroidectomy recurrent nerve injury, it is common to see cords in the paramedian position with lack of tension. With partial recovery, the cord may move to the midline. A cord has never been observed to move to the cadaveric position from the midline position.^{1,3} New and Childrey stated that a cord fixed in the midline may recover and that a cadaveric cord may move to the midline. However, these authors did not distinguish between paramedian and cadaveric positions.

Prognosis on recovery from the paralysis varies in the literature.¹⁻¹² New and Childrey⁵ found that with midline paralysis recovery may take 17 months, whereas with a cadaveric cord the recovery time was 10 months. Smith, Lambert and Wallace⁶ differed in that the majority of their cords were in the cadaveric position, and stated that New and Childrey were too optimistic in the outcome. Clerf and Suehs¹ reported complete recovery of the injured recurrent laryngeal nerve varies from as early as the sixth week to the third month. Mulligan⁸ on the other hand reports a poor prognosis in recurrent nerve paralysis following thyroidectomy in 17 cases. In 16 instances, paralysis of varying degree persisted for years.

The importance of the various positions of the vocal cord in unilateral paralysis may be summarized. The paramedian and midline paralysis may or may not recover. When the cord moves from the paramedian position to the midline position complete recovery is unlikely. The cadaveric or intermediate position with a bowed flaccid paresis indicates complete paralysis. Complete return of function is highly unlikely. The longer the period of paralysis, the less the chance of complete recovery. After one year, the chance for complete recovery is poor. Of particular importance is the susceptibility of the branches of the recurrent nerve close to the larynx to profound damage, especially to the fibers supplying the abductor muscles, in accordance with Semon's Law.

ANATOMIC BASIS FOR THE DECOMPRESSION PROCEDURE

The anatomical variations of the recurrent laryngeal nerve have been described by LeMere,^{10,11} Rustad,¹³ and others.¹⁴⁻¹⁶ Generally, the recurrent nerve courses superiorly more or less in the tracheo-

esophageal sulcus and gives off branches to these structures. The nerve is closely related to the inferior thyroid artery and to the posterior aspect of the thyroid gland. In 200 anatomical dissections of the nerve Rustad found that in 84 or 43 per cent of cadavers the nerve branched into several divisions in either one or both sides. Anatomy texts usually describe the anterior branch as passing superiorly along the crico-arytenoideus muscle to supply the lateralis, thyroarytenoideus, vocalis and aryepiglotticus muscles. The posterior branch is stated to supply the posterior cricoarytenoideus and the arytenoideus muscles.

The extralaryngeal divisions of the nerve are said to pass into the larynx posterior to the cricothyroid articulation. However, the anatomical illustration of Rustad and others of the extralaryngeal divisions of the recurrent nerve show the branches entering the larynx between the cricoid and thyroid cartilages, anterior to the cricothyroid articulation or immediately adjacent and posterior to the inferior cricothyroid articulation, to arc anteriorly between the thyroid and cricoid cartilages.

Observations made in the course of surgical dissections have impressed us with the considerable variation of the anterior division. The nerve enters the larynx immediately adjacent to the inferior thyroid cornu and is located between the thyroid and cricoid cartilages. The zone through which the nerve traverses between these two cartilages may be quite narrow, conceivably where it might be compressed.

Anatomic dissections of the recurrent nerves in four cadavers were performed to determine the relationship of the anterior division of the recurrent nerve to the cricothyroid articulation. Considerable anatomic variations of the cartilages and of the nerve were found. In one of four, the nerve was immediately adjacent to the cricothyroid joint in a particularly narrow zone. In the remainder, there was not only variation of the extralaryngeal nerves, but their entrances were distant enough from the cricothyroid articulation that compression would seem unlikely.

According to Murtagh and Campbell,¹⁷ the actual number of fibers injured will depend on the level of injury to the nerve. Relatively larger and more heavily myelinated fibers constitute the greater

number of fibers in the recurrent nerve and are concerned with adduction. Smaller and less myelinated fibers supply the abductor muscles. There is no histologic or physiologic evidence that the abductor fibers or adductor fibers are contained in separate bundles within the recurrent nerve.¹⁸

REPORT OF CASES

CASE 1. Sudden onset of hoarseness was experienced by a 15 year old boy about two weeks after a playful wrestling scuffle in which he had been subjected to an arm lock about his neck.

A complete medical and neurological workup was negative and the chest plate was negative. The left vocal cord was in a paramedian position. Weekly observations of the larynx were made and no vocal cord motion was observed for four months. After three and a half months' observation some lack of tone was evident but the cord did not assume a cadaveric position.

Since there was no sign of recovery after four months, the possibility that permanent damage had been sustained was considered. An alternative explanation was compression of a nerve anatomically susceptible to consequences of trauma at the time of the scuffle.

At the time of operation, there was no evidence of cartilage fracture, but the anterior division of the recurrent nerve was immediately anterior to the cricothyroid articulation, a narrow pathway. Electrophysiologic observation was made by stimulating this branch of the recurrent nerve, using 15 volts at 1 millisecond intervals. No movement was detected by laryngoscopy. There was no evidence of cricothyroid arthritis. Five days after surgery, distinct motion of the vocal cord was visible. By the tenth day full range of motion was observed. The voice returned to normal and the quality and range has remained excellent to date.

CASE 2. A 20 year old boy suddenly developed hoarseness without any injury or infection prior to the onset of the symptoms. There were no significant findings on examination except that the left vocal cord was fixed in the paramedian position. He was observed at weekly intervals. By the end of the fourth month the cord had moved to the midline, and the cord, previously in the paramedian position, now

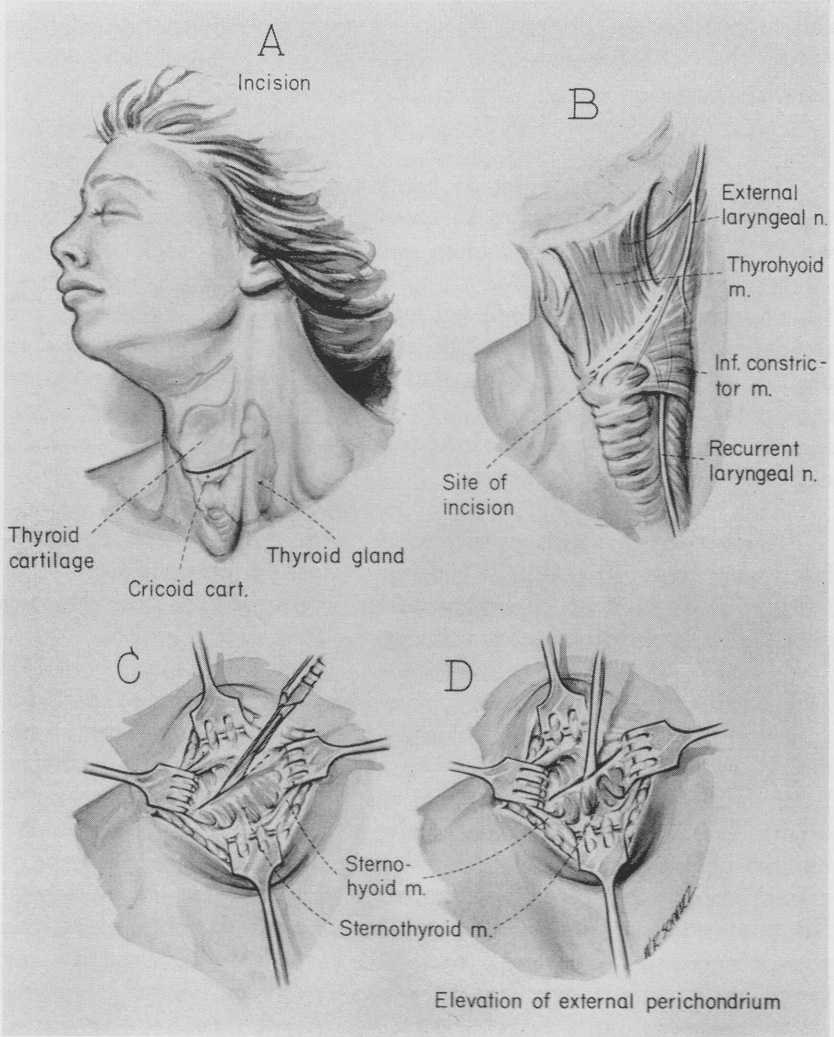


Fig. 1.—Incision and exposure of thyroid cartilage. Site of incision (B) is over oblique line of thyroid cartilage.

appeared to have tension. The voice correspondingly improved but it was not normal.

At operation, the anterior division of the recurrent nerve was found immediately anterior to the cricothyroid articulation. Stimulation studies showed no movement of the vocal cord at laryngoscopy. Distinct movement was observed on the third postoperative day and full movement of the vocal cord and a normal voice were present on the tenth postoperative day.

CASE 3. A 45 year old white female with idiopathic right vocal cord paresis of nine months' duration was screened carefully for obvious causes. No evidence of cricoarytenoid arthritis was found. The right vocal cord was in the paramedian position. A thyroid cartilage decompression was carried out and observations of the cord were made for six months' period after surgery. No return of function was noted, and the voice quality remained the same as prior to surgery.

CASE 4. A 55 year old white male with hoarseness of one year's duration and idiopathic left vocal cord paresis was examined by direct laryngoscopy and bronchoscopy to rule out significant disease. No findings were found to suggest extrinsic causes. The vocal cord was in the paramedian position and tension was absent. The recurrent nerve was immediately posterior to the cricothyroid articulation. Decompression of the thyroid cartilage was performed and observation made for five months after surgery. No return of function was noted, and the quality of the voice remained the same.

TECHNIQUE OF OPERATION

Under local or general anesthesia, a small transverse incision approximately two inches long is made between the superior and inferior border of the thyroid cartilage on the side of the paretic cord (Fig. 1-A, B). After elevation of the skin flaps the ribbon muscles are separated longitudinally to expose the cricothyroid muscle. The thyroid lobe which covers the cricoid cartilage is reflected laterally to identify the anterior and posterior branches of the recurrent laryngeal nerve. In two of the four cases, the anterior division of the recurrent nerve entered the larynx through the cricothyroid membrane close to the cricothyroid articulation. In two others it was immediately posterior to the inferior horn. The oblique line of the

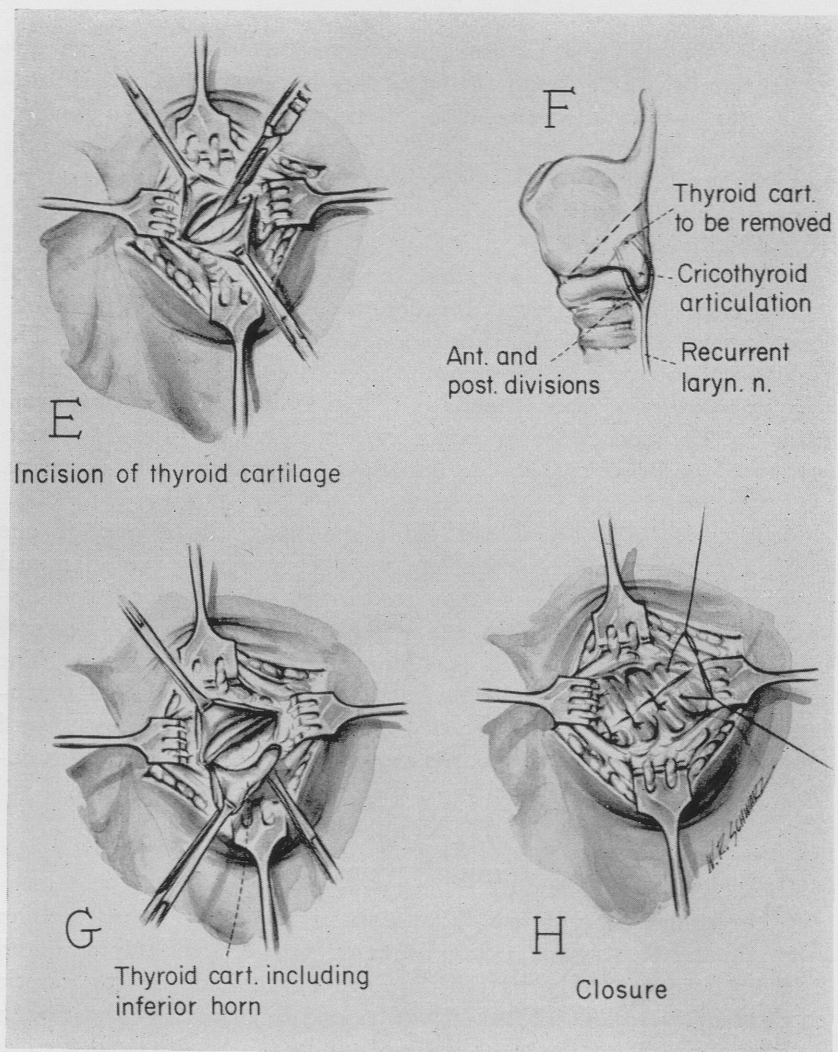


Fig. 2.—Removal of inferior triangular segment of thyroid cartilage. Anterior division of the recurrent laryngeal nerve (F) may be immediately adjacent or posterior to cricothyroid articulation.

thyroid cartilage can be identified on the thyroid lamina and the external perichondrium is incised along this line and elevated inferiorly (Fig. 1-C, D). The cartilage is next incised and a triangular segment of the thyroid cartilage, including the inferior horn, is excised after elevation of the cartilage away from its internal perichondrium (Fig. 2-E, F, G). The external perichondrium is approximated with silk and the skin and subcutaneous tissue approximated with interrupted silk (Fig. 2-H).

COMMENT

In the absence of any specific etiological factors, idiopathic recurrent laryngeal nerve palsy has remained an entity significantly free of surgical implications. In many instances, the cord in the paramedian position with lack of tone, may recover in two to three months. In other instances, the voice may improve when the cord moves to the midline, even though the cord may not regain motility. In some instances, partial recovery of abduction occurs. In rare instances, restoration of function has occasionally been observed after nine months or a year.

The recurrent nerve, particularly its anterior division, is stated to be one of the most vulnerable nerves in the body. General surgeons are aware of the frequency with which palsy of this nerve occurs even with gentle manipulation. The vulnerability of this nerve to trauma has been beautifully shown in experimental studies on dogs by Blalock and Crowe,¹⁹ and Judd, New and Mann.²⁰ Berlin⁴ feels that the variations of anatomic distribution of the nerve are more important than vulnerability. It should come as no surprise that pinching of this nerve between the thyroid and cricoid cartilages can occur with certain anatomic variations.

Electrophysiological studies made at the time of surgery on direct stimulation of the recurrent nerve could represent evidence of either physiological or anatomical interruption. The anatomic findings for compression of the anterior division of the recurrent nerve in two of the four cases, and the rapid return of motion in a previously paralyzed cord by decompression, would provide evidence for a physiological interruption. Unfortunately, electrical stimulation was not carried out immediately after decompression. When the exposed nerve was traced under the internal perichondrium for a short distance

toward the larynx, the nerve did not appear abnormal. However, I did not use magnification.

In one of the two cases that recovered function, the cord had moved to the midline prior to surgery, a finding indicating that spontaneous return of function was unlikely. Where decompression was carried out at four months after onset of paresis, mobility of the cord could be detected within five days.

In the two cases in which function was not restored, the paralysis had been present for nine or more months. Return of function is only rarely observed after paresis of this duration, and where nerve degeneration is probably permanent and regeneration is unlikely.

The permanent restoration to normal functioning cords after "early decompressions" appears to be very convincing. The procedure seems to have merits similar to the surgical decompression for Bell's palsy. Perhaps the spontaneous recovery rate in idiopathic paralysis is high, possibly as high as 75%. In these two cases one might argue that recovery was incidental and not attributable to surgical intervention. This is entirely possible. Larger experience will resolve this question.

In Bell's palsy, 85 per cent of the cases are reported to recover. In groups of various peripheral nerve injuries,²² spontaneous recovery occurred in 68 per cent of the cases, and the statement was made that this is better than that expected from suture repair.

Denny-Brown²³ in a beautiful piece of work demonstrated the effects of pressure, and of ischemia on peripheral nerves. He graded the findings in several degrees; paralysis with rapid recovery on release of pressure; paralysis with delayed recovery without degeneration (intermediate type of pressure lesion), and complete anatomic lesion with degenerative phenomenon. Even with the intermediate form of paralysis vacuolation of the axis cylinders and vacuolation of myelin was demonstrated. Degree of recovery was related to the total duration of pressure and paralysis, and recovery will be poorer, the longer pressure paralysis is allowed to persist.

More of the natural history of idiopathic unilateral paralysis and the frequency of partial and complete spontaneous recovery must be

learned. A larger series of cases should be studied with electrophysiological measurements. More extensive studies of the anatomic variations of the recurrent nerve and the cricothyroid articulation will permit evaluation of the hypothesis of compression as a factor in some cases of idiopathic unilateral vocal cord paresis.

SUMMARY AND CONCLUSION

A preliminary report is made of a surgical approach to the treatment of idiopathic unilateral recurrent nerve paresis. The surgical procedure was designed to relieve a postulated compression. The rapid return of function in two cases suggests that physiologic block was the mechanism of the paresis and tends to support the hypothesis of compression.

The possibility of a time factor is suggested by the successful outcome in the two cases operated on within five months of onset, while the two cases in which recovery did not occur were operated on more than nine months after onset.

The significance of these observations made on this operation for idiopathic vocal cord paresis will have to be deferred until greater clinical experience has been obtained.

640 S. KINGSHIGHWAY

REFERENCES

1. Clerf, L. H., and Suehs, O. W.: Paralysis of the Larynx. *ANNALS OF OTOLGY, RHINOLOGY AND LARYNGOLOGY* 50:762, 1941.
2. Furstenberg, A. C.: An Anatomical and Clinical Study of Central Lesions Producing Paralysis of the Larynx. *ANNALS OF OTOLGY, RHINOLOGY AND LARYNGOLOGY* 46:39, 1937.
3. Lermoyez, M., and Ramadier, J.: La Paralysie respiratoire du larynx est un syndrome de syphilis. *Presse Med.* 1:33 (Jan. 13) 1923.
4. Semon, F.: Clinical Remarks on the Proclivity of the Abductor Fibers of the Recurrent Laryngeal Nerve to be Affected Sooner than the Adductor Fibers, or even Exclusively in Cases of Undoubted Central or Peripheral Injury or Disease of the Roots or Trunks of the Pneumogastric, Spinal Accessory or Recurrent Nerves. *Arch. Laryngology* 2:197-222, 1881.
5. New, G. B., and Childrey, J. H.: Paralysis of the Vocal Cords. Study of Two Hundred and Seventeen Cases. *Arch. Otol.* 16:145-159, 1932.

6. Smith, A. B., Lambert, A., and Wallace, H. L.: Paralysis of the Recurrent Nerve. 235 Cases. *Edinburgh M. J.* 40:344, 1933.
7. Callaghan, W. C.: Unilateral Paralysis of the Larynx. *Arch. Otol.* 50: 605-611, 1949.
8. Mulligan, E. J.: Prognosis of Laryngeal Paralysis Following Thyroidectomy. *Arch. Otol.* 35:732-734, 1942.
9. Arnold, G. E.: Vocal Rehabilitation of Paralytic Dysphagia. *Arch. Otol.* 65:317-336, 1957.
10. Lemere, F.: Innervation of the Larynx. I. Innervation of Laryngeal Muscles. *Am. J. Anat.* 51:417, 1952.
11. Lemere, F.: Innervation of the Larynx. III. Experimental Paralysis of the Laryngeal Nerve. *Arch. Otol.* 18:413-424, 1933.
12. Negus, V. E.: Certain Anatomic and Physiologic Considerations in Paralysis of the Larynx. *Proc. Roy. Soc. Med.* 40:849-853, 1947.
13. Rustad, W. H.: The Recurrent Laryngeal Nerves in Thyroid Surgery. Chas. Thomas, 1956.
14. Holingshead, W. H.: *Anatomy for Surgeons*, Vol. 7. Herber Harper.
15. Armstrong, W. G., and Hinton, J. W.: Multiple Divisions of the Recurrent Laryngeal Nerve. An Anatomic Study. *Arch. Surg.* 62:532-539, 1952.
16. Weeks, C., and Hinton, J. W.: Extra Laryngeal Division of the Recurrent Laryngeal Nerve. *Ann. Surg.* 116:251-259, 1952.
17. Murtagh, J. A., and Campbell, C. J.: The Respiratory Function of the Larynx. II. The Elementary Function of the Recurrent Laryngeal Nerve. *ANNALS OF OTOTOLOGY, RHINOLOGY AND LARYNGOLOGY* 57:465, 1948.
18. Sunderland, S., and Swaney, W. E.: The Intra-neural Topography of the Recurrent Nerve in Man. *Anatomical Record* 114:411-426, 1952.
19. Blalock, A., and Crowe, S. J.: The Recurrent Nerve in Dogs. Experimental Study. *Arch. Surg.* 12:95-116, 1925.
20. Judd, E. S., New, G. S., and Mann, F. C.: Effect of Trauma upon the Recurrent Laryngeal Nerve. *Ann. Surg.* 67:257-262, 1918.
21. Berlin, D. D.: The Recurrent Laryngeal Nerve in Total Ablation of the Normal Thyroid Gland. Anatomical and Surgical Study. *S. G. O.* 60:19-26 (Jan.) 1935.
22. Woodhall, B., and Beebe, G. W.: Peripheral Nerve Regeneration—A Follow-up Study of 3,656 World War II Injuries. V.A. Medical Monograph. Superintendent of Documents, U. S. Government Printing Office, Washington 25, D. C.
23. Denny-Brown, D., and Brenner, C.: Paralysis of Nerve Induced by Direct Pressure and by Tourniquet. *Arch. Neurol. and Psych.* 51:1-26, 1944.

DISCUSSION

DR. LOUIS H. CLERF (St. Petersburg, Fla.): Mr. Chairman, Fellows, I wish to compliment Dr. Ogura and I hope that he may furnish a clue to the etiology as well as the treatment of idiopathic unilateral paralysis of the larynx.

It has been our experience that if recovery occurs the cord will begin to exhibit movement within six months. Paralysis of a cord of more than six months' dura-

tion, without evidence of improvement, in all probability is permanent. Dr. Suehs and I had an opportunity to study a large number of cases of paralysis following thyroidectomy, as well as other known causes, also idiopathic causes and none exhibited any change after six months.

The position of the cord has been one of the most confusing things in laryngological literature. We use designations rather loosely. Cadaveric is not a desirable term to employ in the living human being. Paralysis either is partial or complete, depending upon whether all or only a part of the innervation of the larynx was destroyed. Complete paralysis occurs after complete interruption of the vagus nerve above the origin of the superior laryngeal nerve. If the recurrent laryngeal nerve only is involved, whether partial or complete, the vocal cord may be in a median or paramedian position. In a large number of cases of postthyroidectomy paralysis the cord was found in a median position while in idiopathic paralysis, the position is commonly paramedian.

Now about decompression of the nerve, in the surgical procedure that Dr. Ogura has described, it would appear that the principle governing decompression of a facial does not apply in these cases. I had never visualized the space between the cricoid and thyroid cartilages as being so small that any of the branches of the recurrent nerve could be compressed. I can conceive in his first patient, who sustained an injury to the neck, that definite compression of the nerve may have occurred. I should be interested to know how small the space is and does Dr. Ogura believe that the pinching of the nerve occurred by reason of the close proximity to the cricothyroid articulation.

There always is this matter of coincidence, as he indicated; the fact that in one patient the paralysis was of four months' duration, the other about five months, suggests coincidence. On the other hand, improvement is not as rapid as that. One does not see improvement occurring spontaneously in a matter of days. That requires weeks, in fact several months, but one cannot ignore entirely the matter of coincidence. It is very apparent, from what Dr. Ogura has said, and our observations, too, that if you wait beyond six months you probably will not secure much benefit because the changes will be permanent.

DR. THEODORE E. WALSH (St. Louis): Don't look so surprised that an otologist should be discussing this paper, but I had the privilege of seeing these patients of Dr. Ogura's and it is really dramatic the way that boy, for example, began to talk again.

We discussed this at some length. Dr. Ogura was wondering whether he should operate on this boy or not and we drew the same parallel with Bell's palsy. I agree with Dr. Sullivan and others that the earlier you get at them, the better, in most instances. We can't do it always but at least I think public opinion would be against us if we decompressed a Bell's in the first few days of onset, but certainly we know that if they don't start to recover within a very short period of time, they never recover completely.

It seems to me that these cases of Dr. Ogura's are exactly parallel with those we have seen with Bell's, where if the recovery doesn't start early, you might just as well decompress them because I don't see what harm you can do by having a look at them. I believe that this boy certainly had a pinching of the nerve at the point where Dr. Ogura found it going through into the larynx, between the cricoid and the thyroid. I think it is a most interesting observation and I do hope we will see more of this.

DR. JOEL J. PRESSMAN (Los Angeles): Dr. Ogura is to be congratulated not only upon his election to this society which, in my opinion, has long been overdue, but upon his fine contribution to our knowledge of the recurrent laryngeal nerves.

I had hoped our guest of honor, Dr. Clerf, might refer to his previous well-turned phrase that Semon's law has now been repealed. This repeal, in itself, did a great deal to enhance our knowledge of the subject and much of what we now know has come from having eliminated this "law" from our thinking. Reference in this regard should be made to Dr. Murtagh's classic studies on the paralysis of the nerve trunk.

Dr. Clerf has referred to the confusion that exists in our minds relative to the observations we make relating to the position of the cords following such paralysis. My primary purpose in discussing this is that we have been confused because we have not paid sufficient attention to basic principles resulting from paralysis of this nerve as well as any other nerve.

Paralysis of a recurrent laryngeal nerve is not a single clinical entity, any more than paralysis of a nerve from the brachial plexus to the arm is an entity. We need to take into account that there are two principal kinds of paralysis of nerves, the manifestations of which not only vary from one another but are extreme opposites. Thus, even though a central type of paralysis is relatively rare in the recurrent laryngeal nerves compared to the peripheral types, it results in a spastic paralysis, whereas the peripheral paralyses are flaccid paralyses. It is not to be expected that the position of a vocal cord is to be the same from a spastic paralysis of central origin as it is from a peripheral paralysis which is flaccid.

Therefore, in trying to evaluate these conditions and drawing clinical conclusions from what we see, we must bear this in mind and modify our concepts upon the basis of central spastic paralysis and peripheral flaccid paralysis as giving different clinical pictures. We must also bear in mind that following certain thyroidec-tomies, abnormalities in the movement of the vocal cords, which we call paralysis, may not be paralytic, but be quite the reverse and due to hyperstimulation from irritation of the nerve trunk, such as we find, for example, in cricothyroid spasm.

Therefore, taking cognizance of the principles stated in Dr. Ogura's fine presentation, Dr. Clerf's previous excellent writings, Dr. Murtagh's great laboratory studies and by recognizing this concept of the two types of laryngeal nerve paralysis, I think pretty soon our understanding of the subject will become greatly clarified.

DR. FRANCIS L. WEILLE (Boston): I would like to ask if Dr. Ogura could clarify in my mind just one point. As the operation was described, it goes superiorly almost exactly to the level of the external branch of the superior laryngeal nerve and the removal of the cartilage removes the insertion of the cricothyroid muscle almost exactly. I would like to know if there is any effect on the function of this muscle.

DR. GODFREY E. ARNOLD (New York): Mr. Chairman, I wish to join those congratulating Dr. Ogura for his original contribution. The problem of laryngeal paralysis has always been very dear to me and I am happy that it finds such strong and positive resonance here.

In addition to what has just been said by Dr. Pressman about the hitherto confusing types of vocal cord position, I would like to repeat that this problem has been so perplexing because one did not pay sufficient attention to the *various types of paralysis*. There are the central and peripheral, or spastic and flaccid types; in

bilateral paralysis vocal cord position follows other laws than in unilateral cases; paralysis with sudden onset is different from cases with a slow, progressive course. We distinguish complete and partial paralysis; most importantly, combined and complete paralysis of both laryngeal nerves differs characteristically from isolated paralysis of the recurrent nerve alone: intermediate position of the affected cord in the former versus paramedian position in the latter case.

The problem of vocal cord position in laryngeal paralysis seems to be rather well clarified by now and it is surprising that we still find adherents of the old or classical concept inspired by Semon's law. We know that the first part of Semon's law, which stated that in a slowly progressive lesion the abductor fibers are first afflicted, can easily be verified. All other deductions, and the second part of Semon's law, have subsequently proven to be false; yet, certain physiologic or anatomical evidence is still being offered in support of the old concept.

Such differences in opinion are sometimes due to the numerous and frequent *variations* in the anatomical course and distribution of the recurrent nerve. Moreover, animal experiments cannot be used for clarification of human laryngeal physiology because the larynx of dogs, cats, rabbits, etc. is significantly different from the human larynx. What matters most, vocal physiology in *animals* is completely different from *human* voice physiology because only man talks, and only man has evolved his larynx to that height of expressive power which is typical for the human voice.

Providing the before-mentioned distinctions are kept in mind, I believe Dr. Ogura's operation may be valuable in suitable cases. However, it would have to be done *soon after onset* of the paralysis because with the passage of time the chances for recovery diminish progressively. I never saw a spontaneous remission of laryngeal paralysis after it had persisted for more than six months.

DR. JOSEPH H. OGURA (St. Louis) (closing): I had hoped that this would evoke a lot of discussion and I am certainly happy that it has done so.

In answer to Dr. Clerf's questions, elsewhere in the body where nerves pass through rigid structures such as the facial canal, the spinal cord, neurological manifestations are observed such as paralysis by external pressure. A narrow space is present between the thyroid and cricoid, particularly where the thyroid cartilage overlaps the cricoid. It is very narrow at its articulation. The nerve branches upon entering the larynx close to this articulation will be in a narrow rigid compartment.

On the time factor, I discussed this with Dr. Henry Schwartz. He stated, "This rapid return of function cannot be explained except on a physiologic block."

I believe Dr. Walsh's comment, "No harm," is true. I can see very little, if any, difference in the voice after surgery. I would warn, though, that we not go off wildly on the idea and start taking off cartilages on all idiopathic palsy cases. I would think that the time to operate would be somewhere between the fourth and fifth month. If you don't have return of function by the third month, then I think serious consideration should be given to operating, and I believe the anatomic variation should be looked at at this point.

I would agree with Dr. Pressman and Dr. Arnold that perhaps we now have reason for really studying this more thoroughly, should this operation now prove its merit.

A DISCUSSION OF
FORTY-TWO YEARS' EXPERIENCE WITH
OTOLARYNGOLOGICAL PATHOLOGY

ANDREW A. EGGSTON, M.D.

NEW YORK, N. Y.

I am giving this talk because I feel a great sense of personal obligation to the specialty of otolaryngology and this will be the general theme I will follow. When I took my assignment in 1919, I visualized a new horizon of pathology. I had been teaching general pathology for years in medical schools. When I was offered this position, little did I know what might happen in the years to come, because like most general pathologists, I was little interested in nor familiar with the pathology of otolaryngology and particularly of the neoplastic diseases.

I was fortunate in my early days at the Manhattan Eye, Ear and Throat Hospital to have met some problems in eye, nose and throat neoplastic diagnoses. I had always admired Dr. James Ewing, a great pathologist, and I requested him to review some difficult slides. After studying some of the cases and giving his diagnosis, he spoke to me in a fatherly way, knowing I was still a young pathologist. He told me what a wonderful opportunity the position offered in the diagnosis of difficult tumors. He stated that the most complicated and difficult neoplastic lesions occur in the caudal and cephalic regions of the body and of these, the head and upper respiratory tract offered the greatest variety of difficult tumors to classify and treat. His talk gave me encouragement because I didn't know what a special pathological assignment would offer. In addition to my connection at this special Hospital, I have retained positions in general surgical and autopsy pathology. I have remained at the Manhattan for 42 years—I'll never know why. However, this I do know, nobody ever had a more stimulating and pleasant assignment than I have had. I shall try not to be verbose or pedantic, but only to record some things that have impressed me along the way.

A legion of otolaryngologists have encouraged and taught me an understanding of the problems and an insight functionally and organically of many disease processes of their specialty.

From the Manhattan Eye, Ear and Throat Hospital, New York City, and the Lawrence Hospital, Bronxville, New York.

I have known many devoted specialists of otolaryngology, men who have done yeoman work in formulating the high ideals in the practice as well as research in the specialty. I would like to recite the names of those who have been responsible for my heartfelt respect for otolaryngology. However, such an addendum would be too long for presentation. I recall the pioneer days of laryngectomy by Dr. Mackenty and others equally distinguished in their fields. I recall the influenza epidemic of 1918 and other virus epidemics, followed by a high morbidity of mastoiditis, meningitis, brain abscess and pneumonia. At times the Hospital wards were literally crowded with upper respiratory infections, with a very high mortality rate of meningitis and other severe acute infections. In former days, virus infections seemed to till the soil, such as the farmer does for his grain, for the implantation and growth of the most deleterious and lethal infections that were so common at that time. The organisms encountered in those days were beta hemolytic Streptococci, hemolytic Staphylococcus aureus and Pneumococci. The mortality in those days ran very high. All cases of meningitis with very high spinal leukocytosis usually succumbed to the infection, regardless of all modalities of treatment available at the time: spinal drainage, ventricular drainage, laminectomies and the injection of various drugs intraspinally were of no avail. The end results were always the same, a very sad story indeed. However, about 1936, the earlier sulfa drugs appeared, with a great ray of hope in the possibility of curing some of these patients and some were cured. Soon afterwards, a great array of marvelous drugs became available in the antibiotics. This transition from death-dealing infections to recovery is a memorable transition from the trying story of many lethal complications. Rarely, in the earlier days, was the Hospital without cases of meningitis or brain abscess, the hope of recovery dismal. Meningitis and brain abscess and other infections now respond like a miracle to the modern so-called antibiotics and newer surgical procedures. I remember the time when a senior resident, in three months' tenure, would have from 75 to 100 mastoidectomies. Such cases are rare now. Consequently, when these acute infections practically disappeared there was a void in the enthusiasm and activity of otolaryngology. However, it wasn't long until new vistas of treatment and rehabilitation in otology and laryngology appeared. Very hopeful new chapters, particularly in fenestrations, mobilization and tympanoplasty became useful in the rehabilitation of the deaf, just as corneal grafts have rehabilitated some of the blind. These delicate operations were the result of research in the new surgical techniques. Without these advances we would still see many patients in the darkness of total or partial deafness or blindness. Likewise, there are numerous cases of cancer of the larynx that are living today as the result of adequate surgery and proper radiation.

Basic research is still needed to explore new facts, both anatomically and physiologically. Last year I was greatly stimulated by two scientific papers read before this body by Doctors Beidler³ and de Lorenzo¹⁰ on taste and olfactory nerve endings. By use of electron microscopy they presented new aspects of the receptor cells of those special senses. The future of all medicine depends upon pure and properly evaluated research. There is no room for exploitation of research until the facts are known to be facts. New equipment and devices such as electron microscopy and histochemical techniques open an entirely new field in research.

Forgive me, but I would like to recite a few episodes that have occurred in my experience. Mistakes occur, always disturbing, which may occur in the melee of rushed hospital activities. A woman was admitted for a pansinus operation. She was operated on for this condition and when sent back to the ward, was delivered of a full-term baby. Her history did not offer the suggestion or a clue that she

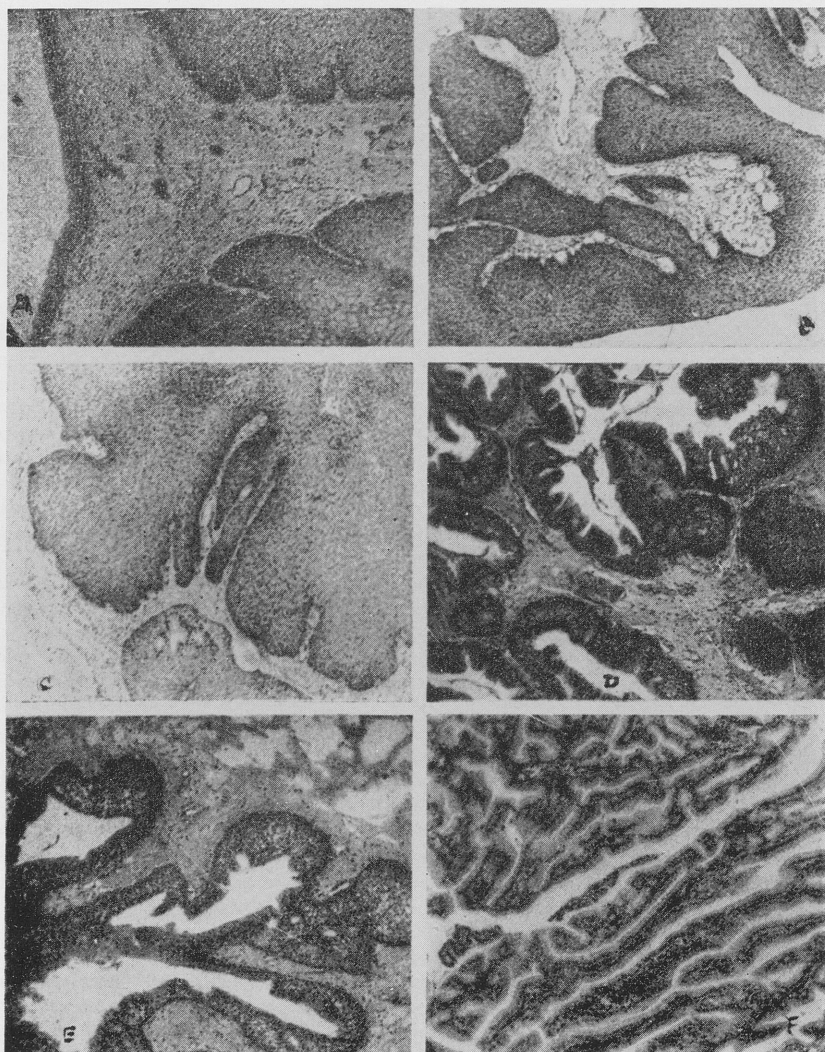


Fig. 1.—Papillary sinusitis (from Eggston and Wolff¹¹). A. Normal and metaplastic epithelium. Hydropic degeneration of cells. B. Metaplastic epithelium. C. Papillary sinusitis of the ethmoid, epidermoid type. D. Papillary sinusitis of the ethmoid, foliate type. E. Papillary sinusitis of the ethmoid, cryptic type. F. Papillary sinusitis of the antrum, filiform type. Erroneously called “nasal” adenoma.

was pregnant, yet she was well taken care of in our special hospital and was grateful. A patient for tonsillectomy was detoured for a mastoidectomy. Patients with a lump in the neck from malignant metastasis, without early discovery of a primary lesion, always cause chagrin to all. Malignant nasopharyngeal lesions are often so insignificant and symptomless. The following are sad observations: I have seen three cases of chancre in the conjunctiva, two on the septum of the nose, three in fingers that were gaffed by tonsillectomy snares and two in hangnails. Many severe pyogenic infections have occurred due to carelessness, with loss of hands, fingers and life. The lesson is, to always be careful of possible infected blood or secretions.

I will discuss some cases of papillomatosis or chronic papillary sinusitis. In 1854, Billroth⁵ considered polypi in the nose to be myxomatous tumors. Later he believed that all nasal polyps were adenomatous. This was refuted by Hopmann,¹⁷ who described a number of proven papillomata that had been confused with the polypi. Permit me a word: A polyp consists of edematous connective tissue stroma. Papilloma consists of marked hyperplasia of surface epithelium. Doctors still, in error, refer to a papillomatous lesion as a polypoid lesion.

In 1895, Wright³⁹ explicitly set forth the distinction between polypi and papillomata. In 1908 he reported two cases which simulated malignant lesions. Others reported similar cases, notably Kieselbach¹⁸ and Arrowsmith.¹ Dr. Jonathan Wright³⁹ did much for otolaryngology. I recommend to otolaryngologists to read all of his books and, in particular, his *History of Otolaryngology*, published in 1914. In 1886, Verneuil³⁷ reported benign papillomata that had recurred in spite of several removals. In 1897, Hellmann¹⁵ wrote upon the nasal papillomata and their transformation into carcinomata. Dr. Ewing¹² reported a case of nasal papilloma that recurred after removal, for ten years, and eventually became carcinomatous. To Hopmann belongs the original observation of soft papillomata of the nose and sinuses and the lesions have been referred to as Hopmann's sinusitis. Hopmann's observations received support from many other confreres of his time, namely, Mackenzie,²⁶ Chiari,⁷ Wright³⁹ and recently by Eggston and Wolff¹¹ and Ash and Baum.²

I see a goodly number of cases of papillomatosis annually, but not nearly as many as polypoid cases. At all times, tissues surgically removed should be analyzed microscopically. Respiratory epithelium in the upper and lower respiratory tract can and does undergo extensive metaplasia due to prolonged infection or irritation, such as smoking. Such a change may be the forerunner of malignancy.

Presentation of my cases will be in abstract.

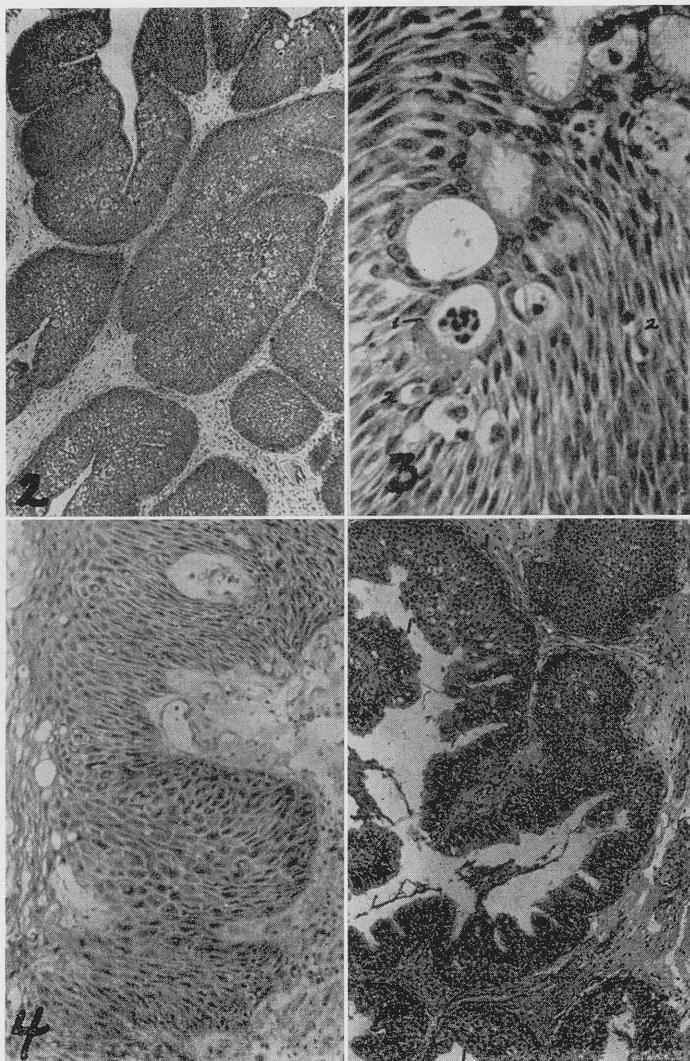


Fig. 2.—Squamous cell type of papillomatosis.

Fig. 3.—Higher magnification of an area from Figure 2 which illustrates in detail the squamous cell type of lesion, vacuoles containing leukocytes (1) and clear halo around some of the nuclei (2); suggestive of virus disease.

Fig. 4.—Carcinoma in situ, of antrum.

Fig. 5.—Metaplasia of the epithelium with areas suggestive of early carcinoma.

PAPILLOMATOSIS

Various types of papillomatous changes are shown in Figure 1. Some cases of benign nasal papillomatosis have come to my observation where radical operations were recommended to which I could not agree. Such benign cases had simple exenteration of the diseased sinus mucosa, without further recurrence. If the papilloma has degenerated into a carcinoma, then, of course, early radical operation should be done.

The first case is of benign papilloma where simple exenteration of the lesion sufficed. The patient is still in good health after five years. A radical operation had been advised, but not done (Figs. 2 and 3).

Next is the case of an otolaryngologist who suffered for years with sinusitis, which terminated in carcinoma. From 1936 to 1941 he was treated for an allergic sinus condition. In 1941 a thorough investigation of the sinuses revealed a marked thickening of the mucous membrane in the left antrum, with a diagnosis of chronic maxillary sinusitis. He preferred occasional washings, which were done intermittently from 1938 until 1954. Repeat x-rays in 1954 revealed the same pathology of the antrum. An exploratory antrotomy was performed in October of 1954 which confirmed the diseased mucous membrane. In the removal of the membrane, the surgeon found a small bony dehiscence, 2 mm in diameter, and suspected a malignancy. A biopsy was done from the antrum and because of several different opinions by several pathologists, in January of 1955 the patient was rebiopsied, followed by a similar difference of opinion by pathologists. However, a positive diagnosis of epidermoid carcinoma was agreed upon. Since surgery would necessarily have to be very radical, the patient elected x-ray therapy and received 5600 r.u. without improvement. The disease progressed until October 1955, when it was evident that there was extension of the process. The patient refused further x-ray treatment. He finally accepted radical surgery. This was done in October 1955, with radical maxillectomy and exenteration of the orbit. The patient ran the usual postoperative course and did very well until April when his discomfort became severe. In September, repeated biopsies revealed carcinoma. The patient desired no further surgery, so further x-ray was instituted, without relief. The disease continued to spread for 18 months before

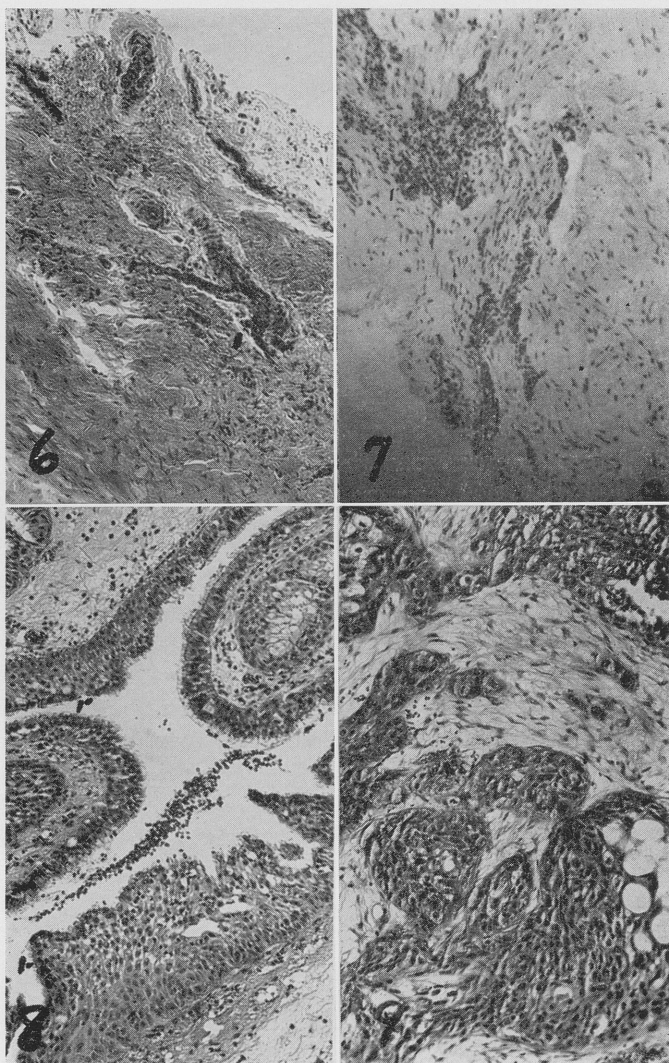


Fig. 6.—Areas (1) showing epidermoid carcinoma.

Fig. 7.—Areas of epidermoid carcinoma.

Fig. 8.—Foliate type of sinusitis areas (1), metaplasia.

Fig. 9.—Anaplastic epidermoid carcinoma. Grade IV.

his demise, from extensive epidermoid carcinomatosis (Figs. 5, 6, 7). At times, the malignancy starts as carcinoma in situ (Fig. 4).

The next case of papillomatosis is of Mrs. K. This 56 year old woman had protracted sinusitis for years. Finally a biopsy revealed an epidermoid carcinoma. Radical surgery and radiation were given with no avail. The patient lived one year and died of carcinomatosis (Figs. 8 and 9).

NON-CHROMAFFIN PARAGANGLIOMA, GLOMUS TUMOR,
GLOMUS JUGULARE, CHEMODECTOMA, ETC.

This presentation includes the glomus tumor group. There are recorded in medical literature as many as 20 synonyms of tumors of the carotid body and other structures. In 1950, Mulligan²⁸ used the word "chemodectoma" to describe the glomus tumors. Such designation does not completely satisfy many pathologists. It does not assay the histogenesis and complete physiology of glomus tumors (Boyd,⁶ Smith³⁴). These ganglion structures are probably chemoreceptors as well as chemodectors and receive chemical stimuli which are transmitted to the central nervous system. It is postulated that the changes in electrolytes, CO₂, sodium, potassium, calcium and oxygen tension have some relationship to the function of these structures. There are numerous locations where paraganglion cells and glomus tumors occur, namely in the carotid body, jugular bulb, the nodosa ganglion of the vagus nerve, ganglia of the glossopharyngeal nerve and tympanic nerves, also the aortic²² and coccygeal bodies and minute pulmonary bodies. Philip M. LeCompte²⁴⁻²⁵ published a complete review of the tumors of the carotid body and related structures as a section of the Atlas of Tumor Pathology in 1951, published by the Armed Forces Institute of Pathology. Costero⁸ et al. demonstrated morphologic properties with nerve and vascular connections to the chief cells of glomus tumors.

The first case is of a woman operated upon in 1943 when 40 years of age. After 18 years, she remains in good health. Dr. Nigro resected the tumor which surrounded the carotid arteries. There were no central nervous system symptoms following the operation because the carotid arteries were constricted. In many cases the vessels are surrounded by tumor which makes complete resection hazardous (Figs. 10, 11).

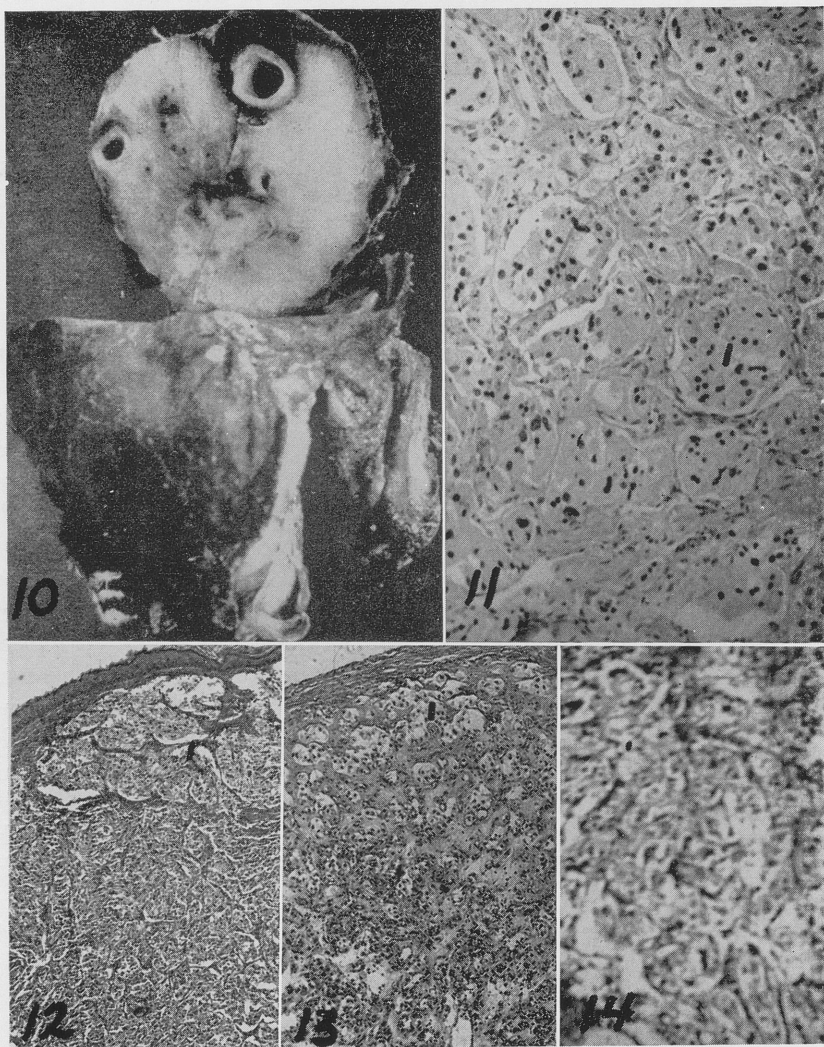


Fig. 10.—Carotid body tumor, surrounding the carotid arteries.

Fig. 11.—Microscopic structure of Figure 10, revealing “Zellballen of chief cells.

Fig. 12.—Glomus tumor, middle ear (x 58), “Zellballen” (1).

Fig. 13.—Same as Figures 12 and 14.

Fig. 14.—Glomus tumor, middle ear (x 100). Higher magnification of (1), Figure 12.

The second case was seen by Dr. Wolcott in May of 1955. The patient had a progressive deafness and pain in the left ear with deep-seated headache and unsteadiness. About a year previously, she consulted another otologist who made a diagnosis of a polyp, which he attempted to remove. This was followed by severe bleeding, necessitating hospitalization and transfusions. There is no record of a microscopic examination done at that time. When examined by Dr. Wolcott, there was, in addition to pain, instability and considerable loss of hearing, also hoarseness. Examination revealed a large fleshy-looking polyp. It filled the external auditory canal, with reduction in hearing, and paralysis of the left vocal cord was present. X-ray revealed an invasive lesion involving the base of the skull and obliteration of the middle ear anatomy. Biopsy was taken by electric snare, followed by considerable bleeding. Microscopic examination revealed a non-chromaffin paraganglioma which was considered inoperable and was treated by x-ray therapy. She first received 2000 r.u. with little improvement, and in 1955 she was given a second course of x-ray treatment which was followed by marked improvement. The lesion in the ear disappeared, although her vocal cord paralysis remained. In April of 1961, she was examined, without evidence of recurrence. Her general health was good, she was only slightly unsteady. However, the paralysis of the vocal cord remained (Figs. 12, 13, 14).

The third case of glomus tumor, E.L., has been previously reported clinically by Dr. F. M. Turnbull.³⁶ I wish to report a more detailed pathological finding in this case. The patient was a white male, 48 years of age, admitted to the Hospital in January, 1952, with a tumor mass in the right upper neck, of 10 years' duration. The mass slowly increased in size, with pain for the past two months. In July 1951, a biopsy was taken and reported as a carotid body tumor. Examination in our Tumor Clinic revealed a tumor mass measuring 9 x 6 cm in the right upper third of the neck and encroaching upon the mandible. The mass was not tender and there was no pulsation. It was rubbery and slightly movable, vertically. Biopsy on January 23 was reported as a carotid body tumor with sarcomatous changes. A right radical neck dissection was performed and the tumor removed. It was encapsulated and firm and intimately adherent to the carotid vessel and the vagus nerve. External and internal carotid arteries were enveloped by the mass. The lumen of the internal carotid artery was occluded. Pathological examination revealed a sarcoma of the carotid body, confirmed by several pathologists, with comments that

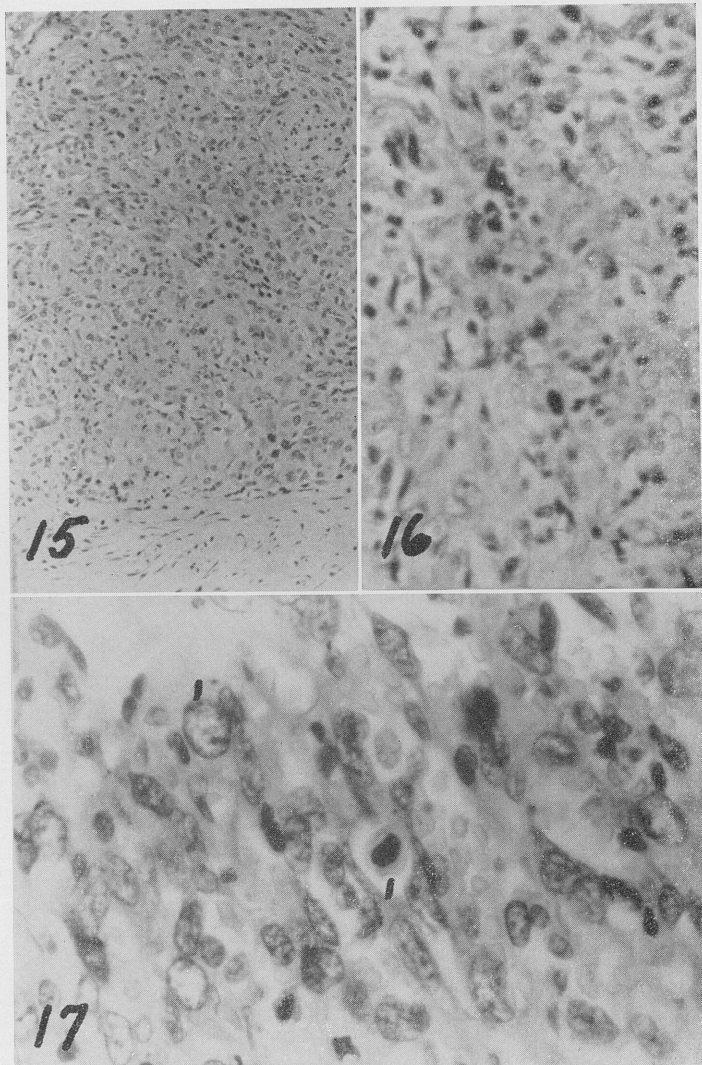


Fig. 15.—Malignant carotid body tumor, (x 60).

Fig. 16.—Malignant carotid body tumor, (x 100).

Fig. 17.—Malignant carotid body tumor, (x 200) showing chief cells and mitosis.

they had never seen a malignancy of carotid body tumors. Sections revealed a pleomorphic cellular mass, chiefly spindle cells. The operation was done in January. In March 1950, the patient returned with a 2 cm tender mass beneath the mastoid process and behind the cervical scar. Another mass was found in the right submental area. He had pain and loss of weight. These recurrences were resected and found of similar histology as the primary tumor. In July 1950, x-ray of the chest revealed metastatic lesions throughout the lungs. The patient was discharged for terminal care. He expired in August of 1952. Autopsy revealed generalized metastasis with extensive involvement of the lung. This case illustrates that if carotid body tumors are allowed to run their own course, a significant number will eventually become malignant (Figs. 15, 16, 17).

NEUROBLASTOMA, ESTHESIONEUROEPITHELIOMA OR
NEUROCYTOMA, ETC.

There are nasopharyngeal tumors that are diagnosed as neuroblastomas, reticulum cell sarcoma, lymphoma, Hodgkin's disease, fibrosarcoma, angiosarcoma, rhabdomyosarcoma and simply as highly anaplastic tumors. Regardless, the course and ultimate outcome is very discouraging as most of these cases are fatal in the young. Salas³¹ reported 16 cases in ages between one and three years who lived from two weeks to eight months. I confess to errors in the pathologic diagnosis in this tumor category.

The first case is of a three year old Puerto Rican girl, presenting a tumor mass in the nasopharynx, at first diagnosed as a fibrosarcoma or neuroblastoma. Later on there was cervical lymph node metastasis. Examination revealed that this was a rhabdomyosarcoma. The patient received extensive radiation. However, within less than a year there was generalized metastasis and the patient expired (Figs. 18, 19).

The second case I wish to present briefly is H.K., a white female, 33 years of age, who was admitted August 1953 and was operated upon for a malignant neuroblastoma of the left antrum. There was a palpable swelling of the left antrum and a bulging mass in the left nares. There was also a mass in the left buccal fold with a dehiscence of the right palate. Biopsy revealed a malignant neuroblastoma. X-ray revealed bony destruction of the left antrum and the left upper antral plate. There was a radical left maxillectomy with exenteration

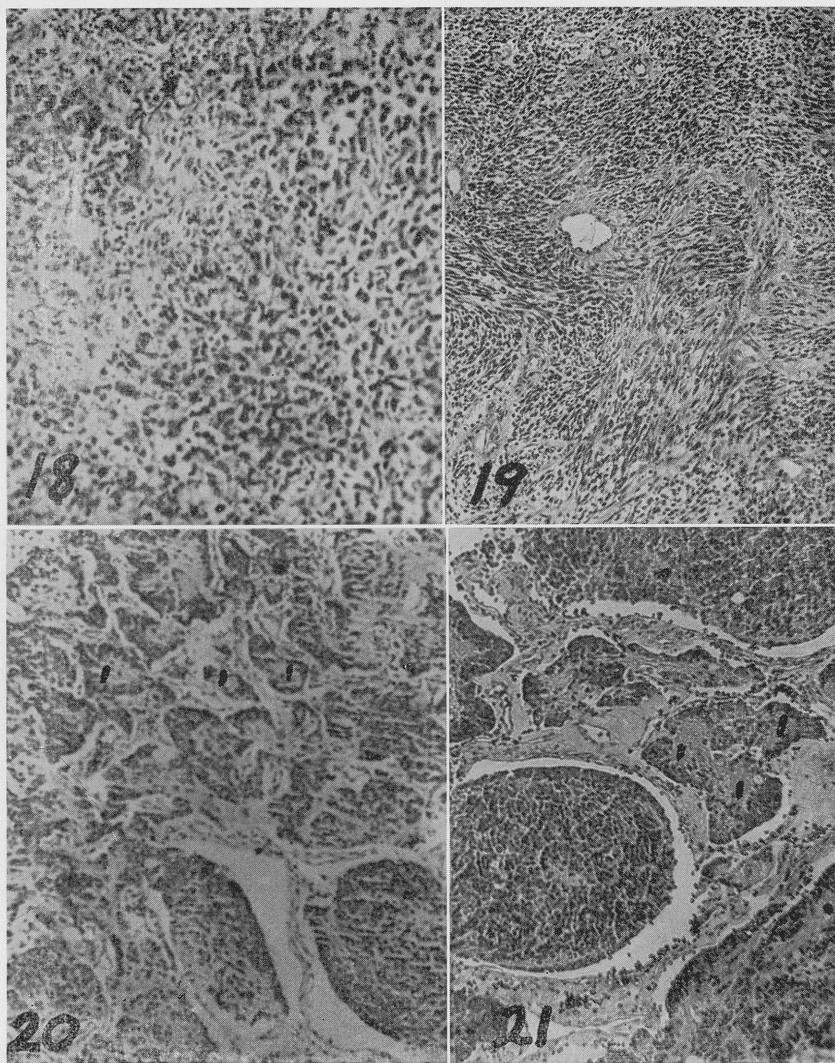


Fig. 18.—Nasopharyngeal tumor, Pt. L, three years, diagnosed as neuroblastoma. (See Figure 19.)

Fig. 19.—Cervical lymph node metastasis, Pt. L, three and one-half years. Diagnosis: rhabdomyosarcoma.

Fig. 20.—Neuroblastoma (Esthesioneuroepithelioma) of antrum, revealing pseudo-rosettes.

Fig. 21.—Neuroblastoma (Esthesioneuroepithelioma), higher magnification of pseudo-rosettes. Note loose fibrous material in central core.

of the left orbit, also the ethmoid, sphenoid and ptergoid fossa were removed. The operation was performed September 4, 1953. On January 2, 1954, there was a recurrence. The patient received x-ray treatments in 1954, of 5000 r. u., with marked improvement. After this the patient returned to the Tumor Clinic in 1954 and yearly until April 5, 1961, without any evidence of recurrence. McCormick and Harris²⁷ reported four similar cases which they preferred to call neurocytoma. Schall³² reported primary intranasal neuroblastoma. Others have reported similar cases (Figs. 20, 21).

The third case is of N.F., white male, 69 years of age. He was admitted to the Hospital March 14, 1957, because of difficulty in nasal breathing. A biopsy revealed a papillary neuroepithelioma.¹¹ X-ray examination revealed four-plus involvement of the right ethmoid and antrum and two-plus of the right sphenoid. The patient was referred for radiotherapy in January 1957, by the tumor clinic, but it was thought that the tumor was radioresistant. A total dose of 5500 r.u. was given without appreciable change in the patient's condition. Patient was operated upon February 14, 1958. There was a right maxillary resection and a right orbital exenteration. On June 27, 1958, there was a recurrence of the tumor and a wide local excision was done. On March 12, 1959, the patient was re-operated upon for a recurrence and a right radical neck dissection was done. Patient returned several times in 1959 and 1960 without any evidence of recurrence. The last visit was in March 1961, without evidence of recurrence.

Frühling and Wild¹³ report four cases of neuroblastoma olfactory esthesioneuroepithelioma similar to those reported by Louis Berger.⁴ These types of tumors have received a great deal more attention in Europe than in this country, particularly in France. They report the clinical symptoms and histology in detail, particularly the true rosettes and neurospongiol cells. They speak of the attenuated malignancies, as they are extremely sensitive to surgical and radiation treatment, resulting usually in cure, as were the two cases above reported (Figs. 22, 23, 24).

I must now end this narrative. I have been greatly inspired and helped in my work and the problems by the understanding and co-operation of many great clinicians and otolaryngologists. In the course of this work, Dr. Dorothy Wolff and I collaborated and published a book in 1947, on the Histopathology of Ear, Nose and Throat, which now needs revision. This was a labor that was very rewarding to both of us.

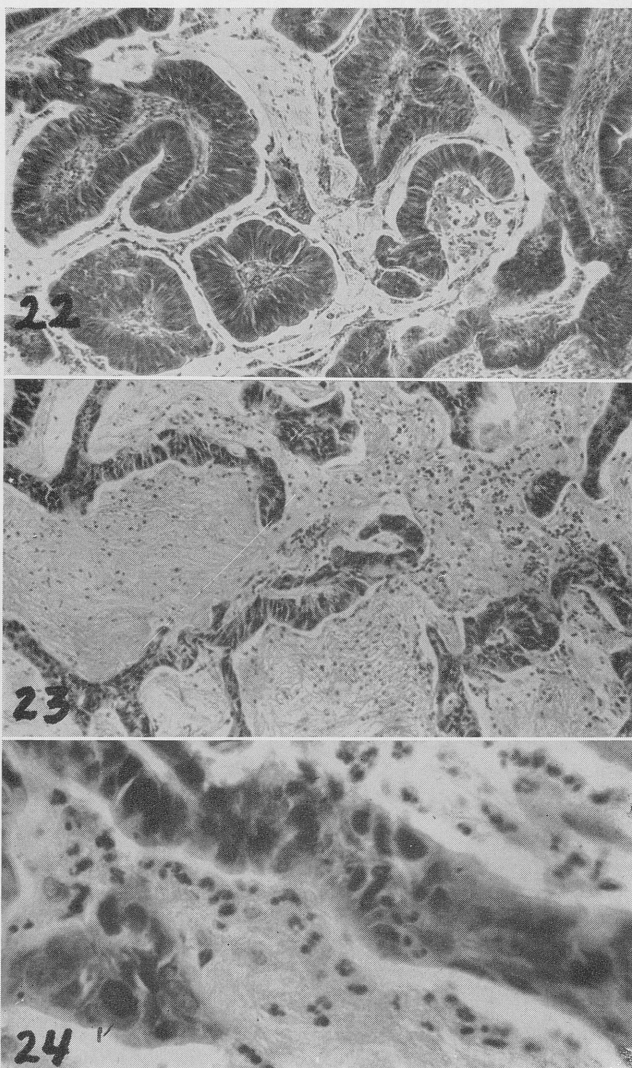


Fig. 22.—Papillary neuroepithelioma (Esthesioneuroepithelioma), (x 100), revealing strands and areas of tall columnar olfactory nerve sensory receptive cells. Some of the cells have hair-like processes on the external borders.

Fig. 23.—Higher magnification of similar trabeculae of olfactory nerve cells.

Fig. 24.—Higher magnification of columnar cells revealing anisocytosis, hyperchromasia and mitosis (1).

I repeat, to have seen so many lethal complicating infections in otolaryngology practically fade into history and now to observe the new phases of rehabilitation in ophthalmology and otolaryngology: all this has been heartwarming. All these things have made my experience and journey deeply impressive to me. Finally, I am most grateful to all those who have made the journey pleasant and profitable. I will never forget the many older otolaryngologists who have passed on, nor the newer generation who so efficiently carry on.

653 PARK AVENUE

REFERENCES

1. Arrowsmith: The Laryngoscope 3:283, 1897.
2. Ash, Col. J. E., and Baum, M.: Epithelial Papilloma. *Atl. of Otolaryn. Pat., Amer. Forces Inst. of Path.* 196-198, 1949.
3. Beidler, L. M., Ph.D.: Physiology of Olfaction and Gustation. *Trans. Am. Laryng. Asso.* 81:27, 1960.
4. Berger, L., Luc and Richards: L'esthesioneuroepitheliome olfactif. *Bull. Assoc. franc. P. l'etude du cancer* 13:410, 1924.
5. Billroth, C. A.: *Surgical Pathology*, 1882. Über den Bau der Schleimpolyphen, Berlin, 1854.
6. Boyd, J. D.: The Development of the Human Carotid Body. *Contr. Embryol. Carnegie Inst. (No. 152)* 26:1-31, 1937.
7. Chiari: *Revue mensuelle de laryngologie* 6:3, 1886.
8. Costero, I., and Barroso-Moguel, R.: Structure of the Carotid Body Tumor. *Amer. J. Path.* 38:2, 1961.
9. deCastro: Sur la structure et l'innervation du sinus carotidien de l'homme et des mammiferes. Nouveaux faits sur l'innervation et la fonction du glomus caroticum. *Trav. du lab. de recherches biol. de l'Univ. de Madrid* 25:331-380, 1927-28.
10. deLorenzo, A. J., Ph.D.: The Electron-microscope of the Olfactory and Taste Pathways. *Trans. Am. Laryng. Asso.* 81:39, 1960.
11. Eggston, A. A., and Wolff, D.: Histopathology of Ear, Nose and Throat. Williams and Wilkins, 648-656, 1947.
12. Ewing, J.: *Neoplastic Diseases*. W. B. Saunders, 4th Ed., 782-783, 1941.
13. Frühling, L., and Wild, C.: Olfactory esthesioneuroepithelioma. *Amer. Arch. Otolaryng.* 60:37-48 (July) 1954.
14. Guild, S. R.: A Hitherto Unrecognized Structure, the Glomus Jugularis in Man. *Anat. Rec.* 79 (suppl. 2) 28, 1941.
15. Hellman, A.: *Für Laryngologie und Rhinologie* 6:171, 1897.
16. Hollingshead, W. H., and Sawyer, C. H.: Mechanism of Carotid Body Stimulation. *Amer. J. Physiol.* 144:79-86, 1945.
17. Hopmann, V. A.: *Virchow's Archives of Path. Anat.* 93:213, 1883.
18. Kiesselbach: *Virchow's Path. Anat.* 132:371, 1893.

19. Kipkie, G. F.: Simultaneous Chromaffin Tumors of the Carotid Body and the Glomus Jugularis. *Arch. Path.* 44:113-118, 1947.
20. Kohn, A.: Das Chromaffine Gewebe. *Erg. Anat.* 12:253-348, 1902.
21. Korn, D., Bensch, K., Liebow, A., and Castleman, B.: Multiple Minute Pulmonary Tumors Resembling Chemodectomas. *Amer. Jour. Path.* 37:6, 1960.
22. Lattes, R.: Nonchromaffin Paraganglioma of Ganglion Nodosum, Carotid Body and Aortic-arch Bodies. *Cancer* 3:667-694, 1950.
23. Lattes, R., and Waltner, J. G.: Nonchromaffin Paraganglioma of the Middle Ear. (Carotid Body-like Tumor, Glomus Jugulare Tumor). *Cancer* 2:447-468, 1949.
24. LeCompte, P. M.: Tumors of the Carotid Body. *Amer. J. Path.* 24:305-321, 1948.
25. LeCompte, P. M.: Atlas of Tumor Path., Armed Forces Inst. Path. 1951.
26. Mackenzie, M.: Diseases of Throat and Nose 2:377, 1884.
27. McCormack, L. J., and Harris, H. E.: Neuroblastomas. *A.M.A.* 157:318, 1955.
28. Mulligan, R. M.: Chemodectoma in the Dog. (Ab.) *Amer. J. Path.* 26: 680-681, 1950.
29. Nonidez, J. F.: Observations on the Blood Supply and the Innervation of the Aortic Paraganglion of the Cat. *J. Anat. Lond.* 70:215-224, 1936.
30. Rosenwasser, H.: Carotid Body Tumor of the Middle Ear and Mastoid. *Arch. Otolar.* 41:54-67, 1945.
31. Salas, M.: Neoplasia in Children Neuroblastomas. *M. Bol. Med. Hosp. Inf.* 11:119-142, 1954, Spanish.
32. Schall, L. R., and Linebach, M.: Primary Intranasal Neuroblastoma. *ANNALS OF OTOTOLOGY, RHINOLOGY AND LARYNGOLOGY* 60:221-229, 1951.
33. Schmidt, C. F., and Comroe, J. H., Jr.: Functions of the Carotid and Aortic Bodies. *Physiol. Rev.* 20:115-157, 1940.
34. Smith, C.: The Origin and Development of the Carotid Body. *Am. J. Anat.* 34:87-131, 1924.
35. Stout, A. P.: Tumors of the Peripheral Nervous System. Atlas of Tumor Path., Wash., D. C., 1949.
36. Turnbull, F. M., Jr.: Malignancy in Carotid Body Tumors with Presentation of Proven Case of Metastasis to Lung. *West. Jour. Surg., Obstr. and Gyn.* 62:382-390 (July) 1954.
37. Verneuil: Bull. et mem de la Societe de Chirurgie de Paris 12:658, 1886.
38. Wright, J.: New York Med. Jour. 60:453, 1894.
39. Wright, J.: A History of Laryngology and Rhinology. Lea and Febiger, 1914.
40. Zachs, S. I.: Chemodectomas Occurring Concurrently in the Neck (Carotid Body), Temporal Bone (Glomus Jugulare) and Retroperitoneum. Report of a Case with Histochemical Observations. (With 10 illustrations). *Amer. J. Path.* 34:2, 1958.

DISCUSSION

DR. JOHN F. DALY (New York): Mr. President, Fellows and Guests: Dr. Eggston's report of his forty-two years' experience as the pathologist in otolaryngology is, indeed, an impressive record of dedication, as impressive a record as you will find anywhere in the annals of medicine. His presentation is filled with information, history and wisdom which is so characteristic of the man, himself.

It is a great honor and privilege to discuss this report. However, I must confess—and this is with no show of humility—that I am unequal to the task. After all, Dr. Eggston has been my teacher; he is the source of information and advice and guidance today when I am in difficulty; and this is the role that he has played at Manhattan Eye and Ear for these past forty-two years.

However, he has created a rather relaxed mood, as is his usual way; he has been a little harassed, as we all are, by the pressure of time, which is unfortunate. I would like to borrow his metaphor. I think he is very much like the farmer who has toiled long and hard and has reaped a great harvest from this very rich field of otolaryngological pathology, and now he has his barns filled, and the only thing that remains is to call in his friends, the otolaryngologists, with whom he has worked, to enjoy the fruits of his labor. And so in this mood which he has created, I may venture a few general comments.

First of all, he has reminded us that we have passed through this period as otolaryngologists in which we dealt mostly with infections. Our concepts of disease at that time were largely influenced by Koch's postulate: a single disease entity must have a single specific cause. He has selected a group of entities today to review out of this vast treasury that are quite different, and I think we may remark on the change. We no longer think that the cause of disease is a single entity, like a virus or bacterial, but multiple conglomeration of factors—heredity, immunity, virus and chemical and electrical causes.

The second observation that I would like to make is this, that in these three pathological entities that he has selected for discussion, there are a couple of generalities that run through all of them. First of all, he has pointed out the difficulty in making the diagnosis merely from the examination of the tissue that is submitted to the pathologist for an analysis of the morphological changes in the cell. He has also pointed out the impossibility of predicting the malignant potentialities of certain tumors merely from the study of their histology. One cannot always predict by looking at sections what the outcome will be when we apply surgery and radiation.

Dr. Eggston has overcome, to a large extent, these limitations of microscopic examination, by his broad interest in medicine and his real interest in the patient, to a degree that is unique among pathologists.

There is one other disease which he has not included in his paper, which I had hoped he would. He has been fascinated by lethal granuloma, and I am sure he left it out simply because he knew he could never fit it in the time allotted. This is a real challenge to anyone who has followed the tradition of morphology of disease—the study of cells. The best analogy that I can give you would be, if you took a movie of the construction of a house and started it with digging the hole, then the carpenters, very busy bringing material together and erecting the house. But when you show it, you showed it in reverse, because the only tissue that is available for the pathologist are granulation tissue, are fibroblasts—these are the

elements that nature reconstructs and builds with. If you took that film and ran it backwards, you would know what this disease appears like and what a challenge this is to the morphological pathologist, because you would see the carpenters very busy; and the busier they were, the faster the house progressively disappeared finally into the ground.

This is the challenge to Virchow's idea that the cell is the final analysis of what is going on and the cell is the sole seat of pathology.

From this report of Dr. Eggston's we realize that we are seeing a new era open up. We are going back to the old humoral investigation of disease, of which Rocketanski was the last advocate.

The new frontiers will be found in the analysis of the immune reactions in the investigations of tissue transplants, and as Dr. Eggston has pointed out, in the use of electron microscopy and histochemistry.

Dr. Eggston has dedicated this report to otolaryngologists and I wish that I could say adequately what he has meant to us in New York City, and particularly at the Manhattan Eye and Ear where he has labored for forty-two years. I am sure other members of this Society could, better than I, tell the story of Dr. Eggston's devotion to pathology in our field. Dr. Mackenty, Dr. Kaufman, Bob Buckley, Joe Kelly, Dan Cuning, Francis White, Charles Imperatori would come to the platform and tell you that here is not only a great pathologist, but a scientist, a gentleman, a scholar and a great medical statesman.

TRENDS IN THE MANAGEMENT OF PAROTID LESIONS

GEORGE SHIMO, M.D.

HARRY S. DOLAN, M.D.

MONTREAL, CANADA

The basic problems in the management of parotid lesions have been largely constituted in a combination of anatomical and pathological considerations. Much has been written in regard to the diagnosis and treatment of these lesions. Tumors, in particular, because of their many disputed features have continued to interest clinicians and pathologists.

Anatomical factors have played such a prominent role in the treatment of parotid lesions that it is well to review some of the features of this rather complicated region.

The parotid, the largest of the three major salivary glands, is situated primarily in the retromandibular fossa which is a deep recess below and in front of the mastoid process of the temporal bone. The gland, roughly in the shape of a three-sided wedge, sprawls anteriorly over a part of the masseter muscle. A forward projection of this portion of the gland is known as the accessory parotid. A portion of the gland extends upward behind the temporomandibular joint filling the area between the joint capsule and the external auditory meatus. Posteriorly and medially the gland faces the mastoid process and the sternocleidomastoid and digastric muscles. Inferiorly the gland extends below the plane of the lower border of the mandible in the space between the mandibular angle and the sternocleidomastoid muscle.

The deeper relations of this gland are to be emphasized. Embedded within the gland for some distance are the external carotid artery and the posterior facial vein. The external carotid divides into

From the Department of Otolaryngology, Royal Victoria Hospital, Montreal, Quebec.

its terminal branches, the internal maxillary and superficial temporal arteries, and the posterior facial vein receives the corresponding venous branches.

The auriculotemporal nerve passes upward through or just deep to the upper portion of the gland. Medially the deep portion of the gland is in relation to the styloid process with its attached muscles, the stylohyoid, stylopharyngeus and styloglossus muscles, and these structures overlie the internal carotid artery and internal jugular vein. Near the base of the skull the vein lies posterior to the artery from which it is separated by the ninth, tenth and eleventh cranial nerves as they emerge from the anterior portion of the jugular foramen. Furthermore, it is to be noted that the medial margin of the gland has a close relation to the lateral wall of the upper pharynx. The superior constrictor muscle of the pharynx stretching across from the medial pterygoid plate to the pharyngeal tubercle posteriorly on the base of the skull leaves a deficiency above its superior margin, the sinus of Morgagni, through which the eustachian tube and the levator veli palatini muscle pass. This deficiency is covered by the pharyngobasilar fascia.

A fibrous capsule formed by a splitting of the superficial layer of the deep cervical fascia invests the parotid gland. It is intimately united to the gland surface and its prolongations divide the gland into lobular compartments. The thick outer layer, the parotid-masseteric fascia, extends over the gland and masseter muscle and is attached above to the zygomatic process. Below, the fascia is thickened to form the stylomandibular ligament which separates the lower pole of the parotid from the submaxillary salivary gland. The capsule is thin over the medial aspect of the retromandibular portion permitting tumors of this area to grow readily toward the pharynx.

The sensory nerve fibers to the gland are contained in the auriculotemporal and great auricular nerves. Infections and tumors of the gland give rise to exquisite pain at times.

The lymphatic and venous systems are closely related in and around the parotid gland. Thus, lymph nodes lie within, superficial and deep to the substance of the gland. Spread of cancer of the gland may involve the parotid, retropharyngeal and superior deep cervical groups of nodes.¹

The outer surface of the gland is related only to the skin and fascia and a few inconstant lymph nodes. The deep portion of the gland is intimately concerned with a potential fascial compartment, the lateral pharyngeal space variously termed the pharyngomaxillary, parapharyngeal, and pterygomandibular space. The relationship of the gland to this compartment is to be considered in instances of parotitis because of the serious consequences of suppuration in this space.

Stenson's duct takes a fairly tortuous course, lying deeply on the masseter muscle initially before it pierces the buccinator muscle to enter the oral cavity. Palpation of the duct is difficult and often inconclusive. A small papilla marks the opening of the duct. This orifice is the narrowest part of the duct and just permits the entrance of a small nasolacrimal probe.

The most important consideration in regard to the surgery of this area is the relationship of the parotid gland to the facial nerve. The presence of this nerve more than any other structure modifies the approach to the treatment of parotid lesions. The nerve not only has a complicated course through the temporal bone, but upon emerging from the stylomastoid foramen becomes wrapped up in the substance of this gland. The nerve takes a forward and downward course from the stylomastoid foramen lying lateral to the styloid process and its attached muscles, and then almost immediately enters the parotid gland. In rare cases the nerve has an aberrant course and may emerge from the anterior surface of the mastoid process.² It divides into two main divisions, an upper temporofacial and a lower cervicofacial, which then usually divide and anastomose to form a plexus within the gland. From this plexus a variable number of fibers emerge from the gland to be distributed to the facial muscles. The parotid duct may be crossed superficially by anastomosing branches of this plexus.

McCormack, Cauldwell and Anson³ as well as State⁴ have described the gland as being composed of superficial and deep lobes separated by the divisions of the facial nerve with an isthmus uniting the two parts. Accordingly, the superficial and deep portions form lobes which are distinct and easily separated and are folded about the nerve. McKenzie⁵ feels that this concept is an over-simplification and he has produced evidence to show that the parotid tissue, ducts

and facial nerve are intimately interwoven with numerous connections uniting the superficial and deep parts of the gland. The latter concept appears to be more reliable, but in any case surgery within the substance of the parotid gland necessarily carries with it the risk of damage to the facial nerve. The superficial portion of the gland can be quite readily dissected free from the nerve but the deeper portion with its prolongations into the depths of this confined area can only be removed in a piecemeal fashion.

Excision of parotid lesions is carried out by first locating the main trunk of the facial nerve using a Y-shaped incision with the upper arms extending anterior and posterior to the auricle and the lower arm extending down into the neck. Adequate exposure of the superficial surface of the gland including the upper anterior one-half of the sternomastoid muscle and mastoid process are carried out. The pre-auricular incision includes the full thickness skin down to the parotid-masseteric fascia and that on the neck extends through the platysma. The great auricular nerve extending diagonally upward over the sternomastoid muscle is identified and divided. The anterior border of the sternomastoid muscle is separated from the posterior border of the parotid gland. Dissection is now taken more deeply hugging the antero-inferior wall of the cartilaginous external auditory meatus until the tympanic plate is felt as a protruding knuckle of bone. The facial nerve can be located in the sulcus formed by the union of the mastoid process and the tympanic plate. The nerve also bisects the angle formed by the cartilage of the external auditory canal and the posterior belly of the digastric muscle. The nerve is traced forward by bluntly separating the superficial portion of the gland from it. The two main divisions of the nerve are traced and their peripheral branches carefully preserved as the parotid tissue is dissected away. Sistrunk⁶ and Adson⁷ recommended identification of the mandibular branch of the nerve which is followed back to the main trunk.

Excision of chronic inflammatory parotid tissue and recurrent tumors can be very difficult because of the dense scarring that is present. Location of the nerve may be difficult when a tumor has compressed it deeply behind the mandibular ramus. The nerve may be displaced outward by a deeply located tumor and excision accomplished by careful retraction of the nerve fibers. The styloid process is a useful landmark because it lies deep to the nerve and it also pro-

vides protection to the internal jugular and internal carotid vessels. Deep tumors are technically difficult to remove not only because of the facial nerve but also because of the restricting bony boundaries of this area: the mandibular ramus in front, the tympanic plate above, the mastoid process behind, and more deeply the styloid process and vertebral column. The parotid space can be widened by rotation and extension of the head to the opposite side and by retraction of the mandibular ramus forward.

Tumors may extend deeply into the pterygomandibular area and inward behind the pterygoid processes into the nasopharynx, oropharynx and soft palate. At times, a portion of the mandibular ramus must be resected to effect adequate removal of tumor in this region. The space between the base of the skull and upper edge of the superior constrictor muscle affords an avenue through which expanding tumor can push into the pharynx compressing and obstructing the eustachian tube and follow the muscular plane of the levator veli palatini into the soft palate. These tumors protruding into the pharynx may be incorrectly considered primary pharyngeal neoplasms.

The clinical diagnosis of parotid lesions is often difficult and misleading. A stationary or slowly growing, painless lump in this area is usually a mixed tumor. It must be emphasized, however, that all lumps in the parotid region are not mixed tumors.

Inflammatory lesions of the parotid and of the lymph nodes within the gland frequently simulate tumor. Furthermore, other benign parotid tumors such as adenoma, lipoma, hemangioma, neurinoma, cystadenoma lymphomatosum or Warthin's tumor may be mistaken for mixed tumor. The malignant tumors, including early carcinoma of the parotid gland, metastatic tumors, lymphomas and so on must be considered in the differential diagnosis.

A tentative diagnosis of a benign parotid tumor can be made when a rounded, firm, smooth nontender mass is palpated in the parotid region. If they are located in the more superficial portions of the gland, as most of them are, they are easily palpated and are usually quite freely movable. The facial nerve function is invariably preserved even when the tumor is large. At times, retromandibular tumors may elicit pain referred to the ear with jaw movements

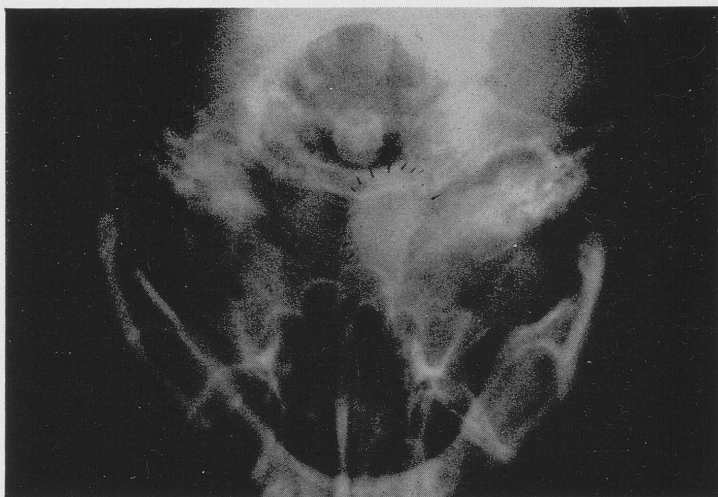


Fig. 1.—A basal view of the skull showing a rounded soft tissue mass protruding into the pharynx and reaching the midline as indicated by the hatched lines. This was a benign mixed tumor of the parotid gland.

caused by the pressure of the mandibular ramus on the gland especially against the anterior wall of the external auditory meatus. Tumors expanding into the nasopharynx may compress the eustachian tube with resultant middle ear complications. A careful nasopharyngeal examination including stereoscopic basal films of the skull is indicated. Other tumors may expand into the soft palate and the tonsillar area interfering with swallowing and speech (Fig. 1).

Malignant tumors are characterized by their wide diversity of symptoms. Early low grade malignant tumors may appear clinically benign. An increase in size of a previously stationary tumor may be an indication of malignant transformation. The occurrence of pain, severe and constant, is often indicative of malignancy. At times, such pain in the absence of any definite parotid mass or swelling becomes a problem in diagnosis. Facial nerve dysfunction may be minimal and overlooked, but in other instances the onset of facial paralysis may be rapid and complete. This may be the only sign for a period before a deep underlying tumor becomes manifest. A hard, fixed mass in this region especially in association with a facial paralysis usually signifies a malignant parotid tumor. It is evident,

however, that other less obvious signs and symptoms must be regarded with suspicion and management directed accordingly.

Roentgenograms of this area are unreliable because of overlapping bony shadows which make accurate interpretation impossible. Sialograms obtained by the instillation of radiopaque solutions such as lipiodol, iodochloral, or a water soluble emulsion such as dionosil are often an aid in the diagnosis of parotid gland pathology. Blady and Hocker⁸ in a study of siaography came to the following conclusions in regard to indications:

1. For demonstrating the relationship of the parotid duct and gland to other adjacent structures.
2. To demonstrate salivary fistulas.
3. To show the presence of calculi, foreign bodies, or strictures of the parotid duct.
4. To demonstrate and confirm the clinical diagnosis of chronic recurrent parotitis.
5. To investigate possible involvement of the gland and duct in a variety of pathological conditions affecting the cheek and parotid region.
6. To determine whether the tumor in the parotid region is an encapsulated growth in the gland substance, a tumor infiltrating the duct system and gland, or a mass extrinsic to the gland and ducts proper.
7. To determine the proximity of the retromandibular process of the gland to a mixed salivary tumor in the tonsillar region.
8. To aid in the planning of an operative procedure in the parotid region.

Blatt⁹ emphasizes that the filling and evacuation phases of sialography will distinguish extrinsic and intrinsic salivary gland neoplasms since the latter usually show retention of the dye in the postevacuation films (Figs. 2 to 6).

An acute suppurative inflammation of the parotid gland is a fairly common occurrence in hospital patients, usually following abdominal operations and favored by debilitation, dryness and bac-

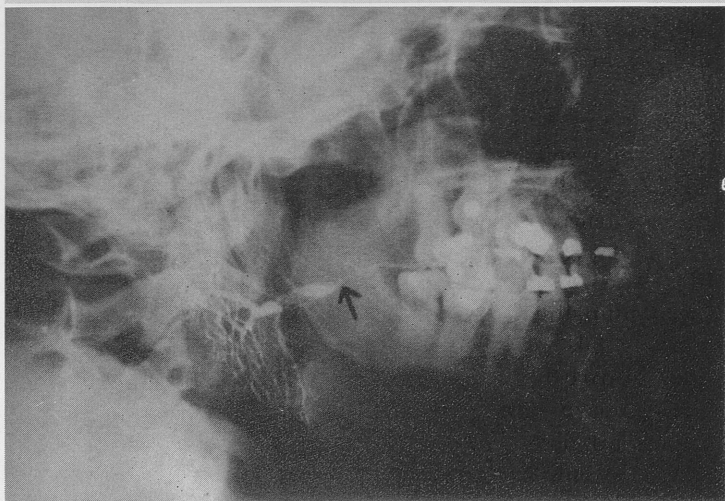
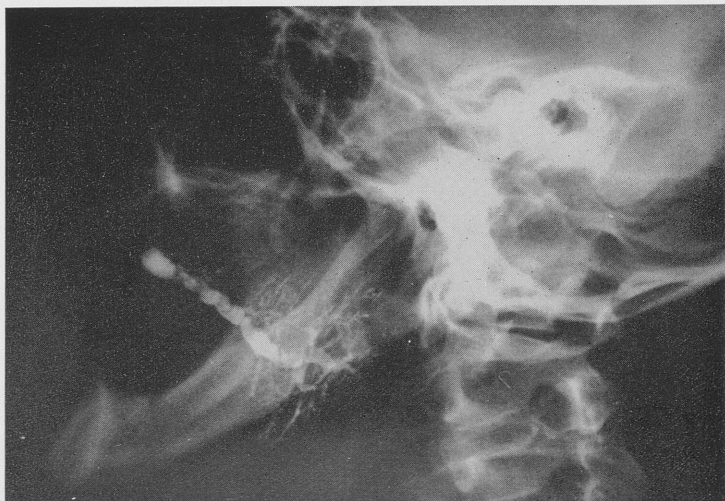


Fig. 2.—A sialogram showing dilatations along the course of Stenson's duct. The finer radicles of the duct system appear normal.

Fig. 3.—The sialogram shows an obstruction of Stenson's duct as indicated by the arrow and a calculus in the dilated proximal portion of the duct.

terial overgrowth in the mouth. The infecting organism is usually the staphylococcus. The infection is characterized by swelling, pain and tenderness over the parotid area.

The overlying skin becomes tense and reddened, and thick purulent material may exude or be expressed from the duct orifice. Multiple fibrous septa prevent early confluence or necrotic foci and many abscesses may form. Fluctuation is difficult to assess because of the thick overlying fascia. Treatment consists of applying hot moist compresses, administering the appropriate antibiotic, irradiation, and moistening and attending to the hygiene of the mouth as well as other measures to improve the patient's general condition. X-ray therapy is of distinct value and should be administered early.¹⁰ Treatment is begun with very small doses of not more than 50 r twice a day for two or three days; this serves to reduce the edema and congestion. When improvement has ensued, the dose may be increased up to 75 r for two to three days until a total dose of approximately 500 to 600 r is administered over a period of a week. Subacute inflammations also respond well to moderate doses of irradiation. Doses of 75 to 100 r three times per week for about two weeks may be administered. When an abscess is evident in the parotid space, a vertical incision just anterior to the ear or behind the angle of the jaw may be indicated. If the process is very extensive, many points of drainage are required in order to open up all possible pockets of suppuration. The thick fascia of the gland is exposed and multiple horizontal incisions are made through which a hemostat is inserted and opened, establishing many points of drainage.

In contrast to submaxillary stones, parotid calculi are often not palpable because of the inflammatory tissue reaction and the encroachment of surrounding structures. They are often difficult to visualize by ordinary x-ray technique. Following routine films to detect possible calculi, the parotid duct is probed with a small nasolacrimal dilator. A slice of lemon to suck may be of aid in locating the duct orifice. The presence of a calculus is indicated by a gritty sensation when the probe touches the stone. Radiopaque dye injected into the duct may reveal the presence of a stenosis or a stone. A non-opaque uric acid stone may be detected in this manner. The usual location of these stones is in the masseteric portion of Stenson's duct. Most of these calculi can be removed by a conservative approach through the mouth.

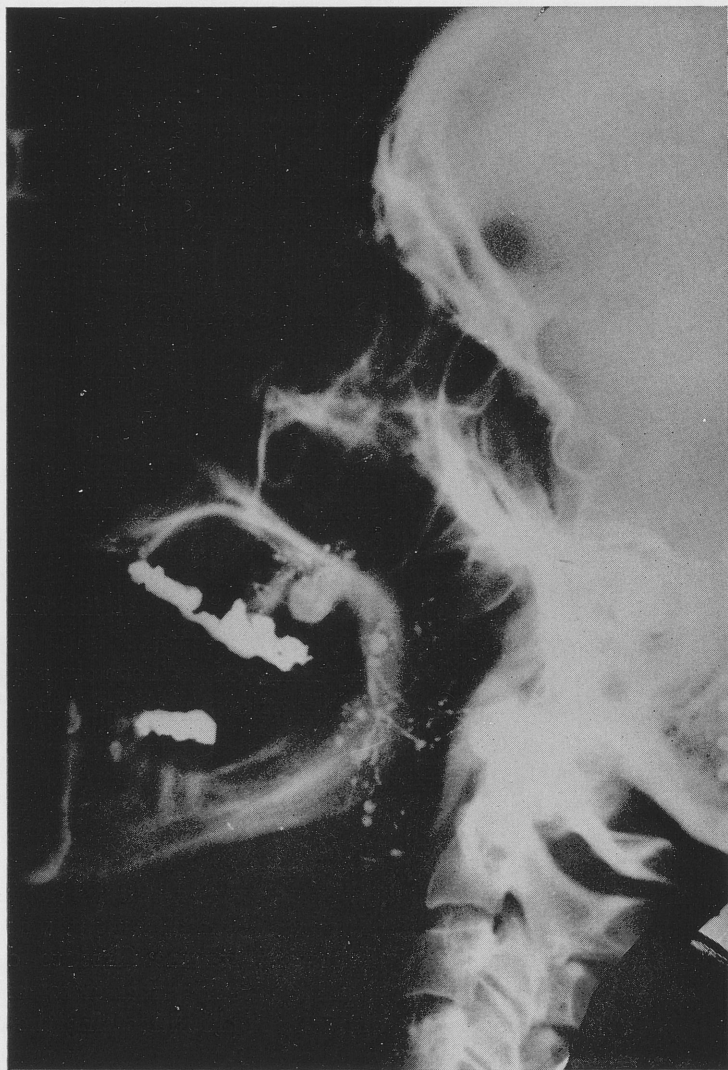


Fig. 4.—The sialogram reveals only moderate arborization of the duct system with several of the ducts showing dilatations and sacculations giving the appearance of sialectasis.

If the calculus is located within the parotid gland an external exposure with partial excision of the gland along with the stone is the better approach rather than a difficult search for the duct and stone through a small horizontal incision on the cheek as described by others.^{11,12} Excision is carried out by first locating the main trunk of the facial nerve.

The etiology of chronic parotitis in the absence of any obvious mechanical obstructions such as calculi and strictures is obscure. Some authors^{13,14} mention the role of a previous attack of mumps as laying the groundwork by the formation of scarring and strictures in the glandular duct system. Allergies have been cited as a factor.^{15,16} Congenital sialectasis as the underlying condition has been mentioned.¹⁵⁻¹⁷ There have been reports of a familial tendency.^{15,16}

The symptoms of chronic parotitis include intermittent swelling and tenderness of one or both parotid glands especially during meals. Pus or turbid material may be expressed from the duct orifice during these episodes. Exacerbations may be mild and the condition may disappear spontaneously, but at times the attacks may be so severe and frequent that the resultant disability becomes serious.

Strictures, as demonstrated by sialography, are usually near the distal end of the main duct. There may be varying degrees of dilatation and elongation of the ducts proximal to the stricture. In other instances the smaller ramifications of the duct system may show irregularities and dilatations or a beaded appearance. More advanced cases may show considerable dilatation and pooling of the injected dye, a condition known as sialectasis.

In the face of severe chronic parotitis constituting a serious disability, refractory to all conservative measures including vigorous and prolonged antibiotic therapy, stricture dilatation or incision, an excision of the gland with preservation of the facial nerve becomes indicated.

At times, an inflammatory swelling developing in one or both parotid glands is difficult to differentiate from a tumor and a parotidectomy not only offers a means for accurate diagnosis but also provides an effective form of therapy in these cases of chronic parotitis.

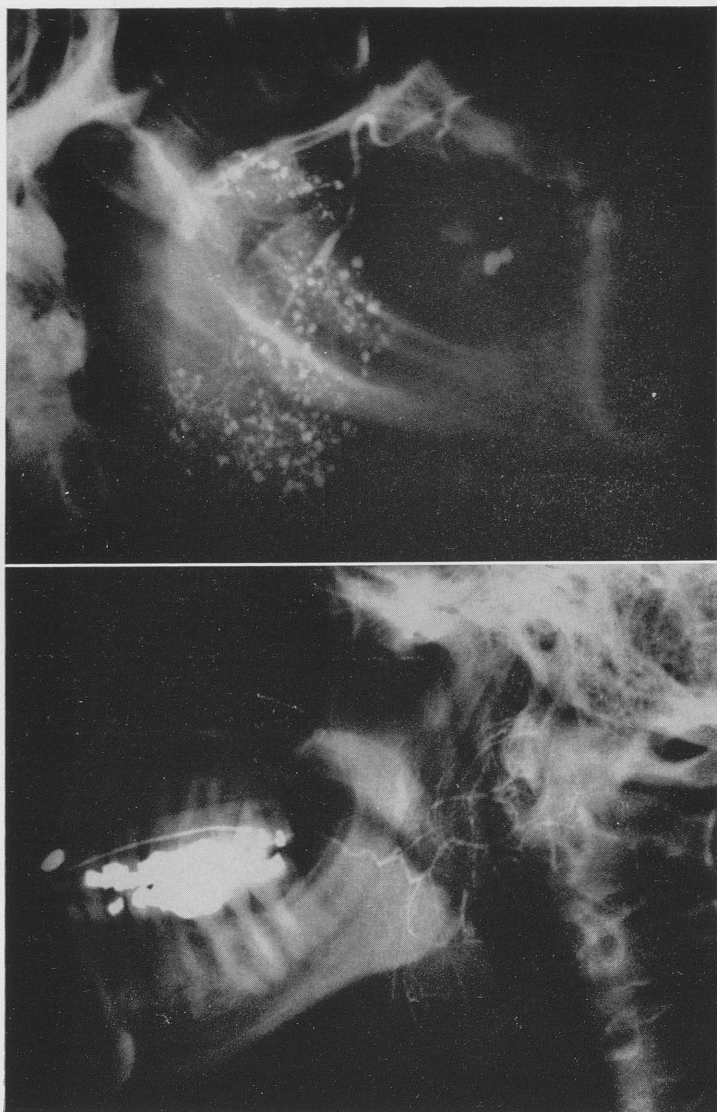


Fig. 5.—The sialogram shows marked sialectasis with defective filling of the duct system in the posterior portion of the gland indicating a tumor mass in this area.

Fig. 6.—The sialogram shows a smooth concentric displacement of the finer radicles of the duct system due to a benign mixed tumor of the parotid gland.

X-ray therapy in chronic parotitis with sialectasis or stenosis is not feasible. Attempts at atrophying the parenchyma will require a tremendous amount of irradiation and are usually unsuccessful.¹⁰

The basic concepts of the treatment of parotid tumors have continued to evolve and develop with the changing picture of disease.

The outstanding histologic feature of both primary and recurrent mixed tumors is the diversity of the structural pattern. However, the study of this varied histologic picture has been of little aid in explaining the high rate of recurrence following surgery.

For many years the favored treatment for mixed tumors has been by surgical enucleation. This approach was determined more by anatomical factors than by any clear understanding of the pathological features of this lesion. Whereas, many, and even a majority, of the patients remained well for long periods following this procedure, too high a proportion of the cases have shown recurrence. In fact, recurrence came to be accepted as typical of the clinical course of the tumor and figures commonly reported range between 20 and 30 per cent. McFarland¹⁸ observed that recurrence was more frequent following excision of small mixed parotid tumors and recommended that surgery be delayed until the tumor was considerably larger. This belief, no doubt, impressed many toward the attitude of watchful expectancy in the management of these lesions. McFarland¹⁹ later postulated the possibility of multicentric origin as the basis for the local recurrence of these tumors.

Attention was then directed toward a combination of surgery and irradiation as a means of controlling these disturbing recurrences. Most surgeons applying the combined treatment have used postoperative irradiation, either x-ray therapy or the heavy radium unit externally, or more commonly buried radium in the operative wound. Patey²⁰ stated in 1940 that the addition of radiotherapy to surgery provided the most hopeful and practical means of overcoming the disadvantages of surgery alone. Brown²¹ in 1950 advocated local excision of these tumors along with the capsule and felt that a margin of a few millimeters of salivary tissue was not indicated because of the possibility of multiple foci of tumor cells being present. He further stated that tumors that were removed without rupture of the capsule, but were thought to be malignant on microscopic study could be followed with external or interstitial irradiation. Kirklin²²

in 1951 also advocated local excision for primary mixed tumors since their prognosis was good as to life expectancy, and spared the 60 or 70 per cent of patients who were not going to have a recurrence the risk of damage to the facial nerve. It was felt, however, that recurrent mixed tumors should be treated more aggressively by wide local excision or total parotidectomy since their recurrence rate was higher. Occasionally, supplementary radon seed implantation was recommended.

Further pathological study has ensued to explain the recurrences following excision. It was observed that recurrent mixed tumors were displayed as an aggregate of multiple nodules of varying sizes whereas the primary mixed tumors were almost invariably solitary nodules. The conclusion was drawn that the recurrent mixed tumor arose from foci of the primary tumor left behind by the surgeon at the first operation. Careful examination of the external aspect of certain mixed tumors has revealed excrescences one millimeter or less in diameter which jut out gently from the capsule. It is felt that these extrusions are of significance in explaining local recurrences. Furthermore, there has been microscopic evidence to show that prolongations of mixed tumor may extend into and beyond the apparently limiting capsule. In addition, in many of these tumors the capsule may be absent or incomplete.²³ These observations appear to offer sufficient explanation for the recurrence of these tumors following simple enucleation (Figs. 7 to 9).

More recently, then, the treatment of these tumors has taken the course of wide excision in the nature of a subtotal parotidectomy with careful exposure and preservation of the facial nerve. For the average-sized superficially located tumor this procedure is well indicated. Some tumors, however, have reached such dimensions that in reality excision constitutes an enucleation. Moreover, tumors involving the deeper, tight confines of the area can be extremely difficult to remove so that capsular rupture with the spilling of tumor cells may eventuate. Under such circumstances the likelihood of seeding tumor cells into the operative site is great and in these instances irradiation following surgery is well justified.

Foote and Frazell²³ report on a case of benign mixed tumor of the parotid which metastasized to the lung. They conclude that such an occurrence is so rare and unpredictable that it should not modify

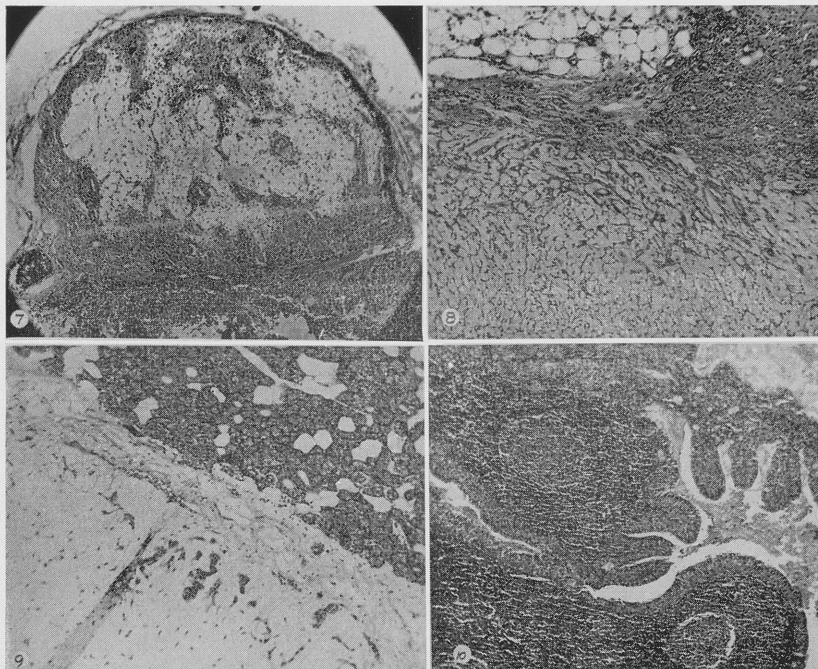


Fig. 7.—Photomicrograph of a nodular excrescence of tumor tissue (many times enlarged) protruding from the periphery of a benign mixed tumor.

Fig. 8.—Photomicrograph of a benign mixed tumor infiltrating the capsule and the adjacent fatty tissue of the parotid gland.

Fig. 9.—Photomicrograph of a portion of the periphery of a benign mixed tumor of the parotid gland showing no evidence of a well defined limiting capsule.

Fig. 10.—Photomicrograph of a papillary cystadenoma lymphomatosum (Warthin's tumor) of the parotid gland. The well defined germinal centers in the subepithelial lymphoid tissue are clearly shown.

the views expressed concerning the usual behavior of, or the clinical management of, benign mixed tumor.

The occurrence of malignancy in a mixed tumor has been a belabored question. Patey²⁰ has stated that while spontaneous malignant change in untouched mixed parotid tumors may occur, its occurrence is so rare that for practical purposes it may almost be dismissed.

Ward and Hendrick,²⁴ on the other hand, state that malignant transformation of mixed tumor is well recognized, and, yet, the observation is made that the varied histological picture of these tumors renders the establishment of satisfactory criteria of malignancy almost impossible. Foote and Frazell²³ have stated that the literature dealing with malignant mixed tumors is scanty and inadequate and that the existence of malignancy in these tumors is not entirely accepted. These authors, however, have presented well illustrated and convincing evidence of the development of malignant transformation. At the present time it would seem rational to direct therapy with the attitude that these tumors are potentially malignant.

Warthin's tumor or papillary cystadenoma lymphomatosum is an interesting and relatively rare type of benign tumor which involves the parotid gland. Brown²⁵ states that they represent six per cent of all parotid tumors occurring in the older age group between 40 to 60 years and 10 times more frequent in males as in females. They are slow growing and relatively asymptomatic and are usually diagnosed clinically as ordinary mixed tumors.

Many theories in regard to the origin of these tumors have been presented. Neisse's²⁶ observation of islands of salivary tissue within the paraparotid lymph nodes led Nicholson²⁷ and more recently Thompson and Bryant²⁸ to postulate the origin of these tumors from this source. This view has been generally accepted and heterotopic salivary tissue is frequently present in lymph nodes near the parotid (Fig. 10).

The tumors are encapsulated although at times the capsule is incomplete with infiltration of the gland parenchyma. Thus, the treatment of these lesions should be wide surgical excision with preliminary exposure of the facial nerve. Plaut²⁹ reported 16 cases that have shown no recurrence one year or more after removal. Foote and Frazell,²³ in a series of 50 cases studied, report no evidence of malignant transformation of either epithelium or stroma.

Malignant neoplasms of the parotid gland occur in many forms and different degrees of malignancy. The histological classification of these tumors has been a difficult and controversial subject. The adenocarcinomas comprise the largest group. Many of these tumors including squamous cell carcinoma and undifferentiated carcinoma

are highly malignant. Others are of low-grade malignancy and usually slow growing. Rawson³⁰ distinguishes three distinct histological types comprising this latter group of epithelial tumors: 1) cylindroma, 2) malignant papillary cystadenoma and 3) muco-epidermoid tumor. Foote and Frazell²³ describe a small group of histologically distinct tumors, the acinic cell adenocarcinomas, which are of low-grade clinical malignancy. The muco-epidermoid carcinomas as described by Stewart and his associates³¹ comprise a group of tumors of high as well as low malignancy.

The clinical differentiation of the low-grade tumors from a benign neoplasm of the parotid is often impossible. Paralysis of the facial nerve is usually not a finding. Many of the cases present long histories of slow growth and repeated local excisions. In nearly a half of the patients with cylindroma or adenoid cystic carcinoma reported by Foote and Frazell²³ local pain was a prominent and sometimes early symptom. In a series of 21 cases of cylindroma reported by Quattlebaum³² pain as well as partial or complete paralysis of the facial nerve were commonly present, features which exemplify the frequent pathologic observation of perineural invasion by tumor cells. In one of our recent patients with cylindroma pain antedated any definite parotid swelling or any other signs by about two years indicating the slow, insidious, relentless growth of these tumors (Figs. 11 to 13).

The relatively slow growing malignant tumors are frequently characterized by a history of multiple recurrences before generalized metastases occur. On initial examination very few show either regional or distant metastases. The latter sites include lung, bone, brain and subcutaneous tissue.

The highly malignant tumors are characterized by their rapid and aggressive growth. On initial presentation they may show the typical findings of a hard, fixed, painful parotid swelling in association with a partial or complete facial paralysis. At times the tumor has extended into adjacent structures such as the mandible, mastoid process, middle ear and base of the skull (Fig. 14).

The treatment of malignant parotid neoplasms has consisted of surgical excision, various forms of radiation or a combination of both, but regardless of the methods used carcinoma of the parotid

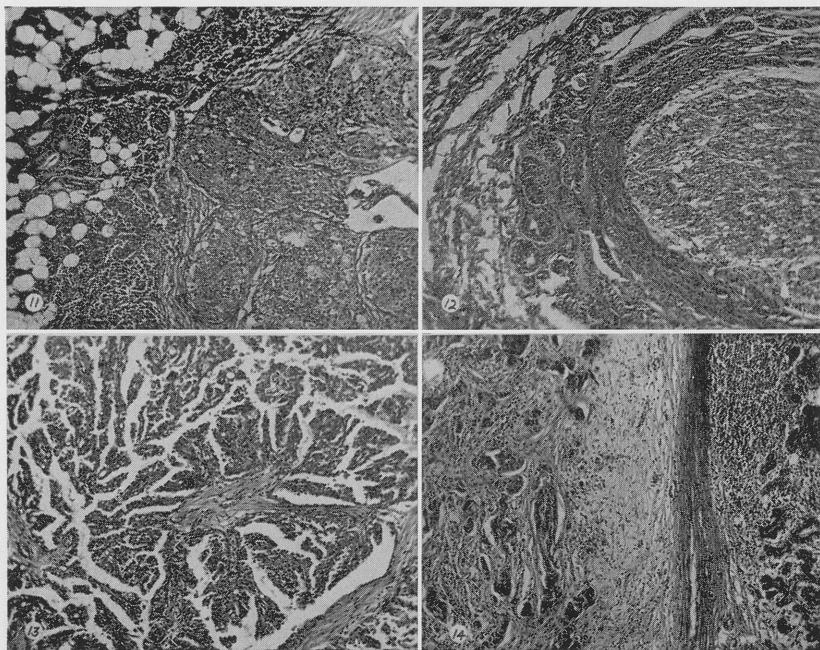


Fig. 11.—The photomicrograph shows a circumscribed low-grade adenocarcinoma encroaching on the surrounding parotid tissue. The tumor was diagnosed clinically as a benign mixed tumor.

Fig. 12.—A photomicrograph showing an adenoid cystic carcinoma (cylindroma) in which tumor cells are clearly evident lying in the sheath of the facial nerve.

Fig. 13.—The photomicrograph shows a malignant papillary cystadenoma. These tumors are of low-grade malignancy.

Fig. 14.—The photomicrograph shows a well-circumscribed highly malignant adenocarcinoma of the parotid gland.

carries a poor prognosis. This may be attributed in part to the technical difficulties of wide removal in the restricted bony confines of this area and to failure of recognition of the signs and symptoms of malignancy in this region.

Quattlebaum³² reports a 75 per cent recurrence rate in the cylindroma group and suggests that more radical surgical procedures

are necessary in order to obtain better results in the treatment of this form of neoplasm. Kirklin²² notes a marked tendency of these tumors to metastasize to the cervical lymph nodes. The highly malignant adenocarcinomas, squamous cell carcinomas and undifferentiated carcinomas are rapidly progressive with a greater propensity for local invasive recurrence and regional and distant metastases. Total excision of the gland combined with a radical cervical lymph node dissection and sacrifice of any intervening structures becomes necessary for effecting any control of these highly malignant tumors. In other instances, where the tumor is discrete and of low-grade malignancy preservation of a part or all of the facial nerve seems justified provided excision can be effected with an adequate margin of healthy tissue. Clinical evidence of facial nerve dysfunction usually necessitates a total parotidectomy with division of the facial nerve in order to obtain complete gland removal in continuity. The excision includes the lymph nodes and areolar tissue from the subjacent internal jugular vein up to the base of the skull. If the tumor extends deeply into the retromandibular area it may be necessary to remove a portion of or the entire ramus of the mandible. Ligation of the external carotid artery is carried out during the course of gland removal. Any overlying skin adherent to tumor is excised along with the operative specimen.

It is believed by many that the combination of surgery and radiation offers better results than if either is used alone in the treatment of these malignant parotid lesions.^{22,30,33,35} It is generally agreed that the use of radiation alone is contraindicated in the treatment of these tumors. Some authors^{24,36} feel that the treatment of parotid neoplasms is almost entirely a surgical problem and that radiation should be used mainly as a palliative measure. According to Bouchard,¹⁰ radiotherapy, in combination with surgery, should be administered aggressively with doses of 6000 to 7000 r and occasionally as high as 9000 r extended over a period of approximately 50 days. He states that total field external radiation is preferable and with proper utilization the complications in regard to skin tolerance, dryness of the mouth and necrosis have been of minor concern.

SUMMARY

The fundamental problems in the management of parotid lesions have been constituted in a consideration of anatomical and patholog-

ical factors. Some of the anatomical features of this region have been reviewed emphasizing the restricting influence of the facial nerve and the confining boundaries of this area. With parotid lesions clinical impressions can be deceptive and the course of therapy consequently misdirected. The impressions of the varying findings and symptomatology of the lesions in this region have been stressed. Sialography has been of valuable assistance in the diagnosis and management of these conditions. The concepts of tumor pathology continue to evolve and the treatment of parotid neoplasms, notably mixed tumors, has developed and improved accordingly. The management of malignant parotid tumors remains unsatisfactory and further study is required in this regard. At the present time, a combination of surgery and radiation appears to afford the best means for the control of malignant disease in this region.

3448 PEEL ST.

REFERENCES

1. Pack, G. T., and Ariel, I. M.: Treatment of Cancer and Allied Diseases. Vol. 3, Tumors of the Head and Neck, 2nd ed., Paul B. Hoeber, Inc., New York, 1959.
2. Hollinshead, W. H.: Anatomy for Surgeons. Vol. 1, The Head and Neck, Paul B. Hoeber, Inc., New York, 1954.
3. McCormack, L. J., Cauldwell, E. W., and Anson, B. J.: The Surgical Anatomy of the Facial Nerve, with Special Reference to the Parotid Gland. Surg., Gynec. and Obst. 80:620, 1945.
4. State, D.: Superficial Lobectomy and Total Parotidectomy with Preservation of the Facial Nerve in the Treatment of Parotid Tumors. Surg., Gynec. and Obst. 89:237, 1949.
5. McKenzie, J.: The Parotid Gland in Relation to the Facial Nerve. J. Anat. 82:183, 1948.
6. Sistrunk, W. E.: Tumor of the Parotid Gland. S. Clin. North America 1:1515 (Oct.) 1921.
7. Adson, A. W., and Ott, W. O.: Preservation of the Facial Nerve in the Radical Treatment of Parotid Tumors. Arch. Surg. 6:739, 1923.
8. Blady, J. V., and Hocker, A. F.: Sialography—Its Technique and Application in the Roentgen Study of Neoplasms of the Parotid Gland. Surg., Gynec. and Obst. 67:777, 1938.
9. Blatt, I. M., Magielski, J. E., Maxwell, J. H., and Holt, J. F.: Secretory Sialography in Diseases External to the Major Salivary Glands. ANNALS OF OTOTOLOGY, RHINOLOGY AND LARYNGOLOGY 68:175, 1959.

10. Bouchard, J., Dept. of Radiology, Royal Victoria Hospital, Montreal: Personal Communication.
11. Blair, J. R.: Diagnosis and Treatment of Parotid Calculi. *Laryngoscope* 65:848, 1955.
12. Thorek, M.: Modern Surgical Technic. J. B. Lippincott Co., Philadelphia, 1938.
13. Florman, A. L.: Recurrent Bacterial Parotitis. *J. Pediat.* 46:682, 1955.
14. Gerry, R. G., and Seigman, E. L.: Chronic Sialadenitis and Sialography. *Oral Surgery* 8:453, 1955.
15. Smith, M.: Familial Incidence of Sialectasis. *Brit. M. J.* 2:1359, 1953.
16. Meyer, H. S.: Chronic Sialodochitis. *J. Pediat.* 4:248, 1934.
17. Bailey, H.: Congenital Parotid Sialectasis. *J. Internat. Coll. Surg.* 8:109, 1945.
18. McFarland, J.: Three Hundred Mixed Tumors of the Salivary Glands, of Which Sixty-Nine Recurred. *Surg., Gynec. and Obst.* 63:457, 1936.
19. McFarland, J.: The Mysterious Mixed Tumors of the Salivary Gland. *Surg., Gynec. and Obst.* 76:23, 1943.
20. Patey, D. H.: The Treatment of Mixed Tumors of the Parotid Gland. *Brit. J. of Surg.* 28:29, 1940.
21. Brown, J. B., McDowell, F., and Fryer, M. P.: Direct Operative Removal of Benign Mixed Tumors of Anlage Origin in the Parotid Region. *Surg., Gynec. and Obst.* 90:257, 1950.
22. Kirklin, J. W., McDonald, J. R., Harrington, S. W., and New, G. B.: Parotid Tumors, Histopathology, Clinical Behaviour, and End Results. *Surg., Gynec. and Obst.* 92:721, 1951.
23. Foote, F. W., and Frazell, E. L.: Tumors of the Major Salivary Glands. Armed Forces Institute of Pathology, Washington, D.C., 1954.
24. Ward, G. E., and Hendrick, J. W.: Tumors of the Head and Neck. The Williams and Wilkins Co., Baltimore, 1955.
25. Brown, J. R.: Papillary Cystadenoma Lymphomatosum. *A.M.A. Archives of Surgery* 63:185, 1951.
26. Neisse, R.: Uber den Einschluss von Parotislapppchen in Lymphknoten. *Anat. Hefte* 10:289, 1898.
27. Nicholson, G. W.: Studies on Tumor Formation. *Guy's Hospital Reports* 2:333, 1922.
28. Thompson, A. S., and Bryant, H. C., Jr.: Histogenesis of Papillary Cystadenoma Lymphomatosum (Warthin's Tumor) of the Parotid Salivary Gland. *Am. J. Path.* 26:807, 1950.
29. Plaut, J. A.: Adenolymphoma of the Parotid Gland. *Annals of Surgery* 116:43, 1942.

30. Rawson, A. F., Howard, J. M., Royster, H. P., and Horn, R. C.: Tumors of the Salivary Glands. *Cancer* 3:445, 1950.
31. Steward, F. W., Foote, F. W., and Becker, W. F.: Muco-epidermoid Tumors of Salivary Glands. *Annals of Surgery* 122:820, 1945.
32. Quattlebaum, F. W., Dockerty, M. B., and Mayo, C. W.: Adenocarcinoma, Cylindroma Type, of the Parotid Gland. *Surg., Gynec. and Obst.* 82:342, 1946.
33. MacFee, W. F.: Malignant Tumors of the Salivary Glands. *Annals of Surgery* 109:534, 1939.
34. Marshall, S. F., and Miles, G. D.: Tumors of Submaxillary and Parotid Gland Areas. *S. Clin. North America* 27:501, 1947.
35. Ahlbom, H. E.: Mucous and Salivary Gland Tumors; Clinical Study with Special Reference to Radiotherapy. *Acta Radiol. Supplement* 23:1, 1935.
36. Frazell, E. L.: Clinical Aspects of Tumors of the Major Salivary Glands. *Cancer* 7:637, 1954.

DISCUSSION

DR. ALBERT C. FURSTENBERG (Ann Arbor): Mr. President, Fellows of the Association and Guests: Perhaps I can make some little contribution to this very fine paper by discussing in some detail one lesion to which Dr. Shimo has referred, namely, the pseudoadenomatous basal cell carcinoma. As you well know, this lesion has many synonyms such as cylindroma, adenoepithelioma, adenocystic basal cell carcinoma, and adenocystic carcinoma. This is a tumor that we have been interested in for more than thirty years and during this time we have had an opportunity to study the clinical behavior of a rather large series of cases.

Dr. James French and Dr. Marvin S. Smout of our Dept. of Pathology have recently collected 65 cases and reported data concerning them which I believe are important as well as interesting.

The location of the tumor has been in the pharynx and sinuses in 19 cases; 14 were found in the parotid gland; 19 in the mouth; 5 in the trachea; 5 in the submaxillary gland, and 3 in the lacrimal gland.

We were surprised to discover that 62% of the tumors were found in females and 38% in males. In our observations in the clinic over the years, we did not realize that the lesion was found nearly twice as frequently in the female as in the male.

The average age was 44 years. However, in those cases in which this lesion was primary in the parotid gland, the average age was 24 years.

Chest metastasis occurred in 30% as determined by radiographic examinations. It was of particular interest to note that these metastatic lesions often required as long as twelve years to put in their appearance. Skull metastases were seen in 5% and the vertebrae and long bone metastases in only 3 cases.

(Slide) In regard to the pathological features of this neoplasm, Dr. Shimo reported the pseudoacinar pattern as the classical concept. This pattern was noted in 53 tumors (81%). Of these, 32 (64%) showed solid areas where the epithelial

cells were closely packed. This same pathologic architecture was observed in Dr. Shimo's and Dr. Dolan's microphotographs.

Nerve trunks were identified in 29 cases and perineural lymphatic extension by neoplasm noted in 28.

Lymph nodes which were found in the sections showed the neoplasm in 4 out of 6 cases.

Three necropsies were performed. One primary tumor in the trachea had no metastasis; one primary in the superior maxilla and one in the nasopharynx showed widespread metastasis. In regard to the prognosis, the statistical study of 65 cases showed that 37 patients were dead with neoplasm; 14 living with definite evidence of residual tumor, and 14 appeared to be clinically free of disease. In this particular group, only 4 have survived five or more years and these 4 patients all had primary lesions in the parotid gland.

The average time from diagnosis to death was 5.4 years. The shortest clinical course was 3 months, and the longest clinical course was 19 years.

In summary I should like to say that these tumors probably arise in mucous glands or ducts. The cranial nerves are frequently involved with oral and nasopharyngeal lesions. Neoplastic extension along nerve trunks is a constant finding when nerve fibers are present in the pathological material studied. However, it may not always indicate a fatal prognosis; 2 patients with tumors of the parotid gland showing perineural invasion have survived eight and twelve years, respectively. Nevertheless, the tumor must be considered an extremely fatal one.

I recommend high voltage irradiation together with surgical interferences in the treatment of the pseudo-adenomatous basal cell carcinoma. Many of them seem to react most favorably to radiation therapy.

Dr. Shimo's and Dr. Dolan's paper is indeed a most interesting and comprehensive one. Both as regards its contents and the well-organized manner in which it has been composed, the highest terms are not misplaced in their praise, and it is with more than ordinary feeling that I compliment them for their splendid presentation.

DR. GEORGE SHIMO (Montreal) (closing): I would like to thank Dr. Furstenberg for his very kind remarks. They are certainly very encouraging. I would like to reiterate his comments on this very dramatic type of tumor, the cylindroma, in that it does appear to extend along the perineural lymphatics and its extension certainly is much more than would appear on initial examination.

The area is certainly challenging and surgery in this area is difficult and requires a thorough anatomical knowledge of the region and of the pathology and a great deal of study certainly is needed to enlighten us further on this subject.

LARYNGEAL AND BRONCHIAL CANCER

A STUDY OF DOUBLE PRIMARY MALIGNANCY

PAUL H. HOLINGER, M.D.

KENNETH C. JOHNSTON, M.D. ROBERT J. JENSIK, M.D.

CHICAGO, ILL.

AND

DIETRICH HURZELER, M.D.

ZURICH, SWITZERLAND

Multiple primary malignant tumors are becoming common clinical problems. Billroth¹⁴ described the first case in 1860, and numerous reports on the subject have appeared since that time. A careful definition of multiple primary malignancies is essential in order to differentiate a case of multiple primary tumors from one of a primary tumor with metastases. The rules formulated by Billroth appear too strict for practical purposes. He listed three criteria as essential in order to consider a case one of multiple primary malignant tumors: 1) each tumor must have a distinct, separate histologic identity; 2) the tumor must arise in different locations; and 3) each tumor must produce its own metastases. The first criterion is accepted without question. The third is not valid since often an unsuspected second primary tumor may not have metastasized. This is particularly true of a second silent tumor found incidentally during a post-mortem examination. The criteria of Warren and Gates¹⁴ are entirely adequate and practical from both a clinical and pathologic standpoint. According to these authors, in order to consider a case one of multiple primary malignancies, each of the tumors must present a definite picture of malignancy; each must be distinct and separate histologically; and the probability of one tumor being a metastasis of the other

From the Departments of Otolaryngology and Surgery, University of Illinois, College of Medicine and the Presbyterian-St. Luke's Hospital, Chicago, Illinois, U.S.A.

must be excluded. The only point of discussion in regard to this definition is the last part, "the probability of one tumor being a metastasis of the other must be excluded." If the tumors grow in different organs and have different histological patterns, there is no problem, even though one of them is a tumor of the lung. However, in a tumor with a varied histologic pattern as, for example, an adenocarcinoma with osseous elements—a so-called mixed tumor—metastases of only part of the tumor may be produced and these metastases may show a less or more mature pattern than the original tumor. But, careful histological study will show the difference between an atypical metastasis and a second primary malignant tumor.

INCIDENCE

It is very difficult to get a true impression of the frequency of multiple primary malignant tumors. Some of the statistical papers are based on findings of postmortem examinations in specialty hospitals. These statistics represent a selection according to the specialty of the hospital, whereas other statistics are based on clinical observations of patients being treated for cancer. Therefore, the incidence of multiple primary malignant tumors in the population as a whole varies from 0.3% to 7.8% in the recorded literature.^{14,15} The incidence of multiple primary tumors of certain organs appears to be far greater than that of the body as a whole. Wynder states that 157 or 11% of 1408 patients with carcinomas of the esophagus had or developed multiple primary carcinomas; this led to the statement that "the most well known pre-cancerous condition is cancer."

But while it is difficult to compare statistics of the incidence of multiple primary malignant tumors, it is even more difficult to correlate them with the mortality rates of the whole population. Only large series of cases could give an impression of the real status. Warren and Gates¹⁴ collected forty multiple primary malignant tumors among 1078 cancer-autopsies, and Warren and Ehrenreich¹⁵ continuing on the same studies found another 194 multiple primary malignant tumors in 2827 cancer autopsies. From these figures it appears certain that cases with multiple primary malignant tumors occur more frequently than could be expected on the basis of chance alone. The frequency of multiple primary malignant tumors observed in these two papers was six or seven to eleven times larger than might be anticipated by statistical calculation. While the figures may only

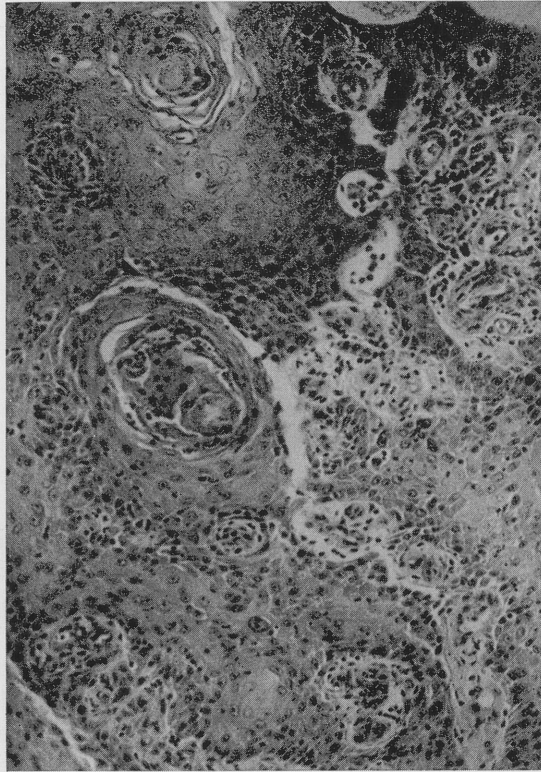


Fig. 1-A.—Photomicrograph of original laryngeal biopsy. The patient refused surgery (laryngectomy) and received a course of radiation therapy.

be approximate, the series are large enough to be of statistical significance.

The reports of Warren and Gates,¹⁴ Warren and Ehenreich,¹⁵ and Wynden¹⁶ show a tendency for multiple primary malignant tumors to occur in the same organ system, as for instance, in the skin, the gastro-intestinal tract or the genito-urinary system. Warren reported only one case of a primary tumor in the larynx and a second in the lung of the same patient, while Wynden added 6 cases of this double primary malignancy. He reported an incidence of 10% of multiple primary malignancies among larynx-cancer patients and an

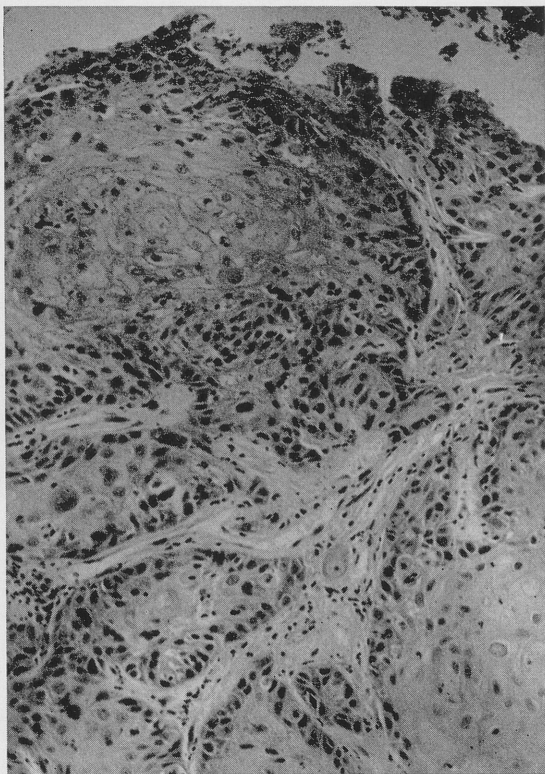


Fig. 1-B.—Photomicrograph of biopsy, Sept. 1955.

incidence of 13% of double primaries among lung-cancer patients, a greater frequency than would be expected from the general occurrence of multiple primaries. Of the six cases of larynx-lung multiple primaries reported by Wynden the first primary was the laryngeal lesion in 4, the bronchial lesion in one, and in one the two lesions were found simultaneously. Cahan, et al.,³ and Cahan² in studies of multiple cancers primary in the lungs and other sites collected a total of 23 cases with separate primary tumors in the larynx and the lungs. In 1956, Lewis and Schaff⁸ added 12 cases, Thompson and Schaff¹³ 7 cases, five of their own and two reported elsewhere, and in 1958, Rubenstein et al.¹¹ reported two additional cases. Thus, a review of

TABLE I
LARYNGEAL AND BRONCHIAL CANCER: A STUDY OF DOUBLE PRIMARY MALIGNANCY

NO.	INIT.	AGE (ALL MALES)	SITE	1ST PRIMARY THERAPY	INTER- VAL (YRS.)		2ND PRIMARY SITE	THERAPY	PRESENT STATUS
1	PB	60	Lung left lower lobe	Pneumonectomy	2 3/4		Larynx vocal cord	Refused	Lost to follow-up.
2	JW	71	Lung right main bronchus	Pneumonectomy	3		Larynx left cord with metastases	X-ray	Living with disease 5 yrs. after 2nd primary. Lost to follow-up thereafter.
3	RN	51	Larynx vocal cord	Thyrotomy and Cordectomy	5 1/2		Lung Rt. lower lobe with metastases	Nitrogen Mustard	Died 2 months later. Br. Ca. metastases. No malignancy in larynx site or neck.
4	CK	65	Larynx left cord	Laryngectomy	5 1/2		Lung rt. main bronchus	Nitrogen Mustard	Died 2 months later. Br. Ca. metastases. No malignancy in larynx site or neck.
5	FW	55	Larynx left cord	Cordectomy; laryngectomy 4 yrs. later	4 1/2		Lung left main bronchus	Pneumon- ectomy	Living 1 year later. Lost to follow-up thereafter.
6	EF	60	Larynx right vocal cord	Laryngectomy	2 1/2		Lung left main bronchus	Nitrogen Mustard	Died 2 months later. Br. Ca. metastases. No malignancy in larynx site or neck.
7	AD	57	Larynx left vocal cord	Laryngectomy	5 1/2		Lung left main bronchus with metastases	Nitrogen Mustard Cobalt	Died 2 months later. Br. Ca. metastases. No malignancy in larynx site or neck.

8	TL	49	Larynx left cord	X-ray laryngectomy	4½	Lung left main bronchus	Pneumon- ectomy	Living, no evidence of carci- noma 2 years after pneumon- ectomy.
9	LL	51	Larynx vocal cord	X-ray Laryngectomy Radical Neck	3	Lung right lower lobe	Lobec- tomy	Died 3 months later. Br. Ca. metastases. No malignancy in larynx site or neck.
10	ZT	42	Epiglottis	Laryngectomy and Bilat. Rad. Neck	1½	Lung right lower lobe	X-ray (Pallia- tive)	Died 2 months later. Br. Ca. metastases. No malignancy in larynx site or neck.
11	JB	61	Epiglottis	Laryngectomy	0	Lung left lower lobe	Lobec- tomy	Living and well 1 year post surgery.
12	CG	54	Trachea and Bronchi	Endoscopic Re- section, Radon, External radiation	7	Larynx left vocal cord	None	Died following malignant tracheoesophageal fistula.
13	LR	69	Epiglottis	Laryngectomy and Rt. rad. neck	2	Lung left	Pneumon- ectomy	Still under treatment.
14	NT	72	Larynx right vocal cord	Laryngectomy and Bilateral neck	0	Lung right upper lobe	Pneumon- ectomy	Living, no evidence of carci- noma.
15	FB	44	Epiglottis and base of tongue	X-ray	15	Lung left upper lobe	None	Died of cerebral metastases of br. ca. No evidence of tumor larynx or neck.
16	GF	61	Larynx right cord	Thyrotomy and Corpectomy plus x-ray therapy	6½	Lung right upper lobe	Resection (incom- plete)	Still under treatment.

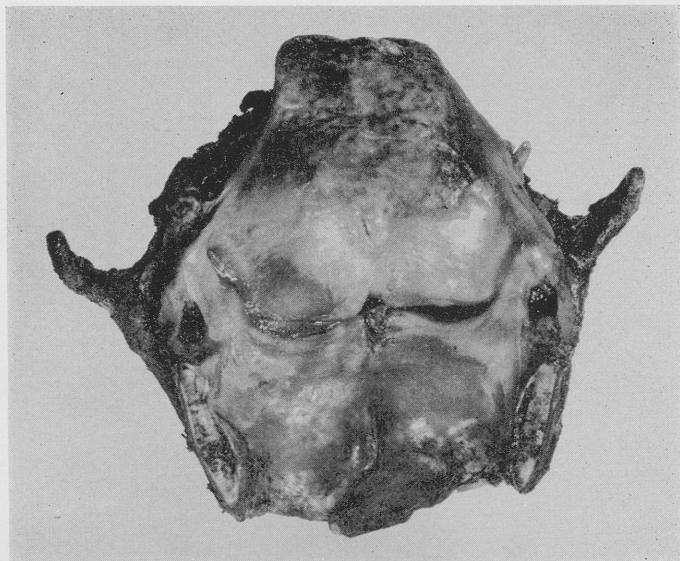


Fig. 2.—Laryngectomy specimen following biopsy shown in Figure 1-B.

the literature reveals a total of 51 cases of multiple primary malignant tumors involving the larynx and lung.

PRESENTATION OF CASES

This study is based on a series of 16 patients with primary malignant tumors in both the larynx and lung. The 16, all males, were between the ages of 42 and 71 years at the time of diagnosis of the first primary tumor; 3 were in the 4th decade, 5 in the 5th, 6 in the 6th, and two in the 7th decade. The average age was 58 years. In 14 of the 16 patients the lesions were metachronous with intervals of from 1 to 15 years, with the average interval of approximately 5 years. In two of the patients, the lesions were synchronous. In 11 of the 16 patients with metachronous lesions the cancer of the larynx preceded the cancer of the lung and in only three did the bronchogenic lesion precede the laryngeal cancer.

The therapy of the first primary lesion varied considerably in the 11 patients in whom the laryngeal carcinoma preceded the broncho-

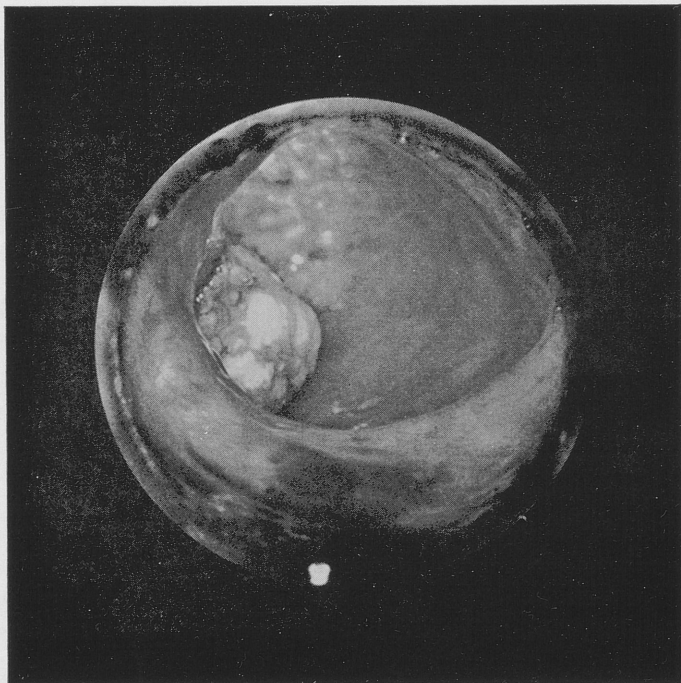


Fig. 3.—Endoscopic photograph of tumor in left main bronchus.

genic carcinoma. Three had a thyrotomy and corpectomy. In one of the three, a laryngectomy was performed four years later for local recurrence and in one the surgery was followed by x-ray therapy; he had no local recurrence when the bronchogenic carcinoma was found six and one-half years later. In three patients the initial therapy of the laryngeal carcinoma was radiation. One had an extensive, inoperable carcinoma of the epiglottis that responded dramatically to radiation. He had no local recurrence when he died fifteen years later of what postmortem examination demonstrated to be cerebral metastases of a small cell bronchogenic carcinoma. One patient (Figs. 1-5) refused surgery on discovery of the laryngeal carcinoma and received a course of x-ray therapy, but because of local recurrence five months later, agreed to total laryngectomy; his bronchogenic carcinoma was

discovered four and one-half years later after the initial diagnosis of the laryngeal cancer. The bronchogenic tumor was treated by total pneumonectomy. In the third patient in this group whose initial therapy consisted of irradiation, the tumor recurred locally one year later and a laryngectomy was performed. Within another year, a contra-lateral neck dissection was done for a metastatic cervical node. Three years later a small cell bronchogenic carcinoma was found. This was resected by a lobectomy since at the time of surgery non-resectable mediastinal metastases were evident. Postmortem examination four months later showed no residual or regional carcinoma that could be considered due to the original laryngeal lesion. In three of the seven patients in whom the initial primary tumor was the laryngeal lesion, a total laryngectomy was performed, and in the remaining two of this group, a laryngectomy and unilateral neck dissection were performed in one and a laryngectomy and bilateral neck dissection were performed in the other.

The therapy of the first primary lesion of two of the three patients in whom the bronchial tumor preceded the laryngeal carcinoma consisted of a total pneumonectomy. The laryngeal lesion in each of these appeared approximately three years after the bronchogenic carcinoma. In one, a laryngectomy and radical neck dissection were recommended because of the extent of the laryngeal carcinoma. His general condition would not permit this surgery and he received palliative radiation therapy only. The second patient had an early laryngeal lesion involving the left vocal cord three years after a pneumonectomy. There were no cervical nodes and the cord was freely movable. X-ray therapy was recommended but the patient refused all therapy and has been lost to follow-up. The third patient in whom the bronchial carcinoma preceded the carcinoma of the larynx actually had a carcinoma of the trachea at its bifurcation with ultimate extension into both the left and right bronchi. The tracheal and bronchial lesions were treated by fulguration and electroresection, radon seed implantation and external irradiation. Seven years after the initial tumor had been identified, a separate, isolated and histologically distinct laryngeal neoplasm was found on the left vocal cord. Because of the mediastinal and bronchial extent of the tracheal lesion no therapy was considered nor indicated for the laryngeal lesion other than endoscopic excision as palliation. He died shortly thereafter following esophageal extension into the mid-thoracic esophagus and the development of a large tracheo-esophageal fistula.

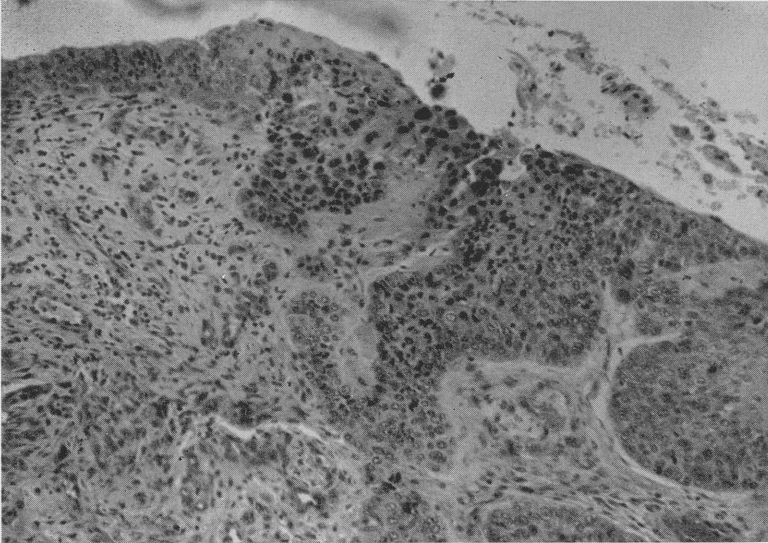


Fig. 4.—Photomicrograph of biopsy of tumor of left main bronchus.

In five of the eleven patients in whom the bronchogenic carcinoma was the second primary malignant tumor, the therapy of the pulmonary lesion was surgical. Three had total pneumonectomies, and two a lobectomy. Three of the remaining six received nitrogen mustard alone, one received nitrogen mustard followed by Cobalt therapy, the fifth received palliative irradiation alone, and in the sixth, the bronchogenic tumor was found on postmortem examination fifteen years after diagnosis and treatment of the laryngeal lesion. As stated above, it was responsible for sudden coma and death prior to clinical examination or diagnosis.

In two patients the laryngeal and bronchial lesions were synchronous. One, 61 years of age, was found to have a squamous cell carcinoma of the epiglottis. Medical and x-ray studies preceding a laryngectomy disclosed a density in the left lower lobe and a bronchoscopic biopsy showed the lesion to be a small-cell bronchogenic carcinoma in the left lower lobe bronchus. In view of the greater potential danger of the broncho-pulmonary lesion, a left lower lobectomy was performed first and a month later the laryngectomy was done.

This patient's history is of further interest in view of a third primary lesion involving the base of the tongue nine years preceding the discovery of the epiglottic and bronchial tumors. Exploratory pharyngectomy had shown this lesion to be inoperable. It was treated by radon seed injection, followed three weeks later by a bilateral neck dissection. Thus, the laryngectomy was performed nine years following a bilateral neck dissection, a rather unusual surgical exercise. While the tumors of the base of the tongue and the epiglottis may be considered to have been in some proximity, the epiglottic lesion was localized to the tip and posterior surface of the epiglottis and did not extend into the vallecula nor the tongue. The laryngeal lesion in this patient, a squamous cell carcinoma, and the bronchogenic tumor, a small cell carcinoma, were of distinctly different cell types.

The second patient in whom the lesions were synchronous was a 72-year old white male whose symptoms were hoarseness of one month's duration, an eighteen-pound weight loss, anorexia, and a productive cough with occasional blood streaking. The mirror examination of the larynx demonstrated an ulcerating mass involving the base of the epiglottis and extending along the right true and false cords. A chest x-ray revealed a mass in the anterior portion of the right upper lobe. Respiratory obstruction necessitated a tracheotomy following which the laryngeal biopsy could be obtained; the lesion was an epidermoid carcinoma. A bronchoscopic examination did not disclose the point of bronchial origin of the right upper lobe tumor but demonstrated compression of the anterior segment of the right upper lobe bronchus. A thoracotomy was performed ten days following the tracheotomy and the tumor found to be adherent to the chest wall, compressing the right pulmonary artery and right bronchus necessitating a total right pneumonectomy. A month later a total laryngectomy and right radical neck dissection were performed with histologic evidence of epidermoid carcinoma in two of 24 cervical nodes but none in the scalene nodes. The only immediate complication of either of these surgical procedures was a pericarditis following the pneumonectomy. Three weeks following the laryngectomy and right neck dissection a node was palpated over the left carotid bifurcation and a left radical neck dissection was performed, with carcinoma demonstrated in 4 of 21 nodes. The patient remained hospitalized for six weeks, being discharged from the hospital 3½ months after admission with no further evidence of malignancy.

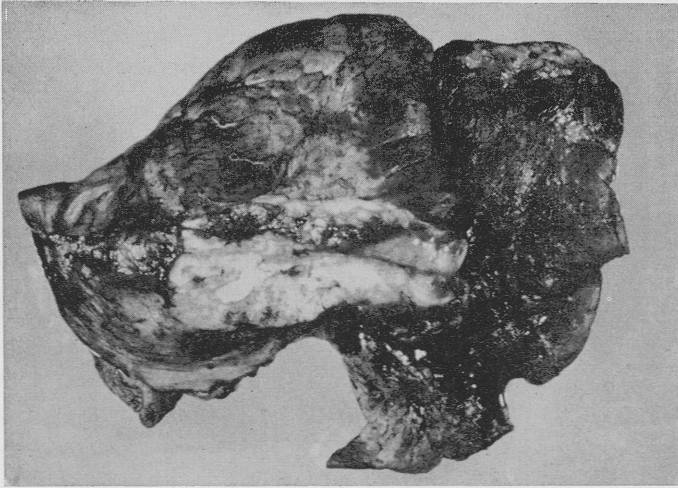


Fig. 5.—Gross surgical left pneumonectomy specimen, Dec. 1959.

in either the neck or chest. The similarity of the histology of the two lesions in this patient raises the question as to whether the pulmonary mass was a metastasis of the primary laryngeal carcinoma. The apparent bronchial origin of the tumor in the resected lung is a strong indication that this lesion was a second primary malignancy.

COMMENT

The difference in degree of malignancy between laryngeal and bronchial carcinoma is apparent in the clinical course of these 16 patients. Eight of the 16 have died of their bronchial carcinomas with no evidence of regional or systemic metastases of the laryngeal lesion. One who had a thyrotomy and a cordectomy in 1948, a laryngectomy in 1952 and a pneumonectomy in 1953, was living and free of disease in 1954, but has since been lost to follow-up. The two patients treated by pneumonectomy whose bronchogenic carcinoma preceded the laryngeal carcinoma are presumed dead. In each the laryngeal tumor followed the pneumonectomy by approximately three years. One refused all therapy at the time of diagnosis of the laryngeal tumor in 1947 and has been lost to follow-up. The second, 74 years of age in 1949 at the time of diagnosis of the laryngeal lesion, had a left vocal cord carcinoma with cervical metastases. He

received x-ray therapy, was known to be living five years later but his medical status was unknown, and he, too, has been lost to follow-up since that time.

Five of the sixteen patients are still living. Two are the patients in whom the lesions were synchronous and their histories are given above. Both are living and apparently free of carcinoma but the diagnosis and treatment of each has been affected within the past year. Two patients whose bronchial lesions appeared two, and six and one-half years after the laryngeal tumor have only recently been operated and are still under postoperative management. One had a pneumonectomy and one a partial pneumonectomy including several ribs; the extent of the rib invasion permitted only an incomplete resection. The fifth patient still living is apparently free of carcinoma; however, he had a severe coronary occlusion in the postpneumonectomy period, one and one-half years ago.

SUMMARY

This report records sixteen additional cases of multiple primary carcinomas involving the larynx and bronchi. The two lesions in each patient were separate histologically and were metachronous in fourteen, separated by an interval of from one and one-half to fifteen years. They were synchronous in two patients in whom the bronchial lesions were discovered during the medical survey preceding surgery for the laryngeal carcinoma. The laryngeal tumor preceded the bronchial tumor in 11 of the 14 in whom the tumors were metachronous and in the remaining three the bronchogenic tumor preceded the laryngeal carcinoma.

All patients were males between the ages of 44 years and 71 years. Therapy of the 11 whose first primary involved the larynx consisted of thyrotomy and cordectomy and in three followed by x-ray therapy in one and a laryngectomy in one. Three had irradiation for the laryngeal primary; in one the tumor had been considered inoperable, one refused surgery but required a laryngectomy five months later for residual laryngeal carcinoma and one had a lesion that appeared suitable for radiation therapy but he required a laryngectomy and a radical neck dissection a year later. In the remaining five patients the therapy of the primary laryngeal tumor was a total laryngectomy in three, a laryngectomy and unilateral neck dissection in one and a laryngectomy and bilateral neck dissection in the other.

The therapy of the second primary, the bronchogenic carcinoma, in the 11 patients in whom the laryngeal tumor preceded the bronchogenic carcinoma, was as follows: In five only palliation was possible and consisted of nitrogen mustard and irradiation; no therapy was possible in a sixth. All six have died with metastases of the bronchial lesions and without evidence of local or regional recurrence of their laryngeal lesions. Pneumonectomies were performed on three, each of whom had had a laryngectomy. A lobectomy was performed on one patient who had had a previous laryngectomy and radical neck dissection. A partial lobectomy and rib resection for invasive carcinoma was performed on the eleventh patient who had had a thyrotomy and corpectomy followed by radiation six and one-half years before.

Two of the three whose bronchogenic lesion preceded the laryngeal cancer were treated for the first primary by pneumonectomy; the third whose lesion originated at the tracheal bifurcation and advanced to the bronchi was treated by local resection and irradiation. The second or laryngeal carcinoma was untreated in two; in one the laryngeal carcinoma was an incidental pre-terminal finding and the second refused therapy and was lost to follow-up. The laryngeal lesion in the third patient was far advanced with regional metastases when the diagnosis was established and only palliative irradiation was possible because of his poor general condition.

The two patients in whom the lesions were found simultaneously, one had a lobectomy and one a total pneumonectomy, the laryngeal surgery in each being performed one month later. One had had an inoperable carcinoma of the base of the tongue treated by radon seed implantation and bilateral neck dissection nine years previously. He has no evidence of residual or metastatic carcinoma from either of the three primary lesions. The second had a pneumonectomy and one month later a laryngectomy and radical neck dissection. Three weeks later a neck dissection was performed on the opposite side.

The sixteen cases of primary carcinoma in both the larynx and tracheobronchial tree herein presented support the evidence of organ susceptibility to cancer. They demonstrate, too, the far more serious malignant potential of bronchogenic carcinoma than cancer of the larynx. And finally, this study emphasizes the statement that the most serious pre-cancerous lesion is cancer.¹⁷

REFERENCES

1. Batson, O. V.: The Function of the Vertebral Veins and Their Role in the Spread of Metastases. *Ann. of Surgery* 112:138, 1940.
2. Cahan, W. G.: Lung Cancer, Associated with Cancer Primary in Other Sites. *Am. J. Surg.* 89:494, 1955.
3. Cahan, W. G., Butler, F. S., Watson, W. L., and Pool, J. L.: Multiple Cancers, Primary in the Lung and Other Sites. *J. Thoracic Surg.* 20:335, 1950.
4. Cracovaner, A. J.: Choice of Operation in Carcinoma of the Larynx. *A.M.A. Arch. of Otolaryng.* 58:655, 1953.
5. Furth, J.: Experiments on the Spread of Neoplastic Cells Through the Respiratory Passages. *Am. J. Path.* 22:1101, 1946.
6. Glaninger, J.: Ueber Haeufigkeit und Art der Fermetastasierung beim Larynxcarcinom. *Msschr. Ohrenheilk.* 93:235, 1959.
7. Latella, P. D.: An Analysis of 240 Cases of Cancer of the Larynx with Respect to the Terminal Phases and Death. *ANNALS OF OTOTOLOGY, RHINOLOGY AND LARYNGOLOGY* 61:266, 1952.
8. Lewis, E. C., and Schaff, B.: Carcinoma of the Larynx Associated with Bronchogenic Carcinoma. *Am. Rev. of Tuberculosis* 74:483, 1956.
9. Longhead, J. R., and Bushnell, J.: Metastasis of Malignant Tumors to the Larynx. *Laryngoscope* 64:50, 1954.
10. Maxwell, J.: The Incidence of Cancer of the Larynx in Relation to the Incidence of Cancer in the Bronchi. *Lancet* 1:193, 1955.
11. Rubenstein, A. S., Graham, J., and Barnes, N.: Associated Carcinoma of Larynx and Lung. *A.M.A. Arch. Otolaryng.* 68:710, 1958.
12. Schall, LeR. A., and Ayash, J. J.: Cancer of the Larynx, A Statistical Study. *ANNALS OF OTOTOLOGY, RHINOLOGY AND LARYNGOLOGY* 57:377, 1948.
13. Thomson, R. V., and Schaff, B.: Carcinoma of the Larynx with Concurrent or Subsequent Development of Bronchial Carcinoma. *Surgery* 39:805, 1956.
14. Warren, S., and Gates, O.: Multiple Primary Malignant Tumors. A Survey of the Literature and a Statistical Study. *Am. J. Cancer* 16:1358, 1932.
15. Warren, S., and Ehenreich, Th.: Multiple Primary Malignant Tumors and Susceptibility to Cancer. *Cancer Research* 4:554, 1944.
16. Wynder, E. L., Bross, I. J., and Day, E.: A Study of Environmental Factors in Cancer of the Larynx. *Cancer* 9:86, 1956.
17. Karhansen, Lucien: The Strasburger-Perella Conference, 1961.

DISCUSSION

DR. F. JOHNSON PUTNEY (Philadelphia): The increase in the absolute number of cases of multiple primary carcinoma as well as the frequency of occurrence probably rightly reflects the general longer survival rate after treatment for cancer, which has permitted more patients to live long enough to develop a second primary

tumor. These studies of Dr. Holinger and others suggest that the existence of one malignancy implies a greater chance for the development of another lesion. Recent experimental work by McLaughlin indicates that some as yet unidentified substance in the blood sera of cancer patients is capable of increasing cancer susceptibility.

The old concept of carcinoma as a single neoplasm intruding itself in otherwise normal tissue is no longer tenable, for the carcinogenic process may involve a large part or all of a given tissue with clinically evident carcinoma occurring primarily at one particular site. This is illustrated in laryngeal cancer when gross involvement is limited to one vocal cord, yet microscopic areas of carcinoma *in situ* are found in the opposite vocal cord far removed from the obvious lesion. The current view has been expressed effectively by Willis who pointed out that the carcinogenic stimuli are applied not to one cell or one small group of cells, but to a more or less extensive area of epithelial tissue. All the epithelium is acted upon similarly though not equally. Neoplasm commences where the stimulus has been maximal, but the neoplastic response may later be manifested by tissue that was subjected to the same original stimulus.

Since there is no reliable clinical means of distinguishing a second primary lesion from solitary metastasis exploration and biopsy are necessary, and the assumption that one tumor is metastatic cannot be made without definite histologic proof. While the majority of workers have agreed that the criteria for multiple primary malignancy established by Warren and Gates as indicated by Dr. Holinger are practical and realistic, it is not easy to determine whether each of the tumors is distinct and separate histologically unless they originate from different underlying cell types, as squamous and glandular epithelium. Histologically primary and metastatic tumors may depart so markedly from each other that identification of the cell type is unreliable. Some tumors may exhibit function in the metastatic site and not the primary or vice versa, notably islet cell tumors of the pancreas. It is this variation in the cells that makes it extremely difficult to differentiate a metastatic from a second primary tumor. It should also be pointed out that in the same tumor one may find areas typical of adenocarcinoma and other areas with typical epithelial pearls.

About five years ago a review of 1442 patients with carcinoma of the larynx at Jefferson Hospital revealed that approximately 4% had two or more primary lesions. In reviewing the statistics at the same institution over the past three years there were 10 out of 328 cases (3.2%) with carcinoma of the larynx that had other primary neoplasms outside the larynx. This somewhat lower than average percentage may be due to the fact that 3 years is not a sufficient time lapse for the development of a second primary. The histologic criteria of our pathologists have been rather strict particularly in regards to the lungs, and in only 3 of the 10 cases was the second primary considered to be in the lung.

The other primary areas were bladder (2), breast, rectum, tongue, abdominal Hodgkins and stomach. An additional 6 cases developed pulmonary malignancy following laryngectomy for cancer, but these were considered metastatic. During this same period there were 588 cases of bronchogenic carcinoma with no concurrent or subsequent primary lesion in the larynx.

This presentation has not only added to the scarcity of reported cases of multiple primary malignant tumors involving the larynx and lung, but also reemphasized that cancer patients have a predisposition to more cancer. After definitive treatment one cannot be content with checking for recurrence or metastasis, but the possibility of a separate lesion developing in other tissues should not be overlooked.

DR. CHARLES M. NORRIS (Philadelphia): This review by Dr. Holinger and his colleagues has been a very informative one on a subject which still has some controversial aspects. During the years 1940 to '53, at the Jackson Clinic, carcinoma of the lung was observed concurrently or subsequently in 15 cases of cancer of the larynx, and as Dr. Holinger and Dr. Putney have both emphasized, to determine with certainty whether these lesions in the lung are primary or metastatic, in our experience, as well as in that of others, has been difficult.

Insisting on the requirement of a different histologic type of course is not of great help because of the great frequency with which the squamous cell carcinoma occurs in both areas. In seven of these cases (two of recurrence following laryngectomy, 3 of cervical node metastases following laryngectomy and 2 in which laryngectomy and radical neck dissection had shown positive nodes), the interval to the appearance of the pulmonary lesion was less than six months. It seemed quite logical that these could be assumed to be metastatic, the probable route being by way of the cervical lymphatics, subclavian, innominate vein, right heart and pulmonary artery.

In the other 8 cases which were also considered as failures statistically, death due to the pulmonary lesions ensued without recurrence or metastasis in the neck. The lung carcinoma in these cases may have been primary, since isolated metastasis to the lung would seem unusual without cervical node metastasis or local recurrence.

In 2 cases in this group multiple nodules suggestive of blood-borne metastasis were found on x-ray and in the remaining 6 a single tumor-like density was found in 4 and lobar atelectasis in 2. Three of these lesions involved the right upper, 2 the left upper and 1 the left lower. Despite the theoretical possibility of mucosal implantation in these 6 cases, the distribution of the lesions does not favor such an hypothesis because of the predilection for the upper portions of the lungs in 5 of these 6 cases.

It might be of interest to recall Auerbach's work on the occurrence of multiple foci of *carcinoma-in-situ* and actual invasive carcinoma in the tracheal-bronchial tree in autopsy cases of bronchiogenic carcinoma and it might be speculated that this same multicentric potential may occur in the entire lower respiratory tract.

The question of implantation is, I think, of particular interest and I would be very much interested in hearing Dr. Holinger's ideas about this, because it has direct implication on the use of endotracheal anesthesia at the time of laryngectomy or radical neck dissection, particularly if the endotracheal tube is put through the larynx. Ormerod and others have felt this is a hazardous procedure, and that the risk of implantation in the lower respiratory tract might be a very real one.

DR. ANDERSON C. HILDING (Duluth): I would like to ask Dr. Holinger how many of these 16 individuals were smokers. One, for whom the history was given, was a smoker. I would like to emphasize what Dr. Putney said about the exposure of the whole epithelium. If you recall the physiology of the ciliary stream and the deposition of air pollutants in the mucous blanket, you can easily understand how this would be. The whole stream flows along from the respiratory bronchus to the esophagus and, on the way, meets obstructions, especially in the root of the lung, where, among the primary bronchi, there are apt to be squamous islands, over which the mucous blanket must be dragged. The bronchial openings also act as obstructions around which the mucous blanket must be maneuvered. In the trachea, there is no particular obstruction; it flows along smoothly and malignancy here is rare. (It should be kept in mind that during this time of drainage, the broncho-

genic contaminant is in the mucous blanket.) The next obstruction the mucous blanket encounters is the vocal cords. That portion which flows up the posterior surface of the trachea flows out, without obstruction, to the esophagus; that on the anterior surface comes up against the squamous epithelium on the edge of the vocal cord, and here it ceases its upward progress, changes direction at right angles, and flows posteriorly, dragging and bumping along the margin of the squamous epithelium, to the arytenoids, where it flows on out. At the anterior commissure, it comes to a dead stop and then must change direction at right angles, and be torn asunder.

One would, therefore, expect most malignancies to be right at the margin of the vocal cord on the inferior surface, and I think this is true. One would expect most to be in the anterior portion of the cord, and, as Dr. Tucker said yesterday, this seems to be true. One would expect to find the greatest activity in the malignancy, as indicated for instance by mitotic figures, in the anterior portion of the tumor, and Multanen has found this to be true.

DR. PAUL H. HOLINGER (Chicago) (closing): I want to thank Dr. Putney, Dr. Norris and Dr. Hilding for adding significant points to this discussion of a problem that has come to mean much to us in the examination of our patients in the post laryngectomy follow-up clinic.

Dr. Hilding's remark about the smokers is based on his work which is so well known and so well documented. I am afraid that I can't give, accurately, the smoking habits of the 16 patients that we reported. We tried to do this but our records do not indicate their smoking habits. Most of them were smokers but information as to how much they smoked and for how long we do not have. However, Dr. Wynder who has done such excellent statistical work on this problem, mentioned that the cases of double primaries in the respiratory tract that they had examined were in the group of the heaviest smokers in their recorded series; so this does seem to have significance.

Dr. Norris added important points to the discussion; the possibility of implantation is one that we have long felt was a possible factor, and we routinely have done the tracheotomy first under local anesthesia and then the laryngectomy after the intratracheal tube has been introduced through the tracheostomy. This is in lieu of introducing the intratracheal tube through the larynx as I believe Dr. McCall showed in his motion picture yesterday. This avoids passing the intratracheal tube through the tumor.

Both Dr. Norris's and Dr. Putney's remarks with regard to histology are very well taken. From our review of these cases, we cannot with absolute certainty say that in each patient the lesions were entirely dissimilar. What we have to come back to is that this is respiratory epithelium. The small cell carcinomas and the squamous cell carcinomas of the lung and of the larynx have such gradations that it is often difficult to say that one is an absolutely distinct tumor from the other. The anatomical description of the lesion is important. The clinical course in these 16 cases has demonstrated that these were separate laryngeal and bronchogenic lesions that had to be handled clinically as either primary bronchogenic lesions that had to be handled clinically as either primary bronchogenic carcinoma by pneumonectomy, lobectomy, and so forth, or in the laryngeal lesion by fissure or laryngectomy; in other words, two separate lesions rather than as multiple lesions of a single primary which might have been due to blood stream metastases.

So far as implantation is concerned this, of course, is still a possibility which we cannot prove, one way or the other.

DEFICITS IN IRRADIATION THERAPY FOR

CARCINOMA OF THE LARYNX

FOLLOWED BY SURGERY

HERBERT H. HARRIS, M.D.

HOUSTON, TEX.

Undoubtedly, there is some deficit in the expected end results when carcinoma of the larynx is treated by irradiation therapy and surgery is performed later. In all instances, surgery is done either because of irradiation necrosis, or incomplete control of the cancer. With the exception of some cases of far advanced cancer and those with metastasis, many cases treated by irradiation could likely have been treated by partial laryngectomy, total laryngectomy, or laryngectomy combined with radical neck dissection as the initial treatment. Some of these patients are treated by irradiation by choice of the laryngologist, and others at the request of the patient. Whenever tissues are subjected to irradiation, the capacity of the tissues to recover after surgical procedures is diminished.

Irradiation therapy for small cancers of the larynx, especially those of the true cords, is a recognized treatment today.¹⁻⁵ In some instances, irradiation therapy gives an over-all better result than does surgery. This depends to some degree on the ability of the surgeon, or the roentgen therapist, on the choice of treatment in relation to the grade of the cancer, the size of the lesion, and whether it is exophytic, or infiltrating. In some instances, for a few selected cases, surgeons prefer irradiation therapy of the lesion followed by surgery.

This paper is presented with several things in mind. In the last few years some very good papers have been presented regarding this subject.⁶⁻⁸ I wish to add to this so that an accumulation of cases

From the Department of Otolaryngology, Baylor University College of Medicine.

may give us a better understanding, and make our selection of therapy be based on the individual case related to anatomy, pathology and physiology. There are several questions which I hope to answer in a review of these cases: What effect does the size of the field of irradiation have to do with future surgery of this area? Just what are the expected deficits as far as the cure of cancer is concerned when irradiation fails and surgery is done? What complications are to be expected in these cases? Since many of my cases have not survived five years following therapy, no conclusions can be drawn from actual survivals, but, must be based on experience and projected results.

The 23 cases, to be presented in group analysis, were from a series of 286 cancers of the larynx (Table I) treated since 1947, in four different institutions associated with the teaching program at Baylor University College of Medicine. Two types of radiation therapy were used: 220 K.V. (conventional apparatus), and 2 M.E.V. (Van de Graaff - electrostatic generator type). Though two or more therapists treated the cases using 220 K.V., the technique was essentially the same except for the size of the field and the variation of the dosage. All received 36 treatments over a period of approximately six weeks.

Those treated with 2 M.E.V. therapy were treated by the same therapist but were treated for a four-week period, or approximately 20 treatments over 28 elapsed days. They were given a smaller total dosage than the ones receiving treatment over a six-week period.

One hundred and twenty-four cases were operated upon either by laryngofissure, hemilaryngectomy, or laryngectomy with and without radical neck dissection. Forty-five cases had major surgical procedures and were irradiated because of local recurrence, or as an adjunct one month following surgery.

Twenty cases of early cordal lesion (limited in size to less than 1 cm in any direction and without fixation) were treated by either 220 K.V. or 2 M.E.V. therapy. Most of these cases were treated on the physician's recommendation.

Sixty-four cases were treated by either 220 K.V. or 2 M.E.V. irradiation. These were either considered to be lesions too large for surgery with distant metastasis or they refused surgery and accepted irradiation therapy as an alternate type of treatment.

TABLE I

	CASES OF CANCER OF LARYNX
Number of cases reviewed in this series	286
Number of patients operated by laryngofissure, hemilaryngectomy, laryngectomy with and without radical neck dissection and/or pharyngectomy and/or cervical esophagectomy	124
Number of patients operated by various major surgical procedures followed by irradiation because of local recurrence or as an adjunct one month after surgery	45
Number of cases of early cordal lesions or small lesions elsewhere in the larynx treated by x-ray	20
Number of patients treated by x-ray because they were inoperable or refused surgery	64
Number of cases that received x-ray treatment and later had some type of neck surgery	23
Number of patients who refused treatment or in whom cancer was too far advanced	11

Eleven cases were not treated either because they refused all types of treatment or were considered so far advanced that surgery or irradiation would be of no value.

Actually, then, the 23 cases operated upon following irradiation were from a group of 110 cases initially receiving x-ray therapy.

For the purpose of discussion, these 23 cases treated initially by irradiation therapy and later operated upon will be divided into four groups:

1. Cases of early carcinoma of the larynx less than 1 cm in any one direction, and without fixation (Table II).
2. Cases of advanced carcinoma of the larynx involving the true cords and endolarynx, larger than 1 cm and with fixation (Table III).
3. Cases of advanced carcinoma of the pyriform sinus, 2 cm or larger, but without metastasis (Table IV).
4. Cases of advanced carcinoma of the vallecula and epiglottis (Table V).

In group one, there are a total of 8 cases; all but one was of the true vocal cords. The one exception was a small lesion of the lateral wall of the pyriform sinus discovered accidentally. It might be noted that all of these were keratinizing type, or tumors well differentiated. The response to healing following surgery was about the same when 220 K.V. therapy was given as compared to 2 M.E.V.

Two were operated by laryngofissure and four by laryngectomy without complications. One was operated for a metastasis to the thyroid gland but there was no evidence of carcinoma in the larynx at postmortem. No doubt, the metastasis was present prior to therapy and would not have been altered by the type of surgery likely recommended. In one instance, a small pyriform sinus lesion was treated successfully by irradiation. Four months later a radical neck dissection was done for cervical node metastasis; prompt healing occurred. The disturbing complication was the marked edema of the larynx finally requiring a tracheotomy. Because of the persistent edema, decannulation was not accomplished for five months.

It might be noted that in no instance was the field of radiation larger than 6x8 cm and the amount of irradiation given was considered a cancericidal dose. All patients were given radiation therapy on the recommendation of the surgeon.

In the second group (Table III), there were eight cases, all with more advanced lesions, all involving the true cords and adjacent areas of the endo-larynx. Of these, four had wide field laryngectomy and four had laryngectomy with radical neck dissection. None of these showed clinical metastasis to the neck, but the radical neck dissection was done for subclinical metastasis. Four of the cases healed without complications and four developed fistulas, one in 12 days and the other in four weeks. In the one instance where the fistula developed in 12 days, the specimen showed no evidence of carcinoma but there was necrosis of the cartilage. Although the fistula was small, it required two small surgical procedures and ten months for complete healing. In the other case, the fistula healed spontaneously after one month.

In the other two cases, the lesion was more extensive than anticipated, and the fistula with necrosis and residual carcinoma resulted in death. In all of these cases, the field of irradiation was only slightly

TABLE II

CASES OF EARLY CARCINOMA OF THE LARYNX LESS THAN 1 CM IN ANY ONE DIRECTION, AND WITHOUT FIXATION

AGE SEX	CHOICE OF TREATMENT	LOCATION OF LESION	GRADE OF LESION	PRE-OPERATIVE IRRADIATION	TYPE OF SURGERY	COMPLICATIONS	EXPECTED RESULTS
69 M	Phy. choice 1957	Lateral wall upper part pyriform sinus	II, well diff.	220 K.V., 5760 R., 6x5 cm Port, 36 treatments	4 months postoperative left radical neck 1957	4 months after sur- gery - Edema of Lar- ynx, Tracheotomy	Expected cure
41 M	Phy. choice 1959	Anterior third of right vocal cord	II, well diff.	220 K.V., 6200 R., 7x6 cm Port, 36 treatments	Early recurrence in thy- roid gland thyroidec- tomy healed 1960	After further radia- tion of neck necrosis no residual tumor on vocal cord	Death in 6 months
53 M	Phy. choice 1955	Anterior half of right vocal cord	II, well diff.	220 K.V., 6000 R., 6x5 cm Port, 36 treatments	18 months later partial laryngectomy & skin graft 1956	None	Well - Mar. 1961 Expected cure
57 M	Phy. choice 1952	Middle third of vocal cord	II, well diff.	220 K.V., 6000 R., 6x8 cm Port, 36 treatments	Recurrence of same area Laryngectomy 1960	None	Well - Mar. 1961 Expected cure
56 M	Phy. choice 1960	Anterior 1/3 of vocal cord	II, well diff.	220 K.V., 5800 R., 6x8 cm Port, 36 treatments	Recurrence in 6 months Laryngectomy 1961	None	Well - Mar. 1961 Expected cure
46 M	Phy. choice 1954	Middle third of vocal cord	II, well diff.	220 K.V., 5800 R., 6x8 cm Port, 36 treatments	Recurrence in 1960 - laryngofissure	None	Well - Mar. 1961 Expected cure
59 M	Phy. choice 1957	Anterior 1/2 of left vocal cord	II, well diff.	2 M.E.V., 5000 R., 4x6 cm Port, 4 weeks	Recurrence in 1960 - Laryngectomy	None	Well - Mar. 1961 Expected cure
42 M	Phy. choice 1959	Anterior 1/3 of right vocal cord	II, well diff.	2 M.E.V., 5480 R., 4x6 cm Port, 4 weeks	Recurrence in 6 months Laryngectomy	None	Well - Mar. 1961 Expected cure

TABLE III
CASES OF MORE ADVANCED CARCINOMA OF LARYNX INVOLVING THE TRUE VOCAL CORDS AND ENDO-LARYNX
LARGER THAN 1 CM AND WITH FIXATION

AGE SEX	CHOICE OF TREATMENT	LOCATION OF LESION	GRADE OF LESION	PRE-OPERATIVE IRRADIATION	TYPE OF SURGERY	COMPLICATIONS	EXPECTED RESULTS
55 M	Pt. choice 1950	Ant. $\frac{2}{3}$ of left vocal cord and ventricle	Well diff.	220 K.V., 5760 R., 6x6 cm, 36 treatments	Laryngectomy after 6 months	None	Well-Mar. 1961 Expected cure
46 M	Pt. choice 1957	Left vocal cord and adjacent area of ventricle	Well diff.	220 K.V., 6000 R., 5x6 cm, 36 treatments	Laryngectomy & left radical neck 3 months following irradiation	Fistula for about 4 weeks - beginning 1 month after surgery	Well-Mar. 1961 Expected cure
55 M	Pt. choice 1957	Ulceration of entire left cord	III, well diff.	220 K.V., 6500 R., 6x8 cm, 36 treatments	Laryngectomy & left neck - 5 mo. after irradiation	Area did not heal due to both irradi- tion and incomplete removal of cancer	Expired - 3 months after surgery
59 M	Pt. choice 1955	Both vocal cords and anterior com- missure - Fixation	II, well diff.	220 K.V., 6500 R., 3.5 x4 cm, 36 treatments	Laryngectomy 6 months after irradi- ation	None	No follow-up since May 1958 Expected cure
60 M	Phy. choice 1955	Left vocal cord	II, well diff.	220 K.V., 6000 R., 6x6 cm, 36 treatments	Laryngectomy & left radical neck	None	Well-Mar. 1961 Expected cure
64 M	Pt. choice 1957	Anterior commissure and ant. half of both cords - No fixation	I, well diff.	2 M.E.V., 5500 R., 2.5x5 cm, 4 weeks	Laryngectomy & left radical neck specimen showed rad. necrosis and infection	Fistula midline oc- curred 12 days after surgery. Healed fol- lowing 2 minor surgical procedures - 10 mos.	Well-Mar. 1961 Expected cure
65 M	Pt. choice 1950	Both vocal cords & base of epiglottis	II, well diff.	220 K.V., 7000 R., 8x8 cm, 8 weeks	Laryngectomy 6 months later	Tracheo-esophageal fistula	Expired - 6 months later
66 M	Pt. choice 1957	Entire left vocal cord with fixation	II, well diff.	2 M.E.V., 6000 R., 5x5 cm, 5 weeks	Laryngectomy 6 mos. after irradiation - 6 mo. later neck dissect.	None	Well-Mar. 1961 Expected cure

TABLE IV
CASES OF ADVANCED CARCINOMA OF PYRIFORM SINUSES 2 CM OR LARGER, BUT WITHOUT METASTASIS

AGE SEX	CHOICE OF TREATMENT	LOCATION OF LESION	GRADE OF LESION	PRE-OPERATIVE IRRADIATION	TYPE OF SURGERY	COMPLICATIONS	EXPECTED RESULTS
73 M	Pt. choice 1956	Large pyriform sinus lesion	II	220 K.V., 5000 R., 6x6 cm, 4 weeks	Laryngectomy	None	Expired - 9 months later of bronchogenic Ca. no recur- rence in neck
40 M	Pt. choice 1958	Large pyriform sinus lesion	II	2 M.E.V., 5000 R., 6x10 cm, 4 weeks	Laryngectomy, partial pharyngectomy, skin graft - 6 months after irradiation	Fistula - radio necro- sis metastasis beneath clavicle, no further surgery thought possible	Expired 6 months after surgery
60 M	Pt. choice 1957	Large pyriform sinus lesion with cellulitis of neck	II	2 M.E.V., 5500 R., 6.5x9 cm, 4 weeks	Laryngectomy and left radical partial pharyn- gectomy, skin graft 5 months after irradiation	Healed completely. Fistula formation two months later with rupture of com- mon carotid artery and ligation. 3 days later hemiparesis	Expired 9 months later, no carcinoma found at post- mortem
65 M	Pt. choice 1959	Two cm pyriform sinus lesion, left rad- ical neck and paro- tidectomy done for an adenocarcinoma 3 years before	II	2 M.E.V., 5000 R., 5x5 cm, 4 weeks	Laryngectomy 6 months after irradiation	Fistula - two weeks closed spontaneously	Patient well 9 months later, but cure ques- tionable

TABLE V
CASES OF ADVANCED CARCINOMA OF VALLECULA AND EPIGLOTTIS

AGE SEX	CHOICE OF TREATMENT	LOCATION OF LESION	GRADE OF LESION	PRE-OPERATIVE IRRADIATION	TYPE OF SURGERY	COMPLICATIONS	EXPECTED RESULTS
64 M	Phy. choice May, 1960	Ca. of vallecula of adjacent 1 1/2 cm of tongue, no nodes in neck. Ca. of prostate 3 years before asymptomatic	II	2 M.E.V., 5000 R., 6x8 cm, 4 weeks	Laryngectomy 6 months later because of pain, hemorrhage and ulceration, no carcinoma found	Healed well until 4th week then ulcer- ation and necrosis became worse. Some hemorrhage at present	Prognosis poor will probably develop fistula
61 M	Pt. choice 1956	Ca. of epiglottis and left aryepiglottic fold	II	2 M.E.V., 6000 R., 6x8 cm, 5 weeks	4 months later left neck - 5 months later right neck, tumor in stri- ated muscle right neck	Healed well	March 1961 - No evidence of recurrence
66 M	Phy. choice 1952	Ca. of vallecula	II	2 M.E.V., 5000 R., 6x8 cm, 4 weeks	Left radical neck 6 months later	None	Died of general- ized metastasis 10 months later no evidence of local recurrence

larger than in the preceding eight cases, but the complications were greater.

It might be noted that all of these patients were irradiated at the patient's request. Only two of the cases have expired and, in the others, three to ten years have elapsed since the surgery was performed and there is no evidence of local recurrence.

In the third group (Table IV), only four cases of advanced pyrim sinus lesions were treated by irradiation, and all were treated by irradiation at the request of the patient. In three, a laryngectomy was performed, and in one a laryngectomy and radical neck dissection. Three expired within the first year. One, of a bronchogenic carcinoma without evidence of neck metastasis; one, with marked radiation necrosis and metastatic carcinoma beneath the clavicle. The third case healed well after surgery, but within 2 months developed a fistula, rupture of the carotid artery, hemiplegia and expired within six months of debility. No carcinoma was found at postmortem. The fourth case developed a fistula two weeks after surgery, but it closed spontaneously. This patient had a parotidectomy and neck dissection three years before for adenocarcinoma of the parotid gland.

Undoubtedly, in three cases, radiation added to complications after surgery but, due to metastasis and radionecrosis, only one of them survived for as long as one year. In the fourth case, there were no complications; however the patient expired in less than one year of a primary bronchogenic carcinoma.

In the fourth group (Table V), there were three cases all involving the epiglottis, the vallecula, and varying portions of the tongue. Two were irradiated on recommendation of the surgeon, and one on the patient's choice. In two there was good local response to irradiation; a radical neck dissection was done later for cervical metastasis. One died in ten months of generalized metastasis without evidence of local metastasis, and one is living and well four years later.

In the third case, irradiation was given on the recommendation of the surgeon; this case showed no evidence of carcinoma six months following surgery. Due to irradiation necrosis and hemorrhage, a laryngectomy and partial removal of the posterior third of the tongue was done. Healing was good for the first six weeks, but infection and

ulcerations have continued in the pharynx and it is doubtful if the ulceration will heal, though no fistula has developed.

SUMMARY

Twenty-three cases of carcinoma of the larynx are reported which have had surgery following irradiation. These have been summarized into four groups: 1) early lesions of the vocal cords, less than 1 cm in size; 2) more advanced lesions of the vocal cords and endo-larynx; 3) advanced lesions of the pyriform sinus, 2 cm or larger; 4) advanced carcinoma of the vallecula and epiglottis.

All cases were given irradiation using a port as small as possible, keeping in mind that surgery might be done later. In none of the cases was a larger port than 8x10 cm used. In all cases a therapeutic dose of irradiation was given. In those cases where 220 K.V. was used, 36 treatments were given over a period of six weeks; the total tumor dose varied between 6000 R and 7000 R. When 2 M.E.V. was used and 20 treatments given, over 28 elapsed days, the tumor dosage varied between 5000 R and 6000 R.

CONCLUSIONS

1. The complications as a result of irradiation except in three cases was not great. It is doubtful if the end results would have been better had surgery been performed initially on those where irradiation necrosis took place.

2. The one striking observation is the rather high rate either recurrence, or lack of response to irradiation in the cases of group one. Here there was recurrence or lack of response in seven of twenty cases, and all of these showed well-differentiated carcinoma. In only two could a laryngectomy be averted. Though only one case has been lost in this group, it is likely death would have occurred had surgery been done initially. There is some deficit here, since a laryngectomy was done in four cases. Laryngectomy may have been prevented in these had a laryngofissure been done initially.

In the second group of cases, all should have had surgery by laryngectomy as the initial treatment, but in only one instance was it felt that surgery might have prevented death had a laryngectomy

been the initial treatment. The morbidity was relatively high in those who survived, because of complications which likely would not have developed had surgery been the initial treatment.

Except in two cases, in the third and fourth groups comprising seven cases, the patient chose irradiation. The end results have been poor and there has been complications in 50 per cent of the cases. In only two were they of such magnitude that pedicle flaps should have been done. Due to other factors, such as the general condition of the patient and distant metastasis, this was not carried out.

Finally, the deficits have not been great in cases of irradiation of the larynx followed by surgery, but it is certainly apparent that the larger the tumor and the field of irradiation the more likely complications will result if surgery follows the irradiation. In these cases, had the proper type of surgery been done initially three of the cases should have recovered, had not time been lost between the x-ray therapy and surgery.

One should weigh carefully the early lesions of the vocal cord in the well-differentiated cancer. Surgery should be considered since laryngectomy may be averted in some.

When irradiation is considered in advanced, but not inoperable, lesions, they should be considered future surgical candidates. By using as small a port as possible, when surgery does follow irradiation it certainly helps in the prevention of complications.

There seemingly is little or no difference in the response of the tissues to surgery when 220 K.V. as against 2 M.E.V. when the tumor dose remains the same, or a comparable dose is given depending on the number of elapsed days and the total number of treatments.

907 HERMANN PROFESSIONAL BUILDING

REFERENCES

1. Jenkinson, Edward L., Kao, Lillian, Holinger, Paul H., Johnston, K. C., and Donnelly, R. W.: Carcinoma of the Larynx. Results of Roentgen Therapy During a Period of Fifteen Years (1937-1952). *Amer. Jour. Roentgenol., Rad. Ther. and Nuclear Med.* 76:942 (Nov.) 1956.
2. Leroux-Robert, Jean: Indications for Radical Surgery, Partial Surgery, Radiotherapy and Combined Surgery and Radiotherapy for Cancer of the Larynx

and Hypopharynx. *ANNALS OF OTOTOLOGY, RHINOLOGY AND LARYNGOLOGY* 65:137 (Mar.) 1956.

3. Schall, LeRoy A.: Cancer of the Larynx. Indications for Treatment. *Amer. Jour. Roentgenol.* 83:6 (Jan.) 1960.

4. Cantril, Simeon T.: Radiation Therapy in Cancer of the Larynx. *Amer. Jour. Roentgenol.* 83:17 (Jan.) 1960.

5. Robbins, Robert: Indications for Radiation Therapy in Laryngeal Cancer. *Amer. Jour. Roentgenol.* 83:21 (Jan.) 1960.

6. Klopp, Calvin T., and Kirson, Stanley M.: The Treatment of Cancer of the Larynx. *Amer. Jour. Roentgenol.* 83:10 (Jan.) 1960.

7. Triple, William M.: The Effect of Pre-operative Radiation on Subsequent Surgery in Carcinoma of the Larynx. *ANNALS OF OTOTOLOGY, RHINOLOGY AND LARYNGOLOGY* 66:953 (Dec.) 1957.

8. Work, Walter P.: Surgery of the Neck Following Radiation Therapy for Cancer. *Trans. Amer. Laryngol. Assn.* 80:90, 1959.

DISCUSSION

DR. JOHN J. CONLEY (New York): Doctor Harris has raised the question of the therapeutic and physiological effects of irradiation upon a wound that has undergone surgery. The incidence of complications under these circumstances appears to be in direct proportion to the size of the port used for the purposes of irradiation, the character and amount of dosage administered and the time interval lapsing between the therapy and the surgical act. Obviously a smaller port creates less tissue damage and consequently permits better healing of the wound. Minimal dosage of irradiation also contributes to less tissue damage and better healing of the wound. A short interval following irradiation does not permit the severe atrophy and fibrosis to occur that requires from one to two years for its full effect and consequently would not have a serious effect upon healing. When these three specific factors, however, are extended in a major and aggressive therapeutic attempt with irradiation the potential wound damage is serious.

There is a direct relationship between the size of the operation and the effect on the postirradiated tissue bed. It is reasonable that a small surgical wound has a better opportunity of healing than a composite resection of one or more organs exposing a potentially infected glottis or oral cavity associated with removal of organs and the exposure of vital tissue areas.

There is a slight to moderate deficit in the combined treatment associated with surgical intervention following irradiation failures. This deficit is less when the lesion is in an exposed area that can be readily examined and treated without great delay upon the recognition of a recurrence. However, in the inaccessible areas and in the sites where submucosal extension is a frequent occurrence, one must accept that the tumor may grow to large proportions without being recognized. This permits it to become well established locally and also to have more time for regional and systemic spread.

It is conceivable that there should be no deficit in the combined treatment of irradiation and elective surgery on the irradiated area and the regional bed. This implies that the area is operated electively whether there is obvious residual tumefac-

tion or not. Indeed it is possible under these circumstances that some augmentation of the salvage rate may occur. There is always the inevitable factor, however, that surgery will be performed in areas where tumefaction has been destroyed by the irradiation and the patient is essentially an irradiation cure. How these various combinations of circumstances will balance themselves out in the final statistical analysis is yet to be seen.

It is a curious feature in this report that there were approximately 30% failures for cancer of the glottis that measured less than 1 cm in diameter. Perhaps Doctor Harris can give us his specific views on this statistic.

I feel that Doctor Harris' paper would have greater significance in other areas if it could be indicated how many supraglottic and hypopharyngeal cancers were treated with irradiation initially, how many were cured and what the relative percentage of local and regional failure was, before the selection of the fifteen cases in these areas that underwent surgical intervention following x-ray failure.

DR. JOSEPH P. ATKINS (Philadelphia): I would like very much to compliment Dr. Harris on this interesting presentation. He has certainly accomplished what he set out to do. This addition to the reported cases will help us achieve a deeper understanding of the factors involved in the selection of treatment. The most informative results have to do with his first two groups, chiefly because they are the larger groups. Group 3, indicating poor results in a group of 4 cases of pyriform sinus lesions, is not out of line with the rather general experience that these are difficult cases to cure. In Group 4, the loss of one of 3 cases of lesions of the epiglottis and indeterminate results in the other 2 is also not out of line with clinical experience, particularly the difficulties that Dr. Harris encountered with post-irradiation necrosis, fistula, and hemorrhage.

With regard to early carcinoma of the larynx, I understand from his figures that he has resorted to surgery following irradiation in 8 of 20 cases. This experience differs from ours which consists of 32 cases of this type in which 4 required subsequent surgical intervention. It has been a policy in our Department to reserve irradiation for the older age groups with a dividing line at a physiologic age of about 65. I notice that all except one of Dr. Harris' patients who required further surgery were in the under-65 age group. I am not sure how large a total group is represented by the 8 cases of more extensive intralaryngeal lesions requiring supplementary surgical care, but I note again that while this group is slightly older, only one of them is over 65. We have preferred not to use irradiation in younger patients to avoid the situation of a patient living for a long time with heavily irradiated tissue in his body because of the well-recognized late complications that can occur in heavily irradiated tissue.

The principal problem that one encounters in evaluating any results in cancer is that we do not have satisfactory means of evaluating the destructive potentialities of the tumor. If there were some crude measure of a tumor's destructive potentiality, an evaluation of the results in any given case would be more meaningful. At the Hospital of the University of Pennsylvania, Dr. Collier and his associates in 1958 made a survey of our bronchogenic carcinomas.* In this study, the observation was made that those tumors which histologically show blood vessel invasion were asso-

* Collier, Frederick C.; Enterline, Horatio; Kyle, Robert; Tristan, Theodore; Greening, Roy: The Prognostic Implication of Vascular Invasion in Primary Carcinomas of the Lung. *A.M.A. Arch. Path.* 66:594-603 (Oct.) 1958.

ciated with a very high percentage of poor results and that most of the salvage was accomplished in that group of tumors showing no evidence of blood vessel invasion. We have been watching this observation in our laryngeal tumors and, after reading Dr. Harris' paper, we made a very sketchy review of our cases. In those pathologic reports in which it was noted whether or not blood vessel invasion was present, we compiled 23 cases. Blood vessel invasion was observed in 11 tumors and was absent in 12.

(Slide) Of the group with blood vessel invasion, 5 are dead and 6 are still alive. Only one of this group of 6 is more than one year postoperative and that patient has lived for three years and eight months, during which time he has been treated by irradiation, radical neck dissection, and laryngectomy with partial hypopharyngectomy. He is apparently tumor free at this moment, six months after laryngectomy and hypopharyngectomy. Of the 12 without blood vessel invasion, 10 are alive and 2 died presumably without tumor from other causes.

This group in which we have follow-ups as long as fourteen years includes only one patient who is less than one year postoperative. Two of this group are believed to be not free of tumor. I would not suggest that these figures are an accurate picture of all our laryngeal cancers because we have not subjected them to a systematic review with regard to this point, but qualitatively these results are sufficiently in harmony with our findings in bronchogenic cancer that it may have some validity and I am hopeful that some means such as this may be available to evaluate not only the results of treatment but the malignancy potential of tumors.

I hope that Dr. Harris will report to us further as the experience with this group of cases ripens. I have enjoyed his paper very much and appreciate the privilege of being permitted to discuss it.

DR. HERBERT HARRIS (Houston) (closing): I want to thank both Dr. Conley and Dr. Atkins for being so kind in their discussion and certainly so helpful in perhaps enabling you better to understand what I was trying to get over.

I certainly agree with what Dr. Conley has said, that tumors elsewhere than on the vocal cord are unpredictable in their growth, their rate of growth, and the extensiveness of them. You will notice that it was only in the lesions of the epiglottis and tongue that we recommended irradiation therapy.

I was a little disturbed when I saw just how poor our irradiation results were in early cordal lesions, perhaps 60-65%. I felt perhaps our radiologist was slipping, and then I heard Dr. Lederman from England speak just a couple of weeks ago. His results were somewhere around that figure. Then I also recently heard Dr. William McComb of the M. D. Anderson Hospital talk, and his five-year survivals are about 70%. Dr. Gilbert Fletcher, whom I think you would all recognize as a capable therapist, does all his therapy. So, I don't feel quite so badly with our results after all.

Many of these lesions were almost leukoplakia or Grade I, possible Grade II, if you wished to grade them according to Broder's. This may make some difference in the response. We were taught years ago that the lower the grade, the less responsive is the tumor to the x-ray therapy.

I certainly feel that I prefer, where possible, surgery and then irradiation, rather than irradiation and then surgery. I don't know that anyone has ever definitely worked out which is the better.

I have purposely stayed away from statistics. I felt that this small group of cases would not lend itself to very good statistical data and would not be very much help in really drawing definite conclusion.

I have not thought much in regard to the age of the patients, as Dr. Atkins has suggested, as related to surgery or irradiation. I think possibly it might be worthwhile to study this further.

Although our radiologist has felt he could do a good job in early lesion, I may further evaluate our group of cases and find out why we are not getting better results. Ideally one is supposed to get about 85-90 per cent cures with laryngofissure. If we are getting only 65 per cent with irradiation, perhaps we should go back and see if that be true and reconsider the type of therapy recommended.

Tumors invading blood vessels should be re-evaluated and restudied. Perhaps this is the reason we see these large tumors of the neck and patients who die of tumors without metastasis elsewhere in the body. These types of tumors may not invade blood vessels. Why some tumors will invade blood vessels and these patients die from hemorrhage with only local lesions, I think should be studied enthusiastically.

ANTERIOR OSTEOPLASTIC FRONTAL SINUS OPERATION

FIVE YEARS' EXPERIENCE

R. L. GOODALE, M.D.

W. W. MONTGOMERY, M.D.

BOSTON, MASS.

The anterior osteoplastic approach to frontal sinus surgery has been previously described by Schonborn¹ and Brieger² in 1894 and 1895 respectively. It was later modified by Winkler,³ Beck,⁴ Hoffman,⁵ Bergara,⁶⁻⁸ Tato,⁹ Gibson and Walker,¹⁰ and Macbeth.¹¹ In the course of the many years which have elapsed since Schonborn and Brieger first suggested such an operation, much has happened to improve our surgical techniques. We have the benefit of antibiotic control of infection and we also have electrically operated instruments which make it much easier to cut a neat bone flap and thus obtain a precise reapproximation.

The purpose of this paper is to report our experiences with this procedure during the last five years at the Massachusetts Eye and Ear Infirmary, based on a "follow-up" study of our cases, some of whom have been previously presented in earlier articles.¹²⁻¹⁴

Those of us who have been brought up in the technique of the transorbital approach to the frontal sinus have believed that in order to obtain a successful result, one should consider that the frontal sinus, the ethmoid and the sphenoid were a system of sinus cavities and that a very thorough cleaning out of all this area was essential to obtain a successful result. However, in the transfrontal approach, one treats the frontal sinus as a separate entity for the purposes of this operation. If the ethmoid also is to be operated upon, this can be done, as others have pointed out previously, by means of a trans-antral, combined transantral and intranasal or as in some of the cases to be reported by a transfrontal approach. The authors have found

many cases also in which the ethmoid was not at all involved and in which the frontal sinus alone was affected. Of course, this would be the most favorable type for this operation.

The authors have felt that there were factors which were inherent in the transorbital approach, which tended to defeat its purpose. Stated briefly: in destroying the orbital wall, separating the nose from the orbit, the nasofrontal duct was also destroyed together with its lining membrane. In too many cases, which were followed over a period of years by several of the Staff^{15,16} of the Massachusetts Eye and Ear Infirmary, it was found the fibrosis which formed in the region of the new surgical nasofrontal duct prevented drainage from the sinus. In fact, there were too many occasions for secondary operations in our series to make one feel really happy about this procedure. The studies of Walsh¹⁷ and Hilding¹⁸ show that the mucous membrane which lines the nasofrontal duct exerts a very positive drag on the mucous mantle within the sinus and that it is this movement of the mucus propelled by the cilia which is a most important factor in removing secretion from the sinus, and therefore not only the bony duct, but its mucosal lining should be preserved in cases not suitable for ablation.

Where there is structural abnormality in the sinus, such as osteoma, fronto-ethmoid cell narrowing, the nasofrontal duct, or mucocele or pyocele, the situation is an ideal one for the osteoplastic approach as it permits the removal of the pathology and entails no interference with the normal membrane which lies within the sinus nor with the nasofrontal duct. This technique is comparable to opening the lid of a box, removing an object from within it and closing the box. There is no destruction of anatomical boundaries nor interference with the physiology of the sinus membrane.

This approach lends itself equally well to the eradication of severe chronic disease in which there is no hope for restoring the mucous membrane to a normal condition and where there is no possibility of preserving or reconstructing a nasofrontal duct. In former times, the authors used the destructive technique of Riedel¹⁹ which removed the anterior wall and the floor and the entire mucosal lining and collapsed the soft tissues of the anterior wall of the forehead against the posterior wall. Although this was a disfiguring operation,

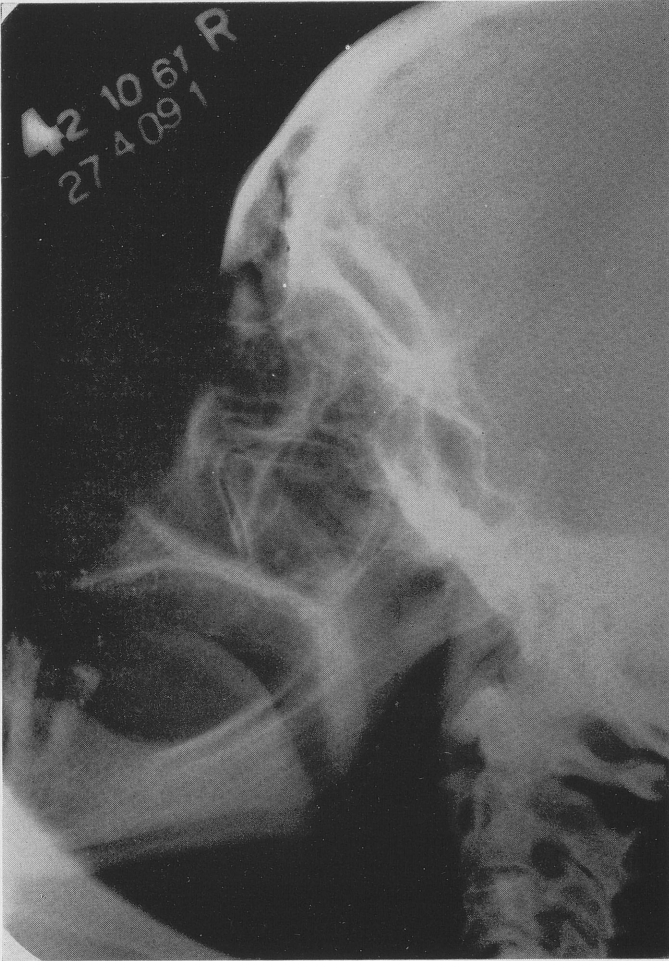

Fig. 1.—Case 1. Mrs. H.C. Postoperative x-rays 1961. This patient had an autogenous fat implant in the right frontal sinus after removal of all mucous membrane by curette and electric burr. Note that although the anterior wall bone flap has healed solidly, the fat implant has not calcified.

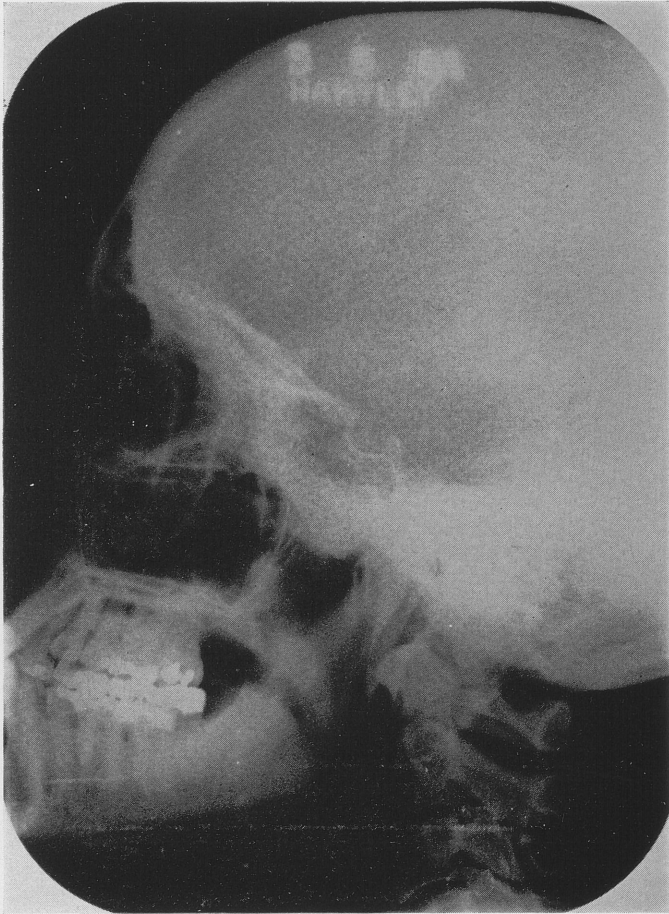


Fig. 2.—Case 4. Four years postoperative, 1961.

it could be repaired very successfully by a secondary plastic insert of bone from the iliac crest. The anterior approach offers an even better way of obtaining obliteration without disfigurement. The anterior wall, after the removal of the pathology, is returned to its original position thus preserving the normal contours of the forehead. Likewise, as has just been mentioned, the orbit is not traumatized surgically. There is no disturbances of the pulley and therefore no

secondary diplopia, which sometimes occurred in both the Lynch²⁰ and Riedel¹⁹ type of operation. The main points to be considered in the oblitative operation by the anterior approach are that the mucous membrane must be completely removed and the nasofrontal duct occluded. In doing this, the authors use not only the curette to remove tissue, but also the electric burr whereby the microscopic remnants of membrane which would often elude the operator as they were so small, are actually ground away from the bone. In approaching the nasofrontal duct, the membrane is cut away and the lining of the duct is pushed downward into the nose. The bony walls of the duct are curetted, they may even be lightly burred to insure removal of membrane here also. The cavity is then filled with a small block of fat taken from the abdominal wall, preferably with some of the rectus aponeurosis attached to it after the techniques of Bergara⁶⁻⁸ and Tato.⁹ The fat is trimmed so that it will fit snugly into the frontal sinus cavity and the anterior wall is then returned to its original position and the wound closed.

TECHNIQUE

The instruments for this operation include those usually provided for any radical external frontal sinus operation. The electrically driven drills and burrs, such as are used in the present day mastoidectomy, and the Stryker saw are essential to this technique. In the first four cases, the senior author (RLG) used a small circular saw for cutting the osteoplastic flap. Subsequently, both authors have used the Stryker saw as there is less danger of the saw cutting soft tissue. If the frontal sinus is very shallow, or if there should be a dehiscence of the posterior wall, some damage might be done to the dura. This danger is obviated by the use of the Stryker saw.

X-rays taken in the lateral, Waters, fluid level, and the frontal views, give the most accurate estimate of the size and depth of sinus, the position of pathology within the sinus and also a means for accurately measuring the outline of the sinus. We cut out of the frontal view film a pattern to show exactly the size and shape of the frontal sinus. We trim this pattern a little closer so that we may be certain that it is slightly smaller than the actual sinus. It is sterilized in aqueous zephiran so it can be handled safely at the time of the operation by the surgeon. Prior to the incision, this cutout is placed on the forehead of the patient to coincide exactly with the position of

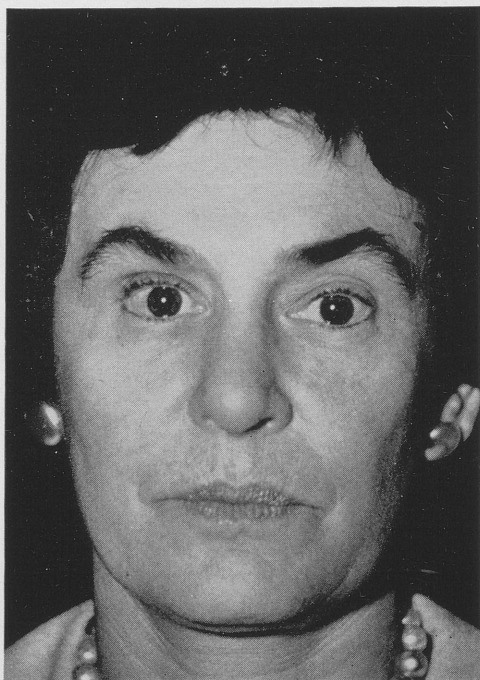


Fig. 3.—Case 4.

the frontal sinus, and a few light scratches are made with the scalpel in the skin around the periphery of the cutout to help as a guide later in determining the position for the cut in the bone. The patient is in a supine position with the forehead in a horizontal plane in order to obtain the best view of the sinus when the flap is turned down. The area is sterilized with aqueous zephiran and the patient is draped in the usual manner as for any frontal sinus surgery. The eyelids on both sides are sutured in order to protect the eye from accidental contact with instruments. In our experience, it is best to have the anesthetist on the patient's left. The surgeon and his assistants then are free to move on the right side of the table and to the head of the table. Later, the view of the cavity from the head of the table is extremely important as it allows one to look directly downward into the nasofrontal duct and examine the floor of the frontal sinus most advantageously. The eyebrows are not shaved. The area of the inci-

sion is then infiltrated with 2% procaine and 1:50,000 epinephrine to reduce the tendency to bleed. As we all know, there are many blood vessels in this area and one should have a generous supply of hemostats to control bleeding. All bleeding must be controlled before the sinus is opened.

It is a general principle, we believe, that the incision should be sufficiently long to allow unhampered operating in the field. Too small an incision means excessive retraction of soft tissues with subsequent injury and an inadequate exposure of the frontal sinus so that later removal of pathology is difficult. We like to carry the incision from the midline along the upper margin of the eyebrow outward in a straight line to slightly beyond the outer limit of the frontal sinus. This incision is carried downward to the periosteum, but great care is taken not to cut through the periosteum, as it is important to preserve the blood supply of the bone flap. The soft tissues are then elevated from the periosteum upward so that an area is exposed somewhat beyond the limits of the frontal sinus. The pattern cut out from the x-ray is then re-applied and the incision is outlined along the upper margin of the cutout. A semicircular incision is then made down to the bone starting from the medial limit of the frontal sinus. This incision marks the position of the bone cut. With either the circular saw or the Stryker saw, the bone is then cut through this incision on the bevel downward in such a way that the bony edges, when the flap is replaced, will slightly overlap. As one approaches the medial and lateral ends of this bone cut, one encounters the harder bone of the supraorbital ridge. This may be cut with the saw or by the chisel. The chisel is then inserted above through the bone flap into the frontal sinus and with a gentle lift it is determined whether the flap is freely movable. Usually it is very movable. It has been suggested that in turning the flap down, dangerous lines of fracture might be produced in the roof of the orbit, but in our experience this bone is so thin that it cracks in a green stick manner without any displacement whatsoever.

This technique gives the operator complete freedom of choice, at this point, as to what further procedure he wishes to perform, either total obliteration with fat implant or the removal of local lesions within the sinus. It gives him a direct visual approach to the nasofrontal duct. We have used this approach for the removal of osteomata, fronto-ethmoidal cells, pyoceles and mucocoeles where the sinus

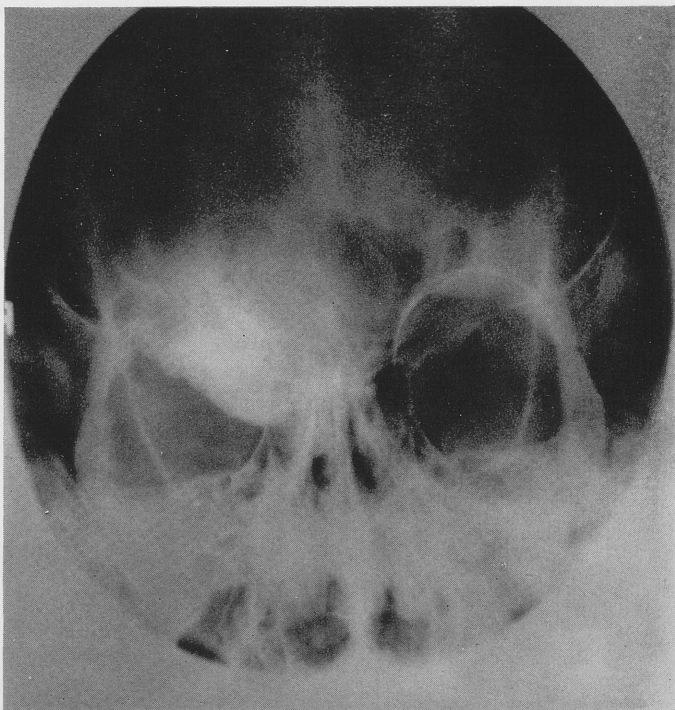


Fig. 4.—Case 6. Pre-operative.

is only affected in part. Where the nasofrontal duct with its membrane and the remaining mucous lining of the sinus appeared to be normal, these areas can be left untouched. In a few cases, we have operated where a previous Lynch procedure had failed because of fibrous occlusion of the nasofrontal duct and in a few of these, we have had to enter the sinus on the opposite side by taking down the interfrontal septum in order to provide drainage by way of the opposite duct. This has violated the principle, which we were taught, that we should never open a normal sinus for fear of infecting it. It is interesting that in our experiences this infection of the opposite side has not occurred.

Now, if one has to proceed to the removal of the entire mucous membrane and the complete destruction of the frontal sinus cavity,

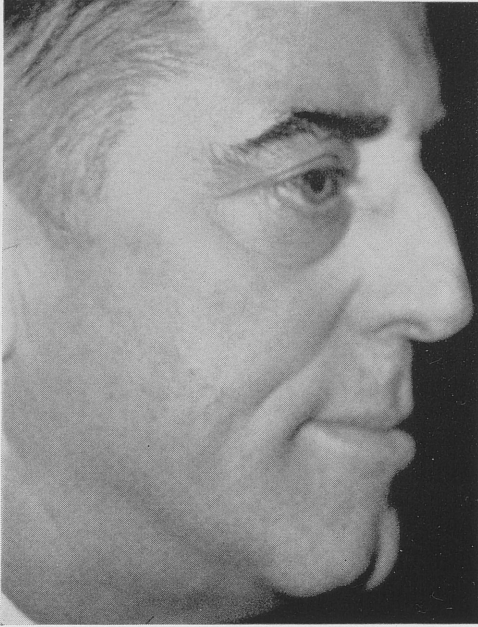

Fig. 5.—Case 6. A.D. Osteoma right frontal sinus. Postoperative photograph, 1961. Note absence of pre-operative displacement of right eye by osteoma.

it is quite simple to dissect away all the membrane that can be removed by curette and periosteal elevator and then grind away the microscopic mucous membrane remnants with the electric burr. As the sinus is wide open, it is very easy to carry the burr around, under any overhang, into any crevice and to take down any partial partition and even to enter the nasofrontal duct to remove the membrane. At this point, the assistant drops out and changes gown and gloves. With an entirely fresh set of instruments he makes a small incision in the abdominal wall, usually in the right or left rectus area and obtains a block of fat as close to the muscle as possible, preferably with a little of the rectus muscle aponeurosis. The block should be just large enough to fill the sinus. The bone flap is turned back into place. After the fat has been inserted in the cavity, it is generally advisable to suture the periosteal incision with two or three absorbable sutures. The soft tissues overlying the periosteum are then returned to place

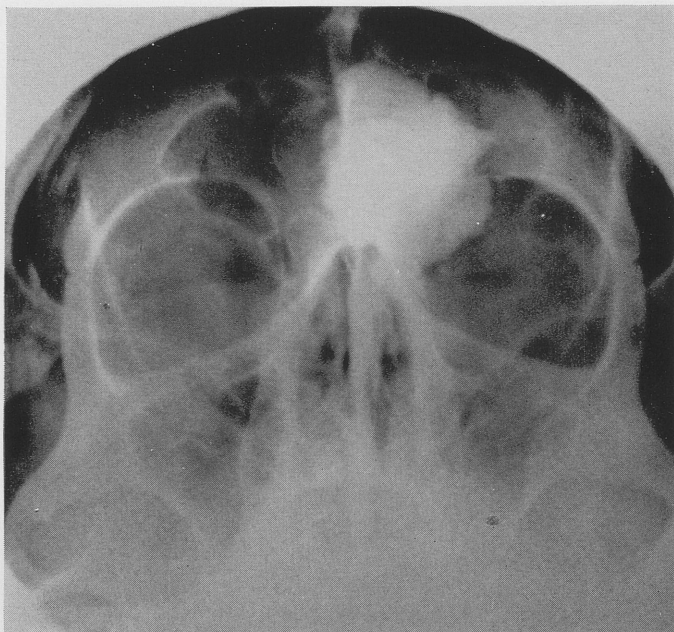


Fig. 6.—Case 7. Pre-operative.

and the wound is closed. A light pressure dressing is applied. The lid sutures are then removed. In all cases, we have found that the wound heals without complication. In four or five days, the sutures may be removed and very light dressing applied.

Since our first operation in 1956, the scope of this approach has been extended to cases of bilateral disease and to cases which had had intracranial complications.

The first operation that was undertaken was on the 19th of June, 1956. Thirty-one cases have been done by the authors and by other members of the Massachusetts Eye and Ear Infirmary Staff. We wish to thank them for an opportunity to include their cases in the overall statistics of this series.

When Beck⁴ described his operation in 1908, objections were raised that there would be considerable danger of causing bone infec-

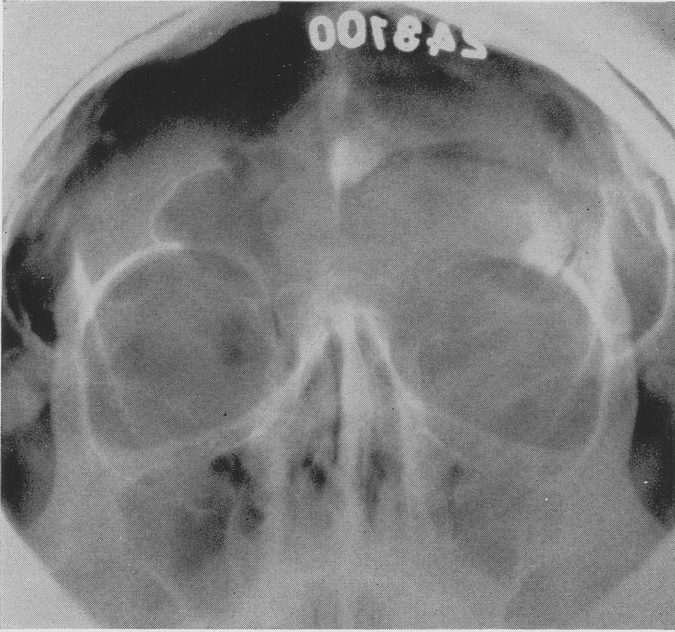


Fig. 7.—Case 7. Postoperative, 2 years.

tion, even osteomyelitis, by cutting through the anterior wall of the frontal sinus and that it would be very difficult if not impossible to obtain a good approximation of the bone flap subsequently. This objection has been entirely removed, we believe, by the use of the electric saw and by cutting the bone on a bevel so that the edges overlap slightly when the flap is returned to its original position. The infections so feared prior to antibiotic treatment, have not appeared and so far we feel there is no danger from secondary infection. In two cases, postoperative hematoma occurred both in the frontal area and in the abdominal wound and required aspiration. However, no infection occurred and there was no loss of fat from the frontal area and the wounds eventually healed up without any sign of complication. In two cases, there was a leakage of the lipoid element of the fat implant through breakdown of a suture, thus causing a temporary fistula. Here again, although the recovery was somewhat delayed, there was no loss of fat stroma and no collapse of the sinus. So far

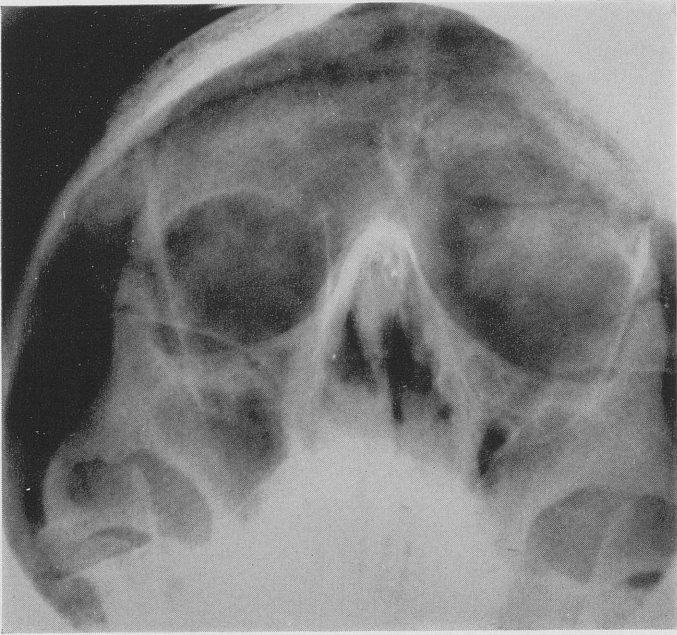

Fig. 8.—Case 8.

as can be determined, the fat is still in place although it is minus some of its lipid content. The fear of infecting a healthy side by removing the interfrontal septum has not been substantiated. In two cases where autogenous fat was used and where x-ray follow-up has been done for $4\frac{1}{2}$ to 5 years, no evidence of calcification has been noted. Bergara used "boilet fat," probably not autogenous, and reported calcification. One case is calcifying without tissue implant. Two cases have been reported at the Massachusetts Eye and Ear Infirmary with similar spontaneous calcification, one without operation and another after a Lynch operation.

This report is a follow-up study of six cases by R. L. Goodale and four cases by W. W. Montgomery. They have been selected from the series to illustrate the various types of pathology to which this technique is applicable.

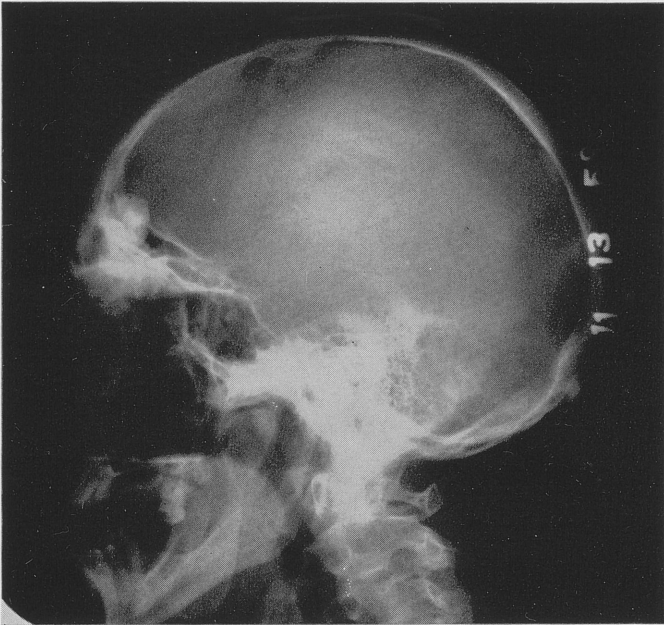


Fig. 9.—Case 9. Pre-operative x-ray.

REPORT OF CASES

CASE 1. Mrs. H.C., aged 36. Patient had had a long history of frontal headache due to right frontal sinusitis. The x-ray showed chronic right frontal sinusitis. The rest of the sinuses were clear. A right Lynch frontal sinusotomy was performed in 1953. In 1955, she required an incision and drainage for empyema of the right frontal sinus. On the 19th day of June 1956, an anterior osteoplastic frontal sinusotomy with an implant of abdominal fat was done. Following the Lynch operation, she developed diplopia. However, following the osteoplastic operation, the diplopia was entirely relieved. She has had no further infection of the frontal sinus. Repeated x-rays to see if the fat, which was implanted, had calcified in the way that has been reported by Bergara, so far indicated that it has not occurred. However, the cavity has remained filled with fat. It is to be noted that the fat in this case and in subsequent cases to be reported is an autogenous tissue and not derived from a tissue bank. This is an obliteration

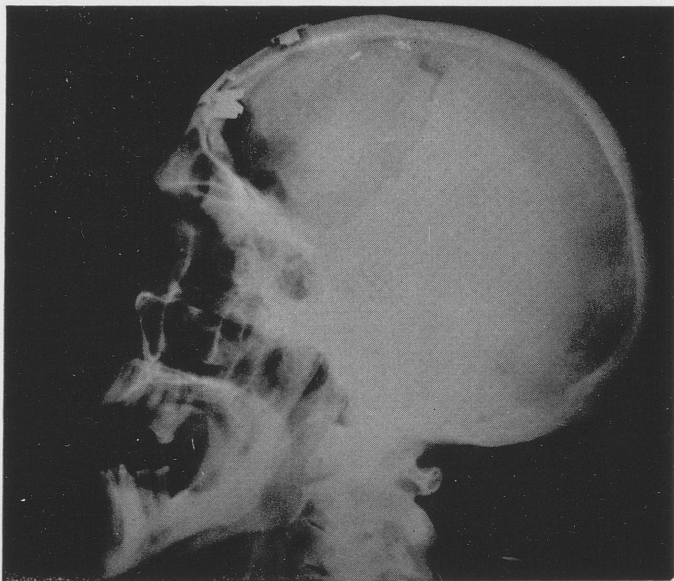


Fig. 10.—Case 9. Lateral x-ray after cranioplasty and removal of osteoma by osteoplastic approach.

tive procedure. The latest x-ray, on February 11, 1961, shows that the bone incision is well healed and in good position.

CASE 2. Mrs. M.M., aged 57. Patient came into the Massachusetts Eye and Ear Infirmary prior to 1950 with a long history of frontal and maxillary sinus infection. A submucous resection and bilateral Caldwell Luc operation were done in 1949. A right Lynch frontal sinusotomy was done in 1950 and again in 1951. As she continued to have reinfection of the right frontal sinus, an obliterative procedure was undertaken in 1953 with implant of bone taken from the iliac crest. Since then, there has been no further trouble with the right frontal sinus, although a few mucocoeles have begun to appear according to the x-ray. The history of the left frontal sinus began in 1952 when it became acutely infected requiring a trephine. Again in 1956, the left frontal sinus became reinfected and another trephine was undertaken. This was followed by osteoplastic operation with fat implant on the 8th of November 1956. She has been




Fig. 11.—Case 9. Postoperative photo.

followed ever since by x-ray and there has been no further infection of any of her sinuses. The postoperative x-ray in 1960 shows that there is good approximation of the bone flap and that the cavity is obliterated with fat. Again there is no evidence of the fat being transformed into bone.

CASE 3. Mr. C.L., aged 58. Prior to 1957, patient had had a right intranasal anterior ethmoidectomy and enlargement of the nasofrontal duct. Since then, there has been repeated acute exacerbations of his frontal sinus infection eventuating in a pyocele occupying the lateral half of the frontal sinus. The floor of the frontal sinus was displaced downward so that there was considerable diplopia. On the 11th of January 1957, an anterior osteoplastic operation was done. The pyocele was found to be separated from the medial half of the sinus by a rather heavy cyst wall. This was removed and pathological




Figure 12.

tissue in the outer half of the sinus was likewise excised. As the medial half of the sinus and the nasofrontal duct seemed to be in good condition, patent and covered with normal membrane, no further removal of tissue was done. The downward bulging floor of the frontal sinus was pushed back into place by pressure from without in the method recommended by Goodyear.²¹ Since then, he has had no further infection of his frontal sinus, no headache, no disturbance of vision and an anosmia which he had had previously also disappeared.

CASE 4. Mrs. P.H., aged 39. She had had repeated attacks of right frontal sinusitis, a right Lynch frontal sinusotomy was done in 1945. Following this, there were still many attacks of frontal sinusitis. She came to me (RLG) for re-operation on the 18th day of October 1957. At that time, there was a pyocele in the right frontal sinus. The floor of the sinus was bulging downward displacing the upper lid and the interfrontal septum was beginning to bulge into the left sinus. The flap was turned down revealing a large pyocele and a dehiscence in the interfrontal septum. The nasofrontal duct

was completely occluded by scar tissue. Pathological membrane was removed where found and as the perforation already existed into the left frontal sinus, this was further enlarged by ronguers and burr, thus converting both sinuses into one cavity which drains now through the left side. The left frontal sinus has never become infected and the left nasofrontal duct seems to operate well, doing duty for both sides. Postoperative x-rays in 1961 show calcification on the right side which has begun to obliterate the cavity. This is spontaneous calcification without tissue implant.

CASE 5. Dr. R.E.P., aged 28 years. Acute left frontal sinusitis in February 1960, required a trephine. In the course of the follow-up x-ray, it appeared that he had a large osteoma occupying the anterior portion of the ethmoid, the adjacent frontal sinus and possibly encroaching upon the cribriform plate. What did not appear at the time but was subsequently discovered in reviewing the x-ray, was a very large fronto-ethmoid cell occupying the entire nasofrontal portion of the frontal sinus. An osteoplastic operation was done on the second of March 1960. It was at this time that the fronto-ethmoid cell was discovered. It was removed. The osteoma, being in a dangerous area and not actually obstructing the frontal sinus drainage, was not removed. He has been symptom-free ever since.

CASE 6. Dr. A.D., aged 50 years. An osteoma slowly had been developing in the right supra-orbital area for many years. Eventually this had encroached on the supra-orbital ridge of his frontal bone and the roof of the orbit, displacing the eye downward and outward and consequently causing marked diplopia. Other than this, there were no symptoms. The x-ray shows a very large osteoma occupying the entire right frontal sinus and encroaching upon the orbit and the supra-orbital ridge. Anterior osteoplastic frontal sinusotomy was done. The osteoma was very large. In removing it, it was necessary to cut it in two by means of the Stryker saw. Following this, the osteoma came away very easily. It was found that the floor of the sinus and the supra-orbital ridge were defective. In spite of this, there is only slightly depression in this area and in the photograph there is no notable difference in the two sides. The diplopia has entirely subsided and the eye is back in its proper position.

CASE 7. W.D., a 37-year-old white male, was admitted in 1957 with a three-months history of diplopia and intermittent frontal

headache. X-rays of his sinuses showed a very large osteoma in the left frontal sinus which markedly displaced the interfrontal septum to the right and was encroaching on the cribriform plate. The osteoma was removed by the anterior osteoplastic frontal sinusotomy technique. The sinus was not obliterated with fat because the nasofrontal duct was patent.

The x-ray demonstrates the outline of the osteoplastic flap and also the site of origin of the osteoma.

The patient has remained symptom-free for four years.

CASE 8. I.J., a 42-year-old woman, had onset of diplopia in 1947 due to a supra-orbital mass depressing the left eye. At this time a submucous resection of the nasal septum and a left external ethmoid were carried out. Two months later a left frontal operation was performed by the Lynch method. A revision was necessary one year later because of recurrent diplopia. In 1957, further revision of this left radical frontal was done to remove a pyocoele in this sinus. Tantalum foil was sutured to the orbital capsule to keep the nasofrontal duct open. In 1958, the patient was admitted because of a recurrent pyocoele. An anterior osteoplastic frontal sinusotomy was performed. The bony posterior wall of her frontal sinus was found to be nearly totally absent. The pyocoele was removed intact. The mucous lining of the osseous walls of the sinus was taken away with a burr. The bone flap was replaced. There was no communication between the frontal sinus and the nose. No fat was inserted because the dura projected anteriorly and completely obliterated the sinus by contact with the anterior wall. The patient has remained symptom-free since this time.

CASE 9. F.P. This 54-year-old male was admitted in November 1959 to the Neurosurgical Department of the Massachusetts General Hospital with a one-week history of seizure, personality change and disorientation. X-rays showed a large osteoma in the frontal sinus which had grown through the posterior wall of the frontal sinus and into the frontal lobe, where a large encapsulated abscess had formed. He was operated upon in two stages.

On November 18, 1959, a large frontal lobe abscess was excised and a portion of the osteoma protruding into the frontal lobe was

excised by cranioplasty. The dura was covered with a polyethylene sheet.

On December 30, 1959, the large osteoma was removed by way of a bilateral anterior osteoplastic frontal sinus procedure. The osteoma displaced 33 cc of water. The sinus was obliterated with abdominal fat. The last x-ray shows the patient's status one year following this procedure. A recent photograph of the patient shows little deformity following this extensive surgery.

CASE 10. P.D., a 48-year-old white male, underwent a left Lynch frontal sinus operation in 1939 for left pansinusitis. Two months following this procedure bilateral Caldwell Luc and ethmoidectomies were carried out. The patient did fairly well until 1959. A pyrocele of the left frontal sinus was diagnosed at that time. A revision was carried out and drainage was established with a portex nasofrontal tube. In less than one year following this the patient had developed a mucocele in both frontal sinuses. A bilateral anterior osteoplastic frontal sinusectomy was performed using abdominal fat to obliterate. The patient has remained well since this time. Recent photographs are shown to demonstrate the deformity on the left side resulting from the Lynch radical frontal sinus procedure and relatively little deformity on the right following the fat obliteration operation.

SUMMARY

Since 1956, upwards of thirty-one frontal sinus diseases of various types have been operated upon at the Massachusetts Eye and Ear Infirmary using the anterior osteoplastic approach. The authors have presented nine cases describing these conditions. Our conclusions are as follows:

1. This technique is applicable to the removal of localized pathology as well as to the obliteration of the frontal sinus.
2. In all cases, the problem of disfigurement has been eliminated.
3. There are distinct advantages in preserving the anatomical structures of the orbit.
4. In cases where obliteration is not indicated, the nasofrontal duct and the normal mucous membrane of the sinus can be preserved.

5. The use of the fat implant has been satisfactory. No secondary infections have occurred, and there has been no necessity for re-operation in these cases. X-ray evidence indicates that where fat has been used, this has remained unchanged and osteogenesis or sclerosis has not obliterated the cavity.

6. There is some evidence that where the entire mucous membrane has been removed without fat implant, osteogenesis does occur and tends to obliterate the cavity.

7. Removing the interfrontal septum in cases of unilateral disease has not affected adversely the normal side.

8. This technique has been used successfully in cases of bilateral disease and in one case of intracranial complication.

R. L. Goodale is Senior Consulting Surgeon, Massachusetts Eye and Ear Infirmary; W. W. Montgomery is Associate Surgeon, Massachusetts Eye and Ear Infirmary, and Assistant to Chief of Otolaryngology.

REFERENCES

1. Schonborn, cited by Willkop, A.: Ein Beitrag zur Casuistik der Erkrankungen des Sinus Frontalis. Wurzburg, F. Frome, 1894.
2. Brieger: Arch. Ohren-Nasen- u. Kehlkopfh. 39:213, 1895.
3. Winkler: Beitrag zur osteoplastischen Freilegung des Sinus frontalis. Verhandl. deutsch. otol. Gesellsch., p. 128, 1904.
4. Beck, J. C.: A New Method of External Frontal Sinus Operation without Deformity. J.A.M.A. 51:451-455 (Aug. 8) 1908.
5. Hoffman: Osteoplastic Operations on the Frontal Sinus for Chronic Suppuration. ANNALS OF OTOTOLOGY, RHINOLOGY AND LARYNGOLOGY, p. 598, 1904.
6. Bergara, A. R., and Itoiz, O. A.: Experimental Study of the Behavior of Adipose Tissue Within the Frontal Sinus of Dog. Argent. rev. oto-rhino-laryng., pp. 184-192 (July-Sept.) 1951.
7. Bergara, A. R., and Itoiz, O. A.: Present Status of the Surgical Treatment of Chronic Frontal Sinusitis. A.M.A. Arch. Otolaryng. 61:616-628 (June) 1955.
8. Bergara, A. R., and Bergara, C.: Chronic Fronto-ethmoidal Sinusitis: Osteoplastic Method According to Authors' Technique. Ann. oto-rhino-laryng. Uruguay 5:192-200, 1955.
11. Macbeth, R. G.: The Osteoplastic Operation for Chronic Infection of the Frontal Sinus. J. Laryng. and Otol. 68:465-477 (July) 1954.

12. Goodale, R. L.: Trends in Radical Frontal Sinus Surgery. *Annals of Oto-Rhino-Laryng.* 66:369 (June) 1957.
13. Goodale, R. L., and Montgomery, W. W.: Experiences with the Osteoplastic Anterior Wall Approach to the Frontal Sinus. *A.M.A. Arch. of Otolaryngology* 68:271-283 (Sept.) 1958.
14. Montgomery, W. W.: Osteoma of the Frontal Sinus. *ANNALS OF OTOTOLOGY, RHINOLOGY AND LARYNGOLOGY* 69:245-255 (Mar.) 1960.
15. Goodale, R. L.: Some Causes for Failure in Frontal Sinus Surgery. *ANNALS OF OTOTOLOGY, RHINOLOGY AND LARYNGOLOGY* 51:648-652 (Sept.) 1942.
16. Weille, F. L.: The Problem of Secondary Frontal Sinus Surgery. *Tr. A. L. A.* 67:150, 1946.
17. Walsh, T. E.: Experimental Surgery of the Frontal Sinus: The Role of the Ostium and Nasofrontal Duct in Postoperative Healing. *Laryngoscope* 53:75-92 (Feb.) 1943.
18. Hilding, A.: Four Physiological Defenses of the Upper Part of the Respiratory Tract: Ciliary Action, Exchange of Mucin, Regeneration and Adaptability. *Ann. Int. Med.* 6:227, 1932.
19. Riedal: Schenke Inaug. Dissertation, Jena, 1898.
20. Lynch, R. C.: The Technique of a Radical Frontal Sinus Operation Which Has Given Me the Best Results. *Laryngoscope* 31:1:1-5, 1921.
21. Goodyear, H. M.: Mucocoele in Frontal and Ethmoidal Sinuses: Simplified Surgical Treatment. *ANNALS OF OTOTOLOGY, RHINOLOGY AND LARYNGOLOGY* 53:242-245 (June) 1944.
9. Tato, J. M., Sibbald, D. W., and Bergaglio, O. E.: Surgical Treatment of the Frontal Sinus by the External Route. *Laryngoscope* 64:504-514 (June) 1954.
10. Gibson, T., and Winkler, F. M.: Large Osteoma of the Frontal Sinus: A Method of Removal to Minimize Scarring and Prevent Deformity. *Brit. J. Plast. Surg.* 4:210-217 (Oct.) 1951.

DISCUSSION

DR. HARRY P. SCHENCK (Philadelphia): The anterior osteoplastic approach to the frontal sinus described by Dr. Goodale and Dr. Montgomery represents a significant advance in frontal sinus surgery because of its safety, cosmetic acceptability and the preservations of the anatomic structures of the orbit. I think you realize that their technique is precise and that it is based on sound anatomic and surgical principles. I agree completely with their contention that the frontal sinus should be considered as a separate entity when surgical intervention is necessary. I believe that most attacks upon the ethmoidal and the sphenoidal sinuses should be by the orthodox intranasal route. Separate consideration should be given the frontal sinus.

I think all of us can remember the depressing train of surgical failures, even after the introduction of antibiotic therapy, that resulted because of obliteration of the nasofrontal communication which either followed the transorbital approach or the attack upon the ethmoidal sinuses by way of a transfrontal approach. I have always believed that a functioning nasofrontal communication must be maintained

in the absence of obliteration of the frontal sinus and this should be brought about in every instance if possible.

Dr. Goodale has made advances which will prevent poor cosmetic results. There is no doubt that this type of surgery will prevent marked deformity.

It is always well to have some difference of opinion, and I have always entered the frontal sinus by way of a small opening below the medial end of the eyebrow and made as small an opening as possible. This is below the supraorbital ridge and minimizes possible postoperative deformity. In many instances everything that needs to be accomplished in the frontal sinus can be accomplished through that opening. It makes access to the nasofrontal duct opening simple.

Very briefly, a nasofrontal duct can be made to be a permanent channel by introducing, after the surgical procedure on the frontal sinus, a 10 mm tube, rubber or plastic, which extends from the frontal sinus to the nasal vestibule. It so happens that one has to rasp the nasofrontal duct in cases where it is abnormal. If it isn't abnormal, then one doesn't touch it. The nasofrontal duct may be filled with granulation tissue, polypoid tissue, or it may be encroached upon by cell walls. In any event, these can all be eliminated by rasping and a tube of this sort inserted. After six weeks the tube may be withdrawn and the channel is then epithelialized. Furthermore, through metaplasia the cells remaining in that channel are ciliated epithelial cells.

The cosmetic result of this procedure is good.

Here is a patient who was operated on for osteomyelitis of the skull and an osteoma, and the incision is on her left. There is a very inconspicuous scar.

Through this opening one can also remove an osteoma. I admit it is more difficult than by Dr. Goodale's technique, because he gets a much wider exposure. Here is a patient that had a large epidural abscess, successfully drained through such an opening, and here the opening is shown with a rasp introduced to enlarge the nasofrontal duct. This shows such a tube in place before it is cut off, with one end in the frontal sinus and the other cut off in the nasal vestibule.

I also am not convinced about the need for fat implants, but I am perfectly willing to be convinced. My concept has always been to leave an air-containing space where the frontal sinus is. I am not concerned about osteogenesis and fibrosis. This is nature's barrier against further insults; I think this is a barrier against further assaults in that area which nature is providing and there may never be further assaults.

I would hesitate to use a fat implant unless Dr. Goodale can convince me of a good reason for this.

I would like to go along with the conclusion that one can break down the interfrontal septum without fear of infecting the sinus on the normal side as long as one sinus has a normal nasofrontal communication. I think that can be done with impunity.

I also agree that osteomyelitis no longer follows surgical procedures on the frontal bone in the presence of infection, because we have the benefit of antibiotic therapy. I know of no instance where osteomyelitis of the frontal bone has occurred following frontal sinus surgery during the last decade.

I want to congratulate Dr. Goodale on the development of a technique that I am sure I will employ, because it gives better exposure. I am not sure I will employ it in every instance, but I think it is a real advance and I think that most of us will benefit by his experience and that of Dr. Montgomery.

DR. FRED W. DIXON (Cleveland): I think Dr. Goodale is to be commended on presenting a paper on an almost forgotten field, the paranasal sinuses, and yet this is a problem that confronts all of us. My great respect for the nasofrontal duct has led me to approach most of these problems by the intranasal route. In my hands this has been very satisfactory, so much so that I limit my approach in surgery on the frontal sinus to osteomyelitis, osteoma, mucocoele or malignancy.

Proper ventilation by removing any obstruction intranasally, plus antibiotic therapy and suction has resolved most of these problems. It is true that some of them recur sometimes once a year or once every several years, but they have usually responded to this type of treatment. I have never had, in the intranasal approach, any closure of the nasofrontal duct or any complication over many years.

There is one question I would like to ask Dr. Goodale and that is, in chronic cases, what is the criterion that he uses when he abandons the intranasal route and uses the external approach.

DR. W. LIKELY SIMPSON (Memphis): It should be understood that correction of deviated septums and intranasal surgery, such as radical antrum, ethmoid or sphenoid the exenteration should be done as a curative measure before the usual external frontal sinus operation. It seems to me the external frontal or the external-ethmo-spheno frontal operation is a procedure which can be done very satisfactorily under local anesthesia. The procedure is usually preceded by H.M.C. No. 1 and No. 2; No. 1 - one hour before the operation, and No. 2 - one half hour before the beginning of the operation. It is not unusual for the patient to awake from the operation and not know the operation has been done.

Just a word about the naso-frontal duct. If the frontal sinus is badly diseased, and the entire frontal sinus is to be exenterated, I invariably make an external incision to the ethmoid and floor of the frontal and remove the entire contents of the ethmoid region, including the naso-frontal duct, as well as the entire content of the frontal sinus. If the mucous membrane of the entire area is very carefully removed, very few complications will occur with later infections in the nose. The entire area must be thoroughly removed with curettes, cutting burrs and polishing burrs. Occasionally in the extremely large frontals, it seems to me it is a good procedure to make a horizontal incision through the skin through the upper extremity of the frontal sinuses, making an opening through the bony wall, so that the entire frontal sinus can be viewed directly. In small or medium sized frontal sinuses, such an incision is not indicated.

I agree with everything Dr. Goodale said except I never have found it necessary to put anything like fat or tissue of any kind in the frontal sinuses, and I have not seen a complication from a well-done external frontal in this antibiotic age. I know before we had antibiotics sometimes we did have complications.

In discussing sinus operations with the residents, I advise them to take two to four hours for the usual external-ethmo-spheno-frontal sinus operation, so that the entire contents of these cavities can be thoroughly exenterated.

DR. LYMAN G. RICHARDS (Wellesley Hills, Mass.): My impression of this is that this is a nice, clean neat procedure. What bothers me about it is the assumption that the pathology is all neatly confined within the frontal sinus.

Certainly most of the chronic sinusitis I have seen has been in conjunction with chronic ethmoiditis and I wonder how Dr. Goodale can so comfortably neglect the idea that there is additional pathology. What about the pathology I have always found in the ethmoid? Does that still remain in the ethmoid to be taken care of afterwards separately as another nasal operation, as Dr. Dixon said?

I would like Dr. Goodale to clarify his feeling that he need only to deal with the frontal sinus and can forget a major, to me, source of infection in the ethmoids which I have always found concomitant with the infection in the frontal sinus.

DR. SAMUEL SALINGER (Palm Springs): I would like to say a few words about fat implants. Dr. Goodale expressed some skepticism with regard to the possibility of the fat implant becoming infiltrated with osteoid tissue. I call your attention to the fact that Bergara showed one particular case in which this was proven. Four years after the operation it became necessary to operate on the opposite frontal sinus. It was found that the intersinus septum was eroded, so he enlarged the opening and took a biopsy from the previously implanted fat. The slides showed definitely that a considerable degree of osteogenesis had occurred. So, I have the feeling that if one will wait long enough the same thing will be observed in Dr. Goodale's cases.

DR. ROBERT L. GOODALE (Boston) (closing): This is just what I had hoped for; that we would start a discussion.

First of all, in regard to the fat implant, we have followed the suggestions of our South American colleagues. I talked to Bergara in 1954 when he came up to Boston and gave a little talk to some of us. I must admit that at that time I had the same skepticism that probably most of you have felt today. I spoke to Tato in Puerto Rico two years later and asked him about it. He said that it works very well. He said, "You can take other tissue, too. You can take fascia lata. You can take gelfoam; you can take, for instance, sterile blood clot."

We used fat simply to follow one line of investigation and so far—let me put it this way—we have had no signs by x-ray of osteogenesis. The one case Dr. Montgomery had a look at postoperatively did show some fibrosis.

We may, as Dr. Salinger said, find in time that it will calcify. I thought it was an interesting observation, though, that in the cases we have followed by x-ray, that so far the fat seems to remain fat, and not become carcified. This might interest some of the otologists who are using fat in the middle ear. We don't know yet what the fate of this fat will be, but so far it has not caused us any anxiety.

I don't want to give the impression that we are following any orthodoxy about this, either. We are keeping our minds free and open and we are willing to change any time. There is no one frontal sinus operation that is applicable to every single case. Last week I reoperated a "Lynch" sinus done by another man, at his request. He said, "I wish you would do it and if you want to put in fat, please feel free to do so."

When I opened the sinus, I found a little shallow mucocoele in the floor. The rest of the frontal sinus had sclerosed. I decided not to put fat in. Why should I put it in when there was already a process of sclerosis going on and all that needed to be done was to remove the mucocoele?

So, I want to leave the impression with you that I am not going to do this in every single case. I want to "play it by ear," you might say. As I get into the frontal sinus I will change my pace according to what I find in there.

In answer to Dr. Grace in regard to tubes in the nasofrontal duct area; I think we have all tried them with more or less success. The Ingals tube, which was advocated recently by Dr. Goodyear also I believe, is one that has given good results. As you know, we have tried tantalum. There have been acrylic molds; there have been portex tubes. Lately we have not had good results with implants of foreign material. Where I have put tantalum in, in most cases it has done very well. In some cases somebody took it out and the duct closed immediately.

I feel that when you use a prosthesis to keep the duct open, you are not really performing an operation that is intrinsically sound. It has a weakness when you need to put something in to keep it going.

I agree with Dr. Simpson that certainly you want to take care of every other condition that can have a bearing on the frontal sinus disease. The ones we have reported and the ones we have used this technique on are those where this has been done. In many cases operations on the septum, antrum, ethmoid have been done, and we reserve this operation for selected cases.

As for local anesthesia, I have used a great deal of that. We now have an anesthesia service that loves to put tubes into the trachea and they do this very nicely. I think that with this operation, the patient would not enjoy a local anesthesia. The saw makes a noise. It isn't a pleasant sensation to the patient. I think he would rather be asleep.

As to the nasofrontal duct, we have had a theory, as you know, based on Mosher's dictum, that you should not violate its virginity, and we still feel that this is an important point. When this nasofrontal duct is traumatized, it can become stenosed. In this technique, we have scrupulously tried to keep away from the duct when we want to maintain normal drainage from the sinus.

On the question of obliterating the sinus, I think, where the nasofrontal duct has been blocked off by scar tissue and perhaps there have been two or three attempts to reopen this and put tubes in, and for one thing and another, they have failed, that there is no point in going any further with that kind of operation. We had better obliterate it and be done with it. Do it by whatever method you prefer.

In reply to Dr. Richards, that we ought to consider surgery of the ethmoid and the antrum as an essential part of the procedure, I suggest we remember Schaefer's description of the nasofrontal duct and the development of the frontal sinus from the frontal recess. As he states, there is a discontinuity between the frontal and ethmoid sinuses in their development. Although clinically in many cases you will find ethmoiditis, this can be taken care of as a separate procedure. That is what the South American doctors are doing and are advocating.

It happens that many of the cases we have had have been just solitary frontal sinus infections. If I had a case where the ethmoids and the frontal sinus were involved, I would operate them in two stages.

As in all surgical problems, we should fit the procedure to the individual case. I suggest that the anterior approach gives the surgeon the most favorable opportunity for dealing with pathology of the frontal sinus.

THE ELECTRONIC SYNCHRON-STROBOSCOPE

ITS VALUE FOR THE PRACTICING LARYNGOLOGIST

HANS VON LEDEN, M.D.

LOS ANGELES, CALIF.

The social and scientific interest in human communications and the development of mass media during the past decades have directed increasing attention to the human voice and to the organ of voice production, the larynx. It would be a pleasure to record that this interest on the part of the lay public had been accompanied by a comparable advance in the diagnosis and treatment of laryngeal problems. However, throughout this period our specialty has been so attracted to the phenomenal discoveries for the surgical restoration of hearing, that in our offices we have concentrated mainly on apparatus for the investigation of the middle and inner ear.

As a result, most of us are still baffled by the disproportion between vocal symptoms and laryngeal findings. We still use our eyes for routine visualization of the larynx, although we may realize the inadequacy of this procedure. How can the human eye, whose perception is limited to five distinct images per second, evaluate the intricate vibrations of the vocal cords, which occur at speeds of 100, 500, or 1,000 excursions per second? This physical limitation in turn has prompted all of us on occasion to advise a patient that there is nothing the matter with his larynx when it is obvious that there must be some reason for this hoarseness. Would we be wrong in comparing our approach to that of an otologist who employed only his visual acumen in the evaluation of deafness and ignored audiometric and other special tests?

The limitations of our vision are shown by a film of a patient with unilateral vocal cord paralysis. The left vocal cord remains in the inter-

From the Institute of Laryngology and Voice Disorders and Northwestern University Medical School.

mediate position indicating a paralysis of central origin; the involved cord appears virtually at a standstill (Fig. 1A). Now observe the same picture in ultra slow motion. Note the vigorous excursions of the paralyzed vocal cord during each vibratory cycle (Fig. 1B)—an amazing transformation! Since the production of voice and hoarseness are directly related to vibratory phenomena, the importance of accurate observations requires no further emphasis.

How can the clinician perform this service for his patient in his own office, without the costly and time consuming medium of ultra high speed photography? The answer lies in the electronic laryngosynchron-stroboscope, which meets the clinical requirements for the evaluation of vocal cord vibrations via indirect laryngoscopy under ordinary office conditions. For an explanation of this effect it becomes necessary to review briefly the principle of stroboscopy and the design of the electronic laryngo-synchron-stroboscope.

Stroboscopy produces an optical illusion in which an object moving rapidly and periodically appears to stand still, or move very slowly. This illusion is obtained by the intermittent but regular presentation of the object to the viewer. The phenomenon is based on Talbot's law, or the persistence of vision in the human eye, which causes each image to linger on the retina for 0.2 seconds after the exposure.

If we apply this principle to the vibrating vocal cords, the rapid movements appear to be arrested or greatly slowed. Synchronization of the illumination with the frequency of vibration results in an apparent standstill of the vocal cords in any desired position, thus permitting accurate inspection of the phonating structures (Fig. 2). To obtain a slow motion effect of the vibratory cycle, one needs only to vary the rate of illumination slightly in relation to the frequency of vibration, so that each successive light impulse strikes a different phase of the vibratory cycle (Fig. 3).

Theoretically, this intermittent effect may be produced a) at the source of illumination, b) between the illumination and the eye, c) at the eye, and d) between the eye and the vibrating vocal cords. Historically, all of these possibilities have been explored.

Towards the end of the 19th century, Oertel¹ described a stroboscope for laryngeal observations, which was based on the regular inter-

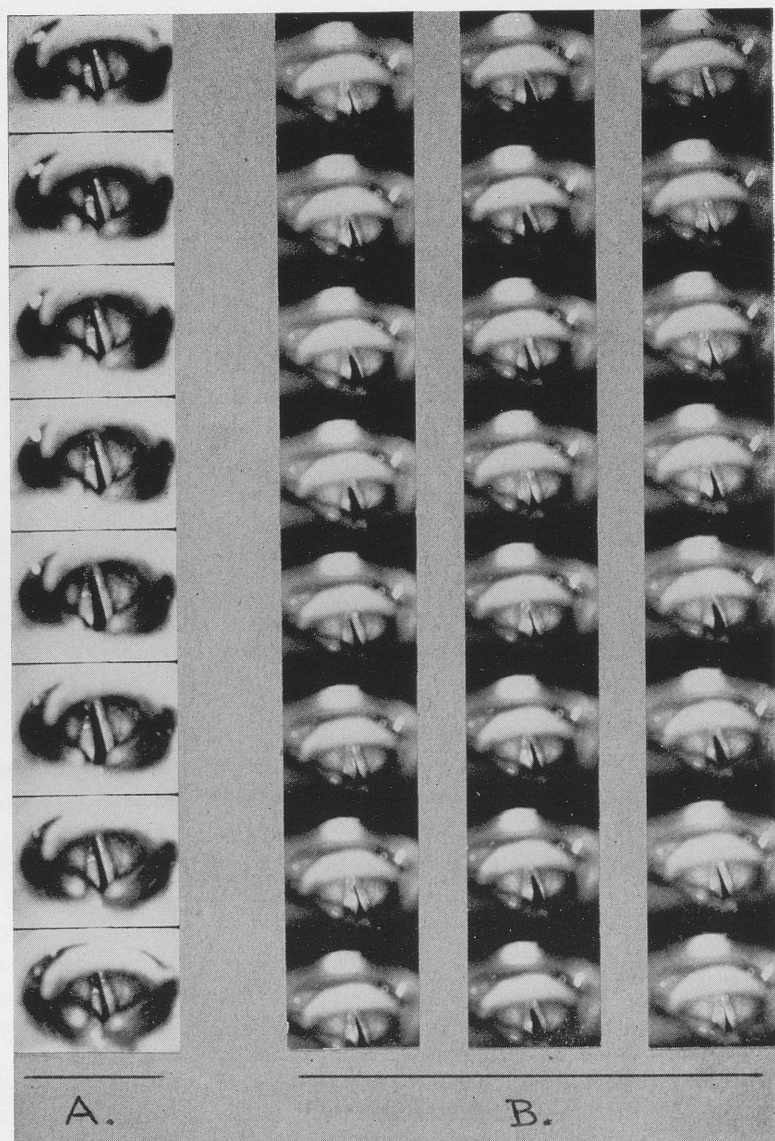

Fig. 1.—Sequence from motion picture of unilateral vocal cord paralysis during phonation. A) Normal speed: the right cord moves freely, while the left vocal cord remains in the intermediate position, apparently motionless. B) Ultra high speed: the vigorous excursions of the paralyzed vocal cord can be clearly observed during each vibratory cycle.

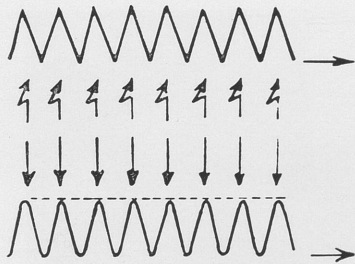


Fig. 2.—Schematic drawing of stroboscopic effect (after Schön-härl). The synchronization of the illumination (upper graph) with the frequency of vibration (lower graph) results in an apparent arrest of motion.

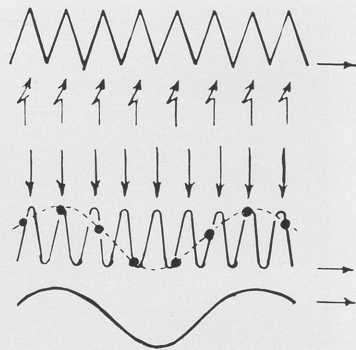


Fig. 3.—Schematic drawing of stroboscopic effect (after Schön-härl). A slight variation in the relative frequencies of the illumination (upper graph) and vibration (middle graph) produces slow motion effect (lower graph).

ruption of the light beam by a perforated disc (Fig. 4). This ingenious invention was developed further by numerous scientists including Hegener,² Panconcelli-Calcia³ and Loebell⁴ in Germany; Stern⁵ in Austria; Tarneaud⁶ in France; and Kallen,⁷ Powell,⁸ and Andrews⁹ in the United States. Unfortunately, the disc stroboscope produced as much criticism as praise, and as a result, this very promising method of examination was discarded before it became widely used.

Many of you remember the justifiable complaints against this method of examination. To mention but a few: objectionable background noise, frequency disturbances with slight variations of electric potential, the difficulty of maintaining the same pitch for prolonged periods, decrease in illumination with increasing frequency, the necessity of changing discs to vary frequencies, and other technical or extraneous difficulties.

Above all, the disc stroboscope called for a trained subject or at least a musical patient who could duplicate and maintain the specific pitch corresponding to the speed of the rotating disc. Small wonder, therefore, that the inexperienced observer did not know whether to ascribe visible irregularities to the apparatus or to his patient, and eliminated this temperamental equipment from further consideration.




Fig. 4.—Oertel's disc stroboscope.




Fig. 5.—Electronic laryngo-synchon-stroboscope (Model Timcke KS-3) showing microphone in position, electronic unit, Xenon lamp and foot pedal.

More recently, the field of laryngeal stroboscopy has progressed along an entirely different direction.¹⁰⁻¹³ The development of powerful gas discharge tubes provides an intensive intermittent beam of light, with sharp flashes at any desired frequency. Electronic connections permit automatic synchronization of the rate of illumination with the pitch or frequency of vocal cord vibrations. This new approach, then, eliminates the admitted faults of the disc stroboscope and provides a simple and effective method for stroboscopic examination of the larynx.

Prominent laryngologists and voice scientists in different countries grasped the potential of this new diagnostic tool, and during the past decade a series of different electronic stroboscopes have been designed specifically for laryngeal examinations.¹⁴⁻¹⁹ After an evaluation of instruments produced in the U.S.A., Germany, France, Scandinavia, The Netherlands, The Argentine and Mexico, I have come to the conclusion that two of these new electronic stroboscopes are super-

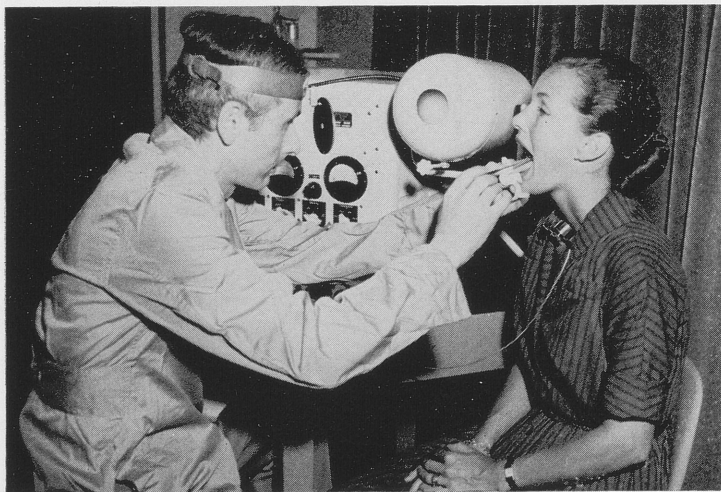


Fig. 6.—Typical stroboscopic examination via indirect laryngoscopy.

ior for an evaluation of laryngeal conditions: 1) the stroboscope designed by Dr. Jw. van den Berg²⁰ at the University of Groningen, which is manufactured by the Phillips Company in The Netherlands, and 2) the stroboscope designed and manufactured by Dr. Rolf Timcke²¹ at Hamburg, Germany. These instruments employ the same general principles; since Dr. Timcke perfected his equipment at our Laryngeal Research Laboratory, I am more familiar with its design, and my subsequent remarks will be limited to this unit.

Timcke's original laryngo-synchron-stroboscope (Fig. 5) consists of four separate parts: the microphone, the light source, the electronic control unit, and a foot pedal. The microphone, which is applied to the patient's neck just below the larynx, directs the sound waves to the electronic control unit where they are filtered and amplified. The fundamental frequency of the sound produced in the larynx is transmitted via electronic pulses to a Xenon lamp which emits an intermittent beam of white light at the same identical rate. Thus the frequency of the light flashes always corresponds to the frequency of vocal cord vibrations, regardless of pitch or pitch change. The light beam is directed by an ordinary head mirror to the laryngeal




Fig. 7.—Clinical electronic synchron-laryngo-stroboscope (Model Timcke KS-4) showing throat microphone, Xenon lamp mounted on control unit and foot pedal.

mirror and thence to the larynx, as in any indirect laryngoscopy (Fig. 6).

A semi-automatic auxiliary light system permits illumination of the larynx before voice production, while the examiner adjusts his head mirror and prepares for the examination. Meters on the instrument panel indicate the fundamental frequency from 65 to 1,000 vibrations per second and the intensity of phonation. The frequency of light flashes can also be controlled directly with a built-in audio frequency generator, if an aphonic or nearly aphonic patient is unable to maintain a satisfactory sound. The foot-pedal permits a change in the phase angle of the light flashes in relation to the sound

impulses to obtain either a stationary image of the vocal cords at any instant of their vibration, or the typical slow motion effect.

Additional attachments permit automatic recording of frequency and intensity variations, faradization therapy, and photography of the phonating larynx. It is apparent that this instrument was designed for experimental use as well as routine clinical observation. In order to produce a simpler and less costly instrument for the practicing laryngologist, Timcke also manufactures a smaller unit (Fig. 7). This apparatus functions on the same basis as the larger equipment and includes all the facilities required for clinical examinations, e.g. throat microphone, pitch indicator, phase variation, auxiliary illumination.

What information may the clinician expect from the employment of this equipment and how can he utilize this knowledge in the practice of laryngology? Other methods of examination, indirect laryngoscopy and direct laryngoscopy, seem to supply adequate information regarding organic lesions of the larynx and permit an accurate interpretation of organic laryngeal disease in most instances. However, any observation which depends upon the unaided human eye is limited to gross movements; in the case of the larynx the traditional forms of examination demonstrate only the gross activity of the arytenoid cartilages and intrinsic laryngeal muscles, and the conductivity of the major laryngeal nerves.

A stroboscopic inspection, on the other hand, affords a glimpse at the larynx in action and rewards the patient observer with valuable information regarding the minute details of laryngeal vibrations. These vibrations in turn depend on 1) the structure of the vocal cords, which is affected by inflammation, infiltration, neoplasms, etc., 2) the tension of the vocal cords, which may be influenced by unusual contractions or paralyses, 3) the condition of the mucous membrane which plays such a complex and vital role during the period of approximation, and 4) the degree of subglottic pressure.

A typical stroboscopic evaluation utilizes both the still and slow motion effects of this technique. The moving picture presents a general orientation regarding the functional adjustments of the vocal cords and the ability of the patient to maintain a constant tone. It also affords information regarding the relative excursions of the

two vocal cords and phase variations within the vibratory cycle, at different levels of pitch and intensity.

The still picture presents a sharp and clear image of the vocal cord margin during the different phases of the vibratory cycle, in contrast to the diffuse blur visible to the naked eye. Deliberate phase variations of the still picture through the full cycle of 360 degrees demonstrate fine details of laryngeal activity, including muscular and mucosal abnormalities, directional changes, or differences in amplitude and approximation. Such minor details of laryngeal behavior are of definite clinical significance, because they may be associated with qualitative changes in the human voice—hoarseness, harshness, breathiness, weakness, etc. Singers, for instance, often become aware of the slightest functional abnormalities, which are indistinguishable to the untrained ear.

The electronic laryngo-synchron-stroboscope thus offers a simple technique of differentiating physiologic and structural abnormalities of the larynx. In many instances the same examination affords valuable etiologic clues and facilitates the choice of the appropriate therapy. Follow-up examinations permit an accurate evaluation of the patient's progress under treatment. With the addition of the pulse current apparatus, the instrument can also be used for physical therapy, i.e. accurate harmonic stimulation of a diseased vocal cord.

Since the introduction of this modern electronic equipment, more and more laryngologists have adopted this technique for routine laryngeal examinations. It would be difficult to find a major laryngeal center on the continent of Europe without at least one electronic stroboscope. Our South American colleagues are following this example. By contrast, there are but five such instruments in regular use in the United States, and to the best of my knowledge none in Canada or the United Kingdom. It is not surprising, therefore, that little information regarding this technique has been disseminated through the recent English literature. However, laryngologists with a reading knowledge of the German language will find a wealth of useful information in a recent book by Dr. Elimar Schönhärl,²² who has pioneered this area.

I have used such an instrument in my office for the past four years, and would not wish to practice laryngology without it. In many instances, my stroboscopic examination has obviated the neces-

sity for a direct laryngoscopy, with its attendant cost and discomfort to the patient. A complete stroboscopic examination should not exceed ten minutes, if one works with a co-operative patient. It is scarcely necessary to mention to this audience of laryngologists that an understanding of the technique and a familiarity with the normal vibratory pattern of the vocal cords are prerequisites for the interpretation of abnormal findings.

After an evaluation of the case histories of several hundred patients, I have been impressed by the following specific diagnostic advantages of my electronic laryngo-synchron-stroboscope:

1) *The Diagnosis of Functional Disorders of the Larynx.* Functional hoarseness and weakness of the voice present a real challenge to the laryngologist. The electronic laryngo-synchron-stroboscope is the only office equipment which permits an accurate evaluation of these cases, and affords controlled supervision during therapy. In many cases changes in pitch, tension, or intensity minimize an abnormal pattern of vibration, a valuable aid in outlining indicated therapy.

2) *The Extent of Organic Disease.* The slow motion effect of the stroboscopic examination permits differentiation between superficial lesions of the mucous membrane and deeper lesions involving the underlying structures, without biopsy. There is little difficulty in distinguishing an edematous nodule which is likely to respond to voice therapy, from a fibrosed node requiring surgical excision. The extent of polyps, cysts, and other benign tumors can be determined satisfactorily before definitive surgery.

3) *The Differentiation Between Benign and Malignant Tumors.* The unilateral absence of vibration on stroboscopy often permits the early diagnosis of a malignant lesion, long *before* the unaided eye detects any limitation of motion.

4) *The Degree and Prognosis of Laryngeal Paralyses.* Stroboscopic inspection affords valuable information regarding the type and degree of laryngeal paralyses; it permits a differential diagnosis between a unilateral paralysis and ankylosis of the crico-arytenoid joint. A return of the typical mucosal pattern on the involved side usually represents the first indication of recovery.

5) *The Evaluation of Laryngeal Trauma.* Changes in laryngeal vibrations indicate the degree of trauma, and assist in the selection of indicated therapy and in the termination of voice rest. The resolution of extravasations and the disposition of scar tissue often produce persistent hoarseness without gross evidence of injury. The abnormal vibratory pattern, however, permits an objective confirmation of the vocal changes, and assures an accurate medico-legal evaluation of the impairment.

SUMMARY

The electronic laryngo-synchron-stroboscope provides an efficient and effective diagnostic tool in office laryngology. A stroboscopic examination provides valuable information regarding functional diseases of the larynx, the differentiation between benign and malignant tumors, and the etiology, extent, and prognosis of various benign lesions. The value of this equipment for physical therapy requires additional investigation.

UNIVERSITY OF CALIFORNIA MEDICAL CENTER

REFERENCES

1. Oertel, M. J.: Das Laryngo-Stroboskop und die Laryngo-Stroboskopische Untersuchung. Arch. f. Laryng. u. Rhin. 3:1, 1895.
2. Hegener, J.: Ein neues Laryngoskop. Vox 24:1, 1914.
3. Panconcelli-Calzia, G.: Zeitlupenaufnahmen und Strobokinematographie von Vorgängen im Kehlkopf. Zeitschr. f. Laryng. Rhin. 17:394, 1929.
4. Loebell, H.: Ein neues Stroboskop. Zeitsch. f. Hals-, Nasen-u. Ohrenh. 15:371, 1926.
5. Stern, H.: Die Stroboskopische Untersuchungsmethodik. Wiener Med. Wochenschr. 81:1596, 1931.
6. Tarneaud, J.: La Stroboscopie du Larynx. Rev. de Laryng. 53:917, 1932.
7. Kallen, L. A.: Laryngostroboscopy in the Practice of Otolaryngology. Arch. Otolaryng. 16:971, 1932.
8. Powell, L. S.: The Laryngo-Stroboscope in Clinical Examination. Eye, Ear, Nose and Throat Monthly 14:265, 1935.
9. Andrews, Albert H., Jr.: Personal communication.
10. Kallen, L. A., and Polin, H. S.: Physiological Stroboscope. Science 80:592, 1934.

11. Gutzmann, H., Jr.: Quoted by Schönhärl, E.(22).
12. Moore, G. P.: A Stroboscopic Study of Vocal Fold Movement. Summaries of Doctoral Dissertations, Vol. 4, Chicago and Evanston, Northwestern University, 1936.
13. Luchsinger, R.: Die Electrostroboskopie und harmonische Vibration mittels eines Tongenerators. Schweiz. med. Wschr. 73:135, 1943.
14. Panconcelli-Calzia, G.: Das Synchron-Stroboskop nach Cremer. HNO 4: 62, 1953.
15. Eigler, G., Podzuweit, G., and Weiland, H.: Ein neues mikrofontesteuertes Lichtblitz-Stroboskop zur Beobachtung von Stimmlippenschwingungen. Zeitschr. f. Laryng. Rhinol. 32:40, 1953.
16. Winkel, F.: Neuentwicklung eines Lichtblitz-Stroboskops für die Laryngologie. HNO-Wegweiser 4:210, 1954.
17. Beck, J., and Schönhärl, E.: Ein neues mikrofontesteuertes Lichtblitz-Stroboskop. HNO-Wegweiser 4:212, 1954.
18. Pantiukhin, V. P.: Novaja model'stroboskopa. Vestn. Oto-rino-laryng. 16:5, 1954.
19. Vallancien, B.: Le strobophone. Transactions of the Société de Laryngologie des Hopitaux de Paris, 1954.
20. van den Berg, Jw.: Personal Communication.
21. Timcke, R.: Laryngostroboskopie mittels eines neuartigen Synchronstroboskops. Zeitschr. f. Hals-, Nasen- u. Ohrenheilk. 169:539, 1956.
22. Schönhärl, E.: Die Stroboskopie in der Praktischen Laryngologie. Stuttgart, Georg Thieme, 1960.

DISCUSSION

DR. ALBERT H. ANDREWS, JR. (Chicago): The stroboscope described by Dr. von Leden is an excellent example of the application of engineering developments to medical science. The stroboscope was first used in the study of vibrating strings and was then applied to the study of rotating machinery and oscillating types of machinery. Its value in this use was so great that a demand arose for it and industry developed the electronic stroboscope.

My experience with the conventional industrial instrument has been unsuccessful in laryngoscopy because the light source was too large and the intensity of the light was too low. The application of the zeon tube, as Dr. von Leden has described, is an excellent and greatly to be emphasized advancement in technique.

I have used the rotating disc type of laryngoscope for some twenty years and I object somewhat to Dr. von Leden's uncomplimentary remarks about the instrument. The use of the autotransformer, in contradistinction to the ordinary rheostat, gives constant speed and good control, and at the same time makes it unnecessary to use more than one disc. The use of a 300 watt projection lamp with a light ratio of 1:10 gives good stroboscopy. The rotating disc is used to cool the lamp and it works out quite satisfactorily.

The degree of illumination, to me, is extremely important. My criterion of adequate illumination is to be able to see the carina in those patients in whom it is anatomically possible, and this can certainly be done with the rotating disc stroboscope.

The substitution of electronic sound instead of compressed air gives a more realistic sound to the stroboscope and makes it easier for the doctor to adapt the scope to the patient's pitch, or vice versa. A speed indicator can be included. These circuits are simple and may be found in publications for hobbyists who are dealing with transistors and similar circuits.

The automatic adjustment of the stroboscopic speed to the pitch of the patient's voice is the factor of paramount importance in the instrument presented this afternoon. The control of vibration and the control of the phase relationship in order to show at standstill or in slow motion is extremely important and I believe warrants our wholehearted support of this type of work.

Dr. von Leden has presented the clinical applications of this instrument. I am sure that I express the regret of the audience that time did not allow him to elaborate on his clinical experiences. One thing that has impressed me has been the variation in pitch observed visually but not audibly in professional singers. Absolute pitch control, I have seen rather rarely. All of the individuals have been non-professional singers, and all under the age of 30 years. Dr. von Leden has stressed the importance of differentiating the gross movements of the vocal cords, that is, abduction and adduction from the vibratory movements. This is extremely important.

Finally, I would like to stress two clinical applications of laryngostroboscopy which I have found helpful. In small benign tumors of the vocal cords, such as polyps, fibromas and papillomas, it is usual to observe vibratory motion. In small carcinomas, on the other hand, it is uncommon. Therefore, when vibratory movements of the vocal cords are absent in a small tumor of the vocal cord, that tumor must be considered carcinoma until proven otherwise.

As another example, following the removal of benign tumors such as, again, a polyp or a nodule, the recovery of vibratory motion as shown by the stroboscope is an excellent indication of healing and furnishes a good criterion for cessation of the regime of silence and institution of a program of progressive resumption of voice use.

We are indebted to Dr. von Leden for this beautiful presentation and for directing our attention to this important advancement in the field of laryngology.

DR. KNUD FAABORG-ANDERSEN (Nykøbing F., Denmark): Mr. President, Fellows and Guests: I want to thank you very much, Dr. von Leden, for your very interesting presentation. We all know your fundamental work in this difficult field, and I agree with you in saying that we need more than indirect laryngoscopy if we are to be able to do something for our patients with voice disorders in diseases of the larynx.

High-speed film gives us a lot of information but this is still quite difficult as a routine examination as well as electromyography, and a rather expensive tool. So far as I can see, this electronic synchron-stroboscope is a very good thing, nearly as good as high-speed film, for studying the movement of the vocal cords.

There is another approach to studying these movements—you know it as well as I—the glottograph designed by the Swedish Dr. Sonesson from Lund. We do

not know yet how much this glottograph is able to tell us about voice disorders. Time will show it. Maybe it will be disappointing. It is my feeling that stroboscopy in the way you are using it is much better.

May I ask you a single question: How many different pitches are you investigating in your routine examination, and how do you change the tone volume? In other words, how are you doing your routine examination of the patient?

DR. EDWIN N. BROYLES (Baltimore): Dr. Von Leden, do you have to use any local anesthesia in the patient's larynx to get a good wide view of the vocal cords?

DR. HANS VON LEDEN (Chicago) (closing): I would like to thank Dr. Andrews, Dr. Faaborg-Andersen and Dr. Broyles for their kind discussion and for the interest their remarks indicate. Doctor Andrews' criticism of my reference to the disc stroboscope is well taken. I am not quite so adept in the use of difficult technical equipment as Dr. Andrews in his beautiful laboratory, and both my patients and I have found the use of the disc stroboscope an awkward procedure. However, my criticism applied to my own experience with this equipment and certainly not that of Dr. Andrews or any member of this distinguished Society.

I appreciate the fact that both Dr. Andrews and Dr. Faaborg-Andersen stressed the importance of stroboscopic examinations for the differentiation of benign and malignant tumors in their early stages and for the controlled treatment of laryngeal problems, particularly in the determination of voice rest. I agree that the electronic stroboscope affords us an opportunity to determine the optimum period of voice rest in each individual case.

In reply to Dr. Broyles' question, a stroboscopic examination of the larynx requires the same preparations as any indirect laryngoscopy. Any patient whose larynx Dr. Broyles can examine in the usual manner—and knowing his skill, this means almost every patient—can be examined stroboscopically. There is no need for any additional or unusual anesthesia.

I employ the following procedure in my stroboscopic examinations: I ask the patient to emit a continuous sound so that I can inspect his larynx both with the moving and with the still picture. Then I ask the patient to change the pitch of his voice so that I can observe any changes in the vibratory pattern. At this time it is helpful to record the significant pitch levels, so that one can test the same frequencies days or weeks later and compare the results.

Differences in sound level are then tested in the same manner. The special meters for pitch and sound level permit a repetition of the same tones at subsequent examinations and accurate comparison of vocal cord vibrations.

I have been impressed by the finding that certain vibratory changes of the vocal cords are most pronounced at specific pitch and intensity levels. I feel this device presents a useful guide in directing a patient to change his pitch or in outlining specific suggestions to a speech pathologist. As laryngologists we ought to be in a position to communicate intelligently with speech therapists in the referral of our patients. We should be able to guide them in their treatment, if we in turn expect the desired results for our patients.

In conclusion may I refer interested laryngologists with a reading knowledge of the German language to the recently published volume on stroboscopy by Dr. Elimar Schönhärl of the University of Erlangen, who has pioneered in this field.

SARCOMA OF THE LARYNX

CHARLES M. NORRIS, M.D.

AUGUSTIN R. PEALE, M.D.

PHILADELPHIA, PA.

Sarcoma of the larynx is an uncommon lesion, probably comprising less than one per cent of all malignant tumors of this organ. A recent review of the English literature by Kratz and Ritterhoff⁸ showed a total of seventy-one cases, of which twenty-six had been previously reported or reviewed by Havens and Parkhill.⁶ Sarcoma apparently is more common in males than in females, though to a less striking degree than carcinoma, and although the predominant incidence is in the later decades, Rigby and Holinger¹¹ report a fibrosarcoma in a young infant.

From the histogenetic point of view, one must recognize the possibility of the occurrence of at least twelve types of malignant tumor of mesenchymal origin. However, the present report will deal with only those instances of sarcoma observed at the Chevalier Jackson Clinic during the years 1941 to 1959, inclusive. These include four cases of fibrosarcoma, one case each of neurogenic sarcoma, Hodgkin's sarcoma and reticulum cell sarcoma, and two of so-called "carcinosarcoma" in which both carcinomatous and sarcomatous elements were found; both of the latter cases are more likely instances of the pseudosarcoma described by Lane⁹ and by Baker,² but are included for comparison.

Criteria for the recognition of these tumors based on gross appearance are difficult to define, because of the variability encountered, even in lesions of similar histologic type. In each of the cases briefly described, the laryngoscopic appearance of the lesion is given,

From the Department of Laryngology and Broncho-Esophagology (Chevalier Jackson Clinic) and the Department of Pathology, Temple University Medical Center.

and in four of those treated by operation, the surgical specimens are illustrated. The histologic features are exemplified in photomicrographs.

FIBROSARCOMA

The clinical behavior of the fibrosarcoma in general appears to reflect the histologic character of the lesion. The well differentiated fibrosarcoma is characterized by an abundance of fibrous stroma, with a relatively small cellular component in which the cells, though showing the usual criteria of malignancy, show less variation in size and shape than the more anaplastic tumors, which are relatively cellular, with a minimum of stroma, showing greater pleomorphism. Metastasis from the fibrosarcoma, when it occurs, is said to be nearly always by the hematogenous rather than lymphatic route. Metastasis of any type from a well differentiated fibrosarcoma is uncommon.

REPORT OF CASES

CASE 1. R.S., a white female 66 years of age, was referred for examination because of hoarseness of two weeks' duration. The laryngoscopic examination showed a rather smooth fusiform reddish elevation on the margin of the mid-portion of the right cord. The tissue removed for biopsy showed numerous spindle-shaped and pleomorphic cells with appreciable numbers of mitoses, and a surface covering of orderly squamous epithelium. Additional tissue was removed two weeks later with similar findings, and the diagnosis of a malignant tumor of mesenchymal origin was again returned. Because of the well localized and sharply margined character of the lesion, the right vocal cord was removed by laryngofissure (Fig. 1).

Microscopic sections of the surgical specimen show a relatively abundant collagenous stroma, within which are spindle-shaped cells of varying size and shape with hyperchromatic distorted nuclei, mitoses and tumor giant cells. The pathologist's diagnosis was "low-grade fibrosarcoma." This patient is living and well without evidence of recurrence or metastasis, after six years and eight months, having been last examined on March 27, 1961.

CASE 2. H.F., a white female 65 years old, was first seen in February, 1942. Hoarseness had been noted about one year before,

and during the six months prior to our first examination, tissue had been removed elsewhere from the vocal cord on three occasions. The first two biopsies had been interpreted as fibroma and granulation tissue, respectively, but the tissue removed at the time of the third biopsy was diagnosed as a fibrosarcoma of well-differentiated type. Grossly, the lesion appeared to involve the anterior extremity of the left cord and the anterior third of the right, without extension above or below the cordal level.

A laryngofissure by the anterior commissure technique was performed by Dr. Chevalier L. Jackson, and microscopic examination of the surgical specimen confirmed the pre-operative diagnosis.

Histologically this was a tumor of somewhat more cellular character than that of the previous case. Otherwise, the histologic criteria for the malignant nature of the lesion are much the same. This patient was living and well after 12 years, without evidence of recurrence or metastasis.

CASE 3. W.C., a white male 63 years of age, was first seen in October, 1957, with a history of hoarseness beginning six months before. A lesion had been removed elsewhere from the right vocal cord shortly after the onset of symptoms, and the voice appeared quite normal for a period, when hoarseness recurred and a second biopsy was performed. The pathologist rendered a diagnosis of sarcoma, and the patient was referred for operation. On direct laryngoscopy, the right cord was found to be somewhat thickened, with a roughened appearance, extending from the tip of the vocal process to the anterior commissure. Motion of the vocal cord was not impaired.

A partial laryngectomy of the fronto-lateral type was performed on October 30, 1957, with excision of the entire right cord, a large portion of the arytenoid and a part of the ventricular band, along with the anterior extremities of the left cord and ventricular band and a vertical anterior segment of thyroid cartilage in continuity (Fig. 2). Convalescence was satisfactory, although some degree of webbing occurred anteriorly. There has been no evidence of recurrence or metastasis after three years and six months, up to and including the last follow-up visit on May 4, 1961.

Histologically, this appeared to be a tumor of moderate cellularity, with numerous atypical nuclei, mitotic figures and tumor giant

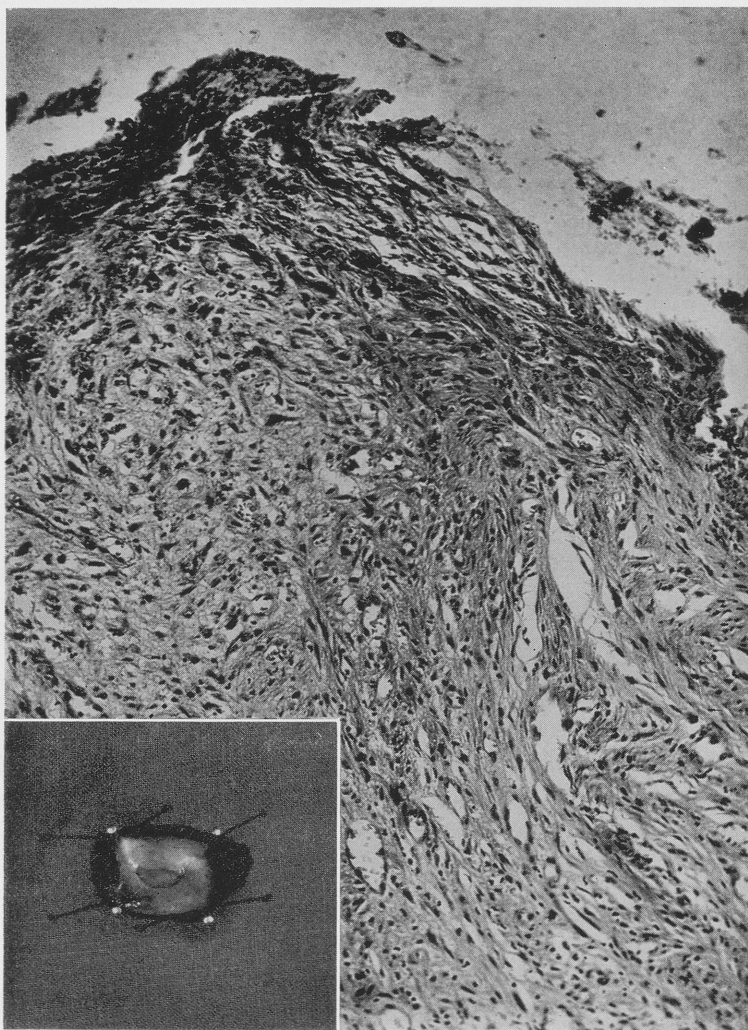


Fig. 1 (Case 1).—Small, well-differentiated fibrosarcoma of vocal cord, removed by laryngofissure. The lesion is well-localized and sharply margined. Photomicrograph (142X) showing the rather cellular collagenous stroma, with spindled nuclei varying somewhat in size, shape and staining quality.

cells. The interlacing bundles of tumor cells and supporting stroma give a "whorl-like" appearance.

CASE 4. D.S., a white female 14 years of age, with hoarseness of four months' duration was referred with a diagnosis of "cellular fibrous tumor" based on direct laryngoscopic biopsy performed elsewhere. The initial direct laryngoscopic examination showed a rounded reddish mass in the ventricular region on the left, with downward extension partially effacing the contour of the vocal cord. Tissue removed for biopsy was reviewed by several pathologists and although the mesenchymal origin of the tumor appeared evident, the malignant character of the lesion was not definitely established. A partial laryngectomy, including partial removal of the left thyroid ala, was performed. The surgical specimen was not reported as showing histologic criteria of malignancy, a non-specific diagnosis of "cellular fibrous tumor" again being rendered.

However, regrowth of neoplastic tissue along the left aryepiglottic fold was noted after about eight months, and the lesion was now recognized as showing the histologic criteria of a fibrosarcoma of a rather cellular type. A laryngectomy was performed. The gross and microscopic character of the lesion is shown in Figure 3.

Two years and four months following laryngectomy roentgen examination of the chest showed hematogenous pulmonary metastasis, with pleural effusion on the left. Nitrogen mustard was given; for several months the patient was relatively free of symptoms and working, then died without evidence of recurrence or metastasis in the neck. In this case, the difficulties in arriving at a definitive histologic diagnosis initially undoubtedly compromised the chance of cure.

CASE 5 (neurogenic sarcoma). W.McG., a white male 59 years of age, was first seen in August, 1942. He had noted hoarseness four months previously, and shortly after this had consulted a laryngologist who found a reddish pedunculated lesion in the anterior commissure and removed it by direct laryngoscopy. The tissue had been reported histologically as "granulation tissue of nonspecific character with no evidence of neoplasm." Rather rapid regrowth of the lesion had been observed within two months.

Our initial laryngoscopic examination showed a rather large irregular reddish lesion occupying the anterior portion of the glottis,

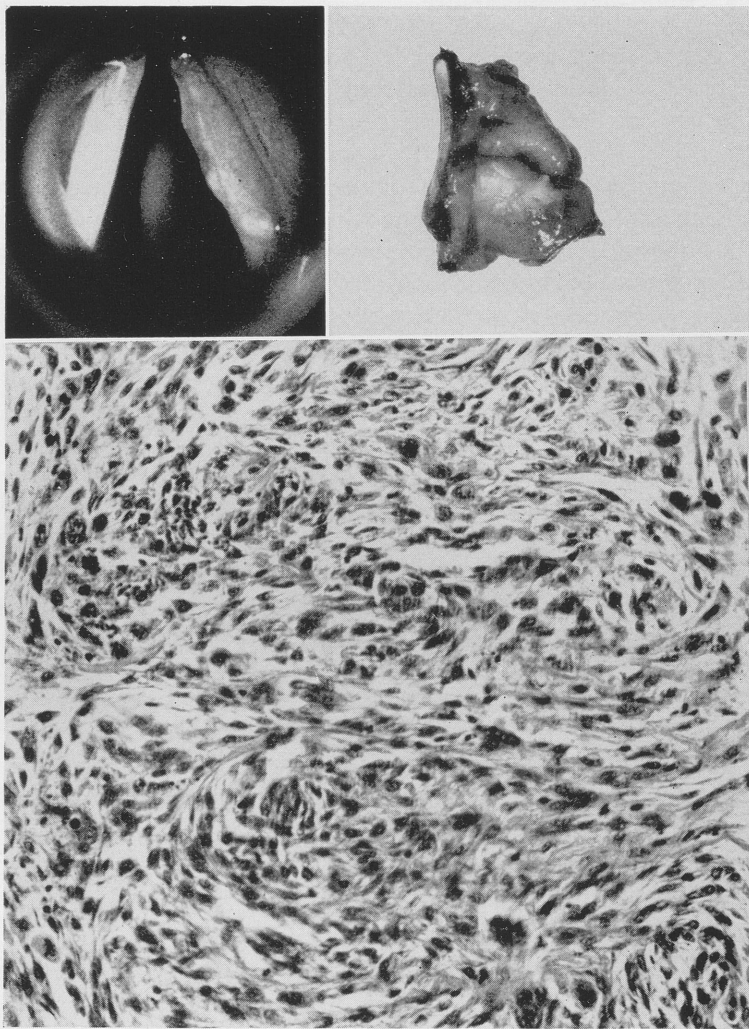


Fig. 2 (Case 3).—Fibrosarcoma of the right vocal cord treated by partial laryngectomy (fronto-lateral technique). As seen on direct laryngoscopy, the lesion is limited to the vocal cord and extends to, but not across the anterior commissure. Microscopic sections (243X) show a cellular spindled stroma. The cells have a whorl-like, fasciculated pattern. Hyperchromatism and pleomorphism are noted.

with a somewhat pedunculated attachment to the anterior extremity of the left vocal cord. The biopsy was reported neurogenic sarcoma of low-grade, and a partial laryngectomy was performed. Within three months, recurrence in the form of multiple small submucosal nodules at and above the glottic level was found and confirmed by biopsy. A laryngectomy was performed; all of the grossly evident recurrence appeared to be encompassed by an adequate margin or normal tissue.

Recurrence just within the tracheal stoma was found within two months; the upper trachea and adjacent tissues were excised and radon seeds implanted. Death from recurrence and metastasis occurred within less than one year. The microscopic appearance of the lesion is shown in Figure 4.

Most pathologists agree that differentiation between fibrosarcoma and the so-called neurogenic sarcoma is difficult. The tendency for fasciculation and palisading favor the latter diagnosis. Whether these tumors arise from the Schwann cell or from the mesodermal fibroblasts of the endoneurium or perineurium is debatable. Stout¹² firmly believes that tumors having the characteristics of fibrosarcoma, regardless of their relationship to nerve, should be called by that name rather than by the debatable term "neurogenic sarcoma." It might be added that smooth muscle tumors likewise display palisaded nuclei. Ewing⁴ has described extension of neurogenic sarcoma along the epineurium, and the multiple nodular recurrences observed in this case may be indicative of such a mode of extension. It goes without saying that if the inherent character of this tumor had been fully appreciated before the initial operation, surgery of a more radical character would have been carried out.

CASE 6 (Hodgkin's sarcoma). E.C., a white female 66 years of age, was first seen eleven months following the onset of hoarseness. Laryngoscopy showed a large reddish nodular lesion involving the right ventricular region and the adjacent portion of the epiglottis, with extension to the anterior portion of the right vocal cord. The tissue removed for biopsy appeared to have the character of a lymphoma of malignant type. Further definitive classification was not accomplished at first, but slides of a lymph node removed fourteen months previously at the time of laparotomy and cholecystectomy elsewhere were reviewed and the diagnosis made elsewhere of malig-

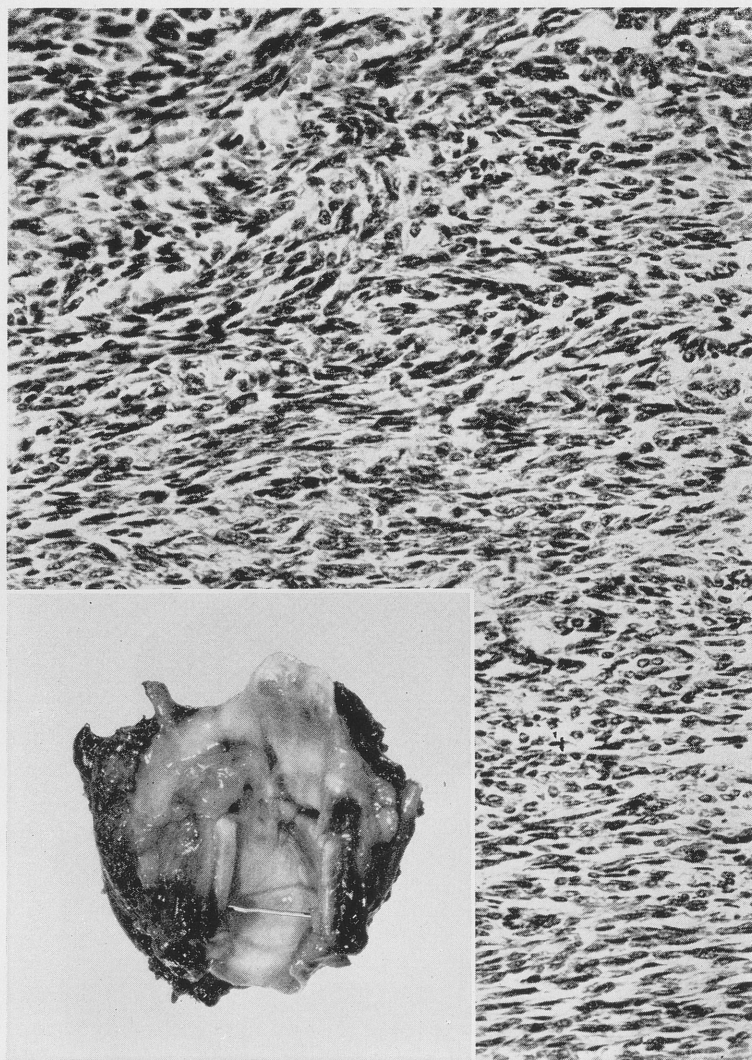


Fig. 3 (Case 4).—A more anaplastic fibrosarcoma treated by laryngectomy following recurrence after partial laryngectomy (see text). The lesion involves the entire left glottic and ventricular region and the aryepiglottic fold. The photomicrograph (243X) shows the extremely cellular character of the lesion, although the cells are fairly uniform. There is little collagen production.

nant lymphoma of the Hodgkin's type was substantiated. The laryngeal lesion has more of the histologic character of a lymphosarcoma and the exact relationship between the two lesions was not fully established; other cases of malignant lymphoma with pleomorphic manifestations have been recorded. A course of deep x-ray irradiation for the laryngeal lesion was administered.

Six and one-half years have elapsed since irradiation and no recurrence in the larynx has been observed. However, within the past year, recurrent disease were found in the pelvis and irradiation administered to this area.

CASE 7 (reticulum cell sarcoma). T.G., a white male 23 years of age, had complained of hoarseness for two and one-half months. Examination elsewhere had shown a large rather smooth mass involving the entire left vocal cord, and occluding the glottic space sufficiently to interfere with normal breathing. Several enlarged lymph nodes were palpable in the left neck. Tissue removed from the larynx and sections of lymph node were reported by the pathologist as reticulum cell sarcoma. Prompt and apparently complete regression followed a course of irradiation, and at the time of the last follow-up report about four and one-half years following treatment, no evidence of recurrence had been noted.

CASE 8 (pseudosarcoma). J.McA., a white male 62 years of age, was referred because of hoarseness of six weeks' duration. The direct laryngoscopy showed a localized, rounded, tumor-like lesion in the anterior portion of the left vocal cord. The biopsy was reported "malignant mesenchymal tumor, probably fibrosarcoma, with carcinoma-in-situ." A partial laryngectomy by the laryngofissure technique was performed on June 17, 1959. At the time of the most recent follow-up visit, nineteen months following operation, there was no evidence of recurrence or metastasis. The microscopic sections (Fig. 5) show a cellular stroma, which is covered on one surface by a thick layer of stratified squamous epithelium. The latter in one area demonstrates severe dyskeratosis, which is interpreted as carcinoma-in-situ. The stroma is composed of interlacing bundles of spindled elements showing loose collagen production. The nuclei are frequently bizarre. Mitoses are uncommon.

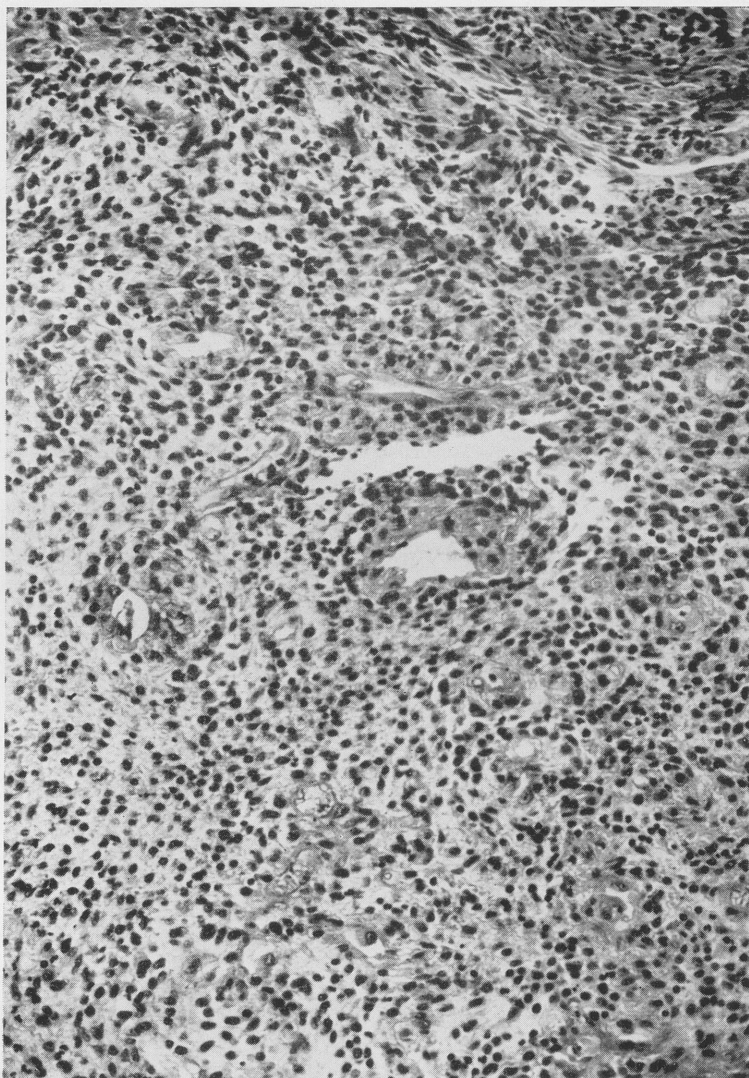


Fig. 4 (Case 5).—This lesion was felt by the pathologist to represent a neurogenic sarcoma. The photomicrograph (243X) shows a suggestion of palisading in some areas. The tumor cells are generally spindled. The stroma is loose and fibrillary.

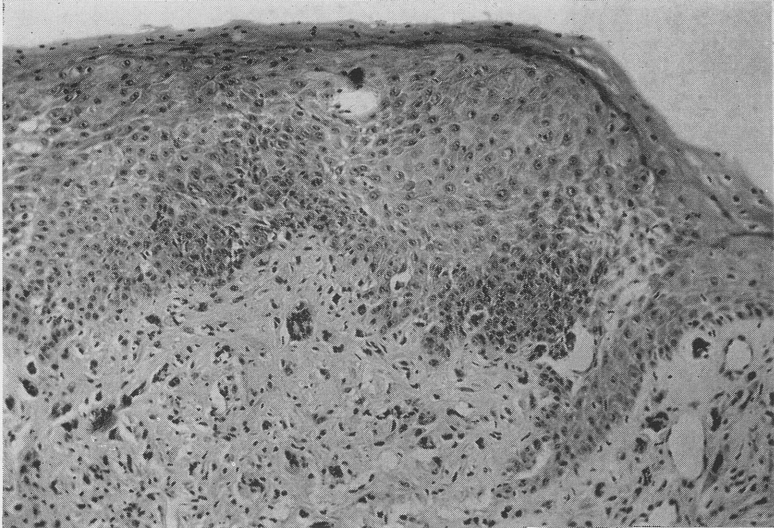


Fig. 5 (Case 8).—Pseudosarcoma. Sections of a rather well localized cordal lesion showing intra-epithelial carcinoma, with an underlying spindled stroma containing bizarre giant cells.

While this picture could represent a carcinosarcoma, we would prefer to classify it as the so-called pseudosarcoma of the type reported by Lane⁹ and more recently by Baker.² Baker cites the opinion of Lane that the apparently sarcomatous components are not malignant locally and do not metastasize.

The terms of carcino-sarcoma, collision tumor and pseudosarcoma are somewhat confusing. Some relate the term carcino-sarcoma to the simultaneous neoplastic growth of the epithelial and stromal components of a tissue, while others attribute the carcinomatous features to metaplasia of the epithelial component. The collision tumor, on the other hand, represents an independent sarcoma and carcinoma, which in their respective growth phenomena invade one another. The pseudosarcoma is usually a pedunculated tumor, whose stroma has a sarcomatous-like pattern, but in addition there is an intra-epithelial or an invasive carcinoma. The sarcomatous element lacks the clinical behavior of a malignant tumor and does not metastasize.

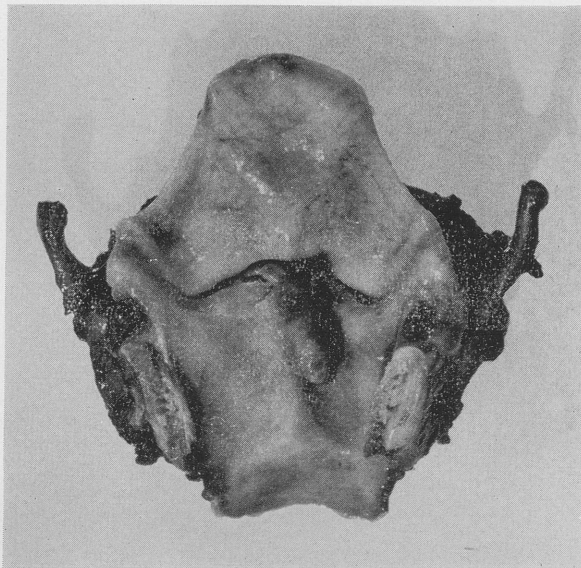


Fig. 6 (Case 9.—Pseudosarcoma, treated by laryngectomy. A previous course of irradiation had not been effective. The pedunculated polypoid character of the lesion is well shown.

CASE 9 (pseudosarcoma). E.G., a white male 69 years of age, had complained of increasing dyspnea of three years' duration, with hoarseness for about one month. He was found to have a rather marked degree of pulmonary emphysema and was orthopneic much of the time. The dyspnea did not appear to be on a basis of laryngeal obstruction, although laryngoscopy showed a grayish rather smooth and well localized lesion in the anterior commissure and on the adjacent portion of the left vocal cord. Motion of the cords was not impaired; the initial biopsy was reported as a moderately well-differentiated squamous cell carcinoma.

Because of the patient's age and advanced pulmonary emphysema with orthopnea, irradiation was given; but examination after four months showed residual neoplastic tissue in the anterior commissure and the immediate glottic region. The biopsy again showed squamous cell carcinoma, but in addition, numerous spindle-shaped anaplastic

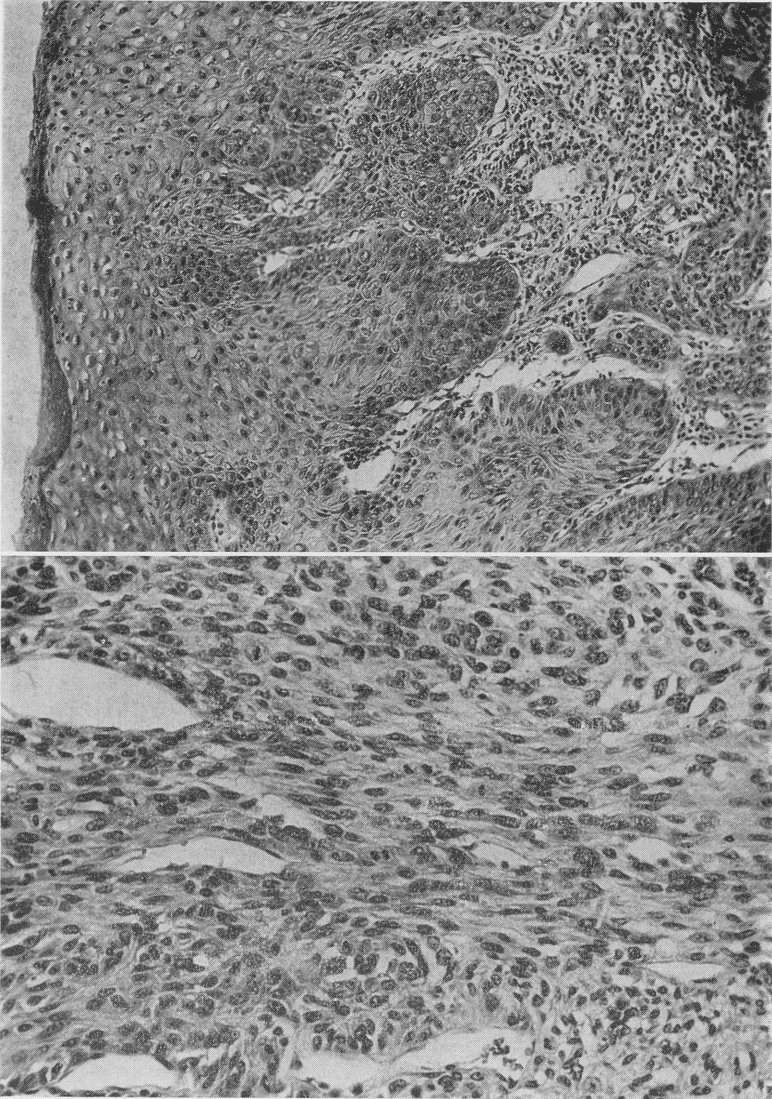


Fig. 7 (Case 9).—Pseudosarcoma. Photomicrograph at top shows early invasive squamous cell carcinoma. Below, the underlying cellular spindled stroma and the frequent mitoses.

cells in a matrix of pink intercellular material were found in some areas. A laryngectomy was performed. The character of the lesion is shown in the photograph of the surgical specimen (Fig. 6).

On a basis of the microscopic sections (Fig. 7), this case has seemed difficult to classify accurately. There is early invasive squamous cell carcinoma, the stroma has a sarcomatous appearance consisting for the most part of interlacing bundles of fibrous tissue elements, although mitotic figures are frequent and in one area there is vague suggestion of osteoid production. On the basis of these latter features we at first considered the lesion to be a carcinosarcoma, although it more likely represents a pseudosarcoma, of the type reported by Lane⁹ and by Baker,² since their lesions have nearly always been found associated with a squamous cell carcinoma, as has also been observed by Picó.¹⁰ This patient was last followed in March, 1961, four years and one month following operation; at that time he was living in Italy and apparently free of disease.

COMMENT

The cases presented illustrate a varied clinical behavior which, in at least two cases, did not appear predictable on a basis of the biopsy material obtained before treatment. The difficulties of accurate histologic diagnosis, as recognized by all pathologists, are exemplified by the fact that in only one of the five cases of fibro- and neuro-sarcoma was the ultimate diagnosis the same as that rendered on the initial biopsy. This is of course partially explained by the rarity of sarcoma of the larynx, but similar problems are encountered elsewhere in the body, where numerous gradations from reactive fibrosis to fibrous neoplasia are observed.

It would appear that well-differentiated sarcomas of fibrous origin may, if small, be adequately treated by conservative surgery, in our experience as well as that of Clerf³ and Figi.⁵ All three patients with lesions of this type have remained well following partial laryngectomy. The more cellular and more anaplastic lesions should undoubtedly be treated by more radical surgery initially. The problem of simultaneous neck dissection has not arisen in our cases, and will probably not occur with any frequency, as expected from the relative rarity with which sarcoma is expected to metastasize by lymph nodes. Irradiation would not be expected to be an effective form

of treatment for the fibrosarcoma, based on behavior of similar lesions in other locations, and this view has been substantiated by the experience of Johnston⁷ in a recent report of three laryngeal cases.

In the case of the pseudosarcoma, as judged by the experience of Lane and Baker, the prognosis is determined by the usually associated squamous cell carcinoma. In the cases of reticulum cell and lymphosarcoma in the present group, roentgen irradiation appeared to be an adequate form of treatment.

SUMMARY

1. Clinical and pathologic features have been reviewed in four cases of fibrosarcoma of the larynx, one case of "neurogenic" sarcoma, one case of Hodgkin's sarcoma and one case of reticulum cell sarcoma. Two cases apparently representing "pseudosarcoma" are included for comparison.

2. Treatment methods and results are described. Conservative surgery appears adequate for small well-differentiated fibrosarcomas of the vocal cord. For larger lesions representing a more cellular or anaplastic fibrosarcoma, more radical operation is of course indicated.

CHEVALIER JACKSON CLINIC
TEMPLE UNIVERSITY MEDICAL CENTER

The photographic material included in this report was provided through funds of the Robert Armour Foundation of the Chevalier Jackson Clinic.

REFERENCES

1. Ash, J. E., and Raum, M.: *An Atlas of Otolaryngic Pathology*. Washington Armed Forces Institute of Pathology, 1949.
2. Baker, D. C.: Pseudosarcoma of the Pharynx and Larynx. *ANNALS OF OTOTOLOGY, RHINOLOGY AND LARYNGOLOGY* 68:471-477 (June) 1959.
3. Clerf, L. H.: Sarcoma of the Larynx; Report of Eight Cases. *A.M.A. Arch. Otolaryng.* 44:517-524 (Nov.) 1946.
4. Ewing, J.: *Neoplastic Diseases*. 4th ed., Philadelphia, W. B. Saunders Co., 1940.
5. Figi, F. A.: Sarcoma of the Larynx. *A.M.A. Arch. Otolaryng.* 18:21-33 (July) 1933.

6. Havens, F. Z., and Parkhill, E. M.: Tumors of the Larynx Other Than Squamous Cell Epithelioma. *A.M.A. Arch. Otolaryng.* 34:1113-1122 (Dec.) 1941.
7. Johnston, K. C.: Fibrosarcoma of the Larynx. *Laryngoscope* 67:1194-1207 (Nov.) 1957.
8. Kratz, R. C., and Ritterhoff, Robert: Sarcoma of the Larynx. *ANNALS OF OTOTOLOGY, RHINOLOGY AND LARYNGOLOGY* 70:239-250 (Mar.) 1961.
9. Lane, N.: Pseudosarcoma of the Larynx (Polypoid Sarcoma-like Masses) Associated with Squamous Cell Carcinoma of the Mouth, Fauces and Larynx. *Cancer* 10:19-41, 1957.
10. Picó, J.: Pseudosarcomatous Lesions of the Larynx. Paper presented at Seventh Pan-American Congress of Oto-Rhino-Laryngology and Broncho-Esophagology, Miami (Mar.) 1960.
11. Rigby, R. G., and Holinger, P. H.: Fibrosarcoma of the Larynx in an Infant. *A.M.A. Arch. Otolaryng.* 37:425-429 (Mar.) 1943.
12. Stout, A. P.: Tumors of the Peripheral Nervous System. *Atlas of Tumor Pathology, Section II - Fascicle 6.* Armed Forces Institute of Pathology, 1949.

DISCUSSION

DR. DANIEL C. BAKER, JR. (New York): Dr. Norris has given an excellent presentation of a relatively rare disease.

In going over the records at Presbyterian Hospital in New York City, only 5 cases of sarcoma of the larynx were found. Four were fibrosarcoma and one was a chondrosarcoma. In addition, I have seen one case of fibrosarcoma and an additional case of chondrosarcoma at other institutions.

The patients that have come under my care were not so fortunate as some of those presented by Dr. Norris. All of my patients succumbed to the disease. They were not seen early enough and the diagnosis was not established in time to allow for curative surgery.

Four patients were operated upon and in each instance, there was either local recurrence or metastatic disease, predominantly in the lungs.

The reticulum cell sarcoma, as reported by Dr. Norris, that responded so well to radiotherapy, is probably similar to the same tumor that is seen in the tonsil, mediastinum and abdomen. The tumor responds well to x-ray, but it may develop in other parts of the body, so that it must be considered as a systemic rather than a local disease.

The diagnosis of a sarcoma of the larynx may be difficult to establish. It is a connective tissue tumor and may present itself, not as an ulcerative process, but as a mass covered with normal epithelium. Biopsy in such instances will be negative because the pathologic process is not represented in the biopsy.

I believe that persistent tumor masses with negative biopsies should be explored by an external approach, either by fissure or by removing a part of the thyroid ala and approaching the lesion directly.

In Dr. Norris' patients, who had a good surgical result, the lesions were on the cord, hoarseness was an early symptom, and it was possible to secure a biopsy and institute treatment while the lesion was still early and conservative surgery was effective. This has not been my experience. Our patients had larger lesions.

I have seen two cases of chondrosarcoma. In both instances, benign chondromata had been removed incompletely. The lesion recurred and eventually they underwent malignant change. One patient was a physician and twenty-four years elapsed before sarcomatous change developed in an extensive chondroma.

I agree with Dr. Norris that surgery is the treatment of choice. X-ray therapy has little to offer for fibrosarcoma and chondrosarcoma, but will benefit patients with reticulum cell sarcoma and lymphosarcoma.

He has reported on two patients with pseudosarcoma. In both instances, there was evidence of a squamous cell carcinoma. This is in keeping with the report of three cases presented before this Society three years ago.

I would like to show a few slides; one on a patient with a diagnosis of leiomyoma of the larynx. The patient is a physician, 68 years of age, who complained of noisy breathing, a feeling of a lump in his throat and phonatory disturbances, but not true hoarseness. The latter symptoms only recently occurred.

Examination showed a large rounded swelling covered by mucous membrane and obscuring the left half of the larynx and left pyriform sinus. The epiglottis was pushed to the right and twisted.

Laryngography showed the mass clearly and it extended down into and lateral to the left cord. The mass felt solid. It was removed by an external approach. The upper half of the left ala of the thyroid cartilage was removed. No difficulty was encountered in finding the tumor, a well encapsulated lobulated mass, which was very friable. There were many cells showing atypism and in some areas, the cellular appearance suggested malignant change. It was decided to observe the patient for possible recurrence. He has remained well since the operation nine months ago.

Early diagnosis is essential in fibrosarcoma and chondrosarcoma. The disease has to be completely removed, otherwise there will be local recurrences and eventually distant metastases with death.

DR. GEORGE A. HENRY (Toronto): Dr. Broyles, Members of the Society and Guests: I, too, would like to congratulate Dr. Norris on his excellent presentation. It is evident that true sarcoma is a rather rare disease. The cases shown today have added materially to our knowledge of this condition.

I am presently concerned with a patient with sarcoma of the larynx. Three years ago, a thirty year old man came to me with a large swollen left arytenoid and aryepiglottic fold. On examination one could see that the epithelium was unbroken. Through the laryngoscope, I made bold enough to puncture through the epithelium. Material was obtained which was diagnosed as spindle cell sarcoma.

I did a laryngectomy and block dissection of the left side of the neck. The glands removed were negative.

In the three years that followed, he has done very well. He is a personable chap, speaks well and became a very successful ladies' hairdresser.

A little over two months ago he developed pneumonia from which he recovered slowly. X-ray pictures showed, to our surprise, two masses in the right lung. (Slide) This is a low power showing masses of spindle cell sarcoma cells. Numerous blood vessels and collagen can be seen.

(Slide) Here is a high power of the same field. A vascular tumor is seen, the tumor cells tend to lie like sheaves of grain.

(Slide) This is a slide showing bronchial washings of the right lung. Numerous irregular cells can be seen. Dr. Ross, our Pathologist, feels that they are similar to the original growth of three years ago.

(Slide) This is a picture of the lung. Two metastatic growths can be seen in the right lung.

DR. CHARLES M. NORRIS (Philadelphia) (closing): I am very grateful to Dr. Baker and Dr. Henry for amplifying the discussion of this subject. We all remember Dr. Baker's fine paper before this Association two years ago in which he elaborated on the subject of pseudosarcoma, and I think from the clinical-pathological point of view, perhaps the most instructive portion of this study has been to make the pathologist aware of the fact that when he sees a sarcoma-like appearance in biopsy material, he must study the epithelial layer very carefully. Paradoxically, as Dr. Lane and Dr. Baker have shown, the pseudosarcoma shows more mitoses, may show more bizarre nuclei and even larger numbers of apparent tumor giant cells than the actual fibrosarcoma; perhaps the most useful histologic criterion of pseudosarcoma is the associated squamous cell sarcoma.

The case which Dr. Henry presented is especially interesting, since in his case of pulmonary metastasis from a connective tissue tumor, it was possible to confirm the diagnosis in the laboratory by bronchial washings.

Memorials



CHARLES DECATUR BLASSINGAME

CHARLES DECATUR BLASSINGAME, M.D.

1884 - 1961

Charles Decatur Blassingame was born in Booneville, Mississippi, December 22, 1884, and died in Memphis, Tennessee, June 20, 1961.

He received his high school education at Chalybeate High School in Tippah County, Mississippi. He graduated from Mississippi College in 1911 (Ph.B. cum laude). He was principal of the Tallahassee County High School in Cacill, Mississippi, the following year.

His first two years of medicine were received at the University of Mississippi at Oxford and his degree of Doctor of Medicine was obtained from Vanderbilt University, Nashville, Tennessee in 1916.

Dr. Blassingame served one year in general practice in Itawanibi County, Mississippi and came to Memphis to practice in 1917. He joined his two cousins, Dr. J. F. Bill (ENT) and Dr. Robert Fagin and Dr. W. Likely Simpson (ENT). That same year he volunteered for the Army and was assigned to the Ear, Nose and Throat Division of Evacuation Hospital No. 49. He remained at this Base Hospital in Joinville, France until the armistice, when he was discharged as a Captain. He remained abroad following his army service and immediately accepted an appointment as Assistant House Surgeon at the Golden Square Throat Hospital in London, where he remained for one year.

On his return to the United States, Dr. Blassingame joined the staff of the Baptist Hospital and was made Assistant Professor at the University of Tennessee. In 1923 he became a Fellow of the American Academy of Ophthalmology and Otolaryngology. He was certified in 1925. In 1926 he became a Fellow in the American College of Surgeons. He was elected to Fellowship in the American Laryngological, Rhinological and Otological Society in 1928, the Laryngological Association in 1938, the Otological Society in 1942 and the Broncho-Esophagological Association in 1946.

Dr. Blassingame was Head Otolaryngologist at Evacuation Hospital No. 49 in World War I. He served as Vice-President of the

Laryngological Association in 1958, Vice-President of the Baptist Hospital Staff, Secretary of the Memphis Eye, Ear, Nose and Throat Society, President of the Tennessee Academy of Ophthalmology and Otolaryngology and held many other offices. He was chief and head of the Department of Otolaryngology at the University of Tennessee Medical School from 1948 to 1954. Dr. Blassingame's contributions to the literature were numerous. He was an avid reader and enjoyed writing. At the time of his death he was preparing a treatise on the treatment of sinusitis.

Dr. Blassingame was one of seven children. He lost his father, William Scott Blassingame, during his high school days. His mother, Elizabeth Patterson Blassingame, accepted the responsibility of the family and was justly proud of her children, including Charles, her eldest. She was associated with the Chalybeate Institute, Chalybeate, Mississippi, which was in those days a fine private school in the community.

In 1934 Charlie married Glenn Johnson, the daughter of Dr. Joseph E. Johnson, the pioneer in plastic surgery in the south. They had no children. They remained a very devoted couple. Their friends, in all walks of life, were numerous.

About nineteen years ago Charlie and Glenn purchased a cottage high on a bluff overlooking Bull Shoals Lake at Forsyth, Missouri. Every summer they would retreat to the Ozarks to enjoy the native people who were their neighbors and entertain their friends and relatives at "Chiggervilla."

His hobbies included his friends, the University and farming. For 25 years he managed and directed a large farm just across the river from Memphis at Proctor, Arkansas until January of 1961 when he sold it.

His library, office equipment and instruments were bequeathed to the Department of Otolaryngology, University of Tennessee. He was on the Board of Stewards of St. John's Methodist Church and was a faithful member.

He is survived by his wife, three brothers, Arthur, Ed and Alex Blassingame of Booneville and a sister, Mrs. Sherrod A. McVay of Memphis.

CHEVALIER L. JACKSON, M.D.

1900 - 1961

Chevalier L. Jackson, A.B., M.D., M.Sc. (Med), a fellow and past Vice-President of the American Laryngological Association, died suddenly at his home near Schwenksville, Pennsylvania, on Friday evening, January 13th, 1961.

His career was a distinguished and remarkably diversified one. As the successor of his illustrious father, Chevalier Jackson, he achieved his own individual role in the development of the sciences of Laryngology and Broncho-Esophagology. The motivating force of his entire professional life, as in that of his father, was an unselfish ambition to teach and train others.

Born on August 19th, 1900, in Pittsburgh, he enrolled in the University of Pennsylvania shortly after moving with his family to Philadelphia in 1916, graduated from the School of Medicine in 1926 and from the Graduate School of Medicine in 1930. When his father, having established departments at Jefferson Medical College and the Medical School and Graduate School of the University of Pennsylvania, was invited in 1929 to accept a newly created chair of Laryngology and Broncho-Esophagology at Temple University, Chevalier L. collaborated in the founding of the "Chevalier Jackson Clinic," remaining after his father's retirement in 1937 as Professor and Chairman of the Department of Laryngology and Broncho-Esophagology.

In post-graduate courses in Philadelphia, as well as in Europe and Latin America, he promoted methods of safe and efficient bronchoscopy and esophagoscopy, and demonstrated the wide field of application of peroral endoscopy in modern medicine. With Huber, he developed and popularized a practical system of segmental bronchial nomenclature which has been universally accepted. He was an author or co-author of seven textbooks which have become standard reference works in the specialty, some of which have been translated into foreign languages, as well as numerous contributions to System of Medicine and Surgery.



CHEVALIER L. JACKSON

A dynamic and dedicated teacher and a gifted lecturer, he was also a sympathetic advisor, respected by his associates and colleagues and revered by his patients. Firm in his opinions, he was nevertheless tolerant of the views of others and always receptive to suggestion. As a master of the art of endoscopy, and particularly in problems of foreign body, he met the challenge of the difficult case with consummate skill, as well as by the development and perfection of numerous instruments and techniques. With a sound and comprehensive experience in laryngeal surgery, he was responsible for the development of several new operative techniques. In his treatment of patients, he was invariably sympathetic and considerate, feeling a genuine interest in the welfare of the unfortunate.

An enthusiastic and fervent believer in internationalism, both medical and non-medical, and an accomplished linguist, he devoted great effort to promotion of international societies. Two of these, the Pan American Association of Oto-Rhinolaryngology and Broncho-Esophagology and the International Broncho-Esophagological Society, he was instrumental in founding, serving as Executive Secretary of both until the time of his death. A special interest in Latin America won the friendship and admiration of numerous colleagues in Central and South America.

An active member in all of the Societies associated with his specialty, he had served as President of the American Broncho-Esophagological Association and the American College of Chest Physicians, and as Vice-President of the American Laryngological Association, the American Academy of Ophthalmology and Oto-Laryngology and the American Laryngological, Rhinological and Otological Society. Among his prized achievements were membership in twenty-two foreign medical societies and honorary faculty appointments in Chile, Uruguay and Mexico. In 1948 he was made a Commander of the Order of the Liberator San Martin (Argentina), and in 1956 a Chevalier of the Legion of Honor of the French Republic. He was a member of the Advisory Board of the American Hospital of Paris.

With a breadth of cultural interests rare among physicians, he engaged in numerous non-medical pursuits. He was an active member of the World Affairs Council, the Alliance Francaise and the International House, as well as a founder member of the World Medical Association. He was also a music lover, having been President of

the Philadelphia Grand Opera Company from its founding in 1950 until the time of his death.

Mr. Maxwell Ellis, the British laryngologist and a long time friend, writes, in the British Medical Journal, "He loved people when meeting them for the first time, and even more, meeting them again. He never forgot a name or a face, as hundreds of people all over the world will recall. This was not a studied politician's technique, but the result of a genuine interest in human beings. He was generous to a degree of both his time and resources and rarely refused a call to go and lecture or demonstrate.

"There was thus scarcely a place in the world to which 'C.L.' had not been, complete with his cameras and laden briefcase full of papers and lantern slides, always enthusiastic. In giving himself so lavishly to life the inevitable happened. A coronary attack which might have made some men invalid for life merely exasperated him, and certainly exerted no check on his subsequent activities.

"It seemed so painfully clear that suddenly, hurrying on some air-field or dashing for some taxi probably many thousands of miles from home, the end would come, but at last, it was in his home, after a day spent working at his desk, that in the evening he sat forward in his arm chair, gasped and died. And laryngology has lost one of its most remarkable and lovable characters, and many of us have lost a great friend."

C.M.N.

JOHN DEVEREUX KERNAN, M.D.

1878 - 1961

Dr. John D. Kernan, an Emeritus Fellow of the American Laryngological Association, was born in Utica, New York, in 1878 and died in July, 1961, in New York City.

At the time of his death, Dr. Kernan was Professor Emeritus of Otorhinolaryngology of the College of Physicians and Surgeons of Columbia University, where he had taught for fifty years. Dr. Kernan had also been Resident Surgeon and Visiting Surgeon in the Department. In 1953 he was awarded a medal by the institution in recognition of his distinguished services. He retired from active practice in 1958.

Dr. Kernan received his A.B. degree from Harvard in 1900, having completed his college work in three years. At Harvard he was a member of the Eight Oar Varsity Crew and a Four Oar Shell, which still holds the record for the course at New London. Dr. Kernan received his medical degree from Columbia in 1903. Subsequently he went to Greenland on one of the supply ships that prepared the way for Admiral Robert E. Peary's trip to the North Pole.

Dr. Kernan was Diplomate of the American Board of Otolaryngology, a member of the New York Academy of Medicine, the American Association for Thoracic Surgery, the American Otological Society, the New York Society for Thoracic Surgery and the Canadian and Turkish Medical Societies.

Dr. Kernan contributed numerous excellent articles to the otolaryngological literature.

Dr. Kernan listed his diversions as hunting, fishing, camping and game-breeding. He described his politics as "Democratic with Socialist leanings."



JOHN DEVEREUX KERNAN

He is survived by two daughters, Mother Mary Charlotte of the Society of the Holy Child and Mrs. Charles C. Hill of Nyack, N. Y.; three sons, John D. Kernan of Englewood, N.J., Lt. Col. Robert M. Kernan, U.S.A.F., and Henry S. Kernan of South Worcester, N. Y.; a sister, Mrs. John A. Johnston and twelve grandchildren.



CARL HEBER McCASKEY

CARL HEBER McCASKEY, M.D.

1877 - 1960

Dr. Carl Heber McCaskey, an Emeritus Fellow of the American Laryngological Association, was born in Rigdon, Indiana, September 1, 1877, and died after a long and useful life on the eighth of October, 1960.

Dr. McCaskey received his medical degree from Indiana University in 1908 and was certified by the American Board of Otolaryngology in 1929.

Dr. McCaskey was Chairman of the Department of Otolaryngology of Indiana University from 1935 to 1952. A bronze plaque at the Indiana University Medical Center commemorates his services as Professor of Otolaryngology and member of the Medical School's Admission Board.

He was President of the American Academy of Ophthalmology and Otolaryngology in 1947, President of Indiana State Medical Association in 1943 and President of the Indianapolis Medical Society in 1934-1936.

Dr. McCaskey was a Fellow of the American Otological Society and of the American Laryngological, Rhinological and Otological Society. He was a Fellow of and one-time Vice-President of the American College of Surgeons.

Other memberships include the World Medical Association, Pan-Pacific Surgical Association, the Highland Golf and Country Club, Columbia Club and Masonic Lodge. He was a Thirty-Second Degree Mason.

Dr. McCaskey's contributions to the medical literature were numerous and excellent.

Survivors include a daughter, Mrs. Edward Farrell, of Silver Springs, Maryland, a brother and two grandchildren.



WILLIAM WESLEY WILKERSON

WILLIAM WESLEY WILKERSON, JR., M.D.

1897 - 1961

William W. Wilkerson, Jr. was born in Nashville, Tennessee, November 11, 1897, and died on March 7, 1961, at his home in Nashville. He was a former president of the Nashville Academy of Medicine and of the Tennessee Academy of Ophthalmology and Otolaryngology. Dr. Wilkerson had been chief of the otolaryngology department at Nashville General Hospital and assistant professor of clinical otolaryngology and assistant in anatomy at Vanderbilt University School of Medicine.

He was a consultant to the Veterans Administration Hospital and a member of the staff of St. Thomas Hospital, Baptist Hospital and the Junior League Home for Crippled Children.

The son of the late William Wesley and Emma Dunn Hill Wilkerson, Dr. Wilkerson received his M.D. degree from Vanderbilt University in 1920 and interned that year at Long Island City Hospital. In 1921-24 he was a resident physician at Bellevue Hospital in New York City.

It was during the 1940's that Dr. Wilkerson spearheaded a drive to establish a hearing and speech center which would serve handicapped children of Middle Tennessee. In 1950 a building on Garland Ave. was turned over to the Tennessee Speech and Hearing Foundation by Vanderbilt University. It was used as an examination and treatment center and a training school for persons interested in working with deaf children.

Dr. Wilkerson led in efforts to win financial support for the institution. Through his work the program of the center expanded and it became a joint project of the State Health Department, the U.S. Children's Bureau, Vanderbilt Medical School, Peabody College and the Tennessee Society for Crippled Children and Disabled Adults.

In 1950 the center was named the Bill Wilkerson Speech and Hearing Center in memory of Dr. Wilkerson's son, W. W. Wilkerson

III, who was killed in action in World War II. Dr. Wilkerson, chairman of the board of the center since 1958, served as medical director and president from 1951 through 1958.

Active for many years in the civic and health agencies of the Nashville community, Dr. Wilkerson had served as chairman of the Tennessee State Tuberculosis Hospitals, chairman of the Nashville Smoke Abatement Committee, a member of the Citizens Anti-Noise Committee, a member of the Davidson County Zoning Committee, a member of the medical advisory committee of the Tennessee Vocational Rehabilitation Service, a member of the Governor's Committee for the Handicapped and a member of the Cordell Hull Foundation.

Dr. Wilkerson was a veteran of World War I, having served as a private in the U.S. Army in 1918.

He was a member and an officer of numerous professional organizations. He was a diplomate of the American Board of Otolaryngology, a fellow of the American College of Surgeons and a past vice president of the Southern Section of the American Laryngological, Rhinological, Otological Society. He was founder and past chairman of the Nashville Postgraduate Assembly.

Dr. Wilkerson was an elder of the Presbyterian Church. He was a member and a former director of the Nashville Chamber of Commerce, a member of Belle Meade Country Club, the American Legion, the Sons of the American Revolution and the Pendennis Club of Louisville, Ky.

In 1924 he was married to the former Miss Fawn L. Parent, who survives. Other survivors are two daughters, Mrs. Walter Joseph Diehl, Jr. and Mrs. Thomas L. Yount, Jr.; a sister, Mrs. Thomas W. Dailey and six grandchildren, all of Nashville.

Executive Sessions

FIRST BUSINESS SESSION

SUNDAY MORNING, MAY 21, 1961

The first Business Session held in connection with the 82nd Annual Meeting of the American Laryngological Association at the Lake Placid Club, Essex County, New York, May 21, 1961, was called to order at 11:45 A.M. by President Edwin N. Broyles. The following men were elected to constitute the Nominating Committee:

DR. BERNARD McMAHON

DR. PAUL MOORE

DR. AUSTIN SMITH

DR. ALDEN MILLER

The following men were unanimously elected to *Active Fellowship*:

Dr. Edley H. Jones, Vicksburg, Miss.

Dr. Robert B. Lewy, Chicago, Ill.

Dr. Joseph H. O'Gura, St. Louis, Mo.

Dr. James J. O'Neil, Omaha, Neb.

Dr. Lup Quon Pang, Honolulu, Hawaii

Dr. Peter N. Pastore, Richmond, Va.

Dr. Oliver H. Suehs, Austin, Texas

The following men were elevated to *Emeritus Fellowship*:

Dr. Howard C. Ballenger, Winnetka, Ill.

Dr. Edward H. Campbell, Philadelphia

Dr. Thomas C. Galloway, Evanston, Ill.

Dr. Oram R. Kline, Camden, N.J.

Dr. Pierre P. Viole, Los Angeles, Calif.

Dr. K. Faaborg-Andersen of Nykobing, Denmark, was elected to *Corresponding Fellowship*.

PRESENTATION OF THE NEWCOMB AWARD

DR. J. M. ROBB: Mr. President: The privilege of presentation of this Award, I feel, rightly belongs to the Chairman of the Newcomb Award Committee, Dr. Likely Simpson, but I am happy that I have been chosen for the part because of my long and close association not only with the one honored but also with his understanding co-worker, his wife.

In a meeting of the Committee early in the year, to be exact, at the time of the meeting of the American Academy of Ophthalmology and Otolaryngology in the Fall of 1960, Chevalier Lawrence Jackson was selected to be the recipient and his untimely death, January 13, 1961, to our regret has resulted in this posthumous presentation.

It is fitting that his faithful wife, Hilda, should accept in his behalf for she has been a tireless worker for and supporter of every one of his endeavors, especially in the scientific field, and has been devoted to all phases of his work, educational, cultural, and professional. His students, his co-workers, his friends were her friends.

This Laryngologist, the worthy son of a distinguished father, carried on the tradition of Laryngology and Broncho-Esophagology at its very best. He never lost sight of the objective not only to practice to the best of his ability but also to teach, to the end that out of training and experience this excellent practice should not be limited to our own United States but spread abroad, particularly to Central and South America. He was especially fitted for this task because of his ability to speak their languages.

This talent enabled him to understand and to be understood by the Laryngologists of the Old World as well as those of the New. The value of this effort is best expressed by his membership in twenty-two foreign medical societies and honorary faculty appointments in Chile, Uruguay, and Mexico. In 1956 he was made a Chevalier of the Legion of Honor of the French Republic.

In the words of the President of the VIII Pan-American Congress of Otorhinolaryngology, "His service at the Temple Hospital of Philadelphia was always open to all and everyone was well received due to his good treatment. He shared his knowledge and personal affection with all who needed it. To the Otorhinolaryngologists of America to speak of Philadelphia was to speak of Jackson's home, his clinic

which was always open to all. * * * We, the specialists of Otorhinolaryngology, should consider Jackson as the symbol of the unity of Anglo-Saxon and Latin American citizens who live in this Continent."

Chevalier Lawrence Jackson was one of the outstanding Laryngologists of our time and this Newcomb Award is the expression of the deep appreciation of the American Laryngological Association for his knowledge of and unceasing devotion to this important specialty.

And so, Hilda, with great humility and real affection I present to you, belatedly for C. L., this Award "As a mark of esteem and appreciation for services to the Association."

PRESENTATION OF THE DE ROALDES AWARD

DR. McMAHON: Dr. Frederick Thayer Hill graduated from Colby College, Waterville, Maine in 1910. He received his Medical Education at Harvard University, and his Residency Training in Otolaryngology at the Massachusetts Eye and Ear Infirmary in Boston. After serving for a year in the United States Army Medical Corps as a First Lieutenant, he returned to the Massachusetts Eye and Ear Infirmary as a member of the Staff until 1920, at which time he started his private practice at Waterville. He was certified by the American Board of Otolaryngology in 1924.

His efforts in maintaining the highest standards of medical practice were unceasing and most effective on the local as well as the state-wide level. Under his direction as Chief of Staff and Medical Director of the Thayer Hospital at Waterville, he helped to make it one of the finest hospitals in Maine. He also personally established and participated in the teaching programs of the Interns and Nurses in the Hospital.

These achievements were all the more noteworthy in the absence of any Medical School affiliation to substantiate his efforts. His idealism for the improvement of Hospital standards further exemplified itself, by his being recognized as one of the foremost authorities in this field, as attested by his election to such offices as the Presidency of the Maine Hospital Association, the Presidency of the New England Hospital Assembly and the Presidency of the Maine Medical Association.

To add to his distinction he was awarded the Degree of Doctor of Science by Colby College in 1926, and the Honorary Degree of

Doctor of Science by the University of Maine in 1942. Truly Dr. Hill is one Prophet who was not without honor in his own country.

At the national level, Dr. Hill has established an enviable reputation for his sagacity, his high principles, and his unswerving devotion to duty. A member of all the national Otolaryngologic Societies, he has held high offices in each of them. He was Vice-President of the Triological Society in 1935 and 1936; Vice-president of the American Broncho-esophagological Society in 1951 and 1952; President of the American Otological Society in 1953 and 1954 and First Vice-president of the American Academy of Ophthalmology and Otolaryngology in 1960 and 1961. He has been a Director on the American Board of Otolaryngology for many years and President from 1953 to 1955.

He has served the American Laryngological Association long and faithfully since his election to active membership in 1928. His record shows that he was Vice-president in 1938 and 1939, and Treasurer from 1939 to 1948, President in 1948 and 1949 and a member of the Council from 1939 to 1953. In that year Dr. Hill was given the well-merited Newcomb Award of the Association. In his 33 years of active membership he attended every meeting that was held and presented nine excellent papers. He was elected to Honorary Fellowship in 1960.

While not a man of snap judgements, his one deviation when he was a younger man was the most fortunate he could have made, when he met a certain attractive young nurse on a "blind date," fell in love with her at first sight, and thus Ruby Choate became Mrs. Frederick Thayer Hill. Ruby recently rendered a terse and illuminating report on their family status when a friend commiserated with her because Ted attended so many medical meetings that he was never home, and Ruby in her quiet way answered, "Well, we have four daughters."

Mr. President, the deRoaldes Award Committee recommends that this highest honor bestowed by the American Laryngological Association be given to a man who is most deserving, because of the faithful performance of all his duties in the American Laryngological Association over the years, his wise counsel, his unselfish and unswerving devotion to the maintenance of the highest ideals of the Specialty of Otolaryngology and the principles of Medical practice, in his teachings

and in his writings and by his sterling example to the younger men—
Frederick Thayer Hill.

Respectfully submitted:

The deRoaldes Award Committee

Bernard J. McMahon, M.D., *Chairman*

William J. McNally, M.D.

Harry P. Schenck, M.D.

Louis R. Clerf, M.D.

Dean M. Lierle, M.D.

* * *

SECOND BUSINESS SESSION

MONDAY MORNING, MAY 22, 1961

The meeting convened at 9:30 A.M. with Dr. Edwin N. Broyles presiding. Secretary Lyman G. Richards read the following report:

REPORT OF THE SECRETARY AMERICAN LARYNGOLOGICAL ASSOCIATION

The Eighty-First Annual Meeting of the American Laryngological Association was held on March 18th and 19th, 1960, at the Deauville Hotel, Miami Beach, Florida. The President, Dr. William J. McNally, presided. Eighteen scientific papers were presented. Seventy-six Fellows and one hundred and fifty guests were in attendance.

The Librarian, Historian and Editor, Dr. Edwin N. Broyles, reported the deaths of:

Honorary Fellows:

DR. F. R. NAGER

DR. GEORGE M. COATES

Emeritus Fellows:

DR. CLAUDE C. CODY, JR.

DR. E. TRIBLE GATEWOOD

Active Fellow:

DR. MERCER G. LYNCH

The de Roaldes Award was presented to Dr. Dean M. Lierle "in recognition of his outstanding otolaryngological contributions as a teacher, educator, surgeon, and humanitarian." The Newcomb Award was presented to Dr. Joel J. Pressman "in recognition of his valuable contributions in the field of laryngological research."

The following officers were elected:

President	Dr. Edwin N. Broyles
First Vice President	Dr. Walter H. Theobald
Second Vice President	Dr. Anderson C. Hilding
Secretary	Dr. Lyman G. Richards
Treasurer	Dr. Francis E. LeJeune
Librarian, Historian and Editor	Dr. Francis W. Davison
First Councilor	Dr. LeRoy A. Schall
Second Councilor	Dr. Harry P. Schenck
Third Councilor	Dr. Fred W. Dixon
Fourth Councilor	Dr. William J. McNally

The Association has lost by death during the past year:

Emeritus Fellows:

DR. CARL H. MCCASKEY

DR. DANIEL S. CUNNING

Active Fellows:

DR. WILLIAM W. MORRISON

DR. JAMES H. MAXWELL

DR. CHEVALIER L. JACKSON

DR. WILLIAM W. WILKERSON

The Council at its Annual Meeting in New York on January 10th, 1961, recommended for:

Active Fellowship:

DR. EDLEY H. JONES, Vicksburg, Mississippi

DR. ROBERT B. LEWY, Chicago, Illinois

DR. JOSEPH H. OGURA, St. Louis, Missouri

DR. JAMES J. O'NEIL, Omaha, Nebraska

DR. LUP Q. PANG, Honolulu, Hawaii

DR. PETER N. PASTORE, Richmond, Virginia

DR. OLIVER W. SUEHS, Austin, Texas

Emeritus Fellowship:

DR. HOWARD C. BALLENGER, Winnetka, Illinois

DR. EDWARD H. CAMPBELL, Philadelphia, Pennsylvania

DR. THOMAS C. GALLOWAY, Evanston, Illinois

DR. ORAM R. KLINE, Camden, New Jersey

DR. PIERRE VIOLE, Los Angeles, California

Corresponding Fellowship:

DR. K. FAABORG ANDERSEN, Nykobing, Falster, Denmark

Dr. Samuel Salinger was reappointed Abstract Editor.

The Council voted to hold the Annual Session of the Association at the Sheraton-Dallas Hotel, Dallas, Texas, on May 4th and 5th, 1962.

The present membership of the Association is:

Active	94
Honorary	5
Corresponding	15
Emeritus	26
	<hr/>
	140

Respectfully submitted,

LYMAN G. RICHARDS, M.D.

Secretary

At the conclusion of his report Dr. Richards made a plea to all Fellows to keep him posted regarding changes of address and to notify him promptly of the death of any of the Fellows.

Dr. Richards' report was approved as read.

Dr. Francis E. LeJeune then presented the Treasurer's report. It was accepted as presented.

Exhibit A

AMERICAN LARYNGOLOGICAL ASSOCIATION

GENERAL FUND OPERATING STATEMENT

For the Fourteen Months Ended April 30, 1961

Income

Dues—92 members @ \$60.00	\$5,520.00	
3 new members @ \$100.00	300.00	\$5,820.00
Registration Fees—Annual Meeting		810.00
Sale of <i>Transactions</i>		916.00
Interest Received—Savings Account		268.00
Refund—Entertainment Advance		200.00
Refund—International Congress		488.44
		<hr/>
Total Operating Income		\$8,502.44

Expenses

Annual Meeting—1960

Banquet and cocktails	1,010.45	
Orchestra	110.00	
Projectionist	209.72	
Reporting Service	260.24	
Guest Speaker—Travel Expense	200.00	1,790.41
	<hr/>	

Council Expenses

Travel Expenses	829.67	
Annual Dinner	70.85	900.52
	<hr/>	

General Expenses

Clerical Hire	500.00	
<i>Transactions</i> —1960	2,589.20	
Stationery, Printing & Postage	1,201.10	
Auditing	100.00	
Treasurer's Bond	62.50	
Advertising	10.00	
President's Key—1960 and 1961	25.76	4,488.56
	<hr/>	<hr/>

Total Expenses		7,179.49
----------------------	--	----------

Addition to General Fund		1,322.95
--------------------------------	--	----------

General Fund Balance, February 29, 1960		4,699.66
---	--	----------

General Fund Balance, April 30, 1961		\$6,022.61
--	--	------------

Exhibit B

AMERICAN LARYNGOLOGICAL ASSOCIATION
TRUST FUND OPERATING STATEMENT
For the Fourteen Months Ended April 30, 1961

Trust Fund Income

Interest—Government Bonds	\$ 1,281.16	
Donations to Memorial Fund:		
Dr. Verling K. Hart	\$100.00	
Dr. Walter H. Theobald	500.00	600.00
	<hr/>	
Total Income		\$ 1,881.16

Trust Fund Expenses

Medal for deRoaldes Award	110.00	
Engraving deRoaldes Award	3.00	
Engraving Newcomb Award	5.00	
Certificates for Casselberry Awards	10.00	
Certificate for C. L. Jackson	6.00	
Exchange on U. S. Government Bonds	1.90	
	<hr/>	
Total Expenses		135.90
		<hr/>
Addition to Trust Fund		1,745.26
Trust Fund Balance, February 29, 1960		43,760.77
		<hr/>
Trust Fund Balance, April 30, 1961		\$45,506.03
Trust Fund Balance Represented by Government Bonds, par		39,500.00
		<hr/>
Remaining Balance Represented by Cash		\$ 6,006.03

Cash Recapitulation

Cash in Trust Fund	\$ 6,006.03	
Cash in General Fund	6,022.61	
	<hr/>	
		\$12,028.64
Cash in Savings Account	\$ 9,405.20	
Cash in Commercial Account	2,623.44	
	<hr/>	
Total Actual Cash	\$12,028.64	

Exhibit C

AMERICAN LARYNGOLOGICAL ASSOCIATION

REPORT OF TRUST FUNDS

April 30, 1961

Fund	Principal	Unused Income 3-1-60	Income 3-1-60 to 4-30-61	Expenses 3-1-60 to 4-30-61	Unused Income 4-30-61	Principal & Unused In- come 4-30-61
Casselberry	\$ 5,000.00	\$ 1,928.10	\$ 204.99	\$ 10.00	\$ 2,123.09	\$ 7,123.09
Johnston	5,000.00	1,148.59	179.36	-----	1,327.95	6,327.95
deRoaldes	3,000.00	1,482.98	128.12	113.00	1,498.10	4,498.10
Newcomb Trust	2,000.00	406.06	76.87	-----	482.93	2,482.93
Newcomb Prize	500.00	78.36	12.81	5.00	86.17	586.17
Research	16,034.42	5,682.26	640.58	1.90	6,320.94	22,355.36
Memorial	1,000.00	-----	625.62 ¹	6.00	619.62	1,619.62
Taylor (temporary)	500.00	-----	12.81	-----	12.81	512.81
Totals	\$33,034.42	\$10,726.35	\$1,881.16	\$135.90	\$12,471.61	\$45,506.03

¹ Includes \$500.00 donation by Dr. Walter H. Theobald, \$100.00 donation by Dr. Verling Hart, and \$25.62 interest.

Exhibit D

AMERICAN LARYNGOLOGICAL ASSOCIATION

TRUST FUND INVESTMENTS

April 30, 1961

<i>Government Bonds</i>	Description	Par Value	Interest Income 3-1-60 to 4-30-61
U. S. Savings -----	2.76 K 1965 -----	\$ 7,000.00	\$ 193.20
	2.76 K 1966 -----	1,000.00	27.60
	--- H 1970 -----	1,500.00	33.75
U. S. Treasury -----	2½ 1964-69 ---	3,000.00	75.00
	2½ 1967-72 ---	1,000.00	25.00
	2¾ 1961 -----	7,000.00	288.75
	3 1995 -----	5,000.00	150.00
	3¼ 1968 -----	3,000.00	104.40
	3¼ 1969 -----	5,000.00	169.70
	3¼ 1978-83 ---	3,000.00	97.50
	3⅝ 1962 -----	1,000.00	36.26
	4 1969 -----	1,000.00	20.00
	4¾ 1969 -----	1,000.00	47.50
Matured Bonds Exchanged -----	-----	-----	12.50
		\$39,500.00	\$1,281.16

ACCOUNTANT'S REPORT

To the Members of the American Laryngological Association
Gentlemen:

I have examined the accounts and financial records of the American Laryngological Association for the fourteen months ended April 30, 1961.

Cash receipts and disbursements were verified and United States Government Bonds were physically counted and examined.

In my opinion, the accompanying statement presents fairly the financial position of the American Laryngological Association as of April 30, 1961, and the results of its operations for the fourteen months then ended.

Respectfully submitted,

CARROLL A. CHAUVIN

Certified Public Accountant

May 9, 1961

COMMENT

To the Members of the American Laryngological Association
Gentlemen:

The financial report this year extends from March 1, 1960 to May 1, 1961. As most of you know, our income is derived solely from dues and the sale of *Transactions*. This income barely covers annual expenses which increase alarmingly each year. Our Trust Funds are dedicated for specific purposes.

The Association received a refund of \$488.44 from the Organizing Committee of the Sixth International Congress of Otolaryngology.

Donations to the Memorial Fund this year were received from Dr. Verling K. Hart and Dr. Walter H. Theobald. Donations such as these are needed to build up this recently created Fund the objectives of which are to aid Research in Rhinolaryngology and to help defray expenses at the discretion of the Council, thereby adding to the security of the Association.

Respectfully submitted,

FRANCIS E. LEJEUNE, M.D.

Treasurer

May 10, 1961

Dr. Bernard J. McMahon, Chairman of the Nominating Committee, submitted the following names for election to the Council:

Dean M. Lierle

Julius W. McCall

Percy E. Ireland

Lyman G. Richards

Francis E. LeJeune

Francis W. Davison

Harry P. Schenck

Fred W. Dixon

William J. McNally

Edwin N. Broyles

The report of the Nominating was unanimously accepted.

Dr. F. W. Davison then read the report of the Librarian, Historian and Editor.

REPORT OF THE LIBRARIAN, HISTORIAN AND EDITOR

May, 1961

Since our last meeting in March, 1961, the following Fellows have passed to the Great Beyond:

Daniel S. Cuning, March 26, 1960

William Wallace Morrison, April 17, 1960

James Hoyt Maxwell, June 2, 1960

Carl Heber McCaskey, October 8, 1960

Chevalier Lawrence Jackson, January 13, 1961

William Wesley Wilkerson, Jr., March 7, 1961

The 1960 meeting was held on March 18 and 19. Dr. Richards received the stenotypist's material June 5, which according to Dr. Richards was six weeks later than the previous year. In order to save time, all discussions were corrected by the Editor and all material for the 1960 *Transactions* was sent on to the Annals Publishing Co. on July 27. Most of the delay in sending on the material to the Annals Publishing Co. was due to the fact that some of the manuscripts were not received until two months after the meeting, despite pleading letters sent to the essayists by both the Editor and the Secretary.

After learning this state of affairs Dr. Proetz commented: "Education, apparently, is no guarantee of good manners."

The galley proofs were received on October 13, were corrected and sent back in two days. The page proofs were received November 12, were corrected and sent back in two days.

In an effort to dispose of some of the back *Transactions*, an advertisement was placed in the Laryngoscope to run for a period of four months, indicating that the sale price of *Transactions* from 1957 to 1960 is \$8.00 per copy and prior volumes are for sale at a cost of \$2.00 each.

According to Council directive, 225 copies of the 1960 *Transactions* were ordered. The cost of publication was \$2625.83.

Labels with Active Fellows' names and addresses were sent to the printer, who mailed the 1960 *Transactions* directly from St. Louis. The balance of the volumes the printer sent by freight to me in Danville. They were received January 10, 1961. All orders on hand at that time (97) were filled by January 17, 1961.

Thirty-two orders were filled outside the continental U.S.A., including 14 copies sent to Peking, China, by way of London. Number of 1960 *Transactions* (Vol. 81) mailed to:

Active Fellows	94
Honorary Fellows	4
Corresponding Fellows	6
Emeritus Fellows	5
Sold to libraries and individuals	90
Complimentary copies to families of deceased Fellows	7
	<hr/>
Total	206
Remaining in hands of Editor	19
Income from sale of <i>Transactions</i> (1960 and back) (plus \$24.00 received after May 1)	\$774.00
Expenses of Editor (\$55.92 of this was for jiffy bags, printing of invoices, labels, envelopes, a 2-yr. supply)	\$135.92
Bills outstanding (libraries \$32.00, individuals \$10.00)	\$42.00

Respectfully submitted,

F. W. DAVISON

Dr. Davison's report was accepted as read.

President Broyles made the comment that the permanent file of the *Transactions* is in the custody of the Secretary, Dr. Lyman G. Richards.

At the request of Dr. Broyles, Dr. Hill gave the report of the American Board of Otolaryngology.

DR. FREDERICK T. HILL: Mr. President and Fellows: From October 3rd to 7th last year the American Board of Otolaryngology conducted examinations of a total of 102 candidates. Of this group, 85 passed, 14 were conditioned and three failed.

This is a very excellent record and it brings the percentage of failures down to a good academic rate of around 17%. It is undoubtedly the best report we have had to make for a number of years.

Dr. Hill's report was accepted as read.

Dr. Paul Holinger then read the report of the Representatives of the American Laryngological Association to the Board of Governors of the American College of Surgeons.

REPORT OF REPRESENTATIVE OF AMERICAN LARYNGOLOGICAL
ASSOCIATION TO THE BOARD OF GOVERNORS OF THE
AMERICAN COLLEGE OF SURGEONS

1. Dr. John Paul North succeeded Dr. Paul R. Hawley as director of the American College of Surgeons on February 1, 1961. He was Clinical Professor of Surgery at Southwestern Medical School of the University of Texas and Chief of Surgical Service at Veterans Administration Hospital in Dallas.

2. The next Annual Meeting of the American College of Surgeons will be held in Chicago from October 2 through October 6, 1961. This is the week preceding the meeting of the American Academy of Ophthalmology and Otolaryngology. There will be a meeting of the Section of Otolaryngology on Friday, October 6, providing as close a continuity of meetings for otolaryngologists as possible. The program will include panel discussions of laryngeal injuries, facial injuries, tumors of the ear and temporal bone and microsurgery of the ear.

3. The Society of Head and Neck Surgery, whose membership is limited to those having Surgical Board Certification has been given representation on the Board of Governors by one Governor. (This is *not* the American Society for Head and Neck Surgery developed under the sponsorship of the Academy. This Society has not as yet applied for representation.)

4. Ways and means of raising the standards of patient care in small hospitals were considered with general approval of inspection teams visiting and advising hospitals which request assistance.

5. Of particular interest to specialists and thus to members of the American Laryngological Association was the report of the Committee headed by Dr. Edward Stafford of Baltimore on "What Constitutes Adequate Training for a Surgeon." The report considers the selection of proper candidates for surgical training, the recruitment and adequate remuneration of desirable trainees, the type of training available and the content of the educational program. A suggestion is made that "there is room for the development of board-approved, cooperative programs of training between university and non-affiliated hospital surgical services, so that two or three years of training in a university service might be followed by a final year as resident on a well supervised service in a non-university hospital affording good clinical opportunities." There is a plea for interchange of training experience between general surgery and the surgical specialties.

6. A Committee with Dr. Otto C. Brantigan of Baltimore as Chairman presented a report on "The Proper Disposal of Insurance Fees of Patients Operated upon by Residents." In brief, the committee recommended that the medical staff of hospitals maintaining training programs for house officers organize charitable, nonprofit foundations to accept money from members of the medical staff or house officer staff earned by work rendered while carrying out their respective duties for the institution. The medical staff in each hospital should determine the rules under which these funds are administered.

The discussion of this report centered about whether such foundations should be organized and administered by the medical staff as a whole or on a departmental or service basis. The entire subject and the report are still under consideration.

7. Dean M. Lierle remained on the Board of Regents. Harry P. Schenck remains a member of the Executive Committee of the Board of Governors.

The Advisory Committee for Otolaryngology consists of:

Daniel C. Baker, New York - term expires 1961

Harry P. Schenck, Philadelphia - term expires 1962 (Chairman)

Paul H. Holinger, Chicago - term expires 1963

Shirley Baron, San Francisco - term expires 1964

Dekle Taylor, Jacksonville - term expires 1965.

Respectfully submitted,

PAUL H. HOLINGER, M.D., term expires 1961

FRED W. DIXON, M.D., term expires 1962

FRANCES LEJEUNE, M.D., term expires 1963

DR. PAUL H. HOLINGER: I would like very much to mention the fact that at the Regional Meeting of the American College of Surgeons, held in Philadelphia, there was a Sectional Meeting on Otolaryngology which was attended by nearly 200 men. This is strength where we need strength. It was a very important and interesting program. The Section on Plastic Surgery was attended, in contrast, by very few men. If we are to have adequate representation in College affairs, it is essential that many otolaryngologists continue to attend the meetings and participation in the College programs.

Dr. Holinger's report was approved as presented.

Representing Otolaryngology on the Board of Governors:

For the American Academy of Ophthalmology and Otolaryngology

Shirley Baron, San Francisco - term expires 1961

No name submitted by Academy - term expires 1962

Wendle L. Hughes - term expires 1963

For the American Laryngological Association

Paul H. Holinger, Chicago - term expires 1961

Fred W. Dixon, Cleveland - term expires 1962

Francis S. LeJeune, New Orleans - term expires 1963

For the Section on Laryngology, Rhinology and Otology, American Medical Association:

John J. Conley, New York - term expires 1961

Harold Owens, Los Angeles - term expires 1962

W. Franklin Keim, East Orange - term expires 1963

For the American Otolological Society:

Shirley H. Baron, San Francisco - term expires 1961

Peter N. Pastore, Richmond - term expires 1962

Jerome A. Hilger, St. Paul - term expires 1963.

(Harry P. Schenck represents the State of Pennsylvania.)

THIRD BUSINESS SESSION

MONDAY AFTERNOON, MAY 22, 1961

The session convened at 4:40 P.M., following the close of the Scientific Session. At the request of President Broyles, the newly elected Council, acting as Directors of the Association, held a brief meeting to determine the offices for the coming year. Their decision was as follows:

President, Dr. Dean M. Lierle

First Vice-President, Dr. Julius McCall

Second Vice-President, Dr. Percy Ireland

Secretary, Dr. Lyman G. Richards

Treasurer, Dr. Francis E. LeJeune

Librarian, Historian and Editor, Dr. Francis W. Davison

First Councilor, Dr. Harry P. Schenck

Second Councilor, Dr. Fred W. Dixon

Third Councilor, Dr. William J. McNally

Fourth Councilor, Dr. Edwin N. Broyles

PRESIDENT BROYLES: Gentlemen: Before we install the new officers, I want to take this occasion to thank the members of the Association for their consideration and especially to thank the essayists who have added so much to the success of the meeting. I also want to thank the management of the hotel who have done everything possible to look after the comfort of the Fellows and their guests.

Last but not least, I want to thank my wife, Eleanor, who has been a tremendous help by listening to my worries and by giving sound advice regarding the many problems that have arisen in planning and carrying out the meeting.

Because Dr. Lierle was not present, retiring President Broyles turned over the gavel to Vice-President-elect Dr. Julius McCall.

DR. MCCALL: Is there any further business to come before the meeting? If not, I declare the 82nd Annual Meeting of the American Laryngological Association adjourned.

(The meeting adjourned at 5 o'clock.)

List of Fellows

LIST OF FELLOWS

Date Indicates Year Admitted to Active Fellowship

Attendance at meetings is shown by figures following each name.

Asterisk (*) indicates year paper was read.

Active Fellows

1958. ALFARO, VICTOR R., 917 - 20th St. N. W., Washington 6, D. C., 1958, '59, '60, '61.
1942. ASHLEY, REA E., 384 Post Street, San Francisco 8, California, 1946, '47, '48, '49, '50, '51*, '53, '54, '56.
1958. ATKINS, JOSEPH P., 3400 Spruce St., Philadelphia 4, Pa., 1958, '59*, '60, '61.
1956. BAKER, DANIEL CLIFTON, JR., 903 Park Avenue, New York 21, N. Y., 1956, '57, '58, '59*, '60, '61.
1944. BOIES, LAWRENCE R., University Hospital, Minneapolis 14, Minnesota, 1944, '46, '47, '48*, '49, '50*, '51*, '53, '54, '55, '56, '57, '58, '59, '60, '61.
1955. BORDLEY, JOHN E., Johns Hopkins Hospital, Baltimore 5, Maryland, 1955, '56, '57, '59, '60.
1941. BOWERS, WESLEY C., 115 E. 61st Street, New York 21, N. Y., 1941, '42, '44, '49.
1959. BREWER, DAVID W., 100 E. Genesee St., Syracuse 10, N. Y., 1959, '60*, '61.
1955. BROWN, LESTER ALEXANDER, 490 Peachtree Street, N.E., Atlanta 8, Georgia, 1955, '56, '57, '58, '59, '61.
1940. BROYLES, EDWIN N., 1100 North Charles Street, Baltimore 1, Maryland, 1940, '41*, '42, '46, '48*, '49, '50, '51*, '52, '53, '54, '55, '56, '58, '59*, '60, '61*.

1945. CAMPBELL, COLONEL PAUL A., USAF (MC), School of Aviation Medicine, Brooks Air Force Base, Texas, 1946, '47, '49, '51, '57*, '61.
1942. CANFIELD, NORTON, 35 Trumbull Street, New Haven 11, Connecticut, 1942, '46, '47, '48, '49*, '50, '51, '56, '57.
1959. CARDWELL, EDGAR P., 965 Broad St., Newark 2, N. J., 1959, '60, '61.
1957. CONLEY, JOHN J., 139 East 36th Street, New York 16, N.Y. 1958*, '60*, '61.
1957. CONVERSE, JOHN MARQUIS, 722 Park Avenue, New York 21, N.Y., '60.
1959. CRACOVANER, ARTHUR J., 103 E. 78th St., New York 21, N. Y., 1959, '60, '61*.
1960. DALY, JOHN F., 140 E. 54th St., New York 22, N. Y., 1960, '61*.
1951. DAVISON, FRANCIS W., Geisinger Memorial Hospital, Danville, Pa., 1951, '52, '53*, '54, '55, '56, '57, '58, '59, '60, '61.
1941. DIXON, FRED W., 1027 Rose Building, Cleveland 15, Ohio, 1941, '42*, '44, '46, '47*, '49*, '50, '51, '52, '53, '54, '55, '56, '57, '58*, '59, '60, '61.
1947. EAGLE, WATT WEEMS, Duke Hospital, Durham, N. C., 1948*, '49, '51, '53, '54, '56, '57, '59.
1954. EQUEN, MURDOCK S., Ponce de Leon Infirmary, Atlanta 8, Ga., 1954, '55, '57, '58, '60.
1952. ERICH, JOHN B., Mayo Clinic, 102 Second Avenue, Rochester, Minn., 1953, '56*, '57.
1955. FITZ-HUGH, GLASSELL SLAUGHTER, 2003 Spottswood Road, Charlottesville, Virginia, 1955, '57, '59, '60, '61.
1956. FRIEDBERG, STANTON A., 122 So. Michigan Ave., Chicago 3, Illinois, 1956, '57*, '58, '59, '60, '61.
1932. FURSTENBERG, ALBERT CARL, Out-Patient Bldg., University Hospital, Ann Arbor, Michigan, 1933*, '36*, '38*, '46, '48*, '50, '51, '53, '54, '55*, '56, '57, '58*, '59, '60, '61.

1959. GOLDMAN, JOSEPH L., 1050 Park Ave., New York, N. Y., 1959, '60*, '61.
1940. GOODALE, ROBERT L., 330 Dartmouth Street, Boston, Massachusetts, 1940, '41, '42*, '44*, '46, '47, '49, '50*, '53, '54, '55*, '56, '57*, '60, '61*.
1928. GOODYEAR, HENRY M., 556 Doctors' Building, Cincinnati 2, Ohio, 1928, '29, '30*, '31, '32, '33, '34*, '35, '36, '37, '38, '39, '40, '44*, '46, '47, '48, '49*, '51, '53, '55, '57, '59, '61.
1950. HALL, COLBY, 1136 West Sixth Street, Los Angeles 14, Calif., 1950.
1933. HARKNESS, GORDON FOLLETTE, Blackhawk Hotel, Davenport, Iowa, 1934, '35, '36*, '40, '41, '44, '46, '47, '48, '49, '50, '51, '52, '53, '54*, '55, '56, '57, '58, '59, '60, '61.
1957. HARRILL, JAMES A., Bowman Gray School of Medicine, Winston-Salem, N. C., 1957, '58, '59, '61.
1960. HARRIS, HERBERT, 907 Hermann Professional Building, Houston 25, Texas, 1960, '61*.
1959. HART, VERLING K., 106 W. 7th St., Charlotte, N. C., 1959, '60.
1942. HEATLY, CLYDE A., 11 North Goodman Street, Rochester 7, N.Y., 1942, '46*, '49, '50, '52, '53*, '54, '55, '57, '58, '60, '61.
1959. HENRY, G. ARNOLD, 170 St. George St., Toronto, Canada, 1959, '61.
1943. HILDING, ANDERSON C., Research Laboratory, St. Luke's Hospital, Duluth 11, Minnesota, 1944*, '46, '47, '48*, '49, '50, '51, '53, '55, '56*, '57, '60, '61.
1955. HILGER, JEROME A., 350 St. Peter Street, St. Paul 2, Minnesota, 1955, '56*, '57, '58, '59, '60.
1945. HOLINGER, PAUL H., 700 North Michigan Ave., Chicago 11, Illinois, 1946, '47, '49, '50*, '51*, '52, '53, '54*, '55, '56, '57, '58*, '59, '60, '61*.

1957. HOLMES, EDGAR M., 330 Dartmouth Street, Boston 16, Mass., 1957, '59, '61.
1944. HOOPLE, GORDON D., 1100 East Genesee St., Syracuse 10, New York, 1946, '47, '48, '49, '50, '51, '52, '53, '54*, '55, '56, '58, '59, '60, '61.
1952. IRELAND, P. E., Room 82, Banting Institute, University of Toronto, Toronto, Ontario, 1952, '53, '54, '55, '56*, '57, '59, '61.
1960. JOHNSTON, KENNETH C., 700 North Michigan Ave., Chicago 11, Ill., 1960, '61.
1961. JONES, EDLEY H., First National Bank Building, Vicksburg, Mississippi, 1961.
1953. LEDERER, FRANCIS LOEFFLER, 1853 W. Polk Street, Chicago 12, Illinois, 1953, '54, '55, '56, '57*, '58, '60, '61.
1936. LEJEUNE, FRANCIS ERNEST, Ochsner Clinic Building, Prytania and Aline Streets, New Orleans 15, Louisiana, 1937, '46*, '47, '50, '51, '52, '53, '54*, '55, '56, '57, '58, '59, '60, '61.
1961. LEWY, ROBERT B., 25 East Washington St., Chicago 2, Ill., 1961.
1933. LIERLE, DEAN M., University Hospital, Iowa City, Iowa, 1933, '34, '35*, '37, '38, '39, '40*, '42*, '44*, '46, '47*, '48, '49, '50*, '51, '52, '53, '54, '55*, '56, '57, '58, '59, '60.
1949. LINDSAY, JOHN R., 950 E. 59th Street, Chicago 37, Illinois, 1949, '50, '51*, '53, '55*, '56, '57, '58, '59, '60, '61.
1941. MARTIN, ROBERT C., 384 Post Street, San Francisco 8, California, 1941, '44, '47, '48, '50, '51, '53, '54, '55, '56, '58, '59, '60, '61.
1952. MCCALL, JULIUS W., 610 Rose Building, Cleveland 15, Ohio, 1952, '53*, '54, '55, '56, '57, '58, '59, '60*, '61.
1951. MCHENRY, LAWRENCE C., 301 N. W. 12th St., Oklahoma City 2, Okla., 1953*.

1933. McMAHON, BERNARD J., 150 No. Meramec Ave., Clayton 5, Missouri, 1934*, '35, '36, '38*, '41, '44, '46*, '47, '48, '49, '50*, '51, '52, '53, '54, '55*, '56*, '57, '58, '59, '60, '61.
1931. McNALLY, WILLIAM JAMES, 1509 Sherbrooke Street West, Montreal, Canada, 1931, '33, '34*, '39, '44, '47, '49, '49, '52, '53, '54*, '55, '56, '57, '58, '59, '60, '61.
1954. MELTZER, PHILIP E., 285 Commonwealth Ave., Boston, Mass., 1954*, '56, '57, '58, '59, '60, '61.
1952. MILLER, ALDEN H., 500 South Lucas Ave., Los Angeles 17, Calif., 1952, '53*, '55, '57, '58*, '61.
1958. MONTREUIL, FERNAND, 1123 St. Joseph Blvd., E., Montreal, Canada, 1958, '60.
1954. MOORE, PAUL M., 10,515 Carnegie Avenue, Cleveland, Ohio, 1954, '55*, '56, '57, '59, '60, '61.
1957. MUNOZ-MACCORMICK, CARLOS EDUARDO, 71 Park Terrace, Santurce, Puerto Rico, 1957, '58, '59, '60, '61.
1953. MURTAGH, JOHN A., 2 Maynard Street, Hanover, New Hampshire, 1953, '54, '55, '56*, '57, '58, '59, '61.
1937. NASH, C. STEWART, Medical Arts Building, Rochester 7, New York, 1937, '38*, '40, '42, '44, '46, '49, '50, '51, '52, '53, '54, '55, '56*, '58, '59, '60, '61.
1956. NORRIS, CHARLES MORGAN, 3401 North Broad Street, Philadelphia 40, Pennsylvania, 1956, '57, '58*, '59, '60, '61*.
1961. OGURA, JOSEPH H., 640 So. Kingshighway, St. Louis 10, Mo., 1961*.
1958. O'KEEFE, JOHN J., 255 S. 17th St., Philadelphia 3, Pa., 1958, '59*, '60.
1961. O'NEIL, JAMES J., 612 Medical Arts Building, Omaha, Nebraska, 1961.
1961. PANG, LUP Q., 52 South Vineyard Street, Honolulu 13, Hawaii, 1961.

1961. PASTORE, PETER N., Box 25, 1200 East Broad St., Richmond, Virginia, 1961.
1954. PRESSMAN, JOEL J., Department of Surgery, UCLA Medical Center, Los Angeles 24, Calif., 1954, '56*, '59*, '60, '61.
1951. PRIEST, ROBERT E., 79, S. Ninth St., Minneapolis 2, Minn., 1951, '53*, '54*, '56, '59, '60*, '61.
1951. PUTNEY, F. JOHNSON, 1712 Locust St., Philadelphai 3, Pa., 1951, '52, '53*, '54, '55, '56, '58*, '59, '60, '61.
1951. RAWLINS, AUBREY G., 384 Post Street, San Francisco 8, Calif., 1951, '53*, '56, '58.
1934. RICHARDS, LYMAN GILDER, 12 Clovelly Road, Wellesley Hills 81, Mass., 1934, '35, '36*, '37, '38, '39, '47, '49, '51*, '54, '56, '57*, '59, '60, '61.
1956. RICHARDSON, JOHN ROBERT, 403 Commonwealth Avenue, Boston 15, Massachusetts, 1957, '58, '59, '60.
1945. ROBB, JAMES M., 633 David Whitney Building, Detroit 26, Michigan, 1946, '48, '49*, '51, '52, '55, '56, '57, '59, '60, '61.
1953. ROBERTS, SAM E., 1100 Professional Bldg., Kansas City, Missouri, 1953, '54*, '55, '56, '57, '58, '59, '60.
1959. SANDERS, SAM H., 1089 Madison Ave., Memphis 3, Tenn., 1959, '60, '61.
1932. SCHALL, LEROY ALLEN, Scudder Lane, Barnstable, Massachusetts, 1934*, '35, '38, '40*, '41, '42, '44*, '46, '47, '48*, '49, '50*, '51, '53*, '54, '55, '57*, '59*, '60, '61.
1934. SCHENCK, HARRY P., 326 South 19th Street, Philadelphia 3, Pennsylvania, 1934, '35, '36*, '37, '38, '39, '40, '41*, '44*, '46, '47, '49, '50, '51, '52, '53, '54, '55, '56, '57, '58*, '59*, '60, '61.
1959. SILCOX, LOUIS E., 102 Lankenau Med. Bldg., Philadelphia 31, Pa., 1959, '60, '61.
1958. SIMONTON, KINSEY M., Mayo Clinic, Rochester, Minn., 1958, '59*.

1939. SIMPSON, W. LIKELY, 512 Physicians' and Surgeons' Building, Memphis 3, Tennessee, 1939, '41, '44*, '46, '47*, '48, '50, '51*, '52, '53, '54, '55, '57, '58, '59, '60, '61.
1950. SMITH, AUSTIN T., Pennsylvania Hospital, 330 So. 9th St., Philadelphia 7, Pa., 1950, '51, '52, '53, '55, '56, '57, '58*, '59, '60, '61.
1954. SOOY, FRANCIS A., 490 Post Street, San Francisco 2, Calif., 1954, '56*, '58, '60.
1961. SUEHS, OLIVER W., 14 Medical Arts Square, Austin, Texas, 1961.
1947. THEOBALD, WALTER H., 307 N. Michigan Avenue, Chicago, Illinois, 1947, '48*, '49, '50, '51, '52, '53, '54, '55, '56, '57, '58, '60, '61.
1954. THORNELL, WILLIAM C., 2508 Auburn Avenue, Cincinnati 19, Ohio, 1955*, '57, '59, '60.
1950. TREMBLE, G. EDWARD, 1390 Sherbrooke St. W., Montreal, Quebec, Canada, 1950, '51, '52, '53, '54, '55*, '56, '57, '58, '60, '61.
1943. VAN ALYEA, OLIVER E., 135 South LaSalle Street, Chicago 3, Illinois, 1944, '46*, '47, '48, '50, '51, '52*, '53, '54, '55, '56*, '57, '58, '59, '60.
1954. WALSH, THEODORE E., 640 S. Kingshighway Blvd., St. Louis 10, Missouri, 1954, '55*, '56, '57, '58, '59, '60, '61.
1940. WEILLE, FRANCIS L., 247 Commonwealth Avenue, Boston 16, Massachusetts, 1940, '41, '42, '44, '46*, '47, '48, '49, '50, '51, '52, '53, '54, '55, '56*, '57, '58, '59, '60, '61.
1948. WHALEN, EDWARD J., 750 Main Street, Hartford, Connecticut, 1948, '50, '51, '52, '54, '55, '57, '59.
1948. WILLIAMS, HENRY L., 2nd, Mayo Clinic, Rochester, Minnesota, 1948, '49, '50*, '51, '52*, '53, '54, '55, '56, '57, '58*, '59, '60.
1951. WOODMAN, DEGRAAF, 156 E. 37th Street, New York 16, N. Y., 1951, '53, '54, '55*, '56, '58, '59, '60, '61.

1953. WORK, WALTER P., 384 Post Street, San Francisco 8, California, 1953, '54, '56, '58, '59*.

Honorary Fellows

1957. (1925) CLERF, LOUIS H., 5575 Eighth Avenue, North, St. Petersburg 2, Florida, 1957, '58, '59, '60, '61.
1960. (1928) HILL, FREDRICK THAYER, Professional Building, Waterville, Maine, 1960, '61.
1943. (1918) LEWIS, FIELDING O., Providence Road, Media, Pennsylvania.
1957. (1930) NEGUS, SIR VICTOR E., 149 Harley Street, London, W 1, England, 1957*.
1957. (1924) PROETZ, ARTHUR W., 12 Westmoreland Place, St. Louis 8, Missouri, 1957, '58, '59, '60.

Corresponding Fellows

1946. ALONSO, REGULES JUSTO E., Mercedes 1233, Montevideo, Uruguay.
1959. BARRETTO, PLINIO DE MATTOS, Ru Cons Torres, Homer 371, Sao Paulo, Brazil, 1960.
1959. BATEMAN, GEOFFREY H., 55 Harley Street, London W.1., England.
1942. BATSON, OSCAR V., 203 South DeKalb St., Philadelphia 4, Pennsylvania, 1942*, '54*.
1943. EGGSTON, ANDREW A., 653 Park Avenue, New York, N. Y., 1944, '49, '55, '60, '61*.
1961. FAABORG-ANDERSEN, K., Central Hospital, Nykøbing, Falster, Denmark, 1961.
1957. HUIZINGA, EELCO, Noorderhaven 7, Groningen, The Netherlands, 1957.
1950. LARSELL, OLOF, University of Oregon Medical School, Portland, Oregon, 1950*.

1957. ONO, JO, 75 Zaimoku-cho, Azabu, Minato-ku, Tokyo, Japan, 1957.
1937. PORTMANN, GEORGES, 25 bis Cours de Verdun, Bordeaux, France, 1947.
1957. RUEDI, LUZIUS, Ramistrasse 100, Zurich, Switzerland, 1957.
1924. SCHAEFER, J. PARSONS, 4634 Spruce Street, Philadelphia 39, Pennsylvania, 1934.
1952. TAPIA ACUNA, RICARDO, Av. Insurgentes Sur 300, Mexico 7 D.F., 1953, '57, '60*.
1936. VIALLE, JACQUES, 27 Rue de France, Nice (Alpes Maritimes), France.

Emeritus Fellows

1961. (1936) BALLENGER, HOWARD C., 723 Elm Street, Winnetka, Illinois.
1941. (1923) BARLOW, ROY A., Musquodoboit Harbor, Nova Scotia, Canada.
1951. (1944) BEATTY, HUGH G., 21 E. State St., Columbus 15, Ohio, 1951, '52, '53.
1961. (1930) CAMPBELL, EDWARD HASTINGS, 133 S. 36th St., Philadelphia 4, Pa.
1958. (1930) FIGI, FREDERICK A., Mayo Clinic, Rochester, Minn.
1946. (1933) FOSTER, JOHN H., Plaza Hotel, Houston, Texas, 1948, '49, '50, '51, '52.
1961. (1936) GALLOWAY, THOMAS CYRUS, 636 Church St., Evanston, Illinois, 1961.
1951. (1928) GITTINS, THOMAS R., 408 Davidson Bldg., Sioux City, Iowa.
1960. (1940) HANSEL, FRENCH, 634 N. Grand Blvd., St. Louis, Missouri.
1957. (1944) HAVENS, FRED Z., 102 Second Avenue S.W., Rochester, Minnesota.

1955. (1930) HOUSER, KARL M., 2035 Delancey Street, Philadelphia 3, Pennsylvania.
1951. (1928) JARVIS, DEFOREST C., Quarry Bank Bldg., Barre, Vt., 1952.
1956. (1939) JOHNSTON, WILLIAM HOWARD, 2030 State Street, Santa Barbara 7, California, 1957, '58.
1960. (1942) KELLY, JOSEPH D., 140 East Fifty-fourth Street, New York 22, N. Y.
1961. (1950) KLINE, ORAM R., 514 Cooper Street, Camden, N. J., 1961.
1954. (1927) LUKENS, ROBERT M., 141 West Heather Road, Wildwood Crest, N. J.
1954. (1928) MACPHERSON, DUNCAN, 2350 Broadway, New York 24, N. Y.
1948. (1939) MYERS, JOHN LLEWELLYN, 1115 Grand Avenue, Kansas City, Missouri.
1959. (1927) MYERSON, MERVIN C., 436 North Roxbury Drive, Beverley Hills, Calif.
1957. (1948) PHELPS, KENNETH A., 1850 Willow Road, Palo Alto, Calif. 1958.
1958. (1938) SALINGER, SAMUEL, 1260 East Alejo Road, Palm Springs, Calif., 1958, '59, '61.
1954. (1930) SEYDELL, ERNEST M., First National Bank Building, Wichita, Kansas, 1957.
1961. (1941) VIOLE, PIERRE P., 1930 Wilshire Boulevard, Los Angeles 5, Calif.
1950. (1922) WHITE, FRANCIS W., 180 Central Park So., New York 19, N. Y.
1951. (1935) WOODWARD, FLETCHER D., 1326 Rugby Road, Charlottesville, Va., 1959, '60, '61.

BENEFACTORS

DR. JOHN F. BARNHILL

DR. FREDERICK T. HILL

DR. GORDON BERRY

DR. & MRS. GEORGE E. HOURN

DR. WILLIAM E. CASSELBERRY

DR. SAMUEL JOHNSTON

DR. LOUIS H. CLERF

DR. JAMES E. NEWCOMB

DR. CORNELIUS G. COAKLEY

DR. HENRY B. ORTON

DR. ARTHUR W. DEROALDES

DR. SAMUEL SALINGER

DR. & MRS. LEE WALLACE DEAN

DR. BURT R. SHURLY

DR. FRED W. DIXON

MR. LESTER T. SUNDERLAND

DR. WILLIAM E. GROVE

DR. H. MARSHALL TAYLOR

DR. WALTER H. THEOBALD

BENEFACTORS OF THE LARYNGOLOGICAL
RESEARCH FUND

DR. JOHN F. BARNHILL

DR. AND MRS. LEE WALLACE DEAN

DR. GORDON BERRY

DR. FREDERICK T. HILL

DR. AND MRS. GEORGE E. HOURN

DR. SAMUEL SALINGER

DR. H. MARSHALL TAYLOR

DR. LOUIS H. CLERF

MR. LESTER T. SUNDERLAND

DR. WILLIAM E. GROVE

DR. BURT R. SHURLY

DR. HENRY B. ORTON



Obverse of the deRoaldes medal

RECIPIENTS OF THE DE ROALDES AWARD

- 1928. DR. CHEVALIER JACKSON
- 1931. DR. D. BRYSON DELAVAN
- 1934. DR. HARRIS P. MOSHER
- 1937. DR. LEE WALLACE DEAN
- 1943. DR. RALPH A. FENTON
- 1949. DR. GEORGE M. COATES
- 1951. DR. ARTHUR W. PROETZ
- 1954. DR. LOUIS H. CLERF
- 1959. DR. ALBERT C. FURSTENBERG
- 1960. DR. DEAN M. LIERLE
- 1961. DR. FREDERICK T. HILL

RECIPIENTS OF THE CASSELBERRY AWARD

1923. DR. GEORGE FETTEROLF AND DR. HERBERT FOX
1928. DR. RALPH A. FENTON AND DR. O. LARSELL
1929. DR. RICHARD A. KERN AND DR. HARRY P. SCHENCK
1929. DR. EDWARD H. CAMPBELL
1931. DR. ARTHUR W. PROETZ
1934. DR. ANDERSON C. HILDING
1936. DR. FRANCIS E. LEJEUNE: DR. JOEL J. PRESSMAN
1939. DR. H. MARSHALL TAYLOR: DR. BRIEN T. KING
1940. DR. FRENCH K. HANSEL
1941. DR. NOAH D. FABRICANT
1946. DR. PAUL H. HOLINGER
1949. DR. HENRY B. ORTON

RECIPIENTS OF THE NEWCOMB AWARD

- 1941. DR. BURT R. SHURLY
- 1942. DR. FRANCIS R. PACKARD
- 1943. DR. GEORGE M. COATES
- 1944. DR. CHARLES J. IMPERATORI
- 1947. DR. HARRIS P. MOSHER
- 1948. DR. GORDON BERRY
- 1949. DR. GORDON B. NEW
- 1950. DR. H. MARSHALL TAYLOR
- 1951. DR. JOHN D. KERNAN
- 1952. DR. WILLIAM J. McNALLY
- 1953. DR. FREDERICK T. HILL
- 1954. DR. HENRY B. ORTON
- 1955. DR. THOMAS C. GALLOWAY
- 1956. DR. DEAN M. LIERLE
- 1957. DR. GORDON F. HARKNESS
- 1958. DR. ALBERT C. FURSTENBERG
- 1959. DR. HARRY P. SCHENCK
- 1960. DR. JOEL J. PRESSMAN
- 1961. DR. CHEVALIER L. JACKSON

PAST OFFICERS

Presidents

(Year of Election)

1879. Louis Elsberg	1909. J. E. Logan
1880. J. Solis-Cohen	1910. D. Braden Kyle
1881. F. I. Knight	1911. James E. Newcomb
1882. G. M. Lefferts	1912. George A. Leland
1883. F. H. Bosworth	1913. Thomas Hubbard
1884. E. L. Shurly	1914. Alexander W. MacCoy
1885. Harrison Allen	1915. G. Hudson Makuen
1886. E. Fletcher Ingals	1916. Joseph L. Goodale
1887. R. P. Lincoln	1917. Thomas H. Halstead
1888. E. C. Morgan	1918. Cornelius G. Coakley
1889. J. N. Mackenzie	1919. Norval H. Pierce
1890. W. C. Glasgow	1920. Harris P. Mosher
1891. S. W. Langmaid	1921. Harmon Smith
1892. M. J. Asch	1922. Emil Mayer
1893. D. Bryson Delavan	1923. J. Payson Clark
1894. J. O. Roe	1924. Lee Wallace Dean
1895. W. H. Daly	1925. Greenfield Sluder
1896. C. H. Knight	1926. Chevalier Jackson
1897. T. R. French	1927. D. Bryson Delavan
1898. W. E. Casselberry	1928. Charles W. Richardson
1899. Samuel Johnston	1929. Lewis A. Coffin
1900. H. L. Swain	1930. Francis R. Packard
1901. J. W. Farlow	1931. George E. Shambaugh
1902. J. H. Bryan	1932. George Fetterolf
1903. J. H. Hartman	1933. George M. Coates
1904. C. C. Rice	1934. Dunbar Roy
1905. J. W. Gleitsman	1935. Burt R. Shurly
1906. A. W. deRoaldes	1936. William B. Chamberlain
1907. H. S. Birkett	1937. John F. Barnhill
1908. A. Coolidge, Jr.	1938. George B. Wood

1939. James A. Babbitt	1951. H. Marshall Taylor
1940. Gordon Berry	1952. Louis H. Clerf
1941. Thomas E. Carmody	1953. Gordon F. Harkness
1942-3. Charles J. Imperatori	1954. Henry B. Orton
1944-5. Harold I. Lillie	1955. Bernard J. McMahon
1946. Frank R. Spencer	1956. LeRoy A. Schall
1947. Arthur W. Proetz	1957. Harry P. Schenck
1948. Frederick T. Hill	1958. Fred W. Dixon
1949. Ralph A. Fenton	1959. William J. McNally
1950. Gordon B. New	1960. Edwin N. Broyles

Vice-Presidents

1879. F. H. Davis	J. O. Roe
1880. W. C. Glasgow	W. Porter
1881. E. L. Shurly	E. F. Ingals
1882. C. Seiler	S. Johnston
1883. S. W. Langmaid	W. H. Daly
1884. J. H. Hartman	G. W. Major
1885. H. A. Johnson	J. N. Mackenzie
1886. E. C. Morgan	S. W. Langmaid
1887. J. N. Mackenzie	C. E. DeM. Sajous
1888. W. C. Glasgow	C. E. Bean
1889. E. Holden	J. H. Hartman
1890. J. O. Roe	S. Johnston
1891. M. J. Asch	J. C. Mulhall
1892. S. Johnston	W. E. Casselberry
1893. J. C. Mulhall	S. H. Chapman
1894. C. C. Rice	A. W. deRoaldes
1895. J. Wright	D. N. Rankin
1896. T. M. Murray	H. S. Birkett
1897. A. W. MacCoy	F. W. Hinkel
1898. J. W. Farlow	M. R. Brown
1899. T. A. DeBlois	A. A. Bliss
1900. H. L. Wagner	D. Braden Kyle
1901. J. W. Gleitsmann	

1902. G. A. Leland	T. Melville Hardie
1903. J. H. Lowman	W. Peyre Porcher
1904. Thomas Hubbard	W. J. Freeman
1905. J. L. Goodale	C. W. Richardson
1906. G. H. Makuen	A. B. Thrasher
1907. J. P. Clark	J. E. Rhodes
1908. E. Mayer	F. R. Packard
1909. C. G. Coakley	H. P. Mosher
1910. Robert C. Myles	J. M. Ingersoll
1911. F. C. Cobb	B. R. Shurly
1912. A. W. Watson	W. Scott Renner
1913. F. E. Hopkins	Geo. F. Shambaugh
1914. Clement T. Theisen	Lewis A. Coffin
1915. J. Gordon Wilson	Christian R. Holmes
1916. Thomas H. Halsted	Greenfield Sluder
1917. John Edwin Rhodes	D. Crosby Greene
1918. G. E. Shambaugh	John R. Winslow
1919. Francis R. Packard	Harmon Smith
1920. Harmon Smith	W. B. Chamberlin
1921. Dunbar Roy	Robert C. Lynch
1922. George Fetterolf	Lorenzo B. Lockard
1923. Hubert Arrowsmith	Joseph B. Greene
1924. Ross H. Skillern	Gordon Berry
1925. John E. Mackenty	Robert Levy
1926. Lewis A. Coffin	William V. Mullin
1927. Charles W. Richardson	Hill Hastings
1928. Robert Clyde Lynch	Francis P. Emerson
1929. William B. Chamberlin	Ralph Albert Fenton
1930. Harris P. Mosher	James A. Babbitt
1931. Joseph B. Greene	E. Ross Faulkner
1932. Gordon Berry	Frank A. Spencer
1933. E. Ross Faulkner	Thomas S. Carmody
1934. Gordon B. New	Samuel McCullagh
1935. Edward C. Sewall	H. Marshall Taylor
1936. William P. Wherry	Harold I. Lillie

1937. Frank R. Spencer	Bernard J. McMahon
1938. Ralph A. Fenton	Frederick T. Hill
1939. John H. Foster	Thomas R. Gittins
1940. Charles H. Porter	Gordon F. Harkness
1941. Arthur W. Proetz	Henry B. Orton
1942-3. Harold I. Lillie	Dean M. Lierle
1944-5. John J. Shea	Thomas C. Galloway
1946. H. Marshall Taylor	C. Stewart Nash
1947. John J. Shea	Frederick A. Figi
1948. Henry B. Orton	Anderson C. Hilding
1949. LeRoy A. Schall	Fletcher D. Woodward
1950. W. Likely Simpson	Lyman G. Richards
1951. Wm. J. McNally	Thomas C. Galloway
1952. J. Mackenzie Brown	Edwin N. Broyles
1953. Claude C. Cody	Daniel S. Cunning
1954. James H. Maxwell	Clyde A. Heatly
1955. Robert L. Goodale	Paul H. Holinger
1956. Henry M. Goodyear	Robert E. Priest
1957. Francis E. LeJeune	Pierre P. Viole
1958. Charles Blassingame	Chevalier L. Jackson
1959. James Maxwell	Oliver Van Alyea
1960. Walter Theobald	Anderson Hilding

Secretaries and Treasurers

1879. G. M. Lefferts	1895. H. L. Swain
1882. D. Bryson Delavan	1900. P. E. Newcomb
1889. C. H. Knight	1911. Harmon Smith

Secretaries

1912. Harmon Smith	1933. William V. Mullin
1918. D. Bryson Delavan	1935. James A. Babbitt
1919. J. M. Ingersoll	1939. Charles J. Imperatori
1920. George M. Coates	1942. Arthur W. Proetz

- | | |
|------------------------|-------------------------|
| 1947. Louis H. Clerf | 1957. James H. Maxwell |
| 1952. Harry P. Schenck | 1959. Lyman G. Richards |

Treasurers

- | | |
|-----------------------------|--------------------------|
| 1912. J. Payson Clark | 1939. Frederick T. Hill |
| 1923. George Fetterolf | 1948. Gordon F. Harkness |
| 1932. William V. Mullin | 1953. Fred W. Dixon |
| 1933. James A. Babbitt | 1958. Francis E. LeJeune |
| 1935. Charles J. Imperatori | |

Librarians

- | | |
|----------------------|------------------------|
| 1879. F. H. Bosworth | 1930. John F. Barnhill |
| 1883. T. R. French | 1934. Burt R. Shurly |
| 1903. J. H. Bryan | 1935. George M. Coates |

Librarian and Historian

- | | |
|------------------------|----------------------|
| 1936. George M. Coates | 1944. Louis H. Clerf |
|------------------------|----------------------|

Librarian, Historian and Editor

- | | |
|--------------------------|--------------------------|
| 1947. Harry P. Schenck | 1955. Edwin N. Broyles |
| 1952. Bernard J. McMahon | 1960. Francis W. Davison |

PAST FELLOWS

Dates indicate original election to the Association

**Deceased*

Honorary Fellows

- *1908. Barnhill, John F., Miami Beach, Florida.
- *1893. Birkett, Herbert S., Montreal, Canada.
- *1878. Bosworth, Francke H., New York City.
- *1917. Coates, George M., Philadelphia, Pa.
- *1918. Dean, Lee Wallace, St. Louis, Mo.
- *1881. Delavan, D. Bryson, New York City.
- *1893. deRoaldes, Arthur W., New Orleans, La.
- *1890. De La Sota Y. Lastra, Ramon, Seville, Spain.
- *1923. Fenton, Ralph A., Portland, Oregon
- *1879. French, Thomas R., Brooklyn, N. Y.
- *1880. Garcia, Senior Manuel, London, England.
- *1903. Harris, Thos. J., New York City.
- *1907. Jackson, Chevalier, Schwenksville, Pa.
- *1878. Johnston, Samuel, Baltimore, Md.
- *1878. Lefferts, George Morewood, Katonah, N. Y.
- *1914. Levy, Robert, Denver, Colo.
- *1883. Mackenzie, John N., Baltimore, Md.
- *1881. Mackenzie, Sir Morel, London, England.
- *1910. Masser, Ferdinand, Naples, Italy.
- *1904. Mosher, Harris P., Marblehead, Mass.
- *1910. Moure, J. J. E., Bordeaux, France.
- *1937. Nager, F. R., Zurich, Switzerland.
- *1918. Oliver, H. K., Boston, Mass.
- *1906. Pierce, Norval Harvey, San Diego, Calif.
- *1909. Semon, Sir Felix, Great Missenden, England.
- *1878. Solis-Cohen, J., Philadelphia, Pa.
- *1889. Swain, Henry L., New Haven, Conn.
- *1914. Thomson, Sir St. Clair, London, Eng.
- *1903. Tilley, Herbert, London, England.
- *1914. Wagner, Clinton, New York City.
- *1890. Wright, Jonathan, Pleasantville, N. Y.

Corresponding Fellows

- *1892. Browne, Lennox, London, England.
- *1938. Blair, Vilray P., St. Louis, Missouri.
- *1940. Colledge, Lionel, London, England.
- *1901. Collier, Mayo, Kearsney Abbey, Kent, England.
- *1893. Desvernine, Carlos M., Havana, Cuba.
- *1930. Emerson, Francis P., Franklin, Mass.
- *1936. Fraser, John S., Edinburgh, Scotland.
- *1901. Grant, Sir James Dundas, London, England.
- *1887. Cougenheim, A., Paris, France.
- *1894. Holden, Edgar, Newark, N. J.
- *1919. Kelly, Adam Brown, Helensburgh, Scotland.
- *1881. Labus, Carlo, Milan, Italy.
- *1931. LasSagna, Francesco, Parma, Italy.
- *1926. Law, Frederick M., New York, N. Y.
- *1921. LeMaitre, Ferdinand, Paris, France.
- *1902. Lermoyez, Marcel, Paris, France.
- *1897. Luc, H., Paris, France.
- *1896. MacDonald, Greville, Haslemere, Surrey, England.
- *1894. MacIntyre, John, Glasgow, Scotland.
- *1903. McBride, P., York, England.
- *1920. McKenzie, Dan, London, England.
- *1919. McKernon, James F., New Canaan, Conn.
- *1880. Meyer, Wilhelm, Copenhagen, Denmark.
- *1910. Moure, J. J. E., Bordeaux, France.
- *1896. Mygind, Holger, Copenhagen, Denmark.
- *1950. Neil, James Hardie, Auckland, New Zealand.
- *1919. Paterson, Donald Rose, Cardiff, Wales.
- *1941. Patterson, Norman, Herts, England.
- *1919. Rogers, John, Jr., New York City.
- *1894. Sajous, C. E. DeM., Philadelphia, Pa.
- *1896. Schmiegelow, Ernst, Copenhagen, Denmark.
- *1946. Segura, Eliseo, Buenos Aires, Argentina.
- *1940. Soto, E. Fernandez, Havana, Cuba.
- *1881. Thornton, Pugin, London, England.
- *1913. Turner, A. Logan, Edinburgh, Scotland.
- *1880. Whistler, W. McNeil, London, England.
- *1901. Wingrave, Wyatt, Lyme Regis, Dorset, England.
- *1894. Wolfenden, R. Norris, Kent, England.

Emeritus Fellows

- *1915. Barnes, Harry Aldrich, Kingston, Mass.
- *1928. Beck, Joseph C., Chicago, Illinois.
- *1921. Berry, Gordon, Worcester, Mass.
- *1901. Brown, J. Price, Toronton, Canada.
- *1891. Bryan, Joseph H., Washington, D. C.
- *1913. Butler, Ralph, Philadelphia, Pa.
- *1897. Clark, J. Payson, Boston, Mass.
- *1899. Cobb, Frederick C., Bradenton, Florida.
- *1939. Cody, Claude C., Jr., Houston, Texas.
- *1905. Coffin, Lewis A., New York City.
- *1893. Coolidge, Algernon, Boston, Mass.
- *1937. Crowe, Samuel J., Baltimore, Maryland.
- *1941. Cunning, Daniel S., New York City.
- *1913. Dabney, Virginius, Washington, D. C.
- *1882. De Blois, Thomas Amory, Boston, Mass.
- *1892. Farlow, John W., Boston, Mass.
- *1922. Forbes, Henry H., New York City.
- *1905. Freer, Otto T., Chicago, Ill.
- *1940. Gatewood, E. Tribble, Richmond, Va.
- *1880. Gleitsmann, Joseph W., New York City.
- *1922. Goldsmith, Perry G., Toronto, Canada.
- *1898. Goodale, Joseph L., Ipswich, Mass.
- *1932. Graham, Harrington B., San Francisco, California.
- *1906. Greene, D. Crosby, Jr., Boston, Mass.
- *1917. Greene, Joseph B., Asheville, N. C.
- *1905. Halsted, Thomas H., Los Angeles, Calif.
- *1896. Hardie, Thomas Melville, Chicago, Ill.
- *1915. Hastings, Hill, Los Angeles, Calif.
- *1888. Hinkel, Frank Whitehill, Buffalo, New York.
- *1895. Hopkins, Frederick E., Springfield, Mas.
- *1927. Hubbard, Thomas, Toledo, Ohio.
- *1919. Hurd, Lee Maidment, Rowayton, Conn.
- *1920. Imperatori, Charles J., Essex, N. Y.
- *1904. Ingersoll, John Marvin, Miami, Fla.
- *1918. Kenyon, Elmer L., Chicago, Ill.
- *1921. Kernan, John D., New York
- *1929. Kistner, Frank B., Portland, Oregon.
- *1885. Knight, Charles H., New York City.
- *1939. Large, Secord H., Cleveland, Ohio.

- *1894. Leland, George A., Boston, Mass.
- *1922. Lillie, Harold I., Rochester, Minn.
- *1943. Lincoln, William R., Cleveland, Ohio.
- *1928. Lyman, Harry Webster, St. Louis, Mo.
- *1886. MacCoy, Alexander W., Philadelphia, Pa.
- *1896. Mayer, Emil, New York City.
- *1951. McCart, Howard W. D., Toronto, Canada.
- *1939. McCaskey, Carl H., Indianapolis, Indiana.
- *1943. McCullagh, Samuel, New York, N. Y.
- *1923. McKinney, Richmond, Memphis, Tenn.
- *1922. New, Gordon B., Rochester, Minn.
- *1878. Porter, William, Ocean Springs, Miss.
- *1901. Myles, Robert C., New York City.
- *1923. Newhart, Horace, Minneapolis, Minn.
- *1903. Packard, Francis R., Philadelphia, Pa.
- *1942. Potts, John B., Omaha, Nebr.
- *1903. Renner, W. Scott, Buffalo, N. Y.
- *1897. Rhodes, John Edwin, Chicago, Ill.
- *1884. Rice, Clarence C., New York City.
- *1905. Richards, George L., South Yarmouth, Mass.
- *1878. Robinson, Beverly, New York City.
- *1921. Sauer, William E., St. Louis, Mo.
- *1923. Sewall, Edward C., Palo Alto, Cal.
- *1907. Shambaugh, George E., Chicago, Ill.
- *1908. Smith, Harmon, New York City.
- *1923. Spencer, Frank R., Boulder, Colo.
- *1927. Tobey, Harold G., Boston, Mass.
- *1925. Tucker, Gabriel, Haverford, Pa.
- *1892. Wagner, Henry L., San Francisco, Calif.
- *1892. Watson, Arthur W., Philadelphia, Pa.
- *1939. Wilson, J. Gordon, Old Bennington, Vt.
- *1905. Wood, George B., Wynnewood, Pa.

Active Fellows

- *1880. Allen, Harrison, Philadelphia, Pa.
- *1917. Arrowsmith, Hubert, Brooklyn, N. Y.
- *1879. Asch, Morris J., New York City.
- *1923. Babbitt, James A., Philadelphia, Pa.
- *1906. Ballenger, William L., Chicago, Ill.

- * 1880. Bean, C. E., St. Paul, Minn.
- * 1949. Beck, August L., New Rochelle, N. Y.
- * 1904. Berens, T. Passmore, New York City.
- * 1924. Bigelow, Nolton, Providence, R. I.
- * 1938. Blassingame, Charles D., Memphis, Tenn.
- * 1893. Bliss, Arthur Ames, Philadelphia, Pa.
- * 1951. Boyden, Guy L., Portland, Oregon
- * 1895. Boylan, J. E., Cincinnati, Ohio.
- * 1932. Brown, John Mackenzie, Los Angeles, Calif.
- * 1892. Brown, Moreau R., Chicago, Ill.
- * 1933. Buckley, Robert E., New York City.
- * 1915. Canfield, R. Bishop, Ann Arbor, Mich.
- * 1934. Carmack, John Walter, Indianapolis, Ind.
- * 1924. Carmody, Thomas E., Denver, Colo.
- * 1889. Casselberry, William E., Chicago, Ill.
- * 1883. Chamberlain, C. W., Hartford, Conn.
- * 1917. Chamberlin, William B., Cleveland, Ohio.
- * 1896. Chappell, W. F., New York City.
- * 1882. Chapman, S. Hartwell, New Haven, Conn.
- * 1902. Coakley, Cornelius G., New York City.
- * 1913. Coffin, Rockwell C., Boston, Mass.
- 1918. Cox, Gerald H., New York City.
- * 1880. Cushing, E. W., Boston, Mass.
- * 1878. Cutter, Ephraim, West Falmouth, Mass.
- * 1880. Daly, W. H., Pittsburgh, Pa.
- * 1878. Davis, F. H., Chicago, Ill.
- * 1941. Davis, Warren B., Philadelphia, Pa.
- 1926. Dennis, Frank Lownes, Colorado Springs, Col.
- * 1901. Dickerman, E. T., Chicago, Ill.
- * 1878. Donaldson, Frank, Baltimore, Md.
- * 1947. Engler, Clarence W., Cleveland, Ohio.
- * 1935. Eves, Curtis C., Philadelphia, Pa.
- * 1919. Faulkner, E. Ross, New York City.
- * 1914. Fetterolf, George, Philadelphia, Pa.
- * 1901. Freeman, Walter J., Philadelphia, Pa.
- * 1917. Friedberg, Stanton A., Chicago, Ill.
- 1940. Fuchs, Valentine H., New Orleans, La.
- 1909. Getchell, Albert C., Worcester, Mass.
- * 1897. Frothingham, Richard, New York City.
- * 1907. Gibb, Joseph S., Philadelphia, Pa.

- *1940. Gill, William D., San Antonio, Texas.
- *1878. Glasgow, William Carr, St. Louis, Mo.
- *1913. Goldstein, Max A., St. Louis, Mo.
- *1905. Grayson, Charles P., Philadelphia, Pa.
- *1934. Grove, William E., Milwaukee, Wisconsin
- *1878. Hartman, J. H., Baltimore, Md.
- *1945. Hickey, Harold L., Denver, Colo.
- *1879. Holden, Edgar, Newark, N. J.
- *1907. Holmes, Christian R., Cincinnati, Ohio.
- *1882. Hooper, Franklin H., Boston, Mass.
- *1893. Hope, George B., New York City.
- *1938. Hourn, George E., St. Louis, Mo.
- *1939. Hunt, Westley Marshall, New York, N. Y.
- *1901. Hyatt, Frank, Washington, D. C.
- *1925. Iglauer, Samuel, Cincinnati, Ohio.
- *1878. Ingals, E. Fletcher, Chicago, Ill.
- *1882. Ives, Frank L., New York City.
- *1938. Jackson, Chevalier L., Philadelphia, Pa.
- *1880. Jarvis, William C., New York City.
- *1878. Johnson, Hosmer A., Chicago, Ill.
- *1879. Johnson, Woolsey, New York City.
- *1944. Jones, Marvin F., New York City.
- *1879. Kealhofer, R. H., St. Louis, Mo.
- *1942. King, Edward D., North Hollywood, Calif.
- *1901. King, Gordon, New Orleans, La.
- *1885. Knight, Charles H., New York City.
- *1878. Knight, Frederick Irving, Boston, Mass.
- *1898. Kyle, D. Braden, Philadelphia, Pa.
- *1880. Langmaid, Samuel W., Boston, Mass.
- *1878. Lincoln, Rufus P., New York City.
- *1911. Lockard, Lorenzo B., Denver, Colo.
- *1913. Loeb, Hanau W., St. Louis, Mo.
- *1897. Logan, James E., Kansas City, Mo.
- *1935. Looper, Edward A., Baltimore, Maryland.
- *1888. Lowman, John H., Cleveland, Ohio.
- *1919. Lynah, Henry L., New York City.
- *1952. Lynch, Mercer G., New Orleans, La.
- *1915. Lynch, Robert Clyde, New Orleans, La.
- *1879. McBurney, Charles, New York City.
- *1927. McGinnis, Edwin, Chicago, Ill.

1936. McGregor, Gregor, Toronto, Canada.
*1913. McKimmie, O. A., Washington, D. C.
*1945. McLaurin, John G., Dallas, Texas.
*1885. McSherry, H. Clinton, Baltimore, Md.
*1914. Mackenty, John E., New York City.
*1898. Makuen, G. Hudson, Philadelphia, Pa.
*1881. Major, G. W., Montreal, Canada.
*1948. Maxwell, James H., Ann Arbor, Mich.
*1881. Morgan, E. C., Washington, D. C.
*1950. Morrison, Lewis F., San Francisco, Calif.
*1940. Morrison, William W., New York City.
*1886. Mulhall, J. C., St. Louis, Mo.
*1925. Mullin, William V., Cleveland, Ohio.
*1914. Munger, Carl E., Waterbury, Conn.
*1892. Murray, T. Morris, Washington, D. C.
*1881. Mynter, H., Buffalo, N. Y.
*1893. Newcomb, James E., New York City.
*1895. Nichols, J. E. H., New York City.
*1927. Orton, Henry B., Newark, N. J.
*1894. Park, William H., New York City.
*1892. Porcher, W. Peyre, Charleston, S. C.
*1927. Porter, Charles T., Boston, Mass.
*1908. Randall, B. Alexander, Philadelphia, Pa.
*1882. Rankin, D. N., Allegheny, Pa.
*1902. Richardson, Charles W., Washington, D. C.
*1930. Ridpath, Robert E., Philadelphia, Pa.
*1879. Roe, John O., Rochester, N. Y.
*1881. Robertson, J. M., Detroit, Mich.
*1913. Roy, Dunbar, Atlanta, Ga.
*1878. Rumbold, T. F., St. Louis, Mo.
*1879. Seiler, Carl, Philadelphia, Pa.
*1928. Shea, John Joseph, Memphis, Tennessee.
*1893. Shields, Charles M., Richmond, Pa.
*1909. Shurly, Burt R., Detroit 1, Mich.
*1878. Shurly, E. L., Detroit, Mich.
*1892. Simpson, William Kelly, New York City.
*1919. Skillern, Ross H., Philadelphia, Pa.
*1909. Sluder, Greenfield, St. Louis, Mo.
*1879. Smith, Andrew H., Geneva, N. Y.
*1932. Smyth, Duncan Campbell, Boston, Mass.

- * 1928. Sonnenschein, Robert, Chicago, Ill.
- 1924. Stein, Otto J., Chicago, Ill.
- 1934. Stevenson, Walter, Quincy, Ill.
- * 1911. Staut, George C., Philadelphia, Pa.
- * 1879. Tauber, Bernhard, Cincinnati, Ohio.
- * 1924. Taylor, Hermon Marshall, Jacksonville, Fla.
- * 1903. Theisen, Clement F., Albany, N. Y.
- * 1899. Thorner, Max, Cincinnati, Ohio.
- * 1892. Thrasher, Allen B., Cincinnati, Ohio.
- * 1937. Tobey, George L., Jr., Boston, Mass.
- * 1888. Van der Poel, S. O., New York City.
- * 1938. Vail, Harris H., Cincinnati, Ohio.
- * 1936. Voislowsky, Antonie P., New York City.
- * 1933. Wanamaker, Allison T., Seattle, Wash.
- 1896. Ward, Marshall R., Pittsburgh, Pa.
- * 1879. Ward, Whitfield, New York City.
- * 1886. Westbrook, Benjamin F., Brooklyn, N. Y.
- * 1924. Wherry, William P., Omaha, Neb.
- * 1924. White, Leon E., Boston, Mass.
- * 1939. Williams, Horace J., Philadelphia, Pa.
- * 1942. Wishart, D. E. Staunton, Toronto, Canada.
- * 1922. Wishart, David J. G., Toronto, Ontario.
- * 1940. Wood, V. Visscher, St. Louis, Mo.
- * 1896. Wollen, Green V., Indianapolis, Ind.
- * 1953. Wilkerson, William W., Nashville, Tenn.

