

Transactions

American Laryngological Association

EIGHTY-THIRD VOLUME

"DOCENDO DISCIMUS"

TRANSACTIONS
OF THE
EIGHTY-THIRD ANNUAL MEETING
OF THE
American
Laryngological Association

1962

HELD AT
THE SHERATON-DALLAS HOTEL
DALLAS, TEXAS
MAY 4 AND 5, 1962

PUBLISHED BY THE ASSOCIATION

ST. LOUIS, MO.

1962

Contents.

	PAGE
List of Officers	7
Registration	9
Remarks by the President, Dr. Dean M. Lierle	11
Presentation of the Casselberry Award	15
The Use of Prostheses in the Larynx and Trachea. Julius W. McCall, M.D. and Clay Whitaker, M.D.	16
Discussion:	
Jerome A. Hilger, M.D.	22
Fred W. Dixon, M.D.	23
Dr. Whitaker (closing)	24
Rehabilitation of the Airway System by Neck Flaps. John J. Conley, M.D.	25
Discussion:	
George F. Reed, M.D.	32
Walter P. Work, M.D.	32
Dr. Conley (closing)	33
Septal Dermatoplasty: Observations, Technique and Results. Robert B. Lewy, M.D. and Anthony Hammond, M.D.	34
Discussion:	
W. H. Saunders, M.D.	41
Dr. Lewy (closing)	42

CONTENTS


	PAGE
Injuries to the Larynx and Cervical Trauma. G. Slaughter Fitz-Hugh, M.D., W. M. Wallenborn, M.D. and Francis McGovern, M.D.	43
Discussion:	
Daniel C. Baker, Jr., M.D.	66
Joel J. Pressman, M.D.	67
Dr. Fitz-Hugh (closing)	68
Studies on Papilloma of the Larynx. Paul H. Holinger, M.D., George Conner, M.D., Kenneth C. Johnston, M.D., Betty Ross Conner, M.S. and Jacob Holper, Ph.D.	69
Discussion:	
Daniel C. Baker, Jr., M.D.	74
Charles F. Ferguson, M.D.	74
Dr. Holinger (closing)	75
Some Observations on Experimental Laryngeal Substitution in Laryngectomized Dogs. Joseph H. Ogura, M.D., Donald A. Shumrick, M.D. and Abra- ham Lapidot, M.D.	77
Discussion:	
Joel J. Pressman, M.D.	96
Dr. Ogura (closing)	97
Tolerance of the Respiratory Mucous Membrane to Trauma. (Surgical Swabs and Intratracheal Tubes). Anderson C. Hilding, M.D. and Jean A. Hilding, B.A.	98
Discussion:	
Joel J. Pressman, M.D.	122
F. Johnson Putney, M.D.	124
Dr. Hilding (closing)	125
Epithelial Malignancies of the Parotid Gland. Brian McCabe, M.D. and Roger Boles, M.D.	126

CONTENTS

	PAGE
Schwannoma of the Cervical Portion of the Vagus Nerve. (A Case Report). Lup Q. Pang, M.D.	133
Discussion:	
John F. Daly, M.D.	141
Dr. Pang (closing)	141
Induced Pharyngeal Sensations and Reflexes. Peter N. Pastore, M.D.	142
Management of Benign Laryngeal Tumors in Children: Pre-Operative, Operative and Post-Operative. James J. O'Neil, M.D. and John A. McGee, M.A.	147
Removal of Benign Tumors of the Larynx Under Endotracheal Anesthesia. Oliver W. Suehs, M.D.	156
Discussion:	
F. Johnson Putney, M.D.	163
Robert B. Lewy, M.D.	164
DeGraaf Woodman, M.D.	164
Francis W. Davison, M.D.	164
Dr. Suehs (closing)	165
Intranasal Injections of Long Acting Corticosteroids. Daniel C. Baker, Jr., M.D. and Raymond B. Strauss, M.D.	166
Discussion:	
Fred W. Alexander, M.D.	172
Arthur W. Proetz, M.D.	172
Lyman G. Richards, M.D.	172
Dr. Baker (closing)	172
Investigations in Laryngeal Physiology: The Canine Larynx - Part I. David W. Brewer, M.D., K. Faaborg-Andersen, M.D. and Sidney T. Dana, M.D.	174
Discussion:	
Joseph H. Ogura, M.D.	175
Dr. Dana (closing)	175

CONTENTS

	PAGE
Papillary Lesions of the Nose and Sinuses. Austin T. Smith, M.D. and John P. Decker, M.D.	176
The Surgical Treatment of Carcinoma of the Nose, Following Excision for Malignancy. John M. Converse, M.D. and Donald W. Smith, F.R.C.S.E.	190
Discussion:	
John J. Conley, M.D.	196
Delmar F. Weaver, M.D.	197
Dr. Converse (closing)	197
Memorials:	
Rea E. Ashley	201
Ernest M. Seydell	203
Executive Sessions and Reports of Officers and Committees	205
Presentation of the Newcomb Award	207
List of Fellows, 1962	223
Active Fellows	224
Honorary Fellows	230
Corresponding Fellows	231
Emeritus Fellows	232
Benefactors	234
Recipients of the de Roaldes Award	235
Recipients of the Casselberry Award	236
Recipients of the Newcomb Award	237
Past Officers	238
Past Fellows	243



THOSE IN ATTENDANCE AT THE EIGHTY-THIRD ANNUAL MEETING

Left to right as one faces the group: *front row*, Meltzer, Lederer, Putney, Boies, Proertz, Ireland, McCall, Robb, Lierle, Richards, LeJeune, Schenck, Dixon, Hilding, Theobald, Salinger; *second row*, Harrell, Conley, Weille, Johnston, Baker, McMahon, O'Keefe, Sanders, Simpson, Goldman, Work, Cracovaner, Lindsay, Harkness, Davison, Galloway, Brewer, Hoople, Woodman, Jones, Atkins, Pressman, Murtagh, Holinger, Pastore, Sisson, Fitz-Hugh, Weaver; *back row*, Ogura, Friedberg, Lewy, Suehs, Smith, Daly, Munoz-MacCormick, Pang, Alfaro, Miller, Hart, Eagle, Van Alyea, Furstenberg, Hilger, Simonton, Arnold, McHenry, Harris, Moore, Alexander.

OFFICERS FOR 1961-62

PRESIDENT

DEAN M. LIERLE, M.D.

FIRST VICE-PRESIDENT

JULIUS W. McCALL, M.D.

SECOND VICE-PRESIDENT

P. E. IRELAND, M.D.

SECRETARY

LYMAN G. RICHARDS, M.D.

TREASURER

FRANCIS E. LEJEUNE, M.D.

LIBRARIAN, HISTORIAN AND EDITOR

FRANCIS W. DAVISON, M.D.

COUNCIL

The above Ex-officio and

HARRY P. SCHENCK, M.D.

FRED W. DIXON, M.D.

WILLIAM J. McNALLY, M.D.

EDWIN N. BROYLES, M.D.

TRANSACTIONS OF THE
EIGHTY-THIRD ANNUAL MEETING

OF THE

American Laryngological Association

HELD AT

THE SHERATON-DALLAS HOTEL

DALLAS, TEXAS

MAY 4 AND 5, 1962

The Eighty-third Annual meeting of the American Laryngological Association was called to order by the President, Dr. Dean M. Lierle, at the Sheraton-Dallas Hotel, Dallas, Texas, on May 4, 1962, at 9:00 A.M.

REGISTRATION

The following Fellows were in attendance:

ALEXANDER, FRED W.

ALFARO, VICTOR R.

ARNOLD, GODFREY E. T.

ATKINS, JOSEPH P.

BAKER, DANIEL C.

BOIES, LAWRENCE R.

BORDLEY, JOHN E.

BREWER, DAVID W.

CARDWELL, EDGAR P.

CONLEY, JOHN J.

CONVERSE, JOHN M.

CRACOVANER, ARTHUR J.

DALY, JOHN F.

DAVISON, FRANCIS W.

DIXON, FRED W.

EAGLE, WATT W.

FITZ-HUGH, G. SLAUGHTER

FRIEDBERG, STANTON A.

FURSTENBERG, ALBERT C.	NASH, C. STEWART
GALLOWAY, THOMAS C.	NORRIS, CHARLES M.
GOLDMAN, JOSEPH L.	OGURA, JOSEPH H.
GOODALE, ROBERT L.	O'KEEFE, JOHN J.
HANSEL, FRENCH	O'NEIL, JAMES J.
HARKNESS, GORDON F.	PANG, LUP Q.
HARRILL, JAMES A.	PASTORE, PETER N.
HARRIS, HERBERT H.	PRESSMAN, JOEL J.
HART, VERLING K.	PROETZ, ARTHUR W.
HILDING, ANDERSON C.	PUTNEY, F. JOHNSON
HILGER, JEROME A.	RICHARDS, LYMAN G.
HOLINGER, PAUL H.	ROBB, JAMES M.
HOOPLE, GORDON D.	SALINGER, SAMUEL
IRELAND, PERCY E.	SANDERS, SAM H.
JOHNSTON, KENNETH C.	SCHENCK, HARRY P.
JONES, EDLEY H.	SILCOX, LOUIS E.
LEDERER, FRANCIS L.	SIMONTON, KINSEY M.
LEJEUNE, FRANCIS E.	SIMPSON, W. LIKELY
LEWY, ROBERT B.	SISSON, GEORGE A.
LIERLE, DEAN M.	SMITH, AUSTIN T.
LINDSAY, JOHN R.	SOOY, FRANCIS A.
MARTIN, ROBERT C.	SUEHS, OLIVER W.
MCCALL, JULIUS W.	THEOBALD, WALTER H.
McHENRY, LAWRENCE C.	TRAMBLE, G. EDWARD
McMAHON, BERNARD J.	VAN ALYEA, OLIVER E.
MELTZER, PHILIP E.	WALSH, THEODORE E.
MILLER, ALDEN H.	WEAVER, DELMAR F.
MOORE, PAUL M.	WEILLE, FRANCIS L.
MUNOZ-MACCORMICK, CARLOS E.	WOODMAN, DEGRAAF
MURTAGH, JOHN A.	WORK, WALTER P.

OPENING SESSION

FRIDAY MORNING, MAY 4, 1962

The Opening Session of the Eighty-third Annual Meeting of the American Laryngological Association, held at the Sheraton-Dallas Hotel, Dallas, Texas, convened in the North Ballroom on Friday morning, May 4, 1962, at nine-thirty o'clock, Dr. Dean M. Lierle, University Hospital, Iowa City, Iowa, President of the Association, presiding.

PRESIDENT LIERLE: I declare the Eighty-third Annual Meeting of the American Laryngological Association in session.

REMARKS BY THE PRESIDENT

PRESIDENT LIERLE: I would like to take this opportunity to thank you for the great honor you have bestowed upon me by making me your President.

We have before us a challenging, excellent program. Of course, as always, time is of the essence. Nevertheless I would like to make a few remarks concerning the present status of otolaryngology and to express myself briefly in regard to my own ideas as to its future.

A recent survey revealed the following facts—and I am going to read these slowly because I think they are rather important:

At the present time there are 133 approved residencies in otolaryngology in this country; there are 153 first-year positions, of which 88 per cent were filled this year. The total number of residency opportunities is 504, of which 91 per cent were filled in 1962.

In medical schools the number of approved residencies is 86. Of the 277 teachers and research workers in this field many are not medically trained. There are only 29 budgeted full-time professorships and we know that there are 12 vacancies. There are only four full-time heads of departments.

I was surprised to learn that there are only 3,306 certified otolaryngologists. Of course, there are many more who are not certified

and there are still a number of combined eye, ear, nose and throat practitioners in this country.

Last month I sent a questionnaire to all of the approved otolaryngological residency training centers in the United States. I received 94 replies from the 133 institutions. Here are the questions and answers:

1. How many residents do you take each year?

In reply 26 institutions reported they offer one position; nine, one or two; 29, two; three, two or three; and 25 said they take from three to nine residents. I think this is rather significant because you see that 26 institutions only offer one position a year.

2. Were you able to fill all of your residency positions for 1961-62?

In reply 72 said yes and 18 reported no. In this latter group nine were lacking one man, six lacked two, and four lacked three.

3. Are you receiving cooperation from the general surgeons in regard to the year of surgery?

Of the group contacted 80 replied yes, five said no, and seven were evasive in their answers. In other words, the majority said yes, but there were five that said no and seven were evasive.

4. Do you feel that the year of surgery has been beneficial as far as your residents are concerned?

To this question 69 responded emphatically in the affirmative, seven said no, and 13 were not sure.

5. How many foreign residents did you take for the year 1961-62?

Sixty-nine took none. Of the remaining 24, 16 had one foreign resident; six had two; one had three; and one had four.

I would like to comment on the progress which otolaryngology has made as a specialty.

Our status has been greatly advanced by the help given by the National Institutes of Health, which have provided funds for the development of well-trained teacher investigators. This project has taken time but a number of trained teacher investigators are now available.

The increased requirements of the Board I feel have resulted in better trained otolaryngologists. The year's training in surgery has been of great value. Many feel that this year is lost unless the resident, during his general surgical training, spends his time in actual surgery. The training, in my opinion, of a competent surgeon involves thorough training in the principles in this field. Such areas as wound repair, fluid balance, pathology, anesthesiology, nutrition, and so on, are very important in the development of a good surgeon.

Despite the fact that there are vacancies in otolaryngological training areas, there is an increase in the number of applicants for residency training in this field. There were fewer vacancies last year that we have had for many years.

We can all be proud of the tremendous progress otolaryngology has made in the field of research. It is possible that many of our colleagues are unaware of the work being done by research workers in otology, laryngology and rhinology. I would suggest that we give more programs and present more films relating to these topics as well as to research in otolaryngology before general programs of national societies.

Please don't think that I believe that all is well as far as otolaryngology is concerned. At the present time we are in a field which has many borderline procedures which are shared by other specialties. As a result of this situation, particularly in institutions which offer limited services, the dilution of many of the so-called borderline procedures is so great that not enough remains to teach adequately residents to be competent in these areas. This situation, of course, must be corrected.

Many things which I have learned from experience might be said along this line but I do not believe that this is the time or place to say them. I do not wish to enter into any jurisdictional dispute but I do hope that some day in the near future men of good will from the various specialties will go to the conference table and attempt to correct some of our mutual problems. Such action would benefit all concerned. Let me say here that the most potent answer to our critics is competency.

Although we have a number of excellent departments of otolaryngology in this country, some are tragically lacking in well-trained teachers, research workers, beds, space and budgets. The best departments, with a few exceptions, are autonomous.

We all appreciate the help that general surgery has given us in most instances. It is most important that we continue to seek and to have the assistance of the general surgeon.

I would like to say a few words about undergraduate study in our field. I realize that anyone worth his salt feels that his specialty is the most important of any. Otolaryngology is a minor specialty so far as undergraduate medical education is concerned, though all will concede that the head and neck are important parts of the body. This is rather hard to get across to deans sometimes. Boies, of Minnesota, and I made a survey in our respective states and found that 25 to 35 per cent of the general practitioner's work had to do with the head and neck.

The hours assigned for otolaryngology for undergraduate medical students are inadequate in many instances. With increased requirements in this field there will be, at first, fewer but better trained otolaryngologists. Consequently the general practitioner should have increased knowledge of our area. He will be required to make diagnoses for referral, as well as doing some of the simple procedures.

There should be more full-time, dedicated teachers. All teachers need not be full-time, of course, but some should be on the ground at all times for supervision and teaching. These individuals should be well-trained, particularly in the principles of surgery.

Maintenance of our present minimal standards is important but we must make provisions for the further training of those individuals going into the subspecialties of otolaryngology. For example, I believe that those wishing to do major surgery of the head and neck, including all phases of maxillofacial surgery and those specializing in otology, should have additional training.

We need to develop more full-time teacher investigators who are well-trained and dedicated. The time factor in training is not the only important consideration. There must also be excellence so far as teaching is concerned. You could have ten years of training and if you didn't have well-trained teachers it wouldn't be of much value.

The future of otolaryngology is indeed very bright if we correct the present-day deficiencies. According to recent estimates—and I want you to pay particular attention to this—we shall need 7,000 well-trained otolaryngologists by 1970. This figure allows only one for a population of 30,000. By 1970 we shall need a minimum of 736

teacher investigators instead of the present 277. We must realize that 1970 is only seven and one-half years from the present time.

PRESIDENT LIERLE: It now gives me great pleasure to announce the winner of the Casselberry Award. You remember the Casselberry Award is for encouraging advancement in the art and science of laryngology and rhinology.

This year the winner presented a most excellent thesis entitled "The Myelastic versus the Neuro-Muscular Theory of Phonation." I would like to ask Dr. Galloway if he will escort Dr. Hans von Leden to the podium.

(Dr. Thomas C. Galloway escorted Dr. Hans von Leden to the podium as requested.)

PRESIDENT LIERLE: Congratulations, Dr. von Leden.

I present this Certificate on behalf of the American Laryngological Association.

DR. VON LEDEN: Thank you, Dr. Lierle.

In accepting this award I would like to express my appreciation to all of those who, by their example, by their encouragement and by their support, stimulated these investigations. Thank you very much indeed.

THE USE OF PROSTHESES IN THE LARYNX AND TRACHEA

A PRELIMINARY REPORT

JULIUS W. McCALL, M.D.

AND

CLAY W. WHITAKER, M.D.

CLEVELAND, OHIO

This is a report of the use of prostheses in the larynx and trachea of humans and experiental animals. Our ultimate aim is to eliminate the tracheostomy opening in the laryngectomized patient. If such a prosthesis can be devised and successfully introduced, it might be feasible to construct a pair of vibrating cords that would produce sound for those patients who did not develop an esophageal voice.

Longmire¹ used a Lucite tube to replace a segment of cervical trachea in a patient who had developed tracheal stenosis following an automobile accident. Gebauer² has reported the use of wire-reinforced dermal grafts in repair of the bronchii and trachea. Pressman³ described the use of autogenous aorta and polyethylene tubes in the tracheas of a series of dogs.

Our own experience with tracheal prostheses began in 1953.

REPORT OF CASES

CASE 1. A 34-year-old white male had a history of an auto accident in 1951 in which he sustained a fracture of the larynx. The patient was in a coma for three months following the accident. We first saw the patient in May 1953 at which time he had paralysis of the left vocal cord, complete stenosis of the trachea from the cricoid to the fourth tracheal ring (with complete loss of voice), cervical esophageal stricture, and a tracheotomy tube in place. Direct laryngoscopy and esophagoscopy were done and a feeding tube was inserted.

In June 1953 the trachea was opened, the scar tissue was excised, and a split-thickness skin graft was placed in the trachea using a

polyethylene tube stint. The stint was removed in July, at which time the graft had apparently taken, and the patient was able to phonate. However, the stenosis recurred and in August the trachea was reopened and a tantalum tube was sutured into the trachea bridging the stenotic segment. The tracheotomy was maintained. The patient was able to return to work in October 1953. In July 1957, the tracheal stoma was closed, but the patient experienced respiratory embarrassment several months later, requiring a re-opening of the tracheal stoma. In retrospect, the diameter of the tantalum was probably not sufficient to provide an adequate airway.

Recent x-rays show that the tantalum tube is still in position (Fig. 1). The patient has a good voice.

CASE 2. A 40-year-old white female had sustained a fractured larynx in an automobile accident in July 1959, necessitating an emergency tracheotomy. We first saw the patient in January 1960, when there was complete stricture of the larynx and marked stricture of the esophagus at the level of the cricoid. A thyrotomy was performed and the scar tissue in the larynx was excised. A split-thickness graft was placed into the larynx, using a foam rubber stint. It was noted at the time of this surgery that there was almost complete loss of the thyroid and cricoid cartilages secondary to chondritis. When the stint was removed several weeks later the larynx again became stenotic. Remembering our experience in Case 1, we elected to place a tantalum tube into the larynx using one of a diameter sufficient to provide an adequate airway. A week later it was necessary to remove the tube because of pressure necrosis of the skin of the neck. In March 1960 an esophageal dilatation was done. On September 8 a second thyrotomy was performed and a polyethylene tube was sutured to the trachea with the tube extending to the base of the epiglottis (Fig. 2). The tube was held in place with tantalum sutures (Fig. 3). Esophageal dilatation was also performed at this time. Two days later the patient was returned to surgery for another dilatation and the insertion of a feeding tube. During this procedure the esophagus was accidentally perforated and the patient developed a right pneumothorax, necessitating a thoracotomy. The patient recovered without further incident, resumed oral feedings, and was discharged from the hospital October 1. She did well until November 1961, when she developed a pneumonitis and was hospitalized at another institution outside of Cleveland. An elective tracheotomy was done below the prosthesis to allow tracheal suction. The tracheal stoma is now

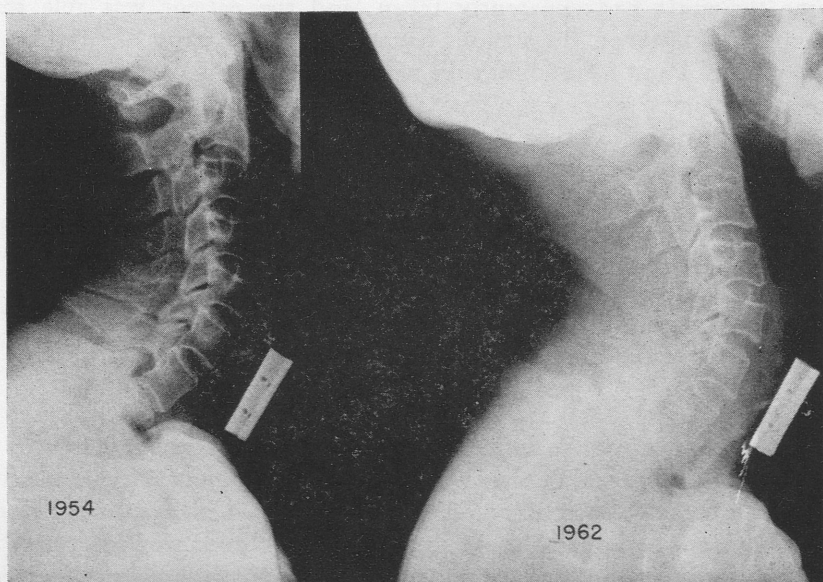


Fig. 1.—X-rays taken 1954, 1962. The position of the tantalum tube in the trachea is not changed.

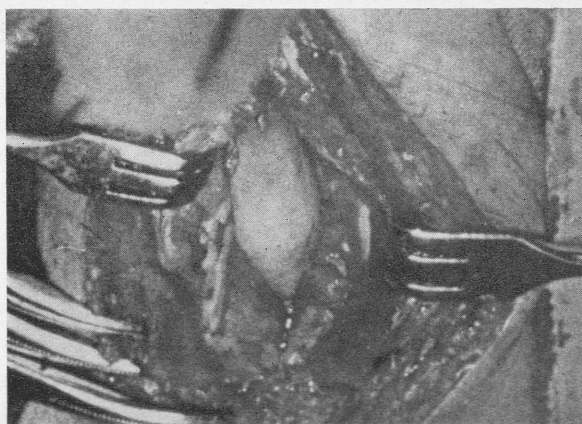


Fig. 2.—Case 2. The polyethylene prosthesis shown in the larynx at surgery.

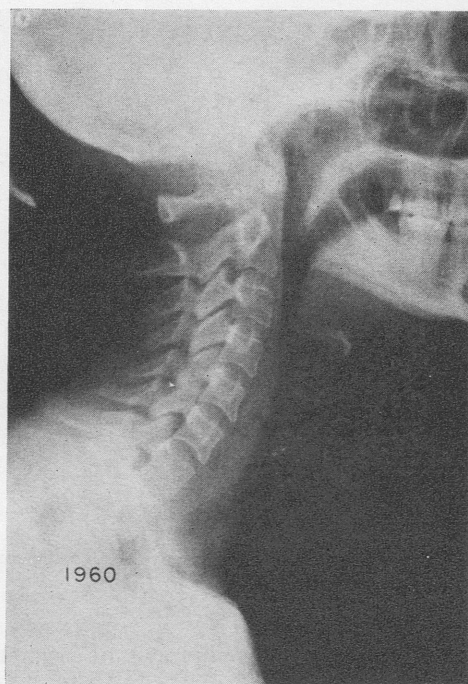


Fig. 3.—X-rays showing polyethylene tube fixed in larynx by tantalum sutures.

closed, the patient is doing well, and she has developed acceptable speech.

CASE 3. A 40-year-old white male had a laryngectomy for carcinoma in September 1960. Nineteen days after the laryngectomy the patient was returned to surgery and a polyethylene prosthesis was sutured between the trachea and the hypopharynx. The patient tolerated this procedure well, but developed a fistula requiring removal of the tube 18 days after its insertion. After removal of the tube the fistula promptly healed.

We now feel that the prosthesis should have been either introduced at the time of laryngectomy or delayed until healing following the laryngectomy had been completed.

Because of the degree of success with a prosthesis in our first two cases, we considered that further investigation was warranted.

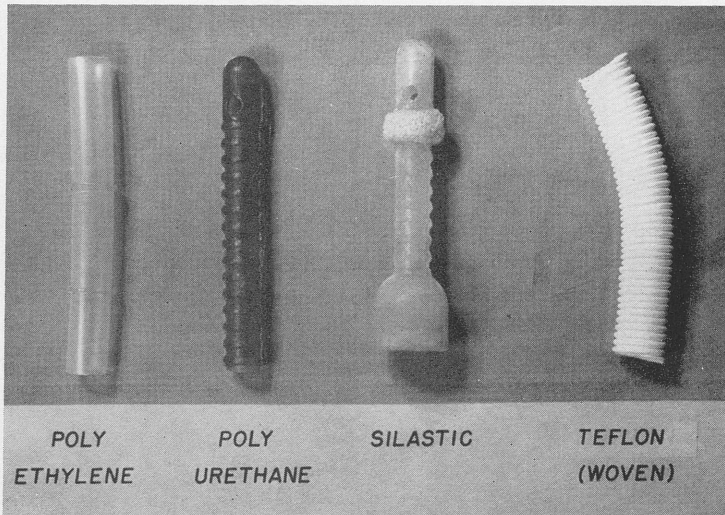


Fig. 4.—The four types of prostheses used in this experimental study.

Our first problem was the development of a suitable prosthetic device. We have tried four different materials—polyethylene, polyurethane, silicone rubber, and woven Teflon (Fig. 4). The principal difficulty remains, namely, to get the epithelium of the hypopharynx to tolerate the prosthesis. At present we are using the silicone rubber tube with a collar of foamed silicone rubber, to which we suture the pharynx and then reinforce the suture line with Eastman's K-910 adhesive (methyl 2-cyanoacrylate) (Fig. 5).

We have so far had limited success in our experimental studies. Our initial technique was to do a total laryngectomy with epiglottectomy, and then suture a polyurethane tube to the trachea and into the pharynx. We have now abandoned this material because polyurethane deteriorates in the tissue. The next tube used was of silicone rubber (Silastic, Dow Corning), which is known from the work of other investigators to be well tolerated by the tissues. This tube is molded from a powder to any desired diameter, gauge, and length. A collar of silicone rubber foam is glued to the tube at the position where the pharynx is to be sutured to the tube. The bell-shaped end fits over the trachea to prevent the possibility of the tube's being displaced into the trachea. We have also tried woven Teflon tubing, the type

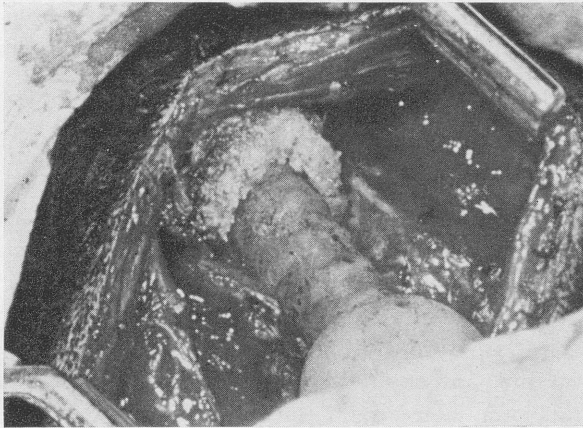


Fig. 5.—Illustration of a silastic prosthesis in an experimental animal.

used for artery grafts. Of all the materials this has been least successful in this work, since the pharyngeal and tracheal secretions penetrate immediately into the tissues of the neck, causing necrosis.

To date we have done nine procedures in nine dogs, with varying degrees of success. No dog has survived. In two dogs we did only a laryngectomy, intending at a second stage to place a prosthesis in the neck. These two dogs had the shortest survival, and illustrated dramatically the effect of the loss of a canine's normal nasal function. Even with 70% humidification of the air both dogs developed severe crusting of the trachea and died of asphyxiation.

Two other dogs had polyurethane tubes placed in the pharynx without tracheotomy. One dog survived five days, and when autopsied was found to have a breakdown of the anastomosis of the pharynx to the prosthesis. The second dog died after eight days, when he succeeded in coughing out the prosthesis, thereby eliminating his airway.

The two dogs with Teflon tubes died within 24 hours of surgery and were found to have marked digestion of the muscles of the neck and pharynx, presumably from the leakage of saliva through the pores of the woven-mesh prosthesis.

In the remaining three dogs we used a silicone rubber prosthesis, and it is in this group we have found the most encouraging result. Our longest survival, sixteen days, occurred in one of these dogs. At

autopsy it was found that there was again breakdown of the pharynx-to-prosthesis anastomosis, as well as severe malnutrition. Since this experiment was have done gastrostomies in order to provide a more nearly normal diet. Intravenous fluids alone are not sufficient.

One of the three dogs died two hours after the operation, very probably from the intravenous sodium pentothal anesthetic.

In the remaining dog, in addition to laryngectomy, we also crushed the hypoglossal nerves to immobilize the tongue. Since these dogs do drink water and since they must lap the water with their tongues, to which the prosthesis is sutured, we felt that if this stress on the anastomosis were reduced there might be a better chance for healing. This dog developed a Cheyne-Stokes type of breathing during the surgery, and expired only four hours later. We are unable to explain this peculiar reaction since it did not occur in any other animal.

Our findings in the experimental laboratory have not been as rewarding as one would hope for, but we are confident that continued effort will result in a suitable prosthetic device and technique which will enable us to dispense with the tracheal stoma; and if this goal is attained, either by us or by someone else, we think it reasonable to expect that the next step, the development of phonation, would readily follow.

610 ROSE BLDG.

REFERENCES

1. Longmire. W. P., Jr.: Repair of Large Defects of Trachea. *ANNALS OF OTOLGY, RHINOLOGY AND LARYNGOLOGY* 57:875-883, 1948.
2. Gebauer, P. W.: Experiences in the Surgical Reconstruction of the Trachea. *American Review of Tuberculosis* 62:176-189, 1950.
3. Pressman, J. J., and Simon, M. B.: Observations upon the Experimental Repair of the Trachea Using Autogenous Aorta and Polyethylene Tubes. *Surgery, Gynecology, and Obstetrics* 106:56-62, 1958.

DISCUSSION

DR. JEROME A. HILGER: The search for a satisfactory replacement technique for the resected tracheal segment has been pursued unsuccessfully for some time. The requisites necessarily are a satisfactory respiratory lumen and adequate ciliary function. Difficulties at the anastomosis, loss of the prosthesis, eventual stenosis, lack of ciliary epithelization—these have been the one or several stumbling blocks in each instance. Pressman, Moncrief, Greenberg, and many in between have varied the tactic and the material. The pursuit continues.

In the effort of laryngeal replacement a great deal can be learned from the problems of the tracheal experiments. The mechanical design of a tube is not difficult. Its incorporation into the host presents problems at the junction points. The laryngeal replacement presents a more difficult problem at the pharyngeal abutment than is present at either end of a tracheal segment implant.

It is well that the work of Dr. McCall and Dr. Whitaker becomes known to us today. None of us is destined to be the beginning or the end of any advance in surgery. Each of us builds upon the foundations laid by his predecessors. The opportunity for others to use the experience of Drs. McCall and Whitaker will be invaluable.

The problems of the prosthetic laryngeal implant can be overcome now in a certain per cent of experimental animal subjects. The available inert materials help in this regard. Uniform dependability is still remote. Junctional leaks and extrusion make transference to routine human surgery uncertain at best. At least this has been our experience in a brief investigative exposure to the problem. We are continuing to work on the problem in the research laboratory as are many others.

More serious long term difficulties can be foreseen once the mechanics of dependable implant adaptation and healing are overcome. The larynx is the physiologic drainage canal for the lower respiratory tract. Without the posterior, interarytenoid ciliation it loses this function. How long or well the adult tracheo-broncho-pulmonary system will withstand the physiologic blockade imposed by a non-ciliated vent is a question. The tussive boost seems a frail crutch upon which to lean for an entire postoperative lifetime.

The investigations of Greenberg and his group encourage one to think toward the eventual possibility of a ciliated prosthetic implant. In the meantime it is good that the experimental work continue in a number of areas so many viewpoints and diverse skills can lend support and encouragement—the one to the other.

In this paper, Julius McCall with characteristic vigor and candor has presented a report of progress in an important investigative project. The larynx is an area in otolaryngology wherein research and progress have lagged. This is no credit to us. His results are stimulating. They should prod chronologically younger men who are older in spirit than he to get into the act and make their contribution.

DR. FRED W. DIXON: I have examined these patients and followed this work of Dr. McCall and Dr. Whitaker with much interest. The satisfaction which these persons have, in being able to speak and breathe normally, has been an incentive in the search for some prosthesis which would be acceptable to the tissues, and to the patients.

Animal experimentation for tracheal repair has been successful; however, prosthesis for the larynx has been disappointing. Most of the failures have been due to the separation at the upper end of the tube where it protrudes into the pharynx. The dog has an unusual ability to expel foreign bodies from the throat. In their efforts to expel this prosthesis, the tissues are under continuous strain. This may account for the fact that they have been more successful with persons who cooperate, rather than in animal work. It appears that they *have* a prosthesis which is acceptable to the tissues and that, in certain selected cases, they will have success. Many patients, however, with cancer of the larynx, are physically unsuited for this procedure and it cannot be tried.

I am interested in the solution used to seal the tissues. Is it absorbed or walled off? Could it be used elsewhere in the body?

We are indebted to Doctors McCall and Whitaker for their pioneering work. I am sure that some day the problem *will* be solved and the laryngectomized patient will then lead a happier life.

DR. WHITAKER (closing): I would like to thank Dr. Dixon and Dr. Hilger for their discussions of our presentation.

Certainly one can't minimize the difficulties we have encountered in the animal laboratory, not only from the difficulty of the cooperation of the dog but also the difficulty of achieving adequate nursing care in the postoperative care of these dogs. The crusting is a problem that has bothered us in spite of the humidification of the air and I feel that with improved nursing care of these animals postoperatively we can overcome much of this problem in those in whom we have to do a tracheotomy.

The use of the prosthesis along with the methyl2 cyanoacrylate cement developed by Eastman that Dr. Dixon referred to—the cement, from the reports that we have, rather meager reports admittedly, are that it is well tolerated in the tissue. However, it is not an essential part of our technique. The suturing alone could suffice in holding the prosthesis in place, we think.

Finally, I would like to say that we will continue this work and we hope that others, as Dr. Hilger is already doing, will continue the work and that at some future date not too far off we will have a further report to make to you.

REHABILITATION OF THE AIRWAY SYSTEM

BY NECK FLAPS

JOHN J. CONLEY, M.D.

NEW YORK, N. Y.

Rehabilitation of the hypopharynx, glottis and trachea has been a perplexing problem for a variety of reasons. The etiological factors associated with the abnormalities in these sites embrace congenital maldevelopment and stenosis following trauma, infection, irradiation and neoplasm. These conditions may appear in infancy and affect the natural growth and development of this area. They may appear later in life after the growth pattern has matured, and present a problem of stenosis in an adult architecture. The basic efforts at amelioration in these conditions have been the utilization of the natural growth factor to its maximum degree, and the correction of the stenosis by repeated, graduated dilatations over months and years, excising scar, technically creating a passageway and maintaining it with a stent or tube. These concepts have been in use for a hundred years, but have never been completely satisfactory because of the chronicity of the treatment and the tendency to restenose after the stent has been removed.

Historically, Professor Chiari of the University of Wien illustrated this in his book on Surgery of the Larynx in 1916 with precise drawings after the technique of Professor Gluk. The use of free skin grafts and improvements in the fittings of molds have made this experience more worth while for the patient, but circumferential defects, large scar deformities, wounds incorporating loss of tissue and support in the airway system and post irradiation stenosis remain persistent problems.

The use of a non-hair bearing skin flap from the neck has been of assistance in solving some of these difficult situations. The use of

From the Head and Neck Department, Park Medical Group, and the Department of Otolaryngology, Columbia Presbyterian Medical Center, New York City.

skin flaps in the creation of a new gullet is well established, but their application to rehabilitating the airway system has, on the whole, remained unexploited.

Advantages derived from a regional pedicle neck flap for resurfacing are minimal contracture and assured viability. Thirty to forty square centimeters can be transposed for resurfacing purposes without difficulty in a single stage procedure in this region. The disadvantages may incorporate a multistage procedure and a small crop of hair in the airway system. This latter curiosity can be mitigated by positioning the flap below the thyroid cartilage where hair follicles are ordinarily not abundant and by depilation.

TECHNIQUE

These flaps may be unilateral or bilateral, depending upon the size of the wound. They are elevated in a horizontal or vertical style so that they will fit naturally into the defect. Their thickness usually includes the platysma muscle. This adds viability to the flap, permits a greater dimension and permits additional surgery to be done on the flap itself. This latter addition would include the formation of artificial vocal cords. Thinner flaps are preferred when bulk augmentation is not necessary and where resurfacing is the prime objective.

Airway stenosis in children is a special problem in reconstruction because of the tiny size of the larynx and trachea, and because of the dependency upon the growth factor for the resolution of this status. Specific surgical intervention in children for the correction of stenosis after tracheostomy has been performed is rarely indicated. The surgeon cannot create an adult trachea in an infant or child, and rarely does the clinical situation permit excision and immediate repair without persistent obstruction. The spontaneous growth of the crippled larynx and trachea, plus dilatation may resolve the problem. In many instances the child must wait until pre-adulthood before definitive rehabilitation can be carried out. One might consider the application of this technique to papillomatosis of the glottis where cicatricial stenosis has complicated instrumentation and abundant papillomata persist. If this should occur and will not respond to conservative dilatation, and local removal, thyrotomy and resurfacing may resolve the problem of stenosis and also the recurrent papillomatosis. The technique includes removal of the mucous membrane lining containing the potential for papillomatous production, and the stenotic scar tissue. Resurfacing here is usually bilateral and accomplished with a thin flap

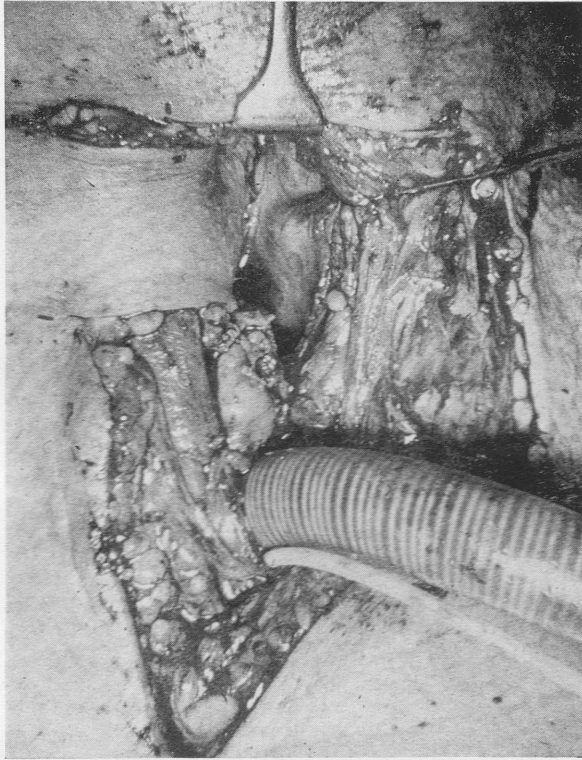


Fig. 1.—Right hemilaryngectomy with pedicle flap transposed into glottis.

not containing the platysma muscle. This technique is not applicable to infants or the uncomplicated case of papillomatosis where repeated local removal can be applied.

In cicatricial contraction, crush or loss of tissue in the airway system, a reconstitution of the passage is attempted by removal of scar and reshaping the hypopharyngeal glottic or tracheal architecture. The size attained should be a generous equivalent of the adult dimensions as a certain amount of contraction always occurs postoperatively. This raw surface is covered with a transposed thin tissue flap from the neck sutured into position with No. 0000 atraumatic chromic catgut. If the correction is extensive, it is preferable to externalize the new trough and close it as a secondary technique. If the architectural structure requires molding, a stent must be inserted. If the

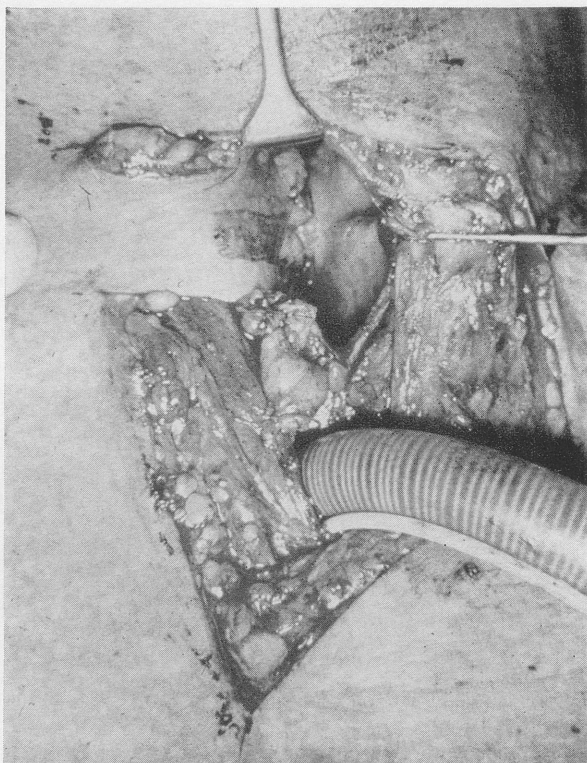


Fig. 2.—“Cord” outlined on pedicle flap.

rehabilitation is circumferential a stent must be incorporated. If the correction is minimum, the wound may be closed immediately by direct approximation after an “epithelial shave” at the inlet to the glottis.

Rehabilitation of the larynx by regional flaps following partial laryngectomy has several advantages. Voice quality is improved by the creation of an imitation vocal cord. The operation may be extended to include all of the glottis anterior to both arytenoids with the assurance of a patent airway and fair voice. Under these circumstances a single or double flap containing platysma muscles is transposed into the glottic wound. Imitation cords are fashioned on this flap by bringing a ribbon flap into relief with mattress sutures. These new structures are positioned in line with the arytenoid cartilages in

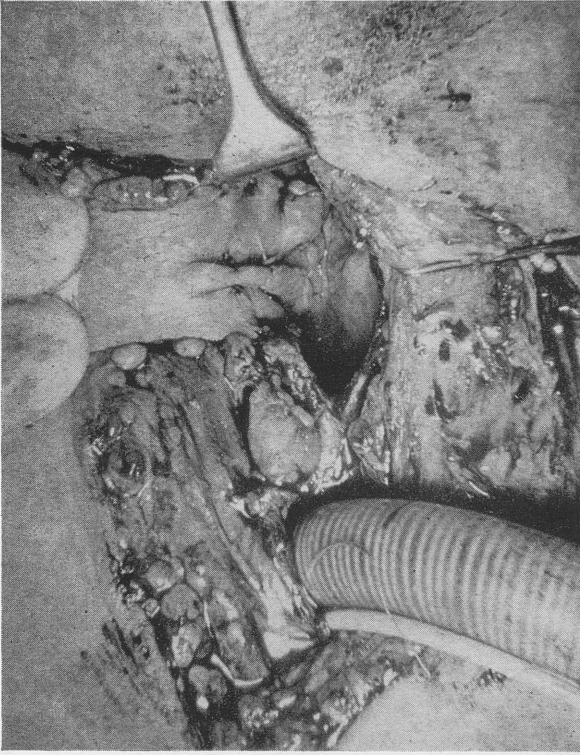


Fig. 3.—“Cord” created and brought into relief.

order to have a mobile posterior commissure. They are fashioned full enough anteriorly to prevent air leak and breathiness. The wound is closed in a single stage by direct approximation after an epithelial shave of the pedicle flap at the inlet to the glottis.

In rehabilitation of the hypopharynx following stenosis from lye burn, the regional flap requirements for resurfacing are larger than that for glottic rehabilitation. The planning is usually vertical rather than horizontal and the flap is transposed through a lateral pharyngotomy approach. Scar contractures involving the constrictor muscles and postericoid area are resected and the posterior wall of the hypopharynx cavity is recreated. The flap is positioned posteriorly so that this portion of the gullet associated with the sphincters of the hypopharynx leading into the cervical esophagus will be established. Strictures may exist at a lower level in the cervical esophagus and

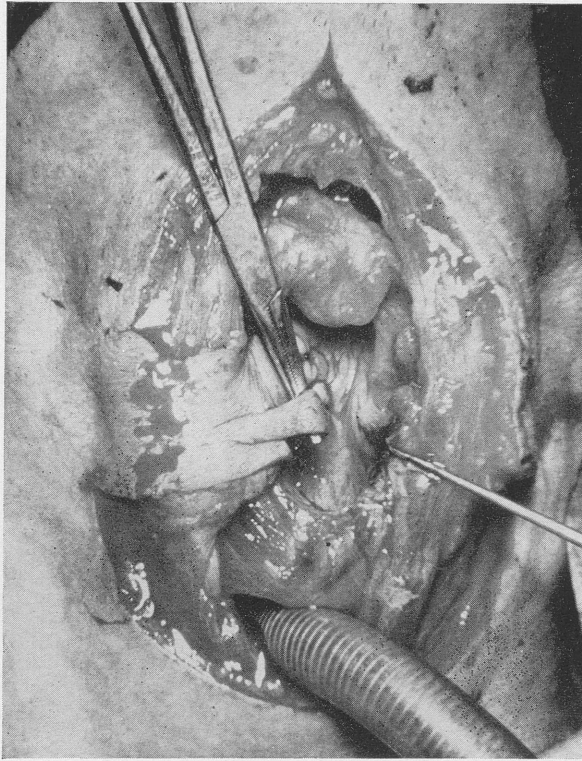


Fig. 4.—Epithelial shave beyond the cord at the anterior entrance to the glottis. This will be the line of closure.

this area should be investigated by finger insertion. Vertical myotomy of the inferior constrictor muscle may assist in relaxing the inlet to the esophagus. A pharyngostome is created and after an interval of three to four weeks, the base of the flap is released in the neck and transposed into the hypopharynx in order to accomplish additional resurfacing. The area of the base of the tongue and epiglottis are often involved with scar contractures and these are resected at this time to prepare a bed for the residuum of the flap. A pharyngeal stent is inserted and the pharyngostome is closed. The stent is removed in approximately two weeks.

Rehabilitation of the trachea presents special problems. In extensive wounds a stent is always required for molding purposes. Total

circumferential repair has a great tendency to recontract. The substitution of a skin lining for ciliated columnar epithelium has the disadvantages of desculmation and being odoriferous. A second stage procedure is indicated when reconstitution of the tube is questionable due to destruction of the architectural support. Under these circumstances a trough is created connecting the air passages. After an interval of several months, a roof is placed over the trough taking care not to compress or tighten the diameter of the trough. This is accomplished by rotating an inverted trap door flap to create an unrestricted dome. The raw area is then covered with a regional transposed flap usually from the upper chest. Rigid architectural support is not indicated under these circumstances and no substitution of a bony cartilaginous or inert framework is carried out. In the extensive problem in the trachea one may be gratified in rehabilitating the facility of speech and retaining a tracheostomy tube to guarantee the airway.

COMPLICATIONS

Two complications have appeared in the use of this technique. The most common one is the appearance of a granuloma in the region of the anterior commissure at the site of the "epithelial shave." This granuloma develops over a period of two to four weeks in approximately 50 per cent of the cases, and must be removed by direct laryngoscopy.

A small fistula may appear in the region of the epithelial shave shortly after the operating measuring 2 to 3 mm in diameter. This fistula usually closes spontaneously.

SUMMARY AND CONCLUSION

The use of nonhair bearing regional neck flaps has a specific application to the rehabilitation of the airway system of the hypopharynx, glottis and trachea. The essential purpose of the flap is to prevent stenosis, maintain patency and contribute to the functional capacity of the airway and glottic systems. The techniques may be concluded in a single stage procedure or may incorporate the use of stents and multistaged procedures. The adaptation of these flaps to the various clinical pathological situations is discussed.

DISCUSSION

DR. REED: It is a pleasure to discuss this paper of Dr. Conley's. As usual, he has presented us with a paper which, like its author, is impeccably tailored to the times and to the occasion.

We are indebted to Dr. Conley for pointing out and stressing the basic principles of reconstructive surgery as they are applied and now very well accepted in our field of otolaryngology.

There is no doubt, of course, that the principle of a pedicle flap with its own blood supply, viability and lack of tendency to contractility, certainly is more favorable than the free grafts that we have used so extensively up to the present time.

As Dr. Conley pointed out, this type of procedure is not necessary in many, or even most problems of interior laryngeal resurfacing. We have all had success using the split thickness graft and, as we saw from Dr. Tabb's paper earlier this week, vein grafts can be used for this purpose in small applications.

The important thing that I see in this paper is in the latter part. Dr. Conley has previously described refashioning one vocal cord, a "pseudo" vocal cord, in a lateral partial laryngectomy. Today he indicates to us that this can be done bilaterally and that all of the interior of the larynx can be removed as far back as the arytenoids, and two pseudo cords, can be refashioned. Now, by the time you have removed both vocal cords back to the arytenoids, you have removed a great portion of the larynx. If we couple this with Dr. McCall's report in which he by-passes the important function of the arytenoids with a tube, it now becomes theoretically "dreamable" that by combining these concepts perhaps the day of being able to remove both cords and both arytenoids with reconstruction by locally transposed flaps may become a reality.

I think this paper also demonstrates that Dr. Conley is indeed a surgeon. As you know, all surgeons were derived from barbers and we find him talking about "haircuts" for hair in the trachea; we find him talking about epithelial "shaves," and lastly somewhere between the copy I received and this one today, he spoke about the importance of non-hair-bearing skin and pre-operative "depilation." I would like to ask Dr. Conley how he achieves this pre-operative depilation.

DR. WORK: Dr. Conley has pointed out problems that involve the airway and he has made an attempt to correct function. He has pointed out that the pedicle grafts are better than free grafts. He has also intimated, and I know he thinks that pedicle grafts, with their blood supply, are much better than alloplastic grafts that one can put in these areas.

His work emphasizes the necessity of the otorhinolaryngologist's being trained in these fields and being able to carry on this work. I think this is excellent. Not only carrying on the work, but he has emphasized that the otorhinolaryngologist is in the position to plan this work before surgery.

This rather unique and ingenious method of repairing the airway is not the ultimate answer because we do not have cilia-bearing transplantations yet.

I wish to point out also that Dr. Conley has noted that we have recognized the transportation of skin, the pedicle graft, in the repair of the gullet and that this is quite accepted.

I would like to ask Dr. Conley, in the repairing of the troughs created by pedicle grafts, what support if any does he plan for in secondary closure? I know

that he limited his paper to small grafts, but I would still like to ask about the large airway grafts and their support.

Dr. Conley yesterday, I believe, pointed out his use of pedicle muscle grafts for the covering of the arterial supply. I wish to present just one extra problem here. There may be associated injuries of the soft tissues in the esophagus. We have added the muscle pedicle graft to repair the esophagus in this instance in some cases.

May I have that one slide, please.

(Slide) This simply shows the injured larynx, the open trough that Dr. Conley mentioned. The esophagus was torn in this area (indicating). In order to close this, after several attempts by direct suture, a muscle pedicle graft was thrown into this area, along the same principles that Dr. Conley has advocated for artery protection. Now, the pedicle graft from the skin of the neck may be used in the repair of the tissues here (indicating). The repair of this trough may be done later.

I wish to thank Dr. Conley for this excellent presentation and also for the advanced thinking that he has been doing in this field.

DR. CONLEY (closing): I want to thank you for showing that slide, Dr. Work, because that illustrates the trough concept very well.

There isn't any easy solution and in most instances no solution for the extended tracheal deformity or defect. In the problem that you demonstrated here I think the important thing in closing that trough is not having some type of inert or biological supportive architecture, but in closing the trough to be generous enough with the dome, with the roof, so that there is no constrictive action. I think this would be the secret of closing that trough. If that trough were lined completely with skin I estimated it to be 10 centimeters long. Here, of course, there is no physiological action, there are no cilia and these individuals all develop an odor to their breath and develop some type of desquamated epithelial products, which become moist and sticky. Some of the scabs can become so large and so sticky that they can cause an airway obstruction.

I had one patient who had a rehabilitation of about this size who choked to death after decannulization on a scab that she formed in this area, so I feel that when the defect is this big, if you can rehabilitate the vocal system that that is about as far as you can go. These individuals perhaps should, at the present time, continue to wear a tracheostomy tube for airway security.

As far as the depilation is concerned, Dr. Reed, I must tell you that I am in the habit of changing my papers and I read this paper about six o'clock this morning and wasn't completely satisfied with it and added several new phrases and words and this was one of the words that I added.

I would like to emphasize, however, that most of these situations pertain to the male and the male is the individual who has the whiskers, consequently the use of the regional flap immediately has limitations. In trying to pick out a place on the neck or the upper chest where you might borrow some of this tissue, I find that a line can be drawn just about the mid-portion of the thyroid cartilage, and immediately below this for a distance of perhaps 3 or 4 centimeters there is often an area that is very scarce in hair. If the individual is a veritable Castro, then I think you would have to give it up and do something else. If he only has a few long hairs, then I think you might use electrolysis on those.

SEPTAL DERMATOPLASTY

OBSERVATION, TECHNIQUE AND RESULTS

ROBERT BARNARD LEWY, M.D.

ANTHONY HAMMOND, M.D.

(by invitation)

CHICAGO, ILL.

One cannot practice otolaryngology for a period of years without seeing a series of cases of hereditofamilial telangiectasia. Since its description as a disease entity by Babington,¹ Osler,² Goldstein, Piskiewicz, Rendu³ and others, it has represented a constant challenge to the rhinologist. Although it is a general disease, the most frequent and evident manifestation is epistaxis. This is annoying, recurring and dangerous and, due to the frequency of the bleeding and the amount of blood loss, in some cases fatal. No wonder, therefore, that when Saunders⁴ presented a method of skin grafting the nasal septum over many of the bleeding points, that his techniques were scrutinized with a hope toward a solution of a previously unresolved clinical problem. In the past many modalities of treatment were used and failed. The number and variety of methods were in themselves abundant evidence of failure. The dermatoplastic procedure gave new hope.

This report concerns itself with a report on a series of four cases in which septal skin grafting was attempted. That there was some measure of success, and that the procedure is a practical one that can be readily learned by a competent rhinologist is the basis for this presentation. An additional technique has been added which also holds some promise and extends the possibilities. There were specific failures which occurred as well. The evaluation of these may be helpful in establishing a standardized surgical technique.

From the Department of Otolaryngology, University of Illinois College of Medicine, Chicago, and Veterans Administration Hospital, Hines, Illinois.

REPORT OF CASES

CASE 1. N.W., one of a family of three brothers, a mother and a sister, all of whom had recurrent epistaxis since childhood. Physical examination revealed telangiectatic areas in nose, lips, buccal mucosa, soft palate and the external surface of the head.

Laboratory findings: Bleeding and coagulation times within normal limits. Hematocrit 36, hemoglobin 11.5 gm. Prothrombin time normal. X-ray series: Prominence of gastric and duodenal mucosal folds shown on gastrointestinal studies.

Septal dermatoplasty was performed on both sides of the septum January 13, 1961. By the third postoperative day there had been no bleeding. The donor site healed well. The grafts took well on both sides of the nasal septum, and there was good healing of recipient areas.

Subsequent course: This patient, six months later, has a very moderate degree of bleeding once a week. Prior to the surgery he had daily episodes of bleeding. He was able to work before the surgery. After six months he again started bleeding daily. This was of smaller amounts than before and constituted some improvement.

CASE 2. G.A. Split thickness graft was applied to both sides of the septum to correct a perforation. The graft appeared good at first. Later it necrosed. This must be considered a failure. In retrospect we feel that the perforation was too large. Perforation was 1.5 to 2 cm in diameter.

CASE 3. J.R., a 37 year old negro male. His mother, mother's father, and mother's brother all had a history of nose bleed. He had some spells of vomiting but never any hematemesis. Physical examination revealed numerous telangiectatic spots on the tongue, septum, and the vermillion borders of both lips (Fig. 5). Diagnosis: Heredito-familial telangiectasia. Proctoscopy revealed no telangiectasia. History of two to four nosebleeds daily with nose packed on several occasions.

Laboratory findings: White blood count 6,400, hematocrit 44%. Urine normal. Thymol turbidity 1. Alkaline phosphatase 2.4. Non-reactive serology.

Hospital course: Septal dermatoplasty January 27, 1961. The patient stated that before surgery he bled every day from the right

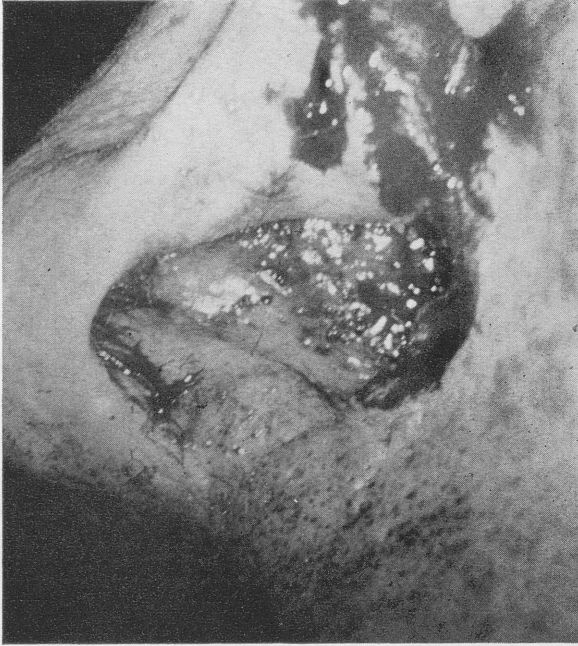

Fig. 1.—Alar flap raised.

side of the nose and frequently from the left side. Since the surgery there has been no bleeding from the left and very occasional bleeding from the right.

CASE 4. J.W., the brother of N.W. (Case 1). This man was a serious bleeder. He has findings of telangiectasia on the tongue and buccal mucosa, on the outside of the head and on the nasal septum. His bleeding has been so profuse that he had had in a period of years a total of 51 blood transfusions. The first operation was performed January 20, 1961. This was a standard bilateral septal dermatoplasty. This was not adequate. Following of his hemoglobin and hematocrit proved this. It was felt that a more extensive flap covering the whole nasal septum could be made if the septum were exposed by a lateral rhinotomy and a separation of the nasal bone from the maxilla. This was done in two separate procedures March 10, 1961 and April 28, 1961. However, despite this more extensive grafting procedure and despite the fact that the graft took well on both sides, there was no

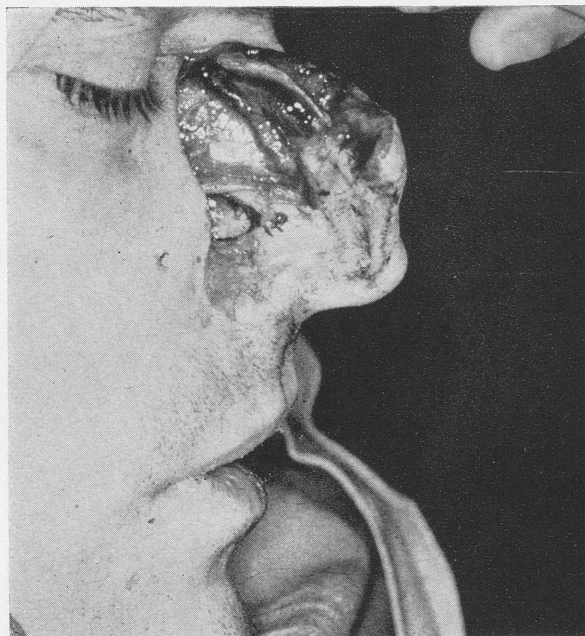

Fig. 2.—Extended flap with complete exposure of nasal septum.

appreciable improvement in the problem of the nasal bleeding. In addition, at the time of surgery, an effort was made to cauterize deeply all lesion seen on the lateral wall and turbinates of the nose at both operations.

TECHNIQUE

The technique is with one specific extension, essentially that suggested by Saunders.⁴ In essence a skin flap is raised, from a nonhairy side of the thigh or buttock. This was about 28 thousandths of an inch thick and large enough to cover the septum. A flap is raised of the ala nasi and this is retracted with a heavy black silk suture. Then a portion of the skin and mucosa of the columella is raised, leaving a margin. This is continued with scissors, scalpel and curette as far as one can go on the septum, again leaving a margin. Great care must be taken to see to it that all of the mucosa is not removed in depth. Removal of the perichondrium would deprive the new covering and the cartilage of its blood supply and cause a slough; once this area

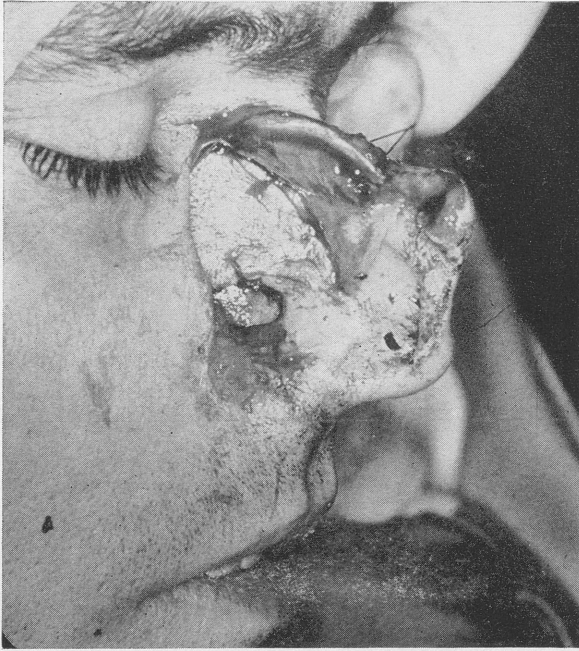

Fig. 3.—View of skin flap in position with extended incision.

is freshened up the flap is patterned to fit. It is lain into place and tacked down with absorbable sutures at its most superior and dependent locations. The temporary flap of the ala nasi is attached in position. As in the clocking technique in a rhinoplasty there is no visible scar. This operation suffices in most cases.

Assuming that this procedure fails, it is possible that a more extensive exposure of the septum might succeed. Therefore, the exposure is increased by continuing the alar incision along the nasofacial groove to near the internal canthus of the eye; from there partially over the nasal dorsum. This incision is carried down to the bone. The junction of the nasal bone with the process of the maxilla is identified. This is separated by chisel and the whole half of the nose rotated forward, creating total septal exposure. After a corresponding, but larger skin flap is placed and tacked into position in the partially denuded septum. Considering the extensiveness of the procedure there is minimal scarring and no deformity.

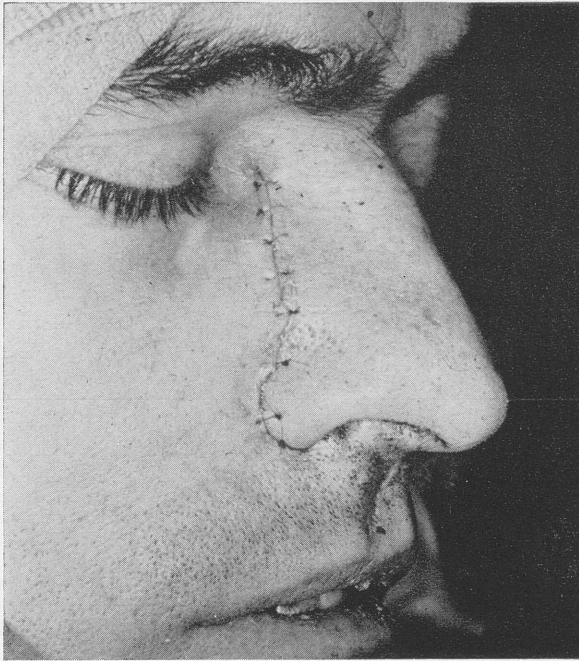

Fig. 4.—Extended flap replaced; note minimal scarring.

COMMENT

Of interest is the new technique suggested in Case 4. After a failure with the usual type of septal dermatoplasty; impressed by the fact failure would mean chronic invalidism (patient had had by this time 50 blood transfusions). It was suggested by one of us (A.H.) that if, instead of raising only a small flap at the ala of the nose, with two procedures, raise each whole side of the nose alternately and place a larger and therefore more effective graft. This was done. The plastic procedure itself was a success. There was no sloughing of tissue and the skin graft took well. In addition this created access for cautery of various areas on the lateral wall of the nose which were not available by the smaller incision. Despite all of this, however, while there may have been a minor reduction in the frequency and intensity of nasal bleeding, it continued. This could not be considered a success. The degree of exposure obtained justified the technique,

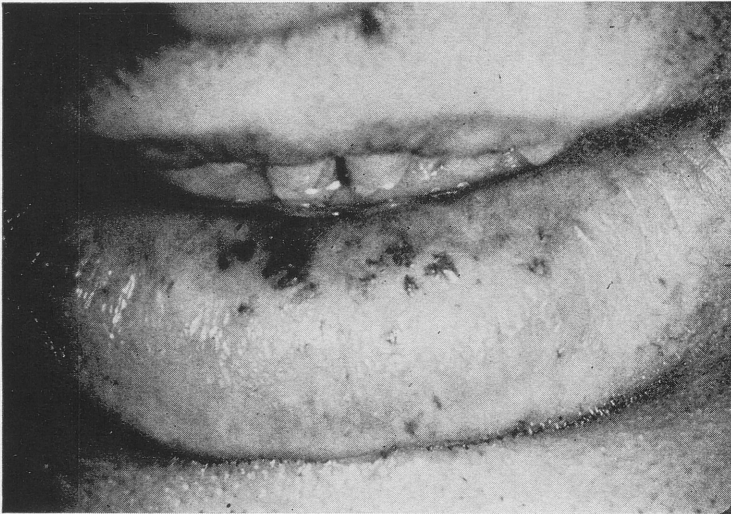

Fig. 5.—Typical lesions (lip), telangiectasia.

however, and the idea is being presented with the hope that it may be successful in some future case.

Concerning the application of this technique, for the correction of septal perforation we have concluded that it will probably succeed only where the greatest diameter of the perforation is 5 mm or less. Our early hopes were late failures.

In this series we had one marked success and one marked improvement. The other two cases can not be considered successful. It is difficult to decide where success can be anticipated. In such a situation, however, there is little risk in the surgery, and everything to gain. Therefore this is one of a small group of surgical situations where an aphorism might be applied—"when in doubt operate." Total evaluation of the patient's pathology is required and some estimate must be evaluated of how much blood is lost through the nose and what fraction may be lost due to telangiectatic spots along the alimentary canal.

CONCLUSIONS

Despite some failures we feel that this operation is useful when the disability from the disease is severe and when previous simpler

modalities have failed. The operation in trained hands is not too difficult to learn and can reasonably become a part of the armamentarium of any rhinologist with a modicum of experience with rhinoplasty. It can be of value in small perforations of the septum. Nutrition to the nasal septum must not be compromised.

This represents a step forward in the control of nasal bleeding with a dread disease, and should be done when indicated. It is not the final solution.

25 EAST WASHINGTON ST.

REFERENCES

1. Babington, B. G.: Hereditary Epistaxis. *Lancet* 2:362-363, 1865.
2. Osler, William: On a Family Form of Recurring Epistaxis with Multiple Telangiectases of the Skin and Mucous Membrane. *Bull. Johns Hopkins Hosp.* 12: 333-337 (Nov.) 1901.
3. Rendu: Epistaxis repetees chez un sujet porteur de petits angiomes cutanes et muqueux. *Bull. et mem Soc. med. hop. Paris*, 13:731-733.
4. Saunders, William H.: Septal Dermoplasty for Control of Nosebleeds Caused by Hereditary Hemorrhagic Telangiectasis or Septal Perforations. *Tr. Am. Acad. Ophth. and Otol.* 64:500-505 (July-Aug.) 1960.
5. Weber, F. Parkes: Multiple Hereditary Developmental Angiomata (Telangiectases) of the Skin and Mucous Membranes Associated with Recurring Hemorrhages. *Lancet* 2:160-162 (July 20) 1907.

DISCUSSION

DR. SAUNDERS: The important thing in septal dermoplasty is to place skin where telangiectases are most likely to bleed. In hereditary hemorrhagic telangiectasia the two most important bleeding sites in the nose are the anterior half of the septum and the anterior ends of the inferior turbinates. Once skin is successfully grafted there is no further bleeding from these sites. Until recently I grafted only the septum but now I find it equally important to graft skin on the anterior aspect of each lateral wall—especially along the anterior ends of the inferior turbinates.

In some 50 patients for whom I have done this operation, no patient has lost an entire graft. A few have lost part of a graft because of improper positioning of the graft when the nose was packed. The excellent blood supply of the nose almost assures a complete take.

I've had occasion to use an extensive incision such as Dr. Lewy showed in only one patient. She was a Canadian woman who had a standing date with the blood bank—she got a two pint transfusion every Friday and said she sometimes needed more. She had no septum at all, and to correct her bleeding a wide exposure was needed. But except in that one case, I have never needed a wider exposure than is provided by a small curved alar incision. Also I never graft all of the septum—only the front part. The posterior part is naturally protected and doesn't bleed, or at least

not much. Again, I would like to repeat: the anterior part of the lateral wall, especially along the inferior turbinate should also be grafted.

I want to thank Dr. Lewy for asking me to discuss his paper. His success with two patients is gratifying, I'm sure. More can probably be done for his patients who still bleed, and particularly if their bleeding is from the lateral wall where skin was not grafted. I'm convinced that skin will grow any place in the nose where it's properly placed, and that once it grows no further bleeding will come from those sites.

DR. LEWY (closing): It is not every day nor on every paper that an essayist has the opportunity to have a gracious addition to his paper rather than a difference of opinion from which a certain number of sparks fly. I am very grateful to Dr. Saunders for the additions which are the result of his greater experience and continuing experimentation with the methods which are involved here. I can't think of any area where there is any difference of opinion between us.

Our interest in picking up this problem was not only to help solve the problem, but also to show that this could become a standard rhinological procedure.

There has been an over-all tendency for certain procedures to be concentrated too much in the hands of originators throughout the country. We need new seedling here and there. We have one new seed now in Chicago and it is my earnest hope, and I know it is Dr. Saunders', that a lot more seeds and seedlings will be developing throughout the country.

INJURIES OF THE LARYNX AND CERVICAL TRAUMA

G. S. FITZ-HUGH, M.D.

CHARLOTTESVILLE, VA.

W. M. WALLENBORN, M.D. F. MCGOVERN, M.D.

CHARLOTTESVILLE, VA.

(by invitation)

DANVILLE, VA.

(by invitation)

In this present day and time, when trauma in its various phases is an ever dominant danger to the population, when the cause of such are the reasons for several well-organized national surveys, when the handling and treatment of the victims therefrom have arouse interest and are creating critical examination and, as a result, we are confronted with a new specialist, a "traumatologist,"¹ which may be good or bad; it does not seem amiss for us to present for consideration at this time some of the aspects of the immediate results of injuries to the larynx and cervical trachea.

If this presentation can be construed, with reservations, as a medium for instruction, it is directed to the interns and residents who man the majority of emergency entrances to hospitals, who in some instances do not have enough experience and knowledge to recognize the need for more mature medical judgment, and, if the reverse be true, may expect a significant time lapse before this becomes available; thus, a mismanagement of these cases will be inevitable.

All agree that in comparison with the total number of injuries of the head and neck, the number of those involving the larynx and trachea will be in the minority. This is true because of the anatomy per se and the anatomical location of these structures.^{2,3} The shelf-like mandible and shoulders will often absorb the initial force and the neck structures will suffer secondarily. When struck, the flexibility and resiliency of the cartilage and attached soft tissue dampen the intensity of force, thus reducing the actual degree of injury.

From the Department of Otolaryngology, University of Virginia Hospital, Charlottesville, Va.

Our presentation deals primarily with the immediate problems of injuries of the laryngotracheal complex and not the chronic, long-term ones, but rather the prevention of these. Before dismissing this chronic group, one is privileged to mention and give credit to some of those who, in earlier days, were handed those unfortunate victims whose airways and powers of phonation were obliterated and limited by scar tissue.⁴⁻⁹ By their persistent and skillful efforts, much was accomplished in the restoration of these faculties. More recent contributions to the field of laryngeal rehabilitation have been demonstrated by new and improved, and now well-known, surgical procedures.¹⁰⁻¹⁴ Continuous progress is assured, as evidenced by the investigative efforts of those head and neck surgeons in our specialty.¹⁵⁻¹⁸

As has been implied, serious external trauma to the laryngotracheal complex is uncommon. The majority of harm, as one would anticipate, is the result of automobile accidents and is a part of multiple injuries. However, the automotive vehicle is not the sole cause of these cervical injuries, as other causes, such as strangulation, fist blows, rocks, knifings, shootings, and trauma received in athletic events, have been encountered by us and by others.¹⁹⁻²³

In the case of injuries not due to cutting from sharp instruments, glass, etc., the blow will usually be of the blunt type, with the larynx, cricoid, and trachea being forced directly against the vertebra, or by an oblique shearing type of impact. The parts may be contused, lacerated, penetrated, avulsed, fractured, or crushed. All of these various types of injury may occur with little evidence of trauma to the skin and soft tissues overlying the airway, thus making the diagnosis or real status of the injury difficult to evaluate, especially to the attending surgeon whose index of awareness may be somewhat limited because of insufficient training and experience in the vagaries of an injured upper respiratory system. One or all of the cartilaginous structures may be involved, including the hyoid.

Our clinical presentation, as has been previously noted, is concerned with recent, early, or emergency injuries of the laryngotracheal regions, caused by external forces. The hyoid bone is considered only as an adjacent structure and is included to a minor degree. There are various ways of classifying these conditions, but for simplification we prefer the two groups: 1) closed injuries of the laryngotracheal structures due to external causes, and 2) open injuries of similar nature.

In surveying our records, although we realized that these injuries are not common, we were surprised to find so few with satisfactory records qualifying them for this clinical study. This confirms the observation by others that in multiple injury cases those of the laryngotrachea may well be considered minor ones and are not included in the final tabulation by the record departments. The accounts are of those patients seen and treated by one or more of us at either of two hospitals, the University of Virginia Hospital and Danville Memorial Hospital, with two exceptions. No cases are included that were not hospitalized. Here we make the observation that we are sure that there are a number of accident victims having minor injuries of the larynx and trachea who are treated without hospitalization and, in fact, we suspect there are an appreciable number who never come under the surveillance of a laryngologist, for various reasons.

The records of 28 patients who received trauma to the hyoid and laryngotracheal regions have been studied. Some details disclosed by this survey are presented in Tables I and II. In order to elaborate and place emphasis upon certain observations, several of the cases will be presented briefly in more detail, accompanied by diagrams depicting the injury.

Before doing this, however, the diagnosis, signs and symptoms, and treatment will be considered generally.

The diagnosis may be established on the basis of the history, caliber of the voice, ease of respiration, external examination by scrutinization and palpation of the cervical areas, indirect and direct examination of the laryngopharyngeal structures (this examination may be precluded by the critical general condition of the patient), and x-rays. The latter are obtained in the severely injured to determine not only the condition of the laryngotracheal structures, but also that of the cervical vertebrae. X-rays aid in demonstrating the absence or presence of air in the tissues, areas of localized swelling and fullness. Conventional views obtained early in the case of acute injury are not too helpful in demonstrating cartilaginous fractures; tomograms later are more beneficial.

The appearance of the neck may be quite misleading as far as the degree of laryngotracheal injury is concerned, for dangerous conditions may exist beneath nearly normal appearing soft tissue. This fact is one of the causes for mismanagement of these cases at the emergency room level, and should be emphasized. The soft tissue

TABLE I
INJURIES OF THE LARYNX AND CERVICAL TRACHEA

Patient	Injury	Etiology	Symptoms	Treatment	Result	Assoc. Injuries and Remarks
1. A.P.M. W.F. 7 yr.	Closed injury Minor skin abrasions Rupture of trachea	Playground accident	Hoarseness Cough Emphysema	Medical	Good	None
2. J.C.H. W.M. 43 yr.	Closed injury Rupture of trachea Hematoma Paresis of left V.C. Slight abrasion of skin	Auto accident	Dysphonia Dysphagia Emphysema	Medical	Residual limitation of left V.C. Slight dysphonia	None
3. E.C. W.M. 35 yr.	Closed injury Hematoma Paresis of left V.C. Fracture of thyroid cartilage	Struck by rock	Dysphonia Dysphagia Dyspnea No emphysema	Medical	Good	No evidence of injury externally
4. E.D. C.F. 40 yr.	Closed injury Bilateral V.C. paralysis	Auto accident	Dyspnea Aphonia Swelling neck	Tracheotomy Exploration of neck	Fair Persistent V.C. paralysis Refuses decannulation	Severe head injury Left hemiparesis Rt. abducens paralysis Stretch injury of neck Possible candidate for aryle- noidectomy later
5. C.W.D. W.M. 24 yr.	Closed injury Bilateral V.C. paralysis Fracture of thyroid, cricoid, and tracheal cartilages Rupture of trachea with sever- ance from larynx by avulsion	Auto accident	Severe dyspnea Emphysema Aphonia	Tracheotomy Exploration Repair Endolaryngeal and tracheal stent (8 mos.)	Limited airway after removal of stent and d cannulation Secondary tracheotomy necessary Anticipate arytenoidec- omy Good result considering injury	Moderate head injury Fractured leg Lacerated eyebrow Awaiting further procedure for possible recovery of V.C. activity Slight movement of left V.C. already noted (10 mos.)
6. G.M.B. W.M. 18 yr.	Closed injury Hematoma of left aryepiglottic fold Several minor endolaryngeal and hypopharyngeal lacerations Paresis of left V.C.	Sleightriding accident	Dysphonia	Medical	Good	Occupation requires much voice use No disability

Patient	Injury	Etiology	Symptoms	Treatment	Result	Assoc. Injuries and Remarks
7. T.E.L. W M. 17 yr.	Closed injury Severe crushing and avulsion of trachea	Fall - elevator shaft	Progressive dyspnea Dysphonia	Tracheotomy without early exploration Revision of tracheotomy Innumerable plastic procedures on trachea in effort to establish unimpeded airway	Poor After 11 yrs. must wear prosthesis (but- ton) to assure airway and voice	Injuries to clavicle, chest and foot Earlier exploration and repair might have prevented complete stenosis by scar in subcricoid and high tracheal area
8. E.L. W M. 9 yr.	Closed injury Contusion of larynx Laryngotracheal fracture	Bicycle accident	Dysphonia Emphysema	Medical	Good	None
9. J.L. W F. 51 yr.	Closed injury Hematoma	Strangulation	Dysphonia Dyspnea	Medical	Good	None
10. J.D. W M. 58 yr.	Closed injury Rupture of trachea	Auto accident	Dyspnea Emphysema	Tracheotomy	Good	None
11. J.M. W M. 48 yr.	Closed injury Massive hematoma of left larynx Paralysis of left V.C. Laceration of right hypopharynx	Auto accident	Dysphonia Dysphagia Dyspnea	Medical	Fair voice Satisfactory airway Paralysis of left V.C.	Fractured femur Surprisingly, tracheotomy not necessary
12. C.L.G. C M. 49 yr.	Closed injury Hematoma	Struck by cow horn	Dysphonia Dyspnea Hemoptysis Emphysema	Medical	Good	None
13. J.H.W. C M. 30 yr.	Closed injury Paralysis right V.C. Hematoma	Auto accident	Dysphonia Dyspnea Emphysema	Medical	Fair Persistent V.C. paralysis	Fracture of rt. leg
14. M.H.C. W M. 25 yr.	Closed injury Hematoma of right endolarynx	Auto accident	Dysphonia Dysphagia	Medical	Good	Laceration of face Fractured teeth

TABLE 1 (Continued)

INJURIES OF THE LARYNX AND CERVICAL TRACHEA

Patient	Injury	Etiology	Symptoms	Treatment	Result	Assoc. Injuries and Remarks
15. E.L. W.F. 18 yr.	Closed injury Hematoma of right false cord Fixation of right arytenoid	Auto accident	Dyspnea Strangling	Tracheotomy Exploration of larynx and trachea Laryngoplasty with hyoid bone graft 6 mos. after injury Right arytenoidectomy 3 yrs. after injury	Decannulated Satisfactory airway Fair voice after multiple operations	Fracture of mandible
16. L.K. W.M. 22 yr.	Closed injury Bilateral V.C. paralysis Fracture of hyoid Avulsion of trachea from larynx	Train accident	Dyspnea	Tracheotomy Exploration of larynx and trachea 7 mos. after injury End-to-end anastomosis Laryngoplasty with stent 10 mos. after injury Multiple dilatations Excision of stenotic area 4 yrs. after injury	Decannulated Satisfactory airway Poor voice after multiple operations	Fracture dislocation of C3 and C4 Injury to arm, chest, and clavicle One of our first experiences with severe laryngotracheal injuries (1948)
17. J.R. W.F. 32 yr.	Closed injury Massive hematoma Paralysis of left V.C.	Auto accident	Dysphonia Dysphagia	Medical Readmitted 4 wks. after injury with dyspnea and URI. Medical treatment Readmitted 2 mos. after injury with dyspnea and URI. Tracheotomy Multiple direct laryngoscopies with removal of granulomata (17 in 5 mos.)	Decannulated 5 mos. after tracheotomy Voice fair Airway fair	Laceration of face Fracture of hip
18. J.N.M. W.M. 24 yr.	Closed injury Hematoma Fracture of larynx	Auto accident	Hemoptysis Dysphonia	Medical	Good	Fracture of metatarsus
19. M.L.G. C.M. 44 yr.	Closed injury Hematoma Paralysis of left V.C.	Altercation	Dysphonia Dysphagia Dyspnea	Medical	Satisfactory Lost to follow-up before recovery from paralysis of cord	None
20. G.J. C.M. 27 yr.	Closed injury Hematoma Slight limitation of motion of both V.C.	Auto accident	Dyspnea Dysphonia Emphysema	Medical	Good	Laceration of forehead

Patient	Injury	Etiology	Symptoms	Treatment	Result	Assoc. Injuries and Remarks
21. P.A.M. C.M. 21 yr.	Closed injury Transsection of trachea between 1st ring and cricoid cartilage Displacement of arytenoid Fracture of cricoid cartilage	Auto accident	Dysphonia Dyspnea Emphysema Hemoptysis	Immediate tracheotomy followed by exploration of laryngotracheal areas Reduction of fractured parts Fixation by internal splinting (poly- ethylene stent) and sutures Stent in place 1 yr. Secondary exploration after inability to decannulate Arytenoid and granuloma removed	Now ready for decannulation Fair airway predicted Poor voice after multiple procedures	Fracture dislocation of 2nd cervical vertebra and mandible Fracture of femur Pneumothorax Result considered good to date (18 mos. post-accident) in view of severity of injuries
22. M.W.B. W.F. 38 yr.	Closed injury Endolaryngeal laceration left false cord Paresis left V.C.	Auto accident	Dyspnea Dysphonia Hemoptysis Emphysema	Tracheotomy Endotracheal tube stent (2 mos.)	Improved Still under observation with tracheotomy tube 2 mos. post-accident Voice improving	Laceration of face Fractures of hyoid, clavicle, arm and leg
23. F.A.M. W.F. J.A. 5	Open injury Laceration of neck involving cricothyroid membrane	Tornado victim	Cyanosis - shock Respiring through neck wounds	Tracheotomy Repair of lacerations Laryngoscopy and removal of granulomata	Decannulated Good airway Good voice	Multiple lacerations of face, head and chest
24. L.S.C. W.F. 3 mos.	Open injury Laceration of soft tissue, larynx, cricoid, trachea and esophagus Bilateral V.C. paralysis	Cut throat victim (attempted infanticide)	Shock Respiring through wound	Tracheotomy Primary repair of wounds Laryngoscopy and dilatation	No voice Could not be decannulated	Expired while still in hospital Cause not determined at autopsy
25. M.B. W.F. 52 yr.	Open injury Laceration of neck and hypopharynx Amputated epiglottitis	Cut throat (attempted suicide)	Shock Respiring through wound	Tracheotomy Repair of wounds	Decannulated Good airway and voice	Laceration of wrists
26. G.W. W.M. 31 yr.	Open injury Laceration of neck Avulsion of trachea Bilateral V.C. paralysis Laceration of esophagus	Auto accident	Dyspnea Dysphonia Emphysema	Tracheotomy Tracheal dilatation Tracheoplasty with skin grafting, core mold, acrylic stent Multiple procedures	Decannulated Good airway Fair voice Recovered motion of one V.C.	Laceration of face Closed head injury Severe injury - excellent result
27. D.B.G. W.M. 38 yr.	Open injury Laceration of neck Laceration of trachea Bilateral V.C. paralysis	Auto accident	Dysphonia Respiring through wound	Tracheotomy Immediate repair of soft tissue and trachea by end-to-end anastomosis	Decannulated Recovery of movement of one V.C.	Fracture dislocation of 3rd cervical vertebra and hip
28. C.S. W.M. 20 yr.	Open injury Laceration of neck Laceration of larynx	Cut throat	Dysphonia Respiring through wound	Tracheotomy Repair of lacerations	Decannulated Good voice Good airway	None

TABLE II

INJURIES OF THE LARYNX AND CERVICAL TRACHEA

<i>Number - 28</i>		<i>Male - 18</i>	<i>Female - 10</i>	<i>Children - 4</i>
<i>Closed Injuries</i>		22	<i>Open Injuries</i> 6	
Tracheotomy required		9	Tracheotomy required 6	
not required		13		
<i>Final Result - 28 Cases</i>				
<i>Completed Cases</i> 24		<i>Incompleted Cases</i> 4		
Airway	Good	16	1. One death 3 months after injury. Bilateral V.C. paralysis. Tracheotomy present. Case 24.	
	Fair	8	2. Progress good. 3 mos. after accident V.C. paresis clearing. Decannulation later. Case 22.	
Voice	Good	14	3. Progress fair. Persistent bilateral V.C. paralysis. Pt. will not permit decannulation. Case 4.	
	Poor	10	4. Unable to completely forego tracheotomy. Anticipated arytenoidectomy. Case 5.	
<i>Multiple Injuries</i>				
Total 18		Major 14	Minor 4	

may exhibit injuries varying from slight contusion and mild abrasion to severe laceration. The voice may be only slightly husky, or there may be complete aphonia. Respiration may vary from the tranquil, free and easy type to dyspnea, effort, and other evidences of obstruction. Slight hemoptysis to dangerous hemorrhage leading to hemic drowning may be present. Swelling of the tissue may be quite rapid and alarming, and, if so, is usually secondary to extravasation of air, aggravated by cough and straining. Cervical swelling can also be the result of hemorrhage into the soft tissue, indicating injury to large vessels. If gross injury to the cartilage has occurred, this may be apparent on palpation. If it is safe and practical to visualize the laryngopharynx by indirect mirror or direct laryngoscopy, and these examinations should be attempted only by the experienced, one may observe edema, hemorrhagic tissues, lacerations, and immobile and displaced disorganized structures. Pain on movement of the lower jaw, tongue, and on deglutition may be present, the degree depending upon the extent of the injury.

In the treatment of this type of injury, first consideration is given to the status of the airway. If it is impaired, low tracheotomy, with or without the aid of some type of endolaryngeal tube, is performed. Next, until the extent of injury is determined, the neck should not be manipulated any more than is absolutely necessary. Splinting and immobilization, as indicated, may be accomplished by sandbags, pillows, or manually by the attendant, thus minimizing the dangers of tragic spinal cord injuries and aggravation of the laryngotracheal ones. In the event of multiple injuries, after the airway problem has been estimated, those who have primary management of the patient, whether they be neuro-, orthopedic, or general surgeons, should be made aware, if necessary, of the danger and resulting disabilities if neglect of the laryngotracheal structures is permitted.

Penetrating wounds of the neck,²⁴ of the type caused by missiles, should be thoroughly explored, especially to repair, if necessary, any injuries to the vascular structures. Location and restoration of the integrity of recurrent laryngeal nerves must obviously be quite difficult, according to our present precepts. However, with the development of surgery using magnification and improved lighting, as practiced in microscopic ear surgery, and utilizing some of the newer methods of nerve approximation,²⁵ progress along these lines is now within the realm of possibility.

In *closed injuries* it has been our experience and that of others that tracheotomy is not often necessary.²⁶ The obstruction to the airway, usually by hematoma formation, occasionally by cord paralysis or arytenoid cartilage dislocation, develops at the time of the injury and does not increase unless aggravated by unusual manipulation of the cervical structures. Subcutaneous emphysema will increase with cough and activity, and if it becomes progressive then tracheotomy is probably indicated, regardless of the lack of disturbing airway obstruction. Incision per se to release subcutaneous air does not appear to be necessary. Distressing dyspnea requires low tracheotomy.

Customarily, the victim is placed at rest in the partially elevated head position, with light splinting by pillows, etc. Mild sedation is administered. An emergency tracheotomy tray is placed in a readily accessible place. An attendant is kept constantly with the patient for the first 24 hours or longer. We prefer also to prescribe an antibacterial drug, a steroid, and an enzyme, although it is debatable

as to the routine need for them. No effort is made to visualize the larynx in the first 48 hours or so if such a maneuver results in retching, coughing, or struggling by the patient.

The decision to explore the laryngotracheal area by the external approach to search for and reduce non-demonstrable fractured cartilages and to relieve possible recurrent laryngeal nerve pressure, is difficult and will depend upon the circumstances, type of injury, and the aggressiveness of the otolaryngological service. We do not believe that evacuation of endolaryngeal hematomas, as has been suggested,^{27,28} is often indicated, and certainly not unless a tracheotomy has been previously performed. The majority of the closed type of laryngotracheal injuries may be satisfactorily treated by conservative medical measures.

Closed injuries requiring tracheotomy may vary from the less dangerous ones, such as bilateral cord fixation, to those of a more serious nature, in which there is surprisingly little evidence of external soft tissue trauma, but, beneath, a severely injured and disorganized laryngotracheal structure, requiring urgent measures to re-establish a satisfactory airway. It is surprising the amount of damage that can be sustained without immediate exitus in some of these cases; their survival before the provision of some type of external cervical airway is amazing to anyone who witnesses it. We have noted in several cases that when an incision is made through the skin in performing an emergency or urgent tracheotomy, air immediately escapes through this initial incision. Further dissection discloses the crushed or avulsed structures. The tracheotomy is established in its proper place, and then plans are made and measures taken to carry out more definitive treatment, as will be described in the next section dealing with open injuries. These measures should be carried out as early as possible. As a rule, any delay is justified only if the treatment may itself be detrimental because of the general condition of the patient, as, for instance, in a severe intracranial trauma.

In the *open type* of laryngotracheal injury, one usually encounters laceration of the soft tissues overlying these structures. The framework of the larynx and trachea may be badly disorganized, as mentioned previously in describing the closed injuries. The airway compromised by the injury may be temporarily and adequately compensated for by virtue of the open type of injury per se. That is, the victim may well be respiring through the soft tissue lacerations and defects in the trachea or larynx. The establishment of a satisfactory airway, as always, is the first consideration in these cases.

As soon as possible a low tracheotomy should be performed according to the accepted techniques.

After a satisfactory airway has been provided, and bleeding has been controlled, then the hyoid, thyroid, cricoid, and cervical tracheal areas should be promptly and thoroughly investigated. In cases of multiple injuries, this may not be accomplished at once, but all those concerned with the treatment of the patient must be made aware of the dangers of permanent disability from delay at this stage. Wide exposure of the wound is desirable. The lacerated mucous membranes should be approximated as neatly as possible with catgut, silk, or cotton suture material. The knots should be tied external to the lumen, and submucosally wherever possible to minimize the opportunity for formation of granulomas.²⁹ Shifting of mucous membranes may aid in covering denuded areas. There should be no more sacrifice of soft tissue or cartilage by debridement than is absolutely necessary. Fractured cartilages, if displaced, are repositioned and fixed in place by sutures and internal splinting.³⁰ In the case of severed or avulsed trachea, end-to-end anastomosis is possible, if too much tissue has not been lost as a result of the injury or debridement.

It is important, from the first efforts at treatment, to plan for the retention of a full endolaryngeal and tracheal lumen. In a crushing injury, one with cartilaginous displacement, we attempt to do this with internal splinting, placing a polyethylene tube extending from just above the vocal cord level to that of the tracheotomy tube. This is fixed in position by wires through the soft tissue, cartilage, and tubing. If there has not been much loss of tissue, this tube is left in place for weeks or months, depending upon the circumstances. In the event of extensive loss of tissue, plans are made for future replacement of the polyethylene splint with skin, various types of stents, prostheses, etc., in an effort to prevent stenosis and to retain a functioning airway.

Possible esophageal injury is considered, and repaired if found. Even in its absence, a feeding tube should be placed in the esophagus at the time of the initial laryngotracheal repair.

We have made an effort to locate and trace the recurrent laryngeal nerves to their destination, but have not been successful as yet in improving their integrity in any manner. In our cases the area has been so traumatized and disorganized that to identify and repair such small structures has been impossible for us.

In Table I are listed cases of laryngotracheal trauma for the treatment of which, with two exceptions, one or more of us has been responsible. From this list we have chosen eight cases illustrating certain points which we consider important for more detailed individual reports.

Some observations with regard to 28 patients sustaining acute injuries involving the larynx and cervical trachea have been presented in the tables. With three exceptions, all of this group were under our care from the beginning of treatment or shortly thereafter. Cases 22 and 28 were treated throughout by former residents of our department. Case 7 was referred to us late, and possibly could be considered outside the realm of this presentation; however, by its inclusion, certain points are emphasized that could not be otherwise. Other records, namely those with residual disabilities, e.g., chronic laryngotracheal stenosis, were eliminated as unsuitable material for this survey.

As one would anticipate, the majority of the injuries resulted from automobile accidents; fifteen. Nineteen occurred in males and four in children.

The larger number of patients sustained closed injuries, 22 compared to six with the open type. Tracheotomy was necessary in nine of the closed type but not in 13 of the same category. It was in the closed type of injury requiring tracheotomy that the greatest difficulty was encountered in treatment, the accomplishment of good results, and successful rehabilitation. This was due mainly to the inability to thoroughly explore the laryngotracheal areas because of the serious general condition of the victim, resulting from multiple injuries. As the majority of this group of 28 patients were seen early by laryngologists, there were only three cases in which delay in thorough investigation could be attributed to failure to recognize the gravity of the consequences resulting from a closed injury.

Open injuries, though usually quite severe, are obvious and require early repair of laceration, etc.; thus exploration of the wound is incorporated in the case of the soft tissues, providing for early definitive care of the laryngotracheal damage.

Many of the closed injuries, 13 in our survey, or almost 60%, may be managed successfully by medical means, without the necessity for tracheotomy. The provision of quiet and rest are most important elements in the treatment.

In evaluating the cases finally, only 24 of the 28 should be considered, for four cases will have to be indeterminate, as at the time of this compilation of results, these four are not completed: Cases 4, 5, 22, and 24.

Perusal of the cases in the tables indicates that practically all of the tracheotomized patients may ultimately be decannulated with the postaccident airway being satisfactory. It will be also noted that, on the contrary, in an appreciable number of cases in which the airway is satisfactory, real proficiency in phonation is not attained. Perhaps in many instances this is due to permanent injury of the recurrent laryngeal nerves or traumatic malfunction of the crico-arytenoid joints.

It is believed from the observation of this group of cases that one should delay giving an opinion as to the permanence of laryngeal nerve damage for a period of at least 12 months following the initial impairment. Case 27 demonstrates unexpected recovery of cord motility after the injury.

Multiple injuries were sustained in 18 of the cases, 14 of major significance and four minor. Because of the additional injuries, there was delay in instituting the definitive treatment in four instances. This was obviously a detriment in these four, to a smaller or greater degree, in the ultimate laryngotracheal welfare of the patients. It was recognized that the general condition of the subject and certain injuries to vital areas, such as the brain, should receive priority in the plan for treatment.

On consideration of the over-all results, one finds that these could be classified as satisfactory in 23 of the determinate group, and the same outcome is anticipated in three others, of the presently non-completed group. One of the unsatisfactory results was obtained in Case 7, in view of the fact that the patient must continue to wear a laryngotracheal prosthesis. The second unsatisfactory result occurred in a three months old child, Case 24, who expired three months after the cut-throat injury, while in the hospital. The baby had a tracheotomy because of bilateral cord paralysis. Although a post-mortem examination was performed, the exact cause of death was not determined.

From an economic position, it appears from reviewing our group that four patients in the determinate group found it necessary to change plans regarding their occupations, because of absence of a

normal voice or airway. Relative to this consideration, speech therapy, vocational rehabilitation, and training services are available if needed for patients in this category.

SUMMARY

A survey of 28 patients, sustaining recent trauma of the larynx and cervical trachea from external causes, has been made. Therefrom, certain observations have evolved which may be of some value to those confronted with these injuries; these will be listed. It has been found convenient to divide the patients into two categories, those with closed injuries and those with the open variety.

1. The majority of the closed injuries are of the minor type that can be managed successfully without tracheotomy. The final result will be satisfactory with no significant interference with airway or phonation.

2. There is a group in the closed injury category who incur severe laryngotracheal injuries with little evidence of this externally. This picture may be confusing to the inexperienced attendant, resulting in real danger to the victim of trauma. Prompt tracheotomy followed by early thorough exploration of the internal neck is mandatory. It is in this group of cases that one encounters the most difficulty in obtaining a satisfactory result.

3. The very nature of open injuries makes for less confusion and indecision as to the necessary treatment. Parts of the laryngotracheal structures will be exposed as a result of the injury; thus, in the treatment of the soft tissues, the laryngotracheal structures will receive early consideration.

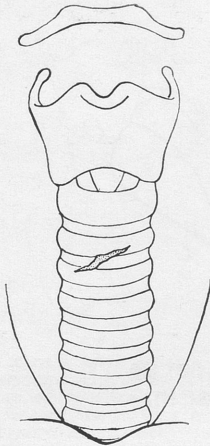
4. From our observation, a good airway may be expected finally in the majority of cases, regardless of the injury category. Chances for a good voice are less favorable, however.

5. The presence of additional injuries, some involving vital areas, other than the larynx and trachea, may be responsible for delay in treatment in a small number of patients.

Everyone, but particularly those who are attendants in the emergency rooms, should be aware of the danger to the airway in cases of trauma to the cervical areas.

REPORT OF CASES

(Numbers refer to Table I)



Tracheal laceration,
(presumptive).

Fig. 1.—Case 1.

CASE 1. A.P.M., a seven year old white female, fell, striking her neck on a metal bar of a playground set, receiving superficial abrasions of the neck. Two hours after the accident, she developed a husky voice and considerable swelling of the neck. There was cough, but no hemoptysis or dyspnea. Upon hospitalization at the University of Virginia Hospital, examination revealed slight contusions of the anterior neck, with subcutaneous emphysema extending from the lower face to the lower rib cage. The larynx was not examined because of the increasing emphysema and the danger of creating more coughing and excitement.

X-rays revealed the soft tissue emphysema plus emphysema of the mediastinum.

Treatment consisted of sedatives and an antibacterial drug. The hospital course was uneventful. She was discharged on the fourth hospital day.

Indirect examination of the larynx two weeks after the injury disclosed no abnormalities. Voice and airway were good. It is believed that this patient had a traumatic rupture of the trachea without laryngeal injury.

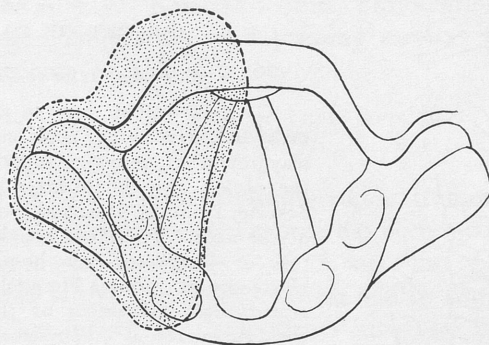
Comment. This patient developed somewhat alarming symptoms and signs after trauma to the laryngopharynx which was initially considered to be of no significance. The rapid development of swelling of the neck, extending later to the thorax, directed the mother first to the local physician who in turn referred her to us for hospitalization. Good judgment was used in making no effort to visualize the larynx initially, as such would have undoubtedly done more to aggravate the situation than aid it. After establishing rest and light sedation, there was no increase in emphysema or evidence of respiratory dyspnea. X-ray of the neck showed only the emphysema. Favorable progress was rapid.

A satisfactory indirect examination of the larynx was obtained two weeks after the injury. Nothing unusual was noted.

We presume that this patient had mild cordal trauma, thus explaining the husky voice, and a small laceration of the upper cervical tissues with secondary emphysema.

This case demonstrates not too severe laryngotracheal trauma requiring hospitalization.

CASE 2. J.C.H., a 43 year old white male, was injured in an automobile collision. Shortly after the accident, he developed dysphonia, dysphagia, and coughed up small amounts of blood. The neck became swollen, due to subcutaneous emphysema. He was admitted to an outlying hospital for 24 hours and then transferred to the University of Virginia Hospital for evaluation of his obvious closed laryngeal injury.



Hematoma. Left vocal cord could not be seen. Indirect laryngoscopy. Later im-mobile left cord.

Fig. 2.—Case 2.

On examination, in addition to the above mentioned symptoms and signs, it was observed that he had no respiratory distress. Several small abrasions of the skin were noted over the anterior neck. Mirror examination revealed marked edema and hypremia of the mucous membrane of the left hypopharyngeal and arytenoid areas. The left vocal cord could not be visualized. The right vocal cord had full range of motion.

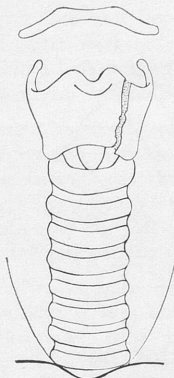
X-rays of the neck revealed emphysema of the soft tissues extending into the thorax and up to the base of the skull. No fractures could be demonstrated. The upper trachea and larynx were displaced to the right of the midline, due to an oval pocket of air which was present adjacent to the trachea. There was mediastinal emphysema.

Treatment consisted of rest, light sedation, steroids, antibacterial drugs, and initially nothing by mouth.

By the fifth postaccident day, mirror visualization disclosed paresis of the left true cord and a hematoma of the false cord area. The patient was discharged on the ninth postaccident day, improved but still demonstrating severe dysphonia.

He was readmitted for evaluation (medicolegal) eleven months later because of persistent dysphonia and dysphagia. Direct laryngoscopy revealed restricted motion of the left true vocal cord. Barium study of the esophagus disclosed nothing unusual and there was no explanation for the dysphagia. It was our opinion that there would be no further improvement in his phonation and as a result of the accident he suffered a permanent but not severe disability.

Comment. This is a case which represents a closed injury of the larynx with rupture of the laryngotracheal complex, and hematoma formation with paresis of the left vocal cord. Tracheotomy was not necessary. The major pathology cleared up rather promptly, but limitation of motion of the left vocal cord, probably due to injury and fibrosis of the cricoarytenoid joint, persisted. As a result, a slight



Fracture of thyroid cartilage, hematoma of left arytenoid surface, left aryepiglottic fold and false cord. Also abductor paralysis of left vocal cord. Visualized by mirror laryngoscopy.

Fig. 3.—Case 3.

but permanent dysphonia prevailed and became the basis for medicolegal compensation claims.

CASE 3. E.C., a 35 year old white male farmer, was struck by a rock, which he had thrown at a cow but which missed and ricocheted, striking him on the left side of the neck. Immediately he developed hoarseness and a choking sensation, as well as gradually increasing respiratory difficulty. He was admitted to the University of Virginia Hospital several hours after the accident.

Examination of the neck revealed no subcutaneous emphysema and no external signs of injury, except, on palpation, a vertical fracture of the left side of the thyroid cartilage, which was also thought to be demonstrated radiologically. Mirror examination of the larynx disclosed marked edema of the left arytenoid, aryepiglottic fold, and false cord. The left true vocal cord was fixed in abduction. There was an adequate airway present five hours postaccident. The right hemilarynx was normal in appearance and function.

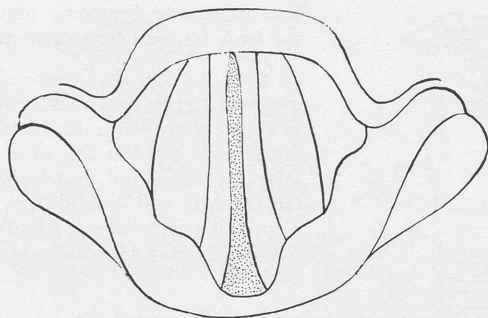
Treatment consisted of enzymes and rest. The edema of the left supraglottic region later was replaced with a hematoma.

The patient was discharged on the eighth postaccident day. Examination of the larynx at this time revealed reduction in the size of the hematoma and some motion of the left true cord. Subsequent examinations disclosed a normal appearing larynx with good voice and airway.

Comment. This case illustrates an oddity as far as the cause of laryngeal injury is concerned. A vertical fracture of the thyroid was palpable by several examiners. Although an endolaryngeal hematoma and immobile vocal cords were demonstrated, there was no demonstrable emphysema. Tracheotomy was not necessary. Full recovery was rapid.

CASE 4. E.M.D., a 40 year old Negro female, was admitted to the University of Virginia Hospital within several hours after sustaining multiple injuries in an automobile accident. She was unconscious, and had a left hemiparesis and right abductens paralysis resulting from a severe closed head injury. There was considerable swelling of the soft tissue of the neck, and a mediastinal mass demonstrated by x-ray was thought to be due to hemorrhage. No emphysema was noted.

Because of respiratory distress and the comatose state, an elective tracheotomy was performed. Direct laryngoscopy disclosed the only noticeable injury in this area to be a failure of motion in both vocal cords, with the position assumed being near the midline. Twenty-five days after the injury, the larynx and trachea were explored by an external approach. No hematoma or injury to the trachea, larynx, or laryngeal nerves was noted. On the thirty-fourth hospital day, the patient was discharged to be followed as an outpatient.



Edema of anterior neck. Abductor paralysis, bilateral. Visualized by mirror laryngoscopy.

Fig. 4.—Case 4.

Five months after the injury, the abductens paralysis and hemiparesis persist. The vocal cords are immobile and situated in the near midline position. There is a glottic space of five to eight mm, resulting in a poor voice, but adequate airway, when the tracheotomy tube is occluded. Decannulation has been proposed, but the patient refuses to discard the tracheotomy tube at this time.

Comment. It is thought that in this case the immobile vocal cords are due to a stretch injury of the neck, affecting the recurrent laryngeal nerves. A central origin was also entertained as the cause, but this was considered very unlikely. Although exploration of the laryngotracheal area resulted only in negative findings, the procedure was definitely indicated and should be carried out in injuries of this type. Decannulation was not urged at the time it was first suggested, as it is thought that if the diagnosis is correct, recovery of motion of the vocal cords can be anticipated. The patient continues under observation.

CASE 5. C.W.D., a 24 year old white male, was admitted to the University of Virginia Hospital following an automobile accident. At the time of his arrival in the emergency room, he had been unconscious for approximately forty minutes. Examination revealed severe respiratory distress, plus marked subcutaneous emphysema of the neck and chest. There were additional injuries, including a fracture of the left femur.

A tracheotomy was performed rapidly, with immediate easing of the respiratory distress. The leg was placed in traction. Subsequent laryngeal examinations disclosed a bilateral immobility of the vocal cords, as well as evidences of collapse of the supporting structures of the larynx.

Ten days after the original injury, the neck was explored. It was discovered that the thyroid cartilage, the cricoid cartilage, and the upper three tracheal cartilages were crushed and fractured. The posterior wall of the trachea was severed from the cricoid cartilage, and this transection extended around the entire circumference of the trachea. The upper trachea was unroofed and an end-to-end anastomosis was performed between the cricoid and first tracheal cartilage. The tracheot-

omy was revised and lowered in position. The fractured parts were reduced and the lacerated parts repaired. A polyethylene stent was wired into position for internal splinting.

The stent and tracheotomy tube were left in position for eight months. After removal of the stent, the airway was found to be limited but adequate. The voice was poor. There was some slight motion of the left arytenoid cartilage and vocal cord. The patient was decannulated.

Several weeks later, during an upper respiratory infection, it was thought wise to reinsert the tracheotomy tube because of respiratory difficulty. This was done, and now the patient is back at his occupation, working with the tube closed. We will not undertake to decannulate him again until approximately 12 months after the initial injury, hoping for further recovery of cord motion. If this does not materialize, an arytenoidectomy is planned to obtain greater glottic space prior to decannulation. Satisfactory airway with only fair voice is anticipated as the ultimate result.

Comment. This patient is one who suffered multiple injuries and was admitted to the Orthopedic Service. The emergency tracheotomy was performed by a general surgical resident. The possibility of grave laryngotracheal injury was not considered seriously until we were consulted, three days after admission. Had we seen this patient in the emergency room, an exploration of the neck would have been performed earlier. However, ten days after the injury, definitive laryngotracheal repair was instituted and carried out as noted, with a polyethylene tube being utilized for internal splinting purposes.

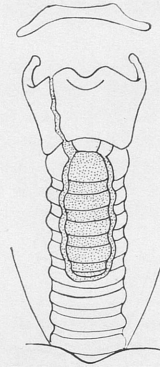
After removal of the internal splint and subsequent decannulation, it was necessary to readmit the patient for reinsertion of the tracheotomy tube. The airway embarrassment was due to an inflammatory laryngitis, plus the near-midline position of the cords, and not to stenosis of the trachea, nor to the presence of granulomata.

If improved motion of the cords does not develop, then an arytenoidectomy will provide sufficient airway for decannulation later. Regardless, a satisfactory result as far as voice and airway are concerned is anticipated.

The closed injury was deceiving to the initial examiner and resulted in delay in the institution of definitive treatment. However, it is not felt that the delay in this particular case jeopardized the chances for a satisfactory result.

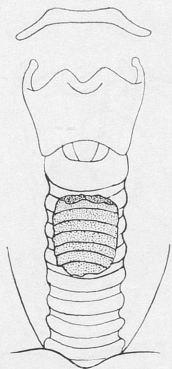
Also, it should be noted that this is a case in which the cricoid cartilage was injured, and stenosis apparently was overcome by proper positioning of this cartilage and the use of prolonged internal splinting.

CASE 7. T.E.L., 17 year old white male, received injuries to the neck, right foot, and clavicle, in an elevator accident when caught between the lift and shaft. Respiratory obstruction developed over the next three days, finally requiring trache-



Fracture of thyroid, cricoid & tracheal cartilages. Rupture of trachea. Severance of trachea from larynx. Stretch injury to recurrent laryngeal nerves.

Fig. 5.—Case 5.



Crush injury with collapse of upper trachea. Traumatic tracheoesophageal fistula, subglottic stenosis, abductor paralysis, bilateral. Trachea exposed by laceration of neck, extending into tracheal lumen.

Fig. 6.—Case 7.

otomy. No exploration of the neck was performed. The tracheotomy tube was removed in three weeks, but had to be replaced within a week because of recurrent respiratory distress.

Three months following the injury, the patient was admitted to the University of Virginia Hospital, because of complete aphonia and lack of laryngeal airway. Laryngoscopy and lamina-grams subsequently disclosed a completely stenotic area approximately two tracheal rings below the cricoid level. Exploration disclosed a dense mass of scar tissue in this subglottic area.

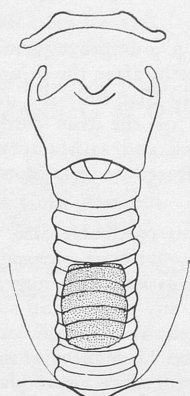
Since 1951 the patient has had twenty operative procedures, incorporating every known and imaginable method to establish and maintain a satisfactory airway that would permit the elimination of the tracheotomy. At the present time (1962), he wears a plastic button stent in the tracheostome. With this prosthesis in place, he is able to phonate and can respire translaryngeally. When it is not worn, there is a tendency for the trachea to stenose.

Comment. In the discussion of the management of this patient, several important points can be mentioned. The patient received severe multiple injuries, the most important of which, as subsequent events demonstrated, was a crushing closed injury to the thyroid and cricoid cartilages and to the recurrent laryngeal nerves, with complete avulsion of the trachea. The neck initially was not explored and when the tracheotomy was performed, the distal avulsed edge was brought up to the skin incision as in a tracheostomy following laryngectomy. No effort was made at this time to establish and maintain a lumen above the tracheotomy. Accordingly, it was noticed at the time of exploration of the area of the laryngotracheal structures that dense scar tissue was present between the distal trachea and the crushed cricoid and laryngeal tissue above. The efforts to restore a useful airway and voice were necessarily tedious, numerous, and, at times, very dismaying to victim and operators. The final result, in which the patient can respire and phonate with the aid of a prosthesis which is not too noticeable, leaves much to be desired, but under the circumstances is considered good. No further operative procedures are planned.

The lesson to be learned here is that early exploration of the laryngotracheal areas, particularly in a closed injury of this type, is mandatory, and every effort must be made to establish and maintain an airway lumen before scar tissue formation totally obliterates the airway and adds further to the disorganized state of these structures.

When there is severe injury to the cricoid cartilage, successful permanent re-establishment of the airway is nearly impossible.

CASE 26. G.M., a 31 year old white male, was hospitalized in a nearby hospital following an automobile accident. Emergency room examination revealed respiratory distress with a deep wound of the anterior neck, through which air was passing directly from the trachea. A tracheotomy tube was inserted through the wound into the cervical trachea. Subsequent efforts to remove the tracheotomy



Tracheal rupture, crushing of mid-cervical tracheal cartilages. Later, complete occlusion of mid-cervical trachea.

Fig. 7.—Case 26.

tube were unsuccessful. He could not breathe without the tube and could not phonate with the tube closed.

Following his referral to the University of Virginia Hospital, examination disclosed nearly complete subglottic stenosis, which later did not respond to repeated efforts at dilatation. X-ray studies with contrast media and direct laryngoscopy confirmed this diagnosis. The vocal cords were fixed midway between abduction and adduction.

Over a period of 19 months after the initial injury, by utilization of tracheoplasty, excision of scar, end-to-end anastomosis, skin grafts, stent, etc., decannulation was accomplished. A very satisfactory airway and voice resulted. Some movement, both abduction and adduction, was regained in the right cord.

Comment. This is an example of a patient who had a severe open injury of the larynx and trachea. No effort was made initially, for good reasons, to explore the wound and institute treatment with the object of re-establishment of an

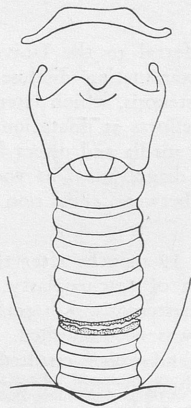
adequate permanent airway and voice. The lacerations were repaired and a tracheotomy tube inserted in a lacerated trachea. None too surprisingly, decannulation was subsequently impossible. Fortunately, the main injury and resultant scarring were just below the level of the cricoid and responded quite satisfactorily, finally, to numerous but well-planned reconstructive procedures. Also, it is interesting to note that after a period of some months, movement of the right cord was recovered to a moderate degree.

CASE 27. D.B.G., a 38 year old white male, was admitted to the University of Virginia Hospital about five hours after he had been injured in an automobile accident. Initial examination revealed a gaping wound above the sternal notch, through which air was escaping directly from the trachea. He also had a fracture dislocation of the right hip and cervical spine.

A tracheotomy tube was inserted directly through the neck wound into the exposed trachea. Shortly thereafter, the patient was taken to the operating room, where exploration of the neck revealed complete transection of the cervical trachea, between the third and fourth tracheal rings, without injury to the esophagus. An end-to-end anastomosis was accomplished, with the tracheotomy being re-established in the region of the fourth tracheal ring.

The subsequent hospital course as regards his laryngotracheal injury was uneventful. He was decannulated on the forty-eighth hospital day, and at that time had a good airway but very poor voice.

Six months after the injury, mirror laryngoscopy revealed fixed vocal cords, the left one being in the midline and the right being situated between the midline and the lateral position. The laryngotracheal airway was good, but the voice was very poor.



Avulsion laceration with exposure of trachea. Trachea transected. Bilateral abductor paralysis.

Fig. 8.—Case 27.

A plastic operation to improve phonation was planned some 12 months after the injury. However, at approximately that time the patient regained good motion of the true cord, with a much improved voice and satisfactory airway. Further operative procedure was not thought necessary.

Comment. In this particular case, early repair of the trachea, without necessity for a stent, resulted in a satisfactory airway without development of any significant stenosis of the trachea, although end-to-end anastomosis was performed. Some 12 months after the injury, although a procedure was planned to improve the very poor voice, good motion of a previously immobile vocal cord developed, giving the patient a satisfactory voice. This points up the fact that it is advisable to delay any planned operative procedure to overcome a fixed vocal cord which could be due to injury of the recurrent laryngeal nerve, for a period of at least 12 months. It has been demonstrated that recovery of nerve function is possible in cases where one would expect it not to be so.

104 EAST MARKET ST.

Case 22 treated by Dr. S. G. Hobart, Jr., Durham, N. C.

Case 28 treated by Dr. J. B. Gorman, Lynchburg, Va.

REFERENCES

1. Wade, P. A.: The Injured Patient and the Specialist. *Bulletin Am. College Surg.* 47:73- (Mar.-Apr.) 1962.
2. Nach, R. L., and Rothman, M.: Injuries to the Larynx and Trachea. *Surg., Gyn. and Obst.* 76:614- (Jan.-June) 1943.
3. Bryce, D. P.: Traumatic Laryngotracheal Injury. *Canadian Medical Assoc. Jour.* 75:400- (Sept.) 1956.
4. Tucker, G.: Laryngoscopy for Laryngeal Stenosis. *Arch. Otolaryng.* 1:157- (Feb.) 1925.
5. Schmiegelow, E.: Stenosis of the Larynx: A New Method of Surgical Treatment. *Arch. Otolaryng.* 9:473- (May) 1929.
6. Clerf, L. H.: Cicatricial Stenosis of the Larynx. *ANNALS OF OTOTOLOGY, RHINOLOGY AND LARYNGOLOGY* 42:1- (Mar.) 1933.
7. Arbuckle, M. F.: Cause and Treatment of Cicatricial Stenosis of Larynx. *ANNALS OF OTOTOLOGY, RHINOLOGY AND LARYNGOLOGY* 39:134- (Mar.) 1930.

8. Jackson, C., and Jackson, C. L.: Diseases and Injuries of the Larynx. Mac-Millan Company, New York, 1942.
9. Woodward, F. D.: The Surgical Correction of Cicatricial Stenosis of the Larynx. *ANNALS OF OTOTOLOGY, RHINOLOGY AND LARYNGOLOGY* 59:488- (June) 1950.
10. Woodman, de Graf: The Open Approach to Arytenoidectomy for Bilateral Abductor Cord Paralysis. *ANNALS OF OTOTOLOGY, RHINOLOGY AND LARYNGOLOGY* 57:695- (Sept.) 1948.
11. McNaught, R. C.: Surgical Correction of Anterior Web of the Larynx. *Laryngoscope* 60:264- (Mar.) 1950.
12. Erich, J. B.: Mechanical Appliance for Cicatricial Stenosis of Larynx and Upper Part of Trachea: Report of Case. *ANNALS OF OTOTOLOGY, RHINOLOGY AND LARYNGOLOGY* 65:799- (Sept.) 1956.
13. Hanckel, R. W.: Traumatic Tracheal Atresia. *Laryngoscope* 65:337- (May) 1955.
14. Work, W. P., and McCoy, G.: Surgical Repair of Cervical Trachea Following Trauma. *ANNALS OF OTOTOLOGY, RHINOLOGY AND LARYNGOLOGY* 65:573- (June) 1956.
15. Pressman, J. J.: Experimental Tracheal Implants. *ANNALS OF OTOTOLOGY, RHINOLOGY AND LARYNGOLOGY* 62:791- (Sept.) 1953.
- 15a. Pressman, J. J., and Simon, M.: Repair of Trachea. *Surg., Gyn. and Obst.* 106:56- (Jan.-June) 1958.
16. Ogura, J. H.: Surgical Decompression of the Recurrent Laryngeal Nerve in Idiopathic Unilateral Vocal Cord Paresis: Preliminary Report. *Trans. of Am. Laryngol. Assoc.* 82:85- (May) 1961.
17. Conley, J. J.: Reconstruction of the Subglottic Air Passage. *ANNALS OF OTOTOLOGY, RHINOLOGY AND LARYNGOLOGY* 62:477- (June) 1953.
18. Norris, C. M.: Use of Acrylic Materials in Laryngology. *Laryngoscope* 69:306- (Mar.) 1959.
19. Bennett, T.: Laryngeal Strictures. *South. Med. Jour.* 53:1101- (Sept.) 1960.
- 19a. Bennett, T.: Laryngeal Trauma. *Laryngoscope* 70:973- (July) 1960.
20. Cracovaner, A. J.: Management of Injuries to the Larynx. *E.E.N.T. Monthly* 39:973- (Dec.) 1960.
21. Cranmer, L. R.: Traumatic Stricture of Larynx. *ANNALS OF OTOTOLOGY, RHINOLOGY AND LARYNGOLOGY* 68:613- (Sept.) 1959.
22. Holinger, P. H., and Johnston, K. C.: The Management of Chronic Laryngeal Stenosis. *ANNALS OF OTOTOLOGY, RHINOLOGY AND LARYNGOLOGY* 67:476- (June) 1958.
- 22a. Holinger, P. H., and Johnston, K. C.: Laryngeal Trauma and Its Complications. *Am. Jour. of Surg.* 97:513-, 1959.
23. Suggit, S.: Some Problems of Laryngeal Injuries and Stenosis. *Jour. Laryngol. and Otol.* 74:22- (Jan.) 1960.

24. Fogelman, W. J., and Stewart, R. D.: Penetrating Wounds of the Neck. *Am. Jour. of Surg.* 91:581- (Apr.) 1956.
25. Conley, J. J.: Facial Nerve Grafting in Treatment of Parotid Gland Tumors. *Arch. Surg.* 70:359-, 1955.
26. Chadwick, D. L.: Closed Injuries of the Larynx and Pharynx. *Jour. of Laryngol. and Otol.* 74:306- (May) 1960.
27. Lynch, M.: Repair of Traumatized Larynx. *Laryngoscope* 61:51- (Jan.) 1951.
28. Putney, E. J.: Hematoma of Larynx from External Trauma. *ANNALS OF OTOTOLOGY, RHINOLOGY AND LARYNGOLOGY* 61:452- (June) 1952.
29. Hood, R. M., and Sloan, H. E.: Injuries of the Trachea and Major Bronchi. *Jour. of Vascular and Cardiovas. Surg.* 38:458- (Oct.) 1959.
30. Shaw, R. R., Paulson, D. L., and Kee, J. L.: Traumatic Tracheal Rupture. *Jour. of Thorac. and Cardiovas. Surg.* 42:281- (Sept.) 1961.

DISCUSSION

DR. DANIEL C. BAKER, JR.: Mr. President, members and guests: Drs. Fitz-Hugh, McGovern, and Wallenborn have made a very thorough study of 28 patients who received trauma to the larynx and trachea. It is an excellent report which is timely and of great importance to the laryngologist and to the public.

The physician who treats injuries should be aware of the dangers of trauma to the larynx. Most often the patient who has been in an accident will suffer injuries to other parts of the body, that is, fractures of the skull, extremities or injuries to the chest and abdomen. The larynx may be overlooked. In this series of cases, there were 22 patients who had sustained closed injuries to the larynx and only six with the open type. This would indicate that the majority of patients showed no external damage to the neck and that the diagnosis was not evident on inspection. Education of interns and residents particularly is necessary to establish early diagnosis and treatment. Tracheotomy was necessary in 15 of the 28 patients and in 9 of the 22 who had a closed injury of the larynx.

We are aware of the dangers to the airway in injuries, and that in patients who may be in coma as a result of a fracture of the skull with brain involvement, a tracheotomy may be necessary. The patient who is alert, and has no breathing difficulty shortly after an accident, may have airway obstruction within a few hours, if the larynx has been traumatized. Hemorrhage into the loose connective tissues over the arytenoids, or in the subglottic area may slowly close off the lumen. In addition, emphysema from a tear in the trachea will contribute to airway difficulties. As the swelling increases, the patient starts to lose his voice and may become aphonic. He is now in need of a tracheotomy and unless it is performed, he can die.

I am not so sure, from having read the paper, as to when Dr. Fitz-Hugh would examine the larynx of the traumatized individual. For instance, if a tracheotomy has been performed, would he consider doing a direct laryngoscopy at the same time? When does he consider the introduction of a polyethylene tube as necessary? After the obstruction is apparent or before the swelling has had a chance to close off the larynx? I ask these questions because not infrequently I will get a long distance telephone call from a fellow specialist seeking information about these questions. My answer has been to tell them to go ahead and introduce a polyethylene tube or other plastic material in order to maintain a lumen. I stress that the preservation

of the lumen at the earliest possible time will save months of rehabilitation later on. In my own personal experience, if I can follow the patient by mirror laryngoscopy and satisfy myself as to the local condition, I do not always introduce a polyethylene tube. I would not hesitate to do a direct laryngoscopy even on a very ill patient.

Like the authors, I have seen paralysis of the vocal cords result from an injury to the trachea. One patient was struck by a metal bar and his upper trachea was severed at the third tracheal ring. An emergency tracheotomy was necessary. It was then possible to inspect the damage to the trachea. It was noticed that there was a 1-centimeter separation between the second and third tracheal rings. These were approximated by suture and the tracheotomy open placed below. There was no evidence of injury to the larynx, but the patient had a bilateral vocal cord paralysis. It was not possible to decannulate the patient until an arytenoidectomy had been performed.

One should be careful about making a good prognosis in patients suffering laryngeal trauma. Perhaps it is best to prepare for the worst, that is putting in a plastic prosthesis and then hoping for the best. Perichondritis which in itself is a deforming complication, can affect an end result.

The authors are to be complimented on their excellent results. They had a satisfactory outcome in 23 of 28 patients. Since this paper deals only with the acute trauma and not the chronic stenosis, it can be expected that measures for the latter will be carried out and that the other patients will also get a good result.

DR. PRESSMAN: Dr. Fitz-Hugh's lucid discussion, excellent results, and ingenious techniques add notably to our knowledge of the treatment of injuries of the larynx and upper trachea. His paper is therefore a most important contribution the details of which should be studied carefully by everyone concerned in the treatment of traumatic lesions of the area. You heard from Dr. McCall a reference to a well-known case of Dr. William P. Longmire in which a polyethylene tube was used to bridge a long gap between the larynx and the lower cervical trachea. Ultimately healing occurred, the prosthesis was removed and an end to end anastomosis between the lower cervical trachea and cricoid cartilage successfully performed. The explanation for the mechanism by which this became possible after many years but could not be accomplished immediately after the injury or even some months later is to be found in a series of experiments I described by a strip of aorta taken from a blood vessel bank. This had one particular advantage in that the aorta fibrosed and in so doing contracted in its length and by shrinking in length it stretched the trachea. I demonstrated this in an exhibit one time at the American Medical Association. This stretching amounted to fifteen times the width, for example, of the membranous rings between the cartilages and demonstrated that this stretching extended over several rings and was significant.

This is exactly what happened in Dr. Longmire's case except the contracting tissue was the fibrous cuff that had grown around the prosthesis. It is particularly appropriate that I should say this here in Dallas for reasons I shall mention.

Upon the completion of the experiment described Dr. Longmire tried to find this patient to get him to come back to California since we suspected that fibrous tissue might have formed about the insert with resultant stretching of the trachea from fibrosis between the cut ends of the trachea just as occurred from fibrosis of the aorta. There had been a very long hiatus, perhaps an inch and a half, at the time of the original injury. We traced the boy to Texas, found he was in Dallas and asked the mother if they would come to Los Angeles and described what we intended to do. They preferred to have the attempt made in Dallas,

which they did. I do not know the name of the surgeon who operated upon him, but the polyethylene tube was removed and it was found that there was now a complete re-establishment of a tracheal lumen with stretching of interspaces between the rings which made it possible to perform an end to end anastomosis several years after the injury. This is the patient to whom Dr. McCall referred.

One more thing about the circumferential stretching of such constrictions, is that there is absolutely no point in trying to dilate a constriction of the trachea or of the larynx while the active process of fibrosis is still going on. The length of time between the initial beginnings of this healing process and the time when one can successfully stretch it is, of course, something that I have not exactly determined; but in the laboratory we find that this process of fibrosis in a dog, for example, will continue for about eight months and no matter what you do, no matter how frequently you dilate it or how large you dilate it, as long as this process of fibrosis and contraction of fibrous tissue is active, you will avail yourself nothing. One should simply try to re-establish a lumen, no matter of what size, and then begin dilatations at a period removed by at least eight months, and possibly in certain extensive injuries this might be even longer.

Thank you very much for permitting me the privileges of this podium and, again, I appreciate the opportunity to discuss Dr. Slaughter Fitz-Hugh's excellent, timely, instructive paper.

DR. FITZ-HUGH (closing): Considering the matter of examination that Dr. Baker mentioned, in the event that we have a tracheotomy in place, we go ahead and perform a direct examination of the larynx just as soon as possible.

In these cases in which the closed injury is of the minor type and in which the necessity for tracheotomy is not apparent, then we like to wait for about a week before we attempt even an indirect examination of the larynx, unless we have a very co-operative patient. You see, particularly in young people, the likelihood to gag, retch, and remonstrate is ever present, and we feel that this will just aggravate the emphysema if it is present, and it usually is. Rest is very important, rest and quiet, in this particular group of closed injury cases.

Of course, any severe injury to the neck would preclude all early attempts at direct laryngoscopy or manipulation of the area.

In the manuscript we give our opinions and comments with regard to the use of antibacterial drugs, steroids, and the other anti-inflammatory and anti-edematous measures that may be taken. We use the antibacterial drugs, steroids, and enzymes in certain cases.

Thank you very much for the privilege of presenting this paper.

STUDIES OF PAPILLOMA OF THE LARYNX

PAUL H. HOLINGER, M.D.

KENNETH C. JOHNSTON, M.D. GEORGE H. CONNER, M.D.

BETTY ROSS CONNER, M.S. JACOB HOLPER, PH.D.

CHICAGO, ILL.

Papilloma of the larynx continues to be a distressing, debilitating clinical problem. It is dangerous to life and often its progressive growth fails to respond to any but palliative measures. The histopathology is specific and is recognized as fingers of connective tissue covered with squamous epithelium with an intact basement membrane. Mitotic figures vary. True laryngeal papillomatosis must, of course, be differentiated from papillary projections of the cords and from papillary keratoses. To include these in statistics of laryngeal papilloma merely confuses the study of this problem.¹ Unfortunately this has already led to a misunderstanding concerning the incidence of malignancy in laryngeal papilloma, with the wide variation in statistics apparently merely a question of definition.²

Certain clinical peculiarities of laryngeal papillomatosis may be mentioned. In our own series, papilloma of the larynx is seen as frequently in infants and children as in adults.³ Yet, the growth and recurrence rate of papilloma in children is more rapid than in adults. Spontaneous resolution at puberty is commonly noted, although spontaneous regression at any age occurs as well; consequently, it is difficult to accurately evaluate response to therapy. The frequent disappearance of the lesions at puberty and the work of Broyles⁴ who indicated a favorable response with topical application of Amniotin suggest an endocrine relationship to papilloma growth. In a previous report³ and in two subsequent cases upon which this report is based, disappear-

From the Department of Otolaryngology, University of Illinois College of Medicine, and the Department of Bronchology, Children's Memorial Hospital, Chicago, Illinois; and the Department of Infectious Diseases, Microbiologic Research Division, Abbott Laboratories, North Chicago, Illinois.

ance of the papilloma during pregnancy was noted. It is of interest that the recent literature records that plantar warts disappeared from the feet of two pregnant women who had had plantar warts for many years.⁵ Yet in one of our patients the papilloma grew exuberantly during pregnancy and regressed after delivery.

Tissue culture growth of laryngeal papilloma has been studied and compared with that of experimental fetal tissue cultures.⁶ Fetal skin, intestine and kidney were grown using the suspended cell technique and approximately twenty tissue culture lines were established. Cell cultures were also established from laryngeal papilloma obtained by direct laryngoscopy from children and adults who had histologically proven papillomatosis, and from other benign and malignant adult tissues. Fetal and neoplastic tissue cultures were more readily established than cultures of normal adult tissues, probably because of the greater proliferative capacity associated with embryonic life and the greater proportion of cells in a phase of active proliferation. In these studies it was noted that adult tissue of laryngeal papilloma obtained from the larynx of both children and adults grew with comparative ease in suitable media. Observations suggested growth occurred more rapidly and with greater ease than any other adult tissues cultured, either benign or malignant. All of the papillomata cultured were considered to be benign, histologically.

The etiology of laryngeal papillomatosis is obscure. However, viruses have been demonstrated as a cause of both skin and mucosal papillomas in dogs, rabbits, cattle and horses. They are both species specific and tissue specific. Neutralizing antibodies have been demonstrated in dogs and cattle and an effective autogenous vaccine has been developed for bovine papillomatosis. Unfortunately, when used in humans, this vaccine is not only ineffective, but produces sterile abscesses.

A review of studies of the possible viral etiology of papilloma of the larynx is presented as a preliminary report.

1. *Embryonate Eggs.* Fresh papilloma tissue was minced with scissors and the ground to a paste with sterile sand in a mortar. One drop of this suspension was innoculated onto the dropped chorioallantoic membrane (CAM) of twelve day old embryonate eggs. White nodules appeared on the CAM in approximately two days. The nodules were again reproduced when the CAM was minced and passed to new embryos. Histologically, the nodules showed hyperplasia of

both the ectodermal and mesodermal layers of the CAM. Electron micrographs revealed inclusion bodies in the outer ectoderm.

2. *Tissue Culture.* Monolayers of monkey kidney cells, swine kidney cells and Hela cells were inoculated with tissue suspensions of laryngeal papilloma as prepared above. No visible cytopathic changes were seen in the Hela or swine kidney cells. However, cytopathic changes were evident in monkey kidney cells after about 28 days. Fluids from tissue culture tubes showing typical cytopathology were passaged eight times thereafter with cytopathic changes evident within five to sixteen days on subsequent passages. The cytopathology consisted of abnormal formations, pile-ups of cells similar to those seen with Rous Sarcoma virus in tissue culture and increased refractability. Electron micrographs showed the presence of possible viral particles.

3. *Serologic Studies.* The cytopathogenic agent present in the monkey kidney cell cultures was used as an antigen in compliment fixation studies with sera from 25 random patients and with pooled monkey serum. Nine of the 25 human sera showed compliment-fixing antibodies. No reaction was obtained to the pooled monkey serum. Thus, it is probable that the cytopathogenic agent in the monkey kidney cell cultures was a human virus capable of producing compliment-fixing antibodies. Other viruses were ruled out by established virology techniques, suggesting a specific virus in the cultures from the papilloma suspensions.

4. *Animal Innoculations.* Using 68 animals (horses, dogs, monkeys, rabbits, mice and guinea pigs), inoculations were made of papilloma suspensions, tissue cultures and third-passage egg cultures. All animal inoculations were negative. This was interpreted as indicating that other viruses such as polio and herpes were ruled out. Of greater importance, this was interpreted as indicating that the papilloma-growth agent was species specific.

5. *Autogenous Vaccines.* Assuming the culture growth is on the basis of a species specific papilloma virus and knowing that bovine papilloma responds to a vaccine, autogenous human vaccines have been prepared. Approximately 0.5 gram of papilloma tissue was rinsed with sterile saline, minced with scissors and ground in a mortar to a paste. The paste was suspended in a 1/1000 concentration of Formalin and incubated at 25 C for twenty-four hours. Sterility was determined by conventional microbiological methods. The vaccine was stored at 4 C until used.

The study includes eight patients, four adults and four children. The results are encouraging but still far from conclusive. The case histories are summarized as follows:

All four of the children receiving autogenous vaccines were girls. One, five years of age who required endoscopic removal of the papilloma at intervals of one to two months, has had no recurrence of papilloma for nine months. A second, three years of age, has shown no change in the rate of regrowth. The third, ten years of age, had required endoscopic removal of papilloma as often as every two to three months. Some recurrence of the growth of papillomatous tissue is noted now, approximately eleven months after the last previous removal when the vaccine was prepared and administered, but the rapidity of growth is obviously markedly lessened. However, this child is entering the age in which a spontaneous regression of papilloma is often noted. The fourth child, four years of age, had a tracheotomy and required almost monthly endoscopic procedures to keep the larynx clear. Papilloma have now disappeared from the larynx but have been found in the trachea.

The adults treated with autogenous vaccines include three men: 21, 40 and 45 years of age, and a woman 48 years of age whose papillomas disappeared with pregnancies. She had required frequent removals of exuberant papillomas, the last in July, 1961, when vaccine was prepared and administered. Her voice and airway have both improved, but she has also reported the onset of the menopause, thus, again introducing the question of an endocrine relationship. Some improvement in the larynx of the 21 year old man is suggested by a slower rate of recurrence; this is difficult to evaluate accurately. Both the 40 and the 45 year old males have shown little change in the clinical picture of their laryngeal disease.

It is obvious that the series is too small to draw final conclusions as to the significance of autogenous papilloma vaccine in the management of laryngeal papillomatosis. The studies are continuing since they are of etiologic as well as therapeutic significance.

SUMMARY

Laryngeal papillomatosis continues to be a serious, debilitating clinical problem. The condition is a true pathological entity and should always be differentiated from papillary keratoses. Placing these two separate entities in the same category has been responsible

for some confusion in the literature concerning the clinical course of laryngeal papillomatosis.

Tissue cultures of laryngeal papilloma appear to grow more rapidly and with greater ease than cultures of embryonic or other adult tissues, either benign or malignant.

The influence of endocrine factors on the growth of laryngeal papilloma is demonstrated by the effect of puberty, pregnancy and direct topical application of hormonal agents.

Viral studies with human laryngeal papilloma tissues have indicated the presence of a species-specific virus capable of producing growth of tissue cultures with regrowth on as many as eight passages.

Serologic studies suggest that the cytopathogenic agent in the tissue cultures is a human virus capable of producing complement-fixing antibodies.

Animal inoculations of papilloma suspensions, egg cultures and tissue cultures of laryngeal papillomata were all negative, indicating an absence of other viruses and that the papilloma growth agent is species specific.

Autogenous vaccines have been prepared for and administered to eight patients with laryngeal papillomatosis; four adults and four children. The series is still too small to draw definite conclusions, but some encouraging results seem to have been obtained.

700 N. MICHIGAN AVE.

REFERENCES

1. Cuning, D. S.: Diagnosis and Treatment of Laryngeal Tumors. *Jour. of Amer. Med. Assn.* 142:73-76 (Jan. 14) 1950.
2. New, G. B., and Erich, J. B.: Benign Tumors of the Larynx: Study of 722 Cases. *Arch. of Otolaryngol.* 28:841-910 (Dec.) 1938.
3. Holinger, P. H., Johnston, K. C., and Anison, G. C.: Papilloma of the Larynx: A Review of 109 Cases with a Preliminary Report of Aureomycin Therapy. *ANNALS OF OTOTOLOGY, RHINOLOGY AND LARYNGOLOGY* 59:547 (June) 1950.
4. Broyles, E. N.: Treatment of Laryngeal Papilloma in Children. *South. Med. Jour.* 34:239-242 (Mar.) 1941.
5. West, J. R., and Perry, H. O.: Pregnancy: Another Treatment for Warts? *Arch. of Dermatol.* 84:671 (Oct.) 1961.
6. West, Robt. A. Jr., Boggs, Jos. D., and Holinger, Paul H.: Studies in Tissue Culture Growth of Laryngeal Papilloma. *Acta Otolaryngologica* 48:1-2:14-15 (July-Aug.) 1957.

DISCUSSION

DR. DANIEL C. BAKER, JR.: Mr. President, members and guests, the presentation of Drs. Holinger and Johnston and their co-workers may be the step forward that we have been waiting for in the treatment of laryngeal papilloma. It is a distressing disease and very difficult to cope with. Statistics that are usually reported as being effective are difficult to evaluate. Patients with recurrent disease frequently consult other doctors, so that unless there is a careful follow-up, one cannot be sure of the end result.

The authors have reviewed the factors of endocrine relationship to the disease. Their attention has been directed to the virus theory as a cause of the papilloma. They point out that papilloma is both species and tissue specific. It has been shown that a Bovine wart vaccine will cure the papilloma of cattle. The same vaccine was tried on humans, and a preliminary report was encouraging. Three of 4 patients were reported to have had excellent results. This study was from a group in the Middle West.

I do not see too many patients with papilloma of the larynx. I kept the idea of Bovine wart vaccine in the back of my mind and intended to use it at the first opportunity. Recently we had 4 children with papilloma admitted to Babies' Hospital. They still have evidences of the disease and would make excellent subjects for vaccine therapy. I wrote to the Fort Dodge Laboratories, who make vaccines for the veterinary. They did not send me any, but referred me to the division dealing with human vaccines of the same parent company. With a little influence through the chairman of the board, I was put through to the medical director. He told me that the Bovine wart vaccine had apparently helped some patients, but they were not pushing it. It seemed that there were too many abscesses that developed at the local site of injection. I asked him why, and he said, "We probably are unable to get the manure out of the vaccine." He was not very encouraging.

The presentation explains why it is not successful, as the disease is specific for the species. It is therefore necessary to make a human wart vaccine. Drs. Holinger, Johnston, and their co-workers have succeeded in doing this. I am a little discouraged in their results. I would have liked them to say it was 100% effective. Perhaps this will come in another report.

I would like to try out their method; and plan to present the problem to our microbiologist. It is to be hoped that this is a start towards the eradication of one of our most difficult problems.

DR. CHARLES F. FERGUSON: I am very grateful for the privilege of discussing this most stimulating and timely paper of Dr. Holinger and his associates. First of all, I should like to compliment him on an excellent and though-provoking presentation, such as we have always come to expect from him and his group. I also appreciate his courtesy in sending me a copy of his manuscript prior to the meeting. In spite of countless treatments for laryngeal papillomatosis which have been developed over the years, the condition today is nearly as distressing as ever, and so far there is no satisfactory definitive treatment. A few years ago, after the antibiotic era had become well established, we began to feel that we were seeing fewer of these troublesome cases in infancy and childhood. Ten years ago or so, Dr. Holinger had hoped that treatment with aureomycin or other antibiotics might be the answer. I have just gone over our records at the Children's Medical Center in Boston for the past 15 years, since the time we reported a 10-year series of 15 cases in 1944. I now find that we have had 21 additional cases during the period 1945 to 1960, so the prevalent use of antibiotics certainly has not changed the overall picture. Only 23% of our recent cases, however, have needed tracheotomies, as

against 60% in our original series nearly 20 years ago. Fewer excisions have been necessary in later years, and spontaneous regressions seem to be more frequent, even before the anticipated resolution at puberty.

At the Washington Congress of Otorhinolaryngology in 1957, a morning-long, plenary session was devoted to papilloma of the larynx. We were all hopeful that the assembled laryngological "greats" of the world would come up with some satisfactory answer to the perplexing problem. The results were disappointing. At that meeting your esteemed secretary commented that we must frankly admit it is the one big question-mark in otolaryngology in which there had been no semblance of progress as to etiology, change of course, or treatment, for generations. Dr. Holinger now seems to have opened a new door which may shed some very important light on both etiology and treatment. His theories are now backed up by sound experimental studies which I am sure are pointing in the right direction.

For years we have believed and taught that this peculiar lesion presumably is initiated by a virus (possibly influenced by hormonal changes), but so far there has been no conclusive evidence in humans to support this contention. As early as 1933, Shope was able to transmit the common cutaneous papilloma of the wild rabbit to domestic rabbits by inoculating a scarified area of the skin with a cell-free filtrate of the tumor. Histologically, this tumor greatly resembles the human laryngeal papilloma, as does the bovine wart. He showed that this lesion was both cell-specific and species-specific, and exclusively dermatotropic. By the application of chemical carcinogens, the transmitted papilloma could be transformed into a true carcinoma. Many of his inoculated animals developed neutralizing and complement-fixing antibodies against the virus, and several of the animals showed resistance to reinfection by that same virus afterwards.

This, as well as other later evidence from animal experimentation, as the authors have mentioned, makes it hopeful that an autogenous *human* vaccine might be effective, whereas in humans the animal vaccine has not been too satisfactory. Since their tissue cultures showed regrowth on as many as eight animal passages, and since their serological studies showed complement-fixing antibodies in 9 out of 25 human sera, it appears that a species-specific (i.e. a human-specific) virus could be the responsible agent. If this is true, a human-specific vaccine should offer more effective results than any of the previously employed treatments, such as bovine vaccine, estrogens, podophyllum, antibiotics, or other tried and usually discarded modalities.

Dr. Holinger has made an excellent contribution in this presentation, and we shall eagerly await his further reports along this line. As he has already admitted, it is impossible to draw hard and fast conclusions as yet on this relatively small series of four children and four adults so treated. We are all aware of the spontaneous regression which many of these lesions show even before the age of puberty, and also of their variable growth-rates at periods of endocrine changes which occur during pregnancy, puberty, or the menopause. However, he has given us some very solid and nourishing food for thought in this area which has been so woefully neglected hitherto. For bringing to us today this very stimulating and encouraging pioneer work, we are most grateful. We trust by next year he may be able to give us further evidence that this is a long hoped-for "break-through."

It was a great pleasure to be able to discuss this important paper, and I am sure we are all most appreciative for this refreshing "new-look" he has brought to an age-old, mysterious and perplexing disease.

DR. HOLINGER (closing): Mr. Chairman and Members: I appreciate the remarks made by both the discussers and particularly the fact that they mentioned

that the subject of laryngeal papillomatosis was presented at the Sixth International Congress. I assume some responsibility for having chosen that subject, in the hope that the solution to at least one of our problems in otolaryngology could be reached at an International Congress. But, although we had very excellent papers on pathology, possible etiologies and various forms of therapy, we did not come to a definite, final conclusion.

Dr. Ferguson mentioned the use of aureomycin in the therapy of papilloma that we reported on some years ago when this antibiotic was first available: We felt at that time that there was definite improvement in the infants and children who were kept on aureomycin for a period of time. I assume now that our good results which proved to be temporary were due to the fact that there was some reduction of the local infection surrounding the papilloma; it is probable that this was responsible for the apparent clinical improvement rather than that the aureomycin had any direct effect on the papilloma itself.

As far as Dr. Baker's remarks were concerned, I think we must repeat the point that our studies indicate: the papilloma virus is not only tissue-specific but species-specific and this is the key to the problem.

A lot can be said in the discussion that isn't in the formal paper. Dr. Holper, who is a very important part of this study, is head of the Microbiological Division of Abbott Laboratories, with whom we have been conducting this work.

The dosage factor is the reason for our difficulty in carrying our further studies to a conclusion. The duration of administration is another problem. In other words, we do not know how one reaches the proper dosage; how does one know what the individual dose should be, how often the material should be administered and for what duration it should be administered?

Our problems in making the vaccine have been considerable. Obtaining the material directly from the patient and getting it to the laboratory in as quick a time as possible is one of the difficulties. The material has to be collected and sent frozen, immediately. We have tried shipping and this is not satisfactory. We have had to revert to direct messenger transfer of the material as soon as the laryngoscopy has been completed.

Another problem arises after the vaccine has been prepared and is the same that one has with the bovine papilloma vaccine, namely, the question of sterility. Attempts will be made time after time to obtain a sterile vaccine but the vaccine cannot be adequately sterilized and obviously, under these circumstances, it cannot be used.

So the questions of transport, of sterility, of dosage and of duration of administration are our present problems.

Dr. Conner, with whom we started this phase of the work, was an E.N.T. resident under Dr. Lederer at the University of Illinois. His wife, Betty Ross Conner, worked in the Biological Laboratories at Abbott under the direction of Dr. Holper. Dr. Conner was called into the Navy and the work stopped for a time to give us an opportunity to evaluate our results and see if we should go further. We have now had an opportunity to check these children and adults who have had vaccine; we have been encouraged and have resumed the production of vaccines and will continue now with further patient administration. Thank you.

SOME OBSERVATIONS ON EXPERIMENTAL
LARYNGEAL SUBSTITUTION IN
LARYNGECTOMIZED DOGS

JOSEPH H. OGURA, M.D.

DONALD S. SHUMRICK, M.D. ABRAHAM LAPIDOT, M.D.
(by invitation) (by invitation)

ST. LOUIS, MO.

The human larynx, a complex integrated organ, is so anatomically placed at the junction of the food and air passages that its primary sphincteric function protects the lower airway from accidental aspiration. Between each act of deglutition or swallow reflex, the larynx must provide for an adequate airway at all times. Speech function has been stated to be of secondary importance.

When patients are faced with the prospect of laryngeal surgery, their concern has been more with the possible loss of communication than with deglutition. Increased experience with conservation operations for cancer has shown that certain "vital" structures of the larynx need not be present to maintain adequate and useful function. After partial laryngectomy, the ability of the patient to adapt and re-educate himself to swallowing has been truly remarkable.

The fact that certain supraglottic structures of the larynx may be removed with rehabilitation and preservation of function has been stated in previous publications.¹⁻³ All of the supraglottic structures, that is, the false cords, the epiglottis, ventricles, one arytenoid, and

From the Department of Otolaryngology, Washington University School of Medicine, St. Louis, Mo.

This research study was supported by grants from the American Cancer Society, New York, N. Y. (T245) and the National Institutes of Health, Bethesda, Maryland (B3408).

large portions of the pharynx may be removed with restitution of good swallowing, preservation of airway and voice. In addition, reasonably good function is maintained even with bilateral cord paralysis.

The principles of the conservation operation are applicable to other situations. Pharyngo-colic anastomosis with resection of the supraglottic areas can be done without greatly altering laryngeal function.⁴ This procedure is used to repair severe cicatricial stenotic burns of the pharynx, larynx and esophagus. Traumatic stenosis of the pharynx and larynx represents another situation of altered function. In this instance the supraglottic structures of the larynx may be removed. The larynx functions sufficiently well from the protective point of view, even though there is only mobility of one cord or even if both cords are paralyzed.⁵

Thus, a larynx can function well with varying anatomic situations under different situations of stress. A surgically created simplified form of larynx can function adequately in contrast to the normal situation in which complex sphincteric arrangements operate for deglutition and voice and speech. If we trace the phylogenetic development of the larynx in the mammalian species, the basic physiological sphincteric properties remain, while the phonatory function varies. Some animals can utter some sounds while others are mute.

Since a simplified form of larynx has been sufficient under ordinary circumstances, the surgical reconstruction of a laryngeal substitute appeared possible. Such a program was instituted in a series of experiments on dogs. If long term observations on a laryngeal substitute should function satisfactorily, these principles may be directly applicable to humans.

REVIEW OF LITERATURE

It should be of interest that Rosewell Park in 1886⁶ wrote on one of the first attempts at an artificial larynx which was a T tube connecting the trachea with the pharynx (Fig. 1). The epiglottis was left in the performance of the laryngectomy, and the T tube airway was connected with the trachea and pharynx. The tracheal tube was left within the patient and, in the act of deglutition, the obturator was inserted into the pharyngeal end to prevent aspiration. The voice of this patient was produced by an artificial reed attached to one end of the tracheostomy tube.

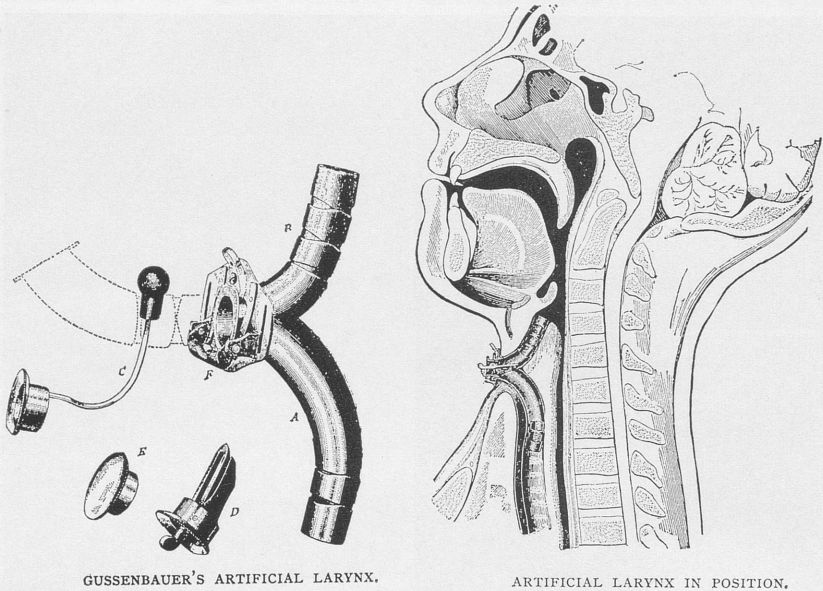


Fig. 1.—Gussenbauer's artificial larynx. The obturator (C) is inserted into the pharyngeal end of the airway with deglutition. (D) is the reed for phonation; and (E) is the cap to occlude the airway opening (F) for phonation.

From that period to the present, no further mention has been made concerning the re-establishment of the airway to the pharynx after total extirpation of the larynx. Although many reports have been made on tracheal substitution or replacement, no work has been done with the intent of laryngeal substitution in animals or humans.

METHOD OF STUDY

Dogs were selected as the experimental animals in this study. The methods employed are given in the order of development and the procedures utilized were divided into four distinct groups.

- I. Artificial laryngeal prosthesis.
- II. Tracheopharyngeal anastomosis with a stent.
- III. Simulated fixed cords.
- IV. Pretracheal sphincter (valve).

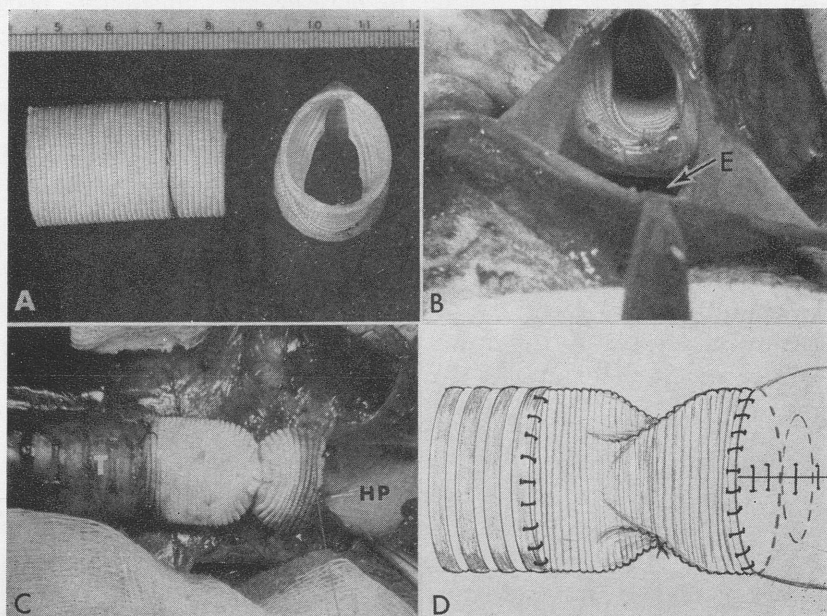


Fig. 2.—Artificial prosthesis. A. A lateral and end view of prosthesis. Note the crimped or simulated fixed cords. B. View of prosthesis from pharyngostoma. C. The position of prosthesis with the hypopharynx; the hypopharynx is partially closed. D. Schematic drawing of the prosthesis.

In the four groups, the objectives were different. Each series of animals had varying procedures employed after total laryngectomy. As each group was evaluated, the technical steps were changed to meet each problem.

The basic extirpative procedure and preliminary care in the four groups of dogs were the same. A temporary gastrostomy was always done as a preliminary operation. Several days later, a tracheostomy was performed followed by a total laryngectomy. Nembutal anesthesia was used for each surgical procedure.

In all of the groups, the technique for laryngectomy was the same. An extra perichondrial dissection of the larynx was carried out with transection of the larynx below the cricoid cartilage and with removal of the epiglottis, but the hyoid bone was left intact. Some attention was given to preserving much of the pharyngeal mucosa.

Postoperative management was the most important factor in animal survival. Great difficulty was encountered in the care of these animals. Great emphasis was placed upon fluid and nutritional requirements, adequate humidification, tracheostomy care and antibiotics for the prevention of infection.

When the wound was healed, records were made on the various physiological processes. Cinefluoroscopic movies were taken on representative animals in each category. If the animal expired, the entire reconstructed anatomical area was removed.

PROCEDURES

I. *Artificial Prosthesis.* Plastic artificial prosthesis was used in this group of 25 dogs as a laryngeal substitute. For survival of the prosthesis, it was necessary to determine if mucous membrane would re-epithelialize its lumen from each end of the graft. The materials used were Teflon, Dacron, flexible Nylon, and Marlex mesh.

Each material used in the animal was selected to conform with the diameter and length of the larynx (Fig. 2). At one third of the distance from one end, a stainless wire loop was used to crimp or narrow the prosthesis, creating simulated fixed cords. The cut margin of the prosthesis was then heat sealed. The material for the prosthesis was varied to compare the responses of healing and repair in each case.

After laryngectomy the mucous membrane of the pharynx was anastomosed with 5-0 arterial silk to the upper lumen of the prosthesis and the lower end was sutured to the first tracheal ring. The technique used for approximating the mucosa to the prosthesis was varied. In 12 animals, the stent was placed outside the first tracheal ring; in the remainder the stent was placed inside the first tracheal ring. The pharynx was closed with fine silk sutures. In 12 instances, the pharyngeal mucosal flaps were invaginated with the "cord" area to assist in epithelialization. In the remainder, the mucosa was approximated to the graft. The strap muscles were then approximated about the stent and the skin was closed with interrupted silk.

II. *Tracheopharyngeal Anastomosis with Stent.* In these animals, our primary concern was to prevent stricture formation at the junctional zones of the pharynx and airway system. Ten dogs were operated upon in this series. The trachea was separated from the

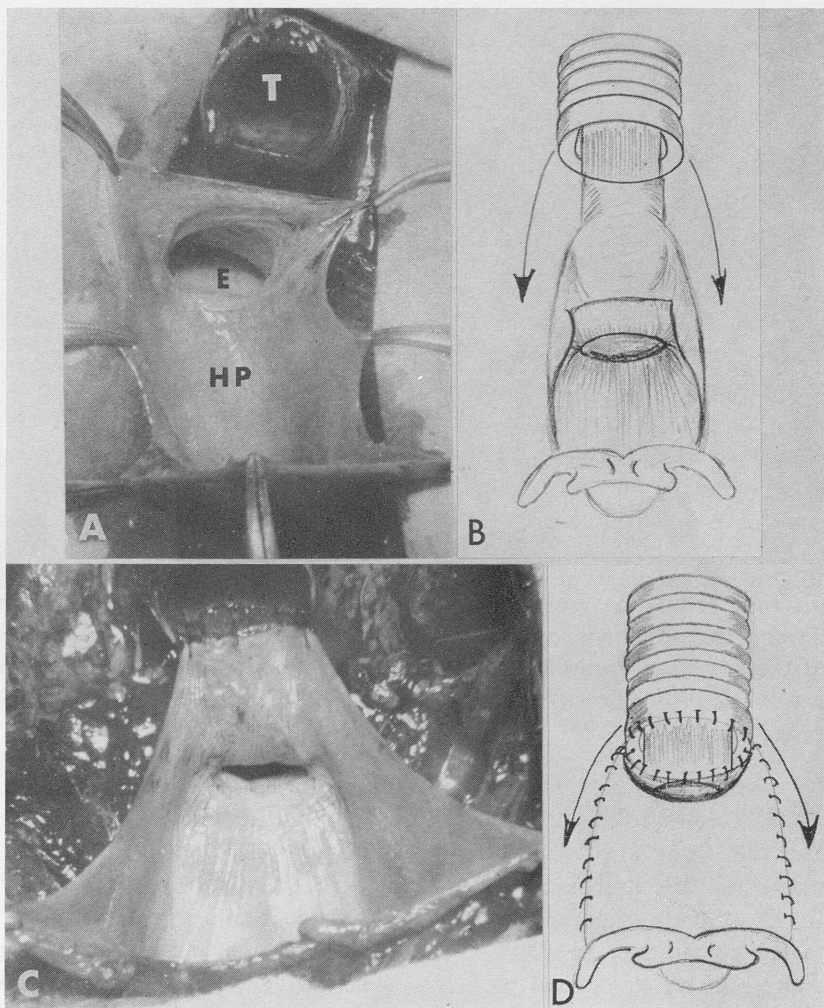


Fig. 3.—Tracheopharyngeal anastomosis with stent. A. View of trachea (T) and pharynx (HP) after total laryngectomy. B. The trachea is mobilized superiorly for anastomosis with the pharynx. C. Anastomosis of the pharynx to the trachea. D. Closure of pharynx.

esophagus for a distance of 5 or 6 tracheal rings after total laryngectomy. The first tracheal ring was then anastomosed with the pharyngostoma (Fig. 3).

Excess pharyngeal mucosa was approximated about the trachea and the mucosa closed together with the strap muscles. In order to give support to the area between the hyoid and the first tracheal ring, an indwelling stent was designed to insert into the trachea to keep the pharynx open. This stent was left in for three weeks.

III. *Simulated Fixed Cords.* The efforts in these animals were directed towards the concept of tracheal airway clearance by the lower respiratory system. To assist in this clearance of the airway, it was thought that a reduction in the diameter of the inlet was important. Reduction of the tracheal lumen was accomplished by creating simulated fixed cords.

In 12 animals, after total laryngectomy, an anastomosis of the first tracheal ring to the pharynx was made. Several methods of making simulated fixed cords were tried. In all animals, attempts were made to achieve an inverted V shaped narrowing to approximately 50 per cent of the original lumen (Fig. 4). The second tracheal ring was divided in the midline and an inward buckling and narrowing of the trachea created by a stainless steel wire. All other conditions of pharyngeal closure were kept the same as in Group II.

IV. *Pretracheal Sphincter (Valve).* In this group of forty animals, many variations in techniques were improvised and designed toward the creation of a functioning sphincter or valve in front of the trachea. Initially, the cricothyroid muscle was used in front of the open trachea. Later, various procedures were performed on the inferior constrictor muscles by anastomosing them to the trachea. In thirty animals, various muscle flaps were made from the inferior constrictor muscle combined with wedge removal of cartilage from the first tracheal ring. In this manner, we hoped to develop a functional sphincter.

Our present method consists of the following steps (Fig. 5). A vertical incision is made into the posterior wall of the cricopharyngeus and pharynx at the median raphe and the mucous membranes are then sutured transversely to give additional width to the esophageal inlet. The first tracheal ring is divided at the midline and laterally in each side. A wedge of cartilage is removed at each site of division

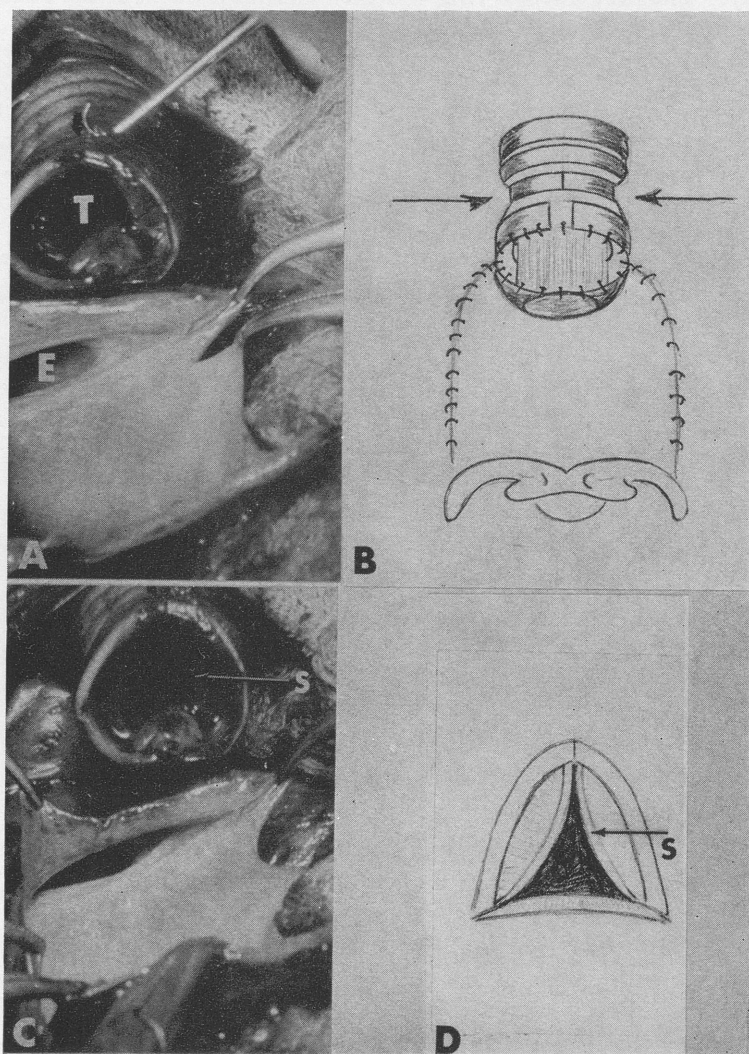


Fig. 4.—Simulated fixed cords. A. The instrument is hooked between the cartilage and perichondrium and cartilage division is made as illustrated in B. (E) esophagus. B. The second tracheal ring is divided anteriorly and stainless steel wire has been placed laterally to cause narrowing of the trachea. The first ring has been divided. C. Appearance of the trachea from above showing effect of simulated fixed cords (S). D. Diagrammatic view of trachea as viewed from above.

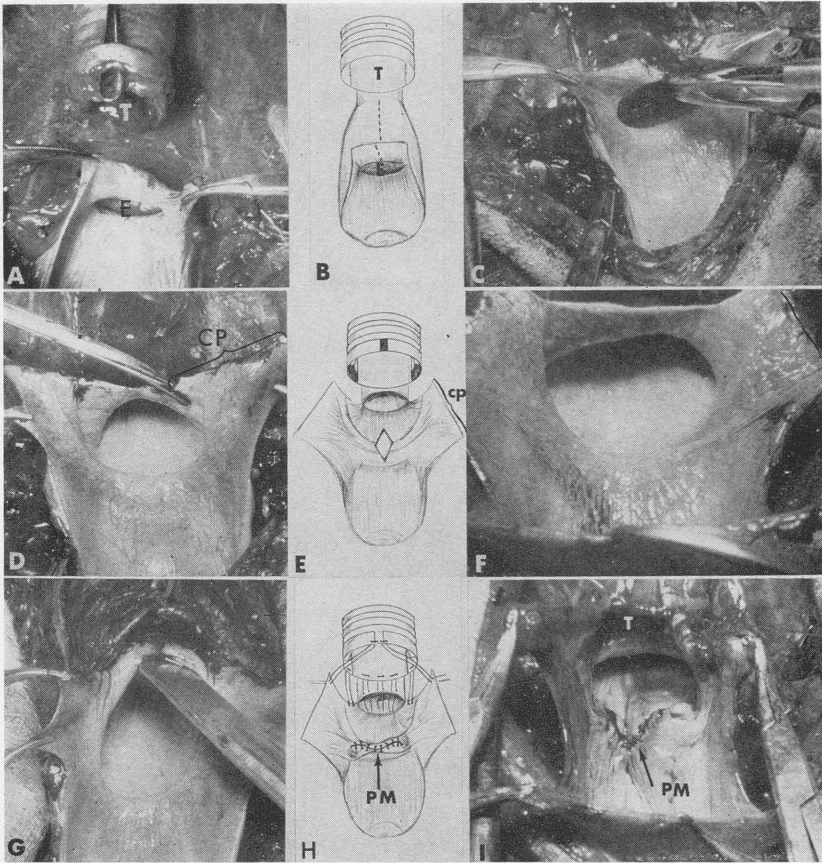


Fig. 5.—Pretracheal sphincter. A. Elevator is shown between the cartilage and perichondrium prior to breaking the spring of the cartilage of the first ring (T). (E) esophagus. B. Incision anterior esophageal wall down to first ring. C. Scissors show actual section along anterior wall of esophagus. D. Note cartilage cuts along anterior and lateral surfaces of first tracheal ring. Note site of posterior myotomy. E. Brackets show flap of cricopharyngeus created by lateral extending cuts. Note increased size of esophageal inlet. F. Partial suturing of cricopharyngeus about tracheal opening. Instrument in esophagus demonstrates direction of closure of sphincter. H. Mucosal closure of cricopharyngeus about first ring. (PM) posterior myotomy incision is transversely closed. I. Note closure of posterior myotomy and mucosal suturing about trachea.




Fig. 6.—Stent. The stent is designed so the T area is inserted into the trachea, and retained with sutures through the stent to the trachea.

from the lateral aspect of the first tracheal ring. A longitudinal section is made along the anterior esophageal wall through the cricopharyngeus area down to the level of the point where the cricoid cartilage was previous to laryngectomy.

Lateral extending incisions are made on each side to form a T-shaped incision. Anastomosis is made between the posterior aspect of the trachea and mucosa of the anterior esophageal wall formed by the horizontal arm of the T incision. The lateral portions of the esophageal sphincter are sutured circumferentially about the first tracheal ring. The esophageal inlet is thus lengthened in its superior-inferior extent. The cricopharyngeus muscle which was divided into the anterior wall of the esophagus is formed into a sphincter by this procedure.

A rather long sphincter is reconstructed and partial narrowing of the airway is assisted by wedge cartilage excisions of the first tracheal ring. A stent is placed into the trachea and left for three weeks (Fig. 6). Pharyngeal closure of the stoma and approximation of the strap muscles was done as in the other groups.

RESULTS (*Table I*)

I. *Artificial Prosthesis Series.* Of the 25 dogs with artificial prostheses, the materials used were Teflon, Dacron, Flexible Nylon and Marlex. Before the materials was anastomosed with the trachea and pharynx, it was coated with blood. Regardless of the material used, every prosthesis was eventually rejected by the animal in periods of time varying from ten days to two and one-half months. Use of steroids and antibiotics did not materially assist or alter the progress of epithelialization and granulations within the stent. In the short survival animals, usually there was no evidence of repair along the lumen of the prosthesis. Occasionally, epithelium did grow for a short distance into the graft in the larger surviving animals, but no prosthesis was tolerated beyond two and one-half months.

All of the animals eventually developed wound infection. Observations were possible in 10 of the 25 animals. Fifteen of the animals died within ten days from infection and in each instance the prosthesis could be seen with little or no evidence of healing. In ten animals surviving beyond ten days, the longest lived for two and one-half months. In two instances, the prosthesis was lined partially by epithelium (Fig. 7). In every instance, infected granulation tissue was present outside of the prosthesis. In five of the ten animals surviving to two and one-half months, stenosis developed at the pharyngeal and tracheal ends. It was surprising, however, that these animals could swallow solid and liquid foods fairly well, but characteristically they would regurgitate after several swallows.

Although we were able to extubate the tracheostomy tube in 5 animals for varying periods of time; because of the stenosis, no animal tolerated permanent decannulation of the tube. It was obvious that, while these animals could swallow, the amount of food ingested was insufficient as their only means for maintaining nutrition. All of the animals exhibited rapid loss of weight even with forced gastrostomy feedings.

Close observations made on the characteristics of their swallowing movements suggested that aspiration was common and in most

TABLE I
RESULTS

No.	Evaluation on survivals	Longest survivals (months)	Present No. survivals	Permanent decannulation tracheotomy	Deglutition	Aspiration	Airway	Bark	
Artificial laryngeal prosthesis	25	10/25	2 1/2	0	2/10	Fair	Moderate	Poor	Fair
Tracheo- pharyngeal anastomosis	10	5/10	2 1/2	0	5/5	Fair	Moderate	Good	Fair (breathy)
Simulated fixed cords	12	8/12	3	0	3/8	Fair	Fair	Poor	Good
Pre- tracheal sphincter (valve)	40	10/30*	4 1/2	4	8/10	Good	? Minimal	Good	Good

*Cricothyroid sphincter excluded.

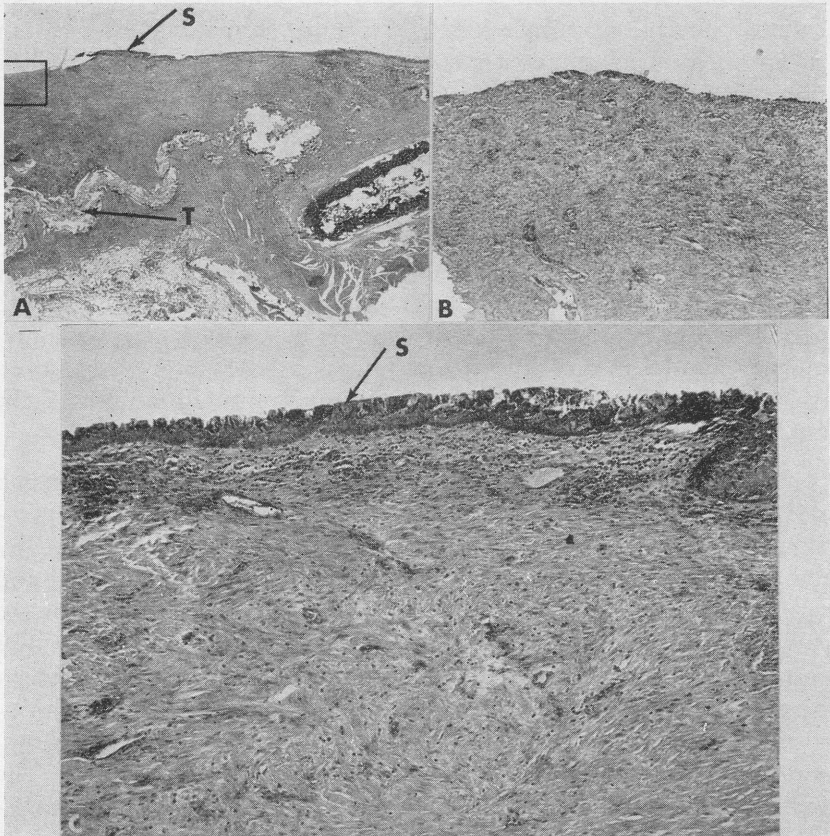


Fig. 7.—A. Low power view of Teflon stent removed from a dog surviving $2\frac{1}{2}$ months. Note that the stratified squamous epithelium has grown for a few millimeters inside the prosthesis (T). B. Granulation tissue at zone visualized in A. C. High power view shows the growth of squamous epithelium at arrow point in A.

cases, bronchopneumonia was present at autopsy. Consistent demonstration of aspiration of barium was shown by cinefluoroscopy. The study in the series was terminated when it became apparent that, regardless of the material used (at least plastics), none was tolerated by dogs and stricture formation was the end result.

II. *Tracheopharyngeal Anastomosis.* In this series of ten dogs, the trachea was anastomosed to the pharynx and no attempt was made to narrow the tracheal inlet. Since the primary problem in dealing

with artificial prosthesis to the pharynx was stenosis, an indwelling stent was placed into the trachea and pharynx at the time of the operation in an effort to minimize stricture formation. It was felt that sufficient information was not known concerning the healing processes in dogs. Evaluation was possible in only five of the ten animals which survived to the two and one-half month period. Decannulation of the tracheostomy was done by the third week in every surviving animal.

Swallowing was no better than with the prosthetic dogs, but there was generally less infection of the wound and the animals were healthier. Of the five dogs which reached the two and one-half month period, only one swallowed fairly well. The others aspirated frequently and all eventually died of infection. At autopsy, however, we were able to demonstrate that the stent prevented stenosis of the tracheopharyngeal inlet.

III. *Simulated Fixed Cords.* Twelve animals were included in this group. Many different techniques were employed to create simulated fixed cords. The inverted V narrowing was accomplished by two methods. In one, the second tracheal ring was removed and reversed to cause inward bowing into the trachea. The spring of the cartilage was broken anteriorly by removal of a wedge of tissue. The posterior aspects of the cartilage and perichondrium were sutured by stainless steel wire to create a narrowing. The second method of narrowing the trachea consisted of making multiple grid cuts of the second tracheal cartilage to break the spring of the cartilage. The posterior aspects of this spring were held together in the same manner with stainless steel wire.

Of the twelve dogs, six had the second tracheal ring reversed and sutured together. In four animals, efforts to create fixed cords eventually resulted in necrosis of the cartilage and infection. In six animals, the second tracheal cartilage was gridded and sutured together. Evaluation was possible in eight animals. When the tracheal diameter was narrowed to less than 50 per cent of the original tracheal diameter, airway was insufficient for ordinary movements. There was difficulty with tracheostomy decannulation. Permanent decannulation was possible in three, and intermittent use of the tracheostomy tube in five.

Swallowing was better compared to the tracheo-esophageal anastomosis group. However, in time these animals could not swallow efficiently because of the development of tracheal constriction and

dyspnea. The amount of aspiration of barium demonstrated by cine-fluoroscopic examination was less than with the tracheo-esophageal anastomosis group. None of the group survived beyond three months, and all of the animals died either from airway obstruction, infection, aspiration, metabolic disturbance, or a combination of these factors. It was quite apparent that simulated fixed cords may be an important factor in preventing ingress of fluids into the trachea, but good function could not be attained without some sphincter mechanism.

IV. *Pretracheal Sphincter (Valve)*. This group was our largest and included 40 animals. At first, the cricothyroid muscle was used in an attempt to create a sphincter or valve. The reconstruction procedures were unsuccessful largely because this muscle lacked length and great difficulty was encountered in suturing this about a rigid trachea. It was then thought desirable to affect a closure of the tracheal lumen by utilizing the cricopharyngeus muscles.

The experience gained in the management of the previous three groups taught us that good care of these animals was difficult to maintain. In the pretracheal sphincter group there was a problem of having enough animals survive long enough to permit long term evaluation and observation. Loss of animals from extraneous causes such as cross infections and worms, were numerous. For this reason, although tracheostomy decannulation was possible in every animal by the third week, we kept the tracheostomy tube in these animals for six weeks as a precautionary measure.

We were able to evaluate the physiological aspects in ten of the 30 animals. Under light anesthesia, one could observe the sphincter or valve to close down partially with each unconscious swallowing act. Significant observations have been made in eight animals extending to the four and one-half month period. At the present time there are four animals up to the four and one-half month period.

The short and longer acts of deglutition in these animals have been dramatically improved and solids and liquids are well handled. Aspiration, while initially present, diminished greatly within a short period of time. Upon permanent decannulation of the tracheostomy tube, the airway has been adequate and bark very realistic.

Cinefluoroscopic examination in several of these animals demonstrated that aspiration was minimal, if it occurs at all, and the sphincter appeared to close in deglutition, and to open for airway. This fact was determined by analysis of strips of film under slow motion.

In the swallowing sequences, the pretracheal sphincter and trachea was found to elevate towards the tongue. It is probable the base of the tongue participated in causing an obturator effect of "sling" closure with the elevated pretracheal sphincter and trachea.

Pathologic examinations were made on all animals dying after the three week postoperative period. One such reconstructed laryngeal substitute with a pretracheal sphincter or valve shows the close relationship between the tongue and the trachea (Fig. 8).

It was surprising that this sphincter resembled a glottis, and, in another aspect, was similar to the common airway of a lung fish. The lung fish lacks a larynx and the respiratory tube enters the pharynx through a linear sphincter.

COMMENT

In this study of the 87 laryngectomized dogs, many methods for substituting a larynx were used. In 25 dogs, the artificial prosthesis was rejected in every instance. In ten others, the common tracheopharyngeal opening functioned inefficiently with evident aspiration even though much of the food was swallowed and the bark was breathy.

The results of these two groups of animals established a fundamental concept. That these animals could swallow at all was quite a surprise. Deglutition was inefficient largely because of the open airway. By contrast, the simulated fixed cord group showed some improvement in swallowing but the problems of airway obstruction became more serious.

The prosthesis group demonstrated another important principle. Rejection of the prosthesis was followed by stenosis of the airway. In the tracheopharyngeal group, the stent was necessary to provide an airway but it became quite apparent that some narrowing mechanism was necessary to prevent aspiration. The simulated fixed cord provided some insight on the possible importance of the tracheopulmonary airway in protective clearance of the upper trachea.

Interpretation of slow motion pictures does lead us to conclude that a functional sphincter or valve was created. With deglutition, a sphincteric narrowing was assisted by partial collapse of the first tracheal ring and some elevation of the trachea. The airway opened upon relaxation of this sphincter.

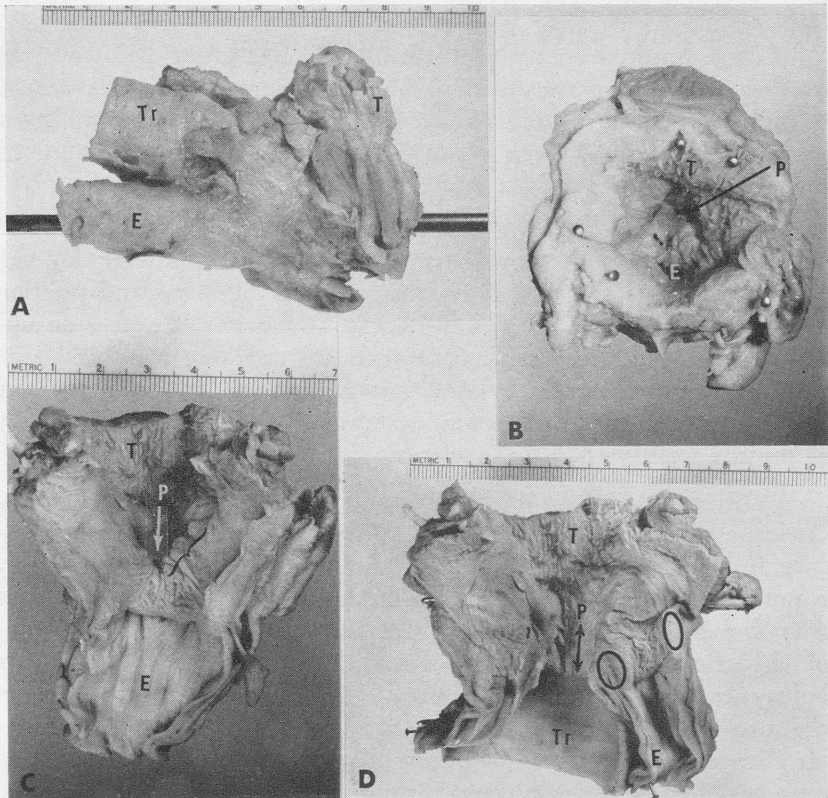


Fig. 8.—Specimen of pretracheal sphincter larynx substitute in dog surviving 3 months after surgery. A. Lateral view—Note metal bar from pharynx into esophagus. (Tr) trachea. (T) lateral view of tongue. (E) esophagus. B. View of pretracheal sphincter from above. (P) sphincter or valve. (T) tongue. (E) esophagus. C. Posterior view—esophagus has been cut vertically exposing pretracheal sphincter (P). Brackets show area of sphincter. Note close association of tongue to sphincter. D. Posterior view through sphincter. Esophagus and trachea have been divided vertically. (P) zone of sphincter to valve. (T) tongue. Area circled is sectioned cricopharyngeal muscle.

The words sphincter and valve have different implications and meaning. A sphincter has the ability to close an orifice by muscle contraction. However, passive closure of an opening can cause a valve-like effect of that same opening by active participation of structures immediately adjacent to this area. The examination of the larynx and pharynx at autopsy shows a structure quite similar to

the simplified larynx left in humans following supraglottic subtotal laryngectomy (Fig. 8).

These findings on the pretracheal sphincter group point out the necessity to develop a program for making longer term observations. Although these four animals are healthy, it is necessary to know whether these animals can maintain their nutrition over a 6 to 12 month period.

Essentially, a dog eats in a horizontal position at least most of the time, but we have shown that the pretracheal sphincter dog can eat with its head elevated above this position. Posture and position of the animal is probably a very important factor. Whether an upright animal with the same operation can swallow, bark and survive for many more months remains to be proven. Currently, we are performing the same operation upon monkeys, but unfortunately at present we have had no survivors.

The results of these studies show that there are many unanswered critical questions. What is the role of the tracheopulmonary air pressure in tracheal clearance? Does the pretracheal sphincter really function as a true sphincter? It appears to close on swallowing, but why should it not open instead? Certainly, the origin and insertions of the cricopharyngeus have become altered by surgery. When a bolus enters the pharynx by closure of the base of the tongue, perhaps the surgery has caused early closure of the sphincter. Perhaps sphincter closure is accomplished by a learned process. Food and liquids can more easily enter the esophageal inlet since this area has been rendered partially incompetent.

The sphincter may not actually close, in terms of active muscle contraction. A sling or passive closure of this area can be caused by elevation of the trachea causing an obturator effect against the base of the tongue. Thus, perhaps this area functions more as a valve-like structure.

In conclusion, it seems evident that several approaches to rehabilitation of the laryngectomized dogs have been found unsatisfactory. However, the procedure in which a pretracheal sphincter has been constructed from the cricopharyngeus muscles is very promising. Further work will be necessary to determine whether this sphincter has active muscle contractions. This will act as a valve, and closure of this structure is caused by secondary factors. Whatever the mechanism, the functioning sphincter or valve substituting for a larynx protected the lower airway, provided an adequate airway without a

tracheostomy and the animals maintained a bark. The fact that this structure functions at all is surprising. Much more information will be necessary for a more accurate appraisal of this area.

Basic neurophysiologic mechanisms of the larynx and pharynx concerned in deglutition, airway and voice need to be re-examined and questioned. Long term observations on other animals and further critical observations are necessary before the principles of this laryngeal substitution procedure may be applied to humans.

SUMMARY AND CONCLUSIONS

1. Total laryngectomy was done in 87 dogs and various methods were employed for a larynx substitute.

2. The best functioning sphincter or valve was the surgical reconstruction of the cricopharyngeus muscle about a collapsible first tracheal ring.

3. The dog with a sphincter or valve appeared to have good function for deglutition, airway and bark.

4. The successful results represented by survival to 4½ months should be observed for stability of function over a long period.

WASHINGTON UNIVERSITY SCHOOL OF MEDICINE

Dr. Shumrick is an N.I.H. trainee.

Dr. Lapidot is an American Cancer Society Fellow.

William E. Powers, M.D., Director of Radiotherapy, Washington University School of Medicine, made all of the cinefluoroscopic motion pictures.

REFERENCES

1. Ogura, J. H.: Supraglottic Subtotal Laryngectomy and Radical Neck Dissection for Carcinoma of the Epiglottis. *Laryngoscope* 68:983-1003 (June) 1958.
2. Ogura, J. H., Jurema, A. A., and Watson, R. K.: Partial Laryngopharyngectomy and Neck Dissection for Pyriform Sinus Cancer. *Laryngoscope* 70:1399-1417 (Oct.) 1960.
3. Ogura, J. H., Saltzstein, S. L., and Spjut, H. S.: Experiences with Conservation Surgery in Laryngeal and Pharyngeal Cancer. *Laryngoscope* 71:258-276 (Mar.) 1961.
4. Ogura, J. H., Roper, C. L., and Burford, T. H.: Functional Restoration of the Food Passages in Extensive Stenosing Caustic Burns of the Pharynx and Esophagus. *Laryngoscope* 71:885-902 (May) 1961.
5. Ogura, J. H., and Roper, C. L.: Surgical Correction of Traumatic Stenosis of Pharynx and Larynx. To be published in *Laryngoscope*.
6. Park, Rosewell: A Case of Total Extirpation of the Larynx. *Annals of Surgery* 3:28-38, 1886.
7. Bosma, J. H.: Deglutition in Pharyngeal Phase. *Physiological Review* 37: 281, 1957.

DISCUSSION

DR. PRESSMAN: Recently in what may even be called a renaissance of surgical laryngology, there has been renewed interest in the preservation of function. Dr. Ogura has been a foremost contributor. His newest studies reported today add notably to his previous contributions and are unique, ingenious and thought-provoking.

Dr. Ogura has permitted his mind to roam in the realm of the unknown and has taken his ideas into the laboratory to be nurtured and developed. Sooner or later his vivid imagination will bear even more fruit, if not from his own tree then from others nourished by his pioneering efforts, and the clinical application of his experiences will lead to the saving of human life. He is to be heartily congratulated.

To comment specifically upon some of the points Dr. Ogura has made, the rejection by the animal of the artificial prosthesis is in keeping with the experimental results reported by everyone, including Dr. McCall this morning. Overwhelming data now available indicate that the use of prosthetics, no matter how appealing, is an impractical approach to the problem; and incidentally Dr. Ogura mentioned this afternoon the placing of a segment of the trachea within a prosthesis. This is foredoomed to failure because the trachea within the prosthesis must slough. The blood supply to the tracheal rings comes in from the side and these vessels are essentially terminal or end vessels, each supplying the ring above and the ring below but not passing beyond it. In other words, if more than two rings are placed within a cuff the rings within the cuff have no blood supply and must slough.

The inevitable mortality in tracheal-pharyngeal anastomosis without creation of a sphincter as reported by Dr. Ogura, is likewise what one might anticipate. It is simply not possible to survive without a tracheal sphincter. This vital structure so essential for life is seldom, in our thoughts upon anatomy and physiology, given the importance due it in so far as a practical functioning organ is concerned.

Dr. Ogura in a significant number of experiments has successfully created a functioning sphincter. This represents a noteworthy advance in the surgery of the larynx, making it possible in the experimental laboratory to preserve life whereas without it death would have been the inevitable result.

The fact that he is able to have success in even one case, much less in several, is a remarkable achievement. He did so by substituting one muscle for another. One of the great problems concerned with the movement of muscles from one site to another is the preservation of the motor nerve supply and the technique by which Dr. Ogura has been able to do this in four animals should be elaborated upon in his closing remarks.

Dr. Ogura does well to distinguish between a sphincter and a sphincter valve. This is an important difference indeed. The original primitive sphincter of the larynx found in the lung fish was a circular, muscular sphincter with no valvular characteristics. The valvular element represents a distinct advance in evolution; but Dr. Ogura's creation of the more primitive form of larynx represented by this circular muscle is adequate and functional.

One can answer the question Dr. Ogura asked in his paper but which he did not mention in his discussion concerning the role of tracheal pulmonary pressure in clearing secretions from the trachea in the tracheotomized animal. We know from experiments I have reported, and which have subsequently been confirmed by others, that in so far as tracheal pulmonary air pressure is concerned the loss of the laryngeal sphincter valve results in a loss of roughly 20 per cent in efficiency.

This sometimes is as high as 37 per cent and in some instances as low as 9, but a mean of 20 is a good average.

My heartiest and warmest congratulations to Dr. Ogura upon having with such ingenuity carried out this amazing series of experiments representing a springboard from which he and others may now venture further, seeking the ultimate, and eventually being able to apply these principles which he has so effectively described, to the living human patient.

DR. OGURA (closing): I wish to thank Dr. Pressman for his very kind remarks. The answers to his questions can be found in the complete paper. I felt that in order to present this paper in twenty minutes I would have to delete a good deal of it.

I am familiar with his writings on the role of the tracheo-bronchial air pressures and this, of course, is the next factor that needs to be evaluated. Electrodes need to be placed into this sphincter as well as into the pharynx and esophagus with a cannula in the trachea for measuring tracheal pressures in these dogs. This is why we need long-term observations.

TOLERANCE OF THE RESPIRATORY MUCOUS
MEMBRANE TO TRAUMA:
SURGICAL SWABS AND INTRATRACHEAL TUBES

A. C. HILDING, M.D.*
AND
JEAN A. HILDING, B.A.**
DULUTH, MINN.

When one observes the introduction of an intratracheal tube for anesthesia purposes, he cannot help wondering, "How much trauma is associated with this maneuver? How much abuse can the respiratory epithelium tolerate?" When the patient, a day or two later, looking at you with accusing eyes, and in a husky voice, asks, "What happened to my throat?" he raises in the surgeon's mind such questions as: How much damage was done? How long will repair require? Will it be complete? Will there be complications or sequelae?

Many others have considered this problem, have attempted to find the answers, and have suggested possible solutions. Some maintain that intubation for anesthesia is harmless and is not followed by complications. Hamelberg and his co-workers, reporting on over 1900 patients, found no serious complications.¹ Neither did Donnelly and his colleagues, who examined 100 patients postoperatively, and reported that even when unskilled residents did the intubation injuries were minimal.²

Most other authors describe complications of more or less serious nature. Parker reports a systematic study of injuries sustained by teeth, tongue, pharynx, tonsillar pillars, epiglottis, larynx, trachea, and bronchi.³ Fields describes a series of injuries, chiefly about the larynx, and believes that most of these could be avoided if principles

* From the Research Laboratory, St. Luke's Hospital, Duluth 11, Minnesota. Supported by grants from the Louis W. and Maud Hill Family Foundation of St. Paul, the Edward C. Congdon Memorial Trust, Miss Elisabeth Congdon, and the Women's Service Guild of St. Luke's Hospital.

** University of Minnesota Medical School, Minneapolis, Minnesota.

of good laryngoscopy were carried out. He is of the opinion that anesthesiologists should have some training in laryngoscopy.⁴ Flagg sent a questionnaire concerning injury from endotracheal tubes in anesthesia to the members of this Society and received response from 154. Ninety per cent were vehemently opposed to blind intubation. Injuries listed in the responses included granulomas, hemorrhages, edema, lacerations, and paralysis of the vocal cords, irritation from zephiran, injury to the tracheal epithelium, edema of the trachea and trauma to the carina. On the other hand, 80 per cent had failed to find pathologic conditions following routine bronchoscopy (by qualified endoscopists).⁵

Laryngeal granulomas following intubation have been studied and reported by many. These granulomas make themselves manifest some weeks postoperatively and are usually located on the cords.⁶⁻¹⁰

Stein studied at autopsy 42 subjects who had died shortly after surgery with intubation anesthesia. Thirty-three showed lesions that could be assigned to the intubation. They were more or less severe and consisted of edema, hemorrhage, desquamation, and ulceration in the larynx and trachea. The ulcers were found especially on the vocal cords. Seven of these patients had developed a membranous type of tracheitis, but in only three was it so marked as to be recognized grossly. None of the membranes had made mechanical difficulty.¹¹

Lu and his co-workers report a very good study on 23 patients who died shortly after intubation. They found a "continuous spectrum (of changes) having as a common denominator intubation." Five of their patients had developed pseudomembranous casts and two of these had suddenly died from acute asphyxia when these pseudomembranes loosened and obstructed the airway.¹²

Muir and Stratton also studied and reported 23 cases. These patients all developed membranous laryngotracheitis and six died, three from obstruction.¹³

Several workers have emphasized that most of these complications can be avoided by skill, gentleness, meticulous care of the instruments, and by using the proper sized tubes.^{9,12,14} One of my own hospital's anesthesiologists has pointed out that when plastic tubes are used they must be replaced at intervals because, in time, they tend to grow stiff.¹⁵

Lueder is making studies of pressure relations between the inflated cuff and the trachea. The first has been published and deals with the elastic properties of the cuff.¹⁶

Plum and his colleagues studied trauma to the trachea and bronchi from aspiration catheters introduced through tracheostomies.¹⁷ They were impressed by the roughness with which the ward personnel made these aspirations and demonstrated in patients and animals that serious damage might result from such treatment. They found pieces of tissue in the aspirate "perhaps 70 per cent of the time." They then developed techniques designed to avoid trauma and demonstrated on both patients and experimental animals that these better techniques were effective in prevention of trauma.

In 1956 Ingelstedt published a very extensive study on the physics of air conditioning in the respiratory tract.¹⁸ More recently, he, Toremalm and Andrén, working at Lund University, have made a series of excellent related studies, including air-flow patterns in tracheal models and their effects on live epithelium; aerodynamics within the larynx and trachea and indications for vapor therapy; the daily amount of tracheobronchial secretions in man; an atraumatic method of continuous tracheal aspiration in the tracheotomized patients; and new types of less traumatizing tracheotomy tubes.¹⁹⁻²² Kistner and McMahon also described a new type of less traumatizing tracheotomy tube.²³ These studies are all germane to an understanding of trauma to and repair of respiratory epithelium.

Many experiments have been done in animals producing severe damage to the epithelium (thermal cautery,²⁴ silver nitrate,^{24,25} formalin, ammonia, chlorine,^{26,27} instrumentation,²⁸ vitamin A deficiency,²⁹ tobacco tars³⁰) and studying the repair. Wilhelm curetted away the epithelium and studied the rate of regeneration (200 microns in 8 hours, 400 in 12 hours and 2 mm in 48 hours).³¹ Burian made deep and extensive damage to the nasal mucosa in rats. This became covered by stratified metaplastic epithelium which was replaced by ciliated columnar in eight to ten weeks.³²

It is not this extensive laboratory damage which I have in mind in this study, but rather the extent of the unintentional trauma incidental to intubation for anesthesia, bronchoscopy, and surgical manipulations. I discussed this briefly in the Wherry Lecture³³ a year ago and would like to go into it in more detail at this time.

EXPERIMENTS SURGICAL DAMAGE - DOG

A series of experiments designed to imitate some of the maneuvers made by surgeons were done on the tracheas of anesthetized dogs.

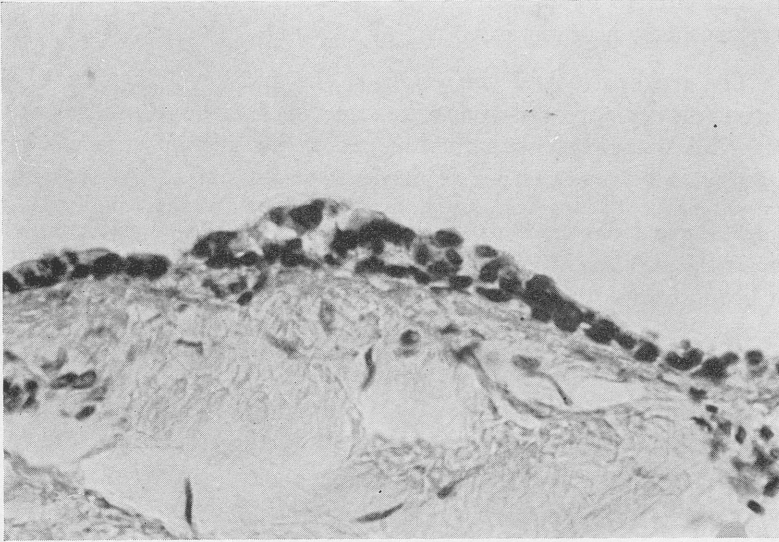


Fig. 1.—Appearance of epithelium at the level of the inflated cuff of an anesthesia tube following 2 to 3 hours of intubation.

Bronchoscopy. In two experiments, the trachea was opened in midline, a bronchoscope entered through the mouth and larynx and under direct vision passed up and down half a dozen times, as it made contact with the right lateral wall of the trachea. Histologic examination of a specimen taken from this region in Dog 1 revealed that the epithelium was intact in most areas. In one area, the superficial cells were stripped off, leaving two layers of replacement cells. Two blocks were cut from Dog 2. In one the epithelial cells were all gone but the basement membrane was intact. In the other, there remained one island with two layers of epithelium next the basement membrane intact, but there were no cilia. The rest of the epithelium was gone.

Effect of Cuff on Intratracheal Tube. Three tracheas were obtained from as many dogs that had been used for experiments under anesthesia and then sacrificed. They had been intubated with tubes furnished with cuffs and the cuffs had been inflated.

In the first of these, the epithelium grossly looked congested opposite the end of the tube, but, at the level of the cuff, appeared pale and normal. Histologically the epithelium at the end of the tube

appeared intact and well ciliated. It was intact also at the cuff level and well ciliated in some areas but not all. The cells looked "somewhat crushed" in some areas.

The trachea looked congested at the cuff level in Dog 4, but microscopically appeared about the same as that above and below the cuff. Cilia were present in all three areas, the only difference being a tendency to bunch together at the level of the cuff.

The third dog had sustained considerable damage to the epithelium at the cuff level. Two layers of disorganized epithelium remained but in most areas there were no cilia (Fig. 1). The epithelium below the cuff level was also thin but it appeared normal and very well ciliated.

Gauze Damage. The trachea was split in the midline anteriorly in a series of four dogs and the left wall of the trachea rubbed with gauze over a gloved finger.

Protocols.

Dog 1. Wall rubbed rather vigorously with gauze. Put in formalin immediately. *Histologic findings:* Epithelium entirely gone with the exception of an island that had been protected by a fold.

Dog 6. Wall rubbed several times, not so vigorously. Specimen for biopsy taken after 48 hours. Thin, purulent fluid found in trachea with some fibrinous material. Animal died of extensive pneumonia a few hours after removing the specimen. *Histologic findings:* Epithelium entirely gone. Lamina propria edematous and densely infiltrated with neutrophils. Covered with fibrin. Glands appeared very active. Examination of other parts of the trachea and bronchioles showed less, but still extensive, loss of epithelium.

Dog 2. Wall rubbed several times with moderate pressure and two blocks taken for biopsy, one immediately and one after 24 hours at a second operation. *Histologic findings:* *Immediate block* - Epithelium entirely gone as well as most of the basement membrane. Some fragments of latter remaining. *Twenty-four hour block* - Epithelium entirely gone. Lamina propria edematous and covered with layer of fibrin and white blood cells. A *control block* was taken from an untouched area of the trachea. *Histologic findings:* One island showed full depth epithelium with cilia but in most areas the epithelium was gone or only the basal layer remained.

The dog died of pneumonia within a few hours after the second operation. The trachea and bronchi were filled with frothy, bloody fluid, and the left lung was deep red and solid. *Histologic findings in lung:* Acute bronchopneumonia. One bronchiole found in which the epithelium was intact.

From these three dogs, it was concluded that a lesser injury was necessary to judge degrees of trauma and that infection (pneumonia) or postmortem change had severely altered the structure of the normal tracheal mucosa in two.

Dog 7. Trachea opened as before and ciliary action tested. It was found to be good—rate of flow 7.5 to 15 mm per minute in 12 runs.

Six specimens were cut for biopsy using a Graefe knife and cutting from the outside of the trachea. Great care was exercised to avoid touching the mucosal surface during the process. *Block I* was taken before any injury and was a control. *Blocks II to VI* were subjected to the passage of gauze on a gloved finger one, two, three, four, and five times respectively. Only a very moderate pressure was used.

Histologic findings - Block I - Normal, intact, ciliated tracheal epithelium. *Block II* - Epithelium entirely gone, no definite basement membrane altho the presenting tissue surface was smooth. *Block III* - Epithelium entirely gone excepting an intact island lying in a fold. *Block IV* - Epithelium entirely gone - lamina propria ragged. *Block V* - Epithelium entirely gone - basement membrane mostly present but gone in spots. *Block VI* - Epithelium entirely gone with the exception of remnants in a gap between two cartilages. Basement membrane gone in spots and here the lamina propria was ragged.

COMMENT

These results indicated that the tracheal epithelium in a living, anesthetized animal could not tolerate the passage of gauze once over the surface, even at a moderate pressure. Even one passage removed the epithelium and injured the basement membrane. To learn how much it will tolerate, it was necessary to devise a lesser injury. This was done with small cotton swabs in chickens.

SWAB DAMAGE - CHICKENS

Experimental lesions were made upon the tracheal epithelium in a series of 14 chickens in such manner as to produce a standard type of injury.

Technique. The birds were anesthetized by an intravenous injection of pentobarbital,* approximately 140 mg per kilo of body weight. In addition one per cent procaine solution, containing a small amount of adrenalin, was injected into the neck tissues to control bleeding. The trachea was exposed and a 6-0 silk suture placed in the anterior wall to mark the site of the lesion. The tracheal wall was then split sufficiently to admit a swab readily. A 2.5 mm dry cotton swab on a short wooden applicator was rested gently against the epithelium on the opposite tracheal wall and rotated through 360° three times, twice clockwise and once counterclockwise. The applicator was rolled gently between the thumb and first two fingers of the right hand at,

* In the form of Somnopentyl. Each cubic centimeter contains: pentobarbital sodium U.S.P. (Recrystallized) 1 gr.; hydroalcoholic diluent c. s.

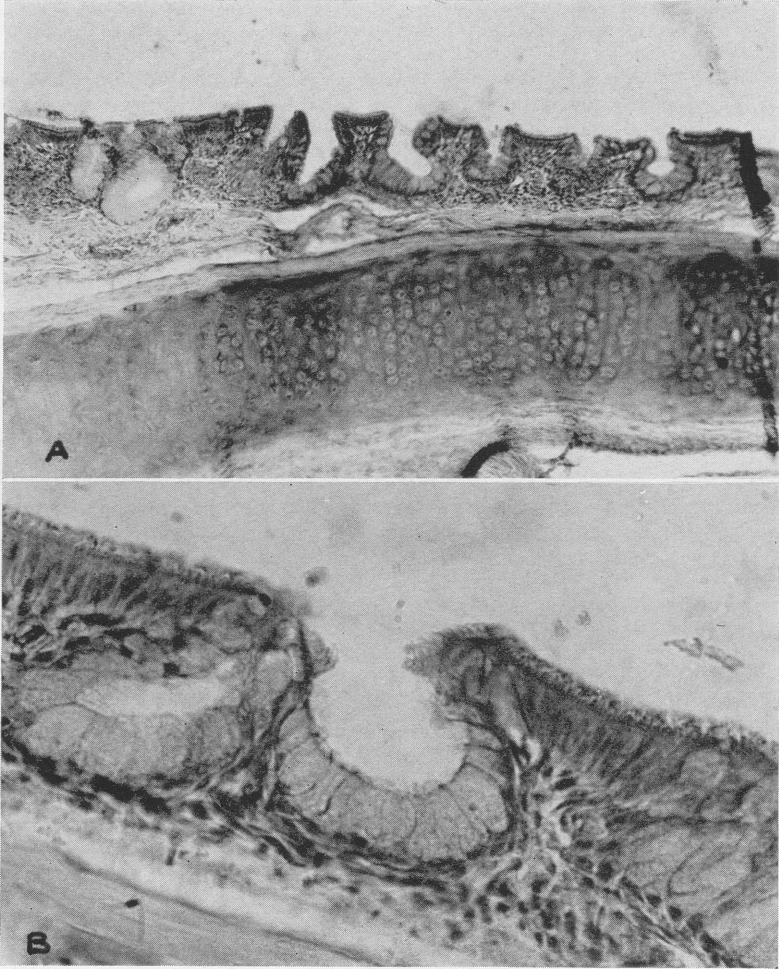


Fig. 2.—A. Normal epithelium from a chicken's trachea. The epithelium contains numerous microscopic folds lying more or less parallel. The interior of these folds is lined by mucus-producing cells and really constitutes glands. B. High power view across one such gland fold. A second one that was probably cut at one end appears on the left.

as nearly as possible, the same pressure in each instance. No pressure was made upon the end of the applicator.

The chickens were operated on in pairs. Numbers 1 and 2 were kept anesthetized for 12 hours and a new lesion made each three hours. The animals were sacrificed after making the fifth lesion and the tracheas were placed in formalin. Thus, in each trachea, there were five lesions respectively 12, 9, 6, 3 and 0 hours old. The other six pairs of birds were sacrificed respectively 6, 5, 4, 3, 2, and 1 days after making of the first lesion. A second lesion was made just before killing the birds.

Normal Chicken Epithelium. The tracheal epithelium in hens is somewhat different in appearance than that in mammals. When viewed from the surface, through a dissecting microscope, it can be seen that the epithelium lies in fine, close folds that extend more or less parallel with one another. If the cilia are living and active and viewed in whole mount preparations, they will be seen end on from above on the ridges between the folds and in profile at the margins of the folds. Histologic sections reveal that the cells in the folds are all mucus-producing and largely devoid of cilia. In other words, the bottoms of the folds are glands—long, single tube glands with the tube open to the surface for its full length (Fig. 2).

RESULTS

In the first pair, the fresh lesion (0 hours) showed severe scrambling of the epithelial cells at all depths. Even the basement membrane seemed to be gone in some areas. The three-hour lesions were not materially different, excepting that some exudate was found on the injured surfaces. The six, nine and twelve hour specimens showed swelling, edema in the lamina propria, and some varying amounts of exudate on the surface. There were no sure signs of regeneration (Fig. 3 A and B).

The one-day lesions did not show definite signs of regeneration from the basement membrane although, in one, the surface looked more smooth than in the fresher lesions and there may have been a new, single layer of epithelial cells migrating from the margin. At two days, a thin, flat epithelium devoid of cilia was present. At three days, the new, flat epithelium was very apparent—still devoid of cilia and the normal folding of the epithelium. By the fourth day, the epithelium was deeper, the cells still appeared flat, especially at the

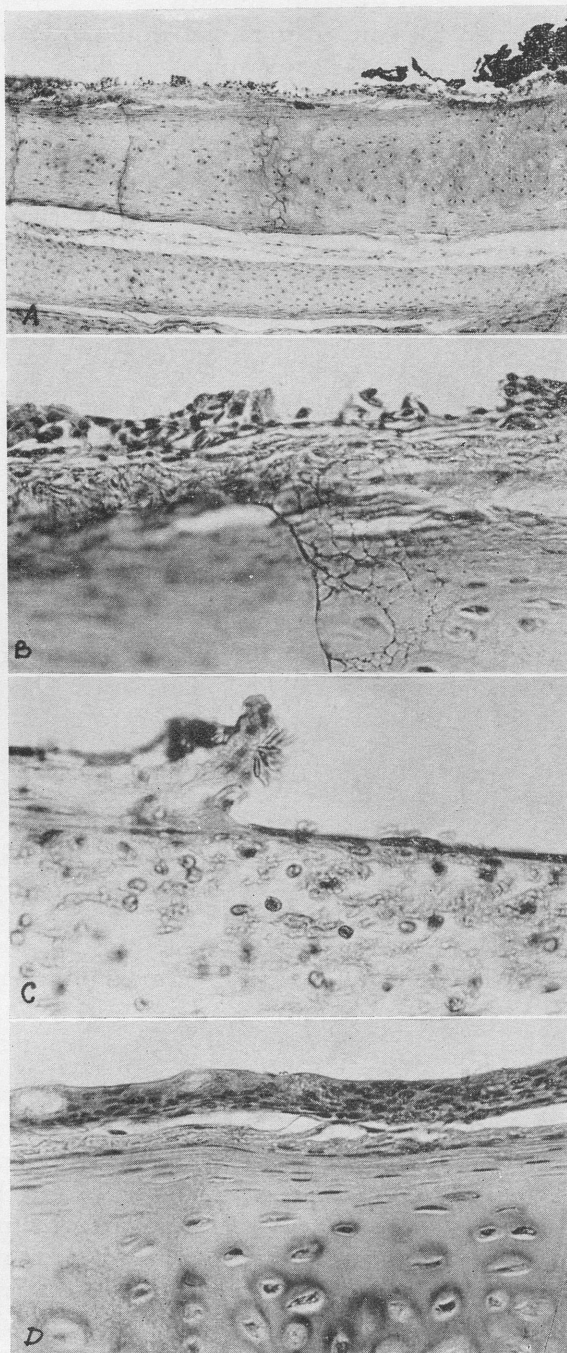


Fig. 3

surface. It appeared squamous-like and without cilia. On the fifth day, the epithelium was four or five layers deep, there was a suggestion of the normal folding, and there were thin patches of short cilia. On the sixth day, the epithelium in one specimen appeared almost normal. In the other, it was thin and flat, ciliated poorly but definitely showed a beginning of normal folds (Fig. 3 C and D).

Mucous flow was tested before putting the specimens in formalin (in all but the first pair). In all, with two exceptions, there was a distinct retardation of flow at the lesions, most marked in the fresh lesions and least marked in the six-day specimens. This retardation was characterized by a cessation of flow or marked slowing such that a crescent formed in the advancing margin of the indicator (in this case, India ink). By traction upon the mucous blanket by surrounding cilia, this crescent was eventually dragged over the site of the lesion and the whole blanket moved on, in some instances leaving a stain at the site of the lesion. The exceptions occurred in both four-day lesions. In neither was there a pause in the flow of the mucous stream. In No. 7 there was a scarcely perceptible pause even at the freshly made lesion. The reason for this is not clear.

COMMENT

The results in this study on regeneration of tracheal epithelium, as illustrated, look rather convincing. As a matter of fact, they are not. The results were not uniform. The experimental lesions were not uniform, doubtless because it was impossible to make exactly the same pressure each time. The lesions showed damage varying from a scrambling of the surface progressively through removal of all cells **excepting** the basal layer, down to and through the basement membrane into the tunica propia. The intention was to remove most of the epithelium leaving only the basal layer. Then regeneration would take place from this basal layer. Undoubtedly this took place in some lesions or in some parts of some lesions. But, when all layers of epithe-

Fig. 3.—A. Fresh lesion in chicken trachea made by a cotton swab held lightly against the epithelium and rotated three revolutions. Ink (right) carried by the ciliary stream piled up on the damaged area. B. High power view of margin of lesion. C. Appearance of one lesion after one day. It appears as though regenerating epithelium were migrating from the margin of the lesion and not coming from the basal layer on the side. Compare with Figure 4A. D. Regenerating epithelium at site of lesion after three days. Of course, one cannot be sure of the extent of the original damage. Compare with Figure 4A.

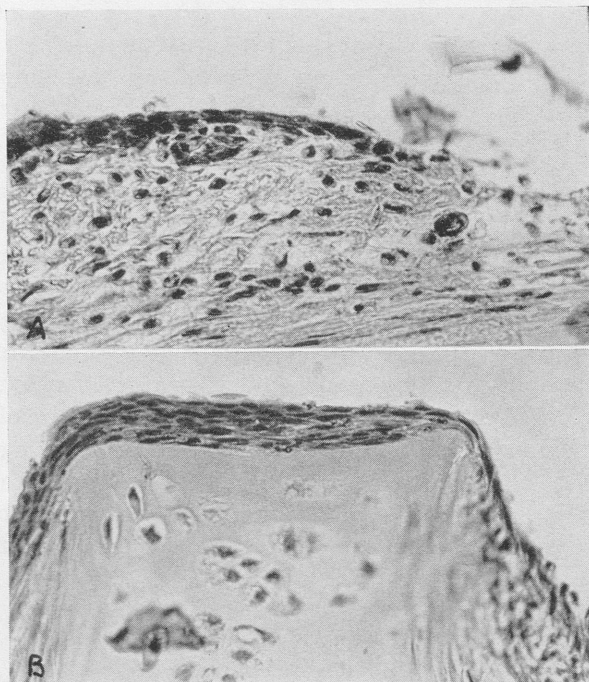


Fig. 4.—Regeneration from the margin of the incision used for entering the trachea. Here all layers were destroyed and regeneration must take place from the margin. *A.* After one day. *B.* After three days when the migrating and regenerating epithelium has covered the cut end of an overriding cartilage.

lium, including part of the tunica propria, were removed (and this also happened), then regeneration would have to take place through migration and growth from the margins. This would be a slower process.

REGENERATION FROM THE MARGINS OF DEEP LESIONS

This could be observed by studying the margins of the incisions through which access was had to the interior of the trachea. Where the scissors or knife divided and crushed the epithelium, it was destroyed through all layers, and regeneration had to take place by extension from the epithelium at the margins of the lesions. Even in these incisions, the damage to the epithelium varied considerably. No definite sign of regeneration could be determined in the three, six

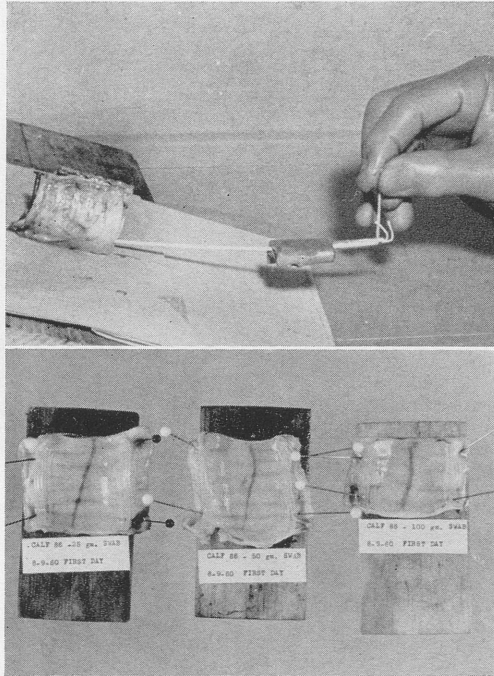


Fig. 5.—A. Manner of passing a weighted swab over tracheal epithelium from freshly killed calf or cow (reprinted through the courtesy of the Transactions of the American Academy of Otolaryngology). B. Tracks, left by 25, 50, and 100 gram swabs, stained with methylene blue in fresh specimen.

and nine-hour incisions. In some of the 12-hour incisions, there was questionable evidence of regeneration. After 24 hours it was definite, and in two days fairly well advanced, and, by the third day, new epithelium covered the cut ends of the cartilage and extended for some distance on the outside of the trachea where the incision gaped (Fig. 4 A and B).

Again, this is not the type of damage or regeneration that we set out to study. Rather, regeneration from the basal layer after the other epithelial layers had been removed.

WEIGHTED SWAB EXPERIMENTS - COWS

Experiments using weighted swabs were done in the tracheas from 10 calves and 21 cows.

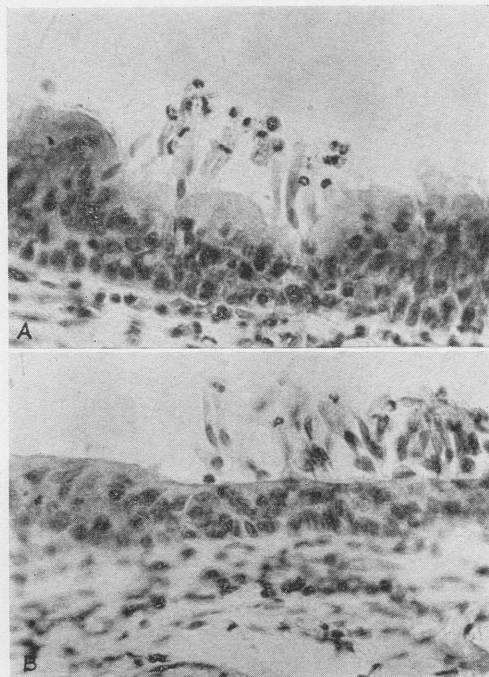


Fig. 6.—A. Relatively small injury from a 5 gram swab. Some of the ciliated columnar cells have been torn out partially or completely. B. A somewhat more severe injury from a 5 gram swab. A secondary surface at the plane of cleavage is readily seen.

Technique. Cotton swabs were prepared by rolling a small amount of cotton on one end of a six-inch wooden applicator, forming a firm swab 3 mm in diameter. A loop of thread was attached to the other end by means of Scotch tape. Then a leaden weight was fixed on the shaft of the applicator and its position adjusted until it delivered, on a balance, a desired amount of pressure when the applicator was held by the thread in a horizontal position. A series of swabs was made to deliver 5, 10, 25, 50 and 100 grams of pressure. Each swab was passed once through a section of trachea inclined at 10° to 15° with the horizontal (Fig. 5 A). Usually all five weights were used in each trachea—one in each of five sections measuring from 5 to 8 mm in length—some 150 of these simple experiments.

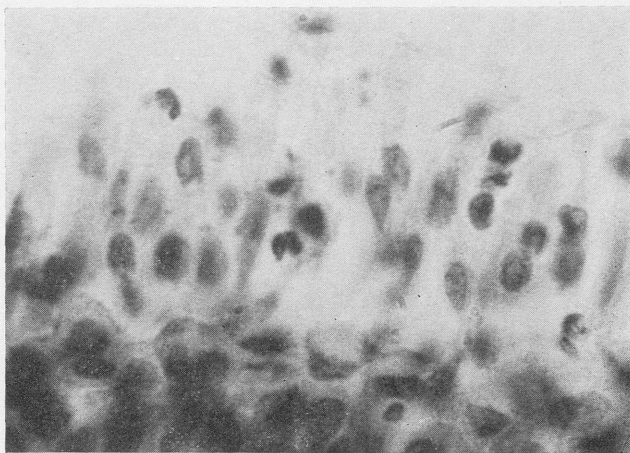


Fig. 7.—Injury from a 25 gram swab. High power view showing changes in the nuclei of damaged cells. They vary in size, are generally smaller and many are pyknotic. Those in the lower portion are normal in size.

After the swab had been passed once in an axial direction, the resulting track was stained with methylene blue and viewed grossly and then dropped into formalin (Fig. 5 B). Some were viewed through a dissecting microscope as whole-mount preparations.

RESULTS

In these whole-mount preparations it could be readily seen that the damage was not uniform. The epithelium tended to roll somewhat. As a consequence, there were areas that were deeply gouged and others that were passed over with little damage. Moreover, the cartilaginous rings made the base uneven, thus enhancing the unevenness of the injury.

In making histologic sections, there was no possibility of missing the swab track. (The round $2\frac{1}{2}$ mm lesions in the chickens could be missed easily.) But, despite that, the damage seen in cross section varied markedly.

All of the swabs from 5 grams to 100 grams made lesions of greater or lesser severity in the epithelium, unless the surface was protected by an unusually heavy blanket of mucus. The force was

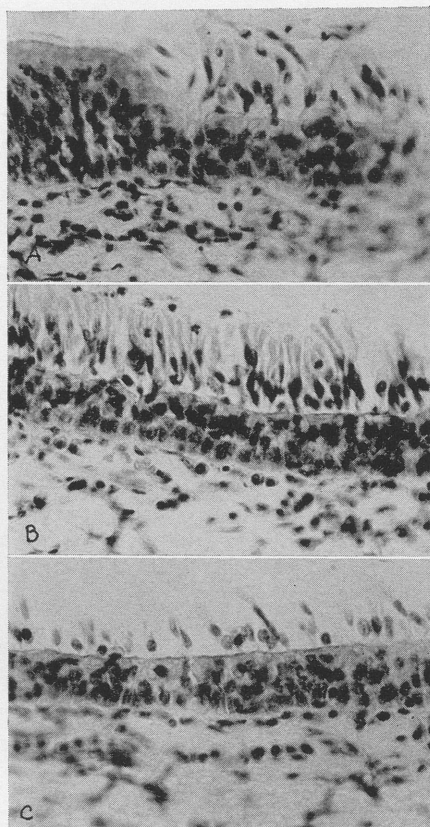


Fig. 8.—Three sections from one track made by a single passage of a 25 gram swab. *A.* At one margin, *B.* in the middle of the track, *C.* near the other margin. If the loose cells had been entirely removed—and this happens frequently—the remaining layers might be mistaken for metaplasia.

a shearing one and the degree of damage depended upon the effective friction brought to bear and the pressure upon the swab. If sufficient mucus were present to act as a lubricant, and prevent the swab from making direct contact, and cause it to slide or skid, damage was greatly minimized. The physical nature of a cotton swab is such that it tends to remove the mucous blanket. A heavier than normal mucous blanket seemed necessary for protection.

The damage appeared in progressive degrees. Minimal damage showed only loss of cilia. The steps of increasing injury were about

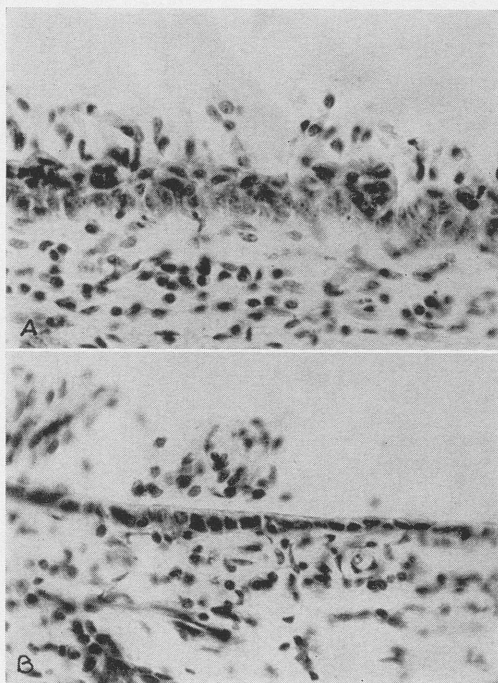


Fig. 9.—A. Track from a 50 gram swab. All layers of the epithelium appear damaged. B. An area in which only the basal layer remains, over which a smooth surface has reformed. The nuclei appear injured and reduced in size.

as follows: loss of cilia, loss of the cytoplasmic zone (that portion of columnar cells between the nuclei and the surface), scrambling of the deeper cells, loss of these leaving only a single layer on the basement membrane, loss of this layer also, rupture through the basement membrane, and finally damage to the tunica propria and the submucosa.

The most striking finding was the cleavage of the epithelium that occurred in many of the specimens, resulting in the formation of two layers. A surface reformed on the deeper layer. When the layer of columnar cells remained attached, although loosened, it appeared as though a layer of ciliated columnar cells were growing over a metaplastic epithelium. When the columnar layer had been removed entirely, the remaining layer looked very much like meta-

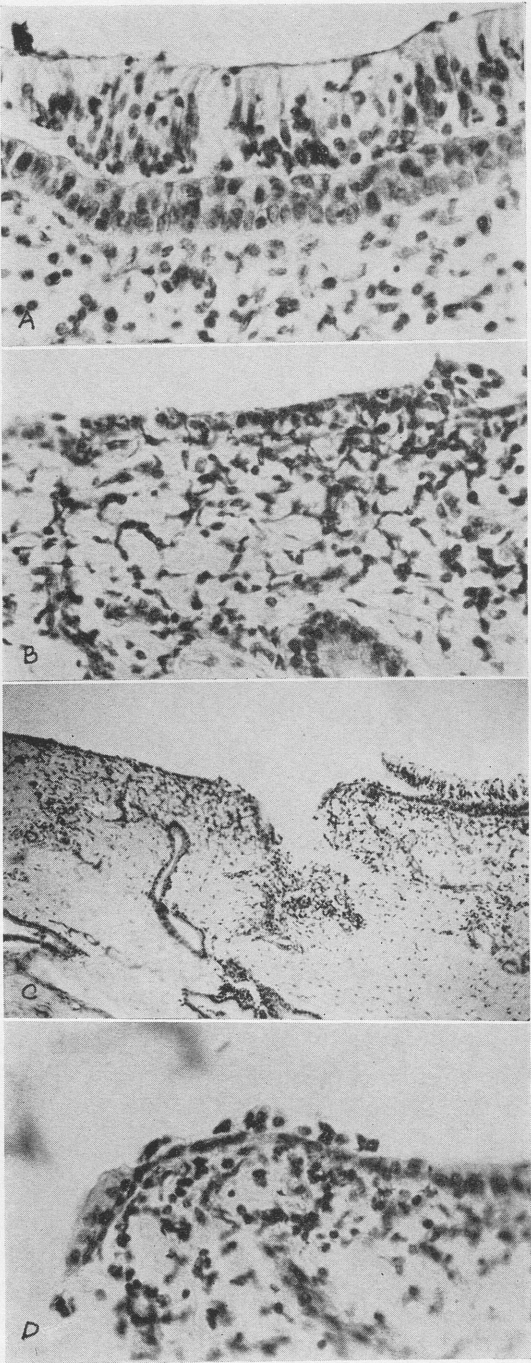


Fig. 10

plastic epithelium. It was necessary to study the individual cells at the surface for signs of maturity, to determine that it was not metaplastic (Figs. 6, 7 and 8).

The depth of cleavage seemed to depend upon the weight of the swab. From light weight swabs, cleavage took place between the columnar cells and the most superficial replacement cells. With heavier swabs, the plane of cleavage was deeper—in some, even at the level of the deepest basal cells. In some the basement membrane was actually ruptured (Figs. 9 and 10).

One cannot help wondering, when viewing these sections, how great the distortion and elongation of the loosened cells (the unloosened ones also) was at the moment the greatest force was applied. I am sure that the cells can be very greatly distorted and yet resume their normal shape and appearance when the force is removed. One also cannot help wondering how many of these normal-appearing cells have received mortal injury and will be sloughed out and replaced—probably many. The loosened columnar cells, even though normal in shape, show marked changes in the nuclei. The nuclei are smaller, less round, and stain much more deeply than in normal cells. I would suppose that all of these are lost (Fig. 7).

COMMENT

The lesions produced by one single passage of very light swabs across the surface of ciliated epithelium demonstrate how very easily this structure is damaged and torn apart. The trauma produced incident to any surgical procedure on the tracheobronchial tree is undoubtedly greater than that found in these experiments. Even so, that does not necessarily mean that the trauma is clinically serious since the reparative powers are so great. It does mean that all possible gentleness is indicated when dealing with this epithelium.

Fig. 10.—Injury from 100 gram swab. A, B, and C were all taken from the same track and show the variability of damage. In A, there has been a sharp cleavage with reformation of a surface on the deeper layer despite the fact that all of the columnar cells still remain and many are attached. In B, only some of the deepest layers remain and these are badly damaged, as apparently is the tunica propria also. C illustrates a break through the basement membrane and deep into the tunica propria. D. High power view of margin of break in C.

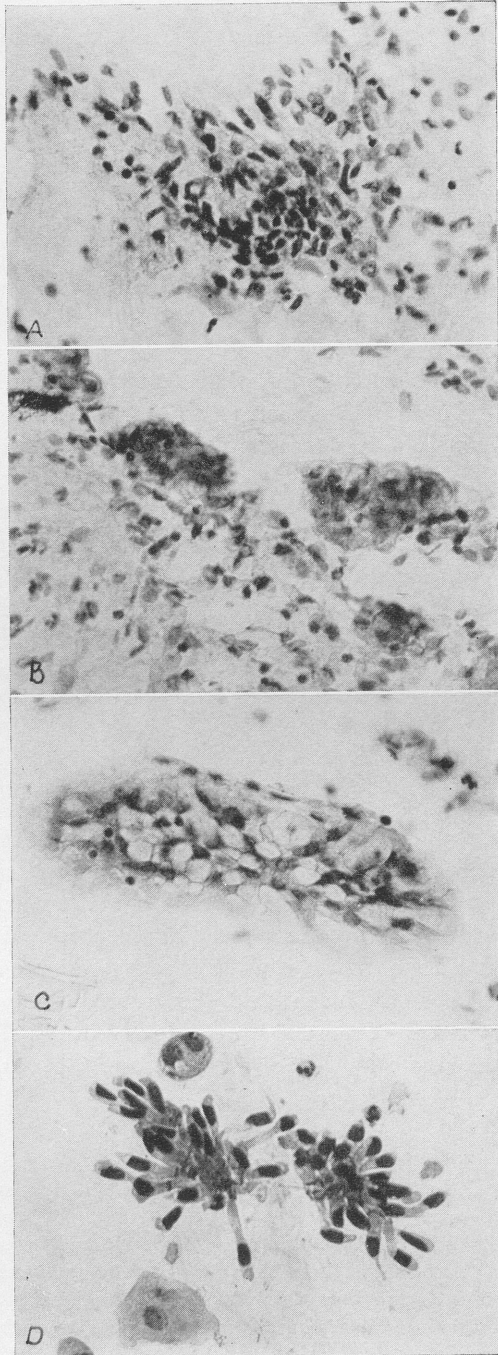


Fig. 11

CELLS IN INTRATRACHEAL SECRETIONS

Smears Taken Through Intratracheal Anesthesia Tubes. In the recovery room, secretion was aspirated from the tracheas of 31 patients through a small catheter from the intratracheal anesthesia tubes. Smears were made and fixed immediately, then stained by means of Papanicolaou stain. In some, also a mass of mucoid secretion was fixed in formalin and sectioned like tissue for histologic examination.

RESULTS

Of the 31 specimens, only one showed no epithelial cells. This sample was purulent. Twenty-one of the specimens contained large numbers of single, ciliated epithelial cells. Twelve also contained large numbers, in groups or masses, of cells, both ciliated and replacement (pieces of tissue). These had apparently been torn out forcibly. The rest, with the one exception, contained moderate numbers or a few, occurring singly or in groups (Figs. 11 and 12).

Squamous epithelial cells were found in large numbers in 11 and in small or moderate numbers in another 11. The source of these was undoubtedly the larynx, pharynx or mouth. Some specimens were undoubtedly contaminated with saliva because of the manner in which they were collected. Presumably, most of these squamous cells also were dislodged by instrumentation.

Macrophages were found in fewer or greater numbers in 24. Some contained very large numbers and in some they were heavily pigmented. These findings are to be expected in respiratory secretion (Fig. 12 D).

White blood cells, largely neutrophils, were found in 19. In most there were relatively small numbers, but, in a few, large numbers, such as the one that was frankly purulent. Some neutrophils and lymphocytes are also to be expected in view of the fact that these are found in considerable numbers in the tunica propria and in fewer numbers in the epithelium itself, both in man and animals, in otherwise normal tracheobronchial trees.

Fig. 11.—Epithelial masses found in tracheal secretion aspirated through endotracheal anesthesia tube. A, B, and C were fixed in formalin and sectioned. D occurred in a smear.

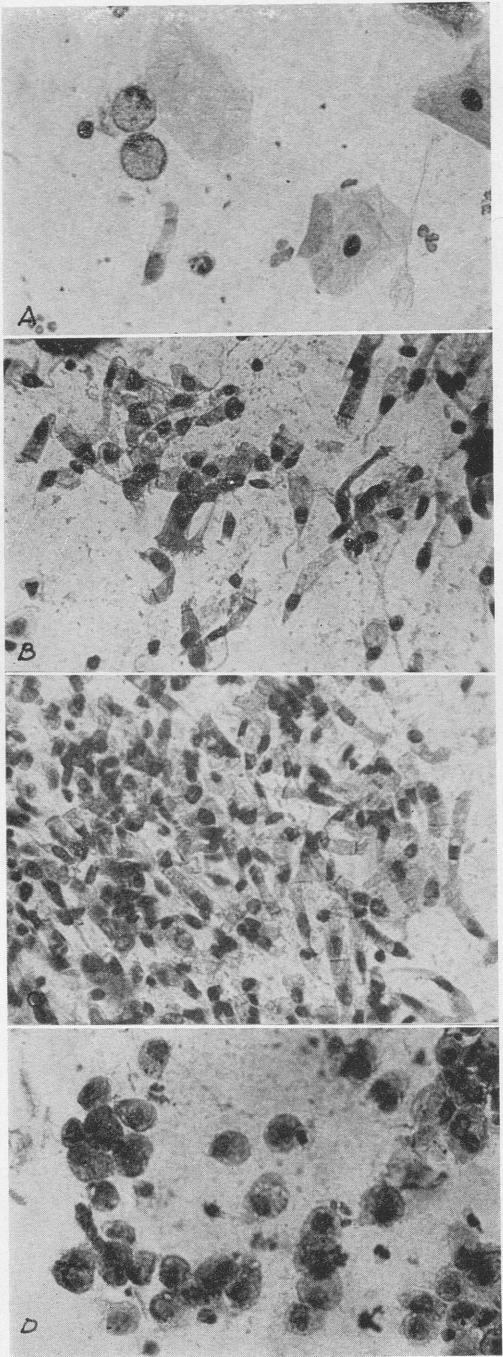


Fig. 12

COMMENT

It is well known that squamous epithelium exfoliates cells continuously at the surface. Just what happens to worn out, ciliated cells is not so clear. Do they produce a final droplet of mucus and then disintegrate in situ? Do they undergo lytic action in situ by enzymes? Are they exfoliated more or less intact into the mucous blanket? If so, one would expect to see them normally in great numbers and this is not the case. In the secretions of the common cold, tremendous numbers are found still alive and active but rounded up into more or less spherical shapes. They are not found in the secretions of allergy.

The ciliated cells found in these smears were not rounded. They maintained their normal shape, as in situ. A great many, both ciliated and replacement cells, were still together in situ in bits of tissue that had been forcibly torn out of the epithelium. Undoubtedly most of the single ones had also been forcibly removed.

PRESSURE EXPERIMENTS

Four experiments were done in each of two cows—the first four on the nasal mucosa and the others on the tracheal mucosa. Three circular leaden weights were placed carefully upon the surface of each of the eight specimens. Then the latter were flooded with formalin while the weights remained in place and fixed for some days. The three leaden weights in each set weighed about 150, 275 and 450 mgm respectively, having been cut by a circular punch from three leaden sheets of different thickness. They varied somewhat in weight. When submerged, the pressures they exerted were respectively about 1.0, 1.75 and 3.40 grams per cm.²

No definite change was found in these few experiments, where pressures up to 3.4 grams per cm² were exerted. The epithelium remained about normal in appearance. Further experiments using greater pressures are planned.

Fig. 12.—Cells found in smears of aspirated tracheal secretions. A. Samples of ciliated columnar and squamous cells, macrophages and neutrophils. B. Ciliated columnar cells showing in situ form indicating that they were forcibly detached. There are some naked nuclei. C. Free, individual epithelial cells may occur in tremendous numbers. D. Group of macrophages from the same smear as C.

SUMMARY

From the data presented here, although admittedly incomplete, it is apparent that the respiratory epithelium is fragile and easily injured by gauze, cotton swabs, aspiration and instrumentation. Even under swabs delivering only five grams of pressure and passed but once, the epithelium may be quite severely disrupted. Relatively small shearing forces may remove the epithelium and damage the basement membrane badly. Doubtless this damage is usually well cared for by nature and is not clinically significant. That it *may be* clinically significant is apparent from the many reports of complications in the literature, especially following intratracheal anesthesia. Some reported complications have been so severe that death resulted.

What is to be done? How can damage to the mucosa be avoided? It probably cannot be avoided entirely but much can be done to mitigate it.

Everyone having to do with the respiratory tract should be impressed by these facts and learn to have great respect for the epithelium. Gentleness and skill and meticulous care of the tubes and instruments will prevent many of the complications. All persons introducing intratracheal tubes should have instruction and learn to do this with skill. All unnecessary invasion of the tract should be avoided—especially aspiration. If the epithelium is undamaged, it will take care of most secretions without difficulty. The techniques for aspiration developed by Plum and his colleagues could well be adopted.

ST. LUKE'S HOSPITAL

ACKNOWLEDGMENTS—I am indebted to the Elliott Packing Company of Duluth, Minnesota, for furnishing the slaughtered beef animals used in this study. I am grateful to Dr. Howard Hanson, University of Minnesota, Duluth, for his counsel on matters involving physics.

REFERENCES

1. Hamelberg, W., Welch, C. M., Siddall, J., and Jacoby, J.: Complications of Endotracheal Intubation. J.A.M.A. 168:1959-1962 (Dec. 13) 1958.
2. Donnelly, W. A., Grossman, A. A., and Gram, F. M.: Local Sequelae of Endotracheal Anesthesia as Observed by Examination of 100 Patients. Anesthesiology 9:490-497 (Sept.) 1948.
3. Parker, G. F.: Complications of Endotracheal Anesthesia. Ohio Med. J. 54:1585-1589 (Dec.) 1958.

4. Fields, J. Allen: Injuries and Sequelae Associated with Endotracheal Anesthesia. *Trans. Amer. Laryng., Rhinol., Otol. Soc.* 63:544-556 (Jan.) 1959.
5. Flagg, P. J.: Incidence and Control of Trauma Accompanying Endotracheal Anesthesia. *A. M. A. Arch. Otolaryng.* 53:439-445 (Apr.) 1951.
6. Howland, W. S., and Lewis, J. S.: Postintubation Granulomas of the Larynx. *Cancer* 9:1244-1247 (Nov.-Dec.) 1956.
7. Quevedo, Julio: Laryngeal Granuloma After Tracheal Intubation. *ANNALS OF OTOTOLOGY, RHINOLOGY AND LARYNGOLOGY* 69:256-262 (Mar.) 1960.
8. Schwartzbart, Adolph: The Management of Intubation Granuloma. *A.M.A. Arch. Otolaryng.* 70:788-792 (Dec.) 1959.
9. Meyerson, Mervin C.: Granulomatous Polyp of the Larynx Following Intratracheal Anesthesia. *A.M.A. Arch. Otolaryng.* 62:182-186 (Aug.) 1955.
10. Jackson, C.: Contact Ulcer Granuloma and Other Laryngeal Complications of Endotracheal Anesthesia. *Anesthesiology* 14:425, 1953.
11. Stein, A. A., Quebral, R., Boba, A., and Landmesser, C.: A Postmortem Evaluation of Laryngotracheal Alterations Associated with Intubation. *Ann. Surg.* 151:130-138 (Jan.) 1960.
12. Lu, A. T., Tamura, Y., and Koobs, D. H.: The Pathology of Laryngotracheal Complications: Lesions of the Larynx and Trachea After Intubation Anesthesia. *A.M.A. Arch. Otolaryng.* 74:323-332 (Sept.) 1961.
13. Muir, A. P., and Straton, J.: Membranous Laryngotracheitis Following Endotracheal Intubation. *Anaesthesia* 9:105-113 (Apr.) 1954.
14. Kowalski, K.: Endotracheal Anesthesia and Trauma Incident to Endotracheal Intubation. *Oral Surg.* 13:543-551 (May) 1960.
15. Jacobson, F. C., Anesthesiologist, St. Luke's Hospital, Duluth, Minnesota: Personal communication.
16. Ludder, M.: Studies of Pressure Stress on the Trachea During the Use of Tube Cuffs. I. Elastic Properties of Tube Cuffs. *Anesthetist* 10:279-81 (Sept.) 1961. (Ger.)
17. Plum, F., and Dunning, M. F.: Technics for Minimizing Trauma to the Tracheobronchial Tree After Tracheotomy. *New Eng. J. Med.* 254:193-200, 1956.
18. Ingelstedt, Sven: Studies on the Conditioning of Air in the Respiratory Tract. *Acta Oto-Laryngologica*, Suppl. 131:1-80, 1956.
19. Ingelstedt, Sven, and Toremalm, N. G.: Aerodynamics Within the Larynx and Trachea: Indications for Vapour Therapy in Acute Laryngo-tracheitis. *Acta Oto-Laryng.*, Suppl. 158:81-92, 1960.
20. Toremalm, N. G.: The Daily Amount of Tracheobronchial Secretions in Man: A Method for Continuous Aspiration in Laryngectomized and Tracheotomized Patients. *Acta Oto-Laryng.*, Suppl. 158:43-53, 1960.
21. Toremalm, N. G.: Air-flow Patterns and Ciliary Activity in the Trachea After Tracheotomy: A Method of Determination in Vitro of the Rate of Ciliary Beat in a Tracheal Model. *Acta Oto-Laryng.* 53:442-454 (May-June) 1961.

22. Andrén, G., Ingelstedt, S., and Toremalm, N. G.: Tracheal Cannulas. *Acta Oto-Laryng.*, Suppl. 158:36-38, 1960.
23. Kistner, Capt. R. F., and McMahon, J. W.: A New Tracheostomy Tube. *Trans. Am. Acad. Otolaryng.* 65:775-777 (Sept.-Oct.) 1961.
24. Adams, W. E., Livingstone, H. M.: Bronchial Injury and Repair: An Experimental Study. *Ann. Surg.* 91:342-360 (Mar.) 1930.
25. Sanderud, K.: Squamous Metaplasia of the Respiratory Tract. 5. A Contribution of the Pathogenesis of Metaplasia. Two Experimental Studies. *Acta path. et microbiol. scandinav.* 44:4:345-362, 1958.
26. Otto, Herbert von: Evaluation of Metaplastic Bronchial Epithelial Regeneration. *Beitr. Path. Anat.* 117:397-424, 1957.
27. Otto, Herbert von, and Wagner, H.: Contribution to the Question of Regeneration of Bronchial Epithelium. *Beitr. path. Anat.* 116:436-460, 1956.
28. Garschin, W. G.: On the Differentiation of Regeneration and the Proliferation of Inflammation in the Epithelium of the Air Passages. *Frankfurter Z. Path.* 49:121-137, 1935.
29. Wilhelm, D. L.: Regeneration of the Tracheal Epithelium in the Vitamin A Deficient Rat. *J. Path. & Bact.* 67:361-365, 1954.
30. Ross, C. A., and Kraus, G. E.: Effect of Tobacco Tars on Regenerating Tracheal Mucosa. *Arch. Surg.* 82:314-317 (Feb.) 1961.
31. Wilhelm, D. L.: Regeneration of Tracheal Epithelium. *J. of Path. & Bact.* 65:543-550, 1953.
32. Burian, K.: On the Regeneration of the Ciliated Epithelium in the Nose After Total Destruction of the Epithelium. *Z. Laryng. Rhinol. Oto.* 39:387-95 (June) 1960.
33. Hilding, A. C.: Experimental Studies on Some Little-Understood Aspects of the Physiology of the Respiratory Tract and Their Clinical Importance. *Trans. Am. Acad. Otolaryng.* 65:475-95 (July-Aug.) 1961.

DISCUSSION

DR. PRESSMAN: I apologize for my triple appearance here as a discussant today. I am sure you realize that in the instance of Dr. Slaughter Fitz-Hugh's excellent paper this morning with its truly remarkable clinical results, I was merely pinch-hitting for a discussant who could not be here; and in the instance of Dr. Ogura's paper, this was moved ahead from tomorrow.

Dr. Hilding's paper, of course, is an outstanding contribution to our knowledge of the surgical pathology of the respiratory tract. One pays it high compliment indeed by saying that it is of a stature equal to Dr. Hilding's other numerous contributions to the advance of science and to the literature of our specialty.

My discussion will be limited to one small phase of the problem having to do with the production of vocal cord contact ulcers and granulomata which follow intubation for purposes of anesthesia. This technique has become so commonplace that at our institution and in many institutions it is virtually the routine method of anesthesia. The detailed anatomy of the larynx is such that there is a predisposition to trauma in the posterior third of the larynx. This is due to the fact that

the rigid vocal process of the arytenoid cartilage and the body of the arytenoid cartilage, which constitute essentially the posterior third of the vocal cords, are submucosal and therefore do not have the "give" which is characteristic of the remainder of the vocal cords which are essentially muscle. In other words, the cartilagenous inner face of the arytenoid cartilage and the corresponding vocal process represent a solid base against which any rubbing action will traumatize the mucosa whereas in the anterior two-thirds of the vocal cords the softer base of the muscle bed is less apt to do so. In addition, of course, a round tube being placed in a triangular chink does not fill the anterior portion of the lumen whereas the greatest diameter of the tube will be within the larynx at the site of the vocal processes in the posterior third.

During the process of anesthesia the laryngeal sphincter reflex is the last of all reflexes to disappear, or certainly one of the last. This reflex is accompanied by an opening and closing of the laryngeal orifice with great force so that any effort to introduce the tube during the closed phase obviously represents a source of trauma far greater than is necessary to produce injury, as indicated by Dr. Hilding's studies. The wonder of it, then, is that erosions of mucosa do not take place with far greater frequency than is the case, and that the incidence of contact ulcers and granulomata is not higher than the records indicate. These lesions heal very slowly if at all. In so far as healing is concerned one can look at the nasal septum as providing a comparable situation. If the erosion itself is deep enough to reach and involve the perichondrium or if this involvement results in secondary infection and the perichondrium is destroyed, the situation is not unlike the more familiar but comparable syndrome within the nasal septum in which chronic ulcers are commonplace.

We know that in the septum under these conditions the healing of the overlying mucosa does not take place and the same is true of the inner aspects of the arytenoid cartilage.

To summarize this discussion, then, clinically the predisposing elements which lead to the development of intralaryngeal trauma during the processes of anesthesia are:

One, attempts to introduce the tube without the larynx having become completely relaxed—and this is a natural error based upon the keen desire of the anesthesiologist to overcome respiratory stridor and laryngeal occlusion during the early phases of the anesthesia, so that there is a strong and almost overwhelming temptation to force the tube into the larynx before the sphincteric reflex has disappeared and while it is in a spastic state. This, of course, predisposes to injury.

Secondly, during the period of anesthesia, when the level of narcosis varies a great deal and the patient is carried intermittently light and heavy, spasm of the larynx occurs and since it is the first reflex to return upon regaining consciousness, this is apt to occur during the latter phase of the anesthesia. This is nature's protective mechanism, but at the same time the constant repeated rubbing of the moving vocal cords against the tube destroys the mucosal surface.

From the practical standpoint, a third predisposing cause is the natural desire of the anesthesiologist to aspirate the tracheal bronchial tree upon completion of the operation. He therefore allows the tube to remain in situ during the process of recovery and it is common practice to let the patient get lighter and to come out of the anesthetic with the larynx opening and closing forcefully or even in a state of spasm. This aspiration is considered good technique and is considered desirable, but is it actually harmless? The alternate opening and closing of the cords with pressure erodes the mucosa over the perichondrium and leads to these important

traumatic complications of granulomatous ulcers. I suggest therefore that all patients be carried under deep anesthesia at least until aspiration has been completed.

Would it not, Mr. Chairman, be an excellent gesture in public relations and a fine step forward in preventive medicine if this Society were to finance the cost of sending reprints of Dr. Hilding's article to every member of the American Society of Anesthesiologists? I would recommend this.

Dr. Hilding has given us a new respect for the mucosa of the respiratory tract. He has demonstrated what we have long suspected, that it is a forgiving structure indeed and its recuperative powers in large measure make up for our clumsy attacks upon it.

Dr. Hilding's studies have indicated without any question of a doubt that the mucosa of the respiratory tract is far more and far more often sinned against than sinning.

DR. PUTNEY: I must again express my admiration for Dr. Hilding's work. This is not new, for all of us are aware of his fine contributions to the literature, meticulous experimentation and significant advances in basic research, and it has been a pleasure to hear this well-documented and stimulating presentation. There is nothing that I can add to the basic tenets of this paper for the fragility of the respiratory mucosa and its reaction to trauma have been amply demonstrated.

In the clinical field all of us doing endoscopy have been impressed by the fact that bronchoscopy using a rigid metal tube has produced fewer laryngeal complications than the endotracheal tubes which are more flexible and presumably made of material better tolerated by the epithelium. The length of time of the trauma may be a factor for the bronchoscope is usually in position less than five minutes whereas an endotracheal tube is producing its traumatic effect generally over periods of an hour or more. I wonder if Dr. Hilding feels that the respiratory injury from a cuffed endotracheal tube is due to actual pressure upon the mucosa or rather the rubbing action of the mucosa against an obstruction during respiration. From the experimental data, I would assume that it probably was more likely due to friction than actual pressure. In England the percentage of minor complications following endotracheal anesthesia affecting the larynx has been reported as over 4%.

Anesthesiologists lubricate their tubes with various medications and these may cause additional trauma from chemical irritation. Also the gaseous mixtures used in anesthesia are generally not properly humidified and in themselves have a drying effect upon the mucosa. One wonders how much damage is actually done by an anesthesiologist forcibly pushing a bag and introducing a blast of dry gas into the tracheobronchial tree. Not only the chemicals but also the mechanical blast may be sufficient to substantially injure the tracheobronchial mucosa. Some of the post-operative complications following lung surgery may be due to the forcible extension of the healthy lung by anesthetic gases rather than a poor cough reflex to which it has been attributed.

I might ask whether there was any significant difference in the aspirates recovered through the endotracheal tube following anesthesia in men and women. The epithelium is thicker in men than women and presumably better able to tolerate injury. Practically all of the cases of significant trauma following intubation that I have observed have been in women, and I have yet to remove an intubational granuloma in a man.

It is fortunate that the respiratory epithelium has excellent powers of regeneration since this presentation has demonstrated that the least manipulation in the larynx and trachea produces loss of cell layers.

DR. HILDING (closing): I want to thank the discussors for their kind remarks.

Dr. Putney brought up a number of questions. I think that he is right that it is the friction and sheering that makes the damage rather than the pressure. I didn't mention some pressure experiments that I have started, putting lead weights on the epithelium just before submerging it in the formalin. So far the greatest pressure used is $3\frac{1}{2}$ grams per square centimeter. With that weight no change was found in the epithelium. Other experiments are under way and may be reported later.

Dr. Putney asked about the mechanical blast. If air passes through a tube, like the trachea, at a low velocity, it flows in layers. At higher velocities it becomes turbulent. According to Ingelstedt and Toremalm, the normal velocity in the trachea is sufficiently great to produce turbulence and, of course, with the air coming through an intratracheal tube, which is much smaller than the trachea, there must be turbulence at the end of the tube, where the velocity of flow suddenly decreases. This would make for impact. By the way, Ingelstedt, Toremalm and Andrén have worked together as a team at the University of Lund, Sweden, doing a whole series of studies on the physics of the air-flow in the tracheal tree and the use of humidification and new types of plastic tubes, and so on. Their publications are well worth reading.

As to Dr. Putney's question concerning the difference in degree of damage from intratracheal tubes in men and women, I have not observed any sex-related difference.

EPITHELIAL MALIGNANCIES OF THE PAROTID GLAND

BRIAN F. McCABE, M.D.

AND

ROGER BOLES, M.D.

(both by invitation)

ANN ARBOR, MICH.

This report is the third in a continuing study of neoplasms of the parotid gland being carried out at the University of Michigan.¹² These reports are an attempt to clarify by a clinicopathologic analysis the seemingly erratic behavior of parotid tumors and to re-assess the apparently wide variations in our efforts to eradicate them. As the total number of tumors treated increases, a pattern of behavior tends to emerge. Identification of this pattern in at least some groups improves our understanding of their response to treatment, and provides a basis for a better appreciation of the use of the tools at our disposal.

The present report concerns itself only with epithelial malignancies. Prior reports included both benign and malignant tumors. There is little to add to numerous excellent studies of the natural history and management of benign parotid tumors, but these aspects of malignant tumors are problems still, and deserve continuing scrutiny. The discouragingly low survival rates of parotid cancers in the last report bear witness to this.

Of 280 tumors previously reported, 48, or 17%, still merit the diagnosis of malignancy, 5 having been reclassified as benign. Since that report in 1952, 294 additional parotid tumors have been treated, and all patients are far enough past treatment to have five year survival rates assessed. Of this number, 38, or 13%, were malignant. The tumor types, clinical characteristics, cure rates, and methods of treatment of this group will be compared and contrasted to the malignant group in the last study. The histological characteristics of most of

From the Department of Otorhinolaryngology, University of Michigan.

these tumors were reviewed by members of the Department of Pathology, and where the clinical course was adjudged incompatible with the presumed tumor type, appropriate reclassification was carried out. Twelve unclassified carcinomas were not included in either case as not serving the purpose of the studies. No supporting tissue malignancies or malignant teratomas were included. The tumors were diagnosed and treated by members of the Departments of Otorhinolaryngology, General Surgery, and Pathology of the University of Michigan Medical Center and St. Joseph's Mercy Hospital, Ann Arbor, Michigan.

CLASSIFICATION

Any scientific classification of neoplasms must be based upon histopathologic considerations. This is extremely difficult in the case of the parotid gland. It is not an unique experience for a surgeon to submit a specimen to four different pathologists and receive four different diagnoses. This is only in part due to a continuously evolving nomenclature, it is also due to the fact that the usual yardsticks of diagnosis of malignancy sometimes do not apply to the parotid gland. For example, a mucoepidermoid tumor may show a high degree of cellularity, cellular atypism, and infiltration of adjacent glandular tissue, and act clinically benign. The distinction between benign and malignant, then, can be made with certainty only by determining what happened to the patient after treatment. In order to achieve a helpful clinical classification, certain missing parts must be brought into the picture. These are first, a large number of cases, and second, a long and complete follow-up. It is the attempt of this study to supply these.

1. *Squamous Cell Carcinoma* (including well and poorly differentiated, medullary, and lymphoepithelioma forms)
2. *Adenocarcinoma*
 - A. *Serous* (acinic) *Cell*
 - B. *Acidophilic* (Eosinophilic, Oxyphilic) *Cell*
 - C. *Adenocystic* (Pseudoadenomatous basal cell, cylindroma, adenomyoepithelioma, etc.) *Carcinoma*
3. *Mucoepidermoid Carcinoma*
4. *Unclassified carcinoma*

Squamous carcinomas are grouped as one without further breakdown because, as will be shown, the degree of differentiation seemed to make little difference in curability. Mucoepidermoid carcinoma is restored to the malignant category. Its lethal character was under ques-

tion in the 1952 study because those "Mucoepidermoid carcinomas" that resulted in mortality, or metastasized, better fit the description of squamous lesions with a mucinous reaction, and those that fit strict histopathologic criteria were uniformly cured. It is not in the nature of malignancies of any type to be uniformly cured. However, two such tumors have now been seen which fulfill all criteria.³ The term "adenocystic carcinoma" seems to have gained wide enough acceptance to warrant its adoption for those tumors called pseudoadenomatous basal cell carcinomas in prior studies.

INCIDENCE

Squamous carcinomas and adenocarcinomas were seen in equal numbers in the 38 cases added in this report, whereas adenocarcinomas were twice as common in the last report. Serous cell carcinomas have increased in incidence, and adenocystic carcinomas have declined.

	1952 Study	1962 Study	Totals
Squamous Cell	16	18	34
Serous Cell	5	9	14
Acidophilic Cell	9	1	10
Adenocystic Ca	18	8	26
Mucoepidermoid Ca	0	2	2
Totals	48	38	86

The marked decrease in number of acidophilic cell carcinomas seen is surprising. It might, however, be expected when one considers it is actually a rare tumor, and an increasing number of malignancies of all kinds are being treated in nonuniversity centers.

Differences in sexual incidence are ordinarily rather unilluminating, but the predilection of parotid malignancies for one sex or the other is striking enough to deserve mention.

Squamous Cell	56% Male	(19 of 34)
Serous Cell	86% Female	(12 of 14)
Acidophilic Cell	70% Male	(7 of 10)
Adenocystic Ca	85% Female	(22 of 26)

Adenocarcinomas with the exception of the rare acidophilic cell carcinoma seem to be significantly more common in females. The distribution is highest in young and early middle age females. The

generally higher degree of malignancy of cancers in the younger age groups may tend to explain the low salvage rate in these tumors.

CURE RATES

The overall cure rate of 86 classifiable parotid carcinomas was 21%. The period of follow-up varies from five to twenty-two years. The final figure represents determinate five year cure rates. Cure rates of different tumors varied significantly, and cure rates from prior studies to this one also varied.

	1952 Study	1962 Study
Squamous Cell	13% (2 of 16)	44% (8 of 18)
Serous Cell	0 (0 of 5)	33% (3 of 9)
Acidophilic Cell	11% (1 of 9)	0 (0 of 1)
Adenocystic Ca	6% (1 of 18)	38% (3 of 8)

The most significant difference appears to be in the squamous cell group where cures almost quadrupled. Reasons for this will be sought later. The most depressing groups continue to be the serous and acidophilic types, and of these, the acidophilic variety seems to be the more nearly uniformly fatal. A few cures of the serous cell variety were effected, but it must be pointed out that the overall number of both types continues to be small and further experience is necessary. Progress seems to have been made in the adenocystic carcinoma, but, as has been pointed out, a five year follow-up may not constitute a cure of this lesion. It is more proper to speak of ten or fifteen year cures, because late recurrence is the rule. The fact that three of the four cures have been free of disease longer than ten years is encouraging.

SQUAMOUS CELL CARCINOMA

Thirty-four patients in this group were treated. Diagnoses ranged from cornifying squamous cell carcinoma to very poorly differentiated medullary carcinoma. Lymphoepitheliomas and those designated as "possible" or "probable" lymphoepitheliomas were included. As in all malignant neoplasms of the parotid, pain (50%) and definite tenderness (82%) were prominent symptoms. Single or multiple facial nerve branch paralyses were present in 44%. Squamous cell carcinoma tended to be a tumor of late middle age and elderly men, and women of all age groups.

Since the cure rates varied widely between this study and the last, the treatment given will be examined in detail. Of the 16 treated during the last study, 3 were too far advanced for any hope of cure, and 13 received wide excision, 4 with a radical neck dissection, and 2 with resection of the facial nerve. The two cured received excision only, one with resection of the facial nerve. No patients receiving neck dissections were cured. Postoperative radiation therapy was administered in at least 5 for recurrences. Of the 18 treated during the present study, 8 received biopsy or partial excision, followed by radiation therapy curing 2, and 10 received wide excision followed by radiation therapy to 7, commencing five to seven days postoperative. Of those 10, six were cured. Only one of those 6 did not receive postoperative radiation therapy. Five radical neck dissections were done but probably played no part in survival because in the two patients receiving this additional surgery who were cured, no positive nodes were found. The one patient in whom the whole facial nerve was sacrificed was not cured. The degree of differentiation of the neoplasm seemed to be no indication of curability.

	Cures	Failures
Moderately or well differentiated	3	4
Poorly differentiated, medullary, or "probably" lymphoepithelioma	5	6

It is impossible to draw conclusions from a statistical dissection of an already small group, but analysis gives several impressions. Increasing cure rates have coincided with an increasing use of postoperative radiation therapy. Radiation therapy was used in this group of 18 in an almost routine manner. Viewing the experience with radical neck dissection, the operation does not seem to have helped these patients. Neck dissection may be indicated in the presence of palpable nodes, but there is no evidence here to indicate that prophylactic dissection would be of value. Two patients only underwent resection of a portion of the facial nerve and both patients survived their disease, indicating that when this nerve is partially involved in neoplasm, it is not necessary to sacrifice the whole nerve. Other possible reasons for the increasing cure rate are that at least some patients are being seen earlier, and as experience has increased, surgical techniques have become better delineated.

In summary, it would seem that squamous carcinomas of all types are best handled by extensive local excision, preserving the

branches of the facial nerve which are clearly uninvolved by neoplasm, followed by radiation therapy as soon as possible, in cancericidal doses.

SEROUS AND ACIDOPHILIC CELL ADENOCARCINOMA

On the basis of only one additional case of the acidophilic cell type, nothing over what has been stated in prior studies can be added. It tends to be a rare tumor of elderly men, locally invasive, and metastasizes via regional lymphatics.

The serous cell variety is quite different in behavior. It is primarily a tumor of women of all adult age groups, and acts more like a sarcoma than a carcinoma in that it is extensively locally invasive, metastasizes by the hematogenous rather than the lymphogenous route, and shows little evidence of radio-sensitivity. Five were seen during the last study and none cured. Of 9 treated during the present study, 3 were cured by parotidectomy with preservation of the facial nerve. Only one of these 3 received radiation therapy (for questionable residual tumor) but all 6 failures received radiation therapy. All three of the patients with five year cures were seen reasonably early, which is the probable reason for their cures. In only one had any degree of local invasion taken place. In five cases lymph nodes were isolated, and tumor was found in none.

ADENOCYSTIC CARCINOMA

This tumor again primarily involves young and early middle aged females. As Smout and French⁴ have pointed out, it is a highly lethal neoplasm but sometimes compatible with a relatively long life after diagnosis. Our experience bears this out. Two of the five failures in the present study had their recurrences after five years, and two others after ten years. The tumor invades local structures extensively, and tends to metastasize via perineural and regional lymphatics, and to lung. Recurrence in lung may appear many years after the disease is apparently controlled locally, hence chest x-rays are important in following these patients. The tumor may be less deadly in the parotid gland than elsewhere in the head and neck, for of 64 cases treated at this institution, no "cures" have been effected except where the parotid was involved. The 3 "cures" underwent parotidectomy, 2 receiving postoperative radiation therapy. They are alive without disease eight, ten, and twenty-two years past diagnosis. This tumor appears to be more radio-sensitive than the other gland cell carcinomas.

MUCOEPIDERMOID CARCINOMA

During the last study, no cases were seen which could be accepted as mucoepidermoid carcinoma, using metastatic activity as the criterion. Of five receiving that diagnosis on other bases such as cellular atypicality, none died of their disease. Since that time, two patients have received that diagnosis, and are dead or dying of metastases. The apparent difficulty of making a histologic distinction between benignity and malignancy will continue to result in some operations more extensive than necessary until histologic criteria become clearer.

SUMMARY

The third study in a continuing review of parotid tumors has been carried out. This study reviewed 86 parotid carcinomas, constituting 15% of 574 parotid tumors of all types. Five year follow-ups are available on all patients. The over-all cure rate was 21%, being highest for the squamous carcinomas, and lowest for the gland cell carcinomas of acidophilic type. Squamous carcinomas involved both sexes nearly equally, while gland cell carcinomas were more common in females. A rising cure rate was noticed for the squamous carcinomas (13% to 44%), it was felt because of the increased utilization of postoperative radiation therapy, earlier diagnosis, and improvement of surgical techniques. A slight improvement was seen in cure rates of the adenocarcinomas except for the acidophilic cell type, a rare tumor.

The treatment given, the response to treatment, and the clinical characteristics of each tumor type are discussed in detail.

OUT-PATIENT BLDG.

REFERENCES

1. Buxton, R. W., Maxwell, J. H., and Cooper, D. R.: Tumors of the Parotid Gland. *Laryngoscope* 59:565-594 (June) 1949.
2. Maxwell, J. H., Buxton, R. W., and French, A. J.: The Surgical Treatment of Parotid Gland Tumors. *Trans. Amer. Acad. Ophth. and Otolaryngol.* 57:711-722 (Sept.-Oct.) 1953.
3. Gray, J. M., Hendrix, R. C., and French, A. J.: Muco-epidermoid Tumors of Salivary Glands. *Cancer*, in press.
4. Smout, M. S., and French, A. J.: Prognosis of Pseudo-adenomatous Basal Cell Carcinoma. *Arch. Path.* 72:107-112 (July) 1961.

SCHWANNOMA OF THE CERVICAL PORTION OF THE VAGUS NERVE

CASE REPORT

L. Q. PANG, M.D.

HONOLULU, HAWAII

Otolaryngologists are often called upon by patients to make a definitive diagnosis of a mass in the neck. Just as often, they are asked in consultation by their medical and surgical colleagues to rule out the possibility of the mass being a metastatic lesion from a focus primary in the head and neck. Frequently, the diagnosis of these tumors are not made until the time of surgery. Such was my experience when I was consulted by a thirty-six year old Hawaiian-Chinese female with a mass in the right side of the neck. At surgery, the tumor proved to be a schwannoma of the vagus nerve in the neck.

Schwannomas or neurilemmomas of the cervical portion of the vagus nerve are so rare that Altany and Picknell¹ were able to collect only seven cases reported in the literature up to 1956. These included individual cases reported by Sekiguchi and Oie in 1926, Cutler and Grose in 1936, Murley in 1948, Paul in 1949, Parnes in 1955 and two by Ehrlich and Martin in 1943. They added three more of their own to this series. Penido,² et al, stated that between the years of 1935 and 1956, ten tumors of the vagus nerve were encountered at the Mayo Clinic. Of these, five were benign schwannomas and one a malignant schwannoma. Of the five schwannomas, only three involved the cervical portion of the vagus nerve. Conley³ in 1955 reported one case occurring in an eleven year old girl. This tumor arose from the superior portion of the vagus nerve in the neck and filled the space from the level of the hyoid bone to the base of the skull. Mitchell⁴ reported a case involving the vagus nerve just distal to its exit from the jugular foramen, with erosion upwards into the base of the medial petrous pyramid. It produced a right paralysis of the vocal cord, facial paralysis, paresis of the palate, a hearing loss,

nystagmus, past pointing and staggering. Due to the undue risk to life, the tumor was not removed. At the time of the report in 1958, the patient was still alive with only a slight weakness of the right vocal cord. My case to be reported makes the sixteenth.

The schwannoma is a benign tumor arising from the cells of Schwann of the neurilemma sheath covering the nerve. It is generally regarded as an ectodermal neoplasm. It was first described by Virocay in 1908 and was referred to by him as a "neurinoma." Since then, the synonyms applied to this tumor include the names perineural fibroblastoma, nurolemoma, peripheral glioma, or neurilemmoma.

A schwannoma may occur in any nerve which possesses a neurilemma sheath. Conley³ states that only 25 per cent of these tumors occur in the head and neck in spite of the presence of the numerous cranial nerves, the nerves of the cervical and brachial plexus and the sympathetic nerves in the neck. The remainder have occurred in the mediastinum, chest and abdominal cavities and the extremities. Cases involving the V, VII, VIII, and X cranial nerves, the phrenic nerve, the cervical and brachial plexus and the cervical sympathetic nerves have been described. Less frequently, the areas of the head and neck involved are the larynx, pharynx, tongue, lips, palate, floor of the mouth, maxillary sinus, eyelids, orbit and salivary glands.

PATHOLOGY

These tumors are usually globular or fusiform in shape and of varying sizes. They are well encapsulated with smooth external surface or a gray or yellowish gray appearance. It is soft in consistency and sometimes fluctuant because of the frequent presence of cystic degeneration.

On section, the tumor is coarsely lobulated with mottled areas ranging from pink to tan and butter yellow color. The central portion is almost always necrotic with scattered areas of hemorrhage beneath the capsule. Degenerated foci of edema and cysts of varying sizes filled with fluid of varying color from straw to red and brown are present.

The microscopic picture is characteristic and is divided according to histologic appearance into the type A and type B tissue of Antoni. The type A is characterized by elongated Schwann cells with the typical nuclei. Passing between these cells is a reticulum of long delicate wavy connective tissue fibers which are arranged in a parallel

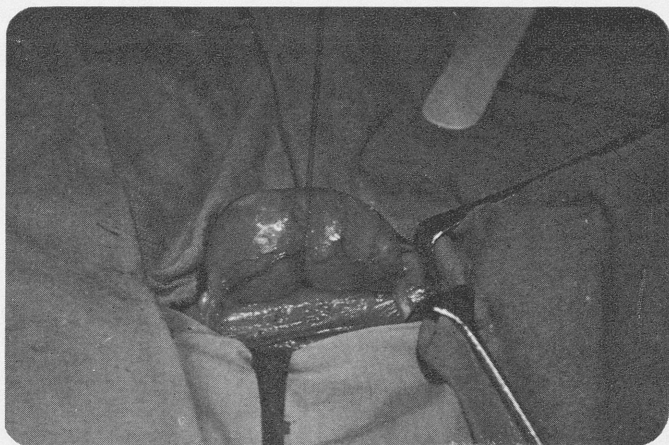

Fig. 1.—Showing tumor lying between the internal jugular vein and the common carotid artery.

manner while the cell nuclei are lined up at the opposite end of the fibers. This palisading of the nuclei in parallel rows is characteristic of the type A. In the type B, there is no palisading of the nuclei. The tissue is loosely arranged due to the intercellular fluid which separates the cells and fibers and the delicate reticulum and microscopic cystic areas.

CLINICAL MANIFESTATIONS

The presenting symptoms of these tumors are extremely varied depending upon the location and the size of the lesion. The chief presenting symptom is a painless mass or localized swelling. There is no pain but as the lesion enlarges, there may be an awareness of some discomfort in the neck. Pressure of the enlarging tumor may cause some dysphagia from localized pressure upon the esophagus and the pharynx. Coughing, hoarseness, paresthesia and mild tachycardia may be the result of a vagal irritation.

These tumors may occur at any age but occur most commonly between the third and sixth decade of life. Both sexes are equally affected. They occur equally in both sides of the neck.

Because of the lack of any characteristic signs and symptoms, the diagnosis is rarely made pre-operatively. It can be differentiated

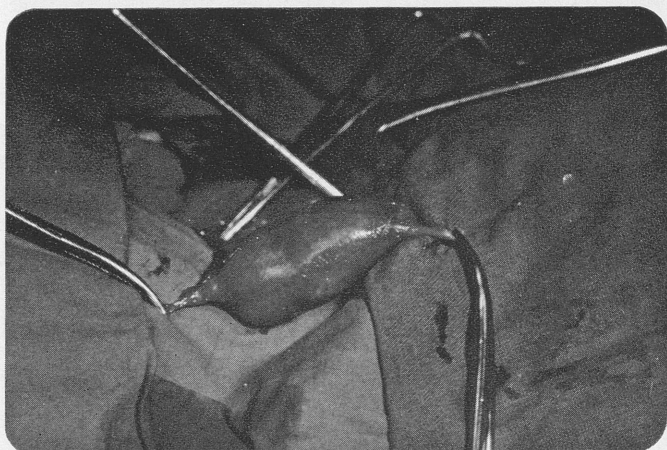

Fig. 2.—Showing tumor transected above and below with a small section of the nerve.

from a malignant cervical metastases by the long duration of the tumor with slow progression, the lack of any intraoral, pharyngeal, or laryngeal lesions and the discrete soft movable character of the mass. However, it is impossible to differentiate it from the other benign soft tissue tumors in the neck. One diagnostic point is that the schwannoma of the neck is partially fixed and moves freely from side to side but not in a vertical direction. This distinguishes it from a carotid body tumor.

Martin⁵ and Conley³ advocate pre-operative aspiration biopsy in an attempt at differential diagnosis.

TREATMENT

The treatment is total surgical excision. During surgery, every attempt should be made to conserve the neural pathway. In the saccular tumors, the nerve is usually pushed over to one side by the tumor and can be preserved by identifying the normal non-involved segment of the nerve on each side of the schwannoma and tracing it to the tumor. In the fusiform type, the tumor may be found inside the main nerve trunk and the nerve fibers are spread out over the tumor mass. An intracapsular "shelling out" of the tumor may be feasible in the saccular type but difficult in the fusiform type and may conceivably lead to a high recurrence rate. In this type, a resection of

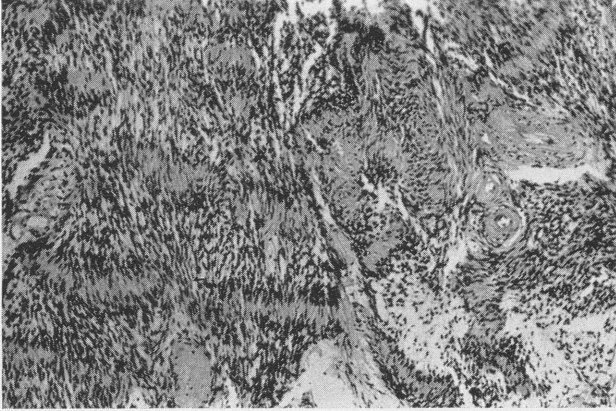


Fig. 3.—Lower power showing Type A tissue of Antoni. Showing cystic and solid areas.

the tumor mass in continuity with a small segment of proximal and distal vagus nerve may be necessary. If the tumor is less than 2 cm in length, Conley³ advises a primary nerve suture after appropriate mobilization of the proximal and distal segments and angulation of the head to avoid tension on the suture lines. If the tumor is over 2.0 cm in length, a nerve graft should be done.

Physiological changes of some vital clinical significance may occur after the division of the cervical portion of the vagus nerve. Martin⁶ states that the vagus nerve in the neck may be cut without any deleterious effect except for the ipsilateral paralysis of the vocal cord. There is no interference with the function of the vagus plexus and the secretion of gastric hydrochloric acid. However, Conley³ has advised that excision of the vagus nerve at a high level of the neck above the superior laryngeal nerve offers numerous difficulties. It may cause dysphagia, regurgitation, esophageal and cardiac and pyloric spasm, and ipsilateral paralysis of the vocal cord and soft palate. Homolateral anesthesia of the pharynx and larynx also results. The symptom complex is characterized by regurgitation of food with aspiration resulting in an aspiration pneumonia, tachycardia and respiratory distress. These complications are averted by a prophylactic tracheostomy and a nasogastric feeding tube, which may be necessary for a rehabilitative period extending from one to three months post-operatively.

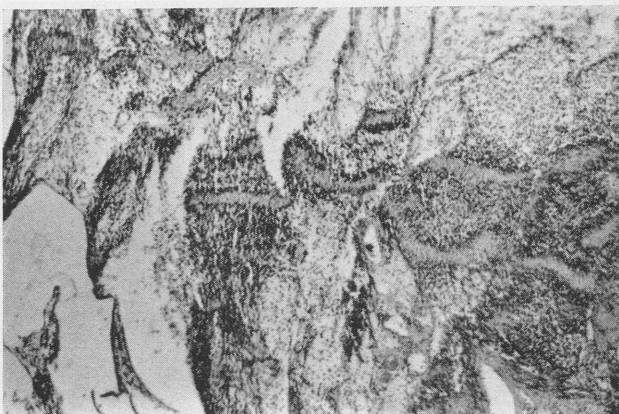

Fig. 4.—High power of same tumor.

It can readily be seen that a direct approximation of the cut ends or a nerve graft is of utmost importance if the vagus nerve is to be severed at a high level of the neck.

REPORT OF A CASE

Mrs. F. F., a thirty-nine year old Hawaiian-Chinese female, was first checked by her family physician in January, 1960, because of a chronic fatigue and a weight gain of thirty pounds in two years. On examination, the only positive finding was a mass in the lower portion of the right side of the neck. Her past history was irrelevant. She had had a tonsillectomy and had been treated for a sinusitis. Her family history was interesting. An older sister had a papillary adenocarcinoma of the thyroid which was treated by a removal of the isthmus and the left lobe of the thyroid. She had been well for eight years without any recurrence.

Examination revealed a well developed and nourished and rather plump female. Her blood pressure was 110/90. The pulse rate was 90. In the region of the right lobe of the thyroid gland, there was a large oval mass about one and one-half inch in width and two and one-half inches in length. It was rather soft and succulent, freely movable under the skin and not attached to the underlying structures. The heart and lungs and the rest of the body were entirely normal.

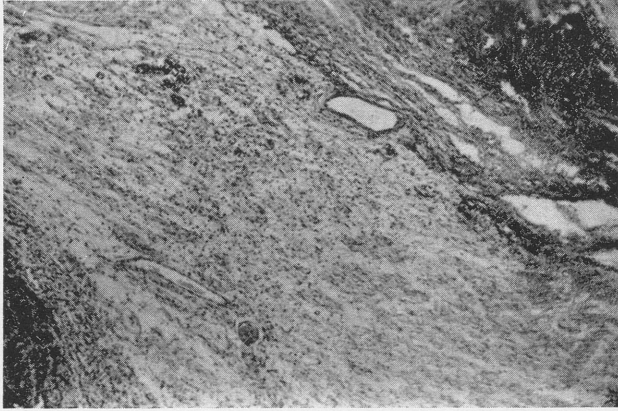


Fig. 5.—Shows vagus nerve running into the tumor mass.

The blood count and urinalysis were normal.

On April 27, 1960, under intratracheal anesthesia, a transverse semicollar incision was made over the anterior portion of the lower right side of the neck directly over the mass down through the platysma muscle. The mass was located directly under the muscle. Upon freeing the surrounding structures, the mass was seen lying between the internal jugular vein and the common carotid artery. Upon further separation, it was discovered that the tumor involved the vagus nerve. It was oval shaped and measured 2 x 6 cm (Figs. 1 and 2). The mass was completely mobilized and isolated and transected above and below. Due to the large distance between the two segments of the nerve, no attempt at suturing the two segments was made. A frozen section revealed a schwannoma.

All during surgery, there was absolutely no change in the pulse rate, respiratory rate or blood pressure. Postoperatively, she was hoarse. An examination revealed a complete paralysis of the right vocal cord. To date, there has been no recurrence and no change in the blood pressure or pulse rate.

PATHOLOGY REPORT

Gross. An ovoid encapsulated, soft, almost fluctuant tumor 6.5 cm long and 2.8 cm in diameter. Coming off each end is a stump of

a large sized nerve trunk about 0.5 cm long and 0.25 cm in diameter. This nerve trunk fades into the capsule of the tumor. On section, the tumor is seen to be coarsely lobulated, and mottled tan and butter yellow. Degenerated foci of edema, and fine cystification and hemorrhage are present. A tiny satellite of yellow tumor is present at one end in the capsule near the nerve stump. This separate node is 0.7 cm in diameter.

Microscopic. Multiple sections of the tumor proper reveal a classical nerve sheath benign neoplasm. It presents typical multicentric foci of edematous and cystic degeneration. In the cellular foci, the cells are lined up in a palisaded or picket-fence pathognomonic fashion. Mitotic figures of nuclear atypism are not apparent and so the lesion appears as it usually is, benign (Figs. 3, 4 and 5). The stumpy projections from either end of the capsular surface of the tumor is seen to be medium or large sized nerve trunks entirely consistent with the vagus.

Diagnosis. Neurilemmoma or schwannoma.

SUMMARY

1. A schwannoma of the cervical portion of the vagus nerve is a rare tumor. My case is the sixteenth case reported in the literature.
2. There are no characteristic signs and symptoms.
3. The tumor is benign and the treatment is local excision.
4. Care should be taken to preserve the nerve trunk if possible.

Section of the nerve below the level of the superior laryngeal nerve results in an ipsilateral vocal cord paralysis. However, section at a high level of the neck offers numerous difficulties. These include dysphagia, regurgitation, ipsilateral paralysis of the vocal cord and soft palate, and homolateral anesthesia of the pharynx and larynx resulting in a symptom complex of aspiration pneumonia, tachycardia and respiratory distress.

5. A case report is presented.

1374 NUUANU AVENUE

ACKNOWLEDGMENT—The author acknowledges with thanks the help of Doctor Raid Chappell, pathologist at St. Francis Hospital, Honolulu, Hawaii, who took the photos of the lesion at the time of surgery and who prepared the slides and the microphotographs of the histopathological sections.

REFERENCES

1. Altany, Franklin E., and Picknell, Kenneth L.: Neurilemmomas of the Vagus Nerve in the Neck. *A.M.A. Arch. Surg.* 73:793-800 (Nov.) 1956.
2. Penido, Joao R. F., Dodge, Henry W. J., Glagett, O. Theron, and Starr, Grier F.: Tumors of the Vagus Nerve. *Proc. of Staff Meetings of Mayo Clinic* 32: 239-249 (May) 1957.
3. Conley, John J.: Neurogenous Tumors in the Neck. *A.M.A. Arch. Otolaryng.* 61:167-180 (Feb.) 1955.
4. Mitchell, F. O.: Extracranial Neurilemmoma of the Vagus. *J. Laryngol. and Otol.* 72:166 (Feb.) 1958.
5. Ehrlich, H. S., and Martin, H.: Schwannoma in the Head and Neck. *Surg.: Gynec. and Obst.* 76:577, 1943.
6. Martin, H., Del Valle, B., Ehrlich, H., and Cahan, W. G.: Neck Dissection. *Cancer* 4:441, 1951.

DISCUSSION

DR. JOHN F. DALY: I was very happy to see that Dr. Pang had selected this topic for his presentation because, as many of you know, yesterday I presented a similar paper, a report of two cases of neurilemmoma involving the cervical sympathetic chain.

One of the things that plagues us in discussions of tumors is a matter of nomenclature. Dr. Purdy Stout in his classical work used the word "neurilemmoma" to describe the benign tumor and reserved the term "malignant schwannoma" for the malignant variety. I wonder if Dr. Pang would consider the term "neurilemmoma" preferable?

I think he is to be complimented for the very thorough presentation he has made on this interesting topic.

DR. PANG (closing): I would like to thank Dr. Daly for his discussion, especially in view of the fact that I had asked him to discuss the paper late this morning and the only reason I asked him to discuss this paper was because he had presented an excellent paper yesterday on a case of schwannoma of the sympathetic nerve and showed some very excellent movies.

I have nothing further to add and I would like to again thank you.

INDUCED PHARYNGEAL SENSATIONS AND REFLEXES

PETER N. PASTORE, M.D.

RICHMOND, VA.

The pharynx, in spite of its easy accessibility, is poorly understood relative to its functions, reflex patterns and interpretation of stimuli and sensations. In early life, especially the first decade, its importance is overshadowed by the behavior of the prominent portions of Waldeyer's ring (tonsils and adenoids) and bacterial or viral reactions of the respiratory tract. In adulthood (once the tonsils and adenoids are eliminated) its role appears less important unless striking objective changes are noted. When areas of residual (granular or infected) lymphoid tissue are not apparent, it seems the natural tendency to allude to allergy, anxiety, emotions, nerves, and cancerophobia as probable factors in subjective symptoms related to the region of the throat.

There are many reasons why the pharynx has not received its justified degree of attention in the past. The ancients were handicapped by lack of surface anesthesia, sufficient artificial light, and proper mirror image for adequate visualization of the more remote portions of the pharyngeal recesses in the living. Rigor mortis and superstitions undoubtedly contributed to the frustrations of the curious or inquisitive scientific mind of any attending physician who dared attempt a sneak examination of the pharynx during "the wake" or at any time before burial. Anatomists, too, must have been disappointed to find only a smooth surface wall leading to more exciting areas such as the nasopharynx and eustachian tubes above and the larynx or esophagus below. Is it any wonder then that the word angina (Ludwig's angina, angina pectoris, lymphangitis, etc.) became associated with so many conditions, near and remote, related to that all encompassing region called the throat?

The latter part of the nineteenth and early part of the twentieth centuries resulted in much writing and accumulation of data relative to objective problems involving the pharynx and especially the supporting structures. Schenck focussed (1935-1955) on the pathophysiology of the pharynx. However, it appears that in the last two decades the ready availability of antimicrobials and of psychiatrists has apparently resulted in a decreased emphasis and interest in functional problems of this area by otolaryngologists.

It is generally noted that the main functions of the pharynx are concerned with deglutition, respiration, voice resonance, and speech. It is not the intention at this time to give major consideration to these. For such data one should consult available texts.¹ Rather an attempt has been made to evaluate sensations or terms frequently used by patients. Some of these are: aching, burning, choking, coughing, dryness, gagging, hoarseness, itching, lump, nagging pain, scratchy pain, shooting pain, numbness, soreness, stiffness, stinging, throbbing, tickling, tightness and "voice cuts off."

GLOSSOPHARYNGEAL NERVE

It will be recalled that 1) motor fibers from the nucleus ambiguus pass to the stylopharyngeus muscle; 2) parasympathetic fibers from the inferior salivatory nucleus pass via the nerve of Jacobson, tympanic plexus, and small superficial petrosal nerve to the otic ganglion, from which the post-ganglionic fibers pass to the parotid gland; 3) sensory fibers arise from the unipolar cells in the petrous and jugular ganglia. Centrally they terminate in the tractus solitarius and its nucleus. Peripherally, they supply general sensation to the pharynx, soft palate, posterior third of the tongue, fauces, tonsils, eustachian tube, and tympanic cavity. Through the sinus nerve they supply special receptors in the carotid sinus concerned with reflex control of the posterior third of the tongue. A few fibers join the auricular branch of the vagus nerve and pass to the external auditory canal.² An attempt has been made by us to observe the effect of only topical stimulation of the sensory portion of the glossopharyngeal nerve.

SELECTION OF SUBJECTS

Group 1. These patients were reporting for evaluation of symptoms not related to the throat and with normal cortical integration and sensory interpretation.

MATERIALS USED

1. *Odorless*. Cocaine powder, cocaine solution 10%, dry cotton, wet cotton, salt grains, salt solution 50%, and silver nitrate solution 10%.

2. *Aromatic*. Clove dust, coffee dust, pepper dust, tobacco dust, vinegar 3%, and alcohol 70%.

METHOD OF TESTING

1. A metal cotton carrier dipped in the test agent containing only sufficient amount of dust or liquid to cover the test surface.

2. Gentle depression of the nonanesthetized tongue to allow visualization of the pharyngeal surface area to be tested.

3. Gentle application of the test agent to not more than one centimeter surface area of the designated pharyngeal mucosa.

4. Request for an immediate reply as to sensation noted.

The results are shown in Table I.

TABLE I

AGENT	AREA STIMULATED	LOCALIZATION	SENSATION REPORTED
Cocaine powder	mid-pharynx	mid-neck	wet - nothing
Cocaine solution 10%	mid-pharynx	mid-neck	cold - nothing
Cotton, dry	mid-pharynx	mid-neck	tickling - nothing
Cotton, wet	mid-pharynx	mid-neck	cold - nothing
Salt solution 50%	mid-pharynx	mid-neck	dryness - burning
Silver nitrate 10%	mid-pharynx	mid-neck	burning - stinging
Cocaine powder	lateral pharynx	lateral neck	nothing - touch
Cocaine solution 10%	lateral pharynx	lateral neck mid-neck	hot - cold
Cotton, dry	lateral pharynx	lateral neck	nothing - burning
Cotton, wet	lateral pharynx	lateral neck	wet - tickling
Salt solution 50%	lateral pharynx	lateral neck	sticky - cold
Silver nitrate 10%	lateral pharynx	lateral neck	burning

Results with odorless test materials disclosed that the nonirritating ones such as cocaine and wet cotton often resulted in no sensation or a very mild consciousness of any kind. Presumably, the often used term of "feels numb" after the use of cocaine did not apply within the 60 seconds of the test period.

Results with the aromatic agents were quite different when compared with the nonaromatic materials. Factors involving the sense of smell and taste could not be overcome without influencing the results.

The sensation of an irritant in many instances stimulated the flow of postnasal, pharyngeal and salivary mucus, which in turn resulted in swallowing and the immediate introduction of taste. This further complicated matters in response to identifying the agent rather than the sensation.

The resultant flow of mucus also served to spread the effect of the test substance making exact localization of the stimulus impractical for the subject. In many instances coughing was noted. It was not always practical to determine whether this was related to direct reflex action from the primary site tested in the pharynx, from possible airborne dust particles of the test agent entering the trachea or from mucus stimulating the laryngeal protective mechanism.

The most frequent descriptive term describing the sensation of the aromatic group was burning and tickling in the order of pepper, tobacco, alcohol, vinegar, cloves, and coffee the least stimulating.

Group 2. These patients were reporting for diagnosis and treatment because of special complaints referable to the throat.

These have been reported in previous communications. The entity, the syndrome of lateral granular pharyngitis, 1953,³ 1959,^{4,5} has been described and will not be repeated here.

SUMMARY

1. The glossopharyngeal nerve is the primary sensory nerve of the pharyngeal mucosa. It has very intimate relation to the structures supplied by the trigeminal nerve and the vagus.⁶ This contributes to the patient's difficulty in describing or interpreting sensations in the region of the throat and ear.

2. Terms used to describe pharyngeal sensations are multiple and vary a great deal.

3. Patients with subjective throat symptoms without objective findings in the pharynx cannot always describe accurately the site of the trigger zone causing their symptoms.

4. The symptom of trigger site is frequently referred to a distant area and may contribute to correct diagnosis difficulty.

5. The reflex pattern of stimulus and interpretation of the normal or asymptomatic pharynx differs from the symptomatic functional or pathophysiologic disturbed pharynx.

6. The relative ease of visibility of the pharynx today is most helpful in eliminating objective lesions. This factor is also helpful in permitting the localization of trigger sites when they exist in patients with subjective symptoms not easily localized or described by the patient.

1200 EAST BROAD STREET

REFERENCES

1. Hollender, Abraham R.: *The Pharynx: Basic Aspects and Clinical Problems* - 1953. Year Book Publishers, Inc., 200 E. Illinois St., Chicago, Ill.
2. Chusid, Joseph G., and McDonald, Joseph J.: *Correlative Neuro-anatomy and Functional Neurology*. Tenth Edition, p. 91, Lange Medical Publications, Los Angeles.
3. Pastore, Peter N.: *Neurologic Disorders of the Pharynx* 29:498-508. Hollander, A. R.: *The Pharynx* - 1953. Year Book Publishers, Chicago, Ill.
4. Tremble, G. Edward: *The Clinical Significance of a Lump in the Throat*. *Arch. of Otolaryngol.* 70:157-165 (Aug.) 1959.
5. Pastore, Peter N., M.D., Richards, Lyman, Aldrich, K., and Lindsay, John: *The Lump in the Throat*. *Trans. Amer. Acad. Ophthal. and Otolaryng.* 59:5:630-637 (Oct.) 1955.
6. Pastore, Peter N., M.D., and Meredith, John: *Glossopharyngeal Neuralgia (tic douloureux of the IX Cranial Nerve)*. *Arch. Otolaryng.* 55:789-794 (Dec.) 1949.

MANAGEMENT OF BENIGN LARYNGEAL TUMORS IN CHILDREN:

PREOPERATIVE, OPERATIVE AND POSTOPERATIVE

JAMES J. O'NEIL, M.D.

JOHN A. MCGEE, M.A.
(by invitation)

OMAHA, NEB.

Management of benign tumors of the larynx in children with their attendant vocal disorders has long been a primary concern of the laryngologist. The inherent tendency of such lesions to progress to dangerous respiratory embarrassment, as in laryngeal polyps; to undergo malignant changes, as in papillomata; and to cause life-long socio-economic difficulties for the want of a normal speaking voice, imposes upon us a constant demand for improvement in our pre-operative, operative and postoperative treatment of these lesions.

It is somewhat paradoxical that although the initial symptom of such lesions is that of a voice disorder pointing directly to the larynx, the laryngologist is frequently the last to be called in consultation to examine the patient. Full understanding of the many ramifications such voice disorders have in the development of the total individual necessitates the attention of many specialties, including the pediatrician, the speech pathologist and the psychiatrist. It is our conviction that this team approach can best be directed by the laryngologist. This obligation of the laryngologist has been pointed out by Brodnitz¹ and it is through his pioneer work and interest in the laryngological aspects of phoniatrics that a broader approach to this important problem is now being made.

The position of the laryngologist as director of this team of specialists demands of him an even greater discipline. For as the antiquated approach which views such lesions as purely mechanical with the solution consisting of simple removal is replaced with the more

accurate broader concept, his responsibilities must extend to all phases of the preoperative, operative and postoperative stages to insure the best results for his patients.

SPECIAL CONSIDERATIONS IN THERAPEUTIC APPROACH

In our therapeutic approach to these problems in children certain special considerations have influenced us. Careful consideration must be given to anticipated goals. We should not expect the postsurgical voice to necessarily resemble the voice of the patient at any previous period of life. We must determine the practical range necessary to communicate adequately at this time, namely: 1) how wide a pitch range is necessary?; 2) can inflectional and step changes in pitch be achieved easily?; 3) is the patient able to control his voice?; 4) is the patient aware subjectively of the various potential "registers" he is capable of using?; 5) are there any direct organic or functional inhibitors to maximum effective use?; 6) what is optimum in terms of a therapy course which will not create a dependency?

Finally, neither the laryngologist nor the speech pathologist should ever feel that the preoperative, operative or postoperative phases have been successful simply because a few or even the majority of these cases have been managed successfully. The extreme importance of the problem and the omnipresent possibility of recurrence demand consistent vigilance on the part of both, and an extended case study for each. Advancement toward excellence or perfection in the management of such benign tumors responsible for voice disorders can only be achieved by this method and the patient increasingly assured of the best results of treatment.

PREOPERATIVE

The preoperative phase of such cases now demands of the laryngologist a meticulous history and a thorough laryngeal examination—either indirect or direct. It has been our experience that a more satisfactory laryngeal examination can be obtained with mild sedation and immobilization than with complete sedation or the use of a general anesthesia, which considerably inhibits laryngeal muscular tone and may actually completely obscure the endolaryngeal tumor mass.

These cases require the basic approach of a new or renewed concept of functional laryngology. By his training and experience the laryngologist can readily extend his knowledge to normal voice pro-

duction and speech pathology and thus be in an improved position to treat and advise his patient. Even in the absence of organic pathology to explain the symptomatology, the patient is entitled to an explanation and recommendations. All too often he is given neither. It is always to be remembered that the treatment of these patients is primarily the responsibility of the laryngologist.

The laryngologist's closest ally in discharging this responsibility is the speech pathologist. This alliance can be strengthened by an aggressive attitude of laryngology in acquiring accurate knowledge and the basic skills of vocal rehabilitation and by similar acquisition of the necessary pertinent medical background on the part of the speech pathologist.

Our experience in the treatment of voice disorders resulting from benign tumors of the larynx in children has increased our appreciation of functional laryngology and the great contributions that are available from speech therapy. Our results have been almost directly proportionate to a systematic combined approach.

For example, laryngologists are all too familiar with the basic mechanical laryngeal factors which affect voice, such as laryngeal size, tension, mass and approximation of vocal cords, as well as the importance of air column pressure, tissue elasticity, and the relationship to the resonance system. However, the functional components such as influence of speech models, compensatory laryngeal habits, psychological factors, and motivation also contributing to the resultant voice are frequently overlooked. The importance of investigation in this field has been attested to by many authors. These same authors also emphasize the dearth of reports in this regard. In fact, Goodstein² points out that only three studies dealing with this problem have been reported.

The experience of most laryngologists in this field is a mixture of success and failure, principally we feel because techniques originally developed for adults are adapted and used for children. Techniques designed solely for children should be investigated further. Present techniques generally are modified approaches based on study of adult voices. For example, the potential adult range of superior speakers includes two to three octaves with natural pitch levels and habitual pitch levels approximately one-fourth of the way from the lowest note. Furthermore, it is probable that a practical pitch range includes as little as a three-eighth note variation from the habitual pitch level.

However, there is no reason to suppose that these relationships would hold for children's voices. The absence of significant representation of this voice group precludes intensive review of such phenomena and we can only base judgement on what we have observed.

To us the most important phase is the pretherapeutic stage in which the decision must be made by the laryngologist as to whether this particular patient should be treated phoniatrically, surgically, or both. This decision determines the final outcome and is arrived at only after the most exhausting history has been obtained from the patient and family; the most complete laryngeal examination conducted and a thorough evaluation by the speech pathologist including tape recordings of the voice as a part of the permanent records for later evaluation of progress. Recorded samples of the voice in the early stages of pathology would be helpful but this is frequently impossible because the laryngologist and speech pathologist are so often the last to see the patient.

In general we have not been impressed with an exclusive medical approach. Our experience has not been as great nor our results as good as those reported by Gerosa³ using endocrine therapy. The prolonged period of time demanded for results plus the danger of the development of incipient or actual Frohlich's syndrome from the prolonged use of cortisone or ACTH has discouraged our use of this regimen. Similarly the dangers of x-ray therapy as pointed out by Galloway, et al.,⁴ have removed this modality from our armamentarium.

In the discrete beginning laryngeal polyp we have recommended phoniatric exercises by our speech therapist with good results. These exercises consist essentially in relaxation of the intralaryngeal vocal apparatus and proper training of the extra-laryngeal apparatus. In this regard game therapy has been used extensively in the treatment of speech problems in children. Wilson^{5,6} suggests a variation for use in vocal problems which promises an approach to therapy without the direct pressures primarily implied in "drill" work.

The decision for endolaryngeal surgical removal is arrived at depending upon the type, location, extent of the benign tumor, and the response to conservative phoniatric treatment. If surgery is decided upon as the treatment of choice we must then consider, with the aid of the speech pathologist, a postoperative program which will complement the operative phase.

OPERATIVE

In our experience, careful endolaryngeal surgical removal of the benign tumor with realignment of the operated cord without damage to the submucosa has resulted in the most dramatic and satisfactory treatment. This has provided the earliest return of a near-normal voice and has permitted the therapist optimal opportunity to correct any residual faulty speech patterns.

We have found in the majority of our cases, depending upon the age, that either immobilization or local anesthesia has been both satisfactory and safe. It is our feeling that the sedated, immobilized patient provides a safer subject and also permits a more accurate surgical procedure on the vocal cords. We have for some time successfully used the laryngoscope holder of Lewy to further immobilize the laryngeal structures permitting a more careful and less hurried delicate surgical removal of the neoplasm and re-alignment of the cord.⁷ We exercise special care not to injure the submucosal surfaces of the vocal cord. Our instrument of choice for exposure and visualization has been the Holinger anterior commissure laryngoscope. His most recent and significant modified improvement with the flared-out proximal and distal portions certainly provides an improved visualization of the laryngeal lesions. A re-arrangement of the Zeiss binocular microscope using the Lynch suspension and the newly re-introduced and improved binocular instrument of Lewy to provide stereopsis and depth perception affords the opportunity for even more delicate endolaryngeal surgery with corresponding improvement in technique and results.

The only required addition to a satisfactory surgical instrumentarium is a series of delicate laryngeal cup forceps of various sizes and angles. With this armamentarium the laryngeal surgeon is well equipped to satisfactorily carry out the endolaryngeal surgical treatment of benign laryngeal tumors in children which are responsible for the aforementioned accompanying speech abnormalities.

POSTOPERATIVE

For superior results in the treatment of such tumors, the postoperative period is of equal importance to the elaborate and extensive pre-operative stage and the careful, delicately executed surgical phase. From a practical standpoint and for purposes of presentation this stage may be divided into: 1) the immediate, and 2) the extended post-

operative period. The immediate postoperative period is from seven to ten days after surgery. The extended postoperative period terminates when a satisfactory normal voice has been re-established. The second stage is directly dependent upon the first and the success of both stages can only be determined by the permanent postoperative voice of the patient.

We have frequently subjected the long accepted dictum of the ten day absolute voice rest period to a crucial test proscribing only against gross abuse of the voice such as yelling, shouting and whispering.

In such cases there was no appreciable deleterious effect or delay in the return of a comparable postoperative voice as compared to that experienced by the patients who were placed on an absolute voice rest regime. Physiologically it is our feeling that imposed disuse may influence the early functional return of the intralaryngeal musculature necessary for phonation.

From this it would seem that the insistence of absolute voice rest in patients of an age group in which assured co-operation is difficult to obtain is not of paramount importance. The patients in this age group are frequently highly suggestible psychologically and laryngologists may be unwisely and inadvertently implying that the patient cannot talk by recommending absolute voice rest. The insistence of absolute voice rest may well cause a psychological block and thus a prolonged postoperative period when the ban of absolute silence is lifted. This has been borne out by our speech pathologist who reported an earlier return of satisfactory vocalization in cases in which the restriction had not been rigidly enforced.

Furthermore, since the only basis for the policy of voice rest is the possible trauma exerted on the healing, operated cord, it is quite feasible that an immediate moderate degree of vocal activity might well serve as a form of physical therapy and even expedite the healing process. Certainly this important aspect is worthy of further investigation and continued observation.

In the immediate postoperative period (seven to ten days) we have found the use of intramuscular Chymar® for the first 24 hours and either Chymoral® or Orenzyme® by mouth for the remainder of this period to be of help in controlling postsurgical edema. The use of steam and the croupette for the initial 24 hours has been thought to be of help only in the patient under the age of seven.

We consider the extended postoperative period to exist from the end of the healing process (seven to ten days) to the time stability in vocal activity has been acquired. This frequently demands that the patient be followed by the laryngologist routinely for at least one to five years or until adult vocal habits have been acquired. This is based on the possibility that a recurrence of the tumor may occur.

The laryngologist should continue to work intimately with the speech therapist during this extended postoperative period by: 1) reporting his laryngeal findings and advising both the patient and the therapist of the significance of these findings; 2) by encouraging the patient to co-operate in a long-term program of voice re-education and 3) by aiding the therapist in continuing or modifying the early phoniatric therapy to insure the attainment of the best possible postoperative voice for the patient.

SUMMARY

We have presented the pre-operative, operative and postoperative management of benign laryngeal tumors responsible for voice disorders in children. It has been our recommendation that a child suffering from voice disorders arising from benign laryngeal tumors should be seen first, and not last, by the laryngologist.

Fully recognizing the importance of the team approach in the management of voice disorders arising from such lesions, it is our considered opinion that the team should be directed by the one most logical to deal with such problems, the laryngologist. While this does demand a renewed interest on the part of the laryngologist in functional laryngology, no one has a better background in laryngeal pathology than the laryngologist which facilitates the acquisition of this important part of laryngology.

It must be remembered that these cases are primarily a physician's responsibility and that they are most accurately evaluated and treated by the laryngologist in co-operation with the speech pathologist. The laryngologist must acquire a basic working knowledge of functional laryngology with the added techniques of vocal rehabilitation to accurately advise the patient and aid the speech pathologist.

Both the laryngologist and the speech therapist must become familiar with, and utilize, techniques which are applicable to the increasing population of children suffering from a disease that can

threaten their immediate life and cut deep psychological scars that will hinder their future development.

The speech pathologist should see the patient pre- and postoperatively. Immediate therapy in the postsurgical stage may well insure optimum results.

The recent innovations in endolaryngeal surgery have been discussed. The adapted Zeiss binocular microscope and binocular vision adaptations were mentioned briefly but not elaborated because of no personal experience with either.

The question of anesthesia was discussed. Sedation or immobilization of the child to be examined has provided the most satisfactory and safest method in our hands.

The operative stage demands the most meticulous endolaryngeal surgery for success. Present methods have been unusually good but recently reported advances promise to improve the laryngeal surgeon's skill and effectiveness.

The postoperative stage is of equal importance to that of the preoperative and operative phases. In the immediate postoperative period we discussed: 1) the question of voice rest versus early vocal use; 2) croupettes and steam inhalation to reduce postoperative edema were found to be of some value in the under seven years of age group while 3) Chymar was found helpful in reducing edema in the over seven years of age group. The extended postoperative phase calls for a continued collaboration between the laryngologist and the speech pathologist. Based on the possibility of tumor recurrence, periodic examinations by the laryngologist and indicated therapy by the speech therapist has proven to be the ideal.

612 MEDICAL ARTS BLDG.

REFERENCES

1. Brodnitz, B. S.: Vocal Rehabilitation. *Am. Acad. of Ophth. and Otolaryng.*, 1959.
2. Goodstein, Leonard D.: Functional Speech Disorders and Personality: A Survey of the Disease. *Jour. of Speech and Hearing Research* 1:4 (Dec.) 1958.
3. Gerosa, H. N., et al.: *Semana Med.* 67:1203, 1960.
4. Galloway, T. C., Soper, G. R., and Elsen, J.: Carcinoma of the Larynx After Irradiation for Papillomata. *Arch. Otolaryngology* 72:73-4 (July) 1960.

5. Wilson, D. Kenneth: Children with Vocal Nodules. *Jour. of Speech and Hearing Disorders* 26:1 (Feb.) 1961.
6. Wilson, D. Kenneth: Vocal Re-Education of Children with Vocal Nodules. *Laryngoscope* 81:45:1 (Jan.) 1962.
7. O'Neil, James J.: The Surgical Management of Hoarseness. *Nebr. State Med. Jour.* 44:227:5 (May) 1959.

REMOVAL OF BENIGN LESIONS OF THE LARYNX UNDER ENDOTRACHEAL ANESTHESIA

OLIVER W. SUEHS, M.D.

AUSTIN, TEXAS

Twenty years ago, many of us would have been reluctant to admit that we had resorted to the use of a general anesthetic to effect the removal of benign lesions of the larynx, for we had been trained to remove them satisfactorily and safely under topical anesthesia. The advancements in the specialty of anesthesiology and availability of new anesthetic agents since that time have changed our thinking with regard to anesthesia for direct laryngoscopy.

The discussion evoked by De Graaf Woodman's¹ presentation last spring, regarding the use of the apneic technique of anesthesia for direct laryngoscopy, indicates that there is increasing interest among laryngologists in the subject of general anesthesia. Le Jeune,² the late Gordon New, and others have used general anesthesia with suspension laryngoscopy for many years. Priest and Wesolowski³ in 1959 reported in detail a method of endotracheal anesthesia for laryngoscopy in adults and described a wasp-waisted laryngostat devised by Priest. They disclaimed originality for this method, stating that Boies and others in Minneapolis had practiced this procedure for at least 15 years.

The author first employed a technique of endotracheal anesthesia, similar to that described by Priest and Wesolowski,³ for the removal of a benign lesion of the larynx in February 1950 when he encountered difficulty in exposing a polyp near the anterior commissure of a stout short-necked patient with an overactive gag reflex.

The present report is based upon the author's experience with the removal of 90 benign lesions of the larynx in children and adults

in his private practice, using standard Jackson instruments under endotracheal anesthesia.

We have not employed endotracheal anesthesia exclusively by any means, but have come to prefer it for the removal of benign lesions in the anterior two-thirds of the larynx for reasons that will be explained subsequently. The decision between topical and general anesthesia is made at the time of mirror laryngoscopy, and is influenced by the wishes of the patient, his ability to co-operate, the controllability of his gag reflex, the anatomical configuration of his neck, the location and gross appearance of the lesion, and his general health.

When a patient is dyspneic for any reason, general anesthesia is not employed.

Lesions suspected of being malignant are biopsied under topical anesthesia as are most of the keratoses and granulomas.

Infants with stridor are of course examined without anesthesia. Direct examination of the larynx in young children is performed under general anesthesia without intubation. When a lesion is to be removed, however, an endotracheal tube is inserted.

TECHNIQUE OF ANESTHESIA

The patient is premedicated with an opiate and either atropine or scopolamine, given hypodermically an hour before the time of surgery. Anesthesia is induced with intravenous sodium pentothal solution (either 0.5% or 2.5% solution). Oxygen and one or more of the gaseous anesthetics are administered by face mask, and a muscle relaxant, usually succinyl choline, is given by intravenous drip. When apnea ensues, the endotracheal tube is inserted by the anesthesiologist and connected to the gas machine, bringing the tube out of the left angle of the patient's mouth. The patient's head is positioned on a folded sheet or a head block and the laryngologist is advised that he may proceed.

As would be expected, the anesthetic agents used vary from year to year and from anesthesiologist to anesthesiologist. In the beginning of this series, curare was the muscle relaxant of choice, but now succinyl choline has almost entirely replaced it. The latter is considered a safer drug because the patient will usually resume breathing spontaneously within three minutes after the drug has been discontinued. When apnea has been induced with curare on the other

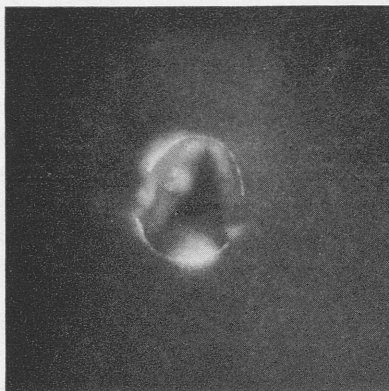

Fig. 1.—Actual view of larynx through twin-lighted anterior commissure laryngoscope showing retention cyst on left vocal cord and endotracheal tube in posterior commissure.

hand, the apneic state may continue for a period of five to ten minutes or longer after discontinuing the drug. In the earlier cases of this series, nitrous oxide and oxygen, in a 50-50 ratio, were the only gaseous agents used, but during the past two and a half years, Fluothane® seems to be added almost routinely. Because of Fluothane's inherent curare-like action, muscle relaxants are being used in lesser quantities.

We employ a semi-soft plastic Magill endotracheal tube (Portex or Davol). A Magill size 4 to 6, corresponding to 25 - 28 French (8.5 to 10 millimeters) is used in adults, whereas a Magill size 2 or 3 is used in children, depending upon the size of the larynx.

We occasionally used a cuffed tube, but have found that a closed system is not necessary. When using a "flow-rate" up to 8 liters per minute, one can still control the patient's respirations with a small tube and an open trachea. If the lesion appears vascular, or in the presence of multiple papilloma, a cuffed tube may be preferable.

In our experience, an uncuffed tube inserted through the nose (nasotracheal tube) has a tendency to curve forward into the anterior half of the larynx, and this of course is undesirable.

The induction, intubation and positioning of the patient requires only five to ten minutes—usually less time than is required for a satisfactory topical anesthetic.

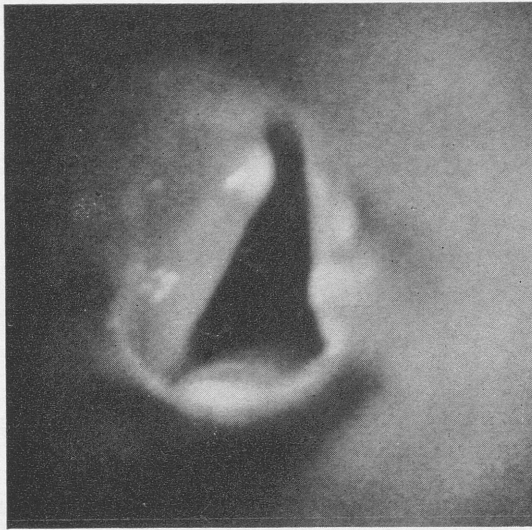


Fig. 2.—Enlarged view of larynx through twin-lighted anterior commissure laryngoscope showing inclusion cyst anterior third left vocal cord. Note endotracheal tube in posterior commissure.

TECHNIQUE OF LARYNGOSCOPY

The larynx is exposed in the usual manner with a standard Jackson or Holinger twin-lighted anterior commissure laryngoscope, working in front of the endotracheal tube. The tube occupies only the posterior third of the glottis and does not interfere in the least with visualization of the anterior two-thirds of the larynx, where most of the lesions occur. In cases of multiple papilloma, one can work around the tube or even displace it forward to expose a lesion in the posterior third when an uncuffed tube is used.

The endotracheal tube serves as a retractor, keeping the vocal cords apart, which is a distinct advantage when removing a lesion from the edge or under surface of a cord in the anterior third.

Other advantages of endotracheal anesthesia are that the laryngologist can devote his entire attention to the pathology with no need to be concerned about the patient's comfort or feeling that he must hurry. The patient is constantly under the control of the anesthesiologist, being adequately oxygenated at all times. Exposure

TABLE I
AGE INCIDENCE

0 - 10 years	10
11 - 20 years	6
21 - 30 years	14
31 - 40 years	20
41 - 50 years	24
51 - 60 years	12
61 - 63 years	4
	—
	90 cases

of the lesion is easier to accomplish because of the muscular relaxation. Coughing and gagging are eliminated.

The author has not found that relaxation of the cords is a disadvantage for one can tense them by increasing the forward pressure on the petiolus with the lip of the laryngoscope when this is desired.

The operating time seldom exceeds five minutes, although one can spend fifteen or twenty minutes if he wishes to demonstrate the lesion to students or other interested observers.

The disadvantages of this method of direct laryngoscopy include the risk of a general anesthetic and the added expense of general anesthesia. It usually precludes doing the procedure on an out-patient basis, although a few patients in this series were discharged from the recovery room. It is not ideal for lesions in the posterior third of the larynx. As stated by Priest,³ one probably should not use an endotracheal tube when malignancy is suspected for fear of dislodging cancer cells down the trachea, although this danger is largely theoretical.

REPORT OF CASES

Age. The youngest patient in this series of 90 cases was a 16 month child with multiple papilloma. An elective tracheotomy was done before removing the endotracheal tube as further repeated removals were anticipated. There were 12 children in this group under 12 years of age, four of them being three and four year olds. No difficulty was encountered with any of the children. On the

TABLE II

LESION	NUMBER OF CASES
Polyps	45
Papillomas	15
Vocal Nodules	14
Cysts	9
Keratoses	2
Granulomas	2
Chronic hypertrophic laryngitis with diffuse polyposis	3
	90 cases

TABLE III

LOCATION OF LESION	NUMBER OF CASES
Anterior third including anterior commissure	18
Junction anterior and middle third	32
Middle third	12
Anterior $\frac{1}{2}$ - $\frac{2}{3}$ of cord	4
Total in anterior $\frac{2}{3}$ of larynx	66 lesions or 73 % of total
Diffuse, multiple and other	24
	90 cases

contrary, the usual struggle and "strong-arm tactics" were eliminated. The ages of the total group are shown in Table I.

Lesions. The lesion most commonly removed under endotracheal anesthesia was the solitary polyp which occurred in 45 patients or exactly half the total. Next in order of frequency were the papillomas, vocal nodules, and cysts. Their respective incidence is indicated in Table II. Although only a few cases of diffuse polyposis are included in this group, the author has gained the impression that the procedure commonly referred to as "stripping of the cords" is made easier by endotracheal anesthesia. One can remove the edematous polypoid mucosa from the upper surface and edge of the cord (one cord at a time) more precisely by this method.

The location of the lesions with reference to their position on the vocal cord is noted in Table III. Approximately 75 per cent of the lesions removed under endotracheal anesthesia were in the anterior two-thirds of the larynx. Some of the remainder were supraglottic and only five involved the posterior third of the larynx.

Results. The results obtained by this method of removal of benign lesions have been at least as good as those obtained under topical anesthesia. In three cases there was a recurrence of a polyp near the original location on the cord within eight months to one year following the first removal. This was probably due to inadequate removal on the first occasion.

Complications. There were no complications in this group of 90 cases. In no instance was there evidence of the lesion having been bruised by the insertion of the endotracheal tube. Laryngospasm during the recovery phase occurred in only one patient and subsided after two or three minutes when oxygen was administered. Postoperative headache and vomiting occurred infrequently. Bleeding and aspiration of secretions was not a problem. With a brief anesthetic, the reaction time is rapid and the cough reflex usually returns within 10 minutes after completion of the procedure. There was less complaint of postoperative soreness than is experienced with topical anesthesia.

SUMMARY

The author's experiences with direct laryngoscopy under endotracheal anesthesia lead him to conclude that it is the method of choice for the removal of benign lesions in potentially difficult cases; especially in children and in apprehensive adults with an overactive gag reflex.

The endotracheal tube in the posterior commissure serves as a retractor, keeping the cord edges apart anteriorly.

The general anesthetic with agents currently available, provides muscular relaxation, facilitating exposure of the anterior commissure with a minimum of discomfort to the patient.

The laryngologist can work leisurely with the assurance that the patient's respirations are under the control of the anesthesiologist and that he is being adequately oxygenated at all times.

This method is recommended to those who have not tried it, if they have confidence in their anesthesiologist.

14 MEDICAL ARTS SQUARE

ACKNOWLEDGEMENT: The author acknowledges the assistance of members of the Austin Anesthesiology Group in the preparation of statements concerning anesthetic agents and technique.

REFERENCES

1. Woodman, De Graff: Laryngoscopy Under General Anesthesia. Trans. Am. Broncho-Esoph. Assn., pp. 48-57, 1961.
2. LeJeune, Francis E.: The Value of Suspension Laryngoscopy in Intralaryngeal Surgery. A.M.A. Arch. Otolaryng. 64:30-35 (July) 1955.
3. Priest, Robert F., and Wesolowski, Stanley: Direct Laryngoscopy Under General Anesthesia. Trans. Am. Acad. of Ophth. and Otolaryng., pp. 639-648 (Sept.-Oct.) 1960.

DISCUSSION

DR. PUTNEY: General anesthesia for endoscopic procedures seems to be increasing in favor with laryngologists, no doubt in part sponsored by the great advances in anesthesiology. It may be preferred in certain laryngeal lesions, and in this category I would place multiple papillomata, large cysts of the ventricular band or ventricle and perhaps large edematous bilateral polyps. I am not convinced that it should be used for small benign tumors and cysts of the vocal cords, such as the illustrations shown or other polyps of a similar nature and location. Dr. Suehs has removed these benign lesions under both general and local anesthesia and has claimed no better results as far as the ultimate outcome is concerned under general anesthesia. The results are determined by the operator's complete removal of the mucosal lesion without injuring the underlying musculature. Using the Jackson type laryngoscope, the type of anesthesia means little provided the larynx is quiet. This can be obtained in the majority of individuals with adequate sedation and topical anesthesia, although I realize in a small group of cases some form of general anesthesia either by using an endotracheal tube or the apnoeic technique may be needed to secure good operating conditions. It seems to me that the advantages of general anesthesia are those of less effort on the part of the operator plus the comfort of the patient, which should not be neglected but are not the principal factors to be considered.

As indicated in the paper the responsibility for the patient's operative condition is largely relegated to the anesthesiologist which may or may not be good, while the laryngologist steps in at the proper moment and removes the lesion. With the continuing advances in anesthesiology these physicians are able to visualize and evaluate the larynx, a trend which will continue, and as more men enter this specialty and it begins to feel the effects of increased competition in the future it is not hard to envision an anesthesiologist after passing an endotracheal tube also using the necessary forceps to remove the pathologic lesion.

The complications of general anesthesia while markedly reduced in recent years are more serious than those of local anesthesia. A recent survey revealed 22 serious anesthetic mishaps with general anesthesia. With topical anesthesia an overdose

of the chemical agent or sensitivity to the drug are about the only serious consequences and ones which cannot be minimized.

The cost of general anesthesia includes not only the services of the anesthesiologist, but also the additional hospitalization time and ancillary work-up that many anesthesiologists require.

Topical anesthesia offers certain advantages. The patient can phonate when asked, which may bring a pedunculated polyp attached to the undersurface of the vocal cord into view that would otherwise be hard to locate. After the lesion has been removed phonation enables the operator to examine the vocal cords in approximation, and at times one will find redundant mucosa remaining after it was thought that all of the pathologic tissue had been removed. This may only be evident on tension and approximation of the vocal cord.

Each individual has to decide for himself which method suits him best. It is my own feeling that the end results are no better when general anesthesia is employed and that the small, benign lesions of the vocal cords should be routinely removed under topical anesthesia, except in certain specific instances.

DR. ROBERT B. LEWY (Chicago): I would like to echo every statement that Dr. Putney made because I am in such complete agreement with him.

In our experience we find that nineteen out of twenty cases can be done very practically, often easily, under local anesthesia. Two things are required to do a good job—a relaxed patient and a relaxed surgeon. The relaxed patient can be acquired by careful attention to the pre-operative medication and on occasion the addition of 50 milligrams of Demerol or some comparable drug, intravenously at the time of the surgery. The relaxed surgeon can be acquired by using chest suspension. In this way, because of the gear power which is available, one can get a very adequate exposure of the anterior commissure. This is easily accomplished, for example, by using the Holinger anterior commissurescope in conjunction with the chest support. We have repeatedly been satisfied with this method.

DR. DEGRAAF WOODMAN (Easton, Md.): I am delighted to hear this paper because Dr. Suehs has carried on his investigations even further than we did by extending the work to the children's age group. Our series was entirely with adults, at least from age eleven and upward.

I think the main factor in determining one's technique is the time factor. If you can accomplish what you are after within three and a half minutes which you are allotted with the *apnoeic oxygenation technique*, then you should use it. **Most** of the cases of polyps, cysts, granulomas and biopsies may be readily accomplished in that period of time. If you will try this on a number of patients, you will soon find how much easier it is on the patient as well as for the doctor. Better work can be done with a patient who is not struggling and under fear and tension.

I was very much interested in the exposure that Dr. Suehs was able to get of the larynx with the small endotracheal tube in the posterior glottic chink. My worry of not having adequate exposure has made me reluctant to use any tube. If one has a case which is going to take extended time, then the tube with cuff would seem in order. Thank you very much for permitting me to discuss this work.

DR. FRANCIS W. DAVISON (Geisinger Medical Center, Danville, Pa.): I agree with Oliver that general anesthesia can be very helpful. During the last six months one of our anesthesiologists, Dr. Hartman, has persuaded us to use the apneic technique as follows:

He inserts a number 14 polyethylene catheter into the trachea and floods the lung with pure oxygen. The patient can be adequately supplied with oxygen in this manner for 30 minutes.

This method is both safe and effective for laryngoscopy and bronchoscopy. Our experience is limited to eight patients, but we plan to continue using this method for children and unusually apprehensive adults.

DR. SUEHS (closing): I want to thank the discussers for their remarks.

I do not believe we need to be concerned about the danger of anesthesiologists going so far as to remove the laryngeal lesion as long as these patients continue to come to us for diagnosis.

After hearing Dr. Hilding's paper yesterday, I appreciate all the more the skill of the anesthesiologists in our area. We just haven't seen the serious complications being reported from other areas.

In my opinion, the safety of endo-tracheal anesthesia is influenced by the following factors:

- 1) The gentleness and skill of the anesthesiologist.
- 2) The size and type of tube used. Using too large a tube, I think, is a common error. I think a cuffed tube may cause more trauma if it is inflated too tightly, especially if the cuff is engaged just below the cords in the subglottic area.
- 3) The length of the operation.
- 4) The degree of relaxation of the cords at the time the tube is inserted. The cords should be paralyzed with Succinylcholine at the time of intubation.
- 5) Correct timing of the removal of the tube, which Dr. Pressman remarked upon yesterday.

A well-trained anesthesiologist is fully aware of these factors and probably many more that I haven't mentioned. When a good anesthesiologist is available, I believe there is a definite place for this method of direct laryngoscopy in selected cases, and I regard it as a useful adjunct to the removal of benign lesions in potentially difficult cases.

In closing, I would like to add that this method of laryngoscopy should not be regarded as a substitute for adequate training in the skillful removal of benign lesions under topical anesthesia.

INTRANASAL INJECTIONS OF LONG ACTING CORTICOSTEROIDS

DANIEL C. BAKER, JR., M.D.

AND

RAYMOND B. STRAUSS, M.D.

(by invitation)

NEW YORK, N. Y.

The most common nasal symptoms that cause a patient to seek the services of the otolaryngologist are nasal blockage and postnasal discharge. Other symptoms include headache, local discomfort of the face and nose, sneezing, mouth breathing, disturbances in the sense of smell, and epistaxis. Patients may complain of having to resort to the frequent use of nose drops in order to get relief. They may have to take antihistamine drugs several times a day. Examination of these patients frequently fails to reveal a specific disorder that is the cause of their symptoms. The sinuses are usually clear. No exudate is observed in the nose. There may be congestion and swelling of the inferior turbinates. The septum may be deviated but not always to the side of the most disturbing symptoms. There may be evidence of nasal allergy.

What is the cause of their symptoms? Holmes and his co-workers¹ studied the reactions of the nose in human subjects during varying life experiences. They have shown that environmental factors have a great influence on nasal functions and nasal disease. This would explain many of the difficulties that are encountered in trying to treat patients with nasal symptoms.

For many years, we have been aware of our incompetence in dealing with these patients. There did not seem to be any one form of therapy that would help all of them. Treating the emotional condition and getting their confidence was as effective as other forms of therapy.

From the Department of Otolaryngology, College of Physicians and Surgeons, Columbia University, New York, N. Y.

All patients had a careful work-up which usually included blood studies, examination of nasal smears, cultures, x-ray of sinuses, skin testing and desensitization. Local treatment often included nasal shrinkage and irrigation, displacement, submucous resection, partial turbinectomy and cauterization of the nasal mucosa with active cautery or by use of chemicals, such as 95% phenol. Antihistamine drugs were also used.

The benefit derived from the use of adrenocorticotrophic hormone (ACTH) in patients with nasal allergy was shown by Bordley.^{2,3} Dill and Bolstead⁴ showed that the topical use of corticosteroids by nasal sprays was ineffective. The injections of cortisone into nasal polyps was described by Semenov⁵ and Myers.⁶ Wall and Shure⁷ gave a favorable report on the intranasal injections of cortisone into the inferior turbinates for symptomatic relief of allergic rhinitis. Sidi and Tardif⁸ injected hydrocortisone acetate into the anterior third of the inferior turbinates for the relief of allergic rhinitis. They reported benefit in 30 of 50 cases. Mowat⁹ treated 59 patients with allergic rhinitis and rhinitis medicamentosa. He injected hydrocortisone into the inferior turbinates and found improvement in 55 (88 per cent). Simmons¹⁰ reported on 419 patients with vasomotor rhinitis who were given a series of three injections of prednisolone (Hydeltra TBA[®]) into the inferior turbinates. Benefit was obtained in 78 per cent of his cases. It was of interest that the improvement lasted for a period of six months or more. We have leaned heavily on the data contained in Simmons' article and followed closely his method of administration of the corticosteroids. Our observations on the effect of the medication have been similar to those expressed in his paper.

The present study extends over a period of 18 months and includes the clinical results obtained in 487 patients. Two corticosteroids were used, prednisolone and methyl prednisolone (Depo-Medrol[®]). Most of the patients had symptoms of nasal obstruction due to vasomotor rhinitis, allergic rhinitis or bacterial rhinitis. Some patients had nasal blockage which probably was on the basis of emotional disturbances as described by Wolfe.¹¹ In almost every instance, postnasal discharge was a very significant symptoms. Other symptoms included anosmia, sinus headache, mouth breathing, snoring, sneezing, cough, sore throat, hoarseness. In other words, the symptoms included just about everything that might be associated with allergy or disease of the nose and paranasal sinuses.

We found it difficult to persuade patients to permit us to inject the corticosteroid into their noses. It was necessary to overcome their

fears of the hormone substance and its possible effect on the rest of their bodies. Also, we had to allay their aversion to the thought of a needle being inserted into the nose. In order to combat their reluctance to undergo the treatment, we made photocopies of the paper by Simmons and gave them to the patients to read. This removed their objection to being made guinea pigs. The fear or aversion to the use of a needle was overcome by having the patients close their eyes at the time of the injection. Practically everyone was surprised to learn that the injections were not painful.

At the start of the study, private patients were used; later, the treatment was also used for clinic patients. After the first injection of the corticosteroid, the patient did not get much relief. More often, there was a complaint of more nasal blockage, sneezing and discharge. This was found to be due to either the secondary effect of the local anesthetic agent or to the use of the cotton pack before and after the injection. Some patients had a hyperesthetic rhinitis to such a degree that they were unable to tolerate any local disturbance of the nasal mucosa. Experience soon showed that swabbing the site of injection with a cocaine solution of varying strength of 1% to 10% was the best anesthetic agent. A 2% pontocaine or 2% aqueous Xylocaine® solution were also satisfactory. The objection to cocaine was in its shrinkage of the mucosa. In some instances, it was difficult to find a suitable site in the submucosa to inject the solution. To overcome any hypersensitivity of the patient to the local disturbance of the nasal mucosa, an antihistamine was given, by mouth, at the time of the injection. In some instances, one of the tablets of a corticosteroid was given by mouth. When the subsequent injections were given, it was possible to know how to handle each patient by their reaction to the first injection. As a rule, the treatment was tolerated without discomfort to the patient.

It soon became evident that of the two corticosteroids employed, prednisolone was the most effective in giving long-lasting benefit to the patient. Methyl prednisolone gave a more immediate result, but the effect disappeared in a shorter period of time. This is explained by the fact that the prednisolone is a tertiary butylacetate with four side chains and is more insoluble than the methyl prednisolone, which has but one side chain. Winter and Porter¹² studied the effects of the side chain upon hydrocortisone esters. Their results indicate that corticosteroids vary as to their local and systemic effect.

There should be no systemic effects from the intranasal injections of the depot corticosteroids.¹³ The amount injected into the inferior

turbinates is very small in comparison with the oral or parental dose used to get a similar local benefit. The rate of absorption of the depot steroid is very slow and takes place over a period of months. The total amount of prednisolone used in any patient did not exceed 1.6 cc or 32 milligrams over a four week period. This figure is determined by adding the 2 mgm injections into each inferior turbinate at weekly intervals for four weeks.

The Hydeltra TBA is a suspension and the particles are of such size that a 25 gauge needle is the smallest that can be satisfactorily used. I prefer a two-inch needle, and insert the point of the needle underneath the mucous membrane and then raise a wheal in the submucosa. It is difficult to inject more than 0.2 cc, as it leaks out around the needle. At the third injection, the site is so contracted as to make it difficult to find a satisfactory resting place for the tip of the needle.

The best results were obtained in patients with vasomotor rhinitis and allergic rhinitis. At least 75 per cent of this group obtained some benefit. So many were helped that it was difficult, as well as disappointing, to understand why there was some failures. In the latter group, phenolization of the mucosa of the inferior turbinate was used as an adjunct. Poor results were obtained in the patient with large or multiple nasal polyps. It was necessary to remove the polyps before a satisfactory response could be obtained. Likewise very large inferior turbinates and septal deviations affected the end result. This was demonstrated by surgical correction of the obstruction and further injections of the corticosteroid, which then gave benefit.

Each patient was an individual problem and other measures employed in the treatment of nasal and sinus disease were carried out. The long acting steroid therapy was helpful in the treatment of acute rhinitis and acute sinusitis. In this group methylprednisolone gave a more immediate effect allowing for better ventilation and drainage, by causing shrinkage of the mucosa of the swollen inferior turbinate. It was necessary, however, to use other accepted methods in the treatment of the acute condition. The injection of the steroids did not prevent a patient from developing an acute upper respiratory infection. It was not unusual for a patient to develop a cold while undergoing treatment. I find this difficult to explain.

Over the past 18 months approximately 2000 injections of Hydeltra TBA have been given intranasally. There was no untoward reaction from the medication in any instance.

RESULTS

The intranasal injections of long acting steroid into the inferior turbinates is of definite benefit to 75 per cent of patients with vasomotor rhinitis and allergic rhinitis. After a series of three or four weekly injections, the swollen inferior turbinates were found to undergo shrinkage, and the patient had less postnasal discharge. Many patients stated they slept better. A few had a return of their sense of smell. Many were relieved of headache. The majority of patients were satisfied with the therapy and when they had a return of symptoms, they requested more injections.

In addition to vasomotor and allergic rhinitis, we found the steroids to be of value in the treatment of the common cold and in acute sinusitis. Methyl prednisolone seemed to be best suited for this purpose as its effect lasted about a week and the response of the patient was more prompt. After the injection, the mucosa of the inferior turbinate usually lost its swollen appearance and the nose was better ventilated. The sinusitis still had to be treated in the usual manner. The medication was also helpful in patients who developed a vasomotor rhinitis from taking hypertensive drugs. It was of benefit to the vasomotor rhinitis seen in pregnancy.

Many patients who were given intranasal injections of the steroid in the spring, found that their hay fever was markedly alleviated and they went through the season with less symptoms, even though the medication had been given several months before.

One could go on at length about individual successes and failures. For those who received benefit, they sent their friends and relatives for similar treatment. It soon became evident that this type of nasal therapy gave both subjective and objective improvement. The steroid definitely shows anti-inflammatory and anti-allergic effects.

There is no hesitation on our part to use the long acting corticosteroid for almost any nasal complaint. It always appeared to improve nasal ventilation, and to reduce postnasal discharge. It is a good adjunct to the desensitization treatment of the allergist. Many of the patients in this series were referred by specialists in this field. Local intranasal measures, such as phenolization, submucous resection, polypectomy and partial turbinectomy, were found to be necessary in some patients, before a good result was obtained.

SUMMARY

A group of 487 patients were given a series of 3 or 4 injections of a long acting corticosteroid. The injections were given at weekly intervals. The study extended over a period of 18 months.

Prednisolone (Hydeltra TBA) acted over a longer period of time and gave benefit for a period of between 6 to 12 months in 75 per cent of the patients.

Methyl prednisolone (Depo-Medrol) also gave benefit but of shorter duration. It seemed to have more value in the acute nasal problems.

There was no untoward local or systemic reaction in more than 2000 injections.

This type of nasal therapy is a definite step forward in the treatment of many common nasal disorders. When used in conjunction with other forms of nasal therapy, it gives a more effective result of longer duration.

903 PARK AVENUE

REFERENCES

1. Holmes, T. H., Goodell, H., Wolf, S., and Wolf, H. G.: *The Nose*. Springfield, Ill.: Charles C. Thomas, 1950.
2. Bordley, J. E.: Observations on Changes Taking Place in Upper Respiratory Tract of Patients under ACTH and Cortisone Therapy. *Bull. Johns Hopkins Hospital* 87:415-424, 1950.
3. Bordley, J. E.: The Effect of ACTH and Cortisone on the Upper Respiratory Tract. *N. Y. St. J. Med.* 51:2635-2639, 1951.
4. Dill, J. L., and Bolstead, D. S.: Observations on the Local Use of Cortisone in the Nose in Allergic Rhinitis. *Laryngoscope* 61:415-422 (May) 1951.
5. Semenov, H.: The Pathology of the Nose and Paranasal Sinuses in Relation to Allergy. *Tr. Am. Acad. Ophth. and Otol.* 56:121-170 (Mar.-Apr.) 1952.
6. Myers, D.: Experiences in the Treatment of the Allergic Nasal Polyp by the Intrapolyp Injection of Prednisolone T.B.A. *Laryngoscope* 58:1-17 (Jan.) 1958.
7. Wall, J. W., and Shure, N.: Intranasal Cortisone; Preliminary Study. *A. M. A. Arch. Otol.* 56:172-176 (Aug.) 1952.
8. Sidi, E., and Tardif, R.: Treatment of Allergic Rhinitis Associated with Eczema with Hydrocortisone Acetate Injected into Nasal Mucous Membranes. *Semaine des Hosp. de Paris* 35:1922 (May 30) 1955.

9. Mowat, G. G.: Submucosal Injections of Hydrocortisone for Allergic Rhinitis and Rhinitis Medicamentosa. *J. Laryng. and Otol.* 75:283-287 (Mar.) 1961.
10. Simmons, M. W.: Intranasal Injection of Corticosteroids. *Calif. Med.* 92: 155-158 (Feb.) 1960.
11. Wolfe, S. G., Jr.: Causes and Mechanisms in Rhinitis. *Laryngoscope* 62:601-614 (June) 1952.
12. Winter, C. A., and Porter, C. C.: Effect of Alterations in Side Chain upon Anti-Inflammatory and Liver Glycogen Activities of Hydrocortisone Esters. *J. Am. Pharm. Assoc.* 46:9:515-519 (Sept.) 1957.
13. Cantwell, Dr. N. H. R.: Personal Communication.

DISCUSSION

DR. FRED W. ALEXANDER (Cleveland, O.): Dr. Baker visited Cleveland a year ago, and discussed this method of treating these cases. Since his visit, we have treated thirty-five patients who had not responded to all types of local and systemic therapy, as well as allergy therapy. We have found, so far, that 80% of them have had relief from nasal stuffiness and congestion for a period of six to eight months. We have not used this method for patients who had nasal polyps. However, we feel that Dr. Baker's method of therapy is very valuable.

DR. PROETZ: In any discussion of injection methods for nasal allergy I should like to add that for years I have successfully treated nasal allergy with systematically applied multiple punctures of the inferior turbinate, without injecting anything at all. The reaction to this insult is so unquestionable that in selected cases I have not used anything else.

I use a minute, flat, right-angled ossiculectomy knife to make punctures, staggered like upholstery tacks on the back of a sofa, down to the periosteum. It usually lasts through the season but may have to be repeated once.

You may remember that if a patient suffering allergic attacks should break a leg, or suffer some other major trauma, the allergic attacks may disappear while healing is in progress, sometimes for a long time afterwards. All this is in print.*

I merely suggest here that the vasotonic reactions induced by the trauma may play a part in the improvement recorded.

DR. LYMAN G. RICHARDS: While Dr. Baker is coming up, I would like to ask him in what part of the inferior turbinate are these injections made? Much of the trouble in many of these patients is the polypoid enlargement of the posterior portion of the turbinate. Do you inject into the posterior or anterior part of the inferior turbinate?

DR. BAKER (closing): Most of these injections have been into the anterior tip, although sometimes they have been used in the posterior tip. I must reiterate that when a person has a physical obstruction that isn't capable of being reduced in size by vasoconstrictors, it should be removed.

I thank Dr. Alexander for his remarks. I had no control over his results, so I think they do have some significance. It is not just a question of what we have

* Dean, L. W., Proetz, A. W., et al.: Allergic Rhinitis, a Symposium. *Trans. Amer. L., R. and O. Soc., Annals O. R. L.* 45:101 (Mar.) 1936.

been able to accomplish in our clinic. This material is being used in England, Russia, Australia and all over the world.

To answer Dr. Proetz' comments: when I started this study I was told that I should make a double blind study. When I went to the people who deal with steroid therapy, they said that double blind studies had been made with this material in other anatomical areas.

I do want to point out that the corticosteroids are anti-allergic and anti-sensitivity drugs and that they are the most powerful drugs we have. This material I have been injecting into the nose is the same material a medical man would inject into a red-hot swollen joint and think nothing of it.

I think my best answer to Dr. Proetz is that I used two drugs, Depo-Medrol and Hydeltra TBA. One gave one response and the other gave a different response. I would have expected Depo-Medrol to give the best response because the manufacturers say it is twice as strong. It also costs five times as much. However, the Hydeltra TBA certainly gave longer benefit.

INVESTIGATIONS IN LARYNGEAL PHYSIOLOGY

THE CANINE LARYNX

Part I

DAVID W. BREWER, M.D. K. FAABORG-ANDERSEN, M.D.

SYRACUSE, N. Y. NYKOBING, FALSTER, DENMARK

SIDNEY T. DANA, M.D.

SYRACUSE, N. Y.

(by invitation)

This 16 mm silent motion picture in color 1) reviews the anatomy of the canine larynx; 2) demonstrates changes in vocal cord position and contour resulting from individual stimulation of each of the intrinsic muscles of the larynx; 3) demonstrates the effects of superior laryngeal and recurrent nerve stimulation and 4) provides a comparison with studies on the human larynx which presently are in progress.

Muscle stimulation in both freshly excised larynges and in the intact preparation examined by suspension laryngoscopy are portrayed.

The unusual results of stimulation of the recurrent nerve following the method of Nakamura¹ are presented.

Following the anatomical review individual stimulation of:

A. Thyroarytenoid shortens and thickens the vocal cord and partially abducts the arytenoid cartilages.

B. Cricothyroid lengthens and thins the vocal cords and produces laryngeal torsion to the contralateral side.

C. Lateral cricoarytenoid causes the tip of the vocal process to approach the midline, carrying the cord with it.

D. Posterior cricoarytenoid causes abduction of the cord and arytenoid with lateral excursion of the tip of the vocal process.

E. Ventricularis causes narrowing of the posterior commissure, the aryepiglottic fold tenses and the false cord abducts.

F. Transverse arytenoid causes narrowing of the posterior commissure and tenses the aryepiglottic fold.

Stimulation of the superior laryngeal nerve causes cricothyroid contraction only. Stimulation of the recurrent laryngeal nerve at 20 cps produces posterior cricoarytenoid contraction only. At 30 cps or higher contraction of all the other intrinsic laryngeal muscles occurs with closure of the glottic chink.

Studies using the freshly excised human larynx thus far show no detectable variations from those noted above except with the interarytenoid, the origin and insertion of which is different in the dog.

1100 EAST GENESEE ST.

REFERENCE

1. Nakamura, F.: Proceedings of International Conference on Research Potentials in Voice Physiology, State University of New York Press.

DISCUSSION

DR. OGURA: Dr. Richards wrote to me some time ago about discussing this paper. I didn't appreciate its contents until Dr. Brewer sent me his paper just a day ago.

I think this piece of work is of fundamental importance, first because of his imaginative approach with this organ isolation nerve muscle stimulation technique. This approach, of course, has many practical applications, namely, that as Dr. Brewer and his associates have pointed out, we are now able to open up new vistas for explaining some of our clinical problems that heretofore have not been understood.

I would, however, like to ask Dr. Brew one question. He mentioned towards the end that a 20 microvolt stimulus caused adduction of the cord and that on increasing this stimulus abduction occurred. Did he mean to imply that this was brought about by a different set of muscles?

DR. DANA (closing): Thank you, Dr. Ogura, for your very kind remarks.

The work which was presented by Dr. Nakamura last Spring at International Voice Conference in Syracuse, N. Y., was primarily of a descriptive nature. He was able to demonstrate differences in vocal cord movement by varying the frequency and intensity of recurrent nerve stimulation. Our own investigations in nerve and muscle stimulation tend to confirm his findings. We believe that a concise answer to your pertinent question will have to be deferred until additional basic studies have been executed and evaluated. These studies will have to correlate electroneurography of the laryngeal nerves, electromyography of the laryngeal muscles and visual changes in the larynx.

I would like to say, in closing, to the many residents attending this meeting that when a resident is invited by his department to work on a laboratory project he need not be disappointed if he is unable to discover something new. If he has done no more than help to clarify the understanding of a difficult clinical or physiologic problem, then we must consider that his time has been very well spent and his activities well directed. Thank you.

PAPILLARY LESIONS OF THE NOSE AND SINUSES

AUSTIN T. SMITH, M.D.

AND

JOHN P. DECKER, M.D.

(by invitation)

PHILADELPHIA, PA.

Papillary growths are characterized by branching strands or ridges of stromal tissue surfaced by epithelium. Such growths occurring in the nose and sinuses are usually termed "polyps," clinically. The clinical designation "polyp" is applied to a wide variety of diseases resulting from inflammatory hyperplasia or neoplastic proliferation including papillomas of the nose and sinuses. There are great differences of opinion concerning the origin of the papilloma, whether inflammatory or neoplastic, and its course, whether benign or malignant. The purpose of this study is to attempt to clarify, both clinically and pathologically, the nature of papillary lesions of the nose and sinuses especially the papillomas.

MATERIAL

The material consists of eleven papillary lesions of the nose and sinuses seen by the senior author in his practice and at the Ear, Nose and Throat Clinics of the Jefferson and Pennsylvania Hospitals. Eight cases are classified as papilloma; three additional cases have been included to illustrate differences between papillomas and clinically similar lesions of other types.

CLINICAL AND PATHOLOGICAL OBSERVATIONS

Papillary Tumors. The clinical data of the eight cases of papilloma are summarized in Table I.

From the Department of Otolaryngology and the Ayer Clinical Laboratory of the Pennsylvania Hospital, Philadelphia 7, Pennsylvania.

Four of the papillomas are presented in greater detail to illustrate some important clinical manifestations and pathologic features common to the group as a whole.

REPORT OF CASES

CASE 1. A 49 year old physician came for treatment in 1956. He gave a history of allergic, polypoid, hyperplastic sinusitis involving the left maxillary sinus. The clinical diagnosis had been established at another hospital and a Caldwell-Luc operation had been recommended; tissue had been removed through a naso-antral window and a diagnosis of benign papilloma of inflammatory origin had been made. Removal of polyps from the left nasal chamber several months earlier caused such severe bleeding as to require anterior and posterior packing. Exposure of the left maxillary sinus by means of the Caldwell-Luc operation revealed the cavity filled with friable, vascular, papillary tissue. The mucosal base was a firm, compact, solid, pale tan tissue which was difficult to detach from the bony walls. Profuse bleeding occurred during the procedure. Pathologic diagnosis was Schneiderian carcinoma, described as a transitional cell tumor of low malignancy more likely to spread outward than to infiltrate deeply. Consultant pathologists who reviewed the sections made diagnoses of Schneiderian papilloma and benign papilloma.

Recurrence was soon apparent and a second operation was performed four months later. The Denker operation, which gave better exposure of the maxillary sinus and ethmoid capsule was performed under general anesthesia and all remaining tissue was cleared from the walls of the maxillary and ethmoid sinuses. Electrocoagulation was used to ensure removal from the angles and corners. The pathologist reported papillary or verrucous carcinoma, the tendency of which was to extend superficially rather than to invade (Figs. 1 and 2). There has been no evidence of recurrence in the five years since the second operation.

CASE 3. A 71 year old woman, who complained of discharge and obstruction of the left nasal chamber, was referred by her physician in 1956 for removal of a polyp which partially occluded the left naris. Examination revealed a granular mass, 0.5 cm in diameter, attached by a stalk to the under surface of the inferior turbinate about 1 cm from its anterior tip. From this point it extended downward into the inferior meatus and into the anterior part of the nasal chamber, effectively blocking the left naris. The nose and sinuses were

TABLE I

CASE	DURATION	COMPLAINT	LOCATION	CHARACTER
<i>Papillomas:</i>				
1	49M 10+ years	Allergic rhinitis, nasal polyps, sinusitis	L maxillary sinus	Sinus filled with friable papillary tissue
2	60M 10+ years	Nasal discharge and obstruction, chronic sinusitis	L maxillary sinus and nasal chamber	Soft polypoid tissue in sinus extending into nose
3	71F Months	Nasal discharge and obstruction, left	Antero-inferior surface, L inferior turbinate	Granular, papillary, soft pedunculated brown mass
4	67M 2 years	Nasal obstruction	L maxillary sinus and nasal chamber	Polypoid mass coming from middle meatus
5	72M 3 years	Bilateral recurrent nasal polyps	L maxillary sinus and nasal chamber	Polypoid masses filling sinus
6	63M 3-4 years	Bilateral nasal obstruction	Septum and vestibule, bilateral	Superficial papillary growths
7	40M 10+ years	Recurrent nasal polyps	R nasal cavity, maxillary, sphenoid and ethmoid sinuses	Large polypoid granular mass filling nasal chamber
8	48M Years	Nasal obstruction, pain	R maxillary sinus and nasal chamber	Polypoid mass extending from maxillary sinus into nasal cavity
<i>Other Papillary Growths:</i>				
9	32F Years	Nasal obstruction, allergy asthma, deafness	Lower L nasal chamber	Pedunculated polypoid mass arising from postero-inferior surface, middle turbinate
10	74M 1 year	Nasal obstruction, recurrent mass	R nasal chamber	Firm, nodular tumor attached to lateral wall, inferior turbinate
11	54M 1 month	Epistaxis, nasal polyp	R septal cartilage	Firm, vascular pedunculated mass

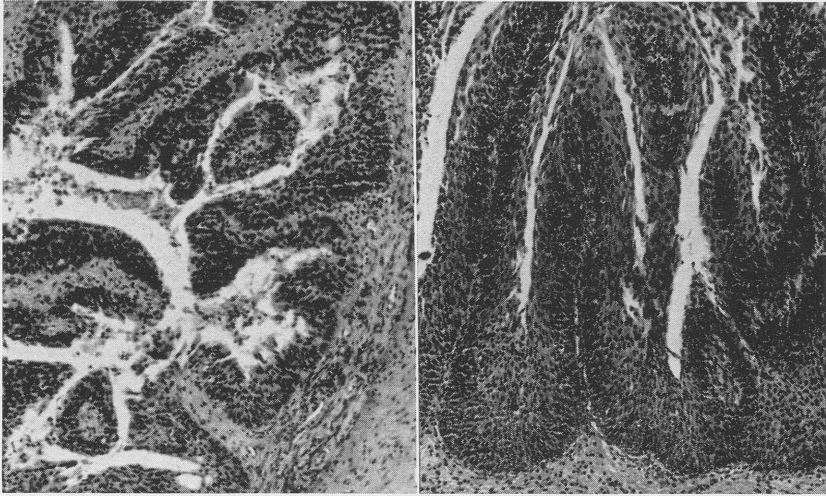


Fig. 1.—Case 1. A villiform papilloma with transitional epithelium.
150 X.

Fig. 2.—Case 1. Verrucous growth in another area is partially squamous.
150 X.

otherwise free of abnormalities. The lesion was soft, friable, superficially attached and easily removed with a biting forceps without undue bleeding. The pathologic diagnosis was epithelial papilloma; the tendency of such a growth to spread over mucosal surfaces and to recur locally was noted.

The patient returned two years later with a papillary mass of similar appearance at the same site; it was again large enough to obstruct the naris. It was removed as before and the site of attachment curetted and electrocoagulated. The pathologic diagnosis was again epithelial papilloma (Fig. 3).

By 1960, the growth had again recurred and obstructed the left nasal chamber. It was removed with the electrocoagulating snare and the site of attachment thoroughly coagulated. The specimen measured 2 cc in volume and consisted of delicately fibrous but generally amorphous, structureless, light tan material. The pathologic diagnosis was papillary carcinoma (Fig. 4). The patient had had no recurrence when seen a year later.

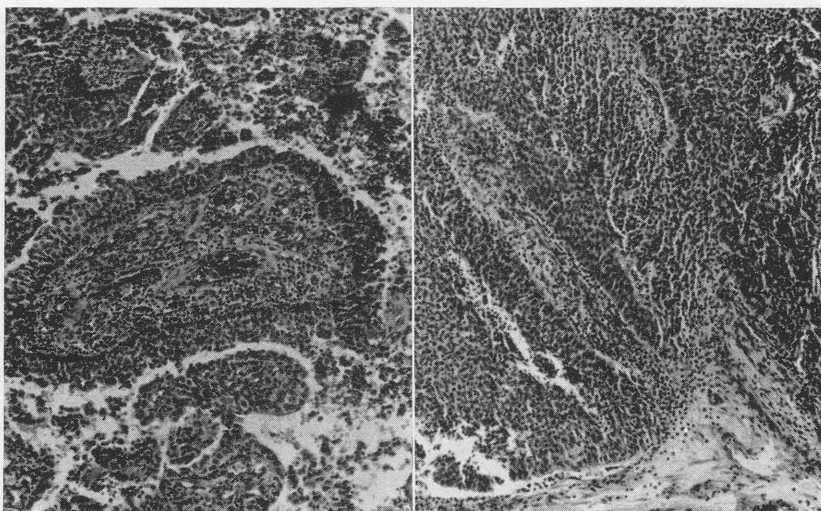


Fig. 3.—Case 3. A papillary frond from the specimen of the second excision. 150 X.

Fig. 4.—Case 3, third excision. The papillary pattern is obscured by epithelial overgrowth; diagnosis was papillary carcinoma. 150 X.

CASE 4. A 67 year old man was first seen in April, 1961, for removal of large polyps of the left nasal chamber. He had been aware of nasal obstruction for two years but had not previously consented to treatment. On examination, a large polypoid mass almost filled the left nasal chamber and extended through the choana. It originated in the middle meatus and was partially removed in several sections by a nasal snare; there was no undue bleeding. On the next day, an oval, soft mass, 3 x 3 cm, was removed under local anesthesia from the right submaxillary region; it was just beneath the superficial fascia and appeared to be an enlarged lymph node unconnected with the nasal disease.

The pathologic diagnosis of the nasal growth was low grade papillary carcinoma (Fig. 5); the diagnosis of the lymph node was metastatic carcinoma. To clarify the problem presented by these findings, the patient was hospitalized for further study. The chest film indicated the presence of pulmonary densities attributed to unresolved pneumonia. Biopsy of scalene lymph nodes yielded no definite results. Needle biopsy of the enlarged, nodular liver was interpreted as meta-

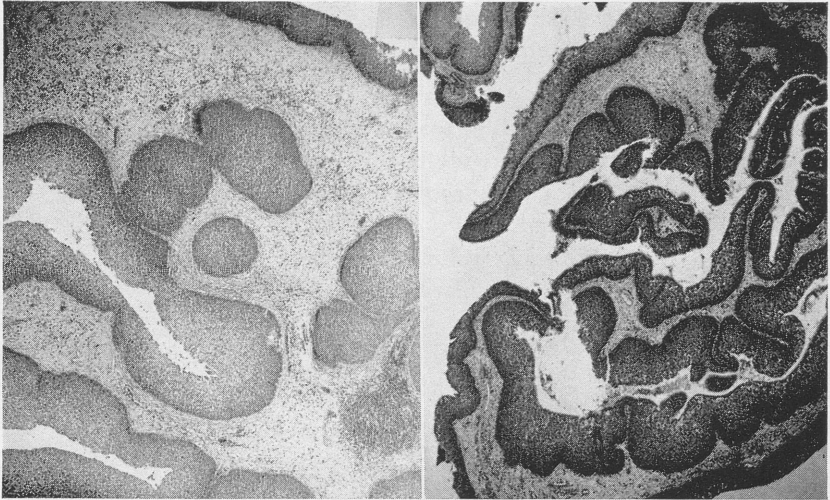


Fig. 5.—Case 4. The stroma of the inverted papilloma is more abundant and denser. 45 X.

Fig. 6.—Case 8. A low power view shows the characteristic inverted papillary form of growth. 40 X.

static undifferentiated carcinoma. The patient died at home after discharge from the hospital and no autopsy was obtained.

CASE 8. A 48 year old man was first seen in 1958 complaining of nasal congestion. His general health was good and there was no history of allergy. Examination revealed a large, polypoid mass filling the lower half of the right nasal chamber and extending back to the nasopharynx. It originated in the right maxillary sinus and entered the nasal chamber through the inferior meatus. There was no discharge or other indication of inflammation. The sinus was dark on transillumination and by x-ray. A diagnosis of probable neoplasm was made. The Denker operation was performed on the right maxillary sinus under general anesthesia. The sinus was filled with polypoid tissue which had eroded through the naso-antral wall beneath the inferior turbinate and extended into the right nasal chamber and through the choana into the nasopharynx. The mass and attached mucosa were readily separated from the walls of the sinus. The original pathologic diagnosis was polypoid sinusitis; on review, this has been changed to papilloma (Fig. 6).

Pathologic Findings. The material removed at operation in the eight cases of papilloma ranged from 0.5 to 10 cc in volume. The tissue presented no distinctive gross appearance, though it was sometimes described as polygoid or granular.

The microscopic appearance was characterized by two growth patterns. The first was the familiar arborescent surface growth in which stalks of connective tissue were covered by epithelium (Figs. 1 and 3). The second, and more common, pattern was that of the inverted papilloma in which strands of connective tissue were broader and the epithelial covering extended into branching clefts (Figs. 5 and 6). In this type, the underlying papillary pattern was often so obscured by stromal overgrowth and infolding of the epithelial covering that isolated nests of epithelium appeared buried within the tumor (Fig. 5). The villiform pattern was present in Cases 1, 3 and 6 and the inverted papilloma pattern in the remainder.

The character of the epithelium varied greatly even within the same tumor (Figs. 1 and 2). Most of the epithelium in these tumors, however, was best designated as transitional, being neither completely columnar nor completely stratified, though possessing features of both (Fig. 7). This epithelium has an active basal zone in which mitotic figures may be seen; superficial cells display increase of cytoplasm and flattening but neither keratinization nor intercellular bridges were typically seen. In many instances, a row of ciliated columnar cells was seen at the surface (Fig. 7). Vacuoles, whose contents stained intensely positive with the periodic acid Schiff reaction, were frequently seen in the transitional epithelium.

The stroma also presented varied patterns. In the villiform growths, the stroma was formed of delicate, branching strands of loose connective tissue enclosing thin walled vessels (Figs. 1 and 3). The stroma of the inverted papillomas was generally composed of denser collagenous fibers, though the loosely structured edematous connective tissue so often seen in the mucous nasal polyps was also encountered. The inflammatory component was varied, consisting of plasma cells, lymphocytes and eosinophils; neutrophils were frequently seen within vacuoles in the transitional epithelium (Fig. 7).

Nuclear anaplasia and stromal invasion was seen in none of these tumors except for the specimen from the third excision in Case 3 (Fig. 4). This was a cellular growth in which columns of epithelial cells were separated by delicate strands of connective tissue; mitotic figures were frequent and lymphatic invasion was present.

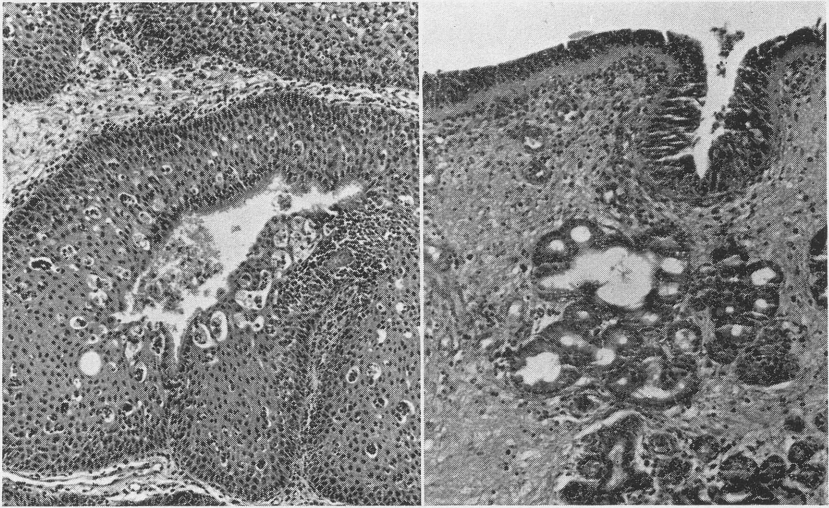


Fig. 7.—Case 7. The transitional epithelium is surfaced by ciliated columnar cells and contains mucus vacuoles. 150 X.

Fig. 8.—Case 9. In the inflammatory polyp, the epithelium is columnar; both respiratory basement membrane and seromucous glands are present. 180 X.

Other Papillary Growths. Three additional cases of papillary growth are presented to illustrate the wide variety of lesions commonly included under the designation polyp or papilloma on clinical appearance alone. Clinical data are summarized in Table I.

CASE 9. A 32 year old woman was first seen in 1955 complaining of left-sided nasal obstruction and deafness. Past history included bronchial asthma, autumnal hay fever and recurrent otitis media. On examination, pallor and edema of the nasal mucosa were typical of allergic rhinitis. A large polypoid mass largely filled the left nasal chamber and extended into the nasopharynx. The left antrum was dark on transillumination; there was edema of the orifice of the left eustachian tube with serous otitis media and deafness of 35 to 60 db for the speech frequencies. Myringotomy and aspiration of fluid from the left tympanum restored hearing to normal. The polypoid mass was attached in the left middle meatus close to the natural ostium of the left maxillary sinus, completely blocking it. The growth was firm, fibrous, relatively avascular and similar to the papillomas presented

previously. It was removed in several portions; the diagnosis was nasal polyp. On examination a month later, all findings were negative.

The patient returned in 1962; at that time, a large polypoid mass again largely filled the left nasal chamber and extended into the nasopharynx. It was attached at the same site as the first tumor. The right nasal chamber was clear; the mucosa was pale and edematous and the ears and sinuses were normal. The recurrent growth was firm, fibrous and relatively avascular, like that removed seven years before. The diagnosis was nasal polyp.

The two specimens were similar grossly and each totalled about 8 cc in volume. They were composed of firm, finely granular pink-tan tissue. On microscopic study (Fig. 8), the surface epithelium was normal respiratory type. The respiratory basement membrane was thickened and seromucous glands were numerous. The surface was convoluted and the dense, fibrovascular stroma contained collections of lymphocytes, plasma cells and neutrophils.

CASE 10. A 74 year old man was first seen in 1961 complaining of right-sided nasal obstruction. Nasal polyps had been removed twice during the previous ten months but histologic examination was not performed. On examination, a firm, smooth dark mass just within the right naris filled the nasal chamber. It was attached to the inferior turbinate and bled readily when touched. The left nasal chamber was normal and blood tinged discharge came from the right choana. The sinuses were clear on transillumination except for the right maxillary which was cloudy. Removal was undertaken by means of a sublabial incision and exposure similar to the Rouge operation. The right naso-antral wall, inferior and middle turbinates were removed with the attached growth back to the sphenoid-ethmoid recess. Pathologic diagnosis was malignant melanoma.

Tumor recurred high in the nasal chamber within two months. A lateral external rhinotomy including exposure of the frontal sinus was done and the mucosa of the maxillary sinus, ethmoid box, frontal sinus, sphenoid sinus and cribriform plate was removed. The growth had penetrated the ethmoid box to some extent but there was no evidence of infiltration of the mucosa or bony walls of any of the sinuses. Pathologic diagnosis was recurrent malignant melanoma. When last seen, there was no evidence of local or metastatic spread ten months after the first operation.

CASE 11. A 54 year old man was referred because of a nasal polyp which obstructed the right nasal chamber and caused troublesome epistaxis. On examination, a moderately large polyp was attached to the right side of the septum opposite the anterior tip of the middle turbinate; it was firm and bled readily when touched. The growth was removed with a snare and the base coagulated. The histologic diagnosis was hemangioma.

COMMENT

Papillomas of the nose and sinuses are uncommon tumors. The present series of eight cases was drawn from the experience of the senior author in his own practice and in two large metropolitan hospitals. Osborn's¹ 61 cases were drawn from 189,224 visits to the Outpatient Department of the Royal National Throat, Nose and Ear Hospital over an eight year period. Henriksson's² 21 cases came from six years' experience in clinics at Lund and Malmö; he estimated that these corresponded to three new cases per year in a hospital district of 1.5 million persons. Pfisterer³ estimated that about 200 cases had been reported to 1961.

The confusion concerning papillomas of the nose and sinuses is exemplified by the variety of terms which have been applied to them: respiratory papilloma,⁴ epithelial papilloma,⁵ true papilloma,⁶ hard and soft papilloma,³ transitional cell papilloma,¹ Schneiderian papilloma and carcinoma, papillary fibroepithelioma.⁷ In the present study, the benign papillary tumors were termed "papillary carcinoma," "low grade papillary carcinoma," "epithelial papilloma" and "polypoid sinusitis" by staff pathologists in one laboratory. On review of the entire series, all appear fundamentally similar except for the one malignant example, Case 3. There are objections to many of the foregoing terms. The designations "hard" and "soft" refer to the clinical appearance of the lesion and not to any differences in behavior. "Epithelial papilloma" is tautological, for all papillomas are epithelial growths. "Papillary fibroepithelioma" assigns too great importance to the variable stromal component. Terms based on the character of the epithelium fail to account for variations in epithelial type within the same tumor. To describe a tumor as Schneiderian merely employs an unfamiliar eponym to locate it in the nose. The simplest terminology is best and the term "papilloma of the nose and sinus" is suggested.

CLINICAL FEATURES

An outstanding clinical feature of papillomas of the nose and sinuses is the large size they may reach before producing significant symptoms. When a diagnosis is made, it is usually that of polyp and considered of little consequence by physician and patient alike.

A distinction must be made, however, between simple polyps and papillary tumors even though apparently similar on clinical examination. The polyps commonly found in allergic rhinitis and sinusitis result from mucosal hyperplasia and edema, often aggravated by secondary infection. Inflammation seemed to play no part in the origin of the papillary tumors in this series; when present, inflammation was coincidental or the result of obstruction of nasal passages or sinus ostia. In cases with a history of allergy, this seemed to play no part in the development of a papillary tumor. All tumors were unilateral and solitary, save for Case 6; this localization is not usual in allergic diseases of the upper respiratory tract. An exception is the unilateral, polypoid inflammatory growth in Case 9 which recurred at the same site after seven years. Histologically, however, this hyperplastic growth was quite different from the papillary tumors despite a similar gross appearance.

The occurrence of many of the papillomas in the maxillary sinus accounts for the large size they may attain before producing symptoms. In the sinus, the tumor has a spacious cavity within which to grow and it does not cause symptoms until it extends into the nasal cavity and impairs nasal breathing. Six of the eight papillary tumors in the present study involved the maxillary sinus; in Case 7, the ethmoid and sphenoid sinuses were also involved. Involvement of sinuses other than the maxillary is rare, though Millar⁸ has recently reported a papilloma in the frontal sinus. Epistaxis may call attention to nasal tumors earlier than to those in the sinuses.

From the cases presented, it is clear that accurate diagnosis of polypoid and papillary lesions in the nose and sinuses on clinical grounds alone is often inaccurate, because examination is limited to visual inspection through the nares and palpation with a probe. Histopathologic study of the lesion is essential; failure to do so may delay a correct diagnosis as in Case 10 where a malignant melanoma was undiagnosed for ten months because tissue was not examined. At times, pathologic diagnosis may be difficult or uncertain, but it remains

the only method whereby a polypoid or papillary lesion can be classified as inflammatory or neoplastic, benign or malignant.

Inflammatory lesions may not require total excision, but the neoplastic papillomas require thorough extirpation in order to prevent recurrence. To accomplish this end, surgical exposure by an external approach is the best procedure.

PATHOLOGIC FEATURES

The problem of the pathogenesis of the papillomas of the nose and sinuses has revolved about their relationship to inflammatory hyperplasia of the mucous membranes. Ringertz⁹ felt that papillomas might arise from polyps though he regarded such a transition as uncommon. Takashi¹⁰ regarded papillomas as precancerous lesions which might be derived from inflammatory polyps. The possibility that papillomas might be viral in origin has been mentioned though supporting evidence is lacking.¹¹ Most writers^{6,7,12,13} have been unable to establish a causal relationship between inflammatory hyperplasia and papilloma, and the present authors support this view.

The striking tendency of papillomas to involve the sinuses, particularly the maxillary, noted in the present series has been commented upon by others. Thirty-one of Osborn's¹ 61 cases involved the maxillary sinus; Kramer and Som⁶ found most of their cases in the ethmoid area with maxillary sinus involved next most frequently; six of Henriksson's² 20 cases were in the sinuses and two of Fleischer's⁷ eight. Bilateral involvement is uncommon; one of eight cases in the present series, one of Henriksson's twenty and four of Osborn's 61. Papillomas tend to occur in men past the age of 40; seven of the eight patients in this series were men aged 40 to 72; the ratio of men to women in Osborn's series was 10:1 with a peak incidence in the fifth and sixth decades; 15 of Henriksson's 21 patients were men aged 17 to 87; all of Henriksson's 21 patients were men aged 17 to 87; all of Fleischer's eight patients were men aged 42 to 62. The tendency of papillary tumors to involve isolated sinuses, to be unilateral and to occur most frequently in men past the age of 40 suggest that papilloma is a distinctive tumor unrelated to inflammatory hyperplasia which lacks these features.

Uncertainty regarding papillomas has arisen because of difficulties in distinguishing them from inflammatory processes both clinically and pathologically. Neither the character of the stroma nor of the

epithelium alone is sufficiently distinctive to separate the two processes; Fleischer⁷ asserts that histologic differences between polyp and papilloma are only quantitative. In the present study, the following features have been found helpful in recognizing the papillomas: awareness that the tumor may present either as a villiform or as an inverted papilloma; absence of the true respiratory basement membrane; and excessive proliferation of transitional epithelium. The presence or absence of eosinophils has been found to be of no differential value.

Probably papillomas may become malignant, though such a transformation is unlikely and requires several years to develop. Case 3 of the present series is an example; Kramer and Som⁶ and Osborn¹ cite similar examples. Metastases have never been recorded from a typical papilloma: Case 4 had metastatic carcinoma in a submaxillary lymph node on the opposite side but there was also metastatic tumor in the liver; the lung is a likely primary site because of the radiographic changes. Long duration alone does not lead to development of carcinoma; Pfisterer³ has reported a case in which a benign papilloma was excised on seven occasions over a 35 year period. The histological recognition of carcinoma has not been difficult and is based upon nuclear atypism, frequent mitosis and stromal penetration.

CONCLUSIONS

1. Eight cases of papilloma of the nose and sinuses are presented. Six involved the maxillary sinus as well as the nasal chamber; one was bilateral. One tumor developed evidence of malignancy after five years.

2. Three clinically similar cases are presented to illustrate the difficulty of differential diagnosis of papillary lesions on clinical grounds. Histopathologic study is necessary for correct diagnosis and rational treatment.

3. In contrast to inflammatory processes, neoplastic papillomas require total excision to prevent recurrence and surgical exposure must be adequate.

4. Papilloma of the nose and sinuses is a distinctive neoplasm unrelated to inflammation. It is usually unilateral, often involves the maxillary sinus and typically occurs in men past the age of 40.

330 S. 9TH ST.

ACKNOWLEDGEMENTS—The authors wish to thank Dr. J. J. Moran for providing pathologic material from the Jefferson Hospital and Dr. Seymour Wagner for assistance in assembling the clinical data.

REFERENCES

1. Osborn, D. A.: Transitional Cell Growths of the Upper Respiratory Tract. *J. Laryngol. and Otol.* 70:547-588, 1956.
2. Henriksson, N. G.: Papillomas of the Nose: A Clinical Survey and Contribution to Our Knowledge of These Tumors. *Acta Oto-Laryngol.* 42:18-29, 1952.
3. Pfisterer, H.: Über das sogen. harte Papillom der Nase und der Nebenhöhlen. *Oto-Rhino-Laryn.* 23:217-232, 1961.
4. Willis, R. A.: Pathology of Tumors, 3rd Ed. Washington: Butterworth, p. 356, 1960.
5. Ewing, J.: Neoplastic Diseases, 4th Ed. Philadelphia: W. B. Saunders, p. 783, 1942.
6. Kramer, R., and Som, M. L.: True Papilloma of the Nasal Cavity. *Arch. Otolaryng.* 22:22-43, 1935.
7. Fleischer, K.: Vergleichende histologische und katamnestische Untersuchungen bei papillaren Fibroepitheliomen der Nase. *Arch. Ohr.-Nas. u. Kehlkopfh.* 173: 225-231, 1958.
8. Miller, H. S.: Transitional Cell Papilloma of the Frontal Sinus. *Jour. Laryng. and Otol.* 75:753-759, 1961.
9. Ringertz, N.: Pathology of Malignant Tumors Arising in the Nasal and Paranasal Cavities and Maxilla. *Acta Oto-Laryng. Suppl.* 100:1-405, 1938.
10. Takashi, M.: Carcinoma of the Paranasal Sinuses: Its Histogenesis and Classification. *Amer. Jour. Path.* 32:501-519, 1956.
11. Verner, J. L., Maguda, T. A., and Young, J. M.: Epithelial Papillomas of the Nasal Cavity and Sinuses. *Arch. Otolaryng.* 70:574-578, 1959.
12. Saxen, A.: The Relationship of Nasal Polyps and Papillomas to Cancer. *Acta Oto-Laryngol. Suppl.* 100:98-9, 1952.
13. Geschickter, C. F.: Tumors of the Nasal and Paranasal Cavities. *Amer. Jour. Cancer* 24:637-660, 1935.

THE SURGICAL TREATMENT OF CARCINOMA OF THE NOSE

JOHN MARQUIS CONVERSE, M.D.

AND

DONALD WOOD SMITH, F.R.C.S.E.

NEW YORK, N. Y.

Malignant disease of the nose may arise from any of the nasal structures, or from extension of lesions of the maxillary sinuses or ethmoid sinuses. The commonest tumors are basal cell carcinoma and squamous cell carcinoma, the latter usually of a low to moderate grade of activity.

Early adequate treatment of basal cell and squamous cell carcinoma is essential as late or recurrent tumor tends to involve bone or cartilage with a marked increase in its rate of growth. Early lymphatic metastases are not a feature of carcinoma of the nose but spread to perichondrium or periosteum is usually followed by a wide and rapid extension along these structures, often without recognizable clinical evidence of such extension. These facts emphasize the need for a careful histological examination of the base and the edges of the lesion and the surrounding tissue at the time of primary excision in order to insure that the lesion is completely removed.

INCIDENCE

The incidence of carcinoma of the nose varies with the age, sex, race, occupation and geo-climactic exposure of the patient. In 1374 patients with basal cell carcinoma of the nose, Pack and LeFevre⁹ found that the average age of the patient was 61 years. Ward and Hendrick's series¹⁰ showed 60% of all cases of basal cell carcinoma appearing in patients over the age of 60 years; 67% of the cases in males. The over-all incidence of carcinoma of the nose is approximately 27% of all carcinomas of the skin. Allison and Wong¹ quote

an incidence of skin carcinoma of 138 per 100,000 for Caucasian races and 3.1 per 100,000 for non-Caucasians in Honolulu; figures for a similar Caucasian population in Dallas are 109 per 100,000, in San Francisco 90 per 100,000, in Philadelphia 39 per 100,000, illustrating the significance of racial and climactic variations in the incidence of carcinoma of the skin. Basal cell carcinoma is encountered approximately twice as frequently as squamous cell carcinoma, squamous cell carcinoma tending to appear in the younger age group (Conway⁵) and to have a poorer prognosis. The patients' occupation is also a factor in carcinoma of the skin, the incidence being significantly higher in individuals who follow an outdoor occupation, farmers or sailors, for example.

PREMALIGNANT LESIONS

The common precursor of carcinoma of the skin is senile keratosis and while estimates vary as to the probability of malignant changes occurring in senile keratosis, a figure of 10 to 15% would not appear unreasonable. The hyperkeratotic lesions usually develop in individuals of fair complexion with a dry skin who have been exposed to the elements over the years; the disease, however, is by no means confined to persons of this group. The earliest change is a thinning of the skin with a depigmentation followed by development of hyperkeratotic plaques, often lightly pigmented and raised above the skin surface. Other less commonly encountered precursors are post-radiation dermatitis, xeroderma pigmentosum, cutaneous horns, and lupus vulgaris or lupus erythematosus.

CLINICAL FORMS

Basal cell carcinoma begins as a waxy discreet nodule with firm consistency and confined to the skin. As the lesion progresses, it develops a scaly center and the edges become rolled and pearly. There are marked differences in the rate of progress of the various basal cell cancers. In the scaling lesion, slight trauma causes bleeding and the scab may be cast off repeatedly; alternatively a thin epithelial cover may appear in the center of the expanding lesion. The growth is local and the degree of surrounding induration variable and appears related inversely to the activity of the neoplastic process, the active so-called "rodent ulcer" having almost no surrounding induration but tending to spread both peripherally and deeply. Lymphatic extension is rare, even in the late stage, but local extension to bone or cartilage may occur with disastrous results.

Squamous cell carcinoma begins as a discreet papule progressing more rapidly than the basal cell carcinoma, occurs in the younger age group, tends to ulcerate in its center, with a serrated border, everted edges, and surrounding induration. Papillary forms are unusual. They have either a broad or pedunculated base and a slower rate of growth than the ulcer variety which can spread rapidly in depth to the underlying bony and cartilaginous structures. On the exterior of the nose, squamous cell carcinomas are usually of a low to moderate grade of activity in contrast to lesions of the interior of the nose. Squamous cell carcinoma of the interior of the nose is unusual, generally arising on the anterior-inferior portion of the septum or in the nasal vestibule and is of high grade activity. This type of lesion tends to early lymphatic spread, a feature not shared by the external nasal carcinomas.

Malignant melanoma, a highly malignant neoplasm, occurs usually but not invariably after puberty, arising in the skin of the exterior of the nose or rarely in the mucous membrane of the nasal cavities. Malignant melanoma usually arises from a nevus showing signs of junctional activity, rarely from a pure intradermal nevus (Masson,⁷ Boyd³). Malignant melanomas usually spread to regional lymph nodes and distant metastases occur early; in the nose, however, metastases occur late. The usual sites in the nasal cavities are the anterior inferior portions of the septum and the inferior turbinates (Pack,⁹ Figi⁶).

Blashi² notes that other types of tumors constitute less than 2% of all malignant tumors involving the nose. Neurofibroma of the nasal vestibule, lymphosarcoma of the turbinates, chondrosarcoma of the nasal septum are the most frequently observed types of unusual neoplasm involving the external nose.

TREATMENT

Adequate treatment of carcinoma of the nose presupposes accurate clinical and pathological diagnosis. An experienced clinician may diagnose basal cell carcinoma and squamous cell carcinoma of skin with a remarkable degree of accuracy. However, even in the most experienced hands occasional errors of diagnosis occur and biopsy should be performed as an essential adjunct to diagnosis. Biopsy and confirmation of the diagnosis is essential prior to submitting the patient to full thickness excision which, of necessity, is often a mutilating and disfiguring procedure.

DIAGNOSIS

Diagnosis of a malignant lesion is made by clinical examination confirmed by biopsy. A careful physical examination in search of metastases in the draining lymph nodes is essential.

Biopsy of the lesion for histological examination may be performed as an excision biopsy in small lesions or a marginal biopsy in large lesions. In biopsy of the larger lesions, it is essential to include a portion of the normal surrounding tissue to allow for accurate interpretation of the pathology. For this reason we feel that such methods as needle and punch biopsy are of little practical value in the accurate diagnosis of malignant lesions of the nose. Biopsy is an essential prerequisite to treatment of lesions by irradiation.

Mohs' method of treatment of basal cell carcinoma involves a continuous excision biopsy of all extensions of the lesion and requires the services of a pathologist trained in this technique. One may not agree that the caustic method is the best method of eradicating basal cell carcinoma, but the contribution made by Mohs is the emphasis laid upon the careful histological examination of all possible extensions of the lesion to insure against recurrence.

Histological examination of the biopsy specimen may be performed by routine paraffin sections or by the frozen section method. In general, it is recommended that the paraffin section method be used, as examination of a frozen section suffers certain limitations. The limitations of the method must be clearly defined, they are the urgency with which the examination must be carried out, the thickness of the section, the use of a stain not always suitable for all methods of diagnosis and the required degree of proficiency in the technique and diagnosis on the part of the pathologist. The frozen section is an aid in helping the surgeon to decide between a limited or a radical operation.

The specimen must be oriented for the pathologist with a suture at the twelve o'clock position on a piece of cardboard with a diagram of the nose drawn upon it.

Careful histological verification of the completeness of the excision is essential before undertaking reconstruction.

IMMEDIATE VERSUS DELAYED RECONSTRUCTION

It is advantageous to do an immediate reconstruction in defects resulting from excision of well delimited carcinomas of the nose, such

as those resulting from excision of lesions of the skin of the nose or those involving the nasal tip, alae or columella. In large lesions involving the skeletal structure of the nose and requiring full thickness excision of a major portion of the nasal pyramid, the skin at the edge of the defect is sutured to the mucous membrane and reconstruction is postponed. This delay permits careful histological verification of the resected specimen and an adequate period of observation. Radiation therapy, if unsuccessful, further complicates the picture by leaving in its wake areas of radiation changes. Radiation also has a delayed action upon the cartilages of the nose and a progressive shriveling and shrinkage of the cartilages often occurs. When in doubt, definitive reconstructive surgery is postponed. A temporary split-thickness graft is applied to the defect. After assurance of eradication of the lesion has been obtained, the split-thickness graft is excised and a more satisfactory repair, by a skin flap, for example, is provided.

In the upper half of the nose, where the skin is loosely bound to the underlying framework, the defect resulting from excision may often be closed by direct approximation or by means of a small transposition or rotation flap. By contrast, closure of defects by direct approximation is not possible in the lower nose where the skin is intimately bound to the cartilagenous framework.

After excision of larger lesions which are mobile over the underlying periosteum, the periosteum constitutes an excellent vascular bed for a skin graft and a full-thickness retroauricular or supraclavicular skin graft can be successfully employed. In the region of the nasal tip, ala or columella, it may be advantageous to use a skin-fat graft from the lobule of the ear in order to avoid a depressed area.

Various types of skin flaps are employed: an advancement flap from the cheek is indicated in the older patient with loose tissue for a defect involving the lateral wall of the nose; nasolabial flaps have also occasionally been employed; forehead flaps are favored in the closure of major defects involving the dorsum of the nose. We have employed an island forehead flap with a subcutaneous pedicle for this purpose.

THE TECHNIQUE OF THE ISLAND FOREHEAD FLAP

The lesion is excised and a pattern of the defect made: a pedicle of appropriate length is outlined over the median aspect of the forehead supplied by the supratrochlear vessels. The full-thickness of

the skin is incised around the inverted pattern of the defect outlining the skin portion of the island flap.

A "V" shaped segment of skin is excised superficially from the area immediately below the island flap in order to facilitate subsequent closure of the forehead defect; a similar inverted "V" is removed from the area immediately above the island flap. The skin of the forehead is then undermined downward over the glabella and the dorsum of the nose as far as the nasal defect. The undermining of the skin is extended laterally toward the vascular pedicle in the supratrochlear region on the appropriate side. The subcutaneous pedicle is then prepared by incising the subcutaneous tissues both medially and laterally to the vessels which are thus included in the pedicle. The island flap and subcutaneous pedicle are now mobilized and rotated 180 degrees through the subcutaneous channel to the defect, the edges of the flap being sutured to the edges of the defect with fine interrupted sutures. Undermining of the margins of the forehead defect facilitates direct approximation of the edges of the secondary defect.

In lesions involving the alar cartilage and the alar margin, repair is best accomplished by means of full thickness excision and the replacement by composite grafts from the external ear. We have recently utilized grafts as large as 2.5 by 2.25 cm with successful results; ice compresses were applied to the grafted area during the first three postoperative days.

Presence of a malignant lesion in the precanthal region calls for a wide extirpation because of the proximity of vital structures and the danger of recurrence in this region. Repairs of defects in this region are accomplished by full thickness retro-auricular skin grafts. A small forehead flap is required if bone is denuded of periosteum.

Massive lesions involving the nasal bones and nasal cartilages require removal of all or part of the nose and a delayed reconstruction; during this period, the patient might use a prosthesis which will permit him to engage in his everyday activities. For total or partial nasal reconstruction, we routinely employ the scalping flap procedure with uniformly satisfactory results.⁴

The scalping flap may be also employed for closure of defects involving the lateral wall of the nose or the alar region which are too large for a composite graft. In this instance, support may be added by the addition of septal or auricular cartilage to form a com-

pound flap prior to mobilization of the scalping flap from the forehead.

550 FIRST AVE.

REFERENCES

1. Allison, S. D., and Wong, A. L.: Skin Cancer: Some Ethnic Differences. *A.M.A. Arch. of Deratology* 76:737-739 (Dec.) 1957.
2. Blashi, S. F.: Unusual Tumors of the Nose. *A.M.A. Arch. Otolaryng.* 70: 120-129, 1959.
3. Boyd, W.: *Pathology for the Surgeon*. Seventh edition, W. B. Saunders Co., 1955.
4. Converse, J. M.: Reconstruction of the Nose by the Scalping Flap Technique. *S. Clin. North America* 39:2:335, 1959.
5. Conway, H.: *Tumors of the Skin*. Thomas, Springfield, Ill., 1956.
6. Figi, F. A., and Foss, E. L.: In *Treatment of Cancer and Allied Diseases*. Second edition, Paul B. Hober, Inc., 3:289, 1959.
7. Masson, P.: My Conception of Cellular Nevi. *Cancer* 4:9, 1951.
8. Pack, G. T., Gerber, D. M., and Schanagel, I. M.: End Results of Treatment of Malignant Melanomas. Report of 1190 Cases. *Ann. Surg.* 136:905-911, 1952.
9. Pack, G. T., and LeFevre, R. G.: Age and Sex Distribution and Incidence of Neo-plastic Disease at Memorial Hospital with Comments on "Cancer Ages." *J. Cancer Res.* 14:167, 1930.
10. Ward, G. E., and Hendrick, J. W.: *The Diagnosis and Treatment of Tumors of the Head and Neck*. Williams and Wilkins Co., 1950.

DISCUSSION

DR. JOHN J. CONLEY (New York, N. Y.): I think this is a splendid demonstration of the basic concept that excisional surgery alone is no longer an adequate concept of the treatment of tumors in those exposed areas of the head and neck. Certainly the position of the excisionist as a solo professional character is in serious jeopardy as long as John Converse is in existence.

I cancelled my twelve-thirty flight on Braniff to a four-forty-five flight on American to hear this paper and I feel that I have been richly rewarded.

I feel that I agree with all of these points and I would only like to add one minor situation that has some psychological implications. I was originally in the habit of trying to reconstruct or rehabilitate the nose immediately. There is a certain rhythm and there is a certain pace which is governed by the biological factors pertaining to the wound and the tissue bed, which I think were very well illustrated on the slides, particularly where there has been fibrosis, contracture and stenosis, and where the airway is involved. These are not single problems but multiple phase problems requiring staging.

I discovered one other thing that I am sure you have, but you didn't mention it, and that is that when you amputate a person's nose and reconstruct the nose

immediately, the patient has never been subjected to the experience of what it is like not to have a nose. Now, I think not having a nose has a profound effect on a patient. It certainly should be only a temporary experience. Many people, however, are dissatisfied when they change from what was their original nose to a new nose. The new nose is often not what they expected. If they change from cancer of the nose to no nose, and if they experience the stress of this situation, they are all very anxious to have this rehabilitated. Then if they go from the status of no nose to a rehabilitated nose, they have had a life experience which is one of great stress but one which causes them a certain amount of emotional maturity. Consequently their satisfaction for this accomplishment is much greater. I have found that these people are much more gratified in this staging experience than if you catapult them right into the final solution.

I have enjoyed this paper tremendously.

DR. DELMAR F. WEAVER (Detroit, Mich.): I have thoroughly enjoyed the paper of Dr. Converse and Dr. Conley's discussion of it.

I want to say, however, that I think there are times when the excisional scar on a forehead justifies the use of a true pedicle flap. I have used this a number of times and have been quite pleased with it. I think it should be considered in some cases when it is necessary to reconstruct these defects.


PRESIDENT LIERLE: Dr. Converse, before you make your closing remarks I would like to express my appreciation. I know it is difficult to be the last speaker. As Dr. Conley told you, there are people here who changed their plane reservations to hear you, so although you have a small crowd you have a very appreciative one.

DR. CONVERSE (closing): Thank you, Dr. Lierle.

I just want to say that I agree so much with what Dr. Conley said in regard to the various phases these patients go through. First, the survival from cancer, then being subjected to the indignity of not having a nose, and then the gratitude that the patient expresses at being able to acquire a nose.

The only other point I want to emphasize is that I have seen so many tragedies in countries all over the world connected with attempts to raise tubed pedicle flaps from the abdomen to the wrist and to the arm. I think at least half of the patients I see from foreign countries have had an attempt to reconstruct the nose by means of an arm flap. I think that the forehead flap, despite the objection of the secondary deformity, in the hands of those of us who are experienced, remains the method of choice.

Memorials



REA E. ASHLEY

REA E. ASHLEY, M.D.

1893 - 1962

Dr. Rea E. Ashley, an Active Member of the American Laryngological Association, was born in Kansas City, Missouri, on July 8, 1893. He died in San Francisco on March 18, 1962, of a coronary occlusion.

Dr. Ashley graduated from the East Denver High School in Denver, Colorado, and then went to the University of Colorado, where he majored in Engineering for three years. He then transferred to Medicine, and went to the University of Illinois Medical School, where he received his Medical Doctor's Degree in 1919. He took a surgical internship at Stanford University Hospital, and in October, 1919, he became the first resident in otolaryngology at that institution.

He began private practice in 1922 in San Francisco, and in 1928, received postgraduate training in Vienna, Austria. In 1936, he became Associate Clinical Professor of Otolaryngology (Department of Surgery) at the Stanford University Medical School, and remained on their staff until his death. Dr. Ashley was also on the staffs of the following hospitals: Children's, Franklin, San Francisco County, St. Luke's, St. Francis, and United States Marine Hospital.

Before World War II, Dr. Ashley was a member of the U. S. Navy Reserve. He entered into service in World War II as a Commander, and later advanced to the rank of Captain. He headed one of the Stanford University Medical Units established at Corona, California. From there, he was sent to the South Pacific, as a member of the famous Lyon I Unit. He was first stationed at Esperito Santo in the New Hebrides, and later, went to the Russell Islands. He later returned to the United States, where he was appointed Head of the Ear, Nose and Throat Department of the Naval Hospital at Mare Island, California. In 1946, he was presented with the Bronze Star. He later was retired from the Navy, due to physical disability.

He was quite interested in nasal allergy, and was one of the early Presidents of the American Society of Ophthalmological & Otolaryngological Allergy. He was an Honored Member of the American Laryngological, Rhinological and Otological Society, the American

Academy of Ophthalmology and Otolaryngology, American Otolological Society, American Laryngological Association, Pacific Coast Oto-Ophthalmological Society, San Francisco County Medical Society, California Medical Association, American Medical Association, and California Academy of Medicine. He was also an Active Member of the Bohemian Club of San Francisco, as well as being a Rotarian.

Dr. Ashley is survived by his wife, the former Drucilla Clay, and by three children: Ann Kidney, William Whitley Ashley, M.D., and Rea Kirkland Ashley, M.D. He was famous for his great sense of humor and was one of the greatest storytellers and toastmasters of our era. He gave unstintingly of himself at medical dinners and banquets and made these affairs into very happy occasions. He will be greatly missed by all who knew him.

ERNEST MORRIS SEYDELL, M.D.

1882 - 1962

Dr. Ernest M. Seydell, an Emeritus Fellow of the American Laryngological Association, was born in Chicago, Illinois, March 29, 1882. Being of an adventurous nature, he left home at the age of eighteen years and according to his own account, spent time on a ranch in Wyoming, mined copper in Montana and helped manage a plantation in Puerto Rico.

Dr. Seydell received his medical degree from Northwestern University Medical School in 1909.

All of his active professional life was spent in Wichita, Kansas.

Dr. Seydell listed his church affiliation as Protestant, his politics as Independent and his diversion as stock-raising.

Dr. Seydell was a member of the American Laryngological, Rhinological and Otological Society, the American Academy of Ophthalmology and Otolaryngology and the American College of Surgeons. He served as Chairman of the Mid-Western Section of the Triological Society. He was a Fellow of the American Otological Society and served as its President in 1941. Dr. Seydell was also a member of the American Broncho-Esophagological Association and of the American Medical Association.

Dr. Seydell had an active and inquiring mind and made more than forty contributions to the otolaryngologic literature. He was especially interested in olfactory disturbances. His paper on this subject, published in the Journal of the American Medical Association, August 20, 1932, is still worth reading. His published articles demonstrate interest in and unusual competence in the entire field of otolaryngology.



ERNEST MORRIS SEYDELL

Executive Sessions

EXECUTIVE SESSION

FRIDAY MORNING, MAY 4, 1962

The Executive Session of the Eighty-third Annual Meeting of the American Laryngological Association, held at the Sheraton-Dallas Hotel, Dallas, Texas, on Friday morning, May 4, 1962, convened at eleven-thirty o'clock, Dr. Dean M. Lierle, presiding.

The following men were unanimously elected to Active Fellowship:

Dr. Fred W. Alexander, Cleveland, Ohio

Dr. Godfrey E. Arnold, New York, N. Y.

Dr. George A. Sisson, Syracuse, N. Y.

Dr. Delmar F. Weaver, Detroit, Mich.

The following men were elevated to Emeritus Fellowship:

Dr. Colby Hall, Los Angeles, California

Dr. LeRoy A. Schall, Barnstable, Mass.

PRESIDENT LIERLE: Gentlemen: You have been elected, in my opinion, to one of the finest medical associations in the world. I would like to emphasize what one of the sponsors said about active interest. If you will take an active interest you will find it will be a most exciting and rewarding experience, so I urge that you really get busy.

The following members were elected members of the Nominating Committee:

Dr. Daniel C. Baker, Jr., New York, N. Y.

Dr. Jerome A. Hilger, St. Paul, Minnesota

Dr. Alden H. Miller, Los Angeles, California

Dr. Verling K. Hart, Charlotte, North Carolina

Dr. Bernard J. McMahon, Clayton, Missouri

PRESENTATION OF THE NEWCOMB AWARD

DR. PRESSMAN: Your Newcomb Award Committee has decided on a Fellow of this Association, who, in our opinion, has filled to overflowing, the cup of qualifications set out in the constitution.

He was born in Chicago, Illinois, received his B.S. degree from the University of Chicago, and his M.S. and M.D. degrees, from Northwestern University Medical School. He interned at the Albany General Hospital. Then was resident at the University of Illinois College of Medicine. He became interested especially in laryngology and broncho-esophagology, and received training under "The Jacksons" at their clinic in Philadelphia. Returning to Chicago, he continued on the staff of the University of Illinois College of Medicine, and is now the professor of broncho-esophagology at that institution. He is on the staff of 3 Chicago hospitals, and a consultant to 12.

He is a past president of his local branch of the Chicago Medical Society, of the Chicago Laryngological and Otological Society, and of the A. B. E. A.

He is an active member of many national and international medical societies, and an honorary member of 29 societies, scattered over the world. He served as Secretary General of the VI International Congress of Otolaryngology, and was the official U. S. delegate to the V and VII Congresses.

His writings and his pictorial demonstrations of pathological lesions of the respiratory tract, his teachings both to graduate and undergraduate students, have won him world-wide acclaim.

He has served as Vice President of this Association, has received our Casselberry Award, and on many occasions has performed valuable services for this Association.

The above are but a few of his accomplishments.

His works have brought fame to him, and distinction to this Association.

We present Dr. Paul Henry Holinger.

Edwin N. Broyles

Jerome A. Hilger

Joel J. Pressman

ANNUAL BUSINESS MEETING

SATURDAY MORNING, MAY 5, 1962

PRESIDENT LIERLE: The first order of business is the report of the Secretary, Dr. Richards.

REPORT OF THE SECRETARY

AMERICAN LARYNGOLOGICAL ASSOCIATION

The eighty-second Annual Meeting of the American Laryngological Association was held on May 21st and 22nd, 1961, at the Lake Placid Club, Lake Placid, New York. The President, Dr. Edwin N. Broyles, presided. Thirteen scientific papers were presented. Seventy-eight Fellows and 111 Guests were in attendance.

The Librarian, Historian and Editor, Dr. Francis W. Davison, reported the deaths of:

Corresponding Fellow:

DR. FERNAND LE MAITRE

Emeritus Fellows:

DR. CARL H. MCCASKEY, DR. DANIEL S. CUNNING

Active Fellows:

DR. WILLIAM W. MORRISON, DR. JAMES H. MAXWELL,

DR. CHEVALIER L. JACKSON, DR. WILLIAM W. WILKERSON

The de Roaldes Award was presented to Dr. Frederick T. Hill in recognition of his many outstanding contributions to Otolaryngology, his devoted service to the American Laryngological Association and his leadership in the broad field of Medicine.

The Newcomb Award was given posthumously to Dr. Chevalier L. Jackson, and accepted by Mrs. Jackson, in recognition of his outstanding contributions, services and achievements in Laryngology and Broncho-esophagology and in appreciation of his indefatigable

efforts in promoting a closer union between Latin America and the United States.

The following men were elected to Fellowship:

Active Fellowship:

Edley H. Jones, Vicksburg, Mississippi
 Robert B. Lewy, Chicago, Illinois
 Joseph H. Ogura, St. Louis, Missouri
 James J. O'Neil, Omaha, Nebraska
 Lup Q. Pang, Honolulu, Hawaii
 Peter N. Pastore, Richmond, Virginia
 Oliver W. Suehs, Austin, Texas

Emeritus Fellowship:

Howard C. Ballinger, Winnetka, Illinois
 Edward H. Campbell, Philadelphia, Penn.
 Thomas C. Galloway, Evanston, Illinois
 Oram R. Kline, Camden, New Jersey

Corresponding Fellowship:

K. Faaborg Andersen, Nykobing, Falster, Denmark

The following officers were elected for the coming year, 1962:

President	Dr. Dean M. Lierle
First Vice-President	Dr. Julius McCall
Second Vice-President	Dr. P. E. Ireland
Secretary	Dr. Lyman Richards
Treasurer	Dr. Francis E. LeJeune
Librarian, Historian, Editor	Dr. Francis W. Davison
First Councilor	Dr. Harry P. Schenck
Second Councilor	Dr. Fred Dixon
Third Councilor	Dr. William J. McNally
Fourth Councilor	Dr. Edwin N. Broyles

The Association has lost by death during the past year:

Actives Fellows:

Dr. Charles D. Blassingame, Dr. Rae E. Ashley

Emeritus Fellows:

Dr. John D. Kernan, Dr. Francis W. White

The Council at its Annual Meeting in New York on January 7th, 1962, recommended for:

Active Fellowship:

Fred W. Alexander, Cleveland, Ohio

Godfrey E. T. Arnold, New York, N. Y.

George A. Sisson, Syracuse, N. Y.

Delmar T. Weaver, Detroit, Mich.

Emeritus Fellowship:

Colby Hall, Los Angeles, Calif.

LeRoy A. Schall, Barnstable, Mass.

Dr. Samuel Salinger was reappointed Abstract Editor.

The Council has voted to hold the Annual Session in 1963 at the Hollywood Beach Hotel, Hollywood, Florida, on April 21st and 22nd.

The present membership of the Association is:

Active	92
Emeritus	24
Honorary	5
Corresponding	14
	<hr/>
	135

Respectfully submitted,

LYMAN G. RICHARDS, M.D.

Secretary

At the conclusion of his report, Dr. Richards made a plea to all Fellows to take time to fill out and return the ballots, so that the Council could be guided by these ballots in the selection of new

Fellows. The merits of the candidates can best be judged by the written opinions of the Fellows who know them.

Dr. Richards' report was approved as read.

Dr. Francis E. LeJeune then presented the Treasurer's Report. It was accepted as presented.

Exhibit A

AMERICAN LARYNGOLOGICAL ASSOCIATION GENERAL FUND OPERATING STATEMENT

For the Eleven and One-Half Months Period Ending April 15, 1962

Income

Dues—86 members @ \$75.00	\$6,450.00	
7 new members @ \$115.00	805.00	\$7,255.00
Sale of <i>Transactions</i>		308.00
Interest Received—Savings Account		257.40
Total Operating Income		\$7,820.40

Expenses

Annual Meeting—1961

Banquet and Cocktails	\$ 561.91	
Projectionist	43.75	
Photography	12.75	
Reporting Service	351.32	
Programs	210.20	
Registration Cards	9.75	
Registration Attendants	42.00	1,231.68

Council Expenses

Travel Expenses	959.40	
Annual Luncheon	132.00	1,091.40

General Expenses

Stationery, Printing and Postage	652.41	
<i>Transactions</i>	2,470.21	
Clerical Hire	500.00	
Auditing	100.00	
Treasurer's Bond	62.50	
Bank Charges	4.25	
President's Key	12.88	3,802.25

Total Expenses		6,125.33
----------------------	--	----------

Addition to General Fund		1,695.07
--------------------------------	--	----------

General Fund Balance, April 30, 1961		6,022.61
--	--	----------

General Fund Balance, April 15, 1962		\$7,717.68
--	--	------------

Exhibit B

AMERICAN LARYNGOLOGICAL ASSOCIATION
TRUST FUND OPERATING STATEMENT

For the Eleven and One-Half Months Period Ending April 15, 1962

Trust Fund Income

Interest—Government Bonds	\$ 1,317.09	
Discount on Government Bond	27.46	
Donations to Memorial Fund:		
Dr. Francis W. Davison	\$ 500.00	
Dr. Sam Sanders (Stock)	517.00	
Dr. Edwin W. Broyles (Stock)	1,170.00	2,187.00
		<hr/>
Total Income		\$ 3,531.55

Trust Fund Expenses

Medal for deRoaldes Award	\$ 120.00	
Engraving for deRoaldes Award	5.00	
Engraving Newcomb Award	8.00	
Tax on Transfer of Stock48	
		<hr/>
Total Expenses		\$ 133.48
Addition to Trust Fund		\$ 3,398.07
Trust Fund Balance, April 30, 1961		45,506.03
		<hr/>
Trust Fund Balance, April 15, 1962		\$48,904.10
Trust Fund Balance Represented by Government Bonds, par..\$44,500.00		
Stock	1,687.00	\$46,187.00
		<hr/>
Remaining Balance Represented by Cash		\$ 2,717.10

Cash Recapitulation

Cash in Trust Fund	\$ 2,717.10	
Cash in General Fund	7,717.68	
		<hr/>
		\$10,434.78
Cash in Savings Account	\$ 7,007.15	
Cash in Commercial Account	3,427.63	
		<hr/>
		\$10,434.78

Exhibit C

AMERICAN LARYNGOLOGICAL ASSOCIATION

REPORT OF TRUST FUNDS

April 15, 1962

Fund	Principal	Unused Income 4-30-61	Income 5-1-61 to 4-15-62	Expenses 5-1-61 to 4-15-62	Unused Income 4-15-62	Principal & Unused In- come 4-15-62
Casselberry	\$ 5,000.00	\$ 2,123.09	\$ 199.93	\$ -----	\$ 2,323.02	\$ 7,323.02
Johnston	5,000.00	1,327.95	199.93	-----	1,527.88	6,527.88
deRoaldes	3,000.00	1,498.10	119.80	125.00	1,492.90	4,492.90
Newcomb Trust	2,000.00	482.93	80.00	-----	562.93	2,562.93
Newcomb Prize	500.00	86.17	20.03	8.00	98.20	598.20
Research	16,034.42	6,320.94	640.96	-----	6,961.90	22,996.32
Memorial	2,100.00	32.43	2,270.90 ¹	.48	2,302.85 ¹	4,402.85
Totals	\$33,634.42	\$11,871.61	\$3,531.55 ²	\$133.48	\$15,269.68	\$48,904.10

¹ Includes \$500.00 donation by Dr. Francis W. Davison, \$517.00 value of stock donated by Dr. Sam Sanders, and \$1,170.00 value of stock donated by Dr. Edwin W. Broyles (a total of \$2,187.00 to be added to the principal for the Memorial Fund).

² Includes \$1,344.55 Income From Pooled Investments, and \$2,187.00 donations as shown in (1) above.

Exhibit D

AMERICAN LARYNGOLOGICAL ASSOCIATION

TRUST FUND INVESTMENTS

April 15, 1962

Government Bonds	Description	Par Value	Interest Income
			5-1-51 to 4-15-62
U. S. Savings	2.76 K 1965 -----	\$ 7,000.00	\$ 193.20
	2.76 K 1966 -----	1,000.00	27.60
	K 1970 -----	1,500.00	54.00
U. S. Treasury	2½ 1964-69 -----	3,000.00	75.00
	2½ 1967-72 -----	1,000.00	25.00
	3 1995 -----	5,000.00	150.00
	3¼ 1968 -----	3,000.00	104.40
	3¼ 1969 -----	5,000.00	179.20
	3¼ 1978-83 -----	3,000.00	97.50
	3⅜ 1966 -----	5,000.00	112.81
	3⅜ 1972 -----	1,000.00	-----
	3⅜ 1968 -----	7,000.00	135.65
	4 1969 -----	1,000.00	20.00
	4¾ 1969 -----	1,000.00	47.50
Matured Bonds Exchanged	-----	-----	95.23
		\$44,500.00	\$1,317.09

ACCOUNTANT'S REPORT

To the Members of the American Laryngological Association
Gentlemen:

I have examined the accounts and financial records of the American Laryngological Association for the eleven and one-half months ended April 15, 1962.

Cash receipts and disbursements were verified and United States Government Bonds were physically counted and examined.

In my opinion, the accompanying statement presents fairly the financial position of the American Laryngological Association as of April 15, 1962, and the results of its operations for the eleven and one-half months then ended.

Respectfully submitted,
CARROLL A. CHAUVIN
Certified Public Accountant

April 18, 1962

COMMENT

To the Members of the American Laryngological Association
Gentlemen:

During the year seven \$1,000.00 U. S. Government Bonds yielding $2\frac{3}{4}\%$ were exchanged for seven \$1,000.00 U. S. Government Bonds yielding $3\frac{7}{8}\%$ and maturing in 1968. Cash in our Trust Fund warranted the purchase of a \$5,000.00 U. S. Government Bond yielding $3\frac{3}{8}\%$ maturing in 1966. We now have \$44,500.00 in Government Bonds in our Trust Fund.

We are grateful to Dr. and Mrs. Francis W. Davison for the donation of \$500.00 to the Memorial Fund. In addition to this the Association has received by donation 26 Shares of McDonnell Aircraft Corporation Stock from Dr. Edwin N. Broyles, one share of I. B. M. Stock from Dr. Sam Sanders and 15 Shares of McIntyre Mines Stock from Dr. Harry Schenck. These shares of stock are to be retained by the Association and allocated to Memorial Fund. It is most gratifying to see such a generous response to the appeal for donations to the Association.

Our financial picture continues to improve and if our economy remains as it is, the prediction of our past worthy Treasurer, Dr. Dixon, that we should show a substantial gain each year, is about to come true.

Respectfully submitted,
FRANCIS E. LEJEUNE, M.D.
Treasurer

FELeJ-bjm

Dr. Daniel C. Baker, Jr., Chairman of the Nominating Committee, submitted the following names for election to the Council:

Dr. LeJeune	Dr. Francis Davison
Dr. Paul Moore	Dr. Fred Dixon

Dr. Jerome Hilger	Dr. McNally
Dr. Lyman Richards	Dr. Broyles
Dr. Alden Miller	Dr. Lierle

The report of the Nominating Committee was unanimously accepted.

REPORT OF THE LIBRARIAN, HISTORIAN AND EDITOR

Since our last meeting in May, 1961, the following Fellows have passed to the Great Beyond:

Ray E. Ashley, M.D., March 18, 1962

Francis W. White, M.D., March 29, 1962

Ernest M. Seydell, M.D.

John D. Kernan, July, 1961

Charles D. Blassingame, June 20, 1961

The 82nd Annual Meeting of the American Laryngological Association was held on May 21 - May 22, 1961, at the Lake Placid Club, Essex County, New York. The discussions were received from the Master Reporting Company about three weeks after the meeting and were promptly mailed to each discussant for correction. Some of the discussions were not sent back promptly, because the men were in Europe attending the International Congress. Those discussions not received by the middle of August were corrected by the Editor and all material for the 1961 *Transactions* was sent to the publisher on August 26, 1961.

During the summer, letters were sent to all Honorary, Emeritus and Corresponding Fellows asking them whether or not they wished to receive the 1961 *Transactions* at the Council-established price of \$5.00. *Transactions* were sent only to those Fellows who requested them.

Dr. Salingers' abstracts were promptly prepared and were sent to the Editors of the Laryngoscope, the Archives of Otolaryngology and Acta Otolaryngologica.

According to Council directive, 250 copies of the 1961 *Transactions* were ordered. The *Transactions* were received on March 21, 1962. The cost was \$2470.21.

Up to the present time the *Transactions* have been distributed as follows:

Active Fellows	94
Honorary Fellows	3
Corresponding Fellows	5
Emeritus Fellows	6
Sold to libraries and individuals	85
Complimentary copies to family of deceased Fellows	3
National Library of Medicine	1
Library of Congress	1
Mailed to Secretary of A.L.A.	3
	<hr/>
Total	201

Remaining in hands of the Editor	49
Income from the sale of <i>Transactions</i>	\$498.00
Expenses of the Editor	69.06

The Editor still has on hand a considerable number of back *Transactions*. At the 1962 Mid-Winter Council Meeting the Editor was instructed to give to libraries or individuals as many copies of the back *Transactions* as they wished, provided the library or individual purchased the three most recent copies for \$8.00 apiece. This ruling was made with the additional stipulation that the Editor should keep four copies of each year's *Transactions* prior to 1952.

Respectfully submitted,

F. W. DAVISON, M.D., *Editor*

Dr. Davison's report was accepted as read.

PRESIDENT LIERLE: The next item is the report of the American Board of Otolaryngology. Dr. Hill couldn't be here, so I shall read his report.

The American Board of Otolaryngology held examinations in Chicago on October 4, 5 and 6, 1961. One hundred and two candidates were examined. Of this group, seventy-eight passed, nineteen were conditioned and five failed.

I might add that we are seeing a much better type of young man, I mean he is better educated, so you will find, I think, as we go along that probably we will have less failures in the future. We hope so anyway. At the same time, we have to keep up standards, too.

PRESIDENT LIERLE: The next order of business is the report of the Laryngological Research Fund Committee. Dr. Proetz!

REPORT OF THE RESEARCH FUND COMMITTEE

DR. ARTHUR W. PROETZ: The Research Fund Committee, having met on May 2, 1962, all members present, has the honor to report to the Council as follows:

1) Through the death of Dr. Rea E. Ashley this Committee has lost a valued member and respectfully requests that the vacancy be filled at the pleasure of the Council.

2) The amount of the Fund, as of this date, is \$22,996.32.

3) Legal opinion has been obtained as to the latitude permitted the Association in the Distribution of this Fund, and the purposes to which it may be applied within the rules laid down for it.

4) With the above in mind, and with a desire to put this small fund to its most effective uses, a suggestion has been made to institute periodic reports at the meetings of the Association of any valuable researches in foreign centers, which through language barriers or other impediments might not normally reach the attention of the Fellows; this through the agency of one of the membership and not through the invitation of foreign guests. The mechanism for obtaining such reports is being studied and suggestions are invited.

5) An application for a grant of \$5000.00 has recently been received, which owing to insufficient information supplied is at present under advisement.

Respectfully submitted,

John E. Bordley, M.D.

Jerome A. Hilger, M.D.

Paul H. Holinger, M.D.

F. Johnson Putney, M.D.

Arthur W. Proetz, M.D., *Chairman*

May 3, 1962

PRESIDENT LIERLE: The next item is the report of the American College of Surgeons.

REPORT TO THE AMERICAN LARYNGOLOGICAL ASSOCIATION
OF ITS REPRESENTATIVE TO THE BOARD OF GOVERNORS
OF THE AMERICAN COLLEGE OF SURGEONS

DR. PAUL H. HOLINGER:

1. The three representatives of the American Laryngological Association to the Board of Governors of the American College of Surgeons for 1962 are:

Fred Dixon, Cleveland - term expired 1962

Francis LeJeune, New Orleans - term expires 1963

Harry Schenck, Philadelphia - term expires 1964

2. Other Otolaryngologists serving as representatives on the Board of Governors are:

For the American Otological Society:

Peter Pastore, Richmond - term expires 1962

Jerome Hilger, St. Paul - term expires 1963

Shirley Baron, San Francisco - term expires 1964

For the Section of O.R.L. of the American Medical Association:

Harold Owens, Los Angeles - term expires 1962

Franklin Keim, East Orange - term expires 1963

Bruce Proctor, Detroit - term expires 1964

For the American Academy of Ophthalmology and Otolaryngology:

George Sisson, Syracuse - term expires 1962

Wendell Hughes (Ophthalmology) - term expires 1963

James Moore, New York - term expires 1964

3. Shirley H. Baron, San Francisco, served as Vice-Chairman of the Nominating Committee of the Governors.

Dean M. Lierle was reelected as Regent of the College for a term of three years.

Harry Schenck was reelected to the Executive Committee of the Board of Governors for a term of three years.

4. Ground has been broken for the new eight-story American College of Surgeons Headquarters Building at 55 East Erie Street, Chicago.

5. A reduction has been effected in the number of representatives on the Board of Governors of certain surgical sections of the American Medical Association, including Otolaryngology, from three to one, effective on expiration of terms of present representatives. A probable further percentage decrease in the representation of specialists on the Board of Governors will follow a second action; namely, a re-apportionment of Governors-at-large so that each state and province will be represented and there will be an increased representation from areas with unusually large membership.

Your representative wrote to Dr. Paul Samson, Chairman of the Board of Governors, pointed out that both moves will act to decrease the representation of the surgical specialties on the Board and increase the percentage of general surgeons. Dr. Samson answered by stating that for the most part the membership of the sections of the American Medical Association is only made up of those attending a single sectional meeting and that geographical representation, based on the number of Fellows per state would be more advantageous. He presented the following statistics:

There are, at present, 188 members of the Board of Governors of the College.

Otolaryngologists constitute 5.8% of the Board and 4% of the total college membership.

Ophthalmologists constitute 4.7% of the Board and 4.9% of the total college membership.

All specialists constitute 39.4% of the Board and 43% of the total college membership.

6. Committee reports on the "Joint Commission on Accreditation of Hospital," "Help for Small Hospitals," "How Laymen Can Choose a Doctor," "Hospital Emergency Room," etc., were reviewed and are available.

7. An interesting "Study on the Dangers of Partial Surgical Training of Practitioners" was given. Using the tonsillectomy operation as an example, Dr. C. Rollins Hanlon, of St. Louis, a thoracic surgeon, gave the following data as partial proof of the importance of training:

In surveying 9,000 T's and A's the rate of hemorrhage as a complication was found to be as follows:

24/1000 cases done by general surgeons

19/1000 cases done by Otolaryngologists

34/1000 cases done by General Practitioners

8. The report of the Graduate Training Committee is of importance to the members of the American Laryngological Association. It was agreed that a basic residency for all who wish surgical training is sound and urgently needed for the advancement of surgery. There is an absolute necessity for collaboration between the general surgeon and the surgical specialist to provide a sincere educational effort, realizing the dangers of increasing the duration of the residency training. This training should be practical and clinical mainly, with no rotation to experimental surgery or research; brief rotation to the pathology service might be desirable. Each institution should work out its own solution through collaboration between the surgical specialists and the general surgeons.

Respectfully submitted,

PAUL H. HOLINGER, M.D., F.A.C.S.

PRESIDENT LIERLE: I think Dr. Holinger brought out something that is very important, namely that we have more representation than we deserve as far as membership is concerned. I don't want to plead for any special society, but I do say that we all should be more active in joining the major surgical societies. I think our fortunes have a lot to do with the way we conduct ourselves in the surgical field. I may be wrong.

Dr. Holinger's report was accepted as read.

EXECUTIVE SESSION

SATURDAY AFTERNOON, MAY 5, 1962

The Executive Session, held following the adjournment of the Scientific Session on Saturday afternoon, May 5, 1962, convened in

the South Ballroom at twelve twenty-five o'clock, President Lierle presiding.

PRESIDENT LIERLE: Will the directors and the members of the Council convene here in front of the podium.

(The directors and members of the Council met briefly.)

SECRETARY RICHARDS: Gentlemen: Your directors have met and elected the following officers of the Association for the ensuing year:

For President, Dr. Francis LeJeune
First Vice President, Dr. Paul Moore
Second Vice President, Dr. Jerome Hilger
Secretary, Dr. Lyman Richards
Treasurer, Dr. Alden Miller
Editor, Dr. Francis Davison
First Councilor, Dr. Fred Dixon
Second Councilor, Dr. William McNally
Third Councilor, Dr. Edwin Broyles
Fourth Councilor, Dr. Dean Lierle

PRESIDENT LIERLE: Francis, it gives me great pleasure to turn the gavel over to you. You will be most competent and I know that next year the American Laryngological will have a very able leader. Congratulations!

PRESIDENT LEJEUNE: Dr. Lierle and Members of the Association: It is extremely difficult for me at this time to adequately express my appreciation for this great honor which has been accorded me. Suffice to say that I am deeply grateful for the privilege of serving as your president for the next year.

Twenty-six years ago, when I became a member of this organization, little did I dream that one day I would stand on the rostrum accepting the presidency of this organization.

To successfully follow in the footsteps of those illustrious men who have served as presidents of this organization is a Herculean task but with your support, your cooperation and your help we shall carry on and we shall look forward to having a meeting next year equally as good as this, 'way down in the sunny State of Florida.

Again may I express my humble thanks for the privilege which you have given me. Thank you, gentlemen.

My first duty as president is indeed a happy one.

Dr. Lierle, will you step up to the rostrum, please.

PRESIDENT LEJEUNE: On behalf of the Council and the Members of this organization I have been instructed to present to you the Laryngological Key, which is symbolic of the high office which you have occupied for the past year and the duties of which you have so successfully accomplished.

For a job well done, congratulations, and with it this Key. May you always treasure it.

DR. LIERLE: Thank you very much.

PRESIDENT LEJEUNE: Are there any other duties to come up before the meeting?

If not, a motion for adjournment is in order.

(Such motion was moved and seconded and the meeting was adjourned at twelve-thirty o'clock.)

List of Fellows

LIST OF FELLOWS

Date Indicates Year Admitted to Active Fellowship

Attendance at meetings is shown by figures following each name.

Asterisk (*) indicates year paper was read.

Active Fellows

1962. ALEXANDER, FRED W., 10515 Carnegie Ave., Cleveland 6, Ohio, 1962.
1958. ALFARO, VICTOR R., 917 - 20th St. N. W., Washington 6, D. C., 1958, '59, '60, '61, '62.
1962. ARNOLD, GODFREY E. T., 6 East 79th Street, New York, N. Y., 1962.
1958. ATKINS, JOSEPH P., 3400 Spruce St., Philadelphia 4, Pa., 1958, '59*, '60, '61, '62.
1956. BAKER, DANIEL CLIFTON, JR., 903 Park Avenue, New York 21, N. Y., 1956, '57, '58, '59*, '60, '61, '62*.
1944. BOIES, LAWRENCE R., University Hospital, Minneapolis 14, Minnesota, 1944, '46, '47, '48*, '49, '50*, '51*, '53, '54, '55, '56, '57, '58, '59, '60, '61, '62.
1955. BORDLEY, JOHN E., Johns Hopkins Hospital, Baltimore 5, Maryland, 1955, '56, '57, '59, '60, '62.
1941. BOWERS, WESLEY C., 115 E. 61st Street, New York 21, N. Y., 1941, '42, '44, '49.
1959. BREWER, DAVID W., 100 E. Genesee St., Syracuse 10, N. Y., 1959, '60*, '61, '62*.
1955. BROWN, LESTER ALEXANDER, 490 Peachtree Street, N.E., Atlanta 8, Georgia, 1955, '56, '57, '58, '59, '61.
1940. BROYLES, EDWIN N., 1100 North Charles Street, Baltimore 1, Maryland, 1940, '41*, '42, '46, '48*, '49, '50, '51*, '52, '53, '54, '55, '56, '58, '59*, '60, '61*.

1945. CAMPBELL, COLONEL PAUL A., USAF (MC), School of Aviation Medicine, Brooks Air Force Base, Texas, 1946, '47, '49, '51, '57*, '61.
1942. CANFIELD, NORTON, 35 Trumbull Street, New Haven 11, Connecticut, 1942, '46, '47, '48, '49*, '50, '51, '56, '57.
1959. CARDWELL, EDGAR P., 965 Broad St., Newark 2, N. J., 1959, '60, '61, '62.
1957. CONLEY, JOHN J., 139 East 36th Street, New York 16, N.Y. 1958*, '60*, '61, '62*.
1957. CONVERSE, JOHN MARQUIS, 722 Park Avenue, New York 21, N.Y., '60, '62*.
1959. CRACOVANER, ARTHUR J., 103 E. 78th St., New York 21, N. Y., 1959, '60, '61*, '62.
1960. DALY, JOHN F., 140 E. 54th St., New York 22, N. Y., 1960, '61*, '62.
1951. DAVISON, FRANCIS W., Geisinger Memorial Hospital, Danville, Pa., 1951, '52, '53*, '54, '55, '56, '57, '58, '59, '60, '61, '62.
1941. DIXON, FRED W., 1027 Rose Building, Cleveland 15, Ohio, 1941, '42*, '44, '46, '47*, '49*, '50, '51, '52, '53, '54, '55, '56, '57, '58*, '59, '60, '61, '62.
1947. EAGLE, WATT WEEMS, Duke Hospital, Durham, N. C., 1948*, '49, '51, '53, '54, '56, '57, '59, '62.
1954. EQUEN, MURDOCK S., Ponce de Leon Infirmary, Atlanta 8, Ga., 1954, '55, '57, '58, '60.
1952. ERICH, JOHN B., Mayo Clinic, 102 Second Avenue, Rochester, Minn., 1953, '56*, '57.
1955. FITZ-HUGH, GLASSELL SLAUGHTER, 2003 Spottswood Road, Charlottesville, Virginia, 1955, '57, '59, '60, '61, '62*.
1956. FRIEDBERG, STANTON A., 122 So. Michigan Ave., Chicago 3, Illinois, 1956, '57*, '58, '59, '60, '61, '62.
1932. FURSTENBERG, ALBERT CARL, Out-Patient Bldg., University Hospital, Ann Arbor, Michigan, 1933*, '36*, '38*, '46, '48*, '50, '51, '53, '54, '55*, '56, '57, '58*, '59, '60, '61, '62.

1959. GOLDMAN, JOSEPH L., 1050 Park Ave., New York, N. Y., 1959, '60*, '61, '62.
1940. GOODALE, ROBERT L., 330 Dartmouth Street, Boston, Massachusetts, 1940, '41, '42*, '44*, '46, '47, '49, '50*, '53, '54, '55*, '56, '57*, '60, '61*, '62.
1928. GOODYEAR, HENRY M., 556 Doctors' Building, Cincinnati 2, Ohio, 1928, '29, '30*, '31, '32, '33, '34*, '35, '36, '37, '38, '39, '40, '44*, '46, '47, '48, '49*, '51, '53, '55, '57, '59, '61.
1933. HARKNESS, GORDON FOLLETTE, Blackhawk Hotel, Davenport, Iowa, 1934, '35, '36*, '40, '41, '44, '46, '47, '48, '49, '50, '51, '52, '53, '54*, '55, '56, '57, '58, '59, '60, '61, '62.
1957. HARRILL, JAMES A., Bowman Gray School of Medicine, Winston-Salem, N. C., 1957, '58, '59, '61, '62.
1960. HARRIS, HERBERT, 907 Hermann Professional Building, Houston 25 Texas, 1960, '61*, '62.
1959. HART, VERLING K., 106 W. 7th St., Charlotte, N. C., 1959, '60, '62.
1942. HEATLY, CLYDE A., 11 North Goodman Street, Rochester 7, N.Y., 1942, '46*, '49, '50, '52, '53*, '54, '55, '57, '58, '60, '61.
1959. HENRY, G. ARNOLD, 170 St. George St., Toronto, Canada, 1959, '61.
1943. HILDING, ANDERSON C., Research Laboratory, St. Luke's Hospital, Duluth 11, Minnesota, 1944*, '46, '47, '48*, '49, '50, '51, '53, '55, '56*, '57, '60, '61, '62*.
1955. HILGER, JEROME A., 350 St. Peter Street, St. Paul 2, Minnesota, 1955, '56*, '57, '58, '59, '60, '62.
1945. HOLINGER, PAUL H., 700 North Michigan Ave., Chicago 11, Illinois, 1946, '47, '49, '50*, '51*, '52, '53, '54*, '55, '56, '57, '58*, '59, '60, '61*, '62*.
1957. HOLMES, EDGAR M., 330 Dartmouth Street, Boston 16, Mass., 1957, '59, '61.
1944. HOOPLE, GORDON D., 1100 East Genesee St., Syracuse 10, New York, 1946, '47, '48, '49, '50, '51, '52, '53, '54*, '55, '56, '58, '59, '60, '61, '62.

1952. IRELAND, P. E., Room 82, Banting Institute, University of Toronto, Toronto, Ontario, 1952, '53, '54, '55, '56*, '57, '59, '61, '62.
1960. JOHNSTON, KENNETH C., 700 North Michigan Ave., Chicago 11, Ill., 1960, '61, '62.
1961. JONES, EDLEY H., First National Bank Building, Vicksburg, Mississippi, 1961, '62.
1953. LEDERER, FRANCIS LOEFFLER, 1853 W. Polk Street, Chicago 12, Illinois, 1953, '54, '55, '56, '57*, '58, '60, '61, '62.
1936. LEJEUNE, FRANCIS ERNEST, Ochsner Clinic Building, Prytania and Aline Streets, New Orleans 15, Louisiana, 1937, '46*, '47, '50, '51, '52, '53, '54*, '55, '56, '57, '58, '59, '60, '61, '62.
1961. LEWY, ROBERT B., 25 East Washington St., Chicago 2, Ill., 1961, '62*.
1933. LIERLE, DEAN M., University Hospital, Iowa City, Iowa, 1933, '34, '35*, '37, '38, '39, '40*, '42*, '44*, '46, '47*, '48, '49, '50*, '51, '52, '53, '54, '55*, '56, '57, '58, '59, '60, '62.
1949. LINDSAY, JOHN R., 950 E. 59th Street, Chicago 37, Illinois, 1949, '50, '51*, '53, '55*, '56, '57, '58, '59, '60, '61, '62.
1941. MARTIN, ROBERT C., 384 Post Street, San Francisco 8, California, 1941, '44, '47, '48, '50, '51, '53, '54, '55, '56, '58, '59, '60, '61, '62.
1952. MCCALL, JULIUS W., 610 Rose Building, Cleveland 15, Ohio, 1952, '53*, '54, '55, '56, '57, '58, '59, '60*, '61, '62*.
1951. MCHENRY, LAWRENCE C., 301 N. W. 12th St., Oklahoma City 2, Okla., 1953*, '62.
1933. MCMAHON, BERNARD J., 150 No. Meramec Ave., Clayton 5, Missouri, 1934*, '35, '36, '38*, '41, '44, '46*, '47, '48, '49, '50*, '51, '52, '53, '54, '55*, '56*, '57, '58, '59, '60, '61, '62.
1931. McNALLY, WILLIAM JAMES, 1509 Sherbrooke Street West, Montreal, Canada, 1931, '33, '34*, '39, '44, '47, '49, '49, '52, '53, '54*, '55, '56, '57, '58, '59, '60, '61.

1954. MELTZER, PHILIP E., 285 Commonwealth Ave., Boston, Mass., 1954*, '56, '57, '58, '59, '60, '61, '62.
1952. MILLER, ALDEN H., 1407 N. Vermont Ave., Los Angeles 27, Calif., 1952, '53*, '55, '57, '58*, '61, '62.
1958. MONTREUIL, FERNAND, 1123 St. Joseph Blvd., E., Montreal, Canada, 1958, '60.
1954. MOORE, PAUL M., 10,515 Carnegie Avenue, Cleveland, Ohio, 1954, '55*, '56, '57, '59, '60, '61, '62.
1957. MUNOZ-MACCORMICK, CARLOS EDUARDO, 71 Park Terrace, Santurce, Puerto Rico, 1957, '58, '59, '60, '61, '62.
1953. MURTAGH, JOHN A., 2 Maynard Street, Hanover, New Hampshire, 1953, '54, '55, '56*, '57, '58, '59, '61, '62.
1937. NASH, C. STEWART, Medical Arts Building, Rochester 7, New York, 1937, '38*, '40, '42, '44, '46, '49, '50, '51, '52, '53, '54, '55, '56*, '58, '59, '60, '61, '62.
1956. NORRIS, CHARLES MORGAN, 3401 North Broad Street, Philadelphia 40, Pennsylvania, 1956, '57, '58*, '59, '60, '61*, '62.
1961. OGURA, JOSEPH H., 640 So. Kingshighway, St. Louis 10, Mo., 1961*, '62*.
1958. O'KEEFE, JOHN J., 255 S. 17th St., Philadelphia 3, Pa., 1958, '59*, '60, '62.
1961. O'NEIL, JAMES J., 612 Medical Arts Building, Omaha, Nebraska, 1961, '62*.
1961. PANG, LUP Q., 52 South Vineyard Street, Honolulu 13, Hawaii, 1961, '62*.
1961. PASTORE, PETER N., Box 25, 1200 East Broad St., Richmond, Virginia, 1961, '62*.
1954. PRESSMAN, JOEL J., Department of Surgery, UCLA Medical Center, Los Angeles 24, Calif., 1954, '56*, '59*, '60, '61, '62.
1951. PRIEST, ROBERT E., 79, S. Ninth St., Minneapolis 2, Minn., 1951, '53*, '54*, '56, '59, '60*, '61.

1951. PUTNEY, F. JOHNSON, 1712 Locust St., Philadelphai 3, Pa., 1951, '52, '53*, '54, '55, '56, '58*, '59, '60, '61, '62.
1951. RAWLINS, AUBREY G., 384 Post Street, San Francisco 8, Calif., 1951, '53*, '56, '58.
1934. RICHARDS, LYMAN GILDER, 12 Clovelly Road, Wellesley Hills 81, Mass., 1934, '35, '36*, '37, '38, '39, '47, '49, '51*, '54, '56, '57*, '59, '60, '61, '62.
1956. RICHARDSON, JOHN ROBERT, 403 Commonwealth Avenue, Boston 15, Massachusetts, 1957, '58, '59, '60.
1945. ROBB, JAMES M., 633 David Whitney Building, Detroit 26, Michigan, 1946, '48, '49*, '51, '52, '55, '56, '57, '60, '61, '62.
1953. ROBERTS, SAM E., 1100 Professional Bldg., Kansas City, Missouri, 1953, '54*, '55, '56, '57, '58, '59, '60.
1959. SANDERS, SAM H., 1089 Madison Ave., Memphis 3, Tenn., 1959, '60, '61, '62.
1934. SCHENCK, HARRY P., 326 South 19th Street, Philadelphia 3, Pennsylvania, 1934, '35, '36*, '37, '38, '39, '40, '41*, '44*, '46, '47, '49, '50, '51, '52, '53, '54, '55, '56, '57, '58*, '59*, '60, '61, '62.
1959. SILCOX, LOUIS E., 102 Lankenau Med. Bldg., Philadelphia 31, Pa., 1959, '60, '61, '62.
1958. SIMONTON, KINSEY M., Mayo Clinic, Rochester, Minn., 1958, '59*, '62.
1939. SIMPSON, W. LIKELY, 512 Physicians' and Surgeons' Building, Memphis 3, Tennessee, 1939, '41, '44*, '46, '47*, '48, '50, '51*, '52, '53, '54, '55, '57, '58, '59, '60, '61, '62.
1962. SISSON, GEORGE A., 1200 E. Genesee St., Syracuse 10, N. Y., 1962.
1950. SMITH, AUSTIN T., Pennsylvania Hospital, 330 So. 9th St., Philadelphia 7, Pa., 1950, '51, '52, '53, '55, '56, '57, '58*, '59, '60, '61, '62*.
1954. SOOY, FRANCIS A., 490 Post Street, San Francisco 2, Calif., 1954, '56*, '58, '60, '62.
1961. SUEHS, OLIVER W., 14 Medical Arts Square, Austin, Texas, 1961, '62*.

1947. THEOBALD, WALTER H., 307 N. Michigan Avenue, Chicago, Illinois, 1947, '48*, '49, '50, '51, '52, '53, '54, '55, '56, '57, '58, '60, '61, '62.
1954. THORNELL, WILLIAM C., 2508 Auburn Avenue, Cincinnati 19, Ohio, 1955*, '57, '59, '60.
1950. TREMBLE, G. EDWARD, 1390 Sherbrooke St. W., Montreal, Quebec, Canada, 1950, '51, '52, '53, '54, '55*, '56, '57, '58, '60, '61, '62.
1943. VAN ALYEA, OLIVER E., 135 South LaSalle Street, Chicago 3, Illinois, 1944, '46*, '47, '48, '50, '51, '52*, '53, '54, '55, '56*, '57, '58, '59, '60, '62.
1954. WALSH, THEODORE E., 640 S. Kingshighway Blvd., St. Louis 10, Missouri, 1954, '55*, '56, '57, '58, '59, '60, '61, '62.
1962. WEAVER, DELMAR F., 571 Fisher Building, Detroit 2, Michigan, 1962.
1940. WEILLE, FRANCIS L., 247 Commonwealth Avenue, Boston 16, Massachusetts, 1940, '41, '42, '44, '46*, '47, '48, '49, '50, '51, '52, '53, '54, '55, '56*, '57, '58, '59, '60, '61, '62.
1948. WHALEN, EDWARD J., 750 Main Street, Hartford, Connecticut, 1948, '50, '51, '52, '54, '55, '57, '59.
1948. WILLIAMS, HENRY L., 2nd, Mayo Clinic, Rochester, Minnesota, 1948, '49, '50*, '51, '52*, '53, '54, '55, '56, '57, '58*, '59, '60, '62.
1951. WOODMAN, DEGRAAF, Talbottown Lane, P. O. Box 560, Easton, Md., 1951, '53, '54, '55*, '56, '58, '59, '60, '61, '62.
1953. WORK, WALTER P., University Hospitals, Ann Arbor, Michigan, 1953, '54, '56, '58, '59*, '62.

Honorary Fellows

1957. (1925) CLERF, LOUIS H., 5575 Eighth Avenue, North, St. Petersburg 2, Florida, 1957, '58, '59, '60, '61.
1960. (1928) HILL, FREDRICK THAYER, Professional Building, Waterville, Maine, 1960, '61.
1943. (1918) LEWIS, FIELDING O., Providence Road, Media, Pennsylvania.

1957. (1930) NEGUS, SIR VICTOR E., 149 Harley Street, London, W 1, England, 1957*.
1957. (1924) PROETZ, ARTHUR W., 12 Westmoreland Place, St. Louis 8, Missouri, 1957, '58, '59, '60, '62.

Corresponding Fellows

1946. ALONSO, REGULES JUSTO E., Mercedes 1233, Montevideo, Uruguay.
1959. BARRETTO, PLINIO DE MATTOS, Ru Cons Torres, Homer 371, Sao Paulo, Brazil, 1960.
1959. BATEMAN, GEOFFREY H., 55 Harley Street, London W.1., England.
1942. BATSON, OSCAR V., 203 South DeKalb St., Philadelphia 4, Pennsylvania, 1942*, '54*.
1943. EGGSTON, ANDREW A., 653 Park Avenue, New York, N. Y., 1944, '49, '55, '60, '61*.
1961. FAABORG-ANDERSEN, K., Central Hospital, Nykøbing, Falster, Denmark, 1961.
1957. HUIZINGA, EELCO, Noorderhaven 7, Groningen, The Netherlands, 1957.
1950. LARSELL, OLOF, University of Oregon Medical School, Portland, Oregon, 1950*.
1957. ONO, JO, 75 Zaimoku-cho, Azabu, Minato-ku, Tokyo, Japan, 1957.
1937. PORTMANN, GEORGES, 25 bis Cours de Verdun, Bordeaux, France, 1947.
1957. RUEDI, LUZIUS, Ramistrasse 100, Zurich, Switzerland, 1957.
1924. SCHAEFER, J. PARSONS, 4634 Spruce Street, Philadelphia 39, Pennsylvania, 1934.
1952. TAPIA ACUNA, RICARDO, Av. Insurgentes Sur 300, Mexico 7 D.F., 1953, '57, '60*.
1936. VIALLE, JACQUES, 27 Rue de France, Nice (Alpes Maritimes), France.

Emeritus Fellows

1961. (1936) BALLENGER, HOWARD C., 723 Elm Street, Winnetka, Illinois.
1941. (1923) BARLOW, ROY A., Musquodoboit Harbor, Nova Scotia, Canada.
1951. (1944) BEATTY, HUGH G., 390 Oak St., Apt. No. 35, Columbus 15, Ohio, 1951, '52, '53.
1961. (1930) CAMPBELL, EDWARD HASTINGS, 133 S. 36th St., Philadelphia 4, Pa.
1958. (1930) FIGI, FREDERICK A., Mayo Clinic, Rochester, Minn.
1946. (1933) FOSTER, JOHN H., Plaza Hotel, Houston, Texas, 1948, '49, '50, '51, '52.
1961. (1936) GALLOWAY, THOMAS CYRUS, 636 Church St., Evanston, Illinois, 1961, '62.
1951. (1928) GITTINS, THOMAS R., 408 Davidson Bldg., Sioux City, Iowa.
1962. (1950) HALL, COLBY, 1136 West Sixth Street, Los Angeles, 14, Calif., 1950.
1960. (1940) HANSEL, FRENCH, 634 N. Grand Blvd., St. Louis, Missouri, 1962.
1957. (1944) HAVENS, FRED Z., 102 Second Avenue S.W., Rochester, Minnesota.
1955. (1930) HOUSER, KARL M., 2035 Delancey Street, Philadelphia 3, Pennsylvania.
1951. (1928) JARVIS, DEFOREST C., Quarry Bank Bldg., Barre, Vt., 1952.
1956. (1939) JOHNSTON, WILLIAM HOWARD, 1515 State Street, Santa Barbara 7, California, 1957, '58.
1960. (1942) KELLY, JOSEPH D., 140 East Fifty-fourth Street, New York 22, N. Y.
1961. (1950) KLINE, ORAM R., 514 Cooper Street, Camden, N. J., 1961.

1954. (1927) LUKENS, ROBERT M., 141 West Heather Road,
Wildwood Crest, N. J.
1954. (1928) MACPHERSON, DUNCAN, 2350 Broadway, New
York 24, N. Y.
1948. (1939) MYERS, JOHN LLEWELLYN, 1115 Grand Avenue,
Kansas City, Missouri.
1959. (1927) MYERSON, MERVIN C., 436 North Roxbury Drive,
Beverly Hills, Calif.
1957. (1948) PHELPS, KENNETH A., 1850 Willow Road, Palo
Alto, Calif. 1958.
1958. (1938) SALINGER, SAMUEL, 1260 East Alejo Road, Palm
Springs, Calif., 1958, '59, '61, '62.
1962. (1932) SCHALL, LEROY A., Scudder Lane, Barnstable, Mass.
1961. (1941) VIOLÉ, PIERRE P., 1930 Wilshire Boulevard, Los An-
geles 5, Calif.
1951. (1935) WOODWARD, FLETCHER D., 1326 Rugby Road,
Charlottesville, Va., 1959, '60, '61.

BENEFACTORS

DR. JOHN F. BARNHILL

DR. GORDON BERRY

DR. EDWIN N. BROYLES

DR. WILLIAM E. CASSELBERRY

DR. LOUIS H. CLERF

DR. CORNELIUS COAKLEY

DR. & MRS. FRANCIS W. DAVISON

DR. & MRS. LEE WALLACE DEAN

DR. ARTHUR W. deROALDES

DR. FRED W. DIXON

DR. WILLIAM E. GROVE

DR. FREDERICK T. HILL

DR. & MRS. GEORGE E. HOURN

DR. SAMUEL JOHNSTON

DR. JAMES E. NEWCOMB

DR. HENRY B. ORTON

DR. SAMUEL SALINGER

DR. SAM H. SANDERS

DR. HARRY P. SCHENCK

DR. BURT R. SHURLY

MR. LESTER T. SUNDERLAND

DR. H. MARSHALL TAYLOR

DR. WALTER H. THEOBALD



Obverse of the deRoaldes medal

RECIPIENTS OF THE DEROALDES AWARD

- 1928. DR. CHEVALIER JACKSON
- 1931. DR. D. BRYSON DELAVAN
- 1934. DR. HARRIS P. MOSHER
- 1937. DR. LEE WALLACE DEAN
- 1943. DR. RALPH A. FENTON
- 1949. DR. GEORGE M. COATES
- 1951. DR. ARTHUR W. PROETZ
- 1954. DR. LOUIS H. CLERF
- 1959. DR. ALBERT C. FURSTENBERG
- 1960. DR. DEAN M. LIERLE
- 1961. DR. FREDERICK T. HILL

RECIPIENTS OF THE CASSELBERRY AWARD

1923. DR. GEORGE FETTEROLF AND DR. HERBERT FOX
1928. DR. RALPH A. FENTON AND DR. O. LARSELL
1929. DR. RICHARD A. KERN AND DR. HARRY P. SCHENCK
1929. DR. EDWARD H. CAMPBELL
1931. DR. ARTHUR W. PROETZ
1934. DR. ANDERSON C. HILDING
1936. DR. FRANCIS E. LEJEUNE: DR. JOEL J. PRESSMAN
1939. DR. H. MARSHALL TAYLOR: DR. BRIEN T. KING
1940. DR. FRENCH K. HANSEL
1941. DR. NOAH D. FABRICANT
1946. DR. PAUL H. HOLINGER
1949. DR. HENRY B. ORTON
1962. DR. HANS VON LEDEN

RECIPIENTS OF THE NEWCOMB AWARD

- 1941. DR. BURT R. SHURLY
- 1942. DR. FRANCIS R. PACKARD
- 1943. DR. GEORGE M. COATES
- 1944. DR. CHARLES J. IMPERATORI
- 1947. DR. HARRIS P. MOSHER
- 1948. DR. GORDON BERRY
- 1949. DR. GORDON B. NEW
- 1950. DR. H. MARSHALL TAYLOR
- 1951. DR. JOHN D. KERNAN
- 1952. DR. WILLIAM J. McNALLY
- 1953. DR. FREDERICK T. HILL
- 1954. DR. HENRY B. ORTON
- 1955. DR. THOMAS C. GALLOWAY
- 1956. DR. DEAN M. LIERLE
- 1957. DR. GORDON F. HARKNESS
- 1958. DR. ALBERT C. FURSTENBERG
- 1959. DR. HARRY P. SCHENCK
- 1960. DR. JOEL J. PRESSMAN
- 1961. DR. CHEVALIER L. JACKSON
- 1962. DR. PAUL H. HOLINGER

PAST OFFICERS

Presidents

(Year of Election)

1879.	Louis Elsberg	1909.	J. E. Logan
1880.	J. Solis-Cohen	1910.	D. Braden Kyle
1881.	F. I. Knight	1911.	James E. Newcomb
1882.	G. M. Lefferts	1912.	George A. Leland
1883.	F. H. Bosworth	1913.	Thomas Hubbard
1884.	E. L. Shurly	1914.	Alexander W. MacCoy
1885.	Harrison Allen	1915.	G. Hudson Makuen
1886.	E. Fletcher Ingals	1916.	Joseph L. Goodale
1887.	R. P. Lincoln	1917.	Thomas H. Halstead
1888.	E. C. Morgan	1918.	Cornelius G. Coakley
1889.	J. N. Mackenzie	1919.	Norval H. Pierce
1890.	W. C. Glasgow	1920.	Harris P. Mosher
1891.	S. W. Langmaid	1921.	Harmon Smith
1892.	M. J. Asch	1922.	Emil Mayer
1893.	D. Bryson Delavan	1923.	J. Payson Clark
1894.	J. O. Roe	1924.	Lee Wallace Dean
1895.	W. H. Daly	1925.	Greenfield Sluder
1896.	C. H. Knight	1926.	Chevalier Jackson
1897.	T. R. French	1927.	D. Bryson Delavan
1898.	W. E. Casselberry	1928.	Charles W. Richardson
1899.	Samuel Johnston	1929.	Lewis A. Coffin
1900.	H. L. Swain	1930.	Francis R. Packard
1901.	J. W. Farlow	1931.	George E. Shambaugh
1902.	J. H. Bryan	1932.	George Fetterolf
1903.	J. H. Hartman	1933.	George M. Coates
1904.	C. C. Rice	1934.	Dunbar Roy
1905.	J. W. Gleitsman	1935.	Burt R. Shurly
1906.	A. W. deRoaldes	1936.	William B. Chamberlain
1907.	H. S. Birkett	1937.	John F. Barnhill
1908.	A. Coolidge, Jr.	1938.	George B. Wood

1939. James A. Babbitt	1952. Louis H. Clerf
1940. Gordon Berry	1953. Gordon F. Harkness
1941. Thomas E. Carmody	1954. Henry B. Orton
1942-3. Charles J. Imperatori	1955. Bernard J. McMahon
1944-5. Harold I. Lillie	1956. LeRoy A. Schall
1946. Frank R. Spencer	1957. Harry P. Schenck
1947. Arthur W. Proetz	1958. Fred W. Dixon
1948. Frederick T. Hill	1959. William J. McNally
1949. Ralph A. Fenton	1960. Edwin N. Broyles
1950. Gordon B. New	1961. Dean M. Lierle
1951. H. Marshall Taylor	

Vice-Presidents

1879. F. H. Davis	J. O. Roe
1880. W. C. Glasgow	W. Porter
1881. E. L. Shurly	E. F. Ingals
1882. C. Seiler	S. Johnston
1883. S. W. Langmaid	W. H. Daly
1884. J. H. Hartman	G. W. Major
1885. H. A. Johnson	J. N. Mackenzie
1886. E. C. Morgan	S. W. Langmaid
1887. J. N. Mackenzie	C. E. DeM. Sajous
1888. W. C. Glasgow	C. E. Bean
1889. E. Holden	J. H. Hartman
1890. J. O. Roe	S. Johnston
1891. M. J. Asch	J. C. Mulhall
1892. S. Johnston	W. E. Casselberry
1893. J. C. Mulhall	S. H. Chapman
1894. C. C. Rice	A. W. deRoaldes
1895. J. Wright	D. N. Rankin
1896. T. M. Murray	H. S. Birkett
1897. A. W. MacCoy	F. W. Hinkel
1898. J. W. Farlow	M. R. Brown
1899. T. A. DeBlois	A. A. Bliss
1900. H. L. Wagner	D. Braden Kyle
1901. J. W. Gleitsmann	

1902.	G. A. Leland	T. Melville Hardie
1903.	J. H. Lowman	W. Peyre Porcher
1904.	Thomas Hubbard	W. J. Freeman
1905.	J. L. Goodale	C. W. Richardson
1906.	G. H. Makuen	A. B. Thrasher
1907.	J. P. Clark	J. E. Rhodes
1908.	E. Mayer	F. R. Packard
1909.	C. G. Coakley	H. P. Mosher
1910.	Robert C. Myles	J. M. Ingersoll
1911.	F. C. Cobb	B. R. Shurly
1912.	A. W. Watson	W. Scott Renner
1913.	F. E. Hopkins	Geo. F. Shambaugh
1914.	Clement T. Theisen	Lewis A. Coffin
1915.	J. Gordon Wilson	Christian R. Holmes
1916.	Thomas H. Halsted	Greenfield Sluder
1917.	John Edwin Rhodes	D. Crosby Greene
1918.	G. E. Shambaugh	John R. Winslow
1919.	Francis R. Packard	Harmon Smith
1920.	Harmon Smith	W. B. Chamberlin
1921.	Dunbar Roy	Robert C. Lynch
1922.	George Fetterolf	Lorenzo B. Lockard
1923.	Hubert Arrowsmith	Joseph B. Greene
1924.	Ross H. Skillern	Gordon Berry
1925.	John E. Mackenty	Robert Levy
1926.	Lewis A. Coffin	William V. Mullin
1927.	Charles W. Richardson	Hill Hastings
1928.	Robert Clyde Lynch	Francis P. Emerson
1929.	William B. Chamberlin	Ralph Albert Fenton
1930.	Harris P. Mosher	James A. Babbitt
1931.	Joseph B. Greene	E. Ross Faulkner
1932.	Gordon Berry	Frank A. Spencer
1933.	E. Ross Faulkner	Thomas S. Carmody
1934.	Gordon B. New	Samuel McCullagh
1935.	Edward C. Sewall	H. Marshall Taylor
1936.	William P. Wherry	Harold I. Lillie

1937. Frank R. Spencer	Bernard J. McMahon
1938. Ralph A. Fenton	Frederick T. Hill
1939. John H. Foster	Thomas R. Gittins
1940. Charles H. Porter	Gordon F. Harkness
1941. Arthur W. Proetz	Henry B. Orton
1942-3. Harold I. Lillie	Dean M. Lierle
1944-5. John J. Shea	Thomas C. Galloway
1946. H. Marshall Taylor	C. Stewart Nash
1947. John J. Shea	Frederick A. Figi
1948. Henry B. Orton	Anderson C. Hilding
1949. LeRoy A. Schall	Fletcher D. Woodward
1950. W. Likely Simpson	Lyman G. Richards
1951. Wm. J. McNally	Thomas C. Galloway
1952. J. Mackenzie Brown	Edwin N. Broyles
1953. Claude C. Cody	Daniel S. Cunning
1954. James H. Maxwell	Clyde A. Heatly
1955. Robert L. Goodale	Paul H. Holinger
1956. Henry M. Goodyear	Robert E. Priest
1957. Francis E. LeJeune	Pierre P. Viole
1958. Charles Blassingame	Chevalier L. Jackson
1959. James Maxwell	Oliver Van Alyea
1960. Walter Theobald	Anderson Hilding
1961. Julius W. McCall	P. E. Ireland

Secretaries and Treasurers

1879. G. M. Lefferts	1895. H. L. Swain
1882. D. Bryson Delavan	1900. P. E. Newcomb
1889. C. H. Knight	1911. Harmon Smith

Secretaries

1912. Harmon Smith	1933. William V. Mullin
1918. D. Bryson Delavan	1935. James A. Babbitt
1919. J. M. Ingersoll	1939. Charles J. Imperatori
1920. George M. Coates	1942. Arthur W. Proetz

- | | |
|------------------------|-------------------------|
| 1947. Louis H. Clerf | 1957. James H. Maxwell |
| 1952. Harry P. Schenck | 1959. Lyman G. Richards |

Treasurers

- | | |
|-----------------------------|--------------------------|
| 1912. J. Payson Clark | 1939. Frederick T. Hill |
| 1923. George Fetterolf | 1948. Gordon F. Harkness |
| 1932. William V. Mullin | 1953. Fred W. Dixon |
| 1933. James A. Babbitt | 1958. Francis E. LeJeune |
| 1935. Charles J. Imperatori | |

Librarians

- | | |
|----------------------|------------------------|
| 1879. F. H. Bosworth | 1930. John F. Barnhill |
| 1883. T. R. French | 1934. Burt R. Shurly |
| 1903. J. H. Bryan | 1935. George M. Coates |

Librarian and Historian

- | | |
|------------------------|----------------------|
| 1936. George M. Coates | 1944. Louis H. Clerf |
|------------------------|----------------------|

Librarian, Historian and Editor

- | | |
|--------------------------|--------------------------|
| 1947. Harry P. Schenck | 1955. Edwin N. Broyles |
| 1952. Bernard J. McMahon | 1960. Francis W. Davison |

PAST FELLOWS

Dates indicate original election to the Association

**Deceased*

Honorary Fellows

- *1908. Barnhill, John F., Miami Beach, Florida.
- *1893. Birkett, Herbert S., Montreal, Canada.
- *1878. Bosworth, Francke H., New York City.
- *1917. Coates, George M., Philadelphia, Pa.
- *1918. Dean, Lee Wallace, St. Louis, Mo.
- *1881. Delavan, D. Bryson, New York City.
- *1893. deRoaldes, Arthur W., New Orleans, La.
- *1890. De La Sota Y. Lastra, Ramon, Seville, Spain.
- *1923. Fenton, Ralph A., Portland, Oregon
- *1879. French, Thomas R., Brooklyn, N. Y.
- *1880. Garcia, Senior Manuel, London, England.
- *1903. Harris, Thos. J., New York City.
- *1907. Jackson, Chevalier, Schwenksville, Pa.
- *1878. Johnston, Samuel, Baltimore, Md.
- *1878. Lefferts, George Morewood, Katonah, N. Y.
- *1914. Levy, Robert, Denver, Colo.
- *1883. Mackenzie, John N., Baltimore, Md.
- *1881. Mackenzie, Sir Morel, London, England.
- *1910. Masser, Ferdinand, Naples, Italy.
- *1904. Mosher, Harris P., Marblehead, Mass.
- *1910. Moure, J. J. E., Bordeaux, France.
- *1937. Nager, F. R., Zurich, Switzerland.
- *1918. Oliver, H. K., Boston, Mass.
- *1906. Pierce, Norval Harvey, San Diego, Calif.
- *1909. Semon, Sir Felix, Great Missenden, England.
- *1878. Solis-Cohen, J., Philadelphia, Pa.
- *1889. Swain, Henry L., New Haven, Conn.
- *1914. Thomson, Sir St. Clair, London, Eng.
- *1903. Tilley, Herbert, London, England.
- *1914. Wagner, Clinton, New York City.
- *1890. Wright, Jonathan, Pleasantville, N. Y.

Corresponding Fellows

- *1892. Browne, Lennox, London, England.
- *1938. Blair, Vilray P., St. Louis, Missouri.
- *1940. Colledge, Lionel, London, England.
- *1901. Collier, Mayo, Kearsney Abbey, Kent, England.
- *1893. Desvernine, Carlos M., Havana, Cuba.
- *1930. Emerson, Francis P., Franklin, Mass.
- *1936. Fraser, John S., Edinburgh, Scotland.
- *1901. Grant, Sir James Dundas, London, England.
- *1887. Cougenheim, A., Paris, France.
- *1894. Holden, Edgar, Newark, N. J.
- *1919. Kelly, Adam Brown, Helensburgh, Scotland.
- *1881. Labus, Carlo, Milan, Italy.
- *1931. LasSagna, Francesco, Parma, Italy.
- *1926. Law, Frederick M., New York, N. Y.
- *1921. LeMaitre, Ferdinand, Paris, France.
- *1902. Lermoyez, Marcel, Paris, France.
- *1897. Luc, H., Paris, France.
- *1896. MacDonald, Greville, Haslemere, Surrey, England.
- *1894. MacIntyre, John, Glasgow, Scotland.
- *1903. McBride, P., York, England.
- *1920. McKenzie, Dan, London, England.
- *1919. McKernon, James F., New Canaan, Conn.
- *1880. Meyer, Wilhelm, Copenhagen, Denmark.
- *1910. Moure, J. J. E., Bordeaux, France.
- *1896. Mygind, Holger, Copenhagen, Denmark.
- *1950. Neil, James Hardie, Auckland, New Zealand.
- *1919. Paterson, Donald Rose, Cardiff, Wales.
- *1941. Patterson, Norman, Herts, England.
- *1919. Rogers, John, Jr., New York City.
- *1894. Sajous, C. E. DeM., Philadelphia, Pa.
- *1896. Schmiegelow, Ernst, Copenhagen, Denmark.
- *1946. Segura, Eliseo, Buenos Aires, Argentina.
- *1940. Soto, E. Fernandez, Havana, Cuba.
- *1881. Thornton, Pugin, London, England.
- *1913. Turner, A. Logan, Edinburgh, Scotland.
- *1880. Whistler, W. McNeil, London, England.
- *1901. Wingrave, Wyatt, Lyme Regis, Dorset, England.
- *1894. Wolfenden, R. Norris, Kent, England.

Emeritus Fellows

- *1915. Barnes, Harry Aldrich, Kingston, Mass.
- *1928. Beck, Joseph C., Chicago, Illinois.
- *1921. Berry, Gordon, Worcester, Mass.
- *1901. Brown, J. Price, Toronton, Canada.
- *1891. Bryan, Joseph H., Washington, D. C.
- *1913. Butler, Ralph, Philadelphia, Pa.
- *1897. Clark, J. Payson, Boston, Mass.
- *1899. Cobb, Frederick C., Bradenton, Florida.
- *1939. Cody, Claude C., Jr., Houston, Texas.
- *1905. Coffin, Lewis A., New York City.
- *1893. Coolidge, Algernon, Boston, Mass.
- *1937. Crowe, Samuel J., Baltimore, Maryland.
- *1941. Cunning, Daniel S., New York City.
- *1913. Dabney, Virginius, Washington, D. C.
- *1882. De Blois, Thomas Amory, Boston, Mass.
- *1892. Farlow, John W., Boston, Mass.
- *1922. Forbes, Henry H., New York City.
- *1905. Freer, Otto T., Chicago, Ill.
- *1940. Gatewood, E. Tribble, Richmond, Va.
- *1880. Gleitsmann, Joseph W., New York City.
- *1922. Goldsmith, Perry G., Toronto, Canada.
- *1898. Goodale, Joseph L., Ipswich, Mass.
- *1932. Graham, Harrington B., San Francisco, California.
- *1906. Greene, D. Crosby, Jr., Boston, Mass.
- *1917. Greene, Joseph B., Asheville, N. C.
- *1905. Halsted, Thomas H., Los Angeles, Calif.
- *1896. Hardie, Thomas Melville, Chicago, Ill.
- *1915. Hastings, Hill, Los Angeles, Calif.
- *1888. Hinkel, Frank Whitehill, Buffalo, New York.
- *1895. Hopkins, Frederick E., Springfield, Mas.
- *1927. Hubbard, Thomas, Toledo, Ohio.
- *1919. Hurd, Lee Maidment, Rowayton, Conn.
- *1920. Imperatori, Charles J., Essex, N. Y.
- *1904. Ingersoll, John Marvin, Miami, Fla.
- *1918. Kenyon, Elmer L., Chicago, Ill.
- *1921. Kernan, John D., New York
- *1929. Kistner, Frank B., Portland, Oregon.
- *1885. Knight, Charles H., New York City.
- *1939. Large, Secord H., Cleveland, Ohio.

- *1894. Leland, George A., Boston, Mass.
- *1922. Lillie, Harold I., Rochester, Minn.
- *1943. Lincoln, William R., Cleveland, Ohio.
- *1928. Lyman, Harry Webster, St. Louis, Mo.
- *1886. MacCoy, Alexander W., Philadelphia, Pa.
- *1896. Mayer, Emil, New York City.
- *1951. McCart, Howard W. D., Toronto, Canada.
- *1939. McCaskey, Carl H., Indianapolis, Indiana.
- *1943. McCullagh, Samuel, New York, N. Y.
- *1923. McKinney, Richmond, Memphis, Tenn.
- *1922. New, Gordon B., Rochester, Minn.
- *1878. Porter, William, Ocean Springs, Miss.
- *1901. Myles, Robert C., New York City.
- *1923. Newhart, Horace, Minneapolis, Minn.
- *1903. Packard, Francis R., Philadelphia, Pa.
- *1942. Potts, John B., Omaha, Nebr.
- *1903. Renner, W. Scott, Buffalo, N. Y.
- *1897. Rhodes, John Edwin, Chicago, Ill.
- *1884. Rice, Clarence C., New York City.
- *1905. Richards, George L., South Yarmouth, Mass.
- *1878. Robinson, Beverly, New York City.
- *1921. Sauer, William E., St. Louis, Mo.
- *1923. Sewall, Edward C., Palo Alto, Cal.
- *1930. Seydell, Ernest M., Wichita, Kansas
- *1907. Shambaugh, George E., Chicago, Ill.
- *1908. Smith, Harmon, New York City.
- *1923. Spencer, Frank R., Boulder, Colo.
- *1927. Tobey, Harold G., Boston, Mass.
- *1925. Tucker, Gabriel, Haverford, Pa.
- *1892. Wagner, Henry L., San Francisco, Calif.
- *1892. Watson, Arthur W., Philadelphia, Pa.
- *1922. White, Francis W., New York, N. Y.
- *1939. Wilson, J. Gordon, Old Bennington, Vt.
- *1905. Wood, George B., Wynnewood, Pa.

Active Fellows

- *1880. Allen, Harrison, Philadelphia, Pa.
- *1917. Arrowsmith, Hubert, Brooklyn, N. Y.
- *1879. Asch, Morris J., New York City.
- *1942. Ashley, Rae E., San Francisco, Cal.

- *1923. Babbitt, James A., Philadelphia, Pa.
- *1906. Ballenger, William L., Chicago, Ill.
- *1880. Bean, C. E., St. Paul, Minn.
- *1949. Beck, August L., New Rochelle, N. Y.
- *1904. Berens, T. Passmore, New York City.
- *1924. Bigelow, Nolton, Providence, R. I.
- *1938. Blassingame, Charles D., Memphis, Tenn.
- *1893. Bliss, Arthur Ames, Philadelphia, Pa.
- *1951. Boyden, Guy L., Portland, Oregon
- *1895. Boylan, J. E., Cincinnati, Ohio.
- *1932. Brown, John Mackenzie, Los Angeles, Calif.
- *1892. Brown, Moreau R., Chicago, Ill.
- *1933. Buckley, Robert E., New York City.
- *1915. Canfield, R. Bishop, Ann Arbor, Mich.
- *1934. Carmack, John Walter, Indianapolis, Ind.
- *1924. Carmody, Thomas E., Denver, Colo.
- *1889. Casselberry, William E., Chicago, Ill.
- *1883. Chamberlain, C. W., Hartford, Conn.
- *1917. Chamberlin, William B., Cleveland, Ohio.
- *1896. Chappell, W. F., New York City.
- *1882. Chapman, S. Hartwell, New Haven, Conn.
- *1902. Coakley, Cornelius G., New York City.
- *1913. Coffin, Rockwell C., Boston, Mass.
- 1918. Cox, Gerald H., New York City.
- *1880. Cushing, E. W., Boston, Mass.
- *1878. Cutter, Ephraim, West Falmouth, Mass.
- *1880. Daly, W. H., Pittsburgh, Pa.
- *1878. Davis, F. H., Chicago, Ill.
- *1941. Davis, Warren B., Philadelphia, Pa.
- 1926. Dennis, Frank Lownes, Colorado Springs, Col.
- *1901. Dickerman, E. T., Chicago, Ill.
- *1878. Donaldson, Frank, Baltimore, Md.
- *1947. Engler, Clarence W., Cleveland, Ohio.
- *1935. Eves, Curtis C., Philadelphia, Pa.
- *1919. Faulkner, E. Ross, New York City.
- *1914. Fetterolf, George, Philadelphia, Pa.
- *1901. Freeman, Walter J., Philadelphia, Pa.
- *1917. Friedberg, Stanton A., Chicago, Ill.
- 1940. Fuchs, Valentine H., New Orleans, La.
- *1897. Frothingham, Richard, New York City.
- 1909. Getchell, Albert C., Worcester, Mass.

- *1907. Gibb, Joseph S., Philadelphia, Pa.
- *1940. Gill, William D., San Antonio, Texas.
- *1878. Glasgow, William Carr, St. Louis, Mo.
- *1913. Goldstein, Max A., St. Louis, Mo.
- *1905. Grayson, Charles P., Philadelphia, Pa.
- *1934. Grove, William E., Milwaukee, Wisconsin.
- *1878. Hartman, J. H., Baltimore, Md.
- *1945. Hickey, Harold L., Denver, Colo.
- *1879. Holden, Edgar, Newark, N. J.
- *1907. Holmes, Christian R., Cincinnati, Ohio.
- *1882. Hooper, Franklin H., Boston, Mass.
- *1893. Hope, George B., New York City.
- *1938. Hourn, George E., St. Louis, Mo.
- *1939. Hunt, Westley Marshall, New York, N. Y.
- *1901. Hyatt, Frank, Washington, D. C.
- *1925. Iglaue, Samuel, Cincinnati, Ohio.
- *1878. Ingals, E. Fletcher, Chicago, Ill.
- *1882. Ives, Frank L., New York City.
- *1938. Jackson, Chevalier L., Philadelphia, Pa.
- *1880. Jarvis, William C., New York City.
- *1878. Johnson, Hosmer A., Chicago, Ill.
- *1879. Johnson, Woolsey, New York City.
- *1944. Jones, Marvin F., New York City.
- *1879. Kealhofer, R. H., St. Louis, Mo.
- *1942. King, Edward D., North Hollywood, Calif.
- *1901. King, Gordon, New Orleans, La.
- *1885. Knight, Charles H., New York City.
- *1878. Knight, Frederick Irving, Boston, Mass.
- *1898. Kyle, D. Braden, Philadelphia, Pa.
- *1880. Langmaid, Samuel W., Boston, Mass.
- *1878. Lincoln, Rufus P., New York City.
- *1911. Lockard, Lorenzo B., Denver, Colo.
- *1913. Loeb, Hanau W., St. Louis, Mo.
- *1897. Logan, James E., Kansas City, Mo.
- *1935. Looper, Edward A., Baltimore, Maryland.
- *1888. Lowman, John H., Cleveland, Ohio.
- *1919. Lynah, Henry L., New York City.
- *1952. Lynch, Mercer G., New Orleans, La.
- *1915. Lynch, Robert Clyde, New Orleans, La.
- *1879. McBurney, Charles, New York City.
- *1927. McGinnis, Edwin, Chicago, Ill.

1936. McGregor, Gregor, Toronto, Canada.
*1913. McKimmie, O. A., Washington, D. C.
*1945. McLaurin, John G., Dallas, Texas.
*1885. McSherry, H. Clinton, Baltimore, Md.
*1914. Mackenty, John E., New York City.
*1898. Makuen, G. Hudson, Philadelphia, Pa.
*1881. Major, G. W., Montreal, Canada.
*1948. Maxwell, James H., Ann Arbor, Mich.
*1881. Morgan, E. C., Washington, D. C.
*1950. Morrison, Lewis F., San Francisco, Calif.
*1940. Morrison, William W., New York City.
*1886. Mulhall, J. C., St. Louis, Mo.
*1925. Mullin, William V., Cleveland, Ohio.
*1914. Munger, Carl E., Waterbury, Conn.
*1892. Murray, T. Morris, Washington, D. C.
*1881. Mynter, H., Buffalo, N. Y.
*1893. Newcomb, James E., New York City.
*1895. Nichols, J. E. H., New York City.
*1927. Orton, Henry B., Newark, N. J.
*1894. Park, William H., New York City.
*1892. Porcher, W. Peyre, Charleston, S. C.
*1927. Porter, Charles T., Boston, Mass.
*1908. Randall, B. Alexander, Philadelphia, Pa.
*1882. Rankin, D. N., Allegheny, Pa.
*1902. Richardson, Charles W., Washington, D. C.
*1930. Ridpath, Robert E., Philadelphia, Pa.
*1879. Roe, John O., Rochester, N. Y.
*1881. Robertson, J. M., Detroit, Mich.
*1913. Roy, Dunbar, Atlanta, Ga.
*1878. Rumbold, T. F., St. Louis, Mo.
*1879. Seiler, Carl, Philadelphia, Pa.
*1928. Shea, John Joseph, Memphis, Tennessee.
*1893. Shields, Charles M., Richmond, Pa.
*1909. Shurly, Burt R., Detroit 1, Mich.
*1878. Shurly, E. L., Detroit, Mich.
*1892. Simpson, William Kelly, New York City.
*1919. Skillern, Ross H., Philadelphia, Pa.
*1909. Sluder, Greenfield, St. Louis, Mo.
*1879. Smith, Andrew H., Geneva, N. Y.
*1932. Smyth, Duncan Campbell, Boston, Mass.
*1928. Sonnenschein, Robert, Chicago, Ill.

- 1924. Stein, Otto J., Chicago, Ill.
- 1934. Stevenson, Walter, Quincy, Ill.
- * 1911. Staut, George C., Philadelphia, Pa.
- * 1879. Tauber, Bernhard, Cincinnati, Ohio.
- * 1924. Taylor, Hermon Marshall, Jacksonville, Fla.
- * 1903. Theisen, Clement F., Albany, N. Y.
- * 1899. Thorner, Max, Cincinnati, Ohio.
- * 1892. Thrasher, Allen B., Cincinnati, Ohio.
- * 1937. Tobey, George L., Jr., Boston, Mass.
- * 1888. Van der Poel, S. O., New York City.
- * 1938. Vail, Harris H., Cincinnati, Ohio.
- * 1936. Voislowsky, Antonie P., New York City.
- * 1933. Wanamaker, Allison T., Seattle, Wash.
- 1896. Ward, Marshall R., Pittsburgh, Pa.
- * 1879. Ward, Whitfield, New York City.
- * 1886. Westbrook, Benjamin F., Brooklyn, N. Y.
- * 1924. Wherry, William P., Omaha, Neb.
- * 1924. White, Leon E., Boston, Mass.
- * 1939. Williams, Horace J., Philadelphia, Pa.
- * 1942. Wishart, D. E. Staunton, Toronto, Canada.
- * 1922. Wishart, David J. G., Toronto, Ontario.
- * 1940. Wood, V. Visscher, St. Louis, Mo.
- * 1896. Wollen, Green V., Indianapolis, Ind.
- * 1953. Wilkerson, William W., Nashville, Tenn.

