Transactions

American Laryngological Association

EIGHTY-FIFTH VOLUME

"DOCENDO DISCIMUS"

TRANSACTIONS

OF THE

EIGHTY-FIFTH ANNUAL MEETING

OF THE

American Laryngological Association

1964

HELD AT

THE ST. FRANCIS HOTEL

SAN FRANCISCO, CALIFORNIA

APRIL 10 AND 11, 1964

PUBLISHED BY THE ASSOCIATION

ST. LOUIS, MO.

1964

Contents.

PAGE

List of Officers 7

Registration 9

President's Address, Anderson C. Hilding, M.D. 11

Introduction, Guest of Honor, Arthur W. Proetz, M.D.: President Hilding 18

Address of Guest of Honor, "How to Smother An Idea," Arthur W. Proetz, M.D. 20

Cartilaginous Tumors of the Larynx. F. Johnson Putney, M.D. and John J. Moran, M.D. 26

Discussion:

Kenneth Devine, M.D. 37

Julius W. McCall, M.D. 37

William W. Montgomery, M.D. 38

Dr. Putney (closing) 38

Observations on the Relationships Between Upper Airway Obstruction and Pulmonary Function: An Experimental Study. Joseph H. Ogura, M.D., J. Roger Nelson, M.D., Richard Dammkoehler, M.S. and M. Kawasaki, M.D. 39

Discussion:

Henry L. Williams, M.D. 62

Joel J. Pressman, M.D. 63

Joseph P. Atkins, M.D. 63

Dr. Ogura (closing) 64

CONTENTS

PAGE

The Effect of Hypothyroidism on the Larynx of the Rat: An Explanation for Hoarseness Associated with Hypothyroidism in the Human. Frank N. Ritter, M.D. 65

Discussion:

Daniel C. Baker, Jr., M.D. 77

William H. Saunders, M.D. 78

Godfrey E. Arnold, M.D. 78

Jerome A. Hilger, M.D. 79

Dr. Ritter (closing) 79

Experiences with Partial Laryngopharyngectomy. Emanuel M. Skolnik, M.D. 80

Discussion:

Joseph H. Ogura, M.D. 88

Joel J. Pressman, M.D. 89

W. Franklin Keim, M.D. 89

Dr. Skolnik (closing) 90

Clinical Application of Recent Advances in Laryngeal Physiology. Godfrey E. Arnold, M.D. 91

Discussion:

Henry J. Rubin, M.D. 107

Joel J. Pressman, M.D. 108

Dr. Arnold (closing) 109

Pharyngeal Implants for Reduction of Air Space in Velopharyngeal Insufficiency. Paul H. Ward, M.D. and Joseph M. Wepman, Ph.D. 110

Discussion:

Godfrey E. Arnold, M.D. 124

Carl R. Mundnich, M.D. 124

Emanuel M. Skolnik, M.D. 125

Francis L. Lederer, M.D. 125

Dr. Ward (closing) 126

CONTENTS

PAGE

Congenital Choanal Atresia in Infants and Children. Charles F. Ferguson, M.D. and Carlyle G. Flake, M.D. 127

Discussion:

Francis H. McGovern, M.D. 142

Francis L. Lederer, M.D. 143

Jerome A. Hilger, M.D. 144

Dr. Ferguson (closing) 144

Morphologic and Histochemical Aspects of Human Ciliated Epithelial Cells in Nasal Secretions. William T. K. Bryan, M.D., Marian Bryan, A.B. and Catherine Smith, Ph.D. 145

Discussion:

Joseph L. Goldman, M.D. 159

Anderson C. Hilding 159

Francis L. Weille, M.D. 159

Dr. Bryan (closing) 159

The Current Status of Radiotherapy in Carcinoma Laryngis. L. Henry Garland, M.D. 160

Discussion:

Paul H. Holinger, M.D. 173

Carl-Axel Hamberger, M.D. 174

Joseph L. Goldman, M.D. 174

Anderson C. Hilding, M.D. 175

Dr. Garland (closing) 176

Clinico-Histological Study of Chronic Pharyngeal Symptoms. J. Thomas Rulon, M.D. and Kinsey M. Simonton, M.D. 177

Discussion:

Kinsey M. Simonton, M.D. 204

Francis W. Davison, M.D. 204

Joel J. Pressman, M.D. 205

Dr. Rulon (closing) 205

CONTENTS

PAGE

The Management of Chronic Inflammation of the Salivary Glands. Frank D. Lathrop, M.D. 206

Discussion:

Albert C. Furstenberg, M.D. 218

Herbert Harris, M.D. 220

Dr. Lathrop (closing) 221

Retropharyngeal Hemorrhage from the Carotid Arteries. Delmar F. Weaver, M.D. and David O. Young, M.D. 223

Discussion:

Lyman G. Richards, M.D. 236

Memorials:

Edward Hastings Campbell 240

James Milton Robb 243

Executive Sessions and Reports of Officers and Committees 247

Presentation of Newcomb Award 249

List of Fellows, 1964 265

Active Fellows 266

Honorary Fellows 273

Corresponding Fellows 273

Emeritus Fellows 274

Benefactors 276

Recipients of the deRoaldes Award 277

Recipients of the Casselberry Award 278

Recipients of the Newcomb Award 279

Past Officers 280

Past Fellows 285

Index 293

THOSE IN ATTENDANCE AT THE EIGHTY-FIFTH ANNUAL MEETING

As you face the group, left to right: *front row,* Lederer, Harrill, Richardson, Montgomery, Saunders, Holinger, Lathrop, Woodman, Atkins, Fitz-Hugh, McHenry; *second row,* Friedberg, Boies, McCall, Broyles, Miller, Davison, Hilding, LeJeune, Richards, Dixon, Clerf, Goodale; *third row,* Tolan, Suehs, Ireland, O'Keefe, Hill, Weille, Conley, Fearon, Ferguson, Schall, Skolnik, Ogura, Putney; *fourth row,* Salinger, Theobald, Alfaro, Munoz-MacCormick, Moore, Alexander, Baker, Weaver, Furstenberg, Keim, Montreuil, O'Neil, Pastore; *fifth row,* Bryce, Pang, Williams, Rawlins, Goldman, Hoople, McMahon, Norris, Eagle, Harris, McGovern, Cody, Simonton.

OFFICERS FOR 1963-64

PRESIDENT

ANDERSON C. HILDING, M.D.

FIRST VICE-PRESIDENT

PAUL M. HOLINGER, M.D.

SECOND VICE-PRESIDENT

LESTER A. BROWN, M.D.

SECRETARY

LYMAN G. RICHARDS, M.D.

TREASURER

ALDEN H. MILLER, M.D.

LIBRARIAN, HISTORIAN AND EDITOR

FRANCIS W. DAVISON, M.D.

COUNCIL

The above Ex-officio and

WILLIAM J. McNALLY, M.D.

EDWIN N. BROYLES, M.D.

DEAN M. LIERLE, M.D.

FRANCIS E. LeJEUNE, M.D.

TRANSACTIONS OF THE
EIGHTY-FIFTH ANNUAL MEETING

OF THE

American Laryngological Association

HELD AT

THE ST. FRANCIS HOTEL

SAN FRANCISCO, CALIFORNIA

APRIL 10 AND 11, 1964

The Eighty-fifth Annual Meeting of the American Laryngological Association was called to order by the President, Dr. Anderson C. Hilding, at the St. Francis Hotel, San Francisco, California on April 10, 1964, at 8:30 A.M.

REGISTRATION

The following Fellows were in attendance:

ALEXANDER, FRED W.
ALFARO, VICTOR R.
ARNOLD, GODFREY E.
ATKINS, JOSEPH P.
BAKER, DANIEL C.
BOIES, LAWRENCE R.
BORDLEY, JOHN E.
BROYLES, EDWIN N.
BRYCE, DOUGLAS P.
CLERF, LOUIS H.
CODY, CLAUDE C., III
CONLEY, JOHN J.
DALY, JOHN F.
DAVISON, FRANCIS W.
DIXON, FRED W.
EAGLE, WATT W.
FEARON, BLAIR
FERGUSON, CHARLES F.

Fitz-Hugh, G. Slaughter
Friedberg, Stanton A.
Furstenberg, Albert C.
Galloway, Thomas C.
Goldman, Joseph L.
Goodale, Robert L.
Harrill, James A.
Harris, Herbert
Hilding, Anderson C.
Hilger, Jerome A.
Hill, Frederick T.
Holinger, Paul H.
Hoople, Gordon D.
Ireland, P. E.
Keim, W. Franklin
Lathrop, Frank D.
Lederer, Francis L.
LeJeune, Francis E.
McCall, Julius W.
McGovern, Francis H.
McHenry, Lawrence C.
McMahon, Bernard J.
Miller, Alden H.
Montgomery, William W.
Montreuil, Fernand
Moore, Paul M.
Munoz-MacCormick, Carlos E.
Nash, C. Stewart
Norris, Charles M.
Ogura, Joseph H.
O'Keefe, John J.
O'Neil, James J.
Pang, Lup Q.
Pastore, Peter N.
Pressman, Joel J.
Putney, F. Johnson
Rawlins, Aubrey G.
Richards, Lyman G.
Richardson, John R.
Salinger, Samuel
Saunders, William H.
Schall, Leroy A.
Silcox, Louis E.
Simonton, Kinsey M.
Skolnik, Emanuel M.
Sooy, Francis A.
Suehs, Oliver W.
Theobald, Walter H.
Tolan, John F.
Violé, Pierre P.
Walsh, Theodore E.
Weaver, Delmar F.
Weille, Francis L.
Williams, Henry L., II
Woodman, DeGraaf

OPENING SESSION

FRIDAY MORNING, APRIL 10, 1964

The Scientific Session of the Eighty-fifth Annual Meeting of the American Laryngological Association, held at the St. Francis Hotel, San Francisco, California, convened on Friday morning, April 10, 1964, at nine o'clock, immediately following the Executive Session, Anderson C. Hilding, M.D., of Duluth, Minnesota, President of the Association, presiding.

PRESIDENTIAL ADDRESS

ANDERSON C. HILDING, M.D.

May I thank you again for the honor of having been President of your Association for the last year. That my thanks is simple does not mean that it is any the less heartfelt.

I want to take this occasion to acknowledge with gratitude the wonderful help of your Secretary, Dr. Lyman Richards. It is through his know-how, hard work, and good judgment that this program became a reality.

Nothing ever seems to stay the same in this world, including the scope of otorhinolaryngology. If otology separates from otolaryngology, of which there are indications, what then? Will what remains constitute a practical specialty? Will the rhinolaryngologists go into head and neck surgery of the type we have seen demonstrated this week?

During my first few years in pratcice, when I took my training in Vienna, in the early 1920s, eye, ear, nose, and throat was considered to be a single specialty, and included everything from refraction and mastoidectomy to endoscopy. As practiced at that time, the field

---

Presidential Address, American Laryngological Association, San Francisco Meeting, April 10, 1964.

From the Research Laboratory, St. Luke's Hospital, Duluth, Minnesota.

was perhaps not too big and, I feel sure, included less than that of just ear, nose, and throat today. Practice consisted largely in refraction and care of suppurative disease in its numerous manifestations—cornea, eyelids, conjunctiva, tear sac, ears and mastoid with complications, cervical nodes, tonsils, sinuses, septum, the skin of the neck, and the pharynx.

Through development and expansion, the field became too large. Ophthalmology, even in my early days in practice, was a mature specialty and was expanding its scope rapidly. People spoke of "*both*" ophthalmology and otolaryngology. Refraction was a well-developed facet. Ocular pathology—thanks to Ernst Fuchs—was already well under way; retinal surgery and the knowledge of ocular disease as related to internal medicine and neurology developed rapidly; the ever-expanding area of ocular physiology, including bio- and physical chemistry, hydrodynamics, and electronics continues to enlarge. Even the knowledge of anatomy continues to progress greatly. At the present time, one man can scarcely encompass all of ophthalmology.

Somewhat more recently, otology has followed a similar pattern. Audiology has developed enormously. The understanding of otologic disease and the development of techniques for middle ear surgery have greatly advanced. The relation of otology to internal medicine and neurology has been increasingly recognized and the ever-expanding physics of hearing and orientation, biochemistry, physical chemistry, hydrodynamics, and electronics develops apace. Even the area of otologic anatomy is by no means exhausted, as witnessed by the papers presented this week by Anson,[1] Dohlman,[2] and my son, David.[3] At the present time, I believe that one man can scarcely encompass all of otology. Day, in his address as Guest of Honor at the Otological Society on Sunday, stated that otology has advanced more in this generation than in all of previous history.[4]

Again, one hears the little disquieting word "*both*," but, instead of being applied to ophthalmology and otolaryngology, it is now applied to otology and rhinolaryngology and one gets the uneasy feeling that otology is also going to break away.

The two sense organs—the eye and the ear—have a great deal in common and, were it not for the size of the fields involved, could well be included in a unified specialty. The similarities—physiological, functional, neurological, even anatomical—are too numerous to mention. Among others, neither sense organ has anything special to

do with the respiratory tract. They are both connected to it in a similar manner, by narrow, cilia-lined tubes—the nasolacrimal duct and the eustachian tube. Otology and ophthalmology, although they overlap into other fields, are well integrated specialties, including all of the activities of their respective organs. The respiratory tract, on the other hand, is not included in one integrated specialty. It is chopped up among a number of specialties. Some practitioners seek to limit their work more or less to deformities of the external nasal pyramid. Others focus attention on the sinuses and attain a reputation and practice in that area and rarely, if ever, use a bronchoscope. Some emphasize malignancy of the nose, sinuses, and larynx, or even the last alone. Others limit their practices largely to the smoking half of the population and become thoracic surgeons, while a number confine their activities to looking down the air and food passages, and still others to the physiology of the alveolus and the smaller air passages.

Perhaps this is necessary. Perhaps this tract, although a physiologic unit, comprises too much for one specialist in practice to encompass. If it *could* be embraced as a unit this would surely be desirable, with one specialist including the whole system. To me it has always seemed surpassing strange that a surgeon who suspects a bronchogenic carcinoma must call in someone else to pass a bronchoscope to look at it. Why doesn't he look himself? I once heard a conversation between a "general" rhinologist and a nasal pyramid specialist quoted. The latter stated that he knew nothing about internal nasal physiology and seemed to take some pride in the fact. The general rhinologist was said to have replied, "Why don't you take an afternoon off and learn the nasal physiology?" It would undoubtedly take more than one afternoon for the thoracic surgeon to learn how to use a bronchoscope, but, since he is capable of doing the type of surgery in which he specializes, there is certainly no good reason why he could not learn to handle a bronchoscope and do all of the pertinent examinations himself. As a matter of fact, some thoracic surgeons now do their own endoscopy. Likewise, having in mind the competence and ability of the endoscopists I know, I feel sure that they would be quite capable of opening a thorax and removing the lesion which they find through the scope.

Be that as it may, the tract is a physiologic unit and should be thought of as such. Anyone working in any part of it should have a good knowledge of the physiology of the whole.

I had occasion about two years ago to explore sketchily the abysmal depths of my own ignorance in the lower tract, when I was invited to take part in a three-day conference on respiratory disease in industry. For 30 years I had been talking about the deposition of particular matter within the respiratory tract and found, to my dismay, that my information on the subject, even politely, could only be called rudimentary or less. The discussions on the size of particles, their specific gravity, physical nature, and electric charge, the relation of velocity, turbulence, impact, medium resistance, and diffusion to deposition was an eye-opener. On the other hand, in the discussion of particle deposition in the respiratory tract, the nose was quite ignored as though non-existent.

The fascinating discussion on surfactants (a new word to me—surface-active materials), the presence of and nature of the fluid surface lining the alveoli was a revelation. The importance of surface tension and the great differences in surface tension during inspiration and expiration were new. Anyone who attempts, for instance, to reduce the viscosity of respiratory secretions, through the use of aerosols or otherwise, should not only be conversant with the ciliary mechanism but should know about the physiology of these vital surface tensions in the respiratory tract and what effect his treatment might be having upon them. If the fluid film lining the alveoli were water or plasma, the surface tension would be low while the alveoli were dilated during inspiration and so high during the contraction of expiration that our lungs would collapse. Instead the thin film lining the alveoli is reported to be a phospholipid that has the reverse effect on surface tension. When the alveoli are dilating, the surface tension goes up, and during contraction of expiration falls very low—practically to zero. One cannot but wonder if a similar surface-active material is present in the middle ear and mastoid to prevent transudation and to keep these cavities air-containing.

On the other hand, some of the erudite scientific minds, which led these discussions on alveolar surface activity, seemed to have only vague notions as to how the ciliary mechanism worked. The nature of the respiratory epithelium and its reaction to injury seemed to be quite as foreign to them as the material of their learned discussions had been to me. These brilliant scientists were like the Washingtonian who announced that he was going back East to Boise, Idaho and the Bostonian, who went out West to Albany—they referred to the bronchioles as the upper respiratory tract—seemingly terra incognita,

lying somewhere far to the north. As to the nose and sinuses, I felt shy about even mentioning them. I'm sure you can detect a little tongue in cheek in this factual reminiscence, but it does serve to emphasize that those of us working on the respiratory tract need much more of an understanding of the tract as a physiologic unit, while we are pursuing our own particular phase of practice or research.

Fortunately, signs of integration of knowledge of the respiratory tract are already in evidence, as witnessed by the panel discussion on minimal training requirements for broncho-esophagology two days ago at the meeting of the Broncho-Esophagological Association,[5] and the papers this week of Caldarola[6] on benign tumors of the tracheobronchial tree, Fearon[7] on respiratory distress in the newborn, Greenberg[8] on pulmonary tissue reaction following Hytrast bronchogram, Atkins[9] on cuffed tracheotomy tubes, and Ogura,[10] who follows soon this morning, on obstruction of the upper airways and pulmonary function, as well as by the paper of the Bryans and Catherine Smith[11] on the histochemistry of nasal epithelium, on our program tomorrow morning.

The subject of the moment—cigarettes and health, especially with reference to diseases of the respiratory tract—points up the need for this integration. At last the ciliary mechanism that we, in our specialty, have been calling attention to more or less futilely (as far as the rest of the profession is concerned) for the last 40 years, is receiving some long overdue recognition. If the physiology of the tract as a whole were better understood, there wouldn't be so much confusion over the fact that malignancy from cigarettes occurs in the root of the lung and in the vocal cords and not in the nose, mouth, and pharynx.

As our specialties continue to evolve, especially if otology breaks away—change is painful—it is just as painful as it is inevitable—perhaps we should do some actual planning to formulate an enlarged, unified field in the respiratory tract—one that would be practical and workable in clinical practice, not just in the big centers, such as San Francisco or New York, but also in Waterloo, Englewood and Mount Vernon. It is practicable and desirable for specialists to limit themselves to endoscopy in New Orleans and Philadelphia, but hardly in towns of 50,000. But, to take in all of the pathology and all of the therapy and diagnosis involved in the respiratory tract would be a very large, formidable undertaking indeed, as attested by the comprehen-

sive text on diseases of the chest by Hinshaw and Garland[12] (the latter is on our program tomorrow morning).

If not all of the respiratory tract, how much should be included in a special field?

I don't pretend to know what is best for our specialty, but it might be wise for all of us to do some specific thinking and planning, in the face of the evolution that seems to be taking place. Some of our educators, as mentioned by Bordley[13] two days ago, are already doing so and this is comforting.

Of this I am sure, no matter how it evolves, the future of otolaryngology is bright!

REFERENCES

1. Anson, Barry: Intraosseous Blood Supply of the Auditory Ossicles. Presented at the San Francisco Meeting of the American Otological Society April 5, 1964.

2. Dohlman, Gösta: Secretion and Absorption of Endolymph. Presented at the San Francisco Meeting of the American Otological Society April 5, 1964.

3. Hilding, David A., and House, Wm. F.: Ultrastructure of the Human Utricle: Normal and in Meniere's Disease. Presented at the San Francisco Meeting of the Triological Society April 7, 1964.

4. Day, Kenneth M.: Otology, Art or Science? Address of Guest of Honor, American Otological Society, San Francisco Meeting, April 5, 1964.

5. Broncho-Esophagology, Minimal Training Requirements for: panel discussion moderated by Herbert W. Schmidt, and discussion by Paul H. Holinger, Jerome A. Hilger, David J. Dugan and Benson B. Roe, at San Francisco Meeting of American Broncho-Esophagological Association April 8, 1964.

6. Caldarola, Vincent T.; Harrison, Edgar G.; Clagett, O. Theron; and Schmidt, Herbert W.: Benign Tumors and Tumor-like Conditions of the Trachea and Bronchi. Presented at San Francisco Meeting of American Broncho-Esophagological Association April 7, 1964.

7. Fearon, Blair; Swyer, Paul R.; and Smith, Code: The Respiratory Distress Syndrome in the Newborn. Presented at San Francisco Meeting of American Broncho-Esophagological Association April 7, 1964.

8. Greenberg, S. Donald: Pulmonary Tissue Reaction Following Hytrast Bronchogram. Presented at San Francisco Meeting of American Broncho-Esophagological Association April 7, 1964.

9. Atkins, Joseph P.: Tracheal Reactions Following the Use of Cuffed Tracheotomy Tubes. Presented at San Francisco Meeting of American Broncho-Esophagological Association April 8, 1964.

10. Ogura, Joseph H.; Nelson, J. Roger; Dammkoehler, Richard; and Kawasaki, M.: Observations on the Relationships Between Upper Airway Obstruction and Pul-

monary Function: An Experimental Study. Presented at San Francisco Meeting of American Laryngological Association April 10, 1964.

11. Bryan, Wm. T. K.; Bryan, Marian; and Smith, Catherine: Morphologic and Histo-chemical Aspects of Human Nasal Ciliated Epithelial Cells. Presented at San Francisco Meeting of American Laryngological Association April 11, 1964.

12. Hinshaw and Garland: Diseases of the Chest. 2nd ed., Saunders, 798 pp., 1963.

13. Bordley, John E.: Presidential Remarks at San Francisco Meeting of Triological Society April 7, 1964.

INTRODUCTION OF THE GUEST OF HONOR

PRESIDENT HILDING: I am somewhat at a loss to know what to select to say about our famous Guest of Honor, Dr. Arthur Proetz. His accomplishments and honors are far too numerous to cite here. To this Association, he has meant much. He has been Council Member, Secretary, Vice-President, and President. In recognition of his scientific accomplishments, the Association awarded him both the de Roaldes medal and the Casselberry prize. His scientific contributions and his addresses to this Association and other medical societies have been many, including the Wherry Memorial Lecture of the American Academy of Ophthalmology and Otolaryngology, and the Semon Memorial Lecture in England in 1952 . Other lectures and papers have been delivered abroad in London, Paris, Copenhagen, Canada, and Chile. He was the President of the VIth International Congress of Otolaryngology, held in Washington, D.C. It was largely through his efforts during the preceding years that this International Congress was such a great success.

He was an active member of the Collegium Oto-Rhino-Laryngologicum for a great many years and voluntarily and generously gave up this active membership a few years ago and accepted an emeritus status to make room for some younger men. Active membership in this organization is limited to ten from any one country.

Arthur Proetz is the author of three books, *Displacement Therapy and Diagnosis, The Physiology of the Nose* and *I Remember You, St. Louis.* When any of you become so tense from the exigencies of your practice that you are all tied up in knots and cannot sleep, I suggest that you read *I Remember You, St. Louis* for relaxation; it is a great tranquilizer and full of laughs.

Dr. Proetz has long been the editor of our wonderful journal, *The Annals of Otology, Rhinology and Laryngology.* For this we owe him a great debt of gratitude.

To attest to the exceedingly well rounded life of our Guest of Honor is his position of Professor of Otolaryngology at Washington University School of Medicine over a period of many years, his work as a researcher in this field, his reputation as a photographer (he has

had his own shows and has written on the subject), his authorship of some musical shows (during his college years), and his scholastic recognition in election to Alpha Omega Alpha and Sigma Xi.

We were shocked to learn a few days ago that he had suddenly become critically ill and we are naturally very disappointed that he cannot be with us in person but rejoice that in the last few days his condition has greatly improved and his condition is no longer precarious.

His address, *How to Smother an Idea,* will be read by his longtime friend, Dr. Bernard McMahon.

SECRETARY RICHARDS: This was sent to me but it is addressed to the Officers and Fellows of the American Laryngological Association:

> Through the years you have extended to me every signal honor and act of fellowship within your reach and today it is a very overwhelming disappointment to be deprived of the joy and pleasure of celebrating with you the presidency of my old and good friend, Anderson Hilding. You may be sure that it is only sudden, complete incapacity that prevents my being there.
>
> I send you all best wishes for a perfect meeting and my fervent hope to be back with you next year.
>
> ARTHUR PROETZ

HOW TO SMOTHER AN IDEA

ADDRESS OF THE GUEST OF HONOR

ARTHUR W. PROETZ, M.D.
(Guest of Honor)
ST. LOUIS, MO.

Not long ago I was trying rather successfully to read myself to sleep when I came upon a sentence that scared me wide awake.

"It is now clear," the man said, "that the scientific paper is a dead duck."

What made this so startling is, first, that the man is a Yale professor, second, that he said it in all seriousness, and third, that he is so absolutely right.

For some time past there has been an uneasy feeling among scientists that the literature is about to get away from us. It is fast becoming impossible for one to keep pace with it if he is to have any time left to make use of it. In some fields knowledge is growing so fast that it can be handled only by machines. While we are not there yet in medicine, still the Index Medicus for 1964 lists some 3,000 bona fide medical journals and 100 of them are new this year.

My professor points out that science can no longer continue to grow laboriously by piling up little facts, brick by brick like building a house.

Only in the last hundred years of man's existence has he noticed that having things like comforts, conveniences and leisure depends upon a knowledge of machinery and what it takes to invent it and make it tick, namely, science. Demand and supply have created wealth, which in turn has created more demand and supply, which goes on at an exponential rate until we have become obsessed with the idea of muchness for its own sake. Asking for a little of this or that is not enough. We say, "Let's have a lot—let's have a big double portion of both."

This cult of muchness extends to the way in which we now go about speeding up progress in science and technology by sheer weight of numbers, even though the quality of the product may suffer. We will not readily admit this, but symptoms are showing.

Perhaps at first glance it may seem immaterial whether science is advanced by a handful of geniuses in leaps and bounds, or by a million average citizens in creeps and budges, but there is a waste of both money and manpower, a spotty distribution of knowledge and the necessity of having to weed out the errors and start over.

Research is not just anybody's toy, it takes talent. Many are bitten by the bug, but the infection is often light. Furthermore, the magic word "research" can mean many things to many people. In the advertising business (sometimes called a game—sometimes even a profession) research can mean simply looking up things in a library. In scientific circles it can happen too.

Our accepted processes of advancing an idea seem to me to be not always too intelligent. Usually they are more the result of habituation than poor planning and of a blind urge to be doing something with the young men.

It would seem logical, when someone comes up with what looks like a break-through in medical science, that the next move should be to submit it quietly to half a dozen seasoned researchers to be checked and proven before it spills over to numerous untrained observers or even the whole medical profession and gets out of control.

The early days of antibiotics furnish a recent example. These got us into trouble so soon after they first became available that from the start the journals were filled with warnings. The warnings went unheeded in the rush to be the first to use the wonder drugs; much damage was done and much of the precious medication was thrown to the winds.

In spite of the stampedes I still believe that something can be done for rational medicine before we turn it over to the machines. I doubt that it will ever be for the best interest of the patient to feed his little symptoms into a machine loaded with all of known medicine and wait a minute for the pink slip with his number, his diagnosis and the infallible instructions.

What fun is it being sick or getting old if instead of a genial palaver with the family doctor all you get is a pink slip which reads: EXTERMINATE HIM?

Nor am I ready to do away with the literature, though frankly it can bear improving. The conscientious man, trying to keep up with it, can waste much time. What can we do for him, and who shall do it? It begins with those who write papers and those who print them. I hate to say this, but it could just be that there are too many of both of us. Much of the literature that gets in our way was not written primarily to advance knowledge and much of it is not even strictly for the reader.

There are fourteen reasons why a doctor may write a paper: To

1. Contribute a new idea.
2. Repeat an old idea.
3. Repeat an old idea for the fortieth time.
4. Report an interesting case.
5. Report an uninteresting case.
6. Oblige a secretary with a program to fill.
7. Summarize a subject.
8. Get a job.
9. Get a grant.
10. Try to keep a grant.
11. Advertise a product.
12. Advertise himself.
13. Get money for it.
14. Retract a previous statement. (rare)

Only four of these are purely for science. Seven are just as clearly for individuals. Most of the latter papers are harmless, except that they pile up and give the impression of progress where none exists.

With the vital motives cut down to four, things look simpler. We still have a long way to go before the rush of good, solid, essential literature defeats us, but some drastic streamlining is in order. Who can do this and how?

It would help if preceptors in schools, whose business it is to launch young scientists, would teach them to be less imitative and generally more effective in their presentation. Unguided they develop bad habits.

We all shun the dreary soul at the cocktail party who tells stories that ought to be side-splitters but kills them first with a tedious approach and ends up by explaining them. This same chap, reading or writing a paper, keeps us waiting several pages for what he set out to tell us while he describes first what a lot of other people told us long

ago, that we have read before. He will likely summarize with the silly statement: "This paper describes 3 cases of such-and-thus, etc." We know that it does. We have just listened to it. Or have we?

How often have we sat glassy-eyed waiting for a speaker to finish a paper that we hadn't a chance of understanding from the beginning. The man who talks over the heads of his audience commits one of three sins: if he does it cynically, expecting the printed version to reach a more sophisticated group, he is a snob; if he does it thinking to be impressive he is apt to end up by being merely pompous; if he does it unknowingly, then he is not as sensitive as a good scientist ought to be, and should not be trusted with research.

Under the head of talking over the head one could mention voluminous tables. Whether on the page or on the screen, they have none of the charm of a sheet of wall paper and are little more informative. Even if the slide is left on long enough to be read, it is unlikely that the audience will care to check for itself the fate of every little hamster.

A secretary, building up his program, cannot, except for his previous experience with a speaker, be of much help here. When he sees the paper it is too late.

Editors are in a slightly better position. They have the advantage of choice and they bear a responsibility to their subscribers to keep the contents fresh and the quality high. Beyond rejecting a paper altogether, they are not censors, and they should not be.

In the last analysis the task falls upon the writer himself. Scientists have to write and they owe it to themselves and to us to learn how. It does not follow that because some very prominent authorities have some very bad writing habits the rest of us should imitate them.

There are several best ways of putting a paper together and I should not presume to lay down rules. To the beginner I would venture a few suggestions—I would say to him:

First, state what you are talking about: the title.

Next, state what you have contributed: the conclusion.

Third, give acceptable evidence for it.

Fourth, state your own views on your findings. Compare them with the views of others when and only to the extent demanded by your thesis.

And that is it.

Go over it carefully and strike out every unessential word and phrase. Granted, the entertainment value of such a presentation could turn out to be small, but it could be completely fascinating if the content is fascinating.

The title should be concise—this is no place for subordinate clauses—and should contain words which can be effectively indexed. (On all counts, the title of the present address is a glittering failure. Would you file it under "Smother"? or "Idea"? or "How"? No reader in his right mind would look for a paper under any of those heads, consequently this offering will soon reach the oblivion it deserves.)

There is one passing thought on the subject of conclusions: As stated, I would prefer to have them put at the beginning of the paper so that, first, we can see what they are and, second, whether there are any. How dismal to stay with the author for many long pages with the growing suspicion that he is not getting anywhere only to have him verify it with the familiar "This present series is admittedly too small to permit of any conclusions and further work will have to be done before" etc., etc. We would gladly have endured the suspense of waiting another year or two until he had something worth reporting, and the literature would have been the better for it. The title of this half-baked paper will appear in many a table of references and waste many people's time.

On the subject of redundant references, which are often only name dropping, we can best quote our late friend, Jos. Beck, who once remarked that it would be refreshing to read something in medicine without being constantly interrupted with what Kussmaul and Rokitansky wrote about it in 1878.

There is currently a fad of coining new words which are disconcertingly like some old ones—a kind of egghead lingo, in a sense, a word explosion. About this a molecular neurologist recently suggested "invisible colleges of interdisciplinary groups" (lovely words!) to tackle the twin problems of making important scientific information interesting and meaningful to the public and of furnishing scientific researchers with data from other disciplines which will help them in their work.

Making scientific truths interesting to the public is a sweet thought but I for one shall be content when they learn to communi-

cate them to other scientists in other "disciplines"—a slick new word that used to be "specialties" or "branches." I believe I am beginning to sense something of what is the matter!

There is an important type of paper which poses a serious publication problem. This is a work which is legitimately long, which requires technical details, symbols and formulas unfamiliar to doctors. It belongs properly in a basic physiological or anatomical journal but borders so closely on clinical medicine that doctors should be aware of it.

Clinical journals cannot carry many of these and hold their subscribers. The reader appeal is limited, the cost is high and space is not available if the authors awaiting publication are to have it within a reasonable time. With grants now available the number of such papers is mounting.

Solutions suggest themselves: one is to print the paper in extenso, for the record, in a basic science journal and a shorter, more palatable version for the doctors in a clinical publication. Another is the supplement, which has been tried with some success abroad. A third is registration with the American Documentation Institute in Washington.

But what, I ask, is wrong with making the paper less cumbersome in the first place? Einstein, I am told, put on his top performances in five or six pages. (And to show you a fine job of smothering, I had the devil's own time locating his original papers, though the shelves are full of interdisciplinary writers trying to tell me what he said.)

I am discovering that it is easier to find fault than to fix things. I once had an astute secretary who, when I got to running on like this, used to say, "If God had only made you his little traffic cop everything would be all right with the world." I thought then that she had something there. Of late I am not so sure.

Now I fear that in closing I am about to fall into another of my own traps by saving my conclusion for the end and finding that I have nothing really monumental to conclude. You see what I mean.

At least, the best way to hide an idea—or no idea—is with words, and more and more and more words.

CARTILAGINOUS TUMORS OF THE LARYNX

F. JOHNSON PUTNEY, M.D.
AND
JOHN J. MORAN, M.D.
(by invitation)
PHILADELPHIA, PA.

While cartilaginous tumors of the larynx are rare they occur in the laryngologist's practice usually as isolated cases. Because of the benign course of both the chondroma and chondrosarcoma the management is aimed at surgical removal of the airway obstruction with conservation of laryngeal function, which commonly can be accomplished primarily but becomes increasingly more difficult with recurrences.

Heusinger[2] has been credited with the first description of a tumor of this type in 1822. Various reports have appeared in the American literature sparked by New's[6] report in 1918. Moore[5] in 1925 was able to collect only 53 cases in the world literature. Since that time McCall et al.,[4] Walter, and Goethals et al.[1] by collection and addition have raised the total to 119. Four more cases are herein reported.

Predominately found in males the age group tends to be somewhat younger than that of carcinoma. The two principal symptoms are hoarseness and dyspnea. The hoarseness, although usually the first symptom, may not be severe enough to bring the patient to the physician due to the common location of the tumor below the vocal cord level laterally or posteriorly giving rise to more of a muffling sound than hoarseness. The increasing dyspnea as the tumor enlarges finally demands attention.

On mirror examination of the larynx a smooth, round, intraluminal mass is observed, frequently below the vocal cord level but encroaching upon the vocal cords and the glottis. The arytenoid,

---

From the Departments of Otolaryngology and Pathology, Jefferson Medical College, Philadelphia, Pa.

thyroid and cricoid cartilages may be the site of origin, but the latter is the more frequent, commonly beginning in the posterior portion of the cricoid cartilage so that the bulging mass is easily seen with a laryngeal mirror. Movement of the vocal cord on the involved side may not be present, but the arytenoid is generally mobile. Limitation of motion is due to the bulk of the tumefaction rather than involvement of the musculature or nerves. The absence of ulceration may suggest the diagnosis although it does not rule out carcinoma. Other lesions such as sarcomas, cylindromas, fibromas, cysts and neurogenic tumors may give a similar appearance although they occur more often supraglottically.

Direct laryngoscopy establishes the hard nature of the tumor, but biopsy may be disappointing. In attempting to secure a piece of tissue for histologic study the bite may not be deep enough to include cartilage and only overlying mucosa is removed. The smooth surface also adds to the difficulties of successful biopsy, but the stony hardness of the presenting mass which moves with the laryngeal cartilages is suggestive.

Both planograms and laryngograms are useful to delineate the lesion and its point of attachment. The smooth contour with a broad base confluent with the cartilaginous skeleton is observed, but soft tissue roentgen films may be needed to demonstrate penetration through the cartilage to the external perichondrium.

Occasionally enlargement or irregularity of the cricoid or thyroid cartilages can be palpated through the neck.

Cartilaginous tumors grow slowly, not only as primary tumors but also when recurrent. They have not been known to metastasize regardless of the histologic appearance. Local recurrence is the rule in chondrosarcoma, but even when this occurs it does not increase the metastatic potentialities. Because of their smooth, sharp outline both the chondroma (Fig. 1) and chondrosarcoma (Fig. 2) appear to be encapsulated, but at operation they are usually found to be intimately entwined in the cartilage itself and no capsule exists, so that they can not be shelled out.

The cricoid cartilage remains the critical area, and at times the tumor involves the cricoid cartilage to such an extent that laryngectomy is needed. Conservative surgical procedures are warranted when sufficient laryngeal tissue can be spared for reconstruction, and wherever possible the maximum amount of the cricoid is preserved. Excision of the cartilaginous tumor including a portion of normal cartilage

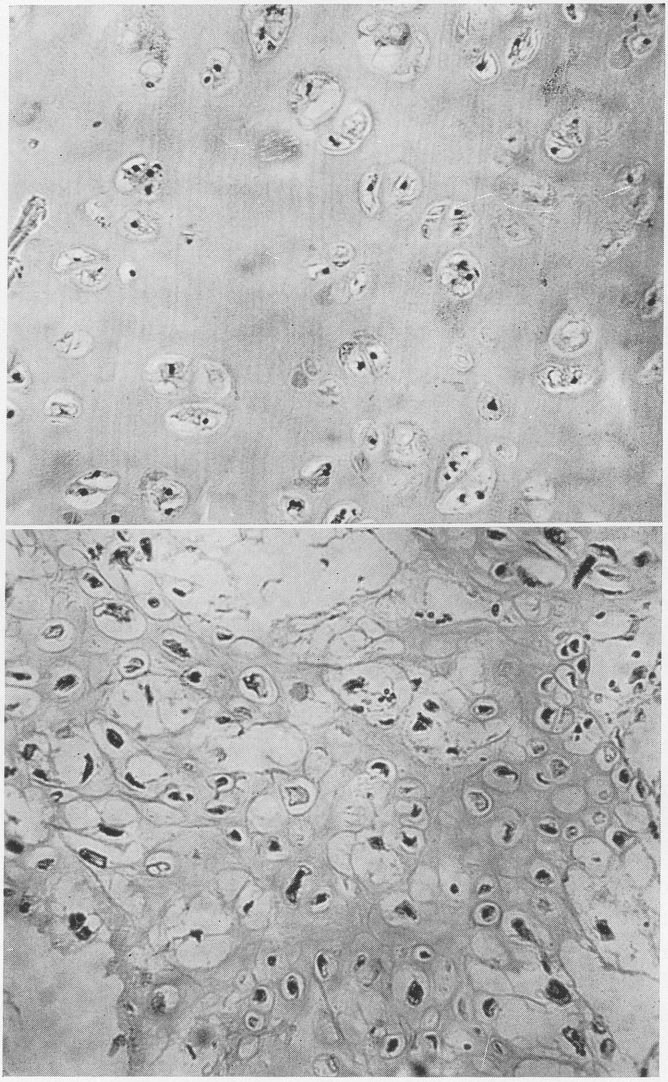

Fig. 1.—Histologic section of chondroma of larynx.
Fig. 2.—Histologic appearance of chondrosarcoma of larynx.

around its base may leave only a small portion of the cartilage, which is particularly significant when the cricoid is involved. The use of an acrylic stent to maintain the airway over a split thickness skin graft when less than two-thirds of the cricoid ring has been removed has resulted in an adequate airway. With greater cricoid involvement anastomosis of the trachea to the remaining cricoid cartilage and thyroid cartilage has proved satisfactory in some primary cases, but in recurrent cases this may not be possible. Sacrifice of larger portions of the thyroid cartilage can be done with less risk of permanent airway stenosis.

REPORT OF CASES

CASE 1. E.T., a white male, aged 44, complained of something in his throat shutting off his wind with a pressure sensation of two months' duration. In addition, he complained of thickness and muffling of the voice accompanied by coughing. Mirror laryngoscopy revealed that the left ventricular band was rounded and its edge projected beyond the midline and upward toward the base of the epiglottis. No inflammation or ulceration was observed.

On direct laryngoscopy the prominent left ventricular band obscured a view of the left vocal cord and could not be displaced. On palpation the mass was quite hard suggesting a chondroma. Adequate tissue was not obtained for histological study.

After the ventricular band and surrounding tissues had been separated from the thyroid cartilage internally at thyrotomy, the left wing of the thyroid cartilage was found to be prominent in the region of the ventricular band suggesting a solid tumor. After separation of the external perichondrium a deep depression over the outer aspect of the left thyroid ala was found with a localized area of cartilage enlargement measuring about 0.5 cm extending through the thickness of the cartilage. The major portion of the left wing of the thyroid cartilage was removed, the ventricular band and vocal cord replaced, and a temporary tracheostomy performed. The histologic diagnosis was chondroma.

The patient has remained well for 14 years without recurrence and with an excellent voice.

CASE 2. C.M., a colored female, aged 49, complained of hoarseness of two years' duration, more marked during the past seven months with difficulty breathing at times. On mirror laryngoscopy

a large swelling was observed in the posterior portion of the larynx extending forward from the interarytenoid area at the vocal cord level. It almost completely obliterated the glottis leaving only a small airway anteriorly, and the large size of the obstruction produced interference with motility of the vocal cords.

On direct laryngoscopy the tumor was fixed and firm giving the impression of bony consistency. In the biopsy specimen only mucosa was obtained.

Roentgen examination revealed a soft tissue shadow which appeared to arise from the superior surface of the vocal cords. There was also an osteoblastic lesion of the 5th cervical vertebra which, at first, was thought to be metastatic tumor but later proved to be benign.

At thyrotomy the mass was found to almost completely occlude the cavity of the larynx crowding the vocal cords upwards and laterally. The mass was firm and irregular and was either attached to the upper portion of the cricoid cartilage or to the arytenoid, its exact base being difficult to ascertain. Although the exact origin could not be definitely determined the left cricoid seemed more likely. The tumor measuring over 2 cm in diameter was removed together with fragments of normal cartilage around the periphery, and was diagnosed histologically as chondrosarcoma.

Postoperative examination revealed good movement of the arytenoids with an excellent voice.

The patient lived for 8 years without difficulty until dyspnea developed. The dyspnea became so severe that a tracheostomy was deemed necessary by her physician, but the patient refused and subsequently died apparently with laryngeal obstruction from recurrence of the chondrosarcoma.

CASE 3. J.L., a 41 year old, white male, complained of difficulty in breathing of six months' duration, becoming progressively worse with a change in voice. Mirror examination of the larynx revealed a large, smooth, obstructing lesion below the vocal cord level and occupying approximately three-fourths of the laryngeal lumen. It appeared to arise from the left subglottic area and the left vocal cord was pushed superiorly.

On direct laryngoscopy the mass was bony hard, smooth and attached by a broad base to the left side of the larynx, probably the

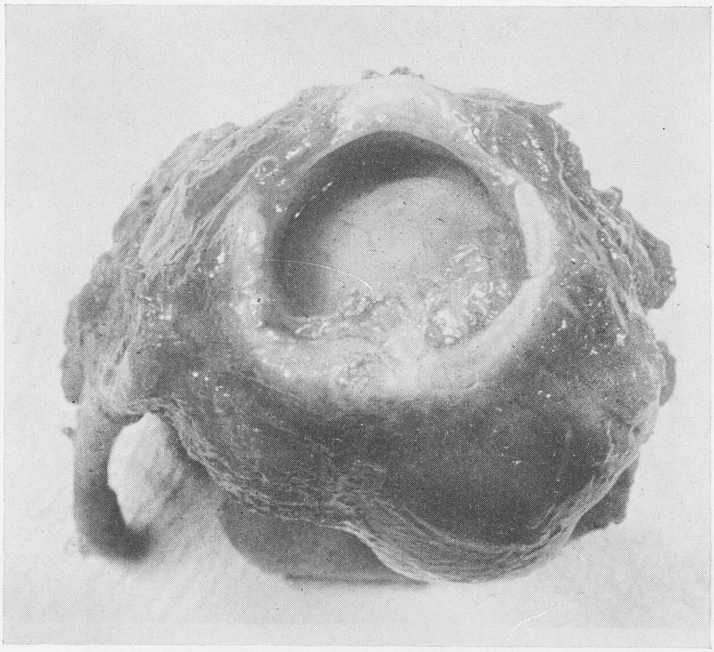

Fig. 3.—View of laryngeal specimen from below. Chondroma has produced marked stenosis bilaterally.

cricoid cartilage. An attempt to remove tissue for histologic study was not successful.

Roentgen studies revealed that the lesion was contiguous with the cricoid cartilage on the left and involved the right side as well.

Because of the marked obstruction to the airway and the involvement of the entire posterior plate of the cricoid cartilage a laryngectomy was performed (Fig. 3). Histologically the tumor was thought to be chondroma although some of the cellular changes suggested a low grade chondrosarcoma.

After recovery from the operation the patient developed an excellent esophageal voice and has carried on his work successfully for the past 17 years with no further difficulty.

CASE 4. P.L., a 41 year old, white male, complained of difficulty in breathing of four weeks' duration accompanied by a wheeze

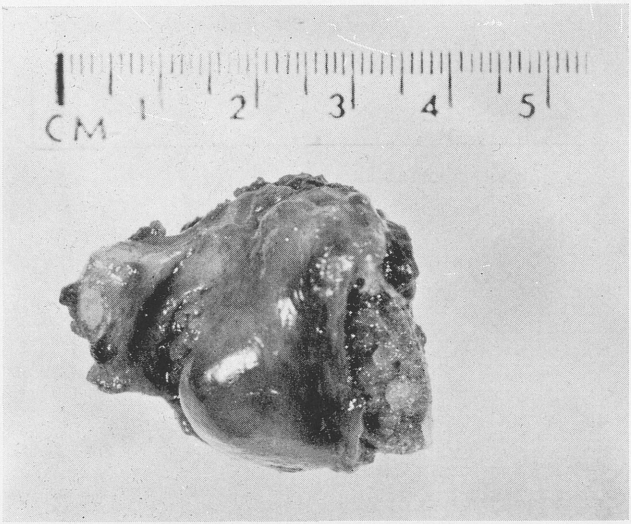

Fig. 4.—Resected specimen of cricoid cartilage containing chondrosarcoma. Normal cartilage was present on both lateral margins.

and a slight cough with mucus expectoration. On mirror examination of the larynx the movement of the vocal cords was normal. A large, smooth mass was observed originating from the left side of the larynx below the glottic chink and extending almost to the opposite wall.

On direct laryngoscopy the mass was hard and attached to the cricoid cartilage posteriorly producing marked stenosis of the airway. Because of its location posteriorly an esophagoscopy was performed to determine if the lesion extended into the hypopharynx, which was uninvolved.

Roentgen studies revealed a tumor below the vocal cord level obstructing the left lateral air column for approximately two-thirds of the lumen and extending down to the level of the suprasternal notch.

At operation the thyroid and cricoid cartilages together with the first tracheal ring were split, and the tumor was found to involve the left lateral wall of the cricoid cartilage extending posteriorly from the

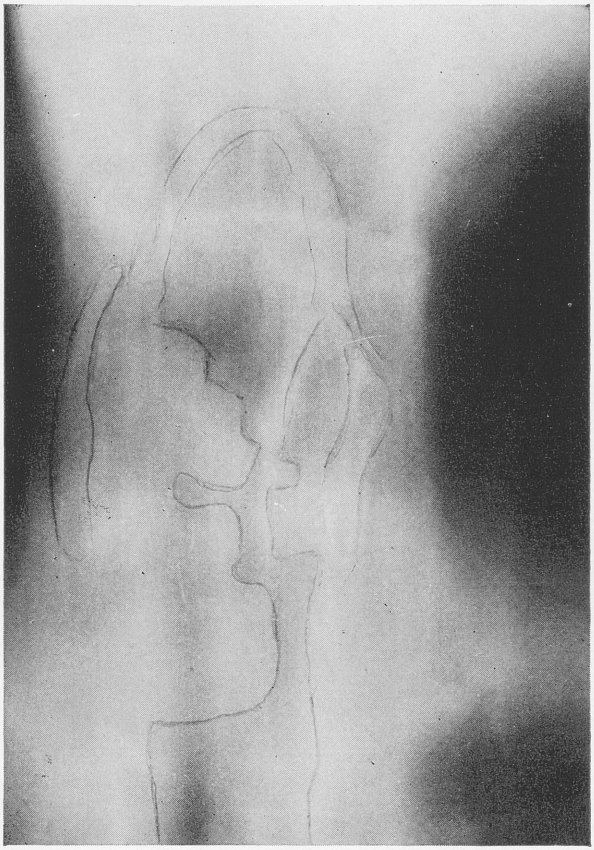

Fig. 5.—Retouched planogram indicating subglottic obstruction due to recurrent chondrosarcoma of cricoid cartilage.

membranous trachea to the midline anteriorly. Following receipt of the frozen section report from the laboratory of a cartilaginous tumor, the entire lesion was removed en bloc together with approximately 1 cm of normal cricoid cartilage on each side (Fig. 4). There was no extension into the thyroid cartilage, esophagus or beyond the tracheal rings. In closure the first tracheal ring was anastomosed to the remaining posterior border of the cricoid and the thyroid cartilage anteriorly. An intralaryngeal stent was not employed, and a tracheotomy tube was inserted through the 4th tracheal ring. The operative area healed with little granulation and epithelialized well. Following

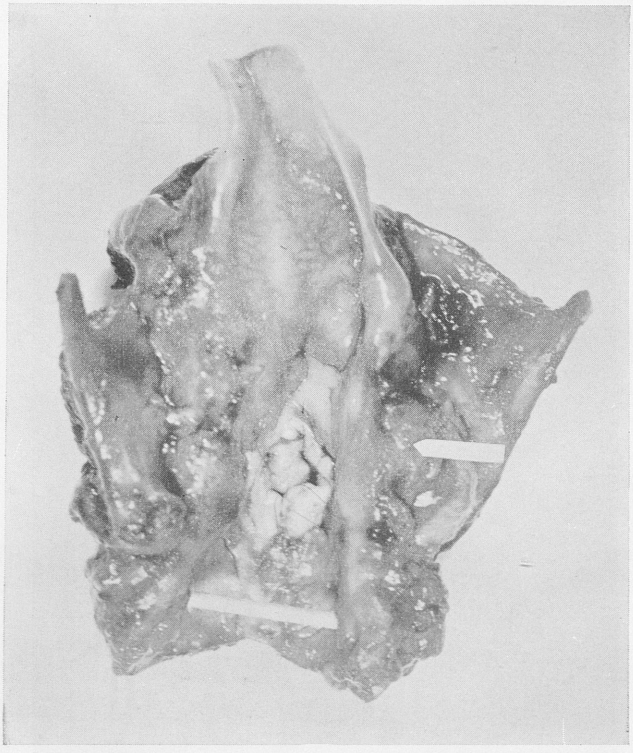

Fig. 6.—Laryngectomy specimen. The skin graft from the previous thyrotomy can be seen in the mid-line anteriorly. Arrow points to additional chondrosarcoma of the right thyroid ala.

decannulation the patient was discharged on the 14th postoperative day.

The patient remained well for 8 years with no airway difficulty and slight hoarseness due to fixation of the left vocal cord. Then increasing difficulty with breathing developed and a smooth, rounded mass was again observed in the center of the subglottic area posteriorly obstructing the airway. Planographic studies (Fig. 5) confirmed this observation.

When thyrotomy was again performed the laryngeal lumen was found to be almost completely stenosed in the region of the cricoid cartilage due to recurrent tumor tissue. The remnant of the cricoid

cartilage on the left side and posteriorly was removed with a portion of the right side for about three-fourths of its circumference preserving only a small area of cricoid cartilage on the right between the thyroid cartilage and the trachea. In addition to the cricoid cartilage the entire left vocal cord was included in the specimen with the line of excision through the ventricle. A split thickness skin graft was taken from the abdomen and sutured around an acrylic stent which was placed in the laryngeal lumen and anchored both above and below the larynx with dacron sutures. The histological diagnosis was recurrent chondrosarcoma of the cricoid cartilage similar to the previous tumor. Tracheostomy was again performed and the acrylic mold was left in place for three months. Upon removal of the stent the airway remained narrow and from all indications there was still activity of the chondromatous lesion, so that the tracheostomy was continued.

After five months the stenosis persisted so that the patient had neither an adequate airway nor a useful voice, and an additional chondrosarcomatous tumor was found in the right ala of the thyroid cartilage. Since the cricoid cartilage had previously been removed and the subsequent tumor developed in the thyroid cartilage laryngectomy was performed (Fig. 6).

The usual criteria for diagnosis of chondrosarcoma in bone as described by Lichenstein[3] were applied to the histological examination of these specimens. The criteria consists of: increase in cellularity, nuclear enlargement and irregularity, acidophilic staining of nuclei, and multinucleation.

Cases 2 and 4 had a background of hyaline cartilage with a very striking increase in cellularity. The nuclei were large and pleomorphic. The nucleus staining of the former case varied from a deep basophilic to red while the latter case had red nuclei. Both cases revealed many multinucleated cells and were designated chondrosarcoma.

Cases 1 and 3 had a background of hyaline cartilage, but little or no tendency to hypercellularity. The nuclei were generally small, uniform and basophilic. No multinucleated cells were present. Both cases were diagnosed chondroma.

In reviewing chondrosarcoma of the larynx in the literature, there appears to be no convincing example of any of these neoplasms giving rise to metastasis. Thus seemingly this tumor of cartilage appears to have a somewhat different biologic behavior compared to

the chondrosarcoma of the bone. The validity of these histologic diagnoses appears to be confirmed by the appearance of local recurrences in both cases of chondrosarcoma as compared to no recurrences in the two cases of chondroma. Similar experiences were reported by Goethals and his associates[1] in which six of eighteen patients with chondrosarcomas of the larynx had local recurrence while none of four chondroma recurred.

SUMMARY

Chondromatous tumors of the larynx grow slowly and produce obstruction to the airway which requires surgical removal. Laryngeal function is preserved whenever possible. In chondrosarcoma local recurrence is common but metastasis does not occur. The development of recurrences takes many years, and conservation laryngeal operations can still be employed unless the cricoid cartilage has been unalterably damaged.

Long term follow-up in four cases indicate a cure in the two cases of chondroma by surgical excision. Recurrences developed in both cases of chondrosarcoma after eight years, one of which caused the patient's death. In the other excision and reconstruction was attempted, but since the uninvolved cricoid cartilage was not sufficient to support the laryngeal structures tracheal extubation was not accomplished. Subsequent laryngectomy became necessary when the chondrosarcoma involved the thyroid as well as the cricoid cartilage.

1712 Locust Street

REFERENCES

1. Goethals, P. L., Dahlin, D. C., and Devine, K. D.: Cartilaginous Tumors of the Larynx. Surg., Gyne., Obst. 117:77 (July) 1963.

2. Heusinger, J.C.C.F. System der Histologie, Erster Theil. P. 91 Eisenach J.F. Barecke, 1822.

3. Lichtenstein, L.: Bone Tumors. 2nd edition, St. Louis: C. V. Mosby, 1959.

4. McCall, J. W., Dupertius, S. M., and Gardiner, F. S.: Chondroma of Larynx. Laryngoscope 54:1 (Jan.) 1944.

5. Moore, I.: Cartilaginous Tumors of the Larynx. J. Laryn. Otol. 40:9,84,145, 1925.

6. New, G. B.: Cartilaginous Tumors of the Larynx. Laryngoscope 28:367 (May) 1918.

7. Walter, W. L.: Chondroma of the Larynx. Annals of Otology, Rhinology and Laryngology 68:1144 (Dec.) 1959.

DISCUSSION

DR. DEVINE: In 1963 we published a study of cartilaginous tumors of the larynx and I should like to read to you our conclusions as it appeared in print:

> "This study of twenty-two cartilaginous tumors in the larynx confirms that the majority arise in the cricoid cartilage and appear posteriorly in the subglottic region.
>
> On the basis of our experience one must conclude that the surgeon can largely ignore the histologically ominous features likely to be reported. His surgical procedure should be as conservative as possible. Local recurrence is not catastrophic, since it probably will be treatable and almost certainly will not give rise to metastasis.
>
> Thyrotomy allows adequate removal of the tumor in the majority of cases."

These conclusions are exactly as Dr. Putney's. However, I feel that further experience leaves me with the impression that our conclusions didn't go quite far enough. Critical analysis of these cases shows that 3 patients out of 15 who had laryngofissure eventually had to have a laryngectomy (20%). One patient refused laryngectomy for a recurrence after external excision. Two others should have had laryngectomy. These were aged patients with large tumors seen in the early 1900's who had only palliative tracheostomy and two patients had a primary laryngectomy. Adding these up we find that 8 out of 22, or approximately 35 per cent, of the patients in our series either had laryngectomy after recurrence, should have had laryngectomy instead of palliative tracheostomy, refused laryngectomy or had primary laryngectomy. Perhaps, then, in our conclusions, we should have added that in rare instances a laryngectomy may be the primary treatment of choice depending upon the size of the lesion and I leave you with this question which you will have to answer for yourselves. How large should the lesion be to justify a primary laryngectomy?

DR. JULIUS W. MCCALL: In 1944 we reviewed the literature of chondroma of the larynx and presented two cases.

Chondroma of the larynx, of the laryngeal cartilages, is not common, as attested by the fact that up to date there have been only 123 cases reported.

It is interesting to observe that Figi stated that laryngectomy for chondroma carried a higher mortality than for carcinoma. The reason for this is the tendency to temporize until the patient's condition deteriorates.

One of our cases, a man, 67 years of age, presented himself with hoarseness and shortness of breath. Laryngeal examination revealed a large, round, smooth tumor filling the left side of the larynx and causing fixation of the left vocal cords. At surgery the tumor was found to arise from the left side of the cricoid cartilage. Total laryngectomy was performed.

A second case was a man 48 years of age who presented himself with hoarseness and severe dyspnea. He was found to have a small-sized mass in the right side of his larynx. A tracheotomy was performed. The patient was lost to follow-up for one year, at which time he returned because of severe bleeding from the larynx. A thyrotomy was done and a large mass removed. During the next seven months the patient required multiple hospital admissions and surgical procedures for incomplete removal of his tumor. A month later a total laryngectomy was done, that included the anterior wall of the hypopharynx and cervical esophagus, the thyroid gland and the upper five tracheal rings.

This man lived a number of years—about ten—and was able to swallow solid food without difficulty.

I think this case illustrates well the need to perform adequate surgery when the patient is first seen.

Dr. William W. Montgomery: During the past year we have had occasion to operate on three chondromas of the cricoid. Each presented with hoarseness and respiratory difficulty. Two of them were treated primarily by the tracheo-cricothyrotomy approach, elevating a mucous membrane flap and removing the lesion.

My purpose in mentioning these cases is the third, which we received second hand from a general surgeon who attempted to remove the chondroma by first performing a thyroidectomy. Unfortunately the end result was a paralysis of this side of the larynx and also a collapse of the cricoid cartilage. It would thus seem that the lateral approach is not the ideal one.

Dr. Putney (closing): I don't agree entirely with Dr. Devine about doing laryngectomy as a primary procedure. If at all possible I think one should conserve the larynx. Here we are dealing with a tumor which primarily causes obstruction, but there is no danger to life as far as metastasis is concerned. If one can spare the larynx and give these individuals an airway and voice through their normal passages as long as eight years, we can temporize with this type of lesion even though laryngectomy may be necessary later.

One of these patients did die from obstruction. That was due to her own fault in not permitting a tracheotomy, which would have relieved the immediate cause of death, and then further surgery could have been attempted.

I agree with Dr. Montgomery wholeheartedly that these tumors have to be approached through the larynx. I don't see how one can get a satisfactory removal without opening the larynx and removing the cricoid cartilage, which is the critical one, along with a portion of normal cartilage around its periphery. Even when that is done recurrence in chondrosarcoma is common.

EXPERIMENTAL OBSERVATIONS OF THE RELATIONSHIPS BETWEEN UPPER AIRWAY OBSTRUCTION AND PULMONARY FUNCTION

JOSEPH H. OGURA, M.D.

J. ROGER NELSON, M.D. (by invitation) RICHARD DAMMKOEHLER, M.S. (by invitation)

MASASHI KAWASAKI, M.D. (by invitation) KIYOSHI TOGAWA, M.D. (by invitation)

ST. LOUIS, MO.

Obstruction of the upper airway as a factor in the alteration of the mechanics of breathing is poorly understood. The importance of this portion of the airway is suggested by the relief of nasal obstruction and difficulty in breathing which often follows removal of the obstruction. The complaint of difficulty in breathing made by these patients is not one of dyspnea on effort. Rather they describe their troubles when they are at rest. The sense of relief after the removal of the obstruction is also enjoyed at rest.

The question to which this study is directed is whether relief might simply be due to less impeded movement of air through the nose, or whether other aspects of breathing mechanics may also be important. This report deals with the development of methods of investigation[1-10] through measurements made on a group of normal individuals and the applications of these methods to a group of patients who were treated for nasal obstruction.

MATERIALS AND METHODS

Definition of Normal Subjects. Normal subjects included in this study were white males, 19 to 39 years. These males were free from

---

From the Department of Otolaryngology, Washington University School of Medicine, St. Louis, Missouri.

Supported by the National Institutes of Health Grant HE-6084-03.

TABLE I

CLASSIFICATION OF NASAL OBSTRUCTION USED IN THIS STUDY

	NORMAL
0	Straight septum, perfectly good airway.
1	Straight septum, slight enlargement of the turbinates, no nasal obstruction.
2	Deviated septum without nasal obstruction.
3	Deviated septum, nasal spur, minimal nasal obstruction (i.e. mild symptomatic, unilateral or bilateral, and intermittent).
	ABNORMAL
4	Anterior deviation of the septum, unilateral impaction of septum, and unilateral upper lateral cartilage collapse, with open airway on the other side. Moderate obstruction (i.e. obstruction is frequently complete on one side, and incomplete for adequate airway on the other side).
5	Same as four, but with bilateral upper lateral cartilage collapse, and moderate bilateral nasal obstruction.
6	Severe anatomic bilateral septal obstruction (is nearly constant) of the nose, from impingement of septal and upper lateral cartilages.

vasomotor or allergic rhinitis, chronic lung disease, laryngeal obstruction, asthma and sinusitis. They were either light or nonsmokers. The nasal obstructions found in some of the subjects were simply anatomic in nature, fixed and constant, and displayed no features of active disease or recurrent vasomotor phenomena.

INSTRUMENTATION

The standard ventilatory tests of pulmonary function[1-3] were carried out for each individual. Results not relevant to the present study will be reported elsewhere.[11] The Functional Residual Capacity (FRC)* measurements were made with the gas dilution method, using the following equipment: a Tissot tank for the collection of gas, a Gilson Amplifier Recorder, a Med-Science Nitralizer, and a Scram mask. (Fig. 1).

* Functional Residual Capacity is abbreviated as FRC. All measurements of FRC are made through the mouth unless otherwise specified.

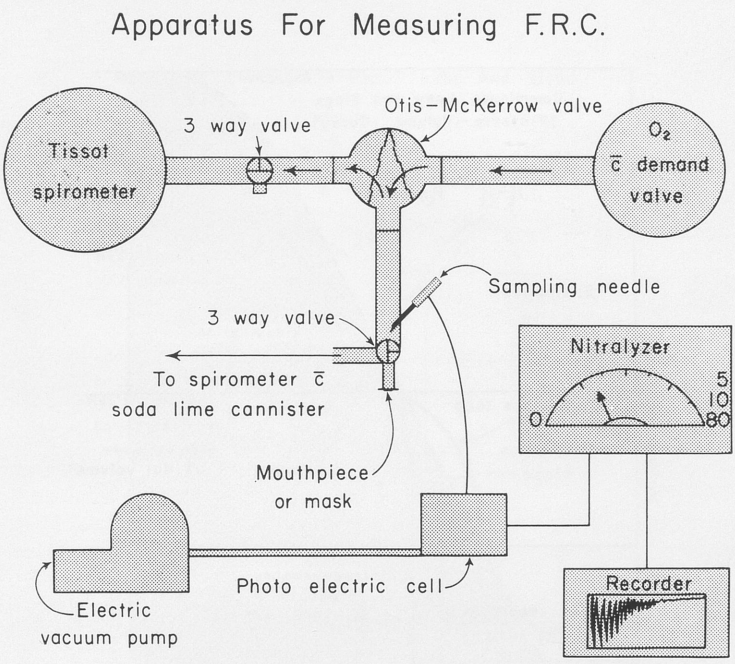

Fig. 1.—Apparatus for measuring Functional Residual Capacity.

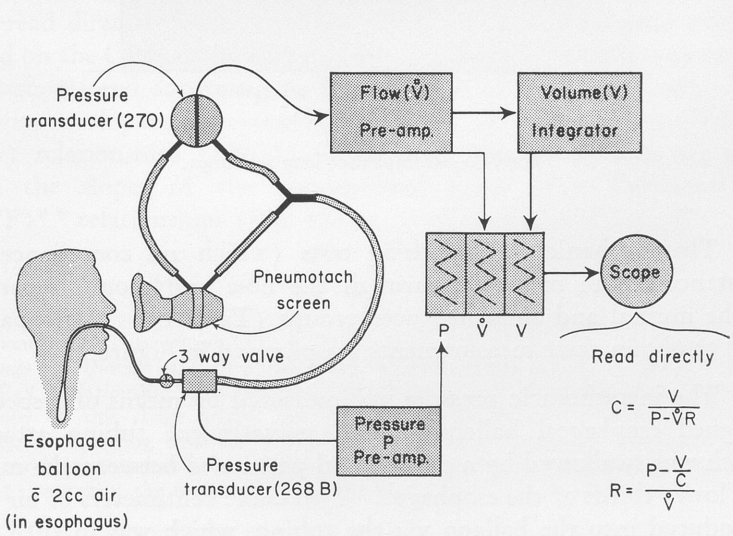

Fig. 2.—Mechanics of breathing apparatus (Compliance and Resistance).

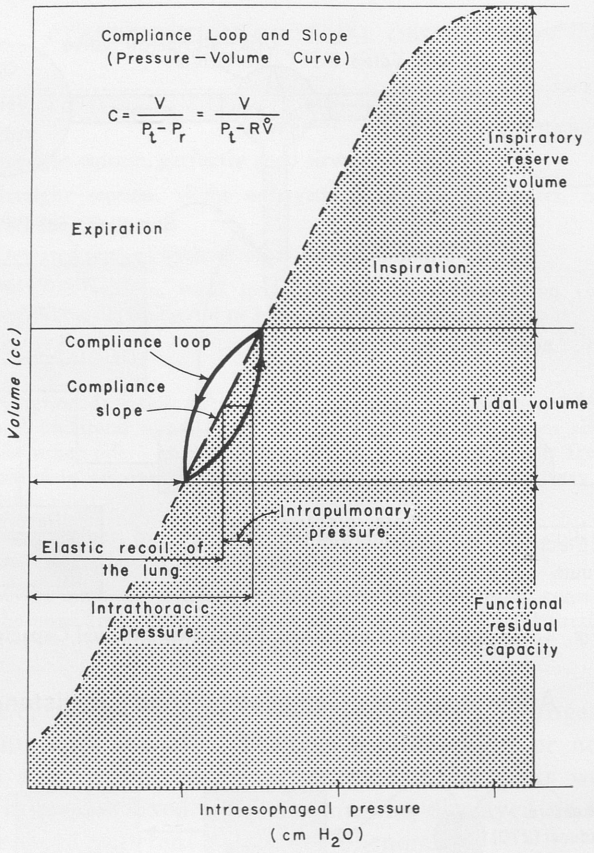

Fig. 3.—Compliance loop and slope.

The mechanics of breathing tests (which are compliance and resistance) were measured through the nose and mouth separately in the normal and abnormal nose groups (Table I). The apparatus used to obtain these measurements are pictured in Figure 2.

The intrathoracic pressure was measured by means of a specially designed esophageal balloon with a polyethylene tubing attached, which was swallowed by a patient and positioned between the middle and lower thirds of the esophagus. Two cubic centimeters of air were introduced into the balloon via the tubing, which was in turn connected to the Sanborn pressure transducer. The patient breathed

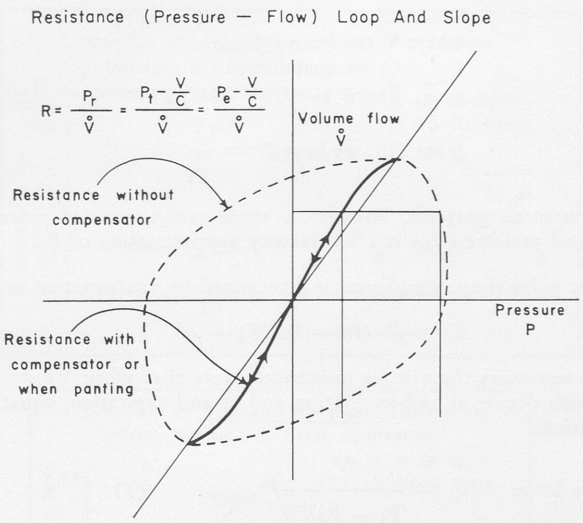

Fig. 4.—Resistance loop and slope.

through a pneumotachograph screen through which the air flow was registered by a flow transducer. The volume was aligned with the flow by the Sanborn integrator. Pulmonary compliance and resistance were read directly from the slopes visualized, by the angular overlay placed on the Cathode Ray Oscilloscope (CRO)* which was electronically monitored according to the methods of Comroe et al.[5] The compliance slopes are compensated loops of the Pressure-Volume (P-V) relationships (Fig. 3). The resistance calculations are read from the slopes of the compensated loops of a Pressure-Flow (P-VF)** relationships (Fig. 4).

MECHANICS OF BREATHING TESTS

Compliance (liters/cm H_2O) is a measurement of the elasticity of the tissues of the lungs and thorax, and is defined as the volume change per unit pressure change. The (P-V) relationship is assumed to be linear over the tidal volume range, and thus the slope of this range relates the volume changes to transpulmonary pressure changes, disregarding absolute pressure. Compliance should be measured under static conditions, and at this zero flow of air, all of the transpulmonary pressure is used to counteract the elastic recoil of the lung only.

---

* Cathode Ray Oscilloscope is abbreviated CRO.

** VF refers to volume-flow contrasted to flow itself.

Thus, pulmonary compliance is determined by the theoretical equation:

$$V = CP_t \quad . \quad . \quad . \quad (1)$$

where V = lung volume
C = compliance
P_t = transpulmonary pressure.

$$\text{from (1), we have } C = \frac{V}{P_t}$$

For clinical research purposes, however, a more easily obtained measurement, the intra-esophageal pressure (P_e) is a satisfactory approximation of P_t.

Dynamic pulmonary compliance is determined by the equation as follows:

$$V = C\ (P_t - R_pVF) \quad . \quad (2)$$

where R_pVF represents the viscous resistance. Note that when $VF = O$, that is at zero flow which occurs at end-inspiration and at end-expiration, equations (1) and (2) are identical.

$$\text{From (2) we have: } \quad C = \frac{V}{P_t - R_pVF} \quad . \quad . \quad (3)$$

Resistance (cm H_2O/liters/sec). Pulmonary resistance is defined as the pressure required to overcome airway, and pulmonary tissue resistance for the given rate of flow through the pulmonary system. This may be mathematically expressed as:

$$R_p = R_t + R_a$$

where R_p = pulmonary resistance
R_t = tissue resistance
R_a = airway resistance

R_t or tissue resistance is a measure of the resistance to the displacement of tissues during respiration. The over-all tissues involved for measurement of total resistance include the lungs, the thorax, the diaphragm, and the abdominal contents.

R_a or airway resistance refers to the friction between the molecules of gas and the walls of the tubes. Since transpulmonary pressure during flow overcomes elastic recoil of the lung in addition to airway resistance and tissue resistance, the Pressure-Flow (P-VF) relationship determining pulmonary resistance (R_p) is given as:

$$VF = \frac{1}{R_p}\left(P_t - \frac{V}{C}\right)$$

$$\text{whence we have } R_p = \frac{P_t - \dfrac{V}{C}}{VF} \quad (4)$$

Equations (3) and (4), the formulae for compliance and resistance, are electronically monitored for direct reading of these values.

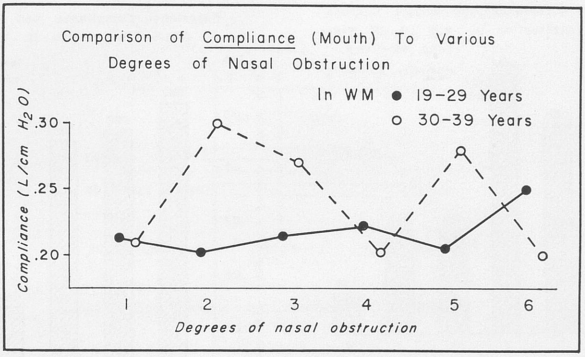

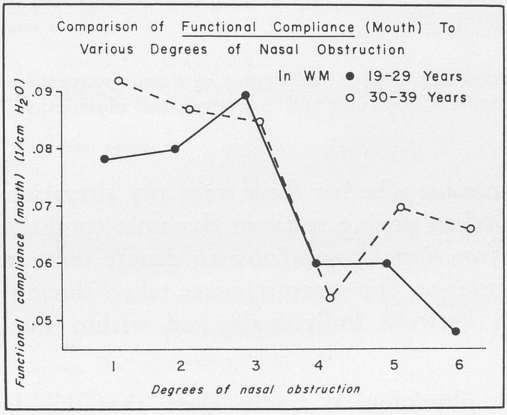

Fig. 5.—Comparison of Compliance to various degrees of nasal obstruction (white males 19-29, 30-39 years).

Fig. 6.—Functional Compliance and degree of nasal obstruction (white males 19-29, 30-39 years).

DEVELOPMENT OF THE EXPERIMENTAL METHOD

In order to evaluate nasal obstruction alone, in the absence of complicating factors, the control group was selected within relatively narrow limits. Preliminary studies employing the usual tests of ventilatory functions were carried out. The results of these studies did not establish that nasal obstruction was consistently associated with alterations in pulmonary function in the control group. The mechanics of breathing tests were then performed and analyzed. The concept of *specific compliance*[2] relating pulmonary compliance with the FRC

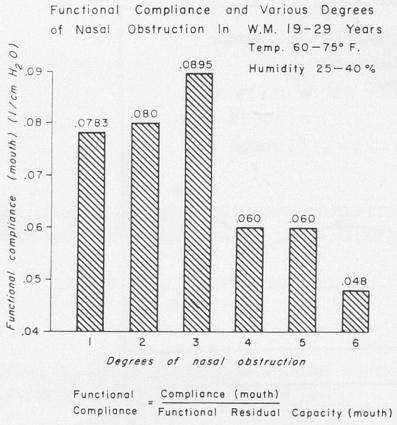

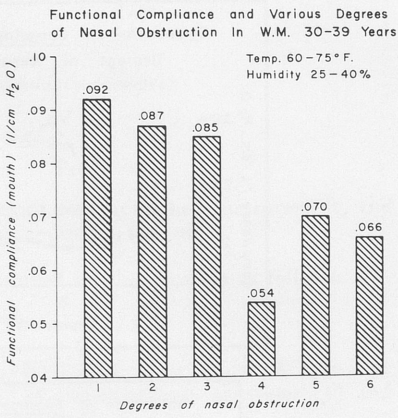

Fig. 7.—Function Compliance and degree of nasal obstruction (age 19-29).
Fig. 8.—Functional Compliance and degree of nasal obstruction (age 30-39).

was used to determine whether there were any alterations when measurements were taken during static or dynamic conditions. We have used the term *functional compliance* to denote more accurately our experimental situation for measurements taken during tidal volume for comparison between individuals, and within the same subject tested.

Pulmonary physiological studies show that the elastic recoil of the lung tends to collapse the lung, while the thoracic cage attempts to overcome the elasticity of the lung. The summation of this relationship can be expressed in terms of compliance as:

$$\frac{1}{\text{Compliance (total or effective)}} = \frac{1}{\text{Compliance (lung or pulmonary)}} + \frac{1}{\text{Compliance (thoracic)}}$$

It is recognized that compliance in our experimental study actually represents dynamic pulmonary compliance. Thus, in this paper, the usage of the word compliance refers to pulmonary compliance taken under dynamic conditions through the mouth unless it is specified by the terms, functional, relative, specific, or otherwise.

When our experimental error was determined to be minimal, we carried out the following studies.

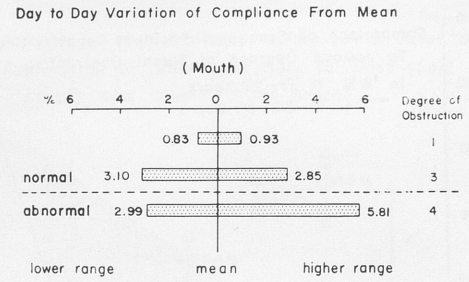

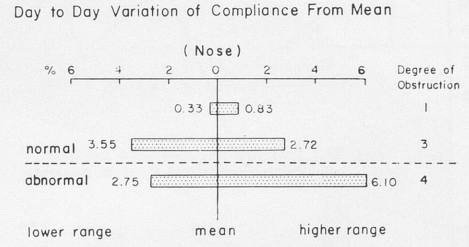

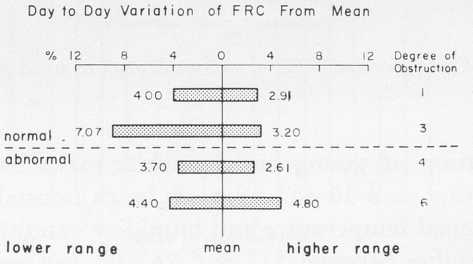

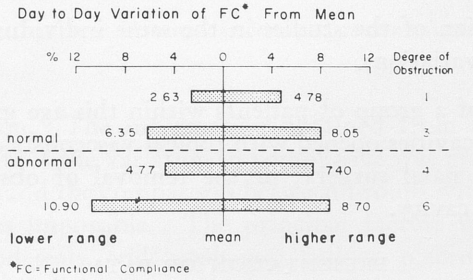

Fig. 9a and b.—Day to day variation of Compliance between mouth and nose.
Fig. 10.—Day to day variation of FRC in normal and abnormal noses.
Fig. 11.—Day to day variation of Functional Compliance.

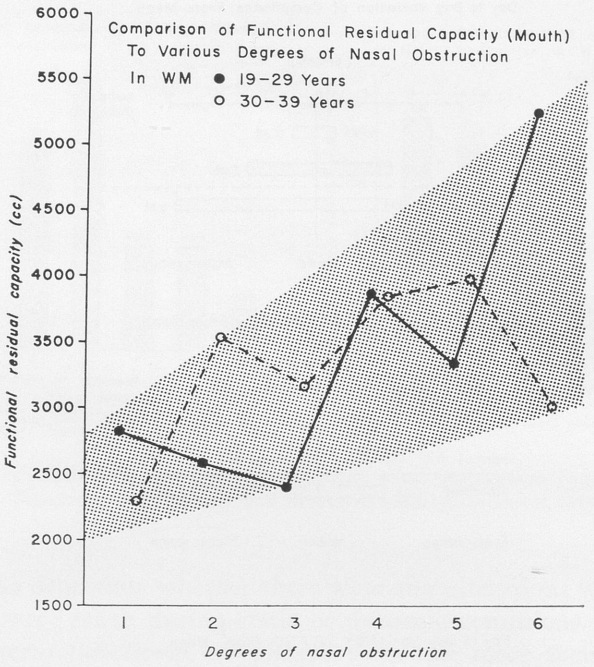

Fig. 12.—Comparison of FRC to various degrees of nasal obstruction.

1. Comparison of young healthy white males between the ages of 19 and 29 years, and 30 and 39 years, with normal and abnormal noses, under normal temperature and humidity conditions. (Normal temperature specifies between 55° and 76° F., and normal humidity being 25 to 40%.)

2. Repetition of the studies in the same individuals for analyses of day to day variations.

3. Study of a group of patients within this age group who have had their nasal cavities opened with topical vasoconstrictors, or before and after their nasal surgery, or the removal of obstructive crusts from the nasal cavity.

PRESENTATION OF DATA

The data presented does not include the first 280 test observations which were made in the initial study of 170 patients with and without

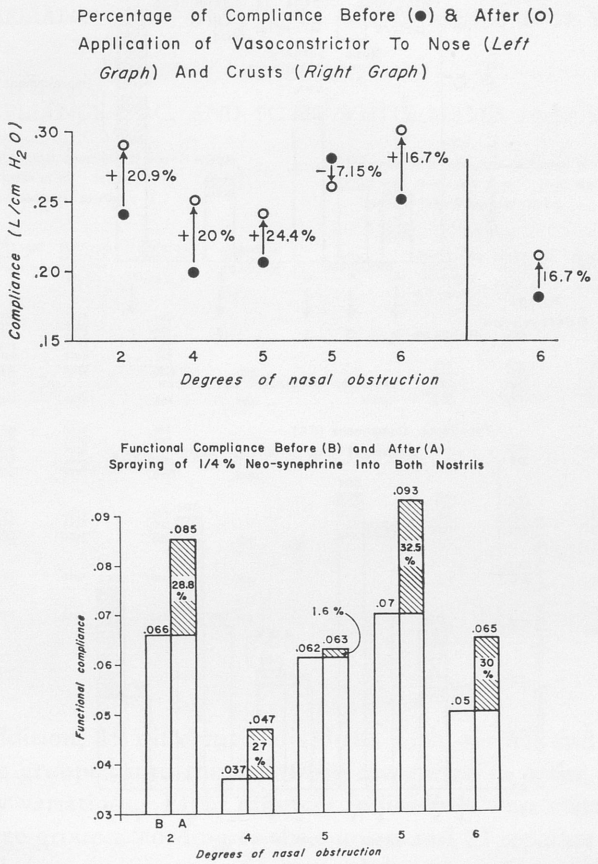

Fig. 13—Changes in Compliance by use of vasoconstrictors and removal of crusts.

Fig. 14.—Changes in FC with vasoconstrictors to nasal cavity.

nasal obstruction. The information obtained from this group was inconsistent in that the variation in compliance was great, the average figure was low, and the comparison between groups with varying nasal obstruction was impossible. The principal factors were air leakage in spite of good seals, and esophageal balloon placement variations. The range of compliance recorded in our original 170 patients varied from 0.07 to 0.250 liters/cm H_2O with a mean of 0.16. The reported range[2] in a controlled group varied from 0.10 to 0.30 liters/cm H_2O

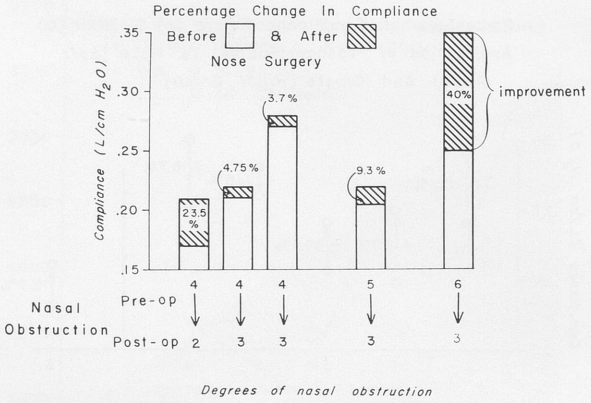

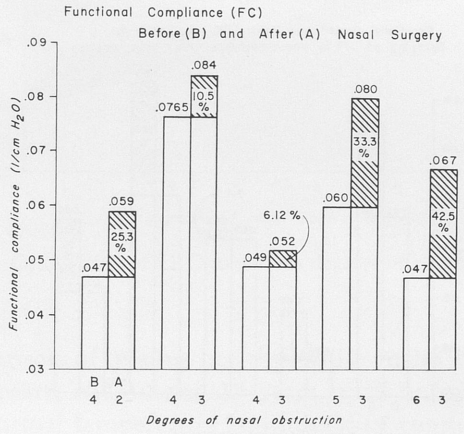

Fig. 15.—Changes in Compliance with nasal surgery.
Fig. 16.—Changes in FC with nasal surgery.

with an average of 0.20. The omission of the FRC measurements made comparison between individuals impossible.

The following number of patients were used for this study. Forty-three individuals were classified as normal and abnormal nose groups in the presence of normal lung findings. For the compliance studies, 14 were in the 19 to 29 year age group, and 10 in the 30 to 39 year age group. Only white males were used in this study. Seven females, and two negroes within these age groups, and nine others who were over the age of 40 were not included in this study.

TABLE II

COMPLIANCE, FRC, AND FC IN WHITE MALES 19-29 YEARS

COMPARISON OF FUNCTIONAL COMPLIANCE TO VARIOUS DEGREES OF NASAL OBSTRUCTION IN WM 19-29 YEARS.
Temp. 60-75°F. Humidity 25-40%

NASAL OBSTRUCTION	COMPLIANCE (mouth) L/cm H_2O	FUNCTIONAL RESIDUAL CAPACITY (mouth) cc	FUNCTIONAL COMPLIANCE (FC) L/cm H_2O	AVERAGE OF FUNCTIONAL COMPLIANCE
1	.210	3019	.069	
	.180	2152	.083	
	.305	4216	.0724	
	.192	2935	.0653	
	.180	1768	.102	
mean	.213	2818	.0783	.0783
2	.205	2576	.080	.080
3	.300	3026	.099	
	.195	2196	.089	
	.190	2027	.095	
	.175	2331	.075	
mean	.215	2395	.0895	.0895
4	.270	3534	.077	
	.175	4223	.043	
mean	.223	3879	.060	.060
5	.205	3343	.060	.060
6	.250	5281	.048	.048

TABLE III

COMPLIANCE, FRC, AND FC IN WHITE MALES 30-39 YEARS

COMPARISON OF FUNCTIONAL COMPLIANCE TO VARIOUS DEGREES OF NASAL OBSTRUCTION IN WM 30-39 YEARS.
Temp. 60-75°F. Humidity 25-40%

NASAL OBSTRUCTION	COMPLIANCE (mouth) L/cm H_2O	FUNCTIONAL RESIDUAL CAPACITY (mouth) cc	FUNCTIONAL COMPLIANCE (FC) L/cm H_2O	AVERAGE OF FUNCTIONAL COMPLIANCE
1	.210	2297	.092	.092
2	.350	4231	.093	
	.300	2772	.109	
	.250	3616	.069	
mean —	.300	3540	.087	.087
3	.270	3179	.085	.085
4	.205	3983	.051	
	.200	3362	.061	
	.200	4286	.049	
mean —	.202	3857	.0537	.054
5	.280	3986	.070	.070
6	.200	3013	.066	.066

In addition, 19 different individuals with normal and abnormal noses were grouped into the following categories, in order to analyze day to day variations. Eight different individuals were classified from a young age group according to their noses, and 27 separate tests were performed for an average of three plus tests. Five patients had repeated tests performed before and after the application of a vasoconstrictor (¼% neosynephrine) to the nose. Five patients classified as nasal obstruction cases were tested before and after nasal surgery. One of the patients within the vasoconstrictor group had had nasal surgery performed. One patient with postirradiation crusts in the nose was tested with and without crusts in the nose. This was the only patient over the age of 40.

Using classification of the nose 0 to 3 (Table I) as normal, and 4 to 6 as abnormal, we noted that when nasal obstruction was present, Maximal Breathing Capacity (MBC), and one second Vital Capacity (1 sec VC) usually decreased when measurements were made through the nose. However, the amount of air moved in these ventilatory tests

TABLE IV

REPLICATED TESTS WITH VASOCONSTRICTORS

Functional Compliance in REPLICATED PRE AND POST VASOCONSTRICTOR TEST.

White male and female subjects were tested, and then their noses were sprayed with 1/4% neosynephrine and retested at about 60-90 minutes.

Nasal Obstruction	Test NO	Compliance L/cm water	FRC (mouth) cc	Functional Compliance 1/cm water	
2	1	0.240	3676	0.066	
	2	.280*	3436	.082	.085
		.300		.087	
		.290		.085	
4	1	.200	5390	.037	
	2	.250	5278	.047	
	1**	.200	5350	.037	
	2	.250	5480	.046	
5	1	.205	3343	.0615	
	2	.240	3820	.063	
5	1	.280	3986	.070	
	2	.260	2790	.093	
6	1	.250	5048	.050	
	2	.300	4636	.065	

* Replicated tests were done 10, 15, & 30 minutes from the time the vasoconstrictor was sprayed with 1/4% neosynephrine.

** Replicated test.

varied also with the size, body build, and athletic stature of the individual, in addition to nasal obstruction. When the tests were repeated within the same subject following the use of the vasoconstrictor to the nose, 1 sec VC and MBC increased. However, variations in observations were so marked that it was difficult to observe any significant differences between the normal and the abnormal nose groups for these parameters.

Compliance was observed within the two general age groups of 19 to 29 years, and 30 to 39 years (Fig. 5, Tables II, III). All these tests were made at normal temperature and at normal relative humidity (see above). From Tables II and III and Figures 7 and 8 for the normal (0-3) nose, the functional or relative compliance was 0.080

TABLE V

TABULATION OF CHANGES IN FC WITH NASAL SURGERY

FUNCTIONAL COMPLIANCE (FC) BEFORE (B) AND AFTER (A) NASAL SURGERY

Time from surgery when test redone		Nasal Obstruction	Compliance Nose	Compliance Mouth	FRC (mouth)	FC = $\frac{C_m}{FRC_m}$
5 Weeks	B	4	.160	.170	3564	.047
	A	2	.200	.210	3594	.059
6 Months	B	4	.290	.170	3534	.0765
	A	3	.295	.210	3234	.084
1 Month	B	4	.200	.210	4286	.049
	A	3	.210	.220	4220	.052
2 Months	B	5	.205	.205	3343	.060
	A	3	.225	.220	2724	.080
2 Weeks	B	6	.250	.250	5281	.0465
	A	3	.360	.350	5221	.067

to 0.109. Whereas compliance showed little tendency to decrease with increasing nasal obstruction (Fig. 5), functional or relative compliance decreased markedly with increasing nasal obstruction when measurements were made through the mouth (Figs. 6, 7, 8).

Compliance showed little variation whether measurements were made through the mouth or nose within the normal nose group of the two age groups (Fig. 9a and b). In the normal nose group compliance for the mouth varied from 0.83 to 3.1%, but for the abnormal nose group compliance variations for the mouth of 2.99 to 5.81% were slightly higher. The decrease in compliance is not apparent where nasal obstruction is studied in the two age groups, but a change

TABLE VI

DATA OF REMOVAL OF CRUST FROM NASAL CAVITY

MECHANICS OF BREATHING TESTS
BEFORE (B) AND AFTER (A) REMOVAL OF
NASAL CRUSTS EFFECTED BY RADIATION (WM47)

TEST		BEFORE CRUSTS REMOVED	AFTER CRUSTS REMOVED
COMPLIANCE	(mouth)	.180	.210
	(nose)	.170	.210
RESISTANCE	(mouth)	3.4	3.1
	(nose)	8.8	3.3
FRC	(mouth)	4319.0	4804.0
$FC_m = \frac{C_m}{FRC_m}$		.0403	.0489

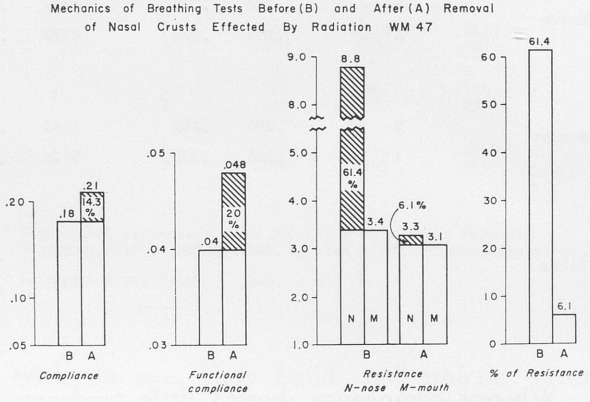

Fig. 17.—Mechanics of breathing tests before and after removal of crusts.

in compliance is significant when nasal obstruction was relieved in the same individual (Figs. 13, 15).

Compliance as a general observation varied from 0.175 to 0.350 liters/cm H_2O in the normal nose group, whereas the abnormal nose group showed a variation from 0.175 to 0.280 liters/cm H_2O (Tables II, III). FRC figures varied from 1.8 to 4.2 liters for the normal nose group between the low and high range respectively, whereas the abnormal nose group varied from 3.0 to 5.3 liters (Tables II, III).

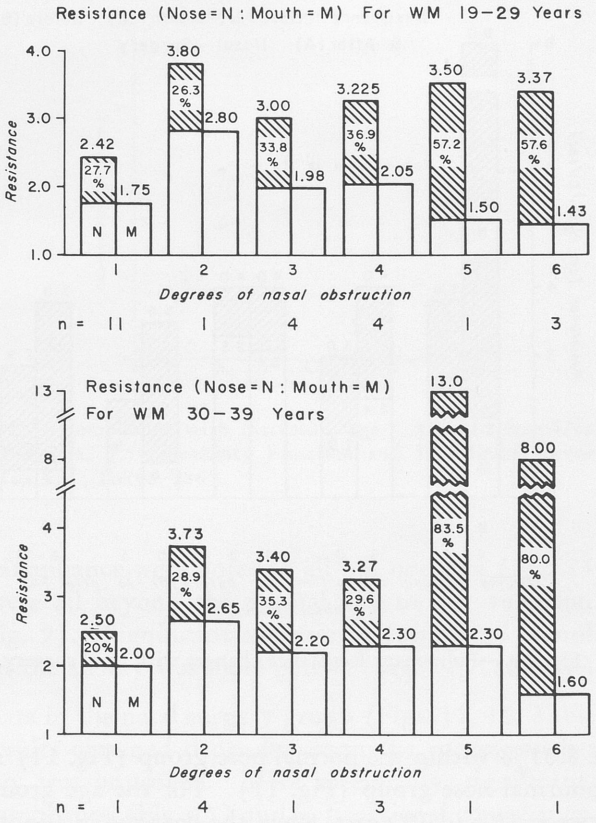

Fig. 18.—Pulmonary Resistance measurement from nose and mouth (age 19-29 years).

Fig. 19.—Pulmonary Resistance measurement from nose and mouth (age 30-39 years).

Variations in compliance of eight patients with 27 repeated tests are charted in Figure 9. In general, less than 3.1% change in compliance existed from test to test in the normal nose group, but shifts to 5.8% were noted when the nose was obstructed.

The variations in FRC are likewise charted in these age groups (Fig. 10). It showed little day to day changes (Fig. 10), but varied according to increasing nasal obstruction (Fig. 12). When the ratio of compliance to FRC was analyzed, the maximal day to day varia-

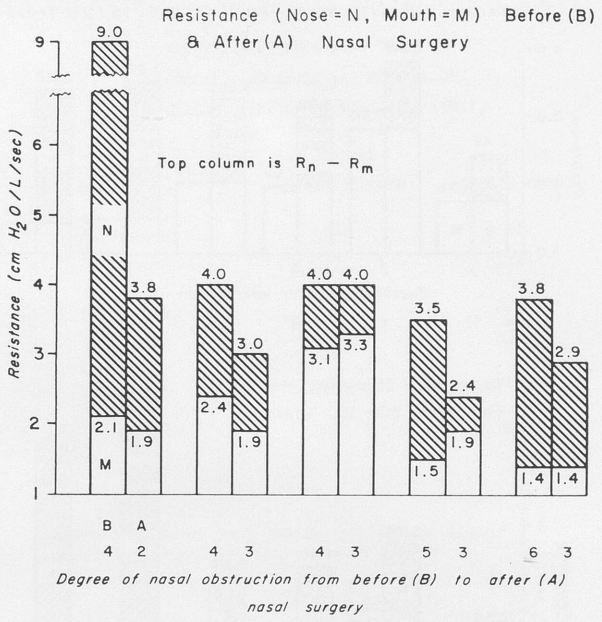

Fig. 20.—Pulmonary Resistance changes with nasal surgery.

tions were 8.05% within the normal nose group (Fig. 11) and 10.9% for the abnormal nose group (Fig. 11). For the age groups studied, that is between 19 and 39 years, when the decrease in functional compliance (Figs. 6, 7, 8) was analyzed, it was found that increasing nasal obstruction appeared to be related to an increase in FRC (Fig. 12. Tables II, III).

Functional or relative compliance was now observed in relation to three different experimental situations: 1) the effect of vasoconstrictors in the nose, 2) following nasal surgery, and 3) the mechanical removal of crusts within the nose.

In the vasoconstrictor group (Fig. 13) following the nose classification (Table I), our routine experimental tests stated previously were performed. Neosynephrine ¼% was applied to the turbinates, and the patient was retested accordingly (Table IV) and at two hour period lapse for the testing of FRC. During this interim, the patient showed no gross changes in his pulse rate, and blood pressure. In-

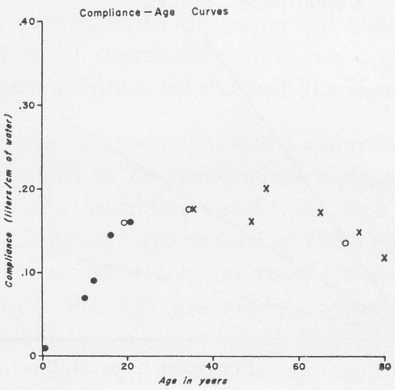

Fig. 21.—Compliance with increasing age. Adapted from Nakamura, T., and Takijima, T.: Pulmonary Function and Its Clinical Investigation. Bunkodo Co. Ltd., Tokyo, 1960.

creases in compliance were noted in all but one case (Fig. 13). These increases were all beyond the normal day to day variation range of 5.81% (Fig. 9). Significant increase in functional compliance was noted when the airway was more patent (Fig. 14, Table IV).

The data in the nasal surgery group (Figs. 15, 16, Table V) show that the results obtained depended upon the success with which the nasal airway was improved. More specifically, significant improvements in compliance (Fig. 15) and in functional compliance (Fig. 16) correlated well with the establishment of a better nasal airway.

The presence of an iatrogenic crusting of the nose following irradiation for a tumor of the nasal cavity afforded an opportunity to evaluate the mechanisms of nasal crusting upon the respiratory axis. These data are summarized in Figure 17 and Table VI. Significant increases in compliance with relatively less increase in FRC were recorded by the mechanical removal of crusts. The over-all result increased the functional compliance by 20%.

Within these three groups of patients (vasoconstrictor, nasal surgery, and nasal crusts) except in one instance, compliance increased towards or even beyond normal, with the relief of nasal obstruction.

Pulmonary resistance in general was 50% higher when measured through the normal nose than when recorded through the mouth

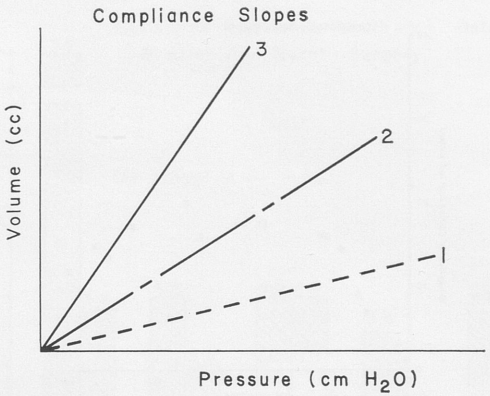

Fig. 22.—Compliance slopes.

(Figs. 18, 19). As the nasal obstruction increased, the nose-mouth differential increased to 500% in some instances (Fig. 19). Resistance measured through the mouth does vary a little as nasal obstruction increases (Figs. 18, 19). Following surgery, marked decrease in pulmonary resistance was recorded when the measurements were made through the nose (Fig. 20).

Day to day variations of resistance were not observed under ideal circumstances. Resistance measurements were made within the tidal volume range, and with deep inspiration. Full inspiration overcomes the very increase in airway resistance that one wishes to measure. We have also found that with panting, resistance yields more consistent results, as resistance measurements were near the FRC.[5,10]

COMMENT

Ventilatory and mechanics of breathing tests were used to compare and contrast the normal noses (classification 0 to 3) (Table I), with abnormal noses (4 to 6) having objective and symptomatic obstruction of the nose. Only patients with normal cardiopulmonary systems were used.

In the present reported series, the comparison between ordinary ventilatory tests in a sample of normal and abnormal nose groups shows that a correlation exists between increased nasal obstruction and a decrease in vital capacity, 1 sec vital capacity, and maximal breath-

ing capacity. When these breathing tests were performed through the mouth, no significant differences were recorded between the normal noses (0 to 3) compared to the abnormal noses (4 to 6). Thus varying degrees of nasal obstruction have no apparent effect upon pulmonary ventilation as measured through the mouth.

However, *compliance* studies showed a different picture. Within the young age group (19 to 29 years, white males) tested under controlled temperature and humidity conditions (see above), the mean compliance measured through the mouth of these subjects with abnormal noses (4 to 6) was slightly lower than the mean compliance of a normal nose group. For any individual, compliance values of the nose and mouth, are relatively the same, whether the subject has a normal or an abnormal nose. When compliance was compared between the age groups of 19 to 29 years, and 30 to 39 years, there was little difference. The reported values are in line with other authors who show a plateau in the compliance curve within this age group (Fig. 21).

Even though it has been determined that day to day tests of compliance in the same individuals varied almost 6%, it is not possible to compare compliance between individuals because of variations in body build. For purposes of comparison, compliance is related to some function of the original lung volume. Functional residual capacity, a parameter which represents a state of the lung, and which is easily measurable, was related to the compliance. This ratio of compliance and functional residual capacity is referred as *functional compliance* or *relative compliance.*

When nasal obstruction increased, the functional compliance decreased by virtue of the increased FRC within the individuals tested. On the other hand, when the individual nasal obstruction groups were studied, all showed an increase in functional compliance when the obstruction was relieved in one manner or another (vasoconstrictor, nasal surgery, or nasal crust removal). In the main, the relief of obstruction was characterized by a decrease in FRC, although in some instances, compliance was increased without a decrease in FRC.

It is unlikely that these changes are due to physical variability of the lung tissue. In the ordinary sense of the word, decreased compliance means a more stiff lung (congestion, fibrosis) as represented by a lesser slope in Figure 22. There is no reason in this group for the lung to be stiffer by invoking actual lung changes. There is a

distinct possibility that a nasopulmonary nervous system arc exists and that the constantly obstructed nose alters pulmonary function in a reflex manner. It is also possible that perhaps nasal obstruction decreased functional compliance by altering the chemical composition of the surfactant at the level of the alveoli.

If in an expanded series of observations, nasal obstruction is constantly observed to effect a decrease in compliance, this would in fact explain the wide values for normal compliance presently obtained by other pulmonary physiologists. The consistency with which FRC is increased with nasal obstruction would be one explanation for the shortness of breath. The FRC increase may shift the tidal volume at the expense of the inspiratory reserve volume.

To separate the important factors in changing compliance and resistance, and to reduce our experimental error further (computed to be 10% approximately) it will be necessary to use a tape recorder incorporated with alignment amplifiers in order to relate these figures to some type of computer analyses; or even to design an on-line LINC type of computer. A body plethysmograph will accurately measure the airway resistance and FRC more easily.

SUMMARY AND CONCLUSION

1. In a small series of observations:

a) Functional or relative compliance measured through the mouth decreased with increasing grades of nasal obstruction.

b) Functional compliance is increased by the use of vasoconstrictors or following nasal surgery where the obstruction is relieved. Changes in functional compliance appear to be due to increases in FRC although improvement in compliance is recorded in individuals when obstruction is relieved. Functional residual capacity increased with increasing nasal obstruction.

c) Functional compliance is essentially constant from day to day in subjects with normal noses, whether measurements are made through the nose or through the mouth. There are wider variations when the nose is abnormal.

d) Pulmonary resistance measured through the nose increased with increasing nasal obstruction.

e) Our findings strongly suggest that obstruction in the nasal airway can alter the mechanics of breathing and ventilatory studies.

f) The reasons for such shifts in functional compliance with increasing nasal obstruction are not certain. It may however be due to a nasopulmonary reflex, or due to changes in surfactant substance. The mechanics of breathing test variations may be due to a shift in the tidal volume, at the expense of the inspiratory reserve volume in these patients.

517 South Euclid Avenue

Doctor Nelson is Director of Pulmonary Physiology Laboratory, Department of Medicine, Washington University School of Medicine.

Mr. Dammkoehler is Director of the Computer Center, Washington University.

We are indebted to Mrs. Suzanne Schmitz and Mrs. Cynthia Stuart, our technicians, for their efforts in this research.

REFERENCES

1. Collins, Warren E.: Clinical Spirometry. Warren E. Collins, Inc.: Boston 15, Mass.

2. Comroe, J. H., Forster, R. E. (II), DuBois, A. B., Briscoe, W. A., and Carlsen, E.: The Lung. Year Book Medical Publishers, Inc.: Chicago, Illinois, 1963.

3. Bartels, H., Bucherl, E., Hertz, C. W., Rodewald, G., and Schwab, M.: Methods in Pulmonary Physiology. Translated by John M. Workman, Hafner Publishing Company Inc.: New York, 1963.

4. Sercer, A.: Interrelationship of Bronchial and Nasal Functions. Arch. Ohren-Nasen u. Kehlkopfh. 161:264-275, 1952.

5. Comroe, J. H., Botelho, S. W., and DuBois, A. B.: Design of Body Plethysmograph for Studying Cardiopulmonary Physiology. J. of Appl. Physiol. 14:3 (May) 1959.

6. Fry, D. L., Ebert, R. V., Stead, W. W., and Brown, C. C.: The Mechanics of Pulmonary Ventilation in Normal Subjects and in Patients with Emphysema. Amer. J. of Med. 16:1:80-97, 1954.

7. Fry, D. L., and Hyatt, R. E.: Pulmonary Mechanics. Amer. J. of Med. 29:4:672-689, 1960.

8. Mead, J.: Control of Respiratory Frequency. J. Appl. Physiol. 15:3:325-336, 1960.

9. DuBois, A. B., Botelho, S. W., and Comroe, J. H.: A New Method for Measuring Airway Resistance in Man Using a Body Plethysmograph: Values in Normal Subjects and in Patients with Respiratory Disease. J. Clin. Invest. 35:327, 1956.

10. Schilder, D. P., Hyatt, R. E., and Fry, D. L.: An Improved Balloon System for Measuring Intra-esophageal Pressure. J. of Appl. Physiol. 14:6, 1959.

11. Unpublished data.

DISCUSSION

DR. H. L. WILLIAMS: The data derived by Dr. Ogura and his co-workers suggest that there is a naso-pulomnary reflex, depending on nasal patency or obstruction, which causes a variation in the expenditure of energy required to carry on pulmonary respiration. Nasal respiratory obstruction was found to decrease both compliance and relative compliance and thus increase the energy requirement for pulmonary respiration. From the clinical standpoint this means that over a period of time nasal respiratory obstruction might produce a sufficient drain on the energy reserve of the body to produce a deficiency in cardio-respiratory function. The authors state that further confirmatory study will be required before the hypothesis can be unreservedly accepted. This is an instance of their cautious scientific approach. It seems likely from the care with which the preliminary investigations were done that confirmation will be obtained. In addition this hypothesis seems to be in concordance with the findings of van Dishoeck as to the existence of naso-pulmonary reflexes discovered by electromyographic methods.

I believe that this is possibly the most important paper given before this society in the past decade because of the present state of Rhinology.

Thirty years ago, Rhinology had developed a poor "public image" owing to surgical excesses. These were corrected by the recognition of the role of allergy in nasal and sinal disease, by the collapse of the theory of focal infection, and the concept of physiological function of nasal tissue. Our President played a major role in the introduction of this last idea.

Over the course of the years, however, these ideas have become restrictive or have been carried to excessive lengths. Nasal physiology is considered to be merely mucosal deep; disorders of the nasal chambers are considered solely allergic, and any possible effect of septic disease in the paranasal sinuses locally or on the body as a whole is denied. Except for cosmetic rhinoplasty, the nasal pyramid is considered merely useful for differentiating the human being from the anthropoid ape. Our young men are often unskilled in even the simpler methods of rhinologic diagnosis and ignorant of the basic techniques for nasal and sinal operative procedures.

In this paper Dr. Ogura and his associates have brought Rhinology back into general medicine. The nose can be considered once more to affect and be affected by the rest of the body. It is hoped that their promise of future physiologic investigations will be abundantly realized.

I wonder if your President will allow me to say a few additional words about the composition of papers, such as this.

Dr. Ogura kindly sent me a preliminary draft of this paper fearing that I would need considerable time to understand it. In this fear he was abundantly justified.

I would like to protest that this need not have been so, however. I shall characterize the English syntax of this paper as muddy. This is the most charitable word that occurs to me at the moment.

In giving a presentation, the most critical period often arrives with the time to set it all down on paper. The protagonists are sick to death of the whole thing and are apt to produce a sloppy job of writing.

I would like to suggest—and this is a serious suggestion—that when a gang of Ph.D.'s and M.D.'s are organized to do an investigation for N.I.H. that an A.B.

in English be added to the group for the purpose of telling the rest of us about it in plain, simple, terse English. Scientific gobbledegook is no better at disseminating information than that of the Federal government or the Department of State. The declared purpose of the scientist, however, is to inform rather than conceal.

DR. JOEL J. PRESSMAN: Dr. Ogura asked that I comment upon the significance of his fine basic and fundamental research, but this is really an anachronism since to do so would require a knowledge of all the facts of life for as long as life will exist.

The unanticipated practical significance of basic observations can be demonstrated in my own experience by the example of studies upon the sphincter mechanism of the larynx which eventually led to our superiority in the air over the German Air Force in World War II.

This might seem far-fetched indeed, but it was noted that the closure of the sphincter during expiration forced more oxygen through the alveoli. As a result there developed the use of pressure breathing in the oxygen system of the allied fighter ships, which was one of the best kept secrets, I think, of aviation medicine during the war. This enabled our fighter pilots to match the altitude potential of their planes and to fly at levels comparable to those of German supercharged bombers. In other words, the principles of normal physiology of the larynx, quantitatively elaborated upon, permitted our fighter pilots to match the supercharged cabins of their bombers, with supercharged tracheas!

I think we needn't go further than the fine address of our President to justify basic research of fundamental problems. Dr. Hilding looked forward to the day when all papers at this meeting were of a fundamental, basic nature. I can go further back than Dr. Hilding's recommendation by quoting in essence, although not in actual words, Dr. Thomas French, who was President of this American Laryngological Association in 1897. He said that as we encourage the presentation of papers of basic and fundamental value leaving to the future the application thereof, so will we rise higher in our own esteem. The acquisition and reporting of such fundamental knowledge is unto itself sufficient.

DR. JOSEPH P. ATKINS: I have enjoyed Dr. Ogura's paper a great deal. I think sometimes when one sees the work that pulmonary physiologists do, you get rather amazed at the number of figures which they can put up in front of you in rapid succession.

We had a chest conference at the University Hospital some years ago. Dr. Julius Comroe and Dr. Julian Johnson were very adept at baiting one another in this conference. They were discussing, one day, the question of whether or not a certain patient could tolerate a pneumonectomy and Dr. Comroe got up and gave all the figures of the pulmonary function of this patient. Then Dr. Johnson said, "Well, now, does this mean that I can operate on this patient or I can't operate on this patient?"

Dr. Comroe said, "Well, now, Dr. Johnson, what you are trying to do is to put me into a corner and say that I will give you a number. Above this number you can operate and below this number you can't operate."

Dr. Johnson said, "That is just exactly what I am looking for."

Of course this is what we are looking for, but with these figures and the way we do pulmonary tests at the present time, we have an idea of what is going

on physiologically but when you come down to saying, "Here is a number and this means exactly that," we haven't reached that stage. I think this is what we are working for and I hope, perhaps, Dr. Ogura will come and give us this number some day.

DR. OGURA: Mr. President, when you asked me to select the discusser I purposely picked Dr. Williams, knowing that I would be chastised.

I want to thank Dr. Pressman and Dr. Atkins because eventually it is our hope to obtain an objective way to equate our nasal problems.

THE EFFECT OF HYPOTHYROIDISM ON THE LARYNX OF THE RAT

AN EXPLANATION FOR HOARSENESS ASSOCIATED WITH HYPOTHYROIDISM IN THE HUMAN

FRANK N. RITTER, M.D.
(by invitation)
ANN ARBOR, MICH.

Some of the very first observations in animal endocrinology established the fact that the thyroid gland liberates a secretion which influences the body's rate of metabolism. In man, research has shown that this thyroid product is thyroxine, which controls metabolism by governing the amount of energy a cell releases during the catabolism of adenosine triphosphate. The synthesis of this hormone occurs in the thyroid gland, where four iodine atoms are oxidized with two tyrosine molecules to yield tetraiodothyronine. This intermediate product is then conjugated with an alpha globulin to form the thyroglobulin which is stored in the thyroid gland and microscopically appears as colloid. Hydrolysis of thyroglobulin yields thyroxine which is circulated to the tissues to act as the metabolic catalyst.[1-3]

Man's rate of metabolism varies with his environment so that when stresses occur or when increased activity is needed all body tissues augment their production of energy. Monitoring these environmental factors is the hypothalamus which initiates the required increase in metabolism by stimulating the pituitary to secrete thyrotropin. This latter hormone causes the thyroid to synthesize and release thyroxine. Only a controlled amount of thyroxine is liberated for an amount in excess of that required by the tissues to produce the necessary energy suppresses the production of thyrotropin. Thus, there exists a sensitive relationship between these two endocrine glands

---

From the Department of Otorhinolaryngology, University of Michigan Medical Center, Ann Arbor, Michigan.

This study was supported by a Grant from the National Institute of Health, No. NB-03540-08.

and the hypothalamus in which each is equally important and necessary to the regulation of the other.[4]

Despite this sensitive neuro-endocrine balance, permanent decreases of thyroxine can still occur. Such decreases most often develop after the surgical removal of the thyroid gland or from diseases which involve the gland and prevent it from synthesizing this hormone. When there is an insufficient production of thyroxine, the body's rate of metabolism falls and symptoms of decreased activity of all organ systems occur. If hypothyroidism is allowed to go untreated for a prolonged period of time, the soft tissues of the body become puffy or edematous. This non-pitting edema, termed myxedema, results from a quantative increase in the amount of connective tissue present in the organs affected. Myxedema involves areolar tissue by increasing the protein and acid mucopolysaccharide content of the connective tissue cells, producing a viscid fluid. This fluid does not further depress cellular metabolism but instead produces symptoms by distorting tissues. Fortunately, hypothyroidism as well as its sequela, myxedema, is correctible either upon treatment of the cause of the hypothyroidism or by substitution with dessicated thyroid.[5]

The soft tissues of the larynx like other body viscera may become subject to myxedema. Although little is written about laryngeal myxedema most authors state that when it occurs it produces a gradual and progressive hoarseness. Although there is agreement on this symptom, there is disagreement on the mechanics which produces it. Barton[6] states that the hoarseness occurs either from myxedematous involvement of the vocal cords or from cordal paralysis, the latter developing as a result of the recurrent laryngeal nerve being stretched by an enlarged thyroid gland which sometimes develops in hypothyroidism. He substantiates this latter theory by describing a patient whose paralyzed vocal cord began to function four months after the surgical removal of a thyroid adenoma.

Hilger[7] more definitely describes the hoarseness as developing from a deposit of the mucoproteinaceous material in the submucosa of the vocal cords. He describes two myxedematous patients with hoarseness whose vocal cords were diffusely enlarged. Successful treatment consisted in reversing the hypothyroidism and mechanically stripping the vocal cords to remove the myxedematous tissue.

Two different sources of hoarseness in myxedema are cited by Ficarra.[8] He states that the symptom is due to an accumulation of

acid mucopolysaccharides either in the cricothyroid muscles of the larynx or centrally in the nucleus ambiguus of the vagus nerve. However, since neither clinical nor pathologic findings are included in this report, these theories are not documented. Nevertheless, such conflicting statements provided the stimulus to study the effects of hypothyroidism upon the larynx.

CLINICAL INVESTIGATION

Most patients developing hypothyroidism are treated, so that myxedema is a rare disease. Therefore, lacking the opportunity to study a patient with myxedemic hoarseness it was hoped that this problem might be solved by studying the larynges of autopsied patients who died while clinically in a hypothyroid-myxedematous state. It was anticipated that specific structural changes might be seen in these larynges which would not be present in the larynx of a euthyroid patient. The autopsy protocols of myxedematous patients who died at the University of Michigan Medical Center since 1950 were obtained. Thirteen patients were autopsied who had this diagnosis at death and two of them had been hoarse. Although the clinical records document this symptom they fail to disclose any statement about the ante mortem appearance of the larynx. Nevertheless, the microscopic sections of these two autopsied larynges were studied. From each patient, the true and false cord of one hemilarynx had been preserved and stained with hematoxylin and eosin. Although carefully studied these sections did not reveal any changes when compared to the larynx of a euthyroid patient.[9] This unsuccessful clinical study therefore necessitated animal investigation.

PROCEDURE

Twenty-five 30-day-old female Sprague Dawley white laboratory rats were selected as the experimental animals and divided into three groups. Into the first group were placed ten animals which were injected with one microcurie of radio-iodine on the 30th day of life and 500 millecuries 20 days later. A single injection of one microcurie is usually sufficient to totally destroy the thyroid gland of the rat within two weeks, but the second injection provided assurance that this occurred.[10]

Into the second group were placed nine rats that were made hypothyroid by putting 1% propylthiouracil in their drinking water

A COMPARISON OF OXYGEN CONSUMPTION OF 10 RATS
TREATED WITH RADIOIODINE & 3 CONTROL ANIMALS

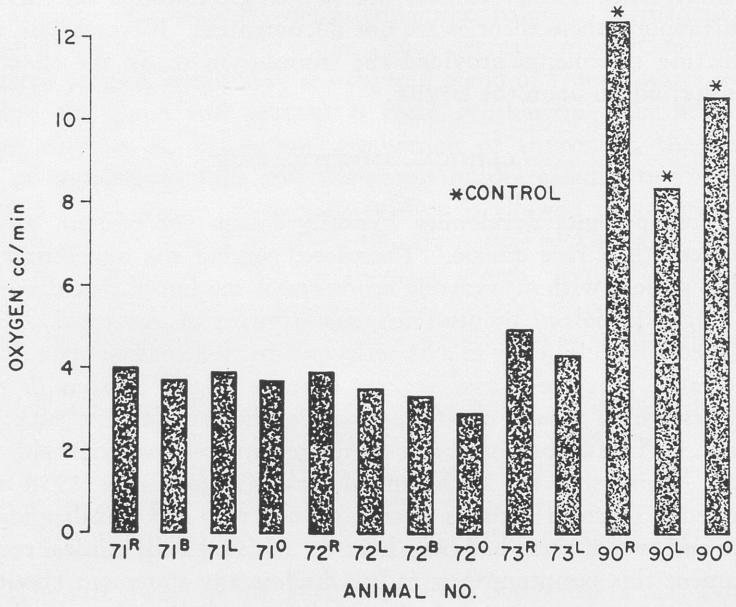

A COMPARISON OF OXYGEN CONSUMPTION OF 9 RATS
TREATED WITH PROPYTHIOURACIL & 3 CONTROL ANIMALS

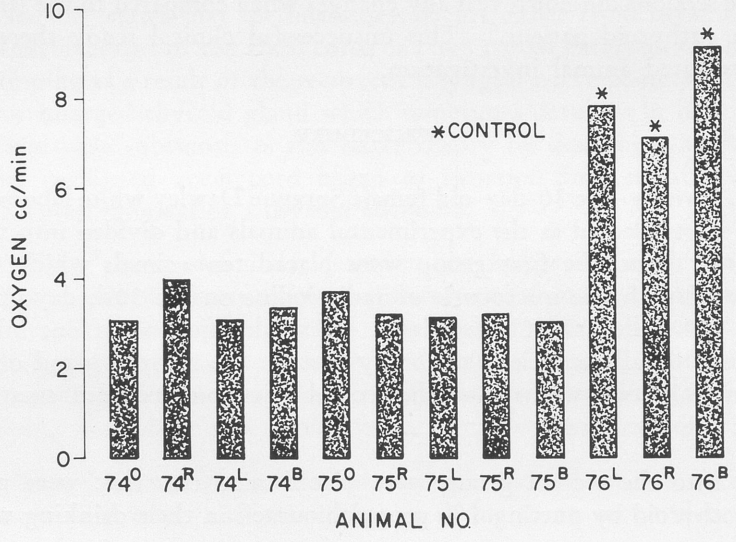

on the thirtieth day of life. This amount of propylthiouracil interferes with the synthesis of thyroxine for it prevents the formation of tetraiodothyronine from di-iodotyrosine.[1,11] The third group contained the remaining six rats for control study. All animals were and is made by placing the animal in a spirometer. This apparatus housed in cages, and fed a commercial rat diet without supplements. At 160 days of age the degree of hypothyroidism was determined and the animals were sacrificed.

DETERMINATION OF THE DEGREE OF HYPOTHYROIDISM

of the amount of oxygen used by the resting animal in one minute

Hypothyroidism in the rat is assessed by techniques similar to the clinical tests used in man. Of the several tests available, the basal metabolic rate (BMR), the protein bound iodine (PBI) and body weight were the ones used in this study. The BMR is a measurement consists of an airtight container which houses the rat during the test. After the rat is placed inside, the container is sealed, flooded with oxygen and connected to a pen which records the rat's consumption of oxygen per minute. In this study the six control rats averaged an oxygen consumption of 9.2 cc per minute, whereas the radioiodine and propylthiouracil treated animals averaged a consumption of only 3.8 cc and 3.2 cc per minute respectively (Figs. 1 and 2). Such a diminished consumption of oxygen indicates a moderately severe state of hypothyroidism.[12]

The second method used to detect hypothyroidism was to measure the amount of iodine bound to protein circulating in the animal's peripheral blood.[13] Since this test is a measure of the amount of circulating thyroxine it is an indirect means of assessing thyroid function. Blood was obtained through a capillary pipette inserted into a blood vessel in the posterior tissues of the anesthetized animal's eye. In this study the PBI for the six control rats averaged 3.7 microgram per cent, whereas it was 2.2 microgram per cent and 1.4 microgram per cent for the rats treated with radioiodine and propylthiouracil respectively (Figs. 3 and 4). In the rat, a numerical value below 3 micrograms per cent indicates decreased thyroid function.

The body weight of the rat was the third measurement used to detect hypothyroidism.[14] Since the thyroid gland was inhibited from

---

Figs. 1 and 2.—The oxygen consumption of the experimental animals is much less than that of the control animals. This indicates hypothyroidism.

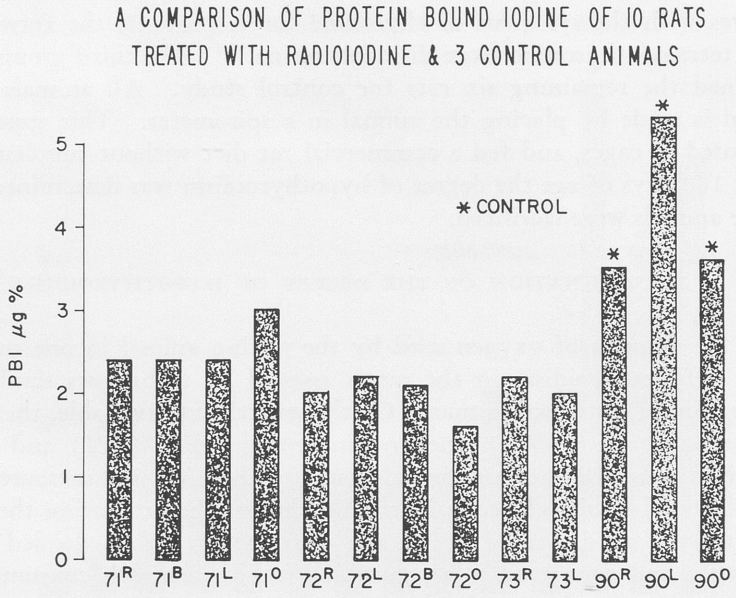

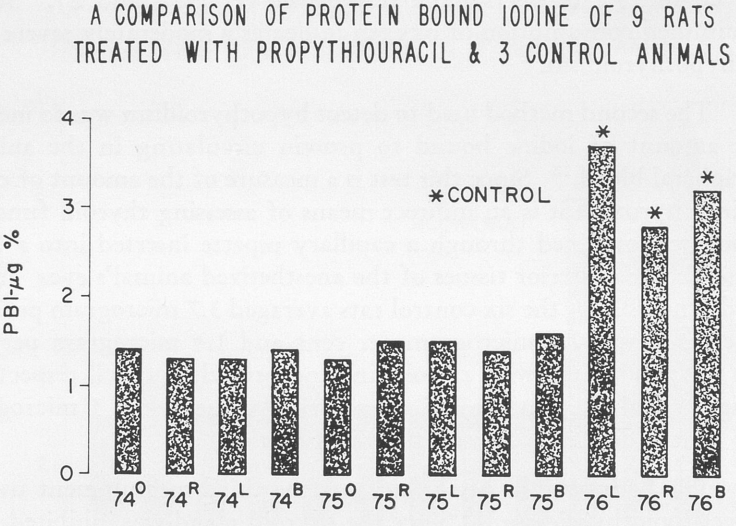

Figs. 3 and 4.—The protein bound iodine determination of the experimental animals is much less than that of the control animals. This indicates hypothyroidism.

producing thyroxine from the thirtieth day of life in all experimental animals, these rats should have failed to gain weight for this hormone is necessary for metabolism and growth. At the time of sacrifice, the six control rats weighed an average of 230.0 grams while the ten radioiodine treated rats averaged a weight of 128.6 grams and the nine propylthiouracil treated animals averaged 115.0 grams. In addition the experimental rats were also less active and their fur lacked the oily sheen observed in the control animals. These findings indicate a severe degree of hypothyroidism although the tissues were not puffy to suggest myxedematous changes.

CHANGES IN THE THYROID GLAND

At the time of sacrifice the trachea was exposed and the gross appearance of the thyroid gland of every animal was noted. Since radioiodine destroys thyroid tissue, no gland was found upon inspection of the anterior tracheal region in those experimental animals receiving this drug. However in those animals receiving propylthiouracil, the thyroid was three to four times larger and darker red in color than that observed in the control animals. This finding was anticipated for propylthiouracil blocks the synthesis of thyroxine and a goiter results for the pituitary continues to secrete thyrotropin in an effort to stimulate the thyroid to produce thyroxine. These findings are in contrast to the thyroid gland of each control animal which was small and pink in color.

For microscopic study the trachea, thyroid gland and larynx were removed en bloc and fixed in formalin or Carnoy's solution. The block was prepared by embedding it in paraffin, cutting it into coronal sections 10 microns thick, and staining with either hematoxylin and eosin or colloidal iron solution. Carnoy's fixative and colloidal iron stain were used for in hypothyroidism there is an increase in the acid mucopolysaccharides of connective tissue, which stain blue with this chemical.[15-17]

MICROSCOPIC CHANGES IN THE THYROID GLAND

Microscopically the thyroid gland of each control rat appears similar. The gland is small, the follicles contain colloid which in hematoxlin and eosin sections appears eosinophilic, whereas the follicular epithelium is basophilic. In those sections stained with colloidal iron, the follicular epithelium and the colloid appear green with some fibrillar processes of the connective tissue cells in the capsule of the

thyroid gland staining blue, indicating the location of acid mucopolysaccharides in this area.

In those rats treated with radioiodine the destroyed thyroid gland is replaced with a focus of dense fibrous tissue which is surrounded by a thick connective tissue capsule. In these sections stained with colloidal iron this fibrous capsule contains blue staining connective tissue in greater amount than that seen in the control animals suggesting an increased deposition of acid mucopolysaccharides. In a similar finding, those rats treated with propylthiouracil whose tissue sections were stained with colloidal iron also demonstrate that the fibrous capsule contains blue staining connective tissue. The amount of blue staining connective tissue in the thyroid capsule of these animals is similar to that found in the rats treated with radioiodine. However in the rats treated with propylthiouracil the thyroid gland was enlarged and the follicles did not contain colloid. These thyroid gland changes in this study in both the control and experimental animals, are similar to that seen in other experiments where hypothyroidism was produced by the use of these two drugs.[10,11]

MICROSCOPIC APPEARANCE OF THE LARYNX OF THE RAT

The rat's larynx contains cartilages and soft tissues similar to man's. It consists of a thyroid, cricoid, arytenoid and epiglottic cartilages and two true and two false vocal cords. Because the hoarseness in human hypothyroidism has been said to result from myxedematous involvement of the central nervous system, the recurrent laryngeal nerve, the vocal cords, and the intrinsic musculature of the larynx, each of these areas were studied microscopically in the rat. However, study of these areas in those hypothyroid rats whose tissue sections were stained with hematoxylin and eosin, failed to reveal any structural changes when compared to the tissues of a control animal.

Changes were found however, in these tissues stained with colloidal iron. In the control animal's larynx, the colloidal iron stains the connective tissue located in the submucosa of the true and false vocal cords, and the tracheal esophageal groove (Fig. 5). The brains, recurrent laryngeal nerves, and intrinsic laryngeal muscles on the other hand are almost totally devoid of any tissue which stains blue. When every hypothyroid animal's larynx is compared to the control animal, increased amounts of the blue stained tissue are found in the submucosa of the true vocal cord (Fig. 6). This deposition is present in the submucosa from the anterior commissure to the vocal process

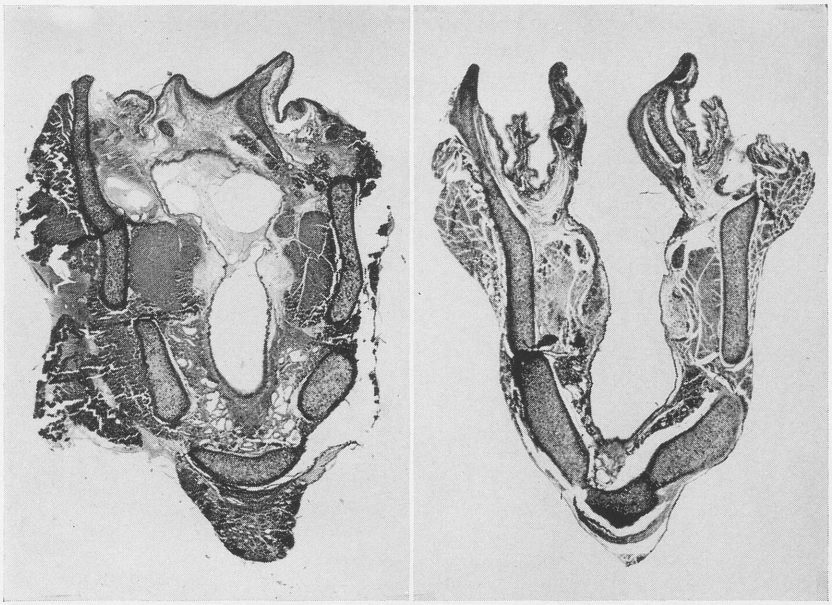

Fig. 5.—A coronal view of the larynx of a control rat. Some normal thyroid tissue is seen overlying the first tracheal ring. In the glottic lumen debris exists but the vocal cords adjacent to the thyroarytenoid muscles appear pale. Colloidal iron stain 36X.

Fig. 6.—A coronal view of the larynx of a rat made hypothyroid with radioiodine. The vocal cords lying adjacent to the thyroarytenoid muscles contain dark staining tissue in the submucosa. This indicates the presence of acid mucopolysaccharides. Colloidal iron stain 36X.

of the arytenoid cartilage. Microscopically it is confined to the fibrillar processes of the connective tissue cells. In some locations there is separation of these fibrillar processes as though fluid had accumulated between them, but otherwise these cells do not appear structurally different from those of the control animals (Fig. 7). The diameter of the vocal cords is not enlarged to suggest polyp formation. While a little blue stained connective tissue is found surrounding the intrinsic laryngeal muscles, none is seen between the muscles fibers or in the recurrent laryngeal nerves or brains of these experimental animals.

COMMENT

In myxedema resulting from hypothyroidism, soft tissues of the body accumulate a viscid fluid which is high in protein and acid

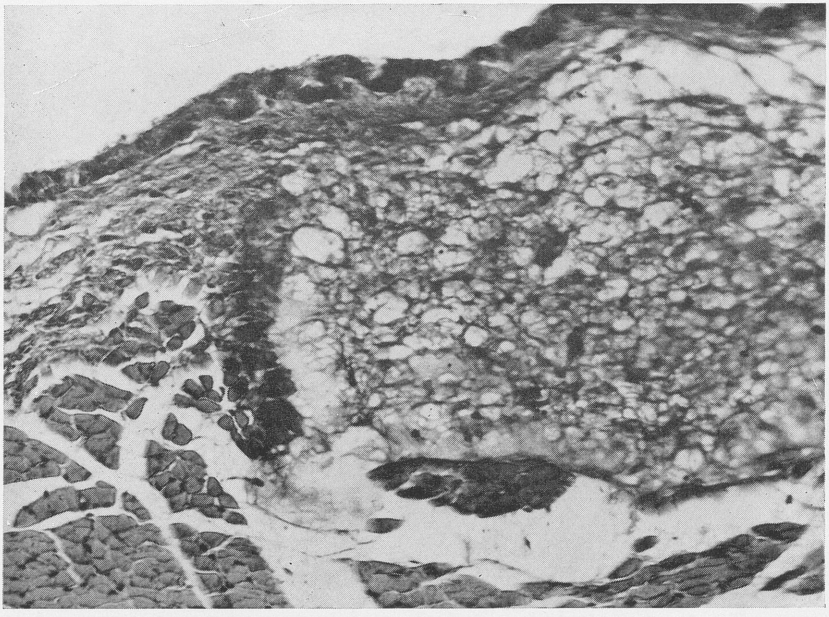

Fig. 7.—Appearance of vocal cord of animal in Figure 2 showing the stain in the connective tissue denoting the presence of acid mucopolysacchar ides. Between the connective tissue fibers are spaces which may have contained mucin. Colloidal iron stain 100x.

mucopolysaccharide content. This fluid is confined mostly to the connective tissues cells lying adjacent to epithelial structures, around synovial joints, or blood vessels. Most likely it develops because the pituitary continues to secrete thyrotropin in order to increase the production of thyroxine. While this fluid does not further reduce cellular metabilism, it causes symptoms by distorting the tissues of the structure it involves.

Since myxedematous fluid can occur in any body organ, hoarseness could be produced from changes affecting the brain, recurrent laryngeal nerves, intrinsic laryngeal muscles, and vocal cords. Most of these sites have been incriminated in the human as producing hoarseness when involved by myxedema. However, vocal cord swelling is the most frequently cited cause producing this dysphonia. This agrees with the behavior of the myxedematous fluid as it primarily infiltrates subepithelial structures for when neural or neural-muscular

tissues are involved, only diminished function occurs, not a paralysis.[18] Therefore it is reasonable to suspect that in man, myxedema causes hoarseness primarily from a purely vocal cord lesion.

Perhaps the reason that the sections of the larynges of the autopsied patients dying with myxedema did not manifest structural changes is that great amounts of this fluid must accumulate in order to be visible microscopically. For this reason the colloidal iron stain was used in this study since it stains acid mucopolysaccharides blue making them identifiable even in small amounts. If this stain had been used on the human laryngeal tissues removed at autopsy, an accumulation of acid mucopolysaccharides may have been detected.

In the control rat's larynx, these stained tissues are seen primarily in the submucosa of the true and false vocal cord and between the trachea and esophagus. In the experimental animals these areas are more heavily stained especially the submucosa of the true vocal cord which indicates a greatly increased accumulation of acid mucopolysaccharide. However, because the stain does not invade any intrinsic laryngeal muscles it is primarily a vocal cord lesion. The hypothyroid rat's vocal cord did not appear polypoid or larger than the control animal for the hypothyroid state was induced for only a period of 130 days. Had the experiment been conducted for a longer period the cords may well have been polypoid.

This iron stain in the laryngeal tissues of the experimental animals is not due to the drug employed for each experimental animal whether made hypothyroid either by radioiodine or propylthiouracil showed these findings. In addition, the thyroid gland showed characteristic changes that should have occurred from the use of these drugs. Thus, the acid mucopolysaccharide accumulated in the vocal cords appears to be a result of hypothyroidism.

The use of animal findings to explain human diseases is not warranted. Nevertheless it is interesting that this animal investigation presented vocal cord findings, which closely agree with Hilger's observation of this same finding in hypothyroidism in the human larynx.

SUMMARY

Hypothyroidism is an illness which reduces body metabolism. When it is present for a prolonged period of time different organ systems of the body develop an accumulation of mucins and acid mucopolysaccharides in their connective tissue component. This is

termed myxedema. When laryngeal myxedema occurs hoarseness results, but the mechanics which produce this symptom are disputed. To clarify this, rats were made hypothyroid and their larynges examined microscopically. By staining the tissues with colloidal iron, which stains acid mucopolysaccharides, the site of myxedematous infiltration was shown to be primarily in the submucosa of the vocal cord. This experimental findings tends to substantiate previously reported observations that the hoarseness of human hypothyroidism occurs from vocal cord swelling.

C6129 University Hospital

REFERENCES

1. Stanbury, J. B., and McGirr, E. M.: Sporadic or Nonendemic Cretinism and Goiter. Am. J. of Medicine 22:712-723, 1957.

2. Grollman, A.: Essentials of Endocrinology. J. B. Lippincott Company, 1947.

3. Godlowski, Z. Z.: Clinical Classification of Thyroid Hormone Physiopathology. Eye, Ear, Nose and Throat Monthly 42:40-48, 1963.

4. Reichlin, S.: Neuroendocrinology. New England J. of Medicine 269:1296-1303, 1963.

5. Donowski, T. S.: Clinical Endocrinology. Vol. II. Williams and Wilkins Company, 1962.

6. Barton, R. T.: Pharyngeal and Laryngeal Symptoms of Thyroid Origin. New England J. of Medicine 244:398-399, 1951.

7. Hilger, J. A.: Otolaryngologic Aspects of Hypometabolism. Annals of Otology, Rhinology and Laryngology 65:395-413, 1956.

8. Ficarra, B. J.: Myxedemic Hoarseness. Arch. of Otolaryngol. 72:75-76, 1960.

9. Schmidt, R.: Personal communication.

10. Golberg, R. C., and Chaikoff, J. L.: Procedure for Thyroidectomy of Newborn Rat without Concomitant Parathyroidectomy. Endocrinology 45:64-70, 1949.

11. Astwood, E. B., and Bissell, A.: The Effect of Thiouracil on Iodine Content of the Thyroid Gland. Endocrinology 34:282-296, 1944.

12. Kao, F. F., and Schlig, B. B.: The Ventilatory Responses during Muscular Activity in Normal, Thyroidectomized and Thyroxinized Rats. Am. J. Physiology 195-229-232, 1958.

13. Barker, J. B.: The Determination of Protein Bound Iodine. J. of Biological Chemistry 173:715-724, 1948.

14. Gemmill, C. L.: Growth of Normal and Thyroidectomized Rats on an Iodine Deficient Diet. Am. J. Physiology 195:381-384, 1958.

15. Rinehart, J. F.: The Role of the Connective Tissue Ground Substances (Mucopolysaccharides) in Allergic Injury. Calif. Medicine 75:335-340 (Nov.) 1951.

16. Rinehart, J. F., and Abul-Haj, S. K.: An Improved Method for Histologic Demonstration of Acid Mucopolysaccharides in Tissues. Arch. of Pathol. 52:189-194, 1951.

17. Weisskopf, A.: Connective Tissue: A Synthesis of Modern Thought and Its Impact on the Understanding of Nasal Disease. Laryngoscope 60:1029-1059, 1960.

18. Sanders, V.: Neurologic Manifestations of Myxedema. New Eng. J. of Med. 266:547-552, 1962.

DISCUSSION

DR. DANIEL C. BAKER, JR.: I had the opportunity to read Dr. Ritter's paper before its presentation today and I was certainly very much impressed with what I read and I am sure that you are also impressed with his presentation.

He has succeeded in his endeavor and he is to be congratulated on an excellent investigative study.

I was present at the meeting in 1956 when Dr. Hilger presented a paper on the otolaryngological aspect of hypometabolism. Hilger at that time discussed two cases of two patients with myxedema. In each instance, he had stripped the vocal cords of the mucosal thickening. On histologic sections, he found an increase in the mucoproteinaceous material in the submucosa of the vocal cords.

In addition to what the essayist has said, I would like to go a little bit further with regard to Ficaro's report. He stated that there was an increase in the mucopolysaccharides in the muscles and also in parts of the brain. This was a report that came out just three years ago and was not substantiated by any laboratory work or even a bibliography.

I have never had a patient with myxedema that I had to strip the vocal cords. I do not see patients with the disease often, because most of these patients have been under treatment and, of course, myxedema is a reversible condition.

I think that Dr. Ritter ought to add one more cause for hypothyroidism in humans and that is hypophysectomy. Having had some experience with total removal of the hypophysis, I do not consider that patient to have a good result unless she becomes severely hypothyroid. All of these patients have to take large quantities of thyroid substance after hypophysectomy.

There are other causes of hoarseness besides myxedema, and I would like to say a word about some of them:

Today hormones are very fashionable and one might say that whether it be a symptom or a disease there is certainly a hormone for it. Not infrequently I get the opportunity to see a young female, between thirty and forty years of age, who for one reason or another, but usually due to an endocrine disturbance, either a menstrual disorder or an ovarian dysfunction, who has been given male sex hormone to counteract the female sex hormone. If such medication is given over a period of months, not infrequently the patient will start to grow hair on her face and the voice will become deeper in pitch. It is well to bear this in mind when one sees a woman who complains of hoarseness. An increase in the depth of pitch of voice requires the observer to ask the patient if they have been on any specific medication.

You are apt to be fooled and you are apt to miss the etiologic factor if this is overlooked.

The unfortunate part about giving male sex hormone to a female is that if they do develop hoarseness or an increase in the depth of voice, it is usually permanent. This is one type of laryngeal change that does not reverse itself. On looking at the larynx of such individuals it has been my impression that the cause of the increased depth of voice has been due to an elongation of the vocal cords.

Others who have written about this feel that any lengthening that takes place in the cords is probably due to the greater action of the cricothyroid muscle.

There are other patients that are given hormones which, in addition to containing female sex hormones, may contain the male hormone too, and it is well to know if the patient is undergoing hormone therapy. Any male hormone should be discontinued if they complain of hoarseness.

To get back to the paper of Dr. Ritter, he certainly has gone through the literature, and has presented the theories as to the cause of hoarseness in myxedema. He has shown how it developed in hypothyroid rats as compared with controls, and that the cause does lie in the vocal cords.

I feel that he has done us all a service with his presentation and that this paper will serve as an important reference with respect to laryngeal manifestations of the disease.

DR. WILLIAM H. SAUNDERS: This very simple and very clear paper will do much to gladden Dr. Proetz when he reads it, and I hope he sees it soon.

I see patients with full blown myxedema fairly often and I think that there may be another factor here that we have overlooked. Part of the hoarseness in these patients does result from a lesion in the larynx but I am not sure that all of it does and I think that sometimes none of it comes from that cause.

It has been for me a constant observation that these patients are hard to examine. One has difficulty in seeing the larynx. I try hard to see it because I want to determine if the cords are longer than they should be, waterlogged, polypoid, or seemingly short, but there is an inability to see the cords as easily as one might see some other larynges. This difficulty with mirror laryngoscopy has called my attention to the fact that another cause of their hoarseness is not laryngeal but is due to the tongue. These patients have thick broad tongues. Asking them to move their tongues in and out rapidly shows at once that this is the case—the tongue moves very slowly. Perhaps this is partially the result of their myxedematous condition, but it is also due to an increase in size of the tongue. I think that, at least in some instances, we mistake for laryngeal hoarseness what is actually a change in the character of the speech because of increase in the bulk of the tongue.

DR. GODFREY E. ARNOLD: I was delighted to hear this excellent presentation because it explains to me what has been known empirically for some time, that a number of patients with hoarseness of unknown etiology do benefit from thyroid medication. In my experience the beneficial result in such cases is seen chiefly in women.

I agree with Dr. Baker in the observation that male hormone treatment in females may change the larynx. Studies have shown that the larynx in a younger female, if stimulated to grow, will grow to male dimensions. The vocal cords become longer, thicker, and heavier, which tunes them to the lower male pitch.

Another factor of vocal virilization is advanced premature calcification of the laryngeal cartilages. Pathological pitch changes do not always reflect a dysfunction

of the cricothyroid muscle. They may result from actual physical overgrowth of the larynx, stimulated by the improper hormones in the wrong sex.

DR. JEROME A. HILGER: I was grateful to Dr. Ritter when he sent me a copy of his paper. Indeed, the commonest source of hoarseness in the hypometabolic patient is the recurrent nerve injury that goes with the over-enthusiastic removal of the gland. In addition to that, I think there is no question that the articulation problem that Dr. Saunders mentioned is a factor, too. This, of course, is articulation in a strict sense. In addition to this, it must be remembered that the hypometabolic patient may be a lethargic person due to central nervous system changes. As a matter of fact, this, added to the complexity of speech formation, may give the hypothyroid patient additional change in the character of his voice in that it lags and is sluggish. But over and above all of these sources of voice change, the mechanical factor that occurs as the result of changes in the mucosa of the cord itself is certainly a very real one.

It is worth mentioning here that, as in most pathologic disturbances, the milder forms of the disorder are much more common than the more pronounced. So it is that in many patients with hypometabolism of a non-myxedema degree there is a subtle voice change due to mucosal alterations which are not outstanding as viewed through mirror laryngoscopy. The ground substance which is affected by the presence or the absence of the thyroid hormone hovers between a state of liquidity and normal gel. This, in the one-plus or two-plus degrees of the disturbance, is difficult to see.

It is true the best treatment is thyroid replacement. I would say that it is exceedingly uncommon that surgery has any place in the problem at all. It is reserved for those instances in which a severe degree of myxedema of the cord has been present for a very long period of time and has combined with the mechanical stress of labored voice production to produce pedunculated mucosal masses. Only here is surgery worth while, and here I think it is probably best to describe the surgery, not as stripping of the cord, but rather as opening of the mucosa and spilling out of the myxedematous jelly-like material. This leaves ample mucosa and the folds of the normal mobile cord edge intact.

DR. RITTER (closing): I wish to thank all the discussers for their very kind comments and for helping us all understand this interesting field of laryngeal endocrinopathy.

EXPERIENCES WITH PARTIAL LARYNGOPHARYNGECTOMY

EMANUEL M. SKOLNIK, M.D.

ARTHUR LOEWY, M.D. (by invitation) JOSE SMOLER, M.D. (by invitation)

CHICAGO, ILL.

We have stressed the concept of adequacy in place of the term "radical" and adequacy can imply extensive or limited resection. The major surgical concept in treatment of accessible carcinoma of the larynx and hypopharynx remains essentially unchanged; complete removal of the primary tumor, with block resection of the associated lymphatic bed when its involvement can reasonably be predicted. A resurgence of general interest in conserving glottic function when dealing with carcinoma of the epiglottis was stimulated by the report of Ogura in 1958.[1] Subsequent reports dealt with glottic conservation in management of tumors of the pyriform sinus[2] and in resection of lesions of the posterior hypopharyngeal wall reported in 1960.[3] Our own interest has run somewhat concurrently, and the series of varied forms of subtotal laryngopharyngectomy with and without neck dissection forms the basis of this report. We were deterred from early acceptance of this adequate but subtotal surgical approach by our belief that thoughts of survival should supersede thoughts of organ function. However, our experiences have alerted us to differentiate between the concept of conservation surgery which may be desirable and conservative surgery which is likely to prove retrograde progress.

The surgical possibilities have been described in detail by Ogura. Basically the resection includes the primary tumor with a surrounding margin judged to be adequate to assure complete removal, but with the preservation of the glottic structures. If such salvage appears to

---

From the Department of Otolaryngology, College of Medicine of the University of Illinois, Medical Center, Chicago.

be dubious at the time of resection, the thoughts of organ conservation must be made secondary to thoughts of organism conservation, and more extensive resection is carried out. The judgment of an adequate, but not excessive margin of safety in the primary resection requires an adaptation of technique to each tumor on an individual basis. It may result in epiglottidectomy with a block including sufficient base of tongue and hyoid to include the pre-epiglottic space. Epiglottis, aryepiglottic fold, and ventricular band and hyoid may constitute the block. We have not applied limited resection to lesions of the postcricoid region because of our past experience in dealing with these tumors. Unless the primary resection was very wide, stomal persistence was a common outcome when tumor involved the postcricoid area.

Evaluation of the effectiveness of the varied supraglottic or extraglottic resection must be judged by several criteria. The primary indicator of an unsatisfactory result is that of local adjacent evidence of subsequent persistence of tumor. This persistence must be differentiated, when possible, from a regional secondary primary tumor. However, if we wish to avoid fogging the concept of primary adequacy, we must not dignify persistence with the term "recurrence." The latter term implies a period of control, and serves only to placate our inadequacy. This, of course, applies to our widest possible resection in the head and neck, and does not apply solely to the results of conservation efforts. Conversely, failure to control spread of the disease is surely a failure of therapy, but may not be due to incomplete removal of the primary tumor. An ultimate death by widespread metastases does not necessarily condemn the adequacy of the primary tumor site resection, but rather reflects the stage of microscopic spread not always apparent or predictable at the time of initial clinical examination. Evaluation of a surgical method must always include an assay of the postoperative course of the patient, for voice preservation itself could be effected at great cost to the total person if feeding problems create an unacceptable social being, or delayed healing were to create an unreasonable exchange for voice function, or if incomplete glottic function is the ultimate outcome.

Our experiences with large numbers of malignancies involving the extraglottic structures such as pyriform sinus, epiglottis and vallecculae, lateral and posterior pharyngeal wall and aryepiglottic fold, where there is normal mobility of the intrinsic larynx and where the surgical treatment had previously been total laryngectomy in continu-

ity with neck dissection, has encouraged us to accept a conservation subtotal surgical approach. Statistics from other investigators' evaluations of short and long term results of laryngectomy and neck dissection for tumors encompassing these specified anatomical areas and classified as extrinsic or extraglottic have shown a relatively low survival rate and further reinforce our philosophy of conservation surgery based on the fundamentals of Trotter and Orton. Short term results with conservation surgery confirm our impressions that such procedures do not jeopardize the patient's chance of survival and yet afford retention of his laryngeal voice.

The selection of patients with malignancies involving the anatomical sites as epiglottis and valleculae, pyriform sinus, ventricular band and aryepiglottic fold, or posterior pharyngeal wall, must fulfill the following criteria for the partial laryngopharyngectomy procedure with preservation of a functioning larynx:

1. The true vocal cords and arytenoids must be free of tumor involvement and preferably mobile.

2. The thyroid cartilage must be free of infiltration.

3. Fixation of the apex of the pyriform sinus contraindicates the conservation surgical approach.

4. Pre-operative irradiation resulting in edema of the arytenoid or decreased motion of the vocal cord does not suggest contraindication, particularly if the extent of the tumor prior to irradiation did not violate the basic criteria.

5. There must be no involvement of the postcricoid region.

6. In posterior pharyngeal wall malignancies, the lesion must be mobile over the prevertebral soft tissues. Fixation in this area implies invasion.

There is no substitute for accuracy of delineation of tumor involvement when the classification conforms to an anatomical definition rather than a generalized area. A description of the architecture of the tumor (exophytic or infiltrating) and the anatomy involved best qualifies categorically the statistical results.

In case selection, tumors involving the epiglottis which are limited to the free surface are preferred, but extension to either or both surfaces and into the valleculae and glosso-epiglottic fold does not contraindicate subtotal resection. Extensive involvement of the base

of tongue often precludes a subtotal surgical procedure. Also, the inferior extent of the tumor should not encroach upon the anterior commissure region, and lateral invasion of the aryepiglottic and arytenoid must not exist. If nodes are palpable the surgery is committed to include neck dissection. In the dissection of the neck and resection of the epiglottis block, the thyroid lobe in the ipsilateral side is removed. Special care is employed to preserve the recurrent laryngeal nerve. The resection of the base of the tongue must not violate the integrity of both lingual arteries. Preservation of the superior laryngeal nerve and hypoglossal nerve will greatly facilitate early rehabilitation of deglutition, phonation and respiration.

Resection of pyriform sinus malignancies include a neck dissection on the side of involvement. However, when the apex of the pyriform region is involved and there is extension to the cricoid, any conservation procedure is inadvisable.[4] Fistula formation is frequent but not out of reasonable proportion as compared to the frequency where total laryngectomy is performed. They are usually small, and spontaneous closure occurs within 7 to 10 days. The postoperative course is prolonged compared to that for a total laryngectomy but preservation of a functional larynx is overwhelmingly in favor of this modality. Wound infection, skin slough, and postoperative hemorrhage may occur as with other surgery; the incidence is not increased.

In the management of posterior pharyngeal wall neoplasms, multicentricity of origin is of great concern and may be present as "satellites" somewhat distant from the primary site. This is demonstrated in several patients in this series. It is imperative that adequate definition of the limits of the tumor be determined. Direct and indirect examinations must be performed, and roentgenograms of the cervical vertebra and prevertebral areas obtained to demonstrate bony invasion or possibly soft tissue infiltration. The tumor must be movable over the deeper structures and a neck dissection is usually included on the side of greater involvement, even if nodes are not palpable. Skin grafts were not required and the healing process occurred without complication. Swallowing of soft to solid foods was instituted within 14 to 21 days.

COMMENT

This presentation is based on a selection of 31 patients considered suitable for partial laryngopharyngectomy. There was no attempt

SUMMARY OF 31 PATIENTS WITH PARTIAL LARYNGOPHARYNGECTOMY

TUMOR GROUP	*Living and Well*	*Living with Disease*	*Died of Disease*	*Died of Other Causes*
Epiglottis Total 13	1^5 2^3 1^2 2^1	0	2^3 3^2	1 5d PO 1 suicide
Pyriform Sinus Total 13	1^5 1^4 1^3 3^2 1^1	1^1	2^2 2^1	1^4
Ventriculor Band and Aryepiglottic Fold Total 1	0	0	1^3	0
Posterior Pharynx Wall Total 4	14	2^1	0	1 12d PO
Present Status:	14	13		4

Exponent = number of years

at discriminating the microscopic or gross appearance of the tumor. The extent of the neoplasm was anatomically defined according to site and to contiguous structures. Cineradiography was performed in two cases to aid in the evaluation of degree of fixation of cancer of the pharyngeal wall and to determine the problem of dysphagia and aspiration relative to the conservation procedure. Of the 31 patients, 4 did not present palpable cervical lymph nodes and did not undergo neck dissection. Twenty-four had unilateral neck dissections and 2 required staged bilateral neck dissection.

The total series comprised 13 malignant tumors involving the epiglottis, 13 involving the pyriform sinus, 4 located in the posterior pharyngeal wall and 1 involving the aryepiglottic fold and ventricular band. It is of interest to note the high incidence of neck dissection in this series. The pyriform sinus lesions showed the highest metastatic rate. According to McGavran,[5] Bauer and Ogura, supraglottic or transglottic lesions with palpable nodes at initial examination need a neck dissection and probably (48%) require the contralateral neck dissection also. Supraglottic tumors (epiglottic) with no palpable nodes at initial examination might be spared a neck dissection (only 4% node involvement).

There were two deaths in the immediate postoperative period; one was from renal failure due to a major transfusion reaction, the

other occurred five days postoperatively. Neither could be ascribed specifically to the subtotal nature of the surgical resection.

A single instance of an unsatisfactory voice result was encountered; it was found to be the result of a right vocal cord paralysis and did improve after several months. The other nonfatal postoperative complications included aspiration pneumonitis in two patients. Fistula formation occurred more frequently with pyriform sinus resection than with the other resections, but did not present a problem of care.

A persistent pharyngostoma requiring secondary closure occurred in one patient. Prolonged inability to swallow and requiring gastrostomy occurred in another patient. The prolonged need for a feeding tube (1 for 66 days, 1 for five months) is worthy of comment. It has been our experience that repeated trials with the tracheotomy tube and feeding tube removed during the period following apparent healing is more likely to encourage the patient in his rehabilitation of swallowing. In the instance of the five-month interval, this management was omitted, and it was assumed that the patient had failed the attempts. When the tube was removed, swallowing was accomplished within hours. The longest period during which a tracheostomy had to be maintained was 65 days. This is presumed to result from some affection of the superior laryngeal afferent arc, and implies a bilateral involvement of the arc. Even though transection is carefully avoided, it is quite possible that an application of a retractor or similar minimal trauma can result in depolarization or other microtrauma to nerve sufficient to cause prolonged delay in return of function. When it is unilateral, it is unlikely to create a major problem in the recovery of reflex action of the glottis. Bilateral involvement, on the other hand, removes the effective lower airway protection and necessitates the continued use of tracheostomy.

Local persistence has been present in three instances to date. It must be assumed that the limited procdure constituted an inadequate resection for the problem at hand, and as has been discussed, this occurrence should be regarded as a failure. It is also a failure in the general terms of tumor management, as it has been axiomatic that the best chances for cure rest in the first attack. The series is not complete, nor is it large enough to project statistically the possible local persistence to be anticipated in those patients who have been observed for only a short period.

A tracheotomy is done regardless of the location or extent of the tumor and surgical excision. This is essential because of the difficulty in swallowing and frequency of "spill" of oral contents into the airway. The patient is fed via nasogastric tube after surgery. This is continued until oral feedings are feasible. This will be determined by the extent of surgery performed. It was not necessary to cut the cricopharyngeus muscle to expedite deglutition, and restitution of swallowing occurred earlier with re-establishment of the laryngeal airway.

Alterations in the mechanism of deglutition and respiration in partial laryngopharyngectomy procedures with neck dissection, are dependent upon several conditions:[6] 1) the degree of cicatrix formation interfering with the normal sphincteric action of the esophagus and closure of the glottis; 2) paralysis as a result of damage to the hypoglossal and vagus nerves greatly increases the functional disability; 3) a normally functioning tongue is important to swallowing, respiration, respiration, and phonation; 4) a mobile hypopharynx aids in the "gulping" action and depends upon the integrity of the pharyngeal constrictors, although resection of a portion of the constrictors does not greatly inhibit the action; 5) early removal of the tracheotomy tube and restitution of the airway is usually helpful in early rehabilitation and establishment of a more functional swallowing mechanism.

PHILOSOPHY CONCERNING SURVIVAL

Our population of patients laryngectomized for cancer of the laryngeal area shows a bimodal pattern. These patients either die of laryngeal cancer by the end of the second postoperative year, or they die more than 10 years postoperatively.

Consequently, it would be most valuable to know what factors might distinguish those that die early from those who die later.

The factors of site of lesion, occurrence of palpable nodes, maturity of cells in the tumor, the degree of invasiveness of the growth and the age of the patient all showed no relationship to this separation. None of these factors appears to relate significantly to the length of survival and none of them identifies the patients who die early or who survive for a long time. The same lesions and the same treatment still resulted in this variation in survival.

Therefore, we conclude that some factor may exist within the patient which creates this difference. The hypotheses which come

to mind are concerned with the tolerances and the responses of the host to this pathological tissue.

Does a neoplasm differ in its ability to flourish when it lies in its seat of origin (the original host tissue) or in tissue foreign to it?

For example, what is the rate of growth of a mucosal lesion within a mucosa as contrasted to its expansion within the connective tissue of muscle and lymphatics? A factor such as this could influence our decision as to site of origin and could be behind the rapid termination of the lives of some patients.

There is also the attractive hypothesis that the tolerance of the tumor by the host varies significantly. Could there be some immune response or an accelerator growth factor, or in contrast, some deficiency of a substance regulating cell structure, maturation and tissue architecture?

If it were possible to predict survival at the outset, it would be possible to evaluate the efficacy of treatment more usefully.

In any case, it appears that we must dream and search our minds and our memories for newer hypotheses and the currently unthought-of ideas if we are to explain tomorrow the discrepancies of today's data.

In the light of statistics of patients with disease living to longevity, one can speculate as to the future of a group of patients in whom an airway and deglutition is maintained but no therapy rendered to the tumor.

CONCLUSIONS

A philosophy is presented to support the rationale for the conservation surgery. Thirty-one patients are presented in this series. The tumor grouping revealed 13 epiglottic lesions, 13 pyriform sinus involvement, 4 posterior pharyngeal wall tumors and 1 involving the ventricular band.

The criteria for the conservation procedures are discussed. Short term results are encouraging in selected cases; especially in the epiglottic lesions. The low incidence of persistence of primary disease is significant. Less than cure benefits have also been forthcoming when surgical attempts have failed to eradicate the tumor. In extensive tumors with poor prognosis or in debilitated patients with a shortened life expectancy, palliative surgery is advantageous to eliminate pain and breakdown of tissue while preserving vocal function.

Continued evaluation of varied surgical management of malignancies of the head and neck is surely in order. Results should be constantly monitored by periodic evaluation and comparison of results in terms of patient survival and social acceptability.

1853 West Polk St.

REFERENCES

1. Ogura, J. H.: Supraglottic Subtotal Laryngectomy and Radical Neck Dissection for Carcinoma of the Epiglottis. Laryngoscope 68:983-1003 (June) 1948.

2. Ogura, J. H., Jurema, A. A., and Watson, R. K.: Partial Laryngopharyngectomy and Neck Dissection for Pyriform Sinus Cancer. Laryngoscope 70:1399-1417 (Oct.) 1960.

3. Ogura, J. H., Watson, R. K., and Jurema, A.A.: Partial Pharyngectomy and Neck Dissection for Posterior Hypopharyngeal Cancer. Laryngoscope 70:1523-1534 (Nov.) 1960.

4. McGavran, M. H., Bauer, W. C., Spjut, H. J., and Ogura, J. H.: Carcinoma of the Pyriform Sinus. A.M.A. Arch. Otol. 78:826-830 (Dec.) 1963.

5. McGavran, M. H., Bauer, W. C., and Ogura, J. H.: Cancer 14:55, 1961

6. Conley, John J., and Seaman, W.: Function in the Crippled Laryngopharynx. Trans. Amer. Laryng. Assoc. 84:191-201, 1963.

DISCUSSION

Dr. Joseph H. Ogura: I am very happy to discuss this paper because this topic, of course, is very close to my heart.

First, in respect to the philosophical aspect mentioned by the essayist, I believe that if you read between the lines, what he is trying to say is that in the past he has taken out too many larynges that he would otherwise have liked to have saved. This responsibility, though, depends on the surgeon when he first sees the patient. He must make the decision as to its resectability, assume the responsibility that he understands the biologic behavior of this tumor. If he decides to include preoperative irradiation, he must know when to operate and finally, if he runs into complications, then he must then be able to handle the problems. These are mainly those of skin sloughs and the use of flaps.

I think that in the zealousness of trying to treat cancer, one very often only presents the patient with but one alternative, either irradiate or take the entire larynx out. The patient should have the opportunity to decide what can be done under less radical procedures, namely that of conservation surgery. This responsibility rests entirely with the surgeon.

If we look at the treatment of cancer over all, I think we can say the following:

That if you start with one hundred cases of cancer of the larynx, you really can cure 76 per cent of them. This is the over-all cure rate for laryngeal cancers. As evaluated by our pathologists, epiglottis cancers have a cure rate of 82 per cent. By subtotal or conservation surgery the aim is just as high. One can see that patients are dying with diseases other than cancer.

If you contrast this with the pyriform fossa or the pharyngeal lesions, of course, one would expect a cure rate that is not as good and without radiotherapy it borders on the line of about 41 per cent. I am sure that with the inclusion of pre-operative radiotherapy this cure rate will be improved.

Now, these are the results so far calculated earlier this year: of the 123 patients treated by conservation procedures. We have 46 that are in the supraglottic group, 47 in the pyriform fossa, 25 in the base of the tongue and 5 in the posterior wall.

You can see that with the uncorrected survival, not taking into account death from coronary disease, and so forth, one can obtain a 77 per cent cure rate for epiglottic cancer by the conservation techniques. Forty per cent by the pyriform fossa, and probably corrected, would come up to about 55 to 60 per cent. The base of tongue is low, as one would expect. Consequently it is in this group, the pyriform fossa and base of tongue, where we should employ pre-operative therapy in combination with subtotal resection.

As far as the anatomic area of resection is concerned, I agree with the criteria stated by the essayist. However, I would go a step further. I believe that the resection can be extended to below one cord.

In addition to the arytenoid, one can resect the true cord and the subglottis, with a reconstruction of the true cord, by using the thyroid cartilage and a rotation of a pharyngeal mucosal flap. The flap is rotated from the posterior wall of the pharynx, rotated up, and a new vocal cord is reconstructed. This means in addition to a suproglottic resection, the false cord and the ventricle and the arytenoid and the true cord and the subglottis.

How do you decide on the reconstructed cord? This decision is made at the operation. The thyroid cartilage is fractured with its perichondrium intact and a mucosal flap reconstructed. General anesthesia is lightened to the point where vocal cord movement can be noted. One must be sure that the remaining cord closure accomplishes complete glottic closure.

The one aspect that Dr. Skilnik did not mention was the cricopharyngeal myotomy. One will soon find out that the cricopharyngeus, when included with a neck dissection, immediately goes into spasm and in our hands a cricopharyngeal myotomy has been very useful in the rapid recovery and restitution of function in these individuals.

Dr. Pressman: Within the recent past I operated upon a patient in the manner described by Dr. Ogura. Following the operation great difficulty with swallowing necessitated the insertion of a feeding tube through the neck into the cervical esophagus. Some weeks later I saw Dr. Ogura and asked his suggestion as to a possible solution. He recommended that I do a resection of the cricopharyngeal muscle complex. Soon after this was completed, swallowing improved until now, about six months postoperative, the patient's swallowing, although not normal, is very satisfactory. This maneuver therefore seems to be an important adjunct to the basic procedure.

Dr. W. Franklin Keim: We have been exploring this field of conservation laryngectomy cautiously. Having been raised somewhat in the Orton tradition, I had a certain amount of skepticism about it at first but I think it has much to offer, particularly in view of one of the papers which was presented yesterday concerning pre-operative irradiation in doses of 2,000 to 3,000 r, the evidence being that reproductive activity of the cells is greatly inhibited. I think that probably in the future this will prove to be a potent weapon.

Dr. Skolnik made two references to the development of tracheal stomal recurrence which I would like to comment on briefly. I am well aware that in the literature it is felt this is brought about by a spread from the subglottic lymphatics, perhaps through the thyroid lymphatics—Dr. Norris has mentioned this in his paper —but I would call to your attention that in our report yesterday it would appear that preliminary or even operative tracheostomy has more to do with tracheal stomal recurrence than does the site of lesion or the spread by lymphatics.

Dr. Skolnik (closng): At the University of Illinois we are in a program of pre-operative irradiation. Two groups of patients are in the study program. One group is given 2,000 r over a period of 5 to 8 days followed by surgery within two days. The second group of patients is treated with 5,500 r in a period of four weeks and then surgerized within four weeks.

I mention this because Dr. Keim has alluded to this type of management. To comment on Dr. Ogura's statement it was possible to compromise the original planned surgical procedure in three patients who had been treated with irradiation.

Although these patients had not been originally planned for a conservation procedure, the circumstances that prevailed at the time of operation, and with the use of frozen sections, it was feasible to accomplish partial laryngopharyngectomy where total laryngectomy had been decided upon prior to irradiation. All of these patients had 5,500 r and the closure proved to be a problem in just one case.

In the light of super voltage therapy and the absence of carcinoma in the tissues irradiated and the experiences with the three cases mentioned, one can speculate as to the increasing frequency of compromised surgery in previously irradiated patients.

The cricopharyngeus muscle was cut in two patients in this series. Deglutition did not appear to be a significant problem in our series.

CLINICAL APPLICATION OF RECENT ADVANCES IN LARYNGEAL PHYSIOLOGY

GODFREY E. ARNOLD, M.D.

JACKSON, MISS.

During the first century of laryngological research and practice the early pioneers and their followers concentrated their interest on life threatening disease and its treatment. The study of laryngeal physiology was regarded the chief domain of philologic phoneticians and medical phoniatrists. A peculiar schism of laryngeal interests developed as an inevitable result. The surgically trained laryngologist felt called upon to treat primarily those laryngeal diseases which are recognized by visible alterations in structure. Abnormal phenomena of function, the so-called functional disorders of the voice, were left to the care of certain medically or psychiatrically inclined laryngologists who abstained from surgical practice. Because these phoniatricians were very few in numbers, various nonmedical specialists joined the ranks of the voice specialists. Among the latter were phoneticians, special educators, teachers of the vocal arts, acousticians, and musical psychologists. Such diversion of basic interest led to a great variety in viewpoints and practical approaches.

This duality of laryngeal work and its separation into two basic orientations, the pathological-surgical and the physiological re-educational, were in contrast to the training of otologists from the earliest beginning of that specialty. Structure and function always meant an undivisable unit to the ear specialist. He was trained to investigate function through auditory and vestibular tests, and to improve it by means of medicinal or surgical techniques. The self-limitation of early laryngology to the gross structural abnormalities and their surgical treatment was in even greater contrast to the global view practiced by ophthalmology. For many centuries, the eye specialist has been an expert in optics, utilizing his physical knowledge to give better vision to his patients. Had the ophthalmologist been educated to limit his interest to the visible abnormalities of the eye, he would have referred

all patients without operable or treatable eye lesions to buy eye glasses in a store.

In analogy to the recent interest in audiology, though somewhat lagging behind its rapid development, phonologic research and practice have revitalized the previously limited attention to one of the chief laryngeal functions, the voice. Patients rightfully expect from the laryngologist to be advised regarding all types of vocal disabilities. The modern laryngologist is therefore no longer satisfied with assuring a patient that the presenting hoarseness is not due to any serious disease. He does not limit himself to conscientiously excluding the possible need for cancer surgery. He wishes to advise his patients regarding the hygienic use of the voice and how to remedy, or prevent, those organic lesions which result from faulty use of the voice.

The practice of otolaryngology includes a fair portion of superficial psychotherapy. Allergy, Menière's disease, or contact ulcer of the larynx, are typical psychosomatic lesions which often respond favorably to the correction of emotional factors. Psychiatric and psychological practitioners are well aware that the voice is a reliable indicator of the emotions which often do not reach the level of conscious verbal expression. The great variety and frequent occurrence of purely psychogenical dysphonias vividly demonstrate the continuous need for paying attention to all vocal disabilities.

STRUCTURE, LESION AND FUNCTION

While there is no dispute regarding the justification of these general viewpoints, it was only in recent years that progressive research in laryngeal physiology has permitted the establishment of certain rules which govern the continuous interaction between structure and function of the larynx. Some of the older masters in laryngology had gained astounding empirical knowledge in the evaluation of laryngeal lesions with regard to the expected residual function. These bits of information remained isolated fragments, however, and did not compose a clear picture of the physical foundations of human vocal expression. This is one reason why the teaching of vocal pathology remained fragmentary for a long time, tinged by the personal convictions of each pioneering investigator.

Almost as many systems of voice pathology existed as books were written on the subject. Moreover, the various investigators of vocal physiology used classifications in accordance with their basic academic

orientation. Many of the previous attempts at nomenclature in the pathophysiology of the voice were directed by purely symptomatic or phenomenologic observations. The various vocal disabilities were classified chiefly by the abnormal sound of the voice, and not by considering the underlying pathology within the larynx or the entire body. These early attempts at labelling pathological voices by some resulting audible impression were about the same as if an audiologist proposed to classify the various types of hearing loss according to some arbitrary criterion, such as high tone versus low tone loss, hypoacousis with or without tinnitus, suddenly occurring or slowly progressive lesions, and the like.

Modern audiometry is based on the strict correlation between structure, recognizable lesion, and specific alteration of function. Modern laryngology aims at accomplishing the same task in the area of vocal function. It was felt by some of the earlier laryngologists that a vocal disability was of lesser concern while the patient's life and welfare were endangered by a dreaded disease, or some traumatic injury. The modern laryngologist pays due attention to the fact that after surviving a life-threatening affliction the patient usually must go back to work and to his social environment, he needs to speak. There is another parallel to recent developments in otologic surgery. Thanks to numerous technical advances, audiosurgery has made it possible to correct or improve certain types of deafness which previously were incurable. By applying acoustical laws to the indication and performance of operations intended for the improvement of laryngeal function, phonosurgery is now in a position to restore vocal function in some cases which previously had to be left alone.

PHYSICAL EVALUATION OF THE LARYNGEAL VOICE GENERATOR

Phonation is similar in physical principle to the production of sound in certain musical instruments, the wood winds and brass. In both instances, air is set into periodic vibration which becomes audible as a specific sound. At least four elements are distinguished in each sound source: activator, generator, resonator, and articulator.

The driving force is delivered by the *activator.* By this is meant the expiratory action of the lungs and their muscle system.

The expiratory airstream sets in motion a vibrating system, be it the lips pressed into the mouthpiece of a trumpet, an airstream trembling across the lip of a flute, the reed of a clarinet, or the vocal cords of the larynx. These vibrating systems are known as the *generator.*

The third portion of all these sound sources is termed *resonator,* or vocal tract in humans. The metallic horn of the trumpet, the wooden tube of a flute or clarinet, or the muscle-lined pharyngo-oral cavities of the mammalian voice organ all serve the same purpose, to shape the individual sound pattern through resonance and damping.

The parallel between musical instruments and the human voice organ goes even further when considering the fourth element in this composite system, the *articulator.* The oral cavity can be shaped into countless forms and graduated sizes by the movement of tongue, palate, lips, and jaw. Widening or constricting, lengthening or shortening the oral resonator, the organs of articulation produce the various vowels and other speech sounds that are graphically transcribed as letters. Touching the holes or valves on musical wind instruments, the player can shorten or lengthen the available resonator, producing the various tones, as prescribed by the printed or written notes on the sheet music.

Another analogy is important to the better understanding of vocal function. A fine musical instrument may be purchased for a given price. The value of this instrument alone, however, by no means determines the quality of performance with such an instrument. The technique and art of playing an instrument must be learned through painstaking study and practice. Exactly the same is true of the human vocal organ. A precious vocal organ, the so-called "singer's golden throat" may be inborn. Again, a superior vocal organ alone cannot guarantee success in the vocal arts. These must be acquired through long study and practice with a good teacher. A fine musical instrument may be quickly ruined in the hands of a clumsy or ignorant person. Likewise, the healthiest larynx can be irreparably damaged through faulty vocal habits. From these interactions between structure and performance results the influence of emotional factors on the voice.

ACOUSTIC EFFECTS OF LARYNGEAL LESIONS

Application of these physical principles to the evaluation of laryngeal function, and their correlation with clinical findings, led to certain rules agreed upon by many laryngologists who were interested in this aspect. The German Handbook of Otolaryngology contains a chapter by H. Marschik (1928) on traumatic lesions of the larynx. Numerous observations were cited therein which correlated specific laryngeal lesions with the ensuing impairment of function.

Based on these findings, the present author summarized his war-time experiences in 1948. Correct evaluation of vocal disability following laryngeal injury must be guided by physiological considerations. The study of vocal physiology has made sufficiently clear which types of laryngeal defects may be associated with a presenting vocal complaint. Following the observation of numerous cases of vocal cord injuries, the correlation between organic defects and reduced vocal function may be summarized in the following manner.

The state of the free vocal cord margin is of primary significance. Any irregularity of the vibrating cord margin causes incomplete glottal closure. Stroboscopic examination and high-speed films promptly demonstrate the cause of the ensuing hoarseness. Incomplete glottal closure increases the opening quotient of each vibratory phase. As a result, part of the phonatory air is not transformed into sound, but escapes as an audible, noisy air stream. This is called "wild air." The more marked the alterations of the free cordal margins are, the greater the roughness of the voice.

Next in importance is the site of the lesion. The closer an injury of the vocal cord is situated toward the anterior commissure, the greater the hoarseness will be. There is an inverse relationship between the danger of a cordal injury to life, and its result on the voice. Lesions of the anterior commissure are least dangerous to life, but they cause the severest vocal disorder. The same relationship is true of vocal nodules or polyps, and of the congenital or traumatic web formations as well. Vocal cord lesions over the anterior third of the glottis cause marked hoarseness. In contrast, the contact ulcer or granuloma of the vocal process often produces but little vocal disability. Poor results of intralaryngeal surgery tend to damage the voice to an increasing extent according to how far forward the scar or deficiency is situated. The explanation is purely physical, understood best with the model of a nutcracker.

Excavation of the vocal cords resulting from paralytic atrophy or traumatic deficiency causes the same vocal signs as found in laryngeal paralysis. There is breathiness, waste of air, loss of vocal intensity, and shortened phonation time. Deficiencies of greater width cause total aphonia. When the glottis assumes a permanently oval shape during phonation, such as from deficiency or atrophy of the vocalis muscle, a general tendency to use the falsetto voice results. In such cases the head voice sounds relatively good, or is the best preserved. Explanation of this phenomenon is based on the fact that the normal

larynx assumes the position of an oval glottis for the production of the physiological falsetto voice.

Deficient adduction of one or both cords, due to paralysis, muscular injury, as well as cicatricial or arthritic fixation of the arytenoids, causes marked degrees of dysphonia or aphonia. The phonic results of such injuries are the same as with recurrent nerve paralysis.

Granulating processes or their scarred results within the anterior commissure push the anterior vocal cord portions apart, causing great vocal disability for a purely mechanical reason. Just as a nutcracker is most efficient when the nut is inserted nearest to its anterior commissure, any space-occupying lesion of the larynx is the more deleterious to the voice the more anteriorly it is situated. Stroboscopy, preferably high speed photography, and even ordinary laryngoscopy demonstrate the mechanical cause of vocal disability in such cases. The cords appear to have great difficulty in beginning to vibrate. They soon lose their contact during glottal closure, and their movement pattern changes into vertical flopping. Following a few irregular periods of vibration, the cords cease to vibrate, and remain in a semi-adducted position. In contrast to the laryngoscopical picture of *transversus paresis* due to posterior glottal deficiency, the triangular gap of the glottis in cases of a space occupying lesion in the anterior commissure appears inverted, its base lying anteriorly.

Physical differences in the vibratory characteristics of both cords may be the cause of diplophonia. By this is meant the splitting of the voice into double tones. Such differences in the physical magnitudes of elasticity and mass may be caused by alterations of one cord with regard to its length, thickness, tension, vascularization, edematous swelling, or specific weight.

Changes in vocal cord length usually reduce the vocal range to a considerable degree, or they may cause total aphonia. Traumatic synechia of the anterior commissure is a typical lesion of this type. In most cases of shortened glottis due to traumatic web formation, the low chest voice is lost. A high-pitched and croaking speaking voice is typically heard, or the organic form of falsetto voice may be the result. In general, vocal pitch is raised in direct proportion to the shortening of the free vocal cord margins. In other cases of partly obstructed glottis, the vocal range may be reduced to a few excessively low tones. This is explained from the physical viewpoint by the flaccidity and plump thickening of the scarred vocal cords, which apparently can no longer be tensed.

Lowering of the speaking voice is the typical sign of any vocal cord injury. The thicker, plumper, and more flaccid the cords become, the lower will be the speaking voice. The same is true for scar bands which usually grow in place of lost vocal cords. After the initial stage of total aphonia has disappeared spontaneously, a very low voice of very limited range is the first sign of compensation. Some of the patients observed in this stage of laryngeal healing possessed only a few tones with a pitch around 65 to 70 cps, very much below the normal male speaking range and similar to the pitch of esophageal phonation. The mid and head voice are totally absent in such cases.

When a granulating swelling or scarred thickening of the ventricular folds obscure the vocal cords, thus damping their free vibratory ability, a dulled, muffled voice without resonance is heard. In view of the physical cause of this deficiency this peculiar timbre of the voice may be described as "dampened." Following surgical removal of the hypertrophic ventricular folds, the voice becomes clear immediately, provided that no other cause of hoarseness is present.

The same laryngeal trauma may occasionally cause the combination of direct injury of one vocal cord with unilateral laryngeal paralysis on the other side. Total aphonia is the usual result because the glottis cannot be closed for phonation.

PHYSICAL INTERPRETATION OF BENIGN LARYNGEAL LESIONS

Morphology and histology of vocal nodules and polyps were discussed in a previous paper,[4] emphasizing that these benign lesions represent inflammatory tissue reactions to vocal cord trauma from habitual abuse of the voice. With rather rigid unanimity, nodules and polyps are said to be found typically at the "junction of the anterior and middle third" of the cord. Only a few authors[10,29,32,35] have noted that the site of predilection is the midportion of the vibrating cord. This peculiar preference of the nodes to grow at that specific point has been explained in various ways. Most commonly, reference has been made to a node of vibration that had allegedly been observed stroboscopically by the earlier phoniatrists. In acoustics, a vibrational node means the point of rest in transversal and longitudinal sine waves. It is now common knowledge that the cords do not vibrate like strings. Therefore, they cannot produce a sinusoidal waveform with alternating maximal and minimal excursion in a pure lateral direction. Vocal cord vibration follows the principle of an oscillating

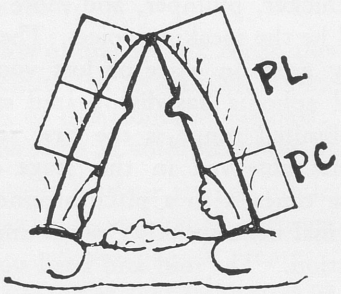

Fig. 1.—Typical sites of three benign laryngeal lesions. Vocal nodules or polyps develop in the middle of the vibrating membranous cord (PL) where the vibratory amplitude is greatest. Contact ulcer and granuloma are found on the vocal process of the cartilagenous cord (PC) where the hammering effect of excessive glottal closure occurs. Pachydermia of the posterior commissure results from chronic infection or physical irritation.

sphincter with the combined vibratory directions of "up-out" and the return "down-in." Modern high-speed motion pictures show this pattern of vibration very clearly.[31,34]

The puzzle of the "vocal cord thirds" may be solved by recalling the structure of the cord, as advocated in this author's lectures for many years.[5] Each cord consists of a membranous (or muscular) portion which occupies the anterior two-thirds. The posterior third of the cord is made up of the cartilagenous portion, or the vocal process. Only the membranous portion of the cord can vibrate to a significant degree. The cartilagenous portion serves for the approximation of the posterior cordal attachments and stabilization of the nonvibratory parts of the larynx. When this posterior closure is grossly deficient, such as in psychogenic paresis of the interarytenoid muscles, a great deal of air is wasted during phonation and breathy hoarseness is heard.

Figure 1 is a schematic drawing of the typical locations of several benign laryngeal lesions. Vocal nodules and polyps usually occur at the midpoint of the vibrating ligamentous cord. At this point the vocal cord vibrations have the widest amplitude, and the mechanical impact between the two vibrating cords is greatest. This is the same as saying that the midpoint is at the "junction of the two anterior thirds" of the entire cord length, including the nonvibrating posterior cartilagenous third.

Similar mechanical viewpoints explain the typical seat of the contact ulcer, and the opposite granuloma, over the medial surface of the cartilagenous vocal processes. It is at this point that the two arytenoids clash together during forceful adduction. Effortful glottal closure occurs in violent coughing, screaming, or in the hard attack of glottal stop, as in the Germanic languages. To be sure, contact ulcer is not caused by sharp vocal cord adduction alone. Most people in Northern Germany speak with hard glottal stops, yet contact ulcer is rare there. Contact ulcer is a psychosomatic disease resulting from emotional tension. The subsequent sympathotonic ischemia of the laryngeal mucosa forms the organic basis on which the hammering effect of the vocal processes may cause the ulcer. In fact, the etiology of contact ulcer of the larynx is similar to that of peptic ulcer of the stomach: neurogenic vasoconstriction is followed by physical, or chemical, ulceration of the blanched mucosa.

A mechanical factor of a different kind is responsible for the third site of predilection of certain lesions in the posterior commissure. Apart from tuberculous granuloma of hematogenous origin, the benign lesion known as laryngeal pachydermia occurs here as a sign of advanced chronic hypertrophic laryngitis. The reasons for this development are readily found when examining cases of acute purulent sinusitis. Pus flowing down from the nasopharynx is seen spilling over the posterior commissure into the larynx. When secretions reach the posterior aspect of the inner larynx, the cough reflex is elicited. Bronchial secretions are likewise coughed up to this area before they are expelled further. Moreover, the irritative substances of inhaled cigarette smoke pass chiefly over the posterior commissure which is thus exposed to many noxious irritations. Care of this area remains entirely within the responsibility of the laryngologist, for its lesions are independent of vocal function.

FALSETTO VOICE OF FUNCTIONAL ORIGIN

Among the earliest observations in vocal physiology was the fact that an oval shape of the glottis and the sound of the male falsetto voice are reciprocally correlated. Production of the normal falsetto voice requires that the glottis remain open with a spindle-shaped slit. Conversely, when the glottis cannot be completely closed and remains permanently oval, phonation favors the falsetto voice which may be relatively clearest, or the only pitch range available in such cases. It follows that the falsetto voice occurs in several forms: the physiolog-

ical falsetto register of the normal male; the mutational falsetto voice in adolescent boys; psychogenical falsetto voice as a hysterical conversion symptom; paralytic falsetto voice in laryngeal hemiparalysis; traumatic falsetto voice associated with excavating lesions of the cords; and dysplastic falsetto voice as a mechanical result of a bowing glottis in cases of congenital vocal cord sulcus.

The mutational falsetto voice is characterized by the continued habitual use of the falsetto voice for speaking. Since the falsetto, or false soprano voice, does not exist in the female, the mutational falsetto voice occurs only in males. In essence, the existence of the mutational falsetto voice represents a functional avoidance of vocal mutation despite the normal growth of the larynx and the potential presence of a normal adult male voice.

One of the first attempts at physiological clarification in scientific voice pathology was the explanation of the mechanism producing the falsetto voice in organically normal males.[17] H. Gutzmann Sr. explained the formal genesis of mutational falsetto voice by functional overcontraction of the cricothyroid muscle. It has been established through myographic studies of cricothyroid muscle function[3] that the external vocal cord tensor is the muscle chiefly responsible for the production of the falsetto register. Similar considerations were followed by T. Flatau[13] in 1899, when he suggested the term "persisting falsetto voice" to differentiate this condition from the voice of the castrato and the eunuchoid voice. In 1899 H. G. Makuen[24] observed that boys who spoke in a habitual falsetto voice demonstrated a pronounced elevation of the entire larynx during phonation. This second sign of faulty laryngeal co-ordination with hyperkinetic overaction of the laryngeal elevators has been stressed by several other authors.

J. S. Greene[16] devoted much thought to the causal genesis of mutational falsetto voice, and pointed out the psychosomatic peculiarity encountered in many cases of this disorder. A large percentage of adolescent boys suffering from mutational falsetto voice are of the asthenic or dysplastic body type. Greene also emphasized the insecure, shy, and infantilistic attitude exhibited by many of these boys. Characteristically, they are led into the examination room by their mothers. During psychological testing it is often revealed that these over-protected boys show a stronger attachment to the mother than is usual. According to the psychosomatic theory advanced by F. Hogewind[18] since 1938, the avoidance of natural vocal mutation and the unconscious fixation of the falsetto register, which resembles

the earlier infantile soprano voice, is interpreted as a neurotic tendency to remain a child. Disturbed by sexual conflict, and unprepared to face the male role in life, these over-protected adolescent boys shun the assumption of male responsibility by delaying the vocal signs of their male maturation.

The first presentation of the patient is rather typical. Not only young boys, but fully grown men over 20 years of age as well, are accompanied by their mothers while the father is usually absent. Physical examination shows normal sexual development. Although physically tall, many of these adolescent boys appear rather youthful in facial expression and dressing habits. An impression of infantilism, both physically and from psychological test results, is often conspicuous. Minor signs of constitutional dysplasia, such as scant facial hair growth or asthenic body structure, may be present. Otolaryngological examination shows normal findings, including normal size, structure, and function of the larynx. A certain hyperemia or congestion of the vocal cords, however, is often seen. These signs of laryngeal irritation are not the cause, but the result of habitual use of the falsetto voice. In most cases, laryngeal structure suggests the potential presence of a baritone voice. Characteristically, the glottis assumes an oval shape during phonation with falsetto voice, or the posterior half of the glottis may close incompletely. The latter sign, known as mutation triangle, is a typical phenomenon of a maturing larynx in both sexes.

Treatment is purely re-educational. Excessive contraction of the cricothyroid muscle is counteracted by pressing the thyroid cartilage inward. At the same time, the entire larynx is held down with the compressing finger. A low baritone voice emerges almost automatically in this manner. Persuasive voice exercises serve to firmly establish the new habit of speaking in a physiologic manner.

FALSETTO VOICE OF CONGENITAL ORIGIN

Vocal experts have been puzzled for a long time by a rarely recognized condition of purely congenital origin, dysplastic dysphonia caused by hypoplasia of the vocalis muscles. In addition to the clearly visible bowing of the phonating glottis, a vocal cord sulcus is present in many of these cases. Application of the recent advances in vocal physiology made it possible to diagnose and treat these cases with better results.

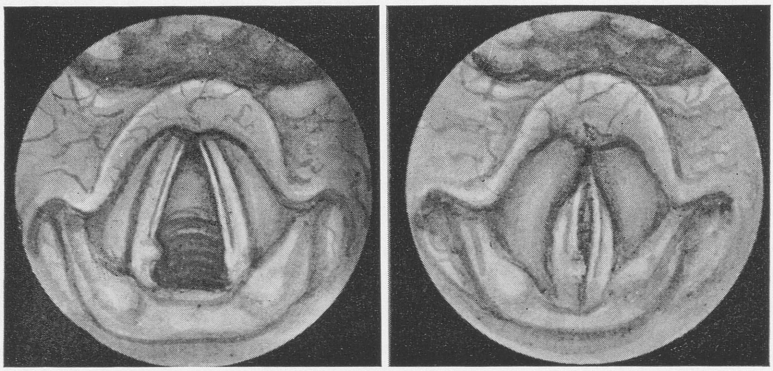

Fig. 2.—Congenital vocal cord sulcus on both cord margins associated with bowing glottis from vocalis muscle hypoplasia. Note compensatory hyperkinesis of ventricular folds with phonation. Secondary contact ulcer and opposite granuloma.

The congenital vocal cord sulcus is a fine longitudinal furrow on the medial edge of the vocal cord (Fig. 2). It may extend along the entire length of the cord, or it may be limited to a segment of variable length. Its depth is also variable, and may range from a faint line to a deep partition of the cord. In the latter case, it divides the cord into two portions, an upper or lateral lip, and a lower or medial lip. This is known as a double vocal cord. There may even be an accessory ventricle behind a very deep sulcus. The sulcus may be unilateral, bilateral, or more noticeable on one side. It is frequently associated with other laryngeal or oral asymmetries as shown in a previous publication.[2] The congenital condition of vocal cord sulcus is rare as far as the general population is concerned. In a specialized voice clinic, however, this anomaly may be seen quite frequently, with an estimated incidence of about one in 1000 cases of voice and speech disorders.

The first observation of a sulcus in a patient was made by E. Lautenschlaeger[23] in 1912. He also recognized that the hoarseness was due to the incomplete closure of the glottis. He suggested therefore that the glottal insufficiency be corrected through the intralaryngeal injection of paraffin, according to the original Bruenings method. In Oertel's[30] case observed in 1912, an acute inflammation and swelling of the vocal cords temporarily improved the hoarseness. This astute observation demonstrated again that the dysphonia in a case of vocal

cord sulcus is due primarily to the bowing glottis. Questioning many patients regarding this symptom, this author ascertained that any acute swelling of the vocal cords compensates temporarily for the glottal insufficiency. Thus, the voice appears markedly improved during an attack of acute laryngitis.

In 1928 W. Berger[11] published the first phoniatric and stroboscopic analysis of congenital dysplastic dysphonia due to vocal cord sulcus, or double vocal cords. He, too, considered the incomplete closure of the glottis to be the chief cause of hoarseness. Further cases were subsequently described by van Caneghem,[36] Kelemen,[20] Fornai,[14] and Tarneaud.[33] In a discussion of four additional cases in 1952, Delaini and De Stefani[12] observed interesting stroboscopic findings. In one case the upper vocal cord portion above the sulcus showed irregular vibrations, while the lower portion of the cord beneath the sulcus did not appear to vibrate at all. Two sisters of this patient's father were found to have the same laryngeal anomaly with chronic dysphonia, suggesting a hereditary tendency.

The investigators who have written on this problem in recent years agree with the original discoverers: the vocal cord sulcus is a congenital malformation. Jackson and Jackson,[19] who saw four cases of supernumerary cords, interpreted this condition as a malformation of atavistic origin. Many authors have referred to the normal presence of the sulcus in various animals, ascribing a regressive significance to its occurrence in man.[12,21,26,33] According to Némai,[28] double cords which are divided by a sulcus are to be found in many species: deer, giraffe, antelope, swine, gibbon, etc. These accessory cords are most notable in the primates. Kelemen[22] stated that duplication of the vocal cords is particularly prominent in the chimpanzee larynx. He believes that the accessory cords are partly responsible for the double tones frequently heard in the voice of the chimpanzee.

When listening to the voice in a case of dysplastic dysphonia, one is impressed by a peculiar hollow and unpleasant quality. It is difficult to describe this type of hoarseness in words, but it reminds one of the sound made by a broken pot. It is as if the two cords were out of tune. The hoarseness due to vocal cord sulcus is so typical that experienced voice therapists are frequently able to make a tentative diagnosis of vocal cord sulcus after having heard the voices in a few such cases. Analysis of the various vocal qualities presents the following general description. There is a breathy quality due to the excessive escape of air between the bowing cords. As a result, phonation time

is short, and vocal volume is weak. The average speaking pitch is often too high, apparently because the high tones are usually clearer. This is due to the bowing glottis, which is physiologic for the male falsetto tones and, thus, does not affect the high tones as much as the low tones. Moreover, the patients tend to abuse their weak voices by faulty attempts at compensation. Instead of exploiting all reserves of projection and resonance, they try to overcome their disability by increased muscular effort. These faulty expiratory and phonic movements lead to various parakinesias: overcontraction of the ventricular folds; phonatory elevation of the larynx; overcontraction of the external strap muscles; or constriction of the supraglottic vocal tract. Habitual hyperkinetic disorders are thus superimposed on the congenital hypokinesis of the vocal cords, producing various combinations of vocal dysfunction (Fig. 2).

INDICATIONS OF PHONOSURGERY

The interrelation between structural changes within the larynx, and the resulting limitation of vocal function is now fairly well understood. It can be predicted with considerable certainty what type and degree of dysphonia may be expected as a direct physical consequence of a demonstrable lesion of the vocal generator. This is the optimum of vocal ability that should potentially be present with a given laryngeal defect. Many persons achieve this potential optimum through perfect compensation. They make the best of their residual structures, using them in a physiologically correct manner. The factors promoting intralaryngeal compensation include the following: young age; good health; emotional stability; determined motivation; and good auditory discrimination, the "musical ear."

The audiogram reflects the optimal pure tone threshold in a given individual. Global hearing, and speech discrimination in particular, may be less good than the pure tone thresholds indicate. Numerous reasons are known which cause such discrepancies, e.g., recruitment, diminished central discrimination ability, or lesions of the nerve trunk.

Analogous central factors of auditory ability, personality structure, or total neuromuscular function influence the laryngeal efficiency as well. For this reason, certain individuals use their voices much less efficiently than may be expected from the appearance of their vocal organs. They suffer from functional vocal disabilities, the various dysphonias of habitual or psychogenic origin. The organic dysphonia is then complicated by a functional overlay in such cases,

a portion of the vocal disability being caused by other than mechanical laryngeal factors. The prerequisites of good compensation are absent in these persons. It is a task of expert vocal analysis to differentiate the components of a given vocal impairment.

These considerations are indispensable to the reliable indication and prognosis of phonosurgical procedures for the improvement of vocal function. It was described in recent papers[4-9] how the present knowledge in vocal physiology may be used for the precise indication and contraindication of phonosurgical interventions. At the present time, the teflon injection procedure is sufficiently advanced to permit reasonably accurate predictions. Its chief objectives are as follows:

1) to increase the bulk of a deficient cord, such as in congenital hypoplasia;
2) to close a bowing deficiency of the glottis, e.g. in laryngeal paralysis;
3) to fill a circumscribed cicatricial defect, for example, following excision of a localized lesion;
4) to shift a permanently abducted cord from the unfavorable lateral position to the midline;
5) to rebuild a deficient band of scar tissue following chordectomy with the aim of creating sufficient glottal closure;
6) to increase the size and stiffness of a weak cord, as if it were to "tune the cord"; and
7) to reduce an excessive glottal width following over-generous laterofixation as suggested by Goff.[15]

SUMMARY

An attempt is made to utilize advanced knowledge in laryngeal physiology for clinical application. Similar to clinical audiology, phonologic research is now in a position to guide the laryngologist in the surgical rehabilitation of certain vocal invalids. Physical effects of laryngeal lesions are reviewed. The mechanical cause of vocal nodules determines their seat of predilection, in the center of the vibrating cord. The influence of a bowing glottis on vocal sound is studied with the model of the mutational (or habitual) falsetto voice. Congenital bowing of the glottis is the chief cause of dysplastic dysphonia, such as in the presence of a vocal cord sulcus. Finally, the

indications for phonosurgical procedures are defined and compared with the physiologic facts governing vocal cord vibration.

2500 N. State St.

REFERENCES

1. Arnold, G. E.: Die traumatischen und konstitutionellen Störungen der Stimme und Sprache. Wien: Urban and Schwarzenberg, 1948.

2. Arnold, G. E.: Dysplastic Dysphonia: Minor Anomalies of the Vocal Cords Causing Persistent Hoarseness. Laryngoscope 68:142, 1958.

3. Arnold, G. E.: Physiology and Pathology of the Cricothyroid Muscle. Laryngoscope 71:687, 1961.

4. Arnold, G. E.: Vocal Nodules and Polyps: Laryngeal Tissue Reaction to Habitual Hyperkinetic Dysphonia. J. Speech Hearing Dis. 27:205, 1962.

5. Arnold, G. E.: Voice Problems and Laryngeal Pathology. Symposium and panel discussion (J. F. Daly, Mod.), Annual Convention, Medical Society of State of New York, May 14, 1962. N. Y. State J. Med. 63:3096, 1963.

6. Arnold, G. E.: Vocal Rehabilitation of Paralytic Dysphonia: X. Functional Results of Intrachordal Injection. Arch. Otolaryngol. 78:179, 1963.

7. Arnold, G. E.: Alleviation of Aphonia and Dysphonia Through Intrachordal Injection of Teflon Paste. Annals of Otology, Rhinology and Laryngology 72:384, 1963.

8. Arnold, G. E.: Paralytic Dysphonia: Methods of Vocal Rehabilitation. EENT Monthly 43:27, 1964.

9. Arnold, G. E.: Further Experiences with Intrachordal Teflon Injection. Laryngoscope. In press.

10. Bajkay, T. von: Über die Pathogenese und Therapie der Stimmbandknötchen. Monatschr. Ohrenheilk. 68:325-332, 1934.

11. Berger, W.: Beitrag zur Frage der doppelten Stimmlippen. Z. Hals- usw. Heilk. 19:426, 1928.

12. Delaini, A., and De Stefani, G. B.: Lo s'doppiamento delle corde vocali. Atti Lab. Fonet. Univ. Padova, 2:105, 1952.

13. Flatau, T. S.: Ueber die persistierende Fistelstimme mit Bemerkungen über die stimmärztliche Anwendung des Phonographen. Berlin. klin. Wschr. 36:15, 1899.

14. Fornai, Due casi di solco glottideo. Otorinolaringol. Italiana 230, 1936.

15. Goff, W. F.: Laryngeal Adductor Paralysis Treated by Vocal Cord Injection of Bone Paste: A Preliminary Investigation. Trans. Pacif. Coast Oto-ophthalm. Soc. 41:77, 1960.

16. Greene, J. S.: Dysphemia and Dysphonia: Cardinal Features of Three Types of Functional Syndromes: Stuttering, Aphonia and Falsetto (Male). Arch. Otolaryng. 26:74, 1937.

17. Gutzmann, H.: Über die persistierende Fistelstimme. Berlin. klin. Wschr. 45, 1908.

18. Hogewind, F.: Zur Ätiologie und Therapie der sogenannten persistierenden Fistelstimme. Arch. Sprach- und Stimmheilk. 5:34, 1941.

19. Jackson, C., and Jackson, C. L.: Diseases and Injuries of the Larynx. Macmillan, New York, 1942.

20. Kelemen, G.: Sulcus glottideus (Citelli) bilateralis. Z. Hals- usw. Heilk. 22:475, 1929.

21. Kelemen, G.: Vergleichende Anatomie und Physiologie der Stimmorgane. Archiv. Sprach- und Stimm-Heilk. 3:213, 1939.

22. Kelemen, G.: Structure and Performance in Animal Language. A.M.A. Arch. Otolaryngol. 50:740, 1949.

23. Lautenschläger, E.: Ein Fall von Doppelbildung der Stimmbänder. Archiv. Laryngol. 26:706, 1912.

24. Makuen, G. H.: Falsetto Voice in the Male. Report of Five Cases. J. Amer. Med. Assn. 32:474, 1899.

25. Marschik, H.: Verletzungen des Kehlkopfes, der Luftröhre und der Bronchien. Handbuch der Hals-, Nasen-, Ohrenheilkunde von Denker und Kahler (edit.), Vol. 3:540, 1928.

26. Némai, J.: Vergleichend-anatomische Studien am Kehlkopfe der Säugetiere. Archiv. Laryngol. 26:3, 1912.

27. Némai, J.: Menschen- und Tierstimme in ihrem Verhältnis zum anatomischen Bau des Kehlkopfes. Archiv. Laryngol. 27:3, 1913.

28. Némai, J.: Das Stimmorgan des Hylobates. Z. Anatom. und Entwickl. 81: 673, 1926.

29. New, G. B., and Erich, J. B.: Benign Tumors of the Larynx: A Study of 722 Cases. Arch. Otolaryng. 28:841-910, 1938.

30. Oertel: Missbildungen des Larynx und der Trachea. Z. Laryngol. 4:125, 1911-12.

31. Rubin, H. J., Hirt, C. C., and Le Cover, M.: The Falsetto: A High Speed Cinematographic Study. Laryngoscope 70:1305, 1960.

32. Rubin, H. J., and Lehrhoff, J.: Pathogenesis and Treatment of Vocal Nodules. J. Speech Hearing Dis. 27:150, 1962.

33. Tarneaud, J.: Laryngite Chronique et Laryngopathies. Maloine, Paris, 1944.

34. Timcke, R., von Leden, H., and Moore, P.: Laryngeal Vibrations: Measurements of the Glottic Wave. Arch. Otolaryng. 68:1, 1958.

35. Vaheri, E.: Zur Klinik und Pathogenese der Stimmlippenpolypen. Acta Otolaryng. 29:273-286, 1941.

36. Van Caneghem: L'étiologie de la corde vocale à sillon. Annales d'Otolaryngol. 47 (Feb.) 1928

DISCUSSION

DR. HENRY J. RUBIN: In drawing specific analogy between recent advances in clinical audiology and otosurgery on the one hand and phonologic research and phonosurgery on the other, Doctor Arnold has modestly refrained from calling attention to what is perhaps the most apt analogy of all—the renascence of stapes surgery for otosclerosis and the injection of synthetics for dysphonia due to unilat-

eral recurrent nerve paralysis. In both cases, after initial success, the procedures were abandoned and then resumed some fifty years later in a technical climate more suited to their survival.

Doctor Arnold is primarily responsible for reviving the injection technique. His assiduous efforts over many years to discover a material which, when injected into vocal cords, combines a maximum of tissue tolerance and safety with a minimum of reaction and absorbability and his demonstration that powdered teflon meets these requirements and is clinically applicable represent a major contribution to laryngology. Personal experience, recently reported, affirms the effectiveness of teflon in the treatment of dysphonia due to unilateral recurrent nerve palsy. Another inert plastic, silicone, was also utilized and, while immediate results were equally good, absorption occurred within three to four months, and the voice returned to its former state, necessitating subsequent injection of teflon.

As Doctor Arnold emphasized, the use of teflon may be extended to a variety of conditions in which dysphonia is produced by defective glottal closure. I call particular attention to myasthenia laryngis in which presenile and senile atrophy of the vocal musculature effects a decrease in cordal mass which may be reconstituted by intracordal injection. In these cases the greatest caution must be exercised or what was only a weak voice becomes a hoarse one as well. It is probably desirable in these patients to inject silicone first to "preview" the voice and then, if satisfactory, follow in several months with teflon.

Although the injection of synthetics reduces somewhat the number of dysphonias in which vocal rehabilitative measures alone are available, many vocal aberrations will continue to depend for their correction solely upon classical orthophonic techniques. It is to be hoped that modern research methods, as exemplified by Doctor Arnold's use of electromyography in investigating the action of the cricothyroid muscle, will eventually establish so-called voice therapy on more than empirical footing.

While Doctor Arnold rightly deplores the duality of laryngeal orientation—that is, surgical as opposed to phonologic—this dichotomy will probably continue. It can be minimized, however, by increased exposure at the resident training level to phonologic problems and their management and by closer liaison with non-medical speech and voice clinicians.

Doctor Arnold's lucid review of recent advances in our knowledge of laryngeal physiology has a double pertinence and interest because of the many fine contributions which he has personally made to their clinical application, and it is a privilege for me to discuss his paper.

DR. JOEL J. PRESSMAN: I would like to ask Dr. Arnold, and Dr. Rubin too, a question. Have they noted any intimate relationship between occurrence of vocal nodes and the pitch of the voice of those so affected. If they would agree that these nodes are more apt to occur in patients with high-pitched voices, then I would like to advance a concept in the etiology of these nodes.

Now, if we accept the concept that the occurrence of vocal nodes is more apt to occur in those with high-pitched voices, then we can envision a situation in which the vocal cords of a given subject have reached their maximum of stretching and the subject begins to invoke the principle of the damping mechanism. In this there is a functional foreshortening of the vocal cords as the posterior segment of one comes into apposition with a corresponding length of its fellow creating a shorter segment of cord free to vibrate.

If this represents the maximum degree of stretching which a vocal cord can undergo, then the next step of raising the tone would be an approximation of a

segment of one cord to the other, so that only this part (the anterior non-approximated segment) is free to vibrate. Just as one fingers a violin keyboard and shortens the vibrating length of the strings to raise the pitch, so will this physiological foreshortening of the vocal cord by the damping mechanism give a higher tone.

In so far as the relationship of pitch levels to vocal nodes is concerned, a very interesting and informative fact that was brought out by the essayist, is the anatomical position of the node relative to the length of the vocal cord.

This corresponds to the anatomical tip of the vocal process. In the damping mechanism the posterior segment of cord damped by its fellow houses the cartilaginous vocal process covered only by a thin layer of mucosa. Is it possible that the trauma of the tip of the vocal process in forceful apposition to that of the opposite cord while the latter are under the great tension required for the production of high tones, results in the formation of nodes at this point of maximum irritation?

If my concept of vocal nodes being more frequent in the higher pitched voices than the low does not hold true, then I withdraw this concept of possible origin of nodes.

DR. ARNOLD (closing): It happened to me the second time that the discussant's remarks and his excellent slides were definitely more impressive, judged from the amount of applause, than the original presentation. I am grateful for this recurrence and I thank Dr. Rubin for his kind words.

I am also grateful to Dr. Pressman for refreshing my memory on the concept he proposed. Of course, I am familiar with it and it has been duly acknowledged in some other writings. Indeed, vocal nodules are definitely more frequent in the high voices, tenor and soprano. If we talk about nodules laryngologically, considering all cases including the screaming children, the incidence of nodules would be more equally distributed. The greater frequency of nodules in professional singers with high voices agrees with Dr. Pressman's concept of the damping factor.

I would like to conclude with a statement which I think is necessary in view of the many inquiries I have received:

The present clinical success of the teflon injection procedure is somewhat marred by certain technical difficulties, that is, the difficulties in obtaining the necessary instruments and the sterile teflon paste. It needs no emphasis that those surgeons who presently perform the injection procedure have no influence whatever on the commercial availability of the technical utensils and we are ourselves much handicapped by the slow delivery of the needed items.

The regulation of new drugs by the Food & Drug Administration is very stringent. Unfortunately teflon is considered a drug when injected through a needle into the larynx, while it is a device, a prosthesis, when inserted with a forceps into the middle ear. It is hoped that the continued interest in this procedure will soon induce the Federal authorities to release the teflon paste for more general distribution.

CHAIRMAN HOLINGER: We appreciate your statement telling us what the problem is in regard to the procurement of teflon, because, of course, all of us are so vitally interested in this problem at the moment.

PHARYNGEAL IMPLANTS FOR REDUCTION OF AIR SPACE IN VELOPHARYNGEAL INSUFFICIENCY

I. AN EXPERIMENTAL STUDY

PAUL H. WARD, M.D.
(by invitation)
AND
JOSEPH M. WEPMAN, PH.D.
(by invitation)
CHICAGO, ILL.

Reasonable competency of velopharyngeal closure of the nasal cavity from the oropharynx is an essential mechanism in the production of normal speech and in swallowing. Separation of the nasopharynx from the oropharynx is accomplished by rather complex palatal and pharyngeal movements. The soft palate moves upward and backward as a result of contraction of the palatine levator muscles while the pharynx is narrowed and the posterior pharyngeal wall moved somewhat anteriorly by contraction of the palatal fasciculi of the superior constrictor muscle.

Speech efforts by patients with imperfect velopharyngeal closure are characterized by excess nasal emission of air with its concomitant hypernasality and inadequate oral air stream. As a result both the quality of the voice and the accuracy of articulation are often seriously affected.

Children and adults with unoperated or poorly repaired cleft palates once made up the largest group of patients with velopharyngeal insufficiency. The advances in techniques of cleft palate surgery have reduced the number of such cases materially. Primary closure of cleft palate defects, by various staphylorrhaphy, uranoplasty, or pharyngeal flap procedures, has been successful in a very high percentage of cases.[1-3] In spite of excellent surgery and good primary healing with palatal approximation, air leak, hypernasality and imperfect speech persisted however, in an estimated 20 to 40 per cent of patients.[4,5] Other etiological factors responsible for velopharyngeal

insufficiency included, congenital shortness of the palate, excessive depth in pharyngeal vault, paresis or muscle palsy of the palate, scarring or incomplete cleft palate repair, and adenoidectomy in patients with unrecognized submucous cleft palates.[6-8] These patients have presented a formidable challenge to surgeons, prosthodontist, speech pathologists and others in their search for methods of correcting such defects and their natural consequences in speech and voice.

The ingeniously fashioned obturators created by the prosthodontist have yielded varying degrees of success in the elimination of air leak. One of the main disadvantages of obturators has been the interference with eustachian tube function with resulting hearing loss. A few patients, with the aid of instructions from the speech pathologist have learned to effect closure by rather unusual muscular gymnastics. The efforts of surgeons generally have been directed toward the development of operations designed to lengthen or move the soft palate posteriorly.[9-13] Recently pharyngoplasty, using superiorly or inferiorly based posterior pharyngeal wall flaps has received renewed attention.[14-16]

Passavant[17] initiated the concept of the posterior pharyngeal ridge (which now bears his name) as being an important functioning structure in velopharyngeal closure. He developed several operations for correction of palatal insufficiency based on the importance of this inconsistently appearing structure. In one of the operations he recommended suture of the velum to the posterior pharyngeal wall and in another he advocated attaching the velum to a shelf like flap created on the posterior pharyngeal wall.

Additional information on the physiology of palatal and pharyngeal movements required modification of Passavant's conception of the posterior pharyngeal wall as a dynamic participant in velopharyngeal closure.[18] However, the fact remains that the velum must approximate the posterior pharyngeal wall to prevent leakage of air during speech. Additional methods of moving the posterior pharyngeal wall forward were the injection or implantation of substances in the submucosal and retropharyngeal areas. The injection of paraffin initially appeared to offer promise.[19-22] With passage of time reports of complications such as displacement of the paraffin into the mediastinum, mediastinitis, embolism and the formation of paraffinomas, caused the use of this substance to fall into ill repute.[23] Even so its use and reports of speech improvement following paraffin injections, persisted as recently as 1927.[24] The implantation of cartilage and

fascia[25] were for a time considered very effective in the creation of an artificial ridge but the results were unpredictable and often transitory because of reabsorption.

Recently Blocksma[26] reported the use of silicone rubber as an implant in 23 cases. Solid, shredded and sponge forms were implanted into a surgically created pocket in the posterior pharyngeal wall or a vulcanizing liquid form was injected through a small stab wound. Tissue tolerance was reported to be excellent. The speech results were rated; 4 excellent, 13 good, 4 fair and 2 poor with no improvement. Since his initial report Blocksma[27] has abandoned the injection technique in favor of a soft solid silicone implant to which a Dacron felt was applied to the posterior surface for the purpose of maintaining position and fixation.

The various surgical procedures, prosthetic obturators and speech corrective efforts have been valuable contributions towards correction of velopharyngeal incompetency. Because of the simplicity and the success (although temporary) of bringing the posterior wall forward when cartilage implants were used, we were stimulated to initiate a search for a permanent injectable implant for this area. Tantalum and teflon in powder form both appeared to offer promise for this purpose. They are inert materials and have been employed successfully as implanted prosthesis by the orthopedic and vascular surgeons for many years. The injection of tantalum and teflon suspensions into unilaterally paralyzed vocal cords as described by Arnold[28-29] and Lewy[30] has received wide acceptance. The tolerance of these substances by the laryngeal tissues was excellent. Tantalum and teflon both appeared to possess the properties of an ideal injectable implant as were enumerated by Arnold,[29] that is: 1) good tissue toleration; 2) must not be reabsorbed in time; and 3) must be finely dispersed in a harmless vehicle in order to be injectible through a needle. Although these substances have been used successfully in animal and human tissues recollection of the failure and even disaster that followed retropharyngeal implantation of paraffin, made it seem imperative that these substances be tested in the posterior pharyngeal walls of animals prior to their attempted use in humans.

METHOD

These experiments were performed on 16 healthy adult cats, which were divided into 4 groups based on the substance injected.

The two larger groups consisted of 12 cats (6 in each group) which received injections of teflon or tantalum (50% by weight suspended in glycerine), into their posterior pharyngeal walls. The remaining 4 cats formed the normal and glycerine control groups and either were not injected or received an injection of glycerine alone.

Initially the cats were anesthetized with sodium pentobarbitol (40 mg/kg of body weight) given intraperitoneally. In the supine position the mouth was held open with a self-retaining gag. Using an electrocautery knife a large V-shaped wedge of the palate, which included the uvula, was resected. The incisions extended from the upper margins of the palatine arches medially to the midline junction of the soft and hard palate. This created a soft palate cleft which was closed by a simple staphylorrhaphy after the injection of the posterior pharyngeal wall. Because of the particularly long palate in cats the clefts were created to facilitate the injection. The resection and subsequent repair also shortened the palate producing an anatomical situation simulating the velopharyngeal insufficiency following cleft palate repair and the submucous clefts found in some humans.

A special syringe designed by Lewy, or a plastic syringe equipped with a curved 15 to 18 gauge needle (Fig. 1), was used to inject one to three cc of teflon or tantalum suspension. Efforts were made to confine the injected materials to the submucosa overlying the region of the junction of the base of the skull to the atlas. Following creation of an adequate ridge in this area, the palatal cleft was closed or where the cleft had been created at a previous operation the edges were freshened and the defect closed by a simple two layer staphylorrhaphy. The animals were given 600,000 units of long acting penicillin intramuscularly after operation and on the third or fourth postoperative day.

Posterior-anterior and lateral x-rays of the head and neck were taken six to twelve weeks after the injections. The physical properties, chemical composition, and methods of sterilizing teflon and tantalum have been described in the literature.[28,29] The first four cats received a teflon suspension with the particle size varying from six to twelve microns. Because of the possibility of passage into the lymphatics the particle size was increased to 50 to 100 microns.

At intervals of four, five and six months after injection the cats were anesthetized, intravitally infused with 10% formalin, decapitated and the specimens placed in 10% formalin. After fixation the head and neck of each cat was divided in a sagittal plane (using an electric

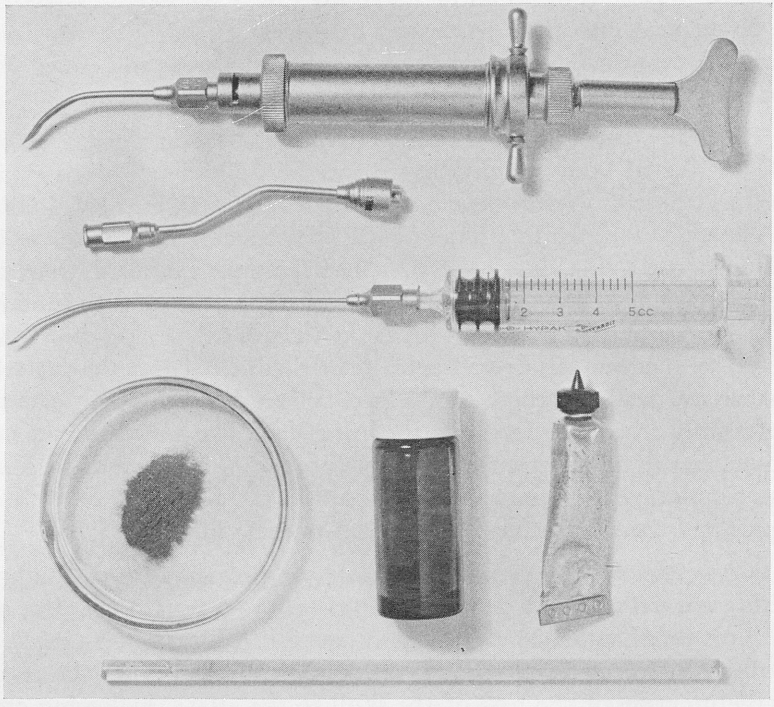

Fig. 1.—Equipment and materials for posterior pharyngeal wall injections include Lewy syringe or plastic syringe, 15 to 18 gauge curved needle, mixing dish, stirring rod, tantalum powder and teflon paste (50% glycerine suspension).

band saw), photographed and a block of tissue and bone containing the implant were removed for decalcification and processing. The block specimens were imbedded in celloidin, sectioned every 20 microns and stained with eosin and hematoxylin in preparation for histological study. In order to determine whether there was any migration of either substance through the regional lymphatics several parapharyngeal and upper jugular lymph nodes were removed from each specimen, processed, sectioned and stained for histological examination.

RESULTS

The operative procedure and the injection of the tantalum, teflon or glycerine were well tolerated. One cat died of respiratory infection

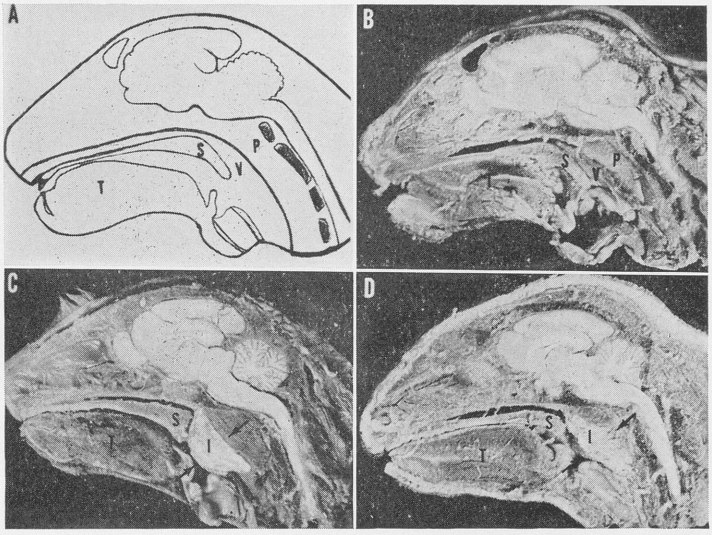

Fig. 2.—Diagrammatic representation (A), and photographs of sagittally sectioned cats heads of normal control (B) and representative posterior pharyngeal wall teflon injected specimens (C, D). The anatomical relationships between the tongue (T), soft palate (S), posterior pharyngeal wall (P), velopharyngeal space (V) and teflon implants (I) are shown.

two weeks after injection of tantalum. By varying the amount of the injected material it was possible to create any size of localized elevation on the posterior pharyngeal wall which was needed to diminish the size of the excessively large surgically created velopharyngeal spaces (Figs. 2 and 3).

Although the injections were performed with the aid of an operating microscope the intended objective of limiting the injection to the submucosal space was not realized. In all specimens the injected material extended from the submucosal region, intramuscularly and into the retropharyngeal space (Fig. 3). In one cat the needle passed through the prevertebral space into an intervertebral space. The injected tefllon caused a small eminence in the spinal canal but there were no observable behavioral abnormalities.

Gross examination demonstrated that both teflon and tantalum remained well localized with good maintenance of the elevated ridge on the posterior pharyngeal wall. X-rays taken six to ten weeks post

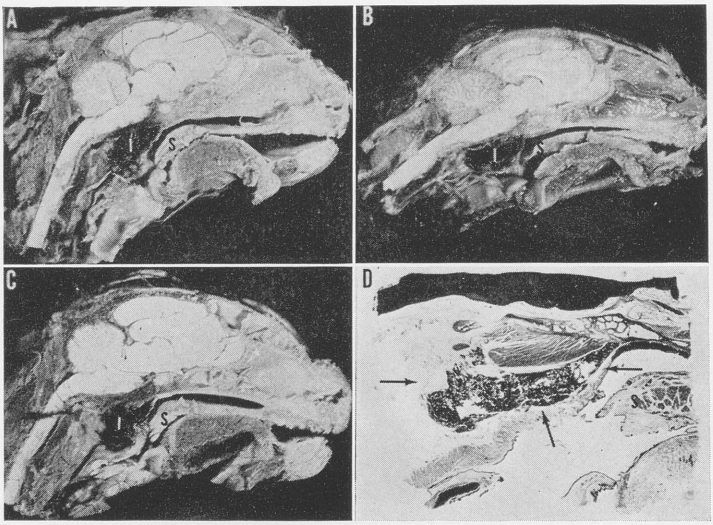

Fig. 3.—Photographs of representative sagittally sectioned specimens (A, B, C) showing the relationships of the soft palate (S) and the tantalum suspension implants (I). Arrows indicate the area of confinement of the tantalum to the retropharyngeal space. (D- Hematoxylin and eosin X3)

injection showed the radiopaque tantalum confined to the injection site with no evidence of migration (Fig. 4). Comparison of the x-rays with the gross specimens further confirmed the permanent retention of the injection material with no downward spread in the retropharyngeal space.

Histological examination revealed that both teflon and tantalum implants were well circumscribed. Both types of implants had been walled off by surrounding layers of thin connective tissue which formed a capsule. Varying degrees of tissue reactivity to the implants were observed and were characterized by infiltrates of mononuclear cells, lymphocytes, macrophages and a few giant cells (Fig. 5). Fibrous stroma with septa extending from the capsule walls into the implant along with the histocytic reaction appeared to provide structural support for the particles. The tissue response was more vigorous in the retropharyngeal space with diminishing reactivity in the submucosa, adenoids and muscle. The larger teflon particles (50 to 100 microns) stimulated greater stromal deposition than did the smaller particles. There appeared to be attempts on the part of the cells to

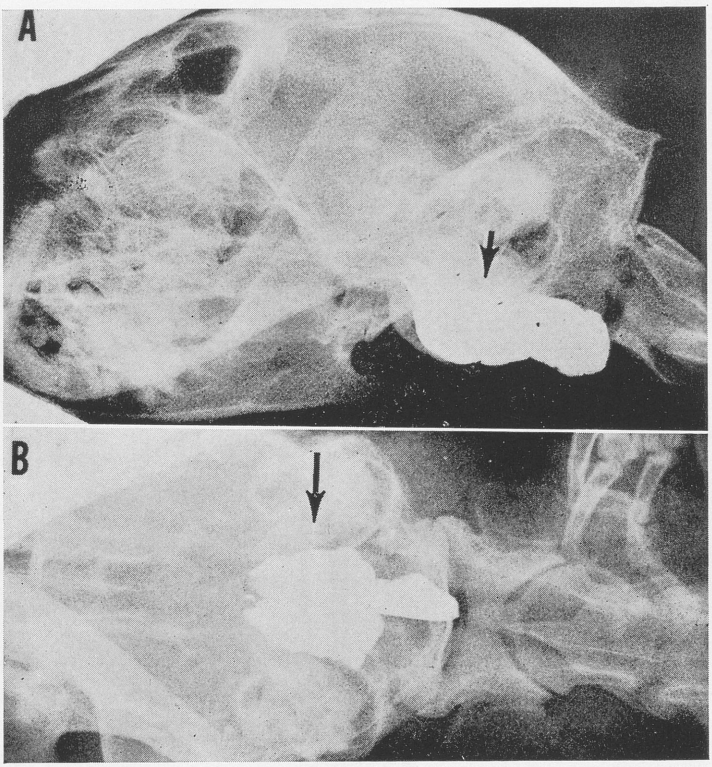

Fig. 4.—Post injection lateral and P-A x-rays, taken at 12 weeks, of the same animal seen in Figure 3 B, D. Radiopaque tantalum implant was confined to the injection site with no evidence of migration.

surround each teflon particle and thus wall it off. The tantalum implants appeared to be much better tolerated than the teflon. The tissue reactions were similar but to a much lesser degree in the tantalum implants.

Gross examination of the lymph nodes showed enlargement with black spots in many of the nodes from the animals that were injected with tantalum. The lymph nodes from the teflon injected cats were enlarged compared to the control specimens but did not otherwise appear abnormal.

Histological study showed the presence of tantalum and teflon particles in all lymph nodes examined from these groups. Relatively

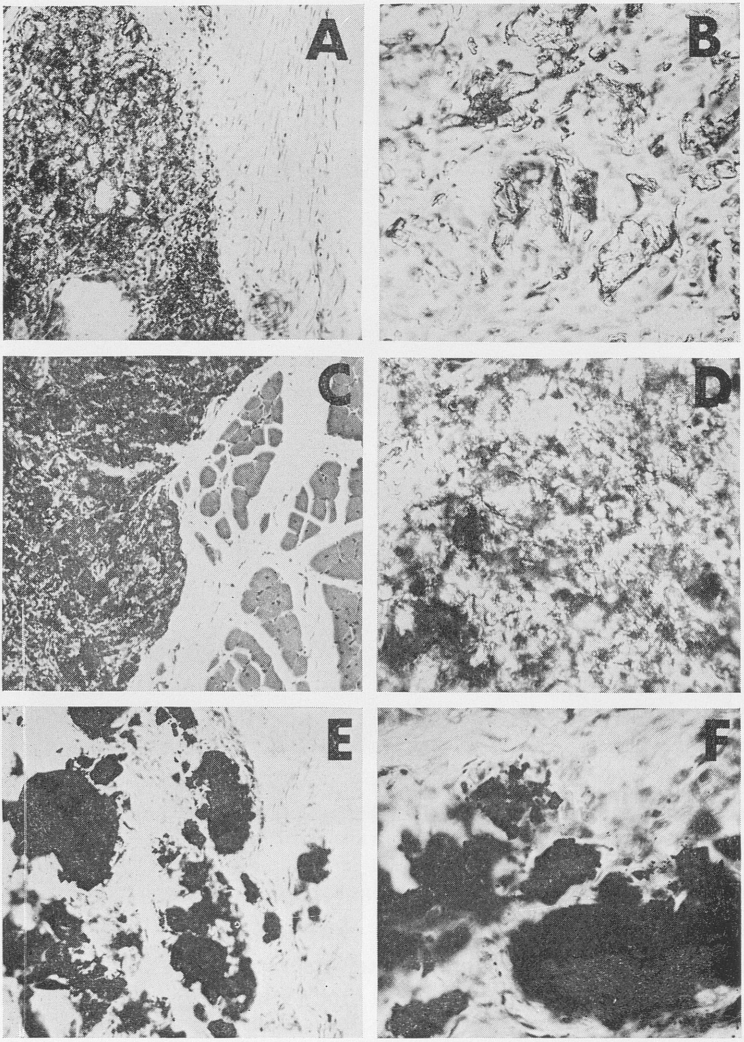

Fig. 5.—Photomicrographs showing various degrees of tissue response to the injected implants: A, teflon 6-12 micron particles, capsule formation, H & E X 91; B, teflon 6-12 micron particles, histocytic reaction, H & E X 232; C, teflon 50-100 micron particles, in muscle, H & E X 91; D, teflon 50-100 micron particles, marked histocytic reaction X 232; E, tantalum, minimal fibrosis and capsule formation, H & E X 91; F, tantalum, histocytic reaction, H & E X 232.

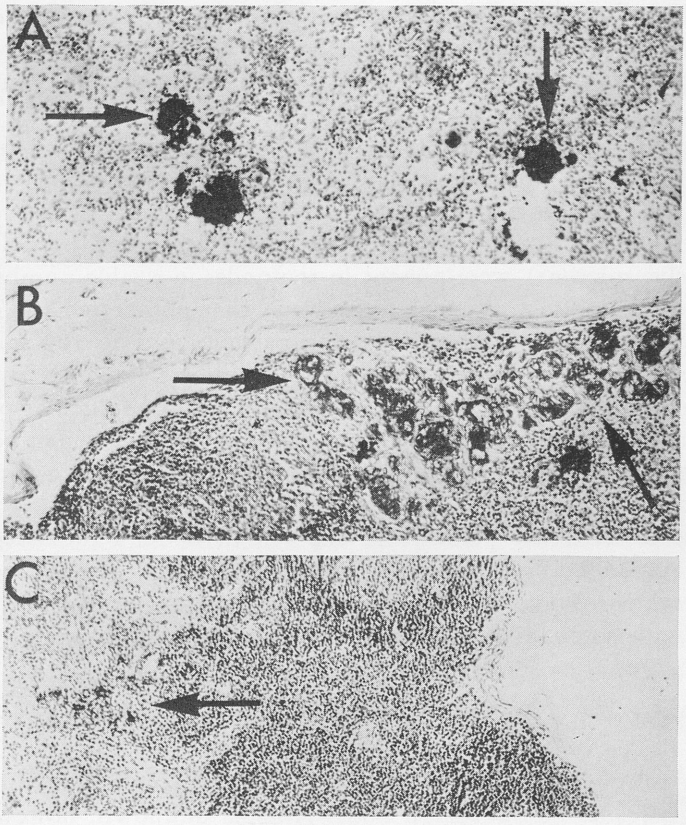

Fig. 6.—Photomicrographs of sections of upper jugular and parapharyngeal lymph nodes. Large numbers of tantalum (A) and teflon (6-12 micron) particles (B) were carried to the lymph nodes. Sections of lymph nodes from the cats injected with the larger teflon particle suspensions (50-100 microns) (C) contained only a few particles (hematoxylin and eosin X 91).

large numbers of the tantalum and small (six to twelve microns) teflon particles were noted in the lymph nodes and appeared to have caused a marked disruption of the normal follicular pattern (Fig. 6 A, B). Only a few particles were seen in the lymph nodes from the cats that were injected with the larger (50 to 100 microns). Teflon suspension and there was persistence of the normal follicular pattern (Fig. 6C).

COMMENT

Tantalum* and teflon powder suspended in glycerine were equally effective in creating an artificial Passavant's ridge when injected into the posterior pharyngeal wall of cats. The size of the ridge was easily controlled by varying the amount of either substance injected. There was grossly good maintenance of the original localization of both materials at the injection site. An interesting observation was that some tantalum and teflon particles were deposited in the regional lymph nodes. Both tantalum and the smaller teflon particles (six to twelve microns) were present in the nodes in sizable numbers and appeared to cause a reticular hyperplasia that obliterated the normal follicular pattern. The larger teflon particles (50 to 100 microns) were also in the nodes but only in small numbers and there was very little reaction and minimal alteration of the normal follicular pattern. The more intense foreign body reaction to the larger teflon particles may have served as a supporting framework helping retain the material at the injection site. In terms of the total quantity of the substances injected the particles in the lymph nodes represented very small amounts. The persistence of a large well localized elevation in the specimens suggested that the small amount of materials carried to the lymph nodes did not significantly reduce its effectiveness in moving the posterior pharyngeal wall forward.

Attention is drawn to the fact that these materials, particularly when the particle size is small, can be carried from the injection site to the regional lymph nodes. The ultimate effect of tantalum and teflon particles in the lymph nodes remains unknown, however, the tolerance of large numbers of carbon particles in lymph nodes examined at autopsy would seem to indicate that inert foreign bodies are of little significance.

The sparseness of the larger teflon particles (50 to 100 microns) in the lymph nodes resulted in the selection of this preparation as our preference over suspensions of smaller particles.

Teflon and tantalum powder suspensions have been used in humans with considerable success. Arnold[28,29] and Lewy[30] introduced and popularized the injection of these materials into the vocal cords of patients with unilateral paralytic dysphonia. To date there

* Since this experiment was initiated the Ethicon Company has withdrawn tantalum powder as an experimental material because of recent stringent Food and Drug Administration rulings.

are no reported adverse effects of the injection of either of these materials into the human larynx. If there has been transport of some of the particles to the regional lymph nodes their presence has not resulted in any recognized ill effects.

Blocksma[26] called attention to the simplicity of bringing the posterior pharyngeal wall forward with inert implants, as compared to the time consuming and expensive attempts to correct velopharyngeal insufficiency by means of obturators or by operative efforts to lengthen the palate. The effectiveness of the old technique of implanting various substances into the posterior pharyngeal wall was never in question. The immediate results after the injection of paraffin or implantation of other materials such as bone, cartilage and fascia were good. The complications encountered of embolism, mediastinitis, the formation of paraffinomas and the resorption of the materials implanted led to the discontinuance of these techniques.

Because of the complications encountered by previous investigators utilizing these techniques it was considered essential to evaluate the use of tantalum and teflon powder and the posterior pharyngeal wall injection techniques, in animals before attempting their use in humans. Efforts to record and study changes in phonation in the animals were unsuccessful. A great deal of information was obtained about the behavior of these substances in the posterior pharyngeal wall tissues and spaces. These experiments indicated that none of the previously described complications are likely to occur with the injection of tantalum or teflon. There was no infection, the local tissue responses were minimal and the materials did not migrate into the mediastinum as was described with the use of paraffin. The tantalum and teflon suspensions were well tolerated when injected into the submucosa, superior constrictor muscle and retropharyngeal space. The retropharyngeal space represents only a potential space which is occupied by loose connective tissue which effectively limited the local spread of the injected materials. The prevertebral space by comparison contained little connective tissue[31] and it is possible that material injected into this region could migrate by gravity into the mediastinum. This did not occur in the one instance where the needle passed through prevertebral space but only a small amount of teflon actually was deposited.

The simplicity and apparent safety of this procedure as demonstrated in experimental animals commends its cautious trial in human patients with velopharyngeal insufficiency. There appeared to be

many advantages of this procedure. Only a minimal amount of equipment is needed and it is anticipated that in adults it could be performed under local anesthetics. If the initial procedure produces an inadequate ridge the injection can be repeated. Injection of the posterior pharyngeal wall does not cause scarring with resulting limitation of palatal motion, as has been attributed to operations designed to lengthen the palate, nor will there be interference with bone growth as has been associated with uranoplasty.

How broad an application teflon powder will have in palatal problems remains to be determined. The injection of the lateral pharyngeal walls and palatal remnants may also prove of value where inadequate tissue prevents surgical closure.

If injection of teflon into the posterior pharyngeal wall of patients with different types of velopharyngeal insufficiency is as well tolerated and is as effective in the creation of an artificial Passavant's cushion as it was in our experimental animals the results should be salutary in the reduction of nasal emission of air. The animal studies indicate the likelihood of success using this procedure especially in patients who retain some degree of activity in their soft palates. The ridge produced is less likely to be effective in patients with totally inert palates.

SUMMARY

Velopharyngeal insufficiency is responsible for many cases of defective speech. The techniques of narrowing the velopharyngeal orifice by bringing the posterior wall of the pharynx forward has met with varying degrees of success in the past.

Portions of the palates of a series of cats were excised to simulate the conditions in humans. Teflon and tantalum powder suspended in glycerine were injected into the posterior pharyngeal wall in an effort to create a permanent Passavant's ridge, and the palatal cleft was closed. The procedure was well tolerated and tissue response to the foreign bodies was minimal.

950 East 59th Street

REFERENCES

1. Stark, R. B.: Plastic Surgery. New York: Harper and Row, 1962.

2. Subtelny, J., Koepp-Baker, H., and Subtelny, J. D.: Palatal Function and Cleft Palate Speech. J. Speech and Hearing Disorders 26:213-224, 1961.

3. Subtelny, J. D.: A Review of Cleft Palate Growth Studies Reported in the Past 10 Years. Plast. and Reconstruct. Surg. 30:56-57, 1962.

4. Lindsay, W. K., Le Mesurier, A. B., and Farmer, A. W.: A Study of the Speech Results of a Large Series of Cleft Palate Patients. Plast. and Reconstruct. Surg. 29:273-292, 1962.

5. Williams, H. B., and Woolhouse, F. M.: Comparison of Speech Improvement in Cases of Cleft Palate After Two Methods of Pharyngoplasty. Plast. and Reconstruct. Surg. 30:36-42, 1962.

6. Berner, R. E.: Hazards of Adenotonsillectomy in the Child with Cleft Palate. J.A.M.A. 181:558-559, 1962.

7. Blackfield, H. M., Miller, E. R., Owsley, J. Q., Jr., and Lawson, L. I.: Comparative Evaluation of Diagnostic Techniques in Patients with Cleft Palate Speech. Plast. and Reconstruct. Surg. 29:153-158, 1962.

8. Randall, P., Blakes, F. P., and Kennedy, C.: Cleft Palate-Type Speech in the Absence of Cleft Palate. Plast. and Reconstruct. Surg. 25:484-495, 1960.

9. Dorrance, G. M.: The Operative Story of Cleft Palate. Philadelphia: W. B. Saunders Co., 1933.

10. Edgerton, M. T.: Surgical Lengthening of the Cleft Palate by Dissection of the Neurovascular Bundle. Plast. and Reconstruct. Surg. 29:551-560, 1962.

11. Peet, E.: The Oxford Technique of Cleft Palate Repair. Plast. and Reconstruct. Surg. 28:282-294, 1961.

12. Steffensen, W. H.: Palate Lengthening Operations. Plast. and Reconstruct. Surg. 10:380-387, 1952.

13. Wardill, W. E. M.: The Technique of Operation for Cleft Palate. Brit. J. Surg. 25:117-124, 1937.

14. Moran, R. E.: The Pharyngeal Flap Operation as a Speech Aid. Plast. and Reconstruct. Surg. 7:202-213, 1951.

15. Webster, R. C., Quigley, L. F., Coffey, R. J., Querze, R. H., and Russell, J. A.: Pharyngeal Flap Staphylorrhaphy and Speech Aid as Means of Avoiding Maxillofacial Growth Abnormalities in Patients with Cleft Palates. A Preliminary Report. Am. J. Surg. 96:820-822, 1958.

16. Webster, R. C., Coffey, R. J., Russell, J. A., and Quigley, L. F.: Methods of Surgical Correction of Velopharyngeal Sphincter Incompetency Using Palatal and Posterior Pharyngeal Tissues: Proposed System of Classification. Plast. and Reconstruct. Surg. 18:474-489, 1956.

17. Passavant, G.: Quoted by Dorrance, G. M.: The Operative Story of Cleft Palate. Philadelphia: W. B. Saunders Co., 1933.

18. Calnan, J.: The Error of Gustav Passavant. Plast. and Reconstruct. Surg. 13:275-289, 1954.

19. Eckstein, H.: Uber subkutane und submuköse Hartparaffinprothesen. Wchnschr. 28:573-576, 1902.

20. Eckstein, H.: Demonstration von subcutanen and submucosen Hartparaffinprothesen. Berl. klin. Wchnschr. 39:315-316, 1902.

21. Eckstein, H.: Hartparaffininjektionen in derhintere Rachenwand bei angeborenen und erworbenen Gaumendefekten. Klin. Wchnschr. 1:1185, 1922.

22. Gersuny, R.: Uber eine subcutane Prosthese. Ztschr. Heilk. 21:199-204, 1900.

23. Arnold, G. E.: Vocal Rehabilitation of Paralytic Dysphonia: I. Cartilage Injection into a Paralyzed Vocal Cord. A. M. A. Otolaryng. 62:1-17, 1955.

24. Woods, Sir Robert: Aids to Palatal Insufficiency After Cleft Palate Operations. Brit. Med. Jour. 1:371-372, 1927.

25. von Gaza, W.: Über freie Fettgewebstransplantation in den retropharyngealen Raum bei Gaumenspalte. Arch. f. klin. Chir. 142:590-599, 1926.

26. Blocksma, R.: Correction of Velopharyngeal Insufficiency by Silastic Pharyngeal Implant. Plast. and Reconstruct. Surg. 31:268-274, 1963.

27. Blocksma, R.: Personal Communication with author.

28. Arnold, G. E.: Vocal Rehabilitation of Paralytic Dysphonia: VI. Further Studies of Intracordal Injection Materials. Arch. Otolaryng. 73:290-294, 1961.

29. Arnold, G. E.: Vocal Rehabilitation of Paralytic Dysphonia: IX. Technique of Intracordal Injection. Arch. Otolaryng. 76:358-368, 1962.

30. Lewy, R. B.: Glottic Reformation with Voice Rehabilitation in Vocal Cord Paralysis. The Injection of Teflon and Tantalum. Laryngoscope 73:547-555, 1963.

31. Grodinsky, M., and Holyoke, E. A.: The Fasciae and Fascial Spaces of the Head, Neck and Adjacent Regions. Am. J. Anat. 63:367-408, 1938.

DISCUSSION

Dr. Godfrey E. Arnold: It is a great privilege to discuss this paper, an outstanding paper, well prepared, convincingly introduced, thoroughly documented and presenting important new data. I am particularly gratified to see another fine example of the new trend in otolaryngology, the integration of anatomical facts and surgical achievements with the postulates of function. The biologic aspects of clinical medicine and the psychologic study of behavior have joined once more for better service to the person in the center, the patient.

The recent interest in teflon as a suitable material for prosthetic implantation is analogous to several developments in modern ear surgery. Again an old idea has been revived with modern approaches. It is my hope that teflon implants into the pharynx for improvement of function will prove the feasibility of the previous proposals, but with permanent results and without the past dangers.

One of the highlights of this paper is the exploration of tissue reaction. It is now established that the particle size of teflon powder is of great importance. Small particles can and will be carried away through the lymphatics. A minimal particle size around 50 microns appears to be optimal. It is also important to heed the authors' warning regarding a potential danger. Care must be taken to inject precisely and not too deeply.

The procedure appears to be good, feasible and predictable. Like any new procedure, it also carries certain potential risks. These must be studied in order to be avoided. The teflon procedure must not be taken lightly. It needs careful practice and preparation, as shown in this excellent contribution to the development of what may possibly—hopefully—become a permanent tool of laryngology.

Professor Carl R. Mundnich: We have a very interesting conference, and I wish to mention a method in cases where the gap between the soft palate and the

posterior pharyngeal void is so big that one can't implant a big amount of inert material. It is helpful to mention a procedure I developed several years ago, a procedure, I think, that is unusual, but it has proved very successful. Therefore I am performing it routinely in cases of a big gap.

I do an incomplete tonsillectomy from below to above with a pedicle in the back. Having done this and formed a hole behind and through the posterior arc of the soft palate, then I cut horizontally the mucous membrane in the naso-pharynx depriving the posterior pharyngeal wall of the mucous membrane. After having done this, the two tonsils are dislocated through the hole into the naso-pharynx and sutured one to the other and sutured and fixed on to the posterior pharyngeal wall. You can get a big amount of wall, and the results are very good because the movement of the soft palate isn't impaired.

Dr. Emanuel M. Skolnik: This is a subject of great interest to me, having spent a number of years in the Cleft Palate Center of the University of Illinois College of Medicine. I would like to thank Dr. Ward for his very excellent presentation. Historically there have been many phases of pharyngeal implants and with the vast experiences through the years in the use of implants and prostheses we have come to the realization that such procedures may have some merit only in such patints in which there is a basically sound velopharyngeal mechanism. These are the patients in which the neuromuscular mechanism is intact. Let me clarify this statement. A patient with normal speech at the age of five who now undergoes a tonsillectomy and adenoidectomy and in whom there is present a submucous cleft or palatal incompetence may have resultant hypernasality or typical cleft palate speech. It is in this patient in whom either a speech appliance or pharyngeal flap or pharyngeal implant would achieve adequate speech. It must be kept in mind that we are dealing with a young population and I would like to caution against the use of injectables of foreign materials in this area of the posterior pharyngeal wall when satisfactory results can be accomplished with surgery. I have used pharyngeal flaps in these patients as well as in patients in whom a resection of the soft palate was performed because of the presence of carcinoma. Limited to the velum, this type of reconstruction resulted in very satisfactory speech.

The use of faucial tonsil as an implant or graft to the nasopharynx has its limitations. We must keep in mind that lymphoid tissue normally undergoes physiologic involution. There are a number of patients in our Cleft Palate Center who had normal speech until they reached the age of 15 and 16. Then because of the underlying inadequacy of the velopharyngeal mechanism and with the physiologic shrinkage of the adenoids there appeared moderate deterioration in the speech pattern.

In patients who have severely scarred immobile soft palates and pharyngeal musculature, and patients with attenuated tissues or an inadequate neuromuscular system, the use of prostheses and implants may offer only minimal improvement.

To re-emphasize, if one can achieve adequate velopharyngeal function with the use of prostheses or implants, equally satisfactory results can be accomplished with surgical reconstruction.

More significant is the fact that the reconstruction is with the use of the patient's tissues and there is less likelihood of a possible serious consequence occurring 15 or 20 years hence by using foreign materials implanted in the posterior pharyngeal wall.

Dr. Francis L. Lederer: I rise to discuss this paper on historical grounds in that it was in 1923, in one of my earliest contributions, that I have had cause at

times to regret but now I am very happy about, which appeared in the journal, *Surgery, Gynecology and Obstetrics* (36:815-823, June). I recited the experience with certain substances (bismuth paste) when used about the head and neck areas caused foreign body reactions (tumors) a great many years later.

I rise, also, from two other points of view:

Recently I have been asked to serve on a national committee that would attempt to regulate the employment of the silicones for medical use. There seems to be a word that is presently sweeping the country and therefore initiates a furore at the outset to do something with materials that can be introduced into tissue. They speak of it as "simple." That is the word, "simple" or "simplified." I think this belies the introduction of relatively inert substances into body tissues. This Committee is being formed mainly because of the very statement that Dr. Arnold made, viz., that the Food and Drug Administration is now interested. Furthermore, from a medicolegal point of view, we are liable with the widespread use of these substances and by misuse, to throw them into disrepute.

I think you must be aware of the fact that there are certain sites in the body that have actively functioning musculature and that there are fascial planes and spaces that can communicate. Certainly for us to go on the basis of short-term studies may be fraught with considerable danger. Therefore, I would like to ask all of you to use some caution.

Dr. Ralph Blocksma, one of the earlier contributors to this field, that Dr. Ward has made reference to, said in his studies that it constitutes no license to extensive use of silicones (these are polymers of dimethylsiloxane) and he mentioned specifically their employment in speech correction in velopharyngeal incompetence. This is a foreign body, no matter how well tolerated it may seem at this point to be. "We continue to feel (states Blocksma, *Cleft Palate Journal* 1:71 Jan. 1964) that the use of autogenous tissue to accomplish the objective would be far superior."

I merely bring this to your attention because there are other areas of interest and application. Plastic surgeons are jumping at the opportunity and conclusions because the technique appears in the literature as a simple method and all you require is this substance and the proper gadgets for its introduction.

Mr. Chairman, I know that we all appreciate the efforts of both Dr. Arnold and Dr. Ward and others who have been working with this and other substances, but I think we need to sound a little warning at this point.

Dr. Ward (closing): Teflon, of course, is not a silicone; it is a plastic polymer. If we are going to put it in the ear I think it is justifiable to consider its use in other areas. Actually it has been used for many, many years in other areas, as prosthetic replacements. This procedure does not interfere with the neurovascular bundle and this was one of the factors that was mentioned in favor of its use.

We are indebted to the Ethicon Company for supplying the materials for use in this experimental study.

CONGENITAL CHOANAL ATRESIA IN INFANTS AND CHILDREN

CARLYLE G. FLAKE, M.D.
(by invitation)
AND
CHARLES F. FERGUSON, M.D.

BOSTON, MASS.

Congenital atresia of the posterior nares, though not one of the more common developmental anomalies, is nevertheless a condition which should be easily recognized and quickly diagnosed by simple measures. In the past twenty years, a number of good papers on this subject have appeared in the literature, and there is no need to review all of this work since adequate bibliographies are available. For many years McGovern and Beinfield have been foremost in calling attention to this condition, and have repeatedly pointed out to obstetricians and pediatricians the importance of early diagnosis as the first step in the control of this preventable cause of neonatal mortality.

At The Children's Hospital Medical Center in Boston, over 50 patients with choanal atresia have been seen during the past 25 years, and 40 of these have had operations. In 1938 the transpalatal approach was first used here by one of us (C.G.F.).

It is the purpose of this paper 1) to report a comparatively large series of infants and young children who have had surgical operations at our hands for the correction of this anomaly, 2) to demonstrate the feasibility of operation at an earlier age than appears to be generally accepted at the present time, and 3) to re-emphasize the importance of determining at birth the patency of the nasal passages before the infant is transferred from the delivery room to the nursery.

In a review of the literature on this subject, the largest series dealing solely with patients in infancy and childhood was reported by

From the Departments of Otolaryngology, The Children's Hospital Medical Center, Boston and the Harvard Medical School.

Craig and Simpson in 1959.[1] All of the ten children in their group were operated upon through a transnasal approach.

In our series of 40 infants and children, most of whom were operated upon by the transpalatal approach, we believe we have demonstrated the feasibility as well as the desirability of definitive surgery at an early age. Although our technique is not new today, since 1938 most of our patients have been operated upon by this method. Many of the operations were performed some time before most of the transpalatal approaches had been described in the literature. We have continued to use the technique as originally devised with only minor variations. It is of passing interest that until 1954, there were only two reported instances in the American literature[2,3] of the transpalatal operation in infants under six months of age.

According to Schwartz and Isaacs,[4] the earliest record of this anomaly is in an article by Roederer, which was published in Göttingen, Germany, around 1755. Otto,[5] whom most of the papers on this subject quote as having first mentioned choanal atresia in 1830, quotes from Roederer: ". . . sometimes the posterior nasal openings are lacking, due to congenital anomaly." Thus the condition was recognized well over 200 years ago. It was not until 1851 that Emmert[6] described the first operation. This was in a 7-year-old boy, and the obstruction was punctured with a trocar. Only in recent years have significant papers, other than case reports, appeared in the literature. Since then various techniques have been described for repair of this anomaly, including the transnasal, transseptal, transantral and transpalatal approaches. Many of these are applicable only to the older child or adult. The problem of the infant and young child, particularly of the newborn, is a much more difficult one, especially when bilateral atresia exists.

There can be no doubt regarding the familial tendency of this anomaly, for several investigators have reported such occurrences. McGovern[7] has noted three instances where this anomaly occurred in a mother and daughter. Wilkerson and Cayce[8] cited Lang as reporting several in one family, including a 15-year-old boy, his 16-year-old sister, his 35-year-old mother, and a questionable atresia in a brother as well as a maternal aunt. Stewart[9] reported bilateral atresia in two sisters, and the history of a brother who was asphyxiated at birth and well may have had the condition. Included in our series are one brother and two sisters, all three of whom were operated upon by us for congenital choanal atresia.

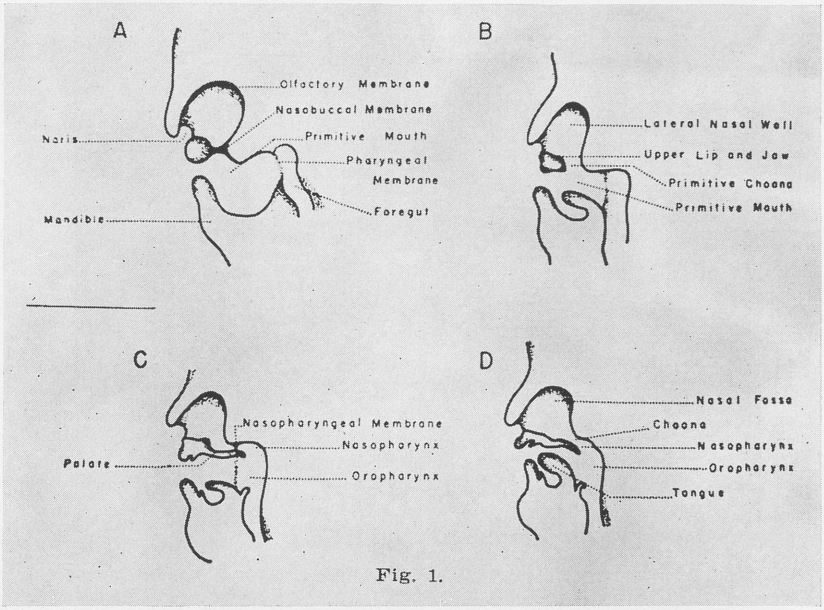

Fig. 1.—Embryological development of choanae (from McKibben, B. G.: Laryngoscope 67:734, 1957).

EMBRYOLOGY

In order to understand the development of choanal atresia, it is necessary to review briefly the embryology of the region, as always in all instances of congenital anomalies. (Excellent reviews of the embryology may be found in papers by McKibben[10] and Poch-Viñals and Calvo.[11])

Around the end of the third, or during the early part of the fourth week of embryonic life, the primitive nasal pits are produced by invaginations of the nasal placodes, which are ectodermal thickenings on either side of the midline of the primitive face. As these pits enlarge by burrowing into the mesodermal bed of the developing face, and extend posteriorly to the region of Rathke's pouch, the primitive nasal pouches (or primitive olfactory cavities) are formed. These cavities come to overlie the primitive mouth (or buccal cavity). The floor of the olfactory cavities (i.e., the roof of the buccal cavity) thins out, the intervening mesoderm disappears, and the nasal and

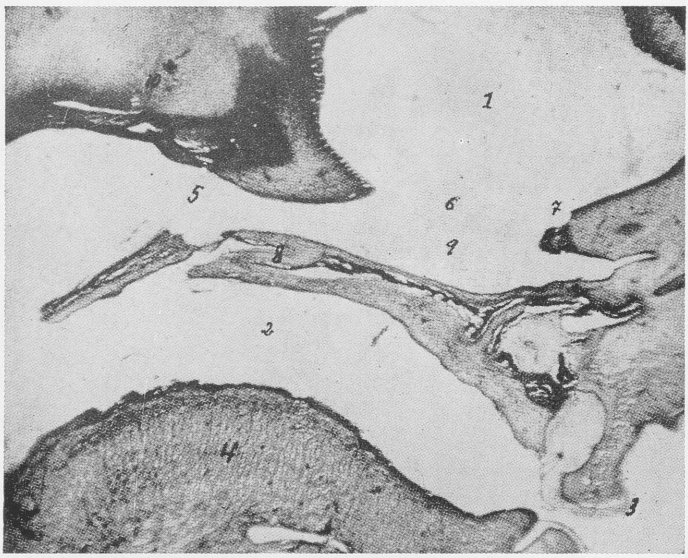

Fig. 2.—Sagittal section through definitive choanae of a 40 mm embryo (from Poch-Viñals, R., and Calvo, R. R.: Arch. Otolaryng. 63:567, 1956). 1. Primitive nasal cavity. 2. Buccal cavity. 3. Upper lip. 4. Tongue. 5. Definitive choana. 6. Primitive choana. 7. Inf. turbinate. 8. Sec. palate. 9. Sec. nasal cavity. 10. Sphenoid.

oral cavities then remain separated by only a thin partition (Fig. 1). This diaphragm (or bucconasal membrane of Hochstetter) normally ruptures between the thirty-fifth and thirty-eighth day of fetal life, producing the primitive choanae, thereby establishing direct continuity between the nose and the mouth. Failure to rupture could produce atresia, but such an atresia should be considerably anterior and superior to the definitive choanae. If mesodermal remnants persist between the nasal and buccal epithelial surfaces, the atresia could be bony, or if the bone has only incompletely resorbed, there may be some bone located peripherally in the diaphragm with a membranous area in the center. Thus the membranous stage may never have been reached to permit perforation to occur. In other words, the anomaly cannot necessarily be ascribed to failure of perforation of the bucconasal membrane, since the region may never have progressed to the membranous stage. In our experience, which bears out that reported in the literature as quoted by Roopenian and Stemmer,[12] less than ten per cent of the atresias are membranous, and over 90 per cent are bony.

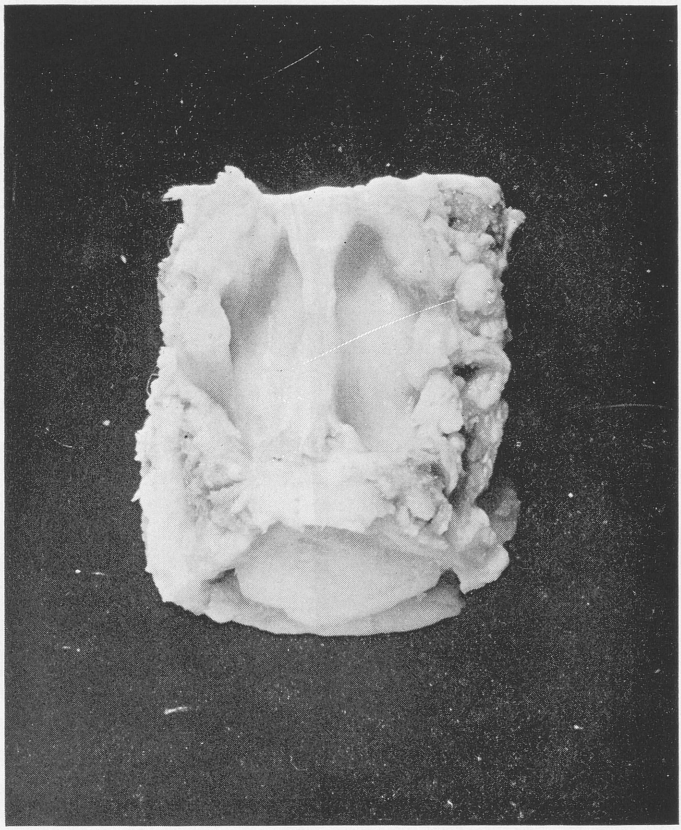

Fig. 3.—Frontal view of bilateral bony choanal atresia in a 3-month-old infant who died of pneumonia after tracheotomy.

The primitive choanae enlarge and should disappear as a result of development of the olfactory labyrinth, and later of the ethmoidal and turbinate structures. With development of the primitive choanae, the primitive palate is left as a wedge of bone between the nasal pits externally and the primitive choanae internally. As the face develops, the lateral palatal processes and the nasal septum grow backward, and the two palatal processes unite medially to form the secondary palate. This anterior wedge of bone which has separated because of the formation of the primitive choanae becomes the premaxilla, which later contains the incisor teeth. As the palate grows posteriorly as a horizontal shelf, it separates the primitive buccal

cavity into the mouth inferiorly, and a small inferior portion of the nasal cavity superiorly, just beneath the region of the primitive choanae. Thus the definitive choanae are a backward extension of the primitive choanae, and are located considerably more posterior and become more verticle (Figs. 2 and 3). Persistence of another membrane (the buccopharyngeal membrane from the foregut) in this narrow posterior position could result in an atresia. This may be the cause of the more posterior membranous atresias which comprise the relatively small five per cent to ten per cent of the entire group. Bone in this region would be hard to explain.

Craig and Simpson[1] doubt the theories of the persistence of either the bucconasal or buccopharyngeal membranes as the cause of choanal atresia, and postulate a theory of congenital adhesions. As upward growth and enlargement of the nasal fossae occur, these adhesions would be in the narrowest portion of the developing cavities, and if they contain mesoderm the atresia could be bony as well as membranous.

Since cartilaginous elements have been found in the atretic bony partitions, it has been postulated that choanal atresia may be due to medial overgrowth of the vertical and horizontal processes of the palatal bones. (Cartilage should not be present in truly membranous bone.) However, most observers have accepted the theory that atresia of the posterior choanae is due to failure of rupture of the bucconasal membrane (or possibly the buccopharyngeal membrane) leaving some type of partition (bony or membranous) separating the nose from the nasopharynx.

DIAGNOSIS AND SYMPTOMS

The fact that congenital atresia of the posterior nares is frequently associated with many other anomalous conditions is well documented in the literature. McNeill and Wynter-Wedderburn[13] have described a child with Treacher-Collins syndrome, who also had bilateral atresia. McGovern[14] has reported heart disease as an accompanying malformation in two instances. He has also reported facial, nasal and palatal abnormalities, and congenital coloboma of the iris and retina, as well as malformations of the external ear and polydactylism.[15] In our series, two instances of congenital coloboma of the iris and retina were noted, as in the patient reported by Thomasson.[16] Coloboma of the retina also occurred in one of Craig and Simpson's[1] infant patients, and would appear to be one of the more commonly

associated anomalies. We have also encountered congenital heart disease, esophageal atresia, tracheo-esophageal fistula, meningocele and craniosynostosis.

Although the sex difference in the patients reported in the literature has been equivocal, there was a two-to-one incidence of females over males in our relatively large series of 40 patients. Twenty-seven were females and only 13 were males. Craig and Simpson[1] reported seven males and three females in their series of ten case reports.

Bilateral atresia of the posterior nares produces symptoms of high airway obstruction, and the infant usually shows considerable difficulty in breathing immediately after birth. He makes vigorous attempts to breathe, yet is unable to produce adequate respiratory exchange. The greater the effort, the tighter the mouth closes, and asphyxia can occur. This might well account for some stillbirths. Mouth-breathing is an acquired habit, and is usually not learned for several days to weeks. Unfortunately, this fact is generally not fully appreciated, and may well be responsible for some instances of neonatal asphyxia. Associated with the obstruction there may be marked retraction of the chest, attacks of cyanosis and severe dyspnea. The cyanosis may be cyclic, relief occurring momentarily if the infant is fortunate enough to cry. When crying ceases, cyanosis and retractions recur until the infant learns to open his mouth again to take in air. There may also be marked difficulty in swallowing feedings due to inability to co-ordinate breathing and swallowing. Aspiration of feedings is, therefore, relatively frequent unless nursing care is of the highest caliber. As the patient grows older, a thick, glairy mucoid discharge drains constantly from the affected side of the nose, but this is usually not infected. Bubbling of this mucus occurs neither on inspiration nor expiration, and the older patient is unable to blow the nose on the obstructed side. The voice sounds are typical of those of an individual with severe nasal obstruction so far as quality is concerned, and anosmia is present if the atresia is bilateral.

On physical examination the mucous membrane of the nose appears to have a pale blue color in some patients, and the turbinates may be boggy and edematous. The nares and upper lip are often excoriated from the constant irritation of the secretions. If the atresia is unilateral, the patient sometimes grows into adult life before it is discovered. Unilateral atresia in the infant should still be of concern, because the normal side may easily become obstructed by

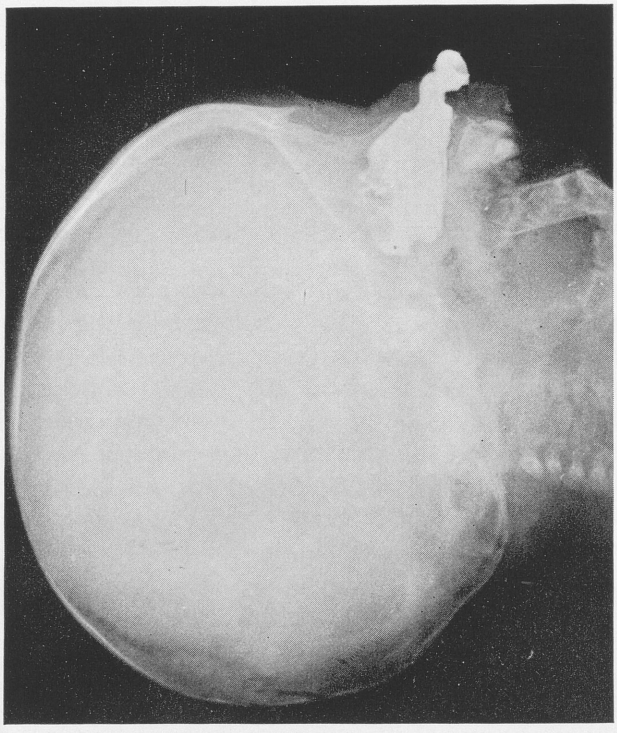

Fig. 4.—Right lipiodol nasogram in a 4-month-old infant showing choanal atresia.

positioning of the patient especially during or after feedings or during sleep, and in such cases the airway may be completely occluded.

The simple maneuver of attempting to pass a catheter through the nose into the nasopharynx will determine the presence or absence of atresia in most cases. Beinfield[17] has determined measurements on many newborns, and feels that if a metal probe cannot be passed beyond 32 millimeters from the edge of the nostril, atresia is present. If the probe can be passed the entire length of 44 millimeters or more, patency is apparent. In general, these figures are found to be accurate. If there is any doubt, a few drops of methylene blue may be dropped into the nostril, and the dye will appear in the pharynx if the choanae are patent. The use of a Politzer bag with a small nasal tip to seal the nostril and allow air pressure to be applied will also give a quick determination of patency. If there is any further question, Lipiodol

or Hytrast nasograms taken in a lateral position will determine the presence or absence of atresia (Fig. 4). In our series of 40 patients, only 21 had the diagnosis made or confirmed by this method, and in general it is not necessary.

In summary, the main factor in diagnosis is a high index of suspicion that the condition may exist. The next step is to determine whether both nostrils are patent all the way through to the nasopharynx by any means such as the passage of a catheter, probe, dye or radio-opaque material. In infants and young children, the postnasal mirror is useless.

McGovern[7] has shown that contrary to expectation, untreated atresia of the posterior choana does not lead to underdevelopment of the nose or nasal sinuses. Nasal physiology in these cases seems little disturbed. He has also demonstrated that x-rays of the sinuses, along with biopsies of the nasal mucous membrane, are generally within normal limits. The physiological action of the nasal cilia also appears to be normal and unimpaired. Ear disease and deafness are relatively uncommon in this particular group of patients. Facial development is also normal, and asymmetry, unless congenital, is decidedly rare. Our experience has corroborated these observations.

TREATMENT

At birth, those infants with bilateral atresia usually present an urgent emergency requiring the immediate establishment of an airway which will remain patent and prevent asphyxia. Various means and methods have been used in the past to accomplish this purpose, including metal, plastic or rubber pharyngeal airways or tubes, and sutures through the tongue to hold the tongue and jaw forward. A more recent method is McGovern's[18] ingenious use of a rubber nipple with a large hole in it, strapped in the mouth by tapes adjusted over the ears. Through this simple and physiological device the infant can not only breathe, but also receive feedings. Whatever method is used, there is no substitute for constant, intelligent nursing care until mouth-breathing is an established fact. Mouth-breathing must be learned, and most infants accomplish this feat in two to three weeks, though one of our patients with bilateral atresia began it within a few hours after birth.

Tracheotomy was performed in only four of our patients (two prior to admission) and it is now generally agreed that this operation is rarely necessary and should be avoided if possible.

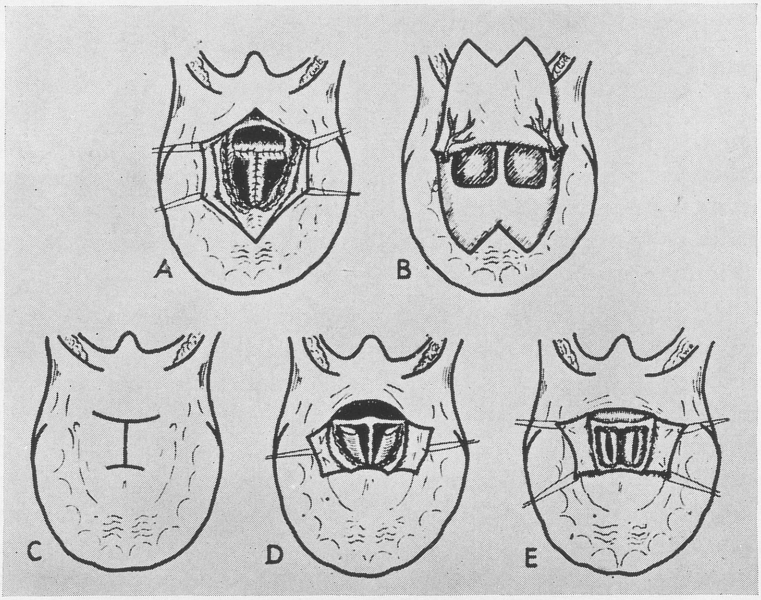

Fig. 5.—Types of operative incisions. A. Blair. B. Steinzeug. C. Schweckendiek. D. Neto (from Ruddy, L. W.: Arch. Otolaryng. 41:435, 1945).

The earliest surgical procedures were blind transnasal puncture operations which continue to be used by many as emergency treatment to establish an airway. Except in the five to ten per cent of patients with membranous obstruction, these openings frequently close and more definitive surgery has to be done. A more important consideration is the risk of perforation into the spinal canal between the atlas and axis, as pointed out by Beinfield.[19] The first record of the transpalatal procedure is that of Brunk[20] in 1909, who operated on a 20-year-old woman for unilateral atresia. The opening closed over in a short time. Blair,[21] in 1931 described the first successful transpalatal operation. This was performed through a longitudinal incision through which he removed a major portion of the hard palate, together with the posterior end of the septum and the obstructing tissue. In 1945 Ruddy[22] described a transpalatal approach in a three-year-old child with unilateral atresia. Ruddy used a transverse palatal incision and his procedure was further modified in 1951 by Owens.[23] In 1956, Cracovaner and Goodman[24] reported a transpalatal approach on a

22-month-old child with bilateral atresia. A transverse, curved incision was made, together with removal of the posterior portion of the nasal septum. No tubes or flaps were used in this procedure. Beinfield[25] and Ruddy[22] have traced the evolution of the operative procedures in thorough reviews and give excellent bibliographies on this subject (Fig. 5). An outline of the operative techniques for the transpalatal approach as used in the present series follows.

Operative Technique. The surgeon works at the head of the table looking down on the field. Intratracheal anesthesia is used, and the anesthetic of choice in our opinion is ether insufflation. The patient is placed in the recumbent position with the feet elevated and the head extended. The surgeon should take particular care in positioning the patient, as the operative area is a difficult one in which to get good visibility, especially in small infants. Position of the head is maintained by a broad strip of adhesive brought across the forehead and carried under the table on each side, to meet and overlap. Using a malleable retractor suitably bent, the tongue and lower jaw are gently retracted and the palate easily exposed. If the position is suitable, the area of the face is cleaned with Zephiran, mucus is suctioned from the nose, and cotton packs moistened with epinephrine (1:1000) are inserted into the nose against the area of obstruction. A vaseline-covered eye pad is always in place before the head towel and drapes are applied. The anesthesia tube is tucked to one side of the tongue, which is retracted forward by an assistant. Using a fine needle, the tissues of the midline of the hard palate and those at the juncture of the hard and soft palates are injected with two per cent procaine containing a few drops of epinephrine; this is usually helpful in controlling oozing. After blanching has occurred, an incision is made through the mucous membrane and periosteum in the midline from the edge of the hard palate anteriorly, about three-quarters of the way to the gingiva. A second incision is made at right angles along the edge of the hard palate, exposing the edge of the hard palate but not extending completely through the soft palate. This incision follows the normal curve of the edge of the hard palate. The lateral extent of this incision in patients who have bilateral atresia may be as far as the pterygomandibular ligament, but in patients where the obstruction is unilateral, it is short on the side of the normal opening. The mucoperiosteal flaps of the hard palate are stripped back with a right-angle elevator and a silk suture is placed through the tip of the flap to evert and retract it laterally. After all bleeding is controlled, the soft palate is detached from the edge of the hard palate

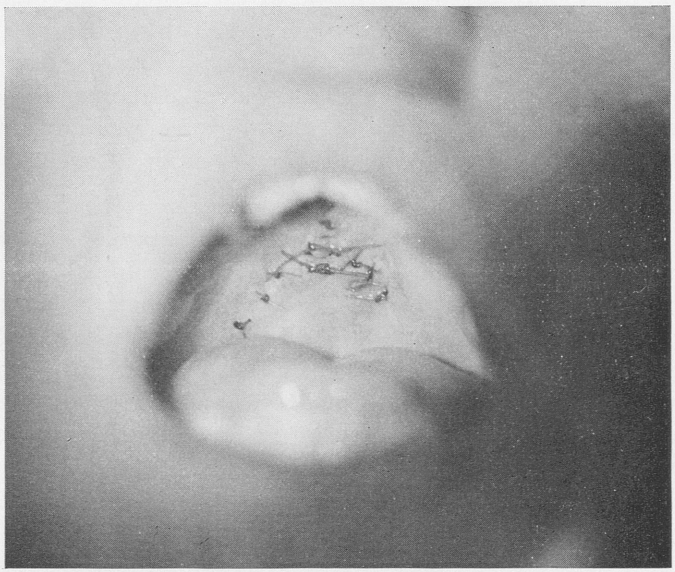

Fig. 6.—Intra-oral view of sutured incision in an 8-year-old girl.

and then retracts towards the pharynx leaving a surprisingly good exposure of the nasopharynx. At this point, a view of the area of the atresia with a small laryngeal mirror will help the surgeon orient himself as to the size of the choana, as well as the location and character of the obstruction. After removal of the cotton packs, palpation through the nose with a probe, while observing with a mirror, will disclose any dehiscence in the bone of the atretic area. Using a sphenoid rongeur, the edge of the hard palate on each side of the septum is removed as far anteriorly as the obstruction. The bony diaphragm is perforated through the nose and a small sphenoid rongeur passed through the nose is used to enlarge the opening in all directions. The bone is usually thin in the center and laterally, but sometimes as thick as a centimeter or more adjacent to the septum. Considerable variation may also exist in the size of the two choanae in the same patient. There are also minor variations in the angle at which the bony-membranous diaphragm joins the septum, as well as the depth of the diaphragm within the choana.

When the obstruction has been removed inferiorly, superiorly and laterally, the edge of the hard palate is further removed in the

area of the origin of the atresia. The entire posterior end of the septum, including the area of atresia is cut with heavy scissors or a gouge and detached from the base of the skull by simply dislocating the bony attachment and cutting the membranous attachment with scissors. In older patients where there is sufficient room to maneuver, one can make an incision around the upper end of the septum which will leave a superior flap and by freeing the mucous membrane from one side of the septum anterior to the atresia, a flap can be created which will cover the posterior end of the septum as well. These latter maneuvers do not appear to be necessary in infants.

The choana of each side should now be wide open and the only significant area not covered by mucous membrane is on the floor of the nose, represented in size by that portion of the hard palate removed at operation. The nasal chambers are cleaned of any debris by suction and irrigation with saline. The original incisions are then approximated with No. 0000 chromic catgut on a malleable cutting needle (Fig. 6). If bleeding has been slight (less than a few cc) and there is no oozing, no packing or tubes of any kind are used in the nose. If a pack is necessary, which is uncommon, a Portex tube is passed through the nose and a vaseline-covered postnasal pack pulled up into the nasopharynx. The Portex tube provides an airway for the patient during recovery from anesthesia and is always used when the nasopharynx is packed. Packs of this kind are removed within 24 hours after operation.

Postoperative care includes the use of antibiotics to control infection and limitation to liquid diet for four to five days after operation.

SUMMARY OF FORTY PATIENTS WITH CONGENITAL CHOANAL ATRESIA IN THE PEDIATRIC AGE GROUP, WHO HAD SURGICAL CORRECTION

In our series of 40 patients, there were 27 females and 13 males. Three of our patients who were operated by the transpalatal route belonged to the same family—further evidence of a genetic influence in this condition. The atresia was found to be bilateral in 18 patients and unilateral in 22. Of the unilateral type, there was no doubt about the preponderance of the right side, since in 15 the obstruction was on the right and in only 7 on the left. Thirty-eight patients had bony obstruction and only 2 were membranous. The incidence of membranous atresia was five per cent in this series as opposed to ten per cent in the literature.

TABLE I

CONGENITAL CHOANAL ATRESIA

Summary of 40 Operated Cases
Females 27 Males 13

Age at Operation		*Type*	
Under 1 month	5	Bilateral	18
1-6 months	14	Right	15
6-12 months	3	Left	7
1-3 years	9		
3-6 years	6	Bony	38 (95%)
6-12 years	3	Membranous	2 (5%)
	40		

As to the time of operation, 19 of our patients (nearly 50 per cent) were operated upon under six months of age (Table I). The youngest was one day old when a transnasal procedure was used. The youngest upon whom a transpalatal approach was made was 15 days of age. Another infant was similarly operated upon at 20 days, and two at 30 days. Fourteen more were operated upon from 1 to 6 months of age: five of these in the period from 1 to 3 months, and 9 in the period from 3 to 6 months. Between the ages of 6 months and 3 years, 12 patients were operated upon: 3 of these between 6 and 12 months; 2 between 1 and 2 years, and 7 between 2 and 3 years. Six were operated upon between 3 and 6 years of age, one at 7½ years, one at 9 years, and the oldest of this pediatric series was a 12½-year-old girl.

Ten intranasal approaches were used, two of these being for the correction of membranous atresias (Table II). Three of the 10

TABLE II

Type of Operation	*Total*	*Good*	*Revised*
Intranasal (Including 2 membranous)	10	7	3
Transpalatal	30*	26	2 (one to be revised)
Tracheotomy	4 (10%)		

* (1 - sclerosing osteitis)

patients were re-operated by the transpalatal approach because of closure. Of the 30 patients operated upon originally by the transpalatal approach, 2 developed temporary fibrous stenosis which cleared up with dilatation. One failed because of sclerosing osteitis, and 2 were re-operated upon with revision. There is one patient remaining in this group who may need a revision at a later date. The results in the remaining 26 cases were good, and patency has continued to remain satisfactory. In one patient who had the transpalatal approach, a fistula developed which closed by the end of a week. In all other instances the palate healed by primary intention.

It seems reasonable to conclude from our experience that definitive surgery through the transpalatal approach can be carried out successfully in the very young patient with the expectation that the results will be as good as in the older individual.

300 Longwood Ave.

REFERENCES

1. Craig, D. H., Simpson, N. M.: Posterior Choanal Atresia, With a Report of Ten Cases. J. Laryng. and Otol. 73:603, 1959.

2. Hanckel, R. W.: Bilateral Choanal Atresia. Annals of Otology, Rhinology and Laryngology 58:852, 1949.

3. Walker, J. S.: Transpalatine Surgery for Congenital Bilateral Choanal Atresia. J.A.M.A. 154:753, 1954.

4. Schwartz, A. A., and Isaacs, M. J.: Congenital Atresia of the Posterior Nares: Report of Two Cases. Arch. Otolaryng. 35:603, 1942.

5. Otto, A. W.: Lehrbuch der Path. Anat. des Menschen und Die Thiere. Berlin: A. Rucker, 1830.

6. Emmert, C. F.: Lehrbuch der Chirurgie. Stuttgart: F. v. R. Dann, 1853.

7. McGovern, F. H.: Congenital Choanal Atresia. Laryngoscope 60:815, 1950.

8. Wilkerson, W. W., Jr., Cayce, L. F.: Congenital Choanal Occlusion. Trans. Am. Acad. Ophth. and Otol. 52:234, 1948.

9. Stewart, J. P.: Congenital Atresia of the Posterior Nares. Arch. Otolaryng. 13:570, 1931.

10. McKibben, B. G.: Congenital Atresia of the Nasal Choanae. Laryngoscope 67:731, 1957.

11. Poch-Viñals, R., Calvo, R. Ramos: Choanal Atresia: Embryological, Clinical and Therapeutic Study. Arch. Otolaryng. 63:559, 1956.

12. Roopenian, A., Stemmer, A. L.: Congenital Posterior Choanal Atresia. Am. J. Surg. 96:802, 1958.

13. McNeill, N. A., Wynter-Wedderburn, L.: Choanal Atresia: a Manifestation of the Treacher-Collin's Syndrome. J. Laryng. and Otol. 67:365, 1953.

14. McGovern, F. H.: The Association of Congenital Choanal Atresia and Congenital Heart Disease. ANNALS OF OTOLOGY, RHINOLOGY AND LARYNGOLOGY 62: 894, 1953.

15. McGovern, F. H., and Fitzhugh, G. S.: Surgical Management of Congenital Choanal Atresia. Arch. Otol. 73:627, 1961.

16. Thomasson, W. J.: Congenital Bony Occlusion of the Right Nasal Choana. Laryngoscope 25:221, 1915.

17. Beinfield, H. H.: Ways and Means to Reduce Infant Mortality Due to Suffocation (importance of choanal atresia). J.A.M.A. 170:647, 1959.

18. McGovern, F. H.: Bilateral Choanal Atresia in the Newborn: a New Method of Medical Management. Laryngoscope 71:480, 1961.

19. Beinfield, H. H.: Bilateral Choanal Atresia in the Newborn. Arch. Otol. 73:659, 1961.

20. Brunk, A. A.: A New Case of Unilateral Osseous Choanal Occlusion: An Operation Through the Palate. Ztschr. f. Ohrenh. 59:221, 1909.

21. Blair, V. P.: Congenital Atresia or Obstruction of the Nasal Air Passages. ANNALS OF OTOLOGY, RHINOLOGY AND LARYNGOLOGY 40:1021, 1931.

22. Ruddy, L. W.: A Transpalatine Operation for Congenital Atresia of the Choana in the Small Child or Infant. Arch. Otol. 41:432, 1945.

23. Owens, H.: Observations in Treating Seven Cases of Choanal Atresia by the Transpalatine Approach. Laryngoscope 61:304, 1951.

24. Cracovaner, A. J., and Goodman, M.: Congenital Bilateral Choanal Atresia. Arch. Otol. 64:267, 1956.

25. Beinfield, H. H.: The Treatment of Complete Unilateral Bony Atresia of the Posterior Nares. Arch. Otol. 53:530, 1951.

DISCUSSION

DR. FRANCIS H. MCGOVERN: Dr. Ferguson's presentation is especially valuable because he has dealt with a meaningful series of patients with a congenital choanal atresia—over 50 patients in the past twenty-five years. In 1961, Fitz-Hugh and I reported twenty-six cases seen in like period of time; since then we have seen six or eight additional cases.

I think the significant feature of Dr. Ferguson's paper is the reporting of his experience in surgically correcting forty cases of this anomaly in infants and young children, mostly by the transpalatine approach.

His success with this approach, even in infants, adds weight to the opinion that the transpalatine operation is the most satisfactory method of removing the atresia, whether unilateral or bilateral. Except in the unusual instance of a membranous occlusion of the posterior nares, the transnasal or transseptal approach is usually followed by a course of tedious and frustrating postoperative care and a high incidence of reclosure or contracted opening.

In order to accomplish an adequate opening and to fashion suitable mucous membrane flaps to cover the raw bony edges, direct vision of the operative site is mandatory. C. P. Wilson has observed that the choanal atresia is rarely a simple

bony partition; the whole choanal region is small, deformed and thickened. The hard palate is often high arched and the septum is deviated to the side of the atresia. In addition, to satisfy the physiologic size relationship between the anterior and posterior nares, which, according to Proetz, the anterior nares should be smaller in section than the choana, the direct approach is the only means of obtaining as large an opening as anatomically possible.

Within the last few years we have been impressed by the advantages of the medical management of bilateral congenital choanal atresia in the newborn. In this method the infant is taught mouth breathing, and the surgical correction of the atresia is postponed until the infant has grown in size and strength. The simple nipple device I described not only provides an airway, but also solves the feeding problem. If surgery can be deferred for a year, the operative area is twice the size of that of a newborn. This method has a special advantage in the presence of an associated congenital anomaly, such as congenital heart disease, or a prematurity, exhaustion, innutrition or other factors increasing the hazard of immediate surgery. Dr. Ferguson has shown he has been able to successfully correct the deformity in infants, using the preferred transpalatine approach, regardless of the small working area.

From a technical point of view, we prefer the Owens type of palatal incision. We contend the T type incision offers a small risk of fistula formation. We agree with most authors that the preservation of as much mucous membrane area as possible to cover the raw surfaces of bone, and the resection of the posterior portion of the nasal septum is essential. Of course in infants the development of mucous membrane flaps is limited.

I should like to ask Dr. Ferguson if the adenoid mass was a problem in his cases, and if the eventual effective opening was generally satisfactory. Although Dr. Ferguson does not recommend an indwelling catheter, we have always used a snug fitting polyethylene tube to retard contracture and maintain an optimal opening; the tube is maintained in place for a month or more.

Dr. Francis L. Lederer: Such presentations are always timely because they are of practical interest.

In our experience tracheotomy has figured more prominently than shown in these figures, mainly because tracheotomy is the weapon of the obstetrician at the time of delivery, who, when acquainted with the early signs, usually is resourceful enough to put in the innter tube of the OO tracheotomy tube.

The insertion of polyethylene tubes into the anterior nares has given us considerable concern because we have had, in two instances, atresia of the anterior nares develop as the result of the large tube causing decubital ulcers. Later we were confronted with what you know is a rather difficult problem, namely, the stenosis.

I think that it would be of interest for all of us to realize that laminography does have a place in this entity in the differential diagnosis and I am certain the roentgenologist in the children's hospital has an awareness of this.

I believe it might have been an inadvertent thought on Dr. Ferguson's part. I do not think he meant the injection of pontocaine. I just had a feeling that maybe he sprayed in the pontocaine.

Certainly one is impressed by the large experience that he has had and the fact that we need to disseminate this kind of information among the obstetricians.

I also like the idea of Dr. McGovern's immediate application of the nipple. I asked him to explain why some children get to be ten years old with bilateral atresia and some of the children cannot even achieve the ten hours' old status.

There must be a number of other factors, other than the principle of the McGovern nipple.

DR. JEROME A. HILGER: I want to lean on Dr. Ferguson's extensive experience.

We have come to differentiate sharply between unilateral and bilateral atresia. In this type of surgery, exposure of the palate and removal of a posterior segment leaves a permanent older-child deformity. The palate does not develop as fully and normally as one would like. As a consequence, it has been our inclination to let the unilateral atresia child grow up and then do an intranasal operation removing the posterior third of the septum to allow the two nasal chambers to have a common posterior communication. This, then, of course, avoids the deforming developmental fault in the palate because of the stripping back and the resection.

As a result of your experience, Dr. Ferguson, do you confine the early operation to the bilateral atresia case?

DR. FERGUSON (closing): I should like to thank the discussers very much. When I was asked whom I would like to have open the discussion, of course, there was obviously only one choice. Dr. McGovern has been *the* authority over the years on this particular condition, and I greatly appreciate his willingness to give us the benefit of his wide experience.

I was interested to see that Dr. Lierle in an editorial comment on one of the articles I found in the 1959-60 *Year Book* (p. 282) said that he felt it was not necessary to use nasal tubes, grafts or flaps, if the posterior part of the septum is removed. We do not generally use tubes. We did in one or two instances, but had some stenosis of the nares in one patient. Therefore, we decided not to use an indwelling tube regularly. We have found that the operated area stays open just as well without them, and heals easily and completely.

As far as Dr. Lederer's question is concerned, we have had a few tracheotomies done before the patients were admitted as new-borns from the Boston Lying-In Hospital. In general we have not felt it was necessary or desirable. Laminography is a very good idea, and I think on the next case of atresia we see we will have our radiologist use the laminography technique.

The "rubber nipple idea," of course, is an excellent suggestion, and it allows the patient to get back to better weight, and better nutritional state. Then we can carry him along for some time with regular medical care. In recent years, since Dr. McGovern has brought out this very simple and very effective method, we can let the patient, even with bilateral atresia, get a little stronger and larger, and safely wait for several months before operating.

I agree entirely with Dr. Hilger that if the condition is unilateral, there is no rush about operating. The patient gets along very nicely breathing through one side of the nose.

Fortunately we have run into no difficulty as far as later development of the palate is concerned. Our oldest patient is now 25 years of age, and the speech is excellent. The palates seem to heal very nicely by primary intention, and there is good length and good mobility. The adenoid problem has not bothered us particularly. We do not remove the adenoids ordinarily—we think we have done enough at the time. Some of the children may come back for adenoidectomy later on, as children are prone to do, and at that time the palate has been found to be perfectly supple, long, and normally movable. Therefore, I do not think that the transpalatal approach interferes with later function or further growth or development of the palate.

HUMAN CILIATED EPITHELIAL CELLS IN NASAL SECRETIONS

MORPHOLOGIC AND HISTOCHEMICAL ASPECTS

WILLIAM T. K. BRYAN, M.D.
(by invitation)

MARIAN P. BRYAN, A.B. (by invitation)
CATHERINE A. SMITH, PH.D. (by invitation)

ST. LOUIS, MO.

The nasal columnar epithelial cells are involved in various aspects of pathology and physiology. From the standpoint of clinical cytology these epithelial cells found in nasal secretions during the common cold and allergy have proved particularly interesting so that it seems worthwhile to investigate certain morphologic and histochemical aspects of their intracellular details. The activity and characteristics of the living exfoliated cells and their tufts magnified with oil immersion are shown in motion pictures. Cytochemical methods and electron microscopy of such cells have been initiated.

Thirty-four years ago in 1930, the president of this Society, Dr. Anderson Hilding,[15] reported a very complete study of the common cold. Those investigations actually were begun in 1926 when he carefully observed the secretions and mucous membranes microscopically. He showed that living ciliated cells were exfoliated in acute upper respiratory infections and he also made a motion picture verifying the motility of the ciliated cells. He found that they moved with a rotary rhythmic movement with the rate varying from 60 to 268 beats per minute. Our findings indicate also that the cells are in different stages of death, some living much longer than others and with the speed and intensity of the beat of the cilia being variable. They are present in the living condition from the first day through the third day, depending upon the severity of the cold. They often disappear very rapidly from the secretions. Hilding also noted ciliated fragments of the exfoliating cells. Similar ones are shown highly magni-

fied in our motion picture. He stated that the pathologic process is that of inflammation of the mucous membrane with rather marked tissue changes, including the loss of many of the surface cells and a proliferation in the submucosa. The epithelium was regenerated and repaired by the growth and multiplication of the stellate cells normally found in the basal layer of epithelium. This was beautifully shown by tissue section from biopsies taken from human volunteers during the common cold.

The next step in the elucidation of the morphologic characteristics of these cells was made in 1950, by Bryan and Bryan,[3] with the application of the Papanicolaou fixation and stain to nasal secretions from the common cold. The study was continued and the reports of 1952,[4] 1953,[5] and 1958[6] showed clearly differentiated epithelial cells and a pattern of degeneration which was pathognomonic of the common cold. The degeneration consists of progressive nuclear pyknosis and the formation of apparent inclusion bodies. As the degeneration progresses the cell may split, separating the nuclear portion from the ciliated cytoplasmic portion.

In 1956 Papanicolaou[25] described similar degenerating epithelial cells in smears of sputum. His impression was that of mass degeneration and destruction of the ciliated cells of the bronchial mucosa. He termed this "ciliocytophthoria" (CCP) (Phthora means destruction). He described nuclear and cytoplasmic changes with inclusion bodies similar to those noted in the nasal secretions.

In 1958 Pierce and Hirsch[28] reported observations of the cytology of sputum with special emphasis on CCP in patients with various types of respiratory disease. They showed that CCP was most frequently found during pulmonary infections of viral etiology. It was strikingly associated with acute respiratory disease of established or probable viral origin. Atypical pneumonia and Asian influenza gave a high incidence of CCP. On the other hand it was rare to find these forms in bacterial pneumonia. These investigators concluded, as we have, that this pattern is a diagnostic aid which can serve to distinguish between infections of viral and bacterial etiologies or combination of both types.

Messerklinger[23,24] in his extensive treatise in 1958 on the nasal mucosa, pictures these dying cells but does not mention the relationship or significance of them in the common cold.

MOTION PICTURE STUDIES

Secretions were taken from a severe afebrile cold (M.P.B.). A drop of blown secretion was placed on a slide, which had previously been ringed with vaseline. This prevented the cells from drying and also made the streaming of the secretion less rapid. The major difficulty at high magnification is to keep the motile cell or tuft in the microscopic field and in focus.

The nuclear portion with halo and inclusion bodies, granular condition of the cytoplasm, and the cilia which are distinct in the stained preparations can be seen in very similar fashion in the living unstained cells and tufts. The whole cell is moved because it is free of support. The movement is so rapid that the cellular detail can be seen to better advantage when the speed is reduced. The pinching or breaking apart of the cell as it degenerates can be seen in the picture. Different views are shown of the varying degrees of motility, distribution of the cilia and the waving rhythmic beat and bend even of an individual cilium. The basal bodies are frequently seen. An additional feature which is not seen in stained preparations but only in the living cells, is the presence of protoplasmic extrusions, which give the impression of cysts or small bubbles of various sizes, more frequently seen protruding from the limiting membrane as a cell or tuft is near death. Certain exfoliated cells have been observed to live as long as 6 to 8 hours in these sealed preparations. From time to time excellent views of the nuclei, inclusions and coarsely granular cytoplasm appear in spite of the active ciliary motility. The cells often assume curious shapes. The ciliated tufts also live for hours separated from the nuclei. The vigorous motion of these is amazing. Death occurs very gradually as the waving motion finally ceases. Proetz[30] emphasized the remarkable vigor and persistence of cilia in the face of most unfavorable conditions. He noted that cilia could persist in beating after the cell to which they were attached was individually teased away from the specimen under the microscope. Here we see them persistently beating even after the cell itself is affected by disease.

HISTOCHEMICAL ASPECTS

Questions as to the chemical make-up of cells and their changes under different conditions constantly challenge our minds. Histochemical stains have been developed for many of the intracellular chemical constituents.

Excellent reports of their application to sectioned nasal mucosa are found in the literature. One of the earliest and best organized reports was made by Miles Taylor,[35] who studied human nasal mucosa and also that of rabbits and rats. He found in man that the cytoplasm of the epithelium of the entire nasal respiratory mucosa contained Periodic acid-Schiff positive material indicating that this material contained mucoprotein and mucopolysaccharides.

Weisskopf and Burn[38] in 1958 worked on histochemical aspects of the ground substance of the nasal turbinates. This was followed in 1959[39] by histochemical studies of the pathogenesis of nasal polyps revealing the constant presence of acid mucopolysaccharides in the ground substance and in all polypoid tissue. Hopp and Burn[17] also reported on the ground substance in the nose in health and disease, and demonstrated that in infection a depolymerization and increased permeability of ground substance occurs.

Others who have studied histochemical aspects of sectioned nasal mucosa include Braun-Falco,[2] Pasavento and Gasparini,[27] Gaini,[11] and Galli and Perucci.[12] Gasparini[13] reported on histochemical characteristics of normal human nasal mucosa again in 1962.

The second part of this study describes the application of the following cytochemical stains to the epithelial cells found in smears of nasal secretions.

1. Feulgen - DNA.
2. Periodic Acid Schiff (PAS) - Polysaccharides.
3. Alcian Blue PAS - Hematoxylin - Acid polysaccharides.
4. Alcian Green Feulgen - Acid polysaccharides plus DNA.
5. Triple Stain (Himes and Moriber[14]) Desoxyribonucleic acid, Polysaccharides and Proteins.
6. Methyl Green - Pyronin for nucleic acids (Kurnick[20,21]).
7. Fluorescent staining with acridine Orange (Pollard and Starr[29]).

FEULGEN STAIN

In 1924 Feulgen and Rossenbeck[10] reported the microscopic chemical identification of DNA in nuclei. This consisted of red-violet staining of DNA with fuchsin sulfurous acid (Schiff's reagent) after the purines had been split off by mild acid hydrolysis. When nucleic acids are treated with warm HCl, aldehyde groups are released

from the desoxypentose sugars but not from the pentose sugars. When treated with Schiff's reagent, DNA reacts positively. This specific staining reaction for DNA known now as the Feulgen reaction, has become one of the most important criteria for providing information of the exact localization of DNA in the chromatin of cells. It was originally noted that in contrast to DNA, RNA was Feulgen negative. Thus these two nucleic acids can be successfully differentiated. The method has been generally accepted as specific for visualizing DNA.

By the use of this reaction we hope to learn something of the nature of the inclusion bodies seen in the degenerating ciliated cells stained with Papanicolaou's method. With the Feulgen stain the nuclear DNA is seen as bright magenta-red aggregates localized within the nuclear halo. The counterstain, Fast Green, colors the cytoplasm and cilia pale green. Inclusion material is not identified so that it is presumably Feulgen-negative. The nucleus of a normal cell stains lighter due to the dispersion of the chromatin.

PERIODIC ACID SCHIFF REACTION - PAS

Modern histochemistry of polysaccharides, mucopolysaccharides and mucoproteins is bound up with the Periodic Acid Schiff reaction. Periodic acid (HIO_4), an oxidizing agent was first used by Malaprade[26] for the chemical estimation of glycols ($CH_2OH.CHOH$). Aldehyde groups created by the periodic oxidation in tissue sections or smears are demonstrated by treatment with Schiff's reagent. This combination was first used for demonstrating mucin by McManus[22] in 1946.

According to Pearce,[26] periodic acid breaks the C-C bonds in various structures where these are present at 1:2 - glycol groups converting them into dialdehydes. The equivalent amino or alkylamino derivatives of 1:2 glycol groups or its oxidation product (CHOH.CO) are also attacked and converted into dialdehydes. Periodic acid is superior because it does not further oxidize the resulting aldehydes which can be localized by combination with Schiff's reagent to give a substituted dye, red in color. Carbonyl groups are thought to be oxidized to carboxylic groups and thus prevented from subsequent reaction with Schiff's reagent. The amount of color developed by the reaction is dependent on the amount of reactive glycol structure present. Although there is agreement that carbohydrates are mainly responsible for the PAS reaction, the data concerning particular carbohydrate components are contradictory (Barka[1]).

To define the PAS reaction of some carbohydrates requires further chemical investigation. According to Barka, most of the complex carbohydrates that give strong PAS reaction belong to the category of mucoproteins. Of the polysaccharides glycogen is strongly PAS-positive. Most of the acid mucopolysaccharides are PAS-negative or weakly positive.

This technique was applied and the specific timing in the various solutions was modified in order to adapt the reaction to the thin nasal smears. Since we know of no previous cytochemical work on the cells of nasal secretions in smears, we can only show visual evidence of what we have thus far found in our attempts to more fully elucidate and correlate the histochemistry and morphology of the columnar epithelial cell as it is affected and infected by the common cold.

The degenerating ciliated epithelial cell as viewed in nasal secretions taken from some colds is PAS-negative; however, when we observe epithelial cells from a person who is highly allergic at the time the cold strikes the cell, we see strongly PAS-positive granules in it. In a non-infected allergic secretion wide distribution of strongly PAS-positive material is seen varying in amounts from cell to cell. The normal cell is viewed in the same field for comparison.

ALCIAN BLUE-PAS

Alcian blue 8 GS, a phthalocyanine dye, was recommended by Steedman (Barka) as a selective stain for acid mucopolysaccharides. Alcian green 2 GX is similar in performance and often stains known acid mucopolysaccharides in low concentration when the other may fail. Even though, according to Pearse,[26] the histochemical specificity of the stains has not been precisely determined, it seems to have certain advantages over all other methods for acid mucopolysaccharides. Both of these dyes have been tried on nasal secretions from colds and allergy. The Alcian blue in cold cells has a tendency to lightly stain all structures so interpretation is difficult. When combined with the PAS stain on allergic material we see two interesting goblet cells which have both PAS-positive material and acid mucopolysaccharides indicated by the blue dye.

ALCIAN GREEN FEULGEN

The Alcian green dye was used on the secretions and counterstained with Feulgen to more distinctly identify nuclear material

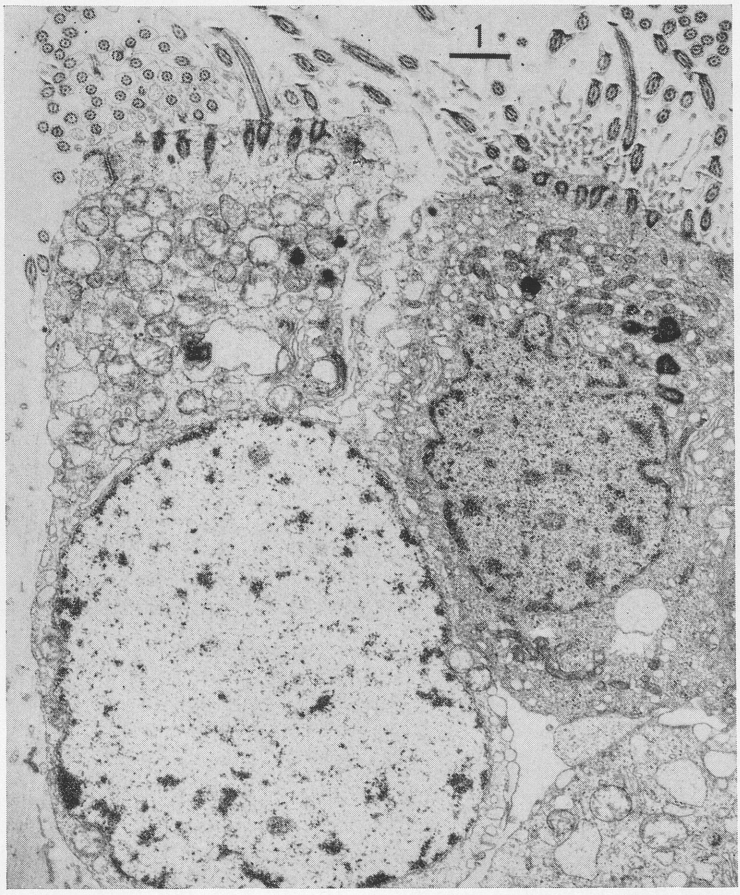

Fig. 1.—Electron micrograph of nasal cells, exfoliated during cold. 1 micron indicated.

as well as acid polysaccharides. The areas of reaction which stain a clear bright green are clearly visualized in the cytoplasm.

TRIPLE STAIN (HIMES AND MORIBER[14]) DESOXYRIBONUCLEIC ACID, POLYSACCHARIDES AND PROTEINS

The triple stain of Himes and Moriber[14] has been found to be very colorful and useful in nasal secretions to demonstrate simul-

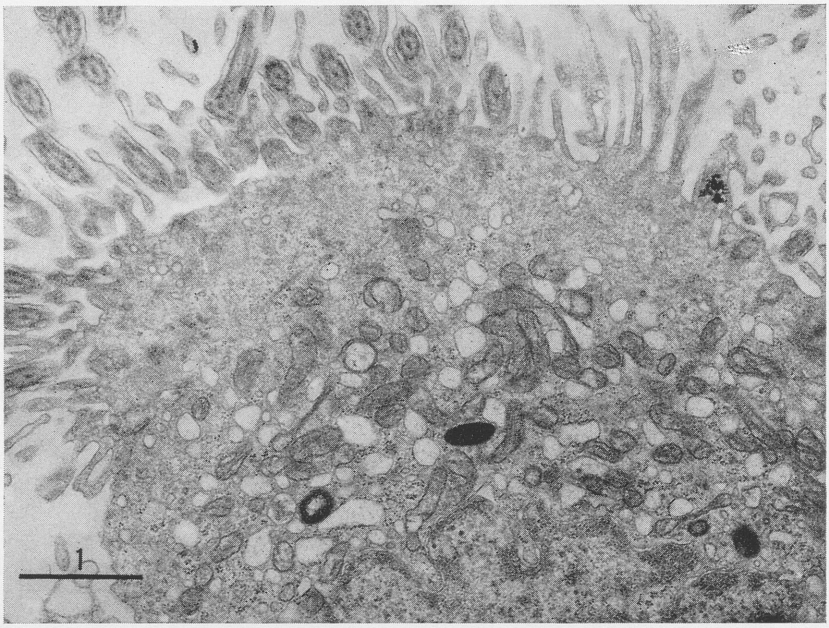

Fig. 2.—Electron micrograph of apical part of cell at right in Figure 1. 1 micron indicated.

taneously in the same slide and cells DNA, proteins and polysaccharides. The development of Schiff reagents from different dyes, such as azure A or acriflavin, which behave the same as the basic fuchsin reagent, has made it possible to demonstrate two different aldehyde reactions with two different colors. In this way, one may stain DNA by the Feulgen Nuclear reaction, using the blue azure A reagent and stain 1,2 - glycols with the periodic-acid-Schiff reaction of Hotchkiss[26] (1948) and McManus[22] (1946), using the common leucofuchsin reagent. A complete separation of the two Schiff reagents is possible when they are used consecutively, each following the aldehyde-releasing procedure. In addition, protein components of tissue may be demonstrated in contrasting color by use of the acid dye, Naphtol yellow S which combines with the available amino groups. According to other authors this method is excellent for qualitative localization of three important chemical components of cells. The adaptation to nasal secretion has proved so successful that it is being considered for use as a routine stain. Ribo-nucleic acid (RNA)

is not demonstrated by this triple stain. It is removed by the acid hydrolysis. Simultaneous demonstration of RNA and protein is impractical because of their overlapping localization.

METHYL GREEN PYRONIN STAIN

In order to show the area of RNA within the columnar epithelial cell, the methyl green-pyronin stain as described by Kurnick[20,21] has been applied to the nasal secretions of the common cold. It is possible that this method can clarify the relationship between the two nucleic acids in the nucleus and RNA in the cytoplasm. DNA is colored bright green and RNA is stained red. Kurnick[20,21] concluded that pyronin distinguishes only different states of polymerization of the nucleic acids rather than chemical differences between the two acids. The inclusion material that is often seen in the nuclear and cytoplasmic areas of the degenerating cold cell is seen as RNA-positive. Pearse[26] states that relatively minor changes can alter very greatly the uptake of basic dyes by nucleic acids. Kurnick[20,21] showed that using the two dyes together, RNA stained pale pink, depolymerized DNA a similar color, and polymerized DNA green. The mechanism of Pyronin binding by the lower polymer RNA has not been completely investigated.

FLUORESCENT ACRIDINE ORANGE

The exfoliating nasal columnar ciliated cells from the cold has also been stained with the acridine orange techniques and studied in the fluorescent microscope.* A slide showing golden fluorescence of the nuclear DNA and light red distribution of the cytoplasmic RNA is shown. Other viruses have been studied by Acridine Orange fluorochrome, reported by Pollard and Starr.[29]

ELECTRON MICROSCOPIC STUDIES

The respiratory epithelium has been studied with the electron microscope by Tremble,[36] Spoendlin,[34] Rhodin,[31,32] and Ricci and Gasparini,[33] Burion and Stockinger,[7] and Engström and Wersell,[8] so the normal and some pathologic aspects of these cells are known.

---

* These observations are being made by Dr. Eino Holopainen, Fulbright Research Fellow (Finland), Washington University School of Medicine, Department of Otolaryngology.

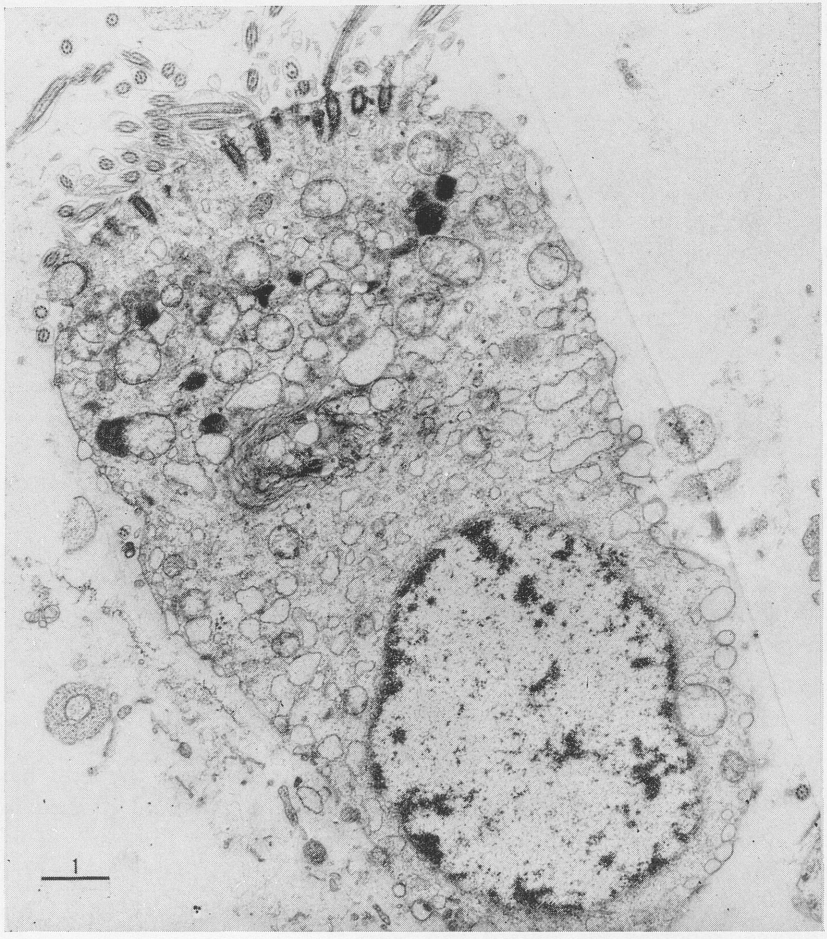

Fig. 3.—Electron micrograph of nasal cell, exfoliated during cold. 1 micron indicated.

Probably the most powerful tool of cytology is electron microscopy. Its application to these exfoliated nasal cells would visualize many as yet unknown details, the value of which only time will tell. Such investigations have been started on alterations in the nasal epithelium due to upper respiratory infections and allergic response.*

* N.I.H. Grant No. NB 00966-08.

Fig. 4.—A similar degenerating ciliated cell stained by Papanicolaou's method.

eral specimens of nasal secretions from the common cold have been appropriately prepared and studied with the electron microscope.

Electron micrographs of plastic embedded exfoliated cells are illustrated in Figures 1, 2, 3. Figure 1 shows a clump of epithelial cells at low power. The nasal secretion was obtained by swabbing the nose and smearing the material on cover slips. The material was then fixed in 1% OsO_4, embedded in Vestopal-W, and the sections stained with uranyl acetate (Fig. 3) or lead hydroxide (Figs. 1 and 2). The presence of cilia indicates that all are epithelial cells. The cell in Figure 2 shows dilation of the cisternae of endoplasmic reticulum with granules of ribonucleic and protein. The cell in Figure 3 gives evidence for greater change. The nucleus shows chromatolysis, with nuclear material remaining marginally. The sacs of endoplasmic reticulum are markedly dilated. Many are located peripherally, and some appear to be ruptured at the cell surface, although this may be artefact. Some layered membrane structures are visible above the nucleus.

In the apex are large rounded structures. The presence of some recognizable cristae indicates these are probably mitochondria. Some electron dense bodies are scatterd among them. The external membrane of some of the cilia is swollen, although the fibers apparently retain their usual arrangement. These studies have only been initiated, and at this time we do not know how representative these alterations are, or what is their significance. Figure 4 illustrates a ciliated columnar exfoliated cell fixed according to Papanicolaou from the same specimen of nasal secretion comparable to the cell studied in the electron microscope (Fig. 3).

SUMMARY

The shape and internal structure of the degenerated epithelial cell are largely those that were shown in the stained specimen. In addition, vesicle-like extrusions were noted in the dying cells. The force, speed and persistence of the cilia are striking. The duration of motion may be observed in some cells for eight hours.

This work has described seven of the many stains that could be used. It would seem that we are entering upon a wide area of cytochemical reactions to be explored and correlated with clinical signs and symptoms in nasal pathology. Nasal secretion is readily available and can be correlated with biopsies when necessary. The wiped nasal smear technique, as emphasized in other papers, can actually be considered a non-traumatic biopsy of the surface nasal mucosa. The technique previously described[3,4] of gently swabbing of the nose is recommended for obtaining material for cytochemical techniques.

The histochemical stains help to localize and show more vividly the areas where mucin is present in the cells and the varying amount of the PAS-positive carbohydrate. The area of DNA coincides with that of chromatin. RNA-positive areas seem to be correlated with inclusions seen in the Papanicolaou and Wright's stains. The Alcian green shows the specific localization of acid mucopolysaccharides.

The electron microscope reveals the finer structure of these epithelial cells. The exact interpretation and significance awaits further observations and study. The material presented demonstrates some of the varied facets of cytology which are interesting and offers a novel method for studying some of our clinical problems. There is a need, when possible, for biochemical data to be applied to clinical material.

950 Francis Place

REFERENCES

1. Barka, T., and Anderson, P. J.: Histochemistry: Theory, Practice and Bibliography. New York: Hoeber, 1963.

2. Braun-Falco, F.: Studies on the Ground Substance of Normal and Pathological Nasal Mucosa. Z. Laryng. Rhinol. Otol. 39:36-41 (Jan.) 1960.

3. Bryan, W. T. K., and Bryan, M. P.: Structural Changes in the Ciliated Epithelial Cell During Upper Respiratory Infection: Preliminary Report. Laryngoscope 60:523 (June) 1950.

4. Bryan, W. T. K., and Bryan, M. P.: Intracellular Morphology of Nasal Secretions with Kodachrome Illustrations. Tr. Am. Acad. Ophth. 56:171 (Mar.-Apr.) 1952.

5. Bryan, W. T. K., and Bryan, M. P.: Structural Changes in the Ciliated Epithelial Cells During the Common Cold. Tr. Am. Acad. Ophth. 57:297 (May-June) 1953.

6. Bryan, W. T. K., and Bryan, M. P.: Cytologic Diagnosis in Otolaryngology. Trans. Amer. Acad. Ophth. and Otolaryn., p. 597 (Sept.-Oct.) 1959.

7. Burian, K., and Tockinger, L.: Elektronenmikroskopische Untersuchungen an der Nasenschleimhaut. Acta Oto-laryng. 56:376 (Mar.-Apr.) 1963 Fasc. 2-3.

8. Engström, H., and Wersall, J.: Some Principles in the Structure of Vibratile Cilia. ANNALS OF OTOLOGY, RHINOLOGY AND LARYNGOLOGY 61:1027 (Dec.) 1952.

9. Fawcett, D. W., and Porter, K. R.: A Study of the Fine Structure of Ciliated Epithelia. J. Morph. 94:221, 1954.

10. Feulgen, R., and Rosenbeck, H.: Mikroskopischchemischer Nachweis einer Nukleinsäure vom Typus der Thymonucleinsäure und die darauf beruhende elektive Farbung von Zellkernen in mikroskopischen Präparaten. Z. Physiol. Chem. 135: 203, 1924.

11. Gaini, G.: Histochemical Study on the Experimentally Induced Inflammatory Degenerative Pictures of Nasal Mucosa. Minerva Otorinolaring. 1:430 (Nov.) 1961.

12. Galli, G., and Perucci, U.: Morphological and Histochemistry Investigation of the Epithelium of the Nasal Mucosa in Man. Boll. Mal. Orecch. 79:376 (July-Aug.) 1961.

13. Gasparini, G.: Contribution to the Knowledge of Certain Histochemical Characteristics of Normal Human Nasal Mucosa. Otorinolaring. Ital. 31:159, 1962.

14. Himes, M., and Moriber, L.: A Triple Stain for Desoxyribonucleic Acid Polysaccharides and Proteins. Stain Techn. 31:67, 1956.

15. Hilding, A. C.: The Common Cold. Arch. Otolaryng. 12:133 (Aug.) 1930.

16. Hilding, A. C.: Studies on the Common Cold and Nasal Physiology. Tr. Am. Laryng. A. 56:253, 1934.

17. Hilding, A. C.: Summary of Some Known Facts Concerning the Common Cold. Tr. Am. Laryng. A. 66:87, 1944.

18. Hopp, E., and Burn, H. F.: Ground Substance in the Nose in Health and Infection. ANNALS OF OTOLOGY, RHINOLOGY AND LARYNGOLOGY 67:480, 1958.

19. Hunason, G. L.: Animal Tissue Technique. W. H. Freeman and Co., 1962.

20. Kurnick, N. B.: Histological Staining with Methyl Green-pyronin. Stain Techn. 27:233, 1952.

21. Kurnick, N. B.: Pyronin Y in the Methyl Green-pyronin Histological Stain. Stain Techn. 30:213, 1955.

22. McManus, J. F. A., and Mowry, R. W.: Staining Methods Histologic and Histochemical. Harper & Row (Sept.) 1960.

23. Messerklinger, W.: Physiologic and Pathologic Changes of Nasal Epithelium. Arch. Ohren Nasen u. Kehlkopfh. 165:475, 1954.

24. Messerklinger, W.: Die Schleimhaut der oberen Luftwege im Blickfeld neuerer Forschung. Arch. Ohren Nasen u. Kehlkopfh. 173:1, 1958.

25. Papanicolaou, G. N.: Degenerative Changes in Ciliated Cells Exfoliating from the Bronchial Epithelium as a Cytologic Criterion in the Diagnosis of Diseases of the Lung. New York State J. Med. 56:17:2647 (Sept.) 1956.

26. Pearse, A. G. E.: Histochemistry Theoretical and Applied. Little, Brown and Co., 1963.

27. Pesavento, G., and Gasparini, G.: Acid Mucopolysaccharides of Normal Nasal Mucosa (Tissue Sections) Research on Their Distribution in Relation to Age. Boll. Soc. Ital. Biol. Sper. 36:919 (Sept.) 1960.

28. Pierce, C. H., and Hirsch, J. G.: Ciliocytophthoria: Relationship to Viral Respiratory Infections of Humans. Pro. So. Exp. Bio. and Med. 98:489, 1958.

29. Pollard, M., and Starr, T. J.: Study of Intracellular Virus with Acridine Orange Fluorochrome. Prog. Med. Viral. 4:54 (Karger, Basel, New York), 1962.

30. Proetz, A. W.: Applied Physiology of the Nose. Annals Publishing Co., 1941.

31. Rhodin, J.: Le Tractus Epithelial Respiratoire Son Ultra-structure et Sa Fonction. Bronekes 7:14, 1957.

32. Rhodin, J.: An Atlas of Ultrastructure. W. B. Saunders, 1963.

33. Ricci, V., and Gasparini, G.: The Structure of the Basal Membrane of the Nasal Mucosa in Man Under the Electron Microscope. Boll. Soc. Ital. Biol. Sper. 36:932 (Sept.) 1960.

34. Spoendlin, V. H.: Elektronenmikroskopische Untersuchungen am Respiratorischen Epithel der Oberen Luftwege. Pract. Oto-rhino-laryng. 21:484, 1959.

35. Taylor, M.: Histochemistry of the Nasal Respiratory Mucosa. J. of Laryng. and Otol. 72:365, 1958.

36. Tremble, G. E.: Observations of Respiratory Cilia with the Electron Microscope. Brit. Med. J. 2:127, 1955.

37. Tremble, G. E.: A Few Highlights Concerning Respiratory Cilia. Annals of Otology, Rhinology and Laryngology, Vol. 64, 1955.

38. Weisskopf, A., and Burn, H. F.: The Ground Substance of the Nasal Turbinates. Annals of Otology, Rhinology and Laryngology 67:292, 1958.

39. Weisskopf, A.: Histochemical Studies of the Pathogenesis of Nasal Polyps. Annals of Otology, Rhinology and Laryngology 68:519, 1959.

40. Weisskopf, A.: Connective Tissue: A Synthesis of Modern Thought and Its Impact on the Understanding of Nasal Disease. Laryng. 70:8 (Aug.) 1960.

DISCUSSION

DR. JOSEPH L. GOLDMAN: Doctor Bryan and his wife should be commended for their persistence in this interesting morphological study over a period of many years.

I think the material which they presented this morning may have considerable significance in our concepts of the antibacterial activity of the nose. I don't know if you are aware of the fact that Fleming discovered lysozyme before he discovered penicillin. Lysozyme may be a very intriguing substance in view of our present knowledge of what we call autobiotics, the natural antibiotics of the body.

It has been shown here that DNA appears in the cells demonstrated and it is possible that DNA in these cells may be the source of lysozyme, which is a very potent antibacterial substance. As a matter of fact, Réné Dubos actually discovered the first antibiotic when he produced gramicidin, or what we call tyrothricin, but this substance couldn't be used because of its harmful influence on cells. He was successful in isolating lysozyme but in such small quantities that he couldn't carry on adequate experimental work with it. However, the source of lysozyme has never been clearly established and to me this is of considerable interest in that it is very possible that these cells which Doctor Bryan demonstrated may be the source of lysozyme, a natural antibiotic.

This concept has considerable significance in the whole field of immunology and I hope that this work will be continued on a histochemical basis to see if these natural antibiotics do originate in these cells.

PRESIDENT HILDING: I would like to just point out that this paper indicates very well how Medicine is progressing, first the gross pathology, then the pathology as seen through a light microscope. Our professor in pathology, the late Dr. Robertson, 45 years ago warned us, "Remember, when you look at a cell, you are looking at the outside of a barn, trying to determine what goes on inside." Now, with the electron microscope, we are inside that barn, looking around, and finding a great deal there. These authors are now studying the intracellular biochemistry and perhaps when looking at the large molecules involved they also can say that we are still on the outside of a barn and that the real pathology is inside of the molecule.

I am particularly interested to hear Dr. Goldman mention lysozyme. I used to talk about that and people said, "It isn't important. It acts only on nonpathogenic bacteria and we are sure these pathogens are the ones that get by the lysozyme."

DR. FRANCIS L. WEILLE: I would like to ask Dr. Bryan if lysozyme can be found in nasal secretions, tears, and saliva. If it is universally present in these areas, is it the agent responsible for the astonishingly clean healing occurring in essentially infected fields, such as the canine fossa approach to the antrum?

DR. BRYAN (closing): I think the discussors point out what we need to do rather than ask questions about lysozyme that I can answer specifically.

I am aware, from reading in immunology, that lysozyme exists and that it is one of the important barriers to bacterial invaders; but as yet we haven't been able, nor have we even attempted, to demonstrate it in these cells—that is in the work to be done, Dr. Weille.

And Dr. Goldman, I think there is no real question to answer.

THE CURRENT STATUS OF RADIOTHERAPY IN CARCINOMA LARYNGIS

L. HENRY GARLAND, M.D.
(by invitation)
SAN FRANCISCO, CALIF.

It is approximately 42 years since Coutard[13] demonstrated that many patients with squamous cell cancer of the vocal cords can be permanently cured by external roentgen therapy, usually with the priceless benefit of preservation of a good voice. His demonstration was received with understandable skepticism on the part of many laryngologists and even radiologists. Until that time radiotherapy had been employed in larynx cancer more for palliation than for cure, and his proposal that treatment be fractionated daily over a period as long as three weeks was regarded as somewhat impractical. Tempora mutantur; nos et mutamur in illis.

Today it is generally accepted that primary untreated carcinoma of the vocal cord "should be treated with x-ray therapy if there is no extension" to the adjacent tissues.[11] "This is true irrespective of whether the lesion is on the middle, the anterior or the posterior portion of one or even both cords. . . ." (ibid.). Further "the concept that subglottic extension must be treated by surgery is no longer true, since 50 per cent of these patients can be cured by radiotherapy."[15]

This paper will summarize our personal experience with radiotherapy in laryngeal cancer, both cordal and extracordal, and discuss certain aspects of the method that are still problematic.

MATERIAL

The conventional anatomic grouping into supraglottic, glottic and infraglottic is employed. All patients had biopsy and microscopic confirmation of diagnosis (and in the reported series were squamous cell carcinomas). Radiographic examination of the larynx is routinely used, partly as a matter of record and partly to aid in confirmation of accurate beam centration. Diligent efforts are made to determine the

presence or absence of palpable nodes, since node metastasis is the single most significant prognostic factor, as well as an important guide to selection of therapy.

The primary tumor is recorded as "small," "moderate sized" (confined to the anatomical site of origin), extending beyond one anatomic region (but still confined to the larynx), or extending beyond the larynx. Clinically palpable cervical nodes which are judged to be metastatic are classified as mobile or fixed. Distant metastases, as determined by clinical or radiological examination, are so recorded.

Details of tumor classification on this T, N, M basis have been published by the American Joint Committee and also may be found in my chapter published in the 1963 edition of Prior's "Otolaryngology."[4] For many years clinical staging has been used in classifying laryngeal cancers. The following is my understanding of the corresponding features:

Stage	*Classified Extent of Disease*		
I	T 1	N 0	M 0
II	T 2 or 3	N 0	M 0
III	T 1, 2 or 3	N 1	M 0
IV	T 1, 2, 3 or 4	N 2	M 0

The significance of node metastasis is recognized by this classification, a small tumor (T 1) with clinically involved node (N 1) becoming automatically a stage III or advanced lesion. Any primary carcinoma of the larynx with distant metastasis (M 1) is also placed in stage IV.

Patients with carcinoma in situ are classified as stage 0. They are not included in this report.

The anatomic site distribution of the lesions in 122 patients with laryngeal cancer treated over 5 years ago by radiotherapy at our hands is as follows:

Supraglottic	44 patients
Glottic	75 patients
Infraglottic	3 patients

The clinical staging of these cases was as follows:

Site	*Stages I and II*	*Stages III and IV*
Supraglottic	10	34
Glottic	38	37
Infraglottic	2	1
Total	50 patients	72 patients

TREATMENT

Most patients with localized cancer, previously untreated, are advised to have radical radiotherapy (i.e. stage I and II lesions, irrespective of site). The cure rate is as good as that obtained with surgery, and the voice is preserved.

Patients with stage III disease are considered in accordance with these modifying factors: location of involved node, and presence or absence of marked infection. In the case of non-infected lesions, in which the clinically involved node can be included within a treatment field of reasonable size (e.g. one up to 8 cm in diameter), radiotherapy is recommended. But in the case of badly infected lesions, or lesions with an involved node at a distance, radical surgery is advised as preferable.

Patients with stage IV disease are seldom cured by either method; very elderly or debilitated persons may be treated by split-course radiotherapy; others may merit attempted cure by radical surgery.

As far as site is concerned, we believe that glottic lesions offer the best chance of cure by radiotherapy. However we have also cured localized supra- and infraglottic cancers by this method, and therefore believe it should be used in otherwise favorable cases. In the event of failure, radical surgery can still be employed with safety and a modest chance of success. We no longer agree that "x-ray therapy has no place in the treatment of subglottic lesions."[11]

METHOD

The usual orthovoltage x-ray beams (200 to 300 KV), and megavoltage rays (telecobalt) are at our disposal; we have observed many patients treated with other modalities (such as telecesium, a linear accelerator and a betatron). In our experience, the results with orthovoltage are as good as if not superior to those obtainable with

the other modalities. It is the radiation that is absorbed, not the radiation that is applied, that is important. By meticulous application of orthovoltage x-rays, a carcinocidal dose can be applied to most localized laryngeal cancers, without the undesirable deep side effects not uncommon with megavoltage (such as connective tissue injury and more marked late deep tissue changes). The warning skin erythema of orthovoltage is a useful clinical tool in our judgment, and one that is absent with megavoltage. The late superficial telangiectasis often present after properly given orthovoltage x-ray therapy is seldom troublesome.

Details of radiosensitivity, fractionation and relative biological effectiveness have been published elsewhere.[4] Dosage is individualized according to the extent of the tumor, the degree of infection, and the age and general status of the patient. In general, most squamous cell carcinomas of the glottis are treated by cross fire technique, using opposing circular or rectangular beams about 5 cm in diameter. One field is treated daily, each treatment being set up and given by the radiologist who initiates the course.

The planned midtumor dose ranges from some 5,000 rads in about four weeks' time to perhaps 6,000 rads in about six weeks. This requires from 3,000 to 3,300 r/air to each of the two lateral fields delivered in 24 to 42 treatment days. Daily dosage and total dosage are individualized to produce a mild mucositis in about the fourth week. Efforts are made to avoid premature or intense reactions. Dosage must sometimes be reduced in the fourth week because of painful pharyngitis. Pain and skin reaction usually subside even though treatment is continued. The tolerance of the deep tissues tends to parallel that of the epidermis under the conditions described. An advantage of orthovoltage treatment is that dosage may be adjusted accordingly.

Conference with the laryngologist should be held in the last week or two of the radiotherapy course in order to confirm the presence and location of the desired mucosal reaction about the tumor. Such a conference is important in those patients who are difficult for mirror examination, especially when the lesion is in the vicinity of the anterior commissure. This area may escape visibility, except with direct laryngoscopy.

If large fields (7 by 8 cm) are necessary to encompass the tumor, the total dose must be reduced, and a carcinocidal level may not be attainable with safety.

The epidermitis present at or near the end of treatment usually equals the degree of mucositis present in the larynx. With conservative management both clear up within two or three weeks, the mucosa more speedily than the skin. In favorable cases, the tumor is greatly reduced in size or gone by the time this mucosal reaction has subsided. Occasionally the tumor shrinks more slowly, taking as long as three or more months to disappear.

When palliation alone is intended, a tumor dose of 3,000 to 4,000 r is usually adequate. Occasional cures have been obtained with doses as small as 4,000 r in four to five weeks.

Our experience has been that a majority of curable cases of laryngeal cancer are controlled with doses in the range of 4,500 to 5,500 orthovoltage rads in periods of four to six weeks. There is some evidence that therapy on alternate days (three times a week) is more effective than daily treatments. This is under clinical investigation.

When telecobalt therapy is used, a similar two-field, opposing-beam technique is usually recommended. The author has employed a 1,200 curie telecobalt unit, at 50 cm distance with fields ranging upward from 5 cm in diameter. This functions as part of a clinical trial study, and is also used for the occasional patient with prior skin changes in the cervical area. With radical treatment courses the midtumor dose is planned at 6,000 to 7,000 r in approximately six weeks. The daily dose is about 300 r/air with small fields, suitably reduced with larger fields. This is given to alternate sides of the neck daily for five days each week.

RESULTS

The following are our results in 122 patients with carcinoma of the larynx treated only by orthovoltage roentgen therapy prior to five years ago:

Anatomic Site	*5 Year Survivors* (and per cent)	
Supraglottic	10/44	(22%)
Glottic	40/75	(54%)
Infraglottic	2/3	("66%")
Total	52/122	(43%)

There were 10 additional patients treated by roentgen therapy who, after apparent failure to cure by that method, had subsequent

radical surgery. Four of these also survived over five years, one of them incidentally showing no microscopic tumor in the resected specimen. Adding these patients, there was a total of 132 cases with 56 five-year survivors, a relative cure rate of 42%.

These data apply to patients who completed most or all of their planned course of radiotherapy, i.e. at least 4,000 rads tumor dose in four to five weeks. There were several patients in clinic practice who were too old, too feeble, or too unco-operative to continue the course of treatment. None of these survived five years, and they are not included in the tabulation. Their inclusion would result in an absolute five-year survival figure of only 31 per cent in our clinic material.

The longest survival following radiotherapy to date has been 21 years; this patient then died of independent causes. There were several survivors, clinically cured and with good voice for over ten years.

The results in patients with relatively localized disease (i.e. stage I or II) were naturally better than those in the entire series, as may be seen in the following:

Anatomic Site	*5 Year Survivors* (and per cent)	
Supraglottic	4/10	("40%")
Glottic	27/38	("71%")
Infraglottic	2/2	("100%")
Total	33/50	(66%)

The results in 48 private patients with glottic tumors were as follows:

Initial clinical cures—44/48.

Four failures in patients with stage III or IV lesions.

Of the 44 primary arrests, 4 died before the lapse of five years, all apparently cured of their disease; 9 developed recurrence within one to three years; a failure rate of 9/48 or approximately 18%. Five of this 9 agreed to subsequent laryngectomy, and 2 of these were cured.

The results in 21 patients with stage I glottic tumors were naturally still better—19 being clinically cured for five or more years or

"90%." There were 2 radiation failures—1 died of his disease three years after radiotherapy, 1 had laryngectomy one year after radiotherapy and is well more than five years thereafter.

These results are reasonably close to those reported in the literature, which may be seen in Table I.*

TABLE I

FIVE-YEAR RESULTS, RADIOTHERAPY ALONE (%)

Site	*Lenz* (N.Y. 1958)	*Lederman* (Lond. 1961)	*Nielsen* (Copen. 1958)	*Garland* (S.F. 1963)
Supraglottic	26	18	32	22
Glottic	39	48	58	54
	—	—	—	—
Infraglottic	33	30	6	2/3
All	34	38	46	43

Lenz's and Nielsen's data[9,12] are based on cases treated by either ortho or megavoltage; Lederman's[7] chiefly on cases treated by megavoltage or its equivalent (teleradium). Dr. Lederman does not think much of orthovoltage in the larynx, but for the nearby nasopharynx he publishes current results with the two modalities that are indistinguishable.

McCabe and Magielski[10] compare collected surgical and radiological results in 951 cases of "limited laryngeal lesions": the "average five-year cure rates" with surgery were 83 per cent and with radiotherapy 75 per cent.

COMPLICATIONS AND MORBIDITY

These have been considered in detail in the reference cited.[4] One particular complication, namely, fistula following post-radiation surgery, is discussed in subsequent paragraphs.

---

* The data from Lederman and Nielsen pertain to larger numbers of cases than reported by Lenz or the writer, and are more critically compiled (closer to absolute than relative).

RADIOLOGICAL FAILURE

The reasons for failure were principally extensive disease, interrupted treatment, or non-responsive tumor. The first is self-explanatory. The second is a problem with some elderly ambulatory patients: its control may require hospitalization or the use of voluntary agency transportation facilities. The third is of unknown origin. A minority of laryngeal carcinomas fail to disappear or fail to remain controlled with radiological techniques successful in many other cases of similar extent and histologic appearance. Pushing the dosage past safe tolerance limits will not cure such cases. Their main hope is radical surgery, after a reasonable interval (two or three months) since tumor regression may take as long as three months in some patients.

In ten patients, mostly with localized disease (stage 1 or 2) in whom radiation failed to achieve tumor disappearance, postradiation laryngectomy was performed by the referring surgeon and achieved four clinical cures. (One of these patients proved to have no microscopic tumor in the excised specimen.) The series is summarized in Table II.

TABLE II

RESULTS OF POST RADIOTHERAPY LARYNGECTOMY

TUMOR			*Interval Between Radiation and*		
Site	*Details*	*Stage*	*Surgery* (Mos.)	*Final Results*	
	R. arytenoid	1	7	D. pulm. embolism	D.D.*
Supraglottic	L. band	3	27	L. 3½ years	D.D.
	Epiglottis	4	4	L. 3 years	D.O.C.
	R. cord	1	12	L. 8 years	L.
	R. cord	1	12	L. 2 years	D.D.
Glottic	R. cord	1	24	L. 6 years	D.O.C.
	Both cords**	2	18	L. ¾ year	D.D.
	L. cord**	2	12	L. 1 year	D.D.
	R. cord**	2	30	L. 2 years	D.D.
Subglottic	R. lat.	1	2	L. 20 years	D.O.C.

* Code: L., living or lived; D.D., died with disease present; D.O.C., died of other causes, no laryngeal cancer evident.

** Cord partly fixed.

There was no failure of wound healing in this particular group of ten patients, two of whom had their surgery at the S. F. G. H. after radiotherapy had failed in our department; the remainder were operated upon in other hospitals. No fistulae were reported.

However in a series of five patients treated at the S. F. G. H. by laryngectomy following radiotherapy elsewhere, three fistulas were encountered. We believe that in two of these patients, the radiation may have been given too rapidly, and in the third to perhaps too large an area. The details are as follows:

REPORT OF CASES

CASE 1. Hosp. No. B 32361. Male, aged 60, with supraglottic tumor, stage II or III. Treated elsewhere by orthovoltage roentgen therapy in March 1959. "5430 r tumor dose via 2 oblique anterior neck fields, 8 x 5 cm size, in 24 elapsed days." Persistent tumor in December 1959. Laryngectomy in January 1960, with postoperative pharyngocutaneous fistula. Died after one year from "cardiorespiratory arrest." Comment: 5430 rads, orthovoltage, in 23 treatments, to so large a field is unduly fast, and apt to exceed tissue tolerance.

CASE 2. Hosp. No. B.12399. Male, aged 59, with supraglottic tumor, stage II. Treated elsewhere by 4 Mev. linear accelerator x-rays in July and August 1957. "6700 r tumor dose, via 2 opposing fields, of 'large size'." Persistent tumor in 1958. Laryngectomy in June 1958, with postoperative oral-cutaneous fistula. Died after five months from "pneumonia and cerebral thrombosis." Comment: 6700 rads, megavoltage, in 47 elapsed days is not above normal tissue tolerance, provided the fields are not too large, as they seem to have been in this case.

CASE 3. Hosp. No. N.125837. Male, aged 71, with glottic tumor, stage II. Treated elsewhere by megavoltage x-rays in September and October 1952. "7100 r tumor dose, via unspecified fields," in 41 elapsed days. Persistent tumor in 1953. Laryngectomy in December 1953, with postoperative pharyngo-tracheostomy fistula. Died after five months apparently from pneumonia. Comment: 7100 r of the quality employed, delivered in about 30 treatments may be unduly fast.

In summary: ten postradiotherapy laryngectomies were performed in our personally treated series reported herewith, without the

development of fistulae. Five were performed in our clinic-patient hospital on patients treated elsewhere, with three fistulae. This totals three in 15 observed cases. Supervoltage did not obviate the complication.

Baker[1] writes "we found very little difference in wound complications" between supervoltage and orthovoltage, the respective incidence being 45 per cent and 43 per cent of 34 patients receiving surgery after irradiation. He believes that the extent of the surgery performed is a more significant factor than the prior irradiation. He reports "6 instances of necrosis and slough of skin flaps; 14 pharyngeal fistulas; and 2 carotid artery hemorrhages."

DIVIDED-COURSE PROGRAM

In any therapeutic program requiring daily treatment visits for several weeks, intercurrent illness, accidents, and other complications may from time to time result in interruptions of the planned course. It has been the experience of many radiologists that despite such interruptions, some patients achieve good reduction in tumor size, and occasional long term control. Scanlon[14] has reported preliminary results in a fairly large number of patients so treated, mostly cases with head and neck cancers, especially of the posterior oropharynx. His program, using orthovoltage x-rays, is as follows: 200 - 250 rads tumor dose daily for about 12 days (i.e. 14 days elapsed time); then about 21 days' rest; then resumption of dosage at the same rate for about 15 days, ending up with a tumor dose of some 5500 rads. This dose therefore is spread over a total period of almost eight weeks.

Other schedules of interruption have been tried, but the difficulty of adequate controls prevents sound conclusion as to the true relative effectiveness of any of them.

We have used a two-week rest period in "mid-course" for a few elderly patients with stage III or IV disease, who refused or were regarded as ineligible for operation. Palliation has been reasonably good. The trial is being continued.

EPILOGUE ON MEGAVOLTAGE

Medical myths die hard. We are all conscious of procedures fashionable in one era and found wanting in the next—witness prolonged bed rest and pneumothorax for tuberculosis, total dental

extraction for focal infection, and bilateral radical antrectomy for "sinusitis." Megavoltage radiotherapy is another partial myth.

a) The clinical *cure rate* of cancers suitable for radical radiotherapy has not been improved with megavoltage, with the questionable exception of retinoblastomas. Easson[3] emphasized a few years ago that "properly controlled clinical trials (involving several hundred patients) show no improvement in five year survival rates with 4 MV x-rays over those obtained with Kilovolt therapy." Jacobs[6] in a careful statistical analysis of 1,495 cases of carcinoma of the tonsil, found no significant difference in megavoltage and orthovoltage survival rates.

Lederman,[7] in his monograph on carcinoma of the nasopharynx, noted that "there is no significant change in survival rates despite outstanding advances in technical equipment." He recorded combined five year results of 15 per cent in the orthovoltage era, and 15.7 per cent in the megavoltage. Cantril[2] several years ago reported these five-year survivals in carcinoma of the larynx: Megavoltage, 41 per cent; orthovoltage, 55 per cent. Wang and Schulz,[15] however, believe that their data show some improvement in larynx cures with megavoltage.

b) The clinical palliation rate of most cancers suitable for palliative radiotherapy has not been improved with megavoltage.

c) While megavoltage does "spare" the skin of some patients, it causes relatively greater insult to the deep tissues. Hunt[5] writes "our primary concern about complications from telecobalt therapy relates to potential injury to the spinal cord and certain other deep structures." Nevertheless, megavoltage is useful if the skin over the tumor site has been seriously injured by prior disease.

d) A minor, but not negligible, factor is that megavoltage therapy (telecobalt, linear accelerator or betatron) costs the average patient (or taxpayer) three times as much as orthovoltage.

Why then do some radiologists persist in the use of the more expensive and more penetrating modality? The reasons are many, and I suspect including the following:

1. Technical: it is sometimes easier for the therapist to plan and apply the desired tumor dose with megavoltage.

2. Psychological: colleagues and patients are impressed by size and numbers; a large 10 million volt linear accelerator must be better

than a small two million-volt-equivalent cobalt unit or a 200,000 volt roentgen unit. The "linac" attracts patients, and helps with the teaching or investigational program. The unit photographs well on Clinic Day.

3. Fiscal: once installed in its expensive concrete and air conditioned igloo, often with physicist or technologist, the upkeep must be faced; the trustees of the institution would be shocked if the unit were not used and, let us hope, amortized.

4. Clinical: in terms of patient comfort, megavoltage is widely acclaimed; this subjective phenomenon is not suitable for valid assay and is a minor item in larynx patients, since their pharyngitis tends to be more marked.

SUMMARY

The optimum treatment for cancer of the larynx is that method which will provide the best probability of cure with preservation of vocal function.

The selection of treatment depends on many factors, notably the anatomic extent of the tumor, the degree of associated infection, and the general health and temperament of the patient.

The classification and clinical staging of disease is important, and is described in the text.

Orthovoltage roentgen therapy is regarded as the radiation modality of choice for most, but not all cases.

Using this modality, the author has obtained the following five-year clinical cure rates:

a. Stage I glottic cancers: 90%
b. Stage I and II glottic cancers: 71%
c. Stages I - IV glottic cancers: 54%.

The results in supraglottic cancers were not so favorable (22% five-year arrests, all stages combined). Only three subglottic tumors were treated (and it happened that two of them were cured).

In ten radiation failures (of glottic and supraglottic tumors) laryngectomy was successful in four instances.

The over-all five-year cure rate, including all sites and stages, plus these surgical controls, was 42 per cent, or 56 of 132 cases.

450 SUTTER ST.

The author wishes to acknowledge the help of many laryngologists in the San Francisco area, the treatment of whose patients is reflected in the personal data published herewith.

REFERENCES

1. Baker, H. W.: Surgical Management of Recurrent Laryngeal Cancer After Irradiation. Cancer 16:774, 1963.

2. Cantril, S. T.: Radiation Therapy in Cancer of the Larynx. Am. J. Roentgenol. 81:456, 1959.

3. Easson, E. C.: Clinical Trials in Radiotherapy. Medica Mundi, Eindhoven, 8:64, 1962.

4. Garland, L. Henry: Radiation Treatment of Carcinoma of the Larynx. Otolaryngology, published by W. F. Prior, Philadelphia, Second Edition, 1963.

5. Hunt, Howard: Personal communication, 1963.

6. Jacobs, L. G.: Cancer Therapy. Evaluation of Supervoltage X-ray. Calif. Med. 97:163, 1962.

7. Lederman, M.: Place of Radiotherapy in Treatment of Cancer of the Larynx. Brit. Med. J. 1:1639, 1961.

8. Lederman, M.: Carcinoma of the Nasopharynx. Thomas, 1961.

9. Lenz, M.: Radiotherapy of Cancer of the Larynx: in Pack, G. T., and Ariel, T. M.: Treatment of Cancer and Allied Diseases. Ed. 2, New York: Paul B. Hoeber, vol. 3, 1958

10. McCabe, B. F., and Magielski, J. E.: Carcinoma of the Larynx. ANNALS OF OTOLOGY, RHINOLOGY AND LARYNGOLOGY 69:1013, 1960.

11. McCoy, G.: Cancer of the Larynx. Calif. Med. 100:192, 1964.

12. Nielsen, J.: Treatment of Cancer of the Larynx: in Pack, G. T., and Ariel, I. M.: Treatment of Cancer and Allied Diseases. Ed. 2, New York: Paul B. Hoeber, vol. 3, 1958.

13. Regaud, C., Coutard, H., and Hautant, A.: Curie-therapie et roentgen-therapie dans le cancer du larynx. Ann. mal. oreille et larynx 41:967, 1922.

14. Scanlon, P. W.: Split Dose Radiotherapy. Am. J. Roentgenol. 90:280, 1963.

15. Wang, C. C., and Schulz, M. D.: Cancer of the Larynx: Radiation Therapy. Radiology 80:963, 1963.

DISCUSSION

DR. PAUL H. HOLINGER: It is refreshing to see a series of cancer cases presented that have passed the five-year mark, using "five-year cure rate" as basic criteria. Dr. Garland will probably say, "naturally," but a critical analysis of many recent cancer papers on our programs have shown figures that include one-, two-, or three-year survivals, justifying this on the basis of new concepts of treatment.

But here our agreement ends and questions arise, although my admiration for Dr. Garland's work continues. It is exceedingly important that he does not include cancer in situ in his series, but lists them as Stage "O". I would like to know how he treates these patients if the lesion is localized and how he treats cancer in situ found diffusely throughout the larynx.

Dr. Garland states, "cure rate with radical radiotherapy of Stage I and Stage II lesions is as good as with surgery and the voice is preserved." One notices that he now uses surgical terminology in the word "radical." This includes some T-3 lesions without node metastases, and I would question whether there is always a preservation of voice or as good a cure rate in T-3 lesions as with surgery. Furthermore, as Laryngologists, we see patients treated with radiation whose voice is not preserved; those with edema, perichondritis, dryness and continuing discomfort in whom voice was stressed in regard to treatment choice, who have severe difficulty in talking after radiation therapy. In all seriousness and not in the sense of needling, I want to ask Dr. Garland how he treates these patients and what one can do for them in a palliative way.

It is of special interest that Dr. Garland prefers Orthovoltage (200 to 300 KV) to Megavoltage or Telecobalt. We are certainly pleased to hear this difference of opinion in an otherwise almost total shift to Telecobalt; but he uses as the reason for his preference of Orthovoltage the very factor that made us shift to Cobalt; namely, the degree of skin reaction which to him serves as a warning. He finds this at 4500-5500 r with Orthovoltage, but with Telecobalt he uses 6000-7000 r as "radical treatment." In our experience with Telecobalt, these figures are 500-1000 r too high. Although they are dosage levels that can be administered without the skin reaction Dr. Garland is used to seeing with Orthovoltage, in our experience these dosages cause edema and perichondritis, particularly as delayed reactions. Dr. Garland uses as evidence of a lack of difference in survival statistics between Orthovoltage and Telecobalt therapy, figures dealing with the treatment of tonsil, bladder, cervix and nasopharyngeal lesions; these are not larynx figures. Without going into a whole new paper, we cannot go into detail in regard to our own experience; but it would seem that our Cobalt series is statistically better than the previous Orthovoltage series. The reactions are milder and there are fewer post-radiation sequelae such as fixation, dryness, edema, perichondritis and pharyngitis. This is in direct disagreement with Dr. Garland. Furthermore, with cross fire laterally, it is difficult to see why the spinal cord might be effected.

We have had no experience with the divided course of therapy that he suggests for older or debilitated individuals. This is an interesting concept with support from other centers as well, and we would like to hear more about it. We would also like to ask Dr. Garland about pre-operative therapy followed by planned surgery in patients with laryngeal cancer. This is returning to favor as evidenced by papers at this meeting and by reports of similar combined treatment of bronchogenic and esophageal carcinoma. There are two phases of this; to make an operable lesion of an otherwise inoperable lesion and to improve therapeutic results in patients with operable lesions. Parenthetically, we do not feel that the Stage I cordal lesion should be included in this type of study since the cure rate already is above 90% and post-irradiation planned surgery would hardly be considered.

Dr. Garland mentioned that there were 122 patients in his treatment series with an additional ten (10) patients who had recurrences with subsequent surgery, and only four of the ten survived. One of the four had no tumor in the resected specimen. One wonders why he was treated with radical surgery under these circumstances. Was the biopsy positive or was this just an extensive, destructive lesion? These figures must certainly answer the statement that is often given the patient that "he should be treated with x-ray first because he can always have surgery later" for any residual or recurrent disease. Here is suggested only a 40% survival of those patients who subsequently required surgery, and death for all others who died after radiation without surgery. Five of nine failures of treatment of glottic tumors in patients operated for recurrence with only two cured seems an exceedingly low salvage rate, and does not give the patient an equal opportunity for cure when he is offered the alternative of immediate surgery or "radiation now and if there is recurrence you can always be operated."

In discussing fistulae following surgery on patients irradiated elsewhere, we agree that the cases described had excessively high dosages, or that therapy was given too fast. 6700 r to 7100 r Cobalt can usually be given without too much skin change at the time of irradiation; but we are encountering an increasing number of patients treated with these high dosages some years ago when Cobalt was first introduced who now have extensive recurrent disease with such extreme fixation that they are totally inoperable. Certainly the minimal skin reaction encouraged the therapist to go too high.

It is difficult to compare statistics when there are so many variables. Nevertheless, we would agree that the Stage I glottic lesions presented by Dr. Garland showing a 90% cure rate can only be matched and certainly not surpassed by the surgical figures. However, a figure of Stage I and Stage II glottic lesions showing a 71% cure is a figure we must question. Obviously, this includes the twenty cases of Stage I with a 90% cure rate; or, for the Stage II glottic lesions, according to his figures this would mean eighteen cases with eight cures or a 42.5% cure. This figure can be almost doubled with a surgical approach to Stage II glottic lesions. Similarly, the Stage I to IV glottic figure of 54% also includes the twenty Stage I glottic lesions, elevating the Stage II, III, and IV figure. I think we can argue with all except the Stage I glottic figure.

It is always a pleasure to hear Dr. Garland give a paper, and an even greater pleasure to have an opportunity to discuss it. I sincerely mean the word "discuss" because his contribution is of great significance in our field, and his presentation of his cases in our literature will constantly be referred to.

Professor Carl-Axel Hamberger: We have about the same experience with roentgen therapy. The most difficult are the carcinoma in situ cases. We do surgery in all these cases and our radiologists in Stockholm absolutely agree with this. We always do a laryngofissure or a cordectomy. Our patients are given speech therapy, very early, a week or two weeks after operation, and we feel that the voice is very good after this type of surgery.

I agree with you that the voice sometimes will be better after radiation. The most important thing is to get an exact biopsy to determine the differentiation. If there is no differentiation, it is always best to give radiation, and there is no problem. Carcinoma of the larynx is always discussed together with the radiotherapist and a decision made as to the radiation or surgery. We have for a long time given radiation, but now we are going over a little bit more again to surgery.

Dr. Joseph L. Goldman: I think that Doctor Garland's presentation has brought to our attention the critical problems which we, as laryngologists, have to

face in the treatment of cancer of the larynx. Actually, we should be very pleased by the fact that there are two modalities available to us and both these modalities have proved their effectiveness. There is one difficulty with this problem, namely, that we always are inclined to compare statistics. This may prove to be misleading. We have reviewed the literature extensively and practically no two papers use the same classification, the same criteria, or the same method of evaluating results. Also, highly competent x-ray therapy is hard to find. There are only certain centers that have the men available to provide the required radiotherapy and the necessary facilities. I don't think the particular apparatus is so important as the ability to administer x-ray therapy well.

Four years ago, in 1960, we reported before this Association 312 cases of carcinoma of the larynv treated over a period of thirty years and these statistics are being confirmed elsewhere. Essentially, the results with either x-ray therapy or surgery are similar.

Lesions of the cord will yield about 90 per cent; intrinsic lesions about 60 per cent; lesions of the epiglottis, false cord, maybe less, about 55 per cent; and lesions of the hypopharynx yield results somewhere between 20 and 30 per cent. It is true that, according to statistics of hypopharyngeal cancer in the literature, surgery shows slightly better results, somewhere between 10 per cent and 30 per cent, and x-ray therapy between 5 and 10 per cent. There is one notable exception. Doctor Clerf, reporting six cases of cancer of the hypopharynx, obtained a 50 per cent five-year cure rate.

These accomplishments have been established. Medicine has to be an evolutionary process and we have to go forward. I believe what we as laryngologists have to consider at this time is, where are we going? And this brings up the question of combined x-ray therapy and surgery.

I don't mean to belabor this issue but it is something that we as laryngologists have to face if we are going to give our patients better care.

I think that we are approaching the time that we should treat the small intrinsic lesion by x-ray therapy. There will be failures but some of these can be salvaged by surgery. Those not suitable for x-ray therapy alone should be treated by combined therapy, x-ray therapy first and then surgery. We have used 5,500 rads and followed this in three weeks by surgery. Others are suggesting smaller dosages with less interval before surgery, but that is beside the point. Correct dosage has to be determined eventually but this is the area where x-ray therapy is going to play an important part in the future. In this regard, I believe that cobalt teletherapy or the betetron will permit surgical intervention in a shorter period of time after radiation. It has been my impression from what I have seen that the 250 KV machine, although it can accomplish as much therapeutically, does give more reaction.

I think that we are facing a crossroads in the treatment of carcinoma of the larynx. We should create cooperative efforts with x-ray therapists. X-ray therapists can play an important role in providing more competent x-ray therapists in other localities. There is no question about the fact that there are many competent surgeons, but a surgeon won't be able to engage in combined therapy unless he has the proper cooperation from an expert x-ray therapist.

PRESIDENT HILDING: Dr. Garland asked me a question about the ciliary mechanism and its destruction by radiation.

I have no specific information, Dr. Garland, but, speaking generally, as you know, all the vital functions of the body have wide margins of safety, a great

compensatory capacity. The ciliary mechanism is no exception. It is very efficient and very persistent. In the extirpated trachea one can make a whole series of obstructing incisions and the cilia will snake the mucous blanket around and between and under and over, and manage to carry it away. I believe that that is what is going on. There must be enough functioning ciliary mechanism left near the destroyed areas to keep the airways clear through traction on the blanket.

Anyone who wishes to encompass as a specialty all diseases of the respiratory tract had better look at the monumental work that Dr. Garland has co-authored on *Diseases of the Chest*. It is really a tremendous field.

DR. GARLAND (closing): In reply to Dr. Holinger, it is not our general policy to treat carcinoma in situ. However, if a patient has repeated lesions of a cord or both cords, and if there are repeated histologic diagnoses of carcinoma in situ, and surgery is refused, I believe that a single course of radiotherapy is warranted and should be successful.

As to postradiation dryness, edema or perichondritis, I know of no really satisfactory treatment. These are conditions which should be prevented rather than treated. Perichondritis, if severe enough, requires radical surgery. It should be pointed out that none of these conditions are common with modern protracted radiotherapy. . . . What would you estimate, Dr. Holinger, about 10% of your patients following radiotherapy?

DR. HOLINGER: Approximately.

DR. GARLAND: It should be emphasized that megavoltage does not diminish the frequency of these complications. Some years ago Dr. Cantril did a controlled study comparing orthovoltage and megavoltage in the treatment of laryngeal cancer. He found no significant improvement in cures and no significant difference in long-term response.

It is my impression, Dr. Holinger, that if you did a controlled study of your own patients today, you would find similar results. You believe that you are getting better results with hard x-rays from telecobalt, but other factors are involved. If your radiological colleague resumed careful orthovoltage radiotherapy of every second patient, I sincerely believe the results would be equally satisfactory.

Professor Hamberger mentioned that in Sweden they use radiation today for undifferentiated carcinoma. It has been my own experience that the degree of differentiation as reported by our pathologists is not a significant factor in determining the response of a given case. In other words, we have had ten year cures in patients with well differentiated carcinoma treated by radiotherapy, and we have had equally long-term cures in some patients who had anaplastic tumors.

Dr. Goldman states that "Good radiotherapists are hard to find." May I perform a small experiment? It is my impression that good surgeons are hard to find. How many of you distinguished gentlemen in this room know the precise surgeon that you would like to have take your larynx out? (Two hands were raised.) I note the hands of Drs. Bryan and Holinger. Am I to conclude that they would permit one or the other to operate, but few else?

If you will let me know the location in which you would like a good radiotherapist I shall do my best to furnish the name of one.

Finally, as to combined therapy: we do not favor this approach.

CLINICO-HISTOLOGICAL STUDY OF CHRONIC PHARYNGEAL SYMPTOMS

J. THOMAS RULON, M.D.
(by invitation)
DETROIT, MICH.
AND
K. M. SIMONTON, M.D.
ROCHESTER, MINN.

Chronic pharyngeal symptoms such as soreness, dryness, postnasal discharge, and a combination of these are well known to every otolaryngologist. They may occur in patients of both sexes, of all ages from teenage generally to old age, and from all socio-economic levels.

The history of these symptoms obtained from patients may vary greatly and seem contradictory when comparing the histories of several patients. For example, one patient may report that the dryness in the throat is worse only in humid weather, while another will state that his dry throat is aggravated only at times of low humidity.

The appearance of the pharynx may also vary greatly in patients reporting the same or similar symptoms. It may appear normal, may be covered with thickened mucus, may appear excessively dry, or appear red and have a granular surface. Otolaryngologists agree that chronic pharyngeal symptoms not only present a problem in establishing an etiology, but also in the successful treatment for permanent relief of the symptoms. The authors have been interested in the patient with chronic pharyngeal complaints for some time because of the large number seen in their practice. The inability to establish a definite etiology for the symptoms and to prescribe a satisfactory treatment in most patients prompted this study. It was decided to select a volunteer group of patients with persisting pharyngeal com-

---

From the Department of Otolaryngology, Henry Ford Hospital, Detroit, Michigan, and the Section of Otolaryngology and Rhinology, Mayo Clinic and Mayo Foundation, Rochester, Minnesota.

plaints and carefully evaluate the clinical history of each patient, carry out a detailed clinical examination, and obtain a biopsy specimen for microscopic review.

A clinical diagnosis of a form of chronic pharyngitis such as hypertrophic or atrophic was not made in any patient because of a lack of exact criteria for establishing such a diagnosis. At the present time, establishing a specific diagnosis for chronic pharyngeal symptoms depends almost solely on the examiner's interpretation of the appearance of the throat and to a lesser extent, on the patient's history. The interpretation, obviously, will vary with several examiners except for the extremes in clinical findings such as a markedly reddened, granular or a dry crusted pharynx. The patients were classified according to their pharyngeal symptoms because this offered a more exact method of classification for our study than the establishment of a specific clinical diagnosis. We also wondered whether with the use of this classification definite clinico-histological patterns might be discovered to establish more exactly a specific diagnosis when the various clinical and histological data were correlated.

It was hoped that the following questions might be answered in part by such an investigation:

1. Is there a correlation between the specific pharyngeal symptom and the gross appearance of the pharynx?

2. Does a correlation exist between the symptoms, the appearance, and the histological findings?

3. Is there a correlation between the duration of the symptoms, the clinical appearance, and the histological findings?

4. Does the clinical history reveal any specific factors common to a majority of patients with specific pharyngeal symptoms?

5. Can anything be learned from the study as to establishing an etiology?

Another study by the authors in which the patients are classified on the basis of the gross appearance of the pharynx and in which a correlation with histopathological features was made will be discussed in a future communication.

Scevola and Leonardelli[1] investigated a group of patients in whom a diagnosis of chronic hypertrophic or chronic atrophic pharyngitis was made, apparently on the sole basis of the gross appearance of the pharynx. A biopsy was obtained of the oropharynx under local

anesthesia. A comparison of histological findings of the two diseases and also with the respective pharyngeal appearance was the principal objective of the study. No correlation was made between the pharyngeal symptomatology and the other data.

A study by Schenck[2] published in 1941 described in detail the histopathological changes occurring in what he termed chronic infection of the pharynx. His particular interest here was the solitary lymph nodule occurring in the pharyngeal mucosa and the histological changes which occur in the nodule in the course of a chronic infection of the pharynx. No correlation of the pharyngeal symptomatology or the clinical history of the patients involved in the study were made by this investigator.

PROCEDURE OF THE STUDY

Patients with chronic pharyngeal complaints or with abnormal appearance of the pharyngeal mucosa examined in the Ear, Nose and Throat Section of the Mayo Clinic between July of 1961 and April of 1962 were also seen by the authors and were asked to participate in this study. Those who volunteered underwent the following:

1. A detailed history concerned with the current pharyngeal symptoms, with the past history of other otolaryngological symptomatology, and with the presence of factors which may be contributing to the current symptoms was obtained.

2. A detailed examination of the nasopharynx, oropharynx, hypopharynx, buccal cavity, and the nose was made and recorded.

3. A colored photograph of the oropharyngeal mucosa was taken, using the Brubaker endoscopic camera. X-rays of the paranasal sinuses were also obtained.

4. Under local anesthesia a biopsy of the pharyngeal mucosa was taken from the posterior wall on the right side at the approximate junction of the nasopharynx and oropharynx (in a plane with the posterior edge of the soft palate). In some instances, more than one biopsy was made especially if the lateral pharyngeal band was prominent. A Meltzer triangular adenoid punch was used to obtain the biopsy. An attempt was always made to obtain sufficient tissues so that all layers of the mucosa and a segment of the muscle layer were contained in the specimen. However, the muscle layer was not always obtained. The biopsy specimen was placed in formalin solution, prepared in paraffin blocks, and stained with hematoxylin and eosin.

5. The microscopic sections of the biopsy specimens were reviewed by a member of the Section of Surgical Pathology and by the authors.

Twenty-seven patients volunteered for the study. In addition, 8 persons volunteered to serve as a control or normal group. The 8 normals underwent the same procedure as outlined above. The patients were then placed in categories of a classification based on their pharyngeal symptoms. This classification follows:

1. Dry throat with or without the sensation of mucus (9 patients)
2. Chronic sore throat (3 patients)
3. Chronic dry, sore throat (4 patients)
4. Postnasal discharge (8 patients)
5. No symptoms but abnormal pharyngeal appearance (3 patients)

RESULTS OF CLINICO-HISTOLOGICAL STUDY

A. *Normal Control Group*

None of the 8 volunteers who served as a control group had ever had chronic pharyngeal symptomatology. No one in the group had an allergic history. All had had their tonsils and adenoids removed.

Three of the volunteers were male and 5 were female. Their ages ranged from 17 to 53 with the average age being 22.1 years. The group included 2 high school students, 3 office assistants, and 3 physicians.

On clinical examination of this group we found a small nonobstructing adenoid pad in 2 persons. The oropharyngeal mucosa was moist, smooth, and pinkish-white in appearance in each person. No clumps of thickened secretion or crusts were present on the mucosa. An irregular network of fine blood vessels could easily be seen in the pharyngeal mucosa. The lateral pharyngeal bands were not conspicuous. Bilateral tonsil tags were present in 2 persons. The tonsil pillars were intact. The nasal mucosa was moist and had a pink, noncongested appearance. Septal deviations without airway obstruction were observed in 3 patients.

The microscopic sections of the biopsy taken in the control group revealed a squamous cell epithelium which ranged from approximately 11 to 18 cell layers in thickness. The superficial layers of the epithelium were flattened and their nuclei elongated and hyperchromatic.

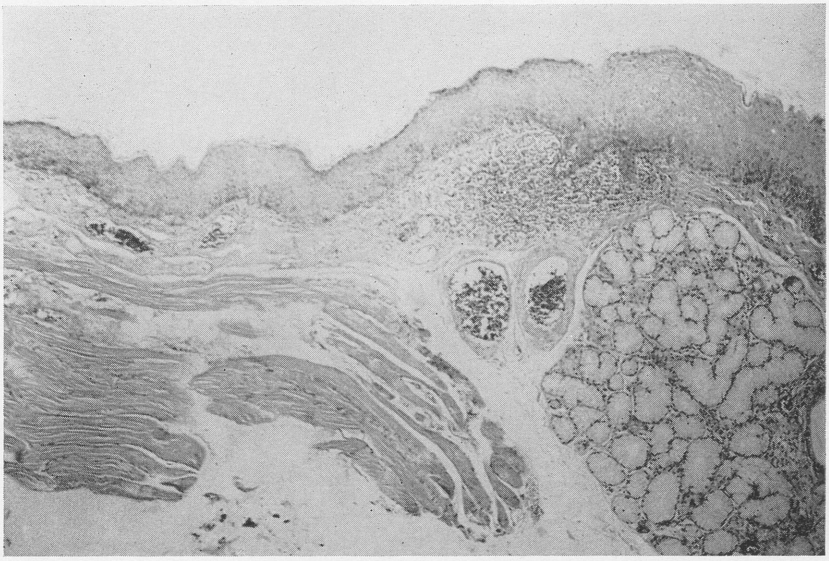

Fig. 1.—Microscopic section of pharyngeal mucosa from normal group. Note focal lymphocytic aggregation in lamina propria, muscle bundles, and mucous glands. (X31.5)

Vacuolation of the occasional squamous cell was noted. The basal cell layer was well defined in all sections. No invasion of the epithelium by other cells was observed. A few small papillae made up of fibrous tissue and minute vascular spaces projected into the squamous layer. The lamina propria was composed of pink staining strands of connective tissue which varied from very fine filaments to dense bundles. Scattered through these strands were individual lymphocytes. In some areas focal aggregations of lymphocytes, usually adjacent to the basal layer, were seen (Fig. 1). Small vascular spaces containing erythrocytes and also small clear spaces lined by a single layer of cells, representing lymphatic channels, were scattered through the lamina propria (Fig. 2). Deep to the lamina propria striated muscle bundles were seen in most of the sections reviewed (Fig. 1). This represented the inner longitudinal muscle layer. Mucous glands were also noted between the lamina propria and the muscle layer and in some instances were incorporated within the muscle bundles. An occasional secretory duct was seen opening onto the surface of the epithelium. At its orifice the duct was lined with cuboidal epithelium

Fig. 2.—Microscopic section from normal group. Note absence of lymphocytes. Clear spaces in lamina propria are lymphatic channels. (X39.3)

and in its deeper aspects the epithelium changed to simple columnar or pseudostratified ciliated columnar epithelium. No serous glands were noted in any of the sections reviewed.

The study of Scevola and Sambataro[3] on the growth and aging of the mucosa of the oropharynx confirms our findings regarding the normal histology of the oropharynx. They studied the normal variations of the epithelium and lamina propria in 41 patients who had died of various causes. Their ages ranged from birth to 83 years. They excluded from their study all cases which during life had any evidence of abnormality of the respiratory or upper digestive tract. A specimen of the oropharyngeal mucosa was taken as soon as possible after death, was fixed in Zenker's formalin, and then prepared using hematoxylin and eosin stain as well as Weigert's stain.

They found that at birth the squamous epithelial layer was quite thin but increased in thickness with age. At about 8 years of age the epithelium became irregular at its base due to the formation of papillae of the lamina propria. The papillae were formed by a thin

connective tissue with fine vascular channels. These papillae penetrated into the thickness of the epithelium in a straight or tortuous fashion. They did not disappear in old age. The lamina propria was composed of a network of connective tissue which was rich in blood and lymphatic spaces. This connective tissue network became oriented in a parallel manner to the squamous epithelium at about the age of 8. In old age the lamina propria became reduced and the connective tissue fibers became more dense generally. Lymphocytic aggregations were noted in the lamina propria in all age groups but not in every microscopic section reviewed. Mucous and serous glands were observed by the authors in the deeper layers of the lamina propria. We did not find serous glands in any of our microscopic sections.

Schenck states that vacuolation of cells and distinct formation of papillae are never found in normal epithelial tissue. However, in both our study of normals and in the Italian study just cited, papillae were quite characteristic of the normal epithelium. In addition, vacuolation of squamous cells was noted in the majority of our microscopic sections of normal pharyngeal tissue.

B. *Category One: Chronic Dry Throat*

Patients whose primary symptom was a persistent dryness of the throat were placed in the first category of our classification. Many in this category also specified that there was a sensation of mucus collecting in the throat but all upon questioning emphasized that the sensation of mucus did not affect the dryness. None of these patients had other throat symptoms. Eight patients believed that the sensation of dryness was always present but could vary in intensity. One man had been aware of a dry throat since a submucous resection had been performed four months previously. A woman had a constant dry throat ever since a tonsillectomy and adenoidectomy had been done 26 years before. A male believed that as the nose became more congested the throat would seem drier. A physician had a dry throat throughout the year but he was especially aware of it through the winter months.

The group included 9 patients, 3 males and 6 females. Their ages ranged from 36 to 77 years with the average age being 50.6 years. The duration of their symptoms ranged from 4 months to 60 years, the average duration being 17.2 years.

The following summary of 2 of the patients in this group will include a brief clinical history, the findings at the clinical examination, and the histopathology of the oropharyngeal biopsy.

CASE 1. Male, aged 47, building contractor.

History: A persistent dry throat had been experienced for 4 months following a submucous resection. The dryness was not noted previously. An occasional feeling of mucus in the throat has occurred which has had no effect on the primary symptom. He has also had a dry sensation in his nose since the nasal surgery. Nasal crusting has been present for about 25 years.

Possible Contributing Factors: None were elicited other than the relation to the nasal surgery.

Clinical Examinatoin: The oropharyngeal mucosa had a pale, pink appearance in which a fine vascular network was seen. The mucosa was dry in the central area on which several small adherent brownish-yellow crusts were seen. In the lateral aspect, strands of thickened secretion extended from the nasopharynx downward. The small tonsils appeared normal. The nasal chambers contained a few crusts bilaterally and a 1.5 centimeter anterior septal perforation. The nasal mucosa had an atrophied appearance.

Microscopic Examination: The squamous cell epithelium averaged 18 to 24 layers in thickness. The superficial layers were flattened and their nuclei were elongated and hyperchromatic. Vacuolation of some squamous cells in the mid area of the epithelium was noted. The basal cell layer was well defined but irregular because of the presence of several stromal papillae. The lamina propria had a loose, pink, fibrous network. An occasional lymphocyte was noted in this network adjacent to the basal layer of the epithelium. Many small vascular spaces containing erythrocytes were scattered through the layer. No glands or muscle bundles were noted.

CASE 9. Male, aged 77, physician.

History: A persistent dry throat has been experienced for about 60 years. It is always worse in the winter months. A sensation of nasal airway obstruction and dryness has accompanied the throat symptoms. Bilateral inferior turbinectomies were performed to relieve nasal airway obstruction in 1904.

Possible Contributing Factors: He has smoked about 40 cigarettes daily until 11 years ago when he stopped. It is not believed that the smoking had any effect on the throat symptoms.

Clinical Examination: On mirror view of the nasopharynx the posterior tips of the inferior turbinates were not seen. The moist oropharyngeal mucosa had a pale, pinkish-white color in which a fine vascular network could be readily seen. Accumulations of thickened yellow mucus were adherent on the mucosa. The tonsils were absent. The dry nasal mucosa had a pronounced atrophic appearance. The inferior turbinates were absent and crusting was seen on the floors of each nasal chamber. The middle turbinates were reduced in size. The nasopharynx could easily be seen on anterior rhinoscopy. A large septal spur projected into the left nasal chamber. The nasal tip drooped moderately and elevation of the tip improved the nasal airway.

Microscopic Examination: The squamous cell epithelium varied in thickness from approximately 8 to 12 cell layers. The superficial layers were flattened and

more darkly stained. Their nuclei were elongated and hyperchromatic. Vacuolation of the squamous cells was prominent. The basal cell layer was not well defined. No stromal papillae were seen. The lamina propria contained very few fine, lightly staining, pink, fibrous strands in which a few lymphocytes and plasma cells were scattered adjacent to the basal layer of the epithelium. In one area there was a focal collection of many lymphocytes. One edge of this lymphocytic collection was crowded close to the basal layer and the epithelium overlying this site was thinner than adjoining areas of the epithelium. There were very few vascular spaces containing erythrocytes present in the lamina propria. A large group of normal appearing mucous glands were present in the deeper aspects of the propria. A secretory duct was seen coursing toward the epithelial surface.

Summary. No correlation could be made between the pharyngeal symptoms and the appearance of the mucosa in category one. Only 2 of the 9 patients actually had a dry pharynx on examination. That is, the usual mucous film overlying the mucosa was absent. Two other patients had raised, red nodules in the pharyngeal mucosa giving it a granular appearance. The remaining 5 had a moist, pale, pinkish-white mucosa. The lateral pharyngeal bands were prominent in only 1 patient.

Three patients complained of chronic nasal dryness. Two of these had a dry nasal mucosa on examination but only 1 of the latter had a dry pharynx as well. Two patients had an atrophic appearing nasal mucosa which was probably secondary to nasal surgery done previously.

Paranasal sinus x-rays of the latter two patients revealed thickened membrane of all sinuses. Thickened membrane of the maxillary sinuses in 2 other patients with normal appearing nasal chambers was noted. Normal appearing sinuses were found in the remaining 5 patients.

No factors were elicited in the history which could be directly attributed to causing or aggravating the pharyngeal symptoms except in 1 patient who stated that the dryness was worse when the humidity was high and also when singing in his church choir. Also, another patient noticed an aggravation of the symptoms in the presence of nasal congestion. Only one patient who smoked believed his symptoms were made worse by this habit. Three patients lived in areas where air pollution from nearby industries was a problem but none believed that their symptoms were related to the pollution. Two patients had known food and inhalant allergies, but the throat symptoms were not altered when the allergies were manifested.

The histological findings did not reveal a characteristic microscopic picture of the pharyngeal mucosa of patients with a complaint

of dry throat. The microscopic sections of the 2 patients with a dry appearing mucosa were dissimilar.

The squamous cell layer varied in thickness, generally being thinner in those patients with symptoms exceeding 20 years. In all patients the superficial layers of the squamous epithelium were flattened. The basal cell layer in all sections was intact. Vacuolation of squamous cells and the presence of stromal papillae were seen in the majority of sections reviewed.

A dense lymphocytic aggregation, obscuring the connective tissue network of the lamina propria, was present in both patients with a granular-appearing pharynx. Lymphocytes had invaded the deeper squamous layers in 1 of these patients. Moreover, 3 other patients without a granular pharynx had a moderate to heavy lymphocytic infiltration of the propria. Germinal centers were present in the infiltration. The remaining 4 patients had a few lymphocytes and plasma cells or small focal lymphocytic collections scattered through the loose, wavy, pink-staining fibrous network of the propria. Vascular spaces containing erythrocytes were scattered through the lamina propria, particularly in the areas not involved by the lymphocytic infiltration.

Normal appearing mucous glands were found in the deep segment of the lamina propria in 4 patients, all of whom had a moist, smooth pharyngeal mucosa. However, the absence of glands in the microscopic sections of the other 5 patients is not necessarily an indication of a lesser number or an absence of glands in the mucosa. The biopsies obtained in this latter group may not have been sufficient to include the deeper lying gland structure or the specific site of the biopsy may possibly not have had gland structures present.

C. *Category Two: Chronic Sore Throat*

The second category included those patients with a primary pharyngeal symptom of constant or recurring soreness. The soreness was experienced almost daily by all patients but did not seem to be worse at a specific time of the day. Gargling or increasing the daily fluid intake seemed to lessen the symptoms. Two patients had been given antibiotic therapy on several occasions without any change in their symptom being noted. In addition, 1 patient had had areas of the pharynx electrocauterized but again the symptom remained unchanged.

Three patients, all males, were placed in this group. Their ages were 29, 37, and 69. The duration of their symptoms ranged from 2½ to over 5 years.

The investigation of 1 patient in this category will be summarized.

CASE 2. Male, aged 29, bank teller.

History: A sore throat had been experienced almost daily for 5 years. The term "raw" was used to describe the sensation of soreness. The left side of the pharynx is usually where the symptoms arise but the entire pharynx is eventually affected. Antibiotics have been prescribed on several occasions with no relief obtained. Areas in the oropharynx have been electrocauterized with no improvement noted. Partial relief is obtained by chewing gum or reducing the number of cigarettes smoked.

Possible Contributing Factors: Smoking definitely increases the symptoms.

Clinical Examination: The moist oropharyngeal mucosa was markedly studded with large, raised, red nodules with fairly discreet margins. This gave the mucosa a very distinct granular appearance. Between these areas the mucosa was pearl gray and a poorly defined vascular network was observed in these latter areas. The lateral pharyngeal bands were very prominent. The tonsils were absent, but several raised, red nodules were noted in each tonsil fossa. The moist nasal mucosa appeared normal. The nasal septum was deviated to the left but no airway obstruction was observed.

Microscopic Examination: Two biopsies were obtained in this case. One biopsy was taken at a site where the mucosa had a relatively normal appearance and the second biopsy was obtained from a raised, reddened, nodular area. The first biopsy revealed a squamous epithelium ranging from approximately 10 to 14 cell layers in thickness. The superficial layers were flattened and their nuclei were elongated. Vacuolation of the cells was prominent in several areas adjacent to the basal layer. The basal cell layers was well defined except for an aggregation of lymphocytes which was located immediately adjacent to it in the lamina propria. Here the basal layer was indistinct and was penetrated by lymphocytes so that the architecture of the invaded squamous cells was obscured. Aside from the single aggregation of lymphocytes, the remaining lamina propria was made up of pink staining, fairly dense, fibrous strands, particularly concentrated adjacent to the basal cell layer. A few lymphocytes and plasma cells were scattered in this fibrous network. Varying sized vascular channels containing erythrocytes were prominent. One cluster of normal appearing mucous glands was noted. The second biopsy, taken from a raised, red area revealed a different picture. The squamous cell layer averaged 18 to 22 cell layers in thickness. The superficial layers of the epithelium were flattened and more darkly stained. Their nuclei were elongated and hyperchromatic. Vacuolation of the squamous cells was very prominent. The deeper layers of the squamous epithelium were invaded at several points by dense aggregations of lymphocytes obliterating the squamous cell architecture. In uninvaded areas the basal layer was fairly well defined. The lamina propria had a very dense lymphocytic infiltration with germinal centers generally obscuring the fibrous network normally seen. A few fibrous strands were threaded through the infiltration. A secretory duct in which the epithelium had undergone squamous metaplasia extended to the surface of the squamous layer. Similar squamous type cells were seen in the lamina propria without a duct lumen being present indicating more metaplastic duct epithelium. Fine vascular channels were spread through the



Fig. 3.—Microscopic section from Category Two. Note dense lymphocytic aggregation in lamina propria with germinal center. (X39.3)

lamina propria. A few mucous glands were noted deep to the lymphocytic mass in a relatively normal appearing stroma.

Summary. Although only 3 patients were included in this category, it is interesting to find that 2 of these patients had raised, red nodules in the pharyngeal mucosa giving it a pronounced granular appearance. In both patients the symptoms had been present for 5 or more years. In addition, the lateral pharyngeal bands were prominent and many nodules similar to those in the pharynx were present in both tonsil fossae of these 2 patients. The third patient had a smooth, pinkish-white pharyngeal mucosa without prominent lateral bands. His nasal mucosa was dry and had an atrophied appearance.

Sinus x-rays of the 3 patients were negative.

One of the patients with a granular pharynx was certain that smoking aggravated the soreness. The third patient admitted that his throat symptoms were worse when he was nervous and possibly when he was experiencing gastrointestinal symptoms.

The microscopic findings were similar in the three cases. The squamous epithelium was less than 15 cell layers in thickness in the

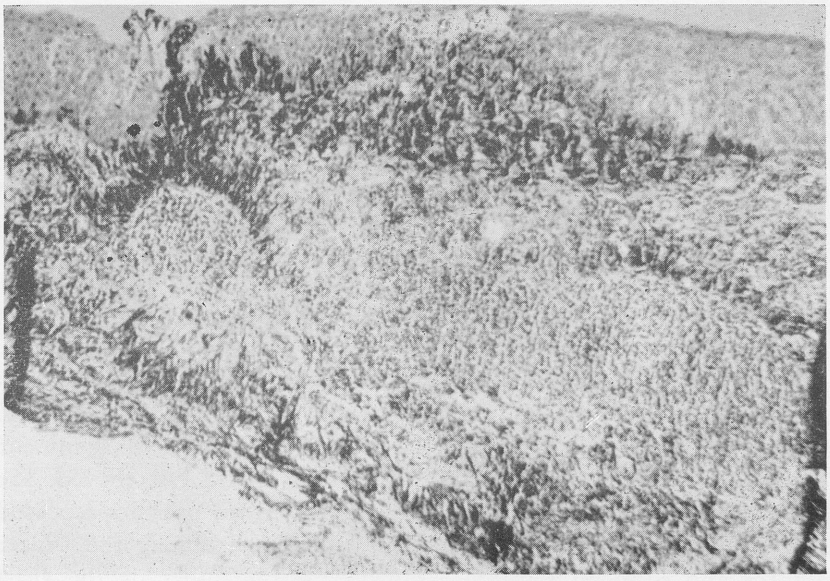

Fig. 4.—Microscopic section from Category Two. Note the invasion of epithelial layer by lymphocytes obscuring the involved squamous cells. (X63)

3 patients except in 1 specimen. Vacuolation of squamous cells was present in all sections, but stromal papillae were absent except for 1 section in which only a few papillae were noted. The superficial layers of the squamous epithelium were flattened and their nuclei hyperchromatic.

The biopsy taken from the nodular or granular areas of patients number 1 and 2 disclosed a very dense lymphocytic infiltration of the lamina propria in which germinal centers were situated. The normal fibrous network was obscured by this infiltration (Fig. 3). The lymphocytes had also invaded the squamous layer for varying depths partially destroying the architecture of the involved squamous cells (Fig. 4). The biopsy taken from patient number 3 showed a large lymphocytic aggregation which was not as extensive as in the first 2 patients, but the squamous layers had been invaded by lymphocytes as well.

In contrast, the biopsy taken from the non-granular areas of patients 1 and 2 had a normal appearing fibrous network in the

lamina propria with only small focal aggregations of lymphocytes appearing.

Vascular spaces containing erythrocytes were very numerous in the lamina propria of these 3 biopsy specimens. No lymph channels were noted.

Normal mucous glands were also present in all sections except 1. Secretory ducts in which metaplasia of the epithelium had occurred were also noted in several of the microscopic sections. No muscle fibers were noted in the biopsies of these 3 patients.

D. *Category Three: Chronic Dry, Sore Throat*

The third category included those patients with combined primary pharyngeal symptoms of dry throat with persistent soreness. All of the patients believed that the dryness was the most prominent of the 2 symptoms and that if the dryness could be relieved, the associated soreness usually was relieved also. Two patients reported that their symptoms were particularly prominent during the winter months and subsided somewhat during the remainder of the year. All of the patients had taken various oral medications including antibiotics, but the symptoms persisted.

This group included 4 patients, 2 females and 2 males. Their ages ranged from 31 to 52 years with the average age being 43 years. The duration of symptoms ranged from 2 years to 7½ years with an average duration of symptoms being 4.5 years.

One of the 4 cases will be summarized.

Case 1. Male, aged 52, farmer.

History: The patient has had a dry, sore throat for 2 years with the symptoms being worse during the winter months. Several medications have been used with no relief obtained.

Possible Contributing Factors:

a. Exposure to dust and diesel fuel vapors on the farm makes the pharyngeal symptoms worse.

b. Pharyngeal symptoms are worse when eating chocolate and when working in or near the area on the farm where the pigs are kept. Skin testing for allergies revealed positive reactions for chocolate, feathers, pig, dog and cow hair.

c. He has smoked about 10 cigarettes daily for 30 years and has quit on several occasions with no change in the pharyngeal symptoms noted.

Clinical Examination: The dry oropharyngeal mucosa was very pale, pinkish-white in color. No crusts were noted. A fine vascular network was easily seen

in the mucosa. The prominent lateral pharyngeal bands were red. The tonsils were slightly enlarged but otherwise appeared normal. The moist nasal mucosa had a normal pink color.

Microscopic Examination: The squamous epithelium ranged from 10 to 16 cell layers in thickness. The superficial layers were flattened and darker stained. Their nuclei were hyperchromatic. An occasional squamous cell showed vacuolation. The basal cell layer was moderately well defined. A secretory duct, lined by ciliated columnar epithelium, was visualized opening onto the surface of the epithelium. The lamina propria had a moderately heavy infiltration of lymphocytes with 2 germinal centers present. A few areas of the propria, not involved by the infiltration, had a fine, wavy, pink-staining fibrous network. In the areas adjacent to the basal layer, this fibrous network was more dense. In addition to the lymphocytes, plasma cells were scattered through the fibrous network. No eosinophils were identified. Vascular channels containing erythrocytes were scattered through the lamina propria particularly in the areas not occupied by lymphocytes. Normal appearing mucous glands were noted in the deeper portions of the propria.

Summary. No typical pharyngeal appearance was established in this category. Two patients did have a dry mucosa. That is, no mucous layer or film was present. Their symptoms had been experienced for 2 and 7 years respectively. A third patient had a moist, granular appearing mucosa with symptoms for 5 years while the remaining patient's mucosa was smooth and moist. One of the patients with a dry pharynx also had several reddened areas in the mucosa which were not elevated or granular in appearance.

Sinus x-rays of all patients revealed no pathology.

Factors which patients in the category believed intensified their throat symptoms were: exposure to dust, certain animal danders, and diesel fuel vapors, excessive voice use, eating chocolate, moving to a different section of the country, and smoking. In addition, 2 patients reported that their parents had previously experienced similar pharyngeal complaints.

An allergic etiology for the symptoms was considered in 1 patient who noted a definite aggravation of symptoms when eating chocolate, when exposed to dust, and when working in the area on the farm where the pigs are kept. Positive skin tests were found for chocolate, feathers, hog, dog, and cow hair. This was the only patient in which we found a definite relationship between the symptoms and an allergy.

Microscopic studies revealed that the squamous epithelium varied in thickness from approximately 8 to 27 cell layers in the 4 patients. The superficial layers of the epithelium were flattened in all sections reviewed. Vacuolation was present in all sections but stromal papillae, like category two, were present in only 1 patient but were very pronounced in the sections from that patient.

Fig. 5.—Microscopic section from Category Three. Dense lymphocytic infiltration of the lamina propria shown. Note lymphocytic penetration of the squamous epithelium to superficial layer. (X31.5)

The only consistent finding observed in all microscopic sections was a moderate to heavy lymphocytic infiltration of the lamina propria such as was seen in category two (Fig. 5). The epithelium was usually thinner in areas where the lymphocytic infiltration crowded close to the basal layer. This was most marked in the patients with a granular pharynx as was noted in category two and also in the patient with a dry pharynx. Lymphocytic penetration of the epithelial layers, partially obliterating the squamous cell architecture, was pronounced in 2 cases (Fig. 5). A few areas of the lamina propria, not involved by this lymphocytic infiltration, had a loose, pink-staining fibrous network.

Vascular spaces were again prominent in the lamina propria especially in areas not invaded by lymphocytes. Clusters of normal-appearing mucous glands were visualized in all slides but one. No muscle fibers or lymph channels were noted in these sections.

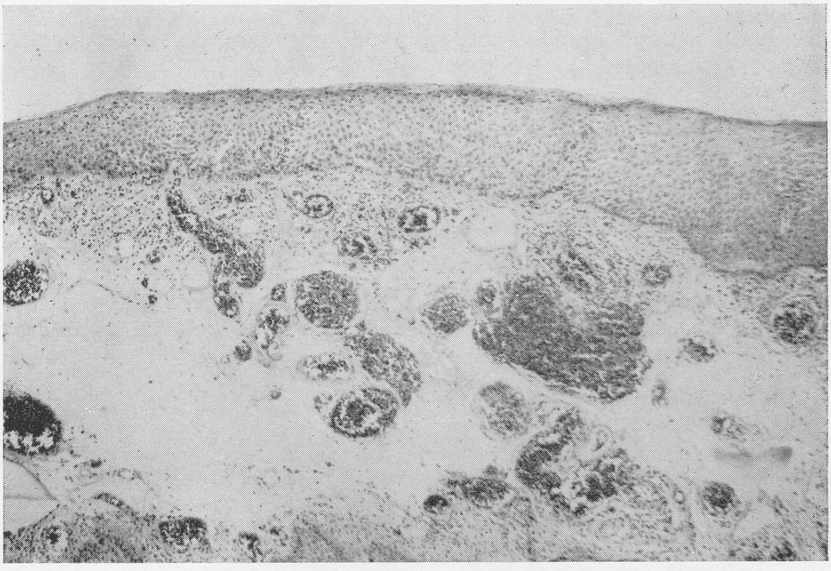

Fig. 6.—Microscopic section from Category Five. Abundant vascular channels in lamina propria shown. (X39.3)

E. *Category Four: Postnasal Drainage*

The fourth category was designated for those patients with a primary complaint of postnasal discharge or the sensation of mucus collecting in the pharynx. The sensation became more prominent as the day progressed. Temporary relief was obtained by most by clearing the throat or coughing or by drinking greater quantities of water. It is significant that 5 patients stated or admitted on questioning that their pharyngeal symptoms were worse when they were under tension or when they were experiencing nervousness. One female in the group related the onset of her symptoms to the time when she commenced divorce proceedings. The symptoms persisted through this period and during the time of adjustment in her second marriage. Another female patient was currently under the care of a psychiatrist and she admitted that the pharyngeal symptoms were particularly prominent when she was having difficulty coping with her personal problems. In 2 patients the examining physician found that the epigastric distress which they complained about in addition to their pharyngeal

symptoms was on a functional basis. No other pharyngeal symptoms were present.

Eight patients, 4 males and 4 females, were placed in the category. Their ages ranged from 17 to 54 with the average age being 37 years. The duration of their symptoms ranged from 9 months to 24 years with the average being 7.1 years.

The case summaries of 2 of the 8 patients included in this category will be reviewed.

CASE 7. Male, aged 54, new car dealer.

History: A constant sensation of mucus in the throat with the urge to clear the throat had been noted since a tonsillectomy 18 years ago. There has been no dryness or soreness of the throat.

Possible Contributing Factors: None were elicited other than the relationship to the previous surgery.

Clinical Examination: The moist oropharyngeal mucosa had a dull, white appearance and was studded with several raised, red nodules of varying size. A fine vascular network was easily seen in the mucosa, particularly where the nodules were absent. The tonsils were absent. The nasal mucosa had a normal pink, moist appearance. The nasal septum was deviated to the right but no airway obstruction was noted.

Microscopic Examination: The squamous cell epithelium ranged from approximately 10 to 16 cell layers in thickness except in one area which overlaid a heavy lymphocytic aggregation in the lamina propria. At this point the squamous cells were partially obscured by invasion of lymphocytes and the thickness averaged 3 to 5 cell layers. Vacuolation was quite prominent throughout the entire epithelial layer. Lymphocytic infiltration of the epithelium was noted at several points. In 2 areas the infiltration reached to the superficial layers. The basal cell layer was well defined in uninvolved areas. No stromal papillae were observed. The lamina propria had a very dense infiltration of lymphocytes particularly at a point adjacent to the basal layer of the epithelium. Within this infiltration of lymphocytes 3 germinal centers were present. Also, within the infiltration there was a secretory duct lined with squamous type cells indicating squamous metaplasia. A few fibrous strands and some small vascular channels containing erythrocytes were scattered through the infiltration. The uninvolved areas of the lamina propria contained a pink-staining fibrous network in which a few lymphocytes and plasma cells were scattered. Vascular channels containing erythrocytes were prominent in these latter areas. A group of mucous glands were situated deep to the lymphocytic infiltration.

Comment. The microscopic findings in this case revealed the most extensive invasion of the epithelium by lymphocytes of all the microscopic sections studied.

CASE 8. Female, aged 38, housewife.

History: Since the age of 14 the patient has had a constant sensation of mucus in the throat. The sensation is worse as the day progresses. She is most aware of it when she becomes tense and nervous. The throat is cleared frequently because of this sensation. She denies any dryness or soreness in the throat but has been aware of a dryness in the nose for several years.

Possible Contributing Factors: None were elicited other than the nervous factor.

Clinical Examination: The oropharyngeal mucosa had a pink central area with a pale, pinkish-white color in the lateral aspects. The mucosa was dry and appeared glazed. No thickened secretion was present on the mucosa. The tonsils were present and recessed into the tonsil fossae. The moist nasal mucosa had a slightly atrophic appearance.

Microscopic Examination: The squamous epithelium ranged from 5 to 10 cell layers in thickness. The superficial layers were flattened and their nuclei hyperchromatic. Vacuolation was occasionally seen. The basal cell layer was well defined. No stromal papillae were present. The lamina propria had a loose, pink-staining fibrous network in most areas. It was more dense in one area where striated muscle bundles and groups of mucous glands crowded close to the epithelial layer. A few lymphocytes and plasma cells were scattered in the propria close to the basal layer.

Summary. No definite correlation could be established between the pharyngeal symptoms and the mucosal appearance in this category. A moist, granular or nodular pharynx was observed in 3 patients, a dry, glazed appearing pharynx in 1, and a moist, smooth, pinkish-white pharynx in 4. Two patients who complained of an associated nasal sensation of dryness, had a reddened, congested and a dry, atrophic nasal mucosa respectively. The latter case also had a dry pharynx.

An interesting observation was the presence of a non-obstructing adenoid mass in 4 patients. In the first 3 categories only 1 patient had adenoid tissue which was visible on examination.

All sinus x-rays were found to be normal except in 1 case where slight thickening of the mucous membrane of the maxillary sinuses was reported.

As was stated previously, 5 patients related that their symptoms were worse when a state of nervousness was experienced. The following factors were also reported to make the symptoms worse: humid weather and exposure to grain dust. None of the patients who smoked were aware of an aggravation of their symptoms with this habit. One patient who had bronchial asthma and was aware of several specific allergies did not believe his postnasal discharge was affected by either.

The histological review did not disclose a singular or typical microscopic pattern. The squamous epithelium was less than 15 cell layers in all cases except one. The superficial layers of the epithelium were flattened. Vacuolation was observed in all sections and was a

pronounced feature in most. Stromal papillae were only noted in 2 cases.

As was noted in the other categories, a moderate to heavy lymphocytic involvement of the lamina propria with conspicuous penetration of the squamous layer occurred only in the patients with a granular pharyngeal mucosa. The lamina propria of the other 5 patients contained a distinct fibrous network through which small focal collections of lymphocytes as well as individual lymphocytes and plasma cells were scattered.

Vascular spaces were plentiful and distinct in the patients without lymphocytic involvement of the propria.

Normal mucous glands were identified in all sections except one. In 1 patient, clear spaces scattered through the acini suggested the presence of fat replacement.

F. *Category Five: No Symptoms But Abnormal Pharyngeal Appearance*

This category included those patients with no pharyngeal symptoms but in whom the clinical examination revealed an abnormal appearance of the pharynx. This category was included in the classification because we periodically would see such a patient as described for a routine ear, nose, and throat examination. We were quite interested to determine what histological changes might occur in an abnormal appearing pharynx when no symptoms were present and to compare these findings with those recorded in the first 4 categories. This category included 3 patients, all males, whose ages ranged from 33 to 69 years. None had ever experienced recurring or persisting pharyngeal symptoms. The summary of the investigation of one of the 3 patients will be presented.

CASE 1. Male, aged 69, insurance investigator.

History: No complaints referable to the throat were elicited. The patient requested the ear, nose and throat consultation because of a clear nasal discharge over the past 6 to 12 months. He denied having had hay fever or asthma. There was no history of specific allergies or sinusitis. He had had nasal plastic surgery for elevation and narrowing of the nasal tip previously.

Possible Contributing Factors: A diagnosis of pernicious anemia was made 11 years ago and the patient has been under medical therapy for this since that time.

Clinical Examination: Adherent yellow-green crusts were noted in the vault area of the nasopharynx. The oropharyngeal mucosa appeared very dry and had

a reddened appearance. Thickened yellowish-white mucus was adherent in the central area of the mucosa. The tonsils were absent. The moist nasal mucosa appeared normal. A large septal spur projected into the right nasal cavity. An adequate nasal airway was present.

Microscopic Examination: The squamous epithelial layer varied considerably in thickness due to the presence of many stromal papillae projecting into the epithelium for varying depths. The epithelium averaged approximately 15 to 25 cell layers in thickness. The superficial layers were flattened and their nuclei elongated and hyperchromatic. Vacuolation of squamous cells was prominent in some areas. The basal cell layer was well defined and revealed hyperactivity. The stromal papillae were made up of fine connective tissue networks in which small vascular spaces containing erythrocytes were noted.

The most striking feature of the lamina propria was the large number of vascular channels containing erythrocytes which were scattered through the layer (Fig. 6). The lamina propria was made up of a fairly dense, pink-staining, fibrous network in which individual lymphocytes were scattered. No lymphocytic aggregations were noted in the propria. In addition, there were several lymphatic spaces of varying size. No glands or muscle fibers were noted in these sections.

Summary. Although the patients in this category denied the presence of pharyngeal symptoms, 2 had markedly dry throats with adherent crusts present in 1 and the third had a pronounced granular appearance in the pharynx.

The sinus x-rays of the 3 patients were normal.

One of the patients with a dry pharynx also had pernicious anemia which had been confirmed 11 years before. He had been under treatment for this since that time. No oral manifestations of pernicious anemia such as a smooth tongue were found at our examination. The other patient with a dry pharyngeal mucosa also had bronchial asthma and was allergic to feathers. He was unaware of any throat symptomatology when experiencing an asthmatic episode.

The histological findings in the 2 patients with pharyngeal dryness were very similar. The squamous epithelium averaged 15 or more cell layers in thickness. Many stromal papillae penetrated into the deeper squamous layers in both patients. In the lamina propria, the vascular channels were abundant and very prominent. Very few lymphocytes were present. Lymphatic channels were also recognized. No gland structures were seen.

In the third patient in whom a granular pharynx was observed the epithelium was less than 15 cell layers in thickness and the lamina propria contained a lymphocytic aggregation surrounding a secretory duct but the remainder of the propria had the usual fibrous network with occasional lymphocytes scattered.

COMMENT

A survey of the literature did not reveal an investigation in which chronic pharyngeal symptomatology was correlated with the pharyngeal appearance and histology.

Schenck[2] investigated the histopathological changes in the pharyngeal mucosa which occurred in chronic infection of the pharynx. No definition of this latter term was given in this published article. The study disclosed that the mucosal changes occur primarily in the solitary lymph nodules and that any change in the other mucosal structures such as the epithelium are secondary to involvement of the lymph nodules.

In the course of a chronic infection the lymph nodules undergo hyperplasia and eventually fibrosis with hyaline degeneration. Polymorphonuclear leukocytes and later fibroblasts may invade the squamous layers as hyperplasia occurs. The number of mucous glands initially will increase, but then decrease as fibrosis sets in.

The gross appearance is related to the microscopic findings during the course of the infection. The nodular or granular appearance is present when hyperplasia predominates. As fibrosis develops and the glandular function is impaired, the pharynx becomes dry and glazed.

Schenck believes that the gross and microscopic appearance of the pharynx in chronic infection depends upon the duration of the disease as well as the invading micro-organisms and the immunity of the individual. Thus, an attempt to classify groups or types of chronic pharyngitis is "entirely artificial," he feels.

Possibly for this reason Schenck does not define chronic hypertrophic or atrophic pharyngitis and attempt to classify chronic infections of the pharynx more specifically.

Scevola and Leonardelli[1] tried to determine if characteristic histological features were present in hypertrophy and atrophy of the pharyngeal mucosa and if these features corresponded to the respective gross appearances of chronic hypertrophic and atrophic pharyngitis. Twenty-eight patients with the former and 25 with the latter type of pharyngitis were examined and oropharyngeal biopsies were taken under local anesthesia. The criteria by which these respective diagnoses were established were not discussed. Pharyngeal symptomatology was not considered in this study.

The authors concluded that a difference did exist between the histology of the two types of infections and that a correlation could be made between the histology and the gross appearance of the respective disease entity.

The hypertrophic form had a greater overall number of mucous glands present, while in the atrophic form the glands were reduced in number and the serous type predominated.

The loose, edematous lamina propria in the hypertrophic state had numerous lymphoid nodules and few stromal papillae. Blood vessels and lymphatic spaces were abundant. In the atrophic infection, the dense propria had few lymphocytic aggregations and more numerous papillae. Few blood and lymphatic channels were observed.

No differences were found in the epithelial layers in the two conditions.

The closest correlation between gross appearance and the histology was based on the degree of edema occurring in the lamina propria. This was a striking feature in hypertrophic pharyngitis and minimal in the atrophic state.

The histology of the pharyngeal mucosa of the 8 "normals" in our study was similar and was consistent with the results of Scevola and Sambataro's work.[3] In both studies, squamous cell vacuolation and stromal papillae were observed. Schenck, on the other hand, stated that neither vacuolation or papillae were found in normal epithelial tissue.

No correlation could be made between pharyngeal symptomatology and gross pharyngeal appearance in our investigation except in category two (chronic dry throat) where 2 of the 3 patients had a markedly granular pharynx. In addition, the tonsil fossae of these 2 patients contained raised, red nodules, similar to those on the pharyngeal mucosa. However, the small number in this category does not make this observation statistically significant. In the other categories, the gross appareance of the pharynx varied from smooth and moist to dry.

In relating symptomatology to histology the patients with chronic sore throats (category two) had several consistent microscopic findings. The squamous layer thickness was generally less than 15 cell layers. The deep squamous layers were invaded by lymphocytes in all sections reviewed, but one. No polymorphonuclear leukocytes

were identified as invading the squamous epithelium as Schenck had observed. Uninvaded sections of the squamous layer which overlay a dense aggregation of lymphocytes in the propria were frequently thinner than the adjacent epithelium. Vacuolation of squamous cells was conspicuous. Lymphocytic aggregations in the lamina propria were very numerous and in some sections, the stromal network was almost completely obscured by the heavy concentration of lymphocytes. The same findings in the lamina propria were present in all patients in category three as well.

In category four the average thickness of the epithelium in all cases except 1 was less than 15 cell layers but considerable variations of the lamina propria was noted.

The duration of symptoms in the various categories extended from 4 months to over 60 years. No inter-relationship between duration and pharyngeal appearance was found in any specific category. However, a correlation between duration and appearance was noted in those patients from all four categories with a granular pharynx. From a total of 8 patients, 6 had pharyngeal symptoms for 4 to 6 years. For comparison, the 5 patients with dry appearing pharynges in the first four categories had symptoms ranging from 4 months to 25 years. A similar wide variation of duration existed for patients with a moist, smooth-appearing pharynx.

When the duration of symptoms and histology were compared, the only significant feature was found in category one. Those patients with symptoms of dry throat in excess of 20 years had a definitely thinner squamous layer than others in this particular category.

The only contributing factor which was reported by a significant number of patients in a single category was the state of nervousness which reportedly intensified the pharyngeal symptoms in 5 of the 8 patients with postnasal discharge (category four). This finding raises the question of what importance psychosomatics plays in persons with this symptom. It also suggests that a psychiatric evaluation might be considered in such cases where a complete medical examination has failed to find an etiology or a successful therapy.

Other possible contributing factors were mentioned but none appeared as significant. However, one patient who reported that his pharyngeal symptoms were worse after eating chocolate and when working near the pigs on his farm was found to have positive skin tests for chocolate and pig hair as well as other animal danders. This

finding suggests that the symptoms of a dry, sore throat could be a manifestation of a true pharyngeal allergy. Sanders[4] states that the cause of many chronic sore throats can be traced to allergies. Inhalant allergies, he believes, are the most common cause of allergic pharyngitis with house dust being a frequent offender. Also, a history of a sore throat occurring during change in weather, especially with a change in humidity, is rather typical of a pharyngeal allergy. It is, therefore, possible that the patients in our study who noted a change in symptoms with change in weather and with exposure to dust may have an allergic pharyngitis.

Another noteworthy observation concerns the relationship of previous nasal or throat surgery to the onset of the throat symptoms. Four patients in category one dated the onset of their symptoms to the time when the surgery had been done. Three patients had had nasal surgery and 1 patient a tonsillectomy and adenoidectomy. The former 3 also had some atrophy of the nasal mucosa and 2 of these had associated symptoms of nasal dryness and nasal airway obstruction. The atrophy in 2 could be directly related to the surgical procedures (i.e., bilateral ethmoidectomies; inferior turbinectomies). Two patients in category four stated that postnasal discharge became apparent shortly after a tonsillectomy had been performed.

No significant relationship between the nose and sinuses and the pharyngeal symptoms was established. In category one 6 of the 9 patients had persistent nasal symptoms and 4 had a dry or atrophied nasal mucosa. Three with nasal complaints had x-ray evidence of thickening of the sinus mucosa. However, only 1 patient in this category believed that his nasal and pharyngeal symptoms were related.

Category five was included in the study because although no pharyngeal symptoms were present the gross appearance of the pharynx was quite abnormal. Two patients had a markedly dry mucosa and the third had a pronounced granular appearance. The former 2 patients, on the sole basis of appearance, would probably be diagnosed by most otolaryngologists as having chronic atrophic pharyngitis and the third as chronic hypertrophic pharyngitis. In other words, these cases grossly represented the extremes in chronic pharyngeal infection.

The numerous stromal papillae and very pronounced vascularity of the lamina propria were outstanding microscopic characteristics in the 2 patients with the dry pharynges. Neither finding was found

to be so pronounced in any other microscopic section in our study. Also, no glands were present in these sections. This may indicate a true reduction in the number of glands or may be due to the fact that the biopsy specimen was taken from an area where no glands existed or that the biopsy was not of adequate depth to include glands. The other histological features in these 2 sections were similar to those noted in patients with a moist, smooth pharyngeal mucosa.

Scevola and his co-worker reported the presence of numerous papillae in the patients with atrophic pharyngitis but the vascularity of the pharyngeal mucosa was greatly reduced. This latter observation is contrary to our findings in similar patients.

We believe that more clinical research should be directed to the pharynx and its disease entities. The short bibliography will testify to the need for such research. The results of such investigation may provide us with more specific criteria for establishing a diagnosis of chronic pharyngitis as well as a better understanding of the pharynx in general.

Such data should allow us to manage the patient with chronic pharyngeal symptoms better.

In a future communication we will discuss the relationship of gross pharyngeal appearance and histological changes.

We were not able to conduct a combined microbiological-viral and histopathological investigation in the present study for technical reasons, but we suggest that such a combined study should be inaugurated to ascertain particularly the role of the former in chronic pharyngitis. The use of more refined research procedures such as electron microscopy and histochemical techniques should also be considered after sufficient histopathological and microbiological data have been compiled.

SUMMARY

An investigation to determine if certain correlations could be established between chronic pharyngeal symptoms and the gross and histological appearance of the pharyngeal mucosa was carried out.

Twenty-four patients were classified according to their pharyngeal symptoms and 3 asymptomatic patients with an abnormal pharyngeal appearance were grouped separately.

No overall close correlation between symptoms and histopathological features was shown.

The investigation did reveal the following:

1. Patients with a persistent sore throat and those with a chronic dry, sore throat had similar histological findings in the lamina propria.

2. The average thickness of the squamous cell layer in all patients with postnasal discharge was less than 15 cell layers.

3. No correlation between duration of a specific symptom and pharyngeal appearance was established but when patients with granular appearing pharynges from all categories were compared, 6 of the 8 had symptoms ranging from 4 to 6 years.

4. Patients with a sensation of a dry throat in excess of 20 years had a thinner squamous cell layer than others in category one.

5. The only significant probable contributing factor to the pharyngeal symptoms was the aggravation of the sensation of postnasal discharge by a state of nervousness.

6. One case of a probable true pharyngeal allergy was encountered.

7. The onset of chronic symptoms was related to previous nose or throat surgery in 6 patients.

2799 W. Grand Blvd., Detroit, Mich.
Mayo Clinic, Rochester, Minn.

REFERENCES

1. Scevola, P., and Leonardelli, G. B.: Contributo Alla Conoscenza Istomorfologica delle Faringiti Croniche Ipertrofiche ed Atrofiche (Histomorphology of Chronic Hypertrophic and Atrophic Pharyngitis). Archivio Italiano di Otologia, Rinologia e Laringologia (Milano) 65:72-86 (Jan.-Feb.) 1954.

2. Schenck, H. P.: Histopathological Changes Occurring in Chronic Infection of the Pharynx. Annals of Otology, Rhinology and Laryngology 50:817-833, 1941.

3. Scevola, P., and Sambataro, C.: Studi Sull'Accrescimento e la Senescenza della Mucosa Dell-Orofaringe (Studies on the Growth and Aging of the Mucosa of the Oropharynx). Archivio Italiano di Otologia, Rinologia e Laringologia (Milano) 66:1-35 (Jan.-Feb.) 1955.

4. Sanders, S. H.: Chronic Sore Throat of Allergic Origin. Eye, Ear, Nose and Throat Monthly 40:490-494 (July) 1961.

DISCUSSION

Dr. Kinsey M. Simonton: In our office we daily see patients who complain of persistent symptoms referred to the pharynx. The symptoms are variously described as soreness, dryness, burning, tickle, discharge and collected mucus. Inspection reveals a wide range of appearance from pale to red, thin smooth to thick granular, and moist to crusted. The terms used to describe the appearance of the pharynx vary with different physicians. Therapeutic efforts cover a wide range but are generally unsatisfactory. Iodides and similar secretion-stimulating drugs are of little benefit. Environmental measures, such as increasing humidity, have limited application. Inquiry often reveals adequate fluid intake.

The end result is frustration for the physician as well as for the patient.

Dr. Rulon was encouraged to undertake this study in an effort to solve some of the problems related to discomfort in the pharynx. The first point of interest was in the glands of the mucosa. This was not revealing. Preliminary study by serial section of the entire pharyngeal mucosa from 9 autopsy specimens showed glands primarily in the lateral regions. Dr. Rulon found glands in specimens for biopsy taken from the posterior wall of the pharynx, although these were not found in all specimens. The glands appeared in the deep layers of the specimens; therefore failure to demonstrate glands may indicate a thin specimen. Normal appearing mucous glands were found in specimens from pharynges which appeared dry on gross inspection. My own empirical conclusion that dry pharynx is due to absence or hypofunction of mucosal glands is not confirmed. The lack of clinical response to iodides cannot be attributed to absence of glands.

Dr. Rulon grouped his patients according to the description of the symptom. Histologic findings do not correlate with this grouping. His observations suggest that descriptive terms used by the patient may vary as widely in cases of pharyngeal discomfort as in cases of disturbed equilibrium. Time did not permit report of grouping of these patients on the basis of physical appearance of the pharynx. Grouping by physical appearance also failed to correlate with histologic findings.

Histologic findings were strikingly similar in specimens from asymptomatic, so-called normal controls, asymptomatic patients with gross abnormality of the mucosa, and symptomatic patients with and without gross abnormality of the mucosa. The question arises: Is persistent discomfort in the pharynx the result of an organic or a nervous disorder?

The most prominent histologic variant is the presence of lymphocytes in the mucosa in some specimens. This finding does correlate with the gross appearance and is noted as "granular" mucosa.

This study has not resolved any of the questions concerning persistent discomfort in the pharynx. It does point out the sparseness of literature on the subject, the lack of an adequate classification of chronic pharyngitis and the need for additional studies, probably of a more sophisticated design, if we are to improve our understanding of this annoying group of symptoms.

Dr. Francis W. Davison: I would like to compliment Dr. Rulon on his most interesting study.

I was glad to hear him mention the psycho-emotional factors, which I think are very often operative in these cases and for which reason I would like to remind our Fellows of Dr. Hilger's article entitled "Carotid Pain." I think it applies to many of these patients.

DR. JOEL J. PRESSMAN: I was delighted to hear Dr. Rulon say that these pharyngeal symptoms bore no relationship to observed pathology. In Southern California people are plagued with pharyngeal symptoms. We know that a very real and significant relationship exists between chemical irritations of smog and symptomatology related to the pharynx, and can find a very definite relationship, for instance, between the altitude in which the patient lives and the incidence of pharyngeal complaints. Housing projects are getting higher and higher into the hills in Southern California and there is a very definite smog level at possibly 2,500 feet. Those who live above it—and I have lately become interested in observing such details—aren't bothered nearly as much as the ones who live below the smog belt. At the University we probably see more of them than one might expect from our patient load, because these distressing symptoms are never cured and the suffering patients come to the University as a last resort. I would like to suggest to Dr. Rulon that he come to Southern California and continue his studies. He would not lack for experimental subjects.

DR. RULON (closing): Dr. Davison, we have felt for a long while that there was a strong emotional factor in many of these patients and we therefore played the role of the psychiatrist to a degree and tried to delve into the history a little more thoroughly in this regard and this is the only way that we were able to pick this up, particularly in this group with the post-nasal discharge.

Dr. Pressman, one of the things that I didn't mention in my paper, because of the time factor, was that we did inquire as to whether there was an irritant factor present in these cases and interestingly enough we did have three patients in our study that all lived in Gary, Indiana. Although they all denied that their symptoms were related to the atmospheric conditions in Gary, Indiana, nevertheless it is interesting that three patients out of twenty-seven came from one particular area in the country.

MANAGEMENT OF CHRONIC INFLAMMATION OF THE SALIVARY GLANDS

FRANK D. LATHROP, M.D.

BOSTON, MASS.

Although chronic pyogenic inflammatory disease of the major salivary glands is not uncommon, its management, at times, may tax the clinical sagacity of the physician. Difficulties in managing chronic sialadenitis of the parotid or submaxillary gland may arise as a result of an erroneous conception of the basic etiology of the suppurative process, failure to treat the inflammatory process adequately as dictated by the pathologic conditions present or too great reliance on the efficacy of antibiotic therapy.

If management of chronic pyogenic inflammatory disease of these glands is to be successful, it must be based on the establishment of the etiology of the inflammatory process whenever possible and the institution of therapeutic measures designed to eliminate it as well as the pathologic process in the gland.

HISTORY

In the majority of instances, the history when correlated with previous experience will frequently suggest the etiology. Thus, the history of a gland which is constantly swollen and from whose duct purulent secretions can be expressed suggests that the etiology may be a stricture of the duct or a calculus of either the duct or gland when the original painful enlargement of the gland occurred intermittently while eating or chewing. Furthermore, if the swelling and discomfort are relatively minor and disappear shortly after completion of a meal, a stricture is more likely to be the cause than a calculus. The latter

---

From the Department of Otolaryngology, Lahey Clinic, Boston, Massachusetts.

is prone to produce more complete obstruction to the flow of saliva from the duct and, as a consequence, is likely to cause more intense pain and greater swelling of the gland. In addition, the swelling produced by a calculus usually persists for a longer period of time than does that produced by a stricture. The determination as to which of these is the basic explanation for the swollen gland frequently requires utilization of special methods of examination.

Unfortunately, a history of this nature cannot be obtained in every instance. On occasion, a parotid gland suddenly will become enlarged and painful without any relationship to eating. The history usually indicates that the initial swelling of the gland never entirely receded despite treatment and actually became progressively more pronounced with succeeding attacks of acute pain and swelling. Special examinations in such instances seldom demonstrate the presence of a stricture or a calculus as the explanation for the chronic enlargement of the gland. It is quite possible that the cause of the original swelling of the gland will never be ascertained in the majority of such cases by the time chronicity has developed. It is possible, however, that the explanation for at least some of these cases lies in inadequate antibiotic therapy of the initial inflammatory attack with the result that infection recurs, producing irreversible pathologic change within the gland.

In some instances, chronic inflammatory disease of the parotid gland may occur as a result of an unrecognized stricture of the punctum of the parotid duct. Strictures in this location have been reported by Furstenberg[1] as occurring particularly in individuals with full dentures. In addition, although of extreme rarity, compression of the duct by circumferential neoplastic disease lying beneath the buccal mucosa of this area may produce swelling and inflammation of the parotid gland.

On rare occasions, swelling of the parotid glands occurs as a result of unrecognized Sjögren's or Mikulicz's disease. The etiology of these conditions is not known, although McCabe[2] has suggested that the etiology of Mikulicz's disease is an auto-immune reaction. In my experience, such cases have frequently been treated as chronic pyogenic inflammation despite a lack in the past history of pain associated with increased enlargement of the parotid gland when chewing because the secretion from the involved glands is sparse, frequently thicker than normal and often cloudy in appearance.

EXAMINATION

With any enlargement of a salivary gland it is important that the character of the secretion expressible from its duct be ascertained. Normally, the secretion is crystal clear with a consistency slightly greater than that of water and can be expressed from the duct of the gland with ease. Any deviation from this description of salivary secretion suggests a pathologic condition of the salivary gland. At times, however, probably because of nervousness on the part of the patient, it is difficult or impossible to express secretion from a salivary duct at the initial attempt although later in the course of the examination salivary secretion can be expressed in the usual quantity. This should not be considered abnormal if the appearance of the secretion otherwise is normal.

Abnormalities in the character of the secretion of the parotid or submaxillary glands vary according to the activity and extent of the pathologic process. Early in the course of the chronic inflammatory process, the secretion expressible from the duct during periods of relative inactivity may be essentially normal in appearance but flakes of whitish, coagulated material are visible. When the pathologic change is more extensive, the secretion expressed from the gland may be relatively colorless but composed of clumps of thicker, jellylike secretion mixed with thin saliva during the periods of comparative quiescence of the inflammation. With increased activity of the inflammatory process, however, the expressed secretion becomes thicker and greyish to yellowish in color because it is composed of a variable mixture of the mucoid and purulent products of the inflammatory process. With prolongation of the chronicity of the inflammatory process, the secretion becomes frankly purulent and the pathologic change more often than not becomes irreversible.

Despite the fact that under ordinary circumstances approximately two-thirds of the total quantity of salivary secretion is derived from the submaxillary glands, the secretion of the parotid glands appears to play an important role in keeping the mucous membrane of the cheeks moist. Thus, when the mucous membrane of the cheek on the same side as that of a swollen parotid gland tends to adhere to a wooden throat stick more than is usually the case, the explanation may be that either the secretory function of the gland is decreased or the flow of saliva from the gland is obstructed. A tendency toward dryness of the mucous membrane of the cheek has not been commonly

associated with chronic pyogenic inflammatory disease of the parotid gland, in my experience, except on those relatively rare occasions when the ductal orifice has been entirely occluded by a stricture or a calculus. However, dryness is frequently encountered early in the course of such noninflammatory conditions as Sjögren's or Mikulicz's disease.

Whether or not a stricture of the duct or a calculus in the duct is obstructing the flow of saliva often can be determined by probing the duct. Under normal circumstances, lacrimal dilators Nos. 1 through 3 successively can be passed without difficulty through the parotid or submaxillary duct, although the No. 3 dilator may be a little tight at the orifice of the duct.

A stricture of the duct is indicated when gripping or inability to pass a dilator smaller than a No. 3 throughout the course of the duct is encountered. Strictures situated at the orifice of the duct may be missed if a dilator is forcefully passed through this area. Normally, Nos. 1 and 2 lacrimal dilators will pass successively through this area without gripping. If one or the other cannot be passed easily, a stricture is present at this point. In either situation, if the obstruction is caused by a stricture, passage of the largest dilator possible will frequently be followed by a free flow of secretion from the duct, and subsequent partial regression of the swelling of the gland, although temporary, will additionally confirm the presence of a stricture. On exceedingly rare occasions, even the gentlest passage of a dilator through an area of suspected stricture will be followed by blood-stained secretions. In such instances, the examiner should suspect that the obstruction is not inflammatory in origin but rather is the result of a neoplasm.

On probing a duct which is obstructed by a calculus, its presence is frequently made evident by a grating sensation passed through the dilator when the calculus is encountered. This is not true, however, when the obstruction is caused by salivary gravel located at the ductal orifice. In such instances, the particle of gravel is brushed aside by the dilator as it is passed and, because of the small size of the stone, grating against the metal of the dilator is not evident. After removal of the dilator, however, a free flow of secretion often follows and careful inspection of the secretion may reveal the presence of particles of gravel in it.

Probing a duct to determine the presence of a calculus frequently is not necessary when the calculus is relatively large for it may have

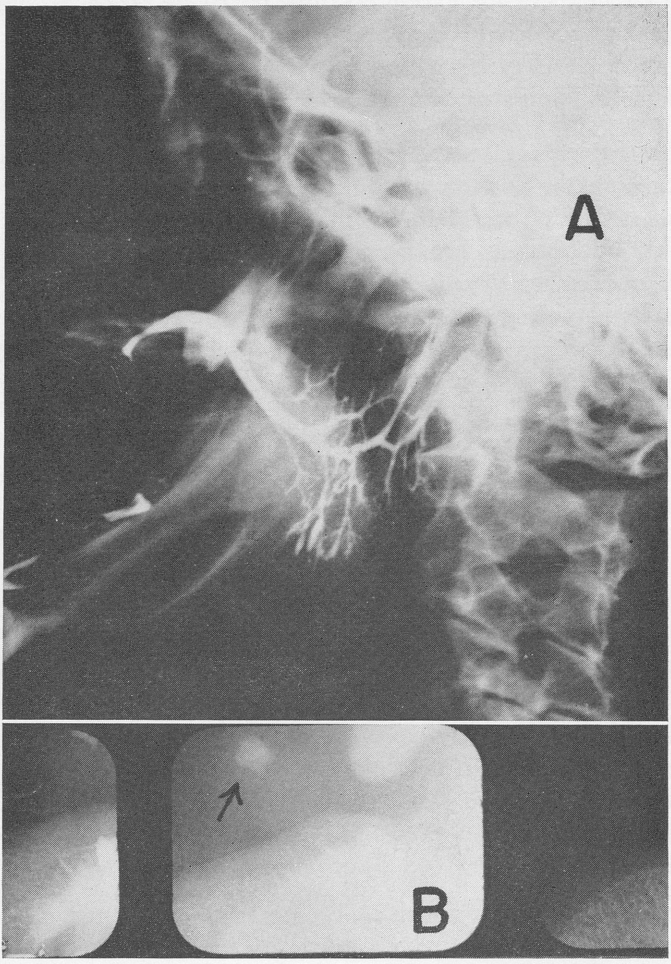

Fig. 1.—*A*, Essentially normal parotid sialogram with no evidence of calculus in duct. *B*, Calculus in parotid duct demonstrated on intra-oral dental roentgenogram over area of duct.

been palpated while the examiner attempted to express secretions from the duct of the involved gland. This is particularly true of stones situated in the duct of the submaxillary gland. In such instances, the smaller stones have a tendency to be situated in the distal half of the duct and the larger stones near the proximal end of the duct. In some instances they may be partially incorporated in the parenchyma of

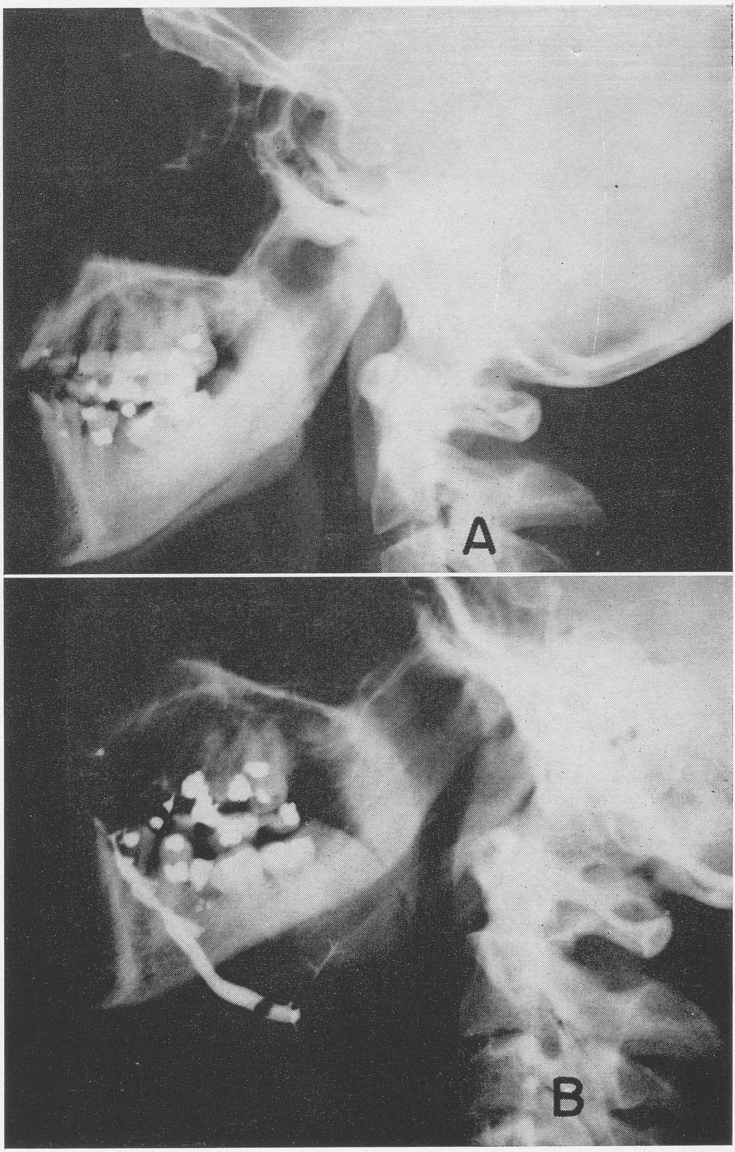

Fig. 2.—*A*, No evidence of a calculus on routine roentgenogram of submaxillary area. *B*, Sialography of submaxillary gland demonstrates nonradiopaque calculus.

the gland in the latter location. Calculi of the parotid duct are less easily palpated and, in my experience, when palpable are situated most often at the anterior border of the masseter muscle.

Roentgen examination of the submaxillary gland and duct is particularly useful in establishing the presence of radiopaque calculi in these regions. Small calculi frequently are not demonstrable in the usual views taken by roentgenologists who have had relatively little experience in this field. However, those who are experienced often will use dental film to obtain intra-oral views of the suspected area. Such films will frequently demonstrate calculi that are not visible on the larger films. Roentgen examination of the parotid gland or duct usually is not particularly helpful in establishing the presence or absence of a calculus because of the density of the underlying mandible. Tangential views, however, will occasionally reveal a calculus when it is large, while a smaller calculus located near the opening of the parotid duct into the mouth may be demonstrated on an intra-oral film (Fig. 1).

Although not necessary in every case, sialography is indispensable, in my opinion, in diagnosing and evaluating chronic inflammatory disease of the salivary glands. It is of particular value in differentiating noninflammatory disease of the salivary glands from inflammatory disease and in evaluating those cases of chronic inflammation which have failed to respond to previous medical or surgical therapy. A properly performed sialogram of a gland involved by chronic inflammation not only will delineate obstruction of a salivary duct caused by a stricture or a nonradiopaque calculus which has not been demonstrated by other diagnostic procedures, but also may demonstrate a portion of the gland which was not removed during previous surgical extirpation of the gland (Fig. 2 *A* and *B*, and Fig. 3). In addition, sialography may also permit evaluation of the residual secretory function of the gland. This may prove helpful in deciding upon the most appropriate treatment to be employed. Other than microscopic examination of the involved gland, sialography is the only procedure available to the examiner that permits a relatively accurate assessment of the pathologic change in the gland.

TREATMENT

The treatment employed for chronic suppurative sialadenitis of the parotid or submaxillary gland is determined primarily by its etiology and the severity of the pathologic change within the substance

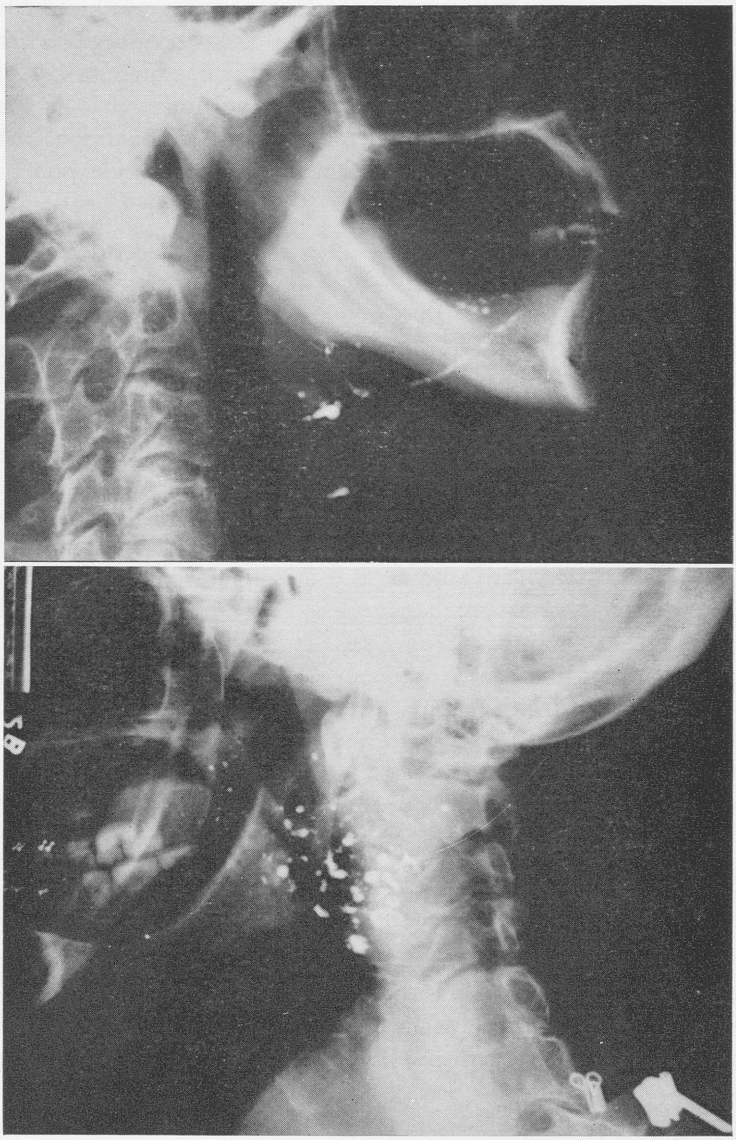

Fig. 3.—Sialogram after operative excision of submaxillary gland demonstrates incomplete removal of gland and duct.

Fig. 4.—Residual lipiodol retained in parotid gland six months after sialography demonstrating irreversible pathologic changes in gland.

of the gland. In general, the longer the history of the inflammatory process, the more extensive must be the therapeutic procedure utilized to alleviate it. Antibiotic therapy has been of little value for chronic inflammation of the salivary glands, although it has been useful when an acute exacerbation of a chronic suppurative process has occurred. Surgical intervention, on the other hand, has been successful whenever the procedure employed has been suited to the pathologic process of the involved gland.

Almost without exception, chronic inflammatory disease of the submaxillary gland is secondary to calculus formation. In some instances, although the calculus is small, it is too large to pass through the punctal orifice of the duct. In such cases, simple dilatation of the opening of the duct on the floor of the mouth often will permit passage of the stone and alleviate the patient's symptoms. In other cases, however, slitting the distal end of the duct and suturing the mucosa of the duct to the mucous membrane of the floor of the mouth may be necessary to prevent recurrent symptoms of obstruction of the duct by additional small stones or salivary gravel. This may be all that is necessary if the inflammatory process subsides and the calculi either do not recur or are small enough to pass out of the submaxillary duct through its enlarged opening on the floor of the mouth. If the inflammatory process does not resolve or if the duct continues to become obstructed by the formation of larger calculi, excision of the submaxillary gland is necessary to obtain a permanent cure.

Larger calculi situated within the duct of the submaxillary gland or obstructing the proximal end of the duct although partially within the substance of the gland can be removed through an intra-oral approach when they are palpable just beneath the mucous membrane of the floor of the mouth. When attempting to remove such a calculus through an intra-oral approach, it is advisable to pass a stabilizing suture posterior to the stone to hold it in position during subsequent manipulations. An adequate linear incision overlying the stone will expose the stone and permit its extraction. When removing a calculus intra-orally, it should be remembered that if the dissection is carried deeper into the gland there is danger of injuring the lingual nerve and causing distressing paresthesias.

Chronic inflammation of the submaxillary gland secondary to multiple calculi situated within the parenchyma of the gland and its duct is amenable only to surgical extirpation of the submaxillary gland. This is true also of recurrent calculus formation. It is impor-

tant, however, when excising the submaxillary gland that it be entirely removed. Not infrequently, the lingual nerve is incorporated in the fascial covering of that portion of the medial surface of the gland which extends beneath the tongue. In order that this portion of the gland may be liberated from the lingual nerve so that it may be removed en bloc with the remainder of the gland without inadvertently sacrificing the nerve, the lingual nerve must be isolated posterior to this area of its attachment to the submaxillary gland. In addition, the submaxillary duct should be dissected as far distally as possible, and the remaining portion palpated bimanually with one finger in the mouth over this area of the duct before it is ligated and sectioned to be certain that a stone does not remain in the retained portion of the duct to cause persistent inflammatory reaction.

Strictures of the duct of the submaxillary gland usually occur as an aftermath of erosion of the duct by smaller calculi situated near its buccal orifice. Although these may respond in some instances to repeated dilatation of the area of stricture, in the majority the duct must be slit past the strictured area and the ductal mucosa sutured to the buccal mucous membrane of the floor of the mouth to create a trough in this area. When strictures occur in the vicinity of the proximal end of the duct as a result of inflammation or previous surgical removal of a larger calculus in this area, excision of the submaxillary gland is indicated.

Chronic suppurative disease occurs less frequently in the parotid gland than in the submaxillary gland. This is fortunate because in many cases of chronic parotitis the etiology cannot be ascertained and, therefore, therapy directed toward its elimination cannot be instituted. When the inflammatory process is secondary to stricture or calculus formation, however, it responds as well to specific therapeutic procedures as does a suppurative process of the submaxillary gland of similar etiology. Thus, a stricture of the parotid duct situated at or near its buccal orifice is easily alleviated by slitting the duct past the area of stricture and suturing its mucosa to the buccal mucous membrane of the cheek. Strictures of the parotid duct situated elsewhere in its course through the soft tissues of the cheek may be eliminated by excision of the stricture and reconstruction of the duct over a polyethylene tube. If the area of excision is small, the ends of the duct may be sutured together, but when the excised area is larger, reconstruction by means of a vein graft is necessary.

Calculi of the parotid duct are rare in my experience. Furthermore, I have never encountered a true salivary calculus situated entirely within the substance of the parotid gland. Those calculi of the duct which I have encountered most often have been situated in the proximal ductal segment just anterior to the anterior border of the masseter muscle. In this situation, with gradual enlargement, they often erode through the wall of the duct and can be palpated through the overlying skin. A linear incision paralleling the course of the parotid duct directly over the area of calculus formation permits exposure and extraction of the calculus. If the duct were intact and a linear incision had to be made to remove the calculus, it could be closed with fine silk sutures without subsequent stricture formation or the occurrence of a salivary fistula. When the stone has eroded through the duct, however, it may be necessary to reconstruct it. If the dehiscence comprises only a small proportion of the circumferential diameter of the duct, a small polyethylene tube inserted into the duct so that one end protrudes slightly from the buccal orifice of the duct and the other end extends proximal to the rent in the duct will allow satisfactory regeneration of the duct wall. The end that protrudes from the ductal orifice is anchored to the buccal mucosa to hold the tube in place for a week to ten days. When the dehiscence is too great to permit spontaneous regeneration without stricture formation, the damaged area of the duct should be excised. The continuity of the parotid duct then may be re-established by the use of a vein graft which is sutured in place over a polyethylene tube in order to eradicate the defect of the duct.

The treatment of chronic suppurative parotitis which is not related to stricture or calculus formation is difficult and often unsatisfactory. It is characterized by acute exacerbations of the suppurative process alternating with periods of relative quiescence. If the patient is seen during a quiescent stage, the gland may be only slightly enlarged and indurated, and purulent secretion mixed with clear saliva can be expressed from the duct. An acute exacerbation, however, cannot be differentiated from an original acute parotitis except by the history of similar recurrent attacks.

During the acute attack, intensive antibiotic therapy based on the identification and sensitivities of the organisms cultured from the parotid secretion is the treatment of choice. On rare occasions, abscess formation occurs which must be treated by appropriate incision and drainage.

Once the acute phase has subsided, the patient is desirous of preventing future acute exacerbations but frequently is reluctant to consider parotidectomy because of the possibility that a facial paresis will ensue. Under such circumstances, frequent "milking" of the gland and occasional irrigations of the parotid duct appear to be helpful in reducing the frequency of acute exacerbations of the infection. Furthermore, if the patient is allowed to have a supply of antibiotic on hand so that he may begin to take it as soon as he feels that an acute episode is about to occur, the acute exacerbation may be prevented. Prolonged antibiotic therapy based on culture and sensitivity tests frequently causes temporary abatement of the inflammatory process. However, it usually fails to effect a cure because of irreversible pathologic changes that have occurred in the gland (Fig. 4). This form of therapy is contraindicated in the management of chronic parotitis because of the possibility of developing an antibiotic resistant organism.

Despite these measures, however, recurrent attacks of acute exacerbations of the inflammatory process usually occur with increasing frequency although the pain may be somewhat diminished in intensity with the later episodes compared to that experienced earlier in the course of the disease. As a result, the patient usually becomes resigned to the necessity for surgical intervention in order to obtain permanent relief from his symptoms. Under such circumstances, a total parotidectomy will effect a permanent cure and, if carefully performed, will not result in a permanent paresis of the face.

SUMMARY

Chronic inflammation of the major salivary glands is not uncommon. In most instances it is related to a stricture of the duct or calculi situated either within the duct or the gland, although chronic suppurative parotitis may occur without apparent cause. In the majority of instances, the etiology of the inflammatory process can be determined by palpation of the gland or its duct, probing the duct, and by carefully performed roentgenologic or sialographic examination.

Strictures of the duct of the submaxillary or parotid glands as well as calculi situated in these ducts are amenable to surgical procedures designed to eliminate them and permit resolution of the chronic inflammatory process in the majority of instances without sacrifice of the involved gland. When, however, calculi are situated in the

parenchyma of the submaxillary gland, are recurrent or the inflammatory process fails to subside in spite of previous removal of a stricture or calculus, excision of the submaxillary gland is the treatment of choice.

Chronic suppurative parotitis without apparent etiology occurs relatively infrequently. Although the acute exacerbations of this disease respond satisfactorily to appropriate antibiotic therapy, the underlying chronic inflammation does not because of the irreversible nature of the pathologic change with which the gland is involved. Total parotidectomy, however, although reluctantly accepted by the patient because of the possibility of a residual facial paresis, will effect a permanent cure.

605 Commonwealth Ave.

REFERENCES

1. Furstenberg, A. C., and Blatt, I. M.: Intermittent Parotid Swelling Due to Ill-fitting Dentures; An Entity; Its Diagnosis and Treatment. Laryngoscope 68: 1165-1181 (July) 1958.

2. McCabe, B. F.: The Evidence for an Auto-immune Mechanism in Mikulicz's Disease. Laryngoscope 71:396-403 (Apr.) 1961.

DISCUSSION

Dr. A. C. Furstenberg: Dr. Lathrop has covered his subject in a comprehensive manner which clearly reveals his long experience with these clinical entities. I can do no more than catch some of the high spots of his paper and treat them briefly in my allotted time.

He has emphasized the value of sialography in understanding the etiology, diagnosis and treatment of inflammatory conditions of the major salivary glands.

Renewed interest in sialography with significant improvement in its technique has been a tremendous help in the diagnosis and classification of obstructive and non-obstructive inflammatory lesions. Sialography was often used to demonstrate the filling pattern of the salivary ducts like one would visualize the tracheobronchial tree but no one gave much thought to the evaluation of the emptying function of the salivary glands in disease. It was Maxwell and Blatt who modified sialography to include both a filling and emptying phase that offered a much improved physiological method of studying the salivary glands radiographically. At the 61st Annual Session of the American Academy of Ophthalmology and Otolaryngology in Chicago in 1956 they discussed the technique of Secretory Sialography and emphasized its value in demonstrating dilatation, obstruction, displacement and obliteration of the salivary ducts as well as interglandular inclusions such as calculi.

Dr. Lathrop has called our attention to an obstructive lesion in the parotid gland and its mode of management namely, sialodochitis. We believe it to be an entity due to an inflammatory stricture of the papilla of Stenson's duct resulting from the trauma of improperly fitting partial or complete dentures. We believe

this condition has a natural history, recognizable clinical manifestations, diagnostic radiographic features and definite histo-pathologic changes. Three of our cases were presented at the 61st Annual Meeting of this Society in San Francisco on May 22, 1958 with a report of the clinical picture, the pathogenesis, radiographic findings and histologic correlation. Secretory sialography was most useful in making the diagnosis and differentiating it from non-obstructive sialectasis. The histologic picture is that of stenosis, scar tissue formation and metaplasia of the duct epithelium; all compatible with trauma of the parotid papilla.

Dr. Lathrop has referred to Sjörgren's and Mikulicz' disease in which swellings of the parotid glands are often present but frequently not recognized. He states that the etiology of Mikulicz' disease is not known and cites McCabe's suggestion that it is perhaps due to an auto-immune reaction. We must admit that we are very much in the dark in our efforts to understand these two chronic non-obstructive salivary gland disorders.

After Dr. Irving Blatt completed his formal training on my staff, he made a thorough and exhaustive study of Sjorgren's and Mikulicz's disease together with chronic suppurative parotitis which Dr. Lathrop has so ably described. He pointed out that "this heterogeneous but clinically related group of diseases have a similar and characteristic sialographic-histologic pattern known as sialectasis. By studying the filling and emptying phases of sialography, the extent of the altered anatomico-physiologic pattern of sialectasis may be identified and classified in four stages:

I. Punctate sialectasis in which the earliest findngs are characterized by diffuse punctate dilatation of the peripheral ducts.

II. Globular sialectasis in which the dilatation of the peripheral ducts increases but with uniform size and distribution in moderately advanced disease.

III. Cavitary sialectasis in which there is coalescence of the globules which now become irregular in size and distribution and decrease in number.

IV. And finally destructive sialectasis, the end-stage in which there is a bazaar pattern which suggests invasion and destruction of the gland parenchyma by neoplasm."

I have reviewed Blatt's material and slides on many occasions and can attest to the fact that his observations in making these four classifications are scientifically valid.

We, of course, do not know the precise etiological influences responsible for these glandular disorders but believe that they are related in some manner because of their similar and characteristic roentgenographic pattern of sialectasis. Blatt believes that the inflammatory nature of the disease was the reason why most workers in this field were reluctant to perform biopsies in these cases. Obviously many pathological studies will need to be made before the true identity of these conditions will be revealed.

I should like to comment on one more observation that Dr. Lathrop has made, as follows: "Despite the fact that under ordinary circumstances approximately two-thirds of the total quantity of salivary secretion is derived from the submaxillary glands the secretion of the parotid glands appears to play an important role in keeping the mucous membrane of the cheeks moist. Thus, when the mucous membrane of the cheeks on the same side as that of a swollen parotid gland tends to adhere to a wood throat stick more than is usually the case, the explanation may be that either the secretory function of the gland is decreased or the flow of saliva from the gland is obstructed. Dryness is frequently encountered early in the course of such non-inflammatory conditions as Sjörgren's or Mikulicz' disease."

When some impairment to the nerve supply of the salivary glands occurs a widespread dysfunction of the salivary mechanism may be the manifest reaction and a dry mouth the symptom for which the patient seeks relief. These patients actually have a dry mouth. The mucous membrane is parched, a wooden tongue blade drawn over the mucous membrane meets the resistance of a sticky surface, the tongue often appears desiccated with thin crusts upon its dorsum and physiological stimulation or pressure upon the glands reveals little or no saliva. Even when the patient is asked to suck a piece of lemon, salivation does not occur. This is the picture frequently seen in patients who have been subjected to irradiation but here the underlying pathological change is an actual disintegration of glandular tissue and its replacement by scar.

The patients to whom we refer are those who demonstrate some physiological disturbance in the end-organs of the nerves supplying the salivary glands.

One is able to classify them only in respect to their symptomatology because the etiology is usually obscure and pathological study impracticable. The disturbance is not an etiological entity, rather does it seem apparent that the causation may be any number of different factors and influences.

Occupational hazards such as exposure to organic dusts and zinc poisoning seem to have been responsible in a few of our patients. Botulinus poisoning was the cause in three individuals.

However, no specific etiological factors have been demonstrated in the majority of patients who have consulted us on account of a dry mouth in which the nervous system has been at fault.

Evidence derived from a therapeutic test clearly indicates that the secretory nerves are defective in this group of patients. We have frequently demonstrated prompt physiological action of the mechanism of salivation after the administration of pilocarpine.

The drug shows predilection for the end-organs of the secretory nerves and the response which it illicits is immutable proof of the presence of some disorder in the secretory fibers of the salivary gland. If administered in large enough doses at regular intervals and under proper conditions, pilocarpine is often a specific agent for the restoration of the normal function of salivation.

Pilocarpine nitrate is administered orally in 10 mg doses three times a day. It should be administered before meals in order to promote salivation when it is most needed. There are instances when a dysfunction of the salivary glands is the result of an end-organ lesion of the peripheral secretory nerves. This fact, I believe, can be substantiated by a production of normal salivary flow when pilocarpine is administered.

The effect of the drug is augmented by the simultaneous ingestion of the acid-forming salt, Ammonium Chloride. The institution of this treatment for a period of three to six weeks has been followed in some of my patients by a return of normal salivation. The exact mechanism by which this result is brought about is not clearly understood; either cellular regeneration occurs spontaneously or medicomentosus stimulation of the salivary glands may favor an adjustment to normal function.

Dr. Herbert Harris: Infection in salivary glands in children is something that has seemed to frequent my office, not in large numbers, but in sufficient numbers that I have been at a loss as to the proper management in some of the cases.

I would like to ask Dr. Lathrop if he operates on very many of these young children who have frequent recurring episodes of parotitis. I have seen a number

in the 5 to 7 year age group, and most of them I have treated conservatively—some of them I have been able to follow, though several either have recovered spontaneously or gone elsewhere for treatment.

Most of the cases have been due to staphylococcus aureus and coagulase positive, which has high antigen properties; autogenous vaccine therapy seems important, combined with long specific antibiotic therapy. Many of the sialograms show a saccular type sialectosis. In these cases I would like to have your opinion and more specific description of the management in these children.

I have had a number of adults with recurring episodes of parotitis, though these attacks are not frequent and may occur every two or three years subsiding promptly with treatment. In cases of the children, the attacks are much more frequent—as often as every two or three months.

There is one type of chronic submaxillary gland infection which I would like to mention. I have had two cases in which there has been an infected root of a tooth remaining in the mandible. In one instance it went unnoticed, and a biopsy of the gland was done with a subsequent draining fistula. I reviewed the x-ray of the mandible and was able to pick up this tooth root. Apparently the abscess had broken through the cortex of the mandible causing the chronic suppuration. Removal of the root completely cured the infection.

The other was actually an abscessed tooth which was not recognized by the dentist. I did remove the submaxillary gland which showed chronic inflammation. I was unable to explain this infection. With the continued submandibular swelling, even after the removal of the gland, a request was made for further evaluation of the possibly infected tooth resulting in complete resolution after the abscessed tooth was removed.

There are two other cases which I think should be mentioned here. I am not sure that Dr. Lathrop mentioned sialitis of the submaxillary gland due to self-introduction of foreign material into the duct. I have been waiting for a third case to report this rather unusual accident. In the first case the infection resulted from the accidental self-introduction of a piece of grass stem into the submaxillary duct of a soldier during the war. This grass was finally recovered from the chronic suppurating sinus over the submaxillary gland with immediate healing of the wound. The other case occurred several years later in a lady who introduced a small piece of broom straw into her mouth with the sudden disappearance of the straw. Several days later she developed a sialitis of the submaxillary gland and exploration of the gland and duct revealed the straw in the primary ducts of the gland. Having had the previous case prompted me to operate this lady. I removed the gland and straw together though a lesser procedure might have effected a cure.

Dr. Lathrop (closing): A discussor, in my opinion, should add to a presentation or constructively criticize it rather than merely agree with an author's views. Dr. Furstenberg commented on several points which were not included in my verbal presentation because of lack of time, and Dr. Harris was sufficiently critical to inquire about aspects of salivary gland inflammation I had not considered.

I did not include Sjögren's or Mikulicz's disease as an inflammation of the salivary glands because I am not convinced that these are truly inflammatory processes. However, they are mentioned as frequently being diagnosed erroneously as chronic suppurative disease for which prolonged antibiotic therapy had been prescribed without benefit. Early in the course of these conditions pilocarpine and ammonium chloride seem to be helpful. However, for all practical purposes, when the secretory elements of the gland have largely disappeared, medication of any kind is without benefit.

I agree with Dr. Furstenberg that the emptying phase of sialography is important. One of the slides of sialography I showed demonstrated the presence of lipiodol retained in a parotid gland for 18 months. When lipiodol has been retained in a gland for such an abnormal length of time it is quite obvious that medical therapy will not produce recovery from a suppurative process involving the gland.

I do not see as many children with inflammation of the salivary glands as does Dr. Harris. Those cases I do see are either due to trauma resulting in a stricture of the duct or, as he has mentioned, secondary to a foreign body in the duct. Intraoral incision of the stricture of the duct or extraction of the foreign body from the duct has usually resulted in recovery. I believe that allergy probably plays a part in the production of swelling of the salivary glands in some children; however, I have never been able to prove this or to establish this by the demonstration of eosinophils in the salivary secretion.

Swelling of the submaxillary gland in association with a dental abscess is not uncommon as Dr. Harris has stated. However, I do not believe the submaxillary gland is involved immediately. The original swelling of the gland occurs as a result of enlargement of lymph nodes normally associated with the submaxillary gland. These nodes, if they break down into abscesses, will secondarily involve the submaxillary gland.

RETROPHARYNGEAL HEMORRHAGE FROM THE CAROTID ARTERIES

DELMAR F. WEAVER, M.D.

DAVID J. YOUNG, M.D.
(by invitation)

DETROIT, MICH.

A 38 year old white man was admitted to the medical service of Dr. David J. Young at Woman's Hospital in Detroit on October 5, 1962. A diagnosis of subacute bacterial endocarditis was made. Roentgenograms of the chest showed enlargement of the heart in the region of the ventricles. The electrocardiogram was normal.

On examination of the blood the hemoglobin was 12.4 gm; red blood cells 4,450,000; white blood cells 12,400. The differential count showed neutrophils 71; filaments 70; non-filaments 1; eosinophils 4; basophils 1; lymphocytes 19; monocytes 5. The first culture of the blood showed streptococcus viridans as did two subsequent cultures. The urine showed red blood cells 2-4 per high powered field and epithelium and mucous plus 1. It was otherwise normal.

One million units of penicillin was given every three hours around the clock and 1 gm of streptomycin was given every 12 hours until it was stopped because of itching palms and wrists two weeks later.

On October 21, sixteen days after admission, the patient developed severe pain in the left side of the neck and throat. This was intensified on swallowing. The left parotid gland became quite swollen, clearly outlined and exquisitely tender. The swelling and tenderness extended to the submaxillary region on that side. There were submucosal hemorrhagic areas in the left soft palate, buccal mucosa, floor of mouth and undersurface of tongue. The temperature was 102.6 and pulse 160 per minute. The patient appeared acutely ill. Penicillin was discontinued because of a skin rash.

A diagnosis of suppurative parotitis was made although Dr. Young mentioned the possibility of an embolus producing the findings.

Prostaphlin and chloromycetin were administered.

Roentgenograms of the left parotid gland showed soft tissue swelling but no evidence of calculus.

On October 30, nine days after the acute local symptoms appeared, the parotid gland was aspirated in two areas, under local anesthesia, by a general surgeon. No fluid, pus or blood was obtained. Two days later, the same surgeon incised the parotid gland through an incision beneath the edge of the mandible. No pus was obtained.

Following this, external irradiation was given over the parotid in two doses of 120 r three days apart.

On November 7, seventeen days after acute symptoms appeared, swelling developed in the left tonsillar area and soft palate and I saw the patient in consultation for the first time. In addition to the findings described above, there was a large, firm left sided retropharyngeal mass displacing the soft palate anteriorly and extending almost to the midline of the posterior pharyngeal wall (Fig. 1). The mass did not pulsate. The tonsils had been removed. I agreed with the diagnosis of parotitis and thought the pharyngeal mass was retropharyngeal extension of a large, extensively swollen parotid gland.

I advised administration of potassium iodide and expected localization of pus to develop.

One week later, I passed a hemostat deeply through the original incision under the mandible toward the pharynx but obtained no pus. Biopsy of the adjacent parotid tissue showed inflammation and fibrosis.

Two days later on November 18, the pharyngeal mass enlarged until the patient could not swallow liquids because of strangling and the passing of liquids into his nose.

Two days later, I performed a left parotid sialogram using the method described by Blatt and Maxwell[1] (Fig. 2). The films showed normal ducts and acini but the gland was displaced laterally and anteriorly by a huge mass lying medially and posteriorly to it. Whether the mass was neoplastic or inflammatory could not be determined.

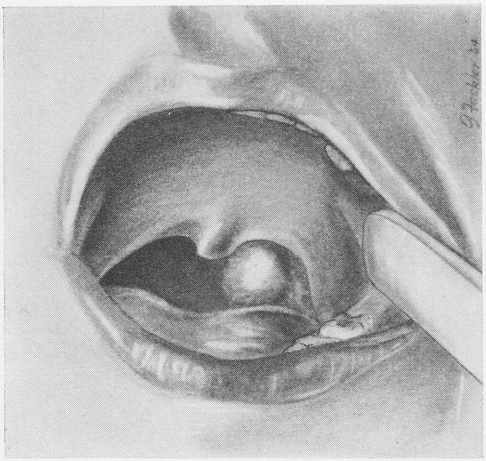

Fig. 1.—Mycotic aneurysm left retropharyngeal space.

The following day, November 21, 1962, under general anesthesia with an intratracheal tube in place, the pharynx was exposed by inserting a Crowe-Davis mouth gag. This was suspended from the Killian Gallows. Since Dr. Young had suggested the possibility of the presence of a mycotic aneurysm, only a small incision was made on the edge of the mass and the wound gently spread with a blunt hemostat which was slowly advanced. Dark, thin blood was rather promptly encountered. This was mixed with some clotted blood and almost immediately fresh blood began to spurt through the small incision. Pressure on the common carotid artery where it passes over the transverse process of the sixth cervical vertebra by my assistant immediately stopped the hemorrhage. Release of the pressure allowed active hemorrhage. My assistant then held pressure over the pharyngeal incision, controlling the hemorrhage in that way. The Crowe-Davis mouth gag was left in place although it was removed from suspension on the gallows. This was necessary in order to position the neck so the carotid arteries could be exposed. After preparing the neck, the common carotid artery was exposed through an incision along the anterior border of the sternomastoid muscle. Umbilical tape was placed around it but not tied. The bifurcation of the common carotid artery was exposed so ligatures could be placed around either the external or internal carotid artery. Unfortunately, at this

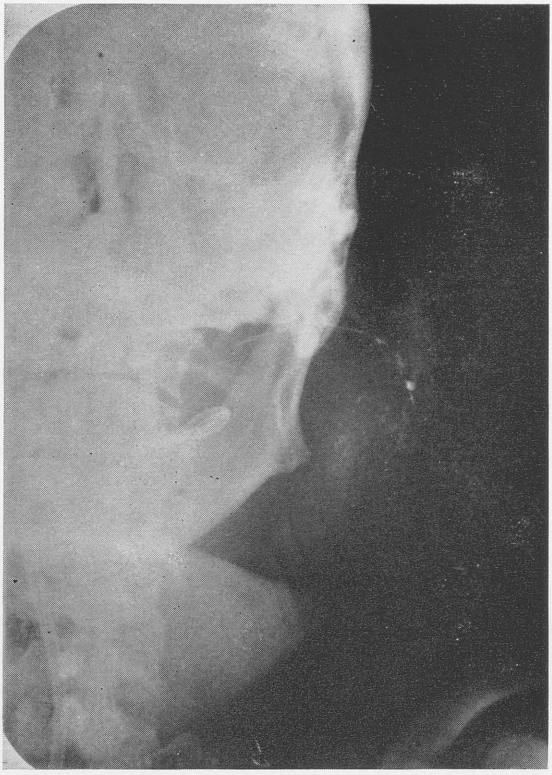

Fig. 2.—Left parotid sialogram. Shows normal ducts and acini but lateral displacement of gland by mass.

point attempts to induce bleeding in the pharynx were unsuccessful. This was probably due to the change of position of the head and neck. Most of the information that I could recall on the subject led me to believe that retropharyngeal hemorrhage is usually from the internal carotid artery and it was felt that this was likely true in this case. However, there was great reluctance to ligate either the common or internal carotid artery in a man of this age without all available evidence of its necessity. Consequently, consultation was held with Dr. Aran S. Johnson, a vascular surgeon, who happened to be nearby and he suggested an operative arteriogram. I then injected 10 cc of hypaque rapidly into the common carotid artery through a No. 18 needle and films taken during the injection showed a normal internal

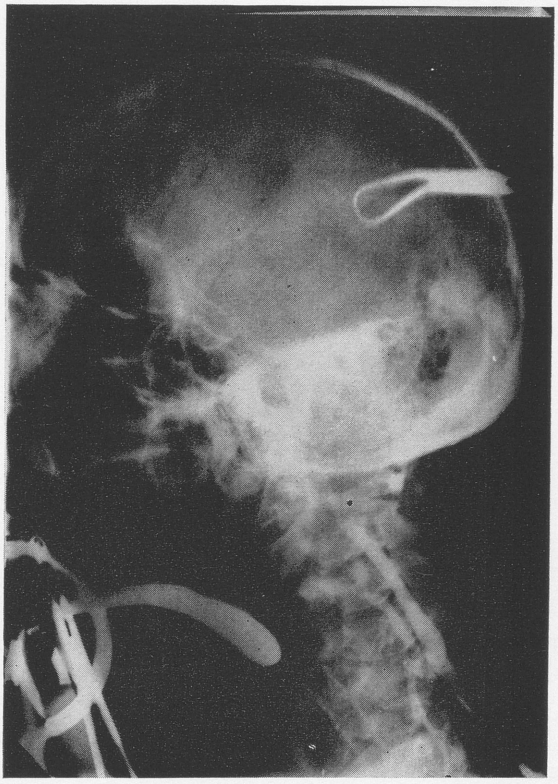

Fig. 3.—Arteriogram showing normal internal carotid artery and opening in external carotid leading into false aneurysm.

carotid artery (Fig. 3). However, there was a defect in the external carotid artery leading into the false aneurysm at the level of the second and third cervical vertebra. This is near the division of the artery into the internal maxillary and the superficial temporal arteries (Fig. 4).

Since we felt we now had complete control of the situation, more vigorous attempts to induce pharyngeal bleeding were made and this time with success. Occlusion of the external carotid artery stopped it immediately. A definite diagnosis of mycotic aneurysm of the left external carotid artery was made.

This artery was then doubly ligated with 2-0 silk and the neck wound closed with drainage. Much of the old blood was then evacu-

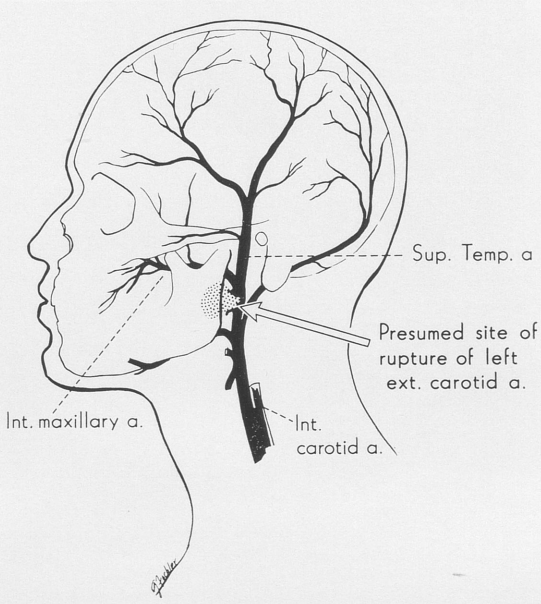

Fig. 4.—Diagram showing opening in external carotid artery.

ated from the aneurysm. This reduced the size of the mass but it required several weeks for it to subside completely.

Improvement in the patient's condition was steady and he left the hospital on the eighth postoperative day after a hospital stay of 55 days.

He has remained in good health and at the present time, 18 months later, is working steadily (Fig. 5).

Dorland and Newman[2] define mycotic aneurysm as one produced by growth of microorganisms in the vessel wall. L. Koch[3] described such a lesion of the superior mesenteric artery in 1851. Sir William Osler[3] is credited with originating the term in 1885.

In 1923 Stengel and Wolferth[4] collected 217 cases and stated that the aorta was most commonly involved with the abdominal and cerebral vessels next in that order. Three per cent of their cases had involvement of the internal carotid artery. There was no mention of involvement of the common or external carotid.

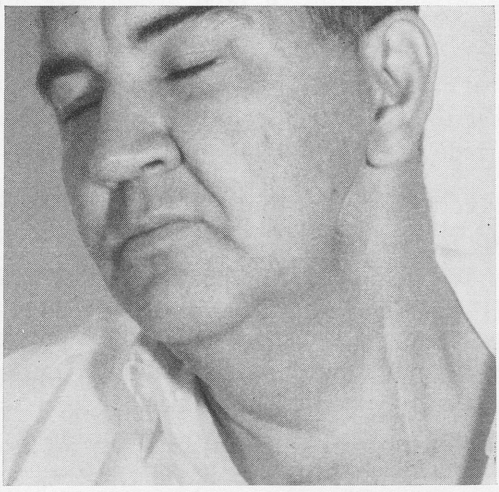

Fig. 5.—Appearance 18 months after recovery.

The aneurysm results from invasion of the artery by infected emboli or bacteria from septicemia, most often that of subacute bacterial endocarditis. The organism, as expected, is most often the streptococcus although others may be found.

The infected embolus may invade the arterial wall by primarily attacking the intima or through the vasa vasorum. The bacteria themselves may enter the wall through the vasa vasorum and the perivascular lymphatics may also be involved in the process. There is marked infiltration of polymorphonuclear neutrophils into the area with weakening of the media and abscess formation may occur in the vessel wall. After the wall of the artery is weakened in this manner, the pressure of blood within it produces rupture. If this involves the distal part of the external carotid or the distal part of the cervical portion of the internal carotid artery, bleeding into the retropharyngeal space will occur. This may be produced by other causes also as well be seen later.

Further bleeding produces increasing tension within the retropharyngeal space. This collection of blood with its connection to the vessel is called a false aneurysm. A fibrous wall may develop in this and become covered by extension of endothelium from the vessel

wall. However, the false aneurysm usually ruptures relatively early and produces serious and often fatal hemorrhage into the pharynx and mouth.

Until the modern antibiotic era so few patients survived the septicemia that the surgical handling of mycotic aneurysms seldom, if ever, occurred.

A recent editorial in the Journal of the American Medical Association[5] stated that mycotic aneurysm should be suspected in any patient with sepsis in whom there is a sudden appearance of a painful, pulsating mass with a bruit over a peripheral artery. While this is true, attention should be called to the fact that pulsation may not be discernible in certain locations. The mass in our patient did not pulsate, as previously stated. The editorial further stated that in the past decade about 25 cases of mycotic aneurysm have been treated successfully by surgical excision.

Smith, Szilagyi and Colville[6] reported four cases that were treated surgically with one death and three successes. None had involvement of the carotid arteries. They stated that as long as virulent micro-organisms are present in the mycotic aneurysm, the danger is great that bacteria will be continually seeded into the circulating blood.

Nasbeth and Deterling[7] reported five cases. None were of the carotids, however.

Another major cause of bleeding from the carotid arteries is the formation of retropharyngeal abscesses which erode into the vessel wall. The development of these in the retropharyngeal space from infected retropharyngeal lymph nodes was relatively common before the modern antibiotic era. For instance, in a recent study at Children's Hospital of Detroit it was found that the diagnosis of retropharyngeal abscess was made 169 times during the three decades from 1934 through 1963. During the first decade from 1934 through 1943 the diagnosis was made 116 times, during the second decade 36 times and during the third 17 times. Figures were unavailable for the tenth year of the third decade. The difference is further emphasized by the fact that the total hospital admissions more than doubled during that same period. There were nine deaths in this group constituting a 5.3 per cent mortality rate. There is no evidence that hemorrhage was a factor in any of these deaths.

In 1936 Dr. Lyman Richards[8] rported a study of 162 cases of retropharyngeal abscess that had been diagnosed over a ten year period at Children's Hospital, Boston. They were associated with sore throat, otitis media, cervical adenitis and tuberculosis in various combinations. Earlier reports can be found in the literature extending back many years. According to Holmes,[9] Galen referred to a case of retropharyngeal abscess in the second century.

These abscesses may be small and appear high on the posterior wall or large enough to extend to the region of the larynx.

Weille and De Blois[10] expressed the opinion that retroesaphageal and mediastinal extension probably occurs more often than is realized. Two of the deaths at Children's Hospital of Detroit were apparently a result of laryngeal obstruction from a large abscess that extended to the larynx. These occurred during direct laryngoscopy. This suggests the need for preliminary tracheotomy in certain cases.

Due to much greater activity of the lymphatic system in infants and young children, this condition is far more common in them. In older children and adults these nodes have usually atrophied so that acute retropharyngeal abscess is relatively rare.

Todman,[11] however, reported a fatal case of spontaneous hemorrhage from the internal carotid artery associated with a retropharyngeal abscess in a 22 year old man.

In 1949 Davidson[12] reported two cases of retropharyngeal abscess in adults. One apparently had Pott's disease since there was destruction of the third cervical vertebra. He said at that time 114 abscesses of the retropharyngeal space in adults had appeared in medical reports.

Richards[8] was prompted to state, "Severe, sudden and often recurrent profuse hemorrhage has been one of the most dreaded complications of retropharyngeal abscess." This is as true now as it was in 1936. There were three cases of hemorrhage in his series of 162 cases. Two of these died and one survived following ligation of the common carotid artery.

Salinger and Pearlman[13] reviewed the anatomy of this region thoroughly and made an exhaustive study of the subject based on 227 cases of hemorrhage from pharyngeal and peritonsillar abscesses and found that while retropharyngeal abscesses, and especially those that involve the parapharyngeal areas, may erode the external carotid artery, the internal carotid is eroded far more often. The internal

carotid artery was found to be eroded for a distance of 2 cm in a fatal case reported by Wishart[14] while a tiny perforation produced fatal hemorrhage in a case reported by Insley.[15]

Greenfield[16] reported results of an investigation of 33 cases of hemorrhage due to peritonsillar abscess and found that postmortem examination showed most of the hemorrhages came from branches of the external carotid artery, namely, the lingual, facial or ascending pharyngeal.

Havens,[17] Lifschutz,[18] Motley[19] and Wendel[20] are only a few of those who have reported a variety of experiences with this problem.

When the false aneurysm first ruptures bleeding into the mouth or nose may be moderate and intermittent for a day or so or massive fatal hemorrhage may occur very suddenly during examination. Fatal hemorrhage may occur immediately after incising the retropharyngeal mass or several weeks after draining the abscess. A study of a large number of these cases discloses the fact that there is no consistent pattern concerning the bleeding from false aneurysms except that they usually bleed and often fatally.

While retropharyngeal abscess formation is relatively uncommon at present and erosion of the carotid arteries from them relatively rare, they can by no means be forgotten. Several cases have been reported in relatively recent times and hospital records show their more recent occurrence.

Another cause of bleeding into the retropharyngeal space from the carotid arteries is perforation by instruments, weapons or projectiles. Instrumental injuries of the carotid arteries in this area are usually by the oral route in connection with operations on the throat.

Salinger and Pearlman[13] have called attention to the fact that a tortuous internal carotid artery may be near the tonsil fossa and Fox[71] reported finding an aneurysm of the internal carotid artery in the fossa immediately after tonsillectomy.

McKenzie and Woolf[22] reported internal carotid artery hemorrhage from an accident during adenoidectomy. The injury was in the region of the fossa of Rosenmueller and required ligation of the common carotid artery. The patient recovered.

We have already mentioned bleeding from the carotid artery in connection with incision of retropharyngeal abscesses.

Beall, Shirkey and De Bakey[23] reported a study of 25 patients with 26 penetrating wounds of the carotid arteries in general. Most were accessible to anastamosis, graft or lateral arteriorrhaphy. The external carotid artery was ligated on three occasions, the internal on three and the common once.

Diamond and Perkins[24] reported a calcified hematoma of the oropharynx secondary to a gunshot wound 17 years previously. The bullet had passed from the malar region to the body of the second cervical vertebra. There was no evidence to indicate which artery had been penetrated.

A final cause of bleeding into the retropharyngeal space is rupture of a true aneurysm in this area from progressive weakness of its wall due to syphilis or arteriosclerosis.

Beall, Crawford, Cooley and De Bakey[25] reported seven cases of extracranial aneurysm of the carotid artery. Most were a result of arteriosclerosis or trauma and were in a location where excision with primary anastamosis or graft or permanent by-pass could be used. However, one aneurysm began in the internal carotid artery about 2.5 cm distal to the bifurcation of the common carotid and extended to the base of the skull. The styloid process was excised in an attempt to gain sufficient exposure of the internal carotid artery distal to the aneurysm to control it but this was not possible. The artery was ligated and divided. This was the only death in the series. There was found an associated deformity of the communicating arteries.

This case is extremely important in connection with our presentation because it is the only instance we have found of an attempt to expose the distal part of the cervical portion of the internal carotid artery for surgical repair. This is obviously extremely difficult, if not impossible and, consequently, maintenance of the circulation through this artery in patients who have hemorrhage from it in this location is at present out of the question. Ligation is the only alternative. While the chance of cerebral complications is high in adults, the chance of fatal hemorrhage is almost certain without it. It is generally recognized that children tolerate this ligation well.

Beekhuis and Croushore[26] have recently described an approach to tumors in the retropharyngeal region after radical neck dissection. They state,[27] however, that in their opinion it is extremely difficult, if not impossible, to expose the artery sufficiently for surgical repair or graft.

It may be theoretically possible to work out an approach allowing insertion of a permanent by-pass or graft from the proximal side of the defect in the artery to the petrous portion of the artery in the carotid canal. It will be recalled that the petrous pyramid may be approached through the glenoid fossa and carotid canal.

Probably the commonest condition occurring in the pharynx that may be confused with retropharyngeal abscess or aneurysm is enlargement of the lymph nodes from lymphoblastoma or metastatic cancer.

Taylor and Nathanson[28] stated that the retropharyngeal lymph nodes may be invaded by cancer from the nasal cavity, the paranasal sinuses, the pharynx, the posterior part of the tongue, the palate and the middle ear.

Rare tumors as neurilemmomas and those of the deep lobe of the parotid gland may appear as a mass in the retropharyngeal region.

If a retropharyngeal abscess is suspected, it should be considered an emergency and drained under circumstances that enable control of hemorrhage if it is encountered. This requires adequate exposure, preferably with some type of self retaining mouth gag which in turn will require general anesthesia, preferably through an intratracheal tube. As stated previously, if there is significant question about the airway, a preliminary tracheotomy may be required. A small incision near the periphery of the mass is advised.

Whether one suspects the presence of a false aneurysm or not, it seems advisable to be prepared to perform an operative arteriogram, if necessary.

If blood is encountered on incising the mass or if there has been bleeding from the mouth prior to operation, the carotid artery system should be exposed and an operative arteriogram performed. There seems to be little advantage in performing the arteriogram as a preliminary procedure except under certain circumstances. One of these could be when the possibility of abscess or aneurysm seems much less than that of neoplasm.

If the hemorrhage is from the external carotid artery, it should be ligated and it is probably better to cut it also. If from the internal carotid artery, the circulation through it must be permanently interrupted by some type of ligation, preferably ligation of the common carotid artery. If this does not control it, the external carotid should

then be ligated. A ligature could be left loosely around it to facilitate exposure, if necessary. If, as may occasionally happen, it bleeds from circulation beyond the perforation, it is either coming from the ophthalmic through its connection with the opposite external carotid or from the vertebral supply to the Circle of Willis. The latter was demonstrated by Weaver, Gates and Nielsen.[29] In the former case one would ligate the opposite external carotid and in the latter a clip could be placed on the petrous portion of the carotid artery in the carotid canal.

We have reported a case of mycotic aneurysm of the left external carotid artery with rupture into the retropharyngeal space and the formation of a large false aneurysm. The diagnosis was made from information obtained on arteriography done as an operative procedure following the occurrence of bleeding while exploring the pharyngeal mass. The patient has been well for 18 months following ligation of the artery. We have encountered no similar case in the medical literature.

A discussion of all causes of hemorrhage into this space has been presented with recommendations for treatment.

571 Fisher Bldg.

REFERENCES

1. Blatt, Irving M., and Maxwell, James: Secretory Sialography. Trans. Amer. Acad. Oph. and Otol. 61:4:492-499 (July-Aug.) 1957.

2. Dorland, W. A., and Newman, A. M.: Medical Dictionary. W. B. Saunders Co.: Phil. and London, 1951.

3. Quoted by Rogers, L.: Mycotic Aneurysms. Brit. Jour. Surg. 43:374-375 (Jan.) 1956.

4. Stengel, A., and Walferth, C. C.: Mycotic (Bacterial) Aneurysms of Intravascular Origin. Arch. Int. Med. 31:527, 1923.

5. Mycotic Aneurysms: Editorial J.A.M.A. 183:477 (Feb. 9) 1963.

6. Smith, R. F., Szilagyi, D. E., and Colville, J. M.: Surgical Treatment of Mycotic Aneurysms. Arch. Surg. 85:663, 1962.

7. Nasbeth, D. C., and Deterling, R. A., Jr.: Surgical Management of Mycotic Aneurysms. Surg. 50:347-353 (Aug.) 1961.

8. Richards, L.: Retropharyngeal Abscess. Tr. Sect. Laryng., Otol. and Rhin. A.M.A., pp. 162-184, 1936.

9. Holmes, E. M.: Middle Ear Suppuration as an Etiologic Factor in Retropharyngeal Abscess. Annals of Otology, Rhinology and Laryngology 15: 848-867 (Dec.) 1906.

10. Weille, F. L., and De Blois, E.: Problems in Treatment of Retropharyngeal Abscesses. Arch. Otol. 39:344-347 (Apr.) 1944.

11. Todman, R. C.: Fatal Case of Spontaneous Hemorrhage from Internal Carotid Artery Resulting from Retropharyngeal Infection. Jour. Laryng. 74:493-496 (July) 1960.

12. Davidson, M.: Retropharyngeal Abscess in Adults. Laryngoscope 59:1146-1170 (Oct.) 1949.

13. Salinger, S., and Pearlman, S. J.: Hemorrhage from Pharyngeal and Peritonsillar Abscesses. Ann. Otol. 18:464 (Oct.) 1933.

14. Wishart, E. S.: Retropharyngeal Abscess: and Erosion of Internal Carotid Artery: with Pathological Specimen. Canad. M.A.J. 13:635, 1923.

15. Insley, J. L.: Hemorrhage from Retropharyngeal Abscess. Case Report. Jour. Laryng. and Otol. 59:428-430 (Nov.) 1944.

16. Greenfield, S. D.: Bacteremia of Otitic Origin: Routes of Infection to Blood Stream: Case Report with Recovery. Laryng. 43:929, 1933.

17. Havens, Fred Z.: Severe Hemorrhage Secondary to Retropharyngeal Abscess. Amer. Jour. Dis. of Child. 58:1256-1258 (Dec.) 1939.

18. Lifschutz, J.: Fatal Hemorrhage Resulting from Extension of a Retropharyngeal Abscess to the Deep Vessels of the Neck. Arch. Otol. 14:149-157 (Aug.) 1931.

19. Motley, F. E.: Massive Hemorrhage as Otolaryngological Complication. Annals of Otology, Rhinology and Laryngology 51:737, 1942.

20. Wendel, Jacob S.: Discussion of a paper of Lewis G. Herrmann on Surgery of the Large Arteries of the Neck. Trans. Amer. Laryng., Rhin. and Otol. Soc. 1956.

21. Fox, S. L.: Aneurysm of Internal Carotid Artery Found During Tonsillectomy. E.E.N.T. Monthly 26:83-84 (Feb.) 1947.

22. McKenzie, W., and Woolf, C. J.: Carotid Abnormalities and Adenoid Surgery. Jour. Laryng. 73:596-602 (Sept.) 1956.

23. Beall, A. C., Jr., Shirkey, A., and De Bakey, M. E.: Penetrating Wounds of the Carotid Arteries. Jour. Trauma 3:276-287 (May) 1963.

24. Diamond, E. H., and Perkins, C. W.: Calcified Hematoma of Oropharynx Secondary to Gunshot Wound. Arch. Otol. 47:64-66 (Jan.) 1948.

25. Beall, A. C., Crawford, E. S., Cooley, D. A., and De Bakey, M. E.: Extracranial Aneurysms of the Carotid Artery. Report of 7 Cases. Postgrad. Med. 32: 93-102 (Aug.) 1962.

26. Beekhuis, G. Jan, and Croushore, James E.: Surgical Approach to Neoplasms of the Nasopharynx. Trans. Amer. Laryng., Rhin. and Otol., pp. 136-155, 1963.

27. Beekhuis, G. Jan, and Croushore, James E.: Personal Communication (Dr. Beekhuis).

28. Taylor, Grantley W., and Nathanson, Ira T.: Lymph Node Metastasis. New York, N. Y.: Oxford Univ. Press, 1942.

29. Weaver, Delmar F., Gates, Edward M., and Nielsen, Aage E.: Traumatic Intracranial Vascular Lesions Producing Late Massive Nasal Hemorrhage. Trans. Amer. Acad. Oph. and Otol. 759-775 (Sept.-Oct.) 1961.

DISCUSSION

Dr. Lyman G. Richards: From its very inception surgery in Otolaryngology has been plagued by two major hazards—one of infection, the other hemorrhage. Today the former has been very largely reduced though not eliminated through the

agency of chemotherapy. Hemorrhage, often unexpected and always unpredictable, remains a source of concern in many conditions, both medical and surgical, relating to the nose and throat. Such hemorrhage differs in two respects from that occurring in many other parts of the body: 1) it occurs in exasperatingly inaccessible areas, and 2) it is not amenable to exact control at the site of the bleeding. An obscure hemorrhage at the back of the nose is far more difficult to check than the seemingly more formidable bleeding from a radial artery. Locally the inefficient and primitive procedure of massive packing still remains in most cases the only effective means of control. With respect to control of retropharyngeal bleeding even packing presents such difficulties and creates such complications of respiratory obstruction as to be of only minimal value. Resort must then be had to ligation of more distant and proximal vessels as exemplified in Dr. Weaver's case.

Simple retropharyngeal abscess occurring chiefly in infants is not commonly a source of concern as to hemorrhage. In my own series of 162 cases mentioned by Dr. Weaver, it occurred in only three instances. Incision and drainage of such an abscess, in the great majority of cases, results in prompt and uncomplicated recovery. In the earlier days of my practice it was customary to seat the patient in a chair in a nurse's arms, palpate the fluctuant mass on the posterior pharyngeal wall blindly with a finger and guide the knife to the abscess. I shudder to think of the results, were such a swelling proved, all too late, to be due not to an abscess but to an aneurism such as described by Dr. Weaver. Dissatisfied with such a method we later approached the abscess in the same manner as if performing a direct laryngoscopy, thus exposing the pharyngeal surface of the swelling and permitting a trial puncture with the point of the knife or even with a needle and so determining its contents before making a wider incision and aspirating its contents. Any evidence that the swelling contained not pus but blood would afford time and opportunity to prepare for the only safe and certain control of future and possible severe bleeding by ligation of either the common, the internal or the external carotid artery.

Sudden and unanticipated bleeding following apparently successful drainage of the abscess may occur so precipitously as to preclude all effort to control it and a fatality is almost certain to ensue. Considering the extensiveness of many deep infections of the neck and their close proximity to the large vessels of the neck, it is surprising that invasion of these vessels with sudden hemorrhage does not take place more often.

In older children and adults the pharyngeal infection and resultant abscess is much more often in a lateral position and so in closer proximity to the carotid vessels than is the retropharyngeal abscess in infants. Hence the lessened likelihood of bleeding in the latter. Dr. Weaver's careful investigation of the nature of the pharyngeal swelling represents the wisest and safest method of dealing with this potentially dangerous situation. Despite absence of demonstrable pulsation one can never safely assume that such a swelling is not closely related to a large vessel and so undertake to incise it with a resultant catastrophe for which no preparation can be made. So long as the potentiality of hemorrhage is kept in mind and preparations made beforehand for its control, as so ably demonstrated in Dr. Weaver's case, the chances of disaster are very small.

There is always the reluctance to ligate the common carotid artery for fear of cerebral complications and it is always a happy discovery to find that trial obliteration of the external carotid will clearly control the bleeding, but one must always be prepared to ligate the internal carotid if investigation, as in Dr. Weaver's case, shows this vessel to be the culprit. Rarely, as in one of my cases, bleeding may be coming from the vertebral artery, a discovery which unhappily was made only at autopsy.

Memorials

EDWARD HASTING CAMPBELL, M.D.

1894 - 1963

Dr. Edward Hastings Campbell, an Emeritus Fellow of the American Laryngological Association, was elected to Active Fellowship in 1930. He was born in Kane, Pennsylvania, on February 8, 1894, and died of coronary thrombosis in the University Hospital, Philadelphia, on December 27, 1963.

Versatility, scrupulous honesty and modesty were his outstanding characteristics. His early interest in music led to his graduation from the Warren Conservatory of Music and he remained an accomplished pianist during his lifetime. A devoted outdoors man, he excelled in golf and won numerous trophies in skeet and trap shooting. As an ardent fisherman, he ranged from the Pacific and the Gulf of Mexico to the Caribbean and as hunter of game, from Canada and Alaska to the Jackson Hole Country of the West.

Dr. Campbell possessed unusual surgical ability in every facet of otolaryngologic practice but, as an early disciple of Dr. Julius Lempert, he soon confined his activities to the study of deafness and the surgical treatment of otosclerosis. His skill, meticulous attention to details and prompt recognition and adoption of sound advances in the field were responsible for his brilliant clinical results.

Throughout his professional career, he carried a prodigious load of teaching assignments at the undergraduate, resident and postgraduate levels, and in later years, trained an impressive number of young otologists in otosclerosis surgery. He was a patient but exacting teacher and generous in his expenditure of time and efforts.

Dr. Campbell received the degree of doctor of medicine from the University of Pennsylvania in 1919 and served an internship at the Lankenau Hospital of Philadelphia (1920-1922) where he was greatly influenced by Dr. John B. Deaver to whom he was indebted for his sound surgical training. Impressed by the need for advances in otorhinolaryngologic surgery, he obtained appointments on the faculty of the School of Medicine and the staff of the Hospital of the University of Pennsylvania in 1922, and served as Professor of Otolaryngol-

EDWARD HASTINGS CAMPBELL

ogy in the School of Medicine and Clinical Chief in the University Hospital from 1939 to 1959. His affiliation with the Graduate School of Medicine of the University of Pennsylvania in 1934 was continuous until his death and he was appointed Chairman and Professor of the Department of Otolaryngology, a position he occupied from 1946 to 1959.

He served as otolaryngologist to St. Christopher's Hospital for Children from 1927 to 1934, and continued as consulting otolaryngologist. His clinical teaching activities at the Children's Hospital of Philadelphia began in 1922 and from 1934 to 1950 he was Chief of Service. From 1938 to 1950, he was Chief of Otolaryngology at the historic Pennsylvania Hospital.

Dr. Campbell served in the R.O.T.C. during World War I and during World War II he served as a Captain in the Medical Corps of the Navy from 1942 to 1946 with duty aboard a hospital ship in the Atlantic Theatre. He was consultant in otolaryngology at the U.S. Naval Hospital, Philadelphia, from 1938 to the time of his death.

He held memberships in a number of scientific societies: the American College of Surgeons, the American Medical Association, the American Academy of Ophthalmology and Otolaryngology, the American Otological Society and the American Laryngological, Rhinological and Otological Society.

In 1929, he received the Casselberry Award of the American Laryngological Association.

Dr. Campbell married Ethel Hanna in 1915. Surviving are his wife, three children, Edward G., Jean H., Thomas M., and eight grandchildren.

H.P.S.

JAMES MILTON ROBB, M.D., F.A.C.S., F.R.C.S. (Edin.)

1884 - 1964

Dr. James Milton Robb was born June 22, 1884 in Bruce Co., Ontario, Canada, and died March 23, 1964 in Detroit, Michigan.

The Robbs emigrated from Scotland in 1745 to Toronto by way of North Ireland. From Toronto Dr. Robb's grandfather and father, then aged sixteen years, walked to Georgian Bay. Dr. Robb's father, David Robb, was left there on Crown land that winter to stake out a claim and the family still have the Crown grant for this farm in Bruce County, near Willis Croft, Ontario. In this frontier community Dr. Robb's two sisters, his brother and, in 1884, he and his twin sister were born.

Their early life was rugged. The mother died when the twins were two years old and several years later the father lost a hand in a threshing machine accident. Dr. Robb was early disciplined to work and hardship, which are the tools needed to make character. At this early age he decided to be a doctor, and a good one; and, since determination, perseverance, integrity and an innate desire to be of service to your fellow man are the traits of the priest as well as the physician, it was Medicine's good fortune that it was chosen instead of the Priesthood.

In 1902 he came to Detroit and accepted a position as bookkeeper to the Acme White Lead and Color Works in order to defray part of his expenses at medical school. He entered the Detroit College of Medicine and Surgery (Wayne University) and in due course was graduated in 1908 with honors and as Valedictorian of his class. Because of his studious habits, perseverance and determination his progress after graduation was steady and uninterrupted.

He progressed from externship to internship in Harper Hospital, to postgraduate school in New York and Vienna, and to work in London at both Moorfield's Eye Hospital and the Golden Square Ear, Nose and Throat Hospital. He also assisted Dr. Don M. Campbell of Detroit and sat at the feet of many other distinguished preceptors. He entered private practice in 1914 and continued in active practice until his death in 1964, a period of fifty years.

Shortly after opening his office he had acquired a large practice and while his patients benefited from his skill and care he acquired the additional virtues of sympathy, humility and tolerance.

In 1920 while on a visit to Memphis, Tennessee, he was fortunate to meet a lovely young girl by the name of Virginia Yerger. Their marriage in due time was blessed by four children, James, Elizabeth, David and Virginia, and they all in turn carved their own niches in this world and each in turn became a credit to their mother and father.

Upon his return from Europe with his wife and much coveted Fellowship of the Royal College of Surgeons of Edinburgh he resumed practice in Detroit. It is interesting to note that his affiliations with Wayne University, Harper Hospital, Receiving Hospital, Herman Kiefer Hospital, Detroit Orthopedic Clinic and the Tuberculosis Sanitorium are all under the category of Professor, Chief or Consultant; and his membership in the Wayne County Medical Society, Michigan State Medical Society, American Medical Association, American College of Surgeons, the Royal College of Surgeons (Edinburgh), American Academy of Ophthalmology and Otolaryngology (President, 1952), American Laryngological, Rhinological and Otological Society (Honor Guest, 1961), American Broncho-Esophagological Association, American Laryngological Association, American Otological Society, and Alpha Omega Alpha is frequently in the category of Councillor, Chairman or President. Nor is this all, for the same holds true of many local medical societies, and local, social, fraternal, religious and civic organizations.

He was a communicant of Christ Episcopal Church at Grosse Point and held a commission in the United States Army as First Lieutenant in 1911. He has received many other awards from many different organizations for his unselfish service. During this period he wrote many medical papers on many types of medical problems within his field and they were published in many different journals.

He also found time to serve as President of the Wayne County Medical Society in 1930 and, as his greatest honor, President of the Michigan State Medical Society in 1932. To this office by precept and example he brought both prestige and faithful service and, if his example had been followed generally, there would be no need today for mediation and grievance committees.

To his wife, Virginia, and to his children, James, Elizabeth, David and Virginia, must go much of the credit for his many accomplish-



JAMES MILTON ROBB

ments for their understanding and love were of inestimable help in carrying him through the long hours of work he assumed each day. He was a skillful surgeon, a wise physician and an inspiring teacher, and his death is mourned not only by his family but by his patients, his colleagues, his friends and his associates. Many young physicians will remember him from his oft quoted advice, namely: "A physician should have at least three important attributes: 1) Availability, 2) Ability, 3) Stability—and the greatest of these is Availability." And, he practised what he preached.

F.D.W.

Executive Sessions

EXECUTIVE SESSION

Friday Morning, April 10, 1964

The Opening Session of the Eighty-fifth Annual Meeting of the American Laryngological Association, held at the St. Francis Hotel, San Francisco, California, convened in the Colonial Room on Friday morning, April 10, 1964, at eight thirty-five o'clock, Anderson C. Hilding, M.D., St. Luke's Hospital, Duluth, Minnesota, President of the Association, presiding. The meeting opened in Executive Session.

President Hilding: I call the Eighty-fifth Meeting of the American Laryngological Association to order.

The first order of business is the election of Honorary, Emeritus and Corresponding Members.

The following men were unanimously elected to Active Fellowship:

Dr. Claude C. Cody III, Houston, Texas

Dr. Blair Fearon, Ontario, Canada

Dr. William F. Keim, East Orange, N. J.

Dr. William W. Montgomery, Boston, Mass.

Dr. William H. Saunders, Columbus, Ohio

Dr. Emanuel M. Skolnik, Chicago, Ill.

The following men were elevated to Emeritus Fellowship:

Dr. Julius McCall, Cleveland, Ohio

Dr. Henry Williams, Minneapolis, Minn.

Dr. Fred W. Dixon, Shaker Heights, Ohio

Dr. Harry P. Schenck, Philadelphia, Pa.

President Hilding: Membership in this Society is an accomplishment and I am sure that you will find it very rewarding, as you have heard from your sponsors. This, however, is not a goal. We expect you to continue contributing as you have in the past, and even more. I think it is only fair to warn you that our Secretary keeps roll each year and forty years from now it can readily be looked up in

your record how many meetings you have attended, how many papers you have read, and how many contributions you have made.

Further, I think it is fair to warn you that when the sad little notice comes fifty years hence of your demise that our efficient Secretary promptly sends your record on to Saint Peter. Welcome to the Society!

The following men were elected members of the Nominating Committee:

Dr. Julius McCall, Cleveland, Ohio

Dr. Bernard McMahon, St. Louis, Mo.

Dr. Peter Pastore, Richmond, Va.

Dr. Lawrence Boies, Minneapolis, Minn.

Dr. Joel Pressman, Los Angeles, Calif.

PRESENTATION OF NEWCOMB AWARD

DR. ALBERT C. FURSTENBERG: Fred W. Dixon, graduate of the Medical School, University of Pennsylvania, in the Class of 1920, former Treasurer and Past President of this Association. His concern for the welfare of our membership and their scientific progress has become his avocation. Under his direction, our Association has widened its scope of interest and activity and put new life into its membership. As a member of the staff of Lakeside Hospital, Chief of the Department of Otolaryngology, St. Alexis Hospital, and Assistant Professor of Otolaryngology, Western Reserve University Medical School, he advanced rapidly in his chosen field to earn the respect and admiration of his friends and colleagues. In a realistic and energetic program of action as President of the American Broncho-Esophagological Association he gave this august body a forward thrust of lasting tribute to its members. Taking the information he had gained from his experience in administration and clinical medicine, he provided his office, as President of the Ohio State Medical Association, an example of executive, scientific, and civil leadership.

Mr. President, on behalf of my committee and the Council of the American Laryngological Association, I have the honor to present Dr. Fred W. Dixon for the Newcomb Award.

ANNUAL BUSINESS MEETING

Saturday Morning, April 11, 1964

The Annual Business Meeting convened in the Colonial Room on Saturday morning, April 11, 1964, at eight-thirty o'clock, President Hilding presiding.

President Hilding: I will now call the meeting to order.

The first order of business is the report of our Secretary, Dr. Lyman Richards.

REPORT OF THE SECRETARY

The Eighty-fourth Annual Meeting of the American Laryngological Association was held on April 21st and 22nd, 1963, at the Hollywood Beach Hotel, Hollywood, Florida. The President, Dr. Francis E. LeJeune, presided. A scientific program of fourteen papers was presented and seventy-eight fellows and two hundred and twenty-one guests were in attendance.

The Librarian, Historian and Editor, Dr. Francis W. Davison, reported the deaths of the following:

Emeritus Fellows:

Dr. John Foster

Dr. William H. Johnston

Active Fellows:

Dr. Gordon Harkness

Dr. Kenneth C. Johnston

The Newcomb Award was presented to Dr. Francis E. LeJeune.

The following were elected to Fellowship:

Active Fellowship:

Dr. James D. Baxter, Montreal, Canada

Dr. Douglas P. Bryce, Toronto, Canada

Dr. Charles F. Ferguson, Boston, Mass.

Dr. Frank D. Lathrop, Boston, Mass.

Dr. John A. Kirchner, New Haven, Conn.

Dr. Francis H. McGovern, Danville, Va.

Dr. George F. Reed, Boston, Mass.

Dr. Harold G. Tabb, New Orleans, La.

Dr. John F. Tolan, Seattle, Wash.

Emeritus Fellowship:

Dr. Wesley C. Bowers, New York, N. Y.

Dr. Henry H. Goodyear, Cincinnati, O.

Dr. Robert C. Martin, San Francisco, Calif.

Dr. Edward J. Whalen, Hartford, Conn.

The following officers were elected for the year 1963-64:

President: Dr. Anderson C. Hilding

First Vice-President: Dr. Paul H. Holinger

Second Vice-President: Dr. Lester A. Brown

Secretary: Dr. Lyman G. Richards

Treasurer: Dr. Alden H. Miller

Librarian, Historian and Editor: Dr. Francis W. Davison

First Councilor: Dr. William J. McNally

Second Councilor: Dr. Edwin N. Broyles

Third Councilor: Dr. Dean M. Lierle

Fourth Councilor: Dr. Francis E. LeJeune

The next Annual Meeting of the Association will be held at the Broadmoor Hotel, Colorado Springs, on May 23rd and 24th, 1965. The following is the schedule of the other society meetings to be held in Colorado Springs:

May 25th and 26th, the American Otological Society.

The meetings of the Triological Society, the American Broncho-Esophagological Association and the American Society for Head and Neck Surgery will be held at the Biltmore Hotel, New York City, June 21 through June 25, 1965, in conjunction with the meetings of the American Medical Association.

The present Fellowship of the Association is:

Active Fellows	96
Honorary Fellows	5
Corresponding Fellows	14
Emeritus Fellows	23
Total Fellowship	138

I would like to thank the fellowship for returning their ballots. This is the best score we have ever had. It is over 90 per cent.

Respectfully submitted,

Lyman G. Richards, Secretary

The Secretary's Report was accepted as read.

PRESIDENT HILDING: We will next have the report of the Treasurer.

Dr. Alden H. Miller, Treasurer of the Association, then presented the following report which was unanimously accepted:

Exhibit A

AMERICAN LARYNGOLOGICAL ASSOCIATION
GENERAL FUND OPERATING STATEMENT

For the Period Beginning April 1, 1963 and Ending March 31, 1964

Income			
Dues—88 members at $75.00		$6,600.00	
9 new members at $115.00		1,035.00	$ 7,635.00
Sale of *Transactions*			550.97
Interest received—Savings account			183.15
Registration fees—Annual meeting			300.00
Miscellaneous			92.95
Total operating income			$ 8,762.07
Expenses			
Annual meeting—1963:			
Banquet and cocktails	$813.15		
Projectionist	77.50		
Reporting service	432.81		
Programs	232.00		
Tickets	11.08		
Travel and entertainment	367.00	$1,933.84	
Council expenses—Annual dinner		1,609.24	
General expenses:			
Stationery, printing and postage	$943.13		
Clerical hire	500.00		
Auditing	155.00		
Treasurer's Bond	62.50		
Donation—Deafness Research Foundation	141.57		
Loss on Canadian Exchange	30.59		
Miscellaneous	1.64	1,834.43	
Total expenses			$ 5,377.51
Addition to General Fund			$ 3,384.56
General Fund balance, April 1, 1963			9,524.84
General Fund balance, March 31, 1964			$12,909.40

Exhibit B

AMERICAN LARYNGOLOGICAL ASSOCIATION
TRUST FUND OPERATING STATEMENT

For the Period Beginning April 1, 1963 and Ending March 31, 1964

Income		
Interest—Government bonds	$ 1,497.26	
Dividends—Common stocks	45.30	$ 1,542.56
Trust Fund balance, April 1, 1963 (Exhibit C)		51,051.56
Trust Fund balance, March 31, 1964 (Exhibit C)		$52,594.12
Trust Fund balance represented by:		
Government Bonds at par value		$44,500.00
Common stocks at market value, date of donation		2,362.00
Total bonds and stocks (Exhibit D)		$46,862.00
Cash		5,732.12
		$52,594.12
Cash recapitulation		
Cash in Trust Fund	$ 5,732.12	
Cash in General Fund	12,859.40	
	$18,591.52	
Cash in Commercial account	$ 5,438.50	
Cash in Savings account	8,153.02	
Cash in Savings deposit receipt	5,000.00	
	$18,591.52	

Exhibit C

AMERICAN LARYNGOLOKICAL ASSOCIATION
REPORT OF TRUST FUNDS

March 31, 1964

Fund	*Principal & Unused Income 4-1-63*	*Income* 4-1-63 to 3-31-64*	*Principal & Unused Income 3-31-64*
Casselberry	$ 7,458.49	$ 225.37	$ 7,683.86
Johnston	6,737.78	203.62	6,941.40
de Roaldes	4,637.36	140.06	4,777.42
Newcomb Trust	2,645.33	79.90	2,725.23
Newcomb Prize	617.43	18.66	636.09
Research	23,735.75	717.14	24,452.89
Memorial	5,219.42	157.81	5,377.23
	$51,051.56	$1,542.56	$52,594.12

* Income has been allocated to each fund by the ratio that each fund bears to the total fund, as of 4-1-63.

Exhibit D

AMERICAN LARYNGOLOGICAL ASSOCIATION
TRUST FUND INVESTMENTS

March 31, 1964

	Serial No.	*Par Value*
GOVERNMENT BONDS		
Negotiable:		
U. S. Treasury Bonds	85-680	$ 1,000.00
	24-955	1,000.00
	24-956	1,000.00
	24-957	1,000.00
	24-958	1,000.00
	24-959	1,000.00
	118-136 F	1,000.00
	118-137 H	1,000.00
	118-138 J	1,000.00
	277-504 D	1,000.00
	8357	5,000.00
	92-341	1,000.00
Non-negotiable:		
U. S. Treasury Bonds	1515	5,000.00
	2485	1,000.00
	2486	1,000.00
	12153 D	1,000.00
	12154 C	1,000.00
	12155 E	1,000.00
Eleven H Bonds		10,500.00
Four K Bonds		8,000.00
		$44,500.00
COMMON STOCK		
International Business Machine, 1 share	K-085881	$ 517.00
McDonnell Aircraft Corp., 26 shares	S-012923	
1 share*	S-020191	1,170.00
McIntyre Porcupine Mines, Ltd., 15 shares	NYA-4817	675.00
		$ 2,362.00
TOTAL BONDS AND STOCK		$46,862.00

* 1 share of McDonnell Aircraft Corporation received as a stock dividend on 1-1-64.

ACCOUNTANTS' REPORT

To the Members of the American Laryngological Association
Gentlemen:

We have examined the accounts and financial records of the American Laryngological Association for the period beginning April 1, 1963 and ending March 31, 1964.

Cash receipts and disbursements were verified and all United States Government Bonds and common stock were physically counted and examined.

In our opinion, the accompanying statements present fairly the financial position of the American Laryngological Association as at March 31, 1964 and the results of its operations for the period beginning April 1, 1963 and ending March 31, 1964.

Very truly yours,
SERENE, KOSTER & BARBOUR
Certified Public Accountants

We just today received a letter from the lawyers probating the estate of Gordon Harkness and in his will your Society was mentioned for a thousand dollars, so his name will be added to those on that list of donors that you have at the end of our official publication.

Respectfully submitted,
Alden H. Miller, Treasurer

PRESIDENT HILDING: The next order of business is the report of the Nominating Committee.

DR. JULIUS W. MCCALL: The Committee nominates the following for membership in the Council:

Dr. Furstenberg	Dr. Putney
Dr. Fitz-Hugh	Dr. Broyles
Dr. Baker	Dr. Lierle
Dr. Richards	Dr. LeJeune
Dr. Miller	Dr. Hilding

(The report of the Nominating Committee was unanimously accepted.)

PRESIDENT HILDING: We will next have the report of the Librarian, Historian and Editor, Dr. Davison.

REPORT OF THE LIBRARIAN, HISTORIAN AND EDITOR

Since our last meeting in April, 1963, the Association has suffered the loss of the following Fellows:

Wesley C. Bowers, M.D. (Emeritus Fellow) June 26, 1963

Edward H. Campbell, M.D. (Emeritus Fellow) Dec. 27, 1963

The Eighty-fourth Annual Meeting of the American Laryngological Association was held April 21 and 22, 1963, at the Hollywood Beach Hotel. The discussions were received from the Martin C. Johnson Reporting Service about three weeks after the meeting and were promptly mailed to each discussant for correction. Those discussions not received by September 1 were corrected by the Editor and all material for the 1963 *Transactions* was sent to the publisher the first week in September.

During the summer, letters were sent to all Emeritus and Corresponding Fellows who subscribed last year, asking them whether or not they wished to receive the 1963 *Transactions* at the Council-established price of $5.00. *Transactions* will be sent only to those Fellows who requested them.

The galley proofs were received from the publisher on February 17, 1964. Necessary corrections were made and the proofs were sent back on February 18.

We regret the delay in publication of the *Transactions* which was due to sickness and death among the personnel of the firm that does the printing for both the ANNALS and the *Transactions*. Because of this delay copies of the 1963 *Transactions* were not mailed to the Fellows until late March, 1964.

One hundred and two copies were mailed directly by the publisher to the Active and Honorary Fellows.

We have Standing Orders for 55 copies and one-year orders for 32 copies of the 1963 *Transactions*.

According to Council directive, twenty sets of back *Transactions* were sold at a package price of $24.00 each. Only ten more sets are available.

Total receipts from sale of *Transactions* from April, 1963, to April, 1964 were $558.97. This amount will be increased by almost

$700.00 when we are paid for the unfilled orders for 87 copies of the 1963 *Transactions*.

There are no outstanding bills.

The Editor's expenses from April, 1963 to April, 1964 for stationery, Express charges and postage were $60.90.

Volume 84 (1963) *Transactions* of the Association has 338 pages because it contains the Index of Subjects and Authors covering the last ten years' volumes (1954 through 1963).

Dr. Salinger's abstracts were promptly prepared and were accepted for publication by the Editors of the Laryngoscope, the A.M.A. Archives of Otolaryngology, the Journal of the Japan Broncho-Esophagological Society, published in Japanese, and the Journal of the Columbian Society of Otolaryngology and Broncho-Esophagology, published in Spanish.

Respectfully submitted,

F. W. Davison, M.D., Editor

(The Editor's report was accepted as read.)

DR. RICHARDS: In this connection, we are trying to complete a set of *Transactions* which have been in the Society's archives for many years, but we lack the year 1917. If anybody has a copy and is prepared to part with it, we would appreciate having it sent to me so that we can at least in one spot have a complete set of the Association's *Transactions*. We have every other volume going back to 1879 except the year 1917.

CHAIRMAN RICHARDS: The next order of business is the report of the representative of the American Board of Otolaryngology.

DR. HOLINGER: The two members of the Board who were designated by the Board to represent the American Laryngological Association on the Board were Dr. Lederer and myself.

REPORT OF THE AMERICAN BOARD OF OTOLARYNGOLOGY REPRESENTATIVES

Three examinations of the American Board of Otolaryngology have been held during the past year since the last American Laryngological Association Meeting.

The first was in Chicago, June 10-14 of 1963. Ninety-three candidates took the examination, of whom 67 passed, 22 were conditioned and 4 failed, a percentage of conditions and failures of 22%.

The second examination was held in New York October 14-18 of 1963. One hundred and three candidates took the examination, of whom 87 passed, 12 were conditioned and 4 failed, or a condition and failure percentage of 16%.

The third examination was held in New Orleans March 28th to April 4th of 1964. Eighty-six took the examination, of whom 62 passed and 24 were conditioned or failed, a percentage of 27%.

Respectfully submitted,

Paul H. Holinger, M.D.

(Dr. Holinger's report was accepted as read.)

CHAIRMAN RICHARDS: Dr. Holinger, we must call on you again for a report of the Laryngological Research Fund Committee, of which you are the Chairman.

DR. HOLINGER: There is no report from this Committee because there have been no applications received for bequests from any of the Funds. The listing of the Funds and the amount available is in the book that you have received.

CHAIRMAN RICHARDS: And finally, if we may call on you again for a special report. You are the representative of the Association to the American College of Surgeons.

DR. HOLINGER: There are three representatives of the American Laryngological Association to the Board of Governors of the American College of Surgeons. Dr. Harry Schenck is the senior of these three at the moment and in his absence I come next on the list and Dr. Work follows me, so I will give the report for Dr. Schenck.

REPORT OF THE REPRESENTATIVE OF THE AMERICAN LARYNGOLOGICAL ASSOCIATION TO THE BOARD OF GOVERNORS, AMERICAN COLLEGE OF SURGEONS

The separation of the Academy and the College meetings to avoid a direct overlap has been effective in strengthening the position of Otolaryngology in both the general program of the College and in Committee assignments in the College. Joint sessions with other spe-

cialties had been established on the program, and Otolaryngologic representation and participation at the specialty sessions had been gratifying.

Of interest to the members of the American Laryngological Association is a report by Dr. E. Lee Strohl of Chicago on Nursing Care. The report was presented at the November 1963 meeting of the Board of Governors of the College. Dr. Strohl indicated that the widening gap between physicians and nursing educators is influencing nursing care and actually influencing medical practice. Dr. Strohl's committee has attempted to analyze this widening gap and suggest a more active physician participation in shaping nursing education programs and qualification principles.

The Committee on Graduate Training is studying the problem of decreasing availability of teaching (surgical) patients because of third party payment. The problem is of increasing concern in many of the teaching centers because of the legal implications that demand the attendance of the Directors of some of the surgical teaching programs to actually be present in the operating room during any surgical procedure. This fails to recognize the gradation of ability and responsibility of residents participating in the longer residency training programs as well as a number of other factors in regard to both medical training and patient service.

Increasing membership in the College is essential if we wish to maintain and strengthen our representation on the College Board of Governors, on the policy making committees and on the Otolaryngologic sections of the program.

At the present time, the Advisory Committee for Otolaryngology of the American College of Surgeons consists of Dr. Shirley Baron (64), Chairman; Drs. Dekle Taylor (65), George Sisson (66), John Daly (67) and Jerome Hilger (68).

Representatives of the American Laryngological Association to the Board of Governors to the College are Drs. Harry F. Schenck (64), Paul H. Holinger (65) and Walter Work (66). The figures after each name indicate the year of termination of the appointment.

Respectfully submitted,

Paul H. Holinger, M.D.

for *Harry P. Schenck, M.D.*

Interpolation:

This report, incidentally, has been published in the *Bulletin* of the College of Surgeons. I think those of you who are interested in this terribly important problem, which influences us all, would do well to read the report. Possibly with action we can help straighten out some of our problems in nursing and in the division that is certainly growing very seriously between nursing educators and physicians.

Paraphrase:

Here again the various programs of training are losing value and effectiveness because of laws that are developing in different states and now are being more carefully implemented, which make it impossible for the various training programs to obtain sufficient teaching material so that their residents can actually do the surgery.

For those of you who haven't encountered this difficult problem, the many subterfuges that are now being used to circumvent these laws are being looked at more and more carefully. In so many areas this situation is growing to very serious proportions. Disciplinary action will fall on us rather than on the resident if we are not actually present at many of the operative procedures, that is, physically present for the operative procedure that in many instances, because of third party payment, the residents are doing but yet for which we are directly responsible according to the law.

(Dr. Holinger's report was accepted as given.)

EXECUTIVE SESSION

Saturday Morning, April 11, 1964

The meeting reconvened in Executive Session in the Colonial Room at twelve fifty-six o'clock, following the end of the Scientific Session, President Hilding presiding.

President Hilding: We are now to elect the Board of Directors. The slate was presented to us by the Nominating Committee and is on the board. May I have a motion?

DR. HENRY L. WILLIAMS: I move the nominations be closed.

(The motion was duly seconded and carried.)

I move that the Secretary cast a unanimous ballot for the slate.

(The motion was duly seconded and carried.)

The directors, then elected, met in a brief meeting.

SECRETARY RICHARDS: The Board of Directors have met and organized as follows for the succeeding year:

For President: Dr. Albert C. Furstenberg

First Vice-President: Dr. G. Slaughter Fitz-Hugh

Second Vice-President: Dr. Daniel C. Baker, Jr.

Secretary: Dr. Lyman G. Richards

Treasurer: Dr. Alden H. Miller

Editor: Dr. F. Johnson Putney

First Councilor: Dr. Edwin N. Broyles

Second Councilor: Dr. Dean M. Lierle

Third Councilor: Dr. Francis E. LeJeune

Fourth Councilor: Dr. Anderson C. Hilding

PRESIDENT HILDING: Will Dr. Furstenberg please come to the platform.

May I congratulate you. This is a very great honor indeed. For myself I have felt that it was "an der ganzen Spitze."

It has been a rich experience and I am sure you will find it the same and you will like to work with our Secretary.

Now I want to present this historic gavel to you and point out to you how beautiful it looks. It was all fixed up and rejuvenated by our Past President, Dr. LeJeune.

And may I offer you a bit of advice? You will sleep better if you remember where you have put it. (Laughter). My wife and I were out in Hawaii a month ago and someone we met there, a lady, asked us to step into the gift shop—she wanted to show us something —and she picked up an ivory gavel. Already I have forgotten what

it was about as far as she was concerned, but I looked at my wife and my wife looked at me and each knew what was in the other one's mind: "Where is that American Laryngological gavel?" And we didn't sleep very well till we got home and my secretary laughed and said, "Don't you remember? We put it in the safe when you got home from the meeting last year." (Laughter and applause)

(President-elect Furstenberg assumed the Chair.)

PRESIDENT FURSTENBERG: I want to say "Danke schön." (Laughter)

Well, gentlemen, I am deeply moved by the honor that you have conferred on me today. With you, I am very proud of the progress that the American Laryngological Association has made over the years. I can take very little credit for this prograss but nevertheless, I want to give it some kind of a forward thrust, if this is possible, and keep on with the wonderful tradition that has been established here by former presidents and particularly by Andy Hilding and by Lyman Richards, who have done a colossal job at this wonderful meeting. I do need their support and their help this coming year and I am perfectly certain that they will not fail me.

In this life rewards come in no better coin than the esteem and the affection of your colleagues and also in the satisfaction of your work and I hope to do everything I possibly can to further the best interests of the American Laryngological Association.

I am very grateful for the good things that I have obtained from this Association over the years, and I am very grateful to all of you who have been so gracious and kind in helping me whenever I had an opportunity to participate in these meetings. So I shall say, Andy and Lyman and members of the American Laryngological Association, I am indeed most grateful for the confidence that you have expressed in me this day.

Now it becomes my duty as the president of the American Laryngological Association to give a key to the retiring President.

And so, Andy, I should like very much to have you come forward and to give you this memento of your great achievement here this last year. Let me say again that you have done a yeoman job and I am sure that all the members of the American Laryngological Association appreciate your efforts and I hope that I may have your counsel during this coming year. (Presenting a key in a velvet box)

IMMEDIATE PAST PRESIDENT HILDING: Thank you so much. You may have my counsel.

I appreciate this more than I can tell you. I can just simply say, "Thank you." I shall cherish it always as a sign of approval. There is no stimulation, you know, like the approval of one's friends. Thank you so much. (Applause)

SECRETARY RICHARDS: Because this is Dr. Davison's last year as Editor, I can't let this occasion pass without my own personal expression of appreciation of all the hard work he has done.

I at one time took on the Triological editorship for ten years and I know a little something of the labor involved. I have worked very closely with Dr. Davison and I think he has done a magnificent job and perhaps to some extent a tedious and thankless task. He has had the able assistance of his wife and together, Editor and Assistant Editor, they have done a magnificent job and I think we are all very grateful to them.

We are also very fortunate in Dr. Putney's willingness to take on this job and I am certain that he will do an equally good one, so that, editorially at least, we are still in good hands.

Francis, my sincere appreciation for all the help that you have given me year after year in your work. (Applause)

DR. DAVISON: Thank you, Lyman.

PRESIDENT FURSTENBERG: I assume that a motion to adjourn is now in order.

(Such motion was duly made and seconded.)

(The meeting was adjourned at three minutes past one o'clock.)

List of Fellows

LIST OF FELLOWS

Date Indicates Year Admitted to Active Fellowship

Attendance at meetings is shown by figures following each name.
Asterisk (*) indicates year paper was read.

Active Fellows

1962. ALEXANDER, FRED W., 10515 Carnegie Ave., Cleveland 6, Ohio, 1962, '63*, '64.

1958. ALFARO, VICTOR R., 917 - 20th St. N. W., Washington 6, D. C., 1958, '59, '60, '61, '62, '63, '64.

1962. ARNOLD, GODFREY E. T., 2500 N. State St., Jackson 6, Mississippi, 1962, '63*, '64*.

1958. ATKINS, JOSEPH P., 3400 Spruce St., Philadelphia 4, Pa., 1958, '59*, '60, '61, '62, '63, '64.

1956. BAKER, DANIEL CLIFTON, JR., 903 Park Avenue, New York 21, N. Y., 1956, '57, '58, '59*, '60, '61, '62*, '63, '64.

1963. BAXTER, JAMES D., 1509 Sherbrooke St. West, Montreal, P.Q., Canada, 1963.

1944. BOIES, LAWRENCE R., University Hospital, Minneapolis 14, Minnesota, 1944, '46, '47, '48*, '49, '50*, '51*, '53, '54, '55, '56, '57 ,'58, '59, '60, '61, '62, '63, '64.

1955. BORDLEY, JOHN E., Johns Hopkins Hospital, Baltimore 5, Maryland, 1955, '56, '57, '59, '60, '62, '63, '64.

1959. BREWER, DAVID W., 1100 E. Genesee St., Syracuse 10, N. Y., 1959, '60*, '61, '62*, '63*.

1955. BROWN, LESTER ALEXANDER, 490 Peachtree Street, N.E., Atlanta 8, Georgia, 1955, '56, '57, '58, '59, '61, '63.

1940. BROYLES, EDWIN N., 1100 North Charles Street, Baltimore 1, Maryland, 1940, '41*, '42, '46, '48*, '49, '50, '51*, '52, '53, '54, '55, '56, '58, '59*, '60, '61*, '63, '64.

1963. BRYCE, DOUGLAS P., 170 St. George St., Room 320, Toronto, Canada, 1963*, 64.

1945. CAMPBELL, COLONEL PAUL A., 321 Park Hill Drive, San Antonio, Texas, 1946, '47, '49, '51, '57*, '61.

1942. CANFIELD, NORTON, Harwood Hospital, Christiansted, St. Croix, Virgin Is., 1942, '46, '47, '48, '49*, '50, '51, '56, '57.

1959. CARDWELL, EDGAR P., 109 So. Munn Ave., East Orange, N. J., 1959, '60, '61, '62, '63.

1964. CODY, CLAUDE C., III, 1600 Memorial Professional Building, Houston, Texas, 1964.

1957. CONLEY, JOHN J., 139 East 36th Street, New York 16, N.Y. 1958*, '60*, '61, '62*, '63*, '64.

1957. CONVERSE, JOHN MARQUIS, 722 Park Avenue, New York 21, N.Y., '60, '62*.

1959. CRACOVANER, ARTHUR J., 103 E. 78th St., New York 21, N. Y., 1959, '60, '61*, '62, '63.

1960. DALY, JOHN F., Faculty Practice Offices, 566 First Ave., New York 16, N. Y., 1960, '61*, '62, '63, '64.

1951. DAVISON, FRANCIS W., Geisinger Medical Center, Danville, Pa., 1951, '52, '53*, '54, '55, '56, '57, '58, '59, '60, '61, '62, '63*, '64.

1941. DIXON, FRED W., 1027 Rose Building, Cleveland 15, Ohio, 1941, '42*, '44, '46, '47*, '49*, '50, '51, '52, '53, '54, '55, '56, '57, '58*, '59, '60, '61, '62, '63, '64.

1947. EAGLE, WATT WEEMS, Duke Hospital, Durham, N. C., 1948*, '49, '51, '53, '54, '56, '57, '59, '62. '64.

1954. EQUEN, MURDOCK S., Ponce de Leon Infirmary, Atlanta 8, Ga., 1954, '55, '57, '58, '60, '63.

1952. ERICH, JOHN B., Mayo Clinic, 102 Second Avenue, Rochester, Minn., 1953, '56*, '57.

1964. FEARON, BLAIR, Medical Arts Building, Toronto 5, Ontario, Canada, 1964.

1963. FERGUSON, CHARLES F., 300 Longwood Ave., Boston 15, Mass., 1963, '64*.

1955. FITZ-HUGH, GLASSELL SLAUGHTER, 2003 Spottswood Road, Charlottesville, Virginia, 1955, '57, '59, '60, '61, '62*, '64.

1956. FRIEDBERG, STANTON A., 122 So. Michigan Ave., Chicago 3, Illinois, 1956, '57*, '58, '59, '60, '61, '62, '63, '64.

1932. FURSTENBERG, ALBERT CARL, Out-Patient Bldg., University Hospital, Ann Arbor, Michigan, 1933*, '36*, '38*, '46, '48*, '50, '51, '53, '54, '55*, '56, '57, '58*, '59, '60, '61, '62, '63*, '64.

1959. GOLDMAN, JOSEPH L., 1050 Park Ave., New York, N. Y., 1959, '60*, '61, '62, '63, '64.

1940. GOODALE, ROBERT L., 330 Dartmouth St., Boston 16, Massachusetts, 1940, '41, '42*, '44*, '46, '47, '49, '50*, '53, '54, '55*, '56, '57*, '60, '61*, '62, '63, '64.

1957. HARRILL, JAMES A., Bowman Gray School of Medicine, Winston-Salem, N. C., 1957, '58, '59, '61, '62, '63, '64.

1960. HARRIS, HERBERT, 907 Hermann Professional Building, Houston 25, Texas, 1960, '61*, '62, '63, '64.

1959. HART, VERLING K., 106 W. 7th St., Charlotte, N. C., 1959, '60, '62.

1942. HEATLY, CLYDE A., 11 North Goodman Street, Rochester 7, N.Y., 1942, '46*, '49, '50, '52, '53*, '54, '55, '57, '58, '60, '61.

1959. HENRY, G. ARNOLD, 170 St. George St., Toronto, Canada, 1959, '61, '63.

1943. HILDING, ANDERSON C., Research Laboratory, St. Luke's Hospital, Duluth 11, Minnesota, 1944*, '46, '47, '48*, '49, '50, '51, '53, '55, '56*, '57, '60, '61, '62*, '63, '64*.

1955. HILGER, JEROME A., 350 St. Peter Street, St. Paul 2, Minnesota, 1955, '56*, '57, '58, '59, '60, '62, '63, '64.

1945. HOLINGER, PAUL H., 700 North Michigan Ave., Chicago 11, Illinois, 1946, '47, '49, '50*, '51*, '52, '53, '54*, '55, '56, '57, '58*, '59, '60, '61*, '62*, '63, '64.

1957. HOLMES, EDGAR M., 330 Dartmouth Street, Boston 16, Mass., 1957, '59, '61, '63.

1944. HOOPLE, GORDON D., 1100 East Genesee St., Syracuse 10, New York, 1946, '47, '48, '49, '50, '51, '52, '53, '54*, '55, '56, '58, '59, '60, '61, '62, '63, '64.

1952. IRELAND, P. E., Room 82, Banting Institute, University of Toronto, Toronto, Ontario, 1952, '53, '54, '55, '56*, '57, '59, '61, '62, '63, '64.

1961. JONES, EDLEY H., First National Bank Building, Vicksburg, Mississippi, 1961, '62, '63*.

1964. KEIM, WILLIAM F., 67 South Munn Ave., East Orange, N. J., 1964.

1963. KIRCHNER, JOHN A., 333 Cedar St., New Haven 4, Conn., 1963.

1963. LATHROP, FRANK D., 605 Commonwealth Ave., Boston 15, Mass., 1963, '64*.

1953. LEDERER, FRANCIS LOEFFLER, 1853 W. Polk Street, Chicago 12, Illinois, 1953, '54, '55, '56, '57*, '58, '60, '61, '62, '63*, '64.

1936. LEJEUNE, FRANCIS ERNEST, Ochsner Clinic Building, Prytania and Aline Streets, New Orleans 15, Louisiana, 1937, '46*, '47, '50, '51, '52, '53, '54*, '55, '56, '57, '58, '59, '60, '61, '62, '63*, '64.

1961. LEWY, ROBERT B., 25 East Washington St., Chicago 2, Ill., 1961, '62*, '63.

1933. LIERLE, DEAN M., University Hospital, Iowa City, Iowa, 1933, '34, '35*, '37, '38, '39, '40*, '42*, '44*, '46, '47*, '48, '49, '50*, '51, '52, '53, '54, '55*, '56, '57, '58, '59, '60, '62*, '63.

1949. LINDSAY, JOHN R., 950 E. 59th Street, Chicago 37, Illinois, 1949, '50, '51*, '53, '55*, '56, '57, '58, '59, '60, '61, '62.

1952. MCCALL, JULIUS W., 610 Rose Building, Cleveland 15, Ohio, 1952, '53*, '54, '55, '56, '57, '58, '59, '60*, '61, '62*, '63, '64.

1963. MCGOVERN, FRANCIS H., 139 South Main St., Danville, Virginia, 1963, '64.

1951. MCHENRY, LAWRENCE C., 301 N. W. 12th St., Oklahoma City 2, Okla., 1953*, '62, '63, '64.

1933. MCMAHON, BERNARD J., 150 No. Meramec Ave., Clayton 5, Missouri, 1934*, '35, '36, '38*, '41, '44, '46*, '47, '48, '49,' 50*, '51, '52, '53, '54, '55*, '56*, '57, '58, '59, '60, '61, '62, '64.

1931. MCNALLY, WILLIAM JAMES, 1509 Sherbrooke Street West, Montreal, Canada, 1931, '33, '34*, '39, '44, '47, '49, '49, '52, '53, '54*, '55, '56, '57, '58, '59, '60, '61.

1954. MELTZER, PHILIP E., 285 Commonwealth Ave., Boston 15, Mass., 1954*, '56, '57, '58, '59, '60, '61, '62, '63.

1952. MILLER, ALDEN H., 1407 N. Vermont Ave., Los Angeles 27, Calif., 1952, '53*, '55, '57, '58*, '61, '62, '63, '64.

1964. MONTGOMERY, WILLIAM W., 243 Charles St., Boston 14, Mass., 1964.

1958. MONTREUIL, FERNAND, 1123 St. Joseph Blvd., E., Montreal, Canada, 1958, '60, '64.

1954. MOORE, PAUL M., 10515 Carnegie Ave., Cleveland 6, Ohio, 1954, '55*, '56, '57, '59, '60, '61, '62, '63, '64.

1957. MUNOZ-MACCORMICK, CARLOS EDUARDO, 71 Park Terrace, Santurce, Puerto Rico, 1957, '58, '59, '60, '61, '62, '63, '64.

1953. MURTAGH, JOHN A., 2 Maynard Street, Hanover, New Hampshire, 1953, '54, '55, '56*, '57, '58, '59, '61, '62, '63.

1937. NASH, C. STEWART, Medical Arts Building, Rochester 7, New York, 1937, '38*, '40, '42, '44, '46, '49, '50, '51, '52, '53, '54, '55, '56*, '58, '59, '60, '61, '62, '64.

1956. NORRIS, CHARLES MORGAN, 3401 North Broad Street, Philadelphia 40, Pennsylvania, 1956, '57, '58*, '59, '60, '61*, '62, '63, '64.

1961. OGURA, JOSEPH H., 640 So. Kingshighway, St. Louis 10, Mo., 1961*, '62*, '63, '64*.

1958. O'KEEFE, JOHN J., 255 S. 17th St., Philadelphia 3, Pa., 1958, '59*, '60, '62, '64.

1961. O'NEIL, JAMES J., 612 Medical Arts Building, Omaha, Nebraska, 1961, '62*, '64.

1961. PANG, LUP Q., 1374 Nuuanu Ave., Honolulu 17, Hawaii, 1961, '62*, '64.

1961. PASTORE, PETER N., Box 25, 1200 East Broad St., Richmond, Virginia, 1961, '62*, '64.

1954. PRESSMAN, JOEL J., Department of Surgery, UCLA Medical Center, Los Angeles 24, Calif., 1954, '56*, '59*, '60, '61, '62, '64.

1951. PRIEST, ROBERT E., 79, S. Ninth St., Minneapolis 2, Minn., 1951, '53*, '54*, '56, '59, '60*, '61.

1951. PUTNEY, F. JOHNSON, 1712 Locust St., Philadelphai 3, Pa., 1951, '52, '53*, '54, '55, '56, '58*, '59, '60, '61, '62, '63*, '64*.

1951. RAWLINS, AUBREY G., 384 Post Street, San Francisco 8, Calif., 1951, '53*, '56, '58, '64.

1963. REED, GEORGE F., Zero Emerson Place, Charles River Park, Boston 14, Mass., 1963.

1934. RICHARDS, LYMAN GILDER, 12 Clovelly Road, Wellesley Hills 81, Mass., 1934, '35, '36*, '37, '38, '39, '47, '49, '51*, '54, '56, '57*, '59, '60, '61, '62, '63, '64.

1956. RICHARDSON, JOHN ROBERT, 403 Commonwealth Avenue, Boston 15, Massachusetts, 1957, '58, '59, '60, '63, '64.

1953. ROBERTS, SAM E., 1100 Professional Bldg., Kansas City, Missouri, 1953, '54*, '55, '56, '57, '58, '59, '60, '63.

1959. SANDERS, SAM H., 1089 Madison Ave., Memphis 3, Tenn.. 1959, '60, '61, '62, '63.

1964. SAUNDERS, WILLIAM H., N-820 University Hospital, Columbus, Ohio, 1964.

1934. SCHENCK, HARRY P., 326 South 19th Street, Philadelphia 3, Pennsylvania, 1934, '35, '36*, '37, '38, '39, '40, '41*, '44*, '46, '47, '49, '50, '51, '52, '53, '54, '55, '56, '57, '58*, '59*, '60, '61, '62, '63.

1959. SILCOX, LOUIS E., 102 Lankenau Med. Bldg., Philadelphia 31, Pa., 1959, '60, '61, '62, '63, '64.

1958. SIMONTON, KINSEY M., Mayo Clinic, Rochester, Minn., 1958, '59*, '62, '64.

1939. SIMPSON, W. LIKELY, 512 Physicians' and Surgeons' Building, Memphis 3, Tennessee, 1939, '41, '44*, '46, '47*, '48, '50, '51*, '52, '53, '54, '55, '57, '58, '59, '60, '61, '62, '63.

1962. SISSON, GEORGE A., 1200 E. Genesee St., Syracuse 10, N. Y., 1962, '63*.

1964. SKOLNIK, EMANUEL M., 1853 West Polk Street, Chicago, Ill., 1964*.

1950. SMITH, AUSTIN T., Pennsylvania Hospital, 330 So. 9th St., Philadelphia 7, Pa., 1950, '51, '52, '53, '55, '56, '57, '58*, '59, '60, '61, '62*.

1954. Sooy, Francis A., 490 Post Street, San Francisco 2, Calif., 1954, '56*, '58, '60, '62, '63, '64.

1961. Suehs, Oliver W., 14 Medical Arts Square, Austin, Texas, 1961, '62*, '63, '64.

1963. Tabb, Harold G., 1430 Tulane Ave., New Orleans 12, La.

1947. Theobald, Walter H., 307 N. Michigan Ave., Chicago 11, Illinois, 1947, '48*, '49, '50, '51, '52, '53, '54, '55, '56, '57, '58, '60, '61, '62, '64.

1954. Thornell, William C., 2508 Auburn Avenue, Cincinnati 19, Ohio, 1955*, '57, '59, '60, '63.

1963. Tolan, John F., 1118 Ninth Ave., Seattle 1, Washington, 1963, '64.

1950. Tremble, G. Edward, 1390 Sherbrooke St. W., Montreal, Quebec, Canada, 1950, '51, '52, '53, '54, '55*, '56, '57, '58, '60, '61, '62, '63.

1943. Van Alyea, Oliver E., 135 South LaSalle Street, Chicago 3, Illinois, 1944, '46*, '47, '48, '50, '51, '52*, '53, '54, '55, '56*, '57, '58, '59, '60, '62, '63.

1954. Walsh, Theodore E., 640 S. Kingshighway Blvd., St. Louis 10, Missouri, 1954, '55*, '56, '57, '58, '59, '60, '61, '62, '63, '64.

1962. Weaver, Delmar F., 571 Fisher Building, Detroit 2, Michigan, 1962, '63, '64*.

1940. Weille, Francis L., 247 Commonwealth Avenue, Boston 16, Massachusetts, 1940, '41, '42, '44, '46*, '47, '48, '49, '50, '51, '52, '53, '54, '55, '56*, '57, '58, '59, '60, '61, '62, '63, '64.

1948. Williams, Henry L., 2nd, 54th St. & 48th Ave., Minneapolis 17, Minnesota, 1948, '49, '50*, '51, '52*, '53, '54, '55, '56, '57, '58*, '59, '60, '62, '63, '64.

1951. Woodman, DeGraaf, Talbottown Lane, P. O. Box 560, Easton, Md., 1951, '53, '54, '55*, '56, '58, '59, '60, '61, '62, '63, '64.

1953. Work, Walter P., University Hospitals, Ann Arbor, Michigan, 1953, '54, '56, '58, '59*, '62, '63*.

Honorary Fellows

1957. (1925) CLERF, LOUIS H., 5575 Eighth Avenue, North, St. Petersburg 2, Florida, 1957, '58, '59, '60, '61, '63, '64.

1960. (1928) HILL, FREDERICK THAYER, Thayer Memorial Hospital, Waterville, Maine, 1960, '61, '63, '64.

1943. (1918) LEWIS, FIELDING O., Providence Road, Media, Pennsylvania.

1957. (1930) NEGUS, SIR VICTOR E., Hill Farm Lodge, Haslemere, Surrey, England, 1957*.

1957. (1924) PROETZ, ARTHUR W., 12 Westmoreland Place, St. Louis 8, Missouri, 1957, '58, '59, '60, '62.

Corresponding Fellows

1946. ALONSO, REGULES JUSTO E., Mercedes 1233, Montevideo, Uruguay.

1959. BARRETTO, PLINIO DE MATTOS, Ru Cons Torres, Homer 371, Sao Paulo, Brazil, 1960.

1959. BATEMAN, GEOFFREY H., 55 Harley Street, London W.1., England.

1942. BATSON, OSCAR V., 203 South DeKalb St., Philadelphia 4, Pennsylvania, 1942*, '54*.

1964. CLEVES, CARLOS, Carrera 14 No. 44-54, Apto. 202, Bogota, Colombia, S.A.

1943. EGGSTON, ANDREW A., 653 Park Avenue, New York, N. Y., 1944, '49, '55, '60, '61*.

1961. FAABORG-ANDERSEN, K., Central Hospital, Nykøbing, Falster, Denmark, 1961.

1957. HUIZINGA, EELCO, Noorderhaven 7, Groningen, The Netherlands, 1957.

1957. ONO, JO, 75 Zaimoku-cho, Azabu, Minato-ku, Tokyo, Japan, 1957.

1964. PEREZ, ALFREDO C., Institito Celis Perez, Avenida Montes de Oca, Apartado 163, Valencia, Venezuela, S.A.

1937. PORTMANN, GEORGES, 25 bis Cours de Verdun, Bordeaux, France, 1947.

1957. RUEDI, LUZIUS, Ramistrasse 100, Zurich, Switzerland, 1957.

1924. SCHAEFER, J. PARSONS, 4634 Spruce Street, Philadelphia 39, Pennsylvania, 1934.

1952. TAPIA ACUNA, RICARDO, Av. Insurgentes Sur 300, Mexico 7 D.F., 1953, '57, '60*.

1936. VIALLE, JACQUES, 27 Rue de France, Nice (Alpes Maritimes), France.

Emeritus Fellows

1961. (1936) BALLENGER, HOWARD C., 723 Elm Street, Winnetka, Illinois.

1941. (1923) BARLOW, ROY A., Musquodoboit Harbor, Nova Scotia, Canada.

1951. (1944) BEATTY, HUGH G., 390 Oak St., Apt. No. 35, Columbus 15, Ohio, 1951, '52, '53.

1964. (1941) DIXON, FRED W., 19101 Van Aken Blvd., Shaker Heights 22, Ohio, 1964.

1958. (1930) FIGI, FREDERICK A., Mayo Clinic, Rochester, Minnesota.

1961. (1936) GALLOWAY, THOMAS CYRUS, 636 Church St., Evanston, Illinois, 1961, '62, '64.

1951. (1928) GITTINS, THOMAS R., 408 Davidson Bldg., Sioux City, Iowa.

1963. (1928) GOODYEAR, HENRY M., 556 Doctors' Building, Cincinnati 2, Ohio.

1962. (1950) HALL, COLBY, 16100 Ventura Blvd., Encino, Calif., 1950.

1960. (1940) HANSEL, FRENCH, 634 N. Grand Blvd., St. Louis 3, Missouri, 1962.

1957. (1944) HAVENS, FRED Z., 102 Second Avenue S.W., Rochester, Minnesota.

1955. (1930) HOUSER, KARL M., 2035 Delancey Street, Philadelphia 3, Pennsylvania.

1951. (1928) JARVIS, DEFOREST C., Quarry Bank Bldg., Barre, Vt., 1952.

1960. (1942) KELLY, JOSEPH D., 140 East Fifty-fourth Street, New York 22, N. Y.

1961. (1950) KLINE, ORAM R., 514 Cooper Street, Camden, N. J., 1961, '63.

1954. (1927) LUKENS, ROBERT M., 141 West Heather Road, Wildwood Crest, N. J.

1964. (1952) MCCALL, JULIUS W., 610 Rose Building, Cleveland 15, Ohio, 1964.

1959. (1927) MYERSON, MERVIN C., 436 North Roxbury Drive, Beverley Hills, Calif.

1957. (1948) PHELPS, KENNETH A., 1850 Willow Road, Palo Alto, Calif. 1958.

1958. (1938) SALINGER, SAMUEL, 1260 East Alejo Road, Palm Springs, Calif., 1958, '59, '61, '62, '63, '64.

1962. (1932) SCHALL, LEROY A., Scudder Lane, Barnstable, Mass., 1964.

1964. (1934) SCHENCK, HARRY P., 326 South 19th Street, Philadelphia 3, Pa., 1964.

1961. (1941) VIOLÉ, PIERRE P., 241 South Windsor, Los Angeles, Calif., 1964.

1963. (1948) WHALEN, EDWARD J., 750 Main Street, Hartford, Connecticut.

1964. (1948) WILLIAMS, HENRY L., II, U. S. Veterans' Hospital, Minneapolis 17, Minn., 1964.

1951. (1935) WOODWARD, FLETCHER D., 1326 Rugby Road, Charlottesville, Va., 1959, '60, '61.

BENEFACTORS

Dr. John F. Barnhill
Dr. Gordon Berry
Dr. Edwin N. Broyles
Dr. William E. Casselberry
Dr. Louis H. Clerf
Dr. Cornelius Coakley
Dr. & Mrs. Francis W. Davison
Dr. & Mrs. Lee Wallace Dean
Dr. Arthur W. deRoaldes
Dr. Fred W. Dixon
Dr. William E. Grove
Dr. Gordon F. Harkness
Dr. Frederick T. Hill
Dr. & Mrs. George E. Hourn
Dr. Samuel Johnston
Dr. James E. Newcomb
Dr. Henry B. Orton
Dr. Samuel Salinger
Dr. Sam H. Sanders
Dr. Harry P. Schenck
Dr. Burt R. Shurly
Mr. Lester T. Sunderland
Dr. H. Marshall Taylor
Dr. Walter H. Theobald

Obverse of the deRoaldes medal

RECIPIENTS OF THE deROALDES AWARD

1928. Dr. Chevalier Jackson
1931. Dr. D. Bryson Delavan
1934. Dr. Harris P. Mosher
1937. Dr. Lee Wallace Dean
1943. Dr. Ralph A. Fenton
1949. Dr. George M. Coates
1951. Dr. Arthur W. Proetz
1954. Dr. Louis H. Clerf
1959. Dr. Albert C. Furstenberg
1960. Dr. Dean M. Lierle
1961. Dr. Frederick T. Hill

RECIPIENTS OF THE CASSELBERRY AWARD

1923. Dr. George Fetterolf and Dr. Herbert Fox

1928. Dr. Ralph A. Fenton and Dr. O. Larsell

1929. Dr. Richard A. Kern and Dr. Harry P. Schenck

1929. Dr. Edward H. Campbell

1931. Dr. Arthur W. Proetz

1934. Dr. Anderson C. Hilding

1936. Dr. Francis E. LeJeune: Dr. Joel J. Pressman

1939. Dr. H. Marshall Taylor: Dr. Brien T. King

1940. Dr. French K. Hansel

1941. Dr. Noah D. Fabricant

1946. Dr. Paul H. Holinger

1949. Dr. Henry B. Orton

1962. Dr. Hans von Leden

RECIPIENTS OF THE NEWCOMB AWARD

1941. Dr. Burt R. Shurly
1942. Dr. Francis R. Packard
1943. Dr. George M. Coates
1944. Dr. Charles J. Imperatori
1947. Dr. Harris P. Mosher
1948. Dr. Gordon Berry
1949. Dr. Gordon B. New
1950. Dr. H. Marshall Taylor
1951. Dr. John D. Kernan
1952. Dr. William J. McNally
1953. Dr. Frederick T. Hill
1954. Dr. Henry B. Orton
1955. Dr. Thomas C. Galloway
1956. Dr. Dean M. Lierle
1957. Dr. Gordon F. Harkness
1958. Dr. Albert C. Furstenberg
1959. Dr. Harry P. Schenck
1960. Dr. Joel J. Pressman
1961. Dr. Chevalier L. Jackson
1962. Dr. Paul H. Holinger
1963. Dr. Francis E. LeJeune
1964. Dr. Fred W. Dixon

PAST OFFICERS

Presidents

(Year of Election)

1879. Louis Elsberg
1880. J. Solis-Cohen
1881. F. I. Knight
1882. G. M. Lefferts
1883. F. H. Bosworth
1884. E. L. Shurly
1885. Harrison Allen
1886. E. Fletcher Ingals
1887. R. P. Lincoln
1888. E. C. Morgan
1889. J. N. Mackenzie
1890. W. C. Glasgow
1891. S. W. Langmaid
1892. M. J. Asch
1893. D. Bryson Delavan
1894. J. O. Roe
1895. W. H. Daly
1896. C. H. Knight
1897. T. R. French
1898. W. E. Casselberry
1899. Samuel Johnston
1900. H. L. Swain
1901. J. W. Farlow
1902. J. H. Bryan
1903. J. H. Hartman
1904. C. C. Rice
1905. J. W. Gleitsman
1906. A. W. deRoaldes
1907. H. S. Birkett
1908. A. Coolidge, Jr.
1909. J. E. Logan
1910. D. Braden Kyle
1911. James E. Newcomb
1912. George A. Leland
1913. Thomas Hubbard
1914. Alexander W. MacCoy
1915. G. Hudson Makuen
1916. Joseph L. Goodale
1917. Thomas H. Halstead
1918. Cornelius G. Coakley
1919. Norval H. Pierce
1920. Harris P. Mosher
1921. Harmon Smith
1922. Emil Mayer
1923. J. Payson Clark
1924. Lee Wallace Dean
1925. Greenfield Sluder
1926. Chevalier Jackson
1927. D. Bryson Delavan
1928. Charles W. Richardson
1929. Lewis A. Coffin
1930. Francis R. Packard
1931. George E. Shambaugh
1932. George Fetterolf
1933. George M. Coates
1934. Dunbar Roy
1935. Burt R. Shurly
1936. William B. Chamberlain
1937. John F. Barnhill
1938. George B. Wood

1939. James A. Babbitt
1940. Gordon Berry
1941. Thomas E. Carmody
1942-3. Charles J. Imperatori
1944-5. Harold I. Lillie
1946. Frank R. Spencer
1947. Arthur W. Proetz
1948. Frederick T. Hill
1949. Ralph A. Fenton
1950. Gordon B. New
1951. H. Marshall Taylor
1952. Louis H. Clerf
1953. Gordon F. Harkness
1954. Henry B. Orton
1955. Bernard J. McMahon
1956. LeRoy A. Schall
1957. Harry P. Schenck
1958. Fred W. Dixon
1959. William J. McNally
1960. Edwin N. Broyles
1961. Dean M. Lierle
1962. Francis E. LeJeune
1963. Anderson C. Hilding

Vice-Presidents

1879.	F. H. Davis	
1880.	W. C. Glasgow	J. O. Roe
1881.	E. L. Shurly	W. Porter
1882.	C. Seiler	E. F. Ingals
1883.	S. W. Langmaid	S. Johnston
1884.	J. H. Hartman	W. H. Daly
1885.	H. A. Johnson	G. W. Major
1886.	E. C. Morgan	J. N. Mackenzie
1887.	J. N. Mackenzie	S. W. Langmaid
1888.	W. C. Glasgow	C. E. DeM. Sajous
1889.	E. Holden	C. E. Bean
1890.	J. O. Roe	J. H. Hartman
1891.	M. J. Asch	S. Johnston
1892.	S. Johnston	J. C. Mulhall
1893.	J. C. Mulhall	W. E. Casselberry
1894.	C. C. Rice	S. H. Chapman
1895.	J. Wright	A. W. deRoaldes
1896.	T. M. Murray	D. N. Rankin
1897.	A. W. MacCoy	H. S. Birkett
1898.	J. W. Farlow	F. W. Hinkel
1899.	T. A. DeBlois	M. R. Brown
1900.	H. L. Wagner	A. A. Bliss

1901.	J. W. Gleitsmann	D. Braden Kyle
1902.	G. A. Leland	T. Melville Hardie
1903.	J. H. Lowman	W. Peyre Porcher
1904.	Thomas Hubbard	W. J. Freeman
1905.	J. L. Goodale	C. W. Richardson
1906.	G. H. Makuen	A. B. Thrasher
1907.	J. P. Clark	J. E. Rhodes
1908.	E. Mayer	F. R. Packard
1909.	C. G. Coakley	H. P. Mosher
1910.	Robert C. Myles	J. M. Ingersoll
1911.	F. C. Cobb	B. R. Shurly
1912.	A. W. Watson	W. Scott Renner
1913.	F. E. Hopkins	Geo. F. Shambaugh
1914.	Clement T. Theisen	Lewis A. Coffin
1915.	J. Gordon Wilson	Christian R. Holmes
1916.	Thomas H. Halsted	Greenfield Sluder
1917.	John Edwin Rhodes	D. Crosby Greene
1918.	G. E. Shambaugh	John R. Winslow
1919.	Francis R. Packard	Harmon Smith
1920.	Harmon Smith	W. B. Chamberlin
1921.	Dunbar Roy	Robert C. Lynch
1922.	George Fetterolf	Lorenzo B. Lockard
1923.	Hubert Arrowsmith	Joseph B. Greene
1924.	Ross H. Skillern	Gordon Berry
1925.	John E. Mackenty	Robert Levy
1926.	Lewis A. Coffin	William V. Mullin
1927.	Charles W. Richardson	Hill Hastings
1928.	Robert Clyde Lynch	Francis P. Emerson
1929.	William B. Chamberlin	Ralph Albert Fenton
1930.	Harris P. Mosher	James A. Babbitt
1931.	Joseph B. Greene	E. Ross Faulkner
1932.	Gordon Berry	Frank A. Spencer
1933.	E. Ross Faulkner	Thomas S. Carmody
1934.	Gordon B. New	Samuel McCullagh
1935.	Edward C. Sewall	H. Marshall Taylor

1936.	William P. Wherry	Harold I. Lillie
1937.	Frank R. Spencer	Bernard J. McMahon
1938.	Ralph A. Fenton	Frederick T. Hill
1939.	John H. Foster	Thomas R. Gittins
1940.	Charles H. Porter	Gordon F. Harkness
1941.	Arthur W. Proetz	Henry B. Orton
1942-3.	Harold I. Lillie	Dean M. Lierle
1944-5.	John J. Shea	Thomas C. Galloway
1946.	H. Marshall Taylor	C. Stewart Nash
1947.	John J. Shea	Frederick A. Figi
1948.	Henry B. Orton	Anderson C. Hilding
1949.	LeRoy A. Schall	Fletcher D. Woodward
1950.	W. Likely Simpson	Lyman G. Richards
1951.	Wm. J. McNally	Thomas C. Galloway
1952.	J. Mackenzie Brown	Edwin N. Broyles
1953.	Claude C. Cody	Daniel S. Cunning
1954.	James H. Maxwell	Clyde A. Heatly
1955.	Robert L. Goodale	Paul H. Holinger
1956.	Henry M. Goodyear	Robert E. Priest
1957.	Francis E. LeJeune	Pierre P. Viole
1958.	Charles Blassingame	Chevalier L. Jackson
1959.	James Maxwell	Oliver Van Alyea
1960.	Walter Theobald	Anderson Hilding
1961.	Julius W. McCall	P. E. Ireland
1962.	Paul M. Moore	Jerome A. Hilger
1963.	Paul M. Holinger	Lester A. Brown

Secretaries and Treasurers

1879.	G. M. Lefferts	1895.	H. L. Swain
1882.	D. Bryson Delavan	1900.	P. E. Newcomb
1889.	C. H. Knight	1911.	Harmon Smith

Secretaries

1912.	Harmon Smith	1919.	J. M. Ingersoll
1918.	D. Bryson Delavan	1920.	George M. Coates

1933. William V. Mullin
1935. James A. Babbitt
1939. Charles J. Imperatori
1942. Arthur W. Proetz
1947. Louis H. Clerf
1952. Harry P. Schenck
1957. James H. Maxwell
1959. Lyman G. Richards

Treasurers

1912. J. Payson Clark
1923. George Fetterolf
1932. William V. Mullin
1933. James A. Babbitt
1935. Charles J. Imperatori
1939. Frederick T. Hill
1948. Gordon F. Harkness
1953. Fred W. Dixon
1958. Francis E. LeJeune
1962. Alden H. Miller

Librarians

1879. F. H. Bosworth
1883. T. R. French
1903. J. H. Bryan
1930. John F. Barnhill
1934. Burt R. Shurly
1935. George M. Coates

Librarian and Historian

1936. George M. Coates
1944. Louis H. Clerf

Librarian, Historian and Editor

1947. Harry P. Schenck
1952. Bernard J. McMahon
1955. Edwin N. Broyles
1960. Francis W. Davison
1964. F. Johnson Putney

PAST FELLOWS

Dates indicate original election to the Association

**Deceased*

Honorary Fellows

*1908. Barnhill, John F., Miami Beach, Florida.
*1893. Birkett, Herbert S., Montreal, Canada.
*1878. Bosworth, Francke H., New York City.
*1917. Coates, George M., Philadelphia, Pa.
*1918. Dean, Lee Wallace, St. Louis, Mo.
*1881. Delavan, D. Bryson, New York City.
*1893. deRoaldes, Arthur W., New Orleans, La.
*1890. De La Sota Y. Lastra, Ramon, Seville, Spain.
*1923. Fenton, Ralph A., Portland, Oregon
*1879. French, Thomas R., Brooklyn, N. Y.
*1880. Garcia, Senior Manuel, London, England.
*1903. Harris, Thos. J., New York City.
*1907. Jackson, Chevalier, Schwenksville, Pa.
*1878. Johnston, Samuel, Baltimore, Md.
*1878. Lefferts, George Morewood, Katonah, N. Y.
*1914. Levy, Robert, Denver, Colo.
*1883. Mackenzie, John N., Baltimore, Md.
*1881. Mackenzie, Sir Morel, London, England.
*1910. Masser, Ferdinand, Naples, Italy.
*1904. Mosher, Harris P., Marblehead, Mass.
*1910. Moure, J. J. E., Bordeaux, France.
*1937. Nager, F. R., Zurich, Switzerland.
*1918. Oliver, H. K., Boston, Mass.
*1906. Pierce, Norval Harvey, San Diego, Calif.
*1909. Semon, Sir Felix, Great Missenden, England.
*1878. Solis-Cohen, J., Philadelphia, Pa.
*1889. Swain, Henry L., New Haven, Conn.
*1914. Thomson, Sir St. Clair, London, Eng.
*1903. Tilley, Herbert, London, England.
*1914. Wagner, Clinton, New York City.
*1890. Wright, Jonathan, Pleasantville, N. Y.

Corresponding Fellows

*1892. Browne, Lennox, London, England.
*1938. Blair, Vilray P., St. Louis, Missouri.
*1940. Colledge, Lionel, London, England.
*1901. Collier, Mayo, Kearsney Abbey, Kent, England.
*1893. Desvernine, Carlos M., Havana, Cuba.
*1930. Emerson, Francis P., Franklin, Mass.
*1936. Fraser, John S., Edinburgh, Scotland.
*1901. Grant, Sir James Dundas, London, England.
*1887. Cougenheim, A., Paris, France.
*1894. Holden, Edgar, Newark, N. J.
*1919. Kelly, Adam Brown, Helensburgh, Scotland.
*1881. Labus, Carlo, Milan, Italy.
*1950. Larsell, Olof, Portland, Oregon.
*1931. LasSagna, Francesco, Parma, Italy.
*1926. Law, Frederick M., New York, N. Y.
*1921. LeMaitre, Ferdinand, Paris, France.
*1902. Lermoyez, Marcel, Paris, France.
*1897. Luc, H., Paris, France.
*1896. MacDonald, Greville, Haslemere, Surrey, England.
*1894. MacIntyre, John, Glasgow, Scotland.
*1903. McBride, P., York, England.
*1920. McKenzie, Dan, London, England.
*1919. McKernon, James F., New Canaan, Conn.
*1880. Meyer, Wilhelm, Copenhagen, Denmark.
*1910. Moure, J. J. E., Bordeaux, France.
*1896. Mygind, Holger, Copenhagen, Denmark.
*1950. Neil, James Hardie, Auckland, New Zealand.
*1919. Paterson, Donald Rose, Cardiff, Wales.
*1941. Patterson, Norman, Herts, England.
*1919. Rogers, John, Jr., New York City.
*1894. Sajous, C. E. DeM., Philadelphia, Pa.
*1896. Schmiegelow, Ernst, Copenhagen, Denmark.
*1946. Segura, Eliseo, Buenos Aires, Argentina.
*1940. Soto, E. Fernandez, Havana, Cuba.
*1881. Thornton, Pugin, London, England.
*1913. Turner, A. Logan, Edinburgh, Scotland.
*1880. Whistler, W. McNeil, London, England.
*1901. Wingrave, Wyatt, Lyme Regis, Dorset, England.
*1894. Wolfenden, R. Norris, Kent, England.

Emeritus Fellows

*1915. Barnes, Harry Aldrich, Kingston, Mass.
*1928. Beck, Joseph C., Chicago, Illinois.
*1921. Berry, Gordon, Worcester, Mass.
*1941. Bowers, Wesley C., New York, N. Y.
*1901. Brown, J. Price, Toronton, Canada.
*1891. Bryan, Joseph H., Washington, D. C.
*1913. Butler, Ralph, Philadelphia, Pa.
*1930. Campbell, Edward H., Philadelphia, Pa.
*1897. Clark, J. Payson, Boston, Mass.
*1899. Cobb, Frederick C., Bradenton, Florida.
*1939. Cody, Claude C., Jr., Houston, Texas.
*1905. Coffin, Lewis A., New York City.
*1893. Coolidge, Algernon, Boston, Mass.
*1937. Crowe, Samuel J., Baltimore, Maryland.
*1941. Cunning, Daniel S., New York City.
*1913. Dabney, Virginius, Washington, D. C.
*1882. De Blois, Thomas Amory, Boston, Mass.
*1892. Farlow, John W., Boston, Mass.
*1922. Forbes, Henry H., New York City.
*1933. Foster, John H., Houston, Texas.
*1905. Freer, Otto T., Chicago, Ill.
*1940. Gatewood, E. Trible, Richmond, Va.
*1880. Gleitsmann, Joseph W., New York City.
*1922. Goldsmith, Perry G., Toronto, Canada.
*1898. Goodale, Joseph L., Ipswich, Mass.
*1932. Graham, Harrington B., San Francisco, California.
*1906. Greene, D. Crosby, Jr., Boston, Mass.
*1917. Greene, Joseph B., Asheville, N. C.
*1905. Halsted, Thomas H., Los Angeles, Calif.
*1896. Hardie, Thomas Melville, Chicago, Ill.
*1915. Hastings, Hill, Los Angeles, Calif.
*1888. Hinkel, Frank Whitehill, Buffalo, New York.
*1895. Hopkins, Frederick E., Springfield, Mass.
*1927. Hubbard, Thomas, Toledo, Ohio.
*1919. Hurd, Lee Maidment, Rowayton, Conn.
*1920. Imperatori, Charles J., Essex, N. Y.
*1904. Ingersoll, John Marvin, Miami, Fla.
*1939. Johnston, William H., Santa Barbara, Calif.
*1918. Kenyon, Elmer L., Chicago, Ill.

*1921. Kernan, John D., New York
*1929. Kistner, Frank B., Portland, Oregon.
*1885. Knight, Charles H., New York City.
*1939. Large, Secord H., Cleveland, Ohio.
*1894. Leland, George A., Boston, Mass.
*1922. Lillie, Harold I., Rochester, Minn.
*1943. Lincoln, William R., Cleveland, Ohio.
*1928. Lyman, Harry Webster, St. Louis, Mo.
*1886. MacCoy, Alexander W., Philadelphia, Pa.
*1941. Martin, Robert C., San Francisco, Cal.
*1896. Mayer, Emil, New York City.
*1951. McCart, Howard W. D., Toronto, Canada.
*1939. McCaskey, Carl H., Indianapolis, Indiana.
*1943. McCullagh, Samuel, New York, N. Y.
*1923. McKinney, Richmond, Memphis, Tenn.
*1939. Myers, John L., Kansas City, Mo.
*1922. New, Gordon B., Rochester, Minn.
*1878. Porter, William, Ocean Springs, Miss.
*1901. Myles, Robert C., New York City.
*1923. Newhart, Horace, Minneapolis, Minn.
*1903. Packard, Francis R., Philadelphia, Pa.
*1942. Potts, John B., Omaha, Nebr.
*1903. Renner, W. Scott, Buffalo, N. Y.
*1897. Rhodes, John Edwin, Chicago, Ill.
*1884. Rice, Clarence C., New York City.
*1905. Richards, George L., South Yarmouth, Mass.
*1878. Robinson, Beverly, New York City.
*1921. Sauer, William E., St. Louis, Mo.
*1923. Sewall, Edward C., Palo Alto, Cal.
*1930. Seydell, Ernest M., Wichita, Kansas
*1907. Shambaugh, George E., Chicago, Ill.
*1908. Smith, Harmon, New York City.
*1923. Spencer, Frank R., Boulder, Colo.
*1927. Tobey, Harold G., Boston, Mass.
*1925. Tucker, Gabriel, Haverford, Pa.
*1892. Wagner, Henry L., San Francisco, Calif.
*1892. Watson, Arthur W., Philadelphia, Pa.
*1922. White, Francis W., New York, N. Y.

Active Fellows

*1939. Wilson, J. Gordon, Old Bennington, Vt.
*1905. Wood, George B., Wynnewood, Pa.
*1880. Allen, Harrison, Philadelphia, Pa.
*1917. Arrowsmith, Hubert, Brooklyn, N. Y.
*1879. Asch, Morris J., New York City.
*1942. Ashley, Rae E., San Francisco, Cal.
*1923. Babbitt, James A., Philadelphia, Pa.
*1906. Ballenger, William L., Chicago, Ill.
*1880. Bean, C. E., St. Paul, Minn.
*1949. Beck, August L., New Rochelle, N. Y.
*1904. Berens, T. Passmore, New York City.
*1924. Bigelow, Nolton, Providence, R. I.
*1938. Blassingame, Charles D., Memphis, Tenn.
*1893. Bliss, Arthur Ames, Philadelphia, Pa.
*1951. Boyden, Guy L., Portland, Oregon
*1895. Boylan, J. E., Cincinnati, Ohio.
*1932. Brown, John Mackenzie, Los Angeles, Calif.
*1892. Brown, Moreau R., Chicago, Ill.
*1933. Buckley, Robert E., New York City.
*1915. Canfield, R. Bishop, Ann Arbor, Mich.
*1934. Carmack, John Walter, Indianapolis, Ind.
*1924. Carmody, Thomas E., Denver, Colo.
*1889. Casselberry, William E., Chicago, Ill.
*1883. Chamberlain, C. W., Hartford, Conn.
*1917. Chamberlin, William B., Cleveland, Ohio.
*1896. Chappell, W. F., New York City.
*1882. Chapman, S. Hartwell, New Haven, Conn.
*1902. Coakley, Cornelius G., New York City.
*1913. Coffin, Rockwell C., Boston, Mass.
1918. Cox, Gerald H., New York City.
*1880. Cushing, E. W., Boston, Mass.
*1878. Cutter, Ephraim, West Falmouth, Mass.
*1880. Daly, W. H., Pittsburgh, Pa.
*1878. Davis, F. H., Chicago, Ill.
*1941. Davis, Warren B., Philadelphia, Pa.
1926. Dennis, Frank Lownes, Colorado Springs, Col.
*1901. Dickerman, E. T., Chicago, Ill.
*1878. Donaldson, Frank, Baltimore, Md.
*1947. Engler, Clarence W., Cleveland, Ohio.
*1935. Eves, Curtis C., Philadelphia, Pa.

*1919. Faulkner, E. Ross, New York City.
*1914. Fetterolf, George, Philadelphia, Pa.
*1901. Freeman, Walter J., Philadelphia, Pa.
*1917. Friedberg, Stanton A., Chicago, Ill.
1940. Fuchs, Valentine H., New Orleans, La.
*1897. Frothingham, Richard, New York City.
1909. Getchell, Albert C., Worcester, Mass.
*1907. Gibb, Joseph S., Philadelphia, Pa.
*1940. Gill, William D., San Antonio, Texas.
*1878. Glasgow, William Carr, St. Louis, Mo.
*1913. Goldstein, Max A., St. Louis, Mo.
*1905. Grayson, Charles P., Philadelphia, Pa.
*1934. Grove, William E., Milwaukee, Wisconsin.
*1933. Harkness, Gordon F., Davenport, Iowa.
*1878. Hartman, J. H., Baltimore, Md.
*1945. Hickey, Harold L., Denver, Colo.
*1879. Holden, Edgar, Newark, N. J.
*1907. Holmes, Christian R., Cincinnati, Ohio.
*1882. Hooper, Franklin H., Boston, Mass.
*1893. Hope, George B., New York City.
*1938. Hourn, George E., St. Louis, Mo.
*1939. Hunt, Westley Marshall, New York, N. Y.
*1901. Hyatt, Frank, Washington, D. C.
*1925. Iglauer, Samuel, Cincinnati, Ohio.
*1878. Ingals, E. Fletcher, Chicago, Ill.
*1882. Ives, Frank L., New York City.
*1938. Jackson, Chevalier L., Philadelphia, Pa.
*1880. Jarvis, William C., New York City.
*1878. Johnson, Hosmer A., Chicago, Ill.
*1879. Johnson, Woolsey, New York City.
*1960. Johnston, Kenneth C., Chicago, Ill.
*1944. Jones, Marvin F., New York City.
*1879. Kealhofer, R. H., St. Louis, Mo.
*1942. King, Edward D., North Hollywood, Calif.
*1901. King, Gordon, New Orleans, La.
*1885. Knight, Charles H., New York City.
*1878. Knight, Frederick Irving, Boston, Mass.
*1898. Kyle, D. Braden, Philadelphia, Pa.
*1880. Langmaid, Samuel W., Boston, Mass.
*1878. Lincoln, Rufus P., New York City.
*1911. Lockard, Lorenzo B., Denver, Colo.

*1913. Loeb, Hanau W., St. Louis, Mo.
*1897. Logan, James E., Kansas City, Mo.
*1935. Looper, Edward A., Baltimore, Maryland.
*1888. Lowman, John H., Cleveland, Ohio.
*1919. Lynah, Henry L., New York City.
*1952. Lynch, Mercer G., New Orleans, La.
*1915. Lynch, Robert Clyde, New Orleans, La.
*1879. McBurney, Charles, New York City.
*1927. McGinnis, Edwin, Chicago, Ill.
1936. McGregor, Gregor, Toronto, Canada.
*1913. McKimmie, O. A., Washington, D. C.
*1945. McLaurin, John G., Dallas, Texas.
*1885. McSherry, H. Clinton, Baltimore, Md.
*1914. Mackenty, John E., New York City.
*1898. Makuen, G. Hudson, Philadelphia, Pa.
*1881. Major, G. W., Montreal, Canada.
*1948. Maxwell, James H., Ann Arbor, Mich.
*1881. Morgan, E. C., Washington, D. C.
*1950. Morrison, Lewis F., San Francisco, Calif.
*1940. Morrison, William W., New York City.
*1886. Mulhall, J. C., St. Louis, Mo.
*1925. Mullin, William V., Cleveland, Ohio.
*1914. Munger, Carl E., Waterbury, Conn.
*1892. Murray, T. Morris, Washington, D. C.
*1881. Mynter, H., Buffalo, N. Y.
*1893. Newcomb, James E., New York City.
*1895. Nichols, J. E. H., New York City.
*1927. Orton, Henry B., Newark, N. J.
*1894. Park, William H., New York City.
*1892. Porcher, W. Peyre, Charleston, S. C.
*1927. Porter, Charles T., Boston, Mass.
*1908. Randall, B. Alexander, Philadelphia, Pa.
*1882. Rankin, D. N., Allegheny, Pa.
*1902. Richardson, Charles W., Washington, D. C.
*1930. Ridpath, Robert E., Philadelphia, Pa.
*1879. Roe, John O., Rochester, N. Y.
*1945. Robb, James M., Detroit, Michigan.
*1881. Robertson, J. M., Detroit, Mich.
*1913. Roy, Dunbar, Atlanta, Ga.
*1878. Rumbold, T. F., St. Louis, Mo.
*1879. Seiler, Carl, Philadelphia, Pa.

*1928. Shea, John Joseph, Memphis, Tennessee.
*1893. Shields, Charles M., Richmond, Pa.
*1909. Shurly, Burt R., Detroit 1, Mich.
*1878. Shurly, E. L., Detroit, Mich.
*1892. Simpson, William Kelly, New York City.
*1919. Skillern, Ross H., Philadelphia, Pa.
*1909. Sluder, Greenfield, St. Louis, Mo.
*1879. Smith, Andrew H., Geneva, N. Y.
*1932. Smyth, Duncan Campbell, Boston, Mass.
*1928. Sonnenschein, Robert, Chicago, Ill.
1924. Stein, Otto J., Chicago, Ill.
1934. Stevenson, Walter, Quincy, Ill.
*1911. Staut, George C., Philadelphia, Pa.
*1879. Tauber, Bernhard, Cincinnati, Ohio.
*1924. Taylor, Hermon Marshall, Jacksonville, Fla.
*1903. Theisen, Clement F., Albany, N. Y.
*1899. Thorner, Max, Cincinnati, Ohio.
*1892. Thrasher, Allen B., Cincinnati, Ohio.
*1937. Tobey, George L., Jr., Boston, Mass.
*1888. Van der Poel, S. O., New York City.
*1938. Vail, Harris H., Cincinnati, Ohio.
*1936. Voislawsky, Antonie P., New York City.
*1933. Wanamaker, Allison T., Seattle, Wash.
1896. Ward, Marshall R., Pittsburgh, Pa.
*1879. Ward, Whitfield, New York City.
*1886. Westbrook, Benjamin F., Brooklyn, N. Y.
*1924. Wherry, William P., Omaha, Neb.
*1924. White, Leon E., Boston, Mass.
*1939. Williams, Horace J., Philadelphia, Pa.
*1942. Wishart, D. E. Staunton, Toronto, Canada.
*1922. Wishart, David J. G., Toronto, Ontario.
*1940. Wood, V. Visscher, St. Louis, Mo.
*1896. Wollen, Green V., Indianapolis, Ind.
*1953. Wilkerson, William W., Nashville, Tenn.

INDEX

to the

TRANSACTIONS

of the

AMERICAN
LARYNGOLOGICAL ASSOCIATION

1964

INDEX

A

Addresses
Guest of Honor: Proetz, Arthur W. 20
President: Hilding, Anderson C. 11

Airway
obstruction of, upper and pulmonary function (Ogura, Nelson, Dammkoehler and Kawasaki) 39

Arnold, Godfrey E.
clinical application of recent advances in laryngeal physiology 91

Arteries
carotid, hemorrhage, retropharyngeal (Weaver) 223

Atresia
choanal, in infants and children (Ferguson) 127

B

Bryan, Marian
(see Bryan, William T. K.)

Bryan, William T. K.
morphologic and histochemical aspects of human ciliated epithelial cells in nasal secretions (with Marian Bryan and Catherine Smith) 145

C

Campbell, Edward Hastings:
obituary 240

Carcinoma
larynx, treatment of, current status of radiotherapy (Garland) 160

Carotid arteries
hemorrhage, retropharyngeal (Weaver) 223

Cartilaginous tumors of larynx (Putney and Moran) 26

Cells
ciliated, epithelial, pathologic and normal morphologic and histochemical aspects of (Bryan, W. T., Bryan, M., and Smith, C.) 145

Choanal atresia in infants and children (Ferguson) 127

Clinical application of laryngeal physiology, recent advances in (Arnold) 91

Clinico-histological study of chronic pharyngeal symptoms (Rulon and Simonton) 177

Current status of radio-therapy in the treatment of Carcinoma Laryngis (Garland) 160

D

Dammkoehler, Richard
(see Ogura, Joseph H.)

E

Effect of hypothyroidism on larynx of rat; explanation for hoarseness in humans (Ritter) 65

Experiences with partial laryngopharyngectomy (Skolnik) 80

F

Ferguson, Charles F.
congenital choanal atresia in infants and children (with Carlyle G. Flake) 127

Flake, Carlyle G.
(see Ferguson, Charles F.)

G

Garland, L. Henry
the current status of radiotherapy in carcinoma laryngis 160

H

Hilding, Anderson C.
President's Address 11

Hoarseness
associated with hypothyroidism (Ritter) 65

Hypothyroidism
effect on larynx of rat; explanation for hoarseness in the human (Ritter) 65

I

Implants
pharyngeal, for reduction of airspace in velopharyngeal insufficiency; experimental study (Ward and Wepman) 110

Inflammation
salivary glands, chronic, management of (Lathrop) 206

K

Kawasaki, M.
(see Ogura, Joseph H.)

L

Lathrop, Frank D.
the management of chronic inflammation of the salivary glands 206

Laryngeal
physiology, clinical application; recent advances in (Arnold) 91

Laryngopharyngectomy, partial, experiences with (Skolnik) 80

Larynx
tumors, cartilaginous (Putney and Moran) 26
effect of hypothyroidism on rat; an explanation for hoarseness in the human (Ritter) 65

laryngopharyngectomy, partial, experiences with (Skolnik) 80

carcinoma, treatment of, current status of radiotherapy (Garland) 160

M

Management of chronic inflammation of the salivary glands (Lathrop) 206

Moran, John J.
(see Putney, F. J.)

Morphologic and histochemical aspects of normal and pathologic ciliated epithelial cells (Bryan, W. T., Bryan, M., and Smith, C.) 145

N

Nelson, J. Roger
(see Ogura, Joseph H.)

O

Obituaries:
Campbell, Edward Hastings 240

Robb, James Milton 243

Observation on the relationship between upper airway obstruction and pulmonary function (Ogura, Nelson, Dammkoehler and Kawasaki) 39

Obstruction
relationship between upper airway and pulmonary function (Ogura, Nelson, Dammkoehler and Kawasaki) 39

Ogura, Joseph H.
observations on the relationships between upper airway obstruction and pulmonary function (with J. R. Nelson, R. Dammkoehler and M. Kawasaki) 39

P

Pharyngeal
symptoms, chronic, clinicohistological study of (Rulon and Simonton) 177
implants, for reduction of airspace in velopharyngeal insufficiency, experimental study (Ward and Wepman) 110

Pharynx
laryngopharyngectomy, partial, experiences with (Skolnik) 80

Physiology
laryngeal, clinical application; recent advances in (Arnold) 91

Proetz, Arthur W.
Address—guest of honor—how to smother an idea 20

Pulmonary function
relationships with upper airway obstruction (Ogura, Nelson, Dammkoehler and Kawasaki) 39

Putney, F. Johnson
cartilaginous tumors of the larynx (with John J. Moran) 26

R

Radiotherapy
larynx, carcinoma, current status in treatment (Garland) 160

Relationships between upper airway obstruction and pulmonary function; an experimental study (Ogura, Nelson, Dammkoehler and Kawasaki) 39

Retropharyngeal hemorrhage from the carotid arteries (Weaver) 223

Ritter, Frank
the effect of hypothyroidism on the larynx of the rat: an explanation for hoarseness associated with hypothyroidism in the human 65

Robb, James Milton: obituary 243

Rulon, J. Thomas
clinicohistological study of chronic pharyngeal symptoms (with K. M. Simonton) 177

S

Salivary glands
inflammation, chronic, management of (Lathrop) 206

Schenck, Harry P.
obituary of Edward Hastings Campbell 240

Simonton, Kinsey M.
(see Rulon, J. Thomas)

Skolnik, Emanuel M.
experiences with partial laryngopharyngectomy 80

Smith, Catherine
(see Bryan, William T. K.)

T

Tumors
larynx, cartilaginous of (Putney and Moran) 26

V

Velopharyngeal insufficiency
pharyngeal implants for reduction of airspace; experimental study (Ward and Wepman) 110

W

Ward, Paul H.
pharyngeal implants for reduction of air space in velopharyngeal insufficiency (with J. M. Wepman) 110

Weaver, Delmar F.
retropharyngeal hemorrhage from the carotid arteries (with D. O. Young) 223

Wepman, Joseph M.
(see Ward, Paul H.)

Woodward, Fletcher D.
obituary of James Milton Robb 243

Y

Young, David O.
(see Weaver, Delmar F.)